

Krishnamurthy Bonanthaya
Elavenil Panneerselvam
Suvy Manuel
Vinay V. Kumar
Anshul Rai
Editors

Oral and Maxillofacial Surgery for the Clinician

OPEN ACCESS

MOREMEDIA



 Springer

Oral and Maxillofacial Surgery for the Clinician

Krishnamurthy Bonanthaya
Elavenil Panneerselvam • Suvy Manuel
Vinay V. Kumar • Anshul Rai
Editors

Oral and Maxillofacial Surgery for the Clinician



 Springer

Editors

Krishnamurthy Bonanthaya
Bhagwan Mahaveer Jain hospital
Bangalore
India

Elavenil Panneerselvam
Associate Professor
SRM Dental College, Ramapuram
Chennai, Tamil Nadu
India

Suvy Manuel
Ananthapuri Hospitals & Research Institute
Kerala Institute of Medical Sciences
Trivandrum, Kerala
India

Vinay V. Kumar
Department of Maxillofacial Plastic Surgery
Uppsala University Hospital
Uppsala
Sweden

Anshul Rai
Associate Professor
Department of Dentistry
All India Institute of Medical Sciences
Bhopal, Madhya Pradesh
India

Video Editors

Jimson Samson
Vice Principal
Prof & Head of Department
Department of Oral & Maxillofacial Surgery
Tagore Dental College & Hospital
Chennai, India

Nehal Patel
Director, DCKH Cleft Center
K. P. Sanghvi Hospital
Surat, India

Illustrator

Mr Brishank Pratap
Goa, India

Voice-over for Videos

Madhulaxmi Marimuthu
Professor
Saveetha Dental College
Chennai, India

Vivek Narayanan
Dean, SRM Dental College
Kaatangulathur
Chennai, India



This book is an open access publication.

ISBN 978-981-15-1345-9 ISBN 978-981-15-1346-6 (eBook)

<https://doi.org/10.1007/978-981-15-1346-6>

© The Association of Oral and Maxillofacial Surgeons of India 2021

Open Access This book is licensed under the terms of the Creative Commons Attribution 4.0 International License (<http://creativecommons.org/licenses/by/4.0/>), which permits use, sharing, adaptation, distribution and reproduction in any medium or format, as long as you give appropriate credit to the original author(s) and the source, provide a link to the Creative Commons license and indicate if changes were made.

The images or other third party material in this book are included in the book's Creative Commons license, unless indicated otherwise in a credit line to the material. If material is not included in the book's Creative Commons license and your intended use is not permitted by statutory regulation or exceeds the permitted use, you will need to obtain permission directly from the copyright holder.

The use of general descriptive names, registered names, trademarks, service marks, etc. in this publication does not imply, even in the absence of a specific statement, that such names are exempt from the relevant protective laws and regulations and therefore free for general use.

The publisher, the authors, and the editors are safe to assume that the advice and information in this book are believed to be true and accurate at the date of publication. Neither the publisher nor the authors or the editors give a warranty, expressed or implied, with respect to the material contained herein or for any errors or omissions that may have been made. The publisher remains neutral with regard to jurisdictional claims in published maps and institutional affiliations.

This Springer imprint is published by the registered company Springer Nature Singapore Pte Ltd.
The registered company address is: 152 Beach Road, #21-01/04 Gateway East, Singapore 189721, Singapore

Preface

An important question that always comes up when a book of this scope and extent is written is: why do we need one more?

This deserves a thoughtful answer and we shall try to do that while tracing the origin and evolution of this book from an idea. Since its inception in 1969, the *Association of Oral and Maxillofacial Surgeons of India* (AOMSI) has made steady and significant progress in terms of its vision and commitment to promote the field. The members of AOMSI have also evolved into a vibrant, multidimensional, passionate, and committed community of oral and maxillofacial surgeons who are making substantial contribution to the field in India and around the world. So it was only natural that the association decided to express its commitment to academic medicine coinciding with its 50th year in existence.

And what better way to express it than publishing an open source comprehensive textbook on oral and maxillofacial surgery. This book showcases the experts and expertise of AOMSI and has been made freely available to surgeons worldwide through generous funding from the association. We are delighted to see this open access book published for free use by worldwide community of MaxFac surgeons, especially the young surgeons and trainees in the field. This book is published with a CCBY license and we encourage associations and institutes to widely distribute the link to this book for maximum possible usage.

The AOMSI was very conscious that the development of our speciality was not an insular one. As we evolved, we looked for guidance and training from colleagues around the world, and in return, we provided our bit of experience and insights. This exchange of knowledge is extremely important for ultimately improving patient treatment methods, techniques, and outcomes. The same spirit was applied in producing this book as well' as we requested eminent clinicians and researchers from around the world along with our members to contribute to this book.

The book has contributions by society's members within India as well as 41 international authors from various countries. Thus, the extent of this makes it one of the most comprehensive textbooks on the topic. The contributors were invited by the AOMSI keeping in mind their scholastic profile while ensuring diversity and inclusiveness as well as a mix of young and experienced surgeons. All the contributors have a track record of being high-volume clinicians and educators in their field of expertise and are generally working at prestigious teaching institutions. This textbook as a scholarly venture condenses and amalgamates both the authors' personal experience as well as being in line with the current evidence-based treatment principles in the field of maxillofacial surgery. In the beginning, the heterogeneous source of knowledge did pose editorial challenges in standardization of the chapter structuring and scope. However, the final outcome has achieved a blend of evidence-based, diverse surgical practices along with cutting-edge technology for the practice of maxillofacial surgery in a fairly uniform format.

As the title suggests, this is meant to be a comprehensive resource for all clinicians, post-graduate trainees, and young surgeons in their day-to-day clinical work. Graduate students and surgeons will find this book useful in preparing for their university exams as well as board-certified exams from professional organizations. The book will help in decision-making, implementing treatment plans, and managing problems that may arise while executing these

plans. Overall, the key objective is to help crystallize current evidence and provide protocols, guidelines, and recommendations to assist dealing with most clinical scenarios. Keeping this objective in mind, we have included components like case scenarios and video recordings of surgical procedures in the book.

Oral and Maxillofacial Surgery for the Clinician is a compilation of 22 sections incorporating 88 chapters dealing with the nuances in the principles and practice of cranio-maxillofacial and head and neck surgery. An important value addition is the library of 68 demonstrational videos that have been compiled to give the readers a more interactive feel with audiovisual inputs.

The book is structured in a step-ladder fashion to guide the reader through the basic principles of surgery before exposing to the full spectrum of specialty cranio-maxillofacial work. The first section is devoted to the origin and scope of oral and maxillofacial surgery as a specialty and a description of the training standards practiced globally. The next four sections are tailored to discuss the prospective patient, investigations, patient preparation, and anesthesia techniques. Subsequent sections focus on minor surgical procedures involving the practice of dento-alveolar surgery, implantology, and orofacial infections. With the above as the basis, the textbook progresses to complex surgical procedures including facial trauma, orthognathic surgery, TMJ, surgical pathology, and craniofacial and reconstructive surgery. The book also features two exclusive sections which provide the readers a perspective on practice management and research and publication.

The editors of the book would like to thank the office bearers of the AOMSI, in particular, the dynamic and effervescent secretary, Pritham Shetty, for the constant support he gave while undertaking this project.

Brishank Pratap, our tireless and innovative illustrator, needs a special mention for his superb rendition of medical and technical illustrations throughout this book.

Our publisher Springer, particularly, Naren Aggarwal and Jagjeet Kaur, deserves our gratitude for constant support and advice throughout the preparation of this book.

Last but not least, we would like to express our deep appreciation for the authors for their time, efforts, and priceless contributions.

We hope this book will be read worldwide, and we look forward to hear its critical reviews.

Bangalore, India
Chennai, India
Trivandrum, India
Uppsala, Sweden
Bhopal, India
Chennai, India
Surat, India

Krishnamurthy Bonanthaya
Elavenil Panneerselvam
Suvy Manuel
Vinay V. Kumar
Anshul Rai
Jimson Samson
Nehal Patel

Contents

Part I Introduction

- 1 Oral and Maxillofacial Surgery in India: How Did We Get Here and Where Are We Going?..... 3**
Kishore Nayak

Part II Preoperative Assessment and Patient Preparation/Optimization

- 2 Preoperative Evaluation and Investigations for Maxillofacial Surgery..... 11**
B. Krishnan and Satyen Parida
- 3 Management of Medical Comorbidities in Maxillofacial Surgery..... 25**
Aditya Moorthy and Shreya Krishna
- 4 Medical Emergencies in Oral and Maxillofacial Surgical Practice 49**
Nallamilli V. S. Sekhar Reddy

Part III Anesthesia for Oral and Maxillofacial Surgery

- 5 Local Anesthesia in Oral and Maxillofacial Surgery..... 61**
Reena Rachel John
- 6 Office-Based Anesthesia in Oral and Maxillofacial Surgery-The American Model and Training 79**
Payal Verma and Deepak G. Krishnan
- 7 Anaesthesia for Maxillo Facial Surgery 95**
Rebecca Jacob, Subramanyam S. Mahankali, Renita Maria, Suman Ananathanarayana, Garima Sharma, and Mary Thomas

Part IV Imaging in Oral and Maxillofacial Surgery

- 8 Radiology for Maxillofacial Surgeons: The Essentials 121**
Shyamsundar K. Joshi and Annie I. Kochuveetil

Part V Principles of Maxillofacial Surgery

- 9 Operating Room Protocols and Infection Control..... 173**
Rishi Kumar Bali
- 10 Pharmacotherapy in Oral and Maxillofacial Surgery..... 195**
Latha P. Rao
- 11 Wound Closure and Care in Oral and Maxillofacial Surgery 217**
Ravi Veeraraghavan

12 Postoperative Care of the Maxillofacial Surgery Patient	239
J. Naveen Kumar and Poornima Ravi	
Part VI Dentoalveolar and Oral Surgery	
13 Principles and Techniques of Exodontia	259
Anuj Jain	
14 Management of Impacted Third Molars	299
George Varghese	
15 Management of Impacted Canines	329
George Varghese	
16 Endodontic Surgery	349
Deepti Simon	
17 Preprosthetic Surgery	361
Bobby John	
Part VII Dental Implantology	
18 Basics of Dental Implantology for the Oral Surgeon	385
Supriya Ebenezer, Vinay V. Kumar, and Andreas Thor	
19 Bone Augmentation Procedures in Implantology	407
Vinay V. Kumar, Supriya Ebenezer, and Andreas Thor	
Part VIII Odontogenic Infections	
20 Odontogenic Infections: General Principles	429
Anand Shukla and Divya Mehrotra	
21 Fascial Space Infections	441
Rajasekhar Gaddipati	
22 Osteomyelitis, Osteoradionecrosis, and Medication-Related Osteonecrosis of Jaws	461
Christian Walter and Christoph Renné	
Part IX Maxillary Sinus and the Oral Surgeon	
23 Maxillary Sinusitis	475
Kandasamy Ganesan and Neelam Rathod	
24 OroAntral Communications and OroAntral Fistula	491
Suvy Manuel	
Part X Nerve Injuries and Neuralgias of Oral and Maxillofacial Region	
25 Trigeminal Nerve Injuries	515
Tara Renton	
26 Trigeminal Neuralgia	531
Kandasamy Ganesan and Asha Thomson	

Part XI Benign Pathologies of the Oral and Maxillofacial Region

- 27 Cysts of the “Oro-Maxillofacial Region”** 549
Neelima Malik
- 28 Benign Odontogenic Tumours** 577
Anjan Kumar Shah
- 29 Reactive Lesions of Oro-Maxillofacial Region** 599
Raja Sekhar Gali
- 30 Fibro-osseous Lesions in the Maxillofacial Region** 615
Taranjit Kaur
- 31 Vascular Anomalies of the Oro-Maxillofacial Region** 629
Sanjiv Nair and Sunil S. Shroff

Part XII Aesthetic Procedures in Oral and Maxillofacial Region

- 32 Non-surgical Modalities of Facial Rejuvenation and Aesthetics** 661
Arun Kumar Panda and Aarti Chowdhary
- 33 Botulinum Toxin and Fillers for Maxillofacial Esthetics** 691
Sainath Matsa
- 34 Hair Transplantation** 707
Sreedhar Reddy Pothula and B. S. Jayanth
- 35 Ear Reconstruction** 731
Paritkumar Ladani
- 36 Management of Facial Scars** 747
Velupillai Ilankovan and Anna Sayan
- 37 Surgical Facelift** 759
Velupillai Ilankovan and Tian Ee Seah
- 38 Rhinoplasty** 775
Nasir A. Nasser

Part XIII Advances in Oral and Maxillofacial Surgery

- 39 Lasers in Oral and Maxillofacial Surgery** 817
Shravan Renapurkar and Robert A. Strauss
- 40 Piezosurgery in Oral and Maxillofacial Surgery** 831
Shravan Renapurkar and Sowjanya Nagamalla
- 41 Computer-Assisted Navigation Surgery in Oral and Maxillofacial Surgery** . . . 841
Shintaro Sukegawa and Takahiro Kanno

Part XIV Practice Management in Oral and Maxillofacial Surgery

- 42 Human Factors Recognition to Enhance Team Working and Safer Patient Care** 865
Peter A. Brennan and Rachel S. Oeppen

43	De Novo Practice of Oral and Maxillofacial Surgery	871
	Srinivas Gosla Reddy and Avni Pandey Acharya	
44	Medicolegal Issues in Maxillofacial Surgery	883
	George Paul and Manjunath Rai	
45	Research and Publishing in Oral and Maxillofacial Surgery	927
	George Dimitroulis	
Part XV Salivary Gland Pathologies		
46	Salivary Gland Pathologies	939
	Nisheet Anant Agni	
47	Obstructive Salivary Gland Disease and Sialendoscopy	975
	Prithvi S. Bachalli and Aditya Moorthy	
Part XVI Maxillofacial Traumatology		
48	Primary Assessment and Care in Maxillofacial Trauma	983
	Saurabh Saigal and Manal M. Khan	
49	Management of Soft Tissue Injuries in the Maxillofacial Region	997
	Abhay Datarkar and Shikha Tayal	
50	Dentoalveolar Injuries and Wiring Techniques	1013
	Omkar Anand Shetye	
51	Principles of Internal Fixation in Maxillofacial Surgery	1039
	Abhilasha Yadav	
52	Fractures of the Mandible	1053
	Anshul Rai	
53	Fracture of the Mandibular Condyle	1085
	Vikas Dhupar	
54	Intraoral Endoscopic Approach for Treatment of Condylar Fractures of the Mandible	1115
	Frank Wilde	
55	Maxillary Fractures	1125
	Oommen Aju Jacob and Akhilesh Prathap	
56	Fractures of the Zygomaticomaxillary Complex	1151
	Elavenil Panneerselvam, Poornima Ravi, and B. Sasikala	
57	Orbital Fractures	1201
	Ananthanarayanan Parameswaran, Madhulaxmi Marimuthu, Shreya Panwar, and Beat Hammer	
58	Frontal and Naso-Orbito-Ethmoid Complex Fractures	1251
	Kannan Balaraman	
59	Gunshot Injuries of the Maxillofacial Region	1267
	Lt Col Rohit Sharma and Maj Anson Jose	
60	Panfacial Fractures	1283
	Kiran S. Gadre, Balasubramanya Kumar, and Divya P. Gadre	

61 Residual Deformities of the Maxillofacial Region	1303
Samson Jimson	
Part XVII Temporomandibular Joint Disorders	
62 Myofascial Pain Dysfunction Syndrome	1343
Mirza Farhatullah Baig and Yashoda Ashok	
63 Internal Derangements of the Temporomandibular Joint	1361
Gary Warburton	
64 Temporomandibular Joint Dislocation	1381
V. B. Krishnakumar Raja	
65 Temporomandibular Joint Ankylosis	1401
Sonal Anchlia	
Part XVIII Orthognathic Surgery	
66 Diagnosis and Planning in Orthognathic Surgery	1437
Johan P. Reyneke and Carlo Ferretti	
67 Surgery-First Orthognathic Approach	1463
N. Viveka Vardhan Reddy and Abhinand Potturi	
68 Orthognathic Surgery for Mandible	1477
Varghese Mani	
69 Orthognathic Surgery for the Maxilla-LeFort I and Anterior Maxillary Osteotomy	1513
Ashok Dabir and Jayesh Vahanwala	
70 Facial Asymmetry	1549
Neelam N. Andrade, Paul Mathai, and Neha Aggarwal	
71 Obstructive Sleep Apnea Syndrome	1577
Suresh Menon	
Part XIX Developmental Deformities of the Oral and Maxillofacial Region	
72 Cleft Lip	1593
Pritham N. Shetty, Jaideep Singh Chauhan, Mamatha Patil, Neha Aggarwal, and Dipesh Rao	
73 Cleft Palate	1633
P. V. Narayanan and H. S. Adenwalla	
74 Alveolar Bone Grafting	1655
Veerabahu Muthusubramanian and Kalarikkal Mukundan Harish	
75 Cleft Maxillary Hypoplasia	1675
Philip Mathew, Mustafa. K, and Paul Mathai	
76 Cleft Rhinoplasty	1703
Sunil Richardson and Rakshit Vijay Sinai Khandeparker	

Part XX Craniofacial Anomalies

- 77 Rare Facial Clefts** 1735
Srinivas Gosla Reddy and Avni Pandey Acharya
- 78 Hemifacial Microsomia (HFM) and Treacher Collins Syndrome** 1769
Manikandhan Ramanathan
- 79 Modern Management of Craniosynostosis** 1813
David Koppel and Jaime Grant

Part XXI Malignant Pathologies of the Oral and Maxillofacial Region

- 80 Premalignant Lesions and Conditions of the Oral Cavity** 1845
El Mustafa, Sat Parmar, and Prav Praveen
- 81 Oral Squamous Cell Carcinoma: Diagnosis and Treatment Planning** 1853
Vijay Deshmukh and Kishore Shekar
- 82 Principles of Surgical Management of Oral Cancer** 1869
Sushma Mehta and Moni Abraham Kuriakose
- 83 Sarcoma of the Maxillofacial/Head and Neck Region** 1893
D' Souza Jacob and Boyapati Raghu
- 84 Adjunctive Therapy in Oral Cancer** 1903
Amit Dhawan
- 85 Access Surgeries and Osteotomies for the Maxillofacial Region** 1915
Madan G. Ethunandan

Part XXII Reconstructive Procedures of the Oral and Maxillofacial Region

- 86 Soft Tissue Reconstruction of the Maxillofacial Region** 1941
Benjamin Turner, John Collin, and Rui Fernandes
- 87 Distraction Osteogenesis of the Maxillofacial Region** 1969
R. S. Neelakandan
- 88 Hard Tissue Reconstruction of the Maxillofacial Region** 1997
Srinivasa R. Chandra and Vijay Pillai

List of Videos

- Video 7.1 Demonstrates the technique of blind nasal intubation
- Video 7.2 Demonstrates the various steps involved in submental intubation
- Video 11.1 Various intra oral suturing techniques
- Video 14.1 Surgical removal of impacted lower third molar (Mesio angular)
- Video 14.2 Surgical removal of impacted lower third molar (Horizontal)
- Video 14.3 Surgical removal of impacted maxillary third molar
- Video 15.1 Surgical removal of impacted maxillary canine
- Video 17.1 Labial Frenectomy
- Video 17.2 Lingual Frenectomy
- Video 18.1 Posterior tooth replacement (Implant)
- Video 18.2 Immediate (Extraction socket) implant placement
- Video 18.3 Multiple teeth implant placement
- Video 18.4 Placement of zygoma implant
- Video 19.1 Chin graft
- Video 19.2 Placement of zygoma implant
- Video 24.1 OAF Closure by buccal advancement flap along with Caldwell luc procedure and nasal antrostomy
- Video 26.1 Ginwala operation
- Video 27.1 Cyst enucleation (mandible)
- Video 27.2 Cyst enucleation (maxilla)
- Video 28.1 Mandibulectomy (marginal)
- Video 28.2 Mandibulectomy (segmental)
- Video 30.1 Surgical management (bone recontouring) of fibrous dysplasia
- Video 32.1 Facial rejuvenation-HIFU
- Video 33.1 Botox injection for facial wrinkles
- Video 34.1 Hair transplant—FUE
- Video 34.2 Hair transplant—FUT
- Video 35.1 Ear reconstruction
- Video 38.1 Rhinoplasty
- Video 46.1 Sialolith-Removal of Sub mandibular calculi
- Video 46.2 Surgical excision of mucocele
- Video 46.3 Superficial Parotidectomy
- Video 47.1 Sialoendoscopy (mandibular)
- Video 48.1 Tracheostomy
- Video 50.1 Eyelet wiring technique
- Video 50.2 Arch bar technique
- Video 50.3 IMF technique
- Video 52.1 ORIF of mandibular symphysis fracture
- Video 53.1 Submandibular incision
- Video 53.2 Transmasstetric approach
- Video 53.3 Retromandibular approach
- Video 53.4 Pre auricular incision

- Video 53.5 Alkayat bramley incision
- Video 53.6 Rhytidectomy incision
- Video 56.1 Gillies temporal approach
- Video 56.2 Lateral brow incision
- Video 57.1 Infra-orbital approach for orbital fracture
- Video 57.2 Trans-conjunctival approach for orbital floor reconstruction with 3D mesh
- Video 63.1 Level 1 Arthroscopy of TMJ
- Video 63.2 Level 2 Arthroscopy of TMJ
- Video 63.3 Level 3 Arthroscopy of TMJ
- Video 65.1 TMJ ankylosis-interpositional gap arthroplasty
- Video 68.1 BSSO with bur
- Video 68.2 BSSO with saw
- Video 68.3 Genioplasty
- Video 69.1 Lefort 1 osteotomy
- Video 69.2 Anterior maxillary osteotomy
- Video 72.1 Millard rotation advancement repair
- Video 72.2 Bilateral cleft lip repair
- Video 73.1 Suspension palatoplasty
- Video 73.2 Revision palatoplasty Furlow
- Video 73.3 Partial palatal split palatoplasty
- Video 75.1 Anterior maxillary distraction
- Video 75.2 Cleft osteotomy (Lefort 1)
- Video 76.1 Cleft rhinoplasty
- Video 81.1 Wide excision of precancerous lesion
- Video 82.1 Modified radical neck dissection (MRND)
- Video 87.1 Extra oral mandibular Molina Distractor
- Video 88.1 Free fibula osteocutaneous flap harvesting

Chapter Contributors and Video Contributors

Contributors

Avni Pandey Acharya GSR Institute of Cranio-maxillofacial & Facial Plastic Surgery, Hyderabad, Telangana, India

H. S. Adenwalla Department of Plastic Surgery, Burns and the Charles Pinto Centre for Cleft Lip, Palate and Craniofacial Anomalies, Jubilee Mission Medical College and Research Institute, Thrissur, Kerala, India

Neha Aggarwal Nair Hospital Dental College, Mumbai, Maharashtra, India
Meenakshi Cleft and Craniofacial Centre, Chennai, Tamil Nadu, India

Nisheet Anant Agni Department of Oral and Maxillofacial Surgery, SMBT Institute of Dental Sciences and Research, Nashik, India

Suman Ananathanarayana Department of Anesthesiology, Columbia Asia Referral Hospital, Yeshwantpur, Bangalore, Karnataka, India

Sonal Anchlia Department of Oral & Maxillofacial Surgery, Government Dental College & Hospital, Ahmedabad, Gujarat, India

Neelam N. Andrade Department of Oral and Maxillofacial Surgery, Nair Hospital Dental College, Mumbai, Maharashtra, India

Yashoda Ashok Department of Oral and Maxillofacial Surgery, Meenakshi Ammal Dental College and Hospitals, Chennai, Tamil Nadu, India

Prithvi S. Bachalli Department of Oral and Maxillofacial Surgery, Rangadore Memorial Hospital, Apollo Hospitals, Bangalore, Karnataka, India

Mirza Farhatullah Baig Department of Oral and Maxillofacial Surgery, Saveetha Dental College, Chennai, Tamil Nadu, India

Kannan Balaraman Department of Oral and Maxillofacial Surgery, Ganga Medical Centre and Hospitals, Coimbatore, Tamil Nadu, India

Rishi Kumar Bali Postgraduate Department of OMFS, DAV Dental College Hospital, Yamunanagar, Haryana, India

Peter A. Brennan Maxillofacial Unit, Queen Alexandria Hospital, Portsmouth, UK

Srinivasa R. Chandra Department of Head and Neck Oncology and Reconstructive Microvascular and Oral and Maxillofacial Surgery, Fred and Pamela Buffett Cancer Center, UNMC, Omaha, NE, USA

Jaideep Singh Chauhan Department of Maxillofacial Surgery, the Smile Train CHL Hospital, Indore, Madhya Pradesh, India

Aarti Chowdhary Department of Periodontology, SD Dental College and Hospital, Parbhani, Maharashtra, India

John Collin Department of Oral and Maxillofacial Surgery, University of Florida, Jacksonville, FL, USA

Ashok Dabir D. Y. Patil University School of Dentistry, Nerul, Navi Mumbai, India
Breach Candy Hospital, Mumbai, India

Abhay Datarkar Department of Oral and Maxillofacial Surgery, Government Dental College and Hospital, Medical College Premises, Nagpur, Maharashtra, India

Vijay Deshmukh Deshmukh Institute of Maxillofacial Surgery and Research Centre, Aurangabad, Maharashtra, India

JIIU'S Indian Institute of Medical Sciences, Jalna, Maharashtra, India

Amit Dhawan Department of Oral and Maxillofacial Surgery, SGRD Dental Institute, Amritsar, India

George Dimitroulis Maxillofacial Unit, St. Vincent's Hospital—University of Melbourne, Melbourne, Australia

Vikas Dhupar Department of Oral and Maxillofacial Surgery, Goa Dental College and Hospital, Bambolim, Goa, India

Supriya Ebenezer Department of Oral Surgery and Stomatology, University of Bern, Bern, Switzerland

El Mustafa Department of Oral and Maxillofacial Surgery, Queen Elizabeth Hospital, Birmingham, UK

Madan G. Ethunandan Consultant Oral and Maxillofacial/Skull Base Surgeon, Honorary Senior Clinical Lecturer, Lead, Head and Neck Cancer, University Hospital Southampton, Southampton, UK

Carlo Ferretti , Johannesburg, South Africa
Department of Maxillofacial and Oral Surgery, University of Pretoria, Pretoria, South Africa

Rui Fernandes Department of Oral and Maxillofacial Surgery, Head and Neck Oncologic Surgery and Microvascular Fellowship, University of Florida, Jacksonville, FL, USA

Rajasekhar Gaddipati Department of Oral and Maxillofacial Surgery, Mamata Dental College, Khammam, Telangana, India

Divya P. Gadre Gadre Clinic, Pune, Maharashtra, India

Kiran S. Gadre Gadre Clinic, Pune, Maharashtra, India
Department of Oral and Maxillofacial Surgery, Bharati Vidyapeeth Dental College and Hospital, Pune, Maharashtra, India

Raja Sekhar Gali Department of Oral and Maxillofacial Surgery, Narayana Dental College and Hospital, Nellore, Andhra Pradesh, India
Medicover Hospital, Nellore, Andhra Pradesh, India

Kandasamy Ganesan Department of Oral and Maxillofacial Surgery, Southend University Hospitals NHS Trust, Southend-on-Sea, UK
University of Leeds, Leeds, UK

Jaime Grant Birmingham Children's Hospital, Birmingham, UK

Beat Hammer CFC Hirslanden Kopf Zentrum, Aarau, Switzerland

Kalarikkal Mukundan Harish Department of Oral & Maxillofacial Surgery, Ragas Dental College, Chennai, Tamil Nadu, India

Velupillai Ilankovan Oral and Maxillofacial Surgery, Poole Hospital NHS Foundation Trust, Poole, UK

D' Souza Jacob Maxillofacial Unit, Royal Surrey County Hospital, Guilford, UK

Oommen Aju Jacob Department of Oral and Maxillofacial Surgery, Ananthapuri Hospitals and Research Institute, Trivandrum, Kerala, India

Kerala Institute of Medical Sciences, Trivandrum, Kerala, India

Rebecca Jacob Department of Anesthesiology, Columbia Asia Referral Hospital, Yeshwantpur, Bangalore, Karnataka, India

Anuj Jain Oral and Maxillofacial Surgeon, Department of Trauma and Emergency Medicine, All India Institute of Medical Sciences, Bhopal, Madhya Pradesh, India

B. S. Jayanth Oral and Maxillofacial Surgeon, ABMSS, Bengaluru, Karnataka, India

Samson Jimson Department of Oral and Maxillofacial Surgery, Tagore Dental College and Hospital, Chennai, Tamil Nadu, India

Bobby John Department of Oral and Maxillofacial Surgery, Government Dental College, Kottayam, Kerala, India

Kerala University of Health Sciences, Thrissur, Kerala, India

Reena Rachel John Department of Oral and Maxillofacial Surgery, Vinayaka Mission's Sankarachariar Dental College and Hospital, VMRF, DU, Salem, India

Maj Anson Jose Oral and Maxillofacial Surgery, ADC R&R, New Delhi, India

Shyamsundar K. Joshi Department of Radiology, SDM College of Medical Sciences and Hospital, Shri Dharmasthala Manjunatheshwara University, Dharwad, India

Takahiro Kanno Department of Oral and Maxillofacial Surgery, Shimane University, Faculty of Medicine, Izumo, Shimane, Japan

Taranjit Kaur Department of Oral and Maxillofacial Surgery, Government Dental College and Hospital, Jamnagar, Gujarat, India

Manal M. Khan Department of Burns and Plastic Surgery, AIIMS Bhopal, Bhopal, Madhya Pradesh, India

Rakshit Vijay Sinai Khandeparker Department of Oral and Maxillofacial Surgery, Goa Dental College and Hospital, Bambolim, Goa, India

Annie I. Kochuveetil Department of Radiology, SDM College of Medical Sciences and Hospital, Shri Dharmasthala Manjunatheshwara University, Dharwad, India

David Koppel Scottish National Craniofacial Service for Children and Young People, Royal Hospital for Children, Glasgow, UK

Shreya Krishna Oral and Maxillofacial Surgery, Rangadore Memorial Hospital, Apollo Hospitals, Bangalore, India

V. B. Krishnakumar Raja Department of Oral & Maxillofacial Surgery, SRM Dental College & Hospital, Ramapuram, Chennai, Tamil Nadu, India

B. Krishnan Department of Dentistry, Jawaharlal Institute of Postgraduate Medical Education and Research (JIPMER), Puducherry, India

Deepak G. Krishnan Oral and Maxillofacial Surgery, University of Cincinnati Medical Center, Cincinnati, OH, USA

Cincinnati Children's Hospital and Medical Center, Cincinnati, OH, USA

Balasubramanya Kumar Department of Oral and Maxillofacial Surgery, St. Marthas's Hospital, Bangalore, Karnataka, India

Bhagwan Mahaveer Jain Hospital, Vikram Hospital, Bangalore, Karnataka, India

Vinay V. Kumar Department of Maxillofacial and Plastic Surgery, Uppsala University Hospital, Uppsala, Sweden

Moni Abraham Kuriakose Cochin Cancer Research Centre, Kochi, Kerala, India

Paritkumar Ladani Swiss Cleft and Craniofacial Centre, BSES MG Hospital, Mumbai, India

Subramanyam S. Mahankali Department of Anesthesiology, Columbia Asia Referral Hospital, Yeshwantpur, Bangalore, Karnataka, India

Neelima Malik Department of Oral and Maxillofacial Surgery, Krishna Institute of Medical Sciences "Deemed to be University", Karad, Maharashtra, India

Varghese Mani Department of Oral and Maxillofacial Surgery, Mar Baselios Dental College, Kothamangalam, Kerala, India

Suvy Manuel Department of Oral and Maxillofacial Surgery, Ananthapuri Hospitals and Research Institute, Trivandrum, Kerala, India

Kerala Institute of Medical Sciences, Trivandrum, Kerala, India

Renita Maria Department of Anesthesiology, Columbia Asia Referral Hospital, Yeshwantpur, Bangalore, Karnataka, India

Madhulaxmi Marimuthu Department of Oral & Maxillofacial Surgery, Saveetha Dental College & Hospital, Chennai, Tamil Nadu, India

Paul Mathai Nair Hospital Dental College, Mumbai, Maharashtra, India

Department of Oral and Maxillofacial Surgery, Jubilee Mission Medical College & Research Institute, Thrissur, Kerala, India

Philip Mathew Department of Oral and Maxillofacial Surgery, Jubilee Mission Medical College & Research Institute, Thrissur, Kerala, India

Sainath Matsa Praseedha Clinic for Maxillofacial Cosmetic Surgery, Chennai, Tamil Nadu, India

Divya Mehrotra Department of Oral and Maxillofacial Surgery, King George's Medical University, Lucknow, India

Sushma Mehta Mazumdar Shaw Cancer Center, Bengaluru, Karnataka, India

Suresh Menon Department of Oral and Maxillofacial Surgery, Vydehi Institute of Dental Sciences and Research Centre, Bangalore, Karnataka, India

Aditya Moorthy Department of Oral and Maxillofacial Surgery, Rangadore Memorial Hospital, Apollo Hospitals, Bangalore, Karnataka, India

Mustafa. K Department of Craniofacial Surgery, Kanachur Institute of Medical Sciences, Mangalore, Karnataka, India

Veerabahu Muthusubramanian Department of Oral & Maxillofacial Surgery, Ragas Dental College, Chennai, Tamil Nadu, India

Sowjanya Nagamalla Department of Oral and Maxillofacial Surgery, Virginia Commonwealth University Medical Center, Richmond, VA, USA

Sanjiv Nair Department of Oral and Maxillofacial Surgery, Bhagwan Mahaveer Jain Hospital, Bengaluru, Karnataka, India

P. V. Narayanan Consultant Plastic Surgeon, Jubilee Mission Medical College & Research Institute, Thrissur, Kerala, India

Nasir A. Nasser Barts & London NHS Trust, Whipps Cross University Hospital, London, UK
University Hospital, Berne, Switzerland

J. Naveen Kumar Oral and Maxillofacial Surgery, Sri Ramachandra Institute of Higher Education and Research, Chennai, India

Kishore Nayak Bhagvan Jain Mahaveer Hospital, Bangalore, India

R. S. Neelakandan Department of Oral and Maxillofacial Surgery, Meenakshi Ammal Dental College and Hospital, MAHER, Chennai, Tamil Nadu, India

Rachel S. Oeppen Consultant Radiologist, University Hospital Southampton, Southampton, UK

Arun Kumar Panda Department of Oral & Maxillofacial Surgery, SD Dental College and Hospital, Parbhani, Maharashtra, India

Elavenil Panneerselvam Department of Oral and Maxillofacial Surgery, SRM Dental College, Ramapuram, Chennai, Tamil Nadu, India

Department of Orbit & Oculoplasty, Aravind Eye Hospital, Chennai, Tamil Nadu, India

Shreya Panwar Department of Oral & Maxillofacial Surgery, Meenakshi Ammal Dental College & Hospital, Chennai, Tamil Nadu, India

Ananthanarayanan Parameswaran Department of Oral and Maxillofacial Surgery, Meenakshiammal Dental College & Hospital, Chennai, Tamil Nadu, India

Department of Orbit, Oculoplasty, Reconstructive & Aesthetic Surgery, Shankara Nethralaya, Chennai, Tamil Nadu, India

Department of Orbit & Oculoplasty, Aravind Eye Hospital, Chennai, Tamil Nadu, India

Satyen Parida Department of Anesthesiology and Critical Care, Jawaharlal Institute of Postgraduate Medical Education and Research (JIPMER), Puducherry, India

Sat Parmar Department of Oral and Maxillofacial Surgery, Queen Elizabeth Hospital, Birmingham, UK

Mamatha Patil Department of Oral and Maxillofacial Surgery, Sparsh Hospital, Bangalore, Karnataka, India

George Paul Kerala University of Health Sciences, Thrissur, Kerala, India

Dr MGR Medical University, Chennai, Tamil Nadu, India

Vijay Pillai Department of Head and Neck Surgical Oncology, Mazumdar Shaw Cancer Center, Narayana Health, Bangalore, Karnataka, India

Sreedhar Reddy Pothula Oral and Maxillofacial Surgery, Pioneer advanced Hair Transplant Centre, Bengaluru, Karnataka, India

Abhinand Potturi SVS Institute of Dental Sciences, Mahabubnagar, Telangana State, India

Akhilesh Prathap Department of Oral and Maxillofacial Surgery, Pushpagiri College of Dental Sciences, Thiruvalla, Kerala, India

Prav Praveen Department of Oral and Maxillofacial Surgery, Queen Elizabeth Hospital, Birmingham NHS Foundation Trust, Birmingham, UK

Boyapati Raghu Maxillofacial Unit, Royal Surrey County Hospital, Guilford, UK

Anshul Rai Department of Dentistry, All India Institute of Medical Sciences, Bhopal, Madhya Pradesh, India

Manjunath Rai Department of OMFS, A. J. Institute of Dental Sciences, Mangalore, Karnataka, India

Faculty of Dentistry, RGUHS, Bangalore, India

Manikandhan Ramanathan Department of Oral and Maxillofacial surgery, Meenakshi Ammal Dental College and Hospital, MAHER University, Chennai, Tamil Nadu, India

Meenakshi Cleft and Craniofacial Centre, Chennai, Tamil Nadu, India

Dipesh Rao Bhagwan Mahaveer Jain Hospital, Bangalore, Karnataka, India

Latha P. Rao Department of Craniomaxillofacial Surgery, Aster Medcity, Kochi, Kerala, India

Neelam Rathod Department of Oral and Maxillofacial Surgery, Southend University Hospitals NHS trust, Southend-on-Sea, UK

Poornima Ravi Department of Oral and Maxillofacial Surgery, SRM Dental College, Ramapuram, Chennai, Tamil Nadu, India

Srinivas Gosla Reddy GSR Institute of Cranio-maxillofacial & Facial Plastic Surgery, Hyderabad, Telangana, India

N. Viveka Vardhan Reddy Oral and Maxillofacial Surgery, SVS Institute of Dental Sciences, Mahabubnagar, Telangana, India

Shravan Renapurkar Department of Oral and Maxillofacial Surgery, Virginia Commonwealth University Medical Center, Richmond, VA, USA

Christoph Renné Group Practice for Pathology Wiesbaden, Wiesbaden, Germany

Tara Renton Oral Surgery, Kings College, London, UK

Johan P. Reyneke Center for Orthognathic Surgery, Mediclinic, Cape Town, South Africa
Department of Oral and Maxillofacial Surgery, Faculty of Health Sciences, University of the Western Cape, Cape Town, South Africa

Department of Oral and Maxillofacial Surgery, University of Oklahoma, Oklahoma City, OK, USA

Sunil Richardson Richardson's Dental and Craniofacial Hospital, Nagercoil, Tamil Nadu, India

Saurabh Saigal Department of Anaesthesiology, AIIMS Bhopal, Bhopal, Madhya Pradesh, India

B. Sasikala Department of Oral and Maxillofacial Surgery, SRM Dental College, Ramapuram, Chennai, Tamil Nadu, India

Anna Sayan Poole Hospital NHS Foundation Trust, Poole, UK

Tian Ee Seah TES Clinic for Face and Jaw, Singapore, Singapore

Nallamilli V. S. Sekhar Reddy Panineeya Institute of Dental Sciences and Research Centre, Hyderabad, Telangana, India

Anjan Kumar Shah Department of Oral and Maxillofacial Surgery, Rajarajeswari Dental College, Bangalore, India

Bhagwan Mahaveer Jain Hospital, Bangalore, India

Garima Sharma Department of Anesthesiology, Columbia Asia Referral Hospital, Yeshwantpur, Bangalore, Karnataka, India

Lt Col Rohit Sharma Oral and Maxillofacial Surgery, 11 Corps Dental Unit, Jalandhar Cantt, India

Kishore Shekar Head and Neck Surgeon (OMFS), Ninewells Hospital and Dundee, University Medical School, Dundee, UK

Pritham N. Shetty Department of Oral and maxillofacial surgery, Bangalore Institute of Dental Science, Bangalore, Karnataka, India

Omkar Anand Shetye Department of Oral and Maxillofacial Surgery, Goa Dental College and Hospital, Bambolim, Goa, India

Sunil S. Shroff Department of Oral and Maxillofacial Surgery, Bhagwan Mahaveer Jain Hospital, Bengaluru, Karnataka, India

Anand Shukla Department of Oral and Maxillofacial Surgery, King George's Medical University, Lucknow, India

Deepti Simon Department of Oral and Maxillofacial Surgery, Government Dental College, Trivandrum, Kerala, India

Kerala University of Health Sciences, Thrissur, Kerala, India

Robert A. Strauss Department of Oral and Maxillofacial Surgery, Virginia Commonwealth University Medical Center, Richmond, VA, USA

Shintaro Sukegawa Division of Oral and Maxillofacial Surgery, Kagawa Prefectural Central Hospital, Takamatsu, Kagawa, Japan

Shikha Tayal Department of Oral and Maxillofacial Surgery, Government Dental College and Hospital, Medical College Premises, Nagpur, Maharashtra, India

Mary Thomas Department of Anesthesiology, Regional Cancer Centre, Medical College Campus, Thiruvananthapuram, Kerala, India

Andreas Thor Department of Maxillofacial and Plastic Surgery, Uppsala University Hospital, Uppsala, Sweden

Asha Thomson Norfolk and Norwich University Hospitals, Norfolk, UK

Benjamin Turner Department of Oral and Maxillofacial Surgery, University of Florida, Jacksonville, FL, USA

Jayesh Vahanwala Department of Oral and Maxillofacial Surgery, Vaidik Dental College & Research Centre, Nani Daman, India

Breach Candy Hospital, Mumbai, India

George Varghese Principal, Professor and Head, Department of Oral and Maxillofacial Surgery, Pushpagiri College of Dental Sciences, Tiruvalla, Kerala, India

Ravi Veeraraghavan Department of Oral and Maxillofacial Surgery, Amrita School of Dentistry, Ernakulam, India

Payal Verma Oral and Maxillofacial Surgery, University of Cincinnati Medical Center, OH, Cincinnati, USA

Christian Walter Oral and Maxillofacial Surgery—Plastic Surgery, Mediplus Clinic Mainz, Mainz, Germany

Gary Warburton Department of Oral and Maxillofacial Surgery, University of Maryland School of Dentistry, Baltimore, MD, USA

Frank Wilde Department of Oral and Plastic Maxillofacial Surgery, Armed Forces Hospital, Ulm, Germany

Department of Oral and Maxillofacial Surgery, University Hospital, Ulm, Germany

Abhilasha Yadav Department of Oral and Maxillofacial Surgery, Awadh Dental College & Hospital, Jamshedpur, Jharkhand, India

Video Contributors

Prithvi S. Bachalli Department of Oral and Maxillofacial Surgery, Rangadore Memorial Hospital, Apollo Hospitals, Bangalore, Karnataka, India

Ramdas Balakrishna Department of Oral and Maxillofacial Surgery, KLE's Institute of Dental Science and Research, Bangalore, India

Anandh Balasubramanian Department of Oral and Maxillofacial Surgery, Tagore Dental College and Hospital, Chennai, Tamil Nadu, India

Mohan Baliga Department of Oral and Maxillofacial Surgery, Manipal College of Dental Sciences, MAHE, Mangalore, Karnataka, India

Biswajit Kumar Biswas Avinash Institute of craniofacial and Reconstructive Surgery, Kolkata, India

Lokesh Bhanumurthy Department of Oral and Maxillofacial Surgery, Tagore Dental College and Hospital, Chennai, Tamil Nadu, India

Rohit Chandra Oral and Maxillofacial Surgeon, Department of Plastic Surgery, Max Hospitals, Vaishali and Noida, India

Jaideep Singh Chauhan Department of Oral and Maxillofacial Surgery, CHL Hospitals, Indore, Madhya Pradesh, India

Anil Kumar Desai Craniofacial Unit, SDM College of Dental Sciences & Hospital, Dharwad, India

Anjaneya Dube Department of Oral and Maxillofacial Surgery, Saptarshi Hospital and Cancer Centre, Jabalpur National Hospital, Jabalpur, India

Gunjan Dube Dube Surgical and Dental Hospital, Jabalpur, Madhya Pradesh, India

Shehzana Fatima Oral and Maxillofacial Surgeon, Dubai Health Authority, Dubai, UAE

S. Girish Rao Oral and Maxillofacial Surgeon, Shri Shankara Cancer Hospital and Research Center, Apollo Hospitals, Sagar Hospitals, Trustwell Hospital, NIMHANS, Bangalore, India

Charu Girotra Department of OMFS, School of Dentistry, D. Y. Patil Deemed to be University, Navi Mumbai, Maharashtra, India

Gaurav Mahesh Gupta Centre for Craniomaxillo Facial and Facial Plastic Surgery, Pushpanjali Hospital & Research Centre, Agra, Uttar Pradesh, India

Rebecca Jacob Department of Anesthesiology, Columbia Asia Referral Hospital, Yeshwantpur, Bangalore, India

Jagadish Chandra Department of OMFS, Yenepoya Dental College, Yenepoya Deemed to be University, Mangalore, India

Samson Jimson Department of Oral & Maxillofacial Surgery, Tagore Dental College & Hospital, Chennai, India

Adarsh Kudva Department of Oral and Maxillofacial Surgery, Manipal College of Dental Sciences, Mahe University, Manipal, India

Deepak Kulkarni Department of Oral and Maxillofacial Surgery, Dr D Y Patil Dental College, Pune, India

Balasubramanya Kumar Department of Oral and Maxillofacial Surgery, Bhagwan Mahaveer Jain Hospital, Vikram Hospital, Bangalore, India

Paritkumar Ladani Swiss Cleft and Craniofacial Centre, BSES MG Hospital, Mumbai, India

Ummar Mangalath Department of Oral and Maxillofacial Surgery, MES Dental College, Perinthalmanna, Kerala, India

Philip Mathew Department of Oral and Maxillofacial Surgery, Jubilee Mission Medical College and Hospital, Thrissur, Kerala, India

Sainath Matsa Praseedha Clinic for Maxillofacial Cosmetic Surgery, Chennai, Tamil Nadu, India

Aditya Moorthy Department of Oral and Maxillofacial Surgery, Rangadore Memorial Hospital, Apollo Hospitals, Bangalore, Karnataka, India

Ravindran Nair Department of Oral and Maxillofacial Surgery, Government Medical College, Manjeri, Kerala, India

Anuradha Navaneetham Department of Oral and Maxillofacial Surgery, M R Ambedkar Dental College, Rajiv Gandhi University, Bangalore, India

Nilesh Pagaria Oral and Maxillofacial Surgeon, Shrikrishna Hospital, Raipur, Chhattisgarh, India

Arun Kumar Panda Department of Oral & Maxillofacial Surgery, SD Dental College and Hospital, Parbhani, Maharashtra, India

Ananthanarayanan Parameswaran Department of Oral and Maxillofacial Surgery, Meenakshi Ammal Dental College & Hospital, Chennai, Tamil Nadu, India

Nehal Patel NuFace Maxillofacial Hospital, Surat, Gujarat, India

Kavitha Prasad Faculty of Dental Sciences, Ramaiah University of Applied Sciences, Bengaluru, India

Satish Kumaran Pugazhendi Department of Oral and Maxillofacial Surgery, M. R. Ambedkar Dental College, Bangalore, India

Gunaseelan Rajan Oral and Maxillofacial Surgeon, Rajan Dental Hospital, Chennai, Tamil Nadu, India

Rajasekhar Gaddipati Department of Oral and Maxillofacial Surgery, Mamata Dental College, Khammam, Telangana, India

Sushmitha Rajmohan Department of Dentistry & Maxillofacial Surgery, ESIC Model Hospital, Indore, India

Aasya the Clinic for Face Jaws & Teeth, Vijaynagar, Indore, MP, India

Vidya Rattan Unit of Oral & Maxillofacial Surgery, Oral Health Sciences Centre, Postgraduate Institute of Medical Education & Research, Chandigarh, India

Pothula Sreedhar Reddy Oral and Maxillofacial Surgeon, Pioneer Advanced Hair Transplant Center, Bangalore, India

Sunil Richardson Richardson's Dental and Craniofacial Hospital, Nagercoil, Tamil Nadu, India

Senthil Murugan Department of Oncology & Reconstructive Microsurgery, Saveetha Dental College, Saveetha University, Chennai, Tamil Nadu, India

DWIJAN Microsurgery Research & Training Centre, Chennai, India

Navin Shah Sunderlal Department of Oral and Maxillofacial Surgery, KM Shah Dental College, Sumandeep Vidyapeeth, A Central deemed to be University, Vadodara, Gujarat, India

Yeshaswini Thelekkat Department of Oral & Maxillofacial Surgery, Azeezia College of Dental Sciences and Research Kollam, Kollam, Kerala, India

Joji Thomas Department of Oral and Maxillofacial Surgery, Cosmopolitan Hospital Pvt Ltd, Trivandrum, Kerala, India

P. Varun Menon The Charles Pinto Centre for Cleft Lip, Palate and Craniofacial Anomalies, Jubilee Mission, Medical College & Research Institute, Thrissur, Kerala, India

Sankar Vinod Vichattu Department of OMFS, Mar Baselious Dental College, Kotamangalam, Kerala, India

B. Vikraman Department of Oral and Maxillofacial Surgery, Ragas Dental College & Hospital, Chennai, Tamil Nadu, India

Gary Warburton Department of Oral & Maxillofacial Surgery, University of Maryland Dental School, Baltimore, MD, USA

About the Editors

Krishnamurthy Bonanthaya did his postgraduate dental studies from Mangalore University, and then he obtained his MBBS from Kasturba Medical College, Manipal. He is also a fellow of the Royal College of Surgeons of England and Royal College of Surgeons of Ireland. He is currently the project director of Smile Train Project treating cleft lip and palate deformities at Bhagwan Mahaveer Jain Hospital, Bangalore. He also holds the position of professor of oral and maxillofacial surgery, Bangalore Institute of Dental Sciences, which involves undergraduate and postgraduate training and the routine mix of maxillofacial surgical management. He is the editor in chief emeritus of the *Journal of Maxillofacial and Oral Surgery* and has numerous publications to his credit.

Elavenil Panneerselvam completed her postgraduation in oral and maxillofacial surgery from the Tamil Nadu Dr. M.G.R. Government Medical University, Chennai, India. She also has a master's degree in business administration, specializing in hospital management, fellowship in Aesthetic Medicine and has been awarded Fellowship in Dental Surgery by the Royal College of Physicians & Surgeons of Glasgow. She has contributed to textbooks on oral anatomy, local anesthesia, plastic surgery, and pediatric TMJ surgery. Presently, she holds a faculty position at the SRM Dental College (Ramapuram), Chennai, as associate professor in oral and axillofacial surgery. She is a recipient of the MM Cooper Memorial Research Award from the Indian Society for Anatomists and the Ginwalla Trophy from the Association of Oral & Maxillofacial Surgeons of India.

Suvy Manuel after his postgraduation from Government Dental College, Trivandrum, University of Kerala, in 2002, gained the Diplomate of National Board in Oral & Maxillofacial Surgery, Membership from the National Academy of Medical Sciences, New Delhi, India; and Diploma of Membership in Oral surgery, Royal College of Surgeons, Edinburgh.

During his tenure in the UK, he attained the Membership of the Faculty of Dental Surgery, Royal College of Surgeons, England. Subsequently, he attained the Fellowship in Dental Surgery, Royal College of Surgeons, Edinburgh. He is the MOMS RCSEd (Diploma of Membership in Oral Surgery) Examiner for the Royal College of Surgeons of Edinburgh in the Faculty of Dental Examiners, as appointed by the Dental Examinations Committee, RCS Edinburgh.

He is former professor and postgraduate guide at the Kerala University of Health Sciences and is a reviewer for the *Journal of Maxillofacial and Oral Surgery*.

Currently, he is attached to the maxillofacial units at Ananthapuri and KIMS Hospitals, Trivandrum, India.

Vinay V. Kumar completed his master's in oral and maxillofacial surgery from Nair Hospital Dental College, Mumbai, India, in 2008. He was an ITI Scholar in the Department of Maxillofacial and Plastic Surgery in Johannes Gutenberg University (JGU) Mainz, Germany, in 2010, where he went on to complete his Doctorate of Medicine in Dentistry (2013), obtain a practicing license, and served as a visiting faculty. He completed the MD and PhD program at the University of Medicine, Rostock, Germany in 2018. He is currently a Specialist Oral and Maxillofacial Surgeon in the Department of Maxillofacial and Plastic Surgery, Uppsala University Hospital, Sweden in the Department of Maxillofacial Surgery, Uppsala University, Sweden.

Anshul Rai is an Associate Professor in Department of Dentistry at All India Institute of Medical Sciences Bhopal, MP. He has 54 publications to his credit out of which 24 belong to prestigious international journals. He has contributed as a coauthor to *Textbook of Oral and Maxillofacial Surgery* by Dr. Borle. He is a Fellow of Indian Board of Oral and Maxillofacial Surgery (FIBOMS) and a fellow of the International Board for the Certification of Specialists in Oral and Maxillofacial Surgery (FIBCSOMS). He is a reviewer for *Journal of Maxillofacial and oral surgery and Indian Journal of Dental Research*.

Jimson Samson completed his postgraduate studies at the prestigious the Tamil Nadu Dr. M.G.R. Medical University, Chennai. Since completing his MDS, he has been in academics. He is a journal reviewer and also a section editor. He has lectured at various national and international conferences. He was also a faculty at OMFS workshops.

His special interest in research has made him Vice-Principal—Research at Tagore Dental College & Hospital, Chennai. In addition, he also heads the Department of Oral and Maxillofacial Surgery. He has published in indexed journals. He is now the Hon. State Secretary of the Association of Oral and Maxillofacial Surgeons of India, Tamil Nadu and Puducherry Branch. He is also an elected member of the Executive Committee of the National Association.

He is a member of the Board of Studies for Postgraduate Studies of Oral and Maxillofacial Surgery at the Tamil Nadu Dr. M.G.R. Medical University, Chennai.

Nehal Patel completed his master's in oral and maxillofacial surgery from A.B. Shetty Institute of Dental Sciences, Mangalore. He did his fellowship in Cleft and Craniofacial Surgery from Mangalore. He did his mini residency in TMJ Arthroscopy and Total Joint replacement from the USA. He worked as consultant cleft and craniofacial surgeon in BSES MG Hospital. He is currently working as Director, ABMSS CLEFT PROJECT in Surat, Gujarat.

Part I

Introduction

Oral and Maxillofacial Surgery in India: How Did We Get Here and Where Are We Going?

Kishore Nayak

1.1 History of Our Missions and Our Challenges

Any discussion about the history of surgery inevitably begins with an invariable reference to *Suśruta* and his contributions to facial surgery, in particular. While the contributions of the sixth-century sage surgeon may somewhat be nebulous in a foggy poorly documented history, they are inevitably (and arguably) numerous but need not be elaborated here in any manner. What is lesser known and not often spoken about is that *Suśruta* considered surgery the first and foremost branch of medicine and stated, “Surgery has the superior advantage of producing instantaneous effects by means of surgical instruments and appliances. Hence, it is the highest in value of all the medical tantras. It is eternal and a source of infinite piety, imports fame and opens the gates of Heaven to its votaries. It prolongs the duration of human existence on earth and helps men in successfully fulfilling their missions and earning a decent competence in life.” [1, 2]

When applied specifically to the context of the specialty of Oral and Maxillofacial surgery (OMS) emerging in India, it raises many important questions on how we have emerged and more importantly what we see ourselves evolving into in the years to come. Perhaps all those debates that we labored along numerous times were all a part of our coming of age!

Like elsewhere in the world, in the mid-twentieth century, we were probably practitioners of dentoalveolar surgery working under very trying circumstances moving on to where we are today. The specialty in India today, is truly all encompassing in its scope. It embraces the entire and extended spectrum of the practice of oral and maxillofacial surgery, and as the Association of Oral and Maxillofacial Surgeons of India (AOMSI) approaches its 50th year in 2019, there is no better time to look back and reflect on the past and contemplate where we are heading. The changes

that we have witnessed have been rapid and hopefully progressive. From being oral surgeons, we transitioned and added maxillofacial surgery and to our quiver and perhaps to the chagrin competing specialties treaded into areas, once considered “gray” and broadened the scope of our practices.

Mino S Ginwalla is regarded as the pioneer of oral and maxillofacial surgery in India. In the 1950s, Dr. Ginwalla arrived in Mumbai following surgical training in Montreal, Canada, and set up his practice at Nair Hospital. He was a part of the founding group of surgeons of the AOMSI in 1969. By the mid-70s, training programs were established in most of the major dental colleges throughout India. Today, there are numerous OMS training programs in India.

The dental qualified persons are governed by the statutes of the Dental Council of India [3]. Currently, the Dental Council of India provides for a comprehensive 3-year program that includes a syllabus and curriculum that exposes trainees to standard procedures covering the full spectrum of oral and maxillofacial surgery [4]. This provides a legal framework for the OMS to function. This qualification itself is only permission to practice the specialty. In today’s system, competence and eventual ownership of key surgical domains often only come from structured post-qualification training.

Thus, traditionally, the specialty in India continues to be predominately a dental subspecialty that leans toward the idea of a surgical branch of dentistry. While many arguments have been made for and against the need for a medical degree to augment the specialty, it is safe to postulate that for the near future, we will remain a dental specialty for a variety of reasons. North Americans seem to have found a middle ground and of the 101 OMS training programs in the US, 55 are single-degree programs (dental degree only) and 43 are dual-degree (dental and medical) programs, and three offer both options.

Drawing comparisons to the international scenario, the specialty has always been on a pendulous path remaining undecided on the idea of whether it wants to stay a dental

K. Nayak (✉)

Bhagwan Mahaveer Jain Hospital, Bangalore, India

specialty or whether it wants to incorporate the medical degree. In the USA where this trend initially started, the practice of the specialty is protected by national, regional, and local legislature as a dental specialty. In reality, there is no perceivable practical difference in the scope of practice between single- or double-degree practitioners in the States. In the UK and many parts of Europe, the specialty has taken leaps and bounds toward the medical path of training and it could very well be only a matter of time before the Specialty remains only remotely associated with Dentistry. The primary challenge was a lack of understanding, which centered on the debate of whether a medical as well as a dental qualification was required prior to surgical training [5].

Oral and maxillofacial surgery remains a specialty of dentistry in India and most training programs involve a graduate study and thesis to obtain the Masters in Dental Surgery (MDS) degree. The dental practice act allows all qualified dentally trained oral and maxillofacial surgeons to practice the unrestricted and full scope of the specialty, similar to what occurs in the European nations that require a medical degree. In most of Europe, OMS has become a medical subspecialty.

Public perception of the scope of practice of the specialty remains below par. The specialty gets confused with other surgical domains within both dentistry and medicine that we share a scope.

1.2 Expertise, Familiarity, and Competence

“Innovation is the combination of different ideas and contribution of the different minds.”

Laskin [6] attempts to address this problem by dividing the scope of oral and maxillofacial surgery into three parts: areas of expertise, competence, and familiarity.

- Areas of expertise include oral pathology/oral medicine, dentoalveolar surgery, preprosthetic surgery (including implantology), and maxillofacial traumatology.
- Areas of competence involve orthognathic surgery, temporomandibular joint surgery, and local reconstructive surgery.
- Areas of familiarity are cleft lip and palate surgery, regional reconstructive surgery, oncologic surgery, craniofacial surgery, and cosmetic surgery.

Laskin’s system of classification, while seemingly appearing comprehensive, opens itself to a lot of debate and question. While there is no doubt that the areas of “expertise” are unique to our specialty, it is our foray into those areas of competence and familiarity that has led to the expansion of

the scope of our specialty. This expansion and contraction of our scope may also be fundamental to continual evolution. A large majority of our colleagues in India and worldwide operate within the boundaries of that scope of practice defined as “expertise.” However, to turn areas of familiarity into competence and expertise will require that the training units and staff have the required skills and volume of cases to ensure hands-on experience and documentation. Only under these circumstances can we be assured that the skill sets and competencies will be transferred and become enduring.

It is ideal that all trainees are trained to achieve competence in craniomaxillofacial trauma, orthognathic surgery, and TMJ surgery (i.e., maxillofacial surgery). This and only this can provide the transition from Oral to Maxillofacial surgery. There, however, is a clear and present reality that not all training programs are equipped to achieve this goal. Even though training standards and syllabi exist, these standards are so broad that even programs with a very limited scope of training will meet accreditation standards by reporting a narrow set of hospital-based procedures that are not representative of the scope of practice required of modern OMS. Further, the interest of the trainee in training in the full scope of surgery is a factor that leads to mediocre training. The system of choosing a postgraduate training in OMS in India is severely handicapped and primitive. The factors that decide a trainee’s choice of an advanced training program have nothing to do with their aptitude or interest in a specialty. It is purely based on their standing in a national entrance examination or their affordability of a position in a private institution. This leads to complete neglect of the student’s natural aptitudes leading to prosthodontists becoming orthodontists and endodontists doomed into the world of oral and maxillofacial surgery. A disinterested trainee will be barely motivated to improve the scope of their practice following completion of their training, often limiting their practice to general dentistry and minimal indulgence in areas of “expertise.”

Bell [7], when contemplating the future of education and training in the specialty, raises some very valid concerns, which seem to reflect the issues that affect the specialty and its future worldwide. Many reasons for the training disparities exist today—including training program location, the presence or absence of a trauma center, limited head and neck surgery experience, and local politics—but regardless, the goal should be the same: to train oral and maxillofacial surgeons to competence in the core areas of the specialty that they will eventually practice.

The key point is that we, as a specialty, should ensure that we train to competence and expertise based on geographic location, years in practice, fellowship training, and academic involvement. In years past, if an OMS graduate wished to obtain training in any areas beyond basics, then he or she often sought it outside of the specialty, in either oto-

laryngology or plastic surgery. With the emergence of several teaching hospitals and colleges as well as standalone independent centers of excellence, this scenario has drastically transformed in India. Further, the development of a number of fellowships that have been facilitated by the AOMSI has resulted in a robust system within the specialty that caters to the trainee's desire, merit, and quite often desire to embrace technique and technology. The rapid and natural advent of OMS into areas of oncology and reconstruction, cleft lip and palate, craniofacial surgery, and aesthetic surgery has been unprecedented and the critical mass of those who now fit in comfortably with these are their areas of expertise is on the rise.

This has been a radical transformation. A few decades ago, wandering beyond the realms of dentoalveolar surgery and facial trauma inevitably encountered a glass ceiling. Today this has been most certainly breached. Moreover, while the majority of the specialty holds itself within the original areas of expertise, there is no doubt that the Big Bang Moment for OMS in India has happened and it is a great time to contemplate where we are heading. What does the future hold for the specialty as we drift on our very own Starship Enterprise?

1.3 Predicting the Future

“Look back over the past, with its changing empires that rose and fell, and you can foresee the future, too.” Marcus Aurelius.

Are we truly at a threshold or are we pieces in some continuum? What factors will drive our evolution as a specialty in India and our extended regions? What trends can we predictably follow to predict our future? Can we perhaps take a page from other fields in medicine to learn about ourselves? Will changing attitudes and aptitude of a new generation have a powerful impact on our profession or will we forever remain loyal to the vestiges of the legacy left behind for us?

Technology will undoubtedly play an important role in our future. Not just technology in patient care, but technology in our lives. Telemedicine and teleconsults will become a part of our everyday practice allowing us to practice beyond geographic limitations. Teleconferencing will make biannual AOMSI face-to-face conferences obsolete. In 2018, the American Association of Oral and Maxillofacial Surgeons (AAOMS) simulcasted their Dental Implant Conference, as did the American Society of Anesthesiologists. Their experience is that the while their total registration at these meetings went up, the number of in-person registrants did not dissipate. Consultant oral and maxillofacial surgeons all over the world have embraced telemedicine naturally, whether they realized it or not. Mobile technology allows the transfer of

patient images and radiographs easily both for opinions and treatment planning. Such ease of access to patient images and documents has become a routine tool in emergency room triages of patients in the evaluation of the priority of care.

While technology in its current form is often perceived, as interruptive to one's lifestyle choices, the advent and immersion of artificial intelligence (AI) will make today's technology ubiquitous without being intrusive. Operating theaters of the future are likely to be guarded by artificial intelligence. Imagine an operating theater that prepares itself based on the radiofrequency identification (RFID) of the surgeon who swipes her/his badge at the door—that surgeon's preference cards get read by the system and a central core will prepare the instruments and supplies based on that surgeon's choices for that particular case booked for him.

Anesthesiology, radiology, and pathology are low-hanging fruits in the AI world. Radiologists in large tertiary-care centers in China, today, do not read radiographs anymore; they simply look at false positives read the previous night by their AI system. The system then learns from such mistakes and makes corrections forever. Computer systems today have the capacity of a thousand human brains to process data. The more data we feed these AI systems, the smarter they get. Google's AI product called LYNA or LymphNode Assistant is a trained algorithm that is capable of spotting the features of tumors that have metastasized, which are notoriously difficult to detect. Self-teaching algorithm systems will likely replace monitoring duties of the anesthesiologists and critical care nurses in the hospital.

Surgical robots are also constantly evolving incorporating precision haptics and AI. Robotic arms can already perform tasks independent of a surgeon yielding it. Imperfections and errors that a surgeon may cause in an operation are avoided in robotic surgery by consistent movements, angles, and access that can only be achieved by that robot. Imagine a robotic arm that can be programed to remove a mesioangular impacted mandibular third molar? The robot surgeon can assess the angulation of the impacted tooth based on the patient's radiograph, adjust its angulation and access, make a buccal trough, and split the tooth precisely. Less error and more precision, perhaps?

The day is not far before a robotic arm can obtain a tissue sample from our patients at a mall kiosk. Algorithms can then diagnose that tissue and their radiographs distancing the patient further away from the conventional practice of medicine. What is the future of our practices and our education in these scenarios? A well-informed patient with access to information and technology may surpass the traditional medicine man for their healthcare. Direct to consumer marketing of healthcare tools such as genetic testing is already prevalent in many countries. Several patients are aware of which chemotherapy may be best effective for the management of

their cancers even before they see their doctor, today. Where does that place a specialist in the future?

In a keynote address at the Royal College of Surgeons in London at the 50th anniversary of the IAOMS, Brian Schmidt DDS, MD, PhD, Director, Bluestone Center for Clinical Research, and Professor of Oral and Maxillofacial Surgery at New York University pondered about the future of OMS internationally. He emphasized three units of care that oral and maxillofacial surgeons provide universally—

1. Management of maxillofacial trauma.
2. Management of oral cancer.
3. Management of craniofacial anomalies.

His views suggested that the advent of seatbelts, airbags, and safer road conditions in most countries is diminishing our total volume of trauma. Further, patterns of wars have changed from the bayonets of World War I to drone-controlled annihilation that ensures death! While bar fights and interpersonal violence continue to create left-sided ZMC and mandibular fractures, the world of facial trauma is most certainly changing.

He recognized examples of how personalized medicine is influencing the care of cancer patients. With our ability to map genomes and mutations, our ability to interpret cancer biology has had a meteoric rise even in the last decade. This leads to personalizing management via either chemotherapy or radiotherapy with predictable success making most cancers chronically manageable diseases rather than a death sentence. The future of personalized medicine will most likely put the cancer surgeon out of an occupation.

He introduced a study that demonstrated how a serendipitous finding in mice with Treacher-Collin's syndrome treated for endometrial cancer with a chemotherapeutic agent knocked out the gene causing the craniofacial anomaly in the following generation. This suggested that we could potentially be looking at gene therapy for craniofacial anomalies, including cleft lip and palate.

Schmidt's observations and predictions suggest that the diseases and conditions that are the mainstay to our profession will alter significantly in the future. Laboratories in Boston are very close to creating a template stem cells construct that will replace dental implants with naturally grown teeth. A dental caries vaccine is pending worldwide use.

How will these fundamental changes alter the practice of our specialty in the future?

Super specialization within the specialty is bound to happen. Attendees of the annual sessions of the British Association of Oral and Maxillofacial Surgeons will be struck by the design of the sessions. There are sessions designed for oral surgeons, implantologists, educators, deformities surgeons, ablative surgeons, and separately for reconstructive surgeons, as there are for minimally invasive

surgery, aesthetic surgeons, and lab research. Larger sister specialties like ENT-Otolaryngology have also separated themselves into subspecialties. In the US, Pediatric otolaryngology, head and neck Surgery, facial plastic surgery, otology, skull-based surgery and surgery for sleep disorders are all recognized subspecialties within ENT in the US, for which fellowship training is offered. The pediatric otolaryngologist who specializes in airway surgery is unlikely to attend a conference organized for the otologists.

Similarly, domains within oral and maxillofacial surgery are already starting to branch out into subspecialty pods and practices are being limited to the practice of such subspecialties. That focus on a specific area within the specialty is also likely to be influenced by reimbursement for services. The subspecialties that rake in more money for the provider will thrive quicker and heftier than the latter. Changes in reimbursement strategies by hospitals will also evolve in this equation. For instance, in the US, where a large third-party payer system exists, clinical production for a practitioner is often not measured in actual dollars, but in revenue value units (RVUs). Complex longer cases like a head and neck disease ablation and reconstruction may not be related to a large reimbursement of dollars for the surgery alone; but the fact that the operating facility was used for several hours with the utilization of other resources such as nursing care, critical care, specialists like physical therapists, speech therapists, nutritionists, and a follow-up rehabilitation facility, all add up value to the health system ensuring reimbursement.

While this model seems to be working for now, the practice of medicine in the future unfortunately will be largely devised by the market and economics. The educational debt for training our future generation is getting out of hand. In a world where access to information is undoubtedly easier, the cost of a formal education is skyrocketing. Alternate models of education may arise disrupting this traditional model. Apprenticeships of the Osler era may be afoot. Centers of excellence are likely to develop that allows a pathway of nontraditional training to an interested and talented trainee. Validation agencies like the International Board of Certification of Oral and Maxillofacial Surgeons (IBSCOMS) will have a bigger role in providing bonafide certification outside of the current commercialized and often-diluted education system.

The millennial and the gen Z student will also play a large role in the evolution of the specialty. Today's trainee learns differently, synthesizes information differently. They grew up on smartphones and Google searches and not in libraries or poring over Encyclopedia Britannica. They are visual learners with a panache for hand-eye coordination. They are multitaskers. No doubt that there will exist friction between a generation of older teachers and this generation of learners. And, that too will only be momentary. The new trainee is

focused on lifestyle choices and is not unabatingly focused on education and patient care. The new trainee values life outside of work just as much as work. This will bring a new kind of diversity to the workplace. To make things worse, they will be treating a generation of aging patients who are used to a different kind of doctor from their times. The average patient is older and healthier and has demands that may have been considered unreasonable at one time. They are likely to be tech-savvy themselves. They will seek many opinions before they commit to the recommendations of their provider. They are likely to choose a surgeon based on the reviews on social media and the internet. Globalization of the medical industry and technology means that they might be willing to travel to have the same procedure and product used elsewhere than their hometown hospital.

Surgeons are working longer than they ever did as well. What impact does that have in a crowded marketplace? Will aging populations of patients and surgeons see an impact on the way we work? Will longevity and increased career years keep the younger ambitious surgeon from getting to the top? The retirement age of surgeons differs all over the world. Surgery is mentally and physically demanding. What effects does that chronic stress have on both the cognitive and physical decline in surgeons? Bhatt et al. did a narrative review on the topics of “ageing” and “surgeon” in Medline in 2016 [8]. They could not find any common ground in these studies. A surgeon who has to hang up his knife at 40 because of severe carpal tunnel in his hands is very different from one that has excellent physical health but severe cognitive decline. The variables were too many for them to consider any consensus on their research question—“when should surgeons retire?” They concluded that, “Competence should be assessed at an individual level, focusing on functional ability over chronological age; this should inform retirement policies for surgeons.”

OMS is like no other branch of medicine or dentistry. It has innovated, expanded, and usurped. It has replicated the old kingdoms, which created vast expanses as it rolled along. Eventually though, experience tells us that it can collapse under its own weight and might. As we look into the future, we must not ignore our past. Empires end for two reasons... problems from within and failure to protect their borders. As for empires, so for OMS. Our mistakes and pettiness must be acknowledged, accounted for, and learned so as not to repeat them.

We might have the ability as a specialty to control most of our destiny, but some of it may be adapted based on our environments. At the end of it all, if the specialty takes heed of three fundamental principles—patient care, education, and meaningful research, we will continue to justify our existence in the future.

References

1. Suśruta Samhita. English translation by Kaviraj Kunja Lal Bhishagratna, Calcutta, 1907, Chapter 16, 152–154.
2. Raju VK. Suśruta of ancient India. *Indian J Ophthalmol.* 2003;51:119–22.
3. Paul G. The future of maxillofacial surgery as a specialty of dentistry. *J Maxillofac Oral Surg.* 2017;16(1):1–2. Published online 2017 Jan 16.
4. Revised 2007 regulation of the Dental Council of India, Gazette of India Extraordinary No DE 22–2007, Government of India, dated 20th November 2007, pp 56–68.
5. Nayak K. Oral and maxillofacial surgery: It’s future as a specialty. *J Maxillofac Oral Surg.* 2011;10(4):281–2.
6. Laskin M. The past, present, and future of oral and maxillofacial surgery. *J Oral Maxillofac Surg.* 2008;66:1037–40.
7. Bryan Bell R. Infinite cornucopia: the future of education and training in oral and maxillofacial surgery. *Oral Surg Oral Med Oral Pathol Oral Radiol.* 2016;121(5):447–9.
8. Bhatt NR, Morris M, O’Neil A, Gillis A, Ridgway PF. When should surgeons retire? *Br J Surg.* 2016;103(1):35–42.

Open Access This chapter is licensed under the terms of the Creative Commons Attribution 4.0 International License (<http://creativecommons.org/licenses/by/4.0/>), which permits use, sharing, adaptation, distribution and reproduction in any medium or format, as long as you give appropriate credit to the original author(s) and the source, provide a link to the Creative Commons license and indicate if changes were made.

The images or other third party material in this chapter are included in the chapter's Creative Commons license, unless indicated otherwise in a credit line to the material. If material is not included in the chapter's Creative Commons license and your intended use is not permitted by statutory regulation or exceeds the permitted use, you will need to obtain permission directly from the copyright holder.



Part II

Preoperative Assessment and Patient Preparation/Optimization



Preoperative Evaluation and Investigations for Maxillofacial Surgery

2

B. Krishnan and Satyen Parida

2.1 Introduction

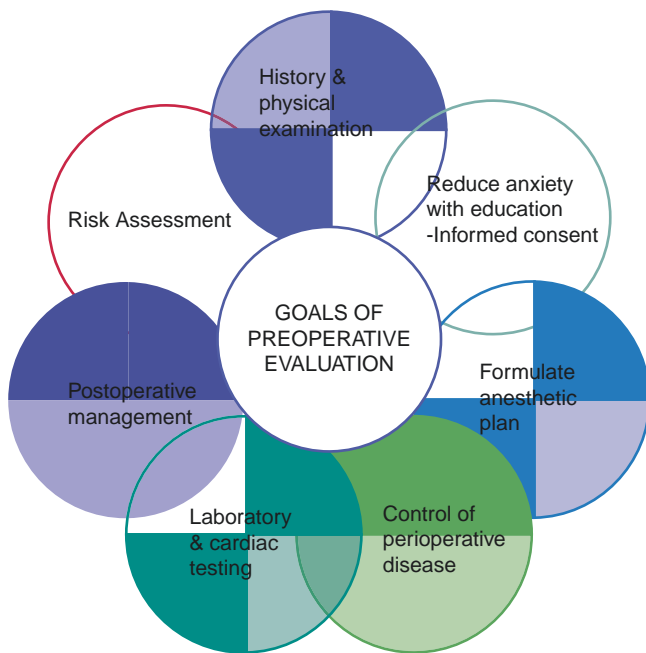
A meticulous preoperative evaluation with the intention of identifying modifiable clinical conditions and understanding the risk stratification is imperative for all patients being subjected to any invasive procedure, inclusive of oral and maxillofacial surgery. Preoperative evaluation of such patients would of course differ, often dictated by age and the overall health condition that they present with. The choice of anesthesia may vary depending on the surgical procedure intended: general anesthesia, conscious sedation, regional blocks, local anesthesia, or various combinations of all of these. The current chapter focuses on the preoperative evaluation of patients posted for maxillofacial surgery under a general anesthetic in a formal operating room setting. Nevertheless, it is essential to realize that a preoperative evaluation is more or less standardized, irrespective of the type of surgery and practice (office-based dentoalveolar surgery, trauma, orthognathic surgery, elective esthetic surgery, craniofacial surgery, etc.) and anesthesia being planned. The goals of preoperative evaluation are summarized in Fig. 2.1 [1]. The intention is to minimize perioperative morbidity and mortality, to the best possible extent. The major step toward this goal requires the surgeon to be conscientiously aware of the general condition and clinical state of the patient so that in the eventuality of a critical event, he can intervene effectively and pertinently. This would involve modifying and customization of the patient's overall management to ensure that perioperative adverse events are avoided.

B. Krishnan (✉)
Department of Dentistry, Jawaharlal Institute of Postgraduate Medical Education and Research (JIPMER), Puducherry, India

S. Parida
Department of Anesthesiology and Critical Care,
Jawaharlal Institute of Postgraduate Medical Education and Research (JIPMER), Puducherry, India

2.2 Preoperative Evaluation

The process of preoperative evaluation often begins with a standard history-taking and physical examination for the particular patient. A detailed history of prior medical problems, any previous surgical procedures, family, personal, and social history, any chronic medications and allergies or addictions needs to be obtained. In addition, it is worthwhile obtaining details about the patient's family physician if any, whether he has health insurance, the employer's details if the patient is employed, contact details of relatives, and any other information that may be deemed appropriate. The maxillofacial surgeon has to judge how the medical problems of the patient will affect perioperative care, and conversely, how perioperative events would influence the management of the patient's medical conditions. The patient's comorbidities could result in a significant physiologic decompensation due to myriad factors such as stress of the surgical procedure, original goals of the surgical intervention not being adequately met, and potential interactions between the regular medications that a patient may be on or with drugs that may be required to be instituted as part of the perioperative protocol. The maxillofacial surgeon should, therefore, be cognizant of what could possibly go wrong, and how those situations could be remedied. Also, it is critical that the surgeon be aware of all the medications (antidiabetic drugs, anticoagulants, antiplatelets, etc.) and medical comorbidities (cardiopulmonary, central nervous system, hepatic and renal disease, etc.) that the patient may be exposed to that could threaten the safe performance of the surgical procedure and have an adverse impact during the postoperative period. It is essential that every member of the perioperative team must be able to perform an independent assessment of the patient. This does not imply being ignorant of the other person's assessment since information needs to be shared by all components of the team, but each member should have his own way of assimilating such information by adding to it by his own independent assessment. This is important because



©Association of Oral and Maxillofacial Surgeons of India

Fig. 2.1 Goals of preoperative evaluation

every specialty would have its independent perspective, about the patient, although they would all be in the latter's best interests. For example, the surgeon might look upon older age in terms of postoperative functional recovery, while the anesthesiologist would be contemplating the various comorbidities that could be associated. Accordingly, each specialist would have his own concerns regarding the state of the patient, and therefore, the preoperative assessment provides a meeting ground for all these concerns after everyone has performed his own independent assessment. The use of a medical history questionnaire provides the maxillofacial surgeon with valuable information about the physical and psychological condition of the patient. Any medical history questionnaire can either be extremely useful or totally worthless and its ultimate value depends upon the ability of the surgeon to interpret the significance of the answers and to elicit additional information through physical examination and dialogue history. A prototype of a health history questionnaire is seen in Table 2.1 [2].

A preoperative physical examination begins with a recording of the patient's vital signs. The oral and maxillofacial system, by virtue of the proposed surgical site, receives close attention by the surgeon. Of particular interest for the surgeon would be recognizing potential difficulties in surgical access and the need for alternative strategies and additional surgeries (e.g., bone grafting/skin grating). The cardiopulmonary examination assesses the rate and rhythm, murmurs, wheezing, rhonchi, and stridor. The musculoskeletal examination will include a range of neck motion and

Table 2.1 Preoperative medical evaluation questions for a healthy patient

Questions
1. Do you usually get chest pain or breathlessness when you climb up two flights of stairs at normal speed?
2. Do you have kidney disease?
3. Has anyone in your family (blood relatives) had a problem following an anesthetic?
4. Have you ever had a heart attack?
5. Have you ever been diagnosed with an irregular heartbeat?
6. Have you ever had a stroke?
7. If you have been put to sleep for an operation, were there any anesthetic problems?
8. Do you suffer from epilepsy or seizures?
9. Do you have any problems with pain, stiffness, or arthritis in your neck or jaw?
10. Do you have thyroid disease?
11. Do you suffer from angina?
12. Do you have liver disease?
13. Have you ever been diagnosed with heart failure?
14. Do you suffer from asthma?
15. Do you have diabetes that requires insulin?
16. Do you have diabetes that requires tablets only?
17. Do you take any regular medications like antiplatelet or anticoagulants?
18. Are you taking any over-the-counter medications, psychiatric medications, natural remedies?
19. Do you have habits like smoking, alcohol, or use of recreational drugs?

potential donor site evaluation. Finally, a neurological examination would assess the patient's mental status and any signs of pre-existing nerve or head injuries. A detailed description of the examination of all systems is beyond the scope of this chapter and the reader is advised to consult the references at the end of this chapter [1, 3–5].

Once the history and physical examination are complete, the clinician would be in a situation to risk stratify the patient according to the American Society of Anesthesiologists' (ASA) classification system (please see chapter on Ambulatory anesthesia for ASA table). Further investigations or specialist consultation is determined by the ASA status. This is especially imperative in patients with ASA Class III or IV who need to be further evaluated for their ability to withstand the proposed surgical procedure. Such patients, almost always, require inpatient admission due to a higher risk of perioperative adverse events. Patients of ASA Class V are extremely moribund and would therefore invariably require admission irrespective of the surgical procedure involved. It is extremely uncommon for a patient in this category to undergo any maxillofacial surgical procedure.

Preoperative risk stratification can also include a surgical classification system [6] (Table 2.2). This classification is quite useful for healthy patients undergoing a surgical procedure, as risk assessment in these patients is now determined solely by the nature of the procedure rather than the ASA

Table 2.2 Cardiac Risk Stratification for Noncardiac Surgical procedures

Cardiac risk stratification	Procedure examples
High Risk (>5%)	Aortic, Major vascular Surgery, Peripheral vascular Surgery
Intermediate Risk (1–5%)	Intraperitoneal and Intrathoracic Surgery, Carotid endarterectomy, Head and neck surgery, Orthopedic Surgery, Prostate Surgery.
Low Risk (<1%)	Endoscopic procedures, Superficial procedures, Cataract surgery, Breast surgery, Ambulatory surgery

classification [7]. A similar surgical severity classification for oral and maxillofacial procedures has also been offered [8].

The preoperative assessment for oral and maxillofacial surgery will also require appropriate radiologic imaging for diagnostic information and treatment planning. These include panoramic, periapical, and occlusal radiographs, ultrasound, CT and MRI imaging. The clinical evaluation and imaging studies should help in the formation of a surgical plan, as to whether the surgery is going to be a simple or a complex one, what kind of instrumentation will be required for the same, or whether it would require the expertise of other surgical specialties such as Ophthalmology, ENT, and Plastic Surgery. The anesthesia team can also examine these imaging modalities to identify potential difficulties that may be encountered while intubating and securing the airway.

2.3 Laboratory Investigations

Preoperative patient assessment, ASA physical status, and severity of the proposed oral and maxillofacial surgical procedure guide the clinician to select the appropriate adjunctive studies for treatment planning. The ordering of adjunctive laboratory and radiological investigations is often determined by a complex interplay of pre-existing attitudes, practice patterns learnt during training, ease of ordering, fear of medico-legal consequences, and patient requests. When ordering a test, clinicians are attempting to discriminate between patients who have normal values and those who have abnormal ones. This is used to determine the possibility of the existence of a pathological condition that could impact the proposed surgical and anesthetic plan. The “normal” reference range for many clinical lab tests excludes the upper and lower 2.5% of results, and therefore 5% of normal individuals will obtain an “abnormal” result. While these “abnormal results” can be ignored, sometimes they are not and the result is an additional unnecessary investigation. Clinicians must be confident that there is a clinical justification for the actual need for the test. Studies indicate that less than 0.25% of all “abnormal” results of preoperative tests before an elective surgery influences the perioperative management [9]. “Routine” investigations, viz.,

those carried out preoperatively on all patients, and not directly related to the planned surgical procedure or the patient’s physical condition, are not recommended [10, 11]. Age-based criteria are controversial as test abnormalities are common in older patients but are not as predictive of complications as information gained from a detailed history and physical examination. “Cost consciousness” and “stewardship of resources” also have to be considered by the clinician as the commonly ordered “battery of tests,” though relatively inexpensive by themselves, can contribute to a significant proportion of healthcare expenditure as a result of the frequency with which they are ordered [12]. Beyond economics, the costs borne by patients include discomfort of needle sticks and blood loss with repeated phlebotomy, exposure to radiation, and additional unnecessary workup of spurious results. Good communication between the surgeon, medical consultant, anesthesia team, and the patient is essential when considering preoperative testing that may affect the timing of the surgery. Fit, young patients who are scheduled for outpatient surgery or low-risk surgery generally do not require any routine preoperative testing and, in the pediatric age group, a thorough clinical examination has been found to be of greater value [13, 14]. Routine urine or blood testing of the pediatric patient is not clinically warranted without a specific indication [15]. In general, test results within the past 6 months are acceptable if the patient’s history has not changed. If the patient’s condition has changed in the interim, adjunctive tests within the past 2 weeks are more favored [1].

The American Association of Oral and Maxillofacial Surgeons (AAOMS) recommendations on adjunctive studies prior to oral and maxillofacial surgery include, but are not limited to, both laboratory and imaging investigations [16] (Table 2.3). Similarly, algorithms based on the ASA classification, surgical procedure, and age of the patient are also available to assist the clinician to choose the appropriate adjunctive preoperative tests [17, 18].

While most standard texts would lead one to believe that extensive investigations in patients who are supposedly normal on history and clinical appraisal are not instrumental in improving outcomes or economically justified, it must be remembered that these perceptions are built upon data accumulated from the West, where regular health checkups and assessments are the norms. In contrast, in countries like India, a patient’s first visit to a hospital may be for the surgery he is being posted for. Patients may also not be aware of existing comorbidities or details of any earlier interventions. This often leaves the clinician with no other option than to do order a “battery” of the so-called routine investigations to screen out potential pathological conditions. Ultimately, the choice of what laboratory investigations a patient may be subjected to is decided by the particular operating unit. It is important that such practices be customized to the population that the hospital caters to, and must be based on reasonable risk-benefit and cost analysis.

Table 2.3 Indications for commonly ordered preoperative laboratory tests based on specific findings during history and physical examination (independent of patient age, American Society of Anesthesiologists' classification, or surgical procedure)

Investigations	Indications
<i>Laboratory investigations</i>	
1. Complete Blood Counts: WBC count	Patients with infection/fever On chemotherapy Myeloproliferative disorders Immune-compromised states (HIV) History of cancer, chemotherapy, or radiation treatment
Platelet count	History of low platelets Bleeding history Thrombopathy Pregnancy Autoimmune disease Splenectomy Liver disease
Hemoglobin/Hematocrit	Anticipated blood loss greater than 500 ml Suspicion of anemia Recent chemotherapy/Radiotherapy (within 2 months) Renal disease Active cardiac symptoms Recent blood loss Sickle cell anemia/thalassemia Recent autologous blood transfusion Older patients undergoing major surgery
2. Chemistry: Electrolytes/BUN/Creatinine	Chronic Kidney Disease Liver cirrhosis Medications (diuretics, ACE inhibitor, digoxin) Diabetes mellitus Malnutrition Dehydration Infections On renal dialysis—K ⁺ tested immediately prior to surgery
Creatinine	Older patients undergoing intermediate-or-high-risk surgery Patient for whom nephrotoxins will be used When large fluid shifts or hypotension is likely
Glucose-(Fasting/Random/ Postprandial/Glucose Tolerance Test (GTT) /HbA1C)	Diabetes mellitus Long-term steroid medications Liver cirrhosis Pregnancy Infections Pancreatic disease Adrenal disease Pituitary disease >45 Years of age with no prior history of diabetes mellitus
3. Coagulation profile Prothrombin Time (PT) International Normalized Ration (INR) Partial Thromboplastin Time (PTT)	Personal/ family history of bleeding diathesis or clotting disorders Evidence of purpura or petechiae On current or recent anticoagulation medications (warfarin/heparin) Liver disease Abnormal liver function (jaundice) Alcoholism Severe malnutrition Chronic renal failure History of stroke Autoimmune disorders
PT (for warfarin) PTT (for heparin)	Repeated on the evening before/morning of the surgery to document normal coagulation parameters after stopping these medications, if indicated.
Bleeding Time (BT)	Not a reliable preoperative indicator of platelet function. Not recommended for presurgical workup
Clotting Time (CT)	Time consuming, poor reproducibility, insensitive to high doses of heparin, and sensitive in only extreme factor deficiencies Not of much value in modern laboratory settings

Table 2.3 (continued)

Investigations	Indications
4. Liver function tests	Cirrhosis Hepatitis Jaundice Hepatomegaly Alcohol abuse Pancreatic disease History of cancer Easy bleeding and bruising Malnutrition
5. Type, screen, and cross-sensitivity	Patients with bleeding or coagulation disorders Surgeries with a potential for blood loss (>500 ml) even if transfusion is not expected. <i>This may help minimize the risk of later transfusion reaction.</i>
6. Pregnancy testing (Serum/Urine)	Premenopausal women of child-bearing age who have not had tubal ligation or hysterectomy (Urine Human Chorionic Gonadotropin—HCG). <i>History and physical examination are insufficient to determine early pregnancy, and patients are often unreliable in suspecting that they may be pregnant. Management protocols often change if it is discovered that the patient is pregnant.</i>
7. Arterial blood gases (ABG)	Only if suspicion for hypoxemia or CO ₂ retention that would affect postoperative management.
8. Pulmonary function tests	Previously unknown obstructive lung disease Severe asthma Symptomatic COPD Scoliosis
9. Urinalysis	Active symptoms of Urinary tract infection (UTI), dysuria <i>No good evidence that preoperative abnormal urinalysis is associated with any postoperative complication in nonurinary tract surgery.</i>
10. Blood cultures	Only if clinical suspicion of septicemia.
<i>Imaging</i>	
1. Chest X Ray	Significant risk factors for postoperative pulmonary complications (severe/uncontrolled COPD, active pulmonary disease/symptoms, abnormal lung sounds on physical examination, recent pneumonia) with no previous chest X-ray for past 1 year may warrant preoperative chest X-ray irrespective of age. Asymptomatic patients older than 50 years with no risk factors—insufficient evidence for ordering a chest X-ray. Should not be considered as an unequivocal indication for extremes of age, smoking, COPD, stable cardiac disease, and recent resolved upper Respiratory Tract Infection (RTI). <i>Without symptoms or pertinent medical history, abnormal chest X rays do not predict a worse clinical outcome.</i>
2. 12 Lead ECG	History of cardiac disease (coronary artery disease, significant arrhythmia, structural heart disease, compensated or prior heart failure) Peripheral artery disease Chest pains Lung disease Morbid obesity History of stroke/cerebrovascular disease Diabetes mellitus Renal insufficiency Patient is having an intermediate- or high-risk surgery <i>Consider in high-risk group based on epidemiology (males >40 years and females >50 years of age)</i>
3. Echocardiogram	Recent myocardial infarction Congestive heart failure Abnormal ECG Unstable angina Significant arrhythmias Severe valvular heart disease Previous history of coronary artery disease Dyspnea of unknown origin History of heart failure with progressive symptoms Unstable cardiomyopathy

2.4 Preanesthetic Evaluation

The preanesthetic evaluation aims at getting a favorable outcome, from the points of view of both the surgeon and the anesthesiologist by focusing on risk stratification and modification, and by developing a plan that appropriately addresses the risk-benefit ratio from the procedure, and also explores the other options available. It involves putting together all the elements of the patient's history, physical examination, medications, allergies, laboratory studies, and certain examinations of interest to the anesthesiologist (e.g., airway). This information is assimilated, and decisions are made regarding the plan for anesthetizing the patient once the full picture emerges. This, however, is a dynamic process, and hence accommodates changes in the plan, if new information surfaces, in the best interests of the patient and surgeon. It is also important to be aware of the strengths and limitations of the set-up in which the particular surgical intervention is being undertaken. Further, the preanesthetic evaluation also attempts to allay patient anxiety regarding the procedure, takes necessary steps for risk reduction and to get informed consent. Finally, it leads to the choice of the anesthetic plan to be followed, guided by the risk factors uncovered by the medical history, which covers the entire perioperative period, inclusive of a plan as to where the patient will be cared for postoperatively, and what kind of pain relief he/she should receive after surgery.

2.5 Aspects of Evaluation Unique to Anesthesia

The perspective of each specialty also drives the way physical examination is conducted by each of them. All clinicians learn early as part of their training that relevant positive and negative points not only direct the elicitation of history but also examination. Airway examination is something that is uniquely specific to anesthesiologists with the intention of predicting a difficult airway, that is, one that might result in difficulty in ventilating or intubating the patient, or both. The ASA task force on the management of the difficult airway stresses importance on the physical examination of the airway [19]. While no single method can be deemed to be fool-proof in this regard, the anesthesiologist is trained to examine different aspects as well as scoring systems to be able to make the assessment of a difficult airway [20–22]. The mne-

monic **LEMON** is a helpful tool for assessing the potential for difficult intubation [23, 24] (Fig. 2.2). The Mallampati classification, which relates tongue size to pharyngeal size, is a common component of a thorough airway examination [25]. The examination is performed with the patient in the sitting position, the head held in a neutral position, the mouth wide open, and the tongue protruding to the maximum. The subsequent classification is assigned according to the pharyngeal structures that are visible: (Fig. 2.3).

Class I: visualization of the soft palate, fauces, uvula, and anterior and posterior pillars.

Class II: visualization of the soft palate, fauces, and uvula.

Class III: visualization of the soft palate and the base of the uvula.

Class IV: soft palate not visible at all.

The important aspects of the airway, which can affect intubation, include the degree of mouth opening, the size of the tongue in relation to other oral structures, and the capability to align the oral, pharyngeal, and laryngeal axes in more or less one straight line, with the patient's head and neck in the sniffing position. While the Mallampati classification relates to soft-tissue sizes and their relationships with each other, apart from mouth opening, there are several other anatomical features that need to be considered in the evaluation of the airway (Table 2.4). Examination of systems, other than the cardiopulmonary system, is dependent upon the proposed surgical procedure and planned anesthesia, along with the clinical features of the patient. For example, a patient with a Le Fort II or III fracture may require a careful neurological and ophthalmological examination. Documentation of the findings of history and physical examination must focus on the positive and negative findings after integrating information from the surgeon, patient, and other sources.

2.6 Assessment of the Pediatric Patient

The objective of preoperative assessment in the apparently healthy child is to discover medical or anatomic issues, hitherto not acknowledged, that will escalate the risk of surgery and anesthesia. Special attention is warranted by virtue of specific anatomical and physiological differences from the adult patient. Additional risk factors in pediatric patients, apart from the surgery-specific and patient-specific risks,

Fig. 2.2 LEMON
Assessment for difficult
intubation

Physical Signs	Less difficult airway	More difficult airway
<u>L</u> ook externally	Normal face and neck No face or neck pathology	Abnormally face shape Sunken cheeks Edentulous Buck teeth Receding mandible Narrow mouth Obesity Face or neck pathology
<u>E</u> valuate 3-3-2 rule	Mouth opening > 3 fingers Hyoid-chin distance > 3 fingers Thyroid cartilage to mouth floor distance > 2 fingers	Mouth opening < 3 fingers Hyoid-chin distance < 3 fingers Thyroid cartilage to mouth floor distance < 2 fingers
<u>M</u> allampatti scale	Class I and II (Can see the soft palate, uvula, fauces, ± facial pillars)	Class III and IV (Can only see the hard palate ± soft palate ± base of uvula)
<u>O</u> bstruction	None	Pathology within or surrounding the upper airway (e.g., peritonsillar abscess, epiglottitis, retropharyngeal abscess)
<u>N</u> eck mobility	Can flex and extend the neck normally	Limited range of motion of the neck

©Association of Oral and Maxillofacial Surgeons of India

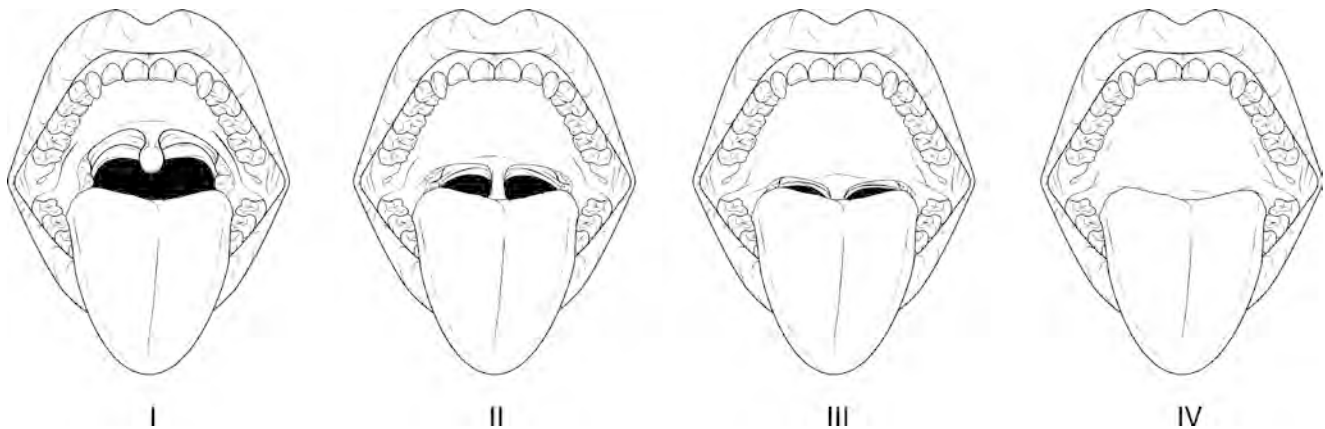


Fig. 2.3 Mallampati Classification for assessment for intubation. Class I: Complete visualization of the soft palate. No additional difficulty. Class II: Complete visualization of the uvula. No additional difficulty. Class III: Visualization of only the base of the uvula. Moderate difficulty. Class IV: Soft palate is not visible at all. Severe difficulty

Table 2.4 Airway compromising conditions

<ul style="list-style-type: none"> • <i>Congenital</i> <ul style="list-style-type: none"> – Pierre-Robin syndrome: micrognathia, macroglossia, cleft soft palate – Treacher-Collins syndrome: auricular and ocular defects, malar and mandibular hypoplasia – Goldenhar's syndrome: auricular and ocular defects, malar and mandibular hypoplasia – Down's syndrome: poorly developed or absent bridge of the nose, macroglossia – Kippel-Feil syndrome: congenital fusion of a variable number of cervical vertebrae, restriction of neck movement – Goiter: compression of trachea, deviation of larynx/trachea • <i>Infections</i> <ul style="list-style-type: none"> – Supraglottitis: laryngeal edema – Croup: laryngeal edema – Abscess (intraoral, retropharyngeal): distortion of the airway and trismus – Ludwig's angina: distortion of the airway and trismus • <i>Arthritis</i> <ul style="list-style-type: none"> – Rheumatoid arthritis: temporomandibular joint ankylosis, cricoarytenoid arthritis, deviation of larynx, restricted mobility of cervical spine – Ankylosing spondylitis: ankylosis of cervical spine, less commonly ankylosis of temporomandibular joints, lack of mobility of cervical spine • <i>Benign tumors</i> <ul style="list-style-type: none"> – Cystic hygroma, lipoma, adenoma, goiter: stenosis or distortion of the airway, fixation of larynx or adjacent tissues secondary to infiltration or fibrosis from irradiation • <i>Malignant tumor, facial injury, cervical spine injury, laryngeal or tracheal trauma</i>: edema of the airway, hematoma, unstable fracture(s) of the maxillae, mandible and cervical vertebrae • <i>Obesity</i>: short thick neck, redundant tissue in the oropharynx, sleep apnea • <i>Acromegaly</i>: macroglossia, prognathism • <i>Acute burns</i>: edema of airway

include the clinician-related risks; an acknowledgment that superior skills are called for in managing this extremely vulnerable patient population. Children with chronic medical problems require appropriate management and prediction of possible difficulties in management, which the preoperative assessment needs to focus on. Especially for infants, enquiries about prematurity, developmental milestones, and medical background check probing for possible congenital diseases of the cardiac and respiratory systems need to be made. Congenital cardiovascular malformations are frequently associated with many facial malformations, which require a thorough preoperative assessment. Another challenge that pediatric patients present, especially for the anesthesiologist, is the pediatric airway management due to a difference in the airway anatomy vis-a-vis adults. The relatively larger soft tissues in the oropharynx, a more cephalad and anterior position of the vocal cords and the larynx, and a shorter length of the trachea are among the few differences between an adult and pediatric airway anatomy [26]. These unique variations can result in airway management issues,

including difficulties in sustaining a patent airway, mask ventilation, insertion of supraglottic airway devices, and endotracheal intubation.

2.7 Assessment of the Elderly Patient

Another vulnerable population is the geriatric age group. This is because older age is associated not only with dwindling functions of almost all organ systems but also an increase in the incidence of comorbidities. Further, as life expectancy increases, clinicians are likely to encounter a substantial number of elderly people in their practice, and it is conceivable that a large proportion of these may present for surgery. It is therefore vital that clinicians dealing with patients of this age group should be able to comprehend the alterations in physiology and pathophysiology that occur with aging. A diminished cardiopulmonary reserve puts this patient population under a higher risk of perioperative adverse events. Incidence of coronary artery disease is also prevalent in the geriatric population. Further, there is an increased risk of cognitive dysfunction such as dementia, delirium, and depression, which may be exacerbated in the acute postoperative phase. Elderly patients have impaired hepatic and renal metabolism and delayed clearance of drugs in the systemic circulation, which can cause increased sensitivity to intravenous anesthetics. Also important in relation to the elderly patient are several anatomical alterations, which can affect management. Predominant among these are changes in airway anatomy, such as nasopharyngeal fragility, macroglossia, microstomia, etc. [27]. These can result in difficulty in mask ventilation and placement of supraglottic airway devices and endotracheal tube.

2.8 Specialist Consultation and Work-up

The initial evaluation of the patient then leads to subsequent work-up, including obtaining consultations from other specialties if deemed necessary, re-evaluating the need for any additional investigations, taking steps to limit perioperative risks as deemed necessary, evolving an anesthetic plan, and getting informed consent from the patient. As more and more areas of concern may develop, further testing, specialist consultation, and varied approaches to risk management strategies may become imperative. As this dynamic process of comprehensive patient assessment evolves, revision of the anesthetic plan and eliciting additional specific terms of consent from the patient may also become inevitable.

Specialist consultations are needed when the particular condition being evaluated does not come under the purview of the training of the anesthesiologist or surgeon. Such consultations must be specific and try to elicit whether the

patient is in the best possible condition with regard to his particular comorbidity to undergo the proposed intervention, or whether the malady for which consultation is being sought, can be further optimized and at what stage of the particular ailment the patient is at. When consultations are merely sent without stating specific objectives of such request, they might meet with a similarly nonspecific response from the consultant that the referral is being sent to, and hence proving to be of not much help for the clarification sought for. Thus, referrals to other disciplines need to be very specific, as to the expectations that the referring unit has of the evaluation and the advice that they should receive. The consultant to whom the referral goes now becomes an important component of the perioperative team. It is essential that this consultant must also appreciate his role in the assessment of the patient, and this would be possible by building support networks among disciplines. This will also save time in the perioperative period, since a few investigations that the consultant being referred to would advise, may be carried out prior to the referral itself. An example would be getting an ECG and echocardiogram done prior to referring a patient with significant coronary artery disease to the cardiologist. Thus, the requirement for circulation of information, among disciplines, is vital and is especially true with regard to communication between consultants. Often, communicating personally with the consultant to whom the patient is being referred to, can expedite the evaluation to a very great extent.

2.9 The Process of Risk Assessment

Following a thorough evaluation and perusal of the results of the investigations, the patient-specific risks are evident, while the surgery-specific risks need to be considered upon, the summation of both of which contribute to the overall risk to the patient. Technical factors such as fluid shifts, total blood loss, as well as the site of the surgical intervention, are components of the surgery-specific factors that contribute to the total risk assessment [28]. Oral and maxillofacial surgery being classified as head and neck surgery, would normally be considered as an intermediate risk surgery, unless undertaken as emergency or anticipated to have a risk of excessive blood loss, wherein it would be classified as a high-risk procedure. The correlation between expected blood loss and specific maxillofacial surgeries has been demonstrated [29]. With improving the safety of anesthesia equipment and medications, the historical dangers of anesthesia administration are quite low, and patient- and surgery-specific risk factors almost completely determine the overall risk to the patient [30, 31].

Once the overall risk of the patient is known and calculated, the next step would be to devise a strategy for risk management.

2.10 Risk Reduction Strategies

Risk reduction blueprints must be assessed and a risk-benefit ratio evaluated in performing any elective oral or maxillofacial surgical procedure. Alternative procedures and occasionally even avoiding any intervention could be considered when the overall risks in terms of morbidity and mortality to the patient are substantial. Obviously, the most critical step in risk reduction would be to get the patient in the best physical condition to undergo an interventional procedure. To this effect, modifiable risk factors should be addressed (e.g., anemia, hyperglycemia, hypertension) always ensuring that the risk-benefit ratio stays in the patient's favor. As an example, in a smoker who is to undergo an intermediate- or high-risk surgery, the obvious risk reduction strategy would be to quit smoking [32, 33].

This then allows the patient's body to reap the benefits of a simple risk reduction maneuver with the risk now decreasing to a degree that might cause a favorable impact on the morbidity and mortality otherwise expected. Appropriate medical management of the comorbidities might be successful in optimizing patients to a state where they can withstand the rigors of the surgical procedure. The particular anesthetic technique apart, there are at least five other areas that may be targeted as part of overall risk reduction strategies, namely: (a) premedication, (b) anti-aspiration prophylaxis, (c) perioperative beta-blockade, (d) postoperative nausea and vomiting (PONV) prophylaxis and (e) effective postoperative pain management.

2.10.1 Premedication [4]

An increase in heart rate is the major factor increasing myocardial oxygen demand in the perioperative period. This makes appropriate anxiolysis and management of postoperative pain absolute vital cogs in the overall care of the patient undergoing surgery since anxiety and/or pain can set off a noxious cycle of events starting with tachycardia and hypertension, which could, in turn, result in perioperative myocardial infarction, the incidence of which is highest in the first 72 h. Benzodiazepines induce anterograde amnesia, anxiolysis with mild sedation. Opiates were previously believed to be a vital part of preemptive analgesia, but later they were found to sensitize patients to pain. Clonidine may also be considered preemptive analgesia, especially when administered epidurally. However, the entire concept of pre-emptive analgesia, or antinociceptive treatment prior to initiation of the pain stimulus that prevents the establishment of altered processing of afferent input, that amplifies postoperative pain, is currently mired in controversy. Clonidine has a cardioprotective effect and also decreases the minimum alveolar concentration (MAC). Antihistamines may be used for their

sedative and antiemetic properties. However, the clinician needs to know that promethazine, the most commonly prescribed antihistaminic, now carries an FDA warning for apnea and death in children. Anticholinergics are no longer used routinely, but rather to produce an antisialagogue effect when desirable (endoscopic procedures), sedation/amnesia, or to prevent reflex bradycardia.

2.10.2 Fasting Guidelines

Patients with a full stomach at the time of induction of anesthesia are perceived to be at high risk of aspiration of gastric contents into their respiratory tract, and also present difficulty with intubation if gastric contents are regurgitated at the time of airway manipulation. This may lead to acute lung injury manifested as pneumonitis, aspiration pneumonia, respiratory failure, or acute respiratory distress syndrome [34]. Following administration of a general anesthetic, patients can no longer have the ability to maintain a patent airway, respiration, or protective reflexes like gagging or coughing. The driving force for inducing aspiration is the barrier pressure, which is the difference between the gastroesophageal sphincter tone that opposes aspiration and the hydrostatic pressure within the stomach. In the presence of a negative barrier pressure, the possibility of regurgitation, vomiting, and aspiration is increased. One of the ways to maintain the barrier pressure positive during the vulnerable period of anesthesia is to instruct the patient to be “nil per oral” prior to surgery, such that the gastric hydrostatic pressure is kept low. What constitutes an appropriate period of fasting before anesthesia has been the subject of substantial research over several years, and current guidelines are based both on the nature of oral intake and the age of the patient [35, 36, 37] (Table 2.5). These recommendations, however, need to be viewed as guidelines, rather than a set of inviolable instructions. The reason why these rules should not be looked upon as impregnable is because these were intended for normal patients. Individual situations may sometimes prevent these nil-per-oral guidelines from providing fool-proof safety from aspiration. Conditions that inhibit gastric emptying, including diabetes, morbid obesity (body mass

index [BMI] >35), pregnancy, bowel obstruction, previous upper gastrointestinal surgery, and gastrointestinal disease such as gastric ulcer, scleroderma, etc. will all escalate the risk of aspiration and deserve as much attention that a full stomach does [38–40]. Another group of patients who are believed to be at high risk for aspiration comprises those with difficult airways, as these patients will require more prolonged airway manipulation and thus a greater time to intubation [41]. The airway remains unprotected and unsecured for a longer time and hence these patients may benefit from prophylaxis against aspiration. The preanesthetic evaluation needs to identify this special category of patients who appear to be at higher risk of aspiration, despite adhering faithfully to standard nil per oral guidelines and premedicate them for elective surgery. A prokinetic drug and an alkalinizing agent could reduce the complications from gastric aspiration by combating the corrosive acidic nature of gastric juice, even if aspiration does occur [3].

The most widely prescribed prokinetic in this regard is the dopamine-antagonist metoclopramide (10 mg orally/IV). However, this drug has the potential to cause extrapyramidal symptoms and should be used cautiously. The other pharmacological agent that increases the pH of gastric juice and makes it less acidic is a Histamine 2 (H2) receptor blocker, viz., ranitidine (150 mg orally; 50 mg IV) or famotidine (20 mg IV). Cimetidine is no longer used due to its ability to induce hepatic enzymes and influence the metabolism of several anesthetic agents. Usually, the prokinetic along with the H2 blocker is administered both on the night before and on the morning of the surgery. Administration of two doses each of both the medications guarantees adequate plasma levels required for an effective action. Lastly, the use of particulate antacids such as citric acid/sodium citrate (30 ml) typically within 2 h prior to the anticipated induction of anesthesia also can neutralize the gastric acid, and reduce the incidence of chemical pneumonitis even if the aspiration occurs. However, its bitter taste and propensity to induce emesis necessitates that it be administered a substantial period prior to intubation.

2.10.3 Perioperative Beta-Blocker Therapy

Organ ischemia is a result of an imbalance between the oxygen supply and demand. The heart is especially vulnerable since myocardial work and oxygen demand are very tightly coupled. However, the precise level of myocardial demand at which it outstrips the supply is unclear. Hence, a patient who is susceptible to the development of myocardial ischemia needs to be managed perioperatively in a manner that keeps the demand lowest, while at the same time maximizing supply. Pharmacological manipulation of the myocardial demand is probably effected easier than a significant manipulation of

Table 2.5 Preoperative fasting recommendations for healthy patients undergoing elective surgery

Liquid and food intake	Minimum fasting period
Clear liquids (Water, tea, black coffee, fruit juice without pulp, carbonated beverages)	2 h
Breast milk	4 h
Nonhuman milk, including infant milk formula	6 h
Light meal (e.g., toast and clear liquids)	6 h
Regular or heavy meal (may include fried or fatty food, meat)	8 h

the supply. Physiologically, tachycardia is the most important parameter that increases myocardial demand, with increases in systemic vascular resistance being the second most important [42–44]. Patients having a significant cardiovascular risk need a cardiologist's opinion for an evaluation of the extent of risk and preoperative optimization [6] (Table 2.6). Obviously, modifiable risk factors and reversible disorders need to be addressed and managed. The ACC recommends perioperative beta-blocker therapy for patients with two or more intermedi-

ate risk factors or a single major risk factor, especially if being posted for an intermediate-to-high-risk surgical procedure [6]. The evaluating physician can be requested to assess the benefits of beta-blockade in the patient scheduled for maxillofacial surgery. The commonest way of introducing beta-blockade is with the drug metoprolol for a target basal heart rate of 60–65 beats per minute (bpm), and to sustain the rates at no more than 85 bpm during the perioperative period. Beta-blockade should, however, be started well before the surgery so that ample time is available to adjust the dose to the target heart rate and address any side effects that may develop. The administration of a beta-blocker just prior to an emergency surgery is controversial as this has been observed to be associated with a greater risk of perioperative strokes [45, 46]. More research is needed to clearly identify which patient subsets might benefit most from the beta-blockade, and in whom the side effects may be substantial.

Table 2.6 Clinical predictors of increased perioperative cardiovascular risk

<p><i>Major clinical predictors (markers of unstable coronary artery disease)</i></p> <ul style="list-style-type: none"> • Myocardial infarction <6 weeks: Delay elective surgery, consultation with cardiologist • Unstable or severe angina (Canadian Cardiovascular Society class III or IV) • Decompensated heart failure • Significant arrhythmias (e.g., causing hemodynamic instability) • Severe valvular heart disease (e.g., aortic or mitral valve stenosis with valve area < 1 cm²) • CABG or PTCA <6 weeks
<p><i>Intermediate clinical predictors (markers of stable coronary artery disease)</i></p> <ul style="list-style-type: none"> • Previous Myocardial infarction >6 weeks but <3 months (> 3 months if complicated) based on the history or presence of pathologic Q waves on the Electrocardiogram • Mild angina (Canadian Cardiovascular Society class I to II) • Silent ischemia (Holter monitoring) • Compensated heart failure, ejection fraction <0.35 • Post CABG or PTCA >6 weeks and < 3 months, or > 6 years, or on antianginal therapy • Diabetes mellitus • Renal insufficiency
<p><i>Mild clinical predictors (increased probability of coronary artery disease)</i></p> <ul style="list-style-type: none"> • Familial history of coronary artery disease • Age > 70 years • ECG abnormalities (arrhythmias, LVH, Left bundle branch block) • Low functional capacity • History of stroke • Uncontrolled systemic hypertension • Hypercholesterolemia • Smoking • Post infarction (> 3 months, asymptomatic without treatment) • Post CABG or PTCA (> 3 months and < 6 years, and no symptoms of angina nor on antianginal therapy)
<p><i>Major clinical predictors:</i> All elective operations should be postponed and the patients properly investigated and treated.</p> <p><i>Intermediate clinical predictors:</i> Proof of well-established but controlled coronary artery disease. Further risk stratification and optimization in consultation with cardiologist.</p> <p><i>Minor clinical predictors:</i> Increased probability of coronary artery disease, but not of an increased perioperative risk. Further risk stratification and optimization in consultation with cardiologist.</p> <p><i>Emergency procedures:</i> Proceed for surgery with perioperative surveillance and postoperative risk stratification and risk factor management.</p>

CABG Coronary Artery Bypass Grafting, PTCA Percutaneous Transluminal Coronary Angioplasty, LVH Left Ventricular Hypertrophy

2.10.4 PONV Prophylaxis [47]

Oral and Maxillofacial surgeries are generally not considered as high risk for the incidence of postoperative nausea and vomiting (PONV) [48]. Risk factors, including female gender, previous history of PONV or motion sickness, non-smoking status, and younger age patients, have been associated with an increased incidence and severity of PONV [49]. Therefore, the preoperative assessment should be sensitive to the presence of these indicators and must devise a plan for offering pharmacological prophylaxis to this patient population. The plan for anesthesia devised preoperatively should also take into consideration that use of volatile anesthetics, opioids, and nitrous oxide may be associated with higher PONV incidence, and thus influence the choice of anesthetic agents used. The choices for PONV prophylaxis are between 5HT₃ antagonists (ondansetron, granisetron, palonosetron, etc.), dexamethasone, subanesthetic doses of propofol, scopolamine patches, etc. [50]. Generally, a combination of agents seems to work much better than a single agent.

2.10.5 Plan for Postoperative Analgesia [51]

Regional anesthesia techniques, including peripheral nerve blocks, are excellent in terms of providing quality analgesia postoperatively, but they do have their own set of risks and may cause discomfort from the ensuing numbness. Hence, it is important that the patient is taken into confidence about the risks and benefits of this modality of pain relief, while also offering alternative approaches that could be opted for. Local anesthesia in adequate concentrations and volume is essential for a pain-free postoperative period. Contrary to earlier practices, the mixing of local anesthetic solutions to

apparently harness the best pharmacological effects of both is an approach, which is currently being discouraged. In fact, a successful preoperative nerve block may also be used so as to minimize the incidence of tachycardia during the intraoperative noxious stimuli, and then repeated at the culmination of the procedure, so that the effect can extend into the postprocedure period. This option can be employed by the maxillofacial surgeon resultant to their expertise in regional nerve blocks of the orofacial region. Opioids have traditionally been the workhorse for postoperative analgesia. Intravenous patient-controlled analgesia is an attractive option for the postoperative pain control for the inpatient in whom the effects of the nerve blocks are expected to wane after a few hours. However, there is accumulating evidence that a multimodal approach to pain management works best, with the intent of reducing the side effects of opioids and improving pain scores. Enhanced recovery after surgery (ERAS) protocols to minimize postsurgery hospital stay are gaining wider acceptance, and an important part of such protocols is the inclusion of multimodal opioid-sparing pain management protocols [52].

2.11 Preoperative Decision Making and Obtaining Informed Consent: The Team Concept [53]

The preoperative plan blends the patient's requirements, the competence of the perioperative team, and the infrastructure provided by the hospital to get the particular intervention done. This, it is expected, would help achieve the favorable outcome of the intervention. Quite often, the optimization of all of these conditions may not always be possible. The onus then is upon both the patient and the operating team to take a decision on what may be the acceptable course of action. Whether to pursue the performance of a particular intervention or not is, therefore, also an integral part of the preoperative decision-making process.

The final element of a comprehensive preoperative assessment is the process of obtaining a valid, written, and informed consent. Obviously, this process can be initiated, only after a thorough risk estimation has been made, based on the preceding evaluation of the patient, and a tentative anesthetic and surgical plan have been evolved, including strategies for management of postoperative pain. For all practical purposes, an informed consent necessitates presentation of the final residual risk that the patient has, which cannot be further optimized, and its expected interaction with the proposed surgical intervention. The main players in the process of obtaining informed are obviously the surgeon, anesthesiologist, and the patient. Typically, any of them has the autonomy to reject or to suggest modifications to the proposed sequence for the intervention. It is important to note that

informed consent is a process of ensuring the patient understands the risks and benefits of the available surgical and anesthetic options. It is not merely signing a consent form. The capacity of a patient refers to the ability to make decisions about their care, and to decide whether to agree to, or refuse, an examination, investigation, or treatment. To have the capacity, a patient must be able to understand and retain information regarding the treatment, evaluate the risks and benefits of treatment, reach a decision regarding their course of treatment, and communicate their decision to the clinician [54]. A patient undergoing surgery is understandably apprehensive, and hence the process of imparting information to him while taking consent must be handled professionally, yet with the utmost sensitivity [55]. It is important that the anesthesiologist and the surgeon should have thrashed out issues relating to perioperative care and broken common ground on all aspects before involving the patient (Table 2.7).

Following discussion and concordance between the surgeon and the anesthesiologist on the course of action, the patient is taken into confidence, informed about the procedure, and his/her consent for the same, sought. The information provided to the patient includes the nature of the risk involved, the benefits, and the alternatives to the proposed plan. If the proposal or any particular element of it is unacceptable to the patient, the operating team must be ready for course correction and should be able to come up with alternatives, which would be acceptable to the patient. However, if no substitute plan can be offered, and the patient is resolute in not accepting the proposed one, there is no option than to abort the proposed surgery. Options, such as referrals to other surgical teams, with different expertise or set-ups that may address the patient's concerns better and satisfy his expectations can be considered. Consequently, acquiring informed consent is a highly interactive process, with the patient being the pivot, to whom the risk-benefit ratio is projected taking into consideration his/her wishes and needs. The Association of Oral and Maxillofacial Surgeons of India consent forms can serve as a useful template for consent taking in one's clinical practice [56].

Table 2.7 Points of concurrence between surgeon and anesthesiologist before seeking informed consent from the patient

• Diagnosis
• Nature and purpose of the proposed treatment or procedure
• Risks, complications, and consequences of the proposed treatment or procedure
• Alternatives to proposed treatment or procedure
• The consequences if the proposed treatment or procedure is refused
• Benefits and expected results if the proposed treatment or procedure is accepted
• Conflicts of interest
• Who will be providing the treatment or procedure

2.12 Conclusion

“Do not operate on a stranger” is the most important mantra to be followed by any surgeon. The preoperative evaluation of oral and maxillofacial surgery patient comprises a critical part of the perioperative period and hence requires a watchful and staged outlook to risk identification and management, putting in place a plan for anesthesia, surgery, and postsurgical pain management. There is no substitute for a properly performed and detailed history and physical examination. Literature suggests that most clinically relevant conditions are recognized during the history and physical examination without the need for further laboratory testing. The surgical team needs to ascertain the risks involved with the comorbidities that the patient may be suffering from, and be able to juxtapose this against the procedure-specific risks to identify the overall risk of the procedure in that particular patient. Risk management and optimization strategies involve the rational use of adjunctive laboratory and imaging studies and professional opinions of consultants of other specialties. This helps evaluate the degree of physiological decompensation a patient might be having due to his comorbidities, and whether this could be either reversed or ameliorated. Acquiring informed consent from the patient involves the development of consensus between the surgeon and anesthesiologist first, with regard to the perioperative plan, irrespective of whether the consent forms for anesthesia and surgery are the same or different documents. This proposed plan, which has the concurrence of both the surgeon and the anesthesiologist, is then presented to the patient along with clear information about the risks and benefits of different clinical strategies, such that the patient can make his up his/her mind, or else request refinement of the proposed plan. This thorough process of preoperative evaluation, it is expected, would be able to keep morbidity and mortality related to the maxillofacial surgery, to an absolute minimum.

References

- Galway UA. Preoperative evaluation. In: Sikka PK, Beaman ST, Street JA, editors. *Basic clinical anesthesia*. New York: Springer; 2015. p. 7–15.
- Hilditch WG, Asbury AJ, Jack E, McGrane S. Validation of a pre-anaesthetic screening questionnaire. *Anaesthesia*. 2003;58:874.
- Wijeyesundera DN, Sweitzer BJ. Preoperative evaluation. In: Miller RD, editor. *Miller’s anesthesia*. 8th ed. Philadelphia: Elsevier Saunders; 2015. p. 1085–155.
- Hata TM, Hata JS. Preoperative patient assessment and management. In: Barash PG, Cullen BF, Stoelting RK, Cahalan MK, Stock MC, Ortega R, Sharar SR, Holt NF, editors. *Clinical anesthesia*. 8th ed. Philadelphia: Wolters Kluwer; 2017. p. 1479–544.
- Gupta A, Shiveley T. The preoperative patient evaluation. In: Ehrenfeld JM, Urman RD, Segal S, editors. *Anesthesia student survival guide—a case based approach*. 2nd ed. New York: Springer; 2016. p. 89–106.
- Fleisher LA, Beckman JA, Brown KA, Calkins H, Chaikpif E, Fleischmann K, et al. ACC/AHA 2007 Guidelines on Perioperative Cardiovascular Evaluation and Care for Noncardiac Surgery: a Report of the American College of Cardiology/American Heart Association Task Force on Practice Guidelines (Writing Committee to Revise the 2002 Guidelines on Perioperative Cardiovascular Evaluation for Noncardiac Surgery). *Circulation*. 2007;116:e418–99.
- Owens WD. American Society of Anesthesiologist physical classification system is not a risk classification system. *Anesthesiology*. 2001;94:378.
- Henry A, Dewi F, Atan R, Patel N, Bhatia S. Pre-operative investigations in patients undergoing oral and maxillofacial procedures. *Oral Surg*. 2016;9:155–9.
- Tasse JL, Janzen ML, Ahmed NA, Chung RS. Screening laboratory and radiology panels for trauma patients have low utility and aren’t cost effective. *J Trauma*. 2008;65:1114–6.
- Bryson GL, Wyand A, Bragg PR. Preoperative testing is inconsistent with published guidelines and rarely changes management. *Can J Anaesth*. 2006;53:236–41.
- Smetana GW, Macpherson DS. The case against routine preoperative laboratory testing. *Med Clin North Am*. 2003;87:7–40.
- Weinberger SE. Providing high-value, cost-conscious care: a critical seventh general competency for physicians. *Ann Intern Med*. 2011;155:386–8.
- Benarroch-Gampel J, Riall TS. What laboratory tests are required for ambulatory surgery? *Adv Surg*. 2013;47:81–98.
- Feely MA, Collins CS, Daniels PR, Kebede EB, Jatoi A, Mauck KF. Preoperative testing before noncardiac surgery: guidelines and recommendations. *Am Fam Physician*. 2013;87(6):414–8.
- Czoski-Murray C, Lloyd Jones M, McCabe C, Claxton K, Oluboyede Y, Roberts J, et al. What is the value of routinely testing full blood count, electrolytes and urea, and pulmonary function tests before elective surgery in patients with no apparent clinical indication and in subgroups of patients with common comorbidities: a systematic review of the clinical and cost-effective literature? *Health Technol Assess*. 2012;16(i–xvi):1–159.
- Parameters of Care; AAOMS clinical practice guidelines for oral and maxillofacial surgery (AAOMS ParCare), 6th ed; 2017; *J Oral Maxillofac Surg* 75:Suppl 1e12-1e33.
- Fattahi T. Perioperative laboratory and diagnostic testing—what is needed and when? *Oral Maxillofac Surg Clin North Am*. 2006;18:1–6.
- National Institute for Health and Care Excellence (NICE) guidelines. Routine pre-operative tests for elective surgery 2016. www.nice.org.uk/guidance/ng45.
- Apfelbaum JL, Hagberg CA, Caplan RA, Blitt CD, Connis RT, Nickinovich DG, et al. Practice guidelines for management of the difficult airway: an updated report by the American Society of Anesthesiologists Task Force on Management of the Difficult Airway. *Anesthesiology*. 2013;118:251–70.
- Prakash S, Mullick P, Bhandari S, Kumar A, Gogia AR, Singh R. Sternomental distance and sternomental displacement as predictors of difficult laryngoscopy and intubation in adult patients. *Saudi J Anaesth*. 2017;11:273–8.
- O’Dell K. Predictors of difficult intubation and the otolaryngology perioperative consult. *Anesthesiol Clin*. 2015;33:279–90.
- Reed MJ, Dunn MJG, McKeown DW. Can an airway assessment score predict difficulty at intubation in the emergency department? *Emerg Med*. 2005;22:99–102.
- Murphy Michael F, Walls RM. Identification of the difficult and failed airway. In: Walls RM, Michael F, editors. *Emergency airway management*. 3rd ed. Philadelphia: Lippincott Williams & Wilkins; 2008. p. 82–93.
- Advanced Trauma Life Support (ATLS) Student course manual. Airway and ventilatory management. 9th ed. Chicago IL, 2012. American College of Surgeons Committee on Trauma: 36.

25. Mallampati SR, Gatt SP, Gugino LD, Desai SP, Waraksa B, Freiburger D, et al. A clinical sign to predict difficult tracheal intubation: a prospective study. *Can Anaesth Soc J*. 1985;32:429–34.
26. Advanced Trauma Life Support (ATLS) student course manual. Pediatric trauma. 9th ed. Chicago IL, 2012. American College of Surgeons Committee on Trauma: 251.
27. Advanced Trauma Life Support (ATLS) student course manual. Geriatric trauma. 9th ed. Chicago IL, 2012. American College of Surgeons Committee on Trauma: 275.
28. Glance LG, Lustik SJ, Hannan EL, Osler TM, Mukamel DB, Qian F, et al. The Surgical Mortality Probability Model: derivation and validation of a simple risk prediction rule for noncardiac surgery. *Ann Surg*. 2012;255:696–702.
29. Akinbami BO, Onajin-Obembe B. Assessment of intraoperative blood loss during oral and maxillofacial surgical procedures in a Nigerian tertiary health care center. *J Blood Transfus*. 2014;2014:301467.
30. Lanier WL. A three-decade perspective on anesthesia safety. *Am Surg*. 2006;72:985–9.
31. Botney R. Improving patient safety in anesthesia: a success story? *Int J Radiat Oncol Biol Phys*. 2008;71:S182–6.
32. Rodrigo C. The effects of cigarette smoking on anesthesia. *Anesth Prog*. 2000;47:143–50.
33. Warner DO. Perioperative abstinence from cigarettes: physiologic and clinical consequences. *Anesthesiology*. 2006;104:356–67.
34. Warner MA, Warner ME, Weber JG. Clinical significance of pulmonary aspiration during the perioperative period. *Anesthesiology*. 1993;78:56–62.
35. Apfelbaum JL, Caplan RA, Connis RT, Epstein BS, Nickinovich DG, Warner MA. American Society of Anesthesiologists Committee. Practice guidelines for preoperative fasting and the use of pharmacologic agents to reduce the risk of pulmonary aspiration: application to healthy patients undergoing elective procedures: an updated report by the American Society of Anesthesiologists Committee on Standards and Practice Parameters. *Anesthesiology*. 2011;114:495–511.
36. Brady M, Kinn S, Stuart P. Preoperative fasting for adults to prevent perioperative complications. *Cochrane Database Syst Rev*. 2003;4:CD004423.
37. Stuart PC. The evidence base behind modern fasting guidelines. *Best Pract Res Clin Anaesthesiol*. 2006;20:457–69.
38. Fleisher LA, Mythen M. Anesthetic implications of concurrent diseases. In: Miller RD, editor. *Miller's anesthesia*. 8th ed. Philadelphia: Elsevier Saunders; 2015. p. 1156–225.
39. Krishnan B. Obese oral and maxillofacial surgical patient. *J Craniofac Surg*. 2009;20:53–7.
40. Hoefnagel A, Yu A, Kaminski A. Anesthetic complications in pregnancy. *Crit Care Clin*. 2016;32:1–28.
41. Neuman MD, Fleisher LA. Risk of anesthesia. In: Miller RD, editor. *Miller's anesthesia*. 8th ed. Philadelphia: Elsevier Saunders; 2015. p. 1056–84.
42. Fox KM, Ferrari R. Heart rate: a forgotten link in coronary artery disease? *Nat Rev Cardiol*. 2011;8:369–79.
43. Tardif JC. Heart rate as a treatable cardiovascular risk factor. *Br Med Bull*. 2009;90:71–84.
44. Braunwald E. Control of myocardial oxygen consumption: physiologic and clinical considerations. *Am J Cardiol*. 1971;27:416–32.
45. Lindholm LH, Carlberg B, Samuelsson O. Should beta blockers remain first choice in the treatment of primary hypertension? A meta-analysis. *Lancet*. 2005;366:1545–53.
46. Bangalore S, Messerli FH, Kostis JB, Pepine CJ. Cardiovascular protection using betablockers: a critical review of the evidence. *J Am Coll Cardiol*. 2007;50:563–72.
47. Fowler MA, Spiess BD. Postanesthesia recovery. In: Barash PG, Cullen BF, Stoelting RK, Cahalan MK, Stock MC, Ortega R, Sharar SR, Holt NF, editors. *Clinical anesthesia*. 8th ed. Philadelphia: Wolters Kluwer; 2017. p. 3854–918.
48. Alexander M, Krishnan B, Yuvraj V. Prophylactic antiemetics in oral and maxillofacial surgery: a requiem? *J Oral Maxillofac Surg*. 2009;67:1873–7.
49. Habib AS, Gan TJ. Evidence-based management of postoperative nausea and vomiting: a review. *Can J Anaesth*. 2004;51:326–41.
50. Cao X, White PF, Ma H. An update on the management of postoperative nausea and vomiting. *J Anesth*. 2017;31:617–26.
51. White PF, Kehlet H, Neal JM, Schrickler T, Carr DB, Carli F, et al. The role of the anesthesiologist in fast-track surgery: from multimodal analgesia to perioperative medical care. *Anesth Analg*. 2007;104:1380–96.
52. Misiołek H, Cettler M, Woron J, Wordliczek J, Dobrogowski J, Mayzner-Zawadzka E. The 2014 guidelines for post-operative pain management. *Anaesthesiol Intensive Ther*. 2014;46:221–44.
53. Barry MJ, Edgman-Levitan S. Shared decision making—pinnacle of patient-centered care. *N Engl J Med*. 2012;366:780–1.
54. General Medical Council (GMC). Consent: patients and doctors making decisions together [online]. GMC, 2008. Available: <http://www.gmc-uk.org/static/documents/content/Consent-English0414.pdf>
55. Sjöling M, Nordahl G, Olofsson N, Asplund K. The impact of preoperative information on state anxiety, postoperative pain and satisfaction with pain management. *Patient Educ Couns*. 2003;51:169–76.
56. Association of Oral and Maxillofacial Surgeons of India (AOMSI): <https://www.aomsi.com/WebPages/downloads.aspx>

Open Access This chapter is licensed under the terms of the Creative Commons Attribution 4.0 International License (<http://creativecommons.org/licenses/by/4.0/>), which permits use, sharing, adaptation, distribution and reproduction in any medium or format, as long as you give appropriate credit to the original author(s) and the source, provide a link to the Creative Commons license and indicate if changes were made.

The images or other third party material in this chapter are included in the chapter's Creative Commons license, unless indicated otherwise in a credit line to the material. If material is not included in the chapter's Creative Commons license and your intended use is not permitted by statutory regulation or exceeds the permitted use, you will need to obtain permission directly from the copyright holder.





Management of Medical Comorbidities in Maxillofacial Surgery

3

Aditya Moorthy and Shreya Krishna

3.1 Introduction

The management of the medically compromised patient is a topic that has received a great deal of attention in recent times. Unfortunately, most of the literature available discusses this topic from a western context. While the human species and the physiology remains unchanged, challenges in South Asia, especially India, stem from a vastly different social structure, a massive urban-rural socioeconomic divide, and social variables that have a major impact on the practice of medicine. In addition, a mixture of patient ignorance, poor training in soft skills of doctors, and an irresponsible fourth estate has vitiated a hitherto-friendly doctor-patient relationship.

While this chapter is not designed to provide a comprehensive guide to the medical management of a maxillofacial patient (which deserves a textbook in its own right), it attempts to provide an insight into the management of medically compromised patients requiring maxillofacial surgery.

3.2 Changing Demographics in India

India encompasses almost a fifth of the world's population with a population estimate of about 1.34 billion [1]. The life expectancy at birth in India has improved from 59.7 years in 1990 to 70.3 years in 2016 for females, and from 58.3 years to 66.9 years for males [1]. In short, the average life span of an Indian has increased by 11 years in the last decade leading to an increase in the geriatric population of the country. The crude death rate has also steadily declined in the last decade

from 7.5 to 6.4 per 1000 population [2]. The population continues to grow, as the birth rate has superseded the death rate. This change, while an indicator of improved healthcare delivery, adds to the health burden of the country, and creates a different spectrum of diseases—particularly lifestyle diseases.

There has also been a shift in the societal patterns. We see an increase in urban nuclear families resulting in unattended elderly parents whose medical conditions stay undiagnosed and uncontrolled.

3.3 Lifestyle Changes in India

There has been a sea of change in the lifestyle of today's population compared to a couple of decades ago. Sedentary lifestyle, processed food, industrialization, occupational hazards, etc. have led India to a “dual disease burden” scenario. So, even as the incidence of lifestyle diseases is steadily on the rise, a vast majority of rural and poor patients still suffer from infectious and acute diseases.

As recently as 2016, cardiovascular diseases like Ischaemic Heart Disease (IHD) and stroke contributed 28.1% toward mortality in India. This was a 34.3% increase over 16 years, suggesting the impact of lifestyle disease on society. The major contributors for this change are rapidly aging population, pollution, high blood pressure, dyslipidemia, high fasting plasma glucose, and an increased BMI (body-mass index) [3]. Respiratory diseases like chronic obstructive pulmonary disease (COPD) and bronchial asthma—are the second-largest contributors to the total mortality burden of India—at 10.9%. Diabetes analysis shows that it contributes 3.1% toward the total mortality burden.

Air pollution is a major risk factor for both cardiovascular and respiratory illness and increases the risks for acute respiratory infections and exacerbates asthma [4]. Such unique challenges raise questions of following treatment protocols based on western studies. A preoperative chest X-Ray may

A. Moorthy (✉)
Rangadore Memorial Hospital, Apollo Hospitals, Bangalore,
Karnataka, India

S. Krishna
Oral and Maxillofacial Surgery, Rangadore Memorial Hospital,
Bangalore, India

find an indication in an apparently fit and healthy 28-year-old living in New Delhi (with record levels of pollution) when it would be considered unnecessary for a similar patient from rural Yorkshire.

With the rise of urbanization and urban migration, the problems of air pollution, inadequate sanitation, and an unhealthy diet are accentuated. Population residing in **urban areas** in India, according to 1901 census, was 11.4%. This count increased to 28.53% by 2001, and the numbers increased to 34% in 2017 [5].

“Cyberchondria” has become a challenge with patients tending to diagnose and treat their problems themselves, and unsurprisingly getting it wrong. India is also among one of the most depressed countries in the world. A World Health Organization (WHO) study states that at least 6.5% of the Indian population suffers from some form of serious mental disorder. The average suicide rate in India is 10.9 for every hundred thousand people with the majority of victims being less than 44 years of age [6]. Diminished mental health is associated with a host of consequences like lack of participation in social activities, odd eating habits, and withdrawal from income generation and employment opportunities—all of which can cascade onto other serious illnesses and even death.

3.4 The Changing Face of Oral and Maxillofacial Surgery

As always, training is struggling to keep up with the changing trends in medicine. Trainees are often unaware of new protocols and the changed scenario of medical comorbidities of the population. Surgery has become heavily technology oriented, sometimes at the cost of clinical expertise. Furthermore, there is improved awareness among medical professionals for crossreferral to review dentition, seen mostly by maxillofacial surgeons rather than general dentists. Referrals are required now before radiotherapy, chemotherapy, cardiac surgery, transplants, etc.

Furthermore, maxillofacial surgery as a specialty has blazed a trail hitherto unimagined with successful foray into head and neck surgery, craniofacial reconstruction, and microvascular surgery. This now has put the onus on the surgeon to educate himself enough to be able to manage a sick patient on the ward to the extent of preventing complications and making appropriate referrals. Gone are the days when a physician could be asked to do the job for us and we could enjoy the comfort of being surgical technicians!

3.4.1 Medical History and India

While veritable treatises about the science and art of history taking, this part of clinical medicine is a unique investigative

effort in the Indian context. The challenges to the maxillofacial surgeon are multifold. The first difficulty is encountered with the patient who may deny illness (often hypertension or diabetes) because he/she is adequately treated and all parameters are within normal limits. The next hurdle is when the patient decides to withhold information wantonly due to social taboos or plain ignorance of its importance to the treating doctor. Dentists and maxillofacial surgeons who question their patients seated on dental chairs in an outpatient setting often experience the latter. This stems from the patients’ assumption that the information is inconsequential to their treatment. The last situation is the uneducated patient who is truly unaware of his medical condition.

With these intricacies, the oral surgeon needs to employ several out-of-the-box techniques to extract the history. This includes the much-derided leading questions, questioning relatives, sometimes in private, and playing Sherlock by asking them to bring in their medication and working backwards. But this effort is still of paramount importance in this technology-driven age and the modern oral and maxillofacial surgeon will do well to assimilate all the conventional history-taking skills and learn a few new ones as well.

3.5 Cardiovascular System

3.5.1 Hypertension

Hypertension is an extremely common condition and often undiagnosed. Since it is mostly asymptomatic, the oral surgeon has the unique opportunity to be the first healthcare professional to identify the condition. Hence, it is imperative that every procedure should begin with recording the patients’ vital signs. The following table offers a guideline for the diagnosis and risk stratification of hypertension (Table 3.1).

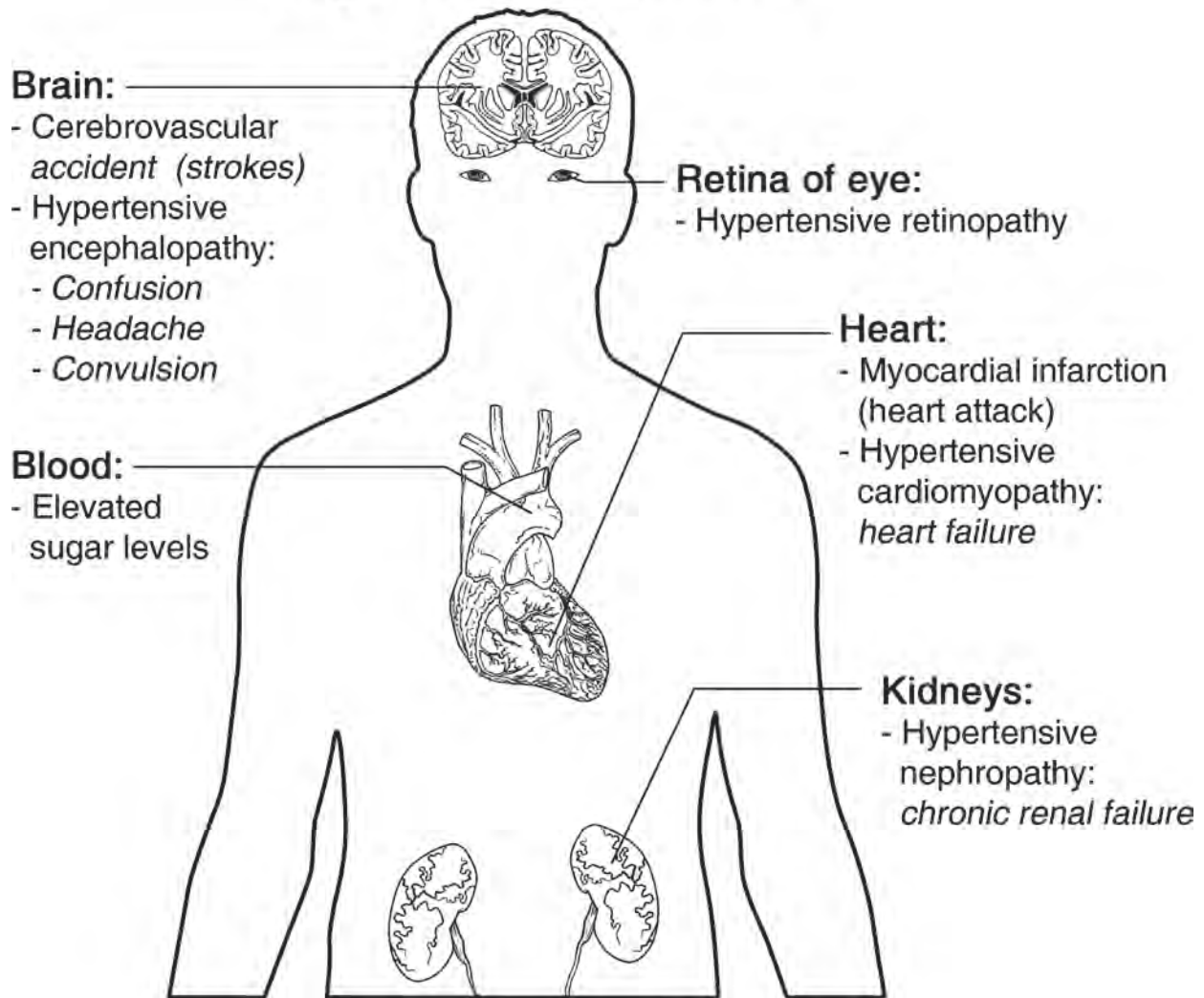
The authors stress that aneroid manometers are more accurate than digital ones. Like any delicate instrument, these too need frequent calibration [8].

The long-term effects of hypertension have far-reaching implications on maxillofacial surgery, especially under general anesthesia (Fig. 3.1).

Table 3.1 Guidelines for diagnosis of hypertension [7]

Category	Systolic (mmHg)	Diastolic (mmHg)
Optimal	<120	<80
Normal	120–129	And/or 80–84
High normal	130–139	And/or 85–89
Grade 1 hypertension	140–159	And/or 90–99
Grade 2 hypertension	160–179	And/or 100–109
Grade 3 hypertension	>180	And/or >110
Isolated systolic hypertension	>140	And <90

Main complications of persistent High blood pressure



©Association of Oral and Maxillofacial Surgeons of India

Fig. 3.1 Long-term effects of hypertension

3.5.1.1 Minor Oral Surgery

A thorough history will elicit symptoms of poor blood pressure control and symptoms of end-organ damage in a known hypertensive.

Conversely, end-organ damage points to poor blood pressure control. If such symptoms exist, elective procedures are to be deferred until good control is achieved. The absolute cut off of blood pressure is supposed to be 180/110 mmHg [9]. However, it is the author's experience that this is too high a cut off in the Indian context with social and logistic challenges. This is especially true for an out-of-hospital stand-alone dental clinic where the average oral surgeon performs his outpatient procedures. This is because there is a lack of clarity on the effect of stress-induced hypertension (white

coat hypertension) and the effect it can have in an already-hypertensive patient. Hence, it is advisable to limit elective extractions to stage 2 hypertension [10] (SBP < 160 mmHg and DBP < 100 mmHg). When minor oral surgery is performed within these parameters, excessive bleeding is an unlikely complication.

3.5.1.2 Major Maxillofacial Surgery

Major surgery introduces two important variables into the mix. First is the procedure itself with surgical trauma and the attendant physiologic response (Table 3.2). The second is the requirement of a general anesthetic. While the anesthesiologist takes the final call on the safety of administering general anesthesia, the surgeon is the one who needs

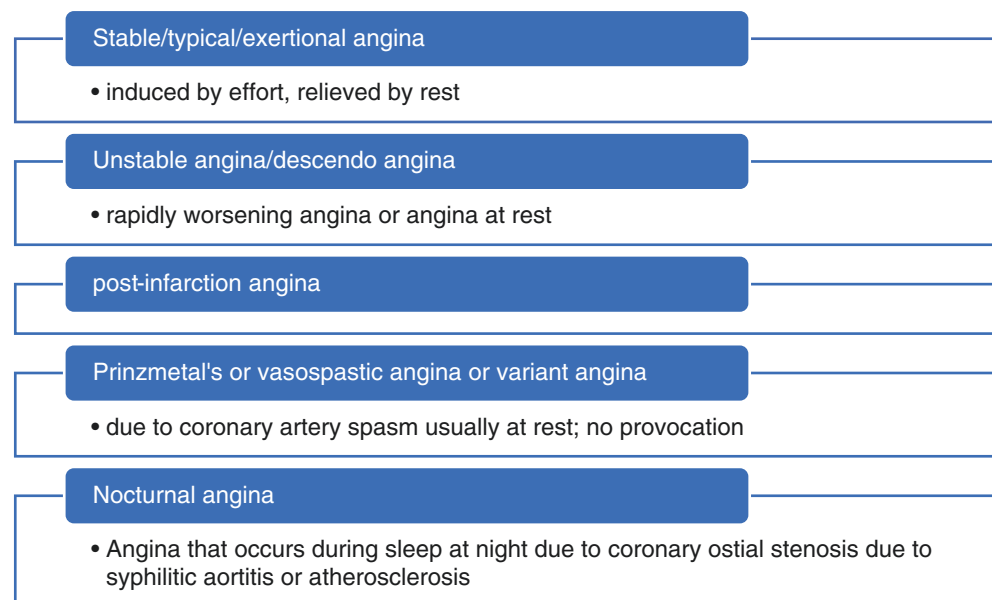
to provide the input regarding the intensity of the surgery. For example, fixing a fractured zygomatic bone can wait while operating on a patient with stridor from Ludwig's angina cannot.

Additionally, perioperative hypotension can also be of significant concern, both systemically and surgically (microvascular flaps need excellent perfusion and hypotension with peripheral vasoconstriction can lead to a flap loss). The surgeon and the anesthetist need to walk a tightrope, especially in a hypertensive patient.

Table 3.2 Causes of hemodynamic changes [7]

Hemodynamic changes	Causes
Hypotension	Systemic vasodilatation (GA)
	Sympathetic blockade (spinal/epidural anesthesia)
	Hypovolemia
	Blood loss
	Mechanical ventilation
	Drugs (angiotensin receptor blockers)
	Arrhythmias
	Acute coronary events
	Pulmonary thromboembolism (high-risk surgery for pulmonary thromboembolism and/or patient predisposing factors)
Hypertension	Laryngoscopy and intubation
	Surgical stimulus
	Inadequate plane of anesthesia/analgesia
	Hypothermia
	Hypervolemia
	Reversal and recovery
	Hypoxia (post-op)
	Inadequate analgesia (post-op)
Full bladder (post-op)	

Fig. 3.2 Types of Angina



©Association of Oral and Maxillofacial Surgeons of India

3.5.1.3 Vasoconstrictors and Hypertension

Vasoconstrictors are routinely used in conjunction with a local anesthetic to reduce bleeding, increase the duration of action, and reduce the requirement of the total volume of the anesthetic. The most commonly used vasoconstrictor is adrenaline. Felypressin (Octapressin) is also available as a vasoconstrictor with Prilocaine—but only in a cartridge. The concentration of adrenaline as a vasoconstrictor ranges from 1:80,000 to 1:200,000.

Physiologic effects of adrenaline in varying concentration [11]:

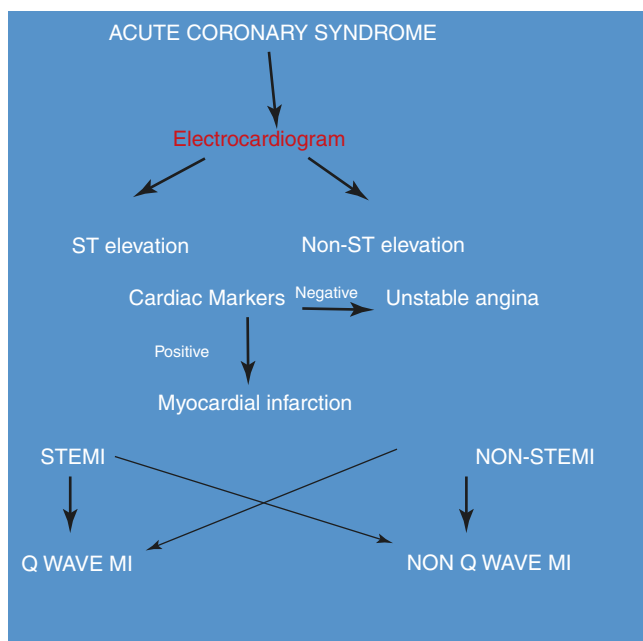
- 1:80,000 significantly increase in systolic blood pressure (SBP), diastolic blood pressure (DBP), and heart rate;
- 1:100,000 concentrations can increase SBP and heart rate; and
- 1:200,000 is limited to an increase in heart rate, but less significant

Pain itself has a significant effect on SBP, DBP on heart rate and adrenaline, even in the concentration of 1:200,000 significantly increases the duration and depth of local anesthetic. Adrenalin has a beneficial effect in this concentration without negative cardiovascular implications [11].

3.5.2 Ischemic Heart Disease (IHD)

Atherosclerosis is a progressive disease involving medium-to-large caliber arteries. It may result in ischemic lesions of the brain, heart or extremities leading to thrombosis, infarction of affected vessels, and end-organ damage.

Ischemic heart disease could present as angina or myocardial infarction (Figs. 3.2 and 3.3). Both conditions are caused



©Association of Oral and Maxillofacial Surgeons of India

Fig. 3.3 Types of Acute Coronary Syndrome

by decreased coronary blood flow, increased myocardial oxygen demand, and form two ends of a spectrum with several subclassifications.

Oral surgical procedures cause significant surgical, physiological, and psychological stress. It is imperative that the patient is assessed thoroughly prior to any intervention. Patients with IHD are susceptible for another cardiac event within 6 months [12]. With changing management strategies in cardiac patients and medicolegal aspects in mind, it is prudent to liaise with the cardiologist for all but the most straightforward of situations.

3.5.2.1 Minor Oral Surgery

Previous myocardial infarction or unstable angina does not form a contraindication for dental extractions. However, timing and planning are of paramount importance. In the quoted study, about 10% of patients have reported postoperative chest pain [12]. While the sample size of the quoted article is small, it underscores the importance of risk-benefit analysis before undertaking these procedures. The treatment planning may need further input from a cardiologist.

If such patients are on antiplatelet medication, it is of extreme importance to note that single antiplatelet agents do not constitute a contraindication for most minor oral surgery [13]. Refer to the section on antiplatelet and anticoagulant drugs and surgery.

3.5.2.2 Major Surgery

Since most surgery considered in this context is emergent or urgent in nature (trauma, oncosurgery, space infec-

tions), the benefit of the life-saving procedure by far outweighs the risk of a further cardiac episode. Such procedures are ideally done in a center equipped to deal with any adverse cardiac event. In a country like India, the onus of keeping the appropriate specialty apprised of the situation before starting the procedure is on the operating surgeon.

3.5.3 Postintervention Cardiac Patients

3.5.3.1 Percutaneous Coronary Angioplasty (PTCA) and Coronary Artery Bypass Graft (CABG) and Valve Replacement Procedures

With access to healthcare improving, it is becoming more common for the surgeon to encounter patients with IHD who have had interventions. These range from conventional CABG to Percutaneous angioplasties with stents in place and minimal access CABGs. In our context, the clinician needs to know what these are not only to analyze the impact these procedures have on the maxillofacial procedure but also to tease the information out of the reluctant historian.

PTCA/PCA

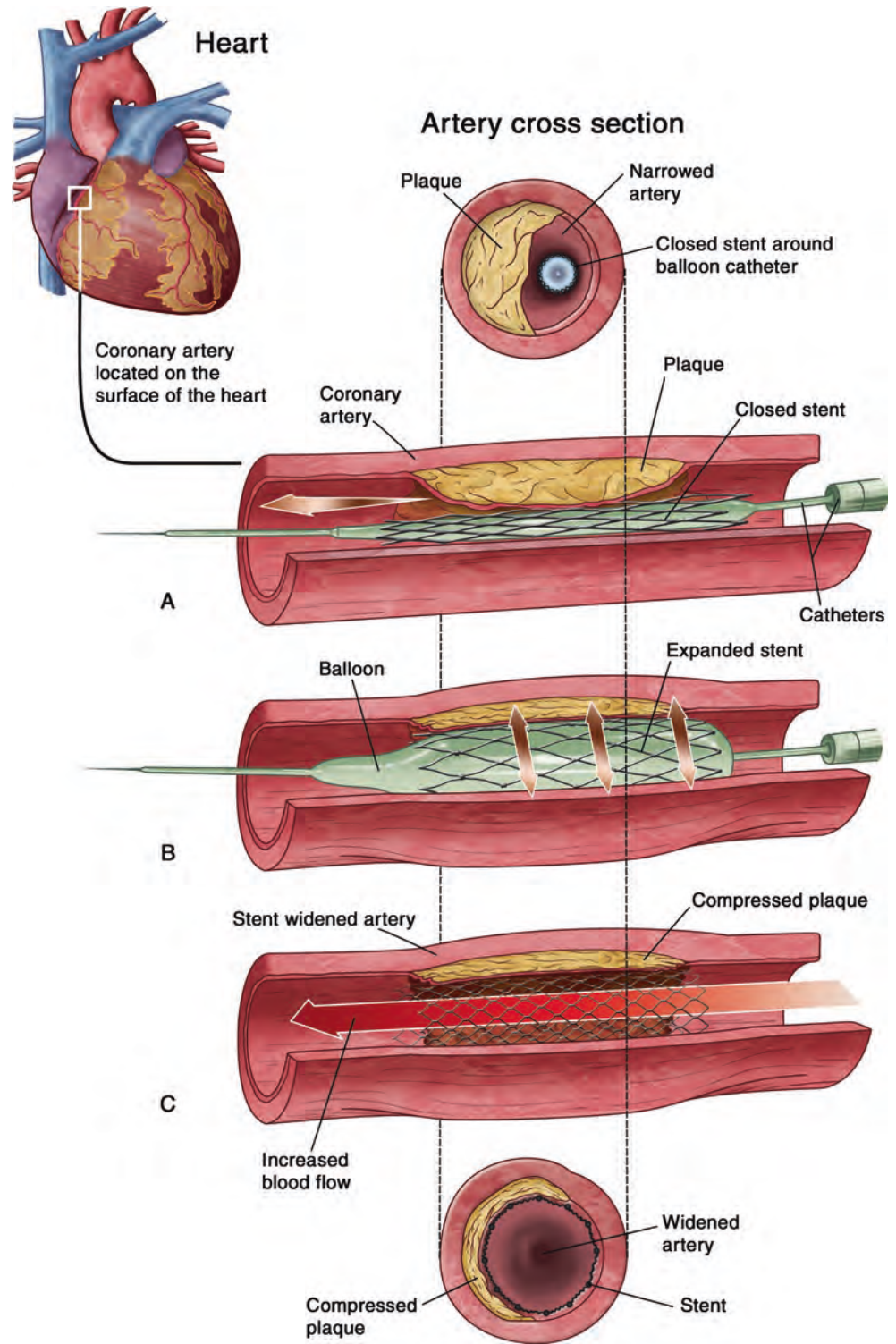
Percutaneous transluminal coronary angioplasty has become the intervention of choice for coronary artery disease. This procedure involves the insertion of a stent in the narrowed portion of the artery (Fig. 3.4). This stent intimately hugs the endothelium of the vessel and is reliably and completely endothelialized in 6 months to a year. The patient is susceptible to stent thrombosis in this period and hence the antiplatelets. There are many varieties of stents and the design and features are always in a state of flux. Therefore, any changes to antiplatelet therapy are to be made in consultation with the treating cardiologist [14].

Types of coronary stents:

- Bare metal stents
- Drug-eluting stents
- Bioresorbable scaffold system
- Drug-eluting balloons

Following successful revascularization procedures, the patient is expected to be in a far better hemodynamic state than before. If the patient remains symptomatic, then he/she requires to be seen by the cardiothoracic surgery team. The only challenge in these patients is the antiplatelet/anticoagulant medication. In the case of patients with prosthetic cardiac valves, it is vital to provide endocarditis prophylaxis (read following content).

Fig. 3.4 Mechanism of PTCA



3.5.4 Conventional Antiplatelets, Anticoagulants, and Novel Oral Anticoagulants (NOAC)

3.5.4.1 Minor Dentoalveolar Surgery: Antiplatelets

There are several concerns regarding the risk of excessive bleeding following minor oral surgery in anticoagulated patients and those on antiplatelet medication. Most of these are unfounded for dentoalveolar procedures. In most dentoalveolar procedures, we have the advantage of a bony cavity where physical pressure can be effectively applied to obtain hemostasis. This can be further augmented with other local hemostatic measures (sutures, surgical R, AbgelR, etc.). This

obviates the need to stop antiplatelet drugs (read following content). However, in patients on dual antiplatelet therapy, the authors suggest caution when operating in critical areas like the floor of the mouth as hematomas can cause airway embarrassment.

Conventional antiplatelets bind irreversibly to platelets and the normal clotting process is restored only with the production of new, unaffected platelets (Fig. 3.5, Table 3.3). It takes 5–10 days for platelets to be produced in the quantity required to produce a clinically normal platelet action. In the interim, if a procedure causes excessive bleeding, the only reliable way to ensure hemostasis is platelet transfusion. However, the newer ones are reversible and can be stopped for 24 h prior to the procedure as a “switch on-switch off”

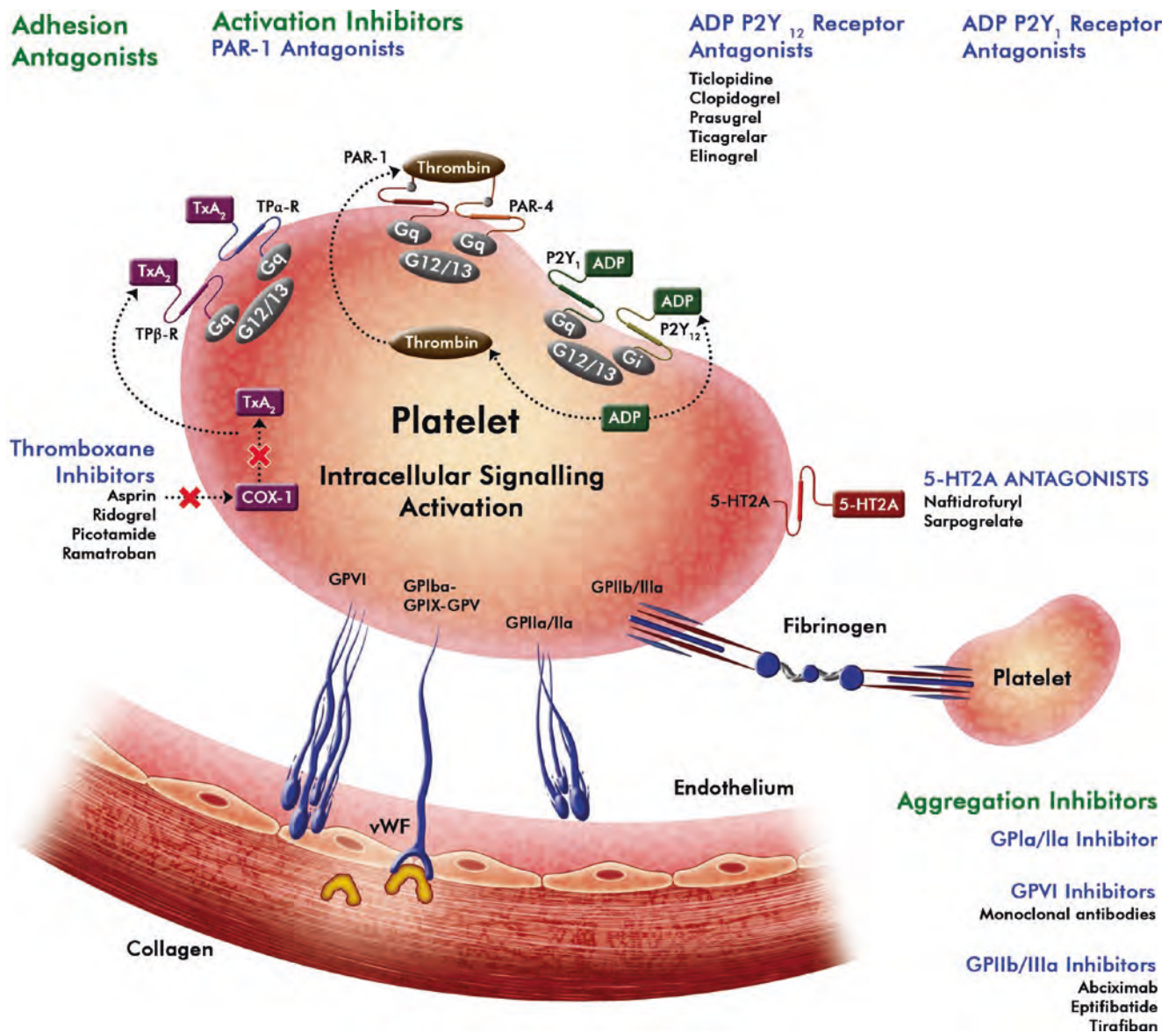


Fig. 3.5 Mechanism of action of commonly used antiplatelet drugs

Table 3.3 Commonly used antiplatelet agents and their characteristics [15]

Drug	Mechanism of action	Loading dose	Maintenance dose	Half-life	Time to recover platelet function after drug withdrawal	Platelet inhibition	Administration route
Aspirin	COX-1 inhibition	325 mg	75–325 mg daily	15–20 min	30% at 48 h	Irreversible inhibition	Oral
Clopidogrel	P2Y12 receptor inhibition	30–600 mg	75 mg daily	7–9 h	40% at 3 days	Irreversible inhibition	Oral
Prasugrel	P2Y12 receptor inhibition	60 mg	10 mg daily	7 h	2–3 days	Irreversible inhibition	Oral
Ticagrelor	P2Y12 and Partly P2Y1 receptor inhibition	180 mg	90 mg twice a day	7–9 h	57% at 24 h	Reversible inhibition	Oral
Cangrelor	Adenosine triphosphate analogue with a high affinity for the P2Y12 receptor	30 µg/kg	2–4 µg/kg/min	3–6 min	Rapid (mins–hours)	Reversible inhibition	i.v
Abciximab	Glycoprotein IIb/IIIa receptor inhibitor	0.25 µg/kg	0.125 µg/kg/min	10–15 min	12 h	Reversible inhibition	i.v
Eptifibatide	Glycoprotein IIb/IIIa receptor inhibitor	180 µg/kg	2 µg/kg/min	2.5 h	2–4 h	Reversible inhibition	i.v
Tirofiban	Glycoprotein IIb/IIIa receptor inhibitor	0.4 µg/kg	0.1 µg/kg/min	2 h	2–4 h	Reversible inhibition	i.v

drug. But these are very expensive and most of the below-poverty-line patients are likely to be on older antiplatelets for some time to come.

3.5.4.2 Maxillofacial Surgery

Patients who need procedures with low risk of bleeding (e.g., fixation of fracture of the parasympysis) may continue oral antiplatelet/anticoagulation therapy. This applies especially to high-risk patients (e.g., mechanical heart valves). However, when the risk of bleeding is obvious, it outweighs the benefit of continuing antiplatelet/anticoagulant therapy. In such cases, heparin is used as bridge therapy.

3.5.4.3 Bridging with Heparin

In cases where the patient is at high risk for a thromboembolic episode, a “bridge”—a balance between surgical bleed and risk of thrombosis may be achieved either with intravenous unfractionated heparin or with subcutaneous low-molecular-weight heparin [16].

3.5.4.4 Anticoagulants and Oral/Maxillofacial Surgery

While several indications exist for the use of anticoagulants, the authors have noted that there is significant resistance in the medical community to prescribe anticoagulants in these cases and they are often replaced by antiplatelets in India. This is especially true for the rural patient who may not have regular access to monitor his anticoagulation status. However, in urban centers, NOAC are in regular use.

Common indications for anticoagulation—prevention of thrombotic events in:

Mechanical Heart Valves.
Atrial Fibrillation.

Deep Vein Thrombosis and Pulmonary Embolism.
Myocardial infarction.
Acute Ischemic Stroke

The target International Normalized Ratio (INR) range for most conditions is between 2.5 and 3.5.

3.5.4.5 Minor Oral Surgery

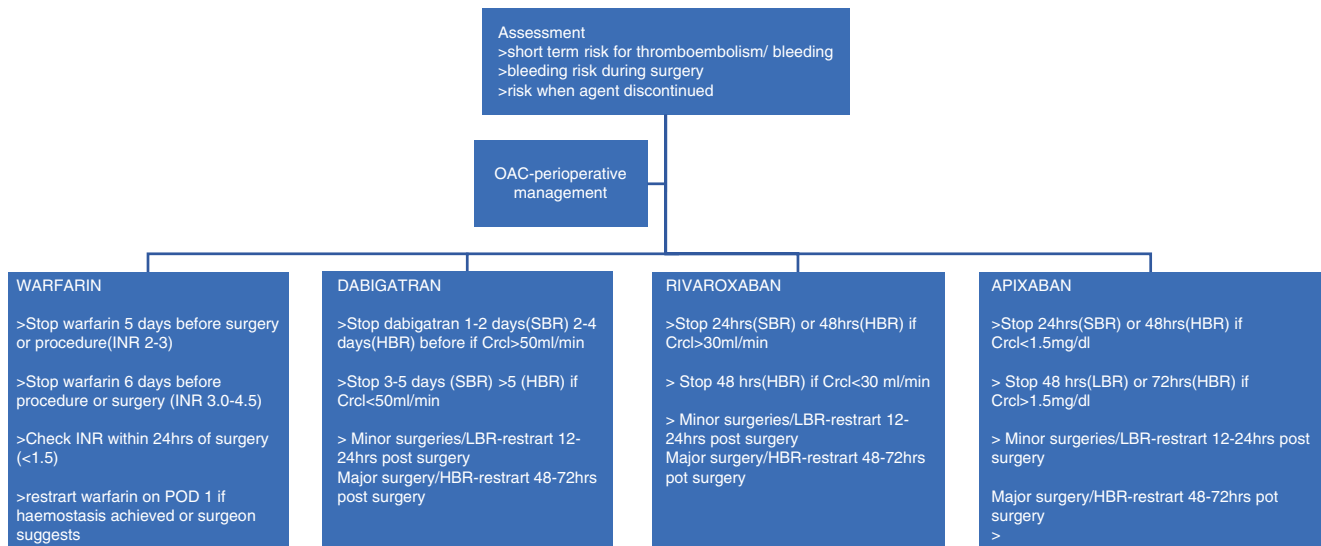
It is beyond doubt that warfarin/acetrom therapy need not be discontinued and INR need not be normalized prior to dento-alveolar surgery. The risk of a thrombotic episode does not justify the risk of a minor bleed that can be controlled by local measures [17]. Simple dentoalveolar surgery (e.g., three simple extractions) can be safely performed with an INR of 3.5 or less with appropriate local hemostatic measures [18]. However, it is imperative that the patient is closely followed. It is sensible to schedule these procedures in the morning.

3.5.4.6 Major Maxillofacial Surgery

Depending on the indication for anticoagulant therapy and the drug used, the decision regarding the control of anticoagulation is made. Ideally the prescribing physician is involved in decision making (Fig. 3.6) (read following content).

3.5.5 Infective Endocarditis Prophylaxis

Much has changed over the years with regard to infective endocarditis (IE) and antibiotic prophylaxis. Since the guidelines change by the year, the authors strongly recommend that the surgeon takes recourse to his smartphone to keep abreast of the changing scenery (Tables 3.4 and 3.5).



*OAC; Oral anticoagulant,POD; Post-operative day, INR; International normalized ratio, LBR; Low bleeding risk, SBR; Standard bleeding risk, HBR; High bleeding risk, CrCl; Creatinine clearance
©Association of Oral and Maxillofacial Surgeons of India

Fig. 3.6 Perioperative management of oral anticoagulants [19]

3.5.6 Implantable Cardioverter Defibrillators (ICD)

An ICD is a battery-powered device implanted in a patient that generates a small electrical impulse. Indications are patients at risk of sudden cardiac death—ventricular fibrillation/ventricular tachycardia, malignant ventricular tachyarrhythmias. ICDs are also used to treat Brugada syndrome [21].

3.5.6.1 Implications

Bleeding: patients may either be on antiplatelets or anticoagulated. (read earlier content).

Devices: Electrocautery, especially monopolar diathermy, may interfere with the device and this may have to be turned to a “safe mode” by the electrophysiology technician. The concerned cardiologist should be able to assist with the technical details.

Infective endocarditis prophylaxis: Risk being low, current guidelines DO NOT recommend prophylaxis for these patients.

3.6 Impact of Central Nervous System Disorders in Maxillofacial Surgery

Of the many conditions which affect this system, the effects of epilepsy and stroke are most commonly encountered in maxillofacial surgical practice.

Table 3.4 AHA, ESC, and NICE guidelines for infective endocarditis prophylaxis

2007 AHA guidelines	2015 ESC guidelines	2016 NICE guidelines
<p>Highest risk of adverse outcomes:</p> <ul style="list-style-type: none"> • Previous IE • Prosthetic valve • Unrepaired cyanotic congenital heart disease (CHD) • 6-month period postprosthetic repair of CHD • Repaired CHD with residual defects • Cardiac transplant with valvulopathy 	<p>Highest risk of IE:</p> <ul style="list-style-type: none"> • Previous IE • Prosthetic valve/ Prosthetic material for valve repair • Any cyanotic CHD • 6-month period postprosthetic repair of CHD <p>Intermediate risk of IE:</p> <ul style="list-style-type: none"> • History of rheumatic fever • Any form of native valve disease • Unrepaired noncyanotic CHD 	<p>Risk of developing IE:</p> <ul style="list-style-type: none"> • Previous IE • Valve replacement • Acquired valvular heart disease • Structural Congenital heart disease • Hypertrophic cardiomyopathy
<p>Antibiotic prophylaxis:</p> <ul style="list-style-type: none"> • All dental procedures involving gingival tissue manipulation or periapical region of teeth or oral mucosa perforation • Procedures on respiratory tract or infected skin/ musculoskeletal tissue. 	<p>Antibiotic prophylaxis: Considered for dental procedures involving gingival tissue manipulation or periapical region of teeth or oral mucosa perforation</p>	<p>Antibiotic prophylaxis: Not routinely recommended</p>

Table 3.5 Revised AHA guidelines for infective endocarditis prophylaxis [20]

Patient group	Antibiotic	Dose (30–60 min before procedure)	
		Adults	Children
Able to take oral medicine	Amoxicillin	2 g	50 mg/kg
Unable to take oral medication	Ampicillin	2 g i.m/i.v	50 mg/kg i.m/i.v
	or Cefazolin/ ceftriaxone	1 g i.m/i.v	50 mg/kg i.m/i.v
Allergic to penicillin or ampicillin and able to take oral medication	Cephalexin ^{a,b}	2 g	50 mg/kg
	or Clindamycin	600 mg	20 mg/kg
	or Azithromycin/ clarithromycin	500 mg	15 mg/kg
Allergic to penicillins or ampicillin and unable to take oral medication	Cefazolin/ ceftriaxone ^b	1 g i.m/i.v	50 mg/kg i.m/i.v
	or Clindamycin	600 mg	20 mg/kg

Note: *i.m* intramuscular; *i.v* intravenous

^aOr other first- or second-generation cephalosporins at equivalent adult and pediatric dose

^bCephalosporins should not be given to a patient with a history of anaphylaxis, angioedema, or urticaria with penicillin or ampicillin

3.6.1 Epilepsy

A seizure is a result of excessive electrical discharges in a group of brain cells, whereas epilepsy is described as a disease characterized by recurrent seizures. A single seizure does not constitute epilepsy, which is defined as having at least two or more unprovoked seizures. The incidence worldwide is approximately 0.5–0.9%, affecting over 50 million individuals [22].

Etiology of epilepsy can be divided as primary or idiopathic, where the cause is unknown and this constitutes the vast majority of cases. In secondary or acquired epilepsy, the cause can be determined and these include metabolic, genetic, structural, and functional abnormalities.

An increase in the incidence in the elderly can be attributed to conditions such as stroke, tumors, trauma, and Alzheimer's disease. Systemic conditions include diabetes, hypertension, infections, electrolyte imbalances and dehydration, or lack of oxygen. Withdrawal from high-dose, long-term use of drugs such as cocaine, heroin, barbiturates, amphetamines, and alcohol can also precipitate seizures [23]. Seizures generally last for a few seconds to minutes. Although many types exist, they are broadly divided into two groups (Fig. 3.7).

Primary generalized seizures—which begin with involvement both sides of the cerebral hemispheres.

Partial seizures—start in a localized area [25].

3.6.1.1 Basic considerations

While recording history, the duration, type, frequency of the seizure as well as the most recent episode must be recorded as well as the type of medication taken, if any. If the patient

is aware of how the seizure starts, if there is any warning or “aura,” this too must be noted [23].

Several factors are capable of provoking seizures. These include improper use of medication, lack of sleep, drug abuse, drug interactions, hypoglycemia, electrolyte imbalance among others. Antiepileptic drugs should generally be continued without alteration.

3.6.1.2 Outpatient maxillofacial considerations

If seizures are predictable, then appointments should be scheduled accordingly. Frequency of seizures determines the urgency of treatment. Procedures, unless emergent, should be postponed if frequency of seizures is high. The clinician must reduce anxiety to the patient. Short morning appointments are ideal. Sudden bright lights, noise, or movements must be avoided as these may trigger a seizure [23].

3.6.1.3 Major Surgical Considerations

Trauma is a common consequence of seizures and may result in lacerations of the face or oral cavity and fractures of the maxillofacial skeleton. Other injuries include hematomas, dislocation of temporomandibular joint (TMJ) fracture/loss of teeth. An electroencephalogram (EEG) along with imaging such as CT/MRI is recommended if there is no previous seizure history. Open reduction should be preferred over closed for treatment of facial fractures, as further episodes of seizures might lead to aspiration if intermaxillary fixation (IMF) is attempted [25].

Local anesthetic is considered safe in well-controlled epileptics, as is sedation. General anesthesia is preferred in uncontrolled epileptics, especially if coupled with a mental deficit, as a seizure might be triggered due to stress from difficulties in communication. One drawback of general anesthetic is temporary anoxia to the brain, which itself might trigger a seizure [26].

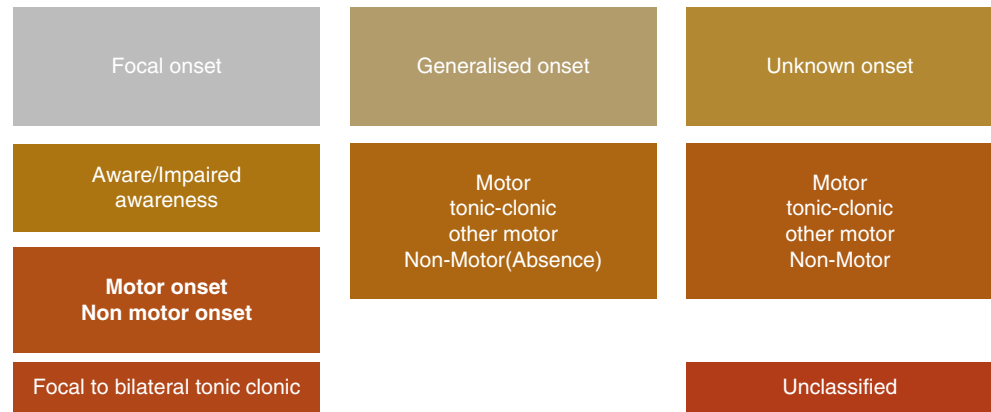
3.6.1.4 Precautions, complications, & management

As mentioned earlier, appropriate recording of history gives an insight into planning the procedure, particularly for elective surgeries. Objects with the potential to cause harm must be kept away from the vicinity of the patient. Antiepileptics such as phenytoin have been known to cause gingival enlargement, which can be managed either by surgery or by a change in medication. Aspirin, antifungal azoles, metronidazole can interfere with phenytoin. Propoxyphene and erythromycin can interfere with carbamezepine. Contraindicated drugs are chlorpromazine, flumazenil, ketamine, lignocaine in large doses and quinolones, tramadol, and tricyclic antidepressants [25].

3.6.1.5 Management of an acute episode on the dental chair

If possible, all foreign body/material should be removed from the oral cavity. The chair should be reclined to a supine position with the patient turned onto their side to minimize the

Fig. 3.7 ILAE 2017 classifications of seizure types basic version [24]



©Association of Oral and Maxillofacial Surgeons of India

risk of aspiration. Passive restraint is used only to prevent them from falling out of the chair. A recurrent seizure or a seizure of more than 3 min requires drug administration. The patient should be monitored to prevent airway obstruction. After the patient recovers, appropriate medical consults should be arranged. Elective treatment should be postponed [23]. However, prolonged seizures, which continue in spite of medication, may lead to status epilepticus, which may be fatal if untreated. Airway patency and peripheral venous access are first line of management. If seizures persist even after administration of drugs such as lorazepam or diazepam, the patient must be shifted to the hospital for further management.

3.6.2 Stroke

Stroke (cerebrovascular accident) is a serious, occasionally fatal neurologic event characterized by the rapid appearance of a focal deficit of brain function. It is estimated that 85% of patients presenting with stroke would have sustained a cerebral infarction because of inadequate blood flow to a part of the brain, with the remainder suffering from an intracerebral hemorrhage. Often, survivors of cerebrovascular accidents are left debilitated in motor function and/or speech [27].

A stroke may be a result of hemorrhage or ischemia as given later (Fig. 3.8).

The initial presentation of stroke includes loss of combination of sensory and motor functions with occasional loss of consciousness. The presenting features include hemiparesis or paraparesis, dysphagia, ataxia, aphasia, dysarthria, loss of vision. Early detection is by assessing facial and arm weakness and any slurring of speech. Mechanism of stroke may be ischemic, primary intracerebral hemorrhage, and subarachnoid hemorrhage. The oral impact of stroke includes facial weakness, dysphagia, and speech impairment [29].

3.6.2.1 Basic Considerations

At the outset, it is paramount to assess the extent of disability of the patient—both physical and mental, as this is vital in determining whether performing the procedure is safe in the

outpatient setting. There may be a dependence on others for basic needs. History of past strokes needs to be elicited: including dates, severity and current neurological deficit. Treatment is performed in consultation with the neurologist and precautions according to the specific characteristics of the stroke.

3.6.2.2 Maxillofacial considerations

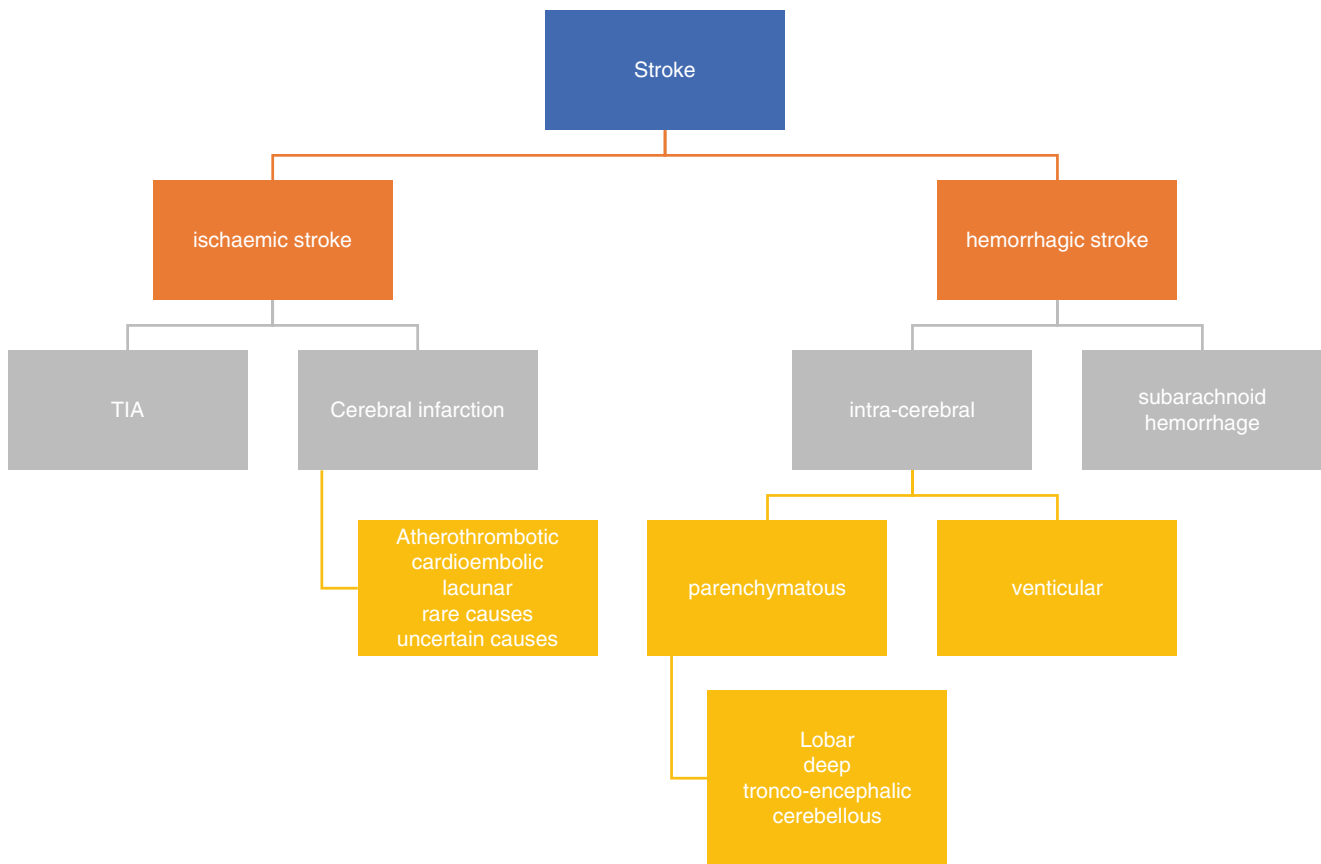
Outpatient appointments must be ideally scheduled in the morning and must be of short duration. Patients must be treated in an upright position as much as possible, as they are more prone to aspiration due to impaired protective reflexes. Another important consideration is difficulty in oral hygiene maintenance due to facial weakness and xerostomia, which may be observed as a side effect of medications prescribed [24]. Although procedures must be deferred for as long as possible, in unavoidable circumstances such as trauma or progressing head and neck cancers, general anesthesia is reasonably safe. Shorter duration surgery, intraoperative monitoring and maintaining cerebral perfusion, anticoagulation status, and precaution all aid in reducing the incidence of a further episode.

Antiplatelets and anticoagulation: Ref previous section.

3.6.2.3 Precautions

Monitoring of Blood pressure pre- and postprocedure is vital, procedures should be deferred if systolic is >180 mmHg or diastolic is >110 mmHg. Poststroke patients are usually on antiplatelet or anticoagulant medications; hence, coagulation status must be ascertained prior to any procedure. Vasoconstrictors are to be used cautiously as they can increase the risk of adverse outcomes like cerebral hemorrhage due to acute hypertension [29].

Opioids are best avoided as they may result in severe hypotension and benzodiazepines may cause respiratory depression. The practitioner must be mindful that sudden loss of consciousness could result from stroke, and emergency management is the protection of airway and shift to hospital [24].



©Association of Oral and Maxillofacial Surgeons of India

Fig. 3.8 Common causes of stroke [28]

3.7 Impact of Psychiatric Disorders in Maxillofacial Surgery

Psychiatric and psychological disorders are of rising concern in modern society, affecting all aspects of a patient's life, including oral health. Poor oral hygiene is usually due to a combination of lethargy, side effect of medications, and possibly fear of treatment [30]. Common disorders encountered in practice are related to mood, anxiety, substance dependence, eating, or somatoform in nature [31].

Occasionally, oral symptoms may be the initial or single manifestations of the underlying issue. Patients who present with atypical facial pain with vague symptoms, oral dysesthesia, abnormal sensation or movement, salivation often with no identifiable physical cause could be suffering from undiagnosed underlying emotional disturbances. Early detection in such cases benefits both the patient and the practitioner [32, 33].

3.7.1 Maxillofacial Considerations

Pain related to the TMJ and associated structures seems to be another condition, which fits into the previous category,

commonly seen and treated by the maxillofacial surgeon. In the absence of an identifiable organic cause, there must be a low threshold for considering an underlying emotional disturbance.

Patients with diagnosed psychiatric conditions and on medication present with obvious oral symptoms. Most common among these are dental caries and periodontal disease. The primary cause of these is due to decreased salivary flow or xerostomia, which is a side effect of medications, including tricyclic antidepressants, lithium carbonate, phenothiazines, and benzodiazepines. Sialorrhea or excessive salivation is a well-known side effect of clozapine and reduction in dose may be of use [32]. Candidiasis is another condition, which may manifest due to xerostomia, especially in denture wearers. Fear of dental treatment is well known. However, recognition of the nature and extent of this fear is important to prevent noncompliance. Anxiety disorders and phobia often stem from two types of experiences, a painful or traumatic procedure, usually at a young age, or a negative interaction with healthcare professional [32]. A specific maxillofacial consideration in this respect is suturing of facial wounds under local anesthetic, in young children. The authors recommend sedation if not a general anesthetic, par-

ticularly in extremely young children, where such procedures are required.

Alcohol, tobacco, and drug abusers are particularly tricky to treat, be it minor or major maxillofacial surgery. The amount of local anesthetic required to produce adequate analgesia tends to be higher in such patients. These groups of patients are at a higher risk of developing oral cancer. Effects of withdrawal can be significant and this must be kept in mind preoperatively, intraoperatively, and postoperatively—especially where procedures of long duration and extended stay are planned. Use of drugs like chlordiazepoxide might be required to offset delirium tremens, particularly in the postoperative period. Head and neck cancer particularly affects the psyche, making a psychologist a very important member of the multidisciplinary team.

Patients suffering from clefts of the orofacial region require multiple surgeries at various stages of their life and the effects of surgery and rehabilitation can be debilitating on both the child and the parents. Timing of surgeries is vital as they disrupt the life of the entire family of the child and for this parental counselling is extremely important [33].

While management of trauma might be comparatively straightforward, one must not underestimate the effect on the psyche in the recovery phase, especially if this is coupled with post-traumatic stress disorder (PTSD). Although these injuries are among the most common treated, these can lead to depression, drug abuse, antisocial behavior, especially in those with a post-traumatic residual defect [34].

Orthognathic surgery, while primarily carried out for cosmetic reasons, occasionally may be performed for functional reasons, as in obstructive sleep apnea. Counselling prior to surgery is useful and the entire process can take up to 3 years. Serious psychological and psychosocial problems have been reported [33].

While awareness of maxillofacial surgery and its benefits is gradually growing in our country, with most centers providing information about technical aspects of surgery, the psychological aspect is often ignored. Communication needs to improve and an assessment of patients' emotional state before and after surgery could help in improving patient satisfaction [33].

3.8 Dental and Maxillofacial Implications in Liver Disease

3.8.1 Introduction

At approximate of 1.4 kg, this reddish, rubbery structure forms an important organ system. Along with the Gall Bladder and Pancreas, the liver works to digest, process, and absorb food. Liver aids in detoxification in the body and is the primary organ of drug metabolism. It also helps in the production and transport of bile [35].

3.8.1.1 The Function of the Liver [36]

Detoxification—Removal of ammonia, exogenous hormones

- (a) Alcohol metabolism
- (b) Synthesis of essential Serum Proteins (Albumin)
- (c) Synthesis—coagulation Factors (V, VII, IX, X), prothrombin, fibrinogen.
- (d) Production of Bile and its transporters
- (e) Regulation of nutrients
- (f) Conjugation of lipophilic compounds

Liver dysfunction hence alters all of these functions, thereby disrupting the homeostasis in the body, which has to be taken into consideration when providing dental and maxillofacial therapy.

Vitamin K levels are significantly lowered in advanced liver disease hampering the production of coagulation factors. This, along with portal hypertension, results in thrombocytopenia, thus resulting in excessive bleeding, which is of consideration during dental and maxillofacial management [37].

3.8.2 Classification of Liver Dysfunctions [35]

Acute or Chronic

- (a) Infective (Hepatitis) & Noninfective (Substance abuse)
- (b) Extent of damage—steatosis (fatty liver), fibrosis, cirrhosis, hepatocellular carcinoma

3.8.2.1 Viral Hepatitis

Hepatitis A—caused due to Hepatitis A virus, spreads via the orofecal route. It is endemic in nature and is self-limiting.

Hepatitis B—caused by (HBV) that replicates within the hepatocyte; it is a dangerous form of viral disease with high risk to healthcare workers. The surface antigen is routinely detected in the saliva of infected individuals, and hence transmission through the saliva is of concern to the Oral Surgeon [38]. Prevalence of HBV infection is three to five times more in dentists than the general population. Younger individuals with chronic HBV infections have a greater prevalence of developing hepatocellular carcinoma.

Hepatitis C—Caused by a bloodborne virus, it is the most common cause for chronic hepatitis, which over long term could lead to cirrhosis or hepatocellular carcinoma.

3.8.2.2 Autoimmune Hepatitis

It is a chronic liver inflammatory disease as a result of IgG Hypergammaglobinemia as a result of environmental or viral factors inciting an autoimmune response leading to cirrhosis [39].

3.8.2.3 Fulminant Hepatitis

A sudden acute and severe dysfunction of the liver with resulting hepatocellular necrosis and encephalopathy with a very poor prognosis. These patients require liver transplant.

3.8.2.4 Cirrhosis

It is the irreversible damage to the hepatic architecture due to long-term fibrous scarring. A rise in the production of total liver collagen and matrix protein that is troublesome to the function and form of the liver [40].

3.8.2.5 Hepatocellular Carcinoma

It is the fifth most common cancer and a life-threatening malignancy with poor survival rates. HBV and HCV are the most common causes of it.

3.8.2.6 Alcoholic Liver Disease

It is the 10th most common cause of death with 3% of fatalities in the industrialized world [35]. Alcoholism results in varied disruption of the hepatic system ranging from simple fatty liver to complicated life-threatening cirrhosis.

3.8.3 Oral Manifestations of Liver Disease

Foetor hepaticus (Breath of the dead odor of rotten eggs with garlic) is a characteristic late feature of liver dysfunction [36]. Evidence of liver diseases has been noted in the oral cavity as icteric mucosal alteration with gingival bleeding and also associated hemorrhagic changes like hematoma, petechiae [37]. HCV-associated hepatitis is noted as a common cause for Sjogren's syndrome and lichen planus in the oral cavity [41]. Alcoholic hepatitis in association with nutritional deficiencies could cause glossitis along with delayed healing post surgery [37]. Occasionally, parotid enlargement is also noted. These oral manifestations are associated with concomitant general symptoms of liver disease such as hepatomegaly, malaise, confusion, fatigue, weight loss, nausea, and altering the well being of the person [37].

3.8.4 Implications of Liver Disease

1. Hepatic metabolism of drugs is Unpredictable
2. Defective hemostatic cascade and poor coagulation
3. Increased risk of infection

3.8.4.1 Liver Disease and Maxillofacial Surgery

Risk of viral contagion and crossinfection is one of the implications of viral hepatic disease. Hep C viruses are found to be stable at room temperatures for approximately 5 days. The virus is also detected at different surfaces in the clinic

after the patient is treated. It is vital to maintain adequate sterilization and observe strict universal protection when treating such patients. Needlestick injury precautions must be adhered to.

Detailed history taking is important to identify any indications of liver disease, including that of hepatitis, jaundice, alcohol intake, recreational drugs, or rank abuse. Abnormal bleeding patterns are elicited in history [42]. Past surgical history provides a valuable indicator for any doubts regarding the adequate functioning of the liver system. Additional information of identifying the etiology for cirrhosis and any continued risk factors like alcohol consumption should be noted [35]. Review of blood investigations such as serum bilirubin, albumin, alanine aminotransferase (ALT), Aspartate aminotransferase (AST), complete blood counts, and coagulation profile must be performed prior to any surgical planning [43].

Elective surgery is contraindicated in acute phases of viral hepatitis and acute liver failure. Patients who present with hepatitis due to alcohol/drug abuse are poor candidates for elective surgery due to liver dysfunction and psychological impact of withdrawal during their hospital stay.

Plasma level of coagulation factors is depressed in liver disease and can potentially alter the hemostasis. Complete blood counts, PT, PTT, INR, and liver functions tests are mandatory in all patients with any signs/symptoms of liver dysfunctions. The goal of surgical therapy is to minimize trauma to the tissues. It is also advisable to involve the hematologist if required. Any dental or minor oral surgical procedure must terminate with the use of local hemostatic agents or antifibrinolytic agents to aid in hemostasis. Maxillofacial surgical work and major invasive oral surgery are ideally performed in the hospital. Fresh Frozen Plasma and Vitamin K infusions to optimize the coagulating process might be required to offset intraoperative bleeding.

Patients with liver disease are more susceptible to infection with a greater risk post invasive dental or maxillofacial procedure. Antibiotic prophylaxis is recommended.

Drug metabolism is altered in these patients (Table 3.6). Unlike serum creatinine, which is an indicator of renal function, the liver function test is more of an indicator for liver damage. Hence, it is difficult to obtain exact dose modification formulae when medicating patients with liver disease. Drug usage, dosage, and interactions must be consulted with the specialist prior to their usage.

The metabolism of these drugs is well tolerated in mild liver dysfunctions but is impaired in severe dysfunction and hence requires modifications and contraindications. The beta lactams mainly utilized in maxillofacial surgery are quite safe. NSAIDS are to be used with caution to avoid gastric bleedings [35]. Hepatotoxic drugs should be avoided eg. erythromycin, ketoconazole, halothane, phenytoin etc. Prilocaine or articaine is preferred over lidocaine. Sedatives,

Table 3.6 Drugs metabolized in the liver [37]

Local anesthetics	Lidocaine, Bupivacaine, Prilocaine,
Sedatives	Barbiturates, Diazepam
Analgesics	Paracetamol, Aspirin, Ibuprofen, Codeine
Antibiotics	Erythromycin, Clindamycin, Tetracycline
Antifungal	Ketoconazole, Fluconazole

hypnotics or opioids should be used with caution. A balance has to be struck constantly to maintain the anesthesia and concern is of the depressive action of alcohol and central nervous system depressors. Postoperative care in view of alcohol withdrawal must be noted. Ensure alcohol-based mouth rinses are avoided.

3.9 Maxillofacial Implications in GI Disorders

3.9.1 Perioperative Maxillofacial Implications

3.9.1.1 GERD

Extraesophageal symptoms of GERD must be identified to prevent any airway issues primarily. Due to delayed gastric emptying, preoperative fasting hours must be prolonged. In high-risk patients, Proton pump inhibitors and H₂ receptor antagonists are potent drugs to increase gastric pH and reduce secretions. Nasogastric suctioning through nasogastric tube aids in protecting the airway from gastric secretions during surgery. It is important to manage nausea and vomiting postoperatively effectively.

3.9.1.2 Peptic Ulcers

Stress reduction protocol is vital. GI symptoms from NSAIDs are delayed and identified when the ulcers are in an advanced stage with a greater risk of bleeding. Corticosteroids must be avoided in these patients along with NSAIDs. GI bleeding due to ulceration could cause anemia and has to be managed prior to any surgery. Surgery is contraindicated in active peptic ulcers. Ranitidine, when used over a long phase for management, could cause thrombocytopenia [44].

3.9.1.3 Ulcerative Colitis

One must rule out anemia in these patients and assess the effect of long-term steroid therapy. Antibiotics such as clindamycin, ampicillin, and cephalosporins are implicated in aggravation of colitis and are hence avoided. If the patient has undergone Vitamin K malabsorption, its effects are considered.

Postoperative nausea and vomiting, though not a complication, is still detrimental in patient management perioperatively. Volatile inhalation anesthetic agents and opioid analgesics are emetogenic and need to be used with caution. Postoperative anxiety, dehydration, and pain could result in nausea and vomiting. Scarred ulcers in the

duodenum delay gastric emptying resulting in vomiting. Antiemetics in these patients must be prescribed at the end of the surgery and dexamethasone 1 h prior to the surgery is helpful if not contraindicated. In high-risk patients, antiemetics must be administered prior to anesthesia itself [45]. Postoperative ileus could occur due to prolonged opiate use during anesthesia, decreased potassium levels, trauma or due to iliac bone harvesting as a complication or resultant severe pain.

3.10 Pregnancy

Pregnancy is often associated with changes in cardiovascular, endocrine, hematological, respiratory, gastrointestinal, and genitourinary system. These alterations may occasionally be subtle and can lead to disastrous complications if not identified [46].

3.10.1 Physiologic Changes

There will be increase in the heart rate leading to an increase in cardiac output. Cardiac output increases mostly in the first trimester and remains fairly unchanged with minimal increase in the final trimester.

During the second and final trimesters, a decrease in blood pressure and cardiac output may occur while the patient is in a supine position. This is caused by the gravid uterus compressing the inferior vena cava leading to a decreased venous return to the heart leading to hypotension, bradycardia, and syncope. This phenomenon is called *supine hypotension syndrome* [47].

The concentration of all coagulation factors, other than factors XI and XIII, is increased. As Thrombin-mediated fibrin generation increases during pregnancy, this combines with an increase in the aforementioned clotting factors and hematocrit, leading to the hypercoagulable state of pregnancy. This leads to a higher risk of deep vein thrombosis (DVT) and pulmonary embolism (PE).

In the abdomen, the enlarging uterus displaces the stomach onto the spleen and liver leading to high intragastric pressure. This and the delayed gastric emptying leads to regurgitation and gastric reflux. Hyperventilation that begins in the first trimester might increase throughout pregnancy. This has obvious implications on drug dosage, route and timing of administration.

In the first trimester, glomerular filtration rate increases 30–50%, which results in an increase in clearance of creatinine, uric acid, and urea. This leads to a decrease in levels of the same. While prescribing drugs, doses may need to be increased to account for this rapid clearance [48].

3.10.2 Treatment Protocol

3.10.2.1 Minor Surgery

While minor oral surgery is not a contraindication in the pregnant patient, it is advised that the oral surgeon should consult with the patient's obstetrician to address specific concerns should dental emergencies arise during the first trimester.

Unless emergency treatment is required, it is advisable to defer treatment during the first trimester because of the potential vulnerability of the fetus. The second trimester is the safest time to perform the routine dental treatment. No elective treatment is advisable late in the third trimester.

3.10.2.2 Dental Radiology

Two important factors to be considered are the dose of radiation to be given and the time of gestation. Animal and human data clearly support the conclusion that no increase in congenital anomalies due to exposures totaling less than 0.05–0.1 Gy during pregnancy. The amount of radiation used in dental radiographs is well below the threshold dose [47]. With modern features such as high-speed film, filtration, collimation, and use of lead aprons, dental radiography is deemed quite safe.

3.10.2.3 Major Surgery

Elective surgery should be postponed until after delivery. If possible, nonurgent surgery should be performed in the second trimester when preterm contractions and spontaneous abortion are least likely. Fetal safety requires that potentially dangerous drugs are avoided and adequate uteroplacental perfusion is ensured. No anesthetic drugs have been proven to be clearly hazardous to the human fetus. However, teratogenic effects of nitrous oxide have been demonstrated in animal models following prolonged administration in high concentration [49].

Anxiety in itself leads to decrease in uteroplacental perfusion secondary to increase in circulating catecholamines. Appropriate timing of surgery and anxiolysis is of paramount importance.

3.10.3 Drug Usage in Pregnancy

Most drugs cross the placental barrier by simple diffusion. Hence, the major concern of drug administration during pregnancy is the potential of teratogenic adverse effects. The period of maximum risk for teratogenicity is during organogenesis. This occurs from the end of the predifferentiation period until the end of the 10th week after the last menstrual period (Table 3.7).

Table 3.7 Commonly used safe and unsafe drugs during pregnancy [46]

Drug	Safe	Unsafe
Local anesthetics	Articaine Lignocaine Prilocaine	Bupivacaine
Analgesics	Paracetamol Ibuprofen (first and second trimesters)	Aspirin Diclofenac Ibuprofen (third trimester) Naproxen
Antibacterials	Amoxicillin Azithromycin Cephalosporins Erythromycin	Aminoglycosides Metronidazole Sulfonamides Tetracyclines
Antifungals	Fluconazole Nystatin	Ketoconazole
Anxiolytics	None	Alprazolam Diazepam

3.11 Endocrine Disorders

3.11.1 Diabetes

Diabetes is an endocrine disease manifesting as hyperglycemia, leading to microvascular and cardiovascular complications. Type 1 diabetes mellitus is an autoimmune pancreatic beta cell destruction leading to inadequate production of insulin. In type 2 diabetes mellitus, there is a condition of insulin resistance in addition to defects in insulin secretion by the pancreatic beta cells, and increased endogenous glucose production, primarily by the liver [50].

The current recommendation for diagnosis of diabetes stands at >126 mg/dl of fasting plasma glucose levels or a 2-h plasma glucose level of 200 mg/dl [51]. The Endocrine Society guidelines indicate that patients with hyperglycemia and glycated haemoglobin (HbA1c) of 6.5% or higher can be identified as having diabetes [52].

Optimal glycemic control is advised in each patient to avoid hyperglycemia or hypoglycemia. The surgical patient with diabetes is at higher risk of perioperative morbidity and mortality and subsequently longer length of hospital stays. This is mainly due to increased chances of surgical site infections and systemic infections, other complications like acute kidney injury, acute coronary syndromes, acute cerebrovascular accidents, hospital-acquired diabetic ketoacidosis, etc [53].

The stress of surgery and anesthesia derails the glycemic control of the patient due to the metabolic response to surgery. Nondiabetic patients evoke a catabolic response with a release of cortisol, glucagon, catecholamines, etc., promoting hepatic glycogenolysis and gluconeogenesis causing hyperglycemia. There is a catecholamine-induced inhibition of insulin production as well as insulin resistance. The type of anesthesia and the length of the procedure are also said to influence the amount of catabolism [54].

The preoperative preparation for a diabetic patient begins with a thorough history, including the type and dosing of medications, any history of cardiac events, or diabetic ketoacidosis. ECG is mandated as these patients have a higher occurrence of hypercholesterolemia, hypertension, macrovascular disease, autonomic neuropathy, and hence silent ischemia. If the ECG does suggest so, further investigation is indicated [55].

Renal function tests should include serum urea and creatinine. Hypertension should be ruled out or treated if present. Diabetic neuropathy should be evaluated as it may cause aspiration, silent myocardial ischemia, or even sudden death. It may manifest as postural hypotension, heartburn, or resting tachycardia [56].

HbA1c is usually advised in diabetic patients undergoing treatment as it reflects mean control over the previous 3 months. This allows one to estimate the quality of glycemic control before the consultation and adaptation of treatment to fixed objectives. It is also important to know the duration of the diabetes, dependence on insulin, and whether the glycemic control is achieved by oral hypoglycemics and lifestyle modification.

3.11.1.1 Management of Patients Undergoing Procedures

The recommendations for target glycemic control vary. The Endocrine Society and the American Diabetes Association/AACE Practice Guidelines recommend that patients on insulin maintain a target preprandial glucose of less than 140 mg/dl and a random Blood Glucose (BG) of less than 180 mg/dl for patients treated [52]. The Joint British Diabetes Societies guideline, however, recommends that insulin therapy be commenced when random blood glucose levels exceed 180 mg/dl [53].

3.11.1.2 Preoperative Glycemic Control in patients on Oral Hypoglycemic Agents

3.11.1.2.1 Minor surgery

Patient should adhere to his daily oral diabetic medication and follow his usual diet [50].

3.11.1.2.2 Major surgery

- Most oral hypoglycemics can be continued till the day before surgery. Sulfonylureas and insulin secretagogues should be stopped on the day of surgery to reduce the chances of hypoglycemia [52].
- If normal oral intake is expected to resume on the day of surgery, metformin may be given on the day of surgery [53].
- Metformin is discontinued if there is either prolonged state of fasting or use of i.v contrast dyes or reduced renal function

- (Dipeptyl Peptidase-4) DPP-4 inhibitors are not contraindicated throughout the perioperative period [54].

3.11.1.3 Preoperative Glycemic Control in Type 2 Diabetics on Insulin

Patients on basal insulin: If they are on twice daily dosing then morning dose to be reduced to 80% of normal dose; whereas if those on single dose then evening dose to be reduced to 80% [57].

If the morning glucose levels are above 120 mg/dl, Neutral protamine Hagedorn (NPH) insulin and premixed formulations are reduced by 20% the evening before surgery and by 50% the morning of surgery. If not, morning insulin dose is withheld [58].

Naturally, these are guidelines and the diabetologist will tailor the doses to the individual requirement of the patient.

3.11.1.4 Preoperative Glycemic Control in Type 1 Diabetics on Insulin

3.11.1.4.1 Minor surgery:

- Well-controlled patients should halve their daily dose of insulin the morning of surgery and also eat their normal breakfast.
- Morning appointments are preferred. If preoperative glucose is between 100 and 200 mg/dl, surgery can be performed.
- If blood glucose is >200 mg/dl, an intravenous infusion of 10% dextrose in half-normal saline is initiated. 10-mEq potassium chloride should be added to each 500 ml of dextrose/saline infusion.
- Rapid-acting insulin is administered subcutaneously.
- Blood glucose should be monitored hourly if the surgery lasts beyond 1 h [50].

3.11.1.4.2 Major surgery:

These patients are at risk of developing stress-induced hyperglycemia and ketoacidosis and hence need insulin coverage during perioperative period. These patients should receive 80% of basal insulin dose the evening before surgery and on the morning of surgery in order to prevent hypoglycemia [54].

3.11.1.4.3 Intraoperative glycemic control:

The endocrine society recommends an intraoperative BG level within 180 mg/dl [52].

Levels above that are treated either with subcutaneous rapid-acting insulin analogs or with an IV infusion of regular insulin. In patients undergoing short surgeries (under 4-h operative time), ambulatory surgeries, expected hemodynamic stability and those expected to resume oral diet soon can be managed with subcutaneous rapid-acting insulin correction scales [3]. When it is used, the BG should be checked every 2 h [52].

An IV insulin infusion is preferred where there is anticipated hemodynamic disturbance, significant fluid shifts, expected changes in temperature, inotropic support, or lengthy operative times (greater than 4 h). In this situation, hourly insulin monitoring is needed.

3.11.1.4.4 Postoperative glycemic control:

For noncritical and non-ICU patients, the subcutaneous sliding scale insulin is used with BG being checked every 2 h. If BG drops below 70 mg/dl, insulin is stopped and oral dextrose or iv dextrose is given. For patients in the ICU, continuous iv insulin infusion is given instead of the subcutaneous sliding scale for BG > 180 mg/dl. Oral antidiabetic agents are best avoided in hospitalized patients due to the limited data available on their safety and efficacy. DPP-4 has shown promising results for in-patient hyperglycemia control [54].

3.11.2 Hypo/Hyperthyroidism

The thyroid gland releases the hormone thyroxine (T4) and its active form T3. The thyroid hormones are released upon stimulation by the thyroid-stimulating hormone (TSH) released from the pituitary gland. This is, in turn, stimulated by thyrotropin release hormone (TRH). Secretion of T3 and T4 is regulated by the negative feedback loop modulating release of TSH [59].

Thyroid hormones play a critical role in maintaining metabolic homeostasis in the adult. Thyroid-related disorders are due to either overproduction of thyroid hormones (thyrotoxicosis) or hormone deficiency (hypothyroidism). These situations may arise due to infectious, autoimmune, proliferative, or tumorous pathologies [60].

Most patients with well-compensated thyroid disease do not need special consideration prior to surgery. Patients with a newly diagnosed thyroid disorder around the time of surgery will need to undergo risk assessment and optimization before surgery.

Routine thyroid screening is not done for asymptomatic patients unless there is a reason to suspect thyroid dysfunction. Thyroid disease present with a myriad of symptoms clinically. These include-unexplained weight changes, and fine tremor or changes in bowel habits, skin, hair, exophthalmos, goiter, abnormal reflexes. Palpitations, tachycardia, or bradycardia are common cardiovascular manifestations. In such situations as well as in patients with a known thyroid disorder, a TSH test should be included in the preoperative analysis [61].

3.11.2.1 Hypothyroidism

Hypothyroidism may be primary (due to thyroid disease) or secondary due to hypothalamo-pituitary disorders. Commonly, it is due to thyroid loss from surgery, irradiation,

autoimmune diseases, or drug induced [59]. The diagnosis is confirmed by blood tests revealing low T3 and T4 levels and high TSH in primary and decreased TSH in secondary hypothyroidism. These patients pose challenges during perioperative period due to their effects on various organ systems.

3.11.2.1.1 Physiologic Challenges

Cardiac disturbances like increased peripheral vascular resistance, decreased cardiac output; Respiratory implications like increased incidence of pneumonia, impaired respiratory drive, respiratory muscle weakness. Decreased renal perfusion, decreased gastric motility, and slower drug metabolism need to be considered.

One of the most serious complications of surgery in hypothyroid patients is myxedema coma. It is associated with a mortality rate as high as 80%. It is characterized by altered mental status, which may manifest as coma or seizure, and hypothermia, bradycardia, hyponatremia, heart failure, and hypopnea. It is precipitated by surgery, infection, cold exposure, and administration of sedatives [61].

3.11.2.1.2 Management

A condition of euthyroidism is usually targeted preoperatively and elective surgery is usually postponed. Once TSH values normalize, surgery can be performed. Use of sedatives, benzodiazepenes and Opioids should be avoided [59].

For urgent and emergent procedures, surgery may be performed in mild-to-moderate hypothyroidism with levothyroxine cover preoperatively. Surgery should be postponed in patients with severe hypothyroidism in case of nonemergent surgery. In an emergency, thyroid hormone levels should be normalized as rapidly as possible, using IV levothyroxine in a loading dose of 200–500 µg followed by 50–100 µg IV daily [62].

3.11.2.2 Hyperthyroidism

It is commonly due to autoimmune disease (e.g., Graves' disease), multinodular goiter, or adenoma presenting as thyroid nodule. The diagnosis is confirmed by elevated serum T3 and T4. It usually causes exophthalmos, heat intolerance, anxiety, sweating, diarrhea, and weight loss [59]. It has a positive inotropic and chronotropic effect on the heart coupled with decreased vascular resistance [61]. Hence, these patients manifest tachycardia, arrhythmias, or cardiac failure frequently.

Thyroid storm is a severe manifestation of uncontrolled hyperthyroidism and is characterized by tachycardia, confusion, fever, gastrointestinal complaints, and potentially leading to cardiovascular collapse. It is precipitated by pain, anxiety, trauma, or GA. Hence, elective surgery should always be postponed in patients with overt untreated hyperthyroidism. Hyperthyroidism is usually treated by β -blockers like atenolol or metoprolol as they decrease the sympathetic overactivity. When there is no time to render a patient euthyroid as in emergency cases, cardiac monitoring and adequate β -blockers with

antithyroid medication should be given [61]. While epinephrine with lidocaine is not contraindicated, caution should be exercised. Benzodiazepines should be avoided. Carbamazepine causes agranulocytosis and this can manifest as oral ulcers.

3.11.3 Adrenal Gland Disorders

3.11.3.1 Primary Adrenocortical Hypofunction

Addison's disease occurs due to autoantibody-mediated destruction of the adrenal cortex leading to failed cortisol and aldosterone secretion. It may also occur due to tuberculosis, histoplasmosis, sarcoidosis, etc [59]. Due to lack of adequate corticosteroid production, these patients are prone to hypotensive collapse, hypoglycemia, profound weakness, and dehydration (Adrenal crisis).

Adrenal crisis is rare in outpatient oral surgery. However, patients with Addison's disease who need surgery should be covered with supplemental steroids. Drugs like barbiturates,azole antifungals, etomidates, phenytoin, and rifampins should be avoided as they accelerate cortisol metabolism.

3.11.3.2 Secondary Adrenocortical Insufficiency

Corticosteroids are prescribed as long-term treatment for various ailments such as inflammatory bowel disease, blood dyscrasias like idiopathic thrombocytopenia, rheumatologic disease, reactive airway disease, and immunosuppression for transplant recipients, etc. due to their immunosuppressive, anti-inflammatory, metabolic, and hemodynamic properties. This external source of long-term steroid can lead to secondary adrenal insufficiency that may manifest in the perioperative period [63].

In a healthy individual, corticotrophin-releasing hormone (CRH) has a diurnal pattern of release from the hypothalamus. This in turn acts on the anterior pituitary to release the Adrenocorticotrophic hormone (ACTH). ACTH acts on the adrenal cortex to release cortisol (hydrocortisone), corticosterone, and mineralocorticoids. Circulating corticosteroids have a subsequent negative feedback effect on CRH and ACTH release. This constitutes the hypothalamic-pituitary adrenocortical (HPA) axis [59].

Normally, an unstressed adrenal gland secretes approximately 8–10 mg of cortisol per day (Table 3.8). Stress, such as illness or surgery, is the stimulus for raised production of

cortisol. During surgical stress, the rate varies between individuals and also upon the type of surgery. It is usually up to 50 mg/day for minor procedures and up to 75–150 mg/day for more complex procedures, rarely exceeding 200 mg/day. However, patients on exogenous corticosteroids aren't able to secrete adequate amounts of corticosteroids in response to stress due to HPA axis suppression and a resulting low level of ACTH and CRH leading to atrophy of the zona fasciculata of adrenal cortex [63]. This may predispose them to develop adrenal crisis, with rapidly developing hypotension, hypoglycemia, collapse, and even death [59].

Even though there is no consensus on the exact dosage of corticosteroids that leads to hypofunction of the adrenal cortex, doses greater than physiologic doses of cortisol lead to suppression [59]. HPA suppression does not extend beyond 1 year after exogenous steroid therapy is stopped [64]. Hence, those at risk are:

- Patients currently taking >5 mg of systemic prednisolone
- Corticosteroids been taken in the past 30 days
- Corticosteroids taken for more than a month during the past 1 year.

These patients require steroid cover/supplementation when undertaken for surgeries. Most dentoalveolar and maxillofacial surgeries result in stress and hence require steroid supplements, but most other dental procedures do not require any additional steroid supplements [59].

Following table shows the normal corticosteroid response to the particular level of stress and the appropriate steroid cover needed in cases of adrenal suppression (Table 3.9):

During the procedure, blood pressure and blood sugar levels should be monitored. NSAIDs should be avoided to avoid increasing risk of peptic ulceration. Prophylactic antibiotics should be given in such patients to avoid postoperative infections.

3.11.4 Renal Disorders

The kidneys are responsible for eliminating metabolic waste; fluid and electrolyte homeostasis; and to maintain acid and base balance. The kidneys also affect the cardiovascular and hematologic systems.

Table 3.8 Approximate potencies of systemic corticosteroids relative to cortisol [59]

Steroid	Glucocorticoid activity	Mineralocorticoid activity	Equivalent dose (IV/PO)
Cortisol (hydrocortisone)	1	1	20
Cortisone	0.8	0.8	25
Prednisone	4	0.8	5
Prednisolone	4	0.8	5
Methylprednisolone	5	0.5	4
Dexamethasone	30–40	0	0.5–0.75

Table 3.9 Normal corticosteroid response to the particular level of stress and the appropriate steroid cover needed in cases of adrenal suppression [63]

Surgery type	Endogenous cortisol secretion rate	Examples	Recommended steroid dosing
Superficial	8–10 mg/day (baseline)	Dental surgery Biopsy	Usual daily dose
Minor	50 mg/day	Multiple extractions LA, Dental implant surgery Inguinal hernia repair Colonoscopy Uterine curettage Hand surgery	Usual daily dose plus Hydrocortisone: 50 mg IV before incision Hydrocortisone: 25 mg IV every 8 h × 24 h Then usual daily dose
Moderate	75–150 mg/day	Minor maxillofacial trauma, Orthognathic surgery Lower-extremity revascularization Total joint replacement Cholecystectomy Colon resection Abdominal hysterectomy	Usual daily dose plus Hydrocortisone: 50 mg IV before incision Hydrocortisone: 25 mg IV every 8 h × 24 h Then usual daily dose
Major esophagectomy	75–150 mg/day	Total proctocolectomy Major cardiac/vascular Hepaticojejunostomy Delivery Trauma	Usual daily dose plus Hydrocortisone: 100 mg IV before incision Followed by continuous IV infusion of 200 mg of hydrocortisone more than 24 h or Hydrocortisone: 50 mg IV every 8 h × 24 Taper dose by half per day until usual daily dose reached plus Continuous IV fluids with 5% dextrose and 0.2–0.45% NaCl (based on degree of hypoglycemia)

The best parameter to assess the function of the kidneys is the glomerular filtration rate (GFR). It is measured by calculating the creatinine clearance based on serum creatinine (SC). The normal value of GFR for an adult male is 130 ml/1.73 m² and is 120 ml/1.73 m² for an adult female. Chronic kidney disease occurs when the GFR is reduced by at least 50 ml/min [65].

Patients with chronic kidney disease who are either on dialysis, dialysis naive, or renal transplant recipients or post-transplant patients require modification of treatment plan from a surgical point of view. These patients always have a risk of developing acute renal failure in the postoperative period either due to pre-existing renal dysfunction or solely due to the effects of surgery.

3.11.4.1 Acute Renal Failure (ARF)

ARF is the rapid loss of renal function over the course of days to weeks, resulting in the patient's inability to clear nitrogenous waste, including creatinine and urea, from the body [66]. The term Acute Kidney Injury (AKI) has replaced acute renal failure in current literature. Perioperative AKI is a leading cause of morbidity and mortality due to increased risk of sepsis, anemia, coagulopathy, and mechanical ventilation.

There are three types of ARF based on etiology: prerenal, renal, and postrenal causes. The most common cause of AKI

in perioperative period is the prerenal cause and the ischemic acute tubular necrosis (renal AKI) due to hypoxic damage to medullary region secondary to hypovolemia, hypotension, and dehydration [67]. Prerenal AKI and ischemic ATN are a part of a spectrum of manifestations of renal hypoperfusion. Hypotension or hypovolemia may be due to preoperative factors like hemorrhage, diarrhea, fasting, use of diuretics, due to intraoperative factors like ongoing blood loss, activation of sympathetic reflexes, and due to postoperative factors like intravascular volume depletion, myocardial infarction, etc [68]. Hypotension and hypovolemia result in activation of the sympathetic nervous system and the renin–angiotensin–aldosterone axis, which compromises GFR by inducing afferent arteriolar renal vasoconstriction. Other common causes of AKI are the use of NSAIDs, ACE inhibitors, nephrotoxic drugs like aminoglycosides, radiocontrast materials, myoglobin, hemoglobin, and amphotericin B. Pre-existing diseases like diabetes, hypertension, and obstructions of the urinary system also lead to perioperative AKI [68].

The strategy around perioperative AKI is ideally prevention. Preoperatively potential risk factors such as volume depletion, hypotension, sepsis, nephrotoxin exposure, and pre-existing chronic kidney disease should be identified and elective surgery should be postponed till optimization is complete. Anemia should be corrected before surgery. The choice of fluid in intra-

operative resuscitation is usually a balanced crystalloid solution like Ringer's lactate and not a chloride-rich crystalloid. Hydroxyethyl starch is best avoided. Mean arterial pressure should be maintained and hemodynamic stability is of utmost importance. Diuretics should be only given in cases of volume overload and not for increasing GFR. Norepinephrine is preferred over dopamine as it maintains renal perfusion pressure, but the role is still not very clear [67].

3.11.4.2 Chronic Renal Failure (CRF)

CRF is permanent renal insufficiency that develops over months or years caused by the structural and intrinsic damage of the glomerulus or tubulointerstitial system. This usually occurs when GFR is reduced by 50 ml/min. If necessary treatment is not started, most cases of CRF would lead to End Stage Renal Disease (ESRD). ESRD is maintained by regular dialysis or by transplant, in the absence of which, death may occur [68].

Preoperative assessment:

Detailed history and physical examination;
 Cardiac work up as dictated by clinical symptoms. ECG and Echocardiogram
 Complete blood count
 Metabolic panel, serum magnesium, and phosphorus levels
 Coagulation profile.

Coronary artery disease and congestive heart failure are commonly found in patients with ESRD and those on dialysis. Hence, cardiac workup and monitoring is required in the perioperative period. Maintaining euolemia perioperatively in ESRD patients is mandatory. For patients not undergoing dialysis, euolemia can be achieved with appropriate hydration or diuresis. Dialysis is usually performed a day before surgery to prevent fluid overload and to reduce uremic complications (bleeding). Postoperative dialysis helps to achieve euolemia if large amounts of fluids were given during surgery. Heparin is withheld if dialysis is performed on the day of surgery.

Anemia complicates CKD due to the decreased production of erythropoietin. Transfusion should be considered in the perioperative period when hemoglobin levels fall below 8–10 g/dl due to surgical blood loss in patients with ESRD. If anemia has been detected, erythropoietin should be initiated several weeks before the elective surgery with iron supplementation to raise hemoglobin to the desired level. Patients who have ESRD may be susceptible to more intraoperative and postoperative bleeding due to platelet dysfunction caused by uremia. Hence, NSAIDs and dipyridamole should not be given within 72 h before surgery to patients who have ESRD due to their effects on platelet function. Hypertension and glycemic control should be tightly monitored in such patients as well.

These patients have inefficient mechanisms of drug clearance that inherently predispose them to adverse drug

responses. Hence, NSAIDs, aminoglycosides, benzodiazepines, morphine, and radiocontrast media are avoided. Drugs like propofol, fentanyl, and inhalational anesthetics are usually the preferred drugs of choice.

3.12 Patients with Non-head and Neck Malignancies

3.12.1 Introduction

The most common cancers in India in women are Breast, Oral, Cervical, ovary, and esophagus. Men tend to be afflicted with head and neck cancers, lung, esophagus, stomach, and colorectal cancer [69]. The cancers that most commonly metastasize to the jaws and oral soft tissues are breast, lung, prostate, thyroid, kidney, stomach, and colon [70]. Another group of malignancies that receive chemoradiotherapy are the lymphoproliferative and hematologic malignancies [70].

Chemotherapy is often employed either with an intent of palliation or for cure. It may be administered as adjuvant therapy or as neoadjuvant therapy. Cytotoxic chemotherapeutic agents have hematologic effects (myelosuppression) as well as nonhematologic effects. The effects of myelosuppression, i.e., leukopenia, thrombocytopenia, and anemia start after 5–7 days with the nadir occurring at 10–14 days. It is usually followed by bone marrow recovery [71]. Hence, the oral surgical treatment should be planned in a manner that it doesn't coincide with the nadir of the myelosuppression where the neutropenia can be as low as 500.

Radiotherapy is a part of treatment for a variety of Head and neck cancers either as primary treatment modality or as adjuvant therapy to the primary tumor or to the associated lymphatic structures. Unlike the effects of chemotherapy, effects of radiotherapy are more long lasting. These include mucositis, xerostomia, trismus, radiation-induced fibrosis, and dysgeusia.

3.12.2 Treatment Protocol

3.12.2.1 Chemotherapy

It is best to undertake a dental screening before the start of the chemotherapy so that the hopeless teeth can be extracted, be restored, periodontal therapy, alveoloplasty be performed, and primary closure be done. After extraction, it takes approximately 10 days to 6 weeks for healing to be enough for chemotherapy to start [72]. Ill-fitting and loose dentures should be discontinued and replaced ideally with implants especially in patients scheduled to take systemic bisphosphonates or RANK-L therapy as it might lead to osteonecrosis of the jaws [73]. Fluoride treatment can also be done.

However, patients suffering from leukemia, lymphomas have a state of myelosuppression even before the start of the

Table 3.10 Modification of invasive dental treatment according to hematologic indices [75]

Platelet count	Treatment modification	Neutrophil count	Treatment modification
>75,000 cells/mm ³	No modification	>1000 cell/mm ³	No need for antibiotic prophylaxis.
40,000–75,000 cell/mm ³	Platelet transfusion may be considered in the preoperative and postoperative (24 h).	<1000 cell/mm ³	Postpone the dental treatment. In cases of emergency, discuss antibiotic coverage and endocarditis prophylaxis before treatment with the medical team. Hospitalization may be required
<40,000 cell/mm ³	Postpone the dental treatment. In the case of dental emergency, contact the patient's physician before dental treatment to discuss supportive measures, such as platelet transfusion, control of bleeding, and need for hospitalization. Other coagulation tests may be necessary in some cases.		

chemotherapy. Only acute situations need to be dealt with. Elective treatments can wait till the time the patient is in optimal clinical and hematological parameters, which is usually until after chemotherapy is over. Hence, extractions of grossly carious and severely periodontally compromised teeth, ill-fitting denture, etc. should be addressed. For extractions to be done, or other invasive dental procedures, hematologic indices should be evaluated and antibiotic prophylaxis should be considered [74] (Table 3.10).

Once the chemotherapy starts, a gap of 1 week before the next cycle is essential before any dental intervention. For surgical procedures that cannot wait, like facial trauma or infection, the complete blood counts should be assessed and consultation should be sought with the medical oncologist to determine the nadir in blood counts, the timing of the chemotherapy cycle, and duration [72]. For platelet levels below 40,000/mm³, platelet transfusions are usually needed [76].

Opportunistic infections may complicate mucositis and may be of viral, fungal, or bacterial origins. Treatment should be guided by culture and sensitivity. Febrile neutropenia needs to be treated usually by intravenous antibiotics like amoxicillin and clavulanic acid with a fluoroquinolone or clindamycin with fluoroquinolone. Hematopoietic growth

factors like granulocyte colony-stimulating factors or granulocyte-macrophage colony-stimulating factors are effective drugs for prophylaxis and treatment of febrile neutropenia. Mucositis occurs in almost all patients and causes great difficulty in feeding, hydrating, and causes pain. It is preferable to manage it with saline mouth rinses rather than with chlorhexidine mouthwashes. Some chemotherapeutic agents are also neurotoxic and cause a deep mandibular pain as well as altered taste sensation and dysgeusia. Most of these symptoms subside after cessation of treatment [72].

3.12.2.2 Radiotherapy

The same prophylactic measures of extraction, restoration, alveoloplasty, etc. have to be taken before radiotherapy as for chemotherapy. Additionally, jaw-opening exercises should be initiated and coronoidectomy should be considered as a part of the ablative procedure [72].

3.12.3 Prevention and Treatment of Osteonecrosis After Chemotherapy and Radiation

Osteonecrosis of the jaws occurring in an irradiated bone is called osteoradionecrosis (ORN). Those occurring in a patient on antiresorptive therapy like bisphosphonates or monoclonal antibodies to RANK-L is termed Antiresorptive osteonecrosis of jaws (AONJ) [72]. The incidence of ORN in areas of jaws that have received greater than 60 Gy of radiation is 5–15%. Incidence of AONJ in patients who have received denosumab is 1.3% and is 1.8% in patients treated with nitrogen-containing bisphosphonates [77, 78].

Acknowledgments Dr Prithvi Bachalli, Consultant Oral and Maxillofacial Surgeon
Rangadore Memorial Hospital, Bangalore
Dr. Prashanth Bhat, Consultant Oral and Maxillofacial Surgeon
Rangadore Memorial Hospital, Bangalore
Dr Shobha Hegde, Registrar Oral and Maxillofacial Surgeon
Rangadore Memorial Hospital, Bangalore

References

1. 'Indians have gained 10 years of life expectancy since 1990'. The Business Line [Document on internet]. Updated on 09 Jan 2018. <https://www.thehindubusinessline.com/news/science/indians-have-gained-10-years-of-life-expectancy-since-1990/article9958774.ece>. Accessed 14 Nov 2017.
2. Central Bureau of Health intelligence. National Health profile 2018 [Document on internet]. New Delhi: India Offset Press. <https://cdn.downtoearth.org.in/pdf/NHP-2018.pdf>. Accessed 27 Apr 2018.
3. Arokiasamy P. India's escalating burden of non-communicable diseases. *The Lancet; Global Health*. 2018;6(12):1262–3.
4. Indian council of medical research, Public health foundation of India, and Institute for health metrics and evaluation. India: Health

- of the Nation's states-The India state-level disease burden initiative. New Delhi: ICMR, PHFI and IHME; 2017. https://www.health-data.org/sites/default/files/files/policy_report/2017/India_Health_of_the_Nation%27s_States_Report_2017.pdf
5. Government of India: Ministry of Housing and Urban Affairs. Urban Growth [document on the internet]. New Delhi; 2019. Last updated 9 May 2019. <http://mohua.gov.in/cms/urban-growth.php#skip>
 6. India is the most depressed country in the world: Mental Health Day 2018. India Today Web Desk, 2018 [Document on the internet]. New Delhi; 2018. Updated: 10 Oct 2018. <https://www.indiatoday.in/education-today/gk-current-affairs/story/india-is-the-most-depressed-country-in-the-world-mental-health-day-2018-1360096-2018-10-10>. Accessed 10 Oct 2018.
 7. Misra S. Systemic hypertension and noncardiac surgery. *Indian J Anaesth.* 2017;61:697–704.
 8. Shahbabu B, Dasgupta A, Sarkar K, Sahoo SK. Which is more accurate in measuring the blood pressure? A digital or an aneroid sphygmomanometer. *J Clin Diagn Res.* 2016;10(3)
 9. Hogan J, Radhakrishnan J. The assessment and importance of hypertension in the dental setting. *J Dent Clin N Am.* 2012 Oct;56(4):731–45.
 10. Foëx P, Sear JW. The surgical hypertensive patient. *Continuing Education in Anaesthesia Critical Care & Pain.* 2004 Oct;4(5):139–14.
 11. Southerland JH, Gill DG, Gangula PR, Halpern LR, Cardona CY, Mouton CP. Dental management in patients with hypertension: challenges and solutions. *Clin Cosmet Investig Dent.* 2016;8:111–20.
 12. Niwa H, Sato Y, Matsuura H. Safety of dental treatment in patients with previously diagnosed acute myocardial infarction or unstable angina pectoris. *Oral Surg Oral Med Oral Pathol Oral Radiol Endod.* 2000;89(1):35–41.
 13. Ferrari E, Benhamou M, Cerboni P, Marcel B. Coronary syndromes following aspirin withdrawal. *J Am Coll Cardiol.* 2005;45(3):456–9.
 14. Zain MA, Siddiqui WJ. Coronary stents. [Updated 24 Jan 2019]. In: StatPearls [Internet]. Treasure Island (FL): StatPearls Publishing; 2019. <https://www.ncbi.nlm.nih.gov/books/NBK507804>
 15. Oprea AD, Popescu WM. Perioperative management of antiplatelet therapy. *Br J Anaes.* 2013;111(Suppl 1):i3–i17.
 16. Yeung LYY, Sarani B, Weinberg JA, McBeth PB, May AK. Surgeon's guide to anticoagulant and antiplatelet medications. Part Two: Antiplatelet agents and perioperative management of long-term anticoagulation. *Trauma Surg Acute Care Open.* 2016;1:1–7.
 17. León AMD, López BC, Esteve CG. Dental management of patients receiving anticoagulant and/or antiplatelet treatment. *J Clin Exp Dent.* 2014 Apr;6(2):e155–61.
 18. Abdullah WA, Khalil H. Dental extraction in patients on warfarin treatment. *Clin Cosmet Investig Dent.* 2014;6:65–9.
 19. Shah SN. Oral anticoagulation in special population and conditions. *J Assoc Phy Ind.* 2014;62. http://www.japi.org/june_2014_special_issue/07_oral_anticoagulation_in.htm
 20. Lam DK, Jan A, Sándor GK, Clokie CM. Prevention of infective endocarditis: Revised guidelines from the American Heart Association and the implications for dentists. *J Can Dent Assoc.* 2008;74(5):449–53.
 21. Shah AH, Khalil HS, Kola MZ. Dental management of a patient fitted with subcutaneous Implantable Cardioverter Defibrillator device and concomitant warfarin treatment. *Saudi Dent J.* 2015;27(3):165–70.
 22. Turner MD, Glickman RS. Epilepsy in the oral and maxillofacial patient: current therapy. *J Oral Maxillofac Surg.* 2005;63:996–1005.
 23. Jacobsen PL, Eden O. Epilepsy and the dental management of the epileptic patient. *J Contemp Dent Pract.* 2008;9(1):1–13.
 24. Scheffer IE, Berkovic S, Capovilla G, Connolly MB, French J, Guilhoto L, et al. ILAE classification of the epilepsies: position paper of the ILAE Commission for Classification and Terminology. *Epilepsia.* 2017;58(4):512–21.
 25. Scully C. Neurology. In: Scully's medical problems in dentistry. 7th ed. Haryana: Churchill Livingstone, Elsevier; 2014. p. 345–93.
 26. Mehmet Y, Senem O, Sülün T, Hümeýra K. Management of epileptic patients in dentistry. *Surg Sci.* 2012;3:47–52.
 27. Bodnar DC, Varlan CM, Varlan V, Vaideanu T, Popa MB. Dental management in Stroke patients. *TMJ.* 2008;58(3–4):228–35.
 28. Arboix A, Pérez Sempere A, Alvarez SJ. Ictus: etiological types and diagnostic criteria. In: Díez Tejedor E, editor. Guide for the diagnosis and treatment of stroke. Barcelona: Prous Science; 2006. p. 1–23.
 29. British Society of Gerodontology. Guidelines for the oral health-care of stroke survivors. June 2010. p. 4–10.
 30. MBA A, Abbas G, Latifeh Y, Hamadah O. The oral manifestations of psychiatric disorders. *Oral Health Dent Manag.* 2018;17(4):1–6.
 31. Al-Atram Majmaah AA. The ability of dentists to identify psychiatric symptoms in their patients. *J Health Sci.* 2017;5(2)
 32. Tomar B, Bhati NK, Kumar P, Bhatia MS, Shah RJ. The psychiatric and dental inter-relationship. *Delhi Psychiatry Journal.* 2011;14(1)
 33. Sousa AD. Psychological issues in oral and maxillofacial reconstructive surgery. *Br J Oral Maxillofac Surg.* 2008;46(8):661–4.
 34. Nassab ISAHG, Samieirad S, Zadeh MV, Aghahi RK, Hashemipour MA. Depression and anxiety disorders in a sample of facial trauma: a study. *Med Oral Patol Oral Cir Bucal.* 2016 Jul 1;21(4):e477–82.
 35. Pamplona MC, Muñoz MM, Pérez MGS. Dental considerations in patients with liver disease. *J Clin Exp Dent.* 2011;3(2):127–34.
 36. Grau-García-Moreno DM. Dental management of patients with liver disease. *Med Oral.* 2003;8:231.
 37. Golla K, Epstein JB, Cabay RJ. Liver disease: current perspectives on medical and dental management. *Oral Surg Oral Med Oral Pathol Oral Radiol Endod.* 2004;98:516–21.
 38. Dienstag JL, Isselbacher KJ. Acute viral hepatitis [Internet]. Columbus, OH: The McGraw-Hill. <http://harrisons.accessmedicine.com.proxy.cc.uic.edu>. Accessed 12 Sep 2004.
 39. Al-Khalidi JA, Czaja AJ. Current concepts in the diagnosis, pathogenesis, and treatment of autoimmune hepatitis. *Mayo Clin Proc.* 2001;76:1237–52.
 40. Iredale JP. Cirrhosis: new research provides a basis for rational and targeted treatments. *Br Med J.* 2003;327:143–7.
 41. Haddad J, Deny P, Munz-Gotheil C, Ambrosini JC, Trinchet JC, et al. Lymphocyte sialadenitis of Sjogren's syndrome associated with chronic Hepatitis C virus liver disease. *Lancet.* 1992;339:1425–6.
 42. Greenwood M, Meecham JG. General medicine and surgery for dental practitioners. Part 5: Liver disease. *Br Dent J.* 2003;195:71–3.
 43. John Firriolo F. Dental management of patients with end stage liver disease. *Dent Clin N Am.* 2006;50:563–90.
 44. Edwards CR, Boucher IA. Davidson's principles and practice of medicine. 17th ed. London: Churchill Livingstone; 1996. p. 405–82.
 45. Gan TJ. Postoperative nausea and vomiting-can it be eliminated? *JAMA.* 2002;287:1233–6.
 46. Scully C. Age and gender issues. In: Scully's medical problems in dentistry. 7th ed. Haryana: Churchill Livingstone, Elsevier; 2014. p. 642–6.
 47. Cengiz SB. The pregnant patient: consideration for dental management and drug use. *Quintessence Int.* 2007;38:777e733-742.

48. Turner M, Aziz SR. Management of the pregnant oral and maxillofacial surgery patient. *J Oral Maxillofac Surg.* 2002;60:1479–88.
49. Upadya M, Saneesh PJ. Anaesthesia for non-obstetric surgery during pregnancy. *Indian J Anaesth.* 2016 Apr;60(4):234–41.
50. Bergman SA. Perioperative management of the diabetic patient. *Oral Surg Oral Med Oral Pathol Oral Radiol Endod.* 2007;103:731–7.
51. Definition and diagnosis of diabetes mellitus and intermediate hyperglycemia: Report of a WHO/IDF consultation (Document on the internet). WHO Document Production Services, Geneva. 2006. https://www.who.int/diabetes/publications/Definition%20and%20diagnosis%20of%20diabetes_new.pdf
52. Umpierrez GE, Hellman R, Korytkowski MT, Kosiborod M, Maynard GA, Montori VM, Seley JJ, Van den Berghe G. Endocrine Society: Management of hyperglycemia in hospitalized patients in non-critical care setting: an endocrine society clinical practice guideline. *J Clin Endocrinol Metab.* 2012;97:16–38.
53. Dhataria K, Levy N, Kilvert A, et al. NHS Diabetes guideline for the perioperative management of the adult patient with diabetes. *Diabetic Med.* 2012;29:420–33.
54. Dugan EW, Carlson K, Umpierrez GE. Perioperative hyperglycaemia management: an Update. *Anesthesiology.* 2017;126:547–60.
55. Plodkowski RA, Edelman SV. Pre-surgical evaluation of diabetic patients. *Clin Diabetes.* 2001;19:92–5.
56. Yoo HK, Serafin BL. Perioperative management of the diabetic patient. *Oral Maxillofacial Surg Clin N Am.* 2006;18:255–60.
57. Rosenblatt SI, Dukatz T, Jahn R, Ramsdell C, Sakharova A, Henry M, et al. Insulin glargine dosing before next-day surgery: comparing three strategies. *J Clin Anesth.* 2012;24:610–7.
58. Likavec A, Moitra V, Greenberg J, Drum M, Sweitzer BJ. Comparison of preoperative blood glucose levels in patients receiving different insulin regimens. *Anesthesiology.* 2006;105:A567.
59. Scully C. Endocrinology. In: Scully's medical problems in dentistry. 7th ed. Haryana: Churchill Livingstone, Elsevier; 2014. p. 171–99.
60. Fauci AS, Kasper DL, Longo DL, Braunwald E, Hauser SL, Jameson JL, Loscalzo J. Harrison's internal medicine. 17th ed. <https://doi.org/10.1111/j.1445-5994.2008.01837>.
61. Palace MR. Perioperative management of thyroid dysfunction. *Health Serv Insights.* 2017; <https://doi.org/10.1177/1178632916689677>.
62. Bennet Guerrero E, Kramer DC, Schwinn DA. Effect of chronic and acute thyroid hormone reduction on perioperative outcome. *Anesth Analg.* 1997;85:30–6.
63. Liu MM, Reidy AB, Saatee S, et al. Perioperative steroid management: approaches based on current evidence. *Anesthesiology.* 2017;127:166–72.
64. Axelrod L. Perioperative management of patients treated with glucocorticoids. *Endocrinol Metab Clin N Am.* 2003;32:367–83.
65. Horio M, Orita Y, Fukunaga M. Assessment of renal function. In: Johnson RJ, Feehally J, editors. *Comprehensive clinical nephrology.* Philadelphia: Mosby; 2000. p. 3.1–6.
66. Anderson RJ, Schrier RW. Clinical spectrum of oliguric and non-oliguric acute renal failure. *Contemporary issues in nephrology, Vol. 6.* New York: Churchill Livingstone; 1980. p. 1–16.
67. Goren O, Matot I. Perioperative acute kidney injury. *Br J Anaesth.* 2015;115(Suppl 2):ii3–14.
68. Carrasco LR, Chou JC. Perioperative management of patients with renal disease. *Oral Maxillofacial Surg Clin N Am.* 2006;18:203–12.
69. India: Globocan 2018. International Agency for research on cancer. 2019. <http://gco.iarc.fr/today/data/factsheets/populations/356-india-fact-sheets.pdf>
70. Scully C. Malignant disease. In: Scully's medical problems in dentistry. 7th ed. Haryana: Churchill Livingstone, Elsevier; 2014. p. 576–93.
71. Motzer RJ, Geller NL, Bosl GJ. The effect of a 7-day delay in chemotherapy cycles on complete response and event-free survival in good-risk disseminated germ cell tumor patients. *Cancer.* 1990;66(5):857–61.
72. Demian NM, Shun JW, Kessel IL, Eid A. Oral surgery in patients undergoing chemoradiation therapy. *Oral Maxillofacial Surg Clin N Am.* 2014;26:193–207.
73. Yamashita J, Mc Cauley LK. Antiresorptives and osteonecrosis of the jaw. *J Evid Based Dent Pract.* 2012;12(Suppl 3):233–47.
74. Zimmermann C, Meurer MI, Grando LJ, et al. Dental treatment in patients with leukemia. *J Oral Oncol.* 2015;2015:Article ID 571739, 14 pages. <https://doi.org/10.1155/2015/571739>.
75. American Academy of Pediatric Dentistry. Guideline on dental management of pediatric patients receiving chemotherapy, hematopoietic cell transplantation, and/or radiation. *J Pediatr Dentistry.* 2013;35(5):E185–93. <http://www.ncbi.nlm.nih.gov/pubmed/24290549>.
76. Lopez BC, Esteve CG, Perez MG. Dental treatment considerations in the chemotherapy patient. *J Clin Exp Dent.* 2011;3(1):e31–2.
77. Jacobson AS, Buchbinder D, Hu K, et al. Paradigm shifts in the management of osteoradionecrosis of the mandible. *Oral Oncol.* 2010;46(11):795–801.
78. Saad F, Brown J, Van Poznacck C, et al. Incidence, risk factors and outcomes of osteonecrosis of the jaws: integrated analysis from three blinded active controlled phase III trials in cancer patients with bone metastasis. *Ann Oncol.* 2012;23(5):1341–7.

Open Access This chapter is licensed under the terms of the Creative Commons Attribution 4.0 International License (<http://creativecommons.org/licenses/by/4.0/>), which permits use, sharing, adaptation, distribution and reproduction in any medium or format, as long as you give appropriate credit to the original author(s) and the source, provide a link to the Creative Commons license and indicate if changes were made.

The images or other third party material in this chapter are included in the chapter's Creative Commons license, unless indicated otherwise in a credit line to the material. If material is not included in the chapter's Creative Commons license and your intended use is not permitted by statutory regulation or exceeds the permitted use, you will need to obtain permission directly from the copyright holder.



Medical Emergencies in Oral and Maxillofacial Surgical Practice

4

Nallamilli V. S. Sekhar Reddy

4.1 Introduction

Oral and Maxillofacial Surgery has evolved over the last few decades. Although it is now practiced as a full-fledged hospital-based specialty, a significant amount of work is still carried out under local anesthesia; predisposing toward a medical emergency precipitated particularly by stress. Oral and Maxillofacial surgeons thus deal with the medical emergencies in an office or hospital setting on a regular basis.

Emergency team response in most countries is prompt. The published guidelines from these countries reflect this in the advice for the general practitioner; doing the essential minimum toward the sustenance of life in case of a medical emergency and to prioritize escalation of call for help to the emergency team. However, in some parts of the world, the response time of the emergency team is expected to be comparatively longer, due to various policy issues. The chapter considers these special circumstances, to suggest some additional measures toward the management of the emergency, while waiting for the arrival of the emergency team.

Also, the general advice in the management of a medical emergency during an outpatient procedure in a clinic is aimed at general practitioners, who may not necessarily be exposed to training in clinical skills like the placement of an intravenous cannula. Oral and Maxillofacial surgeons are expected to be well versed with this life-saving simple clinical skill and the protocols discussed here take this into consideration.

The management of emergency should follow the universally accepted ABCDE approach [1], which helps the clinician to follow a systematic approach in an emergency situation where the most life-threatening condition is assessed and is given the top priority. Lack of airway kills the patient first, then the lack of ability to breathe followed by the absence of circulation. ABCDE approach incorporates:

- A: Airway
- B: Breathing
- C: Circulation
- D: Disability (refers to neurological function)
- E: Exposure

Medical Emergencies that are life threatening and need immediate remedial measures on an emergency basis are discussed here:

1. Acute Asthmatic Attack
2. Adrenal Crisis
3. Airway Obstruction
4. Anaphylaxis
5. Chest Pain
6. Cardiac Arrest
7. Hypoglycemia
8. Tonic-Clonic Seizure
9. Syncope.

4.2 Acute Asthmatic Attack

Stress, Anxiety, and Infection can precipitate an asthmatic attack in individuals who are prone. Unfortunately, all three of them can be part of OMFS practice.

Box 4.1

Note: Asthma that is part of a generalized anaphylactic reaction needs Adrenaline via intramuscular route.

Signs and Symptoms:

- Difficulty in breathing
- Cough
- Wheezing
- Use of accessory muscles of respiration
- Tightness of chest

N. V. S. Sekhar Reddy (✉)
Panineeya Institute of Dental Sciences and Research Centre,
Hyderabad, Telangana, India

- Rapid breathing and Tachycardia
- Pale and anxious-looking face

Management:

- Keep the patient in a sitting position.
- Give two puffs of Salbutamol (100 µg/puff) inhaler [2, 3].
- If no rapid response, give further puffs through a spacer device.
- Consider oxygen supplementation.
- If no improvement, consider urgent transfer to a medical center.

4.2.1 Life-Threatening Acute Asthma

Asthmatic attack can sometimes be severe and may fail to respond to standard bronchodilator therapy. This can be fatal if no proper treatment is given. When an asthmatic attack failed to respond to the treatment and getting worse, the patient will need urgent transfer to appropriate medical center.

Signs and symptoms of severe life-threatening asthma:

- Silent chest, poor respiratory effort, cyanosis
- $SPO_2 < 92\%$
- Exhaustion
- Altered consciousness
- Weak or irregular pulse

Treatment:

- Urgent transfer to hospital is needed.
- Oxygen supplementation.
- Salbutamol 100 µg/puff; give four puffs through spacer device, followed by two puffs every 2 min according to response, up to a maximum of ten puffs or if there is nebulizer available, give salbutamol 5 mg [4].
- Hydrocortisone: 100 mg IV, or Prednisolone: 40–50 mg Orally [4].
- For children 5 years and above, use Oral Prednisolone 30–40 mg.
- For children less than 5 years, give salbutamol inhalation up to a maximum of ten puffs while awaiting transfer to an appropriate medical facility [2].

4.3 Acute Adrenal Insufficiency/Adrenal Crisis/Steroid Crisis/Addisonian Crisis

Sudden and severe hypotension in patients who cannot mount a normal stress-induced cortisol response. The stress can be physiological or psychological. Adrenal crisis can be seen in patients who were taking glucocorticoids regularly or who have taken glucocorticoids for a considerable period of time in the past, patients with Addison's disease, hypopituitarism, or in other conditions associated with decreased adrenocorticotropic hormone (ACTH) production.

Box 4.2

Oxygen—Supports Combustion

Keep cylinders away from open flames and heat sources

Oxygen cylinder should be stored in a well-ventilated area

Do not oil, grease, or lubricate cylinder controls.

Signs and Symptoms:

- Severe hypotension, which can manifest as weakness, confusion, dizziness, drowsiness, loss of consciousness.
- Nausea, vomiting.
- Seizure may occur following deep faint.

Treatment:

- Lay patient flat.
- Give high flow oxygen.
- Arrange for urgent transfer to a medical center.
- Establish Intravenous access.
- Administer Hydrocortisone sodium succinate by IV. Dosage given below [5, 6]:
 - Children from age 2 to 11 years, 2–4 mg/kg body weight.
 - Above 11 years: give adult dose.
 - Adult dose: 100 mg by IV.
 - If unable to secure IV access, give the same dose by IM route.
- Start IV infusion of 0.9% Normal Saline.

4.4 Airway Obstruction

As the mouth is the primary area of our specialty, clinicians may have to deal with acute airway obstruction. As with everything else, prevention is the most important thing.

Signs and Symptoms:

- Distressed patient.
- Abnormal noises like gurgling, crowing, snoring.
- Forced inspiratory efforts.
- No sounds at all in complete airway obstruction
- Various degrees of cyanosis leading to loss of consciousness.

Treatment [7]:

- Encourage the patient to cough.
- If an object could be visualized, retrieve it with an appropriate instrument.
- If obstruction is caused by fluids, use high-volume suction.
- Back slaps: up to five back blows between the scapulae while the patient is supported leaning forward.
- Abdominal thrusts: (Heimlich maneuver) up to five abdominal thrusts by standing behind the patient.

- If obstruction fails to relieve, continue with five back blows alternating with abdominal thrusts.
- If these measures fail, the patient will lose consciousness. Lay the patient down on floor and start with CPR.
 - Start with chest compressions even if there is pulse, as chest compressions can help relieving the obstruction.
- If there is partial obstruction, which could not be relieved by the foregoing means, arrange for emergency transfer to appropriate medical care.
 - Patient may need oxygen supplementation.
- In patients with a completely obstructed airway, where the obstruction could not be relieved with these measures, where there are no facilities or skill to use a laryngoscope, emergency invasive procedures like jet insufflation or cricothyroidotomy may be needed as life-saving measures.
- Jet Insufflation involves placing a wide bore cannula (12–14 gauge) through cricothyroid membrane and connect this to a high flow oxygen source.
- It is advised to read further about Jet insufflation and Cricothyroidotomy as the full detailed description is beyond the scope of this textbook.
- Position the patient in supine position unless the patient prefers to sit up due to breathing difficulties.
- Make arrangements for emergency transfer to appropriate medical center.
- While waiting for transfer [10],
 - Oxygen supplementation at 15 L/min.
 - Keep assessing the airway and provide necessary support.
 - Chlorpheniramine maleate IM or IV.
 - Hydrocortisone sodium succinate IM or IV.
 - Establish Intravenous access.
 - Ringer’s lactate solution or 0.9% Normal saline to support circulation.
 - Reassess the need for further adrenaline.
- Start CPR in case of cardiac arrest.

Box 4.3

Aspiration of small objects like burs, endodontic files, and reamers may not cause immediate life-threatening airway obstruction, but retrieval of these rather small and prickly instruments from lungs is a very difficult task needing bronchoscopy and can result in serious lung infections and damage. Prevention takes priority.

4.5 Anaphylaxis

Sudden onset, severe form of life-threatening allergic reaction, which can be seen following exposure to an allergen. Remember topical anesthetic gels, chlorhexidine mouth wash, and even contact with latex gloves can trigger anaphylaxis in individuals who are sensitive [8].

Prompt recognition and immediate response are key to success.

Signs and Symptoms:

- Face—red and hot.
- Generalized skin rash with itching.
- Various degrees of breathing difficulties manifested as stridor, wheezing, or hoarseness.
- Pulse may initially be rapid but can gradually become weak or impalpable.
- Hypotension can progress to cardiac arrest.

Treatment:

- Make sure airway is clear.
- Administer Adrenaline [9].

Box 4.4

Adrenaline is to be administered if there is severe respiratory distress or when there are signs of shock.

Box 4.5

Adrenaline—Life-saving drug for Anaphylaxis

Repeat after 5 min if not getting better

Supply: 1 mL ampoule containing 1 mg adrenaline in 1:1000 concentration

Site: I.M Anterolateral thigh

Dosage:

Adult: 500 µg IM 0.5 mL

Child More than 12 years: 500 µg IM 0.5 mL

Child 6–12 years: 300 µg IM 0.3 mL

Less than 6 years: 150 µg IM 0.15 mL

Box 4.6**Second-line drugs:**

Hydrocortisone sodium succinate: 100 mg

Route: IM or Slow IV

12 years and adults: 200 mg IM/IV

6–12 years: 100 mg IM/IV

6 months to 6 years: 50 mg IM/IV

Chlorpheniramine Maleate

Supply: Chlorpheniramine Maleate 10 mg/1 mL

Ampoule

Route: IM or IV

12 years and adults: 10 mg IM/IV

6–12 years: 5 mg IM/IV

6 months to 6 years: 2.5 mg IM/IV

4.6 Chest Pain

Experiencing chest pain in an outpatient office can be a frightening experience for both the patient and to the attending clinician. Thorough understanding of the pathophysiology of these acute cardiac events is very important for the clinician to stay composed and initiate appropriate measures to prevent mortality. Myocardial infarction may not always have the typical features of chest pain and especially diabetic patients may not have pain. Hence, a high index of suspicion is what is required.

Causes of chest pain:

- Angina
- Myocardial Infarction
- Hyperventilation

Hyperventilation is associated with anxiety and often a young person who is quite frightened of the intended treatment, the breathing gets very heavy resulting in decreased carbon dioxide levels in the blood.

4.6.1 Angina

Transient decrease of oxygen supply to cardiac muscle precipitates pain.

Precipitating factors:

Anxiety, stress, exertion, strong emotions, heavy meal, and extreme weather conditions.

Signs and Symptoms:

If you are looking for typical symptoms of chest pain, you may miss some cases. List of all possible presentations being:

- Pain, heaviness, or tightness in the chest.
- Pain in the neck, throat, arms, stomach, and back.
- Pain can be associated with light-headedness, nausea, shortness of breath, and sweating.

Management:

- Stop the procedure and reassure the patient.
- Clear the mouth from any foreign bodies.
- Let the patient attain a comfortable position (may not like to lie flat).
- Administer Glyceryl trinitrate sublingual spray or Glyceryl trinitrate sublingual tablets [11].
- Oxygen supplementation.
- Check for any irregularities of pulse.

Simple angina should resolve very quickly with rest alone or with sublingual glyceryl trinitrate spray or tablets. In simple angina, the cardiac output is not impaired, and pulse

should be regular. In a patient with chest pain, having an irregular pulse, suspect MI.

4.6.2 Myocardial Infarction (Heart Attack)

Progressive/Sudden ischemia of the cardiac muscle leads to necrosis of cardiac muscle. This can cause cardiac arrest.

Signs and Symptoms:

- Same as angina but can be more severe in intensity and lasts long.
- Pain in the center of the chest.
- Pain radiates to neck, arms, jaw, back, or stomach.
- Pain associated with sweating, vomiting, shortness of breath, lightheadedness, or dizziness.
- Chest discomfort associated with a feeling of weakness and unwell.
- Chest pain associated with an irregular pulse.
- Chest pain fails to relieve with two doses of Nitroglycerin sublingual Spray.
- Chest pain getting progressively worse.
- Patient with previous experience of angina, now experiencing an unusual type of chest discomfort.
- Weak pulse.
- Falling Blood pressure.
- Skin—pale and clammy.

Management:

- The moment MI is suspected, arrange for an emergency transfer of the patient to an appropriate medical facility.
- Let the patient attain the most comfortable position. The patient may like to sit up to avoid venous congestion on the heart and lungs.
- Administer soluble Aspirin, 300 mg [12]. Chew and swallow for rapid action.
- By this time, the patient should have received at least two doses of sublingual Glyceryl trinitrate spray or tablets [12], this may need a repeating.
- While waiting for transfer, the following measures can be done, but do not delay transfer, early expert care improves outcome.
 - Establish IV access.
 - Give antiemetic Metoclopramide hydrochloride by IV [13].
 - Adult > 60 kg, dose 10 mg
 - Small-sized Adult <60 kg, dose 5 mg
 - Administer analgesia - Paracetamol by slow IV (Morphine, diamorphine 7 fentanyl, are not easily available in India) [13].

Adult >50 kg, dose 1000 mg in 100 mL
 Small-sized Adult <50 kg, dose 750 mg in 75 mL
 When no IV access, alternatively, give Oral
 Paracetamol 650 mg

- Do not routinely administer oxygen. Supplemental oxygen only when hypoxic.
- Patients where consciousness level deteriorates.
 - Watch for signs of cardiac arrest.
 - Start CPR, if cardiac arrest occurs.

Box 4.7

Drugs for MI:

Glyceryl Trinitrate Aerosol Spray: 400 µg/metered dose

Glyceryl Trinitrate: 300-µg tablets

Soluble Aspirin: 300-mg tablets

Metoclopramide: 10-mg solution for IV

Paracetamol: 1000-mg/100-mL solution for IV

Paracetamol: 500-mg tablets

Paracetamol 650 mg tablets

- Not breathing normally (agonal breathing/gasping) or absent breathing
 - Some people may have a seizure when cardiac arrest occurs as a result of severe cerebral hypoxia.

Box 4.8

Chest pain in a patient with previous history of stable angina: Urgent transfer to appropriate medical facility is to be done, if the patient feels the pain is unusual or if the pain doesn't resolve with rest and Sublingual Glyceryl Trinitrate.

Box 4.9

Do not waste time, for example, trying to find a vein while the ambulance is waiting! Antiplatelet medication (aspirin) within few minutes of suspecting MI and early thrombolysis by the Physicians can significantly reduce the mortality associated.

4.7 Cardiac Arrest

Cardiac arrest is a sudden loss of heart function resulting in hypoxic damage to body organs. Lack of oxygen to the brain causes loss of consciousness, victim falls to the ground and stops breathing. Cardiac arrest can occur suddenly with or without any symptoms.

Following cardiac arrest neurons start to die within 4–6 min without oxygen. Chances of survival can be increased by early defibrillation (where indicated) and good-quality Cardiopulmonary Resuscitation, that's instituted quickly and performed with minimal interruptions. Automated External Defibrillators (AED) are increasingly available and these can analyze the rhythm, whether it's shockable or not and can suggest you through the process of CPR by voice commands. In centers where AEDs are not available, CPR is continued until appropriate help arrives. Often, in busy countries like India, this can take quite a considerable amount of time, so hospitals and healthcare establishments should be encouraged to buy AEDs.

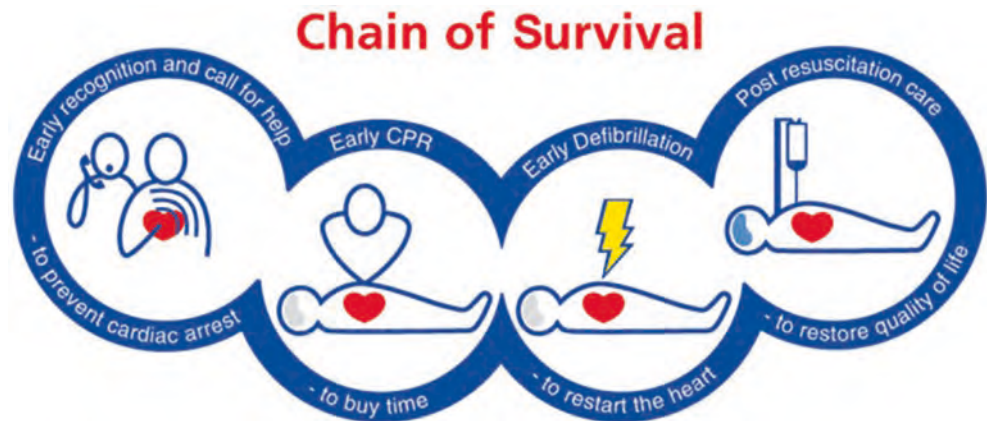Recognition of cardiac arrest:

- Unconscious
- Unresponsive

Management:

- Call for help and ask to bring defibrillator and emergency drug kit.
 - Second person can call for ambulance.
 - Start CPR [14]
 - CPR can be executed in the dental chair.
 - Start with chest compressions.
 - Second person checks airway, gets ready for ventilations, preferably using a bag valve mask.
 - Give 30 chest compressions.
 - Give two ventilations.
 - Carry on CPR at 30:2 until expert help or AED arrives.
 - Stop CPR when patient shows signs of life.
- CPR with AED:
- Continue with CPR while the pads of AED are being attached.
 - Stop CPR and do not touch victim while the AED starts analyzing the rhythm [15].
 - Nonshockable rhythm observed by AED—continue CPR until signs of life or AED starts analyzing rhythm again [16].
 - Shock advised by AED—Make sure no one touches the patient directly or indirectly—Deliver the shock.
 - Continue CPR at 30:2 while the pads remain attached.
 - After 2 min, AED will start reanalyzing the rhythm and the cycle to be continued until the patient shows signs of life.

Fig. 4.1 Chain of survival



- Once the patient regains consciousness, put the patient in recovery position and maintain saturations above 94%, supplemental oxygen may be needed.
- The patient should receive appropriate post-resuscitation care and keep monitoring as chances of a second cardiac arrest is high in the immediate post-resuscitation period.

To improve overall outcome in cardiac arrest patients, it is necessary to follow these four important aspects of care:

1. *Early recognition and call for help*—do not waste time trying to ascertain if pulse is there or not. A patient who is unresponsive and not breathing should be considered in cardiac arrest unless until proven otherwise.
2. *Early CPR*—the victim soon after cardiac arrest will have some oxygen in the blood and starting with chest compressions early will be extremely beneficial to the cells starved of oxygen.
3. *Early Defibrillation*: The chances of reversing a shockable rhythm diminish with the passage of time.
4. *Post resuscitation care*: All patients who have been successfully reversed from cardiac arrest should be transferred to an appropriate center with cardiac care facilities.

The four points are incorporated into this internationally recognized “chain of survival,” which is given here (adapted from the Resuscitation Council UK; website: <https://www.resus.org.uk/EasysiteWeb/getresource.axd?AssetID=3907&type=Full&servicetype=Attachment>) (Fig. 4.1):

Box 4.10

All healthcare workers should undergo proper training in CPR. Healthcare organizations throughout the world are now insisting on a CPR certificate. Such a training has to be done on a periodic basis so that the skills are retained. The reader is strongly advised to undergo training periodically and a valid certificate will prevent you from future litigation if an unfortunate event occurs to one of your patients.

4.8 Hypoglycemia

Glucose is essential for the effective functioning of neurons. When the glucose levels in blood drop to a very low level, brain function will get affected and if the glucose levels are not restored quickly, permanent neurologic damage can occur within 4–6 min. Hypoglycemia can occur in diabetic patients taking Insulin, who skipped meal, and is also the leading cause of loss of consciousness in children. Hypoglycemia occurs when blood glucose level falls below 70 mg/dL.

Signs and Symptoms:

- Anxious, confused, irritable, or aggressive behavior.
- Sweating
- Nausea and vomiting
- Hungry
- Visual disturbances
- Convulsions
- Loss of consciousness.

Management [17]:

Management depends on consciousness level and the ability of the patient to take food orally without the risk of aspiration.

- Conscious patient:
 - 10–20 g of glucose
10 g of glucose in two teaspoons of granulated sugar
Two teaspoons of Glucon-D powder contain 15 g of Glucose
 - Can be repeated in 10–15 min
 - Once the patient’s condition improves, provide a carbohydrate snack or meal as appropriate to raise blood glucose level.
- Unconscious patient:
 - Check if airway is clear—ABCDE approach
 - Put patient in recovery position
 - Oxygen supplementation at 15 L/min

- Give Glucagon by IM route into the anterolateral thigh
- If Glucagon is not available
 - Arrange for emergency transfer of patient
 - Give 100 mL of 10% dextrose by IV route
 - Severe cases of hypoglycemia need 50 mL of 50% Dextrose
 - Higher concentrations of dextrose are thicker solutions, need a larger bore cannula.
 - Once the patient regains consciousness, give oral glucose and carbohydrate as earlier.
- Ascertain hypoglycemia as a possible cause by checking blood glucose level by a finger prick test. This should be done in a patient with no previous history of epilepsy. Hypoglycemia is common in children and in diabetic patients [19].
- Once the convulsions are stopped:
 - Provide reassurance and empathy to the patient
 - Explain what had happened
 - Examine the mouth for any fluids and use suction
 - Examine for any bleeding, lacerations of tongue secondary to biting
 - Place the patient in a recovery position
 - Examine for any other injuries
 - Provide oxygen as required
 - Stay with the patient until the patient is fully recovered
 - Do not give anything orally until the patient is fully conscious, to avoid the risk of aspiration
 - Do not attempt to arouse a patient who is sleeping after a convulsive episode
- Prolonged Convulsions beyond 5 min or repeated seizure activity without proper recovery constitutes—status epilepticus [20], which can be fatal and needs to be managed as:
 - Make arrangements for urgent transfer to appropriate medical center
 - Administer midazolam intravenously [21]
 - Where IV access is not possible:
 - Rectal route can be used effectively, especially in children.
 - Buccal midazolam gel can be instilled into buccal vestibule with the help of a syringe with no needle.
 - Midazolam sprays, which can be used via nasal route, are slowly being available in India.
 - Buccal and nasal routes are increasingly being used and the reader is advised to look up for more up-to-date information as suitable formulations are not routinely available in India.

Box 4.11

Glucagon either by IM or SC route

Dose: Adult—1 mg

Child under 8 years or less than 25 kg should be given 500 µg (0.5 mg)

Keep patient in lateral position to prevent risk of aspiration

4.9 Grand Mal Seizures

Enquire with patients about how frequently they get seizures and their compliance with medication. Patients with frequent seizure history or patients who are irregular with their medications are more likely to have a seizure while having dental procedures. Provide the treatment in a calm, stress-free environment, avoid any seizure-triggering factors.

Signs and Symptoms:

- Seizure activity may have a brief period of aura, where the patient can behave indifferently, spaced out, and detached.
- The patient will go rigid, lose consciousness, lose balance, and may cry-tonic (rigidity) phase.
- After a few seconds, sudden rhythmic jerking movements of the body lasting for up to 2 min.
- Mouth goes rigid. Frothy saliva can be noticed.
- Cyanosis around the mouth can be noticed as breathing stops.
- Possible urination.
- Following the seizure, patient can go into varying periods of confused state and may fall asleep.

Treatment [18]:

- Prevent injury to patient
 - Remove all the sharps away
 - Create safe space around a fitting patient
 - Provide cushions like a pillow or blanket
 - Pay particular attention to head
- Do not restrain
- Do not attempt to insert any object between teeth
- Supplemental oxygen at 15 L/min
- Have a suction readily available, with a yankauer suction tube clear oral cavity of any fluids after seizure stops [19].

Box 4.12

Midazolam Dosage:

I.V route: Above 12 years, 5 mg slowly—patient may need encouragement to breathe after IV midazolam.

I.M route: Adult: 0.2 mg/kg, Not to exceed 10 mg in total.

Child: 0.1–0.2 mg/kg, not to exceed 10 mg in total

Nasal Spray: Child: 0.2 mg/kg body weight (Max: 5 mg/nares)

Rectal: Adult and children above 12 years: 10–20 mg, can be repeated once after 10–15 min if needed

Child 2–11 years: 5–10 mg, can be repeated once after 10–15 min

Box 4.13

Remember generalized tonic-clonic seizures can be seen in:

- Epilepsy
- Head injury
- Hypoglycemia
- Hypoxia
- Alcohol withdrawal
- Drugs
- Local anesthesia overdose or Intravascular injection
- Febrile convulsions

Box 4.14

Midazolam is a benzodiazepine that carries the risk of respiratory depression. Patients need close monitoring after drug administration and may need respiratory support.

Box 4.15

Typical grand mal seizure, in a known epileptic patient, where the seizure has subsided within a couple of minutes, patient can be discharged with the carer, provided all the vital signs are within normal range. Urgent hospital transfer is indicated in all other epileptic seizures.

4.10 Syncope

Energy demands of the brain are met primarily by oxidation of glucose. A regular and constant supply of glucose and oxygen is essential for brain function. Supply of both glucose and oxygen depends on effective perfusion of the brain. When brain perfusion decreases beyond a critical level, the patient loses consciousness and the balance gets affected and the patient falls.

Signs and Symptoms:

- Feeling unwell
- Nausea, Lightheadedness
- Blurred vision
- Pallor
- Sweaty, especially forehead
- Sudden loss of consciousness and collapse
- Seizure, if the patient is not positioned in a horizontal position quickly.

Management [22]:

- Clear airway and reassure
- Change position to a flat or legs elevated
- Let fresh air by opening a window or a fan
- Do not let people to crowd around
- Place cold towel on forehead
- Supplemental Oxygen can be given, but usually, if it's simple faint consciousness should recover very quickly.
- Once recovered, encourage the patient to have a sugary drink.
- Examine for injuries secondary to fall.

4.11 Other Causes of Loss of Consciousness

Although syncope is the most common cause of loss of consciousness, the other causes should also be borne in mind, as some of them can be quite serious, such as:

- Postural Hypotension
- Hyperventilation
- Epilepsy
- Adrenaline crisis
- Hypoglycemia
- Stroke
- Cardiac Arrest

Postural Hypotension:

- Loss of consciousness following a sudden change of posture from supine or sitting to standing upright.
- Usually in patients who are taking antihypertensives or elderly.
- Place them in a supine position and bring them to the upright position slowly.

Hyperventilation:

Excessive breathing in an anxiety state or excessive crying resulting in drop of blood CO₂ level.

- Feeling lightheaded, dizzy
- Chest discomfort to chest pain
- Muscle spasms, especially in hands and feet
- Tingling or numbness in the arms and in the perioral region
- Control the crying/breathing through suggestion
- Use a paper bag to rebreath exhaled air to build up CO₂ levels

4.12 Conclusion

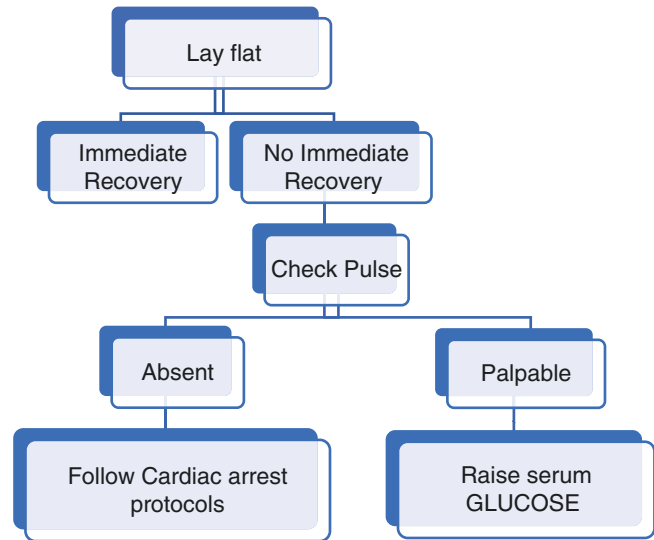
Preparedness for emergency is the key and when you are prepared, emergencies are easier to manage. The maxillofacial surgeon should be able to recognize these conditions and initiate appropriate management before professional emergency help is available. More often, maxillofacial surgeon is the lone clinician and is the sole responder in an emergency. It is prudent for the surgeon to know what to do and what not to do to get the best out of the worst scenario or situation.

It is imperative that the maxillofacial surgeons thoroughly understand the pathophysiology and extend their skills to recognize and manage expeditiously and effectively the emergencies that may arise. It is advisable that the contemporary clinicians update their knowledge and skills periodically with proper training courses.

Protocols given here are based on the currently available evidence, keeping in view of the local healthcare systems and access. As protocols are only suggestive, the clinician is strongly advised to use his or her own discretion when dealing with medical emergencies (Table 4.1; Flowchart 4.1).

Table 4.1 Causes of loss of consciousness and its age distribution

Causes of unconsciousness		
Child	Teen-mid 30	Above 40
Hypoglycemia	Syncope	Cardiovascular causes
Epilepsy	Hypoglycemia	
Congenital heart disease	Epilepsy	



Flowchart 4.1 Management algorithm for a collapsed patient where the cause of collapse is not known

References

1. Thim T, Krarup NHV, et al. Initial asseement and treatment with the Airway, Breathing, Circulation, Disability, Exposure (ABCDE) approach. *Int J Gen Med.* 2012;5:117–21.
2. Saglani S, Fleming L, Sonnappa S, et al. Advances in the aetiology, management, and prevention of acute asthmatic attack in children. *Lancet Child Adolesc Health.* 2019;3(5):354–64.
3. Fergeson JE, Patel SS, Lockey RF. Acute asthma, prognosis, and treatment. *J Allergy Clin Immunol.* 2017;139(2):438–47.
4. Marsh B, Drake MG. Outpatient management of acute exacerbations of obstructive lung diseases. *Med Clin N Am.* 2017;101(3):537–51.
5. Hahner S. Acute adrenal crisis and mortality in adrenal insufficiency. *Ann Endocrinol.* 2018;79(3):164–6.
6. Paur THK, Stikkelbroeck NMMI, et al. Adrenal crisis: still a deadly event in the 21st century. *Am J Med.* 2016;129(3):339.
7. Schwartz A. Airway mangement for the oral surgery patient. *Oral Maxillofac Surg Clin N Am.* 2018;30(2):207–26.
8. Chapman J, Lalkhen AG. Anaphylaxis. *Anaesth Intensive Care Med.* 2017;18(1):16–21.
9. Young NH, Nimmo GR. Anaphylaxis. *Medicine.* 2017;45(3):157–62.
10. Moore LE, Kemp AM, Kemp SF. Recognition, treatment, and prevention of Anaphylaxis. *Immunol Allergy Clin N Am.* 2015;35(2):363–74.
11. Waller JR, Waller DG. Drugs for systemic hypertension and angina. *Medicine.* 2018;46(9):566–72.
12. Dym H, Barzani G, et al. Emergency drugs for the dental office. *Dent Clin N Am.* 2016;60(2):287–94.

13. Herman WW, Ferguson HW. Dental care for patients with heart failure: an update. *J Am Dent Assoc.* 2010;141(7):845–53.
14. Yates EJ, Schmidbauer S, et al. Out of hospital cardiac arrest termination of resuscitation with ongoing CPR: an observational study. *Resuscitation.* 2018;130:21–7.
15. Fernando SM, Vaillancourt C, et al. Analysis of bystander CPR quality out of hospital cardiac arrest using data derived from AED. *Resuscitation.* 2018;18:138–43.
16. Pollack RA, Brown SP, et al. Bystander automated external defibrillator application in non-shockable out of patient cardiac arrest. *Resuscitation.* 2019;137:168–74.
17. Bansal N, Dhaliwal R, et al. Management of diabetes in elderly. *Med Clin N Am.* 2015;99(2):351–77.
18. Johnson EI. Seizures & epilepsy. *Med Clin N Am.* 2019;103(2):309–24.
19. Thijs RD, Surges R, et al. Epilepsy in adults. *Lancet.* 2019;393(10172):689–701.
20. Paris M, Reddy U. Update on the management of status epilepticus. *Anaesth Intensive Care Med.* 2018;19(3):83–6.
21. Papavasiliou AS, Kotsalis C, et al. Intravenous midazolam in convulsive status epilepticus in children with pharmacoresistant epilepsy. *Epilepsy Behav.* 2009;14(4):661–4.
22. Numeroso F, Mossini G, et al. Emergency department management of patients with syncope according to the 2018 ESC guidelines. *Int J Cardiol.* 2019;283:119–21.

Open Access This chapter is licensed under the terms of the Creative Commons Attribution 4.0 International License (<http://creativecommons.org/licenses/by/4.0/>), which permits use, sharing, adaptation, distribution and reproduction in any medium or format, as long as you give appropriate credit to the original author(s) and the source, provide a link to the Creative Commons license and indicate if changes were made.

The images or other third party material in this chapter are included in the chapter's Creative Commons license, unless indicated otherwise in a credit line to the material. If material is not included in the chapter's Creative Commons license and your intended use is not permitted by statutory regulation or exceeds the permitted use, you will need to obtain permission directly from the copyright holder.



Part III

Anesthesia for Oral and Maxillofacial Surgery

Local Anesthesia in Oral and Maxillofacial Surgery

Reena Rachel John

5.1 Introduction

Pain, the dreaded symptom, is an unpleasant sensation that draws the attention of the individual as a whole. Its management has greatly evolved in the field of dentistry, starting from the leaves of a coca tree to articaine, Comfort Control Syringe (CCS) system, Transcutaneous Electrical Nerve Stimulation (TENS), Computer-Controlled Local Anesthetic Delivery System as well as oral and intravenous sedatives. Apart from all these, local anesthesia (LA) is the favored mode of pain control in the profession. The painless surgery under LA is must; otherwise, endogenous catecholamines are released if there is excessive pain during dental treatment, which can alter the hemodynamic status such as an increase in blood pressure and heart rate and even dysrhythmias [1].

5.1.1 Historical Background

The first local anesthetic isolated from the leaves of a coca tree in 1860 by Neiman was cocaine, and it was Karl Koller in 1884 who showed the anesthetic effect of Cocaine. In 1905, Einhorn popularized Procaine as an effective local anesthetic. It was derived from benzoic acid and diethyl amino ethanol. In 1948, the anesthetic property of lignocaine was discovered by Lofgren, and T. Gordh applied it in dental surgery [2].

5.1.2 Definition

Local anesthesia is defined as a reversible loss of sensation in the circumscribed area of the body caused by depression of

excitation in the nerve endings or inhibition of the conduction process in peripheral nerves [2].

5.1.3 Ideal Characteristic of Local Anesthesia

An ideal local anesthetic must have the following characteristics:

- It should be nonirritating and nonallergic.
- It should not cause structural changes to nerve and have low systemic toxicity.
- Its onset of action should be short and should be stable in solution.
- It should be effective as both injectable and topical application.
- Its action should be long enough to allow the procedure to be completed.

5.2 Classification (Tables 5.1 and 5.2)

Table 5.1 Classification of local anesthetic agents: based on chemical structure

Chemical structure	Example
Esters of benzoic acid	Cocaine, Benzocaine, Butacaine, Piperocaine, Tetracaine
Esters of para amino benzoic acid	Procaine, Chloroprocaine, Propoxycaine
Amides	Articaine, Bupivacaine, Lidocaine, Dibucaine, Mepivacaine, Prilocaine
Quinolone derivatives	Centbuclidine

R. R. John (✉)
 Department of Oral and Maxillofacial Surgery,
 Vinayaka Mission's Sankarachariar Dental College and Hospital,
 VMRF DU, Salem, India

Table 5.2 Classification of local anesthetic agents: based on duration of action

Duration of action	Example
Ultra short acting Pulpal anesthesia: less than 10 min Soft-tissue anesthesia: 30–45 min	Chloroprocaine, Procaine
Short acting Pulpal anesthesia: 5–10 min Soft-tissue anesthesia: 60–120 min	Lidocaine, Prilocaine
Medium acting Pulpal anesthesia: 45–90 min Soft-tissue anesthesia: 120–240 min	Mepivacaine, Articaine
Long acting Pulpal anesthesia: 90–180 min Soft-tissue anesthesia: 240–540 min	Bupivacaine, Etidocaine

5.3 Local Anesthetic Agents

The LA agents have been divided into Esters and Amides groups. The commonly used Amides are Lidocaine, Articaine, and Bupivacain [2].

5.3.1 Lidocaine (Lignocaine)

Lofgren in 1943 introduced the prototype amide local anesthetic [2], i.e., Lidocaine.

The other similar names are xylocaine, octocaine, dencocaine. Chemically, it is Diethyl 2, 6 dimethyl acetanilide. The maximum recommended dosage for Lignocaine with vasoconstrictor is 7 mg/kg not exceeding 500 mg and without vasoconstrictor is 4.4 mg/kg not exceeding 300 mg. Its onset of action is 2–3 min and duration of action with vasoconstrictor is 45–75 min, without vasoconstrictor is less than 30 min. Its contraindications include Ehlers Danlos syndrome and Attention-deficit hyperactive syndrome. Lignocaine is available in the form of jelly, spray, patches, and ointments. The toxicity arises from inadvertent intravascular administration or from overdose.

Recently, Howlader et al. [3] suggested open reduction and internal fixation (ORIF) of isolated subcondylar fractures under local anesthesia by using 2% lidocaine with 1:200,000 epinephrine for mandibular nerve block and superior cervical plexus blocks (SCPB).

To anesthetize the cutaneous branches of SCP (lesser occipital, greater auricular, transverse cervical, and supraclavicular nerve), the solution is deposited at the midpoint of the posterior border of sternocleidomastoid muscle border, as well as inferior and superior to that point subcutaneously creating a field block.

The anesthetic agent selection should be based on three main clinical considerations: anesthetic potency and latency, onset, and duration. The composition of the local anesthetic solution is shown in Table 5.3.

Table 5.3 Composition of local anaesthetic solution (Lignocaine with Adrenaline)

Ingredients	Functions
Lignocaine HCl 2% (21.3 mg)	Anesthetic agent
Adrenaline 1:80,000 (0.0125 mg)	Vasoconstrictor, decreased absorption of LA in blood
Sodium Metabisulfite (0.5 mg)	Preservative
Methyl Paraben (1.0 mg)	Preservative to increase shelf life
Sodium Chloride (0.6 mg)	Isotonicity of solution to the tissues
Sodium Hydroxide	To maintain and adjust pH
Thymol	Fungicidal
Distilled water	Dilution
Nitrogen Bubble	1–2 mm in diameter, present to prevent oxygen from being trapped in cartridge and potentially destroying vasopressor or vasoconstrictor.

5.3.2 Bupivacaine

Its chemical name is 1 butyl-2,6piperoloxylidine hydrochloride.

It is four times more potent than prilocaine, lidocaine, and mepivacaine. It is less toxic than lidocaine and mepivacaine and it is metabolized in the liver by amidases and excretion via kidney 16% unchanged. Its onset of action is similar to lidocaine, mepivacaine, and prilocaine. Effective dental concentration is 0.5% and anesthetic half-life is 2.5 h.

Maximum recommended dose is 1.3 mg/kg body wt to a maximum of 90 mg. Because of its long duration of action, it is advisable for use in lengthy surgical procedure and the management of postoperative pain. Hence, the patient's requirement for postoperative opioid analgesics is lessened when bupivacaine is used. Bupivacaine is not recommended in young patients as the risk of self-mutilation is increased.

The duration of soft-tissue anesthesia has been consistently shown to be longer than with lidocaine [4] and thereby reducing postoperative pain experience [5].

5.3.3 Articaine

Its chemical structure is 3-N Propylaminopropionylamino 2-Carbomethoxy 4-Methylthiophene hydrochloride.

The potency of Articaine is 1.5 times more than lignocaine and 1.9 times than procaine. Its onset of action when used with vasoconstrictor is 1–2 min. Half-life is approximately 21 min and it is metabolized to pharmacologically inactive metabolite called articaine acid glucuronide. Since it is rapidly biotransformed to its inactive metabolite, it is a safe local anesthetic agent. It is excreted via kidney

Table 5.4 Maximum recommended dose of common Local Anesthetic used

Local Anesthetic	mg/kg	mg/lb	MRD (mg)
<i>Articaine</i>			
With vasoconstrictor	7.0	3.2	500
<i>Bupivacaine</i>			
With vasoconstrictor	1.3	0.6	90
<i>Lidocaine</i>			
No vasoconstrictor	4.4	2.0	300
With vasoconstrictor	6.6	3.0	500

unchanged (5–10%) and as metabolite (90%). The maximum recommended dosage for articaine is 0.8 mg/kg body weight.

Contraindications for the use of articaine are Idiopathic or congenital methemoglobinuria, hemoglobinopathies, hypoxia, and in patients with cardio-respiratory failures. Prolonged paraesthesia has been reported as a complication following inferior alveolar nerve block (IANB) [6].

Articaine with epinephrine is the best choice to improve anesthesia in both inflamed and in uninflamed tissues with good results, and more effective anesthesia for longer duration can be achieved [7]. Table 5.4 shows maximum recommended dose of commonly used LA.

5.4 Vasoconstrictors

Importance of vasoconstrictors in local anesthetic solution include

1. To decrease the tissue perfusion and therefore to decrease the blood flow at the site of drug administration, which further decreases the absorption of local anesthetics into the circulatory system. Therefore, the blood levels of the anesthetic agents remain low, thereby decreasing the risk of toxicity [2].
2. It also increases the time taken by the local anesthetic to be absorbed from the site of administration and therefore increases the duration of action of the local anesthetic.

Most commonly used vasoconstrictors are epinephrine, norepinephrine, levonordefrin hydrochloride, phenylephrine hydrochloride.

5.4.1 Dilution of Vasoconstrictor

The explanation of 1:1000 vasoconstrictor concentration is that 1 g/1000 mg of solute is present in 1000 ml of the solution, which means 1 mg of solute in 1 ml of solution. In the local anesthetic solution, the concentration of vasoconstrictor is less. The concentrations used are 1:80,000 or 1:100,000 or 1:200,000. The concentration of 1:100,000 of the vasoconstrictor would contain 1000 mg in 100,000 ml of the solution. Therefore, 1 ml of 1:100,000 concentration would contain 0.01 mg in 1 ml.

Table 5.5 Quantity of vasoconstrictor with varying dilutions

Concentration (dilution)	Milligrams per milliliter (mg/ml)	Micrograms per milliliter (µg/ml)	Microgram per cartridge (1.8 ml)
1:1000	1.0	1000	
1:2500	0.4	400	
1:10,000	0.1	100	
1:20,000	0.05	50	90
1:30,000	0.033	33.3	73
1:50,000	0.02	20	36
1:80,000	0.0125	12.5	27.5
1:100,000	0.01	10	18
1:200,000	0.005	5	9

The absorption of vasoconstrictors is dose dependent and may last from minutes to half an hour. The patients with cardiovascular compromise are at increased risk with endogenously released epinephrine in response to stress rather than the epinephrine, which is injected with the local anesthetic (Table 5.5).

5.5 Causes of Failure of LA

1. Anatomic variation
2. Bifid or double nerve supply
3. Secondary supply by a soft-tissue nerve
4. Inadequate dose
5. Injection into the blood vessel
6. Degradation of vasoconstrictor
7. Patient having sepsis

5.6 LA Toxicity and Antidote for Toxicity

Symptoms, which reflect toxicity from the administration of local anesthetic solution, may range from mild cutaneous reactions to severe life-threatening anaphylactic reactions. There are a variety of methods and drugs to treat these reactions symptomatically. However, the reversal of toxicity, including damage to vital organs such as the heart and brain, is still less understood. A clinically efficient antidote for a complete reversal of toxicity is still beyond our grasp currently.

5.6.1 Reversal of Cardiomyotoxicity

Intravenous lipid emulsion (IVLE) is being reported as a rescue measure for LA toxicity. This has been studied and proven in both animal models and in limited human trials with successful resuscitation outcomes. The lipid emulsion acts on the plasma and tissue and extracts the lipophilic anesthetic molecules, thereby reversing their inhibitory myocardial effects. Bolus doses of 1.2–2 ml/kg followed by continuous infusion of 0.25–0.5 ml/kg/min are currently advocated for adequate efficacy. This drug needs to be used

judiciously as optimal dosages have not been established and the risks of overdosage are not clearly understood.

5.7 Reversal of Soft-Tissue Anesthesia

The duration of soft-tissue anesthesia often exceeds that of pulpal or bony anesthesia. This is an important reason for the occurrence of undesirable events like accidental lip or tongue biting, difficulties in speaking, eating, or drinking liquids, etc. Various drugs have been studied to decrease the postoperative duration of anesthesia. Of the various drugs tried clinically, phentolamine is one drug, which has demonstrated appreciable clinical efficacy.

Phentolamine is a nonselective alpha-adrenergic antagonist that is reversible. Its main action is vasodilatation. It has been used effectively for controlling hypertensive emergencies, especially in pheochromocytomas. In dental practice, Phentolamine in the form of phentolamine mesylate injections has been used as a reversal agent against LA by reversing the action of vasoconstrictors in the LA solution and expedites the metabolism of the LA molecules. The recommended dose for phentolamine is the administration of 1.8 ml of the solution containing 0.4 mg of phentolamine mesylate immediately after treatment.

5.8 Plain Local Anesthetic (Without Epinephrine)

It is preferred for patients having comorbidities such as circulatory disorder to avoid complications and adverse systemic effects of vasoconstrictors [8]. Lip laceration is one of the common cases, which are attended to by a maxillofacial surgeon in the emergency department for suturing. Localized blanching caused by the use of local anesthetic with adrenalin at the lacerated wound causes difficulty in locating the exact demarcation between skin, white roll, and lip. Therefore, LA without epinephrine is preferred in such cases before suturing [9].

5.9 Topical Local Anesthetic Agent

The solution used for this purpose is 5% Lignocaine, 10% Lignocaine, combination of 2.5% lignocaine and 2.5% prilocaine [10]. They are indicated in patients [11, 12]

- For removal of maxillary and mandibular arch bars
- Gingival probing
- Deep Scaling
- Closure of facial lacerations in younger children
- Before LA injections in small patients

In suture and staple removal

5.10 Surface Anesthesia

The form of drug used to obtain this includes ointment, gel, viscous, cream, spray, etc. Topical application of these forms can produce anesthesia on the surface, particularly of the oral mucosa.

This is used often, before an actual injection for L.A, at the site of injection, in order to reduce the pain of the needle prick itself. It can also be used to obtund pain in situations where the oral mucosa is breached, as in an ulcer in the oral mucosa. The gel may also be used to anesthetize the surface mucosa, e.g., nasal, pharyngeal, etc., before a diagnostic endoscopy.

The concentration of a local anesthetic applied topically is typically greater than the same drug administered by injection. Drugs that are commonly employed in topical L.A formulations are Benzocaine and Lidocaine.

EMLA, which is a eutectic mixture of local anesthetic agents, lignocaine, & prilocaine in the ratio 1:1 by weight, has been found to be a very useful topical agent to be applied on the skin, before painful procedures like injection, venipuncture, etc. and is used extensively in children. This particular cream, which is oil-in-water emulsion, may also be used for surface anesthesia of the oral mucosa for purposes listed earlier.

5.11 Methods of Local Anesthetic Administration

There are major three different types of methods:

- Local infiltration
- Field block
- Nerve block

In local infiltration, deposition of the local anesthetic solution in the area of the surgery to anesthetize small terminal nerve endings. Field block involves the deposition of anesthetic solution near the large terminal nerve branches to prevent the passage of impulses from teeth to the central nervous system. In nerve block, local anesthesia is deposited away from the site of surgery, but close to the main nerve trunk.

Different techniques for mandibular nerve block anesthesia have been published, including the mental/incisive nerve block [13–15].

1. The standard (Halsted) technique
2. The standard indirect technique
3. Mental nerve (incisive nerve) block
 - standard approach for mandibular anteriors and soft tissue
 - anterior approach
 - extraoral approach
4. Clarke-Holmes technique (1959)

5. Vazirani technique (1960)
6. Akinosi technique (1977) closed-mouth technique
7. Wolfe technique (1992)
8. Sargenti technique (1966)
9. Gow-Gates technique (1973)
10. Ipsilateral open-mouth technique (2007)
11. Morishita (positive aspiration) technique (2007)
12. Extraoral submandibular approach
13. Lateral extraoral approach
14. Anterior extraoral approach. (1969)

Different maxillary nerve block techniques have been described.

1. Anterior-superior alveolar nerve and infraorbital nerve blocks,
 - intraoral approach (bicuspid approach)
 - Bisecting approach (central incisor)
 - extraoral approach
 - nasal approach (1969)
2. Posterior-superior alveolar nerve block (tuberosity block)
3. Middle-superior alveolar nerve block (buccal approach)
4. Middle and anterior-superior alveolar nerve block (palatal approach)
5. Sphenopalatine (incisive) nerve block
6. Greater palatine nerve and lesser palatine nerves block
7. Maxillary nerve blocks,
 - High tuberosity approach
 - Greater palatine canal approach
 - nasal approach
 - lateral extraoral approach
 - suprazygomatic extraoral approach
 - anterior-lateral extraoral approach.

5.11.1 Percentage of Blood Vessel Penetration During IANB

During IANB, the intravenous injection of local anesthetic is very common. Frangiskos F et al. [16], in their study, found positive aspiration (the tip of the needle is in the blood vessel) 20% times. The positive aspiration was more commonly seen in young patient's age ranging from 9 to 19 years. To avoid systemic complications while giving local anesthesia, aspiration is must in each and every case.

5.11.2 Controversy in the Use of Bilateral IANB and Lingual Nerve Block [17]

Has bilateral IAN and Lingual nerve block been given? Some surgeons recommend, while some do not, but there are no published data available regarding its contraindications. The common complications associated with its use are

- Collection of fluid in the oral cavity
- Injury to tongue
- Loss of control of tongue, which can lead to respiratory embarrassment
- Unpleasant effects of bilateral anesthesia [18].

Many authors advocated the use of sodium bicarbonate in addition to the lignocaine solution to reduce the duration of onset of anesthesia, and it is very effective in reducing pain during the injection. Sodium bicarbonate ions also nonspecifically reduce the safety margin for nerve conduction and it has a direct action on the binding of Local anesthetic to the sodium channel [19–21].

5.12 Techniques

5.12.1 Inferior Alveolar Nerve Block (Also Known as Mandibular Nerve Block) [Along with Lingual & Long Buccal Nerve Blocks]

This is the single most important nerve block, whose technique needs to be mastered. With this, we can anesthetize the whole of the mandibular soft and hard tissues, including the cheek, and many procedures in this region can be carried out.

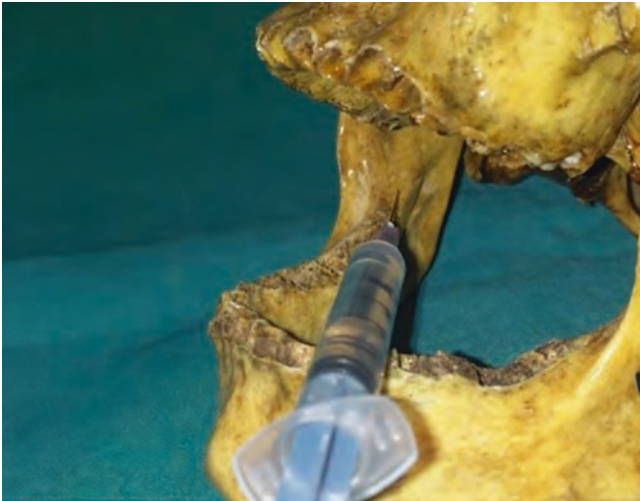
Secondly unlike in the maxilla, infiltration techniques do not provide adequate anesthesia to the hard tissue in the mandible, particularly the teeth. This is due to the dense cortical bone in the mandible, in contrast to the porous maxillary bone, where a paraperiosteal deposition of the solution can allow the solution to diffuse through the bone to the periapical region easily and cause anesthesia of the teeth and their supporting structures.

5.12.2 Technique

This description is for injection on the right side of the patient and for a right-handed operator. The surgeon is on the right side of the patient, in front of the patient. The patient is asked to open the mouth wide.

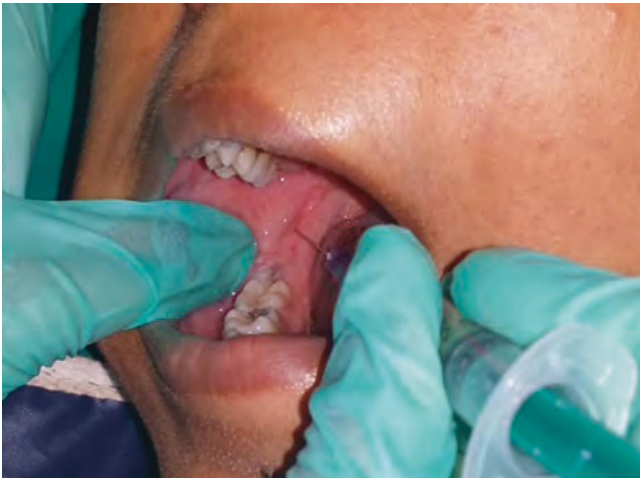With the left hand, the operator palpates the posterior buccal sulcus, runs the index finger posteriorly to feel the external oblique ridge and the anterior border of the coronoid process. As the finger proceeds upwards, palpate the coronoid process up and down to determine the deepest point on its anterior border. This is the coronoid notch. [This is a very important landmark because this determines the vertical height at which the needle should be inserted, the reason being the Mandibular foramen on the medial aspect of the ramus where we want the needle to reach is in direct line with the coronoid notch] Fig. 5.1.

Once the coronoid notch is palpated with the pulp of the index finger, the finger is rotated such that the nail faces medially. At the same time, the finger retracts the soft tissue



©Association of Oral and Maxillofacial Surgeons of India

Fig. 5.1 Dry mandible showing the position of needle and the coronoid notch



©Association of Oral and Maxillofacial Surgeons of India

Fig. 5.2 Picture showing needle insertion position from the soft tissue for IAN block

to reveal a depression called the pterygo mandibular depression, which is medial to the finger between the finger and the pterygo Mandibular raphe (Fig. 5.2).

Now the needle with solution in the syringe is taken in the right hand and is introduced into the mouth from the opposite side (i.e., left side) corner of the mouth/premolar area.

The syringe and needle are kept parallel to the Mandibular occlusal plane and are introduced into the pterygo temporal depression at the same height as the nail of the index finger (on the coronoid notch). The needle is advanced slowly in the soft tissue till the needle strikes the bone and resistance is felt. Now the needle is in the pterygo mandibular space bounded laterally by the medial surface of the ramus of the mandible and it is just above the lingula in the area of the opening of the mandibular foramen.

The syringe is aspirated and 1 ml of the solution is deposited. This will anesthetize the inferior alveolar nerve as it enters the mandible. Now, the needle with the syringe is swung on to the corner of the mouth on the same side, i.e., right, and is slowly withdrawn after about half the length is inserted and 0.5–0.8 ml of the solution is deposited here. This will take care of the lingual nerve, which is anteromedial to the inferior alveolar nerve.

Now the needle is withdrawn completely out of the soft tissue and is reinserted into the cheek, posterior to the last molar teeth at the level of the occlusal plane of the mandibular teeth for a short distance. After aspiration, the remaining 0.5 ml of the solution is deposited. This anesthetizes the long buccal nerve [for the left-sided block, the surgeon is slightly behind the patient on the right side with the left hand coming around].

This classical Mandibular Nerve block of inferior alveolar nerve with lingual & long buccal is done together if the mandibular molars and their adjoining soft tissues need to be anaesthetized. The reason being the pulp and the periodontium of these teeth are supplied by the inferior alveolar nerve. The lingual gingiva is supplied by the lingual nerve and the buccal gingiva by the long buccal nerve.

5.12.3 Areas Anesthetized by This Block

1. *Inferior Alveolar Nerve Block*
 - (a) All mandibular teeth and the bone surrounding them.
 - (b) The buccal gingiva in relation to the Mandibular anterior and premolar teeth.
 - (c) Lower lip on the same half up to the midline.
2. *Lingual Nerve Block*
 - (a) The lingual gingiva of the Mandibular teeth along with the lingual Mandibular mucosa.
 - (b) The Anterior 2/3rd of the tongue on the same side.
3. *Long buccal nerve Block*
 - (a) The cheek mucosa.
 - (b) Buccal gingiva and mandibular mucosa in relation to the molar teeth.

5.12.4 Signs and Symptoms of Anesthesia

It usually takes about 3–5 min before adequate depth of anesthesia is obtained after any injection. In other words, although symptoms of anesthesia may be felt almost instantly after the injection, for the patient to feel no pain during the procedure a wait of at least 5 min is needed.

It has been conventional to confirm the anesthesia obtained with two parameters:

1. Subjective symptoms of anesthesia as experienced by the patient.
2. Objective signs elicited by the surgeon.

Subjective symptoms may or may not be present with certain nerve blocks, e.g., nasopalatine block. However with the classical inferior alveolar/mental nerve block, a *tingling and numbness* on one half of the lip (same side) will be felt. There will be an area of sharp demarcation between the numb side of the lip and the normal side at the midline. The tingling or numbness will start instantly to become heavy in about 3–5 min. Similar sensation of numbness will be felt on the same side of the tongue particularly the tip as a result of the lingual nerve block. There may be no symptoms of numbness felt by the patients in the other anaesthetized areas, e.g., the gingiva, teeth, or the cheek.

The objective sign as elicited by the surgeon is more reliable and may be the only means of ascertaining anesthesia in the absence of subjective symptoms. The objective sign of anesthesia is *lack of pain in the area anesthetized when stimulus is applied* with a blunt instrument, e.g., the end of a periosteal elevator. [It should be noted from the earlier discussion that the patient might feel the pressure of the instrument and an apprehensive patient might occasionally interpret this as pain.]

In checking for anesthesia of the inferior alveolar nerve, the blunt instrument must be applied on the buccal gingiva anterior to the mental foramen, because the lack of sensation in the posterior buccal soft tissue indicates a successful long buccal nerve and not inferior alveolar nerve block. The same blunt instrument must be applied in the gingival sulcus on the lingual side of the tooth to be extracted for lingual nerve anesthesia. The same can be done to check the buccal nerve anesthesia.

5.12.5 Complications (Table 5.6)

These were discussed very briefly as local complications of L.A in the earlier section. Specific complications after an Inferior Alveolar Nerve block include:

1. Failure to obtain anesthesia
2. Hematoma formation
3. Transient facial nerve palsy/weakness
4. Trismus
5. Breakage of the needle.

Table 5.6 Complications with local anesthetics

Local	Systemic
Needle breakage	Syncope
Paresthesia	Adverse drug reactions
Facial nerve paralysis	Overdose drug reactions
Trismus	Psychogenic reactions
Soft-tissue injury	
Hematoma	
Pain on injection	
Burning on injection	
Infection	
Edema	
Sloughing postanesthetic intraoral lesion	

5.12.5.1 Failure to Obtain Anesthesia

It is the most common problem and usually due to the wrong technique. Repeating the block employing the right technique is usually the solution. However, this might be encountered in two other situations.

1. Failure to anesthetize the mylohyoid branch, which might occasionally innervate the site of the procedure.
2. Also as already mentioned, in an apprehensive patient, the symptoms of pressure may be interpreted as pain. In this situation, anxiety reduction techniques may be needed or alternately some other form of anesthesia, e.g., conscious sedation or General Anesthesia may have to be employed. The subjective symptom of numbness in the lower lip (same side) and tip of the tongue will be the distinguishing feature between a faulty technique and an apprehensive patient. In the former, it will be absent, and in the latter very much present.

5.12.5.2 Hematoma Formation

This may occur within the pterygo mandibular space as a result of bleeding induced by the needle prick. It may be a rare problem. The patient might have pain, swelling, & difficulty in opening the mouth. The treatment is symptomatic and possibly prophylactic antibiotic cover. It will resolve spontaneously.

5.12.5.3 Transient Facial Nerve Palsy

May occasionally occur as a result of a faulty technique where the needle is inserted farther posteriorly into the substance of the parotid gland (in this situation, the needle would have failed to encounter bony resistance) and paralyzes the facial nerve.

The patient will have typical signs of ipsilateral facial nerve palsy/weakness, which includes difficulty in closing the eye, absence of wrinkles on the forehead, and drooping of the corner of the mouth ipsilaterally with a possible asymmetry. This effect will be transient, till such time the local anesthetic effect persists (about 1–1½ h) and the patient needs to be reassured.

5.12.5.4 Trismus

Is a relatively more common complication and will be seen usually postoperatively. It could be due to a variety of causes, including:

1. Muscle spasm due to injury
2. Infection
3. Necrosis of tissue due to contact with contaminants, etc.

Most of the time it resolves spontaneously. But on occasion, this will require anti-inflammatory analgesics, muscle relaxants, and vigorous physiotherapy to overcome the problem. Wherever an infection is suspected, a suitable antibiotic cover may also be needed.

5.12.5.5 Accidental Breakage of the Needle

Occurring within the tissues of the pterygo mandibular space, this is a very rare complication today where we use disposable needles for one use only. But when this happens, a radiographic guided exploration and removal of the broken piece may be needed. Gerbino G et al. [22] advocated use of brain LAB vector vision neuronavigation system for the retrieval of broken needle. This Intraoperative navigation system is very helpful in locating the broken needle fragment.

5.13 Vazirani–Akinosi (VA) Versus Inferior Alveolar Nerve Block

The closed mouth VA technique to anesthetize the IAN, lingual, and long buccal nerve simultaneously was described in 1977 [23]. VA is used only secondarily to conventional IAN block.

5.13.1 Indications for VA [24]

1. In patients with restricted mouth opening
2. In cases of failure of IAN blocks
3. Difficult-to-locate landmarks for IAN block

The percentage of Positive aspiration is much higher with IAN block in comparison to VA. This is because of the close proximity of the inferior alveolar artery, which enters the mandibular foramen just behind the nerve [25]. To avoid frequent aspiration, many surgeons prefer VA technique in normal patients also.

5.13.2 Akinosi–Vazirani Technique (Closed-Mouth Technique)

A 25-gauge long needle is used. The operator is in front of the patient on the right side (right-handed operator) for both sides on the patient.

With the left index finger or thumb, the coronoid notch is palpated and the soft tissues on the medial aspect of the ramus are pushed laterally. The needle is held parallel to the maxillary occlusal plane on the same side of the injection and is inserted adjacent to the maxillary third molar into the soft tissue overlying the medial border of the ramus, just adjacent to the maxillary tuberosity. This is now advanced posteriorly & slightly laterally. The bevel of the needle is away from the mandibular ramus and in an average-sized adult the needle is inserted about 25 mm into the tissue. At this point, the tip of the needle will be in the middle of the pterygo mandibular space close to the branches of the mandibular nerve. After aspiration, the LA solution is injected.

The areas anesthetized, signs and symptoms of anesthesia are similar to the open-mouth technique of mandibular nerve block.

Another viable alternative to the VA block is the technique of Gow-Gates described in 1973. In the Gow-Gates technique, anesthesia is administered more proximally, at the neck of the condyle and relies on extraoral landmark [26].

5.13.3 Technique

A 25-gauge long needle is used. The operator stands in front of the patient. It is very essential for the patient to extend his neck & open the mouth as wide as possible. Here the needle is inserted into the mucosa medial to the mandibular ramus on a line parallel to a line drawn from the intertragic notch to the corner of the mouth—just distal to the maxillary second molar. The needle is inserted from the corner of the mouth on the opposite side. The height of insertion is just at the level of the mesiolingual cusp of the maxillary second molar. Slowly advance the needle till the bone is contacted. (The needle here is in contact with the neck of the condyle. The position the patient is asked to assume, i.e., extend neck & open mouth wide, is to facilitate a more frontal position of the condyle closer to the mandibular nerve trunk). The average depth of insertion is about 25 mm. Aspirate & inject 2 ml of the solution slowly. Unlike with the classical method, injection is at one site only in this technique. This anesthetizes the inferior alveolar, lingual, long buccal branches of the mandibular here with similar effect as the classical block (Fig. 5.3a, b).

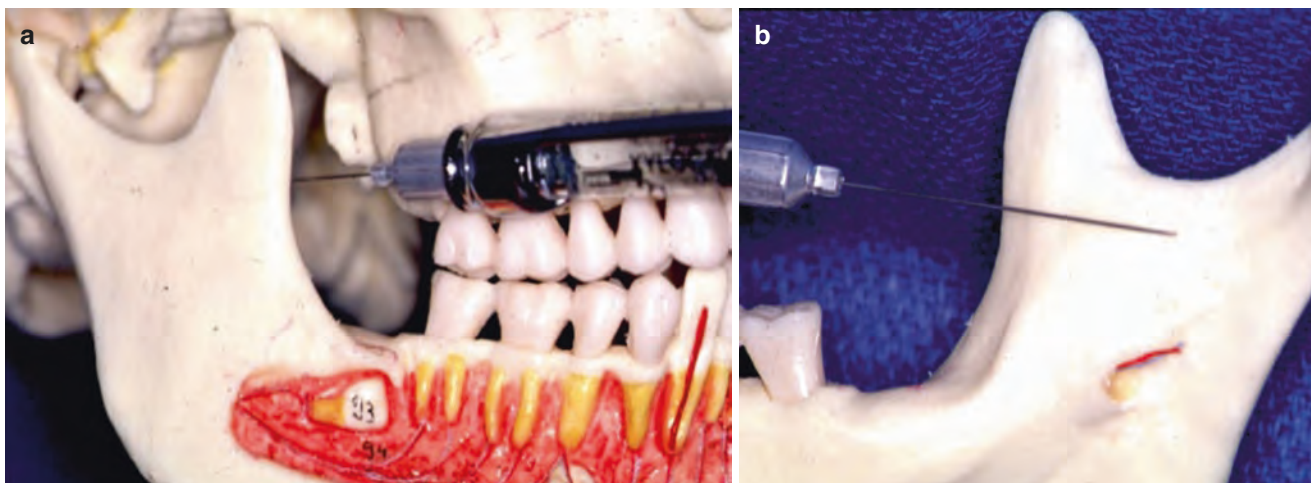
5.14 Mental/Incisive Nerve Block

These are two very similar blocks except that in a mental block the solution is deposited around the mental nerve as it exits the mandible at the mental foramen, whereas for an incisive nerve block, the solution is injected into the mandible through the mental foramen. This blocks the incisive nerve, which is the continuation of the inferior alveolar nerve anteriorly, up to the midline.

5.14.1 Technique

This may be carried out with the operator standing in front of the patient (can also be done easily with the operator standing behind).

With the left-hand thumb or index finger, palpate the mucobuccal fold on the mandible starting in the molar region moving anteriorly when depression will be felt. This is usually in relation to the apex of the premolar teeth where the mental foramen is present. The needle is now directed vertically to be inserted into this area with the bevel facing the bone. With the mental nerve block, the solution is deposited in the soft tissues, whereas for the incisive the needle is inserted into the foramen for a short distance before injection.



©Association of Oral and Maxillofacial Surgeons of India

Fig. 5.3 (a, b) Position of needle from medial and lateral aspect in case of closed-mouth technique

5.14.2 Areas Anesthetized

Mental Nerve Block: Buccal mucosa and gingiva in the mandible anterior to the premolar area, lower lip mucosa, and skin on the same side.

Incisive Nerve Block: In addition to the aforementioned structures, mandibular teeth anterior to the mental foramen, i.e., incisors, canine, and the premolars (which are anterior to the mental foramen).

5.14.3 Signs and Symptoms

Subjective: Tingling and numbness in the lower lip on the same side for both blocks as it is for the inferior alveolar block.

Objective: Lack of pain on probing with a blunt instrument over the buccal gingival/mucosa in the anterior Mandibular region.

Complications: Hematoma formation: If there is bleeding submucosally or subcutaneously, pressure application to stem the flow is all that is needed, with reassurance to the patient that it will resolve spontaneously in a short period of days.

5.15 Nerve Blocks in the Maxilla

As already mentioned, in maxilla buccal & palatal infiltration techniques are often followed because they are effective, particularly if the surgical area is limited, e.g., extraction of a single tooth. However nerve blocks are useful at times, particularly when anesthesia of a larger area is sought.

5.15.1 Posterior Superior Alveolar Nerve Block Technique

The position of the operator is on the front of the patient for both sides, on the right side, for a right-handed operator.

Palpate the maxillary mucobuccal fold after asking the patient to open mouth partially and retracting the buccal soft tissue with the index finger of the left hand. Insert the needle (25/27 gauge—20-mm length) into the height of the mucobuccal fold opposite the upper second (second) molar tooth. Advance the needle in inward, upward, backward direction with the needle at 45° angle to the maxillary plane for about 10–15 mm. The tip of the needle will now be close to the entry of the posterior superior alveolar nerve into the maxilla on its posterior surface. Inject 1–1.5 ml of the solution after aspiration (Fig. 5.4).

5.15.1.1 Areas Anesthetized

1. Buccal alveolar mucosa and gingiva in relation to the maxillary molar teeth.
2. All the three maxillary molar teeth except the mesiobuccal root of the first molar in some instances. (This may be supplied by the middle superior alveolar nerve occasionally. In this case, to anesthetize the first molar tooth completely, a buccal infiltration has to be given in addition to the posterior superior alveolar nerve block if employed.)

Hence, this is a nerve block, which may be used if multiple extractions of molar teeth have to be done in the maxilla or any other procedure in this area.

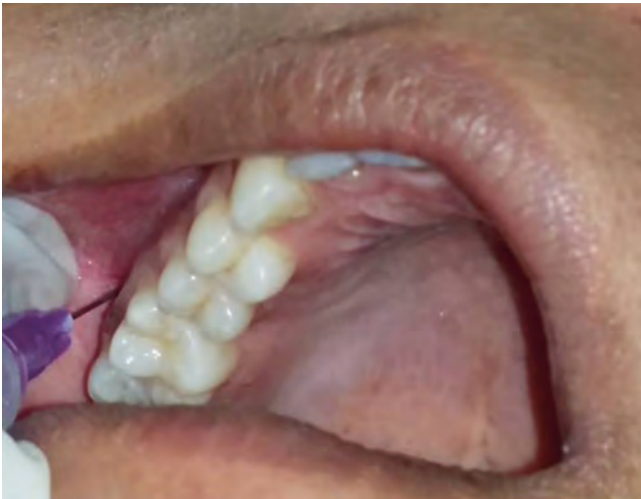5.15.1.2 Signs and Symptoms

Subjective: The patient usually will not feel any tingling or numbness in this case.

Objective: Lack of pain on probing with the blunt instrument as with any other local anesthetic injection.

Complications: Most common problem is a swiftly developing hematoma particularly if the needle goes too far distally into the area of the pterygoid venous plexus.

As in earlier instances, pressure needs to be applied in this case, on the face above the area where the swelling is developing. The sudden swelling can be alarming but is of little consequence once the application of pressure stops flows.



©Association of Oral and Maxillofacial Surgeons of India

Fig. 5.4 Needle insertion position in posterior superior alveolar nerve block

Once again, reassurance to the patient is needed. Prophylactic antibiotics to prevent secondary infection of the hematoma may be considered.

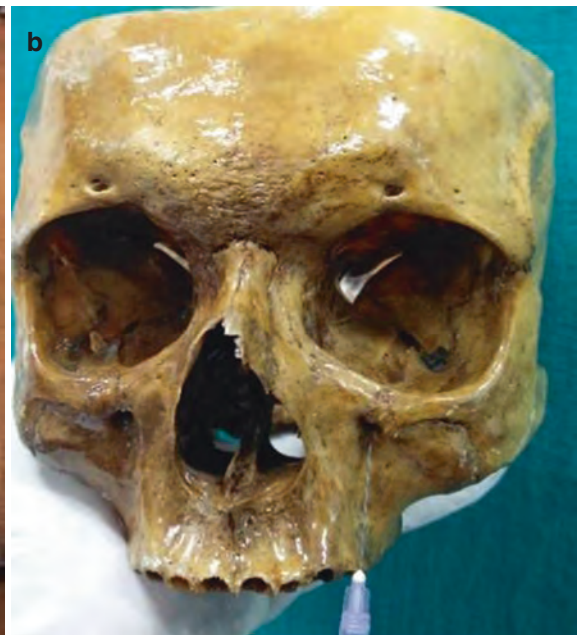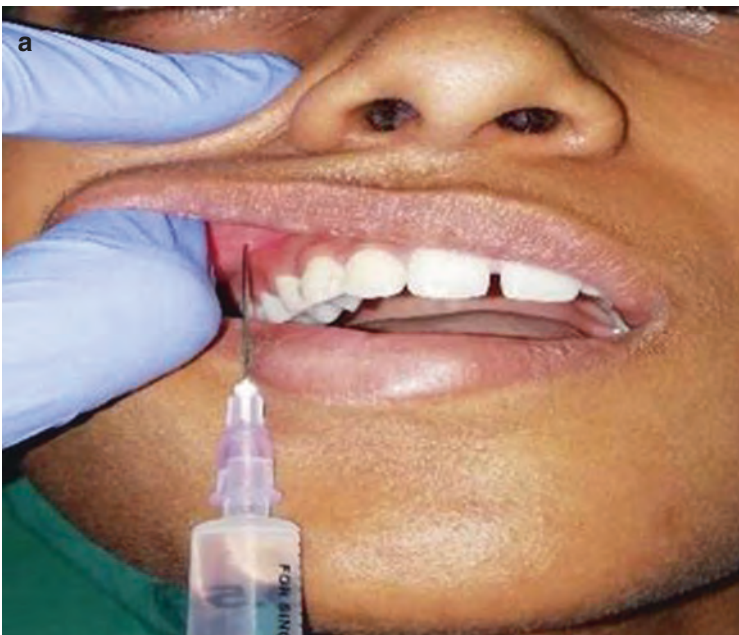5.15.2 Infraorbital Nerve Block [Also Anterior and Middle Superior Nerve Blocks]

5.15.2.1 Technique

The operator (right handed) is on the right side of the patient for both sides, i.e., left & right.

With the left index finger, the infraorbital rim on the face is palpated. A notch is felt on the medial third of this region, the finger is now slid down to feel for depression below this notch on the anterior surface of the maxilla. This is the position of the infraorbital foramen. With the left index finger over the infraorbital foramen, the cheek is retracted with the thumb and a 25-gauge needle is inserted intra-orally into the height of the mucobuccal fold opposite the first premolar with the bevel of the needle directed toward the bone and the needle being parallel to the long axis of the tooth. The needle is advanced until gentle bone contact is made, and this will be the upper rim of the infraorbital foramen.

Aspirate and inject about 1–1.5 ml of the solution. As the solution is deposited, firm pressure is applied over the infraorbital foramen by the left-hand index finger so as to facilitate entry of the solution into the infraorbital canal through the foramen (Fig. 5.5a, b).



©Association of Oral and Maxillofacial Surgeons of India

Fig. 5.5 (a, b) Position of needle insertion and target point in dry skull in Infraorbital nerve block

5.15.2.2 Areas Anesthetized

1. The lower eyelid, lateral side of the nose, and the upper lip on the same side (This is due to blockade of the terminal branches of the infraorbital nerve after it exits the foramen and will happen irrespective of whether the solution has entered into the foramen)
2. The buccal gingiva & mucosa, as well as the upper anterior and premolar teeth on the same side as well as the mesiobuccal root of the first molar if it is supplied by the middle superior alveolar nerve. (For this to happen, the anesthetic solution injected should diffuse into the infraorbital canal in the floor of the orbit from where the branches, anterior, & middle superior alveolar nerve are given off.)

5.15.2.3 Signs and Symptoms of Anesthesia

Subjective: Tingling & numbness in the areas supplied by the terminal branches of the infraorbital nerve, i.e., the lower eyelid, lateral side of the nose, and the upper lip on the same side. (This symptom does not necessarily mean that the anterior & middle superior alveolar nerves have been anesthetized. This can be confirmed only objectively.)

Objective: Like always, lack of pain on probing with a blunt instrument in the area anesthetized.

Complication: Are few. Rarely a hematoma may develop.

5.15.3 Palatal Anesthesia

Injection into the palatal tissues, whether an infiltration or a nerve block, is the most painful. The reason is the palatal mucoperiosteum is tightly adherent to the bone and there is no easy space for the solution to flow. This also makes the process of injection difficult as often there is backflow due to the resistance offered.

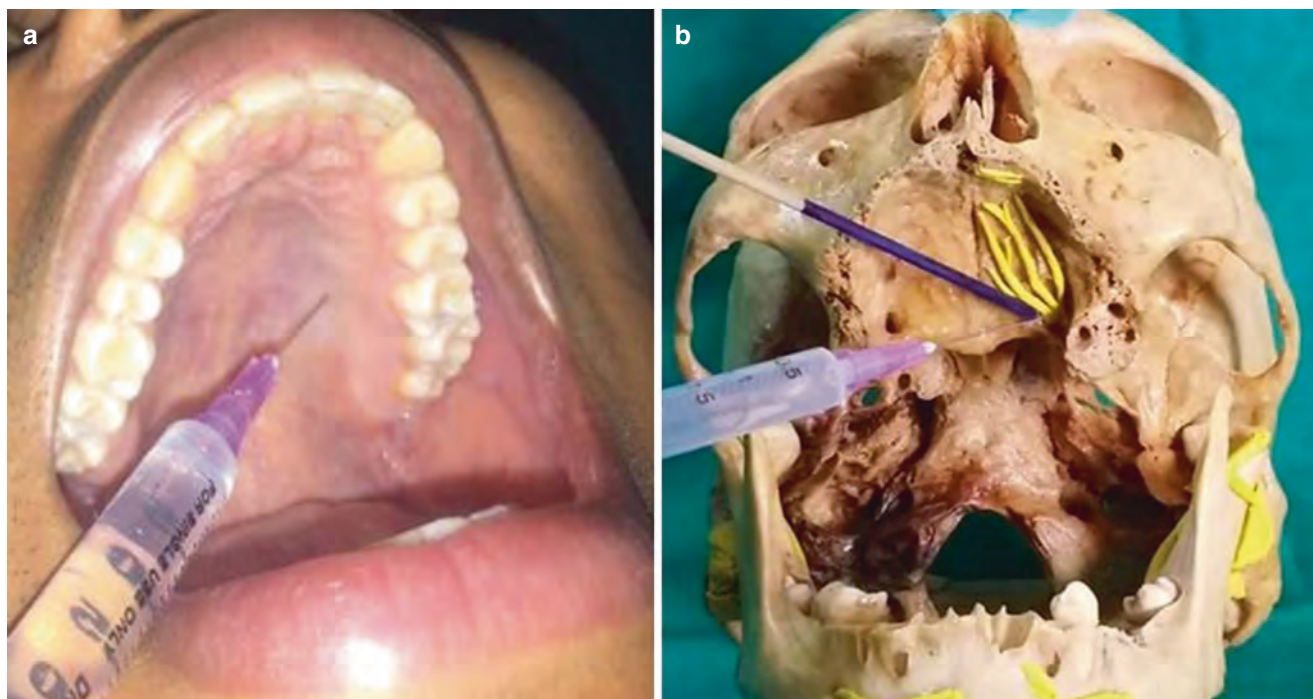
Most often, particularly when a single tooth is involved, infiltration anesthesia is preferred in the palate. However, two nerve blocks are often used particularly when a larger area is involved

1. Greater palatine nerve block
2. Nasopalatine or Anterior Palatine Nerve block.

5.15.3.1 Greater Palatine Nerve Block

Technique: The greater palatine foramen in the adult is usually present on the palatal side of the second molar tooth at the junction of the alveolus and the horizontal palatine bone. (This may be palpated as a depression in this area but need not be done for the purpose of the nerve block.)

A 25/27-gauge short needle is inserted from the opposite side with the operator standing in front (for both sides of the patient) into the area palatal to the second molar at the junction of the alveolus & the palatine bone (Fig. 5.6a, b). A little solution is deposited (0.1–0.2 ml) at the point of entry and



©Association of Oral and Maxillofacial Surgeons of India

Fig. 5.6 (a, b) Intraoral and in dry skull showing insertion of needle in greater palatine nerve block

the needle is advanced into the foramen for a variable distance (0.5–0.7 cm) and the rest, about 0.8 ml is deposited. As usual, always aspirate before depositing any solution.

Areas Anesthetized: The palatal gingiva of the maxillary teeth till the second premolar on the same side as well as the palatal mucosa & bone on the same side till the premolar region.

Signs and Symptoms of Anesthesia

Subjective: May not always be there. However, numbness in the posterior hard palate mucosa may be present.

Objective: Confirmation of anesthesia is always by lack of pain in the area and tested by probing with a blunt instrument.

5.15.3.2 Nasopalatine Nerve Block

Technique: Operator in front with the patient mouth wide open, a 25/27 gauge needle is inserted into the palate just lateral to the incisive papilla. A small amount 0.1–0.2 ml of the solution is injected after aspiration. Now the needle is advanced further into the incisive foramen for a distance of about 0.5–0.75 cm and 1 ml of the solution is deposited as usual after aspiration.

Areas Anesthetized: Probably the only nerve block, which anesthetizes bilaterally symmetrical areas and hence there is no separate right- & left-sided blocks. The palatal gingiva of the anterior teeth up to the first premolar on either side as well as the palatal mucosa and bone in the same anterior region.

Signs and Symptoms

Subjective: May be variable if present there is numbness of the anterior palate.

Objective: lack of pain in the anesthetized area on blunt probing.

The various nerve blocks discussed so far are the commonly used techniques. Usually this set of techniques is sufficient for all requirements of local anesthesia in the oral cavity. There are a number of alternative techniques, intraoral and extraoral, which are described in literature and may be popular in some parts of the world. However, a couple of them will be discussed here because they may have a specific indication or may be a popular technique.

5.16 Regional Blocks in Oral and Maxillofacial Surgery

Regional blocks are fast becoming popular in providing not only local anesthetic support for performing surgical procedures of the head and neck, but also as a method for perioperative pain control in the form of pre-emptive anesthetic techniques.

This section focuses on a few regional blocks, which can be added to the armamentarium of today's maxillofacial surgeon.

1. Maxillary nerve block
2. Mandibular nerve block
3. Greater auricular nerve block
4. Glossopharyngeal nerve block &
5. Sphenopalatine ganglion nerve block

5.16.1 Maxillary Nerve Block

There are numerous techniques for achieving total maxillary nerve anesthesia for dental and maxillofacial surgical procedures. These may be divided into intraoral and extraoral methods [27].

The intraoral techniques include:

1. *The "Greater Palatine Canal" Approach* where a 25-gauge needle is passed and manipulated through the greater palatine canal to reach the maxillary nerve trunk at the pterygopalatine fissure (PTM fissure) and
2. *The "High Tuberosity" Block Technique* where the maxillary nerve is anesthetized as it traverses the pterygomaxillary fissure. The technique involves the insertion of a 1.5-in. 25-gauge needle through the depth of the mucobuccal fold lateral to the maxillary tuberosity in a fashion similar to the posterior superior alveolar nerve block. The depth of penetration is about 30 mm and the target area is the pterygomaxillary (ptm) fissure posterolateral to the maxillary tuberosity.

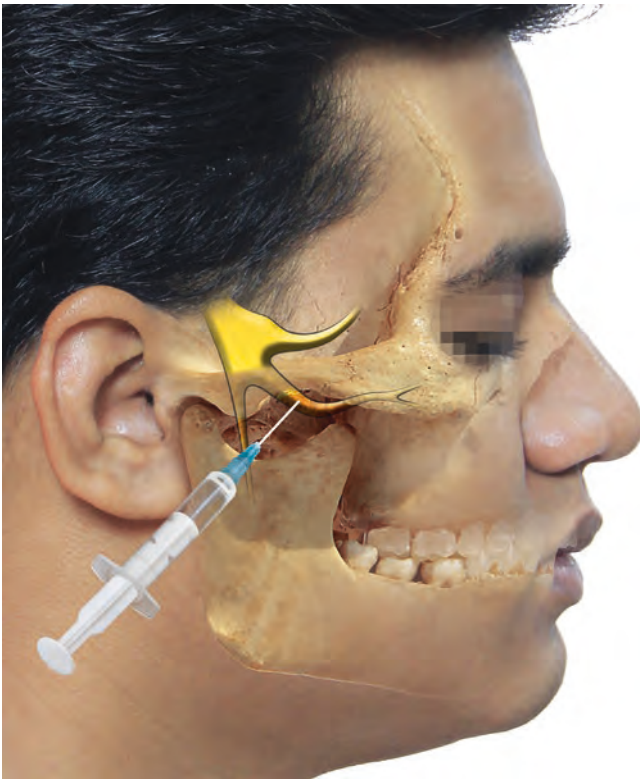
The extraoral technique [28, 29]:

It involves a subzygomatic, technique. The clinical landmarks include the area below the zygomatic arch anterior to the articular eminence. This corresponds to the region above the midpoint of the sigmoid notch of the mandible. A 25-gauge 90-mm-long spinal needle is preferred for this method; the needle is inserted to a depth of about 45 mm till it contacts the lateral side of the lateral pterygoid plate. The needle is then withdrawn half-way and then angulated 15° in the forward and upward directions, which lead it to the region of the superior aspect of the ptm fissure, which corresponds to the exit of the maxillary nerve from the foramen rotundum across the ptm fissure. After negative aspiration, a volume of 2 ml is injected into the space, and the needle is withdrawn (Fig. 5.7).

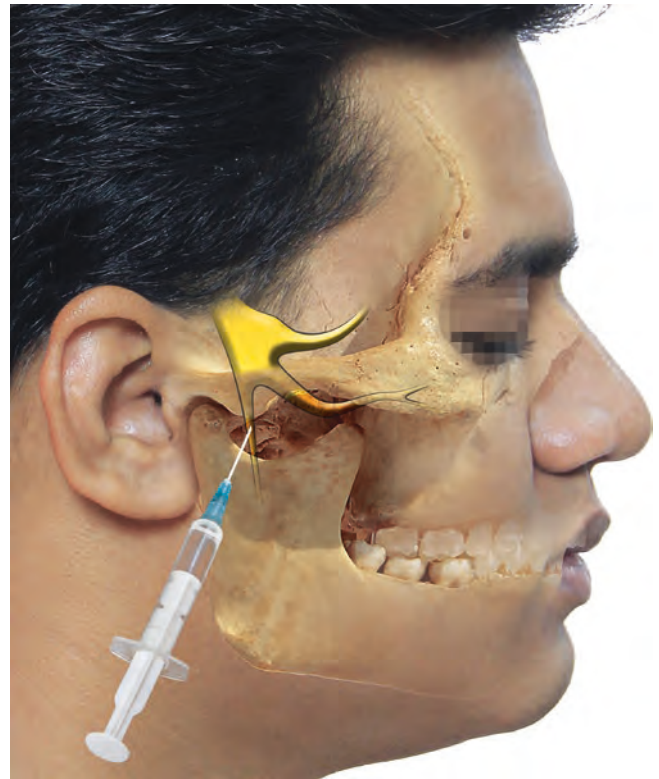5.16.2 Mandibular Nerve Block

The extraoral technique for the mandibular nerve block is very similar to the maxillary nerve block [30].

Technique—The surface landmarks and point of penetration for the block are the same and so is the armamentarium. The needle after penetrating the skin is advanced to



©Association of Oral and Maxillofacial Surgeons of India

Fig. 5.7 Representing pathway of needle in extraoral maxillary nerve block

©Association of Oral and Maxillofacial Surgeons of India

Fig. 5.8 Showing position of needle insertion in extraoral mandibular nerve block

contact the lateral pterygoid plate as described earlier, following which the needle is withdrawn half way and turned posteriorly by 15° to the same depth of 45 mm. This area corresponds to the region just caudal to the foramen ovale through which the mandibular nerve trunk exits the skull base. After negative aspiration, a volume of 2.5–3 ml is injected to anesthetize the mandibular nerve.

The extraoral mandibular nerve block with suprazygomatic access can be safely and efficiently used with this unique approach for the mandibular nerve block to get relief in pain and Trismus. After local infiltration, an 18-gauge insulated and stimulating cannula is inserted into the retrozygomatic space just above the zygomatic arch and directed to the angle of mandible with medial and posterior inclination (Fig. 5.8) [31].

5.16.3 Greater Auricular Nerve Block

This nerve block is performed as an extraoral technique and provides good surface anesthesia to the periauricular skin and skin over the angle of the mandible [32].

Technique—The landmarks used for this technique include the cricoid cartilage and the posterior border of the sternocleidomastoid muscle. With the patient supine or semisupine, a line is drawn from the cricoid cartilage to

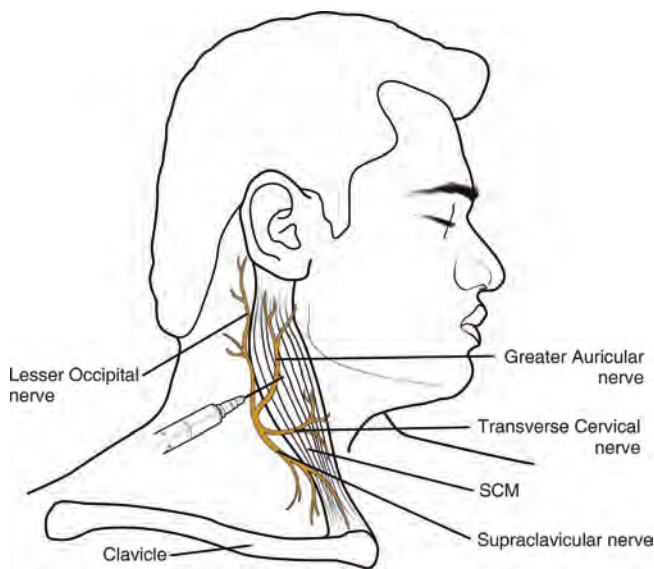
intersect the posterior border of the sternomastoid muscle. This corresponds to the area where the superficial branches of the cervical plexus emerge from under the sternomastoid muscle, wrapping around the posterior border. A small subcutaneous injection of local anesthetic solution (around 2 ml) will anesthetize the greater auricular nerve and its area of distribution (Fig. 5.9).

5.16.4 Glossopharyngeal Nerve Block

The utility of the glossopharyngeal block has been studied in indications such as:

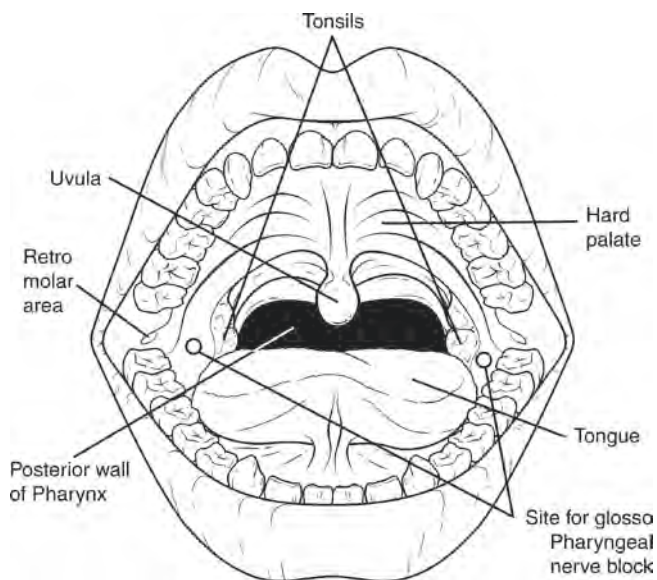
1. Excessive gag reflex during oral procedures
2. Excellent adjuvant for oropharyngeal anesthesia during awake endotracheal intubations (blind nasal or fibro-optic)
3. Management of pain due to glossopharyngeal neuralgias and atypical facial pain secondary to Eagle's syndrome [33–35]. The block can be administered both via an intraoral and an extraoral method. The intraoral technique is a relatively easy and simple technique to administer producing good outcomes.

Technique—A 25-gauge, 1 inch needle is chosen. The landmark for penetration is the base of the anterior tonsillar



©Association of Oral and Maxillofacial Surgeons of India

Fig. 5.9 Showing position of needle for greater auricular nerve block



©Association of Oral and Maxillofacial Surgeons of India

Fig. 5.10 Target area for glossopharyngeal nerve block

pillar lateral to the base of the tongue. The syringe is positioned with the barrel near the maxillary premolar of the contralateral side with the needle facing the base of the anterior tonsillar pillar. The tongue is retracted medially to provide good visualization of the involved site. The needle is then made to pierce the mucosa and advance by 5 mm. This corresponds to the target site for the glossopharyngeal nerve in the submucosal space. After judicious aspiration, if found negative, a volume of 3 ml of anesthetic solution (2% lignocaine) is administered to block the nerve trunk (Fig. 5.10).

5.16.5 Sphenopalatine Ganglion Block

Indications for sphenopalatine ganglion block include:

1. Management of cluster headaches and migraine
2. Treatment for atypical facial pain
3. Palliative pain control for patients with maxillary malignancies and
4. Pre-Emptive nerve blockade for perioperative pain control in surgical procedures of the maxilla and palate [36, 37]

Technique—There are numerous techniques for the administration of sphenopalatine block, but the most commonly followed methods are the greater palatine approach and the transmucosal approach in the posterior aspect of the middle meatus. The greater palatine approach is the same as the maxillary nerve block via the greater palatine canal, which simultaneously blocks the sphenopalatine ganglion as well. The transmucosal method, which is most commonly followed, maybe done blind or using endoscopic guidance. A cotton pledget on a long application stick is dipped in anesthetic solution or gel and is advanced transnasally to the posterior aspect of the middle turbinate to reach the end of the middle meatus. This corresponds to the level of the sphenopalatine ganglion, which is a very superficial structure. The local anesthetic gel is then deposited, which produces anesthesia through transmucosal perfusion. Another recent technique involves the submucosal injection of the anesthetic solution into the posterior aspect of the middle meatus for achieving the block (Fig. 5.11) [37].

5.17 Recent Advances in Local Anesthesia

Research is ongoing to find newer modalities of pain management. In order to administer local anesthesia with less pain and adverse effects, newer technologies have been developed. Some of them are:

5.17.1 Vibrotactile Devices

This device is based on the Gate Control theory, which proposes that pain during injection can be decreased by simultaneous stimulation of nerve fibers by vibration.

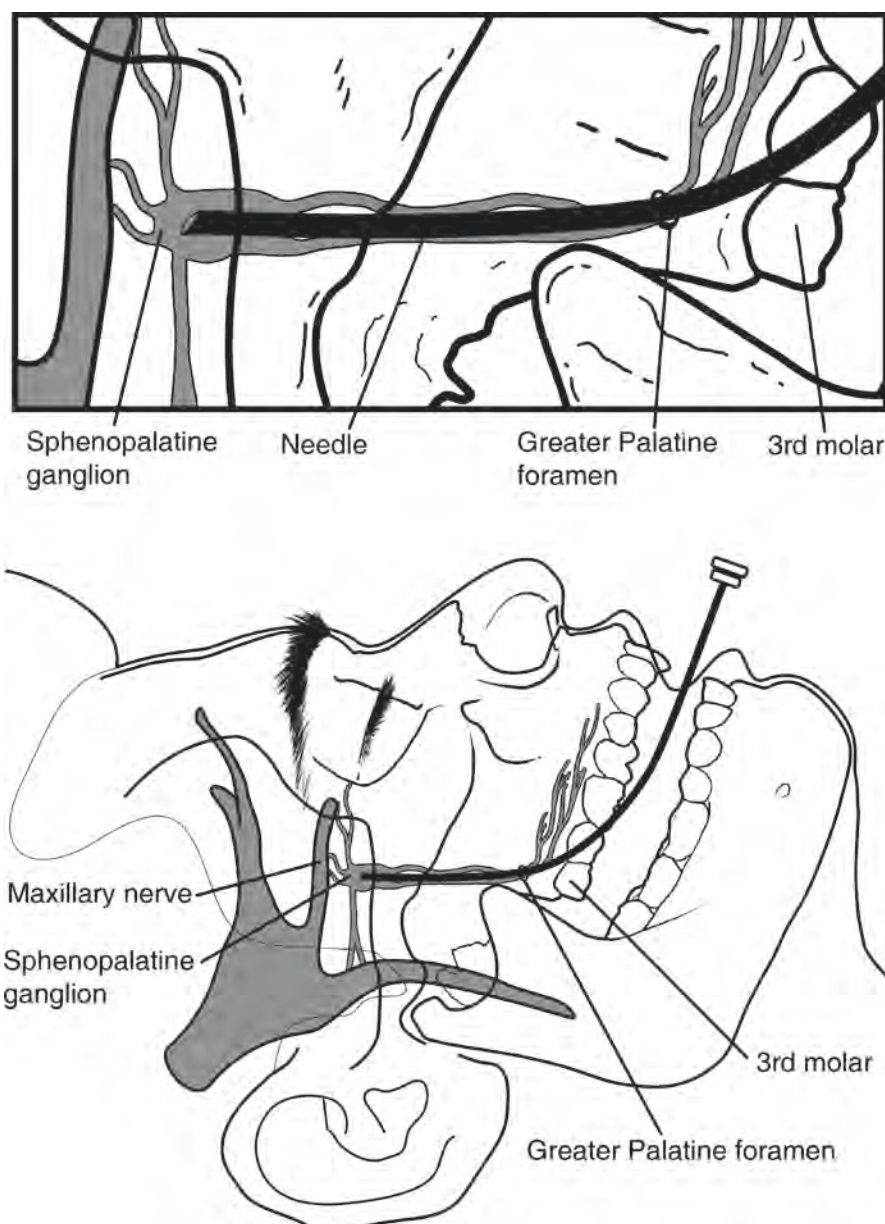
5.17.1.1 Vibraject [38]

An attachment, which is battery operated, is snapped on to the barrel to deliver strong vibrations, which is felt by the patient and therefore reducing the perception of pain.

5.17.1.2 Dental Vibe [39]

It is a handheld device, which delivers pulsed percussive oscillations to the site of injection, thereby closing the pain

Fig. 5.11 Showing technique of sphenopalatine ganglion block



©Association of Oral and Maxillofacial Surgeons of India

gate. It does not have a cord and it can be recharged. Dental vibe significantly lowered the self-reported pain during local anesthesia injections compared to a conventional approach.

5.17.1.3 Accupal

It is a cordless device, which shuts the pain gate by preconditioning the site of injection by pressure and vibration. To energize the dental tissue in and around the site to be punctured by the needle, Accupal incorporates the “Pain Gate theory” [40].

5.17.2 C-CLAD (Computer-Controlled Local Anesthetic Delivery)

With this device, there is a controlled delivery of the anesthetic and hence reduction of pain during injection. With this device, we can slowly administer anesthesia and control the injection speed [41].

Advantages of C-CLAD device

Higher success rates for single tooth anesthesia. The absence of pain especially in pediatric patient with disruptive behavior. More effective than a traditional syringe.

Disadvantage—Difficulty in locating the precise site for needle placement.

C-CLAD technology led to the development of an instrument for medical and dental injections capable of controlling all variables of subcutaneous injection event.

5.17.3 Compu-Flo

Allows instantaneous real-time measurement of fluid exit pressure at the tip of the needle. This approach to fluid exit pressure at the tip of the needle is called dynamic pressure-sensing technology (DPS) technology.

5.17.4 STA—single tooth anesthesia

More predictable, reliable, comfortable anesthesia than high-pressure mechanical syringe. The system incorporates the safety of using dynamic pressure-sensing technology allowing low-pressure administration of local anesthetic drugs. All patients receiving PDL with STA device reported subjective pain responses of minimal or no pain.

5.17.5 Jet Injection

The principle of Jet injection is that the mechanical energy is used to force a thin column of the local anesthetic solution through a small opening into the soft tissue under pressure without causing tissue damage. There is less or no pain during this procedure [42].

5.17.6 MED-JET H III

Local anesthetic solution in extremely small amount is administered under pressure through an orifice seven times smaller than the smallest available.

5.17.7 Safety Dental Syringes [43]

The protective sheath over the needle prevents accidental needle stick injury.

Ultrasafety Plus XL Syringe

The plunger, which is autoclavable and reusable, has a sterile disposable protective shield. It does not have to be disassembled prior to disposal.

Ultrasafe Syringe

Transparent disposable syringe with retractable needle sheath is helpful in aspiration and helps in seeing the aspirated contents in the syringe barrel.

Hyposafety Syringe

Disposable syringe and needle, which is translucent with a retractable needle into the barrel. Hence, less chance of needle stick injury. The main disadvantage is that the needle cannot be re-exposed to readminister the remaining solution.

REV VAC Safety Syringe

It is similar to the standard conventional syringe, the difference being that when the plunger reaches the bottom after all the medicine has been administered, further push on the plunger will cause breakage of the needle, which retracts into the plunger. It can be used only once.

5.17.8 Devices for Intraosseous Anesthesia [44]

Stabident

This device can be used with the armamentarium that is available in the clinic to administer the anesthetic solution. The main disadvantage is that inaccessible areas cannot be anesthetized with this equipment.

X-Tip

It is a single-step method. An initial drill is placed, which allows entry and withdrawal in one step during administration.

5.18 Conclusion

Pain is always a deterrent to seek treatment and hence local anesthesia is a boon to all clinicians and patients alike. Although the medication provides pain relief, its administration has always instilled fear in one and all. The advances in equipment and techniques of local anesthesia administration have undergone continuous research and development to make it as painless as possible.

References

1. Ouchi K, Koga Y, Nakao S, Sugiyama K. Dexmedetomidine dose dependently enhances local anesthetic action of lidocaine. *J Oral Maxillofac Surg.* 2014;72:474.
2. Holmdahl MH. Xylocain (lidocaine, lignocaine), its discovery and Gordh's contribution to its clinical use. *Acta Anaesthesiol Scand Suppl.* 1998;113:8–12.
3. Howlader D, et al. Surgical management of mandibular subcondylar fractures under local anesthesia: a proposed protocol. *J Oral Maxillofac Surg.* 2019;77:1040.e1–9.
4. Burm AG, Van der Meer AD, Van Kleef JW. Pharmacokinetics of the enantiomers of bupivacaine following intravenous administration of the racemate. *Br J Clin Pharmacol.* 1994;38:125.
5. Chapman P. A controlled comparison of the effectiveness of bupivacaine for post-operative pain control. *Aust Dent J.* 1988;33:288.
6. Van Eeden SP, Patel MF. Prolonged paraesthesia following inferior alveolar nerve block using articaine. *Br Oral Maxillofac Surg.* 2002;40:519–20.

7. Da Silva CB, et al. Anaesthetic efficacy of unilamellar and multi-lamellar liposomal formulations of articaine in inflamed and uninfamed tissue. *Br Oral Maxillofac Surg.* 2016;54:295–300.
8. Neal JM. Effects of epinephrine in local anesthetics on the central and peripheral nervous systems: Neurotoxicity and neural blood flow. *Reg Anesth Pain Med.* 2003;28:124.
9. Vempaty S, et al. Is lignocaine with out adrenaline a better choice for lip wounds crossing vermilion border? *Int J Oral Maxillofac Surg.* 2017;46:90–1.
10. Haasio J, Jokinen T, Numminen M, Rosenberg PH. Topical anaesthesia of gingival mucosa by 5% eutectic mixture of lignocaine and prilocaine or by 10% lignocaine spray. *Br J Oral Maxillofac Surg.* 1990;28:99–101.
11. Pere P, Iizuka T, Rosenberg PH, Lindqvist C. Topical application of 5% eutectic mixture of lignocaine and prilocaine (Emla) before removal of arch bars. *Br J Oral Maxillofac Surg.* 1992;30:153–6.
12. Svensson P, Kolsen Petersen J, Svensson H. Efficacy of a topical anesthetic on pain and unpleasantness during scaling of gingival pockets. *Anesth Prog.* 1994;41:35–9.
13. Gow-Gates G, Watson JE. Gow-Gates mandibular block: applied anatomy and histology. *Anesth Prog.* 1989;36:193–5.
14. Gaum LI, Moon AC. The ART mandibular block. *Can J Dent Assoc.* 1997;63:454–9.
15. Aggarwal V, Singla M, Kabi D. Comparative evaluation of anesthetic efficacy of GowGates mandibular conduction anesthesia, Vazirani-Akinosi technique, buccal-plus-lingual infiltrations, and conventional inferior alveolar nerve anesthesia in patients with irreversible pulpitis. *Oral Surg Oral Med Oral Pathol Oral Radiol Endod.* 2010;109:303–8.
16. Frangiskos F, et al. Incidence of penetration of a blood vessel during inferior alveolar nerve block. *Br Oral Maxillofac Surg.* 2003;41:188–9.
17. Jabar J. Should we be giving bilateral inferior alveolar and lingual nerve blocks for third molar surgery? *Br Oral Maxillofac Surg.* 2014;52:16–7.
18. Singh B. Mandibular nerve block for the removal of dentures during trismus caused by tetanus. *Anesth Analg.* 2006;103:252–3.
19. Kashyap VM, et al. Effect of alkalisation of lignocaine for intra-oral nerve block on pain during injection, and speed of onset of anaesthesia. *Br Oral Maxillofac Surg.* 2011;49:e72–5.
20. Vinay M. *Int J Oral Maxillofac Surg.* 2007;36:1031.
21. Milner QJ, Guard BC, Allen JG. Alkalinization of amide local anaesthetics by addition of 1% sodium bicarbonate solution. *Eur J Anaesthesiol.* 2000;17:38–42.
22. Gerbino G, et al. Management of needle breakage using intraoperative navigation following inferior alveolar nerve block. *J Oral Maxillofac Surg.* 2013;71:1819–24.
23. Akinosi JO. A new approach to the mandibular nerve block. *Br J Oral Surg Oral Med Oral Pathol Oral Radiol Endod.* 1977;15:83.
24. Haas D. Alternative mandibular nerve block techniques. *JAMA.* 2011;305:8S.
25. Martinez Gonzalez J, Benito BP, Fernandez FC, et al. A comparative study of direct mandibular nerve block and the Akinosi technique. *Med Oral.* 2003;8:143.
26. Gow-Gates GA. Mandibular conduction anesthesia: a new technique using extraoral landmarks. *Oral Surg Oral Med Oral Pathol.* 1973;36:321.
27. Malamed SF. Techniques of regional anaesthesia in dentistry. *Handbook of local anesthesia.* St. Louis, MO: Elsevier; 2013.
28. Stojcev Stajčić L, Gacić B, Popović N, Stajčić Z. Anatomical study of the pterygopalatine fossa pertinent to the maxillary nerve block at the foramen rotundum. *Int J Oral Maxillofac Surg.* 2010;39(5):493–6.
29. Stajčić Z, Todorović L. Blocks of the foramen rotundum and the oval foramen: a reappraisal of extraoralmaxillary and mandibular nerve injections. *Br J Oral Maxillofac Surg.* 1997;35:328–33.
30. Kampitak W, Tansatit T, Shibata Y. A novel technique of ultrasound-guided selective mandibular nerve block with a lateral pterygoid plate approach: a cadaveric study. *Reg Anesth Pain Med.* 2018;43:763–7.
31. Dziadzko MA, Heritier F. Suprazygomatic access for continuous bilateral mandibular nerve block for pain and trismus relief in the tetraplegic patient. *J Oral Maxillofac Surg.* 2016;74:1947.e1–5.
32. Suresh S, Barcelona SL, Young NM, Heffner CL, Coté CJ. Does a pre-emptive block of the great auricular nerve improve postoperative analgesia in children undergoing tympanomastoid surgery? *Anesth Analg.* 2004 Feb;98(2):330–3.
33. Garg R, Singhal A, Agrawal K, Agrawal N. Managing endodontic patients with severe gag reflex by glossopharyngeal nerve block technique. *J Endod.* 2014 Sep;40(9):1498–500.
34. Rao S, Rao S. Glossopharyngeal nerve block: the premolar approach. *Cranio Maxillofac Trauma Reconstr.* 2018 Dec;11(4):331–2.
35. Henthorn RW, et al. Which method for intraoral glossopharyngeal nerve block is better? *Anesth Analg.* 1995 Nov;81(5):1113–4.
36. Parameswaran A, Ganeshmurthy MV, Ashok Y, Ramanathan M, Markus AF, Sailer HF. Does sphenopalatine ganglion block improve pain control and intraoperative hemodynamics in children undergoing palatoplasty? A randomized controlled trial. *J Oral Maxillofac Surg.* 2018 Sep;76(9):1873–81.
37. Binfalah M, Alghawi E, Shosha E, Alhilly A, Bakhiet M. Sphenopalatine ganglion block for the treatment of acute migraine headache. *Pain Res Treat.* 2018;2018:2516953.
38. Roeber B, et al. Evaluation of the effects of the VibraJect attachment on pain in children receiving local anesthesia. *Pediatr Dent.* 2011;33(1):46–50.
39. Ching D, et al. Effect of the Dental Vibe injection system on pain during local anesthesia injections in adolescent patients. *Pediatr Dent.* 2014;36(1):51–5.
40. Melzack R, Wall PD. Pain mechanisms: a new theory. *Science.* 1965 Nov 19;150(699):971–9.
41. Kwak EJ, et al. Computer-controlled local anesthetic delivery for painless anesthesia: a literature review. *J Dent Anesth Pain Med.* 2016;16:81–8.
42. Lambrianidis T, et al. Dental analgesia by jet injection. *Br J Oral Surg.* 1979–80;17:227–31.
43. Zakrzewska JM, Boon EC. Use of safety dental syringes in British and Irish dental schools. *Br Dent J.* 2003;195:207–9.
44. Feridoz J, Raj JD. Intraosseous anesthesia in dentistry – a review. *Drug Invention Today.* 2018;10:3035–40.

Open Access This chapter is licensed under the terms of the Creative Commons Attribution 4.0 International License (<http://creativecommons.org/licenses/by/4.0/>), which permits use, sharing, adaptation, distribution and reproduction in any medium or format, as long as you give appropriate credit to the original author(s) and the source, provide a link to the Creative Commons license and indicate if changes were made.

The images or other third party material in this chapter are included in the chapter's Creative Commons license, unless indicated otherwise in a credit line to the material. If material is not included in the chapter's Creative Commons license and your intended use is not permitted by statutory regulation or exceeds the permitted use, you will need to obtain permission directly from the copyright holder.





Office-Based Anesthesia in Oral and Maxillofacial Surgery-The American Model and Training

6

Payal Verma and Deepak G. Krishnan

6.1 Introduction

Anxiety and pain control has been the center of dental health provision from its inception. Dentists continue to practice some form of pain and anxiety control throughout the world. In the United States (US), Oral and maxillofacial surgery (OMS) has maintained a unique privilege where the surgeon is able to provide both anesthetic and surgical treatment for most of the procedures that are completed in a setting outside of the operation theater. The extensive, focused training received during OMS residency in the delivery of anesthesia, as well as continued education in anesthesia is central to this privilege. The art and science of alleviating pain and anxiety by providing office-based surgical treatment using various anesthetic techniques is associated with tremendous responsibility. Therefore, appropriate training along with local licensure, credentialing, and continuous education is of paramount importance.

While the Commission on Dental Accreditation (CODA) of the American Dental Association (ADA) stipulates standards in training OMS residents in anesthesia, American Association of Oral and Maxillofacial Surgeons (AAOMS) and state dental societies have developed parameters and protocols that are enforced among practicing OMSs, ensuring patient safety.

For the remainder of this chapter, the term ambulatory anesthesia would refer to the provision of anesthesia outside of a hospital operatory, such as a dental or an OMS office. Generally, this would entail provision of “open-airway” deep

sedation with drugs delivered through an intra-venous (IV), intra-muscular (IM) or inhalational routes.

The American Society of Anesthesiology (ASA) recognizes four stages of anesthesia (Table 6.1) [1]. The most common forms of anesthesia used in an ambulatory office setting are mild-to-moderate sedation as well as deep sedation/general anesthesia with the use of inhalational and intra-venous agents. As defined by ASA, moderate sedation/analgesia (replacing the term “Conscious Sedation,” which has been condoned) is a medication-induced depression of consciousness during which patients respond purposefully to verbal commands, either alone or often accompanied by light tactile stimulation. Other interventions are not required to maintain a patent airway, while spontaneous ventilation is adequate, and cardiovascular function is usually maintained. Whereas deep sedation/analgesia is a drug-induced depression of consciousness during which patients cannot be easily aroused but respond purposefully following repeated or painful stimulation. The ability to independently maintain ventilatory function may be impaired and may require assistance in maintaining a patent airway. However, it is important that the cardiovascular function is maintained.

Given that the process of sedation is a continuum, the patient’s response is unpredictable. Hence, practitioners should be able to rescue the patients whose level of sedation becomes deeper than initially intended. An oral and maxillofacial surgeon is well trained in airway management and advanced life support.

6.2 Brief History of Anesthesia in OMS

Over several decades, Oral and maxillofacial surgeons have been at the forefront of anesthesia and pain control among all dental specialties and have been providing safe outpatient anesthesia.

Nitrous oxide was produced by Joseph Priestly and was termed as “laughing gas” by Humphrey Davy in eighteenth

P. Verma (✉)

Oral & Maxillofacial Surgery, University of Cincinnati Medical Center, OH, Cincinnati, USA
e-mail: vermapl@ucmail.uc.edu

D. G. Krishnan

Oral & Maxillofacial Surgery, University of Cincinnati Medical Center, OH, Cincinnati, USA

Oral & Maxillofacial Surgery, Cincinnati Children’s Hospital and Medical Center, OH, Cincinnati, USA

Table 6.1 Continuum of depth of sedation: definition of general anesthesia and levels of sedation/analgesia

	Minimal Sedation Anxiolysis	Moderate Sedation/ Analgesia ("Conscious Sedation")	Deep Sedation/ Analgesia	General Anesthesia
<i>Responsiveness</i>	Normal response to verbal stimulation	Purposeful response to verbal or tactile stimulation	Purposeful response following repeated or painful stimulation	Unarousable even with painful stimulus
<i>Airway</i>	Unaffected	No intervention required	Intervention may be required	Intervention often required
<i>Spontaneous ventilation</i>	Unaffected	Adequate	May be inadequate	Frequently inadequate
<i>Cardiovascular function</i>	Unaffected	Usually maintained	Usually maintained	May be impaired

century [2, 3]. It was first used as an anesthetic agent in dental practice by Dr. Horace Wells [4] of Connecticut. He demonstrated the use of nitrous oxide for dental extractions that was aimed at the prevention of pain during surgery. Unfortunately, he was dismissed due to lack of medical background. His friend, William T G Morton [4], later demonstrated the use of ether vapors as anesthetic for the removal of a jaw tumor. Morton was therefore credited for the first anesthetic (October 16, 1846; also known as Ether Day). This solidified the foundation for the use of anesthetics in dental practice.

A prominent step forward in the provision of safe ambulatory anesthesia was the development and further refinement of the intravenous route of administration. It provided a safe route for rapid delivery and titration of medications along with giving the surgeon the ability to provide emergency medications. The practice of intravenous techniques allowed fast onset and recovery.

Adrian O. Hubbell [5] was critical in popularizing outpatient general anesthesia among OMS. He completed his training at Mayo Clinic and later demonstrated the safety of administering barbiturate anesthesia in an outpatient setting. He also advocated the utility and safety of recovering patients on their side or abdomen postoperatively to prevent aspiration of vomitus. Sylvan Shane [6] later reported on the use of intravenous drugs (benzodiazepines) for inducing sedation known as a "balanced" anesthetic. It was rapidly accepted due to its property of anxiolysis as a sole agent.

Another drug that became popular was methohexital [7] but was quickly overtaken by the introduction of Propofol [8], which is currently the most favored primary agent. In 1989, Propofol was officially approved for use, and its benefits related to the faster onset, improved recovery, and inherent antiemetic activity were soon recognized.

It became evident soon that to continue the privilege of administering outpatient anesthesia, it was important to receive adequate formal general anesthesia training and to maintain the highest standard of care. Today, Intravenous drug anesthesia is the mainstay of providing sedation in the outpatient setting of oral and maxillofacial surgery and has a history of safety [9].

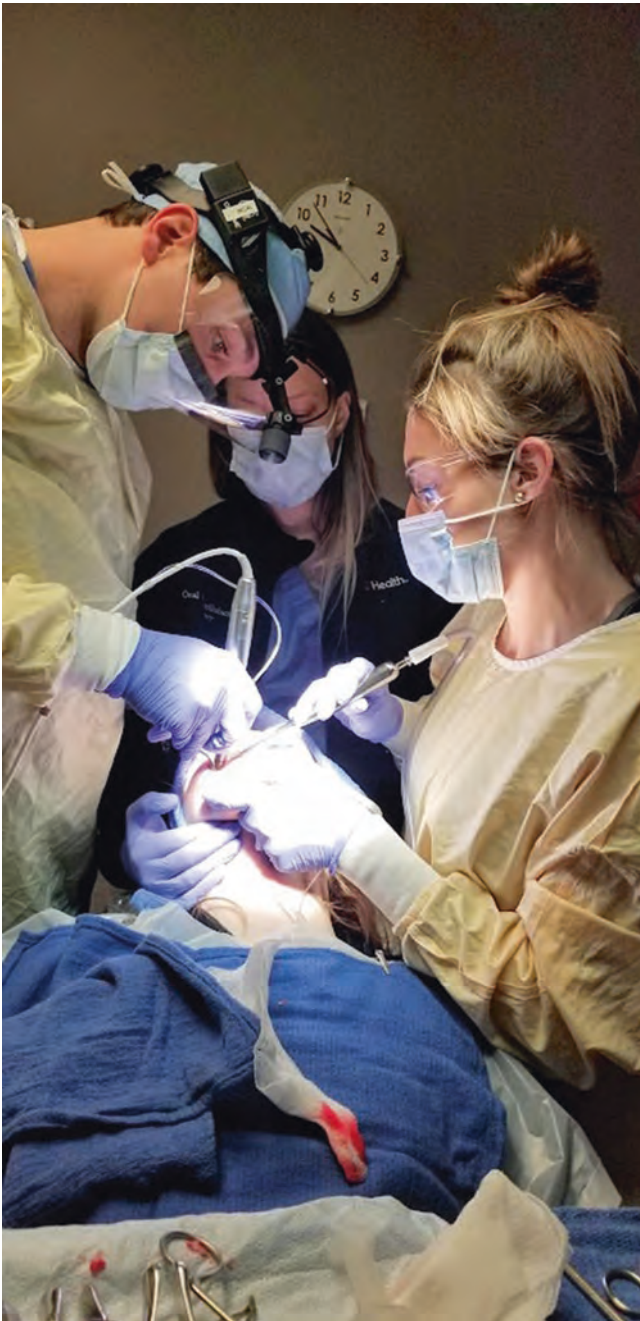6.3 The Anesthesia Team

A majority of the OMSs in the US work in private practice settings where ambulatory anesthesia is the mainstay of practice. This has led to the development of a unique office anesthesia model known as the Anesthesia Team model for OMS practice [10]. This was originally described as the operator-anesthetist model. That was a misnomer because in reality the entire team involved in patient care is trained to monitor and manage the patient under anesthesia in various capacities.

In a typical setting, it is the surgeon who performs the surgery and administers anesthesia. Apart from the surgeon, two or more other team members are present in the room (Fig. 6.1). At least one of these team members is required to be BLS (Basic life support) trained. Most commonly, one trained staff member observes the monitors, records drugs and vitals, and helps with i.v. drug administration, while another member acts as a surgical assistant. Assistant's job is to retract, suction, and irrigate during the surgery along with helping in supporting the airway (Fig. 6.2). Often surgeons employ a registered nurse with advanced cardiac life support (ACLS) training in their offices as well. The entire team is well versed with emergency equipment and is well trained to handle an airway emergency by providing positive pressure oxygen.

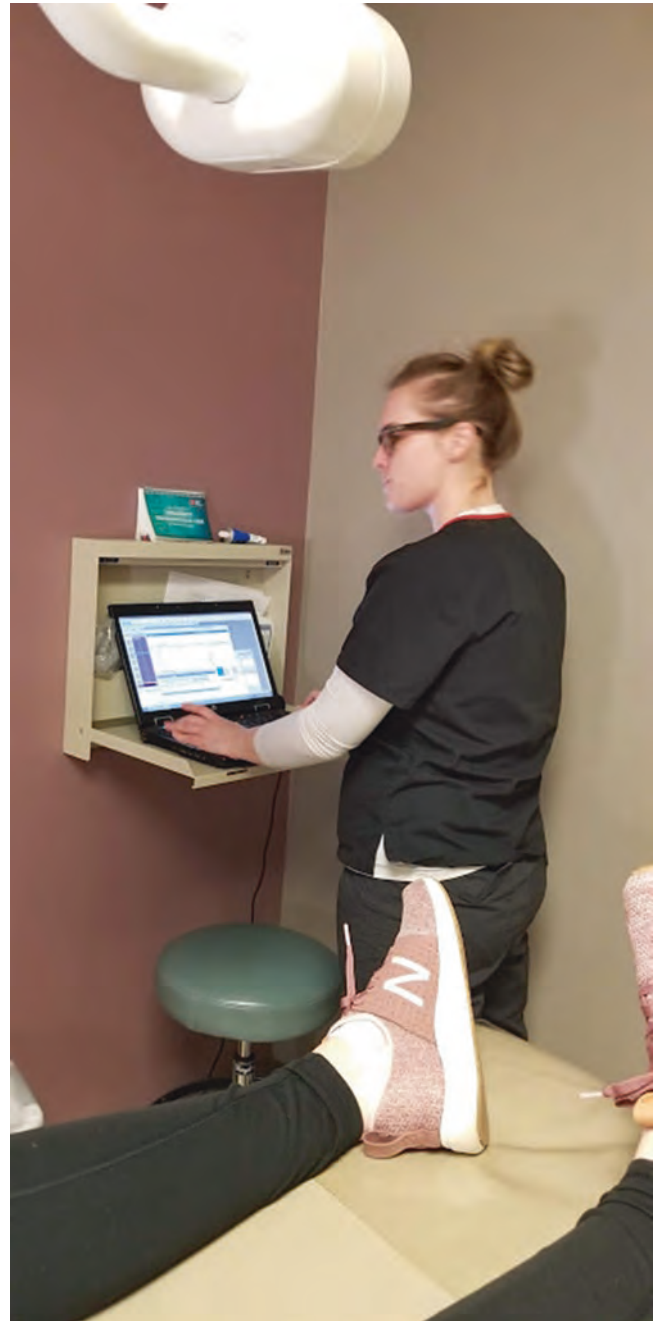
6.4 AAOMS Office Anesthesia Guidelines

AAOMS strives to ensure that its members throughout the country are in compliance with strict and mandated guidelines. It provides these guidelines through often-updated Office Anesthesia Evaluation document made available through the association. These guidelines are created by the Committee on Anesthesia (CAN) of the AAOMS. This committee uses the latest evidence-based recommendations and guidelines to make this document. This document is then vetted by the ASA to ensure that it gets the highest level of scrutiny and approval by that organization. This multilevel peer-review process of the guidelines is important for ensur-



©Association of Oral and Maxillofacial Surgeons of India

Fig. 6.1 Example of the office anesthesia team. The surgeon provides the anesthesia and performs the procedure, one trained staff member supports the airway, and a second staff member is the surgical assistant



©Association of Oral and Maxillofacial Surgeons of India

Fig. 6.2 A dedicated registered nurse with ACLS training is often in charge of monitoring the patient under sedation

ing the safe delivery of anesthesia in the ambulatory OMS setting.

Every AAOMS member (close to 10,000 members) goes through a periodic office anesthesia evaluation process by peers to ensure that each office and team is current and well equipped to perform safe anesthetic practice in

their setting (Fig. 6.3). Failure to pass such an evaluation leads to punitive action and inability to perform anesthesia in the office setting until corrective actions are taken. AAOMS, state dental societies, and third-party insurance carriers take this process seriously. Public safety cannot be compromised.

Sample Anesthesia On-site Inspection and Evaluation Form

Date Sent to Society _____

Name of Practitioner Evaluated	General Anesthesia Permit Number (if applicable)
Location(s) Inspected	Telephone Number
Date(s) of Evaluation	Time of Evaluation

Names of Evaluators _____

A. Personnel

1. ACLS Certificate (Please have doctor's ACLS Certification available)
2. PALS Certificate (if appropriate)
3. Evidence of: one year advanced training in anesthesiology, Fellow of the American Dental Society of Anesthesiology, Diplomate of the American Board of Oral and Maxillofacial Surgery, eligible for examination by American Board of Oral and Maxillofacial Surgery, or Fellow of the American Association of Oral and Maxillofacial Surgeons
4. List of assisting staff's credentials/CV/training:
 - a. _____
 - b. _____
 - c. _____

B. Records

Have available three charts of patients who have been treated in your office with intravenous sedation or general anesthesia.

1. An adequate medical history of the patient.
2. An adequate physical evaluation of the patient.
3. Anesthesia records showing: continuous monitoring of heart rate, blood pressure, and respiration using electrocardiographic monitoring and pulse oximetry, and ventilation by capnography. In patients undergoing inhalational anesthesia, preoperative and postoperative temperature monitoring, and if the procedure is longer than 30 minutes, continuous temperature monitoring.
4. Recording of monitoring every five minutes.
5. Evidence of continuous recovery monitoring, with notation of patient's condition upon discharge and person to whom the patient was discharged.
6. Accurate recording of medications administered, including amounts and time administered.
7. Records illustrating length of procedure.
8. Records reflecting any complications of anesthesia.

C. Office Facility and Equipment

1. **Noninvasive Blood Pressure Monitor**
2. **Electrocardiograph**

3. Defibrillator/Automated External Defibrillator**4. Pulse Oximeter****5. Capnography equipment****6. Operating Theater**

- a. Is the operating theater large enough to accommodate the patient on a table or in an operating chair adequately?
- b. Does the operating theater permit an operating team consisting of at least three individuals to move freely about the patient?
- c. Does the operating theater allow easy access for emergency personnel and transportation equipment?

7. Operating Chair or Table

- a. Does the operating chair or table permit the patient to be positioned so the operating team can maintain the airway?
- b. Does the operating chair or table permit the team to alter the patient's position quickly in an emergency?
- c. Does the operating chair or table provide a firm platform for the management of cardiopulmonary resuscitation?

8. Lighting System

- a. Does the lighting system permit evaluation of the patient's skin and mucosal color?
- b. Is there a battery-powered backup lighting system?
- c. Is the backup lighting system of sufficient intensity and power for an adequate period of time to permit completion of any operation underway at the time of general power failure?

9. Suction Equipment

- a. Does the suction equipment permit aspiration of the oral and pharyngeal cavities?
- b. Is there a backup suction device available?

10. Oxygen Delivery System

- a. Does the oxygen delivery system have adequate full-face masks and appropriate connectors, and is it capable of delivering oxygen to the patient under positive pressure?
- b. Is there an adequate backup oxygen delivery system?

11. Recovery Area (recovery area can be the operating theater)

- a. Does the recovery area have available oxygen?
- b. Does the recovery area have available adequate suction?
- c. Does the recovery area have adequate lighting?
- d. Does the recovery area have adequate electrical outlets?
- e. Can the patient be observed by a member of the staff at all times during the recovery period?

12. Ancillary Equipment

- a. Is there a working laryngoscope complete with an adequate selection of blades, spare batteries and bulbs?
- b. Are there endotracheal tubes and appropriate connectors?
- c. Are there oral airways?
- d. Are there any supraglottic airway devices?
- e. Is there a tonsillar or pharyngeal type suction tip adaptable to all office outlets?
- f. Are there endotracheal tube forceps?
- g. Is there a sphygmomanometer and stethoscope?
- h. Are there an electrocardioscope and defibrillator/automated external defibrillator?

- i. Is there a pulse oximeter?
- j. Is there a capnography monitor?
- k. Is there adequate equipment for the establishment of an intravenous infusion?

D. Drugs

1. Vasopressor drug available?
2. Corticosteroid drug available?
3. Bronchodilator drug available?
4. Muscle-relaxant drug available?
5. Intravenous medication for treatment of cardiopulmonary arrest available?
6. Narcotic antagonist drug available?
7. Benzodiazepine antagonist drug available?
8. Antihistamine drug available?
9. Antiarrhythmic drug available?
10. Anticholinergic drug available?
11. Coronary artery vasodilator drug available?
12. Antihypertensive drug available?
13. Mechanism of response for dantrolene (Dantrium)?

Overall Equipment – Facility _____ **Adequate** _____ **Inadequate**

Comments _____

Recommendations _____

Signature(s) of Evaluators _____

Printed Name(s) of Evaluators _____

Fig. 6.3 (continued)

6.5 Office Requirements

The facilities where ambulatory anesthesia is provided in OMS practices are subject to stringent guidelines [11]. Specific building codes and local fire department regulations have to be followed for installation of remote gases. Proximity to a larger healthcare facility and access to emergency personnel are of paramount importance. Recommendations per Centers for Disease Control (CDC) and prevention on controls for exposure to anesthetic gases and other potential chemical hazards, as well as sterilization of the instruments and facilities are enforced. Office's fire safety and emergency protocols should be known by all staff and easily accessible for reference. Telephone numbers of the local ambulance service and nearest hospital should be clearly displayed and their location known to all office staff.

6.6 Record Keeping

Medical record keeping is paramount in current OMS practice. For the purpose of OMS procedures, proper electronic records have to be maintained. This includes preanesthesia assessment forms, i.e., history and physical evaluation, consent forms, intraoperative anesthesia records, operative notes as well as recovery records (Fig. 6.4). Anesthesia records typically consist of vital signs (recorded every 5 min), type and amount of drugs administered with time of administration, start and end times of anesthesia and surgery, surgeon and other team members' names, and details of complications and management, if any.

6.7 Office Anesthesia Evaluation Program and Parameters of Care

Every practicing AAOMS member agrees to a uniform peer inspection of their properly equipped office and their techniques and preparation for managing emergencies and complications of anesthesia in the treatment of the OMS patient in their office or outpatient setting.

In 1975, the AAOMS established the Office Anesthesia Evaluation Program. This program was conceived, developed, and implemented by the AAOMS through its component state societies to benefit the public, whom its members serve. This ensures a level of safety to the practice of anesthesia in the OMS office, which is often outside a hospital or other healthcare facility. Since 1990, AAOMS Bylaws require official component societies' constitutions and bylaws to include provision for the fulfillment of an onsite office evaluation based on the AAOMS Office Anesthesia Evaluation Program as a prerequisite for active membership.

The office anesthesia evaluation is now required every 5–6 years for every AAOMS member.

AAOMS periodically offers an Office Anesthesia Evaluation Manual [12] with the following intent—"AAOMS Committee on Anesthesia developed the Office Anesthesia Evaluation Manual to provide information that could aid oral and maxillofacial surgeons in preparing themselves and their offices for the management of anesthetic complications. It presents scientific and clinical information and can serve as a reference for the practitioner." The most recent evaluation manual is available for purchase by the members in 2019.

In addition, a separate document called "AAOMS Parameters of Care" [13, 14] is intended to reflect practice considerations for 11 designated areas of oral and maxillofacial surgery and is an additional guide for AAOMS members to establish parameters of care for anesthesia in outpatient facilities. The most recent version of this document was published in 2017. The document provides complementary recommendations for the provision of safe sedation and anesthesia in the office. Members are encouraged to review both documents, which provide essential information on contemporary OMS office anesthesia practice and practice accordingly.

6.8 AAOMS National Simulation Program

AAOMS recognizes that the provision of anesthesia at an OMS office is a team effort. It expects each member of the team—from the surgeon to the assistants—to be highly trained and qualified to address every anesthesia-related situation that may occur during a surgical procedure. This training is initiated in OMS residencies but is continuous throughout the surgeon's career, mandated by continuing education and team exercised. Similar to professional sports teams, successful oral and maxillofacial surgery teams train as a unit to ensure they can seamlessly and quickly manage an unexpected airway emergency. The most recent AAOMS offering to help the office anesthesia team partners with advanced simulation technology making it possible to train surgeons and staff by simulating a full range of real-life emergency airway situations [15]. This program allows participants to practice and master critical techniques for administering and monitoring office-based anesthesia; a standardized approach that ensures that every participant experiences the same simulated events. The program allows for evaluation of each participant's performance and can pinpoint those areas that may benefit from additional training. The three-module program offers oral and maxillofacial surgeons and their staff an effective method of assessing their readiness to meet an office anesthesia emergency situation by practicing these in a low-risk, high-stake simulation scenario.

Sedation and Anesthesia Record

Patient _____
 ID # _____
 Premed _____
 Equipment Check Dx: _____
 Time Out Tx: _____
 Preoperative start time: _____

Date	Age	NPO	ASA	Surgeon	Anesthetist
			1 2 3		
Weight	Height	BMI	Airway	Surgeon Asst.	Anesthetist Asst.
			Mallampati 1 2 3 4		

Agents/Drugs	0	5	10	15	20	25	30	35	40	45	50	55	60	65	70	75	TOTAL
Midazolam																	
Fentanyl 50 mcg/ml																	
Propofol 10 mg/ml																	
Methohexital 10 mg/mL																	
Ketamine																	
Dexamethasone 4 mg/mL																	
Remifentanil mcg/cc																	
Zofran mg																	
Exparel mg																	
Sevoflurane %																	
Lidocaine 2% 1:100 k epi																	
Articaine 4% 1:100 200k epi																	
Mepivacaine 3%																	
Fluids NS RL																	
Nitrous Oxide L/min																	
Oxygen L/min %																	

MONITORS

Auto BP R L

ECG (Lead II)

Pulse Oximeter

Stethoscope

Capnograph

BIS

Temp

SYMBOLS

SBP ∨

DBP ^

Pulse •

Resp ○

Anes x

Anes x̄

Surg ⊙

Surg ⊚

POSITION

Reclined

Supine

	0	5	10	15	20	25	30	35	40	45	50	55	60	65	70	75
ECG																
SpO ₂																
mmHg																
Temp																
200																
180																
160																
140																
120																
100																
80																
60																
40																
20																
0																

IV

22G Catheter x ____

20G Catheter x ____

_____ x ____

R Antecubital x ____

Radial x ____

L Dorsum hand x ____

_____ x ____

AIRWAY

Nasal Cannula

Nasal Mask

Mask

Nasopharyngeal

Oral

LMA

ET Tube

Comments _____ Dr. Signature _____

Fig. 6.4 Sample sedation and anesthesia record form. Available at www.aaoms.org

6.9 Dental Anesthesia Assistant National Certification Examination (DAANCE)

The practice of office-based anesthesia depends largely on the skillset of the assistants in the office as much as it does on the surgeon leading the team. In an effort to elevate the education and knowledge base of the other team members, a program called the Dental Anesthesia Assistant National Certification Examination (DAANCE) was implemented nationwide. This is a continuing education program that comprises 36 h of self-education and a computerized exam to be completed in 6 months. This course is designed primarily for OMS assistants. Upon successful completion of the final examination, certification is provided.

The course is designed to cover important topics, including general review of basic sciences, patient's medical history evaluation, basic knowledge on anesthetic drugs and techniques, role of anesthesia equipment and monitoring, and covers basic maneuvers to handle office anesthesia emergencies.

This course is available to allied staff all year round to register and complete. More and more states in the US are now mandating courses like DAANCE or others to all team members in an effort to keep the practice of ambulatory anesthesia team model safe and viable in the OMS office.

6.10 Anesthesia Training during OMS Residency

OMS trainees in the US have a rigorous curriculum in anesthesia. The Commission on Dental Accreditation (CODA) of the American Dental Association (ADA) is the independent body that accredits all residency training programs. This accreditation is based on a peer-review process that enforces adherence to training standards created and vetted by the CODA. The educational standards for anesthesia read as follows:

4-3.1... Anesthesia Service: The assignment must be for a minimum of 5 months, should be consecutive, and one of these months should be dedicated to pediatric anesthesia. The resident must function as an anesthesia resident with commensurate level of responsibility.

Intent: The pediatric portion could include Pediatric intensive care unit (PICU), Neonatal intensive care unit (NICU), pediatric anesthesia service, or ambulatory pediatric anesthesia. Oral and maxillofacial surgery residents rotating on the anesthesia service have levels of responsibility identical to those of the anesthesia residents, and abide by the anesthesia department's assignments and schedules. Part of this time can be during medical school as long as oral and maxillofacial surgery trainee functions at the anesthesia resident level.

4-9... The off-service rotation in anesthesia must be supplemented by longitudinal and progressive experience

throughout the training program in all aspects of pain and anxiety control. The ambulatory oral and maxillofacial anesthetic experience must include the administration of general anesthesia/deep sedation for oral and maxillofacial surgery procedures to pediatric, adult, and geriatric populations, including the demonstration of competency in airway management. Examples of evidence to demonstrate compliance may include:

- Resident's anesthetic log.
- Clinical tracking system.
- Anesthesia records.
- Oral and Maxillofacial Surgery Benchmarks.

4-9.1... The cumulative anesthetic experience of each graduating resident must include administration of general anesthesia/deep sedation for a minimum of 300 cases. This experience must involve care for 50 patients younger than 13. A minimum of 150 of the 300 cases must be ambulatory anesthetics for oral and maxillofacial surgery outside of the operating room. Intent: The cumulative experience includes time on the anesthesia rotation as well as anesthetics administered while on the oral and maxillofacial surgery service. Locations for ambulatory anesthesia may include dental school clinics, hospital clinics, emergency rooms, and oral and maxillofacial surgery offices.

Examples of evidence to demonstrate compliance may include:

- Resident's anesthetic log.
- Clinical tracking system.
- Anesthesia records.
- Oral and Maxillofacial Surgery Benchmarks.

4-9.2 ...In addition to general anesthesia/deep sedation, the residents must obtain extensive training and experience in all sedation techniques.

Examples of evidence to demonstrate compliance may include:

- Detailed curriculum plans
- Patient charts
- Simulation experience

4-9.3 ...The clinical program must be supported in part by a core comprehensive didactic program on general anesthesia, deep sedation, and other methods of pain and anxiety control. The didactic program must include lectures and seminars emphasizing:

- Patient evaluation
- Risk assessment
- Anesthesia and sedation techniques
- Monitoring and
- The diagnosis and management of complications

4-9.4 ...Advanced Cardiac Life Support (ACLS) must be obtained in the first year of residency and must be maintained throughout residency training and thereafter.

Examples of evidence to demonstrate compliance may include:

- ACLS certification records and cards

4-9.5... Each resident must be certified in Pediatric Advanced Life Support (PALS) prior to completion of training.

Examples of evidence to demonstrate compliance may include:

- PALS certification records and cards

Adherence to these standards is strictly enforced ensuring a standardized education in anesthesia to each OMS resident in training in the US.

6.11 Preanesthetic Evaluation of the Patient

The OMS planning an office-based anesthetic is trained to do a thorough preoperative evaluation of the patient to deem them fit for office anesthesia. Just as an anesthesiologist would evaluate the patient for systemic disease, functional capacity and medications along with a detailed anesthetic history and physical examination to classify every patient into an American Society of Anesthesiologists (ASA) status (Table 6.2) [16], every OMS would do the same for formulating an anesthetic plan for the patient.

Ideally, ASA I and II patients are best suited for office-based anesthetics. Careful preanesthetic patient evaluation is critical in choosing the type and venue for the anesthetic. This evaluation has the following essential steps:

- Reviewing and understanding patient's medical, family, social, surgical, and anesthetic history through questionnaire and interview.
- Full physical examination of all systems.

This detailed preop evaluation gives the OMS the knowledge to classify all according to the ASA classification and adequately plan for an appropriate anesthesia technique.

6.12 Monitoring

Provision of anesthesia in the OMS office requires that monitoring is done according to the ASA standards and more.

This includes the following minimal time-stamped monitoring and documentation [17].

1. Noninvasive monitoring of blood pressure every 5 min
2. Continuous ECG monitoring
3. Continuous pulse oximetry
4. Continuous end-tidal CO₂ monitoring of ventilatory effort

Table 6.2 ASA physical status classification system.

ASA I	A normal healthy patient	Healthy, nonsmoking, no or minimal alcohol use
ASA II	A patient with mild systemic disease	Mild diseases only without substantive functional limitations. Examples include (but not limited to): Current smoker, social alcohol drinker, pregnancy, obesity (30 < BMI < 40), well-controlled DM/HTN, mild lung disease
ASA III	A patient with severe systemic disease	Substantive functional limitations; one or more moderate-to-severe diseases. Examples include (but not limited to): Poorly controlled DM or HTN, COPD, morbid obesity (BMI ≥40), active hepatitis, alcohol dependence or abuse, implanted pacemaker, moderate reduction of ejection fraction, ESRD undergoing regularly scheduled dialysis, premature infant PCA < 60 weeks, history (>3 months) of MI, CVA, TIA, or CAD/stents.
ASA IV	A patient with severe systemic disease that is a constant threat to life	Examples include (but not limited to): Recent (< 3 months) MI, CVA, TIA, or CAD/stents, ongoing cardiac ischemia or severe valve dysfunction, severe reduction of ejection fraction, sepsis, DIC, ARD or ESRD not undergoing regularly scheduled dialysis
ASA V	A moribund patient who is not expected to survive without the operation	Examples include (but not limited to): Ruptured abdominal/thoracic aneurysm, massive trauma, intracranial bleed with mass effect, ischemic bowel in the face of significant cardiac pathology or multiple organ/system dysfunction
ASA VI	A declared brain-dead patient whose organs are being removed for donor purposes	

Developed By: ASA House of Delegates/Executive Committee

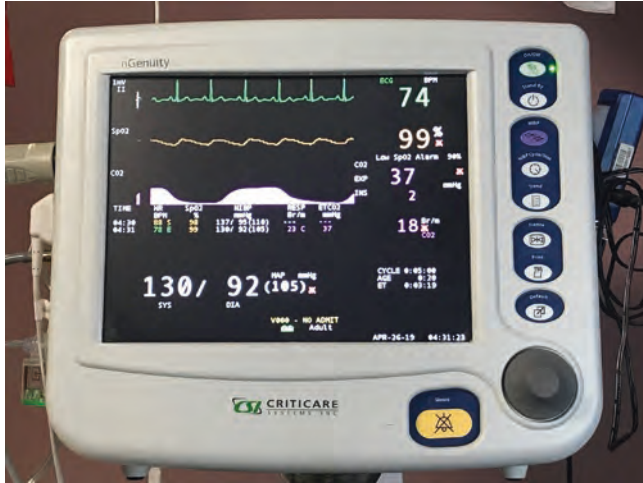5. Ability to measure temperature, i.e., very essential in a setting where Malignant Hyperthermia (MH) triggering agents are in use.

Majority of OMS offices now use monitor units (Fig. 6.5) that interface directly with an electronic health record. The entire team is clued into monitoring with a staff member often dedicated to only monitoring the patient.

All patients receive supplemental oxygen before, during, and after the procedure. Most facilities have a separate recovery area with the same monitors, although there are several offices that recover in the operating room. The goal is the improvement of efficacious monitoring to establish the safe performance of anesthetic without the need for a separate anesthesia provider. It is imperative to have a meticulously trained team to allow for continuous monitoring, thus facilitating immediate recognition of changes in patient's vital signs. A properly evaluated and selected patient is unlikely to have a catastrophe in the OMS anesthetic, but when an untoward event does occur, it is often a respiratory event.

6.12.1 Methods for Monitoring Ventilation

Data available from closed claims cases from the OMS National Insurance Corporation (OMSNIC) allow us as a specialty to audit the near-misses and tragic outcomes from our offices. The data suggest a strong correlation between airway-related failure and adverse events in the open-airway anesthetic techniques. The emphasis is on monitoring of



©Association of Oral and Maxillofacial Surgeons of India

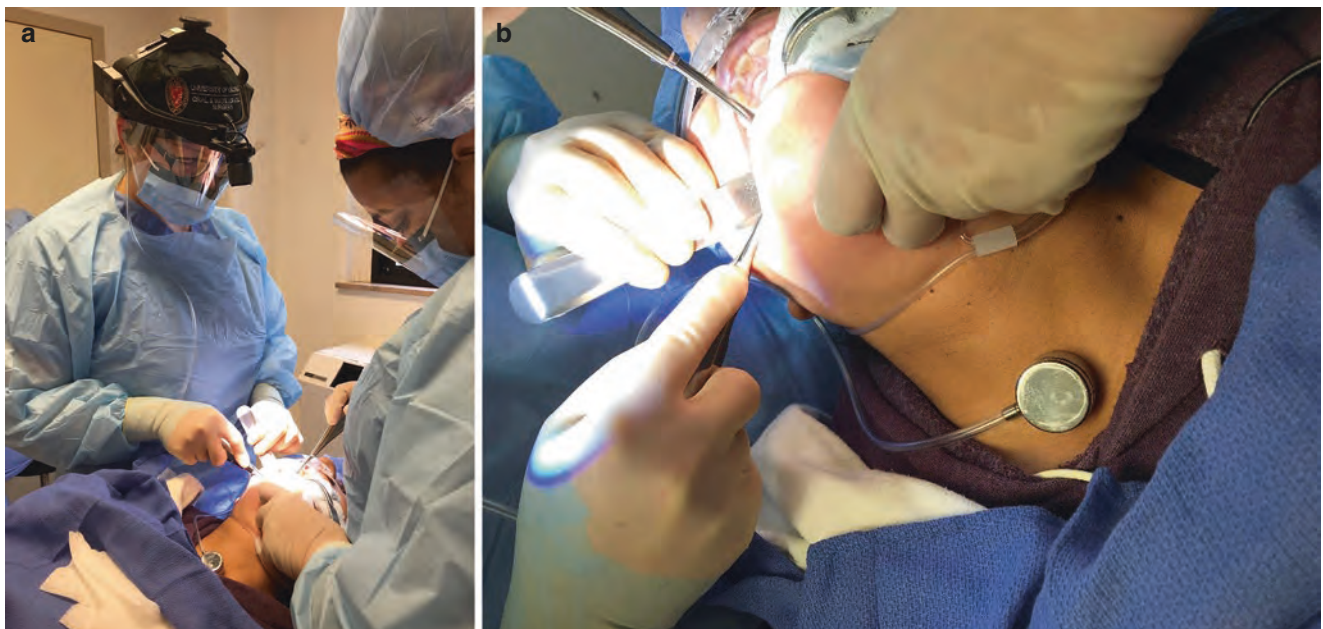
Fig. 6.5 Example of monitor commonly used in oral and maxillofacial surgery anesthetic administration. The single unit clearly displays the electrocardiogram, noninvasive blood pressure monitor, oxygen saturation, and end-tidal carbon dioxide

both ventilation and oxygenation to allow adequate monitoring of the respiratory system during anesthesia. This can be achieved by using a pulse oximeter, which is a device that measures oxygen saturation and provides an indirect indication of oxygenation. Recently, AAOMS recommended a newer ASA standard monitoring of ventilation with continuous capnography. Although chest movements are a reliable method but are least exact, hence the addition of capnography. Most OMSs use a pretracheal/precordial stethoscope (Fig. 6.6) to auscultate while the patient is sedated.

Historically, pulse oximetry has been used for respiratory monitoring. But due to its limitation in lacking real-time responsiveness to major respiratory events like airway obstruction or respiratory depression, there was an imminent need to incorporate a different parameter to provide a real-time assessment. Thus was developed capnography [18], which is the noninvasive measurement of the partial pressure of carbon dioxide (CO₂) from the airway during inspiration and expiration. It can provide real-time sensitivity to early changes in ventilation and is reliable even in low-perfusion states.

Although, in the nonintubated sedated patient, there is loss of CO₂ through the nose and mouth, and thus requires modification of the collection cannula, it still provides valuable clinical information on patient's ventilation during sedation.

It cannot be stressed enough how critical it is to manage intraoperative airway and monitor respiratory status. Ventilation is monitored by inspection of chest movement by the assistants, monitoring of capnography as well as auscul-



©Association of Oral and Maxillofacial Surgeons of India

Fig. 6.6 (a, b) Pretracheal/precordial stethoscope used by the surgeon to auscultate while the patient is sedated

tation with a precordial stethoscope. The newer Bluetooth models of the precordial stethoscope allow wireless speakers that allow the entire team to listen to the patient's respiratory patterns.

Now with multiple modalities such as a real-time capnography tracing, listening to breath sounds with high fidelity, OMS team has an opportunity to assess and act promptly on potential airway threats even before the adverse respiratory event comes to light. With these available modalities, along with surgeon's experience and developed senses, anticipation and prediction of an impending laryngospasm or bronchospasm prompts the team to act preemptively. Even before a drop in oxygen saturation or loss of waveform on capnography becomes apparent, both the depth and rate of breathing as well as the cessation of breathing can be promptly recognized.

6.13 Airway Armamentarium

Despite several preventive modalities available to the OMS performing anesthesia, emergencies are bound to happen. The unit must be prepared to handle airway and other emergencies. All the anesthesia providers should be exceptionally familiar with emergency airway equipment that must be readily accessible in both the operating suites and the recovery area [11].

Emergency airway equipment must include full face mask, bag-valve-mask device capable of providing positive pressure ventilation, oral and nasopharyngeal airways, supraglottic airway devices, endotracheal tubes, and laryngoscope and cricothyrotomy kit. All these equipment should be available in both pediatric and adult sizes. The entire staff should have periodic in-office training to familiarize themselves with the equipment and their use. Apart from emergency airway instruments, all offices are required to have either a basic monophasic defibrillator or automated external defibrillator.

6.14 Oxygen and Supplemental Gas Delivery System

In addition to oxygen, most OMS offices utilize other gases such as nitrous oxide and inhalational anesthetics as well as air. The oxygen delivery system should be able to deliver metered oxygen to the patient under positive pressure. A standard fail-safe mechanism along with scavenging system should be part of all gas delivery machines installed in the office. This prevents delivery of any hypoxic amount of gases. To prevent the accidental administration of an incorrect gas, the gas outlets used should be pin-indexed. The gas delivery machines also are mandated to have periodic cali-

bration records, which should be maintained with proper documentation stored at a known location. Anesthesia equipment, including ventilators, are similarly required to have a periodic inspection by biomedical engineers. The OMS office is responsible for ensuring this happens and the office anesthesia evaluation is a mechanism to keep a check on this.

6.15 Suction Equipment

As trivial as it may seem, the office suction unit (central and portable) is an integral part of both the normal and emergency functions of that office. A portable suction unit must be readily accessible in the operating and recovery area in case of unanticipated power failure or central suction pump failure. Again, routine maintenance of the suction system and its documentation is required.

6.16 Recovery Room

Most OMS offices have a postoperative recovery unit separate from the operating room that allows unobstructed patient observation. The design of this area must allow resuscitation and management of the patient during an emergency. The recovery area should have a suction system, oxygen delivery system, all appropriate monitors and emergency equipment as detailed earlier. It is also the responsibility of the recovery nurse to document the patient's recovery from anesthetic to deem their fitness to leave the office. A recovery checklist such as the Modified Aldrete Scale is useful in making this determination.

6.17 Techniques in Anesthesia

Training in anesthesia exposes the oral and maxillofacial surgeon to the different modalities of anesthesia from light to deep sedation. As described before, levels of anesthesia are a continuum (Table 6.1). The effects of different drugs and techniques may vary between individuals. Patients may achieve deeper or lighter levels of anesthesia than anticipated based on their unique metabolic responses to the different anesthetics administration. The OMS team is prepared to anticipate these differences in responses and intervene accordingly.

The techniques utilized to get to different levels of anesthesia include inhalational anesthesia, oral anesthetic technique, parenteral anesthesia, and local anesthesia. Regardless of the technique employed, the goals of each of these techniques are to reduce anxiety, establish cooperation, amnesia and analgesia, ensuring comfort and hemodynamic stability. In order to choose the level of anesthesia, one should con-

sider the age of the patient, level of anxiety and ability to cooperate, detailed medical history, and prior anesthesia experience.

6.17.1 Enteral Anesthesia

Oral or nasal route of delivery of drugs is the least threatening route of administration of anesthesia. While some anxiolysis is achieved via this modality, it is rarely used to achieve deeper levels of anesthesia. Often the oral route of sedation is used as a premedication prior to IV access in an uncooperative patient. Various ingestives such as syrups, popsicles, needleless syringes, other creative methods are employed to get the patient to consume the medication. Dosing is adjusted in such a way that a higher dose of the drug may be administered in a limited volume to prevent the likelihood of aspiration. Despite that, a crying child or a coughing adult may end up aspirating the medication. The other disadvantages of this technique include a slow onset and variable response to the action of the drug as well as an unpredictable recovery pattern. In an uncooperative patient, patient compliance will limit oral or nasal administration of any drug. Additionally, oral dosing is often empiric with almost predictable erratic absorption. Titration of the drug is difficult via this route.

Yet, it remains a convenient mode of administration, requiring very little training to deliver, and any adverse reactions are slow to the onset and usually less severe and manageable. In the US, a medical provider providing oral sedation in the office does not have an increase in their malpractice premiums because of this practice. In contrast, practitioners of general anesthesia have higher malpractice coverage due to the inherent risks of that practice.

An ideal oral medication must be able to provide rapid absorption, must have a rapid onset, and must have a high therapeutic index allowing rapid and predictable recovery.

The following are the drugs most commonly used in oral sedation techniques:

- Benzodiazepines
- Histamine blockers
- Opioids
- Scopolamine
- Chloral hydrate
- Barbiturates
- Alpha agonists—Dexmedetomidine, Clonidine

Oral sedation techniques are primarily useful in the OMS as a premedication tool. An orally sedated patient is likely to accept a mask or an IV for further induction of anesthesia. Several minor procedures, however, can be performed with oral sedation and good local anesthesia alone.

6.17.2 Parenteral Anesthesia: Intravenous Anesthesia and Inhalational Anesthesia

Hubbell [5] was known to promote the use of intravenous thiopental anesthesia. It was eventually replaced by the shorter-acting barbiturate methohexital. This became the primary agent used for office-based anesthesia for multiple decades. A shortage in supply of methohexital and an increased use of Propofol [8] in the operating theater setting prompted an adaptation of the use of that drug in the office-based anesthetic technique. The basic technique for deep sedation and general anesthetic in the nonintubated patient in the OMS office typically employs a cocktail of medications under strict ASA-mandated guidelines for monitoring with the personnel as described earlier.

These medications include, but are not limited to, the following:

- A benzodiazepine such as Midazolam for anxiolysis, amnesia, sedation, and hypnosis
- A potent narcotic analgesic such as Fentanyl or Remifentanyl
- A potent non-narcotic analgesic such as Ketamine
- A sedative hypnotic such as Propofol. It also acts as an adjunct antiemetic agent.
- Adjuvant drugs such as dexamethasone for prevention of postoperative edema and nausea and vomiting.
- Toradol or i.v. Tylenol for adjunct pain control

Most of these medications are characterized by their ability to have a rapid onset and offset. Medications such as Propofol rapidly redistribute and metabolize and are eliminated from the system. The combination of these medications often results in a cumulative effect of sedation and hypnosis in addition to central analgesia. Discomfort from the administration of local anesthesia is often obtunded by this level of sedation. Patients maintain their ventilation and careful monitoring of their vital signs and protection of their airway allows for smooth sedation. The surgeon who is performing the procedure is in close proximity to the patient's airway understanding its minute undulations and sensing the level of the patient's sedation and acting preemptively to either prolong or discontinue the sedation. It is an art and science that is built on years of training and experience.

The dosing of these medications is based on the patient's ideal body weight. The administration of these medications is through a continuous intravenous catheter infusion with an appropriate IV fluid. Typically, a 20- or a 22-gauge catheter is inserted into a peripheral vein in the upper extremity. Most OMSs practice the bolus technique, which introduces incremental doses of each medication, titrated to effect. Infusion pumps are often utilized in longer cases, while shorter cases of sedation seldom require infusion.

Using a continuous infusion has the following tangible advantages:

- Minimize fluctuations in drug serum concentration
- Smoother intraoperative course
- Enhanced cardiovascular stability
- Enhanced respiratory stability
- Less patient movement
- More rapid recovery
- Minimal drug utilization

6.18 Emergency Drugs

The ninth edition of the AAOMS Office Anesthesia Evaluation Manual [12] provides a detailed list of medications that can be used during anesthetic emergency. OMS offices are recommended to have a refrigerator designated for medications requiring cold storage. Pharmacy boards of different states control the storage and distribution of these drugs.

Listed are suggested drugs used in the event of anesthetic emergencies:

- Intravenous fluids: normal saline, lactated Ringer, etc.
- Cardiovascular medications: Oxygen, Atropine, Nitroglycerin, Dopamine, Epinephrine, Dobutamine, Ephedrine, Phenylephrine, Lidocaine, Propranolol, Procainamide, Verapamil, Amiodarone, Adenosine
- Antihypertensive medications: Diazoxide, Hydralazine, Esmolol, Labetalol
- Diuretics: Furosemide (Lasix)
- Antiemetics: Prochlorperazine, Ondansetron
- Reversal agents: Naloxone (Narcan), Flumazenil (Romazicon)

Additional Drugs

- Dextrose 50%, Dexamethasone (Decadron), Hydrocortisone sodium succinate or Methyl prednisolone sodium succinate (Solu-Medrol), Glycopyrolate (Robinul), Diazepam (Valium), Midazolam (Versed), Albuterol inhaler, Succinylcholine (Anectine), Morphine sulfate, Dantrolene (Dantrium), Lidocaine, Nonenteric-coated aspirin, Famotidine (Pepcid), Diphenhydramine (Benadryl)

6.19 Activism and Leadership in Office-Based Anesthesia

Dental anesthesia is an ADA-recognized specialty in the US as of 2019. Several dental practitioners, including OMSs, practice anxiolysis and sedation in their offices, outside a hospital

operating suite and without a separate anesthesia provider. The concerted efforts by various interested parties to politically organize and better protect our intellectual and political interests in the discipline make this practice a reality in the US.

To ensure the commitment to patient safety, the AAOMS and its Board of Trustees have embraced a multipronged approach:

- undiluted enforcement of educational standards that requires resident rotation on the medical anesthesia service
- a self-imposed mandatory AAOMS Office Anesthesia Evaluation Program
- a devotion to the anesthesia team approach and development of the DAANCE program for the assistants
- the development of anesthesia and emergency management simulation programs such as Basic Emergency Airway Management [BEAM] and Office-Based Crisis Management [OBCM] are some examples of some of this commitment.

The AAOMS developed an Anesthesia Safety Conference for our own specialty that was held on April 27, 2017, at the American Society of Anesthesiologists headquarters in Schaumburg, Illinois. Representatives of the ASA as well as representatives of the appropriate disciplines of dentistry attended this meeting. In April 2019, a second patient safety conference focusing on pediatric sedation was organized at the AAOMS headquarters in Rosemont, Illinois.

By staying on the forefront of office-based anesthesia and by enforcing the highest standards of safety in patient care, OMS as a specialty has become stalwart in this arena. Continued positive momentum with nationwide simulation workshops and a mobile application supporting the office anesthesia evaluation will enhance our role as leaders in ambulatory anesthesia in our offices. The rapid response and emergency system and the healthcare infrastructure in the US allows for OMSs in this country to adapt this technique and methodology into their practices almost effortlessly. In other parts of the world, this may not be a model that is easy to replicate.

Video Links

<https://myoms.org/procedures/anesthesia>

References

1. American Society of Anesthesiologists (ASA). Continuum of depth of sedation: definition of general anesthesia and levels of sedation/analgesia. (Approved by the ASA House of Delegates on October 13, 1999 and last amended on October 15, 2014). Available at: <https://www.asahq.org/standards-and-guidelines/continuum-of->

- [depth-of-sedation-definition-of-general-anesthesia-and-levels-of-sedationanalgesia](#)
2. Bicentenary of nitrous oxide. *Br Med J*. 1972 May 13;2(5810):367-368. PubMed PMID: 4554156; PubMed Central PMCID: PMC1788276.
 3. West JB, Humphry Davy, nitrous oxide, the pneumatic institution, and the royal institution. *Am J Physiol Lung Cell Mol Physiol* 2014 Nov 1;307(9):L661-L667.
 4. Desai MS, Desai SP. Discovery of modern anesthesia: a counterfactual narrative about Crawford W. Long, Horace Wells, Charles T. Jackson, and William T. G. Morton. *AANA J* 2015 Dec;83(6):410-415. PubMed PMID: 26742335.
 5. Hubbell AO, Adams CR. Intravenous anesthesia for dental surgery with sodium ethyl (1-Methylbutyl) Thiobarbituric acid. *J ADA*. 1940;27(8):1186-91.
 6. Shane SM. Intravenous amnesia for total dentistry in one sitting. *J Oral Surg* 1966 Jan;24(1):27-32. PubMed PMID: 5214559.
 7. Lieblisch SE. Methohexital versus propofol for outpatient anesthesia. Part I: Methohexital is superior. *J Oral Maxillofac Surg* 1995 Jul;53(7):811-815. Review. PubMed PMID: 7595796.
 8. Dembo JB. Methohexital versus propofol for outpatient anesthesia. Part II: Propofol is superior. *J Oral Maxillofac Surg* 1995 Jul;53(7):816-820. Review. PubMed PMID: 7595797.
 9. Lieblisch S. Providing anesthesia in the Oral and maxillofacial surgery office: a look Back, where we are now and a look ahead. *J Oral Maxillofac Surg* 2018 May;76(5):917-925. Review.
 10. Drew SJ. Oral and maxillofacial surgery team anesthesia model and anesthesia assistant training. *Oral Maxillofac Surg Clin North Am* 2018 May;30(2):145-153. Review.
 11. Chung WL. Anesthesia equipment for the oral and maxillofacial surgery practice. *Oral Maxillofac Surg Clin North Am* 2013 Aug;25(3):373-383.
 12. American Association of Oral and Maxillofacial Surgeons (AAOMS). Office anesthesia evaluation manual. 9th edition. 2018. Available at: <http://www.aaoms.org>.
 13. American Association of Oral and Maxillofacial Surgeons (AAOMS). Parameters of Care: AAOMS Clinical Practice Guidelines for Oral and Maxillofacial Surgery (AAOMS ParCare) Sixth Edition 2017. Patient assessment. Available at: https://www.aaoms.org/images/uploads/pdfs/parcare_assessment.pdf
 14. American Association of Oral and Maxillofacial Surgeons (AAOMS). Parameters of Care: AAOMS Clinical Practice Guidelines for Oral and Maxillofacial Surgery (AAOMS ParCare) Sixth Edition 2017. Anesthesia in outpatient facilities. Available at: [https://www.joms.org/article/S0278-2391\(17\)30488-3/pdf](https://www.joms.org/article/S0278-2391(17)30488-3/pdf)
 15. Todd DW, Schaefer JJ 3rd. The American Association of Oral and Maxillofacial Surgeons Simulation Program. *Oral Maxillofac Surg Clin North Am* 2018 May;30(2):195-206. Review.
 16. ASA Physical Status Classification System. Developed By: ASA House of Delegates/Executive Committee, Last Amended: October 15, 2014 (original approval: October 15, 2014). Available at: <https://www.asahq.org/standards-and-guidelines/asa-physical-status-classification-system>.
 17. American Society of Anesthesiologists (ASA). Standards for basic anesthetic monitoring. Developed By: Committee on Standards and Practice Parameters (CSPP) Last Amended: October 28, 2015 (original approval: October 21, 1986). Available at: <https://www.asahq.org/standards-and-guidelines/standards-for-basic-anesthetic-monitoring>.
 18. Farish SE, Garcia PS. Capnography primer for Oral and maxillofacial surgery: review and technical considerations. *J Anesth Clin Res* 2013 Mar 18;4(3):295. PubMed PMID: 24459603; PubMed Central PMCID: PMC3897173.

Additional Reading

White Paper by American Association of Oral and Maxillofacial Surgeons (AAOMS). Office-Based Anesthesia Provided by the Oral and Maxillofacial Surgeon. 2016. Available at: https://www.aaoms.org/docs/govt_affairs/advocacy_white_papers/advocacy_office_based_anesthesia_whitepaper.pdf

Open Access This chapter is licensed under the terms of the Creative Commons Attribution 4.0 International License (<http://creativecommons.org/licenses/by/4.0/>), which permits use, sharing, adaptation, distribution and reproduction in any medium or format, as long as you give appropriate credit to the original author(s) and the source, provide a link to the Creative Commons license and indicate if changes were made.

The images or other third party material in this chapter are included in the chapter's Creative Commons license, unless indicated otherwise in a credit line to the material. If material is not included in the chapter's Creative Commons license and your intended use is not permitted by statutory regulation or exceeds the permitted use, you will need to obtain permission directly from the copyright holder.





Anaesthesia for Maxillo Facial Surgery

7

Rebecca Jacob, Subramanyam S. Mahankali,
Renita Maria, Suman Ananathanarayana, Garima Sharma,
and Mary Thomas

7.1 Introduction

Maxillofacial surgery encompasses a wide range of procedures on the head and neck, combining oral and facial procedures with the ear, nose and throat (ENT), plastic surgery, neurosurgery and base of skull specialities. It ranges from simple dental extractions to complex reconstructive and free flap surgery.

Patients of all age groups may present for maxillofacial surgery. The main issues involve managing a shared airway; providing good access to head, neck and oral cavity. The management of difficult airways and measures to reduce tissue bleeding and oedema, both intra- and post-operatively pose a unique challenge to the anaesthetist. Good communication between all members of the team is essential [1].

7.2 Preoperative Assessment

All patients should be assessed preoperatively and an anaesthetic plan should be formulated as these patients may have a suspected or a known difficult airway or are undergoing complex or prolonged surgery. Patients may give the history of poor oral intake and nutritional state due to pain, dysphagia and odynophagia. If dyspnoea is present, it should be evaluated as to whether it is cardiac or respiratory in origin.

Electronic Supplementary Material The online version of this chapter (https://doi.org/10.1007/978-981-15-1346-6_7) contains supplementary material, which is available to authorized users.

R. Jacob (✉) · S. S. Mahankali · R. Maria · S. Ananathanarayana · G. Sharma
Department of Anesthesiology, Columbia Asia Referral Hospital, Yeshwantpur, Bangalore, Karnataka, India

M. Thomas
Department of Anesthesiology, Regional Cancer Centre, Medical College Campus, Thiruvananthapuram, Kerala, India

Previous surgeries, medication history and comorbidities diagnosed earlier should be noted. Medication history is important in all patients, especially elderly patients with cardiac, respiratory or renal involvement. It is also important to ascertain whether the patients have any comorbid ailments like hypertension, diabetes, thyrotoxicosis or myxoedema, a history of epistaxis or bleeding tendency and use of anticoagulants [2, 3].

7.2.1 Patients on anticoagulants

Patients on anticoagulants may present for emergency or elective surgery. The type of anticoagulant the patient is on should be noted during pre-operative assessment. Risk of peri-operative bleeding versus thrombosis on discontinuation of anticoagulants should be stratified and accordingly discontinued or bridged with preferably unfractionated heparin or low-molecular-weight heparin prior to elective surgery. Usually, three half-lives ($T_{1/2}$) discontinuation of anticoagulants prior to surgery is considered optimal to prevent blood loss (Table 7.1) [3].

In emergency situations, the main goals are discontinuation of anticoagulation, delaying semi-urgent procedures as appropriate and employment of reversal strategies like plate-

Table 7.1 Recommendations for discontinuation of anticoagulation prior to elective surgery

Drug	Time of discontinuation
Warfarin	5 days
Factor Xa inhibitors	> 24 h
Rivaroxaban	ROCKET AF ≥ 3 days
Apixaban	Low bleed risk ≥ 24 h High bleed risk ≥ 48 h
Low-molecular-weight heparin	12 h
Prophylactic	24 h
Therapeutic dose	

American College of Chest Physician 2012 Guidelines published in Chest, the RE-LY trial published in Circulation 2014, the ROCKET AF trial, and the manufacturer's recommendations

let transfusions, fresh frozen plasma, vitamin K antagonists, and prothrombin complex concentrates.

The previous anaesthetic charts should be reviewed for the techniques used, ease of mask ventilation, best direct laryngoscopy grade, Endotracheal tube (ETT) size used, and any difficulties encountered and should be noted. The airway of previously operated patients may be altered due to previous surgeries and/or oedema, so this should be taken into account while reviewing the anaesthetic and follow-up records of the patient. If nasal intubation is required, one should enquire about nostril patency (history of nasal polyps or deviated septum). Contraindications to the use of controlled hypotension, e.g. cerebrovascular, reno-vascular and moderate-to-severe coronary artery disease should also be assessed. Specific attention should be given to the needs of each class of patient.

7.2.2 Oncology Patients

Patients with head and neck cancer sometimes constitute the most challenging patients. Their upper airway may be seriously distorted, and they may have tracheal stenosis or hardening and fixation of the soft tissues due to radiotherapy.

In these patients, documents concerning previous surgeries, radiation and chemotherapy should be studied. The difficult airway may have been encountered, tracheostomy and residual tracheal stenosis, limited mouth opening, and neck extension may have been recorded [4].

Symptoms such as hoarse voice, stridor, and dyspnoea will indicate whether there is airway compromise due to stenosis, tumour, nerve damage or oedema. Post radiation, the patients may have tissue fibrosis with limited mouth opening or neck extension. Make a note of chemotherapy drugs, duration and interval since the last cycle of chemotherapy.

7.2.3 Trauma Patients

Trauma patients require a thorough history of the mechanism of injury, which would indicate intracerebral or spinal injury. Drug and/or alcohol ingestion is often a contributory factor, and 15% have other injuries. There is also potential for injuries to other organs and massive blood loss. Cervical spine injury occurs in 5–10% of patients with blunt trauma to the head and face. Therefore, the patient should be evaluated from ‘head to toe’ [5].

7.2.4 Paediatric Patients

Consider age, weight, prematurity, feeding, nutritional status and position during sleep. In patients with craniofacial

abnormalities, look for associated syndromes such as Pierre Robin sequence or Treacher Collins syndrome as in addition to a difficult airway these patients may have involvement of other systems, such as cardiac, as a part of the syndrome, which will require specialist consultation [6].

7.2.5 Toxic Airway/Infections

Infection of dental and facial structures commonly leads to erythema and swelling of tissues. This can result in obstruction of airway and difficulty in airway management. Toxic airways (e.g. Ludwig’s angina, dental cysts and osteomyelitis) with spreading infection often present as acute emergencies and may pose an extreme airway maintenance challenge. Direct laryngoscopy due to trismus, tissue distortion, oedema or abscess cavity and pus may not be possible and other means of securing the airway must be considered [4] (Fig. 7.1a, b).

Examination Table 7.2

7.3 Airway Assessment

A detailed airway assessment based on criteria in the ‘L-E-M-O-N’ method would help to stratify the risk of difficult intubation. The ‘LEMON Law’ can be used to quickly assess for potentially difficult airways [7]. A total score of 10 can be given as per the criteria and higher scores are associated with poor glottic visualization and difficult intubation.

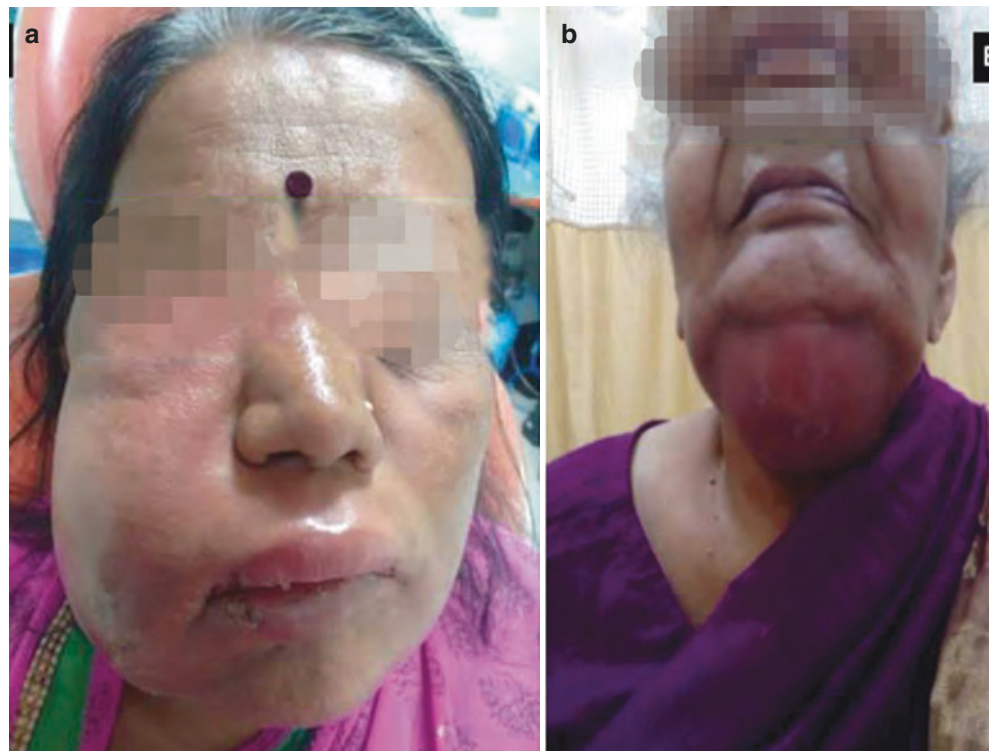Please refer the Fig. 2.2 on LEMON in Chap. 2 on pre-operative evaluation and investigations.

In paediatric patients, the Mallampati score does not accurately predict a poor view of the glottis and there are no standard values for the thyromental and horizontal length of the mandible. Thus, an adaptation is required, and this is found in the ‘COPUR SCALE’ (Table 7.3) [7, 8].

Once the airway assessment is done, check

- Whether mask ventilation would be possible after induction of General Anaesthesia (GA).
- Anticipated view during direct laryngoscopy.
- Whether it would be possible to use a supraglottic airway as a rescue device.
- Possibility and accessibility of a surgical airway in case of a dire emergency.

Fig. 7.1 (a) Buccal abscess
(b) Ludwig's angina



©Association of Oral and Maxillofacial Surgeons of India

Table 7.2 Checklist of things for a safe surgery

Pre-Anaesthesia Checklist
• Age and weight of the patient
• Type of maxillofacial surgery
• Previous surgeries/ associated complications
• Comorbidities and detailed medication list
• Known drug allergies
• CVS, RS, abdomen examination
• Detailed airway examination
• Venous access
• Adequate blood and blood products

7.4 General Physical Examination

Look for pallor, icterus, cyanosis, clubbing, lymphadenopathy and oedema as well as the general nutritional status. Follow this up with pulse rate, blood pressure, respiratory rate, oxygen saturation, signs of dehydration, and responses denoted as AVPU—Alert, Verbal, Pain, Unresponsive.

AVPU is a simplified version of the Glasgow Coma Scale (GCS), which is easy to remember and apply to patients (Table 7.4) [9, 10]. It consists of four possible stages. When recording AVPU, it is important to document the time the observation was taken and to track any changes over time as this will help monitor the progress of the patient (Table 7.4).

Apart from these, specific systemic examination, including cardiovascular, respiratory, per-abdomen and central ner-

vous system, should be done and if in any doubt a specialist should be consulted.

There are various scales used to record a patient's level of consciousness. One of the most detailed is the GCS, which is used worldwide (Table 7.5) [9, 10]. The GCS is a reasonably complicated system, which, unless you use regularly, can be difficult to remember and apply correctly.

7.4.1 Investigations

In addition to routine blood tests like complete blood counts, kidney function tests, blood sugars, coagulation profile, serology, blood grouping and cross-matching is required for major surgery.

Chest X-ray helps in visualising any pathology in the lungs. It may also reveal tracheal deviation. X-ray soft-tissue neck, airway ultrasound, computerized tomography (CT), and magnetic resonance imaging (MRI) scans may be helpful in cancer, infections, abscesses or trauma cases.

For cancer surgery, a nasoendoscopy & indirect laryngoscopy provides valuable information about the upper airway anatomy.

Electrocardiogram (ECG), echocardiogram, cardiopulmonary exercise testing or pulmonary function tests are required if there are symptoms or signs of cardiorespiratory disease.

Table 7.3 Description of COPUR scale

COPUR SCALE	
<i>C = Chin</i>	Normal – 1 Small, moderately hypoplastic – 2 Markedly recessive – 3 Extremely hypoplastic – 4
<i>O – Opening</i> Interdental space between front teeth	> 40 mm – 1 20–40 mm – 2 10–20 mm – 3 < 10 mm – 4
<i>P – Previous intubation or OSA</i>	Previous easy – 1 No attempt/no h/o OSA – 2 OSA, previous difficult intubation – 3 Extremely difficult intubation/tracheostomy/can't lie down supine – 4
<i>U – Uvula</i> Mouth open tongue out	Tip of uvula visible – 1 Uvula partially visible – 2 Uvula concealed/soft palate visible – 3 Soft palate not visible – 4
<i>R – Range</i> Line from eye to orbit, range of motion looking up & down	>120° – 1 60–120° – 2 30–60° – 3 < 30° – 4
<i>Prediction points for ease of intubation</i> 5–7: Easy normal intubation 8–10: Laryngeal help may be required 12: More difficult, may be less traumatic 14: Difficult intubation, fibre optic or other advanced technique may be required 16: Dangerous airway, consider awake intubation/potential tracheostomy	

Table 7.4 AVPU scale described with examples

		Adult Behaviour	Paediatric Behaviour
A	ALERT	Eyes open spontaneously. Appears aware of and responsive to the environment. Follows commands, eyes track people and objects	Child is active and responds appropriately to parents and other external stimuli
V	VOICE	Eyes do not open spontaneously but open to verbal stimuli. Able to respond in some meaningful way when spoken to	Responds only when his or her name is called
P	PAIN	Does not respond to questions but moves or cries out in response to painful stimuli such as pinching the skin or earlobe	Responds only when painful stimuli are received such as pinching the nail bed
U	UNRESPONSIVE	Patient does not respond to any stimuli	No response at all

Table 7.5 Glasgow Coma Scale described in detail

Glasgow Coma Scale		
Behaviour	Response	Score
Eye opening (E)	Spontaneous	4
	To speech	3
	To pressure	2
	None	1
Verbal response (V)	Orientated	5
	Confused	4
	Words, but not coherent	3
	Sounds, but no words	2
	None	1
Motor response (M)	Obeys command	6
	Moves to localised pain	5
	Flexion withdrawal to pain	4
	Abnormal flexion (decorticate)	3
	Abnormal extension (Decerebrate)	2
	No response	1
Total score	Best response	15
	Comatose	< /=6
	Totally unresponsive	3

7.4.2 Counselling and Reassurance

This is essential in all cases but especially so in patients who may have dramatic cosmetic changes or are undergoing cancer surgery like hemi-mandibulectomy. The possibility of tracheostomy and loss of voice must also be discussed with empathy. Video counselling may be resorted to in case of need.

7.4.3 Informed Consent

Any patient above the age of 18 years may give consent for surgery and anaesthesia. In the case of patients younger than 18 years, consent must be obtained from a parent or guardian after full explanation of procedures. The consent must be documented and signed by both the person taking the consent and the person giving the consent.

7.4.4 Transport to Operation Theatre (OT)

Should be with a trained health care worker especially if the patient has been given a sedative premedication. It is advisable for a parent or guardian to accompany younger children to the OT.

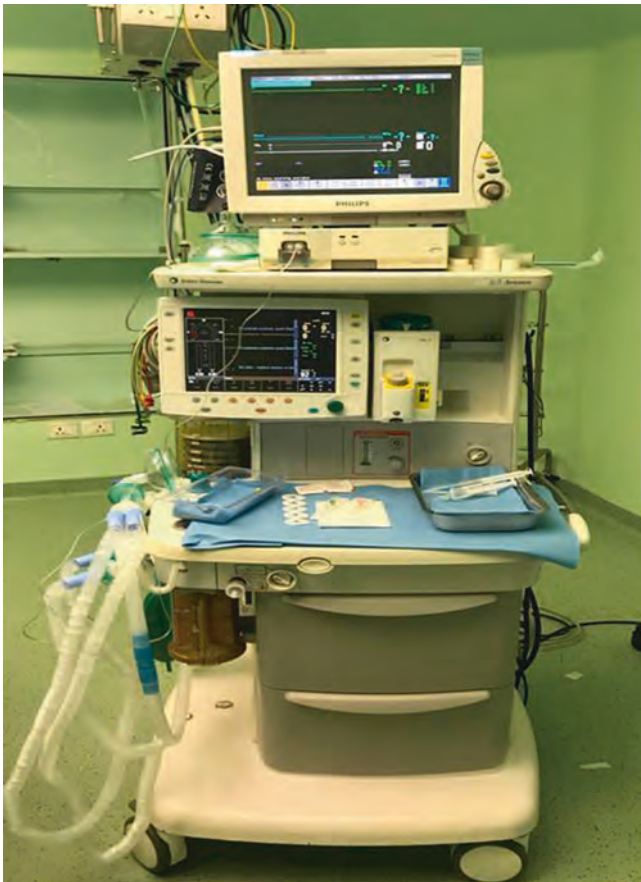7.4.5 Handover Documents

All documents pertaining to the case must be handed over to the OT personnel and the handover documented.

7.5 Intraoperative Considerations

7.5.1 Before Induction (Figs. 7.2, 7.3, 7.4, 7.5, 7.6, 7.7, and 7.8) [6]

- Discuss the procedure and options with the lead surgeon
- Ensure patients vitals are stable
- Check anaesthetic machine and all equipment, including the ‘Difficult Airway’ cart and ‘rescue devices’ like Laryngeal Mask Airway (LMA) and tracheostomy tubes.
- If an ‘uncommon’ ETT like a flexometallic or (RAE) Ring-Adair-Elwyn tube is to be used, ensure that a regular tube of the appropriate size and one size smaller are available
- Ensure you have adequate help and each one knows what is expected of him/her
- Check intravenous (IV) access and all drugs available in the OT—drawn up and labelled.
- Check that blood is available if deemed necessary
- If intubation is difficult do not try more than 2–3 times with any one method (you will precipitate oedema and make matters worse)
- **CALL FOR HELP EARLY**



©Association of Oral and Maxillofacial Surgeons of India

Fig. 7.2 Anaesthetic apparatus

- Continue oxygenation with spontaneous respiration and wake up the patient if intubation is unsuccessful

More patients have died from lack of oxygen than from lack of an endotracheal tube!

Please see Chap. 42 in this book to read about avoidable human errors for a safer patient care. (A case of loss of airway is discussed in Chap. 42).

7.5.2 Induction

Anaesthesia may be induced either intravenously or with an inhalational agent. The choice of technique depends on:

- **Airway factors:** For example, an anticipated ‘difficult airway’ or limited mouth opening
- **Patient factors:**
 - Paediatrics
 - Post radiation
 - Trauma
- **Associated comorbidities:** e.g. ischemic heart disease or emphysema.
 - Nil-per-oral status
- **Surgical factors:**
 - Trauma
 - Cancer surgery
 - Cosmetic
 - Infective
 - Vascular malformation

7.5.3 Monitoring

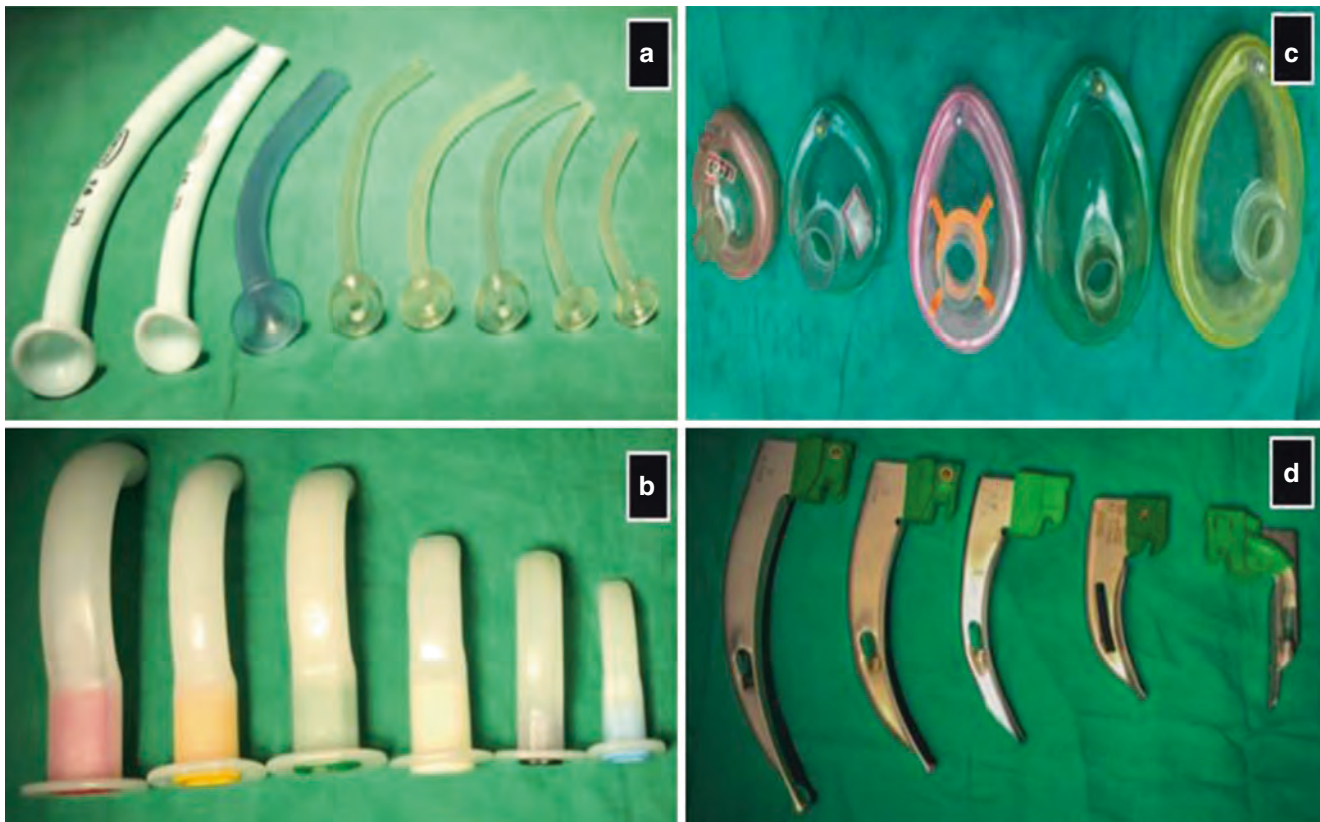
In young patients belonging to ASA (American Society of Anesthesiologists) Grade I and II, standard monitoring will suffice. Invasive arterial blood pressure monitoring may be required if controlled hypotension is planned or if comorbidities warrant. Monitoring of temperature is required in children and those undergoing prolonged surgeries like corrective LeFort osteotomies. Urinary catheterization may be required during prolonged surgeries.

7.5.4 Airway management: (Flow Chart 1)

The method of securing the airway should be discussed with the surgeon. This depends on:

- Patient factors, such as age, obesity, pan-facial trauma or anticipated difficult airway
- Site of operation may require oral or nasal intubation with specially configured tubes.
- Anaesthetists’/surgeons’ preferences.

Other useful Airway Equipment



©Association of Oral and Maxillofacial Surgeons of India

Fig. 7.3 (a) Nasal airway, (b) Oral airway, (c) Ventilation mask and (d) Laryngoscope blades

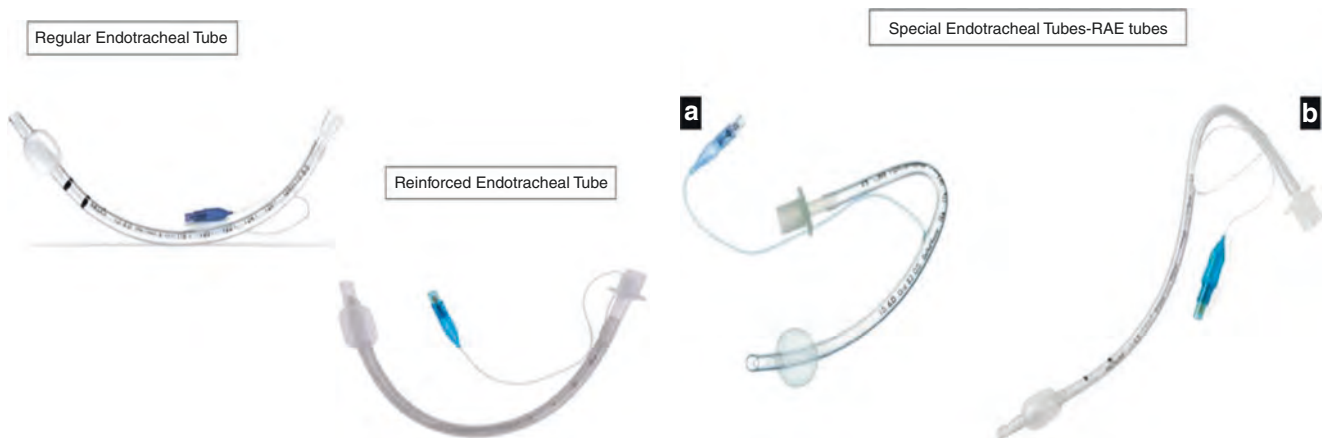

Fig. 7.4 Endotracheal tubes

Fig. 7.5 RAE tubes

Simple intraoral operations with no anticipated difficult airways can be done with standard nasal intubation or oral intubation under general anaesthesia with endotracheal tube pushed to the side opposite of surgery. Use of specially preformed tubes like RAE tubes and Reinforced/Armoured tube can be used to give good access to the surgical area (Figs. 7.4

and 7.5). However, major corrective surgeries will require the oral cavity to be empty and hence warrant nasal intubation, submental intubation or a tracheostomy. Anticipated non-obstructed difficult airway as assessed by history and/or examination or suspected (cervical) C-spine injury should be managed with awake fibre optic bronchoscopy or blind nasal

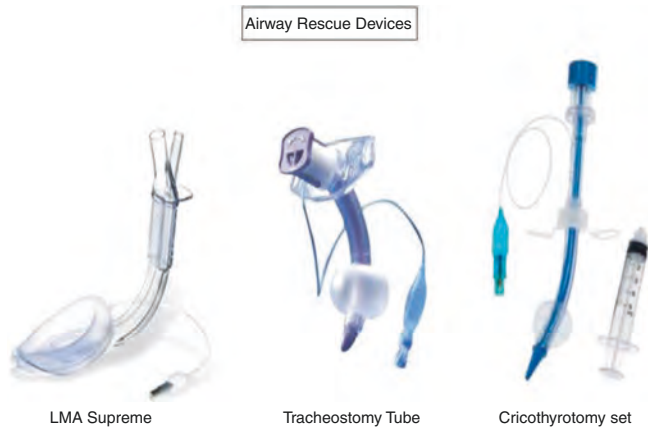


Fig. 7.6 Airway rescue devices

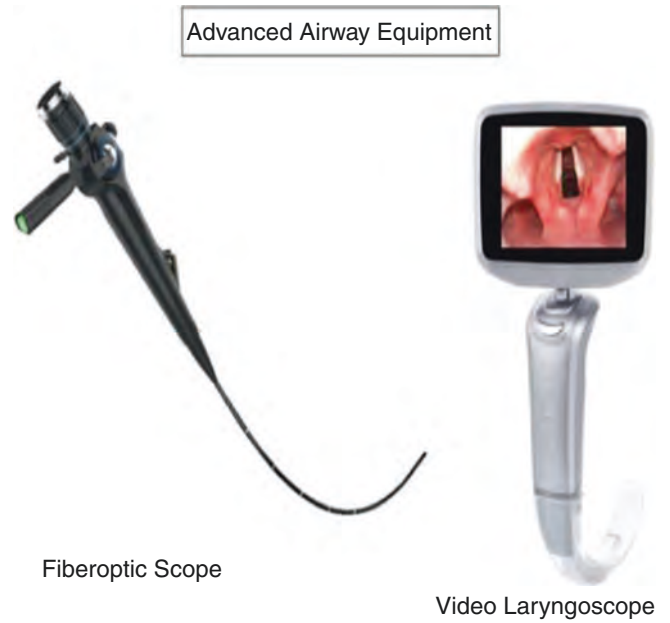

Fig. 7.8 Advanced airway equipment

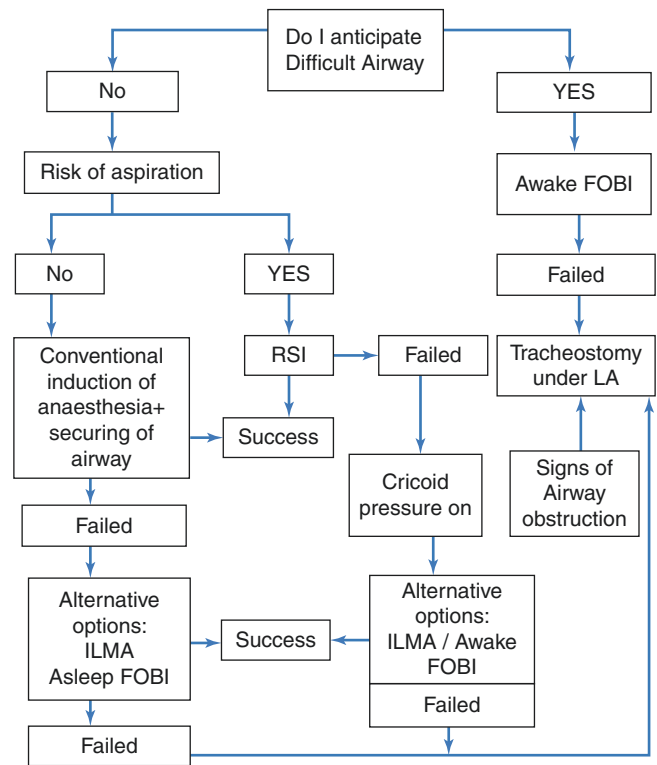


©Association of Oral and Maxillofacial Surgeons of India

Fig. 7.7 Difficult airway cart

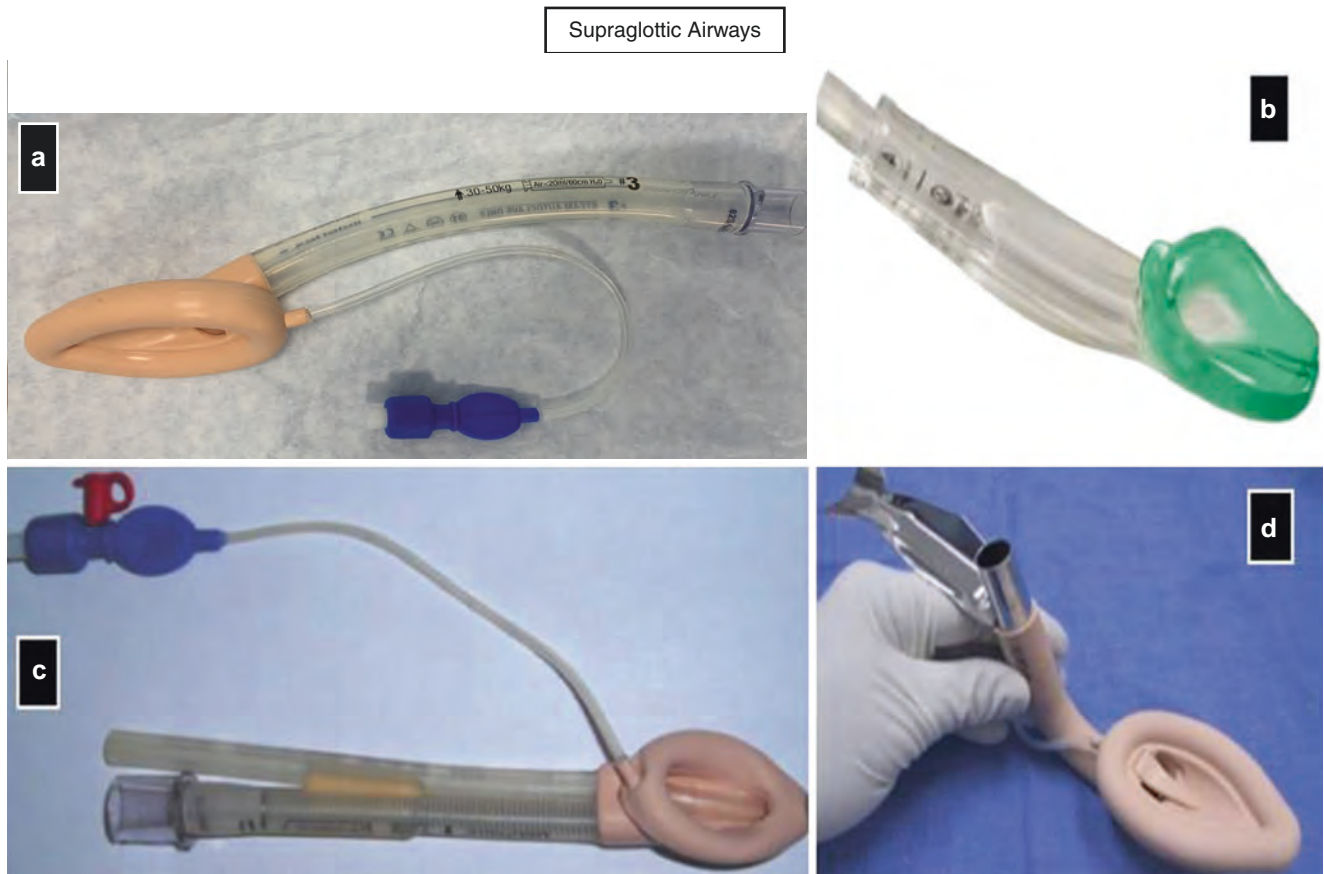
intubation. The safety of awake intubation relies on the maintenance of spontaneous breathing, and the ability to stop and perform a different technique, such as awake tracheostomy, if intubation is unsuccessful. Most anaesthesiologists prefer the nasal route for fibre optic intubation, as it is technically easier. For this, the patency of the nostril should be assessed preoperatively, and roomier nostril should be chosen and prepared with vasoconstrictor drops like oxy-metazoline hydrochloride.

Sedation may enhance the acceptability of awake fibre optic intubation. Dexmedetomidine infusion [11] serves this purpose very well. Airway instrumentation can be facilitated by local anaesthetic topicalisation of airway either by means of lignocaine nebulisation or ‘spray as you



Flow Chart 1 Airway management in oro-maxillo-facial surgery

go’ technique and/airway blocks (glossopharyngeal, superior laryngeal and recurrent laryngeal nerve blocks) [12]. An antisialogogue like glycopyrrolate administered 30–45 min prior will reduce the secretions and will facili-



©Association of Oral and Maxillofacial Surgeons of India

Fig. 7.9 (a,b,c,d) Supraglottic airways

tate awake fibre optic intubation. Airway blocks may not be an option to facilitate awake intubation in cases such as extensive pan-facial fractures or post-radiation fibrosis of the neck. Fibre optic intubation may be impractical in case of oro-maxillofacial trauma if associated with severe airway bleeding that can obscure visibility and other options such as tracheostomy under local anaesthesia (LA) should be considered.

The traditional ‘blind nasal intubation’ is rarely employed these days but may be used if a fibre optic scope is not available or not possible (Video 7.1).

A ‘plan B’ should always be present if intubation by one method is unsuccessful.

During long surgery and if ventilated in the post-operative period, the Endotracheal (or tracheostomy) cuff pressure should be measured using an aneroid manometer. A pressure of 20–30 cm of H₂O is considered as standard in adults.

In supraglottic obstruction—associated with stridor and respiratory distress, as in case of upper airway trauma, rapidly expanding infections like epiglottitis, Ludwig’s angina, etc. awake fibre optic bronchoscopy and intubation may not be the right choice. In such a situation, an awake tracheostomy under local anaesthesia must be considered.

7.5.5 Supraglottic Airway Devices

Several varieties of supraglottic airway devices are available (Fig. 7.9). However, these are not ideal devices for oro-maxillofacial surgeries requiring the oral cavity to be empty, but can be lifesaving as rescue devices in ‘cannot ventilate, cannot intubate’ situations to ventilate a patient until the definitive airway is secured. However, a flexible reinforced LMA can be used for simple dental extractions and nasal, zygomatic and superficial facial surgery. However, obstruction and dislodgement can occur, especially when the mandible is moved.

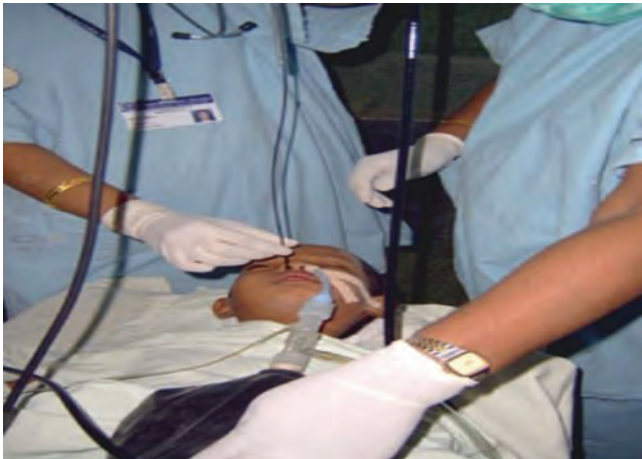7.6 Special Considerations

Paediatrics: [6] Children will not co-operate for awake fibre optic intubation. Hence, in such cases, the airway can be secured after inhalational induction without relaxation after establishing IV access. A nasopharyngeal airway may be passed gently into one nostril and connected to a breathing circuit while monitoring the end-tidal carbon dioxide (EtCO₂) and continuing the anaesthetic and oxygenation via

the airway. The other nostril may now be prepared with a vasoconstrictor and local anaesthetic and used for fibre optic intubation (Fig. 7.10).

7.6.1 Retromolar and Submental Intubation

These techniques were developed as alternatives to tracheostomy in maxillofacial surgeries requiring intra-operative inter-dental fixation for malocclusion correction like comminuted fracture of the mid-face or the nose, where nasal intubation is contraindicated.



©Association of Oral and Maxillofacial Surgeons of India

Fig. 7.10 Fibre optic intubation in children

7.6.1.1 Retromolar Intubation

Pre-operatively check the adequacy of the retromolar space. This is done to prevent kinking of the endotracheal tube in retromolar space by insinuating the index finger behind the third molar and asking the patient to clench his teeth. The patients' airway is then intubated by the conventional method and the ETT is pushed in the retromolar space and brought out from the angle of the mouth and connected to the ventilator. The spiral reinforced/armoured ETT is preferred as it is kink resistant (Fig. 7.11).

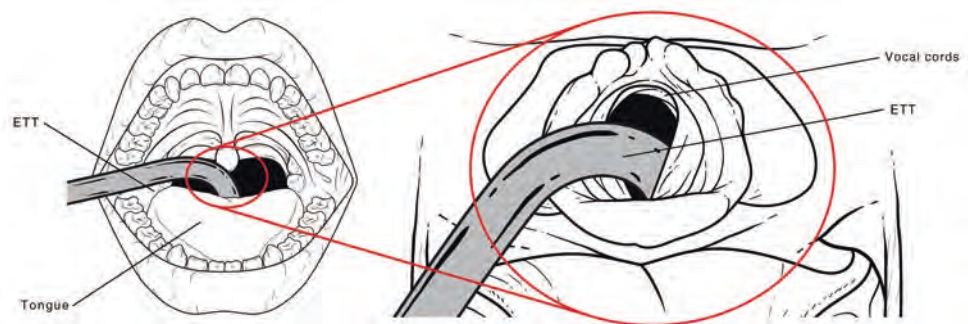
7.6.1.2 Submental Orotracheal Intubation: [13]

(Fig. 7.12a–f)

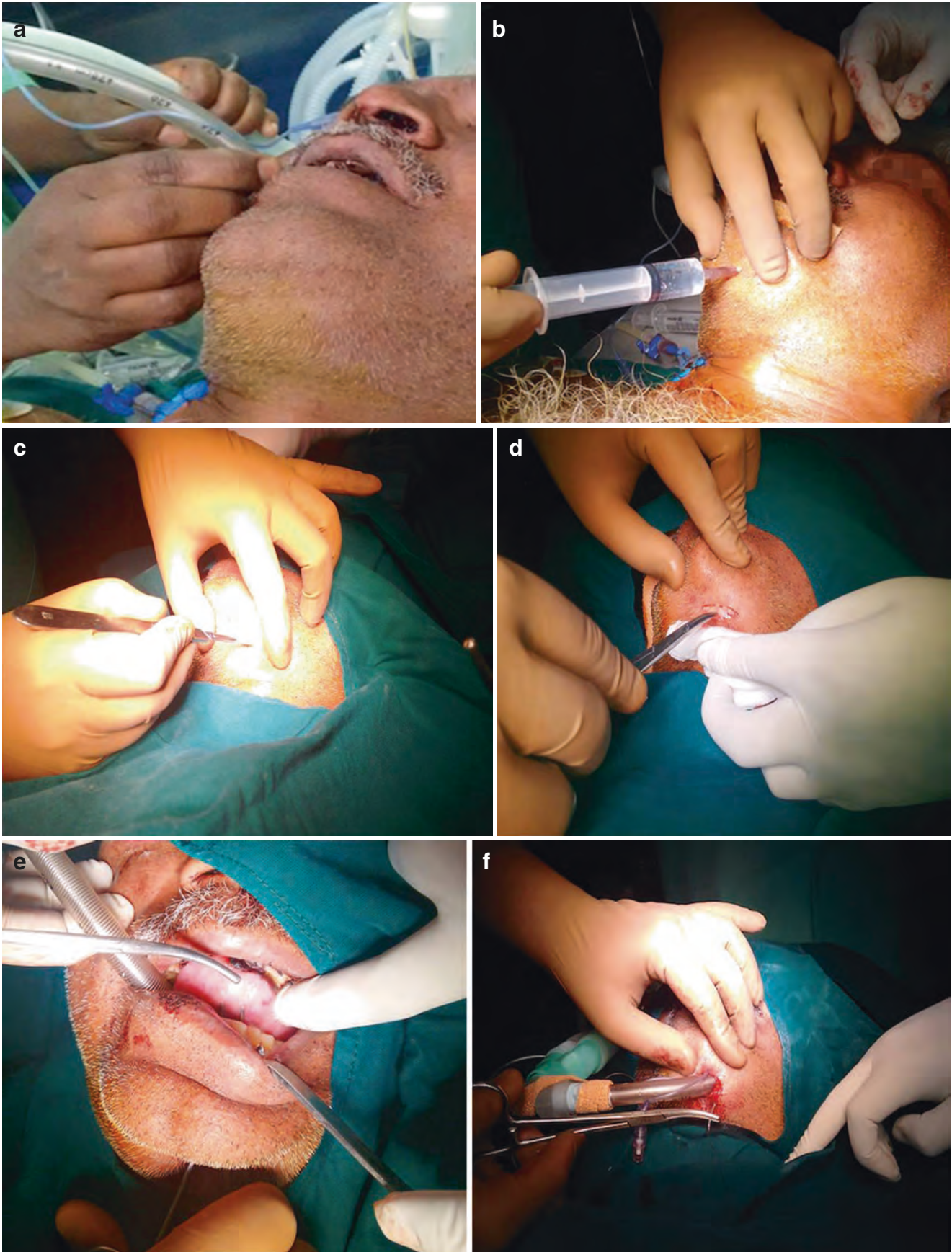(See additional reading material on submental intubation given at the end of the chapter).

Just like retromolar intubation, it also requires the use of a spiral reinforced/armoured ETT in order to prevent the tube from kinking during its usage. Following conventional orotracheal intubation, a 2-cm incision is made lateral to the midline between the chin and the angle of the mandible and an opening is made in the floor of the mouth by the surgeon, avoiding the submandibular salivary glands. The machine end of the ETT without the connector is pulled through the tunnel, using gentle rotational movements. Following this manoeuvre, the tube is connected to the ventilating machine and sutures are used to fix the tube in position. If the procedure of disconnecting the ETT is long and pulling it out is prolonged, there is a possibility of hypoxia. So monitor oximetry closely and use high oxygen concentrations immediately before and after the placement of the submental tube (Video 7.2).

Fig. 7.11 Retromolar intubation



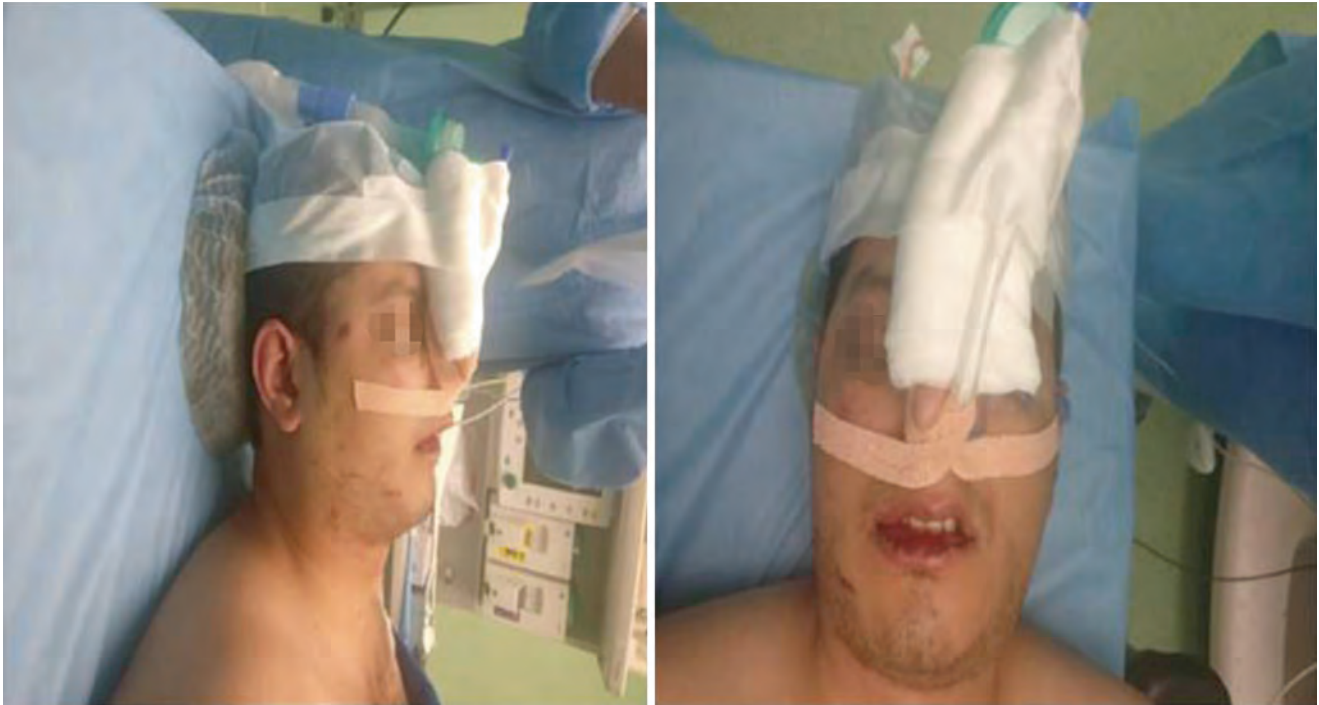©Association of Oral and Maxillofacial Surgeons of India



©Association of Oral and Maxillofacial Surgeons of India

Fig. 7.12 (a–f) Various steps in submental intubation

Securing ETT in Maxillofacial Surgery



©Association of Oral and Maxillofacial Surgeons of India

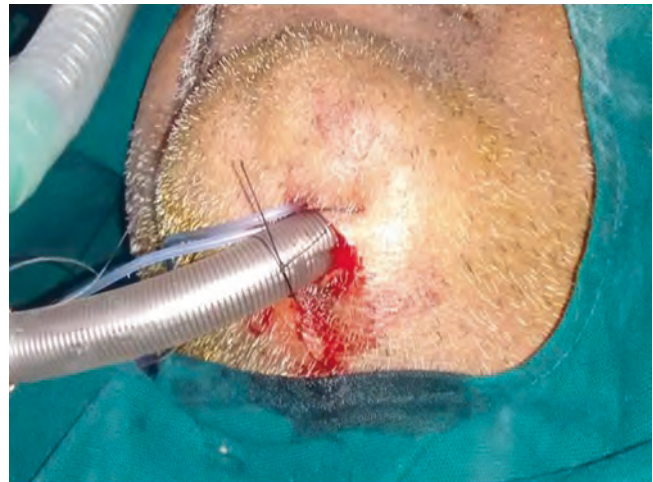Fig. 7.13 Securing ETT in maxillofacial surgery

Securing the Endotracheal Tube

The ETT may dislodge intra-operatively as the airway is shared between the surgeon and anaesthetist; hence, special attention should be paid to securing the ETT. Preformed nasal RAE tubes, if used, should be supported on the nasal bridge and forehead with the help of preformed supports or pads and secured on the forehead with tapes in addition to securing at the nostril (Fig. 7.13). Submental tubes can be secured with sutures (Fig. 7.14). South Pole oral RAE tubes are usually fixed in the middle of the lower jaw with tapes (Fig. 7.15).

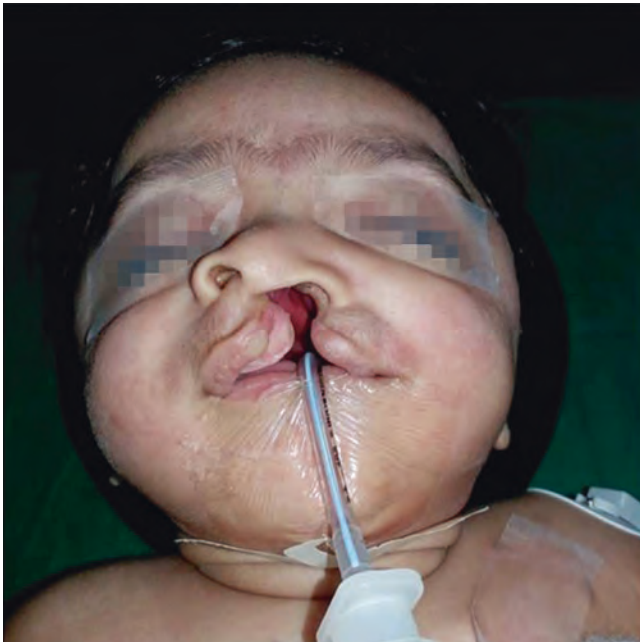7.6.2 Eyes

Preferably taped with transparent dressing or specialized eye pads to capture moisture and prevent drying especially during prolonged surgeries (Fig. 7.15).



©Association of Oral and Maxillofacial Surgeons of India

Fig. 7.14 Securing submental tube with sutures



©Association of Oral and Maxillofacial Surgeons of India

Fig. 7.15 Securing oral south pole tubes/protection of the eyes with tapes

7.6.3 Positioning

Reverse Trendelenburg (anti-gravity) position with shoulder roll for adequate surgical exposure is preferred. Further, the operation table may be turned away from the anaesthetist and the anaesthesia machine by 90° or 180°. Hence, long breathing circuits, IV extensions and long cables for monitoring will be required.

7.6.4 Throat Pack

Saline-soaked throat packs will be required to protect the airway from blood, debris and saliva. It is advised to fix the tail end of the throat pack to the oral endotracheal tube whenever feasible to prevent accidental leaving behind of the throat pack at the end of surgery. Time of insertion and removal of the throat pack should be documented and carefully checked before extubation. If interdental wiring is planned at the end of surgery, then prior to doing so all throat packs should be removed and gauze counts should be confirmed.

7.7 Maintenance of Anaesthesia

Once the airway is secured, anaesthesia can be maintained with total intravenous anaesthesia (TIVA) or with volatile anaesthetics or combination of both as described earlier. Controlled ventilation with an intermediate-acting muscle relaxant such as atracurium or vecuronium is used.

Intra-operative analgesia is preferably provided with short-acting opioids such as fentanyl. Dexamethasone can be administered intra-operatively to reduce post-operative swelling, for its analgesic properties and as a prophylactic against post-operative nausea and vomiting (PONV) [14]. Orthognathic surgeries are associated with a high incidence of PONV; hence, additional antiemetics such as ondansetron should be administered prior to extubation especially if interdental wires are planned. Hypothermia can be a potential complication of prolonged orthognathic surgeries. Hence, temperature should be monitored and warming measures like intra-operative warm I.V fluids, forced air mattresses should be used. If there is a fear of airway compromise post-extubation, a tracheostomy should be done electively.

7.7.1 Deep Vein Thrombosis (DVT) Prophylaxis

Cancer patients and patients undergoing long surgery are at risk of developing thromboembolic complications. One or more of the following methods may be used to reduce its incidence.

Mechanical—Thromboembolic deterrent/Compression stockings (TEDS), pneumatic calf compression boots.

Pharmacological—Low-molecular-weight heparin such as Clexane could be used in patients at high risk for venous thromboembolism (VTE).

7.7.2 Control of Bleeding

The head and neck region receives rich blood supply from the branches of the carotid artery, and hence there is a tendency to bleed profusely during maxillofacial surgeries. Major bleeding can occur from branches of the maxillary artery or from pterygoid venous plexuses, leading to significant blood loss, warranting blood transfusion. Further, some of these procedures especially corrective osteotomies are extensive and time consuming. Surgical haemostasis is hampered by limited access. Risks involved in allogeneic blood transfusion have also been well documented and hence it is important to institute measures to reduce intra-operative blood loss and blood transfusion.

Methods to control intra-operative blood loss include:

Reverse Trendelenburg (anti-gravity) positioning.

Ensuring adequate venous drainage.

Antifibrinolytics, e.g. Tranexamic acid.

Infiltration of the tissues with vasoconstrictors like adrenaline.

Controlled hypotension.

Intermittent positive pressure ventilation and maintenance of mild hypocarbia.

- 1&2. *Positioning and venous drainage:* Reverse Trendelenburg (anti-gravity) positioning by 30° is recommended as it decreases bleeding by causing mild postural hypotension. Neck should be preferably positioned in the neutral position or turned slightly towards the surgeon. Extreme flexion or rotation of the neck to one side should be avoided to prevent venous engorgement. A minimum of 2-finger breadth space is recommended between chin and chest if flexion of neck is required.
3. *Antifibrinolytics:* A number of clinical trials have shown that the use of antifibrinolytics like tranexamic acid (TXA) reduces the peri-operative blood loss and the need for blood transfusion significantly. In 2011 World Health Organization added tranexamic acid (TXA) to its list of essential drugs [15]. The European guidelines on management of major bleeding and coagulopathy following trauma suggests a 1A recommendation for the use of TXA in the case of traumatic and perioperative bleeding [16]. Dose reduction is required in renal impairment. Also, caution should be exercised while administering to patients with history of seizures.
4. *Infiltration of the tissues with lignocaine + adrenaline:* Usually the surgeons infiltrate the tissues with lignocaine, a local anaesthetic (LA), and adrenaline, a vasoconstrictor, prior to incision so as to reduce bleeding. Before doing so, the maximum allowable dose of local anaesthetic and adrenaline must be calculated and not exceeded to avoid toxicity and arrhythmias. A dilution of 1:200000 adrenaline is considered safe. If a local anaesthetic drug has been used for securing the airway, the dose of LA used must be considered in total calculation. ECG should always be monitored during and after infiltration.
5. *Controlled hypotension:* is defined as iatrogenic reversible reduction of the patients mean arterial blood pressure. Controlled hypotension can be achieved either by decreasing peripheral vascular resistance and/or cardiac output [17]. However, hypotension induced by decreasing cardiac output may not be ideal as it decreases tissue perfusion. A reduction by 30% from the baseline mean arterial pressure (MAP) level is generally considered to be safe. But it may be unsafe in some patients such as those with chronic kidney disease, ischemic heart disease and carotid artery disease [17]. Therefore, their suitability for controlled hypotension should be assessed and recorded during the pre-anaesthetic workup.

Over the years, several protocols have been developed. The main strategies are

- Standard anaesthesia with non-pharmacological measures.
- Deep anaesthesia with analgesia.
- Standard anaesthesia with hypotensive drugs.

Standard anaesthesia with Non-pharmacological measures: This relies on

- Optimal anti-Trendelenburg positioning to achieve postural hypotension.
- Intermittent positive pressure ventilation with mild hypocarbia.

Pharmacological measures: It relies on drugs used to either deepen the plane of anaesthesia and/or produce vasodilatation.

The ideal drug used for controlled hypotension should be easy to administer, quick in onset and recovery with predictable effect, no toxic metabolites and should preserve organ perfusion [17]. At present, no such drug is available and hence a combination of drugs is often used.

Deep anaesthesia can be achieved either with volatile anaesthetics or with intravenous agents.

Most volatile anaesthetic agents are potent vasodilators. This property can be exploited to reduce blood pressure. However, when used alone, the minimum alveolar concentration (MAC) values required to achieve this are high and can result in hepatic and renal injury and also delay awakening. They are therefore used at lower concentrations with other pharmacological agents. Most commonly used volatile agents include isoflurane, sevoflurane and desflurane. Halothane is preferably avoided due to its arrhythmogenic potential with adrenaline.

Propofol Infusions: This has been extensively used in neuro anaesthesia for controlled hypotension as part of total intravenous anaesthesia (TIVA). It can be used either as part of TIVA or combined with volatile anaesthetics.

Opioids: Opioids decrease the doses of agents required to produce anaesthesia and hypotension by decreasing pain. Most commonly used short-acting opioids include fentanyl and remifentanyl.

7.7.2.1 Hypotensive Drugs: (Appendix II)

Hypotension should be carried out only to that level needed to reduce bleeding and only for that time of the surgery where it is of benefit in reducing significant blood loss. A number of drugs have been tried either alone or in combination to reduce blood pressure. While using them, one needs to be aware of their potential complications and contraindications. Drugs commonly used are beta-blockers, glyceryl trinitrate and sodium nitroprusside. Newer drugs like dexmedetomidine along with a propofol/remifentanyl combination are gaining popularity [18, 19].

Invasive arterial blood pressure monitoring is recommended if infusions of hypotensive drugs are used for controlled hypotension. Intra-op serial monitoring of ABG (arterial blood gases), acid-base balance and lactate levels

Table 7.6 Potential complications in specific maxillofacial procedures

Complications	Surgery	Pathogenesis	Management
Bradycardia [21]	Levering of zygomatic fractures. Manipulation of midface	Oculocardiac reflex	1. Cessation of stimulus. 2. Anticholinergics: Atropine/ glycopyrrolate
Intra-operative bleeding: Occurs due to high vascularity of the area not amenable to cauterization.	Maxillary osteotomies. LeFort-I osteotomies	Bleeding from Pterygoid venous plexuses. Sphenopalatine artery Descending palatine artery Internal maxillary artery	1. Large bore I.V. cannula. 2. Intraoperative tranexamic acid. 3. Controlled hypotension. 4. Autologous blood donation. 5. Blood transfusion may be needed.
Tracheal tube damage	Lateral nasal osteotomies [20] Le fort surgeries	Direct damage. Bubbling of gas from the nose- Anaesthesia circuit leak with inability to ventilate.	1. Immediate tube change. 2. Laryngeal packing may be attempted. 3. Precautions – Careful surgery 4. Unilateral: Intubate via contralateral nare.
Wiring of tracheal tube to maxilla			
Wide haemodynamic swings – Bradyarrhythmias/ asystole	Radical neck dissections	Carotid sinus stimulation/ stellate ganglion stimulation.	1. Cessation of stimulus 2. Carotid sinus block with LA 3. Stellate ganglion block. 4. Vagolysis.

with hourly urine-output measurement should help to prevent organ dysfunction.

Isovolaemic haemodilution was once considered an adjunct in orthognathic surgeries to induce hypotension to reduce blood transfusion. It has become less common these days. The technique involves preoperative blood donation with IV fluids replacement of circulating volume followed by autologous whole blood transfusion as needed in the intra- or post-operative period.

Intra-op Analgesia can be achieved with NSAIDs, Paracetamol, opioids, intraoral LA infiltration and by mandibular or maxillary nerve blocks performed intra-op by the surgeon.

Intra-operative complications: The anaesthetist must be aware of and prepared for potential intra-operative complications [20, 21] (Table 7.6).

7.7.3 Elective Tracheostomy

Indications for elective tracheostomy are:

- Airway obstruction above the glottis - consider tracheostomy under LA.
 - After extubation, Known or anticipated presence of an obstructed airway.
 - Other general conditions requiring tracheostomy:
 - Certain head injuries
 - Massive chest injuries
 - Incidental pre-existing disease
- Inadequate postoperative nursing care.

7.8 Post-Operative

Emergence and extubation [22] Flow Chart 2—AIDAA (All India Difficult Airway Association) Guidelines for the management of anticipated difficult extubation and Table 7.7.

(flow chart 2 re-used with permission from IJA and AIDAA)

- After discussion with the surgeon, the decision of extubation post-surgery should be taken on a case-by-case basis.
- Before completion of the surgery, the induced hypotension should be ceased and time should be given to the surgeon to check for haemostasis. To check haemostasis, few surgeons prefer to increase mean blood pressure by 20–30% above pre-op level.
- At the end of the surgery, throat packs should be removed and clots or debris should be suctioned from the oropharynx.
- Prior to extubation cuff leak test may be performed to check for no airway oedema.
- A smooth emergence and extubation with less coughing and bucking is desirable. With the risk of the possibility of ongoing bleeding in the upper airway it is usual for patients to be extubated awake. Confirm that the patient is awake and breathing spontaneously.
- The Endotracheal tube should be left in situ, until the patient is fully conscious when the jaws are wired together, or any other airway obstruction is anticipated. Two types of maxillomandibular fixation (MMF) are available: Rigid MMF with jaw wiring, i.e. patients would be extubated with no ability to open their mouths and

Table 7.7 Guidelines for extubation

Decision based on	Individual case
	AIDAA guidelines Flow Chart 2
	Cuff leak test
	Jaws wired - awake extubation
Stop	Jaws not immobilized > Guedel airway/nasopharyngeal airway
	Induced hypotension
Keep ready	Difficult airway cart
	Appropriate anaesthetic drug drawn up
	Surgical team for tracheostomy
	Post op ICU bed
Avoid	Tight face mask ventilation

MMF with elastics often applied, albeit later (from hours to 1 or 2 days) into the recovery phase where mouth opening will not be a problem.

- Guedel's airway or nasopharyngeal tube should be used to maintain the airway if jaws are not immobilized. A nasopharyngeal tube provides an extra dimension of safety in recovery.
- Nasal Endotracheal tubes removal should be gentle. To avoid passing of fresh tube through the vulnerable nasal mucosa, the ETT can be withdrawn into and left in oropharynx to serve as a nasopharyngeal airway. Submental ETT should be removed back from the oral cavity and closure of the submental incision done before the extubation.
- Consider extubation over a tube changer in case of difficult intubation or surgery.
- Avoid applying tight facemask to protect surgical correction after extubation.
- For reintubation, airway equipment / difficult airway chart should be available on standby and in case of failed extubation appropriate anaesthetic drugs drawn up in the required doses.
- In case of MMF, wire cutters or scissors should be available immediately for release of elastics band fixation.
- Until successful extubation and stabilization of patient, the surgical team should remain in the operating theatre.
- Before transfer to recovery, a short period of observation in the theatre should be followed.
- Handover and transfer to recovery should be done by the anaesthetist.
- Careful documentation of surgery details, vital signs, status at transfer, blood loss and replacement, drugs given, analgesia planned and expected problems should be done.

7.8.1 Handover from OT to Recovery Room/ICU

Clinical Criteria for Shifting:

- Patient should be awake and moving all 4 limbs
- Respiration should be regular with adequate depth
- Stable vital parameters
 - SpO₂ > 95% on room air
 - Pulse rate optimum for age
 - Respiratory rate < 30/min
 - Normothermic
- No active bleeding from surgical site

Anaesthesiologist should accompany patient to recovery

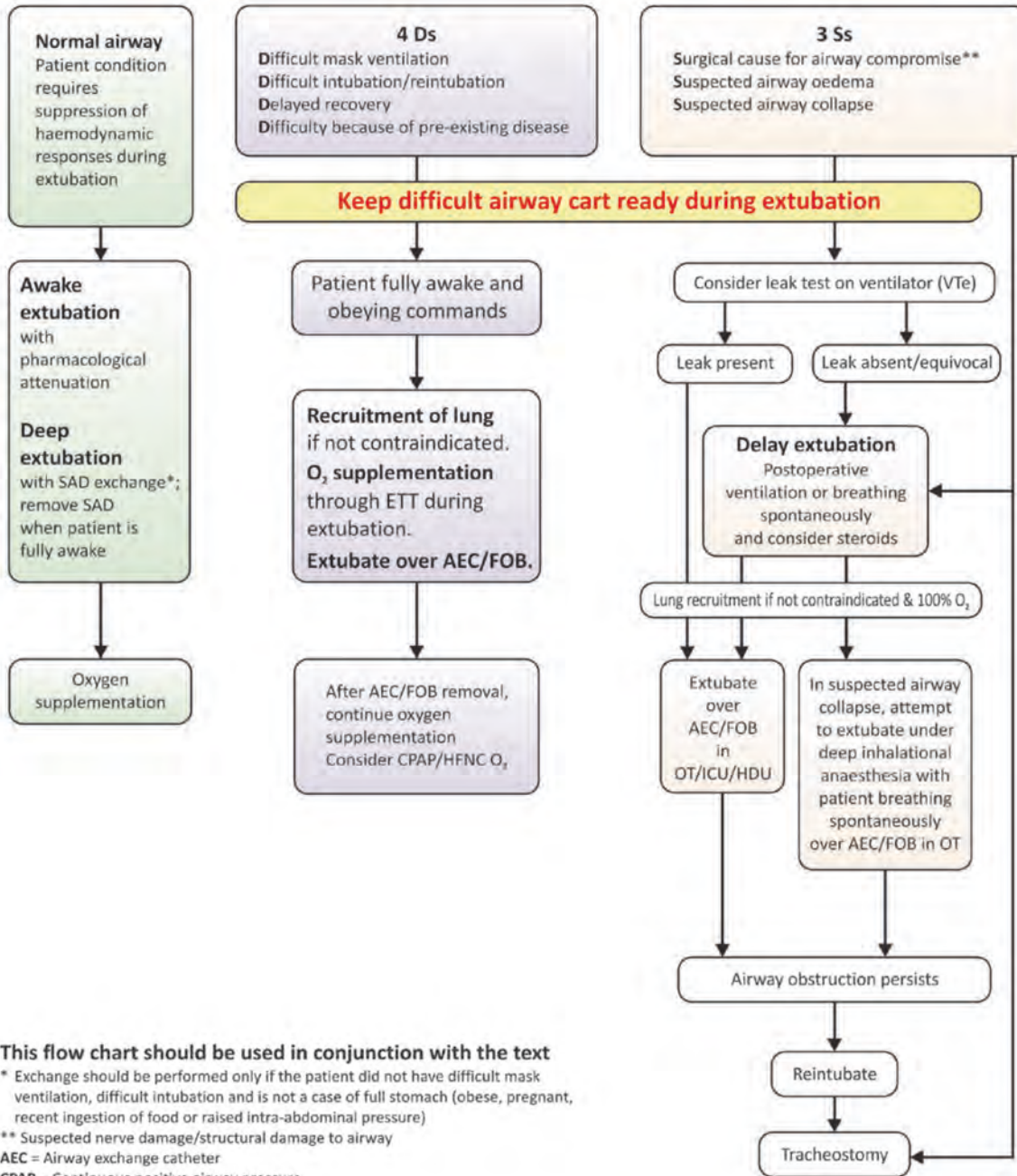
- Give handover to responsible personnel
- Handover should include
 - Name and age of patient
 - Surgery done
 - Any positive history and examination
 - Type of anaesthesia and drugs (time and dose) given, including analgesics.
 - Any intraoperative event
 - Clear postoperative orders
- Complete anaesthesia form and sign and name
- Nursing in the postoperative period should be in the reverse Trendelenburg position to decrease oedema and bleeding.
- In cases of Le Fort II and III fractures, one should be aware that the degree of oedema could worsen in the first 48 h.
- For close observation, some patients need to be admitted to a high dependency unit. Patients sent to ICU are those who remain intubated or ventilated.

In case of inadequate postoperative care facilities like an ICU, the patient may be required to be sent to another hospital (see appendix III and IV).

7.9 Post-Operative Complications and Management

- Immediate
 - Airway Problems
 - Postoperative bleeding and haematoma
- Delayed
 - Nausea and Vomiting
 - Post-operative pain

AIDAA 2016 Guidelines for the Management of Anticipated Difficult Extubation



This flow chart should be used in conjunction with the text

* Exchange should be performed only if the patient did not have difficult mask ventilation, difficult intubation and is not a case of full stomach (obese, pregnant, recent ingestion of food or raised intra-abdominal pressure)

** Suspected nerve damage/structural damage to airway

AEC = Airway exchange catheter
 CPAP = Continuous positive airway pressure
 ETT = Endotracheal tube
 FOB = Fibreoptic bronchoscope
 HDU = High dependency unit
 HFNC = High flow nasal cannula
 ICU = Intensive care unit
 O₂ = Oxygen
 OT = Operation theatre
 SAD = Supraglottic airway device
 VTe = Expired tidal volume

- Post- procedure plan**
1. Treat airway oedema if suspected
 2. Monitor for any complications
 3. Counseling and documentation

Flow Chart 2 AIDAA Guidelines for the management of anticipated difficult extubation [22]

7.9.1 Airway Problems

In the post-anaesthesia care unit (PACU) the close monitoring of complications should be done, which can lead to airway obstruction such as soft-tissue swelling and formation of haematoma. Capnography may provide an earlier warning of serious problems than pulse oximetry when supplemental oxygen is being administered. Even in uncomplicated cases, the effects of residual anaesthetic agents on airway physiology are more pronounced in patients with MMF who may experience increased resistance to breathing.

7.9.2 Post-Operative Haematoma

Haematoma formation in the early postoperative period is an uncommon but potentially airway-threatening complication of some maxillofacial operations, notably neck surgery, thyroid resections and floor of mouth surgery. The rate at which airway compromise occurs is variable. Emergency decompression of the haematoma may be even done at the bedside. It involves removing the clips/sutures and manually evacuating the haematoma with a Yankaur sucker. However, this may not alleviate the airway obstruction adequately due to oedema that results from venous congestion. The airway needs to be secured urgently. The method of securing the airway should take into consideration information from the initial operation, but it is expected to be more challenging and may require expert airway management.

7.9.3 Nausea and vomiting [23]

Factors that predispose to PONV include the female gender, a history of motion sickness, a low threshold for nausea, preoperative anxiety, obesity and gastric distension. Volatile anaesthetic agents, nitrous oxide, opioid usage and intubation have also been implicated as has prolonged surgery, early oral intake and certain types of surgery, including maxillofacial surgery.

Vomiting in patients with MMF is dangerous as it may predispose to aspiration. If the jaws are wired together, there must be wire cutters immediately available, which accompany the patient from theatre, to the PACU, and also to the ward.

Elastics in MMF can be cut easily with ordinary scissors.

PONV prophylaxis is best given round the clock for the first 24 h and longer if opioids continue to be used. If treatment for PONV is required within 6 h of PONV prophylaxis, it should ideally be with a different class of anti-emetic drug to that used initially (*See Appendix I*).

7.9.4 Analgesia [23–25]

After orthognathic surgery immediate postoperative pain is often not severe, and this is contributed to by the generous

intra-operative use of local anaesthesia. A multi-modal analgesia approach should also be utilized perioperatively by combining opioids with paracetamol and non-steroidal anti-inflammatory drugs towards the end of the case.

Patient Control Analgesia (PCA): It allows the patient to self-administer intravenous analgesics by means of a computer-controlled pump. It administers the pre-programmed dose on demand by the individual.

7.10 Case Scenarios

Case 1: Problem-Based Learning Tool

Case 2: Multiple choice questions

7.10.1 Case 1: Cleft Palate

A 10-month-old child presents for surgery with a cleft palate

1. *What are the problems special for cleft babies*
 - Regurgitation and repeated aspiration
 - Repeated respiratory infections
 - Airway obstruction
 - Malnutrition/anaemia
 - Associated syndromes
2. *What are the important features to look for during the pre- anaesthetic/presurgical evaluation?*

History–

 - Feeding—Type of food, difficulty in swallowing, nasal regurgitation
 - Repeated respiratory infections and/or hospitalization
 - Airway obstruction especially during sleep (snoring or sleep apnoea)—position adopted when asleep
 - Previous surgery as for repair of the cleft lip
 - Episodes of cyanosis or referral to a cardiologist
 - Birth history with details of ventilator requirements or neonatal ICU admission,
 - Milestones and immunization

Examination

- Body weight, signs of malnutrition, dehydration or anaemia
- Pulse, BP and Room air saturation, temperature to be recorded
- Mouth opening, neck extension
- Respiratory system—signs of respiratory infection
- Rule out cardiovascular involvement
- Look for associated syndromes the most common of which are Pierre Robin Sequence, Treacher Collins syndrome and Down syndrome.

Investigations

- Hb,- nutritional anaemia is common
- Complete blood picture—white blood counts may be elevated due to repeated infections
- Bleeding parameters—to rule out coagulopathies
- Chest x-ray if repeated chest infections or respiratory signs present on clinical examination
- Cardiology consult: ECG and ECHO cardiogram if cardiac involvement suspected

In addition:

- Meet the parents, allay their anxiety and give full explanation of procedure.
- Explain fasting guidelines with details of timing of feeds
- Solids and milk feeds 6 h prior to surgery and clear fluids, especially with glucose/sugar, 2 h prior to surgery
- Document informed consent form.
- Discuss procedure and requirements with primary surgeon

3. What preparations are necessary on day of surgery?

Preparation: On day of surgery

- Ensure adequate help
- Ensure operating room temperature is not too cold
- Check Equipment and Drugs: Suction, Oxygen, Airway, Pharmacy (the mnemonic SOAP helps)
- Check anaesthesia machine
- Ensure that the difficult airway cart with rescue devices is available

Monitors: ECG, NIBP, Pulse Oximeter, EtCO₂, and airway pressure (once intubated)

4. What are the problems that can present during anaesthesia?

- Induction—intravenous or inhalational?
- Mask ventilation may be difficult especially in cases of facial cleft
- Laryngoscopy. The larynx is anterior, the tongue relatively large and laryngoscope tends to slip into the cleft
- Position of the patient in this case the trunk of the baby should be supported on a large pillow with the neck hyperextended and head stabilized within a head ring.
- Sharing the airway with the surgeon
 - kinking of tube when the gag is placed
 - accidental extubation during positioning of the baby or removal of the gag
 - tube may be pushed endobronchially resulting in one lung ventilation when gag is applied
 - throat pack/other packs may be left behind after surgery causing airway obstruction

- Intraoperative monitoring + access to the monitors difficult—so ensure they are fixed well and working well before patient is draped
- Access to the patient difficult, so make sure that intravenous access is good and fixed well before draping
- Analgesics like paracetamol and short-acting opioids like fentanyl may be used.
- Extubation is often more difficult than intubation. If there is any query regarding obstruction to the airway, place a nasopharyngeal airway and a tongue stitch prior to extubation.

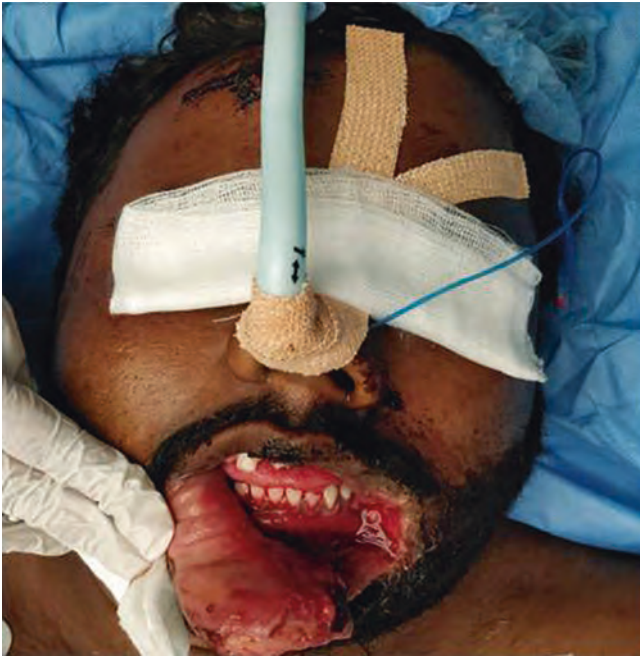5. Could there be any problems post operatively? If so enumerate them.

- Bleeding.
- Airway obstruction.
- Laryngospasm or post extubation stridor due to oedema of the upper airway: Treat with CPAP, humidified oxygen, aerosolized adrenaline, intravenous dexamethasone and nebulized steroids.
- Bronchospasm: Bronchodilators, oxygen and adrenaline, if severe.
- Aspiration: Suck out the mouth, nurse laterally, start antibiotics and chest.
- Physiotherapy along with nebulized bronchodilators.
- Electrolyte imbalance/hypoglycaemia: Send blood for investigations and correct
- Hypothermia/hyperthermia
- Seizures/Anticonvulsants: Rule out hyperthermia (tepid sponging and paracetamol) and hyponatraemia (intravenous normal saline).

7.10.2 Case–2: Polytrauma with Facial Injuries

A 27-year-old male presented with the history of polytrauma following a road traffic accident. He gives a history of brief period of loss of consciousness following injury. No history of seizures, or other comorbidities. On examination, his GCS was 15/15, and he was haemodynamically stable. Airway examination revealed restricted mouth opening of just one finger breadth, a short neck and a lacerated wound on the lower lip and chin with emphysema on the left side of the face extending into submandibular region. Cardiovascular, respiratory, abdominal and central nervous system examination was unremarkable. Blood investigations revealed increased CPK.

CT brain and spine showed a 3.5-mm extra-dural haemorrhage in the right temporal region, right frontal haemorrhagic contusion, an undisplaced fracture of the body of the mandible in bilateral parasymphiseal region with a displaced right zygomatic arch, a comminuted, mildly displaced fracture of right squamous temporal bone and undisplaced fracture of superior facet of C5 vertebra (Fig. 7.16).



©Association of Oral and Maxillofacial Surgeons of India

Fig. 7.16 Photograph of a patient with polytrauma & facial injuries

Questions:

1. Following things are true about blunt trauma to face EXCEPT
 - a. Cervical spine injury occurs in up to 10% of cases
 - b. Drugs and alcohol could be a contributing factor
 - c. Potential for injuries to other organs & massive blood loss
 - d. Injuries in children are less severe than in adults

Answer: d) Injuries in children are usually more severe than in adults
2. In this patient, following could be cause of restricted mouth opening EXCEPT:
 - a. Fracture Mandible
 - b. Presence of trismus
 - c. Cervical collar
 - d. # of superior facet of C5 vertebra

Answer: d) Fracture of Cervical vertebra usually does not restrict mouth opening
3. What is the reason for the presence of subcutaneous emphysema of the face in this patient?
 - a. Pneumothorax
 - b. Tracheal injury
 - c. Soft-tissue injury
 - d. # involving sinuses

Answer: d) Fractures involving air-filled sinuses around face can cause subcutaneous emphysema

4. What is the EXCEPTION to the bedside predictors of difficult intubation in a case like this?
 - a. Receding mandible
 - b. Facial injury
 - c. Edentulous
 - d. Cervical collar

Answer: c) Absence of teeth usually causes difficulty in ventilation rather than difficulty in intubation

5. Which of the following is most useful for detection of Extradural haematoma?
 - a. CT scan of head
 - b. MRI scan of head
 - c. X-Ray Skull
 - d. Careful clinical examination

Answer: a) A CT scan is more appropriate investigation in an emergency

6. What would be your preferred method for securing the airway?
 - a. Conventional laryngoscopy with oral endotracheal intubation.
 - b. Conventional laryngoscopy with nasal endotracheal intubation.
 - c. Fibre optic bronchoscopy with nasal intubation.
 - d. Conventional laryngoscopy with manual in line stabilization with nasal endotracheal intubation.

Answer: b) Conventional laryngoscopy with nasal endotracheal intubation

7. What would be your preferred airway device for securing the airway?
 - a. Regular endotracheal tube
 - b. Nasal RAE tube
 - c. Oral RAE tube
 - d. Reinforced cuffed endotracheal tube

Answer: b) Nasal RAE tube.

8. What do you anticipate with respect to airway in this case?
 - a. Difficult mask ventilation
 - b. Difficult laryngoscopy
 - c. Both a) and b)
 - d. Normal ventilation and laryngoscopy.

Answer: c) Both difficult mask ventilation and laryngoscopy.

9. The following monitoring would be useful during surgery in a case like this EXCEPT:
 - a. Invasive arterial pressure
 - b. Urine output
 - c. Central venous pressure monitoring
 - d. BIS monitoring

Answer: c) Central venous pressure monitoring would not add any additional value in a case like this

10. Where would you shift this patient after the surgery?
 - a. General ward
 - b. Special ward

- c. ICU
- d. HDU

Answer: d). HDU will be an appropriate place to monitor this patient post operatively

11. What is the most suitable method for pain relief in this patient?
- a. NSAIDs
 - b. Nerve blocks
 - c. Tramadol
 - d. PCA Fentanyl

Answer: d) PCA fentanyl will be an appropriate choice as patient has multiple injuries and is being monitored in HDU.

12. Which intravenous fluid is appropriate during the surgery for this patient?
- a. Dextrose-containing solutions
 - b. Balanced salt solutions
 - c. Hypertonic saline
 - d. Colloids

Answer: b) Balanced salt solutions

Appendix I: Dosage of common Drugs

Drug	Action/group	Dosage
Dexmedetomidine ¹¹	α_2 -adrenergic-agonists	Bolus: 1 mcg/kg over 10 mins followed by continuous infusion of 0.2-1mcgs/kg/h
Atropine	Anticholinergic	0.5 mg I. V
Glycopyrrolate	Anticholinergic	Antisialagogue: 3-4 μ /kg I. M 30-60 min prior. Bradycardia: 0.1 mg I.V repeated every 2 to 3 mins.
Topical Lignocaine	Local anaesthetic	Maximum safe dose: Adults: 9-10 mg/kg lean body weight. Paediatrics: 4.5 mg/ kg
Dexamethasone	Adrenocortical steroid: Anti-inflammatory dose Antiemetic [14]	0.1-0.2 mg/ kg 4-5 mg I.V
Ondansetron	Antiemetic—Serotonin antagonist	0.1-0.2 mg/ kg
Prochlorperazine (Stemetil)	Antiemetic—Dopamine receptor antagonist	0.25 mg/kg
Tranexamic acid [15]	Antifibrinolytic	1. Bolus dose: 15 mg/kg can be repeated every 6-8 h (prior to incision) or 2. Continuous infusion during the surgery: 1 g over 10 mins followed by 1 gm over 8 h or 20-25 mg/kg followed by 1-2 mg/kg/h).

Appendix II: Commonly Used Drugs for Controlled Hypotension

Drug	Administration and Dose	Advantages	Disadvantages
Vasodilators: SNP	Infusion: Up to 1.5mcgs/kg/min	Potent venous and arteriolar dilatation.	Reflex tachycardia. Rebound hypertension. Tachyphylaxis. Cyanide toxicity.
NTG	Infusion: - 0.5-2 mcgs/kg/min	Venodilator	Reflex tachycardia. Tachyphylaxis.
Adreno-receptor antagonists: Selective: α -selective: Phentolamine β -selective: Metoprolol Esmolol	Intermittent boluses: 2-5 mg. Intermittent boluses: 0.1 mg/kg. Loading: 1 mg/kg over 1 min followed by Infusion: 0.5-1 mg/kg/h.	Vasodilatation. Heart rate control	Bronchospasm. Negatively inotropic
Non-selective: Labetolol	Boluses: 0.25 mg/kg followed by infusion: 0.5-2 mg/min	Vasodilatation + heart rate control	Bronchospasm
α_2 -adrenergic-agonists: Clonidine	Infusion/boluses: 1mcgs/kg	Vasodilatation with heart rate control. Analgesic properties	Post op sedation. Rebound hypertension.
Dexmedetomidine	Bolus: 1mcgs/ kg over 10 mins followed by infusion of 0.3-1 mcg/kg/hr.	Vasodilatation with heart rate control. Analgesic properties	Post op sedation.
Magnesium sulphate	Bolus: 20-60 mg/kg	Vasodilatation with heart rate control. Analgesic properties	Prolonged neuromuscular block

Appendix III: Handover Form Used for Inter Hospital Transfer**Patient details**

Name:	Age:	Sex: M/F	MRN No:
Diagnosis:			

Brief clinical history:

Clinical summary written by:

Reason for transfer:

Transfer out hospital:

Referring doctor:

Transfer in hospital:

Accepting doctor:

Inter -hospital transfer consent taken: Y/N

Vitals before transfer:

HR: /min	BP: mm Hg	RR:
SpO2: %	O2: l/min	AVPU score:
Airway: Intubated and assisted / Intubated and spontaneous / Not intubated		
Patent IV access:		
Fluid on flow:		
Medications on flow:		
Monitors connected: ECG / Pulse oximetry / NIBP / Others		

Transfer details:

Departure time:	Arrival time :
-----------------	----------------

Duration of Transfer:

Accompanied by:

Critical events during transfer:

Vitals on arrival/admission:

HR: /min	BP: mm Hg	RR:
SpO2: %	O2: l/min	AVPU score:
Airway: Intubated and assisted / Intubated and spontaneous / Not intubated		
Patent IV access:		
Fluid on flow:		
Medications on flow:		
Monitors connected: ECG / Pulse oximetry / NIBP / Others		

Handover details:

Clinical summary: Y / N

Patient records: Y / N

Investigations: Y / N

Handing Over Doctor	Taking over doctor:
Name:	Name:
Sign:	Sign:
Date & time:	Date & time:

Appendix IV: Inter-Hospital Transfer Guidelines

The transfer of the patient to a Centre where intensive care is available may sometimes be required if the facilities at the current hospital are inadequate. Most of these patients are critically ill and need the utmost care and planning to ensure safety during transfer. It is the responsibility of the referring team (surgeon as well as anaesthesiologist) to ensure a safe handover to the new treating team of doctors.

The following guidelines may be used to develop local protocols for inter-hospital transfer.

- The decision to transfer should be done by the treating team of doctors.
- Choose the appropriate hospital.
- The patient's family should be counselled by the treating doctor for the reason of transfer.
- Obtain consent from the patient's family after explaining the need as well as the risks involved in transfer.
- The administrative coordination between the two hospitals, e.g. checking the availability of beds, required doctors, equipment, etc. should be performed telephonically. The verbal consent to accept the patient by the destination hospital authorities should be done and documented.
- A short summary of the patient's clinical condition and handover document should be prepared.
- The transfer team should be identified. It should comprise at least 2 members who are adequately trained in handling sick patients, e.g. while transferring an intubated patient, the team should be trained in managing intubated patients. At least one doctor (preferably an anaesthetist) should accompany/supervise the patient during transfer especially sick patients.
- The departure checklist should include confirming the following:
 - Ambulance services.
 - Sufficient oxygen supply.
 - Shifting trolley.
 - Battery backup for equipment.
 - Mode of ventilation (for intubated patients).
 - Adequate monitoring (ECG, pulse oximetry, blood pressure).
 - Resuscitative medications (prefilled syringes).
 - Required paperwork—clinical summary, patient records and investigations.
 - Knowledge of destination hospital location and contact numbers.
 - Clinical stability of the patient should be confirmed before shifting.
- Patient should be stabilised before transfer. The following should be confirmed just before transfer—a patent IV line, a patent airway access, a functioning monitor with

adequate battery backup. In case of an intubated patient –DO NOT EXTUBATE just prior to transfer.

- Note and record vital signs just before transfer.
- During transfer the vitals should be monitored continuously and documented frequently.
- Anticipation of problems during transfer and preparedness will help ensure safe transfer.
- Upon reaching the destination hospital, the transferring team should ensure that the patient is safely shifted to the desired critical care area and the hand-over formalities completed.

References

1. Allman K, Wilson I. Oxford handbook of Anaesthesia. 3rd ed. Oxford, UK: Oxford University Press; 2011.
2. Shaw I, Kumar C, Dodds C, editors. Oxford textbook of Anaesthesia for Oral and maxillofacial surgery. Oxford, UK: Oxford University Press; 2010.
3. Sherwood MW, Douketis JD, Patel MR, Piccini JP, Hellkamp AS, Lokhnygina Y, et al. Outcomes of temporary interruption of rivaroxaban compared with warfarin in patients with nonvalvular atrial fibrillation: results from the rivaroxaban once daily, oral, direct factor Xa inhibition compared with vitamin K antagonism for prevention of stroke and embolism trial in atrial fibrillation (ROCKET AF). *Circulation*. 2014;129(18):1850–9.
4. Popat M. Difficult airway management. Oxford, UK: Oxford University Press; 2009.
5. American College of Surgeons Committee on Trauma. Advanced trauma life support for doctors. 6th ed. Chicago: American College of Surgeons; 1997.
6. Jacob R. Recognition and management of the difficult paediatric airway. In: Jacob R, editor. Understanding paediatric anaesthesia. 3rd ed. India: Wolters Kluwer (India); 2015. p. 184–94.
7. Kheterpal S, Martin L, Shanks AM, Tremper KK. Prediction and outcomes of impossible mask ventilation: a review of 50,000 anaesthetics. *Anesthesiology*. 2009;110:891–7.
8. Reed MJ, et al. Can an airway assessment score predict difficulty at intubation in the emergency department? *Emerg Med J*. 2005 Feb;22:99–102.
9. Teasdale G, Jennett B. Assessment of coma and impaired consciousness. A practical scale. *Lancet*. 1974;2:81–4.
10. Mackay CA, Burke DP, Burke JA, Porter KM, Bowden D, Gorman D. Association between the assessment of conscious level using the AVPU system and the Glasgow coma scale. *Pre-Hospital Immediate Care*. 2000;4:17–9.
11. Chopra P, Dixit MB, Dang A, Gupta V. Dexmedetomidine provides optimum conditions during awake fiberoptic intubation in simulated cervical spine injury patients. *J Anaesthesiol Clin Pharmacol*. 2016;32:54–8.
12. Ramkumar V. Preparation of the patient and the airway for awake intubation. *Indian J Anaesth*. 2011;55(5):442–7.
13. Pavlakovic L, Lee G. Anaesthesia for maxillofacial surgery. *Anaesthesia and intensive care medicine*. 2014;15(8):379–84.
14. De Oliveira GS Jr, Castro-Alves LJ, Ahmas S, Kendall MA, RJ MC. Dexamethasone to prevent postoperative nausea and vomiting: an updated meta-analysis of randomized controlled trials. *Anesth Analg*. 2013 Jan;116(1):58–74.
15. WHO model list of essential drugs 17th list; March, 2011. <http://www.who.int/medicines/publications/essentialmedicines/en/index.html>

16. Rossaint R, Bouillon B, Cerny V, Coats TJ, Duranteau J, Fernández-Mondéjar E, et al. The European guideline on management of major bleeding and coagulopathy following trauma: fourth edition. 2016;20(1):100.
17. Rodrigo C. Induced hypotension during anesthesia with special reference to orthognathic surgery. *Anesth Prog.* 1995;42(2):41–58.
18. Bajwa S, Kaur J, Kulshrestha A, Haldar R, Sethi R, Singh A. Nitroglycerine, esmolol and dexmedetomidine for induced hypotension during functional endoscopic sinus surgery: A comparative evaluation. 2016;32(2):192–197.
19. Sajedi P, Rahimian A, Khalili G. Comparative evaluation between two methods of induced hypotension with infusion of Remifentanyl and labetalol during sinus endoscopy. *J Res Pharm Pract.* 2016;5(4):264–71.
20. Morosan M, Parbhoo A, Curry N. Anaesthesia and common oral maxillo-facial emergencies. *Continuing education in anaesthesia. Critical Care and Pain.* 2012;12:5.
21. McDermott PJC. Reflex bradycardia in facial surgery. *J Oral Maxillofac Surg.* 1990;48(9):1015–6.
22. Kundra P, Garg R, Patwa A, Ahmed SM, Ramkumar V, Shah A, Divatia JV, Shetty SR, Raveendra US, Doctor JR, Pawar DK, Singaravelu R, Das S, Myatra SN. All India difficult airway association 2016 guidelines for the management of anticipated difficult extubation. *Indian J Anaesth.* 2016;60(12):915–21. <https://doi.org/10.4103/0019-5049.195484>.
23. Patel PK, Morris DE, Gassman A. Complications of orthognathic surgery. *J Craniofac Surg.* 2007;18(4):975–85.
24. Beck JI, Johnston KD. Anaesthesia for cosmetic and functional maxillofacial surgery. *Continuing Education in Anaesthesia Critical Care & Pain.* 2014;14(1):38–42.
25. Lupori JP, Van Sickels JE, Holmgreen WC. Outpatient orthognathic surgery: review of 205 cases. *J Oral Maxillofac Surg.* 1997;55:558–63.

Additional Reading (Sub Mental Intubation)

- Hernández AF. Sub-mental vs. retromolar intubation. *Anaesthesia.* 2006 Nov;61(11):1123–4.
- Altemir FH, Montero SH, Peña MM. About submental intubation. *Anaesthesia.* 2003 May;58(5):496–7.

Open Access This chapter is licensed under the terms of the Creative Commons Attribution 4.0 International License (<http://creativecommons.org/licenses/by/4.0/>), which permits use, sharing, adaptation, distribution and reproduction in any medium or format, as long as you give appropriate credit to the original author(s) and the source, provide a link to the Creative Commons license and indicate if changes were made.

The images or other third party material in this chapter are included in the chapter's Creative Commons license, unless indicated otherwise in a credit line to the material. If material is not included in the chapter's Creative Commons license and your intended use is not permitted by statutory regulation or exceeds the permitted use, you will need to obtain permission directly from the copyright holder.



Part IV

Imaging in Oral and Maxillofacial Surgery

Radiology for Maxillofacial Surgeons: The Essentials

8

Shyamsundar K. Joshi and Annie I. Kochuveetil

Learning Objectives

- To identify the strategies in building an effective working relationship with the imaging department and help plan appropriate imaging investigations.
- To understand the principles of various imaging techniques; the advantages and disadvantages of these techniques in varying clinical scenarios.
- To gain awareness about the benefits and risks of using ionizing radiation and understand the basic principles of radiation protection.
- To establish the role of imaging as a treatment guide following different maxillofacial surgeries.

8.1 Introduction

Accurate diagnosis is the mainstay of proper surgical management in a maxillofacial surgical patient. Definitive diagnosis may be possible in a few patients based on clinical evaluation in the outpatient department or emergency setup. Other cases may require the use of supplementary investigations, including radiological imaging.

Like other medical specialties, the scope of Radiology is vast, playing a significant role in disease management. Penning a chapter on Radiology for a clinical branch-like Maxillofacial surgery is an uphill task. As a clinician, the maxillofacial surgeon, after having made the diagnosis, has the desire to visualize and gain in-depth knowledge of the ongoing disease process within the patient. Radiology plays an important supporting role in helping the clinician visualize within the patient's body. It is hence necessary for clinicians to have basic knowledge of the key concepts of

Radiology, helping them understand its applications in the diagnosis of a patient's clinical condition.

The scope of practice of a practicing MFS includes both surgical and nonsurgical problems that affect the orofacial region, and hence they need to be well versed with the imaging concepts of the head and neck region.

Head and Neck Imaging

Anatomy of the head and neck is complex and imaging in this region poses several challenges and an MFS needs to be cognizant of them.

Modern imaging has the unique advantage of being able to:

- Demonstrate intricate and critical anatomical structures packed in small compact space pockets.
- Define the anatomy pertinent to the region of clinical interest.
- Define the critical relation to vital structures like the brain and cerebral vessels.
- Define the related adjacent critical areas like the airway, orbital contents, and both intra- and extracranial neurovascular elements.
- Define the underlying pathological process.

Conventional Radiography is one of the modalities that have been available from early days, ever since X-rays were discovered by Wilhelm Conrad Roentgen in 1895. However, it is regarded as a poor choice for anatomical evaluation due to overlapping of anatomical structures especially in the head and neck region. Yet it still has a popular role in its own humble way. It is universally available, the least time-consuming imaging investigation, and gives a 'bird's eye view' of the region of interest. It provides instant practical

S. K. Joshi (✉) · A. I. Kochuveetil
Department of Radiology, SDM College of Medical Sciences and Hospital, Shri Dharmasthala Manjunatheshwara University, Dharwad, India

information on the status of the airway and osseous elements, helps inferring the underlying pathological process based on the presence of air pockets or bony destruction, and at times may even reflect systemic pathology. It guides the clinician as to the further steps to be taken for patient management or to the need for further imaging. Despite it being the era of advanced technology, conventional radiography should invariably be the first choice among imaging investigations. In cases of complex maxillofacial injuries and polytrauma, when the patient's clinical status demands the next level of investigation, CT may be performed first, bypassing conventional radiography.

Pioneers in the field of imaging had a yearning to develop modalities that could demonstrate finer anatomical details in the region of interest.

This, coupled with the technological evolution, has paved the way for the development of various radiological imaging technologies that include:

- Ultrasonography (USG)
- Color Doppler
- Computerized Tomographic (CT) scan
- Dentascan
- Cone beam CT
- PET scans
- Radioisotope scanning
- Magnetic Resonance Imaging (MRI)
- Functional imaging, etc.

These advances in imaging techniques have enabled the MFS to diagnose with greater confidence and refine their approach to surgical treatment. This has also led to a reduction in unexpected surprises springing up on the surgical table.

Considering that a range of imaging modalities are available, it is imperative that the MFS has basic knowledge about their functionality, being familiar with the advantages and disadvantages of each so that the appropriate imaging investigation that gives the most optimal information in a given clinical setup can be selected. The rationale behind choosing the right investigation is that it should be easily available, least time consuming, cause least possible discomfort to the patient and be economical. Appropriate use of the concerned imaging modality should provide the maximum possible anatomical and functional information. This is possible if a genuine effort is made by an MFS to understand the basic principles and other related components of specific diagnostic imaging relevant to his field of interest and establish a close rapport with the imaging department.

8.2 Requesting an Imaging Investigation

Prior to requesting a radiological investigation, the MFS needs to have a clear idea about the usefulness of an investigation, its limitations, and whether it will help to improve the patient outcome. A radiological imaging requisition must specify the choice of investigation and the surgeon's expectations from it, so that the information received strengthens his approach in treating the patient.

It must provide mandatory demographic and relevant clinical data, including the patient's symptoms, which primarily brought him to the MFS, their duration, clinical signs, and the clinician's differential diagnosis of the same. In addition to concentrating on the clinical data, entries made available through the Hospital Information system (HIS) and the Radiology Information system (RIS), accurate patient identification by the MFS is essential prior to referral to the imaging department.

8.3 Role of the Maxillofacial Surgeon (MFS) Vs. the Radiologist's expectation from the MFS

An MFS deals with patients suffering from maxillofacial disease processes, but being a clinician primarily he is expected to have basic knowledge of various systemic clinical problems as well. Systemic disease may manifest as disease in the maxillofacial region or vice versa. For instance, a cystic lesion in the jaw could be the primary radiographic finding in a patient suffering from hyperparathyroidism. Similarly, patients suffering from systemic diseases like osteopetrosis, fluorosis, fibrous dysplasia, and other marrow infiltrative disorders could also present with a disease in the maxillofacial region. Further, detection of congenital anomalies in the maxillofacial region is an indication for a more detailed survey to rule out associated anomalies elsewhere.

The surgeon should be able to identify radiological images, correlate the same with the report and the patient's clinical status, and focus on timely decision making and patient management, thus optimizing the patient's outcome. However, in a dire emergency when a radiologist's opinion is not available, or a delay is expected in obtaining the same, an MFS should be able to interpret radiographs that suggest life-threatening conditions like tension pneumothorax, aspiration bronchopneumonia, foreign body aspiration, or pulmonary edema among others. Imaging can help the MFS in narrowing down on the clinical diagnosis, in staging and evaluating the prognosis of a disease process, or in surgical planning by depicting the exact extent of a lesion after diagnosis is confirmed.

MFS' need to communicate with their radiology counterparts the expectations they have from imaging of a case so that the radiologist can provide the relevant anatomical

and functional information from the region of interest. Each imaging modality has its own reporting language and the surgeon needs to be well versed with the language used and have a clear concept of principles of image formation, specific to the energy source used in the particular investigation.

8.4 Role of the Department of Imaging and the Radiologist

The responsibility of the imaging department is conducting the specified diagnostic imaging investigation, interpretation of the tests or procedures by the radiologist and providing the clinician with accurate reports of the performed investigation as early as possible. Clinical radiologists function as key members of multidisciplinary teams, being an integral part of patient care.

8.5 Energy Forms Used in Diagnostic Medical Imaging: Understanding the Basics

Different types of energies are used in diagnostic imaging. These energies are imperceptible to the human eye and when they are passed to the desired location in the body, they interact with the body tissues in different ways. The tissue interactions can reveal information about the tissue, but they need to be interpreted. Access to this information is possible only if it is converted into a visible form on a display system. In essence, the requirements for an imaging investigation are; a reliable and reproducible energy form, a subject (the patient) into whom the energy can be sent, and a format that can convert the invisible image into a visible display.

X-rays and gamma rays are photon energies and members of the electromagnetic spectrum having a wide range of wavelengths and frequencies. X-rays have very small wavelengths being lesser than 1 Å unit and greater than 0.1 Å units. This range of specific frequencies and wavelengths of X-rays give them special properties, gaining popularity in diagnostic imaging.

Gamma rays have shorter wavelengths and higher frequencies than X rays. They are used in nuclear medicine both for diagnostic and therapeutic purposes.

Conventional radiography, including mammography, fluoroscopy, computed tomography (CT), is a modality that generates images of the ionizing radiation. It works on the same basic principle, which essentially involves passing of an X-ray beam through the body followed by absorption and scattering of a portion of the X-ray energy by the body tissues and transmission of the resultant radiographic pattern formed by differential tissue absorption to a detector for recording or further computer processing.

The popularity of X-rays as an imaging modality is due to its optimum penetration power and photochemical and fluorescent properties. Its fluorescent property is useful in converting invisible images into visible light images, while the photochemical property is responsible for conversion of the visible light image into a permanent visible record called radiograph.

Conventional radiography includes plain radiographs of different body parts like chest, skull, PNS, etc., contrast studies of the gastrointestinal tract like Barium studies, contrast studies of the genitourinary tract like Intravenous urography (IVU), and contrast studies of the vascular system like Arteriography, Phlebography, etc.

Fluoroscopy involves a continuous display of real-time movements of moving structures as radiographic images on the monitor, e.g., act of swallowing, movement of the soft palate, movement of the temporomandibular joint, cardiac pulsations, diaphragmatic movements, etc.

Computed Tomography includes cross-sectional imaging with its modifications like 3D, Volume rendering, Multiplanar reconstruction images, C.T. angiography, etc.

Ultrasound imaging or sonography makes use of high-frequency sound waves that are transmitted from the transducer into the body. The reflection of these waves off the body structures forms the basis of ultrasound image formation. The information necessary for image production is provided by the amplitude of the reflected sound signal and the time taken for it to travel through the body. Commonly ultrasound is used in the imaging of the abdomen, fetus, breast, eye, heart, vessels, and the musculoskeletal system. In recent years, there has been much research into ultrasound of the maxillofacial region, and it has been found to have a range of unique applications, including the evaluation of cervical lymph nodes and the detection of space infections and cystic and solid lesions of the head and neck. In early cases of peripherally located carcinoma of the tongue, ultrasonography may be an initial mode of imaging for evaluation.

Ultrasound imaging is not associated with the same risks as ionizing radiation and is considered to be generally safe if used appropriately. Ultrasound energy does have the potential to produce biological effects on the body and can cause minimal heating of tissues and in certain cases produce tiny gas pockets in the tissues and body fluids known as cavitation.

Magnetic resonance imaging makes use of strong magnetic fields and radiofrequency energy to create images. The signals that produce an MR image originate from the protons present in water and fat molecules in the body. Application of a strong magnetic field by the MRI scanner causes the protons within the body to align themselves. Radiofrequency current is then passed into the patient's body creating a varying magnetic field that causes the protons to flip their spins. Turning off the radiofrequency pulse causes the protons to return to their normal spins, producing radio signals that are measured by receivers in the scanner and used to make digital images of the scanned area of the body.

Many forms of MRI exist, diffusion and functional MRI being the most common. Diffusion MRI helps in diagnosing disease processes like stroke that restricts diffusion of water molecules across body tissues, while functional MRI is used to visualize the functional activity of the brain. MRI does not use ionizing radiation but since it uses strong magnets, any form of metal implants like artificial joints and heart valves, pacemakers, cochlear implants, metal plates, screws, and rods do pose a hazard.

Thermography makes use of specialized cameras that can detect electromagnetic light energy in infrared wavelengths. Medical thermography produces a topographic heat map, displayed in the form of various color shades, based on the differential skin temperature at various dermatomes bearing resemblance to the visible image of the body. It is not a structural imaging technology providing information on structural changes like other modalities and does not provide a diagnosis, rather only aids in reaching a diagnosis. It is completely safe and painless, does not make use of any form of radiation, and is a unique form of imaging in that it can document pain, thus helping to differentiate malingering from an organic cause for the pain.

8.6 Basic Radiology for the Nonradiologist: What the MFS should know?

Plain radiographic film interpretation is an essential skill. The current implementation of electronic health records and digitization of the health care system has made radiographic images available throughout the hospital and an MFS may often have to interpret medical images. So, it is important that they know the basics of medical image interpretation, and this knowledge may prove to be crucial in an acute clinical setting. They should be aware of tissue appearances on radiographs and be capable of making a basic distinction between normal and abnormal.

Understanding the concept of density and contrast is fundamental to interpreting an X-ray image (radiographic image). Different body tissues, including bone, soft tissues, fat, and air, all attenuate the X-ray beam differently. Differential absorption of X-ray photons by the body tissues results in variable energy values of emerging photons producing an invisible image, which is converted into visible form as areas of different gray scales. The contrast on the image is the difference between adjacent densities. These densities range from white to black with varying gray shades in between them. If the densities of two tissues adjacent to each other are greatly different (say a white and a black density tissue), then they are said to have high contrast. If the densities of two tissues adjacent to each other are similar,

then they are said to have low contrast. They appear similar in color, differing in their shades of gray. When two body structures of identical density are exactly side by side, the line of demarcation cannot be made out and whole of it appears as one structure.

Consider a chest radiograph. What do you think is the whitest component seen on the radiograph? Most commonly the answers given are heart, bones, below the diaphragm, and so on. Rarely does anyone mention that the “R” marker is the whitest. Similarly, if asked which the darkest component is, the popular answer given is, the lung surrounding the heart, very rarely does one mention that the air surrounding the chest is the darkest. Analyzing as to why the “R” marker is white and the air surrounding is dark, the reasoning is that the chest radiograph is nothing but a representation of the tissues in that region in various gray scales between extreme white and extreme dark, depending upon the variable absorption of X-ray photons in their path through the tissues.

The opacity produced on a radiograph by a specific body tissue is a representation of the actual penetrative ability of X-rays to pass through that tissue and then be incident on the film. Air and fat absorb less radiation, allowing more X-rays to pass through and be incident on the radiograph making their images appear black and pale gray, respectively. Bone and metal as is the “R” marker made of lead absorbs more radiation and so fewer X-rays are incident on the film making them appear white.

Continuing with the example of chest radiograph, what are branching structures that are seen in the lung fields? Are they arteries, veins, bronchi, lymphatics, or a combination of all these? The common answer given is bronchovascular. The correct answer is arteries and their branches, but not the bronchial tree. The explanation is simple. Air in the bronchi is surrounded by air in the alveoli and so no contrast exists between them and they are hence not seen. On the other hand, blood in the arteries is surrounded by air in the alveoli and hence they stand out. Veins do contain blood but are too less in number and do not significantly contribute to the branching structures. Lymphatics are too small to be detected.

If this basis of X-ray image formation is understood, you can easily interpret any radiographic image provided you have sound knowledge of the relevant anatomy, pathology, and pathophysiology.

8.7 Imaging Investigations

8.7.1 Imaging Investigations Using Ionizing Radiation (Photon Energies)

Electromagnetic radiation has a wide range of wavelengths ranging from being smaller than angstrom units to as large

as many miles. Smaller wavelengths have greater energy and penetration power and are called photon energy meaning packets of energy and not particle energy. The two energies that are of concern in the present context are X-rays and Gamma rays. Passage of these energies through body tissues either for diagnostic or therapeutic purposes results in a series of events beginning with an incidence of the X-ray photon into tissue followed by sequential changes at molecular and atomic levels. The transformation of energy from the photon results in ionization, namely, in the discharge of an electron and a free radical. Hence, such energies are called ionizing radiation and the process involves breakage of enzyme bonds and formation of new molecules manifesting in the form of various repairable and irreparable biological effects.

The concept of photon energy and its effect on body tissues can be explained using the following example. Consider a hot iron ball being passed through a pile of corn (Fig. 8.1). The temperature of the ball after exiting the corn pile is grossly reduced. It is because the ball, during its transit through the pile, shares the energy with the corn in contact with it. The corn in very close contact to the ball is burnt to ashes, the corn a little farther away, is burnt to charcoal, corn still further away is converted to popcorn, while corn far away from the ball remains unaffected. The effect on the corn is directly proportional to the energy transferred from the hot iron ball to the corn. The same thing happens when photon energy passes through the body tissues with changes occurring at atomic level.

8.7.1.1 X-Rays

X-rays are a form of electromagnetic radiation. Man-made X-rays are produced when fast-moving electrons undergo sudden deceleration on collision and interaction with the target anode in an X-ray tube. The electrons are emitted by the cathode, on being heated up by the electric current flowing through it.

Though conventional X-ray imaging has evolved over the past 100 years, the basic principle remains the same. On passage of an X-ray beam through the body, the beam is attenu-

ated by the body's internal structures, being partly absorbed and partly scattered. The remnant of the X-ray energy is transmitted to a detector that records the image for later evaluation. The recording of the radiographic pattern may be on film or other electronic devices. The image created is due to weakening of the X-rays by tissues of varying density encountered along the beam's travel path. Bone being dense tissue, absorbs or attenuates a great deal of the X-rays, while soft tissue being much less dense attenuates or absorbs far less X-ray energy. These differences in absorption help in creating images that can clearly show normal tissue appearance as well as different forms of pathology.

Conventional radiography, fluoroscopy, and CT all work on the same basic principle differing only in their purpose. In radiography, a single image is recorded for later evaluation, in fluoroscopy X-ray images are displayed on a monitor in a continuous flow, thus allowing monitoring of a procedure or contrast passage in real time and in CT imaging a multitude of images are recorded as the detector rotates around the patient's body followed by reconstruction of the individual images as cross-sectional images of internal organs and tissues.

8.7.1.2 Computerized Tomography (CT/Spiral CT)

Computerized axial tomography is a computer-controlled radiological study that produces a reconstructed image of a cross-sectional slice of the desired section of the body. Its features include the absence of superimposition, less scatter and better tissue differentiation of the anatomical slice, thinner slices producing a better reconstructed image. The major drawback of conventional radiography is the overlapping of anatomical structures resulting in difficulty in evaluation of desired structures in a particular plane. The imaging method 'Tomography' was introduced to overcome this drawback and involves imaging of anatomical structures at the desired plane with the blurring of overlapping structures. Classical conventional tomography had its own inherent drawbacks, which included poor-quality blurred images, high radiation dosage, and use of complicated techniques which led to it being replaced by tomography assisted by computer technol-



Fig. 8.1 Illustration of passing a hot iron ball through a pile of corn and its effect on the corn

ogy called ‘Computer assisted Tomography’ (CAT). With a rise in popularity, CAT has been replaced by the word C.T. and technological advances have resulted in the development of better equipment capable of scanning the entire body within a few seconds. This provides fine anatomical details of submillimetric structures, allows tracing of blood flow in all its phases, and also permits clear depiction of information related to moving structures like the heart in real time as well as their external and internal morphology. Two types of CT have been described based on the shape of the X-ray beam, the traditional fan beam CT and cone beam CT.

CT Unit Components (Fig. 8.2a, b)

The essential components of a CT unit include:

- **The X-ray tube**—a specialized tube of high heat loading and dissipating capacity with a very small focal spot, as a source of X-ray energy
- **Detectors** that receive and quantify the attenuated X-ray photons
- **A computer** of high capacity that evaluates attenuated photon energy from detectors, stores the values, and converts these values to sectional images
- **A console** that manipulates all data stored in the computer, helping in reconstructing the image at desired planes with volumetric imaging or multiplanar reconstruction, 3D and volume rendering, followed by projection of the desired structures based on their density values, etc.

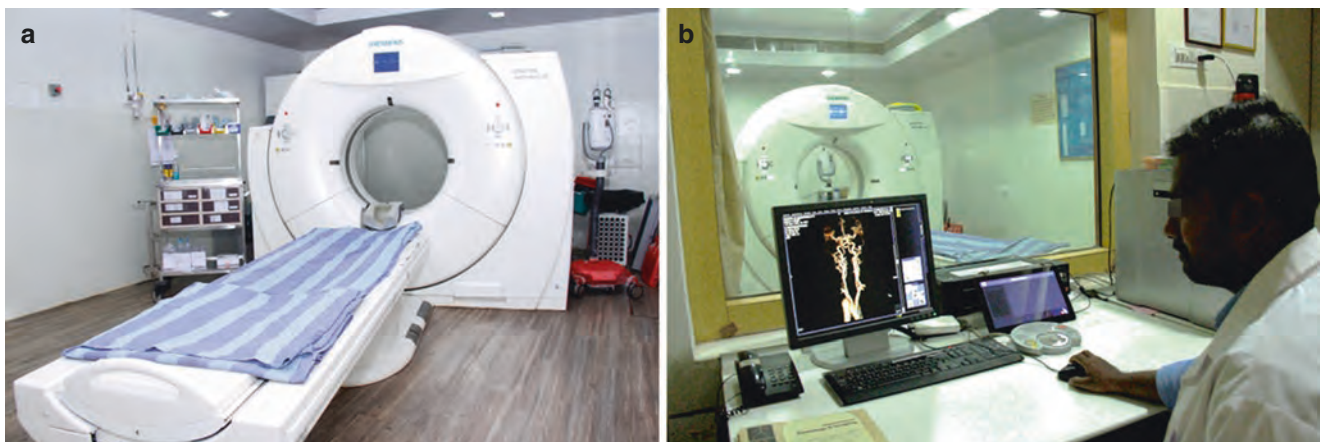
- **A gantry** that houses X-ray tubes, detectors, and related cables with a central aperture for the patient’s body to enter for sectional imaging
- **A moving table** or a couch that facilitates the movement of the body with extreme accuracy at even submillimetric increment

CT scans have many benefits that far outweigh their risk. It is quick and easy, widely available, and provides superior anatomic and bone details. It has Volume Rendering Technique (VRT), Maximum Intensity Projection (MIP), 3D and Shaded Surface Display (SSD) capabilities, provides multiplanar reconstruction images in desired planes, and is the modality of choice for follow-up studies. (Figs. 8.3a, b, 8.4a, b, 8.5a,b, 8.6a, b, 8.7a, b, 8.8a, b, 8.9a, b, 8.10, 8.11, and 8.12).

The possible risks of using CT imaging include exposure to ionizing radiation and the predicament of suffering an allergic reaction due to use of contrast media. One drawback of CT when compared to MRI is the lesser resolution of soft-tissue detail. Other disadvantages are the associated cost and the limitations of its use in the pediatric age group due to the need of sedation.

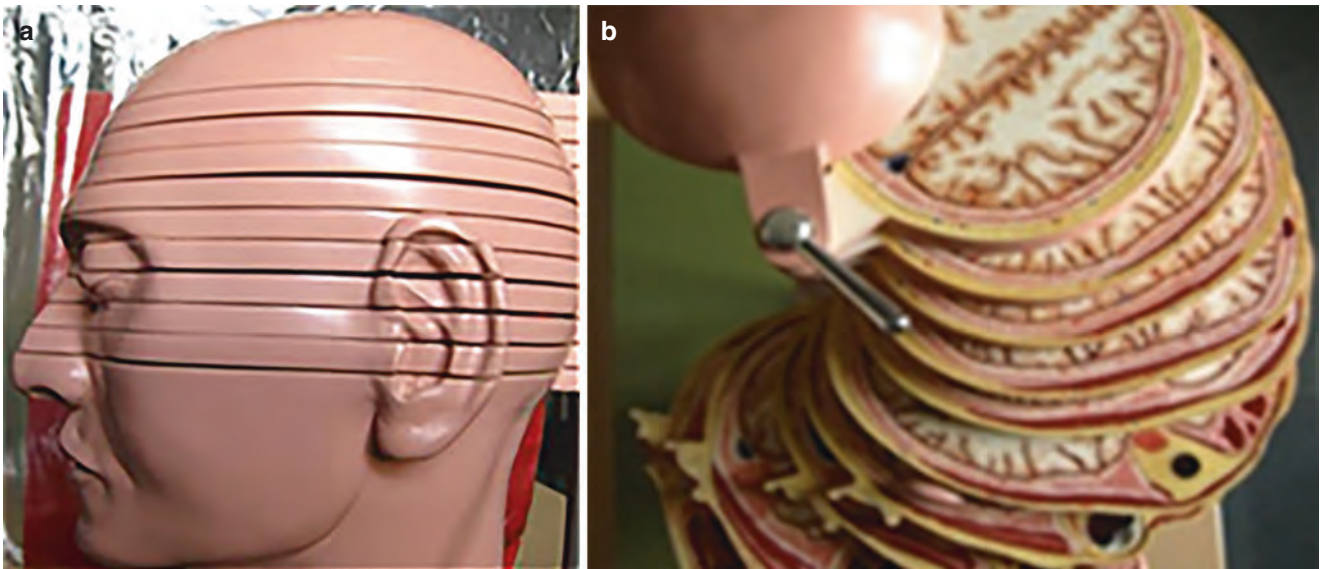
CT Limitations

Motion and beam-hardening artifacts used to be considered as major drawbacks, but they have been markedly minimized with advances in technology. A physical limitation is that the patient needs to weigh less than 300 to 400 lbs. For



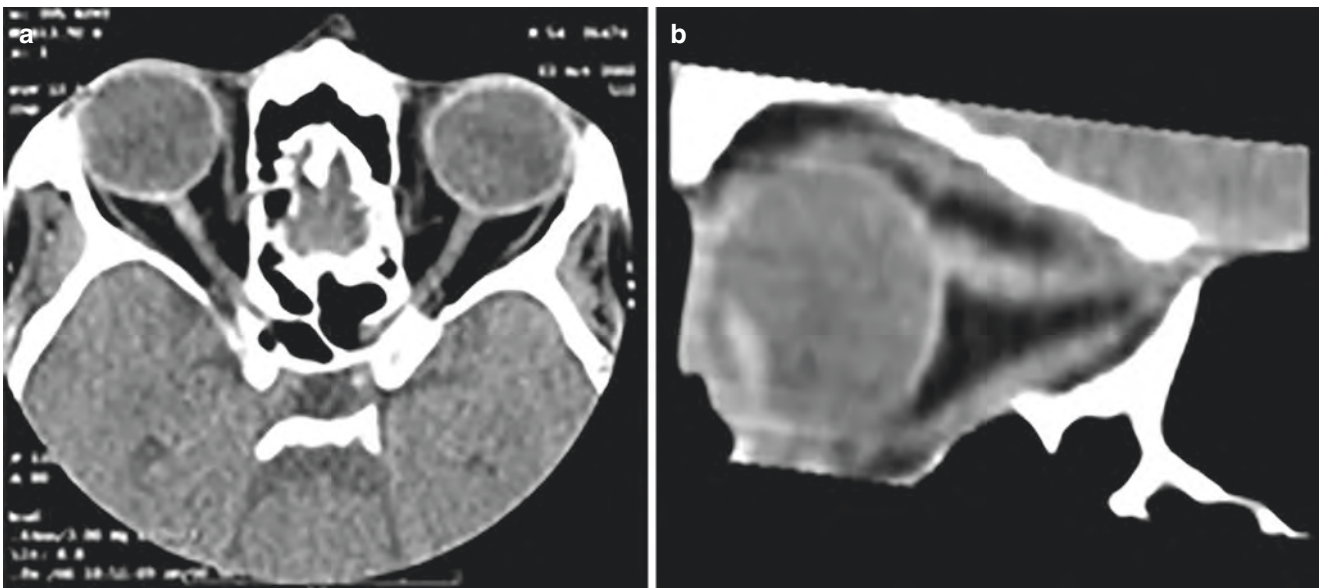
©Association of Oral and Maxillofacial Surgeons of India

Fig. 8.2 (a) CT room shows Gantry, Patient couch, Emergency crash trolley, Central suction, and Oxygen and Pressure Injector. (b) Control room showing a CT technician working with various controls and the image acquisition system



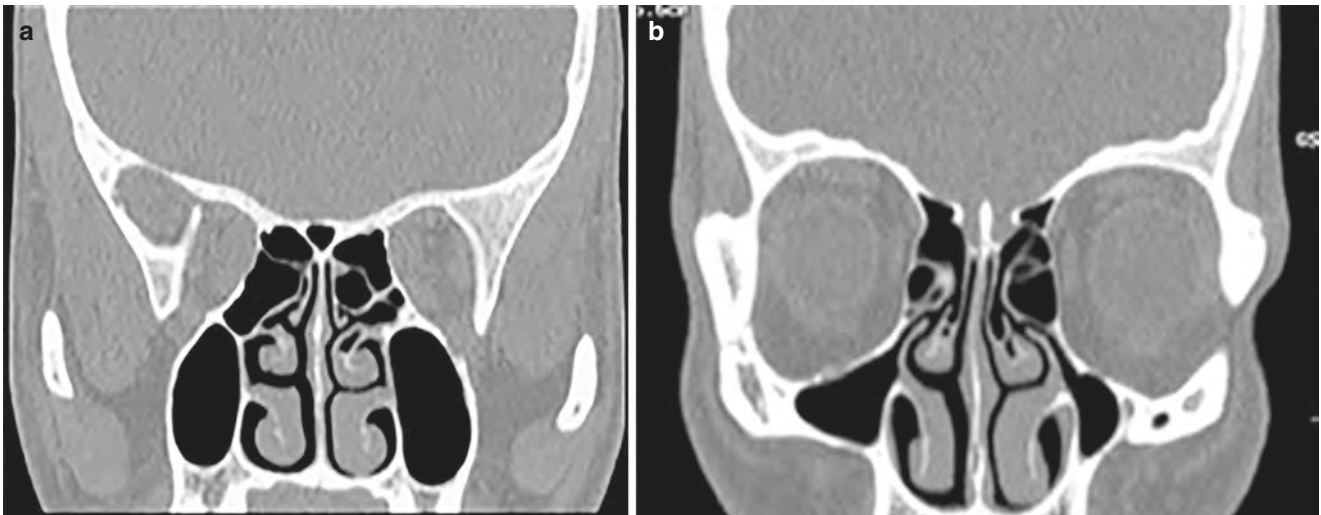
©Association of Oral and Maxillofacial Surgeons of India

Fig. 8.3 (a) Museum Model of head showing how axial slices are planned. The slice thickness varies from submillimeter to 10 mm, depending on the ROI (region of interest) and anatomical structure to be seen. (b) Stacked CT slices showing specific anatomy at a specific slice



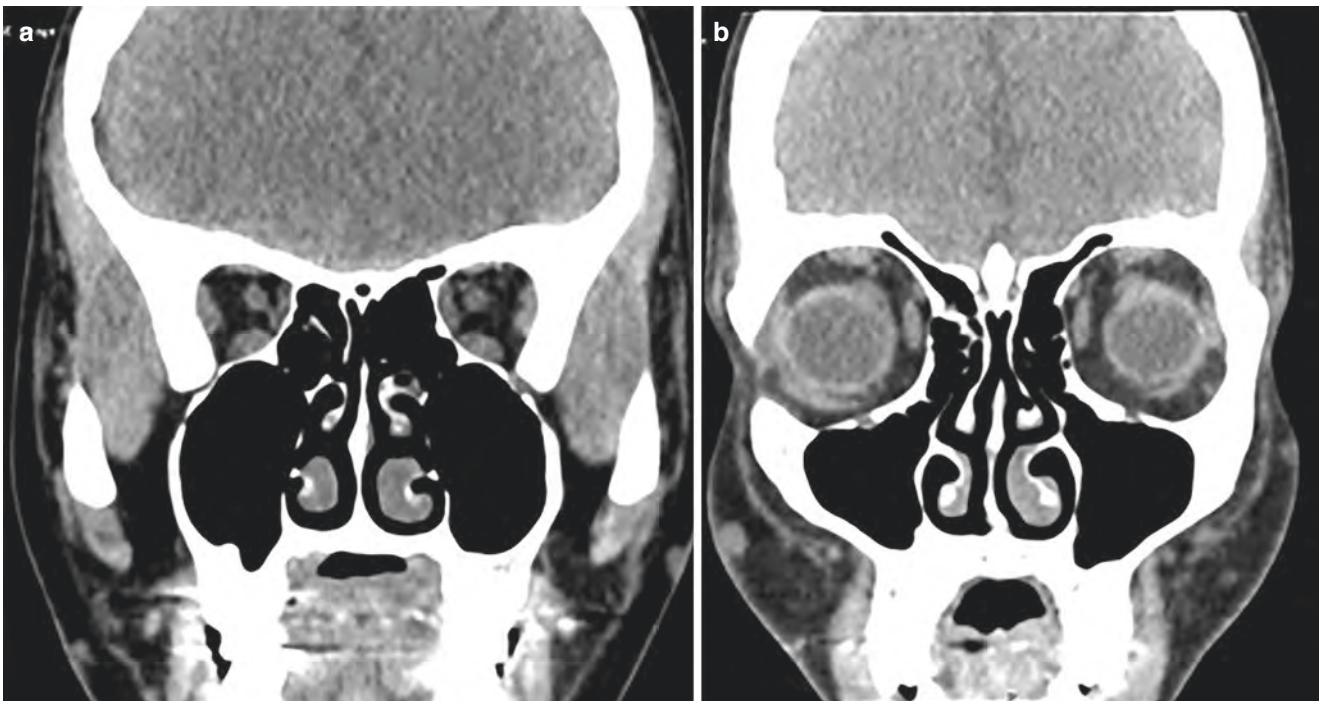
©Association of Oral and Maxillofacial Surgeons of India

Fig. 8.4 (a) CT axial primary slice soft-tissue window at the level of optic nerves showing mediolateral and anteroposterior relations and not supero inferior relations. (b) CT sagittal reconstructed image of the same patient at the level of optic nerve showing anterior, posterior, superior, and inferior relations



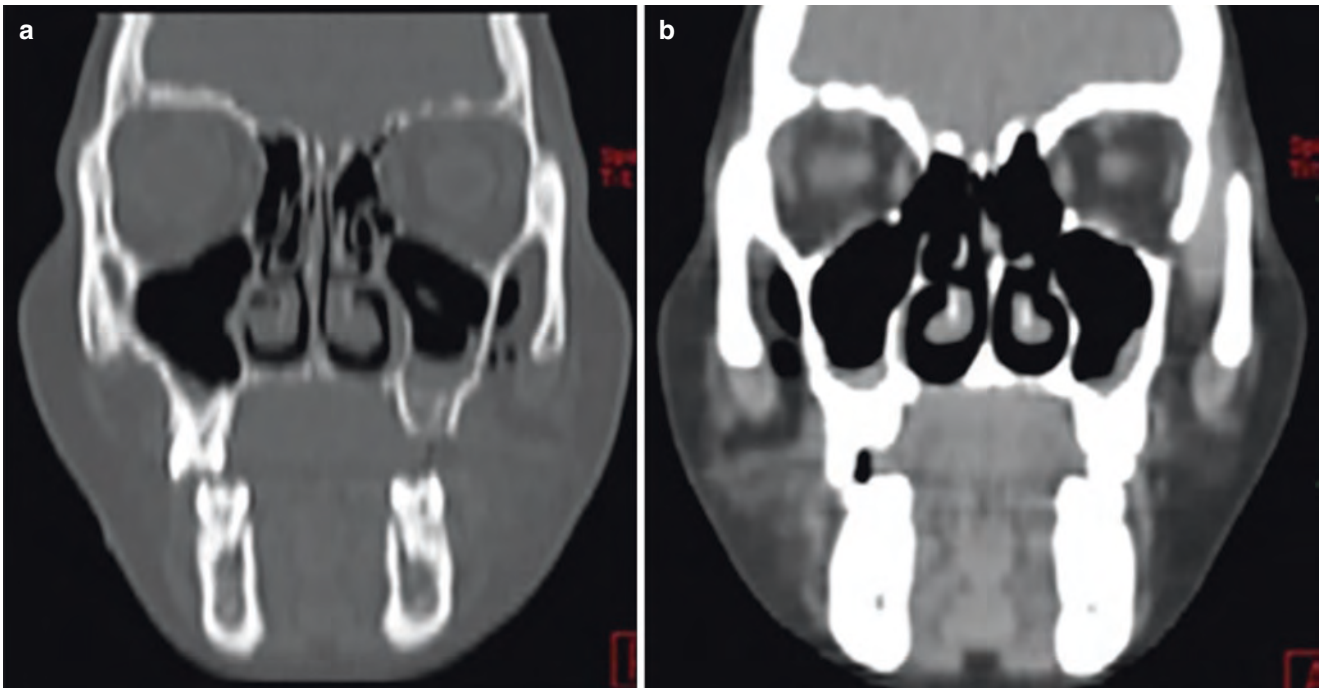
©Association of Oral and Maxillofacial Surgeons of India

Fig. 8.5 (a) and (b).CT coronal bone window primary images at different levels of paranasal sinuses



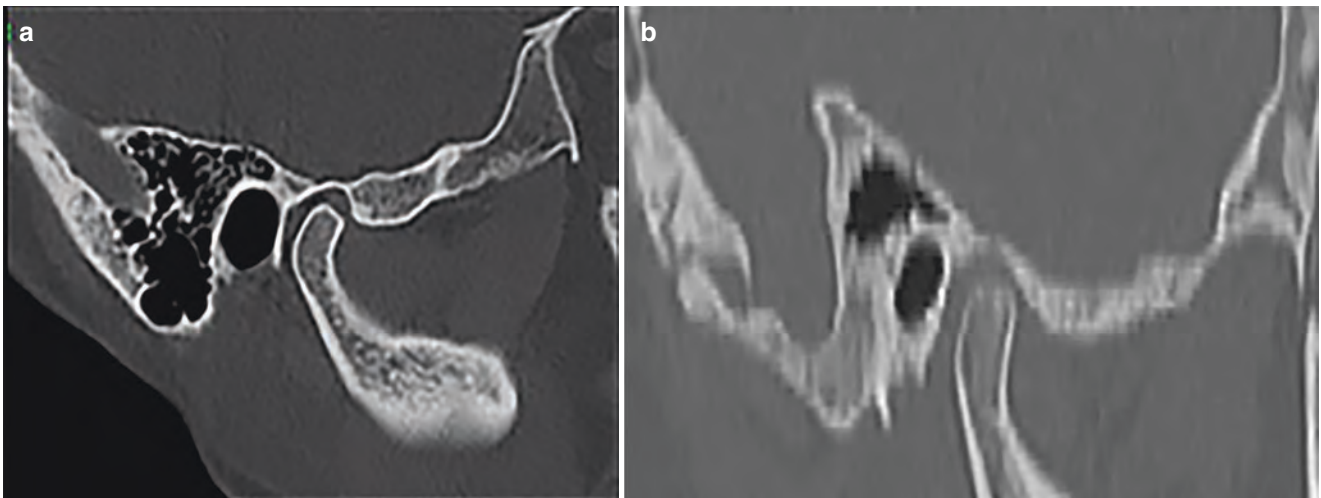
©Association of Oral and Maxillofacial Surgeons of India

Fig. 8.6 (a) and (b).CT coronal soft-tissue window primary images at different levels of Paranasal sinuses



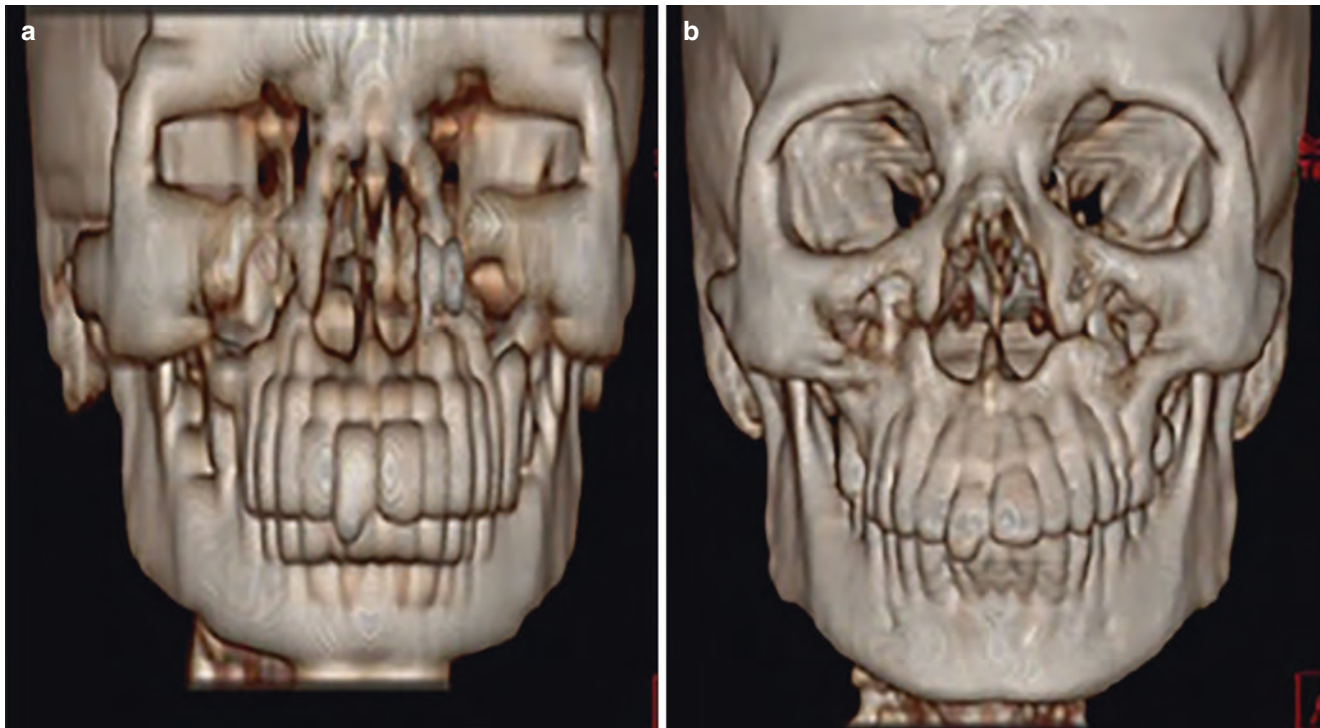
©Association of Oral and Maxillofacial Surgeons of India

Fig. 8.7 (a) and (b). CT reconstructed coronal images from thicker slices of paranasal sinuses at different levels. (a) bone window. (b) soft-tissue window. Note: coarse appearance



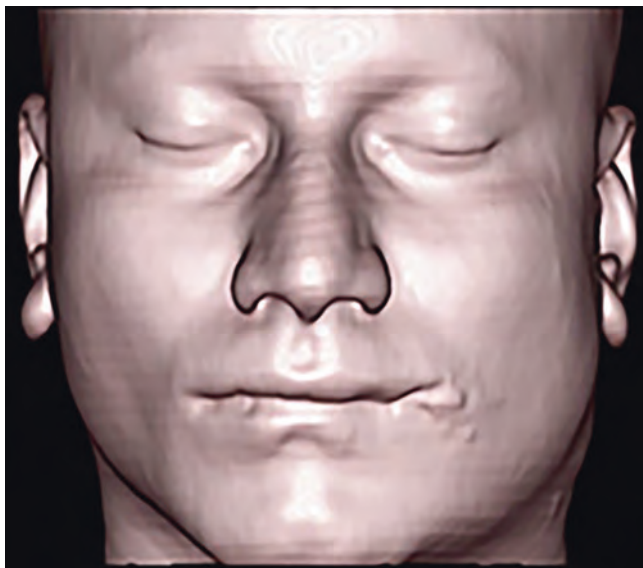©Association of Oral and Maxillofacial Surgeons of India

Fig. 8.8 (a) CT direct slice of T.M. joint in its sagittal plane. Bone window. (b) CT reconstructed image from primary axial thick slices of T.M. joint in its sagittal plane. Note: coarse appearance



©Association of Oral and Maxillofacial Surgeons of India

Fig. 8.9 (a) CT 3D reconstructed image for surface bony details from thicker slices. Note: coarse appearance. (b) CT 3D reconstructed image from thin slices. Note: better and smoother image



©Association of Oral and Maxillofacial Surgeons of India

Fig. 8.10 CT 3D surface rendering reconstructed image for surface soft-tissue details from thinner slices

CT imaging of the head region, axial and direct coronal slices are primarily possible, for the neck region, only axial slices are possible and in the temporomandibular joint region axial and direct sagittal slices are possible. It is

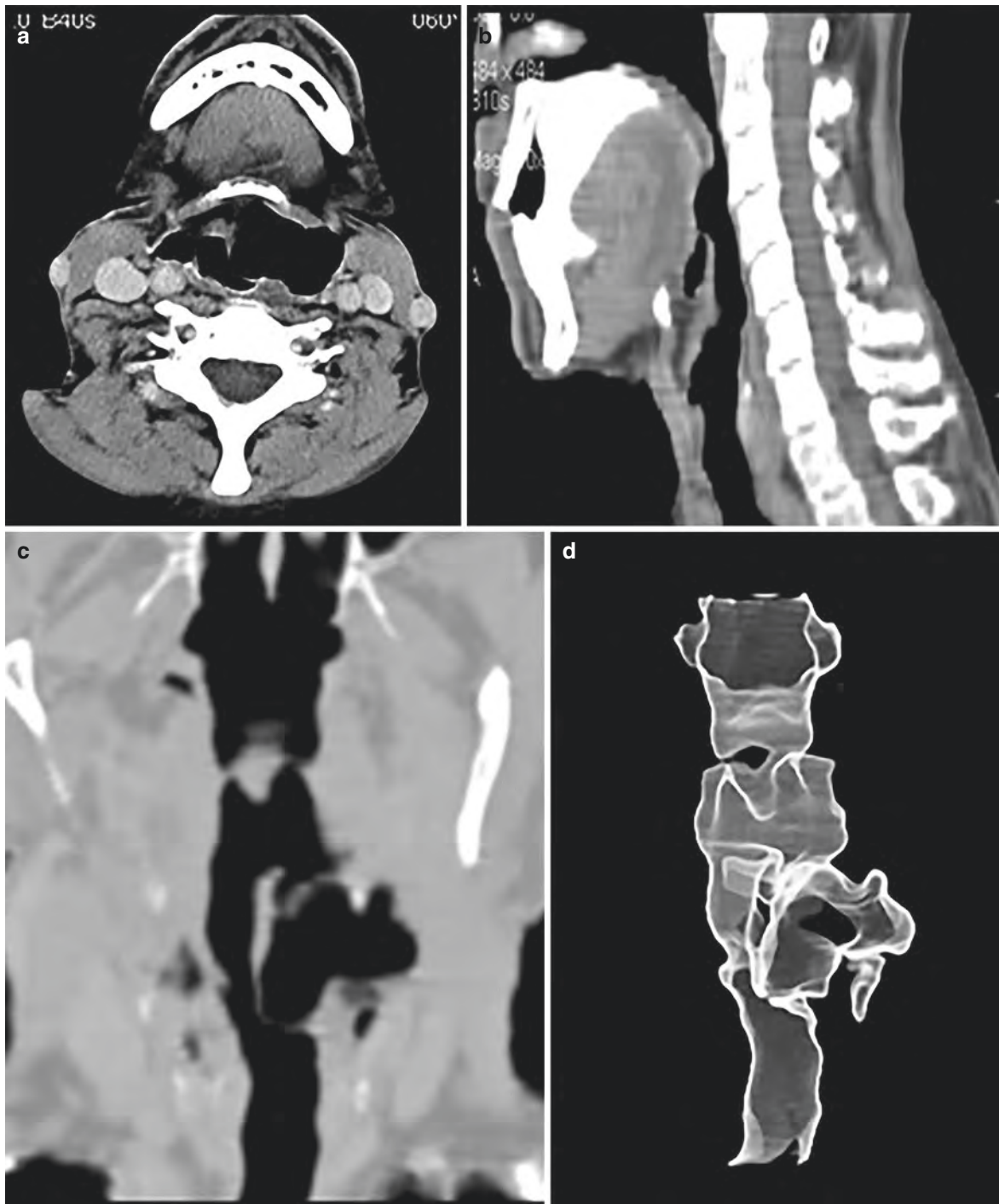
through the raw data thus available that images are reconstructed in any desired plane.

Dentascan

Basic principles of CT Orthopantomography (OPG) and Dentascan

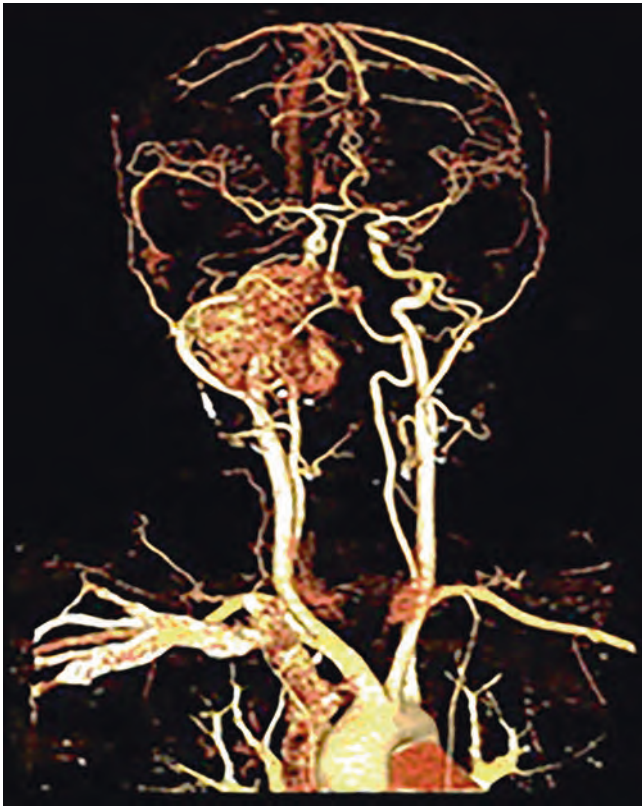Conventional OPG is a first-level diagnostic exam that provides a gross panoramic view and just enough information about alignment of the teeth and any other related gross pathology. Unavoidable overlapping of some of the anatomical structures hinders accurate evaluation. To overcome these drawbacks, Dentascans and CT OPGs are used. They are extended applications of CT scan and involve the acquisition of thin axial submillimeter slices of the region covering the upper and lower jaws (Fig. 8.13). Reconstructed images obtained using these raw data image slices form the CT OPG or Dentascan image (Fig. 8.14a, b).

Coronal reconstructed images form the C.T. OPG (Fig. 8.15a, b, c). It is a second-level imaging technique wherein evaluation of the osseous elements of the maxilla and mandible is far better in comparison to conventional OPG. It provides the MFS with a better understanding of the morphology of the roots and the degree of contiguity between the roots and the mandibular canal. The information acquired is then used in planning and performing minimally invasive surgical procedures [1].



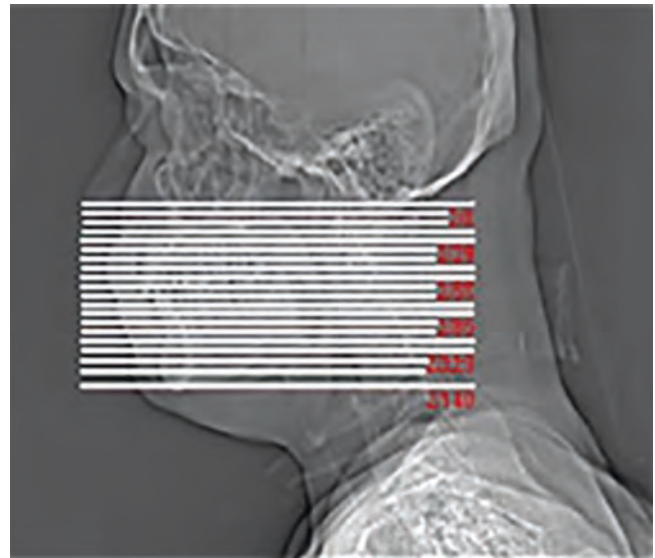
©Association of Oral and Maxillofacial Surgeons of India

Fig. 8.11 (a) CT Primary axial slice of neck at midlaryngeal level. (b) and (c) Sagittal and coronal reconstructed images from sequential CT primary axial slices. (d) CT Volume rendering technique (VRT) image of air column in the pharynx, larynx, and tracheal region as minimum density projection from primary axial slices (a). Note: Better visualization of laryngocele



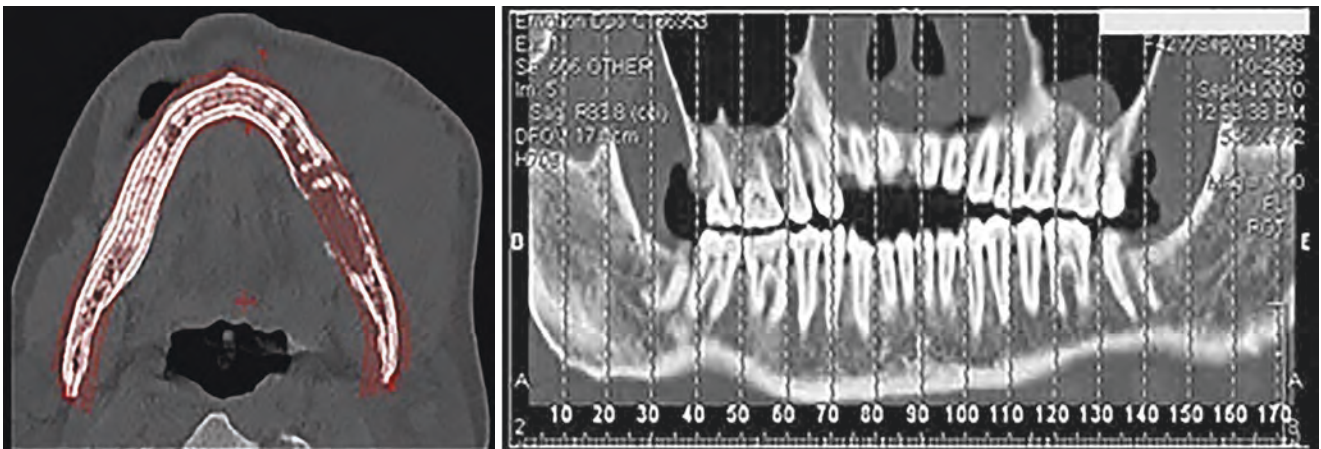
©Association of Oral and Maxillofacial Surgeons of India

Fig. 8.12 CT angiogram: 3D VRT (Volume Rendering Technique) displaying carotid arteries and its branches along with carotid body tumor. It is a reconstructed image from primary thin axial CT slices



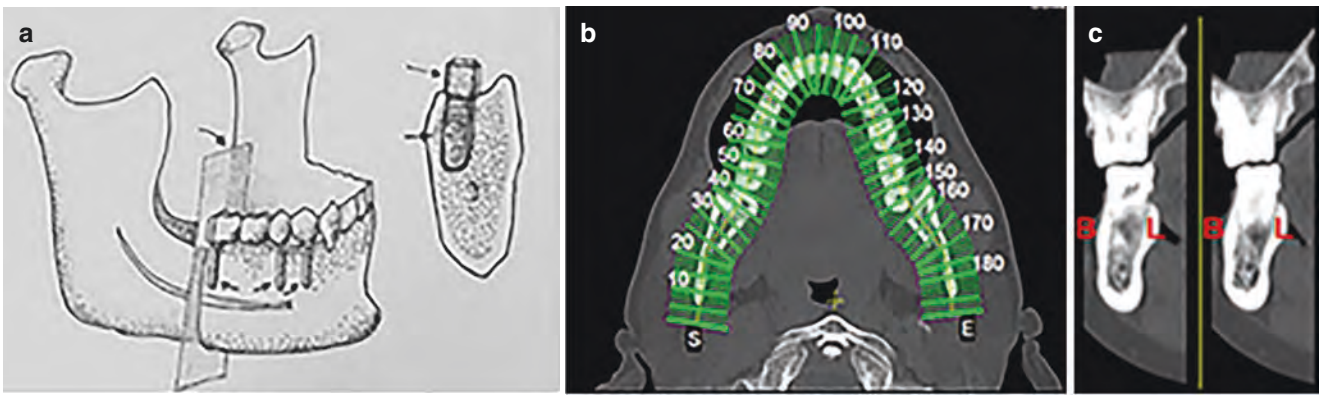
©Association of Oral and Maxillofacial Surgeons of India

Fig. 8.13 CT Scanogram for dentascans showing submillimeter axial slices planning in the region of maxilla and mandible



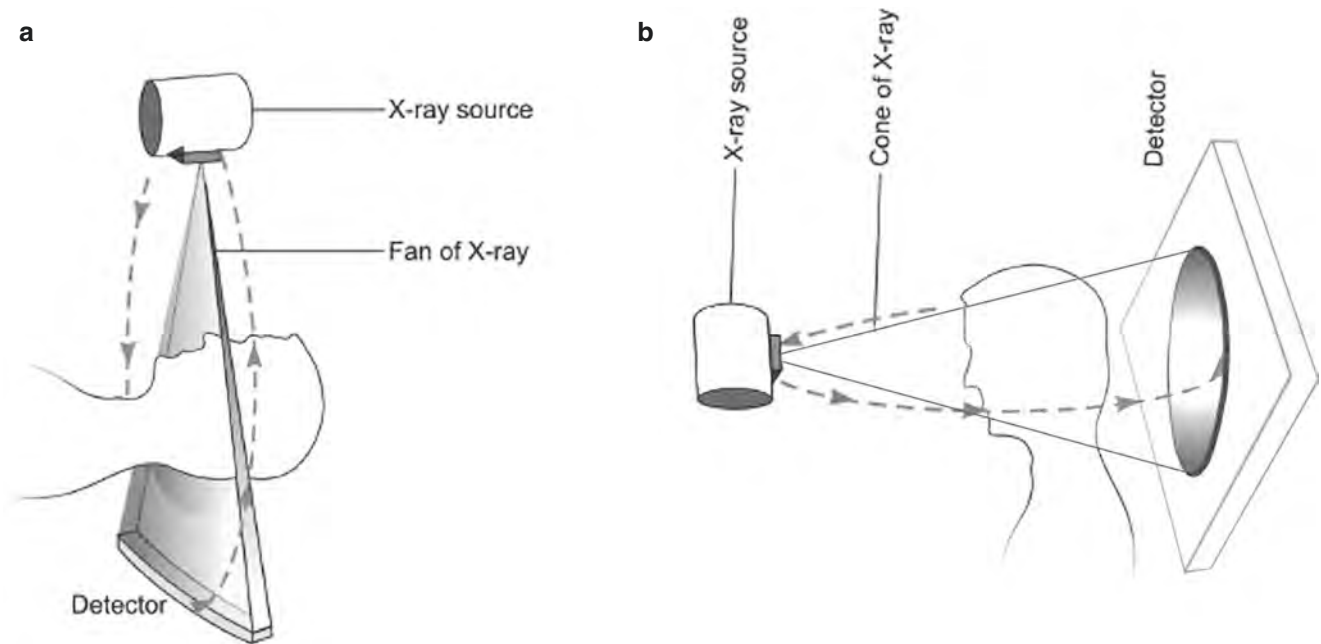
©Association of Oral and Maxillofacial Surgeons of India

Fig. 8.14 (a) and (b) .Reformatted panoramic CT images (b) are procured at desired plane of the jaw by curvilinear graphic lines drawn on the primary axial slice (a) selected



©Association of Oral and Maxillofacial Surgeons of India

Fig. 8.15 (a), (b), and (c). a and b show coronal plain image planning of individual tooth. c shows the coronal reformatted image of tooth



©Association of Oral and Maxillofacial Surgeons of India

Fig. 8.16 (a) and (b). Schematic diagram. (a) shows fan beam of X-rays from X-ray tube with curvilinear row of detectors. (b) shows cone beam of X-rays from X-ray tube with flat detector

Cone Beam CT (CBCT)

Indications for CBCT

CBCT applications have proved helpful in a multitude of dental disciplines and the MFS needs to be aware of it. Its indications include periodontal and endodontic assessment, placement and evaluation of implants, evaluation of jaw bones, temporomandibular joints, bony and soft-tissue lesions, and alveolar ridge resorption and orthodontic evaluation.

Working Principle and System Composition of CBCT System

As the name suggests, it is a form of computed tomography (CT). The basic process involved in CBCT is the scanning of the region of interest using a cone-shaped X-ray beam, making a single rotation around the vertical axis of the patient’s head. The information obtained, from various angles about the structures in the region of interest, is in a digitized format relating to shape and density, which is then processed using

Table 8.1 Comparison between CBCT and Fan Beam CT

Fan Beam CT	CBCT
Conventional CT scanners make use of a fan beam and provide a set of consecutive slices of image.	CBCT makes use of a cone beam, which radiates from the x-ray source in a cone shape, encompassing a large volume with a single rotation.
Makes use of a lie-down machine with a large gantry	Makes use of a sitting up machine of smaller dimensions
Greater contrast and resolution	Ease of operation
Better differentiation between tissue types (bone, teeth, and soft tissue)	Commonly used for hard tissues Especially dental tissues
Higher radiation dose	Lesser radiation dose
Detector type X-axis only	Detector type X- and Y-axes
Volume acquisition requirements are sequential multiple gantry rotations	Volume acquisition requirements are single gantry rotations
Speed of examination is fast	Speed of examination is faster

special software and a three-dimensional (3D) image is reconstructed [2].

CBCT occupies a special place in imaging of the Head and Neck region. It offers a number of advantages over traditional CT technology. It has a multitude of uses in the dental discipline, including dentoalveolar disease and anomalies, jaw tumors, vertical root and dentin fractures, among others. It has also had a positive impact on teaching students about oral and maxillofacial imaging making them adept at operating equipment and related instruments, resulting in greater accuracy in evaluation and analysis of the pathological characteristics of the disease process leading to a proper final clinical diagnosis. Both the traditional fan beam CT and CBCT are third-generation CT scanners but are different in some ways (Fig. 8.16a, b) (Table 8.1).

8.7.1.3 Gamma Rays

Gamma rays are a form of Electromagnetic radiation (EMR). They are similar to X-rays but can be differentiated by the fact that they originate from the nucleus. Gamma-ray photons have the highest energy with their waves having the shortest wavelength in the EMR spectrum. The difference between the two is that X-rays are produced by accelerating electrons when they strike a target, while gamma rays originate from the nucleus of a radionuclide after radioactive decay. Gamma rays damage the DNA of cells and it is this action that is used in the treatment of cancerous tumors, care

being taken not to affect the DNA of the surrounding healthy tissue cells [3].

8.7.1.4 Nuclear Isotope Studies

Scintigraphy or radionuclide imaging is a modality that is readily available and relatively inexpensive. One drawback is that though it can provide specific information, the resolution is poor. It is a functional imaging modality and can assess early physiological changes even before bone mineral changes are evident. Bone scintigraphy is highly sensitive in detection of skeletal osteoblastic activity and the process involves uptake of the radiopharmaceutical Technetium-99 m (Tc-99 m), by the mineral component of the bone due to its affinity for bone. It has proven to be greatly useful in the study of malignant lesions and also in the evaluation of vascularized bone grafts used in reconstruction surgeries of the maxillofacial region [4]. Another use of radionuclide imaging is in evaluating patients with condylar hyperplasia. In these patients, radionuclide imaging of the temporomandibular joint is performed to exclude active condylar growth and in planning the extent of orthognathic surgery. A progressive condition necessitates the removal of the entire condyle and neck while trimming of the enlarged condyle suffices otherwise [5].

8.7.1.5 Positron Emission Tomography (PET)

PET also is a functional imaging technique. It is unique in that it produces images reflecting in vivo changes in tissue metabolism, linking the changes to malignancy. Body images are produced when radiation is emitted from radioactive tracer substances like Carbon-11, Fluorine-18, Oxygen-15, or Nitrogen-13. When a positron emitted from the radioactive substance collides with an electron in the tissue, gamma rays are given off at the site, which are detected by a gamma detector. FDG-PET/CT fusion scans of the head and neck are not primarily for infection identification but for categorizing a clinically questionable lesion as malignant or not.

CT scans detect changes in body structure and only confirms the presence of a mass. PET scan is different from CT in that it can reveal the presence of disease earlier allowing for quicker diagnosis, can detect the extent of disease and whether a detected mass is benign or malignant, helps monitoring treatment and its effectiveness, and can detect abnormalities even before there is any anatomical change. This is based on the fact that glucose consumption by malignant

cells and hence tissue is far higher than that of normal tissue.

The scan involves intravenous injection of a radiolabeled compound like 2-deoxy-2-(18F) fluoro-D-glucose (FDG). After uptake of the compound, it undergoes further breakdown in the cells. Since tumor cells have a high metabolic rate, it is also metabolized by the tumor cells. FDG is metabolized to FDG-6-phosphate, but the tumor cells are incapable of metabolizing it further and in consequence the FDG-6-phosphate accumulates and concentrates within the tumor cells. It is this accumulation that is detected and quantified. As compared to normal tissue, the uptake of FDG by malignant tissue is very high, making it a sensitive method to pick up early malignant tissue [6].

8.8 Radiation: Hazard Awareness and Principles of Protection

Hazardous Nature of X-Rays

When an X-ray photon is incident on tissue, it results in a series of changes at the molecular and atomic level. The transformed photon energy results in the discharge of an electron and a free radical, or ionization in other words. Ionization results in the production of a new molecule due to breakage of enzyme bonds manifesting in the form of different biological effects. These effects may be repairable when there is no appreciable damage, or irreparable when there is definite occurrence of damage, the adverse effect being cumulative in nature.

Myths and Facts about radiation in the field of Diagnosis: Many myths exist regarding radiation hazards associated with medical diagnostic imaging. Possible reasons for this are the available historical data, exaggerated social media reports, results of experimental studies and the complex nature of radiation biology making it difficult to evaluate its mechanism of action. Historical data relates to the reports of visible radiation hazards from studies on victims of the Hiroshima/Nagasaki bomb explosion in 1945 who were followed up for 15-18 years. Exaggerated reporting by social media about nuclear reactor accidents like that at Chernobyl add to the existing myths. The extremely short time for which radiation interacts with matter (10^{-5} Sec) after

absorption, makes it difficult to study the complex nature of radiation biology. The biological process of cell death can take days to months, carcinogenesis can take years to occur while generations may pass before a mutational change is seen.

In reality, the dose of received radiation from man-made X-rays that exist today is minute, in comparison with the massive radiation exposure that occurred in the aforementioned examples. It is true that in the infant stage following discovery of X-rays and its use in diagnosis, visible radiation hazards did occur, which was due to ignorance in the understanding of its potential hazards and the use of crude equipment resulting in high amounts of radiation leak. With passage of time, we have learnt to put the benefits of X-rays to full use, concurrently taking proper precautions to protect ourselves from its hazardous effects. Over the years, improvements in diagnostic equipment using ionizing radiation have led to the production of newer equipment providing the best possible image quality with minimal radiation exposure and improved devices that are protective against radiation. Yet, the fact remains that the best method to reduce the effects of radiation is using it only when it is an utmost necessity [7].

8.9 Imaging Investigations Not Involving Ionizing Radiation

8.9.1 MRI (Magnetic Energy Coupled with Radiofrequency Energy)

This imaging modality does not involve the use of ionizing radiation but makes use of magnetic and radiofrequency energy to obtain information of the internal organs. Components of an MRI unit include the magnet, the console, and the computer.

Image Procurement by MRI

Exploiting the body's magnetic property forms the basis of imaging using magnetic resonance. The human body is abundant in atoms with odd number of protons, or in other words ionized particles or charged atoms. A charged particle spinning around its own axis creates a magnetic field around

itself behaving like a tiny bar magnet. Hydrogen represents one such atom that is present in water molecules and therefore in all body tissues.

The random orientation of the hydrogen atoms cancels out their magnetic fields and so there is no net magnetization at rest. When these protons are placed in a strong magnetic field, a net magnetization is produced that aligns parallel with the main magnetic field. To influence the human body, the external magnetic strength needs to be about 6000 to 80,000 times the earth's magnetic strength. The resultant net magnetization acts as the source of the MR signal and is used to produce MR images. Application of a radiofrequency (RF) pulse results in absorption of energy from the RF pulse causing the net magnetization to rotate away from the direction of the main magnetic field, the amount of rotation or flip angle depending on the strength and duration of the RF pulse. The strength and duration of the RF pulse can be controlled such that the net magnetization can be rotated to any angle [8]. Withdrawal of the RF pulse results in the liberation of energy, with the emission of signals based on the density of protons or hydrogen atoms. These signals are captured by the external antennae, fed into the computer, and processed to produce the image.

Types of Magnets: Their Advantages and Limitations

- External magnets are of two types, the permanent magnet and the electromagnet.
- Permanent magnets are cheaper with no significant recurring cost. However, its limitations include limited strength of less than 0.5 tesla, heavy nature making transportation difficult, production of weak signals, and slower performance with limited range resolution.
- Electromagnets work by the passage of high current around ferromagnetic substances creating the required magnetic field. They are faster, have better resolution, produce better reconstructions, and are lighter than permanent magnets. The drawback is the production of large amount of heat that needs cooling using Liquid Helium. Other disadvantages include the high cost of infrastructure, high consumption of electricity, and recurring expenses.

Preparing a Patient for an MRI

- Detailed history and clinical examination are mandatory.
- Specific history relating to previous surgery with the use of aneurysmal clips or metallic prosthesis needs to be ascertained.
- Patient compatibility for the procedure needs to be evaluated in view of the requirement of lying motionless for a minimum of 30 to 40 min, e.g., Orthopedic patients, COAD patients. Anesthesia might be required for agitated patients and infants.

- A double check for any metallic objects on the patient's body using a metal detector device is necessary.
- Claustrophobic patients need to be reassured and put at ease before the examination begins.
- The procedure needs to be explained in detail prior to the patient entering the MRI magnet room.

CT & MRI are complementary to each other. As far as the MFS is concerned, thin-slice CT with reconstruction is required while evaluating bony lesions, especially in cases of trauma. MRI on the other hand is good for evaluation of soft-tissue tumors and is contraindicated in penetrating injuries of the eye (Table 8.2).

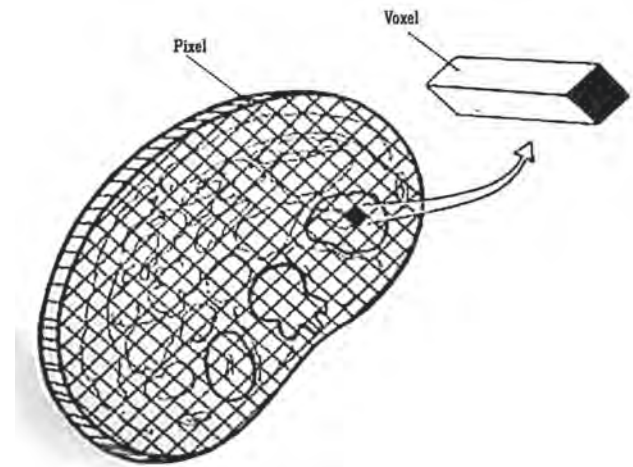
Table 8.2 CT and MRI: A comparison

	CT	MRI
Multiplanar Imaging	Only axial slices are possible. Images need to be reconstructed in multiple planes following acquisition of primary axial sections. Direct sagittal and coronal slices are possible except for TM joint.	Direct multiplanar images can be primarily acquired in any desired plane. Excellent sectional images are possible.
Soft-tissue characterization		Best with MRI than CT
Compact bone/calcified lesions	Best analyzed by CT than MRI	
Bone marrow		Assessment best with MRI than CT
Radiation	Ionizing radiation involved	No ionizing radiation involved
Motion artifacts	Relatively well managed with CT	Very sensitive to any kind of motion. May require anesthesia. Noisy breathing too may affect images
Time required	Faster, with whole body scan from vertex to toe taking 8–10 seconds	Takes longer. Minimum time required for scan of any part is 40–60 min
Contrast media	Invariably required and so contrast-related problems are unavoidable.	Contrast is less frequently used and is relatively safer.
Trauma	Best modality	
Ferromagnetic artifacts		MRI is contraindicated in patients with pacemakers or recently placed implants. MRI compatible supportive gadgets: Pulse Oxymeter, anesthesia equipment, I.V. stands, etc.

How Does CT/MRI Differ from Conventional Radiography?


CT and MRI are sectional imaging methods, in which the whole body or the region of interest is sectioned into serial slices and further into cubes (Fig. 8.3a, b). Each slice surface represents the corresponding sectional anatomy with each slice being made up of small units or cubes with each cube representing the basic nature of the tissue in the digital form (Figs. 8.17 and 8.18a, b). Different modalities produce varied imaging appearances of the same structure. For instance, if a coconut is imaged using different modalities, the fine structural details of the interior of the tender coconut, and its contents are better seen on CT and MRI (Fig. 8.19a-c). Similarly, imaging of a pineapple in axial (Fig. 8.20a-d) and coronal planes (Fig. 8.21a-c) and using the volume-rendering technique (Fig. 8.22) reveals varied appearances on CT and different MRI sequences.

To summarize, in sectional imaging, the region of interest or the whole body is divided into slices and cubes with each cube representing the basic tissue of that region with thinner slices and smaller-sized cubes offering better resolution.



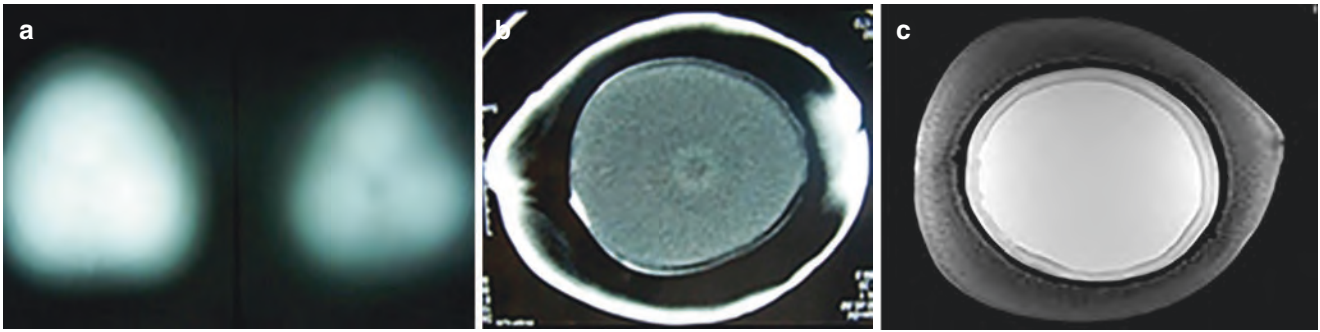
©Association of Oral and Maxillofacial Surgeons of India

Fig. 8.17 Each axial slice is divided into small cubes loaded with digitalized values representing corresponding tissue volume called voxel. Its surface represents a fraction of the grayscale image specific for that region called pixel. Thinner the slice and smaller the pixel, better is the resolution



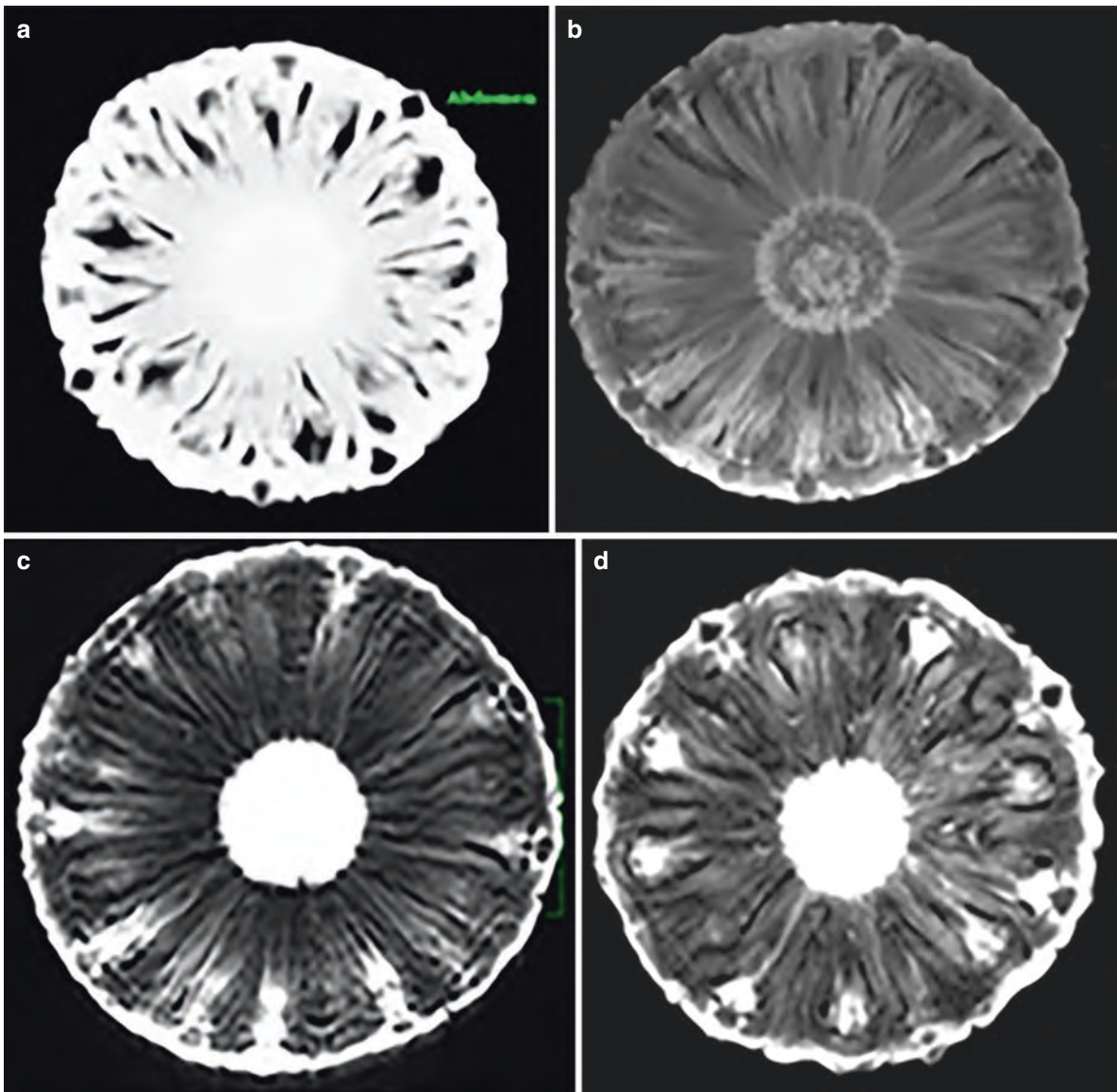
©Association of Oral and Maxillofacial Surgeons of India

Fig. 8.18 (a) and (b). Figures showing unit wise volumetric digitalized information of anatomical structures for retrieval and displayed as sectional anatomical slices



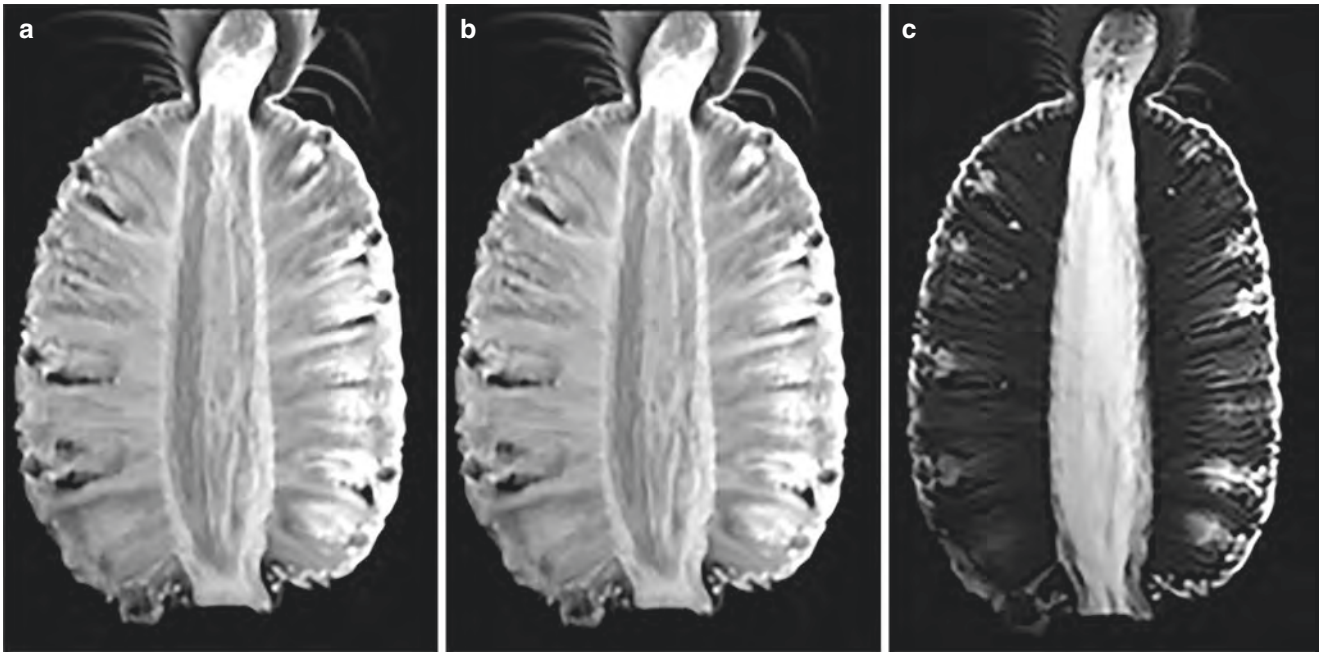
©Association of Oral and Maxillofacial Surgeons of India

Fig. 8.19 (a), (b), and (c). Imaging of tender coconut. (a) Conventional plain Radiograph. (b) CT Axial sectional imaging. (c) MRI sectional imaging. Note: added information with each of these modalities



©Association of Oral and Maxillofacial Surgeons of India

Fig. 8.20 (a), (b), (c), and (d). Axial sectional images of pineapple taken at the same level (a) CT. (b, c, d) MRI various sequences. Note: superior soft-tissue resolution in MRI, highlighting various components of soft tissue in various sequences



©Association of Oral and Maxillofacial Surgeons of India

Fig. 8.21 (a, b and c). Various sequences of MRI of a pineapple showing multiplanar capability to procure sections in any desired plane without reconstruction unlike CT



©Association of Oral and Maxillofacial Surgeons of India

Fig. 8.22 CT 3D surface rendering image of Pineapple

8.9.2 Ultrasound

It seems implausible that sound waves can produce informative images of internal organs of a human body. Yet it is true that technology has evolved so much over the years that it is now possible to obtain information of body structures using sound waves by making use of the echo and Doppler properties of sound waves.

Sound waves can be classified, based on their wavelength and frequency as audible sounds (20 to 2000 cycles/sec), infrasound (less than 20 cycles/sec), and ultrasound (>20,000 cycles/sec). Ultrasound in the range of 2 to 20 MHz is used in medical imaging [8]. The source of these ultrasound waves is piezoelectric crystals. These crystals have the special property of generating electrical pulses on being subjected to pressure. In addition, the passage of electricity through the crystals causes them to get compressed or deformed. Essentially, these crystals are unique in that they have the dual property of converting electrical energy into mechanical energy and mechanical energy into electrical energy. Intermittent passage of electrical current through the crystals makes them alternate between compression and relaxation, resulting in vibration of the crystal, in consequence producing sound energy of small wavelength in the ultrasound range.

Devices, equipped with piezoelectric crystals, having the capability to convert electrical energy to mechanical energy and finally to sound energy as well as having the reverse capabilities of converting sound energy to electrical energy, are termed as Transducers.

Sound waves are useful in imaging due to their property of echo/reflection and due to the Doppler effect. Echo property

refers to the property of sound waves to get reflected at the interface of two media, the strength of the reflected sound echo depending on the density difference of the media through which they traverse. Reflected sound energy gets converted to mechanical energy and finally to electrical energy on striking the crystal, and this electrical energy is represented on a monitor as bright dots of variable gray scales.

Varying density interfaces throughout body tissues, produces variable image brightness with gray scales ranging between extreme bright dots to black dots, representing different organ or tissue sections. The Doppler effect of sound refers to the change in the apparent frequency of a wave when the observer and the source move toward or away from each other. Motion causes a change in pitch with a higher frequency being heard when the sound source approaches the observer, and a lower frequency being heard when the sound source moves away. This Doppler property is used in evaluating the direction and velocity of flow of blood in vessels. The transducer is considered as the fixed source of sound and the blood component, mainly the RBCs act as moving reflecting bodies. At a given point in the vessel by calculating the sudden change in the frequency of reflected sound, we can calculate the velocity of blood and also the direction of blood flow. This helps in the evaluation of percentage of stenosis in a vessel.

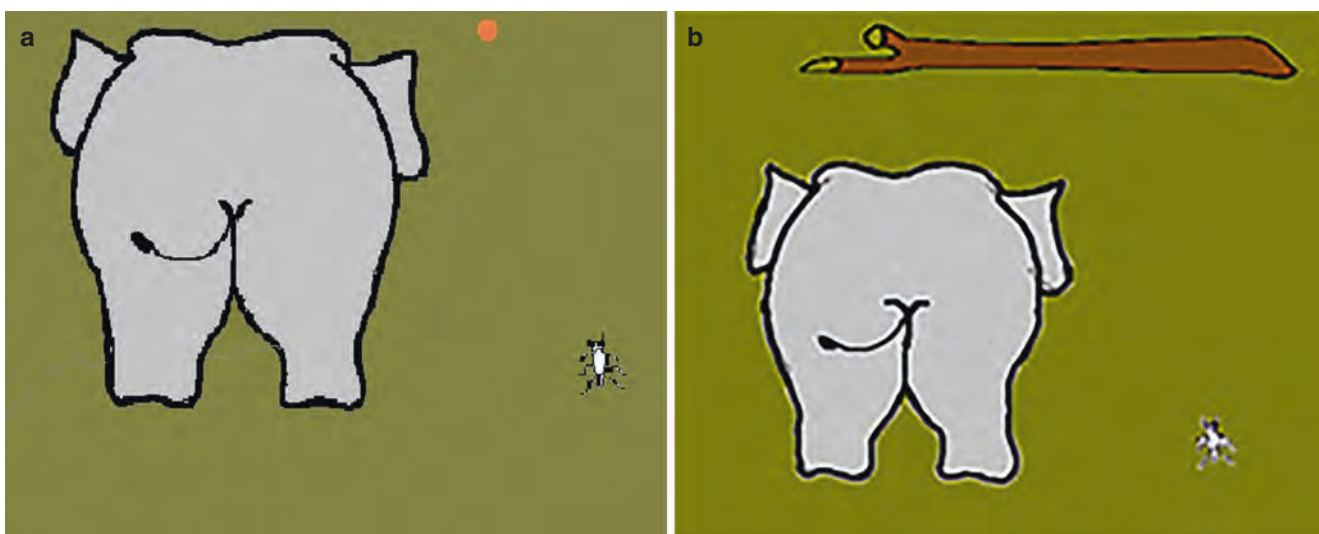
B Mode

A grayscale sectional image has specific echo texture based on tissue content with the display mode being called as the 'B' mode (Brightness mode) or grayscale mode. Higher sound frequency provides better image resolution with delineation of finer tissue components, however, at the expense of depth of penetration. Higher-frequency transducers (7 MHz

to 20 MHz) are hence used for imaging superficial structures like cheek, the maxillofacial region, neck spaces, breast, thyroid, testis, eye, musculoskeletal system and skin, regions where finer analysis of tissue structure is expected. Deeper structures are evaluated by using transducers with frequency in the range of 2 to 5 MHz.

The relation between frequency, resolution, and depth can be understood well, using the hypothetical example of two friends—an ant and an elephant (Fig. 8.23a, b). Both of them are commanded to perform the same tasks, the first being to pick up and bring back a crystal of sugar dropped at a distance of 100 cm from the start line and the second to pick up and bring back a log of wood placed 100 meters from the start line. Both of them proceed to perform the first task. The ant being small is able to easily identify the sugar crystal and get it back; however, the elephant keeps moving around unable to identify the crystal. As to the second task, the ant is able to travel only a short distance after which it dies of exhaustion, unable to reach the log of wood while the elephant travels the distance with ease and brings back the log of wood.

The ant is comparable to the high-frequency short-wavelength sound wave that is able to travel a short distance and bring back finer information about superficial tissues. If, on the other hand, it travels a long distance all its energy is absorbed by interaction with tissues. The elephant is comparable to the low-frequency sound wave with long wavelength that can travel deeper into the tissues and get information of deep structures, but limited tissue details. In a clinical setup, both the ant (high-frequency sound) and the elephant (low-frequency sound) are essential for evaluation, depending on the clinical situation and region of interest.



©Association of Oral and Maxillofacial Surgeons of India

Fig. 8.23 (a) and (b). Example of an elephant and an ant demonstrating their varying capability in picking up large and small objects from varying distances—a pictorial representation for understanding the dif-

ference in the penetration capacity of high- and low-frequency sound waves. (Explained in the text)

Color Doppler

The display of flow of blood in a vessel is color coded. The flow toward the probe is depicted as red and flow away from the probe is blue. Arterial and venous flow, in a given anatomical region, is in opposite directions. Red generally represents flow in arteries, while blue represents venous flow. Turbulent flow is depicted using a mixture of colors.

Power Doppler

This display mode of Doppler conveys information about the overall flow in a given tissue, for instance, assessment of blood flow in a tumor. It helps to determine whether the tumor is hyper- or hypovascular.

Strengths of Ultrasound

- Ultrasound imaging is inexpensive and is free from the risk of radiation.
- Excellent soft-tissue resolution is possible and dynamic studies too can be performed under ultrasound guidance.
- It is the first line of investigation for hepatic, biliary, and renal disease and is an excellent modality for cyst imaging,
- Gynecological and prostate disorders are imaged using endocavitary ultrasound, Doppler studies allow assessment of blood flow, and real-time ultrasound imaging helps in guiding interventional biopsies and drainages.

Weaknesses of Ultrasound

- A long learning curve exists for some areas of expertise and image resolution is dependent on the machine that is available. Ultrasound does not give information of structure behind a bone and also gas filled structures.

Specific Role of High-Resolution Ultrasonography (HRUSG) in the Maxillofacial Region

HRUSG is a grossly underutilized modality in evaluating lesions of the maxillofacial region. This is due to the lack of awareness of its application. The tissues in the maxillofacial region are ideal for sonographic evaluation and hence is widely applied to help diagnose a number of clinical conditions. It can serve as the best possible initial parallel imaging investigation for all the superficial soft-tissue structures of head and neck region.

It is noninvasive and does not involve use of radiation. There are no contraindications to the use of ultrasound, and it can even be performed as a bed side examination. No prior specific preparation is required except for shaving of the beard, which might hamper the study. The study results are immediately available, and it is an excellent modality for evaluating various soft-tissue planes of the cheek. Evaluation of various anatomical spaces such as superficial masticator space, parotid space, carotid space, superficial neck spaces, visceral space, floor of the mouth, and all the infrahyoid neck spaces like the

submandibular and sublingual spaces are possible using HRUSG, as are also pathologies like pre- and paravertebral abscesses, cellulitis, Ludwig's angina, and ranula [9].

High-resolution ultrasound is also capable of evaluating the nature of lymph nodes, assessing fluid and solid components and also assessing tissue vitality. Procedures like drainage of abscesses and biopsies can be conveniently performed under ultrasound guidance. Being a highly economical imaging modality, it is excellent for follow-up studies, excellent as a screening method, and at most times proves to be the conclusive examination [9].

Drawbacks of Ultrasound Examination of the Maxillofacial Region

Drawbacks include difficulty in assessing structures behind bony elements and structures containing gas. In case of huge masses, only partial information may be obtained, while short-necked individuals and obese patients are difficult to evaluate. Structures at the base of the skull cannot be evaluated as are structures medial to ramus. Another limitation is that ultrasound cannot provide information about structures behind bone or any gas-filled structure. Scanning using a hockey stick probe might help overcoming this limitation. Scans need to be performed by individuals having vast experience and expertise.

There needs to be an increase in awareness regarding the developments in the application of HRUSG in the maxillofacial region and a close interaction between the surgeon and the sonologist for creating an atmosphere of better understanding among them.

8.9.3 Thermography

Medical thermography is used for early preclinical diagnosis and treatment of homeostatic imbalances. It is noninvasive and safe since it does not use any radiation. It makes use of body heat to diagnose a wide range of health conditions. By using high-speed computers and thermal imaging cameras, body heat is processed and recorded in the computer as an image map that can be analyzed. The analysis is based on determining the presence of abnormal hot and cold areas that can relate to different conditions.

Applications in the Maxillofacial Region

A variety of conditions related to blood flow in the head and neck vessels can be assessed by thermal imaging. Easy visualization of facial blood vessels by thermography is possible because of its superficial location. Common venues of thermographic use in the head and neck region include evaluation of pain related to differentiation of different types of headache, facial nerve injury following a blow to the face or an accident, and visualization of disorders of the temporomandibular joint.

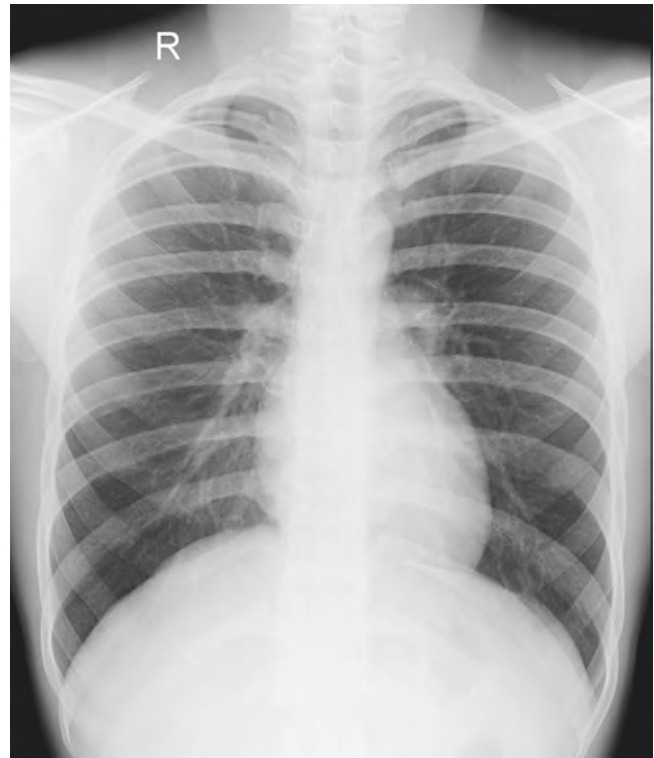8.10 Role of Chest Radiograph in the Practice of Maxillo Facial Surgery

One of the most frequently requested investigations by an MFS is the Chest radiograph. Hence, interpretation of chest radiographic findings is of prime importance in determining the patient's clinical status.

8.10.1 Chest Radiographic Evaluation for Optimum Diagnostic Quality

An ideal chest radiograph, in terms of quality, is one that fulfills the following criteria (Fig. 8.24)

- (a) Well-positioned patient without rotation.
 - *Purpose*—Avoiding problems related to improper positioning that can obscure certain lung regions like the hila and mediastinal lines, can prevent clarity of borders, or can result in distorted position of structures like the trachea, which can be misinterpreted as a paratracheal mass.
 - *Ideal radiograph*—The vertebral spinous processes are equidistant from the medial ends of the clavicle
- (b) Proper lateral location of both scapulae on the radiograph.
 - *Purpose*—avoids superimposition of scapulae over the lung fields
 - *Ideal radiograph*—Medial border of the scapulae should be out of the lung field
- (c) Inclusion of anatomical structures.
 - *Purpose*—inclusion of entire lung fields from apex to diaphragmatic domes
 - *Ideal radiograph*—must include the lower neck, both shoulders, lateral chest walls, and both diaphragms, including upper abdomen
- (d) Proper identification references
 - *Purpose*—Proper patient and radiographic verification.
 - *Ideal radiograph*—must include the patient name, medical record number, date of acquisition, and the side marker (the most important of all)
- (e) Optimum technical factors.
 - *Purpose*—Clear visualization of the normal anatomy or presence of any pathology
 - *Ideal radiograph*—
 - Posterior third of ribs faintly visible through heart shadow
 - Intervertebral spaces faintly visible through the heart shadow
 - Obtained in deep inspiratory effort as revealed by position of diaphragms



©Association of Oral and Maxillofacial Surgeons of India

Fig. 8.24 A Normal Chest Radiograph

8.10.2 Reading a Chest Radiograph: Interpretation Basics

The aim of reading a chest radiograph is to scan the whole image in a methodical way such that no anatomical part included in the radiograph is missed. While interpreting the radiograph, it is necessary for the interpreter to actually feel the structural component of the anatomical part being evaluated.

If, for example, a rib is being evaluated it needs to be traced, consciously keeping in mind, its component parts, the two cortical margins seen as white lines representing compact bone and the less dense central component representing marrow with fine normal trabeculae. This is in addition to evaluation of its number and shape. This meticulous evaluation will prevent missing of rib lesions and interpretation of the lesion is easier with prior knowledge of possible pathologies that affect ribs.

Many ways of methodical scanning have been documented in literature. The WHO-recommended method involves chest radiographic evaluation by beginning at one corner of the film, continuing to horizontally scan till the other corner, followed by sliding down and again continuing to scan toward the other edge, continuing till the whole of the radiograph has been scanned. As part of the examination, both sides of the chest must be compared.

It can be likened to the painting of a wall by a professional painter with a perfect finishing touch. Once the initial pri-

mary scan is complete, specific areas called the lawyer's zone or hidden areas of the lung need to be looked over a second time. These areas include both the hilar regions, both cardiophrenic regions, both apical and clavicular regions, and finally also through the heart and diaphragms.

8.10.3 Requesting a Chest Radiograph: Clinical indications

8.10.3.1 Preoperative evaluation

- i. Cleft lip and palate/any other congenital maxillofacial anomaly
- ii. Infections of the maxillofacial region
- iii. Known malignancy in maxillofacial region
- iv. Trauma.

8.10.3.2 Intra- / Postoperative recovery room

- i. Sudden choking and breathlessness
- ii. Sudden cyanosis
- iii. Sudden cough
- iv. Chest pain.
- v. Fever
- vi. Evaluation of chest tubes and catheters (suggested reference for further reading).

8.10.4 "The Chest Radiograph. A Mysterious Treasure"...the More you Search, the More you Find!!

8.10.4.1 Consolidation

It is one of the most common terminologies used in Radiology. Clinicians and pathology textbooks, however, commonly use the term pneumonia. Any infection of the lung parenchyma is broadly referred to as pneumonia.

Involvement of the alveolar components of the lung parenchyma by the infection is called parenchymal consolidation [10]. It is a disease process in which the air normally present within the small lung air sacs (alveoli) is replaced by liquids like pus, blood, or other fluids, or solids like tumor cells.

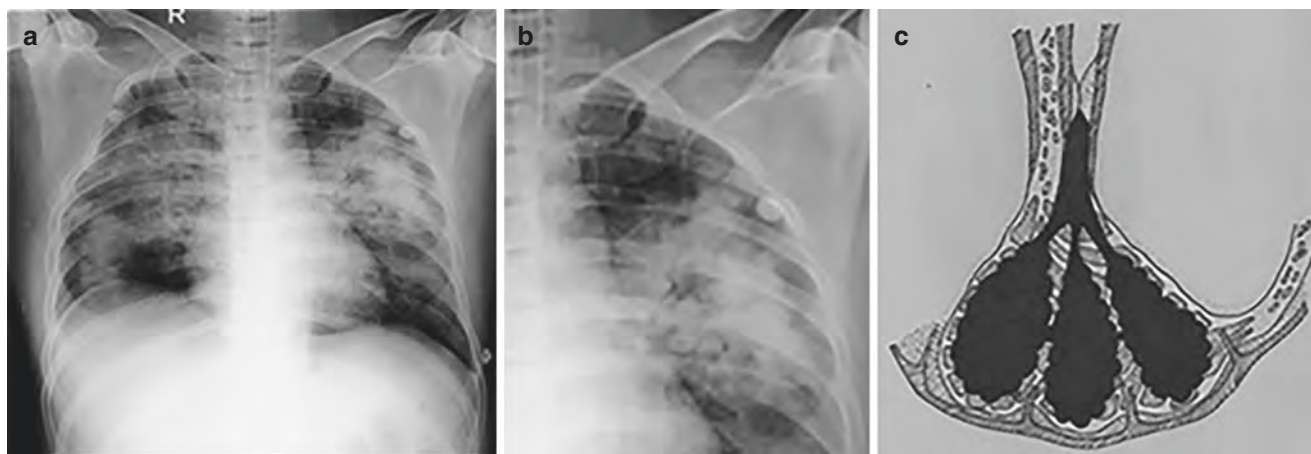
Radiologically, consolidation appears opaque [11]. Normally, the alveoli are filled with air and so the normal opaque pulmonary vasculature can be visualized against the dark background of air. However, as discussed earlier, the replacement of the air spaces by any form of fluid or solid material makes the normally visualized pulmonary vessels inapparent with the air containing bronchi being visualized against the opaque background, which is called the air bronchogram (Fig. 8.25a-c).

The consolidation process involving a single lobe and limited by a fissure is called as lobar pneumonia, while the involvement of the entire lung is known as whole-lung consolidation. At times, the process is not as uniform and is distributed in the form of patchy opacities with intervening nonopacified alveoli, an appearance referred to as the air alveologram, which is seen in Bronchopneumonia.

Pulmonary Edema

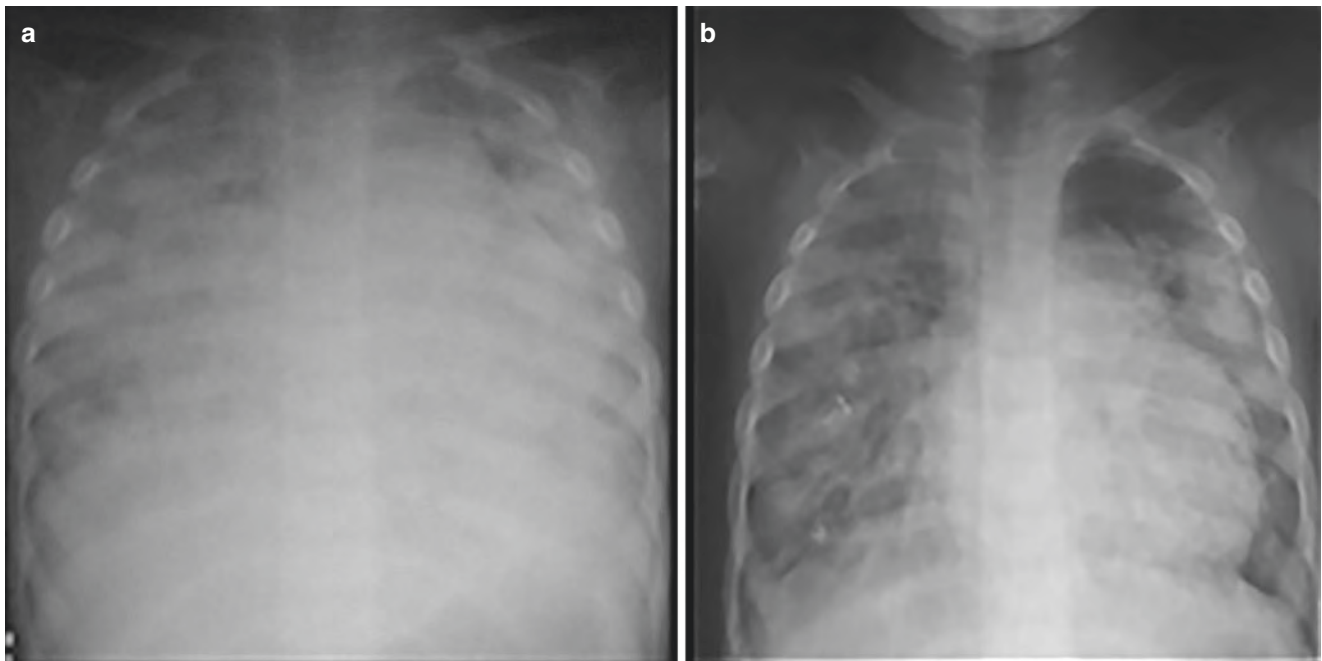
Maxillofacial surgeons are often faced with the problem of patients going into a state of sudden breathlessness in the postoperative recovery room for which the MFS asks for a portable chest radiograph. One of the most common causes of sudden breathlessness in the postoperative recovery room is pulmonary edema. The common confusion for which MFS postgraduates seek the radiologist's opinion is whether the cause of breathlessness is bronchopneumonia or aspiration bronchopneumonia.

In case of acute cardiogenic pulmonary edema caused either due to left ventricular failure or fluid overload, the characteristic radiographic abnormality would reveal bilateral symmetrical areas of consolidation predominantly in the



©Association of Oral and Maxillofacial Surgeons of India

Fig. 8.25 (a) and (b) Consolidation: Homogeneous opacities with "Air-bronchogram" sign. (c) Schematic diagram showing group of alveoli filled with fluid replacing normal air



©Association of Oral and Maxillofacial Surgeons of India

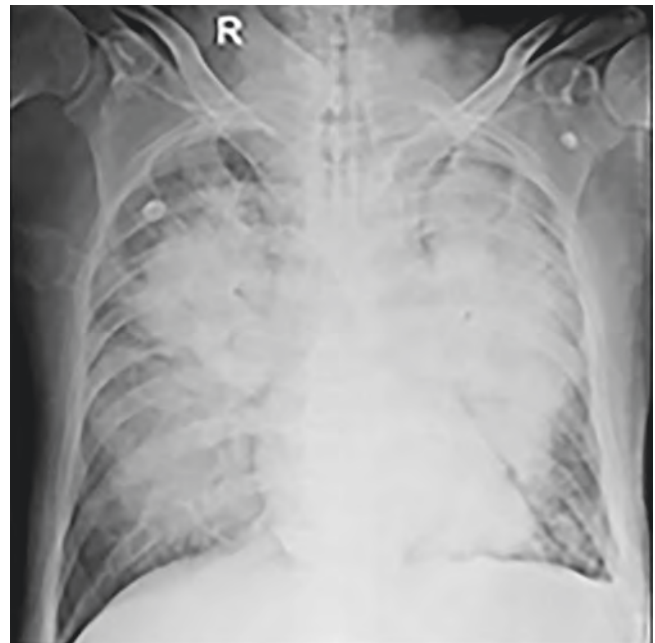Fig. 8.26 (a) Congestive cardiac failure with cardiomegaly and pulmonary edema. (b) Resolution of pulmonary edema after treatment

perihilar and lower lung zones [10] (Fig. 8.26a, b). Noncardiogenic pulmonary edema caused by different pathologies, including fluid overload, acute glomerulonephritis and adult respiratory distress syndrome among others, affects the permeability of the pulmonary capillary membrane (Fig. 8.27). The distribution can vary depending on the position of the patient. The opacities seen on the portable radiograph should not be confused with the appearance of pneumonia (Fig. 8.28).

Rare causes of unilateral pulmonary edema, including raised intracranial pressure and the administration of fluid through the central venous catheter inadvertently placed in the pulmonary artery, need to be kept in mind as well.

Atelectasis

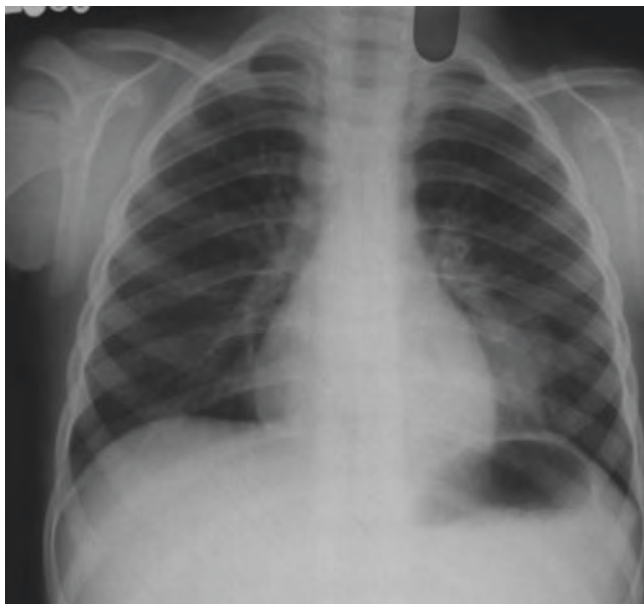
Diminished air within the lung associated with reduced lung volume is termed atelectasis manifesting radiologically as pulmonary opacity accompanied by volume loss. The causes are varied, including resorption, relaxation, adhesive and cicatrization atelectasis. Of these, the form of atelectasis a maxillofacial surgeon commonly deals with is resorption atelectasis, where there is an obstruction in the communication between the alveoli and trachea. The obstruction may be at any level from the common air way to the segmental bronchus; however, common air way obstruction resulting in bilateral atelectasis is a rare occurrence [11]. Radiologically, the appearance is that of a homogeneous opacity without an air bronchogram sign, with loss of lung volume and displacement of structures toward the opacity.



©Association of Oral and Maxillofacial Surgeons of India

Fig. 8.27 Noncardiac pulmonary edema in a patient with renal failure

The maxillofacial surgeon commonly comes across similar radiographs in the postoperative recovery room. The commonest cause of this is the inadvertent placement of the endotracheal tube into one bronchus, causing occlusion of the other bronchus, and resulting in atelectasis as a



©Association of Oral and Maxillofacial Surgeons of India

Fig. 8.28 Aspiration Bronchopneumonia

consequence. Early detection and diagnosis with readjustment of the endotracheal tube is bound to be life saving, helping prevent long-term complications (Fig. 8.29a–c). Thick mucus plugs are other common occluding elements, seen in postoperative recovery rooms resulting in lobar or segmental opacities with loss of volume. Again, early detection and good respiratory physiotherapy are keys to improved lung compliance with a radiograph taken at a later date as follow-up.

Relaxation Atelectasis

Normally negative intrapleural pressure is caused by competing thoracic pressures. Lung elasticity and surface tension of the alveolar fluid create an inward tension, pulling the lung inward, which is countered by opposing forces from the pleural fluid and thoracic wall, the pleural cavity surface tension, and the parietal pleural attachment to the thoracic wall causing outward pull of the lungs. The outward pull is slightly higher than the inward pull with a negative intrapleural pressure of about -4 mm of Hg. When this intrapleural negative pressure is lost as occurs commonly in cases of pneumothorax or pleural effusion, the lung has a natural tendency to recoil, with the loss of lung volume being proportional to the amount of air or fluid collected in the pleural space [11].

Pneumothorax

The presence of air in the pleural space is called pneumothorax, the most common cause of which is trauma either accidental or iatrogenic. In the absence of such causes, it is called

spontaneous pneumothorax. Radiological findings of pneumothorax include increased peripheral translucency, absence of lung markings within this area of translucency, and the identifiable visceral pleural margin of the collapsed lung (Figs. 8.30 and 8.31). The detection of a pneumothorax should prompt the search for an underlying cause like a fractured rib or a ruptured bulla or iatrogenic causes like a central venous catheter procedure. Associated lesions like pneumomediastinum and surgical emphysema should also be looked for.

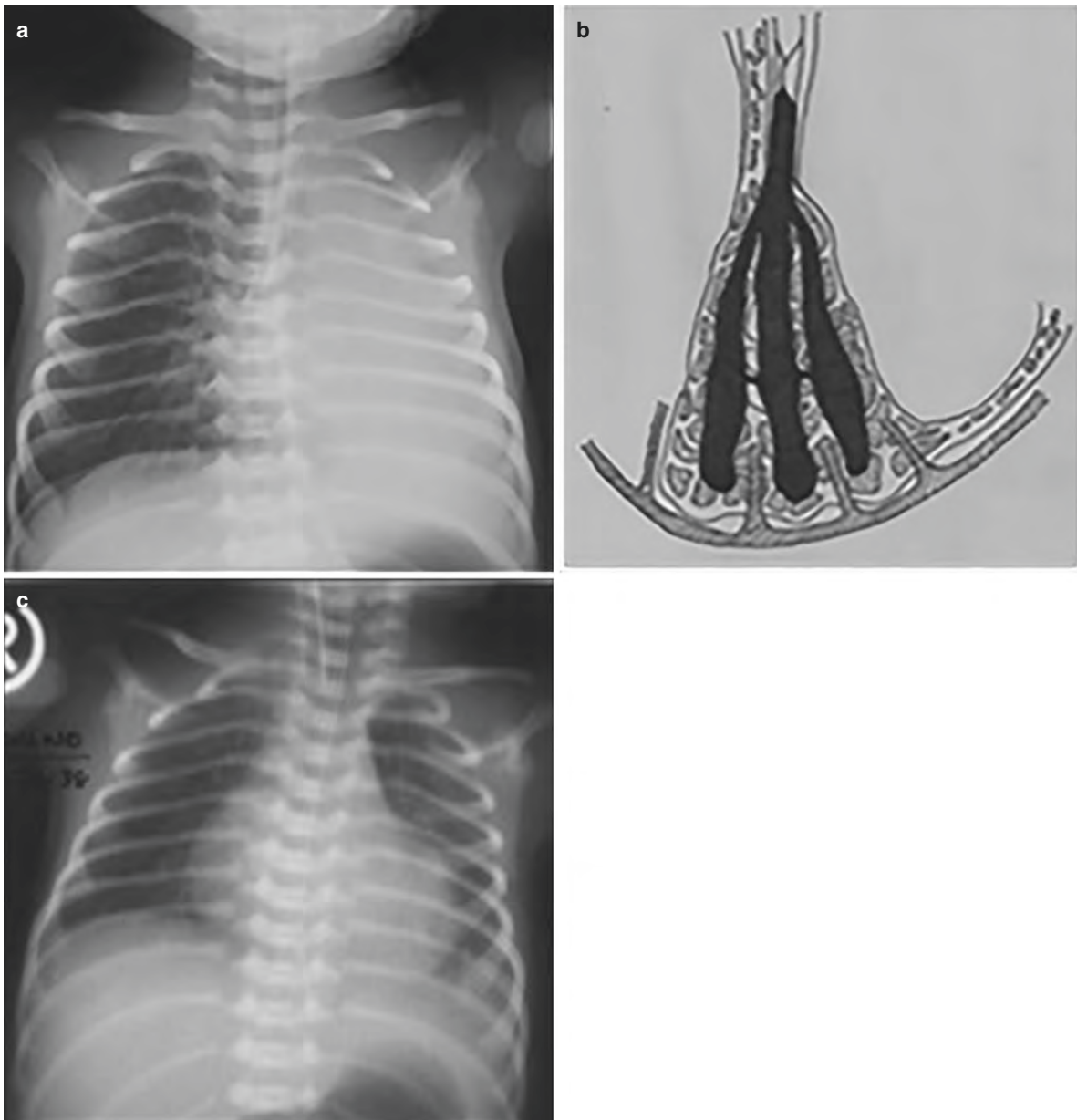
A maxillofacial surgeon might have to read supine portable radiographs of patients presenting with clinical signs suggesting respiratory distress and the presence of pneumothorax might be missed. In such a scenario, the MFS should look for radiographic evidence of pneumothorax at sites adjacent to the diaphragmatic silhouettes on either side and the cardiophrenic and costophrenic angles and he should also be able to appreciate the appearance of an exceptionally sharp cardiac border [11]. The MFS needs to be aware that air trapped within the skin folds can mimic pneumothorax (Fig. 8.32).

Identification of an air fluid level would prompt the diagnosis of a hydropneumothorax. It is difficult to characterize the nature of the fluid as being transudate, exudate, blood, or chylous. An MFS may be unable to diagnose a hydropneumothorax, on an AP supine portable radiograph as the fluid level will not be identified. Here, the collapsed lung tends to float on the fluid, which is dependent posteriorly giving a veil effect (Fig. 8.33).

Pneumomediastinum

It is the collection of air within the pleural boundaries of the mediastinum and can arise secondary to barotrauma from mechanical trauma, intrathoracic, or iatrogenic trauma and infection or can occur spontaneously. A radiographic diagnosis of pneumomediastinum requires depiction of normal anatomic structures being outlined by air as they leave the mediastinum. The mediastinal air can cause elevation of the thymus, collect anterior or posterior to the pericardium, surround the pulmonary artery or its branches, or can collect adjacent to the major aortic branches or major bronchi (Fig. 8.34).

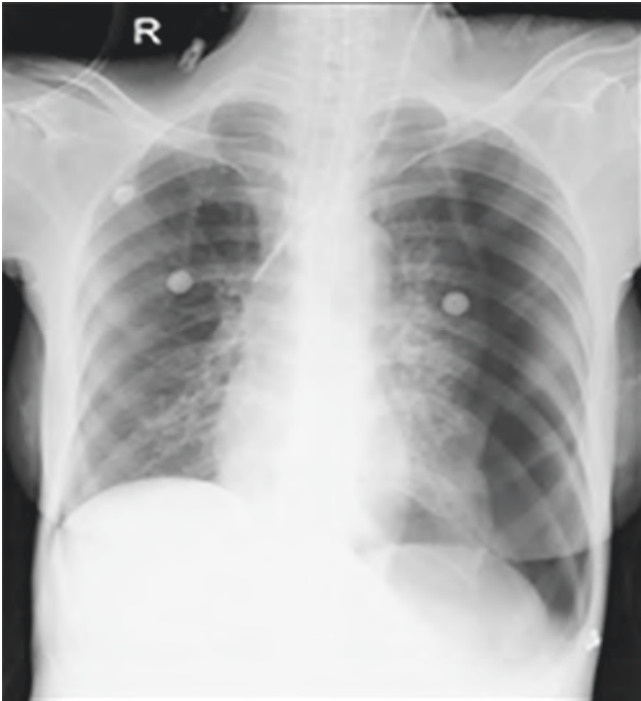Most cases of pneumomediastinum described in maxillofacial surgery literature are as a result of dissection of air down the fascial planes of the neck. Chest radiographic findings need to be carefully examined to make the diagnosis of pneumomediastinum, which is crucial to the MFS in planning appropriate treatment of affected patients. On rare occasions, a significant amount of air in the mediastinum can cause vessel or tracheal obstruction and induce symptoms and signs of tamponade and decreased venous return.



©Association of Oral and Maxillofacial Surgeons of India

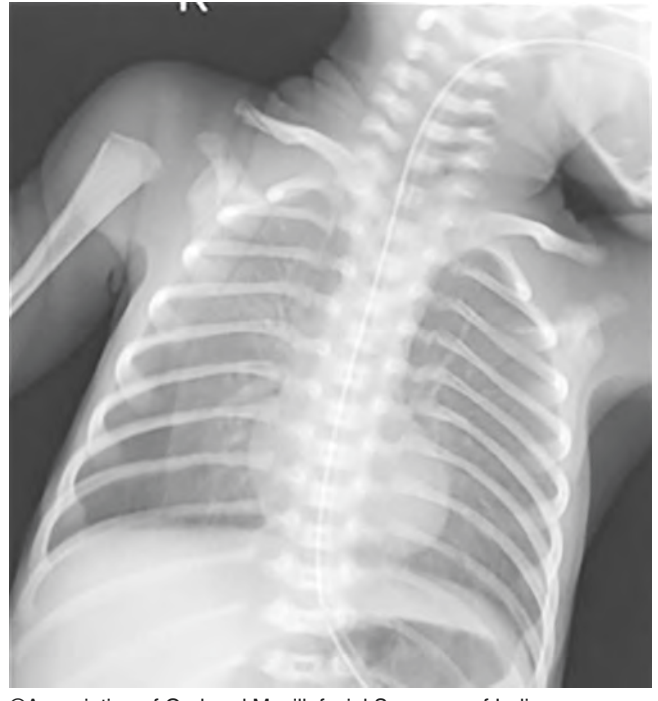Fig. 8.29 (a) Whole lung collapse: Left hemithorax is homogeneously opaque with loss of volume of left lung with displacement of mediastinum to left. Note: Abnormal placement of endotracheal tube blocking

the (Lt.) Bronchus. (b) Schematic diagram showing loss of volume of alveoli as seen in collapse with absence of air. (c) Reversion of normal left lung aeration after repositioning of endotracheal tube



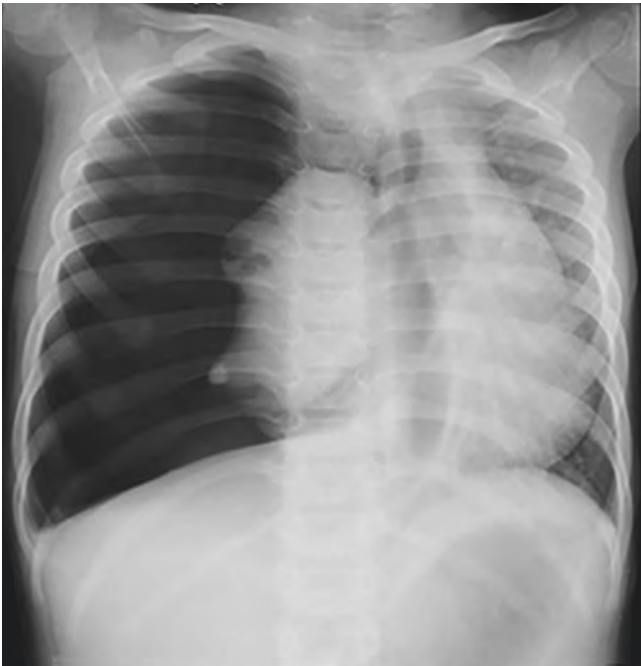©Association of Oral and Maxillofacial Surgeons of India

Fig. 8.30 Left-sided pneumothorax



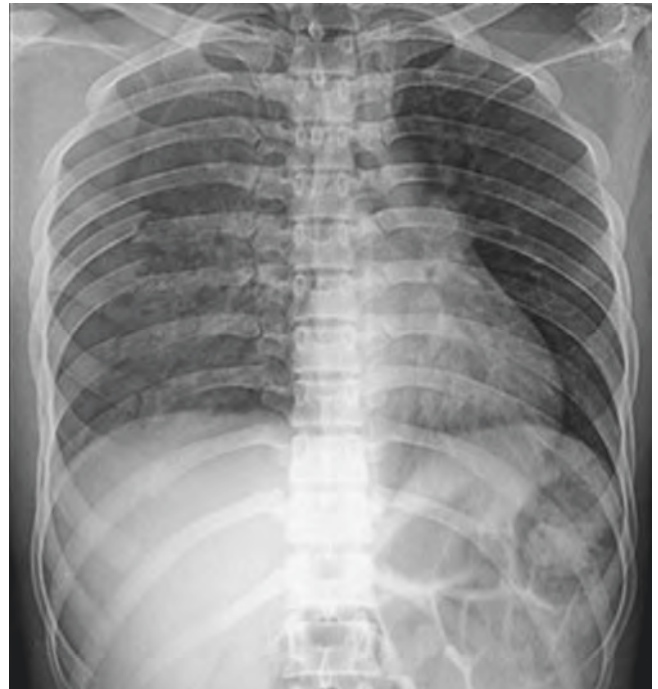
©Association of Oral and Maxillofacial Surgeons of India

Fig. 8.32 Right-sided pseudopneumothorax due to air trapped in skin fold



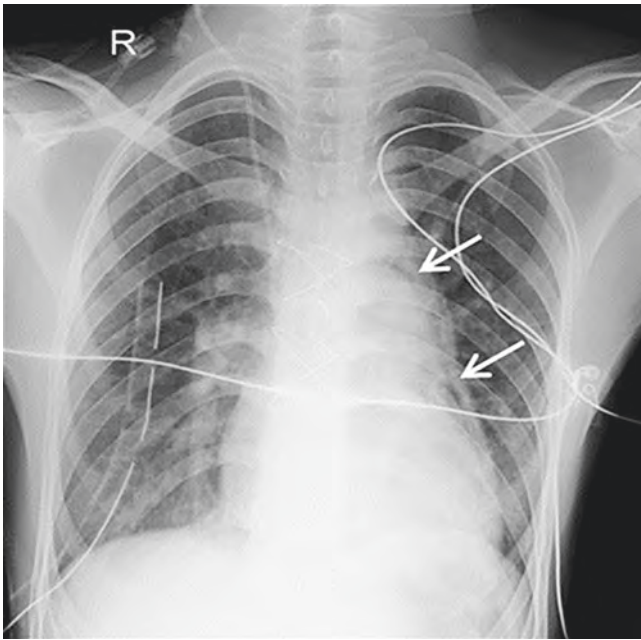
©Association of Oral and Maxillofacial Surgeons of India

Fig. 8.31 Right-sided tension pneumothorax



©Association of Oral and Maxillofacial Surgeons of India

Fig. 8.33 Right-sided hemopneumothorax with multiple rib fractures as seen in supine radiograph



©Association of Oral and Maxillofacial Surgeons of India

Fig. 8.34 Pneumomediastinum. Air around the pulmonary artery and heart.

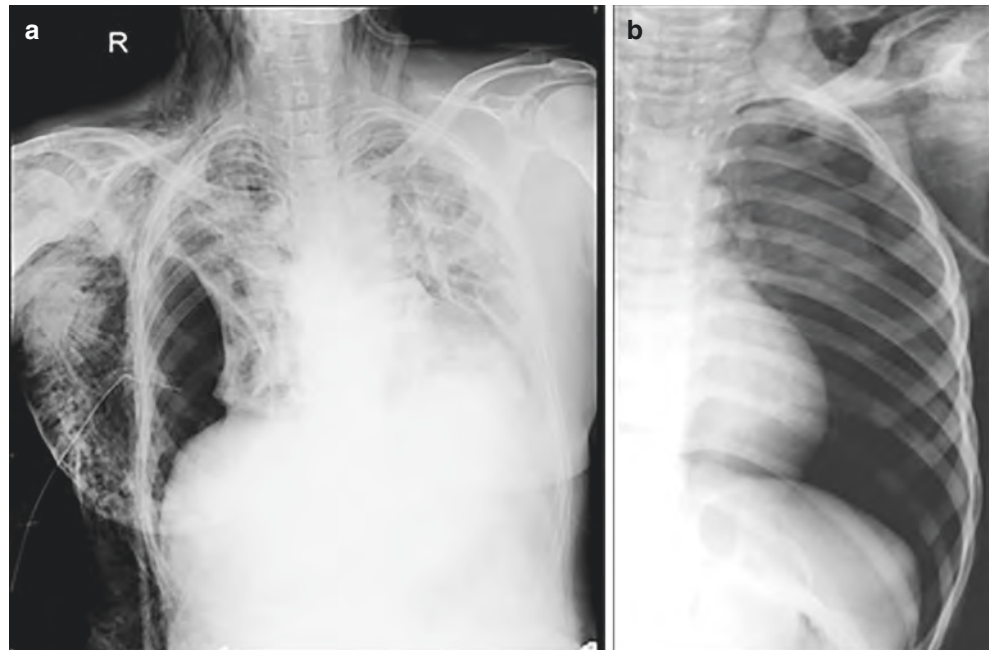
Surgical Emphysema

Though subcutaneous emphysema or surgical emphysema actually means gas in the subcutaneous tissues, it also includes soft-tissue emphysema that dissects into the deeper soft tissues and musculature along fascial planes. The translucent air spreads over the chest wall and axilla into the root of the neck. Fascial planes clearly outline the pectoralis muscle and neurovascular bundles in neck (Fig. 8.35a, b). If trauma is the cause, the gas by itself may not need treatment, but its identification is of importance as it may be the only indication of the presence of other serious injuries requiring urgent management. Surgical emphysema can uncommonly occur as a serious complication of oral and maxillofacial surgical procedures. It may also occur following teeth extraction, endodontic treatment, or procedures like restorative dentistry, periodontal and temporomandibular joint surgery, or facial fracture repair.

Pulmonary Nodules

For all intents and purposes, a nodule seen in the lung (especially in the lower zones) should be considered as metastasis unless proven otherwise, by a maxillofacial surgeon.

Fig. 8.35 (a) and (b). Surgical emphysema with pneumothorax



©Association of Oral and Maxillofacial Surgeons of India

Pulmonary nodules can be characterized, based on some signature findings. In the absence of these findings, the nodule remains nonspecific. Common causes of pulmonary nodules are granulomas, bronchogenic cysts, hydatid cysts, hamartomas, pulmonary hematoma following laceration, rheumatoid nodules, fungal granulomas, and pulmonary metastasis.

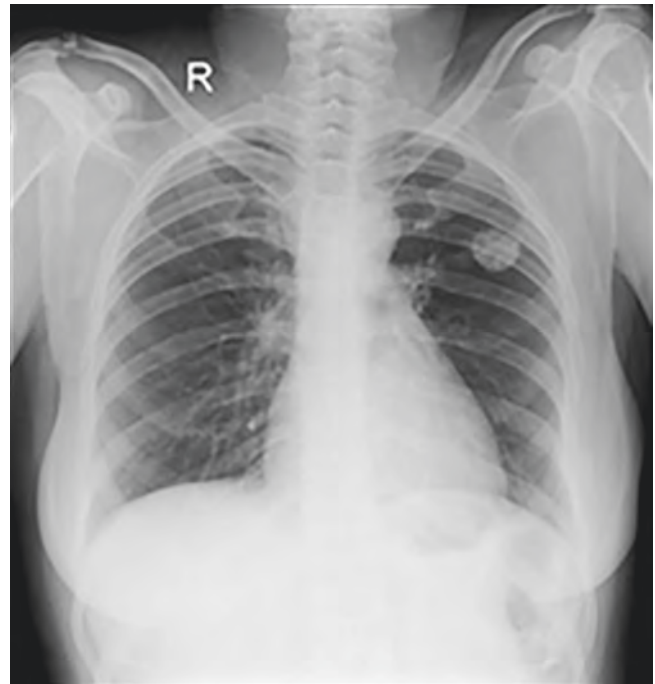
Tuberculomas usually range in size from 1 to 3 cm in diameter, have central calcific lesions, and are surrounded by satellite scarred lesions. They are commonly seen in the upper zones, but they can occur anywhere in the lung (Fig. 8.36).

Bronchogenic cysts are well-defined nodules, around 3 to 4 cm in size, usually seen in the parahilar region, and are sometimes purely in the mediastinum (Fig. 8.37a–e).

Hamartomas are nodules that can occur anywhere in the lung having well-defined margins with central popcorn-like calcification (Fig. 8.38a, b).

Hydatid cysts, too, can occur anywhere in the lung. They have a stenciled outline and vary in size from 1 to 10 cms. The radiographic air crescentic sign is pathognomonic of a hydatid cyst, appearing like the arc of the moon caused by the separation of the endocyst from the exocyst. Continued separation of the endocyst from the exocyst results in an air fluid level typically called the ‘water lily’ appearance. Pulmonary hydatid cysts do not calcify.

Presence of a solitary nodule in the lower lung without any characteristic findings makes pulmonary metastasis a strong possibility, which should be further evaluated with imaging and HPR. Multiple nodules of varying sizes in the lower zones are very much suggestive of pulmonary metastasis. (Fig. 8.39a, b).



©Association of Oral and Maxillofacial Surgeons of India

Fig. 8.36 Pulmonary Nodule—Tuberculoma

A maxillofacial surgeon should be capable of identifying all of these causes of sudden onset of breathlessness in a postoperative patient in the event of the absence of availability of expert radiological opinion and act accordingly. They also need to be aware that patients on ventilators may develop ventilator-dependent complications.

A glance into the future of imaging for Maxillofacial Surgeons

1. Magnetization Transfer Imaging

This is a modified MRI study that helps in

- Prediction of whether the primary tumor is benign or malignant (possible in 80 to 90% cases).
- Differentiation of reactive versus malignant adenopathy.

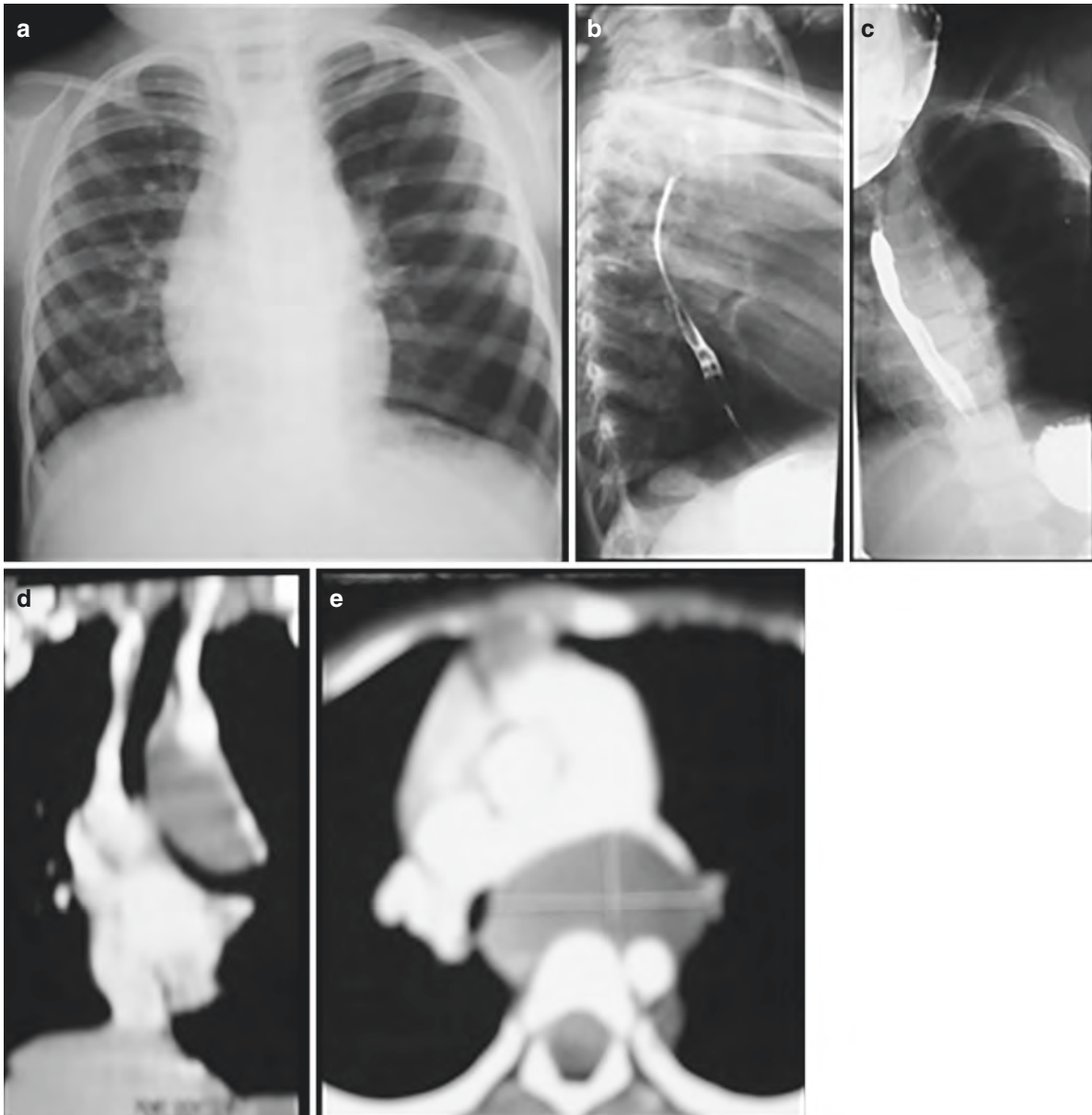
This modality is still in the preliminary stage and needs further study.

2. MRI-guided biopsy procedures need MRI compatible equipment. The procedures are feasible and are usually done in cases that are not amenable to USG guidance.

3. Functional imaging of swallowing.

Role of Chest Radiograph in Cases Developing Sudden Onset of Breathlessness in Postoperative Period

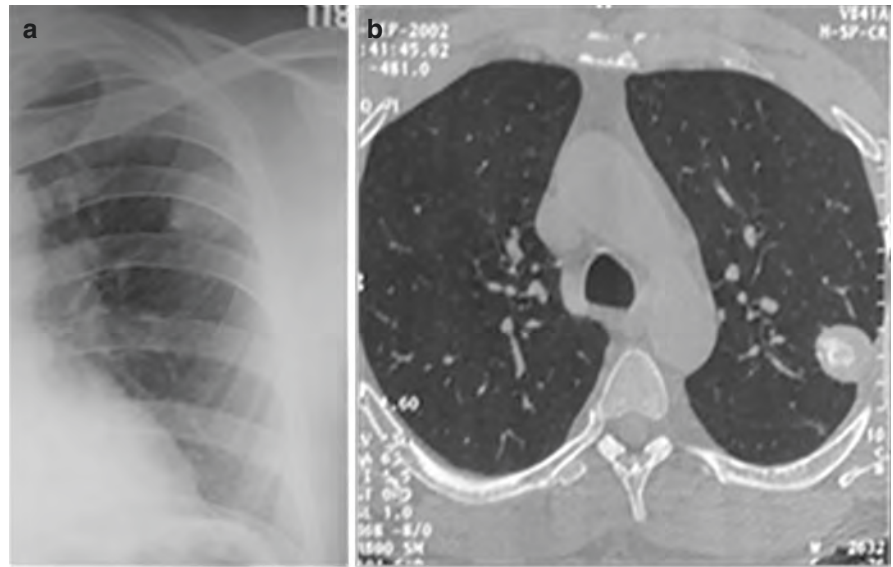
1. Aspiration Bronchopneumonia
2. Pneumothorax
3. Foreign body (Fig. 8.40a–c)
4. Abnormal placement of Endotracheal Tube (Fig. 8.41)
5. Pleural effusion
6. Pulmonary edema and pulmonary embolism



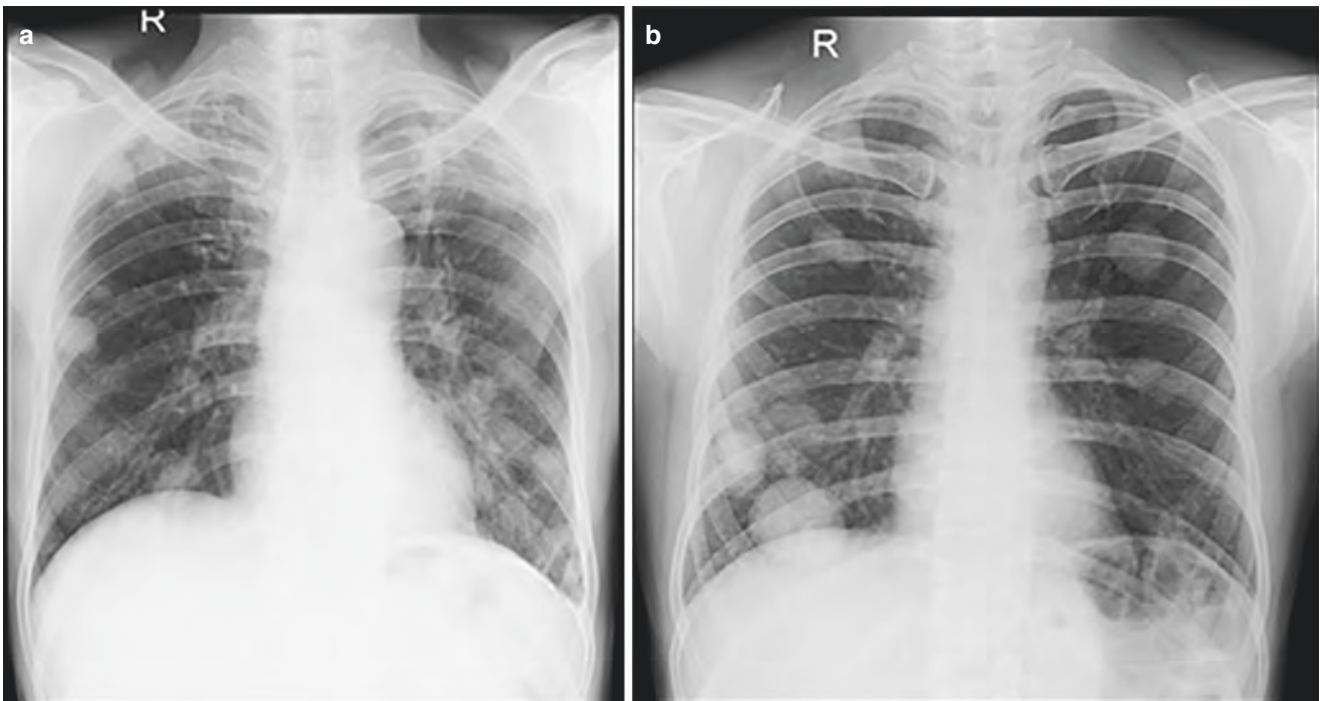
©Association of Oral and Maxillofacial Surgeons of India

Fig. 8.37 (a), (b), and (c). Preop chest radiographs of a patient with cleft lip presenting with dyspnea, more with changing position. (d) and (e) Mediastinal mass—Bronchogenic Cyst confirmed on CT

Fig. 8.38 (a) Pulmonary Nodule-Hamartoma. (b) Confirmed on CT

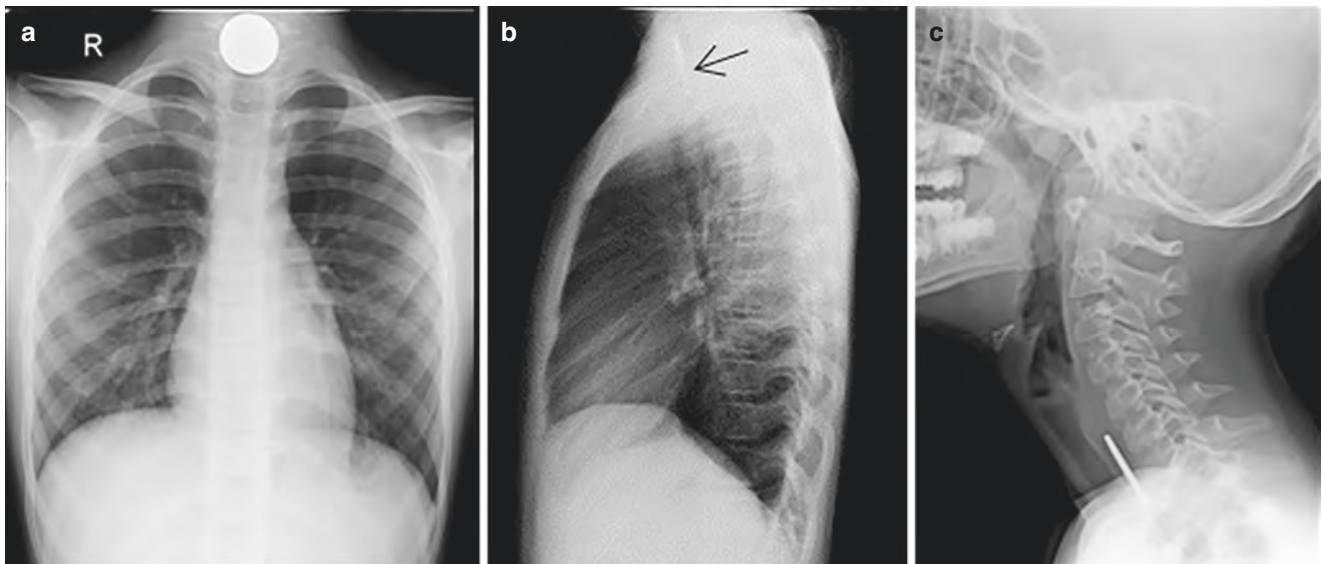


©Association of Oral and Maxillofacial Surgeons of India



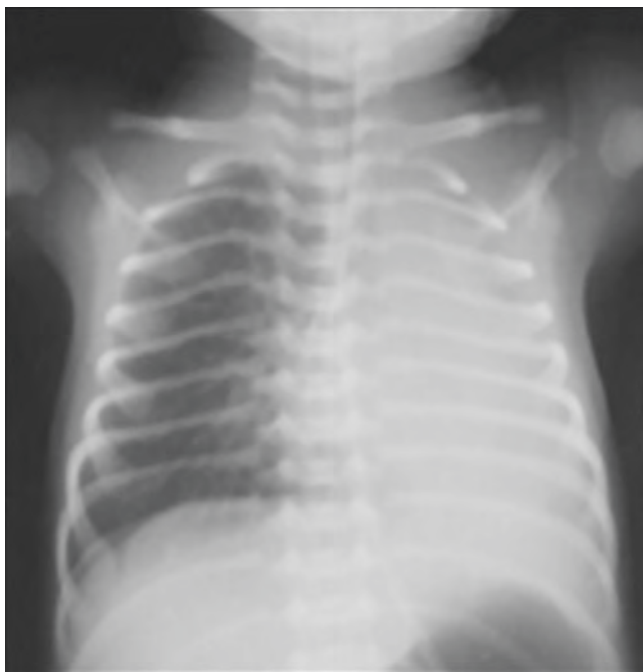©Association of Oral and Maxillofacial Surgeons of India

Fig. 8.39 (a) and (b). Pulmonary metastasis



©Association of Oral and Maxillofacial Surgeons of India

Fig. 8.40 (a), (b), and (c). Foreign body, a coin in the cervical esophagus



©Association of Oral and Maxillofacial Surgeons of India

Fig. 8.41 Abnormal placement of endotracheal tube with collapse of left lobe

8.11 Role of High Resolution Ultrasonography (HRUSG) as a Diagnostic Aid in the Practice of Maxillofacial Surgery

8.11.1 Preface

Primarily the use of HRUSG in the maxillofacial region is directed toward investigation of the cheek and the structures adjacent to it. Despite the layers of the cheek and the adjacent structures having a classical sonographic appearance, literature available on HRUSG of the cheek is limited. Having proper understanding of the relevant anatomy is critical in discerning the wide range of diseases affecting this region. Evaluation of these lesions by ultrasound is possible only once the normal ultrasound anatomy at various levels is defined and a comparison of the suspicious lesion with the normal expected appearance is made. An original attempt toward this goal was made at our institute with comparison of normal cadaveric sections at corresponding levels taken by HRUSG.

High-resolution ultrasonography has broad applications in the maxillofacial region especially in the cheek, which

include evaluations of the unilateral or bilateral swollen cheek painful or pain less, restricted mouth opening, painful chewing without obvious clinical findings, and varied causes of facial swelling. Since early detection decisively influences patient prognosis in case of malignancy, it is one of the prime concerns in a presenting patient. Further, differentiation of lesions as being of benign, malignant, infective, or inflammatory etiology is important in deciding on a treatment plan. HRUSG should however be used to complement and not replace other imaging modalities as it does have its limitations.

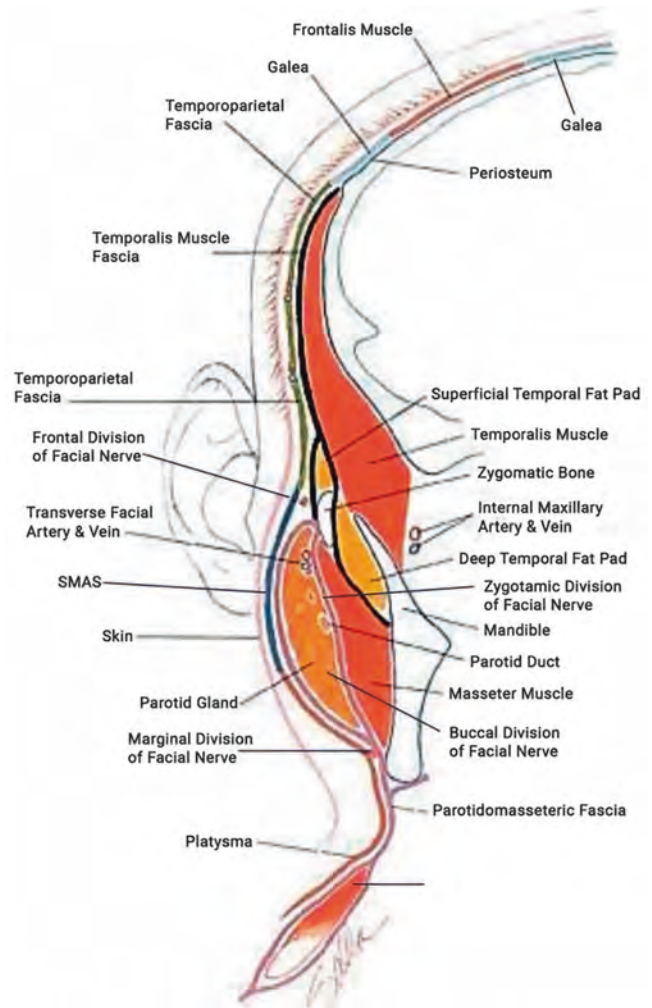
Compared to other facial components, the cheek is predominantly composed of adipose tissue and is relatively small in size. Swelling of the cheek is easily visible and palpable in most patients presenting with cheek masses. Most lesions have nonspecific characteristics on computed tomography (CT) and magnetic resonance imaging (MRI). In contrast, HRUSG is ideal for evaluation of cheek lesions, because of its capability to differentiate between tissues like skin, fat, muscle, gland, ducts, and vessels especially since bony and gaseous interfaces are absent. Further, the superficial location of the cheek makes it easily accessible to ultrasound. Vestibule can be evaluated with fruit jelly technique obliterating the void space.

This short review attempts to aid the MFS in his understanding of HRUSG of the maxillofacial region, with special reference to the cheek.

8.11.2 Gross Cheek Anatomy

In simple terms, the cheek is the fleshy portion of the face, below the eye, extending from the angle of the mouth to the ear. Anatomically, it pertains to the buccomasseteric region comprising the buccal space and its contents, masseteric and buccinator muscles, the buccal fat pad, and Stenson's duct.

The region is continuous anteriorly with the lips. Its external anterior demarcation is formed by the nasolabial fold and groove extending from the side of the nose to the angle of the mouth. The mucosa lining the inner aspect of the cheek adheres to the buccinator muscle, while the gingival mucosa covers the mandibular and maxillary alveolar processes. The gingivobuccal sulcus is the junction formed between the gingival and buccal mucosae. The vestibule is the region of the mouth between the teeth, lips, and cheek, which is bound superiorly and inferiorly by buccal mucosal reflections onto the mandible and maxilla. Posteriorly the vestibule is continuous with the oral cavity proper (Fig. 8.42) [12, 13].



©Association of Oral and Maxillofacial Surgeons of India

Fig. 8.42 Anatomical layers of the cheek

8.11.3 Floor of Mouth, Anatomy (Relevant to HRUSG)

The part of the oral cavity located underneath the tongue is called the floor of the mouth and it can be involved by a myriad of pathological processes. Superficial lesions involving the mucosal surface are easily visualized and may not need imaging. Disease involving the deeper structures of the floor needs to be evaluated by imaging, and HRUSG is many times the first line of investigation because of its superior soft-tissue differentiation capability, thus allowing for clear depiction of contents of the floor [14].

Inflammatory processes, malignancies, and vascular abnormalities can affect the floor contents, while certain conditions like ranula and obstruction of the submandibular gland are specific to this location [14].

8.11.4 Defining the HRUSG Anatomy of Maxillofacial Region (Predominantly Cheek)

Normal Ultrasound Cheek

Various cheek layers have varying sonographic echogenicity and echotexture, and hence ultrasound is an invaluable tool in the characterization and localization of cheek lesions.

Depending on tissue density, the sound wave transmission, absorption, or reflection capability of each tissue varies. Tissues, having high water content like blood, appear black and are called anechoic because they conduct sound waves well. In contrast, tissues that are poor conductors reflect most of the sound wave energy back to the transducer appearing bright and are termed hyperechoic, examples of which include bones, tendons, and fascial planes. Tissues like muscle reflect less of the sound wave energy and have a hypoechoic appearance. In the cheek, the mucosal and submucosal layers appear hyperechoic, the mucosa more so. Muscle tissue appears hypoechoic, while fatty tissue appears echogenic (Fig. 8.43).

Compared to other imaging modalities, ultrasound has proven to be superior as regards identification of small lesions, detection of lesion plane, and lesion characterization (Fig. 8.44).

The cheek layers and neighboring structures that can be identified by HRUSG are.

Cheek

- Skin
- Subcutaneous plane
- Buccal pad of fat
- Buccinator muscle
- Submucosal layer
- Mucosal layer
- Masseter muscle and its lateral relations.

- Temporalis muscle
- Temporomandibular joint (TMJ)

Neighboring Structures

- Vestibule
- Gingiva
- Buccogingival Sulcus
- Periodontal tissue, etc.
- Tongue, lips
- Floor of mouth, Sublingual space
- Submandibular space
- Parotid gland / duct
- Retromandibular space
- Interdental space
- Alveolar margin
- Mental foramina
- Infraorbital foramina
- External nose
- Various other facial planes and spaces
- Arteries

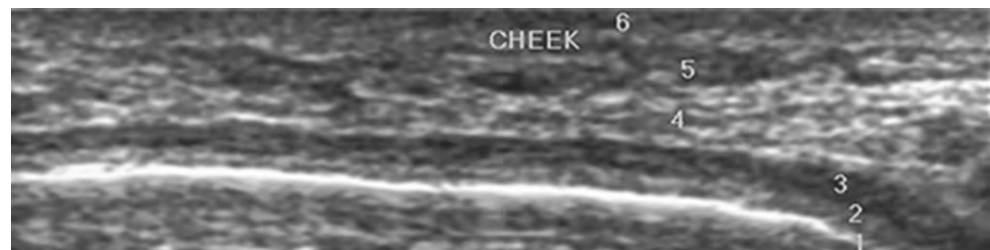
8.11.5 Techniques of HRUSG of Cheek

For ultrasound examination, the cheek is considered to be a rectangular area bordered as follows (Fig. 8.45).

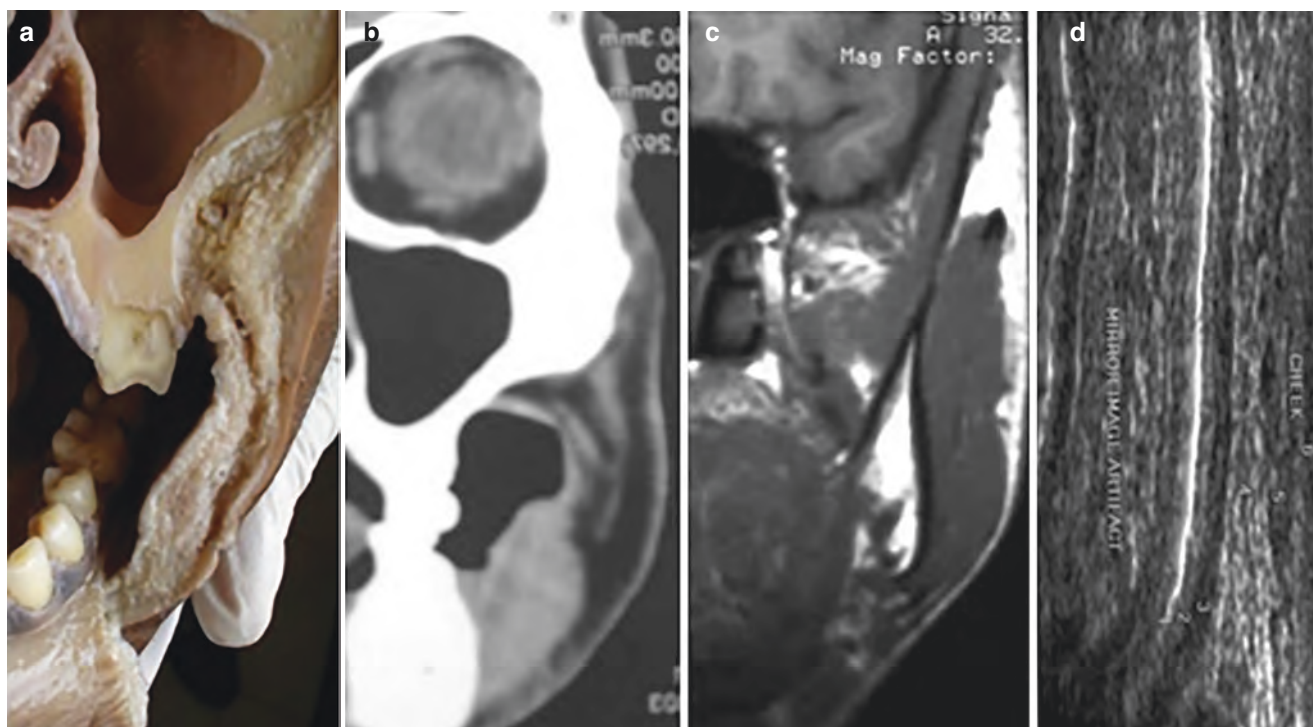
- by an imaginary line beginning at the angle of mandible and extending along its lower border to the level of angle of mouth inferiorly,
- by an imaginary line beginning at the angle of mandible and running along the posterior border of the mandibular ramus to include the temporomandibular joint posteriorly,
- by an imaginary line along the zygomatic arch superiorly and,
- by an imaginary vertical line at the level of angle of mouth that joins the superior and inferior lines anteriorly [15].

Various techniques, including the resting (neutral) and Puffed (Blow out) cheek technique, the tongue touch technique, and fruit jelly technique, were experimented with, each having their own advantages and limitations [15].

Fig. 8.43 Normal Cheek/
Buccal layers on ultrasound

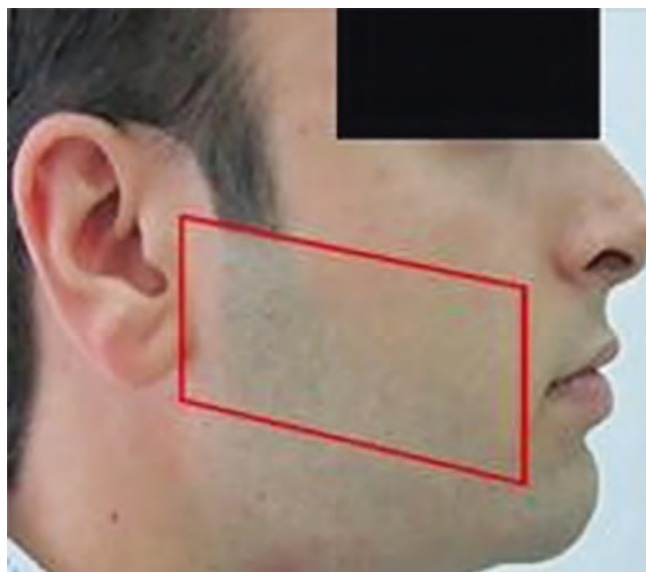

©Association of Oral and Maxillofacial Surgeons of India



©Association of Oral and Maxillofacial Surgeons of India

Fig. 8.44 (a-d) Cheek anatomy—a comparison. Comparative cheek anatomy- (a) cadaveric specimen, (b) CT, (c) MRI, and (d) Ultrasound



©Association of Oral and Maxillofacial Surgeons of India

Fig. 8.45 Area of Cheek ultrasound study

(a) *Resting (Neutral) and Puffed (Blow out) Cheek Technique* (Figs. 8.46 and 8.47).

- Patient is instructed to blow, and ultrasound is performed in puffed cheek status.
- Images obtained in axial and coronal planes.
Advantage: Improved visibility of cheek layers and accurate definition of lesion size.

Limitation: Occurrence of mirror image artifact.

Less sensitivity in evaluation of lesions of the vestibule (gingivobuccal sulcus).

(b) *Tongue Touch Technique* (Fig. 8.48a–c).

- Patient is instructed to feel the cheek lesion with the tongue.
- Lesion is brought closer to the probe creating a better acoustic window.
- Lesions of the superficial buccal mucosa and tongue lesions on its anterior half and corresponding lateral borders can be evaluated better.

Advantage: Better visualization of lesion details.

Limitation: Inaccessibility to tongue lesions along the posterior half and corresponding lateral borders.

(c) *Fruit Jelly Technique*.

(Figs. 8.49a, b, and 8.50a–d)

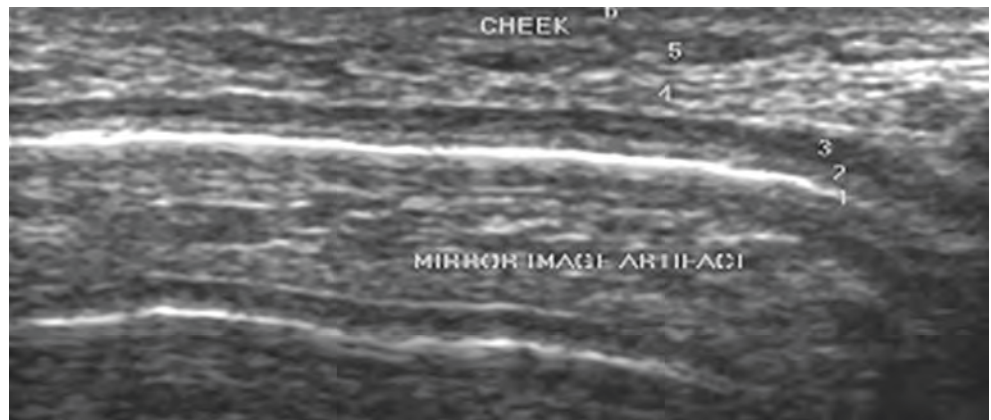
- Commercially available edible “Fruit jellies” are placed in the upper and lower gingivobuccal sulcus.
- Patients are then instructed to close their mouth and ultrasound is performed.

Advantages:

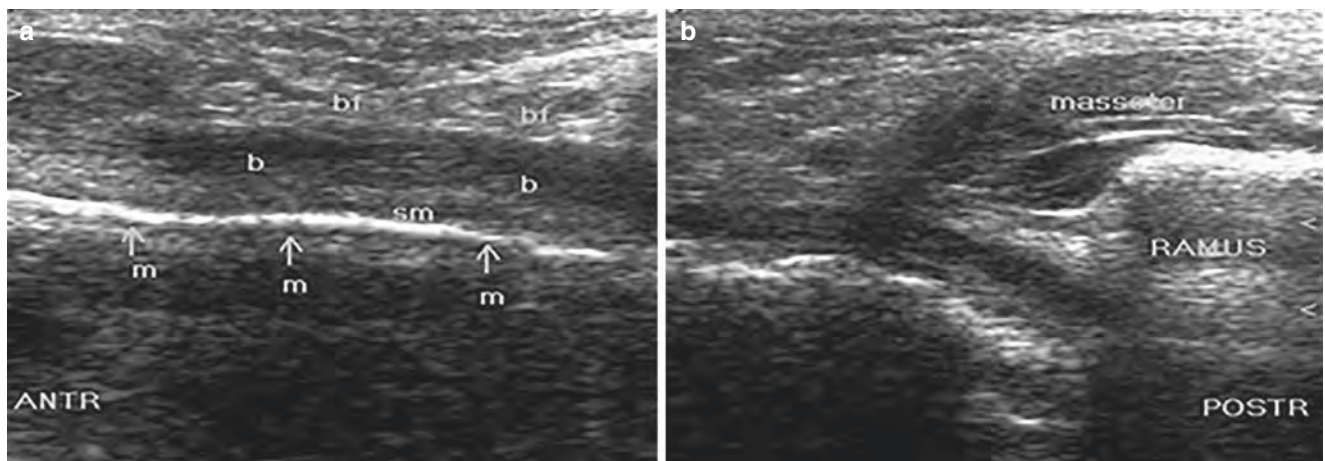
- Useful in elderly and facial nerve palsy patients having difficulty holding puffed cheek for prolonged periods.
- Absence of artifacts due to vestibular air.
- Enhanced structural delineation and better evaluation of vestibular extension of lesion.

Limitation: Inability to evaluate lesions involving far posterior aspect of Vestibule.

Fig. 8.46 Cheek layers by “Puffed Cheek” Technique. (1) Mucosa. (2) Submucosa. (3) Buccinator. (4) Buccal fat. (5) Subcutaneous tissue. (6) Skin

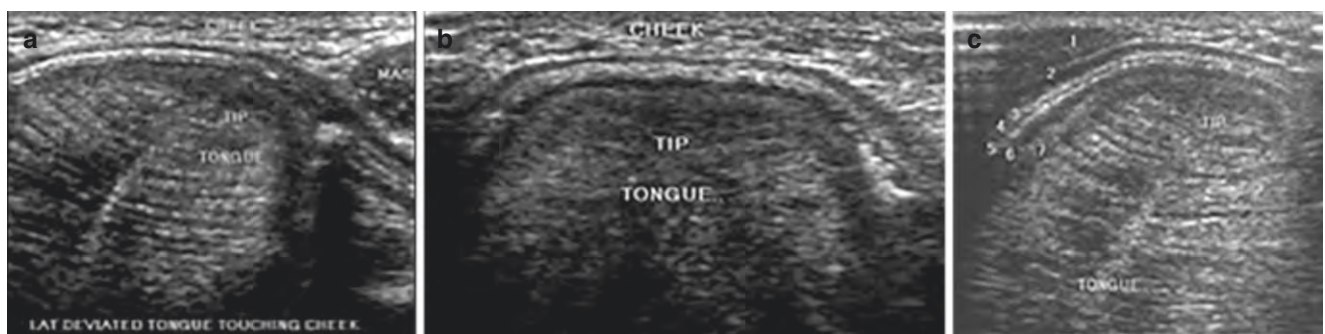

©Association of Oral and Maxillofacial Surgeons of India



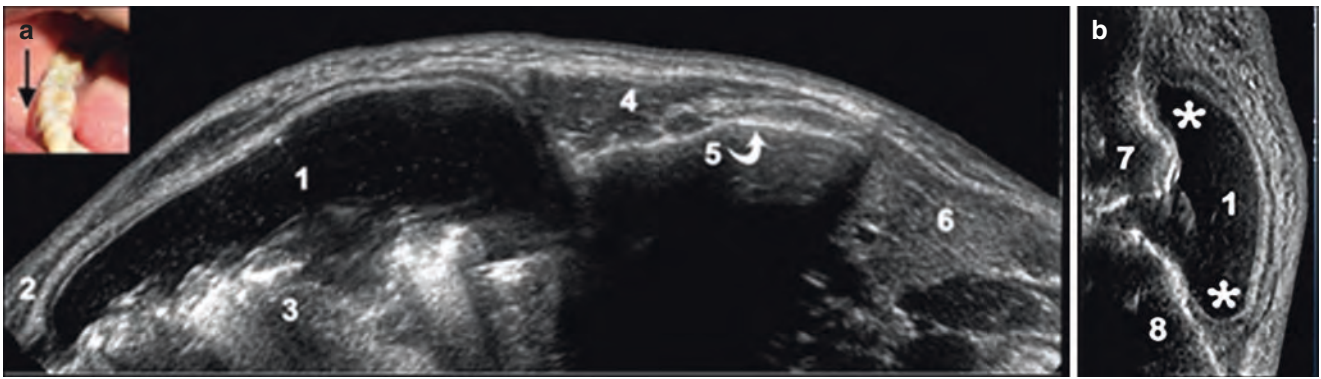©Association of Oral and Maxillofacial Surgeons of India

Fig. 8.47 (a, b) Cheek layers by “Puffed Cheek” Technique. m-mucosa, sm-submucosa, b-buccinator, bf-buccal fat



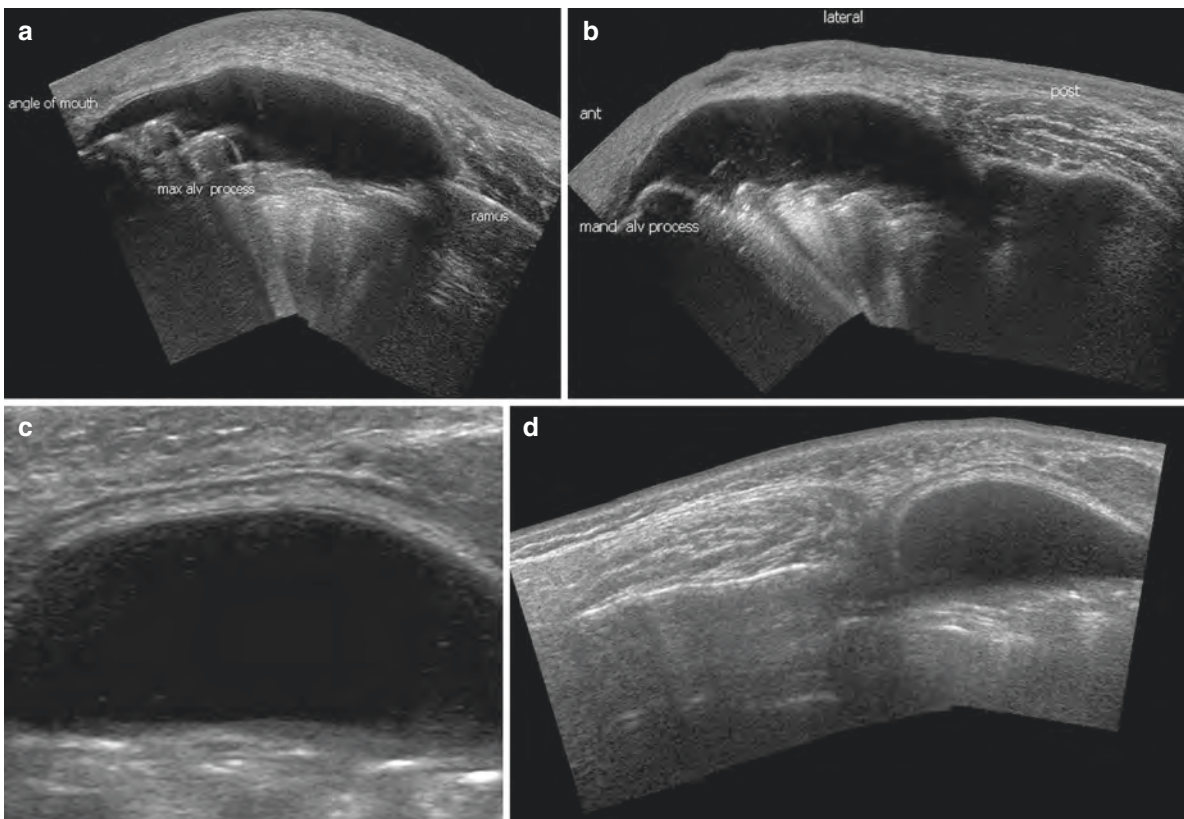
©Association of Oral and Maxillofacial Surgeons of India

Fig. 8.48 (a), (b), and (c). “Tongue Touch” Technique. Anterior tongue, its tip and lateral borders and cheek layers



©Association of Oral and Maxillofacial Surgeons of India

Fig. 8.49 (a) Axial panoramic (b) Coronal Cheek layers by “Fruit Jelly” Technique. (1) Jelly (2) Angle of mouth (3) Alveolar process (4) Masseter (5) Mandible (6) Parotid (7) Maxilla (8) Mandible (Asterisk)- Upper and lower gingivobuccal sulcus



©Association of Oral and Maxillofacial Surgeons of India

Fig. 8.50 (a, b, c, and d).Cheek layers by “Fruit jelly” Technique. Panoramic axial slices. Coronal slices showing superior and inferior vestibules along with layers of cheek/alveolar surfaces

8.11.6 Case Presentation

HRUSG Cheek: Scope of Use and Limitations

Scope of practice of HRUSG cheek includes

- Cases where limitations are posed by the clinical presentation as in case of trismus or lesions that mimic others in their clinical presentation resulting in diagnostic difficulty
- Estimation of the extent of a lesion, thus helping in tumor staging
- Cases where the use of plain radiography is limited
- Inherent drawbacks of imaging modalities like CT and MRI and their high cost

Limitations

- Structures medial to the mandibular ramus
- Difficulty in obtaining information of intact bone
- Intra-articular structures of the temporomandibular joint
- Postoperative scar tissue or a large external wound
- Very thick patients, muscles, and nerves of the face

Clinical Conditions that Can Be Evaluated

- Swollen cheek: Painful, painless, unilateral, or bilateral.
- Limited mouth opening

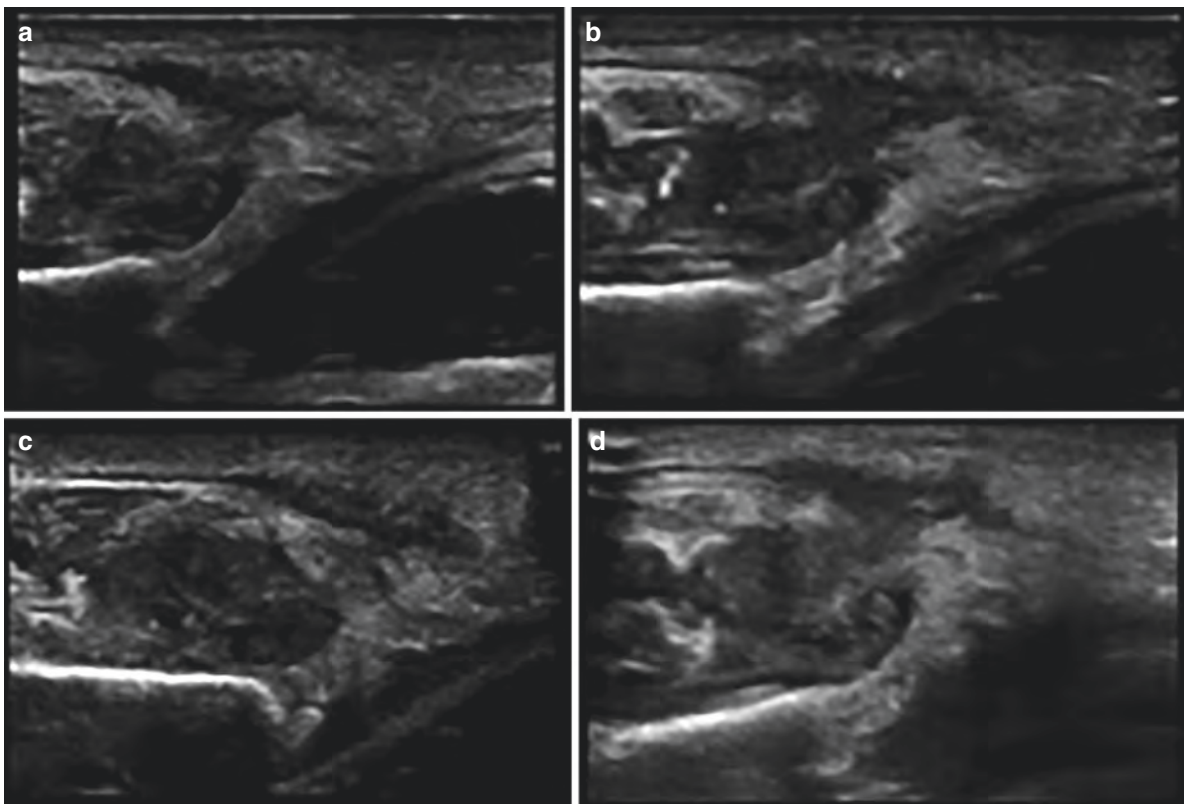
- Painful chewing
- Swelling of the face involving the midline or parasagittal plane, floor of the mouth, TM joint region, submandibular region, nose, lip, gums, etc.
- Tongue lesions (Lateral margin).

Notifiable Lesions

- Cheek—Growth, hemangioma, lymphangioma, Oral sub-mucous fibrosis, abscesses, discharging sinuses, etc.
- Masseter—evaluation of contraction, benign hypertrophy, trauma, Space infection, trauma, etc.
- Masticatory space.
- TMJ—swelling, click.
- Lytic lesions of jaws.
- Gum—evaluation. Lip lesions.
- Midline swellings.
- Tumor staging.
- Salivary gland.
- Space infections.
- Tongue.
- Lymph node evaluation.

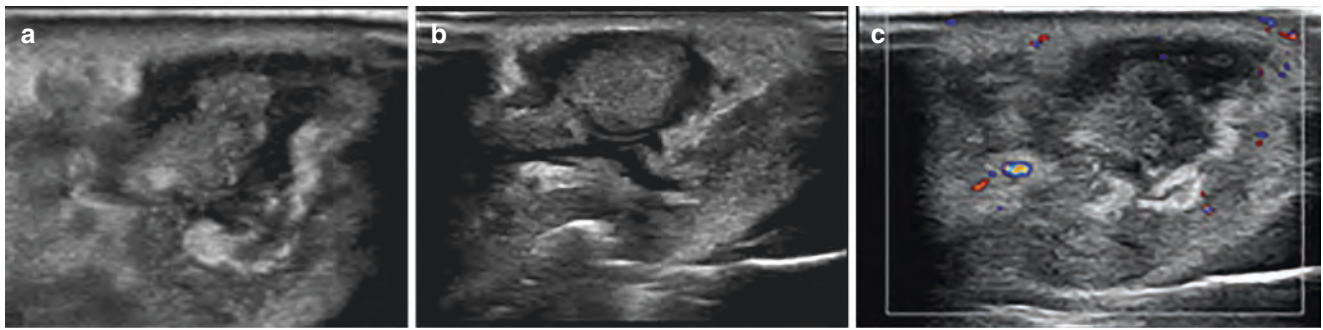
1. Inflammatory / Infective Pathology

(a) *Cheek cellulitis with evolving abscess* (Fig. 8.51a–d).



©Association of Oral and Maxillofacial Surgeons of India

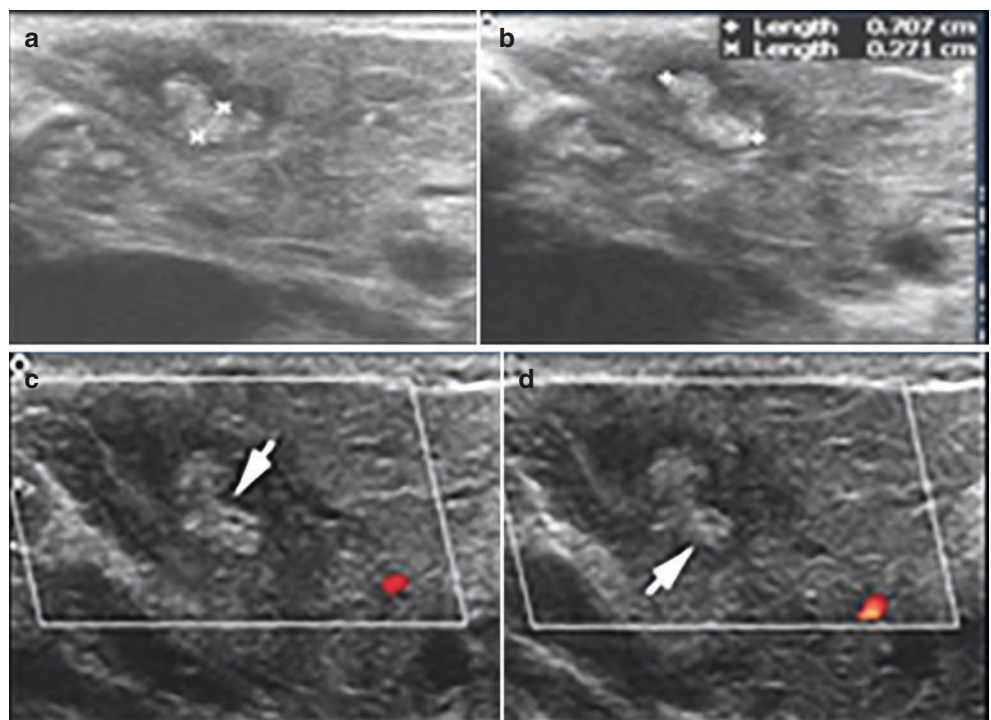
Fig. 8.51 (a, b, c, and d). Cheek cellulitis with evolving abscess. Diffuse soft-tissue thickening, edema of deep subcutaneous fat plane, edematous buccinators and submucosal plane with mild echogenic tracking collection within the fascial planes



©Association of Oral and Maxillofacial Surgeons of India

Fig. 8.52 (a, b and c). Cheek abscess. Focal organized thick echogenic collection in the deep subcutaneous plane with minimal extension into buccinator muscle (45 year old male, with habit of chewing betel nut)

Fig. 8.53 (a–d) Chronic osteomyelitis mandible. HRUSG showing hyperechoic lesion with hypoechoic halofungal granuloma



©Association of Oral and Maxillofacial Surgeons of India

(b) Cheek abscess (Fig. 8.52a–c).

(c) Chronic osteomyelitis mandible (Fig. 8.53a, b).

(d) Cysticercosis parotid (Fig. 8.54).

(f) Painless unilateral swollen cheek (Intramasseteric lipoma) (Fig. 8.60).

(g) Stenson's Duct calculus (Fig. 8.61a, b).

(h) Polycystic disease of parotid (Fig. 8.62a, b).

2. Benign Pathology.

(a) Oral submucosal fibrosis (OSMF) (Fig. 8.55a–c).

(b) Lesion at opening of Stenson's Duct (Fig. 8.56a, b).

(c) Intraoral Mucocele (Fig. 8.57a, b).

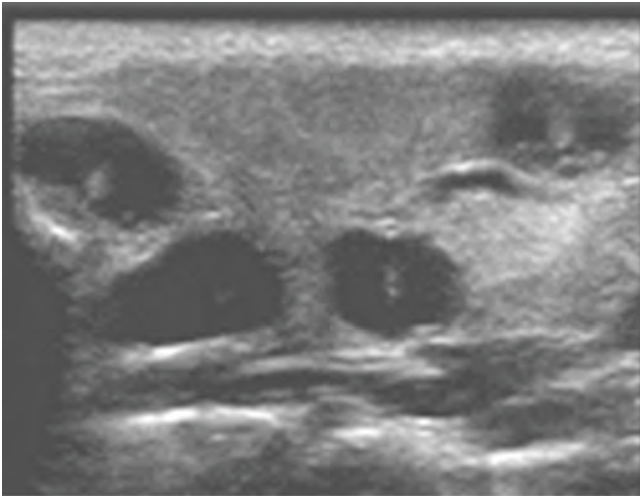
(d) Cheek lymphangioma (Fig. 8.58a–d).

(e) Epidermoid cyst of cheek (Fig. 8.59a, b).

3. Malignant Pathology.

(a) Buccal mucosal malignancy with intact submucosa and buccinator (Fig. 8.63).

(b) Buccal mucosal squamous cell carcinoma (Fig. 8.64 a-c).



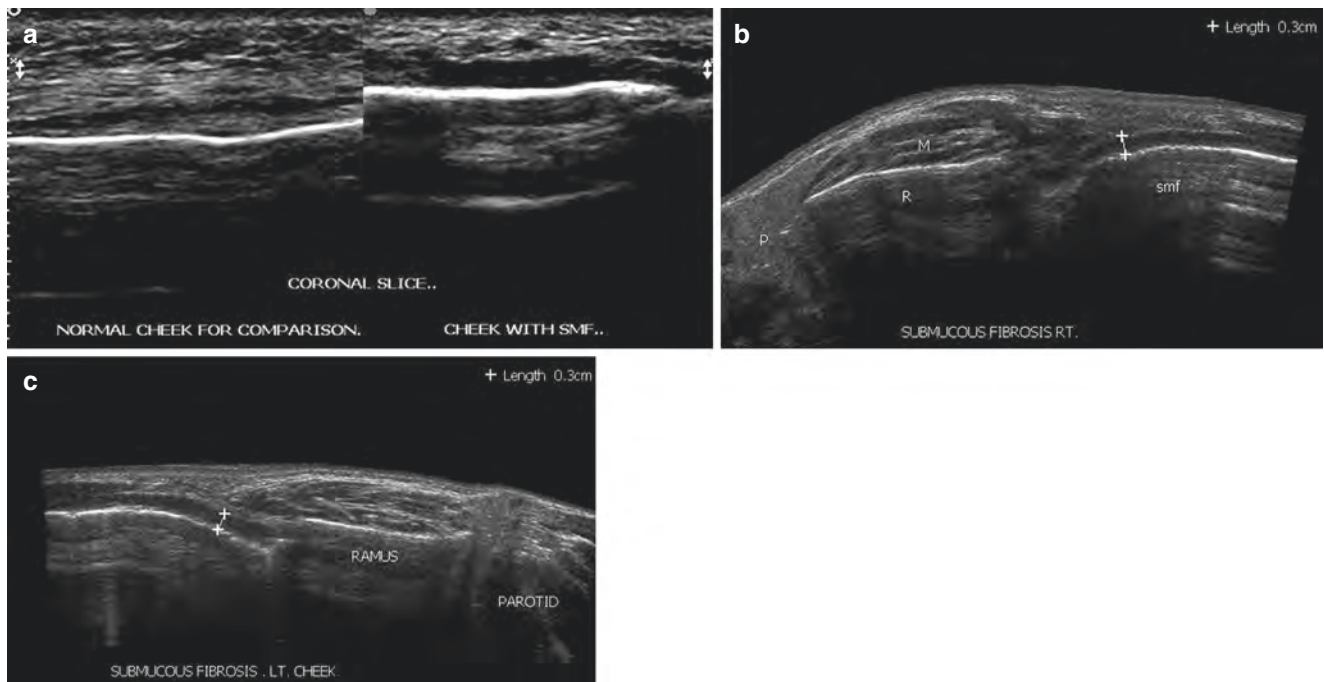
©Association of Oral and Maxillofacial Surgeons of India

Fig. 8.54 Cysticercosis parotid

- (c) Buccal mucosal carcinoma with mucosal and submucosal involvement, mandibular destruction and sparing of buccinator (Fig. 8.65).
- (d) Buccal mucosal carcinoma comparative evaluation (Fig. 8.66a, b).
- (e) Superior vestibular malignant mass (Fig. 8.67a–c).
- (f) Tongue malignancy-Tongue touch technique (Fig. 8.68a, b).
- (g) Buccal malignancy with mandibular infiltration (Fig. 8.69a–d).

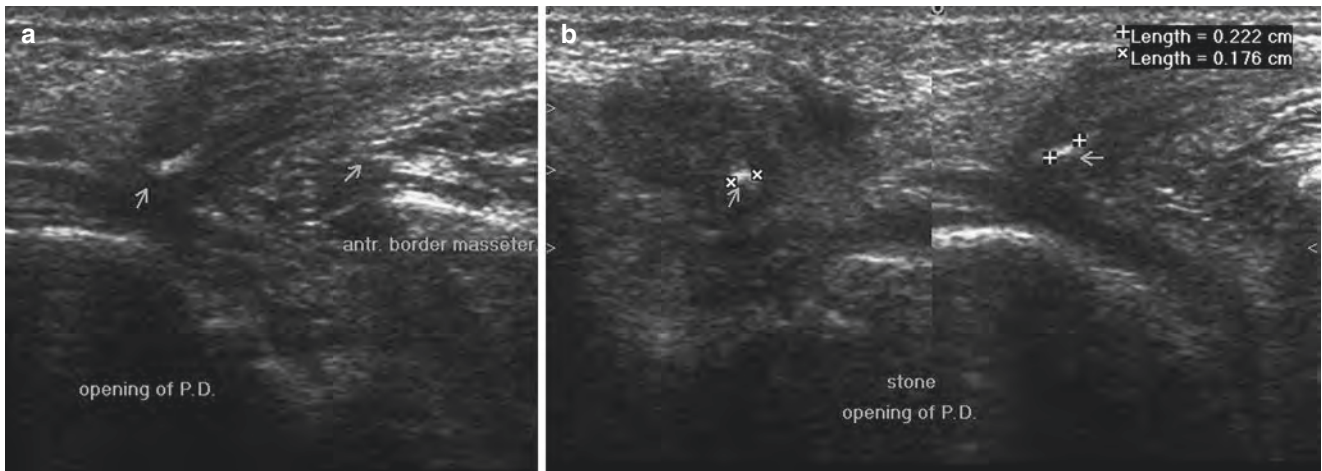
4. Vascular malformations

- (a) Arteriovenous malformation cheek (Fig. 8.70a–d).
- (b) Cheek hemangioma (Fig. 8.71).



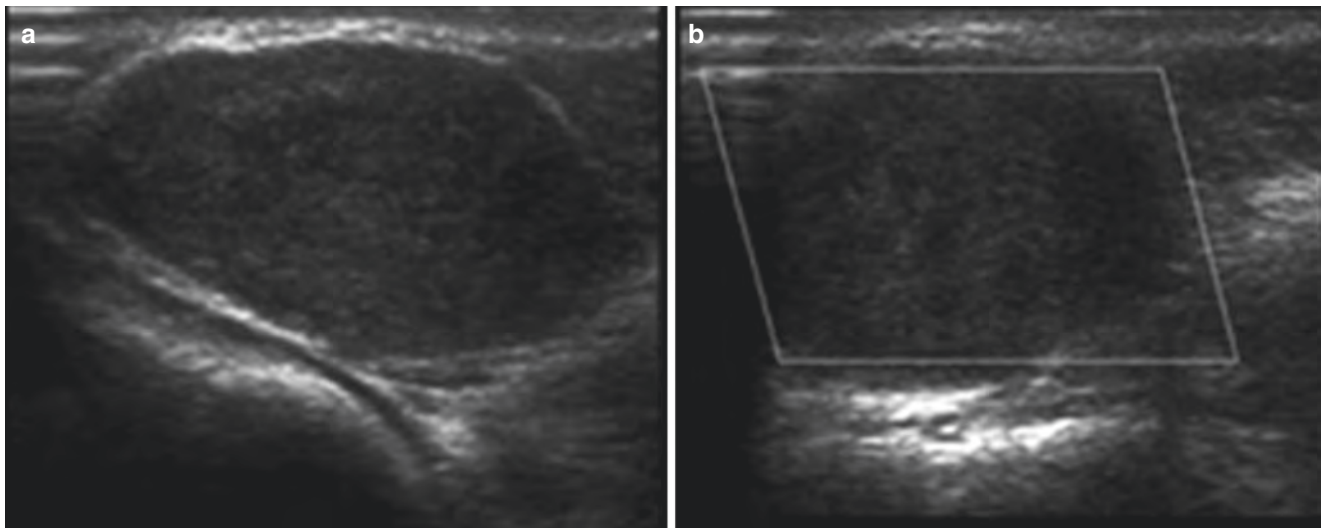
©Association of Oral and Maxillofacial Surgeons of India

Fig. 8.55 (a, b and c) Oral submucosal fibrosis. Axial slice showing thickening of the submucosal layer in OSMF in comparison to the normal thickness of the submucosal layer



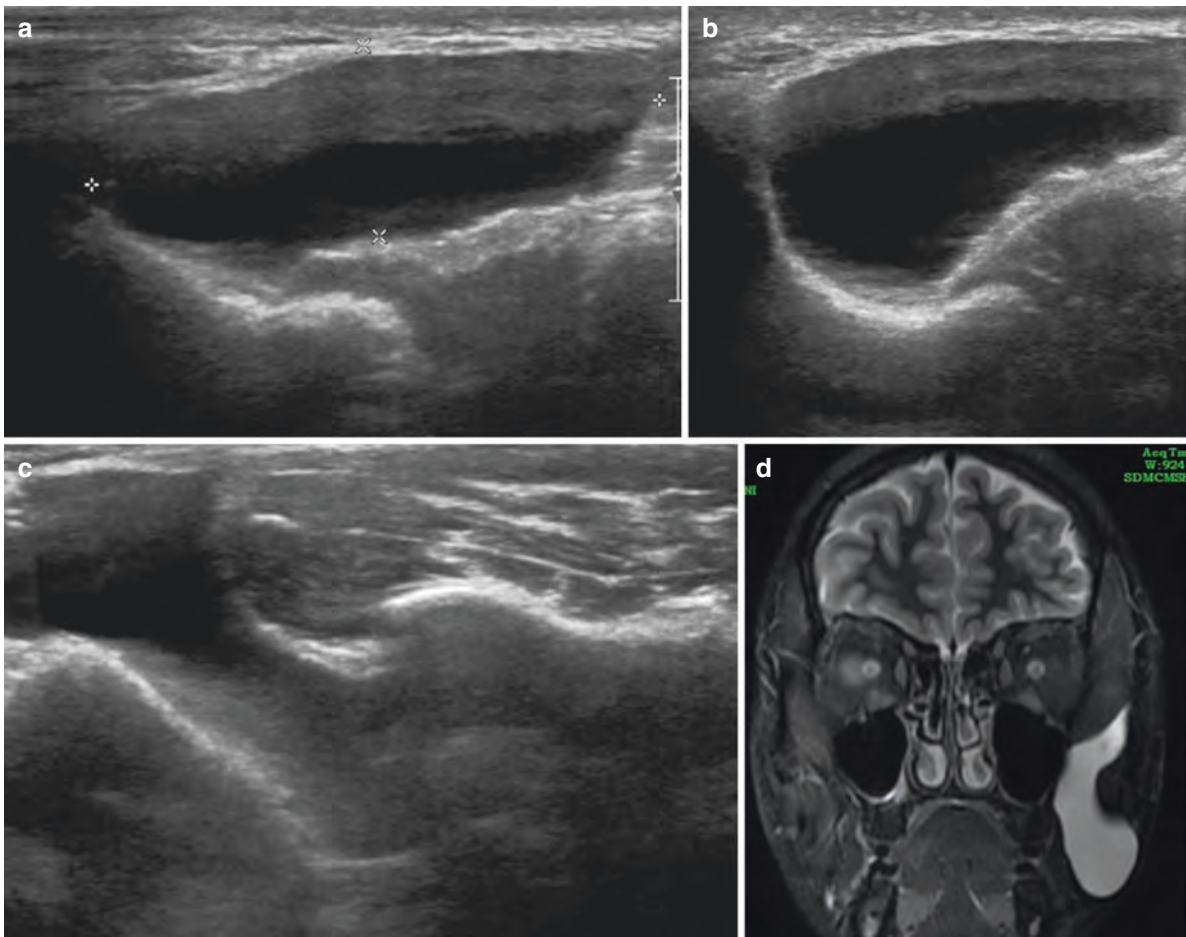
©Association of Oral and Maxillofacial Surgeons of India

Fig. 8.56 (a) and (b). Tiny calculus of about 1.2 mm revealed by HRUSG at Stenson's duct opening. (Pain while chewing food. No swelling)



©Association of Oral and Maxillofacial Surgeons of India

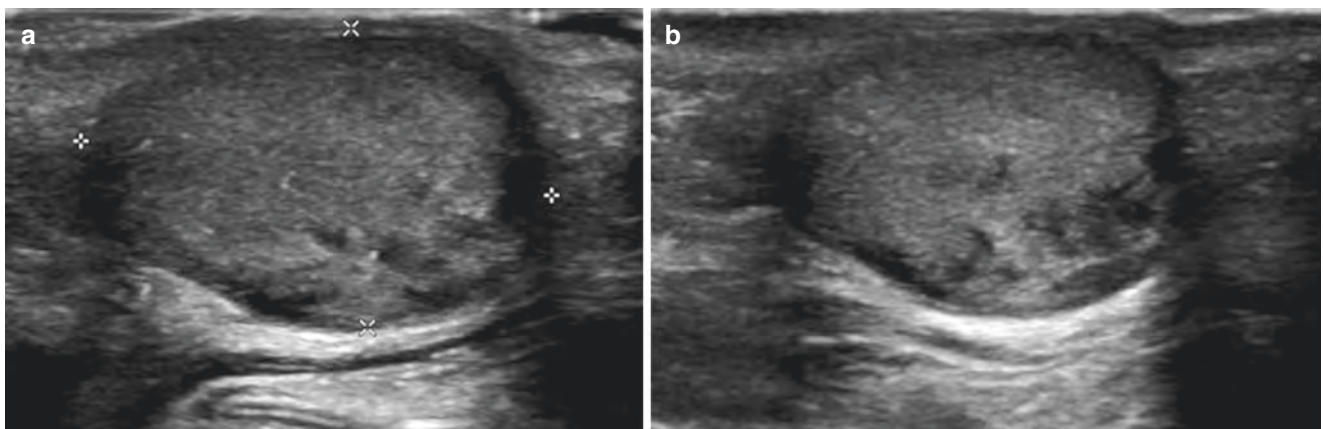
Fig. 8.57 (a) and (b). Intraoral Mucocele. Well-defined cystic lesion in the submucosal layer with internal minimal echogenic contents. Possible diagnosis of mucocele given, later confirmed by HPR. (35 year old female, presenting with right-sided cheek swelling and mild pain)



©Association of Oral and Maxillofacial Surgeons of India

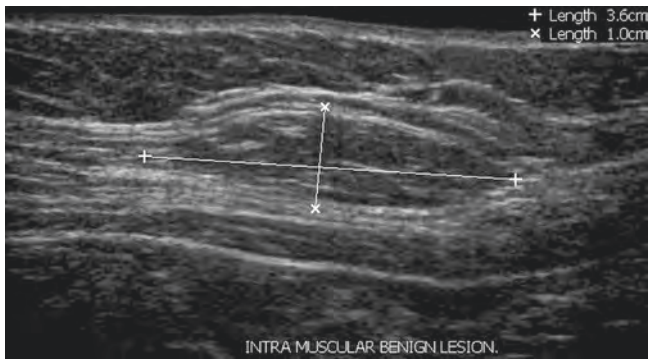Fig. 8.58 (a, b, c, and d). Cheek lymphangioma. Fluid-filled cystic lesion deep to submucosal layer with deep space extension adjacent to the masseter medial to mandibular ramus MRI coronal T2W imaging

confirms hyperintense fluid along left side of cheek extending into infratemporal fossa (25 year old male, presenting with soft, painless swelling of left cheek)



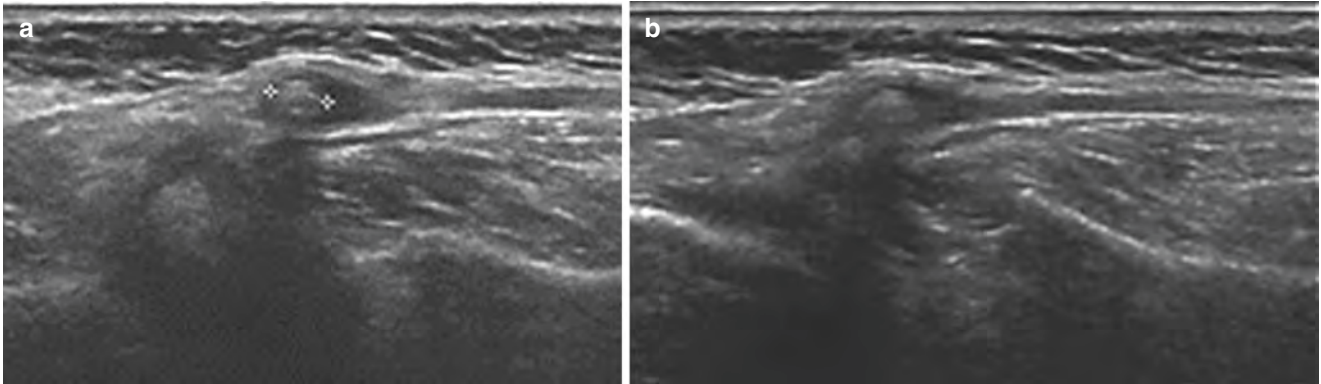
©Association of Oral and Maxillofacial Surgeons of India

Fig. 8.59 (a) and (b). Epidermoid cyst of cheek. Well-defined complex cystic lesion in the subcutaneous plane with internal echogenic contents causing displacement of underlying cheek layers (28 year old male presenting with painless left cheek swelling)



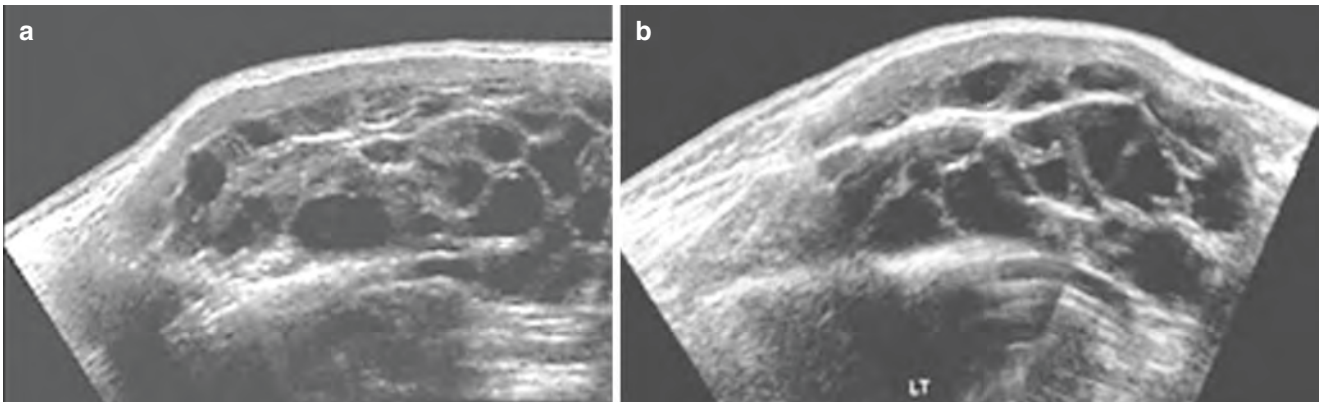
©Association of Oral and Maxillofacial Surgeons of India

Fig. 8.60 Intramasseteric Lipoma. Elongated intramuscular lesion isoechoic to the subcutaneous fat with internal echogenic strands representing intramasseteric lipoma. (30 year old female, presenting with painless swelling of cheek)



©Association of Oral and Maxillofacial Surgeons of India

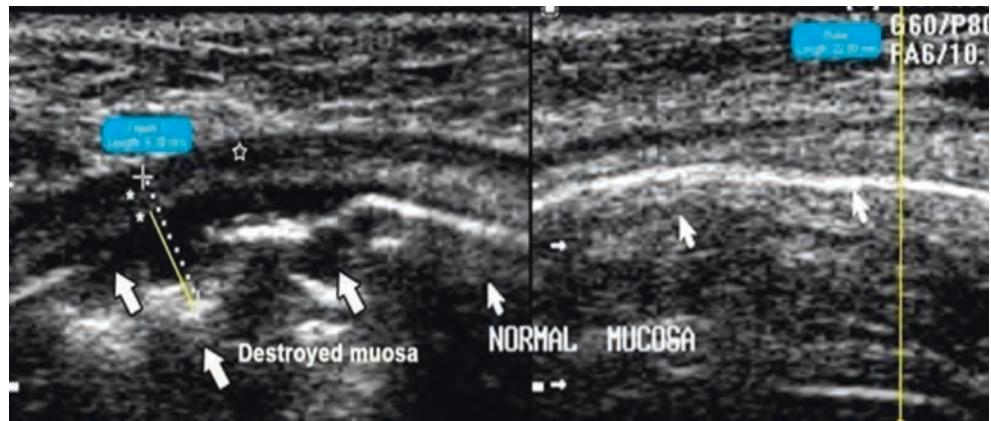
Fig. 8.61 (a) and (b). Stenson's duct calculus. Hyperechoic calculus in the Stenson's duct with nondilated duct proximal to the calculus (23 year old male, with history of intermittent pain on right side of the cheek)



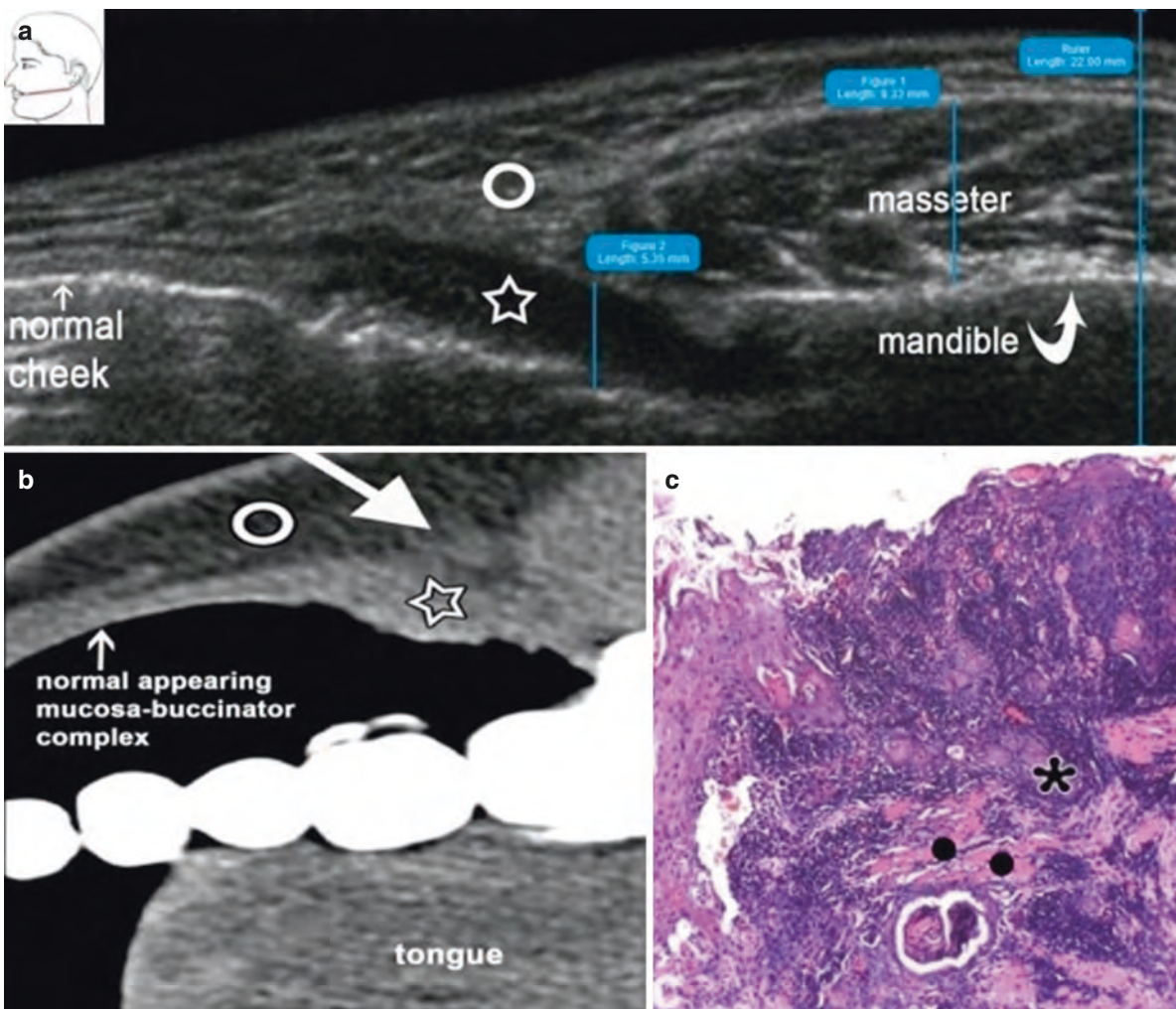
©Association of Oral and Maxillofacial Surgeons of India

Fig. 8.62 (a) and (b). Polycystic disease of parotid. (22 year old male Bilateral painless swollen cheek 7–8 yrs duration)

Fig. 8.63 Buccal mucosal malignancy with intact submucosa and buccinator. Growth predominantly involving the mucosa, distinct from submucosa (between asterisk) buccinator (star) appears normal. (55 year old male with irritating nonhealing ulcer left cheek)

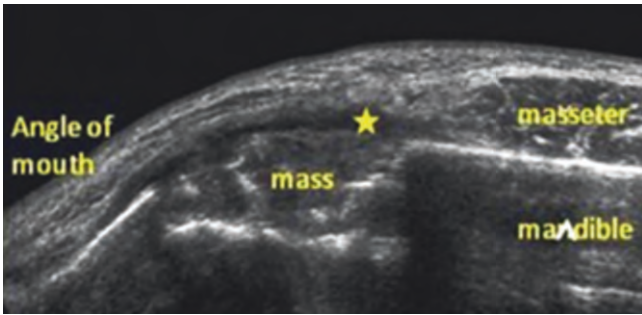


©Association of Oral and Maxillofacial Surgeons of India



©Association of Oral and Maxillofacial Surgeons of India

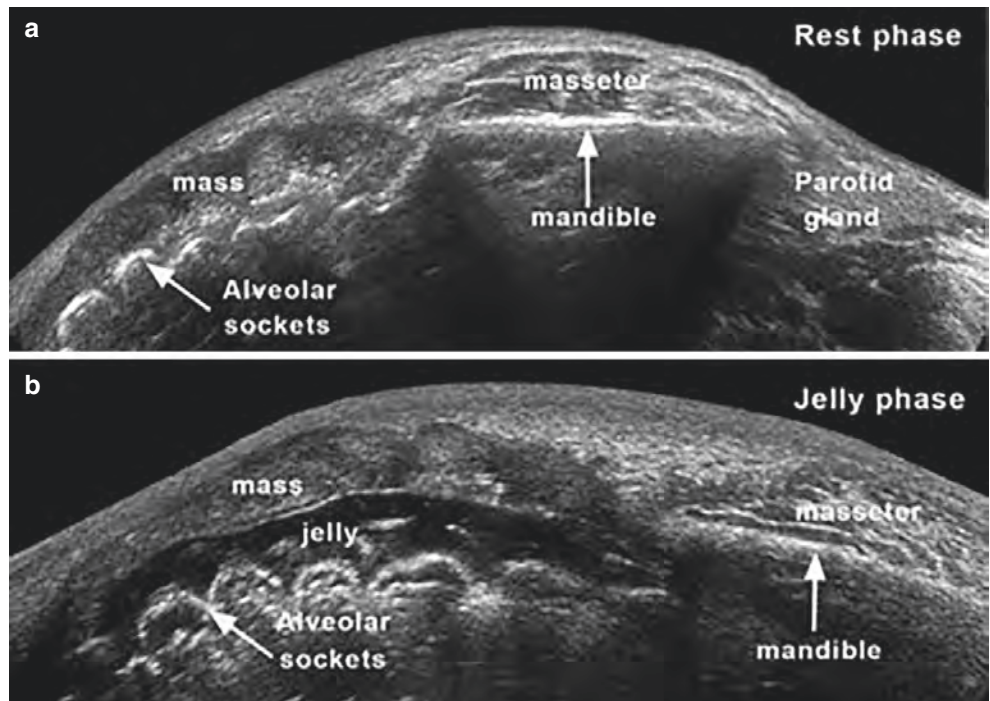
Fig. 8.64 (a, b, and c). Early Carcinoma of the cheek better seen on HRUSG than by CT slice at the same level. Proved by Histopathology (52 year old male with squamous cell carcinoma of the buccal mucosa)



©Association of Oral and Maxillofacial Surgeons of India

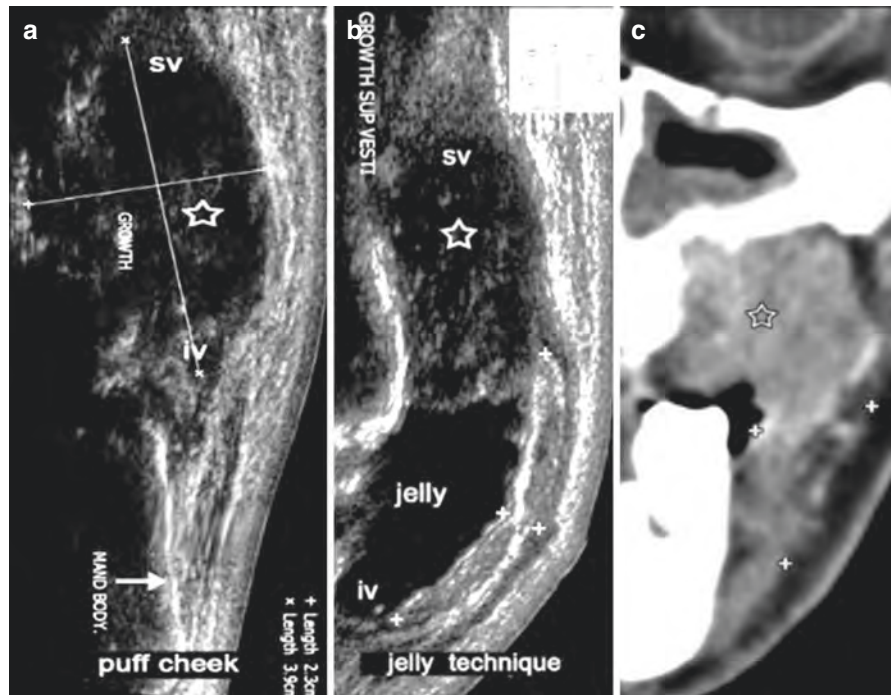
Fig. 8.65 Buccal mucosal carcinoma

Fig. 8.66 (a) Buccal mucosal carcinoma (Resting phase). (b) Buccal mucosal carcinoma (Fruit jelly technique). Patient was unable to perform the puffed cheek technique. Mass involving the mucosa, submucosa, buccinator, and fat

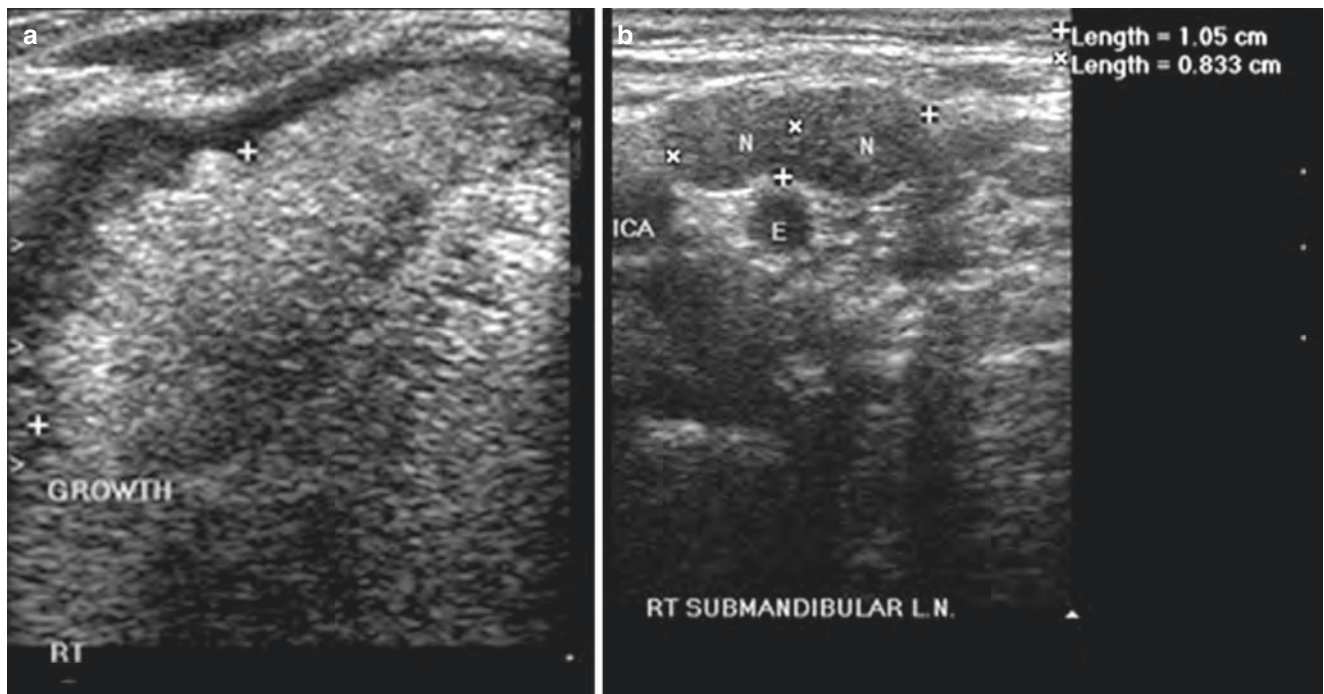


©Association of Oral and Maxillofacial Surgeons of India

Fig. 8.67 (a, b and c). Superior vestibular malignant mass. Coronal sections revealing predominantly hypoechoic, superior vestibular mass with irregular margins extending into cheek layers and causing underlying bony destruction. Comparison between (a) neutral cheek, (b) fruit jelly Technique and (c) CT

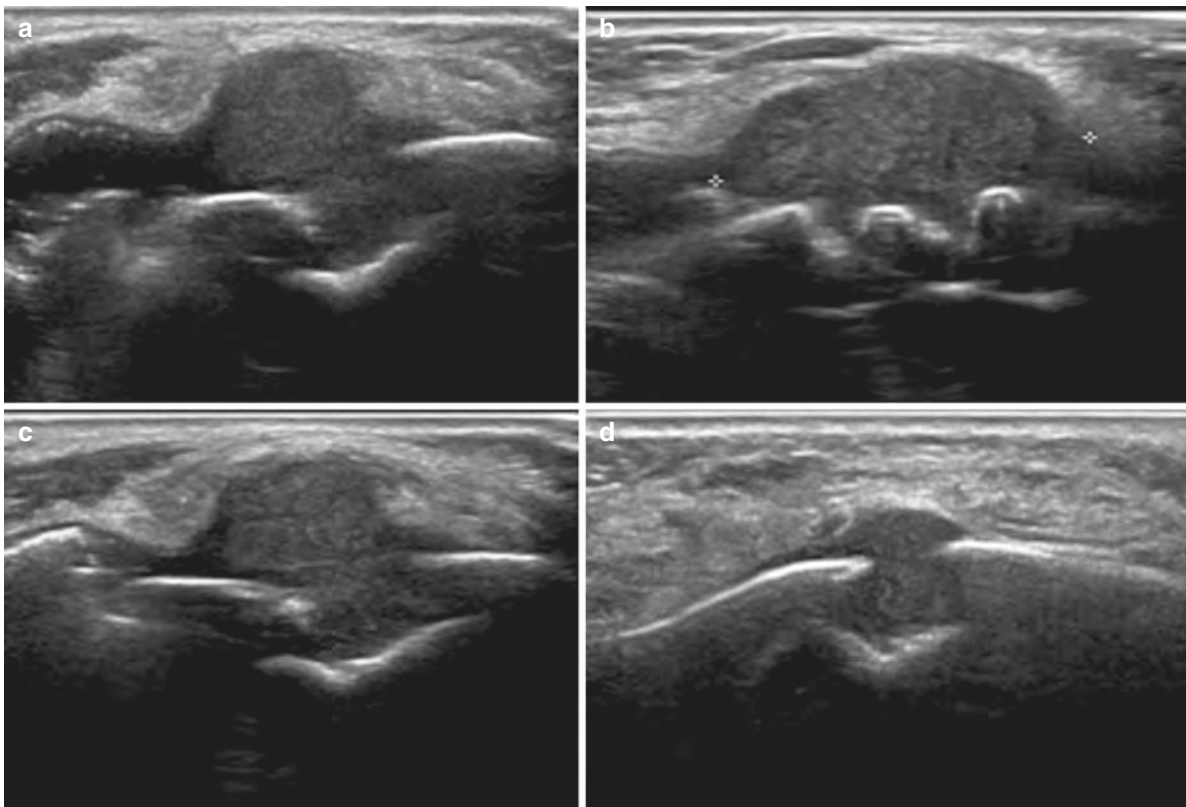


©Association of Oral and Maxillofacial Surgeons of India



©Association of Oral and Maxillofacial Surgeons of India

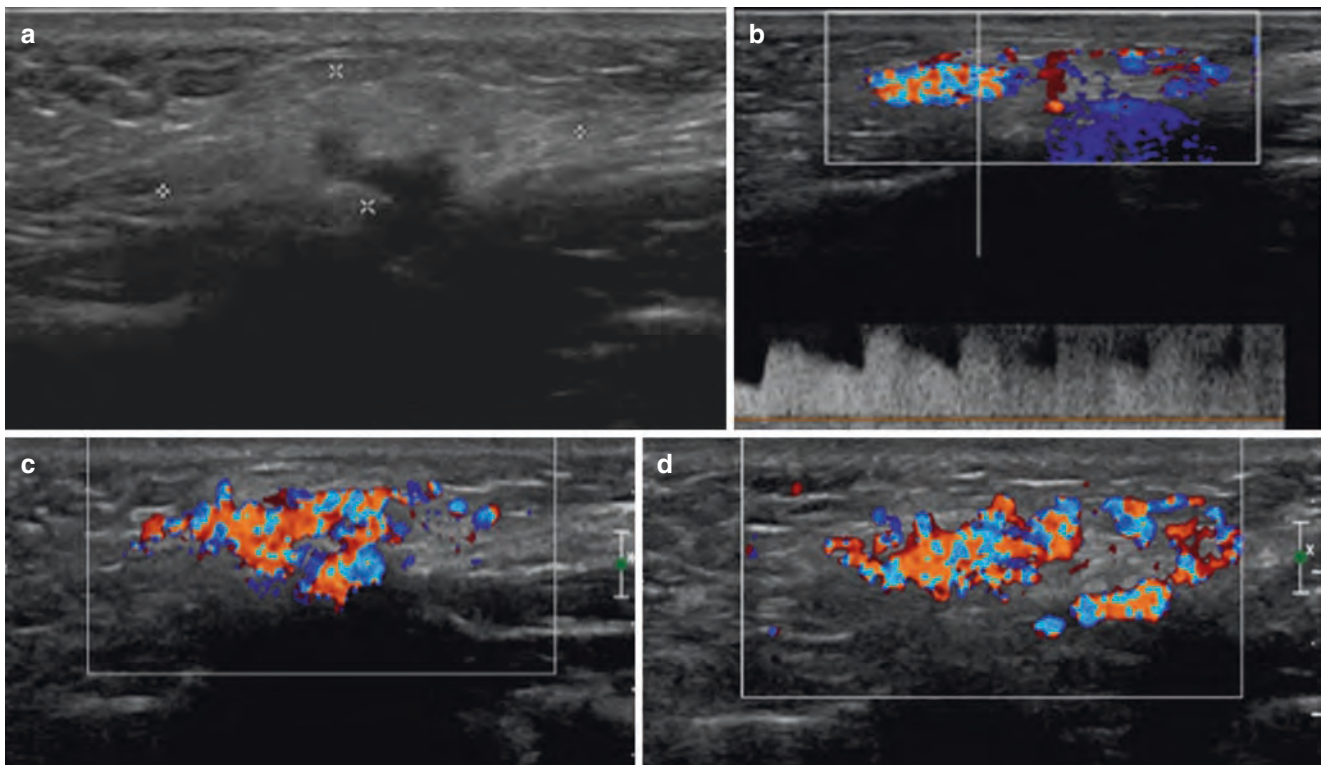
Fig. 8.68 (a) and (b). Tongue malignancy against cheek wall. Irregular lesion along the Right anterolateral margin of the tongue by “Tongue touch” technique. Few enlarged lymph nodes are also noted with loss of hilar anatomy representing metastatic lymph nodes. (40 year old male, with complaint of swelling over the tongue)



©Association of Oral and Maxillofacial Surgeons of India

Fig. 8.69 (a, b, c, and d) Buccal malignancy with mandibular infiltration. Heterogeneous mass lesion along the buccal mucosa extending into lower buccogingival sulcus with infiltration into submucosa and

buccinator muscle. Focal cortical break is also noted in the mandibular bone with intraosseous infiltration. (48 year old male tobacco chewer presenting with right cheek swelling)

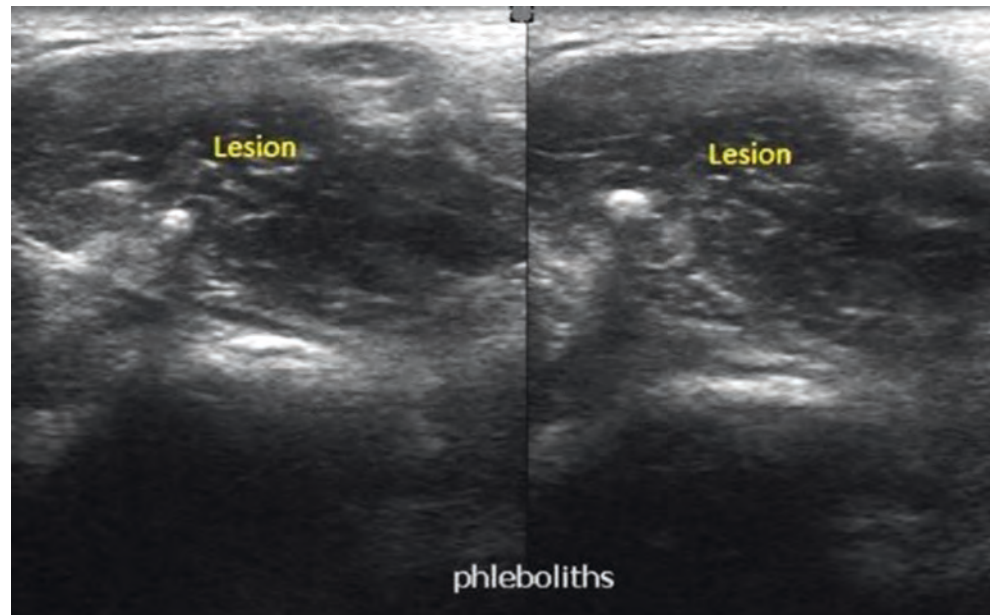


©Association of Oral and Maxillofacial Surgeons of India

Fig. 8.70 (a, b, c, and d) Arteriovenous malformation (AVM) cheek. Focal soft-tissue thickening with internal hypoechoic areas. Doppler study shows multiple vascular channels with high velocity, low resis-

tance flow suggestive of AVM. (40 year old female presenting with history of swelling and intermittent pain)

Fig. 8.71 Cheek Hemangioma. Mixed echoic hemangioma with phlebolith. Absence of flow signals due to low-velocity flow



©Association of Oral and Maxillofacial Surgeons of India

8.12 Conclusion

It is extremely difficult to limit radiology to a chapter and what has been written does not represent the whole of maxillofacial radiology. Only the relevant aspects and the bare minimum essentials of radiology for maxillofacial surgeons have been covered in this chapter. The entire range of radiology for maxillofacial surgeons, dealing with surgical problems pertinent to the maxillofacial region, would require more expansive and elaborate writing.

This chapter on radiology provides an outlook to the surgeon, who can proceed to applying radiology in his everyday surgical practice. In the event of encountering any lacunae in the book, the MFS must refer to the textbooks dedicated to maxillofacial radiology. Being a surgeon, the MFS should be aware of the use of the chest radiograph and its applications in his practice. The role of high-resolution ultrasonography has also been emphasized in this chapter. Dental radiology, both extra and intraoral, has not been included since all maxillofacial surgeons have extensive knowledge of the same in their surgical practice.

Since it is the MFS who is acquainted with the patient's clinical status, he must properly plan the imaging pathway

for the patient. It is for this purpose that the MFS should be aware of the various imaging modalities as regards their nature, mode of image formation, their usefulness over other modalities, and their drawbacks. Radiation safety and cost effectiveness of a specific imaging modality also need to be kept in mind. The imaging method selected should be one that provides the required information within the shortest time possible, be the safest option for the patient, and be the most economical, while at the same time providing maximum information.

The MFS can commence with simple basic imaging methods like plain radiography or USG and later proceed to higher imaging methods in case the basic methods were not enough to satisfy the surgeon's needs for patient management. A recent costlier imaging method does not necessarily mean it is the best. Many times, it is the simpler basic imaging methods that provide more crucial findings that help in understanding complex disease processes.

Acknowledgments The authors would like to acknowledge & thank Dr Niranjana Kumar, M.Ch FRCS. ; Honorable Vice-Chancellor, Shri Dharmasthala Manjunatheshwara University for his valuable constructive suggestions and constant support towards this endeavour.

References

1. Fusaro F, Constantinides F, Maglione M, Dalessadri D, Vettori E, Lenarda RDI. Comparison of orthopantomography (OPG) and computed tomography (CT) accuracy in predicting inferior alveolar nerve injury following lower third molar surgical extraction [Internet]. 2017 [cited 2019Jun3]. Available from: https://www.researchgate.net/publication/319548814_Comparison_of_orthopantomography_OPG_and_computed_tomography_CT_accuracy_in_predicting_inferior_alveolar_nerve_injury_following_lower_third_molar_surgical_extraction
2. Abramovitch K, Rice DD. Basic principles of cone beam computed tomography. *Dent Clin N Am*. 2014;58(3):463–84.
3. Lucas J. What are gamma-rays? Available from: <https://www.livescience.com/50215-gamma-rays.html>
4. Ferreira RI, de Almeida SM, Boscolo FN, Santos AO, Camargo EE. Bone scintigraphy as an adjunct for the diagnosis of oral diseases. *J Dent Educ*. 2002;66(12):1381–7.
5. Appadurai R, Lingeswar D, Venugopal S, Christina RD. Bone scintigraphy as a diagnostic tool in condylar hyperplasia [Internet]. 2017 [cited 2019Jun3]. Available from: <http://www.joomr.org/article.asp?issn=2321-3841;year=2017;volume=5;issue=3;spage=84;epage=89;aulast=Appadurai>
6. Griffeth LK. Use of PET/CT scanning in cancer patients: technical and practical considerations [Internet]. Proceedings (Baylor University. Medical Center). Baylor Health Care System; 2005 [cited 2019Jun4]. Available from: <https://www.ncbi.nlm.nih.gov/pmc/articles/PMC1255942/>
7. Williams N, O'Connell PR, McCaskie AW. Bailey and Love's short practice of surgery. 27th ed. New York: CRC Press; 2018.
8. Pooley RA. AAPM/RSNA Physics Tutorial for Residents Fundamental Physics of MR Imaging [Internet]. 2005 [cited 2019Jun3]. Available from: <https://pubs.rsna.org/doi/pdf/10.1148/rg.254055027>
9. Singh GP, Dogra S, Kumari E. Ultrasonography: maxillofacial applications. *Annals of Dental Specialty*. 2014;2(3):104–7.
10. Kumar V, Abbas AK, Aster JC. Robbins and Cotran pathologic basis of disease. 9th ed. Philadelphia: W.B. Saunders; 2015.
11. Fraser RS, Muller NL, Colman N, Pare PD. Fraser and Pare's diagnosis of diseases of the chest. 4th ed. Philadelphia: W.B. Saunders; 1999.
12. Christopoulos A. Mouth Anatomy [Internet]. Overview, Gross Anatomy: Oral Vestibule, Gross Anatomy: Oral Cavity Proper. 2015 [cited 2019Jun5].
13. Surgical fascial spaces [Internet]. online presentation [cited 2019 Jun 7]; Available from: <https://en.ppt-online.org/369373>
14. La'Porte SJ, Juttla JK, Lingam RK. Imaging the Floor of the Mouth and the Sublingual Space [Internet]. RadioGraphics. 2011 [cited 2019Jun5]. Available from: <https://pubs.rsna.org/doi/full/10.1148/rg.315105062>
15. Joshi SK, Kamalapur MG, Joshi AS, Hallikeri K. Ultrasonographic evaluation of carcinoma of buccal mucosa: Ultrasound technique and evaluation of neoplastic conditions. *J. Evid. Based Med. Healthc*. 2016;3(34):1649–55.

Further Reading

- Mosier K. Functional imaging of swallowing. In: Mukherji SK, Casterlijns JA, editors. Head and neck imaging. Berlin: Springer; 2000. p. 79–86.
- Yousem DM (2000) Magnetization transfer imaging of the Extracranial head and neck. In: Mukherji SK, Casterlijns JA (eds). Modern head and neck imaging. Springer, Berlin, pp1–16.
- Sanjay N. Jain (2019) a Pictorial essay: radiology lines and tubes in the intensive care unit. *Indian J Radiol Imaging*. 2011;21:182–90.

Open Access This chapter is licensed under the terms of the Creative Commons Attribution 4.0 International License (<http://creativecommons.org/licenses/by/4.0/>), which permits use, sharing, adaptation, distribution and reproduction in any medium or format, as long as you give appropriate credit to the original author(s) and the source, provide a link to the Creative Commons license and indicate if changes were made.

The images or other third party material in this chapter are included in the chapter's Creative Commons license, unless indicated otherwise in a credit line to the material. If material is not included in the chapter's Creative Commons license and your intended use is not permitted by statutory regulation or exceeds the permitted use, you will need to obtain permission directly from the copyright holder.



Part V

Principles of Maxillofacial Surgery



Operating Room Protocols and Infection Control

9

Rishi Kumar Bali

9.1 Introduction

A study comprising data from 56 countries in 2004 stated that the annual major surgery volume was estimated to be 187–281 million operations, accounting for approximately one operation annually for every 25 human beings alive [1]. In subsequent studies, data were obtained from a total of 194 Member States of the World Health Organization for the years 2005–2012. According to these studies, 312.9 million operations took place in 2012, showing an increase from the 2004 estimate of 226.4 million operations. 6.3% and 23.1% of operations were carried out in *very-low* and *low-expenditure* countries representing only 36.8% (2573 million people) and 34.2% (2393 million people) of the global population of 7001 million people, respectively [2]. The incidence of postoperative infections reported among the developed countries like UK and USA was approximately 5% and 5–6%, whereas in developing countries like India it is much higher, accounting for approximately 10–25%. [3, 4].

The main problem encountered in the practice of surgical safety is that existing safety practices are not adequate in some countries. Lack of resources is the main reason behind this, particularly in developing countries. Good infection prevention and control is essential to ensure the safety of the patient undergoing any surgical procedure in the operating theater. The surgical site infections (SSIs) constitute 20% of the total hospital-acquired infections [4]. These infections cause substantial patient mortality and morbidity and burden healthcare systems with massive costs. Since these infections are primarily acquired during the operative procedure when the wound is still open, stringent protocols need to be followed at this point to minimize their onset.

R. K. Bali (✉)

Postgraduate Department of OMFS, DAV Dental college hospital, Yamunanagar, Haryana, India

9.2 Terminology

To establish surgical protocols, it is important to understand the basic concepts of sterilization, asepsis, and infection control. In this respect, the following terminologies are very commonly used:

Antibiotics

These agents are a by-product of certain microorganisms, which either have the capacity to destroy or inhibit the growth of other microorganisms at low concentrations.

Anti-Infective

A substance (or drug) capable of killing microorganisms or inhibiting their growth, in particular, pathogenic microorganisms. This is a general term used to encompass those drugs that specifically act on certain types of microorganisms, including antibacterial (antibiotics), antifungal, antiviral, and antiprotozoal agents.

Antimicrobial Agent

Any agent synthetically or naturally obtained that can destroy or attenuate the microorganisms.

Antisepsis

It is the process in which microbial agents on a living surface are either killed or their growth is arrested.

Antiseptic

These are the substances applied on the living tissues to reduce the possibility of infection, sepsis, and putrefaction by inhibiting the activity or growth of the microorganisms.

Asepsis

The state of being free from living pathogenic organisms.

Aseptic

Free of or using methods to keep free from microorganisms.

Aseptic Processing

It is defined as the processing and packaging of a sterile product into sterilized containers followed by proper sealing with a sterilized closure in a manner to control microbiological recontamination.

Bactericide

It is an antimicrobial agent that has the capacity to destroy both nonpathogenic and pathogenic organisms but may not destroy bacteria in spore form.

Bacteriostatic

It is an antimicrobial agent that inhibits the growth of microorganisms but is not capable of killing them.

Bioburden

The occurrence of viable microorganisms on a surface or object before the sterilization procedure.

Biologic Indicator (BI)

A standardized test preparation of bacterial spores used to demonstrate effective sterilizing conditions by providing a defined resistance to a specific sterilization process.

Chemical Indicator

These are agents or devices used to monitor or confirm the attainment of one or more of the parameters required for a satisfactory sterilization process or used in a specific test of the sterilization equipment.

Chemisterilant

It is an agent, chemical in nature with properties that kills all forms of microbial agents, including spores.

Cleaning

It is the process of removing all forms of foreign materials (from objects using detergents & water, soaps, and enzymes) by employing the mechanical action of washing or scrubbing the object.

Contamination

It is the process of entry of microbial agents into tissues or any aseptic environment.

Crossinfection

The spread of infection from one person, object or place to another.

Decontamination

The process by which a person or a surface is made free from all the agents that contaminate the surface and lead to the spread of infections. [5]

Detergent

It is a chemical agent with cleansing actions in dilute solutions, which, on combining with impurities and dirt, make them more soluble.

Disease

Disruption of the normal performance of the vital functions of a plant or animal by an infection.

Disinfectant

This is an agent, usually a chemical, applied on inanimate objects that destroys microorganism in the vegetative form but not the spores.

Chemical disinfectant agents are categorized into low level, intermediate, and high level (depending on the product claims and regulatory requirements in different parts of the world).

- High-level disinfection (HLD): It is a process in which a small number of spores or certain bacteria are killed by the use of certain antimicrobial agents at a specific temperature and appropriate concentration.
- Intermediate-level disinfection (ILD): It is a process in which vegetative forms of all microorganisms are destroyed but affect the activity of spores of certain bacteria.
- Low-level disinfection (LLD): It is a process in which vegetative forms of all microorganisms are destroyed having no activity on spores of bacteria at very low concentrations.

Disinfection

Antimicrobial process to remove, destroy, or deactivate microorganisms on surfaces or in liquids. Disinfection is often considered as a reduction of the numbers and types of viable microorganisms (or “bioburden”) but may not be assumed to render the surface or liquid free from viable microbial contamination (in contrast to sterilization).

Droplet Nuclei

These are those particles of 1–10 μm that are implicated in the spread of airborne infections.

Exogenous Infection

The infecting microorganism comes from an external source.

Fomites

Any inanimate object that is capable of absorbing or transmitting infectious microorganisms from one person to the other.

Fumigation

The process of disinfecting or purifying an area or object with the fumes of certain chemical agents.

Germicide

Agents that are designed to kill and destroy pathogenic organisms on the surface of different things.

Infection

It is the process of invasion of the tissues by microorganisms and their multiplication in the body of the host to produce disease.

Microorganisms or Microbe

Microscopic organisms, which may exist in its single-celled form or in a colony of cells.

Minimum Effective Concentration (MEC)

The lowest concentration of a chemical or product, used in a specified process that achieves a claimed activity.

Minimum Recommended Concentration (MRC)

The lowest concentration of a chemical or product specified by the equipment manufacturer to be used in a process.

Nosocomial

This comes from two Greek words, i.e., “*nosus*” meaning “*disease*” and “*komeion*” meaning “*to take care of*.” Also known as “hospital-acquired infections.” These are the infections originating or taking place in a hospital.

Operating Room (OR)

The operating room or operating theater is a facility within a hospital where surgical procedures are carried out in an aseptic environment.

Pathogen

A pathogen is a tiny living organism, such as a bacterium or virus that is capable of producing disease in an individual.

Resistance

It is the natural ability of the agent to oppose the effects of any harmful agents.

Soil

Natural or artificial contamination on a device or surface following its use or simulated use.

Sterile Barrier System

Packaging that prevents the ingress of microorganisms following a sterilization process, thereby preserving the sterile state.

Sterilizer

Equipment designed to achieve sterilization.

Sterilizing Agent

Physical or chemical agent (or combination of agents) that has sufficient microbicidal activity to achieve sterility under defined conditions.

Septic

Contaminated or infected.

Spores

These are the reproductive forms of some microorganisms that can survive harsh environmental factors and have the capability of developing into new viable microbes.

Sterilization

Sterilization is a process that destroys or removes all microbial life completely, including spores by means of certain chemical or physical processes.

Sterile

Free from living microorganisms.

Sterilize

Total destruction of all living forms.

Vector

It is an organism that does not cause disease itself but which spreads infection by conveying pathogens from one host to another.

Virulence

It is a pathogen's ability to infect, sustain, or spread infection in a living a host. Historical background of present day protocols is enumerated in Table 9.1.

9.3 Surgical Site Infections

Approximately 2–5% of all surgical patients tend to acquire surgical site infections (SSIs) [4]. In developed & high-income countries (HICs), SSIs are the second most common cause of healthcare-associated infections [6], whereas in Low- & Middle-Income Countries (LMICs) or underdeveloped & developing countries these infections are the most common ones. Thus, to reduce the risk of surgical site infections, a more systematic approach has to be adopted, based on proper knowledge regarding the status of the patient, type, & time of the operation, personnel involved and the health care facilities available during a surgical procedure. The main pathogenic source of surgical site infections is the endogenous flora (usually aerobic gram positive cocci) of the patient present in the skin, the mucous membranes, or the hollow viscera. The exogenous sources of infection include

Table 9.1 Historical background leading to proper sterilization and disinfection protocols

Year	Event
• First century BC.	<i>Varo and Columella</i> postulated that diseases were caused by invisible beings, “animals minutia,” inhaled or ingested
• 500 AD	<i>Sushruta</i> instructed operating team members to clean and fumigate the operating theater with vapors of certain disinfectants prior to all surgical procedures
• 1493–1541	<i>Paracelsus</i> , called the father of medicine, reformed pharmacopeia and introduced compositions of lead, copper, sulfur, iron, and mercury
• 1546	<i>Fracastorius</i> proposed a “contagion vivum,” as the possible cause of infectious diseases.
• 1827–1912	<i>Joseph Lister</i> , “father of modern surgery,” demonstrated that antisepsis could prevent infections; also known as “Listerian era”
• 1889	<i>William Stewart Halsted</i> introduced rubber gloves for his scrub nurse
• 1882	<i>Robert Koch</i> introduced the use of mercuric bichloride as antiseptic agents and isolated the bacilli of tuberculosis
• 1880s and 1890s.	Sterilization of instruments, hand washing, and the wearing of masks, caps, gloves, and gowns was introduced

members of the surgical team, environment of the operating theater and tools, materials & instruments brought to the sterile zones during the surgical procedure. Various strategies employed to prevent or control the occurrence of surgical site infections include reducing the contamination by microorganisms on the sterile surgical instruments as well as the body of the patient, prophylactic preoperative antibiotic coverage, carrying out the surgical procedure carefully, proper handling of the operating room.

9.4 Surgical Safety

Surgical safety is of utmost importance in order to prevent major and life-threatening complications leading to undue loss of life and patient morbidity. Thus, a list of ten essential objectives with a surgical safety checklist have been elucidated by the WHO to be followed by all the personnel present in the operating room to reduce the risk of such complications [7] (Tables 9.2 and 9.3).

9.5 Environmental Control and Design

Operating Room (OR)

The operating room or operating theater is a facility within a hospital where surgical procedures are carried out in an aseptic environment. Since the operating theater is a highly sterile, aseptic, and restricted area in a hospital setting, it is

Table 9.2 WHO: Ten essential objectives for safe surgery

(1) The operating team must ensure that the correct surgical procedure is to be carried out on the correct patient.
(2) The operating personnel should have adequate knowledge regarding the anesthesia, its methods of administration as well as its effects so that minimum pain is experienced by the patient.
(3) The operating personnel should be well prepared for any life-threatening conditions like loss of airway or respiratory function.
(4) The operating team should be prepared for risk of high loss of blood.
(5) The operating team should be well versed with the history of the patient in order to prevent or induce any allergic or adverse drug reactions that can cause a significant risk for the patient.
(6) Care must be taken to minimize the formation of surgical site infections by using proper measures.
(7) Proper care must be taken to not leave any instrument or any foreign material at the surgical site.
(8) All specimens should be carefully identified and secured for further investigations.
(9) Proper communication must be present among the operating team personnel for the safe conduct of the surgical procedure.
(10) A routine surveillance of the surgical volume, safety protocols, capacities, and the outcomes must be carried out by all the hospitals and the health care systems.

mandatory for all the personnel concerned to have a proper understanding of the working of the operation theater abiding by certain laws, regulations, and professional guidelines. Integrated infection control in the operation theater is the key to decreasing morbidity and mortality among the patients undergoing surgery.

Following essentials must be present in an operating room:

- Adequate lighting
- Proper ventilation with 20 (ACH) air changes/hour
- Correct and sufficient instruments needed in the surgery
- Proper machines and equipment for monitoring the condition of the patients during the surgeries
- Emergency drugs and other items
- Separate rooms should be present to carry different procedures
- Location of the Operating Theater: The location of the operation theater should be such that adequate natural light and proper ventilation is present. For this, a two- or three-story building away from the general hustle and bustle of the hospital is preferred.
- Operation rooms: The standard recommended size of the operation theater is 6.5 m × 6.5 m × 3.5 m and can be modified as per requirement
- Doors and Windows: There should be separate entry and exit doors. The width of the door should be approximately

Table 9.3 WHO's Surgical Safety Checklist

Before induction of anesthesia	Before skin incision	Before patient leaves operating room
Sign in	Time out	Sign out
Patient has confirmed <ul style="list-style-type: none"> • Identity • Site • Procedure • Consent 	Confirm all team members have introduced themselves by name and role	Nurse verbally confirms with the team <ul style="list-style-type: none"> • The name of the procedure recorded • The instrument, sponge, and needle counts are correct (or not applicable) • How the specimen is labeled (including patient name) • Whether there are any equipment problems to be addressed
Site marked/not applicable	Surgeon, anesthesia professional and nurse verbally confirm <ul style="list-style-type: none"> • Patient • Site • Procedure 	
Anesthesia safety check completed	Anticipated critical events <ul style="list-style-type: none"> • Surgeon reviews: What are the critical or unexpected steps, operative duration, anticipated blood loss • Anesthesia team reviews: Are there any patient -specific concerns • Nursing team reviews: Has sterility (including indicator results) been confirmed? Are there equipment issues or any concerns? 	Surgeon, anesthesia professional and nurse review the key concerns for recovery and management of this patient
Pulse oximeter on patient and functioning	Has antibiotic prophylaxis been given in the last 60 min? <ul style="list-style-type: none"> • Yes / not applicable Is essential imaging displayed <ul style="list-style-type: none"> • Yes/not applicable 	
Does patient have a known allergy <ul style="list-style-type: none"> • No/yes Difficult airway /aspiration risk <ul style="list-style-type: none"> • No • Yes, and equipment /assistance available Risk of >500 ml blood loss (7 ml/kg in children) <ul style="list-style-type: none"> • No • Yes and adequate intravenous access and fluids planned 		

1.2 to 1.5 m. Sliding doors are preferred than spring-loaded doors in order to minimize the generation of the air currents during the opening and closing of the doors. Windows made from glass are preferred, which are to be planned on one side only.

- The surface/flooring: The flooring must be such that it is nonslippery, strong, & with minimum joints to decrease the accumulation of dust and other tiny particulate matter within it.
- Walls: Washable light and soothing painted walls should be present
- Ceiling: Hard, impervious surface, plaster painted ceiling should be present.

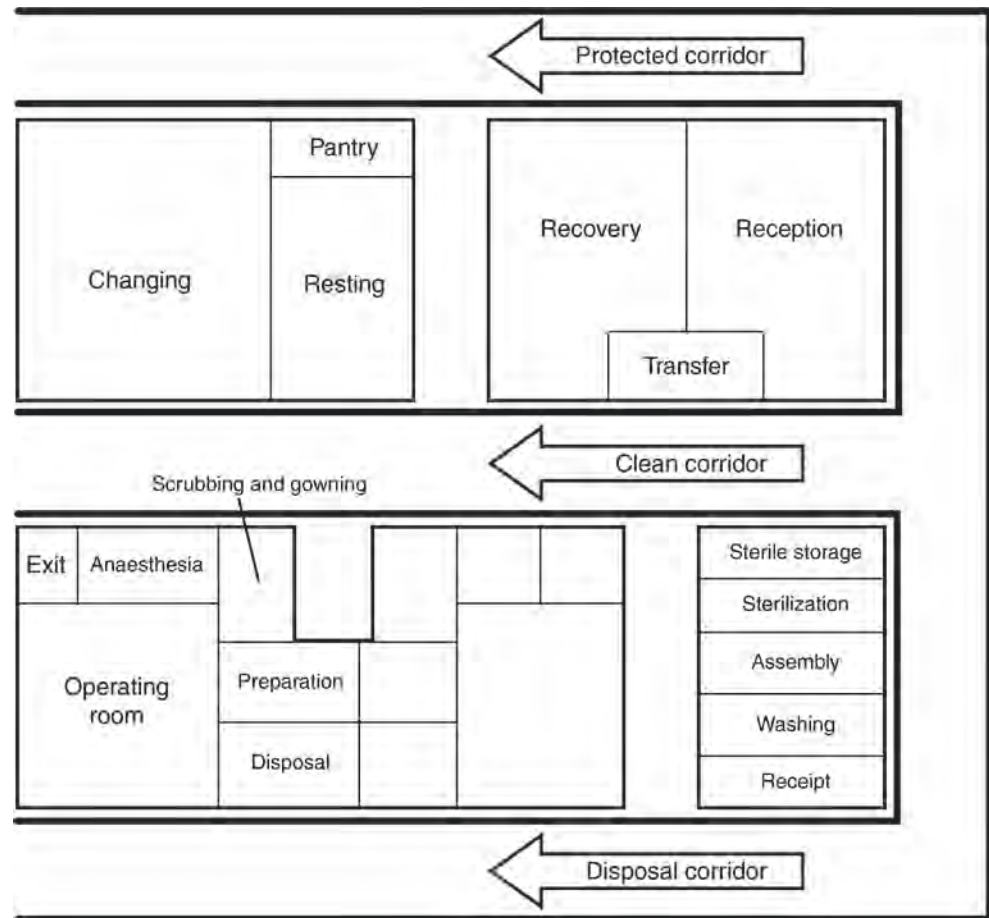
Different Zones of Operation Theater Complex

There are four different zones observed in any operating room complex described on the basis of type of cleanliness present,

presence or absence of microorganisms, and the different procedures to be carried out in each zone (Fig. 9.1).

1. *Protective zone*: It includes
 - Changing room for all the concerned persons
 - Transferring passage for the materials, equipment, and the patient
 - Rooms for administrative staff
 - Storage & record maintenance
 - Pre- and postoperative
 - Intensive and Coronary Care Units
 - Storage rooms to keep the sterilized objects
2. *Clean zone*: Links the protective zone to the aseptic zone
 - Clean rooms
 - Storage room for equipment
 - Rooms designed for surveillance, maintenance, and firefighting
 - Exit areas in case of emergencies exists

Fig. 9.1 Different zones of operation theater complex



©Association of Oral and Maxillofacial Surgeons of India

3. *Aseptic zone*: houses the operating rooms
4. *Disposal zone*: separate exit for disposing contaminated linen /used materials and instruments

Important Points

- The sterilized materials are transported from a sterile area to the operation theater on a covered cart, thus preventing any accumulation of the dust particles on their surfaces.
- Before entering the operation theater, all supplies/materials must be removed from their shipping or transported containers.
- All the blood-coated or soiled instruments/equipment must be transported in a covered wrap or container from the operating room to the decontamination or reprocessing area.
- Care must be taken that the soiled instruments/equipment must not to be stored with the sterilized goods.
- Proper ventilation should be checked regularly and the filters should be changed as required.
- At the time of maintenance or inspection or observation of any fault in the working of the operation theater, the members of The Infection Control team should be informed. The theater should be thoroughly examined by the members of the team and appropriate measures must be taken to maintain the infection control protocols. The operation theater must only be functional after being carefully evaluated and cleared by the infection control team.
- Back-up facility for operation theater in all aspects should be present in any setup to provide any uninterrupted sessions at the time of maintenance or any fault observed.

9.6 Disinfection and Sterilization

Sterilization is the ultimate procedure in controlling the undesired activities of microorganisms that are outside of the human body. Its purpose in the operating field is to prevent the spread of infectious disease, and in surgery, it primarily

Maintenance in the Operation Theater

- The machinery must be surveyed at least every week.

relates to processing reusable instruments. Surgical instruments are an integral part of surgical field and, being reusable, have greater chances of spreading the microorganisms if any of the reprocessing steps fails. Steps of reprocessing include cleaning, repackaging, disinfection or sterilization, and reusing. Cleaning, being the first step in the cycle of reprocessing,

is the major step in the removal of any organic matter present on the surface of the instruments. Any failure in the removal of the visible soil at the initial stage can create a discrepancy in the efficacy of the subsequent disinfection and sterilization procedures. Sterilization is more effective a process than disinfection. The process of disinfection is carried out with the use of various chemical agents. Chemical disinfecting agent necessarily does not kill all microorganisms or spores present on an inanimate object but instead reduces the number of microorganisms to a level that is not harmful to health. Depending on their potency against microbes, they are classified as *High-, Intermediate-, or Low-level* disinfectants.

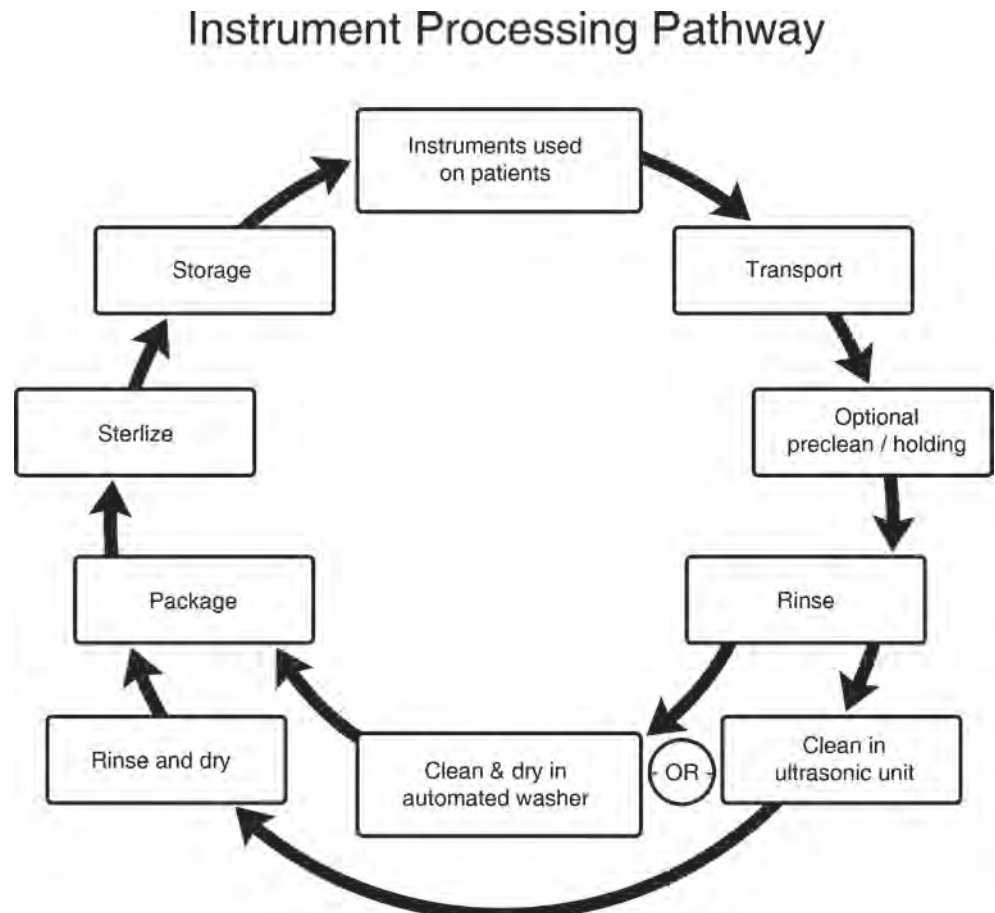
Table 9.4 Spaulding Classification of Medical Devices And Level of Disinfection

- **Critical:** An instrument that has a direct contact with sterile tissues or vascular system [8]; such items are to be sterilized and made free from all microorganisms. Examples are extraction forceps, scalpel blades, bone chisels, periodontal scalers, surgical burs, needles
- **Semicritical:** An instrument that does not usually penetrate the sterile tissues but does come in contact with intact mucous membrane. These items are made free from microorganisms by high-level disinfection. Examples include endoscopes, amalgam condensers, air/water syringe, impression trays, dental hand piece, dental mirrors
- **Noncritical:** An instrument that does not touch the patient directly or come in contact with the intact skin only. These items may be cleaned or disinfected by low-level disinfection. Examples include light arm/handles, dental chair, dental X-ray equipment, chair side computers, chair switches.

The type of the sterilization procedures to be carried out for an object depends upon the classification of the instruments based according to the Spaulding Classification of the medical devices, the type of material of which the object is made of, the microorganisms to be present on the object, and availability of the sterilization methods and equipment (Table 9.4).

The Instrument Processing (Decontamination Steps)
(Fig. 9.2)

Fig. 9.2 Instrument processing steps



Various methods of decontamination include.

- Physical cleaning.
- **Water purification**
- **Ultrasonic cleaning**
- **Disinfection**
- **Antisepsis**
- **Sterilization**

Processing of the clinical or surgical items is a two step procedure.

A. **Cleaning**, being the first step, is the most essential one, which is succeeded either by Disinfection or Sterilization

- Cleaning is the process of removing all the foreign particles present on the surface of the object, which is accomplished by means of two main steps, i.e., cleaning by friction to remove foreign particles and rinsing away by fluids to remove the debris so cleaned.
- If the objects to be sterilized, remain soiled with foreign materials, the microorganisms will be trapped in the organic matter and may interfere with the proper sterilization or disinfection procedure. Therefore, thorough cleaning should always precede the sterilization process.
- Cleaning may be manual or mechanical and is normally accomplished by the use of water, detergents, and mechanical agents. Detergent is essential to dissolve proteins and oil that can reside on instruments and equipment after use.

1. Mechanical cleaning

With the advancement in the sterilization equipment, most units are automated and there is very less handling of dirty equipment by the concerned staff. The equipment to be processed is placed in trays and is ready for washing.

- *Washing machine*: It gives a cold rinse followed by a hot wash at 71 °C for 2 min. This is followed by a 10-second hot rinse at 80–90 °C and then by dry heat at 50–75 °C.
- *Ultrasonicator*: The ultrasonicator is a device, which is extremely efficient in removing the debris. 0.44 W/cm³ of power is used to remove the debris by the process of sonic waves produced. The solution used most often to clean is an enzymatic presoak (protease formula that dissolves protein).

2. Manual cleaning

It is an active method that is carried out by thoroughly brushing the item with the help of a toothbrush under water to prevent the release of aerosols. The brush should be thoroughly cleaned after use and should be dried. The cleaned items are then dried and made ready for the proper sterilization procedure to be carried out depending

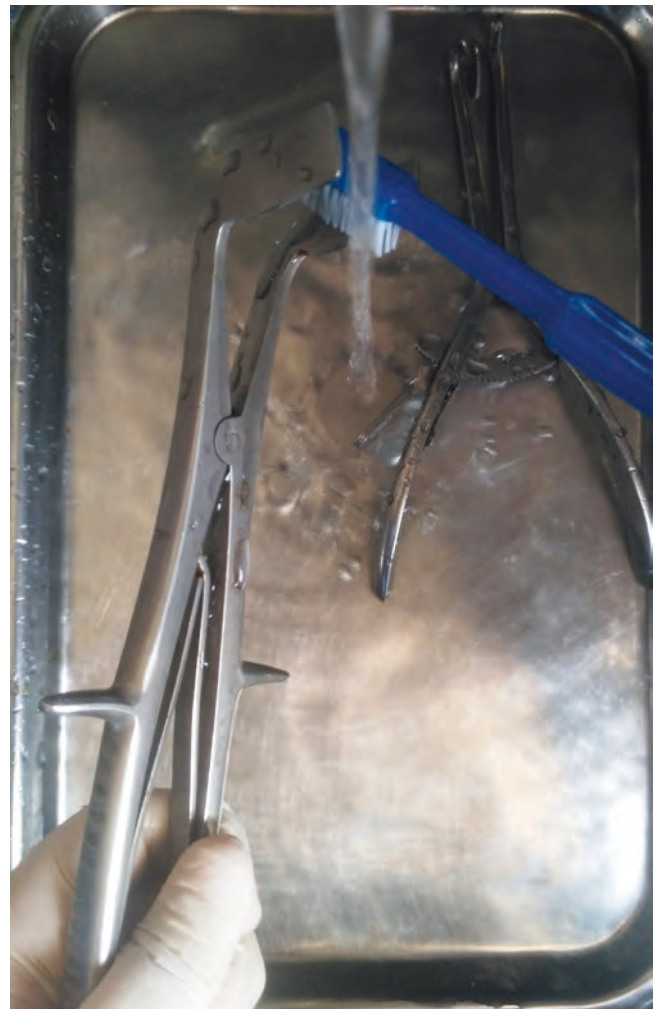upon the material of which they are made and the use they perform.

Manual cleaning is necessary when:

- Cleaning of instruments by mechanical means is not possible
- Instruments to be cleaned are delicate in nature
- Objects to be cleaned have a narrow lumen (Fig. 9.3)

3. Soaking of instruments prior to cleaning:

There are times when cleaning alone cannot remove the debris present on the surface of the objects as the items become highly soiled with foreign materials. For this, it is sometimes necessary to soak instruments/objects prior to cleaning. A container having a deeper base is filled with detergent & water and all the instruments are kept in it for 3–5 min. The solution prepared is agitated by shaking it vigorously. The cleaned instruments are now removed from the container and placed over a tray for air drying.



©Association of Oral and Maxillofacial Surgeons of India

Fig. 9.3 Manual Cleaning

B. Disinfection and Sterilization

• *Disinfection* can be achieved by either thermal or chemical processes. The thermal disinfection procedure is more easily controlled, more reliable, nontoxic and leaves no residue on the surface and is preferred more than chemical disinfection procedures. The main indication of chemical disinfectant use is the heat-sensitive objects. Chemical High-level disinfection (HLD):

(a) Most commonly used for heat-labile instruments/objects (e.g., endoscopes) where single use is not cost effective.

(b) Disinfectants used for this purpose are

- Glutaraldehyde: 2% for 20 min.
- Hydrogen peroxide: 6%–7.5% for 20–30 min.
- Per acetic acid: 0.2–0.35% for 5 min.
- Ortho-phthalaldehyde (OPA) for 5–12 min.

(c) Steps:

- All items to be disinfected are cleaned and dried.
- Fresh disinfectant solution should be made each day in a sterile container. If a previously prepared solution is to be used, an indicator strip is dipped in the solution to check for the effectiveness of the solution.
- Open all hinged instruments and disassemble whichever possible.
- Place all items in the solution completely submerged in the container.
- The container is covered and the instruments are allowed to soak in for 20 min.
- Remove the items using dry, high-level disinfected pickups.
- Rinse thoroughly with boiled water.
- Air-dry by placing on disinfected tray.
- Items disinfected are covered in a disinfected container and used within a week.

Sterilization

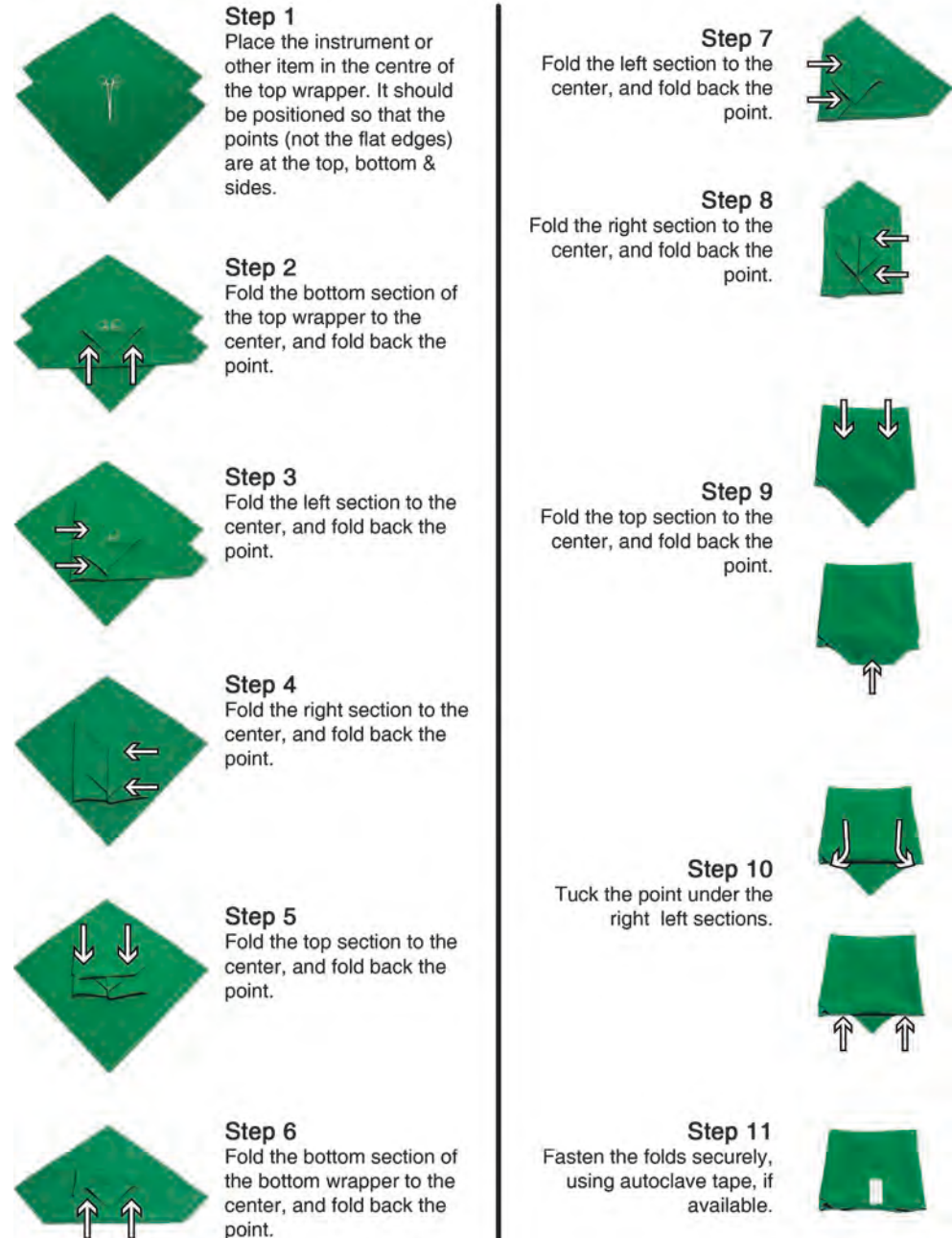
Sterilization is a method by which an article, medium, or surface is made free from all microbial invasions, including spores. The main aim of sterilization of instruments is proper delivery of sterilized instruments at the operating field, thereby maintaining a sterile environment and reducing the spread of infections from one person to another. Proper handling of the sterilized instruments is done by appropriate wrapping and storage of the instruments, thereby increasing the shelf life of the sterilized instruments. The instruments should be bagged or wrapped in a muslin cloth or clear pouches or paper before and after the procedure and the wrapping should be sealed with tape. No pin, staple, or any paper clips are to be applied on the wrapping as these may create small openings, which may allow entry of microorganisms, thereby hampering the process of sterilization. Sterilization is accomplished by:

1. *Steam sterilization (autoclaving):-*

- This is the most simple and efficient means of sterilizing instruments. It is also commonly called steam sterilizing or autoclaving.
- The steam autoclaves best suited for outpatient practice are usually made to operate in the following range.
 - Temperature 121 °C (250 °F) at a pressure of 15 pounds per square inch (psi) for 15 min.
 - Temperature 134 °C (270 °F) at a pressure of 30 psi for 3 min. This process termed “flash sterilization” has practical use in the operating room where fast sterilization of instruments may be necessary.
- This combination of moisture and heat provides the bacteria-destroying power currently most effective against all forms of microorganisms.
- Mainly used for items that are wrapped or porous.
- Autoclaves are either classified as horizontal or vertical (based on design) and gravity displacement or vacuum type (based on functioning).
- Autoclaves can also be classified as Type “N” and Type “B.”
- Type “N” autoclaves are the ones that do not remove air from the sterilization chamber with the help of a vacuum pump. These are used for solid loads.
- Type “B” autoclaves remove air from the sterilization chamber with the help of a vacuum pump. Wrapped and hollow instruments, which can be sterilized and used later, are to be sterilized by this type of autoclave.
- Importance of bagging the instruments for sterilization.
 - The main aim of bagging or wrapping the instruments prior to sterilization procedure decreases the chances of contamination of the items after the sterilization procedure is complete.
 - Two-layer wrapping of objects should be preferred and the materials used for this can be cotton fabric or muslin, paper, newspaper (Fig. 9.4).
- Monitoring of sterilization.
- Sterilization monitoring is a process by which adequate sterile environment and the effectiveness of the procedure is determined by assessing the biological, mechanical, and chemical parameters.
- The most widely used and accepted parameter of assessing the sterilization procedures is the use of biological indicators (BIs) that directly inhibit the growth of highly resistant microorganisms, rather than merely testing the physical and chemical conditions necessary for sterilization. Since the spores present in a biological indicator are in a much higher number and are highly resistant by nature compared to the other and common microorgan-

Fig. 9.4 Diagram depicting the way the instruments are wrapped for sterilization

Cleaning, Disinfection & Sterilization of Medical Equipment



©Association of Oral and Maxillofacial Surgeons of India

isms found on items used for the patient, an inactivated biological indicator indicates that the other microorganisms are killed depicting an effective sterilization procedure. A control BI, from the same lot as the test indicator and not processed through the sterilizer, should be incubated with the test BI; the control BI should yield positive results for bacterial growth.

- Assuring the temperature & the cycle time, and observing the gauges or display for the pressure on the sterilization equipment for each set of items to be sterilized come under the mechanical monitoring of sterilization.
- Certain chemical agents are used to check the efficacy of the sterilization procedure being carried out by undergoing chemical changes in their properties on

being exposed to the sterilizing conditions. These chemical agents are called the chemical indicators and these include TST (Time-Steam-Temperature) Strip. This TST strip is to be placed in a big surgical wire basket and when exposed to a critical time, steam, and temperature it undergoes a change in color from yellow to dark blue indicating complete sterilization procedure. Another strip is to be used when double-layered packing of instruments in crepe paper is done to assess the parameters inside the sterilizer.

- Another form of sterilizing monitor is the use of the external indicators. These are usually in the form of Tapes. The main indication of the complete sterilization procedure is the change in color of the strips of the tape from yellow to dark brown or black.
 - *How to store the sterilized instruments/objects*
 - There must be a separate area for storing of the sterile instruments and single-use (disposable) products.
 - The storing of the bagged sterilizer objects can be depicted either by the date on which they are sterilized or the procedure for which it is to be used or an event causing it to become contaminated.
 - All the packed items must be carefully inspected before using to verify the integrity of the outer covering and the condition of the packing (dry/wet).
 - Once the packing is assessed and if any breach is seen in the packing, the wrapping should be replaced and the instruments again sent for the sterilization procedure.
 - All the sterilized instruments must be kept in covered drawers.
 - Care must be taken that all instruments should be placed away from the place where chances of getting wet are higher.
 - *Expiry of the sterilized instruments*
 - The expiry of the materials and objects undergoing the sterilization procedure depends on the type and time of the sterilization process, the efficacy of the process, and the handling of the sterilized instruments.
 - Once all the sterile conditions are met, 4 weeks is the maximum time for which the items are considered sterilized and safe for use. However, the contaminated instruments are preferred processing and sterilization prior to every procedure.
2. *Ethylene oxide:*
- It is used for sterilization of heat-labile and moisture-sensitive items, supplies, and equipment.
 - The operating cycle ranges from 2–24 h and it is a relatively expensive process.
 - It can be used for glass, paper surfaces, clothing, plastics and metals, food stuffs, and dental equipment.
 - It is unsuitable for fumigating rooms because of its explosive property.

3. *Dry heat:*

- It may be used for sterilization of instruments with cutting surfaces.
- No corrosion occurs with this method of sterilization.
- Dry heat sterilization, which usually occurs consists of hot air oven has typical cycles of 1 h at 171 °C or 2 h at 160 °C.
- Air is a poor conductor of heat and requires a long time for getting the instruments effectively sterilized.

4. *Chemical sterilization and disinfection:*

- This is also a choice for some limited circumstances.
- Some instruments cannot be subjected to high temperatures and in a field environment chemical sterilization may have to be used.
- The disinfectant must remain in contact with the surface for appropriate time.
- Disinfectants include Chlorine solutions, 2–3.2% glutaraldehyde, iodophors, and phenols.

9.7 Operating Room Decorum

1. *Hand hygiene:*

Hand hygiene by operation theater persons is the most efficient way to reduce the risk of spread of infections.

2. *Surgical hand wash:*

- Surgical hand wash or surgical hand rub should be carried out prior to the procedure in order to decrease the residing flora of the hand.
- Steps:
 - All jewellery from wrists and hands must be removed.
 - The temperature of water is to be adjusted so that it is slightly warm. Hands and forearms are to be washed 5 cm above the level of the elbows to remove any particles of dirt.
 - Before performing the first scrub of the day, a nail cleaner is used to clean the fingernails and the nail beds.
 - The nails should be cut short and no nail polish should be used.
 - Antimicrobial agent is to be applied on the hands and in circular motion; lathering should begin at the finger tips of one hand and between the fingers, continuing from the fingertip to 5 cm above the elbow. The same process is to be repeated for other arm and hand.
 - The rubbing should be done for a period of 3–5 min.
 - Each arm is to be washed separately at the level of elbow, starting at the fingertips.
 - One side of the sterile towel is used to dry the fingertips up to the elbow of one hand and the other side is used to dry the same on the other hand.

3. Barrier techniques:

Barrier techniques are useful where the chances of spread of infection are higher.

(a) Head Cover

Prior or during the procedure, all facial and head hair should be tied properly and covered by means of head covers. Ideally head covers should be disposable and made of soft, nonporous cloth like material. If one has long hair, the hair should be tied in a bun. In situations where tying a bun is not possible, use of helmets or hoods or headgears is of utmost significance.

(b) Masks

- Tuberculosis is one of the most common infectious diseases that can spread through airborne route,
- The main aim of using a mask is the prevention of transmission of infectious agents from the member of the operating team to the patient's wounds and also protecting the operating team members from the splashes and sprays from the patient.
- The masks, which are disposable in nature, are always preferred.
- The mask should be made of synthetic fibers, must be flat with two or three pleats that expand to cover the area up to chin, and should have filters of polypropylene or polyester (Fig. 9.5).

(c) Scrub suits and cover gowns

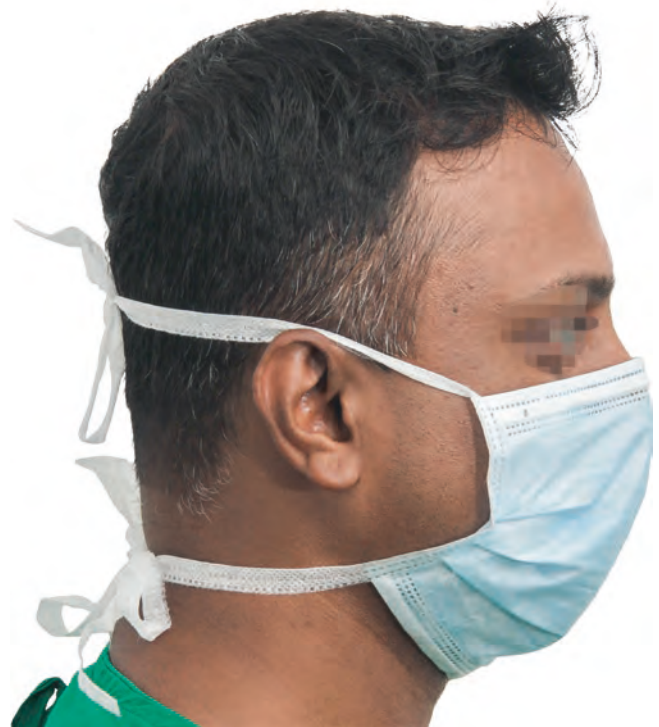These are the pair of garments to be worn over, or instead of regular clothing of the persons involved in the surgical procedures to protect the transmission of any infectious agent present on the regular clothing from the operating personnel to the patient or any other personnel. These should have a simple design, should be comfortable, should be easy to clean and wash, should be economical, easily replicable if damaged and should have minimal place for the contaminants to hide.

(d) Surgical gowns

These are a loose pair of clothing to be worn over the scrub suits or cover gowns at the time of the surgery to protect both the patient and the operating personnel from transfer of microorganisms, blood or body fluids, and another particulate matter.

Steps of wearing gown:

- Dry the hands completely and hold the gown in such a manner that it is at the least risk of contamination.
 - Slip arms into the sleeves through the armholes, keeping at the shoulder level and away from the body.
 - Hold arms out and slightly up.
 - The circulating person must pull the gown over the shoulders touching only inside of the gown.
- All the belts and loops are to be tied securely (Fig. 9.6).



©Association of Oral and Maxillofacial Surgeons of India

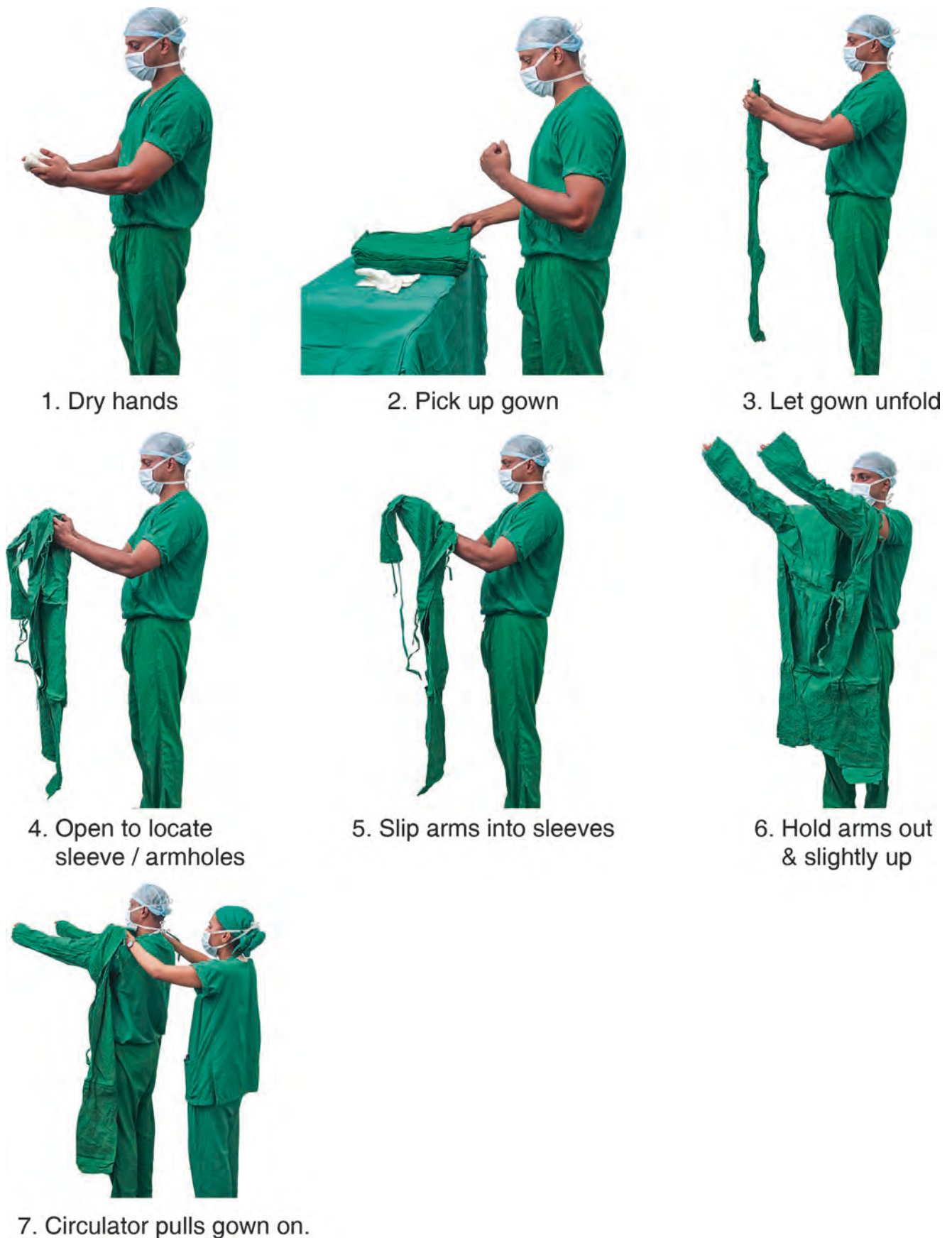Fig. 9.5 Surgical Mask

(e) Gloves

They help to protect the operator from infection by bacteria and viruses from patient's blood. Gloving is essential to protect both the surgeon and the patient from blood-borne viruses and to prevent wound from becoming contaminated with the surgeon's skin flora. The "open gloving" and "closed gloving" technique of donning the gloves should be employed for wearing gloves.

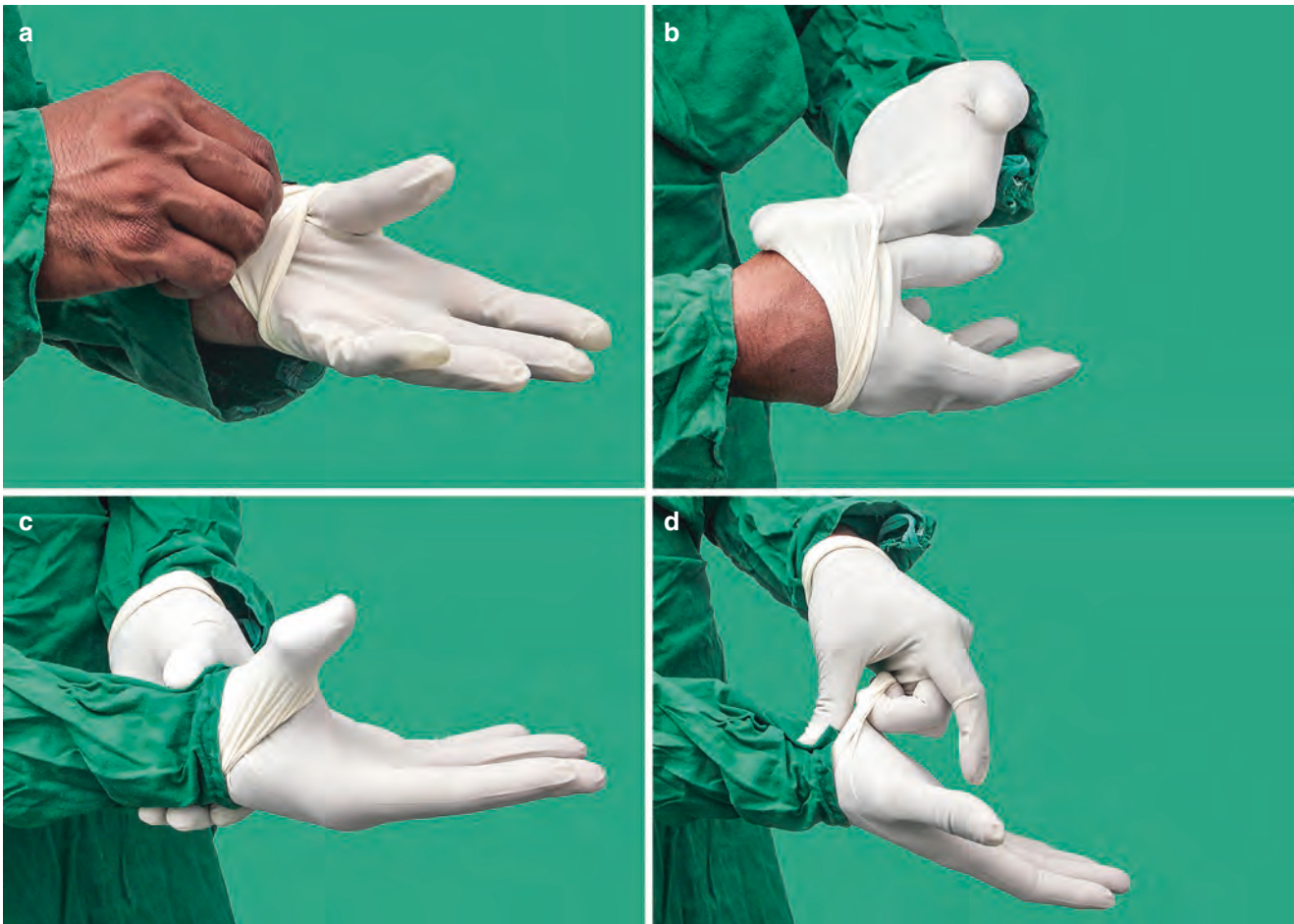
• Steps in wearing gloves by Open Gloving Technique

- Handwashing must be performed under aseptic conditions.
- Inspect the outer covering for the integrity. Open the first nonsterile packaging by peeling it completely off the heat seal exposing the inner sterile wrapper, but without touching it.
- The inner sterile packing is kept on a dry area, without touching the outer surface. Open the package and fold it toward the bottom so as to unfold the paper and keep it open.
- By using index finger and thumb of one hand, the folded edge of the glove is grasped.
- In a single movement the other hand is slipped into the glove.
- The second glove is picked by using the cuff of the other glove and sliding the fingers of the gloved hand into it.



©Association of Oral and Maxillofacial Surgeons of India

Fig. 9.6 Putting on the sterile gown



©Association of Oral and Maxillofacial Surgeons of India

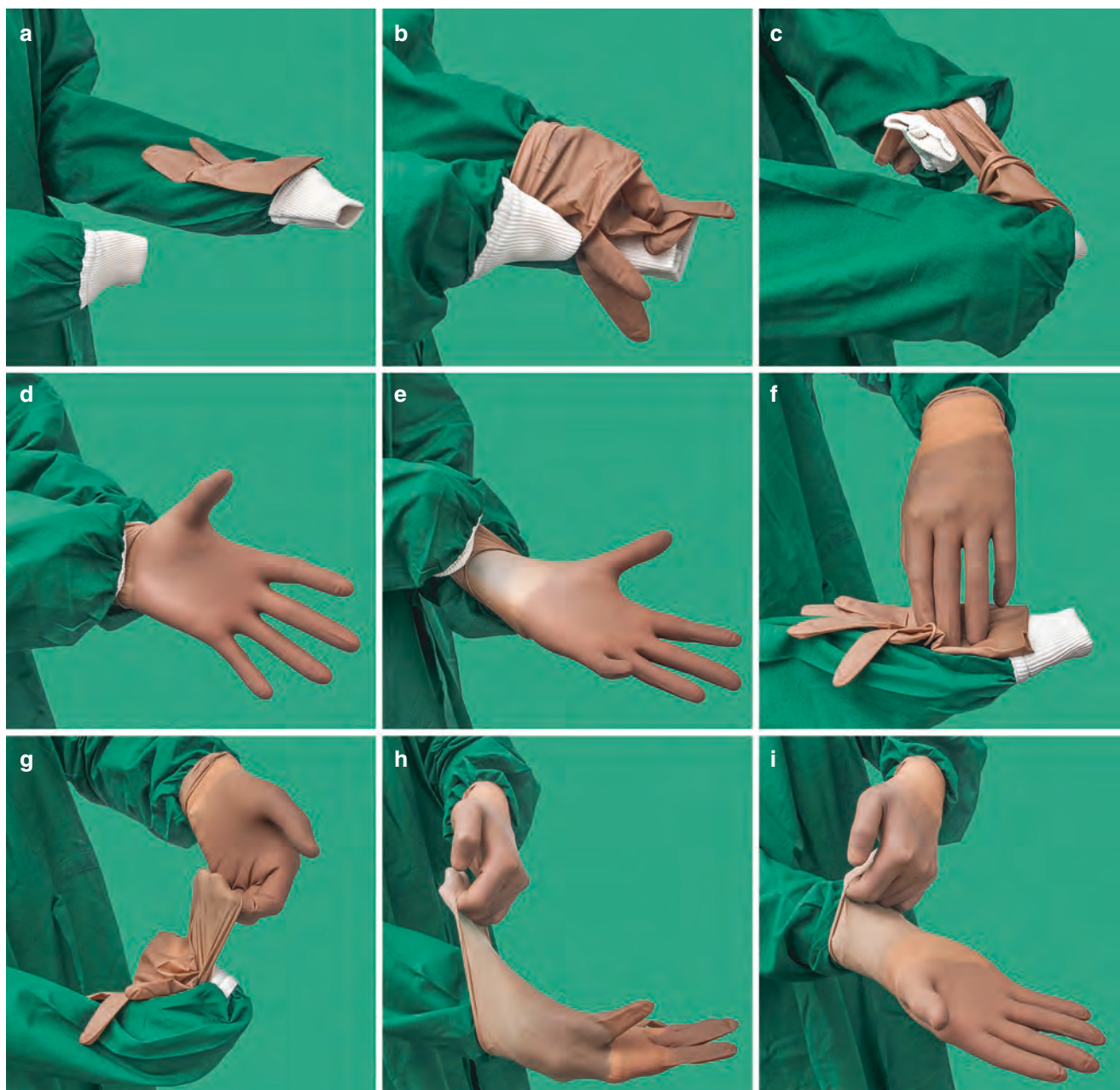
Fig. 9.7 Putting on sterile gloves by open gloving technique

- In a single movement, slip the second glove on to the ungloved hand while avoiding any contact/resting of the gloved hand on surfaces other than the glove to be donned (Fig. 9.7).
- Steps of wearing gloves by closed gloving technique
 - If the cuffs are not fitting, a tuck is taken in each gown.
 - The circulating person should open the outer covering of the glove and should flip them onto the sterile field.
 - The inner packing containing the gloves is opened carefully and the glove is picked up by the folded cuff edge with the hand covered by the sleeve.
 - The glove is placed on the sleeve of the opposite gown, the palm facing downwards, with the fingers of the glove pointing toward the shoulder.
 - The gloves should be placed in such a manner that the rolled cuff edge of the gloves connects the sleeve to the gown cuff. Bottom cuffed and rolled edge of the glove is grasped at the bottom with the index finger and thumb.
 - With the opposite hand, the outermost edge of the cuff of the gloves is held taking care that the uncovered fingers are not exposed by it.
 - Stretch the glove over the hand
 - By using the opposite hand covered with sleeve, both the cuffs of the sleeve and the glove are seamed and the glove is pulled over the hand.
 - The same procedure is to be followed for the other hand. The fingers are adjusted to properly fit in the glove (Fig. 9.8).
- 4. The role of drapes:

Drapes are used during surgical procedure to protect the contacting of the unprepared surfaces/areas and maintaining the sterility of environmental, equipment, and the surrounding of the patients.

The different drapes available are:-

 - Towel drapes, which are used for squaring off the operative site, wrapping syringes & small instruments, and



©Association of Oral and Maxillofacial Surgeons of India

Fig. 9.8 Putting on sterile gloves by closed gloving technique

drying of the hands. These must be more resistant to water and must be made of cotton compared to linen.

- Lap sheets are used for covering the patient. They are large and long, usually made of lightweight cotton, and provide limited protection and coverage to the patients or staff or the surface areas.
- Site drapes are made of cotton and have a circular opening in the center that is placed over the prepared operative site. These drapes are primarily intended for use with minor surgical procedures (Fig. 9.9).

9.8 Classification of Surgical Wounds

A widely used classification of surgical wounds is based on an estimate of likelihood of bacterial contamination of the operative site. In 1964 [9], National Academy of Sciences/ National Research Council defined five general classes of operations:

1. *Refined-Clean*: Elective operations not drained and primarily closed.



©Association of Oral and Maxillofacial Surgeons of India

Fig. 9.9 Different types of drapes

2. *Other-Clean*: Clean cases other than refined clean.
3. *Clean-Contaminated*: Oral cavity, gastrointestinal, or respiratory tract entered without significant spillage, entrance of genitourinary tract in presence of infected urine, entrance of biliary tract in presence of infected bile or minor break in technique.
4. *Contaminated*: Major break in operative techniques (e.g., surgical entrance of unprepared bowel without gross spillage of bowel contents); acute bacterial inflammation without pus; fresh, traumatic wound from a relatively clean source.
5. *Dirty*: Presence of pus or perforated viscous (prior to operation), old traumatic wound, or traumatic wound from a dirty source.

Currently, this classification has been condensed into four groups for general use, without a subdivision of the clean category and in the modified form it is categorized into four categories [10]

1. *Clean sites (wounds)*:
 - Elective (not urgent or emergency).
 - Primary closed.
 - No acute inflammation or transection of tracheobronchial, biliary, gastrointestinal, oropharyngeal tracts.
 - No technique breaks.
2. *Clean-contaminated sites (wounds)*:
 - Emergency or urgent cases that are otherwise “clean.”
 - Elective procedures.
 - Reoperation via “clean incision” within 7 days.
 - Blunt trauma, intact skin, and negative exploration.
3. *Contaminated sites (wounds)*:
 - Acute nonpurulent inflammation.
 - Major technique break or major spill from hollow organs.
 - Entrance of genitourinary or biliary tracts in presence of infected urine or bile, respectively.
 - Penetrating trauma less than 4 h old.
 - Chronic open wounds to be grafted or covered.
4. *Dirty sites (wounds)*:
 - Purulence or abscess.
 - Preoperative perforation of tracheobronchial, biliary, gastrointestinal, oropharyngeal tracts.
 - Penetrating trauma more than 4 h old.

9.9 Risk Factors Affecting the Rate of Postoperative Wound Infections

“*Cut Well, Sew Well, Heal Well*” is an axiom favored by surgeons but is not always destined to be true. Altemeir and Culbertson (1965) [11] depicted that the risk of infection varies:

- (a) The risk of infections is proportional directly to the dose of contamination to bacteria.
- (b) The microbial virulence is also directly proportional to the risk of infections.
- (c) The patient’s ability to control and inhibit the resistance is proportional inversely. [12]

These factors interact in a complex way to fasten the development of infection. Since the days of Altemeier, clinical and epidemiologic studies have identified the risk factors that affect the rate of postoperative surgical site infection. This can be best explained by the classical epidemiological triangular model, i.e., model of interaction between agent host and environment resulting in disease (Fig. 9.10).

The risk of postoperative wound infection also depends on the patient factors, pre and intraoperative factors (Table 9.5). Haley et al. (1985), in the Study of the Efficacy of Nosocomial Infection Control “(SENIC),” [13] identified four independent and additive risk factors for postoperative wound infection. These factors are operation on the abdomen, operation lasting for more than 2 h, contaminated or dirty wounds (NRC CLASSIFICATION), and the presence of more than three discharge diagnoses.

- Hair removal should not be performed on routine basis to decrease the risk of surgical site infection. Razors should not be used to remove the hair as they increase the chances

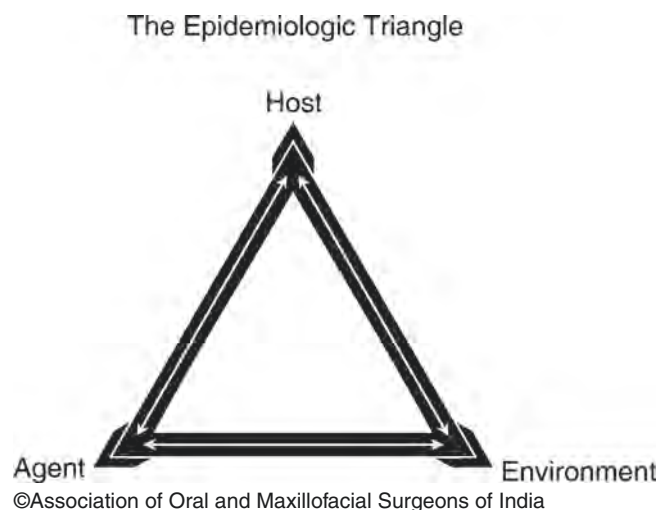


Fig. 9.10 Classical Epidemiological triangle

Table 9.5 Factors that predispose a patient to infection

<i>Patients factors</i>	Preoperative factors	Intraoperative factors
Age • Malnutrition • Obese persons • Underlying diseases • Hidden infections • Immunosuppressive therapy • Any recent surgery • Longstanding illness	• Longer duration of hospital admission • Improper scrubbing prior to procedure • Removal of hair • Preoperative prophylactic coverage	• Contamination at the time of procedure • Longer duration of the procedure • Any foreign object • Transfusion reactions occurring at the time of the procedure

of infections [14]. Electric clippers with disposable heads must be used only for removing hair few hours prior to the surgical procedure.

- The treatment protocols and the condition of the patient during the hospital stay make them more prone to the spread of infections.
- Wound dressings: Cover surgical incisions with an appropriate interactive dressing at the end of the operation.

9.9.1 Factors Influencing the Development of Nosocomial Infections

9.9.1.1 The Microbial Agent

Hospital infections occur as a result of a variety of microorganisms. The microorganisms causing the disease may be divided into the following categories:

1. Conventional pathogens are the ones that are capable of causing a disease in normal and healthy person.
2. Conditional pathogens are the ones that initiate the onset of a disease in persons who have decreased immunological response to infection or when implanted directly into sterile area or tissues.
3. Opportunistic pathogens are the ones that normally do not harm its host but can cause disease when the host's resistance to the microorganisms is low.

During the stay in a hospital, the patient comes in contact with various kinds of microbial agents (such as viruses, fungi, parasites, and bacteria), which are the main cause of the occurrence of infections in a patient. This exposure is not the only reason for the development of hospital-acquired infections. The other possible reasons are the host's natural defense mechanisms (healthy/compromised/immunosuppressed), conditions present in a hospital environment, microbiology of the microbial agents (characteristic features), infective material present on the microbial agent, resistance to the antimicrobial agents, and other factors. The hospital-based infections may be a result of the spread of

infection from one person to the other or by the residential flora of the patient or from any contaminated sources or from sources of the external origin (e.g., airborne diseases).

Following are the factors that are the main sources of spread of hospital-based infections:

9.9.1.2 Susceptibility of the Patient

Patient factors that lead to the occurrence of infection are age, host's immune response, presence of any disease, and interventions, which either help in diagnosing or treating any condition. Patients, either infant or older individuals, are at a higher risk of acquiring infections. Patients having a compromised immune system, undernourished, having some underlying chronic disease (AIDS, leukemia, malignant tumors, renal failure, diabetes mellitus, etc.), undergoing irradiation therapy, all at the highest risk of being infected by the hospital-based infections. Certain processes like catheterization, biopsy, intubations, etc. make the patient more vulnerable to these infections.

9.9.1.3 Resistance of the Bacteria

Resistance of bacteria to antimicrobial agents is seen with the prolonged or prophylactic use of these agents. The microbial agents present normally in the human flora have both sensitive and resistant strains. Some antimicrobial agents have their action on sensitive strains by suppressing their activity, whereas the resistant strains are still active. These active resistant strains are the major cause of the development of resistance against the antimicrobial agents. Examples of resistant microbial agents are Multiresistant Klebsiella, strains of pneumococci, staphylococci, etc. In low-income or middle-income countries, this is the major problem faced due to unavailability and unaffordability of the better drugs.

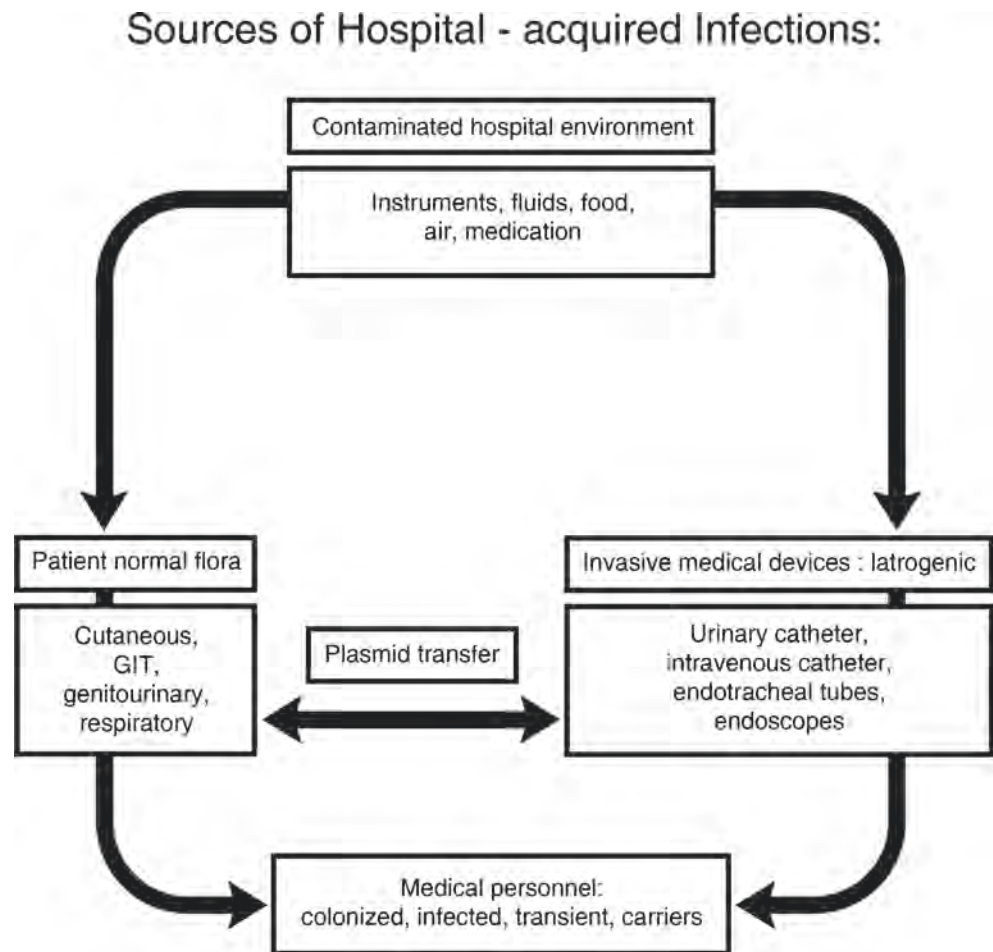
9.9.1.4 Month of Operation

The possible explanation for increased infection rates in summer is the relatively high environmental temperature leading to humid climate, resulting in excessive sweating. In addition, excessive sweating results in the displacement of bacteria lodged in skin appendages to the surface.

9.9.1.5 Use of Electric Cautery

The use of electric cautery for cutting and coagulation during surgery causes more inflammation; more necrosis and abscess than the conventional use of scalpel and thus it increases the susceptibility of tissue for infection. Soballe et al [15], in their experimental study, found that electric cautery lowers the contamination threshold for infection of laparotomies and concluded that electric coagulation current should be used only when the need for meticulous hemostasis outweighs the considerably increases risk of infection.

Fig. 9.11 Sources of hospital-acquired infections



©Association of Oral and Maxillofacial Surgeons of India

9.9.1.6 Duration of Operation

There is a direct correlation between the infection rate and time taken for the procedure. This may be the result of the more complicated operations being of longer duration, increased wound contamination from airborne bacteria, increased damage to the tissues due to large exposure of the wound, and increased manipulation; moreover, local resistance of tissue is reduced due to drying.

9.9.1.7 Spread of Infection

The microbial agents are spread by different ways in a health care setup. The different ways with which the agents can spread are contacting, droplets, airborne route, via vehicle, and vector-borne (Fig. 9.11).

Sources of the infectious agents are either external, i.e., from one person to the other, or from the hospital's environment; or internal, i.e., within the patient himself.

- *Contacting* is the most frequent and important route of spread of infections. It is further of two types, i.e.

- *Direct* contacting is the spread of infection directly from the person infected from the infection to other normal who has increased chances of being infected. It also occurs among two patients where one acts the source of microbial agents and the other becomes the one to receive the infection.

- *Indirect* contacting is the spread of infection indirectly from one person/object to the other. It involves contact of a susceptible host with a contaminated intermediate object. Droplets spread results due to generation of droplets from the source person mainly during coughing, sneezing, and talking, and during the performance of certain procedures such as bronchoscopy, which can travel a shorter distance via air and get deposited on the body of the other susceptible person.
- *Airborne transmission* results from spreading of small particulate matter (approximately 5 µm or smaller in size) through the air, which remain suspended in the air for a longer period of time. These particles are passed from one individual to the other by the process of inhalation of

these particles. The main diseases to be spread via the airborne route are Tuberculosis, Influenza, Common cold, etc.

- *Vehicle spread* is the spread of infectious microbial agents to the individuals by means of contaminated items such as food, water, medications, devices, and equipment.

Vector-borne transmission occurs when vectors such as mosquitoes, flies, rats, and other vermin transmit microorganisms.

- Bronchoscopy
- Cardiopulmonary resuscitation
- Sputum induction
- Surgery on the lungs
- Nebulizer therapy
- Noninvasive positive pressure ventilation (BIPAP, CPAP)
- An autopsy on the lungs
- High-speed devices such as those used for surgery, post-mortem
- Dental procedures

9.10 COVID 19 and Maxillofacial Surgery

The occupational risk of acquiring viral diseases has been well known in Maxillofacial Surgery [16]. The WHO announced the Corona virus pandemic also known as COVID-19 as a public health emergency of international concern on January 30, 2020.

Coronaviruses are RNA viruses infecting many species of animals including humans, name coronavirus was derived from corona meaning crown like because of the morphology observed for these viruses in the electron microscope. This family of viruses includes Middle East Respiratory Syndrome (MERS-CoV), Severe Acute Respiratory Syndrome (SARS-CoV), and novel Coronavirus (n CoV).

Coronavirus is enveloped having round, spherical, or sometimes pleomorphic structure, with size ranging from 80 to 120 nm in diameter, containing a positive-strand RNA. The virus is made up of lipid bilayer envelop, membrane protein, and nucleocapsid, these structures also protect the virus when the virus is outside the host cell. The lipid bilayer forms the viral envelop which anchors the membrane protein, envelop protein, and the spike protein. The spike protein (S-protein) is responsible for the crown-like structure of the coronavirus as it forms the protrusions from the surface which bind to the host cells.

9.10.1 Mode of Transmission of SARs-CoV 2

Human to human transmission is due to respiratory droplet transmission and contact transmission. Spread occurs through coughing, sneezing, spitting, contacting the body fluids of the infected patient. The COVID-19 can remain infectious on inanimate surfaces from 2 h to 9 days, depending on the humidity, temperature, surface type, and viral load [17]. It has become an occupational threat to health care providers worldwide.

Some of the known routes of spread of infection to health care providers are:

- Manual ventilation with a bag and mask
- Intubation
- Open endotracheal suctioning

Aerosols generating procedures (AGP) create widespread environmental contamination and therefore pose a greater risk of transmission of infection to healthcare workers. Oral and maxillofacial surgeons are particularly vulnerable to this transmissible disease by way of the droplet or aerosol transmission due to the area of work and the type of instrumentation [18].

The incubation period is long and unpredictable ranging from 0 to 27 days with a mean of 6.4 days. Recent studies have shown that asymptomatic patients and those within the incubation period are also potential spreaders of the disease [19].

9.10.2 Symptoms

Symptoms may range from mild symptoms to severe respiratory distress and some patients may be asymptomatic.

- Common symptoms may include fever, cough, fatigue, shortness of breath, loss of taste, and smell.
- Less common symptoms may include myalgia, headache, sore throat, and chills.
- Rare symptoms may include nausea, vomiting, nasal congestion, diarrhea, palpitation, and chest congestion.

9.10.3 Radiographic Findings

- **Chest X-ray** may show findings that of atypical pneumonia showing bilateral consolidations in lateral lower lobes, bronchovascular thickening.
- **Chest CT** ground-glass opacity and areas of consolidation laterally.

9.10.4 Testing and Laboratory Findings

The real time polymerase chain reaction (RT-PCR) of respiratory secretions from bronchoalveolar lavage, endotracheal aspirate, and nasopharyngeal or oropharyngeal swab is the definitive test.

Other laboratory findings include lymphopenia, increased prothrombin time, and mildly raised CRP and ESR.

9.10.5 General Preventive Measures

COVID 19 has shifted the focus on teleconsulting which includes tele screening, telemedicine, and triage. Telemedicine should be practiced whenever possible to decrease the footfall.

Thorough history should be obtained from the patient regarding COVID 19 illness and elective procedures should be postponed and only emergent conditions should be taken up for surgery.

Patient should be called on the basis of appointments, time between two appointments should be sufficient enough to perform all necessary sanitization measures and ensure minimal patient to patient overlap. In the waiting area, posters should be displayed to encourage hand hygiene and the wearing of masks and the area should be well ventilated. A minimum of 2 m distance should be maintained between the individuals.

Extraoral radiographs should be preferred as an alternative to intraoral periapical radiographs.

In the operatory there should be minimum personnel present, Air Conditioners should be avoided, doors and windows are advised to be kept open. The operating room should be spacious with adjoining two rooms for donning and doffing of the PPE's. No touch sensor-based sanitizer dispenser should be installed at the entry and exit of OR [20].

All the surfaces of equipment like OR table, motor drills etc., should be covered with plastic sheets and sheets to be changed after every patient.

OT's should be equipped with HEPA filter (0.1 micron efficiency) and high frequency of air changes (ideally 25 per hour) should be ensured to reduce the viral load [20].

High-volume suctions should be used with one-third of suction jars prefilled with povidone-iodine solution.

The Povidone Iodine solution has been shown to have significant viricidal activity up to 3 h and it has been advised to coat the oral cavity and nasal passages of both the patient and the operating team before the surgery [21, 22].

Fogger machines with 0.5% sodium hypochlorite can be used for sterilization of dental chairs, tables, doors, door-knob, etc. [20]. One-minute contact of the chemical ensures viral kill.

9.10.6 Personal Protective Equipment

- Masks including three-ply surgical masks, N95, N99 (FFP3), and the Powered air-purifying respirators (PAPR's) provide viral filtration in the increasing order. It is important to mention that N95 masks were not found to be adequate to prevent transmission in Chinese surgeons

and PAPR's had to be used to prevent transmission from COVID patients [23].

- Surgical gloves.
- Goggles and cover all gowns.
- Triple protection gowns and face shield protect the surgeon from exposure to any kind of infected aerosols, body fluids of the patient. Disposable gowns are made of non-woven material and protect from liquid penetration. Personal protective equipment like basic kit 45 GSM, medium kit 70 GSM for surgery, and advance kit for ICU 180 GSM are recommended to be worn [20].

9.10.7 Specific Precautions to Be Taken During Surgery

- Surgery on COVID patient should be performed in a negative pressure theater or in airborne infection isolation room [20].
- Focus should be on minimally invasive techniques whenever possible which could reduce the time of surgery and/or reduce aerosol generation.
- Local anesthesia with appropriate sedation should be preferred over GA.
- The surgeon should enter the theater after 20 min following intubation with complete PPE to minimize the exposure to aerosols [23].
- Scalpels should be preferred over cautery.
- Use of high-power drills, oscillating saw, and forceful irrigation should be avoided.
- Absorbable sutures should be used to avoid unnecessary trips of the patient [18].

As the COVID-19 situation is a dynamic evolving one and there is no definitive treatment available proper planning and implementation of infection control protocols are key to preventing transmission of the disease in the Maxillofacial settings.

9.11 Control of Nosocomial Infections

CDC elucidated certain guidelines to check the nosocomial infections in the Study on efficacy of nosocomial infection control (SENIC). These guidelines have decreased the emergence of hospital-acquired infections by a greater number. However, any breach in the infection control procedures can lead to spread of such infections.

Certain conditions leading to improper infection control and spread of such infections are:

1. Improper sterilization and disinfection procedures.
2. Presence of contaminants in the food or water

3. Environment of the health care setup.
4. Untrained and inadequate personnel
5. Insufficient knowledge of Infection control principles and practices among the staff.
6. Antibiotic abuse both in the community and in the hospital.

9.11.1 Prevention from Nosocomial Infections

Following are the steps that can be taken by the staff in a hospital setup to prevent the spread of such infections:

- Isolation rooms for persons suffering from contagious diseases such as COVID 19 and tuberculosis.
- Hand-scrubbing practices prior to performing any procedure.
- Disinfecting all the areas in a health care setup.
- Adequate sterilization and disinfection protocols to be followed everywhere.
- The wound dressings should be changed at an appropriate time with the use of proper agents.
- The antimicrobial agents should be carefully used. Prolonged use should be avoided whenever possible to avoid the emergence of the resistance.
- Proper management of the biomedical waste.

9.12 Conclusion

Preventing and controlling infections is the key factor in improving care and ensuring safety of both the patient and the health care worker. Infection control addresses factors related to the spread of infections within the operation theater complex (whether patient-to-patient, from patients to staff and from staff to patient, or among staff), including prevention (via hand hygiene/hand washing, cleaning/disinfection/sterilization, vaccination, monitoring).

Integrated infection control in the operation theater has various aspects, ranging from its designing ,environmental cleaning , management of biomedical waste and adherence to theatre attire. Use of Personal Protective Equipment (PPE) including gloves, gowns, face masks ,respirators and full face visors are essential to minimize risks of occupational infections. Whether in developed or developing country, where resources are limited, thorough knowledge about the principles of infection control and a little ingenuity will suffice to solve the problem of hospital-acquired infections.

Surgical site infections are a result of microbial invasion in a sterile atmosphere. The main sources of microbial

invasion in the operating theater include the atmosphere of the operating theater, the medical and the paramedical staff present at the time of the procedure, surgical instruments, and the patient at times also. Proper designing of operation theater, appropriate microbiological monitoring, proper sterilization, and strict adherence to barrier techniques form the basis to prevent infections in an operating environment.

References

1. Weiser TG, Regenbogen SE, Thompson KD, Haynes AB, Lipsitz SR, Berry WR, Gawande AA. An estimation of the global volume of surgery: a modelling strategy based on available data. *Lancet*. 2008 Jul 12;372(9633):139–44.
2. Weiser TG, Haynes AB, Molina G, Lipsitz SR, Esquivel MM, Uribe-Leitz T, Fu R, Azad T, Chao TE, Berry WR, Gawande AA. Size and distribution of the global volume of surgery in 2012. *Bull World Health Organ*. 2016 Mar 1;94(3):201.
3. Bali R, Sharma P, Nagrath S, Gupta P. Microbial isolations from maxillofacial operation theatre and its correlation to fumigation in a teaching hospital in India. *Journal of maxillofacial and oral surgery*. 2014 Jun 1;13(2):128–32.
4. de Lissovoy G, Fraeman K, Hutchins V, Murphy D, Song D, Vaughn BB. Surgical site infection: incidence and impact on hospital utilization and treatment costs. *Am J Infect Control*. 2009 Jun 1;37(5):387–97.
5. Block SS. Definition of terms. Disinfection, sterilization, and preservation. Philadelphia: Lippincott Williams & Wilkins. 2001:19–28.
6. Bratzler DW, Houck PM, Workgroup SI. Antimicrobial prophylaxis for surgery: an advisory statement from the National Surgical Infection Prevention Project. *Am J Surg*. 2005 Apr 1;189(4):395–404.
7. Safety WP, World Health Organization. WHO guidelines for safe surgery: 2009: safe surgery saves lives. Geneva: World Health Organization; 2009.
8. Petersen BT, Chennat J, Cohen J, Cotton PB, Greenwald DA, Kowalski TE, Krinsky ML, Park WG, Pike IM, Romagnuolo J, Rutala WA. Multisociety guideline on reprocessing flexible gastrointestinal endoscopes: 2011. *Gastrointest Endosc*. 2011;73(6):1075–84.
9. B'erard F. Postoperative wound infections: the influence of ultraviolet irradiation of the operating room and of various other factors. *Ann Surg*. 1964;160(1):1–92.
10. Knight R, Charbonneau P, Ratzer E, Zeren F, Haun W, Clark J. Prophylactic antibiotics are not indicated in clean general surgery cases. *Am J Surg*. 2001 Dec 1;182(6):682–6.
11. Altemeier WA, Culbertson WR, Hummel RP. Surgical considerations of endogenous infections—sources, types, and methods of control. *Surg Clin N Am*. 1968 Feb 1;48(1):227–40.
12. Cheng H, Chen BP, Soleas IM, Ferko NC, Cameron CG, Hinoul P. Prolonged operative duration increases risk of surgical site infections: a systematic review. *Surg Infect*. 2017 Aug 1;18(6):722–35.
13. Haley RW, Culver DH, Morgan WM, White JW, Emori TG, Hooton TM. Identifying patients at high risk of surgical wound infection: a simple multivariate index of patient susceptibility and wound contamination. *Am J Epidemiol*. 1985;121(2):206–15.
14. Edmiston CE, Lee CJ, Krepel CJ, Spencer M, Leaper D, Brown KR, Lewis BD, Rossi PJ, Malinowski MJ, Seabrook GR. Evidence for a standardized preadmission showering regimen to achieve maximal antiseptic skin surface concentrations of chlorhexi-

- dine gluconate, 4%, in surgical patients. *JAMA Surg.* 2015 Nov 1;150(11):1027–33.
15. Soballe PW, Nimbkar NV, Hayward I, Nielsen TB, Drucker WR. Electric cautery lowers the contamination threshold for infection of laparotomies. *Am J Surg.* 1998 Apr;175(4):263–6.
 16. Bali R, Sharma P, Garg A. Incidence and patterns of needlestick injuries during Intermaxillary fixation. *Br J Oral Maxillofac Surg.* 2011;49:221–4.
 17. Kampf G, Todt D, Pfaender S, Steinmann E. Persistence of coronaviruses on inanimate surfaces and their inactivation with biocidal agents. *J Hosp Infect.* 2020;104(3):246–51.
 18. Bali RK, Chaudhry K. Maxillofacial surgery and COVID-19, The pandemic!! *J Maxillofac Oral Surg.* 2020;19(2):159–61.
 19. Meng L, Hua F, Bian Z. Coronavirus disease 2019 (COVID-19): Emerging and future challenges for dental and oral medicine. *J Dent Res.* 2020;99(5):481–7.
 20. Datarkar A, Purohit S, Tayal S, Bhawalkar . Operating room protocols in OMFS during Corona virus (Covid-19) pandemic. *J Maxillofac Oral Surg.* 2020;19(3):327–31.
 21. Eggers M, Koburger-Janssen T, Eickmann M, Zorn J. In vitro bactericidal and virucidal efficacy of povidone-iodine gargle/mouthwash against respiratory and oral tract pathogens. *Infect Dis Ther.* 2018;7:249–59.
 22. Kirk-Bayley J, Challacombe S, Sunkaraneni V, Combes J. The use of povidone iodine nasal spray and mouthwash during the current COVID-19 pandemic may protect healthcare workers and reduce cross infection. *Br Dent J.* 2020;228(12):902.
 23. <https://aocmf3.aofoundation.org/#o=News%20Date%20Facet,Descending>. Accessed 30 Mar 2020

Additional Reading

Surgical site infections: prevention and treatment.
<https://www.nice.org.uk/guidance/cg74>

Open Access This chapter is licensed under the terms of the Creative Commons Attribution 4.0 International License (<http://creativecommons.org/licenses/by/4.0/>), which permits use, sharing, adaptation, distribution and reproduction in any medium or format, as long as you give appropriate credit to the original author(s) and the source, provide a link to the Creative Commons license and indicate if changes were made.

The images or other third party material in this chapter are included in the chapter's Creative Commons license, unless indicated otherwise in a credit line to the material. If material is not included in the chapter's Creative Commons license and your intended use is not permitted by statutory regulation or exceeds the permitted use, you will need to obtain permission directly from the copyright holder.





Pharmacotherapy in Oral and Maxillofacial Surgery

10

Latha P. Rao

The human fascination—and sometimes infatuation—with chemicals that alter biological function is ancient and results from long experience with, and dependence on, plants. Many plants produce harmful compounds for defense that animals have learned to avoid and humans to exploit [1]

10.1 Introduction

With phenomenal increase in the knowledge about mechanism of action of chemical compounds and rapid introduction of new drugs, pharmacology—the science of drugs—has become increasingly important to all health professionals. Practice of maxillofacial surgery utilizes drugs either as primary treatment modality or as a facilitator of surgical procedures. A detailed description of the pharmacodynamics & pharmacokinetics of these drugs is beyond the scope of this chapter. The readers are encouraged to refer to the standard textbooks of pharmacology for the same.

10.2 Antimicrobial Agents

Infections caused by microorganisms have threatened human life since time immemorial. Some of the organisms had the potential to spread from one infected person to another at an alarming rate causing worldwide pandemics and epidemics. With the discovery of the first antibiotic, “the magic bullet”—Penicillin, patients could effectively be cured of many life-threatening infections [2].

Antimicrobial agents are of the few classes of drugs that effectively treat the etiology of conditions and not simply alleviate the symptoms of the diseases.

10.2.1 Definition

The term antibiotic was first used by Selman Waksman et al. to describe any substance produced by a microorganism that is antagonistic to the growth of other microorganisms in high dilution [3]. This definition excluded substances like gastric juices and hydrogen peroxide that kill bacteria but are not produced by microorganisms. It also excluded synthetic antibacterial compounds like the sulfonamides. In current usage, however, the term “antibiotic” is applied to any medication that kills bacteria or inhibits their growth, regardless of whether that medication is produced by a microorganism or not.

10.2.2 Classification

The antibiotics have been classified in many ways, based on their chemical nature, mechanism of action, type of organisms against which primarily active spectrum of activity, etc. (Table 10.1). The antibiotics exert their remarkably specific action on the microorganisms, sparing the host, due to their selectivity for target components, which are either absent or not very important in humans. Among these targets are bacterial and fungal cell wall synthesizing enzymes, the bacterial ribosome, the enzymes required for nucleotide synthesis and DNA replication, etc.

10.2.3 Oral Microflora

The infectious diseases associated with the oral and maxillofacial region have unique microbiological features because of the abundance and variety of microorganisms in this region. The normal flora of the oral cavity consists of up to 10^{11} bacteria per gram of tissue, with anaerobic bacteria predominating [4]. Although the subtypes and proportions of organisms differ, the general pattern of the indigenous

L. P. Rao (✉)
Department of craniomaxillofacial surgery, Aster Medcity,
Kochi, Kerala, India

Table 10.1 Different classes of antibiotics—based on their chemical structure and mechanism of actions

Class of antibiotics	Common examples	Mechanism of action	Bacteriostatic / Bactericidal
<i>Beta lactams</i> —most widely used	(a) Penicillins (b) Cephalosporins	Inhibit bacterial cell wall synthesis	Bactericidal
<i>Sulfonamides</i> —first commercial antibiotics	(a) Sulfanilamide (b) Sulfadiazine (c) Sulfizoxazole	Prevent bacterial growth and multiplication	Bacteriostatic
<i>Aminoglycosides</i>	(a) Streptomycin (b) Neomycin (c) Kanamycin (d) Paramomycin	Inhibit bacterial protein synthesis	Bactericidal
<i>Tetracyclines</i> —more chances of resistance formation	(a) Tetracyclines (b) Doxycycline (c) Oxytetracycline	Inhibit bacterial protein synthesis	Bacteriostatic
<i>Chloramphenicol</i> —first line of drug only in conjunctivitis		Inhibit bacterial protein synthesis	Bacteriostatic
<i>Macrolides</i> —second most prescribed	(a) Erythromycin (b) Clarithromycin (c) Azithromycin	Inhibit bacterial protein synthesis	Bacteriostatic
<i>Glycopeptides</i> —last-resort drugs	(a) Vancomycin (b) Teicoplanin	Inhibit bacterial cell wall synthesis	Bactericidal
<i>Ansamycins</i> —have antiviral activity also	(a) Geldanamycin (b) Rifamycin (c) Naphthomycin	Inhibit bacterial RNA synthesis	Bactericidal
<i>Quinolones</i> —rapid development of resistance	(a) Ciprofloxacin (b) Levofloxacin (c) Trovafloxacin	Inhibit bacterial cell wall synthesis	Bactericidal
<i>Streptogramins</i> - two groups of antibiotics that act synergistically	(a) Pristinamycin I A (b) Pristinamycin II A	Inhibit bacterial protein synthesis	Bactericidal
<i>Oxazolidinones</i> —potent last-resort drugs	(a) Linezolid (b) Posizolid (c) Tedizolid (d) Cycloserine	Inhibit bacterial protein synthesis	Bacteriostatic
<i>Leptopeptides</i> —instances of resistance rare	(a) Daptomycin (b) Surfactin	Disrupt multiple cell-membrane functions	Bactericidal

microflora is similar in healthy individuals. However, systemic diseases and concurrent use of medications result in the presence of unusual organisms as part of the normal flora and an increase in diseases caused by normal organisms that usually are considered to have low pathogenicity. Usually, the microorganisms are held in check by the body's defense mechanisms. When these mechanisms are impaired, infection may result from an otherwise minor bacterial exposure.

The pathobiology of mixed odontogenic infection is relatively clear. The early cellulitis is the result of streptococci, the moderate-to-severe infection is caused by a combination of aerobic and anaerobic bacteria, and the well-circumscribed chronic abscess is caused primarily by anaerobic bacilli alone [5]. A complex mix of strict anaerobes and facultative anaerobes account for most of the odontogenic infections. Empirical antibiotic choices can be made in this situation where the microbiological pattern is well established (Table 10.2).

10.2.4 Guidelines to the Therapeutic Use of Antibiotics

Understanding that infections are ultimately dealt by the host's immune systems, and antibiotics play only an adjunctive role, is critical. Antibiotic therapy should be reserved for those with clearly established infection. Surgical treatment of the infection also should be initiated as early as possible.

Antibiotics help in preventing infections after a contamination has happened or they can abort a developing infection, if administered early. Antibiotics should not be used as a substitute for the needed surgical treatment.

In most clinical situations, it is easy to determine whether a patient has an infection—local and systemic findings would point to the diagnosis. Diagnostic difficulty arises when a patient who has had a maxillofacial procedure performed, during the second or third day after surgery, develops swelling and pain. Similarly, elevated temperature and white blood cell count also may be found. Surgical insult and

Table 10.2 Efficacy of commonly used antibiotics against head and neck pathogens and dosage

Antibiotics	Aerobes	Staphylococcus	Anaerobes	Dose
Penicillin	Excellent	No action	Guarded against prevotella, porphyromonas, fusobacterium, bacteroides	Penicillin G- 6,00,000 – 1,200,000 u q4h im/iv Penicillin V – 250-500 mg q6h orally
Amoxicillin / clavulanate	Excellent	Active	Guarded against prevotella, porphyromonas, fusobacterium, bacteroides	375-625 mg q8h orally 1.2 g q8h im/iv
Cefuroxime	Excellent with all except guarded action against capnocytophaga and no action against eikenella	Active	No action against prevotella, porphyromonas, fusobacterium, bacteroides	1.5 g q8h im/iv
Erythromycin	Good, guarded against capnocytophaga & eikenella	Active	Guarded action against fusobacterium, no action against prevotella, porphyromonas, bacteroides	250-500 mg q6h orally 1-4 g /day in divided doses q6h iv for severe infections
Clindamycin	Excellent	Active	Active	150–300 mg q8h orally 1200–2400 mg /day in divided doses q8h for severe infections
Ciprofloxacin	Good	Guarded action	Guarded action	500 mg q12h orally 400 mg q12h iv
Metronidazole	No action	No action	Active	400 mg q8h orally 500 mg q8h iv

prolonged general anesthesia often result in these symptoms. Clinical judgment is important in making the diagnosis, and the clinician should weigh all information available before making the diagnosis of infection.

There are a few basic guidelines to be followed in the administration of antibiotics (Table 10.3).

10.2.5 Consistency in Route of Administration

In severe infection, parenteral antibiotics are needed to get adequate blood levels. But with an initial response within couple of days, one is always tempted to switch to oral administration. When this is done, the infection may recur because blood levels achieved with oral dose are suboptimal. Maintenance of peak blood levels of antibiotic, until eradication of bacteria, is important, which may take 5–6 days. After the fifth day of parenteral administration, the blood levels achievable with oral administration are usually sufficient.

10.2.6 Cross-allergenicity between Penicillins & Cephalosporins

A frequently asked question about penicillin allergic patients is whether the cephalosporins can be used safely. Overall the frequency of crossallergenicity between the two groups of drugs is low (7–18%) [10, 11]. Cross-allergenicity appears to be most common among penicillin, aminopenicillins, and early-generation cephalosporins, which share similar R-1 side chains; this is thought to increase the risk

of cross-reactivity. Patients with a history of anaphylaxis to penicillins should not receive first- or second-generation cephalosporins, while third- and fourth-generation cephalosporins should be administered with caution, preferably in a monitored setting.

10.2.7 Patient Monitoring

The patient should be monitored for the response to treatment and any deterrent should be identified and rectified. A second empirical choice should be avoided, if at all possible because the likelihood of success is substantially less. Repeat cultures may also be attempted.

In some cases, the patient may respond well to the empirical antibiotics, but the culture and sensitivity report would reveal that the organisms isolated are resistant to the antibiotics being used. The combined surgical and antibiotic treatment, along with natural host defenses, would have resulted in resolution of infection. The antibiotic may or may not have played an important role. The antibiotic that was clinically effective for the patient should be continued despite the contradictory data.

10.3 General Considerations in the Prophylactic Use of Antibiotics

The original guidelines for timing and use of antibiotics to prevent infection postoperatively were established by Burke and Miles et al.'s experimental observations [12, 13]. They

Table 10.3 Guidelines for the use of antibiotics

1. *Empirical therapy*
2. *Identification of the organisms*—obtain culture & sensitivity in
 - (a) Compromised host defenses
 - (b) Persistence of infection in spite of appropriate antibiotics & surgical therapy.
 - (c) Postoperative infection
 - (d) Suspected cases of actinomycosis, osteomyelitis
3. Use of *specific narrow-spectrum antibiotic*—to prevent/minimize bacterial resistance [6] & superinfections [7].
4. Reserve *combination therapy* for:
 - (a) Patient with life-threatening sepsis of unknown cause
 - (b) Increased bactericidal effect against a specific organism is required
 - (c) Prevention of rapid emergence of resistant bacteria—e.g., tuberculosis
 - (d) Empiric treatment for certain odontogenic infections—that are rapidly progressing posteriorly around the neck space
5. Use of antibiotics with proven history of success
6. Use of the least toxic antibiotic
7. Use of a *bactericidal* rather than a bacteriostatic drug
8. *Proper administration*: Dose, time interval, route of administration, & consistency in the route of administration
9. Cost of the antibiotics
10. *Patient compliance*—decreases with increasing number of pills [8]
11. *Patient monitoring*—initially a subjective sense of feeling better, then look for reduction in swelling, pain, & temperature [9]
12. *Causes of failure of antibiotic therapy*:
 - (a) Inadequate surgical intervention –
 - (i) Failure to drain pus,
 - (ii) Increasing pressure inside tissue spaces,
 - (iii) Retained nonvital tissue or foreign body.
 - (b) Other sources of infection—IV catheter, Foley’s catheter
 - (c) Reduced or compromised host defenses—immunocompromised, malnourished, dehydrated patients
 - (d) Mistakes in antibiotic administration
 - (i) Improper route of administration,
 - (ii) Inadequate dosage,
 - (iii) Patient noncompliance,
 - (iv) Incorrect carrying out of physician’s orders.
 - (e) Wrong culture report or misinterpretation of the culture report

noted that antibiotics must be given within 4 h after injection of bacteria into a surgical site to prevent the aggressive level of infection that occurs when no antibiotics are administered.

Antibiotic prophylaxis entails administering the antibiotic appropriate for the potential microbial contamination before the surgical insult, at a high enough dosage to establish an appropriate bacteriologic titer [14].

1. *Indications for antibiotic prophylaxis* [15, 16] are given in Table 10.4.
2. *Condition & bacterial contamination of the surgical area*: Surgical wounds are generally classified into clean, clean-contaminated, contaminated, and dirty/infected [16–18] (Table 10.5).
With judicious use of antibiotics, the infection rates are known to be lesser [16, 18].

Table 10.4 Indications for antibiotic prophylaxis

1. Compromised host defenses
 - (a) Physiological—old age, obesity, malnutrition
 - (b) Disturbances in circulation—massive transfusion, recent surgery
 - (c) Disease related—poorly controlled diabetes, cancer, leukemia, alcoholic cirrhosis, end-stage renal diseases
 - (d) Compromised immunity—multiple myeloma, total body irradiation, splenectomy
 - (e) Immunosuppressants—cytotoxic drugs, glucocorticoids, azathioprine, cyclosporine
2. Potential for bacterial contamination of a sterile field
3. Procedures with high infection rate
4. Surgical procedures in which there is a high mortality / morbidity rate following infection
5. When a foreign body is inserted into the tissues

Table 10.5 Classification of surgical wounds

Type	Incidence of infection (values given for general surgical cases)	Examples for the types of surgical wounds in maxillofacial surgery
Clean	1-5%	Temporomandibular joint surgery, facial cosmetic surgery
Clean-contaminated	3-11%	Orthognathic procedures, extractions
Contaminated	10-17%	Maxillary fracture with active maxillary sinusitis
Dirty wound	>27%	Mandibular fracture through an infected third molar socket

Table 10.6 Need for postoperative antibiotics

1	Compromised immunity
2	Inflammation at the surgical site
3	Evidence of wound dehiscence
4	Active periodontal disease
5	Poor oral hygiene
6	Inadequate surgical skill
7	Prolonged surgery
8	Wound contamination during surgery

3. The *selected antibiotic should be bactericidal* against the most common microorganisms that cause infection in the oral cavity. The bactericidal antibiotics rely less on the host defense mechanisms providing faster results [18].
4. The *concentration of antibiotics* in the tissue should be sufficient to fight the bacteria that may enter the surgical wound at incision or during the course of surgery. To achieve a blood concentration of *three-four fold that of minimum inhibitory concentration*, the antibiotic is typically given at twice the treatment dose *1 h prior to surgery* [14, 16].
5. Usually antibiotics can be administered as a single preoperative dose. In cases where the surgeon feels that postoperative infection is a high possibility, the drug can be *extended post-operatively as deemed necessary* [19] (Table 10.6).

One must be vigilant in identifying cases where antibiotics are required for the success of surgery, as antibiotic usage and overusage have considerable risks [6, 7, 20, 21]—gastrointestinal disturbances, toxicity reactions, antibiotic resistance and superinfections, anaphylaxis, pseudomembranous colitis, etc.

10.3.1 Prophylactic Uses of Antibiotics in Maxillofacial Surgery

Infection, one of the most common postoperative complications, can be prevented by the timely use of appropriate antibiotic. In spite of many studies in literature, a definitive conclusion cannot be made regarding the need for antibiotic prophylaxis in maxillofacial surgery and, if needed, the dose required. The antibiotic prescription pattern is still hugely based on personal preferences and shows wide regional variation, which many a time is inappropriate. The drugs would be initiated either at an incorrect time, or would be continued beyond the time required, and this has greatly contributed to the emergence of resistant bacteria [6].

Prophylactic use of antibiotics should be evidence based taking into consideration the effectiveness and the possible adverse outcomes of antibiotic therapy. Moreover, a thorough knowledge of the likely organisms involved in the infection is needed to prevent the prescription of unsuitable antibiotics. Antibiotics, if needed, should have a spectrum of activity that involves streptococci, anaerobic Gram-positive cocci, and anaerobic Gram-negative rods, which are considered the most pathogenic for oral infections and should be bactericidal and the least toxic agents available - amoxicillin being the most common choice of the clinicians [12, 18].

The need for antibiotic prophylaxis and the preferable drugs for wisdom teeth removal, orthognathic surgery, dental implants, maxillofacial trauma, and in special circumstances like patients with diabetes mellitus, patients—pre- and post-organ transplant, rheumatic heart disease—valve replacements, oncological surgery & reconstruction, cleft surgeries, etc. are mentioned in the following sessions.

10.3.2 Antibiotic Prophylaxis in the Surgical Removal of Wisdom Teeth

Though one of the most commonly performed minor oral surgical procedures, the reported infection rate with the removal of mandibular third molars is $\leq 10\%$ [22]. However, the rate can be as high as 25% when the patient's immunity is compromised [20]. The infection rate associated with the corresponding procedure in maxilla is quite low, $<1\%$ [20, 22]. The higher rate of postoperative infection in relation to

mandibular third molar has been attributed to the reduced vascularization and the gravity-induced pooling of bacterial-rich saliva.

The prophylactic use of antibiotics in wisdom teeth removal had been an issue of many debates. There are studies for [20, 23] and against [24, 25] the practice of antibiotic prophylaxis in third molar removal. Considering the potentially contaminating oral environment in which the third molar removal is carried out, it is reasonable to favor antibiotic prophylaxis. Moreover, since the postoperative infection and alveolar osteitis, an inflammatory response whose etiology could be traced to bacterial contamination and fibrinolysis of the socket blood clot, cause debilitating pain and severe functional impairment, it is only prudent to consider the use of prophylactic antibiotics.

Studies have shown that preoperative administration of antibiotics reduces the postoperative infection when administered 1-2 h prior to the procedure [26, 27]. Amoxicillin/amoxicillin—clavulanic acid is the widely used antibiotic in the prophylaxis for the surgical removal of impacted teeth [28] and when given as a single dose preoperatively is found to reduce postoperative infection and alveolar osteitis [21]. But certain other studies have failed to show a considerable difference between amoxicillin, clindamycin, metronidazole, and placebo in terms of postoperative infection rates [25]. Studies have found topical tetracycline [29], chlorhexidine irrigation [30], & metronidazole dressings [31] into the mandibular third molar sockets, effective in reducing the postoperative infection & the incidence of dry socket. Review of literature does not give definite indication to use of antibiotics as prophylaxis in healthy patients or asymptomatic impacted teeth and in case of the removal of maxillary wisdom teeth [22].

Studies have advocated the use of antibiotic prophylaxis in immunocompromised patients to prevent infection after surgical removal of impacted teeth [22].

Two recent meta-analyses [28, 32] summarize the antibiotic prophylaxis in wisdom teeth removal (Table 10.7).

10.3.3 Antibiotic Prophylaxis in the Placement of Dental Implants

Dental implants play a crucial role in the successful restoration of missing dentition. The success rate of dental implants is high, with only 0-10% of reported failure rates [33]. However, risk of failure is high during the first year after implant placement [34]. The implant surfaces can become colonized by oral and perioral microorganisms during surgery (perioperative contamination) [35]. This can lead to pain, swelling, bone loss, and eventually failure of implants. The failure of the dental implants is multifactorial (Table 10.8).

Table 10.7 Antibiotic prophylaxis in wisdom teeth removal—Key points

1	Factors influencing the rate of postoperative infection [20, 32] <i>may need to consider postoperative antibiotics</i> History of pericoronitis Smoking Old age Poor oral hygiene Duration of surgery Amount of bone removal Presence of foreign bodies—hemostats or devitalized bone fragments Operator skill
2	Amoxicillin & Amoxicillin—clavulanic acid equally effective [28]
3	Systemic administration more effective [32]
4	Single preoperative dose: 30–90 min prior to procedure [18, 32]
5	Usually double the usual strength is given preoperatively [18, 26]
6	Antibiotics reduce incidence of alveolar osteitis [21].
7	Topical tetracycline [29], chlorhexidine [30], & metronidazole [31] effective in reducing the infection rate
8	Preoperative and extended postoperative doses may be required in immunocompromised patients [22]
9	No antibiotic prophylaxis required in removal of asymptomatic mandibular third molars and maxillary third molars in healthy individuals [22]

Table 10.8 Factors affecting the survival of implants [33, 34]

Local factors	<ol style="list-style-type: none"> 1. Pre-existing infections 2. Quality & quantity of bone 3. Bone grafts—autogenous vs allogenic 4. Ill-fitting prostheses 5. Bad oral hygiene 6. Irradiated bone
Systemic factors	<ol style="list-style-type: none"> 1. Immunocompromised diseases 2. Diabetes 3. Long-term steroids 4. Malnutrition 5. Elderly patients 6. Smoking
Surgical factors	<ol style="list-style-type: none"> 1. Incorrect instruments 2. Overheating during placement 3. Lack of attention to sterility. 4. Increased duration of the procedure [20] 5. Operator skill [20]

Hence all these local, systemic, surgical, and procedural factors contributing to implant failure should be eliminated before considering infection as the reason for failure [33].

Because of the morbidity associated with infection of the implants, antimicrobial therapy is routinely used with the aim of prevention of surgical site infection. Though by definition, dental implant placement is a clean-contaminated surgery with 3–11% chances of infection, the infection rate can be brought down to about 1% by proper patient selection, attention to surgical details, and by judicious use of antibiotics [18].

There are studies supporting antibiotic use to reduce implant failures [33, 34] and studies that fail to show any

added benefits of antibiotics against implant failure [36]. Few other studies have observed similar failure rates for the implants with a single preoperative dose and routine use of antibiotic for 7 days [37].

The currently advocated dose of antibiotic prophylaxis for implant surgery is 2–3 g of amoxicillin 2 h prior to multiple implant placement, especially along with bone graft [33]. If the patient is allergic to penicillin group, 600 mg clindamycin should be given 1 h before surgery. For sinus augmentation, 1.2 g of amoxicillin/clavulanic acid starting day before the surgery is the prophylaxis of choice [33]. Chlorhexidine gluconate mouth rinses have been known to reduce the number of pathogenic microorganisms, by lysing the bacterial cell membranes, and by virtue of its substantivity, can get retained in the oral soft tissues and get released slowly for up to 12 h [30, 33]. The key points in the antibiotic prophylaxis for dental implants are given in Table 10.9.

10.3.4 Antibiotic Prophylaxis in Orthognathic Surgery

Orthognathic surgical procedures aim to correct the facial deformities and malocclusion, thereby improving the functional disorders of the stomatognathic system. It is an elective procedure, usually carried out in young healthy adults. It is considered as a clean-contaminated procedure with a reported infection rate of 3–11% [18, 39]. But certain studies have reported the rate of infection after orthognathic surgery to be as high as 6–33.4% [39]. The postoperative infection was found to be related to poor oral hygiene and the habit of smoking.

The surgical site infections (SSIs) that develop can be incisional SSIs and organ and space SSIs [40]. Both types of SSIs can occur after orthognathic surgery and may develop within the first few weeks after surgery. The development of SSIs increased the total length of hospital stay and expenditure. Though the potential for postoperative infections after orthognathic surgery is known for a very long time, a consensus has not yet been achieved with regard to the drug that is useful, the dose, and the duration of administration.

The specific orthognathic procedure that has been associated with higher infection rate was mandibular sagittal split osteotomy, especially where a transbuccal approach had been adopted for fixation [38]. Increased rate of infection associated with mandibular procedures has been attributed to the diminished vascularity of mandible in comparison with maxilla and pooling of food and saliva along the vestibular incision line in the mandible. Till the incision seals off, oral microflora can freely enter the deeper tissues from the pooled saliva. Though concomitant extractions, especially of partially erupted mandibular third molars had been implicated as a risk factor for the development of postoperative infec-

Table 10.9 Antibiotic prophylaxis in dental implants—Key points

	<p><i>Care to be taken</i> [35]:</p> <p>Through oral prophylaxis & measures to improve oral hygiene</p> <p>Stabilize oral focus of infection</p> <p>Procedure in a well-monitored aseptic environment—disinfection, draping, hand scrubbing, sterile gowns & gloves, sterile instruments</p> <p>Prevent contamination of implants with contact with skin, infected oral mucosa, & sinus lining</p> <p>Bactericidal antibiotic with coverage against pathogenic oral microflora [12, 18, 33]</p> <p>Preoperative administration of antibiotics—1 h before the procedure, twice the therapeutic dose [18, 33]—Amoxicillin 2gm, / clindamycin 600 mg 1 h prior to surgery</p> <p>Chlorhexidine gluconate rinses—hugely effective in controlling the immediate local infection [30, 33].</p>
1	<p><i>Only Chlorhexidine 0.12% rinse twice daily in healthy individuals</i> [33]</p> <p>(a) Simple implant,</p> <p>(b) Short duration,</p> <p>(c) No bone graft,</p> <p>(d) Sterile environment is ensured..</p>
2	<p><i>Single preoperative dose + Chlorhexidine 0.12% rinse twice daily in healthy individuals</i> [33]</p> <p>(a) Multiple implants with minimal tissue reflection,</p> <p>(b) Immediate extraction & implant placement,</p> <p>(c) Socket bone grafting.</p>
3	<p><i>Single preoperative dose + 3 doses / day X 3 postoperative days + Chlorhexidine 0.12% rinse twice daily in healthy individuals</i> [33]</p> <p>(a) Multiple implants with extensive tissue reflection,</p> <p>(b) Multiple extractions & implant placement,</p> <p>(c) Bone grafting—allografts,</p> <p>(d) Long duration.</p>
4	<p><i>Single preoperative dose + 3 doses / day X 5 postoperative days + Chlorhexidine 0.12% rinse twice daily</i> [33]</p> <p>(a) In medically compromised patients,</p> <p>(b) Extensive tissue reflection,</p> <p>(c) Full arch implants,</p> <p>(d) Block bone grafting—autografts,</p> <p>(e) Indirect sinus floor lift procedures,</p> <p>(f) Active periodontal disease.</p>
5	<p><i>Loading dose on the previous day + 3 doses / day X 5 postoperative days + Chlorhexidine 0.12% rinse twice daily</i> [33]</p> <p>In sinus lift procedure</p>

tion, studies were not able to support or refute this [38, 41] Longer surgeries involving multiple/segmental procedures also show a higher rate of infections [12, 18, 38].

Use of various antibiotics has been proposed—penicillin [42], ampicillin [43], amoxicillin with or without clavulanate [43], clindamycin [42], or a member of the cephalosporin group [19, 41]. Literature fails to report a significant difference in the infection rate when using a penicillin or nonpenicillin group of antibiotics or among the various types of penicillins [18, 19, 44]. Based on the bacteriological studies, penicillin, amoxicillin, or amoxicillin—clavulanic acid or cephalosporins is commonly recommended in the preoperative antibiotic prophylaxis for orthognathic surgery [19, 38, 41–44].

The preoperative single dose of antibiotic increases the level of the drug in circulation prior to incision. Whether short-term antibiotics (single dose or dose \times 24 h) [42] or extended-term antibiotics (for more than 24 h) [41, 43] is beneficial in the prevention of postoperative infection after orthognathic surgery is still a debatable question [19, 38, 41, 44].

10.3.5 Is Antibiotics Needed when Bone Plates and Screws Are Being Inserted?

One question that keeps on surfacing is whether prophylactic antibiotics are needed in cases where bone plates and screws are used to hold the bony segments together. Any foreign body inserted into the body, be it a medical device or implant, may elicit a foreign body reaction. Moreover, the microorganisms can colonize on the implant surface in a biofilm, while they are being inserted, and as the physical presence of the implants may compromise the blood supply to the region, thereby reducing the delivery of body's immune cells to the region and resulting in infections at the host–implant interface by normal flora with low virulence [45, 46]. The oral biofilm and its toxins, adhered to the surface of titanium plates and screws used for stabilization of osteotomy segments, could be a source of local or regional infectious complications [19]. Hence, the use of antibiotic prophylaxis is justified.

Take-home points regarding antibiotic prophylaxis in orthognathic surgery are mentioned in Table 10.10.

10.3.6 Antibiotic Prophylaxis in Maxillofacial Trauma

In today's world of fast-moving vehicles and expressways, hundreds of thousands of people get involved in road traffic accidents. Head and face are among commonly injured body parts. Both the soft and hard tissues of the face may be involved in the trauma. Firearms, contact sports, and interpersonal violence are other reasons for facial injuries. The management of these injuries should follow protocols and be done in a systematic manner. With advances in anesthetic and surgical techniques and availability of better implant materials with favorable metallurgy, open reduction and internal fixation (ORIF) has become the norm. The re-establishment of form, function, & cosmesis is of paramount importance. To arrive at this goal, the probable complications of ORIF need to be prevented or managed correctly. Of the various complications reported, none has generated more interest and controversy than the occurrence of postoperative infection. By adhering to the standard surgical protocols and strict aseptic techniques, the occurrence of postoperative

Table 10.10 Antibiotic prophylaxis in orthognathic surgery—Key points

1.	Risk factors for SSIs [47, 48] (a) Longer surgery; (b) Short-term antibiotic prophylaxis; (c) Extraction of a third molar during surgery; (d) Greater number of osteotomies performed; (e) Older age; (f) Smoking; (g) Poor oral hygiene; (h) Compromised immune system.
2.	Orthognathic surgery - clean-contaminated wound—with the osteotomized maxilla / mandible exposed to oral / nasal / antral cavities [48].—Antibiotics needed
3.	Need for antibiotics in presence of bone plates & screws [45, 46].
4.	Loading dose of double strength 1 h prior to incision [18].
5.	Confusion between—single loading dose + short-term doses × 24 h vs long-term antibiotics for more than 24 h [19, 44].
	Commonly isolated organisms— aerobic bacteria—streptococci (43%) & anaerobic bacteroides (50%) [18, 39]
6.	Amoxicillin / amoxicillin—clavulanic acid—best suited [19, 42–44].
7.	Higher infection rate—mandibular osteotomies with transbuccal approach for fixation [38].
8.	Longer procedures & segmental osteotomies—more prone for infection [38].
9.	Concomitant removal of mandibular third molars does not increase the risk for postoperative infection [39], though may cause issues with fixation.

infection can be brought down considerably. But the presence of the microorganisms in the oral cavity and facial skin and possible contamination from environment necessitate the consideration of antibiotics in the maxillofacial trauma management.

Though prophylactic antibiotics were considered essential in the management of maxillofacial trauma for many years [18], the evidence for this preventive intervention was weak and confusing. Among facial fractures, mandibular fractures are most commonly studied, because of the compound nature of the fractures, except in the ramus—condyle unit, where the fractures usually do not communicate with the external environment. Fractures of the mandibular condyles or Lefort fractures of maxilla are rarely infected when compared with the fractures involving mandibular angle, body, or symphysis [49, 50].

The decision to use antibiotic prophylaxis depends on whether the fracture is an open or closed type and whether it is going to be managed with open or closed reduction. Open procedures were four times more commonly prone to postoperative infections according to a few studies [41, 51, 53, 54], whereas certain other studies reported no difference between the patients treated with closed reduction and maxillomandibular fixation and those who underwent open reduction and internal fixation [54]. The microbiology of the infected fractures was mixed and responded to beta-lactam antibiotics well.

Table 10.11 Antibiotic prophylaxis in maxillofacial trauma—Key points

1.	Risk factors for SSIs [22, 32, 51, 56] (a) Longer surgery; (b) Older age; (c) Smoking; (d) Poor oral hygiene; (e) Compromised immune system.
2.	Mandibular fractures/ fractures of the teeth-bearing area—open / compound fractures.—Antibiotics needed [49, 50, 53, 54].
3.	Need for antibiotics in presence of bone plates & screws [45, 46]
4.	Loading dose of double strength 1 h prior to incision [18, 56].
5.	Beta-lactam antibiotics—preferred [56].
6.	Higher infection rate—in fractures involving mandibular teeth-bearing areas [49]
7.	Longer duration of antibiotics in immunocompromised patients [49, 52].
8.	Chances of infection more with open reduction than in those treated with closed reduction with no antibiotic prophylaxis [16, 50, 51]. But with single dose of perioperative antibiotics, no significant difference between closed & open reduction [51, 54]
10.	Delayed healing and increased infection rate with tobacco smoking [51].

Studies have shown that single dose of preoperative antibiotic prophylaxis is sufficient to prevent wound infection [51, 54]. If the surgery extends beyond the half-life of the antibiotic, the antibiotic can be redosed [51]. The need for postoperative antibiotics in the maxillofacial trauma too has been extensively studied [16, 49, 53, 55, 56]. These studies reported no statistically significant difference in the development of SSIs between the patients who had received perioperative antibiotics and those who had received extended antibiotics in the postoperative period.

Longer antibiotic usage has been advocated in the immunocompromised patients [32, 52, 56]. The habit of tobacco smoking was found to have a deleterious effect on the healing of mandibular fractures by inducing hypovascularity and prolonged inflammation [54]. The other major factors, which contribute to the occurrence of SSIs, are poor oral hygiene, extremes of age and malnutrition [22, 32].

Important points mentioning the need for antibiotics in the management of maxillofacial trauma are given in Table 10.11.

10.3.7 Diabetes Mellitus & Antibiotic Prophylaxis in Maxillofacial Surgery

Diabetes mellitus is a metabolic disorder resulting in elevated glucose levels, due to inadequate insulin secretion (type I) or reduced insulin secretion with an accompanying insulin resistance (type II). Diabetic patients pose a special challenge to the surgeon as the balance between the insulin they can secrete and the hyperglycemia induced by surgical stress-adaptive hormones catecholamines, cortisol, growth

hormone, and glucagon is lost. Patients, who are nondiabetic, usually are able to handle this glucose overload effectively, whereas diabetic patients may have issues resulting in cardiovascular complications, infection, and reduced rates of wound healing. Moreover, the defective polymorphonuclear leukocytes function and macro- and microvascular dysfunction resulting in compromised local circulation increases the susceptibility to infections [57]. With the vast microbiological colonization of the oral cavity, it has always been assumed that maxillofacial surgical procedures carry a high risk of infection and prolonged or delayed wound healing. The guidelines as to the prophylactic use of antibiotics in diabetic patients had been vague as "...are more prone to infection necessitating routine antibiotic prophylaxis for all maxillofacial procedures" [58].

In many of the literature surveys, authors have noted that well-controlled diabetic patients are at no increased risk of postoperative infection than normal healthy patients and delayed wound healing is not a pressing concern due to the rich vascularity of the region [59, 60]. Antibiotic prophylaxis is warranted only in conditions where a normal patient also would benefit from it. Poorly controlled diabetic patients would require normalization of their hyperglycemic state prior to elective procedures. In emergency situations, antibiotic prophylaxis prior to the surgical incision is desirable and attempts should be made to control the glycemic level during the peri- and postoperative period [58–60].

10.3.8 Antibiotic Prophylaxis in Head and Neck Oncology

Head and neck oncology patients usually require a major surgical procedure +/- with radiation therapy. The surgical site tends to be large, the surgical time and postoperative immobilization period longer. The surgical management attempts at removal of the tumor, clearance of the neck nodes, and involves an additional surgical site from where flap is harvested for reconstruction—either microvascular flaps or pedicled ones [61]. The large wound area exposed to local flora of the oral cavity and the skin is at risk of wound contamination and infection. Nosocomial infections are known to run a protracted course and pre-existing general comorbidities further increase the morbidity and, thus, the hospital expenses associated with these surgeries.

The reasons for increased infection rate are mainly the number of procedures carried out in the same operation (excision, neck dissection, tracheostomy, and distant flap harvest), the pooling of saliva due to difficulty in swallowing, leading to aspiration, and the inability in obtaining a watertight closure when the flap is inset in the recipient bed leading to salivary leak and contamination of neck wounds with saliva [62, 63].

Table 10.12 Key points in oral oncology & antibiotic prophylaxis

Increased risk of SSIs [62]
Multiple procedures done at a single operation,
Large wound area,
Long procedure,
Tobacco & alcohol abuse
Immunocompromised patients
Probable pathogens [62] - Escherichia spp. & staphylococcal spp
Preferred antibiotic [62] - ampicillin & sulbactam
Bartella et al. (2017) [62] - Statistically significant reduction in infectious complications with postoperative antibiotics

The need for antibiotic prophylaxis is well established in the oncologic surgery, but the need for a long postoperative course of antibiotics is still debated upon. There are studies, which have shown benefits of prolonged antibiotics in preventing postoperative infections like pneumonia, urinary tract infections, sepsis, and SSIs in patients who had oral squamous cell carcinoma [64], and there are studies, which have shown no extra benefits of prolonged postoperative antibiotics [63, 64].

Escherichia spp. and Staphylococcus spp. are predominantly responsible for the infections and in 72% were sensitive to ampicillin & sulbactam [62].

A few key points, which would be beneficial in making a decision, are given in Table 10.12.

10.3.9 Antibiotic Prophylaxis in Cleft Surgeries

Orofacial clefting is one of the more common congenital anomalies and cleft lip & palate deformity is the most common among them. Management of cleft lip & palate deformity involves staged procedures and spans over 12–16 years. The management aims at correction of the deformity so that function and cosmesis are restored as much as possible and the psyche of the individual is minimally scarred. Postoperative infections can result in wound breakdown, poor speech & esthetics, and nasal regurgitation of food in cleft lip and palate patients.

Various authors had reported on obtaining swabs from nose and oral cavity to identify the possible pathogens and using antibiotics according to the culture reports before cleft lip and palate repair [65–67]. The pathogenic bacteria isolated from the swabs were Staphylococcus aureus and beta hemolytic streptococci [67]. But later studies demonstrated that there were not many differences between the group that underwent swab acquisition and corresponding antibiotics therapy and the group that didn't receive any antibiotics in terms of postoperative complications [68]. The rate of complications was found to be independent of the potential pathogens in the mouth [65].

Factors, which have been implied as contributing factors to wound dehiscence, are given in [66, 67] Table 10.13.

Table 10.13 Factors contributing to wound dehiscence in cleft surgeries

Wide clefts
Closure under tension
Bilateral clefts
Long duration of surgery
Poor technique—traumatized nasal mucosa
Independent of potential oral pathogens

In a recent prospective study, Azner et al. (2015) noted a statistically significant reduction in the incidence of palatal fistulas with 5 days of postoperative antibiotics [69]. But 80% of their control group, who had received no postoperative antibiotics, too healed without any complications. Both study and control groups had received a single dose of cefuroxime 30 mg / kg body weight, before incision. The use of one dose of antibiotics before incision has been advocated by other authors also and may be more effective in preventing complications related to wound infection than a prolonged course of postoperative antibiotics [68].

10.3.10 Organ Transplant and Antibiotic Prophylaxis

The concept of organ donation had always excited mankind. Twentieth century saw developments that made the dream of replacing a diseased organ with a healthy one a reality. Understanding the human immunology and the development of powerful immunosuppressant drugs laid the foundation for modern transplant medicine, making transplantation of kidney, liver, lungs, and heart a successful treatment option. As the transplant science advanced, so did the numbers and life span of transplant patients and their need for dental/maxillofacial surgical procedures. As these patients are on immunosuppressants, they are more prone to opportunistic infections and their sequel. Hence, care must be given to treat or remove the existing/potential sources of infection before the transplant procedures.

In a pretransplant patient, the need for maintaining oral hygiene should be stressed upon. The treating physician should be consulted with regard to the fitness to undergo the planned procedures and the safety of using any drugs if required. Drugs, which have a hepatic metabolism or renal clearance, should be used with caution in patients with compromised liver or kidney function. The selection of antibiotics is made after careful evaluation of the existing pathology and the chances of spread of infection with the planned dental treatment.

In the immediate post-transplant period—the first 3 months post-surgery, the graft, and the patient are very vulnerable to any insult—graft anastomoses are susceptible to endarteritis due to bacterial colonization as they are not yet

Table 10.14 Key points—organ transplant and antibiotic prophylaxis

Pretransplant patients—stress on
1. Elimination of potential focus of infection,
2. Oral hygiene,
3. Liver / kidney friendly drugs.
Post-transplant patients:
Immediate postop:
1. Only emergency procedures,
2. Aggressive management of infections.
3 months postop—noninvasive elective procedures
6 months postop—invasive elective procedures under antibiotics
Beta-lactam antibiotics - relatively safer to be used in renal and hepatic transplant patients [72]
No consensus on minimally invasive procedures in patients with meticulous oral hygiene [71]

fully epithelialized. Hence, only emergency procedures should be done. Any acute orofacial infection developing should be managed aggressively, surgical drainage, culture and sensitivity of the organism, and appropriate antibiotics would be required [70]. After 3 months, elective, noninvasive procedures can be carried out. Since the patients who have undergone organ transplantation are immunosuppressed and are at high risk of infection, prophylactic antibiotics need to be considered for any invasive dental procedures, even after 6 months. Beta-lactam antibiotics are relatively safer to be used in renal and hepatic transplant patients [71]. But for those with meticulous oral hygiene, there is no consensus regarding the need for antibiotic prophylaxis for minimally invasive procedures [71]. The decision to use antibiotics should be done on a case-to-case basis.

Important points to be kept in mind while contemplating antibiotic prophylaxis in organ transplant patients are given in Table 10.14.

10.4 Infective Endocarditis

Bacterial endocarditis, a rare but life-threatening condition, was initially described by Lewis & Grant in 1923 [72]. They suggested that bacteria released into the blood stream after a dental procedure colonize on the heart valves or the endocardium. The bacteremia associated with infections of skin and soft tissues, genitourinary tract, and gastrointestinal tract are also known to result in infective endocarditis (IE). Bacteria can gain direct access to the bloodstream through the indwelling catheters. The American Heart Association (AHA) came up with the first guidelines to reduce the risk of IE following invasive procedures in 1955 [73]. The AHA guidelines have been updated regularly since then and the latest one was released in 2007 [74]. The 2007 guidelines categorized cardiac conditions into having a low risk, moderate risk, and high risk of developing IE and advocated the use of antibiotic prophylaxis only in

Table 10.15 High-risk cardiac conditions, which require antibiotic prophylaxis [75]

Prosthetic cardiac valves
Congenital heart diseases—unrepaired, with palliative shunts or conduits or repaired with prosthetic material or those repaired, but with residual defects
Previous IE
Cardiac transplants who have developed valvulopathy

high-risk-category patients (Table 10.15) who were to undergo dental procedures that involved the manipulation of gingival tissues or the periapical region of teeth or incision of the oral mucosa.

The guidelines prescribed a single dose of antibiotic 30-60 minutes prior to the procedure—Amoxicillin 2 g PO, Cephazolin/Cephtriaxone 1gm IV/IM, or Clindamycin 600 mg PO/IM/IV, depending on whether the patient is unable to take oral preparations or is allergic to penicillin or not [74]. The reason for the revision of the antibiotic policy was predominantly the observation that IE is more likely to result from transient bacteremias caused by routine daily activities, like chewing food, and by regular oral hygiene care. The authors concluded that maintaining optimal oral hygiene is more important in reducing the risk of IE and the adverse effects of antibiotics exceeded the benefits of antibiotic prophylaxis. The British Society for Antimicrobial Chemotherapy (BSAC) also recommend antibiotic prophylaxis only in those who have a history of healed IE, prosthetic heart valves, and surgically constructed conduits [75]. The advice to the patient is to concentrate on achieving and maintaining meticulous oral hygiene as this has been found to reduce the risk of IE. Similar observations were made by the National Institute for Health and Care Excellence (NICE) [76] and the European Society of Cardiology (ESC) [77].

There has been a rising concern over the potential for an increased incidence of IE and a worse prognosis for the diseased since the guideline changes by the AHA, NICE, ESC, BSAC. Several studies have been carried out to assess the impact of these changes on the disease incidence in adults and pediatric population. Whereas earlier studies showed not much difference pre- and post-guideline changes in incidence [78], recent studies have noted a definite increase in the incidence of IE post-guideline changes [79]. Sakai et al. in 2017, though noting no change in the incidence and severity of IE in pediatric patients, pre- and post- guideline changes, reported an increase in the viridans group streptococci (VGS)—induced IE in older age group [79]. The data from these studies point to the need for further investigation into the effectiveness of 2007 guidelines, though it has been argued that the increase in IE incidence may be related to the increasing life span of the patients with congenital heart diseases and prosthetic devices and increase in the number of invasive procedures being performed on them.

10.5 Postoperative Pain Management in Maxillofacial Surgery

The International Association for the Study of Pain (IASP) defines pain [80] as: “an unpleasant sensory and emotional experience associated with actual or potential tissue damage or described in terms of such damage.”

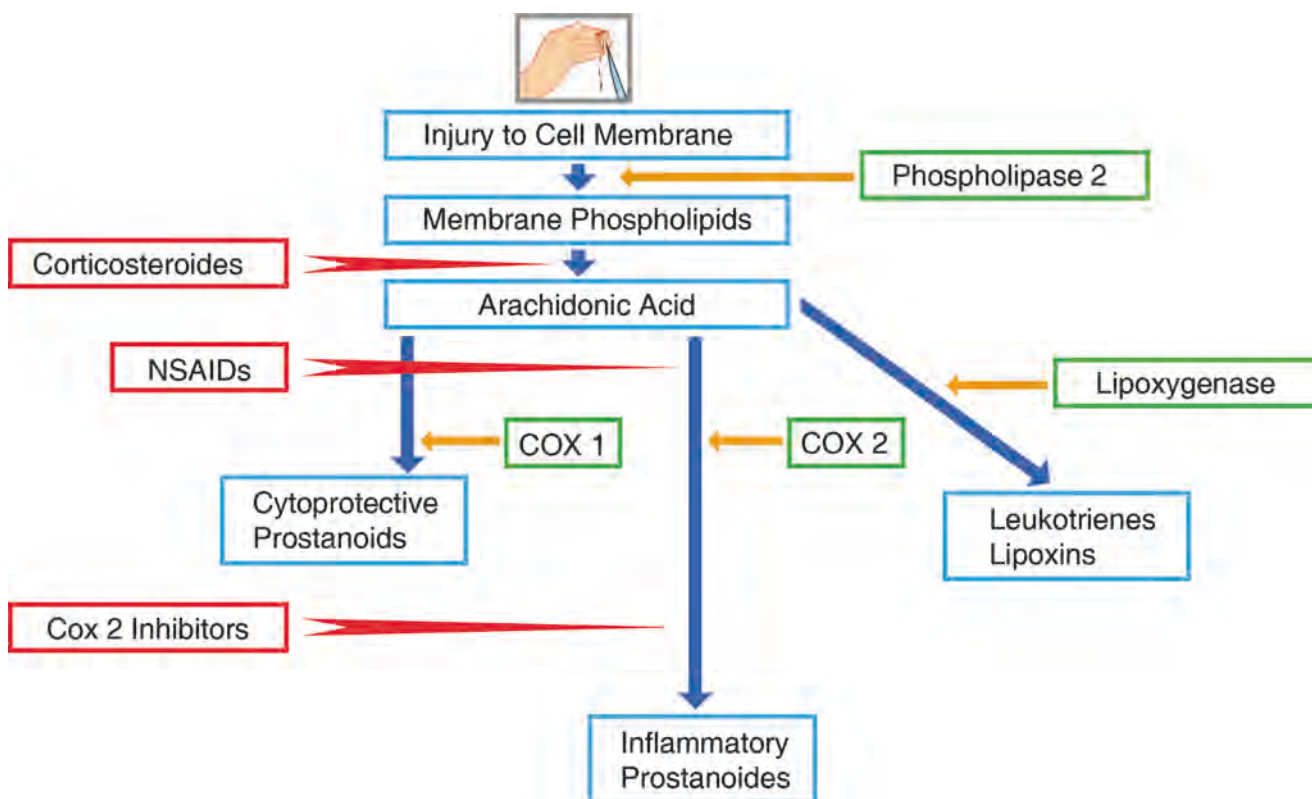
Pain is the most debilitating postoperative symptom and its control or elimination is usually the primary goal in postoperative management of a patient. Inadequate pain control resulting in patient distress is the most common cause of an increased length of hospital stay. The postoperative pain, inflammatory in character, is a temporary one persisting only until healing. But severe, acute, repetitive, postoperative pain increases the risk of the pain becoming chronic and may lead to allodynia and hyperalgesia [81]. Orthognathic surgery patients may continue to feel the pain even after 1 year of surgery [82]. Hence, appropriate pain management is critical to achieving a successful surgical outcome. Prevention of pain is more efficient than the treatment of pain. For this, an understanding of basic pathophysiology behind pain mechanism is important.

10.6 Pathophysiology of Postoperative Pain

Pain is initiated by the excitation of nociceptors, receptors that respond to noxious - mechanical, thermal, and chemical stimuli. Sensory nociception is disproportionately greater in the head and oral cavity when compared with other parts of the body. Often a patient’s overanxiety about undergoing an elective surgery would result in an increased intensity of the perceived pain [83].

Surgical insult results in tissue trauma and initiates a chain of inflammatory events, causing a release of chemical substances responsible for nociceptor excitation. Trauma releases tissue phospholipids, which are converted into arachidonic acid due to the action of phospholipase A2 and the consequent conversion of this substance into prostaglandins, prostacyclins, and leukotrienes due to the action of cyclooxygenase (Cox) and lipoxygenase enzymes. These locally released chemical mediators sensitize the nociceptors and cause vasodilatation, with a consequent increase in cell permeability and edema. Trismus after a maxillofacial surgery is a sequela to the postoperative edema around the masticator muscles and is aggravated by pain [84]. The physiological responses to tissue trauma, pain & edema, can be managed successfully by inhibiting the pathways that produce the chemical mediators, before the occurrence of surgical trauma (Fig. 10.1).

Similarly, mechanisms, which enhance the endogenous pain inhibition and anxiolysis and patient education, can



©Association of Oral and Maxillofacial Surgeons of India

Fig. 10.1 Pharmacologic interventions in arachidonic acid metabolism

modify cortical processing of pain perception [85]. All these measures collectively lead to an efficient postoperative pain management.

10.6.1 Pre-Emptive Analgesia

Postoperative pain has a protective function as it allows for undisturbed healing of the operated tissue by restricting movements. The aim of postoperative pain management is to reduce pain significantly, but not to eliminate it completely [86]. Overall postoperative pain experience could be reduced by paying attention to lessening of the pain during the surgical procedure itself. Pre-emptive analgesia is defined as an antinociceptive treatment that is started pre-operatively and is active during surgery, reducing the physiological consequences of nociceptive transmission [87]. Since the introduction of the concept of pre-emptive analgesia by Woolf in 1983, many attempts to reduce the pain by using analgesics and adjunctive measures, such as the administration of long-acting local anesthesia, corticosteroids, and intraoperative nitrous oxide analgesia, have been reported [88]. These should be given before the surgical incision and should be timed so that the maximum plasma

concentration of the drug is reached at the time of surgical incision. This will prevent the release of the inflammatory mediators, giving immediate analgesic effects. The use of IV analgesia has an added benefit over oral administration, as following oral administration analgesics reach maximum concentration after 1.5 h, whereas intravenous administration results in maximum concentration in a short period.

Numerous studies have shown beneficial effects of the preoperative administration of ibuprofen with paracetamol [89] piroxicam [90], ketorolac [91], meloxicam [92], parecoxib [93], and dexamethasone with rofecoxib [94]. There had been contradictory reports also in which the authors fail to find a clear-cut benefit for pre-emptive NSAIDs [95, 97]. The authors state that the pre-emptive intake of analgesics should not be used in all patients as a general rule. They base their recommendations on the lack of enhanced analgesic effects and on the potential adverse effects such as increased intraoperative bleeding [95].

Despite the confusion regarding the effectiveness of the pre-emptive analgesia, it has been strongly advised to start systemic analgesics before the local anesthesia effect wears off and/or give a nerve block with long-acting agent like bupivacaine [86].

Table 10.16 Predictors of postoperative pain

Patient-related factors	Surgical indicators
Age [98, 99]	Major surgeries—long duration
Female sex [98]	Bony surgery > soft tissue surgery [100]
Anxiety & apprehension, fear of the procedure	Bi-jaw surgery vs single jaw surgery
Pre-existing or chronic pain	Mandibular surgery > maxillary surgery
Preoperative use of opioids / neuropathic analgesics [98]	Oncological surgery
	Emergency procedures [101]

10.6.2 Postoperative Pain Management

Postoperative analgesia has traditionally been achieved by prescribing analgesics with instructions to take as and when necessary. Experience with this approach was that many patients would not take the medication until the onset of significant pain. This practice earned the maxillofacial surgery the reputation of being an extremely painful one. The truth is that the postoperative pain management can be successfully achieved by carefully planning the delivery of the pain control measures at the appropriate time in the peri- and postoperative periods.

Pain perception is a subjective feeling, which is amplified by many factors and identification of the patients who are “at risk” for the development of severe postoperative pain would help in charting out an individualized management plan [97] (Table 10.16).

Identifying predictors of postoperative pain in patients before surgery, educating patients at the preoperative visit regarding the expected pain, and presenting the postoperative pain management plan will prepare patients better and relieve some of their anxiety regarding the procedure. An increased awareness of the importance of the psychological factors will allow more effective pain management.

10.6.3 Pharmacological Management of Postoperative Pain

The postoperative pain management is usually done with opioids and nonsteroidal class of anti-inflammatory drugs.

10.6.3.1 Opioids

Opioids have been in use for moderate-to-severe pain relief for a long period. References to opium poppy can be found in Sumerian and Egyptian culture, as back as 300 BC. The opium poppy, *Papaver somniferum*, gives rise to more than

Table 10.17 Opioid analgesics

Drug name	Dose
Codeine	15–60 mg orally q4–6h
Hydrocodone	5–10 mg orally q3h
Oxycodone	5–7.5 mg orally q6h
Meperidine	50–150 mg orally q3–4h
Pentazocine	50 mg orally q3–4h
Tramadol	50–100 mg q4–6h, max 400 mg /day

Table 10.18 Side effects of opioid analgesics

Respiratory depression
Sleepiness
Constipation
Nausea & vomiting
Addictive potential [102]
Drug overdose death [103]
Pharmacological tolerance → opioid-induced hyperalgesia [102, 104]

20 different alkaloids [100]—morphine and codeine being the main ones (Table 10.17).

Opiate alkaloids exert their action by acting on the opioid receptors- μ , κ , δ (mu, kappa, and delta), which otherwise provide sites for activation of endogenously released opioid substances - beta-endorphins, enkephalins, and dynorphin compounds, which produce endogenous central analgesia. Opiate agonists produce analgesia by inhibiting excitatory neurotransmission of substance P, acetylcholine, noradrenaline, and dopamine.

Unfortunately, opioid use, even when prescribed for short periods, comes with certain risks (Table 10.18).

For these reasons, most opioid agents used in outpatient postsurgical pain management are formulated in combination with non-narcotic analgesics [104]. This formulation potentiates the analgesic effects of the individual agents within the formulation while minimizing the side effects of pure opioid administration [105].

10.6.3.2 Tramadol

Tramadol, a synthetic substance with both opioid and non-opioid properties, is structurally related to codeine. It exhibits antidepressant and anxiolytic-like effects, in addition to analgesic action. It is considered safe for long-term use unlike NSAIDs with their potential for impairment of renal function and gastrointestinal complications, and with respect to other opioid medications for its low addiction rate and favorable safety profile. The most common adverse effect of tramadol is nausea and vomiting, especially with oral administration. Tramadol is contraindicated in patients with poorly controlled epilepsy because of its excitatory serotonergic effects. It is available either

as a single drug or in combination with acetaminophen. Submucosal injection of tramadol at the extracted site of third molars has been proven effective in reducing the postoperative pain [106]. It suffers no side effects of systemic administration.

10.6.3.3 Nonsteroidal Anti-Inflammatory Drugs (NSAIDs)

NSAIDs have been in use for the treatment of pain, fever, and inflammation since late 1800 [107]. The anti-inflammatory and analgesic properties of these drugs without the side effects and the addictive potential of opioids have made this class of drugs the first choice in ambulatory dentoalveolar procedures (Table 10.19).

They are a group of chemically heterogeneous compounds with several similar pharmacologic actions like anti-inflammatory, antipyretic, analgesic, and antiplatelet actions. They primarily act at the site of tissue injury by inhibiting the synthesis of prostaglandins within the endoperoxide pathway (Fig. 10.1).

Table 10.19 Nonsteroidal anti-inflammatory drugs

Drug name	Action	Analgesic Dose
Salicylic acid derivative—Acetyl salicylic acid	Analgesic, anti-inflammatory, antiplatelet, antipyretic—Nonselective cox inhibitor	325-650 mg orally q4h / 1000 mg orally q6h.
Propionic acid derivative—Ibuprofen	Analgesic, anti-inflammatory, antipyretic—Nonselective cox inhibitor	400–600 mg orally q4–6h
Propionic acid derivative—Naproxen	Analgesic, antipyretic—Nonselective cox inhibitor	550 mg orally initially, then 275 mg orally q6–8h
Acetic acid derivative—Keterolac	Analgesic, antipyretic—Nonselective cox inhibitor	30 mg IV or 60 mg IM q6h / 20 mg orally initially, then 10 mg orally q4–6h
Acetic acid derivative—Diclofenac	Analgesic, anti-inflammatory—Nonselective cox inhibitor	50–75 mg orally/IV q12h
Oxicams—Piroxicam	Analgesic, anti-inflammatory—Nonselective cox inhibitor	10-20 mg orally q 12 h
N- phenyl—anthranilates—Mefenamic acid	Analgesic, anti-inflammatory—Nonselective cox inhibitor	500 mg load, then 250 mg q6h orally
Celecoxib	Cox 2 inhibitor	200 mg orally q24h / 100 mg orally q12h

Historically, majority of the NSAIDs were nonselective COX inhibitors with side effects related to the blockade of cytoprotective prostanoids - gastric irritation, increased bleeding time, and renal impairment. Over the past few years, selective COX2 inhibitors have been developed, which block the COX-2-mediated prostaglandins while maintaining the physiologically beneficial effects of the COX-1 isoenzyme [108].

Overall, NSAIDs are safe drugs to be used in the management of acute/postoperative pain. Parenteral use of NSAIDs has shown to be more effective in pain control [109]. About 60% of the patients would respond to the first NSAID, and the rest would show benefit with another NSAID. Ibuprofen is a widely used NSAID, with proven efficacy [110]. About 5% people experience “aspirin-sensitive asthma,” probably due to the inhibition of Cox enzyme. Because of the probable mechanism of inducing asthma, it is felt that selective Cox 2 inhibitors may not cause asthmatic attacks [111].

10.6.3.4 Paracetamol

Paracetamol or acetaminophen is a widely available analgesic with an antipyretic action. It acts by inhibition of the COX-3 isoenzyme, reducing the production of prostanoids in the central nervous system. This central inhibition explains the antipyretic action of paracetamol. Paracetamol shows an excellent result in relieving mild-to-moderate pain relief and fever [112]. When used in combination with other analgesics, it shows superior analgesic power, thereby reducing the dose of opioids required [96].

10.6.4 Guidelines to the Use of Analgesics

Since there is no definitive evidence or clear algorithms, the selection of NSAIDs, to a large extent, depends on clinical experience and side effects. Patient convenience and cost also play a minor role in the selection of analgesics.

Laskarides (2016), in his review on control of dental pain, puts forward his observations (Table 10.20) [113].

10.6.4.1 Analgesic Ladder

WHO initially described the concept of “pain ladder” in their guidelines for the use of drugs for the management of cancer pain [114]. The concept has been now accepted in the management of all types of pain [104]. The concept is based on the use of first line of drugs for the mild-to-moderate pain and then climb the ladder to more potent drugs if pain still persists. Please see chapter on postoperative care, to view the analgesic ladder.

Table 10.20 Key points in using analgesics

1	Care to administer correct dose of opioids [100–103]
2	Opioids + NSAIDs—centrally acting - + peripherally acting analgesia → moderate-to-severe pain relief
3	Tramadol—opioid & nonopioid properties—safe for long-term use [106].
4	Ibuprofen—excellent analgesia, transition drug to wean off from opioids [110, 113].
5	Use NSAIDs with caution—cardiovascular conditions & gastric irritation.
6	Paracetamol, tramadol, & short-acting opioids—drugs of choice [113].
7	NSAIDs drug interactions – Sulfonyl urea & other hypoglycemic agents Oral anticoagulants Phenytoin Sulfonamides
8	Paracetamol + NSAIDs—superior analgesic power [89, 112].
9	Maximum daily dose of paracetamol 4 g decides the dose of combination therapy [113].

10.6.4.2 Preventive/Protective/Multimodal Analgesia

Pain is multifactorial in origin and multiple techniques and drugs may be required to achieve control over it. The simultaneous use of different classes of analgesics and techniques has been called preventive, protective, or multimodal analgesia [115]. This approach uses a combination of drugs that act at different sites of action on the nervous system by different mechanisms to prevent peripheral and central sensitization of pain. It results in additive analgesia, but with lowered side effects than the single agents when used alone. Intraoperative local anesthesia followed by a range of analgesic drugs have been found to be effective in controlling the pain in day cases and reduces the need for opioid analgesics [116].

The complex surgeries involving multiple surgical sites as in head and neck oncological cases and craniofacial surgeries would gain hugely from the administration of multimodal analgesia. Multimodal analgesia can be successfully achieved by combining the currently available analgesic modalities (Table 10.21).

10.6.4.3 Patient-Controlled Analgesia (PCA)

Patient-controlled analgesics are intravenous agents, delivered through a microprocessor-controlled infusion pump, in which a predetermined dose can be delivered by the press of a button, and a lockout time can be set, so that patient cannot overdose himself [119]. PCA is usually used in patients who are distressed at the thought of postoperative pain. Fentanyl, morphine, & combinations are the usually used medications. Though PCA was initially thought to reduce the patient pain perception, thereby reducing the length of stay (LOS), studies have failed to show any statistically significant difference

Table 10.21 The analgesics and adjuncts that can be used in multimodal analgesia [117]

Drugs	Examples	Mechanism of action
A. Opioids [102].	Codeine, Hydrocodone Tramadol	Inhibits excitatory neurotransmission of substance P, acetylcholine, noradrenaline, & dopamine.
B. Local anesthesia [86, 118] techniques.	Bupivacaine, levobupivacaine & ropivacaine—nerve blocks & infiltration	Blocks the pain transmission
C. Acetaminophen [112].	Weak analgesic	IV administration raises the plasma & CSF concentration rapidly to achieve adequate analgesia
D. Nonsteroidal anti-inflammatory drugs (NSAIDs) [108, 110].	Ibuprofen, Diclofenac, Mefenamic acid, nasal spray of ketorolac	Blocks arachidonic acid metabolism
E. Cyclooxygenase (COX)-2-specific inhibitors [108].	Celecoxib	Cox 2 inhibitor
F. Adjuncts.		
1. <i>Steroids</i> [80].	Dexamethasone, hydrocortisone	Blocks lipoxigenase & cox pathways
2. N-methyl-d-aspartate (NMDA). <i>Antagonists</i> [97, 115, 117]	Ketamine	Effects on central sensitization & neural modulation
3. <i>Alpha – 2 agonists</i> [97, 115, 117].	Clonidine, Dexmedetomidine	Sedative and analgesia-sparing effects via central actions in the locus ceruleus and in the dorsal horn of the spinal cord, respectively
4. <i>Anticonvulsants</i> [97, 115, 117].	Gabapentin, pregabalin	Inhibits central sensitization through presynaptic or postsynaptic inhibition of calcium influx, which inhibits the release of neurotransmitters

in the pain score and the LOS between the PCA group & non-PCA group of patients after orthognathic surgery [119, 120]. This could be attributed to the fact that the subjects in the PCA group were predominantly bijaw surgery patients for whom the surgical time was longer and the surgical procedure resulted in more tissue injury. But from patient's perspective, PCA is the preferred method, as they feel in charge of their own pain control [121].

10.7 Corticosteroids in Maxillofacial Surgery

When tissue damage occurs as a result of injury, body's natural defense mechanism is inflammation and body tries to heal. But overt inflammation results in pain, edema, and limitation of movement, trismus. These symptoms may not be evident immediately, but peak after the second day, returning to normal by seventh postoperative day [122]. Corticosteroids suppress the inflammation (Fig. 10.1) by interfering with the capillary dilatation, fluid transudation, fibrin deposition, leukocyte migration, and phagocytosis. Under normal nonstressful conditions, the body produces approximately 15 to 30 mg of hydrocortisone/cortisol per day. During stressful situations, 300 mg of hydrocortisone per day can be produced. Generally speaking, to suppress inflammation, the dose of exogenous corticosteroids must exceed the normal physiological amounts of hydrocortisone released [123].

The first reported clinical use of the anti-inflammatory properties of corticosteroids was in the treatment of rheumatoid arthritis [124], following which its efficacy was tried in maxillofacial surgical procedures. The use of steroids and their effectiveness have been extensively studied in the third molar surgeries—the most commonly performed maxillofacial surgical procedure [125]. Markiewicz et al. noted that postoperative findings of swelling, trismus, and pain were significantly lower in the group who received corticosteroids, than in the control group in the immediate postoperative period (1–3 days) [126].

The use of dexamethasone and methyl prednisolone, in controlling the postoperative sequel of third molar surgery when these drugs are administered via parenteral [127], oral

[128] submucosal [129, 130] and topical [131] routes, has been reported.

Studies have evaluated different formulations, dosages, and routes and sites of administration of corticosteroids, without any consensus. (Table 10.22).

Dexamethasone has a longer duration of action than methylprednisolone and is considered more potent. Intralesional/intramasseteric injection of dexamethasone is found to be better than the intravenous or parenteral administration in controlling postoperative edema & trismus and has an additional benefit of being given through an already-anesthetized area [130, 132].

Almeida et al. (2019) [133] failed to note any benefit of submucosal injection of steroid at the local site. Authors gave the reason for this as the displacement of the medicine from the local site when mucoperiosteal flap is reflected to expose the tooth. Similarly, the merits of intravenous administration of steroids perioperatively in major surgeries have been questioned by a group of authors [134]. Kainulainen et al. [134] reported infectious complications—pneumonia, gastrostomy site infections, & surgical site infections in oncological cases.

Though the reduction of edema brings about some reduction in discomfort, steroids alone do not have a clinically significant analgesic effect [130, 135] This has been attributed to the inability of the steroids to block the production of neurotransmitters by the injured tissues and central sensitization to pain. The combination of dexamethasone with tramadol or diclofenac sodium has been proven more effective in controlling postoperative pain and trismus, as opposed to corticosteroids alone [136]. Alexander & Thronson [127] summarized few salient points with regard to usage of steroids, based on their review (Table 10.23).

Table 10.22 Commonly used steroids with their anti-inflammatory potency & equivalent dose and commonly used doses [1]

Drug	Duration of action	Anti-inflammatory potency	Equivalent dose	Dose
Dexamethasone	Long acting	25	0.75 mg	0.5–5 mg /day PO, 4–20 mg /day IV
Betamethasone	Long acting	25	0.75 mg	0.5–5 mg /day PO, 4–20 mg /day IV
Prednisolone	Intermediate acting	4	5 mg	5–60 mg /day PO 10–40 mg / day IM or IV
Methyl prednisolone	Intermediate acting	5	4 mg	4–32 mg /day PO
Triamcinolone	Intermediate acting	5	4 mg	4–32 mg /day PO 5–40 mg intra-articular
Hydrocortisone	Short acting	1	20 mg	100 mg IV/IM bolus

Table 10.23 Summary of corticosteroid use in maxillofacial surgery

1	Preoperative intralesional / parenteral administration of steroids to reduce the inflammation associated with surgery [125, 132].
2	No adrenal suppression with small doses [125]
3	Long-term use—adrenal suppression interference with immune system & infection [126]
4	Usually tapering of dose is not required for short-term uses [137]
5	Contraindications [138]: Active tuberculosis Active viral / fungal infections Active acne vulgaris Primary glaucoma Patients with psychoses
6	Use with care [138]: Diverticulitis Peptic ulcers Cushing's syndrome Renal insufficiency Uncontrolled hypertension Uncontrolled diabetes mellitus Pregnancy & lactation Chronic infections Myasthenia gravis
8	Exogenous steroid dose > endogenous cortisol level [123, 138]

10.8 Conclusion

Maxillofacial surgical practice involves use of many therapeutics to facilitate the treatment or promote healing. A careful evaluation of these drugs or reported literature, a detailed knowledge about their side effects, interactions with other chemicals, and how any alterations in the patient's physiology enhance or suppress the mechanism of action of these drugs is needed before their use or prescription. It is always prudent to remember that no medicine is without side effects and the benefits of using them should be weighed against the risks involved.

References

- Dandon RH, Bruhal LL. Goodman & Gilman's manual of pharmacology and therapeutics. 2nd ed. New York: McGraw Hill Education; 2014.
- Gaynes R. The discovery of penicillin—new insights after more than 75 years of clinical use. *Emerg Infect Dis.* 2017;23(5):849–53.
- Waksman SA. What is an antibiotic or antibiotic substance? *Mycologia.* 1947;39(5):565–9.
- Salit IE. Diagnostic approaches to head and neck infections. *Infect Dis Clin N Am.* 1988;2:35–55.
- Kuriyama T, Karasawa T, Nakagawa K, Saiki Y, Yamamoto E, Nakamura S. Bacteriologic features and antimicrobial susceptibility in isolates from orofacial odontogenic infections. *Oral Surg Oral Med Oral Pathol Oral Radiol Endod.* 2000;90:600–8.
- Paterson SA, Curzon MEJ. The effect of amoxicillin versus penicillin V in the treatment of acutely abscessed primary teeth. *Br Dent J.* 1993;174:443–9.
- Chang C, et al. Overview of penicillin allergy. *Clinic Rev Allerg Immunol.* 2012;43:84–97.
- Raz R, Elchanan G, Colodner R, et al. Penicillin V twice daily vs four times daily in the treatment of streptococcal pharyngitis. *Infect Dis Clin Pract.* 1995;4:50–4.
- Martin MP, Longman LP, Hill JB, et al. Acute dento alveolar infections: an investigation of the duration of antibiotic therapy. *Br Dent J.* 1997;183:135–7.
- DePestel DD, et al. Cephalosporin use in treatment of patients with penicillin allergies. *J Am Pharm Assoc.* 2008;48:530–40.
- Kelkar PS, Li JT. Cephalosporin allergy. *N Engl J Med.* 2001;345:804–9.
- Burke JF. The effective period of preventative antibiotic action in experimental incisions and dermal lesions. *Surgery.* 1961;50:161–8.
- Miles AA, Miles EM, Burke J. The value and duration of defense reaction of the skin to the primary lodgment of bacteria. *Br J Exp Pathol.* 1957;38:79–96.
- Classen DC, Evans RS, Pestotnik SL, et al. The timing of prophylactic administration of antibiotics and risk of surgical-wound infection. *N Engl J Med.* 1992;326:281–6.
- Pallasch TJ. Antibiotic prophylaxis: the clinical significance of its recent evolution. *J Calif Dent Assoc.* 1997;25(619–24):26–32.
- Kamolratanakul P, Jansisyanont P. A review of antibiotic prophylaxis protocols in oral and maxillofacial surgery. *J Oral Maxillofac Surg Med Pathol.* 2018;30:395–404.
- Garner JS. CDC guideline for prevention of surgical wound infections, 1985. Supersedes guideline for prevention of surgical wound infections published in 1982. (originally published in November 1985). Revised. *Infect Control.* 1986;7:193–200.
- Peterson LJ. Antibiotic prophylaxis against wound infections in oral and maxillofacial surgery. *J Oral Maxillofac Surg.* 1990;48:617–620.
- Tan SK, Lo J, Zwahlen RA. Perioperative antibiotic prophylaxis in orthognathic surgery: a systematic review and meta-analysis of clinical trials. *Oral Surg Oral Med Oral Pathol Oral Radiol Endod.* 2011;112:19–27.
- Sancho-Puchades M, Herraes-Vilas JM, Berini-Aytes L, Gay-Escoda C. Antibiotic prophylaxis to prevent local infection in Oral surgery: use or abuse? *Oral Med Oral Patol Oral Cir Bucal.* 2009;14:E28–33.
- Lewis MAO, McGowan DA, Macfarlane TW. Short – course, high-dosage amoxicillin in the treatment of acute dento-alveolar abscess. *Br Dent J.* 1986;161:299–302.
- Lodi G, Figini L, Sardella A, Carrassi A, Del Fabbro M, Furness S. Antibiotics to prevent complications following tooth extractions. *Cochrane Database Syst Rev.* 2012;11:CD003811.
- Figueiredo R, Valmaseda-Castellon E, Formoso-Senande MF, Berini-Aytes L, GayEscoda C. Delayed-onset infections after impacted lower third molar extraction: involved bacteria and sensitivity profiles to commonly used antibiotics. *Oral Surg Oral Med Oral Pathol Oral Radiol Endod.* 2012;144:43–8.
- Sekhar CH, Narayanan V, Baig MF. Role of antimicrobials in third molar surgery: prospective, double blind, randomized, placebo-controlled clinical study. *Br J Oral Maxillofac Surg.* 2001;39:134–7.

25. Adde CA, Soares MS, Romano MM, et al. Clinical and surgical evaluation of the indication of postoperative antibiotic prescription in third molar surgery. *Oral Surg Oral Med Oral Pathol Oral Radiol.* 2012;114(5 Suppl):S26–31.
26. Lacasa JM, Jimenez JA, Ferras V, Bossom M, Sola-Morales O, Garcia-Rey C, et al. Prophylaxis versus pre-emptive treatment for infective and inflammatory complications of surgical third molar removal: a randomized, double-blind, placebo-controlled, clinical trial with sustained release amoxicillin/clavulanic acid (1000/62.5 mg). *Int J Oral Maxillofac Surg.* 2007;36:321–7.
27. Pasupathy S, Alexander M. Antibiotic prophylaxis in third molar surgery. *J Craniofac Surg.* 2011;22:551–3.
28. Menon RK, Gopinath D, Li KY, et al. Does the use of amoxicillin/amoxicillin–clavulanic acid in third molar surgery reduce the risk of postoperative infection? A systematic review with meta-analysis. *Int J Oral Maxillofac Surg.* 2018;48(2):263–73.
29. Poeschl PW, Eckel D, Poeschl E. Postoperative prophylactic antibiotic treatment in third molar surgery—a necessity? *J Oral Maxillofac Surg.* 2004;62:3–8. Discussion 9
30. Larsen PE. The effect of chlorhexidine rinse on the incidence of alveolar osteitis following the surgical removal of impacted mandibular third molars. *J Oral Maxillofac Surg.* 1991;49:932–7.
31. Lyall JB. Third molar surgery: the effect of primary closure, wound dressing and metronidazole on postoperative recovery. *J R Army Med Corps.* 1991;137:100–3.
32. Ren Y-F, Malmstrom HS. Effectiveness of antibiotic prophylaxis in third molar surgery: a meta-analysis of randomized controlled clinical trials. *J Oral Maxillofac Surg.* 2007;65(10):1909–21.
33. Resnik RR, Misch C. Prophylactic antibiotic regimens in oral implantology: rationale and protocol. *Implant Dent.* 2008;17:142–50.
34. Rasmusson L, Roos J, Bystedt H. A 10-year follow-up study of titanium dioxide-blasted implants. *Clin Implant Dent Relat Res.* 2005;7(1):36–42.
35. Friberg B. Sterile operating conditions for the placement of intra-oral implants. *J Oral Maxillofac Surg.* 1996;54:1334–6.
36. Esposito M, Coulthard P, Oliver R, Thomsen P, Worthington HV. Antibiotics to prevent complications following dental implant treatment. *Cochrane Database Syst Rev.* 2003;CD004152.
37. Hossein K, Dahlin C, Bengt A. Influence of different prophylactic antibiotic regimens on implant survival rate: a retrospective clinical study. *Clin Impl Dent Rel Res.* 2005;7(1):32–5.
38. Davis CM, Gregoire CE, Steeves TW, et al. Prevalence of surgical site infections following orthognathic surgery: a retrospective cohort analysis. *J Oral Maxillofac Surg.* 2016;74:1199–206.
39. Chow LK, Singh B, Chiu WK, Samman N. Prevalence of postoperative complications after orthognathic surgery: a 15-year review. *J Oral Maxillofac Surg.* 2007;65:984–92.
40. Horan TC, Gaynes RP, Martone WJ, Jarvis WR, Emori G. CDC definitions of nosocomial surgical site infections, 1992: a modification of CDC definitions of surgical wound infections. *Infect Control Hosp Epidemiol.* 1992;13(10):606–8.
41. Danda AK, Ravi PE. Ectiveness of postoperative antibiotics in orthognathic surgery: a meta-analysis. *J Oral Maxillofac Surg.* 2011;69:2650–6.
42. Posnick JC, Choi E, Chavda A. Surgical site infections following bimaxillary orthognathic, osseous genioplasty, and intranasal surgery: a retrospective cohort study. *J Oral Maxillofac Surg.* 2017;75:584–95.
43. Danda AK, Wahab A, Narayanan V, Siddareddi A. Single-dose versus single-day antibiotic prophylaxis for orthognathic surgery: a prospective, randomized, double-blind clinical study. *J Oral Maxillofac Surg.* 2010;68:344–6.
44. Brignardello-Petersen R, Carrasco-Labra A, Araya I, Yanine N, Cordova Jara L, Villanueva J. Antibiotic prophylaxis for preventing infectious complications in orthognathic surgery. *Cochrane Database Syst Rev.* 2015;1:CD010266.
45. Mangram AJ, Horan TC, Pearson ML, et al. Guideline for prevention of surgical site infection, 1999. Centers for Disease Control and Prevention (CDC) hospital infection control practices advisory committee. *Am J Infect Control.* 1999;27:97–132.
46. Peel TN, Busing KL, Choong PF. Prosthetic joint infection: challenges of diagnosis and treatment. *ANZ J Surg.* 2011;81:32–9.
47. Fridrich KL, Partnoy BE, Zeitler DL. Prospective analysis of antibiotic prophylaxis for orthognathic surgery. *Int J Adult Orthodontics Ortho Surg.* 1994;9(2):129–31.
48. Laskin DM. The use of prophylactic antibiotics for the prevention of postoperative infections. *Oral Maxillofac Surg Clin North Am.* 2003;15:155–60.
49. Abubaker O, Rollert MK. Postoperative antibiotic prophylaxis in mandibular fractures: a preliminary randomized, double-blind, and placebo-controlled clinical study. *J Oral Maxillofac Surg.* 2001;59:1415–9.
50. Haug RH, Assael LA. Infection in the maxillofacial trauma patient. In: Topazian RG, Goldberg MH, Hupp JR, editors. *Oral and Maxillofacial Infections.* Ed 4. Philadelphia: PA, Saunders; 2002. p. 359–80.
51. Andreasen JO, Jensen SS, Schwartz O, Hillerup Y. A systematic review of prophylactic antibiotics in the surgical treatment of maxillofacial fractures. *J Oral Maxillofac Surg.* 2006;64:1664–8.
52. Dillon JK, Christensen B, McDonald T, et al. The financial burden of mandibular trauma. *J Oral Maxillofac Surg.* 2012;70:2124–34.
53. Shridharani SM, Berli J, Manson PN, et al. The role of postoperative antibiotics in mandible fractures: a systematic review of the literature. *Ann Plast Surg.* 2015;75:353–7.
54. Gaal A, Patel Y, Smiley N, et al. Limiting antibiotics when managing mandible fractures may not increase infection risk. *J Oral Maxillofac Surg.* 2016;74:2008–18.
55. Baliga SD, Bose A, Jain S. The evaluation of efficacy of postoperative antibiotics in the open reduction of the zygomatic and mandibular fracture: a prospective trial. *J Maxillofac Oral Surg.* 2014;13:165–75.
56. Miles BA, Potter JK, Ellis E. The efficacy of postoperative antibiotic regimens in the open treatment of mandibular fractures: a prospective randomized trial. *J Oral Maxillofac Surg.* 2006;64:576–82.
57. Goodson WH III, Hunt TK. Wound healing and the diabetic patient. *Surg Gynecol Obstet.* 1979;149:600–8.
58. Zoeller GN, Kadis B. The diabetic dental patient. *Gen Dent.* 1981;29:58–61.
59. Rahimi-Nedjat RK, Sagheb K, Pabst A, et al. Diabetes and hyperglycemia as risk factors for postoperative outcome in maxillofacial surgery. *J Surg Res.* 2017;217:170–6.
60. Ramaraj PN, Cariappa KM. Is there a need for antibiotic prophylaxis after routine dental extraction in diabetic patients? *Br J Oral Maxillofac Surg.* 2006;44:421.
61. Lee DH, Kim SY, Nam SY, Choi SH, Choi JW, Roh JL. Risk factors of surgical site infection in patients undergoing major oncological surgery for head and neck cancer. *Oral Oncol.* 2011;47:528–31.
62. Bartella A, Kamal M, Teichmann J, et al. Prospective comparison of perioperative antibiotic management protocols in oncological head and neck surgery. *J Cran-Max-Fac Surg.* 2017;45:1078–82.
63. Zhang Y, Dong J, Qiao Y, He J, Wang T, Ma S. Efficacy and safety profile of antibiotic prophylaxis usage in clean and clean-contaminated plastic and reconstructive surgery: a meta-analysis of randomized controlled trials. *Ann Plast Surg.* 2014;72:121–30.
64. Ariyan S, Martin J, Lal A, Cheng D, Borah GL, Chung KC, et al. Antibiotic prophylaxis for preventing surgical-site infection in plastic surgery: an evidence-based consensus conference statement from the American Association of Plastic Surgeons. *Plast Reconstr Surg.* 2015;135:1723–39.

65. Mercer NSG. The use of preoperative swabs in cleft lip and palate repair. *Br J Plast Surg*. 2002;55:176–7.
66. Moss ALH. The use of preoperative swabs in cleft lip and palate repair. *Br J Plast Surg*. 2002;55:533–4.
67. Chuo CB, Timmons MJ. The bacteriology of children before primary cleft lip and palate surgery. *The Cleft Palat-Craniofac J*. 2005;42(3):272–6.
68. Rennie AL, Treharne LJ, Richard B. Throat swabs taken on the operating table prior to cleft palate repair and their relevance to outcome: a prospective study. *Cleft Palate Craniofac J*. 2009 May;46(3):275–9.
69. Aznar ML, Schönmeier B, Echaniz G, et al. Role of postoperative antimicrobials in cleft palate surgery. *Plast Recon Surg*. 2015;136(1):59e–66e.
70. Douglas LR, Douglass JB, Sieck JO, Smith PJ. Oral management of the patient with end-stage liver disease and the liver transplant patient. *Oral Surg Oral Med Oral Pathol Oral Radiol Endod*. 1998;86:55–64.
71. Guggenheimer J, Mayher D, Eghtesad B. A survey of dental care protocols among US organ transplant centers. *Clin Transpl*. 2005;19:15–8.
72. Lewis T, Grant RT. Observations relating to subacute infective endocarditis. *Br Heart J*. 1923;10:21–77.
73. Jones TD, Baumgartner L, Bellows MT, et al. Prevention of rheumatic fever and bacterial endocarditis through control of streptococcal infections. *Circulation*. 1955;11:317–20.
74. Wilson W, Taubert KA, Gewitz M, et al. American Heart Association. Prevention of infective endocarditis: guidelines from the American Heart Association: a guideline from the American Heart Association rheumatic fever, endocarditis and Kawasaki disease committee, council on cardiovascular disease in the young, and the council on clinical cardiology, council on cardiovascular surgery and anesthesia, and the quality of care and outcomes research interdisciplinary working group. *JADA*. 2008;139(suppl):3S–24S.
75. Gould FK, Elliott TSJ, Foweraker J, et al. Guidelines for the prevention of endocarditis: report of the working party of the British society for antimicrobial chemotherapy. *J Antimicrob Chemother*. 2006;57:1035–42.
76. Prophylaxis against infective endocarditis. National institute for health and care excellence. 2008.
77. Habib G, Hoen B, Tornos P, et al. Guidelines on the prevention, diagnosis, and treatment of infective endocarditis (new version 2009): the task force on the prevention, diagnosis, and treatment of infective endocarditis of the European society of cardiology (ESC). Endorsed by the European society of clinical microbiology and infectious diseases (ESCMID) and the international society of chemotherapy (ISC) for infection and cancer. *Eur Heart J*. 2009;30:2369–413.
78. Pasquali SK, He X, Mohamad Z, et al. Trends in endocarditis hospitalizations at US children's hospitals: impact of the 2007 American Heart Association antibiotic prophylaxis guidelines. *Am Heart J*. 2012;163:894–9.
79. Sakai Bizmark R, Chang R-KR, Tsugawa Y, et al. Impact of AHA's 2007 guideline change on incidence of infective endocarditis in infants and children. *Am Heart J*. 2017;189:110–9.
80. Pain terms: a list with definitions and notes on usage. Recommended by the IASP Subcommittee on taxonomy. *Pain*. 1979;6:249–52.
81. Feizerfan A, Sheh G. Transition from acute to chronic pain. *Contin Educ Anaesth Crit Care Pain*. 2015;15:98–102.
82. Luo Y, Svensson P, Jensen JD, et al. Quantitative sensory testing in patients with or without ongoing pain one year after orthognathic surgery. *J Oral Facial Pain Headache*. 2014;28:306–16.
83. Desjardins P. Patient pain and anxiety: the medical and psychologic challenges facing oral and maxillofacial surgery. *J Oral Maxillofac Surg*. 2000;58(2):1–3.
84. Pedersen A. Interrelation of complaints after removal of impacted mandibular third molars. *Int J Oral Surg*. 1985;14:241–4.
85. Crane M, Green P, Gordon N. Pharmacology of opioid and non-opioid analgesics. *Oral Maxillofac Surg Clin N Am*. 2001;13:1–13.
86. Coulthard P, Bailey E, Patel N, Coulthard MB. Pain pathways and pre-emptive and protective analgesia for oral surgery. *Oral Surg*. 2013;7(2):74–80.
87. Woolf CJ, Chong MS. Preemptive analgesia treating postoperative pain by preventing the establishment of central sensitization. *Anesth Analg*. 1993;77:362–79.
88. Woolf CJ. Evidence for a central component of postinjury pain hypersensitivity. *Nature*. 1983;306:686–8.
89. Viswanath A, Oreadi D, Finkelman M, Klein G, Papageorge M. Does pre-Emptive Administration of Intravenous Ibuprofen (Caldolor) or intravenous acetaminophen (Ofirmev) reduce postoperative pain and subsequent narcotic consumption after third molar surgery? *J Oral Maxillofac Surg*. 2019;77(2):262–70.
90. Hutchison GL, Crofts SL, Gray IG. Preoperative piroxicam for postoperative analgesia in dental surgery. *Br J Anaesth*. 1990;65:500–3.
91. Ong KS, Seymour RA, Chen FG, Ho VC. Preoperative ketorolac has a preemptive effect for postoperative third molar surgical pain. *Int J Oral Maxillofac Surg*. 2004;33:771–6.
92. Aoki T, Yamaguchi H, Naito H, Shiiki K, Izawa K, Ota Y, Sakamoto H, Kaneko A. Premedication with cyclooxygenase-2 inhibitor meloxicam reduced postoperative pain in patients after oral surgery. *Int J Oral Maxillofac Surg*. 2006;35:613–7.
93. Desjardins PJ, Grossman EH, Kuss ME, Talwalker S, Dhadda S, Baum D, Hubbard RC. The injectable cyclooxygenase-2-specific inhibitor parecoxib sodium has analgesic efficacy when administered preoperatively. *Anesth Analg*. 2001;93:721–7.
94. Moore PA, Brar P, Smiga ER, Costello BJ. Preemptive rofecoxib and dexamethasone for prevention of pain and trismus following third molar surgery. *Oral Surg Oral Med Oral Pathol Oral Radiol Endod*. 2005;99:e1–7.
95. Møiniche S, Kehlet H, Dah JB. A qualitative and quantitative systematic review of preemptive analgesia for postoperative pain relief: the role of timing of analgesia. *Anesthesiology*. 2002;96:725–34.
96. Aznar Arasa L, Harutunian K, Figueredo R, et al. Effect of preoperative ibuprofen on pain and swelling after lower third molar removal: a randomized controlled trial. *Int J Oral Maxillofac Surg*. 2012;41:1005–9.
97. Evans SW, McCahon RA. Management of postoperative pain in maxillofacial surgery. *Br J Oral Maxillofac Surg*. 2019;57(1):4–11.
98. De Cosmo G, Congedo E, Lai C, et al. Preoperative psychologic and demographic predictors of pain perception and tramadol consumption using intravenous patient-controlled analgesia. *Clin J Pain*. 2008;24:399–405.
99. Coulthard P, Haywood D, Tai MA, Jackson-Leech D, Pleuvry BJ, Macfarlane TV. Treatment of postoperative pain in oral and maxillofacial surgery. *Br J Oral Maxillofac Surg*. 2000;38(6):588–92.
100. Mobini A, Mehra P, Chigurupathy R. Postoperative pain and opioid analgesic requirements after orthognathic surgery. *J Oral Maxillofac Surg*. 2018;76:2285–95.
101. Moore PA, Hersch EV. Analgesic therapy in dentistry - from a letter to the editor to an evidence-base review. *Dent Clin N Am*. 2019;63:35–44.
102. Fletcher MC, Spera JF. Management of acute postoperative pain after oral surgery. *Dent Clin N Am*. 2012;56:95–111.
103. Rudd RA, Seth P, David F, Scholl L. Increases in drug and opioid involved overdose deaths—United States, 2010–2015. *Morb Mortal Wkly Rep*. 2016;65:1445–52.

104. Patel N, Bailey E, Coulthard P. Opioids for pain after oral surgery. *Oral Surg*. 2013;7(4):196–202.
105. Moore RA, Derry S, McQuay HJ, Wiffen PJ. Single dose oral analgesics for acute postoperative pain in adults. *Cochrane Database Syst Rev*. 2011;9:CD008659.
106. Cecchetti MM, Negrato GV, de Melo Peres MP, et al. Analgesic and adjuvant anesthetic effect of submucosal tramadol after mandibular third molar surgery. *Oral Surg Oral Med Oral Pathol Oral Radiol*. 2014;117(3):e249–54.
107. Power I, Barratt S. Analgesic agents for the postoperative period: nonopioids. *Surg Clin North Am*. 1999;79:275–95.
108. Moore P, Hersh E. Celecoxib and rofecoxib, the role of COX-2 inhibitors in dental practice. *J Am Dent Assoc*. 2001;132:451–6.
109. Seymour RA, Moore U, Hawkesford J, Coulthard P, Jackson-Leech D, Thomas D, Hill M, Combs ML, Renton T, McGurk M. An investigation into the efficacy of intravenous diclofenac in post-operative dental pain. *Eur J Clin Pharmacol*. 2000 Sep;56(6-7):447–52.
110. Derry CJ, Derry S, Moore RA, McQuay HJ. Single dose oral ibuprofen for acute postoperative pain in adults. *Cochrane Database Syst Rev*. 2009;3:CD010210.
111. Gyllfors P, Bochenek G, Overholt J, et al. Biochemical and clinical evidence that aspirin intolerant asthmatic subjects tolerate the cyclooxygenase 2-selective analgesic drug celecoxib. *J Allergy Clin Immunol*. 2003;111:1116–21.
112. Weil K, Hooper L, Afzal Z, et al. Paracetamol for pain relief after surgical removal of wisdom teeth. *Cochrane Database Syst Rev*. 2007;3:CD004487.
113. Laskarides C. Update on analgesic medication for adult and pediatric dental patients. *Dent Clin N Am*. 2016;60:347–66.
114. World Health Organization. WHO Pain Ladder. 2013. Available from URL: <http://www.who.int/cancer/palliative/painladder/en/>.
115. Buvaendran A, Kroin JS. Multimodal analgesia for controlling acute postoperative pain. *Curr Opin Anaesthesiol*. 2009;22:588–93.
116. Yong SL, Walsh T, Coulthard P. Protective analgesia for postoperative pain following third molar surgery [protocol]. *Cochrane Database Syst Rev*. 2010;9:CD008692.
117. Rosero EB, Joshi GP. Preemptive, preventive. *Multimodal Analgesia Plast Recon Surg*. 2014;134:85S–93S.
118. Rood JP, Coulthard P, Snowdon AT, Gennery BA. Safety and efficacy of levobupivacaine for postoperative pain relief after the surgical removal of impacted third molars: a comparison with lignocaine and adrenaline. *Br J Oral Maxillofac Surg*. 2002 Dec;40(6):491–6.
119. Chang FSC, Burrows A, Gebauer DP. Patient-controlled analgesia and length of hospital stay in orthognathic surgery: a randomized controlled trial. *J Oral Maxillofac Surg*. 2019;77:818–27.
120. Geha H, Nimeskern N, Beziat J. Patient-controlled analgesia in orthognathic surgery: evaluation of the relationship to anxiety and anxiolytics. *Oral Surg Oral Med Oral Pathol Oral Radiol Endod*. 2009;108:e33–6.
121. Hudcova J, McNicol ED, Quah CS, Lau J, Carr DB. Patient controlled opioid analgesia versus conventional opioid analgesia for postoperative pain. *Cochrane Database Syst Rev*. 2006;4:CD003348.
122. Peterson LJ. Postoperative patient management. In: Peterson LJ, Ellis E, Hupp JR, Tucker MR, editors. *Contemporary oral and maxillofacial surgery*. 3rd ed. St Louis: Mosby; 1998. p. 251.
123. Gilman AG, Rall TW, Nies AS, et al. *The pharmacological basis of therapeutics* (ed 8). New York, NY: Macmillan; 1990. p. 1436–52.
124. Axelrod L. Adrenal corticosteroids. In: Miller RR, Greenblatt, editors. *Handbook of drug Theravau*. New York, NY: Elsevier; 1979. p. 809–40.
125. Beirne OR, Hollander B. The effect of methylprednisolone on pain, trismus, and swelling after removal of third molar. *Oral Surg Oral Med Oral Pathol*. 1986;61:134–8.
126. Markiewicz MR, Brady MF, Ding EL, Dodson TB. Corticosteroids reduce postoperative morbidity after third molar surgery: a systematic review and meta-analysis. *J Oral Maxillofac Surg*. 2008;66(9):1881–94.
127. Alexander RE, Thronson RT. A review of perioperative corticosteroid use in dentoalveolar surgery. *Oral Surg Oral Med Oral Pathol*. 2000;90:406–15.
128. Montgomery MT, Hogg JP, Roberts DL, et al. The use of glucocorticosteroids to lessen the inflammatory sequelae following third molar surgery. *J Oral Maxillofac Surg*. 1990;48:179–87.
129. Pedersen A. Decadronphosphate in the relief of complaints after third molar surgery. *Int J Oral Maxillofac Surg*. 1985;14:235–40.
130. Grossi GB, Maiorana C, Garramone RA. Effect of submucosal injection of dexamethasone on postoperative discomfort after third molar surgery: a prospective study. *J Oral Maxillofac Surg*. 2007;65:2218–26.
131. Messer EJ, Keller JJ. The use of intraoral dexamethasone after extraction of mandibular third molar. *Oral Surg Oral Med Oral Pathol*. 1975;40:594–8.
132. Brucoli M, De Andreis M, Boffano BP, et al. Comparative assessment of dexamethasone administration routes for the management of postoperative symptoms following third molar surgery. *J Stomatol Oral Maxillofac Surg*. 2019.
133. de Almeida AC, Lemos CAA, de Moraes SLD, et al. Efficacy of corticosteroids versus placebo in impacted third molar surgery: systematic review and meta-analysis of randomized controlled trials. *Int J Oral Maxillofac Surg*. 2019;48:118–31.
134. Kainulainen S, Lassus P, Suominen AL, et al. More harm than benefit of perioperative dexamethasone on recovery following reconstructive head and neck cancer surgery: a prospective double-blind randomized trial. *J Oral Maxillofac Surg*. 2018;76:2425–32.
135. Dionne RA, Gordon SM, Rowan J, et al. Dexamethasone suppresses peripheral prostanoid levels without analgesia in a clinical model of acute inflammation. *J Oral Maxillofac Surg*. 2003;61:997–1003.
136. de Sousa Santos JAS, DaSilva LCF, de Santana Santos T, et al. Comparative study of tramadol combined with dexamethasone and diclofenac sodium in third-molar surgery. *J Cranio-Maxillo-Facial Surg*. 2012;40:694–700.
137. Matheny JL. Adrenocorticosteroids: systemic and topical therapy. In: Holroyd SV, Wynn RL, Requa-Clark B, editors. *Clinical pharmacology in dental practice*. 4th ed. St Louis: Mosby; 1988. p. 238–45.
138. Butler RCD, Vorono AA, Finstuen K. Dosage effects of pulsed steroid therapy on serum cortisol levels in oral and maxillofacial surgery patients. *J Oral Maxillofac Surg*. 1993;51:750–3.

Additional Reading

Odontogenic microbiological spectrum.

Lewis MAO, Macfarlane TW, McGown DA. A microbiological and clinical review of acute dentoalveolar abscesses. *Br J Oral Maxillofac Surg*. 1990;28:359–66.

Poeschl PW, Spusta L, Russmueller G, Seemann R, Hirschl A, Poeschl E, et al. Antibiotic susceptibility and resistance of the odontogenic microbiological spectrum and its clinical impact on severe deep space head and neck infections. *Oral Surg Oral Med Oral Pathol Oral Radiol Endod*. 2010;110:151–6.

Antibiotic prophylaxis.

- Moreno-Drada JA, Garcia-Perdomo HA. Effectiveness of antimicrobial prophylaxis in preventing the spread of infection as a result of oral procedures: a systematic review and meta-analysis. *J Oral Maxillofac Surg.* 2016;74:1313–21.
- Antibiotics in third molar surgery.*
- Bezerra TP, Studart-Soares EC, Scaparo HC, Pita-Neto IC, Batista SH, Fonteles CS. Prophylaxis versus placebo treatment for infective and inflammatory complications of surgical third molar removal: a split-mouth, double-blind, controlled, clinical trial with amoxicillin (500 mg). *J Oral Maxillofac Surg.* 2011;69:e333–9.
- Monaco G, Tavernese L, Agostini R, Marchetti C. Evaluation of antibiotic prophylaxis in reducing postoperative infection after mandibular third molar extraction in young patients. *J Oral Maxillofac Surg.* 2009;67:1467–72.
- Lopez-Cedrun JL, Pijoan JI, Fernandez S, Santamaria J, Hernandez G. Efficacy of amoxicillin treatment in preventing postoperative complications in patients undergoing third molar surgery: a prospective, randomized, double-blind controlled study. *J Oral Maxillofac Surg.* 2011;69:e5–14.
- Antibiotics in implants.*
- Chrcanovic BR, Albrektsson T, Wennerberg A. Prophylactic antibiotic regimen and dental implant failure: a meta-analysis. *J Oral Rehabil.* 2014;41:941–56.
- Antibiotics in orthognathic surgery.*
- Bentley KC, Head TW, Aiello GA. Antibiotic prophylaxis in orthognathic surgery: a 1-day versus 5-day regimen. *J Oral Maxillofac Surg.* 1999;57(3):226–30. Discussion 230-2
- Tan SK, Lo J, Zwahlen RA. Are postoperative intravenous antibiotics necessary after bimaxillary orthognathic surgery? A prospective, randomized, double-blind, placebo-controlled clinical trial. *Int J Oral Maxillofac Surg.* 2011;40:1363–8.
- Brignardello-Petersen R, Carrasco-Labra A, Araya I, et al. Antibiotic prophylaxis for preventing infectious complications in orthognathic surgery. *Cochrane Database of Systematic Reviews.* 2015.
- Lindeboom JA, Baas EM, Kroon FH. Prophylactic singledose administration of 600 mg clindamycin versus 4-time administration of 600 mg clindamycin in orthognathic surgery: a prospective randomized study in bilateral mandibular sagittal ramus osteotomies. *Oral Surgery, Oral Medicine, Oral Pathology and Radiology and Endodontics.* 2003;95(2):145–9.
- Steroids in third molar surgery.*
- Graziani F, D’Aiuto F, Arduino PG, et al. Perioperative dexamethasone reduces post-surgical sequelae of wisdom tooth removal. A split-mouth randomized double-masked clinical trial. *Int J Oral Maxillofac Surg.* 2006;35:241–6.
- Lim D, Ngeow WC. A comparative study on the efficacy of submucosal injection of dexamethasone versus methylprednisolone in reducing postoperative sequelae after third molar surgery. *J Oral Maxillofac Surg.* 2017;75:2278–86.
- Steroids in orthognathic surgery.*
- Dan AEB, Thygesen TH, Pinbolt EM. Corticosteroid administration in oral and orthognathic surgery: a systematic review of the literature and meta-analysis. *J Oral Maxillofac Surg.* 2010;68:2207–20.

Open Access This chapter is licensed under the terms of the Creative Commons Attribution 4.0 International License (<http://creativecommons.org/licenses/by/4.0/>), which permits use, sharing, adaptation, distribution and reproduction in any medium or format, as long as you give appropriate credit to the original author(s) and the source, provide a link to the Creative Commons license and indicate if changes were made.

The images or other third party material in this chapter are included in the chapter's Creative Commons license, unless indicated otherwise in a credit line to the material. If material is not included in the chapter's Creative Commons license and your intended use is not permitted by statutory regulation or exceeds the permitted use, you will need to obtain permission directly from the copyright holder.





Wound Closure and Care in Oral and Maxillofacial Surgery

11

Ravi Veeraraghavan

11.1 Wound Management

Management of soft tissue wounds needs a careful assessment of the wound, a good understanding of wound types and healing as well as adequate knowledge and skill for wound care. The various steps in wound care include cleansing and debridement, hemostasis, tetanus immunization and antibiotic medication and wound closure.

Wound closure can be accomplished in diverse ways, but suturing remains the mainstay. A wide variety of materials are available for wound suturing. One has to choose the right material and technique depending on the wound type and closure needs. Alternate techniques such as staples, tapes and adhesives are fast gaining popularity.

Wounds are treated by

1. Cleansing and debridement,
2. Haemostasis,
3. Tetanus immunisation,
4. Wound dressings,
5. Wound closure,
6. Antibiotic medication.

11.2 Wound Closure

Artificial closure of the wounds is required if significant connective tissue is exposed. Wound closure leads to faster wound healing with reduced complications. Even though suturing is the mainstay of wound closure, other alternatives are fast gaining popularity.

Electronic Supplementary Material The online version of this chapter (https://doi.org/10.1007/978-981-15-1346-6_11) contains supplementary material, which is available to authorized users.

R. Veeraraghavan (✉)
Department of Oral and Maxillofacial Surgery, Amrita School of Dentistry, Ernakulam, India

11.2.1 Purposes of Wound Closure

Before going into the intricacies of material selection and techniques of wound closure, one needs to be clear about the actual need for artificially closing a wound. The main indication for wound closure is significant exposure of connective tissue. In general, there are five reasons behind the concept of wound closure.

1. *Healing by Primary Intention*

This is the most important purpose of wound closure. The open wounds, which are likely to heal by secondary intention, are made to heal in a 'more' primary manner by the intervention of wound closure. This hastens the healing process and also reduces scar formation, with resultant advantages in aesthetic and functional facets.

2. *Coverage of Deep Tissues*

When the epithelium is breached and connective tissue is bared, it exposes the inner tissues to mechanical and biological threats. This threat becomes even more serious when deeper structures such as the viscera or bone is exposed.

3. *Prevent Contamination*

An open wound is under constant attack by the pathogenic microorganisms, more so in the oral cavity. Such relentless contamination is likely to lead to a full-blown infection and/or delayed healing. Sooner the wound is closed, the lesser the risk of major contamination.

4. *Haemostasis*

This is not one of the primary purposes of wound closure. But sutures may help in impeding blood loss by preventing mechanical disturbance to the clot.

5. *Prevention of Dead Space*

If only the superficial cutaneous sutures are placed over a deep wound, a dead space can result beneath the surface. This condition usually leads to wound breakdown and/or wound infection. Dead space is prevented by closing the deep tissues in multiple layers.

11.3 Wound Suturing

Suturing is the process of wound closure by holding the edges of the wound together using a thread. This thread, called a 'suture', is used to approximate the wound edges together and to hold them in position till the tissue healing is sufficiently advanced to maintain themselves in the corrected anatomic position and alignment to each other. The surgeon uses a 'suture needle' to pass the thread through the tissues on either side of the wound so as to hold the separated edges in the proper position.

11.3.1 Suturing Instruments

Apart from the suture thread and needle, some instruments are used to perform the suturing process. Commonly used instruments include a needle holder, a tissue holding forceps and a pair of scissors.

11.3.1.1 Needle Holder

The needle holder (needle driver) is the primary instrument used for suturing. Similar to a haemostat, it is used to grasp and manipulate the suture needle to which the thread is attached. A needle holder has three parts—a pair of beaks, a joint ('pivot') and a pair of handles with rings. Many designs are available, examples being Webster, Halsey and Mayo-Hegar. Most designs have a serrated or cross-hatching pattern of teeth for the beaks. This helps to grip the needle securely without damaging it. A locking mechanism similar to haemostats is present to lock the needle grasp.

The classical way to hold the instrument is to engage the handle-rings with the thumb and the fourth finger. The middle finger is used for support and the index finger is used to direct or orient the instrument in the required direction. Alternatively, while suturing on tough tissues, one may be 'palmed', i.e. may be held against the palm with fingers around. While palming the needle holder, some surgeons still rest the fourth finger lightly in the handle-ring.

11.3.1.2 Tissue Holding Forceps

The pickup forceps are used to delicately handle and manipulate the wound edge which is being sutured. The fine-toothed Adson forceps is the workhorse for most interior and cutaneous wound closures. The forceps is held in the non-dominant hand and is used to grasp, lift and evert the wound edge so that the surface is made more amenable to a perpendicular needle entry. Fine skin hooks may also be used for the same purpose.

11.3.1.3 Suture Cutting Scissors

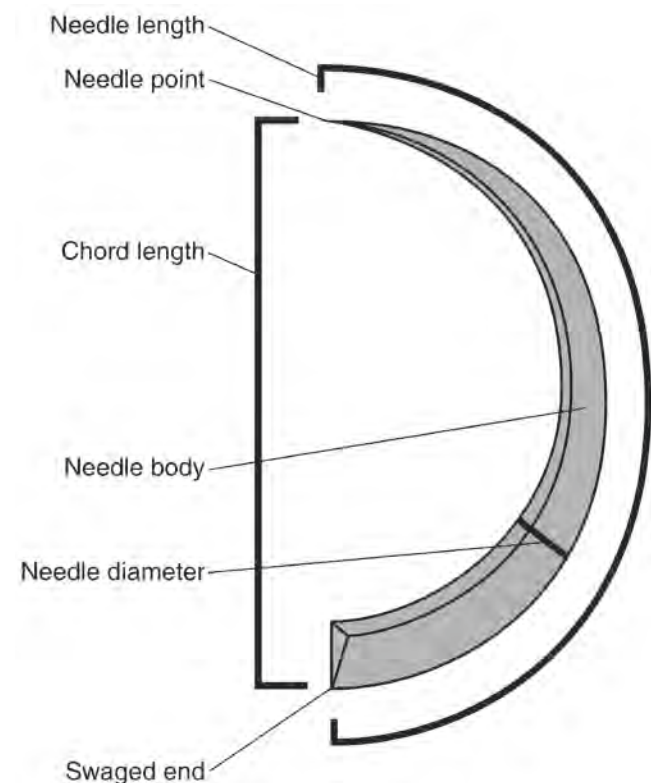
The suture cutting scissors is used to cut the suture thread tags after the knot is tied. It is also used to cut the thread during suture removal.

These scissors should be differentiated from scissors used for cutting tissue. Many of them have specifically designed blades and tips, which are uniquely shaped to lift and grasp up the hanging tags or the tied suture thread away from the tissue and to cut it safely without injuring the tissues. Short and long versions are available. The tip may be straight or curved and may have a sharp slot for the thread to be cut. Some manufacturers have incorporated a cutting component in the needle holder itself, using which the surgeon can cut the suture tag without switching instruments.

11.3.2 Suture Needles

The suture needles help to pass the suture threads through tissues. In ancient days, needles were made of natural materials such as bones, ivory, horns, wood or thorns. In fact, eyed needles from as early as 30,000 AD have been unearthed. Later, metals such as silver, copper and aluminium bronze were used. The modern needles are diligently shaped and contoured as per use and are smooth and strong so that they withstand the stresses of suturing and least traumatic to tissues at the same time.

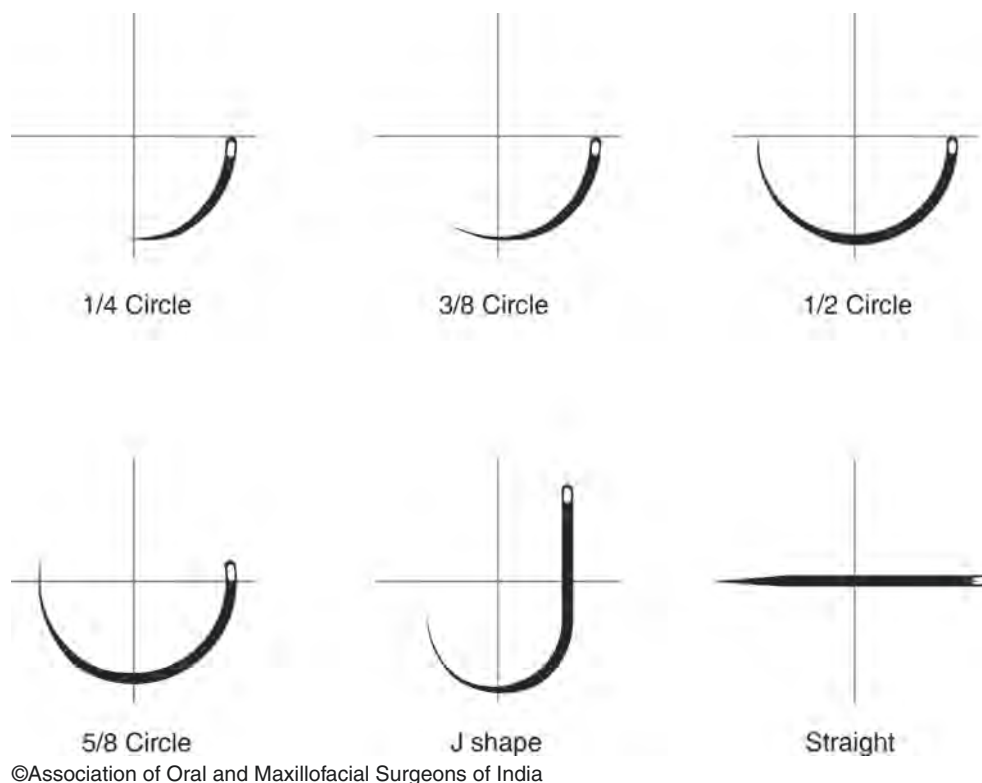
The suture needle has three parts: the tip, the body and the suture attachment. Made of stainless steel or carbon steel, they are thin, smooth and sharp, designed to pass through tissues with ease (Fig. 11.1).



©Association of Oral and Maxillofacial Surgeons of India

Fig. 11.1 Parts of suture needle

Fig. 11.2 Needle shapes/curvature



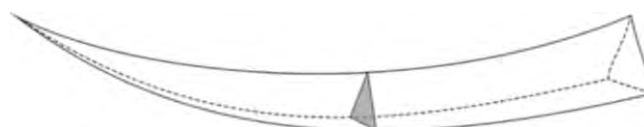
11.3.2.1 Needle Shape

The suture needles are usually curved as an arc of a circle. Straight needles, though available, have very limited practical applications. The curvature is described as the span of the arc, in terms of $\frac{1}{4}$, $\frac{3}{8}$, $\frac{1}{2}$ and $\frac{5}{8}$ of a circle. Most of the regular suturing in oral and maxillofacial surgery is done with half circle needles. A smaller arc such as $\frac{3}{8}$ can be used for suturing flat skin surfaces. Longer arc, i.e. $\frac{5}{8}$ circle, needles are used in narrow tunnelled surgical fields such as in cleft palate or inside the nose (Fig. 11.2).

The cross section and the tip of the needles can be widely varied. Depending on these aspects, the suture needles can be.

1. Round bodied,
2. Conventional cutting (Fig. 11.3) or
3. Reverse cutting.

Round bodied needles are generally used to suture viscera and other internal structures such as muscle and fascia. It can also be effective on non-keratinised mucosa. The tip of the round-bodied needle can be blunt or sharp. The blunt tip needle is specifically used in the inner abdominal wall and in friable tissues. The sharp tip is used for most other purposes. But even the sharp tip is hard to pass across the skin and keratinised mucosa. The shape of the 'cutting' needle overcomes this problem. In the cutting needles, the needle cross section is a triangle, with the inner curve side being pointed



©Association of Oral and Maxillofacial Surgeons of India

Fig. 11.3 Needle cross section of a conventional cutting needle

and the outer convex side flat. This shape enables the needle to 'cut' through the dense tissues to make the needle passage easier. But the cutting design presented a new problem. Even under minimum tension, the needle behaved like a knife, and the sharp edge often tended to lacerate the tissue resulting in a 'cut-through' of the wound edge. This was solved by the reverse-cutting design, wherein the inner curve is flat and the outer curve is pointed. This helps to retain the cutting nature while avoiding the risk of wound edge laceration. In oral and maxillofacial surgery, the tissues encountered may be keratinised (skin, gingiva and palate) or non-keratinised (buccal mucosa, floor of mouth and lips). Mostly, reverse-cutting needles are now being used since they are well-suited to pass through all oral tissues without causing inadvertent tears.

11.3.2.2 Needle Size

The suture needle size generally depends on the size of the suture. In general, smaller the suture size, smaller the needle. It is important to recognise the various dimensions of a needle.

The ‘needle length’ refers to the end-to-end measurement along the curve of the needle. The straight line distance from the tip to the other end is called ‘chord length’. The chord length determines the bite-width of the needle in the tissues. The bite-depth into the tissue is defined by the ‘chord diameter’ which is perpendicular from the chord length to the centre of the needle body. Needle diameter and needle radius are dimensions which refer to the cross-sectional thickness and not to the needle curve.

11.3.2.3 Eyed vs Swaged Needles

The eye of the needle is a small hole at one end for attaching the suture thread. This necessitates an increase in the needle thickness at the attachment end, increasing the risk of potential tissue trauma. The suture is passed through the eye, and may then be tucked or tied for better retention. Both tucking and tying further increases the tissue drag and causes additional trauma. The attached suture now follows the needle through the tissues. The eyed needles are cheaper and can be reused after resterilisation.

Modern suture needles do not have an eye. Instead, the suture thread is sealed inside the needle for a permanent attachment. This mechanism, called ‘swaging’, reduces the tissue trauma significantly as the needle diameter is not increased for thread attachment. Further, only a single thread strand passes through the tissue at all times. So these needles are often called ‘atraumatic needles’. The swaged needle with thread is available as a sterile pack, and cannot be reused.

11.4 Suture Thread

Many different types of suture threads are available for use. Each type has its specific benefits and indications for application (Table 11.1).

A basic classification divides them into ‘natural’ and ‘synthetic’. Suture materials sourced from natural sources include catgut, steel and silk. Synthetic plastic materials such as nylon, polypropylene and polymers of glycolic acid, lactic acid, etc., have become popular in recent decades.

Suture materials can also be classified as absorbable and non-absorbable. Absorbable sutures hold the tissues together till they have healed sufficiently to withstand normal stress, and are then absorbed by the tissues where they are embed-

ded. Non-absorbable sutures, on the other hand, are not absorbed, and they should be removed after the initial stabilisation of the wound edges has occurred. In reality, most or all natural materials will get absorbed by the body in due course of time. Thus, for clinical practice, a suture is considered non-absorbable if it retains its tensile strength in tissues for more than 60 days.

According to the filament type, the sutures may be monofilament or multifilament. A monofilament suture is essentially a single strand of fibre. This simple structure enables these sutures to pass through tissues with least resistance. Though this makes it the material of choice in delicate tissues such as the vascular tissues, there are some notable drawbacks. The handling and knot-tying are generally more taxing, and the knot has less friction to keep its position. In addition, the cut edges tend to be stiff leading to probable irritation of movable and delicate regions like the tongue and buccal mucosa.

The multifilament sutures are made of multiple fibre strands, which are either coated or braided together to make one fine thread. The process of braiding bestows a higher tensile strength as well as better pliability and flexibility. This improves the handling characteristics and the ease of knot-tying. They also better resist the tendency of the knot to untie itself. The cut edges are usually smooth and soft, and are not irritating to oral tissues. The disadvantages of multifilament sutures include the higher risk of harbouring pathogens in its structure and the tendency to ‘wick’ the oral fluids into deeper tissues through the suture track. This, in turn, can lead to occurrence to unaesthetic suture tracks visible on the skin.

11.4.1 Suture Thread Size

The suture thread is available in different thicknesses. The thickness is usually mentioned as ‘number of zeroes’. This system follows the U.S. Pharmacopeia, and has gained wide acceptance. The most commonly used thread size for intra-oral use is mentioned as 3-0 or 000 size. Sutures are available from size 6 to 11-0 (Table 11.2).

Table 11.1 Suture material classification

Basis of classification	Types
Source	Natural, synthetic
Absorbability	Absorbable, non-absorbable
Thread size	3, 2, 1, 0, 1-0, 2-0, 3-0.....11-0
Filament type	Monofilament, multifilament (braided)

Attributes of an Ideal Suture Material

1. Sterile or sterilisable,
2. Good handling characteristics,
3. Ensure a secure knot,
4. Adequate tensile strength,
5. Retention of strength during the healing phase,
6. Rapid absorption after healing.
7. Stay inert in tissues without causing antigenicity or other adverse tissue reaction.

Table 11.2 Suture sizes—U.S. Pharmacopeia designation and equivalent metric measurements

USP designation	11-0	10-0	9-0	8-0	7-0	6-0	5-0	4-0	3-0	2-0	0	1	2	3
Diameter (mm)	0.01	0.02	0.03	0.04	0.05	0.07	0.1	0.15	0.2	0.3	0.35	0.4	0.5	0.6

It is beyond the purview of this chapter to go into the details of all the types of suture materials available in the market, chemical structure, method of resorption, qualities, indications, advantages, etc. Details of few suture materials widely used in oral and maxillofacial surgery are given below.

11.4.2 Natural Absorbable Sutures (Absorbed by Proteolysis)

The absorbability characteristics of many natural materials had been recognised for millennia. All absorbable natural suture materials contain predominantly collagen. Over the years, they have progressively fallen out of favour due to the risk of antigenicity and adverse tissue reaction [1].

11.4.2.1 Catgut

Catgut has been the most popular material in this group. Its use has been prevalent at least from the time of Galen of Pergamon (200 AD). This material is made of tissue taken from the submucosal layer of sheep intestine or from the serosal (adventitial) layer of the cattle small intestine intima. The collagen strands are twisted together and the resultant thread is precision-ground to form a monofilament. Catgut has long been a popular fibre to make string instruments and tennis racquets. For many centuries, catgut (surgical gut) had been the only absorbable suture material available. The absorption is by proteolytic biodegradation brought about by proteolytic enzymes.

Performance-wise, catgut has good flexibility but relatively poor tensile strength, poor knot stability and high tissue reactivity. Full tensile strength remains only for 7 days.

11.4.2.2 Chromic Catgut

It has been found that many poor characteristics of catgut can be overcome by impregnating the suture material with chromic salts. This modified product, called chromic catgut, has higher tensile strength and delayed absorption time. Chromic catgut retains its maximum tensile strength for about 2 weeks. It also has reduced tissue reaction as compared to plain gut.

Manufacturers package catgut sutures soaked in the disinfectant isopropyl alcohol solution to retain the flexibility and to increase shelf life. This necessitates rinsing of the suture in sterile saline to remove the irritant alcohol before use. Some manufacturers use a glycerine coating on chromic catgut to do away with the alcohol in packaging. Glycerine-

coated chromic gut is smoother and thicker and has better handling characteristics.

11.4.3 Natural Non-absorbable Sutures

These are the oldest suture materials known to mankind. People tended to use any threaded material known to them for holding the wound edges together. Non-absorbable natural materials include cotton, linen, steel and silk.

11.4.3.1 Cotton and Linen

Cotton and linen sutures primarily contain cellulose polymer. Both the materials get absorbed in due course, but are considered non-absorbable because of delayed absorption time. Cotton is sourced from the hair of the cotton seed while linen is made from flax. The fibres are twisted to form a suture. It has good tensile strength, but there is moderate tissue reaction. Handling is average but knot-holding is good. Linen has the advantage that it gains tensile strength when wet.

Cotton and linen have largely fallen out of favour because of adverse tissue reactions and the high 'wicking' effect which causes seepage of fluids into the suture track.

11.4.3.2 Silk

Silk has been a well-known textile material from fourth millennium BC. It is produced by the silkworm larvae to form the cocoon. Natural silk is a protein fibre, the main components being fibroin and sericin. Fibroin forms the basic structure and contributes to the tensile strength. Sericin is a gum layer which holds the strands together. The silkworm larvae are cultivated and once they start pupating, the cocoons are dissolved in boiling water to extract the individual fibres which are fed into the spinning reel. To make it suitable as a medical product, the sericin protein component is later removed by a degumming process.

Silk is the most widely used natural non-absorbable suture material. Surgical silk is made from the larvae of the silkworm *Bombyx Mori*. The silk suture consists of a group of strands braided around a core and has a wax or silicon coating. It is usually dyed black in colour for better visibility.

The most impressive property of the silk suture is the ease of handling. It is extremely pliable and smooth and has good knot-holding capability. But the tensile strength is pretty low. The other drawbacks include high levels of tissue friction, capillary action and tissue inflammatory response. The wax coating helps to counteract all these negative attributes.

Silk is now not considered an appropriate material for cutaneous suturing, except on specific sites such as eyelids and lips. It is very often used for ligating blood vessels and for hitching drains. It is the most popular material used in dentistry. Its soft and pliable nature makes it suitable for use in oral mucosa which is mobile and wet.

11.4.4 Synthetic Non-absorbable Sutures

11.4.4.1 Polyamide/Nylon (Ethilon, Dermalon)

Nylon belongs to the first generation of commercially successful synthetic thermoplastic polymers, having started production in 1927. It is made of repeated units linked by aliphatic or aromatic amide links (polyamide). It has been a very versatile material and has been used as fabric, fibres, films, coatings and moulded shapes for wide applications in diverse fields.

Nylon surgical sutures were introduced in 1940. Monofilament nylon sutures are very popular for cutaneous suturing. The main advantages are their high tensile strength, exceptional elasticity and low tissue reaction. The elasticity helps the material to accommodate tissue swelling and maintain wound edge apposition. The nylon sutures are dyed black in colour.

The biggest shortcoming of this material is its shape memory, which negatively affects its knot-tying and knot-holding properties. Often, one needs 3–4 knots to hold a stitch in place. Also, the monofilament may be stiff. Multifilament nylon sutures are available with increased pliability and handling features. Addition of fluid (alcohol) in the package reduces the shape memory and improves pliability.

11.4.4.2 Polypropylene (Prolene, Surgipro)

Polypropylene is another thermoplastic polymer used as a non-absorbable suture material. It is produced by chain-growth polymerisation of the monomer propylene. It is pigmented blue to enhance visibility, hence the name polypropylene blue.

Similar to nylon, polypropylene has a very high tensile strength, excellent elasticity and minimal tissue reaction. It can extend up to 30% without breakage, making it highly suitable for suturing cutaneous wounds. The shape memory is also similar to nylon and can contribute to knot slippage. This feature, though, is advantageous in subcuticular suturing since it slides out smoothly during suture removal.

The excellent mechanical properties and inert nature have made polypropylene the material of choice in stressful sites. It is widely used in the management of hernia and vaginal prolapse, often in the form of a mesh in addition to sutures.

11.4.4.3 Polyester (Ethibond, Surgidac, Dacron)

Polyester is a general term used for any organic polymer which has an ester functional group in the main chain. More specifically, the term is used for the material polyethylene terephthalate. It is a type of petroleum-based plastic, made by mixing ethylene glycol and terephthalic acid. Because of its durability, cleanability, anti-wrinkle and quick-drying characteristics, it swiftly made a name in the textile industry as a reliable material.

Polyester is a non-absorbable, braided, surgical suture with high tensile strength and low tissue reactivity. The braided nature adds to enhanced handling, knot-tying and retentivity. Thus, it combines the positive features generally attributed to monofilaments and multifilaments. It is thus the suture of choice in cardiovascular surgery, prosthetic implants and facelifts.

Polyester braided sutures are usually dyed green in colour. They may be coated or uncoated. The uncoated variant has a rough surface which produces drag in the tissues. The coating is made of PTFE or polybutylate.

11.4.4.4 Polybutester (Novafil, Vasculfil)

Polybutester is a relatively new thermoplastic material with unique stress-strain properties. It is a copolymer comprised of polybutylene terephthalate and poly teramethylene ether glycol, and is coated with polytribolate. The polybutester monofilament sutures are designed to have high strength, elasticity and pliability. The flexibility and lack of memory allow it to be handled with ease resulting in a high knot security. The unique features have made this a popular material for abdominal wound closure.

The elasticity of polybutester is phenomenal. It can stretch 50% of its length at initial loads. It has a biphasic expansion curve wherein it expands well in response to initial stress and maintains pressure without cutting the tissue, and at the same time withstanding creep by not undergoing permanent deformation even under constant pressure.

11.4.4.5 Polytetrafluoroethylene (Gore-Tex, Cytoplast, Coreflon, Teflon)

Polytetrafluoroethylene (PTFE) is a synthetic material which has found extensive application globally. It is a fluoropolymer of tetrafluoroethylene ($-\text{CF}_2-\text{CF}_2-$), made by free-radical polymerisation of monomer units. PTFE is a strong, tough, waxy, non-flammable material popular for its non-stick properties.

PTFE suture is considered as the ideal material for oral surgeries, especially for dental implant surgeries. It is inert, non-absorbable and monofilament in nature. The strong fluoro-carbon bond is thought to be the reason for its inertness. Unlike other synthetic monofilament sutures, PTFE is smooth, supple and soft. The cut ends cause no

irritation to delicate oral tissues. It has no shape memory. It is well tolerated in the oral cavity and has excellent handling, knot-tying and knot-holding abilities. Thus, it has most of the positive attributes of braided sutures, at the same time avoiding the risk of bacterial contamination by wicking effect.

11.4.4.6 Stainless Steel

Surgical stainless steel non-absorbable surgical suture is composed of 316 L austenitic stainless steel. It can be monofilamentous or multifilamentous. The obvious advantages of stainless steel sutures are strength and low tissue reaction. Its drawbacks include very poor flexibility that makes it highly demanding in suturing skills. Incorrect technique can cause an excessive pull or tear on the tissues resulting in necrosis of wound edges. Barbs at the end can cause glove punctures and trauma to adjacent tissues.

Stainless steel suture is used in sternal closure and in orthopaedic procedures involving cartilage and tendon repair. It is also sparingly used for abdominal wound closure and hernia repair.

11.4.5 Synthetic Absorbable Sutures (Absorbed by Hydrolysis)

Till polyglycolic acid sutures were introduced in the 1970s, all absorbable sutures were natural. The synthetic absorbable sutures are all polymers based on glycolic acid, L-lactic acid, paradioxanone, trimethylene carbonate and ϵ -caprolactone [2]. They are sterilised either by ethylene oxide gas or by gamma radiation. These polymers have definite advantages over chromic catgut in clinical use. They are much stronger, evoke minimal tissue reaction, stay longer before absorption and leave no reactive changes after they are resorbed. They are absorbed typically by hydrolysis reaction which breaks the polymer chains. The hydrolysis end products are CO_2 , H_2O and the monomer.

11.4.5.1 Polyglycolic Acid (Dexon, PolySyn, PGA)

Polyglycolic acid suture, introduced in the early 1970s, was the first absorbable synthetic suture material. It is braided homopolymer of glycolic acid. The uncoated version is beige in colour while the polycaprolate-coated product may be undyed or dyed green, violet or bicoloured. When compared to catgut, the tensile strength and knot security are excellent. It retains 65% of its tensile strength after 2 weeks, by which time catgut would have lost all its strength.

The polyglycolic acid soon became very popular but fell out of favour later as better products were developed in due course of time.

11.4.5.2 Polyglactin 910 (Vicryl, Polysorb)

Polyglactin 910 is a synthetic heteropolymer consisting of 90% glycolic acid and 10% lactic acid. Introduced in 1974, this is a multifilamentous, braided suture with a lubricant coating of polyglactin 370 (30:70 ratio) and calcium stearate. The final product is usually dyed violet in colour, but an undyed beige version is also available. Polyglactin 910 is among the most popular absorbable sutures used for surgical wound closure today.

The main advantages of polyglactin over polyglycolic acid include consistently higher residual tensile strength and faster absorption. The absorption happens between 40 and 70 days. The coating ensures smooth passage. Since the coating is made of similar material, the risk of flaking is very low. Calcium stearate used in the coating is an absorbable organic lubricant. The shelf life of polyglactin is as high as 5 years.

As the material became very popular and widely used, manufacturers began to bring out modified products providing specific benefits. One of them is a monofilament version which does not require a coating. Another one is an 'antibacterial suture' with embedded triclosan, which is said to be very effective in preventing surgical site infections. Yet another useful modification is 'rapidly absorbing polyglactin' (Vicryl Rapide/Velosorb Fast). By treating the coating with γ -radiation, it is made to lose strength by second week and is fully absorbed by sixth week. This variant is widely used in oral surgery, where faster resorption is desired.

11.4.5.3 Polydioxanone (PDS, PDO)

Polydioxanone was the first monofilament suture available of large size (larger than 3–0). It is a polyester product and is synthesised through the ring opening of the monomer paradioxanone (1, 4-dioxan 2-one). As a monofilament suture, it has much less drag through the tissues than polyglactin or polyglycolic acid. Since it retains its tensile strength over a long span of time (80% strength at 2 weeks and 60% after 6 weeks), it is considered a better alternative to polyglactin for suturing of fascia.

A modification called PDS II is chemically similar but is annealed above melting temperature to soften the external surface, imparting improved flexibility to the final product.

11.4.5.4 Poliglecaprone 25 (Monocryl/Biosyn/ Petricryl Mono/Monoglyde)

Often seen as the monofilament alternative to polyglactin, poliglecaprone is a segmented block polymer consisting of 75% glycolide and 25% ϵ -caprolactone. It is available as an undyed or a violet dyed version. The key feature that differentiates poliglecaprone from other monofilament sutures is the high level of pliability and handling properties. This is

achieved through the formation of an interim soft polymer chain ‘pre-polymer’ which is high in caprolactone. In the ensuing stages of manufacturing, more glycolide is added to supplement hard segments to the pre-polymer. In this way, we get a final product with high tensile strength without compromising on the pliability.

The tensile strength of the undyed poliglecaprone suture degrades to 50% in 1 week and 30% in the second week. The dyed version retains 70% strength after 1 week. Complete absorption by hydrolysis happens in about 100 days.

11.4.5.5 Polyglyconate (Maxon)

This copolymer has a molar ratio of 64% glycolic acid and 36% trimethylene carbonate. It is an uncoated monofilament which may be undyed or dyed dark green. Polyglyconate has good handling properties. But its main advantage is the retention of tensile strength over a long time span. It retains at least 50% of its strength 4 weeks after implantation, making this an excellent choice in situations where long-term retention is needed. The slow absorption makes it relatively unsuitable for subcuticular sutures, since the dyed suture may be visible under the surface.

11.4.5.6 Glycomer 631 (Biosyn)

It is a synthetic absorbable coated monofilament polyester suture. It is a tri-block copolymer and contains glycolide (60%), trimethylene carbonate (26%) and p-dioxanone (14%). It may be undyed or dyed violet. It has high flexibility, low memory and minimal tissue reactivity.

It passes through the tissues easily but has poor knot-holding capability. Degradation and absorption are similar to polyglactin. Full absorption is complete in around 100 days.

11.4.5.7 Polyglytone 6211 (Caprosyn)

Polyglytone 6211 is the only suture available with four different monomers in its core structure. It is a polyester copolymer of glycolide, caprolactone, trimethylene carbonate and lactide in the ratio 6:2:1:1. It is a monofilament, uncoated, absorbable suture which is undyed or dyed violet.

Polyglytone 6211 is a suture for the short-term approximation of tissues. Because of its quick disintegration, it offers an inert alternative to catgut that can evoke inflammatory response. Its strength decreases to 50–60% at 5 days and to 20–30% at 10 days post-implantation.

11.5 Knot-Tying

The suture knot-tying can be accomplished by using an instrument (usually the needle holder) or using hands. Three main techniques are described.

11.5.1 Two-Handed Tie

The two-handed tie is cumbersome and is not routinely used. The suture is tied together by holding one tag in each hand and intertwining them.

11.5.2 One-Handed Tie

The one-handed tie is the most popular hand-tie method. It is quicker and can be accomplished in a smaller space. One end of the suture thread tag (‘the long end’) is held with thumb and forefinger of the dominant hand. The other side tag (‘the short end’) is placed a bit distal to the first tag, running in the same direction. The middle finger is folded and is used to guide the short end around the long end, and then the two tags are pulled away.

11.5.3 Instrument Tie

Instrument tie is the most popular technique for tying a suture knot. The long end is wrapped around the needle holder. Then the needle holder beaks are opened to grasp the short end, which is then pulled to form a tie. One such tie is called a ‘throw’.

11.6 Suture Knots

The suture thread tags are intertwined to form a knot. The knot should be firm and tight, and should not lie on the wound/incision line. It is important that the knot stays tight and maintains strength during the healing phase. Knot slippage or breakage before healing can be detrimental to the wound. In general, knot security is higher for braided and uncoated sutures because of higher friction coefficient.

The knots placed for the surgical suturing are of simple design. Those employed commonly are the square knot, surgeon’s knot and granny’s knot. These three variants are very similar to each other and differ from each other only in minor aspects.

11.6.1 Square Knot/Reef Knot

A square knot is among the simplest of the knot designs. It involves a simple intertwining of the two threads. This ‘half-hitch’ knot (one ‘throw’ around the instrument) need to be complemented with an additional similar throw to make it secure. Preferably the second hitch should be in the opposite

direction, i.e. if the first throw is in clockwise direction, the second one should be in anticlockwise orientation.

The classical square knot formed by a clockwise and a counterclockwise hitch can be further complimented by more similar hitches in alternatively changing directions.

11.6.2 Surgeon's Knot

A surgeon's knot is a minor modification of the square knot in which the initial intertwining is doubled. This is accomplished by doubling the first throw, by doing two turns of the thread around the instrument. This is followed by a regular second throw in the opposite direction.

11.6.3 Granny's Knot

In the granny's knot, two initial throws are placed in the same direction, followed by a third throw in the opposite direction.

Principles of Wound Suturing

Regardless of the specific technique, some basic principles are to be followed while performing a suturing procedure. It is to be remembered that these are only general principles, and can be modified or rejected in specific situations depending on the clinical context.

1. The suture needle is to be held with the needle holder about $\frac{3}{4}$ th of the distance from the needle tip.
2. The selected suture size should be the smallest possible which will hold the wound edges securely.
3. The needle tip should enter the tissue perpendicular to the tissue surface.
4. The needle penetrations should be at equal distances from the wound edge on both sides of the wound. The actual distance depends on the suture/needle size but is generally agreed to be 2–3 mm.
5. The passage of the needle through the tissues should follow the curvature of the needle.
6. When one side of the wound is fixed to the underlying tissues, one should first engage the mobile wound edge.
7. When one side of the wound is thicker than the other, the thinner wound edge should be engaged first.

8. When one side is deeper and the other more superficial, the deeper side should be engaged first.
9. The depth of needle penetration should be more than the distance from wound edge to needle penetration point. This will ensure eversion of wound edges.
10. The sutures should ensure proper tissue approximation of wound edges at the same time avoiding excessive tension on the tissues. Excessive tissue tension can lead to blanching, tear and necrosis. In case the edges are not approximating passively, the flaps may be undermined to achieve better mobilisation so that a tension-free closure can be achieved.
11. The knot should lie on one side of the wound, and not over the wound edges.
12. The spacing between the individual sutures depends on the type of tissue and the size of sutures. Generally placed 3–4 mm apart, they should be closer together at areas of underlying muscular activity and when the sutures are smaller in size.

11.7 Specific Suturing techniques [3] (Video 11.1)

There are quite a large number of techniques available to stitch a wound. Only the commonly used methods are mentioned.

Factors to Be Considered on Specific Material and Technique

1. Type of tissue,
2. Type of wound,
3. Time available,
4. Aesthetic requirements,
5. Functional needs,
6. Likely tension on the wounds.
7. Expected time for tissue healing.

11.7.1 Simple Interrupted Suture

A simple interrupted suture ('simple loop') is the most common method to suture a wound. This is the simplest design of wound closure. The suture passes once through each side of the wound in a simple loop and is then tied in a knot

above the surface. Multiple such ties are made over the length of the wound, resulting in several independent sutures collectively securing the tissue edges together. The same technique is frequently employed for internal suturing of tissue layers also [4].

The needle penetrates the surface 2–3 mms away from the wound edge on one side and proceeds into the subcutaneous tissue. The curve of the needle is then used to pass it through to the subcutaneous tissue on the opposite side. The needle then exits through the surface. The initial and final tags, now outside of the tissues, are then tied in a knot. The configuration inside the tissue is thus in the form of a loop. If the wound sides are of unequal depth, then the needle should travel deeper in the lower side while staying superficial on the higher side. This will help to correct the depth disparity and ensure proper surface levelling.

This technique is easy to learn and employ. This suture provides good tensile strength and carries minimal risk of wound oedema or impaired circulation. Several adjustments to the design are possible with this method depending on the wound characteristics. Since there is a series of multiple sutures, even if one suture fails, the others may provide sufficient strength to keep the wound edges together (Fig. 11.4).

The major drawback of this method of suturing is the high possibility of ‘rail-road track’ shaped scars caused due to the ingrowth of epithelium into the suture tracks. There is also a tendency to cause ‘wound inversion’ (depression of the surface at the wound site) due to tissue contracture during healing. The inversion can be prevented by making the suture configuration ‘flask-shaped’ inside the tissues, by making the needle travel farther laterally away from the wound within the tissues. When compared to continuous suturing

techniques, the interrupted method is more time-consuming as it requires many more knots need to be tied.

11.7.2 Simple Buried Suture

The buried suture is a modification of the simple interrupted suture and is reserved for stitching the inner (deeper) tissue layers. The only difference is that the knot ends up in the tissues deeper to the suture loop, i.e. away from the surface. In essence, this is a simple interrupted suture in the reverse orientation.

The wound edge is first reflected using fine forceps or hooks. The needle is then inserted into the underside of the dermis on one side. The needle then proceeds along its curvature to exit in the wound edge more superficial to the initial bite. The needle then pierces the dermis wound edge (near the surface) on the opposite side, proceeds in a path mirroring its motion in the first side and comes out at a deeper point which corresponds to the first bite. Though the tie is done outside, the knot gets buried deep inside the tissues as it is tightened (Fig. 11.5).

This technique is extremely useful in suturing the inner tissue layers before the surface closure. As the knot is buried deep, it does not interfere with the closure of superficial layers. This aspect is extremely useful while closing cutaneous facial wounds.

Two major drawbacks have been observed with this suture. One is a skin dimpling which typically happens if the suture arc inadvertently involves the epidermis. Another problem is the tendency for wound inversion to occur. Small modifications such as a set-back dermal buried suture or a vertical mattress buried suture can be employed to overcome this

Fig. 11.4 Simple interrupted suture technique

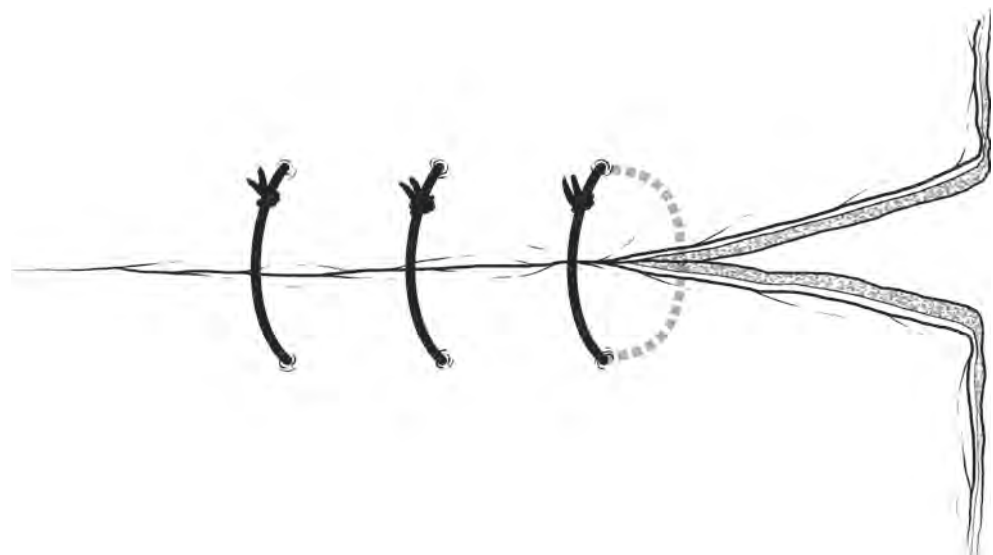
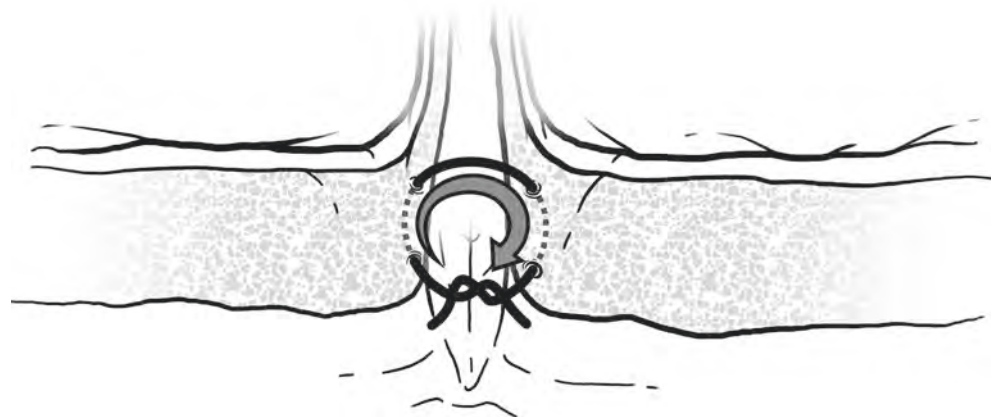
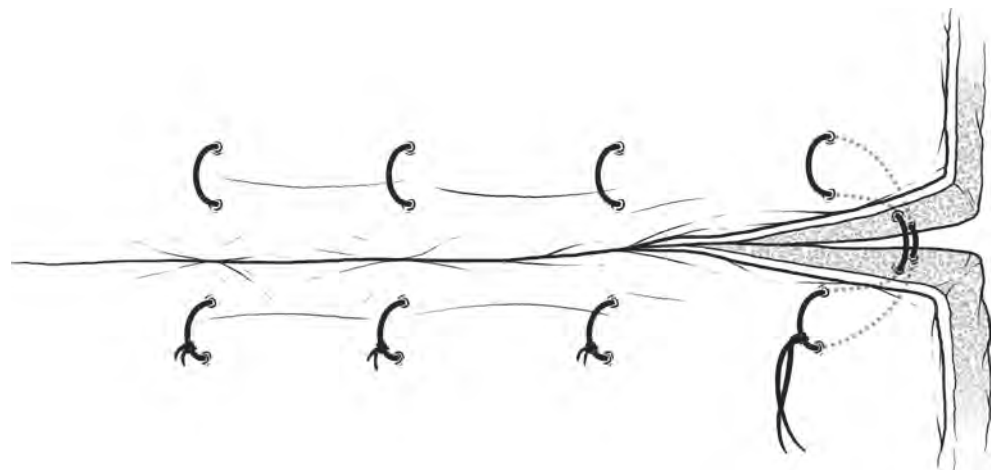


Fig. 11.5 Buried suture

©Association of Oral and Maxillofacial Surgeons of India

Fig. 11.6 Vertical mattress suture

©Association of Oral and Maxillofacial Surgeons of India

problem. These modifications attempt to pass the bridging suture segments to be deeper, thus resulting in wound eversion.

11.7.3 Vertical Mattress Suture

The vertical mattress suture is in part similar to simple interrupted sutures but includes an additional suture bridge close to the wound edge. Also known as Donati Suture, or ‘far-far, near-near’ suture, this is the most frequently used suturing technique to obtain wound eversion [5]. This suture design is very popular in abdominal and limb surgeries.

The needle is first penetrated far from the wound edge (about 6 mm), and then proceeds through the deeper tissue to the opposite side and emerges out at an equal distance from the edge. The needle is then reinserted at a point closer (2–3 mm) to the wound edge on the second side itself. It is then rotated superficially through the tissues and is exited on the other side at a corresponding near point. This results in a double bridging of the wound, one deep in the tissues and

another superficial and nearer to the wound edge. Thus, both tags of the thread are now on one side of the wound. They are tied together gently (Fig. 11.6).

The primary advantage of this suture is the resultant wound eversion. This eversion is expected to compensate for the anticipated contracture occurring along the wound margin. As the suture is bridging the wound twice, the binding strength is more. Elimination of dead space is another obvious advantage. The suture thread does not pass the wound edge on the surface, minimising the chance of track marks.

On the flip side, fine wound edge approximation is almost never achieved with this suture. Excessive tightening could lead to over-constriction and sometimes exposure of the raw area. This may necessitate placement of additional interrupted sutures for better results.

The vertical mattress concept can be used in a buried suture situation also by ensuring that the more superficial suture thread passed back to the first side in a path parallel to the first, deeper suture bridge. This will result in a better wound eversion.

11.7.4 Simple Continuous Suture

Simple continuous suture ('running loop', 'standard running suture') is a good method for rapid closure of small wounds. It gives an even distribution of tension all along the wound span. It combines many benefits of the simple interrupted sutures with the additional advantage of a quicker finish.

The technique is very simple. The first part follows the same process as a simple interrupted suture. The first knot becomes the anchoring knot for the ensuing running line. The tags are not cut and the longer tag (with the needle) is used for making the remaining loops. The needle is inserted back into the tissues a few millimetres away from the first piercing. Then the needle (followed by the thread) passes through the tissues in a path parallel to the first loop. Once it comes out of the second loop, it is not tied. Instead, the loop is tightened and the thread crosses over obliquely across the wound and enters the tissue surface again, a few millimetres away from the second piercing. This process continues over and over until one reaches the other end of the wound. As the last loop goes through the tissues, the thread is only partially pulled through, leaving some loose thread on the opposite side. The suture is then tied to this loose thread for the final knot. Thus, the suture material runs across the wound in repetitive loops, and there are only two knots—one at either end (Fig. 11.7).

The obvious advantages of this technique are the quickness of suture placement and the ease of avoiding many knots. Also, if the tissue wells up in one site, the remaining part of the suture can provide some compensatory slack.

The principal drawback is that the integrity of the entire suture line is vested in just two knots. Any breakage to the suture at any point leads to the entire line getting untied. Since the loops are in continuous succession, fine-tuning of design for each loop is not possible. Also, since the tension is

the same across all loops, the areas of the wound with greater tension, usually the central part, may tend to gape.

11.7.5 Locking Continuous Suture

This is a variation of the simple continuous suture technique used for surface wounds. Each loop of the continuous suture is 'locked' on itself before making the next loop. This is the most popular continuous suturing technique especially for closing wounds over long spans. As with other superficial continuous sutures, this method is frequently used as a surface layer after the internal tissue layers have been closed.

Similar to the simple continuous technique, the first loop is passed and the knot tied. After the second loop has gone through the tissues and exited, the suture is not immediately tightened. The needle and the leading thread it is made to pass through the earlier loop. After making this 'lock', the suture is tightened and is then passed into the tissues for the third loop. The assistant should maintain this tension until the next loop is passed. This process is repeated for the entire line of succeeding loops (Fig. 11.8).


The locking helps to align the tissues in a proper anatomic orientation perpendicular to the wound. There is an added haemostatic effect due to the tension on tissues. Uniform degree of tension is maintained across all the loops. At the same time, the running locks partially detach the tension on the individual loops from one another. Thus, to an extent, individual control of tension depending on the site can be obtained.

This technique inherits the main disadvantage of the simple continuous sutures of being dependent on only two knots, and the risk of complete loss of suture integrity in case of breakage at any point. The locks, if they are too tight, may cause vascular compromise of underlying tissues.

Fig. 11.7 Simple continuous suture




Fig. 11.8 Locking continuous suture



©Association of Oral and Maxillofacial Surgeons of India

Fig. 11.9 Subcuticular suture



©Association of Oral and Maxillofacial Surgeons of India

11.7.6 Subcuticular Suture

This is a mostly buried, continuous, epidermal wound closure which is used for surface closure. The suture ends exit a few mms away from the wound corner. The subcuticular suture is employed only after the deeper structures and dermis have been secured well with absorbable sutures. It is popular as an aesthetic suture for face [6].

The suture may be absorbable or non-absorbable, and is usually thin (size 5-0 or 6-0). The needle insertion is at one end of the wound, 2–5 mm away from the apex. It is passed along the curve into the wound, where it exits in the interior, close to the apex. Then the needle is inserted again into the dermis on any one side of the wound edge walls. Thereafter, it passes horizontally parallel to the surface, and following the needle curve to come out into the wound interior a small distance away. The same step is then repeated on the other side of the wound. This process is repeated till one reaches the other end of the wound, wherein the needle is made to

pierce the far end apex and to come out in the surface. This last step is a mirror image of the initial steps. Then each of the suture tags on both sides is tied separately on to itself. Alternatively, the tags may be secured with adhesive strips, surgical tape or tissue glue (Figs. 11.9 and 11.10).

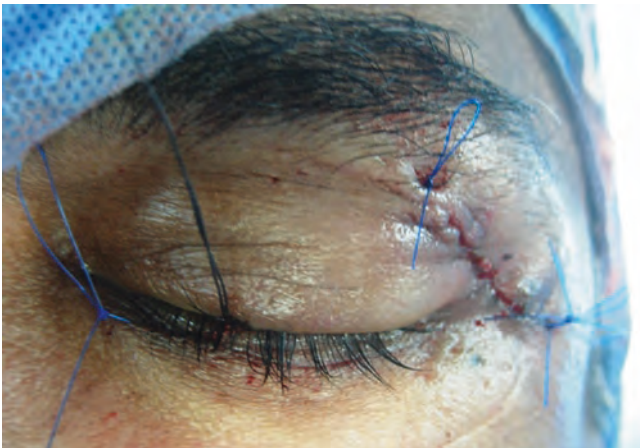
The biggest advantage of this technique is the much decreased risk of scars. The close approximation achieved in the dermis region makes the need for a further surface suturing unnecessary. The tension is aligned centrally across the wound and is evenly distributed all along the length of the suture. Also, this technique is highly suitable in cases where the suture material is required to stay in place for a long period of time.

On the negative side, the subcuticular suture takes longer time to perform. Leaving a large quantity of foreign material in situ can increase the risk of foreign body reaction and infection. If non-absorbable material is used, there is a minor risk of long and thin suture track following removal. If absorbable material is used, an undyed suture should be cho-

sen to prevent cutaneous visibility. Incorrect technique can leave small segments of exposed raw area, which need to be addressed with additional surface sutures.

11.7.7 Purse-String Suture

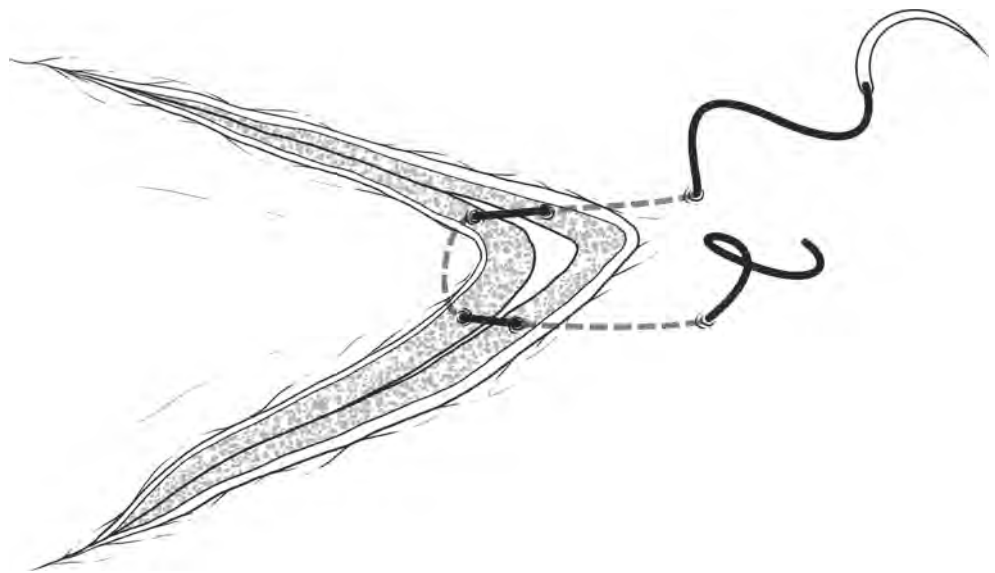
This is essentially a modification of the simple continuous suture, and is designed to reduce the size of a two-dimensional surface defect. It is not a cosmetically superior technique and is rarely used in the face. The purse-string effect causes a puckering in the surrounding skin tissue. But this is an effective method to reduce wound area. It may also be used to achieve haemostasis.



©Association of Oral and Maxillofacial Surgeons of India

Fig. 11.10 Subcuticular suture at the subciliary incision site and at the pre-existing lateral orbital laceration in a case of zygomatic complex fracture fixation

Fig. 11.11 Three-point suture technique



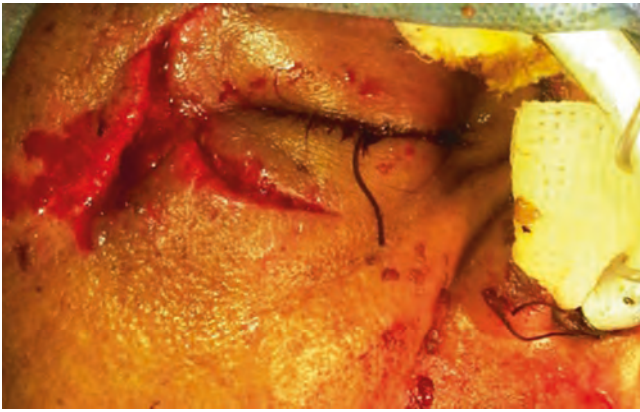
©Association of Oral and Maxillofacial Surgeons of India

At first, the wound edges of the defect need to be freshened and underlined. The needle and thread is passed along the edge of the defect in a course running parallel to the wound edge. Thereafter, it continues in a series of loops running along the edge of the surface wound along its entire circumference. As the thread completes the full distance and reaches near the initial needle entry, it is pulled taut, leading to complete or partial closure of the wound. Then the tags are tied together.

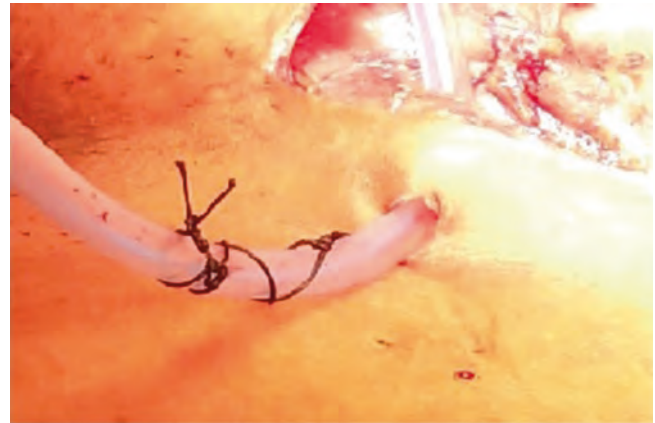
11.7.8 Three-Point Suture

Also known as ‘tip stitch’ or ‘half-buried horizontal mattress suture’, this technique is used for managing a situation where three ends of the tissue have to be sutured together. In maxillofacial surgery, this situation is encountered while repairing V-shaped lacerations and while closing flaps with sharp corners (such as the triangular flap at the vermilion border for cleft lip repair)

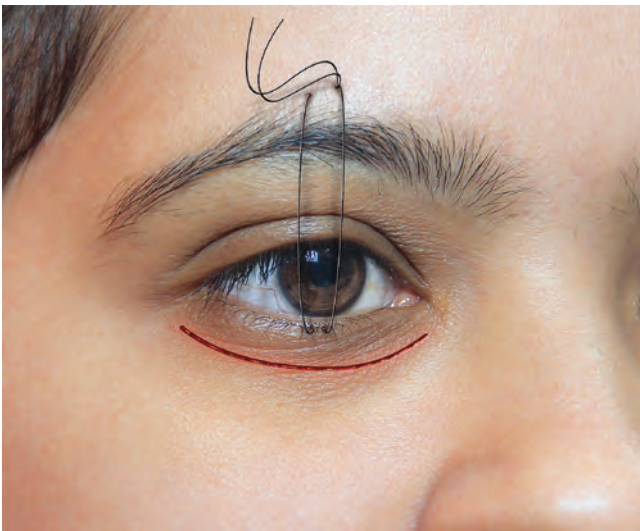This suture is placed only after the flaps are brought into position using buried dermal sutures. The surface suture thread is used, that is, 6-0 for face and 3-0 for scalp. The needle is first inserted into one side of the non-flap side of the wound. It follows the needle curve to exit in the inner aspect of the wound. The next tissue insertion is into the superficial dermis of the flap tip. Then the needle passes horizontally and comes out through the dermis on the other side of the flap tip. After releasing from the flap tip, it re-enters the dermis of the non-flap side on the other side and comes out through the skin at a point corresponding to the initial entry. The tags are then knotted together (Figs. 11.11 and 11.12).



©Association of Oral and Maxillofacial Surgeons of India

Fig. 11.12 A laceration that needs three-point suturing

©Association of Oral and Maxillofacial Surgeons of India

Fig. 11.14 Drain anchoring suture

©Association of Oral and Maxillofacial Surgeons of India

Fig. 11.13 Frost suture

11.7.9 Frost Suture

The Frost suture is a temporary eyelid suspension suture, used to ensure proper lower eyelid placement during the post-operative period [7].

After the closure of the lower eyelid incision, a needle bite is taken on the tarsal plate or just inferior to it. Then a second bite is taken just above the eyebrow, ensuring the anatomic position and alignment of the lower lid. These tags are then tied or secured with tapes or tissue glue (Fig. 11.13).

These sutures may be removed on third post-operative day, but need to be kept longer if there has been significant trauma to the tissues.

11.7.10 Drain Anchoring Suture

Different types of drains are used in surgery, such as corrugated rubber drain, the suction drain, intercostal drain, etc. After the drain has been inserted, it needs to be securely fixed to the body to prevent displacement.

The most common means to secure drains is the Roman Garter method, which uses silk sutures. A strong bite is first taken on the skin near the drain entry site. After making a knot, the two suture tags go around the drain tube in a series of windings. A knot may be tied after each 2 or 3 turns around the tube. The large number of windings around the tube increases the friction, holding the tube in position without dislodgement (Fig. 11.14).

Other techniques which have been described include the use of nylon suture, safety pin, drain clip, adhesives and Tie-lok.

11.8 Dentoalveolar Suturing

The tissues and the surgical environment in the dentoalveolar region are different from other parts of the body. Consequently, the wound closure requirements also differ. Wound closure in dentoalveolar surgery involves suturing in situations such as

1. Suturing of buccal and/or lingual flaps back to its place after dentoalveolar surgery around teeth or implant accessories.
2. Wound closure after tooth extraction.
3. Flap closure in edentulous ridge.

In most cases, the needle passage is through keratinised mucosa with little or no subcutaneous tissue, obviating the need for multilayered closure. The presence of teeth or artificial crown on one side of the flap forces the surgeon to innovate on the basic suture design. Another difference is when the extraction wound is closed—the wound is usually closed only at the edges and is largely left open in the middle. Also, the suture site will have to endure itself in a challenging environment with the presence of saliva, food materials and a very dynamic milieu where tongue movements and masticatory forces abound [8].

If marginal gingiva is not involved in the flap (as in a semilunar flap), the wound closure models are usually not different from the general cutaneous designs which were discussed in the previous section.

11.8.1 Simple Interrupted Suture (Interdental Suture)

As in any case of wound closure, the simple interrupted suture is the mainstay in closing dentoalveolar flaps [9]. In general, it involves suturing the detached interdental papillae together. The needle passes from the buccal aspect of the buccal flap, emerges on the inside of the flap and then passes between the tooth roots to enter the inner aspect of the lin-

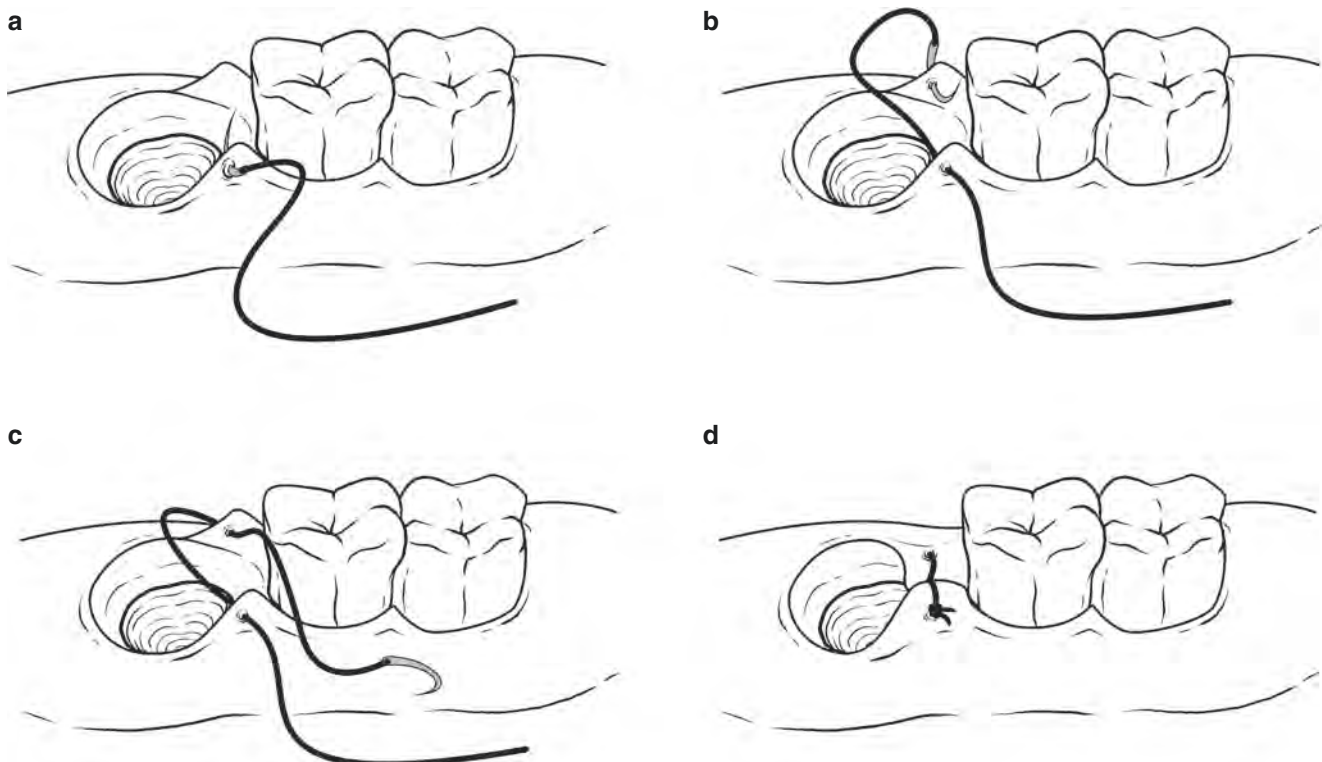
gual flap. As it pierces the lingual flap and emerges through the mucosa, the needle is turned back and is taken back via the interdental region to the buccal side. The two suture tags are then tied together. Thus, the knot remains on the buccal side and is accessible for removal.

If only one flap (usually buccal) has been raised, the needle can still pass through the attached lingual flap and the suture design stays the same. In post-extraction wounds also, the procedure is the same, and the tooth socket space is not totally closed.

11.8.2 Interrupted Reversing Suture

In this modified interrupted suture, the direction of the needle is reversed for engaging the lingual papilla. Once it passes through the buccal papilla and reaches the lingual side, the needle orientation is reversed and it is made to enter the lingual papilla from outside (lingual side). The needle exits the flap on the inside, passed across to the buccal side and is then tied. Thus, both the papillae are engaged in an ‘outside-to-inside’ orientation, ending in a figure-of-eight formation in the vertical plane (Fig. 11.15).

This technique is especially useful in cases where both buccal and lingual flaps are raised during surgery, such as in periodontal surgeries.



©Association of Oral and Maxillofacial Surgeons of India

Fig. 11.15 Interrupted reversing interdental suture

11.8.3 Vertical Mattress Suture

Vertical mattress technique in dentoalveolar surgery is a modification of the papilla-attaching simple interrupted technique. After the initial passage of the needle through the buccal and lingual papillae, the needle is turned back and picks a small bite at the tip of the lingual papilla before passing back to the buccal side. Then it again pierces the tip of buccal papilla before knot-tying.

While this technique helps in pressing the papilla into the interdental space, it is not a popular technique because of the difficulty in getting a solid bite at the papilla tip without 'cutting through'. Obviously, one needs to use an atraumatic needle with a small thread (4-0 or smaller) for this purpose.

11.8.4 Horizontal Mattress Suture

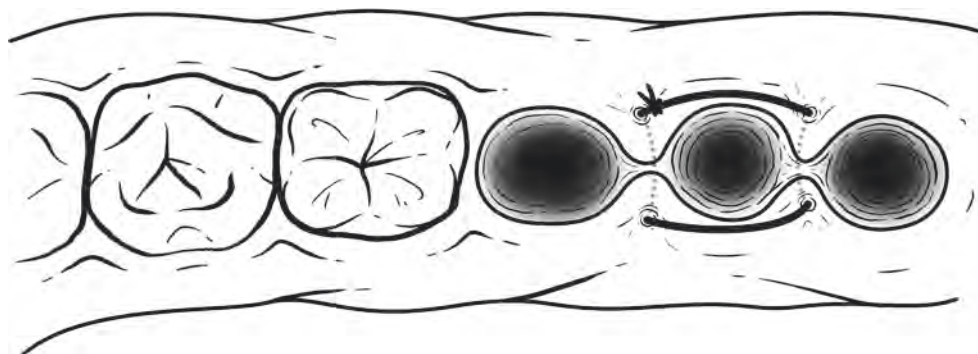
This is a two-dimensional suturing technique where the suture thread is spread in a horizontal fashion in the tissues. It is not very popular for general cutaneous suturing but is especially useful in dentoalveolar surgery.

When closing flaps in edentulous areas, the needle first passes through both flaps. Then it is reinserted into the flap on the same side, a little distance away from the earlier exit point. The reinserted needle now passes through both flaps and emerges out a similar distance away from the initial entry point. Both the thread tags, now on the same side, are tied together (Fig. 11.16).

In dentulous areas, this technique sutures two adjacent papillae together, eventually tying four papillae segments around a tooth in a horizontal square fashion. To close extraction wounds, only the papillae are approximated and the tooth socket space is not closed completely.

The advantage of this technique is that a single horizontal mattress suture serves like two separate interrupted sutures, thus helping to reduce the number of sutures. It compresses the wound from four corners and helps in haemostasis. It also results in some degree of wound eversion.

Fig. 11.16 Horizontal mattress suture (extraction wound)



©Association of Oral and Maxillofacial Surgeons of India

11.8.5 Horizontal Mattress Modification: Dental Anchor Suture

In this modification, the suture does not pass through the lingual soft tissues. After passing through the buccal papilla, the suture passes through the interdental region into the lingual side. Without engaging the lingual papilla, it goes around the tooth and comes back to the buccal side via the interdental space on the other side. Then it engages the buccal papilla before being tied. In this way, it secures the papilla to the bone using the tooth as its 'anchor'.

This technique can also be used in a reversing fashion, where only the papilla on the lingual side is engaged and the buccal side papillae are not pierced.

11.8.6 Horizontal Mattress Modification: Mattress Sling Suture

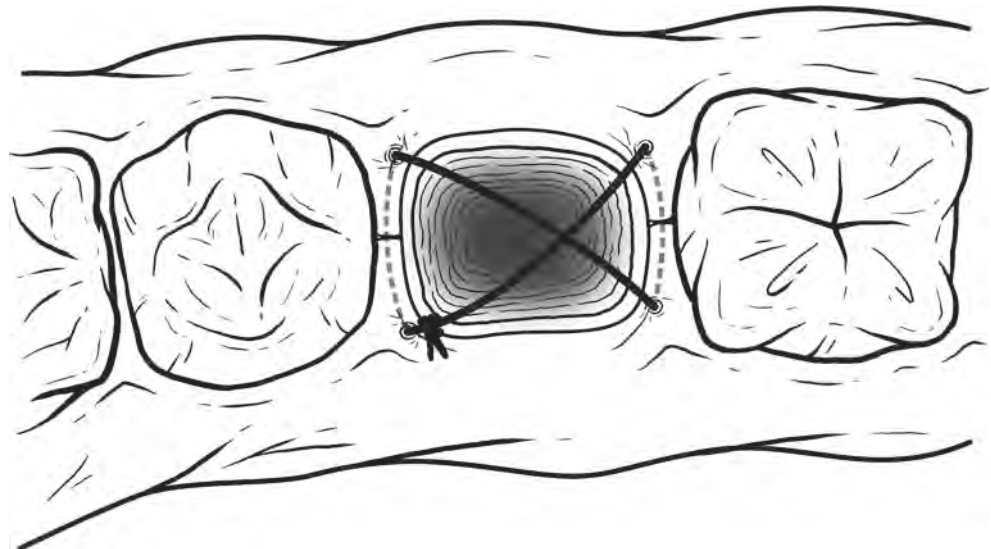
This technique attempts to combine the benefits of vertical mattress suture with those of horizontal mattress suture. The basic technique goes similar to the horizontal mattress but the final tag re-enters the buccal papilla at the tip and traverses a reverse path around the tooth to exit near the initial entry. In this way, it ensures the engagement of both buccal papillae in a vertical mattress fashion.

11.8.7 Horizontal Mattress Modification: Figure-of-Eight Suture (Cruciate Mattress Suture/Cross Suture)

The figure-of-eight suture is the most popular modification of the horizontal mattress technique. This is used mostly in closure of extraction wounds, and never in the presence of teeth at the wound site.

The needle first penetrates the buccal papilla on one side and then the lingual papilla. Then the thread crosses across the edentulous site, and the needle is reversed in orientation to pierce the buccal papilla of the other side from outside

Fig. 11.17 Figure-of-eight suture



©Association of Oral and Maxillofacial Surgeons of India

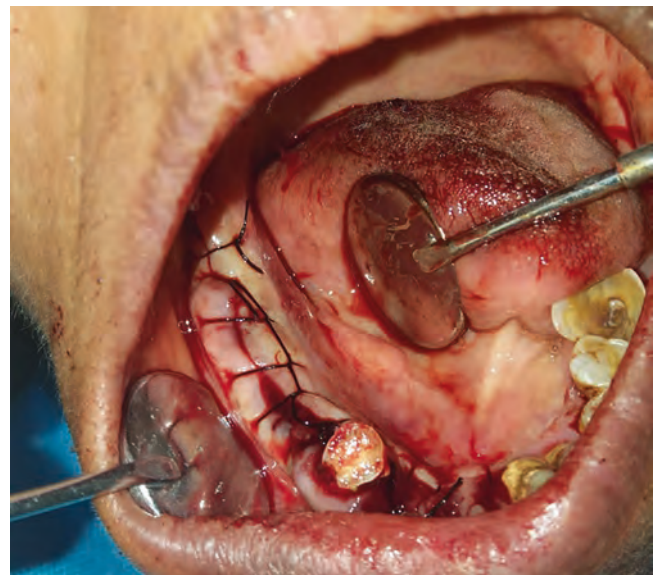
(buccal side) to pass through the lingual papilla and exit on lingual side. Then the thread passes across the site to be tied with the initial tag. The suture thus ends with the appearance of suture material crossing the wound site in a 'cross' shape (Fig. 11.17).

Many surgeons consider the figure-of-eight suture to be the most comprehensive way to suture a single tooth extraction site. This method ensures an even tension on the tissues from four corners, effectively constricting the wound. There is a positive effect on haemostasis also, due to the tension on the flap and due to its presence a mechanical barrier to clot loss.

11.8.8 Simple Continuous Suture

The continuous sutures are almost exclusively used for edentulous situations including post-extraction closure. After making a conventional interrupted suture knot, the longer tag is not cut and is instead used to make a series of 'running loops' approximating the succeeding pair of papillae one after the other. Gentle tension must be maintained on the thread to keep the loops tight while the needle passes through the next tissue. Knots are not tied for each loop but is done only at the other end of the long wound. Some surgeons prefer to tie a knot after 3 or 4 running loops. In the end, the part of the suture passing through the inner tissues are perpendicular to the wound, and the superficial, exposed parts lie across the wound in an oblique fashion.

The continuous sutures save time and effort while closing wounds of long span. It also ensures an even distribution of tension across the wound. The obvious disadvantage is the fact that if one loop or part of the suture is compromised (by



©Association of Oral and Maxillofacial Surgeons of India

Fig. 11.18 Continuous locking suture (dentoalveolar)

untying, cutting through or loosening), the entire suture line gets loosened.

11.8.9 Continuous Locking Suture

The continuous locking suture is a continuous suture in which a 'lock' is incorporated by passing the thread under the previous loop before it is pulled through the tissue. It is important to keep maintaining the tension on the previous loops as the needle makes the next pass through the tissue (Fig. 11.18).

This technique ensures a better orientation of the sutures with respect to the wound. The superficial, exposed parts of the suture are oriented perpendicular to the wound, leading to better anatomic wound approximation.

11.9 Suture Removal

Non-absorbable sutures on skin and mucosa should be removed after the wound surface has achieved initial stability. The timing of suture removal is very important. They should remain in tissue long enough to prevent dehiscence and scar spread. On the other hand, early removal reduces tissue reaction and suture marks.

Sutures on facial skin and in oral cavity are usually removed in 5–7 days. The recommended interval is 3–5 days for eyelids, 7 days for neck and 7–10 days for scalp. Those on trunk and limbs should remain in place for 10–14 days.

The suture line is cleansed with antiseptic. The knot is grasped and is pulled away mildly from the surface and to one side of the wound. An uncontaminated segment of the thread is exposed on the other side by this pull. The thread is cut at this segment near to the surface. Then the suture is pulled out, making sure that no contaminated (exposed) part is ragged through the tissues.

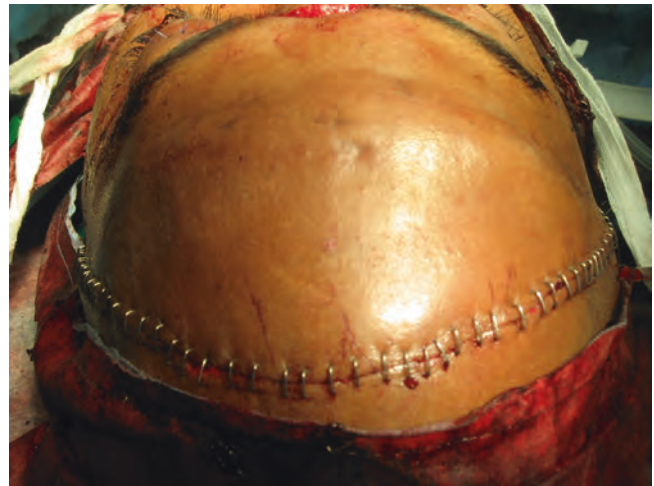
In the case of a continuous suture, every single loop should be cut and pulled out separately. A subcuticular suture is removed by cutting the knot off at any one end, and then pulling the suture out gently from the other end. It is important to make sure that the suture does not break within the tissues.

11.10 Other Wound Closure Methods

11.10.1 Staples

The use of specialised staples for wound closure was popularized in 1900s by the Hungarian surgeon Hümér Hürtl, known as the ‘father of surgical stapling’. Compared to suturing, surgical stapling is a quicker method to close the skin in large wounds, and the inflammatory response is relatively less. Staples provide good wound edge eversion without strangulation of the tissue. It is an excellent method to employ in cases which require quick wound closure and where aesthesis is not a major concern [10] (Fig. 11.19).

Though titanium staples were initially used, almost all of the contemporary hardware is stainless steel. However, titanium retains the advantages of being biocompatible and MRI-compatible. Bioresorbable staples, based on polyglycolic acid, are also available. The stapler device itself may be of stainless steel (reusable) or plastic (disposable), into which the disposable staple cartridges can be loaded.



©Association of Oral and Maxillofacial Surgeons of India

Fig. 11.19 Stapled scalp incision in a coronal approach

In maxillofacial surgery, staples are frequently used to close scalp wounds and neck incisions, following the closure of internal layers with conventional sutures. Staples are also popular in reconstructive surgery to secure skin grafts and to close the flap donor sites. They are not generally used to close facial wounds, since there is a tendency to produce ‘rail-road track’ scars. Skin staples are removed after 7–10 days with a specialized staple remover device.

11.10.2 Tapes

Different types of surgical adhesive tapes are used to effect wound closure, to reduce tension on sutured wounds and to reinforce wound site after suture removal.

The indications of this method for wound closure per se are limited. Tapes can be used to close superficial lacerations where tissue tension is minimal. They are also employed in the closure of superficial layer after buried dermal sutures have been employed for wound edge approximation and tension reduction. A major indication is its use as an additional reinforcement and protection over sutured wounds. The advantages of using tapes for wound closure are.

- (a) They are rapid and easy to perform.
- (b) The tape application is painless (patient anxiety and discomfort are minimal).
- (c) Residual suture track scars are avoided.
- (d) There is no need for a review visit to remove the tape.
- (e) Tapes, being non-invasive, are less prone to infection than other methods.
- (f) They are suitable for thin, fragile skin of the elderly and infants.

On the other hand, there are significant limitations to the use of tapes to close wounds. The most obvious contraindication is an area under significant tension. Tapes are difficult to apply on to highly convex surfaces, irregular wounds and in areas of tissue laxity. They do not attach well to wet surfaces (e.g. oral mucosa). They may get detached easily in hairy areas and those which tend to sweat.

These tapes are typically made of synthetic reinforced material with a hypoallergenic adhesive and are made porous to make them 'breathable' for skin. Some products are made elastic to account for oedema tension while some have incorporated antibiotic to reduce the incidence of surgical site infection. Modifications of tape-based wound closure include incorporation of a zip-lock mechanism and a clip attachment, both techniques designed to pull the wound edges together for better approximation.

11.10.3 Adhesives

The use of tissue adhesives is an efficient way to close wounds in select cases. Just like surgical tapes, tissue adhesives can be used to approximate wounds that do not require deep-layer closure and do not have significant tension on the edges [11].

All currently available tissue adhesives are chemically cyanoacrylates (esters of cyanoacrylic acid). These compounds were discovered by Ardis in 1949 and were first used in surgery by Coover in 1959. These are chemically similar to methacrylates, the only difference being the methyl (CH₃) group substituted with cyano/nitrile (CN) group. The water present on the skin or mucosal surface activates the acryl groups in the resin to rapidly polymerise and form long, strong chains. Three types of tissue adhesives are currently available for clinical use—2-octyl cyanoacrylate, N-butyl-2-cyanoacrylate and isoamyl 2-cyanoacrylate. The adhesion involves two mechanisms—mechanical interlocking into the surface irregularities and chemical covalent bonding with the nucleophilic amine groups on skin surfaces.

Tissue adhesives are mainly used to treat superficial skin tears (that do not extend past the dermis) and for surface closure after the deeper layers are secured with sutures. Other indications include stabilisation of bone fragments during plating, sealing of CSF leaks and sinus perforations, attaching grafts, achieving peripheral nerve reanastomosis and closure of dentoalveolar flaps [12]. They are also widely used to achieve haemostasis at surgical sites and as a biologic cover on ulcers. The relative contraindications include wounds over or near joints and wounds under significant static or dynamic skin tension. Also animal bite wounds, crushed wounds and wounds in high friction areas and those with

cross mucocutaneous borders are not considered suitable for a closure using adhesives.

The procedure for using the tissue adhesives for surface closure involves thorough cleaning and haemostasis. Though moisture is a prerequisite for adhesion, the presence of excessive water or blood at the site is detrimental to a good result. The surface is dried before applying the adhesive in at least three to four thin layers along the length of the wound's surface. It is advisable to extend it approximately 5–10 mm from each side of the wound. The edges of the wound are held together for at least 1 minute as the adhesive dries.

The main advantages of tissue adhesives over other wound closure methods are the rapidity and painless application [13]. In addition, the suture track scars are avoided, leading to a much better cosmetic result. The risk of suture site infection is also found to be less. The material sloughs off in 5–10 days, as the skin sheds.

The obvious disadvantage is that it cannot be used in areas of tension. Additionally, there is a minor risk of toxicity and foreign body reactions. If the clinician's gloved fingers, gauze or plastic instruments contact the tissue adhesive during application, these materials may adhere to the patient's skin.

11.11 Conclusion

Wound care primarily involves measures to ensure that the wound heals quickly without going through adverse situations such as infections. Along with mechanical debridement, antibiotic medication and dressings, the various wound closure methods form the foundation of wound care practices. Depending on the patient needs and the wound types, one should choose from a wide variety of materials and techniques to implement effective wound closure.

References

1. Buckley MJ, Keller JC. Emerging biomaterials and tissue engineering. *Oral Maxillofac Surg Clin North Am.* 2002 Feb;14(1):ix.
2. Herford AS, Haug RH. Emerging biomaterials and techniques in tissue regeneration. *Oral Maxillofac Surg Clin N Am.* 2017;29(1):1–120.
3. Kador J. Atlas of suturing techniques. Approaches to surgical wound, laceration, and cosmetic repair. New York: McGraw-Hill; 2016.
4. Hupp JR. Guide to suturing. Section 2. *J Oral Maxfac Surg.* Aug 2015;73(Suppl 1):9–35.
5. Kudur MH, Pai SB, Sripathi H, Prabhu S. *Sutures and suturing techniques in skin closure.* *Indian J Dermatol Venereol Leprol.* 2009;75(4):425–34.
6. Gusman DN. Suture materials and techniques. In: *Lower extremity soft tissue and cutaneous plastic surgery, vol. 1.* Nottingham: Saunders; 2012. p. 77–100.

7. Connolly KL, Albertini JG, Miller CJ, Ozog DM. The suspension (frost) suture: experience and applications. *Dermatol Surg.* 2015 Mar;41(3):406–10.
8. Koshak HH. Dental suturing materials and techniques. *Glob J Otolaryngol.* 2017;12(2):1–11. GJO.MS.ID.555833
9. Griffin TJ, Hur Y, Bu J. Basic suture techniques for oral mucosa. *Clin Adv Periodontics.* 2011, Nov;1(3):221–32.
10. Iavazzo C, Gkegkes ID, Vouloumanou EK, Mamais I, Peppas G, Fallagas ME. Sutures versus staples for the management of surgical wounds: a meta-analysis of randomized controlled trials. *Am Surg.* Sept 2011;77(9):1206–21.
11. Tuptis A, Salma I. Fibrin sealant in maxillofacial surgery (literature review). <https://www.rsu.lv/en/scientific-papers/fibrin-sealant-maxillofacial-surgery-literature-review>. 2015.
12. Kaderi MA, Menaka KB, Metgud RM, Gharat MR, Naik PS, Ajmani JM, et al. In-vitro evaluation of antibacterial potential of cyanoacrylate tissue for intra-oral wound closure. *J Dent Mater Tech.* Sep 2017;6(4):163–9.
13. Oladega AA, James O, Adeyemo WL. Cyanoacrylate tissue adhesive or silk suture for closure of surgical wound following removal of an impacted mandibular third molar: a randomized controlled study. *J Craniomaxillofac Surg.* 2019 Jan;47(1):93–98.

Open Access This chapter is licensed under the terms of the Creative Commons Attribution 4.0 International License (<http://creativecommons.org/licenses/by/4.0/>), which permits use, sharing, adaptation, distribution and reproduction in any medium or format, as long as you give appropriate credit to the original author(s) and the source, provide a link to the Creative Commons license and indicate if changes were made.

The images or other third party material in this chapter are included in the chapter's Creative Commons license, unless indicated otherwise in a credit line to the material. If material is not included in the chapter's Creative Commons license and your intended use is not permitted by statutory regulation or exceeds the permitted use, you will need to obtain permission directly from the copyright holder.





Postoperative Care of the Maxillofacial Surgery Patient

12

J. Naveen Kumar and Poornima Ravi

Postoperative care of the patient encompasses the time from the completion of the surgical procedure to the complete return of the patient to the normal physiological state. This is divided into three phases. Phase I is early recovery and takes place in the postanesthesia care unit (PACU). Phase II is intermediate recovery, and takes place in the ward. Phase III is late recovery that occurs after discharge.

12.1 Assessment of the Patient After Surgery

12.1.1 Assessment of the Patient Immediately After Surgery

Postoperative care of the patient begins immediately after the surgical procedure has been completed, even before the anesthesia is reversed. The first step is clearing the airway of blood and debris. Maxillomandibular fixation and occlusal splints, if placed earlier need to be removed [1]. The next step is the removal of the throat pack.

12.1.1.1 Care of the Airway

The decision to extubate or not must be made in conjunction with the anesthetist. Cases in which there is a high risk of airway edema will require the ET tube to be retained [1]. These include:

- Space infections compressing on the airway, e.g. Ludwig's angina.
- Severe facial trauma where there is likelihood of blood ooze, edema, or tongue fall back.
- Prolonged surgery, e.g. Free flap reconstructions.

In other cases, the patient may be extubated on the table. Awake extubation is usually preferred for head and neck surgery. The patient may be extubated when the following criteria are met [1]:

- No bleed from surgical site or secretion in the oropharynx.
- Patient is able to follow verbal commands.
- Patient is able to sustain head lift for at least 5 seconds.
- Patient is breathing on his own, with respiratory rate less than 24/min, tidal volume greater than 5 ml/kg, and Spo₂ > 90%.

Once the extubation is done, an oropharyngeal airway can be inserted to prevent clenching of teeth and the tongue from falling back, which can cause obstruction. Alternatively, a nasopharyngeal airway can be used in case the surgeon deems oral cavity unfit for manipulation using the former. This must remain in place until the patient is conscious and obeys commands.

Some patients, such as those who have undergone extensive face and neck resection, may have required a tracheostomy prior to surgery. The tube must be secured after surgery by taping the stay sutures to the neck or chest. Tracheostomy care in the postoperative period is critical; a blocked or dislodged tube can have disastrous consequences [2].

1. The tube must be checked at frequent intervals.
2. The tube stoma must be covered with a humidifying bib, or a moist gauze.

J. N. Kumar (✉)
Oral and Maxillofacial Surgery, Sri Ramachandra Institute of Higher Education and Research, Chennai, India
e-mail: naveenkumarj@sriramachandra.edu.in

P. Ravi
Department of Oral and Maxillofacial Surgery, SRM Dental College, Ramapuram, Chennai, Tamil Nadu, India

3. The tube must be suctioned regularly to prevent clogging due to secretions. The suction catheter must be inserted to half of its length, which will correspond to the carina (Patients usually cough when this point is reached). Suction is then applied while simultaneously withdrawing the catheter.
4. To break up secretions, small quantities of sterile water can be syringed in and suctioned immediately.

12.1.1.2 Need for Ventilation in the PACU

In some instances, ventilation may be required even after anesthetic recovery. Some examples include:

1. Patients who have history of COPD.
2. Severe trauma or infection.

While monitoring the patient who is on a ventilator, it is important to be aware of the various modes that the ventilator operates on [3]. These have been summarized in Table 12.1. Patients who have been on the ventilator for long periods of time need to be weaned off slowly. OMF surgeons frequently come across such patients in neurosurgical ward having concomitant traumatic brain injuries and craniomaxillofacial fractures. This may be done by setting the ventilator in CPAP mode (Continuous Positive Airway Pressure). This allows the patient to breathe, with the ventilator taking over if the patient is unable to do so.

12.1.1.3 Monitoring in the PACU

Once the patient has been shifted to the recovery room, the cardiac monitor and pulse oximeter must be attached for

proper monitoring. The following parameters must be monitored continuously:

- *Oxygen Saturation:* Hypoxia can occur in the postoperative period and the patient must be kept on oxygen for 1–2 h (2–6 L/min) to prevent this. Oxygen may be delivered using a face mask or through nasal prongs.
- *Pulse, blood pressure:* Increase in these parameters may indicate pain. Serious complications (Infarction, Malignant hyperthermia) may produce a drastic change in these parameters and must be recognized.
- *ECG waveform:* To monitor cardiac status.
- *Postanesthesia tremors/shivering:* This can occur on the table during recovery from anesthesia. It can occur if the patient is hypothermic, and is commonly associated with the use of halogenated anesthetics. Management consists of rewarming the patient. Tramadol and meperidine may be used to stop uncontrollable shivering [4].

The suction apparatus must be kept handy to evacuate blood ooze or secretions that may hamper the airway. It is advisable to avoid Maxillomandibular fixation (MMF) in the immediate postoperative period; if required, this may be done after 24 h.

Detailed surgical notes must also be recorded, along with the number and type of implants that were used. Postoperative instructions must also be documented in detail. A list of notes to be completed by the surgeon before leaving the operation theater complex is summarized in Table 12.2.

12.1.1.4 Briefing the Patient and Family

Immediately after the surgery, the surgeon must interact with the patient's immediate caregivers, giving them the details of the procedure, and any anticipated complications.

12.1.1.5 Discharge from PACU to Ward

This is done when the patient has regained consciousness, with adequate respiratory function and stable vitals. Decisions can be made based on a standard scoring system, such as the Aldrete scoring system [5]. The scoring system which was originally proposed in 1970, underwent modifications in 1995 and 1999. The various factors considered

Table 12.1 Ventilator modes and settings

Ventilator mode	Type of setting	Description/indications
Volume control	Continuous mandatory ventilation (CMV)	Patients with respiratory muscle weakness or LV dysfunction If patient breathes rapidly, may cause hyperinflation and respiratory alkalosis
	Synchronous intermittent mandatory ventilation (SIMV)	Patient breathes partially on their own; meant for patients who breathe rapidly on CMV Mandatory breaths are synchronized with spontaneous breathing
Pressure control	Pressure controlled ventilation (PCV)	Patients with neuromuscular disease but normal lungs who can control volume.
	Pressure support ventilation	Used during weaning, patient determines respiratory volume and frequency, but the ventilator provided continuous positive airway pressure (CPAP)

Table 12.2 Checklist for completion before leaving the theater complex

Checklist to complete before leaving the OT
Surgical notes
Details of implants and hardware used
Postoperative instructions to be followed by nursing staff
Postoperative fluid management instructions
Postoperative medication dose and schedule
Biopsy requisition form
Requisition form for aspirates/swabs and others
Investigation requisition form

Table 12.3 Subjective assessment of the patient

Subjective parameters evaluated	Assessment made
Pain (use visual analog scale- VAS/ faces scale)	Whether the pain medication is adequate or whether it needs to be increased or discontinued (see Sect. 12.2.2.1)
Nausea/vomiting	If the patient has experienced this, assess the need for antiemetics, and insertion of nasogastric tube to decompress the stomach. (Sect. 12.2.5.5)
Mobility	The patient must be encouraged to sit up and walk by the first postoperative day. (Section IID)
Function- e.g. swallowing, speech, nerve function	It is important to evaluate branches of the facial nerve and trigeminal nerve that may have been at risk of damage during surgery
Passing urine/stools/ flatulence	Inability to pass urine may indicate inadequate fluid therapy, and may lead to acute renal failure. (see Sect. 12.2.5.6) Inability to pass stools may be a sign of paralytic ileus; may occur after iliac crest harvest

are patient activity, respiration, circulation, consciousness, O₂ saturation, pain, surgical site bleeding, and nausea/vomiting. Patients scoring greater than 9 on this scale can be moved to the ward for the next phase of care. Readers are advised to refer the article for getting a detailed idea of the scoring table.

12.1.2 Comprehensive Assessment of the Patient in the Ward

This is done according to the SOAP format [6]. SOAP is an acronym for Subjective, Objective, Assessment, and Plan. In Subjective evaluation, the patient must be asked if they have any complaints. Specific complaints are recorded. In Objective evaluation, a thorough evaluation of the patient is done by the physician. This includes evaluation of the vital signs, fluid intake and output, as well as an assessment of the surgical site. Helpful information may be obtained from the TPR chart, input/output chart, and nurses' notes. Based on the subjective and objective evaluation, the patient's current status is assessed (Tables 12.3 and 12.4). This is used to formulate a plan.

12.1.2.1 Postoperative Investigations

Sometimes investigations may be required in the postoperative period, either to check the health status of the patient or to confirm the diagnosis of certain complications. A list of investigations that may be ordered and the indications for the same are summarized in Table 12.5.

Table 12.4 Objective assessment of patient

Objective parameters evaluated	Assessment made
<i>Vital signs</i>	
Temperature	Is postoperative fever present? If so, it must be worked up (Sect. 12.2.5.2)
Pulse	
Blood pressure	
Respiratory rate	Changes in pulse and blood pressure have several causes (Sect. 12.2.5.3) If abnormal, evaluate whether the patient has respiratory distress (Sect. 12.2.5.4)
<i>Fluid input/output</i>	
	Is the input adequate? (Sect. 12.2.1) Is urinary output adequate? This helps assess renal function(Sect. 12.2.5.6)
<i>Surgical site evaluation</i>	
	The wound must be inspected, and assessed for healing. (Sect. 12.3)

Table 12.5 Postoperative investigations

Investigation	Indications
Hemoglobin	If there has been extensive blood loss during surgery, to determine the need for blood transfusion.
Serum electrolytes	Suspicion of electrolyte imbalances (seizures, palpitations, muscle cramps)
WBC TC/DC	Suspicion of spreading infection
Chest x-ray	Suspicion of atelectasis/aspiration pneumonia
OPG/other facial radiographs	To check the accuracy of reduction and status of plating.

12.2 Formulating a Plan of Care Based on Assessment

12.2.1 Fluid Therapy in the Postoperative Period

The patient is usually 'nil per mouth' for a few hours prior to surgery and after surgery. Apart from this, there is a loss of blood and body fluids in any surgery, which requires replacement. It is therefore essential to infuse intravenous fluids during this period [7, 8]. This is done for two purposes.

Replacement Any fluid deficit that has occurred must be replaced by infusion. This could have occurred during either of the following periods:

- Preoperative period: This could be due to
 - NPO status.
 - Blood or fluid losses that may have occurred due to trauma, burns, etc.
- Intraoperative period: Surgical blood loss of greater than 500 ml or 7 ml/kg requires replacement.

Maintenance This is to maintain the ongoing fluid requirements, till the patient resumes oral intake of fluids. Maintenance fluids are essential to maintain proper pH and electrolyte balance and for adequate organ perfusion.

12.2.1.1 Types of Fluids Used

There are three types of fluids that can be used—crystalloids, colloids, blood and blood products. The preference of one type of fluid over another has several controversies, and there are no clear-cut guidelines available [9]. A few indications for each fluid type are given below.

Crystalloids

Crystalloids are balanced salt solutions with or without the addition of a buffering agent. When infused into the bloodstream, crystalloids tend to leave the capillaries and enter the extravascular fluid compartment. Crystalloid infusion will increase fluid in the extravascular tissues and does little to expand the circulating blood volume. In maxillofacial surgery, crystalloids are favored as maintenance fluids during the postoperative period.

Colloids

Colloids are protein-containing solutions. Since these proteins have a large molecular size, under ordinary circumstances, these are prevented from crossing the capillary endothelial cells and going into the extravascular space. Therefore, they tend to expand vascular volume alone. Colloids are mostly used in the intraoperative period if there has been significant blood loss and the plasma volume needs to be expanded. It is not common to use colloids in the postoperative setting.

Commonly used iv fluids are listed in Table 12.6.

Table 12.6 Commonly used postoperative IV fluids

IV Fluid	Composition (in meq/l)	Indications	Risks
<i>Crystalloids</i>			
Lactated Ringers (RL)	Na –130; Cl –109; K –4; Ca –3; Lactate –28	Fluid of choice in postoperative maintenance	Lactic acidosis if liver function is poor
Dextrose Normal Saline (DNS)	Na –154; Cl –154; Dextrose –50 g	Alternative to RL	Hyperchloremic acidosis
Normal Saline (NS)	Na –154; Cl –154	Alternative to DNS in diabetics	Hyperchloremic acidosis
5% Dextrose (D5W)	Dextrose 50 g	Replacing free water deficit	Hyperglycemia in diabetics
<i>Colloids</i>			
Hetastarch	6% hydroxyethyl starch	Plasma volume expansion	Nephrotoxicity, coagulopathy

12.2.1.2 Strategy for Estimating Fluid Requirement

- The input-output chart must be verified before determining the fluid requirement. This will help to estimate fluid excess (positive balance), or deficits (negative balance) and plan requirements.
- Calculate the Estimated Fluid Requirement (EFR) for each hour:
This is done using Holliday and Segar's formula (The 4-2-1 rule) [10].
 - First 10 kg: 4 cc/kg.
 - Next 10 kg: 2 cc/kg.
 - Above 20 kg: 1 cc/kg.
 E.g. a 60 kg adult will require $(4 \times 10) + (2 \times 10) + (1 \times 40) = 40 + 20 + 40 = 100$ ml/h.
- Calculate the total Estimated Fluid Deficit: This depends on the number of hours from the last oral intake to the next oral intake. For example, if the patient has not had oral intake for 12 h:
 $EFD = EFR \times \text{no. of NPO hours} = 100 \times 12 = 1200$ ml.
- Estimate the surgical blood loss. If crystalloids are used to replace this blood loss, for a particular volume of blood, three times the volume of crystalloids are used for replacement. If colloids are used, the same volume is sufficient.
- Estimate the amount of fluids that have already been infused during anesthesia.
- Total postsurgical fluid requirement:
 $EFD + (\text{blood loss} \times 3) - \text{fluids replaced during surgery}$.
In the above scenario, if 300 ml of blood was lost, and one liter of fluid was infused during surgery, then:

Total postsurgical fluid requirement:

$$1200 + (300 \times 3) - 1000 = 1200 + 900 - 1000 = 1100 \text{ ml.}$$

12.2.1.3 Liberal Versus Restrictive Fluid Therapy

In recent years, the above method of estimating fluid requirements has been criticized, as it tends to overestimate the amount of fluids needed by a patient [11]. Excessive fluid infusion may cause fluid shift into the extravascular compartment, which in turn can result in overload complications such as renal injury, acute respiratory distress syndrome, etc. On the other hand, liberal fluid infusion can reduce postoperative complications such as nausea, vomiting, and drowsiness.

For major systemic surgeries, the current trend is either to follow a 'restrictive' approach or a goal-directed therapy. Goal-directed therapy measures hemodynamic parameters such as stroke volume, and fluids are given accordingly. While this has been found useful in major surgeries, particularly abdominal surgeries, there is no evidence on its effectiveness in postoperative recovery for maxillofacial surgery. A liberal approach may be preferred for most kinds of

Table 12.7 Risks vs. benefits of blood transfusion

Risks of blood transfusion	Benefits of blood transfusion
Transmission of infections that cannot be identified by screening (cytomegalovirus, Epstein-Barr virus, B-19 parovirus, dengue, chikungunya, HHV-8, malarial parasite)	Better functional status
Transfusion reactions	Lower morbidity and mortality (for levels below 7.0 mg/dl)

Table 12.8 Indications for postoperative blood transfusion

Postoperative hemoglobin level	Risk factors/compensatory mechanisms present	Transfusion requirement
<6 g/dl		Required
6–8 g/dl	No risk factors	Not required
	Presence of risk factors (coronary artery disease, heart failure, cerebrovascular disease/limited mechanisms of compensation)	Required
	Presence of symptoms indicative of hypoxia (physiological transfusion triggers: Tachycardia, hypotension, electrocardiographic signs of ischemia, lactic acidosis, etc.)	Required
8–10 g/dl	Presence of symptoms indicative of hypoxia (physiological transfusion triggers: Tachycardia, hypotension, electrocardiographic signs of ischemia, lactic acidosis, etc.)	Required
	Absence of above symptoms	Not required
	>10 g/dl	

maxillofacial surgery, which generally fall under low or intermediate risk procedures. Nevertheless, as long as postoperative fluids are being administered, the patient must be monitored for signs of overhydration such as peripheral edema, dyspnea, high blood pressure, and a bounding pulse. If any of these are present, the current fluid regimen must be reassessed [12].

12.2.1.4 Transfusion of Blood and Blood Products

Postoperative blood transfusion is rarely required in routine maxillofacial surgery. It has been stated that the risks of blood transfusion outweigh the benefits [13] (See Table 12.7), and currently a restrictive approach to blood transfusion is favored.

If there has been extensive blood loss during surgery, or preexisting anemia, the postoperative hemoglobin must be assessed, and the decision to transfuse is based on this level [14]. This is described in Table 12.8.

12.2.2 Postoperative Medication

The maxillofacial surgeon must be aware of the type and dosage of medication that is required in the immediate post-

operative period. Pain control and prophylaxis against infection are the most important factors to be kept in mind while prescribing medication.

12.2.2.1 Pain Control

Pain control is an important goal after every surgical procedure as it can not only affect the patients' attitude, but it can also impair oxygenation and thereby delay wound healing. The pain must be assessed subjectively, by asking the patient to rate their pain on a standard scale (e.g. Visual Analogue scale or Faces pain scale). If the patient is in pain, pain medication must be increased or changed.

Preemptive analgesia is an evolving, controversial technique that involves the administration of analgesics prior to the onset of noxious stimuli. This is believed to limit the sensitization of the nervous system, thereby reducing the need for postoperative analgesia [15]. One effective preemptive technique is the infiltration of a long-acting local anesthetic, such as bupivacaine, into the incision site before closure. This provides effective pain relief throughout the postoperative period.

In the postoperative period, various classes of analgesics may be used [16]. Some of the commonly used analgesics are summarized in Table 12.9.

The best method of choosing the appropriate analgesic is using the WHO analgesic ladder (Fig. 12.1). If the pain is not well controlled, the patient can move to the next step of the ladder. Once the pain is controlled, patients must be weaned by moving down the ladder [17]. This step ladder approach is just a broad lattice and has its own share of controversies and modifications. Readers are encouraged to read appropriate references for getting a broader picture of the analgesic ladder and a detailed discussion is beyond the scope of this chapter.

Patient-controlled Analgesia Postoperative patients often require immediate pain relief at varied intervals. PCA allows the use of iv pumps which, when the patient presses a button, allows a bolus dose of analgesic to be delivered for immediate relief [18]. This allows analgesics to be tailored to the patients' requirements and also records the amount of opioid being administered per day.

12.2.2.2 Anti-inflammatory Drugs

The role of corticosteroids in postoperative care is controversial. Corticosteroids are potent anti-inflammatory agents and are often used after surgery. It has been established that corticosteroids reduce pain and inflammation [19]. There is also evidence that single doses of steroids can reduce postoperative nausea and vomiting, and improve fatigue after surgery. However, the benefit of extended doses of steroids seems controversial and comes with the risk of impaired wound healing, infectious complications, and hyperglycemia. It is

Table 12.9 Analgesics commonly used for postoperative pain control

Drug	Classification	Dosage and frequency	Precautions and adverse effects
Diclofenac	NSAIDS (aryl acetic acid derivatives)	75 mg bd adults 1.5 mg/kg bd children	Has been linked to adverse cardiovascular events—Avoid in patients with heart disease Gastric ulceration and bleeding may worsen Nephrotoxic; avoid in patients prone to kidney disease
Aceclofenac		100 mg bd adults Safety not established in children	Less than diclofenac, mild GI symptoms have been reported
Ketorolac	NSAIDS	20–30 mg q6hr 0.5 mg/kg q6hr	GI symptoms, hypertension reported in few patients
Acetaminophen (paracetamol)	NSAIDS (Para-amino phenol derivative)	0.5–1 g tds adults 10–15 mg/kg children	Hepatotoxicity
Tramadol	Synthetic opioid	50 mg bd or sos Safety not established in children.	May worsen nausea and vomiting. Like all opioids, respiratory depression is higher.
Morphine	Natural opioid	0.2–0.8 mg/kg bd	Respiratory depression, nausea, vomiting, constipation. Not suitable in immediate postop as consciousness cannot be evaluated

therefore recommended that steroids be used only till the first postoperative day. Dexamethasone 8 mg is generally used twice a day. For single day dosing, taper is not generally required.

Enzymatic anti-inflammatory medication is also used to reduce postoperative edema [20]. These include serratiopeptidase (10 mg tds) or trypsin:chymotrypsin (chymoral, 100,000 IU). However, its efficacy is based mostly on anecdotal reports and there is hardly any scientific evidence to back its use.

12.2.2.3 Antibiotic Prophylaxis

The use of antibiotic prophylaxis (for wound infections) in maxillofacial surgery is a controversial area. Literature evidence is insufficient to ascertain whether prophylaxis is required or not, and the duration of prophylaxis has no definite guidelines. Based on recent systematic reviews, Table 12.10 sums up current recommendations [21, 22].

Preferred antibiotics for prophylaxis include:

Amoxicillin-Clavulanate 1.2 mg IV bd.

Amoxicillin 500 mg per oral tds (OR) Cefotaxime 1 g IV bd with Metronidazole 500 mg IV tds.

Prophylaxis must be started 30–90 min before the surgical procedure. The postoperative regimen has no clear guidelines, but must continue for at least 24 h after the procedure. After this, the wound must be monitored for infection, and therapeutic antibiotics may be instituted only if required. This section is covered in more detail in Chap. 10, of this book

12.2.2.4 Medication to Prevent Postoperative Gastritis and Vomiting

Preoperative and intraoperative fasting, as well as drugs used in the postoperative period, can induce gastric irritation in the surgical patient. To counter this, drugs that reduce the acidity of gastric secretions may be used. Ranitidine, a H₂ blocker, may be used in a dose of 50 mg bd. An alternative drug is Pantoprazole, which may be used in a dose of 40 mg once a day.

Prevention of postoperative nausea and vomiting is an important factor in postoperative care. One of the important drugs used for the management of PONV is Ondansetron, which is given in a dose of 4 mg [23]. This is usually a rescue medication and is not given on a routine basis.

12.2.2.5 Drugs for Thromboprophylaxis

Patients undergoing prolonged surgery or hospitalization may be at increased risk of developing thromboembolic events, namely deep vein thrombosis and pulmonary embolism. Additional risk factors include smoking, pregnancy, oral contraceptives, and malignancy. These patients must be placed on thromboprophylactic drugs. In indicated cases, TED (thromboembolic deterrent) stockings have to be used in the postoperative patients. The guidelines are summarized in Table 12.11 [24].

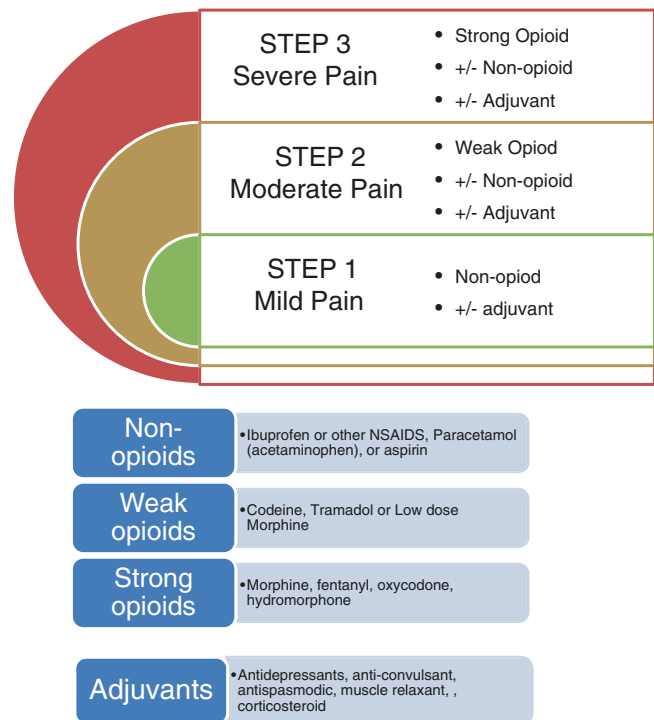
12.2.2.6 Other Drugs That May be Required Based on the Patients' Medical History

If the patient has other medical comorbidities, medication that was being taken prior to the procedure may need to be continued or modified. It is best to confer with the patients' physician to determine the dosage and kind of drugs needed. These have been summarized in Table 12.12.

12.2.3 Nutritional Status in the Postoperative Period

Maxillofacial surgical procedures provide a unique challenge to the nutritional status in the postoperative period. Pain and edema in the oral region often prevent the patient

Fig. 12.1 WHO analgesic ladder



©Association of Oral and Maxillofacial Surgeons of India

Table 12.10 Recommendations for antibiotic prophylaxis

Type of surgery	Recommendation for antibiotic prophylaxis
Orthognathic surgery	Strongly recommended
Trauma—compound fractures	Recommended
Resections involving oral and cervical region	Recommended
Reconstruction	Weak evidence; physician judgment
Cleft surgery	Weak evidence; physician judgment
Minor oral surgery	Weak evidence; physician judgment

from taking food comfortably, and there is a tendency to eat less or not at all. In patients with intermaxillary fixation, there is an inability to open the mouth and chew food. In certain kinds of surgery, such as reconstructive flaps involving the oral region, the patient is asked to avoid taking food by mouth at all to prevent the possibility of infection and flap failure in the postoperative period.

It is important, however, that the nutritional status is maintained. Inadequate nutrition has been shown to increase morbidity and mortality and can delay wound healing. It also increases the patient’s susceptibility to infection. In the young, healthy adult patient, nutritional support may not be required, as the body compensates for decreased intake by increased glycogenolysis, gluconeogenesis, lipolysis, and amino acid oxidation. However, in young children, patients

Table 12.11 Thromboprophylaxis guidelines

Risk level	Criteria	Thromboprophylaxis required
Low	Minor surgery, age < 40 yrs., no additional risk factors	Early and persistent mobilization
Moderate	Minor surgery in age 40–60 yrs., with risk factors Major surgery <40 yrs., no risk factors Patients with medical illnesses or burns, with one risk factor Neurosurgical patient with one risk factor	Low molecular weight heparin, <3400 units per day OR intermittent pneumatic compression devices
High	Minor surgery >60 years Major surgery >40 years with risk factors Patients with malignancy Patients with medical illness or burns with two or more risk factors Neurosurgical patient with two or more risk factors Trauma patients with one or more risk factors	Low molecular weight heparin, >3400 units per day OR intermittent pneumatic compression devices
Highest	Patients with multiple risk factors, pelvic and lower extremity trauma or surgery, head injuries	Low molecular weight heparin, >3400 units per day AND intermittent pneumatic compression devices

Table 12.12 Additional drugs that may be required in the postoperative period

Medical comorbidity	Drugs to be administered
Diabetes mellitus	Insulin based on insulin sliding scale
Patient with chronic hypertension	Patient's regular antihypertensive regimen to be restarted within 24 h
Patient on anticoagulants	Low molecular weight heparin for 24 h, after which warfarin should be resumed
Patient on long-term steroids	Hydrocortisone 50 mg three times a day, (equivalent to dexamethasone 2 mg) in addition to patient's normal dose, for up to 72 h

with preexisting malnutrition, and patients with wasting diseases, supplementation may be required for even routine procedures. Patients who do not have adequate oral intake for 7–14 days (3–10 days in children) will require support to avoid malnutrition [25].

Nutritional status must be evaluated in the postoperative patient. This usually calls for consultation by a dietician. For long-term patients, nutritional status can also be measured using certain tools. The accepted tool for assessment is the subjective global assessment scale [26].

In patients on intermaxillary fixation, the classic use of the nasogastric tube must be discouraged. Patients may be educated on taking food through the retromolar region, using a feeding tube. NG tubes may be reserved for cases in whom oral feeds are contraindicated to avoid infection. Nutritionally complete formulas (e.g. Ensure) are available for enteral feeds. The patient may be started on 50 ml formula every 4 h, and this may be gradually increased in 50 ml increments until the desired target is achieved. After each feed, the tube must be flushed with 30 ml water to prevent blockage.

In cases of extensive neck surgery, where swallowing may be impaired, percutaneous gastrostomy (PEG) or jejunostomy tubes may be placed. For these tubes, infusion feeds (at the rate of 20 ml/h, increased in 20 ml increments every 4 h) may be given.

Total parenteral nutrition is usually not preferred because it has been linked to higher rates of infectious complications as compared to enteral nutrition. Patients who have complete block of the gastrointestinal system or those who cannot tolerate or retain enteral feeds are candidates for TPN. Dextrose solutions are preferred, with a dose of 10–20 g/kg/day of glucose. This is used in conjunction with amino acid solutions (0.5–3.5 g/kg/day) and lipid emulsions (50 ml/hr) [25].

12.2.4 Postoperative Mobilization of the Maxillofacial Surgery Patient

After the surgical procedure, early mobilization is recommended for all patients. Early mobilization is believed to enhance recovery by reducing the incidence of postoperative

complications. It reduces secretions in the lungs, accelerates peristalsis, and improves venous blood flow to the extremities, thereby preventing thrombophlebitis and deep vein thrombosis [27]. Immobilization increases the risk of complications such as DVT and pressure sores. It can also lead to urinary retention.

For most maxillofacial procedures, the patient may be allowed to sit up with legs dangling 6 h after surgery. The patient may be mobilized within 24 h, and it is recommended that they ambulate every 4–6 h (during waking hours) till discharge. Caution must be employed in patients who have had grafts or flaps taken from the fibula. While the early mobilization protocol must be followed, protected weight bearing may be employed.

For patients who require prolonged bed rest, the use of alternating pressure mattresses or gel mattress overlays must be considered to prevent pressure sores.

Chest physiotherapy forms an important component of postoperative care. The in-hospital patient is prone to increased lung secretions and infections, which may be cleared using chest physiotherapy.

12.2.5 Management of Complications in the Postoperative Period

12.2.5.1 Sudden Airway Obstruction

Maxillofacial surgery and surgery to the neck carry a risk of edema and hematoma developing in the postoperative period that can compress on the airway. The airway must be monitored closely, both in the immediate postoperative period and during the stay in the ward.

If the patient presents with hypoxia and airway obstruction, the head tilt-chin lift-jaw thrust maneuver must be employed. The airway must be checked manually and cleared of obstruction such as vomitus or blood. If the airway obstruction is at or above the oropharynx, insert an airway (such as Guedel's) to keep the passage patent. If there is a hematoma compressing the airway, surgical sutures must be removed to allow a release of pressure. In extreme cases, emergency airway procedures such as cricothyroidotomy may need to be performed.

12.2.5.2 Fever in the Postoperative Period

Fever is defined as a rise in body temperature above 38 °C (100.4 °F). Postoperative fever represents a diagnostic challenge for most surgeons. Although most cases of fever are self-limiting, some can be serious and need urgent intervention. The timing of postoperative fever often gives a clue as to its diagnosis and management [28, 29].

Immediate Fever (During Surgery or Within the First 24 h).

Fever in the immediate postoperative period is most likely to be an inflammatory response to surgery. The surgical proce-

dures causes *release of pyrogenic cytokines*, which stimulate the anterior hypothalamus to release prostaglandins, causing a rise in body temperature. The extent of fever depends on the amount of tissue trauma, but usually resolves in 24 h. Laboratory and diagnostic workup is not warranted for this kind of fever.

Occasionally, immediate fever can occur due to more serious reasons, and it is important to identify these. *Malignant hyperthermia* is a rare, life-threatening disorder that can manifest in susceptible individuals when they are exposed to inhalational anesthetics, or succinylcholine. There is an immediate rise in body temperature during or up to 1 h after surgery. It may be recognized by an immediate rise in ETCO_2 , tachypnea, tachycardia, and muscle rigidity. Prompt intervention is required to avoid muscle lysis and organ system failure. Treatment involves immediate intravenous Dantrolene sodium (2.5 mg/kg), repeated every 5 min till reversal occurs, or till the maximum dose is reached (10 mg/kg).

If the fever occurs during or immediately *after a blood transfusion*, it is a sign of transfusion reaction. Transfusion of incompatible (mismatched) blood can cause a severe hemolytic reaction, which, in addition to fever, can present with dyspnea, fever, and myoglobinuria. In such cases, the transfusion must be discontinued immediately. Sometimes, febrile reactions can also occur with compatible blood, due to reaction of recipient antibodies with antigens in the transfused blood. This fever will be accompanied by headache, nausea, and vomiting. Slowing the transfusion may suffice, but it must be stopped if the reactions become severe.

Adverse drug reactions can rarely cause fever. This is usually a diagnosis of exclusion, and if suspected, all drugs must be discontinued one at a time to identify the offender. If replacement is necessary, a chemically unrelated drug must be used.

Early Postoperative Fever (24–48 h After Surgery)

A serious cause of postoperative fever in this time period is *deep vein thromboembolism*. This must be suspected if the patient has known risk factors, such as a history of smoking, malignant disease, prolonged surgery, advanced age, or prolonged immobility after surgery. Diagnosis is made by ultrasound or impedance plethysmography. If present, prompt systemic anticoagulation must be started to avoid fatal pulmonary embolism. The use of Homan's sign (Pain in the calf on forced dorsiflexion of the foot) is no longer recommended because of the risk of dislodging the thrombus into circulation. A suspected PE may be confirmed with a ventilation-perfusion (V/Q) scan of the lungs.

Thrombophlebitis can also cause a rise in body temperature. Any iv line in place for more than 24 h can cause phlebitis. This presents with pain, erythema, and edema at the affected site. The iv line must be removed and replaced, and anti-inflammatory drugs may be given. A topical ointment containing heparin and benzyl nicotinate (thrombophob) may be applied locally.

Atelectasis was once thought to be a cause of fever, but it is now believed that fever and atelectasis are unrelated, though they can coexist. *Aspiration pneumonia* is more likely to be a respiratory cause of fever, but it presents 3–5 days after surgery.

Delayed Postoperative Fever (After 48 h)

Surgical site wound infections can result in fever 3–5 days after surgery. The surgical site must be examined for pain, swelling, and pus discharge if fever occurs during this period. If an infection is present, it must be managed as detailed in the following sections.

Aspiration pneumonia can occur if the gastric fluid is aspirated into the lungs, owing to a depressed cough reflex after surgery. The risk increases in patients on maxillomandibular fixation.

Fever Beyond Fifth Postoperative Day

Fever beyond the fifth postoperative day is usually a sign of systemic infection and needs a diagnostic workup. The most common infections that can occur are *urinary tract infection* and *upper respiratory tract infection*.

Indwelling urinary catheters are the main source of UTIs. Women are at greater risk because they have a shorter urethra; however, both genders can develop UTI if the catheter is in place for more than 72 h. Concomitant signs such as burning sensation on passing urine may be present. Urine will appear cloudy. Diagnosis is best confirmed by urine culture; empirical antibiotics may be started in the meantime.

Respiratory tract infections can range from sinusitis to hospital-acquired pneumonia. In Hospital Acquired Pneumonia (HAP), chest auscultation may reveal crackles or rales, and diagnosis is made by chest x-rays. Treatment is by empirical antibiotics.

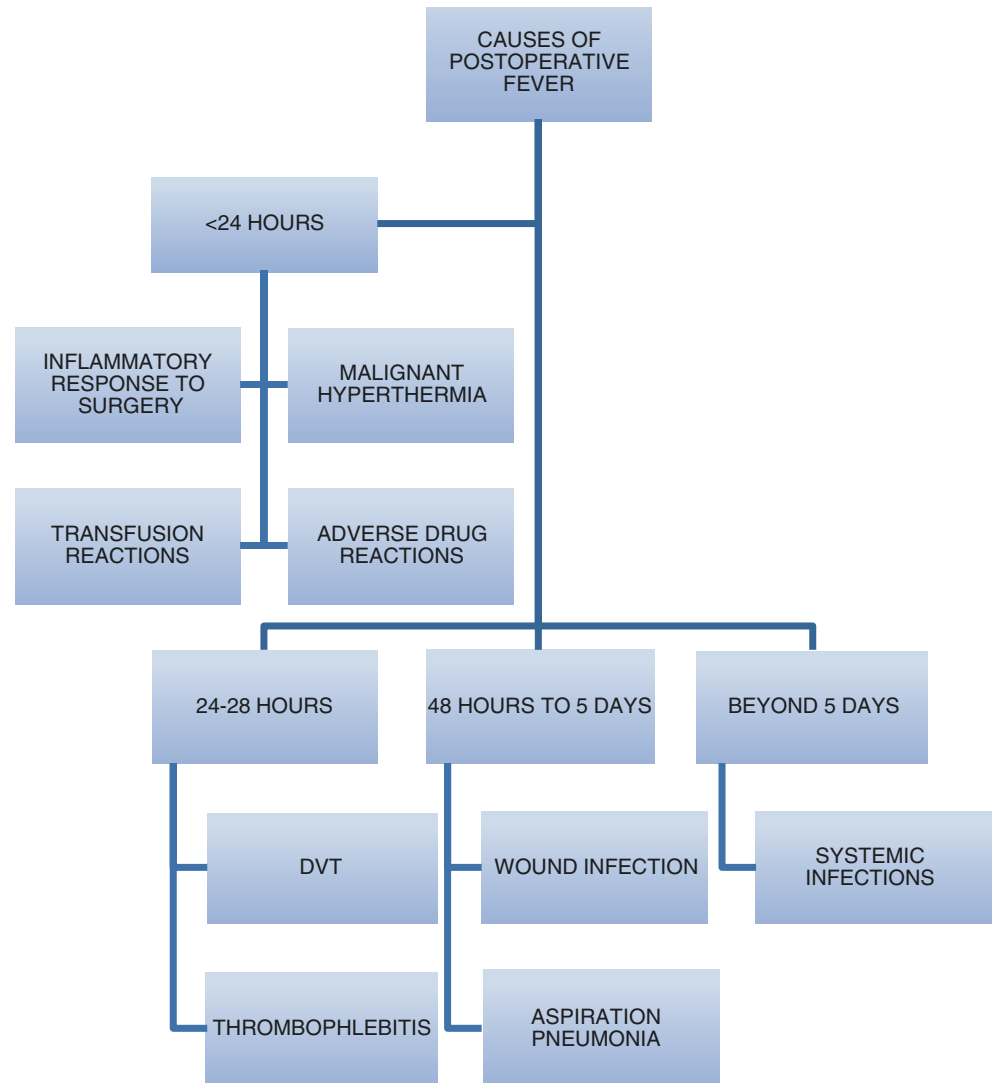
A rare infection that can occur beyond the fifth day is *necrotizing soft tissue infection*. Although this is more common after colorectal surgery, cervical necrotizing infection has been reported after maxillofacial surgery as well [30]. Diagnosis may be made by detecting subcutaneous 'gas' on x-rays or CT imaging. Treatment involves the use of broad spectrum antibiotics and fluid resuscitation.

With all systemic infections, blood culture must be done to rule out sepsis. It is also important to monitor the patient's vitals closely to ensure that the patient does not go into septic shock.

It may be of interest to know that in the literature there is a mnemonic of 6 W's, with regard to causes of postoperative fever. The W's being *Waves* (ECG changes, MI), *Wind* (atelectasis, pneumonia), *Water* (UTI), *Wound* (surgical site infection), *Walking* (Venous thromboembolism), *Wonder* drugs (drug-related fever).

The workup for postoperative fever is shown in Fig. 12.2.

Fig. 12.2 Postoperative fever workup



©Association of Oral and Maxillofacial Surgeons of India

12.2.5.3 Changes in Pulse and Blood Pressure

Any gross deviation from the normal vital signs must be looked into. Changes in pulse (tachycardia or bradycardia) are usually associated with changes in the other vital signs as well, and these must therefore be evaluated first.

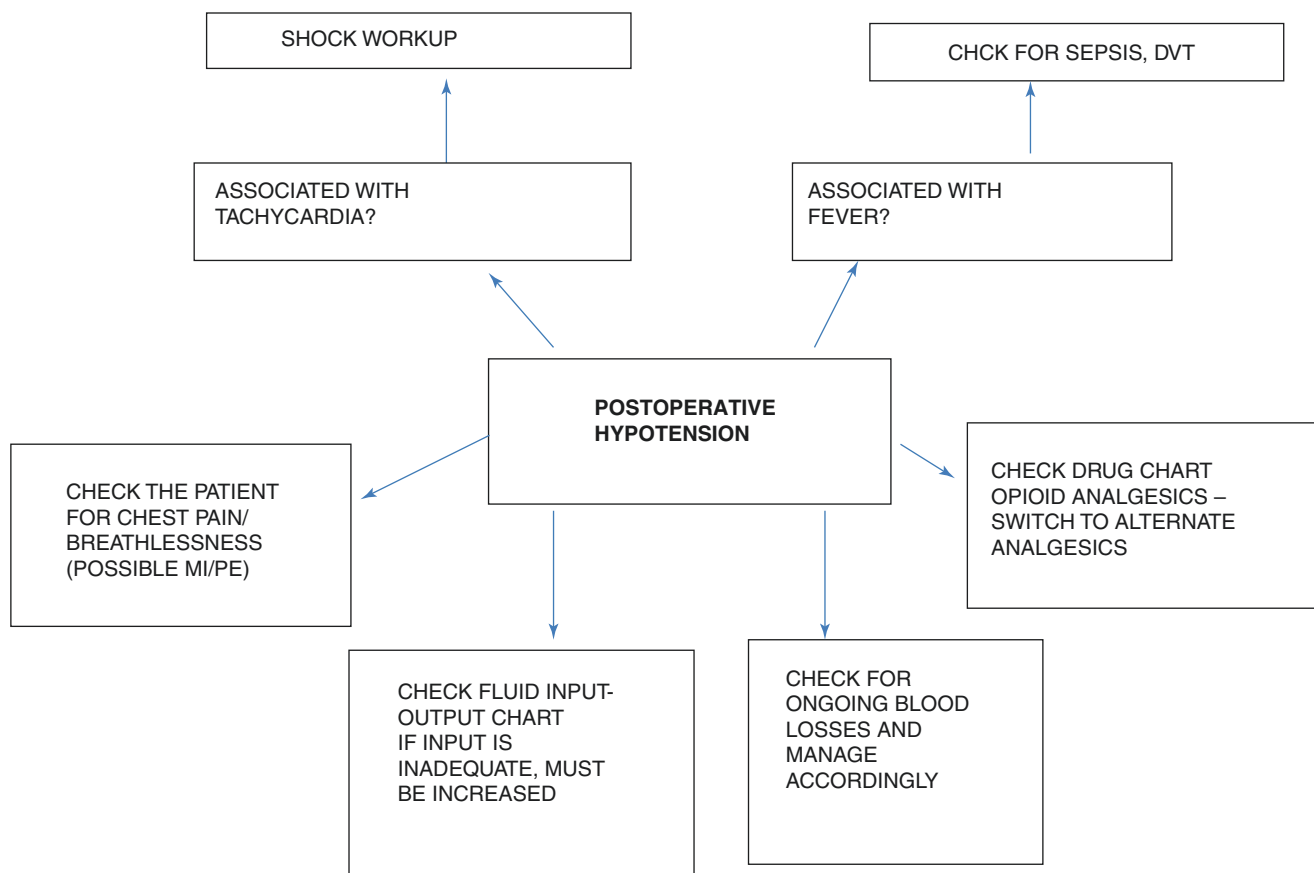
Hypotension in the postoperative period can occur due to several causes [6] (Fig. 12.3). Hypotension is usually the result of reduced plasma volume; this may be due to inadequate fluid resuscitation, or ongoing blood loss. Excessive use of opioid analgesics may also cause a fall in blood pressure. A myocardial infarction and blood sepsis may also present with hypotension. Hypotension with tachycardia can be a sign of developing shock; which must be treated immediately with a fluid challenge (rapid bolus of fluid). Regardless of the cause, hypotension must be managed by

increasing fluid input and supplemented by high-flow oxygen to improve the perfusion.

Raised blood pressure usually occurs in patients who have had preexisting hypertension. If the patient has a history of ischemic heart disease or cerebrovascular disease, it must be managed with appropriate medication, to reduce the risk of developing myocardial infarction or stroke postoperatively. Sometimes, hypertension may occur in healthy adults with no history. In these cases, it could reflect pain and anxiety, or distension of the bowel and/or bladder. Excessive fluid resuscitation may also result in hypertension [6].

12.2.5.4 Changes in Respiration

Increase in respiratory rate (tachypnea) is usually a sign of respiratory distress, and may be accompanied by decreased



©Association of Oral and Maxillofacial Surgeons of India

Fig. 12.3 Postoperative hypotension workup

oxygen saturation, and use of accessory muscles of respiration [6]. Sudden acute shortness of breath may be a sign of pulmonary embolism. Gradual onset that occurs within 2–5 days of surgery is commonly due to atelectasis. Atelectasis is the collapse of a small segment of the lung and commonly occurs after general anesthesia. Atelectasis after maxillofacial surgery may be obstructive in nature, occurring secondary to epistaxis or mucus secretion. Another reason for the slow onset of respiratory distress is Acute Respiratory Distress Syndrome (ARDS), which can occur secondary to hypovolemia, sepsis, or trauma. Respiratory infection and cardiac causes such as myocardial infarction or cardiac failure can also alter respiratory rate. The various causes are illustrated in Fig. 12.4.

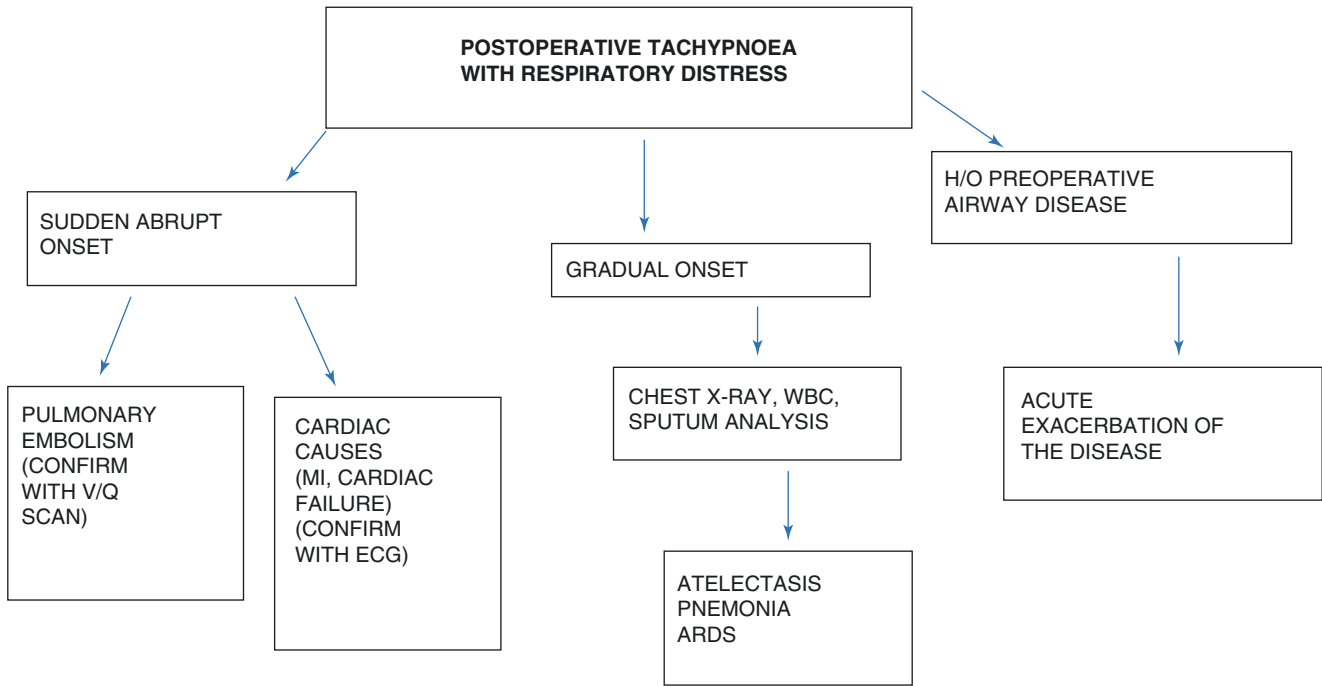
If a person experiences shortness of breath, high-flow oxygen must be started, and a chest x-ray and EKG must be taken. Laboratory tests including cardiac enzymes and arterial blood gases must be performed to ascertain the cause. If sputum is present, it must be sent for culture and gram staining.

12.2.5.5 Postoperative Nausea and Vomiting

This is a common complication that occurs due to activation of the nucleus tractus solitarius and vomiting center by inhalational anesthetics. Patients who undergo maxillofacial surgery, particularly orthognathic surgical procedures, are at increased risk of developing postoperative nausea and vomiting, due to accumulation of blood in the throat. It can affect 20–80% of all patients, the risk being higher in young patients, females in the first 8 days of their menstrual cycle, and obese patients [23]. This complication is best managed symptomatically using antiemetics such as ondansetron and metoclopramide.

12.2.5.6 Oliguria and Acute Renal Failure

The normal urine output is 1 ml/kg/h in infants, 0.5 ml/kg/h in children, and at least 400 ml/day in adults. Any drop below this level is referred to as oliguria and this must be addressed to prevent acute kidney injury (AKI). AKI is diagnosed as oliguria, along with serum creatinine levels 1.5 times above baseline [6]. The various causes of postoperative oliguria and management are outlined in Table 12.13.



©Association of Oral and Maxillofacial Surgeons of India

Fig. 12.4 Postoperative respiratory distress workup

Table 12.13 Types of postoperative oliguria and management

Type of oliguria/ AKI	Cause	Management
Prerenal	Hypovolemia	Fluid challenge of 250 ml iv fluid over 1 h
	Hypotension	Address the cause of hypotension
Renal	Nephrotoxic drugs: NSAIDS, aminoglycosides, steroids Sepsis	Discontinue the offending drug Aggressive treatment with broad spectrum antibiotics and fluid resuscitation
Post-renal	Blocked Foley’s catheter Blocked ureter	Relieve obstruction

12.3 Care of the Surgical Wound Site

12.3.1 Immediate Care in the Operating Room

Care of the surgical wound site begins even before closure of the wound has been completed. It may be necessary to place drains or catheters within the wound.

Surgical Drains

A drain is a device that is intended to evacuate fluids and air from the surgical wound site. By evacuating accumulated pus, blood, and serous fluid, they help prevent infection of the surgical site. By evacuating air, they help eliminate dead spaces, which results in faster wound healing.

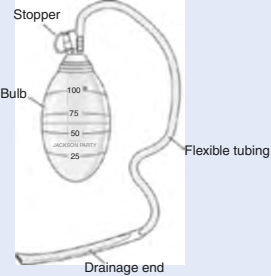
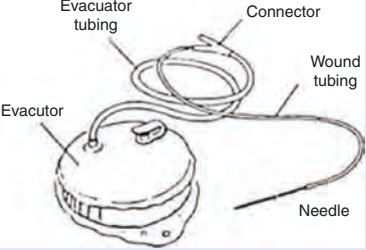
The various kinds of drains are summarized in Table 12.14. Drains may be classified as:

- Active drains: These work under negative pressure and actively remove fluids and air from the surgical site.
- Passive drains: They drain fluids passively, and are dependent on gravity. Passive drains may be open or closed.

Technique of inserting a surgical drain:

- The drain must be inserted before the last layer of sutures is placed.
- The drain tube has a needle at one end and perforations at the other end.
- The needle is inserted from the deeper edge of the surgical wound, and pulled out through the skin surface, about 2 cm away from the wound margin. The end with the perforations must remain within the surgical site.
- The exit of the needle must be in a dependent area, lower than the incision line.
- The needle is cut off from the tube and discarded safely.
- The drain tube is secured with sutures to the skin surface.
- The bulb or container is deflated completely, to ensure negative pressure, and is then attached to the exit end of the tube.
- Dressing with betadine gauze is done around and over the drain tube.

Table 12.14 Types of drains

Type of drain	Example	Indications for use	Image
Active	Jackson-Pratt drain	Inserted into the surgical site to drain blood and serous fluid; to eliminate dead spaces	
	Hemovac		
Passive	Open	Corrugated rubber drain	To drain pus from infected abscesses and anatomical spaces
		Penrose drain	
	Closed	Nasogastric tube, Foley's catheter	To drain body secretions (gastric fluid, urine)

Surgical Site Catheters

Catheters may be inserted directly into the surgical site beneath the skin sutures. These may serve the following purposes:

- Analgesia: An intravenous cannula inserted into the surgical site may be used for delivering local analgesia. Long-acting anesthetics, such as ropivacaine and bupivacaine, are delivered through this into the surgical site. This is especially useful in the iliac crest after harvest of autogenous bone.
- Local antibiotic therapy: Infected spaces or osteomyelitic bone may benefit from local antibiotics that are delivered via catheters.
- Marsupialization: Decompression of a cystic lesion may be followed by catheter insertion into the cystic cavity. This allows continued drainage of fluid from the cyst.

Wound Dressing

Once complete suturing of the wound has been completed, appropriate dressing of the wound site must be carried out. Various types of dressing material are available [31]. These are detailed in the Chap. 11 on soft tissue injuries and management.

12.3.2 General Guidelines for Postoperative Wound Care [32]

- Aim to leave the wound undisturbed for at least 48 h after surgery.
- Premature removal of the wound dressing may, however, be required in certain situations. These include:
 - Excess exudate or blood soaking through the dressing.
 - Suspicion that the wound site is infected (e.g. Postoperative fever with no other attributable cause).
 - The dressing is no longer serving its purpose (e.g. Falling off).
- If the wound dressing is being changed, check if there is excess exudate or devitalized tissue that may delay wound healing. If these are present, the wound must be cleansed. This is done by gentle irrigation of saline (for the first 48 h) or clean tap water (after 48 h) using a syringe. The wound must never be swabbed with gauze, as this can delay healing.

Postoperative Care of Drains and Catheters

- The drain must be monitored every 4 h and more frequently if the discharge from the wound is excessive.
- The drain container must be evacuated at least once every day.
- Once the drain fluid collection goes below 25–50 ml/day, the drain may be removed.

Surgical site catheters must be removed by the third postoperative day.

12.3.3 Surgical Site Complications

Postoperative Bleeding, Hematoma, and Seroma

Bleeding after surgery is classified as primary (occurs during or immediately after the surgical procedure), reactionary (occurs after few hours, possibly due to slipped ligatures), and secondary (occurs after few days, commonly due to infection). Active, ongoing bleeding is referred to as hemorrhage.

Hematoma refers to a clotted collection of blood below the tissues, which occurs due to damage to vessel walls. Most hematomas are self-limiting. Larger hematomas can be treated with ice packs or compression dressings. Analgesics may be given if the swelling is painful. Hematomas in the submandibular and neck region, or other regions which can potentially compress the airway, must be drained surgically.

Seromas are collections of serous fluid that generally develop 5–7 days after surgery. They are more common in extensive surgeries, particularly in neck dissection, where lymph nodes have been removed. Small seromas resolve over time. If the seroma is large and painful, the fluid may be aspirated and a pressure dressing can be applied.

Infected Wound

As maxillofacial procedures are clean-contaminated surgeries, they carry a higher risk of developing infection as compared to clean surgeries. Signs and symptoms of an infected wound include:

- Unexplained fever 3–5 days after surgery.
- Localized pain at the wound site.
- Erythema around the wound.
- Wound dehiscence, with pus discharge from the wound.

If the wound appears infected, a few sutures must be removed and pus must be drained out. A swab must be sent for culture and sensitivity testing, and the patient must be started on empirical antibiotics. The patient must be monitored closely for signs of systemic infection. The infected wound can be treated by local debridement and antibiotic irrigation.

Wound Dehiscence

This generally occurs as a result of one of the above complications, most commonly subacute infection. Sometimes, however, it may simply be the result of excessive wound tension due to inadequate tissue undermining. If the wound is uninfected less than 24 h postoperatively, re-suturing may be attempted. Otherwise, the wound is best left to heal by sec-

ondary intention. Resistant wound dehiscence may lead to orocutaneous communications and may become difficult to handle. The decision to either allow these to granulate or surgically provide a cover depends on individual scenarios.

12.4 Postoperative Care for Specific Types of Surgeries

While the general rules apply to all kinds of surgeries, there may be extra measures which are required in each specific surgery type. These are outlined below [2].

Postoperative Care for the Trauma Patient

- In the immediate postoperative period, the airway must be monitored. This may get compromised due to bleeding or edema.
- For fractures of the zygoma and orbit, monitoring for retrobulbar hemorrhage is important. This can be diagnosed by the three Ps—pain (in the orbit), proptosis, and pupillary defects [33]. The postoperative care team is generally required to check pupillary reflexes on an hourly basis for the first 6 h which can be relaxed to once in 2 h for the next 6 h. Any impending sign of diminishing vision or pupillary inactivity is brought to the notice of the consultant and steps initiated accordingly.
- Assess and document paresthesia along any nerves involved in the fractured segment. This includes the inferior alveolar nerve for mandibular fractures and infraorbital nerve for zygomaticomaxillary complex fractures.
- The accuracy of reduced fractures must be checked on the first postoperative day using radiographs. For fractures involving the dentoalveolar segments, occlusion may be used as a guide.

Postoperative Care for Orthognathic Surgery Patients

- As with trauma patients, airway compromise due to bleeding and edema must be monitored.
- Considerable facial swelling is common. Ice packs and systemic steroids can help reduce swelling.
- Occlusion must be checked on the first postoperative day, and elastics must be placed if required. Class II elastics are placed from the upper anterior teeth to lower posterior teeth. Class III elastics are placed from lower anteriors to upper posterior teeth.

Postoperative Care for Oncology and Reconstruction Patients

- These patients usually undergo extensive surgery that lasts for hours, and will therefore need intensive monitoring in the postoperative period. Tracheostomy care may be required (See Sect. 12.1.1).

- Most of these patients will be unable to feed properly till wound healing is complete. Ryle's tube or PEG insertion must be done on the day of surgery or the first postoperative day.
- Patients must be on DVT prophylaxis. The malignancy, prolonged surgery, and in-hospital stay increase the risk of the patient developing DVT.

Flap Monitoring

- Reconstructed flaps must be monitored for vitality. If the blood supply to the flap is lost due to thrombi, it may be salvageable within the first 48 h. Periodic monitoring ensures prompt surgical intervention if the need arises.
- Flaps may be monitored using a handheld Doppler. Capillary refill may be assessed for flaps which are not buried. The needle prick test is simple, but must be done only to confirm congestion or loss of vitality.
- Flaps must be monitored hourly for the first 24 h, and 4 hourly for the next 48 h.

12.5 Postoperative Complications Specific to each Type of Surgery

Table 12.15 lists the complications that may be encountered with each specific surgery.

12.6 Criteria for Discharging the Patient

Prolonged hospital stay increases the patient's risk of developing nosocomial infections. Therefore, the patients must be discharged as soon as feasible. Criteria for discharge are as follows:

- Patient is hemodynamically stable, and all vitals are stable.
- Patient can take nutrition independently or with the aid of a caregiver.
- Wounds are healing well with no signs of infection.

Discharge summary: This is a record given to the patient, detailing the diagnosis, procedure performed, and any implants that were used. Instructions and medications to be taken must also be noted.

Follow-up appointments must be made for review. In case facial and neck incisions were placed, an appointment for suture removal must be given.

Table 12.15 Specific postoperative complications

Type of surgery	Complication	Management
Trauma	Malunion/nonunion	Reopen, remove cause of malunion, induce bleeding, use of graft
	Ptosis, diplopia, enophthalmos (orbital and ZMC repair)	Secondary surgical correction
	Persistent paresthesia	Palliative
TMJ surgery/ condylar fractures	Frey's syndrome (gustatory sweating)	Botox injection, surgical intervention
	Sialocele, salivary fistula	Debride the fistula lining and keep the area clean till healing occurs.
Orthognathic surgery	Facial nerve palsy	Temporary—Palliative care Permanent—Facial nerve reanimation
	Condylar malpositioning leading to anterior open bite (BSSO)	Re-surgery, removal of plates, repositioning the condyle and re-fixation
	Inferior alveolar nerve paresthesia	Palliative management
	Alar base widening (maxillary surgery)	Alar cinching
	Nasal septal deviation	Septoplasty
	Aseptic necrosis of segment	Removal and reconstruction
Neck dissections	Malocclusion	Orthodontic treatment
	Chyle leak	Chyle duct repair
	Shoulder syndrome (spinal accessory nerve damage)	Physiotherapy
	Paresthesia of sensory nerves, e.g. greater auricular, lingual nerves	Palliative
	Carotid blowout	Surgical emergency, immediate repair needed.

12.7 Conclusion

Postoperative care requires a thorough understanding of the patient, the procedure they have undergone, and the expected outcome. Surgeons must realize that more often it may be the first experience for a patient in going under the knife and lying at the ICU or ward. Hence, a perfect coherence of scientific and psychological views is required of the surgical team at all levels. The chapter emphasizes the need for comprehensive management of the maxillofacial patient at the ward after their procedure. The reader is expected to understand that outcome depends, but not ends at operating room or ward/ICU.

References

- Ogle O. Postoperative care of oral and maxillofacial surgery patients. *Oral Maxillofac Surg Clin North Am.* 2006;18(1):49–58.
- Cascarini L, Schilling C, Gurney B, Brennan P. *Oxford handbook of oral and maxillofacial surgery.* Oxford: Oxford University Press; 2018 August 2.
- Chatburn RL, Primiano JF. A new system for understanding modes of mechanical ventilation. *Respir Care.* 2001 Jun;46(6):604–21.
- Buggy DJ, Crossley AW. Thermoregulation, mild perioperative hypothermia and post-anaesthetic shivering. *Br J Anaesth.* 2000 May 1;84(5):615–28.
- Aldrete JA. The post anaesthesia recovery score revisited [letter]. *J Clin Anesth.* 1995;7:89–91.
- Williams N, O'Connell PR, editors. *Bailey & love's short practice of surgery.* 26th ed. Boca Raton, FL: CRC Press; 2013 Feb 18.
- Alfonsi P. Postanaesthetic shivering. *Epidemiology, pathophysiology and approaches to prevention and management.* *Minerva Anesthesiol.* 2003;69:438–41.
- Giannakopoulos H, Albakoff J. Fluid and electrolyte management and blood product usage. *Oral Maxillofac Surg Clin North Am.* 2006;18:7–17.
- Kayilioglu SI, Dinc T, Sozen I, Bostanoglu A, Cete M, Coskun F. Postoperative fluid management. *World J Crit Care Med.* 2015;4(3):192–201.
- Chesney RW. The maintenance need for water in parenteral fluid therapy, by Malcolm A. Holliday, MD, and William E. Segar, MD, *Pediatrics.* 1957; 19: 823–832. *Pediatrics.* 1998 Jul 1;102(Supplement 1):229–30.
- Doherty M, Buggy D. Intraoperative fluids: how much is too much? *Br J Anaesth.* 2012;109(1):69–79.
- Della Rocca G, Vetrugno L, Tripi G, Deana C, Barbariol F, Pompei L. Liberal or restricted fluid administration: are we ready for a proposal of a restricted intraoperative approach? *BMC Anesthesiol.* 2014;14(1):62.
- Chao J. Transfuse or not to transfuse: for postop anemia. *Am J Clin Med.* 2011;8(1):11–4.
- Liumbruno GL, Bennardello F, Lattanzio A, Piccoli P, Rosetti G. Recommendations for the transfusion management of patients in the peri-operative period. III. The post-operative period. *Blood Transfus.* 2011;9:320–35.
- Ong CK, Lirk P, Seymour RA, Jenkins BJ. The efficacy of preoperative analgesia for acute postoperative pain management: a meta-analysis. *Anesth Analg.* 2005 Mar 1;100(3):757–73.
- Coulthard P, Haywood D, Tai M, Jackson-Leech D, Pleuvry B, Macfarlane T. Treatment of postoperative pain in oral and maxillofacial surgery. *Br J Oral Maxillofac Surg.* 2000;38(6):588–92.
- Vargas-Schaffer G. Is the WHO analgesic ladder still valid? Twenty-four years of experience. *Can Fam Physician.* 2010 Jun 1;56(6):514–7.
- Grass JA. Patient-controlled analgesia. *Anesth Analg.* 2005 Nov 1;101(5S):S44–61.
- Fleischli J, Adams W. Use of postoperative steroids to reduce pain and inflammation. *J Foot Ankle Surg.* 1999;38(3):232–7.
- Bhagat S, Agarwal M, Roy V. Serratiopeptidase: a systematic review of the existing evidence. *Int J Surg.* 2013;11(3):209–17.
- Escobar JIS, de Velasco AAF. Antibiotic prophylaxis in Oral and maxillofacial surgery. *Med Oral Patol Oral Cir Bucal.* 2006;11:E292–6.

22. Kreutzer K, Storck K, Weitz J. Current evidence regarding prophylactic antibiotics in head and neck and maxillofacial surgery. *Biomed Res Int*. 2014;2014:1–7.
23. Dobbeleir M, De Coster J, Coucke W, Politis C. Postoperative nausea and vomiting after oral and maxillofacial surgery: a prospective study. *Int J Oral Maxillofac Surg*. 2018;47(6):721–5.
24. Lachiewicz PF. Comparison of ACCP and AAOS guidelines for VTE prophylaxis after total hip and total knee arthroplasty. *Orthopedics (Online)*. 2009 Dec 1;32(12):74.
25. Fang J, Chirag D, Dym H. Nutritional aspects of care. *Oral Maxillofac Surg Clin North Am*. 2006;18(1):115–30.
26. da Silva FJ, Daniel de Mello P, Daniel de Mello E. Subjective global assessment of nutritional status – a systematic review of the literature. *Clin Nutr*. 2015;34(5):785–92.
27. Dolgun E, Giersbergen M, Aslan A, Altunbaş Y. The investigation of mobilization times of patients after surgery. *Asian Pac J Health Sci*. 2017;4(1):71–5.
28. Ansari R. Fever work-up and management in postsurgical oral and maxillofacial surgery patients. *Oral Maxillofac Surg Clin North Am*. 2006;18(1):73–9.
29. Jadwani S, Bansod S, Chug A, Misra B. Management of postoperative fever in oral and maxillofacial surgery patients. *Asian J Oral Maxillofac Surg*. 2010;22(1):2–6.
30. Tung-Yiu W, Jehn-Shyun H, Ching-Hung C, Hung-An C. Cervical necrotizing fasciitis of odontogenic origin: a report of 11 cases. *J Oral Maxillofac Surg*. 2000;58(12):1347–52.
31. Ovington LG. Advances in wound dressings. *Clin Dermatol*. 2007 Jan 1;25(1):33–8.
32. Yao K, Bae L, Yew WP. Postoperative wound management. *Aust Fam Physician*. 2013;42(12):867–70.
33. Bater MC, Ramchandani PL, Brennan PA. Post-traumatic eye observations. *Br J Oral Maxillofac Surg*. 2005 Oct 1;43(5):410–6.

Open Access This chapter is licensed under the terms of the Creative Commons Attribution 4.0 International License (<http://creativecommons.org/licenses/by/4.0/>), which permits use, sharing, adaptation, distribution and reproduction in any medium or format, as long as you give appropriate credit to the original author(s) and the source, provide a link to the Creative Commons license and indicate if changes were made.

The images or other third party material in this chapter are included in the chapter's Creative Commons license, unless indicated otherwise in a credit line to the material. If material is not included in the chapter's Creative Commons license and your intended use is not permitted by statutory regulation or exceeds the permitted use, you will need to obtain permission directly from the copyright holder.



Part VI

Dentoalveolar and Oral Surgery



Anuj Jain

13.1 Introduction

Exodontia is the removal of tooth from its socket in the alveolar bone with the help of anesthesia. It is a challenging procedure in itself as the dental surgeon has to work in an oral cavity, access to which is restricted by patient's lips and cheeks. Also, the movement of the tongue and the jaw makes the procedure troublesome. Another factor which complicates the procedure is saliva. The oral cavity communicates with the pharynx which further communicates into larynx and esophagus, due to which there is always a potential risk of aspiration or deglutition of the extracted tooth. Hence, it is of paramount importance that the exodontia must be performed judiciously and be based on sound surgical principles.

Apart from the competence and practical skills of the dental surgeon, patient's cooperation also holds the key to an uneventful extraction of a tooth. Patient's cooperation is dependent on various factors like misinformation, myths, anxiety, pain phobia, patient's previous exodontia experiences, and trust over the operator. A dental surgeon must have a calm, patient, and reassuring approach towards the patient to gain his/her confidence. This empathetic nature of the doctor must be superadded with good principles of patient management and pharmacokinetics. This combination helps in controlling patient's anxiety and fear toward the procedure.

13.2 Definition

Exodontia or tooth extraction is defined as the painless removal of a whole tooth or tooth root, with minimal trauma to the investing tissues, so that the bone heals uneventfully and no postoperative prosthetic problem is created [1].

A. Jain (✉)
Oral and Maxillofacial Surgeon, Department of Trauma and
Emergency Medicine, All India Institute of Medical Sciences,
Bhopal, Madhya Pradesh, India

13.3 History

The thought of how extractions were performed in eleventh century is disturbing. The operator used to hold the patient's head between his knees, the soft tissue was cut with a sharp scalpel, and the tooth was pulled out in single direction. Often the wound was cauterized with a red hot iron and a repellent mouthwash was prescribed [2].

Historically, dental extractions were carried out as a prophylactic as well as therapeutic treatment for a variety of illnesses. Before the discovery of antibiotics, exodontia was a preferred treatment. Dentistry was not a separate profession at that time and mainly the barbers were extracting the tooth popularly known as 'barber surgeons'. They used to hang rows of rotten teeth outside their shops to advertise their services as tooth pullers [3].

Various kinds of instruments were used in different geographical areas of the globe and can be grouped as forceps, pelicans, keys, screws, and elevators. The modern-day forceps have been evolved over time and are highlighted in Table 13.1.

Regarding Indian history, Sushruta is to be credited for his description of surgical instruments. He highlighted two types of instruments viz. 'Yantra or blunt' and 'Shastra or sharp'. And among the category yantra, 'dantasanka' – a special forceps for extraction of teeth is described [6]. Vagbhata, around 650 AD, described forceps for extraction of tooth [7].

13.4 Applied Surgical Anatomy

Knowledge of Anatomy is the foundation for an uneventful surgery.

The jaw bones namely maxilla and mandible harbor the teeth in their respective alveolar process within the shape-appropriate sockets designed by nature. Sharpey's fibers of periodontal ligament attach the teeth to their alveolar sockets with the joint called gomphosis.

Table 13.1 Evolution of dental forceps

1	Seventeenth Century BC	It can be assumed that extractions were carried out considering the prominent carvings of forceps on the walls of Egyptian caves in the work of Edwin Smith Papyrus [4].
2	Fifth century BC	Hippocrates referred that the dental forceps have been discovered in Greece. These forceps were made up of Iron and called 'Odontagra' [4].
3	Fourteenth century	Guy de Chauliac invented pelicans for dental extraction. They were named after the bird from their resemblance to the shape of the beak. The early drawing of the pelican showed a straight shaft, a wheel-shaped bolster, and a single claw attached to the shaft by a rivet [2].
4	Sixteenth century	Pierre Fauchard, 'father of modern dentistry', modified the pelican with proper dimensions and advised regarding patient and operator position. His pelican was double hooked and held the tooth firmly, following which 'shaking' of tooth was done to achieve extraction [5].
5	Eighteenth century	Dental key (also known as clef de Garengot, fothergill key), an instrument modeled after a door was popular. It was first inserted horizontally into the mouth, then its claw would be tightened over the tooth to be extracted. Once secured, rotation movements were carried out to loosen the tooth. It was continuously modified for better results; however, its use was often associated with complications [2].
6	By the end of the nineteenth century	The introduction of modern-day forceps was made popular notably by sir John tomes making the dental key obsolete [2].

13.4.1 Maxilla (Fig. 13.1)

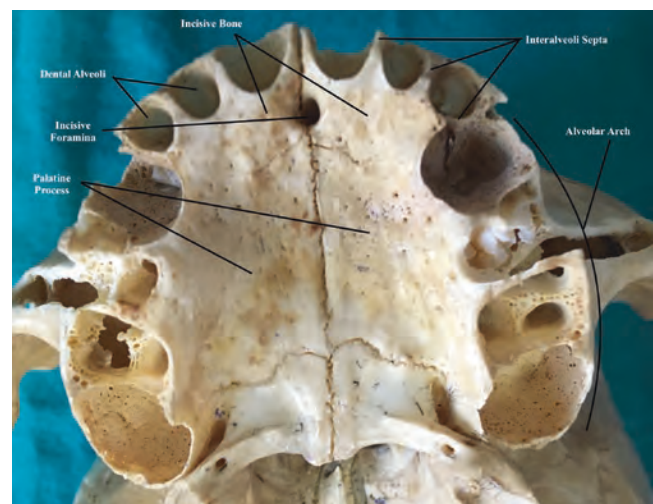
It is a paired bone forming the midface of a person, bearing upper teeth separating the oral cavity from the nasal cavity and maxillary sinuses. Compared to the mandible, it is composed of spongier bone with thinner cortical plates. Palatal processes extend from both the maxillary bone and meet in the midline to form the roof of the oral cavity. The branches of *Maxillary Nerve* innervate the maxillary teeth and their periodontium (Table 13.2).

Exodontia becomes easier in maxilla due to following reasons:

1. The maxilla is characterized by thin cortical plates with spongier bone due to which the alveolar sockets expand easily on the application of pressure, facilitating extraction.
2. Due to thin cortical plates, mere para periosteal infiltrations of local anesthetic solutions produce adequate anesthesia to perform a dental extraction. However, in cases where adequate anesthesia is not achieved, a nerve block is desirable.
3. Maxilla has better vascularity as compared to mandible due to which the healing is faster with minimum complications.

Following factors complicate exodontia of maxillary teeth:

1. Use of heavy elevators is associated with the risk of fracture of the alveolar bone. Hence, their use must be judicious.
2. The root apices of maxillary molars are in close proximity to the floor of maxillary sinus with a thin bone separating them. Due to which there are chances of.
 - (a) Oroantral communication during the extraction of maxillary molars.
 - (b) Spread of periapical infection into the sinus leading to odontogenic maxillary sinusitis.



©Association of Oral and Maxillofacial Surgeons of India

Fig. 13.1 Alveolar process of maxilla

- (c) Displacement of the root into maxillary sinus if injudicious retrieval is attempted in the event of a root fracture.
3. The maxillary third molar is present in the maxillary tuberosity as it is the last tooth to erupt. There are high chances of maxillary tuberosity fracture in patients with unfavorable and bizarre root patterns especially in the elderly as the tuberosity is made up of spongy bone.

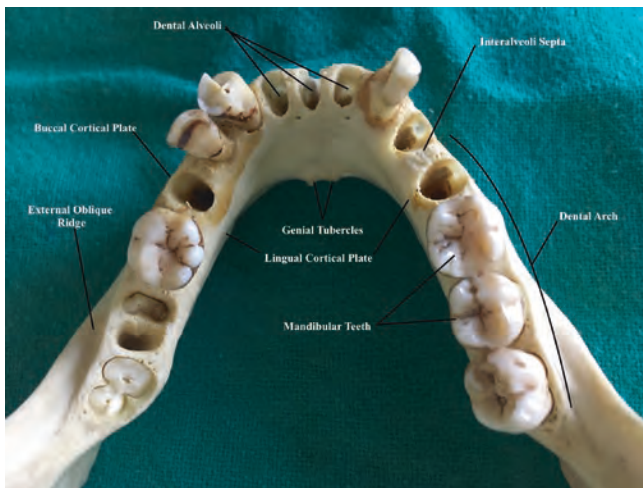
13.4.2 Mandible (Fig. 13.2)

It is horseshoe shaped, mobile and the heaviest bone of the craniofacial skeleton. Compared to maxilla, it has less spongy bone as well as vascularity and has thick cortices. The branches of *Mandibular Nerve* innervate the mandibular teeth and their periodontium (Table 13.3).

Table 13.2 Nerve supply of maxillary teeth with periodontal tissue

Teeth	Nerve supply	Nerve blocks
Central incisor	ASAN: Tooth and its buccal soft tissue Anastomosis with opposite side NPN: Palatal soft tissue	Infraorbital nerve block Local infiltration on buccal aspect Nasopalatine nerve block
Lateral incisor and canine	ASAN: Tooth and its buccal soft tissue NPN: Palatal soft tissue	Infraorbital nerve block Nasopalatine nerve block
Premolars	MSAN: Tooth and its buccal soft tissue GPN: Palatal soft tissue	Infraorbital nerve block Greater palatine nerve block
First molar	MSAN: Mesiobuccal root PSAN: Tooth and its buccal soft tissue GPN: Palatal soft tissue	Local infiltration on buccal aspect Posterior superior alveolar nerve block Greater palatine nerve block
Second and third molar	PSAN: Tooth and its buccal soft tissue GPN: Palatal soft tissue	Posterior superior alveolar nerve block Greater palatine nerve block

Abbreviations: *ASAN* Anterior Superior Alveolar Nerve, *NPN* Nasopalatine Nerve, *MSAN* Middle Superior Alveolar Nerve, *GPN* Greater Palatine Nerve, *PSAN* Posterior Superior Alveolar Nerve



©Association of Oral and Maxillofacial Surgeons of India

Fig. 13.2 Alveolar process of mandible**Table 13.3** Nerve supply of mandibular teeth with periodontal tissue

Teeth	Nerve supply	Nerve blocks
Incisors and canine	Inferior alveolar nerve: Teeth Mental nerve: Buccal soft tissue Lingual nerve: Lingual soft tissue	Inferior alveolar nerve block Mental nerve block Lingual nerve block
Premolars and molars	Inferior alveolar nerve: Teeth Long Buccal nerve: Buccal soft tissue Lingual nerve: Lingual soft tissue	Inferior alveolar nerve block Long Buccal nerve block Lingual nerve block

Following factors complicate exodontia of mandibular teeth:

1. Presence of thick cortical plates makes it a requirement to apply more pressure for luxation and extraction of teeth as the sockets do not expand readily.
2. Due to less vascularity, healing is slower as compared to maxilla.
3. Mandible is depressed when the mouth is open. Hence, there are high chances of temporomandibular joint injury or dislocations if the mandible is unsupported with the application of forces in a long-standing procedure.

13.4.3 Teeth

Apart from the bone, the anatomy of teeth also plays a pivotal role in an uneventful extraction. The shape of crown and roots must be assessed carefully, preoperatively. A narrow tapering crown requires the use of a lighter beaked forceps whereas a bulbous crown needs to be extracted using heavy beaked forceps. If the tooth is multirooted, it offers more resistance than a single-rooted tooth and cannot be extracted using a rotational force, as such a motion will lead to root fracture. In cases where the roots are divergent, the application of heavy forces will lead to root fracture. Dilacerated roots are also prone to fracture on the application of injudicious forces. Also, a more careful approach is required while extracting non-vital and endodontically treated teeth, as they fracture readily due to their fragile and brittle nature secondary carious undermining and loss of pulpal tissue.

13.5 Indications for Exodontia

Extraction of the teeth can be either prophylactic or therapeutic. Following are the indications for exodontia (Box 13.1).

1. *Dental Caries*: Extensively damaged teeth due to caries which cannot be preserved/restored by any conservative or endodontic procedure. (Fig. 13.3a).
2. *Pulp Pathology*: Pulpal necrosis or any pulpal pathology which cannot be treated by endodontic therapy (Fig. 13.3b).
3. *Severe Periodontal Disease*: Periodontally compromised teeth with mobility and irreparable loss of periodontal tissue (Fig. 13.3c).
4. *Periapical Pathology*: To prevent the spread of infection, in cases where all the reparative measures for periapical pathology have failed (Fig. 13.3d).
5. *Orthodontic Reasons*: There are a few conditions when a tooth is indicated for extraction during the course of orthodontic treatment.
 - (a) *Malposed teeth*: The teeth which are misaligned and cannot be reoriented within the proper arch form with orthodontic treatment.
 - (b) *Creation of Space*: To gain space to align malposed teeth. In such cases, premolars are commonly extracted.
 - (c) *Serial Extractions*: During the mixed dentition stage, a few deciduous teeth are extracted in a sequential manner to avoid malocclusion in permanent dentition as the child grows.
6. *Preprosthetic Extractions*: Total extraction for the fabrication of a complete denture or extraction of a few undesirable teeth to provide better design and stability to a removable partial denture.
7. *Fractured Teeth*: The teeth which are fractured and cannot be conserved (Fig. 13.3e).
8. *Root Fragments*: Root fragments which may cause various problems like recurrent ulcerations under a denture, initiation of bony pathologies, and numbness if in close proximity to nerve. However, considerably small asymptomatic root fragments may be left alone but the patient needs to be kept under regular follow-up (Fig. 13.3f).
9. *Supernumerary Teeth*: These teeth may be malposed or impacted. They predispose to malocclusion, pain, periodontal disturbance, pathologies, or sometimes esthetics. If there is no advantage in retaining a supernumerary tooth, it must be subjected to extraction (Fig. 13.3g).
10. *Retained Deciduous Teeth*: Deciduous teeth which are retained beyond the age of exfoliation.
11. *Impacted Teeth*: Teeth impacted in the jaw and creating discomfort to the patient or identified incidentally and found to be initiating some pathological changes within the bone (Fig. 13.3h).
12. *Tooth in fracture line* (Fig. 13.3i): The extraction of tooth in fracture line has always been controversial. In earlier times, all the teeth in fracture line were extracted but in recent times a more conservative approach is advocated. The teeth in fracture line are indicated for extraction if the tooth is a source of infection at the site of the fracture, the tooth itself is fractured, or the retention of the tooth in fracture line may interfere with the fracture reduction or healing.
13. *Teeth associated with pathologies* (Fig. 13.3j): Teeth involved in cyst formation and associated with other pathologies like tumors, osteomyelitis, or neoplasms.
14. *Teeth in firing line of radiations*: In the past, prophylactic extractions were carried out before the patient was subjected to radiation therapy. This practice was done as the effects of radiation, such as loss of vascularity of bone and radiation caries of the tooth, leading to a risk of osteoradionecrosis. However, with betterment in technology, it is not commonly practiced anymore.

Indications of Exodontia

1. Dental Caries
2. Pulp Pathology
3. Severe Periodontal Disease
4. Periapical Pathology
5. Orthodontic Reasons
6. Preprosthetic Extractions
7. Fractured Teeth
8. Root Fragments
9. Supernumerary Teeth
10. Retained Deciduous Teeth
11. Impacted Teeth
12. Tooth in Fracture Line
13. Teeth associated with pathologies
14. Teeth in firing line of radiations

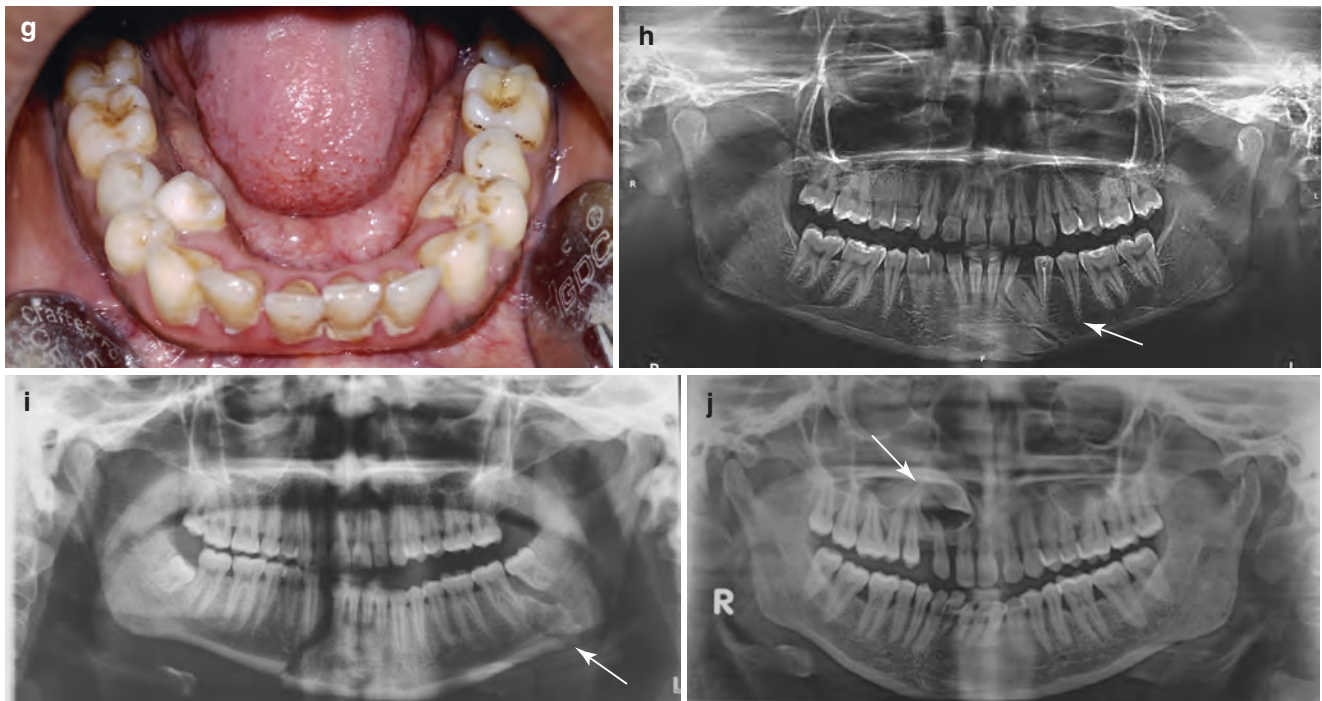
©Association of Oral and Maxillofacial Surgeons of India

Box 13.1 Indications of exodontia

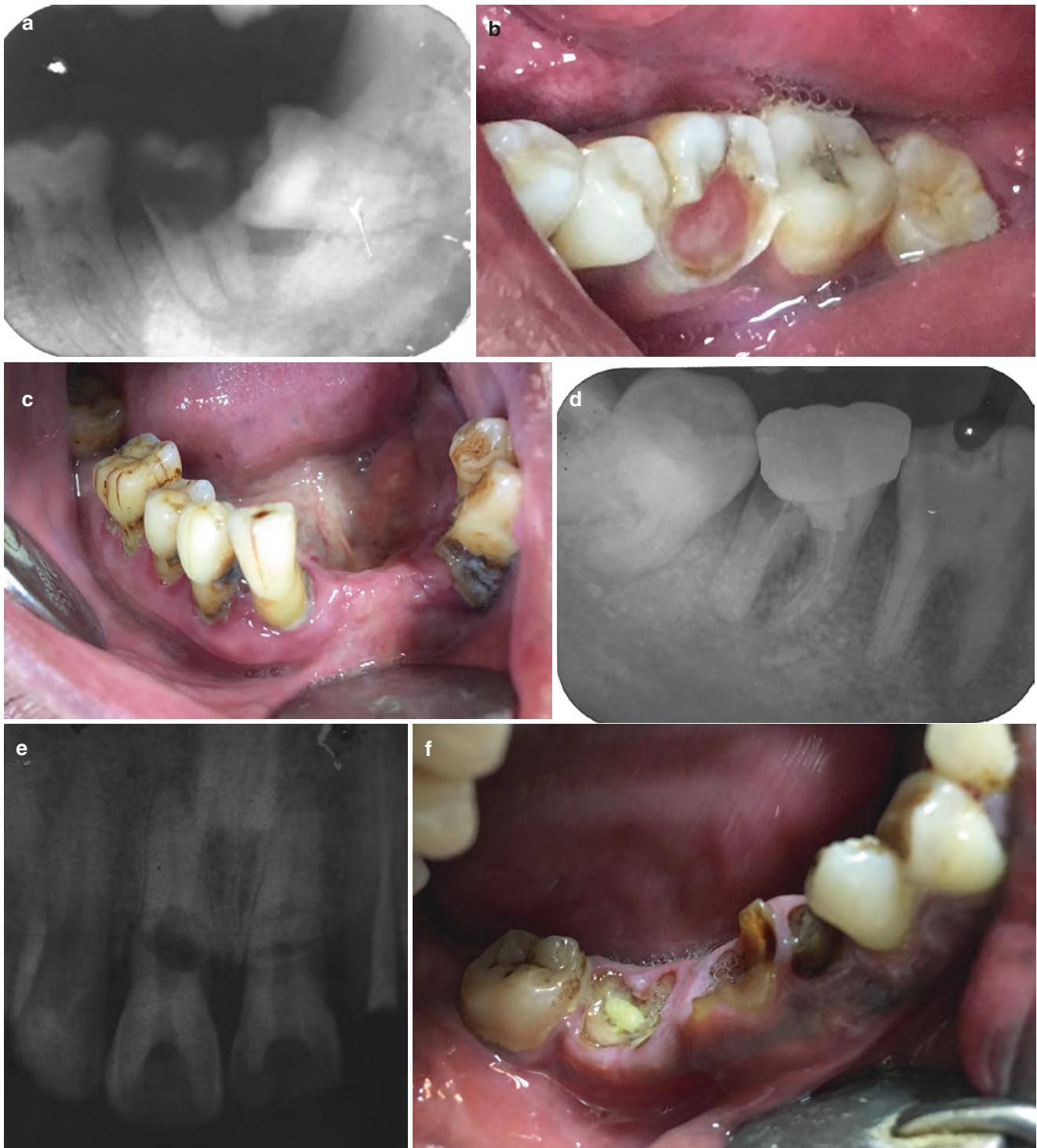

Fig. 13.3 (a) Intraoral periapical radiograph showing grossly carious second molar indicated for extraction. (b) Clinical Photograph showing pulpal pathology. (c) Clinical Photograph showing generalized periodontitis. (d) Radiograph showing developing root caries following endodontic treatment. (e) Radiograph showing fractured central inci-

sors. (f) Clinical Photograph showing root pieces. (g) Clinical Photograph showing supernumerary teeth. (h) OPG showing impacted mandibular canine. (i) OPG showing left mandibular third molar in fracture line. (j) OPG showing cyst associated with impacted maxillary canine



©Association of Oral and Maxillofacial Surgeons of India

Fig. 13.3 (continued)

13.6 Contraindications for Exodontia

A tooth may be indicated for extraction, but the presence of certain factors makes it contraindicated for extraction at that particular time. Any medical disorder in an uncontrolled, severe, or acute state may become a relative contraindication for extraction. However, once the underlying medical condition is controlled, the patient may be fit to undergo extraction. These relative contraindications may be classified as systemic or local contraindications.

13.6.1 Systemic Contraindications

Any uncontrolled systemic disease becomes a relative contraindication.

1. *Neurological disorders* like stroke and epilepsy.
2. *Pulmonary disorders* like bronchial asthma, tuberculosis, chronic obstructive pulmonary disease, and pulmonary effusion.
3. *Cardiovascular disorders* like hypertension, cardiomyopathy, valvular disorders, ischemic heart disease, and chronic cardiac failure.
4. *Hepatic disorders* like acute liver infections and liver cirrhosis.
5. *Renal disorders* like glomerulonephritis, uremia, and chronic renal failure.

6. *Metabolic disorders* like diabetes mellitus, thyrotoxicosis, Addison's disease, myxedema, and long-term steroid therapy.
7. *Hematologic disorders* like severe anemia, leukopenia, thrombocytopenia, pancytopenia, leukemia, agranulocytosis, patients on anticoagulant drugs, and bleeding and clotting disorders.
8. *Immunocompromised patients*.

13.6.2 Local Contraindications

1. *Tooth in a malignant growth*: Cases where a tooth is associated with a malignant tumor is generally mobile due to the destruction of periodontal tissues because of the underlying disease process and patients often insist for extraction. Extraction of such tooth must be considered as a relative contraindication because extraction may cause seeding of malignant cells into the capillaries subsequently leading to distant metastasis of the tumor [6].
2. *Tooth associated with vascular lesions*: There is a high risk of catastrophic bleeding while extracting the tooth associated with vascular lesions like hemangiomas, aneurysms, arteriovenous malformations, etc. Hence, such extractions should be carried out while treating the pathology in a controlled environment.
3. *Tooth in close proximity to vital structures*: The extraction should be avoided to prevent injury to vital structures.

However, if it is unavoidable, may be performed, but meticulously.

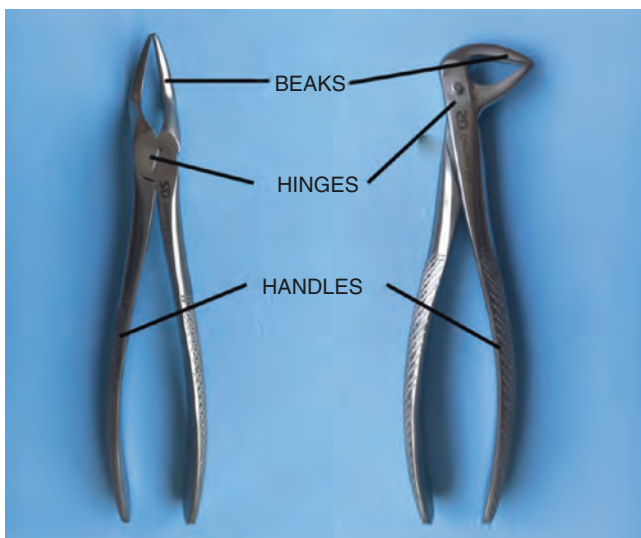
4. *Tooth in an irradiated jaw*: An irradiated jaw is highly avascular; carrying out the extraction of a tooth in such condition is associated with a high risk of osteoradionecrosis. However, such a tooth can be extracted after a considerable period of time following radiation therapy [8].
5. *Tooth with an acute infection*: If a tooth associated with acute infective pathology is extracted, there is a risk of extension of infection into deeper tissue planes due to loss of natural barriers during surgery. Also, there are chances of ingress of microorganisms into blood stream resulting in bacteremia. This may cause pyrexia and bacterial endocarditis in susceptible patients. Hence, in such a situation, the tooth must be extracted under proper antibiotic coverage. Apart from antibiotics, local measures for the drainage or decompression of the infective pathology should be carried out if possible. This relieves the pain and discomfort of the patient [9].

13.7 Armamentarium for Exodontia [10, 11]

13.7.1 Forceps

Forceps are the basic instruments used to perform exodontia. They are based on principles of simple machines. Forceps are designed to provide adequate access to the targeted tooth without injuring the neighboring tissues. Forceps basically have three components: (Fig. 13.4).

- The handle: Handle is the area of forceps from where the operator holds the instrument in a palm grip. It has serrations to facilitate firm grip. It is longer as compared to the beaks,



©Association of Oral and Maxillofacial Surgeons of India

Fig. 13.4 Components of forceps

corresponding to the longer arm of the lever, providing maximum mechanical advantage.

- The Hinge: It is the area where the beaks and handle unite with each other and this part corresponds to the fulcrum of the lever.
- The beaks: Beaks are shorter as compared to the handle and correspond to the short arm of the lever, providing maximum mechanical advantage. The beaks of maxillary forceps are parallel to the handle, whereas the beaks of mandibular forceps are at a right angle. This helps in the application of beaks parallel to the long axis of the tooth. The beaks are curved and designed specifically for different teeth for proper two-point contact. The outer surface of beaks are smooth and tapering, facilitating wedging between the tooth and alveolar process. However, the inner surface of beaks are serrated to provide a firm grip over the tooth.

The forceps are of two types:

1. English Pattern: These forceps have a hinge that is directed vertically to the handles of the forceps.
2. American Pattern: These forceps have a hinge that is directed in a horizontal direction with the handles of the forceps.

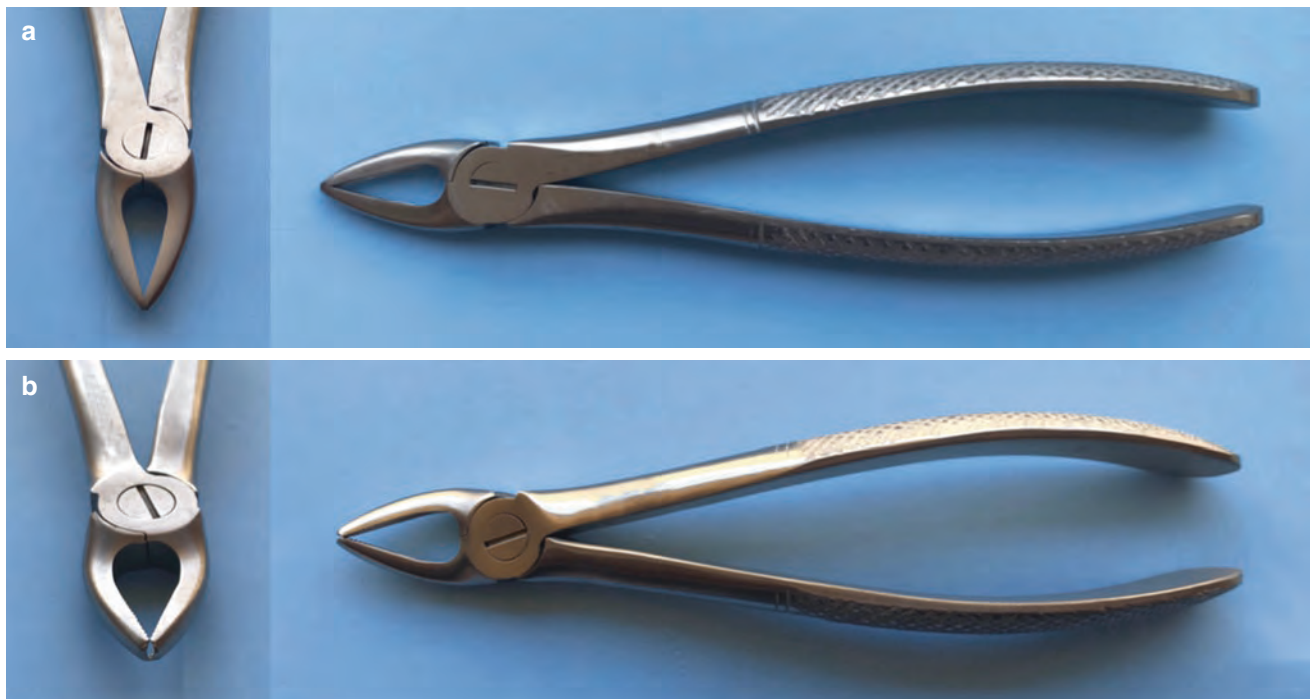Tables 13.4 and 13.5 describe various maxillary and mandibular forceps with their salient features, respectively.

Maxillary forceps must be held in a 'palm up' position (Fig. 13.7a) and mandibular forceps must be held in a 'palm down' position (Fig. 13.7b). These forceps majorly apply five different motions: (Fig. 13.8).

1. Apical pressure: With the force in this direction, the tooth movement is minimal in apical direction; however, the socket expands due to insertion of beaks in the periodontal ligament space. Also, the center of rotation of tooth displaces apically, resulting in less amount of force at the apical portion of root preventing it from getting fractured. (Fig. 13.9).
2. Buccal/Labial pressure: This results in expansion of buccal cortical plate, specifically at the crest of the ridge. However, at the same time, it results in lingual apical pressure. However, excessive pressure must be avoided to prevent fracture of buccal bone and the apical portion of the root.
3. Palatal/Lingual pressure: Similar to the buccal/labial pressure, but in opposite direction aiming in the expansion of lingual cortical plate.
4. Rotational pressure: Here the tooth is rotated resulting in internal socket expansion and tearing of periodontal ligaments. This force must only be applied to the teeth with single and conical roots. Teeth with multiple or dilacerated roots are prone to fracture on the application of this force.

Table 13.4 Maxillary forceps with their salient features

Sr. No.	Forceps	Description	Use
1	Maxillary anterior forceps (Fig. 13.5a)	Beaks are approximated with each other and handle is straight	Extraction of maxillary incisors and canines.
2	Maxillary premolar forceps (Fig. 13.5b)	Beaks do not approximate. Handle has concavity on one side to provide better grip and access.	Extraction of maxillary premolars.
3	Maxillary molar forceps (Fig. 13.5c)	These are paired forceps having asymmetrical and broader beaks. Beak is pointed on one side which engages the buccal bifurcation of roots and blunt on the other side engaging palatal root. Handle is similar to that of premolar forceps.	Extraction of maxillary molars.
4	Maxillary cow horn forceps (Fig. 13.5d)	These are also paired forceps having beaks that resemble the horns of the cow, pointed on one side engaging buccal bifurcation and notched on the other engaging palatal root.	Extraction of maxillary molars with extensive loss of coronal structure.
5	Maxillary third molar forceps (Fig. 13.5e)	Beaks are curved and angulated to engage the crown of third molars. Handle is long for accessing the posterior region.	Extraction of maxillary third molars
6	Maxillary bayonet forceps (Fig. 13.5f)	Beaks of the forceps are narrow, symmetrical, and approximating. Handle is angulated to provide access to posterior areas as well.	Extraction of maxillary roots.

**Fig. 13.5** (a) Maxillary anterior forceps, (b) Maxillary premolar forceps, (c) Maxillary molar forceps, (d) Maxillary cow horn forceps, (e) Maxillary third molar forceps, (f) Maxillary bayonet forceps

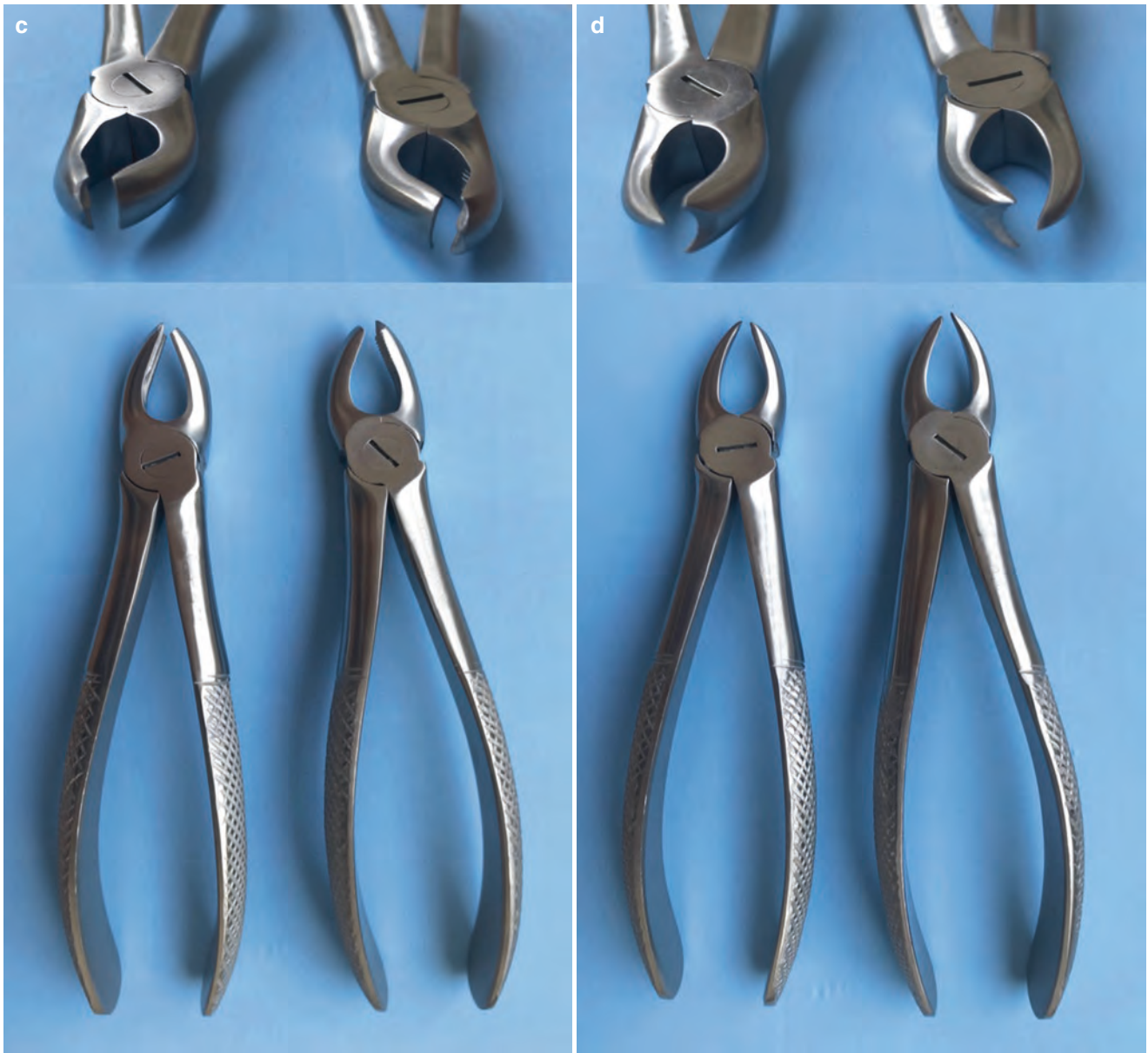
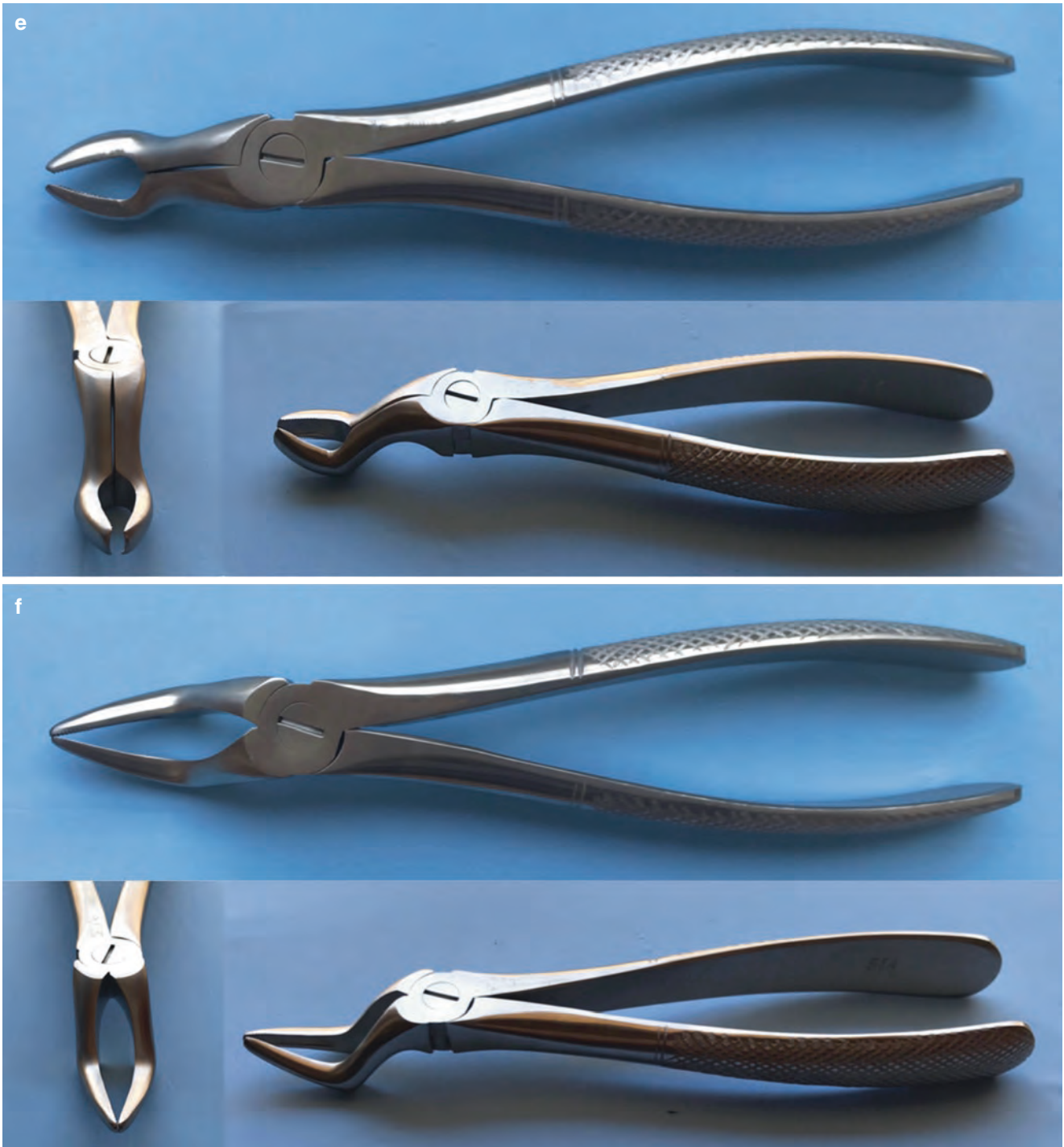
Fig. 13.5 (continued)

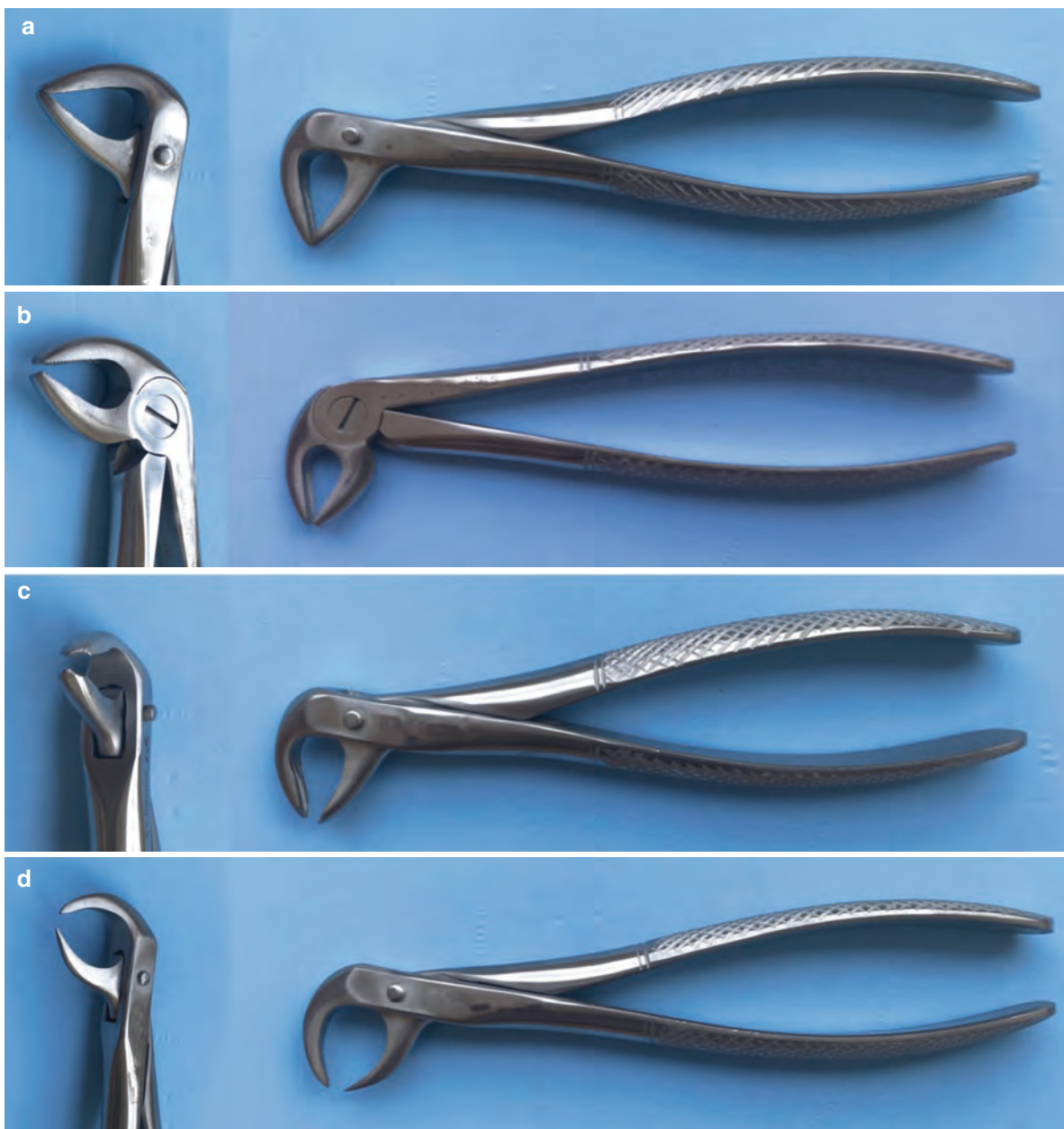

©Association of Oral and Maxillofacial Surgeons of India

Fig. 13.5 (continued)

Table 13.5 Mandibular forceps with their salient features

Sr. No.	Forceps	Description	Use
1	Mandibular anterior forceps (Fig. 13.6a)	Beaks are perpendicular to handle, approximating each other, and handle is straight with no curvature	Extraction of mandibular incisors and canines
2	Mandibular premolar forceps (Fig. 13.6b)	Beaks do not approximate. Handle is similar to the anterior forceps	Extraction of mandibular premolars
3	Mandibular molar forceps (Fig. 13.6c)	Beaks are broader with triangular projections to engage the buccal and lingual furcations	Extraction of mandibular molars
4	Mandibular cow horn forceps (Fig. 13.6d)	Beaks are pointed and conical resembling the horns of cow. Beaks engage the furcations	Extraction of mandibular molars with extensive loss of coronal structure
5	Mandibular third molars (Fig. 13.6e)	These are paired forceps having an angulated beak to reach up to the mandibular third molars. Both beaks have triangular projections to engage the buccal and lingual furcation	Extraction of mandibular third molars
6	American pattern mandibular molar forceps (Fig. 13.6f)	Beaks are similar to that of mandibular molar forceps except that they are facing forward toward each other at right angles	Extraction of mandibular molars

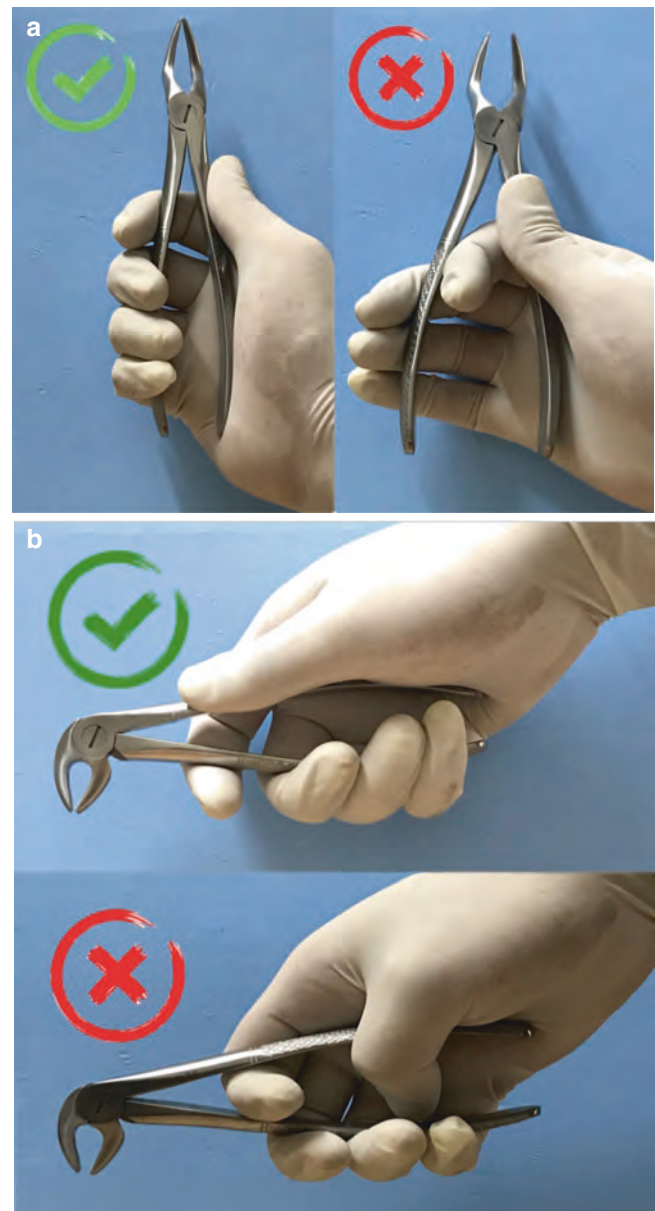
**Fig. 13.6** (a) Mandibular anterior forceps, (b) Mandibular premolar forceps, (c) Mandibular molar forceps, (d) Mandibular cow horn forceps, (e) Mandibular third molar forceps, (f) Mandibular molar forceps (American pattern)



©Association of Oral and Maxillofacial Surgeons of India

Fig. 13.6 (continued)

5. Tractional forces: This delivers the tooth out of the socket. This force should be gentle and the tooth should not be pulled out of the socket. However, if excessive force is required, other maneuvers must be carried out to improve luxation.

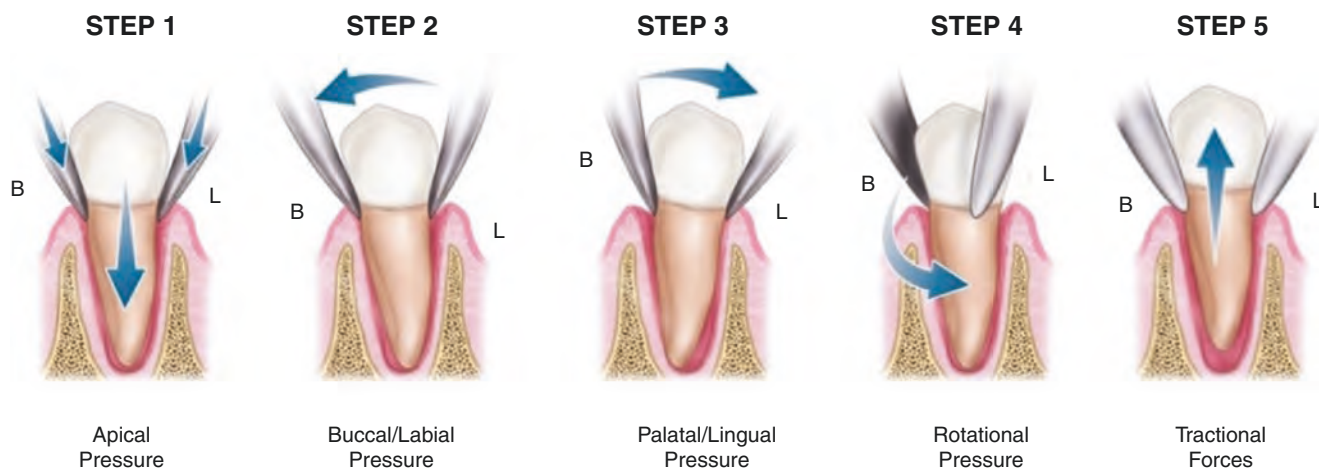


©Association of Oral and Maxillofacial Surgeons of India

Fig. 13.7 (a) Correct way of holding maxillary forceps, (b) Correct way of holding mandibular forceps

13.7.2 Elevators

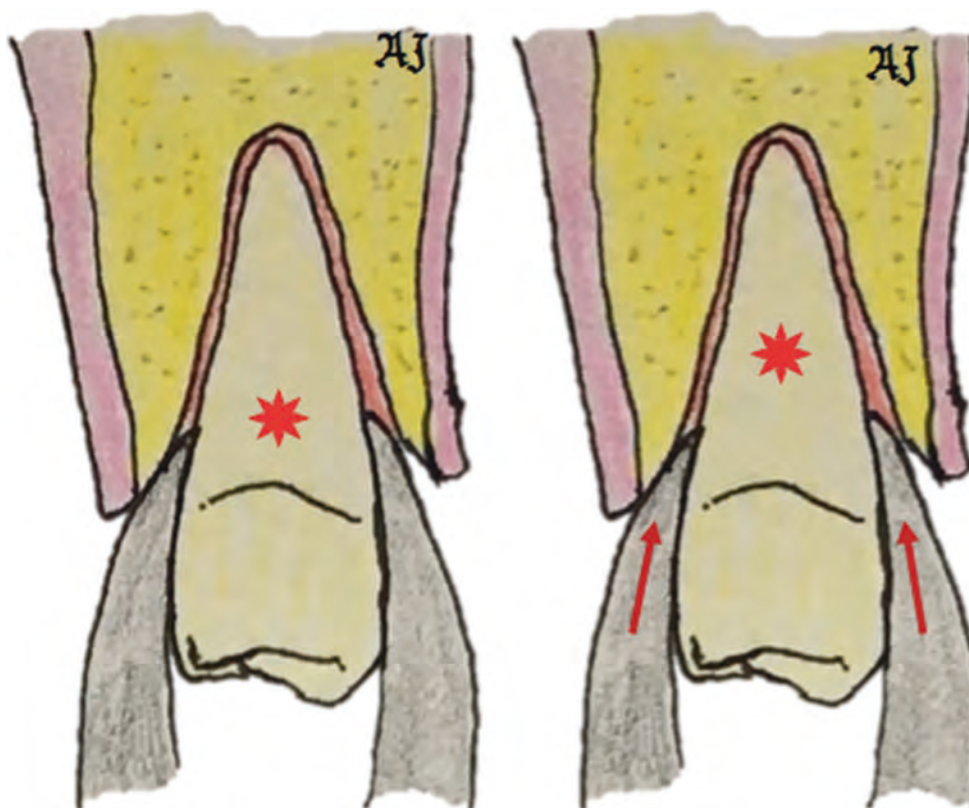
Elevators are the instruments used for luxating (loosening) the teeth before application of forceps making extraction easier, subsequently avoiding complications like fracture of crowns, roots, and bone. They are also used to remove fractured or surgically sectioned roots. Elevators are single-bladed instruments designed for specific purposes deliver-



©Association of Oral and Maxillofacial Surgeons of India

Fig. 13.8 Sequential motions performed using forceps

Fig. 13.9 Center of rotation of tooth gets displaced apically when the forceps is inserted beyond cemento enamel junction



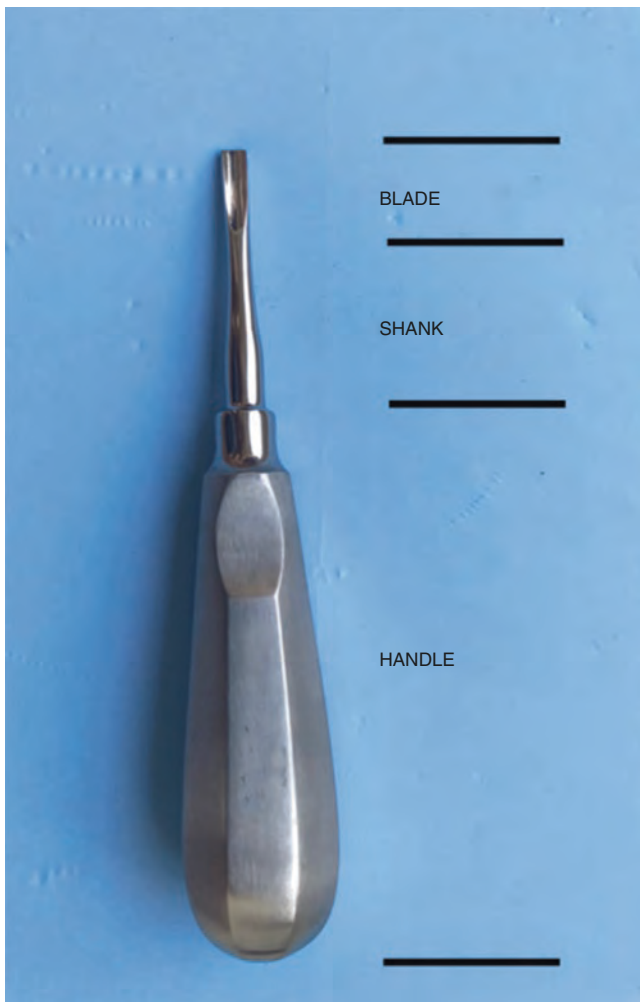
©Association of Oral and Maxillofacial Surgeons of India

ing maximum mechanical advantage with minimum efforts. Elevators have three components (Fig. 13.10):

- **Handle:** It is of generous size for proper grip and delivering adequate but controlled force. Handle can be a continuation of the shank or at a right angle to the shank.
- **Shank:** It connects the handle with the working end or blade of the elevator. It is strong enough to transmit the force from the handle to the blade.

- **Blade:** It is the working end of the instrument and transmits the force to the tooth, bone, or both to achieve the desired action.

Table 13.6 highlights various types of elevators used for exodontia and Fig. 13.12 shows the proper way to hold an elevator.



©Association of Oral and Maxillofacial Surgeons of India

Fig. 13.10 Components of elevator

Elevators works on principles of

1. Wedge
2. Lever
3. Wheel and Axle
4. Combination of the above

Table 13.6 Elevators with their salient features

Sr. No	Elevator	Description	Use
1	Straight elevator (Fig. 13.11a)	The blade, shank, and handle are in one line. Blade is pointed with one surface serrated and other convex.	Luxation of maxillary and mandibular teeth
2	Coupland elevator (Fig. 13.11b)	The blade, shank, and handle are in one line. Blade is sharp and straight cut having one surface concave and other convex.	Acts as a wedge to create purchase. Splitting of tooth
3	Apexo elevator (Fig. 13.11c)	These are paired elevators with blade at an angulation of 45° to shank. This facilitates its reach up to roots' apical region.	Extraction of root pieces
4	Cross Bar elevator (Fig. 13.11d)	These are paired elevators with blade at a right angle to shank and shank at a right angle to handle. The blade is triangular with slight curve and pointed tip.	Extraction of mandibular roots
5	Cryer elevator (Fig. 13.11e)	There are paired elevators similar to cross bar elevator. The only difference is that the handle is parallel to the shank.	Extraction of roots Elevation of upper third molars
6	Warwick James elevator (Fig. 13.11f)	The blade is short with a rounded end and the handle is flattened. There are three elevators, two angled (mesial and distal) and one straight.	Extraction of retained roots, deciduous teeth, maxillary third molars, and teeth with less resistance
7	Root tip elevator or root fragment ejector (Fig. 13.11g)	It can be a single or double ended instrument similar to Apexo elevators. The only difference is that they are smaller with more pointed blades	Removal of apical root tips/fragments of roots

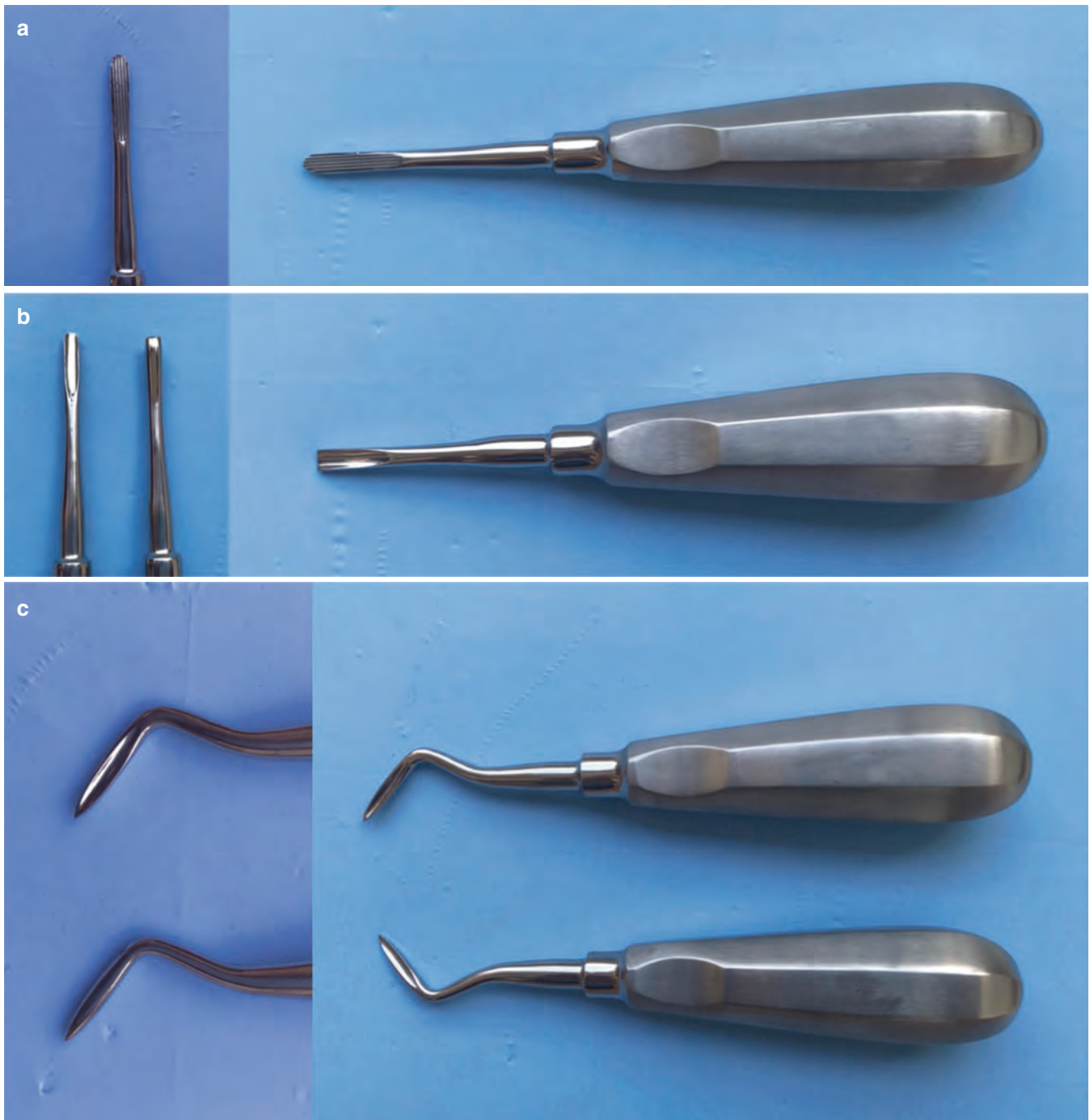


Fig. 13.11 (a) Straight elevator, (b) Coupland elevator, (c) Apexo elevator, (d) Cross bar elevator, (e) Cryer elevator, (f) Warwick James elevator, (g) Root tip elevator

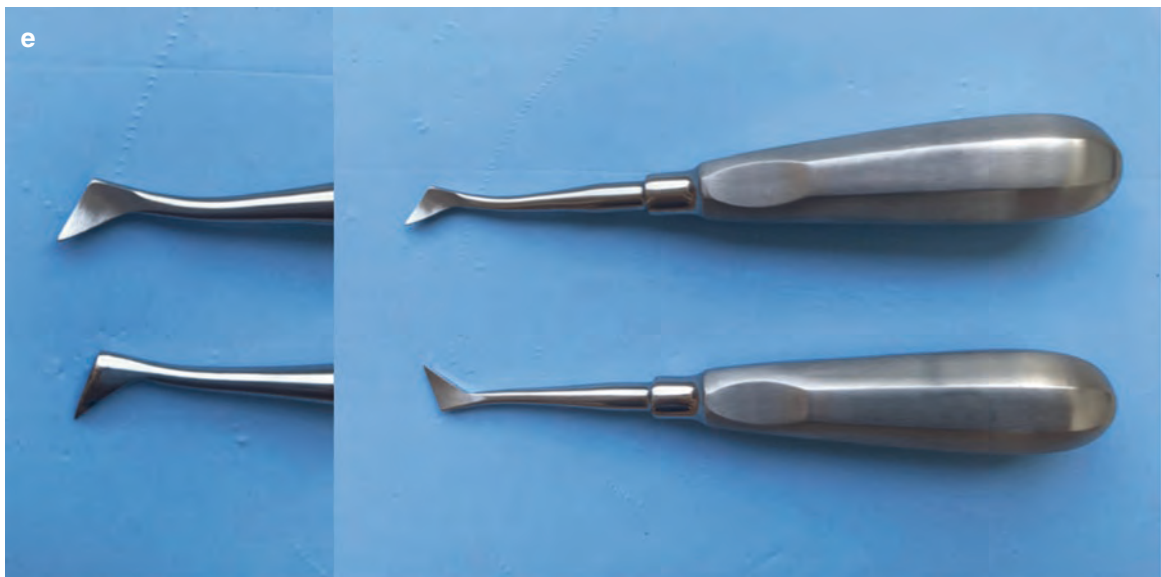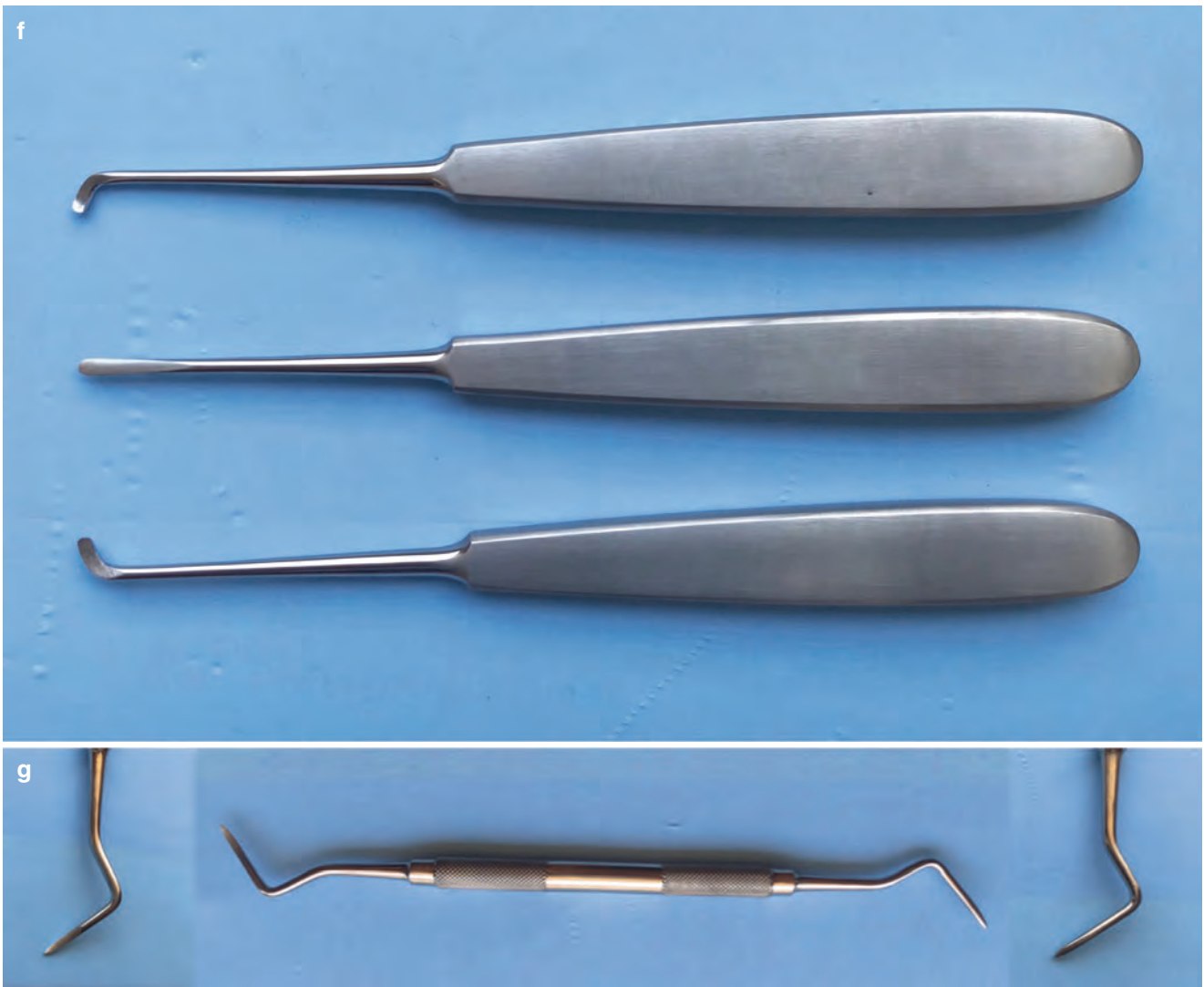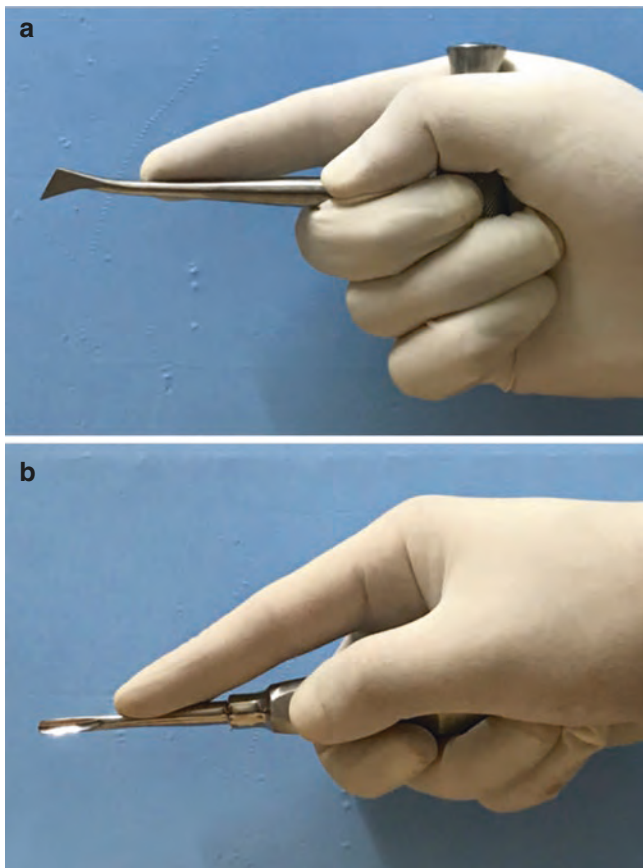


Fig. 13.11 (continued)



©Association of Oral and Maxillofacial Surgeons of India

Fig. 13.11 (continued)



©Association of Oral and Maxillofacial Surgeons of India

Fig. 13.12 (a, b) Correct way of holding an elevator

1. **Wedge Principle:** Introduction of the blade of an elevator between the bone and tooth parallel to the long axis of the tooth is wedging. A wedge is basically a movable inclined plane which overcomes a larger resistance at right angle to the applied effort. The resistance has its effect on the slant side when the effort is applied at the base of the plane (Fig. 13.13a and b).
2. **Lever Principle:** The elevator is the lever of first class. To gain mechanical advantage in first-class lever, the effort arm must be longer (3/4th of the total length) than the resistance arm divided by the fulcrum which lies on the bone (Fig. 13.14a and b).
3. **Wheel and Axle Principle:** In this principle, the effort is applied to the circumference of a wheel, which turns the axle generating the force to raise a weight (Fig. 13.15).

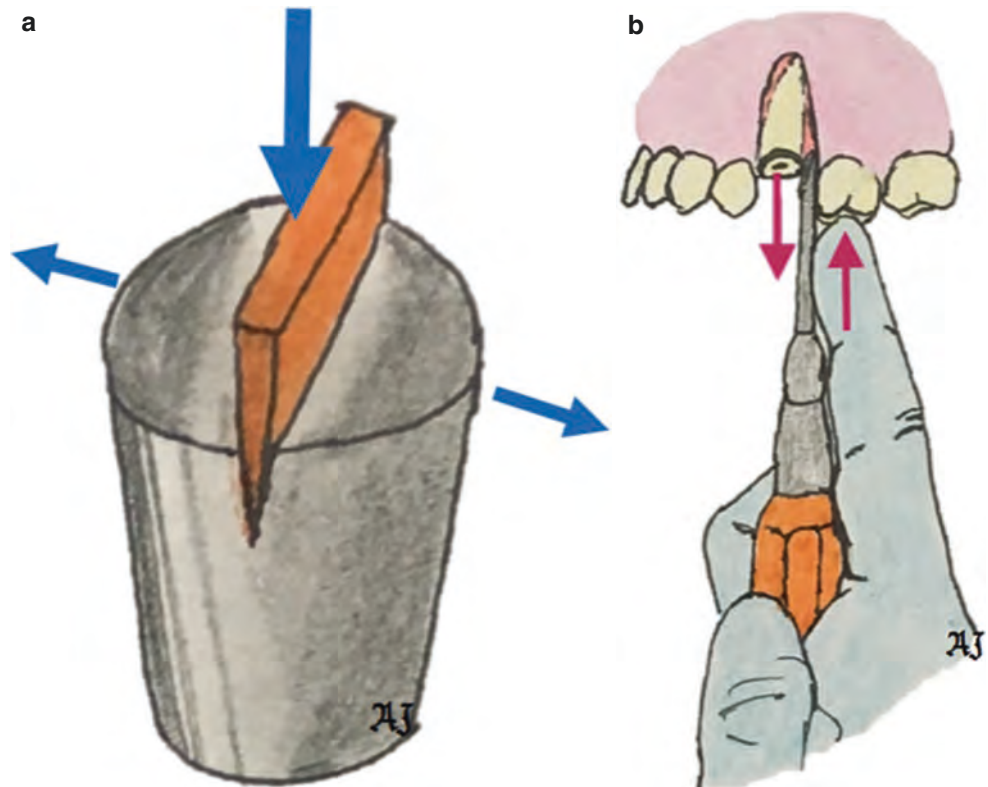
13.8 Sequential Procedure of Exodontia [6, 10]

The procedure of exodontia is a blend of surgical principles and elementary physics mechanics. When this combination is applied efficiently, a tooth can be removed with no great difficulty and finesse without requiring a large amount of force. For an uneventful extraction to be carried out, a proper sequential procedure must be followed.

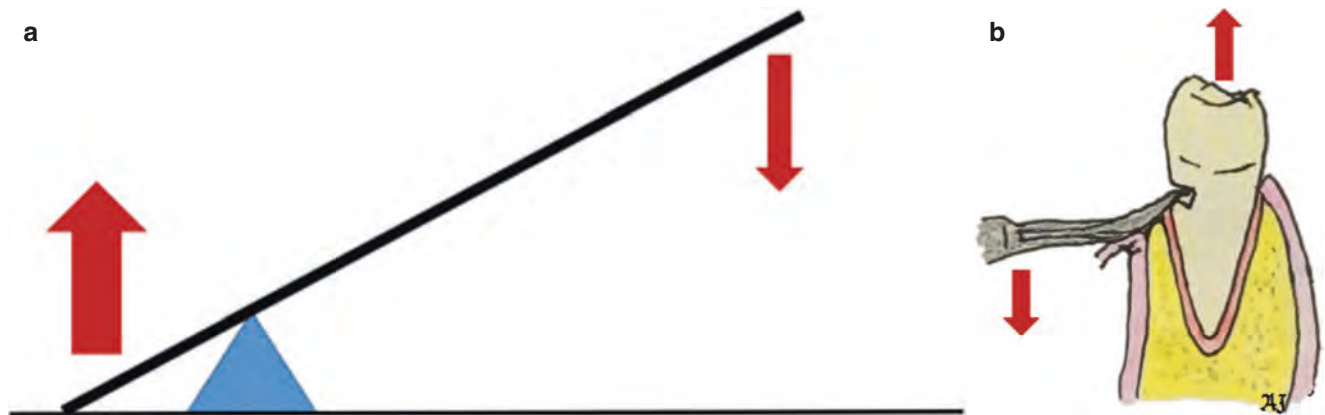
13.8.1 Presurgical Assessment

- **Presurgical Medical Risk Assessment:**
The approach of a dental surgeon must not be localized to a diseased tooth. It should always be kept in mind that we are not treating a tooth but we are treating an individual with a diseased tooth. It is critical that the surgeon must examine the patients' medical status. Patients may suffer from a variety of medical ailments requiring modification in treatment planning. Medical management must be carried out first for safe extraction procedure for the patient.
- **Emotional Condition of the patient:**
Due to various myths like weakening of eyesight and impact on mental health following extraction as well as severe intolerable pain during the procedure, the patients are generally apprehensive to undergo extraction. Such patients are liable to go into syncope or aggravation of their medical condition. A proper counseling is required in such cases before proceeding for exodontia. However, in extremely anxious patients, where counseling is not enough, premedication like Diazepam/Alprazolam (Anxiolytics) for reduction of anxiety may be considered.
- **Extraoral Examination:**
The patient must be examined for the presence of any extraoral swelling, cellulitis, abscess, or lymphadenopathy. Presence of any swelling is suggestive of extension of infection into surrounding soft tissue space which may require another surgical procedure. Presence of trismus must also be examined as it affects the access to the tooth to be extracted.
- **Intraoral Examination:**
It includes an examination of the size of the tongue, bulky buccal fat pad, and hyperactive gag reflex as these fac-

Fig. 13.13 (a) Wedge principle where a wedge is used to expand, split, and displace portions of the substance that receives it, (b) The blade of the elevator is used as a wedge to displace the tooth root out of the socket



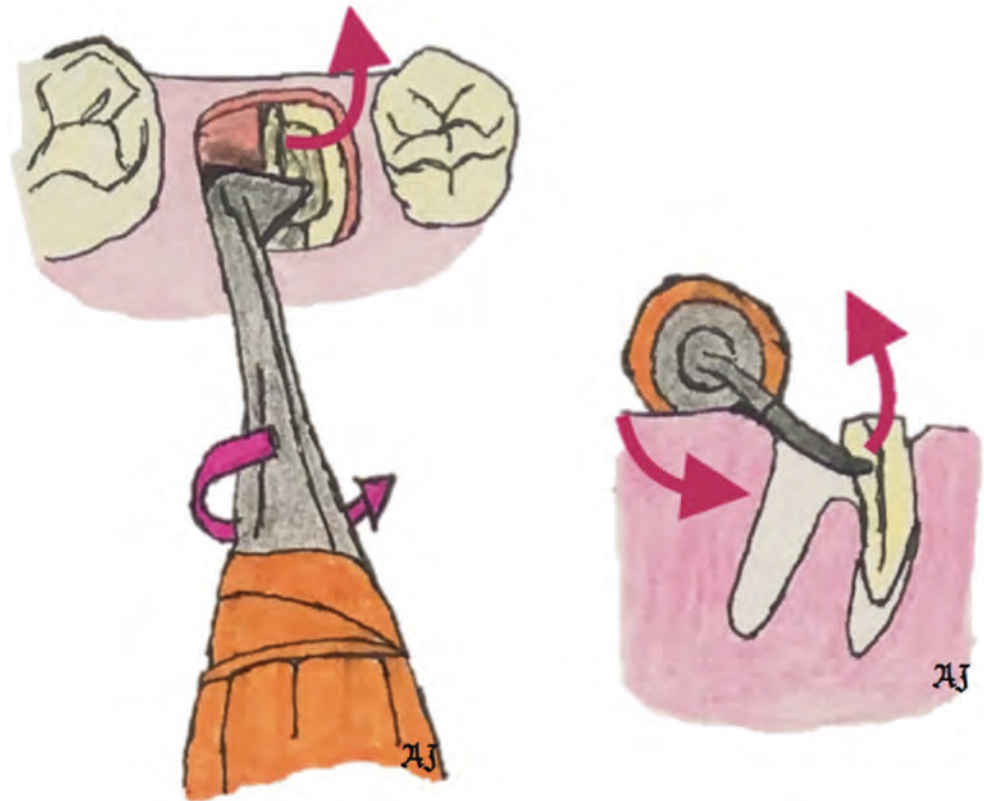
©Association of Oral and Maxillofacial Surgeons of India



©Association of Oral and Maxillofacial Surgeons of India

Fig. 13.14 (a) The small force and large movement transformed to small movement and large force by the first-class lever, (b) The tooth is elevated out of the socket where the bone acts as a fulcrum

Fig. 13.15 The elevator acting on the principle of Wheel and Axle aids in retrieval of root from the socket



©Association of Oral and Maxillofacial Surgeons of India

tors may hamper the access to the surgical site. Acute signs of infection like inflammation, edema, and pus discharge must also be assessed and the procedure must be performed under local antiseptic care and antibiotic coverage.

- Examination of the tooth in question.
 - This step includes a thorough examination of
 - Crown size
 - Form
 - Shape
 - Presence of caries
 - Mobility
 - Previous endodontic therapy
 - Tooth Angulation
 - Malposition

These factors play a significant role in the extraction procedure. The status of the adjacent tooth should also be examined as in its absence the interdental bone cannot be used as a fulcrum. Moreover, if it is carious, there are chances of fracture of the adjacent tooth while application of elevator in the interdental space.

- Radiographic Examination.
 - It is advisable to take a proper radiograph for any tooth which is to be extracted. Generally, an intraoral periapical

radiograph provides accurate and sufficient details of the tooth, its root/s, and the surrounding tissue.

Examination of the following factors must be done:

- Configuration of roots
- Size of roots
- Shape of roots
- Number of roots
- Root form
- Presence of dilacerations
- Resorption
- Hypercementosis

A proper radiograph also gives an idea regarding the proximity of the root to the vital structures such as inferior alveolar neurovascular bundle and maxillary sinus. Moreover, the condition of surrounding bone can also be identified for the presence of sclerotic bone or periapical pathologies like cyst, abscess, or granuloma.

13.8.2 Treatment Planning

As the proverb says '*Failing to plan is planning to fail*', it is of paramount importance to devise a proper treatment plan before carrying out an extraction procedure. The degree

of difficulty must be anticipated during the pre-extraction period. On assessment, if it is believed that the degree of extraction is high or the initial attempts of extraction confirm it, a deliberate surgical approach must be planned. A large amount of force during simple exodontia must be avoided as it may injure local soft tissue and damage surrounding bone and teeth. There are also chances of crown fracture which makes the procedure more difficult. Also, the application of excessive force aggravates the intraoperative and postoperative discomfort of the patient.

13.8.3 Administration of Local Anesthesia

Extraction of the tooth can be effectively carried out under local anesthesia. Hence, administration of local anesthesia must be carried out with proper technique and appropriate agent. For different teeth, different nerve blocks are to be given (Tables 13.2 and 13.3). Once the local anesthesia, nerve block and/or local infiltration is administered, surgeon must wait for it to act and confirm the same by subjective and objective tests.

13.8.4 Surgeon and Patient Preparation

The principle of universal precaution states that all the patients must be viewed as having blood-borne diseases that can be transmitted to the surgical team and other patients. Hence, to avoid transmission of diseases, a surgeon and the assistant must wear surgical gloves, surgical mask, eye-wear with shields, surgical cap, and a long-sleeved surgical gown. Before the patient is subjected to the extraction procedure, a sterile drape should be put over the patient's chest to decrease the risk of contamination. It is advisable to reduce the bacterial contamination in the patient's mouth by making him/her rinse the mouth vigorously using an antiseptic rinse like chlorhexidine prior to the procedure. Some surgeons prefer to keep a partially unfolded 4 × 4 inches' gauze loosely into the back of the mouth to prevent the tooth or its fragment from potential aspiration or swallowing. However, it should not be kept posterior enough to trigger gag reflex.

13.8.5 Position of Operator, Patient, and Chair

The positions of the operator, the patient, and the chair are very important for comfortable and successful extraction. The best position is one that is comfortable for both the patient and surgeon and which allows the surgeon to have maximum control during the procedure.

Table 13.7 Chair and patient positions for extraction

	Maxillary extraction	Mandibular extraction
Operator standing	<ul style="list-style-type: none"> Chair tipped backward Maxillary Occlusal plane at 45° to the floor Patient's mouth should be at the level between the operator's shoulder and elbow 	<ul style="list-style-type: none"> Upright position Mandibular occlusal plane parallel to floor Patient's mouth should be at the level slightly below the operator's elbow
Operator sitting	<ul style="list-style-type: none"> Supine position (10° to ground) Patient's mouth should be at the level of operator's elbow 	<ul style="list-style-type: none"> Supine position (20°–30° to ground) Patient's mouth should be at the level slightly above the operator's elbow

Table 13.8 Operator's standing position for extraction

Teeth	Position for right handed operator	Position for left handed operator
All maxillary teeth and mandibular anterior teeth	7 O' clock – 8 O' clock	4 O' clock – 5 O' clock
Mandibular left posterior teeth	7 O' clock – 8 O' clock	1 O' clock
Mandibular right posterior teeth	11 O' clock	4 O' clock – 5 O' clock

- Chair and Patient's Position (Table 13.7).
- Operator's Position (Table 13.8) (Figs. 13.16 and 13.17).

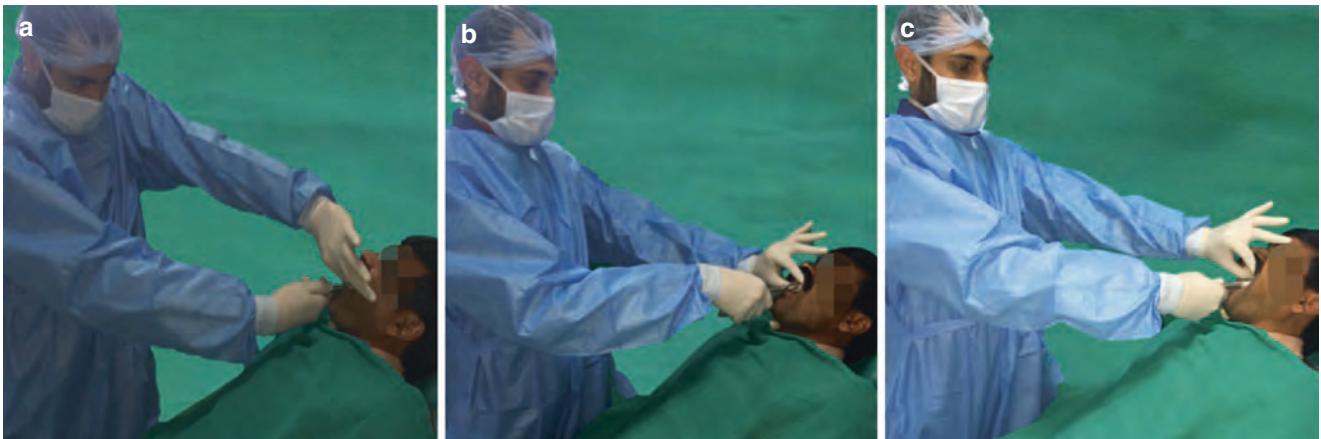13.8.6 Exodontia Procedure

Choosing the correct technique and following fundamental principles, leading to an atraumatic extraction. The three fundamental requirements for a good extraction are:

- (a) Adequate access and visualization of the surgical field.
- (b) An unimpeded pathway for the removal of the tooth, and
- (c) Use of controlled force to luxate and remove the tooth.

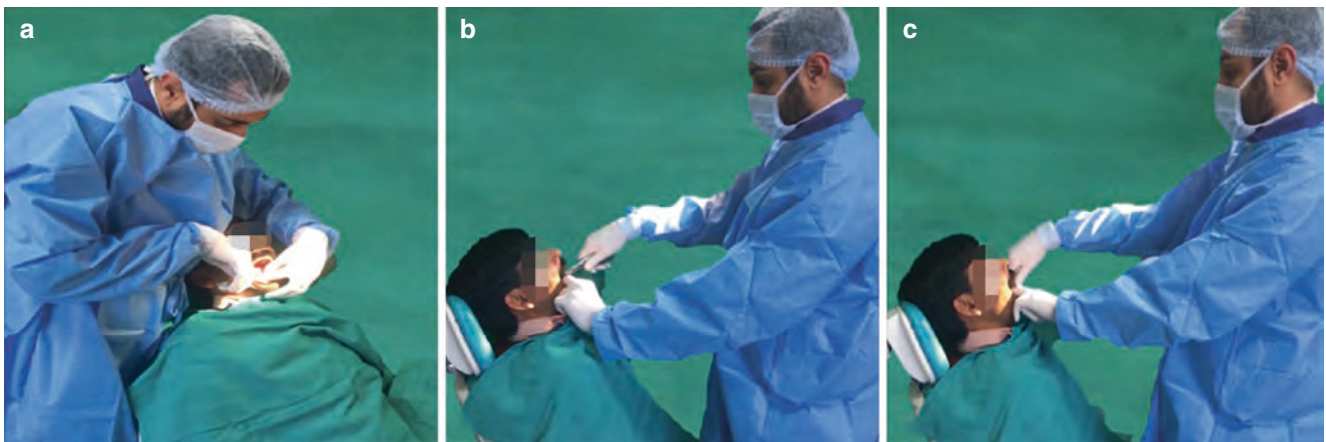Dental extractions are based on three mechanical properties, which are as follows:

1. *Expansion of alveolar socket*: The tooth itself is used as a dilating instrument to expand the alveolar socket in order to permit the removal of its harbored tooth. This is performed mainly in 'intra-alveolar exodontia' by holding the tooth firmly with a forceps and carrying out lateral movements in buccal and lingual directions (Fig. 13.18). This expansion depends on the elasticity of the bone which is maximal in young bone and decreases with age. Dilatation of socket results in microfractures in the bony



©Association of Oral and Maxillofacial Surgeons of India

Fig. 13.16 Operator's position for maxillary teeth extraction, (a) Right posterior, (b) Anterior, and (c) Left posterior



©Association of Oral and Maxillofacial Surgeons of India

Fig. 13.17 Operator's position for mandibular teeth extraction, (a) Right posterior, (b) Anterior, and (c) Left posterior

wall and interradicular septa. The bony fragments retain the periosteal attachment in almost all the cases and hence must be digitally compressed unless an implant placement is planned.

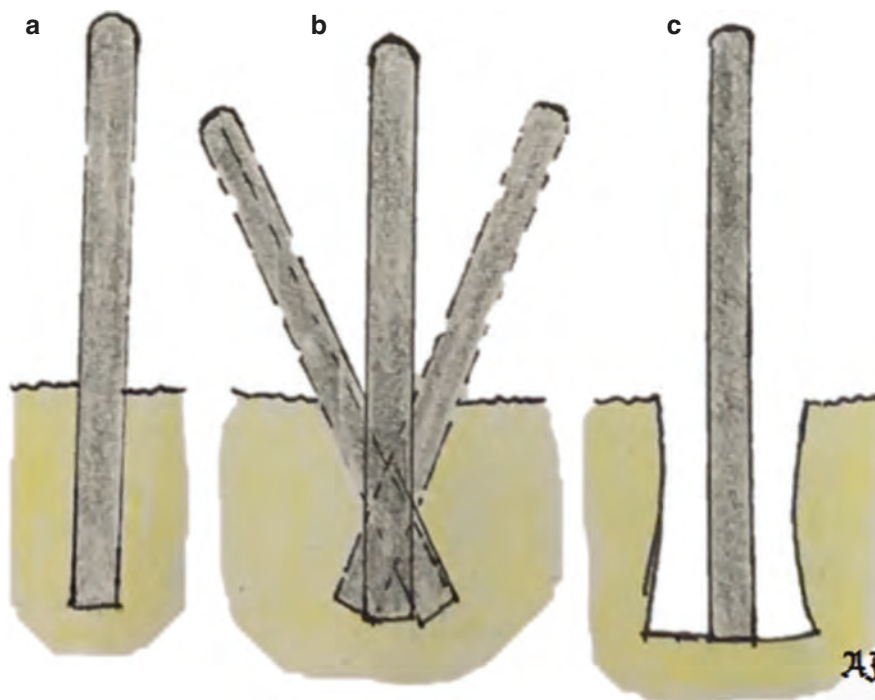
2. *Use of Lever and Fulcrum*: This principle is used to luxate the tooth or root and force it out of the socket along the path of least resistance. This principle is the basic factor which governs the use of elevators to extract tooth or tooth root (Fig. 13.14b).
3. *Insertion of a wedge of wedges*: Insertion of wedge between the tooth/root and bony socket wall leads to the rise of tooth in the socket (Fig. 13.19). Lesser the elasticity of bone, more are the effects of wedging. This is the reason that sometimes on application of blades of forceps, the conical rooted mandibular premolars shoot out of the sockets.

The two methods of exodontia are as follows:

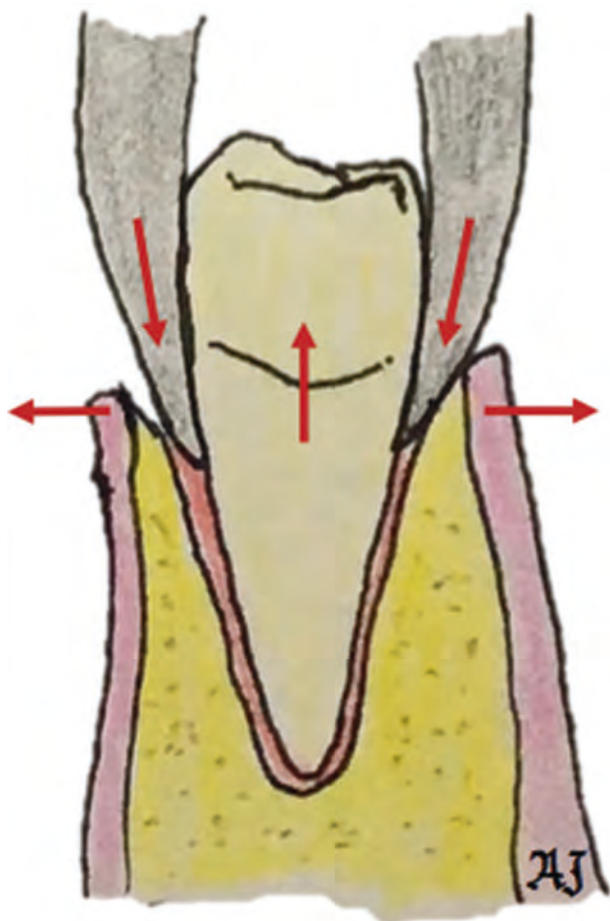
1. *Intra-alveolar Exodontia*: This method of extraction is also referred to as closed method or routine exodontia, usually practiced for extraction of erupted and intact tooth with enough structure to grasp with a forceps and pull the tooth out of alveolar socket. Instruments used are forceps or elevators or both. This technique is the most frequently used technique for almost every extraction. However, if the operator believes that the extraction will require an excessive force or if a substantial amount of crown is missing or covered by tissue, an open technique may be opted.

5 sequential steps are to be followed for exodontia by closed technique (Fig. 13.20). Other than these 5 steps, the opposite hand also plays a vital role during the procedure which is highlighted in Table 13.9.

Fig. 13.18 (a) Exodontia by expansion of bony socket is similar to the removal of a post embedded in the ground, (b) The post is moved laterally in a to and fro motion, (c) This results in displacement of soil surrounding the post and permitting the post to be removed out



©Association of Oral and Maxillofacial Surgeons of India



©Association of Oral and Maxillofacial Surgeons of India

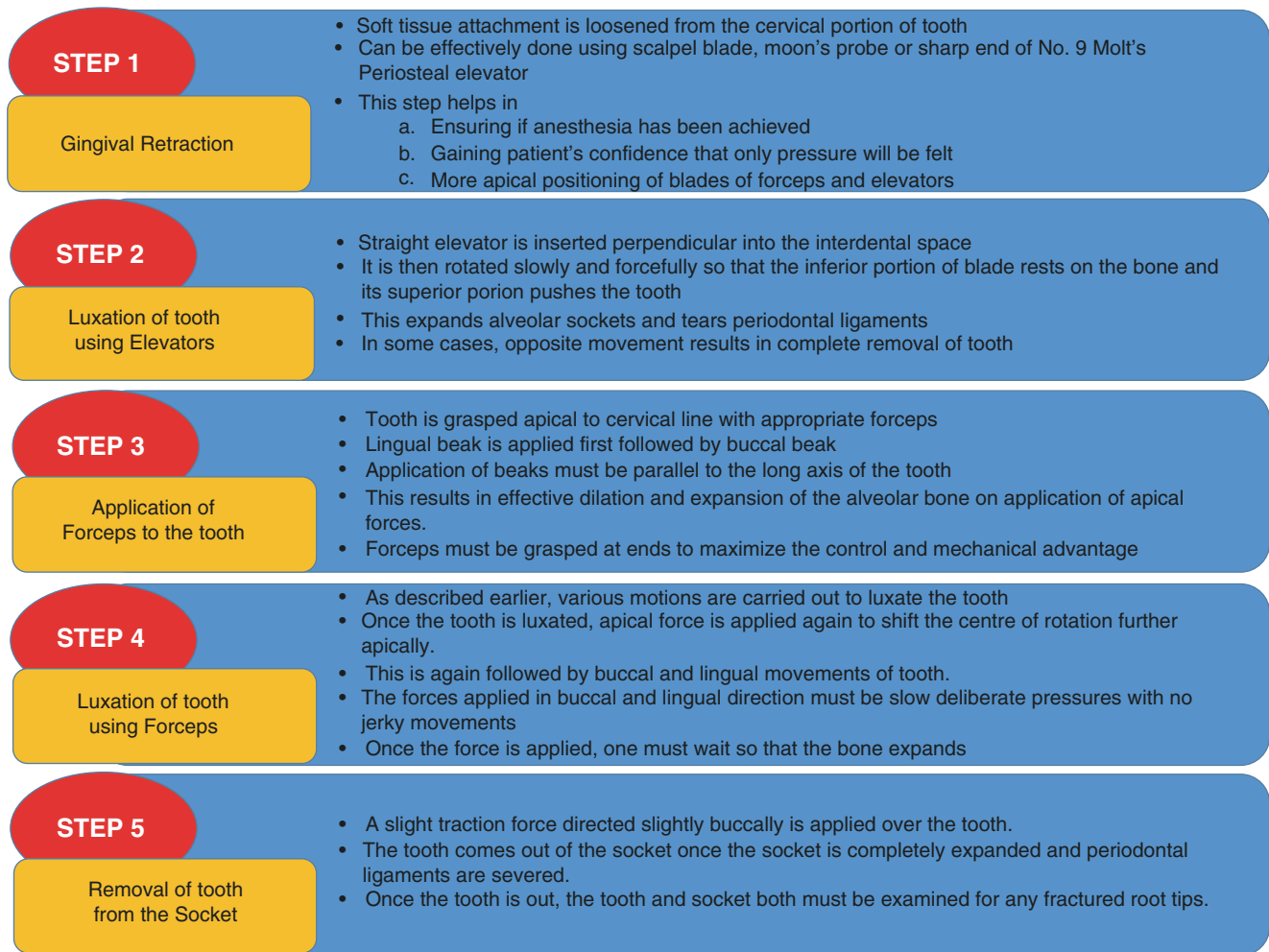
Fig. 13.19 Insertion of wedge-shaped forceps blades resulting in rise of the tooth in the socket

2. *Transalveolar Exodontia*: This method includes removal of alveolar bone to access and extract the tooth. It is generally practiced for extraction of impacted teeth, root pieces, or teeth with unfavorable root form. It is often termed as surgical extraction or complicated exodontia. Indications for open technique are enlisted in Box 13.2. For an open technique exodontia, 5 steps are to be followed: (Fig. 13.23) (Clinical Case, Fig. 13.24a–f).

13.9 Various Mucoperiosteal Flap Designs for Transalveolar Extraction

Transalveolar exodontia necessitates incision making and subsequent mucoperiosteal flap reflection for adequate exposure of the underlying alveolar bone. The flap must be an adequate sized full-thickness mucoperiosteal flap with a broader base which is made on intact bone, avoiding injury to the local vital structures. The various types of flaps used in transalveolar exodontia are:

1. *Envelope Flap*: When a crevicular incision without any releasing incision is given, it produces an envelope flap. Usually, this flap provides adequate access to perform the surgery (Fig. 13.25a).
2. *Triangular Flap*: When a crevicular incision has one vertical releasing incision, it produces a triangular flap. It is also known as a two-sided or three-cornered flap. The three corners are posterior end of the crevicular incision, inferior



©Association of Oral and Maxillofacial Surgeons of India

Fig. 13.20 Steps for Intra-alveolar exodontia

Table 13.9 Role of opposite hand during exodontia

Functions of opposite hand	Grasp of opposite hand
<ul style="list-style-type: none"> • Reflection of soft tissues of the cheeks, lips, and tongue • Protection of other teeth from the forceps • Stabilization of patient's head (along with opposite arm) • Supporting the jaw during mandibular extraction • Supporting the alveolar process providing tactile information regarding expansion 	<ul style="list-style-type: none"> • Pinch grasp: While extracting maxillary teeth, the operator grasps the alveolar bone around the tooth to be extracted by a pinch grasp (Fig. 13.21) • Sling grasp: While extracting mandibular teeth, the operator grasps the alveolar bone around the tooth to be extracted by a sling grasp (Fig. 13.22)

aspect of vertical releasing incision, and the superior aspect of the vertical releasing incision. When a greater exposure is required, this flap is preferred (Fig. 13.25b).

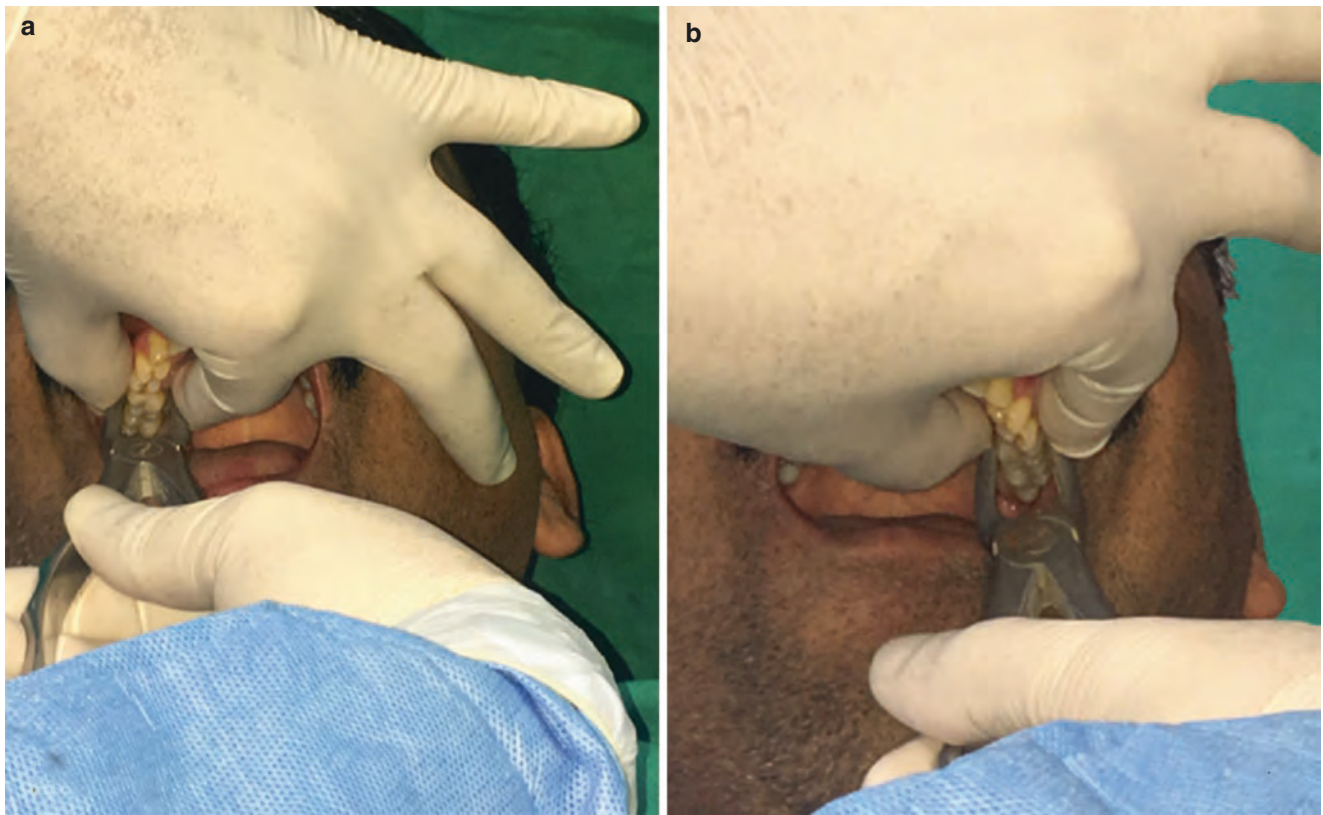
3. *Trapezoidal Flap*: When a crevicular incision has two vertical releasing incisions on either sides, it produces a

trapezoidal flap. It is also known as a three-sided or four-cornered flap. Two corners are at the superior aspect of the releasing incisions and the other two corners are at the ends of the crevicular incision. The vertical releasing incisions are not vertically placed but are directed obliquely to allow a broader base (Fig. 13.25c).

Transalveolar or complicated exodontia can be further described in two types.

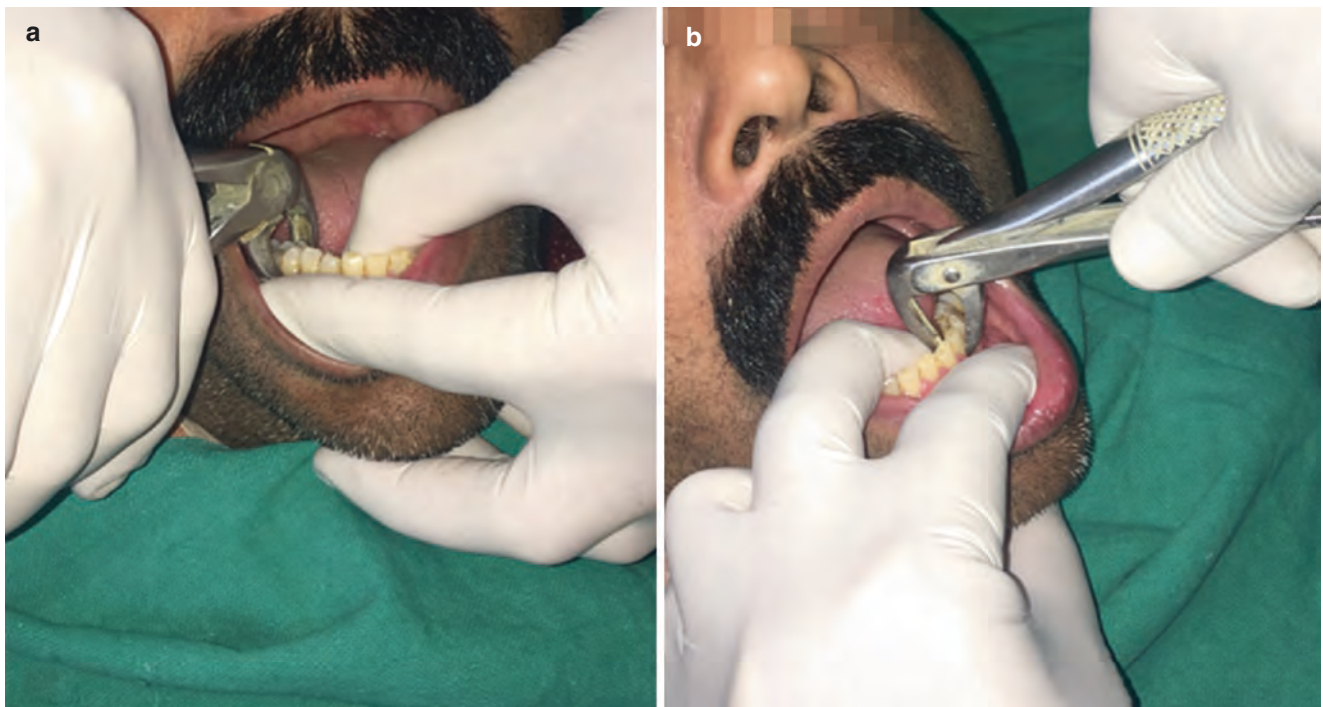
1. *Complicated Exodontia of Single rooted tooth.*

It starts by incision making and reflecting a sufficiently large flap to provide adequate visualization and access. Mostly an envelope flap is preferred which is extended at least two teeth anterior and one tooth posterior to the tooth that has to be extracted. If required, a releasing incision can be placed. Once the flap is reflected adequately and the surgical site is exposed sufficiently, extraction of the tooth/root must be performed by using one of the various options.



©Association of Oral and Maxillofacial Surgeons of India

Fig. 13.21 Pinch grasp for maxillary teeth (a) Right posterior, (b) Left posterior



©Association of Oral and Maxillofacial Surgeons of India

Fig. 13.22 Sling grasp for mandibular teeth (a) Right posterior, (b) Anterior

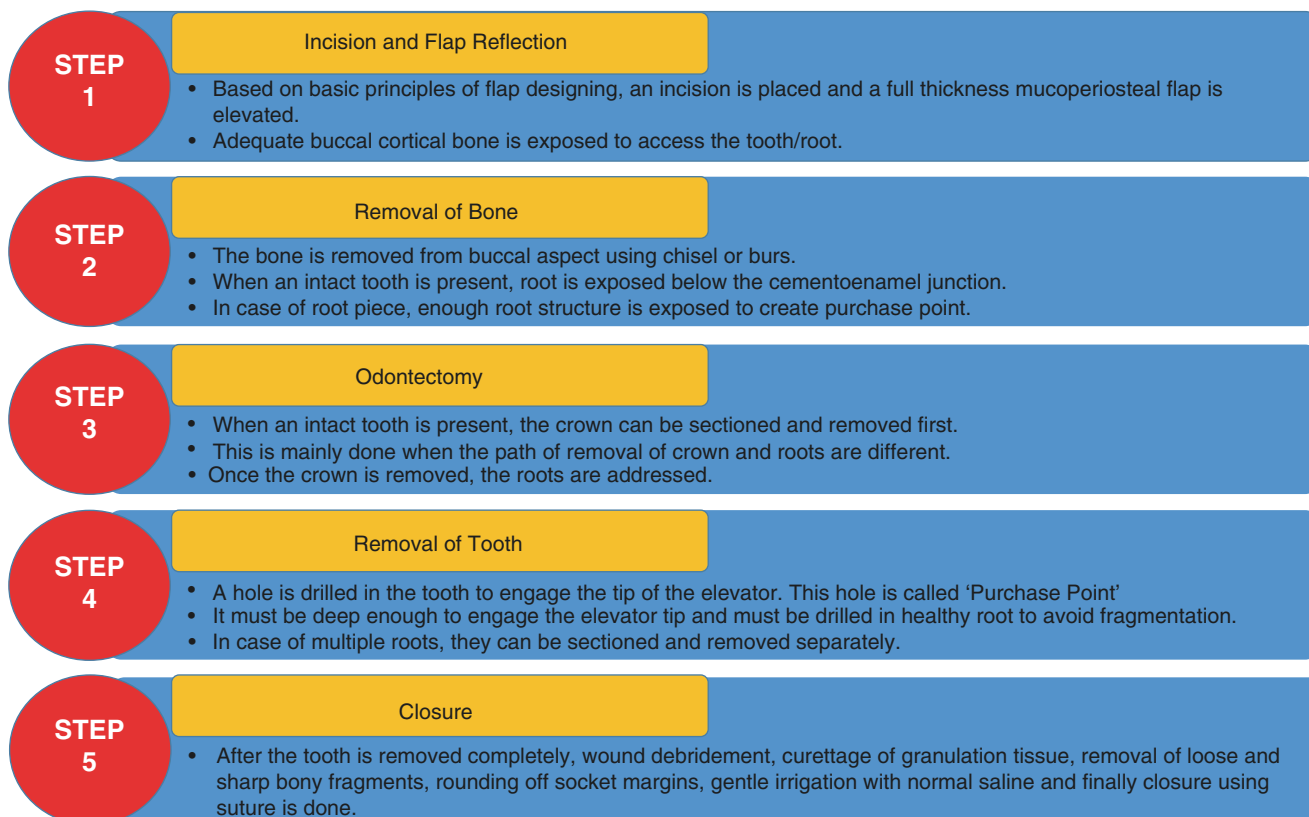
- (a) First option is to reseat the extraction forceps under direct visualization achieving a better mechanical advantage and removing the tooth without removing any bone.
- (b) Second option is to grasp a bit of buccal bone along with the root in order to obtain a better mechanical advantage. In this case, a small amount of buccal bone is pinched off and removed along with the tooth (Fig. 13.26a).
- (c) Third option is to push the tooth out of the socket by inserting a straight elevator into the periodontal ligament space of the tooth. A small to and fro movement should be used to insert the straight elevator as a wedge by expanding the periodontal ligament space to displace the root in an occlusal direction (Fig. 13.26b).
- (d) Fourth option is to remove the bone covering the buccal aspect of root with the help of a bur along with ample irrigation. The width of the bone to be removed must be essentially equal to the mesiodistal width of the root. Also, the amount of bone to be removed in the vertical dimension should be approximately one half or two thirds the length of the root (Fig. 13.26c). Removal of this much amount of bone minimizes the force necessary for the displacement of the root, making the procedure easier. The extraction can be carried out using forceps or elevator.
- (e) In some cases, removal of the root is still difficult even after the removal of bone. In such cases, a purchase point can be made in the most apical position of the exposed root with the help of a round bur. This purchase point must be 3 mm in diameter and deep

Indications of Trans alveolar exodontia

- Teeth with Severely undermined crown
- Fractured teeth
- Endodontically treated teeth
- Root pieces
- Teeth with unfavourable root form like bulbous or dilacerated roots
- Multiple divergent roots
- Ankylosed teeth
- Hypercementosis
- Presence of dense bone
- Malposed tooth
- Impacted tooth
- Tooth in proximity to vital structures
- Long standing tooth with grossly carious crown

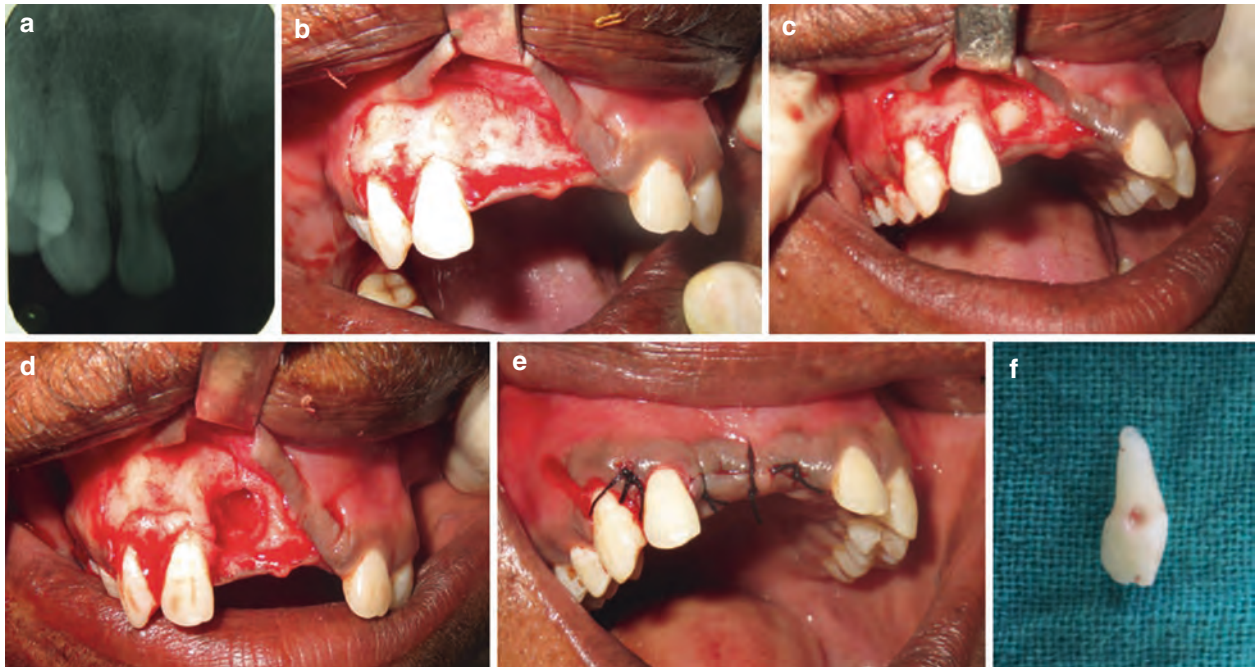
©Association of Oral and Maxillofacial Surgeons of India

Box 13.2 Indications of transalveolar exodontia



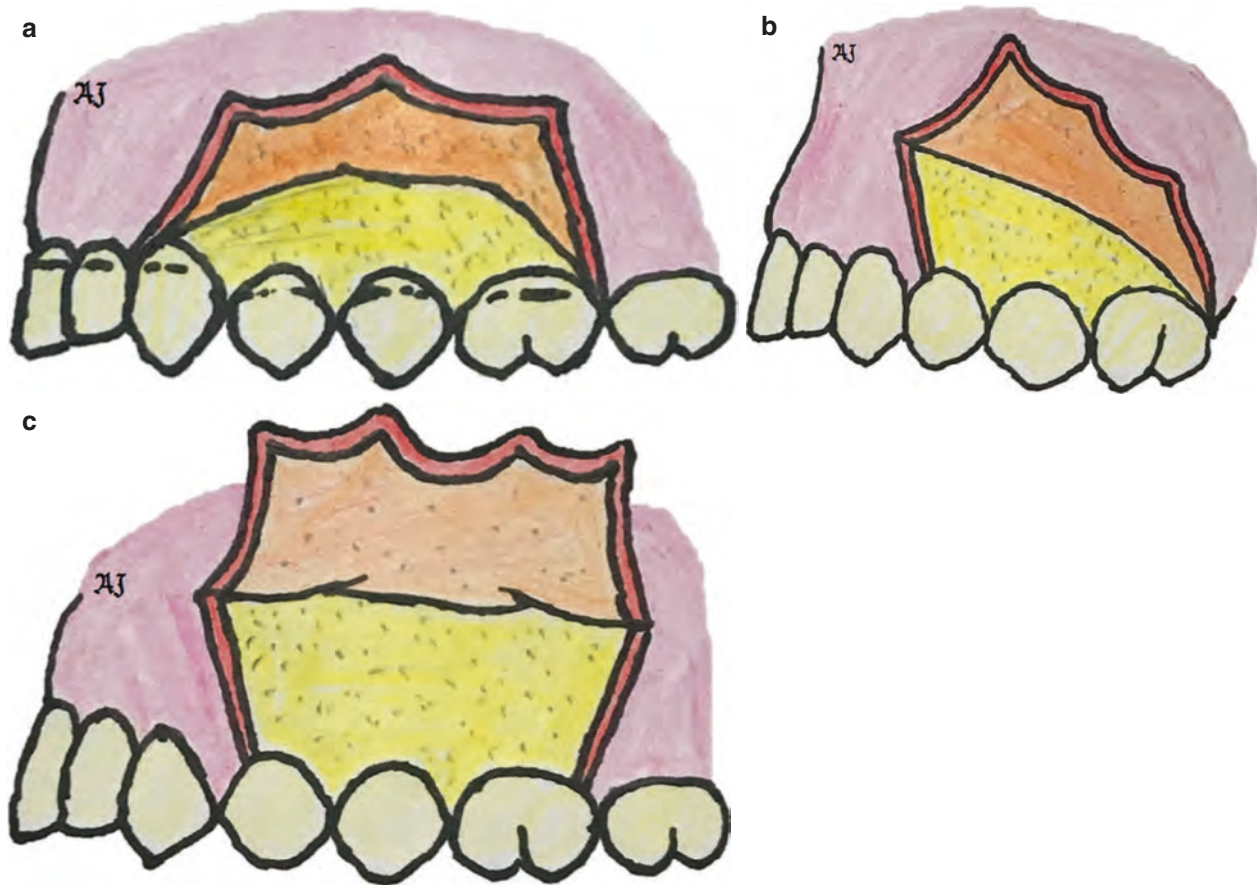
©Association of Oral and Maxillofacial Surgeons of India

Fig. 13.23 Steps for transalveolar exodontia



©Association of Oral and Maxillofacial Surgeons of India

Fig. 13.24 Transalveolar extraction of impacted tooth: (a) IOPA showing impacted tooth, (b) Incision and flap reflection (Triangular flap), (c) Bone removal, (d) Extraction socket (e) Closure, (f) Extracted tooth



©Association of Oral and Maxillofacial Surgeons of India

Fig. 13.25 (a) Envelope flap, (b) Triangular flap, (c) Trapezoidal flap

enough to engage the tip of an instrument to be used for elevation of the tooth.

Once the tooth is delivered, the sharp bony edges must be smoothed using a bone file and the whole surgical site must be thoroughly irrigated using copious amount of sterile saline. The flap must be repositioned and sutured into place.

2. *Complicated exodontia of multirrooted teeth.*

If a treatment plan of complicated exodontia is devised for a multirrooted tooth, it is extracted with the same technique as of single-rooted tooth. The only difference is that the tooth is divided using a bur to convert into two or three single-rooted fragments (odontectomy). Following incision and flap reflection, once the tooth is converted into multiple single-rooted fragments, the extraction procedure is carried out in a similar way as of single-rooted tooth. Also, the immediate postoperative procedures like smoothing of bony fragments, irrigation, and closure also remains the same. The following text describes different techniques of splitting a multirrooted tooth in different scenarios.

(a) Mandibular molar with intact crown: First step involves the exposure of bifurcation by removing a small amount of crestal bone. The tooth is usually sectioned buccolingually to split the tooth into mesial and distal halves (Fig. 13.27a). These halves are then mobilized using a straight elevator and are treated as two single-rooted teeth. These teeth are then extracted with the help of mandibular premolar forceps.

Alternatively, mesial root is sectioned using a bur to convert the molar into single-rooted tooth (Fig. 13.27b). The tooth along with distal root is removed with the help of forceps followed by the removal of mesial root. This mesial root is extracted with the help of a Cryer elevator.

(b) Mandibular molar with lost crown: The roots are separated in a buccolingual direction with the help of a bur in two separate mesial and distal roots (Fig. 13.27c). A small straight elevator is inserted in between the roots and rotated to mobilize the roots and elevate the mesial root. With the help of the Cryer elevator, the mesial root is delivered out of the socket by engaging the tip into the created purchase point and rotating in a wheel-and-axle manner. The distal root is then extracted by inserting the opposite member of the Cryer instrument into the empty socket and rotating again in a wheel-and-axle manner through the interradicular bone.

(c) Maxillary molar with an intact crown: The roots of maxillary molar are three in number and are divergent. Sometimes, an open technique of extraction

causes less morbidity than the closed technique as the extraction of maxillary molar requires excessive force during forceps' extraction. Once the flap is raised, a small amount of crestal bone is removed to expose the trifurcation. With the help of a straight bur, the mesiobuccal and distobuccal roots are sectioned horizontally at the level of trifurcation. This separates the two buccal roots converting the molar into single-rooted tooth (Fig. 13.27d). The molar with palatal root is then extracted using the maxillary molar forceps with gentle but firm bucco-occlusal forces. The two buccal roots are then mobilized with the help of a straight elevator. These roots are then delivered out with the help of a straight or Cryer elevator. The operator must take precaution to maintain controlled force in an apical direction during removal of these roots using the straight elevator as maxillary sinus might be in a close proximity to these roots. Uncontrolled and excessive force may result in an oroantral communication or displacement of the root into the sinus.

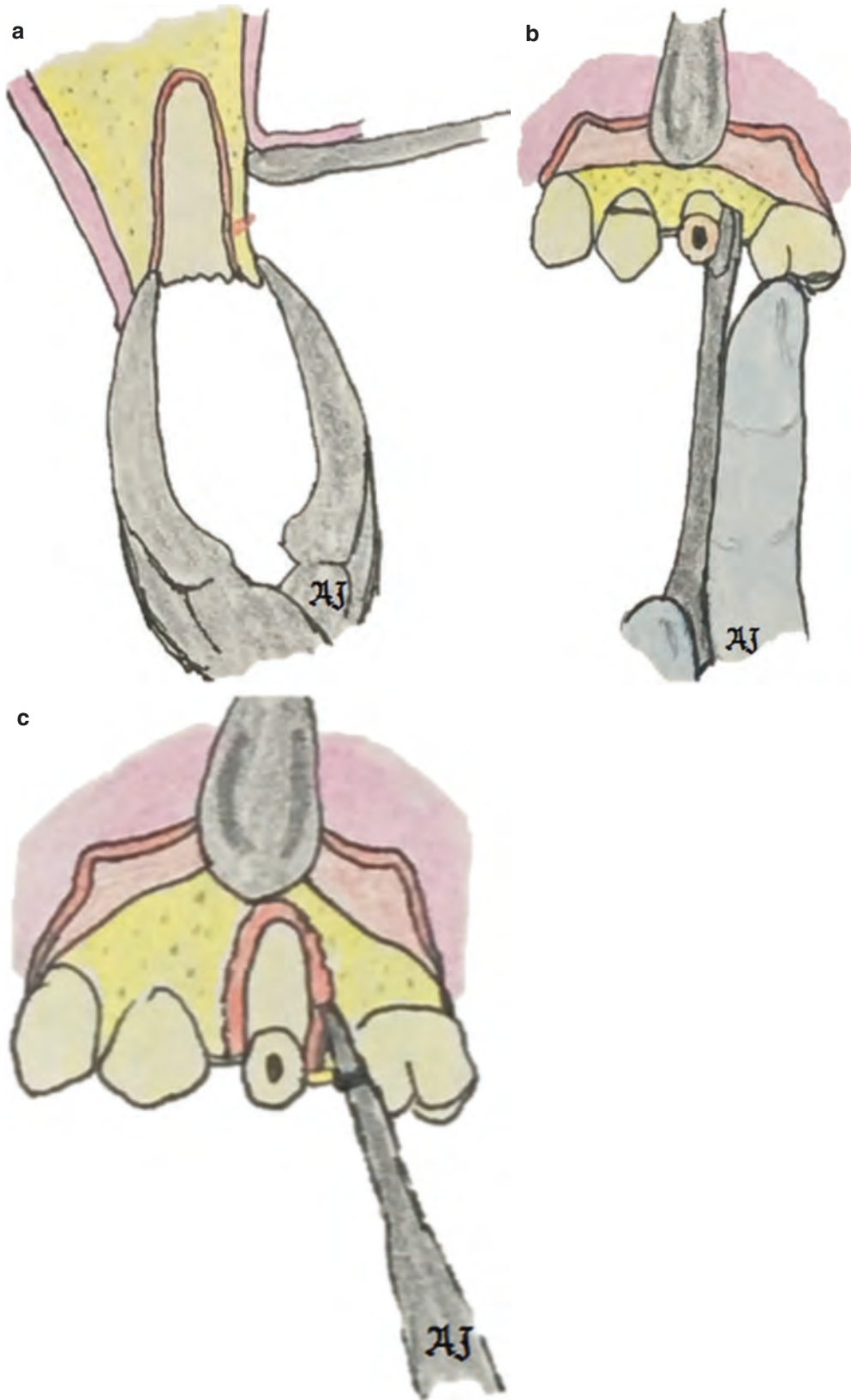
(d) Maxillary molar with lost crown: A small amount of buccal bone is removed to expose the roots and is divided into two buccal and palatal roots (Fig. 13.27e). The roots are mobilized with the help of a straight elevator and are extracted with the help of bayonet forceps or Cryer elevators. Generally, buccal roots are approached first followed by palatal root.

During exodontia, once completed either by closed technique or by open technique, a few important things must be kept in mind which are listed in Box 13.3 and the patient should be instructed properly as listed in Box 13.4. During exodontia, either closed or open, an assistant may be really helpful and plays an important role during the procedure (Box 13.5).

13.10 Multiple Extractions

If multiple adjacent teeth are indicated for extraction, a few key points are to be taken into consideration.

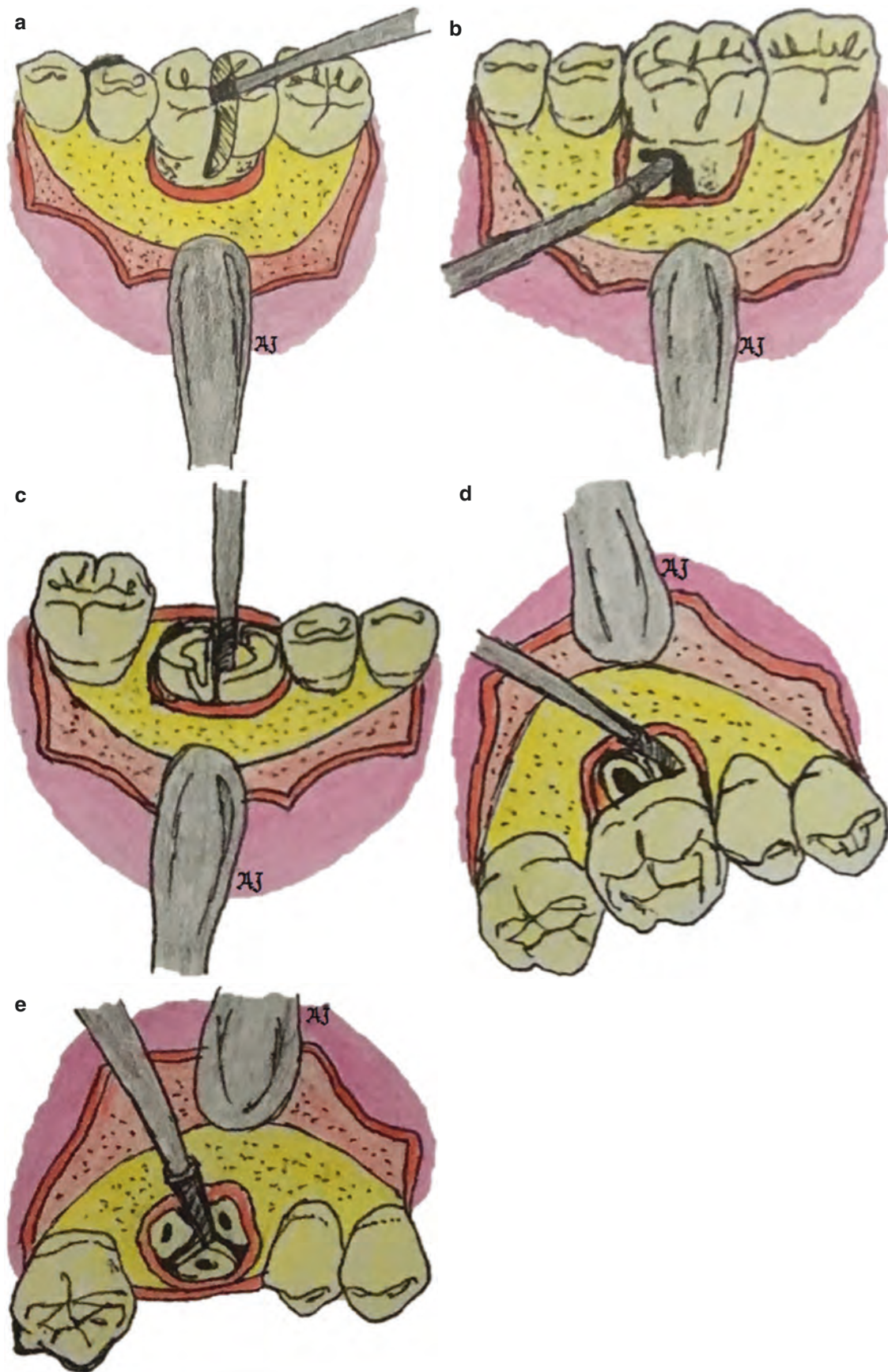
1. Soft tissue must be reflected to expose the crestal bone around all the teeth in the quadrant.
2. If removal of any tooth requires excessive force, a small amount of buccal bone should be removed to prevent fracture and excessive bone loss.
3. All the teeth must be luxated well enough before extraction.



©Association of Oral and Maxillofacial Surgeons of India

Fig. 13.26 (a) A small portion of buccal bone is grasped along with the root in cases when the root is fractured at the level of alveolar bone (Alveolar Purchase Technique), (b) A small straight elevator is being

used to luxate the broken root, (c) Bone is removed from the buccal aspect of the root using a bur



©Association of Oral and Maxillofacial Surgeons of India

Fig. 13.27 (a) Sectioning of tooth into mesial and distal halves, (b) Separation of mesial root from the tooth, (c) Separation of roots of mandibular molar, (d) Buccal roots are sectioned from the tooth, (e) Separation of roots of maxillary molar

Box 13.3 Immediate post-extraction careImmediate Post -extraction Care

- Inspect the tooth and root to ensure complete removal
- Visualize the socket by thoroughly drying the socket and the adjacent field
- Inspect the socket for excessive bleeding which could be due to injured vessel (forceful bleeding) or friable granulation tissue (steadily flowing blood) and curette the socket
- Inspect for foreign bodies like fragments of tooth, calculus tags, granulation tissue, sharp bony fragments and remove using a mosquito artery if present
- Palpate the edges of socket to rule out any sharp bony margins. If present smoothen them using a file
- Compress the expanded socket with digital pressure (simple alveoloplasty). Not recommended if implant is planned
- Application of pressure pack to arrest bleeding using a moistened sterile gauze rolled over cotton wool
- Loose approximating sutures are placed following extraction to stop bleeding and prevent food impaction if required.
- Analgesics can be prescribed to the patients

©Association of Oral and Maxillofacial Surgeons of India

Box 13.4 Postoperative instructionsPost-operative Instructions

- Maintenance of pressure pack for 30 – 60 minutes (Initial clot is soft and friable. Clot retraction takes 30-45 minutes)
- Swallow the saliva and not to spit or rinse till 24 hours post extraction
- Soft and cold diet for 24 hours so as not to disturb the clot and for vasoconstriction
- Warm saline rinses after 24 hours to enhance healing of socket
- Avoid smoking as it may dislodge the clot and lead to bleeding
- No hot fomentation, only cold compressions in the immediate post-operative phase

©Association of Oral and Maxillofacial Surgeons of India

4. Maxillary teeth are extracted first because.
 - (a) Infiltration anesthesia has a more rapid onset in maxilla leading to early start of the procedure.
 - (b) Profound anesthesia is lost early in maxilla.
 - (c) If mandibular teeth are extracted first, debris such as fractured crowns, bone chips, and portions of restorative material may fall in the empty mandibular sockets during extraction of maxillary teeth.
5. Hemostasis must be achieved with maxillary sockets before the extraction of mandibular teeth as the hemorrhage may interfere with mandibular surgery.
6. Extraction should be started with the most posterior teeth as it allows the effective use of dental elevators to luxate and mobilize the teeth.
7. While extracting multiple mandibular anterior teeth, an elevator is inserted between the two adjacent teeth and is rotated. This movement luxates both the teeth simultaneously aiding in the extraction of both the teeth. This technique is known as Stobies technique.
8. Canine is the most difficult tooth to extract, hence it should be extracted last.

Role of Assistant during Exodontia

- Helping surgeon to visualize or gain access to the surgical site
- Suction away blood, saliva and irrigating solutions
- Helps in protecting the teeth of opposite side
- Stabilize the head of the patient
- Support the jaw of the patient
- Psychological and Emotional support for the patient

©Association of Oral and Maxillofacial Surgeons of India

Box 13.5 Role of assistant

9. If maxillary and mandibular teeth of one side are to be extracted in one sitting, the sequence of extraction recommended is: Maxillary Posterior Teeth – Maxillary Anterior Teeth – Maxillary Canine – Mandibular Posterior Teeth – Mandibular Anterior Teeth – Mandibular Canine.
10. Post-extraction, the buccal and lingual plates are repositioned to the original position using digital pressure unless implants are planned.

11. If removable partial or complete dentures are planned, the undercuts and bony spicules must be identified and primary alveoloplasty must be carried out.
12. Soft tissue must be inspected for excessive granulation tissue; if present, it should be removed as it may prolong postoperative hemorrhage.
13. Papillae should be sutured in position. Primary closure must not be performed at the cost of vestibular depth, because if the vestibular depth decreases, it may interfere with denture construction.

13.11 Extraction of Root Fragments and Tips

Ideally, when the apical one-third of the root (3–4 mm) is fractured, it should be removed as it may act as a septic focus or may result in the formation of cyst or other pathologies. To extract these root tips, the two most important requirements are excellent light and excellent suction with a tip of small diameter.

Once the fracture of root tip has been diagnosed, the operator must reposition the patient to achieve proper visualization and suction. Initially, closed technique must be attempted; if unsuccessful, then the open technique must be carried out for retrieval of root tip.

- Initial attempt of root tip removal must be made by vigorous irrigation of the socket using normal saline. Following irrigation and suction, the socket must be inspected properly to check if the root has been removed or not.
- If unsuccessful, the root tip may be teased out of the socket with the help of a root tip elevator (Fig. 13.28a). The blade of the elevator is inserted in the periodontal ligament space and the root is teased out of the socket gently. Root tip elevator is a delicate instrument; hence excessive force must be avoided as it may result in bending or fracture of the blade. For larger fragments, a small straight elevator may also be used.
- If the closed technique is unsuccessful, the operator must shift to an open technique. A full-thickness mucoperiosteal flap is elevated and reflected to expose the buccal bone. The buccal bone is removed using a bur to expose the root fragment. The root is then delivered buccally with the help of an elevator (Fig. 13.28b). The socket is irrigated, flap is repositioned, and closure is performed.
- If the buccal bone has to be preserved, a modification of open technique can be performed. This technique is known as open window technique. In this technique, once the flap is reflected, the apical area of the root fragment is identified and a hole is drilled with the help of a bur. This exposes the root tip. An elevator is inserted through this

hole and the root fragment is guided out of the socket (Fig. 13.28c and d).

However, if the risk during retrieval of root fragment is comparatively more than the benefit of its removal, it is advisable to leave the root in situ. If the surgeon decides to retain the root, it should be documented and informed to the patient. The criteria for retaining the root are highlighted in Box 13.6. The policy of dealing with fractured apical root tips of maxillary molars and the management of root tips displaced into the antrum is elaborated in Chap. 24 of this book.

13.12 Extraction During Menstruation

If permissible, extractions should be avoided during menstruation because during this period there is a high level of estrogen circulating in the blood streams which results in increased tissue bleeding. Menstrual cycle could be a determinant risk factor for alveolar osteitis. Also, both exodontia and menstruation are stressful conditions, it is better not to subject the patient to increased stresses [12].

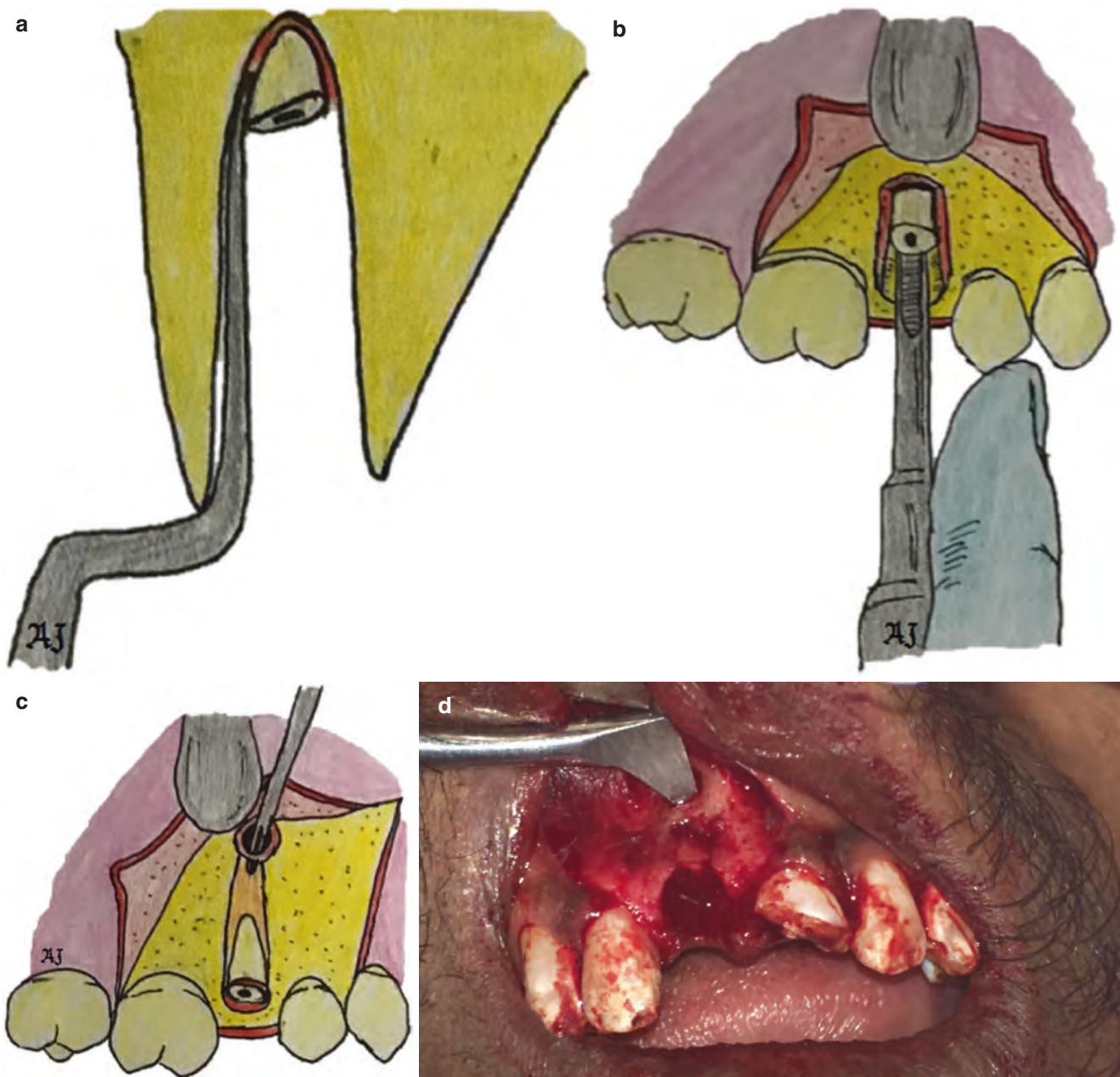
13.13 Extraction During Pregnancy

Pregnancy: Second trimester is considered to be relatively safer for carrying out minor oral surgeries. However, in other trimesters, if the potential risk of retaining the tooth outweighs the complications of performing the surgery, one must plan to carry out extraction with the utmost care and avoiding use of drugs and radiographs as much as possible. Caution should be exercised to evaluate teratogenic potential of drugs when prescriptions are warranted.

During first trimester, the fetus is at risk of developmental defects if the extraction is carried out as it undergoes organogenesis. The best course of action is to prevent the patient from all kinds of infection. During the third trimester, there are chances of premature labor or even an abortion. However, if an exodontia is planned, the patient must be kept in a left lateral position. If the patient is maintained in a supine position, there are chances of obstruction of venous return resulting in supine hypotension syndrome [13, 14].

13.14 Healing of Extraction Socket [15]

Along with understanding the general principles of exodontia, it is pivotal for a dental surgeon to thoroughly know the phenomenon of healing of extraction wounds. An extraction socket heals in a similar fashion as any other wound in the body except for minor variations which occur due to the anatomic structures in and around the socket.



©Association of Oral and Maxillofacial Surgeons of India

Fig. 13.28 (a) The root tip elevator is inserted into the periodontal ligament space to elevate the root tip, (b) Open technique for removal of fractured root fragment, (c) Open Window technique for removal of fractured root fragment, (d) Clinical picture of open window technique

Box 13.6 Criteria for retaining root piece

Criteria for leaving root piece in situ

- If it is small (<2 – 3mm in length)
- If it is deep seated
- If it requires excessive bone removal
- If it is not infected
- If there is no presence of periapical infection
- If it is in close proximity to vital structures which may be injured during retrieval
- If during exploration there are chances of its displacement to adjacent anatomical spaces.

©Association of Oral and Maxillofacial Surgeons of India

Blood present in the socket immediately after extraction of tooth coagulates and red blood cells become entrapped in the fibrin meshwork. This initial time period postextraction is critical because if the clot dislodges, healing becomes delayed and painful. Alterations in the vascular bed such as vasodilatation along with engorgement of blood vessels of periodontal ligament and transport of leukocytes around the clot occur during first 24–48 hours. A thick layer of fibrin covers the clot which shows signs of contractions. This clot forms a scaffold over which cells associated with healing grow.

In the first week following extraction, fibroblasts from remnants of PDL begin to grow in the periphery of clot and a thick layer of leucocytes gather over the clot. Osteoclastic activity starts in the crest of alveolar ridge. Blood clot undergoes organization by fibroblast and endothelial cell proliferation, signaling the growth of small capillaries in the PDL area.

Epithelial proliferation over the surface of the clot increases during the second week of healing leading to a more organized blood clot with new capillaries in the center. Remnants of PDL undergoing degeneration are no longer visible. Margins of alveolar socket appear frayed due to osteoclastic activity. Surfaces of small wounds epithelize completely by this time.

By the third week, fibrin meshwork of the original clot is replaced by mature granulation tissue. Young trabeculae formed by osteoblasts derived from pluripotent cells of PDL form around the periphery of wound. Crest of alveolar bone appears rounded due to resorption. All kinds of wound epithelize by this stage of healing.

Wound enters the final stage of healing in the fourth week. There is deposition and resorption of bone of alveolar socket which continues for several weeks. Newly formed bone is poorly calcified; therefore, the bone after extraction becomes radiographically evident only after 6–8 weeks. Loss of crestal and buccal bone during transalveolar extractions leads to smaller alveolar ridges post healing.

13.15 Complications of Exodontia [10]

Surgical procedures are associated with complications and exodontia is no different. Various complications related to exodontia are highlighted in Table 13.10.

Modalities to manage hemorrhage are as follows:

- Pressure packing.
- Injecting local anesthetic solution containing vasoconstrictor.
- Curettage of granulation tissue.
- Suturing.
- Use of resorbable oxidized cellulose (Surgicel) or gelatin foam (Gelfoam).
- Mechanical obstruction using bone wax.

- Tying or coagulation of visible blood vessel.

Displacement of tooth in Antrum: Operator must be careful while extracting maxillary molars to avoid displacement of tooth/root into maxillary antrum. Excessive and uncontrolled force in the apical direction may lead to displacement of tooth/root in the maxillary sinus. If displaced, it can be retrieved by carrying out sinus exploration [16].

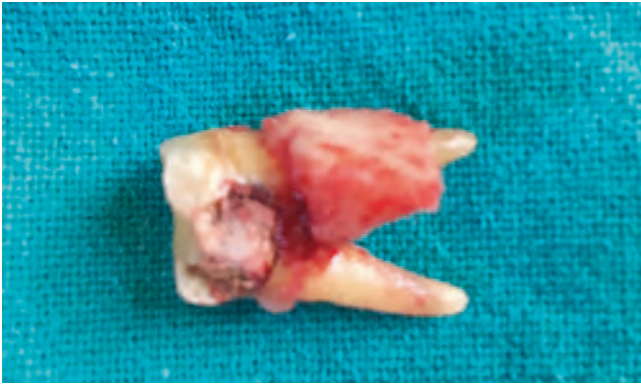Displacement into adjacent spaces: Tooth/root might get displaced into adjacent anatomic spaces. If it happens, retrieval must be attempted. However, delayed retrieval can also be done as foreign body reaction aids in localization of the tooth/root [17].

Loss of tooth in pharynx: During exodontia, if the tooth is lost in pharynx, one must get a chest radiograph done to rule out aspiration. If the tooth is aspirated, bronchoscopy has to be done for retrieval of tooth [18].

Injury to Temporomandibular Joint: It is mainly due to the application of excessive forces while extracting mandibular teeth and failure to support mandible. It can be avoided by using mouth gags and supporting mandible properly. Unsupported mandible may lead to dislocation of temporomandibular joint. If occurred, it must be reduced immediately by mechanical reduction.

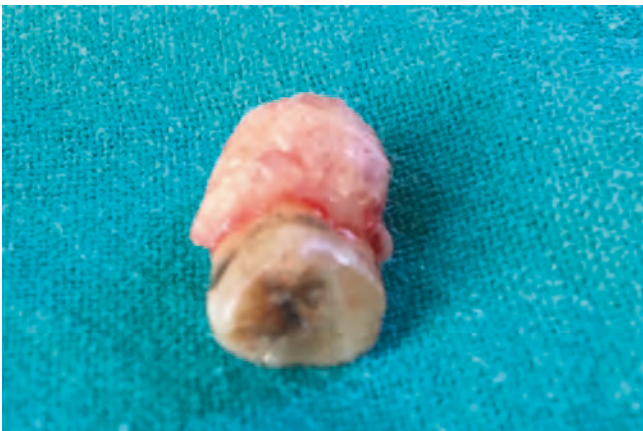Table 13.10 Complications of exodontia

Complications
1. General complications
(a) Postoperative pain
(b) Hemorrhage
2. Problems with tooth being extracted
(a) Root fracture
(b) Root displacement in adjacent spaces or antrum
(c) Loss of tooth in pharynx
3. Injury to adjacent teeth
(a) Fracture or dislodgement of adjacent tooth restoration
(b) Luxation of adjacent tooth
(c) Extraction of wrong tooth
4. Injury to soft tissue
(a) Abrasion
(b) Puncture wound
(c) Tear of mucosal flap
5. Injury to osseous structure
(a) Fracture of alveolar process (Fig. 13.29)
(b) Fracture of maxillary tuberosity (Fig. 13.30)
6. Injury to adjacent structures
(a) Injury to regional nerves
(b) Injury to regional vessels
(c) Injury to Temporomandibular joint
7. Oroantral communication and fistula
8. Fracture of mandible
9. Delayed healing and infection
(a) Infection
(b) Wound dehiscence
(c) Dry socket (Fig. 13.31)
(d) Osteomyelitis



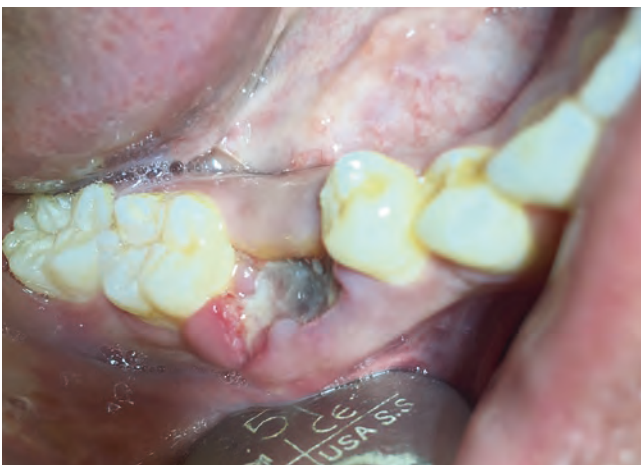©Association of Oral and Maxillofacial Surgeons of India

Fig. 13.29 Fractured alveolar process



©Association of Oral and Maxillofacial Surgeons of India

Fig. 13.30 Fractured maxillary tuberosity



©Association of Oral and Maxillofacial Surgeons of India

Fig. 13.31 Dry socket

Hemorrhage: It is classified as

1. Primary hemorrhage: bleeding at the time of surgery.
2. Reactionary hemorrhage: it is seen a few hours after surgery due to cessation of vasoconstriction of damaged blood vessels.
3. Secondary hemorrhage: evident up to 14 days post-operatively due to infection.

Mechanical reduction is done by an operator standing in front of the patient and holding the mandible with both hands. The thumbs should be placed over the external oblique ridge/molars and the fingers holding the lower border of mandible. Once held firmly, mandible should be moved in inferior, posterior, and superior directions in a sequential manner [6].

Oroantral Communication and Fistula: Oroantral communication (OAC) is a pathologic communication between oral cavity and maxillary antrum; however, once epithelized, it is termed as oroantral fistula (OAF). OAC must be closed immediately if it is larger than 5 mm. In cases of OAF, fistulectomy followed by closure is the treatment of choice [19].

Refer the Chap. 24 on oroantral communication and fistula for further reading.

Dry Socket: Dry socket or alveolar osteitis denotes delayed healing with moderate to severe pain. Birn's, hypothesis is the most accepted explanation of dry socket. It states that trauma and inflammation cause release of stable tissue activator from adjacent bony socket and soft tissue. Tissue activator converts plasminogen to plasmin which causes lysis of blood clot and pain. Management of dry socket involves relief of pain and ameliorating healing. A loose dressing composed of zinc oxide and oil of cloves on cotton wool is tucked into socket. Analgesic tablets and warm saline rinses are prescribed and patient is kept on regular follow-up [20, 21].

Osteomyelitis: It is 'an infection of the bone and the bone marrow which can be caused by an infection in the body spreading in the blood stream from point of origin to the bone'. Appropriate antibiotics for an extended period of time is the line of treatment. In chronic cases, surgical debridement becomes mandatory [22, 23].

13.16 Technological Advances in Exodontia Techniques [24]

Evolution never stops, this can be prominently justified by the fact that a variety of new techniques and instruments have been introduced to revolutionize the field of oral and

maxillofacial surgery. Some of the technological advancements for dental extraction are highlighted here.

13.16.1 Powered Periosteal Elevator

It is an electric unit which contains a controller box with adjustable power settings and a periosteal elevator mounted on a handpiece that is activated by a foot control. Use of standard periosteal elevator is cumbersome as the force delivered is uncontrolled; however, this powered periosteal elevator is characterized by complete control over the force delivery and the depth to which it travels into the periodontal ligament space.

This device functions by wedging and severing mechanisms. The thin metal blade of periosteal elevator is wedged into the periodontal ligament space in a circumferential manner severing the Sharpey's fibers. Once most of the Sharpey's fibers are severed, tooth can be extracted with minimal lateral movement. Hence, it allows flapless removal of tooth maintaining the periosteal blood supply with reduced risk of fracture of buccal or lingual cortical plate and decreased postoperative pain and discomfort.

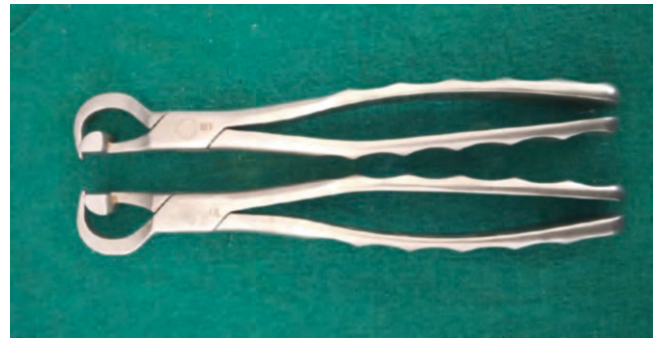
13.16.2 Physics Forceps (Fig. 13.32)

Golden-Misch [25, 26] based on Class I lever mechanics designed the Physics Forceps to perform exodontia atraumatically. These forceps have a bumper which acts as a fulcrum, is placed at the mucogingival junction on the facial aspect applying steady, unrelenting pressure. Other than the bumper, there is a lingual beak, which is positioned on lingual or palatal root, making a single point contact with the tooth.

Due to the pressure applied by the bumper, periodontal ligament is traumatized resulting in the release of hyaluronidase. Once the enough chemical breakdown of periodontal ligament is achieved by the hyaluronidase, the tooth is released from its attachment to the alveolus aiding in easy removal. Physics forceps releases more hyaluronidase than conventional forceps in a shorter period of time, resulting in more efficient extraction of tooth with minimal trauma to the alveolar bone.

13.16.3 Use of Implant Drills for Extraction Prior to Implant Placement

Yalcin and colleagues [27] suggested a novel and minimally invasive technique to perform exodontia with minimal risk of damaging the thin buccal bone. The implant's drills were inserted into the root canals making the roots walls thin leading to extraction with application of much less force.



©Association of Oral and Maxillofacial Surgeons of India

Fig. 13.32 Physics forceps

13.16.4 Use of LASER

Laser offers a noncontact and low vibration bone cutting without any visible, negative, and thermal side effects. Er:YAG laser can be used for surgical extractions to ablate the covering bone layer by layer exposing the portion of the root. Once the tooth/root is uncovered, they can be conventionally removed [28]. However, laser osteotomies are time consuming and require constant suctioning to achieve a dry field for effective cutting.

13.16.5 Piezo Surgery

Piezo surgery is very effective in bone cutting as it works selectively without injuring any soft tissue structure. Hence, it is very advantageous over the conventional burs which have potential to cause injury to soft tissue. Also, a clearer field is obtained while using piezo surgery. However, the time required while using piezo surgery is more [29].

13.17 CASE Scenario

CASE 1 [18, 30]

Patient is subjected to an extraction of a tooth and during the procedure, the extracted tooth is lost leaving an empty alveolar socket. The tooth is nowhere to be seen in the oral cavity neither it could be found in the surrounding area.

Possibilities:

1. Aspiration of the tooth.
2. Ingestion of the tooth.

Clinical Features:

- *Aspiration.*

Signs and symptom of aspiration depends on the site where the tooth is present. A laryngotracheal obstruction

presents with dyspnea, cough, and stridor. It also results in difficulty in breathing with or without cyanosis. Chocking is also characterized by the sign of hands clutched to the throat, depending on whether the chocking is partial or complete. However, tooth in bronchus is associated with cough, diminished airway entry, dyspnea, and wheezing. Sometimes, the patient may remain asymptomatic for several months if the aspirated tooth is very small. However, long-term retention may result in late complications including postobstructive pneumonia, atelectasis, bronchiectasis, pneumothorax, hemorrhage, lung abscess, vocal cord paralysis, and death.

- **Ingestion.**

Generally, the passage of ingested tooth through the gastrointestinal tract is uneventful. In cases of obstruction, the most frequently noticed symptoms are dysphagia and odynophagia. Esophageal obstruction presents with gagging, coughing, chest pain, drooling of saliva, nausea, hematemesis, regurgitation, muscular incoordination, and incessant twitching. Abdominal pain is one of the symptoms other than fever, nausea, vomiting, and abdominal distensions in cases of abdominal impactions.

Management:

- Patient must be kept in a Reverse Trendelenburg position.
- If the patient has visible Airway Obstruction, he must be asked to cough and Heimlich maneuver must be attempted to relieve obstruction.
- If the object is dislodged, it should be identified and confirmed. If not, then cricothyroidectomy must be done to secure airway. If not possible in the clinic, then the patient must be rushed to the emergency unit for securing airway.
- In cases with no airway obstruction, the entire oral cavity must be examined. If the object is found, it should be identified and confirmed.
- If the object is not found in the oral cavity, the patient must be subjected to Chest radiography and Ultrasonography Abdomen.
- For radiolucent objects, bronchoscopy and Computed Tomography of Chest and Abdomen are preferred.
- If the object is in respiratory tract, bronchoscopy must be planned for retrieval.
- If the object is in Esophagus, Endoscopic removal must be done.
- If the object is in Gastrointestinal tract (GIT), beyond esophagus, patient must be monitored for 2 weeks with serial radiographs. Stool examination must be done till the object is expelled.
- If the object is retrieved, identify and confirm.
- If the object is not retrieved, radiographic examination must be repeated.

- Radiographic examination reveals the absence of object in GIT, it should be assumed that the object has passed out. The patient must be reassured, however, must be kept on follow-up.
- If the radiographic examination reveals the presence of object in GIT, the patient must be referred to a gastroenterologist for removal either by surgery or by endoscopy.
- During the whole process, the patient must be reassured time and again.

CASE 2 [31]

A 33 year-old male reported with a chief complaint of a firm, diffuse swelling of size approximately 2 × 1 cm in left mandibular body region with occasional pus discharge from the extraoral skin fistula (Fig. 13.33a). He also complained of associated intermittent pain and fever.

History

On further questioning, he revealed that he had visited a private clinic 6 months back for the complaint of dental caries. Following clinical and radiographic examination, the dentist had planned to extract the tooth. To the patient's knowledge, the extraction was done uneventfully, but one root was lost during the procedure. Patient was prescribed with antibiotics and analgesics for a period of 5 days. The patient became apprehensive and uneasy in the following days. The fear of further complications kept him from visiting the dentist again and the condition went on worsening. Finally, after 6 months, he reported to an oral and maxillofacial surgeon.

Investigations

An orthopantomogram was taken which revealed a displaced root fragment in left first molar region. (Fig. 13.33b).

Diagnosis

Displacement of Mandibular molar root in buccal space.

Management

After obtaining patient's consent, under antibiotic coverage and local anesthesia, surgical exploration was done through the existing skin fistula extraorally. With the digital pressure, the root piece was delivered out (Fig. 13.33c). Curettage and debridement was done carefully and patient was kept on follow-up. Closure was not performed. Antibiotics, analgesic, and nonsteroidal anti-inflammatory drugs were prescribed postoperatively. Patient recovered without further incident. In the late period of follow-up, no complication was observed except extraoral scarring.

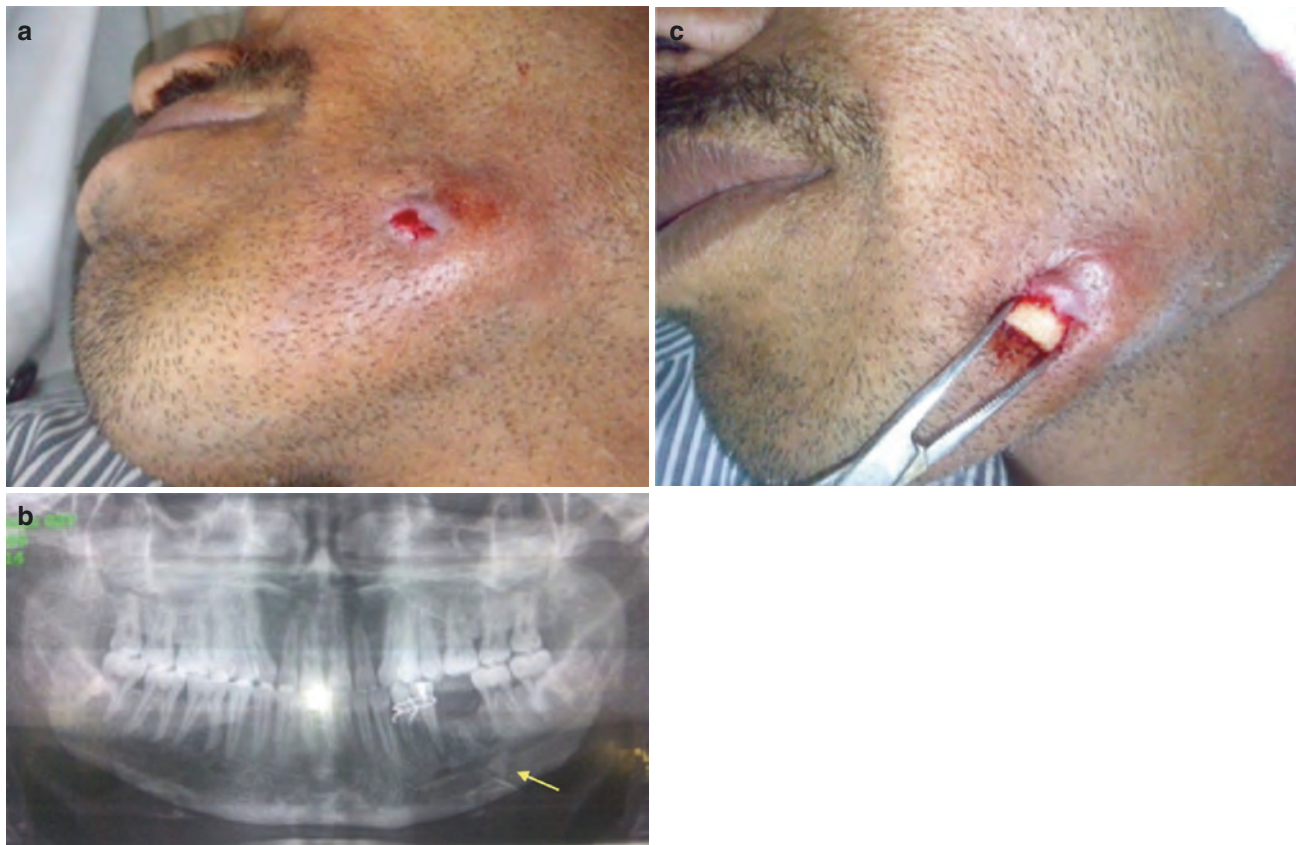

Fig. 13.33 (a) Patient with extraoral swelling and skin fistula. (b) Orthopantomogram showing displacement of left first mandibular molar root into adjacent space. (c) Retrieval of root from buccal space

References

1. Howe GL. The extraction of teeth. 2nd ed. Bristol: J Wright; 1974.
2. Bennion E. Antique dental instruments. London: Sotheby's Philip Wilson Publishers; 1986.
3. Kumar A. Dentistry in historical perspective. *IJO CR*. 2013;1(2): 51–4.
4. Ring ME. Dentistry: An illustrated history. New York/St Louis, Toronto: Harry N Abrams/The CV Mosby Company; 1992.
5. Atkinson HF. Some early dental extraction instruments including the pelican, bird or axe? *Aust Dent J*. 2002;47(2):90–3.
6. Borle RM. Textbook of oral and maxillofacial surgery. 1st ed. New Delhi: Jaypee Brothers Medical Publishers; 2014.
7. Teja MV, Teja TS, Shetty S, Kashyap R. The rise of Indian orthodontics: a historical perspective. *J Ind Orthod Soc*. 2013;47(3):113–20.
8. Koga DH, Salvajoli JV, Alves FA. Dental extractions and radiotherapy in head and neck oncology: review of the literature. *Oral Dis*. 2008 Jan;14(1):40–4.
9. Johri A, Piecuch JF. Should teeth be extracted immediately in the presence of acute infection? *Oral Maxillofac Surg Clin North Am*. 2011 Nov;23(4):507–11.
10. Hupp J, Ellis E III, Tucker M. Contemporary oral and maxillofacial surgery. 6th ed. London: Elsevier, RELX; 2017.
11. Moore UJ. Principles of oral and maxillofacial surgery. 6th ed. Hoboken: Blackwell Science; 2011.
12. Eshghpour M, Rezaei NM, Nejat A. Effect of menstrual cycle on frequency of alveolar osteitis in women undergoing surgical removal of mandibular third molar: a single-blind randomized clinical trial. *J Oral Maxillofac Surg*. 2013 Sep;71(9):1484–9.
13. Beard RW, Roberts GM. Supine hypotension syndrome. *Br Med J*. 1970 May 2;2(5704):297.
14. Steinberg BJ, Hilton IV, Iida H, Samelson R. Oral health and dental care during pregnancy. *Dent Clin N Am*. 2013 Apr;57(2):195–210.
15. Farina R, Trombelli L. Wound healing of extraction sockets. *Endod Top*. 2012;25:16–43.
16. Fickling BW. Oral surgery involving the maxillary sinus. *Ann R Coll Surg Engl*. 1957 Jan;20(1):13–35.
17. Huang IY, Wu CW, Worthington P. The displaced lower third molar: a literature review and suggestions for management. *J Oral Maxillofac Surg*. 2007 Jun;65(6):1186–90.
18. Elgazzar RF, Abdelhady AI, Sadakah AA. Aspiration of an impacted lower third molar during its surgical removal under local anaesthesia. *Int J Oral Maxillofac Surg*. 2007;36:362–4.
19. Dym H, Wolf JC. Oroantral communication. *Oral Maxillofac Surg Clin North Am*. 2012 May;24(2):239–47.
20. Tarakji B, Saleh LA, Umair A, Azzeghaiby SN, Hanouneh S. Systemic review of dry socket: aetiology, treatment, and prevention. *J Clin Diagn Res*. 2015 Apr;9(4):ZE10–3.
21. Houston JP, McCollum J, Pietz D, Schneck D. Alveolar osteitis: a review of its etiology, prevention, and treatment modalities. *Gen Dent*. 2002 Sep–Oct;50(5):457–463. quiz 464–5.
22. Lorè B, Gargari M, Ventucci E, Cagioli A, Nicolai G, Calabrese L. A complication following tooth extraction: chronic suppurative osteomyelitis. *Oral Implantol (Rome)*. 2013 Oct 15;6(2):43–7.

23. González-Navarro B, Arranz-Obispo C, Albuquerque R, Jané-Salas E, López-López J. Osteomyelitis of the jaw (with pathological fracture) following extraction of an impacted wisdom tooth. A case report. *J Stomatol Oral Maxillofac Surg.* 2017 Oct;118(5):306–9.
24. Weiss A, Stern A, Dym H. Technological advances in extraction techniques and outpatient oral surgery. *Dent Clin N Am.* 2011 Jul;55(3):501–13.
25. Golden RM, inventor; GoldenMisch Inc, assignee. Dental plier design with offset-ting jaw and pad elements for assisting in removing upper and lower teeth utilizing the dental plier design. US patent 6,910,890. June 28, 2005.
26. Misch C, Perez H. Atraumatic extractions: a biomechanical route. *Dent Today.* 2008;27:8.
27. Yalcin S, Aktas I, Emes Y, et al. A technique for atraumatic extraction of teeth before immediate implant placement. *Implant Dent.* 2009;18:6.
28. Giovannacci I, Giunta G, Pedrazzi G, Meleti M, Manfredi M, Migliario M, Bruccoli M, Greco Lucchina A, Mortellaro C, Vescovi P. Erbium yttrium-aluminum-garnet laser versus traditional bur in the extraction of impacted mandibular third molars: analysis of intra- and postoperative differences. *J Craniofac Surg.* 2018 Nov;29(8):2282–6.
29. Badenoch-Jones EK, David M, Lincoln T. Piezoelectric compared with conventional rotary osteotomy for the prevention of postoperative sequelae and complications after surgical extraction of mandibular third molars: a systematic review and meta-analysis. *Br J Oral Maxillofac Surg.* 2016 Dec;54(10):1066–79.
30. Yadav RK, Yadav HK, Chandra A, Yadav S, Verma P, Shakya VK. Accidental aspiration/ingestion of foreign bodies in dentistry: a clinical and legal perspective. *Natl J Maxillofac Surg.* 2015;6:144–5.
31. Jain A. Accidental displacement of mandibular first molar root into buccal space: a unique case. *J Stomatol Oral Maxillofac Surg.* 2018;119(5):429–31.

Articles for Additional Reading

- Dym H, Weiss A. Exodontia: tips and techniques for better outcomes. *Dent Clin North Am.* 2012;56(1):245–66.
- Araújo MG, Silva CO, Misawa M, Sukekava F. Alveolar socket healing: what can we learn? *Periodontol* 2000. 2015;68(1):122–34.
- Nayyar J, Clarke M, O’ Sullivan M, Stassen LF. Fractured root tips during dental extractions and retained root fragments. A clinical dilemma? *Br Dent J.* 2015;218(5):285–90.
- Lodi G, Figini L, Sardella A, Carrassi A, Del Fabbro M, Furness S. Antibiotics to prevent complications following tooth extractions. *Cochrane Database Syst Rev.* 2012;11:CD003811.

Open Access This chapter is licensed under the terms of the Creative Commons Attribution 4.0 International License (<http://creativecommons.org/licenses/by/4.0/>), which permits use, sharing, adaptation, distribution and reproduction in any medium or format, as long as you give appropriate credit to the original author(s) and the source, provide a link to the Creative Commons license and indicate if changes were made.

The images or other third party material in this chapter are included in the chapter's Creative Commons license, unless indicated otherwise in a credit line to the material. If material is not included in the chapter's Creative Commons license and your intended use is not permitted by statutory regulation or exceeds the permitted use, you will need to obtain permission directly from the copyright holder.





George Varghese

14.1 Introduction

Even as the scope of practicing oral and maxillofacial surgery grows and continues to evolve, the mainstay of practice remains dentoalveolar surgery. In this area, the surgical removal of impacted teeth is one of the commonest procedures that is performed. Among the teeth that are commonly impacted, the mandibular molars rank first, followed by the maxillary third molars and the maxillary canines. Less commonly, impaction of other teeth such as the mandibular canines, maxillary and mandibular premolars, and the second molars are also seen.

14.1.1 Terminology

The term impaction comes from the term “impactus,” which is of Latin origin. Its general usage refers to the failure of an organ or structure in achieving its normal position because of an abnormal mechanical condition.

Archer [1] defined impacted tooth as a tooth that is partially or completely unerupted and is positioned against another tooth or bone or soft tissue so that its further eruption is unlikely.

Lytle [2] proposed a definition that is intimately related to that of Archer. An impacted tooth is a tooth that has failed to erupt into its normal functional position beyond the time usually expected for such appearance. Eruption may have been prevented by adjacent hard or soft tissue including tooth, bone, or dense soft tissue.

Electronic Supplementary Material The online version of this chapter (https://doi.org/10.1007/978-981-15-1346-6_14) contains supplementary material, which is available to authorized users.

G. Varghese (✉)
Principal, Professor and Head, Department of Oral and Maxillofacial Surgery, Pushpagiri College of Dental Sciences, Tiruvalla, Kerala, India

Andreasen et al. [3] defined impaction as a cessation of the eruption of a tooth caused by a clinically or radiographically detectable physical impediment in the eruption path or by an ectopic position of the tooth.

- An *unerupted tooth* is the one lying within the jaws, entirely covered by soft tissue, and partially or completely covered by bone. This tooth is undergoing the eruption process and will probably erupt into occlusion based on clinical and radiographic findings.
- A *partially erupted tooth* is one that has failed to erupt fully into a normal position. The term implies that the tooth is partly visible or in communication with the oral cavity.
- An *impacted tooth* is a tooth which is prevented from completely erupting into a normal functional position. The reason may be due to lack of space, obstruction by another tooth, or an abnormal eruption path.

14.1.2 Incidence of Impaction

Archer observed that the following types of teeth, in order of frequency, are most likely to be impacted:

maxillary third molars,
mandibular third molars,
maxillary cuspids,
mandibular bicuspid,
mandibular cuspids,
maxillary bicuspid,
maxillary central incisors,
maxillary lateral incisors.

14.2 Management Techniques for the Impacted Tooth

Although the standard management strategy is usually considered to be surgical removal of the impacted tooth, the following methods listed below also should be considered depending upon the case:

1. Conservative method—Leaving the tooth alone with regular follow-up clinically and radiographically. For instance, a deeply asymptomatic third molar may be left as such especially in an older age group patient.
2. Operculectomy—This procedure can be considered in a mandibular third molar that has partially erupted, and has sufficient space to come into occlusion, but is prevented from doing so by thick overlying mucoperiosteum. If the tooth still fails to erupt fully, it has to be considered for removal.
3. Autogenous transplantation—Occasionally, the third molars can be considered for autogenous transplantation, usually to a first molar socket site. Because of the low success rate with such procedures, it is not widely used except in special circumstances.
4. Orthodontically guided eruption—This is usually suited to impacted maxillary and mandibular canine teeth. Orthodontic guidance enables the tooth to reach a functional position within the arch. This technique can also be applied to impacted premolars and, in some instances, even impacted mandibular molars.
5. Procedures that activate eruption—When indicated, these are usually applied to developing teeth.

14.2.1 Controversies on Prophylactic Removal of Third Molars

The benefits of prophylactic surgical removal of impacted third molars that are disease-free is quite controversial [4–6]. There are opinions that retaining the teeth may be more cost-effective than prophylactic removal, at least in the short to medium term. Nevertheless, there may still be clinical situations that demand prophylactic surgery. Each clinical scenario needs an individualized evaluation and the consequences of all management techniques must be discussed with the patient. Thomas Dodson in [4] brought out a classification based upon the presence/absence of symptoms and the presence/absence of disease. He proposed to use this method to decide on the removal vs retention of third molars.

14.3 Etiology of Impaction

Generally, the third molars or the wisdom teeth are the last teeth to erupt and they erupt between 18 and 25 years of age. Since they erupt at about the time when the youth goes off

into the world to become “wise,” the name “wisdom teeth” was used.

A number of theories have been put forth to explain the phenomenon of impaction. The following are the most commonly accepted ones:-

1. Discrepancy between the tooth size and the arch length.
2. Differential growth pattern of the mesial and distal roots.
3. Delayed maturation of the third molar—dental development of the tooth lags behind the skeletal growth and maturation.
4. Incidence of extraction of permanent molars is decreased in the mixed dentition period, providing less room for eruption of third molars. This is very pertinent in the present day due to better awareness of the population and dental treatments are started early in childhood.
5. Inadequate development of jawbones due to consumption of more refined food which causes reduced functional stimulation for the growth of jaw bone.
6. Evolution theory.

Berger [7] listed the following local causes for impaction of teeth:

1. Irregularity in the position and pressure of an adjacent tooth.
2. The increased density of the overlying or surrounding bone.
3. Continued chronic inflammation with subsequent increase in density of the overlying mucous membrane.
4. Lack of space due to underdeveloped jaws.
5. Prolonged retention of the primary tooth.
6. Early loss of primary tooth.
7. Acquired diseases such as necrosis due to infection or abscess.

Impaction may also be found with no local predisposing conditions cited above.

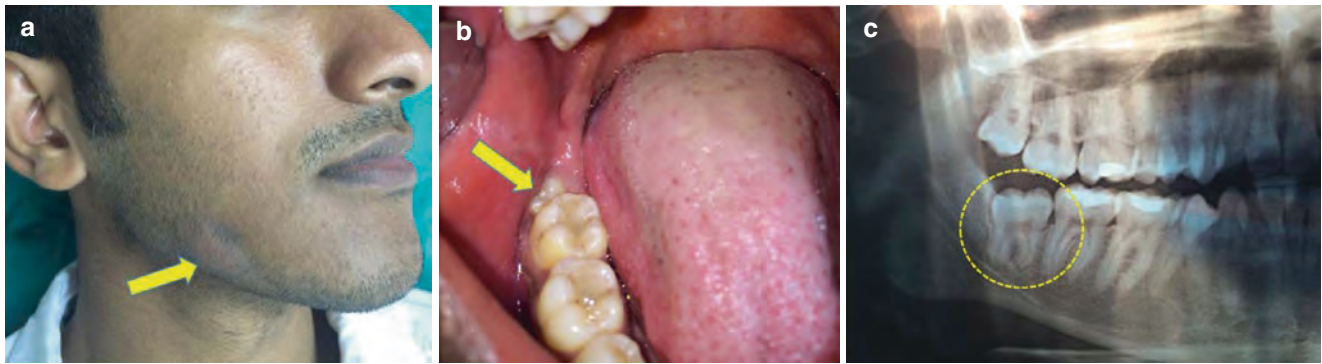
According to Berger, the following are the systemic causes of impaction:

- (a) Prenatal causes—Hereditary and miscegenation.
- (b) Postnatal causes—Rickets, anemia, congenital syphilis, tuberculosis, endocrine dysfunction, and malnutrition.
- (c) Rare conditions—Cleidocranial dysostosis, oxycephaly, progeria, achondroplasia, and cleft palate.

14.4 Indications for Removal

Despite the fact not all unerupted/impacted teeth cause problems, all have that potential. Based on extensive clinical studies, indications for removal have been identified.

1. *Pericoronitis and Pericoronal abscess* (Fig. 14.1a, b, c)—This is the most common cause for extraction of mandibular third molars (25–30%). Pericoronitis is frequently found to be associated with distoangular and



©Association of Oral and Maxillofacial Surgeons of India

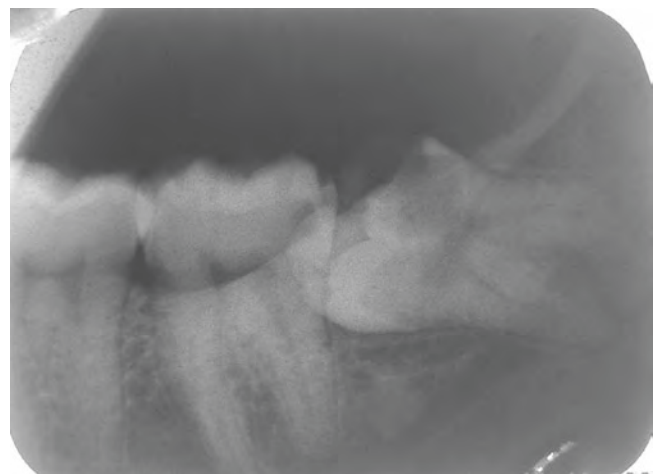
Fig. 14.1 (a, b, c) Impacted right mandibular third molar with pericoronitis causing extraoral abscess (a) Extraoral abscess (Yellow arrow), (b) Impacted 48 with pericoronitis (yellow arrow), (c) OPG showing impacted 48 (Yellow circle)

vertical impaction. If treated inadequately, the infection may extend posteriorly resulting in submasseteric abscess.

2. *Dental Caries*—Incidence of caries of the second molar or third molar is about 15%. The reason for this high incidence is attributed to difficulty to perform oral hygiene measures in the third molar area (Fig. 14.2).
3. *Periodontal diseases*—Repeated food impaction and collection of food debris between the impacted third molar and the erupted second molar can lead to periodontal disease and subsequent bone loss. This weakens the bone support for the second molar and can cause pulpo-periodontal disease in the second molar (Fig. 14.3).
4. *Orthodontic reasons*

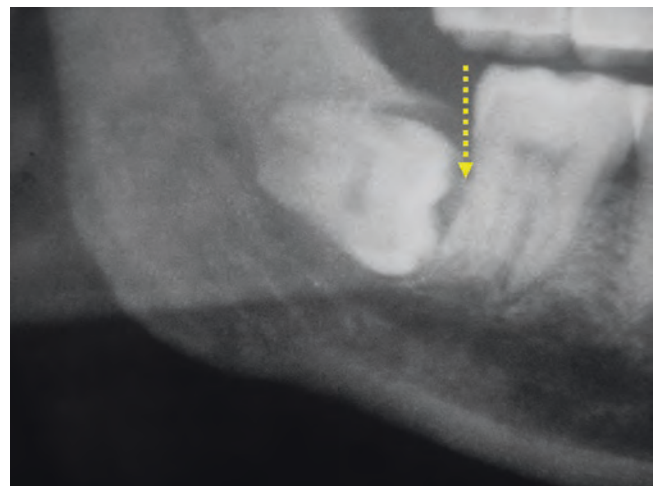
(a) *Crowding of incisors*: Third molars has the potential to generate force in an anterior direction, which in turn can cause mandibular incisor crowding. Hence, removal of third molars has been recommended during or after orthodontic treatment. The hypothesis that the mesial pressure from the third molars is transferred through the contact points resulting in the narrow contacts of the lower incisors is slipping. Contemporary studies have questioned this hypothesis. However, it is still believed by certain clinicians, and third molars may be removed for these reasons.

(b) *To facilitate orthodontic treatment*—Since the recent trends in orthodontics prefer non-extraction modalities of treatment, distalization of molars has become ever more popular, particularly with regard to Class II malocclusions. In such cases, in order to expedite the distal movement of maxillary molars, the impacted or erupted maxillary third molar tooth may be extracted.



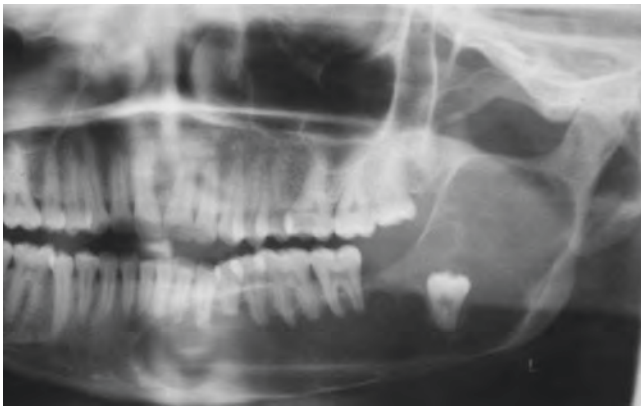©Association of Oral and Maxillofacial Surgeons of India

Fig. 14.2 IOPA X-ray of Horizontally impacted tooth 38 with dental caries



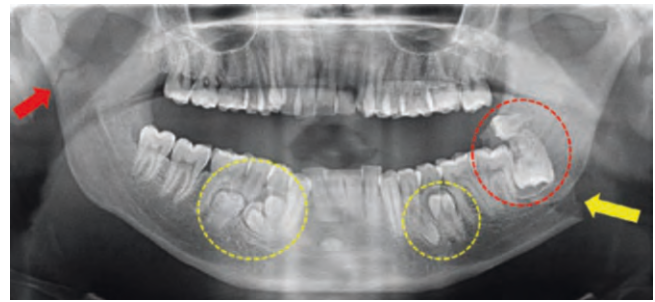
©Association of Oral and Maxillofacial Surgeons of India

Fig. 14.3 Horizontal impaction of 48 causing bone loss (yellow arrow) distal to 47



©Association of Oral and Maxillofacial Surgeons of India

Fig. 14.4 OPG showing impacted 38 associated with dentigerous cyst of mandible involving the left ramus, angle, and body



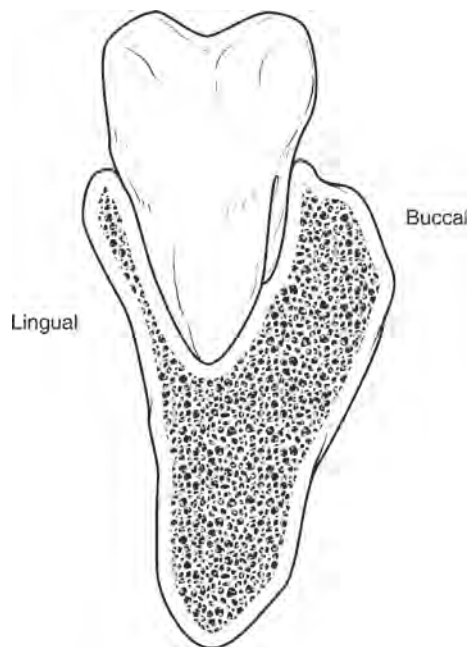
©Association of Oral and Maxillofacial Surgeons of India

Fig. 14.5 OPG showing impacted left mandibular third molar in inverted position associated with supernumerary (red circle) with fracture of left angle mandible (yellow arrow). Note multiple impacted supernumeraries (yellow circles) and fracture of right condyle (red arrow)

5. *To facilitate orthognathic surgery*—Removal of third molars should be considered in the presurgical preparation for orthognathic surgery. Making bone cuts in Bilateral sagittal split osteotomies (BSSO) is easier after third molars are removed. To ensure that adequate bone exists in this region, these must be extracted at least one year before the planned osteotomy.
6. *Odontogenic cysts and tumors*—Cysts and tumors may develop from the retained follicle around the impacted tooth (Fig. 14.4). To prevent this, extraction of asymptomatic third molars is recommended.
7. *Unexplained pain*—Sometimes, unexplained pain may be alleviated simply by removing impacted teeth, although the mechanism is still unclear. However, the pros and cons must be discussed with the patient.
8. *Resorption of the adjacent tooth root*—Pressure from the impacted tooth can cause the root of the second molar to resorb. When this is identified, the third molar must be removed as early as possible to avoid further damage.
9. *For placement of dental prosthesis*—The removal of impacted teeth under dental prosthesis must be assessed carefully, with the evaluation of risk versus benefits. Removal may be done for teeth that are superficial. However, sometimes the impacted tooth may lie deep within the mandible and in such cases, the tooth is better off left in situ.
10. *Prevention of jaw fracture*—For those engaged in contact games, it may be better to prophylactically remove the impacted third molars, as this area may be prone to fracture due to lowered bone resistance (Fig. 14.5).
11. *Infection of deep fascial spaces*—When pericoronitis is associated with impacted tooth, infection can track into deep fascial spaces.
12. *To remove a potential infection source* (e.g. prior to administration of radiotherapy)—Teeth which are at risk of infection like partially erupted third molar tooth may lead to local complications like osteoradionecrosis or systemic complications like endocarditis. Removal must be considered for these cases as well as other procedures such as chemotherapy, organ transplantation, or insertion of alloplastic implants.
13. *Removal for autogenous transplantation*—Even though this was a very popular procedure in the past, it fell into disrepute due to unpredictable results. However, it is worth considering when indicated for first molar replacements.

14.4.1 Relative Contraindications for Removal of Impacted Tooth

1. *Compromised systemic status*—It may not be advisable to undertake surgical removal of impacted third molars in patients with uncontrolled or poorly controlled systemic disease, as they can develop complications during or after the procedure. Hence, a proper history, physical examination, and, if needed, appropriate laboratory investigations must be performed.
2. *Advanced age*—Bone sclerosis increases with advancing age. This leads to poor healing, a larger defect size, and increased difficulty of the procedure. Risk of mandibular fracture is also high in these cases.
3. *Damage to any adjacent structures*—If the inferior alveolar canal is in close contact with the impacted tooth, inadvertent damage can result in paresthesia.
4. *Questionable status of the second molar*—If the second molar is badly decayed and unrestorable, removing it may allow the third molar to come into a



©Association of Oral and Maxillofacial Surgeons of India

Fig. 14.6 Coronal section of mandible in the region of the third molar showing a thick buccal alveolar bone and a thin lingual plate

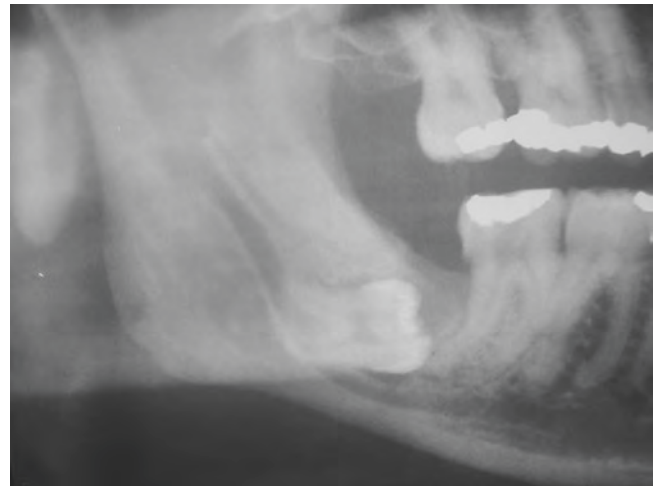functional position. The third molar may also serve as a bridge abutment. Such cases require multidisciplinary evaluation with the prosthodontist and endodontist.

5. *Deeply impacted third molars* which do not appear to be associated with local or systemic pathology must not be removed.

14.5 Surgical Anatomy

The mandible comprises of a body which is horseshoe shaped and has the ramus on either side, which are flat and broad rami. Each ramus has two processes at the superior end—the coronoid process, which is more anterior, and condylar process, which is continuous with the posterior border.

The mandibular third molar tooth is usually present at the distal end of the mandibular body, which adjoins a thin ramus. The body-ramus junction is a weak area that can fracture if excessive force is employed during the elevation of the third molar. The tooth lies between the buccal cortical plate, which is thick, and the thin lingual cortical plate (Fig. 14.6). In most instances, the thickness of the lingual plate may be less than 1 mm, and the tooth may get displaced into the lingual pouch if untoward force is applied.



©Association of Oral and Maxillofacial Surgeons of India

Fig. 14.7 Radiograph showing the proximity of impacted third molar roots to the mandibular canal

14.5.1 Neurovascular Bundle

The mandibular canal lies beside or below the third molar roots. Usually, the canal lies slightly buccal and apical to the third molar roots, but this varies frequently (Fig. 14.7). The canal contains the inferior alveolar neurovascular bundle including the artery, vein, and nerve within a sheath of fascia. The third molar roots may sometimes be indented by the canal, but actual penetration is rare. In these cases, attempting to elevate fractured root tips may result in the displacement of the tips into the mandibular canal. If the canal vessels get injured by instruments or forceful intrusion of the tooth roots, profuse hemorrhage may result.

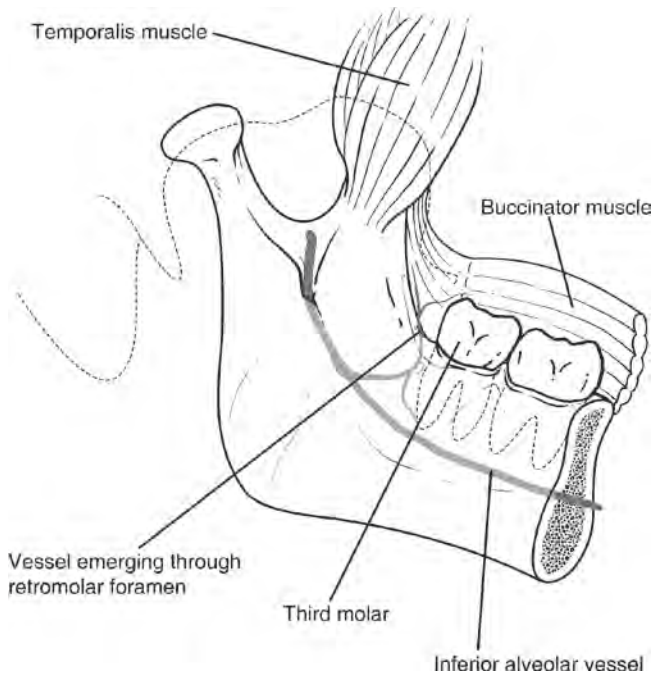
14.5.2 Retromolar Triangle

This is a depressed roughened area behind the third molar bounded by the buccal and lingual alveolar ridge crests. The retromolar fossa is a shallow depression that occurs just lateral to the retromolar triangle. Mandibular vessel branches may emerge at the fossa or triangle and can be injured during surgical exposure of the third molar region if the incision is not taken laterally. This can result in brisk hemorrhage (Fig. 14.8).

14.5.3 Facial Artery and Vein

The facial artery and anterior facial vein are related to the mandibular body, anterior to the masseter muscle, where they cross the inferior border of the mandible. They lie below

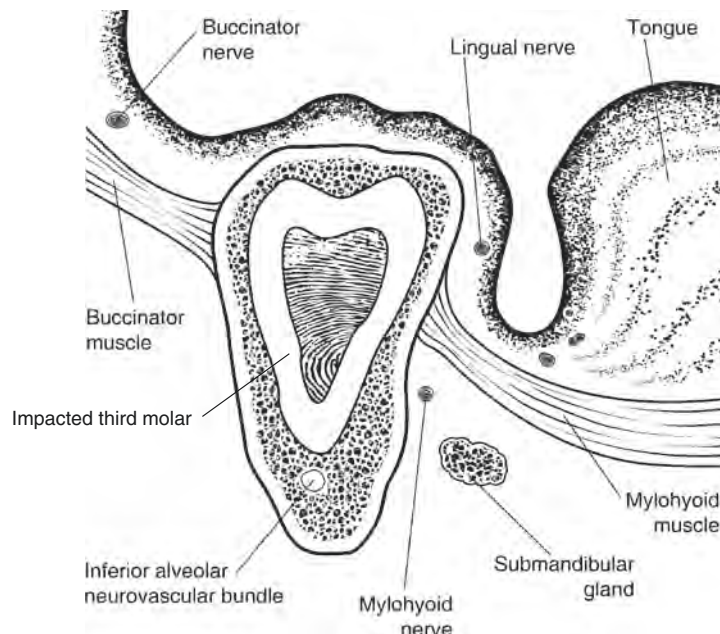
the second and third molar teeth and may be injured when a buccal incision is placed at an inferior level. To avoid this, it is best to start the incision at the sulcus depth and move upward toward the tooth.



©Association of Oral and Maxillofacial Surgeons of India

Fig. 14.8 Schematic diagram showing the retromolar vessel emerging through retromolar foramen

Fig. 14.9 Schematic diagram showing coronal section through the third molar region and the relationship of important anatomical structures



©Association of Oral and Maxillofacial Surgeons of India

14.5.4 Lingual Nerve

The lingual nerve often runs below and behind the third molar, and contacts the periosteum over the lingual cortex at a sublingual level. Cardinal anatomic studies have shown the close relation of the lingual nerve to the lower third molar region [8, 9].

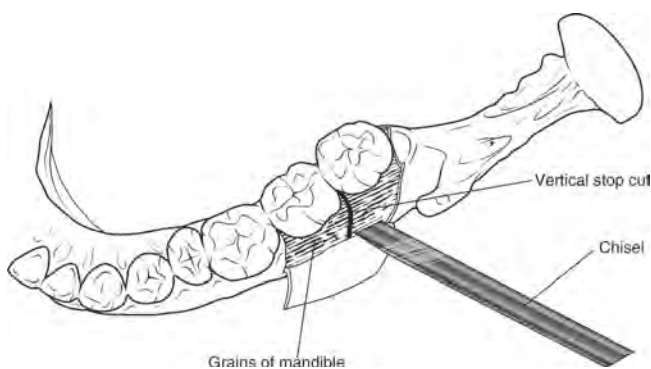
The lingual nerve usually lies 2.3 mm below the lingual alveolar crest, and 0.6 mm medial to the mandible, when viewed from a frontal plane.

Since the lingual nerve is close to the third molar, it is at risk of damage during surgical removal of the tooth. This may lead to anesthesia of the tongue in its anterior two-thirds, and also loss of taste sensation in this area.

The surgeon should also be aware of the course and direction of the mylohyoid and long buccal nerve to prevent inadvertent injuries to these nerves (Fig. 14.9).

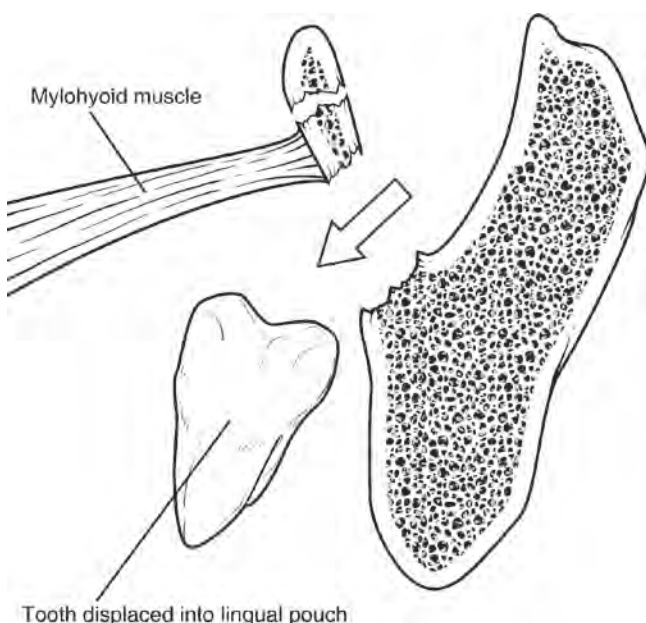
14.5.5 Bone Trajectories of Mandible

The bone trajectories of the mandible, referred to as grains, course in a longitudinal direction. Even though the technique of chisel and mallet has almost become obsolete, it is important to know the bone trajectories. On the buccal side, a horizontal chisel cut that is oriented parallel to the superior border may cause extensive splitting till the first molar region due to the grain direction. To prevent this, the operator must make a “vertical stop cut” (Fig. 14.10), with the bevel ori-



©Association of Oral and Maxillofacial Surgeons of India

Fig. 14.10 Bone trajectories of the mandible



©Association of Oral and Maxillofacial Surgeons of India

Fig. 14.11 Whole tooth displaced into lingual pouch beneath the mylohyoid muscle

ented posteriorly, just distal to the second molar. The chisel must be angulated correctly at all times to avoid fracture of mandible distal to the third molar.

14.5.6 Lingual Plate

Since the lingual plate is very thin, it may be perforated by the apices of lower third molar roots. If the roots are fractured, attempting to elevate may cause them to be displaced into the “lingual pouch,” from where it will be difficult to retrieve. The entire tooth also may rarely be pushed into the lingual pouch (Fig. 14.11).

14.6 Classification of Impacted Mandibular Third Molar

To assess surgical difficulty, several classifications have been proposed, which can help formulate a treatment plan that is efficient and has minimum morbidity. Either the periapical radiograph or the Orthopantomogram is used to analyze the impacted tooth for its classification.

The most commonly used are:-

1. *Angulation* [10] of the impacted tooth (Fig. 14.12) (George Winter classification).

Vertical,
Mesioangular,
Horizontal,
Distoangular,
Buccoangular,
Linguoangular,
Inverted,
Unusual

2. *Relationship* between the impacted tooth and the *anterior ramal border* [11]—This assesses the amount of space present between the anterior border of the ramus and the distal wall of the second molar. This indicates the effective space available for the tooth to erupt (Fig. 14.13).

Class I—There is enough mesiodistal space between the anterior border of ramus and second molar to accommodate the third molar.

Class II—Space between anterior border of the ramus and second molar is less than the mesiodistal width of the crown of the third molar.

Class III—No mesiodistal space available and the third molar is almost completely within the ramus.

Class III impactions present greater difficulty in removal.

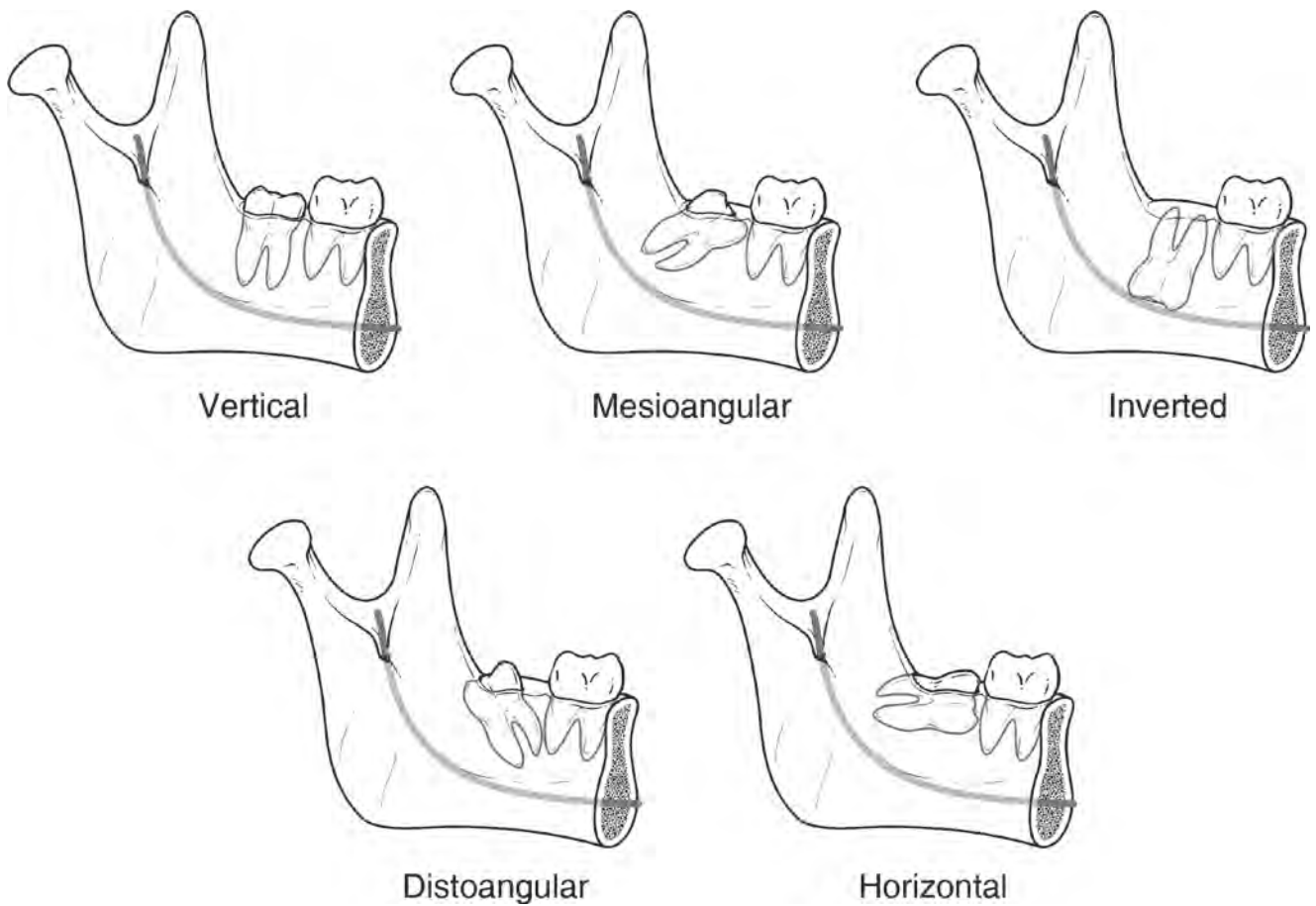
3. *Depth of the impacted tooth* and tissue type that overlies the tooth (Pell and Gregory Classification based on occlusal level of the tooth)—i.e. soft tissue, partial bony, or complete bony impaction (Fig. 14.14).

Position A—The highest point of the tooth is at the same level of the occlusal plane or above it.

Position B—The highest point of the tooth is above the cervical line of the second molar but below the occlusal plane.

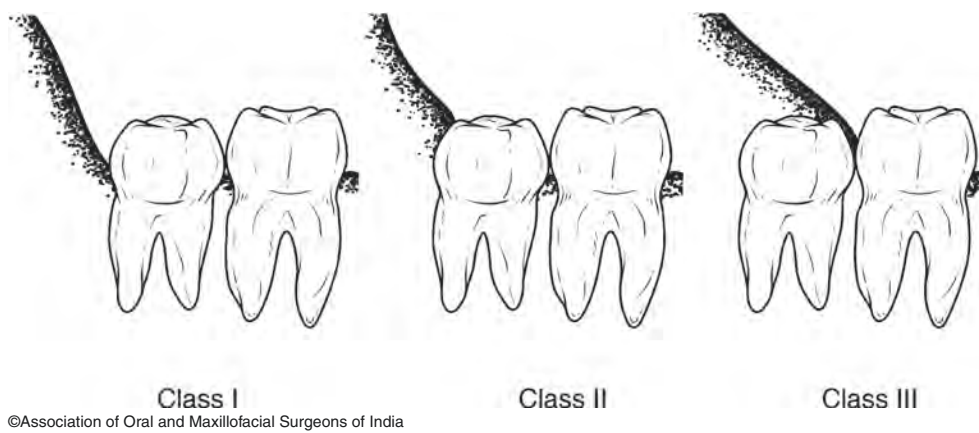
Position C—The highest point of the tooth is well below the cervical line of the second molar (Figs. 14.15 and 14.16).

4. *Type of tissue that lies over the tooth*—i.e. soft tissue, partial bony, or complete bony impaction.
5. *Level of Eruption*
 - (a) Erupted.
 - (b) Partially erupted.
 - (c) Unerupted.



©Association of Oral and Maxillofacial Surgeons of India

Fig. 14.12 Classification based on angulation of tooth (Winter's classification)



©Association of Oral and Maxillofacial Surgeons of India

Fig. 14.13 Pell and Gregory Classification based on relationship to the anterior border of ramus

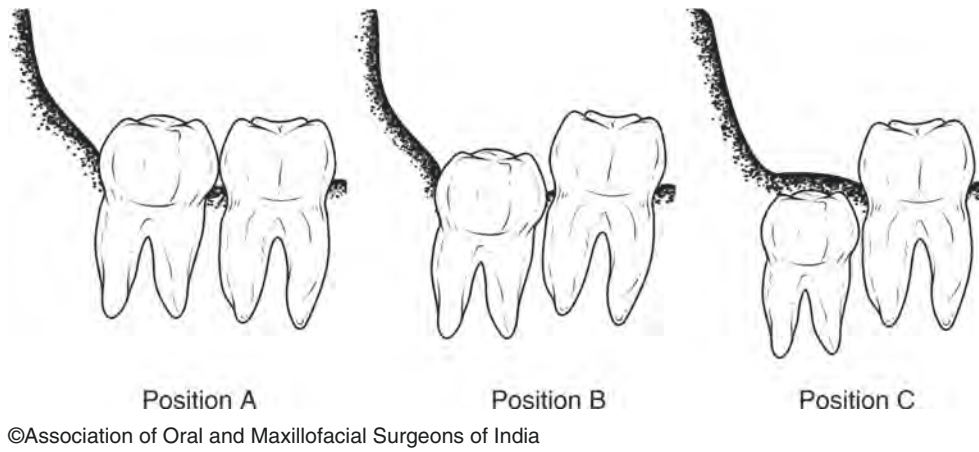


Fig. 14.14 Pell and Gregory Classification based on relationship to the occlusal plane of the impacted tooth to that of the second molar

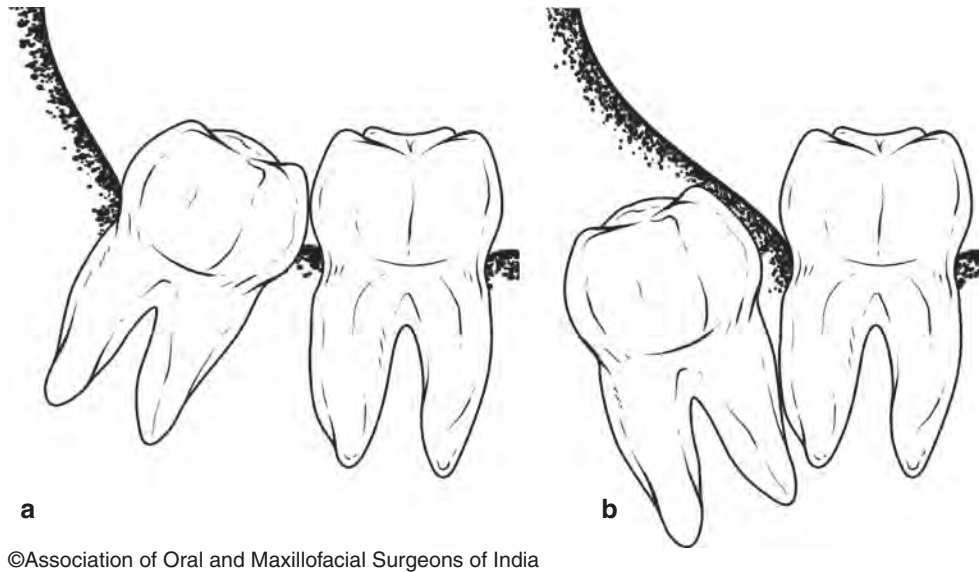
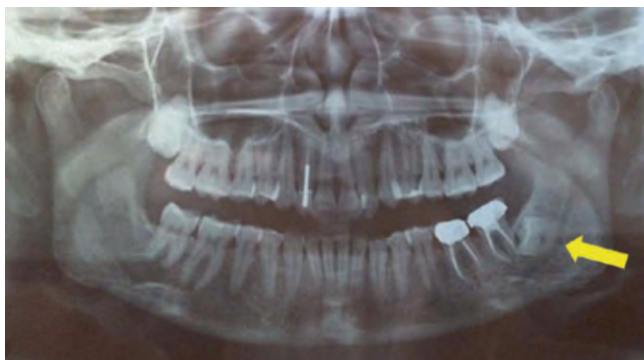

Fig. 14.15 Examples of impaction showing combination of angulation of tooth, relationship to anterior border of ramus and depth of impaction. **(a)** Mesioangular impaction in Class I ramus relation and Position

A depth—an impacted tooth easy for removal. **(b)** Distoangular impaction in Class III ramus relation and Position B depth—an impacted tooth difficult for removal



©Association of Oral and Maxillofacial Surgeons of India

Fig. 14.16 OPG showing impacted mandibular third molar displaying only crown of the tooth with no roots visible (yellow arrow) with close proximity to inferior alveolar canal in a 52-year-old male. Surgical removal of 38 was attempted without taking CT or CBCT. During surgery, there was accidental fracture of left angle for which internal fixation has to be done. Note impacted 18 and 28

14.7 Preoperative Planning

Presence of an impacted third molar must be diagnosed systematically using the patient's chief complaint and history, clinical examination, and appropriate investigations.

The impacted third molar must be evaluated both clinically and radiographically prior to surgery for successful and speedy removal. Ideally, a periapical radiograph must be taken and an OPG must be added if the intraoral radiograph does not provide enough information about the tooth or adjacent structures.

Manuel et al. has [12] developed a simple format for evaluation of third molar impactions.

This comprehensive format is ideal for residents in oral surgery during their learning years. Using this format, third molar impactions may be analyzed, and difficulty level may be assessed and anticipated. Residents can judge problems that they may encounter during the procedure and can evaluate the patient better postoperatively.

14.7.1 Clinical Examination

This includes taking the patient's history, clinical examination extraorally and intraorally.

1. History taking

Complaints of the patient—Impacted teeth are usually asymptomatic and patients are aware of their existence only when told by the dental practitioner. Symptoms, if any, are usually due to acute or chronic pericoronitis, or due to acute pulpitis secondary to dental caries.

2. Extraoral examination

The clinician must examine the face and neck for redness and swelling related to infection. The lower lip is tested for anesthesia or paresthesia. The regional lymph nodes must be assessed by palpation for any tenderness or enlargement.

3. Intraoral examination

- The following points are noted:
- Mouth opening—The ability of the patient to open the mouth is analyzed, and any trismus, fibrosis, or hypermobility of the joint is noted. The size of the mouth (microsomia/macrosomia) is also checked. Third molar access may be restricted if the mandible is retrognathic, while a prognathic mandible offers good access.
 - General examination of oral cavity- oral mucosa, teeth, and oral hygiene.
 - Examination of the third molar area for signs of pericoronitis and state of eruption of the tooth.
 - Condition of the impacted tooth- presence of caries, dental fillings, and internal resorption (which may resemble caries). The angle of the tooth and locking beneath second molar must be noted and confirmed with appropriate radiographs.
 - Condition of first and second molars—presence of caries, fillings, or crowns; root canal treatment may put the second molar at risk of fracture and the patient must be warned of this. Distal periodontal pocketing, root resorption, and absence of the second molar must also be noted.
 - Space present between the second molar distal surface and the ascending ramus: A small distance makes access difficult, and a large distance makes the tooth more accessible. For maxillary teeth, the distance between the second molar and tuberosity must be considered. Access can also be decreased by distal tilting of second molar.
 - Adjacent bone may develop infection, which can spread along the mesial surface of the tooth and affect the second molar, which would then require extraction. Infection/osteomyelitis can spread to the ramus in the case of distoangular impacted third molars, through recurrent submasseteric abscesses in this region.
 - Systemic skeletal diseases may cause pathological complications which should be noted. For instance, conditions such as osteogenesis imperfecta and osteosclerosis may cause fractures during the procedure. In acromegaly, the mandibular bone is massive which makes the procedure difficult because the mandible consists of massive bone. In Paget's disease also tooth removal is difficult as the bone is affected by resorption and repair.

- (i) Presence of cysts and tumors—The impacted tooth may be associated with eruption cysts or large odontogenic cysts can occur in relation to impacted tooth. By and large, they cause displacement of the tooth. Benign and malignant tumors such as ameloblastoma may also be found involving the tooth. Odontomes may also be present in relation to the third molar.

14.7.2 Radiography of Impacted Mandibular Third Molar

Any factor that increases the difficulty of third molar removal can be analyzed from the preoperative radiograph.

The following radiographs may be used for analysis:

1. Intraoral periapical radiograph.
2. Occlusal X-ray of mandible.
3. Lateral oblique view of mandible.
4. Panoramic radiograph (Orthopantomogram).

An essential criterion for a good film is that the buccal and lingual cusps of the second molar must be superimposed on each other in the same vertical and horizontal plane. This appearance of the second molar is referred to as 'enamel cap'.

1. *Periapical radiograph*: The radiograph should include the entire third molar tooth along with the investing bone. It should also show the anterior border of ramus, the second molar, and the inferior alveolar canal.
2. *Lateral oblique view of the mandible*: This radiograph is inevitably distorted because the opposite side of the mandible is rotated away from the beam during film exposure. Therefore, it is inferior to the periapical X-ray, but it has its use in certain clinical situations:
 - When periapical X-ray cannot be taken due to trismus or retching.
 - To provide supplementary information like height of mandible in the region of the third molar, or bone height beneath a deeply buried tooth. The latter is useful to assess the risk of pathological fracture in thin mandible, or in cases of cysts or tumors.

Since the introduction of OPG, the use of lateral oblique view is limited and is only considered when an OPG is unavailable.
3. *Orthopantomogram (OPG)*: This provides the same information as the lateral oblique view, with less distortion. The OPG is now used routinely to precisely locate impacted teeth.

14.7.2.1 Interpretation of Periapical X-ray

The following points must be noted in the periapical radiograph:-

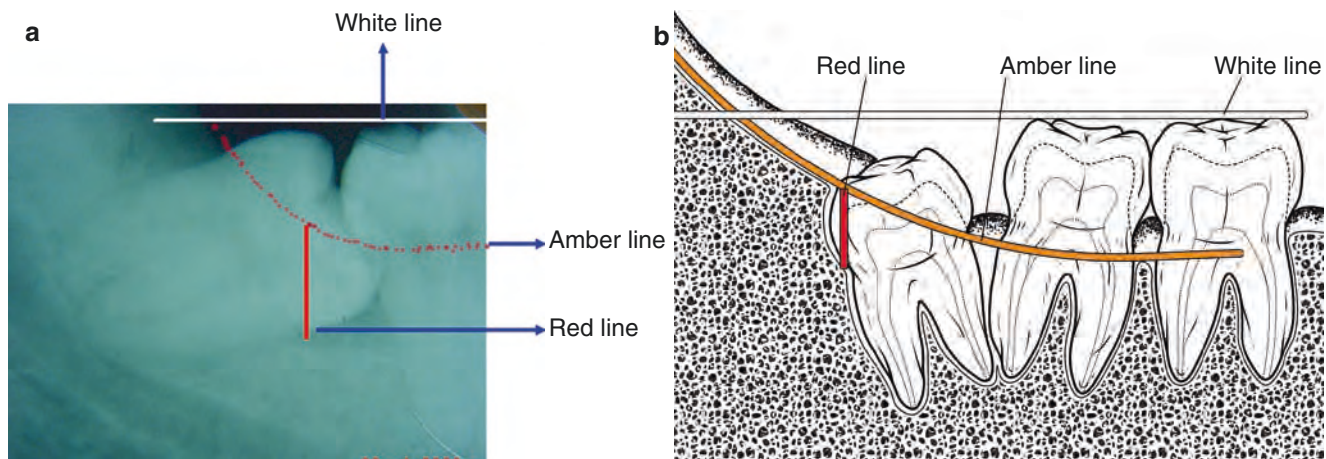
- (a) Access.
 - (b) Depth and position of the tooth.
 - (c) Root pattern of impacted tooth.
 - (d) Shape of crown.
 - (e) Texture of investing bone.
 - (f) Relation to inferior alveolar canal.
 - (g) Root pattern and position of second molar.
- (a) *Access*—By observing the inclination of the radio-opaque line that is formed by the external oblique ridge, the ease of access can be ascertained. A vertical line implies poor access and a horizontal line, good access.
 - (b) *Position and depth of impacted tooth*—These can be evaluated using Winter's technique of WAR lines (described by George Winter). WAR refers to three imaginary lines drawn on the radiograph, namely, the "white," "amber," and "red" lines (Fig. 14.17a, b).

The first line or "white" line extends across the occlusal cusp tips of the erupted mandibular molars and is drawn distally over the third molar region. This line indicates the axial inclination of the impacted tooth. For example, the white line is parallel to the occlusal surface of the third molar if the tooth is vertically impacted, whereas, the "white" line converges with the occlusal surface in front of the tooth in distoangular impactions.

The "white" line also indicates the depth of the tooth as compared to the erupted second molar.

The second "amber" line extends from the bone surface distal to the third molar and is drawn to the interdental septum crest between the first and second molar. When drawing this line, it must be clearly differentiated from the external oblique ridge shadow, which can lie above and in front of the posterior end of the "amber" line. The posterior end is the shadow cast by the bone in the retromolar fossa and not the external oblique ridge. The "amber" line shows the margin of the alveolar bone enclosing the tooth. Hence, when soft tissues are reflected, the portion of the visible tooth will be the part that was lying above and in front of the "amber" line in the radiograph. The rest of the tooth will be covered by bone.

The third line or "red" line assesses how deep the impacted tooth is within the mandible. This is drawn by dropping a perpendicular from the "amber" line to the point at which the elevator will be applied to elevate the tooth (an imaginary point). This point usually lies on



©Association of Oral and Maxillofacial Surgeons of India

Fig. 14.17 (a) White, amber, and red lines (Winter's WAR lines) marked in the periapical X-ray. (b) WAR lines drawn on a distoangularly impacted mandibular third molar. Note that in distoangular impac-

tions, the perpendicular "red" line should be dropped to the cemento-enamel junction on the distal side of the impacted tooth and not on the mesial side as in other angulations

the mesial surface of the impacted tooth, at the cemento-enamel junction, except in the case of distoangular impactions. The longer the red line, the more deep the tooth is impacted, and the surgical procedure will be more difficult.

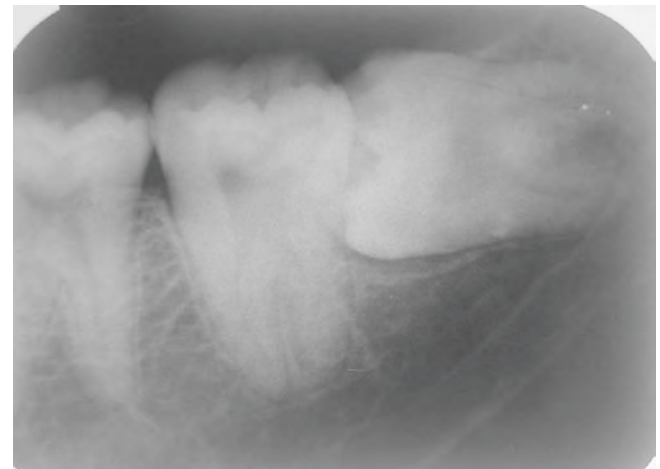
- (c) *Root pattern of impacted tooth*—The number, shape, and curvature of roots are noted. Hypercementosis is noted if present. If the root apex takes a sharp bend toward the X-ray beam, it may appear blunt and short on the image. This finding should therefore be investigated in more detail.

The type of root morphology dictates the difficulty of the surgical procedure. If root development is limited, it can result in a "rolling" tooth, which is challenging to remove.

- (d) *Shape of crown*—If the tooth has prominent cusps, or large, square crowns, the difficulty increases as compared to small crowns and flat cusps. The size and shape of the crown of third molar is particularly important with regard to the "line of withdrawal." Sometimes, the path of crown removal can be obstructed by the second molar crown (Fig. 14.18).

In these cases, the cusp of the third molar appears to be superimposed on the distal surface of the second molar in the radiograph. If elevation is attempted by applying force on the mesial surface of the impacted tooth, the second molar may get displaced from the socket, and there is a risk of mandible fracture. The risk is especially high for second molars with conical roots. In such cases, sectioning the third molar is advisable.

- (e) *Texture of the investing bone*—As age advances, the bone undergoes sclerosis and becomes less elastic. The bone texture can be analyzed by visualizing the size of the cancellous spaces and the bone density. Bone that



©Association of Oral and Maxillofacial Surgeons of India

Fig. 14.18 "Locking of the crown" of impacted third molar by the second molar. Note that the cusp of third molar is superimposed upon the distal surface of second molar

has large spaces and fine structure is generally elastic. On the contrary, sclerotic bone has small spaces and dense bone structure. Dense bone does not expand easily during luxation and more bone removal may be required.

- (f) *Inferior alveolar canal*—Although radiographs often show the canal crossing the third molar roots, this is usually due to superimposition. Sometimes, however, this may indicate grooving or perforation of the root. The classical papers by Howe and Poynton [13] and Rood and Shehab [14] have given predictable signs to assess the relationship between the nerve and the third molar roots.

1. If there is a band of reduced radio-opacity that crosses the roots, and this band coincides with the outline of

the inferior alveolar canal, this is a sign that the tooth root may be grooved by the canal. This sign reflects the lesser amount of tooth structure lying between the X-ray source and the film.

2. The roof and floor of the canals are formed of compact bone, which is indicated by continuous, parallel radio-opaque lines. If the lines lose continuity, it is an indication that the root is grooved by the inferior alveolar canal. These grooves usually form on the lingual side of the roots.
3. In cases where the radiolucent band crosses the apex of the root and if only the upper white line is broken, a notching of the root is present.
4. Characteristic narrowing of the radiolucent band with loss of white lines is suggestive of perforation of the root by the inferior alveolar canal.

The following signs have been demonstrated to be associated with a significantly increased risk of nerve injury during third molar surgery: (Fig. 14.19a, b, c)

- Diversion of the inferior alveolar canal (IAC).
- Darkening of the root where crossed by the canal.
- Interruption of the white lines of the canal.

In the presence of any of the above findings, great care should be taken in surgical exploration and the decision to treat is carefully reviewed. If on the initial panoramic radiograph there is an evidence of a close relationship between the roots of the lower third molar and the IAC, a second radiograph should be taken using different projection geometry.

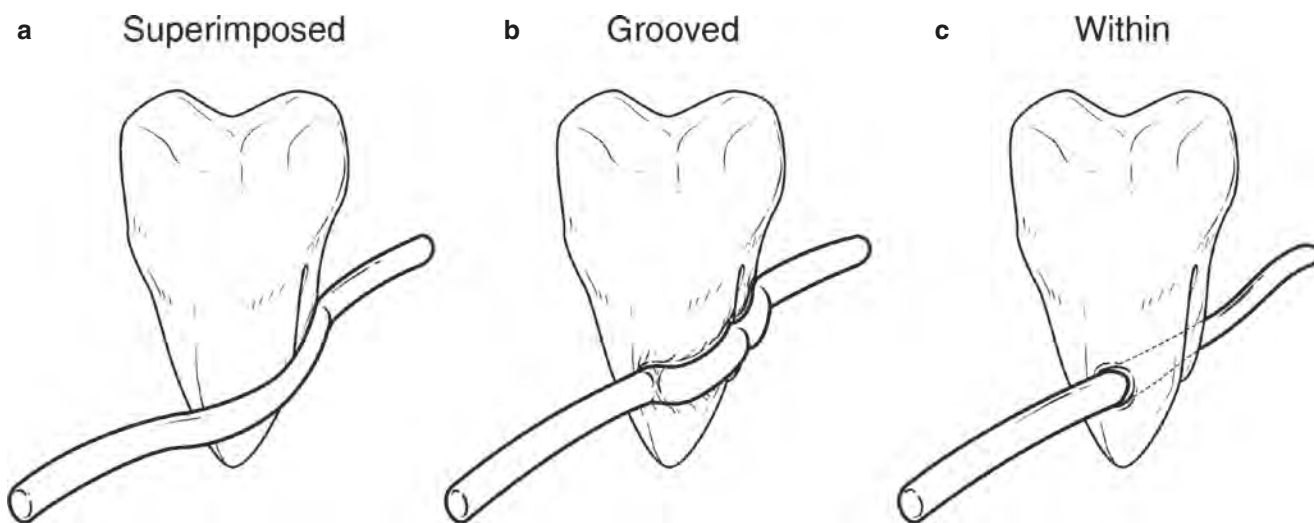
If the third molar is found to be in close relationship with the inferior alveolar canal, the patient should be informed in advance regarding the likelihood of impairment of labial sensation following the surgical removal of the tooth. This should be recorded in the case record and in the consent form. In such cases, authors have recommended coronectomy (partial tooth removal, intentional root retention, partial odontectomy) as an option. However, this technique cannot be considered foolproof and long-term studies are required to know the success of coronectomies [15, 16]

- (g) *Position, root pattern, and nature of crown of second molar.*

The space between the distal surface of the second molar and the mesial surface of the impacted third molar has an effect on the ease of removal of the third molar. The closer the third molar is to the second molar, the more challenging the surgery becomes. If the long axis of the second molar is tilted distally, it is more difficult to remove.

Cone beam computed tomography (CBCT) (Fig. 14.20a, b, c) CBCT is now available for dental use and offers low dose imaging in multiple planes.

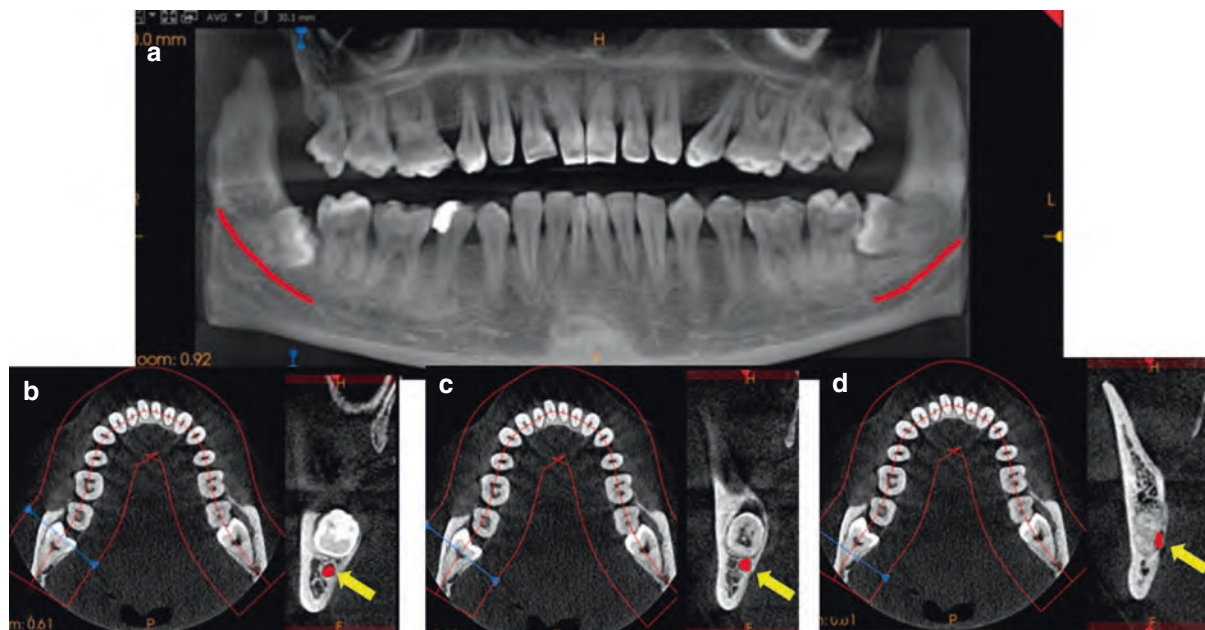
Using this modality, accurate three-dimensional imaging can be done to determine the relationship between the roots of the third molar and the inferior alveolar nerve (IAN). The recent recommendation is that when the OPG suggests a close relationship between the roots of the lower third molar and IAN, cone beam CT scanning should be advised [17–19]. The effective dose from CBCT is comparatively less than the conventional CT scan and also at a lower expense.



©Association of Oral and Maxillofacial Surgeons of India

Fig. 14.19 (a–c) Radiographic relationship of third molar root to inferior alveolar nerve (a) Cortical outline of the canal is intact. This probably represents superimposition only. (b) There is loss of cortical outline of the nerve canal. The nerve may be grooving the tooth. (c)

There is loss of cortical outline as well as narrowing and deviation of the nerve canal, denoting an intimate relationship of the nerve with the tooth and possibly perforation of the tooth roots by the nerve



©Association of Oral and Maxillofacial Surgeons of India

Fig. 14.20 (a) CBCT Panoramic view showing the relationship of 38 and 48 to the inferior alveolar canal (IAC) [red line]. The changing relationship of the IAC to 48 can be noted in (b–d). Relationship of IAC

(yellow arrow) at coronal level (b), at cervical level (c), and at apical one third level (d)

14.7.3 Lingual Nerve Protection and Injury

Locating the lingual nerve clinically and by imaging is more challenging. Lingual nerve injury although less common than inferior alveolar nerve (IAN) injury is often more unbearable to the patient. Patients find it difficult to tolerate lingual nerve damage, including loss of taste and sensation of tongue, as compared to IAN damage. Unlike the IAN, the lingual nerve is not usually imaged prior to third molar surgery. In cases where distal, distolingual, and lingual bone is to be removed, technique of raising the lingual flap and protecting the lingual nerve by a broad smooth lingual flap retractor in a subperiosteal plane has been advocated by certain authors and this technique is followed in certain parts of the world. Again, there are conflicting reports where the lingual flap retraction itself has caused an increase incidence of lingual nerve paresthesia [8, 20–22].

The incidence of IAN involvement 1–7 days after surgery is around 1–5% and the incidence of lingual nerve involvement one day after surgery (excluding the use of lingual flap elevation) varies from 0.4 to 1.5% [23, 24].

14.7.4 Preoperative Evaluation of Difficulty of Removal

Various techniques have been suggested for the preoperative evaluation of difficulty, but these have often been of limited

value. Pederson [25] recommended a scale to evaluate the difficulty index.

Although the Pederson scale can be used for predicting operative difficulty, it is not extensively used [26] because it does not take various other relevant factors into account, such as bone density, flexibility of the cheek, and mouth opening.

Surgical removal impacted third molar becomes difficult with the following factors:-

1. Unfavorable root morphology- Excessive curvature, divergent roots, hypercementosis, proximity to canal
2. Third molar crown is locked beneath the second molar.
3. Condition of the impacted tooth (Carious or with filling).
4. Condition of second molar- carious or with filling/ crown or any resorption.
5. Sclerosis of adjacent bone.
6. Mouth opening—If the patient has a small commissure, or trismus, access becomes limited.
7. Large follicular sac around the crown—makes procedure easier.
8. Width of the periodontal membrane—In patients past middle age, the space containing it is much smaller than in young patients. This makes removal difficult.
9. Existing fracture of the jaw.
10. Local or systemic pathologic conditions.
11. Age of the patient.

Surgical removal of impacted teeth may be easier in younger patients because of incompletely formed roots, large follicular space, incompletely formed roots separated from inferior alveolar canal, and greater elasticity of bone. In young patients, the bone texture is usually soft and resilient, but in older adults, the bone becomes progressively more dense, hard, and brittle. Therefore, the extraction of a partially erupted/impacted tooth in an elderly adult with sclerotic bone may cause great difficulty. While a tooth with adverse root morphology in soft, resilient bone of a young adult can be elevated expeditiously.

To summarize, the difficulty of the surgical procedure is dictated by 3 major factors:- (1) Depth of impaction (2) Type of overlying tissues, and (3) Age of the patient.

As a general rule, the more difficult and time-consuming the surgical procedure is, the more difficult and protracted is the postoperative recovery period.

14.8 Operative Procedure

Any standard operative plan consists of the following stages:-

1. Placement of an incision to access the region of the impacted tooth.
2. Removal of enough bone to allow for delivery.
3. Sectioning the tooth and delivering it from the socket.
4. Debridement of the surgical site.
5. Wound closure.

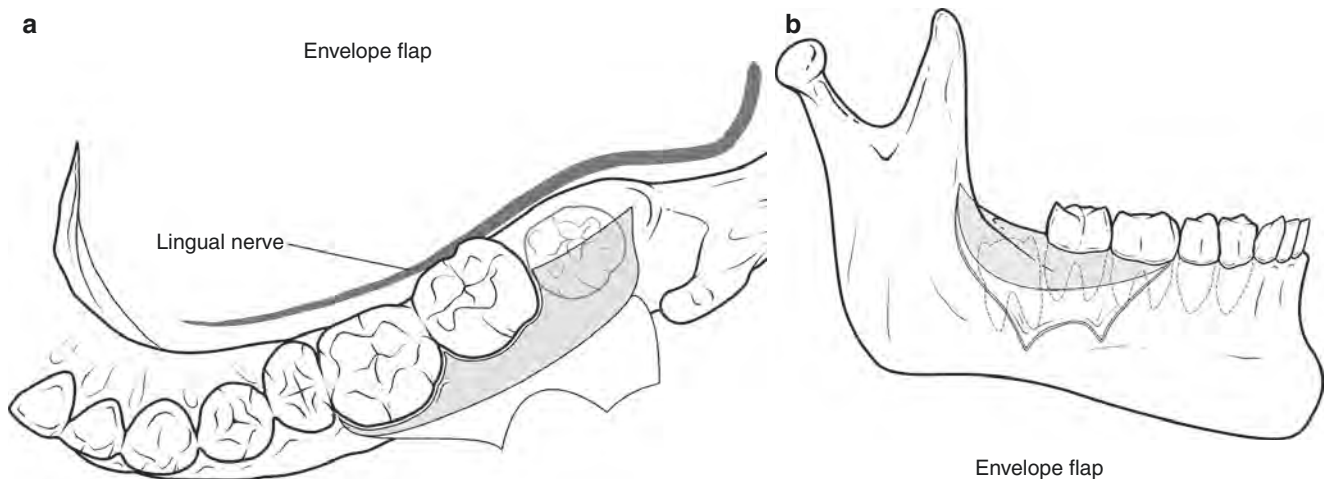
14.8.1 Incision and Designing the Flap

Envelope flap, which is commonly used, extends from the posterior margin of the impacted tooth, and runs forward till the level of the first molar. The posterior end of the incision is directed buccally along the external oblique ridge (Fig. 14.21a, b).

If greater access is required, the envelope flap will not be adequate. In such cases, a release incision is given on the anterior-most point of the incision, which creates a triangular flap (Fig. 14.22a, b). This incision must begin at a point that lies approximately 6 mm below the gingival margin in the buccal sulcus and then extend upward in an oblique fashion to the gingival margin. The incision ends on the margin at a point between posterior and middle thirds of the second molar.

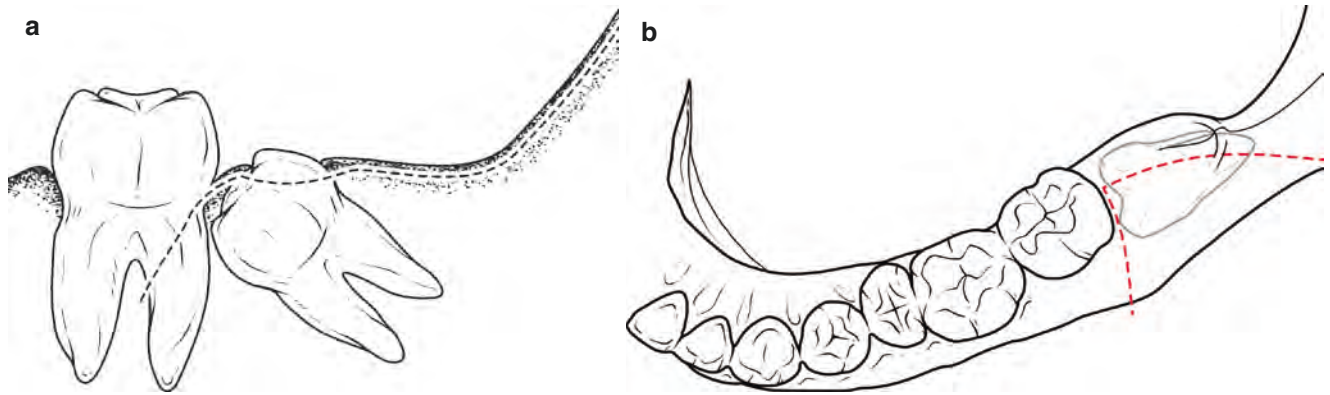
The envelope incision has been associated with fewer complications, and healing occurs faster as compared to the triangular flap. A small artery, the buccal artery, may sometimes be encountered while placing the releasing incision, and mild bleeding can result if this is injured. If more exposure is needed, the vertical release incision can be brought forward, and placed between the second and first molar as shown in the Fig. 14.23a, b.

The incision is then continued along the cervical line of the second molar and reaches the middle of its posterior border. The incision continues in a posterior and lateral direction, along the anterior border of the ramus, depending on the exposure required. It is essential that this arm of the incision is oriented laterally, and not in a straight line, because the mandible diverges laterally. If the incision is extended straight, the knife may cause lingual nerve damage. The lateral extension will also preserve small vessels that emerge from retromolar fossa (Fig. 14.24).



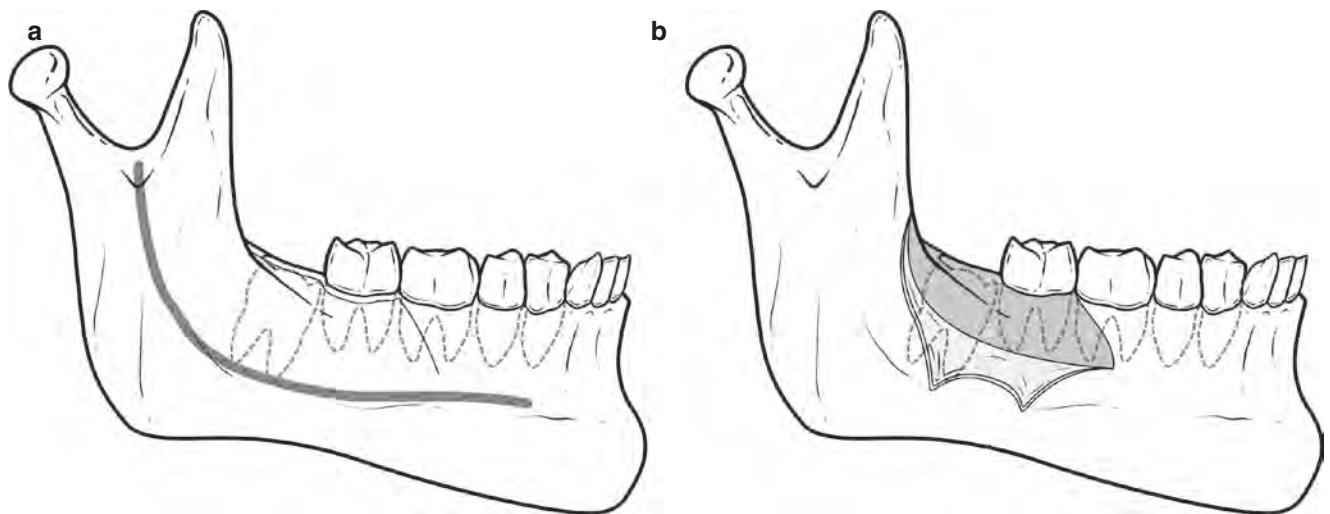
©Association of Oral and Maxillofacial Surgeons of India

Fig. 14.21 (a, b) Envelope flap design



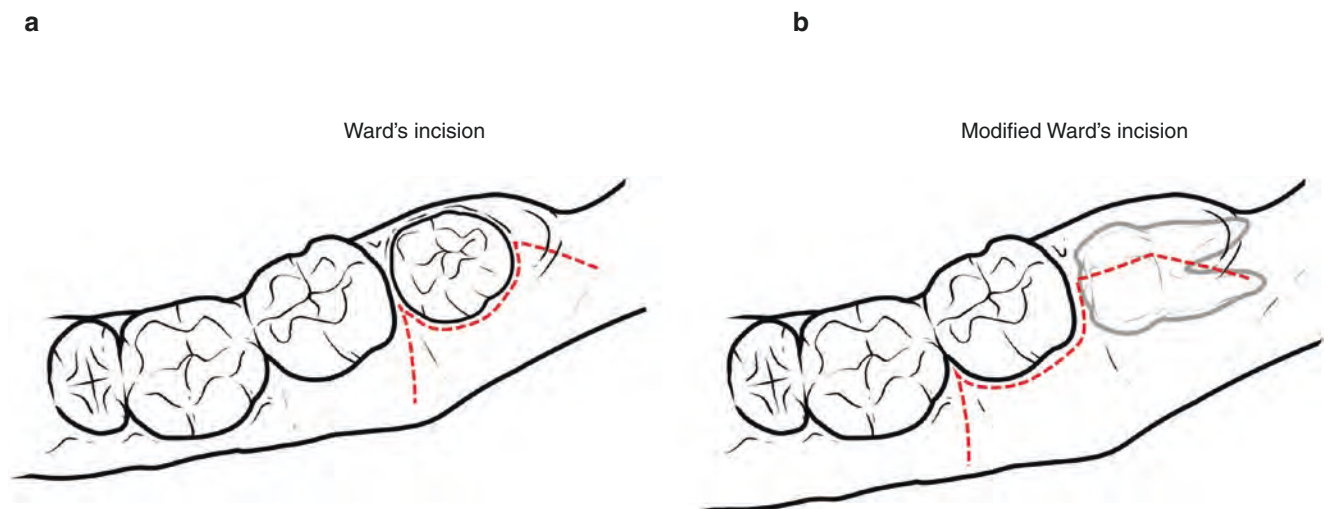
©Association of Oral and Maxillofacial Surgeons of India

Fig. 14.22 (a, b) Standard triangular flap with a release incision in the anterior aspect



©Association of Oral and Maxillofacial Surgeons of India

Fig. 14.23 (a, b) Where more exposure is needed, the vertical release of the triangular flap is placed between the second and first molar



©Association of Oral and Maxillofacial Surgeons of India

Fig. 14.24 (a) Classical Terrence Ward's incision, (b) Modified ward's incision

The mucoperiosteal flap is then reflected laterally with a periosteal elevator. An Austin's retractor (third molar retractor) is used to hold the flap in position. The "Minnesota retractor" may also be used to hold the flap. This retractor must be placed just lateral to the external oblique ridge. Stability is achieved by resting against the lateral surface of the mandible. While holding the retractor, fingers must rest at its distal end so that the retractor can be moved laterally without blocking the vision of the operator.

The literature shows various flap designs with modifications for lower third molar impactions with each claiming its own merits [27, 28]. However, for the majority of the cases, the conventional flap designs will serve the purpose.

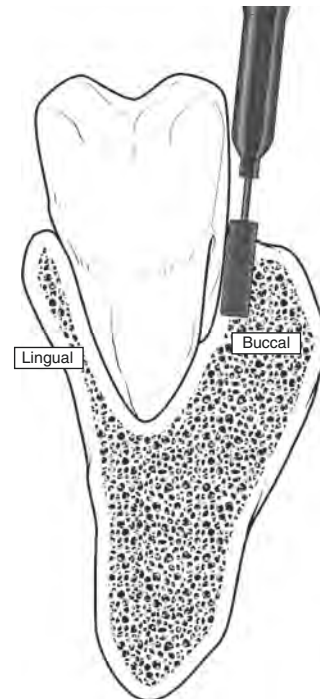
14.8.2 Bone Removal

After flap reflection, the next step is bone removal from around the impacted tooth. The amount of bone to be removed will depend on the depth of impaction. This can be done either by use of bur/rotary instruments or by chisel and mallet or ultrasonic devices/peizo surgery [29, 30] or laser devices [31]. The method used may depend on individual preference. Sufficient amount of bone must be removed, both to free the tooth from obstruction and to provide a point of application for the elevator.

The buccal cortex plays an important role in maintaining the strength of the mandible. Hence, the removal of buccal bone should be minimized, in order to prevent weakening and fracture of the mandible. The bone buccal to and distal to the impacted tooth must be removed until the cervical line of the tooth. Beyond this, bone removal must be done judiciously, in such a way that the strength of mandible is not affected, but, at the same time, the efficiency of surgery is maintained. To achieve this, a deep vertical gutter is drilled on the buccal side, and, if required on the distal side of the tooth. This "guttering method" maintains the buccal plate height, does not weaken the mandible, and at the same time, creates adequate space around the tooth to permit its free movement (Fig. 14.25).

The "Postage stamp" method of bone removal used in transalveolar extractions can also be used to remove the buccal bone, but this method may be more time-consuming. The surgical removal of an impacted tooth is basically a transalveolar extraction and all the basic principles, right from the mucoperiosteal flap design to bone removal and closure has to be followed religiously to achieve good healing.

Bone can also be removed from the mesial aspect of the impacted tooth using this method. In this region, bone removal must be extremely conservative to avoid damage to the distal aspect of the adjacent second molar. Extreme



©Association of Oral and Maxillofacial Surgeons of India

Fig. 14.25 "Guttering method"- A deep vertical gutter using bur is made alongside the buccal aspect and if required on the distal aspect of the tooth

care is taken while removing bone on the distolingual aspect, and proper retraction must be used to prevent lingual nerve damage from the bur. Due to the likelihood of damage to the lingual nerve, bone must not be removed on the lingual aspect. The commonly used burs for bone removal are the #8 round bur and a #703 fissure bur, although a wide variety may be used based on individual preference.

After the tooth is exposed, a point of application is created for the elevator. This allows the tooth to be displaced using only moderate force. If the tooth is resistant, further bone removal or tooth sectioning must be considered.

14.8.3 Elevation of Tooth from the Socket

Once bone removal is complete, tooth elevation can be attempted. Undue force should not be used for this purpose. Applying inappropriate amount of force, especially without sufficient bone removal, can cause the tooth to fracture, or can even cause fracture of the mandible. Because of the above risk, the use of instruments with high mechanical efficiency is contraindicated for third molar removal. These instruments include dental extraction forceps and cross bar

elevators. Once the obstructing bone has been removed, only a small amount of force alone is needed to deliver the tooth. Elevators such as the Warwick James elevator (both straight and curved types) and Coupland elevator, which have lower mechanical efficiency, may be used for this purpose.

14.8.4 Sectioning and Tooth Delivery

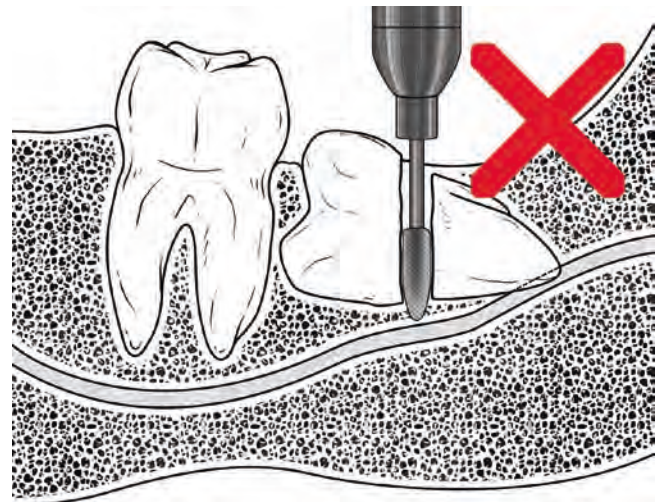
If the tooth has been sufficiently exposed but is still resistant to moderate force, tooth sectioning must be considered. The tooth is sectioned into appropriate pieces for easy delivery from the socket. Sectioning of the tooth not only avoids additional bone removal, but it also reduces operating time. Tooth sectioning can be carried out using a bur, which is preferred, or a chisel. In the standard technique, sectioning is carried out using the bur at the neck of the tooth, which facilitates crown removal first, followed by the roots in a single piece. Alternatively, the tooth may be divided horizontally also. Nevertheless, in cases of divergent roots, or where the path of withdrawal is complex, the roots may have to be divided and removed separately.

The manner of sectioning of crown and root must be decided individually for each case and the standard technique need not be followed exactly (Fig. 14.26).

14.8.5 Modifications of standard technique

Although the principles of third molar removal remain fundamentally the same, the angulation of the tooth may dictate certain modifications. Angulation dictates the site of application of the elevator, as the path of withdrawal of the third molar should be along the line of least resistance. Therefore, the angulation, in terms of mesioangular, horizontal, vertical, and distoangular impactions must be considered.

The *mesioangular* impaction (Fig. 14.27a, b, c) (Video 14.1) is generally considered to be the least difficult to remove. After elevating the mucoperiosteal flap and exposure of the crown, the buccal guttering is carried out till the mesial surface of impacted tooth, to a point below the cemento-enamel junction. This allows the tip of the elevator to be introduced to engage beneath the cervical cementum on the mesial side of the tooth. When the elevator is rotated, the interdental bone is used as the fulcrum and the tooth rotates distally. Thus the tooth, which had an initial mesial angulation, now occupies a vertical position. When more force is applied using the elevator, the tooth is delivered. In some instances, although the tooth becomes vertical, further movement is prevented by the distal bone. This obstruction may be relieved by one of the following methods:



©Association of Oral and Maxillofacial Surgeons of India

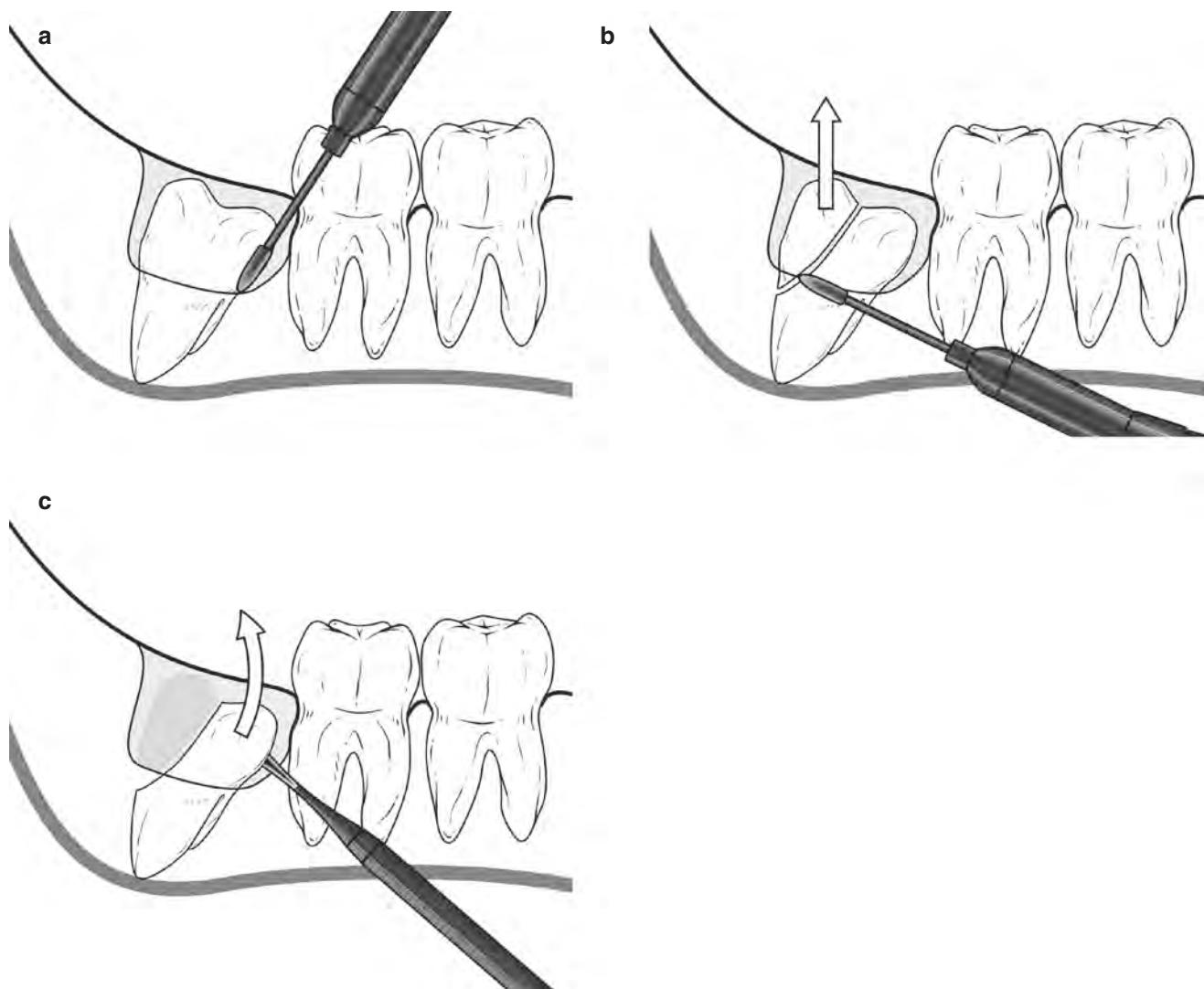
Fig. 14.26 Possible damage to inferior alveolar neurovascular bundle if the bur is carried to the full width of the tooth inferiorly. Hence, bur is used to cut only three-fourth width of the tooth and the rest of the tooth is separated using a suitable instrument

- Using a bur, distal bone may be removed and the tooth may be dislodged distally. Then the tooth is removed.
- The distal half of the crown may be sectioned by slicing from the buccal groove to a point just below the cervical line on the distal side of the tooth. This slice is removed, and then the remainder of the tooth is delivered using a straight elevator placed on the mesial aspect.
- The point of application of the elevator is changed from mesial to the buccal side and a firm upward force is exerted. A purchase point can be created with a bur and the tooth can be delivered using a Cryer's elevator.

Sometimes, the mesioangular tooth may be entrapped beneath the distal convexity of the crown of the second molar. In such cases, the tooth may be divided at the cervical region to separate the crown, which is then removed by applying force beneath its inferior surface. The roots may then be delivered by engaging at the bifurcation.

If the tooth roots are in close contact with the mandibular canal, applying levering force can force the root apex downward which may damage the neurovascular bundle. Crown sectioning must be preferred in such cases, which will allow the roots to be delivered upward away from the canal. This would prevent damage to the canal.

The *horizontally impacted* (Fig. 14.28a, b, c, d) (Video 14.2) tooth may need more bone to be removed as compared to mesioangular impaction. A deeply impacted tooth tends to engage either the crown or root of the second molar. This makes its removal difficult. Adequate bone is removed superiorly to expose the entire crown width, as well as the upper third of the root. The point of application of elevator is pro-



©Association of Oral and Maxillofacial Surgeons of India

Fig. 14.27 (a, b, c) (see text for details) Steps in the surgical removal of mesioangular impaction. (a) Bone removed up to cemento enamel junction using bur, (b) Sectioning of tooth, (c) Tooth delivery using elevator

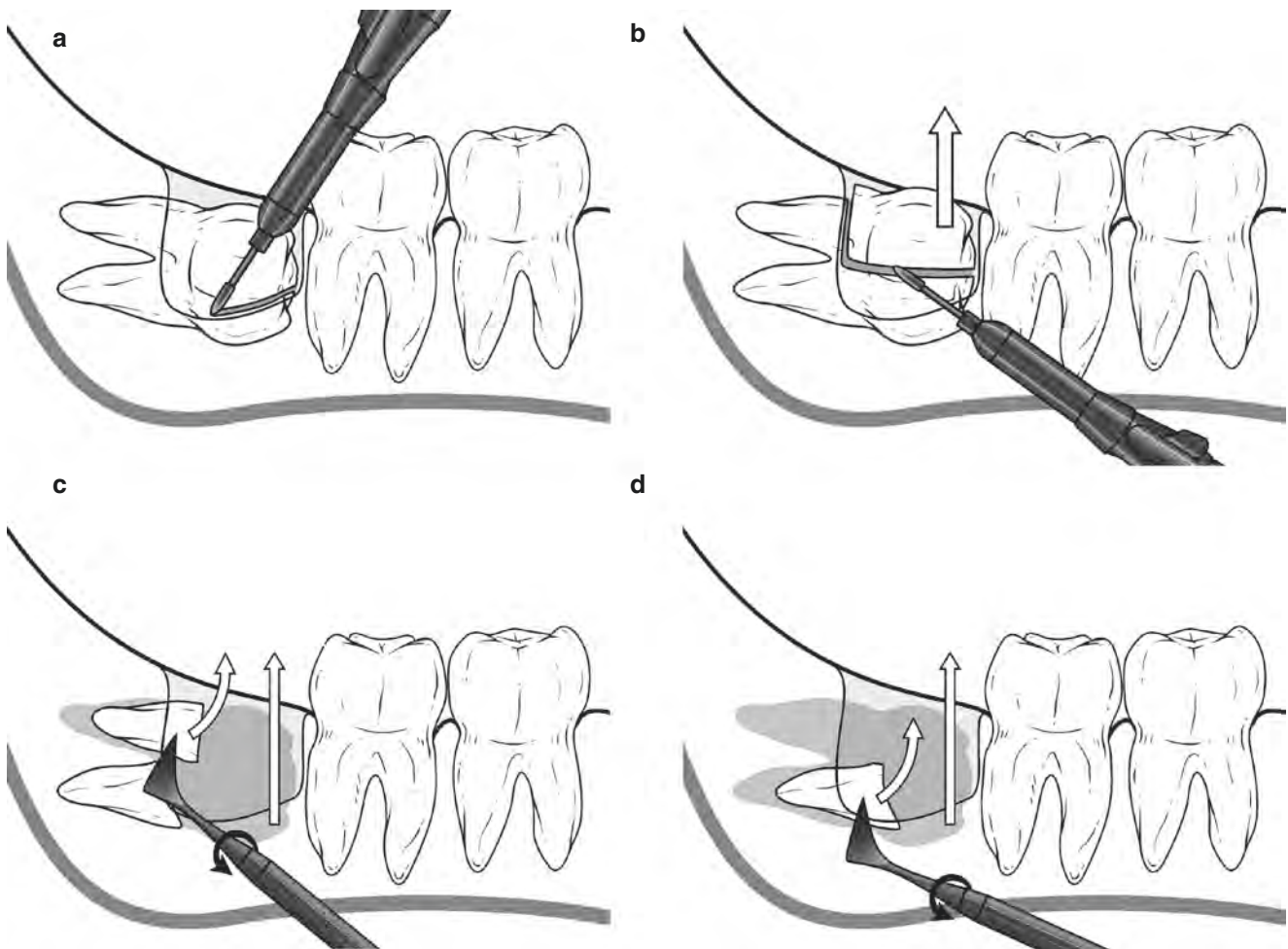
cured below the mesiobuccal aspect of the impacted crown. The tooth is then sectioned at the cervical region and the crown is removed from the socket. The root is then brought forward into the vacant space previously occupied by the crown and it is then removed either in a single piece or after sectioning.

In cases where the impacted tooth is not locked beneath the distal convexity of the crown of the second molar and when an adequate amount of distal bone has been removed, it is possible to turn the tooth into a vertical position by application of force in the mesial aspect. This is similar to the procedure already described for the removal of mesioangular impactions. Use of further force with the elevator will expel the tooth out of the socket or force can be applied on the buccal side to remove the tooth.

Another method of removing horizontal impactions is to split the tooth horizontally into two by sectioning via the

buccal groove into separate mesial and distal roots (technique shown in Fig. 14.29). The distal root with the attached crown part is elevated out first followed by the deeply lying mesial root and part of the crown. If there is difficulty in elevating the deeply placed mesial root segment, it can be again sectioned into two at the cervical region and the crown and the root parts may be removed separately.

The *vertical impaction* (Fig. 14.29a, b, c) is one of the more difficult ones to remove, especially if it is impacted very deeply. The procedure for bone removal and the sectioning is similar to that of a mesioangular impaction. Here also the bone is removed first from the occlusal, buccal, and distal aspect. The distal half of the crown is then sectioned and removed, and the tooth is elevated by applying a small straight elevator at the mesial aspect of the cervical line. Alternatively, similar to mesioangular impactions, a pur-



©Association of Oral and Maxillofacial Surgeons of India

Fig. 14.28 (a, b, c, d) Steps in the surgical removal of a horizontally impacted mandibular third molar. (a) Bone removal to expose the width of the crown and the upper third of the root, (b) Crown may be sectioned into two as shown in the figure and elevated separately. Another technique is to divide the tooth at cemento enamel junction and elevate the crown as a single piece, (c) After removal of the crown, the distal

root sectioned at the furcation is brought forward into the space occupied by the crown, (d) Removal of the mesial root. (the technique shown in Fig. 14.29 can also be used for horizontal impactions where the tooth is sectioned via the bifurcation and distal crown and root is elevated out first, followed by the mesial crown and root)

chase point can be made on the buccal side of the tooth, and a Cryer's elevator may be used to deliver the tooth.

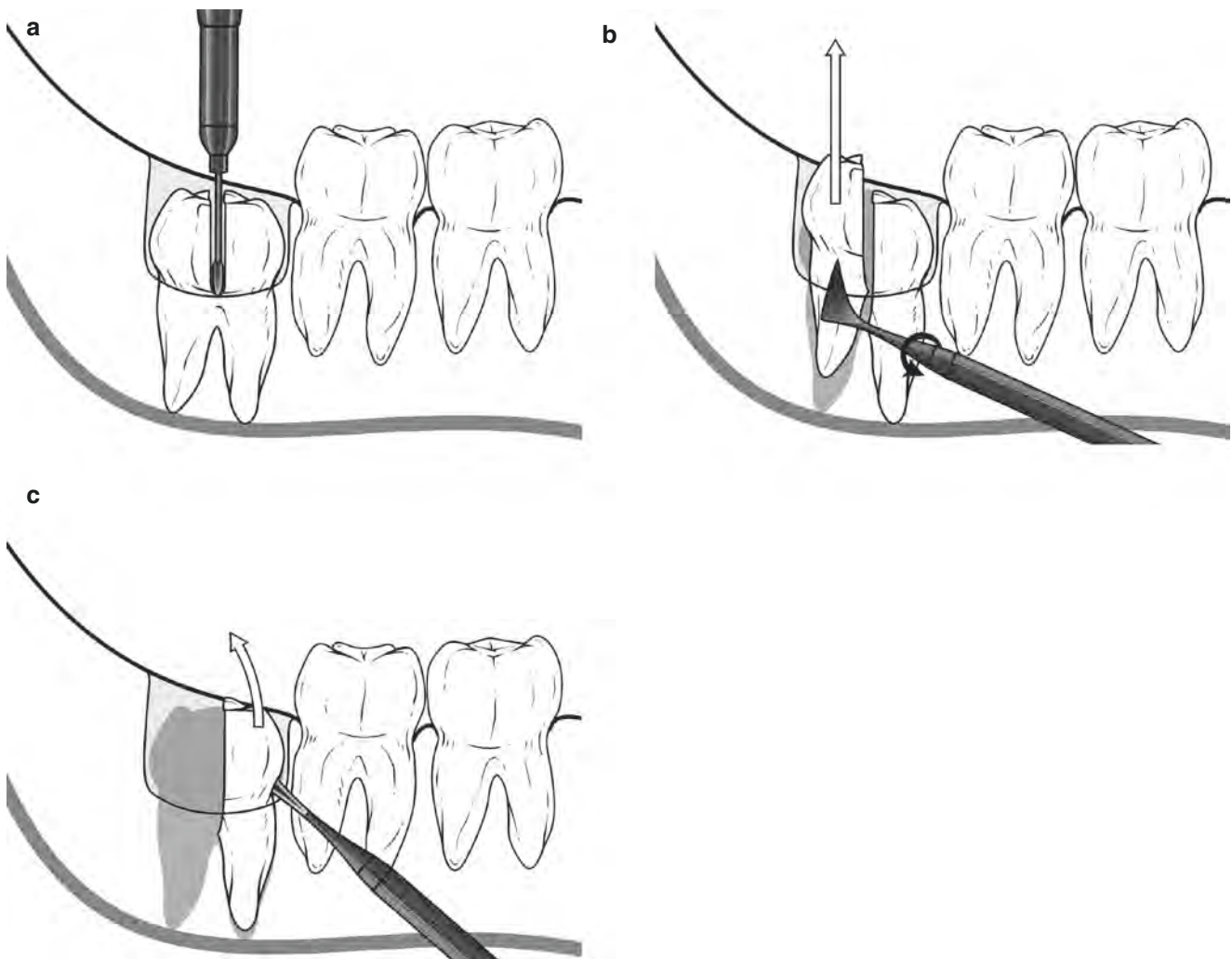
The *distoangular impaction* (Fig. 14.30a, b, c) is considered to be the most difficult tooth to remove. The goal of the technique for removal of these teeth is to create an adequate buccal and distal trough (guttering) around the crown of the tooth to a depth below the cervical line. This will permit to make a point of application of elevator on the buccal aspect of the tooth. Then, using the buccal cortical plate as the fulcrum, force is applied to elevate the tooth out of the socket upward and distally. If some movement is obtained, the distal portion of the crown or the complete crown can be sectioned in a horizontal fashion from the roots and removed. It is preferable in this case to section the tooth segments further as needed rather than to remove more bone. It would be wise to remember the adage

that "Tooth belongs to the surgeon and Bone belongs to the patient". This will ensure preservation of the structural integrity of the mandible. The roots are then delivered together or sectioned and delivered independently with a Cryer's elevator.

In cases where tooth sectioning is required, the distal root should be elevated first followed by the mesial root.

14.8.6 Debridement

After tooth delivery, all bone debris and tissue must be removed from the socket. This is best accomplished by irrigation with saline and mechanically debriding the socket and the area under the flap with a cruet. A bone file or a large bur is used to smooth any rough and sharp edges of the



©Association of Oral and Maxillofacial Surgeons of India

Fig. 14.29 (a, b, c) Steps in the surgical removal of a vertically impacted mandibular third molar. (a) Bone removal to expose the width of the crown, (b) Distal half of the crown sectioned up to the furcation

bone. Any remaining dental follicle must be removed using a mosquito hemostat, to prevent cyst formation. An artery forceps may be used to remove fractured interdental septum or large pieces of bone. The socket and the wound margins (including under surface of mucoperiosteum) is irrigated with saline or sterile water to remove bone and tooth debris.

14.8.7 Wound Closure

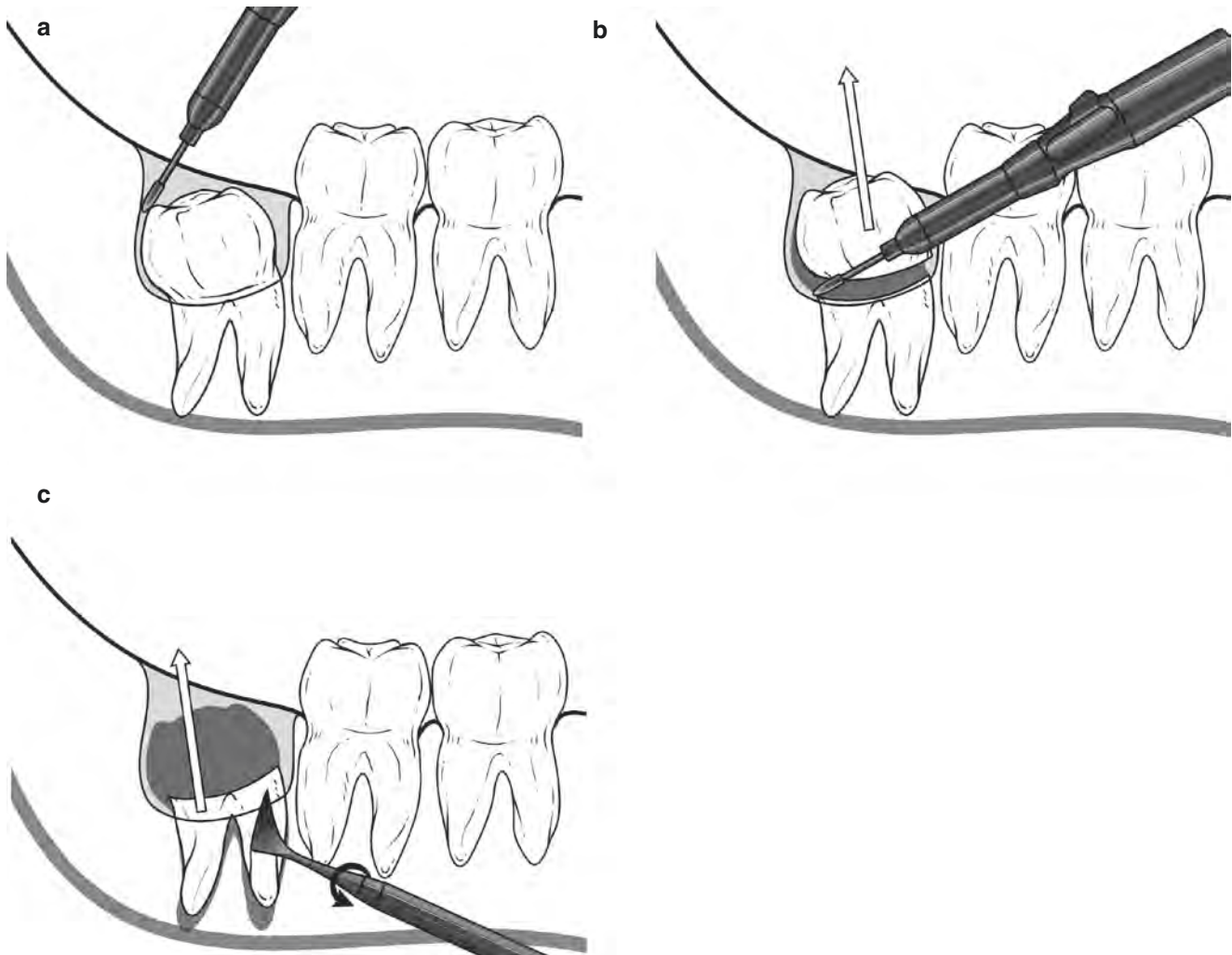
Before attempting closure, bleeding from the socket is completely arrested. Further bleeding from the socket can be controlled using bone wax, Surgicel, or Gelfoam. If there is bleeding from the socket underneath a tight suture, blood will accumulate in surrounding tissue spaces leading to buccal or lingual hematoma or ecchymosis. The flap is then

and it is removed along with the root, (c) Mesial half of the tooth is elevated by mesial application of force at the cervical line

replaced to its original position and the initial suture placed just distal to the second molar. This suture reduces the possibility of the development of periodontal pocket distal to the second molar. The needle is passed from the buccal to the lingual side. Additional sutures are then placed as necessary. The sutures should be just tight enough to hold the flap. Over tightening should be avoided. The vertical component of the incision is left unsutured since it will act as a wound toilet.

Following the procedure, oral and written postoperative instructions given to patient and bystander ensure better patient compliance.

The influence of lower third molar impactions on the periodontal health of the adjacent second molar and the influence of third molar removal on the periodontal attachment of the second molar is a very contentious topic and multiple studies have been done in this regard [32].



©Association of Oral and Maxillofacial Surgeons of India

Fig. 14.30 (a, b, c) Steps in the surgical removal of a distoangularly impacted mandibular third molar. (a) Bone removed to expose the full crown of the tooth to a depth below the cervical line, (b) Crown sectioned in a horizontal fashion from the roots and removed (some sur-

geons prefer to remove only the distal portion of the crown of third molar, so that a point of elevation is available distal to the second molar tooth), (c) Roots are then delivered together or sectioned and delivered independently with a Cryer's elevator

14.8.8 Other Methods for Removal/Partial Removal of Impacted Lower Third Molar

In addition to the standard surgical technique described above, there may be occasions where other methods of surgical removal also have to be considered. This is because no technique is suited to every case and it will be ideal to learn the different methods and choose the suitable one depending upon the case. Readers are advised to refer the concerned publications to get more details.

Some of the other methods seen in the literature are

1. Removal via sagittal split osteotomy [33].
2. Buccal corticotomy technique [34].
3. Lingual split bone technique [35, 36].
4. Lateral trephination technique [37, 38].
5. Partial odontectomy/Coronectomy [15, 16, 39].
6. Removal of the tooth after orthodontic extrusion [40, 41].

14.9 Impacted Maxillary Third Molar (Video 14.3)

Surgical management of upper third molars in general is less complicated compared to lower third molars. They cause less discomfort, are more likely to erupt and are simpler to remove unless unerupted and encased in bone. Removal of upper third molars results in far less postoperative morbidity.

The commonest type of impaction in maxillary third molar is vertical [42].

Classification of impacted maxillary third molars—The system of classification of impacted upper wisdom tooth is basically the same as that for mandibular third molar. However, there are some additional parameters to be considered which will aid in preoperative assessment of the case and guide in planning the surgery for a successful outcome.

1. State of eruption.

- (a) Fully erupted.
- (b) Partially erupted.
- (c) Unerupted:
 - within the bone
 - immediately beneath the soft tissues

2. Angulation of the tooth (Fig. 14.31).

- (a) Vertical.
- (b) Mesioangular.
- (c) Distoangular.
- (d) Laterally displaced with the crown facing the cheek, horizontal, inverted, and transverse positions.
- (e) Aberrant position sometimes associated with pathological condition such as cyst.

3. Pell and Gregory classification—This is based on the relative depth of the impacted maxillary third molar, (Fig. 14.32).

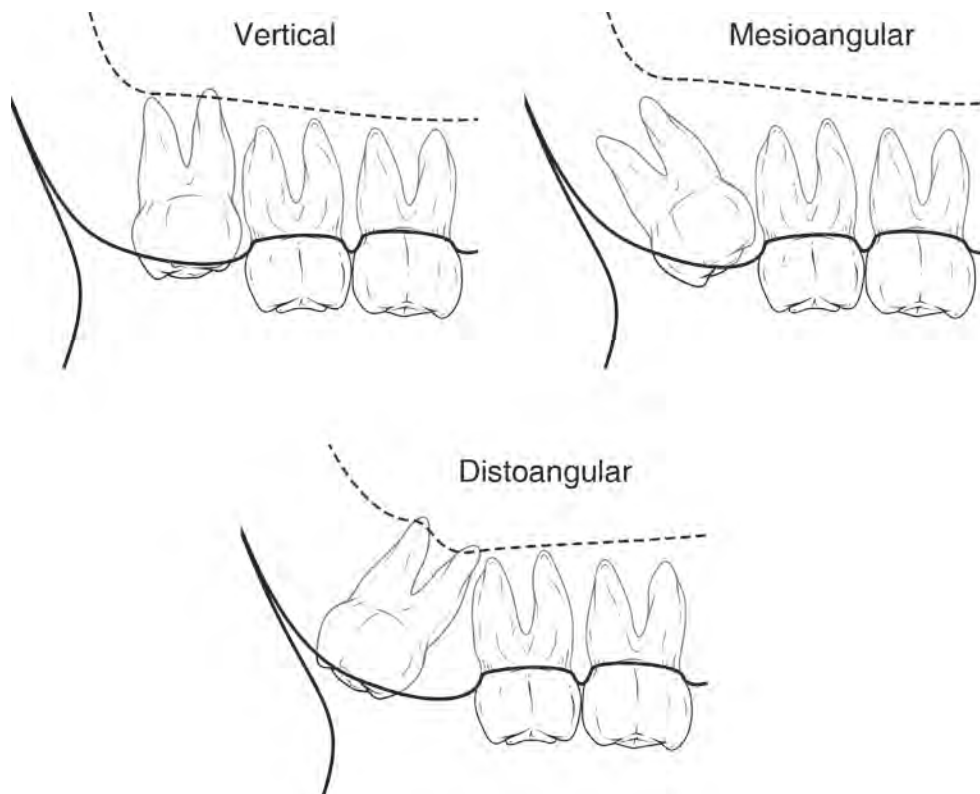
Position A—Occlusal surface of the third molar is at the same level as that of the second molar.

Position B—Occlusal surface of the third molar is located between the occlusal plane and cervical line of the second molar.

Position C—Occlusal surface of the third molar is at or above the cervical line of the second molar.

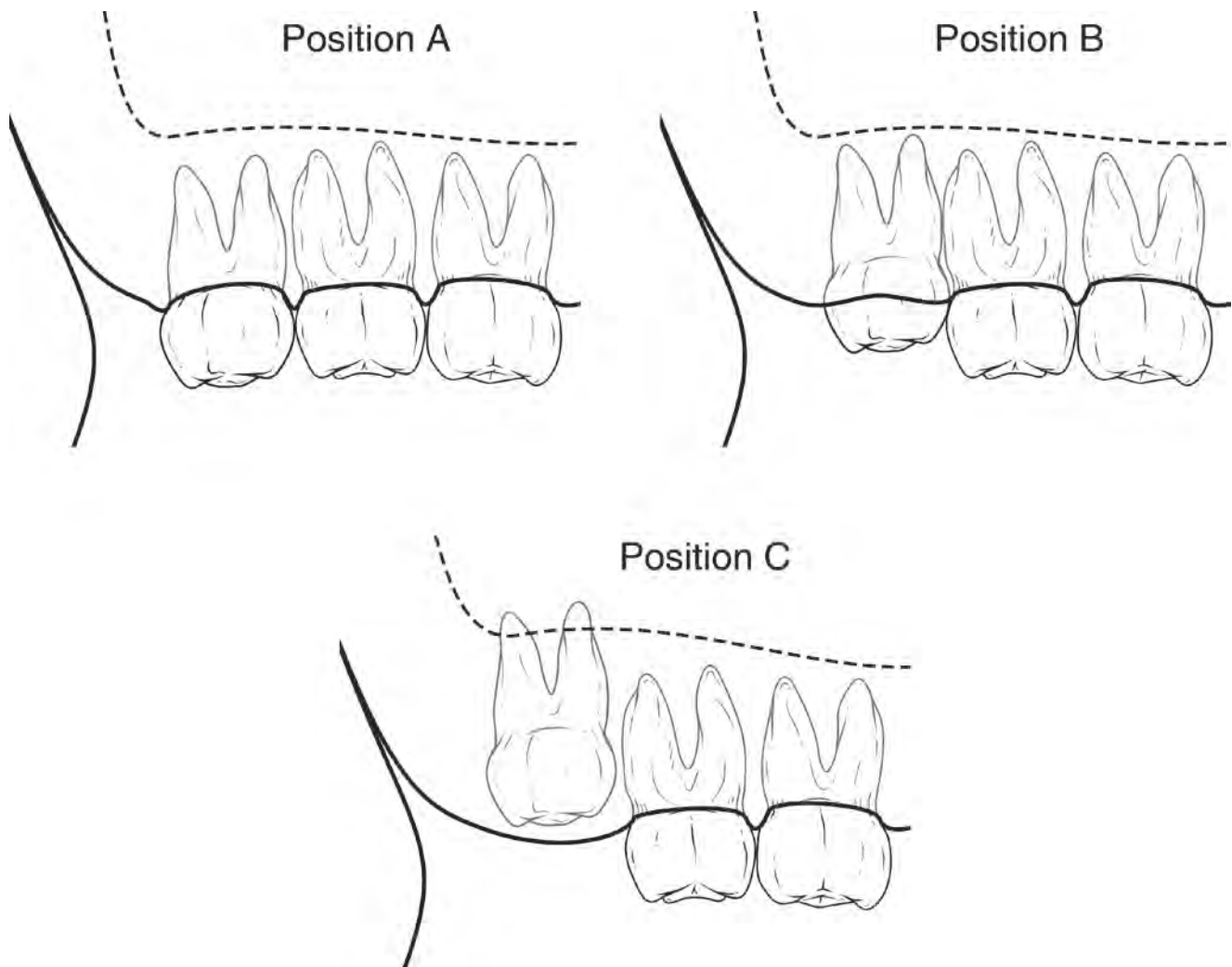
4. Relationship of impacted maxillary third molar to the maxillary sinus.

- (a) Sinus approximation (SA)—No bone or a thin partition of bone between the impacted maxillary third molar and maxillary sinus.
- (b) No sinus approximation (NSA)—2 mm or more bone between the impacted maxillary third molar and maxillary sinus.



©Association of Oral and Maxillofacial Surgeons of India

Fig. 14.31 Classification of impacted maxillary third molar based on angulation



©Association of Oral and Maxillofacial Surgeons of India

Fig. 14.32 Pell and Gregory classification based on relative depth of impacted maxillary third molar

5. *Nature of roots.*

- (a) Fused (conical).
- (b) Multiple—Favorable/Unfavorable.

14.9.1 Radiographic Examination

The following are the useful radiographs:

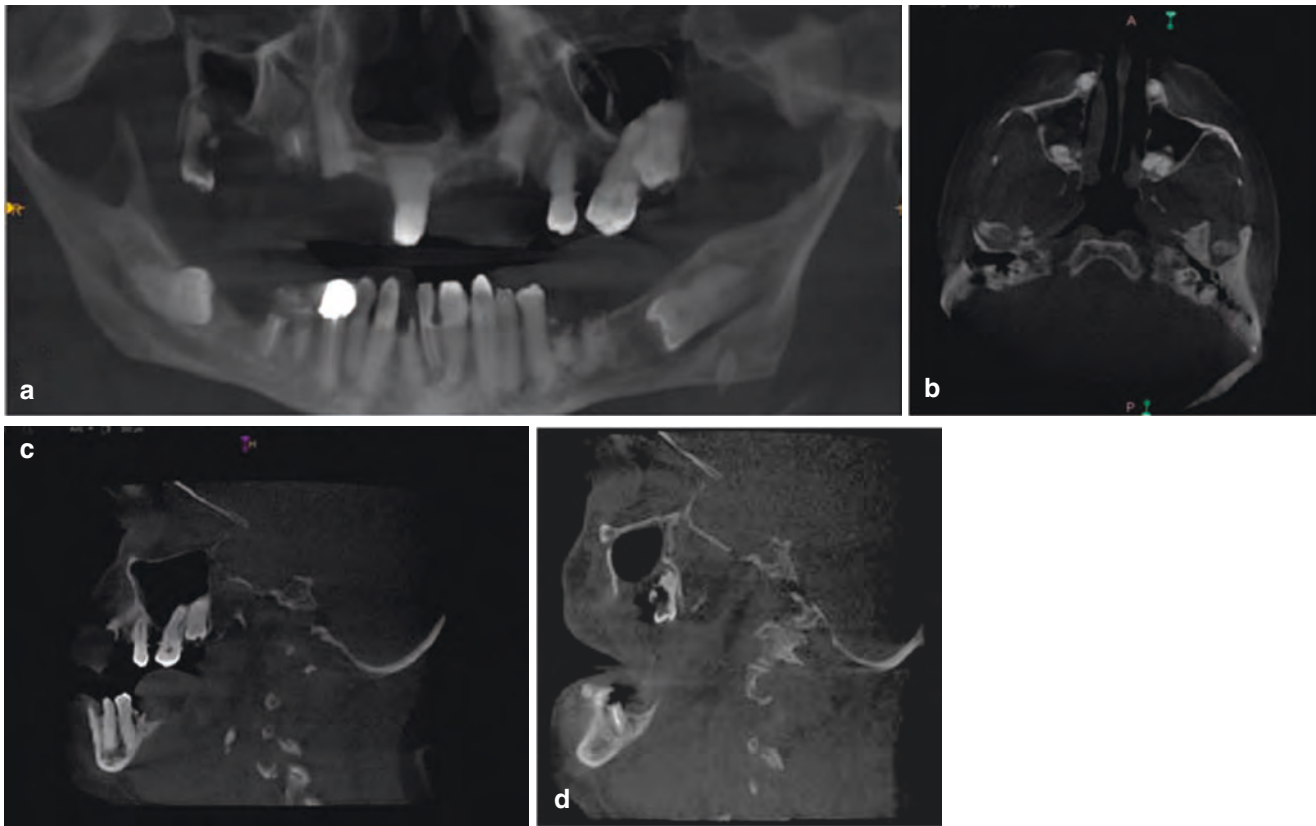
1. Periapical X-ray.
2. Orthopantomogram (OPG).
3. Occlusal X-ray.
4. True lateral view—occasionally helpful.
5. Paranasal sinus view: useful to view pathologies associated with the tooth.
6. CT scan—more useful for suspected pathologies in relation to the impacted tooth.

14.9.2 Indications for the Removal of Maxillary Third Molar

1. Unrestorable dental caries.
2. Recurrent pericoronitis.
3. A tooth that has erupted in a buccoverted or distal direction, which cause cheek bite, or abnormal bite patterns.
4. Tooth involved in pathological process such as cyst.
5. Overerupted and nonfunctional upper third molar.
6. Interference with the placement of prosthesis.

14.9.3 Adjacent Anatomical Factors to be Considered: (Fig. 14.33a–d)

- Proximity to maxillary sinus (Fig. 14.34).
- Proximity to maxillary tuberosity.



©Association of Oral and Maxillofacial Surgeons of India

Fig. 14.33 (a–d) Impacted third molars in a 75-year-old male. (a) OPG showing impacted 28, 38, and 48 with multiple root stumps and dental caries for 18. (b) Axial CBCT showing close relationship of 18

and 28 to maxillary sinus, (c) Sagittal view showing sinus approximation of roots of 27 and 28, (d) Sagittal view showing close relationship of 18 to sinus floor

- Buccal pad of fat.
- Pterygopalatine fossa.
- Infratemporal fossa.

14.9.4 Surgical Removal of Impacted Maxillary Third Molar (Figs. 14.35a–d and 14.36a, b)

The main difficulty here is that the coronoid process may block access to this region, which may be overcome by limiting the amount of mouth opening.

The procedure for maxillary third molar surgical removal is almost the same as that of the mandibular third molar.

14.9.4.1 Incision

It starts from the mesial aspect of the first molar and extends distally beyond the distobuccal aspect of the second molar and is then continued into the tuberosity. In case of a deeply impacted tooth if greater access is required, a triangular flap may be raised by placing a release incision mesial to the second molar.

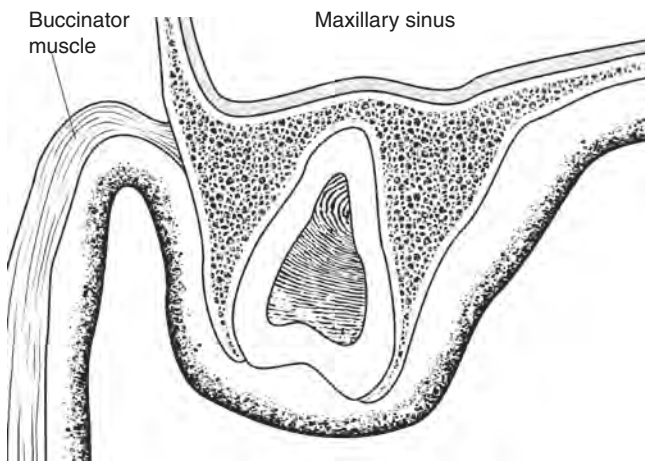
The mucoperiosteum is then reflected using a Howarth's periosteal elevator, which may also be used to retract the flap.

14.9.4.2 Removal of Overlying Bone

Bone removal is generally limited to the occlusal and the buccal aspect of the tooth down to the cervical line to expose the entire crown (Figs. 14.35b and 14.36a). This is done using bur. To create space for the elevator to be inserted, more bone may be removed from the mesial part of the tooth, at a point above the maximum bulge of the crown.

Unlike mandibular third molars, *maxillary third molars rarely need sectioning*, as maxillary bone expands easily, being thin and elastic. Instances where the bone is thicker, sclerotic and less elastic as in old patients, tooth removal is enabled by bone removal rather than tooth sectioning. Chisel is contraindicated to section the tooth due to the danger of displacement of the tooth into the maxillary antrum.

Maxillary third molar teeth must not be sectioned unless absolutely necessary, as displacement of small fragments into the sinus or infratemporal fossa may occur.



©Association of Oral and Maxillofacial Surgeons of India

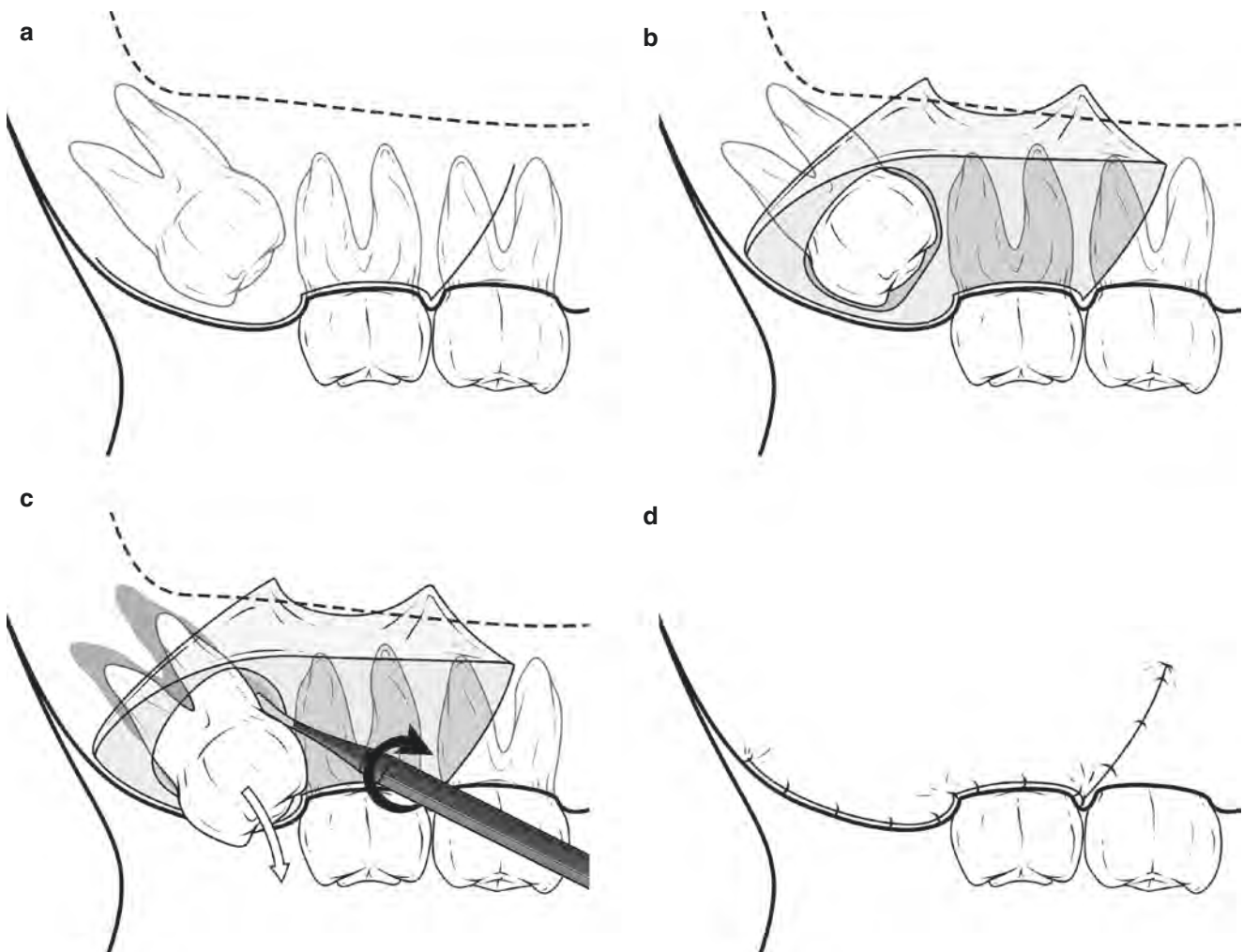
Fig. 14.34 Schematic diagram showing the relationship of impacted maxillary third molar to the floor of the maxillary sinus

14.9.4.3 Delivery of the Tooth

This is achieved using small straight elevators or angled elevators with force exerted in the distobuccal direction. If angled elevators are used, access may be easier. Angled elevators which can be used for this purpose are the Warwick James, Cryer, Pott's, and the Apex elevator. During surgical removal, placement of Laster retractor will help in better access and vision and may also prevent accidental displacement of the maxillary third molar into tissue space beyond the tuberosity.

During tooth elevation, one must remember the following points:-

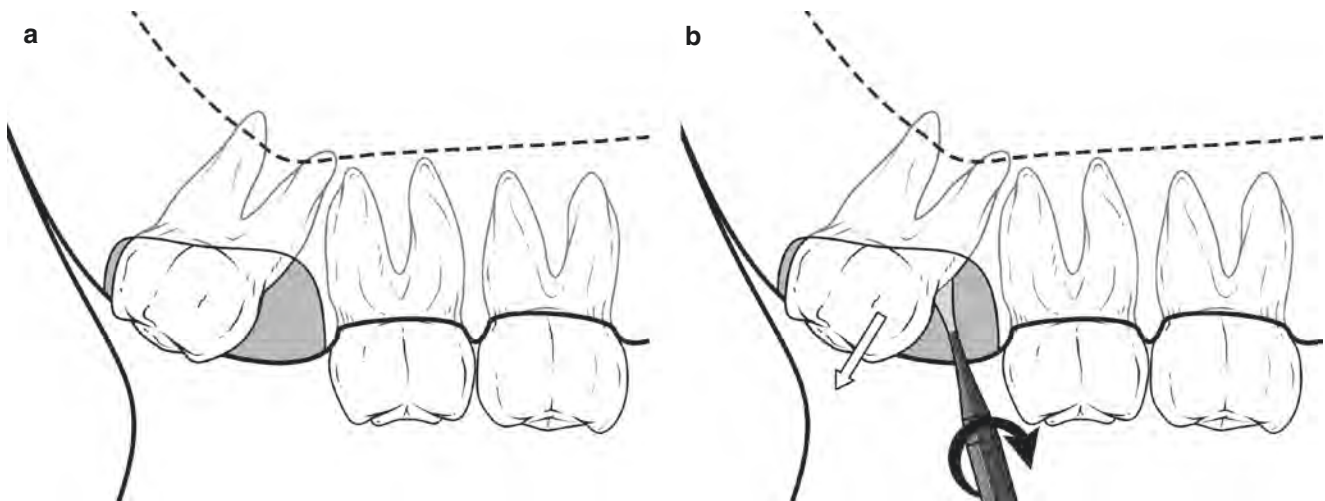
1. Due to the proximity of the maxillary sinus and the infra-temporal fossa, pressure should not be exerted in the superior direction during bone removal and delivery of the tooth.



©Association of Oral and Maxillofacial Surgeons of India

Fig. 14.35 (a-d) Steps in the surgical removal of a mesioangularly impacted maxillary third molar. (a) Incision to raise a triangular flap, (b) Mucoperiosteal flap reflected, (c) Overlying bone removed from

occlusal and buccal aspect up to the cervical line and elevation of tooth, (d) Suturing completed



©Association of Oral and Maxillofacial Surgeons of India

Fig. 14.36 (a) Bone removal achieved on the occlusal and the buccal aspect of tooth down to the cervical line to expose the entire crown, in a disto angular maxillary third molar impaction (b) Delivery of the tooth using an elevator

2. Sufficient space is created between the height of contour of the crown (i.e. above the maximum bulge of the tooth) and surrounding bone so that the tip of the elevator can be placed above the height of contour of the tooth. Then pressure is exerted in a distobuccal direction.
3. Moderate pressure is then exerted distally, buccally and occlusally (i.e. downward and outward) with the fore finger placed posterior to maxillary tuberosity to detect tuberosity fracture if it occurs.
4. In case an accidental opening into the sinus is suspected, every effort should be made to ensure proper closure and the patient is instructed appropriately to prevent the development of an oro-antral fistula.

14.9.5 Complications That Occur During Surgical Removal of Impacted Maxillary Third Molar

1. *Tooth displacement into maxillary sinus*—This usually occurs in cases of partially erupted maxillary third molars, which have conical roots and are located close to the floor of the sinus. The risk increases if the root apex is in contact with the floor of the sinus, and the initial position of the tooth is high.

If this complication occurs, the tooth may have to be removed from the sinus in order to avoid infection. Initially, a suction tip may be placed at the sinus opening to retrieve the tooth. Alternately, saline irrigation into the sinus may be followed by applying the suction tip. If these methods do not work, it is best to stop

attempts and place the patient on antibiotics and nasal decongestants. The tooth may be retrieved later through Caldwell-Luc approach, and the oro-antral fistula may then be closed. The tooth may also be removed using endoscopic sinus surgery [43, 44]. Detailed sequential approach of dealing with root/tooth displaced into the sinus is mentioned in the Chap. 24 on Oro antral communication and fistula in this text book.

2. *Dislodgement into soft tissues*—The upper third molar can be inadvertently displaced into the buccal soft tissues [45] or into the infratemporal fossa [46]. Usually, this happens: (a) when the flap raised buccally is not adequate for access, (b) there is insufficient visibility during the procedure, (c) improper extraction technique, (d) disto-lingual angulation of tooth, and (e) the crown of the third molar is at a level above the root apices of the adjacent molar tooth. Dimitrakopoulos et al. [46] have discussed the various methods to remove a maxillary third molar that has been displaced into the infratemporal fossa.
3. *Damage to adjacent second molar.*
4. *Fracture of maxillary tuberosity.*
5. *Oro-antral communication/fistula.*

14.10 Complications of Impaction Surgery

Complications of removal of impacted tooth can happen during the procedure and late after the procedure. Mild post operative pain, swelling and trismus can be expected

inmost case and these three can be considered as a sequelae of surgical removal of impacted wisdom teeth:-

- (a) *The actual surgical procedure.*
- (b) *Late after surgery.*

A. Complications that can occur during the Surgical Procedure:

These can happen at various steps in the procedure, including:

1. Placement of incision.
 2. Removal of bone.
 3. Sectioning of the tooth.
 4. Tooth elevation and delivery.
1. *Complications during incision:*
 - (a) Bleeding from retromolar vessels.
 - (b) Bleeding from facial vessels.
 - (c) Damage to lingual nerve.
 2. *Complications during bone removal:*
 - (a) *Use of bur.*
 - Accidental burns.
 - Laceration of soft tissues.
 - Injury to inferior alveolar neurovascular bundle.
 - Injury to adjacent tooth.
 - Injury to lingual nerve.
 - Necrosis of bone.
 - Emphysema.
 - (b) *Use of chisel*
 - Splintering of bone.
 - Fracture of mandible.
 - Displacement of tooth into lingual pouch.
 - Injury to lingual nerve.
 - Injury to the soft tissues or second molar.
 3. *Complications during sectioning of tooth.*

During bur usage

 - Sectioning along an incorrect line.
 - Injury to mandibular canal.
 - Breakage of bur.
 4. *Complications during elevation of tooth:*
 - Fracture of impacted tooth/root.
 - Injury to second molar.
 - Fracture of mandible.
 - Displacement of the entire tooth or crown alone into the lingual pouch or lateral pharyngeal space.

B. Postsurgical Sequelae and Complications

1. Pain
2. Edema
3. Trismus
4. Haemorrhage
5. Infection
6. Alveolar osteitis (Dry socket)
7. Nerve Injury:
 - (a) Lingual nerve injury
 - (b) Inferior alveolar nerve injury
8. Surgical Emphysema
9. Hematoma
10. Pain during swallowing
11. Pyrexia
12. Osteomyelitis
13. Temporomandibular joint (TMJ) complications
14. Fracture of instruments
15. Periodontal pocket formation distal to second molar
16. Aspiration/Swallowing of tooth

The management of impacted third molars involves several considerations, and several controversies also exist in this area. Some of these are as follows:

- Whether to remove Asymptomatic/Disease-free tooth [4–6].
- Age of removal [47].
- Flap designs [20–22].
- Technique of removal: bur/laser [31]/peizo surgery [29, 30].
- Primary closure of socket/secondary closure of socket [48].
- Drains in socket/No drains in socket [49].
- Whether to graft the Socket with PRP [50]/PRF [51–53].
- Reconstruction of distal periodontal defect of the second molar [54].

At present, the various evidence-based guidelines available should help the clinician in taking informed decisions regarding third molar impactions [55–57]. Efforts have been made to reach a consensus in various areas, which itself shows conflicting propositions, and only time will prove the best methods which can be used in the management of third molar impactions.

References

1. Archer WH. Oral and maxillofacial surgery, vol. I. 5th ed. Philadelphia: W.B. Saunders; 1975.
2. Lytle JJ. Indications and contraindications for removal of impacted tooth. *Dent Clin of North Amer.* 1979;23(3):333–46.
3. Andreasen J.O, Petersen J.K, Laskin D.M. Textbook and color atlas of tooth impactions, 1, Copenhagen, Munksgaard 1997.
4. Dodson TB. The management of the asymptomatic, disease-free wisdom tooth: removal versus retention. *Atlas Oral Maxillofac Surg Clin North Am.* 2012 Sep;20(2):169–76.
5. Rafetto LK. Removal of asymptomatic third molars: a supporting view. *J Oral Maxillofac Surg.* 2006 Dec;64(12):1811–5.
6. Hill CM. Removal of asymptomatic third molars: an opposing view. *J Oral Maxillofac Surg.* 2006 Dec;64(12):1816–20.
7. Berger A. As cited by Archer, W. H., Oral and maxillofacial surgery, vol. I, 5th ed. Philadelphia: W.B. Saunders; 1975.
8. Pogrel MA, Renaut A, Schmidt B, et al. The relationship of the lingual nerve to the mandibular third molar region: an anatomic study. *J Oral Maxillofac Surg.* 1995;53:1178–81.
9. Behnia H, Kheradvar A, Shahrokhi M. An anatomic study of the lingual nerve in the third molar region. *J Oral Maxillofac Surg.* 2000;58:649–51.
10. Winter GB. Principles of exodontia as applied to the impacted third molar. St Louis: American Medical Books; 1926.
11. Pell GJ, Gregory BT. Impacted mandibular third molars: classification and modified techniques for removal. *Dent Digest.* 1933;39:330–8.
12. Suvy Manuel, Surej Kumar LK, Mathew P Varghese. A comprehensive proforma for evaluation of mandibular third molar impactions. *J Maxillofac Oral Surg.* 2014 Dec; 13(4):378–385.
13. Howe G, Poynton HG. Prevention of damage to the inferior alveolar nerve during the evaluation of mandibular third molars. *Br Dent J.* 1960;109:355–63.
14. Rood JP, Shehab BA. The radiological prediction of inferior alveolar nerve injury during third molar surgery. *Br J Oral Maxillofac Surg.* 1990 Feb;28(1):20–5.
15. Pogrel MA, Lee JS, Muff DF. Coronectomy: a technique to protect the inferior alveolar nerve. *J Oral Maxillofac Surg.* 2004;62:1447.
16. Renton T, Hankins M, Sproate C, McGurk M. A randomised controlled clinical trial to compare the incidence of injury to the inferior alveolar nerve as a result of coronectomy and removal of mandibular third molars. *Br J Oral Maxillofac Surg.* 2005;43:7.
17. Tantanapornkul W, Okouchi K, Fujiwara Y, et al. A comparative study of cone-beam computed tomography and conventional panoramic radiography in assessing the topographic relationship between the mandibular canal and impacted third molars. *Oral Surg Oral Med Oral Pathol Oral Radiol Endod.* 2007;103:253.
18. Ohman A, Kivijarvi K, Blomback U, Flygare L. Pre-operative radiographic evaluation of lower third molars with computed tomography. *Dentomaxillofac Radiol.* 2006;35:30.
19. Danforth RA, Peck J, Hall P. Cone beam volume tomography: an imaging option for diagnosis of complex mandibular third molar anatomical relationships. *JCDA.* 2003;31(11):847–52.
20. Gargallo-Albiol J, Buenechea-Imaz R, Gay-Escoda C. Lingual nerve protection during surgical removal of lower third molars. *J Oral Maxillofac Surg.* 2000;29:268.
21. Pichler JW, Beirne OR. Lingual flap retraction and prevention of lingual nerve damage associated with third molar surgery: a systematic review of the literature. *Oral Surg Oral Med Oral Pathol Oral Radiol Endod.* 2001;91:395.
22. Pogrel MA, K.E. Goldman: lingual flap retraction for third molar removal. *J Oral Maxillofac Surg.* 2004;62:1125.
23. Gulicher D, Gerlach KL. Sensory impairment of the lingual and inferior alveolar nerves following removal of impacted mandibular third molars. *Int J Oral Maxillofac Surg.* 2001;30:306.
24. Valmaseda-Castellon E, Berini-Aytes L, Gay-Escoda C. Inferior alveolar nerve damage after lower third molar surgical extraction: a prospective study of 1117 surgical extractions. *Oral Surg Oral Med Oral Pathol Oral Radiol Endod.* 2001;92:377.
25. Pederson GW. Oral surgery. Philadelphia: WB Saunders; 1988. (Cited in: Koerner KR. The removal of impacted third molars—principles and procedures. *Dent Clin North Am.* 1994; 38:255–78)
26. Yuasa H, Kawai T, Sugiura M. Classification of surgical difficulty in extracting impacted third molars. *Br J Oral Maxillofac Surg.* 2002 Feb;40(1):26–31.
27. Erdogan O, Tath U, Ustün Y, Damlar I. Influence of two different flap designs on the sequelae of mandibular third molar surgery. *Oral Maxillofac Surg.* 2011 Sep;15(3):147–52.
28. Goldsmith SM, De Silva RK, Tong DC, Love RM. Influence of a pedicle flap design on acute postoperative sequelae after lower third molar removal. *Int J Oral Maxillofac Surg.* 2012 Mar;41(3):371–5.
29. Rullo R, Addabbo F, Papaccio G, D'Aquino R, Festa VM. Piezoelectric device vs. conventional rotative instruments in impacted third molar surgery: relationships between surgical difficulty and postoperative pain with histological evaluations. *J Craniomaxillofac Surg.* 2013 Mar;41(2):e33–8.
30. Piersanti L, Dilorenzo M, Monaco G, Marchetti C. Piezosurgery or conventional rotatory instruments for inferior third molar extractions? *J Oral Maxillofac Surg.* 2014 Sep;72(9):1647–52.
31. Stübinger S, von Rechenberg vB, Zeilhofer HF, Sader R, Landes C. Er:YAG laser osteotomy for removal of impacted teeth: clinical comparison of two techniques. *Lasers Surg Med.* 2007 Aug;39(7):583–8.
32. Krausz A, Machtei E, Peled M. Effects of lower third molar extraction on attachment level and alveolar bone height on the adjacent second molar. *Int J Oral Maxillofac Surg.* 2005;34:756.
33. Amin M, Haria S, Bounds G. Surgical access to an impacted lower third molar by sagittal splitting of the mandible: a case report. *Dent Update.* 1995;22:206–8.
34. Tay Andrew BG. Buccal corticotomy for removal of deeply impacted mandibular molars. *Br J Oral Maxillofac Surg.* 2007;45:83–4.
35. Ward TG. The split bone technique for removal of lower third molars. *Br Dent J.* 1956;101:297.
36. Farish SE, Bouloux GF. General technique of third molar removal. *Oral Maxillofacial Surg Clin N Am.* 2007;19:23–43.
37. Henry CB. Excision of the developing mandibular third molar by lateral trepanation. *Br Dent J.* 1969;127:111–8.
38. Chiapasco M, Crescentini M, Romanoni G. Germectomy or delayed removal of mandibular impacted third molars: the relationship between age and incidence of complications. *J Oral Maxillofac Surg.* 1995;53(4):418–22.
39. Pogrel MA. Partial odontectomy. *Oral Maxillofacial Surg Clin N Am.* 2007;19:85–91.
40. Checchi I, Alessandri Bonetti G, Pelliccioni GA. Removing high risk impacted mandibular third molars: a surgical-orthodontic approach. *J Am Dent Assoc.* 1996;127:1214.
41. Alessandri Bonetti G, Bendandi M, Checchi V, Checchi I. Orthodontic extraction: riskless extraction of impacted lower third molars close to the mandibular canal. *J Oral Maxillofac Surg.* 2007;65(12):2580–6.
42. Peterson LJ, Ellis E, Hupp JR, Tucker MR. Contemporary oral and maxillofacial surgery. 4th ed. St. Louis: Mosby; 2003. p. 185–237.
43. Bouloux Gary F, Steed Martin B, Perciaccante VJ. Complications of third molar surgery. *Oral Maxillofacial Surg Clin N Am.* 2007;19:117–28.
44. Pogrel M. Complications of third molar surgery. *Oral Maxillofac Surg Clin North Am.* 1990;2:441.

45. Matthew I. What should I do if a maxillary third molar is inadvertently displaced into the adjacent soft tissues during surgical removal? [point of care]. *J Can Dent Assoc.* 2007;73(4):311–2.
46. Dimitrakopoulos I, Papadaki M. Displacement of a maxillary third molar into the infratemporal fossa: case report. *Quintessence Int.* 2007;38(7):607–10.
47. Haug RH, Perrott DH, Gonzalez ML, Talwar RM. The American association of oral and maxillofacial surgeons age-related third molar study. *J Oral Maxillofac Surg.* 2005;63(8):1106–14.
48. Pasqualini D, Cocero N, Castella A, Mela L, Bracco P. Primary and secondary closure of the surgical wound after removal of impacted mandibular third molars: a comparative study. *Int J Oral Maxillofac Surg.* 2005 Jan;34(1):52–7.
49. Rakprasitkul S, Pairuchvej V. Mandibular third molar surgery with primary closure and tube drain. *Int J Oral Maxillofac Surg.* 1997 Jun;26(3):187–90.
50. Simon D, Manuel S, Geetha V, Naik BR. Potential for osseous regeneration of platelet-rich plasma--a comparative study in mandibular third molar sockets. *Indian J Dent Res.* 2004 Oct-Dec;15(4):133–6.
51. Varghese MP, Manuel S, Kumar LKS. Potential for osseous regeneration of platelet-rich fibrin-a comparative study in mandibular third molar impaction sockets. *J Oral Maxillofac Surg.* 2017 Jul;75(7):1322–9.
52. Canellas JVDS, Medeiros PJD, Figueredo CMDS, Fischer RG, Ritto FG. Platelet-rich fibrin in oral surgical procedures: a systematic review and meta-analysis. *Int J Oral Maxillofac Surg.* 2019 Mar;48(3):395–414.
53. Al-Hamed FS, Tawfik MA, Abdelfadil E, Al-Saleh MAQ. Efficacy of platelet-rich fibrin after mandibular third molar extraction: a systematic review and meta-analysis. *J Oral Maxillofac Surg.* 2017 Jun;75(6):1124–35.
54. Dodson T. Is there a role for reconstructive techniques to prevent periodontal defects after third molar surgery. *J Oral Maxillofac Surg.* 2005;63:891.
55. Task Force for Third Molar Summary. Summary of the third molar clinical trials: report of the AAOMS task force for third molar summary. *J Oral Maxillofac Surg.* 2012 Sep;70(9):2238–48.
56. <https://www.nice.org.uk/guidance/tal>
57. https://www.aaoms.org/docs/govt_affairs/advocacy_white_papers/white_paper_third_molar_data.pdf

Open Access This chapter is licensed under the terms of the Creative Commons Attribution 4.0 International License (<http://creativecommons.org/licenses/by/4.0/>), which permits use, sharing, adaptation, distribution and reproduction in any medium or format, as long as you give appropriate credit to the original author(s) and the source, provide a link to the Creative Commons license and indicate if changes were made.

The images or other third party material in this chapter are included in the chapter's Creative Commons license, unless indicated otherwise in a credit line to the material. If material is not included in the chapter's Creative Commons license and your intended use is not permitted by statutory regulation or exceeds the permitted use, you will need to obtain permission directly from the copyright holder.



George Varghese

Impacted canines are one of the common problems encountered by the oral surgeon. Patients may present at different ages and many cases will be incidental findings. Close interaction with the paedodontist and orthodontist is required to get an optimal outcome. Surgical removal may not be the best treatment in all the cases and particular treatment plan will have to be tailored for the needs of the patient. Localising the impacted canine seems not a challenge any more with the advent of CBCT, in indicated cases. This chapter elaborates on canine impaction, keeping in mind the basic principles mentioned in the chapter on third molar impactions. Premolars, incisors and other teeth may be impacted but most of the surgical principles and approaches mentioned for canine can be applied to them as well.

15.1 Introduction

Maxillary canine is the second most commonly impacted tooth, after the mandibular third molar. The permanent maxillary canine may be considered as impacted when the eruption of the tooth lags behind as compared to the eruption sequences of other teeth in the dentition. Diagnosis of maxillary canine impaction may be made by clinical examination and by radiography.

The normal path through which maxillary canines erupt may be altered due to changes in the eruption sequence in the maxilla, and also by space limitations due to crowding. It is essential to diagnose and treat this condition early, to prevent

the development of complications. An ideal management protocol for impacted permanent maxillary canines should involve an interdisciplinary approach linking the specialties of oral and maxillofacial surgery, periodontology and orthodontics.

15.2 Aetiology of Canine Impaction

Although the exact cause of impacted maxillary canines remains unknown, multiple factors may play a role. Primary causes that have been linked to impacted maxillary canines include the rate at which roots resorb in the deciduous teeth, any trauma to the deciduous tooth bud, disruption of the normal eruption sequence, lack of space, rotation of tooth buds, premature root closure and canine eruption into a cleft. Secondary reasons include febrile diseases, endocrine disturbances and Vitamin D deficiency. Impacted canine can be concomitant with other conditions.

Except the third molars, maxillary canines are among the last teeth to erupt. They usually develop high in the maxilla and need to travel a considerable distance before they erupt.

Local factors may also play a role in canine impaction, and these include:

1. A longer eruption path that the tooth has to traverse from its point of development to normal occlusion [1].
2. Thick palatal bone and mucoperiosteum, which can obstruct eruption of palatally oriented canines.
3. More developed root at the time of eruption, which may minimize the eruptive force.
4. Disorder of the primary canine can affect the position of the permanent one. This is because the crown of the developing permanent canine lies just palatal to the apex of the primary canine root.

Electronic Supplementary Material The online version of this chapter (https://doi.org/10.1007/978-981-15-1346-6_15) contains supplementary material, which is available to authorized users.

G. Varghese (✉)
Principal, Professor and Head, Department of Oral and Maxillofacial Surgery, Pushpagiri College of Dental Sciences, Tiruvalla, Kerala, India

5. Canines are more susceptible to environmental influences as they are among the last teeth to erupt (except the third molars).
6. Limited space for eruption as the canines erupt between teeth which are already in occlusion. The second molar may further reduce the space.
7. The permanent canine has a greater mesiodistal width than the primary canine.

15.3 Classification of Impacted Maxillary Canines

15.3.1 The Following Classification Suggested by Archer (1975) [2] is Very Practical

Class I: Impacted canines in the palate.

1. Horizontal
 2. Vertical
 3. Semivertical
- *Class II: Impacted canines located on the labial surface.*
 1. Horizontal
 2. Vertical
 3. Semivertical
 - *Class III: Impacted canine located labially and palatally—crown on one side and the root on the other side.*
 - *Class IV: Impacted canine located within the alveolar process—usually vertically between the incisor and first premolar.*
 - *Class V: Impacted canine in edentulous maxilla—* Impacted canine can be in unusual positions like inverted position.

15.3.2 Field and Ackerman (1935) Classification [3]

Maxillary Canines

1. Labial position
 - Crown in intimate relation with incisors.
 - Crown well above apices of incisors.
2. Palatal position
 - Crown near surface.
 - Crown deeply embedded in close relation to apices of incisors.
3. Intermediate position
 - Crown between lateral incisor and first premolar roots.
 - Crown above these teeth with crown labially placed and root palatally placed or vice versa.
4. Unusual position
 - In nasal or antral wall.
 - In infraorbital region.

Mandibular Canines

1. Labial
 - Vertical
 - Oblique
 - Horizontal
2. Aberrant
 - At inferior border.
 - On the opposite side.
 - Mental protuberance.

Complications that Can Occur Due to Canine Impaction

1. Adjacent teeth may undergo internal or external resorption.
2. Change in alignment or proclination of lateral incisor (Fig. 15.1).
3. Odontogenic Cyst formation.
4. Development of Odontogenic Tumour.

The clinical signs that indicate an impacted maxillary canine include:

1. Prolonged retention of the primary canine [4] and or delayed eruption of the permanent canine.
2. Lack of a bulge on the labial side of the alveolus in the canine region.
3. Delayed eruption of the lateral incisor, or an incisor that is tipped distally or migrated.
4. Loss of vitality or increased mobility of the permanent incisors.

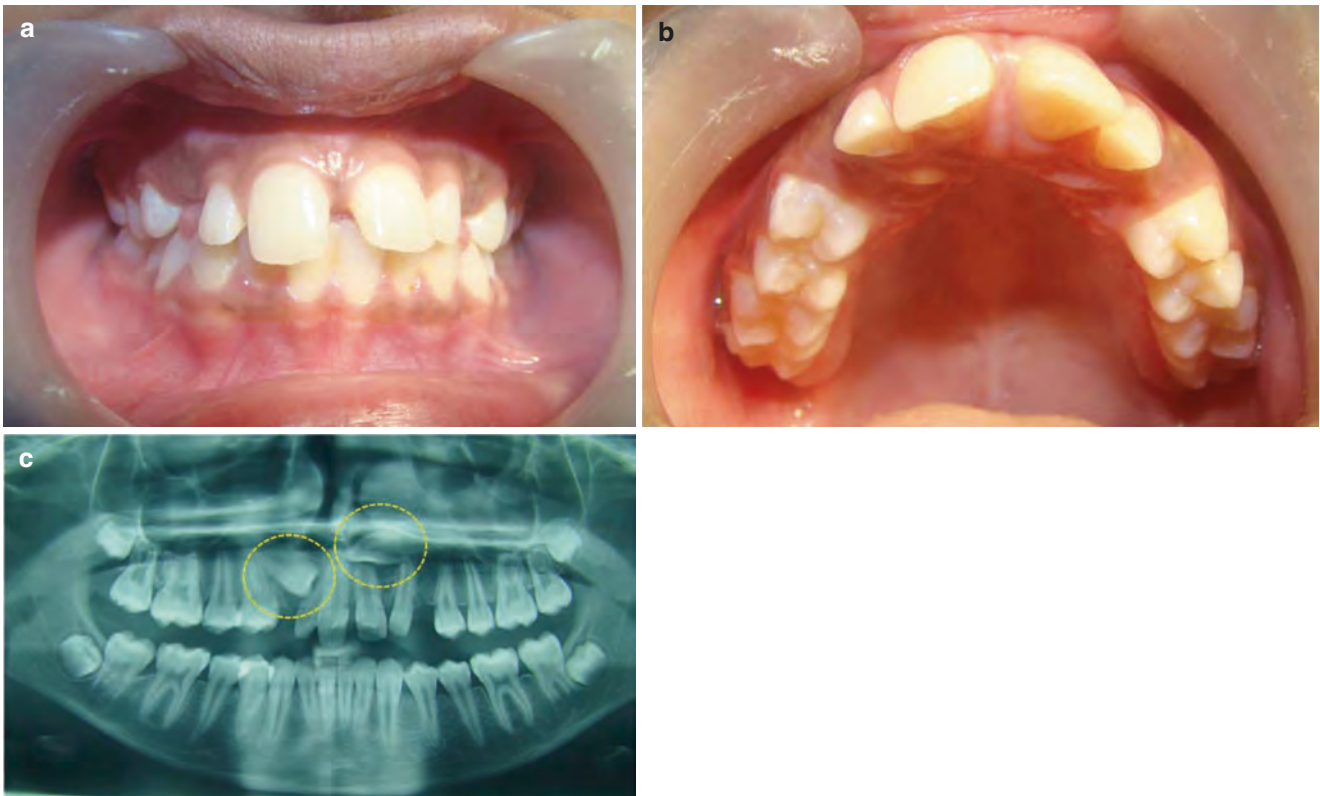
15.4 Radiographic Localization of Impacted Canine

The position of the impacted canine may be determined by visual inspection, palpating intraorally or by radiography.

Radiographic examinations may include periapical X-ray with cone shift technique, occlusal radiography, anteroposterior and lateral radiographic views of maxilla, OPG, CBCT, CT scan.

15.4.1 Radiographic Features to Consider

- Labiopalatal position of the canine relative to the erupted teeth—either labial, palatal or directly above the teeth.
- Orientation of the long axis of the canine in relation to the adjacent teeth.
- Size and shape of the canine, and its root pattern.
- Status and health of the adjacent teeth.



©Association of Oral and Maxillofacial Surgeons of India

Fig. 15.1 Bilaterally impacted maxillary canine causing proclination and spacing of incisors. (a) Frontal view, (b) Occlusal view, (c) OPG showing impacted canines (yellow circle)

- Location and orientation of the crown and root in relation to the adjacent teeth, in three dimensions (vertical, mesio-distal and labiopalatal).
- Presence of associated cyst, odontomas or supernumerary teeth.
- Curvature of the root of impacted tooth.

Going into the fine details of localization of canine is beyond the purview of this chapter. It is an area which has been extensively studied with regard to the various imaging modalities and their advantages.

Various radiographic methods are considered routinely by practitioners for localization. A few of them are mentioned below.

15.4.1.1 Parallax

This was first introduced by Clark [5], and involves two radiographs taken at two different horizontal angles, but using the same vertical angulation. Owing to parallax error, the object that is further away appears to travel in the same direction as the direction in which the tube was shifted. The object nearer to the tube appears to move in the opposite direction [Same Lingual Opposite Buccal (SLOB) rule].

This technique can also be performed with differing vertical angulations (vertical parallax). There are different combinations of parallax techniques:

1. Clark technique: Two intra-oral periapical radiographs are taken using different horizontal angulations [5].
2. Southall and Gravely technique: One maxillary anterior occlusal radiograph and one maxillary lateral occlusal radiograph are taken [6].
3. Rayne technique: This involves differing vertical angulations, with one periapical and one maxillary anterior occlusal radiograph being taken [7].
4. Keur technique: This is also a vertical parallax method, in which one panoramic and one maxillary anterior occlusal radiograph are taken [8].

15.4.1.2 OPG

1. Magnification

The magnification technique depends on a principle known as 'image size distortion'. According to this, for a given 'focal spot'—film distance, objects that are far away from the film will appear more magnified than those that are closer to the film. This has been applied using

OPGs for the impacted canine. (Wolf and Matilla [9]; Fox et al. [10]). In the OPG, if a canine looks bigger as compared to the adjacent teeth in the arch or the contralateral canine, it is probably located closer to the tube (palatal). If it is relatively small, it is located further away from the tube (labial). This method can be applied effectively only when the canine is not rotated, does not touch the incisor root and the incisor is not tipped [11].

Kuftinec [12, 13] asserts that if the canine's cusp is mesially at the root of the lateral incisor, the impaction is probably palatal but if the cuspid is found overlapping the distal half, a labial impaction is more probable.

2. Chaushu et al. [14] stated that a single panoramic radiograph could be used to assess the mesiodistal dimensions of the canine and the ipsilateral central incisors. The canine would be palatally placed if the ratio of the sizes between the canine and the central incisors is 1.15 or greater.
3. Katsnelson [15] et al. suggested a technique that used a horizontal line that extended from the mesiobuccal cusp tip of the right and left maxillary first molars, along the long axis of the impacted canines. The degree of inclination of the canine as compared to the midline is recorded. If the inclination is greater than 65° , the canine is 26.6 times more likely to be buccally placed than palatal.

15.4.1.3 Computed Tomography

Computed Tomography readily provides excellent tissue contrast and eliminates blurring and overlapping of adjacent teeth [16]. However, since CT exposes the patient to a high dose of radiation, the unfavourable relationship between cost and benefit to the patient determines its use only in particular cases, such as in the presence of craniofacial deformities. CT makes it possible to easily identify the position of impacted teeth and evaluate precisely the location of nearby anatomical structures and identify any root resorption in the adjacent teeth.

15.4.1.4 Cone Beam CT

Conventional CT imaging is associated with high radiation dose and high cost. Cone Beam Computed Tomography (CBCT) have been used instead for localization of the impacted canine. As CBCT uses cone-shaped radiation, the radiation dose is significantly reduced, and a high spatial resolution is achieved [17, 18].

Reason for Surgical Removal of Impacted Canines

- Associated cyst/tumour with the impacted tooth.
- Development of caries.
- For prosthetic replacement.
- For orthodontic reasons.
- Resorption of roots in adjacent tooth.
- Malalignment of adjacent teeth.
- Pain referred to other regions.

Treatment Options for Impacted Canines

1. Observation.
2. Surgical exposure.
3. Surgical exposure and orthodontic traction.
4. Surgical removal.

15.5 Modalities of Management of Impacted Canine

The impacted maxillary canine may be managed by several different techniques. The chosen method would depend on the degree of impaction, age of the patient, stage of root formation, presence of any associated pathology, dental condition of the adjacent teeth, position of the tooth, patient's willingness to undergo orthodontic treatment, available facilities for specialized treatment and patient's general physical condition.

1. *Extraction of primary canine.*

This method is as an interceptive form of management. Extraction of the deciduous tooth may be considered when the maxillary permanent canine is not palpable in its normal position and the radiographic examination confirms the presence of an impacted canine. However, this treatment will not necessarily correct the problem. Surgical intervention may be required if the permanent canine fails to erupt within one year of the deciduous extraction.

2. *No treatment—Leave the tooth in situ.*

In some asymptomatic cases, no treatment may be required apart from regular clinical and radiographic follow-up. There is a small risk of follicular cystic degeneration, although the incidence of this is unknown. Rarely, odontogenic tumours may develop in relation to the impacted tooth.

3. Surgical exposure of the tooth.

This technique may be used in cases where there is enough space for the canine to erupt, and where the root formation is incomplete. Surgically exposing the crown of the canine may allow it to come into position by normal eruptive forces.

4. Surgical exposure and orthodontically assisted eruption.

This is the most appropriate approach for an impacted canine. For attempting this technique, the case must fulfil the following criteria:

- (a) The impacted canine must be favourably positioned.
- (b) The patient must be compliant with both surgery and long term orthodontics.
- (c) The patient must not have associated medical problems.

5. Surgical removal of the impacted tooth.

This technique is preferred for teeth that are in an unfavourable position, and which are likely to cause problems in the future. It may also be considered when a patient is not willing for orthodontic treatment or cannot afford it, even if the impacted tooth is in a favourable position.

6. Surgical repositioning/Autotransplantation.

Impacted canines that are malpositioned, but have a favourable root pattern (without hooks or sharp curves) may be considered for autotransplantation into the dental arch. This may be done by utilizing the socket of deciduous canine or first premolar, depending on the amount of space needed and available.

15.5.1 Surgical Exposure of Impacted Canines

Surgical Exposure Techniques

- Gingivectomy and exposure of crown/ surgical window.
- Closed eruption method (Repositioned flap) [19, 20].
- Apically repositioned flap technique (window flap) [19, 20].
- Tunnel Technique [21].

Various studies have compared the effects of the different exposure techniques in the periodontium; however, a consensus is yet to be reached [22–24].

Chapokas et al. in 2012 have brought out a useful classification of maxillary canine impactions based on which the exposure technique may be decided [25].

15.5.1.1 Procedure

1. Palatally positioned canine

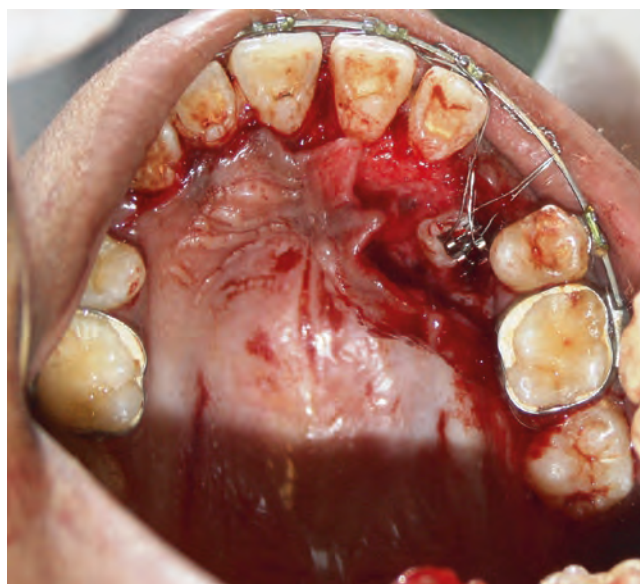The location of the crown of the impacted canine may be determined by radiographs. The possible position of the crown is determined, and a cruciform incision made over this. Along the incision arms, flaps are elevated on four sides so that the crown is uncovered. The flaps may be excised. If there is haemorrhage, it can usually be controlled by pressure application. If there is any bone overlying the crown, it is removed and sharp edges are smoothed so that the crown lies in a saucer-shaped bony cavity. To prevent soft tissue regrowth over the exposed crown, a pack (such as a perio pack or roller gauze impregnated with iodoform or antibiotics) may be inserted or sutured in place. Another alternative technique is to use a crevicular incision, expose palatally and place orthodontic brackets as shown in Fig. 15.2.

2. Labially positioned canines

Any one of the following techniques may be employed depending on the depth and position of the impacted tooth:

- (a) *Creating a surgical window/Gingivectomy:* This is done if the tooth lies just underneath the gingiva. The overlying soft tissue is simply excised to expose the crown.

If the impacted canine is close to the alveolar crest, or if a broad band of keratinized tissue covers the tooth, a surgical window may be created. Gingivectomy may be done when it is possible to uncover at least one



©Association of Oral and Maxillofacial Surgeons of India

Fig. 15.2 Exposure of a palatally impacted canine

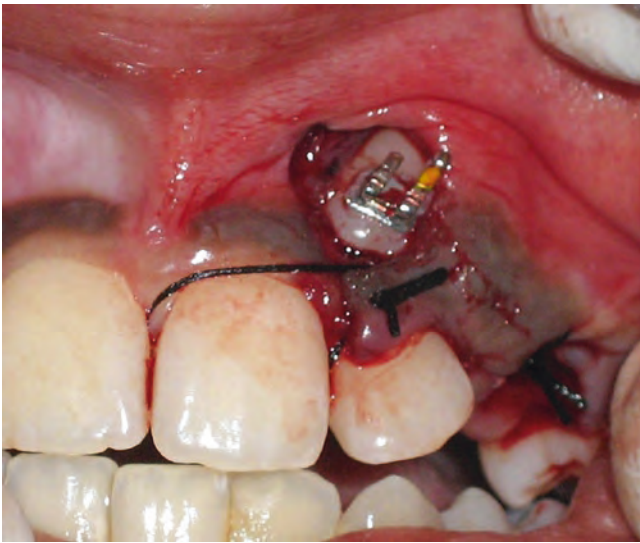
half to 2/3 of the crown, leaving at least 3 mm of gingival collar. Usually in these cases, the tip of the impacted tooth lies near the cemento-enamel junction of the adjacent tooth (Fig. 15.3).

- (b) *Closed eruption technique*: If the impacted canine lies in the middle of the alveolus, near the nasal spine, or high in the buccal vestibule or the palate, this technique may be indicated (Vermette et al., 1995) [19]. A flap is first elevated over the area of the impacted tooth. If necessary, the crown is then exposed after removal of the overlying bone. An orthodontic bracket may be bonded to the crown and to the bracket, a traction wire is affixed. The flap is then sutured, with the traction wire left exposed to the oral cavity. Sufficient time is given for the flap to undergo initial healing. Later on, the traction wire may be connected to an archwire and optimal force may be

applied as needed for the tooth to erupt. Drawback of this technique is that the tooth cannot be inspected directly once the flap has been sutured (Fig. 15.4).

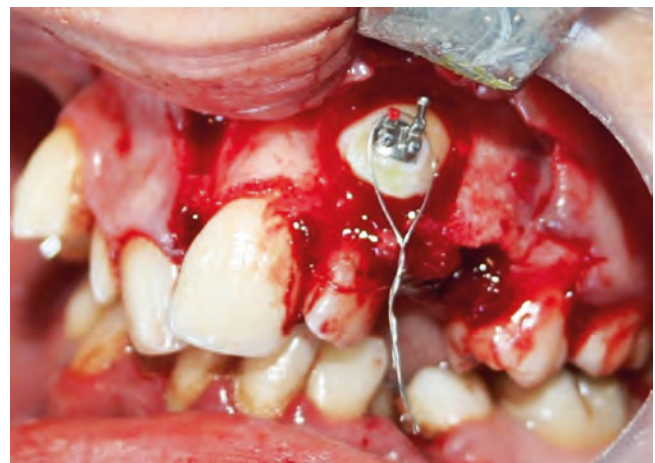
- (c) *Apically positioned flap*: In cases where the cervical portion of the crown does not lie within the attached gingiva, removal of the soft tissue may cause the attached gingiva to be lost. Later on, this can lead to periodontal problems. In such a case, it may be better to use an apically repositioned flap.

The flap is designed in such a way that vertical incisions are placed on the soft tissue at the distal side of the lateral incisor and at the mesial side of the first premolar. Then a horizontal incision is made that links the two vertical incisions. Subsequently, after locating the crown of the impacted tooth, the flap may be sutured back into at the apical end, while the crown is exposed to the oral cavity (Fig. 15.5a, b).



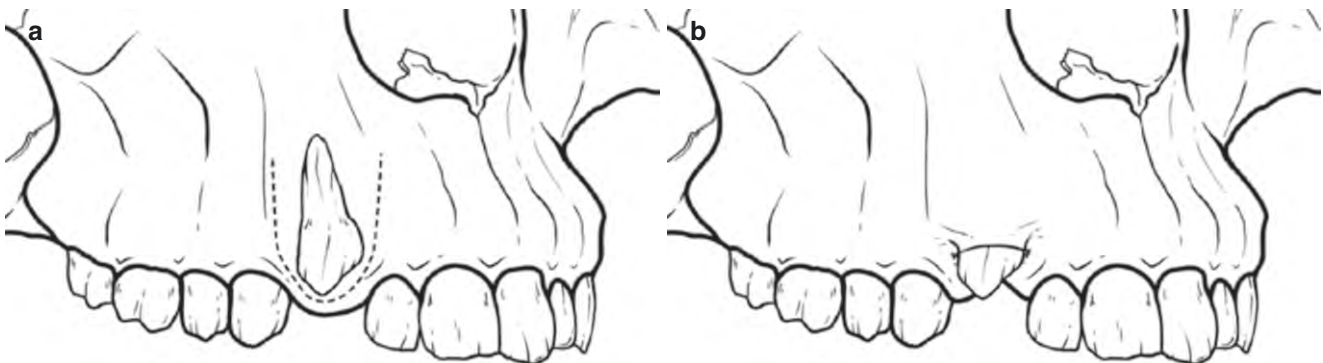
©Association of Oral and Maxillofacial Surgeons of India

Fig. 15.3 Exposure of labially impacted canine by surgical window technique



©Association of Oral and Maxillofacial Surgeons of India

Fig. 15.4 Closed eruption technique for labially impacted canine



©Association of Oral and Maxillofacial Surgeons of India

Fig. 15.5 (a, b) Schematic diagram of apically positioned flap for exposure of a labially positioned crown. (a) Incision, (b) Suturing

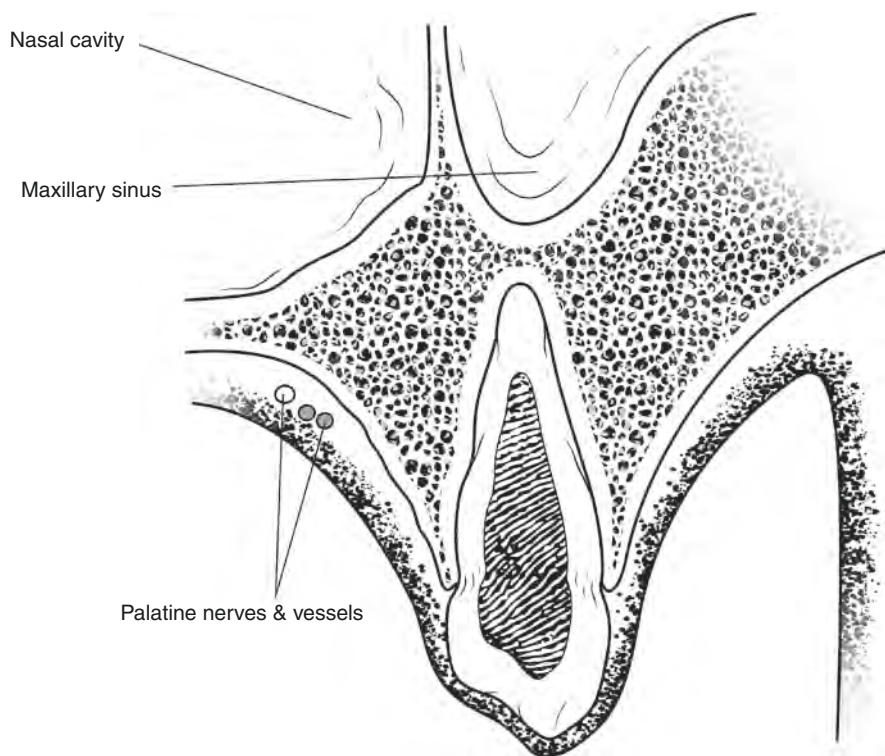
15.5.2 Surgical Removal of Palatally Impacted Maxillary Canines

If the impacted maxillary canine is in an unfavourable position, and cannot be brought into normal occlusion, it should be removed earlier rather than later. This is because increasing age increases the difficulty of the procedure, and by removing early, damage to the adjacent structures may be minimized.

15.5.2.1 Surgical Anatomy

The impacted canine is separated by a thin layer of the bone from the maxillary sinus and nasal cavity (Fig. 15.6). Infrequently, this bone may be absent. In these cases, the risk of tooth or root displacement into the maxillary sinus is high. It is also not uncommon to have the likelihood of creating a communication between the oral cavity and antrum, which may lead to post-operative nasal bleeding.

Fig. 15.6 Surgical anatomy of maxillary canine area. Note the close relationship of the root of the impacted canine to the floor of the maxillary sinus and nose



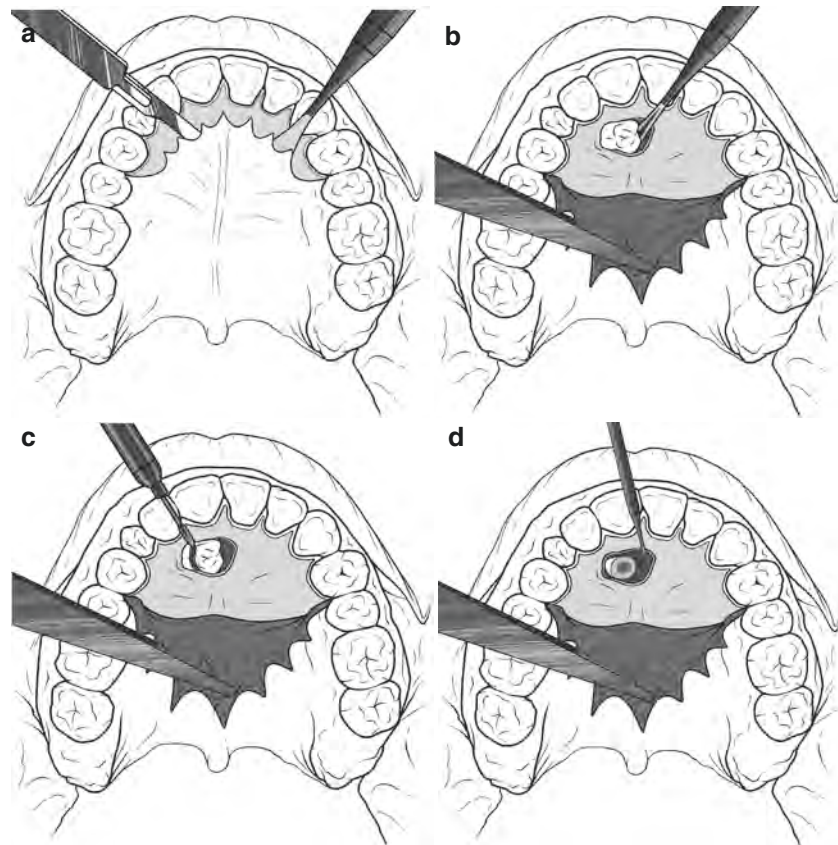
15.5.2.2 Procedure (Fig. 15.7a–d) (Fig. 15.8a, b)

The incision is initiated in the gingival margin on the palatal side from the ipsilateral first premolar and, depending on the position of the impacted tooth, is extended up to the contralateral lateral incisor or premolar.

In cases of unilateral impaction, instead of extending the incision to the contralateral side, a vertical incision may be given in the mid palatal region. In situations where there is bilateral canine impaction and both teeth are close to the midline, the incision should always extend between the first or second premolars of both sides (Fig. 15.8). Elevation of a single palatal flap not only avoids sloughing but also provides adequate visualization. This method may pose a risk of haemorrhage from the nasopalatine vessels which can, however, be controlled by pressure pack or by electrocautery.

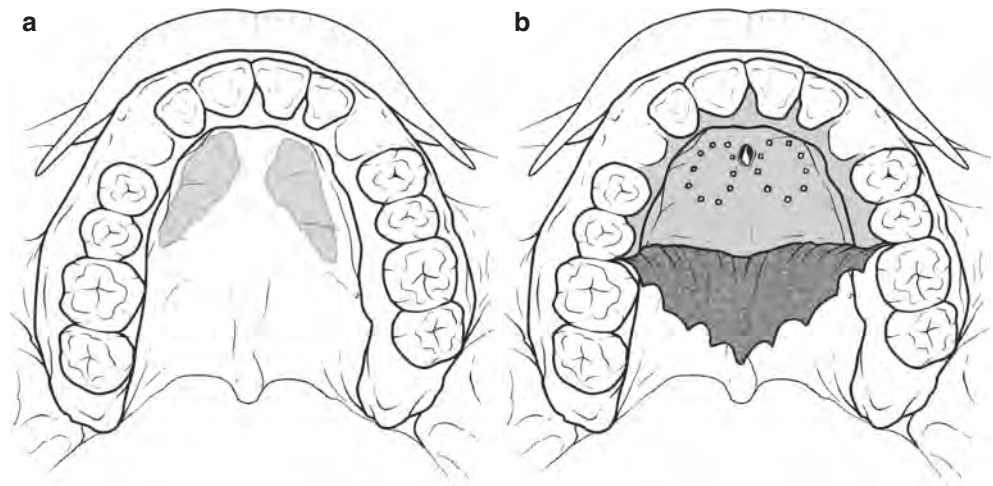
The mucoperiosteal flap is then reflected to reveal the palatal bone and the tooth. Division of the nasopalatine vessels and nerve may be done for further exposure.

Fig. 15.7 (a–d) Schematic diagram showing steps in the surgical removal of palatally positioned impacted maxillary canine (a) Reflection of the flap, (b) Removal of bone to expose the crown, (c) Sectioning of the crown, (d) Removal of the root

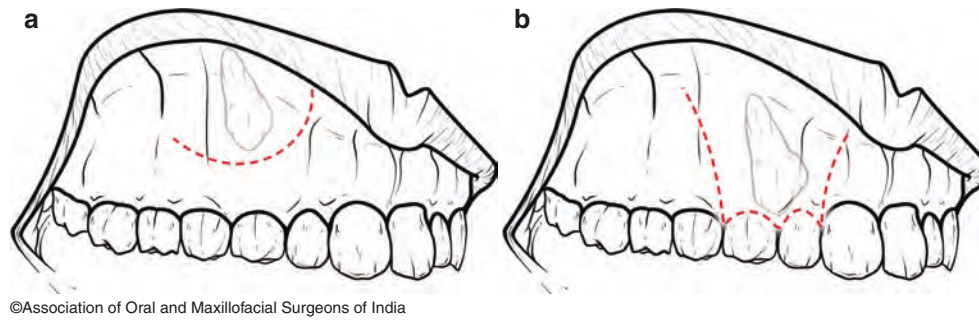


©Association of Oral and Maxillofacial Surgeons of India

Fig. 15.8 (a, b) Palatal flap elevation for exposure of bilaterally impacted palatally positioned canine. (a) Flap outlined from the second premolar on one side to the second premolar of the opposite side, (b) Following reflection of the mucoperiosteal flap, multiple drill holes are placed in the bone overlying the crown. These drill holes are then connected together to remove the bone thereby exposing the crown



©Association of Oral and Maxillofacial Surgeons of India



©Association of Oral and Maxillofacial Surgeons of India

Fig. 15.9 (a, b) Incisions for removal of labially placed canine. (a) Semilunar incision, (b) Trapezoidal (3 sided) incision

The crown of the tooth may be visible occasionally, or a bulge may be felt. Bone around the area is removed with bur, taking care to protect the roots of the adjacent teeth from damage. Once adequate bone is removed, a groove is prepared on the mesial side and an elevator may be inserted into it. An attempt is made to luxate the tooth. Once the crown is moved out, it may be grasped using an upper anterior or premolar forceps. Dislodgement of the root apex may require a certain amount of torsion, as this is often curved.

If the tooth is resistant to elevation, more bone removal is done to enlarge the opening. Tooth sectioning (odontotomy) may be carried out using a straight fissure bur if there is any obstruction to movement (Fig. 15.7c, d). The crown portion is removed first. A portion of the root may then be visualized. If not, bone is removed to expose the root. A hole is created in the root and an elevator is used to engage this and remove the root.

Meticulous debridement and curettage is done to remove the tooth follicle. Saline irrigation is used to clear out bone debris. The flap is replaced and sutured into position. It is held in close contact with the palatal bone by pressing a gauze pack with the dorsum of the tongue, for an hour or two. Healing follows without any complications.

To decrease chances of hematoma formation, a prefabricated clear acrylic plate may be used to cover the palate post-operatively.

15.5.3 Surgical Removal of Labially Positioned Impacted Maxillary Canine (Fig. 15.9a, b) (Video 15.1)

15.5.3.1 Incision

A semilunar incision (Fig. 15.9a) is usually used, and it provides good exposure. The lower part of the incision must lie at least 0.5 cm away from the gingival margin.

For cases that are deeply impacted, triangular flaps (2 sided) or trapezoidal flaps (3 sided) may be used, with incisions along the gingival margin and relieving incisions. (Fig. 15.9b).

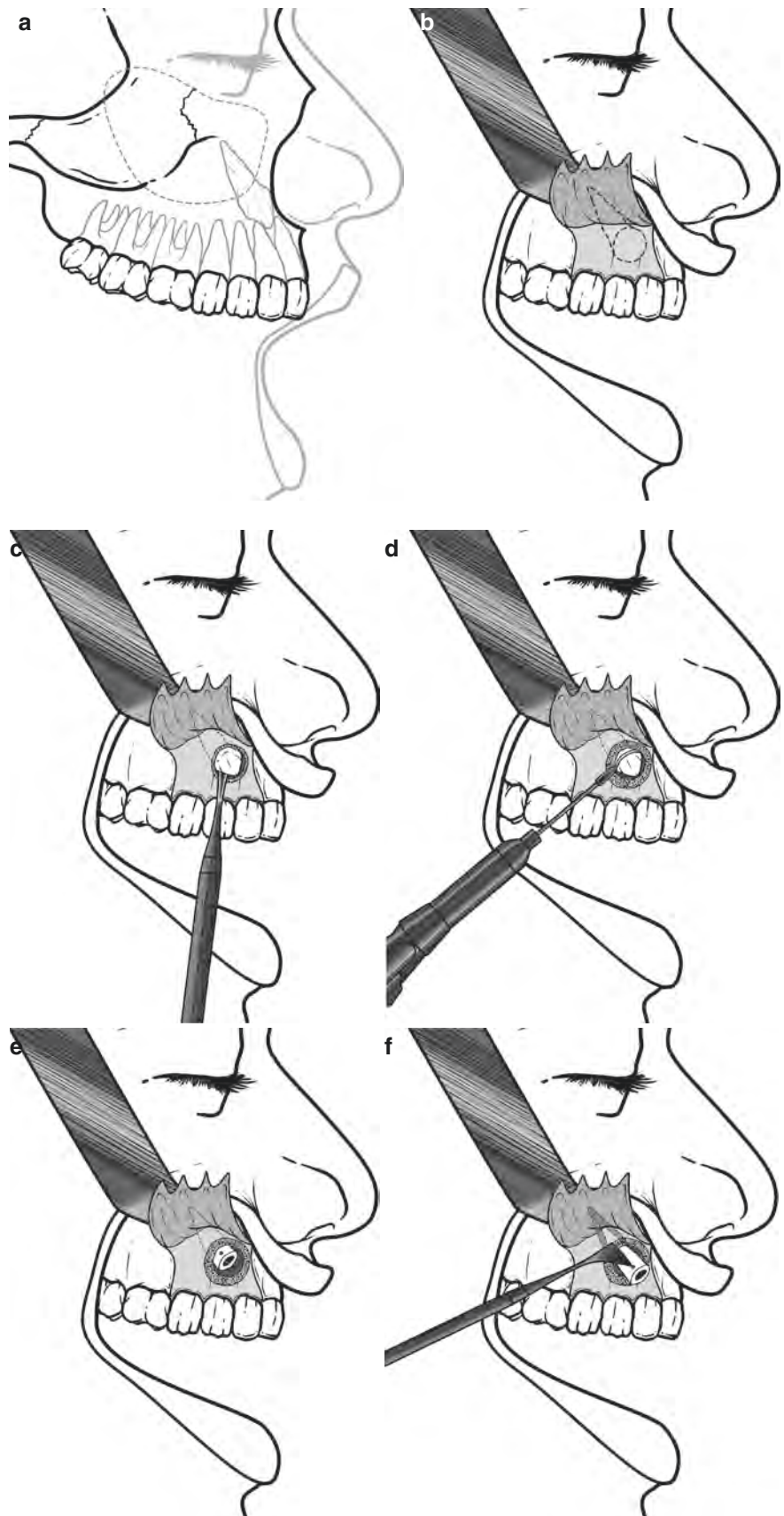
15.5.3.2 Operative Procedure (Fig. 15.10a–f) (Fig. 15.11a–i)

The mucoperiosteal flap is elevated and the bone with the tooth bulge is exposed. Using a bur, a window is created over the crown prominence. The window is enlarged so that the entire crown is exposed, taking care not to cause damage to the adjacent tooth roots. The tooth is then luxated using an elevator.

If there is any resistance during elevation, the tooth must be sectioned, so that the fragments can be removed easily. If three fragments are created, the middle one may be removed first, and the remaining two fragments may be elevated using the resultant space (Fig. 15.10a–f).

The area is carefully debrided and checked for a residual follicle, which must be removed. The mucoperiosteal flap is repositioned and sutured (Fig. 15.11a–i) shows the localisation and surgical removal of a labially positioned impacted maxillary canine.

Fig. 15.10 (a–f): Schematic diagram showing surgical removal of labially impacted maxillary canine. **(a)** Impacted maxillary canine. Note the relationship of the cuspid to the roots of the adjacent teeth, nasal cavity and maxillary sinus. **(b)** trapezoidal mucoperiosteal flap reflected. **(c)** Drill holes placed in the cortical plate overlying the crown so as to expose the crown, after the full exposure of the crown, elevator is applied beneath the crown to mobilize the tooth, **(d)** If the tooth is resistant to elevation, the crown is sectioned using bur and it is removed, **(e)** Cavity created following removal of crown, **(f)** The root is moved into the space created by the removal of the crown and it is then removed



15.5.4 Removal of Maxillary Canine in an Intermediate Position (Fig. 15.12a–h)

The impacted maxillary canine may be located in an intermediate position, with the root oriented labially and the crown palatally, or vice versa. Removing a maxillary canine in the intermediate position may be challenging and may take more time as it may require a labial and palatal approach. The risk of damaging adjacent teeth is also higher with teeth in an intermediate position. CBCT or CT scan is very useful to locate the exact position of such a tooth. Figure 15.12a–h illustrates the steps involved in

removing an impacted canine that has its root oriented labially and crown palatally.

Complications of removal of maxillary canines:

- Perforation through the nasal or antral mucosa.
- Tooth or root displacement into the maxillary sinus
- Haemorrhage
- Adjacent tooth root damage
- Fracture of apical third of the root of the impacted tooth.

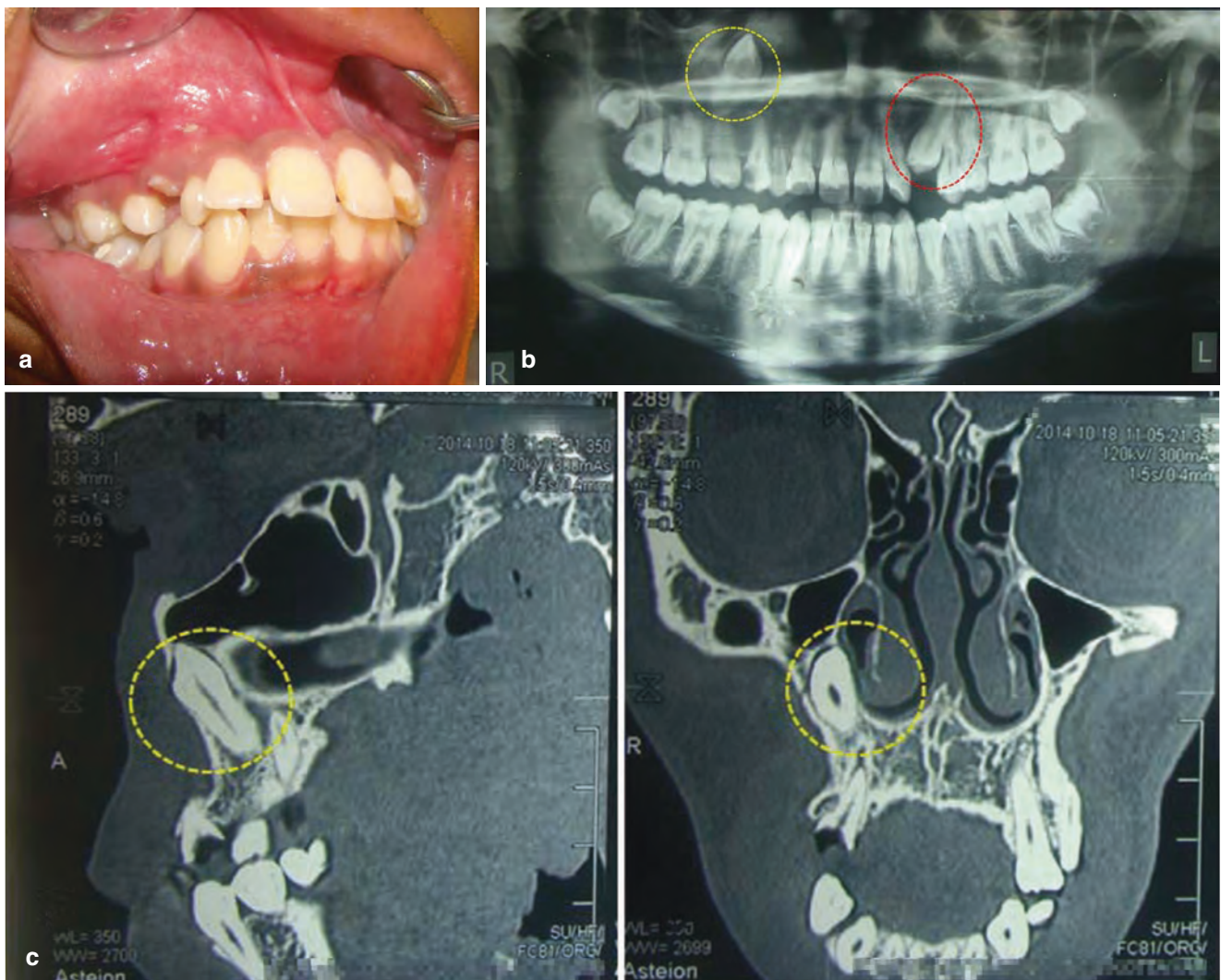
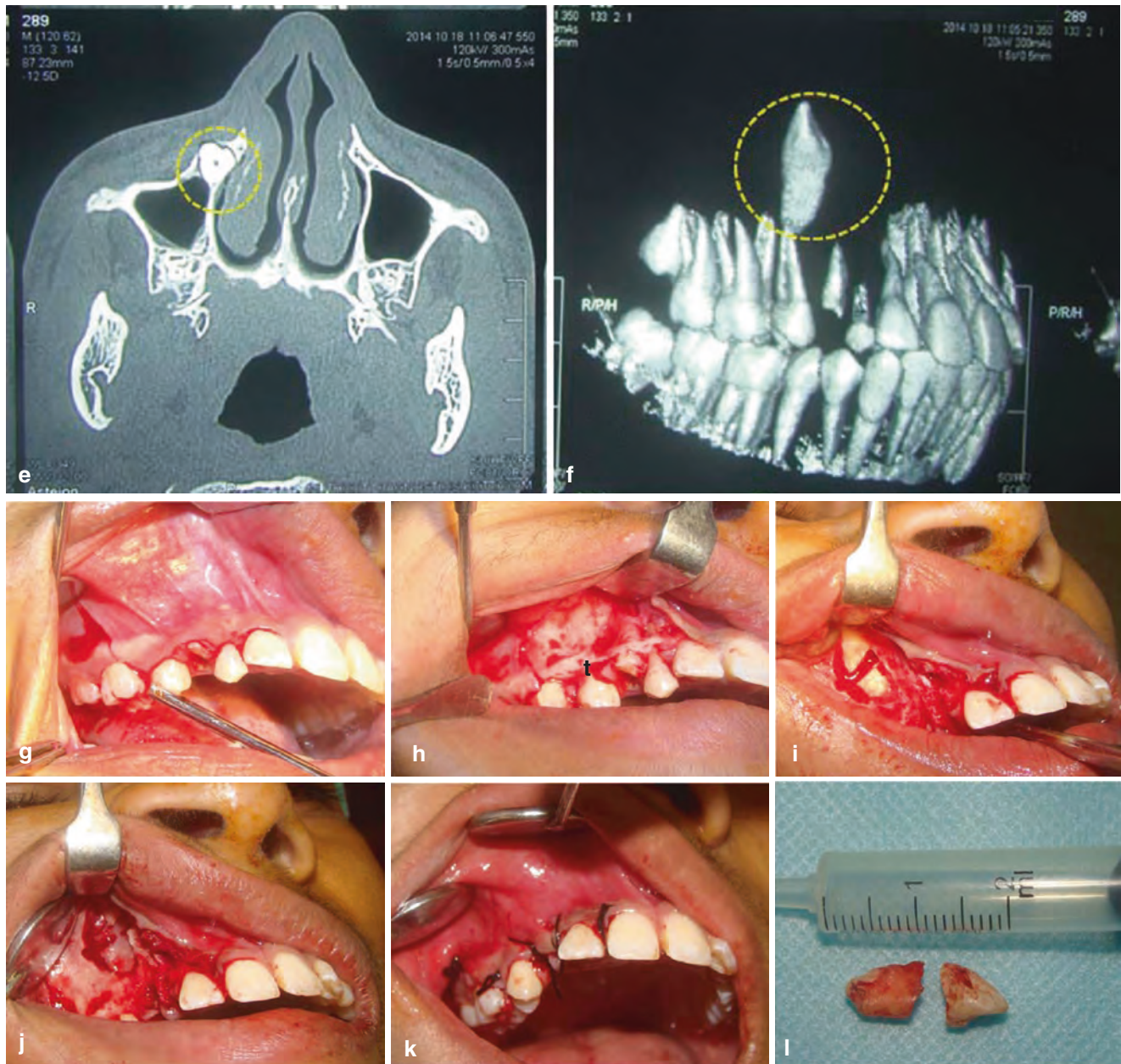


Fig. 15.11 (a–l) show the clinical and radiographic images of the steps in removing a labially impacted canine by odontectomy. Bilaterally impacted maxillary canines (a) Intra-oral right lateral view, (b) OPG showing 13 in inverted position (yellow circle) with close proximity to maxillary sinus and impacted 23 (in red circle). CT of the same patient showing the relationship of the inverted 13 (yellow circle) to adjacent

structures such as maxillary antrum, nasal floor and nearby teeth. (c) Sagittal view, (d) Coronal view, (e) Axial view, (f) 3-D view. Steps in the surgical removal of impacted 13. (g) Incision marked, (h) Mucoperiosteal flap reflected, (i) Tooth division done, (j) Tooth removed and debridement (k) Suturing completed, (l) Specimen



©Association of Oral and Maxillofacial Surgeons of India

Fig. 15.11 (continued)

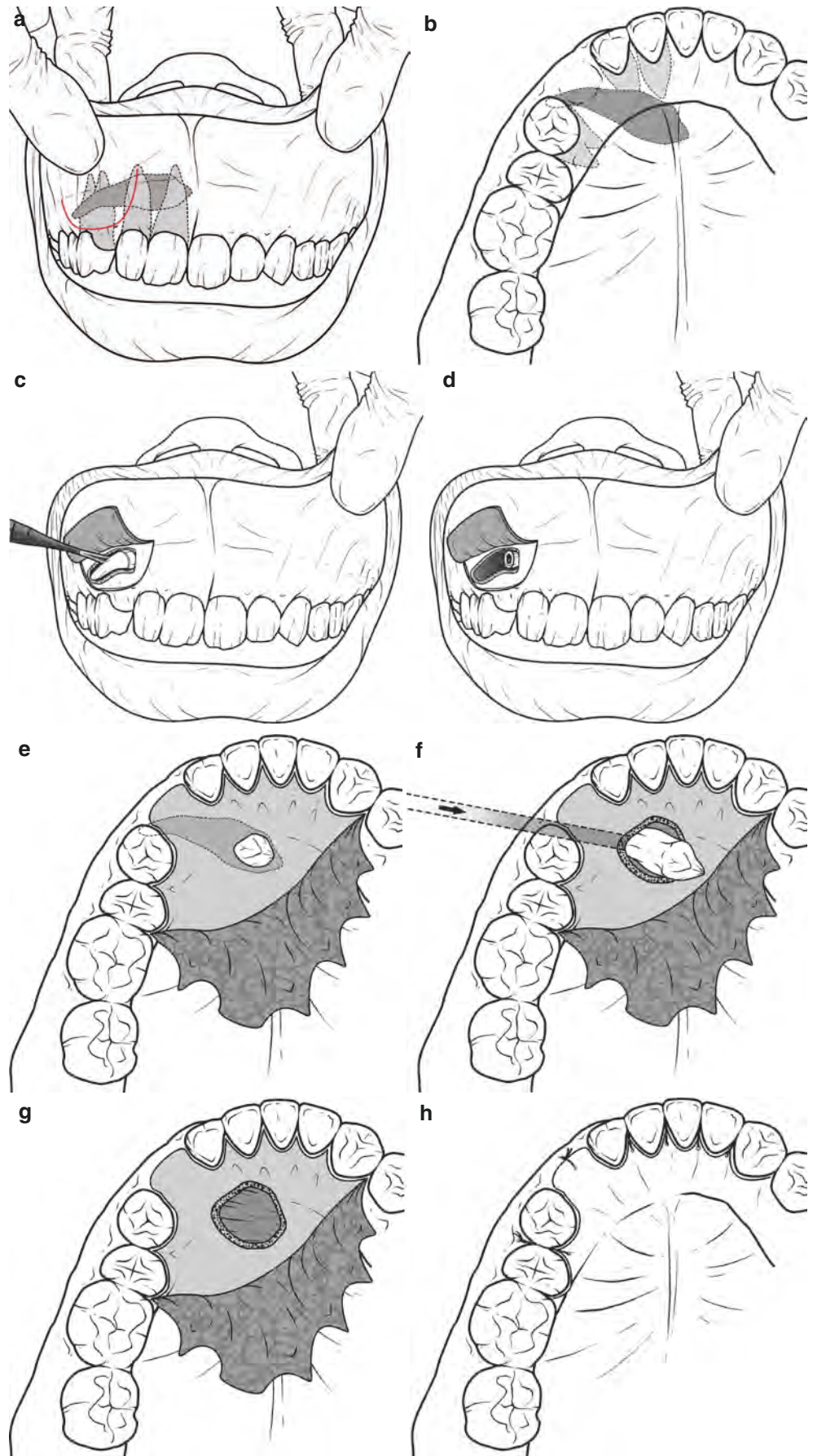
15.5.5 Management of Impacted Mandibular Canines

Impacted mandibular canines are not as frequent as maxillary canines, and are usually found in a labial position. However, they may occasionally migrate to the mental protuberance or even the lower border of mandible, where they can lie in a transverse position. They can also drift to the opposite side of the mandible, referred to as transposition/transmigration of the canine. It must be noted that

these teeth retain their original innervation, which is important to consider while administering local anaesthesia.

The diagnosis of an impacted mandibular canine is similar to that of the impacted maxillary canine, and it presents with similar features. These include retained primary teeth, proclination/displacement of adjacent incisors or clinical features associated with cyst formation. Impacted canines may not be associated with any symptoms, and may be accidentally discovered during the routine radiographic exami-

Fig. 15.12 (a–h) Schematic diagram showing the steps in the surgical removal of impacted maxillary canine with root on the labial side and crown on the palatal side. (a) Outline of the impacted canine and its relation to the roots of the adjacent tooth. Note the semilunar incision marked. (b) Outline of the crown of the impacted canine on the palatal aspect, (c) Mucoperiosteum reflected on the buccal side overlying the bone to be removed and the root of the impacted tooth sectioned. An elevator is being used to dislodge the root, (d) Empty socket after removal of the root. (e) Palatal flap is outlined and reflected. Bone covering the crown of the impacted tooth is removed using bur. (f) Using a blunt instrument placed in the socket of the tooth on the buccal side, pressure is exerted on the cut end of the crown (see black arrow) to push the crown palatally, (g) Empty socket on the palatal side after removal of the crown, (h) Flap is replaced back and suturing completed



nation, or during the investigation of other dental conditions. Sometimes, however, these teeth can cause recurrent pain and infection.

Dalessandri et al. in 2017 opined that the most common treatment strategies for the treatment of mandibular canine impactions are surgical extraction and orthodontic traction. Surgical extraction and radiographic monitoring were suggested for transmigrant mandibular canines: The authors proposed a decision tree in order to guide practitioners through the treatment plan of impacted mandibular canines [26].

15.5.5.1 Treatment Options

The impacted mandibular canine may be treated using one of the following strategies:

1. *Observation*
2. *Exposure and orthodontic repositioning*
3. *Surgical repositioning*
4. *Surgical removal of the tooth*—The impacted mandibular canine may be removed if one of the following conditions is present:
 - (a) Pathology such as follicular cyst or tumour in relation to the impacted tooth.
 - (b) Orthodontic reasons, such as the need to move an adjacent tooth into the area of impaction.

15.5.5.2 Surgical Anatomy (Fig. 15.13)

The bone in the mandibular canine region consists of a thick lingual cortex and a thin buccal cortex. The impacted tooth usually lies mesial or distal to the actual canine region. A buccal flap must ideally be used for surgical access, as a lingual flap may not provide adequate access, and is associated with increased post-operative morbidity. While raising the buccal flap, the mentalis muscle insertion (at the mental fossa) and incisive muscle insertion (at the height of the canine alveolus) are divided.

15.5.5.3 Removal of Mandibular Canine (Figs. 15.14 and 15.15)

For tooth exposure, a trapezoidal (3 sided) flap is used. Alternately, a horizontal incision may be made below the attached gingiva. If the tooth lies close to the lower border of the mandible, an additional incision may be needed extra-orally for proper exposure. As in the case of maxillary canine in the labial position, bone removal is done with bur. The tooth may be elevated in toto, or may require sectioning if resistance is met (Figs. 15.14a–h and 15.15).

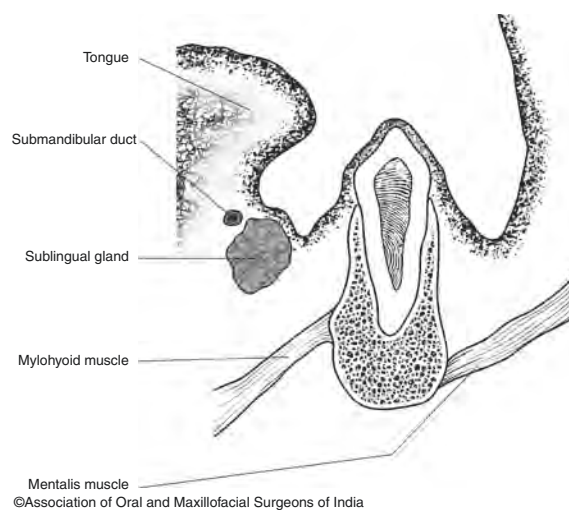


Fig. 15.13 Surgical anatomy of mandibular canine area

15.5.5.4 Complications of Surgical Removal

These Include the Following

1. *Injury/mobility of the adjacent tooth*—This can occur during bone removal, if the supporting bone of the lateral incisor is removed accidentally. This is managed by splinting the lateral incisor to the adjacent tooth.
2. *Mental nerve injury*—If the distal vertical incision is extended too far backwards and inferiorly, the mental nerve may accidentally be severed.

15.6 Summary

The management of impacted canine teeth requires skilful handling and careful observation on the part of an oral and maxillofacial surgeon. If any tooth is absent in the dental arch after the normal time of eruption has lapsed, the surgeon must investigate. The management of an impacted tooth is simple if the basic principles of surgery are followed appropriately for all the teeth. The case must be evaluated carefully for proper diagnosis and treatment planning. Treatment planning requires a multidisciplinary approach, and the general dental surgeon must consult with the oral and maxillofacial surgeon, orthodontist and paedodontist for achieving optimal results.

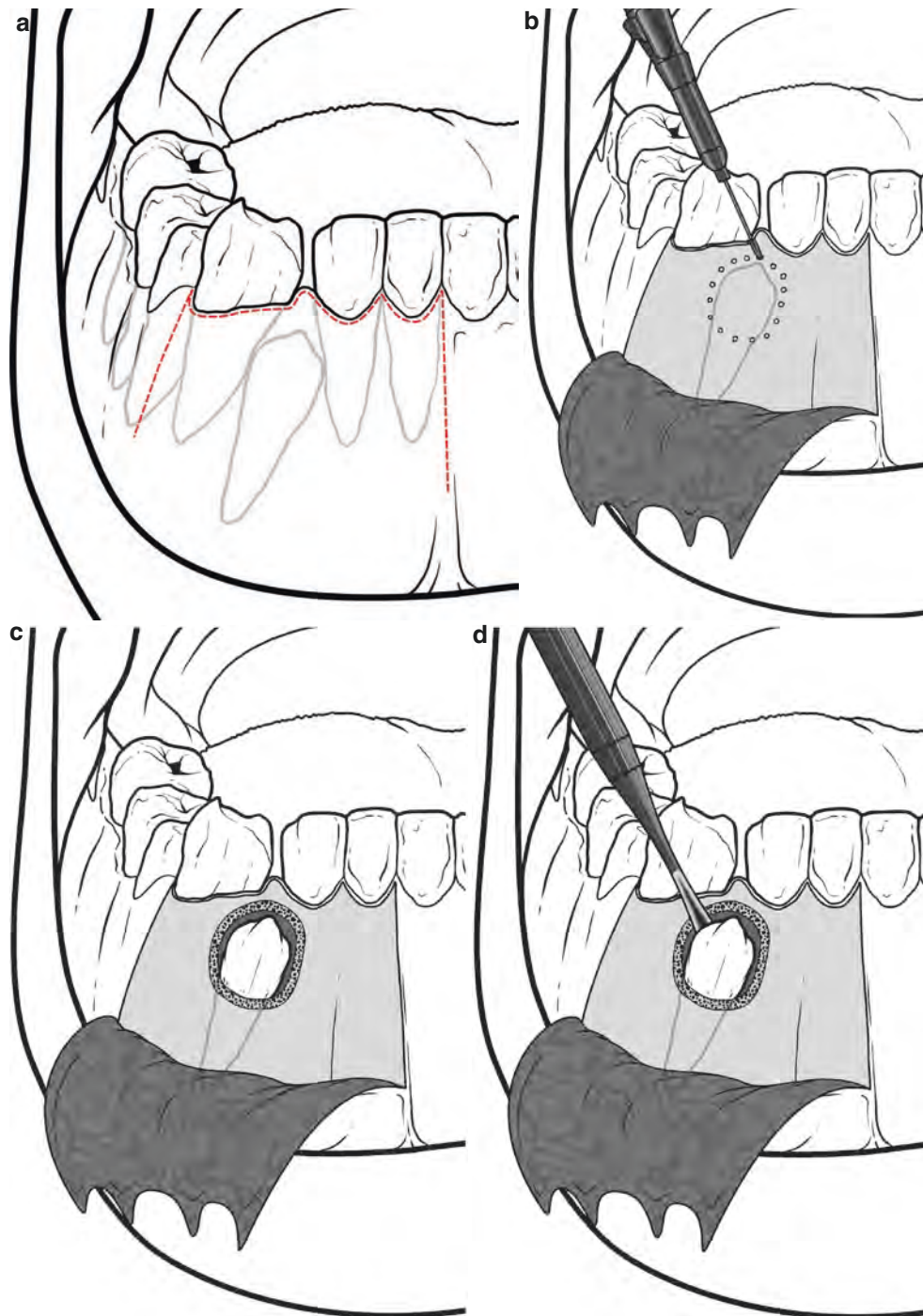
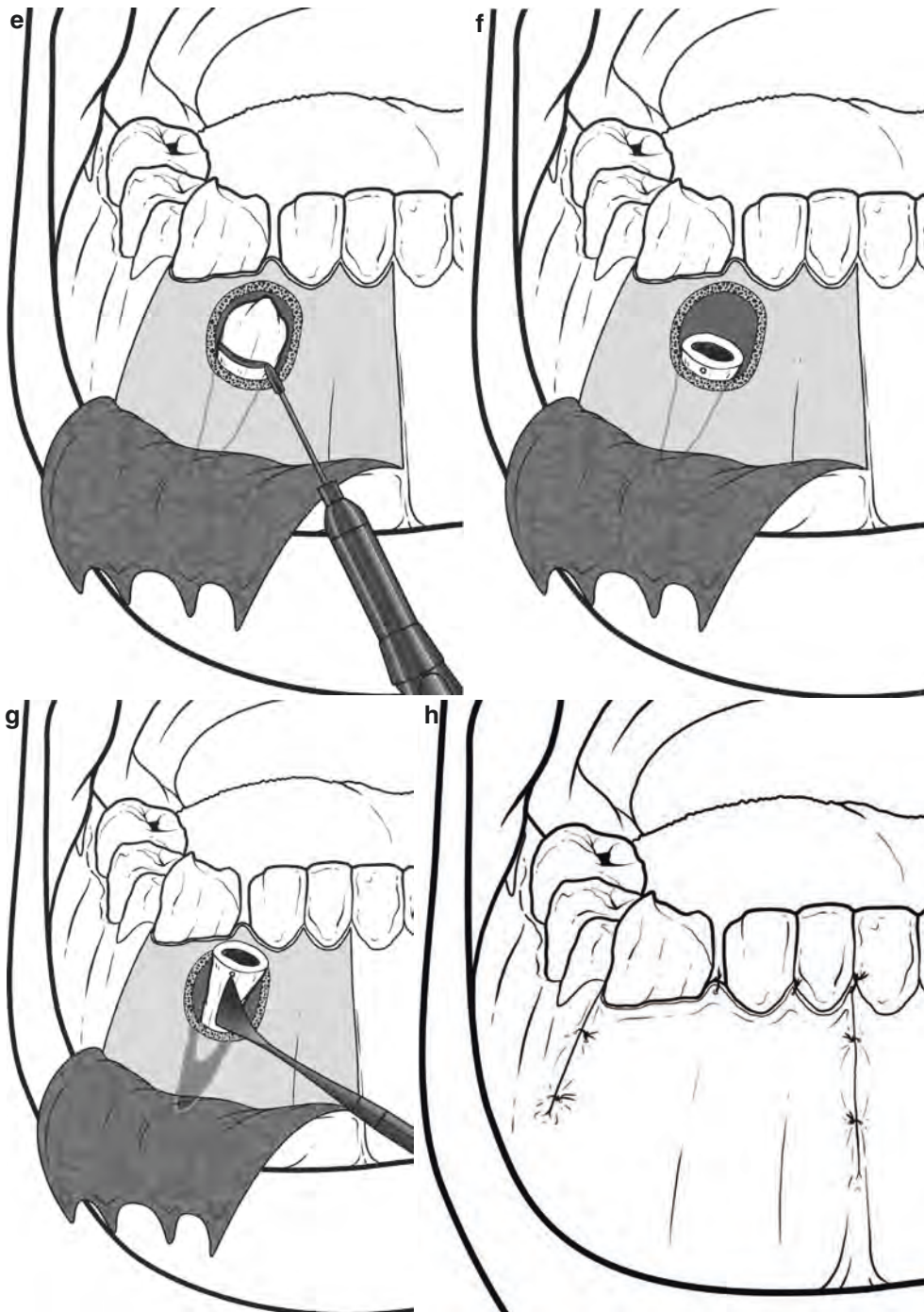


Fig. 15.14 (a-h) Schematic diagram showing steps in the surgical removal of impacted mandibular canine. (a) Incision to raise a trapezoidal flap, (b) Mucoperiosteal flap reflected and the bone overlying the crown removed using bur and chisel, (c) Crown of impacted canine exposed, (d) Elevator is applied in an attempt to luxate the tooth. (e) if

elevation unsuccessful tooth division is performed using bur, (f) Crown removed and more of the root exposed to create a purchase point on the root using bur, (g) Root removed using an elevator applied at the purchase point, (h) Closure of the incision



©Association of Oral and Maxillofacial Surgeons of India

Fig. 15.14 (continued)

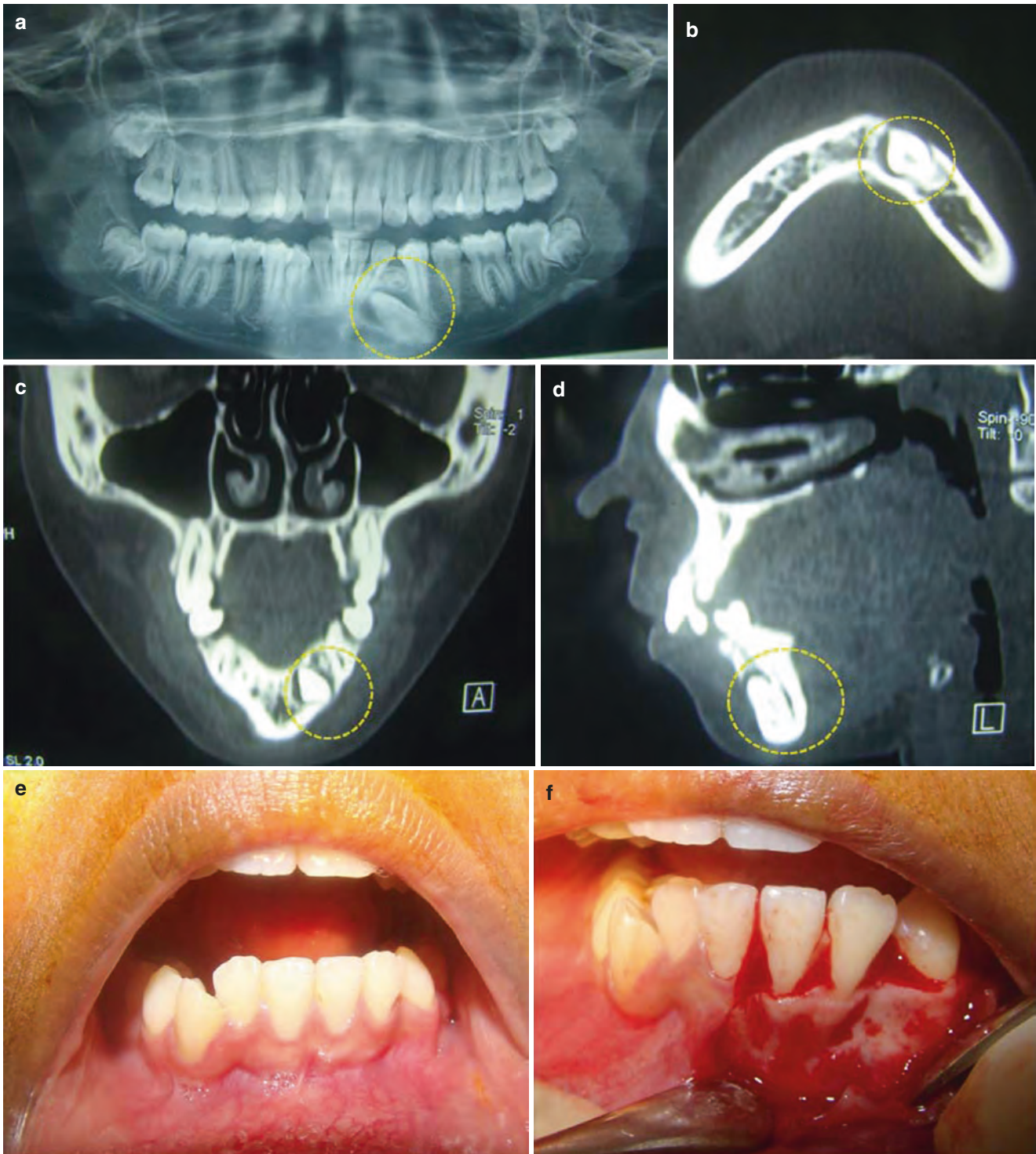


Fig. 15.15 (a–m) Shows the clinical and radiographic images of the steps in removing a labially impacted canine by odontectomy. Impacted left mandibular canine (yellow circle) with an associated odontome (a) OPG showing impacted 33, (b) CT Axial view, (c) Coronal view, (d) Sagittal view. (e) Intra-oral view, (f) Mucoperiosteal flap reflected, (g)

Overlying odontome exposed, (h) Odontome removed and crown of 33 exposed. (i) Sectioning of crown of 33, (j) Removal of crown and root of 33 followed by debridement, (k) Suturing completed (l) Specimen of 33 with follicle and odontome, (m) Pressure dressing applied to reduce oedema

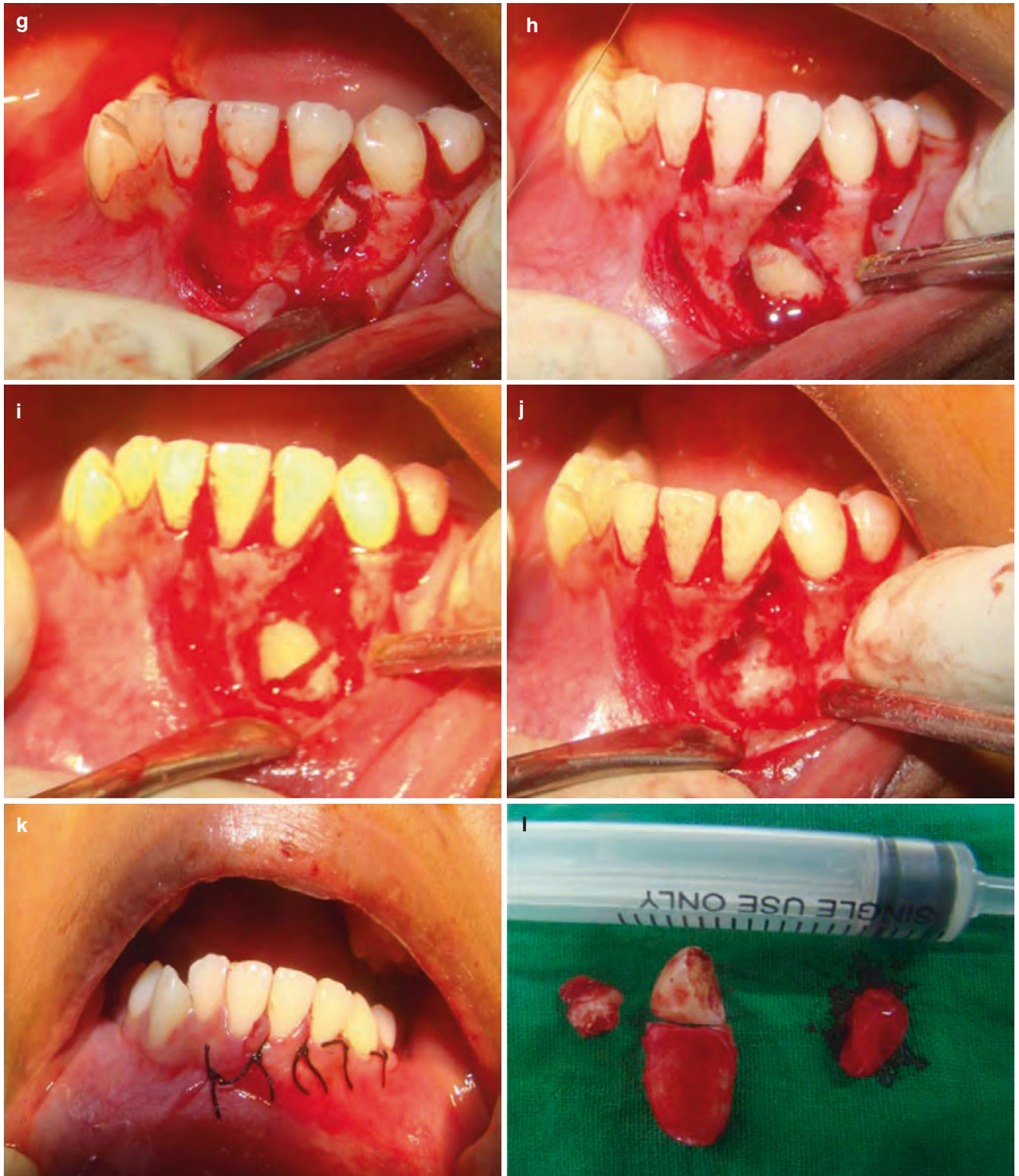
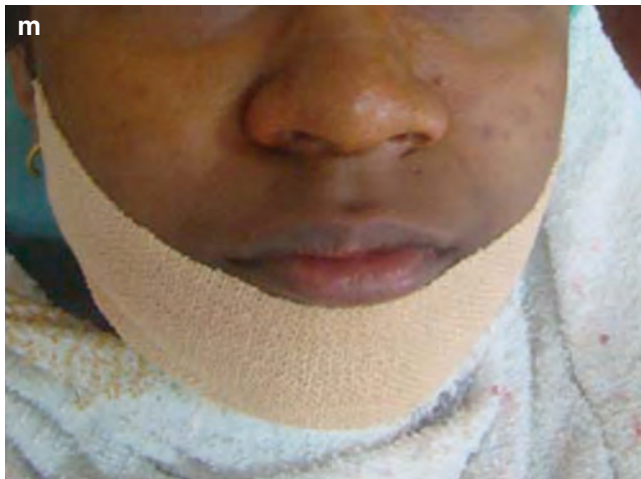

Fig. 15.15 (continued)



©Association of Oral and Maxillofacial Surgeons of India

Fig. 15.15 (continued)

References

- Dewel B. The upper cuspid: its development and impaction. *Angle Orthod.* 1949;19:79–90.
- Archer WH. Chapter 5, Oral and maxillofacial surgery, vol. 1. 5th ed. Philadelphia, PA: WB Saunders; 1975. p. 325.
- Field HJ, Ackerman AA. The impacted upper Cuspid. *Dent Cosmos.* 1935;77:378.
- Thilander B, Jakobsson SO. Local factors in impaction of maxillary canines. *Acta Odontol Scand.* 1968;26(2):145–68.
- Clark C. A method of ascertaining the position of unerupted teeth by means of film radiographs. *Proc R Soc Med.* 1909;3:87–90.
- Southall PJ, Gravely JF. Vertical parallax radiology to localize an object in the anterior part of the maxilla. *Br J Orthod.* 1989;16:79C.
- Rayne J. The unerupted maxillary canine. *Dent Pract.* 1969;19:194N.
- Keur JJ. Radiographic localization techniques. *Aust Dent J.* 1986;31:86H.
- Wolf JE, Mattila K. Localization of impacted maxillary canines by panoramic tomography. *Dentomaxillofac Radiol.* 1979;8:85–9.
- Fox NA, Fletcher GA, Horner K. Localizing maxillary canines using dental panoramic tomography. *Br Dent J.* 1995;179:416.
- Mason C, Papadakou P, Roberts GJ. The radiographic localization of impacted maxillary canines: a comparison of methods. *Eur J Orthod.* 2001;23:25.
- Kuftinec MM, Shapira Y. The impacted maxillary canine: I. review of concepts. II. Clinical approaches and solution. *J Dent Child.* 1995;62:317–34.
- Maverna R, Gracco A. Different diagnostic tools for the localization of impacted maxillary canines: clinical considerations. *Prog Orthod.* 2007;8(1):28–44.
- Chaushu S, Chaushu G, Becker A. Reliability of a method for the localization of displaced maxillary canines using a single panoramic radiograph. *Clin Orthod Res.* 1999;2:194.
- Alexander Katsnelson A, Flic WG, Susarla S, Tartakovsky JV, Miloro M. Use of panoramic X-ray to determine position of impacted maxillary canines. *J Oral Maxillofac Surg.* 2010;68:996–1000.
- Preda L, La Fianza A, Di Maggio EM, Dore R, Schifino MR, Campani R, et al. The use of spiral computed tomography in the localization of impacted maxillary canines. *Dentomaxillofac Radiol.* 1997;26:236–41.
- Liu D, Zhang W, Zhang Z, Wu Y, et al. Localization of impacted maxillary canines and observation of adjacent incisor resorption with cone-beam computed tomography. *Oral Surg Oral Med Oral Pathol Oral Radiol Endod.* 2008;105:91–8.
- Walker L, Enciso R, Mah J. Three-dimensional localization of maxillary canines with cone-beam computed tomography. *Am J Orthod Dentofacial Orthop.* 2005;128(4):418.
- Vermette ME, Kokich VG, Kennedy DB. Uncovering labially impacted teeth: apically positioned flap and closed-eruption techniques. *Angle Orthod.* 1995;65(1):23–32.
- Chaushu S, Becker A, Zeltser R, Branski S, Vasker N, Chaushu G. Patients perception of recovery after exposure of impacted teeth: a comparison of closed-versus open-eruption techniques. *J Oral Maxillofac Surg.* 2005 Mar;63(3):323–9.
- Crescini A, Clauser C, Giorgetti R, Cortellini P, Pini Prato GP. Tunnel traction of infraosseous impacted maxillary canines. A three-year periodontal follow-up. *Am J Orthod Dentofac Orthop.* 1994 Jan;105(1):61–72.
- Incerti-Parenti S, Checchi V, Ippolito DR, Gracco A, Alessandri-Bonetti G. Periodontal status after surgical-orthodontic treatment of labially impacted canines with different surgical techniques: a systematic review. *Am J Orthod Dentofacial Orthop* 2016 Apr;149(4):463–472. Review.
- Schmidt AD, Kokich VG. Periodontal response to early uncovering, autonomous eruption, and orthodontic alignment of palatally impacted maxillary canines. *Am J Orthod Dentofac Orthop.* 2007;131:449–55.
- Quirynen M, Op Heij DG, Adriansens A, Opdebeeck HM, van Steenberghe D. Periodontal health of orthodontically extruded impacted teeth. A split-mouth, long-term clinical evaluation. *J Periodontol.* 2000 Nov;71(11):1708–14.
- Chapokas AR, Almas K, Schincaglia GP. The impacted maxillary canine: a proposed classification for surgical exposure. *Oral Surg Oral Med Oral Pathol Oral Radiol.* 2012 Feb;113(2):222–8.
- Dalessandri D, Parrini S, Rubiano R, Gallone D, Migliorati M. Impacted and trans migrant mandibular canines incidence, aetiology, and treatment: a systematic review. *Eur J Orthod* 2017 Apr 1;39(2):161–169. Review. (Open Access).

Open Access This chapter is licensed under the terms of the Creative Commons Attribution 4.0 International License (<http://creativecommons.org/licenses/by/4.0/>), which permits use, sharing, adaptation, distribution and reproduction in any medium or format, as long as you give appropriate credit to the original author(s) and the source, provide a link to the Creative Commons license and indicate if changes were made.

The images or other third party material in this chapter are included in the chapter's Creative Commons license, unless indicated otherwise in a credit line to the material. If material is not included in the chapter's Creative Commons license and your intended use is not permitted by statutory regulation or exceeds the permitted use, you will need to obtain permission directly from the copyright holder.





Deepti Simon

16.1 Definition

Endodontic surgery is a dental procedure to treat apical periodontitis in cases that did not heal after nonsurgical retreatment or, in certain instances, primary root canal therapy [1]. It is the branch of dentistry that deals with the diagnosis and treatment of lesions of endodontic origin, which cannot be treated by or do not respond to conventional root canal therapy.

16.2 Historical Frame of Reference

Guerini documented the first endodontic surgery as incision and drainage of an acute endodontic abscess, approximately 1500 years ago [2]. Infected root sections were removed, and the healthy tooth portion was retained in attempting to cure infected teeth for about 200 years. Histological bone regeneration was demonstrated in treated cases of infected periapical lesions in 1930 [3]. For a long time, pulpless teeth were implicated in a plethora of systemic disorders like nephritis and arthritis by the exponents of the focal theory of infection [4].

The terms apicoectomy, periapical surgery, periapical endodontics, root end surgery, apical microsurgery, and surgical endodontics have been used in the literature. Apicoectomy, which means cutting the root apex, limits the understanding of the procedure, which includes removal of the irritants in the root canal system and the periapical pathology as well. Today, endodontic surgery is one of the most puissant branches of dentistry and falls in the twilight zone among surgery, dentistry, and endodontics. Recent

advances in techniques and materials have resulted in a paradigm shift toward a more judicious strategy for treating periapical pathologies. The new benchmark for success is tissue regeneration. Nonsurgical retreatment for endodontic failures and surgical endodontics has been radically revolutionized by the introduction of the “microscope”.

A periapical lesion is defined as any radiolucent image exceeding 1 mm in the periapical vicinity of the tooth. Lesions with a mean diameter > 5 mm are classified as large lesions, and those less than or equal to 5 mm are classified as small lesions [5]. In lesions greater than 10 mm, tooth extraction may or may not be done after considering factors like tooth mobility, pain, and the periodontal condition [6]. A periapical lesion may be noticed clinically or radiographically at a dimension of 5 mm [7].

16.3 Indications for Endodontic Surgery [8]

1. Failures of nonsurgical treatment (treatment should have been done at least twice)
2. Failure of nonsurgical treatment and retreatment is not feasible or impractical due to calcified canals, silver point filling, apical perforation, severely curved roots, and the presence of post and core or if the tooth is fractured at its apical one third
3. To obtain a biopsy from the periapical region
4. To retrieve broken instruments

16.3.1 Updated Indications (The European Society of Endodontology) (2006) [9]

1. Radiological findings of apical periodontitis and/or symptoms associated with an obstructed canal (the obstruction proved not to be removable, displacement of the obstruction did not seem to be feasible, or the risk of damage was too great)

D. Simon (✉)

Department of OMFS, Government Dental College,
Trivandrum, Kerala, India

Kerala University of Health Sciences, Thrissur, Kerala, India

2. Extruded material with clinical or radiological findings of apical periodontitis and/or symptoms continuing over a prolonged period
3. Persisting or emerging disease following root canal treatment when root canal retreatment is inappropriate
4. Perforation of the root or the floor of the pulp chamber and when it is impossible to treat from within the pulp cavity

16.4 Relative Contraindications

1. Compromised medical status of the patient
2. Anatomical considerations
3. Surgeon's skill and clinical expertise
4. Vertically fractured tooth
5. Unrestorable tooth
6. Tooth with compromised periodontal support
7. Nonfunctional tooth
8. Tooth with short roots

Principles of Endodontic Surgery

1. Preoperative assessment and planning
2. Achieving adequate anesthesia and hemostasis
3. Appropriate surgical access through overlying soft and hard tissues
4. Periapical curettage and root end preparation
5. Wound closure and care
6. Postoperative management of the local surgical site

Classification of Endodontic Surgery [8]

1. Fistulative Surgery
 - (a) Incision and drainage
 - (b) Cortical trephination
 - (c) Decompression procedures
2. Periapical Surgery
 - (a) Curettage
 - (b) Root end resection
 - (c) Root end preparation
 - (d) Root end filling
3. Corrective Surgery
 - (a) Perforation repair
 - (i) Mechanical (iatrogenic)
 - (ii) Resorptive
 - (b) Periodontal management
 - (i) Root resection
 - (ii) Tooth resection
 - (iii) Intentional replantation

16.5 Preoperative Assessment and Planning

16.5.1 Anatomical Reflections

The nasal floor, maxillary sinus, inferior alveolar, and mental and greater palatine neurovascular bundles offer potential road blocks to the surgeon.

16.5.2 Important Considerations in the Maxilla and Maxillary Sinus

If the roots of the maxillary anteriors are very long and the lesion extends superiorly, proximity to the nasal floor should be borne in mind. Eberhardt et al. have commented that the mesiobuccal root apex of the maxillary second molar is closest to the sinus floor and the buccal root apex of the maxillary first premolar is the farthest [10]. The greater palatine neurovascular bundle presents a risk while working on the palatal roots of maxillary molars. If the vessel is severed, pressure must be applied by packs or bone wax and the eventuality of external carotid artery ligation should not be precluded. Vertical releasing incisions on the palate are to be eschewed, and if these are unavoidable, it is prudent to place the same between the maxillary canine and first premolar, where the artery has a narrow caliber. Palatal roots can be accessed buccally or across the sinus or palatally (direct approach). The contour and depth of the palatal vault greatly determine the surgeon's accoutrement; greater the depth, greater the comfort.

Inadvertent loss of root tips into the maxillary sinus should be avoided and retrieved endoscopically if such a situation arises. Sinus communications, if they occur seldom, pose an impediment to healing neither are they implicated in sinusitis [11]. The sinus membrane usually regenerates, and a thin bone forms at the apex [12]. Shallow vestibule, palatally or lingually inclined roots, compounds the surgeon's difficulties.

16.5.3 Important Considerations in the Mandible

In the mandible, the facial artery, mental nerve, and inferior alveolar neurovascular bundle should be reckoned with. The facial artery can be safeguarded if incisions placed in the vicinity of the mandibular first molar are not extended beyond the vestibular depth. The route taken by the inferior alveolar neurovascular bundle is of particular significance. It winds buccal (second molar) to lingual (first molar) and then again buccal (the second premolar) before it exits the mental foramen [12]. In the vertical dimension, the mandibular sec-

Table 16.1 Anthropometric measurements of significance in endodontic surgery [10, 12]

Sl. No	Landmarks	Distance in mm
1.	Apex of mesiobuccal root of the maxillary second molar and sinus	0.83
2.	Apex of buccal root of the maxillary first premolar and sinus	7.05
3.	Apex of the maxillary second premolar and sinus	2.8
4.	Apex of mesiobuccal and distobuccal root of the maxillary first molar and sinus	2.8
5.	Apex of the mandibular second molar and mandibular canal	3.7
6.	Apex of mesial root of the mandibular first molar and mandibular canal	6.9
7.	Apex of the mandibular second premolar and mandibular canal	4.7
8.	Buccal cortical plate and distal root of the mandibular second molar	8.5
9.	Apex of maxillary canine and buccal cortical plate	1.64

ond molar is closest to the canal as when compared to the mandibular first molar or second premolar. For all practical purposes, the mandibular second molar is not conducive to endodontic surgery and should be attempted bearing in mind these encumbrances. The mandibular anteriors offer a particular challenge while performing perpendicular root resection [12].

Excessive salivation, shallow vestibule, thick alveolus, and small rima oris are other determinants. A comprehensive assessment of all these variables is mandatory prior to embarking upon endodontic surgery (Table 16.1).

16.6 Investigations

Until recently, periapical radiographs were the workhorse of endodontic surgery. Their obvious shortcomings were due to compression of three-dimensional structures into a two-dimensional image and geometric distortion of anatomy. In the year 2000, Cone Beam Computer Tomography (CBCT) was introduced to dentistry. The limited CBCT offers higher resolution, and images are displayed in three planes: axial, coronal, and sagittal. Simultaneously, radiation dose is comparable to panoramic x-rays, and superimposition of neighboring structures is obviated [12]. The relationship between the teeth apices and anatomic structures, variations in root morphology, additional canals, and external root resorption are just a few of the diagnostic conundrums that can be assessed via CBCT.

Surgical workup also includes complete blood count, routine urine examination, viral markers, and a thorough medical history. Appropriate regulation of insulin, anticoagulants,

and other drugs should be undertaken in liaison with the attending physician.

A well-informed patient is the best patient. The importance of informed consent cannot be overdrawn, and the patient is entitled to know about the prognosis, benefits, and surgical complications, anticipate damage to vital structures, and follow up. Communication regarding the above details is mandatory, and the patient should be made aware of alternate treatment modalities like extraction followed by implant placement.

16.7 Anesthesia and Hemostasis

16.7.1 Premedication

Nonsteroidal anti-inflammatory drugs (NSAIDs) in conjunction with a long-acting local anesthetic can scale down postoperative pain. Ainsworth surmised that routine use of prophylactic antibiotics in periapical surgery is unwarranted [12]. A presurgical mouth rinse with chlorhexidine gluconate (0.12%) will reduce the salivary bacteria significantly, especially their growth on sutures and wound margins, but may obtrude with fibroblast reattachment to the root [12].

Most patients tolerate the surgical procedure under local anesthesia but for the apprehensive, conscious oral sedation with benzodiazepines or nitrous oxide/oxygen inhalation should be opted for. Diazepam 10 mg can be started on the night before the surgery, and another dose can be administered 1 hour before the procedure [13].

16.7.2 Local Anesthesia and Sedation

The merits and demerits of various local anesthetics have been elaborated in detail elsewhere in this book. Conventional nerve blocks are augmented by local infiltration. Of equal momentousness is the preference for the vasoconstrictor. Adrenaline in concentrations ranging from 1:50,000, 1:100,000, and 1:200,000 have performed commendably.

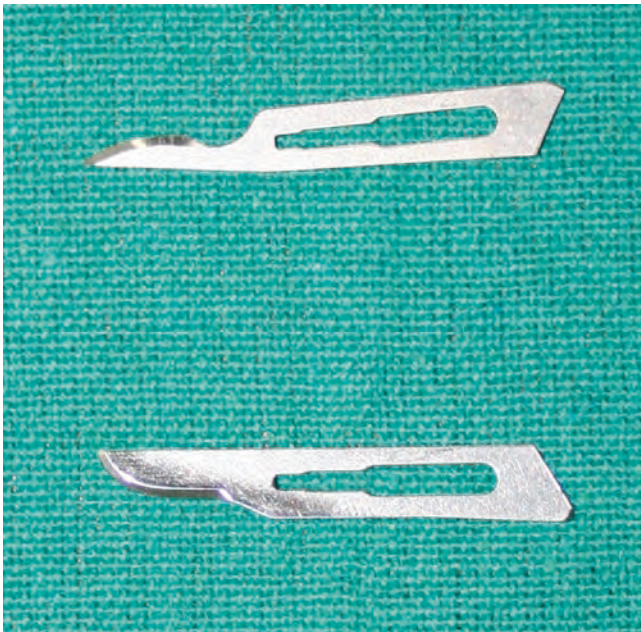16.8 Surgical Access

16.8.1 Armamentarium

Incisions can be placed with no.11, no. 12, no 15, or no. 15-C blades (Fig. 16.1). Sharp, blunt dissection and elevation of the mucoperiosteal flap are accomplished by a Molts' or Howarths' periosteal elevator (Fig. 16.2). Endodontic tissue retractors like Austin, Seldon, or Minnesota should be judi-

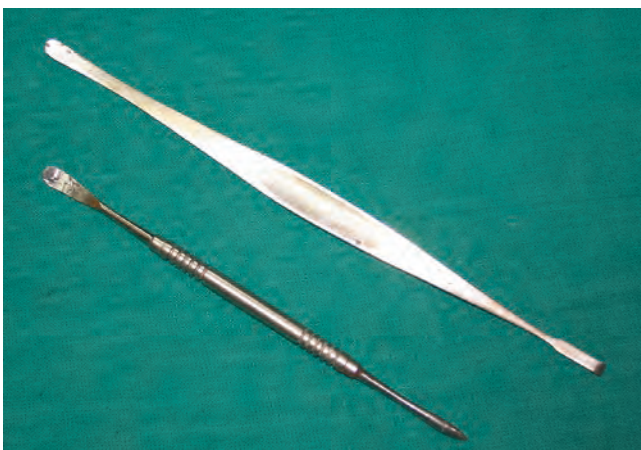ciously selected in order to minimize trauma to the mucoperiosteal flap and neurovascular bundles (Fig. 16.3). Overlying bone is cut with No.4/6/8 round burs or 701/702 fissure burs (Fig. 16.4). These can be used to resect the root apex as well. Surgical handpiece with 45 ° angle head and rear air exhaust is advocated. Sharp surgical curettes like Lucas curette, angled periodontal curettes, and spoon excavators help to remove the inflamed soft tissue from the bony cavity (Fig. 16.5).

Root end resections can be done either with conventional burs or lasers (Er-YAG or Ho-YAG lasers) [14, 15].



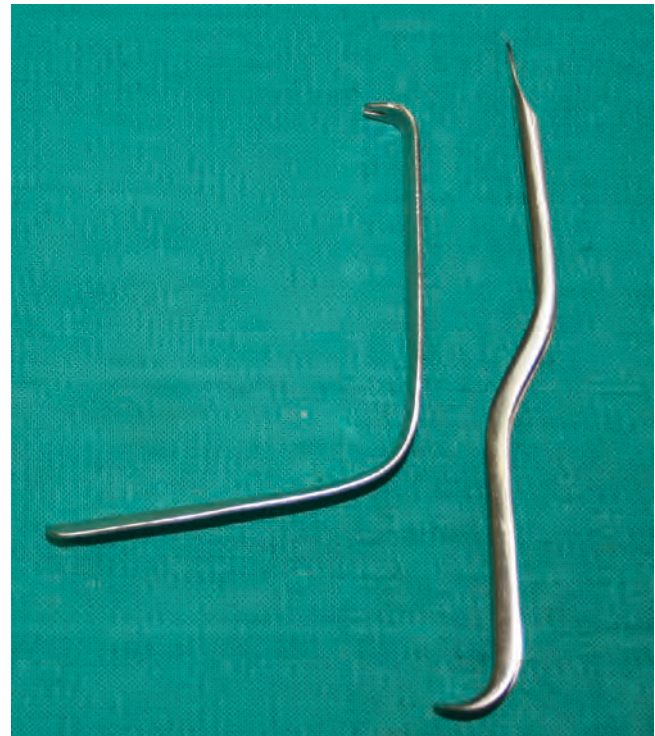©Association of Oral and Maxillofacial Surgeons of India

Fig. 16.1 No. 15 and No. 15 C Blades



©Association of Oral and Maxillofacial Surgeons of India

Fig. 16.2 Molt's Periosteal Elevator and Howarth's Elevator



©Association of Oral and Maxillofacial Surgeons of India

Fig. 16.3 Austin retractor and Minnesota retractor

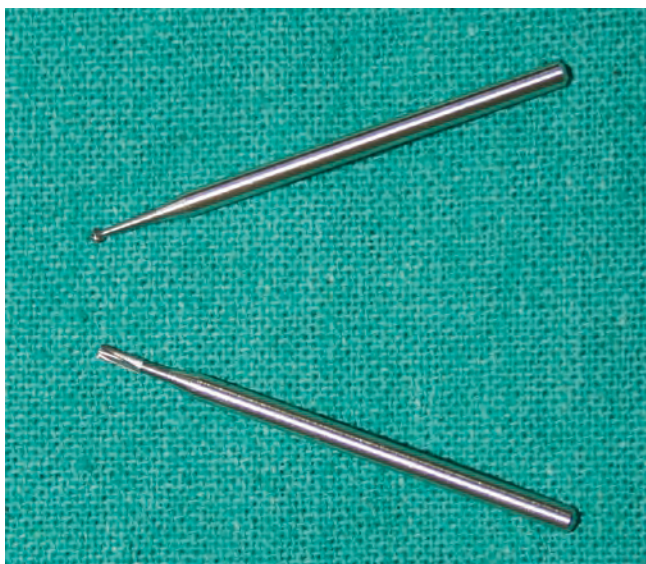
The advantages of lasers include greater patient comfort, decreased vibrations, lesser surgical site contamination, and minimal trauma to the juxtaposed tissues.

Ultrasonic microsurgical tips are invaluable for root end preparation. Earlier, hand files and rotary burs were used. Teflon sleeves, pluggers, and Messing gun-type syringes can be used to place various root-end filling materials like MTA (Fig. 16.6). Review of literature validates the superiority of microsurgical techniques over conventional surgery (97% to 59%) [1]. The dental operating microscope, ultrasonic tips, and diamond coated micromirrors (Fig. 16.7) have found their niche in the surgeon's armamentarium. Micromirrors (Fig. 16.8) can be used to inspect the buccal and lingual walls of the retrocavity. Microsurgical scalpels are useful for incising the intrasulcular areas and dissection of the interproximal papillae.

16.8.2 Surgical Management

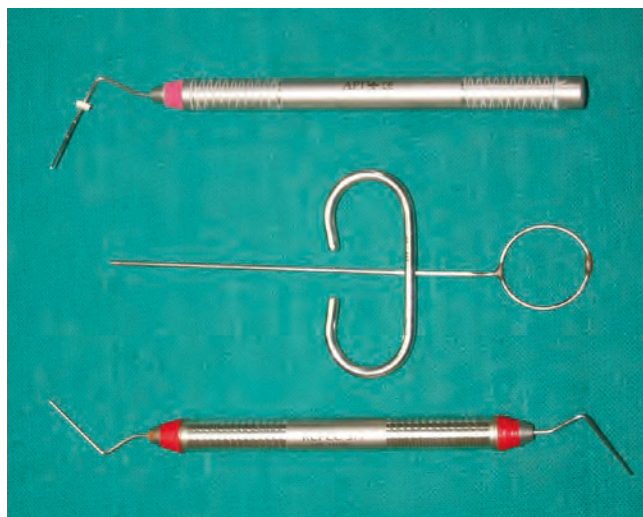
The aims of periapical surgery are to visualize and debride the affected area and provide hermetic seal at the root end that aids in periodontal regeneration (Figs. 16.9, 16.10 and 16.11). Gutmann and Harrison [4] have categorized flaps as

1. Full mucoperiosteal flaps
2. Limited mucoperiosteal flaps



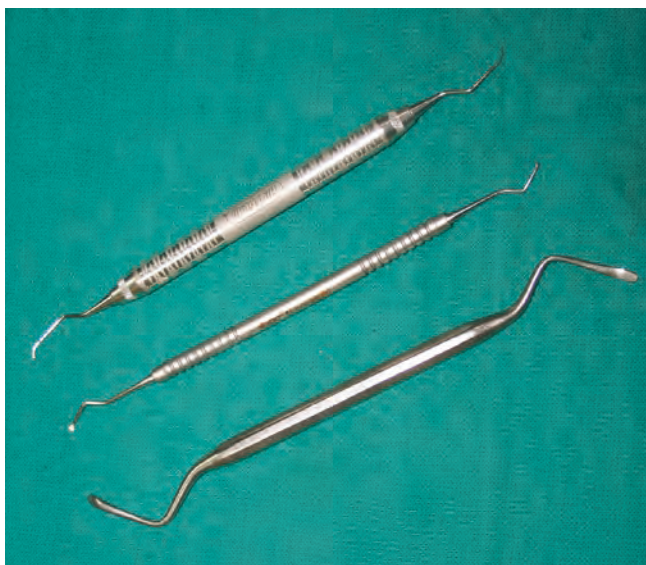
©Association of Oral and Maxillofacial Surgeons of India

Fig. 16.4 No.701 bur and No.4 bur



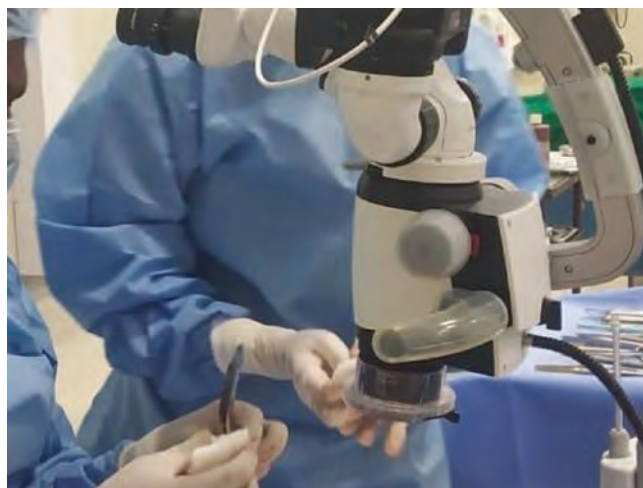©Association of Oral and Maxillofacial Surgeons of India

Fig. 16.6 Pluggers and Messing gun syringe



©Association of Oral and Maxillofacial Surgeons of India

Fig. 16.5 Lucas curette, Spoon excavator, and Periodontal curette

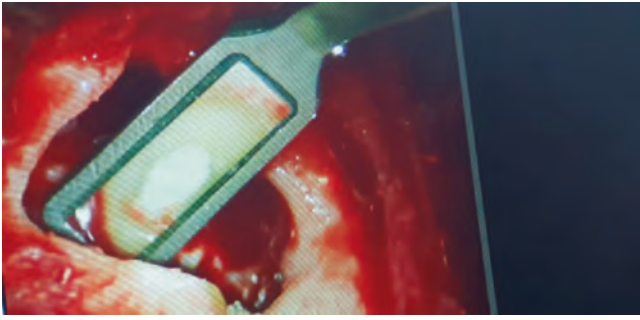


©Association of Oral and Maxillofacial Surgeons of India

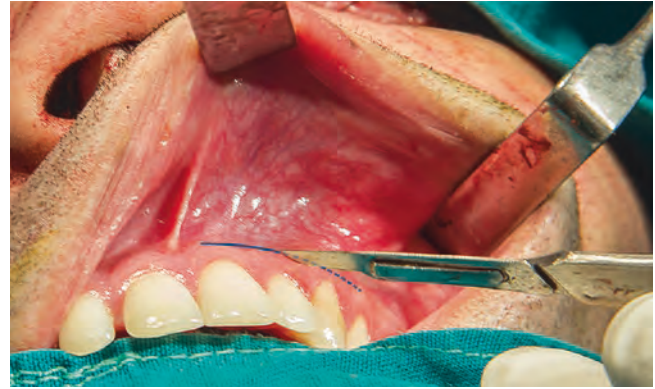Fig. 16.7 Microsurgical root end surgery

The main difference is that marginal interdental tissues are included in the full flaps, whereas the latter conserves them. Researchers opine that limited flaps prevent loss of papilla height, but careful adaptation of the reflected soft tissues rarely causes changes in gingival attachment level. It is vital to preserve the root attached tissues. In the absence of periodontal pathology, anatomic and functional status quo can be maintained via full mucoperiosteal flaps. Elevating palatal flaps is by

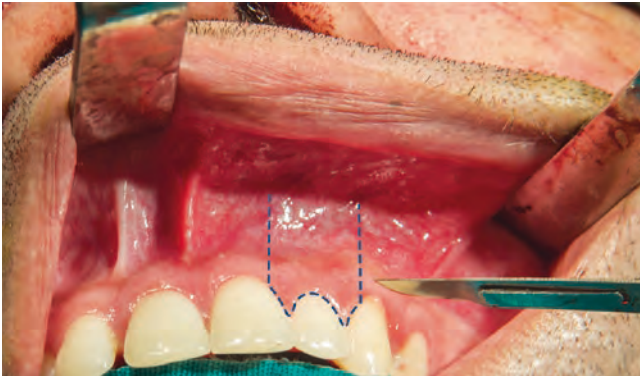
and large a cumbersome affair. If the clinical situation demands a palatal approach, the envelope and triangular flaps can be considered. Contrary to popular teaching, vertical incisions can be placed on the palate, rather than stretching and renting a flap, which may impede healing. This approach is best reserved for palatal roots for posteriors. Anterior palatal cysts can be accessed labially or palatally, according to the surgeon's discretion. To aid in surgical access, it is prudent to pass a long suture through



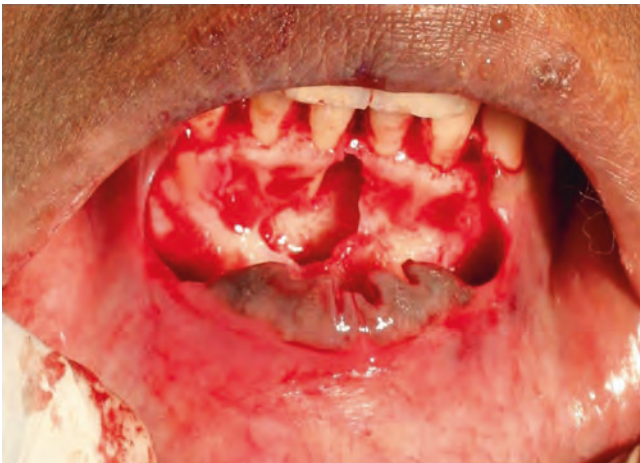©Association of Oral and Maxillofacial Surgeons of India

Fig. 16.8 Diamond-coated mirror

©Association of Oral and Maxillofacial Surgeons of India

Fig. 16.11 Submarginal incision

©Association of Oral and Maxillofacial Surgeons of India

Fig. 16.9 Trapezoidal flap

©Association of Oral and Maxillofacial Surgeons of India

Fig. 16.10 Clinical image of a trapezoidal flap for periapical lesion in lower anterior region

the palatal flap and have the assistant retract the tissue. Table 16.2 details the advantages and disadvantages of various types of flaps that can be used for endodontic surgery.

16.8.3 Basic Principles of Flap Design

1. Straight or parallel incisions are preferred over severely angled ones, in order to preserve the suprapariosteal blood supply of the attached gingiva and submucosa. Fewer vessels and collagen fibers are transected with parallel incisions, resulting in less hemorrhage and flap shrinkage
2. Root eminences of canines and maxillary premolars are covered by thin bone with a poor blood supply and should be spared. Incisions should be placed between adjacent teeth on interdental bone
3. Flaps should lie on solid healthy bone. At least 5 mm of bone should be present between the defect and incision line
4. Do not incise frena and muscle attachments as it compromises the healing
5. Do not incise through the dental papilla
6. The entire mucoperiosteum should be included in the flap; this is imperative for uneventful healing
7. Retractors should rest on solid bone
8. The horizontal incision should extend at least one tooth beyond the pathologic area of interest

The position of the tooth in the arch, the dimensions of the periapical pathology, gingival recession, and the presence of artificial crowns also determine the choice of the incision that is placed.

16.8.4 Flap Elevation

The horizontal element of a full mucoperiosteal flap commences in the gingival sulcus and severs the gingival attachment fibers to the crestal bone. The interdental papilla should be incised at the midcol level. While incising a limited flap, the horizontal component must conform to the contour of the marginal gingiva and should be 2 mm apical to the depth of

Table 16.2 Various flap designs used in endodontic surgery [4, 12]

Name and description	Recommended	Advantages	Disadvantages
Triangular flap (full) horizontal, intrasulcular incision, one vertical releasing incision	Maxillary incisors and posteriors	Rapid wound healing due to good vascular supply Facilitates in bone graft placement	Limited access
Rectangular flap (full) horizontal, intrasulcular incision, two vertical releasing incisions	Mandibular anteriors and Maxillary canines	Extensive surgical access Facilitates in bone graft placement	Difficult wound closure and more sutures
Trapezoidal flap (full) horizontal, intrasulcular incisions, two divergent angled, vertical incisions	Not recommended	Base is wider than apex	Damage to suprapariosteal vessels and hence more bleeding and flap shrinkage
Horizontal /envelope flap (full). No vertical releasing incision	Limited use Only in repair of cervical defects, hemisections, and root amputations	Rapid healing	Limited access
Papilla based flap (full) Shallow first incision at the base of the papilla second incision directed to crestal bone	Esthetically important regions	Conserves the papilla	Technically challenging
Submarginal curved/semilunar flap (limited). Curved incision in alveolar mucosa and attached gingiva	Not recommended	–	Limited access and poor healing unaesthetic scarring Exact location of the root should be known
Submarginal scalloped rectangular /Luebke-Ochsenbein (limited). Scalloped horizontal incision follows the shape of the marginal gingiva on the attached gingival At least 2 mm of attached gingiva is retained Also called freeform rectilinear	Maxillary teeth where esthetics of crown margins are important	No exposure of crestal bone Prevents papillary recession and clefting	Unaesthetic scarring. More bleeding and flap shrinkage Depth of gingival sulcus should be measured

the gingival sulcus. The vertical incision should begin in the alveolar mucosa and proceed toward the crown till it abuts the horizontal incision. To achieve the above objectives fresh, sharp blades should be opted for.

Hemostasis and healing are enhanced if the entire muco-periosteal flap is elevated as a single unit, due to adherence of the flap with its microvasculature. The broad end of the elevator can be maneuvered beneath the vertical incision, a few millimeters from the junction of the horizontal and vertical incision in the attached gingiva. This preserves the supracrestal root-attached fibers. This is followed by coronal dissection, and forces are directed toward the periosteum and bone. This technique is termed undermining elevation and should be continued throughout the length of the horizontal incision and apically to the alveolar mucosa [4]. An approximate distance of 1 cm from the apex should be exposed for adequate access. The bleeding tags seen on the bone contain periosteum that aids in healing and reattachment of the flap.

16.8.5 Flap Retraction

The soft tissues must be gently retracted to preclude the possibility of inadvertent crushing. This may lead to flap hypoxia, swelling, ecchymosis, and/or delayed healing. The

retractor of a correct size should be selected and placed on cortical bone in such a way that the tissue is prevented from engaging with rotary instruments.

The periosteal surface of the flap should be irrigated with sterile, cool, and physiologic saline to keep it hydrated. The superficial surface is more resistant to dehydration due to the stratified squamous epithelium [16, 17].

16.8.6 Hard Tissue Management

Once the flap is raised, the surgeon encounters either intact cortical bone over the lesion or the lesion sans cortical bone. In the former scenario, it is imperative to localize the lesion and remove bone in the adjacent periapical area. Well-angled radiographs can aid in this aspect. Sounding the bone with the sharp end of the periosteal elevator can also be useful, as there is a change in resonance when one approaches the diseased area. It is also prudent to identify the root by calculating twice the crown length and then shave the thin bone at the apex. If digital technology is used, the distance from the alveolar crest to the root apex can be measured using the ruler function [3]. The root is smooth, hard, and yellow in color, surrounded by a periodontal ligament, and does not bleed on probing. Methylene

blue dye staining can aid in locating the periodontal ligament.

Bone is vulnerable to thermal damage at any temperature above the normal body temperature. This is the crucial aspect of periapical surgery and influences the choice of burs, coolants, and handpieces. Bone when subject to temperatures between 40 °C and 50 °C undergoes a spectrum of irreversible changes. These include reduction in microcirculation, tissue necrosis, fatty cell infiltration, and decrease in alkaline phosphatase.

While selecting bone cutting burs, sharp ones with wide spaces between the flutes are preferred. Round burs meeting these criteria promote excellent healing. Chilled saline effectively reduces the heat produced and flushes out the debris, thus enhancing efficiency. Excess pressure applied to the bone is detrimental to the tissues and handpiece. Gentle shaving or brushing motion must be used in short, multiple phases.

Hirsch et al. have used a piezoelectric device to create a bony aperture while performing apicoectomies in maxillary anteriors. The buccal bone was removed, preserved in Hank's Balanced Salt Solution (HBSS), and later replaced in the bony crypt after the procedure, thus acting as an autologous bone graft. This is feasible in cases where there is minimal bone loss or in the presence of intact bone over the lesion [18].

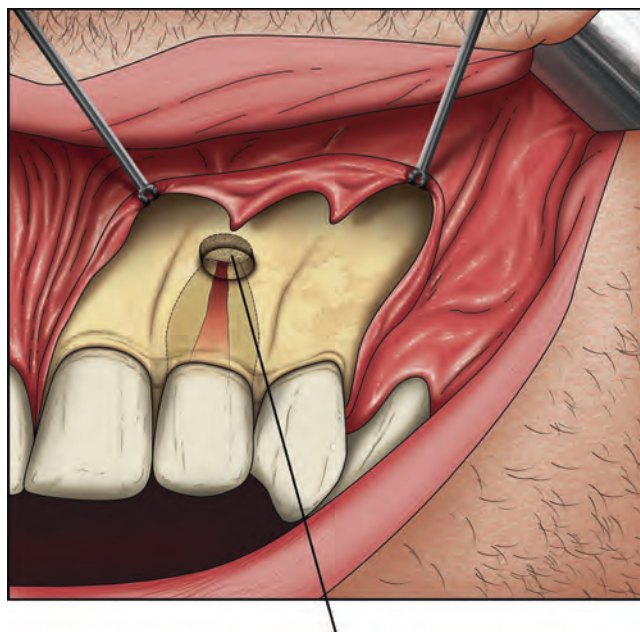
The bony aperture should be wide enough to permit visual and surgical access into the lesion, enabling the insertion of bone curettes and excavators. In traditional root surgery, the size of the aperture is approximately 8–10 mm and 3–4 mm in microsurgery. The rate of healing is faster when the size of osteotomy is smaller. Granulomas and granulation tissues exhibit a propensity to bleed profusely, hindering the surgery. To circumvent this, local anesthetic with a vasoconstrictor can be injected within. Using a curette of appropriate dimension, the surgeon works from the periphery toward the center. The instrument is inserted between the tissue and the lateral edge of the cavity with its concave face toward the bone. This is continued all around the circumference of the cavity and slowly progresses toward the depth of the crypt in a scraping manner. After freeing all the tissue, it is gently grasped with a pair of tissue forceps and immersed in 10% buffered formalin solution. The specimen should not be left to dry. Lin et al. opine that complete curettage is not mandatory, if the irritant is eliminated [19]. Though a majority of periapical lesions have been diagnosed histopathologically as granulomas or cysts, there have been documented reports of perfectly innocuous looking periapical lesions diagnosed as odontogenic keratocysts, central giant cell granulomas, or squamous cell carcinoma [20, 21].

16.8.7 Root end Preparation

16.8.7.1 Root end Resection (Fig. 16.12)

Regeneration of alveolar bone, periodontal ligament, and cementum in the periapical area can be encouraged by removing the diseased root end tissues and placing a root end seal to stop the recontamination of the periapical region. Resection of apical 3 mm of the root apex will eliminate 78% of apical ramifications and 93% of lateral canals, which could contain material that would contribute to the periradicular disease [12]. The isthmus area should be included in the resection in roots with multiple canals. Anatomical obstructions, broken instruments, and perforations can be removed, orthograde sealing can be assessed, and trapped lingual tissue can be curetted out. In the case of apical fenestration, the apex can be reduced below the surrounding cortex to enable bone formation over the apex. The resection should enable the surgeon to prepare a root end cavity and place a restoration within.

A smooth, flat resected surface is considered ideal. This should be assessed for cracks, anatomical variations, and orthograde obturating material by means of an operating microscope at high power magnification and methylene blue staining [2]. The resection is made in order to surround the filling by normal dentin. Conventionally, a 30–45° bevel was placed, but the advent of the microscope has enabled a resection perpendicular to the long axis of the tooth. This substantially decreases the number of exposed dentinal tubules. Cohen opines that this aids in root end cavity preparation beyond the



©Association of Oral and Maxillofacial Surgeons of India

Fig. 16.12 2 to 3 mm root tip resection

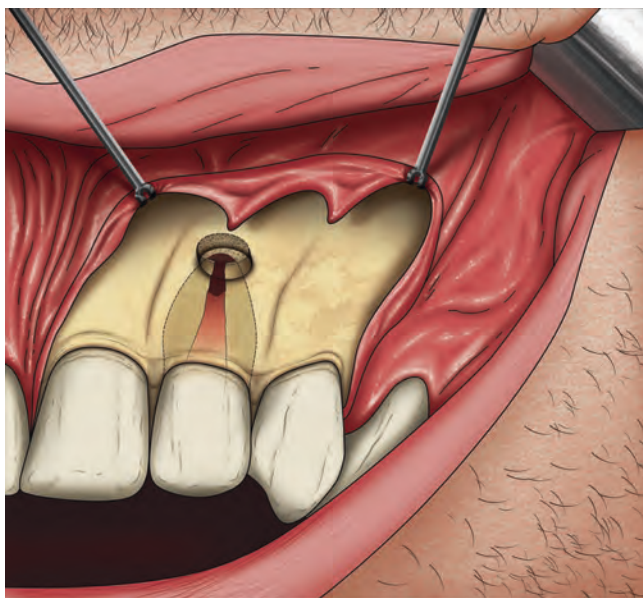
coronal extent of the root surface and apical stresses are well distributed, thus reducing apical fractures [11].

After the perpendicular root resection, the root must be conditioned to remove the smear layer produced. This exposes the collagen matrix of dentin and promotes growth. 5% aqueous citric acid has been used for this purpose. EDTA and tetracycline have also been studied, but have not found clinical popularity.

16.8.7.2 Root end Cavity Preparation

A 3 mm-deep Class I cavity is prepared along the long axis of the tooth, in order to place the filling material [22]. Ultrasonic tips have been specifically designed for this purpose. The tips produce less smear layer, need less beveling, and can be inserted through a smaller aperture. However, the ultrasonic vibrations can predispose to root fractures. This can be minimized when it is used at the lowest setting and with water coolant. Ultrasonic tips coated with stainless steel, diamond, or zirconium nitride are superior to uncoated tips. If the tips have a curvature of 70° or more, they are prone to fracture [23]. The root end filling is placed into the prepared cavity. When bonded materials like Retroplast are used, no root end preparation is needed; the filling is placed like a dome onto the resected root. This is termed bonded cap approach.

It is imperative to have a dry bloodless field prior to placement of the root end filling regardless of the setting properties of individual filling materials. To achieve this, adrenaline-saturated pellets, bone wax, Gelfoam, surgical calcium sulfate, thrombin, collagen, or ferric sulfate may be used. Electrocautery may also be used, but this may delay bone healing.



©Association of Oral and Maxillofacial Surgeons of India

Fig. 16.13 Root end filling

16.8.7.3 Root end Filling (Fig. 16.13)

Amalgam used to be the quintessential retrograde filling material as it is cheap, easy to use, and radio opaque. However, it may stain the tissues and is sensitive to moisture [3]. Research has yielded a plethora of retrofilling materials, which has enhanced the outcome of endodontic surgery (Table 16.3).

Table 16.3 Synopsis of root-end filling materials [4, 12]

Sl. No	Material	Composition	Characteristics
1.	Zinc oxide eugenol	Zinc oxide powder eugenol liquid	Affected by powder-liquid ratio. Eugenol can inhibit prostaglandins and cause fibroblast toxicity; final compound has high solubility
2.	Intermediate restorative material (IRM)	Zinc oxide, polymethyl methacrylate powder, eugenol, and acetic acid—Liquid	Not affected by powder liquid ratio. No evidence of cementogenesis
3.	Super EBA (epoxy benzoic acid)	Zinc oxide, aluminum oxide, natural resins—powder, eugenol, and o-methoxybenzoic acid-liquid	No evidence of cementogenesis
4.	Glass ionomer	Calcium aluminosilicate—powder and polyacrylic acid liquid	Moisture sensitive. Risk of detachment from teeth
5.	Retroplast	Paste A- Bis-GMA/TEGDMA 1:1, benzoyl peroxide N,N-di-(2-hydroxyethyl)-p-toluidine, and butylated hydroxytoluene; Paste-B ytterbium fluoride aerosil ferric oxide	Dentin bonding composite resin. Hard tissue formation seen, probably cementum. Evidence of PDL regeneration seen. Biocompatible. Adequate setting time and compressive strength. Strict control of hemorrhage is mandatory
6.	Mineral trioxide aggregate (MTA)	Calcium silicate, calcium carbonate, bismuth sulfate, calcium sulfate, and calcium aluminates	Evidence of cementogenesis seen. Long setting time ≈ 3 h, unaffected by blood and moisture. Gray MTA can cause tooth discoloration. Least amount of microleakage. Less marginal gap formation. Better adaptation
7.	Bioceramics	Calcium silicate, monobasic calcium phosphate, and zirconium oxide	Newer material. Biocompatible. Antimicrobial activity present. Needs more clinical evaluation.

After placing the root end filling, a radiograph must be obtained to assess its quality. If the radiograph reveals an incomplete root resection or an inadequate retrofill, the surgeon must rectify the above-said deficiencies. These are the most common surgical pitfalls that contribute to endodontic surgical failures.

The surgical site is gently cleaned and irrigated with sterile saline to remove debris of hemostatic agents and filling materials. Bone grafts or guided regeneration barriers can be placed into the crypt if indicated, but sterile technique should be adhered to, at all times to obviate infection. Calcium phosphate bioceramics, bioactive glass composite, and bioactive self-setting cements have been evaluated *in vitro* as well as *in vivo* [24, 25]. The flap is repositioned and delicately compressed with a moist gauze to vent out the excess blood, and tissue fluids 4–0 Silk or 6–0 monofilament suture materials are used. Tissue adhesives like cyanoacrylate and fibrin may be used as alternatives in the future. Suturing commences at the corners, approximately 2–3 mm from the wound margins. Interrupted sutures and sling sutures work well for closure of full mucoperiosteal flaps. Continuous locked suturing can also be done in marginal flaps as it reduces the time taken for suturing.

Following wound closure, moist gauze is placed on the flap for 5 min to stabilize clot formation and hemostasis. Compressing the flap with sterile ice packs in the immediate postoperative period minimizes the thickness of the fibrin clot and enhances wound healing. Intermittent cold compresses for 20 min on the day of surgery aids in patient comfort. Analgesics are prescribed, and verbal and written instructions are given to the patient and primary care provider. The wound must be cleaned gently with cotton. Chlorhexidine mouthwash is beneficial and can be continued till sutures are removed, *i.e.*, on the fifth day postoperatively. Sutures can be removed after 3 days in microsurgical procedures.

16.9 Biology of Wound Healing [12]

The dynamics of healing in endodontic surgery involve various mechanisms germane to the nature of the individual tissues. The soft tissue incision heals by primary intention, whereas the bone defect and resected root surface heal via secondary intention. The endpoint of surgery should be regeneration, rather than repair where the normal tissue architecture and function are restored instead of a fibrous scar tissue.

The soft tissue healing progresses through three phases, *i.e.*, inflammatory, proliferative, and maturation. The inflammatory phase begins with clot formation. The local microvasculature contracts, the platelets release serotonin, and a protein-rich exudate enters the wound site. Intravascular aggregation of platelets forms a platelet plug, and the extrin-

sic and intrinsic pathways are activated. This results in a randomly arranged thick fibrin clot. Within 6 hours of clot formation, polymorphonuclear leukocytes enter the wound and decontaminate the area by phagocytosis of bacteria. Their activity tapers off by 96 hours; monocytes and macrophages continue the phagocytic activity. A reduction in macrophages hampers the next phase of wound healing, especially in the older population where there is a step down of estrogen regulation of macrophages. The proliferative phase is dominated by fibroplasia and angiogenesis. The granulomatous nature of the wound transforms into granulation tissue by the activity of cytokines like platelet derived growth factor (PDGF), fibroblast growth factor (FGF), and insulin-like growth factor (IGF-1). By the third day, fibroblasts lay down Type III collagen, which matures to Type I. Myofibroblasts orient themselves parallel to the wound surface and contract, thus drawing the wound edges together. Concurrently, capillary networks form within the wound stimulated by proangiogenic factors like vascular endothelial growth factor (VEGF), FGF, transforming growth factor α , β (TGF- α , β), and interleukin-1 (IL-1). An epithelial seal is formed on the surface of the fibrin clot by the first day. In the next 5–7 days, the wound matures by the formation of larger collagen bundles.

In the osseous crypt, there is a hematoma and proliferation of granulation tissue, callus formation, and woven bone deposition, which is converted to lamellar bone. These events are regulated by TGF- β , PDGF, FGF, IGF, and bone morphogenic protein (BMP). At the root end, cementum forms over the resected surface. Cells responsible for cementogenesis are believed to originate from the ectomesenchymal cells in the tooth germ. By 28 days, the root end is covered by cementum.

16.10 Postoperative Complications

1. Flap necrosis and breakdown, due to poor design and careless handling
2. Transient paresthesia of mental and inferior alveolar nerves
3. Exposure of the maxillary sinus, which heals in a majority of cases
4. Perforation or Fracture of tooth roots
5. Gingival recession and Scar tissue formation
6. Staining of gingival tissues due to retrofilling materials like amalgam

16.11 Outcome of Endodontic Surgery

Clinical and radiographic assessments are made to determine the outcome of periapical surgery. The Periapical Index (PAI) has been used for radiographic assessment in both sur-

gical and nonsurgical series [26]. Ingle opines that the terms ‘healed’, ‘healing’, ‘disease,’ and ‘asymptomatic’ can be used to describe the outcome.

1. Healed cases show complete clinical and radiographic normalcy with no signs and symptoms or residual radiolucency
2. Healing cases show a decrease in the size of the radiolucency and clinical normally within 4 years of surgery
3. Diseased cases show radiolucency, new, increased, unchanged, or decreased after 4 years, regardless of radiographic appearance
4. Asymptomatically functional teeth show clinical normalcy with or without persistent radiolucency, decreased or unchanged

16.12 Aids to Endodontic Surgery

Loupes, endoscopes, and the operating microscope have enhanced visualization of the operating field and thereby the quality of surgery.

16.12.1 Endoscopes

It has a rod lens system, camera head, and control unit with a monitor and light source placed on a mobile rack. The depth of perception is comparable with the naked eye. Tactile perception is excellent; diseased tissue behind and between roots can be visualized. Irrigation fluids can be used without clouding the visual field. Fabbro and Taschiere have reported success rates of 91.1 and 90.7% using the endoscope [27]. They offer rapid and easy adjustment of the viewing angle, direct viewing sans micromirrors, which is versatile and transportable.

16.12.2 Dental Operating Microscope

The resolution of the human eye is 0.2 mm. The power can be increased by moving closer to the surgical field, but can pose strain to the eye. Hence, magnifying lenses and illumination are used to bypass this problem.

The operating microscope offers up to 30 times magnification, coaxial light supply, and shadow free illumination. 200 mm objective lenses and 180° inclinable binoculars are optimum configurations. Light can be sourced from either xenon or quartz halogen bulbs. Digital camera, video camera, and co-observation tube are included in the setup. Endodontic microsurgery amalgamates magnification, illumination, and microinstrumentation, leading to predictable

treatment outcomes. Deeper root end cavities can be prepared, which follow the contour of the root, hence minimizing lateral perforation [28]. The high cost of the equipment and need for specialized training deter many from adopting this tool on a routine basis, but the high success rates should be sufficient encouragement for clinicians and patients to adopt this new tool.

16.13 Future Perspectives

The role of mesenchymal stem cells in regeneration of periapical tissues has been explored with great enthusiasm. Dental pulp stem cells (DPSCs) and those from exfoliated deciduous teeth are multipotent in capacity and can be used along with scaffolds and signaling molecules [29]. These entities, when combined in the ideal proportion, aim to recreate the embryonic milieu, hence augmenting the biological concepts of wound healing. The future may usher in radical changes in our approach to endodontic surgery in terms of materials and techniques with respect to regenerative medicine.

Acknowledgments Dr. Khaleel Ahamed Thaha, Assistant Professor, Department of Conservative Dentistry and Endodontics, Government Dental College, Kozhikode, Kerala.

References

1. Frank CS, Sweta BS, Meetu RK, Bekir K, Syngcuk K. Outcome of endodontic surgery: a meta analysis of the literature – part I: comparison of traditional root end surgery and endodontic microsurgery. *JOE*. 2010 Nov;36(11):1757–65.
2. Guerini VA. History of dentistry. Philadelphia: Lea and Febiger; 1909. p. 117.
3. Franco PB, Karlis V. In: Kademani D, Tiwana PS, editors. Apicoectomy in atlas of oral and maxillofacial surgery. St. Louis, MO: Elsevier; 2016.
4. Gutmann JL, Harrison JW. Surgical endodontics. St. Louis, MO: Ishiyaku euro America; 1994.
5. Quality assurance guidelines. Chicago: American Association of Endodontists; 1987, p. 1–27.
6. Simsek-Kaya G, Saruhan N, Yapia-Yavuz G, Ertas U. A decision analysis for periapical surgery: retrospective study. *J Clin Exp Dent*. 2018 Sep;10(9):e914–20.
7. El-Swiah JM, Walker RT. Reasons for apicoectomies: a retrospective study. *Endod Dent Trauma*. 1996;12:185–91.
8. Glickman GN, Hartwell GR. Endodontic surgery in Ingle's endodontics. 6th ed. Hamilton, ON: BC Decker Inc; 2008.
9. European Society of Endodontology. Quality guidelines for endodontic treatment: consensus report of European society of endodontology. *Int Endod J*. 2006;39:921–30.
10. Eberhardt JA, Torabinejad M, Christiansen EL. A computed tomographic study of the distances between the maxillary sinus floor and apices of the maxillary posterior teeth. *Oral Surg Oral Med Oral Pathol Oral Radiol Endod*. 1992;73:345.
11. Benninger MS, Sebak BA, Levine HL. Mucosal regeneration of the maxillary sinus after surgery. *Otolaryngol Head Neck Surgery*. 1989;101:33.

12. Johnson BR, Fayad MI, Hargreaves KM, Berman LH, editors. Periradicular surgery in Cohen's pathways of the pulp. 9th ed. St. Louis, MO: Elsevier.
13. Jastak JT, Yagiela JA. Regional anesthesia of the oral cavity. St. Louis, MO: Mosby; 1981.
14. Nedderman TA, Hartwell GR, Portell FR. A comparison of root surfaces following apical root resection with various burs: scanning electron microscope evaluation. *J Endod.* 1988;14:423.
15. Komori T, Yokoyama K, Matsumoto Y. YAG laser root resection of extracted human teeth. *J Clin Laser Med Surg.* 1997;15:9.
16. Harrison JW, Jurosky KA. Wound healing in the tissues of the periodontium following periradicular surgery. I. The incisional wound. *J Endod.* 1991;17:425.
17. Harrison JW, Jurosky KA. Wound healing in the tissues of the periodontium following perpendicular surgery. II. The dissectinal wound. *J Endod.* 1991;17:544.
18. Hirsch V, Meetu RK, Kim S. Apicoectomy of maxillary anterior teeth through a piezoelectric bony window osteotomy: two case reports introducing a new technique to preserve cortical bone. *Restor Dent Endod.* 2016 Nov;41(4):310–5.
19. Lin LM, Gaengler P, Langeland K. Periradicular curettage. *Int Endod J.* 1996;29:220.
20. Garlock JA, Pringle GA, Hicks ML. The odontogenic keratocyst: a potential endodontic misdiagnosis. *Oral Surg Oral Med Oral Pathol Oral Radiol Endod.* 1998;85:452.
21. Jeevanand D, Ratika S, Rachappa M. Giant radicular cyst of the maxilla. *BMJ Case Rep.* 2014; <https://doi.org/10.1136/bcr-2014-203678>.
22. de Lange J, Putters T, Baas EM, van Ingen JM. Ultrasonic root end preparation in apical surgery: a prospective randomized study. *Oral Surg Oral Med Oral Pathol Oral Radiol Endod.* 2007;104:84.
23. Walmsley AD, Lumley PJ, Johnson WT, Walton RE. Breakage of ultrasonic root-end preparation tips. *J Endod.* 1996;22:287.
24. Komath M, Varma HK, Annie J, Vinod K, Simon D, Ramanathan M, Bhuvaneshwar GS. Designing bioactive scaffolds for dental tissue engineering in regenerative medicine: laboratory to clinic. Berlin: Springer; 2017.
25. Simon D, Manuel S, Varma HK. Novel nanoporous bioceramic spheres for drug delivery application: a preliminary in vitro investigation. *Oral Surg Oral Med Oral Pathol Oral Radiol.* 2013 Mar;115(3):e7–14.
26. Friedman S. Treatment outcome: the potential for healing and retained function in Ingle's endodontics. 6th ed. Hamilton: BC Decker Inc; 2008.
27. Del Fabbro M, Taschieri S. Endodontic therapy using magnification devices: a systematic review. *J Dent.* 2010 Apr;38(4):269–75.
28. von Arx T. Failed root canals: the case for apicoectomy (periradicular surgery). *J Oral Maxillofac Surg.* 2005;63:832–7.
29. Shiehzadeh V, Aghmasheh F, Shiehzadeh F, Joulae M, Kosarieh E, Shiehzadeh F. Healing of large periapical lesions following delivery of dental stem cells with an injectable scaffold: new method and three case reports. *Indian J Dent Res.* 2014 Mar–Apr;25(2):248–53.

Additional Reading (Algorithm for Periapical Surgery)

- Lieblisch SE. Periapical surgery: clinical decision making. *Oral Maxillofac Surg Clin N Am.* 2002;14:181.
- Leiblich S. Current concepts of periapical surgery. *Oral Maxillofac Surg Clin N Am.* 2015;27(3):383–2.

Open Access This chapter is licensed under the terms of the Creative Commons Attribution 4.0 International License (<http://creativecommons.org/licenses/by/4.0/>), which permits use, sharing, adaptation, distribution and reproduction in any medium or format, as long as you give appropriate credit to the original author(s) and the source, provide a link to the Creative Commons license and indicate if changes were made.

The images or other third party material in this chapter are included in the chapter's Creative Commons license, unless indicated otherwise in a credit line to the material. If material is not included in the chapter's Creative Commons license and your intended use is not permitted by statutory regulation or exceeds the permitted use, you will need to obtain permission directly from the copyright holder.



Bobby John

The human mandible has no one design for life. Rather it adapts and remodels through the seven stages of life, from the slim arbiter of things to come in the infant, through a powerful dentate machine and even weapon in the full flesh of maturity, to the pencil-thin, porcelain like problem that we struggle to repair in the adversity of old age.

Poswillo

17.1 History

The management of discontented denture patients by the act of preprosthetic surgical procedures to enhance the denture-bearing areas of the intraoral cavity is a daunting task, which has been performed by the oral and maxillofacial surgeon from time immemorial. Preprosthetic surgery encompasses a distinguished and evolving category of soft and hard tissue procedures.

Pre-prosthetic surgery has emerged from being virtually unknown, passed through a period of opposition and into a state of venerability, and has ultimately made a powerful impact on oral surgery and prosthetic dentistry alike.

A meticulously nurtured and evolved repertoire of ingenious salvage procedures is now alarmingly threatened by a populist ‘implants-first’ belief that usurps, rather than expands, the traditional prosthodontic treatment spectrum.

Willard [1] is honoured to be the first American dentist to call attention to proper preparation of the mouth for full dentures. Beers [2] in 1876 advocated excision of the alveolus after extraction of teeth, especially if the alveolar process is unusually exhibiting protuberance. Surgery has always been an integral part of the preparation of alveolar ridges for dentures. The last few decades have witnessed an escalating interest in preprosthetic surgery, which has harboured the development of many new techniques.

Electronic Supplementary Material The online version of this chapter (https://doi.org/10.1007/978-981-15-1346-6_17) contains supplementary material, which is available to authorized users.

B. John (✉)
Department of Oral and Maxillofacial Surgery, Government Dental College, Kottayam, Kerala, India

17.2 Pattern of Resorption

Immediately after extraction, the socket will suffer a reduction in the dimensions both in buccolingual and apicocoronal aspects. This catabolic process can be counteracted by the placement of implants. The resorption of the walls occurs in two phases, which are overlapping in nature. The first phase is characterised by the resorption of bundle bone and replacement with woven bone. The second phase involves the outer surfaces. The exact aetiology for this bone loss is unknown. Roux [3] opined the loss of alveolar bone occurring after tooth loss in the old age is an illustration of disuse atrophy. According to studies by Wolff [4], the mass and structure of the bone can get adapted to the mechanical demands. The resorption is a multifactorial, biomechanical process that results from a combination of anatomic, metabolic, and mechanical determinants. Since all of these factors vary from one patient to the next, these different cofactors may combine in infinite variety of ways, thus explaining the variations in resorption between patients. So ridge resorption is a chronic, progressive, irreversible, and cumulative phenomenon resulting from physiologic, environmental and pathologic components.

Mercier [5] illustrated the general resorptive changes that take place in an edentulous ridge. He summarised the stages as follows:

1. The ridge is wide enough at its crest to accommodate the recently extracted teeth.
2. The ridge becomes thin and pointed.
3. The pointed ridge flattens to the level of the basal bone.
4. The flattened ridge becomes concave as the basal bone resorbs.

Based on these stages, he grouped the residual ridges as

- Group 1—minor ridge remodelling.
- Group 2—sharp atrophic residual ridge.
- Group 3—basal bone ridge.
- Group 4—basal bone resorption.

The pattern of resorption in maxilla differs from that of the mandible. Also, the pattern varies with the site in maxilla and mandible. The extensive study by Cawood and Howell [6] depicts the following conclusions.

Basal bone does not change shape significantly. But if subjected to harmful local effects, it undergoes change.

Alveolar bone exhibits significant changes in shape in both horizontal and vertical axes.

In anterior mandible, the bone loss is vertical and horizontal, but in posterior mandible, the bone loss is mainly vertical.

In anterior maxilla, the bone loss is both vertical and horizontal. The same pattern is exhibited in the posterior maxilla. To summarise, the stage of bone loss varies anteriorly and posteriorly and between the jaws.

Box 17.1 Effects of Edentulism

- Typical overclosed appearance.
- Neurosensory disturbances.
- Encroachment of muscle tissues leading to instability.
- Prolonged effects of edentulism culminates in pathological fracture.

Box 17.2 Goals of Preprosthetic Surgery

- Rehabilitation of tissues.
- Relieving of interferences.
- Repositioning of attachments.
- Restoration of alveolar ridge dimensions.
- Re-establishing maxillomandibular relationships in all spatial dimensions.
- Satisfying aesthetics and function.

17.2.1 Types of Ridges

Ridges can be classified by their shape. There are V-shaped, U-shaped and knife edged types. The U shaped is the ideal while the V shaped, though successfully distribute the stress but may be unable to retain the peripheral seal during the jaw

movements. Knife edged ones are a constant source of soreness under the stress.

A more scientific categorisation is made by Cawood and Howell [6].

Cawood and Howell [6] classification of edentulous jaws:

- Class I—dentate.
- Class II—Immediately post-extraction.
- Class III—well-rounded ridge form, with adequate height and width of the alveolar process.
- Class IV—knife-edge form with adequate height but inadequate width of the alveolar process.
- Class V—flat-ridge form with inadequate height and width.
- Class VI—depressed ridge form with evident basal bone loss.

17.3 Treatment Planning

The preliminary step is the assessment of the patient, which commences from the history taking to the physical examination. The role of radiograph is relevant especially the panoramic view to reveal the deep-seated disorders. Storer [7] found 32% of edentulous patients had an asymptomatic pathologic condition, which warrants the need for radiographic examination. Crandell and Trueblood [8] also advised radiographic examination to rule out the presence of pathologies, root remnants, and even impacted tooth. Radiographic assessment is one of the parameters in detecting bone quality.

Lekholm and Zarb [9] categorise bone quality as follows

Type 1: bone in which almost the entirety is composed of homogeneous compact bone.

Type 2: bone in which a thick layer of compact bone surrounds a core of dense trabecular bone.

Type 3: bone in which a thin layer of cortical bone surrounds a core of dense trabecular bone.

Type 4: bone characterised as a thin layer of cortical bone surrounding a core of low-density trabecular bone of poor strength.

Box 17.3 Preprosthetic Surgical Procedures can be Classified

Ridge correction procedures

Hard-tissue correction

- Alveoloplasty
- Alveolectomy
- Reduction of,
 - Genial tubercles
 - Mylohyoid ridge,
 - Maxillary tuberosity.
- Correction of tori, exostoses.

Soft-tissue correction

- Frenectomy
 - Labial
 - Lingual
- Excision of hypertrophic tissues

Ridge extension procedures

Vestibuloplasty

Ridge augmentation procedures

- Superior border
- Inferior border
- Interpositional grafting
- Visor osteotomy
- Combined with orthognathic surgery

smooth the edges, but large irregularities may be rectified by rotary instruments. Ensure saline irrigation to keep the temperature below 47 degrees to prevent necrosis. Once the hard tissue is removed, the excess soft tissue is trimmed to prevent the instability of the prosthesis. Closure with absorbable sutures in running or lock stitch fashion is achieved.

17.4.2 Intercortical Alveoloplasty

In situations where the alveolar process is prominent but regular, the need for alveoloplasty by the removal of interseptal bone and collapsing the buccal or labial cortical plates to meet the palatal or lingual plates is warranted. This method was propagated by Dean and Mackay [10]. This is an ideal procedure in case of immediate denture placement and usually carried out in the anterior region (Fig. 17.1a and b). This is done by the placement of vertical bone cuts in the canine region through subperiosteal tunnels. Apply the digital pressure to infracture the bone. If unsuccessful, the labial plate can be fractured with an osteotome inserted through a horizontal subperiosteal tunnel made through the vertical lateral incision. The bone distal to the canine is rounded off to maintain the contour. Mucosa is sutured appropriately to retain the new position of the cortices and if needed an acrylic splint may be used to stabilise it.

17.4 Ridge Correction Procedures

17.4.1 Alveoloplasty

The term refers to the restructuring or resurfacing of the alveolar process bone to provide a functional skeletal relationship. Simple plasty insists on the reshaping of the alveolar bone during the extraction procedure. The sharp edges of the alveolus will impede the healing process with symptoms of pain and discomfort. The shape of the ridges with sufficient width and height should be able to distribute the forces properly.

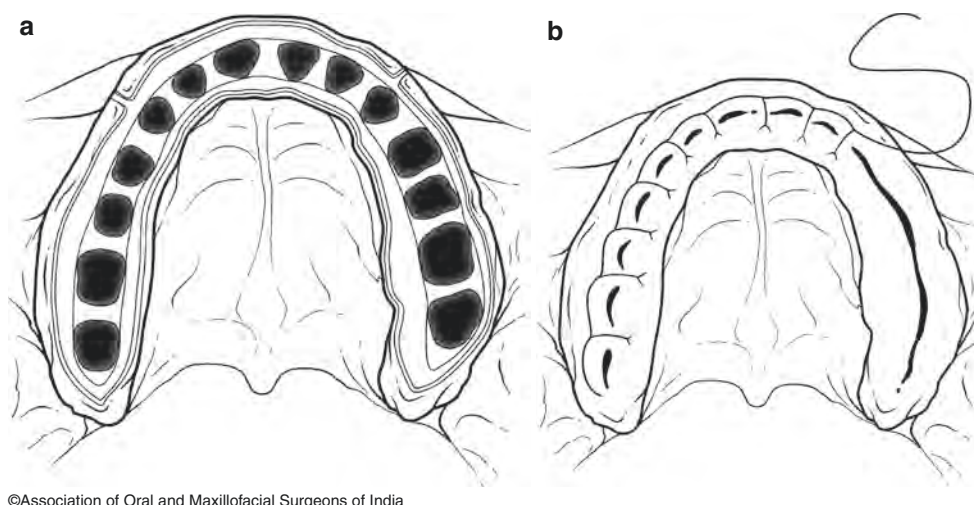
Preservation of alveolar bone is of utmost importance in the extraction procedure. Simple alveolar contouring includes compression and infracture of the socket, but overcompression and reduction should be avoided. If extractions are carried out before the prosthesis fabrication, attempts are made to preserve the alveolus. In multiple extractions, postextraction irregularity exists, which warrants the need for extended alveoloplasty. Here, mucoperiosteal flap may be raised by a crestal incision to get adequate access for the bone reshaping. Extreme care has to be taken during flap elevation since the soft tissues are tightly adhered to the bony irregularities. The use of bone rongeur or file is needed to

17.4.3 Genial Tubercle Reduction

Genioglossus muscle is one which is adhered to the lingual aspect of the anterior mandible and when the resorption continues, the genial tubercle becomes more prominent and along with the attached muscles creating a displacement of prosthesis. In this case, the pronounced tubercle may be trimmed and released. This procedure may be done alone or in combination with procedures suggestive of lowering the floor of the mouth.

17.4.3.1 Procedure

A crestal incision from the midline to the midbody of mandible is made to get adequate access, followed by dissection in subperiosteal fashion, thus exposing the tubercle and the attached muscle. Muscle may be excised from the bony attachment by using a monopolar electrocautery with care to be taken to achieve haemostasis or else chance of airway embarrassment by the occurrence of expanding hematoma. The exposed genial tubercle is trimmed by round or fissure bur. Further smoothing is made by bone file. The flap is returned to the original position and closed by nonresorbable



©Association of Oral and Maxillofacial Surgeons of India

Fig. 17.1 (a) Incision for intercortical alveoloplasty (b) closure of wound

sutures. Anderson [11] proposed reattaching the genioglossus and geniohyoid muscles at a lower level. Here, he advocated using a sagittal incision in the midline in the periosteum and exposing the genial shelf. The tubercle is reduced and the incision is closed with absorbable sutures.

17.4.4 Mylohyoid Ridge Reduction

In cases of extensive resorption, the ridge becomes prominent and creates hurdle for the smooth placement of denture; hence, the need for ridge reduction occurs. The denture flanges impinge on the sharp mylohyoid ridge and patient experiences pain and discomfort. The advent of implants may obviate the need for such a surgical procedure, yet in many cases where implant placement is not feasible, the dentures become a necessity and the mylohyoid ridge reduction needs to be accomplished.

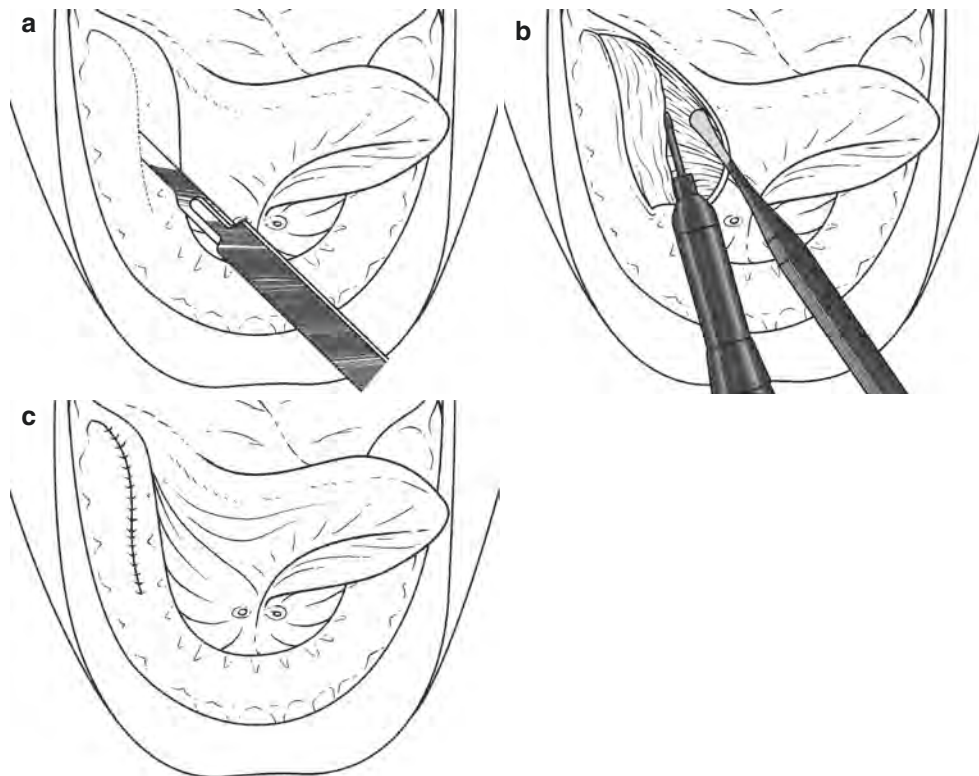
17.4.4.1 Procedure

The procedure can be carried out under local anaesthesia or sedation. After successful nerve block, the incision is carried out along the crest of the ridge in the posterior mandible area followed by subperiosteal dissection and exposure of the mylohyoid ridge and the attached muscle (Fig. 17.2a and b). The muscle is detached and relieved. The residual ridge is smoothed with file, flap returned, and closed with sutures (Fig. 17.2c). Care is ensured to obtain haemostasis.

17.5 Maxillary Tuberosity Reduction

Maxillary tuberosity may be enlarged in size and it engorges the intermaxillary space and interferes with denture placement. The reduction of the tuberosity may be needed to create space for the placement of dentures. Generally, the

intermaxillary distance should be at least 1 cm when patients are placed into the correct or planned vertical dimension of occlusion. The excessiveness of the tuberosity and the need for its reduction can be assessed by some clinical manoeuvres. An instrument like a dental mirror can be used to assess the vertical clearance by passing it between the tuberosity and retomolar tissues. The mirror may be positioned in the lateral aspect and the patient is instructed to open and close mouth so as to determine the need for reduction of tuberosity in the horizontal plane. The pneumatization status should be ascertained before the reduction procedure is undertaken since the maxillary sinus may descend into the tuberosity. So a radiographic examination is essential prior to surgical management. An elliptical incision is made followed by subperiosteal dissection. The engorged tuberosity is trimmed to the desired level and excessive tissue is removed from both buccal and palatal side. The amount of bone removal can be dictated by a surgical guide that was created from study models. Rotary instrumentation, rongeur and a bone file may be used to remove the bone. The flaps are trimmed to leave the excess redundant tissue and sutured in place (Fig. 17.3a–f). Guernsey [12] proposed a different technique for the reduction of the tuberosity. He advised placing a horizontal incision superiorly in the vestibule from the premolar area to the posterior aspect of the tuberosity and a mucoperiosteal flap is released inferiorly to get access to the tuberosity region. Any excessive soft tissue of fibrous nature is removed from within the flap and excessive bone is also removed by using suitable instruments. To correct the redundancy of tissues, soft tissue may be removed from the superior aspect of the incision and flap is sutured back to the periosteum and a stent is placed. This method claims to increase the vestibular depth to some extent (Fig. 17.4a–d). Antral communication should be checked and if present managed accordingly.



©Association of Oral and Maxillofacial Surgeons of India

Fig. 17.2 (a) Incision along the crest of the ridge (b) flap raised and bone trimmed (c) sutured the incision

17.6 Torus Removal

Tori, meaning ‘to stand out’ or ‘lump in Latin, refer to innocuous bony outgrowths. The aetiology of the occurrence is unclear. Early description of the occurrence of tori is found in the Proceedings of the Royal Society of Medicine by Rickman Godlee [13], which was followed by the reports from various authors and later beautifully summarised by Garcia Garcia [14]. In dentate individuals, the removal of torus may not be needed unless it impedes with functions or it generates discomfort. But in edentulous, the presence of tori precludes the smooth placement of denture, so the removal becomes mandatory. Other indications include mucosal surface getting traumatised with frequent episodes of ulceration, presenting with deep undercuts and multiple nodules and psychological issues. Literature also suggests tori as donor sources of autogenous bone for intraoral grafting procedures. Morraes et al. [15] and Hassan et al. [16] describe the versatility of the grafts from torus for reconstructive methods.

Classification of tori was initially proposed by Kolas [17], who classified them according to number of nodes and their

placement as bilateral single, bilateral multiple, unilateral single, and unilateral multiple [18].

Haugen [19] formulated the categorisation of torus based on the size. It is illustrated as.

Type A—small tori into less than 2 mm in their largest diameter.

Type B—medium—2–4 mm in their largest diameter.

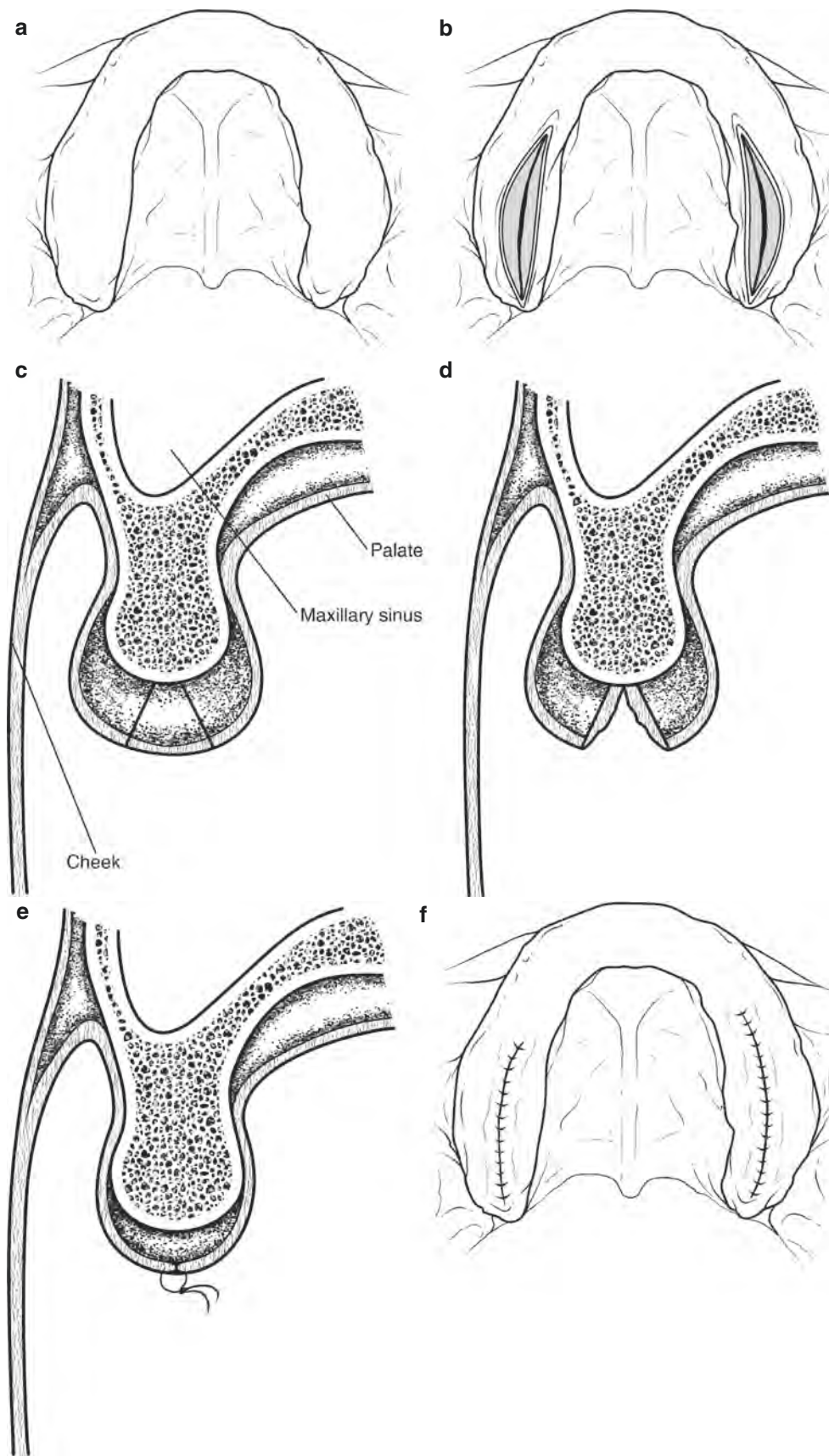
Type C—large- and more than 4 mm in their largest diameter.

Reichart [20] in his modification of Haugen’s classification suggested few changes:

Grade I—Tori up to 3 mm in their largest dimension,

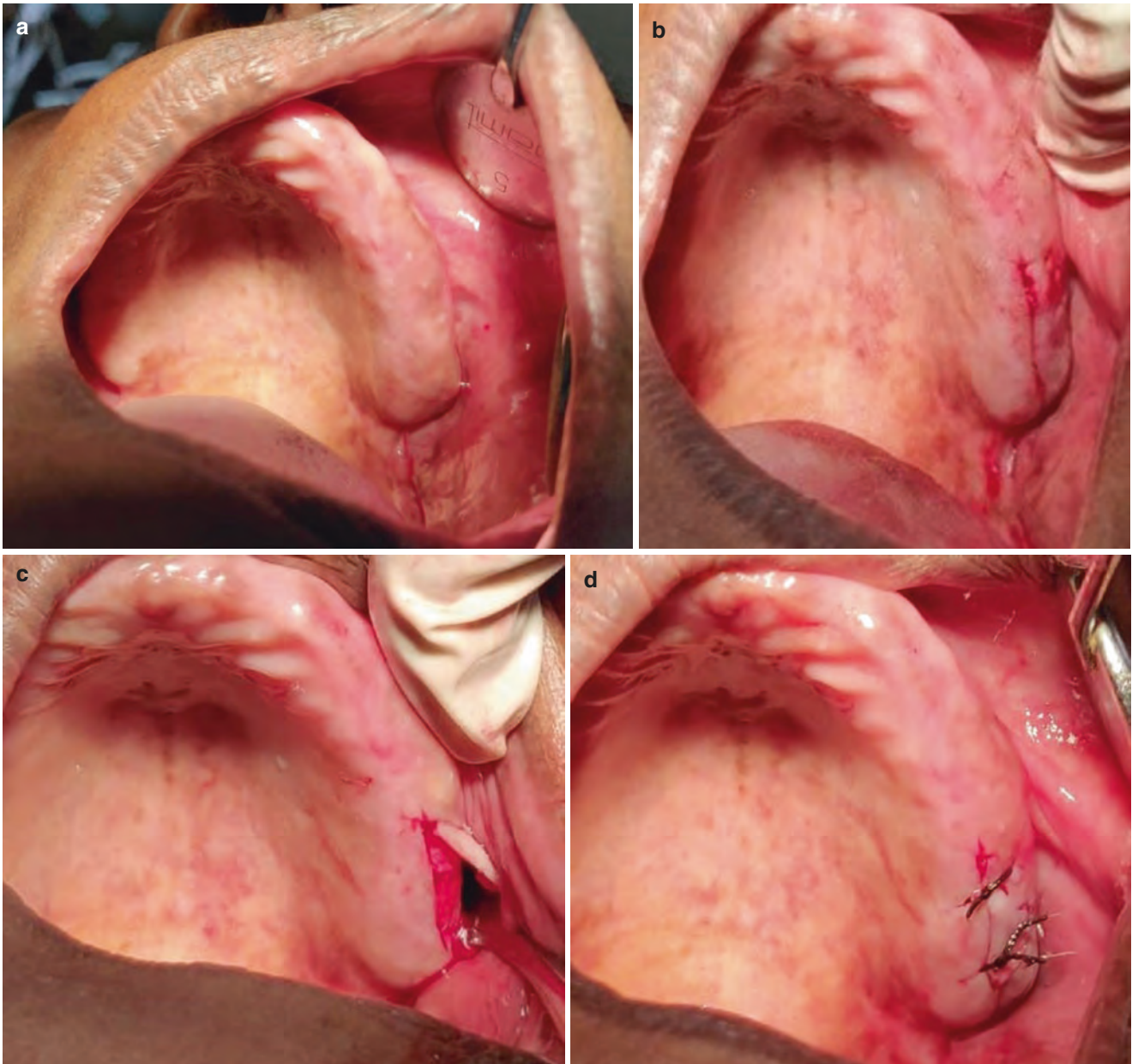
Grade II—Tori up to 6 mm in their largest dimension and.

Grade III—Tori above 6 mm belong to this group.



©Association of Oral and Maxillofacial Surgeons of India

Fig. 17.3 (a) Bulbous tuberosity, (b) incision placed and flap raised (c and d) reduction, (e and f) sutured incision



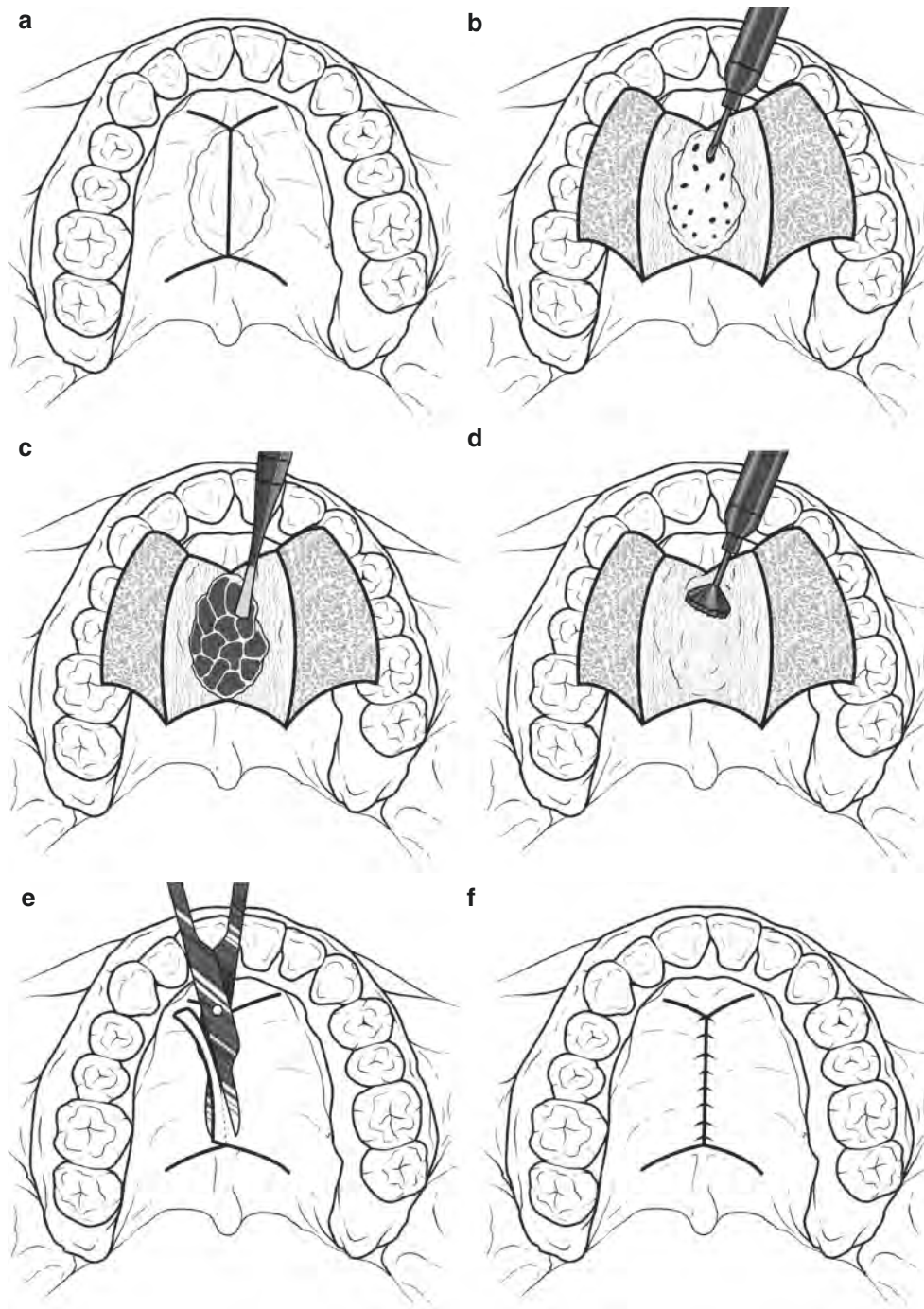
©Association of Oral and Maxillofacial Surgeons of India

Fig. 17.4 Clinical photograph showing (a) bulbous tuberosity (b) incision (c) flap reflection (d) sutured wound

17.6.1 Palatal Tori Removal

As in any surgical procedures, here also the general systemic condition of the patient may be ascertained and the patient should be warned of the potential complications like the perforations leading to oronasal communication and wound dehiscence. To overcome this problem, preoperatively an impression may be made and cast is fabricated and splint is

prepared. Palatal tori may be of different shapes, like lobulated or nodular. The morphology of the torus dictates the incisions required to expose it. Surgical access is accomplished by various types of incisions, “C-” or “U-” shaped incision, palatal incision or double “Y” incision also known as open-door technique. Most commonly used is double Y incision (Fig. 17.5a–f). After successful anaesthesia, a mid-line incision in anteroposterior direction is made from a few

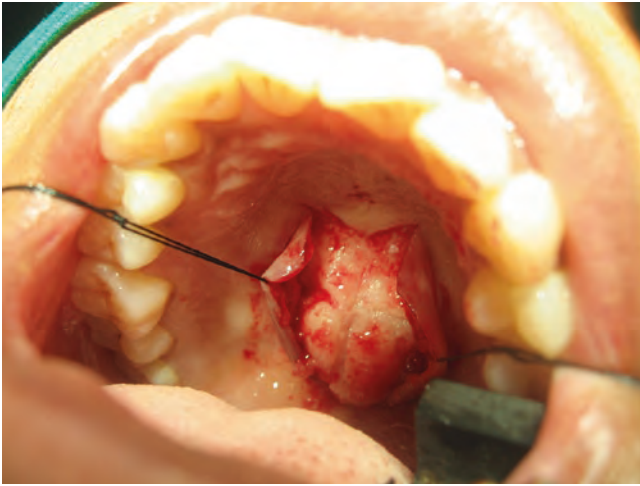


©Association of Oral and Maxillofacial Surgeons of India

Fig. 17.5 (a) Incision, (b) flap raised, (c) multiple grooves made, (d) final trimming by acrylic trimmer, (e) excess soft tissue trimmed, (f) closure

mm ahead of the anterior margin of the torus and continued posteriorly to the most posterior visible point of the torus. Oblique-releasing incisions may be placed at the anterior end of the midline incision and may be extended laterally and anteriorly to end lateral to the lateral margins of the torus. From the posterior end of the midline incision without

violating the soft palate, posterior releasing incisions may be placed to extend obliquely in a lateral and posterior direction. Thus, a fair access is obtained. The subperiosteal flap is raised. The small torus can be easily removed by round. But in case of large ones, grooves are created and separated into discrete segments with bur and then by osteotome (Fig. 17.6).



©Association of Oral and Maxillofacial Surgeons of India

Fig. 17.6 Clinical photograph showing palatal tori and surgical exposure, double Y-incision used

Copious irrigation is done to clear the debris and flap repositioned in primary fashion. The fabricated stent may be placed to avoid the haematoma and the dead space formation.

17.6.2 Lingual Torus

The lingual tori are found in the lingual aspect of the alveolar ridge in the canine and premolar regions. They vary in size and shape; some are pedicled, while others are broad based. An intrasulcular incision without releasing is made from the lingual midline to a point beyond the posterior limit of the tori. In edentulous case, the incision may be placed in the crest of the alveolar ridge. A full-thickness flap is raised to expose the tori and if needed local anaesthetic may be injected in the area to balloon the tissues for easy elevation of the flap. The vertical-releasing incision should be avoided to prevent the vascularity compromise.

The lingual torus may be removed by bur or osteotome. Smaller ones can be easily removed by bur, but the larger require cleavage plane created by bur and later completed by osteotomes. After the removal of the tori, it is essential to check the surface and clear of the irregularities by the use of rongeur and bone files. The flap repositioned and sutured.

17.7 Exostosis

It is a benign osseous hypertrophic formation with more predilections to the maxilla. A mucoperiosteal flap is elevated after adequate infiltration of the mucosa. The bone is resected

and smoothed with an osteotome or a bur. The smooth placement of the prosthesis is achieved by the facilitation of the errorless foundation, constituted by both hard and soft tissues. In many cases, the hard-tissue framework may be normal, but the soft-tissue impediments affect the stability of the prosthesis. So, the correction of the interferences by the abnormal soft tissues is needed.

Apart from hard tissues, sometimes soft-tissue interferences inhibit the smooth placement of the prosthesis. The unfavourable soft-tissue framework affects the stability of the prosthesis and needs correction by various procedures.

17.8 Excision of Reactive Inflammatory Papillary Hyperplasia

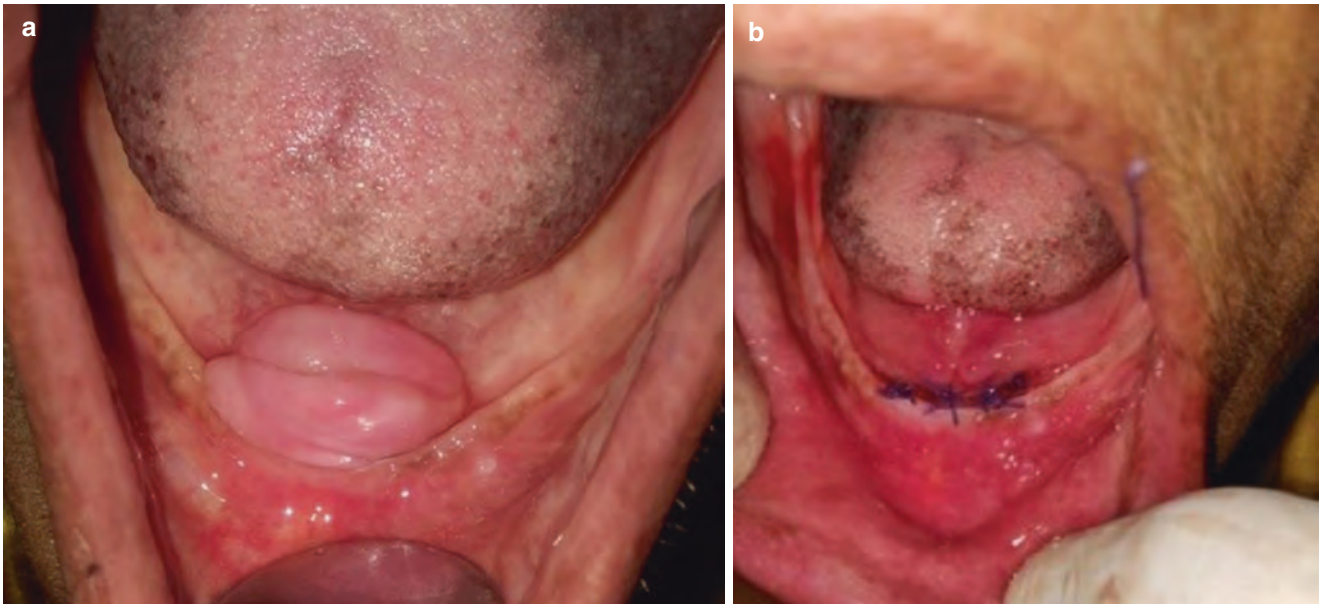
This is commonly associated with prolonged wearing of an ill-fitting denture. The condition is recognised as reddened, nodular, or papillary excrescences arising from the palatal mucosa. It can be seen in areas where the denture flanges rest. Removal is accomplished by local anaesthesia or sedation (Fig. 17.7).

17.9 Frenectomy

Active and strong frenal attachments interfere with the placement of dentures and the relief of attachments are needed. Various incisions like v-y, z plasty, and diamond-shaped incisions are used in frenectomy procedures.

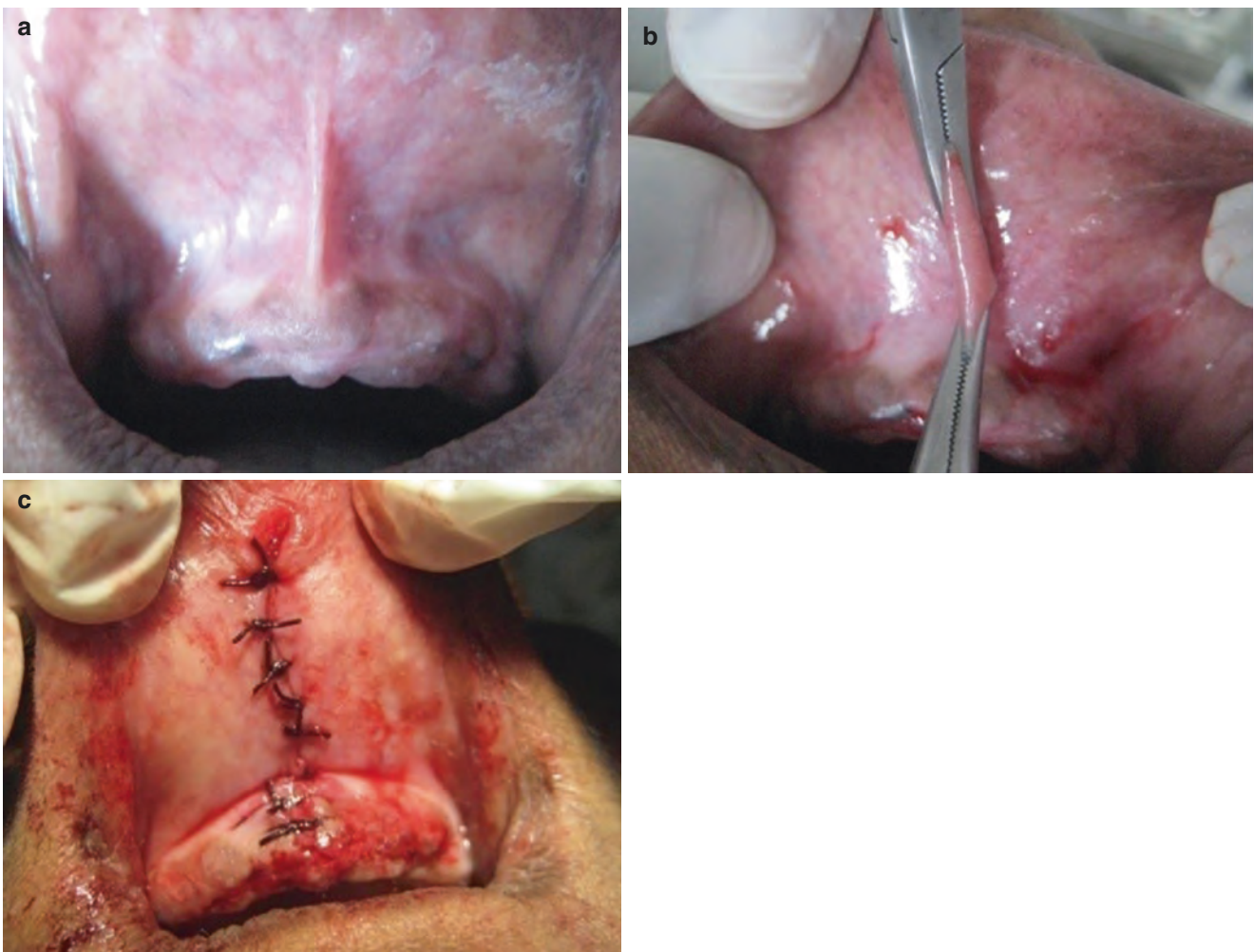
17.9.1 Labial Frenectomy (Video 17.1)

In the edentulous state, the abnormal frenal attachment gets irritated by the denture flanges leading to instability. The denture area can be relieved but it may be unaesthetic, so the need for frenectomy arises. Z plasty is used to eliminate the abnormal attachment. Another method is the V-Y procedure but has a disadvantage of creating excessive bulk of tissue at the depth of vestibule. The operative procedure is as follows (Fig. 17.8a, b and c). It is carried under local anaesthesia, but the tissue should not be overdistended. The lip is extended and everted to tense the frenum. The V-shaped piece of tissue is held by tissue forceps or Allis clamp, and an incision is made down to the periosteum on either side of the frenum. Resorbable sutures are preferred since the removal is difficult in this area. The first suture should be placed at the depth of the vestibule and should engage the periosteum to prevent the loss of the vestibular depth (Fig. 17.9a-e).



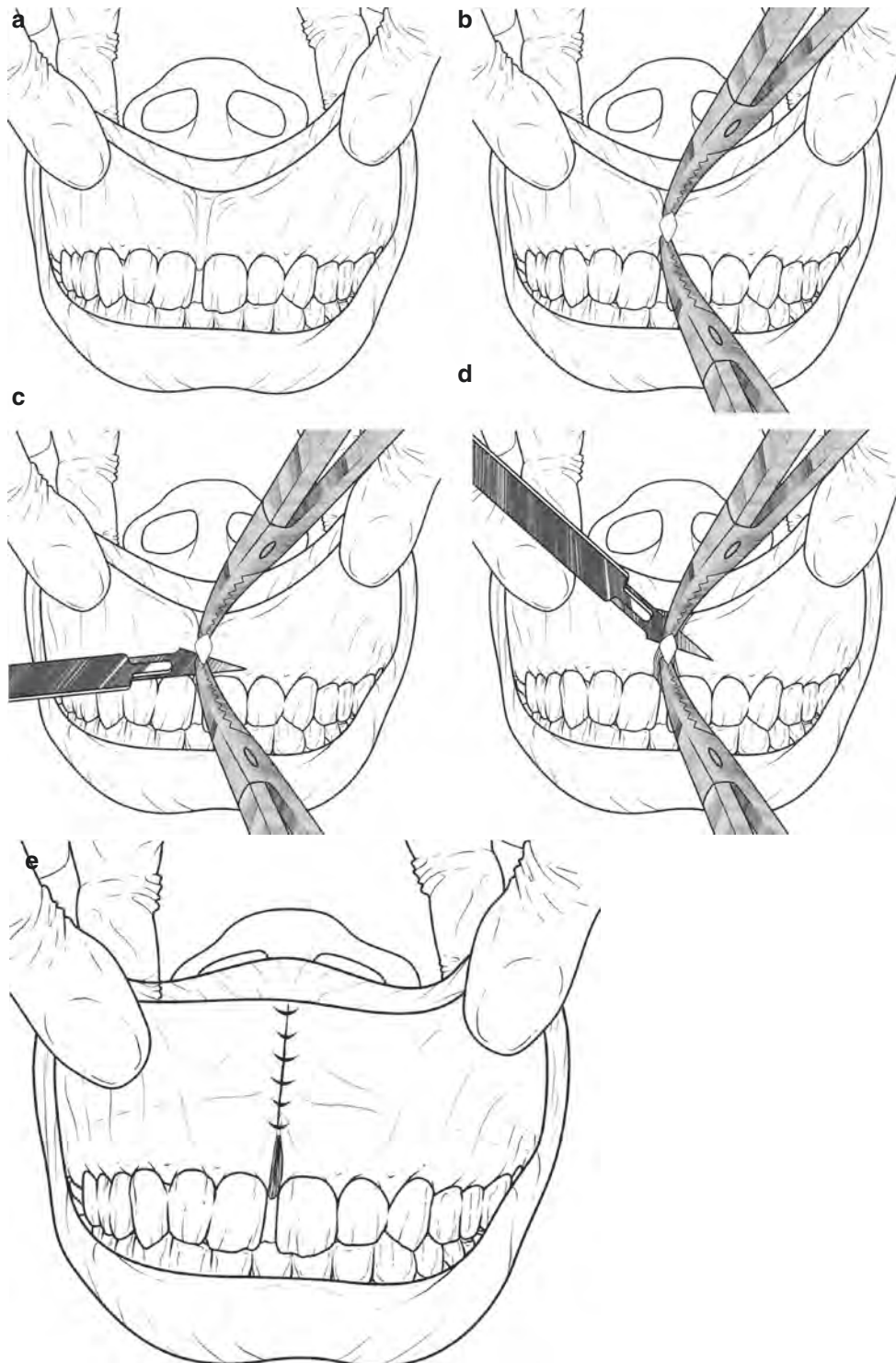
©Association of Oral and Maxillofacial Surgeons of India

Fig. 17.7 Clinical photographs showing (a) lingual papillary hyperplasia (b) suturing after excision



©Association of Oral and Maxillofacial Surgeons of India

Fig. 17.8 Clinical photographs showing (a) abnormal attachment of frenum (b) tissue held with mosquito forceps (c) suturing



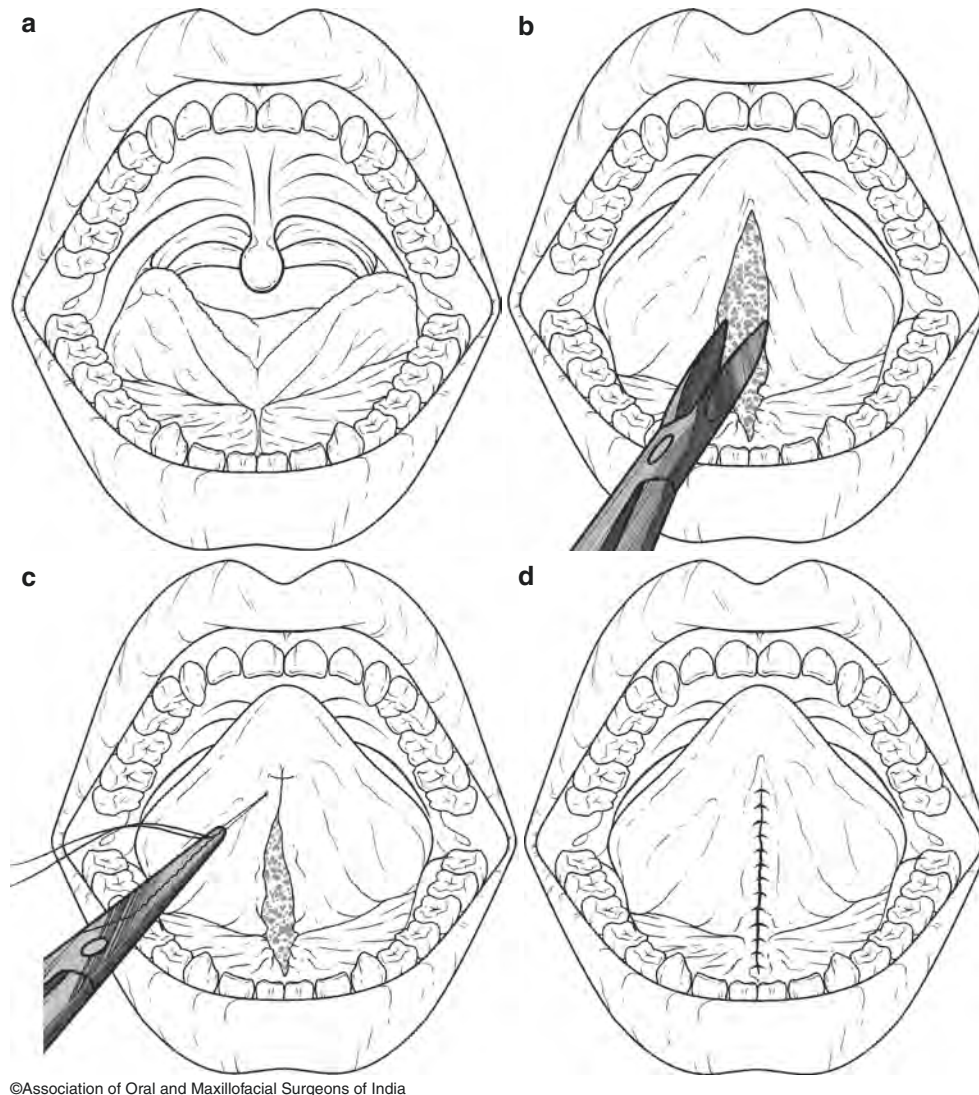
©Association of Oral and Maxillofacial Surgeons of India

Fig. 17.9 (a) low attached frenum, (b) frenal tissue grasped by forceps, (c and d) diamond-shaped tissue removal, (e) closure

17.9.2 Lingual Frenectomy (Video 17.2)

If the frenal attachment is near the crest of the lingual aspect, it will displace the denture. So the need for relief of the high attached frenum is needed. This procedure can be done

under local anaesthesia or general anaesthesia (Fig. 17.10a–d). When local anaesthesia is used, bilateral lingual nerve block and infiltration are used. The tongue is grasped with traction sutures or forceps and the attachment of frenum to the ridge is cut and the wound is closed with sutures. In



©Association of Oral and Maxillofacial Surgeons of India

Fig. 17.10 (a) High attached lingual frenum, (b) excision of frenum, (c and d) closure

some, a more extensive procedure is needed. Here, a transverse incision is made between ventral aspect of tongue and caruncle of submandibular duct. Sectioning of some fibres of the genioglossus muscle may yield greater degree of freedom. Diamond-shaped defect is closed with interrupted sutures. Postoperative pain is managed by analgesics and oedema controlled by steroids. There may be some ecchymosis in the floor of the mouth.

17.10 Ridge Extension Procedure

They are defined as the procedures surgically designed to uncover the existing basal bone of the jaw by repositioning the overlying mucosa and muscle attachments to an inferior position in mandible or to a superior position in maxilla. This will enable to accommodate the larger denture

flanges, thus contributing to stability and retention (Tables 17.1 and 17.2).

17.10.1 Vestibuloplasty [Sulcoplasty, Sulcus Extension] (Box 17.4)

The reduction or obliteration of the sulcus is caused by [1] resorption of the alveolar process, [2] abnormally high muscle attachment in mandible or low on the maxilla, [3] scar tissue resulting from trauma or infection from the contiguous soft tissue.

Vestibuloplasties are carried out in mandible and maxilla. In mandible, both labial and lingual vestibuloplasties are performed. Stability of a denture can be improved by deepening the mandibular sulcus, generating more attached tissues over the functional ridge, and permanently maintaining the

Table 17.1 Mandibular ridge extension procedures

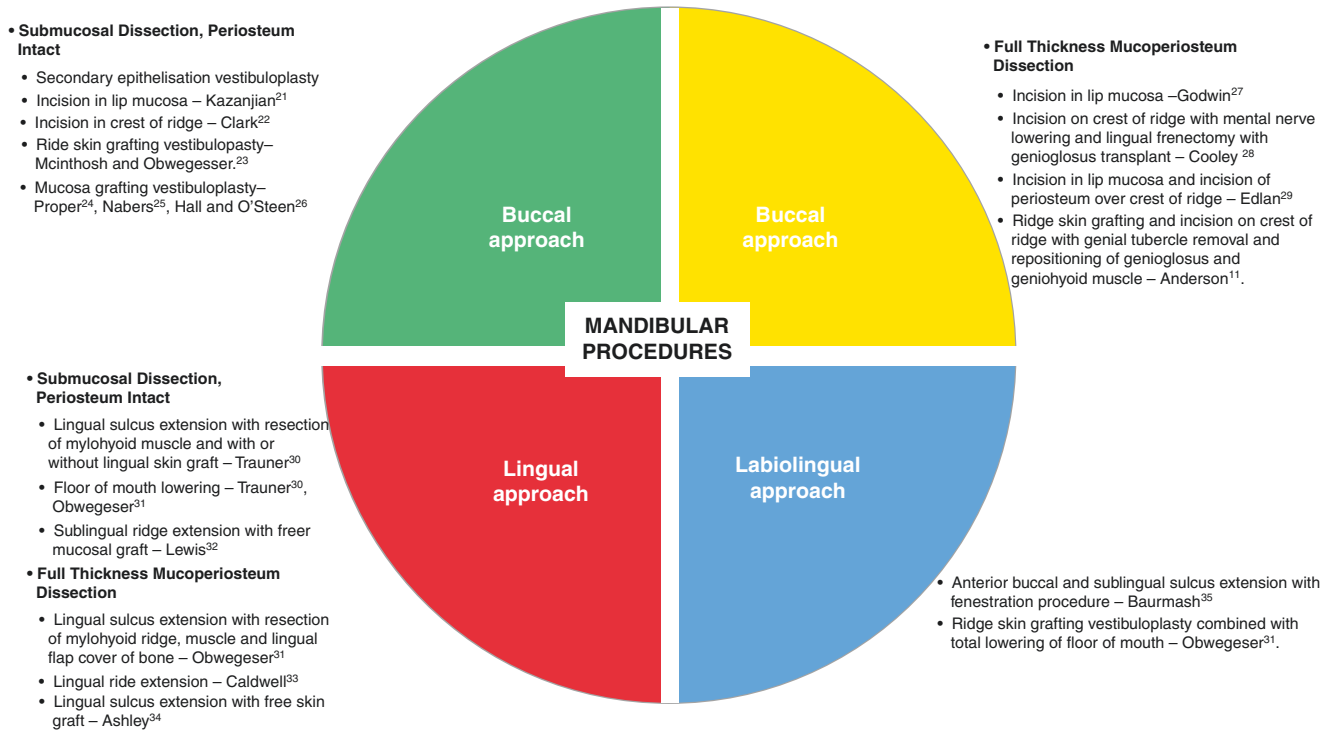


Table 17.2 Maxillary ridge extension procedures

Maxillary procedure

Buccal approach

- 1.Secondary epithelization vestibuloplasty
 - a.Full thickness mucoperiosteal dissection-Collett³⁶
 - b.Submucosal dissection,periosteum intact-Szaba³⁷

- 2.Submucosal vestibuloplasty-Obwegeser³¹,Yrastorza³⁸
- 3.Ridge skin grafting vestibuloplasty-Weiser³⁹, Schuchardt⁴⁰
- 4.Buccal sulcus skin grafting-Esser⁴¹,Gilles⁴²

- 5.Ridge mucosa grafting vestibuloplasty-Obwegeser³¹,Steinhauser⁴³,Maloney and associates⁴⁴

improved vestibular depth. Mandibular vestibuloplasty is carried out to predictably increase and maintain the functional alveolar ridge.

Preoperative preparation of the vestibuloplasty patients includes history, clinical examination, and suitable radiographs. Radiographs, especially orthopantomograph, help to evaluate the ridge height. The commonly performed ones are discussed in this section.

17.10.2 Transpositional Flap Vestibuloplasty [Lip-Switch Procedure]

The credit of this procedure goes to Kazanjian [21], later modified by many in the literature. Kethley and Gamble [45] modification finds more acceptance in the literature. The selection criteria for this procedure are the minimum bone height of 15 mm between the mental foramen areas.

Box 17.4 Other Historically Relevant Vestibuloplasty Methods

Kazanjian's [21] Flap is raised supraperiosteally from the lower lip. Mobilised to the new vestibule and positioned. Stabilised by stent or dentures. The raw area in the lower lip is allowed to heal by secondary epithelisation.	Clark's [23] The facial surface of the ridge is chosen to raise the flap. The dissection in supraperiosteal fashion is done. The raw area is in the ridge surface.
Godwin [27] modification A similar technique, except subperiosteal stripping, was performed.	Obwegessor [31] modification The use of skin grafts over the denuded surface to facilitate healing.
Kethley and Gamble [45] modification of Kazanjian —the lip switch technique A labial mucosal flap is raised and extended to the crest of the ridge from the lip incision placed initially.	Tortorlli [46] Fenestrations are made in the periosteum along the base of the newly created vestibule in a horizontal fashion.

17.10.2.1 Procedure

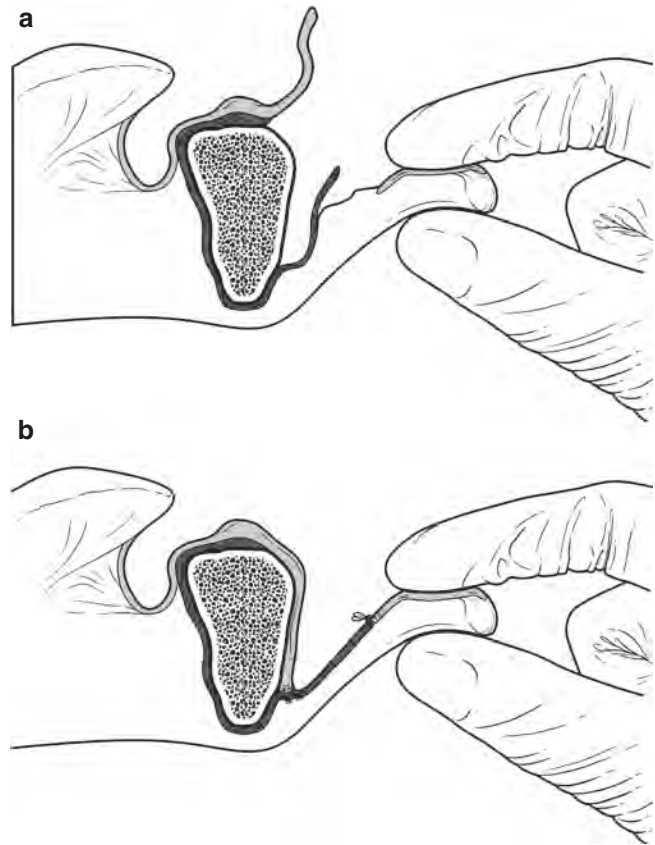
The technique involves the administration of local anaesthesia followed by mucosal incision. The mucosal flap is elevated and pedicled near the crest of the ridge (Fig. 17.11a and b). An incision is placed near the superior portion of the periosteum. A supraperiosteal dissection is carried in the inferior direction, thereby removing the attachments of the muscular and connective tissues to the indicated vestibular depth. The labial periosteal margin is sutured to the incised lip mucosa. This is followed by the suturing of the pedicled flap to the periosteum at the depth of the vestibule.

17.10.3 Mandibular Vestibuloplasty with Grafting

Indicated in cases where the lip switch procedure is not possible due to the inadequate tissue availability. The options permissible in such cases were either secondary epithelisation or covering the denuded areas with grafts. The former became less popular because of wound contraction leading to the loss of vestibular depth. Here, the desired alveolar height between the mental foramina is not less than 10 mm in contrast to the minimum of 15 mm in lip switch.

17.10.3.1 Procedure

An incision is placed at the mucogingival junction and a supraperiosteal dissection carried out to the desired vestibular depth. During the dissection, care is taken not to dissect more than half of the mentalis muscle to avoid the chance of



©Association of Oral and Maxillofacial Surgeons of India

Fig. 17.11 Lip switch vestibuloplasty (a) Labial mucosa pedicled near the crest of the ridge (b) pedicled flap sutured to the depth of the vestibule

the ptosis of the submental tissues referred as 'witch chin'. The margin of the incision is now sutured to the periosteum in the depths of the vestibule. The harvested graft is now placed over the recipient bed after ensuring adequate haemostasis. The graft is contoured to the correct shape, fenestrated, placed, and fixed on the periosteum with the help of stent or by sutures.

The grafts may be harvested from cutaneous or mucosal areas or allogenic in nature. The best sites for skin graft harvesting are medial thigh or caudal to the iliac crest, where fewer adnexal structures are present in the skin. Areas where smaller grafts are needed, mucosal grafts may be considered, which may be taken from the palate or buccal mucosa. Cultured skin grafts are also becoming popular but lack the mechanical and functional elements of the autogenous grafts. The narration of techniques of grafting is beyond the scope of this chapter.

17.10.4 Lingual Vestibuloplasty: Anterior Region

The severe atrophy of the mandible in the anterior region makes the genial tubercles prominent and affects the stability

of the denture by the attached muscles. The exposure of the tubercles and the detachment of the genial muscles are accomplished by the procedure of lingual vestibuloplasty. Initially proposed by Kazanjian [21] and later modified by Lewis [32], the disadvantage of this procedure may be the loss of tongue function and difficulty in swallowing, which is encountered if more than half of the muscle is removed.

17.10.4.1 Procedure

Incision is made in the anterior aspect of the crest of the alveolar ridge and subperiosteal flap is elevated. Dissection continued till the prominent genial tubercle with the attached muscle is encountered. The genial muscles are separated from the ridge and the tubercle is trimmed with bur and smoothed with bone file. The flap along with the muscle is lowered to the desired depth and it is maintained in the new position by stent and extraoral sutures. The exposed area is allowed for secondary re-epithelisation.

17.10.4.2 Lingual Vestibuloplasty: Posterior Region

If the amount of the resorption is severe that it results in the displacement of the denture by the action of mylohyoid, then lowering of the mylohyoid muscle should be considered. This can be done alone or in combination with labial vestibuloplasty. The amount of the available depth can be assessed by a clinical manoeuvre, by placing a gloved finger along the lingual side of the mandible and asking the patient to touch the palate with the tip of the tongue. If this action displaces the finger, lowering the floor of mouth should be considered.

Trauner's Technique [30]

Incision is made from the retromolar area to the premolar area of the lingual aspect of the alveolar crest. Mucoperiosteal flap is raised and exposes the mylohyoid and the overlying periosteum. Dissection in the supraperiosteal plane is preferred to avoid the chance of the damage of the lingual nerve. The muscle with the flap is lowered to the desired depth. Sutures are passed through the mylohyoid and mucosa and secured to the skin extraorally. The exposed area is allowed for secondary re-epithelisation (Fig. 17.12a–f).

17.10.4.3 Other Variations Include (Box 17.5)

Brown [47]—incision similar to Trauner's but a full-thickness mucoperiosteal flap is reflected to reveal the mylohyoid ridge. Here, the muscle is detached and the ridge is smoothed. The difference here is the sulcus is not deepened, but the problem with the ridge prominence is solved.

Caldwell [33]—here a crestal incision is employed and a supraperiosteal approach to access the mylohyoid ridge and the attached muscle. The flap is sutured to the original

position. The new position is secured by a stent or a modified denture. Instead a polyethylene tubing can be also used to maintain the position.

Eddan [29]—here, a combination of the lip switch vestibuloplasty and lowering the floor of mouth is accomplished. Incision is made in the buccal sulcus instead of the crest of alveolar ridge. Plastic tubes are used to maintain the depth of the sulcus.

Hopkin [48]—mentioned as Hopkin's operation in the literature, it uses the combined modalities like labial vestibuloplasty, submucous sulcoplasty to remove the buccinator insertion and bilateral mylohyoid ridge reduction.

17.11 Ridge Augmentation Procedures

In atrophic maxilla, the alveolus may be accentuated by different options; earlier, vestibuloplasty was the choice of procedure. But the results achieved were not long lasting because of the continued resorptive process. So, the advent of augmentation came into action. In severe resorbed and atrophic ridges of Cawood and Howell [6] classes IV–VI, augmentation became mandatory. Unfortunately, this area of preprosthetic surgery has gained little attention, possibly there seemed to be no effective operation for ridge augmentation using an extraoral method; moreover, the penetration into the oral cavity during the procedure was deemed tantamounting to failure, as the surgeons are reluctant to perform the elective augmentation of mandible (Table 17.3).

Classification of alveolar ridge deficiency by Kent et al. [49] acts as a yardstick to identify the ridge nature and the grafting options.

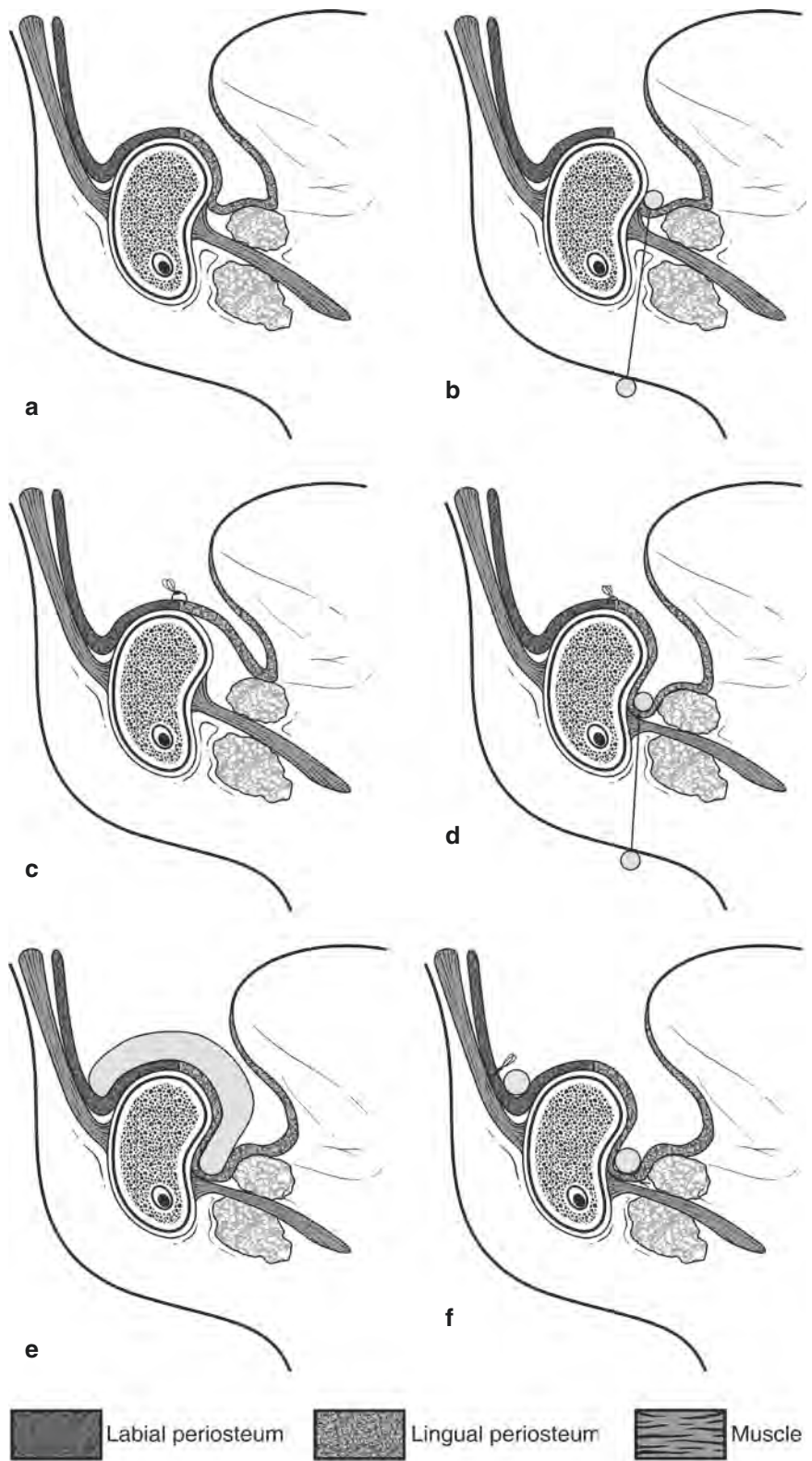
Class 1—alveolar ridge is adequate in height but inadequate in width, usually with lateral deficiencies or undercut areas. Patient receives hydroxyapatite alone.

Class 2—alveolar ridge is deficient in both height and width and presents a knife-edge appearance. Patient receives hydroxyapatite alone.

Class 3—alveolar ridge has been resorbed to the level of the basilar bone producing a concave form in the posterior areas of mandible and a sharp bony ridge form with bulbous mobile soft tissues in the maxilla. Patient receives hydroxyapatite with or without autogenous cancellous bone.

Class 4—there is resorption of the basilar bone producing pencil-thin flat mandible or maxilla. Patient receives both hydroxyapatite with autogenous bone.

Fig. 17.12 Lingual vestibuloplasty methods (a) Normal, (b) Trauner, (c) Brown, (d) Caldwell, (e) Hopkins, (f) Edlan

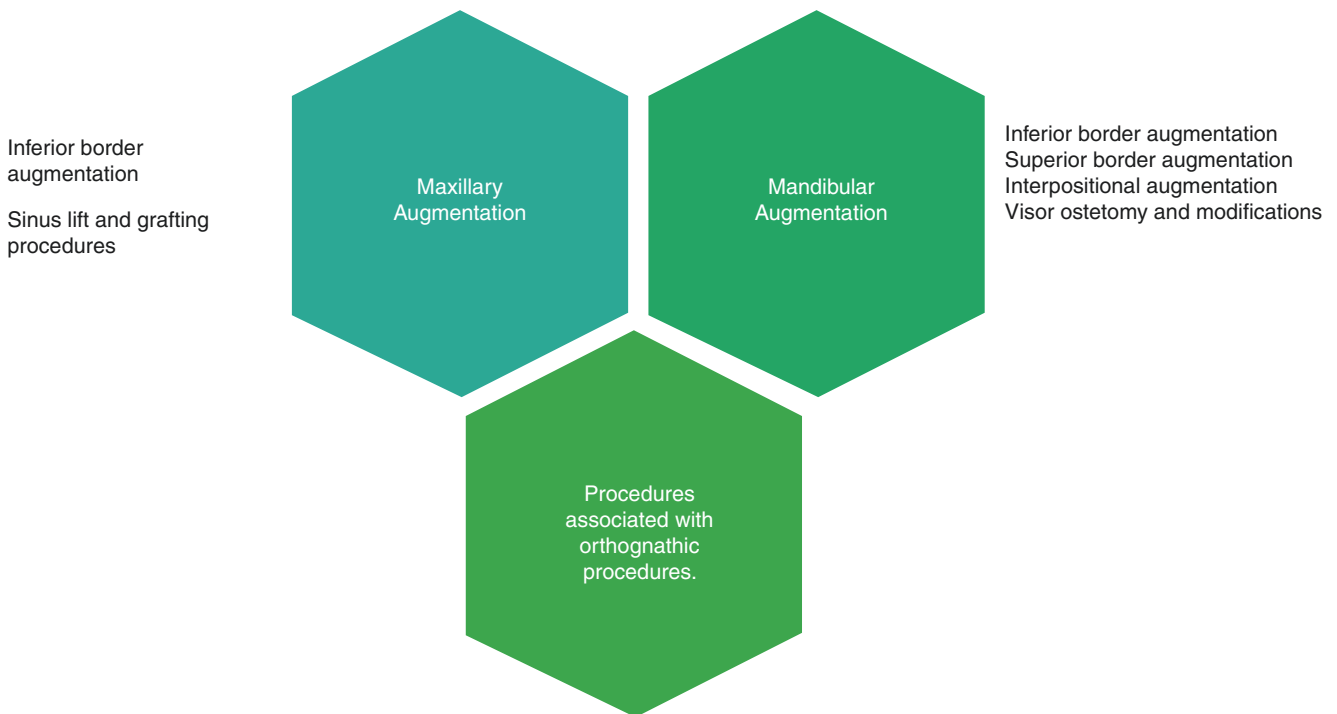


©Association of Oral and Maxillofacial Surgeons of India

Box 17.5 Lingual Vestibuloplasty Techniques

Trauner [30]	Brown [47]	Caldwell [33]	Edlan [29]
Carried over the posterior areas from retromolar pad to the premolar region with supraperiosteal dissection	Full thickness mucoperiosteal flap reflected	Carried over both posterior and anterior areas	Combination of lip switch vestibuloplasty with floor of mouth procedure
Mylohyoid muscle lowering is performed	Ridge is smoothed after the mylohyoid muscle is released Not used alone but is combined with other vestibuloplasties	Detachment of mylohyoid and genioglossus muscle is done	

Table 17.3 Ridge augmentation procedures



Autogenous bone grafting remains the ideal option to rectify the deficiency but accompanied by disadvantages like the need for hospitalisation and general anaesthesia, donor site morbidity, extensive surgical procedure, professional expertise and patient compliance.

17.11.1 Inferior Border Augmentation

The resorption of the mandible has been so extensive that it results in the severely atrophic condition and liable for a pathological fracture. In such a case, augmentation has to be achieved in the inferior border. The procedure was originally proposed by Marx and Sanders [50] and later modified by Quinn [51]. The procedure carries the advantages of non-obliteration of the sulcus, allowing the placement of the

interim denture and making the secondary vestibuloplasty easier. But the procedure carries the burden of an extraoral scar and the chance of altering the facial appearance. Access to the lower border is gained by different ways by different authors. Some literature supports the use of incision used in the neck dissection, viz. a supraclavicular incision. It extends from the anterior border of sternocleidomastoid to the opposite counterpart. According to Sanders [50], a continuous submandibular incision from angle to angle is sufficient. Ridley and Mason [52] proposed the use of three small submandibular incisions connected by subperiosteal tunnels. The latter is opposed by Sanders [50] for the high chance of resorption by the pressure on the graft. Dissection is carried out to expose the inferior border of mandible. Two ribs of 15 to 20 cm long are harvested and bent to adapt the shape. Three or four transosseous holes are drilled in the lower bor-

der of mandible and wires are passed through these holes. One rib is placed against the lingual aspect and the other abutted against the buccal aspect. The space between the ribs is packed with available cortical chips. Ribs are secured in place by interosseous wires in circumferential pattern. Closure is achieved in layers and pressure dressing is applied. The narration of the technique of graft harvesting is beyond the limit of this chapter.

17.11.2 Superior Border Augmentation

The superior border enhancement is needed [53] in cases where the resorption is so severe that the height of the mandible is insufficient to accommodate the prosthesis or in cases where the patient suffers from pain during mastication, secondary to the pressure on the mental neurovascular bundle (Fig. 17.13a and b).

Recipient site is prepared and the mucosa is infiltrated with local anaesthetic solution containing epinephrine to achieve haemostasis. Crestal incision from the retromolar area to the opposite retromolar area is made and mucoperiosteal flap is raised. Care to be taken to avoid the mental nerve if it is near the superior border. Depending on the position, it may be lowered or freed. The existing superior border is exposed and prepared to receive the graft. The lingual flap is reflected to the level of the mylohyoid muscle. Davis and colleagues [54] described the technique of ridge augmentation, which uses two rib grafts of 15 cm. The ribs may be adjacent or alternate. One rib may be contoured by vertical scoring on the inner surface or by bending. Leake [55] recommends splitting the rib longitudinally and then bending it with forceps. The second rib is cut into pieces and packed against the solid rib. Before the placement of the rib, the superior aspect of the mandible is already prepared and suited to receive it. The posterior aspect of the rib should be in contact with mylohyoid shelf, slightly on the lingual aspect of the ramus. The ribs

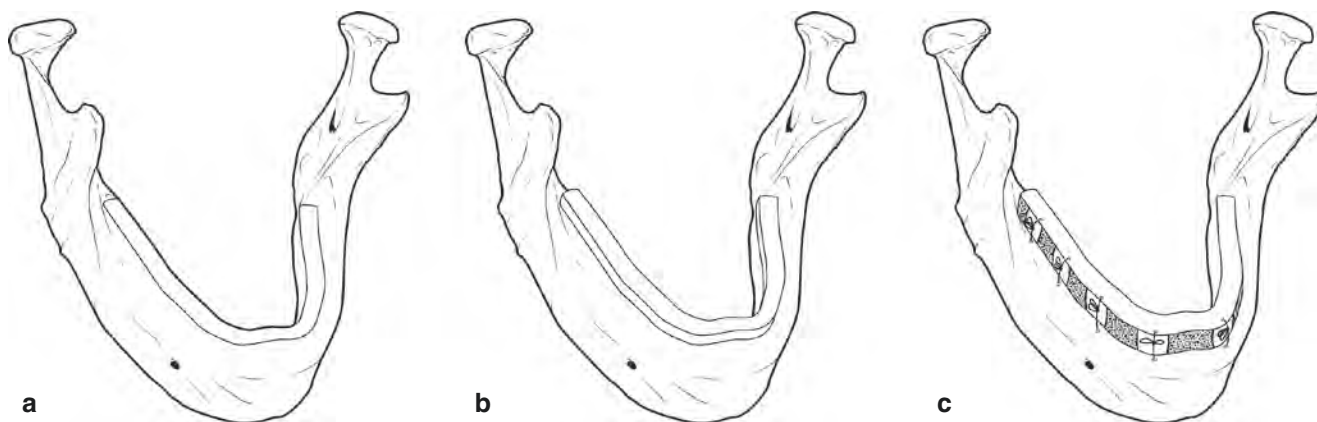
are fixed by three interosseous wires, one placed through each mylohyoid shelf and the other in the anterior region in the midline. Flaps returned to cover the graft.

17.11.3 Interpositional Grafting

Concept of placing bone grafts between the osteotomised segments of the mandible was initially proposed by Barros saint and Pasteur [56] and later experimentally proved by Danielson and Nemarich [57]. The horizontal osteotomy is achieved by an incision made inferior to the crest of the ridge. The length of the incision is determined by the area to be augmented. Incision is designed from the retromolar area to the other. A buccolabial mucoperiosteal flap is raised and the flap is greatly undermined to get adequate coverage of the graft. Issues are left untouched to ensure the patency of the vascular supply. The horizontal osteotomy is made by burs and osteotomes, and precise osteotomy is obtained by use of saws. The cut may be placed either above or below the canal, depending on the proximity to the inferior border. Transosseous holes are drilled in the lower and upper segments. The harvested graft is interposed between the osteotomised segments and stabilised by the wires. The flap is returned and approximated with sutures (Fig. 17.13c and Table 17.4).

17.11.4 The Visor Osteotomy and Modified Visor




The procedures of vestibuloplasty and floor of the mouth lowering may not be always successful to provide a stable and adequate basis for the prosthesis. The situation of the reduced vertical height needs to get addressed. Harle [58] published a report of an original and promising method to augment the alveolar ridge by means of a pedicled bone



©Association of Oral and Maxillofacial Surgeons of India

Fig. 17.13 (a and b) Superior border augmentation, (c) Interpositional grafting

Table 17.4 Mandibular ridge augmentation procedures

Superior border augmentation	Interpositional grafting	Visor osteotomy
		
<input type="checkbox"/> Two rib grafts of 15cm- Davis ⁵⁴	<input type="checkbox"/> Bone graft between the osteotomized segments of the mandible- Barrors Saint and Pasteur ⁵⁶	<input type="checkbox"/> Mandible in frontal region osteotomised and lingual fragment slid upwards- Harle ⁵⁸
<input type="checkbox"/> Splitting rib longitudinally and then bending with forceps- Leake ⁵⁵		<input type="checkbox"/> Combination of osteotomy and vestibuloplasty along with lowering of FOM- Bosker ⁵⁹

graft. This procedure possesses less danger of infection and rejection of the transplant and of resorption by remodelling processes. The muscles and periosteum in the labial side are reflected and the mandible in the frontal region is osteotomised and split in the length. The mobile lingual fragment is slid upwards, together with the adherent soft tissue, and fixed to the basal part of the mandible by intraosseous and perimandibular wiring. Bosker [59] improved this method by combining the osteotomy and the vestibuloplasty and lowering of the floor of the mouth in a one-stage procedure.

The advantage of this modified technique of Bosker [59] is it needs only single operation and hospitalisation of the patient, the prosthesis can be made in 4–6 weeks sooner, and the operative procedure is simpler.

Sladen and Peterson [60] describe the body sagittal osteotomy and raising the lingual cortical portion of the mandible without detaching the lingual soft tissues for the intact vascular pattern. The raised lingual ridge is positioned in the new place, while the buccal counterpart is augmented with cancellous marrow. This procedure is now referred to as visor osteotomy in the literature.

The incision and the mode of raising the mucoperiosteal flap is essentially the same as that used in the horizontal osteotomy as described earlier. Sagittal cut is made between the buccal and lingual cortical plates from the third molar to the opposite third molar area. Precise cutting is achieved by the use of oscillating and reciprocating saws. The lingual segment, which is pedicled to the mylohyoid, digastrics and genial musculature and the soft tissues, is elevated vertically and fixed in the preplanned position with wires through the transosseous holes. The lateral aspect of the elevated segment may be filled with the cancellous bone to compensate the height deficiency created by the vertical repositioning. The flap is returned and wound is closed by sutures.

17.11.5 Graft Materials

Iliac bone crest and rib have traditionally been applied to augment the jaws. Boyne [61] suggested a bone regeneration method, which employs a vitalium mesh tray containing haematopoietic bone marrow encased in a nylon-reinforced

Millipore filter. The filter prevents the connective tissue elements accessing the defect and thereby enhances the osseous regeneration. The concern regarding the graft material is the resorption shrinkage in the future. Many attempts are done by surgeons to minimise the resorption shrinkage of the grafted bone. Danielson and Nemanich [57] advocated the subcortical insertion of bone graft. Farrell [62] and associates went ahead with interpositional bone graft with simultaneous vestibuloplasty. Sanders and Cox [50] proposed the use of inferior border rib grafting for augmentation. Notched rib can be contoured to the arc of the mandible, but 50% loss by shrinkage is a great disadvantage with rib. The literature suggests the use of pure cancellous iliac graft, iliac cortical—cancellous sectional grafts with appropriate immobilisation showing excellent healing even in the event of occasional incision dehiscence.

17.11.6 Augmentation with Synthetic Graft Materials

A myriad of materials is used for the augmentation of the atrophied ridge. It consists of resorbable and nonresorbable materials. The former finds its application in periodontal pockets, while the latter is extensively used in the management of alveolar atrophy. Hydroxyapatite, a calcium phosphate material with physical and chemical attributes, is nearly similar to dental enamel and cortical bone and has been successfully used for decades. Studies by Kent et al. [49] and Drobeck et al. [63] illustrate the usage. Kent et al. [49] used hydroxyapatite in combination with corticocancellous autogenous bone for augmentation. This combination provides additional strength to the mandible as advised by Jarcho et al. [64]. Though block forms are used by Frame and Brady [65], the granular forms also get used in the augmentation process as guided by Kent et al. [51]. When anterior mandible needs augmentation, a single midline vertical incision is used, while for the complete augmentation of mandible, bilateral vertical incisions anterior to mental foramen are used. A subperiosteal tunnel is formed, which can be assessed by a dental mirror and the syringe loaded with graft material is inserted

through the tunnel and delivered in place. After the tunnel is filled with graft material, the incision is closed with interrupted or horizontal sutures.

In maxilla, a single vertical incision in midline may be sufficient, but in many cases bilateral incisions in the canine regions may accommodate more amount of graft material. It is similar to the procedure in mandible except for the palatal dissection, where the ridge width is needed. Denture can be placed at about 1 month in cases where augmentation is carried out by hydroxyapatite alone or 6–8 weeks in which both hydroxyapatite and bone are used together. If vestibuloplasty is planned, Kent [49] advocated a waiting period of 8 weeks after graft placement.

17.12 Conclusion

The art of designing the soft- and hard-tissue framework for the smooth placement of the prosthesis is a challenging task. This task is achieved by the meticulous planning and execution of the planned presurgical procedures in a systematic manner. The intimidating impressive trends of implantology might have downsized the charm of preprosthetic surgery, yet in certain avenues the preprosthetic surgical manoeuvres become inevitable. The magnitude of vestibuloplasty and ridge augmentation procedures associated with the anticipated patient discomfort should not demote the benefits of preprosthetic surgery in deserving patients, where they suffer from pain or embarrassment by a juggling ill-fitting denture. Such corrections may alter their present situations and successful denture wearing is ensured. So it is not possible to completely thwart or baffle the procedures belonging to the preprosthetic surgery as an obsolete one.

Acknowledgments Fig. 17.6 - Suvy Manuel.

References

- Willard AT. Preparing the mouth for full sets of artificial teeth. *Dent News Letter*. 1853;6:238.
- Beers WG. Notes from practice. *Mo Dent J*. 1876;8:294.
- Roux W. *Der Kampf der Teile im Organismus. Ein Beitrag zur Vervollständigung der mechanischen Zweckmässigkeitslehre*. Leipzig: Verlag von Wilhelm Engelmann; 1881.
- Wolff J. *Das Gesetz der Transformation der Knochen*. Berlin: August Hirschwald; 1892.
- Mercier P. Residual alveolar ridge atrophy: classification and influence of facial morphology. *J Prosthet Dent*. 1979;8:24.
- Cawood JJ, Howell RA. A classification of the edentulous jaws. *Int J Oral Maxillofac Surg*. 1988;17:232–5.
- Storer R. A radiographic survey of edentulous mouth. *Br Dent J*. 1957;102:344.
- Crandell CE, Trueblood SN. Roentgenographic findings in edentulous areas. *Oral Surg Oral Med Oral Pathol*. 1960;13:1343.
- Lekholm U, Zarb GA, Albrektsson T. Patient selection and preparation in Per-Ingvar Branemark et al Tissue-Integrated Prostheses. Chicago: Quintessence; 1985. p. 199–209.
- Dean OT. Surgery for the denture patient. *J Am Dent Assoc*. 1936;23:2124.
- Anderson JO. Intra oral skin grafts-an aid to alveolar ridge extension. *J Oral Surg*. 1969;27:427.
- Guernsey L. Preprosthetic surgery. In: Kruger GO, editor. *Oral and maxillofacial surgery*. 6th ed. St. Louis: C V Mosby.
- Godlee RJ. The torus palatinus. *Proc R Soc Med*. 1909;2:175.
- García García AS, Martínez González JM, GómezFont R. Current status of the torus palatines and torus mandibularis. *Med Oral Patol Oral Cir Bucal*. 2010;15:e353.
- Moraes Junior EF, Damante CA, Araujo SR. Torus palatinus: a graft option for alveolar ridge reconstruction. *Int J Periodontics Restorative Dent*. 2010;30:283.
- Hassan KS, Alagl AS, Abdel H. A Torus mandibularis bone chips combined with platelet rich plasma gel for treatment of intrabony osseous defects: clinical and radiographic evaluation. *Int J Oral Maxillofac Surg*. 2012;41:1519.
- Kolas S, Halperin V, Jefferis K, Huddleston S, Robinson HB. The occurrence of torus palatinus and torus mandibularis in 2478 dental patients. *Oral Surg Oral Med Oral Pathol*. 1953;6:44.
- Kalaigan P, Mohan JS, Jayakumar A. Determination of grading for maxillary and mandibular Tori- an in vivo study. *Biomed Pharmacol J*. June 2018;11(2):679–88.
- Haugen LK. Palatine and mandibular tori: a morphologic study in the current Norwegian population. *Acta Odontol Scand*. 1992;50:65.
- Reichart PA, Neuhaus F, Sookasem M. Prevalence of torus Palatinus and torus mandibularis in Germans and Thai. *Community Dent Oral Epidemiol*. 1988;16:61–4.
- Kazanjan VH. Surgery as an aid to more efficient service with prosthetic dentures. *JADA*. 1935;22:566–81.
- Clark HB Jr. Deepening the labial sulcus by mucosal flap advancement: report of a case. *J Oral Surg*. 1953;11:165.
- Mcintosh RB, Obwegeser H. Preprosthetic surgery: a scheme for its effective employment. *J Oral Surg*. 1969;27:427.
- Propper RH. Simplified ridge extension using free mucosal grafts. *J Oral Surg*. 1964;22:469.
- Nabers JM. Free gingival grafts. *Periodontics*. 1966;4:243.
- Hall RD, Steen O. Free grafts of palatal mucosa in mandibular vestibuloplasty. *J Oral Surg*. 1970;28:565.
- Godwin JG. Submucous surgery for better denture service. *J Am Dent Assoc*. 1947;34:678.
- Cooley DO. Method of deepening maxillary and mandibular sulci to correct deficient edentulous ridges. *J Oral Surg*. 1952;10:27.
- Edlan A, Mejchar B. Plastic surgery of the vestibulum in periodontal therapy. *Int Dent J*. 1963;13:593.
- Trauner R. Alveoplasty with ridge extensions on the lingual side of the lower jaw to solve the problem of a lower dental prosthesis. *Oral Surg*. 1952;5:340.
- Obwegeser H. Surgical preparation of the maxilla for the prosthesis. *J Oral Surg*. 1964;22:127.
- Lewis ET. Surgical correction to the sublingual region. *J Am Dent Assoc*. 1963;67:364.
- Caldwell J. Lingual ridge extension. *J Oral Surg*. 1955;13:287.
- Ashley FN, Schwartz AN, Dryden MF. A modified technique for creating a lower lingual sulcus. *Plast Reconstr Surg*. 1953;22:204.
- Baumash H, Mandel L, Strelieff M. Mandibular sulcus extension – a new technique: preliminary report. *J Oral Surg*. 1962;20:390.
- Collett HA. Immediate maxillary ridge extension. *Dent Dig*. 1954;60:104.
- Szaba, Garner, Rumpel. Surgical preparation of the maxilla for prosthesis. *J Oral Surg*. 1964;22:127.

38. Yrastorza JA. Mandibular sulcus deepening: a modified technique. *J Am Dent Assoc.* 1963;67:859.
39. Weiser R. Ein Fall von ankylose, verlust des alveolar forsatzes under. *Zahnheilk.* 1918;34:147.
40. Schuchardt K. Die epidermis transplantation bie der mund vorhof-plastik. *Dtsch Zahnarzt Z.* 1952;7:364.
41. Esser JF. Studies in plastic surgery of the face. *Ann Surg.* 1917;65:297.
42. Gillies HD, Millard DR. Principles and art of the plastic surgery. Boston: Little Brown; 1957.
43. Steinhäuser EW. Vestibuloplasty- skin grafts. *J Oral Surg.* 1971;29:777–85.
44. Maloney PL. Mucosal grafts in oral reconstructive surgery. *J Oral Surg.* 1974;32:705.
45. Ketheley J, Gamble J. The lipswitch – a modification of Kazanjian’s labial vestibuloplasty. *J Oral Surg.* 1978;36:705.
46. Tortoerelli AF. A technique for vestibular sulcus extension. *J Prosthet Dent.* 1968;20(1):14–20.
47. Brown LJ. A surgical solution to a lower denture problem. *Br Dent J.* 1953;95:215.
48. Hopkins R, Staford GD. Pre prosthetic surgery of the edentulous mandible. *Br Dent J.* 1980;148(7):183–8.
49. Kent JN, et al. Alveolar ridge augmentation using nonresorbable hydroxylapatite with or without autogenous cancellous bone. *J Oral Maxillofac Surg.* 1983;41:629.
50. Sanders B, Cox R. Inferior border rib grafting for augmentation of the atrophic edentulous mandible. *J Oral Surg.* 1976;34:897.
51. Kent JN, Quinn JH. Correction of alveolar ridge deficiencies with nonresorbable hydroxylapatite. *J Am Dent Assoc.* 1982;105:993.
52. Ridley MT, Manson KG. Resorption of rib graft to inferior border of mandible. *J Oral Surg.* 1978;36:46.
53. Blackstone CH, Parker ML. Rebuilding the resorbed alveolar ridge. *J Oral Surg.* 1956;14:45.
54. Davis WH. Rib graft augmentation to the superior border of the mandible. In: *Preprosthetic oral and maxillofacial surgery.* Saint Louis: C V Mosby; 1980.
55. Leake D. Contouring split ribs for the correction of severe mandibular atrophy. *J Oral Surg.* 1976;34:940.
56. Barros saint- pasteure: plastia reconstructive del rebord alveolar: neustra investigacion clinicoquirurgica. *Acta Odont Venez* 1970;8:168.
57. Danielson PA, Nemarich AN. Subcortical bone grafting for ridge augmentation. *J Oral Surg.* 1976;34:887.
58. Harle F. Visor osteotomy to increase the absolute height of the atrophied mandible- a preliminary report. *J Maxillofac Surg.* 1975;3:257.
59. Bosker, et al. Visor osteotomy and vestibuloplasty – A one-stage procedure. *Int J Oral Surg.* 1977;6:127–30.
60. Slade E. Text book of maxillofacial surgery. In: Kruger GO, editor. Personal communication. 6th ed. Saint Louis: C V Mosby; 1977, July.
61. Boyne PJ. Restoration of the alveolar ridge by intramandibular transposition osseous grafting. *J Oral Surg.* 1968;26:569.
62. Farrell CD. One stage interpositional bone grafting and vestibuloplasty of the atrophic maxilla. *J Oral Surg.* 1976;34:901.
63. Drobeck HP, et al. Histologic observation of soft tissue responses to implanted, multifaceted particle and discs of hydroxylapatite. *J Oral Maxillofac Surg.* 1984;42:143.
64. Jarcho M, et al. Hydroxylapaptite synthesis and characterization in polycrystalline form. *J Mater Sci.* 1976;11:2027.
65. Frame JW, Brady CH. Augmentation of an atrophic edentulous mandible by interpositional grafting with hydroxylapatite. *J Oral Maxillofac Surg.* 1984;42:89.

Open Access This chapter is licensed under the terms of the Creative Commons Attribution 4.0 International License (<http://creativecommons.org/licenses/by/4.0/>), which permits use, sharing, adaptation, distribution and reproduction in any medium or format, as long as you give appropriate credit to the original author(s) and the source, provide a link to the Creative Commons license and indicate if changes were made.

The images or other third party material in this chapter are included in the chapter's Creative Commons license, unless indicated otherwise in a credit line to the material. If material is not included in the chapter's Creative Commons license and your intended use is not permitted by statutory regulation or exceeds the permitted use, you will need to obtain permission directly from the copyright holder.



Part VII

Dental Implantology



Basics of Dental Implantology for the Oral Surgeon

18

Supriya Ebenezer, Vinay V. Kumar, and Andreas Thor

18.1 History and Evolution of Dental Implants

Modern implant dentistry started more than 50 years ago when Dr. P.I. Brånemark, a Professor from the University of Gothenburg (Sweden), discovered in rabbit studies that titanium chambers placed in the fibula became firmly anchored in bone and could not be removed. Later, this direct bone-to-implant contact was termed osseointegration [1]. He demonstrated that titanium was structurally integrated into living bone with a high degree of predictability and without long-term soft-tissue inflammation or fixture rejection. He introduced a two-stage threaded root form pure titanium implant that was placed in patients in 1965. Therefore, Prof. P.I. Brånemark is recognized as the most important pioneer in modern implant dentistry.

The second pioneer is Prof. Andre Schroeder from the University of Bern (Switzerland) experimented with prototype dental implants in the early 1970s and could demonstrate first osseointegration in nondecified histologic sections [1]. Both pioneers with their teams, independent of each other, performed several preclinical and clinical studies to establish the current scientific basis for dental implantology. This was the start to successful osseointegration in dentistry.

Between the 1970s and the 1980s, companies presented different implant designs such as the Tübingen implants made of aluminum oxide, the IMZ titanium plasma-sprayed

surface, and the American Core vent implants made of titanium aluminum vanadium alloy [1]. However, based on the research from Albrektsson, commercially pure titanium became the material of choice. One-piece implants slowly evolved to two-piece implants to provide prosthetic flexibility.

Over the next 15 years, implantology shifted from the treatment of fully edentulous patients to the treatment of partially edentulous patients as well. Prosthetic components for the rehabilitation of different edentulous situations emerged, and different surgical techniques and regenerative materials were developed to improve the hard and soft tissues around implants. Concepts of implant placement, loading, occlusion, and maintenance evolved. Progress was made in implant surface technology, which permitted the use of shorter and narrower implants and reduced loading time [2]. Over the last decade, development has included strategies to provide long-term stability with optimum functional, esthetic, and phonetic results along with reduced complications. Advanced diagnostic aids, such as cone beam computed tomography (CBCT), enabled proper assessment of the surgical site and surgical planning to provide better outcomes. Devices to examine implant stability objectively, using resonance frequency analysis, improved the quality of treatment provided. Digital technology is increasingly being incorporated to improve accuracy, minimize invasiveness, and fulfill esthetic demands. On the material front, ceramic implants and implants using alloys of increased strength have been introduced [2]. The field of implantology is a fast-evolving one where the clinician has to be constantly updated to keep pace.

Electronic Supplementary Material The online version of this chapter (https://doi.org/10.1007/978-981-15-1346-6_18) contains supplementary material, which is available to authorized users.

S. Ebenezer (✉)
Department of Oral Surgery and Stomatology, University of Bern,
Bern, Switzerland

V. V. Kumar · A. Thor
Department of Maxillofacial and Plastic Surgery, Uppsala
University Academic Hospital, Uppsala, Sweden

18.2 The Concept of Osseointegration

Titanium implants could become permanently incorporated within bone, such that the two could not be separated without fracture [3]. Osseointegration was the term given to this con-

tact and refers to a direct bone to metal interface without interposition of soft tissue seen at the optical microscope level. Osseointegration is defined as “a direct structural and functional connection between ordered living bone and the surface of a load-carrying implant.” [4]

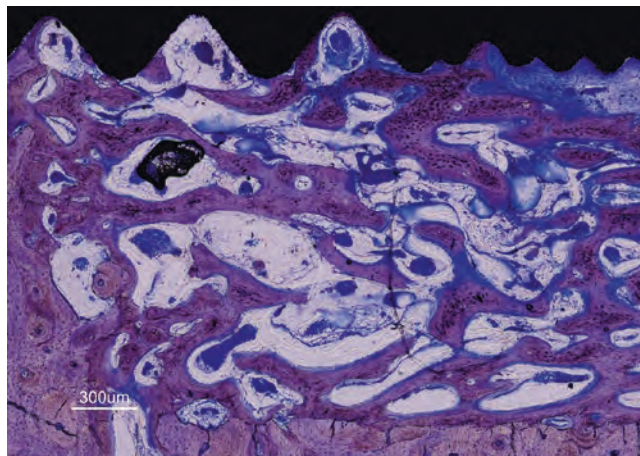
18.2.1 The Biological Process of Osseointegration

The cellular response after implantation depends on implant surface characteristics, the stability, and healing injuries of the host bone. Bone healing around implants involves a cascade of cellular and extracellular biological events (similar to fracture healing) until the entire implant surface is embedded in bone.

The first biological component to contact the implant surface is blood and blood cells from the surrounding vasculature. These blood cells are activated and release cytokines and other growth and differentiation factors on and around the implant. Platelets undergo biochemical and morphological changes due to contact with the implant surface and undergo adhesion, spreading, and aggregation. They induce phosphotyrosine, increase intracellular calcium, and cause hydrolysis of phospholipids to form a fibrin matrix that regulates cell adhesion and binding of minerals. This matrix is a calcified afibrillar layer consisting of osteoid and lamina limitans (organic layer) that is rich in calcium, phosphorus, osteopontin, and bone sialoprotein [5]. This matrix acts as a scaffold for osteogenic cells to migrate and differentiate to form osteoid and trabecular bone (osteoconduction), which will ultimately remodel to form lamellar bone around the implant surface. The ability of the implant surface to retain fibrin attachment during the initial phase is critical in determining if the migrating cells reach the fibrin clot. Roughened surfaces promote osteoconduction. The chemistry of the implant surface also influences osteoconduction, and for example, hydrophilic implant surfaces have increased osteoconduction as compared to hydrophobic surfaces.

Peri-implant osteogenesis occurs in two ways with the native bone as described by Osborn and Newesley in 1980.

1. Distance osteogenesis is a phenomenon that occurs from the native bone toward the implant surface. The existing bone surface provides a population of osteogenic cells, which lay down matrix, slowly encroach on the fibrin-meshwork-covered implant surface, and connect to this network as osteogenesis progresses. Osteoclasts, derived from mononuclear cells from the surrounding marrow spaces, remodel the old bony surface before new bone is laid down [5].
2. Contact osteogenesis occurs from the surface of the implant toward the healing bone. The fibrin-covered



©Association of Oral and Maxillofacial Surgeons of India

Fig. 18.1 Histology of osseointegration. Osseointegration is defined as the direct apposition of bone onto the titanium implant surface as seen in this histology section

implant surface that has attracted osteogenic cells slowly has calcified afibrillar tissue forming into it. Blood vessels and mesenchymal cells fill up the spaces in between. Cement lines of poorly mineralized osteoid separate the areas of resorption and initiation. Woven and trabecular bone fill the initial gap and provide biological fixation to the implant at about 10–14 days postsurgery. However, the random orientation of the collagen fibers gives it reduced mechanical properties as compared to lamellar bone. This biological fixation differs from primary stability obtained at implant placement and is commonly seen with rough implant surfaces. Woven bone is slowly remodeled in response to stress and mechanical loading and replaced by lamellar bone until it reaches a high degree of mineralization. At approximately 3 months postimplant placement, the bone is a mixture of both woven and lamellar matrix [6].

(Figure 18.1: histology showing adequate osseointegration)

18.2.2 Assessment of Osseointegration

An implant is considered to be osseointegrated when an implant is in direct contact with the bone, and there is no relative movement between the implant and the bone. In other words, osseointegration is expressed clinically as long-term state of stability of the implant in the vital bone. According to Albrektsson (1985), a loaded implant is considered osseointegrated if the average surface contact with bone is a minimum of 50% [7]. Initially, the strength of the interface (initial stability) between bone and implant is high due to mechanical stability; however, it decreases over the next

few weeks due to bone remodeling and then increases again due to new bone formation (secondary stability). The stability also depends on biophysical stimulation and the healing time. To clinically evaluate osseointegration mobility tests, standardized radiographs and Resonance Frequency Analysis (RFA) are used [6].

18.2.3 Factors that Determine Osseointegration

There are many factors that influence the formation and maintenance of bone at the implant surface [3, 6].

1. *Biocompatibility of the implant material* - Commercially pure titanium (CpTi) is widely used as an implant material as it is highly biocompatible, it has good resistance to corrosion and no toxicity on macrophages or fibroblasts and lacks inflammatory response in peri-implant tissues, and it is composed of an oxide layer and has the ability to repair itself by re-oxidation when damaged. Alloys of titanium such as Ti-6Al-4 V (Aluminum 6% and Vanadium 4%) and other Aluminum and Vanadium-free alloys of Titanium have been popularly used. Currently, a Ti-Zr alloy (Titanium 83–87% and Zirconium 13–17%) has been introduced, which has mechanical properties superior to those of CpTi and Ti-6Al-4 V [8].
2. *Implant geometry* - The shape of the implant determines the surface area available for stress transfer and the initial stability of the implant. Implants were previously available as cylinders, but currently, most implants come in screw-shaped (threaded) designs. Threaded implants with a circular cross section provide easy surgical placement and provide a greater functional surface area. These implants provide initial rigid fixation and limit micromovement during wound healing. The shape of the thread alters the force transmitted to the bone; it can be square, V, or reverse buttress shaped. The thread depth increases the surface area of the implant. Length of the implant contributes to the overall surface area. Increasing the length within limits increases the bone to implant contact for an implant, which is essential for osseointegration. Shorter implants are recommended today only with strict selection criteria and preferably work well only when splinted with other implants. Considering the width of an implant, although a wider implant increases the surface area for osseointegration, width depends on factors related to the surgical site. Overall, the shorter and smaller diameter implants have lower survival rates than their longer or wider counterparts. Longer implants have been suggested to provide greater stability under lateral loading conditions [9].
3. *Surface characteristics* - With exposure to air, Ti and its alloys form an oxide layer on the surface (TiO₂). The oxide layer protects against corrosion and also helps in calcium and phosphate ion exchange at the surface. Surfaces were modified to increase microroughness and hence the surface area for osseointegration. The additive processes are Ti plasma spraying, hydroxyapatite coating, discrete crystalline deposition (DCD), and electrochemical anodization (to increase the TiO₂ layer). These processes increased the surface area for bone contact with the implant surface, which increases the osseointegration. Subtractive processes to increase microroughness were also utilized in several implants to increase the microroughness, which also contributed to better osseointegration. Sandblasting, acid etching, and laser modification are some of the subtractive processes. Sandblasting produces a macrotexture, which is converted to a microtexture by acid etching. This surface promotes greater osseous contact at earlier time points compared to plasma-sprayed coated implants. Titanium surfaces were treated with fluoride, and this roughened the surface and demonstrated better bone anchorage, as compared to unmodified titanium surfaces [10]. Research is currently oriented toward making biomimetic implant surfaces that shorten healing times and provide better bone to implant contact [11].
4. *Systemic factors* - Irradiation of the region, osteoporosis, smoking, and diabetes although not absolute contraindications for implant placement can interfere with the normal healing process and osseointegration. Heavy smoking results in significantly lower success rates with oral implants [12]. The local site anatomy such as the amount of residual ridge for successful implant placement can also affect the outcome [13].
5. *Surgical technique* - The extent of tissue manipulation, thermal irritation by use of rotary instruments, and protocols for a surgical procedure can affect the outcome of osseointegration [14].
6. *Occlusal load* - During the initial healing phase, the absence of micromotion is critical for implant osseointegration. Based on the primary stability achieved, different protocols for loading are selected. The amount of force and timing of loading are critical for osseointegration [15].

18.3 Comparison Between Implant and Tooth Surface [16]

Figure 18.2a, b, and c show the differences between implants and tooth.

Implant prosthetics provide highly esthetic results that mimic the natural tooth; however, certain critical differences in the structure of the peri-implant tissues and periodontal structures exist. The lack of a periodontal ligament is the most striking difference; this absence means that the connec-

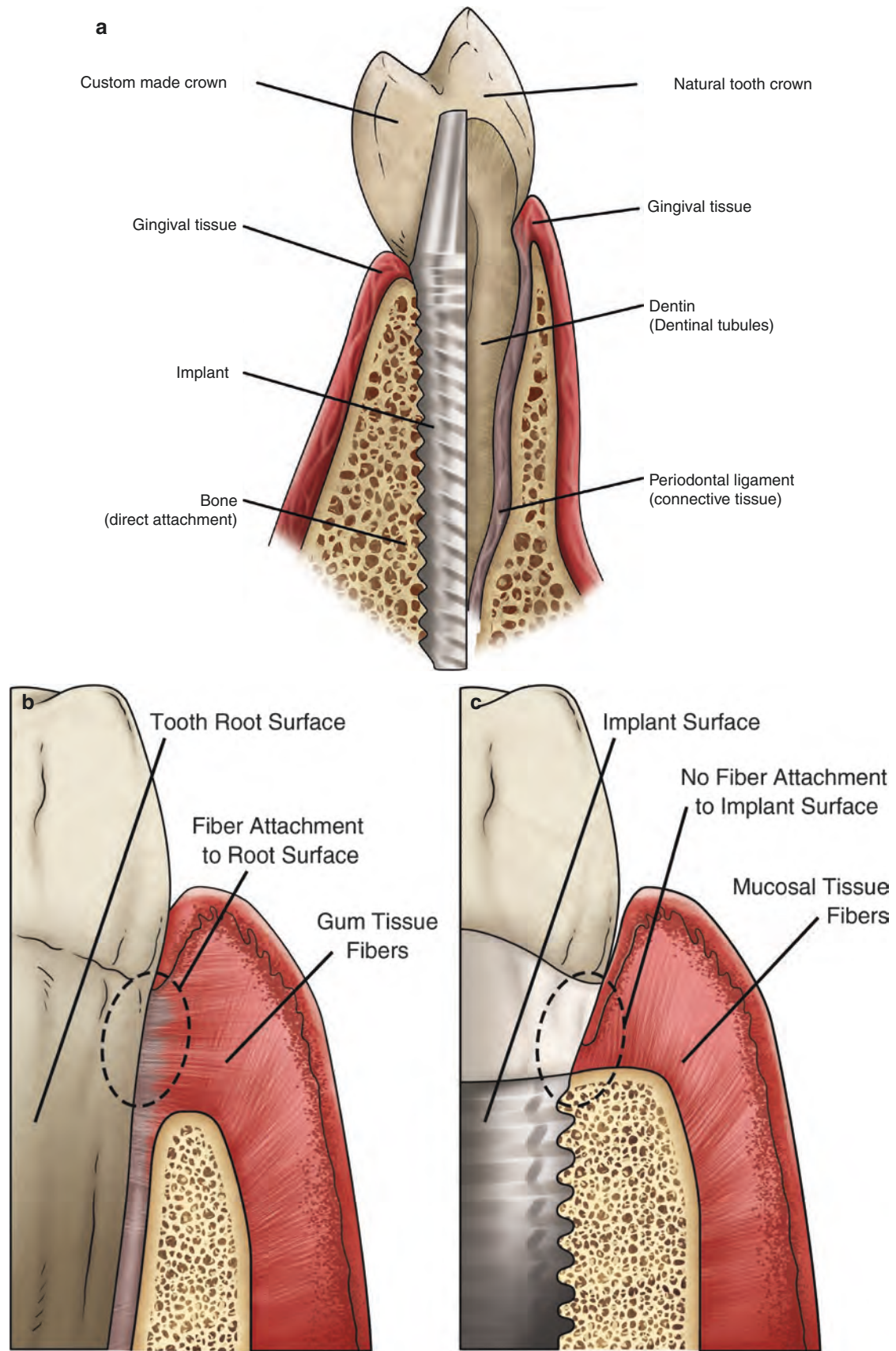


Fig. 18.2 (a, b, and c) show diagrammatic representation of the biological differences between an implant and a tooth in longitudinal section

tion between the implant and the surrounding bone is not as resilient as that around the tooth. Implants, unlike teeth, do not intrude or migrate to compensate for premature contacts, and hence, the repercussions of occlusal disharmony can be detrimental. Implants lack proprioception and reflex function due to the absence of the periodontal ligament. This is critical when implant-supported prosthesis opposes each other. Implants do not supraerupt with time and hence lead to occlusal disharmonies when used as replacements for young and growing individuals. Hence, any form of overload on an implant causes fracture in the prosthesis, the implant structure, or bone loss surrounding the implant.

18.4 Types of implants

- (a) Based on the type of material:
- (i) Pure titanium and titanium alloys:

Commercially pure titanium (CpTi) was the material of choice due to its high biocompatibility and resistance to corrosion. CpTi is available in Grades I to IV; however, to improve the mechanical properties, alloys of titanium such as Ti-6Al-4 V have been used. Several alloys with Ti, such as Ti-Au, Ti-In, Ti-Sn, Ti-Pb, Ti-Cu, and Ti-Nb, have been tested. A Ti-Zr alloy (Titanium 83–87% and Zirconium 13–17%) is presently very popular as it has mechanical properties superior to those of the previously used alloys as well as high corrosion resistance.
 - (ii) Zirconia implants:

These implants are made from the oxide form of Zirconia (ZnO_2) and are “ceramic” implants that have high biocompatibility and ability to osseointegrate. In addition to the high mechanical properties, they were introduced especially for esthetic areas and in patients who maybe potentially allergic to titanium. The drawback of these implants is that most of the designs are one piece and only a few systems have two-piece implants. The idea of zirconia implants seems to be potential; however, no long-term evidence for its success exists at this time.
- (b) Based on the shape:
- (i) Screw-type implants:

Threads in screw-type implants increase the surface area for osseointegration. Threads help in stabilization by improving bone to implant contact and in stress distribution. There are several differences in thread shape, thickness, pitch, thread-face angle, etc. based on the manufacturers. These are the most widely used and documented form of implants.
 - (ii) Cylindrical and tapered implants:

Based on the shape of the implant body, implants are considered cylindrical (with parallel walls) or tapered. When the endosseous part of a cylindrical implant narrows in diameter toward the apex, an implant is considered tapered. The taper can be in the cervical, middle, or apical parts only or continuously taper from the cervical to the apex. Tapered implants were introduced to improve initial stability in less dense bone.
 - (iii) Platform switch implants:

When a smaller-diameter abutment is used on a larger-diameter implant collar, the implant-abutment junction shifts inward toward the central axis of the implant. This is considered to be a major factor in limiting crestal bone resorption especially in esthetic sites.
 - (iv) Bone-level and tissue-level implants:

Tissue-level implants have a butt joint transition from the smooth collar to the rough portion, and this transition zone is placed almost level with the bony crest. This design is generally used for non-submerged healing; here, the implant-abutment microgap is away from the bony tissues. Bone-level implants have minimal/no smooth collar and are completely microrough, and they are inserted almost level with the bone. This is meant for submerged healing, and here, the implant-abutment microgap is adjacent to the bone crest. In these implants, platform switch is used to limit crestal bone resorption.
- (c) Based on implant surface:
- (i) Machined (Brånemark surface):

These are the minimally rough implant surfaces made of turned CpTi, which were not further treated. These were used earlier and are also well documented. However, with a need to increase the surface area for bone attachment especially in less dense bone and to reduce time for osseointegration, these surfaces were modified. Smooth surfaces had an advantage of reduced attachment of plaque biofilms.
 - (ii) Textured/rough surfaces:

The smooth surfaces of the implants were altered to a textured surface to increase the surface area for osseointegration. They were classified as macro-, micro-, and nano-sized topologies based on the scale of roughness [17, 18]. Macrotopographic profiles of dental implants had

a surface roughness in the range of millimeters to microns. This roughness was directly related to geometry of the implant, threaded screw, and macroporous surface treatment. Microrough topographies were in the range of 1 and 10 μm . A profile roughness average of 1–2 μm is optimal for osseointegration [19]. The surfaces were altered by different processes. Additive processes resulted in these popular types—sintered porous surfaces, titanium plasma sprayed, and hydroxyapatite plasma sprayed. Subtractive processes also created a rough texture, and they were sandblasting, acid etching, and laser alteration. Rough surfaces were demonstrated to have better bone to implant contact, which resulted in better osseointegration [20, 21]. Over the years, nanotopographies have been explored. Compaction of nanoparticles (such as titanium dioxide), molecular self-assembly method, and acid/alkali treatments or peroxidation for nanoparticle deposition have been advocated to increase nanoroughness.

(iii) Hydrophobic and hydrophilic implant surfaces [22]:

Initially, modification of implant surfaces concentrated on surface topography, and hence, the surfaces were hydrophobic. It was observed that porous devices should have a hydrophilic surface to induce the adsorption of bodily fluids into small pores and cavities of the structure. The surface chemistry of implants was altered to allow for hydrophilicity, and these surfaces have enhanced bone apposition during the initial phases of healing [23].

- (d) Based on length (Al-Johany 2017) [24].
- (i) Extra-short: 6 mm in length or less.
 - (ii) Short: From more than 6 mm to less than 10 mm.
 - (iii) Standard: From 10 mm to less than 13 mm.
 - (iv) Long: More than 13 mm.
- Although traditionally, the concept was to get implants “as long as possible” for good osseointegration, the current trend with improved surfaces is “as long as needed”. The introduction of shorter implants is to reduce the invasiveness and reduce morbidity.
- (e) Based on diameter (Al-Johany 2017) [24].
- (i) Extra narrow: Less than 3.0 mm.
 - (ii) Narrow: From 3.0 mm to less than 3.75 mm.
 - (iii) Standard: From 3.75 mm to less than 5 mm.
 - (iv) Wide: 5.0 mm or more.

Earlier, implants with diameters as wide as the tooth being replaced were used. Changing concepts of jumping gap, preserving the buccal cortical plate, and optimal 3-dimensional position coupled with improved surfaces encouraged slightly narrow diam-

Box 18.1 Types of Implants

Implants can be classified as follows:

- (a) Implant Material
 - (i) Titanium and titanium alloys
 - (ii) Zirconia
- (b) Shape:
 - (i) Screw type implants
 - (ii) Cylindrical, apically tapered, and fully tapered
 - (iii) Platform-switch implants
 - (iv) Bone level vs. tissue level implants
- (c) Implant surface
 - (i) Machined (Brånemark surface)
 - (ii) Textured/rough surfaces
 - (iii) Hydrophobic/Hydrophilic surfaces
- (d) Implant length
- (e) Implant diameter

eters as compared to previous trends. Extra-narrow and narrow-diameter implants are used in deficient sites to minimize invasiveness and morbidity.

18.5 Preoperative Examination of Potential Implant Patients

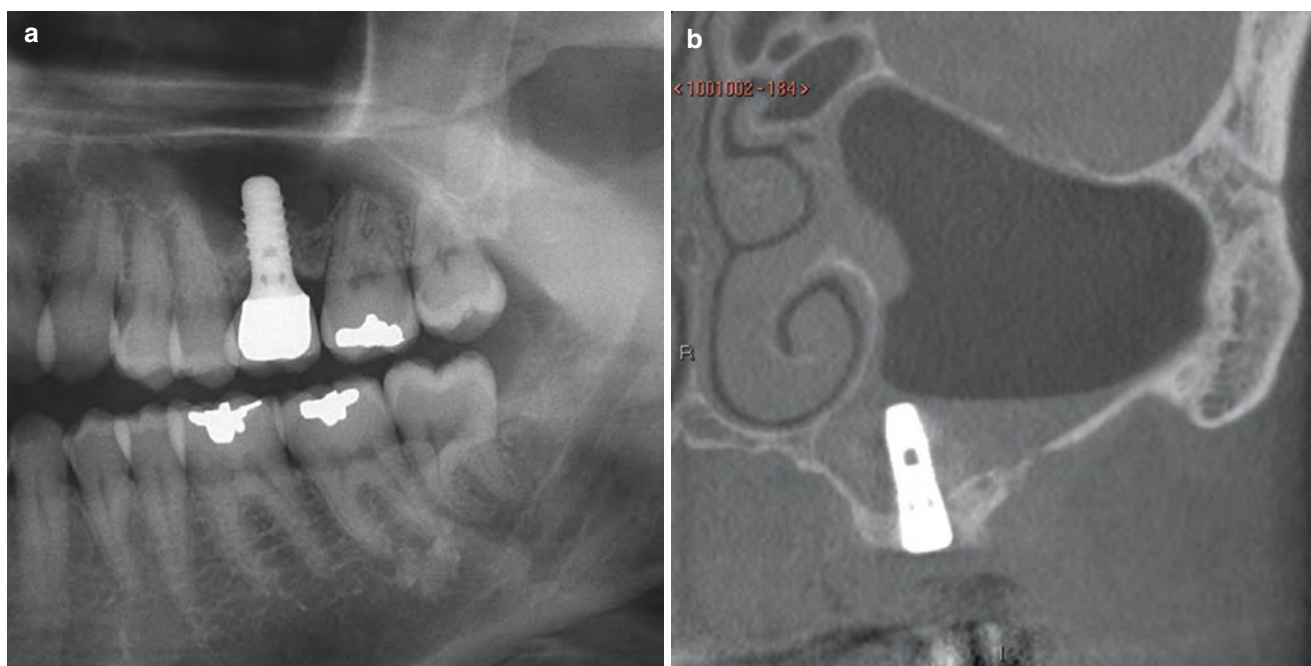
18.5.1 Clinical Examination

Before implant treatment, a careful analysis should be conducted. This includes patient’s current health status and medications and details of past medical history and medical treatments.

Patients should be questioned about parafunctional habits, oral hygiene, and personal habits such as tobacco, alcohol, and drugs. The compliance, motivation, attitude, understanding, and expectations of the patient are important for optimal treatment outcome.

Clinical examination should include extra-oral examination, i.e., lip line, lip competence, and temporomandibular joint. Intraoral assessment should include assessment of the edentulous space, occlusion, status of adjacent and opposing teeth, overall periodontal status, presence of other implants and restorations, shape of the teeth, gingival biotype, and any other local factor that may impact the success of the treatment.

Diagnostic study models and intraoral clinical photographs are essential for documentation as well as for the further assessment of spatial and occlusal relationships.



©Association of Oral and Maxillofacial Surgeons of India

Fig. 18.3 (a and b) show examples of two-dimensional and 3-dimensional examination of an implant placed with sinus floor elevation

18.5.2 Radiographic Examination

Figure 18.3a and b show examples of two-dimensional and 3-dimensional examination of the maxillary sinus.

Radiographic examination should be done in the evaluation phase to determine the status and anatomy of the underlying bone, if implant placement is possible and if any other surgical procedures are required before implant placement. A 2-dimensional radiograph of the area is desired; however, this is insufficient to provide a detailed 3-dimensional assessment of the site. Hence, the radiograph of choice is the Cone Beam Computerized Tomography (CBCT) as it provides a detailed three-dimensional analysis of the edentulous area along with the neighboring anatomical structures. With the software for CBCT, it is possible to measure accurately the dimension of the site and distances from critical structures and accurately plan which implant dimension would be appropriate. CBCT imaging also gives us information on which sites require augmentation and if so the location and extent required.

18.5.3 Correct 3-Dimensional Position for an Implant

For the site of implant placement, the available space should be evaluated in three dimensions, i.e., mesiodistal, buccolin-

gual, and apicocoronal dimensions. A graduated periodontal probe can be used for clinical measurements; however, this information is best recorded from imaging techniques such as CBCT. While evaluating the available space, factors such as proximity to adjacent anatomical structures such as maxillary sinus, mandibular nerve, nasal floor, adjacent tooth roots, etc. should be considered.

The minimal space required for an implant depends on the size of the implant to be used (in terms of length and diameter), whether the implant is placed adjacent to two natural teeth or adjacent to an implant and the apicocoronal distance in the bone.

1. Implant adjacent to a natural tooth: Buser et al. (2004) suggested a concept for correct 3-dimensional implant placement [25]. They designated zones called as comfort zones (which is the ideal position for an implant) and danger zones (in which implants should not be placed). This was defined in three directions mesiodistally, coronapically, and orofacially. (Figure 18.4 a, b, and c show diagrammatic representation of the correct positioning of implants in a 3-dimensional manner). The ideal mesiodistal distance between a natural tooth and the shoulder of an implant is 1.5 mm [25]. The zone up to 1–1.5 mm from the adjacent teeth on either side was the danger zone. Between the danger zone was the comfort zone that is safe for implant placement [25]. For

example, if an implant of 4.1 mm in diameter is placed between two natural teeth, the minimum mesiodistal distance available should be 7 mm (to allow 1.5 mm between the implant and the natural teeth on either side).

If placed too close to the adjacent teeth, it causes bone loss. In the orofacial dimension, the implant shoulder is positioned palatal to the incisal edge of the future restoration (or 1 mm palatal to the point of emergence of the

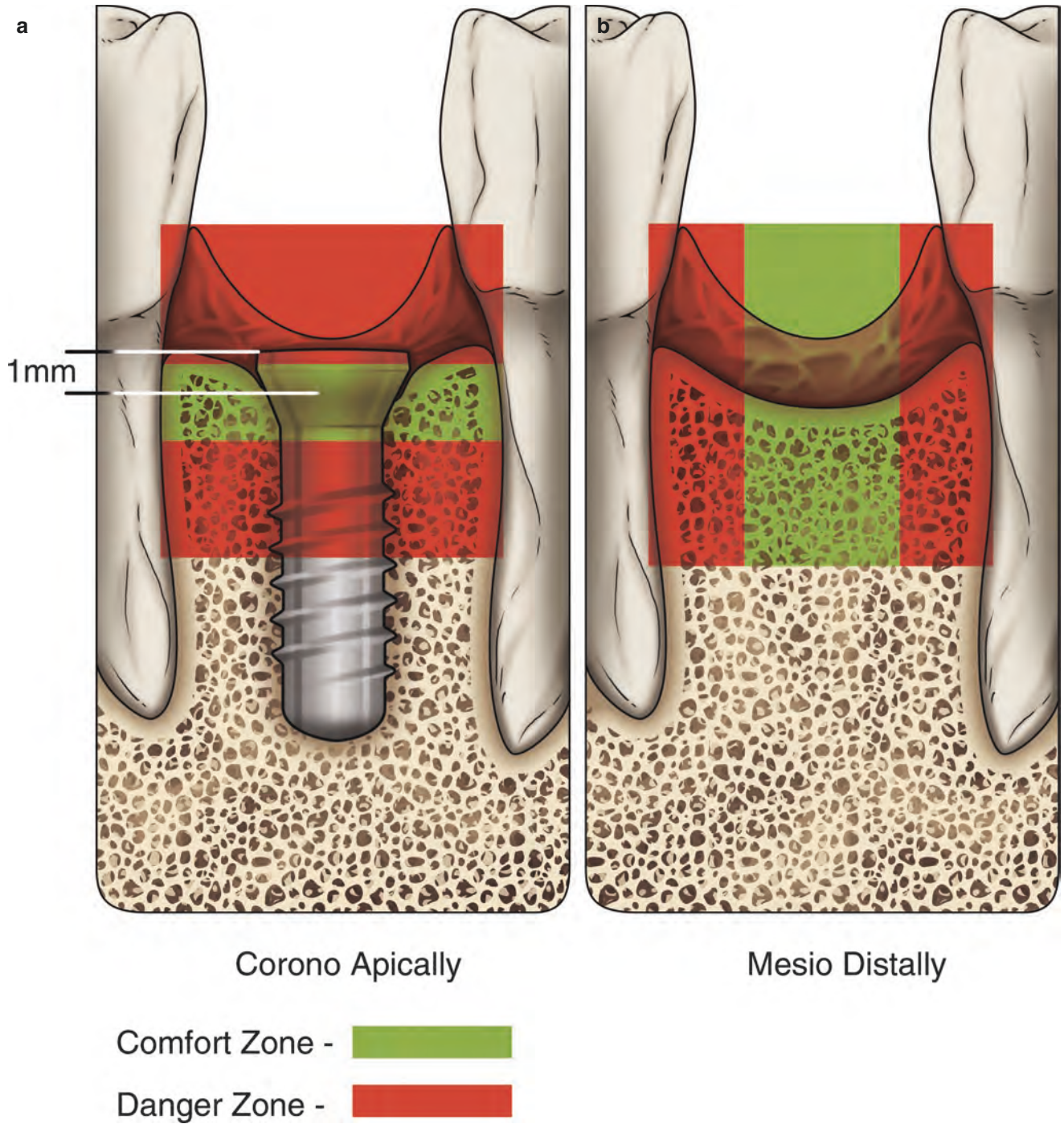
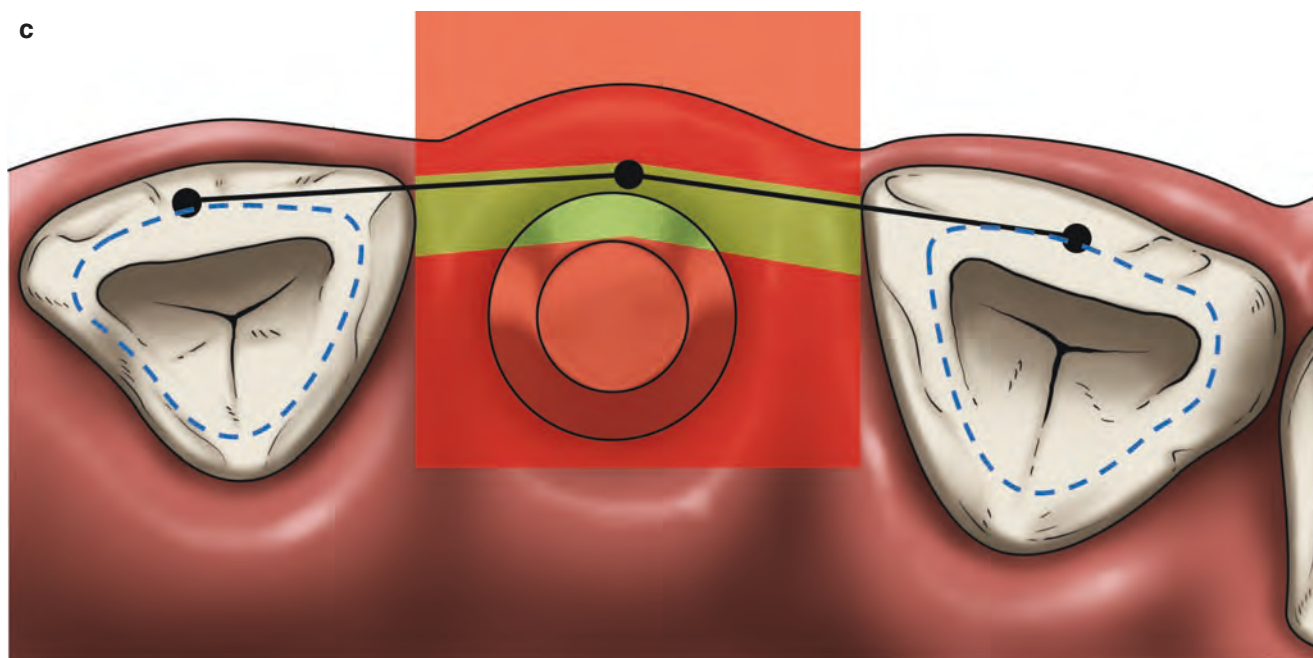



Fig. 18.4 (a, b, and c) diagrammatic representation of ideal placement of a single implant in green shadow and unideal positions that could lead to complications (in red shadow). (a) ideal coronoapical position, (b) ideal mesiodistal position, and (c) ideal orofacial position



Comfort Zone - 

Danger Zone - 

©Association of Oral and Maxillofacial Surgeons of India

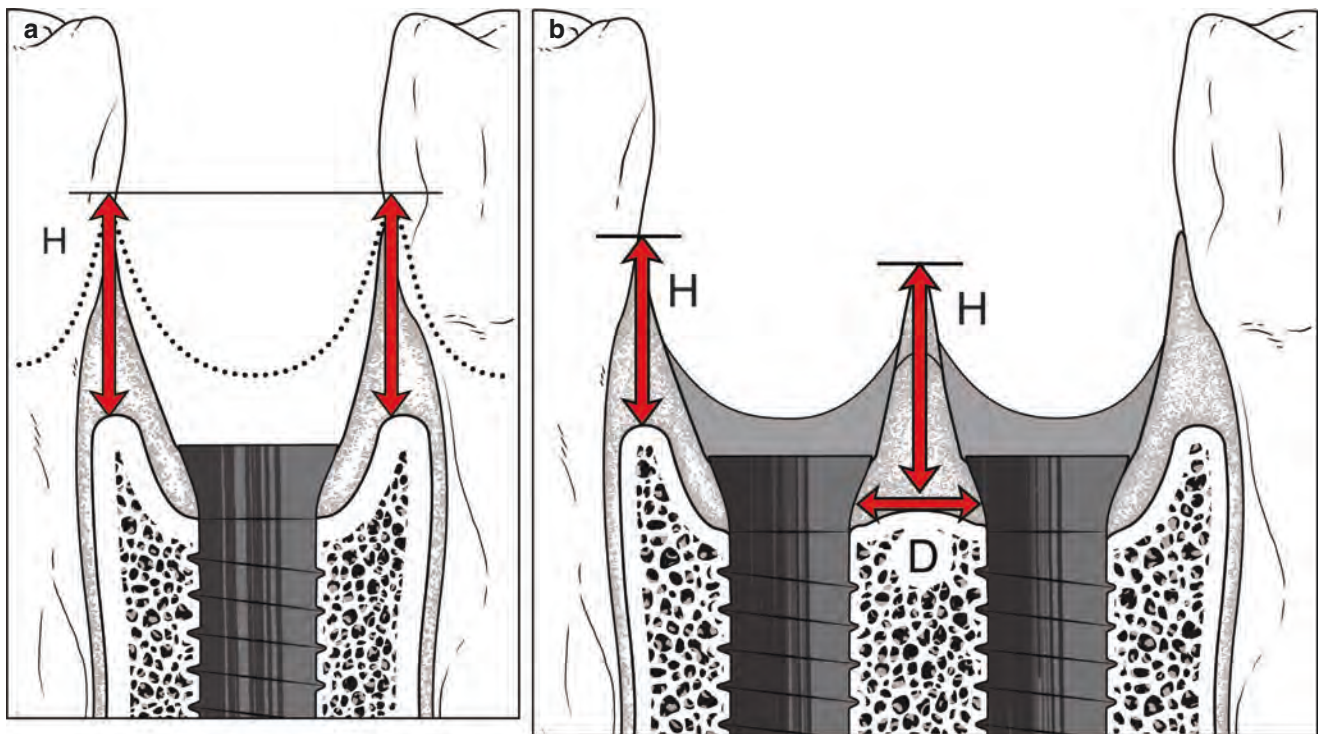
Fig. 18.4 (continued)

adjacent teeth). The oral aspect has a danger zone as well, indicating that an implant should not be placed too far orally to prevent the use of a ridge lap restoration. Too far facially will result in increased mucosal recession. In the apicocoronal direction, the apex of the implant should be at least 1-2 mm away from any anatomical structure such as nerve, sinus, or tooth roots. Also, in the shoulder of the future implant should be at least 1 mm apical to the cemento-enamel junction of the adjacent teeth to allow for a proper emergence profile [25]. Placing an implant too deep will result in too much countersinking, difficult handling, and facial mucosal recession. Placing an implant too superficially will cause the metal margin to be visible and improper emergence profile. In addition to this, the ideal facial bone thickness should be 2 mm [26] and the lingual bone thickness should be 1.5 mm. Hence, for a 4.1 mm implant, minimum orofacial distance should be approximately 7.5 mm. Also, to prevent the appearance of black triangles, the apicocoronal distance from the interdental contact point to the crest of bone should not exceed 5 mm. (Figure 18.5a shows diagrammatic repre-

sentation of the distance between interdental contact point and the crest of bone, for adequate papilla preservation).

2. Implants adjacent to each other: The mesiodistal distance between the implants should be at least 3 mm [25, 26]. This is critical to allow adequate interimplant bone and hence the formation of a soft tissue papilla overlying the bone. The other requisites for mesiodistal, orofacial, and apicocoronal dimensions, as previously mentioned, apply in addition. (Figure 18.5b shows diagrammatic representation of the distance between interdental contact point and the crest of bone, for adequate papilla preservation).

When the space for an implant of a particular diameter is less than ideal, a decision should be made either to augment the site with bone or to choose an implant of smaller diameter. However, this decision requires clinical expertise as augmentation procedures are technique sensitive and using smaller diameter implants depends on evaluation of the occlusal forces in the area. The interocclusal distance also needs to be evaluated prior to implant placement as it determines the choice of prosthetic rehabilitation of the implant. If the interocclusal distance is reduced,



Critical Dimension : $H < 5\text{mm}$

©Association of Oral and Maxillofacial Surgeons of India

Critical Dimensions : $H < 5\text{mm}$ $D > 3\text{mm}$

Fig. 18.5 (a and b) diagrammatic representation of the critical dimensions in implant placement in relation to interdental papilla. (a) The height (H) of the interdental contact from the crest of the interdental alveolar bone should not be more than 5 mm for obtaining adequate

interdental papillary morphology. (b) The interimplant distance (D) should be at least 3 mm for obtaining adequate interdental papillary morphology

the choice would be to use a screw-retained prosthesis over a cement-retained one. Screw-retained prosthesis, however, is the more preferred technique due to ease in retrievability and cleansability.

The amount of keratinized tissue in the site should also be evaluated before surgery as this determines the location of the incision. Ideally, a band of at least 2 mm (minimum 1 mm) keratinized tissue should surround the implant, and this is critical to the long-term success of the implant. If this is not achievable, procedures to augment the keratinized mucosa should be planned. Keratinized mucosa is necessary as it provides a physical barrier to oral plaque and to the forces of mastication as compared to nonkeratinized mucosa [27].

18.6 SAC Classification

The International Team for Implantology (ITI) proposed a classification of sites for implant placement based on the analysis of several factors [28].

Based on these factors, sites for implant surgery could be classified as straightforward (S), advanced (A), and complex (C).

This provides the clinician an assessment of the site for implant placement before the surgery is planned and is based on the level of expertise of the clinician who can either treat or refer to a specialist.

The determinants of the classification are.

1. Esthetic or nonesthetic site: Any case in the esthetic zone or has an esthetic risk should be considered as advanced or complex.
2. Complexity of the process: The level of complexity can be assessed by considering the number of steps and the number of areas in which an acceptable outcome has to be achieved.
3. Risk of complications: The SAC Classification can be used to identify and quantify risks for complications. This allows pretreatment planning to control and minimize risks.

The general modifying factors are.

1. Clinical competence and expertise: The SAC Classification for a case type is independent of the clinician's skill and competence. A Straightforward case is an uncomplicated

procedure, and a Complex case is the one that is difficult to manage.

2. Compromised patient’s health: Patients with risk factors such as smoking, diabetes, irradiated bone, history of periodontal disease, poor oral hygiene, and bruxism need to be monitored as they have a higher risk for complications.
3. Growth considerations: Implants placed in the jaws of growing individuals are modifying factors as they present esthetic and functional issues.
4. Iatrogenic factors: Suboptimal planning and treatment outcomes increase the difficulty in the implant treatment phase. For example, incorrect three-dimensional implant placement will complicate the restorative process.

Tables 18.1, 18.2, and 18.3 show the esthetic, surgical, and restorative modifying factors to be considered during implant treatment planning and execution.

Table 18.1 The esthetic modifying factors are determined by the Esthetic Risk Assessment (ERA)

Esthetic factors	Level of risk		
	Low	Medium	High
Medical status	Healthy and co-operative patient with an intact immune system.	–	Reduced immune system
Patients’ esthetic expectation	Low	Medium	High
Smoking habit	Nonsmoker	Light smoker (<10 cigs/day)	Heavy smoker (>10 cigs/day)
Lip line	Low	Medium	High
Shape of tooth crowns	Rectangular		Triangular
Gingival biotype	Low scalloped and thick	Medium scalloped and medium thick	High scalloped and thin
Bone anatomy of alveolar crest	Alveolar crest without bone deficiency	Horizontal bone deficiency	Vertical bone deficiency
Bone level at adjacent teeth	≤5 mm to contact point	5.5 to 6.5 mm to contact point	≥7 mm to contact point
Soft tissue anatomy	Intact soft tissue		Soft tissue defects
Width of edentulous span	1 tooth (≥7 mm)	1 tooth (≤7 mm)	2 teeth or more
Restorative status of neighboring teeth	Virgin		Restored
Infection at implant site	None	Chronic	Acute

Adapted with permission from Dawson A, Chen S, Buser D, Cordaro L, Martin W, Belser U. The SAC Classification in Implant Dentistry. Editors: Dawson A, Chen S. Quintessence Publishing Co. Ltd. 2009

The above-mentioned modifiers have to be considered for every implant case during the assessment and planning phase of treatment. Risks can be identified prior to treatment, thus minimizing complications. To classify as Straightforward, Advanced, or Complex for a specific case, the specific features of the case can be matched with the descriptions in the tables. The level that best matches the factors of the individual case will provide the SAC Classification for that case.

The final treatment plan including additional surgical procedures (if required) should be formulated after accurate diagnosis and consideration of the patient’s systemic and local factors, bearing in mind the requirements of the patient.

Table 18.2 Surgical modifying factors

Site factors	Risk or degree of difficulty		
	Low	Moderate	High
Anatomic risk			
Proximity to vital anatomic structures	Minimal risk of involvement	Moderate risk of involvement	High risk of involvement
Bone volume			
Horizontal	Adequate	Deficient, but allowing simultaneous augmentation	Deficient, requiring prior augmentation
Vertical	Adequate	Small deficiency crestally, requiring slightly deeper coronapical implant position. Small deficiency apically due to proximity to anatomical structures, requiring shorter than standard implant lengths.	Deficient, requiring prior augmentation
Esthetic risk			
Esthetic zone	No		Yes
Biotype	Thick		Thin
Thickness of facial bone wall	Sufficient ≥1 mm		Insufficient <1 mm
Complexity			
Number of prior or simultaneous procedures	Implant placement without adjunctive procedures	Implant placement with simultaneous procedures	Implant placement with staged procedures
Complications			
Risk of surgical complications	Minimal	Moderate	High
Consequences of complications	No adverse effect	Suboptimal outcome	Severely compromised outcome

Adapted with permission from Dawson A, Chen S, Buser D, Cordaro L, Martin W, Belser U. The SAC Classification in Implant Dentistry. Editors: Dawson A, Chen S. Quintessence Publishing Co. Ltd. 2009

Table 18.3 *Restorative modifiers*: These are the restorative factors that influence the SAC classification

Issue	Notes	Degree of difficulty		
		Low	Moderate	High
Oral environment				
General oral health		No active disease		Active disease
Condition of adjacent teeth		Restored teeth		Virgin teeth
Reason for tooth loss		Caries/trauma		Periodontal disease or occlusal parafunction
Occlusion				
Occlusal scheme		Anterior guidance		No guidance
Involvement in occlusion	The degree to which the implant prosthesis is involved in the patient's occlusal scheme	Minimal involvement		Implant restoration is involved in guidance
Occlusal parafunction	Risk of complication to the restoration, but not to implant survival	Absent		
Restorative volume				
Interarch distance	Refers to the distance from the proposed implant restorative margin to the opposing occlusion	Adequate for planned restoration	Restricted space, but can be managed	Adjunctive therapy will be necessary to gain sufficient space for the planned restoration
Mesiodistal space	The arch length available to fit tooth replacements	Sufficient to fit replacements for missing teeth	Some reduction in size or number of teeth will be necessary	Adjunctive therapy will be needed to achieve a satisfactory result
Span of restoration		Missing tooth	Extended edentulous space	Full arch
Volume and characteristics of the edentulous saddle	Refers to whether there is sufficient tissue volume to support the final restoration, or some prosthetic replacement of soft tissues will be necessary	No prosthetic soft-tissue replacement will be necessary		Prosthetic replacement of soft tissue will be needed for esthetics or phonetics
<i>Provisional restorations</i>				Present
During implant healing		Not required		Fixed
Implant supported provisionals needed	Provisional restorations will be needed to develop esthetics and soft tissue transition zones	Not required	Restorative margin <3 mm apical to mucosal crest	Restorative margin >3 mm apical to mucosal crest
<i>Materials/manufacture</i>	Materials and techniques used in the manufacture of definitive prostheses	Resin-based materials ± metal reinforcement	Porcelain fused to metal	
<i>Loading protocols</i>	To date, immediate restoration and loading procedures are lacking scientific documentation	Conventional or early loading		Immediate loading
<i>Maintenance needs</i>	Anticipated maintenance needs based on patient presentation and the planned prosthesis	Low	Moderate	High

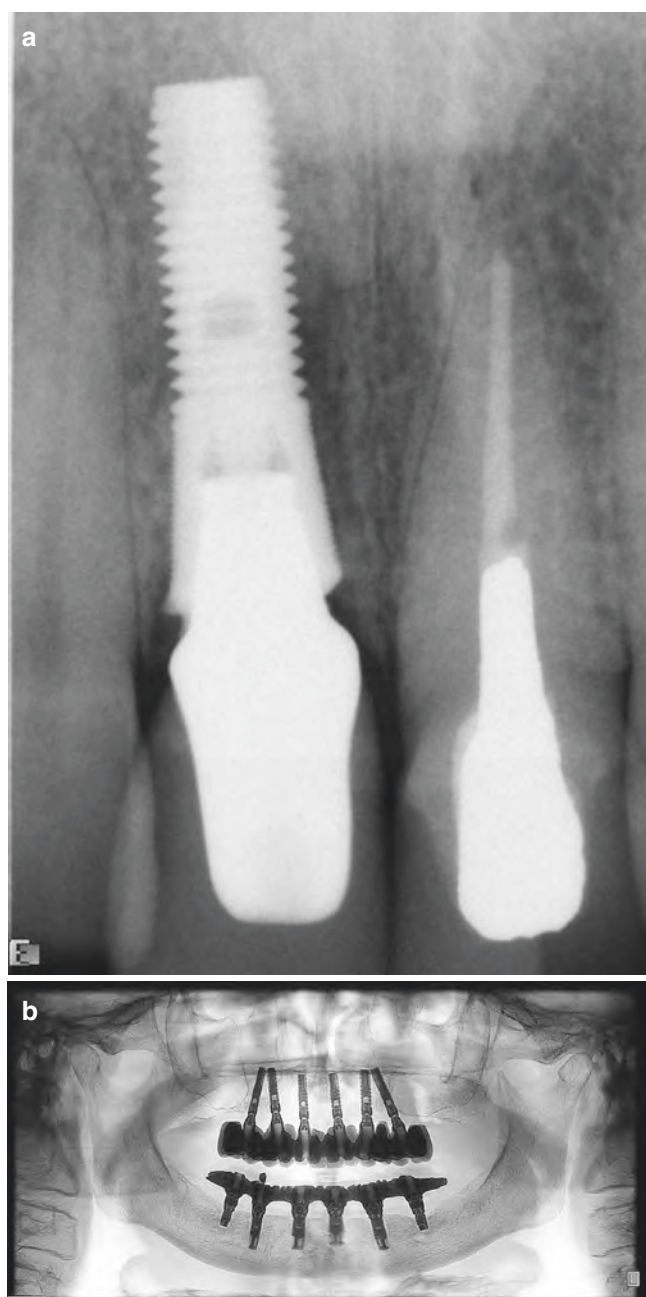
Adapted with permission from Dawson A, Chen S, Buser D, Cordaro L, Martin W, Belser U. The SAC Classification in Implant Dentistry. Editors: Dawson A, Chen S. Quintessence Publishing Co. Ltd. 2009

18.7 Implant Solutions for Different Edentulous Situations

Implants can be used as replacement options for all kinds of edentulous situations varying from single tooth gaps to completely edentulous jaws (Figure 18.6 shows an example where an implant has been used for the restoration of single tooth, and 7b shows an example where implants have been used for the replacement of the edentulous upper and lower jaws). The treatment plan varies in complexity as the number of teeth replacements increases, if it is an esthetic site or not

and if the opposing dentition is implant-supported or not and depending on the occlusal load. As few as possible but as many as needed should be the key when placing implants. The selection of the size of the implant (length and width) and the number of implants especially in areas of poor bone quality is important for providing the correct solution.

For large edentulous spans, it is preferable to use as many implants as required, to support the occlusal forces in that area. Cantilever prosthesis on implants has to be used with discretion and is limited to areas of low occlusal demand. It is not preferable to splint implant with natural teeth as



©Association of Oral and Maxillofacial Surgeons of India

Fig. 18.6 (a) shows an example where an implant has been used for the restoration of single tooth, and (b) shows an example where implants have been used for the replacement of the edentulous upper and lower jaws

implants cannot intrude with force like natural teeth. Long-span bridges on implants are not advisable in soft bone, e.g., in the completely edentulous maxilla, a fixed prosthesis can be given on six implants, while in the mandible, the same can be achieved with only four implants. For removable prosthesis, in an edentulous maxilla, four to six are sufficient, while in the edentulous mandible, the similar prosthetic solution can be achieved with two to four implants. There are several concepts of implant replacement for long edentulous spans

and several designs of implants indicated for specific types of sites; however, the details of these are beyond the scope of this chapter.

18.8 Timing of Implant Placement Postextraction

18.8.1 Hard and Soft Tissue Alterations Postextraction

Studies in beagle dog revealed that postextraction, the bundle bone resorbs as the blood supply to this bone is compromised due to tooth extraction [29, 30]. This results in vertical bone loss in both facial and lingual walls of the socket, but it is more pronounced on the facial aspect as most often it is thinner in width than the lingual wall [30]. In human studies, ridge width reduction of up to 50% occurred during the first year after tooth loss in premolar and molar sites, and two-thirds of the total change took place within the first 3 months following extraction [31]. Dimensional alterations occurred in both height and width, with approximately 2.6–4.5 mm in width and 0.4–3.9 mm in height being lost in the healed sockets [32]. Histologically, the density of vascular structures and macrophages reduced from 2 to 4 weeks, the osteoclastic activity slowly decreased over a 4-week period, and osteoblasts peaked at 6–8 weeks remaining almost stable thereafter [33]. Thin facial walls seem to be prone for resorption, and sites with facial bone wall thickness of 1 mm or less had vertical bone loss of 7.5 mm (62%) of the original bone height after an 8 week healing period. Patients with thick wall phenotype, having facial bone wall thickness of more than 1 mm, had only about 1.1 mm (9%) vertical bone loss [34]. Also, for single extraction sites, the dimensional alteration occurred mainly in the central mid-facial area of the socket wall, while the proximal areas that had viable periodontal ligament of the adjacent teeth remained nearly unchanged after flapless tooth extraction at 8 weeks of healing [35]. With this pattern of resorption, a thin wall phenotype will develop a two-wall defect, while a thick-wall phenotype will result in a three-wall defect after initial remodeling [34]. Thus, the evaluation of facial wall thickness is critical to predict the future of bone loss prior to extraction [13]. With the above findings related to the pattern of bone remodeling and the timing of the cellular activity, in thin bone wall phenotypes, it is recommended to allow the initial postextraction remodeling to take place before initiating regenerative procedures. An early implant placement would be recommended for thin bone phenotypes. Immediate implant placement would be recommended only for thick wall phenotypes and thick gingival biotypes where minimal remodeling would be expected.

The soft tissue thickness in maxillary anterior teeth is thin in most patients, ranging from 0.5 mm to 1 mm. This soft tis-

sue thickness has not shown significant correlation to the underlying facial bone wall thickness [36]. For single extraction sites, 50% of the soft tissue change occurs within the first 2 weeks postextraction. The increase in soft tissue thickness significantly depends on the underlying bone dimensions. In thick wall phenotypes, the soft tissue dimensions do not significantly change. In these defects, the alveolus acts as a self-contained bony defect and favors the growth of bone-forming cells from the adjacent socket walls. In thin wall phenotypes, the facial bone wall resorbs rapidly and the highly proliferative soft tissue occupies its position. There is a sevenfold increase in soft tissue occupying the crestal area of the socket defect, and this is termed as spontaneous soft tissue thickening [13]. The tissue formed is highly vascularized granulation tissue with fibroblasts migrating into it, some of which differentiate into myofibroblasts that are involved in the thickening phenomenon. At 8 weeks, there is a peak in endothelial cell density, BMP-7, and osteocalcin expression, indicating that the molecular and cellular mechanisms that regulate new bone formation also influence the soft tissue thickening. The clinical implications of this soft tissue thickening are that, after an 8 week healing period, the soft tissues are sufficiently thickened and provide increased keratinized tissue in the site that allows for primary closure favoring bone regeneration. With this thickened soft tissue, there is no requirement for additional soft tissue grafts. However, this soft tissue thickening can mask the underlying bone defect, often misleading the clinician while selecting the appropriate treatment protocol [37].

18.8.2 Concept of Timing for Implant Placement

Implant placement can be classified based on the timing of implant placement. According to the ITI Consensus Conferences in 2003 and 2008, it is classified as Type 1, Type 2, Type 3, and Type 4 implant placement [38].

Box 18.2 Concept of Timing for Implant Placement

Type 1: When placed immediately after tooth extraction, it is called immediate implant placement.

Type 2: When placed 4–8 weeks after tooth extraction, it is an early implant placement with only soft tissue healing

Type 3: When placed 12–16 weeks after tooth extraction, it is an early implant healing with partial bone healing

Type 4: When placed after 6 months after tooth extraction, there is complete bone healing, and this is called delayed implant placement.

The choice of timing of implant placement depends on several factors. The four options are available to the clinician, who can select the option based on the following criteria, provided that they have the required clinical expertise.

- *Immediate implant placement (type I)* is recommended to be performed only by experienced clinicians in sites that have ideal anatomic conditions, such as:
 - (i) a completely intact, thick wall phenotype (i.e., >1mm) facial bone wall at the extraction site
 - (ii) thick gingival biotype,
 - (iii) absence of acute infection at the extraction site, and
 - (iv) adequate volume of bone apical and palatal of the extraction site to allow sufficient primary stability of the implant while placing it in the correct 3-dimensional position.
- *Type 2 placement* is recommended when the above ideal conditions are not met.
 - (i) In situations where there is inadequate keratinized tissue, this technique allows an additional 3-5 mm of tissue as the tissues heal spontaneously.
 - (ii) In sites where there is a thin facial bone, the bundle bone spontaneously resorbs and a spontaneous soft tissue thickening takes place to fill the extraction socket.
 - (iii) Acute and chronic infections resolve leaving the future implant site free of infections.
 - (iv) Bone forms in the apical portion of the socket, thus allowing primary stability from the apical bone during implant placement. At the stage of implant placement, a guided bone regeneration procedure with bone graft and membrane is most often required.
- *Type 3 implant placement* is recommended in cases where either primary stability cannot be achieved even after 4–8 weeks of healing postextraction or where the proper 3-dimensional position for implant placement cannot be achieved. The healing time in these cases is extended to 12–16 weeks to allow partial bone healing. This is generally ideal for multirooted teeth such as mandibular molars. In this case also, guided bone regeneration with bone graft and membrane is often required.
- *Type 4 implant placement* is often not a preferred treatment by the patient. However, the indications for this type of implant placement are determined by certain patient-related factors or site-specific factors. Patient related factors include.
 - (i) patients with systemic conditions that require treatment to be deferred, e.g., pregnant patients,
 - (ii) adolescent patients who are too young to receive implants and require the treatment to be deferred, and
 - (iii) patients who are unable to make an early appointment due to personal reasons.

Site-related factors include.

- (a) Large Apical Lesions
- (b) Impacted or ankylosed teeth that cause a lot of bone removal in the apical aspect of the site. In all these cases, it is recommended that socket grafting with a low substitution filler is used to reduce ridge alterations and ridge atrophy. The crestal bone resorption is inevitable; however, the use of socket grafting minimizes the need for ridge augmentation at a later date.

18.8.3 Healing Modality: Concept of Submerged and Nonsubmerged Healing

When an implant is placed, the operator can choose to either submerge the implant (completely enclose it within the healing tissues) or keep it nonsubmerged (implant is visible through the healing soft tissue). (Figure 18.7 shows diagrammatic representation of submerged and nonsubmerged healing).

In the nonsubmerged/one-stage approach, the healing cap/abutment of the implant emerges through the mucosal tissues at the time of flap closure after implant placement. Nonsubmerged implants can be one-piece or two-piece implants. In one-piece implants, there is no micromovement

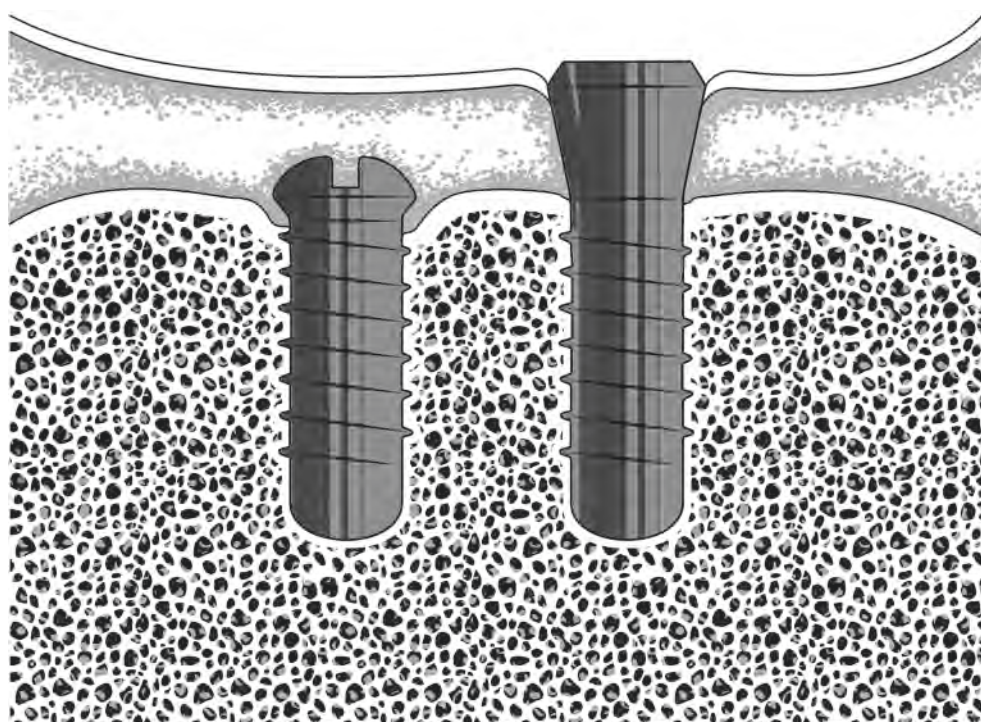
and no microgap between the implant and the abutment. In the two-piece nonsubmerged implants, there is no need for a second surgical procedure to expose the implant for prosthetics; however, the potential of the microgap between the two components exists. This technique is generally preferred for standard implant placement procedures where there is no need to augment the site.

In the submerged/two-stage approach, the healing cap/cover screw is completely covered with the soft tissue flap after implant placement surgery. The implants are allowed to osseointegrate in a closed environment without loading or any form of micromovement, for a period of time. The submerged protocol is used for implant placement with simultaneous bone augmentation. Following this healing period, the implant is surgically exposed to place the abutment. Both these techniques are well accepted and can be selected based on the treatment plan.

18.9 Surgical Procedure for Conventional Implant Placement

As mentioned before, the most important step before implant surgery is the analysis of the general patient factors and then the local edentulous site factors. Depending on whether it is an implant replacement for a single tooth, multiple teeth, or a completely edentulous ridge, the planning differs. The

Fig. 18.7 Diagrammatic representation of submerged and nonsubmerged healing



©Association of Oral and Maxillofacial Surgeons of India

treatment protocol also differs depending on whether it is an esthetic site or not. Single tooth replacements in a nonesthetic site are simpler as compared to multiple teeth replacements in an esthetic site.

For standard implant placement:

1. Local anesthesia: the area of surgery including at least two teeth mesial and distal should be well-anesthetized.
2. Incision: a scalpel blade no 15 is used to make a horizontal paracrestal incision. This bisects the existing zone of keratinized mucosa with at least 2 mm on the buccal aspect of the future implant. The incision extends to one tooth mesially and distally with a papilla sparing incision. If required, a vertical release incision can be given on the distal aspect to create a triangular flap.
3. Flap elevation: A full thickness mucoperiosteal flap is elevated on the buccal and on the lingual aspect. A retraction suture can be placed in the buccal and lingual flaps if required. The crestal bone should be exposed sufficiently so as to get visible access to the implant site as well to check the palatal and buccal curvature of the ridge.
4. Flattening of the ridge: A large round rose bur is used to flatten the ridge, thus removing any bony slopes in the crestal area. This also allows removal of the narrower portions from the crest of the ridge; however, extensive removal in short ridges should be done judiciously.
5. Drilling of the osteotomy: all drilling should be done along with copious amounts of cold saline irrigation with the speed as specified by the manufacture for each particular bur/drill (generally in the range of 800–1500 rpm). It is important to keep an eye for the correct positioning and the neighboring anatomic structures during each stage of drilling.
 - (a) Initially, a small diamond bur is used to mark the site. The mark created corresponds to the center of the osteotomy and should be in the correct mesiodistal and buccolingual position. This bur is used to make a hole of 1–2 mm deep to create a start point for the pilot drill.
 - (b) The pilot drill is the first twist drill used to create the osteotomy up to the desired length. Ideally, the length of the osteotomy should be slightly more than the implant so that the implant can be placed slightly subcrestal (to compensate for future crestal bone resorption). Also, the shoulder of the future implant should be 1 mm apical to the cemento-enamel junction of the adjacent teeth in esthetic areas to allow for a proper emergence profile. While drilling, the correct axis should be maintained. The drills should be repeatedly pumped in and out of the osteotomy to expose the bone debris to the water coolants for clearing. If multiple implants are to be placed, a guide pin is used in the first osteotomy to align the second implant before commencing the second osteotomy preparation.
 - (c) Subsequent drills are used in the same way as the pilot drill to enlarge the osteotomy to the desired depth.
 - (d) Profile drills or countersink drills are used between the sequential drills to widen the crestal part of the osteotomy to allow the next drill into the osteotomy. The countersink drill also flares the preparation to allow the placement of the cover screw over the implant without any bony interference.
 - (e) Bone tapping is an optional step that is required only in very dense bone. This is done at very slow speeds (20–40 rpm) without water irrigation.
6. Implant placement: implants are placed with a handpiece at slow speeds (18–25 rpm) or by hand using a torque wrench. Implant insertion should follow the same path of insertion as that of the osteotomy. For multiple implants, guide pins serve as a direction indicator to obtain parallelism. Care is taken to insert the implant such that the microrough surface of the implant is 1–1.5 mm subcrestal. This prevents exposure of the rough surface of the implant to the environment during the eventual crestal bone remodeling. The implant should also be placed such that the shoulder of the implant should be at least 3–4 mm apical to the cemento-enamel junction of the adjacent teeth. It is also important that primary stability is achieved at placement and the average insertion torque should be 35 Ncm²; however, ISQ values are a more accurate recording as they can be measured from time to time and a comparison can be obtained unlike insertion torque, which is only a one-time measurement. Once the desired position and stability are achieved, the cover screw (for submerged healing)/healing abutment (nonsubmerged healing) should be fitted over.
7. Flap closure and suturing: the flap should be approximated so as to provide tension-free closure. If required, a periosteal release incision can be done. If a submerged healing is planned, the flap should be completely closed over the implant by primary closure. If a nonsubmerged healing is intended, then the flap is closed around the healing abutment. Although any technique of suturing is acceptable, it is preferable that for long horizontal spaces, horizontal mattress sutures along with interrupted sutures

are placed in 4–0 or 5–0 nonresorbable sutures. Suturing of vertical incisions and papillae is generally done with 5–0 or 6–0 nonresorbable sutures.

8. Postoperative care: Simple implant surgery in a healthy patient does not require antibiotic coverage; however, if the patient has any systemic complications or at risk of infection, it is advisable to put the patient on postoperative antibiotic coverage. Analgesics are recommended for the first few days after surgery. Patient is given routine postsurgical instructions such as use of ice packs for the first 24 h, soft diet, no vigorous rinsing, no brushing on the surgical site, no tobacco smoking, and no vigorous exercise. Provisional replacements should not transmit direct forces to the underlying implant and should be adequately relieved from the surgical site, particularly in the early healing period (4–8 weeks). Patient is recalled on the second postsurgical day and after that 1 week postoperatively to check for healing.
9. Prosthetic phase: depending on the choice of timing to load the implant, the reopening phase can be planned. For nonsubmerged implants, often, no second surgery is required as the healing abutment is exposed. For submerged implants, the healing cap/abutment can be exposed by a small surgical procedure and a taller healing abutment can be inserted so as to allow the mucosal tissue to heal around and create an emergence profile.

(Figure 18.8 shows an example of the surgical phase of single implant placement)

18.10 Concepts of Implant Loading

An implant loading protocol is the time period between implant placement and the attachment of the prosthesis. The loading protocols have changed over the years, and the ITI Consensus Conferences in 2003, 2008, and 2013 had slight variations in defining them. The current definition as per the ITI Consensus Conference 2018 is as follows [39]:

- immediate loading,
- early loading,
- and conventional loading.

Box 18.3 Concepts of Implant Loading

- (a) *Immediate loading*: Loading of dental implants earlier than 1 week after implant placement. This can be done with either a provisional prosthesis or a final prosthesis. The provisional prosthesis is used to reshape the peri-implant soft tissues for better esthetic outcomes, modify the occlusion, or evaluate a planned implant prosthesis. A final prosthesis can be directly given in cases with low esthetic risk and in areas of stable occlusion. This protocol significantly reduces the treatment time, and both soft tissue and bony healing occurs under functional loading.
- (b) *Early loading*: Loading of dental implants between 1 week and 2 months after implant placement. In this treatment approach, functional forces are exerted on the implants during the later stages of bone healing. Soft tissues are still healing, and by two months, they are almost completely healed. Here also, the time between placement and loading is reduced.
- (c) *Conventional loading*: Loading of dental implants more than 2 months after implant placement [40, 41]. This allows for a complete healing of bone and peri-implant soft tissue and requires a longer treatment time between implant placement and loading. This protocol is selected in cases when there are medical or risk factors, low implant stability at surgery, and extensive augmentation in the implant site and with short or narrow diameter implants.

Patient-related factors such as medical and systemic risk factors, surgical site factors (augmented site), and implant stability as assessed by insertion torque (20–50 Ncm²) and resonance frequency analysis (>55 ISQ) are determinants for selecting the loading protocol. Implant design and characteristics also affect the loading protocol, surface modification of implants has added to faster healing rates of bone around implants, and hence, the healing period before loading has reduced [23]. Hence, selection of a correct loading protocol is case specific.

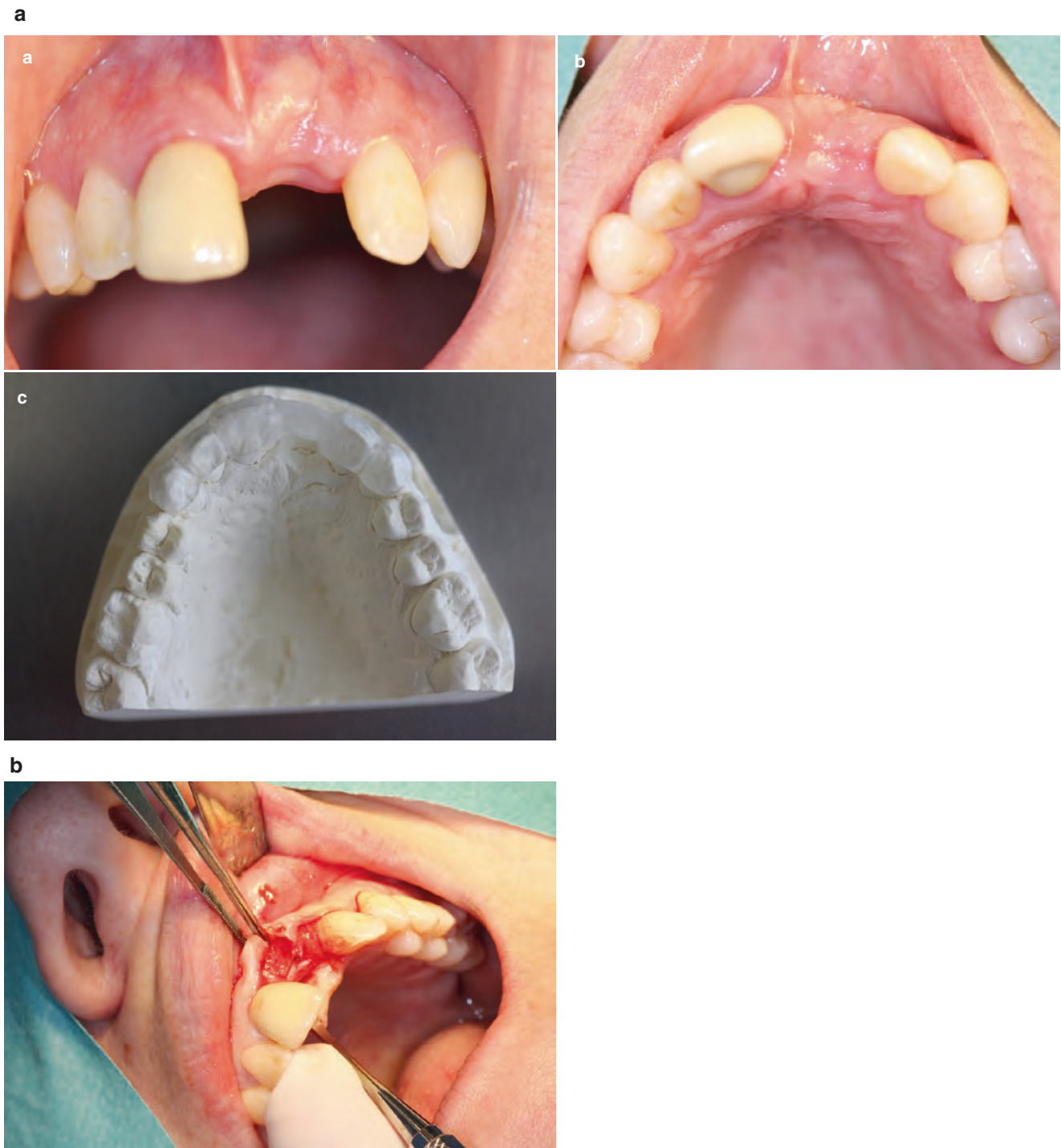

Fig. 18.8 These series of figures show steps in implant placement with restoration of a single tooth edentulous space. **(aa)** Preoperative facial view of edentulous space. **(ab)** Preoperative occlusal view of edentulous space. **(ac)** Preoperative master cast with surgical splint. **(b)** Incision and reflection of mucoperiosteal flap. **(ca)** Initial drilling. **(cb)** Checking for ideal placement of initial drill with surgical guide, which would lead to *prosthodontically* driven implant placement and a favor-

able emergence profile. **(cc)** Checking for the depth of implant osteotomy using a depth gauge. **(da)** Subsequent drilling to accommodate the chosen dimension of the implant. **(db)** Subsequent drilling to accommodate the chosen dimension of the implant. **(e)** Implant insertion. **(f)** Placement of healing abutment for transmucosal/ non submerged healing. **(g)** Suturing and wound closure

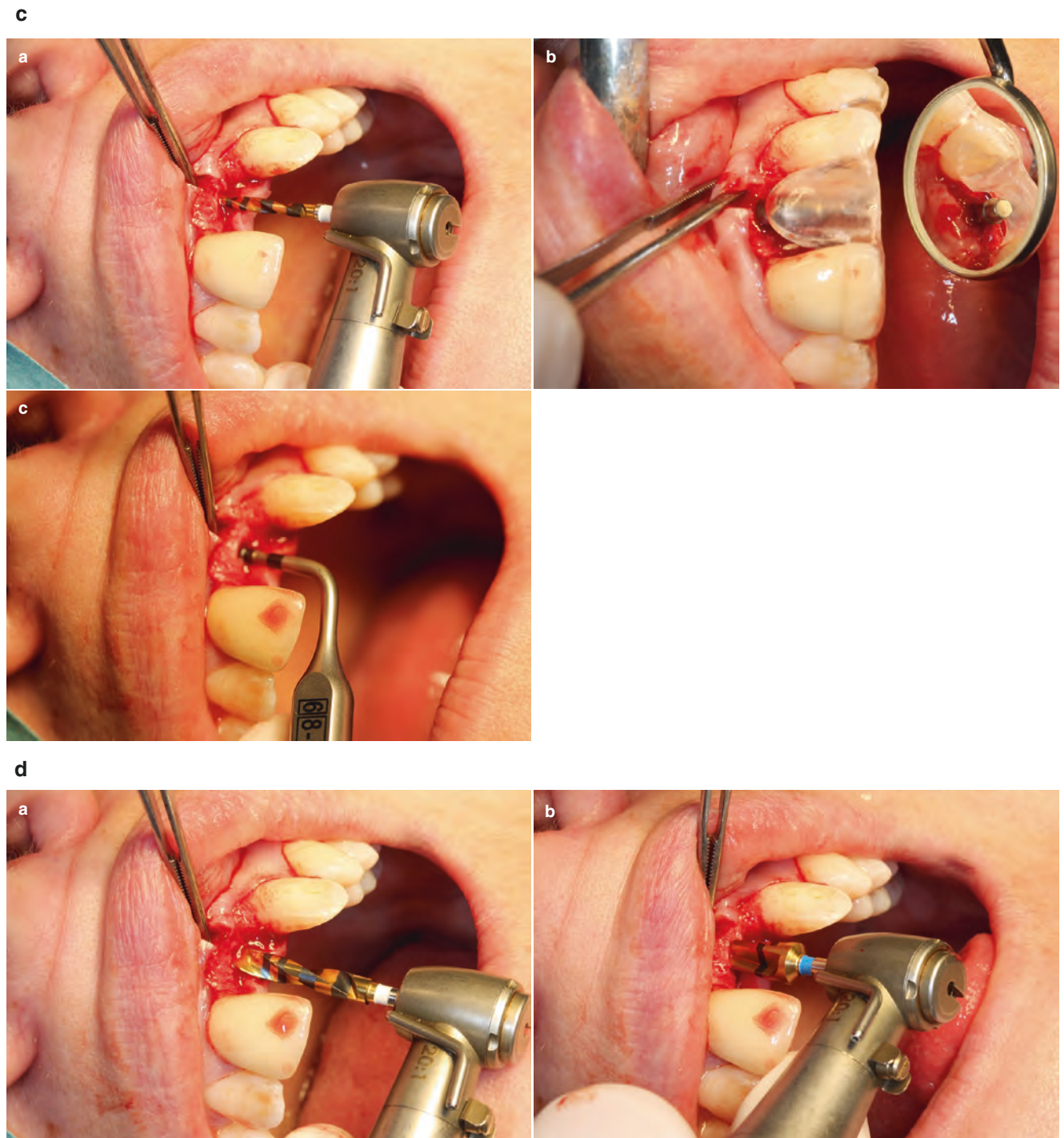
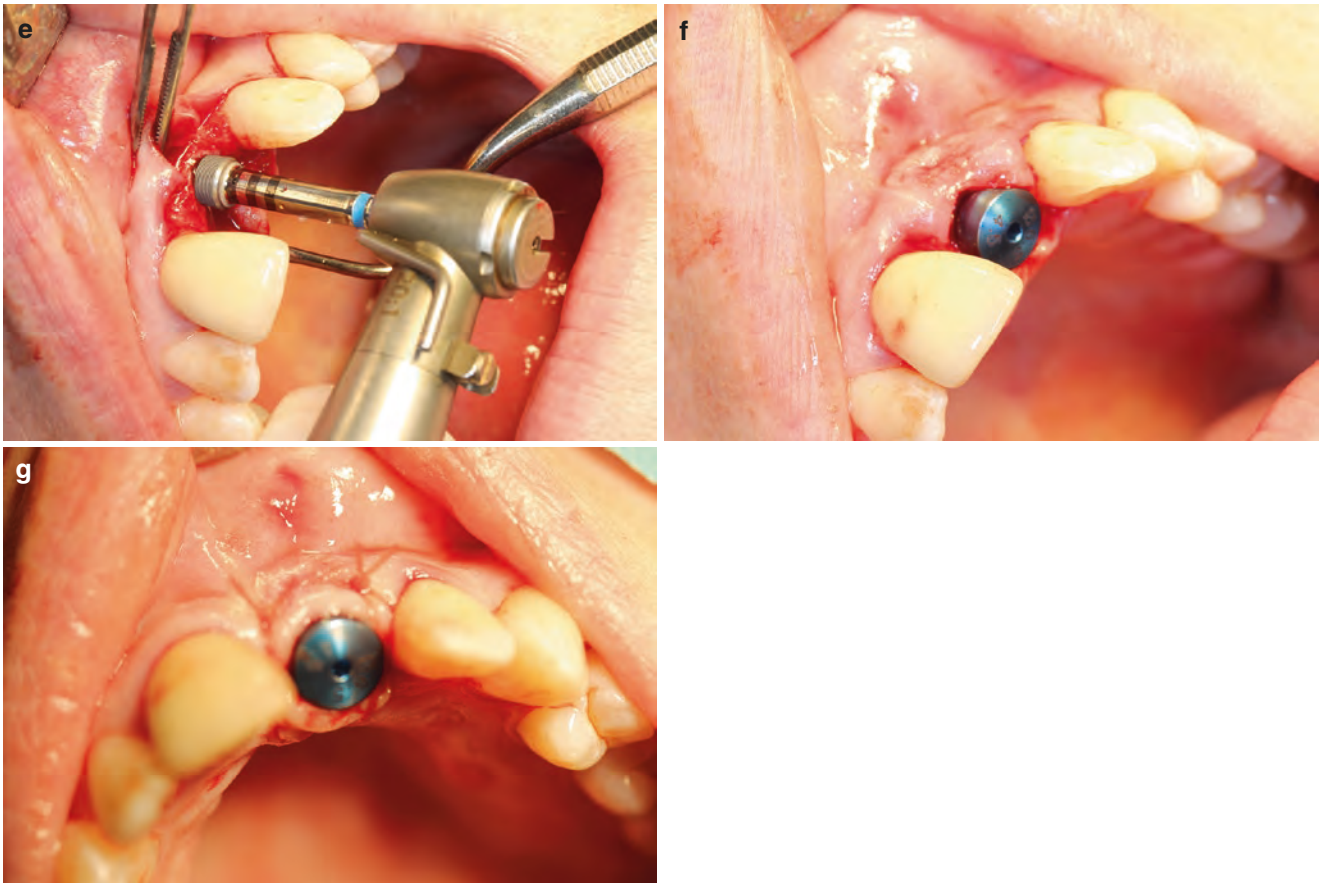

Fig. 18.8 (continued)



©Association of Oral and Maxillofacial Surgeons of India

Fig. 18.8 (continued)

18.11 Suggested Reading

ITI Treatment guides 1–10.

References

1. Abraham CM. A brief historical perspective of dental implants, their surface coatings and treatment. *Open Dent J.* 2014;8(Suppl 1-M2):50–5.
2. Buser D, Sennerby L, De Bruyn H. Modern implant dentistry based on osseointegration: 50 years of progress, current trends and open questions. *Periodontol 2000.* 2017;73(1):7–21.
3. Mavrogenis AF, Dimitriou R, Parvizi J, Babis GC. Biology of implant osseointegration. *J Musculoskelet Neuronal Interact.* 2009;9(2):61–71.
4. Brånemark PI. Introduction to osseointegration. In: Brånemark PI, Zarb G, Albrektsson T, editors. *Tissue integrated prostheses. Osseointegration in clinical dentistry.* Chicago and Tokyo: Quintessence; 1985. p. 350.
5. Stanford CM, Keller JC. The concept of osseointegration and bone matrix expression. *Crit Rev Oral Biol Med.* 1991;2(1):83–101.
6. Reddy VK. Osseointegration. *Int Dent Med J Adv Res.* 2015;1:1–7.
7. Albrektsson T, Albrektsson B. Osseointegration of bone implants. A review of an alternative mode of fixation. *Acta Orthop Scand.* 1987;58(5):567–77.
8. Osman RB, Swain MV. A critical review of dental implant materials with an emphasis on titanium versus Zirconia. *Materials (1996–1944).* 2015;8(3):932–58.
9. Vootla NR, Reddy KV. Osseointegration- key factors affecting its success-an overview. *IOSR J Dent Med Sci (IOSR-JDMS).* 2017;16(4):62–8. e-issn: 2279-0853, p-issn: 2279-0861
10. Ellingsen JE, Johansson CB, Wennerberg A, Holmen A. Improved retention and bone-to-implant contact with fluoride-modified titanium implants. *Int J Oral Maxillofac Implants.* 2004;19:659–66.
11. Novaes AB Jr, de Souza SL, de Barros RR, Pereira KK, Iezzi G, Piattelli A. Influence of implant surfaces on osseointegration. *Braz Dent J.* 2010;21(6):471–81.
12. Moraschini V, E dS P B. Success of dental implants in smokers and non-smokers: a systematic review and meta-analysis. *Int J Oral Maxillofac Surg.* 2016;45(2):205–15.
13. Chappuis V, Araujo MG, Buser D. Clinical relevance of dimensional bone and soft tissue alterations post-extraction in esthetic sites. *Periodontology 2000.* 2017;73:73–83.
14. Eriksson AR, Albrektsson T. Temperature threshold levels for heat-induced bone tissue injury: a vital-microscopic study in the rabbit. *J Prosthet Dent.* 1983 Jul;50(1):101–7.

15. Parithimarkalaignan S, Padmanabhan TV. Osseointegration: An update. *J Indian Prosthodont Soc.* 2013;13(1):2–6.
16. Fiorellini J, Wada K, Stathopoulou P, Klokkevold PR. Chapter 71: periimplant anatomy, biology, and function in carranza's clinical periodontology. 12th ed. Amsterdam: Saunders, Elsevier Inc; 2015.
17. Stanford CM. Surface modifications of dental implants. *Aus Dent J.* 2008;53(1 Suppl):s26–33.
18. Le Guehennec L, Soueidan A, Layrolle P, Amouriq Y. Surface treatments of titanium dental implants for rapid osseointegration. *Dent Mater.* 2007;23:844–54.
19. Albrektsson T, Wennerberg A. Oral implant surfaces: part 1--review focusing on topographic and chemical properties of different surfaces and in vivo responses to them. *Int J Prosthodont.* 2004 Sep–Oct;17(5):536–43.
20. Buser D, Schenk RK, Steinemann S, Fiorellini JP, Fox CH, Stich H. Influence of surface characteristics on bone integration of titanium implants. A histomorphometric study in miniature. *J Biomed Mater Res.* 1991;25:889–902.
21. Wennerberg A. The role of surface roughness for implant incorporation in Bone. *Cells Mater.* 1999;9(1):1–19.
22. Lang NP, Salvi GE, Huynh-Ba G, Ivanovski S, Donos N, Bosshardt DD. Early osseointegration to hydrophilic and hydrophobic implant surfaces in humans. *Clin Oral Implants Res.* 2011 Apr;22(4):349–56.
23. Buser D, Broggini N, Wieland M, Schenk RK, Denzer AJ, Cochran DL, Hoffmann B, Lussi A, Steinemann SG. Enhanced bone apposition to a chemically modified SLA titanium surface. *J Dent Res.* 2004;83(7):529–33.
24. Al-Johany SS, Al Amri MD, Alsaeed S, Alalola B. Dental implant length and diameter: a proposed classification scheme. *J Prosthodont.* 2017 Apr;26(3):252–60.
25. Buser D, Martin W, Belser UC. Optimizing esthetics for implant restorations in the anterior maxilla: anatomic and surgical considerations. *Int J Oral Maxillofac Implants.* 2004;19(suppl):43–61.
26. Grunder U, Gracis S, Capelli M. Influence of the 3-D bone-to-implant relationship on esthetics. *Int J Periodon Restor Dent.* 2005;25:113–9.
27. Klokkevold PR, Cochran DL. Clinical evaluation of the implant patient. Chapter 72, carranzas clinical periodontology. 12th ed. Amsterdam: Elsevier. p. 693–705.
28. Dawson A, Chen S, Buser D, Cordaro L, Martin W, Belser U. In: Dawson A, Chen S, editors. *The SAC classification in implant dentistry.* Chicago, IL: Quintessence Publishing; 2009.
29. Cardaropoli G, Araujo M, Lindhe J. Dynamics of bone tissue formation in tooth extraction sites. An experimental study in dogs. *J Clin Periodontol.* 2003;30:809–18.
30. Araujo MG, Lindhe J. Dimensional ridge alterations following tooth extraction: an experimental study in the dog. *J Clin Periodontol.* 2005;32:212–8.
31. Schropp L, Wenzel A, Kostopoulos L, Karring T. Bone healing and soft tissue contour changes following single-tooth extraction: a clinical and radiographic 12-month prospective study. *Int J Periodontics Restorative Dent.* 2003;23:313–23.
32. Ten Heggeler JM, Slot DE, Van der Weijden GA. Effect of socket preservation therapies following tooth extraction in non-molar regions in humans: a systematic review. *Clin Oral Implants Res.* 2011;22:779–88.
33. Trombelli L, Farina R, Marzola A, Bozzi L, Liljenberg B, Lindhe J. Modeling and remodeling of human extraction sockets. *J Clin Periodontol.* 2008 Jul;35(7):630–9.
34. Chappuis V, Engel O, Reyes M, Shahim K, Nolte LP, Buser D. Ridge alterations post-extraction in the esthetic zone: a 3D analysis with CBCT. *J Dent Res.* 2013;92:195S–201S.
35. Chen ST, Buser D. Clinical and esthetic outcomes of implants placed in postextraction sites. *Int J Oral Maxillofac Implants.* 2009;24(Suppl):186–217. Review
36. Chappuis V, Engel O, Shahim K, Reyes M, Katsaros C, Buser D. Soft tissue alterations in esthetic postextraction sites: a 3-dimensional analysis. *J Dent Res.* 2015 Sep;94(9 Suppl):187S–93S.
37. Morton D, Chen ST, Martin WC, Levine RA, Buser D. Consensus statements and recommended clinical procedures regarding optimizing esthetic outcomes in implant dentistry. *Int J Oral Maxillofac Implants.* 2014;29(Suppl):216–20.
38. Buser D, Chappuis V, Belser U, Chen S. Implant placement post extraction in esthetic single tooth sites: when immediate, when early, when late? *Periodontology 2000.* 2017;73:84–102.
39. Gallucci GO, Hamilton A, Zhou W, Buser D, Chen S. Implant placement and loading protocols in partially edentulous patients: a systematic review. *Clin Oral Implants Res.* 2018;29(Suppl. 16):106–34.
40. Gallucci GO, Benic GI, Eckert SE, Pappaspyridakos P, Schimmel M, Schrott A, Weber HP. Consensus statements and clinical recommendations for implant loading protocols. *Int J Oral Maxillofac Implants.* 2014;29(Suppl):287–90.
41. Weber HP, Morton D, Gallucci GO, Rocuzzo M, Cordaro L, Grutter L. Consensus statements and recommended clinical procedures regarding loading protocols. *Int J Oral Maxillofac Implants.* 2009;24(Suppl):180–3.

Open Access This chapter is licensed under the terms of the Creative Commons Attribution 4.0 International License (<http://creativecommons.org/licenses/by/4.0/>), which permits use, sharing, adaptation, distribution and reproduction in any medium or format, as long as you give appropriate credit to the original author(s) and the source, provide a link to the Creative Commons license and indicate if changes were made.

The images or other third party material in this chapter are included in the chapter's Creative Commons license, unless indicated otherwise in a credit line to the material. If material is not included in the chapter's Creative Commons license and your intended use is not permitted by statutory regulation or exceeds the permitted use, you will need to obtain permission directly from the copyright holder.





Bone Augmentation Procedures in Implantology

19

Vinay V. Kumar, Supriya Ebenezer, and Andreas Thor

19.1 Introduction

Dental implants have been used successfully to rehabilitate patients with edentulousness. For implant dentistry to be successful, the implants have to be placed in an appropriate three-dimensional manner that supports the prosthesis adequately. This means that implants have to be placed in a prosthodontically driven predetermined position. This requirement often results in a clinical situation where there is a lack of bone volume to completely embed the implant in an ideal position.

Implants that do not have an adequate amount of bone covering them in all aspects (at least 1.5 mm bone buccal and lingual to the implant shoulder or about 2 mm in aesthetic zones) are at high risk for crestal bone loss with concomitant inflammation and infection of the surrounding soft tissues due to exposure and colonisation of the implant surfaces by bacterial biofilms [1]. This in turn results in soft-tissue recession, which leads to further loss of bone and eventually failure of the implant. Hence, bone augmentation is often necessary to ensure adequate bony housing around implants [2].

The most commonly used bone-augmentation surgical procedures are guided bone regeneration (GBR), block bone grafting and maxillary sinus floor elevation (SFE). When deciding to augment, there are multiple sources of bone-augmentation materials ranging from autogenous, allogenic, xenogenic and synthetic materials. A knowledge of these materials is essential prior to undertaking augmentation procedures. Knowledge of bone biology and bone physiology is also important.

Electronic Supplementary Material The online version of this chapter (https://doi.org/10.1007/978-981-15-1346-6_19) contains supplementary material, which is available to authorized users.

V. V. Kumar (✉) · A. Thor
Department of Maxillofacial and Plastic Surgery,
Uppsala University Hospital, Uppsala, Sweden

S. Ebenezer
Department of Oral Surgery and Stomatology, University of Bern,
Bern, Switzerland

It is obvious that a thorough medical history should be obtained before implant treatment and prior to augmentation procedures. Patients should be evaluated regarding their general health status, medical history, history of any medication, allergies, the use of tobacco and compliance to oral hygiene methods. Patients with conditions that affect bone healing would be poor candidates for augmentation procedures. Patients with a history of head and neck radiotherapy, uncontrolled diabetes, transplant patients undergoing prolonged immunotherapy, patients undergoing bisphosphonate therapy or medications that could induce osteonecrosis of the jaws, heavy smokers and patients with neuropsychiatric disorders are high-risk patients to undergo augmentation.

It is also obvious that prior to undertaking augmentation procedures, adequate radiographic assessment of the region should be performed. In most situations, Cone Beam Computed Tomography (CBCT) is the imaging of choice.

The use of tilted or angulated implants, narrow implants, zygomatic implants, short implants or the use of non-implant-supported prosthesis can avoid the need for augmentations, and this should be discussed with the patient prior to undertaking augmentation surgery [3, 4].

19.2 The Alveolar Bone-Resorption Pattern and the Need for Augmentation

The alveolar bone is functionally and macroscopically unique. It is that functional area of the maxilla and mandible that is responsible for the anchorage of teeth. Both the mandible and the maxilla are irregular bones and are of mesenchymal origin. The maxilla consists for the most part of cancellous bone with a thin cortex layer, whereas the mandible has more cortical bone and is denser. As the alveolar process of the maxilla and mandible are basically functional components to support the teeth, after tooth loss, the alveolar bone starts to resorb. However, the pattern of bone resorption in the two bones is different. The maxillary alveolar bone

resorbs from the labial plate inwards and the mandibular alveolar bone from the lingual plate outwards. Therefore, in the cases of long-standing edentulousness, this resorption pattern results in a narrower maxilla and mandible. The bone height is also reduced in a vertical direction in areas of tooth loss, leading to a reduced alveolar bone height in the maxillary posterior area (beneath the sinuses) and a reduced distance from the crest to the mandibular canal in the posterior mandible. The sagittal relation is also affected due to jaw atrophy, leading to an often retrognathic maxilla in relation to the wider mandible. In short, both the width of the bone (also called the volume of bone) and the quality of bone (described by Lekholm & Zarb and Cawood & Howell), [5, 6] must be taken into consideration before implant placement. Additionally, due to ridge resorption, the vertical and sagittal bone relations between the upper and lower jawbones and the toothless space must be taken into consideration before implant placement and bone augmentation, when treatment is planned from a prosthodontic point of view. Figure 19.1 shows the changes in edentulous jaws and the classification of bone quality and bone quantity as described by Lekholm and Zarb, 1985.

Also, in patients with tooth loss secondary to other reasons of bone loss such as trauma, pathologies, etc.; bone should be replaced to reconstruct the lost tissue as well as to support placement of implants in the best prosthetically driven position.

19.3 Bone Biology

Depending on the macroscopic form and mechanical function, bone can be designated as cancellous bone (also called spongiosa or trabecular bone) and cortical bone (also called

compact bone). Cortical bone is the dense outer aspect of bone that is responsible for the mechanical strength. The inner cancellous part of the bone that predominantly consists of bone marrow and provides nutrition to the bone [7].

Microscopically cortical bone consists of concentric circles of osteons (also known as Haversian systems) (Fig. 19.2). Each osteon consists of a central canal of nerves and blood vessels that is surrounded by layers of compact bone. Microscopically, cancellous bone architecture consists of bone organised into a three-dimensional lattice framework called trabeculae. The trabecular spaces are filled with blood vessels and marrow. Bone marrow is a specialised connective tissue that produces erythrocytes, leucocytes, platelets and osteoblasts. Depending on age and location, bone marrow additionally contains fat cells and other connective tissue elements [8].

Under higher magnification, bone can be further designated as woven or lamellar bone. Woven bone is immature bone that forms following injury to mature bone (such as fractures or tooth extraction) or during the foetal growth period. After an injury to mature bone that causes a break in its continuity such as tooth extraction, a haematoma results and following this woven bone is formed rapidly to fill the defect in the bone. This bone is mechanically weak and its collagen fibrils have a random orientation. Woven bone is then replaced by mature and mechanically strong lamellar bone that has collagen fibrils arranged parallelly and regularly into distinct layers.

Bones of the human body are in a constant state of renewal, the process known as bone remodelling. Bone remodelling is essential to regulate mineral balance in the bone and circulatory system, as well as to maintain bone strength. Regular day stress and strain causes microdamage in bone, which is repaired and replaced by new bone by the

Fig. 19.1 Classification of bone for implant placement by Lekholm and Zarb, 1985. Adapted from Lekholm and Zarb, 1985 [6]

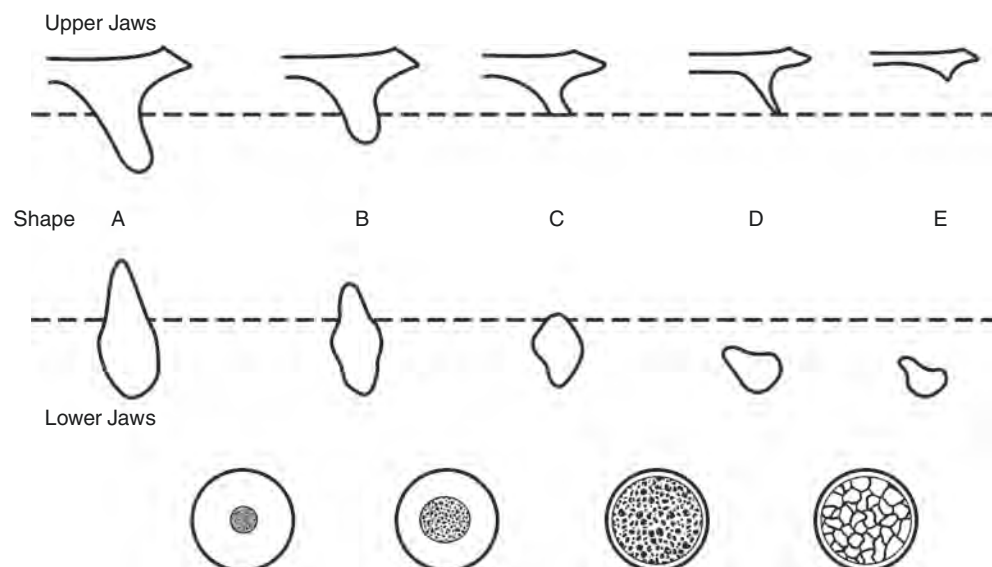
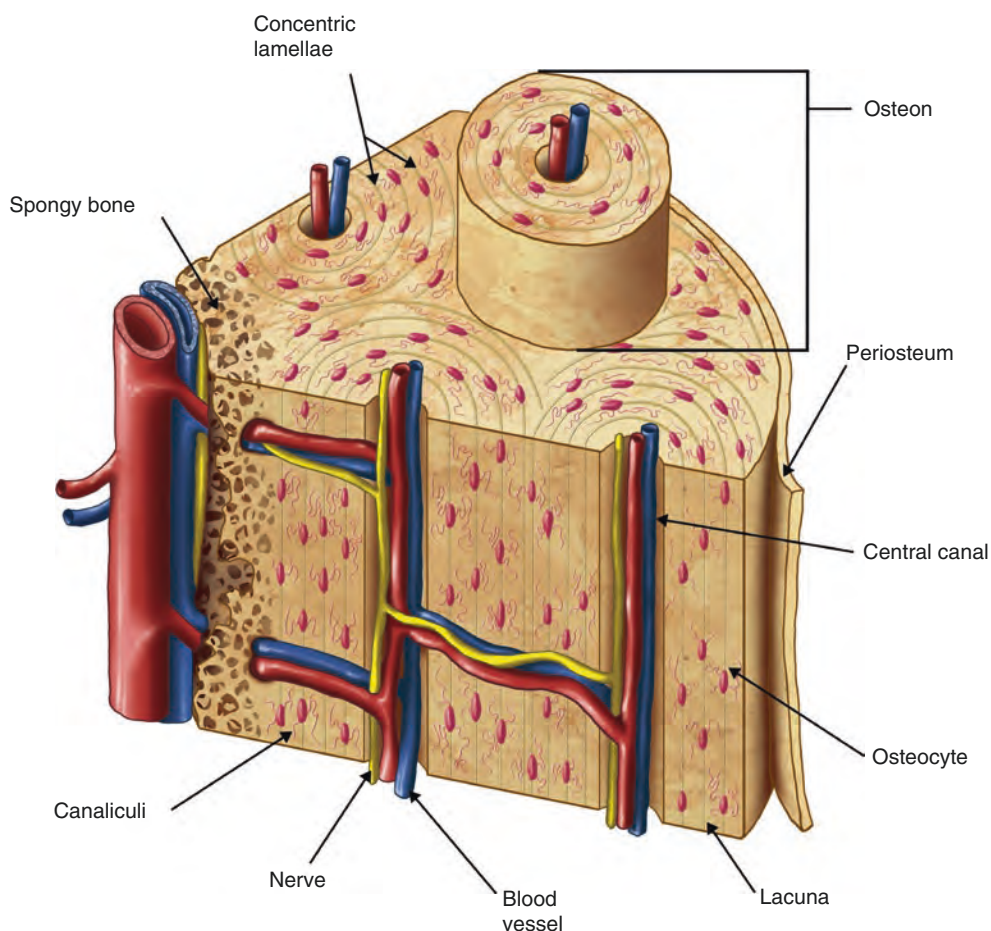


Fig. 19.2 Cross-section of bone showing a cortical bone and spongy/cancellous bone. Please note the osteon containing a central canal with blood vessels and nerves surrounded by concentric lamellae with osteocytes and lacunae



©Association of Oral and Maxillofacial Surgeons of India

process of bone remodelling. Therefore, the process of bone remodelling helps the bone to adapt to changing mechanical and biologic needs during the lifetime of the individual. For the ease of description, bone remodelling can be divided as consisting of four continuous stages:

bone resorption,
reversal phase,
mineralisation phase
and resting phase (Fig. 19.3).

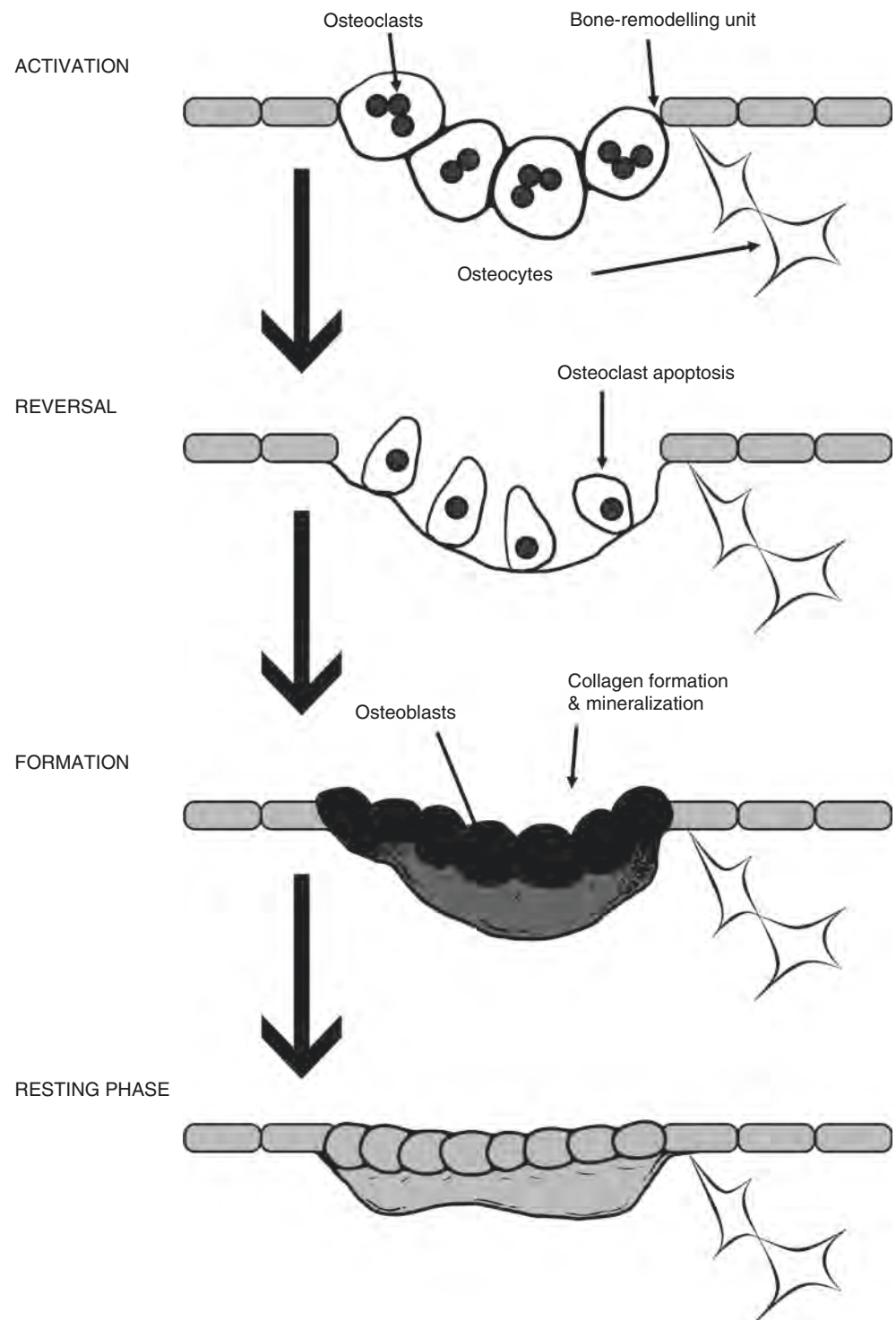
During the resorption phase, specialised cells called osteoclasts are activated, which eat away old bone. In the reversal phase, bone-forming cells known as osteoblasts begin to appear on the surface of the resorbed bone. In the bone-formation phase, the osteoblasts lay down osteoid, which is the unmineralised organic portion of bone and bone mineralisation occurs when calcium hydroxyapatite and other minerals are incorporated into the organic unmineralised osteoid, thereby providing mechanical strength. Bone remodelling occurs all throughout life and consists of a closely coupled phenomenon of bone apposition and resorp-

tion. Under normal healthy conditions in adults, bone resorption and apposition during remodelling are balanced in time, space and amount so that the bone mass of the body remains more or less constant.

19.3.1 Composition of Bone

Bone is a connective tissue that consists of bone cells (approximately 10%) in a connective tissue matrix (approximately 90%). Cells of the bone are the osteoblasts, the osteocytes and osteoclasts. The osteoblasts are large uninucleate cells that form bone. They work in groups and predominantly lay down the collagen matrix known as osteoid. Osteoblasts also produce proteins such as bone morphogenetic proteins that stimulate bone healing and mineralisation. About 10% of the osteoblasts become entrapped inside the calcified bone matrix and are known as Osteocytes. Osteocytes reside in small bone cavities known as lacunae and are interconnected with each other and with osteoblasts and lining cells on the bone surface. Osteoclasts, on the other hand, are multinucleated cells that line the surface of the bone where resorption takes place.

Fig. 19.3 describes the four phases of bone remodelling



©Association of Oral and Maxillofacial Surgeons of India

These cells release powerful degrading enzymatic proteins that are responsible for the removal of bone minerals.

The extracellular bone matrix consists of about 35% organic and 65% inorganic materials. About 90% of the organic phase is collagen type I fibres, while the remaining

10% consists of various non-collagenous proteins. The bone matrix also contains growth factors such as the bone morphogenetic proteins important for bone healing. The inorganic phase of the bone matrix consists of low-crystallinity carbonated hydroxyapatite [9].

19.4 Bone Grafts and Bone Substitutes

Currently, there are a wide variety of biomaterials that can be used for bony augmentation [10].

Table 19.1 describes the classification of bone grafts [11] (Adapted from Katsuyama H., Jensen S.S. Treatment Options for Sinus Floor Elevation).

Most commonly, bone grafts and bone substitutes are classified according to their source of origin in relation to the intended recipient. Autogenous or autologous bone grafts are obtained from the same individual. Allogeneic bone grafts or allografts are obtained from a genetically distinct individual of the same species. In contrast, xenogeneic bone grafts or xenografts are obtained from a different species than the intended recipient. Alloplastic bone substitutes are synthetically produced materials.

Autogenous bone graft or autograft refers to bone originating from the same patient, and it can be harvested from intra-oral or extra-oral sites. It is preferred to harvest the bone as close to the surgical defect as possible in order to avoid donor-site morbidities. However, of course this decision is dependent on the amount of bone required. For smaller augmentations and guided bone regeneration, bone is commonly harvested from the bone tissue neighbouring the defect site. In this case, donor-site access can be gained from the same incision that is used to access the recipient site. In cases where slightly larger amounts are needed, bone can be harvested from the anterior mandibular ramus or the mandibular symphysis. These are the most common intra-oral bone donor sites. Although one may need an additional

incision to harvest bone in intra-oral sites, these can be obtained in the same surgical area. When even larger amounts of bone are needed, harvesting from extra-oral sites is needed. The most commonly used donor sites are the iliac bone, the calvarium and the tibia. In most of these cases with the need of an extraoral donor-site harvest, the surgical time as well as hospital stay is often prolonged. A more detailed explanation of different donor sites is provided in the section on onlay bone grafting. In the case of very large bony reconstructions where the defect size is more than 6 centimetres, vascularised bone containing free flaps are used, such as the free fibula flap [12, 13]. These procedures are commonly carried out for benign and malignant tumours, and are not described in this chapter, but described in detail in the relevant chapter of this textbook.

Allogeneic bone graft or allograft refers to bone originating from another human, either a living donor or following the death of an organ donor. Usually, the allogeneic bone is harvested from the iliac bone or tibia and can be fresh-frozen, freeze-dried or processed as demineralised freeze-dried bone.

Xenogeneic bone substitute or xenograft is bone-substitute material originating from another species. These could be sea algae, corals, equine (originating from horses), porcine (originating from pigs) or most commonly, bovine (originating from cows).

Bone-substitute materials can also be manufactured purely by synthetic means, produced in the laboratory. These are called *alloplastic graft materials* examples of these are hydroxyapatite, beta-tricalcium phosphate, calcium silico-phosphate, bioglasses, polymers, titanium particles or a combination of these.

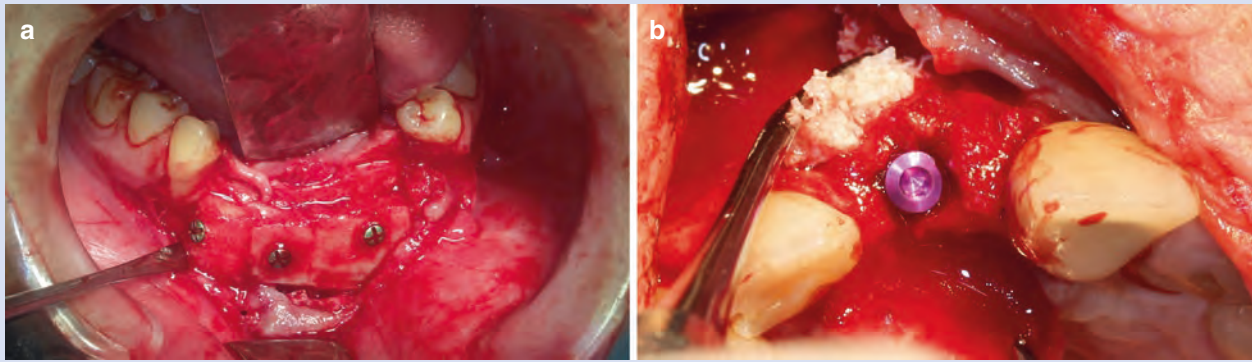
Table 19.1 Classification of bone-grafting materials

Autogenous bone Origin: the same person	Allogenic bone Origin: another human	Xenogenic bone Origin: another species	Alloplastic bone Origin: synthetic
Block graft	Fresh frozen bone	Bone from another animal such as bovine, porcine	Calcium phosphates
Particulate bone	Freeze-dried bone allograft	Materials from corals	Glass ceramics
	Demineralised freeze-dried bone allograft	Materials derived from calcifying algae	Polymers
	Deproteinised bone allograft		Metals

Adapted from Katsuyama H and Jensen S.S: 2011 [11]

Box 19.1

Block bone grafts/Particulate bone grafts: Depending upon the shape and constitution of the bone graft, they can be described as block bone grafts or particulate bone grafts or a combination of these. Bone blocks are large pieces of autogenous bone. Autogenous bone that has been harvested by bone scrapers and chisels is in the form of small chips and is referred to as a particulate graft. Particulate grafts can also be made from block grafts by using special milling machines to break down the block (Fig. 19.4a, b).



©Association of Oral and Maxillofacial Surgeons of India

Fig. 19.4 (a) an example of block bone graft (b) an example of a particulate bone graft

19.4.1 Classification of Bone Grafts Based on the Mechanism of Action

Bone grafts can also be described and classified based on the mechanism of action and biological activity into *osteogenic*, *osteoinductive* and *osteoconductive*.

Box 19.2

Osteogenic grafts provide a source of new bone formation by the osteoblasts that are present in the graft material. At present, this can only be seen in the cases of autogenous bone grafts, where the donor bone is from the same subject and the transplantation procedure has preserved the viability and vitality of osteoblasts in them. Developments using stem cell harvesting may enable development of osteogenic bone grafts without the use of the subject's own bone tissue.

Osteoinduction is defined as the mechanism whereby a bone-substitute material induces bone formation by stimulating undifferentiated mesenchymal cells to turn into osteoblasts, which in turn produce new bone. Many proteins such as bone morphogenetic proteins are being investigated for their osteoinductive properties.

Osteoconduction is the mechanism whereby bone formation is enhanced by providing a scaffold for osteogenic cells that are present in the local environment of the host. Osteoconductive materials form a passive support for cells to migrate and colonise the scaffold and then produce new bone.

In spite of the large number of products available in the market, the gold standard in bone augmentation is autogenous bone. Depending on the indication for grafting and the amount of graft needed, autogenous bone can be used in a particulate form that is used either stand alone, or mixed with a bone-substitute material, used encased in titanium meshes or membranes, as a block graft, or as combination of any of these. Vascularised autogenous bone grafts such as the free fibula flap, the iliac crest and scapula free flap can be used not only as bone flaps but also as composite tissue to reconstruct complete jaws.

Bone augmentation and healing of the graft occurs in the following stages [14]: The surgical intervention gives rise to a haematoma and an acute inflammatory reaction, which is similar to the most cases of tissue trauma. This inflammatory reaction invokes a migration of inflammatory cells into the region, along with osteoblasts and osteoblast precursor cells. In a day's time, proliferation of blood vessels and the beginning of granulation tissue formation occur. This phase is followed by the resorption of the graft by osteoclast precursor cells, and in the case of autogenous bone, this releases bone morphogenetic proteins from the bone matrix, marking the start of the osteoinductive activity. At the same time, osteoblasts from the host bone start to migrate into the grafted region and begin to produce new bone, marking the phenomenon of osteoconduction. The graft is over time incorporated into the regional host bone by undergoing varying degrees of resorption and remodelling.

Although the procedure is largely similar regardless of the origin of the bone graft, the properties of osteoinduction and osteoconduction as well as biocompatibility can vary depending upon the particular bone-substitute material in

use. Most bone-substitute materials are osteoconductive and vary in the resorption and bone turn-over rates. As a result, certain materials are shown to completely resorb within a period of a few months, whereas certain bone-substitute materials are present after many years.

Autogenous bone is the only type of graft that contributes to bone regeneration via all three mechanisms. A limited number of osteoblasts survive the procedure of grafting and these cells contribute towards osteogenesis; the graft itself provides a scaffold for osteoblasts from the host site to migrate into, facilitating osteoconduction; finally, the growth factors included within the graft matrix and released during graft resorption facilitate osteoinduction. Autogenous bone also has a high rate of resorption.

Allogeneic bone grafts are classified as mineralised and demineralised. Mineralised allografts—such as fresh frozen bone allograft and freeze-dried bone allograft—contribute to bone regeneration primarily through osteoconduction, but they may also possess some potential for osteoinduction. On the other hand, demineralised freeze-dried bone allograft is said to contribute to bone regeneration primarily through osteoinduction, and only secondarily by osteoconduction. However, it should be noted that variations in the processing of allogeneic bone grafts from different tissue banks using different methodologies result in a large variation in the composition as well as osteoconductive potential of demineralised freeze-dried bone.

The choice of a commercially available bone-substitute material is most commonly based on the preference of the recipient patient (some patients would not like bone substitutes from an animal source or a cadaveric source), the available product information and documentation of clinical success, product availability, the ease of use and the preference of the clinician.

19.5 Barrier Membranes

Barrier membranes are an important component for the success of the GBR procedure. Ideally, the barrier membranes must be non-toxic, biocompatible, cell occlusive with a certain degree of permeability for diffusion of nutrients, permit bonding and ingrowth of connective tissue during healing, should be of sufficient rigidity to maintain the space created and not collapse into the defect, it should be easy to handle clinically and should be able to be trimmed to tailor the material as per the size of the defect [15].

Although traditionally many materials such as PTFE had been developed as membranes, currently most membranes being used are made up of collagen (type I, type III or a com-

ination of these) [16]. These collagen membranes are derived from porcine or bovine sources [17]. Collagen membranes resorb as a result of enzymatic action of macrophages and polymorphonuclear leukocytes. Some manufacturers cross-link collagen membranes with glutaraldehyde to reduce the rate of membrane resorption, thereby prolonging the barrier function. However, crosslinking with glutaraldehyde can result in cytotoxic residues in the membrane following its manufacture. Resorbable membranes have a less likelihood to cause early membrane exposure, and that additionally due to the property of being resorbable, they do not need to be removed at a second surgical procedure.

Clinically, the main advantage of resorbable membranes is their decreased susceptibility to infective complication. If premature membrane exposure occurs, secondary soft tissue healing takes place within 4 weeks, and the bone-regenerative outcome remains favourable. Collagen membranes are also easier to handle clinically and adapt well to the surgical site once they are wet with blood or saline. Significantly, the membranes do not need to be removed via a second surgical procedure because they biodegrade. The main disadvantage is that non-cross-linked collagen membranes collapse easily because they do not have space-maintaining properties.

When a membrane with insufficient stiffness and rigidity is used in larger defects, there is a high likelihood of membrane collapse. Collapse of the membrane would lead to a situation where there would be no space for guided bone regeneration. Hence, clinically this problem is solved by using a bone graft or a bone-substitute material that fills the bone defect and provides support to the membrane. Other methods to support the barrier membranes include the incorporation of bendable titanium frameworks into PTFE material, tenting screws to support the membrane and titanium mesh that can be shaped and adapted to the site. However, these procedures would require an additional surgical procedure to remove the hardware [18].

19.5.1 Success Parameters of Autogenous Bone Graft Healing

The success of bone augmentation is dependent on the ability of the augmented bone to support an implant fixture at the desired position. However, in biological terms the extent of graft incorporation, turnover, replacement, the volume stability and the time taken for healing are dependent on many factors such as surgical factors, patient-related factors and material-related factors. It has been shown in multiple systematic reviews and innumerable clinical studies that there is no one single superior bone-substitute material [14]. Bone

augmentation, although having well-documented success rates, depends upon surgical as well as patient-related factors. Amongst the surgeon-related factors are the training of the surgeon, their surgical expertise, the adherence to protocol and treatment of the graft material as well as the recipient site, adequate fixation of the graft to prevent movement between the graft and recipient bone and so on.

Patient-related factors that contribute to healing include underlying systemic diseases such as immunodeficiency, diabetes; local factors and habits such as oral hygiene and oral health, smoking and use of tobacco and defect-related factors such as the size of the defect and the morphology of the defect. It should be noted that smaller augmentations in a three-walled defect are more successful than large only vertical bone augmentation.

Regarding the influence of the grafted material used, it has been shown that particulated autogenous bone has the advantage of relatively fast incorporation in comparison with autogenous bone blocks [19]. However, particulate bone lacks structural stability and is prone to undergo unpredictable and extensive resorption. In contrast, autogenous bone blocks provide structural stability leading to better dimensional stability. However, block grafting requires a longer healing period of at least 6 months with about 50% (half the initial augmented volume) resorption at the end of the healing period.

Regarding the influence of bone-substitute materials, there exists a large variation in the physicochemical characteristics of the various bone substitutes available in the market, including their composition, particle size and form and surface properties. These differences can result in varying outcomes following augmentation.

Differences in the amount of new bone formation can be due to true differences in the osteoconductive potential of the biomaterial, but may also partly be explained by differences in resorption capacity amongst the various bone substitutes, which in turn determine the space available for new bone tissue formation within the defect site. For example, beta-tricalcium phosphate is replaced rather quickly, while sintered bovine bone is resistant to resorption and will be present in the augmented site for decades.

19.6 Commonly Carried Out Augmentation Procedures

Currently implantology has developed rapidly. Newer techniques and materials are constantly being introduced. The choice of procedure depends mainly upon the surgeon. Based upon the amount of bone augmentation required, the commonly carried out procedures are:

GBR (guided bone regeneration)

Onlay bone grafting

Sinus floor elevation

These procedures are described in detail below.

19.7 Guided Bone Regeneration

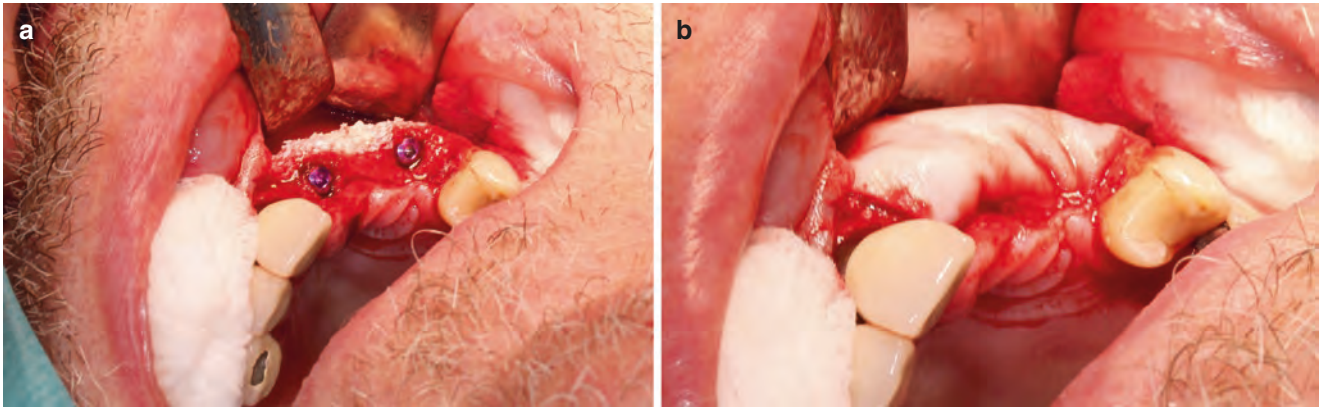
Guided bone regeneration is a bone-augmentation technique that uses the principle of space maintenance within a bony defect with the use of a barrier membrane. The barrier membrane excludes rapidly proliferating epithelial cells and connective tissue fibroblasts, thus allowing the ingrowth of slower-growing bone cells and blood vessels into the blood clot within the defect.

The concept of guided bone regeneration was introduced and developed first by Nyman and colleagues; Dahlin and colleagues in the early 1980s [20, 21]. Multiple animal studies showed that bone defects protected by a barrier membrane, which did not permit ingress of cells, had increased bone fill as compared to defects that were not protected by a barrier membrane. Although the technique was first described for periodontal defects around natural teeth, later studies showed that GBR was also predictable in forming bone around implant defects.

Clinically, GBR is performed by raising a mucoperiosteal flap and exposing the bony defect. This defect is filled with a bone substitute and then covered with a barrier membrane. The bone defect with the bone substitute is filled with blood, which later clots and forms a haematoma. Over a period of time, the haematoma is ingressed by blood vessels and osteoprogenitor cells from the surrounding environment, which over a period of time forms bone tissue by resorbing the existing substitute and replacing it or growing into the substitute that acts as a scaffold. The barrier membrane prevents the ingress of fast proliferating fibroblasts and epithelial cells into the bone defect, thereby creating a space for bone to form and mature.

However, GBR does not produce similar successful outcomes in all morphology of defects [22]. The more the bone walls the defect contains, the better the bone fill following GBR. Bone walls provide an exposed surface of bone-recruiting cells. With more bone walls, an increased number of osteogenic cells are able to migrate along newly proliferating blood vessels into the haematoma in the defect. When two or three walls are present, the blood clot is less likely to be moved and better protected during the healing phase.

Guided bone regeneration can be applied for the correction of minor requirements of bone augmentation. They are documented to be successful in the following clinical situations:



©Association of Oral and Maxillofacial Surgeons of India

Fig. 19.5 (a, b) Shows a clinical case of GBR for a 2 walled defect

1. Used to augment 2- or 3-walled crestal bone defects when implants are placed into extraction sites.
2. Used for augmenting bone when there is an apical fenestration following implant placement.
3. GBR can be used for ridge preservation.
4. GBR can be performed as a combination to other larger augmentation procedures.
5. GBR can be used for contour augmentation to increase the thickness of the facial bone for aesthetic reasons.

19.7.1 Augmentation of 2 and 3 Walled Defects

Guided bone regeneration can be successfully used in cases with crestal bone defects that are seen while placement of implants into extraction sites. If an implant can be placed with sufficient primary stability and results in a 2 or 3 walled defect, or if the defect is well contained in the bony envelope, GBR can be successfully performed at the time of implant placement. If these factors are not present, the augmentation must be performed prior to implant placement as a staged approach. In these cases, depending on the size and morphology of the defect, augmentation can be performed either by GBR, or by other augmentation methods described later in the chapter.

Figure 19.5a, b shows a case of GBR augmentation of 2 walled defect.

19.7.2 For Augmenting Apical Fenestrations

Often when implants are placed in the correct prosthetic position, with the correct angulation in order to provide screw retained restorations, the ideal angulation of placement would result in an apical fenestration, with the apical

part of the implant threads being exposed. In these situations, the fenestration defects can be covered by using particulate bone/substitute material, covered with a membrane, as per the principles of GBR.

19.7.3 GBR for Ridge Preservation

During preoperative assessment and after extraction of a hopeless tooth that is planned to be restored with an implant, it is essential to inspect the shape of the resulting socket. In many situations, either due to trauma or chronic infection, the facial bone wall is missing. In these cases, it is important to augment the ridge/preserve the ridge at the time of tooth extraction. GBR can be well employed for this procedure known as ridge preservation/alveolar ridge preservation. In cases of acute infection in the sockets, ridge preservation can be carried out at a later stage after the infection has subsided.

19.7.4 GBR in Combination with Other Larger Augmentation Procedures

In the cases of localised prolonged ridge atrophy, GBR can be combined with other methods of augmentation such as with block grafts or ridge split techniques. In the cases of prolonged ridge atrophy affecting a complete segment of the jaws, the bone defects would often contain a single wall or two walls with a requirement for larger volumes of grafting. GBR alone will not provide a sufficient amount of bone augmentation. In these situations, it is advisable to augment using block grafting, and in addition use particulate bone graft around the blocks and protect the augmented particulate material with a membrane. Implant placement can then be carried out after a period of around 6 months.

19.7.5 GBR for Contour Augmentation

One successful method of placing implants is following 4–8 weeks of healing. In this situation, in contrast to immediate implant placement, soft tissue healing would have taken place, thereby permitting the clinician with better quality of soft tissues while placing implants. However, in this scenario, especially in the aesthetic zone, the resorption of the facial bone would produce crater-like bone defects. GBR can be done in these situations, to over correct the lost facial bone as well as provide bulk to the region of implant placement. This procedure is also called ‘contour augmentation’ [23]. By doing this procedure, the buccal bone wall is intentionally overbulked so as to provide long-term stable aesthetic results as shown by multiple studies [24].

19.8 Onlay Bone Grafting

Onlay bone grafting is a predictable procedure carried out for the correction of cases with severe ridge resorption, either horizontally or vertically [25]. Autogenous bone grafts are the most documented and commonly used donor bone, although recently other allogenic and xenogenic materials are being clinically investigated. For augmentation of severe ridge defects (less than 2 walls and require more than 3 mm of augmentation), augmentation utilising autogenous bone blocks results in increased success rates as compared to guided bone regeneration alone. However, irrespective of the augmentation technique, vertical-ridge augmentation is less predictable as compared to horizontal-ridge augmentation [26].

Donor sites for autogenous onlay bone augmentation may be intra-oral or extra-oral. Most common intra-oral donor sites are the mandibular symphysis and the ramus of the mandible. Most common extra-oral donor sites for harvesting non-vascularised bone grafts are the iliac crest, the calvarium and the tibial bone. Most common vascularised bone containing free flap donor sites are the free fibula flap, the DCIA-free flap and scapula-free flap.

Once the bone graft is harvested, they should be trimmed and shaped to fit into the recipient site defect, stabilisation with osteosynthesis screws followed by adequate soft tissue mobilisation and tension-free primary closure of the grafted site. It is advisable to over-augment the defect in order to compensate for the eventual resorption. A mixture of particulate bone, slow-resorbing xenografts either alone or in combination is used to fill up the area between a corticocancellous block and the recipient site. The augmented material may be protected with a barrier membrane prior to being enveloped by the soft-tissue closure.

19.8.1 Harvesting Bone from the Donor Site

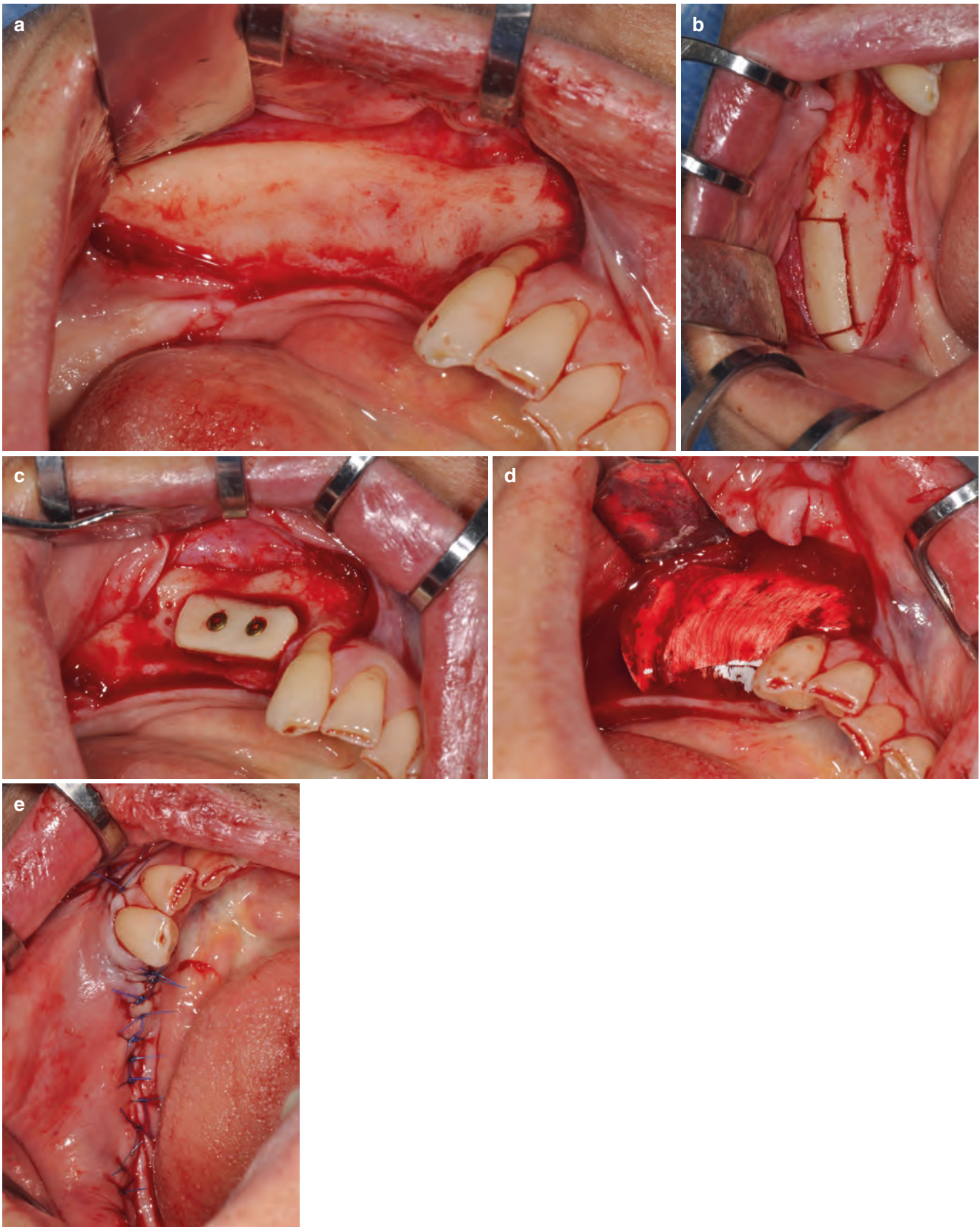
19.8.1.1 Mandibular Ramus as the Donor Site

The outer cortical plate of the ascending ramus of the mandible is a popular choice for the harvest of intra-oral bone. This is probably because many oral and maxillofacial surgeons are well accustomed to the approach to the ramus during routine mandibular third molar surgeries or routine orthognathic surgeries. (Fig. 19.6a, b, c shows harvest of bone from the mandibular ramus).

The incision starts with a crevicular incision around the last standing molar teeth and continues along the ridge curving buccally upwards along the external oblique ridge. After elevation of the mucoperiosteal flap, and gaining adequate access to the anterior and lateral border of the ascending ramus of the mandible and the angle region, bone harvesting can begin. Usually, a block graft of approximately 30 mm × 15 mm can be harvested. The block thickness depends on the thickness of the lateral cortical bone plate of the ascending ramus and can vary from about 3 to 4 mm. The outline of the graft is usually made with two parallel anterior and posterior osteotomy cuts of about 3 mm in depth, on the lateral surface of the ramus of the mandible till the cortical bone is penetrated completely. Round bur points can also be made outlining the bone graft prior to making parallel cuts. Use of piezosurgery is advantageous in the cases of bone grafting. The two horizontal osteotomies are then joined by the sagittal bone cut superiorly. This cut corresponds to the thickness of the cortical bone. Once the sagittal bone cut is complete, the bone graft can be gently fractured and mobilised by the introduction of an osteotome or a periosteal elevator. Some surgeons prefer to make a cortical cut at the inferior end of the bone block prior to introducing the periosteal elevator to prevent unfavourable fractures of the block graft. After bone harvest, the surgical area is irrigated well and a haemostatic agent is applied if necessary and the wound is closed in layers. Some surgeons prefer to insert a glove drain that will be removed after 3 days.

19.8.1.2 Chin (Anterior Mandible) as the Donor Site

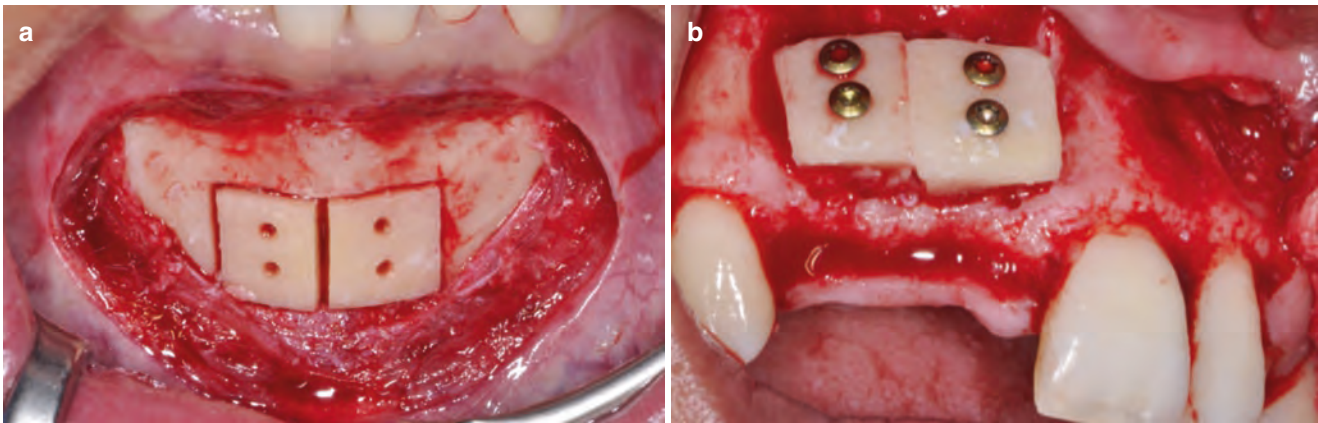
The chin is also a popular donor site, predominantly because of the ease of access to the donor site. However, block grafts from the chin have shown an increased risk towards complications, especially neurosensory and vascularity disturbances to the mandibular incisors. Bone grafts of 50 mm in length and about 8 mm of width can be harvested. The cortical portion of the anterior mandible is thicker (around 3–11 mm) and hence the chin would provide a thicker area of bone and would be a choice for thick bone grafts. It is also popular to harvest bone grafts from the chin using trephine



©Association of Oral and Maxillofacial Surgeons of India

Fig. 19.6 Shows harvest of bone from the mandibular ramus. (Picture courtesy PD Dr.med.dent. Simone Janner, Department of Oral Surgery and Stomatology, University of Bern, Switzerland). (a) Incision for

access to ascending ramus. (b) Outline of the osteotomy. (c) Graft fixed at recipient site. (d) Coverage with membrane following additional particulate augmentation. (e) Closure



©Association of Oral and Maxillofacial Surgeons of India

Fig. 19.7 (a, b) Shows harvest of bone from mandibular symphysis. (Picture courtesy PD Dr.med.dent. Simone Janner, Department of Oral Surgery and Stomatology, University of Bern, Switzerland). (a) Harvest of bone from symphysis. (b) Graft secured at recipient site

burs of varying diameters (7–12 mm), and using upto 4 trephine harvests. (Fig. 19.7a and b shows harvest of bone from mandibular symphysis).

The access to the chin is by a standard vestibular incision from one canine to another with approximately 15 mm away from the mucogingival margin. Once the mucosa is incised, the underlying mentalis muscle is seen, which is incised obliquely to reach the symphysis of the mandible. Full thickness flap is elevated and the donor site inspected. For harvesting larger grafts, it is advisable to expose both the mental foraminae. Once the donor site is exposed as per the requirement, the boundaries of bone harvesting are carefully noted. An intact area of 5 mm must be preserved inferior to the root ends of the anterior teeth and 5 mm above the lower border of the mandible. Bone graft can be outlined within these borders, either using piezo surgical device or round burs or fissure burs or most popularly, trephine burs. After the outline of the bone graft is made, osteotomy of the cortical portion is done and connected. An osteotome or a periosteal elevator is then gently introduced to tease out the graft.

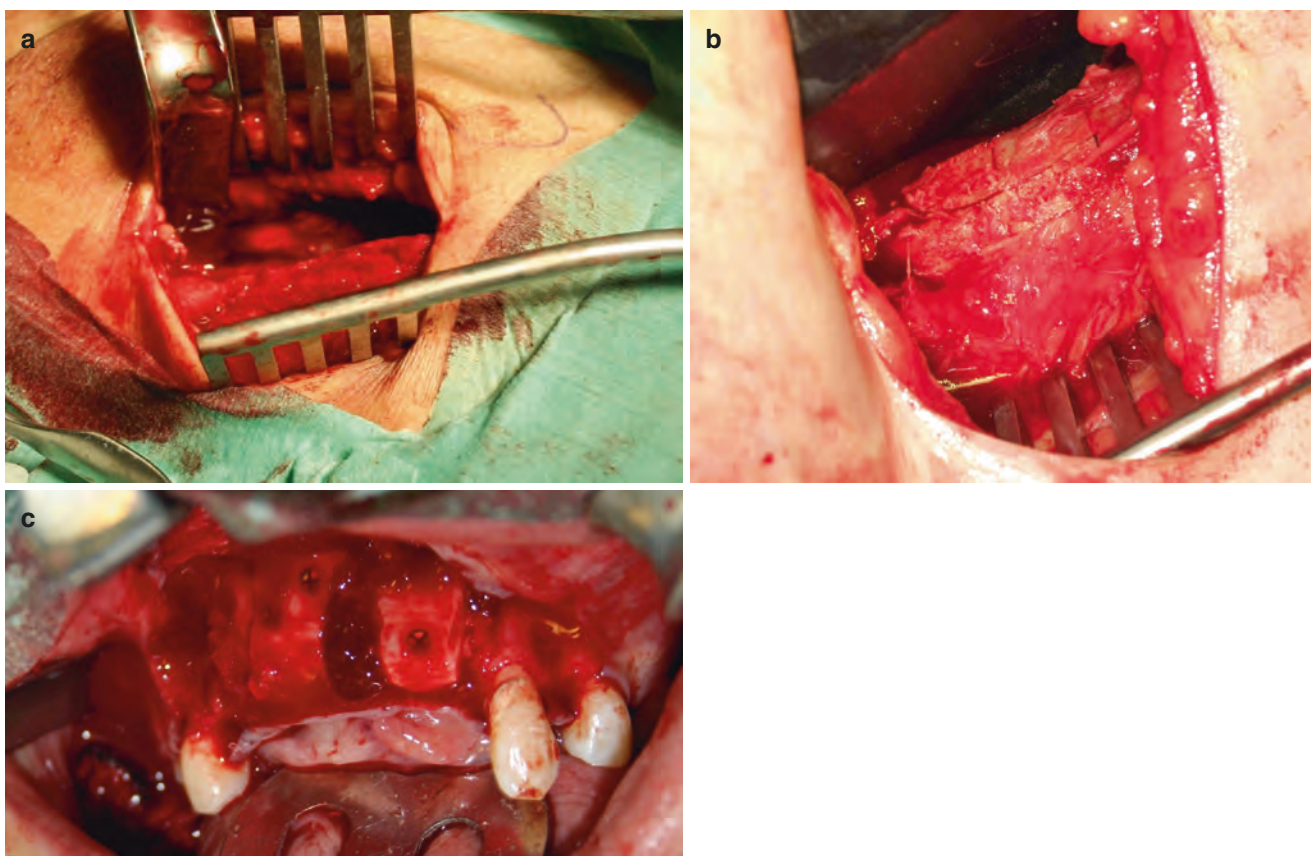
After harvesting of the bone graft, haemostasis is achieved and the wound closed in layers. It is important to close the periosteal layer and approximate the mentalis muscle prior to mucosal closure. A compressive chin dressing is provided to apply pressure to the donor-site region.

19.8.1.3 Iliac Crest as the Donor Site

Iliac bone provides a large quantity of bone and is the preferred donor site for large bone augmentation as it is an excellent source for cortical and cancellous as well as corticocancellous bone. Both the anterior and posterior iliac crest can be used as a donor site. Anterior iliac crest grafts are associated with higher complication rates of

sensory disturbances, gait problems and untoward ilium fracture. Posterior crest grafts are associated with lesser complications but increased post-operative pain. Additionally, posterior crest grafts require the patient to be repositioned and hence many surgeons prefer the anterior iliac crest. (Fig. 19.8a, b, c shows a case of harvest of bone from iliac crest).

The harvest of bone from the anterior iliac crest is generally performed with the patient under general anaesthesia. The patient is positioned supine and the side of the pelvis to be operated on is raised by placing surgical towels or sandbag towels underneath the hip. The skin over the crest is made taut by placing a fist above the iliac crest and only pushing the abdominal wall medially. The skin incision is made generally about 2 cm larger than the intended length of the bone harvest, running parallel to the iliac crest, so that after relaxation of the taut skin, it lies lateral to the iliac crest thereby avoiding mechanical irritation of the scar. After skin is incised, blunt dissection of the subcutaneous tissue is made until the periosteum of the iliac crest is seen. Bleeding should be controlled during dissection. The periosteum of the iliac crest is incised and the periosteal layer with the attached muscle is elevated and reflected medially. The iliac fossa is dissected to the desired depth. Care should be taken to avoid injury to the lateral femoral cutaneous nerve. Bone can be harvested using an oscillating saw or a piezosurgical device as per the preference of the surgeon by splitting the outer cortex of the iliac crest and transverse bone cuts. The two transverse cuts are then joined by a cortical osteotomy at the inner table paralleling the crestal cut. An osteotome is used to gently fracture the bone graft. This results in a cortico cancellous bone graft. Additional cancellous bone



©Association of Oral and Maxillofacial Surgeons of India

Fig. 19.8 (a, b, c) Shows a case of harvest of bone from iliac crest used to augment anterior maxilla. (a) Shows the exposure of the anterior iliac crest for bone harvesting. (b) Shows the osteotomy of iliac crest for harvest of bone. (c) Shows the harvested bone fixed at recipient site

can be taken with a large curette if needed. The wound is meticulously closed in layers and a pressure dressing is applied.

19.8.1.4 Calvarium as a Donor Site

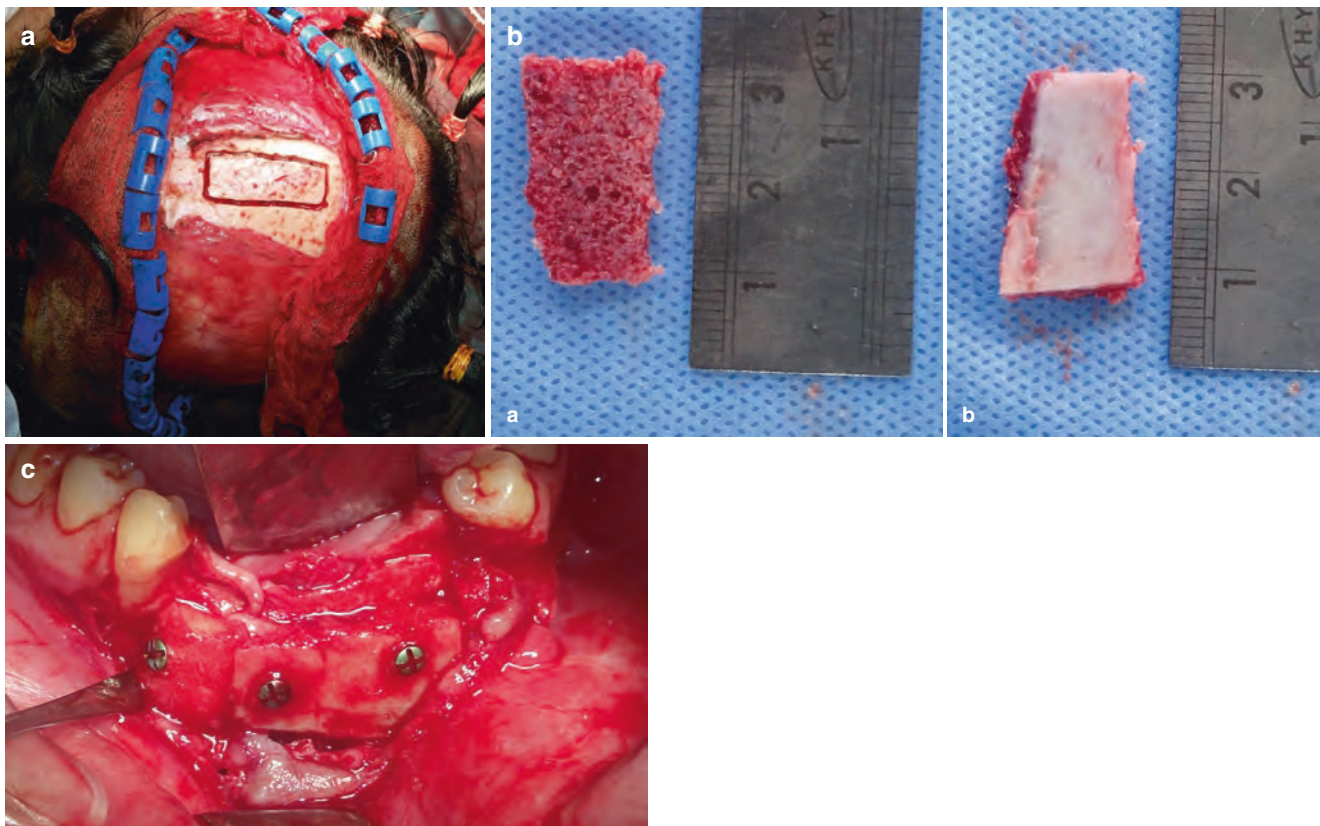
Calvarium is a good source of cortical bone graft due to its high density and is opined by some surgeons as being the most resistant to resorption [27]. The location of the donor site is at the parietal bone lateral to the sagittal suture. The bone has distinct outer and inner table at this region separated by a diploic layer. A typical situation where calvarial bone grafts are harvested is in the cases of residual deformities following trauma, where a bicoronal flap and exposure of the parietal bone are already planned. (Fig. 19.9a, b, c shows a case of calvarial bone harvest used for bone augmentation of the anterior mandible).

The harvest is performed under general anaesthesia and the parietal bone exposed as part of the bicoronal flap. The outline of the bone graft is first made with round burs and then joined with straight fissure burs. The outline of the graft

is broadened to permit placement of a chisel that would fracture the outer cortical plate at the diploic space. Haemostasis is achieved and the wound is closed.

19.8.2 Recipient Site Preparation and Completion of the Procedure

The preparation of the recipient site is done by a crestal incision with adequate releasing incisions as required. The surface of the bone is cleared of soft tissue and the cortical bone plate of the recipient site is perforated with a small round bur to produce bleeding and gain access to the cancellous part of the recipient bone. The harvested bone is then placed onto the recipient site and fixed with osteosynthesis screws. Some surgeons prefer to use lag screws for additional compression. The spaces between the block graft and recipient bone can be filled with particulate bone, especially at the borders. A resorbable membrane may be used to cover the augmentation. Adequate soft tissue release must be performed prior to



©Association of Oral and Maxillofacial Surgeons of India

Fig. 19.9 (a, b, c) shows a case of calvarial bone harvest used for bone augmentation of the anterior mandible. (a) Shows the exposure of the donor site with the outline of bone to be harvested. (ba) Shows the

cancellous side of the harvested bone. (bb) Shows the cortical side of the harvested bone. (c) Shows the harvested bone further shaped and fixed at the recipient site

closure, so as to provide a tension-free watertight closure. Onlay grafts are usually left to heal for at least 6 months, after which implant placement can be carried out as another surgical procedure.

Another variation of onlay bone grafting is to use the cortical shell technique, where a thin cortical shell of bone is harvested and cancellous bone marrow placed in between the cortical shell and the recipient bone wall.

Other methods of bone augmentation include ridge split for lateral augmentation, alveolar distraction osteogenesis for vertical augmentation, interpositional bone grafting and free flap reconstruction of extremely resorbed ridges [28, 29]. These procedures will not be described in detail as they are not the most commonly carried out procedures.

19.9 Sinus Floor Elevation

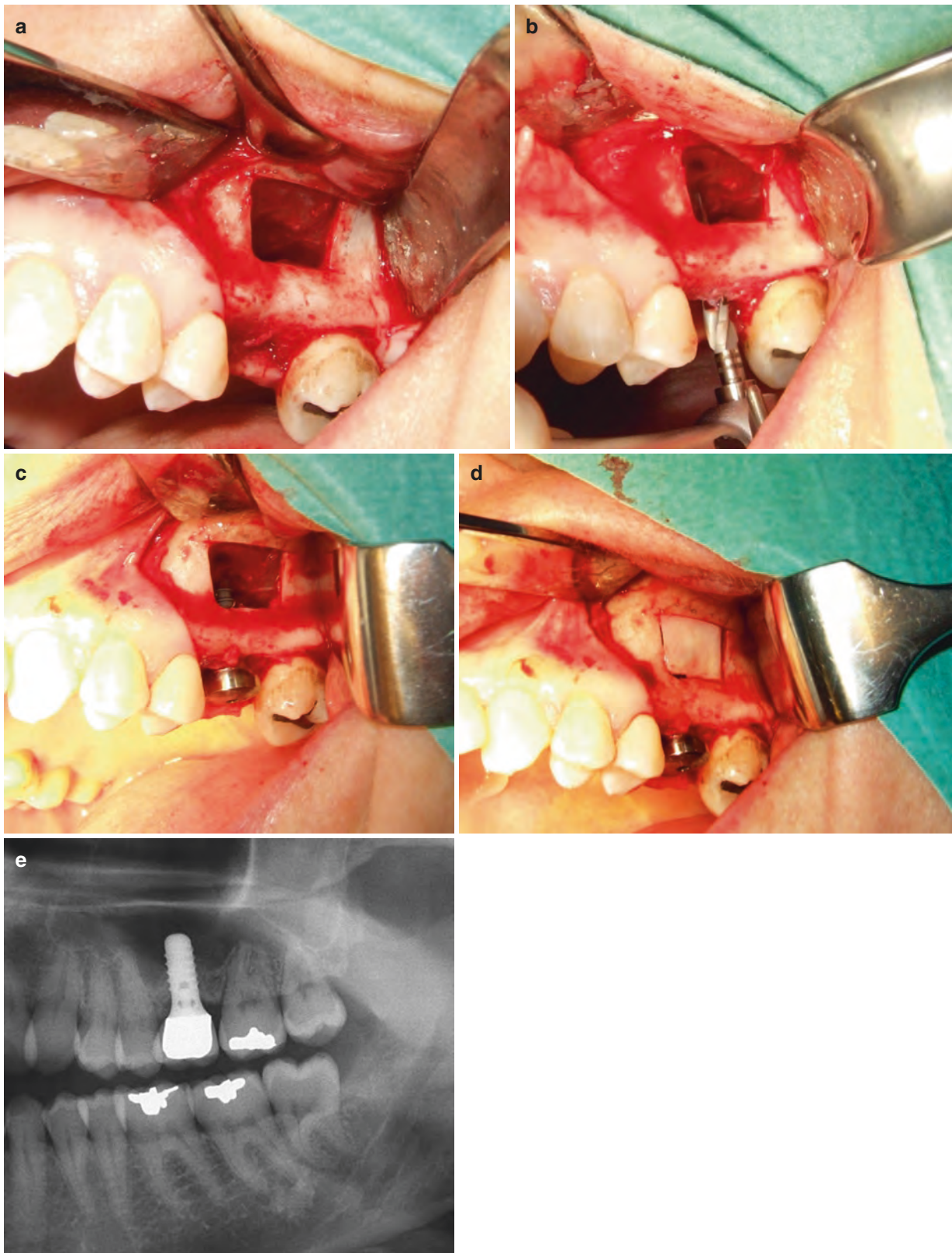
Sinus floor elevation, also known as sinus augmentation or sinus lift is a bone-augmentation procedure to gain an increased bone volume to support in the maxillary sinus following sinus pneumatisation. The bone augmentation is done

to provide an adequate quantity of bone that would permit dental rehabilitation with implants.

Maxillary sinus floor elevation can be performed by either as a transcrestal technique (also known as indirect sinus floor elevation) or a lateral window technique (also known as direct sinus floor elevation).

Irrespective of the individual techniques, the principle is to elevate the Schneiderian membrane and to create space for bone to fill up between the elevated Schneiderian membrane and residual maxillary bone. Although most clinician commonly use bone grafts to fill the space between the membrane and the floor, it has also been shown that bone fill occurs irrespective of using a bone substitute or leaving the elevated area to be occupied by a blood clot that eventually forms bone [30–32]. (Fig. 19.10a, b, c, d shows a clinical case of sinus floor elevation with blood clot and no additional biomaterial).

The maxillary sinus is a pyramidal-shaped cavity in the posterior region of each of the maxillary bones. The base of this pyramid is the lateral nasal wall and the tip of the pyramid is within the zygomatic buttress. The infraorbital floor, the posterior maxillary wall and the alveolar process form the walls of the pyramid. The maxillary sinus communicates



©Association of Oral and Maxillofacial Surgeons of India

Fig. 19.10 (a, b, c, d, e) shows a clinical case of sinus floor elevation with blood clot and no additional biomaterial. (a) Preparation of lateral window and elevation of the sinus membrane. (b) Implant osteotomy taking care to protect the membrane. (c) Implant placed (note the space

between the implant and membrane that will eventually fill with blood clot). (d) Closure of the lateral window. (e) Long-term follow-up radiograph showing successful implant placement and restoration

to the lateral nasal wall through the semilunar hiatus at the posterosuperior aspect below the medial nasal concha. At birth, the maxillary sinus is very small and underdeveloped. As the permanent teeth begin to erupt, the maxillary sinus increases in size and continues to grow along with age. The sinus floor (the alveolar bone) is concave in shape with the lowest dip corresponding to the maxillary molar region. However, after the loss of maxillary posterior teeth, the sinus usually dips into this region. Over a period of time due to the increasing pneumatisation of the sinus, the sinus may surround the roots of the maxillary posterior teeth. In the case of the loss of maxillary posterior teeth, the maxillary sinus expands thinning the floor of the alveolar process that may result in a thin shell of bone. In many situations, this expansion of the maxillary sinus leaves an inadequate amount of bone to support successful implant placement. In these situations, maxillary sinus floor elevation is the procedure of choice to augment bone. However, it is also important to bear in mind that alveolar bone resorption may give rise to vertical and horizontal deficiencies in the posterior maxillary sinus. In prolonged cases, this might give rise to a situation where along with sinus floor elevation, it would also be necessary to augment bone both horizontally and vertically by onlay bone augmentation.

The morphology of the maxillary sinus floor can vary. Maxillary sinus floors are often irregular corresponding to the elevations and depressions of the teeth roots. The floor of the sinus also may be divided by septae. Some maxillary floors are broad and flat whereas others may be irregular and narrow. The lateral wall of the maxillary sinus can also vary in thickness, from being paper thin to being about 3 mm in thickness. The thicker the lateral wall, the more difficult would be the lateral sinus floor-augmentation procedure.

The blood supply of the maxillary sinus arises from the branches of the maxillary artery namely: the posterosuperior alveolar artery and the greater palatine artery as well as the infraorbital artery. Care must be taken to look out for the posterosuperior alveolar artery that may be encountered while preparation of the lateral sinus floor augmentation, although it is unlikely to cause excessive bleeding.

As required for all surgical procedures, a thorough preoperative assessment must be carried out prior to sinus floor elevation. Acute sinusitis, oro-antral communications, chronic periodontitis and poor oral hygiene pose a high risk for sinus floor elevation. Moderate risk factors include smoking, chronic sinusitis and extremely poor bone density, amongst others.

19.9.1 Classification and Treatment Options for the Posterior Edentulous Maxilla

According to the International Team for Implantology, the edentulous posterior maxilla can be classified into 4 types [11]:

Group 1: where there is an insufficient sub-antral bone height to place implants, however with an adequate width of the alveolar ridge with acceptable vertical and horizontal interarch relations. These cases can be treated with a sinus floor elevation procedure alone.

Group 2: where there is an insufficient subantral bone height, and an inadequate width of the alveolar ridge with acceptable vertical interarch relation. In these cases, sinus floor elevation should be performed along with horizontal-bone augmentation.

Group 3: where there exists an insufficient subantral bone height, and an adequate width of alveolar ridge with acceptable horizontal interarch relations but with unfavourable vertical interarch relationship. In these cases, sinus floor augmentation should be performed along with vertical-ridge augmentation.

Group 4: There exists insufficient subantral bone height, and unfavourable interarch relations in addition to advanced horizontal and vertical crestal resorption. These cases must be treated with sinus floor elevation along with horizontal and vertical-ridge augmentation.

Misch 1987 [33] classified the edentulous posterior maxilla based on the amount of subantral bone available into:

SA1: more than 12 mm of the subantral bone height.

SA2: 0–2 mm less than the ideal bone height (10–12 mm).

SA3: 5–10 mm of the subantral bone height.

SA4: less than 5 mm subantral bone height.

19.9.2 Decision-Making: Lateral Versus Transcrestal Technique

Transcrestal technique avoids the use of a large surgical flap and an osteotomy for a lateral window and hence is much reduced in invasiveness and decreased post-operative morbidity to the patient. However, the transcrestal technique can predictively increase bone height to about 4–5 mm and, therefore, cannot be used for severely atrophic cases. Additionally, in situations where the sinus floor is not uniform (or at oblique angles), there is an increased tendency to perforate the sinus mucosa. In such cases, it is preferable to perform lateral sinus floor elevation. It must be remembered that the transcrestal technique is in essence a blind procedure and it is not possible to inspect the sinus mucosa for perforations or pathologies using this technique, hence in the cases of intra-operative perforation, a lateral sinus floor elevation procedure must be performed. Hence, it is wise to always obtain a consent for the lateral technique prior to undertaking the transcrestal procedure.

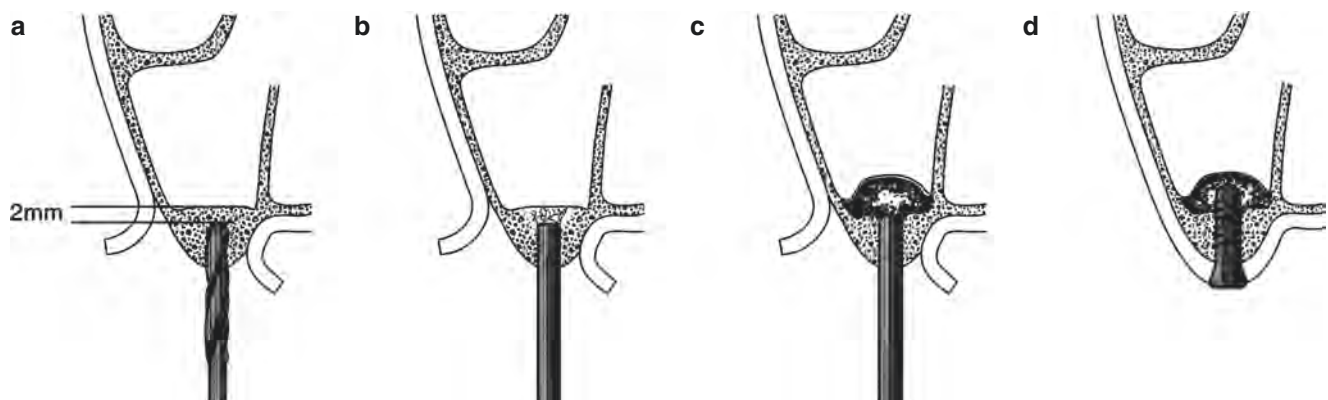
19.9.3 Decision-Making: Simultaneous Versus Staged Approach

The prerequisite of simultaneous implant placement is the possibility to obtain sufficient primary implant stability [33, 34]. In cases where primary implant stability cannot be obtained, implants should be placed at a second surgical procedure 2–6 months following sinus floor elevation. Decreased residual bone volume and poor bone density are factors that predispose towards poor primary implant stability. Traditionally, less than 5 mm was considered as the minimum amount of sub-antral bone height required for simultaneous implant placement. This has, however, been challenged and many recent studies have shown sufficient primary stability in cases with lesser sub-antral bone height. Implant stability has been achieved in these cases by using a tapered implant design, implants with engaging threads, by using the underdimensional drilling protocol and by using bone-condensing drills. Conventionally, it is understood that while undertaking a transcrestal procedure, implants would be placed simultaneously.

Armamentarium for sinus floor elevation consists in addition to the regular minor surgical kit and the implant kit, hand and rotary instruments that are specifically designed for sinus floor elevation. Many companies have introduced kits specifically for this procedure. Some surgeons prefer the use of piezosurgery for access to the lateral window. Additionally, implant companies have also introduced specific burs and elevation kits that reportedly make sinus floor elevation easier to perform. It is ultimately the preference of the surgeon in choosing the armamentarium.

19.9.4 Transcrestal Surgical Technique

After local anaesthesia, a crestal incision is made and the implant osteotomy is performed according to the instructions of the respective implant manufacturer. The osteotomy is made 2 mm short of the sinus floor. A periapical radiograph can be taken to confirm this. After the depth has been defined, remainder of the implant preparation is done as per the respective manufacturers protocol. Following preparation of the implant bed of appropriate dimension (it is recommended to use an implant of at least 4.0 mm diameter till further evidence suggests otherwise), an osteotome is introduced into the implant bed and with the help of a mallet, gentle tapping is performed till the sinus floor is fractured. Care should be taken that the osteotome does not perforate the sinus mucosa and enter the sinus cavity. Once the sinus floor has been fractured, a part of the membrane can be visualised to be intact. A careful Valsalva procedure can also be performed to test the patency of the sinus floor. An appropriate graft material is introduced through the implant preparation onto the sinus mucosa. Incremental introduction of the graft material is done, which will push the sinus membrane upwards creating a space between the sub-antral bone and the sinus mucosa. After introducing the appropriate amount of graft material, an implant is inserted to the desired three-dimensional position. Following implant installation, the crestal incision is closed with either a transmucosal or submerged healing protocol. Implant loading is done as per the instructions of the manufacturer, generally within 3 month time. (Fig. 19.11a, b, c, d shows a diagrammatic representation of transcrestal sinus floor elevation).



©Association of Oral and Maxillofacial Surgeons of India

Fig. 19.11 (a, b, c, d) shows a diagrammatic representation of transcrestal sinus floor elevation. (a) Implant osteotomy made 2 mm short of the sinus floor. (b) Osteotome introduced through the implant oste-

otomy to fracture the sinus floor. (c) Biomaterial introduced to elevate the sinus membrane. (d) Implant placement completed

A periapical radiograph must be taken at the end of the procedure to confirm no breach of the sinus floor. A well-circumscribed dome-shaped elevation around the apex of the implant confirms no breach of the sinus membrane. In contrast, if the bone graft is seen around the sinus floor and poorly localised, it denotes a perforation of the sinus floor membrane and in this case, a lateral window approach should be immediately done to clean the sinus cavity.

19.9.5 Lateral Window Technique

The lateral window technique can be done alongside lateral and vertical augmentation of the ridge, and with or without simultaneous implant placement. After adequate local anaesthesia, a crestal incision is made with releasing incisions well away from the planned window. A mucoperiosteal flap is elevated and the lateral wall of the maxillary sinus is exposed. A bony window is made according to the local bone anatomy. If vertical septae are present, two bony windows are made on either side of the bony septae. The bony window should be large enough to introduce the graft materials, as well as big enough to permit exploration of the floor, the anteroposterior aspect of the floor to the medial aspect of the maxillary sinus. When the lateral window is made, care should be taken to avoid perforation of the sinus membrane. The lateral window can either be removed from the underlying sinus mucosa or be attached to the to it and pushed inwards. The sinus floor is then slowly teased and reflected away from the floor of the maxillary sinus and elevated using special instruments that resemble a curette to create space for the graft material. It is important to elevate the membrane

medially and anteriorly in the areas where augmentation is planned.

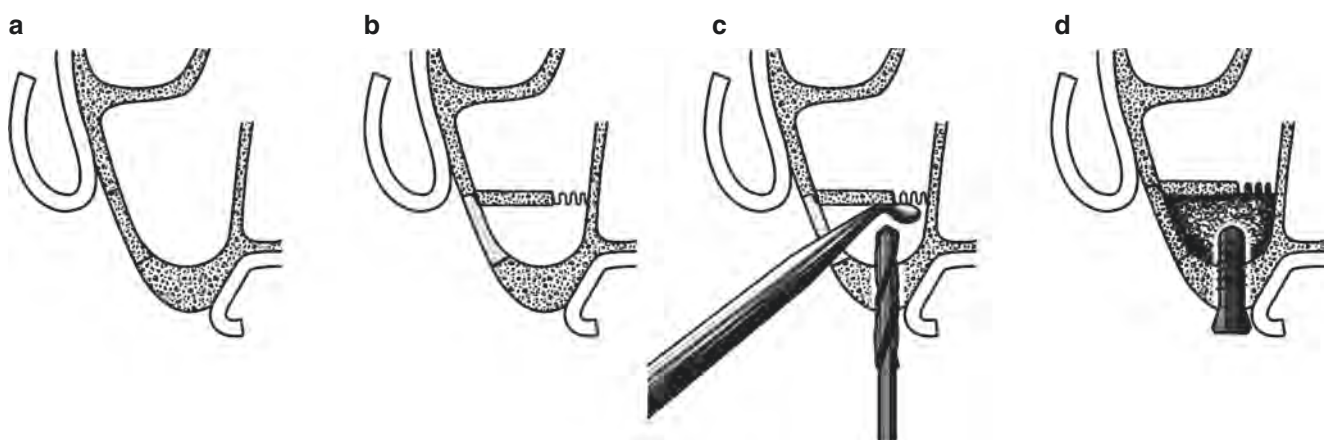
(Fig. 19.12a, b, c, d shows diagrammatic representation of the procedure for sinus floor elevation using a lateral window).

If simultaneous implant placement is planned, implant osteotomies should be carried out with the elevated mucosa well protected with an instrument in such a way that the implant drills do not come in contact with the sinus mucosa. Bone graft material is now introduced into the space created by elevation of the membrane. After adequate filling of the space with augmentation material, implants can be placed if planned. The lateral window bone wall (if preserved) can be replaced, or the window can be covered with a barrier membrane. The mucoperiosteal flap is then closed and tension-free suturing should be placed.

Although, bone graft materials and membranes are commonly used it is not mandatory for the success of sinus floor elevation. Some suggest, elevation of the sinus mucosa and placement of the implant that tents the membrane up, the blood clot that is formed into the space eventually forms bone to surround the implant.

19.9.6 Complications Following Sinus Floor Elevation

Sinus perforation is the most common complication following sinus floor elevation. Other complications include (but not limited to) poor primary implant stability, implant migration into the sinus, graft migration into the sinus and intra-operative and post-operative bleeding, wound dehiscence and infection.



©Association of Oral and Maxillofacial Surgeons of India

Fig. 19.12 (a, b, c, d shows diagrammatic representation of the procedure for sinus floor elevation using a lateral window). (a) Mucoperiosteal flap elevated to access the lateral wall of the maxillary sinus. (b) Lateral

wall bony window made and in-fractured. (c) Implant osteotomy done. (d) Placement of biomaterial and implant

Alternatives to sinus floor elevation: The use of short implants [35], angled or tilted implants [3], zygomatic or pterygoid implants [36] are treatment alternatives that may avoid the need for maxillary sinus floor elevation.

19.10 Suggested Reading

ITI Treatment guides Volume 5: Sinus floor elevation

ITI Treatment guide Volume 7

ITI Treatment guide series Volume 1–10

ITI Online Academy

Contemporary implant dentistry: Carl Misch

References

- Chappuis V, Rahman L, Buser R, Janner SFM, Belser UC, Buser D. Effectiveness of contour augmentation with guided bone regeneration: 10-year results. *J Dent Res*. 2018;97(3):266–74.
- Chappuis V, Araujo MG, Buser D. Clinical relevance of dimensional bone and soft tissue alterations post-extraction in esthetic sites. *Periodontol 2000*. 2017;73(1):73–83.
- Toljanic JA, Ekstrand K, Baer RA, Thor A. Immediate loading of implants in the edentulous maxilla with a fixed provisional restoration without bone augmentation: a report on 5-year outcomes data obtained from a prospective clinical trial. *Int J Oral Maxillofac Implants*. 2016;31(5):1164–70.
- Trbakovic A, Bongenhielm U, Thor A. A clinical and radiological long-term follow-up study of narrow diameter implants in the esthetic area. *Clin Implant Dent Relat Res*. 2018;20(4):598–605.
- Cawood JI, Howell RA. A classification of the edentulous jaws. *Int J Oral Maxillofac Surg*. 1988;17(4):232–6.
- Lekholm U, Zarb GA. Patient selection and preparation. In: Branemark PIZG, Albrektsson T, editors. *Tissue integrated prosthesis: osseointegration in clinical dentistry*. Chicago IL: Quintessence; 1985. p. 199–209.
- Kumar VV, Sagheb K, Klein MO, Al-Nawas B, Kann PH, Kammerer PW. Relation between bone quality values from ultrasound transmission velocity and implant stability parameters--an ex vivo study. *Clin Oral Implants Res*. 2012;23(8):975–80.
- Lindhe J, Bressan E, Cecchinato D, Corra E, Toia M, Liljenberg B. Bone tissue in different parts of the edentulous maxilla and mandible. *Clin Oral Implants Res*. 2013;24(4):372–7.
- Mackiewicz Z, Niklinska WE, Kowalewska J, Chyczewski L. Bone as a source of organism vitality and regeneration. *Folia Histochem Cytobiol*. 2011;49(4):558–69.
- Jensen SS, Terheyden H. Bone augmentation procedures in localized defects in the alveolar ridge: clinical results with different bone grafts and bone-substitute materials. *Int J Oral Maxillofac Implants*. 2009;24(Suppl):218–36.
- Katsuyama H, Jensen SS. Treatment options for sinus floor elevation. In: Chen S, Buser D, Wismeijer D, editors. *ITI treatment guide sinus floor elevation procedures*. ITI treatment guide. Berlin: Quintessence Publishing; 2011. p. 34–59.
- Kumar VV, Jacob PC, Ebenezer S, Kuriakose MA, Kekatpure V, Baliarsing AS, et al. Implant supported dental rehabilitation following segmental mandibular reconstruction- quality of life outcomes of a prospective randomized trial. *J Craniomaxillofac Surg*. 2016;44(7):800–10.
- Kumar VV, Ebenezer S, Kammerer PW, Jacob PC, Kuriakose MA, Hedne N, et al. Implants in free fibula flap supporting dental rehabilitation – implant and peri-implant related outcomes of a randomized clinical trial. *J Craniomaxillofac Surg*. 2016;44(11):1849–58.
- Bosshardt D, Schenk RK. Bone regeneration: biologic basis. In: Buser D, editor. *20 Years of guided bone regeneration in implant dentistry*. 2nd ed. Chicago, IL: Quintessenz; 2009. p. 15–45.
- Caballe-Serrano J, Munar-Frau A, Ortiz-Puigpelat O, Soto-Penalosa D, Penarrocha M, Hernandez-Alfaro F. On the search of the ideal barrier membrane for guided bone regeneration. *J Clin Exp Dent*. 2018;10(5):e477–e83.
- Caballe-Serrano J, Munar-Frau A, Delgado L, Perez R, Hernandez-Alfaro F. Physicochemical characterization of barrier membranes for bone regeneration. *J Mech Behav Biomed Mater*. 2019;97:13–20.
- Gruber R, Stadlinger B, Terheyden H. Cell-to-cell communication in guided bone regeneration: molecular and cellular mechanisms. *Clin Oral Implants Res*. 2017;28(9):1139–46.
- Caballe-Serrano J, Abdeslam-Mohamed Y, Munar-Frau A, Fujioka-Kobayashi M, Hernandez-Alfaro F, Miron R. Adsorption and release kinetics of growth factors on barrier membranes for guided tissue/bone regeneration: a systematic review. *Arch Oral Biol*. 2019;100:57–68.
- Maestre-Ferrin L, Boronat-Lopez A, Penarrocha-Diago M, Penarrocha-Diago M. Augmentation procedures for deficient edentulous ridges, using onlay autologous grafts: an update. *Med Oral Patol Oral Cir Bucal*. 2009;14(8):e402–7.
- Nyman S. Bone regeneration using the principle of guided tissue regeneration. *J Clin Periodontol*. 1991;18(6):494–8.
- Dahlin C, Linde A, Gottlow J, Nyman S. Healing of bone defects by guided tissue regeneration. *Plast Reconstr Surg*. 1988;81(5):672–6.
- Urban IA, Monje A. Guided bone regeneration in alveolar bone reconstruction. *Oral Maxillofac Surg Clin North Am*. 2019;31(2):331–8.
- Buser D, Chappuis V, Kuchler U, Bornstein MM, Wittneben JG, Buser R, et al. Long-term stability of early implant placement with contour augmentation. *J Dent Res*. 2013;92(12 Suppl):176S–82S.
- Buser D, Chappuis V, Bornstein MM, Wittneben JG, Frei M, Belser UC. Long-term stability of contour augmentation with early implant placement following single tooth extraction in the esthetic zone: a prospective, cross-sectional study in 41 patients with a 5- to 9-year follow-up. *J Periodontol*. 2013;84(11):1517–27.
- Thor A, Wannfors K, Sennerby L, Rasmusson L. Reconstruction of the severely resorbed maxilla with autogenous bone, platelet-rich plasma, and implants: 1-year results of a controlled prospective 5-year study. *Clin Implant Dent Relat Res*. 2005;7(4):209–20.
- Dasmah A, Thor A, Ekkestubbe A, Sennerby L, Rasmusson L. Marginal bone-level alterations at implants installed in block versus particulate onlay bone grafts mixed with platelet-rich plasma in atrophic maxilla. A prospective 5-year follow-up study of 15 patients. *Clin Implant Dent Relat Res*. 2013;15(1):7–14.
- Smolka W. Calvarial grafts for alveolar ridge reconstruction prior to dental implant placement: an update. *Oral Maxillofac Surg*. 2014;18(4):381–5.
- Chiapasco M, Casentini P, Zaniboni M. Bone augmentation procedures in implant dentistry. *Int J Oral Maxillofac Implants*. 2009;24(Suppl):237–59.
- Milinkovic I, Cordaro L. Are there specific indications for the different alveolar bone augmentation procedures for implant placement? A systematic review. *Int J Oral Maxillofac Surg*. 2014;43(5):606–25.
- Riben C, Thor A. Follow-up of the sinus membrane elevation technique for maxillary sinus implants without the use of graft material. *Clin Implant Dent Relat Res*. 2016;18(5):895–905.
- Riben C, Thor A. The maxillary sinus membrane elevation procedure: augmentation of bone around dental implants without grafts-a review of a surgical technique. *Int J Dent*. 2012;2012:105483.

32. Duan DH, Fu JH, Qi W, Du Y, Pan J, Wang HL. Graft-free maxillary sinus floor elevation: a systematic review and meta-analysis. *J Periodontol.* 2017;88(6):550–64.
33. Misch CE. *Contemporary implant dentistry.* St. Louis: Mosby; 1987.
34. Stefanski S, Svensson B, Thor A. Implant survival following sinus membrane elevation without grafting and immediate implant installation with a one-stage technique: an up-to-40-month evaluation. *Clin Oral Implants Res.* 2017;28(11):1354–9.
35. Srinivasan M, Vazquez L, Rieder P, Moraguez O, Bernard JP, Belser UC. Survival rates of short (6 mm) micro-rough surface implants: a review of literature and meta-analysis. *Clin Oral Implants Res.* 2014;25(5):539–45.
36. Tuminelli FJ, Walter LR, Neugarten J, Bedrossian E. Immediate loading of zygomatic implants: a systematic review of implant survival, prosthesis survival and potential complications. *Eur J Oral Implantol.* 2017;10(Suppl 1):79–87.

Open Access This chapter is licensed under the terms of the Creative Commons Attribution 4.0 International License (<http://creativecommons.org/licenses/by/4.0/>), which permits use, sharing, adaptation, distribution and reproduction in any medium or format, as long as you give appropriate credit to the original author(s) and the source, provide a link to the Creative Commons license and indicate if changes were made.

The images or other third party material in this chapter are included in the chapter's Creative Commons license, unless indicated otherwise in a credit line to the material. If material is not included in the chapter's Creative Commons license and your intended use is not permitted by statutory regulation or exceeds the permitted use, you will need to obtain permission directly from the copyright holder.



Part VIII

Odontogenic Infections

Odontogenic Infections: General Principles

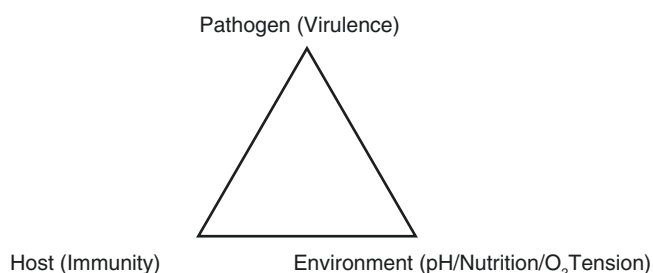
20

Anand Shukla and Divya Mehrotra

20.1 Introduction

Relationships like symbiosis, commensalism, ectoparasitism, and endoparasitism exist between various species in the biological world. An infection is a classic example of either ectoparasitism or endoparasitism. All infections occurring in the human body are usually of microbial origin and odontogenic infections are no exception.

This relationship is based on discordance in the delicate balance between the host defense mechanism and pathogenicity or the virulence of the infecting microbes depending upon their potentially harmful biomolecules viz. exotoxin, endotoxin, enzymes, and others that disrupt the host defense. Essentially, the environment also seems to play an important role in the overall pathogenic behavior of the microorganism. This interrelationship can be expressed by a simple triangle.



In short, when a low host resistance, pathogen-friendly environment, and a pathogen of high virulence are seen in states of physical being, we refer to as Infections

A. Shukla · D. Mehrotra (✉)
Department of Oral and Maxillofacial Surgery, King George's
Medical University, Lucknow, India

20.2 Host Defense Mechanisms

As a generalization, host defense mechanisms may be studied as

1. Local.
2. Systemic

- Local Mechanisms:

1. Oral Mucosa:

The oral mucosa forms the first line of defense against the pathogens with an epithelialization rate of 4–5 days wherein the entire oral mucous membrane is replaced by newer more equipped cells take its place. The cells that are infected or otherwise worn out are replaced. As both the skin and oral mucosa are keratinized structures, water and along with it the microbes cannot naturally percolate into the deeper tissues. The oral mucosa is water resistant and relatively dry and does not form a congenial niche for microbial adherence and growth.

2. Natural spillways:

Human dentition has evolved to chew the food we eat. The surface anatomy of the occlusal surfaces is such that with a fibrous diet, the food automatically spills off the occlusal table into the labio-lingual vestibule. The interdental contacts are also evolved and provide natural spillways for masticated food.

3. Dental Histology:

The microscopic structures of our dentition reveal the hardest substance of the human body (the dental enamel) to cap its relatively softer structures (dentin and pulp). Thus, even if microbes are able to hold onto the enamel layer, the sheer density and mineralization of this layer are sufficient enough to handle most of the microbial attacks.

4. Saliva:

By virtue of evolution, the human race has been privileged with 3 pairs of major salivary glands and numerous minor salivary glands. Their secretions, on the one hand, keep the oral environment moist to avoid inadvertent trauma and, on the other hand, help transform the chewed food into a bolus to be swallowed. Salivary secretion continues throughout the awake state, so even if one is not eating, the salivary secretions flush out the food debris deposited on the hard and soft surfaces of the mouth, in conjunction with the movements of the muscular elements of oral region such as lips, cheek, tongue, etc. Other physiological properties of the human saliva such as pH (6.5–8.5) and the presence of immunoglobulins (IgG and IgA) makes saliva a biological bacteriostatic fluid.

5. Oral sub mucosal immune system (OSMIS):

A large number of immunocompetent cells, such as the mononuclear leukocytes, T cells, and B cells, are present between the oral mucous membrane and are responsible for the production of antibodies as well as offering a direct cellular immune response to the host and oral environment. The cell concentrations of IgG, IgA, and IgM may remarkably reach 85, 72, and 75%, respectively, with respect to plasma concentration, in the gingival sulcular fluid. However, generally only IgA levels are high in the oral mucosa, while the concentrations of IgG may rise dramatically during infectious states. Also, the true ponderance of mast cells in the submucosal layer and the presence of IgE explain the immediate hypersensitivity (type I) reaction. The role of these immunoglobulins is to neutralize the microbial toxins and maintain hemostasis in the oral environment.

6. Dentinal reparative mechanisms:

If the bacterial attack breaks the enamel barrier, the toxins reach the dentinal tubules and through them irritate the pulp. This may or may not be symptomatic but pulpal reaction is evident with the formation of reparative dentin to seal off the breach as part of the defense mechanism. When this occurs, we know it as arrested caries and the dentin so formed is the affected dentin. If due measures are not taken at this stage, an advanced carious lesion may result.

7. Waldayer's Ring:

The OSMIS, lingual tonsil, palatine tonsil, all other lymphoid structures in the naso-oropharyngeal region together make a ring-like primary defense mechanism against microbes in the oro-digestive tract and are constitutionally known as the Waldayer's ring.

- *Systemic Mechanisms:* Broadly speaking, the systemic host immunity may be classified as.

1. Cellular.
2. Humoral.

Both these immune systems may be either innate (natural) or acquired (adaptive). Majority of pathogens are dealt with by the innate component of the host systemic immunity. However, when the innate response is overwhelmed, the adaptive or active immunity comes into play.

Components of Innate Immunity:

- Physical barriers/skin/mucosa.
- Neutrophils.
- Macrophages.
- Dendritic cells.
- Natural killer cells.
- Lymphoid cells.
- Complement system.

Components of Acquired Immunity:

- B-lymphocytes.
- Dendritic cells.
- T-lymphocytes.
 - Helper.
 - Cytotoxic.
 - Regulatory.

Innate immunity is basically a receptor-pattern recognition mechanism, where about 100 intracellular and extracellular receptors (e.g., toll-like receptors, NOD-like receptors, KIG like receptors, etc.) recognize over 1000 different cell injury-related patterns generated from bacterial, viral, or fungal inflictions [1]. These receptors generate a response mediated by cytokines and antiviral interferon and stimulate the most proactive immune response.

Acquired immunity is of two types, viz. humoral immunity, mediated by soluble proteins known as antibodies (produced by B lymphocytes) and cell-mediated immunity effected by T lymphocytes (T cells). While antibodies provide protection against extracellular pathogens in blood, mucosa, and tissues, T lymphocytes work to defend against intracellular microbes to kill ingested microbes by production of soluble proteins mediators, the cytokines (produced by helper T cells).

20.3 The Infectious Microbes

The concept of an infectious agent was established by Robert Koch. Koch's postulates became the standard for defining infectious agents, but they do not apply to uncultivable

organisms (e.g. *M. leprae*) or members of normal humoral flora (e.g. *E. coli*).

Koch's postulates:

1. The same organism must be present in every case of that disease but not in any healthy individual.
2. The organism must be isolated from the diseased individual and cultured.
3. The isolate must cause the disease, when inoculated in a healthy individual.
4. The organisms must be re-isolated from inoculated diseased individual.

Odontogenic infections arise within or around the dentition, initiating from simple dental caries, periodontal diseases, and pulpitis, and may spread way beyond their loco-regional origin, invading deeper structures of the face, oral cavity, head and neck, and even mediastinum or the vertebral column.

These infections are principally bacterial in nature Tables 20.1 and 20.2. These bacteria are a part of normal oral flora found in the dental plaque, mucosal surfaces, and the gingival sulcus. These primarily are aerobic gram positive cocci, anaerobic gram positive cocci, and gram negative rods [3].

Table 20.1 Types of bacteria in periapical abscess [4]

Types of bacterial infections	Percentage
Anaerobic only	50%
Mixed anaerobic and aerobic	44%
Anaerobic only	6%

Table 20.2 Common bacterial species in periapical abscess

Endodontic	Periodontal [2]
1. Anaerobic gram negative bacteria	(a) <i>Aggregatibacter actinomycetemcomitans</i>
(a) <i>Treponema</i>	(b) <i>Treponema denticola</i>
(b) <i>Dialister</i>	(c) <i>Campylobacter rectus</i>
(c) <i>Porphyromonas</i>	(d) <i>Prevotella intermedia</i>
2. Facultative gram negative bacteria	(e) <i>Tannerella forsythia</i>
(a) <i>Neisseria</i>	(f) <i>Porphyromonas gingivalis</i>
(b) <i>Capnocytophaga</i>	
(c) <i>Haemophilus</i>	
3. Anaerobic gram positive bacteria	
(a) <i>Actinomycetes</i>	
(b) <i>Peptostreptococcus</i>	
4. Facultative gram positive	
(a) <i>Enterococcus</i>	
(b) <i>Streptococcus</i>	

20.4 Pathways of Odontogenic Infection

Odontogenic infections have two major origins (Fig. 20.1).

- (a) Periodontal- due to bacterial inoculations into underlying tissues via deep periodontal pockets and
- (b) Periapical-, more common, and occur subsequent to pulpal necrosis, reaching the periapical structures (Fig. 20.2).

Once the periodontal or periapical tissues get inoculated with bacteria, the infection may spread equally in all directions but mostly follows the path of least resistance. It travels through the cancellous bone to reach the cortical plate. If the cortical plate is thin, infection easily perforates it to enter the surrounding soft tissue. Periapical enzymes that help the bacteria in doing so include collagenase, hyaluronidase, and streptokinase, which dissolve through the organic matrix of the bone, while the acids produced by the bacteria eliminate the mineral content.

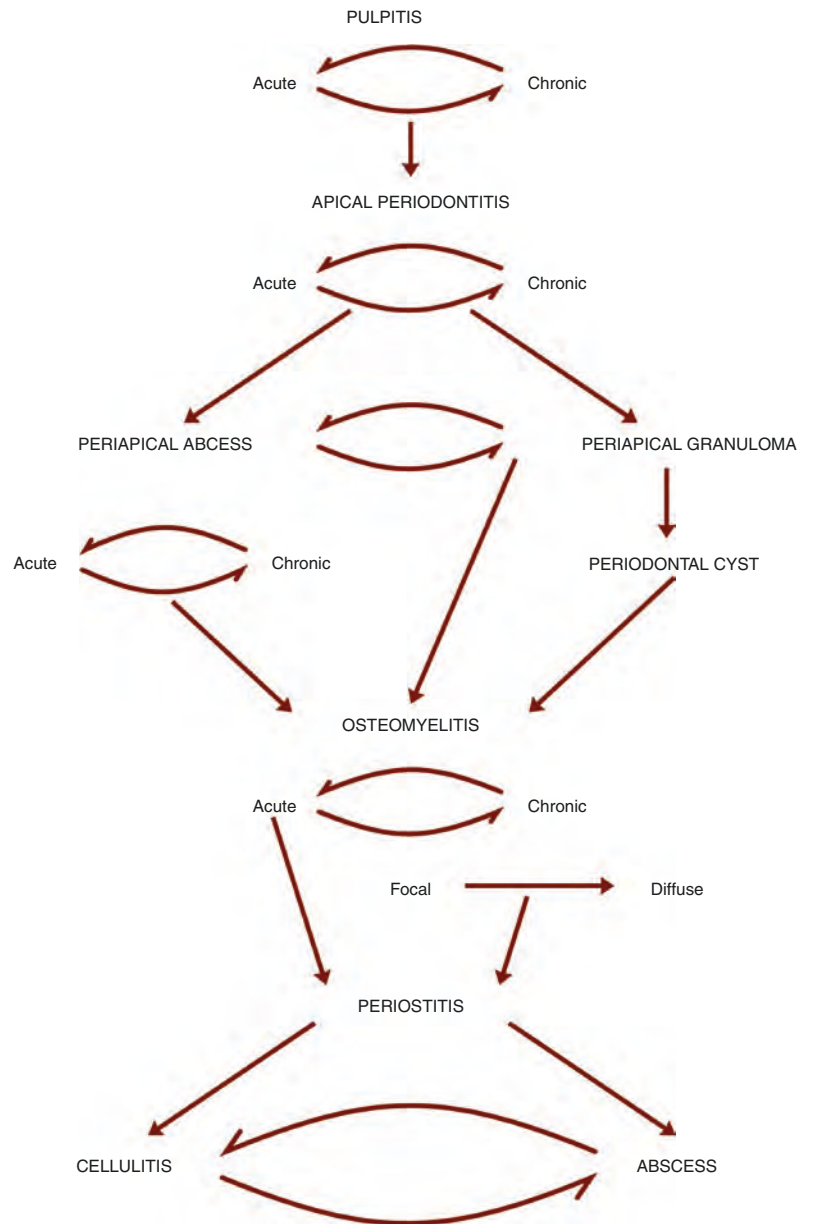
At this stage, if an intervention such as an endodontic or periodontal procedure or dental extraction is done, the further spread may be arrested or even abolished with judicious antibiotics. Antimicrobials alone may not cure the condition as the focus of infection from necrotic pulp or periapical tissues still remains and may cause recurrence of the infection, if the therapy is stopped [5].

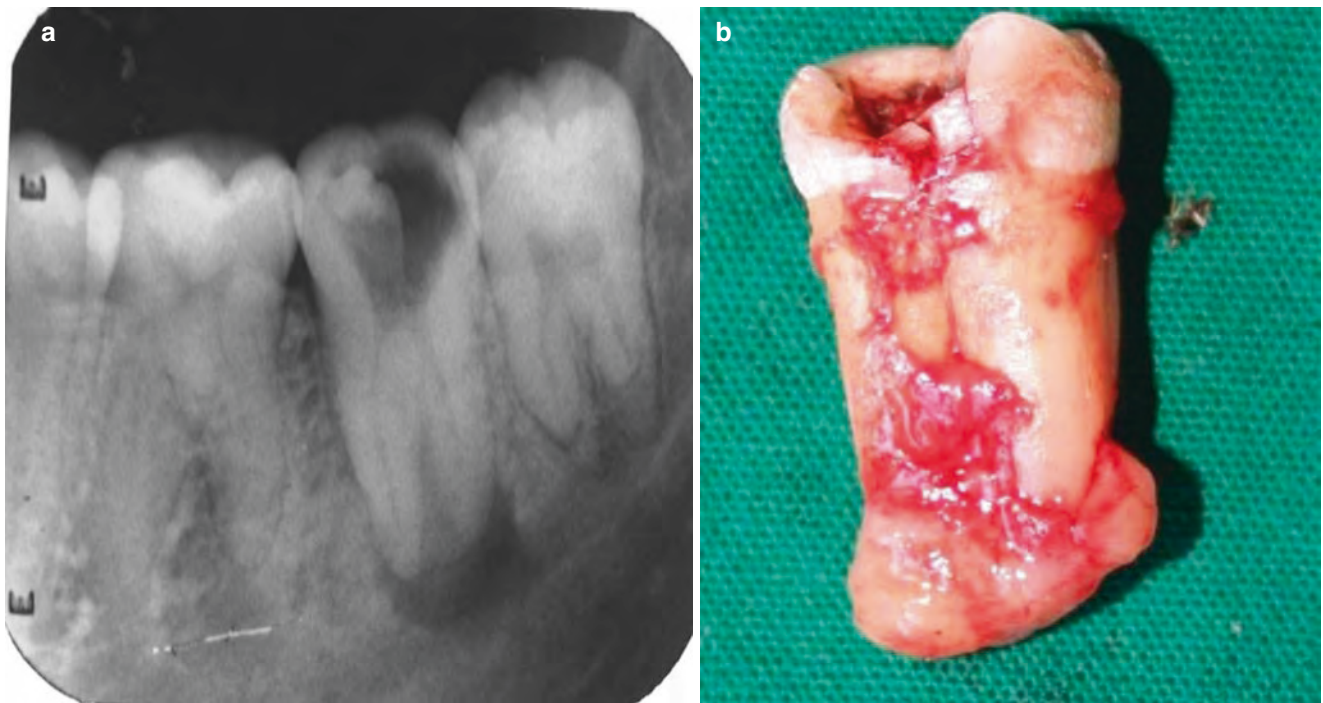
When left untreated, the infection continues to spread depending principally on the thickness of bone and the type of muscle attachment. For example, if maxillary anterior tooth gets involved in the periapical region and the inclination of the root is such that the apex is closer to the labial cortical plate, the soft tissue reaction would present as swelling on the labial side (Fig. 20.3a) and if the apex is closer to the palatal cortical plate, swelling would be palatal. (Fig. 20.3b). Similarly, in case of carious involvement of maxillary first molar: if the apices of the buccal roots lie above the attachment of the buccinator, swelling is likely to occur facially (Fig. 20.4a) and if apices are below, a vestibular swelling is more likely to occur (Figs. 20.4b and 20.5).

Apart from these factors, the angulation of root apex is also important. For example, in periapical abscess with respect to maxillary lateral incisor, swelling is likely to occur on the hard palate rather than labial vestibule as its root apex is slightly palato-distally curved. (Fig. 20.6).

Muscle attachment is another influencing factor. Supposing a mandibular second molar gets apically infected and the apices lie above the external oblique ridge, infection following the path of least resistance and assisted with gravity, may manifest as swelling in a more anterior region of the jaw, buccally than the relative position of the first mandibular molar. Similarly, in the mandibular posterior region, the lingual cortex is closer to the root apices and relatively thinner

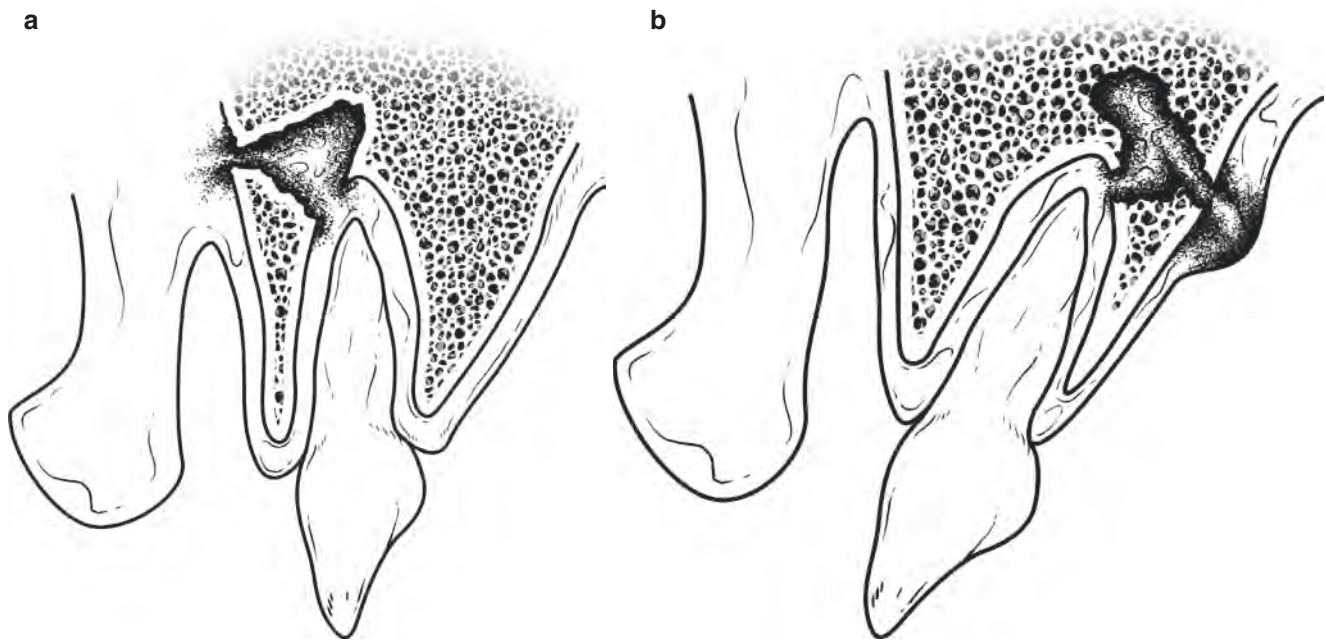
Fig. 20.1 Natural progression of odontogenic infection





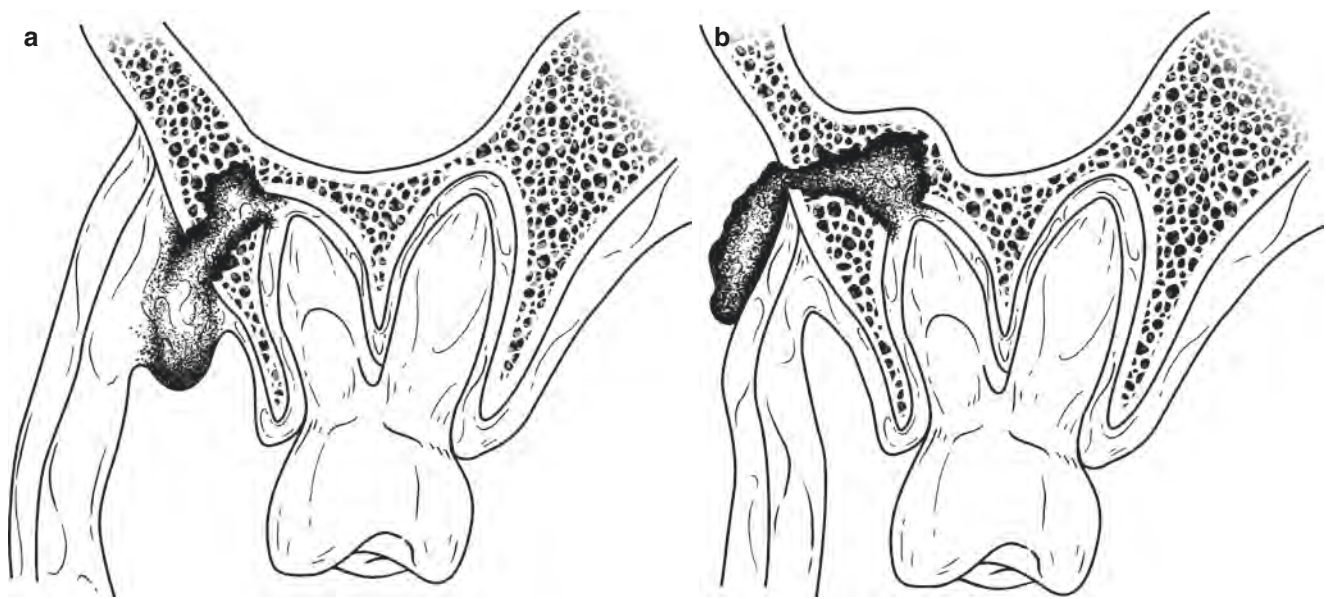
©Association of Oral and Maxillofacial Surgeons of India

Fig. 20.2 (a, b) shows a lower left second molar with a periapical radiolucency. On extraction, the periapical granuloma can be seen attached to the root. If this tooth was not extracted, the infection would have progressed in any of the pathways as shown in Fig. 20.1



©Association of Oral and Maxillofacial Surgeons of India

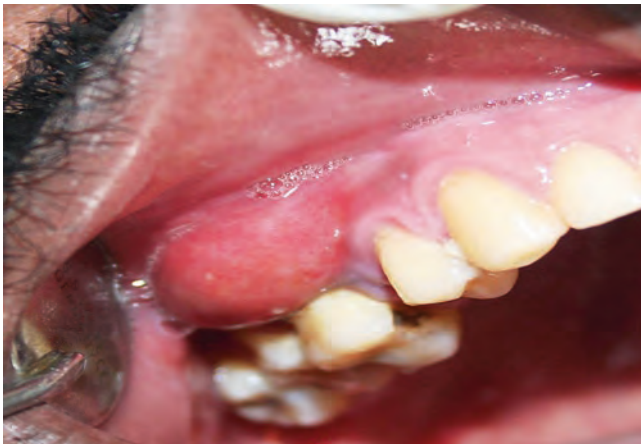Fig. 20.3 (a, b) Infection following the path of least resistance in case of maxillary incisors based on angulation of root



©Association of Oral and Maxillofacial Surgeons of India

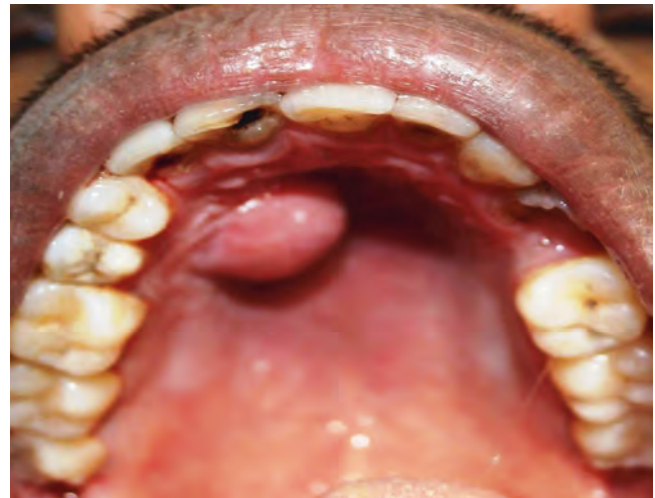Fig. 20.4 (a, b) Effect of buccinator muscle attachment on the site of appearance of swelling in case of maxillary molars. In (a) the infection has localised to the vestibule while in (b) the infection has spread to the

buccal space, as the root apex is situated above the attachment of the buccinator muscle



©Association of Oral and Maxillofacial Surgeons of India

Fig. 20.5 Shows the clinical picture of a vestibular abscess arising from an infected upper right first molar



©Association of Oral and Maxillofacial Surgeons of India

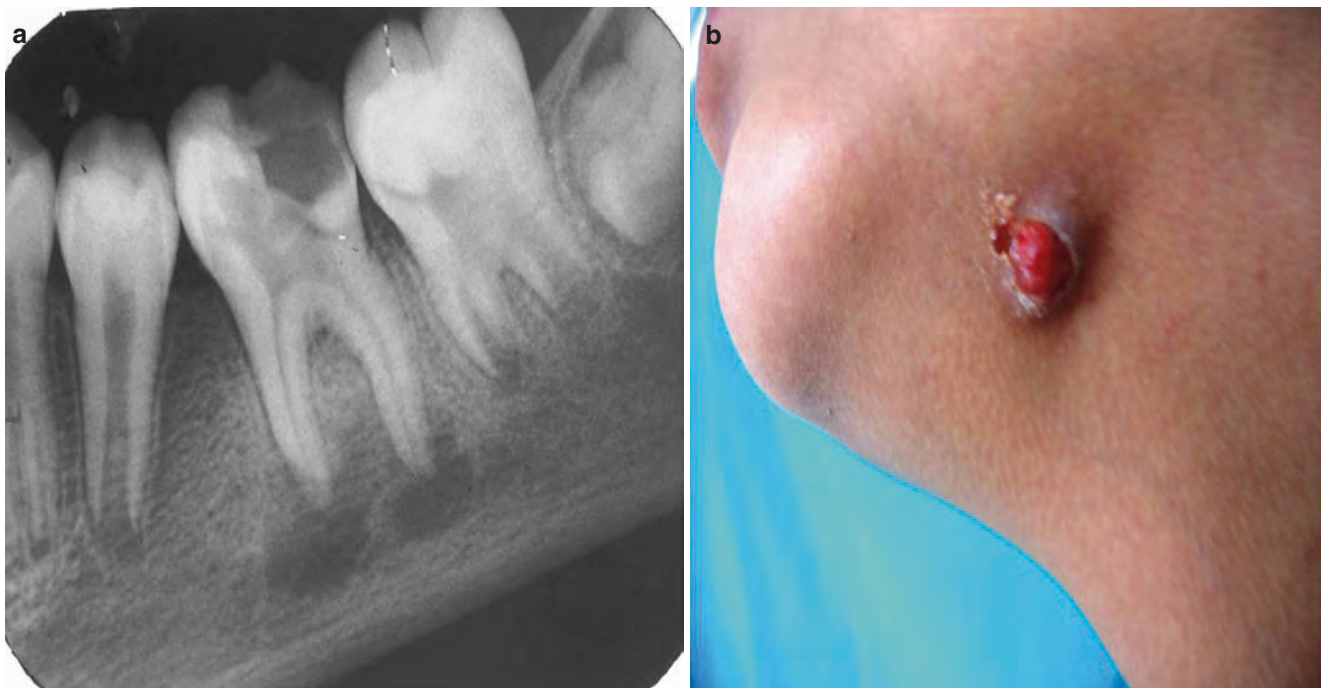
Fig. 20.6 Palatal abscess arising from upper incisors

as compared to the buccal cortical plate. If this gets perforated above the mylohyoid line, a sublingual swelling occurs and if below it, a submandibular swelling occurs.

The commonest manifestation of odontogenic infections is either a palatal or a vestibular abscess. When untreated, it may lead to an intraoral or extraoral drainage, in due course establishing a sinus tract. The treatment involves removing the cause (endodontically or via exodontia) and management of the sinus tract. In certain cases, the sinus tract resolves by itself, following the treatment of the offending cause (Fig. 20.7).

20.5 Pathways of Spread of Periapical Infections

An odontogenic infection follows the path of least resistance. A periapical infection may perforate the nearest or the weakest cortex and travel along the soft tissue, initially as cellulitis and eventually resulting in abscess formation. This abscess may drain spontaneously, extraorally or intraorally and may involve one or more anatomically potential spaces. When this happens, it is known as a space infection.



©Association of Oral and Maxillofacial Surgeons of India

Fig. 20.7 (a, b) Shows the periapical lesion in lower left first molar in a 14-year-old patient causing extraoral sinus at the left lower border mandible region

Following are frequently affected anatomic spaces, (Fig. 20.8):

1. With any tooth.
 - Subcutaneous.
 - Vestibular.
 - Buccal.
2. With any offending maxillary tooth.
 - Buccal.
 - Maxillary along with other para nasal sinuses.
 - Infraorbital.
 - Infratemporal.
 - Temporal.
3. With any offending mandibular tooth.
 - Medullary space of mandibular body.
 - Submandibular.
 - Sublingual.
 - Submental.
 - Masticator.
 - Submasseteric.*
 - Pterygomandibular.*
 - Superficial temporal.*
 - Deep temporal.*
4. Deep fascial spaces.
 - Lateral pharyngeal.
 - Retropharyngeal.
 - Pretracheal.

Danger (Alar space).
Prevertebral.

Various spaces involved in an infection differ in their relative severity depending upon the proximity of the vital anatomic structures in their vicinity. This may be seen as follows.

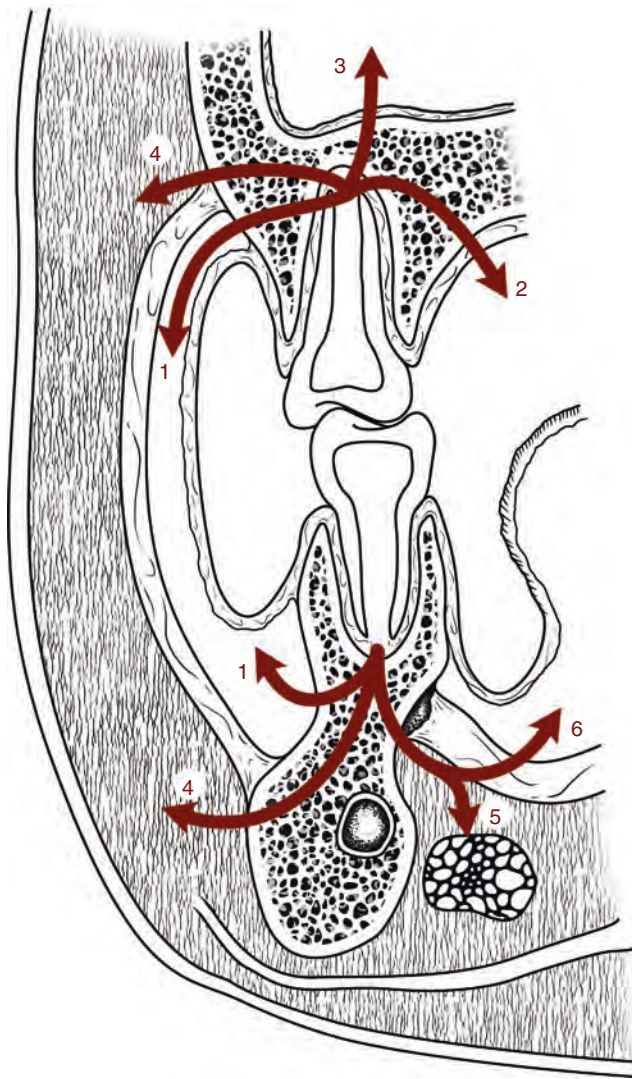
20.6 Various Space Infections and Their Relative Severity

MILD—Vital structures and airway may be mildly threatened

- Subperiosteal.
- Infraorbital.
- Buccal.
- Vestibular.
- Osteomyelitis of the mandible.

MODERATE—Airway may be compromised

- Pterygomandibular.
- Superficial temporal.
- Submandibular.
- Sublingual.
- Submental.



©Association of Oral and Maxillofacial Surgeons of India

Fig. 20.8 Pathways of spread of periapical infection. (1) Vestibular space. (2) Palatal abscess. (3) Maxillary sinus/odontogenic sinusitis. (4) Buccal space. (5) Submandibular space. (6) Sublingual space

- Submasseteric.
- Infratemporal.
- Deep temporal.
- Masticator.

HIGH—Vital structures or airway under direct threat

- Lateral pharyngeal.
- Retropharyngeal.
- Danger space (Alar space).
- Pretracheal.
- Cavernous sinus thrombosis.
- Intracranial infections (brain abscess).

- Mediastinal.
- Prevertebral.

20.7 Basic Therapeutic Principles

1. Delineation of cause and severity.
2. Assessment of host's immune response.
3. Role of specialist.
4. Surgical intervention.
5. Pharmacotherapeutics.
6. Follow-ups.

1. *Delineation of cause and severity:* As a standard protocol, a proper history should be recorded in chronological order stating the patients' chief complaints in his/her own words.

Once the chief complaint is noted, history of present illness is determined with an estimation of how long back the patient was absolutely symptom free. Usually, infections have a short history of onset as compared to tumors in their acute state [6].

Next thing to be noted is any change in the patients' state of physical well-being since the symptoms first appeared, i.e. if they have been the same, improved, or worsened with time. Since the response to an infection is essentially an inflammatory one, classic sign of inflammation are always looked for (tumor, rubor, dolor, color, and loss of function). Principal presenting feature is pain, so the nature of pain, site, and diurnal variation should be noted. A sharp, piercing, and lancinating type of pain is generated by A δ nerve fibers that usually awake the patient at night (in accordance with the hydrodynamic theory of pulpal pain by Brannstrom [7]); however, a dull, aching, and gnawing kind of pain arises due to stimulation of slowly firing "c" type nerve fibers.

Swelling, redness, and rise of temperature should be inquired for and inspected even during history taking if these are apparent. Loss of function may manifest in the form of dyspnea, dysphagia, difficulty in chewing, or trismus [8]. A feeling of general malaise usually indicates a physical or physiological response against moderate to severe infection [9].

At this point, an enquiry into any previous treatments by another dentist, specialist, and/or self-treatment should be made and recorded. After carefully listening to the chief complaints and history of present illness, a comprehensive medical history should be recorded. The most efficient means of doing so is either by personal structured interview or by means of a questionnaire along with a discussion with the patient for any positive findings.

History taking is followed by a physical examination that begins with the recording of patients' vitals as temperature, pulse rate, respiratory rate, and blood pressure. Patients with infections usually have elevated body temperature, and increased pulse and respiratory rates [10]. If the pain is significant, patient's blood pressure may be elevated. However, hypotension is seen in septicemic states. Since odontogenic infections are inflammatory states, a partial or complete upper airway compromise may occur owing to an extension of the current infection to the deep facial spaces of the neck [11]. The patients may present with fatigue, fever, and malaise or so-called toxic appearance (Table 20.3) [12].

Palpation of swellings should be done to know the tenderness and consistency of the swelling. Consistency of a swelling may vary from normal, firm, fleshy (dough like) to indurated (consistency of a taught muscle/wooden like/brawny hard), or fluctuant (feel of a fluid-filled balloon). Fluctuation almost always indicates presence of pus in the center.

Intraoral examination gives a fair amount of idea as to the cause of the infection, i.e. the offending tooth. A careful look may reveal a grossly carious tooth/teeth, periodontal diseases, and/or a fractured tooth.

Investigative phase begins with a radiograph; intraoral periapical (IOPA) or orthopantomogram (OPG) depending on the symptomatology and clinical examination. CT scan may be required in severe cases to assess the pathway of the spread of infection [13].

If any surgical intervention is required, a routine blood assessment is always helpful in deciding the type of procedure to be followed.

A decision has to be made as to the stage of the infection, i.e. inoculation, cellulitis, or abscess stage. Usual attributes are as follows.

2. *Assessment of Immune response:* General medical history is the guide to detect any interfering systemic conditions that may compromise the host defense mechanism and may worsen patient's condition rapidly. Conditions of compromised host defense mechanism are as under:

Table 20.3 Stages of infection

Stage of infection	Clinical features
Inoculation	Edema/Inflammation
Cellulitis	Acute pain
	Firm to borderline swelling/induration
	Diffuse borders
	All cardinal features of inflammation
Abscess	Localized pain (acute abscess)
	Fever (more often than not)
	Fluctuant swelling

- (a) **Diabetes Mellitus (type I and II):** When uncontrolled, it results in an overall decrease in the immunity owing to decreased phagocytosis, chemotaxis, and generalized decrease in leukocyte function. However, in patients with moderate to severe infection, an increased random blood sugar cannot be a diagnostic criteria for underlying diabetes. Since these are high-stress states, the body gluconeogenic mechanisms are upregulated to meet the increased BMR. So, a more comprehensive analysis like HBA₁C is performed to know the long-term glycaemic status.
- (b) **Leukocytic upsurge** is expected in infection. The baseline leukocyte/neutrophil count serves as a marker to track the response of the patient to medical and surgical intervention in a case of severe odontogenic infection.
- (c) **Immuno-deficient states:** HIV infection principally affects the T lymphocytes, meaning that the humoral immune system is still intact. Odontogenic infections are generally bacterial and usually well defended by the patients' immune system, but in immunocompromised states, the basic host defense mechanism no longer functions. When the disease advances to involve even the B-cells, then, even simple infections may become serious life-threatening issues in such patients. It is hence important to know that such immunocompromised HIV-positive individuals need more intensive therapy than a normally infected individual.
- (d) Another example of systemic immuno-deficient states may be prolonged corticosteroid therapy. Here the inflammatory cascade itself gets modulated, and affects the immune system as a whole, resulting in decreased production of the cell adhesive molecules, deficient leukocyte chemotaxis, and decreased cytokines production (IL-1, TN α , IL-6, etc.). No apoptotic activity results in generalized lymphocytopenia along with IL-2 mediated cyto-proliferative responses. When used long enough or in high doses, delayed-type hypersensitivity (type IV) response is inhibited along with decreased antibody formation. Such patients soon develop oral thrush and other superimposed bacterial or viral infections of the oral cavity, worsening of an existing odontogenic infection being no exception.
- (e) **End Stage Renal Diseases (ESRD):** End stage renal diseases affect almost all aspects of the innate and acquired immunity, and many such patients will be on maintenance hemodialysis. ESRD patients having odontogenic infections also may have to be managed

comprehensively where adequate support from the allied speciality is available.

(f) **Drug-induced immuno-incompetence:** While blood counts less than 1000 cells/ml are typically seen in patients on anti-cancer chemotherapy, patients who undergo organ transplants have to be on immune-suppressive therapy (IST). Drugs like corticosteroids and cyclosporins have decreased B and T lymphocyte function and consequently deficient immunoglobulin production. As such, patients are likely to have exaggerated manifestation for even mild odontogenic infections.

(g) **Alcoholism and/or Hepatic insufficiency:** Alcoholics are usually malnourished and have pending hepatic damage that leads to poor qualitative and quantitative immunoglobulin supply.

Above discussion reinforces that while assessing a patient, a thorough medical history as well as a history of habits provides vital clues for the action to be adopted for his/her management.

3. **Role of Specialist:** Role for patient care should shift from a general dentist to a maxillofacial surgeon. Antibiotics should be started if indicated as in Table 20.4. When the situation demands, either a hospital admission or immediate surgical care under regional or general anesthesia is required. The following criteria may be adopted for making this vital discussion in patient's interest:

- (a) Failed earlier management.
- (b) Medically compromised patients.
- (c) Toxic appearance patients.
- (d) Febrile patient: temperature greater than 101 °F.
- (e) Signs of dehydration.
- (f) Dyspnea.
- (g) Difficulty swallowing (dysphagia).
- (h) Moderate to severe trismus (with mouth-opening between 10 and 20 mm).
- (i) Need for general anesthesia.
- (j) Airway compromise.
- (k) Signs of ascending or descending facial infections (cavernous sinus thrombosis/deep neck infections/mediastinitis).

Table 20.4 Indications for antimicrobial therapy

1. Trismus (mouth opening between 10 and 20 mm).
2. Cellulitis (infection may not have drained completely).
3. Lymphadenopathy (lymph nodes may harbor residual infection).
4. Temperature > 101 °F (bacteremia).
5. Osteomyelitis.
6. Severe soft tissue involvement (e.g. necrotizing fasciitis).
7. Swelling extends beyond alveolar anatomy.
8. Systemically compromised patient.

4. **Surgical Intervention:** Surgical drainage and removal of the course of infection is the mainstay of surgical management of odontogenic infection [14]. This may be as simple as endodontic therapy to wide incision in the submandibular/neck region that may require mediastinal exploration. The removal of the cause is the primary goal and drainage of the accumulated pus and necrotic debris is the secondary goal.

Incision and drainage principally includes insertion of a drain in the abscess cavity to prevent premature closure of the mucosal/skin incision. Purpose of this procedure is to achieve adequate drainage, if it is not possible by endodontic means (especially in mandibular teeth) (refer Chap. 21 for details on incision and drainage).

Pus culture and Sensitivity Tests: This must be done before the incision and drainage procedure if possible. The site is prepared with antiseptics and a thick needle is used to aspirate pus, may be in multiple directions, under negative pressure of syringe, and taking due care to prevent relevant anatomic structures. In case of complex space infections involving the digastric/carotid triangle, ultrasound-guided aspiration must be done. This culture when obtained from sites of cellulitis (Ludwig's Angina) usually contains serosanguinous fluid but harbors sufficient bacteria for culture. This aspirate is inoculated into both anaerobic and aerobic cultures (sterile tubes having sterile swabs and bacterial transport medium) with viable shelf life [15].

20.8 Antimicrobial Therapy

Once the culture and sensitivity reports are available, specific antimicrobial therapy may be installed but meanwhile empirical antibiotics should be started immediately [16]. The choice of antibiotic should be carefully thought off to prevent unnecessary disturbance of the essential microflora of the gut and development of cross resistance (Also refer Chap. 10 of this book).

Cases of moderate to severe infection generally need postoperative antibiotics, where the host defense cannot be solely relied upon to fight the residual infection. Since the antibiotic sensitivity of usual causative organisms of odontogenic infections is fairly well known and consistent, an empirical therapy may include clindamycin, metronidazole, and penicillin. Metronidazole being narrow spectrum covers only obligate anaerobic population and the rest may be covered by other drugs dealing with facultative microbes. Odontogenic infections are complex entities, both, on the basis of the plethora of flora associated and mechanism of their spread to the adjacent as well as distant anatomic

Following principles should be additionally borne in mind before prescribing antibiotics [17]:

1. Use of narrowest possible spectrum- prevents bacterial resistance.
2. Use of antimicrobial with least toxicity and side effects- prevents vital organ damage.
3. Use of bactericidal rather than bacteriostatic drug- prevents residual infection.
4. Weigh cost to benefit ratio- prevents over expenditure.
5. Use only in prescribed dose and duration- restricts side effects and maintains efficacy.
6. Use the appropriate route of administration- restricts side effects and maintains efficacy.

sites. Fortunately, culture and sensitivity behaviors of the causative microbes are fairly consistent and well understood. As such timely management should alleviate most of the dangerous outcomes but still these infections remain one of the leading cause of maxillofacial morbidity and at times mortality.

20.9 Conclusion

Odontogenic infection can be severe enough and become life threatening, hence should be dealt with very carefully. Proper evaluation of the signs and symptoms guide the clinician to make the diagnosis. Radiographic assessment may suggest the involvement of one or more teeth. Surgical intervention includes drainage of abscess, and pus be sent for culture and sensitivity to help choose the right antibiotic regime.

References

1. Chinen J, William T. Secondary immunodeficiencies. *Am Acad Allerg Asth Immunodef.* 2010;125(2 Suppl 2):S195–203.
2. Socransky SS, Haffajee AD. Periodontal microbial ecology. *Periodontol* 2000. 2005;38:135–87.
3. Newman M, Takei H, Klokkevold P, Carranza F. Carranza' clinical periodontology. 12th ed. Saunders: Elsevier; 2014.
4. Brook I, Frazier EH, Gher ME. Aerobic and anaerobic microbiology of periapical abscess. *Oral Microbiol Immunol.* 1991;6(2):123–25.
5. Chandra S. Grossmann's endodontic practice. 13th ed. South Holland: Wolters Kluwer; 2014.
6. Walker B, Colledge NR, Ralston S, Penman I. Davidson's medicine. 22nd ed. Edinburgh: Churchill Livingstone; 2014.
7. Brännström M. The hydrodynamic theory of dentinal pain: Sensation in preparations, caries, and the dentinal crack syndrome. *J Endod.* 1986;12(10):453–7.
8. Mathew GC, Ranganathan LR, Gandhi S, Jacob ME, Singh I, Solanki M, et al. Odontogenic maxillofacial space infections at a tertiary care center in North India: a five-year retrospective study. *Int J Inf Dis.* 2012;16:e296–302.
9. Hupp JR, Ellis E III, Tucker MR. Contemporary oral and maxillofacial surgery. 6th ed. St Louis Mosby: Elsevier; 2014.
10. Al-Malik M, Al-Sarheed M. Pattern of management of orofacial infection in children: a retrospective. *Saudi J Biol Sc.* 2017;24:1375–9.
11. Kuo J, Lin Y, Lin YT. Odontogenic cellulitis in children requiring hospitalization. *J Dent Sc.* 2013;8:129–32.
12. Alotaibi N, Cloutier L, Khaldoun E, Bois E, Chirat M, Salvan D. Criteria for admission of odontogenic infections at high risk of deep neck space infection. *Eur Ann Otorhinolaryngol Head Neck Dis.* 2015;132:261–4.
13. Yonetsu K, Izumi M, Nakamura T. Deep facial infections of odontogenic origin: CT assessment of pathways of space involvement. *Am J Neuroradiol.* 1998;19:123–8.
14. Sánchez R, Mirada E, Arias J, Paño JR, Burgueño M. Severe odontogenic infections: epidemiological, microbiological and therapeutic factors. *Med Oral Patol Oral Cir Bucal.* 2011;16(5):e670–6.
15. Kumar V, Abbas A, Aster J. Robin's pathological basis of disease. 10th ed. Philadelphia, PA: Elsevier; 2017.
16. Kuriyama T, Karasawa T, Nakagawa K, Nakamura S, Yamamoto E, et al. Antibiotic susceptibility of major pathogens of orofacial odontogenic infections to 11 β lactam antibiotics. *Oral Microbiol Immunol.* 2002;17:285–9.
17. Topazian RG, Goldberg MH, Hupp JR. Oral and maxillofacial infections. 4th ed. Philadelphia: WB Saunders Company; 2002.

Open Access This chapter is licensed under the terms of the Creative Commons Attribution 4.0 International License (<http://creativecommons.org/licenses/by/4.0/>), which permits use, sharing, adaptation, distribution and reproduction in any medium or format, as long as you give appropriate credit to the original author(s) and the source, provide a link to the Creative Commons license and indicate if changes were made.

The images or other third party material in this chapter are included in the chapter's Creative Commons license, unless indicated otherwise in a credit line to the material. If material is not included in the chapter's Creative Commons license and your intended use is not permitted by statutory regulation or exceeds the permitted use, you will need to obtain permission directly from the copyright holder.



21.1 Introduction

There is considerable amount of change in the behavior of infections for the past one decade. The severity of infection is far greater than before which may be due to increased co-morbid conditions, demanding swift action and aggressive treatment.

Fascial spaces do not exist in a normal healthy individual. These are latent spaces created by distention of tissues secondary to infection from the dental pulp, periodontal tissues and bone, where the infection perforates the cortical plate and discharge into the surrounding spaces.

The infections range from simple superficial periapical abscess to deep infections in the neck region; some resolving with little consequences and some lead to life-threatening conditions.

Shapiro states that “The fascial planes are potential areas between layers of fascia. These areas are normally filled with loose connective tissue, which readily breakdown when invaded by infection”. The infection started in any area is automatically limited by tough fascial layers. If the infection becomes massive, it breaks through a nearby fascial barrier into the next fascial space [1].

21.2 Definition of Fascial Space

The fascial spaces in the Head and Neck are the potential spaces between the various fascia normally filled with loose connective tissue and bounded by the anatomical barriers usually of bone, muscle, or fascial layers [2].

Facial planes offer anatomic highways for infection to spread superficially to deep planes. Antibiotic availability in fascial spaces is limited due to poor vascularity.

R. Gaddipati (✉)
Mamata Dental College, Khammam, Telangana, India

21.3 Spread of Infection

The spread of the infections could be either through tissues, blood, or lymphatics leading to fatal consequences like Airway obstruction, Meningitis, and Septicemia; however, various factors influence the spread of infection.

They are as follows:

- Virulence of the organism.
- Pathogenicity of the organisms.
- Immune status of the patient.
- Malnutrition.
- Thickness of bone adjacent to the offending tooth.
- Position of muscle attachment in relation to root tip.

In the Oral and Maxillofacial region, fascial spaces are almost always of relevance due to the spread of odontogenic infections. As such, the spaces can be classified according to their relation to the upper and lower teeth, and whether infection may directly spread into the space called primary space, or must spread via a primary space to the secondary space [3].

21.4 Classification of Spaces

21.4.1 Primary Spaces and Secondary Spaces

Failure to adequately treat a primary space infection or a compromised host results in secondary space involvement (Table 21.1).

21.4.1.1 Cervical Spaces

Since hyoid bone is the most important anatomic structure in the neck that limits the spread of infection, the spaces can be classified according to their relation to the hyoid bone:

Table 21.1 Classification of spaces in odontogenic infections based on mode of involvement

Mode of Involvement
Primary spaces (Direct)
<i>Primary maxillary spaces</i>
• Canine space
• Buccal space
• Infratemporal space
<i>Primary mandibular space</i>
• Buccal space
• Sub-mental space
• Sub-mandibular space
• Sub-lingual space
Secondary spaces (Indirect)
• Masseteric space
• Pterygomandibular space
• Temporal (Superficial & Deep) spaces
• Temporal (Superficial & Deep) spaces
• Para-pharyngeal (Lateral & Retro) spaces
• Pre-vertebral space

Table 21.2 Severity score for spaces [4]

Severity score	Risk	Spaces involved
1	Low risk	Subperiosteal space Vestibular space Buccal and Infraorbital space
2	Moderate risk	Submandibular space Submental space Sublingual space Pterygomandibular space Submasseteric space and Temporal spaces
3	High risk	Lateral pharyngeal space Retropharyngeal space and pretracheal space
4	Extreme severe	Danger space Mediastinum Intracranial infection

- Suprahyoid (above the hyoid).
- Infrahyoid (below the hyoid).
- Fascial spaces traversing the length of the neck.

21.4.1.2 Severity Score Anatomic Space [4]

The severity score for a given patient is the sum of the severity scores for all of the spaces involved by cellulitis or abscess, based on clinical and radiological examination (Table 21.2).

The fascial spaces are divided into:

- Spaces around the Maxilla.
- Spaces around the Mandible.

The infections arising from the maxillary anterior teeth spread to Canine space, while the infection from molars spread to Buccal space, Infratemporal space, or cause palatal abscess. Likewise, the infection from the mandibular anterior teeth spread to Submental space or cause gingival abscess. Infection from mandibular molars spread to the Sublingual space or the Submandibular space. While the infection from

Table 21.3 Characteristic features of cellulitis and abscess

Clinical feature	Cellulitis	Abscess
Duration	Acute	Chronic
Pain	Severe and generalized	Localized
Size	Large	Small
Localization	Diffuse borders	Well defined
Palpation	Doughy to indurated	Fluctuant
Pus formation	No	Yes
Seriousness	Greater	Lesser
Bacteria	Aerobic	Anaerobic

mandibular third molars spread to Submasseteric space, Pterygomandibular space and Lateral Pharyngeal space.

However, it is not a “rule of thumb” for the involvement of a particular space with a specific tooth infection.

21.5 General Principles of Management of Infection

1. Remove the cause.
2. Establish drainage.
3. Institute antibiotic therapy.
4. Supportive care, including proper rest and nutrition.

Pyogenic infections are primarily managed by surgical intervention comprising decompression or drainage. It is better to proceed with decompression at the earliest, without waiting for the localization of the infection (abscess formation), thereby preventing the spread of infection in tissue planes and mounting of pressure under the skin (Table 21.3).

Early decompression has the following benefits:

1. Prevents the spread of infection.
2. Prevents ischemic necrosis of the tissues.
3. Prevents pressure in the tissues.
4. To get rid of toxic purulent discharge.
5. Improves the drainage, by opening the lymphatic and venous channels, which were blocked by the edema and congestion.
6. To allow better perfusion of blood thereby improving the delivery of antibiotics and defensive elements to the required site.
7. Prevents further complications.

21.6 Hilton's Method of Abscess Drainage (Figs. 21.1a and 21.1b)

This is a method of abscess drainage which ensures that no blood vessel or nerve in the vicinity of the incision is damaged.

1. Topical anesthesia is achieved by ethyl chloride spray.
2. Stab incision with the help of 11 number blade is made at the most dependent area along the skin crease.
3. Sinus forceps is inserted through the incision and all the locules in the abscess are explored.
4. Purulent discharge, toxic material, gases, and necrotic tissue drained through the incision.
5. Pus collected and sent for culture and sensitivity test.
6. Abscess cavity is irrigated with antiseptic solution.
7. Corrugated rubber drain is inserted deep into the abscess cavity and secured to the edge of the incision and the drain is removed once there are no active exudates.
8. Dressing placed over the incision.

Fig. 21.1a Hilton's method of transoral incision and drainage. (a) Abscess associated with tooth. (b) Stab incision given with blade. (c) sinus forceps is entered into the cavity and opened. (d) Drain entered into the cavity. (e) Drain secured with suture

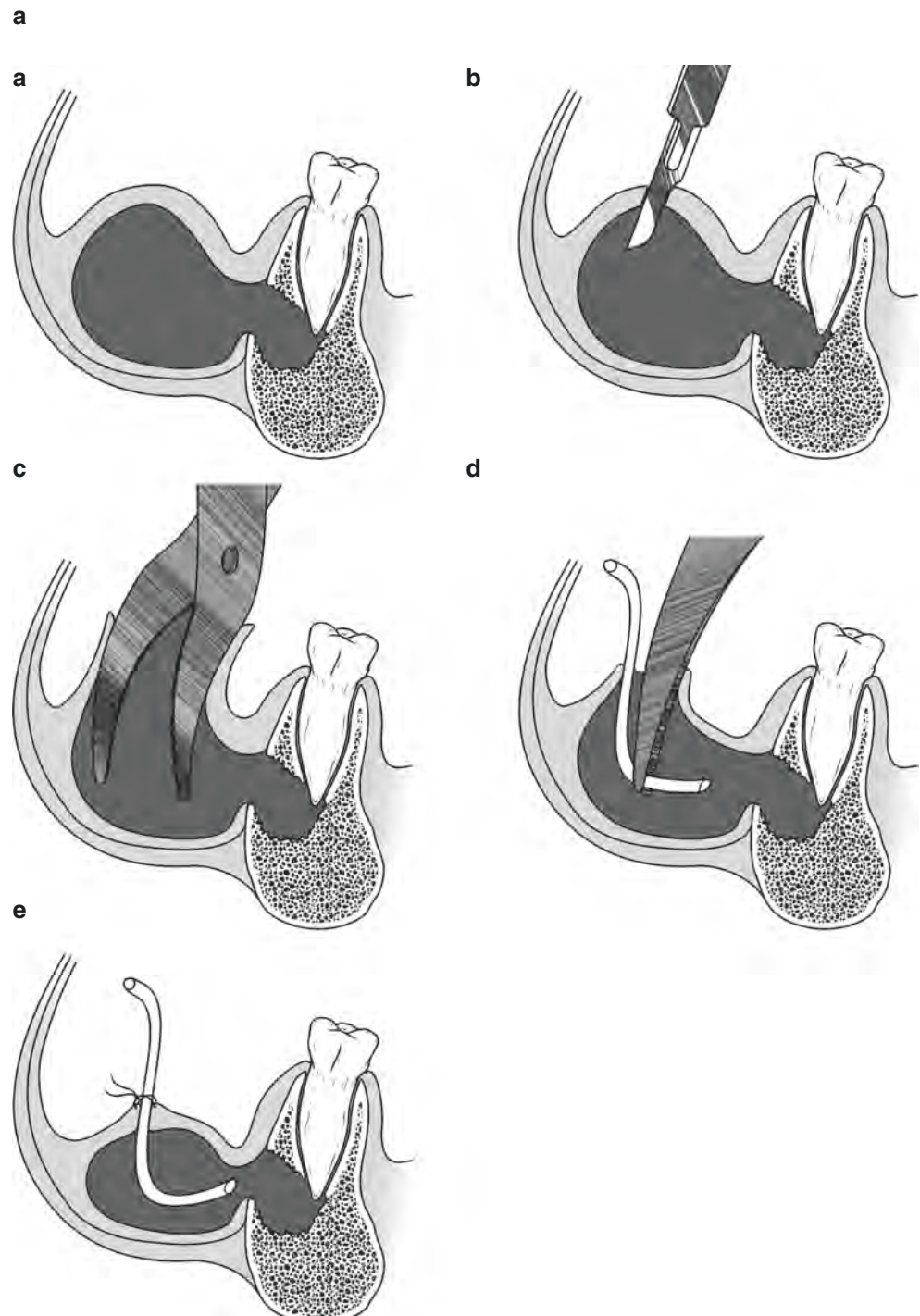
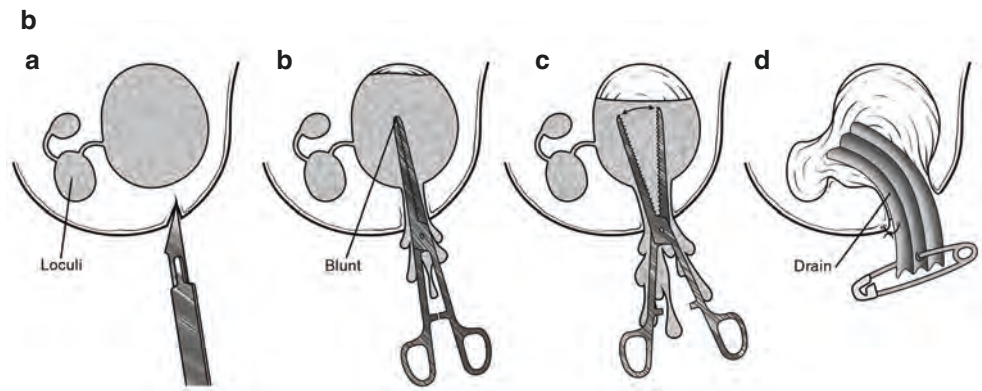


Fig. 21.1b Hilton's method of incision and drainage (extra oral site). (a) Incision given at the dependent site of the abscess. (b) Sinus forceps entered into the abscess cavity. (c) Sinus forceps opened in the cavity and removed. (d) Drain entered into the cavity and secured with suture



Removal of the source of the infection is mandatory apart from drainage.

21.7 Medical Management

Supportive management is mandatory in the form of antibiotics, anti-inflammatory, and electrolytes. The reader is also advised to refer the chapter on general principles of management of facial infections (Chap. 20).

21.7.1 Antibiotic Therapy

Antibiotics are advised depending upon the patient's systemic condition; initially, after pus collection, empirical antibiotic is given; later, after the culture and sensitivity is performed, -specific antibiotics are advised.

Route of administration depends upon the general condition and severity of the infection. Para-enteral route is preferred when the infection is acute and severe or when the patient is nutritionally or medically compromised.

With evidence of slough, gas, crepitus, and foul smell, anaerobic infection may be suspected and appropriate antibiotics have to be given.

Principles of choosing appropriate antibiotic

- Causative organism,
- Sensitivity,
- Specific, narrow-spectrum antibiotic,
- Least toxic antibiotic,
- Drug history (success, allergic, and toxic).

Flynn TR [5] in their systemic review concluded that antibiotics should be chosen which are safe and cost effective, because no one antibiotic is clearly superior to all others. In otherwise healthy patient, a 3–4-day regimen of antibiotic

Table 21.4 Choice of empirical antibiotics (also refer Chap. 10)

Severity/Penicillin allergy	Antibiotics of choice
In patient	Ampicillin/Sulbactam Clindamycin Penicillin + metronidazole Ceftriaxone
Penicillin allergy	Clindamycin Moxifloxacin Vancomycin + metronidazole
Out patient	Amoxicillin Clindamycin Azithromycin
Penicillin allergy	Clindamycin Azithromycin Metronidazole Moxifloxacin

therapy should be adequate. The primary importance should be given to the surgical treatment consisting of incision and drainage, extraction, or endodontic therapy of the involved tooth. According to their review, the choice of empiric antibiotics for odontogenic infections is listed in Table 21.4.

Martins JR et al. [6] suggests that after incision and drainage/removal of the cause is mandatory. Antibiotics should be administered for the shortest duration possible and should act as an adjuvant for the primary surgical treatment in countering any regional or systemic co-morbidities.

21.8 Fluid and Electrolytes

Apart from antibiotics and anti-inflammatory drugs, administration of fluids and electrolytes is mandatory, as there is a loss of fluids due to infection and fever. In non-ambulatory patients, intravenous fluids are administered depending on their systemic status.

Daily calorie requirement also increases by up to 13% for each degree rise in temperature, which needs to be addressed for a speedy recovery.

Supportive therapy.

It involves those modalities which aid the patient's own body defenses. It consists of the following:

1. Administration of antibiotics.
2. Hydration of patient through IV route, maintain adequate nutritional status-high protein intake.
3. Analgesic.
4. Bed rest.
5. Application of heat in the form of moist pack, advice mouth rinses.
6. Dental management by extraction or root-canal treatment for drainage.

21.9 Selection of Anesthesia

A simple and superficial abscess can be drained comfortably under local anesthesia, while deep-seated, multi-loculated abscesses may not be amenable for treatment under local anesthesia and may be managed under procedural sedation provided the patient has adequate mouth-opening and patent airway.

Fiber-optic intubation or tracheostomy may be considered in; patients with limited mouth opening (trismus) or in patients

having intra-oral and pharyngeal infections (sub-lingual, lateral/retropharyngeal spaces) where the chances of aspiration is high in the event of oro/naso-tracheal intubations.

21.10 Spaces Around the Maxilla

21.10.1 Canine Space/Infraorbital Space

The canine space, synonymous with Infraorbital space, is situated in the anterior surface of the maxilla at the infraorbital region above canine fossa.

21.10.1.1 Source of Infection

- From upper canine and bicuspid.
- Skin infections of upper lip [7].

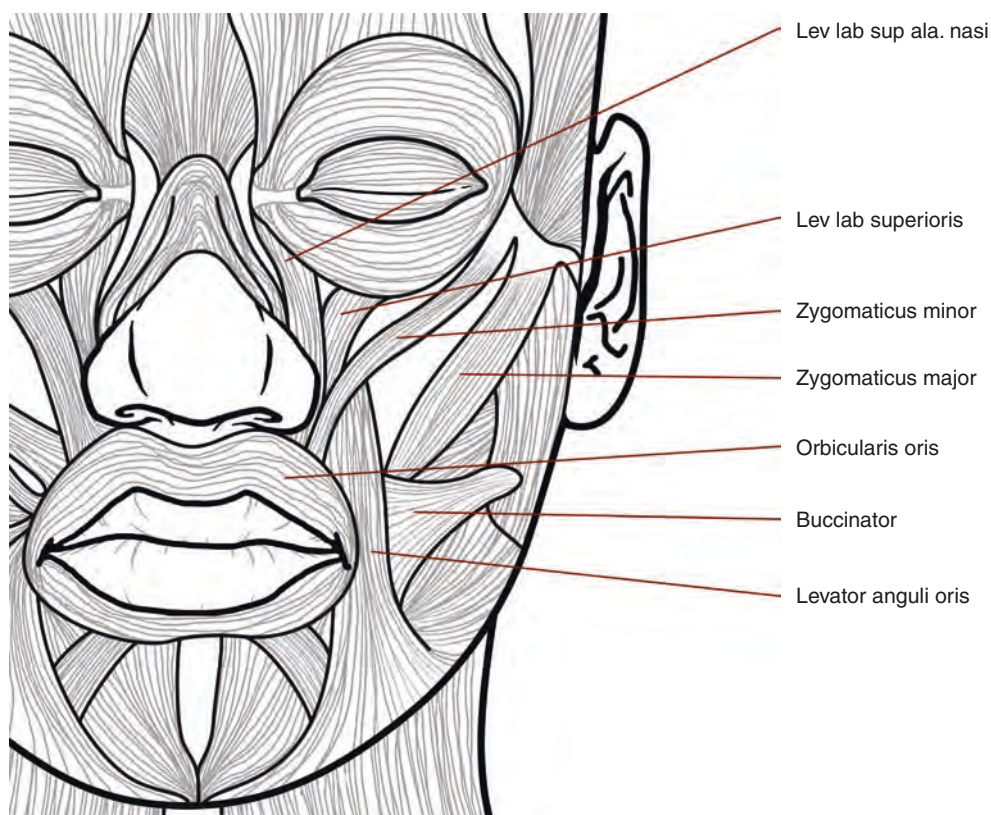
21.10.1.2 Boundaries (Fig. 21.2)

- Anterior—Elevator muscles of upper lip (Orbicularis oris).
- Posterior—Anterior surface of Maxilla.
- Medial—Levator Labii Alaeque nasi.
- Lateral—Zygomaticus major.

21.10.1.3 Contents

- Angular artery and vein.
- Infraorbital nerve.

Fig. 21.2 Shows boundaries of canine (infraorbital) space



21.10.1.4 Clinical Features

1. Pain and tenderness.
2. Swelling in the anterior cheek region.
3. Obliteration of Nasolabial folds.
4. Edema of lower eyelid and upper lip.
5. Obliteration of labial vestibule.

21.10.1.5 Management

Drainage of the space infection either intraorally or percutaneously is done; intraoral incision and drainage are preferred as these will not produce a facial scar. Drainage is made by making an in-depth incision of the maxillary vestibule near canine fossa. Sinus forceps is inserted superiorly, laterally, and medially for complete breakage of locules and drainage. Care is taken while using sinus forceps, so as to not damage the infraorbital nerve and its branches.

Aggressive antibiotic therapy is mandatory to prevent the spread as it lies in the danger area of the face and also to prevent Cavernous sinus thrombosis from septic thrombi entering into angular vein.

The involved tooth is either removed or subjected to root canal treatment with multiple dressings. Patient is advised good hydration and rest.

21.10.2 Buccal Space

The buccal space occupies the portion of the subcutaneous space present between the fascial skin, buccinator muscle, and masseter muscle [8].

Source of infection—From maxillary premolar and molar teeth root apices above buccinator attachment.

From mandibular premolar and molar teeth root apices below the buccinator attachment.

21.10.2.1 Boundaries

- Medial: Buccinator muscle, buccopharyngeal fascia, and mucosa.
- Lateral: Skin of cheek and subcutaneous tissue.
- Anterior: Posterior border of zygomaticus major above and depressor anguli oris below.
- Posterior: Edge of masseter muscle.
- Superior: Zygomatic arch.
- Inferior: Lower border of mandible.

21.10.2.2 Contents

- Buccal pad of fat.
- Stenson's duct.
- Facial artery.

21.10.2.3 Clinical Features

1. Pain and tenderness.
2. Diffuse swelling on the side of the cheek.

3. Obliteration of buccal vestibule.
4. Swelling of upper/lower lip (Fig. 21.3).

21.10.2.4 Management

Drainage of the space infection either intraorally or percutaneously is done; intraoral incision and drainage are preferred as these may not produce a facial scar. Drainage is made by making an in-depth incision of the maxillary vestibule near the involved tooth. Sinus forceps is inserted superiorly, laterally, and medially for complete breakage of locules and drainage. Care is taken while using sinus forceps, so as to not damage duct and artery (Fig. 21.4a, b, c).

For mandibular buccal space infection, intraoral drainage may not achieve the desired result, hence extraoral drainage at the lower border of mandible is made taking care of the facial artery and marginal mandibular nerve.

The involved tooth is either removed or subjected to root canal treatment as required. Literature advocates early extraction of the involved tooth/teeth. According to Igoumenakis D et al. [9], extraction of the involved tooth shortens the hospital stay and provides faster recovery on a biological level.

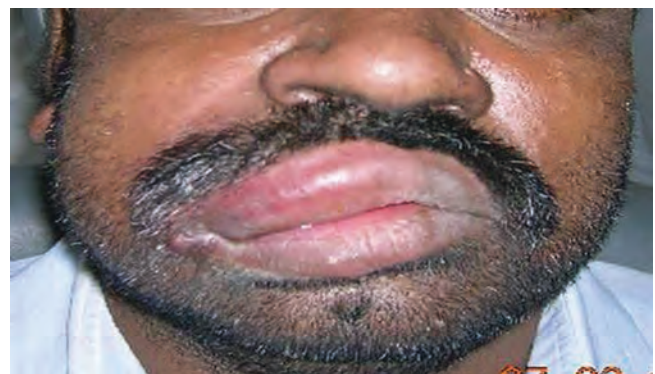21.10.3 Temporal Pouches

Infections in this region are relatively rare to occur when involved swelling occurs at the temporal region above zygomatic arch and behind the lateral orbital rim [10]. They are two in number—*Superficial temporal space* and *Deep temporal space* (Fig. 21.5).

21.10.3.1 Superficial Temporal Space

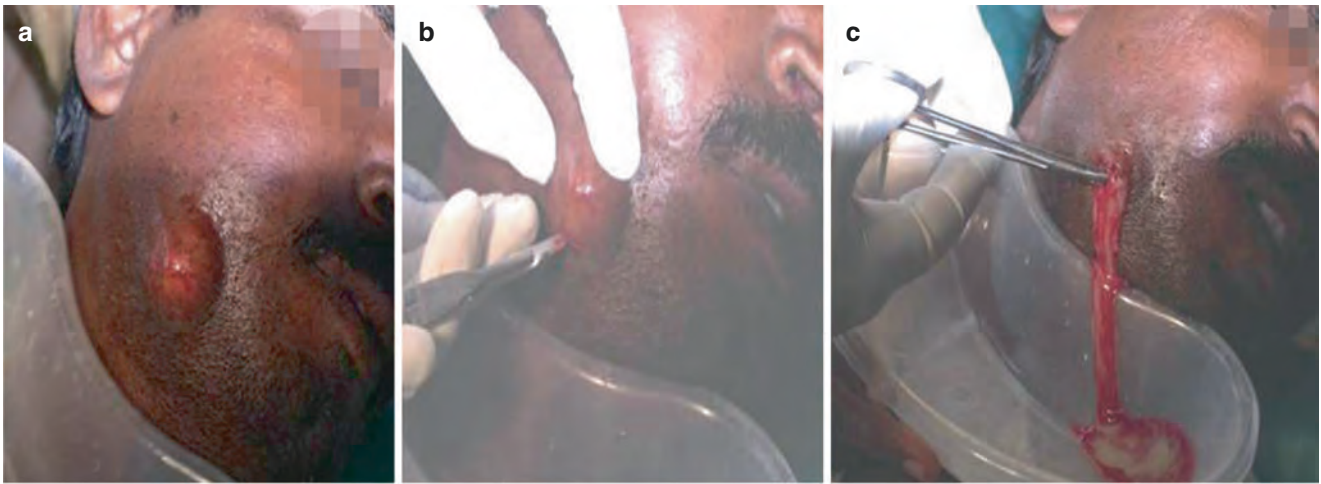
This space lies between the temporal fascia and temporalis muscle.

Source of infection—From upper third molars and infection from other spaces.



©Association of Oral and Maxillofacial Surgeons of India

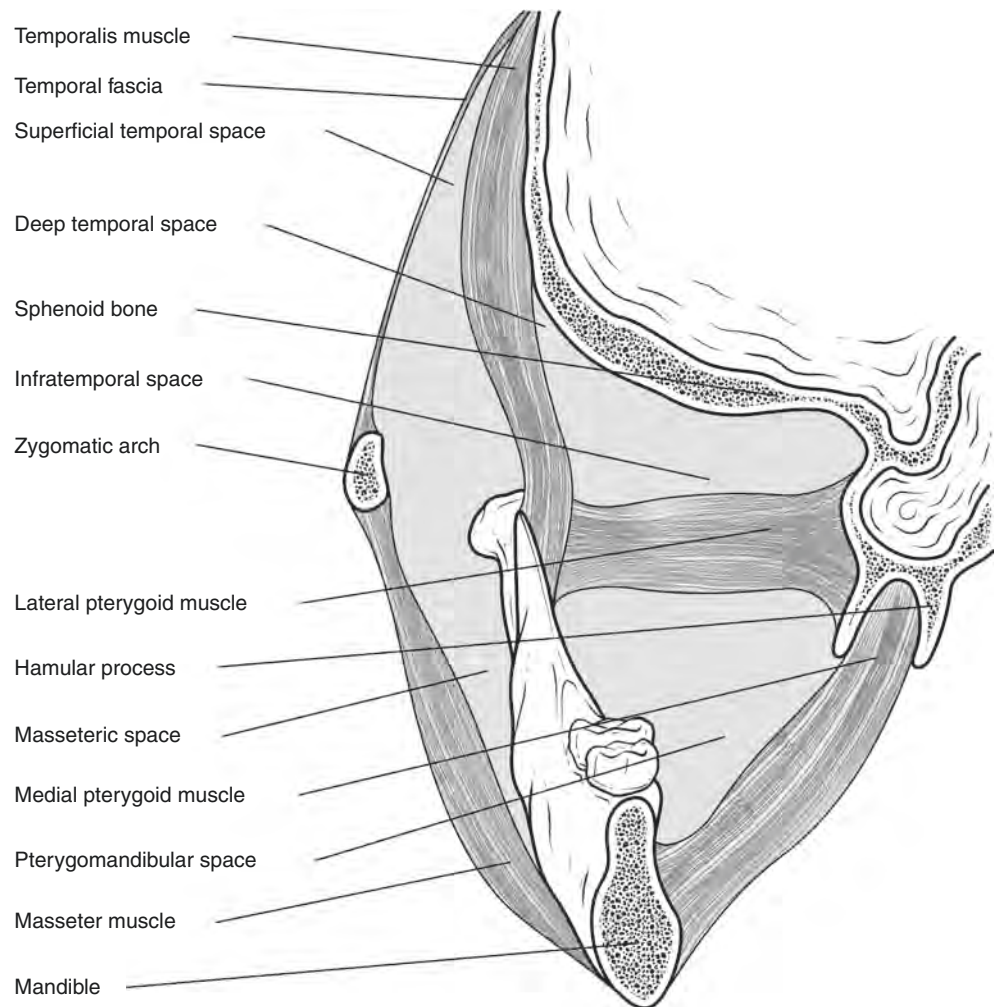
Fig. 21.3 Clinical picture showing the buccal space infection



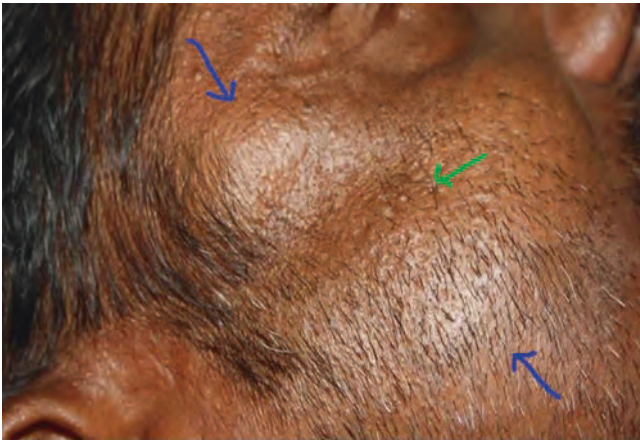©Association of Oral and Maxillofacial Surgeons of India

Fig. 21.4 (a, b, c) Clinical pictures showing the procedure of incision and drainage for buccal space infection (also see Fig. 21.1B)

Fig. 21.5 Shows the superficial and deep temporal spaces



©Association of Oral and Maxillofacial Surgeons of India



©Association of Oral and Maxillofacial Surgeons of India

Fig. 21.6 Clinical image of the classical dumb bell swelling (blue arrows). The isthmus of the swelling at the zygomatic arch is shown by the green arrow

21.10.3.2 Boundaries

- Superior—superior temporal lines.
- Inferior—zygomatic arch.
- Lateral—superficial temporal fascia.
- Medial—temporalis muscle.
- Anterior—posterior surface of lateral orbital rim.
- Posterior—fusion of temporal fascia with pericranium.

21.10.3.3 Contents

- Temporal fat pad.
- Temporal branch of Facial nerve.

21.10.3.4 Clinical Features

1. Pain and tenderness at the temporal region.
2. Swelling is present above and below zygomatic arch, leading to classical “Dumb bell” shaped appearance (Fig. 21.6).
3. Trismus may be present.

21.10.3.5 Management

Surgical drainage is carried out through an incision made above the zygomatic arch; sinus forceps is inserted through the skin incision and passed through the superficial fascia and the temporal fascia.

21.10.4 Deep Temporal Space

This space lies between the temporalis muscle and the skull. Slightly below the level of zygomatic arch; both the superficial and deep temporal spaces communicate with each other.

Source of Infection—Upper third molar and spread from other spaces.

21.10.4.1 Boundaries

- Superior—Attachment of temporal fascia to the cranium.
- Inferior—Lateral pterygoid muscle.

- Medial—Medial pterygoid plate and lower part of infratemporal fossa.
- Lateral—Medial surface of the temporalis muscle.

21.10.4.2 Contents

Branches of Internal maxillary artery.
Mandibular division of trigeminal nerve.

21.10.4.3 Clinical Features

1. Pain.
2. Swelling at the infratemporal region and lateral aspect of the eye.
3. Obliteration of buccal sulcus at tuberosity area.
4. Trismus due to proximity of masticatory muscles.
5. Infection may extend to the infratemporal and pterygo-mandibular region.

21.10.4.4 Management

If the trismus is not severe, intraoral incision is given in the buccal sulcus at the second and third molar region. With the sinus forceps, the space is entered medial to coronoid process superiorly and the pus is drained. Corrugated rubber tube is placed and secured with a suture.

In case of severe trismus, extraoral incision is made above the zygomatic arch at the junction of frontal and temporal process of zygoma, sinus forceps is inserted and directed inferiorly and medially to enter the space and drain the pus. The disadvantage of this approach is that it cannot produce dependent drainage.

21.11 Spaces Around the Mandible

21.11.1 Submental Space

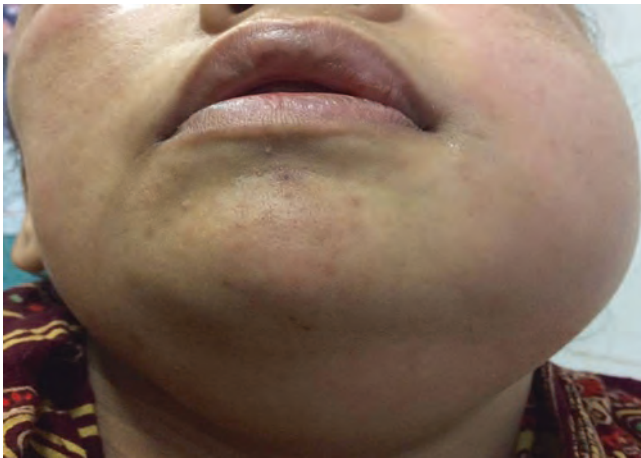The infection from any of the six anterior teeth in the mandible may perforate the labial bone inferior to the mentalis muscle attachment and the pus may present at the anterior and lower border of the mandible and below the mylohyoid muscle lingually [11].

21.11.1.1 Source of Infection

- Infection from lower anterior teeth.
- Infected symphyseal or parasymphyseal fractures.
- Suppuration of submental lymphnodes.

21.11.1.2 Boundaries (Fig. 21.7)

- Lateral: Skin, superficial fascia, platysma, superficial layer of deep cervical fascia.
- Medial: Mylohyoid, hyoglossus, and styloglossus.
- Inferior: Anterior and posterior belly of digastric muscles.
- Posterior: Hyoid bone.
- Superior: Medial aspect of mandible and the attachment of mylohyoid muscle.



©Association of Oral and Maxillofacial Surgeons of India

Fig. 21.7 Clinical picture showing spread of infection to the submental space and buccal space

21.11.1.3 Contents

- Submental nodes.
- Anterior jugular vein.

21.11.1.4 Clinical Features

1. Pain and tenderness in the chin region.
2. Firm swelling at the chin.
3. Difficulty in swallowing.
4. Tenderness of lower anterior teeth.

21.11.1.5 Management

Transcutaneous approach in the chin region is the most effective drainage; incision is made below the symphysis menti to produce dependent drainage. Sinus forceps is inserted upward and backward to break the locules and the pus is drained. A corrugated rubber drain is inserted and secured with a suture. Intraoral approach is cumbersome as we need to pierce mentalis muscle to reach the submental space and also drainage against gravity is not possible.

21.11.2 Sublingual Space

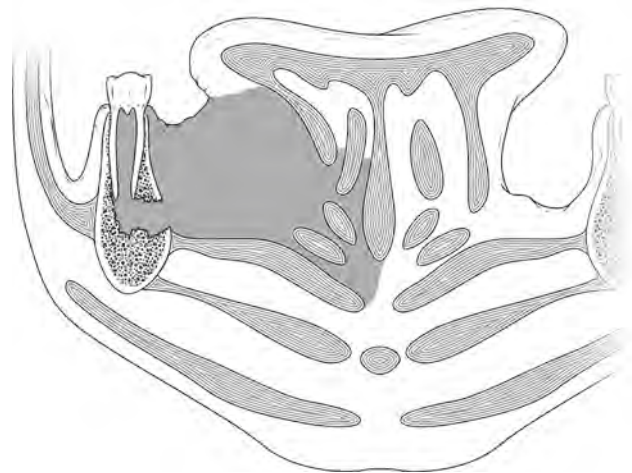
The space is V-shaped lying lateral to the muscles of the tongue and in the lingual aspect of the body of the mandible. Anteriorly communicates with submental space and posteriorly communicates with the submandibular space at the edge of the mylohyoid muscle [12].

21.11.2.1 Source of Infection

- Periapical infection from mandibular teeth is situated above mylohyoid muscle.
- Infection from sublingual gland.

21.11.2.2 Boundaries (Fig. 21.8)

- Anterior: Lingual aspect of mandible.



©Association of Oral and Maxillofacial Surgeons of India

Fig. 21.8 Shows the spread of infection to the sublingual space (grey shaded area)

- Posterior: The body of hyoid bone.
- Superior: Mucosa of oral cavity.
- Inferior: Mylohyoid muscle.
- Medial: Geniohyoid, genioglossus, and styloglossus muscle.

21.11.2.3 Contents

- Lingual nerve and Hypoglossal nerve.
- Deep part submandibular gland and duct.

21.11.2.4 Clinical Features

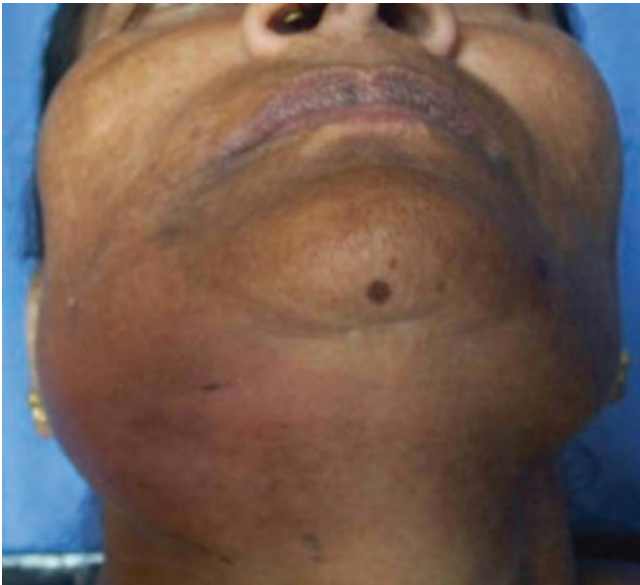1. Pain and discomfort during deglutition.
2. Due to edema, there is elevation and protrusion of the tongue.
3. In case of laryngeal edema, there may be breathlessness.
4. Speech may be affected.
5. Enlarged and tender submandibular nodes.

21.11.2.5 Management

- An intraoral incision is made close to lingual cortical plate, near premolar region taking care of lingual nerve and the Wharton's duct. Sinus forceps or a thin mosquito forceps is inserted and the pus is drained.
- If an extraoral approach is planned, then incision is placed at the submandibular region, taking care of the facial artery and marginal mandibular nerve; a sinus forceps is inserted piercing the mylohyoid muscle to drain the pus and a corrugated rubber drain is inserted and secured with a suture, as this approach provides gravity-dependent drainage.

21.11.3 Submandibular Space

- The submandibular space is present at the inferior border of the mandible between the anterior and posterior bellies of digastric muscles [13].



©Association of Oral and Maxillofacial Surgeons of India

Fig. 21.9 Clinical picture showing the submandibular space infection

21.11.3.1 Source of Infection

- Infection from the periapical region of molar teeth below mylohyoid muscle.
- Septic fractures of the mandible body region.
- Infections from submandibular salivary gland.
- Infections from submental and sublingual.
- Infection from other space.

21.11.3.2 Boundaries

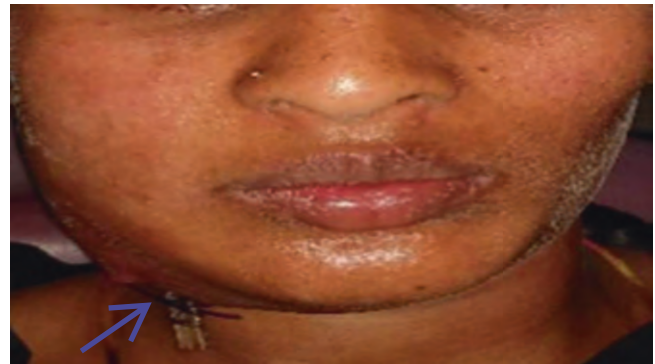- Laterally: Skin, superficial fascia, platysma, and superficial layer of deep cervical fascia.
- Medially: Mylohyoid, hyoglossus, and styloglossus.
- Inferiorly: Anterior and posterior belly of digastric muscles.
- Posteriorly: Hyoid bone.
- Superiorly: Medial aspect of mandible and the attachment of mylohyoid muscle.

21.11.3.3 Contents

- Submandibular salivary gland.
- Submandibular nodes.
- Facial artery and vein.

21.11.3.4 Clinical Features (Fig. 21.9)

1. Pain and tenderness.
2. Swelling is situated at the submandibular region, inferior to the lower of the mandible.
3. Swelling is firm to soft in consistency.
4. Submandibular nodes are palpable and tender.
5. Intraoral—the involved teeth are sensitive.
6. Mild trismus may be noticed.



©Association of Oral and Maxillofacial Surgeons of India

Fig. 21.10 Clinical pictures showing drain inserted for submandibular space infection

21.11.3.5 Management

It is managed through an extraoral approach; incision is placed at the submandibular region in the most dependent area to facilitate gravitational drainage, taking care of the facial artery and marginal mandibular nerve; a sinus forceps is inserted superiorly, medially, and laterally piercing through the superficial fascia. A drain is inserted and secured with a suture to facilitate dependent drainage (Fig. 21.10).

21.12 Masticator Space

Masticator space is formed by splitting of the investing fascia into superficial and deep layers. The superficial layer lies along the lateral surface of the masseter and lower half of the temporalis. Deep layer passes along the medial surface of the pterygoid muscles before attaching to the base of the skull superiorly.

The masticator spaces comprise the following four spaces:

- *Submasseteric space.*
- *Pterygomandibular space.*
- *Temporal space.*
- *Infratemporal space.*

21.12.1 Submasseteric Space

Masseter consists of three layers which are firmly attached anteriorly and loose posteriorly. The space is present lateral to ascending ramus of the mandible.

21.12.1.1 Source of Infection

- Infection from buccally placed lower third molar.
- Septic foci from infected angle fracture.
- Infection from other space.

21.12.1.2 Boundaries

- Anterior: Facial extension of parotidomasseteric fascia.
- Posterior: Parotid fascia and deep portion of parotid gland.
- Superiorly: Level of zygomatic arch.
- Lateral: Medial surface of the Masseter muscle.
- Medial: Lateral surface of the ramus.

21.12.1.3 Clinical Features

1. Pain and tenderness at angle mandible.
2. Moderate size swelling at the angle region.
3. Firm consistency swelling.
4. Severe trismus.

21.12.1.4 Management

The drainage of the infection is done through two approaches.

In intraoral approach, incision is placed at the retromolar area along the anterior border of the ramus of mandible. The sinus forceps is inserted through the incision laterally between the mandibular ramus and the masseter muscle to explore the Submasseteric space. The disadvantage of intraoral technique is that incision and drainage is not gravity dependent.

In extraoral approach, the incision is placed on the skin at the angle and inferior border of the mandible; sinus forceps is inserted directing superiorly piercing the subcutaneous tissue and masseter muscle. Abscess drained corrugated rubber

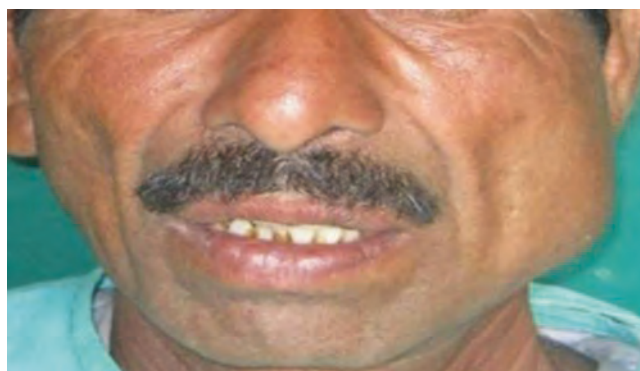tube is placed and secured with a suture. Precautions are taken not to damage the marginal mandibular nerve (Figs. 21.11 and 21.12).

21.12.2 Pterygomandibular Space

One of the most frequently encountered space in dental office is pterygomandibular space [14].

21.12.2.1 Source of Infection

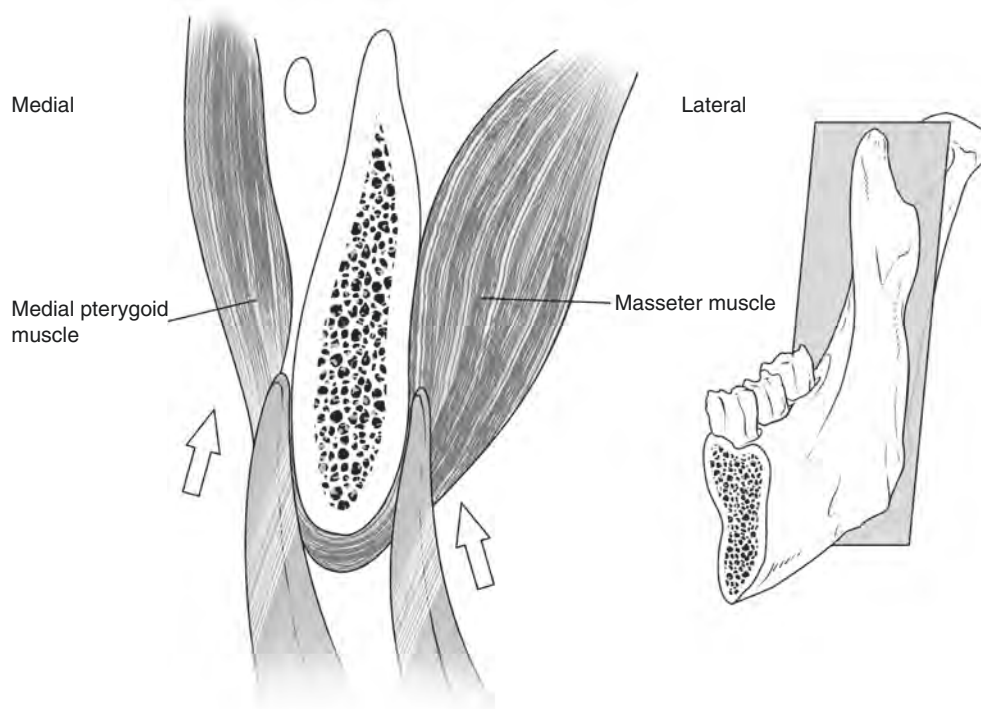
- From lower third molar.
- Contaminated needle used during inferior alveolar nerve block.



©Association of Oral and Maxillofacial Surgeons of India

Fig. 21.12 Clinical picture showing submasseteric space infection left side, pus was drained extraorally

Fig. 21.11 Schematic representation of approaches to the masticator spaces



©Association of Oral and Maxillofacial Surgeons of India

- Septic fractures of the mandibular angle.
- Infection from other spaces (Superficial temporal).

21.12.2.2 Boundaries

- Lateral: Medial surface of mandible.
- Medial: Lateral aspect of medial pterygoid muscle.
- Anterior: Pterygomandibular raphe.
- Posterior: Deep part of parotid gland.
- Superior: Lateral pterygoid muscle and infratemporal surface of greater wing of sphenoid bone.

21.12.2.3 Contents

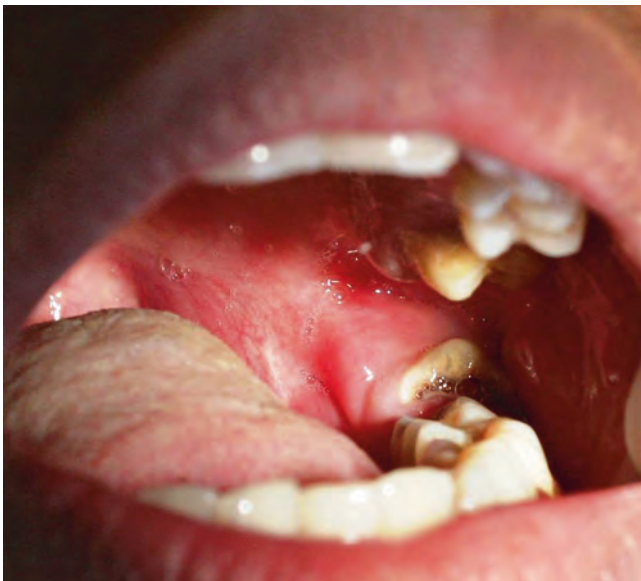- Inferior Alveolar Nerve and artery.
- Lingual Nerve.
- Long Buccal Nerve.
- Nerve to Mylohyoid.

21.12.2.4 Clinical Features (Fig. 21.13)

1. Pain at the retromolar region.
2. Dysphagia.
3. Trismus.
4. No obvious swelling extraorally.
5. Swelling near anterior tonsillar pillar.
6. Deviation of Uvula.

21.12.2.5 Management

Generally, incision and drainage are done through intraoral approach; however, in case of severe trismus, extraoral approach may be indicated. Drainage is done either under general anesthesia or by giving mandibular nerve block.



©Association of Oral and Maxillofacial Surgeons of India

Fig. 21.13 Clinical picture of left pterygomandibular space infection forming a decayed impacted lower left third molar. Note the limited mouth opening

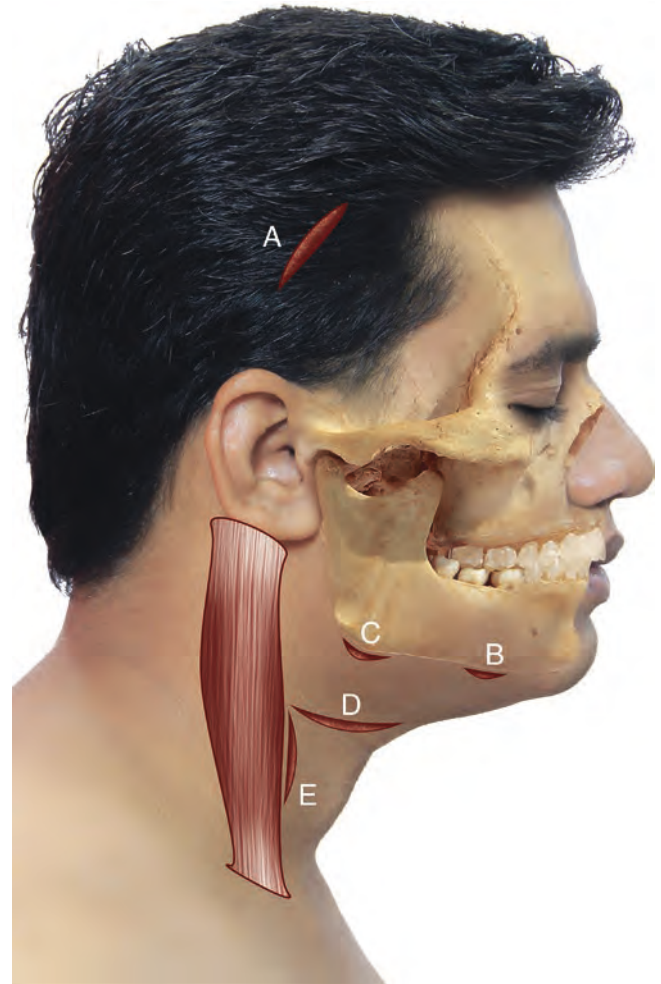
Intraoral Approach

A vertical incision of 1.5 cm is made at the anterior and medial aspect of the mandible, sinus forceps is inserted into the abscess cavity, and pus is evacuated. Corrugated rubber drain is inserted and sutured to the margins of the incision to prevent dislodgement.

Extraoral Approach

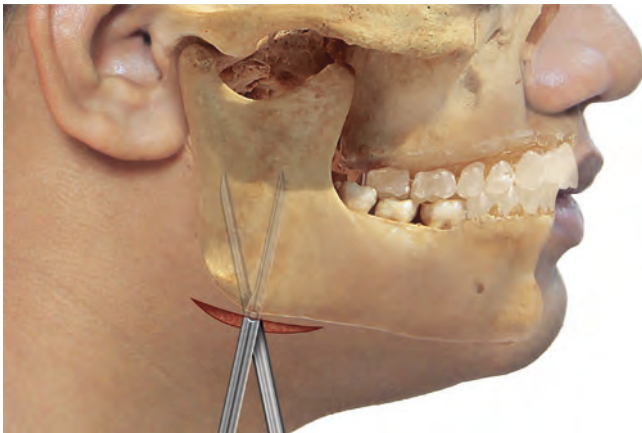
In case of severe trismus, this approach is advised, an incision of 1.5 cm is made on the skin, toward the inner aspect of the angle region. Sinus forceps is inserted toward the medial aspect of the mandible directing superiorly close to the bone. Pus is evacuated and rubber drain is inserted and sutured to the margins of the incision.

Figure 21.14 shows various approaches which can be used for fascial space infections and Fig. 21.15 shows submandibular approach to the medial and lateral masticator spaces.



©Association of Oral and Maxillofacial Surgeons of India

Fig. 21.14 Shows the extraoral incisions for the space infections, (a) temporal space, (b) submental space, (c) submandibular space, (d) lateral pharyngeal space, (e) retropharyngeal space



©Association of Oral and Maxillofacial Surgeons of India

Fig. 21.15 Diagrammatic representation of the approach to the pterygoid space (medial) or masseteric space (lateral) via submandibular incision

21.13 Spaces of Neck

21.13.1 Parapharyngeal Spaces

The spaces around the pharynx form a ‘Ring’ and a pathway for spread of infections from the orofacial region to the neck and mediastinum. The Parapharyngeal space includes Lateral Pharyngeal space and Retropharyngeal space.

21.13.2 Lateral Pharyngeal Space

It is a potential space lying lateral to the pharynx, extending from base of the skull to the hyoid bone. The space is conical in shape, base being toward the base of the skull and apex toward the hyoid bone.

21.13.2.1 Source of Infection

- From other spaces which includes.
- Pterygomandibular space.
- Submandibular space.
- From Tonsils.
- From the lower third molar region.

21.13.2.2 Boundaries

- Superior: Base of the skull.
- Inferior: Hyoid bone.
- Anterior: Pterygomandibular raphe, Superior and middle pharyngeal constrictor.
- Posterior: Carotid sheath, Stylohyoid, Styloglossus, and Stylopharyngeus.
- Medial: Superior constrictor of Pharynx and Retropharyngeal space.
- Lateral: Medial pterygoid muscle, Deep lobe of the parotid gland.

21.13.2.3 Contents

- Lymph nodes.
- Ascending Pharyngeal artery and Facial artery.
- Carotid sheath.
- Glossopharyngeal nerve, Spinal Accessory nerve, Hypoglossal nerve.

21.13.2.4 Clinical Features

1. No or minimal external swelling on the lateral aspect of the neck.
2. Moderate limitation of mouth opening.
3. Rotation of neck to contralateral side is painful.
4. Dysphagia.
5. Uvula is pushed to opposite side.
6. Pharyngeal bulging is seen (Swelling over pillars of fauces and superior constrictor).

21.13.2.5 Management

A combination of intra-oral and extra-oral approaches are advised for the management of infections of the lateral pharyngeal space. They are preferably done under general anesthesia with care taken to secure the airway.

Intraoral approach—A 1.5 cm incision is made on the Pterygomandibular raphe, sinus forceps is passed through the raphe on the medial surface of the mandible, medial aspect of the medial pterygoid muscle, and lateral aspect of the superior constrictor muscle.

Extraoral approach—An incision of 2.5 cm is made in the submandibular region, blunt dissection is then carried through the fascia just anterior to the sternocleidomastoid muscle, and digital palpation can enter and dissect the lateral pharyngeal space bluntly (Fig. 21.16). The landmarks to be palpated are the angle of the mandible anterolaterally, the carotid sheath posterolaterally, the transverse processes of the cervical vertebrae posteromedially, and the endotracheal tube, if present, anteromedially. Caution must be taken not to perforate the posterior oropharyngeal wall by aggressive finger dissection toward the oropharynx [15].

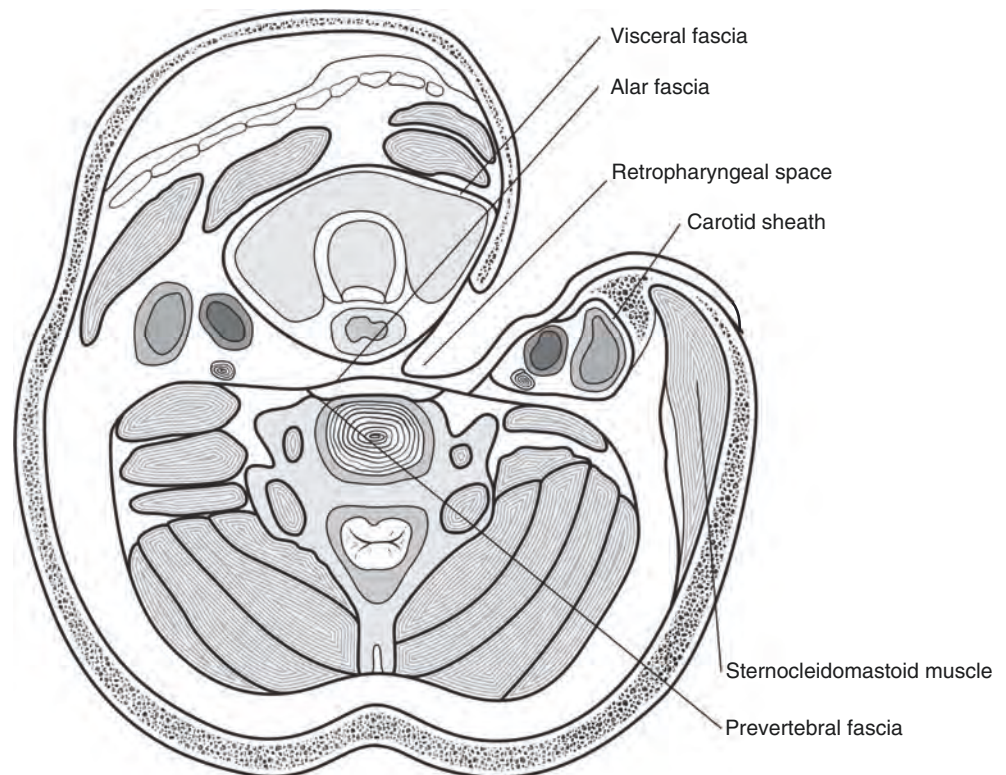
Combined approach—Intraoral incision is made on the mucosa at the medial aspect of the ramus of the mandible, curved hemostasis is inserted lateral to superior constrictor muscle and medial to medial pterygoid muscle and the blunt dissection is carried out postero-inferiorly below the angle of the mandible. The tip of the instrument is palpated at the anterior border of the sternocleidomastoid muscle extra-orally and cutaneous incision is made over the tip. A drain is inserted and sutured to the wound margin to allow drainage.

Maintaining the endo-tracheal tube or tracheostomy may be considered depending on the severity of infection and the success of drainage.

21.13.3 Retropharyngeal Space

It is also called as prevertebral space, which is a potential space present in the midline between the pharyngobasilar

Fig. 21.16 Shows the approach for the retropharyngeal space infection



©Association of Oral and Maxillofacial Surgeons of India

fascia and prevertebral fascia. This space is continuous with retropharyngeal space into the posterior mediastinum.

21.13.3.1 Source of Infection

- From Lateral pharyngeal space.
- From the lymph nodes that drain into Waldeyer's ring.
- Rarely from upper respiratory infections.

21.13.3.2 Boundaries

- Superior—Base of the skull.
- Inferior—Fusion of alar and Prevertebral fascia.
- Anterior—Superior and Medial constrictors.
- Posterior—Alar fascia.
- Lateral—Carotid sheath and Lateral pharyngeal space.

21.13.3.3 Contents of the Space

- Lymph nodes.

21.13.3.4 Clinical Features

1. Stiff neck.
2. Sore throat.
3. Dysphagia.
4. Lateral neck swelling and occasional erythema.
5. Fever.

6. Dyspnea.

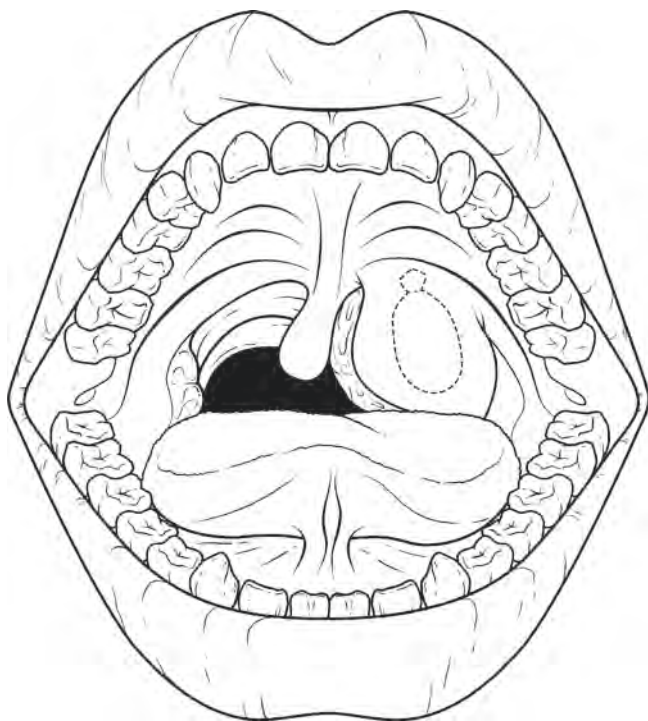
7. Mediastinitis is the most feared complication of this space.

21.13.3.5 Management

Most important is to secure airway, may be an elective tracheostomy or fiber optic intubation is considered for airway maintenance.

Intraoral approach is generally done for the suprahyoid part of the retropharyngeal infection, procedure is similar to the one done for lateral pharyngeal space infection. Intraoral incision is made on the mucosa at the medial aspect of the ramus of the mandible, curved hemostat is inserted lateral to superior constrictor muscle and medial to medial pterygoid muscle, and the blunt dissection is carried out further inferiorly.

Extraoral approach is better for the infection at the infrahyoid region, incision is made transcutaneously anterior to the sternocleidomastoid muscle at the level of the angle of the mandible to the level of the hyoid bone. Both sternocleidomastoid muscle and Carotid sheath are identified, and retracted. Blunt dissection is carried out into lateral and retropharyngeal spaces, later being verified by the palpation of anterior process of the cervical spine posteriorly and the endotracheal tube anteriorly [16]. Drain is placed and secured to the edges of the cutaneous incision.



©Association of Oral and Maxillofacial Surgeons of India

Fig. 21.17 Shows the boundaries of peritonsillar abscess

21.13.4 Peritonsillar Abscess: (Quincy)

It is a localized infection near the tonsils, usually occurring as a secondary infection from the local sites.

21.13.4.1 Source of Infection

- From tonsillitis.
- Rarely from Pericoronitis.
- From Lateral pharyngeal space.

21.13.4.2 Boundaries

- Anterior—Anterior pillar of fauces.
- Posterior—Posterior pillar of fauces.
- Medially—Tonsil.
- Laterally—Superior constrictor muscle (Fig. 21.17).

21.13.4.3 Clinical Features

1. Pain in the throat radiating to ear.
2. Fever.
3. Dehydration.
4. Dysphagia.
5. Swelling visible at anterior pillar of tonsillar fauces.
6. Redness and edema may be extended to soft palate.
7. Drooling of saliva.
8. Change of voice and speech difficulty in case of bilateral involvement.
9. Mouth opening difficulty may not be present.

21.13.4.4 Management

Intraoral approach, superficial incision made at the most prominent area of the swelling near anterior pillar and the soft palate, sinus forceps is inserted deep into the tissues to break all the locules and drain the pus [17].

21.14 Sequelae of Space Infections, if Ignored

Possible life-threatening complications may be developed if the space infections of the jaws are not addressed adequately; for ease of understanding, the complications are classified as follows (Table 21.5).

Specific warning signs in space infections include:

- Dyspnea (difficulty breathing).
- Dysphagia (difficulty/pain with swallowing).
- Severe trismus.
- Rapidly progressive swelling.
- Edema of eyelids and abnormal eye signs.
- Impaired vision or eye movement or both.
- Change in voice quality.
- Lethargy.
- Agitation, restlessness due to hypoxia.
- Evidence of meningeal irritation-severe headache, stiff neck, vomiting.
- Decreased level of consciousness.

21.14.1 Ludwig's Angina

It was first described by Wilhelm Friedreich Von Ludwig in 1836, and the term Ludwig's Angina was coined by Camerer in 1937. The word Angina is derived from Latin language meaning suffocation or choking.

Ludwig's Angina is defined as an acute, firm, non-suppurating, necrotizing cellulitis involving bilateral Submandibular, Sublingual, and Submental spaces. The condition has been described by medical practitioners, by three unique features, starting with the alphabet 'F'—Feared, Fluctuant rarely, Fatal often.

Many terminologies were used for this condition like Marbus Strangularis, Angina Maligna, and Garotillo.

Table 21.5 Sequelae of space infections if ignored

Complications from spaces around mandible	Complications from spaces around maxilla
Ludwig's angina	Cavernous sinus thrombosis
Necrotizing fasciitis	Meningitis

21.14.1.1 Source

Predominantly (90%) odontogenic in origin, from the lower jaw.

Infection from 2nd and 3rd molar teeth may be Acute denoalveolar abscess, Periodontal Abscess.

- Pericoronar Abscess. Infected cyst at the body and the angle of the mandible.
- Traumatic injuries especially to the mandible, either ignored or not managed well leading to sepsis.
- Salivary gland infections.
- Iatrogenic reasons.
- Hematogenous infections.

21.14.1.2 Predisposing Factors

- Immunosuppression.
- Uncontrolled Diabetes.
- Steroid therapy.
- Debilitating conditions.

21.14.1.3 Clinical Features (Table 21.6)

The infection of the sublingual space rapidly spreads along to its base which is present at the hyoid bone. A characteristic feature is edema of the epiglottis and the vocal cords, due to the spread of infection in a postero-inferior direction from

Table 21.6 Clinical features of Ludwig's angina

General/Systemic	Regional/Local
Patient appears toxic	Firm to hard swelling
Fever	Tense, nonfluctuant, non-pitting, and wood like/brawny
Dehydrated	Tender
Anorexia	Trismus
Malaise	Mouth open appearance
Difficulty in swallowing	Fetid odor
Hoarseness of voice	Raised floor of the mouth
	Shallow breathing

the sub-lingual space to the laryngeal inlet. This may produce acute respiratory obstruction and death [18].

21.14.1.4 Management

It should be treated as life-threatening situation and intervened aggressively

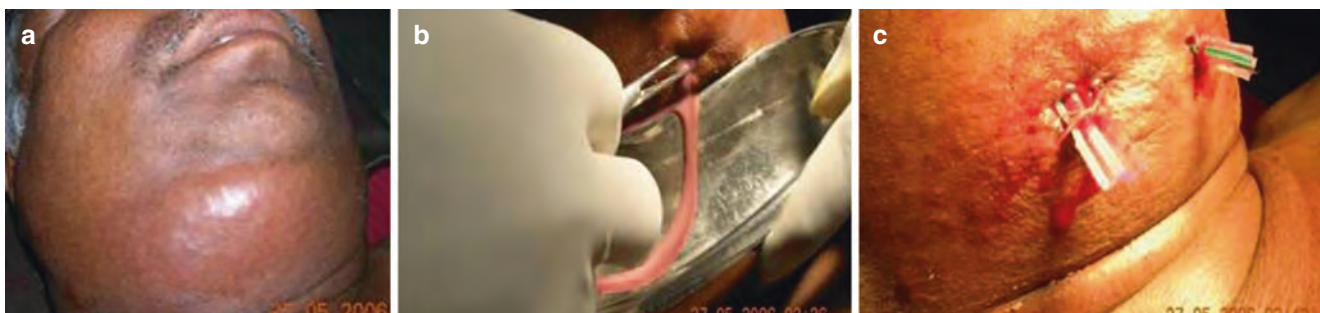The treatment of Ludwig's Angina is primarily surgical. The first priority in the management is always the life-saving measure. If the patient shows any signs of dyspnea, Tracheostomy should be performed promptly

Treatment protocol is as follows:

- Early diagnosis.
- Maintenance of airway.
- Intravenous broad spectrum antibiotics and fluids.
- Necessary investigations.
- Removal of the cause and surgical drainage and decompression of fascial spaces.

Endotracheal intubation is nearly impossible due to trismus, tongue elevation, and laryngeal edema. A skilled anesthetist with fiber optic laryngoscope may try Nasoendotracheal intubation, while the patient is conscious and awake, while the tracheostomy kit is kept on standby, in case of emergency (please refer Chap. 7 to read about anesthesia procedures in patients with space infections).

Once the airway is secure, the next step is surgical decompression of spaces and tissue planes; this is achieved by giving multiple cutaneous incisions in the submandibular and submental regions. Decompression of sublingual space is very important, which is achieved by piercing the mylohyoid muscle. This can also be achieved by placing an incision in the floor of the mouth, parallel to the lingual vestibule. There may not be much pus to drain as the condition is usually non-suppurative (Fig. 21.18a, b, c). Corrugated rubber drain may be left in situ to keep the incisions patent and to drain the exudates [19]



©Association of Oral and Maxillofacial Surgeons of India

Fig. 21.18 (a, b, c) Clinical pictures showing the drainage of Ludwig's angina

Purpose of decompression is threefold:

1. Reduces tension within the tissue planes and prevents further spread of infection.
2. As the pressure in the tissue drops, circulation improves and facilitates the reduction of the edema.
3. Drains septic material and prevents bacteremia.

After decompression, simultaneous removal of the cause is important, as this is the source of the condition.

Intravenous fluids are administered to maintain proper fluid and electrolyte balance and to fulfill the nutritional requirement of the patient. Definitive antibiotics are given intravenously based on the culture and sensitivity reports. Other symptomatic medicines like anti-inflammatory and analgesics may be prescribed. Local wound care is taken care of by irrigation and dressings. Drains to be changed every 48 hrs and maintained until the condition resolves.

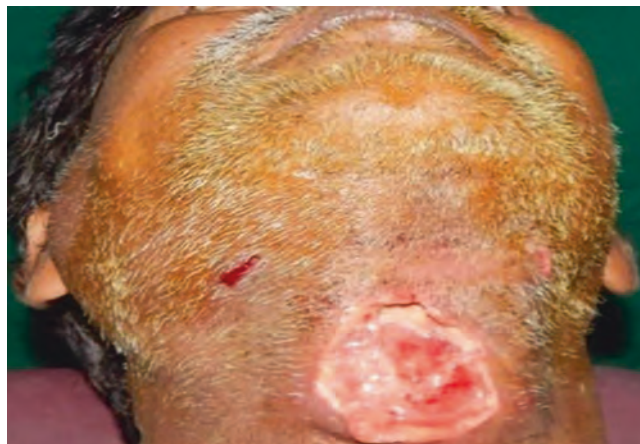21.14.2 Necrotizing Fasciitis

Necrotizing fasciitis is an uncommon soft tissue infection, occurs due to polymicrobes and spreads rapidly in the subcutaneous tissue and above superficial fascia, and as the disease progresses, muscle and skin involve giving rise to myonecrosis. The other name for this condition is Hospital Gangrene given by Brooks in 1966 and Hemolytic streptococcal gangrene. Necrotizing fasciitis may affect any part of the body; however, it most commonly affects the extremities, abdominal wall, and the perineum following trauma or surgery.

The condition shows no clear boundaries or palpable limits, mainly occurs with immunocompromised patients and those suffering from systemic illnesses (Fig. 21.19).

21.14.2.1 Source

The causative organisms in this condition are multiple like Aerobic Group A—hemolytic Streptococcus and Staphylococcus and later identified microbes are Bacteroids, Proteus, coliforms, and peptostreptococcus. In most cases, the pathogens gain entry through disruption of the skin caused by trauma or surgery. Continuous bacterial overgrowth and synergy cause a decrease in oxygen tension and develop local ischemia and proliferation of anaerobic bacteria. The fulminating nature of the necrotic process is the result of the symbiotic relationship between the bacteria.



©Association of Oral and Maxillofacial Surgeons of India

Fig. 21.19 Clinical picture showing the necrotizing fasciitis

Table 21.7 Clinical features of necrotizing fasciitis

Systemic	Local
High fever	Involved area is swollen and erythematous
Weakness	Change of overlying skin color to dusky with purple mottling
Dehydration	Visible slough on the surface with underlying necrotic fascia
Toxic appearance	Paraesthesia of the affected area
Tachycardia	Foul smell
Sepsis	
Hemolysis	

21.14.2.2 Clinical Features (Table 21.7)

21.14.2.3 Investigations

- Complete blood picture (Leukocytosis, Band cells, and Toxic granules in Leukocytes).
- Ultrasonography of the neck—Shows the collection in the superficial planes.
- CT Scans are useful in detecting the deep-seated collections and the necrosis.

21.14.2.4 Management

Early recognition and aggressive surgical intervention is mandatory; taking the medical parameters into consideration and airway maintenance, general anesthesia is preferred in most cases.

Initially, intravenous broad spectrum antibiotics are administered to control the spread of the infection; these antibiotics may be changed once the culture report is obtained.

Surgical treatment is obligatory with incision and drainage, in addition to vigorous debridement of the necrotic fascia, subcutaneous tissue, muscle, and skin. Excision of tissue to the point of fresh bleeding is advised. Multiple and regular change of dressings are needed till the condition is resolved.

Some centers may follow Hyperbaric oxygen therapy for this condition.

21.14.3 Cavernous Sinus Thrombosis

Cavernous sinuses are the venous sinuses situated on either side of the sella tursica. The cavernous sinus on either side communicates freely with each other by anterior and posterior intracavernous sinuses they also communicate with sagittal sinus, transverse, sinus and sigmoid sinus. The cavernous sinus communicates extra cranially with veins of the head and neck.

1. The ophthalmic vein and angular veins into the anterior facial vein.
2. Through emissary veins from the pterygoid plexus of veins.

External route—Infection from face and lips carried by facial and angular veins and nasofrontal veins to the superior ophthalmic vein passes through the superior orbital fissure and enters the cavernous sinus.

Internal route—Infection from the posterior maxillary region to the pterygoid plexus to the inferior ophthalmic vein through the inferior orbital fissure and then through the superior orbital fissure to the cavernous sinus.

21.14.3.1 Source

The area of the face between the inner canthus of the eyes and the corners of the mouth is called 'Danger Triangle' of the face and any kind of severe sepsis in this area can spread in a retrograde manner and can extend to the cavernous sinus through the angular vein and ophthalmic vein.

Causative agents identified are Streptococcus, Staphylococcus, and Gram negative microbes.

21.14.3.2 Clinical Features

- High fever.
- Sweating.
- Swelling (cellulitis) of the face.
- Edema, congestion, and tenderness of the eyelids.
- Ptosis.
- Exophthalmus.
- Diplopia due to involvement of 3rd, 4th, and 6th cranial nerves.

- Increased intracranial pressure due to venous congestion and cerebral edema.
- Altered level of consciousness.
- Pyogenic meningitis leading to brain abscess.
- Erosion of the internal carotid artery leading to fatal intracranial hemorrhage.

21.14.3.3 Eagleton Criteria

Diagnostic criteria were suggested by Eagleton, prior to modern investigative methods.

1. Known site of infection or septicaemia.
2. Evidence of blood stream infection.
3. Early signs of venous obstruction in the retina, conjunctiva, or eyelid.
4. Paresis of the third, fourth, and sixth cranial nerve.
5. Abscess formation in the neighboring soft tissue.
6. Evidence of meningeal irritation.

21.14.3.4 Management

The patient should be given broad spectrum intra venous antibiotics preferably those which cross the blood brain barrier. Aminoglycosides and Clindamycin are started in high therapeutic doses. IV Mannitol is given to decrease the intracranial pressure. Anticoagulant Heparin 20,000 units in 1500 ml of 5% Dextrose is advised to reduce thrombosis.

Neurosurgical intervention is mandatory.

21.14.4 Meningitis

It is one of the neurological complications resulting from the infection of oro-facial region. It may develop from metastatic spread or may be due to nearby thrombophlebitis.

21.14.4.1 Clinical Features

1. High fever with chills
2. Irritability and mental confusion
3. Head ache
4. Vomiting
5. Stiff neck—Brudzinski's sign
6. Positive Kernig's sign
7. Convulsions

21.14.4.2 Diagnosis

Diagnosis is based on cerebrospinal fluid analysis. In CSF polymorpho-nuclear leukocytes, elevated protein levels and decreased glucose levels are noticed.

21.14.4.3 Treatment

- Initially with Chloramphenicol 4 g/day-IV associated with Penicillin G 24 million units per day IV

- Mandatory neurosurgical consultation.
 - For raised intracranial pressure IV Mannitol is given.
- Maintenance of hydro-electrolyte balance is recommended. Change of antibiotics if required after culture and sensitivity report.

21.15 Conclusion

Odontogenic infections are typically polymicrobial. The pathogenesis of odontogenic infections depend on a synergistic relationship between aerobic and anaerobic bacteria.

The last decade showed a notable change in the behavior of odontogenic infections. The severity of these infections is far greater than in the past, demanding swift recognition of the disease followed by prompt and more aggressive treatment. Failing to identify and treat these infections promptly may result in disastrous outcomes.

Definitive treatment includes airway management, adequate resuscitation and optimization of pre-existing medical conditions prior to removal of the source of infection, and drainage of pus.

Oral and high-dose intravenous antibiotics should be administered as required depending on the severity of infection and based on the decision whether the patient is treated on an outpatient or inpatient basis, with the initial choice of antibiotics modified in the light of subsequent bacteriological reports. The treatment of all odontogenic infections must include removal of the focus of infection and drainage of pus.

References

1. Shapiro DS, Schwartz DR. Exposure of laboratory workers to *Francisella tularensis* despite a bioterrorism procedure. *J Clin Microbiol.* 2002;40(6):2278–81.
2. Standring S, editor. *Gray's anatomy: the anatomical basis of clinical practice.* Philadelphia: Elsevier Churchill Livingstone; 2005.
3. Guidera AK, Dawes PJD, Fong A, Stringer MD. Head and neck fascia and compartments: no space for spaces. *Head Neck.* 2014;36(7):1058–68.

4. Mirochnik R, Araidy S, Yaffe V. Imad Abu El-Naaj severity score as a prognostic factor for Management of Infections of odontogenic origin, a study of 100 cases. *Open J Stomatol.* 2017;7:25–34.
5. Flynn TR. What are the antibiotics of choice for odontogenic infections, and how long should the treatment course last? *Oral Maxillofac Surg Clin N Am.* 2011;23:519–36.
6. Martins JR, et al. The use of antibiotics in odontogenic infections: what is the best choice? A systematic review. *J Oral Maxillofac Surg.* 2017;75:2606.e1–2606.e11.
7. Grodinsky M, Holyoke E. The fascial and fascial spaces of the head and neck and adjacent regions. *Am J Anat.* 1938;63:367–407.
8. Ansari MK, et al. Management of Odontogenic Buccal Space Infection in patient with severe hemophilia A-case report. *Int Arch Oral Maxillofac Surg.* 2008;2:1–4.
9. Igoumenakis D, et al. Effect of causative tooth extraction on clinical and biological parameters of odontogenic infection: a prospective clinical trial. *J Oral Maxillofac Surg.* 2015;73:1254–8.
10. Fiscoletti D, Sorli A. A-temporal physical space and introduction to the theory of everything. *Sci Inq.* 2007;8:65–80.
11. Carter LM, Layton S. Cervicofacial infection of dental origin presenting to maxillofacial surgery units in the United Kingdom: a national audit. *Br Dent J.* 2009;206:73–8.
12. Kao S, Jo C. Oral and Maxillofacial Infections. Clinical review of oral and maxillofacial surgery. Mosby. 2014:95–118.
13. Rizzo PB, Da Mosto MC. Submandibular space infection: a potentially lethal infection. *Int J Infect Dis.* 2009;13:327–33.
14. Khoury JN, Mihailidis S. Applied anatomy of the pterygomandibular space: improving the success of inferior alveolar nerve blocks. *Aust Dent J.* 2011;56:112–21.
15. Qureshi FG, Newman KD. Pediatric surgery. 7th ed; 2012. p. 737–43. Lymph Node Disorders
16. Albert T, Balderston R, Northrup B. Surgical approaches to the spine. Philadelphia: Saunders; 1997.
17. Scott GM, Fung K, Roth KE. Novel high-fidelity peritonsillar abscess simulator. *Otolaryngol Head Neck Surg.* 2016;154:634–7.
18. Farr J, Stanhope ED. Ludwigs angina. *Br Med J.* 1945;3:295–6.
19. Ramadhan A, et al. One incision approach to multiple facial spaces: technical note incision approach to multiple facial space. *Int J Oral Care Res.* 2017;5:9–14.

Additional Suggested Reading

- Flynn TR. Oral and maxillofacial infections: 15 unanswered questions. *Oral Maxillofac Surg Clin North Am.* 2011 Nov;23(4):ix–x.

Open Access This chapter is licensed under the terms of the Creative Commons Attribution 4.0 International License (<http://creativecommons.org/licenses/by/4.0/>), which permits use, sharing, adaptation, distribution and reproduction in any medium or format, as long as you give appropriate credit to the original author(s) and the source, provide a link to the Creative Commons license and indicate if changes were made.

The images or other third party material in this chapter are included in the chapter's Creative Commons license, unless indicated otherwise in a credit line to the material. If material is not included in the chapter's Creative Commons license and your intended use is not permitted by statutory regulation or exceeds the permitted use, you will need to obtain permission directly from the copyright holder.





Osteomyelitis, Osteoradionecrosis, and Medication-Related Osteonecrosis of Jaws

22

Christian Walter and Christoph Renné

22.1 Introduction

Bones belong to the connective tissue. Their main function is the internal support and source of inorganic ions. Bones have an organic matrix that is secondarily calcified with calcium salts, mainly hydroxyapatite. The organic matrix consists of a huge extent of type I collagen. Only 5% are other proteoglycans and non-collagenous proteins [1].

There are two major bone parts: The outer compact and the interior cancellous part. In the compact bone, the collagen fibrils form concentric lamellae around a central canal that is called the Haversian canal. These canals harbor vessels which are interconnected by further vessels lying in the Volkmann's canals. The fibrils in neighboring lamellae have a perpendicular orientation resulting in higher stability of the bone. In between the calcified lamellae are therefore concentric orientated osteocytes. Their main function seems to be the mineralization of the bone [1]. The compact bone is responsible for approximately 80% of the entire bone weight [2]. The main function of the compact bone is mechanical stability whereas the cancellous bone mainly has a metabolic function [1]. The cancellous bone consists of small lamellae and has a surface 10 times bigger than the compact bone [2]. On the outside of the compact bone is the periosteum, on the inside the endosteum.

There are three kinds of bone cells: The osteoblasts, the osteocytes, and the osteoclasts.

22.1.1 Osteoblasts

Osteoblasts derive from a multipotential stem cell that differentiates via an osteoprogenitor cell into osteoblasts. Osteoblasts form new bone by the production of the inorganic matrix that mineralizes eventually. After a cycle of bone resorption and consecutive bone formation, most osteoblasts become lining cells covering the surface of the bone [1].

22.1.2 Osteocyte

During the course of bone formation, approximately 10% of the osteoblasts build themselves into the bony structure and become osteocytes [2]. It is assumed that the number of osteocytes is 10 times higher than the number of osteoblasts in the adult human body. The osteocytes are stellate cells that have lots of slim processes that are connected to surrounding cells. Osteocytes with their three-dimensional network seem to play the key role in bone remodeling [1].

22.1.3 Osteoclast

From all bone cells osteoclasts represent the smallest fraction. Osteoclasts are multinucleated giant cells that resorb bone. They derive from the monocyte macrophage line. Their only function is to resorb mineralized tissue as it is necessary for bone growth, remodeling, and tooth eruption. Most bone diseases are associated with an increased function of the osteoclasts. Therefore, osteoclasts are often the pharmaceutical target in the therapy of bone diseases such as malignancies or metabolic diseases as osteoporosis. Osteoclasts are regulated by the RANK RANKL OPG system [1, 3].

C. Walter (✉)
Oral and Maxillofacial Surgery – Plastic Surgery, Mediplus Clinic
Mainz, Mainz, Germany
e-mail: walter@mainz-mkg.de

C. Renné
Group Practice for Pathology Wiesbaden, Wiesbaden, Germany

22.1.4 RANK RANKL OPG

The receptor activator of nuclear factor κ B ligand (RANKL) is an osteoclast differentiating factor mainly expressed by osteoblasts. Secretion of RANKL leads to the differentiation of osteoclasts out of precursor cells, and the activation of osteoclasts to resorb bone by binding on RANK that is expressed on both the precursor cells and the mature osteoclasts. Osteoprotegerin (OPG) is the osteoclastogenesis inhibitor factor and functions as a decoy receptor for RANKL so that the osteoclasts cannot be activated. The RANK RANKL OPG system seems to be the most important part in the communication between the bone cells.

This system is not exclusively organizing the communication between osteoblasts and osteoclasts. This system has been proven to be responsible for the formation of the mammary gland and lymph nodes. RANK and RANKL are also expressed in the kidney, spleen, thymus, and brain, where it might influence the thermoregulation [3].

22.2 Osteomyelitis

The clinical picture of the different kinds of osteomyelitis is very inhomogeneous so that there are many definitions and classifications. In textbooks, the osteoradionecrosis and medication-associated osteonecrosis of the jaws are often subentities of the osteomyelitis. In this book, these entities are described in their own subheadings (Sects. 22.3 and 22.4 of the chapter).

22.2.1 Definition

The actual term “osteomyelitis” refers to an inflammation (“itis”) of the bone marrow (“osteomyel”) only but means an inflammation of the entire bone including the periosteum, the cortical, and cancellous bone as well as the bone marrow.

22.2.2 Classification

There are many different classifications that are either based on the etiology, pathogenesis, pathologic or anatomic differences, the clinical course of the disease, or radiologic patterns. This makes a comparison between different studies very complicated or impossible.

The Zürich classification [4] differs between three different kinds of osteomyelitis: The *acute osteomyelitis*, the *secondary chronic osteomyelitis*, and the *primary chronic osteomyelitis* (Table 22.1). The secondary chronic osteomyelitis results from the acute osteomyelitis and therefore is

Table 22.1 The table describes the Zürich classification of osteomyelitis on the left-hand side. In the right column are the different kinds of osteomyelitis that are included in the respective group of the Zürich classification [4]

Zürich classification [4]	Different types of osteomyelitis
Acute osteomyelitis	Neonatal osteomyelitis
Secondary chronic osteomyelitis	Trauma-associated osteomyelitis
	Odontogenic osteomyelitis
	Foreign body-induced osteomyelitis
	Osteomyelitis based on a bone disease
	Osteomyelitis based on a systemic condition
	• Diabetes
	• Autoimmune diseases/ immunosuppression
	• AIDS
	• Agranulocytosis
	• Anemia
• Leukemia	
• Syphilis	
• Malnutrition	
• Cancer/chemotherapy	
• Alcohol/tobacco/drugs	
• Herpes zoster/Cytomegaly	
Primary chronic osteomyelitis	Juvenile chronic osteomyelitis
	Adult onset osteomyelitis
	Syndrome associated
	• SAPHO
• CRMO	

the same disease at a different time stage. Once the osteomyelitis persists for more than 4 weeks, it is defined as chronic [4].

22.2.3 Epidemiology

Due to the different classifications and terms used for the entire group of osteomyelitis, it is hard to give general data regarding its epidemiology. Approximately 17% of all osteomyelitis cases belong to the group of the acute osteomyelitis, 70% to the secondary chronic osteomyelitis, and 10% to the primary chronic osteomyelitis [4]. The average age at the time of diagnosis is a little bit over 40 years for the acute and the secondary chronic osteomyelitis [4]. Because of the inhomogeneity of the secondary chronic osteomyelitis, a general age group cannot be given.

22.2.4 Etiology

In the etiology of the *acute osteomyelitis* and the *secondary chronic osteomyelitis*, usually an odontogenic infection can be identified such as a dead tooth, a periodontal disease, or conditions after dentoalveolar surgery. A hematogenous spread from a different primary location into the region of the jaws is extremely rare [4].

The etiology of the *primary chronic osteomyelitis* is an infection of unknown origin [4].

22.2.5 Pathogenesis

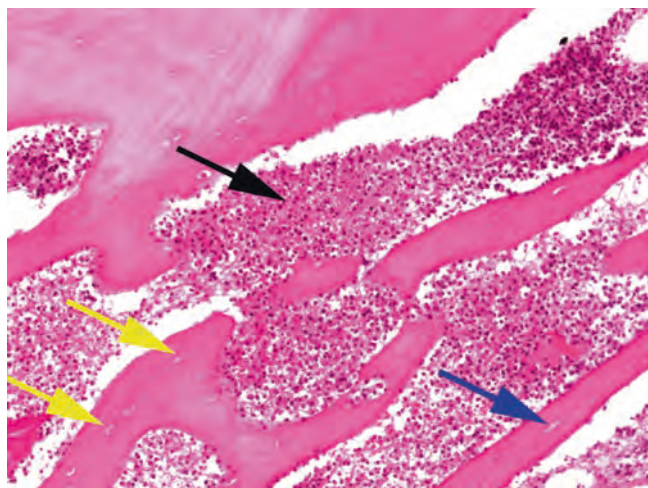
The acute osteomyelitis and secondary chronic osteomyelitis are caused by a local infection due to bacteria from the oral cavity. The likelihood of the development of the infection depends on the virulence and number of bacteria and the quality of the local immune response and the blood flow [4].

Therefore, general diseases affecting the immune system are risk factors in the development of osteomyelitis, e.g., diabetes, autoimmune diseases, or anemia.

A typical course of the acute and secondary chronic osteomyelitis is the contamination of the bone with bacteria. The bacteria proliferate and colonize the bone marrow and reach via the Haversian and Volkmann canals the periosteum. The edema under and in the periosteum disturbs the blood flow resulting in ischemic bone parts and potentially sequestrum building.

22.2.6 Histology

The *acute osteomyelitis* and the *secondary chronic osteomyelitis* are characterized by an inflammatory exudate, primary in the medullary spaces with fibrin, leucocytes, and macrophages that replace the fatty tissue and hematopoietic marrow (Fig. 22.1). In addition, necrotic debris and bacteria can



©Association of Oral and Maxillofacial Surgeons of India

Fig. 22.1 In this case of acute osteomyelitis, the medullary hematopoietic cells and the fatty tissue are completely replaced by cell debris, fibrin, and an inflammatory infiltrate mainly composed of neutrophil granulocytes (black arrow). Besides the vital bone with filled lacunae of osteocytes (yellow arrow), necrotic bone can be seen with loss of osteocytes (blue arrow)

be found [4, 5]. The most common bacteria being detected is *Staphylococcus aureus* (85%) [4]. Due to the blood flow disturbances (see pathogenesis), parts of the bone die so that empty osteocytic lacunae can be observed. Sequestrae may be present. New bone formation under the periosteum is not uncommon.

In cases of secondary chronic osteomyelitis, sequestrum formation is more common than in the acute osteomyelitis. The more chronic the course is, the more likely is the development of bone marrow fibrosis and sclerosis of the bone. Bacteria might be present. Actinomyces drusen are typical.

In the *primary chronic osteomyelitis*, plasma cells are predominant in the inflammatory infiltrate. The proportion of neutrophils, lymphocytes, and macrophages is rather small. The bone marrow is altered due to fibrosis. New bone formation is a common sign. Osteoclastic activity leads to repeated bone remodeling without a distinct histological bone formation pattern. Microabscesses might be observed [4].

22.2.7 Symptoms

In cases of *acute osteomyelitis*, patients present with high fever and are listless. Local swelling can be observed with pain on palpation. The affected area is reddish, a trismus might be present, and quite often the teeth have higher mobility with pus coming out of the periodontium. If the inferior alveolar nerve is affected, patients report paresthesia of the lips (Vincent symptom [4]). There are cases in which the symptoms are not very distinctive.

Symptoms of the *secondary chronic osteomyelitis* are the painful swellings that are usually not as prominent as in the acute osteomyelitis. A common finding is a periosteal reaction causing a solid swelling. Further symptoms are sequestrum formation and fistulas.

The *primary chronic osteomyelitis* is characterized by a nonsuppurative inflammation and sometimes only barely noticeable symptoms. In active periods, the patients notice pain, swelling, and mouth-opening limitations. Due to the bone formation, permanent swelling will develop eventually [4].

22.2.8 Complications

A typical complication of the acute osteomyelitis is a shift into the chronic osteomyelitis that is very hard to treat sufficiently.

Further complications are the development of the Vincent syndrome, fistula, abscess and sequestrum formation, and potentially fractures [4].

22.2.9 Diagnosis

The diagnosis is based on the clinical course. This is completed by radiology: panoramic radiograph, cone beam CT, CT, or MRI. Changes in the bone can only be seen after a 30 to 40% reduction of the mineralized part of the bone. Therefore, the changes in the acute osteomyelitis are marginal at the beginning. In complex cases of osteomyelitis, a bone scintigraphy might be used to detect further active spots in the skeleton, e.g., in the diagnosis of chronic recurrent multifocal osteomyelitis or the SAPHO syndrome (SAPHO: Synovitis, acne, pustulosis, hyperostosis, osteitis) [6].

Radiological signs of *acute osteomyelitis* are: Bone resorption with increased radiolucency, loss of spongy structure of the bone, potentially sequester formation.

Radiological signs of the *secondary chronic osteomyelitis* are: Bone resorption with increased radiolucency, sequester formation, periosteal reaction, and pathological fractures.

Radiological signs of the *primary chronic osteomyelitis* are: Increased radiopacity with loss of trabecular bone, bone resorption, and periosteal reaction (Fig. 22.2) [4].

22.2.10 Differential Diagnoses

In the differential diagnosis, one should rule out malignancies in unclear cases so that biopsies should be performed.

22.2.11 Therapy

The therapy of the acute and secondary chronic osteomyelitis mainly consists of the therapy of the infection and of the

improvement of the local blood flow. This is achieved via antibiotics and removing of the infected parts of the bone. A decortication supports this and helps to get well-vascularized tissue onto the bone.

Acute osteomyelitis is immediately treated with antibiotics. If an antibiogram suggests different antibiotics, an adaptation should be performed after the initial antimicrobial therapy. Mouth rinses, hygiene, and cold application can be applied. In general, the highly mobile teeth should not be extracted since they will gain stability again after the acute stadium of the osteomyelitis is over.

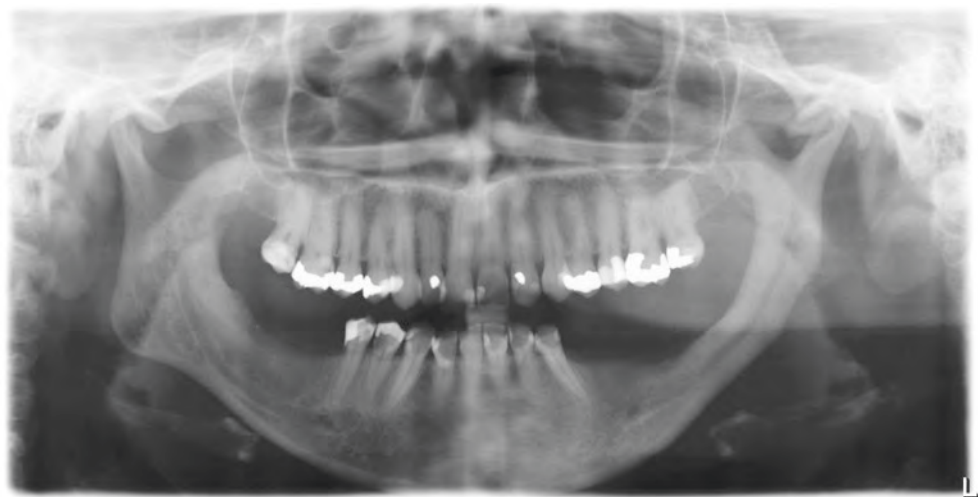
The therapy of the *secondary chronic osteomyelitis* aims at sufficient pain management, limitation of the spread of the affected areas, fracture prevention, and the prevention of the onset of further active periods. Secondary diseases such as diabetes need to be treated as well.

The therapy of the *primary chronic osteomyelitis* consists of a surgical intervention to remove the necrotic bone parts and a potential disfigurement can be corrected. But recurrences of the symptoms are very common. Therefore, other treatment options should be used as well including antibiotics, nonsteroidal anti-inflammatory drugs (NSAIDs), steroids, and bisphosphonates (mainly pamidronate).

22.2.12 Prognosis

The therapeutic success is higher in patients with acute and secondary chronic osteomyelitis than in patients with primary chronic osteomyelitis. Approximately 75% of the acute and secondary chronic osteomyelitis are symptom-free after intervention whereas only about 25% are symptom-free of the patients with primary chronic osteomyelitis [4].

Fig. 22.2 Panoramic radiograph of a patient with primary chronic osteomyelitis after several surgeries have been performed. Several infusions of pamidronate prevented the occurrence of further active periods. In the left mandible, typical sclerosis can be seen with a prominent nerve canal



22.3 Osteoradionecrosis

The osteoradionecrosis is a side effect in the therapy of malignant diseases to the head and neck area with ionizing radiation.

22.3.1 Definition

Osteoradionecrosis describes the exposed necrotic bone due to radiation. The infected osteoradionecrosis describes the additional infection of the necrotic bone [7].

22.3.2 Epidemiology

The prevalence of osteoradionecrosis ranges from 0 to 23% of the patients with head and neck radiation [8]. Usually, older patients are affected (60 years \pm 10 years) since the primary disease causing the head and neck radiation are diseases in patients with advanced age [9]. Men are affected more than twice as often [9].

22.3.3 Etiology

The etiology of the osteoradionecrosis is radiation therapy to the head and neck area. Usually, another trigger is required in the development of the osteoradionecrosis (see pathogenesis).

22.3.4 Pathogenesis

Due to the radiation therapy, the vessels of the bone change and become hyalinized. It results in a lack of nutrition and hypoxia with the subsequent death of osteocytes [7]. This seems to be more likely in radiation doses above 40–50 Gy [10]. The radiation has additional side effects to all tissues being in the radiation field including the skin, the muscles, and the salivary glands. Due to the resulting xerostomia radiation, caries develops so that an osteoradionecrosis might develop.

The osteonecrosis occurs more often in the mandible most probably to the greater extent of cortical bone and the more critical vascularization of the mandible. And the mandible most probably is more often in the radiation field due to the location of the primary tumor [10].

There are several risk factors that are associated with a more frequent occurrence of the osteoradionecrosis. Those

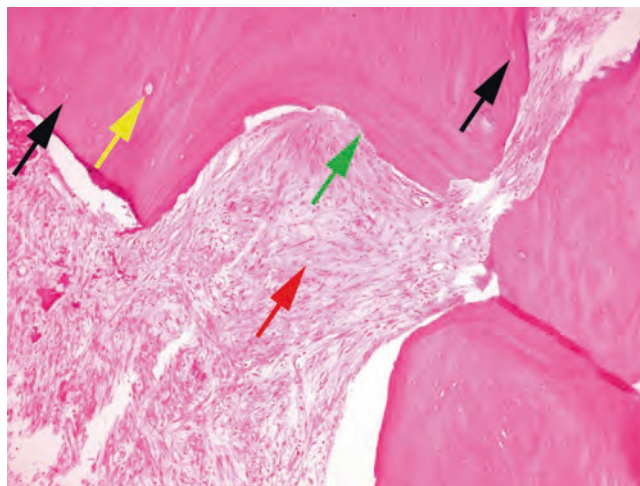
are male gender, insufficient oral hygiene, pressure denture sores, a tumor localized in the tongue, alveolar process of the mandible, the floor of the mouth, and retromolar as well as persisting alcohol and nicotine consumption. Next to these, there are therapy-linked risk factors, namely a tumor resection including resection of the bone and dentoalveolar surgery performed in timely proximity to the radiation therapy [10].

22.3.5 Classification

It is mainly differed between the aseptic osteoradionecrosis and the infected osteoradionecrosis. Another very common staging system uses the potential benefit of a rather controversially discussed therapy option the hyperbaric oxygen treatment and therefore won't be discussed in further detail.

22.3.6 Histology

The lacunae of the osteocytes in osteoradionecrotic bone are empty (Fig. 22.3). There is a lack of osteoblastic rimming and the Haversian and Volkmann canals do not harbor any blood vessels. The marrow of the bone shows acellular collagen. The periosteum is acellular and avascular [5].



©Association of Oral and Maxillofacial Surgeons of India

Fig. 22.3 The examination of the osteoradionecrosis under the microscope shows avital bone with irregular fissured borders. The lacunae of the osteocytes are empty without osteocyte cell nuclei (black arrows) and also the blood vessels in the Haversian canals have undergone necrosis, so that only empty spaces are the visible remnants (yellow arrow). The necrotic bone is missing the osteoblastic rimming (green arrow). The bone marrow is replaced by a collagen fiber-rich scar like connective tissue (red arrow)

22.3.7 Symptoms

Symptoms are the exposed necrotic bone that can be visible or palpable with a probe. Further symptoms are pain, swelling, the development of granulation tissue, foetor ex ore, oral and extraoral fistulas, potentially increased mobility of the adjacent teeth, altered sensibility, and occlusion [10].

22.3.8 Complications

Main complications are extended infections of the site, the development of fistulas, and pathological fractures. This might result in resections of the altered bone including the loss of the continuity of the bone or the opening of the nasal cavity or sinus. This results in a reduced masticatory function. Due to the fibrosis of the soft tissues, trismus might occur. All these factors lead to a reduced quality of life [10].

22.3.9 Diagnosis

The diagnosis is a clinical one. There needs to be a mandatory head and neck radiation and the exposed necrotic bone.

Typical radiologic findings are bone destruction, altered bone density, the occurrence of sequestra, and pathological fractures.

22.3.10 Differential Diagnoses

Differential diagnoses are osteomyelitis and the medication-associated osteonecrosis of the jaws as well as the existence of malignancy so that a histological sample should be assessed.

22.3.11 Therapy

As already mentioned, the evidence of the use of hyperbaric oxygen treatment is rather low and is not recommended [11, 12]. Smaller necrotic areas can be treated conservatively using antiseptic mouth rinses, antibiotics, and pain killers. In some cases, a wait and see strategy is reasonable. Sometimes circumscribed debridement might be performed. Extended necrotic areas should be surgically removed [13]. The aim is to preserve damage to the alveolar nerve and to avoid a continuity defect of the mandible. The operation should be as atraumatic as possible. The periosteum should not be removed if possible. The necrotic areas should be removed, sharp edges need to be smoothed, and the bone should be covered with soft tissue. The surgery should be performed with perioperative antimicrobial therapy.

22.3.12 Prognosis

The risk for a recurrence of an osteoradionecrosis is high. Pressure denture sores, wound healing deficiencies, and mucositis are risk factors for a recurrence.

22.3.13 Prevention

A 3D-planning of radiation therapy might help to reduce the radiation doses in the bone. In addition, a splint inserted in the patient's mouth during the radiation might help to reduce the burst of the local mucosal membranes due to secondary radiation that might occur due to metallic dental restorations. An additional splint to provide fluorides to strengthen the teeth might help prevent the development of radiation caries.

It is feasible to reduce the existence of risk factors that might later on trigger the development of an osteoradionecrosis. Therefore, an initial dental checkup and therapy preceding the radiation therapy should be performed including the extraction of all non-restorable teeth. The patient should be motivated for exceptional good oral hygiene [10].

22.4 Medication-Associated Osteonecrosis of the Jaws

There are several pharmaceutical agents that cause osteonecrosis of the jaws. In the following, the main focus will be on the bisphosphonate-associated osteonecrosis.

22.4.1 Bisphosphonate-Associated Osteonecrosis of the Jaws

22.4.1.1 Bisphosphonates

Bisphosphonates are used in patients with an increased osteoclastic activity due to malignancy such as solid tumors with osseous metastases or the multiple myeloma or due to metabolic bone diseases such as osteoporosis. The main target of bisphosphonates that can be administered orally or IV is the osteoclasts.

Bisphosphonates are classified into nitrogen- and non-nitrogen-containing bisphosphonates. The non-nitrogen-containing bisphosphonates are built into ATP and can no longer be used as a source of energy in the cells. The nitrogen-containing bisphosphonates inhibit the farnesyl pyrophosphate synthase in the mevalonate pathway leading to decreased osteoclastic function [14]. In 2003, the bisphosphonate-associated osteonecrosis was first mentioned in a scientific paper [15].

22.4.1.2 Definition

The bisphosphonate-associated osteonecrosis is defined as the occurrence of the necrotic bone of the jaws that has been persistent for at least 8 weeks with a current or previous history of bisphosphonate use (Fig. 22.4). Furthermore, it is demanded that the patient had had no former head and neck radiation [16].

The last demand seems arbitrary since the coexistence of a further risk factor simply increases the risk of osteonecrosis development so that there is a special risk constellation. There is evidence that it is even possible to histologically distinguish an osteonecrosis derived from bisphosphonates compared to osteoradionecrosis [17].

22.4.1.3 Epidemiology

The prevalence and incidence of the bisphosphonate-associated osteonecrosis of the jaws depend on the primary disease, comedication, and the existence of local trigger factors. The highest risk is present in oncologic patients with

further compromising medications. Incidences for patients with malignant diseases range from 1 to 20% [18–20]. The prevalence of secondary osteoporosis is about 1% and for primary osteoporosis 0.1% [21]. There is only a small difference between the genders. Women are affected a little bit more often than men. Most probably due to the osteoporosis and breast cancer cases vs. the prostate cancer cases that exclusively occur in men. The average age is approximately 60 years \pm 10 years (standard deviation) [9].

22.4.1.4 Etiology

The main factor is the use of nitrogen-containing bisphosphonates. Administered bisphosphonates will be incorporated in the bone. It is unclear if and how long these bisphosphonates are active. The development of bisphosphonate-associated osteonecrosis can be triggered by oral factors—this is usually a wound in the oral cavity: peri-odontal disease, surgical procedures, etc. [9, 22].

22.4.1.5 Pathogenesis

The main target of the bisphosphonates is the osteoclast, thereby inducing reduced bone remodeling. Due to the unspecific interaction with cells, not only the osteoclasts are affected, but also, in lower concentrations, osteoblasts are stimulated [23]. The effect is an increase in total bone. Other affected cell lines are blood vessel cells, fibroblasts, and keratinocytes. The antiangiogenic function of bisphosphonates [24, 25] leads to decreased vascular exploitation [26]. This results in fewer potentially less potent vessels that have to support more bone. In addition, the soft tissues covering the bone are affected by the bisphosphonates so that potential wounds are less prone to heal [24]. In older articles, it is often described that tooth extractions are responsible for the development of the bisphosphonate-associated osteonecrosis of the jaws. This theory might not be right. It is more likely that these teeth have been extracted too late since they were extracted out of an already-existing, altered, infected, or necrotic bone [27].

22.4.1.6 Classification

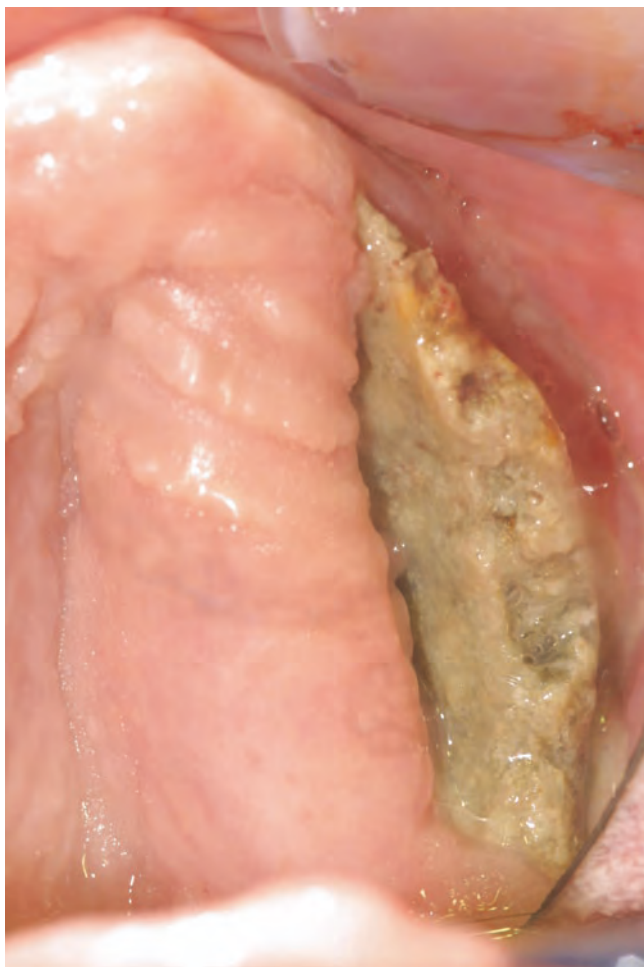The bisphosphonate-associated osteonecrosis of the jaws is classified into several different stages. At-risk patients are all those receiving bisphosphonates.

Stage 0 patients are patients that do have some symptoms without any visible uncovered bone.

Stage I, the necrotic bone becomes visible. Patients in this stage usually do not have any symptoms.

Stage II, an additive infection is existent.

Stage III, further complications occur such as necrotic areas involving the base of the mandible or the sinus or pathologic fractures are existent [16].

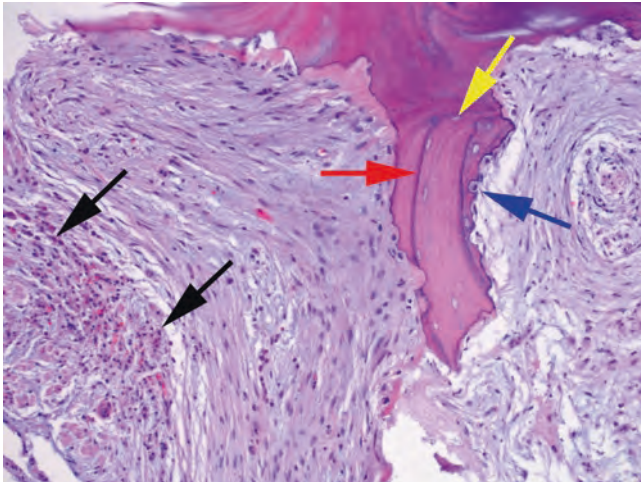


©Association of Oral and Maxillofacial Surgeons of India

Fig. 22.4 Huge bisphosphonate-associated osteonecrosis of the left maxilla in a patient with non-Hodgkin lymphoma and a zoledronate treatment for 2.5 years before a pressure denture sore triggered the osteonecrosis

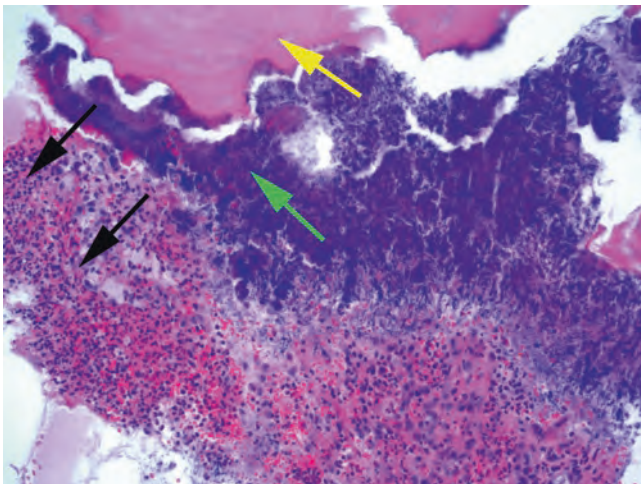
22.4.1.7 Histology

Usually, there is a mucosal damage above the necrosis, perhaps some granulation tissue (Fig. 22.5). The necrotic bone is often avascular and covered in bacteria, especially *Actinomyces* (Fig. 22.6) [28]. The osteonecrotic bone has



©Association of Oral and Maxillofacial Surgeons of India

Fig. 22.5 In this case, the bone necrosis is induced by bisphosphonates. Besides necrotic bone showing empty osteocyte lacunae (yellow arrow), inflammatory cellular infiltrate can be seen in the medullary cavity (black arrows). It is mainly composed of lymphocytes, neutrophil granulocytes, and also plasma cells. Here, signs of the bone remodeling are also visible. The dark line within the bone, the border of the periosteum before necrosis (red arrow) separates necrotic bone in the center from the new-built bone with a lining of active osteoblasts (blue arrow) on the outside



©Association of Oral and Maxillofacial Surgeons of India

Fig. 22.6 *Actinomyces* species (green arrow) frequently can be found next to necrotic bone (yellow arrow) in the jaws. Dense clouds of bacteria affecting the bone leading to deep excavations of the necrotic bone. An inflammatory infiltrate of neutrophil granulocytes and macrophages in fibrin-rich exudate fills the bone marrow (black arrows) as a border which limits bacterial growth

parts with empty osteocytic lacunae next to viable osteocytes so that there are necrotic areas of the bone that harbor parts of the viable bone. Inflammatory infiltrates are seen in nearly all cases consisting of granulocytes and lymphocytes. The obliteration of mainly the segmental arteries is not existent in every case [28]. The periosteum is usually viable [5].

22.4.1.8 Symptoms

The classical symptoms are the visible necrotic bone and pain in case of an additional infection of the bone so that the symptoms are very unspecific.

22.4.1.9 Complications

The typical complications are the progress of the initial small necrosis so that big parts of the bone might be affected by the osteonecrosis. Since the bone is no longer covered with soft tissue, an additive infection can cause typical symptoms and leads to a shift to a different stage of the osteonecrosis. Major complications are the loss of the integrity of the bone and extraoral fistulas or abscesses.

The quality of life might essentially get affected in patients with medication-related osteonecrosis of the jaws [29].

22.4.1.10 Diagnosis

The diagnosis is primarily a clinical one if all criteria are fulfilled (see definition). Unfortunately, there is no sensitive radiological tool that shows neither the exact location of the osteonecrosis nor the extent of the necrosis [30]. Once there is a destruction of the bone due to the infection, changes can be seen in the radiologic pictures. But these changes are not specific for the changes (Figs. 22.7 and 22.8a, b). There is evidence that the potential osteonecrosis can be detected at a very early stage via scintigraphs [31].

22.4.1.11 Differential Diagnosis

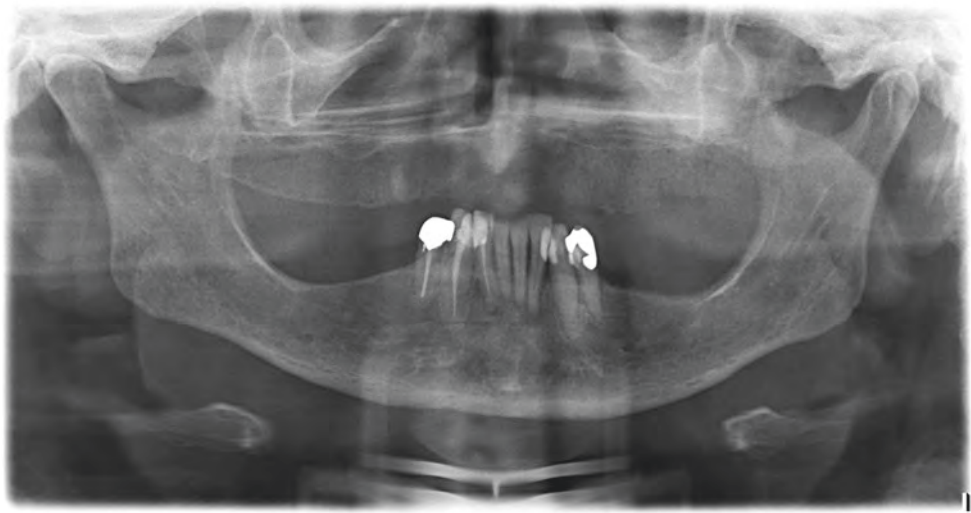
Regarding the clinical picture, osteomyelitis and osteoradionecrosis are the other typical potential diagnoses. In addition, malignant diseases should be ruled out, especially the ones why the bisphosphonates were given in the first place, e.g., breast cancer or prostate cancer.

22.4.1.12 Therapy

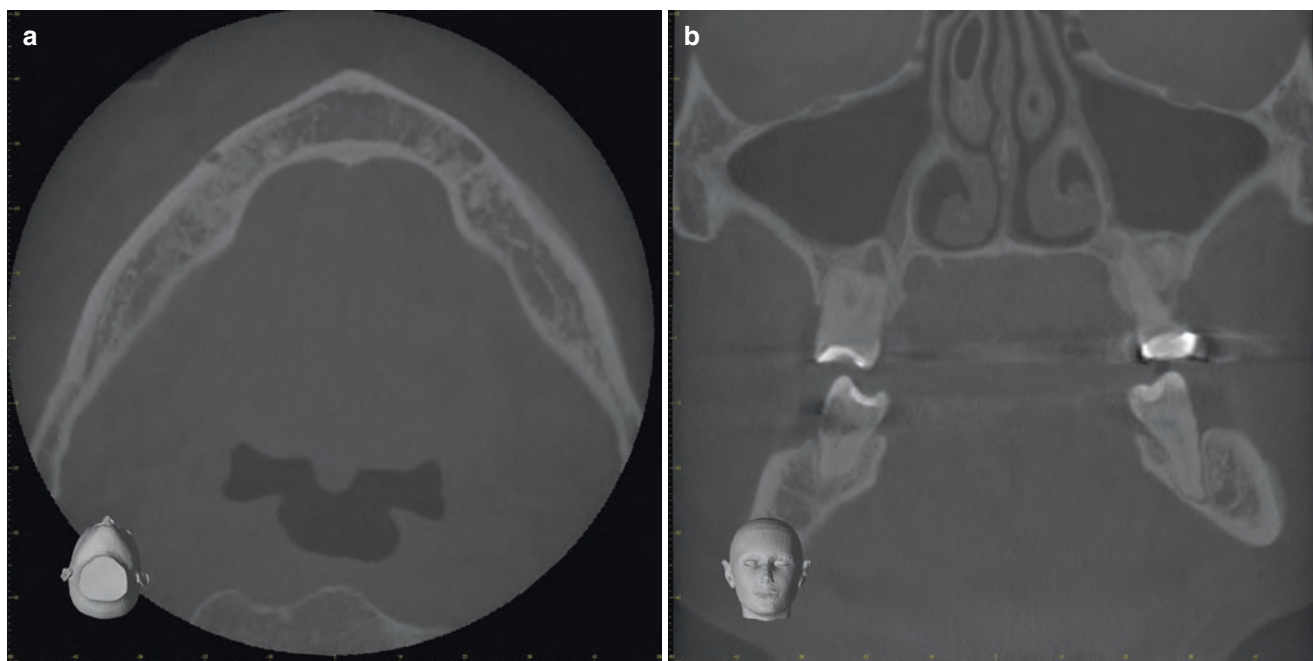
The osteonecroses should be treated since the lack of treatment usually ends in the progression with more extended areas of necrotic bone and a potential switch in the stage of the osteonecrosis.

There are several approaches in the therapy of the bisphosphonate-associated osteonecrosis of the jaws. Smaller osteonecroses can be treated conservatively or with a moderate surgical intervention. Perioperative antibiotic treatment should be initiated. After the debridement or resection of the necrotic bone, a plastic coverage of the bone should be performed.

Fig. 22.7 This is the same patient as seen in picture 4. There are nearly no changes visible that indicate the existence of osteonecrosis. A very typical change that can be seen is the thickened and sclerotic lamina dura in the mandible and the honeycomb pattern of the bone due to the sclerotic trabeculae of the bone



©Association of Oral and Maxillofacial Surgeons of India



©Association of Oral and Maxillofacial Surgeons of India

Fig. 22.8 Two slices from a cone beam CT from a patient with a malignant primary disease and bisphosphonate intake. (a) Axial slice from a patient with osteonecrosis of the left and the right mandible. On the right-hand side, a thickening of the cortical bone can be observed and sclerosis of the cancellous bone. On the left-hand side, the periosteal

reaction is visible. (b) Coronal slice with a periapical translucency of the molar on the right-hand side as a potential trigger of the osteonecrosis that reached the level of the alveolar nerve canal. On the vestibular side of the left mandible the periosteal reaction can be seen

Extended or multiple osteonecrotic areas should be resected. This might include an inpatient setting with the postoperative use of a nasogastric tube and antibiotic iv treatment [32].

22.4.1.13 Prognosis

The recurrence rate of the osteonecrosis depends on the mode of therapy and is the lowest for surgical interventions

and the highest for purely conservative treatments. In the latter case, complete closure of the mucosal membrane cannot always be achieved [32].

22.4.1.14 Prevention

It should be differed between preventive measures before initiating a bisphosphonate therapy and measures during or

after the course of bisphosphonate therapy. Since the bisphosphonate-associated osteonecrosis of the jaws is usually triggered by an oral wound, potential dental foci should be eliminated before the start of bisphosphonate therapy [32].

If surgery needs to be performed in patients with bisphosphonate therapy, anti-microbiological prophylaxis should be performed [32].

22.4.2 Osteonecrosis of the Jaws Due to Other Medications but Bisphosphonates

There are other medications that can cause osteonecrosis of the jaws. The definition is the same compared to the osteonecrosis due to bisphosphonates.

22.4.2.1 Denosumab

The most frequent osteonecroses can be observed in patients with denosumab that is administered in the same patients that receive bisphosphonates. The definition, etiology, classification, symptoms, complications, diagnoses, differential diagnoses, therapy, prognosis, and prevention are the same or similar to the ones of the bisphosphonate-associated osteonecrosis of the jaws.

The pathogenesis might be different since denosumab only affects the RANK/RANKL/OPG mechanism that is predominant in the communication between osteoblasts and osteoclasts. Therefore, an impact on the soft tissues including the vessels seems unlikely so that the likewise reduced bone remodeling seems to be the major component in the development of the denosumab-associated osteonecrosis of the jaws.

22.4.2.2 Sunitinib

Sunitinib is an inhibitor of a tyrosine kinase and therefore has a less specific mode of action. It is given in patients with gastrointestinal cancers, renal cell carcinoma, and pancreatic neuroendocrine tumors [33]. A side effect in the use of sunitinib is the development of osteonecroses of the jaws [34].

22.4.2.3 Imatinib

Imatinib is another tyrosine kinase inhibitor. Osteonecrosis in imatinib-only use has been described [35].

22.4.2.4 Bevacizumab

Bevacizumab is a vascular endothelial growth factor-(VEGF-) inhibitor and is used in several oncologic treatment concepts, e.g., breast cancer, colorectal cancer, and lung cancer. Several cases of osteonecroses of the jaws have been described [36, 37].

22.4.2.5 Ziv-aflibercept

Ziv-aflibercept is a recombinant vascular endothelial growth factor- (VEGF-) receptor. Several cases of the development of osteonecroses of the jaws have been described in patients that did not receive any of the other typical medications causing osteonecrosis [38]. In the pathogenesis, the antiangiogenic factor might be the reason for the development of the osteonecrosis.

22.4.2.6 Everolimus

Everolimus is a mammalian Target of Rapamycin (mTOR) inhibitor. It is used in several oncologic diseases and was associated with the development of osteonecroses in the jaws [39].

22.4.2.7 Corticosteroids

There is evidence that the use of corticosteroids increases the risk of osteonecrosis development of the jaws [40]. The femoral head osteonecrosis has been described in patients with long-term corticosteroid use [41].

It should be stated that the use of several of these agents in combination might further increase the risk of osteonecrosis development.

22.4.2.8 Crystal Meth

Next to therapeutically used agents, some drugs are responsible for the development of osteonecroses. Crystal Meth is the crystalline form of methamphetamine hydrochloride. It functions as a sympathomimetic and has a very high potential for abuse and dependency. One side effect is the meth mouth with serious tooth and damage to the oral cavity including the development of osteonecroses [42]. The exact mechanism of osteonecrosis development is unclear. Methamphetamine causes the release of noradrenaline which increases the blood pressure by the increase of the peripheral blood vessel resistance.

References

1. Bilezikian JP, Raisz LG, Rodan GA. Principles of bone biology. San Diego: Academic Press; 2002.
2. Bartl R, von Tresckow E, Bartl C. Bisphosphonat-manual. Berlin: Springer; 2006.
3. Liu W, Zhang X. Receptor activator of nuclear factor-kappaB ligand (RANKL)/RANK/osteoprotegerin system in bone and other tissues (review). *Mol Med Rep*. 2015;11(5):3212–8.
4. Baltensperger MM, Eyrich GK. Osteomyelitis of the jaws. Berlin: Springer; 2009.
5. Marx RE, Tursun R. Suppurative osteomyelitis, bisphosphonate induced osteonecrosis, osteoradionecrosis: a blinded histopathologic comparison and its implications for the mechanism of each disease. *Int J Oral Maxillofac Surg*. 2012;41(3):283–9.

6. Muller-Richter UD, Roldan JC, Mortl M, Behr M, Reichert TE, Driemel O. SAPHO syndrome with ankylosis of the temporomandibular joint. *Int J Oral Maxillofac Surg.* 2009;38(12):1335–41.
7. Marx RE. Osteoradionecrosis: a new concept of its pathophysiology. *J Oral Maxillofac Surg.* 1983;41(5):283–8.
8. Schuurhuis JM, Stokman MA, Witjes MJ, Dijkstra PU, Vissink A, Spijkervet FK. Evidence supporting pre-radiation elimination of oral foci of infection in head and neck cancer patients to prevent oral sequelae. A systematic review. *Oral Oncol.* 2015;51(3):212–20.
9. Walter C, Sagheb K, Bitzer J, Rahimi-Nedjat R, Taylor KJ. Analysis of reasons for osteonecrosis of the jaws. *Clin Oral Investig.* 2014;18(9):2221–6.
10. Krüger M, Hautmann M, Bartella A, Al-Nawas B, Grötz KA. S2k-Leitlinie: Infizierte Osteoradionekrose (IORN) der Kiefer. AWMF Online 2018.
11. Annane D, Depondt J, Aubert P, Villart M, Gehanno P, Gajdos P, et al. Hyperbaric oxygen therapy for radionecrosis of the jaw: a randomized, placebo-controlled, double-blind trial from the ORN96 study group. *J Clin Oncol.* 2004;22(24):4893–900.
12. Sultan A, Hanna GJ, Margalit DN, Chau N, Goguen LA, Marty FM, et al. The use of hyperbaric oxygen for the prevention and Management of Osteoradionecrosis of the jaw: a Dana-Farber/Brigham and Women's Cancer center multidisciplinary guideline. *Oncologist.* 2017;22(3):343–50.
13. Pitak-Arnnpop P, Sader R, Dhanuthai K, Masaratana P, Bertolus C, Chaîne A, et al. Management of osteoradionecrosis of the jaws: an analysis of evidence. *Eur J Surg Oncol.* 2008;34(10):1123–34.
14. Hagelauer N, Ziebart T, Pabst AM, Walter C. Bisphosphonates inhibit cell functions of HUVECs, fibroblasts and osteogenic cells via inhibition of protein geranylgeranylation. *Clin Oral Investig.* 2015;19(5):1079–91.
15. Marx RE. Pamidronate (Aredia) and zoledronate (Zometa) induced avascular necrosis of the jaws: a growing epidemic. *J Oral Maxillofac Surg.* 2003;61(9):1115–7.
16. Ruggiero SL, Dodson TB, Fantasia J, Goodday R, Aghaloo T, Mehrotra B, et al. American association of oral and maxillofacial surgeons position paper on medication-related osteonecrosis of the jaw—2014 update. *J Oral Maxillofac Surg.* 2014;72(10):1938–56.
17. Hansen T, Kirkpatrick CJ, Walter C, Kunkel M. Increased numbers of osteoclasts expressing cysteine proteinase cathepsin K in patients with infected osteoradionecrosis and bisphosphonate-associated osteonecrosis—a paradoxical observation? *Virchows Arch.* 2006;449(4):448–54.
18. Rugani P, Walter C, Kirnbauer B, Acham S, Begus-Nahrman Y, Jakse N. Prevalence of medication-related osteonecrosis of the jaw in patients with breast cancer, prostate cancer, and multiple myeloma. *Dent J (Basel).* 2016;4(4):32.
19. Walter C, Al-Nawas B, Frickhofen N, Gamm H, Beck J, Reinsch L, et al. Prevalence of bisphosphonate associated osteonecrosis of the jaws in multiple myeloma patients. *Head Face Med.* 2010;6:11.
20. Walter C, Al-Nawas B, Grotz KA, Thomas C, Thuroff JW, Zinser V, et al. Prevalence and risk factors of bisphosphonate-associated osteonecrosis of the jaw in prostate cancer patients with advanced disease treated with zoledronate. *Eur Urol.* 2008;54(5):1066–72.
21. Grötz KA, Piesold U, Al-Nawas B. Bisphosphonate-assoziierte Osteonekrose (BP-ONJ) und andere Medikamenten-assoziierte Kiefernekrosen. AWMF [Internet]. 2012; (007/091):1–18.
22. Walter C, Grotz KA, Kunkel M, Al-Nawas B. Prevalence of bisphosphonate associated osteonecrosis of the jaw within the field of osteonecrosis. *Support Care Cancer.* 2007;15(2):197–202.
23. Koch FP, Merkel C, Ziebart T, Smeets R, Walter C, Al-Nawas B. Influence of bisphosphonates on the osteoblast RANKL and OPG gene expression in vitro. *Clin Oral Investig.* 2012;16(1):79–86.
24. Walter C, Klein MO, Pabst A, Al-Nawas B, Duschner H, Ziebart T. Influence of bisphosphonates on endothelial cells, fibroblasts, and osteogenic cells. *Clin Oral Investig.* 2010;14(1):35–41.
25. Ziebart T, Pabst A, Klein MO, Kammerer P, Gauss L, Brullmann D, et al. Bisphosphonates: restrictions for vasculogenesis and angiogenesis: inhibition of cell function of endothelial progenitor cells and mature endothelial cells in vitro. *Clin Oral Investig.* 2011;15(1):105–11.
26. Pabst AM, Ziebart T, Ackermann M, Konerding MA, Walter C. Bisphosphonates' antiangiogenic potency in the development of bisphosphonate-associated osteonecrosis of the jaws: influence on microvessel sprouting in an in vivo 3D Matrigel assay. *Clin Oral Investig.* 2014;18(3):1015–22.
27. Saia G, Blandamura S, Bettini G, Tronchet A, Totola A, Bedogni G, et al. Occurrence of bisphosphonate-related osteonecrosis of the jaw after surgical tooth extraction. *J Oral Maxillofac Surg.* 2010;68(4):797–804.
28. Hansen T, Kunkel M, Springer E, Walter C, Weber A, Siegel E, et al. Actinomycosis of the jaws—histopathological study of 45 patients shows significant involvement in bisphosphonate-associated osteonecrosis and infected osteoradionecrosis. *Virchows Arch.* 2007;451(6):1009–17.
29. Kyrgidis A, Triaridis S, Kontos K, Patrikidou A, Andreadis C, Constantinidis J, et al. Quality of life in breast cancer patients with bisphosphonate-related osteonecrosis of the jaws and patients with head and neck cancer: a comparative study using the EORTC QLQ-C30 and QLQ-HN35 questionnaires. *Anticancer Res.* 2012;32(8):3527–34.
30. Berg BI, Mueller AA, Augello M, Berg S, Jaquiere C. Imaging in patients with bisphosphonate-associated osteonecrosis of the jaws (MRONJ). *Dent J (Basel).* 2016;4(3):E29.
31. Thomas C, Spanidis M, Engel C, Roos FC, Frees S, Neisius A, et al. Bone scintigraphy predicts bisphosphonate-induced osteonecrosis of the jaw (BRONJ) in patients with metastatic castration-resistant prostate cancer (mCRPC). *Clin Oral Investig.* 2016;20(4):753–8.
32. Otto S, Pautke C, Van den Wyngaert T, Niepel D, Schiödt M. Medication-related osteonecrosis of the jaw: prevention, diagnosis and management in patients with cancer and bone metastases. *Cancer Treat Rev.* 2018;69:177–87.
33. Imbulgoda A, Heng DY, Kollmannsberger C. Sunitinib in the treatment of advanced solid tumors. *Recent Results Cancer Res.* 2014;201:165–84.
34. Koch FP, Walter C, Hansen T, Jager E, Wagner W. Osteonecrosis of the jaw related to sunitinib. *Oral Maxillofac Surg.* 2011;15(1):63–6.
35. Viviano M, Rossi M, Cocco S. A rare case of osteonecrosis of the jaw related to imatinib. *J Korean Assoc Oral Maxillofac Surg.* 2017;43(2):120–4.
36. Estilo CL, Fornier M, Farooki A, Carlson D, Bohle G 3rd, Huryn JM. Osteonecrosis of the jaw related to bevacizumab. *J Clin Oncol.* 2008;26(24):4037–8.
37. Santos-Silva AR, Belizario Rosa GA, Castro Junior G, Dias RB, Prado Ribeiro AC, Brandao TB. Osteonecrosis of the mandible associated with bevacizumab therapy. *Oral Surg Oral Med Oral Pathol Oral Radiol.* 2013;115(6):e32–6.
38. Mawardi H, Enzinger P, McCleary N, Manon R, Villa A, Treister N, et al. Osteonecrosis of the jaw associated with ziv-aflibercept. *J Gastrointest Oncol.* 2016;7(6):E81–E7.
39. Yamamoto D, Tsubota Y, Utsunomiya T, Sueoka N, Ueda A, Endo K, et al. Osteonecrosis of the jaw associated with everolimus: a case report. *Mol Clin Oncol.* 2017;6(2):255–7.

40. Saad F, Brown JE, Van Poznak C, Ibrahim T, Stemmer SM, Stopeck AT, et al. Incidence, risk factors, and outcomes of osteonecrosis of the jaw: integrated analysis from three blinded active-controlled phase III trials in cancer patients with bone metastases. *Ann Oncol.* 2012;23(5):1341–7.
41. Drescher W, Bunker MH, Weigert K, Bunker C, Hansen ES. Methylprednisolone enhances contraction of porcine femoral head epiphyseal arteries. *Clin Orthop Relat Res.* 2004;423:112–7.
42. Pabst A, Castillo-Duque JC, Mayer A, Klinghuber M, Werkmeister R. Meth mouth-a growing epidemic in dentistry? *Dent J (Basel).* 2017;5(4):E29.

Open Access This chapter is licensed under the terms of the Creative Commons Attribution 4.0 International License (<http://creativecommons.org/licenses/by/4.0/>), which permits use, sharing, adaptation, distribution and reproduction in any medium or format, as long as you give appropriate credit to the original author(s) and the source, provide a link to the Creative Commons license and indicate if changes were made.

The images or other third party material in this chapter are included in the chapter's Creative Commons license, unless indicated otherwise in a credit line to the material. If material is not included in the chapter's Creative Commons license and your intended use is not permitted by statutory regulation or exceeds the permitted use, you will need to obtain permission directly from the copyright holder.



Part IX

Maxillary Sinus and the Oral Surgeon

23.1 Introduction

Sinusitis, also known as rhinosinusitis with the association of rhinitis, is a common presentation within the primary care setting, due to the effect it can have on individuals' quality of life. It is defined as the inflammation of the mucosal lining in at least one of the paranasal sinuses with an acute presentation lasting for less than 12 weeks and chronic extending to durations greater than this. The maxillary sinus is the largest of four paranasal sinuses and, with its close relationship to the underlying dentition, it is often susceptible to inflammatory processes. This chapter explores the anatomy, physiology of the maxillary sinus, the aetiology, assessment and management of maxillary sinusitis.

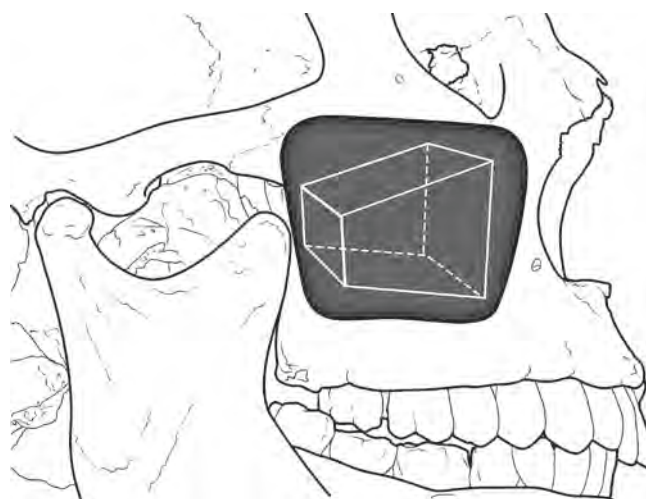
23.2 Anatomy of Maxillary Sinus

The maxillary sinus is the largest of the paranasal sinuses and develops during day 65–75 of gestation, with a volume of approximately 1 cm³ at birth. Up until an average age of 12, pneumatization of the maxillary sinus continues as the space occupied by tooth germs is freed through their eruption [1]. In the latter stages of development, it pneumatizes inferiorly, guided by the eruption pathway of the permanent dentition.

The main function of the maxillary sinus is involved in the humidification and warming of inspired air as well as prevention of microorganism ingress through mucociliary action. In addition to this, the paranasal sinus contributes to voice reso-

nance. A possible evolutionary function may also be as a 'crumple zone' during trauma, thus protecting the brain (Fig. 23.1).

In an adult, the maxillary sinus takes the form of a quadrangle pyramidal shape, with the base adjacent to the nasal cavity and the peak extending towards the zygomatic process, and a volume in the region of 15 cm³. The roof of the sinus is formed of the orbital floor in the centre of which runs the infra-orbital neurovascular bundle. The anterior wall of the maxillary sinus is the weakest of the walls, with the thinnest section superior to the canine resulting in the canine fossa. It is also perforated by the infraorbital nerve that supplies the maxillary sinus, along with the greater palatine nerve. The posterior wall of the sinus lies in front of and shelters the internal maxillary artery, sphenopalatine artery, Vidian canal and the greater palatine nerve. The inferior wall is the most varying in shape, with invaginations corresponding to the alveolar bone of the maxilla; the anatomical root structures of maxillary molars and the hard palate. The bone separating the dental roots can be varying



©Association of Oral and Maxillofacial Surgeons of India

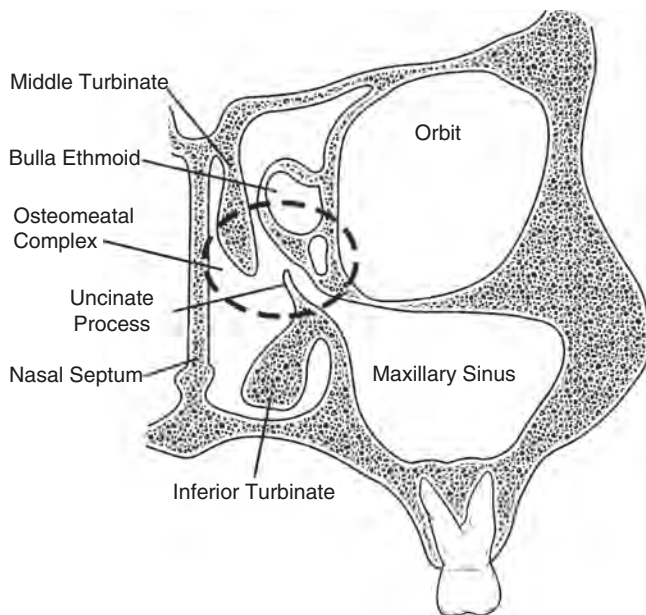
Fig. 23.1 Schematic diagram of the maxillary sinus with representation of the geometric shape of the cavity

K. Ganesan (✉)
Department of Oral and Maxillofacial Surgery, Southend
University Hospitals NHS Trust, Southend-on-Sea, UK

University of Leeds, Leeds, UK
e-mail: mailme@kandyganesan.com

N. Rathod
Department of OMFS, Southend University Hospital NHS Trust,
Southend-on-Sea, UK
e-mail: n.rathod@nhs.net

in its quantity; from complete absence to thicknesses of up to 12 mm [2]. This close proximity is a contributing factor towards the likelihood of dental iatrogenic and inflammatory pathology presenting in the maxillary sinus. The medial wall that is parallel to the nasal cavity communicates with it through the natural sinus ostium at the postero-superior aspect of sinus. This ostium opens in to a triangular space of approximately 15 mm² diameter formed by the uncinete process medially, the lamina papyracea laterally and the ethmoidal bulla posteriorly before



©Association of Oral and Maxillofacial Surgeons of India

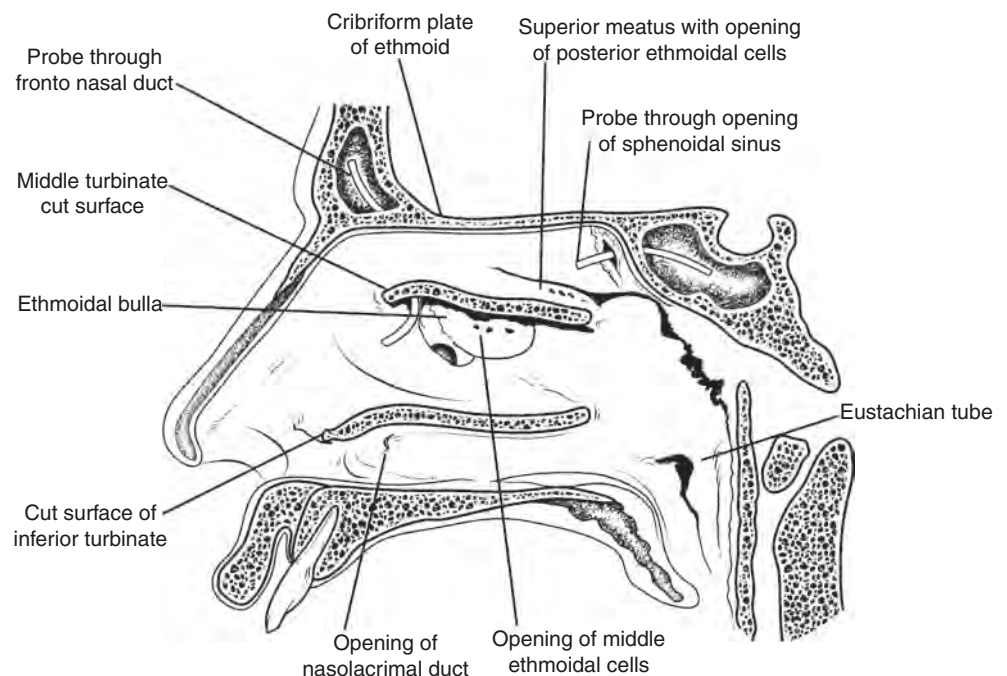
Fig. 23.2 Schematic diagram showing a coronal cross section of the maxillary sinus and the osteomeatal complex

communicating with the nasal cavity through a semilunar hiatus in the middle meatus. This is an area of common drainage from the maxillary, anterior ethmoidal and frontal sinuses. Some individuals may exhibit anterior/posterior fontanelles; bony dehiscences inferior to this, covered with mucosa. These can act as accessory ostia, points of drainage when the main osteomeatal complex is blocked or there is a change in sinus pressure. An osteomeatal complex (OMC) is an important functional unit and is also a key area for the pathogenesis of chronic rhinosinusitis. It consists of multiple bony structures, air spaces and ostia. The bony structures include the middle turbinate, uncinete process of the ethmoid and bulla of the ethmoid. Air spaces are formed by the frontal recess, infundibulum of the ethmoid and the middle meatus. Ostia consists of anterior ethmoid, maxillary and frontal sinuses. The classic OMC as mentioned above has been described as the anterior osteomeatal unit. The sphenothmoidal recess and the superior meatus are referred to as the posterior meatal unit (Fig. 23.2).

Maxillary sinus septa, present in approximately 28.4% of cases [3], are thin projections of cortical bone that divide the sinus into more than one compartment either in the transverse, sagittal or horizontal plane, usually in the region of the first or second molar.

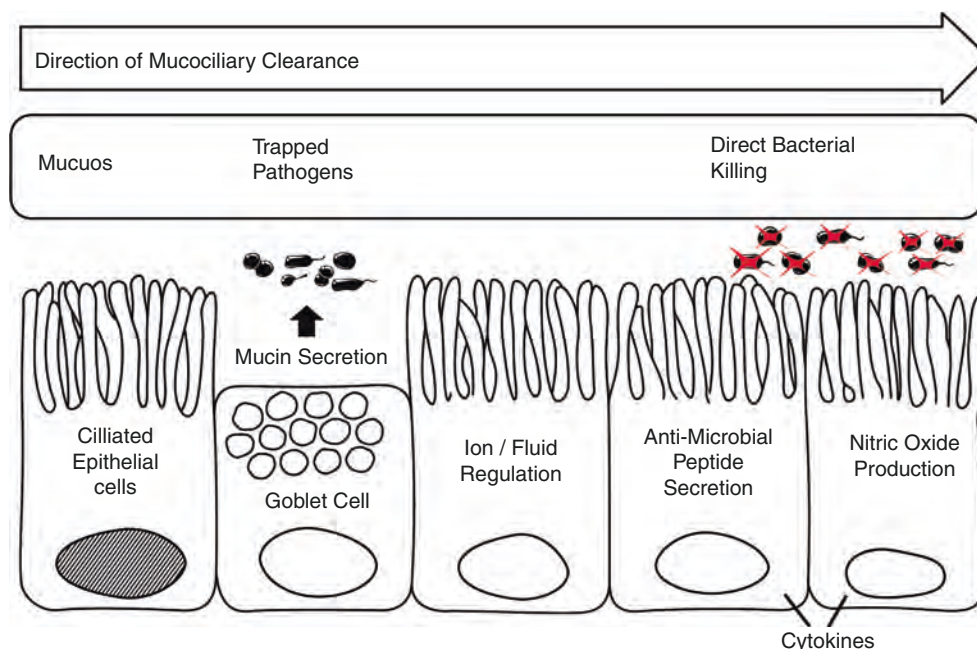
Smaller air-filled compartments in the periphery of the maxillary sinus can include Haller cells and Concha bullosa. Haller cells are air cavities encompassed in the ethmoidal capsule and are located below the inferomedial aspect of the orbital floor, and lateral to the ethmoidal cells. These can be present in a range of sizes as well as unilaterally or bilaterally. Concha bullosa is another variant air-filled cavity pneumatized in to the middle turbinate. These particular anatomical (Fig. 23.3) varia-

Fig. 23.3 Schematic diagram with a sagittal cross section of the nasal cavity and the respective openings in to it



©Association of Oral and Maxillofacial Surgeons of India

Fig. 23.4 Schematic diagram of the secretory and clearance of the mucous via the mucociliary cells



©Association of Oral and Maxillofacial Surgeons of India

tions have the potential to influence the dimensions of the osteomeatal complex, increasing the likelihood of sinus disease [4].

23.3 Maxillary Sinus Physiology

At a histological level, the maxillary sinus consists of ciliated columnar cells, basal cells and goblet cells and thus forming respiratory epithelium architecture. Unlike the rest of the respiratory pathway, the sinuses have fewer ciliated and goblet cells; friable epithelium and fewer seromucous cells, making them prone to microorganism ingress and related pathology.

The clearance of secretions from the sinuses is through a combination of ciliary and mucous action. The mucous secreted by the goblet cells consists of 96% water, with the rest consisting of glycoproteins, immunoglobulins, histamines, lactoferrin, prostaglandins and lysozymes [5]. It functions to trap foreign body and defend against bacterial ingress. This is combined with the ciliary action that promotes a spiral action of movement of the mucous through active transport from the base of the sinus towards the natural ostium in the supero-posterior aspect of the medial sinus wall and thus working against the forces of gravity.

Normal flora within the maxillary sinus is usually a combination of sterile aerobic and anaerobic organisms including bacteria organised in a complex biofilm within the sinus mucus layer. These usually include mainly aerobic B-hemolytic streptococci, staphylococci and *haemophilus spp.* The anaerobic organisms, that are fewer in quantity, include peptostreptococcus, *fusobacterium sp* and bacteroides. Whether these organisms are present in normal physiol-

ogy or transiently is poorly understood. Host specific and non-specific defence against these bacterial species is also part of normal physiology with the sinus mucosa producing secretion including antimicrobial peptides, proteins, neutrophils, macrophages coupled with the mucociliary transport towards the ostium (Fig. 23.4).

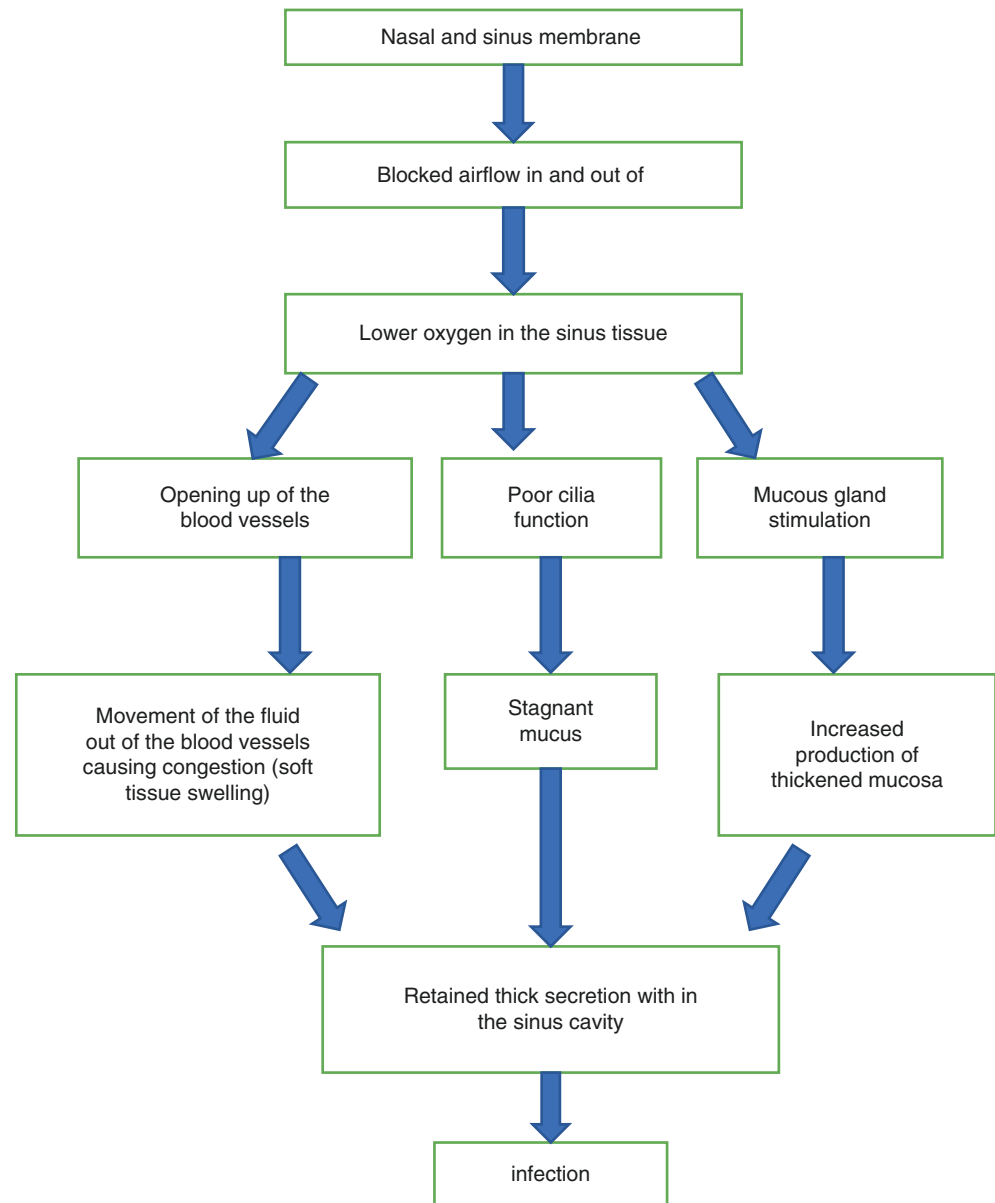
23.4 Sinusitis Pathophysiology

Due to the narrow size of the ostium opening, occlusion and related pathology of the maxillary sinus space are very likely possibilities. Obstruction of the sinus ostium can either be primary to the sinusitis process or secondary inflammation originating from elsewhere in the sinus.

With obstruction of the natural ostium, there is reduced oxygenation and gas exchange within the maxillary sinus, alongside reduced mucociliary action and mucous stasis. In the most common acute form of sinusitis, viral upper respiratory tract infections result in significant nasal congestion that results in maxillary sinus blockage and stasis. Anatomical differences such as large middle turbinates, deviated nasal septums or concha bullosa can increase the likelihood of ostium occlusion. Polyps, in particular those originating from the ethmoid, may also obstruct the maxillary sinus opening (Table 23.1).

Any form of obstruction and subsequent stasis in the maxillary sinus produce a favourable environment for the flourishing of an anaerobic environment, encouraging the formation of purulent secretions. In addition to this, changes in the sinus pressure, coupled with local mucosal inflammation, contribute to the symptoms of pain and pressure in the region [6]. The initial lower sinus pressure is caused by the

Table 23.1 Membrane swelling leading to sinus infection



consumption of the finite oxygen within the blocked and confined maxillary sinus cavity. This is followed by a transient increase in pressure where there is a greater production of carbon dioxide and sinus secretion.

Chronic rhinosinusitis has features of long-term inflammation, rather than primary infection, of the nasal passages and paranasal sinuses with an unknown underlying cause. It is likely to be part of a cycle involving inflammation, infection and subsequent obstruction of the ostium [7]. Without the presence of polyps, chronic sinusitis may be multi-factorial in nature, with one or several predisposing factors as outlined below.

Nasal polyps are oedematous masses of the mucosal membrane found in the nasal passages and paranasal sinuses. Histologically, they show squamous epithelial proliferation, a thickened basement membrane, absence of neurosensory

filaments and inflammatory cell infiltrate with high numbers of eosinophils [8]. The pathogenesis in the formation of polyps and its contribution towards chronic rhinosinusitis is poorly understood. One in vivo study involving rabbits with stimulated maxillary sinusitis observed the formation of inflammatory-type polyps in subjects with purulent infection and granulation based polyps in both purulent and non-purulent infections. In both infective processes, epithelial damage to the mucosal lining appeared to be a significant factor in the initiation of polyp formation [9]. Other evidence shows that high levels of interleukin 5, 13 and histamines in the polypoid tissue may also have a contributing role [10]. The general consensus of studies shows a high level of inflammatory mediators in the initiation and presence of nasal polyps, suggesting chronic inflammation to be a key factor.

23.4.1 Microorganisms of Sinusitis

The polymicrobial nature of maxillary sinusitis has been well documented. The initial aerobic bacterial infective organisms often include *Streptococcus pneumoniae*, *Haemophilus influenzae* and *Moraxella catarrhalis* in acute sinusitis [11]. Chronic sinusitis has found to harbour the aforementioned organisms in addition to *Prevotella* species, *Fusobacterium* species and anaerobic streptococci [12]. More recent studies have cultured *Staphylococcus aureus*, in particular methicillin resistant-type from sinus mucosal samples [13].

23.5 Predisposing Factors

23.5.1 Anatomical Variation

Any variation deemed to alter the volume or the size of the maxillary ostium may contribute to an increase risk of sinusitis. This includes [14]:

- Haller cells.
- Concha bullosa.
- Reduced infundibular width.
- Septal deviation.
- Choanal atresia.
- Nasal polyps.
- Hypoplasia of the sinus.
- Maxillary dentition roots in the sinus.

23.5.2 Atopy (Allergy)

The distinct relationship between the allergy and inflammation remains unclear. Current hypothesis predicts that with the ventilation passage in continuum with the nasal mucosa, inflammation along the rest of the airway can affect the nasal passages, thus causing narrowing of the ostium. This is supported by the high incidence of chronic rhinosinusitis with allergies driven by IgE mediators.

23.5.3 Asthma

The association between chronic sinusitis, mainly with nasal polyps, and asthma has been well documented. Several studies have shown radiographic sinus mucosal abnormalities in individuals with asthma, in particular with those suffering from severe steroid-dependent asthma [15]. Similar studies show a trend in the severity of sinusitis correlating to the severity of asthma experienced, supporting the theory of inflammation of a unified mucosal airway concept of the dis-

ease process. The association between asthma and sinusitis is further indicated with studies showing individuals reporting improvement in their asthma symptoms subsequent to medical and/or surgical treatment of their sinusitis [16].

23.5.4 Aspirin

Aspirin/NSAID hypersensitivity has been found to have an association with a persistent form of chronic sinusitis, usually with the presence of nasal polyps. Along with severe asthma, this disease process has been named the ‘Aspirin-triad’. The mechanism of pathogenicity is thought to be linked to cyclooxygenase inhibition and inhibition of arachnoid acid metabolism rather than an underlying immunological process. The presence of hyperplastic sinus mucosa contributes to a high level of recurrence in nasal polyps subsequent to sinus surgery for removal [14].

23.5.5 Environmental

Several environmental factors have been associated with an increased incidence of sinusitis with changes in air quality acting as suggestive stimulants. Greater prevalence has been identified in patients exposed to chemical air pollutants including pharmaceutical products, photocopying ink by-products, smoke and dampness [14, 17].

23.5.6 Ciliary Impairment

This may be present in the form of reduced cilia or ciliary cells, causing impairment of mucociliary flow and thus creating environments favourable for bacterial or viral sinusitis.

23.5.7 Smoking

Smoking is likely to diminish the presence of normal microbiological flora in the nasal and paranasal spaces, allowing for the growth of pathogenic microorganisms and thus eliciting a hypersensitivity reaction in the sinonasal mucosa [14].

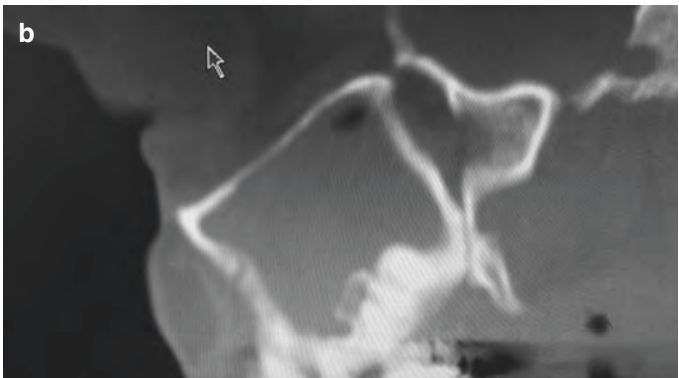
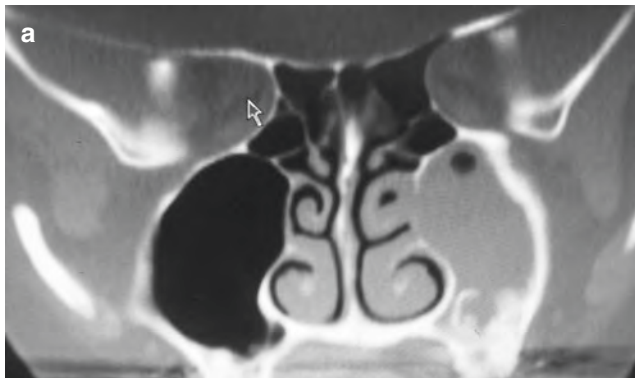
23.5.8 Gastro-Oesophageal Reflux

It has been suggested that inflammation may be elicited when the oro- and nasopharynx comes in contact with gastric acids during reflux and subsequently contributing to sinusitis [18].

23.5.9 Odontogenic Maxillary Sinusitis

As part of the examination process, this should be evaluated at the early stages and could prevent prolonged periods of investigations and symptomatic management (Fig. 23.5). Approximately 15–24% of unilateral maxillary sinusitis cases are believed to be of odontogenic origin [19], with some studies indicating this figure to be as high as 40% [20]. In a meta-analysis of 15 observational review studies consisting 770 cases, the first molars were found to be the most common tooth to be causative for odontogenic sinusitis (22.51%), followed by third molars (17.21%), second molars (3.97%), premolars (5.96%) and lastly canines (0.66%). The etiological contribution to the sinusitis was found most commonly to be from iatrogenic factors (55.97%), periodontal disease (40.38%) and odontogenic cysts (6.66%) [21]. Figure 23.6 outlines the distribution of the iatrogenic processes leading to sinusitis [21].

The disruption in maxillary sinus floor, from whichever odontogenic source, causes localised inflammation that remains persistent in that area or spreads along the sinomucosal surface with subsequent obstruction of the sinus ostium. Bacterial colonisation have been shown to consist of both aerobic and anaerobic species in 75% of cases, with the other 25% predominantly anaerobic in nature. *Staphylococcus aureus* and streptococcus pneumonia were the predominant aerobic bacteria isolated. When looking at the anaerobic bacteria distribution, Peptococcus and Prevotella species dominated and haemophilus and Moraxella species were absent in cases of odontogenic maxillary sinusitis [20].



©Association of Oral and Maxillofacial Surgeons of India

Fig. 23.5 (a) A coronal section of a CT of maxillary sinus showing extensive left-sided maxillary sinusitis. A periapical radiolucency on the upper left first molar with a breach in the cystic area to allow the pus

23.6 Classification of Sinusitis

Sinusitis is defined as an inflammation of the paranasal sinus mucosal lining; however, it rarely presents in isolation and is usually coupled with the inflammation of the nasal mucosa, thus being termed as rhinosinusitis. The cardinal features, of which two are required for a suggestive diagnosis of a rhinosinusitis, are outlined in the 2012 European position paper by the International Rhinology Society (Table 23.2). The condition is broadly classified based upon the chronicity of the condition as well as whether there is presence of polyps.

23.6.1 Acute Rhinosinusitis

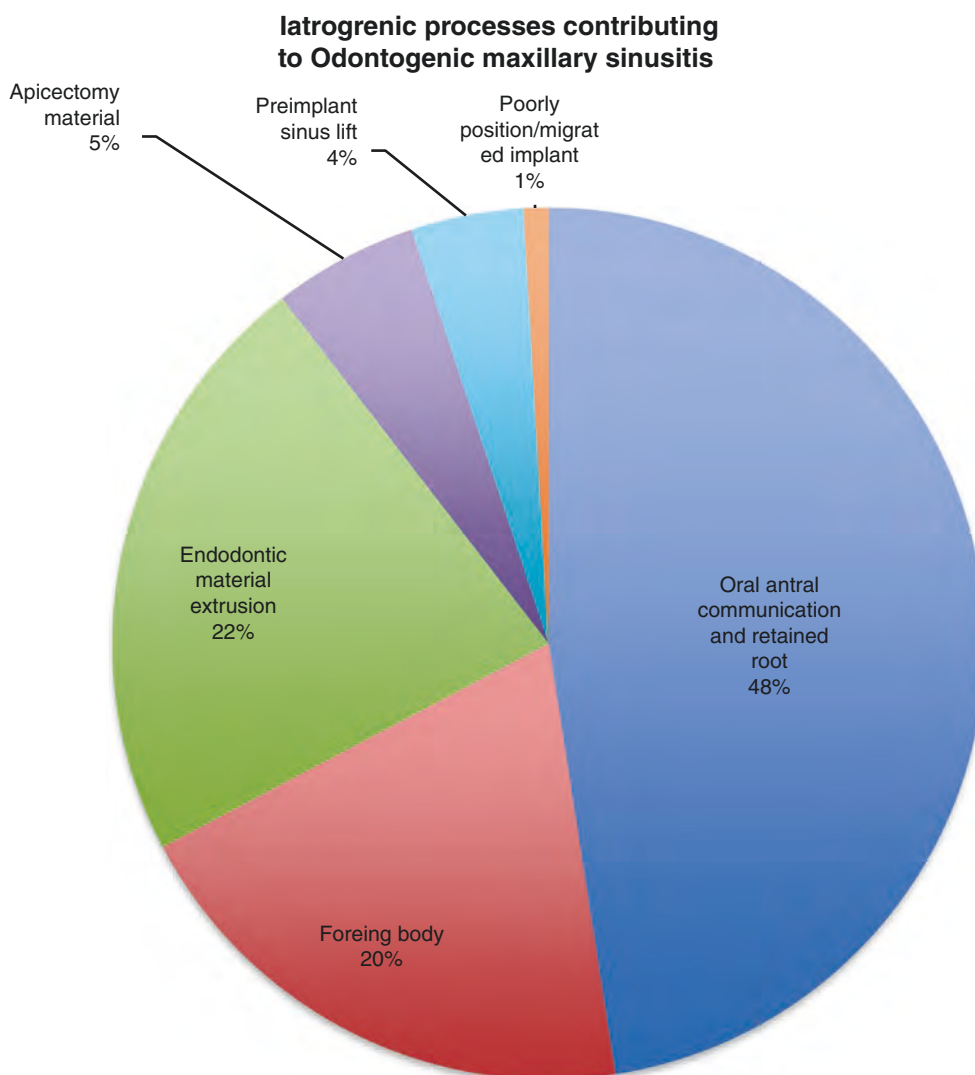
Acute rhinosinusitis (ARS) is defined as persistent sinusitis that resolves within a 12-week period. It is a common presentation within the populations globally, with prevalence rates between 6 and 15% [14].

23.6.2 Chronic Rhinosinusitis

Chronic rhinosinusitis is defined by the persistence of sinusitis symptoms for greater than 12 weeks, with no resolution after initial sinusitis treatment. It is further subdivided into whether there is a clinical and radiographic presentation of nasal polyps.

to enter the sinus and causing the sinusitis. (b) A sagittal section same image showing the extent of the sinusitis. A periapical radiolucency is noticeable in relation to mesiobuccal root of upper left first molar

Fig. 23.6 A pie chart illustrating a distribution of the iatrogenic processes contributing to odontogenic sinusitis [21]



©Association of Oral and Maxillofacial Surgeons of India

Table 23.2 Features of rhinosinusitis [14]

Symptoms	Endoscopic signs of	CT changes
<ul style="list-style-type: none"> Nasal obstruction/blockage Nasal congestion Anterior/posterior nasal discharge Anosmia/Hyposmia Facial pain/pressure 	<ul style="list-style-type: none"> Nasal polyps, Mucosal oedema/obstruction of the middle meatus, Mucopurulent discharge mainly from the middle meatus 	<ul style="list-style-type: none"> Mucosal change in the sinus Mucosal change in the osteomeatal complex

23.6.3 Fungal Rhinosinusitis

This subtype of chronic rhinosinusitis involves the inflammation of the maxillary sinusitis that is attributed to a fungal pathogen and can be classified into acute fungal rhinosinusitis, fungus balls or fulminant invasive fungal rhinosinusitis.

Acute fungal rhinosinusitis (AFRS), as described by Bent and Kuhn, is characterised by five properties [22]:

1. Nasal polyps.
2. Type I hypersensitivity to fungi (skin test or serum IgE testing).
3. Sample positive for fungal staining.

4. Eosinophilic mucin that does not invade into sinus tissue.
5. Characteristic CT radiopaque sinus findings.

The predicted pathogenesis of AFRS is believed to be an allergic, immediate hypersensitivity reaction to an inhaled fungal organism resulting in a chronic inflammatory response in a predisposed individual, usually with asthma. The most common isolated fungal species include *Bipolaris*, *Curvularia*, *Aspergillus*, and *Drechslera* species.

Fungal balls are non-invasive, dense collections of fungal debris within the maxillary sinus. Found in mostly immunocompromised and elderly individuals, they are formed commonly of *aspergillus*, in response to prolonged exposure to the fungi through inhalation of airborne spores or oral antral communication.

Acute invasive fungal sinusitis is a rapidly infiltrating growth of the fungi with a high risk of morbidity and mortality. Immunocompromised individuals that are predisposed to this include those with:

- Diabetes,
- Leukaemia,
- Hard and soft tissue malignancy with neutropenia,
- Steroid therapy,
- Severely impaired cell-mediated immunity (congenital or acquired).

Initial clinical presentation involves an acute onset of facial/head pain, fever, epistaxis and, in severe cases, of bony erosion with extrasinus infiltration and possible mental status change. Urgent surgical management and post-operative antifungal therapy is required.

23.7 Clinical Diagnosis

Diagnosis of sinusitis is primarily through clinical history and examination with the possible adjuncts of imaging studies and/or laboratory testing. The signs and symptoms of sinusitis can be categorised in to major and minor. Major features include infraorbital and maxillary facial pain, pressure sensation, congestion/obstruction sensation, purulent rhinorrhoea, hyposmia and fever [23]. Minor features are present in some of the individuals with suspected sinusitis and include headache, fatigue, dental pain, halitosis, cough and ear pain/fullness.

The acute form of rhinosinusitis is indicated usually when a patient has recently suffered with the symptoms of an upper respiratory tract infection that is viral in nature. After an initial 7–10 day phase of viral infection with gradual recovery, patients give history of worsening symptoms. Evaluation of nasal discharges show secretions that were once clear at the

at the initial stages of the viral infection that become yellow, green or grey in nature at the latter aspect of the biphasic disease process. Unilateral disease process provides greater indication towards sinusitis. Palpation over the infraorbital sinus region would elicit tenderness due to the pressure build-up from stasis and inflammation of the sinus cavity.

Patients with suspected chronic rhinosinusitis may present with symptoms of acute rhinosinusitis but to a milder degree, with the absence of a predisposing upper respiratory tract infection including fever. The presenting complaint may often be of the lack of effectiveness in acute medical management techniques [24]. Regardless of whether the causative factor in the chronicity of their sinusitis is from the presence of nasal polyps or not, patients will often present with facial pain or pressure, anterior or posterior nasal discharge and slight fatigue. Those that suffer from chronic sinusitis without the presence of polyps may also experience anosmia or hyposmia. Thus, the ambiguity in presentation makes the diagnosis of chronic sinusitis with clinical history and examination alone challenging, but nonetheless provide a vital role in their diagnosis and long-term management.

Endonasal examination in the form of anterior rhinoscopy may also be performed with headlighting and a speculum; alternatively with the large speculum of an otoscope. It can play a supportive role in visualising inflamed nasal mucosa, presence and quality of nasal discharge and the turbinates with an indication of nasal polyps or anatomical variation that may not have been suspected previously.

Nasal endoscopy provides an enhanced technique for direct visualisation of the nasal passage. Abnormalities in the nasal passage can be seen including the middle, superior turbinates and the osteomeatal mucociliary drainage passage. Where acute rhinosinusitis is diagnosed mainly through clinical history and simple examination, this method is more relevant for incidences of chronic rhinosinusitis. Nasal endoscopy can be used at 3, 6, 9 and 12 monthly intervals in chronic disease process to assess the degree of inflammation, discharge and size of nasal polyps.

Intraoral assessment should include assessment of both soft and hard tissues. The dentition requires close evaluation to rule out primary aetiology which can account for 5–10% of acute rhinosinusitis cases [25]. Detailed assessment for extensive dental caries, periapical and/or periodontal infections for teeth distal to the canine is required. Where multiple teeth are unilaterally tender to percussion with a lack of correlation to dental pathology clinically or radiographically, sinusitis not of dental cause is a probable diagnosis. This sensation may also be elicited with facial or head movements. This is due to the close neural relationship between the maxillary sinus and upper molars. Pain or pressure sensation is also elicited from palpation in the most superior aspect of the maxillary buccal sulcus. In some cases, posterior discharge in to the nasopharynx that is either characteristically

Table 23.3 Differential diagnosis for maxillary sinusitis, NICE guidelines 2018 [26]

- Upper respiratory tract infection.
- Allergic rhinitis.
- Adenoiditis or tonsillitis.
- Sinonasal tumour.
- Turbinate hypertrophy.
- Migraine.
- Giant cell arteritis.
- Temporomandibular joint dysfunction.
- Neuropathic or atypical facial pain.

clear or coloured in nature can be visualised during intraoral assessment.

Recurring episodes of acute rhinosinusitis (more than three episodes a year) requires wider consideration of the primary causative factor. Peters et al. has attributed recurrent acute rhinosinusitis to various reasons such as immunodeficiency, cystic fibrosis, ciliary dysfunction and anatomic abnormalities [16] (Table 23.3).

Severe episodes of acute rhinosinusitis originating from the maxillary sinuses are a rare presentation. Complications can arise with the involvement of the ethmoidal and frontal sinuses that are in close proximity to vital structures including the anterior cranial cavity and the orbits with associated venous drainage systems [27].

As per Ah- See et al. [28], certain features of sinusitis that require urgent intervention are:

- Bleeding.
- Proptosis/diplopia.
- Maxillary paresthesia.
- Intraorbital/intracranial complications.
- Osteomyelitis.
- Immunocompromised patients.

23.8 Clinical Imaging

Clinical imaging is a useful adjunct to the diagnosis of sinusitis. It can provide confirmatory and characteristic information to guide management of the condition.

Plain radiography is an accessible and cost-effective means of visualising the maxillary sinus. An orthopantomogram (OPG), though focusing on the dentition, maxilla and mandible, also includes a significant proportion of the maxillary sinuses and provides an opportunity to identify the presence of pathological features. Indication of sinusitis would be from the presence of unilateral or bilateral generalised diffuse radiopacity within the maxillary sinus. Causative disease process can also be visualised including the proximity of periapical pathology from the maxillary dentition, periodontal disease, cystic lesions of dental origin, foreign body presence, sinonasal mucocele or polyps. The significant level

of artefact from overlying structures however limits the usefulness of this imaging modality. Where dental disease is a suspected contributing factor, dental periapical radiographs can be considered for a targeted and enhanced dental evaluation. Consequently, a dental cause for sinusitis can be challenging to diagnose, in particular in cases of chronic sinusitis.

The occipitomeatal view, also known as the 'Water's view', can additionally offer visualisation of the entire sinus as well as other paranasal sinuses, with fluid collection and mucosal thickening evident at varying angles. Care must be taken to differentiate between a benign mucosal cyst and a fluid level. A diagram showing the difference in the appearances between the two is shown in Fig. 23.7.

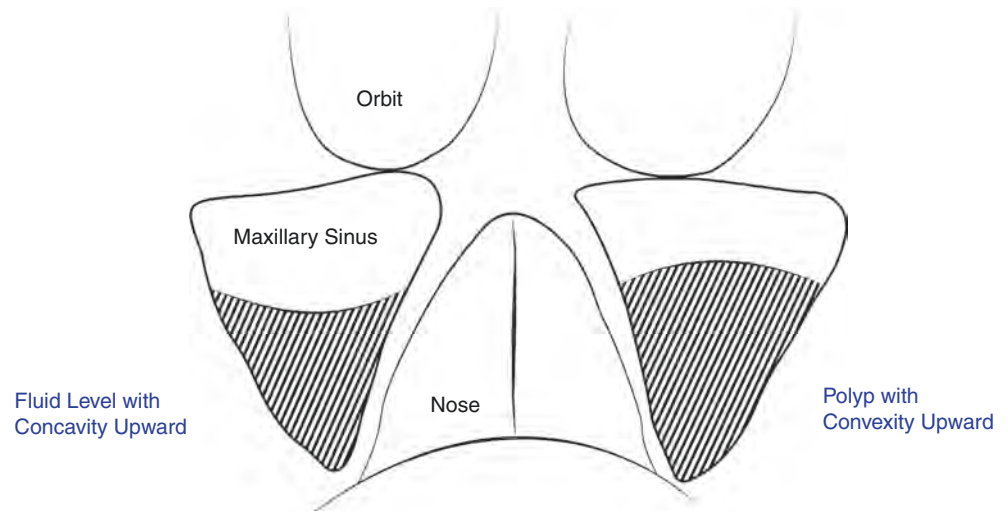
Despite the efficiency with which these images can be taken, one should consider whether the overall information gained for sinusitis diagnosis justifies the exposure to radiation. Plain imaging does not offer a comprehensive view of the maxillary sinus ostium, the occlusion of which will often be the causation of subsequent sinusitis. Apart from suggestion in the presence or absence of disease process, it does not offer information on the severity of the condition. With significant overlap, diagnosis of sinus masses can also be difficult.

Computer tomography (CT) (Fig. 23.8) offers the three-dimensional visualisation of the sinuses and can be confirmatory in the presence or absence of sinus disease. These should be considered only where a patient's symptoms are vague or first-line medical management has thus far failed to offer significant relief of symptoms. Contrast medium is not required as they do not offer additional value towards diagnosis or management. It should also be noted that where CT scans of sinuses are taken, maxillary teeth should also be included to assess for their involvement in the disease process.

With appropriate manipulation of imaging sections, the location and severity of sinus disease can be gauged. Mucosal thickening is distinctly evident on CT scans, being more pronounced in cases of sinusitis with polyps. Further diagnostic information is available on the sinus content including air-fluid levels. The patency of the sinus discharge tract can be assessed with detailed view of the osteomeatal complex on coronal sections thus allowing for surgical planning. The presence or absence of nasal masses can be confirmed in CT cases but can be used to differentiate between sinus polyps, cysts or tumours. Generalised thickening or sclerosis of the maxillary sinus walls may be indicative of chronic sinusitis whereby early infective processes cause demineralisation of the sinus wall and prolonged reactive host responses that result in sclerotic bone deposition. Where sclerosis is more localised in the maxillary sinus wall, there may be indication towards enquiry of previous sinus surgery.

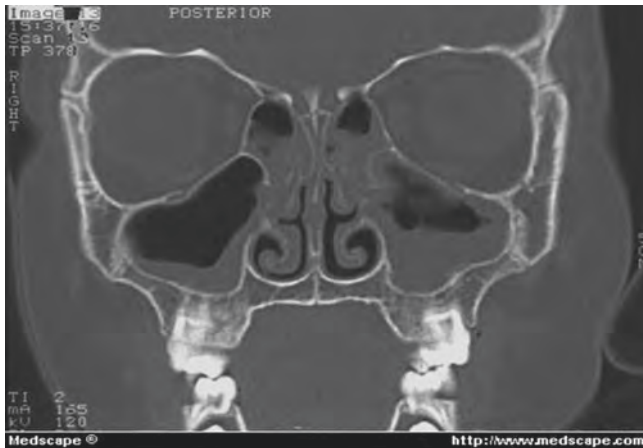Cone beam computer tomography (CBCT) can provide enhanced information on the pathological processes contrib-

Fig. 23.7 Diagram showing the difference between the fluid level and the mucosal cyst/polyp



Differentiating sinus fluid and polyp on water's radiographic view

©Association of Oral and Maxillofacial Surgeons of India



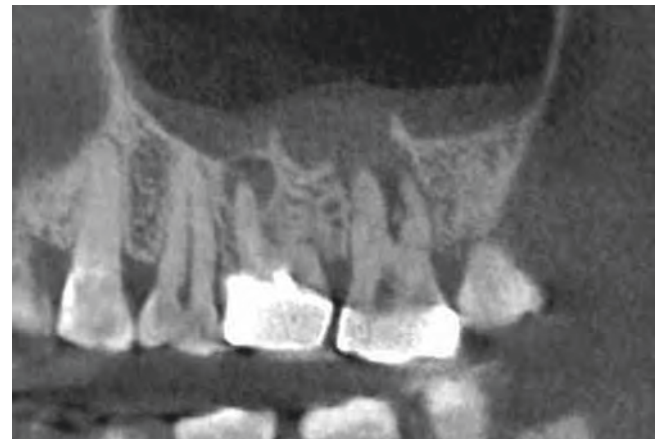©Association of Oral and Maxillofacial Surgeons of India

Fig. 23.8 A coronal view of a CT scan showing thickened mucosal lining of the both maxillary sinus with a fluid level on the left maxillary sinus

uting towards sinusitis, with slices as fine as 0.4 mm as well as offering a lower radiation dose exposure, in the region of 10%, in comparison to a fine slice CT scan (Fig. 23.9).

This is more relevant for cases of maxillary sinusitis of dental origin in which pathological processes can be tracked from the tooth to the sinus structure.

MRI scans offer an imaging modality that allows some enhanced interpretation in the appearance of the soft tissue within the sinus. This is not relevant in the majority of uncomplicated maxillary sinusitis presentations. The use of MRI is limited to cases where there is opacification of the maxillary sinus with no obvious obstruction, osseous abnormality or odontogenic pathology. It allows the differentiation between mucosal inflammation, complete fluid collection or a tumour within the maxillary sinus as well as its origin.



©Association of Oral and Maxillofacial Surgeons of India

Fig. 23.9 CBCT of the sinuses showing upper second molar with a breach in the periodontal ligament space and periapical area opening into the maxillary sinus causing sinusitis—a classic odontogenic sinusitis

23.9 Treatment

23.9.1 Conservative Management

In acute sinusitis cases, with a primary virus and secondary bacterial infection, the aim of treatment focuses around relieving of symptoms including pain, nasal congestion and discharge during the 2–3 week period that it will take to resolve. Antibiotics in the early stages are not recommended. Advice can be offered in the management of systemic virus infection including physical rest, adequate analgesia and increased fluid intake.

The pain sensation from the maxillary sinus region is attributed to pressure changes caused by occlusion of the

ostia and thus, treatment to promote unblocking will inherently contribute towards pain reduction. During this process, analgesia in the form of paracetamol and ibuprofen can be utilised for management of pain.

Nasal saline and decongestants have been shown in some literature to be an effective means of opening the ostia and encouraging ventilation.

Nasal saline mists and irrigations can offer a breakdown of nasal blockages, dilution of irritants and allergens, reduction of postnasal drainage and overall more effective mucociliary clearance [29]. Lavage/irrigation of the nasal passage can be performed using small quantities of salt or bicarbonate dissolved in warm water. These can be administered by inhaling small volumes of the self-made formulation in cupped hands through each nostril until nasal ventilation feels clearer. Alternative over-the-counter devices such as squeeze-bottles and syringes can be used. Humidified air and steam inhalation can also be utilised as a means of nasal secretory blockage breakdown. These irrigative techniques can offer supportive relief to other symptomatic management methods but are not deemed effective as monotherapy [30].

Where there is indication of chronic sinusitis, potential risk factors should be identified and addressed, including avoidance of triggers that may exacerbate allergies and asthmatic flare-ups. Where applicable, patients should be encouraged to stop smoking or being exposed to passive smoke.

23.9.2 Medical Management

Where acute sinusitis symptoms last for longer than 10 days, medical treatment modalities can be offered.

23.9.2.1 Nasal Decongestants

Topical nasal decongestants can be offered as a means of improving sinonasal ventilation through reducing mucosal secretion, nasal congestion and thus improved patency of the osteomeatal complex. Topical formulations can include phenylephrine (0.25%), oxymetazoline (0.5%) and xylo-metazoline [31]. These should be limited to use twice a day for up to 3 days. These formulations have a sympathomimetic effect causing vasoconstriction with subsequent reduced fluid secretion and mucosal inflammation. Long-term use of these agents can produce a rebound effect with the absence of sustained vasoconstriction.

23.9.2.2 Topical Nasal Glucocorticosteroids

Topical intranasal glucocorticosteroids may be considered in the management of prolonged acute rhinosinusitis or chronic rhinosinusitis as an adjunctive or monotherapy prior to the consideration of antibiotic prescription [32]. These can be utilised for up to 3 months in adult patients depending on the formulation used and especially where allergy is deemed a

significant risk factor. Common formulations utilised include budesonide, ciclesonide, fluticasone furoate, fluticasone propionate, mometasone furoate and triamcinolone acetonide. These have been deemed an effective means of clearing nasal and sinus air passages in several studies when used in a retroclined, head tilt action to encourage exposure towards the middle meatus.

23.9.2.3 Systemic Glucocorticosteroids

The use of systemic glucocorticosteroids has been reserved for refractory cases of chronic rhinosinusitis, in particular those with allergy [2], as well as initial treatment for patients with suspected allergic fungal rhinosinusitis. It can provide symptomatic relief through improving ventilation through the sinuses, reducing the size of polyps and thus restoring some sense of smell. Current British guidelines suggest prednisolone 0.5 mg/kg for 5–10 days as well as the adjunct therapy with betamethasone nasal drops [33], taking relevant consideration of those already on steroids for other conditions.

23.9.2.4 Antimicrobial Therapy

There is limited evidence to support the use of antibiotics in the short term for acute rhinosinusitis. A Cochrane review of 10 trials based in the primary care environment found that irrespective of treatment modality with or without antibiotics, 71% of patients' symptoms of uncomplicated acute sinusitis had resolved by the 2-week mark [34]. Where symptoms of sinusitis arise, the microbes of dominance usually include aerobic streptococcus pneumonia, haemophilus influenza and *Moraxella catarrhalis*. Antibiotic therapy should be reserved for cases of acute exacerbations of rhinosinusitis where symptoms haven't resolved after 7–10 days or for severe cases involving signs of systemic spread including fever and severe unilateral facial pain. Though the evidence is limited, some literature supports the use of amoxicillin for 7–14 days. This is mostly effective; however, approximately 20–30% of haemophilus influenza strains have been found to be resistant to amoxicillin due to the production of lactamase [35]. During persistent periods of acute sinusitis or during exacerbations of chronic sinusitis, there is a shift towards a mixture of anaerobic and aerobic pathogenesis. The Infectious Diseases Society of America recommends amoxicillin clavulanate as the first choice of antibiotic for 5–7 days [36], with clindamycin, doxycycline, levofloxacin or moxifloxacin for those with an allergy to penicillin. This can be used in combination with topical glucocorticosteroids to attain more efficient symptom relief [32]. In cases of chronic sinusitis, use of low-dose macrolides has shown some effectiveness [14]. In all cases, where viable, the choice of antibiotic should be guided by microbiological culture growth, attained from discharges from the middle meatus or surgically guided sample collection.

23.9.3 Surgery

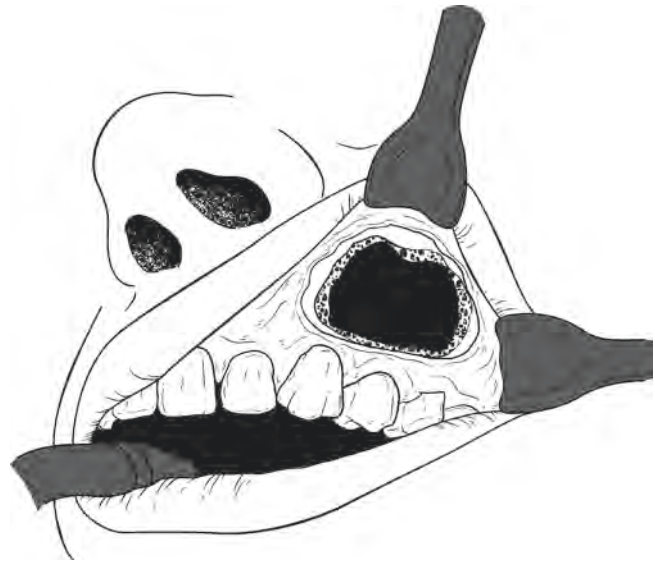
Surgical intervention is routinely carried out by Ear, Nose and Throat speciality and is usually indicated in the failed medical management of chronic sinusitis or as the first treatment for acute fungal rhinosinusitis. The aim of surgery is to attain normal function through restoration of ventilation and allowing physiological mucociliary drainage of the sinuses. This can be through opening and widening of the osteomeatal complex, removing foreign body and polypoid tissue, clearing the sinus of infected mucin, removal of chronically inflamed mucosal and bony tissue whilst throughout preserving as much of the virgin, healthy mucous membrane in the sinus as possible.

Extra-oral or intra-oral approaches can be taken. The classically used internal access is the Caldwell-Luc approach. George W Caldwell first published this technique in the New York Medical Journal in 1893, where he utilised the canine fossa approach to gain access to the sinus and perform intranasal drainage, significantly improving surgical outcomes. Henry Luc, a french surgeon, further adapted this method in 1897 for surgical treatment of chronic sinusitis where performed antrostomy in the middle meatus whilst Caldwell had performed an inferior meatal antrostomy.

23.9.3.1 Surgical Method: Caldwell-Luc Approach

Advanced imaging like CT or CBCT should be used for the procedure. Particular awareness is required for the presences of any septae that may interfere with the Caldwell-Luc access in to the sinus. In addition, assessment is required of the availability of a window on the anterior wall of maxillary sinus, with short maxillary sinus height creating challenges in this approach.

This procedure can be done either under a general or a local anaesthetic with sedation support; though complete painrelief and anaesthesia with the latter option is difficult to achieve (Fig. 23.10). Once adequate anaesthesia has been achieved, the upper lip is retracted an incision is made 2–3 mm above the mucogingival junction, parallel to the occlusal surface of the teeth. A full-thickness mucoperiosteal flap can be raised with a molt's periosteal elevator to reveal the underlying bone. Often, bulbosities caused by the root projections of the upper canines and premolars are noticeable and they can be used as anatomical landmarks to avoid damaging the roots of the teeth. The periosteum can be raised elevated all the way to infraorbital foramen and care must be taken not to stretch the infraorbital nerve. Then a bony window can be made with a Rosehead bur 2–3 mm above the root apices of the teeth. On entry in to the sinus, a microbiology swabbing of the sinus content is done for culture and sensitivity. Once the swab has been taken, this is followed by stripping of the sinus lining, espe-



©Association of Oral and Maxillofacial Surgeons of India

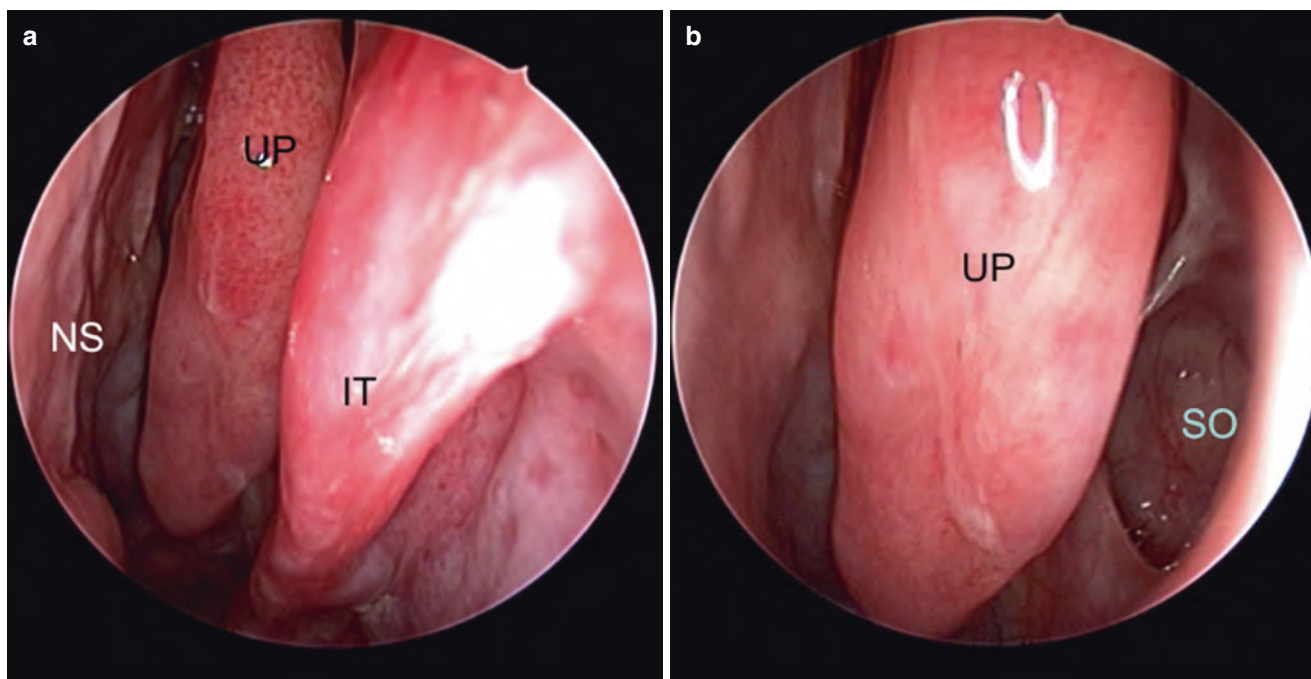
Fig. 23.10 A diagram showing the intraoral approach for the Caldwell-Luc technique

cially when treating chronic, persistant sinusitis. The lining can be removed with a microdebrider, Freer's elevator and curettes. Care must be taken not to remove tissue from the roof of the sinus due to the fact infraorbital nerve can be seen through the canal resorbed by maxillary sinusitis.

Any soft tissue curetted from the sinus can be sent for histopathological examination. A 30 or 45 degree endoscope is used to visualise the floor of the sinus which is not feasible with a standard 0 degree FESS. To complete the procedure, an intranasal antrostomy can be done to improve the drainage of the sinus. This procedure can be done by passing a curved haemostat through the nasal aperture to penetrate the lateral nasal wall, 1-1.5cm posterior to the anterior attachment of the inferior nasal turbinate. Care should be taken to avoid injuring the opening of nasolacrimal duct. The projection of the haemostat can be visualised with an endoscope in the sinus simultaneously. Forceps are used to remove the fragments of bone created from the enlargement of the ostium and thus complete the intranasal antrostomy. The intra-oral Caldwell-Luc access is used to provide a final saline-wash within the sinus, prior to achieving haemostasis and would closure, often with resorbable sutures.

23.9.3.2 Complications with Caldwell-Luc approach

Complications associated with this surgical technique include infraorbital nerve parasthesia that is often transient and may last up to 6 months. Similarly there may be numbness of the attached gingivae and associated teeth or even possible devitalisation. If the lacrimal apparatus has been encountered, there may also be the risk of dacryocystitis.



©Association of Oral and Maxillofacial Surgeons of India

Fig. 23.11 (a and b) Naso endoscopic pictures showing as the scope enters the left nostril. Nasal septum (NS) on the left and Inferior turbinate (IT) on the right and the uncinete process (UP). Further up showing maxillary sinus ostium (SO) and Uncinate process (UP)

23.9.3.3 Surgical Method: Functional Endoscopic Sinus Surgery

With technology continually advancing, many prospective studies report functional endoscopic sinus surgery (FESS) (Fig. 23.11) to be a safe and effective means of managing chronic sinusitis. For the FESS approach to be an effective surgical method in the management of chronic sinusitis, appropriate patient and surgical instrumentation related factors require consideration. Standard preparation for FESS involves an oral endotracheal tube which can be positioned based on surgeon's convenience to improve the access. Prior to donning surgical scrubs, the neuro-patties soaked in a vasoconstrictor solution may be placed along the floor and middle portion of the nasal cavity such that it is effective at the start of the operation. In addition, all Endoscopic acumen should be ready for the beginning of the procedure. Endoscopic instrumentation includes a 0, 30, and 70 degree angle scope, a powered debrider with a 4 mm straight and a 60 degree cannula, 4 mm long curved suction, various types of punch forceps, curettes and a monopolar suction cautery.

Before the start of the procedure, neuro-patties are removed and 1% lidocaine and 1:100000 adrenaline injected into the septum, middle turbinate and uncinete process for the maxillary sinus-related issues. To survey the width and depth of the nasal cavity and also to establish the boundaries to avoid any complications, a systematic examination of the nasal cavity carried out with a 30 degree scope attached to an endoscopic tower/viewing screen. All the nasal structures

should be visualised including posterior nasal choana and the inferior turbinates.

Systematic intranasal survey with the scope is also carried out as a part of the surgical planning to identify any nasal septal spur, septal deviations and turbinate hypertrophy to improve the access and to prevent any complications. Additionally, any polyps can be removed to improve the access. An angled probe is used to reflect the uncinete process to visualise hiatus semilunaris and infundibulum. Back fracturing the uncinete process finally allows visualisation of the maxillary sinus ostium and medial wall of the orbit. A 4 mm trimmer can be used to remove uncinete and part of the middle turbinate to gain access to maxillary sinus ostium. The superior border of the sinus ostium is an important anatomical landmark as it is the junction of the medial wall of the orbit and the lamina papyracea. At this point of dissection, a decision can be taken to do a minimal or extensive dissection process, and this depends on the extent of the disease process. Mostly, a minimal dissection (expansion of the ostium) is all that is necessary.

23.9.3.4 Complications with the FESS Approach

FESS is an essentially safe procedure in the hands of a trained and experienced surgeon; however there are a wide range of risks associated with this procedure due to the proximity of anatomical structures such as the orbits and their content, major arterial and venous structures and the base of the skull. Severe complications can include orbital content penetration that may lead to fat herniation, enophthalmous

and damage to extraocular muscles; penetration in to the skull base can result in cerebrospinal fluid leakage and carotid artery dissection may cause a stroke or even death. Orbital content penetration leading to fat herniation, enophthalmos and damage to extraocular muscles. Crusting, septal perforation, mild bleeding, nasal obstruction, anosmia, minimal fat herniation from orbital wall perforation and crusting of the nasal mucosa are examples of what are believed to be minor complications.

Sinus surgery should be supported with medical management post-operatively to prevent further inflammation developing, particularly in the case of polyp removals that may re-establish without maintenance therapy.

23.10 Conclusion

Sinusitis can be a debilitating condition for patients whether acute or chronic. With close proximity to the dentition, symptoms of dental pain can result in presentation to the maxillofacial and dental professional. A succinct clinical history and examination is vital in attaining an accurate diagnosis. Though management is guided by diagnosis, management should commence with symptom relief.

Acknowledgements We would like to acknowledge Mr. Martyn Barnes and SurgTec for the endoscopic pictures attached to this chapter. More endoscopic images and videos can be accessed from www.surgtech.net website.

References

1. Lawson W, Patel ZM, Lin FY. The development and pathologic processes that influence maxillary sinus pneumatization. *Anat Rec: Advances in Integrative Anatomy and Evolutionary Biology: Advances in Integrative Anatomy and Evolutionary Biology*. 2008 Nov;291(11):1554–63.
2. Ugincius P, Kubilius R, Gervickas A, Vaitkus S. Chronic odontogenic maxillary sinusitis. *Stomatologija*. 2006;8:44–8.
3. Pommer B, Ulm C, Lorenzoni M, Palmer R, Watzek G, Zechner W. Prevalence, location and morphology of maxillary sinus septa: systematic review and meta-analysis. *J Clin Periodontol*. 2012 Aug;39(8):769–73.
4. Stallman JS, Lobo JN, Som PM. The incidence of concha bullosa and its relationship to nasal septal deviation and paranasal sinus disease. *Am J Neuroradiol*. 2004 Oct 1;25(9):1613–8.
5. Benninger MS. Rhinitis, sinusitis and their relationship to allergy. *Am J Rhinol*. 1992;6:37–43.
6. Aust R, Stierna P, Drettner B. Basic experimental studies of ostial patency and local metabolic environment of the maxillary sinus. *Acta Otolaryngol Suppl*. 1994;515:7–10. Discussion 1
7. ENT UK and Royal College of Surgeons. Commissioning guide: chronic rhinosinusitis. London: ENT UK and Royal College of Surgeons; 2016.
8. Pawankar R. Nasal polyposis: an update. *Curr Opin Allergy Clin Immunol*. 2003 Feb 1;3(1):1–6.
9. Norlander T, Fukami M, Westrin KM, Stierna P, Carlsöö B. Formation of mucosal polyps in the nasal and maxillary sinus cavities by infection. *Otolaryngol Head Neck Surg*. 1993 Sep;109(3):522–9.
10. Drake-Lee AB, McLaughlan P. Clinical symptoms, free histamine and IgE in patients with nasal polyposis. *Int Arch Allergy Appl Immunol*. 1982;69:268–71.
11. Gwaltney JM Jr, Scheld WM, Sande MA, Sydnor A. The microbial etiology and antimicrobial therapy of adults with acute community-acquired sinusitis: a fifteen-year experience at the University of Virginia and review of other selected studies. *J Allergy Clin Immunol*. 1992;90:457–61. Discussion 62
12. Finegold SM, Flynn MJ, Rose FV, et al. Bacteriologic findings associated with chronic bacterial maxillary sinusitis in adults. *Clin Infect Dis*. 2002;35:428–33.
13. Brook I, Foote PA, Hausfeld JN. Increase in the frequency of recovery of methicillin-resistant *Staphylococcus aureus* in acute and chronic maxillary sinusitis. *J Med Microbiol*. 2008;57:1015–7.
14. Fokkens WJ, Lund VJ, Mullol J, et al. European position paper on rhinosinusitis and nasal polyps 2012. *Rhinol Suppl*. 2012;(23):3 p preceding table of contents, 1–298.
15. Serrano E, Neukirch F, Pribil C, Jankowski R, Klossek JM, Chanal I, et al. Nasal polyposis in France: impact on sleep and quality of life. *J Laryngol Otol*. 2005;119(7):543–9.
16. Peters AT, Spector S, Hsu J, Hamilos DL, Baroody FM, Chandra RK, Grammer LC, Kennedy DW, Cohen NA, Kaliner MA, Wald ER. Diagnosis and management of rhinosinusitis: a practice parameter update. *Ann Allergy Asthma Immunol*. 2014 Oct 1;113(4):347–85.
17. Koskinen OM, Husman TM, Meklin TM, Nevalainen AI. The relationship between moisture or mould observations in houses and the state of health of their occupants. *Eur Respir J: Official Journal of the European Society for Clinical Respiratory Physiology*. 1999 Dec;14(6):1363–7.
18. Report of the rhinosinusitis task force committee meeting Alexandria, Virginia, August 17, 1996. *Otolaryngol Head Neck Surg*. 1997;117(3 Pt 2):S1–68.
19. Vestin Fredriksson M, Öhman A, Flygare L, Tano K. When maxillary sinusitis does not heal: findings on CBCT scans of the sinuses with a particular focus on the occurrence of odontogenic causes of maxillary sinusitis. *Laryngoscope Investig Otolaryngol*. 2017 Dec;2(6):442–6.
20. Patel NA, Ferguson BJ. Odontogenic sinusitis: an ancient but underappreciated cause of maxillary sinusitis. *Curr Opin Otolaryngol Head Neck Surg*. 2012 Feb 1;20(1):24–8.
21. Arias-Irimia O, Barona-Dorado C, Santos-Marino JA, Martínez-Rodríguez N, Martínez-González JM. Meta-analysis of the etiology of odontogenic maxillary sinusitis. *Med Oral Patol Oral Cir Bucal*. 2010 Jan 1;15(1):e70–3.
22. Bent JP III, Kuhn FA. Allergic fungal sinusitis/polyposis. *Allergy Asthma Proc*. 1996;17:259–68.
23. Rosenfeld RM, Andes D, Bhattacharyya N, et al. Clinical practice guideline: adult sinusitis. *Otolaryngol Head Neck Surg*. 2007;137(suppl):S1–S31.
24. Tan BK, Chandra RK, Pollak J, et al. Incidence and associated pre-morbid diagnoses of patients with chronic rhinosinusitis. *J Allergy Clin Immunol*. 2013;131:1350–60.
25. Williams JW, Simel DL. Does this patient have sinusitis? Diagnosing acute sinusitis by history and physical examination. *JAMA*. 1993;270:1242–6.
26. National Institute for Health and Care Excellence. Sinusitis. London: NICE; 2018.
27. Cummings CW, Haughey BH, Thomas JR, Harker LA, Flint PW, Haughey BB, et al. Cummings otolaryngology: head & neck surgery. 4th ed. Philadelphia: Mosby; 2005.

28. Ah-See KW, Evans AS. Sinusitis and its management. *BMJ: Brit Med J.* 2007 Feb 17;334(7589):358.
29. Hauptman G, Ryan MW. The effect of saline solutions on nasal patency and mucociliary clearance in rhinosinusitis patients. *Otolaryngol Head Neck Surg.* 2007;137:815–21.
30. Harvey R, Hannan SA, Badia L, Scadding G. Nasal saline irrigations for the symptoms of chronic rhinosinusitis. *Cochrane Database Syst Rev.* 2007;3:CD006394.
31. Kretschmar DP, Kretschmar CJ. Rhinosinusitis: review from a dental perspective. *Oral Surg Oral Med Oral Pathol Oral Radiol Endod.* 2003 Aug 1;96(2):128–35.
32. Zalmonovici A, Yaphe J. Steroids for acute sinusitis. *Cochrane Database Syst Rev.* 2007;(2):CD005149.
33. Scadding GK, Durham SR, Mirakian R, Jones NS, Drake-Lee AB, Ryan D, et al. BSACI guidelines for the management of rhinosinusitis and nasal polyposis. *Clin Exp Allergy.* 2008;38:260–75.
34. Lemiengre MB, van Driel ML, Merenstein D, Young J, De Sutter AI. Antibiotics for clinically diagnosed acute rhinosinusitis in adults. *Cochrane Database Syst Rev.* 2012;10:CD006089.
35. Fairbanks DN. Inflammatory diseases of the sinuses: bacteriology and antibiotics. *Otolaryngol Clin N Am.* 1993;26:549–59.
36. Chow AW, Benninger MS, Brook I, et al. IDSA clinical practice guideline for acute bacterial rhinosinusitis in children and adults. *Clin Infect Dis.* 2012;54:e72–e112.

Open Access This chapter is licensed under the terms of the Creative Commons Attribution 4.0 International License (<http://creativecommons.org/licenses/by/4.0/>), which permits use, sharing, adaptation, distribution and reproduction in any medium or format, as long as you give appropriate credit to the original author(s) and the source, provide a link to the Creative Commons license and indicate if changes were made.

The images or other third party material in this chapter are included in the chapter's Creative Commons license, unless indicated otherwise in a credit line to the material. If material is not included in the chapter's Creative Commons license and your intended use is not permitted by statutory regulation or exceeds the permitted use, you will need to obtain permission directly from the copyright holder.



OroAntral Communications and OroAntral Fistula

Suvy Manuel

Routine exodontia is a common procedure performed by the general dental practitioner and the oral surgeon alike. Most of the maxillary premolar/molar extractions heal uneventfully but some may cause inadvertent opening into the maxillary sinus, manifesting as immediate oro antral communications (OAC) or delayed oro antral fistulae. The common reasons being difficulty encountered in the extractions intra operatively due to myriad reasons or the OAC may be due to a pre existing pathology in the peri apical region or within the sinus lining. Whatever the reason be , its paramount that the surgeon identifies the problem and approach it in a sequential manner to avoid long term consequences and to attain a perfect closure. The timing of the closure is crucial which is dependent upon the sinus health and the socket condition. This may be complicated by a missing root tip which is lying in the sinus. This chapter aims to walk the reader through these events in a logical fashion, so that they can take appropriate decisions and use the correct surgical technique which will ensure a successful closure of the defect.

24.1 Introduction

Maxillary sinus is an anatomical area, which is intimately associated with the field of oral and maxillofacial surgery. Many of the procedures done violate the integrity of the maxillary sinus, as in orthognathic surgeries, or when the sinus is involved per se as part of midface trauma or in odontogenic pathologies that infringe upon the sinus.

The relevance of the sinus in day-to-day minor dentoalveolar surgical procedures is that the sinus floor is in very

Electronic Supplementary Material The online version of this chapter (https://doi.org/10.1007/978-981-15-1346-6_24) contains supplementary material, which is available to authorized users.

S. Manuel (✉)

Department of Oral and Maxillofacial Surgery, Ananthapuri Hospitals and Research Institute, Trivandrum, Kerala, India

Kerala Institute of Medical Sciences, Trivandrum, Kerala, India

close approximation with the roots of the maxillary posterior teeth, especially the molars [1].

Eberhardt, in 1992, did a CT study to evaluate the distance between maxillary sinus floor and the apices of the maxillary pre-molar/molar teeth. The buccal first premolar showed the largest value of 6.18 mm (SD 1.60 mm). It is quite disturbing to know that the mesiobuccal root of maxillary second molar is only 0.83 mm (SD 0.49 mm) away from the maxillary sinus floor, as per this study results. Readers are advised to refer the table in reference [1] to have a better picture of this relevant CT study.

This intimate relation with the root of maxillary molars causes many a time inadvertent communication between the sinus and oral cavity causing acute OroAntral communication (OAC). If the OAC is unrecognized or not dealt with primarily, either it may undergo spontaneous healing if the circumstances are favourable or it may progress into a full-fledged OroAntral fistula (OAF), which will need secondary intervention for closure.

This section of the book deals with OAC and OAF caused during exodontia and minor dentoalveolar surgical procedures, cyst enucleation and small-sized tumour excision.

Communications caused due to excision of moderate to large pathologies, post-oncosurgery defects, major maxillofacial trauma, gunshot/missile injuries, osteoradionecrosis and developmental and congenital deformities usually may require locoregional/free flap transfers and/or prosthetic rehabilitations. Such communications are dealt with elsewhere in this book.

This section is limited to closure of OAF caused after exodontia; however, many surgical techniques used for OAF closure do overlap with surgical closure techniques of oronasal and palatal fistulas. Those techniques are dealt with in relevant sections of the book.

This chapter also deals with managing and retrieving root/root tips, which are inadvertently displaced into the sinus (Root in sinus).

Most of the surgical procedures aimed at correction of OAC/OAF are doomed to fail if the underlying sinus is not

healthy before the anticipated closure. The “Antral regime procedures” are aimed at ensuring a disease-free sinus before anticipated elective closure of a post-extraction OAF. When patients are referred to oral surgeons for treatment of OAF, depending upon the duration of complaint, the sinus may be in various stages of the disease. It is difficult to ascertain whether the sinus was diseased primarily at the time of exodontia, accentuating the chance of an OAF formation or whether the sinus had been secondarily infected following the formation of OAF due to direct communication with the oral cavity. Another possibility is that the sinus lining would have been secondarily involved by a periapical pathology and removal of the involved tooth was conducive to the formation of the OAC.

The role of an otorhinolaryngologist cannot be understated, and at times, the closure has to be attempted after consulting with them regarding the sinus health. Their presence may be required during the closure for allied procedures in the sinus like FESS (Functional Endoscopic Sinus Surgery).

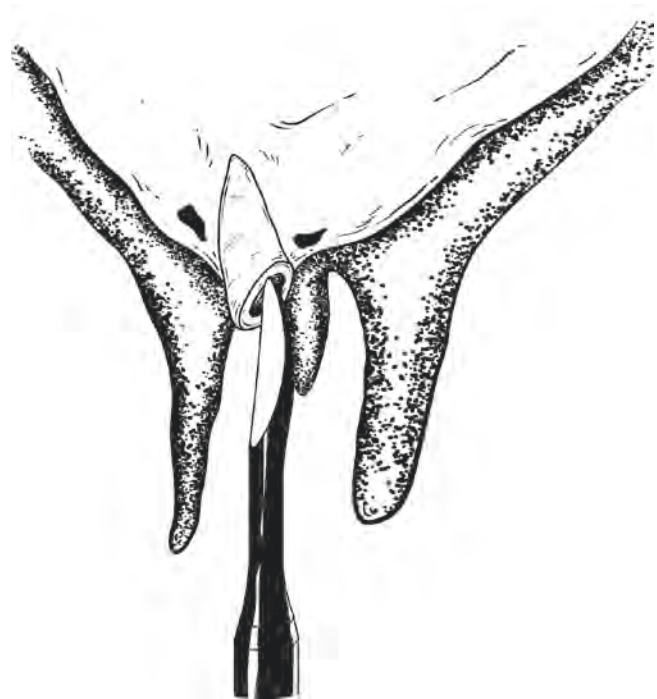
24.2 Aetiology of OAC

The common causes for OAC during dentoalveolar procedures are

1. Aberrant anatomy causing the sinus floor to dip down between the roots of premolars and molars/decreased thickness of sinus floor.
2. Unusually long roots, which lie in close proximity to the sinus floor/Schneiderian membrane.
3. Dense alveolar bone causing difficult extractions.
4. Removal of root canal-treated maxillary molars is usually difficult due to the brittle nature of the tooth.

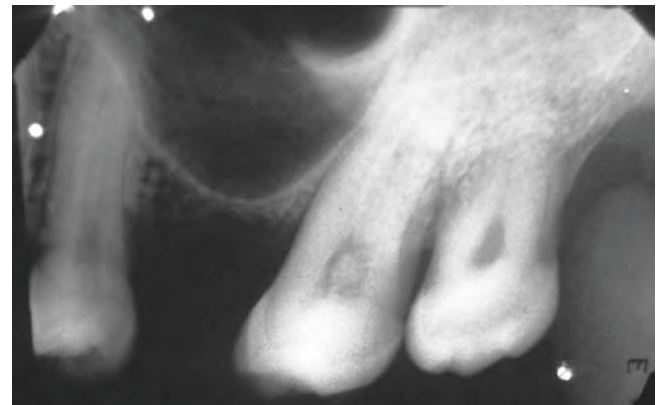
Attempted removal of brittle root tip fractures in such teeth shows an increased chance of getting OAC.

5. Improper use of dental elevators when attempting to remove root tip can cause undue vertical forces, which may push the roots into the sinus (Fig. 24.1).
6. Progressive pneumatization of the sinus as age advances, especially around lone standing molars (Fig. 24.2).
7. Progressive pneumatization is also a cause for OAC during removal of maxillary third molars especially when associated with tuberosity fractures.
8. Teeth, which have periapical pathologies, cause bone loss/erosion at the sinus floor and are at a higher chance of causing OAC after extractions. It is imperative that such cases are identified pre-operatively, adequate radiographic examinations are done, the patients are pre-warned and necessary measures are to be taken to close the OAC, if they occur during the procedure (Fig. 24.3a, b and c).
9. Occasionally, odontogenic infections/abscess may spread to the sinus, which may manifest “Fluid levels” in the sinus on paranasal sinus X-rays. Extraction of such teeth involves a greater chance of having OAC.



©Association of Oral and Maxillofacial Surgeons of India

Fig. 24.1 Improper use of dental elevators causing pushing of root tip into maxillary sinus

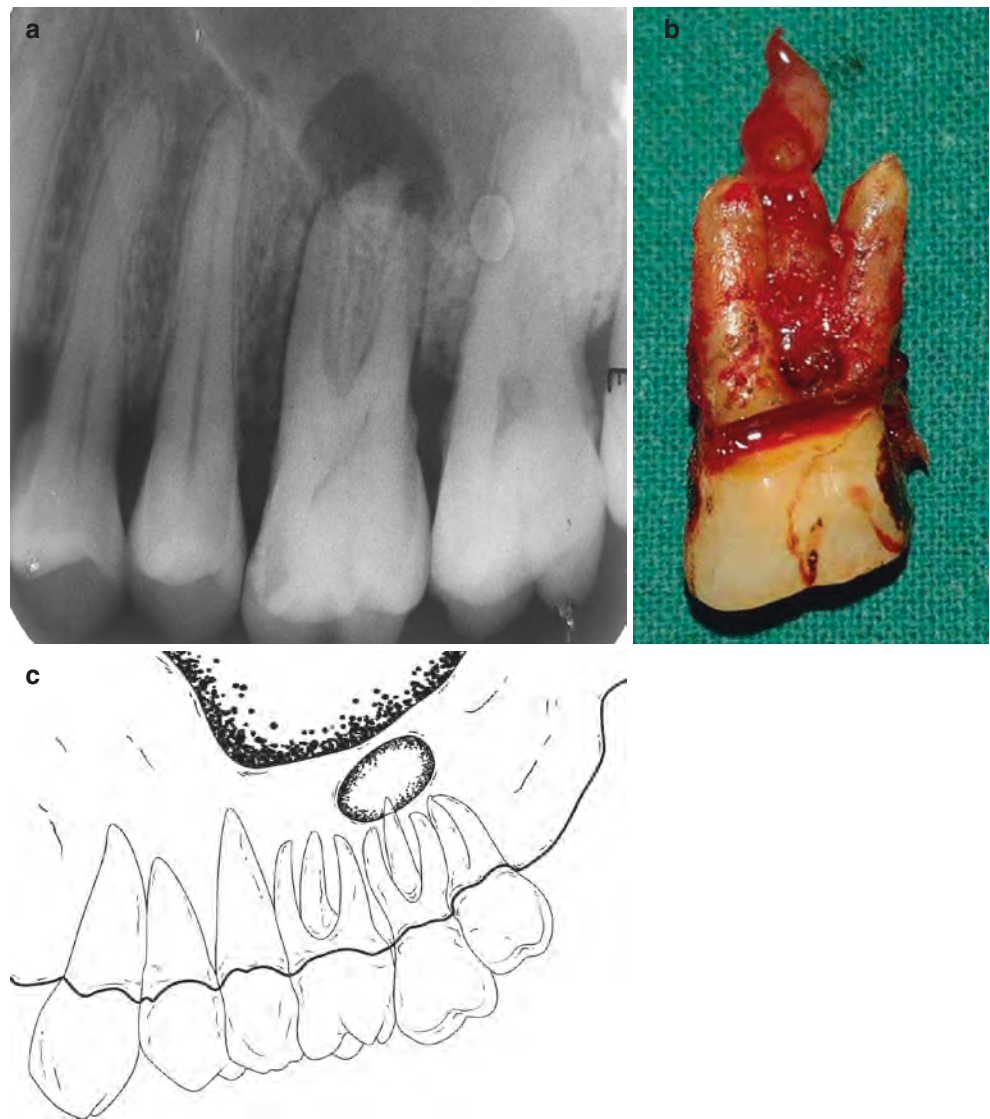


©Association of Oral and Maxillofacial Surgeons of India

Fig. 24.2 Sinus dipping down in a long-standing edentulous area of upper left first molar (IOPA)

10. Lack of adherence to basic principles of dentoalveolar surgery or overzealous/aggressive attempts to remove or retrieve fractured root tips of maxillary posterior teeth may cause OAC. It is the judgement of the concerned clinician whether to attempt removal of a fractured root tip; if the clinician can remove the root tip via the socket through closed intra-alveolar technique well and good, if not the clinician should be able to remove the tip via transalveolar technique based on sound dentoalveolar surgical principles and should be able to close the OAC if it occurs. If the clinician feels that he is not able to perform the above-mentioned procedure, it may be wise

Fig. 24.3 (a) IOPA of a molar showing periapical lesion, (b) Extracted molar with the lesion attached to the root tip, (c) Diagrammatic representation of periapical lesion close to sinus floor



©Association of Oral and Maxillofacial Surgeons of India

not to vigorously attempt to remove the root tip. Either he should get expert help or it would be judicious to leave the root tip behind and attempt removal later if required when expert help is available (Fig. 24.4).

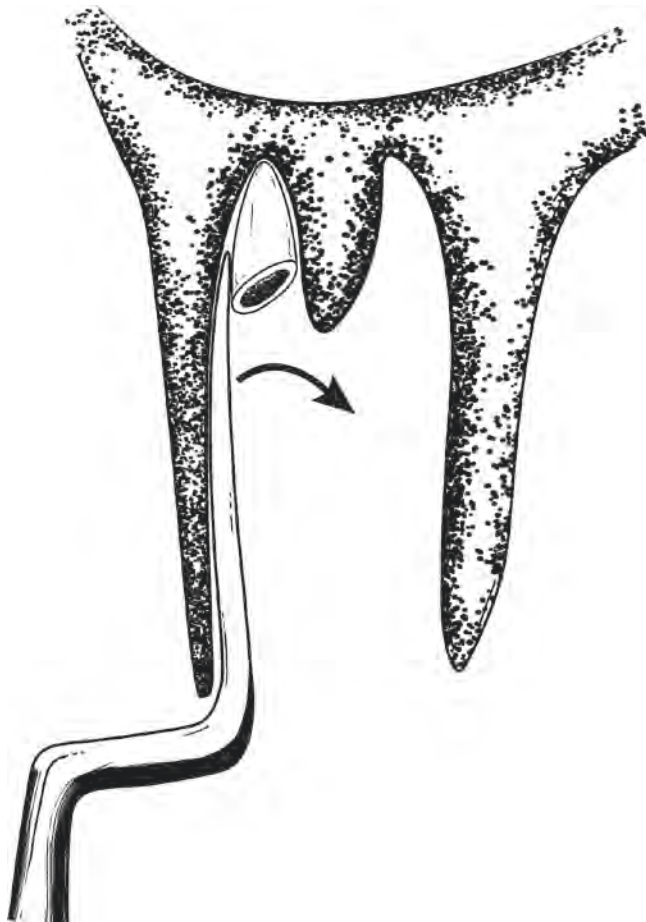
11. Teeth, which have aberrant root anatomies, dilacerations, hypercementosis and ankylosis, are all at risk of developing OAC.

24.3 Clinical Features of OAC

The basic rule to be followed when we suspect an OAC is never to enlarge or aggravate the existing communication. Most of the time OAC goes unrecognized, and it may heal spontaneously if it is less than 3–5 mm in diameter [2]. If a bigger OAC is not recognized and adequate measures are not taken for closure, it may progress to OAF. Unless

it is an evident OAC, confirmatory tests are not done in order to prevent enlarging the OAC. Literature also says that sinusitis will ensue if the OAC is not closed within 24–48 h.

1. Bubbling of mucous or blood may be seen at the socket opening when the patient exerts pressure via a closed nostril (Valsalva manoeuvre).
2. Patient may feel oronasal regurgitation or leaking of oral fluids via nose if they hold water in mouth.
3. There may be unilateral epistaxis on the affected side.
4. Close examination of the socket apex under direct light vision may show the sinus lining or opening into the sinus.
5. There may be changes in the resonance of the voice.
6. An OAC should be suspected if a piece of antral floor is attached to the root end after extraction (Fig. 24.5).



©Association of Oral and Maxillofacial Surgeons of India

Fig. 24.4 Diagram showing the importance of slow, careful and fine movements to remove root tips with straight probes, fine mosquito forceps or apical fragment ejectors

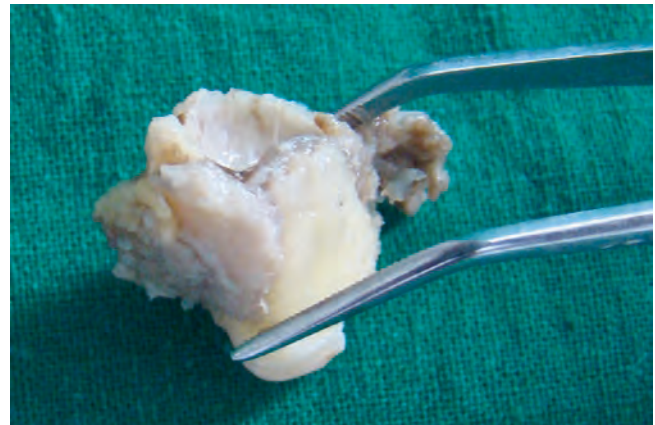24.3.1 Radiological Features of OAC

There may not be radiological evidence of a small OAC on a routine IOPA, unless there is sizeable loss of antral floor or breach in antral floor, which will manifest as a direct communication between the sinus and socket. It is not advisable to insert a probe or radiopaque marker into the socket and take an x-ray as it may enlarge the OAC.

24.3.2 Management of OAC

The OAC may be managed in the following step wise approach:

1. If you suspect an OAC, it is prudent to inform the patient about the anticipated treatment plan and the sequel.



©Association of Oral and Maxillofacial Surgeons of India

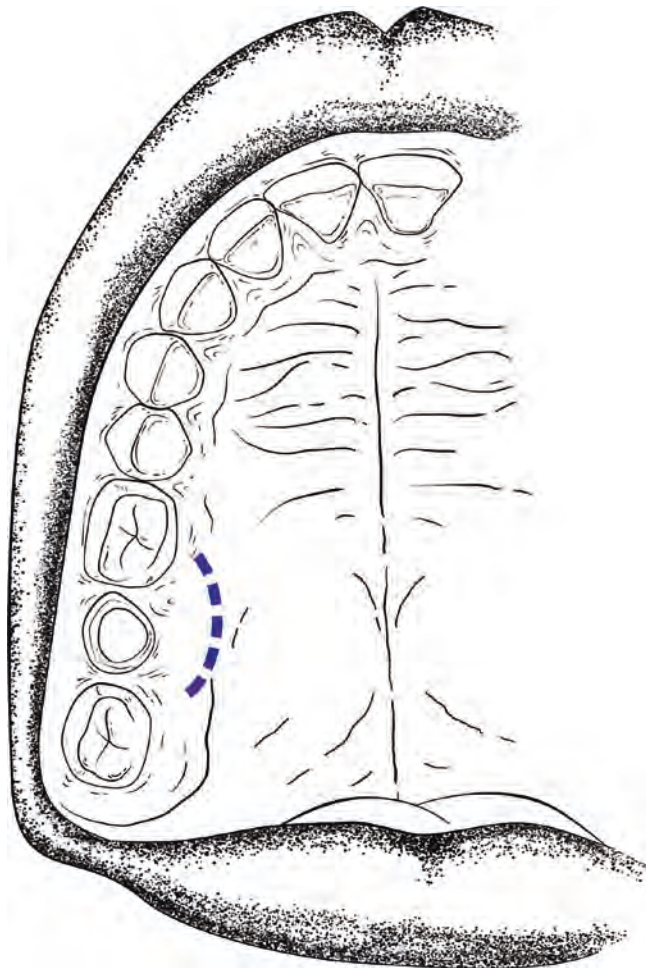
Fig. 24.5 Note the sinus floor attached to the roots of an upper third molar after extraction, with associated tuberosity fracture. It is a definite case of OAC, which warrants primary closure if conditions are favourable

Patient has to be aware of the condition as post-operative compliance form of the patient is of paramount importance in order to prevent any dehiscence or clot break down at the OAC closure site. (*See antral regime section.*)

2. Openings less than 3–5 mm in size may be left without any intervention hoping for spontaneous healing, or a primary closure may be attempted depending upon individual case scenarios. If left for spontaneous healing, patients are specifically instructed to avoid any manoeuvres, which may increase the intra-sinus pressure.

A routine suturing across the socket in maxillary premolar/molar extraction sites may not suffice in suspected cases of OAC, as the buccal and palatal gingivae may not approximate primarily and healing may be secondary in nature. Suturing in such cases just plays a role in supporting the clot. If aiming at primary closure to treat OAC, the buccal and palatal gingivae may be approximated by the following additional measures:

- (a) Reduce the height of the buccal/palatal alveolar bone in order for the sutures to approximate.
- (b) As it is the palatal mucoperiosteum that is more adherent, a semilunar relaxing incision may be placed about 5 mm away from the palatal gingival edge and the flap is advanced buccally to meet the buccal gingivae (Fig. 24.6).



©Association of Oral and Maxillofacial Surgeons of India

Fig. 24.6 Depicts releasing incision in the palate, to advance the flap in order to achieve primary closure of the socket

Beyond these two steps, any attempt at closing the OAC would mean that the surgeon is using techniques that are common with established techniques of closing an OAF. If primary closure is not obtained by (a) or (b), the next logical step would be to raise a buccal full thickness three-sided (trapezoidal/rectangular/4 cornered) flap and advancing it to the palatal side. At this stage, if adequate relaxation is not present for the flap, the mucoperiosteum may have to be scored and the details of this are given in OAF surgical closure section of this chapter.

If the sinus is healthy, the best chance of closing an OAC is at the time of occurrence and the surgeon may use any of the techniques in his armamentarium, and these decisions are taken on a case-by-case basis.

Clinical Scenario 1

A simple clinical scenario is given here as food for thought for the young readers (Fig. 24.7).

I believe that there may be different opinions, with few possible ones being

1. Extract the tooth and allow the lesion to regress/observe periodically.
2. Extract the tooth and curette/attempt enucleation via socket.
3. Extract the tooth via transalveolar technique and enucleate the lesion.
4. Further investigations/imaging before attempting extraction.
5. Assess the sinus condition before performing any extraction.
6. Be aware of the possibility of an OAC after extraction and be prepared for the possible technique of closure.

This case was included just to show how perplexing a routine clinical situation could be and to stress on the importance of a solid pre-operative plan before attempting such cases.

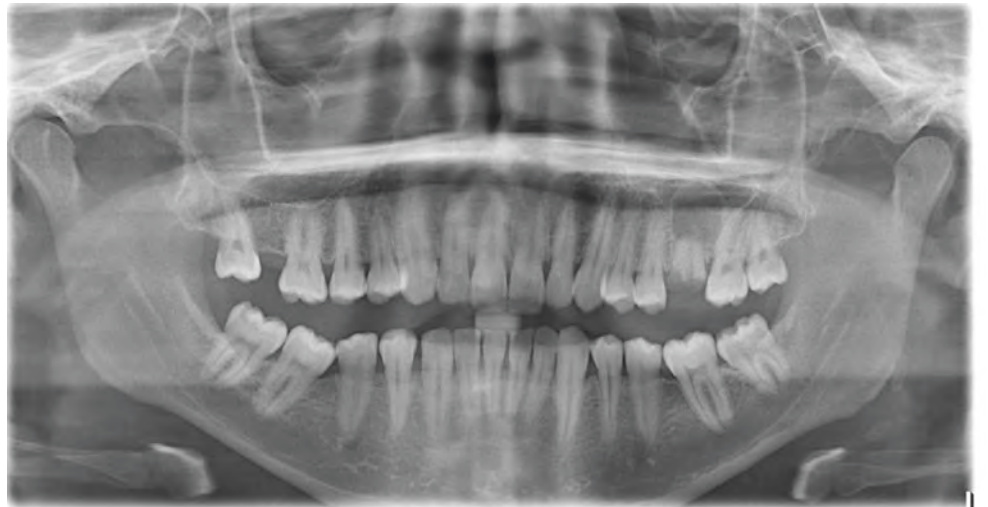
24.4 OroAntral Fistula

Intrusion into the maxillary sinus and establishment of direct communication with the oral cavity are referred to as an oro-antral fistula (Fig. 24.8a and b). An oroantral fistula is a pathological condition in which the oral and antral cavities have a permanent communication by means of a fibrous connective tissue fistula coated by epithelium. Once an unrecognized OAC does not heal or there is failure of attempted closure, the condition progresses to an OAF, which means that the epithelization of the communicating tract has occurred. Usually, such cases get referred to the oral surgeon from the general dental practice within 2–3 weeks of the occurrence, when patient notices oronasal regurgitation.

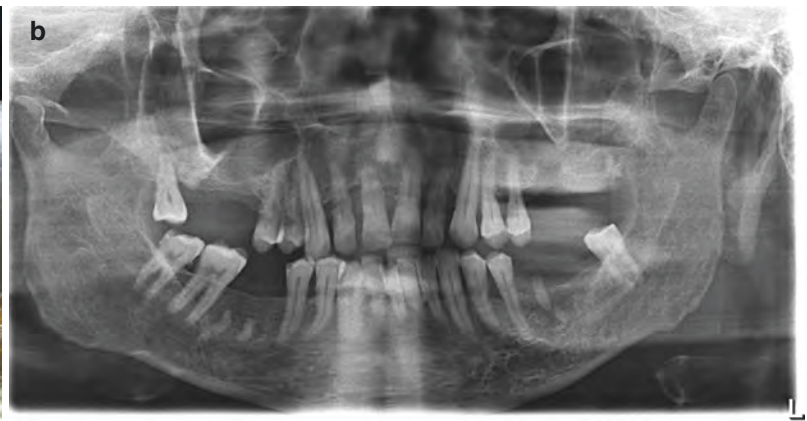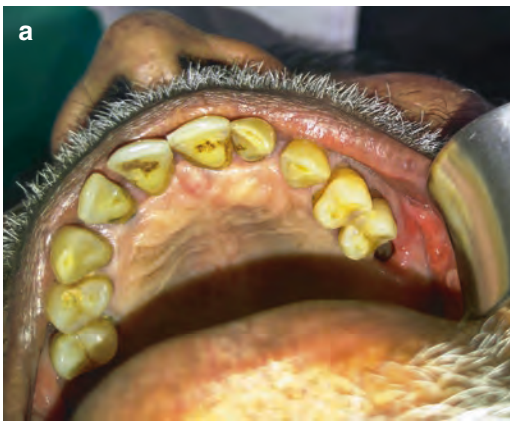24.4.1 Aetiology of OAF

The causes for OAF are similar to those of OAC mentioned earlier. Apart from this, if the sinus has pre-existing sinusitis/antral pathology/fungal infections/fungal balls, the

Fig. 24.7 This is the OPG of a 25-year-old man who reported for routine extraction of root stump of upper left first molar tooth. OPG shows an incidental finding of a periapical lesion (which is probably a periapical cyst that appears to be very close to the sinus floor or probably pushing the sinus lining up). How would you manage this case?



©Association of Oral and Maxillofacial Surgeons of India



©Association of Oral and Maxillofacial Surgeons of India

Fig. 24.8 (a) Note the OAF on upper left first molar extraction site. The socket edges are well-healed, epithelized and rounded off. (b) OPG of the above case showing a defect in the alveolar ridge in the 26 socket region and direct communication of the sinus with the oral cavity

chance of healing of OAC is decreased and may progress to OAF.

Among patients who do not follow the post-extraction instructions or where the clot is deficient/gets dislodged, chances of OAF are increased in susceptible cases. Failed sinus lift procedures, ailing and failing implants and peri-implantitis are all potential causes for causing OAF.

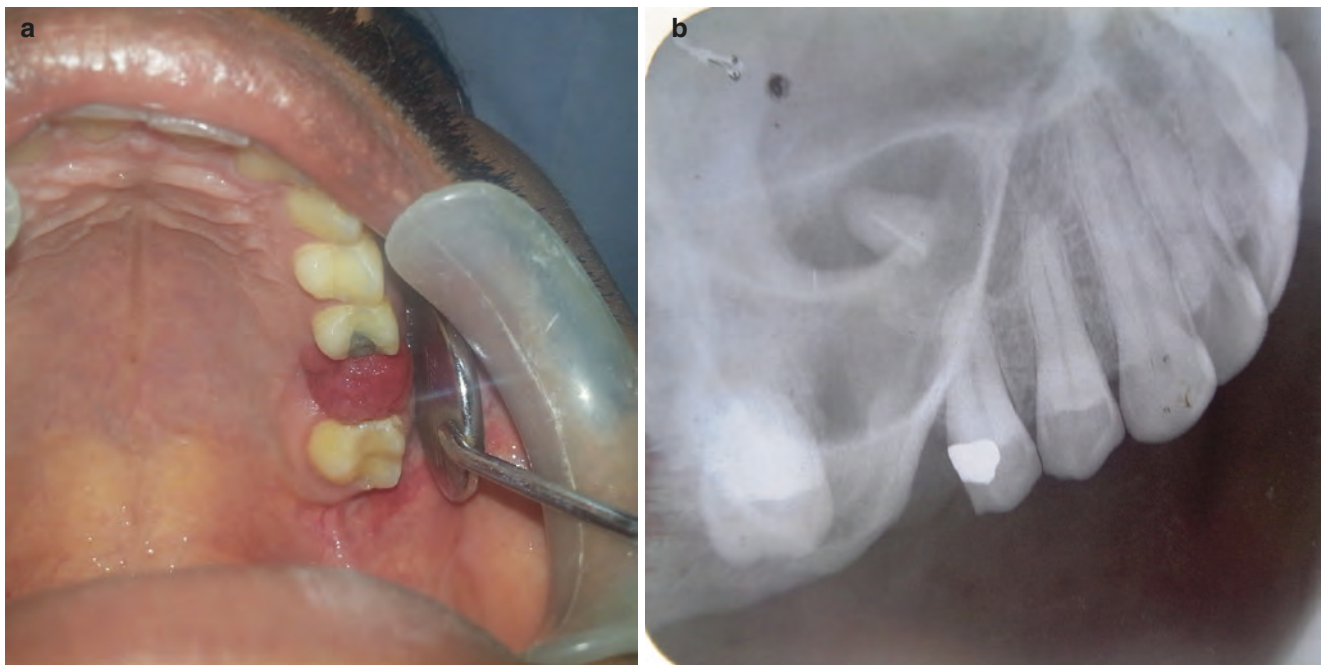
24.4.2 Clinical Features

1. Primary complaints in established OAF cases are mainly oronasal regurgitation and burning sensation in sinus on having food.
2. Patients may visit the ENT surgeon with complaints of acute sinusitis, secondary to infection of sinus via unrecognized OAF.
3. In certain cases, there may localized pain, tenderness, foul smell, unpleasant tasting discharge, persistent nasal discharge and post-nasal drip.

4. In long-standing untreated cases, there will be clinical and radiological features of chronic sinusitis. The antral lining will undergo thickening/hyperplasia, and eventually, sinus gets obliterated or there may be evidence of sinus polyps.

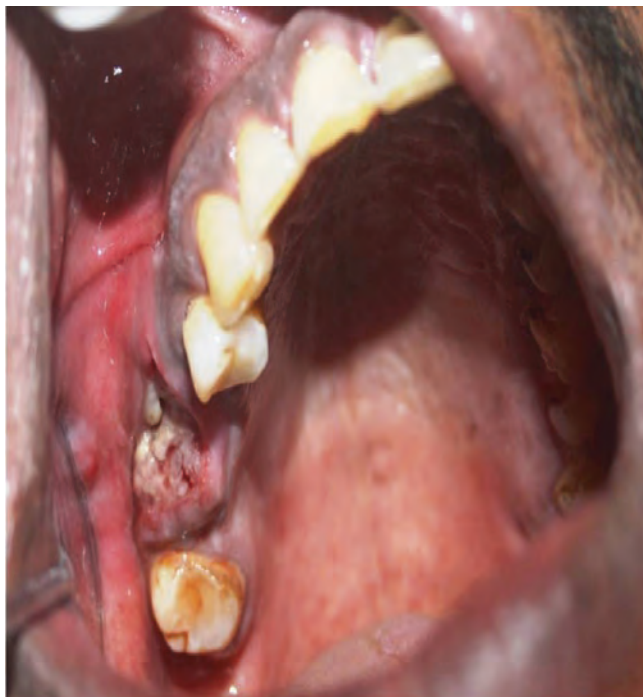I have seen a case where the patient was referred with a protruding sinus polyp through the socket of an untreated OAF in a maxillary molar site (Fig. 24.9a and b). In this particular case, a root was displaced into the sinus as well. It was not sure whether this polyp ensued secondary to OAF or whether pre-existing sinus polyp leads to the OAF.

We should also be aware that antral malignancies may protrude through the unhealed socket of maxillary molars. Most of the times, the surgeon being ignorant of the disease would have extracted the tooth due to mobility caused by the erosion due to the malignant lesion, and a few weeks after, the patient may present, with the lesion protruding through the socket (Fig. 24.10).



©Association of Oral and Maxillofacial Surgeons of India

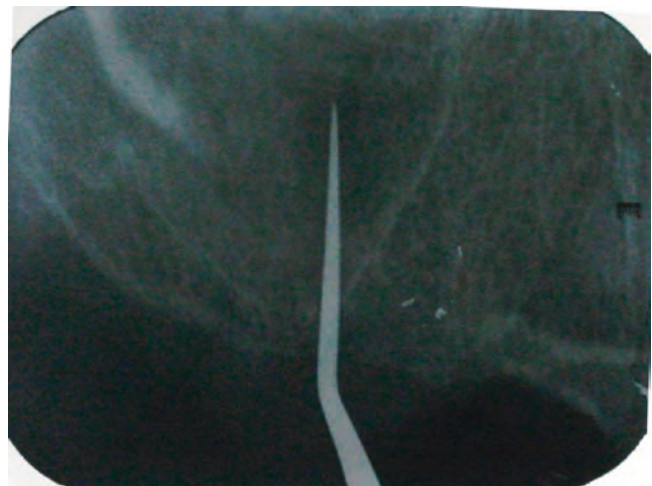Fig. 24.9 (a) Clinical picture showing an antral polyp protruding through the sinus. Some clinicians may consider this to be a Post-extraction granuloma possibly of a reactive nature due to the root in the sinus. (b) Occlusal X-ray view showing root in the sinus



©Association of Oral and Maxillofacial Surgeons of India

Fig. 24.10 A case of extraction of upper right second molar due to mobility by dental surgeon, who was unaware of the cause of mobility being antral malignancy. Couple of weeks after extraction, the lesion was seen protruding through the socket

5. The mucosal edges of the socket will be rounded off, and an evident opening may be seen via the socket into the sinus.



©Association of Oral and Maxillofacial Surgeons of India

Fig. 24.11 IOPA x-ray showing metal probe entering the sinus via a minute unhealed OAF defect

6. In certain cases, the ridge will clinically look well-healed; however on careful probing, an unhealed tract will be seen, leading to the sinus (Fig. 24.11).

24.4.3 Confirmatory Tests of OAF

1. Holding water in the mouth and exerting pressure with mouth closed may elicit oronasal regurgitation.
2. Hold a piece of cotton wisp with tweezers at the OAF opening site, and request the patient to blow through the

- nose with the nostril closed. The wisp will vibrate under the flow of air via the OAF (cotton wisp test/butterfly test).
3. The patient may find it difficult to hold pressure within the sinus, and a whistling sound may be appreciated by the examiner during the Valsalva manoeuvre.
 4. Holding a mouth mirror near the opening of OAF will cause fogging of the mirror.
 5. Place the nozzle of the suction at the opening of the fistulae. A sound similar to blowing through the mouth of an empty bottle may be heard.

24.4.4 Treatment Modalities for OAF

Techniques for OAF closure have evolved over a long period of time and have a robust history. Many techniques have been time tested and well-established, form the mainstay of OAF closure and will be discussed in this section. Literature is replete with various technical modifications; it is not possible to discuss all these in detail and will be beyond the purview of this chapter. The reader is advised to look into the references if a thorough review of techniques is required [3, 4]. Figure 24.1, in reference [4] (Visscher et al. JOMS 2010), gives an excellent overview of the various treatment modalities for oroantral communications Awang et al. [5] back in 1988 have published an excellent review of techniques, which were established at that time.

Since a plethora of techniques are available, the surgeon has the freedom to choose the technique, which works well in his hands based on the training received and surgical competence. One cardinal rule, which may be followed in OAF closure, is to start with the simplest technique available and reserve the complex technique in case the first attempt fails. A sequential option may be followed, the patient is to be warned that there are chances of failure and a secondary or tertiary surgery with more complex techniques may be required at times.

At this stage, it is worth remembering a quote which I have come across somewhere: “*Re-operation after past failures at the hands of other surgeons should be approached with due humility*”.

The options for treatment can be broadly categorized under the following headings:

- Local flaps.
- Regional flaps.
- Combined with autografts.
- Combined with allografts.
- Prosthetic options.

The most widely used local flaps can be classified as

1. Buccal advancement mucoperiosteal flap (Moczair flap/Rehrmann flap/Berger flap).
2. Buccal advancement flap with buccal fat pad grafting (Two-layer closure).

3. Palatal pedicled flap (Ashley’s rotational flap).
4. Tongue flaps: anterior and posterior based.

The multitude of techniques and variations has made the literature on OAF closure a trifle confusing. It is interesting to know that even third molar auto transplantation has been found to be successful in closure of immediate OAC (Kitagawa 2003) [6].

In this chapter, we will only be discussing the time tested and commonly performed buccal/palatal flaps with a reasonable amount of success rate. The tongue flaps are a second option, but the difficulty is caused to the patient in the post-operative period until the pedicle is divided and the need for patient compliance, difficulties in feeding, mastication; speech and maintenance of oral hygiene should be taken into consideration before performing them.

As there are multitude of variations and modifications in OAF closure techniques, the author feels that it is wise to present all the relevant modifications in a sequential order (Box 24.1). If the reader refers to the historical evolution of techniques given in the box format, it is evident that different flap designs have been advised ranging from advancement, sliding, pedicled, rotation, bridge, hinged, transverse buccal, double flaps, island flaps, bipedicled flaps, submucosal connective tissue flap, osteoperiosteal flaps, buccinator myomucosal flaps, etc. Each technique has been presented with its own indications and advantages. The reader is advised to read individual publications to get details of these techniques if required.

Irrespective of the technique used, the success of the closure warrants that the basic sound principles of mucoperiosteal flap design are used. *The flap should have adequate blood supply, should be handled gently, and should lie in the advanced position without tension.*

24.4.5 Assessment of OAF

The following factors should be assessed while planning the technique of closure in an OAF.

Size of the communication (Bone defect is always bigger than the visualized soft tissue defect)

- Location of defect.
- Health of the sinus/presence of infection.
- Time of diagnosis of fistula.
- Condition of tissue available.
- Amount of tissue available.

24.4.6 Objectives in Treatment of OAF

When treating an OAF, the surgeon should have the following objectives in mind [7]. (This can be called the 4 E’s).

1. Elimination of the antral pathology.
2. Elimination of the epithelial lining of the fistulous tract.

3. Establishment of stable closure of fistula.
4. Establishment of satisfactory drainage.

Box 24.1 Historical Evolution of OAF Closure Techniques

- Welty CF 1920: buccal mucoperiosteal flap [8].
- Moczair 1930: buccal sliding trapezoidal flap [9].
- von Rehrman 1936: vestibular buccal mucoperiosteal flap [10].
- Berger 1939: Buccal advancement flap [11].
- Ashley 1939: palatal rotation flap [12].
- Kruger GO 1984: V-shaped excision of lesser curvature of palatal rotation flap [13].
- Kazangian 1949: bridge flap [14].
- Mc Clung 1951: tantalum foil [15].
- Schuchardt 1953: transverse buccal flap [16].
- Guerrero- santos 1966: Tongue flaps for OAF [17].
- Rintala 1971: palatal hinged flap (inversion/reverse palatal flap) [18].
- Zeimba 1972: double flaps (reverse palatal & buccal [19]).
- Meyerhoff 1973: gold foil [20].
- Henderson 1974: palatal island flap [21].
- Choukas 1974: Palatal rotational advancement flap [22].
- Gullane P 1975: modified palatal island flap, relieved vessel at greater palatine foramen [23].
- Cockerham 1976: Bone grafting [24].
- Egeydi 1976: bucket handle flap (bipedicled buccal flap) [25].
- Egeydi 1977: Buccal fat pad and split thickness graft [26].
- Sachs 1979: posteriorly based lateral tongue flap [27].
- Ito & Hara 1980: submucosal connective tissue pedicle palatal flap [28].
- Quale 1981: double flap [29].
- Brusati 1982: osteoperiosteal flap + vestibule mucoperiosteal flap [30].
- Al sibahi 1982: used soft polymethacrylate [31].
- Mitchell 1983: used collagen [32].
- Carstens MH 1991: anteriorly based buccinator myomucosal island flap [33].
- Zide 1992: Hydroxyapatite block closure [34].
- Shaker 1995: used Zenoderm [35].
- Hanazawa 1995: pedicled fat pad graft [36].
- Hori M 1995: Deans extended interseptal alveotomy technique [37].
- Paul salins 1996: anteriorly based palatal flap [38].
- Pandolfi 2000: Three layer closure of oroantral cutaneous defect—palatal flap + buccal fat pad + skin flap [39].

- Lee JJ 2002. Repair of OAC in the third molar region by random palatal flap [40].
- Haas 2003: Monocortical bone grafts [41].
- Kitagawa 2003: third molar transplantation [6].
- Ogunsalu 2005: GTR membrane [42].
- Martin S 2008: metal plates and aluminium foils [43].
- Visscher 2010: biodegradable polyurethane foam [44].
- Sandhya 2016: Resorbable GTR Membrane and FDMB Sandwich Technique [45].
- Ram H 2016: used auricular cartilage [46].

24.5 The Buccal Advancement Flaps

The names of Moczair, Berger and von Rehrman have been used interchangeably when speaking of buccal flaps in the literature. The buccal flap designed by Moczair [9] was a sliding trapezoidal flap, while the ones designed by Berger [11] and Von Rehrman [10] were buccal straight advancement mucoperiosteal flaps.

Von Wowern (1982) [47] in a study of 90 patients compared Moczair with Rehrman flaps and advocated the former for treating OAF in edentulous patients. Killey and Kay (1967) [48] proved the efficacy of buccal flap in a large series of 250 cases. The buccal flap technique can be satisfactorily employed in the treatment of small and medium-sized communications where there is clear sinus lavage through OAF, and proper antral regime has been maintained 4–5 days prior to the surgery.

The technique of raising a buccal flap is given along with the 2 layer BFP closure technical note box (Box 24.2) and is essentially the same. A few words are needed to elaborate on the buccal flap and periosteal scoring. The buccal flap raised is a full thickness trapezoidal (rectangular/4 sided) mucoperiosteal flap. There are 2 releasing incisions, one anterior and one posterior. The incisions are put in such a way that the flap looks tongue/funnel-shaped and is feasible for advancement palatally without tension. Great care is given to raise it gently without causing any ‘button holing’/fenestrations in the flap. The base should be broad enough to have good random blood supply, and flap margins should be incised sharply in order to avoid ragged edges. It is the periosteum that gives tension and may prevent advancement palatally. In order for the flap to lie passively, the periosteum alone is scored gently with a number 12 or 15 blade, horizontally at the level of the base of the buccal flap. This will release the tension and help in advancement. The scoring is a fine procedure, and the surgeon should be aware that, if the scoring goes deep beyond the level of periosteum, the mucosa may be incised which may even jeopardize the viability of the flap by affecting the blood supply emanating from the base (Fig. 24.12).

Box 24.2 Technical Notes of a 2 Layer BFP Closure

- Anaesthesia.
- Fistula tract excision with No 11 BP blade.
- Curette the granulation tissue.
- Buccal and palatal margin freshened with No 15 blade.
- Palatal margin made into a semilunar shape to accept the buccal flap.
- Flap to rest on sound bone on the palatal side.
- Extended trapezoidal flap placed on the buccal side.
- Posterior vertical release of flap slightly curved towards vestibule to facilitate advancement anteriorly.
- Reduction of alveolar bone height if required.
- Periosteal scoring of buccal flap.
- Posterior periosteum teased open to identify the BFP.
- BFP mobilized gently with non-toothed forceps (blunt dissection, avoid tension).
- BFP sutured to palatal margin with 3 'O' non-cutting vicryl rapide.
- Buccal flap advanced palatally to cover the BFP.
- Buccal flap sutured to palatal margin with horizontal mattress vicryl sutures.
- Anterior vertical release sutured.
- Posterior vertical release usually needs no suturing.

One disadvantage of all buccal advancement procedures is the decrease in the vestibular depth, which may be problematic for prosthetic rehabilitation.

24.5.1 Step-by-Step Technique of Doing Buccal Advancement Flap + Buccal Fat Pad Grafting (BFP)

The step-by-step procedure for 2 layer closure technique is given in the box format (Box 24.2). The steps of performing a 2 layer closure are similar to the buccal advancement alone, except that the BFP is raised, advanced and sutured primarily to the palatal edge.

The use of the buccal fat pad (BFP) as a grafting source in the closure of intra-oral defects has gained popularity in the last quarter of the twentieth century. Its use as a pedicle graft for oral reconstruction was first reported by Egyedi in 1977 [26]. Studies have proved through a series of cases that the use of buccal pad fat in the closure of oroantral communications has significantly reduced the failure rate of the treatment. The closure of OAF with single-layered buccal mucoperiosteal advancement flaps (Berger/Reherman) has been well documented in the literature. Without much change in the surgical steps, adding a second layer of BFP will enhance the success rate of closure.

The buccal fat pad (BFP) as an anatomic element was first mentioned by Heister in 1732 and was described by Bichat in 1802 [49]. The BFP (Bichat ball) is an anatomically rounded and biconvex structure that is of great importance in the facial contour. It is an adipose tissue surrounded by a thin capsule

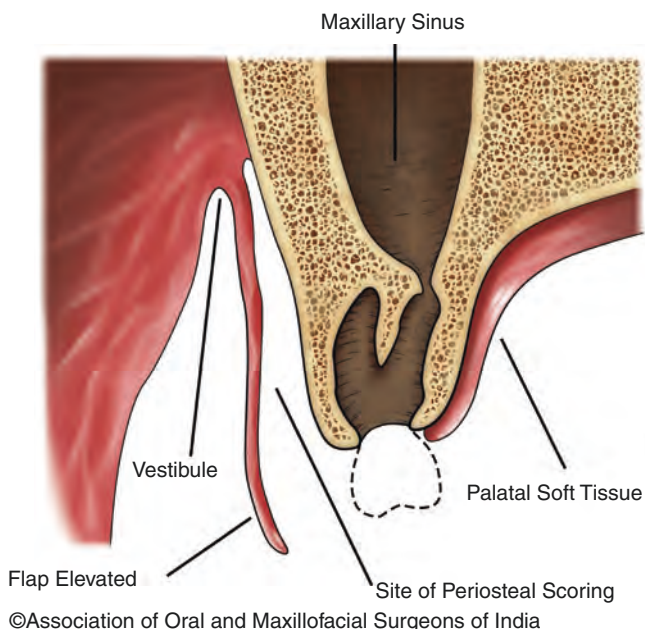


Fig. 24.12 Diagrammatic representation of raising a buccal trapezoidal flap and periosteal scoring

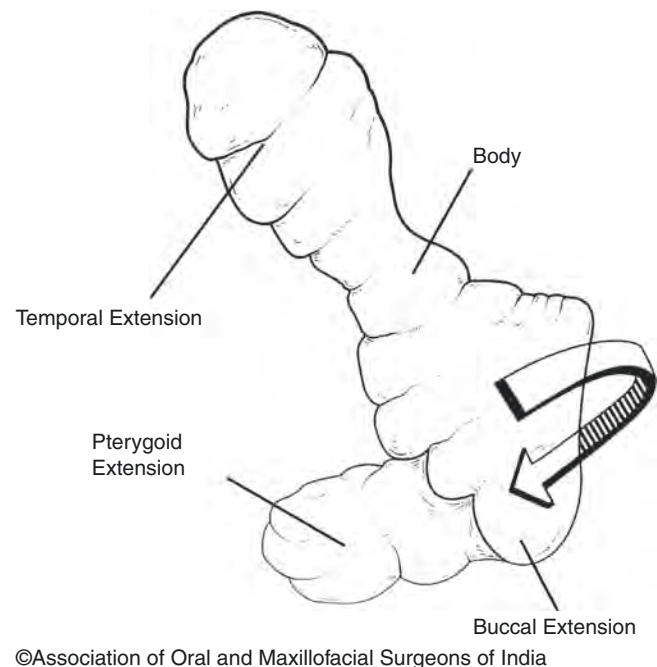


Fig. 24.13 Anatomical representation of the buccal fat pad

and located inside both masticatory spaces in the oro-maxillofacial region (Fig. 24.13). The BFP has a central body with four extensions: pterygopalatine, temporal, pterygoid and buccal. The central body and buccal extension account for approximately 50% of the BFP and are the most clinically significant portions. The BFP has a 10 mL volume, a thickness of 6 mm and an approximate weight of 9.3 g. The BFP is surrounded by a thin fibrous capsule. Blood supply is provided by the vestibular and deep branches of the maxillary artery, the transverse facial branches of the superficial temporal artery and branches of the facial artery. The rich blood supply may explain the high success rate. It also may be one reason for the quick epithelialization of the fat. The buccal fat pad is a mass of specialized fatty tissue called as *syssarcosis*, a fat that enhances muscular motion. It is distinct from the subcutaneous fat and shows marked similarity to the orbital fat. It can easily cover small to medium sized defects of about 4 cm in diameter. When properly dissected and mobilized, the BFP provides 7 × 4 × 3 cm of a pedicled graft. (Box 24.3).

24.5.2 Clinical Pictures Demonstrating 2 Layer Closure Technique with BFP (Fig. 24.14a, b, c, d and e) [50]

Figure 24.14a, b, c, d and e: Reprinted with permission from springer nature customer service centre GmbH: springer publisher: Journal of maxillofacial and oral surgery: The versatility in the use of Buccal Fat Pad in the closure of oro-antral fistulas. Suvy Manuel et al. [COPYRIGHT 4524640093264] (2015).

Box 24.3 Advantages of Buccal Fat Pad

- Easy access.
- Relatively easy to perform.
- Minimum dissection.
- Great versatility.
- Good mobility.
- Reliable blood supply.
- Low rate of complication.
- No donor site morbidity.
- Low risk of infection.
- Shortened surgical time.
- No scar.
- Fast cover by epithelium.
- High success rate.

24.6 Palatal Rotational Flap (Ashley's Flap)

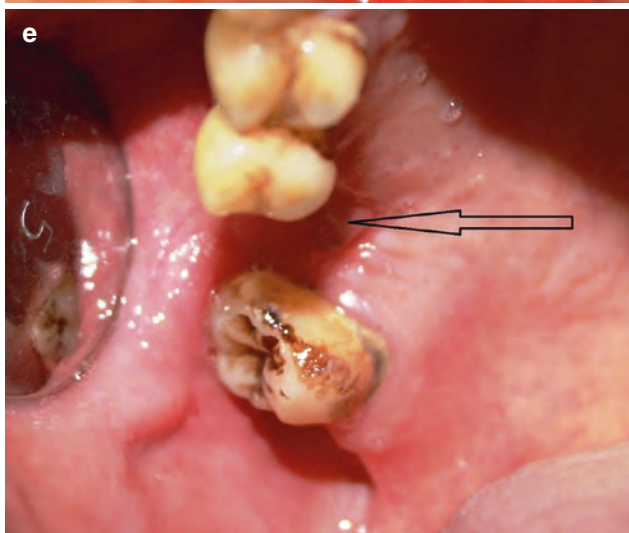
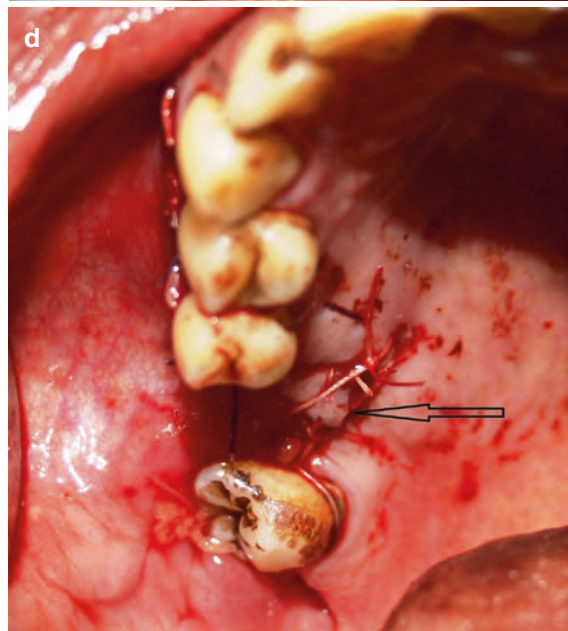
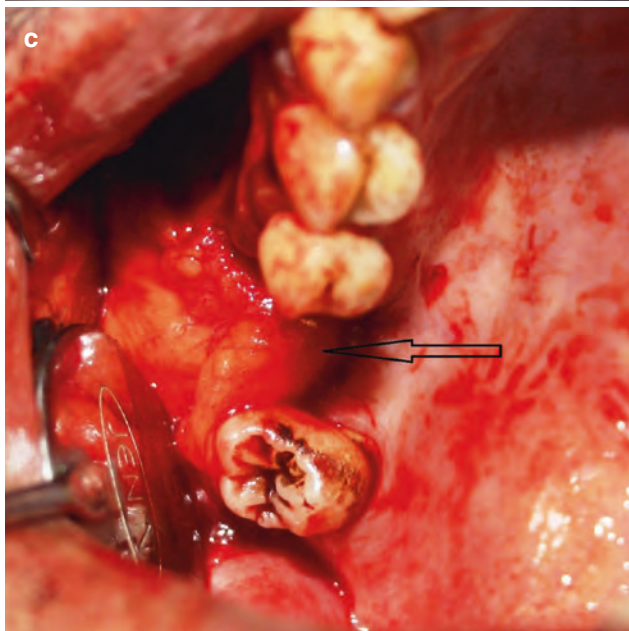
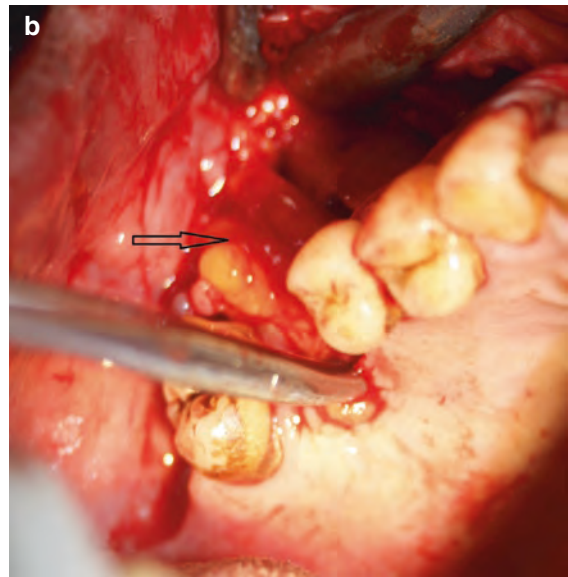
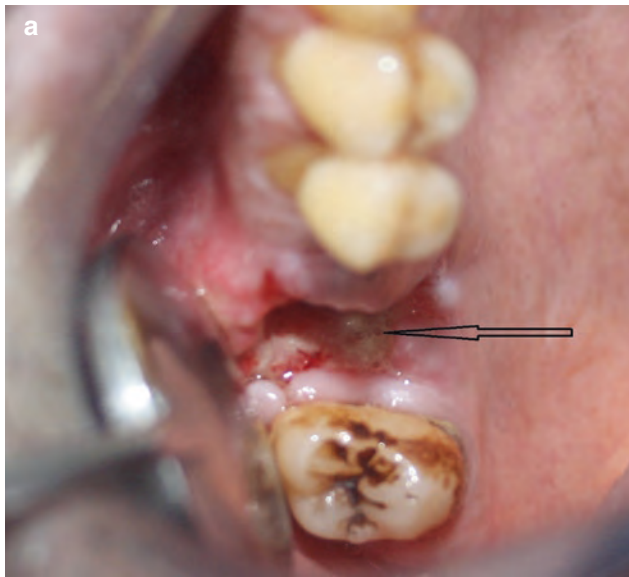Among palatal flaps, there are 2 main types: The palatal straight advancement flap (Fig. 24.15) and the palatal rotational flap (Fig. 24.16).

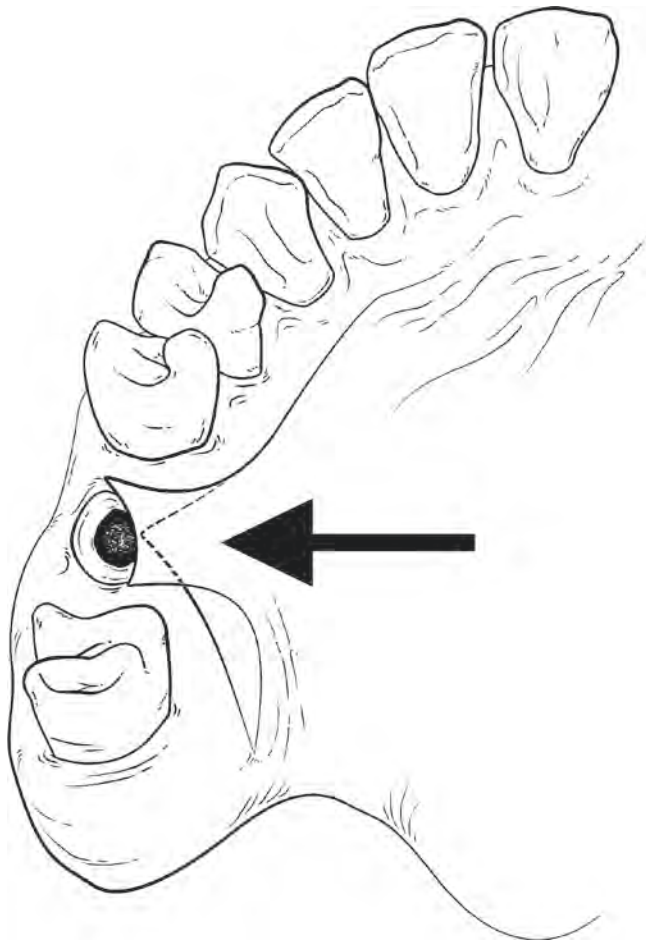
However, the palatal rotational flap proposed by Ashley in 1939 [12] has stood the test of time. It is a pedicled flap, posteriorly based on the greater palatine vessel. A tongue-shaped full thickness mucoperiosteal flap is raised on the side of the OAF. The OAF site is freshened, and the fistula is excised as a preparation to receiving the flap. The flap is rotated and sutured on to the OAF site. In order to avoid kinking at the site of rotation near the palatal margin of the socket, a V-shaped area may be excised (Kruger's [13] modification). The raw site is packed with dressing to allow secondary healing. This is a thick, bulky and vascular flap, which is quite reliable and serves often as a second line of defence when the buccal advancement flap fails. Different authors have given various names for this flap-like rotational, advancement and transposition.

Other types of palatal flaps mentioned or published in the literature are the palatal island flaps (Henderson 1974 [21]), palatal hinged/inverted/reverse flap (Rintala 1971 [18]) and sub-mucous connective tissue flap (Ito & Hara 1980 [28]). Palatal flaps are also used as part of double flap techniques as proposed by Zeimba in 1972 [19] and Quayle in 1981 [29].

24.7 Importance of Timing of Closure of OAF

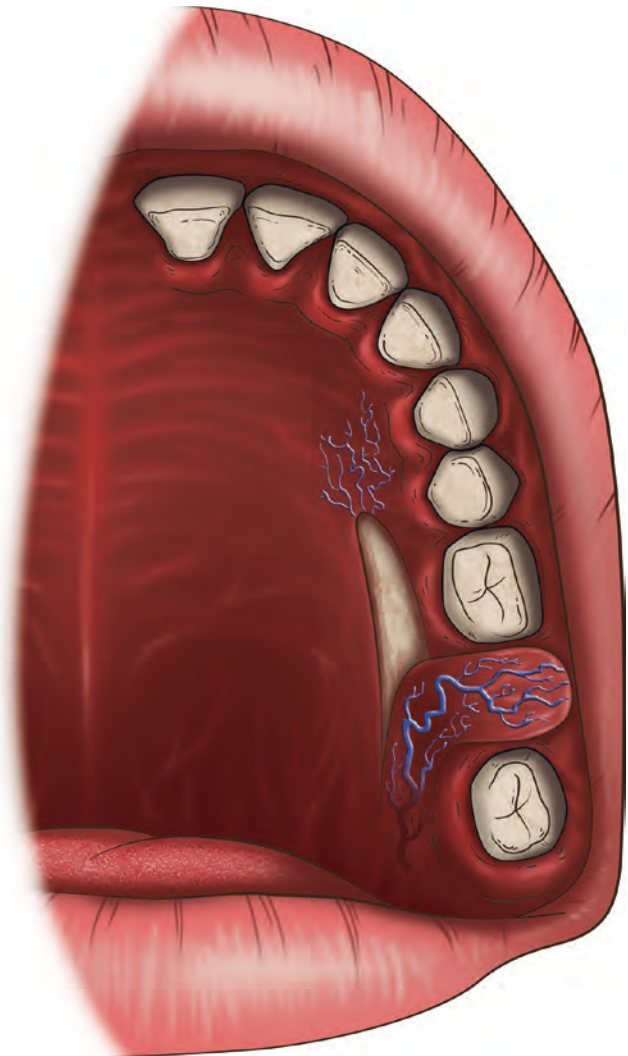
The health and status of the socket edges and margins play an important role in deciding the success of the closure, irrespective of the surgical technique used. An OAF, which is well-rounded margins and does not show any evidence of oedema/inflammation, is a good recipient area for the closure. Oral surgeons may often get referred cases with history of difficult extraction of maxillary molars/attempted removal of fractures root tips/cases with established OAC and/or with missing root tips. Often, the socket may show evidence of traumatic extraction with ragged margins, tissue loss, irregular bony edges, congestion, tenderness and oedema. Such sites are not favoured for an OAC/OAF closure, and surgeons should not be tempted to attempt a closure. The chances of failure of the closure are high due to unhealthy mucosal condition and its prudent to wait for a couple of weeks for good healing of the wound edges and then consider closure. It may be argued that the sinus health may deteriorate during this waiting period, and all these are decisions to be taken by the surgeon on their individual merit (Fig. 24.17a and b).





©Association of Oral and Maxillofacial Surgeons of India

Fig. 24.15 Diagrammatic representation of a palatal straight advancement flap



©Association of Oral and Maxillofacial Surgeons of India

Fig. 24.16 Diagrammatic representation of a palatal rotational flap

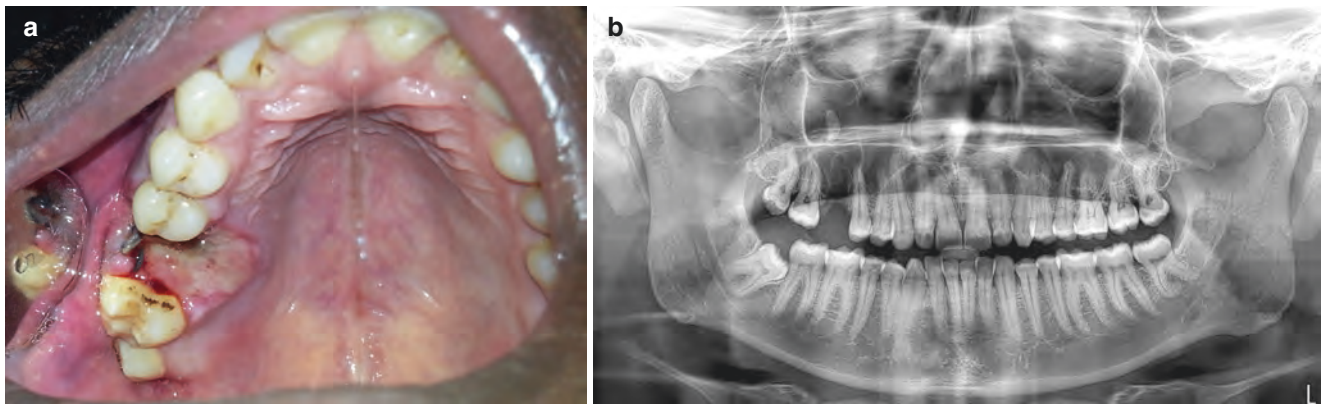
24.7.1 Role of Health of Sinus and Antral Regime

Depending upon the duration of OAF, the sinus may be in various stages of disease. In acute OAC, unless there is pre-existing disease, the closure may be attempted with a fair

chance of success. In untreated cases of OAF, patients may have acute episodes of sinusitis or progress into a chronic stage manifesting thickened antral lining and fluid/exudates/pus collection in sinus or antral polyps. In cases of acute nature, the sinusitis has to be under control before closure (Fig. 24.18).

Fig. 24.14 (a) Oroantral fistula seen at the maxillary right first molar extraction site (b) Buccal fat pad being teased out from the buccal vestibule. (c) The buccal fat pad being advanced and sutured to the palatal

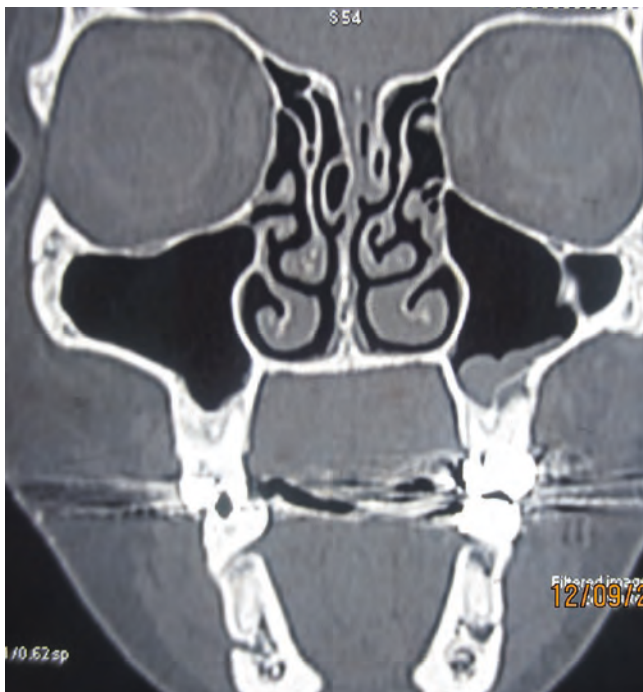
margin. (d) The buccal mucoperiosteal flap sutured to the palatal margin and covering the buccal fat pad. (e) Excellent healing of the closure site (2 month post-operative view) [50]



©Association of Oral and Maxillofacial Surgeons of India

Fig. 24.17 (a) Clinical picture of a referred case in a 30-year-old male, who had a traumatic extraction of upper right first molar 1 week back. One complete root has been pushed into the sinus (see OPG, Fig. 24.17b). Note the traumatized, congested, oedematous and ragged

sutured wound edges/tissue loss and slough in the palatal tissue. He is not a candidate for closure immediately. It is preferable to wait until complete healing and schedule the procedure electively. (b) OPG of the above case showing the root in the sinus cavity



©Association of Oral and Maxillofacial Surgeons of India

Fig. 24.18 A coronal CT scan, showing periapical widening/lesion in a maxillary left molar, which is close to the sinus floor and reactive sinus lining thickening in that region. Possible OAC resulting from this extraction may have a decreased chance of success after immediate closure

24.7.2 The Antral Regime

Antral regime is usually helpful, which is usually started about 5–7 days before the anticipated closure. It includes.

1. Antibiotics to control sinusitis.
2. Anti-inflammatory agents if required.
3. Steam inhalation at prescribed intervals.

4. Nasal decongestant drops to increase the drainage of the sinus and open up closed ostium.
5. Antihistamines to decongest the sinus and also to avoid sneezing, which may increase the sinus pressure and have a deterrent effect on the success of the closure.

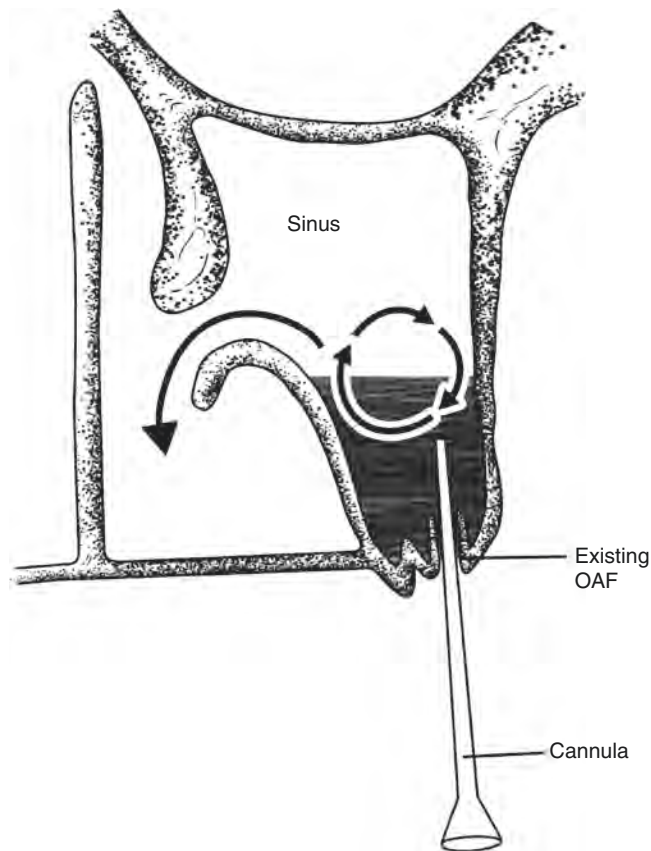
The antral regime may be continued for a few days (3–7 days) after the closure as well to ensure a trouble-free healing. After closure, the patient is advised to have certain restrictions in the initial healing phase, in order to avoid break down of the closure, i.e.

1. Avoid vigorous sneezing/coughing/blowing through the nose.
2. If coughing cannot be avoided, do cough with mouth open.
3. Avoid smoking to avoid negative pressure in the oral cavity.
4. Avoid using straws to drink fluids.
5. Avoid vigorous gargling or swishing in the oral cavity.
6. Do not disturb the surgical site with tongue movements.
7. It would be preferable to review the patient at least once in 2–3 days during the initial healing period to assess the healing status. The clinician may irrigate the surgical site with saline removing the collected debris/slough if any.
8. Some author's advice to keep a pre-fabricated custom-made acrylic splint at the site of closure as a support.

However, there are thoughts that the splint may irritate or traumatize the sutured edges on the alveolar ridge and be a deterrent for the healing.

24.7.3 Antral Lavage

At times, the antral lavage is done daily or on alternate days along with the antral regime to clear the exudate from the



©Association of Oral and Maxillofacial Surgeons of India

Fig. 24.19 Diagrammatic representation of antral lavage via the existing OAF

sinus. The presence of exudate/pus can be seen as a ‘fluid level’ in a paranasal sinus X-ray, or there may be generalized opacification of the involved sinus in the X-ray. The closure is attempted, only when the surgeon feels that the antral washouts are clear, and the sinus is reasonably healthy to receive the closure.

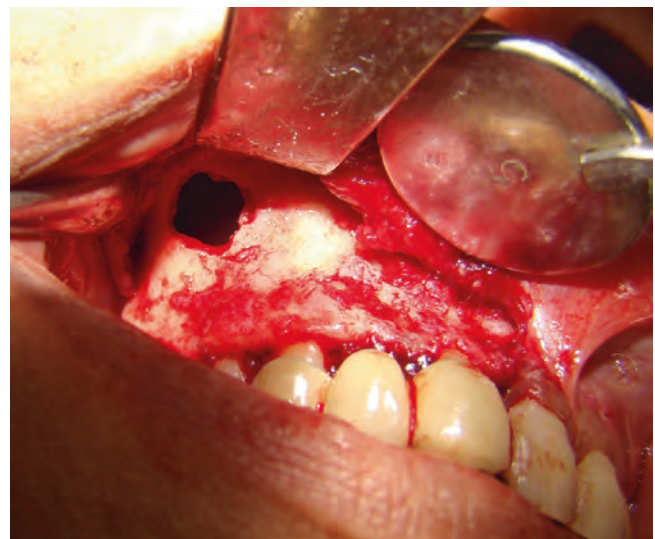
ENT books describe different methods of antral lavage, either via a Caldwell Luc opening or via the nasal meatus depending upon the case. However, from an oral surgical perspective for most cases, antral lavage may be done via the existing OAF (Fig. 24.19). 10–20 ml of saline is flushed through the OAF via a syringe, and patient is seated at a forward position with head bent down. The washout will flow out through the nasal cavity or via the OAF, and the washout is collected in a tray positioned before the patient. In the initial days of lavage, the washout will have a cloudy/opaque appearance, and after few days, we should expect the washout to be clear.

24.8 Caldwell Luc Procedure

This procedure was developed independently by two surgeons, George Caldwell in New York (1893) and Henry Luc in Paris (1897) (Box 24.4).

Box 24.4 Technical Note: Caldwell Luc Procedure in Oral Surgery Context

- Upper lip retracted.
- Horizontal U-shaped incision in the vestibule-few mm above gingival attachment or
- Mucoperiosteal flap-raised upward to the point of emergence of the infra-orbital nerve.
- Do not damage infraorbital nerve
- Chisel or dental bur is used to create a window on anterior wall of sinus above root of teeth of that area.
- Opening enlarged using Rongeur’s forceps until it is of the size of an index finger.
- Sinus exposure gained and required procedure performed.
- Soft tissue placed and sutured over bone with resorbable sutures.
- Good closure is important as the dehiscence itself-will cause an OAF.



©Association of Oral and Maxillofacial Surgeons of India

Fig. 24.20 Clinical picture showing a Caldwell Luc procedure via extended crevicular flap for removal of a root in sinus. Note the defect made in the anterior maxilla wall

It involves making an opening in the anterior wall of sinus in the canine fossa region, to get good access to the sinus. The procedure is done either via a sublabial incision or by extended crevicular incisions (Fig. 24.20). In the context of OAF, this approach has relevance when combined along with the closure of OAF. The approach may be used to retrieve root tip or to surgically treat chronic sinusitis as in polyps. In combined cases, the extended crevicular flap with adequate releasing incisions may be used to remove root tip and may

be used as a buccal advancement flap with or without buccal fat pad graft for the closure of OAF.

The indications for Caldwell Luc procedure are given below:

1. Recovery of entrapped foreign body from the sinus cavity proper, displaced tooth or root.
2. Excision of sinus polyps, tumours and cysts.
3. Treatment of blowout orbital fracture.
4. Management of haematomas of antrum.
5. Chronic maxillary sinusitis.
6. Neoplasm of maxillary sinus.
7. Removal of impacted canines.

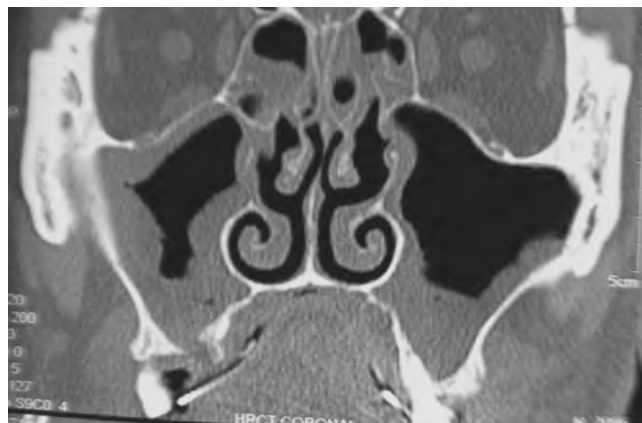24.9 OAF with Chronic Sinusitis

Such cases are more difficult to manage and will need a combined oral surgery/ENT approach. There may be severe antral lining hyperplasia and lack of natural drainage by blockage of the ostium or antral polyps. The line of management has to be decided on an individual basis. Occasionally, the sinus problem may have to be addressed before attempting a closure, which may require two surgeries. Sometimes, the oral surgeon may be in for a surprise during OAF closures to see fungal balls in the sinus. The reasons for c/c sinusitis should be evaluated and addressed accordingly.

The second option is to attempt closure along with the treatment of chronic sinusitis. In such cases, a formal Caldwell Luc opening may be made to remove the unhealthy lining. If that is the case, the buccal flaps are modified as per requirement to get a tension-free closure at the OAF site. In situations where FESS is used, oral surgeon can visualize the sinus and see the OAF from the nasal/antral side. The use of FESS gives a two pronged approach, i.e. the unhealthy lining from the antral side of the OAF can be removed and closure performed. This means that in OAF with c/c sinusitis, a general anaesthesia will be necessary, unlike uncomplicated OAF cases where most of the established techniques may be done under local anaesthesia if required.

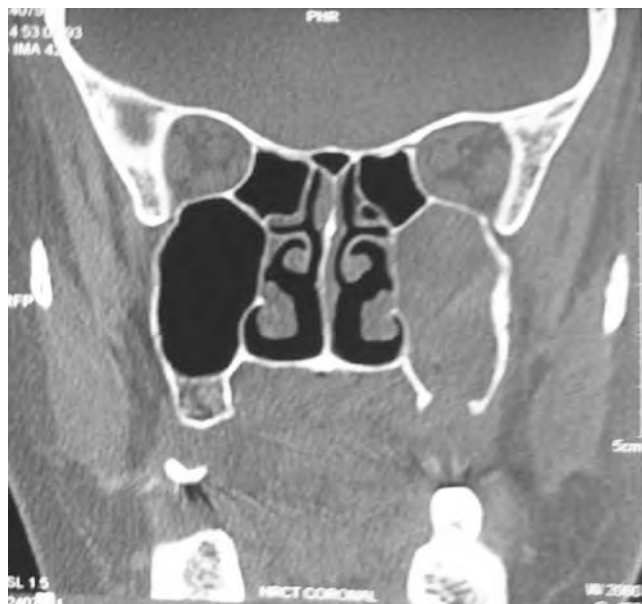
Adams (2015) [51] has reported on the success of using combined FESS and BFP closure. The sequence followed by Adams included pre-operative computed tomography, antibiotic therapy, exploration and removal of sinus pathologic tissues, rotation of a pedicled fat pad graft into the oral opening, repair and closure of oral mucosa, exploration of involved sinuses with excision of sinus and nasal tissues necessary for establishment of osteomeatal drainage and follow-up.

Cases of fulminant pansinusitis have been encountered arising from long-standing untreated OAF. This involves the contralateral side, and such cases need a comprehensive joint approach with the allied specialities, before embarking upon closing the OAF.



©Association of Oral and Maxillofacial Surgeons of India

Fig. 24.21 Coronal slice CT scan, showing hyperplasia of sinus lining, especially on the right side, where the OAF can be Appreciated

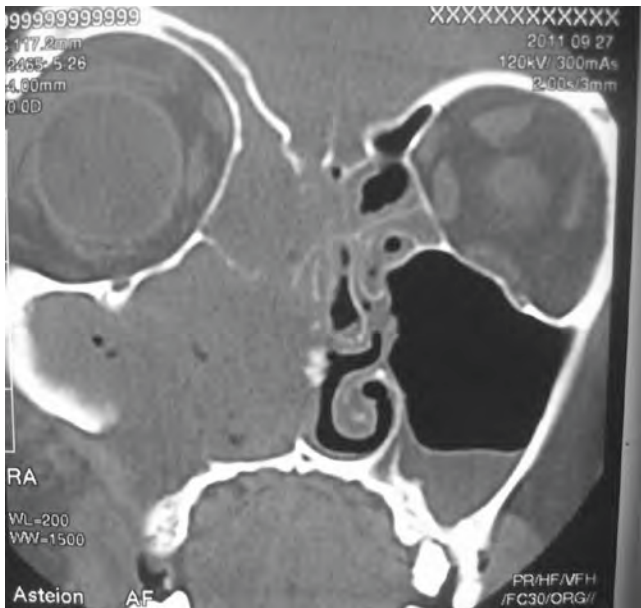


©Association of Oral and Maxillofacial Surgeons of India

Fig. 24.22 Coronal CT scan of a 50-year-old male, who had normal extraction of upper left second molar, which was followed by break down of clot and resulted in OAF. He later developed infection with pus discharge from socket. CT scan shows the fully opacified left sinus. Under GA (joint case with ENT surgeon), a 2 layer BFP closure was done, accompanied by FESS and Caldwell Luc approach via extended mucoperiosteal flap. Intraoperatively, the sinus was filled with fungal balls, which could have been the cause for the formation of OAF

Figures 24.21, 24.22 and 24.23 show coronal CT slices of different case scenarios where OAF was accompanied by chronic sinusitis.

In Video 24.1, the video contributing Surgeon has managed an OAF associated with chronic sinusitis, by a combination of Caldwell-Luc procedure, Nasal antrostomy, and layered closure by buccal advancement flap. Layered closure has been achieved by suturing of sub mucosa and mucosa of the advanced buccal flap.



©Association of Oral and Maxillofacial Surgeons of India

Fig. 24.23 Coronal CT view showing pan sinusitis in 58-year-old male, who developed an OAF in the anterolateral wall of maxilla from a previous failed surgery, probably for a cyst enucleation in the maxilla (previous records not available)

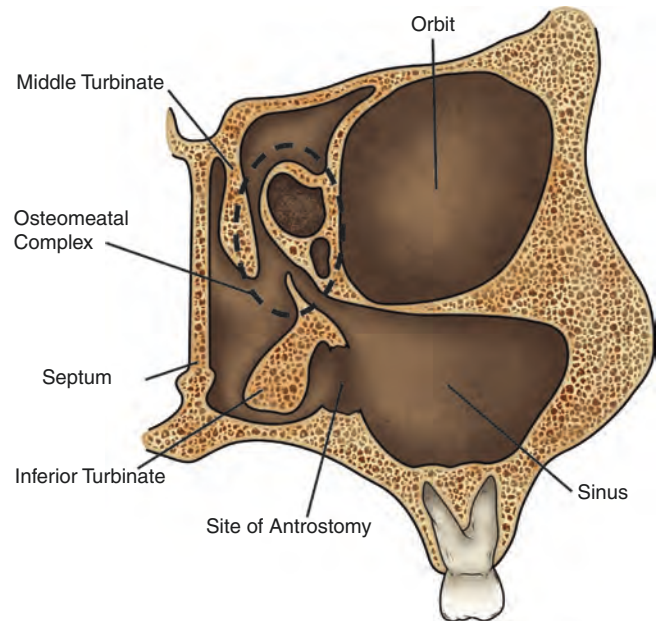
24.10 Nasal Antrostomy

The ostium of maxillary sinus opens into middle meatus, which is at a higher level than the sinus floor (Fig. 24.24). In normal healthy sinus, this is not a problem as the normal ciliated respiratory epithelium will help in the drainage. Briefly saying, nasal antrostomy is a procedure where an opening is made in the inferior meatus, either from the nasal or sinus side to facilitate drainage of sinus in a dependent manner. Nasal antrostomy is an adjuvant procedure, which can be done along with cyst enucleations of the sinus or in selected cases of OAF closure. The need for nasal antrostomy has decreased now with changing philosophies, the advent of FESS and the importance given to the osteomeatal complex. Recent studies (Huang YC [52] 2012) have also proved the decreased need for inferior meatal antrostomy following sinus surgeries.

For elaborate details of Caldwell Luc and nasal antrostomy procedures, readers are advised to refer the concerned speciality books.

24.11 Root in Sinus

In situations where a fragment of a root or a full root or roots is missing during extraction of maxillary premolars or molars, the surgeon will have to take certain decisions and some questions should flash through his or her mind.



©Association of Oral and Maxillofacial Surgeons of India

Fig. 24.24 Diagrammatic coronal section of sinus demonstrating the sinus drainage

- Should I locate the root tip and where should I look for it.
- If located, should I attempt to retrieve it or decide to leave it.
- Will the root retrieval necessitate GA and if so when to schedule the procedure.
- Should the root tip left behind be removed later at an elective date or not removed and remove only if any symptoms occur.
- If the root has gone into the sinus, an OAC would have been formed. Should I remove the root tip and close the OAC, or should I leave the root tip and close the OAC or plan for a combined removal of root and OAC/OAF closure later on an elective date.

While attempting removal of a root tip, if it suddenly disappears, make sure that the tip is not there in the following places.

- Lying freely elsewhere in the oral cavity/vestibules/lingual sulcus.
- Tip is not attached with cotton/gauze pieces.
- Tip has not stuck to suction drains or bottles.
- Tip has not been accidentally swallowed or aspirated.

If the root tip is assumed to be pushed upwards into the sinus cavity, the tip may lodge in the following areas:

- A fenestration would have happened in the apical labial/palatal alveolar bone, and the tip would be lodged between the labial/palatal alveolar bone and the mucoperiosteum.

- (b) Rarely, the tip would have perforated the buccal mucoperiosteum and get lodged near the buccinator muscle.
- (c) Tip would be lying between the sinus lining and the sinus floor. In strict sense, it may be assumed that an OAC is not formed as the integrity of the membrane is not lost.
- (d) Tip may have pierced through the sinus membrane and entered the sinus cavity (theoretically causing an OAC).

X-rays in two different planes (IOPA/OPG/Occlusal) will be helpful to give an idea about the root tip position especially when it is inside the sinus. When the root tip is retaining its lamina dura on an IOPA x-ray, it may be assumed that it is still lying within the bone and not have entered the sinus cavity. Paranasal sinus view will confirm that the root is in the sinus and CBCT also may be helpful in localization.

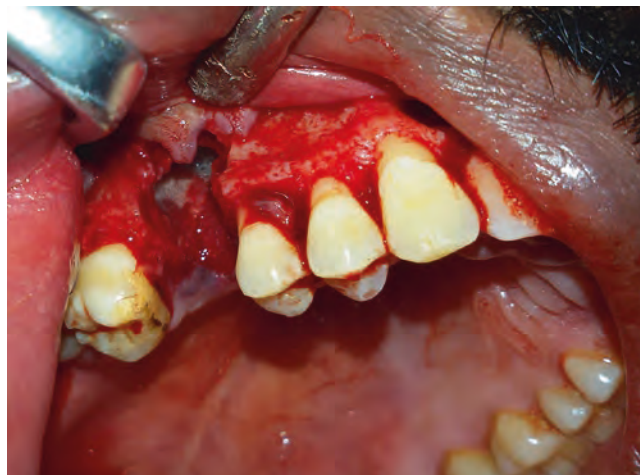In situation (a), Transalveolar approach will help in removing the root tip.

In situations (c) and (d), the following methods are suggested in the literature and the resulting OAC is closed primarily or at a later stage depending upon the surgeons' choice.

1. If the root tip is visible through the socket, it is gently removed with the help of probes/tweezers/mosquito forceps.
2. If not visible, the sinus is flushed with saline and it is hoped that the root tip will float in the sinus. A metal suction tip is placed at the socket apex, and the clinician may expect the root tip to be lodged at the end of the suction tube.
3. A gauze piece may be inserted into the sinus via the socket and pulled out in a jerky fashion hoping that the root tip will get entangled in the gauze piece.
4. The tip may be removed through the socket, by enlarging the communication. This may require removal of the inter-radicular bone and visualizing the sinus to get better approach, vision and access. This technique is usually successful, but the flip side is that the chance of failure of closure is increased as the surgeon is dealing with a communication of considerable size (Fig. 24.25).
5. Another option would be to remove the root via the Caldwell Luc approach or FESS. This is usually done on an elective basis.

24.11.1 Policy of Leaving Root Tip In Situ

It is important to say a few words on this topic at this juncture, even though there may be difference of opinion and contentions on the points given below. These can be applied to all root tips being left behind. If the clinician



©Association of Oral and Maxillofacial Surgeons of India

Fig. 24.25 In this case, the surgeon is attempting to remove the root in sinus, which has been dislodged superiorly during the extraction, by enlarging the socket and an extended mucoperiosteal flap has been raised. The sinus can be visualized via the socket. This technique is usually not recommended as the resulting OAC will be of considerable size; however, in this case, the OAC was closed by a 2 layer BFP technique

feels that removing a fractured root tip of an upper premolar/molar is beyond his or her level of competence or there is a possibility of causing OAC, which he or she cannot deal primarily, the root tip may be left behind in the following situations;

1. The root tip is less than 2–3 mm in length.
2. It is not associated with any periapical pathology.
3. It may not interfere with any future prosthetic rehabilitation.
4. Aged/patients with considerable medical co-morbidities.
5. Attempts at removal of the tip may cause more damage and surgical procedures when compared to the benefits of removal.

The patient should be well-informed about this situation and should be informed that the tip may be removed later if they wish so. Adequate documentation in the form of x-rays and clinical notes is mandatory, in order to follow up the case and to avoid any future medico-legal issues.

Clinical Scenario 2

An interesting clinical Scenario for the benefit of young clinicians.

A 40-year-old female had routine extraction of root stumps of upper left first molar. A pre-operative IOPA was not taken. After extraction, to the surprise of the dental surgeon, there was pus discharge through the socket (See Fig. 24.26a and b)

The probabilities are that either there was a pre-existing sinusitis, which was unrecognized, or the root stumps caused the odontogenic infection to spread into the sinus.

How will you Manage this Case?

There may be different opinions, but the following sequence may be followed in this particular case, which is given as clinical pearl section below.

Clinical Pearls (Management of Case in Fig. 24.26a and b)

- Temporary closure of socket and no flap advancement.
- Anti-biotics.
- Discuss with patient.
- Record in case file.
- ENT consultation to assess the sinus health.
- Required radiographs and CT scans.
- Fix elective date for OAC closure.
- Routine work up/lab investigations.
- Decide on type of closure technique/anaesthesia.
- Decide whether there is need for Caldwell luc/FESS/nasal antrostomy after sinus evaluation.
- Start antral regime.
- Start antral lavage until clear washout is achieved.
- Execute the surgery.
- Follow up to assess the status of closure.

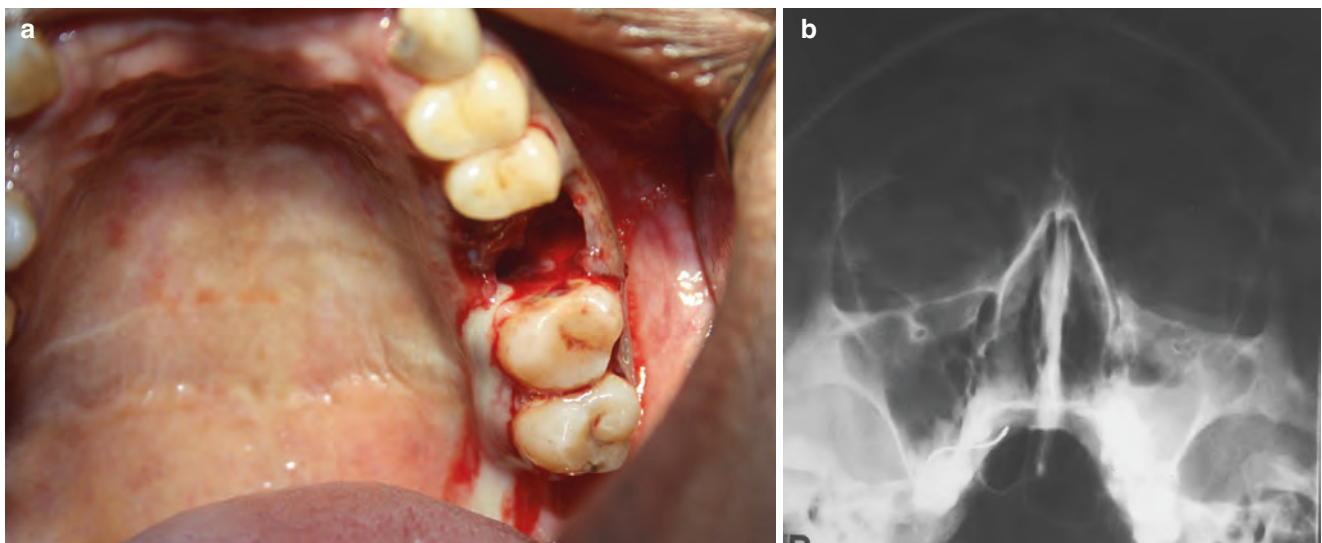
Clinical Scenario 3 (Fig. 24.27a, b, c and d)

Another interesting clinical scenario, which I came across in a maxillofacial trauma case recently, is given as follows:

A 36-year-old male sustained RTA and facial fractures as seen in Fig. 24.27a and b. Tooth numbers 15 and 16 (upper right first pre-molar and molar) were avulsed with comminution of labial cortical plate and the alveolar process creating an oroantral communication (Fig. 24.27c). You can appreciate the bubbling of mucus at the OAC site. CT showed bilateral haemosinus, fracture maxilla and mandible, The right posterior alveolar segment containing 17,18 (upper right second molar and third molar) was mobile and extruded due to a posterior right parasagittal fracture of the maxilla.

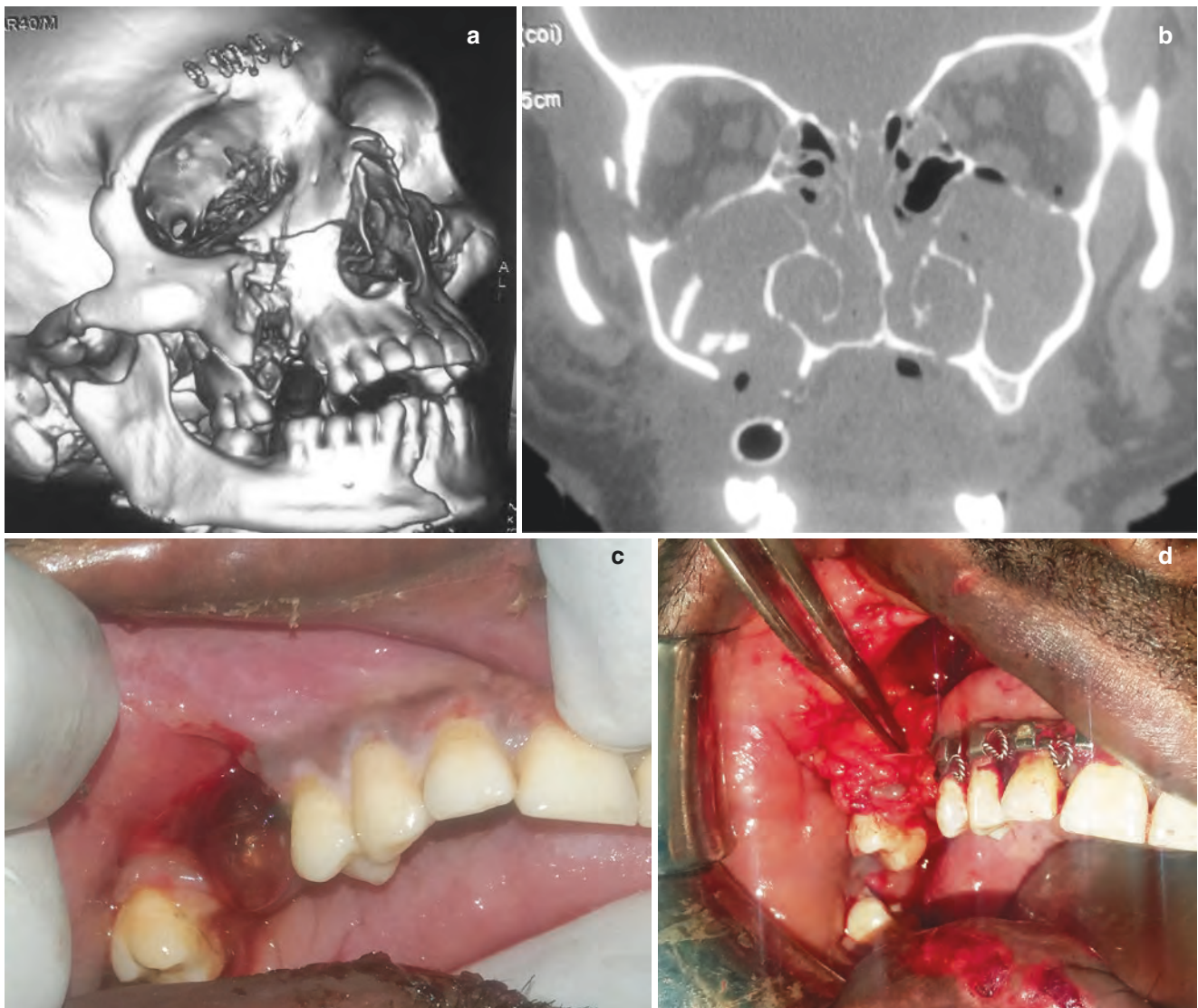
It was a challenging case to plan and execute.

The upper sub-labial incision, given for the maxillary fracture exposure, was curved down distal to 14 (upper right first pre-molar) and continued as a full thickness crevicular mucoperiosteal flap. The distal release was not given, for fear of jeopardizing the vascularity of the posterior alveolar segment. The BFP was mobilized in the conventional way (Fig. 24.27d), and a good two-layered primary closure was attained after reduction and fixation of the fractures. The posterior alveolar segment had to be fixed to the main segment via transosseous wiring. This segment was extruded, and to achieve healing and occlusion, post-operative IMF was given. This particular patient was on Ryles Tube feeding for few days, mainly due to other injuries and tracheostomy, which would have helped in the good healing of the OAC closure.



©Association of Oral and Maxillofacial Surgeons of India

Fig. 24.26 (a) Surprise finding of pus from socket after extraction of upper left first molar root stumps, (b) PNS view taken after extraction shows fluid level in the sinus, probably due to pre-existing sinusitis



©Association of Oral and Maxillofacial Surgeons of India

Fig. 24.27 (a, b, c and d) OAC following maxillofacial trauma (see the text for details)

24.12 Conclusion

The clinician should be cautious of not deliberately causing an OAC while performing exodontia and dentoalveolar procedures in maxillary posterior region. An OAC should be ruled out in suspected cases, and if it occurred, necessary steps should be taken to ensure a closure primarily if possible. Even as this chapter is going to the publishers, clinicians are exploring the possibilities of new techniques, of which the flapless closure techniques of acute OAC seem to be quite promising. Closing OAC with PRF membrane/collagen composite [53, 54] offers easier, less traumatic methods to close OAC, which may even obviate the need for special surgical expertise. Materials like acellular dermal/

bone matrix are also being used recently [55] However, only time will prove the obduracy of these path breaking methods.

Visscher [56] in a retrospective study of 308 oroantral closures found that about 10% needed re-operation, and patients with maxillary sinusitis had 15 times higher risk of developing a recurrence.

Dealing with OAF cases is interesting in the sense that it involves assessing the health of sinus and choosing and performing the most suitable surgical technique, most of which are fine surgeries. It is indeed rewarding to see a symptom-free patient with a well-healed OAF closure site.

References

- Eberhardt JA. A computed tomographic study of the distances between the maxillary sinus floor and the apices of the maxillary posterior teeth. *Oral Surg Oral Med Oral Pathol.* 1992;73(3):345–6.
- von Wowern N. Correlation between the development of an oro-antral fistula and the size of the corresponding bony defect. *J Oral Surg.* 1973;31:98.
- Dym H. Oroantral communication. *Oral Maxillofac Surg Clin N Am.* 2012 May;24:239–47.
- Visscher S, et al. Closure of oroantral communications: a review of the literature. *JOMS.* 2010;68:1384–91.
- Awang MN. Closure of oroantral fistula. *IJOMS.* 1988;17:110–5.
- Kitagawa Y. Use of third molar transplantation for closure of the oroantral communication after tooth extraction: a report of 2 cases. *Oral Surg Oral Med Oral Pathol Oral Radiol Endod.* 2003;95(4):409–15.
- Procacci P. Surgical treatment of oroantral communications. *J Craniofac Surg.* 2016;27(5):1190–6.
- Welty CF. Closure of fistulous opening through alveolar process in the antrum of Highmore. *JAMA.* 1920;75:867–9.
- Moczair L. Nuovo methodo operatiopela chisura delle fistole del seno maxillare di origina dentale. *Stomatol (Roma).* 1930;28:1087–8.
- Rehrmann VA. Eine methods zur Schliessung von Kieferhohlen perforationen. *Deutsche Zahnärztliche Wochenschrift.* 1936;39:1136–9.
- Berger A. Oroantral openings and their surgical corrections. *Arch Otolaryngol.* 1939;130:400–2.
- Ashley RE. Method of closing antroalveolar fistula. *Ann Otol Rhinol Laryngol.* 1939;48:632.
- Kruger GO. Text book of oral and maxillofacial surgery. 6th ed. St Louis: CV Mosby; 1984. p. 291–3.
- Kazanjian VZ, Converse JM. The surgical treatment of facial injuries. Baltimore: Williams; 1949.
- McClung EJ. Tantalum foil used in closing antro-oral fistulas. *US Armed Forces Med J.* 1951;7:1183.
- Schuchardt K. Methodik des Verschlusses von Defekten im alveolarforsate zahn-lose oberkiefer. *Dtsch Zahn Mund Kieferheilk.* 1953;17:366–9.
- Guerrero-Santos J. The use of lingual flaps in repair of fistulas of the hard palate. *Plast Reconstr Surg.* 1966;38(2):123–8.
- Rintala A. A double, overlapping hinge flap to close palatal fistula. *Scand J Plast Reconstr Surg.* 1971;5(2):91–5.
- Ziamba RB. Combined buccal and reverse palatal flap for closure of oral-antral fistula. *J Oral Surg.* 1972;30(10):727–9.
- Meyerhoff W. Gold foil closure of oroantral fistula. *Laryngoscope.* 1973;83:940.
- Henderson D. The palatal island flap in the closure of oroantral fistulae. *British JOS.* 1974;12:141.
- Choukas NC. Modified palatal flap technique for closure of oroantral fistulas. *J Oral Surg.* 1974;32(2):112–3.
- Gullane PJ. Palatal island flap for reconstruction of oral defects. *Arch Otolaryngol.* 1977;103(10):598–9.
- Cockerham S. Closure of a large oroantral communication by bone grafting. *J Oral Surg.* 1976;34(12):1098–100.
- Egyedi P. The bucket-handle flap for closing fistulae around the premaxilla. *J Maxillofac Surg.* 1976;4(4):212–4.
- Egyedi P. Utilization of the buccal fat pad for closure of oro-antral and/or oro-nasal communications. *J Maxillofac Surg.* 1977;5:241.
- Sachs SA. Treatment of a persistent oro-antral fistula with a posteriorly based lateral tongue flap. *Int J Oral Surg.* 1979;8(3):225–8.
- Ito T, Hara H. A new technique for closure of the oroantral fistula. *J Oral Surg.* 1980;38(7):509–12.
- Quayle AA. A double flap technique for the closure of oro-nasal and oro-antral fistulae. *Br J Oral Surg.* 1981;19(2):132–7.
- Brusati R. The use of an osteoperiosteal flap to close oroantral fistulas. *J Oral Maxillofac Surg.* 1982;40(4):250–1.
- Al-Sibahi A. The use of soft polymethylmethacrylate in the closure of oro antral fistula. *J Oral Maxillofac Surg.* 1982;40:165–6.
- Mitchell R. Immediate closure of oro-antral communications with a collagen implant. A preliminary report. *Br Dent J.* 1983;154(6):171–4.
- Carstens MH. A new approach for repair of oro-antral-nasal fistulae. The anteriorly based buccinator myomucosal island flap. *J Craniofac Surg.* 1991;19(2):64–70.
- Zide MF. Hydroxylapatite block closure of oroantral fistulas: report of cases. *J Oral Maxillofac Surg.* 1992;50(1):71–5.
- Shaker MA. Competent closure of chronic oroantral fistula with Zenoderm. *Egypt Dent J.* 1995;41(3):1237–42.
- Hanazawa Y. Closure of oroantral communications using a pedicled buccal fat pad graft. *J Oral Maxillofac Surg.* 1995;53(7):771–5.
- Hori M. Application of the interseptal alveolotomy for closing the oroantral fistula. *J Oral Maxillofac Surg.* 1995;53(12):1392–6.
- Salins PC, Kishore SK. Anteriorly based palatal flap for closure of large oroantral fistula. *Oral Surg Oral Med Oral Pathol Oral Radiol Endod.* 1996;82(3):253–6.
- Pandolfi PJ. Three-layer closure of an oroantral-cutaneous defect. *Int J Oral Maxillofac Surg.* 2000;29(1):24–6.
- Lee JJ. Repair of oroantral communications in the third molar region by random palatal flap. *Int J Oral Maxillofac Surg.* 2002;31(6):677–80.
- Haas R. A preliminary study of monocortical bone grafts for oro-antral fistula closure. *Oral Surg Oral Med Oral Pathol Oral Radiol Endod.* 2003;96(3):263–6.
- Ogunsalu C. A new surgical management for oro-antral communication: the resorbable guided tissue regeneration membrane – bone substitute sandwich technique. *West Indian Med J.* 2005;54(4):261–3.
- Steiner M. Metal plates and foils for closure of oroantral fistulae. *JOMS.* 2008;66:1551–5.
- Visscher SH, van Minnen B, Bos RR. Closure of oroantral communications using biodegradable polyurethane foam: a feasibility study. *J Oral Maxillofac Surg.* 2010 Feb;68(2):281–6.
- Sandhya G, et al. Surgical management of oro-antral communications using resorbable GTR membrane and FDMB sandwich technique: a clinical study. *J Maxillofac Oral Surg.* 2013;12(3):254–9.
- Ram H. Use of auricular cartilage for closure of oroantral fistula: a prospective clinical study. *J Maxillofac Oral Surg.* 2016;15(3):293–9.
- von Wowern N. Closure of oroantral fistula with buccal flap: Rehrmann versus Móczár. *Int J Oral Surg.* 1982;11(3):156–65.
- Killey HC, Kay LW. An analysis of 250 cases of oro-antral fistula treated by the buccal flap operation. *Oral Surg Oral Med Oral Pathol.* 1967;24(6):726–39.
- Bichat FMX. Anatomie generale: appliquee a la physiologie et la medecine, Paris; 1801. Cited in Stuzin JM, Wagstrom L, Kawamoto HK, Baker TJ, Wolfe A The anatomy and clinical applications of the buccal fat pad. *Plast Reconstr Surg* 1990;85:29.
- Manuel S, Surej Kumar LK, Parvathi R Nair: the versatility in the use of Buccal fat pad in the closure of oro-antral fistulas. *J Maxillofac Oral Surg.* 2015;14(2):374–7.
- Adams T. Repair of oroantral communications by use of a combined surgical approach: functional endoscopic surgery and buccal advancement flap/buccal fat pad graft. *J Oral Maxillofac Surg.* 2015;73(8):1452–6.
- Huang YC. Caldwell-Luc operation without inferior meatal antrostomy: a retrospective study of 50 cases. *J Oral Maxillofac Surg.* 2012;70(9):2080–4.
- Gülşen U. Etal. Flap-free treatment of an oroantral communication with platelet-rich fibrin. *Br J Oral Maxillofac Surg.* 2016;54(6):702–3.

54. Pandikanda R, Singh R, Patil V, Sharma M, Shankar K. Flapless closure of oro-antral communication with PRF membrane and composite of PRF and collagen – a technical note. *J Stomatol Oral Maxillofac Surg*. 2018 Dec 29;120(5):471–3.
55. Li XY, Wu J, Cao J, Yang W, Wu B, Xie C. Clinical analysis of acellular dermal matrix and acellular bone matrix in oro-antral fistula repair. *Hua Xi Kou Qiang Yi Xue Za Zhi* 2018 Dec 1;36(6):633–637. <https://doi.org/10.7518/hxkq.2018.06.010>. Chinese.
56. Visscher SH, van Roon MR, Sluiter WJ, van Minnen B, Bos RR. Retrospective study on the treatment outcome of surgical closure of oroantral communications. *J Oral Maxillofac Surg*. 2011 Dec;69(12):2956–61.

Open Access This chapter is licensed under the terms of the Creative Commons Attribution 4.0 International License (<http://creativecommons.org/licenses/by/4.0/>), which permits use, sharing, adaptation, distribution and reproduction in any medium or format, as long as you give appropriate credit to the original author(s) and the source, provide a link to the Creative Commons license and indicate if changes were made.

The images or other third party material in this chapter are included in the chapter's Creative Commons license, unless indicated otherwise in a credit line to the material. If material is not included in the chapter's Creative Commons license and your intended use is not permitted by statutory regulation or exceeds the permitted use, you will need to obtain permission directly from the copyright holder.



Part X

**Nerve Injuries and Neuralgias of Oral
and Maxillofacial Region**



Tara Renton

There are infinite opportunities in dentistry to damage the trigeminal nerve. Nerve damage from surgery can cause chronic post-surgical pain; however, this is limited in dentistry as a result of Local anaesthetic (LA) infiltration injections but more commonly associated with injuries to the nerve trunks of division two and three caused by implants, endodontics and third molar surgery (or other high-risk extractions). Fortunately, painful post-traumatic trigeminal neuropathy (PPTTN) is rare in dentistry compared to other common general surgical procedures where 20–45% of patients experience persistent pain after surgical limb amputation, thoracotomy and breast surgery. This chapter highlights the prevention (using risk assessment, optimal surgical techniques, early post-surgical follow-up protocols and other strategies) and optimal management of trigeminal nerve injuries.

Trigeminal nerve injury (TNI) associated with chronic pain is the most problematic consequence of dental surgical procedures with major medico-legal implications [1]. The incidence of lingual nerve injury has remained static in the UK over the last 30 years, but is increasing in the US, as is the incidence of inferior alveolar nerve injury in the UK, with the latter being due to implant surgery and endodontic therapy [2]. Third molar surgery-related inferior alveolar nerve (IAN) neuropathy or inferior alveolar block injections are usually temporary but can persist and become permanent (by definition at 3 months). There are rare reports of resolution of implant and other cause-related IAN neuropathies at over 4 years, [3] but these are not similar reports of other peripheral sensory nerve injuries [4–7]. In dentistry, frequently, a treat delay is 3–6 months [5], which is inappropriate when compared to other peripheral sensory nerve injuries where immediate repair and exploration are recommended. We now understand that known or suspected, restorative

(endo and implant)-induced nerve injuries require intervention ideally immediately, within 30 h or within 3 months, dependent upon the mechanism of injury, to optimize resolution from injury and prevent the permanent central and peripheral changes within the nervous system [6, 7].

Paraesthesia is often inappropriately used in the dental literature to mean neuropathy. However, paraesthesia is only a descriptive term, meaning altered sensation and not a diagnosis. When sensory nerves are injured, a neuropathy (malfunction) may arise, and this may be painful or non-painful.

The trigeminal nerve has the largest representation in the sensory cortex, reflecting the disproportionate sensory input from the orofacial region. It protects vital structures that underpin our very survival, providing sensory supply to the eyes, airway, brain, mouth and ears. It is no ‘wonder’ that when the threat or actual pain arises in the trigeminal nerve area that the patient is neurophysiologically wired to ‘run for the hills’ from the dental chair. Iatrogenic (caused by surgery or medicine) trigeminal nerve injuries (TNIs) result in 70% pain in patients seen seeking treatment on our clinic [7]. The ongoing or evoked pain results in interference with eating, speaking, sleeping, applying makeup, shaving, kissing, tooth brushing and drinking; just about every social interaction, we take for granted. As a result, these injuries have a significant negative effect on the patient’s self-image, quality of life and psychology [7].

With the increasing age of the patient, the time elapsed since the injury and the proximity of the injury to the cell body (the more proximal lesions have a worse prognosis) will dictate the persistence of any peripheral sensory nerve injury.

There are many non-surgical causes for trigeminal neuropathy, and these must be borne in mind if the patient presents with an unclear onset of motor or sensory neuropathy [8].

Sensory nerve injuries caused by implant and endodontic treatments are mainly permanent. Only LA nerve injuries have a 75% likelihood of recovery and lingual access third molar surgery and have 90% potential for recovery [9].

T. Renton (✉)
Oral Surgery, Kings College London, London, UK
e-mail: Tara.renton@kcl.ac.uk

Referral of patients with these nerve injuries before 4 months [2] is too late for optimal resolution or management as inferior alveolar nerve injuries often require an immediate implant or endo-treated tooth removal within 24–30 h. We now understand that after 3 months, permanent central and peripheral changes occur within the nervous system subsequent to injury, which are unlikely to respond to surgical intervention [10].

Nerve damage is likely to result from a combination of poor risk assessment, poor technique, lack of recognition and the acute management of intra-operative and post-operative signs of neuropathy. Risk assessment involves the patient selection, pre-operative planning, both clinical and radiographic, appropriate selection of implant site and type (width and length) and suitable treatment protocol and follow-up.

It is important that the clinician is familiar with the nerve injury risk factors, specific for each of the types of invasive procedures. For example, in the case of protrusion through the IDC and resultant direct IAN mechanical injury by implant drill, a “sudden give” or an “electric shock” type feeling, even with local anaesthesia working, is reported by most of the patients seen in our clinic with post-traumatic neuropathy. This should result in the clinician stopping surgery, not reaching for another LA block injection and reassessing their surgical position with regard to the injured nerve.

The problem with implant-related nerve injuries is that they are entirely avoidable as this is elective surgery, thus negligent, and likely to be permanent and painful for the patient [11]. In addition, persistent nerve injuries cannot be resolved. Surgical intervention for hypoaesthetic nerve injuries does not return the patient to normality [10], and surgery for patients with pain and hyperaesthesia is not appropriate as the pain is not abated and patients are faced with long-term anti-epileptics or anti-depressants for chronic pain [11].

When assessing patients with surgically induced nerve injuries, we recommend a more holistic approach in assessing patients with nerve injury [8]. The definition ICHD 3 (International Craniofacial pain and Headache Disorders) of painful post-traumatic trigeminal neuropathy (PPTTN) includes development of neuropathy within 3 months of injury with sensory neuropathy and pain. The author believes that the neuropathy develops immediately after trauma, unless related to endodontic procedure where there may be a 2–3 days delay in neuropathy development. Features of iatrogenic trigeminal nerve injury worthy of assessment include

- Focal sensory neuropathy (mostly present). There is almost always an area of abnormal sensation (neuropathy with the exception in Trigeminal neuralgia which is NOT post-traumatic), and the maximum reported pain is associated with the area of sensory deficit (i.e. suffering from

a mixture of pain, numbness and altered sensation). This is an important diagnostic feature for sensory nerve neuropathy.

- Pain discomfort, altered sensation and numbness (anaesthesia). Neuropathic pain is commonly present with allodynia (pain on non-noxious stimuli), hyperalgesia (increased pain to noxious stimuli) and hyperpathia (continuous altered sensation or pain after stimulation ceases). In 50–70% of patient reports, a combination of numbness, altered sensation and pain is experienced, the pain may be spontaneous ongoing pain, which often had a burning character, spontaneous shooting or electric shock-like sensations (neuralgia) [7]. Evoked pain due to touch or cold often leads patients to have difficulties with daily function, such as eating, socializing, kissing, speech and drinking. As a consequence, patients are often anxious and tearful and had psychological repercussions of surgery. These symptoms were often compounded by the lack of informed consent, which was given by only 30% of patients, most of whom were not specifically warned about potential nerve injury [7].
- Daily function problems (drinking, kissing, eating, sleeping, speaking, tooth brushing and avoidance) [12],
- Psychological (anxiety, stress, post-traumatic stress disorder and anger) [12].

The following sections address the prevention and management of trigeminal nerve injuries related to

- Local anaesthesia.
- Implants.
- Third molar and other high-risk extractions.

25.1 Local Anaesthetic-related Nerve Injuries

Local block injection-related nerve injury is an acknowledged complication in relation to surgery [13]. Dentistry is the only speciality that still trains clinicians to aim for nerves rather than avoiding neural contact (often using ultrasound), which likely explains the continued prevalence of LA-related nerve injuries in dentistry. All other block injections are undertaken using ultrasound in order to avoid nerve injury. One report highlights that the prevalence of IDB-related nerve injuries in UK General dental practise is 1:14,000 blocks, or 1:56 K IDB patients experience permanent lingual or inferior alveolar nerve injury of which this 25% of nerve injuries are permanent [9]. It is estimated that every practising dentist will experience causing 4–6 temporary nerve injuries and one permanent nerve injury related to IDBs during their working life based upon current practice.

Nerve injury may be due to many causes including physical (needle, compression due to epineural or perineural haemorrhage), ischaemic or chemical (haemorrhage or LA contents). The site of the injury may also vary and combine peri-, epi- and intra-neural trauma causing subsequent haemorrhage, inflammation and scarring, resulting in demyelination (loss of nerve lining) [14]. Only 1.3–8.6% of patients get an ‘electric shock’ type sensation on application of an IAN block and 57% of patients suffer from prolonged neuropathy having not experienced the discomfort on injection, and thus, this is not a specific sign [15]. Routine practice in Germany includes warning patients of potential nerve injury in relation to dental block injections. Risk factors for persistent local anaesthesia nerve injuries are summarized in Table 25.1.

The lingual nerve (LN) is at increased risk of permanent injury compared to the IAN during local anaesthesia, possibly related to the reduced number of fascicles in the LN compared to the IAN [16].

Higher concentration agents are more neurotoxic and, therefore, more likely to cause persistent inferior dental block (IDB)-induced nerve injury [17–22]. Irrefutably, Schwann cell death is related to increased concentration and

time exposure to LA [22]. Articaine is provided in 4% concentration and Lidocaine in 2% solution in most countries. A recent prospective randomized study reports that there is no benefit or using 4% Articaine IDBs compared to 2% Lidocaine [23], which is substantiated by other evidence [24–27]. Thus, logically why would anyone use a higher concentration agent for an IDB when there is no increased efficacy and higher risk of nerve injury? [28]

Intra-operatively, all clinicians should document unusual patient pain reactions occurring during injections or surgery (such as sharp pain or an electrical shock-like sensation), as neuralgia during injections is associated with increased persistence of nerve injury [15]. Thus, it is important that the clinician uses an appropriate LA method to prevent proximity of the injection/surgical instruments to the IDC, for example, infiltration anaesthesia for implant surgery.

25.1.1 Avoiding Block Anaesthesia by Using Infiltration Dentistry

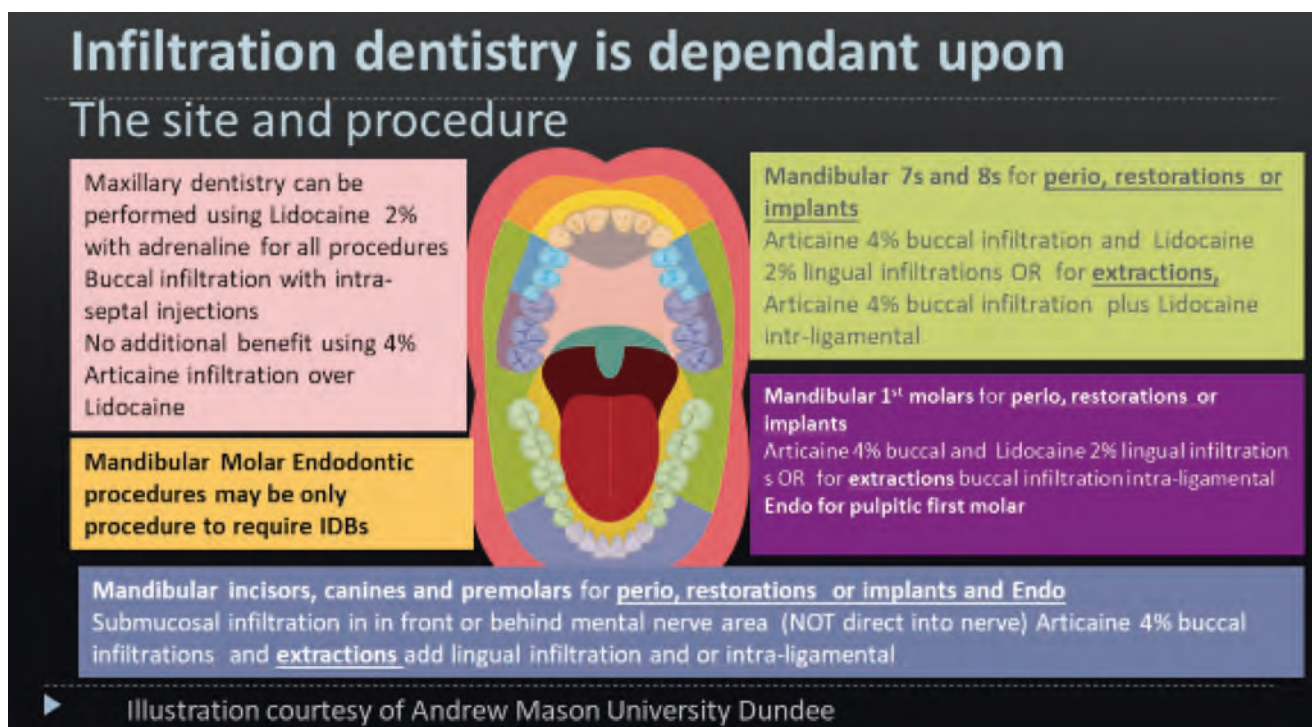
Daublander et al. reported that in a 2014 [23] survey of German dental LA practise, 74% were using infiltration dentistry routinely and rarely giving IDBs (personal communication). Improved patient comfort is reported by patients with preference for having full lingual sensation and shorter duration LA anaesthesia after dental treatment.

There is further evidence to support the notion of infiltration dentistry can be successful in many aspects of dentistry

Table 25.1 Risk factors for persistent neuropathy related to IDBs

In order to minimize complications related to dental LA, you need to consider modifying the following risks:
<ul style="list-style-type: none"> • Block anaesthesia: nerve block injections should be undertaken without intent on direct ‘hit’ of the nerve. 60% of patients who experience the ‘funny bone’ neuralgia due to the IDB needle being placed too close to the lingual or inferior alveolar nerves experience persistent neuropathy • Lingual nerve > IAN: is this technique related or anatomically related (less fascicles in LN lower capacity for recovery). Perhaps, the direct IDB approach may place the lingual nerve at increased risk compared to the indirect technique • Concentration of LA: any increased concentration of any agent leads to increased neural neurotoxicity • Volume of LA: there is no evidence to support this suggestion, but all chemicals are neurotoxic, and depending upon the proximity, LA concentration and neural damage, additional volume would add to potential neurotoxicity • Multiple injections: second or subsequent injections that impede directly on or in neural tissue may not be associated with the usual ‘funny bone’ neuralgic pain. Thus, the patient does not self-protect as effectively possibly rendering the nerves more at risk of direct damage • Severe pain on injection: 60% increased occurrence of persistent neuropathy after IDBs • Type of LA: agent bupivacaine most neurotoxic of all LA agents • Type of vasoconstrictor? The role of vasoconstrictor in nerve damage is unknown • Sedated or anaesthetized patients? There is no evidence to support unresponsive patients, who are less likely to protect themselves when neuralgia (funny bone reaction) occurs as the IDB needle encroaches too close to the nerve • Lack of LA aspiration? There is no evidence to support that aspiration during IDB results in lower persistent neuropathies, but a pragmatic view may infer less chemical injected intra-neurally will cause less chemical nerve injury

- *Maxillary infiltration anaesthesia*
Studies report that 4% Articaine to be more effective than 2% lidocaine for lateral incisors but not molars [25], differing from other reports [23, 25]. A recent randomized controlled trial reported a statistically significant difference advocating the use of 4% Articaine in place of 2% lidocaine for buccal infiltration in patients experiencing irreversible pulpitis in maxillary posterior teeth [24, 26]. This has been superseded by a metaanalysis that reports there is no advantage in using 4% Articaine for maxillary infiltration anaesthesia and that 2% Lidocaine is suffice for dental interventions.
- *Pulpal anaesthesia in the anterior mandible compared to inferior dental block (IDBs) [25].*
Meechan provides evidence supporting the significantly increased rates of pulpal anaesthesia using infiltration anaesthesia when compared to IDB anaesthesia particularly for premolar and incisor teeth (Fig. 25.1).
- *Pulpitic mandibular molars in adults [23, 25, 29, 30].*
A recent systematic review reports that Articaine is 3.4 times more effective for pulpitic mandibular molars when compared to lidocaine, but there is no difference between Articaine and Lidocaine maxillary infiltrations or IDBs [31].



©Association of Oral and Maxillofacial Surgeons of India

Fig. 25.1 Summary of infiltration methods to minimize nerve injury

- *for exodontia in adults and children [32].*
Paedodontic extractions do not require IDBs as the bone is very porous and susceptible to absorption of infiltrative anaesthesia.
- *is ideal for implant surgery,*
Several reports of supra-periosteal infiltration anaesthesia not only are sufficient for posterior mandible implant surgery but also may be protective of the IAN [33].
- *is suitable for periodontal surgery.*
The standard care for periodontal and implant surgery is infiltration LA [34].

Intra-ligamental anaesthesia for extractions and avoiding IDBs is also gaining population [34].

Key Facts for Prevention of local anaesthetic nerve injuries.

Thus, prevention of LA nerve injuries is possible and some simple steps may minimize LA-related nerve injuries:

- Avoid high concentration LA (Articaine 4%) for block injections and for ID blocks (use 2% Lidocaine as standard) as the efficacy is equal.
- Avoid multiple blocks where possible.
- Avoid nerve contact during block injections.
- Avoid block anaesthesia by using Infiltration dentistry and, thus, prevent LA-related nerve injury, for which there is no cure.

25.2 Management of LA Nerve Injuries

Evidence base remains limited for managing dental LA-related nerve injuries; we only know that 25% are permanent and that there is no ‘magic bullet’ to fix them. A sit and wait approach has to be adopted with reassurance of the patient and therapeutic management of their symptoms

- **HOME CHECK**—If you cause pain during an IDB injection in your patient, do follow them up the next day and check they are OK. If the patient reports numbness, altered sensation and/or pain, reassure them.
- Continue to support, reassure your patient and advise them to visit to confirm the presence of neuropathy. If the neuropathy affects most of the dermatome ± associated with severe neuropathic pain, nerve injury must be suspected. Reassure your patient that 75% of these injuries resolve.
- Say SORRY as this is NOT an admission of guilt.
- Initiate medical management (recommended for other peripheral sensory nerve injuries).
 - High-dose oral NSAIDs (400–800 mgs Ibuprofen PO QDS) for 2 days only. Bandolier Oxford league table summarizes the optimal analgesia for post-operative pain, and combined Ibuprofen and paracetamol have the smallest number needed to treat.

- GMP prescription for Prednisolone 5 day step down does 50-40-30-20-10 mg PO (not for patients with contraindications for steroids or NSAIDs).
- Vitamin B complex (Riboflavin 400 mg once daily for maximum of 3 months plus other Vit B complex).
- Arrange a review of the patient. All advice is summarized on the Trigeminalnerve.org.uk website.
- Long-term management of patients with non-resolving LA nerve injuries. The reality for these patients is that if they have persistent neuropathic pain and have to be treated as such with psychological and medical management. Topical local anaesthetic (Lidocaine 5%) patches may assist the patient in sleeping and playing sports in cold weather [35]. Psychological interventions play a significant role in managing these patients, and recommendations for treatment of trigeminal neuropathic pain are also well described by Renton & Zakzewska [36].

25.3 Implant-related Nerve Injuries

Implant-related IANs incidence varies from 0–40% [37]. Two recent studies highlight persistent neuropathic pain due to implant IANs [38, 39]. Prevention of nerve implant IANs can be attributed to the avoidance of direct damage to the Inferior dental canal (IDC) during preparation [40]. A good clinical and radiographic pre-assessment protocol is required to mitigate damage due to proximity of implant bed preparation to the inferior dental canal (IDC) and are recommended [41, 42]. The risk factors for implant nerve injury are summarized in Table 25.2 [41, 42, 45–52].

A limited window is available to maximize inferior alveolar nerve injury resolution in relation to dental implants, endodontics and mandibular wisdom teeth. A report illustrated that early removal of implants (within 30 h) may maximize neuropathy resolution; however, the evidence remains weak [37]. Prevention of implant-related nerve injuries includes;

- *Pre-operatively*
 - undertake a good risk assessment,
 - ability to read and use CBCT to plan a sufficient safety zone (know difference between drill length and implant length),
 - extra diligence in planning implants in the parasymphyseal region near the mental nerve (loop and incisal branches),
 - Screen out neuropathic pain pre-implant.
- *Operatively:*
 - make sure the implant bed preparation is above the safety zone,
 - stop drilling if patient reports intraoperative pain and reassess depth,
 - use drill guides and stops,

Table 25.2 Risk factors for implant-related nerve injury

<i>A. Inadequate preoperative assessment and planning due to</i>
• Surgeon lack of knowledge/inexperience/training
• Inadequate informed consent-all options provided and related risk benefit for each option of treatment. Implants are elective treatment. Sublingual haematoma that can require the need for tracheostomy post-implant treatment and rare events of death
• Lack of identification of existing pre-surgical neuropathy (especially important in edentulous patients)
• Poor planning in risk assessment and positioning the implant. A sectional DPT is recommended as a minimum for mandibular implant planning. If there is limited bone depth, a CBCT may be used to quantify and qualify bone density and volume. The clinician must be able to read and analyse the CBCT, depending upon technicians, software or radiologist specialist (who are not present with you intra-operatively)
– Bone assessment quality and quantity
– Know where the nerve is. Nerve localization, risk factors when assessing IAN position (mental loop, characteristics of IAN position in various sites of mandible) and Parasymphyseal zone that is of high risk.
– The accuracy of estimating the position of the IDC based on plain films or CT scans is highlighted in the radiographic assessment section
– Safety zone- the recommendation is 2 mm (by ITI and ADI), which may be insufficient considering that most-implant drills are 1.5 mm longer than implants. This increases the risk perforation of a canal surrounding IDC or even direct perforation and damage to the nerve
• Selection of implants 10 mm + (short implants <8 mm to simplify procedure and minimize morbidity)
<i>B. Surgical procedure should include the execution of</i>
• Local Anaesthesia (use infiltration LA techniques to allow patients to notify the surgeon or intraoperative neuralgia; if pain is reported, intra-operatively stop surgery and reassess preparation depth and width)
• Flap design
• Use surgical guides to minimize morbidity
• Surgical stents [43]
• Using intra-operative radiographs, ITI recommends stopping drilling after 60% of planned depth and reassess with bed marker and Long cone PeriApical radiograph
• Drill stops [44]
<i>C. Post-operative care should attend to</i>
• Early post-operative recognition of neuropathy (HOMECHECK).
• Prompt management of neuropathy (removal of implant if indicated) [44]
– Acute phase
– Late phase
• Early or late post-operative infection

- intra-operative reassessment of implant bed depth using marker and LCPA films at 60% of planned depth,
- Record any events that may indicate operative nerve injury,
- extreme pain during LA IDB, or during implant bed preparation
- Suddenly give and/or profuse haemorrhage arising from the implant bed (possible breach of IDC).
- In such situations, stop surgery, do not reach for more LA and reassess your surgical position,

- *Post-operatively.*
- take appropriate post-operative periapical radiographs (CBCTs not indicated) to confirm proximity and/or breach of the inferior dental canal or around the mental foramen before patient discharge.
- If nerve injury is suspected or identified, the patient should be informed, Immediate removal of the implant should be arranged and appropriate medical management should be instituted with arranged review with the treating clinician and specialist if required.
- **HOME CHECK** -Contact must be made by the clinician and the patient between 6 and 24 h after surgery to confirm that the patient is experiencing any persistent neuropathy. This builds on the relationship of the clinician with the patient, which will be premised upon good consent process.
 - Continue to support and reassure your patient and advise them to visit return to your clinic. If the neuropathy affects most of the dermatome ± associated with severe neuropathic pain, nerve injury must be suspected.
 - Say SORRY this is NOT an admission of guilt. When neuropathy is confirmed, check who you must notify as in many countries, IANIs are reportable events. It is essential to be honest with your patient.
 - Additional scanning or radiography may not be essential. Post-traumatic neuropathy is a clinical diagnosis. You will already be aware of the proximity of the implant bed to the IDC, and whether there was likely breach into the IAN canal.
 - If nerve injury is suspected, the implant must be removed within 24–36 hours of placement in order to maximize recovery from nerve injury [37].
 - Arrange a review of the patient to confirm neuropathy.
 - Initiate medical management (recommended for other peripheral sensory nerve injuries).
 - High-dose oral NSAIDs (400–800 mgs Ibuprofen PO QDS) for maximum 2 days.
 - GMP (General Medical Practitioner) prescription for Prednisolone 5 day step down does 50-40-30-20-10 mg PO (not for patients with contraindications for steroids or NSAIDs).
 - Vitamin B complex (Riboflavin 400 mg once daily for a maximum of 3 months plus other Vit B complex).
- Arrange a further review of your patient.
- Long-term management of patients with non-resolving nerve injuries. The reality for these patients is that if they have persistent neuropathic pain and have to be treated as such with psychological and medical management. Psychological interventions play a significant role in managing these patients, and recommendations for treatment of trigeminal neuropathic pain are also well described by Renton & Zakzrewska [36].

25.4 Mandibular Third Molar Extraction-related Nerve Injuries

The nerves at risk of damage in mandibular third molar extraction are the terminal nerves of the third branch of the trigeminal nerve [53, 54], i.e. the inferior dental nerve (IDN) and lingual nerve (LN). The reported risk of neurosensory deficit ranges from 0.26 to 8.4% for IDN [55] and from 0.1 to 22% for LN [7]. Patients with IDN injury suffer from paresthesia, anaesthesia or dysesthesia in the lip, chin or gingiva on the affected side, while patients with LN injury have a sensitivity deficit at the homolateral half of the tongue, with or without taste alteration [7]. Transient and permanent lesions should be differentiated; permanent lesions often remain after 6–12 months, and spontaneous recovery cannot be expected in these cases [56].

Damage to the LN or IDN during third molar extraction is among the most frequent causes of litigation in dentistry [57]. Highly varying results have been published by numerous studies on risk factors related to neurosensory deficit in lower third molar surgery. The objective of a recent literature review was to identify and analyse studies on factors related to IDN and/or LN injury in lower third molar extraction, allowing clinicians to take appropriate measures to minimize this risk [58]. Several radiological risk factors have been identified that increases the risk of nerve injury during removal by ten-fold (from 0.2 to 2% permanent injury and 2–20% temporary nerve injury) [59, 60].

Key Facts

Factors that may be implicated in nerve injury after lower third molar surgery were classified into four groups:

- Risk assessment—diagnostic radiographic techniques.
- IDN injury risk factors.
- LN injury risk factors.
- Alternative surgical approaches.

25.4.1 Risk Assessment

A recent review included three cohort studies and various randomized clinical trials (RCTs) on the influence of diagnostic radiographic techniques. They generally reached similar conclusions, finding that the non-utilization of CBCT was not an additional risk factor for nerve injury in patients examined by conventional panoramic radiography [61–63].

Korkmaz et al. [64] and Lee et al. [65] reported a lower frequency of transient but not permanent IDN damage when

CBCT was also used. This may be because in cases where the relationship between third molar and the IDN is doubtful, there is likely to be no direct contact and the injury would result from pressure due to haemorrhage or haematoma so that the association would be less detectable on panoramic radiology. In contrast, cases of direct contact are readily observed using both radiographic techniques.

25.4.2 Patient Factors

Various authors reported a significantly lower frequency of nerve injury with younger age. [66–70] Thus, no cases of nerve injury were observed among patients under 23 years of age in the cohort study of 1050 patients by Zhang et al. [71], while Kjolle et al. [66] confirmed a significant association with age ($p = 0.007$), finding a higher frequency of permanent injury in patients over 30 years of age. These findings may be attributable to an increased difficulty of the surgery at older ages due to a greater likelihood of hypercementosis, lower bone elasticity and, above all, completed root formation, in addition to lesser vascularization, reducing the regenerative capacity of the nerve. Nevertheless, other researchers found no significant relationship with age [72] although the sample sizes were smaller than that in the aforementioned studies. All reviewed articles observed a higher frequency of nerve injuries in females [62] although this difference was only statistically significant ($p = 0.005$) in the multiple logistic regression analysis of 320 cases conducted by Selvi et al. [68] Gender differences have been attributed to the generally smaller mandible of females, implying a smaller gap between third molar root and IDN.

25.4.3 Anatomical

The mandibular canal is evidently more susceptible to nerve injury with greater depth and, therefore, closer proximity of the impacted third molar, reducing the surgical accessibility and visibility. A statistically significant association was demonstrated by all three articles that studied this risk factor [62]. A higher risk of IDN injury was associated with mesio-angular impactions and with horizontal impactions [62], but these associations were not found to be statistically significant.

25.4.4 Radiological Factors

In 1990, Rood and Shehab [59] proposed seven radiological signs identifiable by panoramic radiography, which indicate a close relationship between lower third molar and IDN: root narrowing, root darkening, apex darkening and bifid images,

changes in root direction, dental canal narrowing, dental canal diversion and interruption of the white line of the dental canal. Only four of these signs were reported to be significant indicators of IDN risk in the reviewed articles: interruption of the radiopaque band of the canal [62, 66, 69, 73–76], canal diversion [59, 74, 76], root darkening [59, 62, 74, 76] and mandibular canal narrowing. [70, 74, 76] In contrast, a retrospective study by Pippi et al. [72] found that none of these signs were significantly associated with nerve injury, even when two or more were observed. CBCT radiological signs have also been associated with IDN damage. Detection of contact between lower third molar and mandibular canal has been found to potentially influence the resulting nerve damage, [62, 68, 69, 72, 77] which is associated by Kim et al. [70] with a 21-fold higher risk of paraesthesia. Various studies [67, 69, 73, 78, 79] have associated nerve injury with the lingual position of the mandibular canal with respect to the third molar root, attributed to the more likely interruption of the mandibular canal cortex due to the direction of extraction manoeuvres. The RCT reported by Ghaeminia et al. [62] found the risk of nerve injury to be 16-fold higher when the localization was lingual versus buccal. In addition, some authors have described a higher risk of IDN injury for dumbbell-shaped versus round-, oval- or drop-shaped canals [72, 73, 76, 77].

Key Facts

There are seven radiological signs identifiable by panoramic radiography, which indicate a close relationship between lower third molar and IDN: root narrowing, root darkening, apex darkening and bifid images, changes in root direction, dental canal narrowing, dental canal diversion and interruption of the white line of the dental canal.

25.4.5 Surgical

Two studies related the type of anaesthesia to IDN injury. Nyugen et al. [67] found a significantly higher ($p = 0.007$) frequency of permanent damage in lower third molar surgery under general versus local anaesthesia, and Costantinides et al. [80] reported a 2–16-fold greater risk of IDN injury under the former. One explanation is that the absence of patient feedback with general anaesthesia means that surgeons are less aware of the force applied. Hasegawa et al. [69] observed a significantly higher ($p < 0.05$) IDN injury rate in patients with versus without nerve exposure during the surgery. However, Pippi et al. [72] reported nerve injuries in only 6.5% of cases in which the nerve was exposed versus

9.3% of cases in which it was not, suggesting that IDN exposure may simply reflect the close proximity of tooth and nerve and cannot per se be considered an indicator of potential nerve damage. Three studies associated haemorrhage during third molar extraction with IDN injury [62, 75, 81], without elucidating whether the bleeding resulted from mandibular canal fracture or a haematoma or other causes of nerve compression.

With respect to the experience of the clinician, Nguyen et al. [67] found a significantly higher frequency of permanent IDN injury ($p = 0.026$) amongst inexperienced dentists in comparison to oral specialists or maxillofacial surgeons, possibly related to inappropriate force and less instrumental control in the hands of those with less experience. The same study also explored the effect of surgery duration, finding a higher nerve injury rate when this was more than 20 min (from incision to completed tooth extraction), mainly because a longer surgical time implies a more challenging extraction. With regard to the surgical approach, Jain et al. [73] reported a significantly ($p = 0.04$) higher nerve injury rate in patients who underwent odontosection versus those who did not. This may be explained by the less extensive osteotomy often associated with this procedure although odontosection can be a direct risk factor for IDN injury in the extraction of horizontal third molars [82].

25.5 LN Injury Risk Factors

Demographics A prospective study by Charan Babu et al. [83] reported that older age was a significant risk factor for LN injury ($p < 0.05$), but Kjoelle et al. [66] found no differences in permanent nerve damage amongst age groups. No significant gender differences in LN injury rate were found in any study.

Anatomical Charan Babu et al. [83] observed a significantly ($p < 0.01$) higher risk of LN injury with greater impaction depth, attributed to the more difficult extraction and, therefore, more extensive osteotomy. A higher LN injury rate was observed for distoangular impactions [67, 83] generally due to the more difficult extraction and for horizontal extractions [83], possibly because of the larger amount of bone removed. However, these associations were not statistically significant.

Surgical Charan Babu et al. [83], Osunde et al. [84] and Yadav et al. [85] reported a significantly higher LN injury rate ($p < 0.01$, $p < 0.001$ and $p < 0.001$, respectively) in patients who had undergone lingual flap

retraction before third molar extraction than in those who had not.

This injury was found to be transient in the RCT by Shad et al. [86], who suggested that permanent injury can be produced when the lingual flap is not separated from the bone. Three studies [62, 85, 87] observed a significant association between higher LN injury risk and the requirement for odontosection in third molar surgery.

25.6 Role of Alternative Surgical Techniques

Various authors have proposed alternative surgical techniques to avoid nerve damage in lower third molar extraction, but their findings should be considered with caution due to major study limitations (e.g. no control group and small sample size), and there has been little research on this issue. In a study of 53 patients, Bataineh et al. [88] reported a modified flap that appeared to reduce LN lesions caused by flap retraction, considering all known anatomical variations of LN. Ge et al. [89] observed lower nerve injury rates when type III lower third molars in lingual position were extracted by piezosurgery in a lingual split approach in comparison to published rates reported using the conventional lingual split technique. The persistence in defending lingual access third molar surgery is inappropriate, in that it significantly increases the risk of temporary lingual nerve injury and 10–12% of these injuries will be permanent [90]. A recent literature review recommends avoidance of lingual flaps in third molar surgery to minimize lingual nerve injury [91].

A recent surgical technique to mitigate the risk of high risk third molars in close proximity to the IDC is a coronectomy. Coronectomy, in which the dental crown is removed and the root is retained in the jaw, has been recommended to reduce IDN injury risk in cases of close proximity between nerve and third molar, and the majority of the reviewed studies described any IDN injury with the utilization of this approach [60]. Nevertheless, this technique is not free of controversy, even when clearly indicated, given the possibility of infectious complications around the root or its migration [92–95]. Extraction by orthodontic traction may also be useful when there is a high risk of nerve injury, and Wang et al. [96] found no cases of nerve injury in patients undergoing this procedure although account should be taken of study design limitations and the small sample size. There is a strong evidence base to support the prevention of IDN nerve injuries using the coronectomy technique [43, 44, 53, 54, 97].

Table 25.3 Risk factors for third molar surgery-related nerve injury

<i>Lingual nerve injury</i>	
Increased patient age	
Increased duration surgery	
Lingual access surgery	
Inexperience of surgeon	
Distoangulation of third molar	
Depth of impaction	
<i>Inferior alveolar nerve injury</i>	
Proximity of tooth root to inferior dental canal	
Increased patient age	
Increased duration surgery	
Inexperience of surgeon	
Distoangulation of third molar	
Depth of impaction	

Summary prevention of third molar surgery-related nerve injury (Table 25.3) [98, 99].

- Nerve injury risk does not appear to be influenced by the diagnostic imaging technique used (CBCT or panoramic radiograph) although the utilization of CBCT may possibly reduce the risk of transient injuries. Studies with larger sample sizes are needed to clarify this issue.
- Older age, female sex, mesioangular position, impaction depth, utilization of general versus local anaesthesia, haemorrhage, inexperience of the clinician and certain signs on panoramic radiography and CBCT appear to be associated with a higher risk of IDN injury.
- Lingual flap retraction, older age, horizontal and distoangular positions, impaction depth and odontosection may be possible risk factors for LN injury.
- Coronectomy is evidence based to prevent IDN injuries in selected cases, High-risk third molar, healthy and cooperative patients and vital tooth.
- Definitive conclusions are limited by the variability in study design (with the inclusion of some retrospective studies), reduced sample sizes and differences in the experience of clinicians, amongst other factors. However, buccal approach technique (when undertaken properly) will minimize lingual nerve injury.

25.7 Prognosis of Nerve Injuries (Table 25.4) [43]

It is not possible to classify the degree or outcome of a sensory nerve injury based on patients' presentation early post-injury. Just as with phantom limb pain patients, who may express non-existence or existence of a 'normal feeling' limb (after amputation, the most catastrophic nerve injury) with or without pain, numbness or altered sensation, these symptoms do not reflect the degree of injury or prognosis. Thus, in order to assess the end results of nerve injury, the patient must be reassessed and/or treated if indicated. The type and

Table 25.4 Resolution rates of inferior alveolar nerve injury (IANI)

Procedure	Recovery rate
Third molar surgery [7]	IANI – 67%; LNI – 72% Buccal access TMS LIN – Lingual access TMS 88%
Mandibular fractures [7]	IANI – 91%
Orthognathic surgery	IANI – 87% Bilateral sagittal split osteotomy (BSSO) IANI (patients 80–92%)
Local anaesthesia inferior dental block (mainly Lidocaine) [14]	75%
Implant-related IANI [87]	Complete recovery – 50% Partial recovery – 44% No change – 6%

A review of common operations such as groin hernia repair, breast and thoracic surgery, leg amputation and coronary artery bypass surgery found an incidence of chronic post-surgical pain in 10–50% of patients [100].

Table 25.5 Timing for intervention of Trigeminal nerve injury

Event	Recovery	
Endodontic	<24–36 h	Remove tooth and remove over fill or over instrumentation
Implant	<24–36 h	Remove implant
Wisdom teeth- inferior alveolar nerve injury	<2 weeks	Consider earlier intervention
Radiographic evidence of retained tooth fragments or IDC damage		Access via extraction socket and remove retained roots ± repair nerve
Wisdom teeth -lingual nerve injury	>3–6 months	Consider earlier intervention
If CBCT confirmation of breach, lingual plate	Consider earlier intervention	Access via extraction socket and remove retained roots ± repair nerve
Local anaesthetic nerve injuries (LN or IAN)		Therapeutic management only
Orthognathic nerve injuries		Therapeutic management only
Mandibular fracture nerve injuries		Therapeutic management only

A known or suspected sectioned/damaged nerve should undergo immediate exploration repair

related permanency of trigeminal nerve injuries are summarized in Table 25.4.

Summary of type and timing of management (Table 25.5 and Fig. 25.2) Management of third molar-related nerve injuries will depend upon the presentation of the patient (pain, functional and psychological implications) duration and cause of the nerve injury [56, 98]. Figure 25.2 summarizes the management and timing of intervention for trigeminal nerve injuries based upon the current evidence base [56, 98]. It is recognized that neuropathic pain does not respond to surgical intervention, and thus, prevention and early management are paramount in preventing chronic life-long pain after routine surgery in these patients. Advice is summarized on the Trigeminalnerve.org.uk website.

MANAGEMENT OF TRIGEMINAL NERVE INJURIES RELATED TO DENTAL PROCEDURES					
Timeline	During surgery	Post surgery 2-6 weeks	12 weeks	> 12 weeks	
Psychological intervention					
Medical intervention					
High risk nerve injury/ or patient high risk of developing neuropathic pain consider pre-emptive Amitriptyline or Pregabalin		Reported neuropathy immediate post-surgery <ul style="list-style-type: none"> • NSAIDs Ibuprofen 6—mg TDS 5 days (MH permitting) • step down Prednisolone 50-10mg over 5 days (exclude known risk of DU and or PU) • Vitamin B complex (long term during recovery) • Review 		If required: Psychological support (for PTSD and sleep disorders) and Therapeutic management of neuropathic pain (NICE Guidance Ne Pain in adults) <ul style="list-style-type: none"> • Step 1 Amitriptyline or Nortriptyline • Adjunctive topical agents (Lidocaine, Capsaicin) • Step II Gabapentin or Pregabalin 	
Surgical intervention					
Known or suspected nerve Inferior alveolar or lingual injury	Post Local anaesthesia or orthognathic surgery or trauma	Post Implant or endodontic surgery	Post M3M surgery	Patient presents with persistent non-resolving LINGUAL nerve injury after lingual access(lingual retraction +/- lingual split) surgery	Patient presents with persistent non-resolving Inferior alveolar nerve injury OR LINGUAL nerve injury after M3M surgery
Duty of candour inform patient immediately	Duty of candour inform patient immediately	Confirm extensive dermatome affected, anaesthesia, +/- paraesthesia, +/- neuropathic pain	Confirm extensive dermatome affected, anaesthesia, +/- paraesthesia, +/- neuropathic pain	Confirm extensive dermatome affected, anaesthesia, +/- paraesthesia, +/- neuropathic pain	Confirm extensive dermatome affected, anaesthesia, +/- paraesthesia, +/- neuropathic pain
Repair nerve immediately	Surgery not indicated	Within 30 hours	Lingual nerve (buccal approach) DPT confirms retained roots CBCT confirms lingual plate defect due to M3M surgery	Consider exploration @ 12 weeks +/- nerve repair dependent upon surgical findings	N.B Surgical repair DOES NOT IMPROVE neuropathic pain
Or refer for immediate repair to a specialist centre	Medical and psychological therapies	Remove implant or endodontically treated tooth and reassess patient combined with medical intervention above	Consider early exploration (IAN via M3M socket) +/- nerve repair dependent upon surgical findings		
<ul style="list-style-type: none"> • New developments • MRI micro neurography may assist in confirmation of damage to IAN and LN (currently available in US under development London) • Larger IAN defects can be optimally repaired using Axogen cadaveric nerve graft (currently NICE approved for hand surgery in UK) 					

©Association of Oral and Maxillofacial Surgeons of India

Fig. 25.2 suggested management of nerve injuries related to mandibular third molar surgery

The patient with the nerve injury must be treated, NOT the nerve injury in isolation. The neuropathy, pain, numbness or paraesthesia, with associated functional and psychological impact, will be the driving force behind the patient seeking treatment [98]. These factors must be assessed, and the potential outcomes, good or bad, should be discussed and agreed with the patient [99].

Patients sustaining LA, orthognathic, oncology and trauma-related nerve injuries will mainly be managed therapeutically [101–104].

Overall, there is poor evidence to support late surgical intervention for Trigeminal nerve injuries [6, 105]. Most studies report on repair procedures undertaken too late, and early repair is imperative to minimize central irreversible changes and possibly chronic pain. Generally, surgical repair of the trigeminal nerves never returns the patient to peroperative neural function; in addition, there is a risk of making a numb patient into one with chronic post-surgical pain [100, 106]. As with other post-trauma sensory neuropathies, it is recognized that immediate repair is optimal; [107, 108] how-

ever, this is rarely applied to dental nerve injuries with the misconception that we should sit and wait for resolution (only for 3 months for lingual nerve injuries related to lingual access third molar surgery), resulting in long delays before surgical intervention [109–111].

Some recent studies have highlighted immediate repair with cadaveric-treated human nerve graft successful in managing various sized defects in planned resection of nerves related to benign tumour resection or trauma [112, 113].

Recent reports have also concluded that, similar to other surgical sites, neuropathic pain does not resolve with surgery, with this being the main driver for surgical repair [114, 115].

Many reports have recommended the use of conduits (venous, prosthetic), sural nerve grafts and other techniques without sufficient evidence and many with poor outcomes including neuropathy and pain from the donor sites! The future may prove that nerve growth factors, other growth-promoting chemical and anti-neuropathic pain agents and specialized conduits may play a role in improving

repair of trigeminal nerve injuries, and the overall conclusion from reviews in this area is that we have a lot of evidence base to harness [105, 106, 116]. The singular consensus is that prevention of these nerve injuries is possible and optimal.

The timing of intervention and mechanism of injury are paramount in decision making in the treatment of trigeminal nerve injuries (summarized in Table 25.5).

1. Counselling is the most useful effective tool for managing patients with problematic permanent sensory nerve injuries.
2. Medical intervention is indicated for patients with pain or discomfort or with anxiety and/or depression in relation to chronic pain. However, due to the multiple noxious side effects of chronic pain medication, less than 18% of patients remain adherent with medication.
 - acute (medical),
 - late (chronic pain management with psychological interventions).
3. Surgical intervention is indicated for:
 - Immediate surgical repair for suspected or known nerve injury or intended surgical defect after removal of benign tumour or recent trauma [98].
 - Removal of implant.
 - or overfill or RCT-treated tooth with 36 h if related to the development of neuropathy [99].
 - Within 2–4 week, exploration if clinical presentation of persistent neuropathy is paramount and radiographic follow-up is not necessary; however, if there is CBCT evidence of breach of lingual plate or IDC, consider immediate action-nerve exploration ± repair;
 - Lingual nerve neuropathy patients with CBCT evidence of damage to lingual plate adjacent to third molar surgical site.
 - Inferior alveolar nerve with retained roots or evidence of bone inclusions or compression of IDC.
 - Within 3 months of injury;
 - Non-resolving lingual or inferior dental nerve injuries: Exploratory surgery for lingual or inferior alveolar nerve injuries within 3 months post-injury. Surgical intervention is not effective for neuropathic pain, and if this is the driving force behind seeking surgery, it should be reconsidered.
 - There are reported exciting results of allografting lingual and inferior alveolar nerve injuries. Using a pre-prepared human-treated cadaveric allograft, the IDN and LN can be repaired with minimal tension. This is undertaken using microscopy and described in several publications by John Zuniga and Michael Miloro [109]. This is likely to be the treatment of choice if repair is indicated and direct re-anastomosis cannot be undertaken most commonly for the IDN. One of the

main issues regarding nerve repair is the early identification of the neuroma related to the patients 'symptoms and the connectivity of the nerve itself, i.e. is the nerve actually functioning. Recent developments with Magnetic Resonance Neurography (MRN) have availed the surgeon to identify the nerve lesion and neural functionality to facilitate appropriate and earlier nerve repair intervention [117, 118].

25.8 Conclusions

Unfortunately, none of these interventions 'fix' the patient, but the aim is to manage their symptoms as best as possible, improve function and allow them time to accommodate to these unfortunate events, which is often not very satisfactory.

This chapter was intended to acknowledge and share some key issues around iatrogenic trigeminal nerve injuries and to provide some key take home messages including:

- Neuropathic pain as well as altered sensation and numbness is what most patients experience with iatrogenic sensory nerve injury. This has a significant and unpleasant effect on the patient (improve your consent!)
- The majority of iatrogenic nerve injuries are avoidable.
- Inferior alveolar nerve injuries in relation to implant and endodontic dentistry are permanent and 'unfixable' unless treated quickly within 30 h.
- Owing to the significant problems following nerve injury, pre-operative strategies for minimizing this risk of nerve damage need to be considered carefully. Peri-operative planning, operative execution and post-operative care need improving to minimize and hopefully abolish these injuries.
- Several strategies are presented to assist in preventing nerve injuries.
- There is a need for a consensus and standardization of risk assessment and management, a holistic approach in managing the pain, related effect on functionality and psychological implications caused to the patients affected by iatrogenic nerve injury.

References

1. Caissie R, Goulet J, Fortin M, Morielle D. Iatrogenic paresthesia in the third division of the trigeminal nerve: 12 years of clinical experience. *J Can Dent Assoc.* 2005;71(3):188–92.
2. Hillerup S. Iatrogenic injury to oral branches of the trigeminal nerve: records of 449 cases. *Clin Oral Investig.* 2007 Jun;11(2):133–42. Epub 2006 Dec 22.

3. Elian N, Mitsias M, Eskow R, Jalbout ZN, Cho SC, Froum S, Tarnow DP. Unexpected return of sensation following 4.5 years of paresthesia: case report. *Implant Dent*. 2005 Dec;14(4):364–7.
4. Loescher AR, Robinson PP. The effect of surgical medicaments on peripheral nerve function. *Br J Oral Maxillofac Surg*. 1998 Oct;36(5):327–32.
5. Hegedus F, Diecidue RJ. Trigeminal nerve injuries after mandibular implant placement—practical knowledge for clinicians. *Int J Oral Maxillofac Implants*. 2006;21(1):111–6.
6. Ziccardi VB, Assael LA. Mechanisms of trigeminal nerve injuries. *Atlas Oral Maxillofac Surg Clin North Am*. 2001;9(2):1–11.
7. Renton T, Yilmaz Z. Profiling of patients presenting with post-traumatic neuropathy of the trigeminal nerve. *J Orofac Pain*. 2011 Fall;25(4):333–44.
8. Carter E, Yilmaz Z, Devine M, Renton T. An update on the causes, assessment and management of third division sensory trigeminal neuropathies. *Br Dent J*. 2016 Jun;220(12):627–35.
9. Renton T, Adey-Viscuso D, Meechan JG, Yilmaz Z. Trigeminal nerve injuries in relation to the local anaesthesia in mandibular injections. *Br Dent J*. 2010;209(9):E15. <https://doi.org/10.1038/sj.bdj.2010.978>.
10. Zuniga JR, Yates DM, Phillips CL. The presence of neuropathic pain predicts postoperative neuropathic pain following trigeminal nerve repair. *J Oral Maxillofac Surg*. 2014 Dec;72(12):2422–7.
11. Leung YY, Cheung LK. Longitudinal treatment outcomes of microsurgical treatment of neurosensory deficit after lower third molar surgery: a prospective case series. *PLoS One*. 2016 Mar 4;11(3):e0150149.
12. Smith JG, Elias LA, Yilmaz Z, Barker S, Shah K, Shah S, et al. The psychosocial and affective burden of posttraumatic neuropathy following injuries to the trigeminal nerve. *J Orofac Pain*. 2013;27(4):293–303.
13. Renton T, Janjua H, Gallagher JE, Dalglish M, Yilmaz Z. UK dentists' experience of iatrogenic trigeminal nerve injuries in relation to routine dental procedures: why, when and how often? *Br Dent J*. 2013;214(12):633–42. <https://doi.org/10.1038/sj.bdj.2013.583>.
14. Pogrel MA, Schmidt BL, Sambajon V, Jordan RC. Lingual nerve damage due to inferior alveolar nerve blocks: a possible explanation. *J Am Dent Assoc*. 2003;134(2):195–9.
15. Smith MH, Lung KE. Nerve injuries after dental injection: a review of the literature *J Can Dent Assoc* 2006 Jul–Aug;72(6):559–564. Review.
16. Pogrel MA, Thamby S. Permanent nerve involvement resulting from inferior alveolar nerve blocks. *J Am Dent Assoc*. 2000;131(7):901–7.
17. Haas DA, Lennon D. A 21 year retrospective study of reports of paresthesia following local anesthetic administration. *J Can Dent Assoc*. 1995;61(4):319–20, 323–316, 329–330
18. Hillerup S. Iatrogenic injury to oral branches of the trigeminal nerve: records of 449 cases. *Clin Oral Investig*. 2007;11(2):133–42.
19. Hillerup S, Jensen R. Nerve injury caused by mandibular block analgesia. *Int J Oral Maxillofac Surg*. 2006;35(5):437–43. <https://doi.org/10.1016/j.ijom.2005.10.004>.
20. Pedlar J. Prolonged paraesthesia. *Br Dent J*. 2003;195(3):119. <https://doi.org/10.1038/sj.bdj.4810421>.
21. Perez-Castro R, Patel S, Garavito-Aguilar ZV, Rosenberg A, Recio-Pinto E, Zhang J, Blanck TJ, Xu F. Cytotoxicity of local anesthetics in human neuronal cells. *Anesth Analg*. 2009 Mar;108(3):997–1007.
22. Kämmerer PW, Schneider D, Palarie V, Schiegnitz E, Daubländer M. Comparison of anesthetic efficacy of 2 and 4% articaine in inferior alveolar nerve block for tooth extraction—a double-blinded randomized clinical trial. *Clin Oral Investig*. 2017 Jan;21(1):397–403.
23. Daubländer M, Kämmerer PW, Willershausen B, Leckel M, Lauer HC, Buff S, Rösl B. Clinical use of an epinephrine-reduced (1/400,000) articaine solution in short-time dental routine treatments—a multicenter study. *Clin Oral Investig*. 2012 Aug;16(4):1289–95.
24. Evans G, Nusstein J, Drum M, Reader A, Beck M. A prospective, randomized, double-blind comparison of articaine and lidocaine for maxillary infiltrations. *J Endod*. 2008 Apr;34(4):389–93.
25. Oliveira PC, Volpato MC, Ramacciato JC, Ranali J. Articaine and lignocaine efficiency in infiltration anaesthesia: a pilot study. *Br Dent J*. 2004 Jul 10;197(1):45–6.
26. Vähätalo K, Anttila H, Lehtinen R. Articaine and lidocaine for maxillary infiltration anesthesia. *Anesth Prog*. 1993;40(4):114–6.
27. Srinivasan N, Kavitha M, Loganathan CS, Padmini G. Comparison of anesthetic efficacy of 4% articaine and 2% lidocaine for maxillary buccal infiltration in patients with irreversible pulpitis. *Oral Surg Oral Med Oral Pathol Oral Radiol Endod*. 2009 Jan;107(1):133–6.
28. Meechan JG. The use of the mandibular infiltration anesthetic technique in adults. *J Am Dent Assoc*. 2011 Sep;142 Suppl 3:19S–24S. Review.
29. Zain M, et al. Comparison of Anaesthetic efficacy of 4% Articaine primary Buccal infiltration versus 2% Lidocaine inferior alveolar nerve block in symptomatic mandibular first molar teeth. *J Coll Physicians Surg Pak*. 2016 Jan;26(1):4–8.
30. Poorni S, et al. Anesthetic efficacy of four percent articaine for pulpal anesthesia by using inferior alveolar nerve block and buccal infiltration techniques in patients with irreversible pulpitis: a prospective randomized double-blind clinical trial. *J Endod*. 2011 Dec;37(12):1603–7.
31. Kung J, McDonagh M, Sedgley CM. Does articaine provide an advantage over lidocaine in patients with symptomatic irreversible pulpitis? A systematic review and meta-analysis. *J Endod*. 2015;41(11):1784–94.
32. Thakare A, Bhate K, Kathariya R. Comparison of 4% articaine and 0.5% bupivacaine anesthetic efficacy in orthodontic extractions: prospective, randomized crossover study. *Acta Anaesthesiol Taiwanica*. 2014 Jun;52(2):59–63.
33. Etoz OA, Er N, Demirbas AE. Is supraperiosteal infiltration anesthesia safe enough to prevent inferior alveolar nerve during posterior mandibular implant surgery? *Med Oral Patol Oral Cir Bucal*. 2011 May 1;16(3):e386–9.
34. Dumbrigue HB, Lim MV, Rudman RA, Serrano A. A comparative study of anesthetic techniques for mandibular dental extraction. *Am J Dent*. 1997 Dec;10(6):275–8.
35. Khawaja N, Yilmaz Z, Renton T. Case studies illustrating the management of trigeminal neuropathic pain using topical 5% lidocaine plasters. *Br J Pain*. 2013;7(2):107–13.
36. Renton T, Zakrzewska JM. Chapter 22 Orofacial pain. In: Shaw I, Kumar C, Dodds C, editors. *Oxford textbook of anaesthesia for oral and maxillofacial surgery*. Oxford: Oxford University Press; 2010. p. 283–298 isbn:978-0-19-956421-7.
37. Khawaja N, Renton T. Case studies on implant removal influencing the resolution of inferior alveolar nerve injury. *Br Dent J*. 2009;206(7):365–70. <https://doi.org/10.1038/sj.bdj.2009.258>.
38. Alhassani AA, AlGhamdi AS. Inferior alveolar nerve injury in implant dentistry: diagnosis, causes, prevention, and management. *J Oral Implantol*. 2010;36(5):401–7.
39. Fukuda K, Ichinohe T, Kaneko Y. Pain management for nerve injury following dental implant surgery at Tokyo dental college hospital. *Int J Dent*. 2012;2012:209474. <https://doi.org/10.1155/2012/209474>.
40. Renton T, Dawood A, Shah A, Searson L, Yilmaz Z, Renton T, Yilmaz Z. Post-implant neuropathy of the trigeminal nerve. A case series. *Br Dent J*. 2012;212(11):E17. <https://doi.org/10.1038/sj.bdj.2012.497>.
41. Juodzbalys G, Kubilius M. Clinical and radiological classification of the jawbone anatomy in endosseous dental implant treatment. *J*

- Oral Maxillofac Res. 2013 Jul 1;4(2):e2. <https://doi.org/10.5037/jomr.2013.4202.N>.
42. Harris D, Horner K, Gröndahl K, Jacobs R, Helmrot E, Benic GI, Bornstein MM, Dawood A, Quirynen M. EAO guidelines for the use of diagnostic imaging in implant dentistry 2011. A consensus workshop organized by the European Association for Osseointegration at the Medical University of Warsaw. *Clin Oral Implants Res.* 2012 Nov;23(11):1243–53.
 43. Leung YY, Cheung LK. Coronectomy of the lower third molar is safe within the first 3 years. *J Oral Maxillofac Surg: Official Journal of the American Association of Oral and Maxillofacial Surgeons.* 2012;70(7):1515–22.
 44. Cervera-Espert J, Pérez-Martínez S, Cervera-Ballester J, Peñarrocha-Oltra D, Peñarrocha-Diago M. Coronectomy of impacted mandibular third molars: a meta-analysis and systematic review of the literature. *Med Oral Patol Oral Cir Bucal.* 2016 Jul 1;21(4):e505–13.
 45. Greenstein G, Tarnow D. The mental foramen and nerve: clinical and anatomical factors related to dental implant placement: a literature review. *J Periodontol.* 2006 Dec;77(12):1933–43.
 46. Thoma DS, Cha JK, Jung UW. Treatment concepts for the posterior maxilla and mandible: short implants versus long implants in augmented bone. *J Periodontal Implant Sci.* 2017 Feb;47(1):2–12.
 47. Bartlett G, Mansoor J. Articaine buccal infiltration vs lidocaine inferior dental block – a review of the literature. *Br Dent J.* 2016 Feb 12;220(3):117–20.
 48. Al-Ani O, Nambiar P, Ha KO, Ngeow WC. Safe zone for bone harvesting from the interforaminal region of the mandible. *Clin Oral Implants Res.* 2013 Aug;24(Suppl A100):115–21.
 49. Van Assche N, van Steenberghe D, Guerrero ME, Hirsch E, Schutyser F, Quirynen M, Jacobs R. Accuracy of implant placement based on pre-surgical planning of three-dimensional cone-beam images: a pilot study. *J Clin Periodontol.* 2007;34(9):816–21.
 50. De Kok IJ, Thalji G, Bryington M, Cooper LF. Radiographic stents: integrating treatment planning and implant placement *Dent Clin N Am* 2014 Jan;58(1):181–192. <https://doi.org/10.1016/j.cden.2013.09.008>. Review.
 51. Burstein J, Mastin C, Le B. Avoiding injury to the inferior alveolar nerve by routine use of intraoperative radiographs during implant placement. *J Oral Implantol.* 2008;34(1):34–8.
 52. Greenstein G, Greenstein B, Desai RN. Using drill stops on twist drills to promote safety and efficiency when creating osteotomies for dental implants. *J Am Dent Assoc.* 2014 Apr;145(4):371–5.
 53. Szalma J, Lempel E. Protecting the inferior alveolar nerve: coronectomy of lower third molars. *Rev Orv Hetil.* 2017 Nov;158(45):1787–93.
 54. Ali AS, Benton JA, Yates JM. Risk of inferior alveolar nerve injury with coronectomy vs surgical extraction of mandibular third molars—a comparison of two techniques and review of the literature. *J Oral Rehabil.* 2018 Mar;45(3):250–7.
 55. Cheung LK, Leung YY, Chow LK, Wong MC, Chan EK, Fok YH. Incidence of neurosensory deficits and recovery after lower third molar surgery: a prospective clinical study of 4338 cases. *Int J Oral Maxillofac Surg.* 2010;39(4):320–6.
 56. Renton T, Yilmaz Z. Managing iatrogenic trigeminal nerve injury: a case series and review of the literature. *Int J Oral Maxillofac Surg.* 2012;41(5):629–37. <https://doi.org/10.1016/j.ijom.2011.11.002>.
 57. Koskela S, Suomalainen A, Apajalahti S, Venta I. Malpractice claims related to tooth extractions. *Clin Oral Investig.* 2017 Mar;21(2):519–22.
 58. Leung YY, Cheung LK. Risk factors of neurosensory deficits in lower third molar surgery: a literature review of prospective studies. *Int J Oral Maxillofac Surg.* 2011;40(1):1–10.
 59. Rood JP, Shehab BA. The radiological prediction of inferior alveolar nerve injury during third molar surgery. *Br J Oral Maxillofac Surg.* 1990;28(1):20–5.
 60. Renton T. Notes on coronectomy. *Br Dent J.* 2012;212:323–6.
 61. Petersen LB, Vaeth M, Wenzel A. Neurosensory disturbances after surgical removal of the mandibular third molar based on either panoramic imaging or cone beam CT scanning: a randomized controlled trial (RCT). *Dentomaxillofac Radiol.* 2016;45(2):20150224.
 62. Ghaemina H, Gerlach NL, Hoppenreijts TJ, Kicken M, Dings JP, Borstlap WA, et al. Clinical relevance of cone beam computed tomography in mandibular third molar removal: a multicentre, randomised, controlled trial. *J Cranio-Maxillo-Fac Surg: Official Publication of the European Association for Cranio-Maxillo-Fac Surgery.* 2015;43(10):2158–67.
 63. Matzen LH, Schou S, Christensen J, Hintze H, Wenzel A. Audit of a 5-year radiographic protocol for assessment of mandibular third molars before surgical intervention. *Dentomaxillofac Radiol.* 2014;43(8):20140172.
 64. Korkmaz YT, Kayipmaz S, Senel FC, Atasoy KT, Gumrukcu Z. Does additional cone beam computed tomography decrease the risk of inferior alveolar nerve injury in high-risk cases undergoing third molar surgery? Does CBCT decrease the risk of IAN injury? *Int J Oral Maxillofac Surg.* 2017;46(5):628–35.
 65. Lee B, Park Y, Ahn J, Chun J, Park S, Kim M, et al. Assessment of the proximity between the mandibular third molar and inferior alveolar canal using preoperative 3D-CT to prevent inferior alveolar nerve damage. *Maxillofac Plast Reconstr Surg.* 2015;37(1):30.
 66. Kjolle GK, Bjornland T. Low risk of neurosensory dysfunction after mandibular third molar surgery in patients less than 30 years of age. A prospective study following removal of 1220 mandibular third molars. *Oral Surg Oral Med Oral Pathol Oral Radiol.* 2013;116(4):411–7.
 67. Nguyen E, Grubor D, Chandu A. Risk factors for permanent injury of inferior alveolar and lingual nerves during third molar surgery. *J Oral Maxillofac Surg: Official Journal of the American Association of Oral and Maxillofacial Surgeons.* 2014;72(12):2394–401.
 68. Selvi F, Dodson TB, Nattestad A, Robertson K, Tolstunov L. Factors that are associated with injury to the inferior alveolar nerve in high-risk patients after removal of third molars. *Br J Oral Maxillofac Surg.* 2013;51(8):868–73.
 69. Hasegawa T, Ri S, Shigeta T, Akashi M, Imai Y, Kakei Y, et al. Risk factors associated with inferior alveolar nerve injury after extraction of the mandibular third molar—a comparative study of preoperative images by panoramic radiography and computed tomography. *Int J Oral Maxillofac Surg.* 2013;42(7):843–51.
 70. Kim JW, Cha IH, Kim SJ, Kim MR. Which risk factors are associated with neurosensory deficits of inferior alveolar nerve after mandibular third molar extraction? *J Oral Maxillofac Surg: Official Journal of the American Association of Oral and Maxillofacial Surgeons.* 2012;70(11):2508–14.
 71. Zhang QB, Zhang ZQ. Early extraction: a silver bullet to avoid nerve injury in lower third molar removal? *Int J Oral Maxillofac Surg.* 2012;41(10):1280–3.
 72. Pippi R, Santoro M. A multivariate statistical analysis on variables affecting inferior alveolar nerve damage during third molar surgery. *Br Dent J.* 2015;219(4):E3.
 73. Jain N, Thomas S, Prabhu S, Jain S, Pathak AD, Pillai A, et al. Influence of tooth sectioning technique and various risk factors in reducing the IAN injury following surgical removal of an impacted mandibular third molar. *Oral Maxillofac Surg.* 2016;20(2):149–56.
 74. Huang CK, Lui MT, Cheng DH. Use of panoramic radiography to predict postsurgical sensory impairment following extraction of impacted mandibular third molars. *J Chin Med Assoc.* 2015;78(10):617–22.
 75. Pathak S, Mishra N, Rastogi MK, Sharma S. Significance of radiological variables studied on orthopantomogram to predict

- post-operative inferior alveolar nerve paresthesia after third molar extraction. *J Clin Diagn Res.* 2014;8(5):ZC624.
76. Ueda M, Nakamori K, Shiratori K, Igarashi T, Sasaki T, Anbo N, et al. Clinical significance of computed tomographic assessment and anatomic features of the inferior alveolar canal as risk factors for injury of the inferior alveolar nerve at third molar surgery. *J Oral Maxillofac Surg: Official Journal of the American Association of Oral and Maxillofacial Surgeons.* 2012;70(3):514–20.
 77. Shiratori K, Nakamori K, Ueda M, Sonoda T, Dehari H. Assessment of the shape of the inferior alveolar canal as a marker for increased risk of injury to the inferior alveolar nerve at third molar surgery: a prospective study. *J Oral Maxillofac Surg: Official Journal of the American Association of Oral and Maxillofacial Surgeons.* 2013;71(12):2012–9.
 78. Ye Z, Yang C, Abdelrehem A. Prediction of inferior alveolar nerve injury in complicated mandibular wisdom teeth extractions: a new classification system. *Int J Clin Exp Med.* 2016;9(2):3729–34.
 79. Kim HG, Lee JH. Analysis and evaluation of relative positions of mandibular third molar and mandibular canal impacts. *J Korean Assoc Oral Maxillofac Surg.* 2014;40(6):278–84.
 80. Costantinides F, Biasotto M, Maglione M, Di Lenarda R. Local vs general anaesthesia in the development of neurosensory disturbances after mandibular third molars extraction: a retrospective study of 534 cases. *Med Oral Patol Oral Cir Bucal.* 2016;21(6):e724–30.
 81. Xu GZ, Yang C, Fan XD, Yu CQ, Cai XY, Wang Y, et al. Anatomic relationship between impacted third mandibular molar and the mandibular canal as the risk factor of inferior alveolar nerve injury. *Br J Oral Maxillofac Surg.* 2013;51(8):e215–9.
 82. Mavrodi A, Ohanyan A, Kechagias N, Tsekos A, Vahtsevanos K. Influence of two different surgical techniques on the difficulty of impacted lower third molar extraction and their post-operative complications. *Med Oral Patol Oral Cir Bucal.* 2015;20(5):e640–4.
 83. Charan Babu HS, Reddy PB, Pattathan RK, Desai R, Shubha AB. Factors influencing lingual nerve paraesthesia following third molar surgery: a prospective clinical study. *J Maxillofac Oral Surg.* 2013;12(2):168–72.
 84. Osunde O, Saheeb B, Bassey G. Indications and risk factors for complications of lower third molar surgery in a Nigerian teaching hospital. *Ann Med Health Sci Res.* 2014;4(6):938–42.
 85. Yadav S, Verma A, Sachdeva A. Assessment of lingual nerve injury using different surgical variables for mandibular third molar surgery: a clinical study. *Int J Oral Maxillofac Surg.* 2014;43(7):889–93.
 86. Shad S, Shah SM, Alamgir AMM. Frequency of lingual nerve injury in mandibular third molar extraction: a comparison of two surgical techniques. *J Ayub Med Coll Abbottabad.* 2015;27(3):580–3.
 87. Agrawal A, Yadav A, Chandel S, Singh N, Singhal A. Wisdom tooth complications in extraction. *J Contemp Dent Pract.* 2014;15(1):34–6.
 88. Bataineh AB, Batarseh RA. The effect of modified surgical flap design for removal of lower third molars on lingual nerve injury. *Clin Oral Investig.* 2016;21(6):2091–9.
 89. Ge J, Yang C, Zheng J, Qian W. Piezosurgery for the lingual split technique in lingual positioned impacted mandibular third molar removal: A retrospective study. *Medicine.* 2016;95(12):e3192.
 90. Blackburn CW, Bramley PA. Lingual nerve damage associated with the removal of lower third molars. *Br Dent J.* 1989 Aug 5;167(3):103–7.
 91. Pippi R, Spota A, Santoro M. Prevention of lingual nerve injury in third molar surgery: literature review. *J Oral Maxillofac Surg.* 2017 May;75(5):890–900.
 92. Leung YY, Cheung LK. Long-term morbidities of coronectomy on lower third molar. *Oral Surg Oral Med Oral Pathol Oral Radiol.* 2016;121(1):5–11.
 93. Agbaje JO, Heijsters G, Salem AS, Van Slycke S, Schepers S, Politis C, et al. Coronectomy of deeply impacted lower third molar: incidence of outcomes and complications after one year follow-up. *J Oral Maxillofac Res.* 2015;6(2):e1.
 94. Monaco G, De Santis G, Pulpito G, Gatto MR, Vignudelli E, Marchetti C. What are the types and frequencies of complications associated with mandibular third molar coronectomy? A follow-up study. *J Oral Maxillofac Surg: Official Journal of the American Association of Oral and Maxillofacial Surgeons.* 2015;73(7):1246–53.
 95. Frenkel B, Givol N, Shoshani Y. Coronectomy of the mandibular third molar: a retrospective study of 185 procedures and the decision to repeat the coronectomy in cases of failure. *J Oral Maxillofac Surg: Official Journal of the American Association of Oral and Maxillofacial Surgeons.* 2015;73(4):587594.
 96. Wang Y, He D, Yang C, Wang B, Qian W. An easy way to apply orthodontic extraction for impacted lower third molar compressing to the inferior alveolar nerve. *J Cranio-Maxillo-Fac Surg: Official Publication of the European Association for Cranio-Maxillo-Facial Surgery.* 2012;40(3):234–7.
 97. Long H, Zhou Y, Liao L, Pyakurel U, Wang Y, Lai W. Coronectomy vs. Total removal for third molar extraction: a systematic review. *J Dent Res.* 2012;91(7):659–65.
 98. Renton T. Oral surgery: part 4. Minimising and managing nerve injuries and other complications. *Br Dent J.* 2013 Oct;215(8):393–9.
 99. Ziccardi VB, Zuniga JR. Nerve injuries after third molar removal. *Oral Maxillofac Surg Clin North Am.* 2007 Feb;19(1):105–15, vii. Review.
 100. Kehlet H, Jensen TS, Woolf CJ. Persistent postsurgical pain: risk factors and prevention. *Lancet.* 2006;367(9522):1618–25. [https://doi.org/10.1016/s0140-6736\(06\)68700-x](https://doi.org/10.1016/s0140-6736(06)68700-x).
 101. Greenstein G, Carpentieri JR, Cavallaro J. Nerve damage related to implant dentistry: incidence, diagnosis, and management. *Compend Contin Educ Dent* 2015 Oct;36(9):652–659. quiz 660.
 102. Juodzbalsys G, Wang HL, Sabalys G, Sidlauskas A, Galindo-Moreno P. Inferior alveolar nerve injury associated with implant surgery. *Clin Oral Implants Res.* 2013;24(2):183–90. <https://doi.org/10.1111/j.1600-0501.2011.02314.x>.
 103. Bede SY, Ismael WK, Al-Assaf DA, Omer SS. Inferior alveolar nerve injuries associated with mandibular fractures. *J Craniofac Surg.* 2012;23(6):1776–8. <https://doi.org/10.1097/SCS.0b013e318266fda3>.
 104. Iannetti G, Fadda TM, Riccardi E, Mitro V, Filiaci F. Our experience in complications of orthognathic surgery: a retrospective study on 3236 patients. *Eur Rev Med Pharmacol Sci.* 2013;17(3):379–84.
 105. Kushnerev E, Yates JM. Evidence-based outcomes following inferior alveolar and lingual nerve injury and repair: a systematic review. *J Oral Rehabil* 2015 Oct;42(10):786–802. <https://doi.org/10.1111/joor.12313>. Epub 2015 Jun 7.
 106. Coulthard P, Kushnerev E, Yates JM, Walsh T, Patel N, Bailey E, Renton TF. Interventions for iatrogenic inferior alveolar and lingual nerve injury. *Cochrane Database Syst Rev.* 2014 Apr 16;4:CD005293.
 107. Susarla SM, Kaban LB, Donoff RB, Dodson TB. Does early repair of lingual nerve injuries improve functional sensory recovery? *J Oral Maxillofac Surg.* 2007;65(6):1070–6. <https://doi.org/10.1016/j.joms.2006.10.010>.
 108. Ziccardi VB, Steinberg MJ. Timing of trigeminal nerve microsurgery: a review of the literature. *J Oral Maxillofac Surg.* 2007 Jul;65(7):1341–5.
 109. Zuniga JR. Sensory outcomes after reconstruction of lingual and inferior alveolar nerve discontinuities using processed nerve allograft—a case series. *J Oral Maxillofac Surg* 2015

- Apr;73(4):734–744. <https://doi.org/10.1016/j.joms.2014.10.030>. Epub 2014 Nov 13.
110. Bagheri SC, Meyer RA, Khan HA, Kubmichel A, Steed MB. Retrospective review of microsurgical repair of 222 lingual nerve injuries. *J Oral Maxillofac Surg*. 2010;68:715–23.
111. Strauss ER, Ziccardi VB, Janal MN. Outcome assessment of inferior alveolar nerve microsurgery: a retrospective review. *J Oral Maxillofac Surg*. 2006;64(12):1767–70. <https://doi.org/10.1016/j.joms.2005.11.111>.
112. Salomon D, Miloro M, Kolokythas A. Outcomes of immediate allograft reconstruction of Long-span defects of the inferior alveolar nerve. *J Oral Maxillofac Surg* 2016 Dec;74(12):2507–2514. <https://doi.org/10.1016/j.joms.2016.05.029>. Epub 2016 Jun 14.
113. Yampolsky A, Ziccardi V, Chuang SK. Efficacy of Acellular nerve allografts in trigeminal nerve reconstruction. *J Oral Maxillofac Surg*. 2017 Oct;75(10):2230–4.
114. Zuniga JR, Yates DM, Phillips CL. The presence of neuropathic pain predicts postoperative neuropathic pain following trigeminal nerve repair. *J Oral Maxillofac Surg* 2014 Dec;72(12):2422–2427. <https://doi.org/10.1016/j.joms.2014.08.003>. Epub 2014 Aug 11. PMID:25308410.
115. Zuniga JR, Renton T. Managing post-traumatic trigeminal neuropathic pain: is surgery enough? *J Neurol Neuromed*. 2016;1(7):10–4.
116. Rosén A, Tardast A, Shi TJ. How far have we come in the field of nerve regeneration after trigeminal nerve injury? *Curr Oral Health Rep*. 2016;3(4):309–13.
117. Zuniga JR, Mistry C, Tikhonov I, Dessouky R, Chhabra A. Magnetic resonance Neurography of traumatic and nontraumatic peripheral Trigeminal Neuropathies. *J Oral Maxillofac Surg* 2018 Apr;76(4):725–736. <https://doi.org/10.1016/j.joms.2017.11.007>. Epub 2017 Nov 16.
118. Chhabra A, Madhuranthakam AJ, Andreisek G. Magnetic resonance neurography: current perspectives and literature review. *Eur Radiol* 2018 Feb;28(2):698–707. <https://doi.org/10.1007/s00330-017-4976-8>. Epub 2017 Jul 14.

Open Access This chapter is licensed under the terms of the Creative Commons Attribution 4.0 International License (<http://creativecommons.org/licenses/by/4.0/>), which permits use, sharing, adaptation, distribution and reproduction in any medium or format, as long as you give appropriate credit to the original author(s) and the source, provide a link to the Creative Commons license and indicate if changes were made.

The images or other third party material in this chapter are included in the chapter's Creative Commons license, unless indicated otherwise in a credit line to the material. If material is not included in the chapter's Creative Commons license and your intended use is not permitted by statutory regulation or exceeds the permitted use, you will need to obtain permission directly from the copyright holder.



26.1 Introduction

Neuralgia can be defined as paroxysmal, intense intermittent pain that is usually confined to specific nerve branches of the head and neck. The trigeminal nerve is responsible for sensory innervation of the scalp, face and mouth, and damage or disease to this nerve may result in sensory loss and/or pain. Trigeminal Neuralgia (TN), also referred to as ‘Tic Douloureux,’ is sought to be the most intense and well-known neuralgias, which displays classical features of intense sharp, stabbing sensations with or without burning pain throughout the face. It is considered as one of the most chronic painful conditions known within the body. The pain, which is often initiated by just a light touch to an area of skin, can occur at any time without warning and depending on the severity of the condition, the frequency of the attacks can vary.

This severe medical condition affects one or more branches of the fifth cranial nerve known as the trigeminal nerve, which is the largest cranial nerve and has both sensory and motor functions. >85% of cases of trigeminal neuralgia are of the classic type known as classical trigeminal neuralgia (CTN), while the remaining cases can be separated to secondary trigeminal neuralgia (STN). STN is thought to be

initiated by multiple sclerosis or a space-occupying lesion affecting the trigeminal nerve, whereas the leading cause of CTN is known to be compression of the trigeminal nerve in the region of the dorsal root entry zone by a blood vessel.

Investigation of the cause of the neuralgia present and treatment planning of these symptoms can pose a challenge for any clinician and the importance of detailed assessment and history taking of orofacial pain should be highlighted. Extreme care must be taken to identify the underlying cause of the symptoms experienced by the patient, who may often present in distress, as suffering from head and neck neuralgia can severely affect a patient’s quality of life.

There is no guaranteed cure for the condition of trigeminal neuralgia, but there are several treatment options that may give symptomatic relief. In this chapter, we will review the common neuralgias occurring within the oral and maxillofacial region with specific emphasis on trigeminal neuralgia. We will discuss the historical evolution of treatment including the medical and surgical modalities with the use of current literature and newer developments. This highlights the need for further studies and investigation into the phenomenon of neuralgia to improve patient management and treatment outcomes.

This chapter will also cover surgical interventions such as, peripheral neurectomies, which can be done by an Oral and Maxillofacial Surgeon.

Electronic Supplementary Material The online version of this chapter (https://doi.org/10.1007/978-981-15-1346-6_26) contains supplementary material, which is available to authorized users.

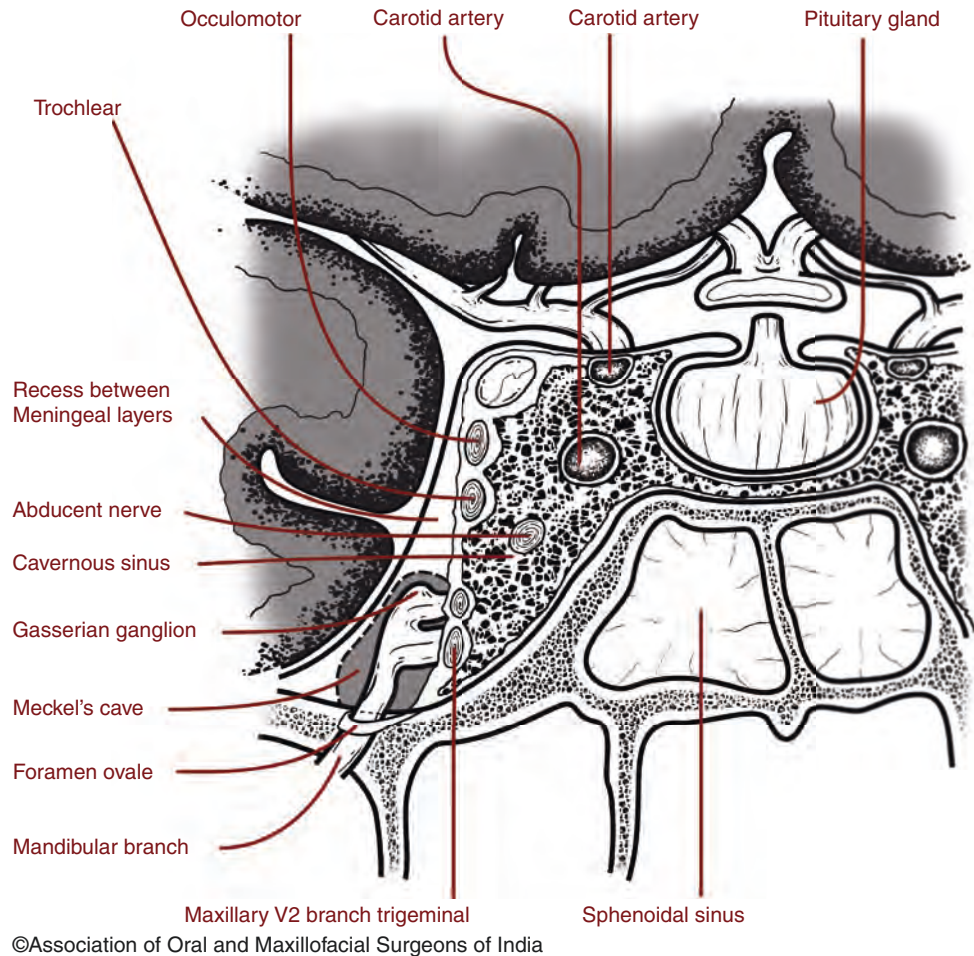
K. Ganesan (✉)
Department of Oral and Maxillofacial Surgery, Southend
University Hospitals NHS Trust, Southend-on-Sea, UK
University of Leeds, Leeds, UK
e-mail: mailme@kandyganesan.com

A. Thomson (✉)
Norfolk and Norwich University Hospitals, Norfolk, UK
e-mail: ashathomson1@nhs.net

26.2 Anatomy of the Trigeminal Nerve

This is the largest cranial nerve with both sensory and motor components. It provides sensory nerve supply to the face, the scalp, the nasal cavity and the oral cavity including the teeth. It carries proprioception from the periodontal ligaments of the teeth and masticatory muscles. The trigeminal nerve provides motor supply to the muscles of mastication, tensor tympani, tensor veli palatini, mylohyoid and anterior belly of digastric. Its name is derived from its three main

Fig. 26.1 Schematic diagram showing the Meckel's cave within the dura layer lateral to cavernous sinus



branches ophthalmic, maxillary and mandibular. This nerve can be divided into various anatomical segments by its course from the brain stem, cisternal, Meckel's cave, ganglionic and finally to peripheral divisions (Ophthalmic, maxillary and mandibular). For trigeminal neuralgia, understanding of the anatomy of cisternal and Meckel's cave segments is important.

The trigeminal ganglion is located in the Meckel's cave, which is a recess between the two layers of the dura in the posteromedial portion of the middle cranial fossa. Any disease process in and around the Meckel's cave can develop the symptoms of trigeminal neuralgia. The anatomy of the Meckel's cave is detailed through the use of Fig. 26.1.

Arachnoid membrane from the posterior cranial fossa extends into the Meckel's cave and continues along the rootlets of the trigeminal nerve to as far as the trigeminal ganglion [1].

26.2.1 Peripheral Distribution of Trigeminal Nerve (Fig. 26.2 and Table 26.1)

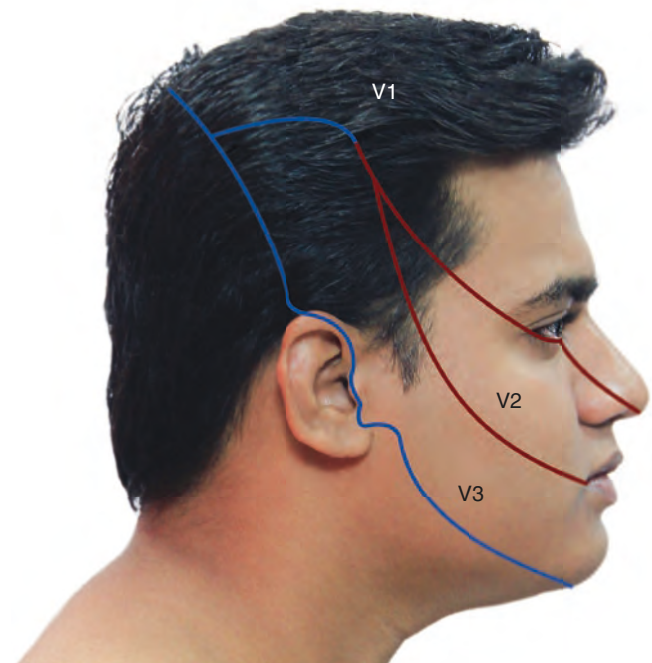


Fig. 26.2 Diagram showing peripheral distribution of trigeminal nerve

Table 26.1 Branches of the 3 divisions of the trigeminal nerve

Nerve	Branches
<i>V1—Ophthalmic</i>	
1. Frontal nerve	a. Supraorbital nerve b. Supratrochlear nerve
2. Lacrimal nerve	
3. Nasociliary nerve	a. Long Ciliary nerve b. Anterior and Posterior Ethmoidal nerves c. Infratrochlear nerve
<i>V2—Maxillary</i>	
1. Meningeal Branches	
2. Ganglionic Branches	a. Greater Palatine nerve b. Lesser Palatine nerve c. Nasopalatine nerve d. Nasal Branches
3. Posterior Superior Alveolar nerve	
4. Infraorbital nerve	a. Anterior Superior Alveolar nerve b. Middle Superior Alveolar nerve
5. Zygomatic nerve	a. Zygomaticofacial nerve b. Zygomaticotemporal nerve
<i>V3—Mandibular</i>	
1. Nervous Spinosus	
2. Motor Branches	
3. Anterior Division	a. Nerve to Lateral Pterygoid b. Masseteric nerve c. Deep Temporal nerve d. Buccal nerve
4. Posterior Division	a. Auriculotemporal nerve b. Lingual nerve c. Inferior Alveolar nerve i. Nerve to Mylohyoid ii. Mental nerve

26.3 Aetiology of Trigeminal Neuralgia

26.3.1 Neurovascular Compression

Myelin sheath surrounds the cranial nerves formed by oligodendrocytes in the central nervous system and Schwann cells in the peripheral nervous system. The main function of the myelin sheath is to provide mechanical insulation and metabolic support for the axons. This myelin sheath at the transition zone (TZ), between the central and peripheral nervous systems is a vulnerable area in the context of neurovascular compressions. The TZ is more relevant and not always located in the same position as root entry zone (REZ) [2].

Neurovascular compression at the REZ is found to be a reason for 80% of the TN but not a consistent finding in all the TN patients. This neurovascular contact at the REZ is also found in non-TN patients. A superior cerebellar artery alone or in association with another vessel is found in 88% as a source for vascular compression. Other vessels such as anterior cerebellar artery, the basilar artery and vertebral artery are also found to be in contact with RTZ [3].

26.3.2 Multiple Sclerosis (MS)

In 1950, the first finding of a connection with multiple sclerosis is reported [4]. A comprehensive review of pain in MS patients identified the prevalence to be TN to be 3.8%, which is lower than headaches (43%) and neuropathic extremity pain (26%) [5].

From this review, TN was the first symptom of MS in 9–14% of patients and the mean age of onset ranged from 33 to 51, highlighting younger patients than patients with TN alone. In addition to this, TN due to MS is often associated with numbness and paraesthesia [6]. Neuralgic pain, over a period of time, evolves with atypical features and involves an increase in the number of divisions of trigeminal distribution. Additionally, 6% became bilateral and literature shows MS precedes TN, however several studies showed TN as a first symptom before any other MS symptom [7, 8].

Electrophysiologic testing of MS-related TN patients showed up to 89% abnormal trigeminal reflexes such as the blink reflex compared to 3% in idiopathic TN patients. In MS, plaques result in neural damage causing TN but not as a result of neurovascular compression however, both can play a role in the aetiology of TN [9].

In MS, ephaptic nerve conduction is effected due to an increase in inflammatory activity in the plaques with a high T-cell activity [10].

26.3.3 Tumour and Cyst

Tumours alone are shown to be aetiology in TN from 0.8 to 11.6%, but this increased to 5.7 to 13.4% when aneurysms, angiomas or vascular malformations are present. Tumours may cause TN by compression, wrapping around the nerve root, neurovascular compression and/or neoplastic factor-related chemical irritation [6].

26.3.4 Diabetes Mellitus

The involvement of diabetic neuropathy is more common in the 3rd, 4th and 6th cranial nerves than in the trigeminal nerve. Diabetic patients tend to have more of a neuropathic pain than neuralgic pain, which may present as hot, burning, electric with a pins and needles sensation, especially in the peripheral areas such as the hands and legs. Often, this tends to be bilateral, and may present worse at night [11].

Hyperglycaemia is known to cause aggravated nerve damage, and this also applies for the increased risk of developing TN however, more studies need to be done in order to validate the underlying pathophysiology between the association of diabetes and TN [12].

26.3.5 Herpes Simplex

Post-herpetic TN after herpes zoster-shingles has been documented [13] and can present as a burning persistent severe pain for the patients. The reactivation of the latent herpes zoster virus from the dorsal root ganglion results in TN affecting the ophthalmic branch in over 80% of cases. When antivirals are administered within 72 h from the onset of the rash, they are known to reduce the duration of the rash, pain and also the incidence of post-herpetic neuralgia [14–17].

26.4 Pathophysiology of TN

The exact aetiopathogenesis of TN remains unclear. The most common hypothesis is the “ignition theory,” which is a result of abnormalities in the afferent neurones of the trigeminal root or ganglion. Injury to the axons can make them hyperexcitable and also cause central sensitisation, leading to TN [18].

Demyelination at the trigeminal REZ where central and peripheral myelin meets results in generation of ectopic impulses. This in turn can cause cross-talk between touch and pain sensations which is thought to decrease the central pain gating mechanisms. Which, can conversely result in trigeminal nerve remyelination. This may explain the spontaneous remission in some patients; however, the same cannot be applied for rapid electrophysiologic recovery and pain relief after microvascular decompression treatment [6].

The affected (demyelinated) nerves can spontaneously discharge electric impulses. Touch sensation carrying A- β fibres aligned near the pain carrying (nociceptive pathway) A- δ and C fibres in the REZ, leading to ephaptic cross-talk between the two pathways. This may explain how trivial touch sensation triggers pain in TN [18].

The trigeminal ganglion itself can show pathological changes such as hypermyelination [19, 20]. Demyelination is common in many patients with TN and is caused by a compression by vascular structures, MS, tumours and vascular malformations.

Compression on the REZ should cause a continuous pain, but TN patients suffer paroxysmal attacks, which are most likely to be caused by spontaneous discharges where the threshold for the repetitive firing has been altered. It is also notable in TN that such firing occurs not only spontaneously but also by trivial tactile stimuli. This type of firing behaviour is also observed within in dorsal root ganglions [20].

Rappaport and Devor [21] explained that the development of atypical features of the TN may be due to central sensitization following a prolonged barrage of nerve impulses and also from progressive damage to trigeminal afferents, which become the source of continuous ectopic discharges [20].

Interestingly, literature shows that different treatments of TN yield similar results in pain control however, the long-

term results show that decompression provides prolonged pain relief compared to destructive peripheral procedures [20]. In addition, destructive procedures may cause some degree of sensory loss along with the same duration of pain relief [22].

26.5 Historical Perspective

Historically, reviews dating back to 2 AD demonstrates the existence of TN or a similar condition described by Aretaeus of Cappadocia, a contemporary of Galen. The same author is known for the description of migraine, and in the 11th century [23], an Arab physician Jujani describes a unilateral facial pain causing spasms and anxiety. He explains that the cause of the pain is ‘proximity of the artery to the nerve’ [24].

Wells Cathedral, an Anglican cathedral in Wells, Somerset, England, dedicated to St Andrew the Apostle, contains the tomb of Bishop Button, who died in 1274. He was canonized, and many pilgrims and toothache sufferers left offerings at the tomb, in commemoration of which the capitals of the pillars bear carvings of people depicted with facial neuralgia. One is famed as the toothache figure and because of the surprising rarity of dental caries at that time (confirmed when the sarcophagus was opened in 1848), Wilfred Harris pointed out the probable relevance to trigeminal neuralgia [25].

A first Royal account in relation to TN is by John Locke, the famous philosopher and physician who wrote a series of letters to Dr John Mapletoft in 1677 [26] describing TN suffered by Countess of Northumberland, wife of Ambassador to France.

Nicolas Andre invented the term *tic douloureux* in 1756 in a book, *Observations pratiques sur les maladies de l’urethre et surplusiers faits convulsifs* [27].

John Fothergill publishes the first account of TN to the Medical Society in London in 1773 and described TN as a ‘paroxysmal unilateral facial pain, evoked by eating, speaking or touching, starting and ending abruptly, and associated the condition with anxiety [23].

Between the eighteenth and nineteenth centuries, Pujol, Chapman and Tiffany completed the clinical picture and differentiated TN from other facial pain conditions. Later, Oppenheim highlighted the association between TN and MS [28].

Treatment of TN including microvascular decompression has been available since 1925 [29]; however, it took another 50 years to become an accepted neurosurgical intervention. During 1950 to 60, Gardner and Miklos [30] promoted neurovascular decompression theory and continued to modify the technique, but a major shift in this practice happened after a large clinical series published by Jannetta [31]. Throughout the last century, ablative neurosurgical procedures continued to evolve to balance

the best possible outcome between pain control and adverse effects. The latest in this process is radiosurgery. And even although surgical practice was continuing to evolve, medical therapy had little success in the same period. In 1942, Bergouignan's discovery of phenytoin was the first medical intervention in effective control of pain paroxysms [32]. In 1953, Walter Schindler discovered Carbamazepine and marketing was started in 1962. Although it was originally used for epilepsy, trials showed their effectiveness in TN pain control.

26.6 Clinical Presentation

Within the maxillofacial region, neuralgias can present in different severities and can affect patients from any race, gender and age. Certain conditions may be distinctive to certain groups of people, but there is no current classification followed for the diagnosis and management of neuralgic pain; however, groups do exist in order to distinguish the categories that they may be separated into.

These pain episodes experienced may last from seconds up to several minutes and can be described by the patient as an 'electric shock' feeling. This sensation may occur frequently per day (up to hundreds of times) over weeks and months and then suddenly stop with pain-free periods in between. It may also present infrequently with periods of remission, which may possibly last for years [13]. The pain often occurs unilaterally, does not usually cross the midline of the face and is often unbearable for the patient. It has been shown that only 3% of cases are known to be bilateral in nature [13].

26.6.1 Risk Factors

Sex

It has been highlighted that TN affects females more than males [13].

Age

In patients over 80 years old, males tend to have a higher incidence (45/100,000) [13, 33–36].

It can be prominent within all age ranges, but most frequently, TN affects individuals over the age of 50. Approximately 70% of the patients develop TN after they reach 60 years of age and it is known that the incidence of TN increases with age, and has been emphasised that this condition is rare to affect people younger than 40 years old [36, 37]. This is therefore highly important in suggesting that multiple sclerosis may be present in younger patients who suffer from TN [38].

26.6.1.1 Initiating Factors

The pain felt can be precipitated by trigger areas or factors of light touch on specific areas of the face, and patients often avoid these actions, which they may feel causes the attacks.

These activities may include:

- Shaving
- Applying make-up or face cream
- Brushing the teeth
- Speaking
- Smiling
- Yawning
- Face washing
- Swallowing
- Vibration
- Exposure to cold such as cold wind, breeze on the face or air conditioning
- Eating, chewing or biting into something
- Touching or washing certain areas of the face

26.6.2 Prevalence

A systematic review highlighted that the range of TN prevalence was 0.03–0.3%, mostly women were affected, and the affected age range was 37–67 years old. The affliction was marked by unilateral symptoms, most commonly in the maxillary and mandibular branches [39].

NICE guideline data and studies [13] indicate that a survey carried out within general practice in the United Kingdom, which highlighted that the annual incidence of trigeminal neuralgia was 8 per 10,000.

The true prevalence of this condition remains unclear as there is little data to support the evidence of how common this condition is [13]. It is evident that even with studies carried out, further research is required to validate the prevalence of trigeminal neuralgia due to the complexity of the condition including diagnosis difficulties and heterogeneity of the disease characteristics [39].

26.6.3 Clinical Diagnosis

26.6.3.1 Pain History

Accurate diagnosis relies greatly on a detailed history of symptoms from the patient, with pattern and nature of the pain highlighting the condition as there is no definitive diagnostic test yet available. SOCRATES is a useful assessment tool (Table 26.2), which is often used to help clinicians in achieving an accurate pain history.

Table 26.2 SOCRATES assessment tool

Site/localization	Can the pain be localized to a specific area?
Onset	Sudden or gradual? when—day/night/spontaneous?
Characteristic of pain	Sharp, stabbing and dull ache
Radiation	Does the pain radiate elsewhere?
Associated signs and symptoms	Any associated signs or symptoms?
Timing/duration	Seconds/minutes/hours? (constant, paroxysmal-recurrent and slowly/rapidly progressive)
Exacerbating or relieving factors	Does anything make it better/worse?
Severity	How intense is the pain? Scale 1–10

Trigeminal neuralgia may be misdiagnosed for dental pathology, and so it is important that unnecessary dental treatment is not carried out without full investigation of the source of the pain. When patients suffer from the condition, it often becomes apparent that their quality of life decreases as they may be unable to carry out their normal daily activities and suffer from weight loss due to problems in eating, and as a result the condition may lead to depression and/or isolation.

On clinical examination, trigeminal reflex testing may be used to test all three divisions of the nerve and may reveal loss of sensitivity in the cutaneous region, which may be related to the affected nerve. This may present as partial numbness (hypoesthesia) or complete numbness (anaesthesia) and occasionally may present as hyperaesthesia causing considerable discomfort.

The classical symptoms of trigeminal neuralgia are as follows:

- Severe shooting or stabbing pain, which may feel like an ‘electric shock’ on a focussed part or wider area of the face.
- Pain usually only affects one side of the face at one time.
- Bouts of pain may last from a few seconds to several minutes.
- Spontaneous attacks of pain may occur with or without triggers.
- As time progresses, the painful attacks may increase in frequency and intensity.

26.6.3.2 Other Causes

Trigeminal neuralgia can occur as a result of several causes such as trauma, tumours, infectious or demyelinating diseases, connective tissue diseases and can also be idiopathic in nature. This poses a challenge to the clinician when trying to investigate the cause of the pain. The importance of the causative factors may highlight the possibility that trigeminal neuralgia can present as the first manifestation of an underlying systemic disease. This emphasises that careful and in-depth investigations with detailed history taking are required in order to appropriately treat this life-affecting condition. A referral to a specialist in pain management or neurologist should be considered in severe cases [13, 38].

As trigeminal neuralgia is suspected when a patient has severe and intense pain in the orofacial region, other reasons may need to be explored for patients who have physical signs of motor or sensory problems. Neoplasms, infective conditions such as HIV, multiple sclerosis and even cerebrovascular disease may cause neuralgic pain, and so it is important to be aware of the differential diagnosis that could be derived from neuralgia within the head and neck.

TN is restricted to one or more branches of the trigeminal nerve distribution with an exception of TN in MS patients, where one side of the face may be affected. It is sudden in onset and typically lasts for a few seconds to a maximum of 2 min. Pain can be spontaneous but can also be triggered by innocuous mechanical stimuli or facial movements. In between the episodes, patients can remain pain-free and very rarely, patients suffer continuous pain in TN.

26.6.4 Glossopharyngeal Neuralgia

Glossopharyngeal neuralgia (GPN) is a rare uncommon painful neuralgic condition involving pharyngeal/orofacial region including the ear, base of the tongue, tonsillar fossa and submandibular region. It has similar etiopathogenesis to TN with neurovascular compression and demyelination of the 9th or the 10th cranial nerves. The prevalence rate is 0.2–0.7 per 100,000 and accounts for 0.2–1.3% of the orofacial neuralgias [40].

Clinical history taking is important to differentiate different types of neuralgias. GPN clinically presents as a unilateral, severe and paroxysmal pain involving the ear, base of the tongue, tonsillar fossa and submandibular region. Painful symptoms are described very similar to TN symptoms such as, sharp, stabbing or electric shock like pain. Similar to TN, GPN is triggered by innocuous stimuli/function like swallowing, chewing, talking, coughing and yawning.

According to the criteria put forward by the International Classification of headache disorders (ICHD) [41]:

- TN pain should be unilateral with at least three attacks
- Occurring in one or more divisions of the trigeminal nerve, with no radiation beyond the trigeminal distribution.
- Pain should have at least three of the following characteristics
 - recurring in paroxysmal attacks lasting from a fraction of a second to 2 min
 - severe intensity
 - electric shock-like, shooting, stabbing or sharp in quality
 - precipitated by innocuous stimuli to the affected side of the face
- There should be no clinically evident neurological deficit

The International Association for the Study of Pain (IASP) current classification

Classical TN	Caused by vascular compression of the trigeminal nerve root, resulting in morphological changes of the root
Secondary TN	Caused by major neurological disease, e.g. a tumour of the cerebellopontine angle (TN attributed to space-occupying lesions) or MS
Idiopathic TN	No apparent cause

The readers may access the detailed classification at the following open access publication [42]. <https://doi.org/10.1007/s40265-018-0964-9>.

26.7 Investigations

A thorough pain history and a clinical examination including cranial nerve examinations are important for the diagnosis of TN due to the fact that MS and tumours may be found in this cohort. Any deficiency in the cranial nerve examination, especially a sensory loss, should prompt further imaging.

In order to rule out possible diseases, specific tests may be carried out in adjunct by radiographic examinations such as plain radiographs including intra-oral (periapicals) and orthopantograms. These may be carried out in the first instance to rule out dental pathology, and orthopantograms may also be able to detect temporomandibular joint pathol-

ogy. Cranial computed tomography scan (CT) may also be used in order to identify any changes of the maxillary sinus.

Magnetic resonance imaging (MRI) is an important investigation to investigate and to differentiate between patients suffering from trigeminal neuralgia due to tumours and MS [18]. It may demonstrate the close and potentially causative relationship between the trigeminal root and adjacent blood vessel and can be of specific value to exclude posterior cranial fossa lesions [38]. TN caused by MS should be ruled out, specifically in the younger patient, and this may be aided by MRI. Clinical Knowledge Summaries (CKS). NICE [13] guidelines recommend MRI assessment specifically for younger people, patients presenting atypical symptoms, non-responders to initial therapy or anyone for whom neurosurgery is being considered. Even though MRI is commonly used, from previous studies carried out, the suggestion of its sensitivity and specificity seems to be variable [43–50]. As a result, emphasis is placed on the challenge in identifying the cause of trigeminal neuralgia as a relationship between the clinical symptoms and radiological findings as this may not be clear.

In idiopathic forms of trigeminal neuralgia, it is typical for no cause to be detected with the patient having both normal neurological and MRI examinations, which can cause difficulty with treatment planning. MRI finding of an aberrant loop of a blood vessel at RTZ is the most common cause, and this is reported in about 60–90% of the cases described in neurosurgical/neuroradiological series [51–54].

Meaney et al. have designed a set of specific parameters to visualise the blood vessels using thin slices to create the reconstruction of nerve and vessel in any orientation. This is called magnetic resonance tomographic angiography (MRTA) [55]. This reconstruction between the vessels and the nerves allowed us to identify the neurovascular compression. In comparison to MRTA, MR angiography only provides image of the blood vessels. Meaney et al. then validated their findings by comparing the MRTA findings with surgical findings. In a series of 52 consecutive cases, MRTA findings were comparable to surgical finding in 50 out of 52 cases. In four cases, MRTA misclassified veins as arteries; otherwise, MRTA is a sensitive and specific method in demonstrating neurovascular compression [44].

26.8 Management

26.8.1 Medical Management

It has been highlighted that first line of treatment for trigeminal neuralgia is still pharmacological treatment. The desired

outcome of these patients is to treat the pain experienced, manage the symptoms and with time preferably, eradicate these symptoms in order to improve the patient's quality of life. Where appropriate, referral to a specialist pain service and/or neurologist may be necessary with clear information and given to the patient.

There are several drugs that have been delivered systemically or topically in the use of treating trigeminal neuralgia, which include:

Baclofen
Dextromethorphan
Lamotrigine
Gabapentin
Pregabalin
Sumatriptan
Levetiracetam
Eslicarbazepine
Pimozide
Proparacaine
Tizanidine
Tocainide
Topiramate

The most common therapy of choice is Carbamazepine for pain control [56] and after carrying out a systematic review of the literature, The American Academy of Neurology and the European Federation of Neurological Societies support Carbamazepine (200–1200 mg/day) [57] as the first-line treatment to be offered due to strong evidence supporting this pharmacological treatment. In addition to this, another drug of preferred choice is Oxcarbazepine (600–1800 mg/day) [57], which is known to have better tolerability and is also supported by existing guidelines [13, 58].

All the above drugs have been evaluated using RCTs, whereas other drugs such as capsaicin cream, phenytoin, clonazepam, gabapentin, oxcarbazepine, mexiletine and tramadol have been assessed from case reports and case series. Studies involving many of these drugs regarding the full benefit and effect on the treatment of trigeminal neuralgia are limited, and so further evaluation is required [59, 60]. The response to the drugs mentioned is unique to each patient, and it is evident that the doses also vary between patients in order to achieve a beneficial effect to counteract the symptoms experienced. It has been highlighted that it may be helpful for the patient to keep a pain diary in order to record episodes and help the patient and clinician identify possible trigger factors and timing of the pain. This may aid treatment planning and may give patients back a sense of control, which has been lost due to their condition.

26.8.1.1 Carbamazepine and Oxcarbazepine

Based on existing evidence, carbamazepine also known with the trade name 'Tegretol' is an anti-convulsant drug used primarily in the treatment of epilepsy [61] and remains the drug of choice for standard first-line treatment of trigeminal neuralgia in patients over 18 years of age [13, 57, 58]. It is considered to be of diagnostic help if complete resolution or reduction of symptoms occurs after its use [38]; however, carbamazepine must be used prophylactically and continuously for long periods, with tiered dosages prescribed to suit individual patients in regard to their response. Carbamazepine should be used with caution, and as it is not an analgesic, it is not appropriate to use this medication during a pain episode for relief as it will not have an analgesic effect on symptoms. Patients can often misinterpret what the purpose of the medication is, and so this in turn highlights the importance of patient communication. The mechanism of the medication, the instructions in terms of dosage titration, timing of effects and the possible adverse side effects associated with its use should be highlighted. From current guidelines such as—NICE [13], it has been advised that if no sinister or red flag symptoms are evident and carbamazepine is not contraindicated for the patient, then, the following dosage guideline can be offered:

- 100 mg up to twice daily, titrated in increments of 100–200 mg every 2 weeks until pain has been relieved
- 200 mg three or four times daily (600–800 mg daily) is seen in the majority of people to be the dosage of choice sufficient to manage pain
- 1600 mg maximum dose daily
- Once pain is in remission, the dosage should be gradually reduced to the lowest possible maintenance level or even discontinued until a further episode occurs.

Frequent side effects have been reported with the use of carbamazepine drug therapy with specific emphasis on elderly patients [61–63]. When patients are treated with carbamazepine, it is strongly advised that a full blood count and liver function tests are carried out prior to starting treatment and then reviewed periodically in order to monitor the possible effects of the drug. Hyponatraemia, which refers to low sodium levels, is thought to occur in 20% of patients, and NICE guidelines [13] suggests that carbamazepine in concurrent use with sertraline can also increase this risk. Serum levels of the drug are not routinely monitored unless carbamazepine toxicity is suspected but within the British National Formulary (BNF), all information is available in regard to drug interactions, adverse effects and contraindications and cautions. Within primary care settings, this is the standard first choice of treatment if the physician is confident with the diagnosis; otherwise, it is advised to refer the patient to a secondary care specialist for further investigations and treatment.

In several studies, the effectiveness of carbamazepine was demonstrated with specific outcomes found in the reduction of both intensity and frequency of the painful paroxysms [36, 57, 64–68]. In addition to this, the pharmacological drug of choice was found to be equally effective on the reduction of both trigger touch and spontaneous attacks [59, 66]. Due to the possible side effects from carbamazepine, oxcarbazepine may often be used as initial treatment due to the decreased potential drug interactions and possible greater tolerability acceptance [57, 63, 68].

26.8.1.2 Gabapentin

It is known for its effective role in the management of neuropathic pain especially post-herpetic neuralgia, but there is a lack of evidence on its role in the management of TN. There is one randomized-controlled trial showing improvement in pain control with fewer side effects. This study compared the use of combination of both gabapentin and ropivacaine injected to trigger points and gabapentin alone [18].

26.8.1.3 Baclofen

Baclofen is used to control the symptoms in MS, and therefore, it is generally accepted to use in TN patients with MS [59]. It may well control the symptoms without adding carbamazepine. Its side effects including sedation and loss of muscle tone and abrupt discontinuation may cause seizures and hallucinations.

26.8.1.4 Lamotrigine

Lamotrigine is used when Carbamazepine is not tolerated well, or it is used in addition to carbamazepine when it is not effective on its own. There is not enough evidence to support the use of lamotrigine from studies carried out with relation to patients with TN [18].

26.8.1.5 Evolving Medical Therapy

Due to the known difficulty in treating trigeminal neuralgia, new therapeutic modalities are being investigated and have been tried [57]. It has been evident from recent reviews [18] that the combination of the pharmacological drug gabapentin with the addition of regular ropivacaine injections into specific sites, which may be ‘trigger sites,’ has had a positive outcome on pain control with an improvement in quality of life.

Botulinum Toxin A (BTX-A) has also been suggested as an effective treatment of trigeminal neuralgia from a systematic review [69] carried out on patients suffering from this condition. No major adverse events were reported, and it was concluded that with an approximate 60–80% reduction in mean pain intensity and frequency, this medical treatment may be a future recommendation. Cruccu and Truini [42] were in agreement with these findings who have also reviewed the literature on possible medical treatments for

Trigeminal Neuralgia. It was highlighted that there is possible increasing evidence for BTX-A injections as a treatment option, specifically prior to considering surgical options or for patients who do not want surgery. In relation to this, it is emphasised that further evidence is needed with regard to this treatment option with more investigation and well-designed studies to take place.

Finally, it has been highlighted that local anaesthesia injected into the specific trigger area, 8% lidocaine spray and the use of intravenous infusion of fosphenytoin may be an option to provide temporary relief for patients suffering from severe pain [18].

26.8.2 Surgical Management

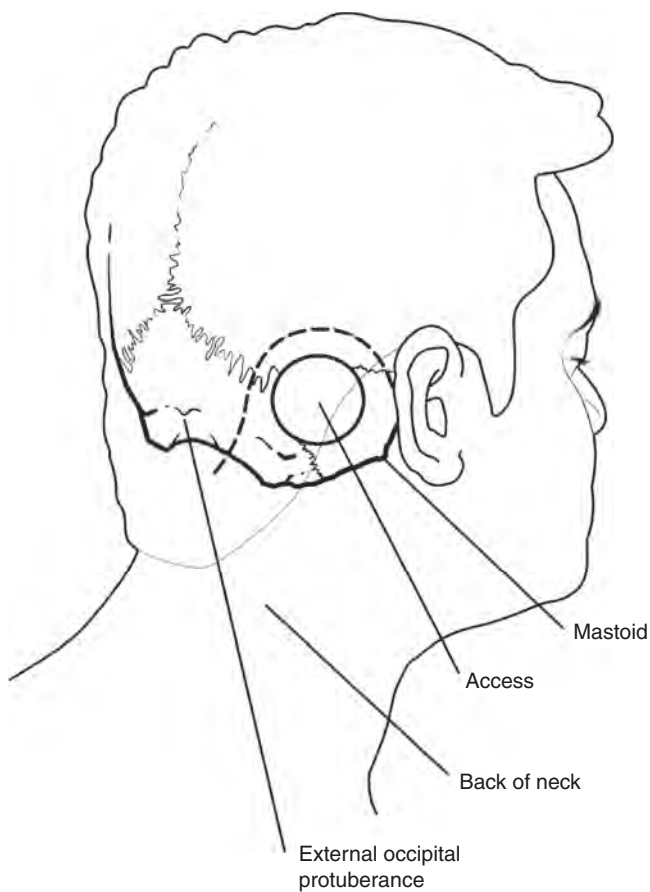
A successful surgical intervention of TN is determined by elimination of pain. Currently available surgical options are

1. Invasive technique:
 - (a) Open:
 - (i) Microvascular decompression
 - (b) Percutaneous:
 - (i) Radiofrequency rhizotomy
 - (ii) Retrogasserian glycerol rhizotomy
 - (iii) Balloon compression of trigeminal nerve
 - (iv) Stereotactic radiosurgery—Gamma knife
2. Non-invasive technique:
 - (i) Peripheral neurectomy
 - (ii) Alcohol injections
 - (iii) Cryotherapy
 - (iv) Selective radiofrequency thermocoagulation

26.8.2.1 Microvascular Decompression (MVD)

The original theory was outlined by Dandy in 1925, and vascular decompression of the trigeminal nerve was first described by Gardner and Miklos in 1959 [70] and was further refined by Jannetta et al. in 1967 [71]. Advances in anaesthesiology, use of operating microscopes and evolving surgical techniques allowed the MVD as a safer and effective procedure. MVD further evolved in the next 50 years to become accepted as one of the best surgical options.

Surgical target is the trigeminal nerve-pons junction. To reach this target, the posterior cranial fossa needs to be accessed via suboccipital craniotomy. On entering via craniotomy site, cerebrospinal fluid will be aspirated. Further advancing is done towards the nerve by gently retracting part of the cerebellum (Fig. 26.3). It is common to find a segment of superior cerebellar artery compressing on the REZ. Less



©Association of Oral and Maxillofacial Surgeons of India

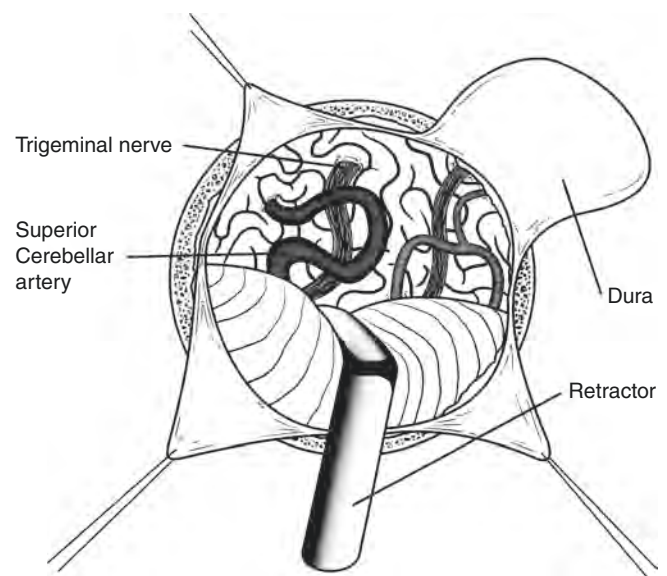
Fig. 26.3 Diagram showing suboccipital access

commonly, a variation with an anterior inferior cerebellar artery or the superior petrosal vein can be found as a cause of the neurovascular compression [72]. Once the vessel is freed of the REZ, a piece of Teflon is placed to keep the nerve and the vessel apart (Fig. 26.4).

Utmost care should be taken to avoid any post-operative hearing loss. This is usually done by monitoring the brain-stem evoked potential as hearing loss is due to the pressure on the eighth cranial nerve due to retraction. A timely release of retraction improves this and literature recommends the removal of a section of the root when there is no vascular compression or there may be difficulties in mobilizing the artery. Deliberate Bruising of the nerve in addition to decompression is also recommended [73].

Literature shows that MVD can be done in any age group. Both Resnick et al. and Roski et al. concluded that MVD can be done with good outcomes in the paediatric population [74, 75]. It is also unique that in the paediatric population, venous compression is more common than arterial.

The long-term outcome of MVD for TN suggests 87–98% have immediate pain relief but this is reduced slightly to



©Association of Oral and Maxillofacial Surgeons of India

Fig. 26.4 Craniotomy access showing a retracted and a cerebellar artery resting on the nerve. A piece of Teflon to be placed between the vessel and the nerve

75–80% in a 1–2 year review [76–82]. This proportion of patients with pain relief further reduced to 58–64% this is also associated with 4–12% of recurrence.

Several studies showed that the outcome of MVD is better with an arterial compression compared to venous [77, 79, 83]. Lee et al. showed a recurrence rate of 31% when there is TN due to venous compression and mostly recurred within the first 12 months [83]. Literature shows that there are poor outcomes on patients who have had previous neuroablative surgery, but this is not substantiated by other studies [76, 84, 85]. Review of literature in the management of recurrence following MVD in TN did not provide a general consensus but suggested re-exploration and neuroablative procedures [86–88]. A good quality imaging system may enable the surgeon to pinpoint the reason for the recurrence and choose an appropriate remedial surgical intervention.

In terms of the outcomes, complication rates seem to be minimal with an experienced neurosurgical team with innovations. Although a rate of 0.2–1% mortality is shown in the earlier literature, two large studies with a patient population of 444 [79] and 1995 [52] showed 0% mortality. A recent retrospective study listed other complications such as cerebellar injury (0.45%) 8th cranial nerve injury (0.8%) and CSF leak (1.85%) [52].

Although this study showed low complication rates, other centres reported higher complication rates [80, 81]. This wide range in the outcomes is likely due to the experience of the surgical team and their advanced perioperative monitoring systems.

Despite the increasing popularity of MVD, its advantage over the neuroablative procedures continues to be debated at various levels [22, 89]. In the absence of well-structured clinical studies, varying interventions will be preferred based on the individual centre experience.

26.8.2.2 Gamma Knife Radiosurgery (GKRS)

In the 1950s, the term and the concept of radiosurgery and Gamma Knife were introduced by Lars Leksell. GKRS is used to treat various benign and malignant brain tumours and also various non-neoplastic conditions such as vascular malformations without an open intracranial surgical access. For the next few decades, GKRS is evolved with technology as the precision targeting has improved [90]. The 'Gamma Knife' technique was based on the fact that radiation may block the conduction of excessive sensory information responsible for triggering the pain episodes [91]. This would affect the radiosurgery targets with no significant change outside the target nerve, with the myelin sheath being primarily affected by radiosurgery [92]. It is indicated in typical or atypical TN, with or without vascular compression, failed MVD, TN patients in MS and patients with significant medical comorbidities.

This procedure [90–92] is done under local anaesthetic with or without sedation. Once the patient is supine under the collimator head, local anaesthetic is used to secure the stereotactic frame to the patient's head. MRI is then performed to locate the trigeminal nerve. Gamma knife is made up of 201 intercepting beams of gamma radiation with a dose of 70–100 Gy, and it is targeted at REZ of trigeminal nerve. Radiosurgery can be done with or without frame-based method, with MRI or computerized tomography (CT) planning when there is contraindication to MRI.

GKRS can also be given using one or two isocenters/target areas and targeting radiosurgery posteriorly at dorsal REZ or anteriorly in retrogasserian zone. Lower dosages to the root can be associated with fewer side effects, whereas higher dosages provide better pain control with less risk of recurrence but more side effects such as facial numbness. The benefits and risks of a higher dose must be carefully discussed with patients since bothersome facial numbness may be an acceptable option for patients with severe pain.

Two studies showed that approximately it takes a month for pain relief [91]. One of them is a multicentre study of 50 patients with a median follow-up of 18 months, which showed the results of 58% pain free and 36% had significant pain relief with a 6% failure rate.

However, when recurrence is evident after GKRS, repeat GKRS provides a similar rate of pain relief as the first procedure. The best responses are observed when there is good pain control after first procedure, with new sensory dysfunction and in single division nerve distribution typical TN.

26.8.2.3 Percutaneous Balloon Compression (PBC)

PBC was described by Mullen in 1980 [93]. It relieves TN pain by injuring the large myelinated fibres involved in the sensory trigger. It is especially useful in managing TN with first division involvement as it selectively spares small myelinated fibres, which mediate the corneal/blink reflex. It gained its role in management of TN due to its low cost and simplicity.

The procedure is performed under a short general anaesthetic, with a fluoroscopic control. A 14-gauge cannula is inserted into foramen ovale but does not pass beyond. A negative cerebrospinal fluid confirms it further. A catheter advanced through the needle, and balloon inflated slowly up to a pressure of 1.3–1.6 atm. Balloon can also be inflated with 0.5–1.0 ml of contrast dye until it occupies Meckel's cave, and radiographic confirmation of its position is achieved. Up to 6 min of duration of compression is achieved. Typically, patients awaken with a mild subjective sensory loss with immediate pain relief up to 80–90% [94, 95]. This subjective numbness resolves in few weeks.

PBC is most helpful when pain involves multiple divisions including the first division, patients with MS, significant comorbidities and failed MVD.

26.8.2.4 Radiofrequency Thermocoagulation (RFTC)

Failures and complications in failing to control the spread of alcohol in ganglionolysis led to thermocoagulation of the Gasserian ganglion. This procedure thermocoagulates the ganglion at temperatures above 65 °C, which selectively ablates the A δ and C pain fibres [96, 97].

The procedure is carried out under a short-intermittent general anaesthesia either under fluoroscopic control or radiologically guided. Patients are awake for the part of the procedure to ensure correct positioning of the needle. The radiofrequency needle with a stylet is introduced through the foramen ovale into Meckel's cave using bony landmarks. Transient bradycardia may occur at this juncture. Once the needle position at the trigeminal rootlet is confirmed by fluoroscopy and radiographs, the stylet can be removed to introduce the electrocoagulation needle. The patient is awakened, and the stimulation of the nerve root can be tested. A mapping of the paraesthesia is carried out to the trigger zones of the neuralgia. Then, the patient is anaesthetized again for thermocoagulation, which is achieved with 0.2–1 V. The same procedure is repeated for 45–90s cycles at temperatures of 60–90 °C. After each episode of thermocoagulation, the patient is awakened and the sensory mapping is repeated again [19].

26.8.2.5 Glycerol Rhizotomy

This procedure was a chance finding by Håkansson and colleagues whilst working on stereotactic gamma radiation for TN. They used glycerol mixed with tantalum dust as a radio-opaque marker to visualize the trigeminal cistern and discovered that it also abolished pain. They published the first series of 75 patients with a mean follow-up of 18 months [98].

This procedure is done under local anaesthesia with sedation. Similar to other percutaneous in the treatment of TN, the aim is to safely place the needle at the gasserian ganglion [99]. The advantage of being done awake allows the patient to sit up, and a small dose of sterile glycerol is injected in small increments. Up to a total of 0.1–0.4 ml can be used based on the number of divisions involved. Patients remain seated for up to 2 h to allow glycerol to reach the intended root.

This method is well tolerated with negligible mortality. Commonly reported complications are meningitis, cranial nerve palsies, local haematomas, reactivation of herpes labialis and permanent masseter weakness [100].

26.9 Peripheral Nerve Procedures

26.9.1 Infraorbital Neurectomy

Peripheral neurectomies are a safe and cost-effective option for patients with medical co-morbidities, elderly and for population where there is lack of highly skilled neurosurgical centres. Pain relief can be lasting from 15 to 24 months. Loss of sensation and recurrences are associated with peripheral neurectomy. These are carried out by oral and maxillofacial surgeons, and it is under reported to evaluate its benefits over central neurosurgical interventions.

Access to infraorbital nerve is gained through a maxillary vestibular approach. The infraorbital foramen is identified as it is exiting foramen and the nerve is released from the foramen by raising the periosteum around it. Care should be taken as to ensure that there is no ‘pull’ to trunk of the nerve from the infraorbital canal. Reeling of the nerve is also a common practice, but sectioning of the nerve is done to eliminate the touch sensation, and there is no need to remove the infraorbital canal portion of the nerve.

The nerve is then sectioned using diathermy to have a bloodless field and nerve branches on the soft tissue side may be closed over by releasing the surrounding periosteum to avoid regeneration. Similarly, infraorbital canal can be obturated with bone wax or chips of the bone carved around the canal.

Khanna and Galinde [101] published their successful experience of 118 patients with 75% pain relief at a 1–5 year follow-up.

Oturi et al. published their 7 years follow-up series comparing alcohol block, neurectomy and thermocoagulation. They have found that up to 78% had recurrence with the neurectomy cohort, and sadly, one of half of it recurred within a month. They reported the complications rate under 10% (dysesthesia and eye problems) on thermocoagulation and alcohol ganglionolysis patients [102].

26.9.2 Inferior Alveolar Nerve or Mental Nerve Neurectomy

Ali FM et al. [103] suggest peripheral neurectomy in a rural set-up where there is a lack of highly trained and equipped neurosurgical facilities. It is an effective option for elderly patients and who are reluctant for opting for neurosurgical intervention.

26.9.2.1 Inferior Alveolar Neurectomy via Ginwala’s Access [103] (Video 26.1)

This procedure is done under local anaesthesia, with access gained to the medial aspect of the ramus using an inverted Y-shaped incision. Once the incision is made, the mucoperiosteal flap is raised along the anterior aspect of the ramus. The tendon of the temporalis and the medial pterygoid muscle is raised off the bone for access to the lingula and once the inferior alveolar nerve is dissected free off the surrounding tissues, the neurovascular bundle is clamped and cut below the clamp by electrocoagulation to achieve haemostasis. Following this, a separate buccal sulcus incision is made to identify the mental foramen and the end of inferior vascular bundle is identified and dissected off the surrounding tissues. The bundle is then clamped and sectioned to avulse the neurovascular bundle from the canal.

Based on the available literature, there is a role for peripheral neurectomy in selective cases where other treatments have failed, and in patients with comorbidities and where there is reluctance of either clinician or the patient to opt for neurosurgical procedures. However, it is difficult to conclude its role as a primary interventional procedure.

26.9.3 Cryotherapy

Peripheral procedures in the management of TN result in permanent sensory loss with the aim of achieving pain free results, and therefore, alternative forms were sought. Cryofreezing is performed on the surgically exposed nerve endings with temperatures of –50 to –70 °C [104]. Literature shows that this procedure is well tolerated by the patients; however, the results are sub-optimal. In a study published in 1988, 145 patients underwent 348 sessions of which 56%

had more than one session. The pain-free effect lasted less than 6 months in one half of patients, and at 12 months, only 27% were pain-free [105]. It is also important to note that 61% of the patients remained on their previous medications. The treatment is well tolerated by the patients and were willing to undergo repeated cryofreezing and the distinct advantage is that the nerve damage is reversible. It is likely that adjacent nerve branch reconnecting is the reason for the recurrence of the pain. Although the sensation is preserved and nerve injury is reversible, its outcomes fall short of other peripheral procedures. It is reported that 4% of the patients developed post-operative infections warranting antibiotic therapy and about 40% had suffered, some from pain ranging from burning sensation, pins and needles to symptoms such as a dull ache [105].

In summary, despite patient outcomes with this procedure and preserved sensation, there is little evidence to support this procedure in the role of management of TN where other surgical procedures are available.

26.9.4 Alcohol Block

Percutaneous ganglionic blocks and peripheral blocks have been used since the 1930s. Direct deposition of alcohol into the affected nerve peripheral branch causes chemical ablation of the nerve. Essentially, alcohol causes destruction of nerve fibres. It can seep into the adjacent tissues and cause necrosis, resulting in pain and local oedema. With a high-risk recurrence of pain and with a moderate risk of developing dysesthesia, its use is restricted only in the elderly or patients with comorbidities or those who are reluctant to undergo extensive neurosurgical procedures.

An injection of 0.5–1.0 ml of absolute alcohol is injected directly into the affected nerve bundle under local anaesthesia and injections have to be placed accurately to avoid dissipation, which may result in local damage. Utmost care must be taken to avoid intravascular injections and not to inject into the subcutaneous tissues [106].

The duration of pain relief varies from 6 to 24 months, and there is variation with different peripheral branches. Only a short pain relief with third division is observed compared to the second with a longer duration of pain relief with in the first division [106].

26.9.5 Other Peripheral Procedures

Other peripheral neurolysis procedures seen in the literature are radiofrequency coagulation and chemical neurolysis with glycerol, phenol, mixture of lignocaine with streptomycin and high concentration of tetracaine. Evidence in the litera-

ture fails to support their true efficacy and long-term benefits.

26.10 Conclusion

TN is the most severe type of pain humans ever face for an innocuous touch without any force, and it is debilitating to an extent that it was described historically as “suicide disease” until the development of the medications and various surgical procedures in the 1950s.

As an OMF surgeon, obtaining a good clinical history is to rule out other potential pathologies including dental focus. Patients may be initially present to a primary care dentist or a physician with facial pain, and they should be aware of the medical management and the secondary care team (oral medicine specialists, OMFS and neurologists) involved to deliver the appropriate course of action. Usually, only those who are refractory to the drug therapy or unacceptable drug-related side effects will be escalated further to tertiary care for the consideration of complex central surgical procedure.

Peripheral surgical procedures are suitable for those who are unable or unwilling to undergo complex and expensive neurosurgical procedures. Peripheral procedures are safe with minimal morbidity and almost no mortality; however, there is a lack of evidence to show the recurrence rate and associated long-term complications.

The management of TN patients should be carried out in a multidisciplinary setting to allow the patients to choose the best-suited option for them. It is also important to set up self-help groups to enable them to share knowledge and information for themselves and their family members for the best possible outcomes.

References

1. Joo W, Yoshioka F, Funaki T, Mizokami K, Rhoton AL Jr. Microsurgical anatomy of the trigeminal nerve. *Clin Anat*. 2014;27:61–88.
2. Haller S, Etienne L, Kovari E, Varoquax AD, Urbach H, Becker M. Imaging of neurovascular compression syndromes: trigeminal neuralgia, hemifacial spasm, vestibular paroxysmia, and glossopharyngeal neuralgia. *AJNR Am J Neuroradiol*. 2016;37:1384–92.
3. Sindou M, Howeidy T, Acevedo G. Anatomical observations during microvascular decompression for idiopathic trigeminal neuralgia (with correlations between topography of pain and site of the neurovascular conflict): prospective study in a series of 579 patients. *Acta Neurochir*. 2002;144:1–12.
4. Harris W. Rare forms of paroxysmal trigeminal neuralgia, and their relation to disseminated sclerosis. *Br Med J*. 1950;2:1015–9.
5. Foley PL, Vesterinen HM, Laird BJ, Sena ES, Colvin LA, Chandran S, et al. Prevalence and natural history of pain in adults with multiple sclerosis: systematic review and meta-analysis. *Pain*. 2013;154:632–42.

6. Toda K. Aetiology of trigeminal neuralgia. *Oral Sci Int.* 2007;4:10–8.
7. Mohammad-Mohammadi A, Recinos PF, Lee JH, Elson P, Barnett GH. Surgical outcomes of trigeminal neuralgia in patients with multiple sclerosis. *Neurosurgery.* 2013;73:941–50.
8. Zakrzewska J, Jianhua WU, Tricia S, Brathwaite L-A. Systematic review of the management of trigeminal neuralgia in patients with multiple sclerosis. *World Neurosurg.* 2018;111:291–306.
9. Cruccu G, Biasiotta A, Di RS, Fiorelli M, Galeotti F, Innocenti P, et al. Trigeminal neuralgia and pain related to multiple sclerosis. *Pain.* 2009;143:186–91.
10. Reder AT, Arnason BG. Trigeminal neuralgia in multiple sclerosis relieved by a prostaglandin E analogue. *Neurology.* 1995;45:1097–100.
11. Tesfaye S, Selvarajah D. Advances in the epidemiology, pathogenesis and management of diabetic peripheral neuropathy. *Diabetes Metab Res Rev.* 2012;38:8–14.
12. Xu Z, Zhang P, Long L, He H, Zhang J, Sun S. Diabetes mellitus in classical trigeminal neuralgia: a predisposing factor for its development. *Clin Neurol Neurosurg.* 2016;151:70–2.
13. NICE. NICE Guidance (online). 2017. Available at <http://guidance.nice.org.uk/CG173>
14. Dworkin RH, Nagasako EM, Johnson RW, Griffin DR. Acute pain in herpes zoster: the famciclovir database project. *Pain.* 2001;94:113–9.
15. Beutner KR, Friedman DJ, Forszpaniak C, Andersen PL, Wood MJ. Valaciclovir compared with aciclovir for improved therapy for herpes zoster in immunocompetent adults. *Antimicrob Agents Chemother.* 1995;39:1546–53.
16. Davis LE, King MK. Shingles (herpes zoster) and post-herpetic neuralgia. *Curr Treat Options Neurol.* 2001;3:401–11.
17. Schmader K. Herpes zoster in older adults. *Clin Infect Dis.* 2001;32:1481–6.
18. Zakrzewska JM, Linskey ME. Trigeminal neuralgia. *BMJ Clin Evid.* 2014;10:1207.
19. Nurmikko TJ, Eldridge PR. Trigeminal neuralgia—pathophysiology, diagnosis and current treatment. *Br J Anaesth.* 2001;87:117–32.
20. Amir R, Michaelis M, Devor M. Membrane potential oscillations in dorsal root ganglion neurons: role in normal electrogenesis and neuropathic pain. *J Neurosci.* 1999;19:89–96.
21. Rappaport ZH, Devor M. Trigeminal neuralgia: the role of self-sustaining discharge in the trigeminal ganglion. *Pain.* 1994;56:127–38.
22. Taha JM, Tew JM, Buncher CR. A prospective 15-year follow up of 154 consecutive patients with trigeminal neuralgia treated by percutaneous stereotactic radiofrequency thermal rhizotomy. *J Neurosurg.* 1995;83:989–93.
23. Rose FC. Trigeminal neuralgia. *Arch Neurol.* 1999;56:1163–4.
24. Amir R, Devor M. Functional cross-excitation between afferent A- and C-neurons in dorsal root ganglia. *Neuroscience.* 2000;95:189–95.
25. Harris W. The facial neuralgias. London: Oxford University Press; 1937. p. 13–4.
26. Pearce JMS. HISTORICAL NOTE—Trigeminal neuralgia (Fothergill's disease) in the 17th and 18th centuries. *J Neurol Neurosurg Psychiatry.* 2003;74:1688.
27. André N. *Traité sur les maladies de l'urèthre.* Paris: Delaguette; 1756.
28. Fromm GH, Sessle BJ. Introduction and historical review. In: Fromm GH, Sessle B, editors. *Trigeminal neuralgia: Current concepts regarding pathogenesis and treatment.* Boston: Butterworth-Heinemann; 1991. p. 1–26.
29. Dandy WE. Section of sensory root of the trigeminal nerve at the pons. *Bull Johns Hopkins Hosp.* 1925;36:105.
30. Gardner WJ, Miklos MV. Response of trigeminal neuralgia to 'decompression' of sensory root: discussion of cause of trigeminal neuralgia. *JAMA.* 1959;170:1773–6.
31. Jannetta PJ. Treatment of trigeminal neuralgia by suboccipital and transtentorial cranial operation. *Clin Neurosurg.* 1977;24:538–49.
32. Bergouignan M. Cures heureuses de névralgies faciales essentielles par le diphenyl-hydantoïnat de soude. *Rev Laryngol Otol Rhinol (Bord).* 1942;63:34–41.
33. MacDonald BK, Cockerell OC, Sander JW, Shorvon SD. The incidence and lifetime prevalence of neurological disorders in a prospective community-based study in the UK. *Brain.* 2000;123(Pt 4):665–76.
34. Katusic S, Beard CM, Bergstralh E, Kurland LT. Incidence and clinical features of trigeminal neuralgia, Rochester, Minnesota, 1945–1984. *Ann Neurol.* 1990;27:89–95.
35. Katusic S, Williams DB, Beard CM, Bergstralh EJ, Kurland LT. Epidemiology and clinical features of idiopathic trigeminal neuralgia and glossopharyngeal neuralgia: similarities and differences, Rochester, Minnesota, 1945–1984. *Neuroepidemiology.* 1991;10:276–81.
36. Zakrzewska JM. Trigeminal neuralgia. *Clin Evid.* 2003;9:1490–8.
37. White JC, Sweet WH. *Pain and the neurosurgeon: a 40-year experience.* Springfield, IL: Charles C Thomas; 1969. p. 123–5.
38. Coulthard P, Horner K, Sloan P, Theaker E. Facial pain, oral and maxillofacial surgery, radiology, pathology and oral medicine, Second Edition Master Dentistry Volume One, Edinburgh: Churchill Livingstone Elsevier, Chapter 14. pp. 228–9; 2008.
39. De Toledo I, Conti Réus J, Fernandes M, Porporatti A, Peres M, Takaschima A, Linhares M, Guerra E, De Luca Canto G. Prevalence of trigeminal neuralgia—A systematic review. *J Am Dent Assoc.* 2016;147(7):570–6.
40. Lu VM, Goyal A, Graffeo CS, Perry A, Jonker BP, Link MJ. Glossopharyngeal neuralgia treatment outcomes after nerve section, microvascular decompression, or stereotactic radiosurgery: a systematic review and meta-analysis. *World Neurosurg.* 2018;120:572–82.
41. Headache Classification Committee of the International Headache Society (IHS). *The International Classification of Headache Disorders*, 3rd edition. Cephalalgia. 2018;38:1–211.
42. Di Stefano G, Truini A, G. Cruccu current and innovative pharmacological options to treat typical and atypical trigeminal neuralgia. *Drugs.* 2018;78:1433–42.
43. Meaney JF, Miles JB, Nixon TE, Whitehouse GH, Ballantyne ES, Eldridge PR. Vascular contact with the fifth cranial nerve at the pons in patients with trigeminal neuralgia: detection with 3D FISP imaging. *Am J Roentgenol.* 1994;163:1447–52.
44. Meaney JF, Eldridge PR, Dunn LT, Nixon TE, Whitehouse GH, Miles JB. Demonstration of neurovascular compression in trigeminal neuralgia with magnetic resonance imaging: comparison with surgical findings in 52 consecutive operative cases. *J Neurosurg.* 1995;83:799–805.
45. Masur H, Papke K, Bongartz G, Vollbrecht K. The significance of three-dimensional MR-defined neurovascular compression for the pathogenesis of trigeminal neuralgia. *J Neurol.* 1995;242:93–8.
46. Korogi Y, Nagahiro S, Du C, et al. Evaluation of vascular compression in trigeminal neuralgia by 3D time-of-flight MRA. *J Comput Assist Tomogr.* 1995;19:879–84.
47. Majoie CB, Hulsmans FJ, Castelijns JA, et al. Symptoms and signs related to the trigeminal nerve: diagnostic yield of MR imaging. *Radiology.* 1998;209:557–62.
48. Boecher-Schwarz HG, Bruehl K, Kessel G, Guenther M, Perneczky A, Stoeter P. Sensitivity and specificity of MRA in the diagnosis of neurovascular compression in patients with trigeminal neuralgia: a correlation of MRA and surgical findings. *Neuroradiology.* 1998;40:88–95.

49. Jawahar A, Kondziolka D, Kanal E, Bissonette DJ, Lunsford LD. Imaging the trigeminal nerve and pons before and after surgical intervention for trigeminal neuralgia. *Neurosurgery*. 2001;48:101–6.
50. Patel NK, Aquilina K, Clarke Y, Renowden SA, Coakham HB. How accurate is magnetic resonance angiography in predicting neurovascular compression in patients with trigeminal neuralgia? A prospective, single-blinded comparative study. *Br J Neurosurg*. 2003;17:60–4.
51. Jannetta PJ. Neurovascular compression in cranial nerve and systemic disease. *Ann Surg*. 1980;192:518–25.
52. McLaughlin MR, Jannetta PJ, Clyde BL, Subach BR, Comey CH, Resnick DK. Microvascular decompression of cranial nerves: lessons learned after 4400 operations. *J Neurosurg*. 1999;90:1–8.
53. Love S, Coakham HB. Trigeminal neuralgia: pathology and pathogenesis. *Brain*. 2001;124:2347–60.
54. Zakrzewska JM. Diagnosis and differential diagnosis of trigeminal neuralgia. *Clin J Pain*. 2002;18:14–21.
55. Meaney JF, Watt JW, Eldridge PR, Whitehouse GH, Wells JC, Miles JB. Association between trigeminal neuralgia and multiple sclerosis: role of magnetic resonance imaging. *J Neurol Neurosurg Psychiatry*. 1995;59:253–9.
56. Montano N, Conforti G, Di Bonaventura R, Meglio M, Fernandez E, Papacci F. Advances in diagnosis and treatment of trigeminal neuralgia. *Ther Clin Risk Manag*. 2015;11:289–99.
57. Cruccu G, Gronseth G, Alksne J, Argoff C, Brainin M, Burchiel K, Nurmikko T, Zakrzewska J. AAN-EFNS guidelines on trigeminal neuralgia management. *Eur J Neurol*. 2008;15(10):1013–28.
58. Zakrzewska JM. Trigeminal neuralgia. In: *Clinical evidence*. Issue 7. London: BMJ Publishing; 2002. p. 1221–31.
59. Fromm GH. Baclofen as an adjuvant analgesic. *J Pain Symptom Manag*. 1994;9:500–9.
60. Wiffen P, Collins S, McQuay H, Carroll D, Jadad A, Moore A. Anticonvulsant drugs for acute and chronic pain. *Cochrane Database Syst Rev*. 2000;3:CD001133.
61. Wiffen P, McQuay H, Moore R. Carbamazepine for acute and chronic pain. *Cochrane Database Syst Rev*. 2005;3:CD005451.
62. Jensen TS. Anticonvulsants in neuropathic pain: rationale and clinical evidence. *Eur J Pain*. 2002;6(Suppl A):61–8.
63. Killian JM, Fromm GH. Carbamazepine in the treatment of neuralgia. Use of side effects. *Arch Neurol*. 1968;19(2):129–36.
64. Nicol CF. A four-year double-blind study of tegretol in facial pain. *Headache*. 1969;9(1):54–7.
65. Rockliff BW, Davis EH. Controlled sequential trials of carbamazepine in trigeminal neuralgia. *Arch Neurol*. 1996;15(2):129–36.
66. Wiffen PJ, Derry S, Moore RA, Kalso EA. Carbamazepine for chronic neuropathic pain and fibromyalgia in adults. *Cochrane Database Syst Rev*. 2014;4:CD005451.
67. McQuay H, Carroll D, Jadad AR, Wiffen P, Moore A. Anticonvulsant drugs for management of pain: a systematic review. *BMJ*. 1995;311(7012):1047–52.
68. Kutluay E, McCague K, D'Souza J, Beydoun A. Safety and tolerability of oxcarbazepine in elderly patients with epilepsy. *Epilepsy Behav*. 2003;4(2):175–80.
69. Hu Y, Guan X, Fan L, et al. Therapeutic efficacy and safety of botulinum toxin type A in trigeminal neuralgia: a systematic review. *J Headache Pain*. 2013;14:72.
70. Gardner WJ, Miklos MV. Response of trigeminal neuralgia to decompression of sensory root: discussion of cause of trigeminal neuralgia. *J Am Med Assoc*. 1959;170:1773–6.
71. Jannetta PJ. Arterial compression of the trigeminal nerve at the pons in patients with trigeminal neuralgia. *J Neurosurg*. 1967;26:159–62.
72. Rhoton AL. The cerebellopontine angle and posterior fossa cranial nerves by the retrosigmoid approach. *Neurosurgery*. 2000;47(Suppl):S93–129.
73. Adams CBT. Trigeminal neuralgia: pathogenesis and treatment. *Br J Neurosurg*. 1997;11:493–5.
74. Resnick DK, Levu EI, Jannetta PJ. Microvascular decompression for paediatric onset trigeminal neuralgia. *Neurosurgery*. 1998;43:804–8.
75. Roski RA, Horwitz SJ, Spetzler RF. Atypical trigeminal neuralgia in a 6-year-old boy. *J Neurosurg*. 1982;5:424–5.
76. Barker FG, Jannetta PJ, Bissonette DJ, Larkins MV, Jho HD. The long-term outcome of microvascular decompression for trigeminal neuralgia. *N Engl J Med*. 1996;334:1077–83.
77. Burchiel KJ, Clarke H, Haglund M, Loeser JD. Long-term efficacy of microvascular decompression in trigeminal neuralgia. *J Neurosurg*. 1988;69:35–8.
78. Kolluri S, Heros RC. Microvascular decompression for trigeminal neuralgia. A five-year follow-up study. *Surg Neurol*. 1984;22:235–40.
79. Kondo A. Follow-up results of microvascular decompression in trigeminal neuralgia and hemifacial spasm. *Neurosurgery*. 1997;40:46–52.
80. Lee KH, Chang JW, Park YG, Chung SS. Microvascular decompression and percutaneous rhizotomy in trigeminal neuralgia. *Stereotact Funct Neurosurg*. 1997;68:196–9.
81. Platt JH, Wilkins RH. Treatment of tic douloureux and hemifacial spasm by posterior fossa exploration: therapeutic implications of various neurovascular relationships. *Neurosurgery*. 1984;14:462–71.
82. Slettebø HJ, Eide PK. A prospective study of microvascular decompression for trigeminal neuralgia. *Acta Neurochir*. 1997;139:421–5.
83. Lee SH, Levy EI, Scarrow AM, Kassam A, Jannetta PJ. Recurrent trigeminal neuralgia attributable to veins after microvascular decompression. *Neurosurgery*. 2000;46:352–6.
84. Barba D, Alksne JF. Success of microvascular decompression with and without prior surgical therapy for trigeminal neuralgia. *J Neurosurg*. 1984;60:104–7.
85. Hunn MK, Eldridge PR, Miles JB, West B. Persistent facial pain following microvascular decompression of the trigeminal nerve. *Br J Neurosurg*. 1998;12:23–8.
86. Kureshi SA, Wilkins RH. Posterior fossa exploration for persistent or recurrent trigeminal neuralgia or hemifacial spasm: surgical findings and therapeutic implications. *Neurosurgery*. 1998;43:1111–7.
87. Liao J-J, Cheng W-C, Chang C-N, Wei K-C, Hsu Y-H, Lin T-K. Reoperation for recurrent trigeminal neuralgia after microvascular decompression. *Surg Neurol*. 1997;47:562–70.
88. Rath SA, Klein HJ, Richter H-P. Findings and long-term results of subsequent operations after failed microvascular decompression for trigeminal neuralgia. *Neurosurgery*. 1996;39:933–40.
89. Kitt CA, Gruber K, Davis M, Woolf CJ, Levine JD. Trigeminal neuralgia: opportunities for research and treatment. *Pain*. 2000;85:3–7.
90. Kondziolka D. Functional neurosurgery. *Neurosurgery*. 1999;44:12–20.
91. Kondziolka D, Lunsford LD, Flickinger JC, Young R, Vermeulen S, Duma C, Jacques D, Rand RW, Regis J, Peragut JC, Manera L, Epstein M, Lindquist C. Stereotactic radiosurgery for trigeminal neuralgia: a multi-institution study using the gamma unit. *J Neurosurg*. 1996;84:940–5.
92. Kondziolka D, Perez P, Flickinger JC, Habeck M, Lunsford LD. Gamma knife radiosurgery for trigeminal neuralgia. *Arch Neurol*. 1998;55:1524–9.

93. Mullan S, Duda EE, Patronas NJ. Some examples of balloon technology in neurosurgery. *J Neurosurg.* 1980;52(3):321–9.
94. Tatli M, Satici O, Kanpolat Y, Sindou M. Various surgical modalities for trigeminal neuralgia: literature study of respective long-term outcomes. *Acta Neurochir.* 2008;150(3):243–55.
95. Bergenheim AT, Asplund P, Linderth B percutaneous retrogasserian balloon compression for trigeminal neuralgia: review of critical technical details and outcomes. *World Neurosurg.* 2013;79(2):359–68.
96. Sweet WG. Proceedings: analgesia dolorosa after differential retrogasserian thermal or mechanical rhizotomy: tactics employed to decrease its influence. *J Neurol Neurosurg Psychiatry.* 1975;38(4):407.
97. Liu JK, Apfelbaum RI. Treatment of trigeminal neuralgia. *Neurosurg Clin N Am.* 2004;15(3):319–34.
98. Håkansson S. Trigeminal neuralgia treated by the injection into the trigeminal cistern. *Neurosurgery.* 1981;9:638–46.
99. Young RF. Glycerol rhizolysis in the treatment of trigeminal neuralgia. *J Neurosurg.* 1988;69:39–45.
100. North RB, Kidd DH, Piantadosi S, Carson BS. Percutaneous retrogasserian glycerol rhizotomy. Predictors of success and failure in treatment of trigeminal neuralgia. *J Neurosurg.* 1990;72:851–6.
101. Khanna JN, Galinde JS. Trigeminal neuralgia. Report of 140 cases. *Int J Oral Surg.* 1985;14(4):325–32.
102. Oturai AB, Jensen K, Erikson J, Marsden F. Neurosurgery for trigeminal neuralgia: comparison of alcohol block, neurectomy and radiofrequency coagulation. *Clin J Pain.* 1996;12:311–5.
103. Ali FM, Prasant MC, Pai D, Aher VA, Kar S, Safiya T. Peripheral neurectomies: a treatment option for trigeminal neuralgia in rural practice. *J Neurosci Rural Pract.* 2012;3:152–7.
104. Nally FF. A 22-year study of paroxysmal trigeminal neuralgia in 211 patients with a 3-year appraisal of the role of cryotherapy. *Oral Surg.* 1984;58:17–23.
105. Zakrzewska JM, Nally FF. The role of cryotherapy (cryoanalgesia) in the management of paroxysmal trigeminal neuralgia: a six-year experience. *Br J Oral Maxillofac Surg.* 1988;26:18–25.
106. McLeod NMH, Patton DW. Peripheral alcohol injections in the management of trigeminal neuralgia. *Oral Surg Oral Med Oral Pathol Oral Radiol Endod.* 2007;104(1):12–7.

Open Access This chapter is licensed under the terms of the Creative Commons Attribution 4.0 International License (<http://creativecommons.org/licenses/by/4.0/>), which permits use, sharing, adaptation, distribution and reproduction in any medium or format, as long as you give appropriate credit to the original author(s) and the source, provide a link to the Creative Commons license and indicate if changes were made.

The images or other third party material in this chapter are included in the chapter's Creative Commons license, unless indicated otherwise in a credit line to the material. If material is not included in the chapter's Creative Commons license and your intended use is not permitted by statutory regulation or exceeds the permitted use, you will need to obtain permission directly from the copyright holder.



Part XI

**Benign Pathologies of the Oral
and Maxillofacial Region**



Neelima Malik

Learning Targets

1. Definition and classification of the Cysts of the Oro-maxillofacial region.
2. Etiopathogenesis, general features, and management of cysts in general
3. Pathogenesis, clinical features, radiological picture, histopathology, and surgical management of common cystic lesions.

27.1 Introduction

A cyst is essentially an enclosed sac formed by the cluster of cells, which group together. The unique characteristic of a cyst is that the cells that form the outer covering of the sac are abnormal from the surrounding normal cells of that specific region. There are various categories of cysts, which can occur almost anywhere within the human body's hard and soft tissues, and their occurrences are very common. They vary in size from tiny microscopic to huge macroscopic varieties, and the large cysts can displace the adjoining normal anatomical structures.

Once formed, sometimes, a cyst may resolve on its own, but in most cases, it keeps growing and needs surgical intervention depending on its type and location. Cysts are usually nonaggressive, but certain groups of cysts show aggressive behavior. The cysts of the oral and maxillofacial region are the commonest pathological entities. Historically, mummified specimens in Egypt (400 BC to 2800 BC) showed the presence of cysts [1].

Electronic Supplementary Material The online version of this chapter (https://doi.org/10.1007/978-981-15-1346-6_27) contains supplementary material, which is available to authorized users.

N. Malik (✉)

Department of Oral and Maxillofacial Surgery, Krishna Institute of Medical Sciences “Deemed to be University”, Karad, Maharashtra, India

27.2 Definition

A cyst is explicitly defined as “A pathological (uni- or multi-ocular) sac that may or may not be lined by an epithelium and filled with a fluid, semifluid, or gaseous contents and not created by the accumulation of pus” [1, 2].

27.3 General Histopathological Common Components of a Cyst

Cysts can be found in the facial bones as well as in the soft tissues of the orofacial region.

Cysts lined by an epithelium are more common in both jawbones than any other regions of the body because of great many epithelial cell rests present in close proximity to the developing jaw bones, and they are called True Cysts, e.g., radicular cyst, dentigerous cysts, etc.

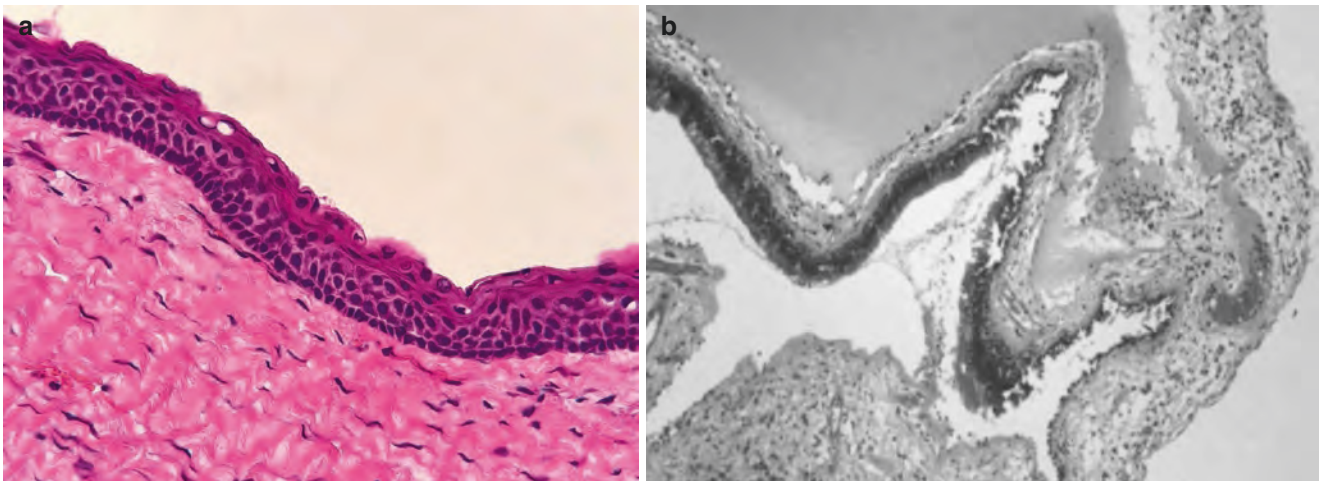
Pseudocysts do not have an epithelial lining, e.g., solitary bone cysts, Cysts of maxillary antrum, etc. [1] (Fig. 27.1).

A cyst is a tissue-space occupying lesion/sac with a cavity in the center known as a Lumen. There is an outer fibrous connective tissue wall that separates the cyst from surrounding normal tissues. On the inner aspect of this wall, there is a cystic lining of epithelium, mostly made up of stratified squamous epithelium (Fig. 27.2). In some cases, there can be lining other than squamous epithelium.

27.4 Etiopathogenesis

The etiopathogenesis of orofacial cysts basically originates from the remnants of the complex processes of embryonic tissue responsible for jaw and dental development. Such a conversion does not occur in any other part of the body.

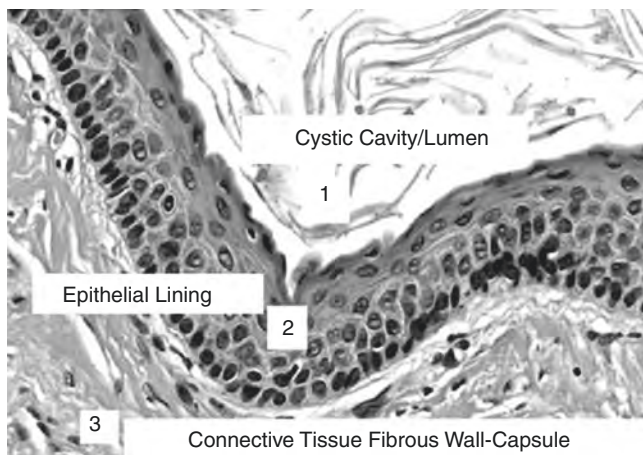
All True Cysts have their genesis from the epithelial remnants along with strong proliferative impetus and capability for bone remodeling. Odontogenic cysts are derived from



©Association of Oral and Maxillofacial Surgeons of India

Fig. 27.1 Histological picture of a true (a) and pseudocyst (b)

Various Histopathological Components of A Cyst



©Association of Oral and Maxillofacial Surgeons of India

Fig. 27.2 General broad histopathological characteristic components of a Cyst; Epithelial lining-various types of epithelium can line a cyst

remnants of odontogenic epithelium of stomodeum, and inflammatory cysts are derived from infective process (Table 27.1).

Pathogenesis of a cyst is mainly divided into three stages:

(1) Cyst Initiation, (2) Cyst Formation, and (3) Cyst enlargement or expansion

1. *Cyst Initiation*—unknown stimulus promotes the rapid increase of epithelial rest cells via cytokine synthesis. The factors, which are suggested to be responsible for cyst initiation phase, are mainly genetics, loss of immunological surveillance, inflammatory mediators, or some local fac-

Table 27.1 Classification of cysts based on the embryological derivation sources (modified from Regezi et al. [3])

Type	Source	Origin of cell rest	Cyst variety
Odontogenic rests	Cell rests of malassez	Epithelial hertwig's root sheath	Periapical (radicular) cyst
	Reduced enamel epithelium	Enamel organ	Dentigerous cyst
Nonodontogenic Rests	Rests of dental lamina (rest of Serres)	Epithelial connection between mucosa and enamel organ	Glandular odontogenic cyst, Lateral periodontal cyst, Odontogenic keratocyst, and Gingival cyst of newborn & adult
	Remnants of nasopalatine duct	Paired nasopalatine duct-vestigial	Nasopalatine canal cyst and Fissural cysts
	Remnants of maxillary sinus epithelium		Cysts of the maxillary sinus

tors like decreased oxygen tension along with increased CO₂ tension.

The residual epithelial cells (Table 27.1) are implicated to initiate the process of cyst formation. Initiation is followed by the rapid growth of the epithelial cells and the development of a cystic lesion.

2. *Cyst Formation*—Nutritional deficiency theory

After initiation, proliferating epithelial cells form a mass inside the sac and the innermost central cells become deprived of nutrients/blood supply, as they are far from the source of nutrients. The innermost cells do not get adequate blood supply, and so there is an ischemic liquefactive necrosis in the center, leading to a cavity for-

mation, which is surrounded by growing epithelial cells. Enhancement in intercellular edema and acid phosphatase activity leads to the formation of microcysts, which slowly start to form a larger cyst [4].

3. Cyst enlargement or expansion

Once formed, the cyst continues to enlarge slowly, over the months.

The process is similar for all epithelial lined cysts with some variations. Many debatable hypotheses have been put forward regarding the definitive mechanism of cyst enlargement.

27.4.1 Theories of Cyst Enlargement/Expansion

27.4.1.1 Mural Growth & Peripheral Cell Division

(a) Epithelial proliferation-peripheral cell division, (b) Accumulation of the contents within the lumen.

Due to Proliferation or rapid increase in the number of cells and by the active division of peripheral lining epithelial cells, surface area of cystic sac increases and the enlargement of a cyst at the circumference is noted along with the accumulation of cellular contents [4, 5].

27.4.1.2 Hydrostatic Enlargement

Biomechanical Theory

Intraluminal concentration and pressure differences between the cystic cavity and the peripheral growth surroundings influence fluid movement into the cyst, bringing about an increase in size.

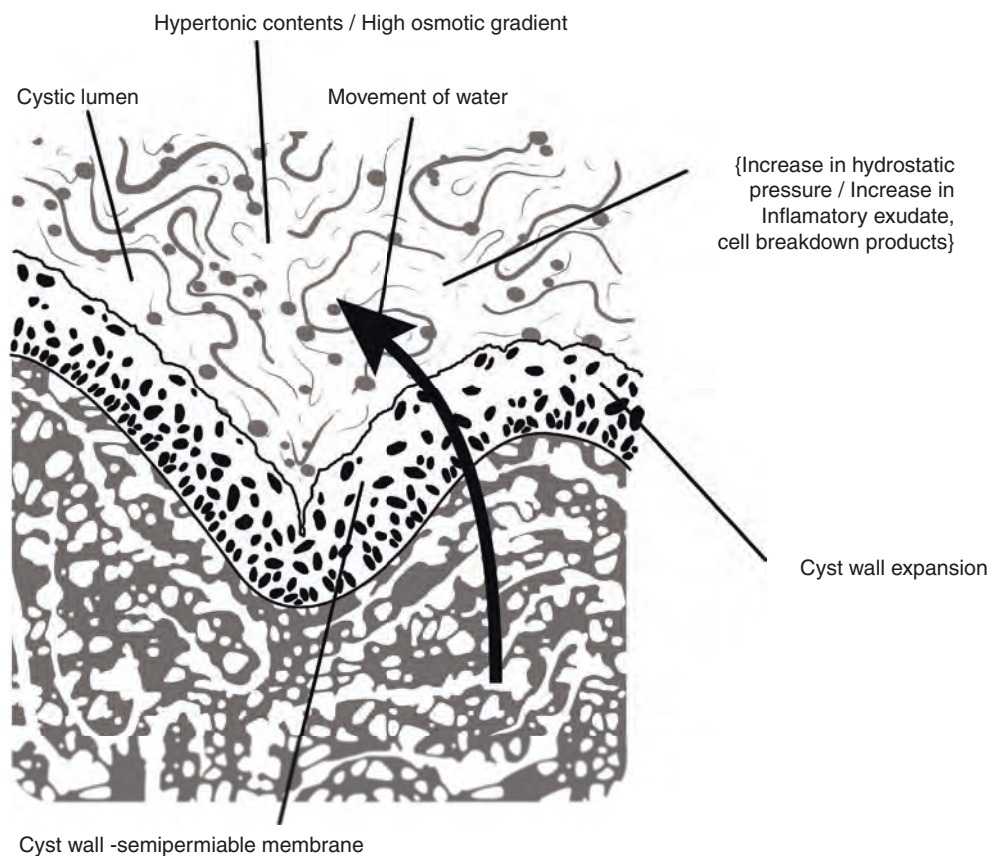
Cyst starts expanding and growing in size, with the increase in intracystic pressure due to the intake of fluids inside the cyst from the surrounding area. (The center of the cyst has higher concentration of sodium than the surrounding serum, and so it tends to absorb water.)

This increase in cyst size process is different from the true autonomous growth, which is found in tumor cells [5, 6].

Secondary proliferation of epithelial cells is, thus, a result of increased volume pressure within the cystic cavity, as a result of osmosis. An osmotic concentration gradient is created as a result of degradation and metabolic by-products, which are taken up inside the cyst.

Due to the rapid increase in the osmotic gradient, the fluid from the surrounding region diffuses in the cystic cavity, increasing internal hydrostatic pressure and thereby resulting in the expansion of the cyst (Fig. 27.3).

Fig. 27.3 The phase of enlargement of a cyst



27.4.1.3 Bone Resorbing Factor

In intraosseous cysts, resorption of the surrounding bone also increases the size of bony cavity.

Biochemical and Cellular Aspects of the Cyst Proliferation

Newer research points to the role of molecular biology in cyst proliferation, over older theories of bone loss resulting from osmotic gradient. The cystic capsule produces bone resorbing factors like prostaglandins, leukotrienes, and osteoclasts.

(A) Bone degeneration in the jaw bone is brought by Collagenase (breakdown of collagen), providing room for cysts to develop. Body’s immune mechanism releases cytokines and growth factors due to the connective tissue breakdown, which contributes to the mobilization and proliferation of epithelial cells in the area.

Evidence-based studies showed that collagenase activities in cystic capsule result in bone degeneration by destruction of the collagen [6, 7].

(B) Prostaglandin theory—Bone resorption caused by metabolism of acidic matter produced in the cysts leads to the cystic growth. These are the substances produced by the cyst itself, which include Prostaglandin-2 and Interleukin-1. Along with the epithelial cell division, the cyst enlarges within the jaw bone due to bone resorption

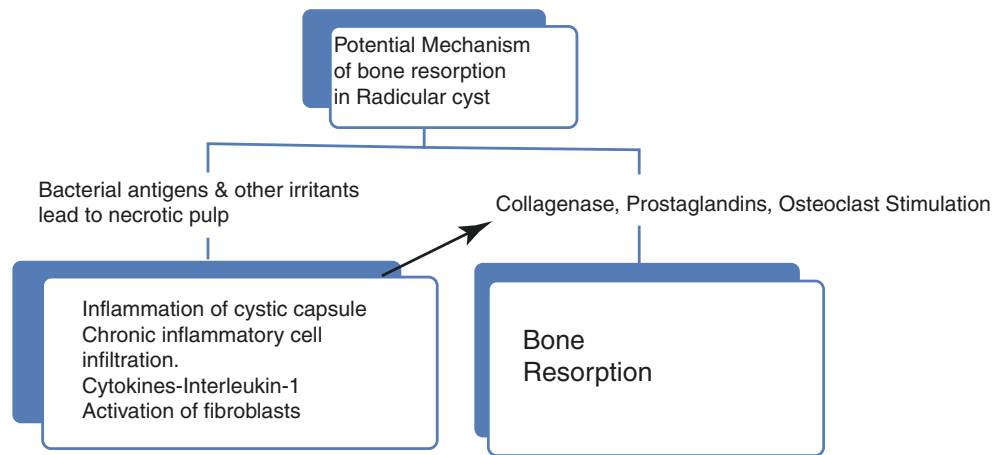
caused by Prostaglandin-induced osteoclastic activity. Bone resorption is mediated as a result of production of PGE-2 and PGE-3 by dental cysts. Prostaglandin-2 and other by-products are part of arachidonic acid metabolism [8].

The production of prostaglandin-2 can be triggered by Interleukin-1. Meghji et al. [9] summarized that odontogenic cysts produce interleukin-1, which in turn triggers the production of Prostaglandin-2, resulting in osteoclastic bone resorption and cyst enlargement. Most dental cysts demonstrate a common growth mechanism though radicular and developmental cysts may be initiated by different factors (Flow Chart 27.1).

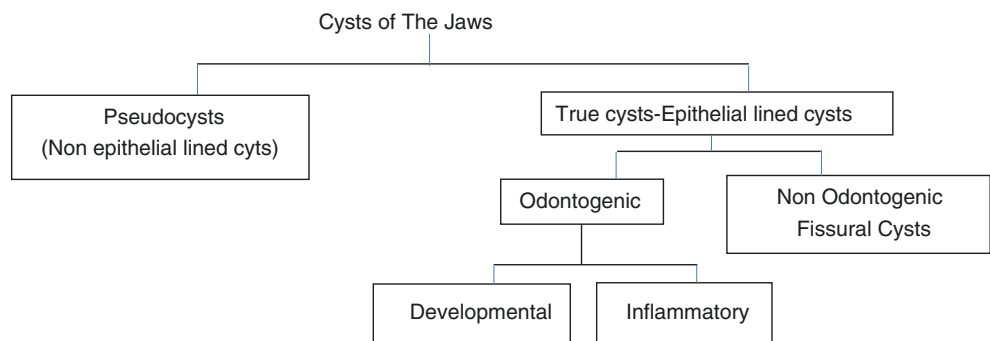
27.5 Historical Evolution of the WHO Classification Systems

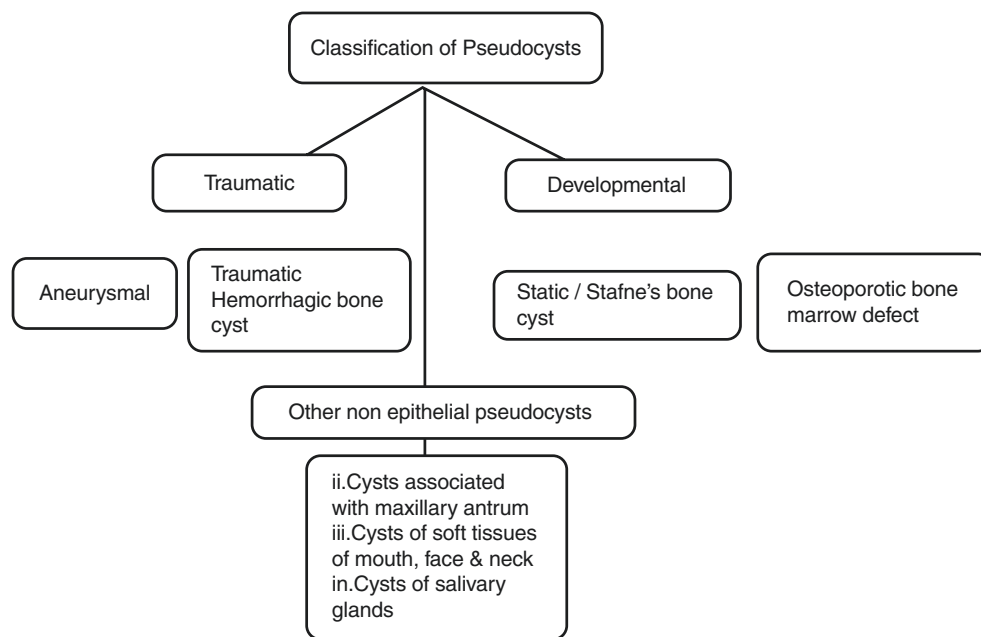
Many researchers including WHO have tried to put forward a uniform, globally accepted nomenclatures and classifications for the cysts of orofacial region. But still there is a continuous debate going on, and therefore, various classifications are cited in the literature. WHO in 1992 [2] had classified cysts into two main categories as odontogenic and nonodontogenic, with further subsets as developmental and inflammatory (Flow Charts 27.2 and 27.3).

Flow Chart 27.1 Potential mechanism of bone resorption in a radicular cyst



Flow Chart 27.2 Basic classification of cysts of jaws



Flow Chart 27.3 Classification of pseudocysts**Table 27.2** According to Shear [1], cysts of orofacial region are categorized under three major groups:

I.	Cysts of the jaws
II.	Cysts associated with the maxillary antrum
III.	Cysts of the soft tissues of the mouth, face, and neck.

This simple classification did not include Calcifying odontogenic cyst (COC), cysts involving maxillary sinus and nonodontogenic soft tissue cysts. WHO in 2005 [10] reclassified the cysts into epithelial and nonepithelial varieties, which were further divided into odontogenic and nonodontogenic types. At this time, COC—calcifying odontogenic cyst—and Odontogenic Keratocysts (OKCs) were not considered as cystic entities, but they were listed as keratocystic odontogenic tumors—KCOT—and calcifying cystic odontogenic tumors—CCOT—respectively. The justification for this new OKC designation was the high recurrence rate and aggressive behavior along with association with mutations in PTCH gene. This reclassification led to a lot of confusion, and it was not accepted by many. But in 2017, the peer group of WHO did not think that there was sufficient affirmation for classifying both OKC and COC as neoplasms. Therefore, in 2017 again, both these lesions were put back in the cyst category [11].

Among so many classifications, Shear (2007) has suggested a comprehensive classification of cysts with good understanding of cystic lesions of mouth, face, and neck region [1] (Table 27.2).

The cysts of the jaws are divided into those that are:

- I. Cysts of the jaws
 - A. Epithelial-lined cysts
 1. Developmental origin
 - (a) Odontogenic Developmental cysts
 - (i) Odontogenic keratocyst
 - (ii) Dentigerous cyst
 - (iii) Developmental lateral periodontal cyst
 - (iv) Gingival cyst of infants
 - (v) Eruption cyst
 - (vi) Gingival cyst of adults
 - (vii) Glandular odontogenic cyst
 - (viii) Calcifying odontogenic cyst
 - (ix) Botryoid odontogenic cyst
 - (b) Nonodontogenic Developmental cysts
 - (i) Midpalatalraphé cyst of infants
 - (ii) Nasolabial cyst
 - (iii) Nasopalatine duct cyst
 2. Odontogenic Inflammatory origin
 - (i) Radicular cyst, apical, and lateral
 - (ii) Paradental cyst and juvenile paradental cyst
 - (iii) Residual cyst
 - (iv) Inflammatory collateral cyst
 - B. Nonepithelial-lined pseudocysts
 - (i) Solitary bone cyst
 - (ii) Aneurysmal bone cyst
- II. Cysts associated with the maxillary antrum
 - (i) Retention cyst
 - (ii) Mucocele

- III. Cysts of the soft tissues of the mouth, face, and neck
- (i) Dermoid and epidermoid cysts
 - (ii) Thyroglossal duct cyst
 - (iii) Lymphoepithelial (branchial) cyst
 - (iv) Anterior median lingual cyst (intralingual cyst of foregut origin)
 - (v) Nasopharyngeal cyst
 - (vi) Oral cysts with gastric or intestinal epithelium (oral alimentary tract cyst)
 - (vii) Cystic hygroma
 - (viii) Thymic cyst

27.6 Prevalence of Cysts

Quite a large number of studies are conducted on jaw cysts, but detailed information on demographic profiles in different populations is limited and most have focused on odontogenic cysts [12, 13] (Box 27.1 and Fig. 27.4).

Box 27.1 Prevalence of Dento-orofacial Cysts

Incidence:

- The jaw cysts are more common than cysts of other bones in the body [12].
- Prevalence of odontogenic cysts is higher (90%) than nonodontogenic cysts in the jaws [12, 13]
- The commonest varieties are periapical cyst (65%), dentigerous cyst (24%), and OKC (5–8%) [12, 13]
- Inflammatory cysts account for 36%, whereas developmental cysts represent 27% of all cysts. 4% cysts are either unclassifiable or nonepithelial (Lucas and WHO classification) [12, 13]

Age: Range from the 1st to 9th decades. Peak incidence is seen between 21 and 30 years of age.

Sex: More prevalent in males, with a male to female ratio of 1.4:1 [12, 13]

Site: Review of literature suggests mandibular preponderance and may imply a higher tendency for activation of cell rests to cystic degeneration in the mandible.

Box 27.2 Diagnosis of the Cystic Lesion Can Be Arrived by the Following Steps

- A. History
- B. Clinical Examination (signs and symptoms, site, inspection, palpation, percussion, teeth vitality check, and aspiration of the cystic content)
- C. Radiographic examination
- D. Biopsy (to ascertain histopathological features leading to final diagnosis)

Box 27.3 History

History: Duration of the complaints/progress is also important. History of pain, loose teeth, occlusion change, intraoral/extraoral swelling/discharge, or sinus track, missing teeth, and delayed eruption of teeth should be noted.

27.7 General Key Attributes Regarding an Oro-maxillo-Facial Cyst-Signs & Symptoms (Boxes 27.2 and 27.3)

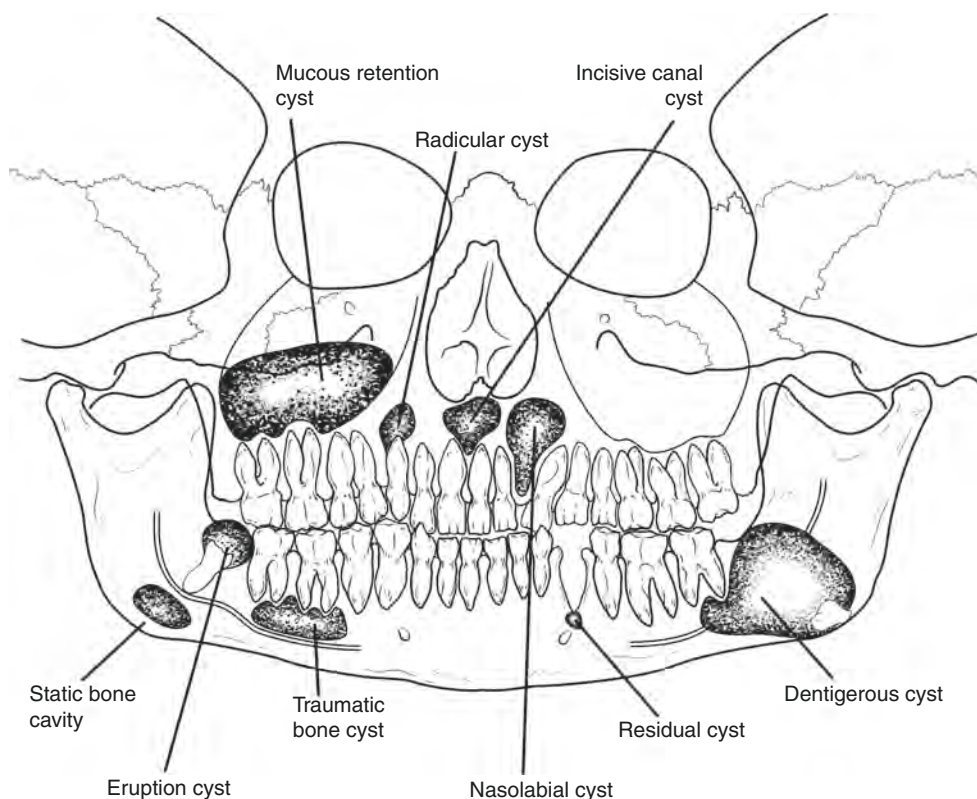
Signs and symptoms of a cyst depend on its size and site. Small cysts are detected as an incidental finding during routine radiographic examination. Large cyst after enlargement can be noticed first by the patient himself, or there can be facial disfigurement noticed by others. Generally, cysts are symptoms free, unless they get infected secondarily.

If the cyst has not enlarged beyond its normal anatomical boundaries of the jaw bone, then its lump cannot be palpated intraorally or extraorally. The majority of cysts expand very slowly, and the surrounding bone gets time to form fresh subperiosteal new bony layer around the lesion, which isolates the lesion.

On Palpation

1. During early stage, smooth, bony hard, and painless prominence can be felt.

Fig. 27.4 Typical locations of odontogenic and nonodontogenic cysts



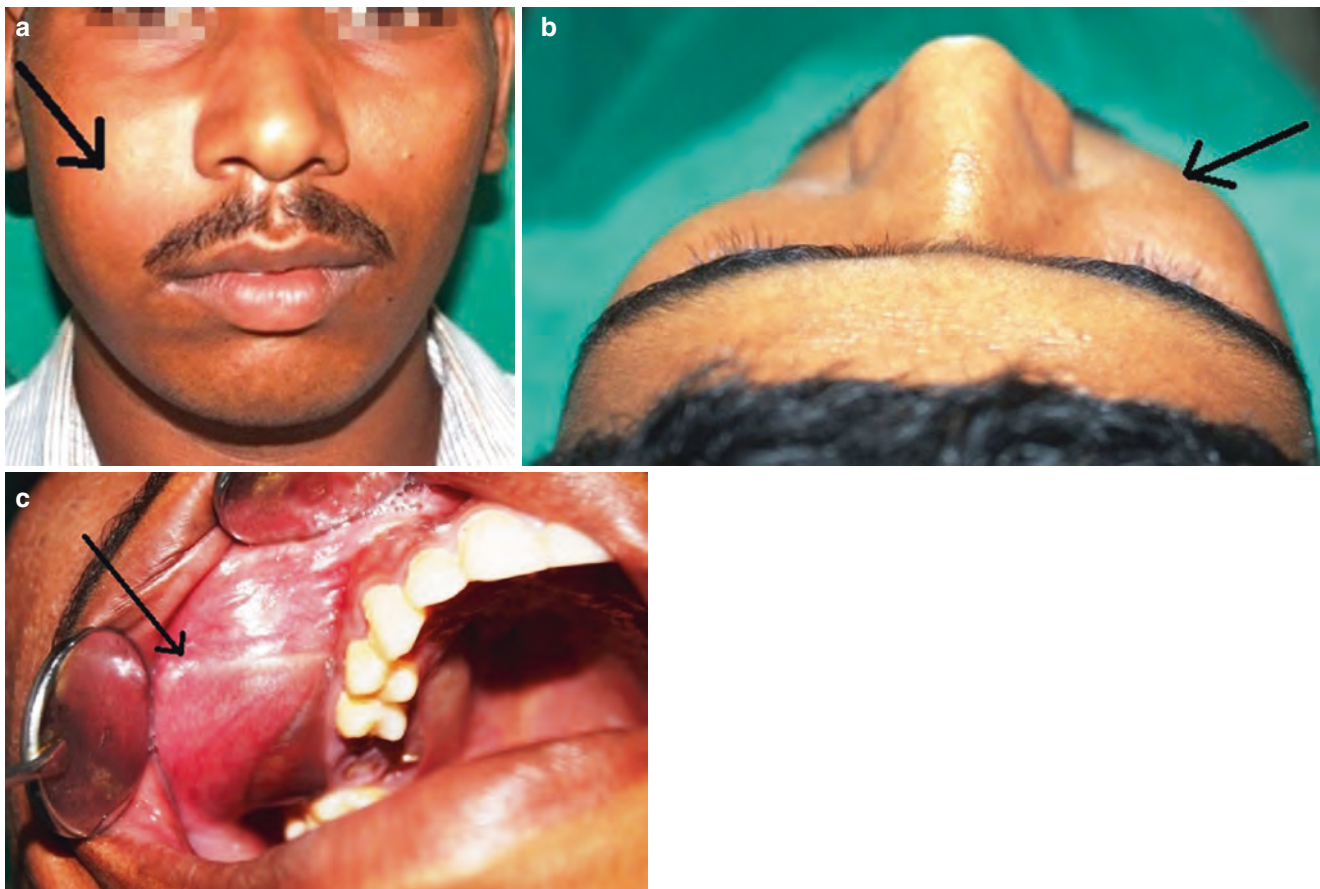©Association of Oral and Maxillofacial Surgeons of India

2. Later on "eggshell crackling" can be felt at the thinned out less mineralised *cortex*.
3. When the cyst grows in volume, the outer cortex is thinned out, due to the loss of bone mineral content and may show "Ping Pong/Table Tennis Ball" springy consistency, or
4. Fluctuation can be felt in its center, where the cyst has eroded the bone and the cystic sac fuses with oral mucosa. Cysts, which show buccal cortical expansion, are still mostly covered with a thin layer of the new bone. Cysts are typically slow growing and tissue space occupying lesions and have the capacity to displace or replace normal tissues. They form compressible, fluctuant swelling, if encroached into the soft tissues, and if they are very close to the mucosal surface, then bluish tinge is seen. A majority of cysts show buccal cortical expansion as the cyst grows in size, but in some aggressive cases, lingual or both buccal and lingual expansion can be seen, which produces facial disfigurement.

A cyst may become secondarily infected, and pus discharge may be seen into the oral cavity via a sinus tract.

Examination of the sinus track and discharge from sinus track should be checked for cholesterol crystals or pus. Salty, sweet, or unpleasant taste of the discharge is noted.

At this stage, patient may complain of pain. Loosening of adjacent teeth or displacement of the teeth out of their normal arch alignment can happen. Very rarely, depending on the variety of cyst, as it enlarges to an enormous size, it may resorb adjoining teeth/roots, as well as bone, and may end up in pathological fracture of the jaw bone. As most cysts enlarge at a slow pace, and even in the large lesions, the inferior alveolar canal usually gets displaced and there will be no altered sensation (anesthesia or paraesthesia). Paraesthesia and/or anesthesia of the lower lip can exist in aggressive or acutely infected cysts. Percussion of involved teeth will produce a dull or hollow sound. Usually, high-pitched sound is obtained on the uninvolved teeth. Edentulous patient will complain of ill-fitting denture due to the bulge. Periapical cysts are always seen in relation to one or more nonvital teeth. A large maxillary anterior region cyst may cause distortion of nostril shape and show nasal congestion. Diagnosis can vary as per the site of the lesion,



©Association of Oral and Maxillofacial Surgeons of India

Fig. 27.5 Clinical examination: extraoral inspection; (a) extraoral swelling on the right cheek area, (b) head position for inspection of swelling and comparison with normal side, and (c) intraoral examina-

tion showing obvious bulge in right buccal vestibule. (Courtesy Dr. Kumar Nilesh, SDS, Karad)

age of the patient, clinical, radiological, and histopathological examination (Fig. 27.5).

27.7.1 Vitality Test of the Involved Teeth in the Lesion

In cysts other than radicular cysts or inflammatory periodontal cyst, there is no compromise in blood supply of the teeth, and so teeth vitality is preserved. Vital teeth are associated with odontogenic keratocyst, solitary bone cyst, lateral periodontal cyst, etc. In inflammatory cysts, the vitality of all involved and adjoining teeth should be checked.

27.7.2 Radiographic Examination

Radiographic picture of a cyst is not always pathognomonic. It will depend not only on cyst category, but also the variants related to its duration, location, and degree of expansion and the presence or absence of infection. When the patient is referred for X-rays, the type of film used will depend on the

size of a lesion. Dental panoramic or maxillofacial Cone Beam CT provides good imaging for most of these cystic lesions. They help to define site, size, extent, and marginal outline of the lesion.

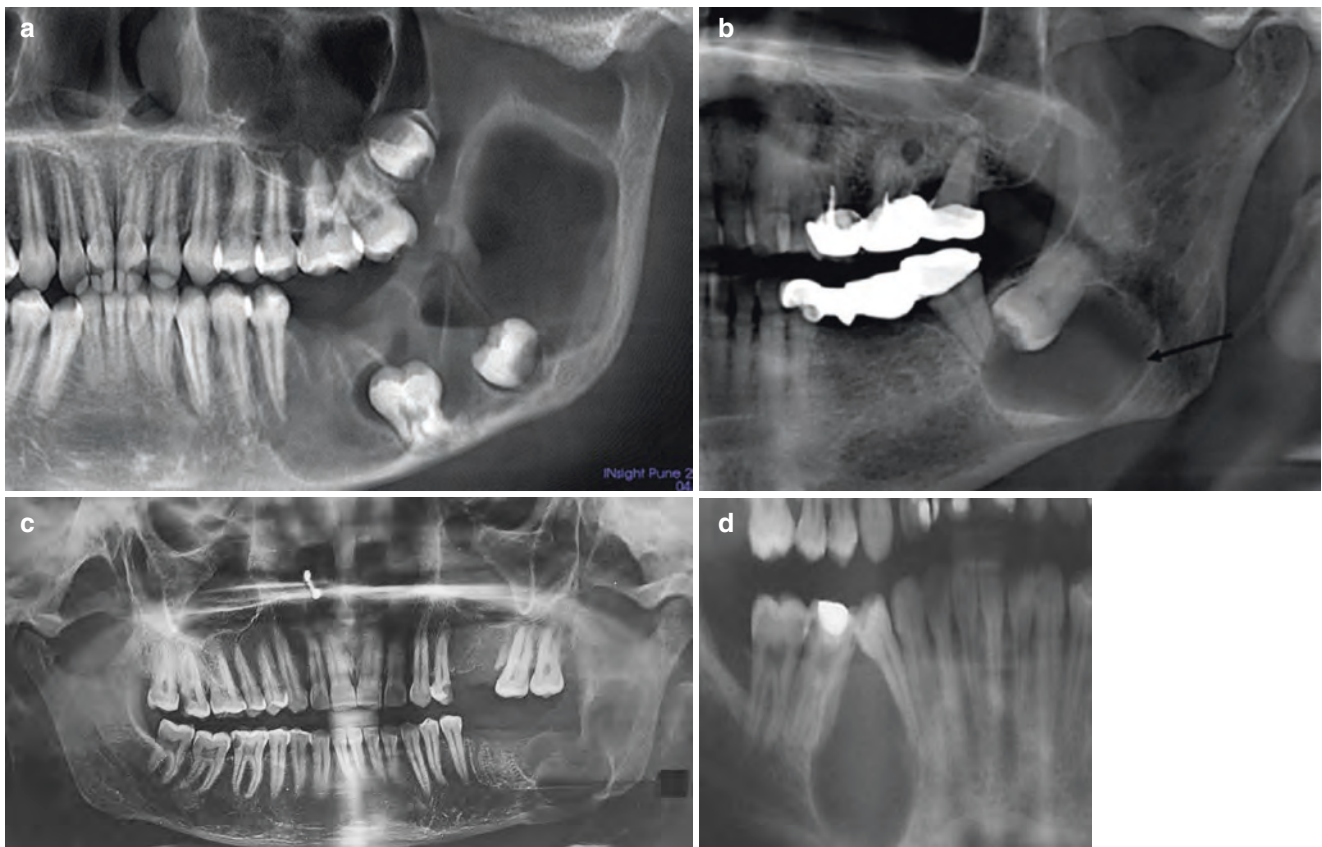
Intraoral film: For smaller lesions, minimum of two films are taken at right angles to one another. Periapical and occlusal views may be taken.

Extraoral film-used for larger lesions. Panoramic/Orthopantograms, Lateral oblique views, and Water's view may be taken.

Patient may be referred for CT scan or MRI in cases of extensive aggressive lesion or recurrent lesions to know the exact expanse, proximity to the important vital structures/adjacent anatomical structures, perforations, and multilobulated/multicystic character. If there is suspicious extraosseous lesion with soft tissue extension or malignancy, then it is also indicated. Postoperative imaging helps to assess the rate of regression and bone regeneration.

27.7.2.1 General Radiographic Picture

1. Radiographically, intrabony cysts, small or large, form sharply defined unilocular or multilocular radiolucency with or without cortication.



©Association of Oral and Maxillofacial Surgeons of India

Fig. 27.6 Different radiological picture of the cystic lesions as per the types: (a) replacement type (cyst in place of third molar), (b) envelopmental type (cyst enveloping lower third molar), (c) extraneous type

(ascending ramus cyst away from teeth), and (d) collateral type (adjacent to the roots of the teeth)

2. The presence of septae can be seen.
3. The shape of a cyst will vary, depending on the type; round or oval in radicular or dentigerous cysts, scalloped margins in odontogenic keratocyst, traumatic bone cyst, pear-shaped, heart-shaped in nasopalatine or incisive canal cyst.
4. Cortical expansion, perforations, or pathological fractures may be seen.
5. Displacement or compression may be noticed on the adjacent dentition, maxillary sinus, or neurovascular bundle.

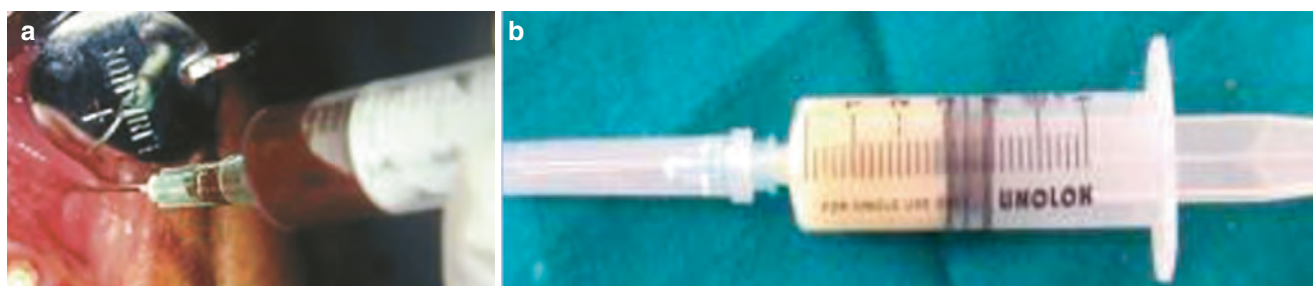27.7.2.2 Radiological Classification of Jaw Cysts (Shear) [1]

- Replacement type: cyst that forms in place of normal tooth
- Envelopmental type: cyst that embraces an adjacent unerupted tooth
- Extraneous type: cyst that occurs in ascending ramus away from the teeth
- Collateral type: cyst that occurs near the roots of the teeth (Fig. 27.6)

27.7.3 Aspiration

The orofacial cyst contains fluid in its cystic cavity, which varies in consistency, color, and protein content, and helps in differentiating and arriving at a provisional diagnosis based on these observations. These findings should be remembered to be able to diagnose any cyst, which may be encountered in the clinical practice. An aspiration biopsy of a cyst is the norm for initial diagnosis of all cysts.

- Aspiration with syringe is always positive for most of the odontogenic cysts. Aspiration can be carried out after the clinical examination is over or at the time of planned incisional biopsy. Aspiration and excision biopsy can be done in the same sitting for small lesions.
- Aspiration of Intralesional fluid is done using a wide bore needle of 18 gauge and 5 ml syringe under local anesthesia. It is a very valuable provisional diagnostic aid with simple procedure with least discomfort. Inability to retract the plunger may be due to a solid mass. Introduce a needle occlusally, as this area is usually thinner than buccal or lingual side (Fig. 27.7).



©Association of Oral and Maxillofacial Surgeons of India

Fig. 27.7 Aspirated cystic fluid; (a) aspiration from infected radicular cyst, (b) aspiration from infected keratocyst

27.7.4 Cystic Fluids

Cystic contents are different ranging from clear yellow fluid to a creamy or cheese like semisolid liquid. The content can be examined for its color, consistency and for the existence shimmering cholesterol clefts or crystals (microscopic examination of cholesterol crystal shows an envelope with cut-corner appearance). Electron microscopic examination reveals the presence of various protein fractions like alpha and beta globulin, albumin, flecks of keratin, as well as total protein content along with inorganic phosphates [14] (Table 27.3).

27.7.4.1 Biochemical Analysis of the Cystic Fluid

Toller has opined that by an active cellular transport mechanism, the proteins are drawn into the cystic fluid by immunoglobulin (Ig) producing cells. Estimation of IgA, IgG, and IgM levels in cystic fluid can be done quantitatively [15]. Smith et al. [16] concluded in their study that the most of the cystic fluids show the presence of proteins with higher molecular weight. This is due to the fact that the semipermeable intraepithelial channels facilitate the passage of lactoferrin into the cystic lumen.

The cystic fluid, which is collected via aspiration biopsy, can be biochemically analyzed for their protein content estimation by Cellulose acetate membrane (CAM) electrophoresis. First, the cystic fluid is transferred to the centrifuge machine for the removal cell debris and deposits at 2000 rev/min for 5 min.

Since electrophoresis studies the movement of charged particles through an electrolyte, which is subjected to an electric field, and it separates different proteins as per their physical properties, the fluid free of debris is then studied qualitatively and quantitatively. The protein mixture is applied to the end of the CAM strip. Scanning of these impregnated CAM strips can be carried out using a densitometer for the quantitative estimation of protein fractions.

Table 27.3 Various cystic lesions and their aspirates

Types of cysts	Aspirate color	Aspirates' other findings
Dentigerous Cyst	Absolutely Clear and faint straw/golden color liquid	Shimmering Cholesterol crystals.
Inflammatory Cyst		Resembles serum. Aggregate Total protein >4 gm/100 ml.
Odontogenic Keratocyst	Dirty, creamy white, and viscid/thick suspension	Floating of desquamated keratin flakes, Less than 4 gm/100 ml of Aggregate Total protein. The predominant presence of Albumin is seen, which is less soluble.
Periodontal Cyst	Absolutely Clear and faint straw/golden color liquid	Cholesterol clefts/crystals. Aggregate Total protein 5–11 gm per 100 ml.
Infected radicular Cyst	Presence of Pus or brown color fluid	Polymorphonuclear leukocytes and cholesterol crystals
Mucocele and Ranula	Sticky, viscous, and thick Mucus	Secreted by salivary glands
Gingival Cysts	Clear fluid	
Solitary Bone Cyst	Serous type of fluid; sometimes, blood is aspirated, or empty cavity is found	Necrotic material in blood clot
Stafne's Bone Cyst	On aspiration air is drawn—Empty cavity	
Idiopathic bone cavity		
Dermoid Cyst	Sebaceous thick material	
Fissural Cysts	Mucoid liquid	
Unicyclic ameloblastoma	chocolate brown fluid	
Hemangioma-intramandibular cavernous	Syringe full of fresh venous blood	
A-V malformation	Bright red blood, pulsatile, pushes plunger	
Arterial or arteriovenous malformation		

27.7.5 Biopsy

Incisional (for large lesions) or excisional (for small lesions) biopsy and histopathological examination of the specimen is the gold standard to arrive at final diagnosis.

27.8 Various Surgical Treatment Modalities for Cystic Lesion

With all the investigation results in hand, the surgeon will have a clear idea of the type, the location, extent, and behavior of the lesion. A final diagnosis is then obtained, and a suitable surgical line of treatment is decided upon (Boxes 27.4, 27.5, 27.6, 27.7, 27.8, 27.9, and 27.10).

Box 27.4 Clinical Tips

Incisional Biopsy: For large lesions, a “representative” section of the lesion is incised with the help of a scalpel along with the normal tissue and sent for histopathological evaluation. An elliptical, wedge-shaped tissue is obtained with the “V” of the wedge converging into the deeper tissues. The depth of the biopsy should be enough to obtain a representative area of the lesion.

Excisional Biopsy: It is a combination of diagnostic and curative procedure and is suitably smaller for lesions <1 cm. In these cases, the entire lesion is excised in toto at the same sitting and sent for histopathological examination.

Box 27.5 Reasons for the Definitive Treatment

- Cysts continue to grow and show a tendency to increase slowly in size
- They can get secondarily infected
- Cyst can make the jaw bone weak, leading to pathological fracture
- Few cysts can undergo transformation to aggressive pathological lesions like ameloblastoma or squamous cell carcinoma
- Cysts prevent eruption of teeth (as in the case of a dentigerous cyst)
- Cysts can involve neighbouring structures like teeth, maxillary sinus, nasal cavity, inferior alveolar nerve, etc.

Box 27.6 Goals of Surgery

- Complete elimination of the pathology, minimizing the recurrence rate & morbidity for the patient, and improving the quality of life postsurgically
- Minimum trauma to the adjacent important structures like dentition and nerves
- Restore/Preserve/Maintain function & esthetics

Box 27.7 Factors for the Choice of Optimum Surgical Strategy/Treatment

Patient factors & lesion characteristics

- Patient’s age & general health and coexistence of NBCCS-Nevoid Basal Cell Carcinoma Syndrome/ any other syndrome
- Patient’s reliability to follow up
- Size of the lesion & whether solitary/multiple
- Uni/multilocular
- Location of the lesion-surgical access
- Cortical perforation/Soft tissue/adjacent structure involvement
- Presence or absence of infection
- History of recurrence/previous surgery
- Histological variant

Box 27.8 Conservative Surgical Treatment

- Decompression alone-placement of a drainage tube-palliative (decrease in lesion size)
- Decompression followed by Enucleation along with adjuvant therapy (two-staged procedure)
- Marsupialization Alone (creating a pouch)
- Marsupialization followed by Enucleation (Waldron’s method) [17] (two-staged procedure)
- Enucleation Alone with packing, with primary closure, or with primary closure with bone grafting/reconstruction
- Enucleation along with excision of overlying oral mucosa (Stoelinga protocol [18])
- Enucleation followed by various Adjuvant Therapies

Box 27.9 Enucleation with Adjunctive Modalities to Eliminate the Microscopic Pathologies

- Peripheral ostectomy (Mechanical/physical methods, Hand instruments like curettes, & use of rotary bur for removal of perimeter of investing bone)
- Chemical cauterization treatment with Carnoy solution (1.5 mm depth of bone penetration/5 min)
- Electrocauterization is used for buccal and lingual perforation area.
- Cryotherapy (use of liquid nitrogen after enucleation)
- Multidisciplinary Sequential treatment (MST) Approach (decompression, enucleation, peripheral ostectomy, and cauterizing bone cavity by carbolic acid) (Sun et al. [19])

Box 27.10 Aggressive Surgical Treatment

- Resection without causing a continuity defect—peripheral ostectomy
- Resection with a continuity defect—segmental resection
- Resection along with disarticulation of condyle

27.8.1 Conventional Surgical Options

The objective of the choosing any particular surgical method is to minimize patient morbidity and reduce the recurrence rate. Surgical procedures for treating cystic lesions are often put into two categories; conservative or aggressive (Boxes 27.8, 27.9, and 27.10).

Decompression and marsupialisation (cystotomy): Partsch I operation of the cysts is presumably the earliest treatment. Enucleation or cystectomy with primary closure is also known as Partsch II procedure (Partsch 1892, 1910) [17].

Decompression, marsupialisation: both methods achieve evacuation of the cystic contents by creating a surgical opening in the cystic wall. These procedures preserve the continuity of the cystic lesion with the oral/nasal cavity or maxillary sinus.

27.8.1.1 Decompression

Decompression of a cyst is achieved by a minor surgical procedure, which decreases the intracystic hydrostatic pressure, which is responsible for cyst expansion. Subsequently, decompression allows for the bone remodeling and bone fill.

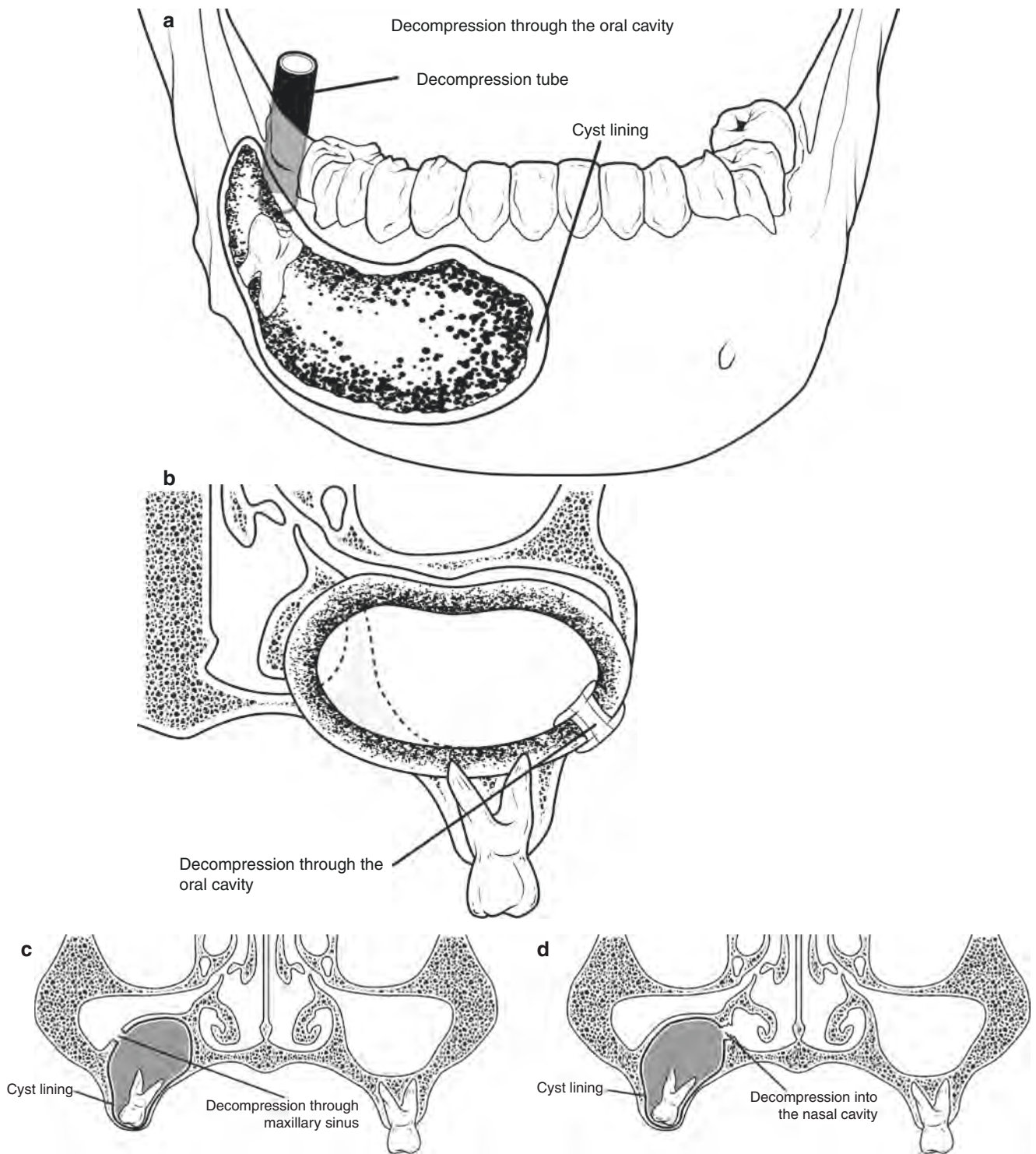
Decompression can be achieved under L.A. by creating a small opening in the cystic wall and keeping it patent with a surgical drain. Acrylic tubes, Luer syringes, polyethylene tubes, nasopharyngeal airways, or nasal cannula or intravenous tubes have been used by fixing them with sutures or wires to keep the opening in the cyst patent, through which the cystic lumen is flushed twice/thrice everyday with saline/antiseptic wash.

Cysts of the lower jaw are normally evacuated through opening into the oral cavity, and maxillary cysts can be drained either into the oral cavity, the maxillary sinus or nasal cavity [17] (Fig. 27.8).

27.8.1.2 Marsupialization

It is a surgical procedure, whereby a cystic sac is modified or deroofed to convert it into a pouch. This results in a self-sustaining stoma/opening or outlet, which in turn reduces intracystic hydrostatic pressure. It is basically a surgical externalization of the cystic cavity by creating an opening in the superficial aspect of the cyst. The resected portion is sent for histopathological study. The remainder borders of the cystic wall are then sutured to the surrounding edges of the oral mucosa, thus converting an enclosed sac, into an open pouch, exposing the cystic lining or epithelium to the oral environment. This procedure decreases the volume and size of the lesion and promotes the speedy healing and new bone formation. This option is more precise compared to the decompression method. Marsupialization may be used as a solo treatment regime for a cyst or as a prior step to final second stage enucleation [17].

Surgical Procedure In Marsupialization, after locally anesthetizing the buccal/labial area, an oval/elliptical incision is taken to make a surgical window spanning 1 cm into a cyst; the window cover consisting of oral mucosa, thinned out bony cortex and cystic lining, is removed, and the boundaries of the cystic lining around the surgical opening are sutured to the surrounding oral mucosa. In the case of a thick bony cover over a cyst, an inverted U-shaped incision is planned with a wider base in the buccal sulcus, mucoperiosteal flap is reflected, and bony window is removed cautiously with burs or rongeurs. The excised tissue of the window created must be subjected to histopathological study. The contents of the cyst are sucked out, and the residual lining of the cyst is inspected. The remainder cystic cavity is irrigated thoroughly to lavage any residual debris. The residual cystic cavity is inspected carefully for any abnormal findings like ulcerative lesions or possible dysplastic/neoplastic areas. The cystic cavity is then packed with ribbon gauze strip soaked with tincture of benzoin or iodoform/white head's varnish or paraffin, or an antibiotic ointment, or bismuth iodine paraffin paste-BIPP, with its end protruding through the opening.



©Association of Oral and Maxillofacial Surgeons of India

Fig. 27.8 Decompression of a cystic lesion by creating a small opening and keeping it patent by inserting a drain. (a, b) Decompression through oral cavity, (c) maxillary sinus, (d) nasal cavity

This packed gauze strip is left in situ for 2 weeks, until the line of junction between the cystic lining and oral mucosa is healed. After it is removed from the cystic cavity, the patient needs to irrigate/gargle with antiseptic mouthwash frequently in a day to prevent food accumulation. The flushing has to be continued for many following months, until the bone fill and complete healing is noticed.

Later on, acrylic plate or plug/obturator can be prepared to protect the healing cavity and used until it gets obliterated over a period of time, but as the healing progresses, the plug needs periodic adjustments (Table 27.4).

27.8.2 Modification of Marsupialization-Waldron's Method—Two-Staged Procedure [17]

Usually, once the cystic lesion regresses in size after initial marsupialization procedure, enucleation is carried out as a second stage surgery.

The larger or inaccessible cyst is initially marsupialized, and bony healing in progress is observed. As the cystic cavity decreases to a relatively small size, then complete surgical removal is possible by enucleation. The proper time for secondary enucleation is when bone covers adjoining vital structures. This protective shield of new bone prevents their injury during secondary enucleation, also provides adequate strength to the basal jaw bone, and prevents pathological fracture.

In a cyst associated with developing tooth bud, as soon as the tooth erupts into the dental arch alignment, there may not be any residual cystic lining left to enucleate. Decompression and/or marsupialization with less morbidity and preservation of adjoining vital structures has a good rate of success over many other aggressive treatments (Figs. 27.9 and 27.10).

27.8.3 Enucleation or Cystectomy or Partsch II (Videos 27.1 and 27.2)

Enucleation or Cystectomy or Partsch II with and without adjunct procedures has been validated as the most appropriate surgical modality for almost all cysts of the orofacial region, with various adjunct procedures as deemed fit for individual case.

To enucleate is “complete removal or excision in toto from its envelope without rupture.” With this, no bone, other than required for surgically accessing the lesion, is removed.

It is the most versatile treatment modality, and many researchers have said that the surgical enucleation of a cyst in one piece has been known to reduce the rate of recurrence.

An enucleation procedure is possible because of the presence of a fibrous connective tissue layer in between the epi-

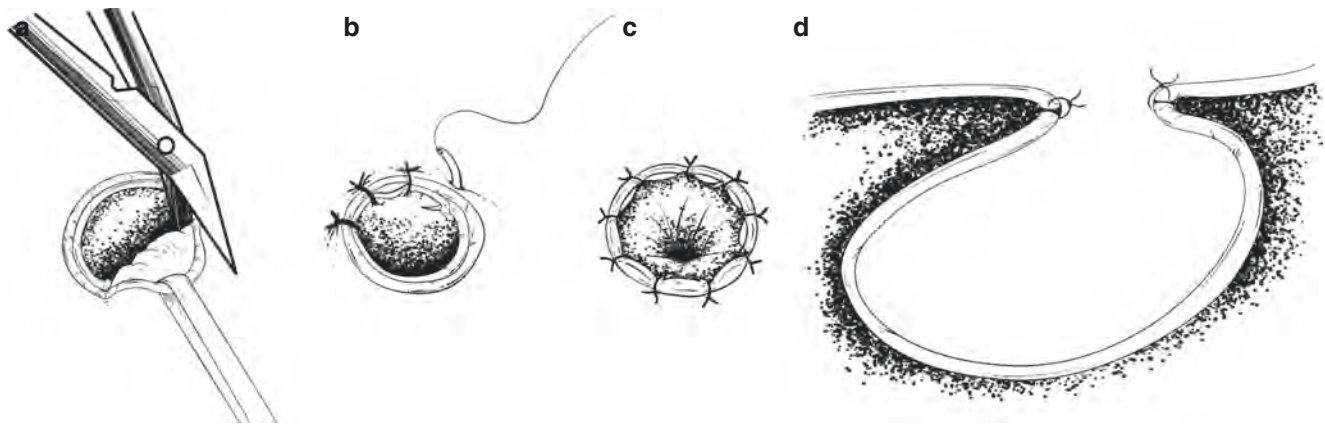
Table 27.4 Indications, advantages & disadvantages of decompression & marsupialization

Indications	Advantages	Disadvantages
<ul style="list-style-type: none"> • Very large cyst in proximity to vital structures • When apices of many adjacent teeth are involved in large cyst • Guided Assistance for eruption of developing teeth- young children with developing teeth buds or unerupted teeth • Possibility of creating a pathological fracture of a jaw bone • Difficult Surgical access for large multilocular cyst • Medically compromised or debilitated patients • To detect any occult Pathology by visual inspection 	<ul style="list-style-type: none"> • Very simple procedures, not much skill needed, and done under L.A. • Prevents iatrogenic injury to vital structures • Avoids pathological fracture • Gradually decreases the cystic cavity, preserving adjacent oral tissues • Maintains the pulp vitality, avoiding dental extractions • There is a change in the nature of the fragile cystic lining, which becomes thick or converts to normal mucosa, and thereby, secondary enucleation becomes easy. • Reduce the intracystic pressure and induce endosteal bone formation 	<ul style="list-style-type: none"> • Leaves pathological tissue behind • It takes longer healing time • Needs patient commitments to maintain hygiene with repeated irrigations and for long follow-up • Second surgical intervention may be needed. • Not recommended for mentally challenged patients with multiple cystic lesions. • Inability to examine the whole cystic lining histopathologically is also a matter of concern sometimes and may miss out mural pathologic changes

thelial lining of a cyst and cystic cavity bony wall. This layer acts as a cleavage point for separating the cystic lining from the jaw bone and makes surgical procedure of enucleation easy, as we carry out stripping of periosteal layer from the jaw bone. The surgical cavity gets filled with the blood clot and eventually gets organized into bone formation.

27.8.3.1 Surgical Procedure

The small cysts can be treated with local anesthesia, but larger cysts need to be treated under general anesthesia. As per the size and site of the lesion, the mucoperiosteal flap is designed, following the right surgical principles. If the bone over the lesion is thinned out, access can be gained by removal of the cortical bone by rongeurs. But if the bony cortex overlying the access area is hard and thick, then the osseous window is created by using rotary burs.



©Association of Oral and Maxillofacial Surgeons of India

Fig. 27.9 Diagrammatic representation of Marsupialization procedure; (a) creation of opening on the buccal side of a cyst, (b) suturing remaining cystic lining to oral mucosa, (c) final suturing to keep the

cystic cavity open into oral cavity, and (d) diagrammatic representation of Marsupialization procedure

After complete enucleation procedure is over, the entire cavity is inspected for proximity of the adjoining vital structures and for the remnants of the pathological tissues. In large extensive cysts, usually the neurovascular bundle is pushed to one side by the slowly growing lesion, and in these cases, atraumatic enucleation should be carried out. Irrigation and cleaning of the entire bony cavity with saline will assist in visualising/inspecting it. The roughened bony edges of the cavity are then smoothed with a file or rotary bur before final suturing.

Cysts that include tooth roots or certain areas of the jaws, which are surgically inaccessible, require thorough curettage, in order to remove fragile cystic lining fragments. If devitalization of the teeth is brought about during enucleation, then the affected teeth should be treated with root canal fillings.

Clinical Tips: If the patient is young and the lesion is involving multiple anterior teeth, the teeth can be retained after root canal treatment and apicectomy, provided thorough inter-radicular curettage by using small periodontal instruments.

If the teeth show a great degree of mobility and in the case of recurrent lesion, they should be extracted.

Enucleation of a cyst is followed by watertight suturing over the sound bone. To achieve this, sometimes, mobilization of the soft tissue flaps with advancement is required. If complete surgical suturing is not possible, then the defect should be packed with stripped ribbon gauze soaked with an antibiotic ointment or BIPP/White head's varnish. Frequent

change of this packing is advocated after irrigating the cavity, until new granulation tissue has filled up the cavity and complete epithelisation of the wound has taken place (Fig. 27.11).

27.8.3.2 Enucleation Along with the Adjunct Procedures

Enucleation with different adjuncts has been carried out since many years.

A. Enucleation with Peripheral Osteotomy

It is basically used as an additional adjunctive step for peripheral bone trimming for avoiding resection, as almost all hypotheses for recurrence point out toward the possibility of leaving residual pathological fragments behind, especially, in the large cyst with scalloped borders or cysts with difficult access. Here, a greater risk of incomplete excision may exist. Adjunct procedure of peripheral osteotomy may be carried out in cases of cysts, which have high recurrence rate, e.g., Odontogenic Keratocyst. A peripheral osteotomy with rotary bur with sterile irrigation helps to remove all the microscopic residual pathological tissue. The procedure is followed to remove the lesion in one piece along with an enveloping border of bone, and hence, the possibility of iatrogenic rupture of the cystic capsule or leaving its fragments behind is greatly reduced. A minimum 2–5 mm bony margin inclusion for peripheral osteotomy is supposed to be adequate. In the case of thin inferior border of mandible, reinforcement with reconstruction plate is advocated. This can also be accomplished by means of mechanical hand instruments like a sharp curette. The recurrence of the cyst can be prevented by this procedure.

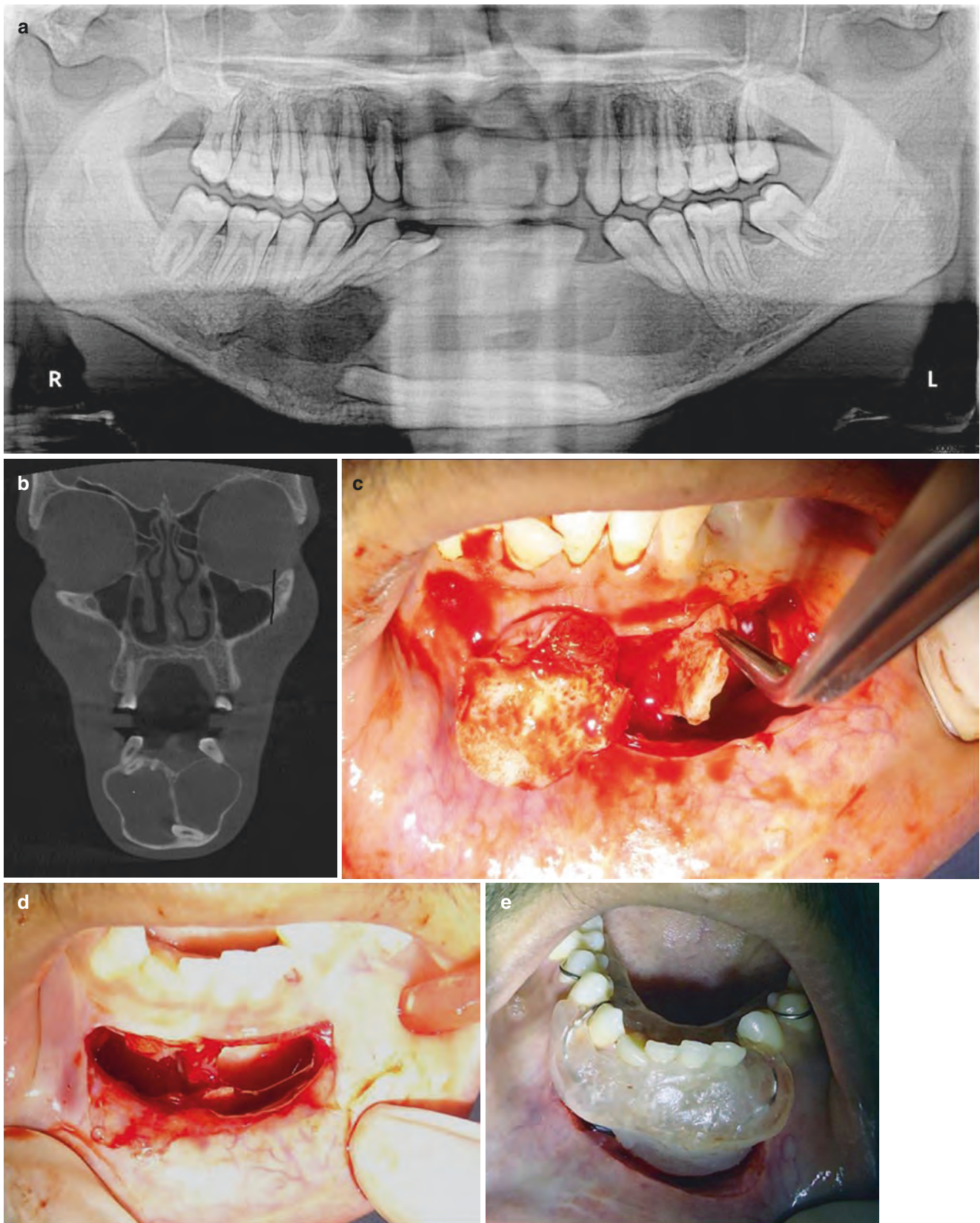
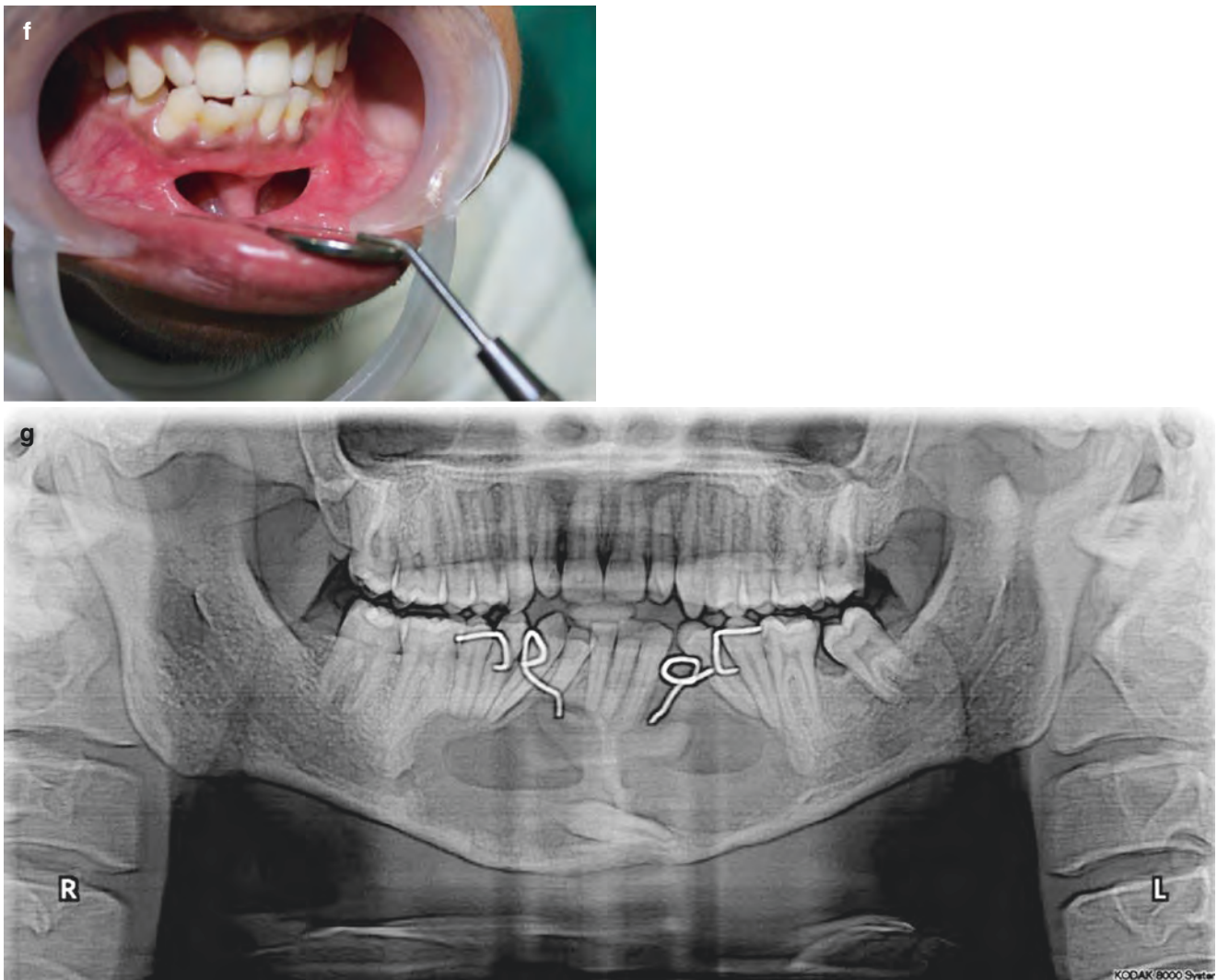


Fig. 27.10 (CLINICAL CASE SCENARIO): (a) OPG showing the large radiolucent lesion extending in the mandibular body with impacted canine at the inferior border, (b) CT scan of the same patient showing multilocular radiolucent lesion with embedded canine, (c) a large opening was created in the anterior body mandible region, and roof of the cyst along with oral mucosa was removed along with the evacuation of

the cystic content, (d) healing of the wound after marsupialisation, (e) acrylic plate was constructed to cover the wound, (f) 6 months follow-up, lesion reducing in size, and (g) OPG after six months showing the reduction in size of the cyst. The patient is advised to undergo second stage surgery for enucleation and extraction of impacted canine. *Courtesy-Prof. Vidya Rattan, PGI, Chandigarh*



©Association of Oral and Maxillofacial Surgeons of India

Fig. 27.10 (continued)

B. Enucleation and application of Carnoy solution to the bony defect

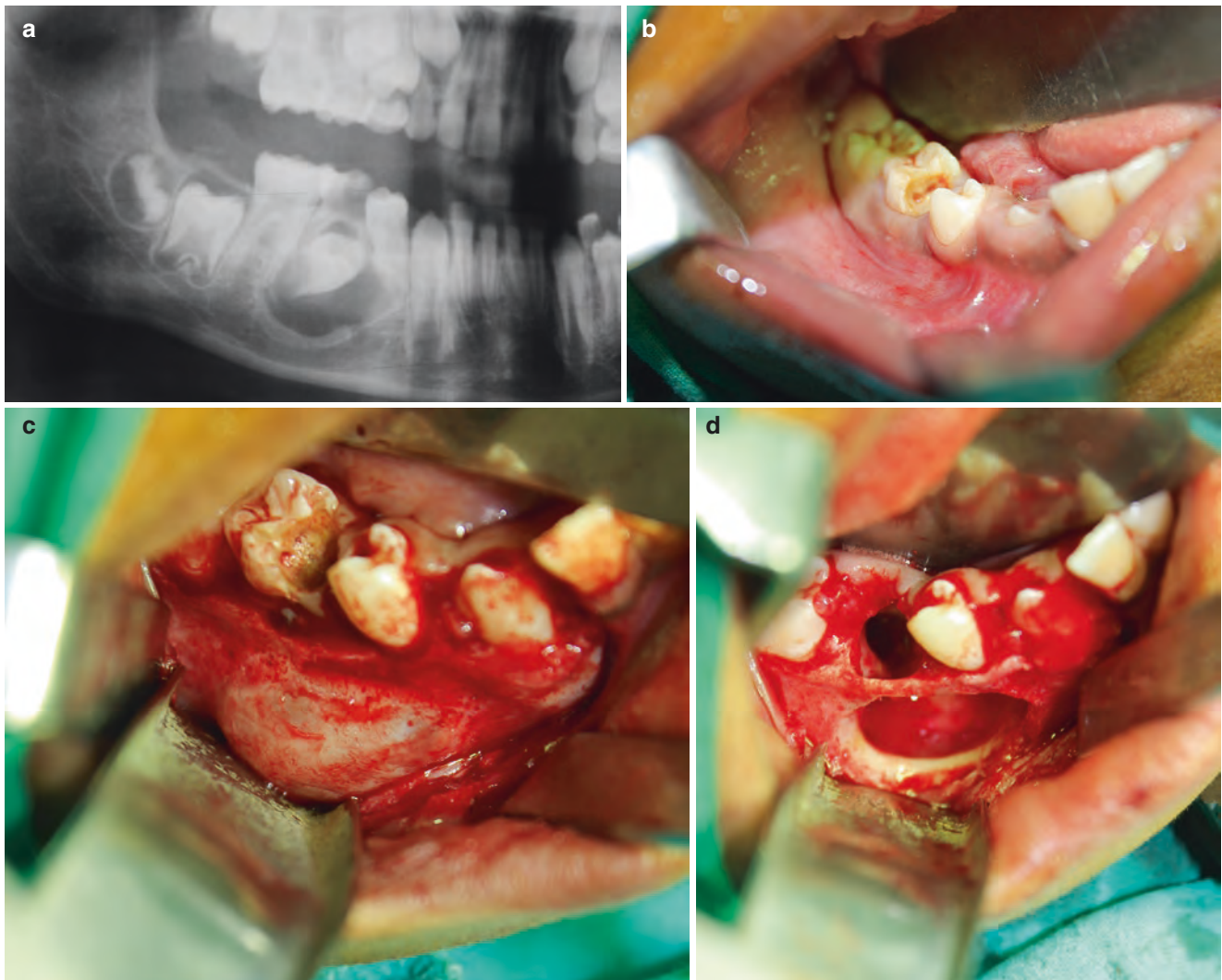Many a times, due to the thin, friable wall and the presence of many small satellite cysts, there is a difficulty of enucleating it in one piece. Hence, the surgical treatment is focused on eliminating all residual epithelial fragments. In order to achieve this, a mild, judiciously penetrating, and cauterizing agent like Carnoy's solution is utilized. It has a mean bone penetration depth of 1.54 mm, with an application time of 5 minutes. (Carnoy's solution's composition is 3 ml of chloroform, 6 ml of absolute ethanol, 1 ml of glacial acetic acid, and 1 g of ferric chloride) [18, 20–22]. This is adequate to bring about chemical cauterization of the residual pathologic fragments. Literature shows the use of modified Carnoy's solution without chloroform, as it is currently listed as a carcinogenic agent.

The protocol of carrying out enucleation followed by the application of Carnoy's solution in the treatment of locally aggressive cysts, like OKCs, lowers the recurrence rate and morbidity. During the application of Carnoy's solution, the neurovascular bundle can be protected by using bone wax cover or wooden spatula or paraffin gauze.

Dashow et al. studied and compared the use of Carnoy's solution versus modified Carnoy's solution in cases of OKCs and stated that the recurrence is almost eliminated, and the results are comparable to those of the resection without carrying out the morbid surgery [22].

C. Enucleation followed by liquid nitrogen cryotherapy

The aggressive cysts are best treated by enucleation followed by cryotherapy, using liquid nitrogen. This therapy is commonly used for the treatment of many locally aggressive jaw lesions, such as ameloblastoma, OKC, or ossifying fibroma [23]. Cryotherapy destroys the residual



©Association of Oral and Maxillofacial Surgeons of India

Fig. 27.11 (CLINICAL CASE SCENARIO) (a) OPG showing the presence of a dentigerous cyst in a 7 years old child, (b) clinical intraoral picture of the same, (c) reflected flap to expose the underlying expanded

buccal cortex, and (d) enucleation of the lesion in toto. *Courtesy Dr. Kumar Nilesh, SDS, Karad*

epithelial lining cells or satellite cysts and leaves behind the inorganic bony matrix intact, which is helpful for osteoconduction. Liquid nitrogen causes bone devitalization due to direct effect/damage from ice crystal formation, which takes place in the cellular and extracellular compartments and due to the subsequent osmotic and

electrolyte disturbances [23]. The routine first step in surgery of the lesion is enucleation of a cyst, followed by cryotherapy. The adjoining tissues are then shielded by sterile wooden spatula and gauze strip, and the residual cavity is treated with liquid nitrogen spray—two swipes for 1 min each, with a 5 min thaw break between two

spray freezes. After cryotherapy, it is possible to place the bone graft in the cystic cavity to strengthen the jaw bone. Finally, the wound is sutured in a watertight manner [23] (Box 27.11 and Table 27.5).

Box 27.11 The Advantages and Disadvantages of Liquid Nitrogen Cryotherapy After Enucleation

Advantages:

1. The matrix shell of basal bone is left behind, which acts as a scaffold and induces new bone formation.
2. In order to accelerate the bony healing and strengthening the jaw bone, immediate bone grafting can be done. This avoids pathological fracture.
3. It decreases bleeding and scarring.

Disadvantages:

1. Unpredictable results are usually due to utilization of uncontrolled spray of liquid nitrogen to the area. This may lead to bone necrosis and postoperative swelling.
2. If liquid nitrogen comes into contact with unprotected inferior alveolar nerve, there will be altered sensation/paraesthesia or total anaesthesia. In most of the cases, partial or total recovery of sensation is expected within 3 months [23].

27.8.3.3 Enucleation Followed by Bone Grafting

Indications

1. To avoid pathological fracture,
2. To avoid long-term esthetics and functional problems in larger cystic cavity, more than 4 cm.

Autogenous bone grafts possess characteristic osteoconductive and osteoinductive qualities due to the presence of abundant osteoprogenitor cells. The use of Autogenous cancellous bone grafts for large defects to obliterate the cavity and stimulate osteogenesis is the gold standard, but the issue of donor site morbidity is always there. The dead space elimination after enucleation of a large defect is recommended by packing the defect with autogenous bone graft or its synthetic substitute. Calcium phosphates, α - and β -tricalcium phosphate (TCP), bioactive glasses, calcium sulfate, glass ionomers, hydroxyapatite (HA), etc. are some of the synthetic graft materials available in the market, which can be used instead of autogenous bone grafts, for filling up the defect after enucleation. The blood clot in the cystic cavity is stabilized by these synthetic grafts, thereby minimizing the postoperative infection. These synthetic grafts are also osteoconductive in nature and promote new bone formation by facilitating the migration of osteoprogenitor cells [24, 25].

Table 27.5 Indications, advantages, & disadvantages of enucleation along with adjunct procedures

Indications	Advantages	Disadvantages
1. For smaller and accessible lesions.	1. Better alternative than radical treatment.	1. After primary closure, it is not possible to observe the healing cavity.
2. Medically fit patients with larger lesions.	2. Cyst-oriented treatment	2. In younger patients, erupting teeth have to be extracted.
3. If it is possible to enucleate without jeopardizing the vitality & integrity of teeth & adjacent vital structures.	3. Entire pathological tissue is removed, which is available for histopathological examination.	3. Large cyst enucleation may end up in fracture or perforation/damage to adjoining soft tissues.
4. Enucleation as a second stage procedure after decompression or marsupialization.	4. Chances of recurrence are reduced with adjunct procedures. (Elimination of satellite cysts & epithelial remnants)	4. Possibility of damaging adjacent vital structures.
5. Enucleation along with adjunct procedures.	5. Healing period is reduced.	5. May lead to pulpal necrosis/devitalization of adjacent teeth.
	6. Maintenance of oral hygiene is easy.	6. Enucleation with fragmentation in inaccessible areas may end up in recurrence.
	7. Enucleation with water tight suturing eliminates the need for long postoperative treatment.	
	8. Good patient compliance.	
	9. Comfortable for patient.	

27.8.4 Block Resection, With or Without Preservation of the Continuity of the Jaw

Resection of a jaw bone can be done either as (1) marginal resection procedure or (2) segmental resection procedure. In marginal resection procedure, the lesion is smaller, which is excised in toto, and hence, it is possible to maintain the continuity of the jaw bone by preserving the portion of the uninvolved bone. In segmental resection procedure, since the lesion is extensive, the complete segment/portion of maxilla or mandible is sacrificed, and hence, continuity of the jaw bone is lost after this radical treatment. Since this procedure ends up in considerable morbidity, there is always a need for rehabilitating the patient functionally and esthetically by various reconstructive measures [26]. Many researchers felt that there is no need for aggressive therapy in the case of cystic lesions, as their management can be done by using relatively noninvasive means [26].

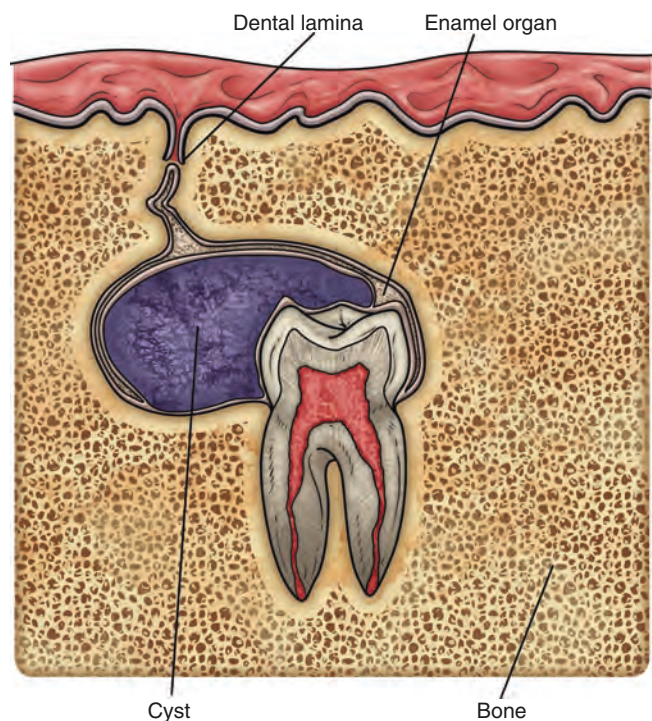
Blanas et al. [21] carried out a systematic review and found that following resection, there was 0% recurrence rate, but it is always associated with the high morbidity rate. Their study suggested that enucleation followed by the use of Carnoy's solution gives similar low recurrence rates, as resection, without unwarranted radical surgery. Complete resection of the mandibular/maxillary bone is considered as morbid overtreatment for large locally aggressive cysts. The only main disadvantage of a conservative treatment is prolonged therapeutic time [27].

In this chapter, we will be discussing only briefly Dentigerous and Keratocyst varieties prototypes.

27.9 Dentigerous Cysts or Follicular Cysts

Dentigerous Cysts or Follicular Cysts, The term dentigerous is a Latin word, literally means "tooth bearing/producing". Paget in 1853 first coined the term "Dentigerous cyst", in this entity, there is an enclosure of the crown of a tooth, which is unerupted, and cyst is attached to the CE junction and is formed by the enlargement of its follicle [1]. There is always an association of this cyst with the crown of fully or partially impacted or submerged tooth (Fig. 27.12).

Depending on the location and extent of the cystic degeneration in relation to the crown of an unerupted tooth, the cyst can have central, lateral, or circumferential variety [28]. In central type, initially, the crown may be enclosed by a cyst symmetrically, but as it expands, crown of the mandibular third molar may be shifted to the inferior border of the mandible or



©Association of Oral and Maxillofacial Surgeons of India

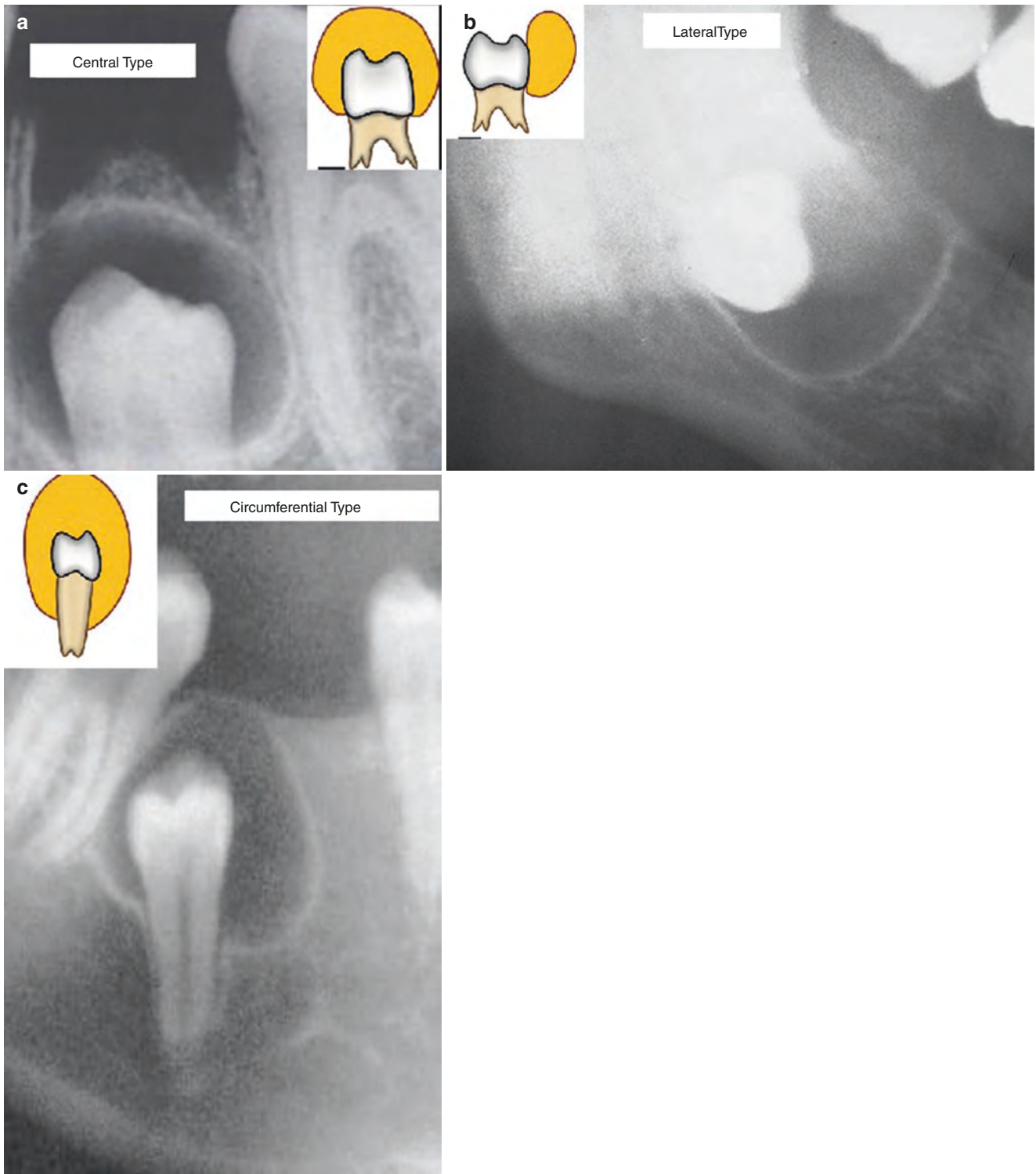
Fig. 27.12 Formation of a dentigerous cyst

migrated high up in the ascending ramus and similarly, maxillary canine or third molar may be seen at the orbital floor or high in maxillary sinus. The lateral type will be because of expansion of cyst only on one particular side of the crown, and it will be seen in cases of partially erupted mandibular third molars. In circumferential type, the radiograph will show a radiolucency enveloping the entire tooth (Fig. 27.13).

27.9.1 Differential Diagnosis

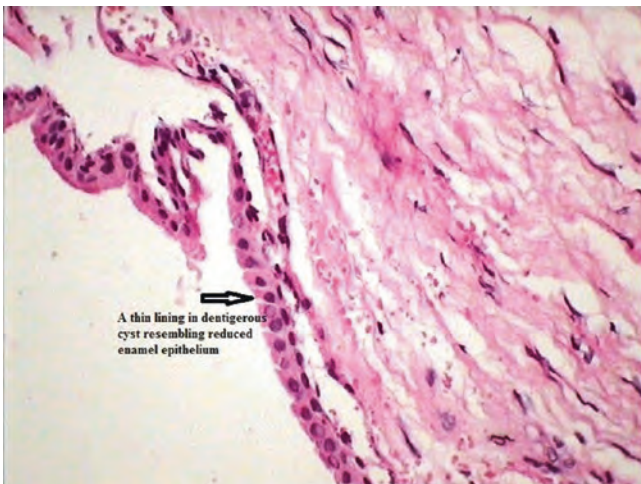Hyperplastic follicle-Normal follicular space size is 2–3 mm; if it exceeds 5 mm, then dentigerous cyst should be suspected.

Differential diagnosis of unicystic ameloblastoma, an odontogenic keratocyst, Calcified odontogenic cyst, Ameloblastic fibroma, Adenomatoid odontogenic tumor, or radicular cyst must be considered in such cases comparable to the radiographic details, but the incidence of all the above lesions is rare in the first decade of life. Since radiographs alone cannot differentiate the above-mentioned lesions, a histopathological examination should be performed.



©Association of Oral and Maxillofacial Surgeons of India

Fig. 27.13 Types of dentigerous cysts and their radiological picture of central, lateral, and circumferential type (a–c)



©Association of Oral and Maxillofacial Surgeons of India

Fig. 27.14 Arrow pointing to a thin lining in dentigerous cyst resembling reduced enamel epithelium histologically

27.9.2 Histology

Thin layer of nonkeratinizing stratified squamous epithelium lining the lumen is seen, and no rete ridges are seen. Connective tissue wall shows bundles of collagen fibers; sometimes, many odontogenic epithelial islands are seen. The cystic lumen contains thin, watery, and yellowish fluid (Fig. 27.14).

27.9.3 Potential Complications of Dentigerous Cyst

1. As it is known that dentigerous cysts have potential for neoplastic proliferation in the form of cystic or mural ameloblastoma, in these cases, there is a nodular thickening at some places in the cystic wall, which cannot be discerned clinically, but is a tumor manifestation itself, and therefore, histopathologist is requested to carry out thorough gross and microscopic examination of the whole specimen for nodular thickening, etc. in the cystic wall.
2. Epidermoid carcinoma—cyst lining, which shows longstanding keratin metaplasia, should be considered as a marker for the initiation of carcinomatous changes.
3. Mucoepidermoid carcinoma—dentigerous cyst may contain cells with the potential of mucus secreting ability, which may transform into mucoepidermoid carcinoma [28].

27.10 Odontogenic Keratocyst

OKC has got its name because it exhibited keratinization of cystic lining. Its lumen contains a cheesy material resembling keratin debris and clear fluid. It is a Dilemmatic, Distinctive, Odontogenic Developmental, and Intraosseous cyst of epithelial origin of Oral & maxillofacial region, with specific characteristics, such as rapid Infiltrative growth, aggressive nature, high recurrence rate and defined histopathological features [26, 27]. Since 1956, for the last six decades, many researchers started focusing on this entity. Journey of this changing nomenclature is pretty interesting (Box 27.12).

Box 27.12 History of OKC

1774	Dental cyst (John Hunter)
1876	Dermoid cyst (Mikulicz) identified & described as a part of familial jaw condition
1926	Cholesteatoma (Hauer)
1945	Primordial cyst as per origin
1956	Odontogenic Keratocyst (OKC) (Philipsen first coined the word)
1963	Aggressive growth/high tendency for recurrence rate (described by Pindborg & Hansen)
1967	Regarded OKC as a benign tumor (Toller)
1992	OKC as preferred term for keratinized cysts (WHO)
2004	Keratinizing Cystic Odontogenic Tumor (KCOT) (Reichart & Philipsen)
2005	Keratocystic Odontogenic Tumor (KOT) (WHO working group)
2017	Odontogenic Keratocyst (WHO)

In 2004, Reichart and Philipsen suggested a new classification for the odontogenic tumors, redesignated OKC as Keratinizing cystic Odontogenic Tumor (KCOT), and put it under the subcategory of “benign neoplasm of odontogenic epithelium with mature, fibrous stroma” due to its propensity for local destruction, aggressive biological behavior, and high recurrence rate and mitotic figures seen in the suprabasal layers [29]. Shear had re-emphasized that OKC shows increased proliferative activity & high recurrence tendency and stressed on association of OKC with the Gorlin-Goltz syndrome/Nevoid Basal Cell Carcinoma syndrome (NBCCS). Some of these OKCs had association with the PTCH 1 gene mutation and increased immunohistochemical expression of proliferation markers Ki 67 and presence of PCNA (Proliferating cell nuclear antigen marker of cell rep-

lication) and p53 in KCOT. All this evidence led to change in nomenclature by WHO in 2005 [10].

This shift in tumor category suggested change in management protocol for OKC, which created a lot of skepticism, and the concept was not widely accepted, with the reason being not all OKCs possess identifiable PTCH mutation. There were no clear-cut suggestions such as neoplastic title was to be applied to all OKC or to just a small subset. All relevant sequencing data on the odontogenic keratocysts has not yet been presented and still under research.

Researchers have suggested that marsupialization can revert the fragile cystic lining epithelium to normal oral mucosa or from parakeratin to orthokeratin type [30, 31].

Extensive debate (for 12 years) over putative neoplastic nature of the lesion took place. So, in 2017, a WHO expert panel declared that there is no strong affirmation to rationalize to label OKC as a neoplasm, and therefore, Odontogenic Keratocyst-OKC should be put back in cyst category and the term keratocystic odontogenic tumor (KCOT) was eliminated from the new classification (Boxes 27.13, 27.14, 27.15, 27.16, 27.17 and 27.18).

Box 27.13 Epidemiology of OKC

Incidence: Second most prevalent cysts of odontogenic origin (10–12% of all odontogenic cysts) [32].

Age: Wide age range. Range of occurrence between the 1st and 9th decades of life. Bimodal age distribution (first peak at 20–30 & second at 50–60 years of age) and Predominantly in younger patients in syndromic cases.

Sex: Male predilection (1.6:1 ratio), More Female predilection in syndromic cases.

Race: predominantly in white population.

Box 27.14 Site Predilection of OKC

Central intraosseous Lesion—Thrice more prevalent in mandible. Seen more at various sites in following order—angle-ascending ramus, maxillary third molar region (*may involve sinus, nasal floor premaxilla, presence of impacted third molar seen, and occasionally floor of orbit involvement*), mandibular, premolar area, and maxillary canine.

Peripheral OKC in buccal gingiva (female predominance 2.2:1 ratio [33])

Box 27.15 Number of Cysts in OKC

- Usually solitary/sporadic/nonsyndromic lesions
- *Syndromic:* Multiple OKCs are often one of the manifestations of genetically inherited Nevoid Basal cell Carcinoma Syndrome (NBCCS), Gorlin-Goltz syndrome, etc. [In syndromic cases, multiple cysts can be seen in one patient at a time or during lifetime occurrence, many cysts can happen at different times [34].
- *Nonsyndromic multiple cysts* [34]

Box 27.16 Syndromic Associations of OKC

- Basal cell nevus syndrome, Nevoid Basal cell Carcinoma Syndrome (NBCCS), or Gorlin-Goltz syndrome
- Marfan syndrome
- Noonan syndrome
- Orofacial Digital Syndrome
- Simpson–Golabi–Behmel syndrome

Box 27.17 Latest Histopathological Groups of OKC

As per the occurrence of satellite/daughter cysts & squamous islands found in the cystic wall (Kahraman et al. [35]) (Fig. 27.17)

Group I: Unicystic, without any satellites (63%)

Group II: With few satellite/microcysts & squamous islands in the cystic lining less than (10–27%)

Group III: Abundant presence of satellite/daughter cysts and squamous islands (6–10%)

27.10.1 Etiology and Pathogenesis

Various origins—Two sources are implicated.

1. Remnants of dental lamina and
2. It can originate from downgrowth or implantation following trauma of the offshoots of epithelial basal layer of the oral gingiva and mucosa [27]. Islands of Epithelium and/or daughter cysts are seen in 50% of the cases, in overly-

Box 27.18 Reasons for Recurrence of OKC (13–62%; Nakamura et al. [36])

1. Thin walls and fragile epithelial lining
2. Epithelial lining is weakly attached to capsule
3. Extension of the cyst into cancellous bone
4. Dental lamina remnants in bone/overlying mucosa
5. In the case of perforation of the cortex, cyst lining adheres to adjoining bone or buccal or lingual mucosa (especially, lingual perforation is difficult to access during enucleation)
6. In dentate area (residual remnants in intraradicular areas)
7. Scalloped margins in multilocular variety
8. Desire to preserve adjacent vital structures
9. Location with difficult access
10. Extensive lesion involving coronoid/ascending ramus (difficult access)

ing mucosa. (In the past designated as basal cell hamartias). Genetic factors are also always key players, especially PTCH gene aberration.

27.10.2 Unique Growth Pattern—Peculiar Behavior—Pattern of Bone Involvement in OKC

Unlike other cysts, lesion grows by extension in medullary space in anteroposterior direction, compared to osmotic expansion.

Finger-like projections are seen in marrow spaces, and enlargement goes on relentlessly along the path of least resistance. When it reaches a considerable size, it expands buccolingually also (Figs. 27.15 and 27.16).

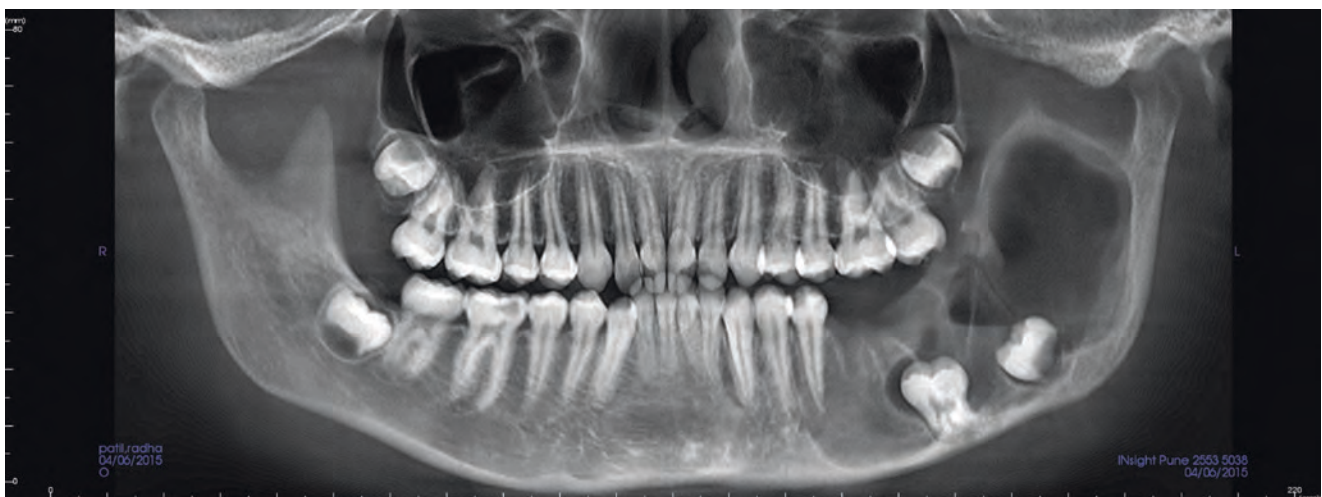27.10.3 Radiographic Differential Diagnosis

OKC is a great mimic; many times, the radiographic picture is nonpathognomonic. Radiographically, the following differential diagnosis for Odontogenic Keratocyst has been suggested:

Dentigerous cyst, residual cyst, radicular cyst, lateral periodontal cyst, Nasopalatine cyst, Unicystic/multicystic ameloblastoma, A-V malformation, fibro-osseous lesion at initial stages, Benign intraosseous neoplasms, traumatic cyst. Patients with multiple jaw cysts should always be evaluated for basal cell nevus syndrome.

27.10.4 Aspiration

- Cheesy, straw color, caseous, dirty milky white semifluid, and viscid content—Keratin-varying consistencies reflect various densities of keratinous debris.
- Protein content less than 3.5/4 g per 100 ml by electrophoresis, mostly albumin is present.
- Protein-53 is positive in NBCC Syndrome, indicating active proliferation of cells.
- Exfoliative cytology/smear is stained & examined for keratin cells, and Estimation of Keratocyst Antigen (KCA) and Lactoferrin levels is helpful.
- Immunohistochemistry for cytokeratin is also a useful diagnostic tool



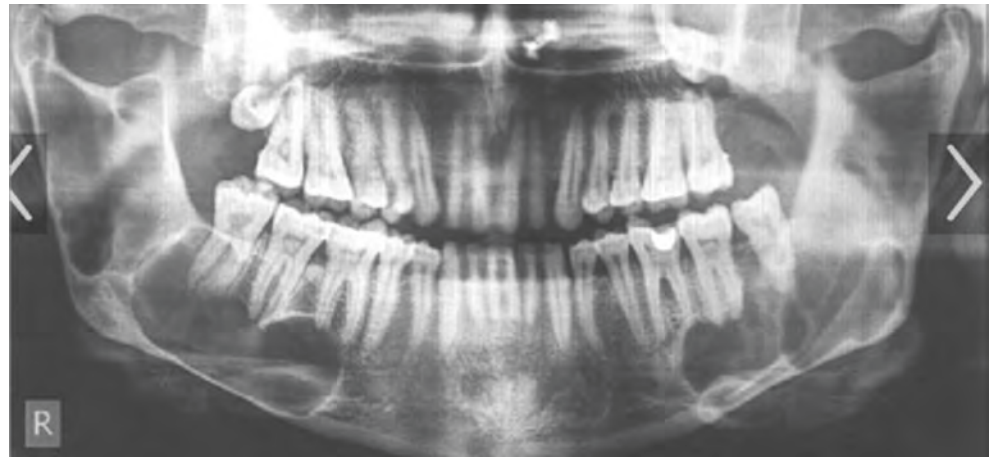
©Association of Oral and Maxillofacial Surgeons of India

Fig. 27.15 OPG showing how lesion grows in medullary space (in anteroposterior direction), multiloculated radiolucency in left angle, and ascending ramus with impacted teeth diagnosed as OKC

27.10.5 Surgical Treatment

Incidence of these lesions is seen more in younger age group and the supportive evidence of success of conservative treatment options like marsupialisation for large expanding OKCs or two-staged surgical procedures, plus the fact of alteration of the remaining epithelium, i.e., return to more normal oral epithelium after decompression/marsupialisation has prompted many to opt for these procedures. The lesions, which are easily accessible, can be enucleated by adjunctive methods.

Fig. 27.16 Multiple cysts in the same individual, involving both maxilla and mandible



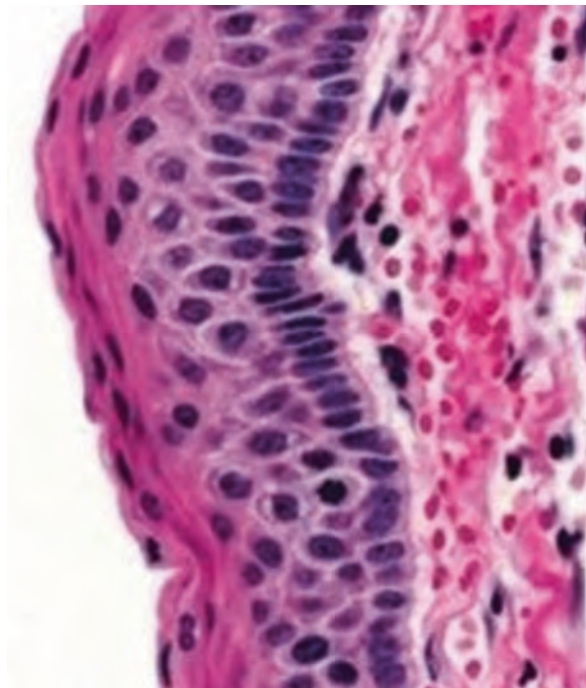©Association of Oral and Maxillofacial Surgeons of India

27.10.5.1 Resection

- It should be used as a last alternative method
- Resection of the jaw bone results in morbidity and requires extensive reconstruction/rehabilitation, which is unwarranted in the treatment of benign lesions, and hence, most of the times, more conservative approaches are sought.

Absolute indications

- Multiple recurrences



©Association of Oral and Maxillofacial Surgeons of India

HISTOPATHOLOGIC CRITERIA OF OKC-SHEAR & PINDBORG (1960–62)

- Thin, collapsed and folded, corrugated lining
- Zone of uniform parakeratinized stratified squamous epithelium 5–8 cell layers with no rete pegs
- Picket fence / tombstone appearance of hyperchromatic palisaded basal cells with reversed polarity
- Weak epithelial connective tissue interface
- Presence of daughter satellite cyst

Fig. 27.17 Typical histopathological picture of OKC showing all the features

- Extensive soft tissue invasion and multiple large perforations
- Resection is used only in aggressive extensive cases or under extraordinary situations
- Condylar involvement or lesions that have undergone ameloblastomatous/malignant transformation

Follow-up

- After surgery, yearly follow-up till 5 years postoperatively
- After 5 years of follow-up, once in 2 years as long as patient cooperates
- Lifelong follow-up is a must-more than 10–20 years

27.10.6 Basal Cell Nevus Syndrome/Nevoid Basal Cell Carcinoma Syndrome

It is also known as bifid rib syndrome or Gorlin and Goltz syndrome or multiple jaw cyst syndrome. This is a genetically inherited uncommon affliction with autosomal dominant trait/inheritance and high penetration.

This syndrome's complex manifestations include relative frontal bossing, Ocular hypertelorism, brain tumors, midface hypoplasia, mandibular prognathism, mental retardation, schizophrenia, multiple basal cell nevi/epitheliomas on the skin, calcification of the falx cerebri, bifid ribs and vertebral anomalies, palmar pitting (the pits later develop into basal cell carcinoma), ovarian tumors, CNS disturbances, hypogonadism in males, cleft lip and palate, etc., and 50% of cases show multiple KCOT-now OKCs. Multiple KCOTs (OKCs) are indicative of basal cell nevus syndrome until diagnosed otherwise. 5% of the patients with KCOT/OKC are diagnosed having basal cell nevus syndrome. Early identification of these patients with their associated manifestations along with proper treatment planning and long-term follow-up will improve the long-term survival rate and quality of life.

27.11 Conclusion

Cysts of the jaw bones are considered as one of the most common pathologies in the oral and maxillofacial region. Various tumors mimic the clinical features of cysts and, thus, can be confused with the same. Radiography alone cannot be the diagnostic tool to distinguish various jaw cysts. Cysts are benign lesions, but few will show locally aggressive and destructive behavior. The detailed present and past history of the patient accompanied by a thorough clinical examination along with aspiration biopsy will lead to probable differential diagnosis. Both conservative and aggressive surgical

treatment modalities have been used in the past to treat oro-facial cysts with variable results, depending on the type of cyst. Correct final diagnosis, thorough planning, meticulous surgery with stringent protocols, and watchful long-term postoperative follow-up will ensure high success rate.

References

1. Shear M, Speight PM, editors. Cysts of the oral and maxillofacial regions. 4th ed. Oxford: Blackwell Munksgaard; 2007.
2. Kramer IRH, Pidborg JJ, Shear M. Histological typing of odontogenic tumors. Berlin: Springer-Verlag; 1992.
3. Regezi J, Sciubba J, Jordan R. Oral pathology: clinical pathological correlations. 4th ed. St. Louis: Elsevier Health Sciences; 2016. p. 244–54.
4. Browne RM. The pathogenesis of odontogenic cysts: a review. *J Oral Pathol.* 1975;4(Suppl 1):31–46.
5. Harris M, Toller P. The pathogenesis of dental cyst. *Br Med Bull.* 1975;31(Suppl 2):159–63.
6. Shrestha P, Yamada K, Higashiyama H, Takagi H, Mori M. Epidermal growth factor receptor in odontogenic cysts and tumors. *J Oral Pathol Med.* 1992;21(Suppl 7):314–7.
7. Sakamoto S, Sakamoto M, Goldhaber P, Glimcher M. Collagenase and bone resorption: isolation of collagenase from culture medium containing serum after stimulation of bone resorption by addition of parathyroid hormone extract. *Biochem Biophys Res Commun.* 1975;63(Suppl 1):172–8.
8. Harvey W, Guat-Chen F, Gordon D, Meghji S, Evans A, Harris M. Evidence for fibroblasts as the major source of prostacyclin and prostaglandin synthesis in dental cyst in man. *Arch Oral Biol.* 1984;29(Suppl 3):223–9.
9. Meghji S, Harvey W, Harris M. Interleukin 1-like activity in cystic lesions of the jaw. *Br J Oral Maxillofac Surg.* 1989;27(Suppl 1):1–11.
10. Barnes L, Eveson JW, Reichart P, Sidransky D. Pathology and genetics of head and neck tumours: WHO classification of tumours. 3rd ed. Lyon: IARC Press; 2005. p. 107–62.
11. Wright JM, Vered M. Update from the 4th edition of the World Health Organization; classification of head and neck tumours: odontogenic and maxillofacial bone tumors. *Head Neck Pathol.* 2017;11(Suppl 1):68–77.
12. Martin L, Speight PM. Mini-symposium: pathology of the jaws. Odontogenic cysts. *Diagn Histopathol.* 2015;21:359–69.
13. Olojede O, Adisa AO, Effiom O, Warith AA. Cysts of the orofacial region: a clinicopathologic review of 403 Nigerian cases. *East Afr Med J.* 2017;94(Suppl 2):116–24.
14. Das AK, Prajapati VK. Concentration of proteins in intra osseous jaw cysts as an adjunct to diagnosis. *Int J Sci Stud.* 2015;2:150–5.
15. Toller PA, Holborow EJ. Immunoglobulins and immunoglobulin containing cells in cysts of the jaws. *Lancet.* 1969;2(Suppl 7613):178–81.
16. Smith AJ, Matthews JB, Mason GI, Browne RM. Lactoferrin in aspirates of odontogenic cyst fluid. *J Clin Pathol.* 1988;41(Suppl 10):1117–9.
17. Pogrel MA. Treatment of keratocysts: the case for decompression and marsupialization. *J Oral Maxillofac Surg.* 2005;63(Suppl 11):1667–73.
18. Voorsmit RA, Stoelinga PJ, van Haelst UJ. The management of keratocysts. *J Maxillofac Surg.* 1981;9:228–36.
19. Sun J, Wu J, Zhou N, Meng N, Lin Y. A prospective study of jaw odontogenic keratocyst treated by multidisciplinary sequential treatment. *Int J Oral Maxillofac Surg.* 2009;38(Suppl 5):537.

20. Morgan TA, Burton CC, Qian F. A retrospective review of treatment of odontogenic keratocyst. *J Oral Maxillofac Surg.* 2005;63(Suppl 5):635–9.
21. Blanas N, Freund B, Schwartz M, Furst IM. Systematic review of the treatment and prognosis of the odontogenic keratocyst. *Oral Surg Oral Med Oral Pathol Oral Radiol Endod.* 2000;90(Suppl 5):553–8.
22. Dashow JE, McHugh JB, Braun TM, Edwards SP, Helman JI, Ward BB. Significant decreased recurrence rates in keratocystic odontogenic tumour with simple enucleation and curettage using carnoy’s versus modified carnoy’s solution. *J Oral Maxillofac Surg.* 2015;73(Suppl 11):2132–5.
23. Schmidt BL, Pogrel MA. The use of enucleation and liquid nitrogen cryotherapy in the management of odontogenic keratocysts. *J Oral Maxillofac Surg.* 2001;59(Suppl 7):720–5–6–7.
24. Ochandiano CS. Bone cavity filling with alloplastic material in maxillofacial surgery. *Rev Esp Cir Oral Maxillofac.* 2007;29(Suppl 1):21–32.
25. Ettl T, Gosau M, Sader R, Reichert TE. Jaw cysts—filling or no filling after enucleation? A review. *J Craniomaxillofac Surg.* 2012;40(Suppl 6):485–93.
26. Stolinga PJ. Long term follow-up on keratocysts treated according to a defined protocol. *Int J Oral Maxillofac Surg.* 2001;30(Suppl 1):14–25.
27. Giuliani M, Grossi GB, Lajolo C, Bisceglia M, Herb KE. Conservative management of large odontogenic keratocyst: report of a case and review of the literature. *J Oral Maxillofac Surg.* 2006;64(Suppl 2):308–16.
28. Neville BW, Damm DD, Allen CM, Bouquot JE. *Oral and maxillofacial pathology.* 3rd ed. Philadelphia: WB Saunders; 2004.
29. Reichart P, Philipsen H. *Odontogenic tumours and allied lesions.* 3rd ed. New Malden: Quintessence Publishing; 2004.
30. Wushou A, Zhao YJ, Shao ZM. Marsupialization is the optimal treatment approach for keratocystic odontogenic tumour. *J Craniomaxillofac Surg.* 2014;42(Suppl 7):1540–4.
31. Maurette PE, Jorge J, de Moraes M. Conservative treatment protocol of odontogenic keratocyst: a preliminary study. *J Oral Maxillofac Surg.* 2006;64(Suppl 3):379–83.
32. Chirapathomsakul D, Sastravaha P, Jansisyanont P. A review of odontogenic keratocysts and the behaviour of recurrences. *Oral Surg Oral Med Oral Pathol Oral Radiol Endod.* 2006;101(Suppl 1):5–9.
33. Chuong R, et al. The odontogenic keratocyst. *J Oral Maxillofac Surg.* 1982;40:797–802.
34. Auluck A, Suhas S, Pai KM. Multiple odontogenic keratocysts: report of a case. *J Can Dent Assoc.* 2006;72(7):651–6.
35. Kahraman D, Gunhan O, Celasun B. A series of 240 odontogenic keratocysts: should we continue to use the terminology of “keratocystic odontogenic tumour” for the solid variant of odontogenic keratocyst? *J Craniomaxillofac Surg.* 2018;46(6):942–6.
36. Nakamura N, et al. Marsupialization for odontogenic keratocyst: long term follow up analysis of the effects and changes in growth characteristics. *Oral Surg Oral Med Oral Pathol Oral Radiol Endod.* 2002;94(Suppl 5):543–53.

Open Access This chapter is licensed under the terms of the Creative Commons Attribution 4.0 International License (<http://creativecommons.org/licenses/by/4.0/>), which permits use, sharing, adaptation, distribution and reproduction in any medium or format, as long as you give appropriate credit to the original author(s) and the source, provide a link to the Creative Commons license and indicate if changes were made.

The images or other third party material in this chapter are included in the chapter's Creative Commons license, unless indicated otherwise in a credit line to the material. If material is not included in the chapter's Creative Commons license and your intended use is not permitted by statutory regulation or exceeds the permitted use, you will need to obtain permission directly from the copyright holder.



Anjan Kumar Shah

28.1 Introduction

The region of Head and Neck has a wide range of pathological disorders due to the complex nature of the tissues in this region. The tooth-forming tissues can give rise to a wide array of tumours, both benign and malignant. They vary in size from tiny swelling to a large variety, causing cortical bone perforation with the displacement of the adjoining normal anatomic structures. Odontogenic tumours are slow growing and generally non-aggressive, with aggressive behaviour shown by certain tumours.

It is important for the clinician to have a thorough knowledge of the pathology, clinical as well as radiological presentation in order to manage these conditions.

According to W.H.O [1]

‘Odontogenic tumours and tumour-like lesions constitute a group of heterogeneous diseases that range from hamartomatous or non-neoplastic tissue proliferations to benign neoplasms and finally malignant tumours with metastatic potential. They are derived from epithelial, ectomesenchymal and/or mesenchymal elements of the tooth-forming apparatus. Odontogenic tumours are rare, some being extremely rare, but can pose a significant diagnostic and therapeutic challenge.’

The WHO first classified benign odontogenic tumours in 1971 followed by in 1992, 2005 and the recent classification was in 2017. The origin-based sub-classification was first defined in 1992, which is still in use, i.e. the tumours are sub-classified into Epithelial origin, Mixed origin and

Mesenchymal origin. The metastasising (malignant) ameloblastoma is included in epithelial origin tumour in 2017 WHO classification and desmoplastic ameloblastoma was excluded from the classification of benign odontogenic tumour. In 1992 classification, adenomatoid odontogenic tumour (AOT) was considered under mixed origin but in 2005 and 2017 classification, it is included in the epithelial origin tumour [2].

The dentinogenic ghost cell tumour (DGCT) comes under the spectrum of ghost cell lesions. Gorlin et al. in 1962 first described calcifying odontogenic cyst (COC) as the earliest ghost cell lesions. In 2005 WHO classification, COC is renamed as calcifying cystic odontogenic tumour (CCOT). Fejerskov and Krogh used the term calcifying ghost cell odontogenic tumour for DGCT in 1972. Dentigerous ghost cell tumour term was given by Praetorius et al. in 1981, which is still retained in 2005 and 2017 WHO classification. In between, Shear in 1983 used the term dentinoameloblastoma, whereas Ellis and Shmookler proposed epithelial odontogenic ghost cell tumour. Hong et al. in 1991 suggests the term epithelial odontogenic ghost cell tumour [3, 4].

28.2 WHO (2017) Classification of Odontogenic Tumours [5]

28.2.1 Benign Odontogenic Tumours

28.2.1.1 Epithelial Origin

- Ameloblastoma, conventional
- Ameloblastoma, unicystic type
- Ameloblastoma, extraosseous/peripheral type
- Metastasising (Malignant) ameloblastoma
- Squamous odontogenic tumour
- Calcifying epithelial odontogenic tumour
- Adenomatoid odontogenic tumour

Electronic Supplementary Material The online version of this chapter (https://doi.org/10.1007/978-981-15-1346-6_28) contains supplementary material, which is available to authorized users.

A. K. Shah (✉)
Department of OMFS, Rajarajeswari Dental College,
Bangalore, India

Bhagwan Mahaveer Jain Hospital, Bangalore, India

28.2.1.2 Mixed (Epithelial-Mesenchymal) Origin

- Ameloblastic Fibroma
- Primordial odontogenic tumour
- Odontoma, complex type
- Odontoma compound type
- Dentinogenic ghost cell tumour

28.2.1.3 Mesenchymal Origin

- Odontogenic Fibroma
- Odontogenic myxoma/myxofibroma
- Cementoblastoma

28.2.2 Malignant Odontogenic Tumours

- Ameloblastic carcinoma
- Primary intra-osseous carcinoma, NOS
- Sclerosing odontogenic carcinoma
- Clear cell odontogenic carcinoma
- Ghost cell odontogenic carcinoma
- Odontogenic carcinosarcoma
- Odontogenic sarcomas

28.3 Ameloblastoma

28.3.1 Introduction

It is the most common odontogenic tumour arising from odontogenic epithelium.

Ameloblastoma originates from sources, which include [6]

- Epithelial cell rests of Malassez, which are the residual epithelium of the tooth-forming apparatus.
- Epithelium of the enamel origin and of odontogenic cysts
- Surface epithelium of the basal cells
- Heterotopic epithelium from the extra-oral sites such as pituitary gland

Edited 2017 WHO classification of odontogenic tumours has simplified the classification of Ameloblastomas. It has removed the various pathologically descriptive classification terminologies such as follicular, plexiform, basaloid, granular or desmoplastic as these terminologies do not have any relevance to clinical behaviour. Conventional-type Ameloblastomas are characterised by multilocular, expanding behaviour. The histological margin is characterised by

the infiltrating margin, requires wide excision with a margin of 0.5–1 cm of normal bone, or one anatomical layer if grown out of the confines of the bone. That is if bony cortex invaded, then take muscle or subcutaneous tissue to maintain periosteum as anatomical barrier.

28.3.2 Definition

‘It is a true neoplasm of enamel organ-type tissue, which does not undergo differentiation to the point of enamel formation’ proposed by WHO. Robinson [7] defined it as a “Non-functional, unicentric, intermittent in growth, anatomically benign and clinically persistent type of tumour’

28.3.3 Incidence

It represents 19.3–41.5 % of all odontogenic tumours [8, 9]. Posterior Mandible is the commonest site of occurrence in almost 80% of ameloblastomas [10]. It occurs over a broad range; cases ranging from adults older than 90 to the children younger than 10 years. Most frequently, they occur in the second and fourth decade of life. Some authors found no gender predilection [11] while many studies showed female predilection [12] between the first and the third decade of life [13].

28.3.4 Clinical Features

1. Swelling of maxilla or mandible
2. Facial disfigurement
3. Tooth displacement and mobility
4. Paraesthesia
5. Ulceration or Nasal obstruction

28.3.5 Radiological Features

- Ameloblastomas commonly originate within the bone, thus often they are detected on routine dental x-rays or on orthopantomogram (OPG).
- Root resorption of the involved teeth
- The solid/multilocular-type ameloblastomas, which is most common, classically shows “soap bubble appearance” [14]
- Computed tomography (CT) is very helpful in surgical planning by giving exact cortical destruction and soft tissue extension, it typically demonstrates well-defined radiolucent uni/multilocular lesions [15]
- Magnetic resonance imaging (MRI) is very helpful in maxillary lesions for defining the extension of ameloblastomas into paranasal sinuses, orbit and skull base [16]
- PET–CT generally indicated in patients with metastatic ameloblastomas.

28.4 Solid/Multicystic Ameloblastoma

In 2005 WHO classification, the Ameloblastoma, solid/multicystic type, was mentioned, which is replaced by Ameloblastoma alone in 2017 classification again. Historically, the Ameloblastoma is classified into Unicystic and Multilocular or Solid.

The solid/multicystic or intra-osseous ameloblastoma is locally invasive, slow-growing and odontogenic tumour of epithelial origin with a high rate of recurrence if not removed or treated properly. It has no tendency to metastasise. It invades the bone marrow spaces.

It has no gender predilection and occurs equally in both sexes. Most commonly diagnosed between 30 and 60 years of age. The posterior mandible region affected in more than eighty percent of the tumour cases. It may present as variably sized swelling of jaws. Pain and paraesthesia are rare. It usually appears multilocular (soap bubble appearance) in radiographs.

It occasionally is associated with an impacted tooth and causes expansion of the bony cortex, with the possibility of resorption of roots of the involved teeth [17, 18]. The most common histological patterns found are plexiform and follicular types. The others are desmoplastic, acanthomatous, granular and basal [2]. To confirm the diagnosis, the combination of imaging (plain as well as computed tomography) and biopsy can be performed.

The tumour infiltrates through the medullary spaces and might erode the cortical bone. After resorbing the cortical bone, it may extend into the adjacent tissues. The maxillary tumours of the posterior region tend to obliterate the maxillary sinus and may extend to infiltrate the skull base.

28.4.1 The Treatment Goals

- Complete removal of tumour
- Aesthetic reconstruction with minimal disfigurement
- Good prognosis
- Long-term follow-up

The treatment depends on the best judgement of the surgeons and individual status of the patient. The surgical planning should be based on the lesions present in the mandible or maxilla. The maxilla has got higher percentage of cancellous bone, which facilitates the spread of tumour in comparison to the mandible having thick and dense cortical plates, which limit the spread of neoplasm.

The treatment of the conventional/multicystic variant is classified into radical and conservative. The conservative methods include

- Curettage
- Enucleation
- Peripheral ostectomy with surgical excision
- Surgical excision with other adjuvant therapy such as cryotherapy or use of carnoy's solution
- Liquid nitrogen therapy [19]
- Marsupialisation

Radical treatment includes resection of bone. At least 1 cm of the surrounding healthy tissues should be removed along with the tumour in cases of cortical bone perforation because if tumour cells are left behind, they may give rise to locoregional recurrence even several years after resection [20]. There is a 1.26-fold increase in the chance of the recurrence rate with the increase in the size of every 10 mm of tumour [21].

In mandible, resection can be carried out on the basis of the extension of the lesion in the form of alveolectomy, marginal mandibulectomy, segmental resection, hemimandibulectomy or hemimandibulectomy with disarticulation depending on the extension of the tumour. Based on the extension of tumour, maxillectomy (partial, total or subtotal) has been performed in radical treatment of maxillary lesions [22].

Enucleation and curettage are inadequate because the tumour invades the adjoining cancellous bone. However, some conditions in which it is carried out are given below:

28.4.1.1 Indications of Enucleation and Curettage

1. In medically compromised patient or conditions in which patient is unfit for general anaesthesia.
2. Very young or old patient who is not willing for segmental resection.

If enucleation and curettage has to be done, it is preferable to be carried out in association with chemical cauterisation with the help of modified carnoy's solution and peripheral ostectomy.

The surgical treatment of solid/multicystic variant is controversial. A high rate of recurrence is reported if it is not adequately excised or resected. According to some authors, the initial treatment should be conservative as the tumour has low metastatic potential and the radical treatment should be done in cases of recurrence. While others believe that when-

ever possible complete removal of the tumour with preservation of lower border of the mandible will be the treatment of choice [23].

Conservative treatment has a recurrence rate ranging from 33 to 90%, as compared to the rate of recurrence by radical treatment, i.e. 7–25% in the literature. However, the patients experience serious functional and aesthetic impairments with radical treatment [24, 25]. Hasegawa et al. [26] also reported the recurrence rate of 43.5% following conservative management.

Enucleation alone showed the highest rate of recurrence amongst all the modalities of conservative management [27]. According to Esquillo ME [28], small multicystic and solid lesions can be treated by marsupialisation with good results. This will maintain good facial aesthetics of the patient, lessening the treatment cost but patients have to keep on long-term follow-up.

About 40% of intra-osseous Ameloblastomas did not recur after conservative management, which led to the conclusion that the small intra-osseous ameloblastomas can be treated with conservative management initially, leading to fewer post-operative complications and if the lesion recurs, the radical treatment can be carried out in the second-stage surgery aggressively [29].

Almeida AC et al. [30] in the systematic review and meta-analysis concluded that the bone resection should be the treatment of choice for primary multicystic ameloblastoma, also the chances of recurrence were 3.15 fold more when the conservative treatment was performed in comparison to radical treatment. Hendra FN et al. also suggest that the rate of recurrence was less when radical treatment was opted for the treatment of intra-osseous ameloblastoma in their systematic review and meta-analysis [31].

Antonoglou GN and Sandor GK [32] in the systematic review and meta-analysis concluded that no strong recommendations have been made regarding the treatment options regarding the intra-osseous ameloblastoma. However, radical treatment in the form of resection is the treatment of choice for solid/multicystic ameloblastoma.

Pogrel MA and Montes DM [33] concluded that Enucleation alone should not be the choice of treatment for multicystic or solid lesions. In the case of maxilla, partial maxillectomy and in mandibular lesions, segmental resection with 1 cm margin will be preferred to avoid recurrence.

Sampson DE and Pogrel MA [34] suggested the management algorithm for management of mandibular ameloblastoma, which is, in the case of mandibular ameloblastoma, if lesion is less than 1 cm, in plain radiograph, then curettage and cryotherapy is the treatment of choice and patient is to be kept on long-term clinical and radiological follow-up. If the

lesion is more than 1 cm, CT scan is to be done. If findings are positive, then segmental resection with involved soft tissue is carried out with suitable reconstruction and patient is to be kept on long-term clinical and radiological follow-up.

Sammartino et al. advocated the following treatment plan in Mandibular tumour management [24]. In the cases of small lesions, box resection has to be done and the patient has to keep for long-term follow-up to 10 years. For large lesions if cortical perforation is there on CT examination. Then segmental or marginal resection has been carried out along with excision of overlying soft tissues, if cortical perforation is absent then curettage is the choice of treatment with 0.5–1 cm of clinically uninvolved surrounding bone. In both cases, 10-year followup of patients is mandatory. If no recurrence occurs, orthopantomogram has to be done in every 2–3 years on the other hand if recurrence occurs, then the first or second small recurrence can be treated with marginal resection while for the third recurrence, the segmental resection is the choice of treatment.

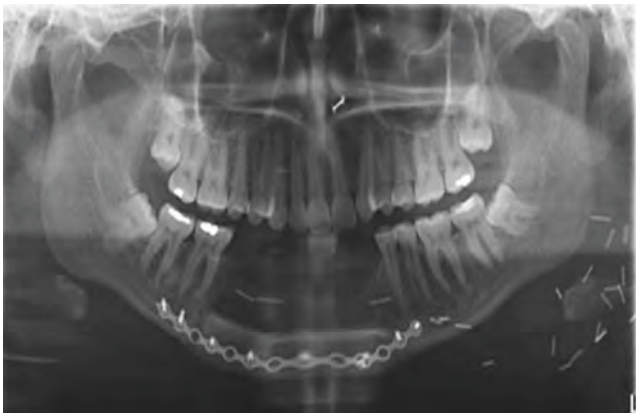
28.4.2 Surgical Management of Ameloblastoma According to the Anatomic Locations

28.4.2.1 Mandibular Anterior Region (Canine to Canine)

According to Gardner, anterior mandible should be approached conservatively because no important major anatomic structures are present in the anterior mandible. However, if curettage is used as a choice of treatment, recurrence is anticipated and it is preferred in smaller lesions. Always an attempt should be made to preserve the inferior border of mandibular in the anterior region because the tumour infiltration is less, due to the thick cortical bone of the symphyseal region. In large lesions with cortical perforation, marginal mandibulectomy will be the choice of treatment followed by long-term follow-up (Fig. 28.1). After marginal mandibulectomy, the lower border of mandible is reinforced with a reconstruction plate, to avoid pathological fracture in future (Videos 28.1 and 28.2).

28.4.2.2 Posterior Mandible (Bicuspid to Condyle)

Marginal mandibulectomy should be the choice of surgical treatment for the posterior mandible and body region while maintaining the inferior and posterior border whenever possible for solid/multilocular variant. Maxillomandibular fixation might be required after marginal resection without



©Association of Oral and Maxillofacial Surgeons of India

Fig. 28.1 Orthopantomogram representing marginal mandibulectomy, lower border protected with reconstruction plate

continuity defects to avoid the chances of pathological fracture. A reconstruction plate may be contoured before resection, in order to maintain the normal anatomic relationship between proximal and distal segments by marking the points of screw fixation on the normal bone. In recent years, mandibular reconstruction using intra-oral microvascular anastomosis following segmental resection in cases of ameloblastomas has been carried out with great success. Most commonly, free fibular graft has been used for the same, followed by dental rehabilitation with the help of dental implants [35, 36].

28.4.2.3 Anterior Maxilla (Canine to Canine)

Goodcell JF reported 2% ameloblastomas in anterior maxilla [37]. However, Sehdev MK et al. show 9% of ameloblastomas occurs in the canine and incisor region [38]. Less-aggressive treatment has been advocated in anterior maxilla when compared to posterior, because a sufficient distance from the vital structures allows being less radical. Radical treatment in the form of partial or total maxillectomy may result in significant deformity.

28.4.2.4 Posterior Maxilla (Bicuspid to Pterygoid Plates)

Ameloblastoma occurs 47% in the molar region, 15% in the maxillary antrum and floor of the nose, while 9% in the premolar region.

Lack of cortical bone in maxilla makes it much more dangerous than mandibular ameloblastomas. The definitive treatment becomes difficult in the posterior maxillary

region because tumours are not well confined by the thin maxillary cortical bone and easily spread beyond the maxillary bone boundaries. Early detection is also very difficult. Posterior maxillary tumours are rarely treated by conservative management. Extra-oral or intra-oral resection of the tumour is carried out, sometimes Le fort I down fracture is required to access the tumours of maxillary sinus or the tumour invades the posterolateral wall of the maxillary sinus.

Weber Fergusson incision and mandibulotomy can be used for accessing the tumors of maxilla, pterygoid and infra temporal fossa. When reconstruction of the defect after maxillectomy has been planned by temporalis muscle, Rai A et al. [39] advocated use of Borle's extension weber fergusson incision.

Various surgical options in management of maxilla/mandible tumours.

Benign Mandible Tumours

Type or surgery depends on number of factors

1. Type of pathology—Benign/Benign aggressive
2. Extent of involvement—e.g. Sufficient lower border of mandible present or not
3. Site of tumour—Anterior mandible/Posterior mandible

Based on this options starting from the most conservative to most radical are:

1. Marsupialisation
2. Enucleation or curettage
3. Peripheral ostectomy or En bloc resection
4. Segmental resection

Access incisions:

1. Intraoral transmucosal access
2. Combined Intraoral and extraoral submandibular access
3. Combined Intraoral and Visor incision

Repair:

1. Primary mucosal closure
2. Packing cavity and healing by secondary intention
3. Reconstruction plate with primary mucosal closure
4. Reconstruction plate with free bone graft
5. Vascularised Bone free flap

Benign Maxillary Tumours

Type or surgery depends on number of factors

1. Type of pathology—Benign/Benign aggressive
2. Extent of involvement—e.g. Involvement of sinus/pterygoids/infratemporal fossa
3. Site of tumour—Anterior maxilla/Posterior maxilla

Based on this the following excision options are possible:

1. Marsupialization into Oral cavity/Maxillary Sinus
2. Enucleation/Curettage
3. Enbloc resection—Low level/High level maxillectomy

Access incisions:

1. Transoral access
2. Weber Ferguson incision—Good for anterior tumours
3. Mandibulotomy access approach—This provides excellent access for posterior tumours especially when access to the pterygoids/intratemporal region is required

Repair:

1. Primary closure
2. Packing cavity to allow healing by secondary intention with a Healing plate
3. Obturator
4. Local flap—e.g. Temporalis
5. Free flap reconstruction

28.5 Reconstructive Modalities After Surgical Resection of Ameloblastoma

Need for Reconstruction:

1. For restoration of movements and equilibrium of mandible
2. For maintenance of normal occlusal plane, floor of the mouth and tongue's anatomical position
3. For restoration of near normal feeding
4. For acceptable aesthetics and function.
5. For more favorable social acceptance
6. To establish the arch form, width and alveolar height.
7. To establish the bone continuity and maintain facial contours

28.5.1 Timing of Reconstruction

Immediate reconstruction is usually performed with the help of microvascular-free flaps, harvested from fibula, scapula, iliac crest and ribs. For the reconstruction of the mandible, free fibula flap is the treatment of choice. It is superior to iliac crest graft. Scapula flap for maxillary reconstruction may be a good alternative because of its long pedicle and good bone quality. For soft tissue reconstruction, the radial forearm-free flap is the choice of treatment. Most of the surgeons still prefer to use Titanium reconstruction plate for reconstruction when free flaps are not possible as an immediate reconstruction modality. Delayed reconstruction (second stage) can be performed for reconstruction with the help of a titanium reconstruction plate. The immediate reconstruction significantly improves the patients' health-related quality of life, many patients prefer immediate reconstruction [40].

Lawson et al. [41] reported 90% success rate with delayed reconstruction in comparison to immediate, which is 46% using non-vascularised bone grafts.

Autogenous bone graft selection (Vascularised free flaps vs non-vascularised bone graft) depends on following factors

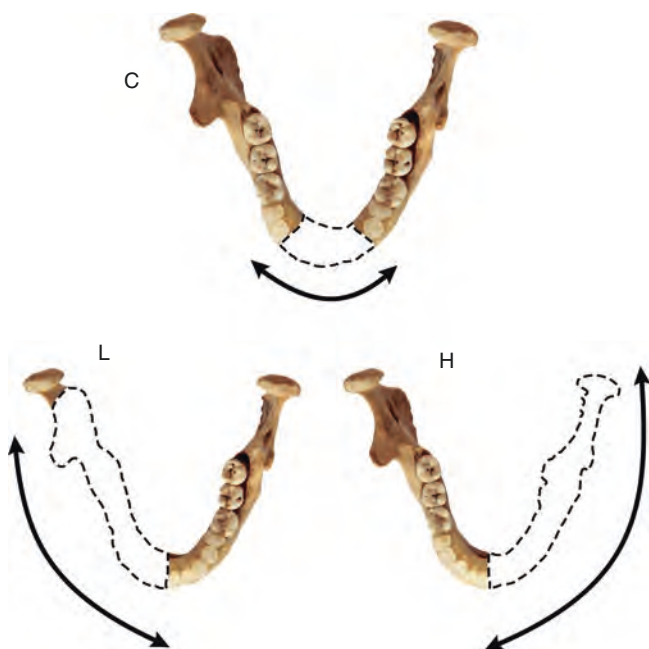
1. Experience of the surgeon
2. Contour and size of the defect
3. Size and quality of the soft tissue available

The HCL classification [42, 43] is used as an aid in classifying mandibular defects. The defect from canine to canine, i.e. the central defect is designated as 'C'. The lateral segment defect excluding condyle designated as 'L' and when condyle is included in resection with lateral mandible the defect is designated 'H' (Fig. 28.2). The importance of this classification indicates that reconstruction of lateral defect can be done by straight bone segment while defect located centrally required osteotomies.

28.5.1.1 Case Scenario 1 (Fig. 28.3a–g)

A 38 year old male patient reported to our outpatient department with the chief complaint of painless swelling of lower jaw since last 6 months (Fig. 28.3a). History of present illness represents swelling initially was of lemon size and increasing gradually to reach the present size, extending from right side of the body region of the mandible to the ramus region of the opposite side. On intra-oral examination, a diffuse swelling was present from one side of the molar region extending to the other side of the molar region of the mandible (Fig. 28.3b).

The orthopantomogram (Fig. 28.3c) and the CT scan (Fig. 28.3d) showing the multilocular lesion extending from the right side of the first molar to the ramus region of the contralateral side. The incisional biopsy of the lesion confirmed the diagnosis of solid/multicystic ameloblastoma. Under general anaesthesia, the resection of the lesion was done, the complete resection of lesion was confirmed in the specimen radiography (Fig. 28.3e). The reconstruction of the



©Association of Oral and Maxillofacial Surgeons of India

Fig. 28.2 The HCL Classification

defect was done with the help of microvascular free fibula flap and with the titanium reconstruction plate (Fig. 28.3f), post-operative OPG representing reconstruction (Fig. 28.3g).

28.5.2 Bone Graft Substitutes

The calcium phosphate cement (Hydro set) is the commonly used material, which converts in situ to hydroxyapatite, serving as an effective osteointegrative and osteoconductive material [44]. The other implantable material options include high-density porous polyethylene implants [45]. Using rapid prototype models, the custom-made implants are commonly used for the reconstruction of maxillofacial defects with good results [46].

The titanium mesh tray filled with autologous cancellous bone blocks fixed with the residual segment of bone and also titanium mesh cage filled with fresh bone marrow, recombinant human bone morphogenic protein (BMP) and xenogenic bone mineral are used for reconstruction of mandibular defect. The BMP is the key activator of bone induction [42].

Recent advances in mandibular reconstruction include transport disc distraction osteogenesis, modular endoprosthesis and tissue engineering. Dental implants are commonly used in autogenous bone grafts for the rehabilitation of masticatory functions [42].

28.6 Unicystic-Type Ameloblastoma

Robinson and Martinez [47] first described Unicystic Ameloblastoma (UA) in 1977.

In 1988, Ackermann GL et al. [48] reclassified UA with prognostic and therapeutic implications into three types

Type 1: Unilocular cystic lesions lined by epithelium exhibiting features of ameloblastoma.

Type 2: Epithelial nodules arising from cystic lining and projecting into the cyst lumen.

Type 3: The presence of invasive islands of ameloblastomatous epithelium in the connective tissue wall of the cyst and these islands may or may not be connected to the cyst lining.

28.6.1 Clinical and Radiographic Features

Most of the UA clinically and radiographically resemble dentigerous cysts in behaviour. Embedded teeth are associated with some UA and hence resembles residual or primordial cysts.

UA most commonly occurs in the second and third decade of life and have predilection to mandible [48]. UA many times are associated with mandibular third molars. There will be well-corticated unilocular and often pericoronal radiolucency

In some cases, root resorption can occur.

28.6.1.1 Case Scenario 2 (Fig. 28.4a, b)

A 14 year old female reported with swelling on the left side of the ramus region for the past 3 weeks. OPG (Fig. 28.4a) and PA view (Fig. 28.4b) showed a large unilocular radiolucent lesion involving the whole of the ramus of the left mandible. Tooth bud of lower left third molar was absent. The lesion seemed to arise from the impacted tooth bud of lower left second molar and the lesion was also involving the roots of lower left first molar. Under the provisional diagnosis of a dentigerous cyst, the lesion was enucleated under anaesthesia and primary closure was done and the impacted tooth bud was removed in this case. The histopathology report was that of an unicystic ameloblastoma with mural changes. The child was on follow-up with no evidence of recurrence.

On histological examination, various situations may be found such as shown in Fig. 28.5

1. The ameloblastomatous epithelial lining
2. An ameloblastoma nodule projects into the lumen (Luminal Ameloblastoma)
- 3a. Ameloblastoma islands present in the connective tissue wall of an apparently non-neoplastic cyst.
- 3b. Proliferation of ameloblastoma into the connective tissue wall from cystic lining. (One of the Mural variant)

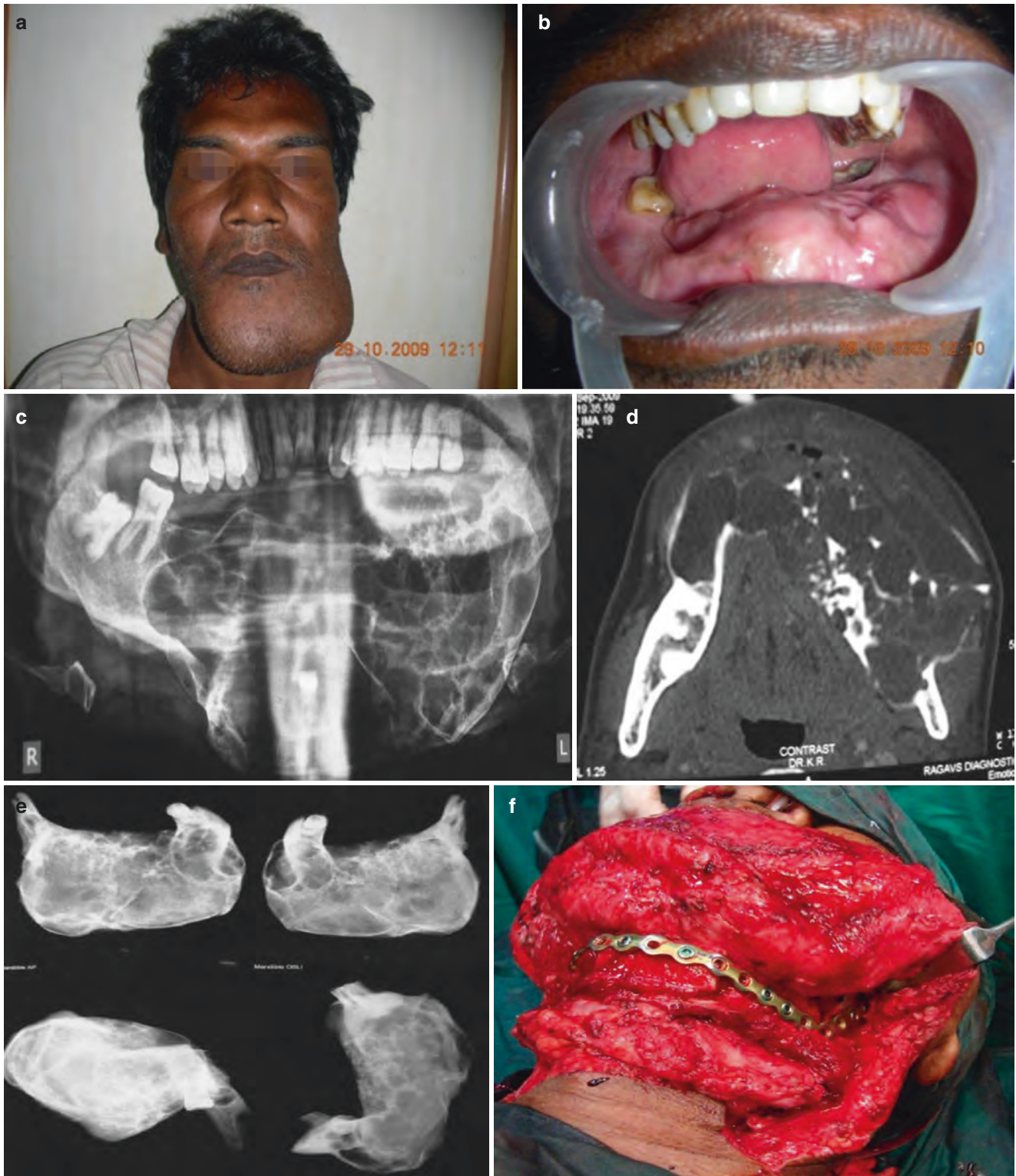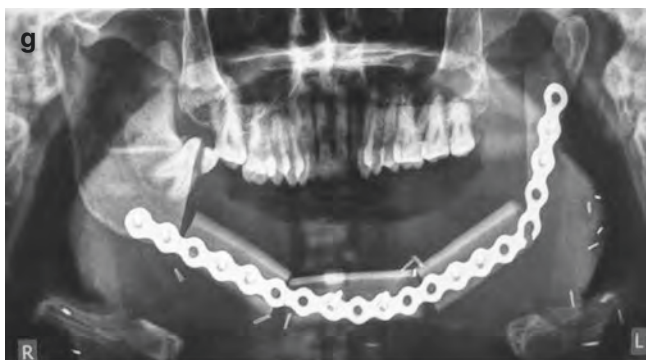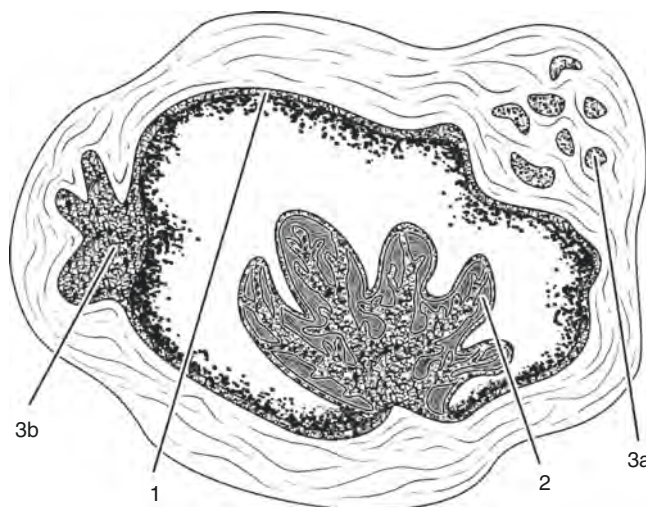


Fig. 28.3 (a) Pre-operative extra-oral view. (b) Pre-operative intra-oral view. (c) Pre-operative OPG. (d) Pre-operative CT Scan of the patient. (e) Specimen Radiography. (f) Clinical picture showing reconstruction with the reconstruction plate. (g) Post-operative OPG



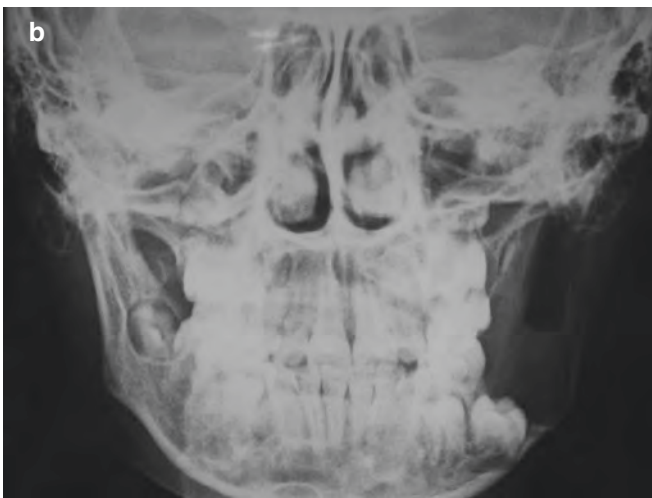
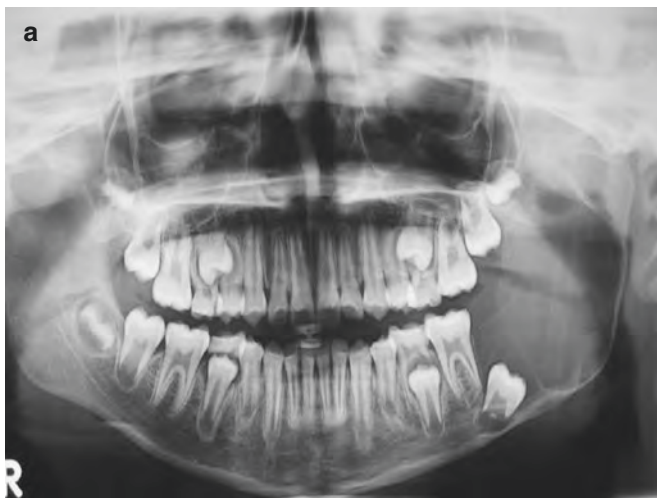©Association of Oral and Maxillofacial Surgeons of India

Fig. 28.3 (continued)



©Association of Oral and Maxillofacial Surgeons of India

Fig. 28.5 Various situations of Unicyclic Ameloblastoma found on Histological examination. 1. The ameloblastomatous epithelial lining. 2. An ameloblastoma nodule projects into the lumen (Luminal Ameloblastoma). 3a. Ameloblastoma islands present in the connective tissue wall of an apparently non-neoplastic cyst. 3b. Proliferation of ameloblastoma into the connective tissue wall from cystic lining. (One of the Mural variant)



©Association of Oral and Maxillofacial Surgeons of India

Fig. 28.4 (a, b) OPG and PA view showing Unicyclic Ameloblastoma

28.6.2 Management

UA treatment is controversial and can be grouped into

- Enucleation
- Marsupialisation or decompression
- Radical resection

Conservative management has been advocated by cakarer et al. in their study on large benign aggressive lesions of the jaws, where they performed decompression followed by curettage if required [49].

Zheng et al. in 2019 published a long-term follow-up study on 116 cases of UA and have concluded that marsupialisation as an effective treatment option for UA. They found the recurrence rate more for the mural sub-types and the predictors for outcomes were resorption of the root, perforation of the cortical bone and histopathological sub-types [50].

Usually, initial treatment for UA is enucleation because they appear clinically as cysts, and the histopathology type is known only in the excision biopsy report as mural changes can be picked by the pathologist only when the full specimen is available. For histologic type showing luminal changes, the treatment of choice is Enucleation, but has to be followed up for 5–10 years. In types where the ameloblastoma infiltrates the adjacent cancellous bone, marginal resection is the treatment of choice after initial Enucleation and curettage [51]. This means that patient has to undergo two surgeries based on the histopathological examination.

There is some controversy on its management, with some authors advocating aggressive management, especially for the mural variant, while others advocating conservative management such as curettage, peripheral ostectomy and various adjuvant materials such as Carnoy's solution and Liquid Nitrogen [33, 52, 53]. If adequate follow-up is possible, the UA of posterior mandible can be treated conservatively with curettage or peripheral ostectomy.

According to LAU and Samman [54], 30.5% recurrence rate reported with enucleation alone. Application of carnoy's solution along with Enucleation decrease the recurrence rate to 16% and the least percentage of recurrence was seen with resection of tumour, i.e. only 3.6%

28.7 Use of Carnoy's Solution in Ameloblastomas

- Stoelinga and Bronkhorst [55] in 1987 suggested the use of carnoy's solution for UA as a chemical cauterisation. The carnoy's solution consists of chloroform 3 ml, absolute Alcohol 6 ml, 1 ml glacial acetic acid, sclerosing agent ferric chloride 1 gm for the management of fistulae and cysts as a fixative.
- The modified carnoy's solution avoids the use of chloroform due to concerns about its carcinogenicity [56]. However, the recurrence rate is lower with application of conventional carnoy's solution after enucleation and curettage in comparison to modified carnoy's solution [57].
- The use of carnoy's solution reduces the risk of recurrence by fixing the residual tumour tissues after enucleation of UA with mural invasion, but conventional multicystic ameloblastoma and some UA are unlikely to be effective by carnoy's solution. The recurrence experienced more in patients treated with Enucleation alone without the application of carnoy's solution.
- The solution is applied for 5 min with the help of cotton applicator or gauze soaked in carnoy's solution in the bony cavity. Irrigation with normal saline is done after

that. The nerve and vessels should be avoided by contact of the carnoy's solution as much as possible. The method and duration of application of carnoy also is contentious where different regimes have been proposed by various authors.

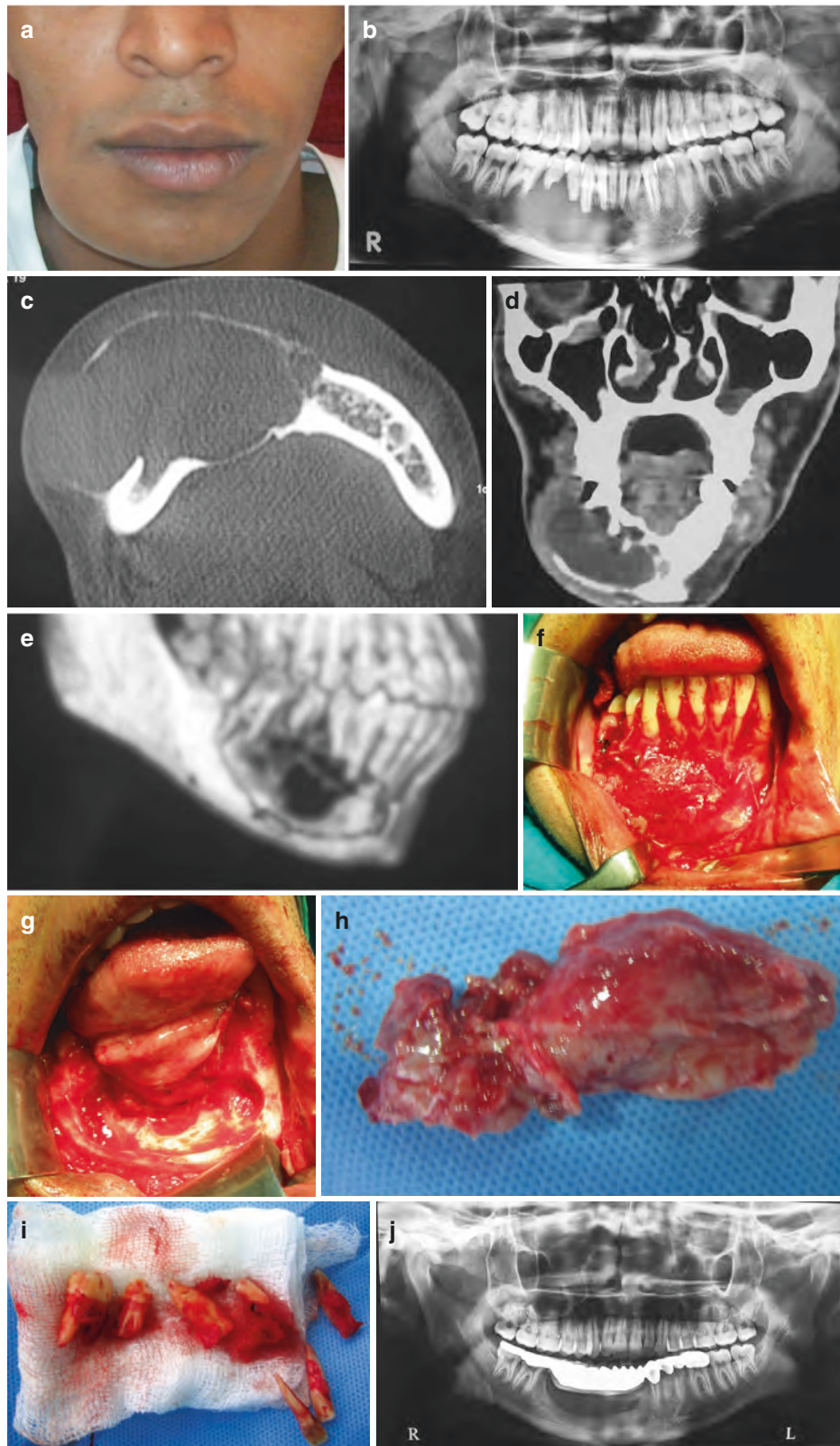
28.7.1 Case Scenario 3 (Fig. 28.6a–i)

Case scenario 3 is provided to show that conservative management with adjunctive procedures will give reasonably good results thereby avoiding major resective and reconstructive surgeries. A 21-year male reported with gradually growing swelling right side body mandible (Fig. 28.6a). OPG (Fig. 28.6b) showed an unilocular expansile lesion in right side body mandible with resorption of the associated roots. There was intra-oral vestibular swelling and it was fluctuant on palpation due to thinning of the labial cortex. CT views (Fig. 28.6c–e) show the lesion to be unilocular, expansile with loss of both labial and lingual cortices. An incisional biopsy was performed, which gave the report as Unicystic ameloblastoma. This could be considered as an aggressive form as there was root resorption. Considering the age of the patient, a less-radical approach was taken, which involved excision of the lesion by raising an intra-oral crevicular mucoperiosteal flap (Fig. 28.6f), extraction of all the involved teeth (Fig. 28.6i), performing a peripheral ostectomy and applying carnoy's solution (Fig. 28.6g) and also excising the overlying mucosa, which was in direct contact with the lesion. The excised cystic lesion was quite thick walled and an in toto enucleation was possible (Fig. 28.6h). A reasonable thickness of the lower border of mandible was left behind and as the alveolar part of labial and lingual cortices was removed, excess tissue was available for achieving a tension-free primary closure. The postoperative OPG at one and half years (Fig. 28.6j) shows no evidence of recurrence and prosthetic rehabilitation performed. The patient is recurrence free for past 7 years.

28.7.2 Case Scenario 4 (Fig. 28.7a–f)

This case scenario is given to show that at times complex resection and reconstructive procedures may be avoided in ameloblastomas considering, the patients age and general health and other social background. In such cases where a conservative approach is used, the adjunct measures of peripheral ostectomy and carnoy's solution will serve as adjunct methods to give an overall good prognosis (readers are also advised to refer chapter 27 on odontogenic cysts for use of these adjunct measures in odontogenic keratocyst).

A 67 year old male patient presented with loosening of teeth and swelling of gums in the anterior mandible



©Association of Oral and Maxillofacial Surgeons of India

Fig. 28.6 (a) Clinical image showing swelling right body mandible. (b) opg showing the radiolucent lesion right body mandible with root resorption. (c) Axial CT image showing the expansile lesion with thinning of the labial cortex. (d) Coronal CT image showing the expansile nature of the lesion. (e) 3D CT showing the erosion of both labial and lingual cortical walls. (f) Intra-oral intra-operative view showing the

lesion exposed by crevicular flap. (g) Intra-oral view of the surgical bed after extraction of teeth, excision of lesion and peripheral osteotomy. (h) Image of the excised cystic lining, with thick walls. (i) Images of the extracted teeth showing the root resorption, (j) post operative radiograph after prosthetic rehabilitation

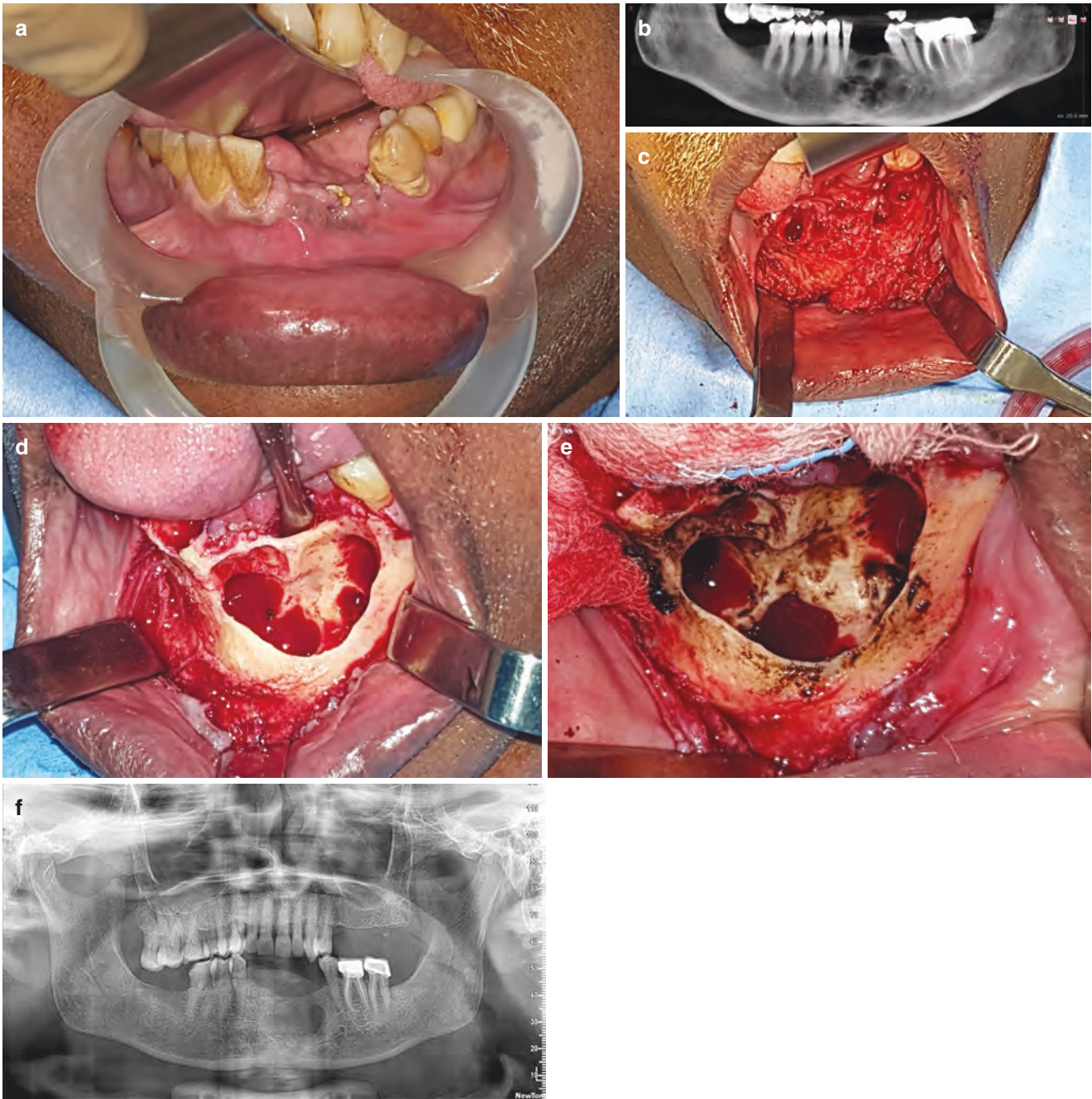


Fig. 28.7 (a) loosening of teeth and expansion of the gums in the anterior lower mandible. (b) A OPG and CBCT showing multilocular radiolucency in the anterior mandible. (c) Lesion exposed (d) lesion excised and peripheral osteotomy done (e) Carnoy's solution applied to surgical bed (f) sixteen month post operative OPG

(Fig 28.7a). A CBCT scan (Fig 28.7b) confirmed the presence of a multilocular radiolucency in between right lateral incisor and left first premolar region. An incisional biopsy confirmed a diagnosis of a plexiform ameloblastoma.

Considering the patient's age and general health, it was decided to follow a conservative line of treatment to avoid the need for complex reconstruction.

The lesion was exposed under general anesthesia (Fig 28.7c) and the involved teeth and tumour lining was

removed. A Large round bur was then used to remove 3mm of bony walls around the locules left by the lesion (Fig 28.7d). The lesion was treated with modified Carnoy's solution for 3 minutes (Fig 28.7e) followed by irrigation with normal saline and primary closure achieved.

Excision pathology confirmed the diagnosis of a Plexiform ameloblastoma. The healing was uneventful. A 16 month post operative radiograph showed good bony healing (Fig 28.7f) without any recurrence and the patient is on long term follow-up.

28.8 Extrasosseous/Peripheral Ameloblastoma (PA)

The tumour was first described by Kuru [58] 1911. The PA is defined as the tumour having intra-osseous ameloblastoma characteristics histologically but occurs in the soft tissues overlying the tooth-bearing areas of mandible and maxilla. In comparison to the intra-osseous solid/multicystic ameloblastoma, it is the extrasosseous counterpart [59].

PA representing only 1–5% of all ameloblastomas considering it as a very rare odontogenic tumour. It is also called ameloblastoma of soft tissue, mucosal origin ameloblastoma and gingival ameloblastoma. It arises from the remnants of the odontogenic epithelium within the lamina propria gingival or from the gingival epithelium of the basal cell layer.

It is painless, firm and exophytic growth with a smooth, granular and warty surface. Most commonly located in the oral mucosa or the gingiva. It occurs in wide age range groups, i.e. from 1 to 92 years with more than 64% of cases occurring in the fifth to seventh decade of life. In edentulous areas, it affects the alveolar mucosa. The ratio of 2.4:1 is noted in mandible: maxilla. Intra-osseous ameloblastoma rarely extends to the gingival tissues and merge with gingival epithelium creating PA of the exophytic type [60]. Histopathologically same histomorphologic cell types of odontogenic epithelium seen in solid/multicystic variant as consist in PA.

28.8.1 Differential Diagnosis

1. Peripheral odontogenic fibroma
2. Peripheral variant squamous odontogenic tumour

It does not show invasive behaviour and the treatment of choice will be conservative excision with adequate disease-free margins. The recurrence is low, but patients are to be kept on long-term follow-up.

28.9 Metastasising (Malignant) Ameloblastoma

‘Malignant Ameloblastoma (MA)’ term was proposed by Sloomweg and Muller [61] in 1984. According to them, it is well-differentiated ameloblastoma that metastasises but which maintains the characteristic cytologic features of original tumour [62]. The ameloblastic tumour that undergoes malignant cytologic transformation; the term ‘Ameloblastic carcinoma’ is used.

Metastasis is the only factor that distinguishes ameloblastoma from MA. Its clinical behaviour is helpful in diagnosing the tumour.

Lung shows maximum 75% metastatic deposits, 15% each by spine and cervical lymph nodes followed by

cervical lymph nodes and spine (15% each) [63]. Small bowel, liver, skull, brain and kidneys were the other locations, which show metastases but with lower incidence [64].

MA is very rare with an occurrence rate of 2% of all benign ameloblastomas [65]. The age ranges from 5 years to 74 with 34.4 years mean age. 1:1.2 is the male to female ratio. The majority cases were localised in the mandible. The survival time ranges from 3 months to 5 years after the appearance of metastases. Most MA are histologically plexiform type but not significantly different from the metastatic type in their histologic and cytologic features [66].

The initial tumours were treated with Enucleation and curettage while advanced with resection (block or segmental). Open thoracotomy is indicated in discrete and isolated lung metastases and wedge resection. Occasionally, chemotherapy gives successful results. Inoperable metastatic deposits can be treated with radiation therapy but having an unpredictable response [67, 68].

28.10 Squamous Odontogenic Tumours

28.10.1 Introduction

Squamous odontogenic tumour (SOT) was first described by Pullon et al. [69] as a rare benign odontogenic tumour in 1975. It affects all the age group and equally occurs in both the jaws. SOT histologically characterised by squamous epithelial islands, which are surrounded by mature connective tissue stroma. The SOT is occasionally misdiagnosed as squamous cell carcinoma, keratocanthoma, ameloblastoma and verrucous carcinoma. It is hamartomatous epithelial proliferation, arising probably from cell rests of Malassez [70]. The differential diagnosis of SOT may be acanthomatous and desmoplastic ameloblastoma variants, squamous cell carcinoma (well differentiated).

28.10.2 Definition

“SOT is a locally infiltrative, benign neoplasm consisting of islands of well-differentiated squamous epithelium in a fibrous stroma. The epithelial islands shows foci of central cystic degeneration occasionally” (WHO).

28.10.3 Clinical Features [71]

1. Swelling, which is painless
2. Mildly painful gingival swelling
3. Loosening of involved teeth
4. Occurs in the mean age of 38 years with age ranges from 8 to 74 years.

5. Multiple SOT, which involves several quadrant of mouth in few patients have been reported, a family of 3 siblings having multiple lesions has been reported.
6. Absence of periodontal ligament between the lesion & the root of the tooth, suggesting that lesion arises from Malassez rests cell in the periodontal ligament or closely adjacent mucous membrane.
7. Equally affects maxilla and mandible, but most commonly involves incisor-cuspid area in maxilla and bicuspid-molar area in mandible

28.10.4 Radiographic Features [72]

1. Unilocular radiolucency of the triangular or semicircular type located in alveolar bone along the roots' lateral surface.
2. In some cases, vertical bone loss appears
3. The radiolucent area may show ill-defined or well-defined margins
4. Sometimes, tumour appears as an intra-bony pocket between the teeth
5. Peripheral lesions may cause saucerisation of underlying bone, which is likely because of the pressure phenomenon rather than infiltration of the tumour.
6. Few extensive lesions show multilocular radiolucency, pushing the maxillary sinus and involving the mandibular body region.

28.10.5 Treatment and Prognosis

Conservative treatment in the form of local excision, enucleation and curettage may be done for the successful management of SOT. Recurrent and clinically aggressive lesions have been treated with en bloc excision. Extraction of the associated teeth along with the conservative treatment is mandatory. It has a very low recurrence rate [73].

Cortical bone erosion of maxilla and mandible exhibits aggressive biological behaviour. Aggressive treatment should be followed for the lesions, which show early recurrence [74].

28.11 Calcifying Epithelial Odontogenic Tumour

Pindborg in 1955 first introduced the calcifying epithelial odontogenic tumour (CEOT) in the scientific literature [75]. It is well known as 'Pindborg Tumor' since then. CEOT is slow growing, benign and occasional locally invasive odontogenic neoplasm, which is epithelial in its origin.

WHO accepted and adopted the term calcifying epithelial odontogenic tumour (CEOT) in its first edition of 'Histological typing odontogenic tumours, jaw cysts and

allied lesions', and recognised it as a distinct entity [76]. It may be extra-osseous or intra-osseous.

28.11.1 Definition

CEOT is a epithelial odontogenic neoplasm, which is locally invasive and is characterised by the presence of amyloid material that may become calcified (WHO)

28.11.2 Epidemiology

It accounts for less than 1% of all odontogenic tumours, hence considered uncommon. It commonly occurs between the age of 8 and 92 years with the mean age of 36.9 years.

The intra-osseous variant occurs in the third, fourth and fifth decade of life in 64% of patients [77]. CEOT has no gender predilection, and occurs equally in both the sexes. Premolar and molar regions are the commonest site of occurrence, although can occur at any site. Anterior gingiva is most commonly affected by the peripheral lesions. Maximum cases reported are of intra-osseous lesions, only 6% arise in extra-osseous locations. Mandible is affected by intra-osseous lesions more frequently than maxilla, with a ratio of 2:1.

28.11.3 Clinical Features

CEOT is slowly growing, painless, expansile and hard bony swelling, which can cause thinning of the cortical bone and infiltration of soft tissue subsequently. It can cause rotation, tipping, migration or mobility of tooth secondary to resorption of roots. In the anterior region, there is also a distinctly uncommon peripheral variant of CEOT, limited to soft tissue only, presenting as a nodular mass on the gingiva.

28.11.4 Radiographic Features

The larger or the mature tumour will be mixed radiolucent—radiopaque, although the early tumour may be completely radiolucent. CEOT is often associated with unerupted teeth. It may be unilocular and cystic in appearance. It can demonstrate a mixture of large and small multilocular spaces described as 'soap bubble' and 'honey comb' in appearance. The radiographic borders in almost all cases between surrounding tissues and tumour appear to be circumscribed and well defined [78].

CEOT on CT examination demonstrating thinning and expansion of lingual and buccal cortical plates with well-defined mass containing scattered radiopaque areas of different size and signal intensity in mandible. Pindborg tumour on MRI reveals predominantly a hypointense lesion on T1-weighted images and mixed hyperintense lesion on T2-weighted images [79].

28.11.5 Treatment

Surgical management is the treatment of choice for CEOT. Conservative treatment in the form of Enucleation or curettage followed by judicious removal of the thin layer of bone adjacent to the tumour is the choice of treatment in small, intra-bony lesions with well-defined borders. However, the tumours treated with curettage and enucleation show a recurrence rate ranging from 15 to 30% after 2–4 years with the overall recurrence rate of 14% [77].

According to Melrose RJ [80], even the small CEOTs are infiltrating in nature. A margin of about 1 cm normal bone should be removed along with the tumour excision. Peripheral tumours are treated with smaller margins 0.5 cm because they are less aggressive. Few recurrences have been reported with the tumours treated with jaw resection. However, the patient should be kept for follow-up upto 5–10 years.

The recurrent lesions and the tumours, which are diagnosed late in their clinical course, which over an extended time becomes larger and extensive (more than 4 cm in size) may not respond well to conservative management-like surgical excision only. Segmental resection such as partial or hemimandibulectomy or hemimaxillectomy will be the treatment of choice. However, it may leave a significant bony discontinuity requiring grafting or extensive soft tissue reconstruction.

The incidence of malignant transformation is very low; however, Veness et al. [81] reported a case of metastatic spread and malignant transformation with CEOT.

28.12 Adenomatoid Odontogenic Tumour

Stafne in 1948, first described the adenomatoid odontogenic tumour (AOT) as an odontogenic neoplasm [82]. It was referred as ameloblastic adenomatoid tumour or adenoameloblastoma initially, because it was considered as a variant of ameloblastoma [83]. The term AOT, which is generally accepted today suggested by Philipsen and Birn [84].

28.12.1 Definition [85]

A neoplasm of locally invasive nature was characterised by ameloblastoma-like islands of epithelial cells in a mature connective tissue stroma. Aberrant keratinisation may be found in the form of ghost cells in association with varying amounts of dysplastic dentin (WHO).

Three variants of AOT are recognised, i.e. Follicular, Extra follicular and peripheral.

The peripheral type arises from the gingival tissues and is very rare. The follicular type is commonly associated with impacted tooth and found in 75% of cases; on the other hand, the extrafollicular type is located between the roots of adjacent teeth and is not related to an unerupted teeth [86].

28.12.2 Clinical Features

- AOT commonly occurs in the anterior region of jaws, particularly the maxilla.
- It occurs commonly in young patients, two-thirds of the cases occurring between 10 and 19 years of age. However, the age ranges from 3 to 82 years [87].
- Females are affected more than males with a ratio of 5.6:1.
- Size of AOT ranges from 2 to 7 cm with more than 60% involving the entire quadrant [88].
- The most common tooth associated with AOT is impacted canine followed by premolars and lateral incisors [89].

Radiographically, the most common appearance will be a well-demarcated unilocular radiolucency associated with unerupted tooth. Sometimes, intra-bony cases show scattered radiopacities within the radiolucency. Intra-oral periapical radiographs found to be better than OPG are best suited for showing discrete calcified deposits [90].

The AOT is usually well-encapsulated tumour so the treatment of choice will be Enucleation and Curettage. The recurrence is extremely rare [91].

28.13 Mixed (Epithelial-Mesenchymal) Origin

28.13.1 Ameoblastic Fibroma

Ameloblastic Fibroma (AF) was first reported by Kruse in 1891 [92]. AF consists of odontogenic ecto-mesenchyme resembling the dental papilla, epithelial strands and nests resembling dental lamina and enamel organ. Dental hard tissues are absent in it. The lesion is referred to as ameloblastic fibro-dentinoma if there is dentin formation. It is a rare odontogenic mixed tumour in which ectomesenchymal and epithelial elements are neoplastic. It accounts only 2% of all odontogenic tumours [93].

28.13.1.1 Clinical Features

AF occurs in young adults and children with an age range from 1.5 to 42 years, with the average age ranging from 14.5 to 15.5 years [94]. It was occasionally reported in middle-aged individuals. There is no gender predilection. More than 50% of patients present with a sign of swelling. Failure of tooth eruption, pain, tenderness and discharge are the other common findings [95]. Posterior mandible is the commonest site of occurrence and first permanent molar and second primary molar areas were involved in more than 70% of cases.

28.13.1.2 Radiographic Features

Multilocular radiolucency with sclerotic margins is the most common radiographic appearance. Unilocular radiolucency is the feature of small tumours, while large tumours extend through the bony cortices. The size typically ranges from 1

to 8 cm [96]. Ameloblastic fibrosarcoma is the differential diagnosis of AF.

Enucleation and curettage of the adjacent bone along with the extraction of affected teeth is the treatment of choice for AF. They occur rarely but required a long-term followup. In order to preserve the teeth involved in the tumour, the chances of recurrence increase after conservative management [97, 98].

The ameloblastic fibro-odontoma is composed of connective tissue characteristic of an ameloblastic fibroma and calcified tissue identifying the tumour as a complex odontoma. The ameloblastic fibro-odontoma diagnosis is based on the histologic evidence of ameloblastic fibroma with active odontogenic epithelium embedded in an embryonal connective tissue. The differential diagnosis of ameloblastic fibroma and ameloblastic fibro-odontoma is based on the absence (ameloblastic fibroma) and presence (ameloblastic fibro-odontoma) of enamel and dentin. A tumour is called ameloblastic fibro-dentinoma when exclusive dentin formation is observed. A tumour is called an ameloblastic fibro-odontoma in the presence of both enamel and dentin. In ameloblastic fibroma, no dental hard tissues are present [99]. AFO is similar to AF described by the WHO, and [they also show inductive changes that lead to both enamel and dentin formations]. Moreover, AFO and AF are defined as hamartomatous lesions and they are believed to be stages of formation of odontoma. That means the above-mentioned lesions should not be considered as distinct entities [100].

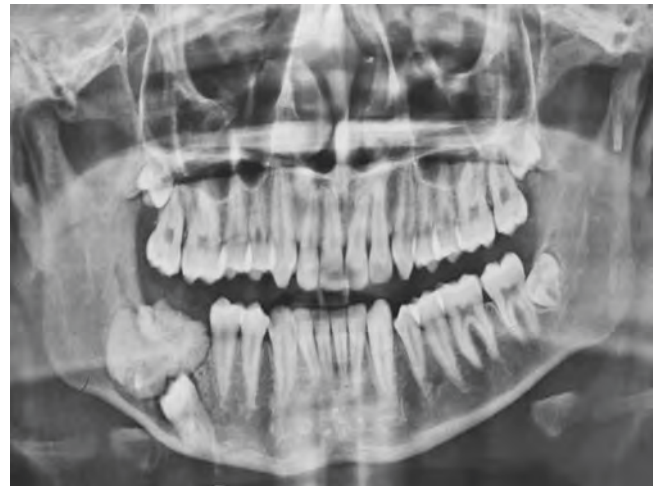28.13.2 Odontoma (Compound, Complex Types)

In 1866, Broca coined the term 'Odontome' [101]. The term 'Odontoma' was given by Thoma and Goldman, to include tumours that were composed of well-differentiated tooth structure [102]. Odontoma defined as a tumour that differentiated and developed enough to produce dentin, enamel and cementum in varying proportions [103].

Compound odontoma is defined by the WHO as a malformation in which all the dental tissues represented in a more orderly pattern than complex odontoma, so that lesions consist of many tooth-like structures.

Complex odontoma is a type of malformation in which all dental tissues are represented and individual tissues are well formed, but occur in a disorderly pattern [104].

Compound-type odontomas are more common than complex odontomas [105]. According to Regezi, the compound odontomas are 37% and complex odontomas were 30% of all the reported odontogenic tumours [106]. Odontomas occur equally in both sexes. They are rarely associated with deciduous teeth but more frequently associated with permanent teeth. Anterior maxilla is the most common site for the occurrence of compound-type odontome while posterior mandible (Fig. 28.8) is affected more commonly in complex odontomes followed by anterior maxilla [107].



©Association of Oral and Maxillofacial Surgeons of India

Fig. 28.8 OPG showing complex odontome in mandible right molar region

They are small, painless and hard mass. Permanent impacted or retained deciduous teeth are present as a common symptom. The second most common complaint is swelling. Complex odontoma may become large and produce asymmetry with bone expansion [108, 109].

On radiological examination, the lesion consists of densely opaque masses of varying size, usually associated with unerupted or impacted teeth. The radiolucent line surrounds the opaque masses. The collections of tooth-like structures of different shapes and sizes are the features of compound odontomes, the teeth are of diminutive sizes. The complex-type odontomes appear as calcified masses that have consistency the same as the tooth structure.

The treatment of choice for odontomes is surgical excision and recurrence is very rare.

28.14 Mesenchymal Origin Tumours

28.14.1 Odontogenic Myxoma

Myxoma is very uncommon. It accounts for 0.5 to 20% of all odontogenic tumours and has a incidence of 0.07/million [110]. It arises from mesenchymal stroma and is a benign, locally aggressive tumour. Bone, soft tissues and most frequently the myocardium are favourite sites for myxomas. Jaws myxomas are both odontogenic and osseous in the origin. Myxoma according to WHO is defined as a locally invasive neoplasm, consisting of angular and rounded cells that lie in an abundant mucoid stroma [111].

28.14.1.1 Clinical Features

The myxomas have a predilection for molar and premolar regions of mandible and maxilla, however they can occur

anywhere in the jaws. One third of myxomas located in the maxilla while two third in mandible. In maxillary myxomas, the cortical expansion and perforation of bone are common and often extend into the sinus [112].

It is reported to have a slight female predilection (1.5:1) while other authors reported equal gender predilection between females and males. Odontogenic myxomas most commonly occur in the second and third decade of life with the average age ranging from 25 to 30 years [113].

The periapical radiographs and OPGs are the first indicators of myxomas of jaws. Odontogenic myxomas radiographically present as unilocular lesions to large multilocular neoplasms, which often cause displacement of teeth but resorb the roots less frequently. The unilocular lesions are small in size on the other hand multilocular myxomas are greater than 4 cm in size. 5% Myxomas have association with unerupted tooth [114].

28.14.1.2 Treatment and Prognosis

Surgical excision is the treatment of choice of odontogenic myxomas. The rate of recurrence is quite high, i.e. nearly 25% during first two years after removal. At least 1 cm of medullary bone should be resected along with tumour and always try to involve one tumour-free anatomic barrier at its periphery [78]. Subramaniam S [115] used endoscopes in the resection of pterygoid plates for the complete treatment of odontogenic myxoma. Use of endoscopes eliminates the use of extra-oral incisions.

28.14.2 Cementoblastoma

Dewy in 1927 first described Benign cementoblastoma [116]. It is a rare tumour of mesenchymal origin. Cementum-like tissue formation around the roots of the teeth is its important characteristic.

Cementoblastoma has predilection of mandible with 79.5% and most commonly in the premolar and molar region. They rarely occur in maxilla.

The roots of vital erupted permanent tooth are affected by the cementoblastoma. The most common tooth involved is the mandibular first molar. It has slight male predilection and occurs most commonly in the second and third decade of life. Cementoblastoma can cause teeth displacement, expansion of bone and maxillary sinus invasiveness, and aggressive tumours usually present with the symptoms of swelling and pain [117].

The diagnosis of cementoblastoma is very challenging as hypercementosis is also associated with roots of the teeth, that is the reason why hypercementosis is always included in the differential diagnosis. Cementoblastoma is slow growing, but can cause perforation and expansion of the cortices. The most common symptom is pain [118]. Radiographically the lesion will appear as a radiopaque

mass fused with roots of the teeth, surrounded and limited peripherally by a radiolucent halo.

Complete excision of cementoblastoma is the gold standard treatment with extraction of the involved teeth [119]. It must be removed early, otherwise it may continue to grow. Maxillary lesions at times can involve the entire maxillary sinus making the prognosis poor. Recurrence is very rare, however incomplete removal may result in recurrence.

The tooth associated with cementoblastoma may be preserved under the following conditions [120]

1. In slow-growing tumour
2. In asymptomatic patients, with no pain
3. Perforation of cortical plates is absent
4. Patient refusal for teeth extraction

28.15 Recent Advances

Genetic marking has helped identify gene mutations, which may in the future help with histological and clinical management of these lesions. The most promising of these is the BRAF V600E mutation that is present in 90% of ameloblastomas and in the unicystic mural variant, suggesting predisposition to infiltrative behaviour. In the future, gene therapy may be possible using this gene marker [121].

The sonic hedgehog (SHH) and PI3K/Akt/Mtor signaling pathways may soon provide non-surgical options for treatment of ameloblastoma. The tumours that depend on active SHH signalling for growth/survival and maintenance may be susceptible targets for combined chemotherapy with SHH-specific inhibitors together with PI3K, Akt or mTOR blocking agents [122]. Jhamb T and Kramer JM advise to check molecular markers and accordingly decide the treatment plan [123]. Effiom OA et al. reported that explanation of molecular factors that arrange pathogenesis and recurrence of ameloblastoma will lead to new targeted drug therapies and diagnostic markers for ameloblastoma [124].

28.16 Case Scenario 5 (Fig. 28.9a–j)

A 25 year old male patient presented with an expanding lesion around the left upper posterior teeth (Fig. 28.9a). Radiographs suggested a cystic lesion and a CT scan confirmed bony destruction by a multilocular lesion extending from the first molar to the tuberosity (Fig. 28.9b). An incisional biopsy of the lesion confirmed a diagnosis of follicular ameloblastoma.

The patient had excision of the lesion with a posterior partial maxillectomy, with a mandibular split [125] for access (Fig. 28.9c, d). The defect was reconstructed with a temporalis muscle flap (Fig. 28.9e, f, g). The mandibulotomy site was fixed with titanium plates (Fig. 28.9h).

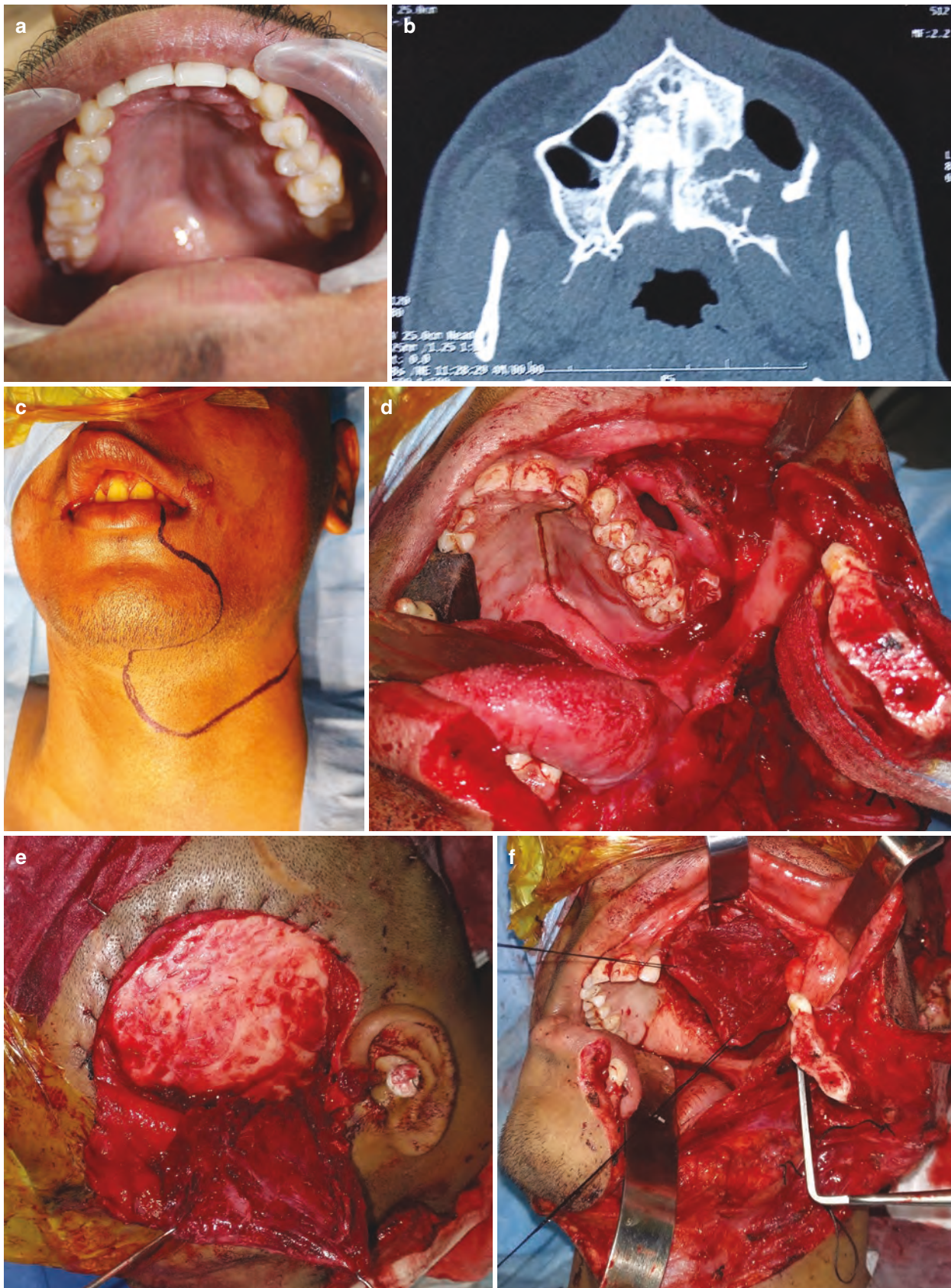


Fig. 28.9 (a) expanding lesion around the left upper posterior teeth. (b) CT scan confirmed bony destruction by a multilocular lesion extending from the first molar to the tuberosity. (c) Incision marked for partial maxillectomy via mandibular split access (d) left posterior partial maxillectomy being performed (e) temporalis muscle flap being

harvested (f) temporalis flap being advanced to the partial maxillectomy defect (g) Intraoperative view after suturing of the temporalis flap to cover the defect (h) Fixation done at the mandible split region (i) post-operative intra oral view showing good healing (j) extra oral view showing good cosmetic and functional result

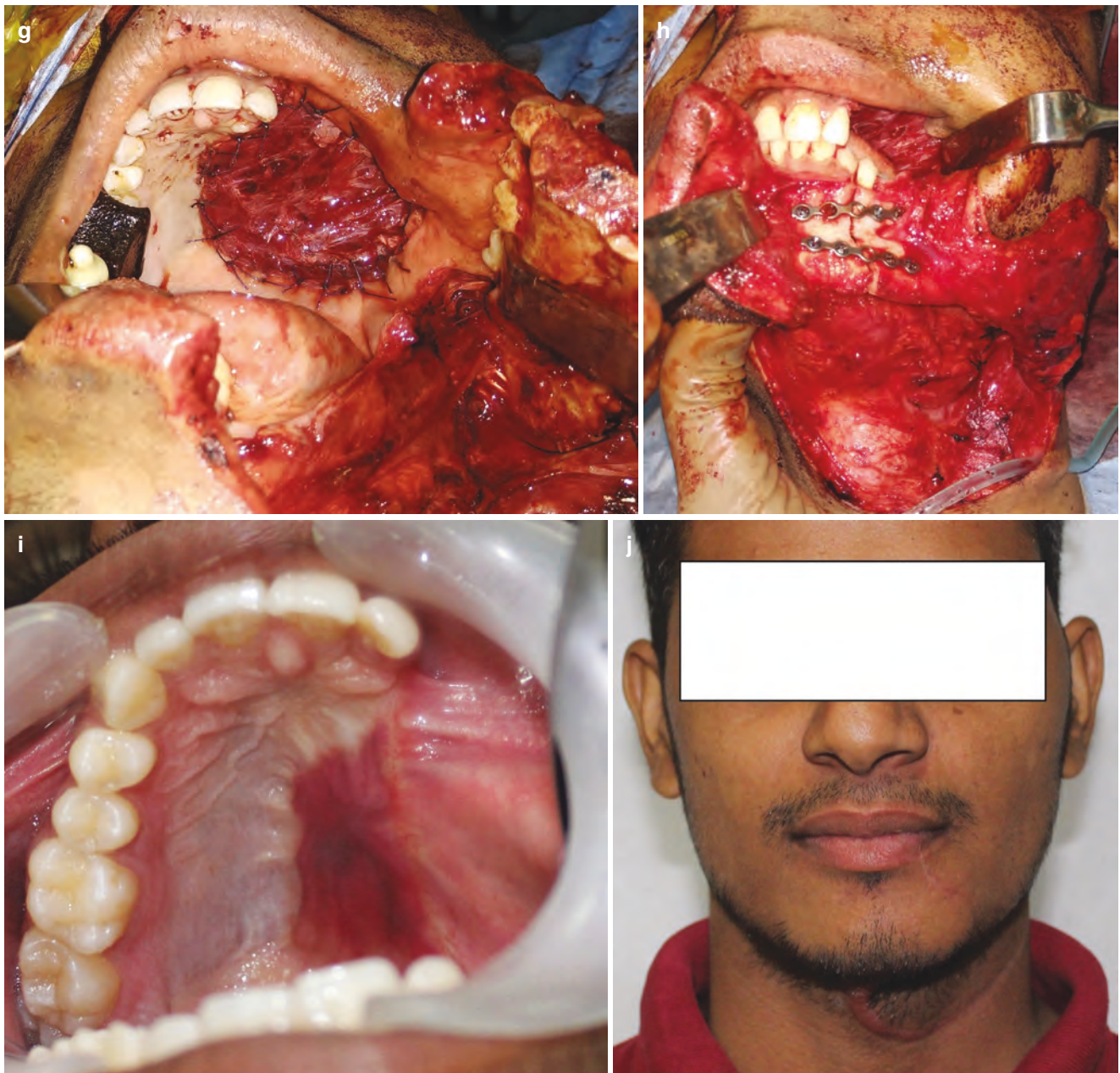


Fig. 28.9 (continued)

The healing was uneventful. Pathology reports confirmed the diagnosis of Follicular Ameloblastoma with clear excision margins. He had an excellent intra oral and cosmetic (extra oral) post-operative result (Fig. 28.9i, j).

Maxillectomy through mandibulotomy approach has been followed by author in a series of cases [125].

The readers are advised to refer chapter 85 of this book for detailed reading on access surgeries and osteotomies for the maxillofacial region.

28.17 Conclusion

Posterior mandible and cuspid areas of maxilla are the most common sites for the odontogenic tumours to occur. However, they can occur anywhere in the tooth-forming apparatus. The detailed history, thorough radiological and clinical evaluation is important in making the probable diagnosis. Conservative and aggressive surgical management has been used according to the size and extent of the tumour.

Proper aesthetic reconstruction should be carried out to avoid facial disfigurement. To check for recurrence, patients should be kept on regular follow-up and ensure long-term successful results.

Acknowledgements for Figs. 28.4 and 28.6 (case scenarios 2 and 3) to suvy manuel

References

- Barnes L, Eveson JW, Reichart PA, Sidransky D. WHO Classification. Head and neck tumors. In: Odontogenic tumors. Lyon: IRAC Press; 2005. p. 283–318.
- Wright JM, Soluk TM. Odontogenic tumors: where are we in 2017? *J Istanbul Univ Fac Dent.* 2017;51(3 Suppl 1):S10–30.
- Gorlin RJ, Pindborg JJ, Clausen FP, et al. The calcifying odontogenic cyst: a possible analogue of the cutaneous calcifying epithelioma of Malherbe. *Oral Surg Oral Med Oral Pathol Oral Radiol Endod.* 1962;15:1235–43.
- Ledesma-Montes C, Gorlin RJ, Shear M, Praetorius F, Mosqueda-Taylor A, Altini M, et al. International collaborative study on ghost cell odontogenic tumours: calcifying cysticodontogenic tumour, dentinogenic ghost cell tumour and ghost cell odontogenic carcinoma. *J Oral Pathol Med.* 2008;37:302–8.
- Wright JM, Vered M. Update from the 4th Edition of the World Health Organization Classification of head and neck tumours: odontogenic and maxillofacial bone tumors. *Head Neck Pathol.* 2017;11:68–77.
- Ritchie A. *Boyd's text book of pathology.* 9th ed. Philadelphia: Lea and Febiger; 1990.
- Robinson HBG. Ameloblastoma: a survey of three hundred and seventy-nine cases from the literature. *Arch Pathol.* 1937;23:831.
- Osterne RL, Brito RG, Alves AP, et al. Odontogenic tumors: a 5-year retrospective study in a Brazilian population and analysis of 3406 cases reported in the literature. *Oral Surg Oral Med Oral Pathol Oral Radiol Endod.* 2011;111:474.
- Jing W, Xuan M, Lin Y, et al. Odontogenic tumours: a retrospective study of 1642 cases in a Chinese population. *Int J Oral Maxillofac Surg.* 2007;36:20.
- Reichart PA, Philipsen HP, Sonner S. Ameloblastoma: biological profile of 3677 cases. *Eur J Cancer B Oral Oncol.* 1995;31B(2):86–99.
- Avelar RL, Antunes AA, Santos T, et al. Odontogenic tumors: clinical pathology study of 238 cases. *Braz J Otorhinolaryngol.* 2008;74:668.
- Fernandes AM, Duarte EC, Pimenta FJ, et al. Odontogenic tumors: a study of 340 cases in a Brazilian population. *J Oral Pathol Med.* 2005;34:583.
- LFA A, et al. Clinical, radiographic, histological characteristics and ameloblastoma treatment: retrospective study. *Int J Oral Maxillofac Surg.* 2019;48:279–80.
- Underhill TE, Katz JO, Pope TL Jr, Dunlap CL. Radiologic findings of diseases involving the maxilla and mandible. *AJR Am J Roentgenol.* 1992;159(2):345–50.
- Cohen MA, Hertzanu Y, Mendelsohn DB. Computed tomography in the diagnosis and treatment of mandibular ameloblastoma: report of cases. *J Oral Maxillofac Surg.* 1985;43(10):796–800.
- Kawai T, Kishino M, Hiranuma H, Sasai T, Ishida T. A unique case of desmoplastic ameloblastoma of the mandible: report of a case and brief review of the English language literature. *Oral Surg Oral Med Oral Pathol Oral Radiol Endod.* 1999;87(2):258–63.
- Hertog D, Bloemena E, Aartman IHA, van-der-Waal I. Histopathology of ameloblastoma of the jaws: some critical observations based on a 40 years single institution experience. *Med Oral Patol Oral Cir Bucal.* 2012;17:76–82.
- Bataineh AB. Effect of preservation of the inferior and posterior borders on recurrence of ameloblastomas of the mandible. *Oral Surg Oral Med Oral Pathol Oral Radiol Endod.* 2000;90:155–63.
- Pogrel MA. The use of liquid nitrogen cryotherapy in the management of locally aggressive bone lesions. *J Oral Maxillofac Surg.* 1993;51(3):269–73.
- Lello GE, Smith I. Ameloblastoma with multiple delayed recurrences: a case report. *Head Neck Surg.* 1987;9:295–8.
- Au SW, et al. Risk factors for recurrence of ameloblastoma: a long-term follow-up retrospective study. *Int J Oral Maxillofac Surg.* 2019;48:1300–6.
- Rastogi V, Pandilwar PK, Maitra S. Ameloblastoma: an evidence based study. *J Maxillofac Oral Surg.* 2010;9:173–7.
- Carlson ER, Marx RE. The ameloblastoma: primary, curative surgical management. *J Oral Maxillofac Surg.* 2006;64:484–94.
- Sammartino G, et al. Effectiveness of a new decisional algorithm in managing mandibular ameloblastomas: a 10-years experience. *Br J Oral Maxillofac Surg.* 2007;45:306–10.
- Nakamura N, Higuchi Y, Mitsuyasu T, Sandra F, Ohishi M. Comparison of long-term results between different approaches to ameloblastoma. *Oral Surg Oral Med Oral Pathol Oral Radiol Endod.* 2002;93:13–20.
- Hasegawa T, Imai Y, Takeda D, Yasuoka D, Ri S, Shigeta T, et al. Retrospective study of ameloblastoma: the possibility of conservative treatment. *Kobe J Med Sci.* 2013;59:E112–21.
- Fregnani ER, et al. Clinicopathological study and treatment outcomes of 121 cases of ameloblastomas. *Int J Oral Maxillofac Surg.* 2010;39:145–9.
- Esquillo ME. Conservative management of ameloblastoma using modified marsupialization and radical marsupialization. *Int J Oral Maxillofac Surg.* 2019;48:91–2.
- Hammarfjord O, et al. Surgical treatment of recurring ameloblastoma, are there options? *Br J Oral Maxillofac Surg.* 2013;51(8):762–6.
- Almeida Rde A, Andrade ES, Barbalho JC, Vajgel A, Vasconcelos BC. Recurrence rate following treatment for primary multicystic ameloblastoma: systematic review and meta-analysis. *Int J Oral Maxillofac Surg.* 2016;45(3):359–67.
- Hendra FN, Natsir Kalla DS, Van Cann EM, de Vet HCW, Helder MN, Forouzanfar T. Radical vs conservative treatment of intraosseous ameloblastoma: systematic review and meta-analysis. *Oral Dis.* 2019;12:1683–96.
- Antonoglou GN, Sándor GK. Recurrence rates of intraosseous ameloblastomas of the jaws: a systematic review of conservative versus aggressive treatment approaches and meta-analysis of non-randomized studies. *J Craniomaxillofac Surg.* 2015;43(1):149–57.
- Pogrel MA, Montes DM. Is there a role for enucleation in the management of ameloblastoma? *Int J Oral Maxillofac Surg.* 2009;38(8):807–12.
- Sampson DE, Pogrel MA. Management of mandibular ameloblastoma: the clinical basis for a treatment algorithm. *J Oral Maxillofac Surg.* 1999;57(9):1074–7.
- Nkenke E, et al. Mandibular reconstruction using intraoral microvascular anastomosis following removal of an ameloblastoma. *J Oral Maxillofac Surg.* 1983;72:1992.
- Vayvada H, Mola F, Menderes A, et al. Surgical management of ameloblastoma in the mandible: segmental mandibulectomy and immediate reconstruction with free fibula or deep circumflex iliac artery flap (evaluation of the long-term esthetic and functional results). *J Oral Maxillofac Surg.* 2006;64:1532.
- Goodsell JF, Yamashita DD, Moody R. Ameloblastoma of the anterior maxillae. *J Surg Oncol.* 1977;9:407.

38. Sehdev MK, Huvos AG, Strong EW. Ameloblastoma of maxilla and mandible. *Cancer*. 1974;33:324.
39. Rai A, et al. Modified Weber-Fergusson incision with Borle's extension. *Br J Oral Maxillofac Surg*. 2010;48(5):e23-4.
40. Li X, Zhu K, Liu F, Li H. Assessment of quality of life in giant ameloblastoma adolescent patients who have had mandible defects reconstructed with a free fibula flap. *World J Surg Oncol*. 2014;12:201.
41. Lawson W, Loscalzo LJ, Baek SM, et al. Experience with immediate and delayed mandibular reconstruction. *Laryngoscope*. 1982;92:5.
42. Kumar BP, Venkatesh V, Kumar KA, Yadav BY, Mohan SR. Mandibular reconstruction: overview. *J Maxillofac Oral Surg*. 2016;15(4):425-41.
43. Jewer DD, Boyd JB, Manktelow RT, Zuker RM, Rosen IB, Gullane PJ, Rotstein LE, Freeman JE. Orofacial and mandibular reconstruction with the iliac crest free flap: a review of 60 cases and a new method of classification. *Plast Reconstr Surg*. 1989;84(3):391-403.
44. Takagi S, Chow LC, Markovic M, Friedman CD, Costantino PD. Morphological and phase characterizations of retrieved calcium phosphate cement implants. *J Biomed Mater Res*. 2001;58(1):36-41.
45. Rai A, et al. Utility of high density porous polyethylene implants in maxillofacial surgery. *J Maxillofac Oral Surg*. 2014;13(1):42-6.
46. Arora A, et al. Custom-made implant for maxillofacial defects using rapid prototype models. *J Oral Maxillofac Surg*. 2013;71:e104-10.
47. Robinson L, Martinez MG. Unicystic ameloblastoma: a prognostically distinct entity. *Cancer*. 1977;40:2278.
48. Ackermann GL, et al. The unicystic ameloblastoma: a clinicopathological study of 57 cases. *J Oral Pathol*. 1988;17:541-6.
49. Cakarar S, Isler SC, Keskin B, et al. Treatment for the large aggressive benign lesions of the jaws. *J Maxillofac Oral Surg*. 2018;17:372-8.
50. Zheng CY, et al. Marsupialisation for the treatment of unicystic ameloblastoma of the mandible: a long-term follow up of 116 cases. *Br J Oral Maxillofac Surg*. 2019;57(7):655-62.
51. Gardner DG. A pathologist's approach to the treatment of ameloblastoma. *J Oral Maxillofac Surg*. 1984;42:161-6.
52. Haq J, Siddiqui S, McGurk M. Argument for the conservative management of mandibular ameloblastomas. *Br J Oral Maxillofac Surg*. 2016;54:1001-5.
53. Rosenstein T, Pogrel MA, Smith RA, Regezi JA. Cystic ameloblastoma—behavior and treatment of 21 cases. *J Oral Maxillofac Surg*. 2001;59(11):1311-6.
54. Lau SL, Samman N. Recurrence related to treatment modalities of unicystic ameloblastoma: a systemic review. *Int J Oral Maxillofac Surg*. 2006;35:681-90.
55. Stoelinga PJW, Bronkhorst FB. The incidence: multiple presentation and recurrence of aggressive cysts of jaws. *J Craniomaxillofac Surg*. 1987;15:184-95.
56. Ecker J, et al. Current role of Carnoy's solution in treating keratocystic odontogenic tumors. *J Oral Maxillofac Surg*. 2016;74:278-82.
57. Dashow JE, et al. Significantly decreased recurrence rates in keratocystic odontogenic tumor with simple enucleation and curettage using Carnoy's versus modified Carnoy's solution. *J Oral Maxillofac Surg*. 2015;73:2132-5.
58. Kuru H. Ueber das adamantinoma. *Zentralbl Allg Pathol*. 1911;22:291.
59. Buchner A, Sciubba JJ. Peripheral epithelial odontogenic tumors: a review. *Oral Surg*. 1987;63:688.
60. Philipsen HP, Reichart PA, Nikai H, et al. Peripheral ameloblastoma: biological profile based on 160 cases from the literature. *Oral Oncol*. 2001;37:17.
61. Slootweg PJ, Muller H. Malignant ameloblastoma or ameloblastic carcinoma. *Oral Surg Oral Med Oral Pathol*. 1984;57:168.
62. Lee FE, White WL, Totten RS. Ameloblastoma with distant metastasis. *AMA Arch Pathol*. 1959;68:23.
63. Laughlin EH. Metastasizing ameloblastoma. *Cancer*. 1989;64:776-80.
64. Reichart PA, Philipsen HP. Metastasizing, malignant ameloblastoma. *Odontogenic tumours and allied lesions*. London: Quintessence Publishing; 2004. p. 207-13.
65. Houston G, Davenport W, Keaton W, Harris S. Malignant (metastatic) ameloblastoma: report of a case. *J Oral Maxillofac Surg*. 1993;51:1152-5.
66. Kunze E, Donath K, Luhr HG, Engelhardt W, De Vivie R. Biology of metastasizing ameloblastoma. *Pathol Res Pract*. 1985;180:526-35.
67. Lanham RJ. Chemotherapy of metastatic ameloblastoma. A case report and review of the literature. *Oncology*. 1987;44:133-4.
68. Miyamoto CT, Brady LW, Markoe A, Salinger D. Ameloblastoma of the jaw. Treatment with radiation therapy and a case report. *Am J Clin Oncol*. 1991;14:225-30.
69. Pullon PA, et al. Squamous odontogenic tumor. Report of six cases of a previously undescribed lesion. *Oral Surg*. 1975;40:616-30.
70. Baden E, Doyle J, Mesa M, et al. Squamous odontogenic tumor. *Oral Surg Oral Med Oral Pathol*. 1993;75:733.
71. El-Naggar AK, JKC C, Grandis JR, et al., editors. *World Health Organization classification of head and neck tumours*. 4th ed. Geneva: World Health Organization Press; 2017.
72. Philipsen HP, et al. Squamous odontogenic tumour: a benign neoplasm of the periodontium. A review of 36 reported cases. *J Clin Periodontol*. 1996;23:922-6.
73. Lin Y-L, White DK. Squamous odontogenic tumor. *Oral Maxillofac Surg Clin North Am*. 2004;16:355.
74. Moussa M, ElShafei MM. Squamous odontogenic tumor: a case report. *Int J Case Rep Images*. 2013;4:607.
75. Pindborg JJ. Calcifying epithelial odontogenic tumour. *Acta Pathol Microbiol Scand*. 1955;111:71.
76. Philipsen HP, Reichart PA. Calcifying epithelial odontogenic tumor: biological profile based on 181 cases from the literature. *Oral Oncol*. 2000;36:17-26.
77. Franklin CD, Pindborg JJ. The calcifying epithelial odontogenic tumor: a review and analysis of 113 cases. *Oral Surg Oral Med Oral Pathol*. 1976;42:753.
78. Marx RE, Stern D. *Oral and maxillofacial pathology*. Chicago, IL: Quintessence Publishing; 2003. p. 635-703.
79. Cross JJ, Pilkington RJ, Antoun NM, et al. Value of computed tomography and magnetic resonance imaging in the treatment of a calcifying epithelial odontogenic (Pindborg) tumour. *Br J Oral Maxillofac Surg*. 2000;38:154.
80. Melrose RJ. Benign epithelial odontogenic tumors. *Semin Diagn Pathol*. 1999;16:271.
81. Veness MJ, Morgan G, Collins AP, et al. Calcifying epithelial odontogenic (Pindborg) tumor with malignant transformation and metastatic spread. *Head Neck*. 2001;23:692.
82. Stafne EC. Epithelial tumors associated with developmental cysts of the maxilla: report of 3 cases. *Oral Surg*. 1948;1:887.
83. Neville BW, Damm DD, Allen CM, et al. *Oral & maxillofacial pathology*. Philadelphia, PA: Saunders; 1995. p. 529.
84. Philipsen HP, Birn H. The adenomatoid odontogenic tumor; ameloblastic adenomatoid tumor; or adenoameloblastoma. *Acta Pathol Microbiol Scand*. 1969;75:375.
85. Barnes L, Eveson JW, Reichart P, et al., editors. *World Health Organization classification of tumors. Pathology and genetics of head and neck tumors*. Lyon: IARC Press; 2005. p. 304-5.
86. Bedrick AE, Solomon MP, Ferber I. The adenomatoid odontogenic tumor: an unusual clinical presentation. *Oral Surg*. 1979;48:143.
87. Rick GM. Adenomatoid odontogenic tumour. *Oral Maxillofac Surg Clin North Am*. 2004;16:333-54.
88. Mohamed A, et al. Adenomatoid odontogenic tumour: review of the literature and an analysis of 33 cases from South Africa. *Int J Oral Maxillofac Surg*. 2010;39:843-6.
89. Jeong KL. Adenomatoid odontogenic tumor: a case report. *J Oral Maxillofac Surg*. 2000;58:1161-4.

90. Philipsen HP, Reichart PA, Siar CH, et al. An updated clinical and epidemiological profile of the adenomatoid odontogenic tumour: a collaborative retrospective study. *J Oral Pathol Med.* 2007;36:383–93.
91. Chuan-Xiang Z, Yan G. Adenomatoid odontogenic tumor: a report of a rare case with recurrence. *J Oral Pathol Med.* 2007;36:440–3.
92. Neville BW, et al. Odontogenic cysts and tumors. In: *Oral maxillofacial pathology*. 2nd ed. Philadelphia: W B Saunders; 2002. p. 626–32.
93. Blankestijn J, Panders AK, Wymenga JP. Ameloblastic fibroma of the mandible. *Br J Oral Maxillofac Surg.* 1986;24:417.
94. Gorlin RJ, Chaudhry AP, Pindborg JJ. Odontogenic tumors. Classification, histopathology, and clinical behavior in man and domesticated animals. *Cancer.* 1961;14:73.
95. Trodahl JN. Ameloblastic fibroma. *Oral Surg.* 1972;33:547.
96. Cawson RA, Binnie WH, Speight PM, et al. *Lucas's pathology of tumors of the oral tissues*. 5th ed. Hong Kong: Churchill Livingstone; 1998. p. 65–9.
97. Leider AS, Nelson JF, Trodahl JN. Ameloblastic fibrosarcoma of the jaws. *Oral Surg Oral Med Oral Pathol.* 1972;33:559.
98. Dallera P, Bertoni F, Marchetti C, et al. Ameloblastic fibroma: a follow-up of six cases. *Int J Oral Maxillofac Surg.* 1996;25:199.
99. Friedrich RE. Recurrent ameloblastic fibro-odontoma in a 10-year-old boy. *J Oral Maxillofac Surg.* 2001;59:1362–6.
100. Surej Kumar LK, Manuel S, Khalam SA, Venugopal K, Sivakumar TT, Issac J. Ameloblastic fibro-odontoma. *Int J Surg Case Rep.* 2014;5(12):1142–4.
101. Broca P. *TraiteV des tumeurs*, vol. 1. France: P. Asselin; 1866. p. 350.
102. Thoma KH, Goldman HM. A classification based on observations of the epithelial, mesenchymal, and mixed varieties. *Am J Pathol.* 1946;12:433–71.
103. Gorlin RJ, Goldman HM. *Thoma's oral pathology*, vol. 1. 6th ed. St. Louis: The C. V. Mosby; 1970. p. 481–507.
104. Kramer IRH, Pindborg JJ, Shear M. The WHO histological typing of odontogenic tumours. *Cancer.* 1992;70:2988–94.
105. Miki Y, Oda Y, Iwaya N, Hirota M, Yamada N, Aisaki K, et al. Clinicopathological studies of odontoma in 47 patients. *J Oral Sci.* 1999;41:173–6.
106. Regezi JA, Kerr DA, Courtney RM. Odontogenic tumors: analyses of 706 cases. *J Oral Surg.* 1978;36:771–8.
107. Philipsen HP, Reichart RP, Pratorius F. Mixed odontogenic tumors and odontomas: considerations on interrelationship. Review of the literature and presentation of 134 new cases of odontomas. *Oral Oncol.* 1997;33:86–99.
108. Shafer WG, Hine MK, Levy BM. Cysts and tumors of odontogenic origin. In: *A textbook of oral pathology*. 4th ed. Philadelphia: WB Saunders; 1983. p. 258–317.
109. Blinder D, Peleg M, Taicher S. Surgical considerations in cases of large mandibular odontomas located in the mandibular angle. *Int J Oral Maxillofac Surg.* 1993;22:163–5.
110. Gomes CC, Diniz MG, Duarte AP, et al. Molecular review of odontogenic myxoma. *Oral Oncol.* 2011;47:325–8.
111. Kramer IRH, Pindborg JJ, Shear M. *Histological typing of odontogenic tumors*. 2nd ed. New York: Springer-Verlag; 1992.
112. Kaffe I, Naor H, Buchner A. Clinical and radiological features of odontogenic myxomas of jaws. *Dentomaxillofac Radiol.* 1997;26:299–303.
113. King TJ, et al. Pediatric maxillary odontogenic myxoma: a report of 2 cases and review of management. *J Oral Maxillofac Surg.* 2008;66:1057–62.
114. Williams T. Aggressive odontogenic cysts and tumors. In: *Oral and maxillofacial surgery clinics of North America*, vol. 9. Philadelphia, PA: WB Saunders; 1997.
115. Subramaniam S. Endoscopic resection of the pterygoid plates following incomplete transoral resection of an odontogenic myxoma. *Br J Oral Maxillofac Surg.* 2017;55:e19–20.
116. Dewey KW. Osteoma of a molar. *Dentist Cosmos.* 1927;69:1143.
117. Ulmansky M, Hjorting-Hansen E, Praetorius F, Haque MF. Benign cementoblastoma. A review and five new cases. *Oral Surg Oral Med Oral Pathol.* 1994;77:48.
118. Ohki K, Kumamoto H, Nitta Y, et al. Benign cementoblastoma involving multiple maxillary teeth: report of a case with a review of the literature. *Oral Surg Oral Med Oral Pathol Oral Radiol Endod.* 2004;97:53.
119. Iannaci G, Luise R, Iezzi G, et al. Multiple cementoblastoma: a rare case report. *Case Rep Dent.* 2013;2013:828373.
120. Borges DC. Conservative treatment of a periapical cementoblastoma: a case report. *J Oral Maxillofac Surg.* 2019;77:272.e1–7.
121. Brown NA, Rolland D, McHughJb, Weigelin HC, Zhao I, limMs, Elenitoba-Johnson ks, Betz Bl. Activating FGFR2-ras-braF mutations in ameloblastoma. *Clin Cancer Res.* 2014;20:5517–26.
122. Sauk JJ, Nikitakis NG, Scheper MA. Are we on the brink of non-surgical treatment for ameloblastoma? *Oral Surg Oral Med Oral Pathol Oral Radiol Endod.* 2010;110(1):68–78.
123. Jhamb T, Kramer JM. Molecular concepts in the pathogenesis of ameloblastoma: implications for therapeutics. *Exp Mol Pathol.* 2014;97(3):345–53.
124. Effiom OA, Ogundana OM, Akinshipo AO, Akintoye SO. Ameloblastoma: current etiopathological concepts and management. *Oral Dis.* 2018;24(3):307–16.
125. Nair S et al. Maxillectomy through mandibulotomy—a retrospective clinical review. *J Oral Maxillofac Surg.* 2011;69(7):2040–7.

Additional Reading

- Haq J, Siddiqui S, McGurk M. Argument for the conservative management of mandibular ameloblastomas. *Br J Oral Maxillofac Surg.* 2016;54(9):1001–5.
- Suluk-Tekkeşin M, Wright JM. The World Health organization classification of odontogenic lesions: a summary of the changes of the 2017 (4th) edition. *Turk Patoloji Derg.* 2018;34(1):1–18.
- Troiano G, et al. Conservative vs radical approach for the treatment of solid/multicystic ameloblastoma: a systematic review and meta-analysis of the last decade. *Oral Health Prev Dent.* 2017;15(5):421–6.

Open Access This chapter is licensed under the terms of the Creative Commons Attribution 4.0 International License (<http://creativecommons.org/licenses/by/4.0/>), which permits use, sharing, adaptation, distribution and reproduction in any medium or format, as long as you give appropriate credit to the original author(s) and the source, provide a link to the Creative Commons license and indicate if changes were made.

The images or other third party material in this chapter are included in the chapter's Creative Commons license, unless indicated otherwise in a credit line to the material. If material is not included in the chapter's Creative Commons license and your intended use is not permitted by statutory regulation or exceeds the permitted use, you will need to obtain permission directly from the copyright holder.



Raja Sekhar Gali

29.1 Introduction

The tissues of the oral and maxillofacial region are constantly exposed to a plethora of inflammatory stimuli that can be of bacterial, physical, chemical or immunologic in the origin. Chronic/long-standing, low-grade inflammatory stimuli can induce a heightened/escalated reparative response in the oral tissues resulting in the occurrence of non-neoplastic, hyperplastic lesions that are collectively referred to as reactive lesions [1].

Though the occurrence of exophytic reactive proliferation in the oral cavity is relatively common, certain malignant (metastatic/primary) and benign tumours, vascular lesions can closely mimic these lesions leading the clinician to misdiagnosis and sub-optimal treatment. A thorough understanding of the clinical presentation, differential diagnosis and the required diagnostic workup is the key to appropriate treatment.

Additional features of the chapter:

- Pearls, Perils & Pitfalls
- Case Scenarios
- Recent Advances

29.2 Classification

These lesions can be peripheral/extra-osseous (Soft tissues-Gingiva, oral mucosa etc.) or Central (intra-osseous) in occurrence.

R. S. Gali (✉)

Department of Oral and Maxillofacial Surgery, Narayana Dental College and Hospital, Nellore, Andhra Pradesh, India

Medicover Hospital, Nellore, Andhra Pradesh, India

Peripheral reactive lesions:

Eversole classified the common peripheral hyperplastic lesions of gingiva and other oral mucosal sites into the following categories [2, 3].

1. Pyogenic Granuloma
2. Peripheral Giant Cell Granuloma
3. Peripheral Ossifying Fibroma
4. Peripheral fibroma (Focal Fibrous hyperplasia/ Fibrous Epulis) [2].

Central reactive lesions:

The intra-osseous reactive lesions include the following categories [4, 5].

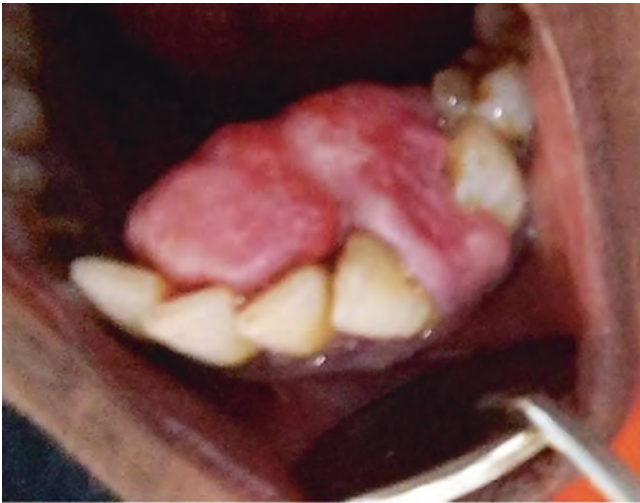
1. Central giant cell Granuloma
2. Aneurysmal Bone Cyst
3. Brown's Tumour of hyperparathyroidism
4. Chronic Sclerosing Osteomyelitis and Garre's osteomyelitis/Proliferative Periosteitis [4, 5].

29.3 Pyogenic Granuloma

29.3.1 Clinical Features and Aetiopathogenesis

Pyogenic Granuloma presents as a painless pedunculated or sessile, soft fleshy mass that bleeds easily with a normal or occasionally ulcerated overlying surface (Fig. 29.1). Gingiva is the most common intra-oral site, although it can affect lips, mucosa and tongue [3].

It is a localised proliferative mass occurring as a result of an exuberant reparative response to various stimuli such as chronic local irritation (calculus, overhanging restoration, a sharp margin of crown etc.), trauma, hormonal changes (Pregnancy), bone marrow transplants and reac-



©Association of Oral and Maxillofacial Surgeons of India

Fig. 29.1 Exophytic gingival growth associated with chronic gingivitis with heavy bands of calculus. The lesion easily bleeds on palpation and can occasionally cause displacement of teeth

tion to grafts. Pulp polyp or hyperplastic pulpitis is also a type of pyogenic granuloma arising in response to low-grade chronic infection [1]. The term pyogenic granuloma is a misnomer as it does not contain pus and it is not a true granuloma [1, 3].

It can occur across all the age groups and both genders, but with a distinct predominance in females in the 2nd decade of life due to the increased levels of circulating hormones like oestrogen and progesterone [6]. Equal incidence has been reported in both the jaws with a slight predilection to anterior maxilla [1].

29.3.2 Differential Diagnosis

Other peripheral reactive lesions that resemble pyogenic granuloma are peripheral giant cell granuloma and peripheral ossifying fibroma [3]. Peripheral ossifying fibroma has a firm consistency and a lesser tendency to bleed. Specific proliferative malignant lesions can closely mimic pyogenic granuloma misleading the clinician leading to sub-optimal treatment. These can be primary or metastatic squamous cell carcinomas, fibrosarcoma, Kaposi's sarcoma, oral metastatic deposits from distant primary foci like thyroid, lung kidneys etc [1].

29.3.3 Diagnostic Workup

Radiological Features Appreciable radiological changes are generally not seen in pyogenic granuloma, but occasion-

ally cup-like resorption of underlying alveolar bone can be seen in a peri-apical view or an orthopantomogram. Ruling out the presence of large osteolytic lesions is required to exclude malignant lesions.

Histopathological Features Histologically pyogenic granulomas are classified into two distinct sub-types- the non-lobular capillary haemangioma type (non-LCH type) and Lobular capillary haemangioma (LCH) type [6]. The non-LCH type comprises of highly vascular proliferation that is similar to granulation tissue with foci of fibrous tissue whereas the LCH type shows proliferation of blood vessels that are aggregated in a lobular fashion without any signs of inflammation and or reparative response.

29.3.4 Recent Concepts

Epivatianos A et al. had demonstrated that these two sub-types have a different origin, clinical behaviour and immunohistochemical properties [7]. Their study had shown that non-LCH pyogenic granuloma presented clinically as a pedunculated mass and was mostly associated with identifiable aetiological factors and showed a histological picture of a reparative response. However, LCH pyogenic granuloma presented as a non-ulcerated sessile mass without any identifiable aetiology and histological evidence of lobulated vessel pattern and the absence of inflammatory reaction. This has led to the concept that LCH pyogenic granuloma represents a benign tumour of the vascular origin that develops due to unknown factors just like other benign tumours.

29.3.5 Treatment

Surgical excision of the lesion followed by removal of local irritants such as calculus, foreign body etc. is the standard treatment. Excision up to the periosteum is required in gingival lesions followed by either primary closure by mobilisation of adjacent mucoperiosteum, or surgical defect is left to heal by secondary intention by the placement of Coe pack. Brisk bleeding is often encountered during excision that would require electrocoagulation. Other treatment options include electrocautery, cryosurgery, sclerotherapy and laser-assisted excision.

29.3.6 Prognosis

Complete excision of the lesion till the periosteum and removal of local aetiological factors will eliminate the chances of recurrence.

29.4 Peripheral Giant Cell Granuloma

Peripheral giant cell granuloma is the most commonly encountered giant cell containing lesion of the oral cavity that closely resembles pyogenic granuloma.

29.4.1 Clinical Features and Aetiopathogenesis

It is thought to originate mainly from the connective tissue of the gingiva or the periosteum of the alveolar ridge. It has been reported in all age groups but with a peak incidence in the 3rd and 4th decades of life with a female predominance [8]. The lesion presents as a soft proliferative mass occurring at gingiva or even at edentulous alveolar ridge. It has a tendency to bleed and may or may not be pedunculated [9].

The term 'reparative' was dropped from its nomenclature as the reparative nature could not be demonstrated histopathologically. The aetiology of this lesion remains unclear, but irritating local factors such as poor restorations, prostheses calculus etc. are thought to contribute to its origin (Fig. 29.2).

29.4.2 Differential Diagnosis

Clinically pyogenic granuloma and peripheral giant cell granuloma are indistinguishable. Erosion of cortical bone is more commonly seen with peripheral giant cell granuloma than with pyogenic granuloma.

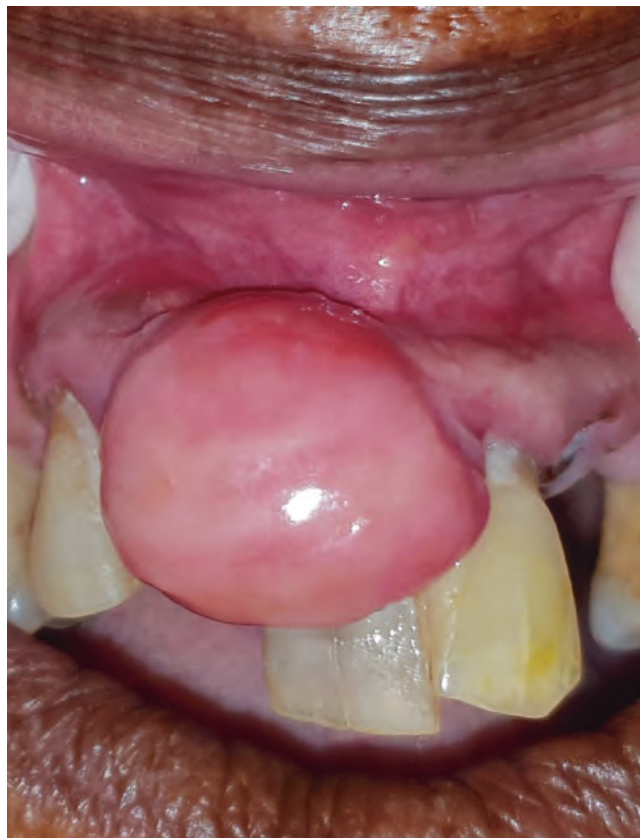Histopathologically, the lesion is very similar to central giant cell granuloma, its intra-osseous counterpart [9].

29.4.3 Radiologic Features

Since the lesion is peripheral in the origin and location, radiologic changes are rarely seen. Longstanding, larger lesions can exhibit superficial cortical erosion and may also show widening of adjacent periodontal ligament space.

29.4.4 Histopathological Features

Hyperplasia of fibroblasts with abundant multi-nucleated giant cells, with scattered areas of chronic inflammatory cells and neutrophils are seen [9]. Controversy exists about the origin of the giant cells; some believe that they are of the osteoclast origin while others state that they are formed by the fusion of mono-nuclear cells. Irrespective of their origin, they are non-functional in these lesions as they are not involved either in phagocytosis or bone resorption [9].



©Association of Oral and Maxillofacial Surgeons of India

Fig. 29.2 Peripheral giant cell granuloma, presenting as an exophytic gingival growth firm to hard in consistency causing displacement of adjacent teeth

29.4.5 Treatment

Complete surgical excision including the periosteum or periodontal ligament as applicable followed by the removal of local factors is the optimum treatment for peripheral giant cell granuloma. Recurrences are rare, but have been reported and are believed to be due to non-inclusion of periosteum or periodontal ligament during excision.

29.4.6 Prognosis and Complications

Recurrence of PGCG is infrequent, ranges as little as 5–11% have been reported. Extensive clearing of the base of the lesion, eradication of the source of irritation prevents recurrence [9].

29.4.7 Recent Advances

Increasing incidence of peripheral giant cell granulomas occurring in association with dental implants has been reported [10, 11]. Local irritant factors, inflammation of

peri-implant tissues are the causative factors. Clinically, these proliferations are similar to the classic peripheral giant cell granulomas and usually develop within months to years following placement of dental implants. If early detection and complete surgical excision are not performed, such lesions can lead to peri-implantitis, ultimately leading to failure of the implant necessitating its removal.

29.5 Peripheral Ossifying Fibroma

The peripheral ossifying fibroma is a reactive gingival proliferation presenting as nodular mass firm in consistency with or without ulceration. It contains fibroblastic cellular tissue with varying amounts of mineralised content that can be either bone, cementum or dystrophic calcification.

The term 'peripheral ossifying fibroma' literally means a benign tumour of fibrous connective tissue origin. However, this lesion is a non-neoplastic reactive proliferative lesion, so this term is a misnomer for this pathology [12].

29.5.1 Clinical Features and Aetiopathogenesis

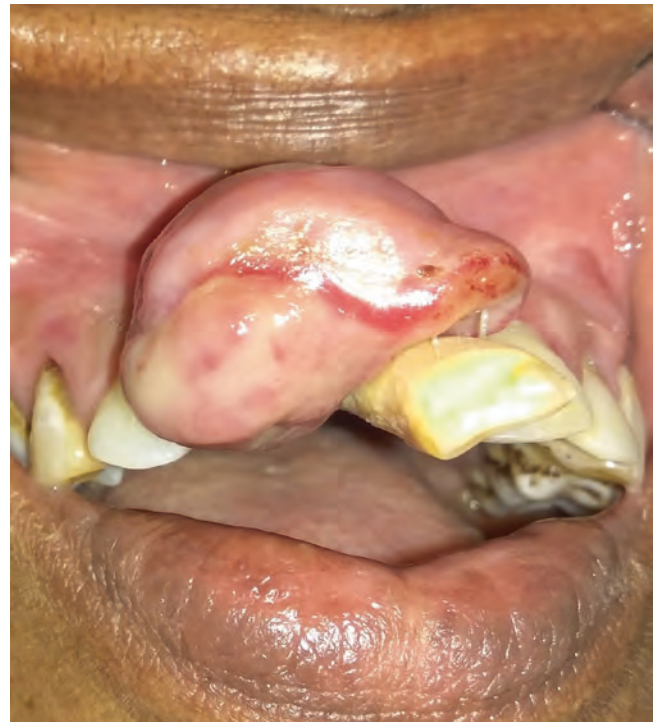The lesion presents as a slow-growing solitary gingival growth commonly seen during the second decade of life, predominantly in women in the anterior region of either of the jaws. The lesion is believed to originate from periodontal ligament in response to local irritation or inflammation, commonly seen at the inter-dental region as a pedunculated or sessile mass (Fig. 29.3). The exact pathogenesis of peripheral ossifying fibroma is controversial. Some authors believe that it initially develops as a pyogenic granuloma that subsequently undergoes fibrous maturation and calcification. It is thought that these two lesions represent progressive stages of the same reactive pathology [13].

29.5.2 Differential Diagnosis

Histopathology is the only method by which one can distinguish a peripheral ossifying fibroma from a pyogenic granuloma or peripheral giant cell granuloma [14].

29.5.3 Radiologic Features

Radiographs may occasionally demonstrate specks of calcifications in these lesions (Fig. 29.4a–c).



©Association of Oral and Maxillofacial Surgeons of India

Fig. 29.3 Exophytic sessile mass over gingiva at anterior maxilla associated with heavy bands of calculus and is seen to be causing displacement of teeth

29.5.4 Histopathologic Features (Fig. 29.4c)

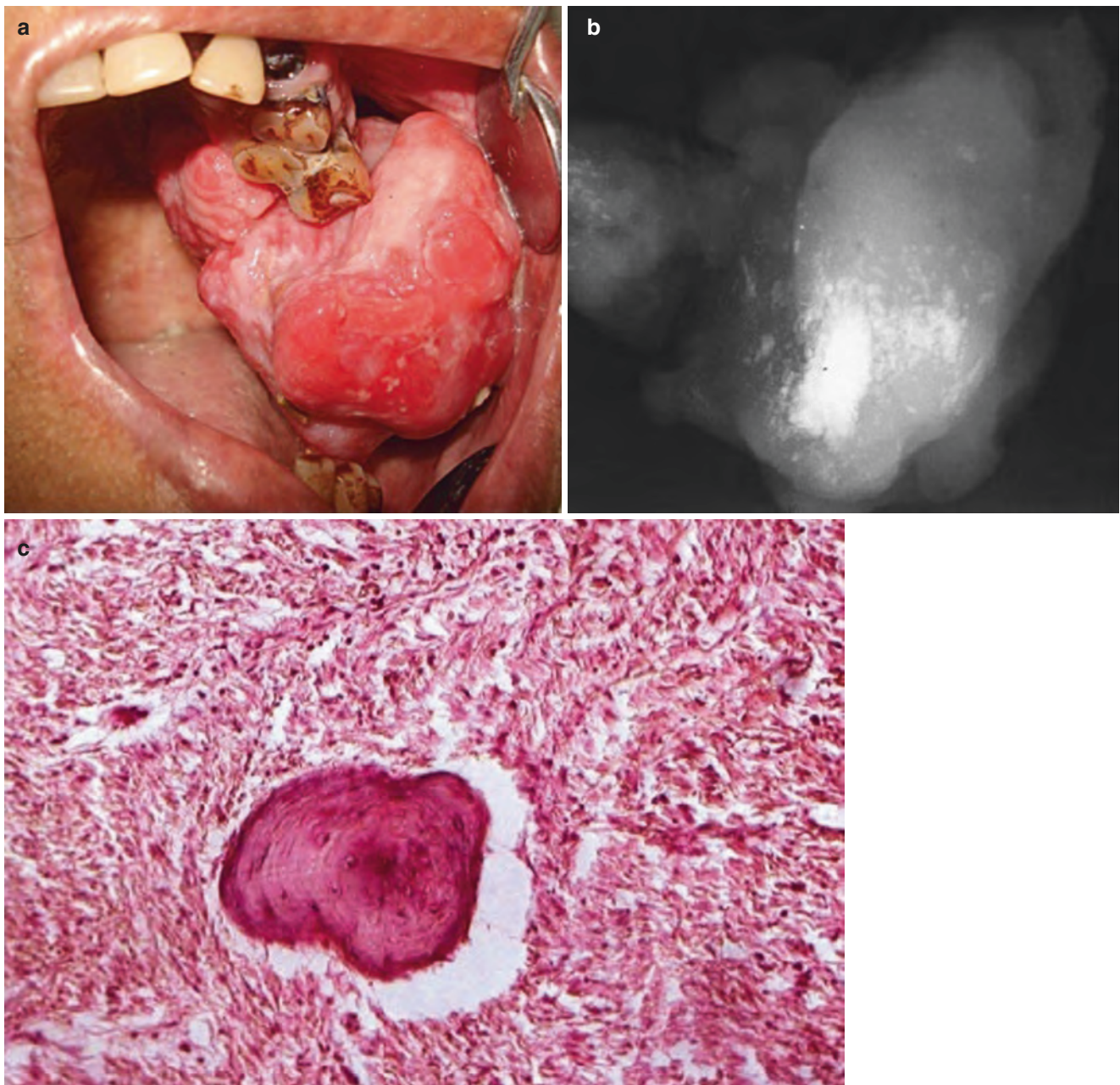
The peripheral ossifying fibroma consists of rich fibro-cellular tissue with focal areas of mineralised deposits containing bone, cementum or dystrophic calcification. A chronic inflammatory cell infiltrate is observed at the periphery of the lesion.

29.5.5 Treatment

Complete surgical excision of the lesion with circumferential margins of 3mm of healthy gingival tissue and deep margins down to the bone, including the adjacent periosteum and periodontal ligament has to be performed to reduce the chances of recurrence [1]. Extraction of the involved teeth is to be considered in the cases of recurrent or multi-focal lesions of peripheral ossifying fibromas.

29.5.6 Prognosis and Complications

The reported recurrence rate for peripheral ossifying fibroma is surprisingly high for a reactive proliferation. The recurrence rate has varied from 4 to 75% [15, 16].



©Association of Oral and Maxillofacial Surgeons of India

Fig. 29.4 (a) Large peripheral ossifying fibroma of 6×7 cm in size, in a 64-year-old female, 5 years duration presenting as firm mass. (b) Radio-opacities on the radiograph observed in the excised lesion. (c) Histopathological view showing the woven bone (H&E stain, original

magnification $400\times$). (Adapted from A rare massive exophytic gingival growth: Suvy Manuel et al.; Clinics and Practice. 2012 Mar 30; 2(2): e38. Open Access DOI <https://doi.org/10.4081/cp.2012.e38>, copy right S. Manuel et al, CC BY-NC 3.0, Licensee PAGEPress Italy)

Pearls, Perils and Pitfalls: Peripheral Reactive Lesions:

1. The most common proliferative masses of Gingiva are a Triad of reactive lesions—The 3 P's—Pyogenic Granuloma, Peripheral giant Cell granuloma & Peripheral Ossifying fibroma.
2. Pyogenic granulomas and peripheral giant cell granulomas are more vascular, which is reflected by their tendency to bleed and their red or reddish-blue colour.
3. Unlike pyogenic granuloma, peripheral giant cell granuloma can occur on edentulous alveolar ridges arising from the periosteum
4. POF is firm to hard in consistency due to the mineralised content like cementum/bone/dystrophic calcification
5. Complete Surgical excision of these lesions with circumferential margins of 3 mm of healthy gingival tissue and deep margins down to the bone, including the adjacent periosteum & periodontal ligament has to be performed to reduce the chances of recurrence. This should be followed by removal of putative local factors like calculus, plaque faulty restoration/prosthesis etc.
6. Extraction of the involved but firm teeth should be considered in the cases of recurrent/multi focal lesions.

29.6 Central Giant Cell Granuloma (Figs. 29.5 and 29.6)

Synonyms Central giant cell Lesion, Central reparative giant cell granuloma and Giant cell tumour of jaw bones.

29.6.1 Introduction

The central giant cell granuloma is one of the few maxillofacial pathologies that have generated a significant amount of discussion and controversy. The true biological nature of the lesion remains to be understood and the debate about labeling it as a tumour still exists [12].

Initially, it was described as Giant cell 'reparative' granuloma by Jaffe in 1953 [17] suggesting that it was a reactive response to intra-bony haemorrhage and inflammation. Later, the term 'reparative' was dropped, as prior traumatic/inflammatory episodes could not be elicited in most cases and clinical progression of disease was inconsistent with the repair process of bone.

The aggressive clinical behaviour of specific lesions demonstrated by osteolysis, cortical expansion, perforation and extension into soft tissue has led to the view that it is a benign tumour similar to the giant cell tumour of long bones [18]. The exact relationship between these two pathologies remains to be understood. The concept that these lesions represent two points in the spectrum of a single-disease process has been put forth [19, 20]. Considering the variability in clinical presentation, individual authors have classified it as a rapidly growing & destructive—aggressive form and a slow-growing, incidentally picked up lesion—the non-aggressive form [19, 20].

Since the true neoplastic nature is yet to be established and the histologic features do not represent a true granulomatous lesion, the term central giant cell 'lesion' had been proposed by Whitaker & Waldron [20].

29.6.2 Clinical Features and Aetiopathogenesis

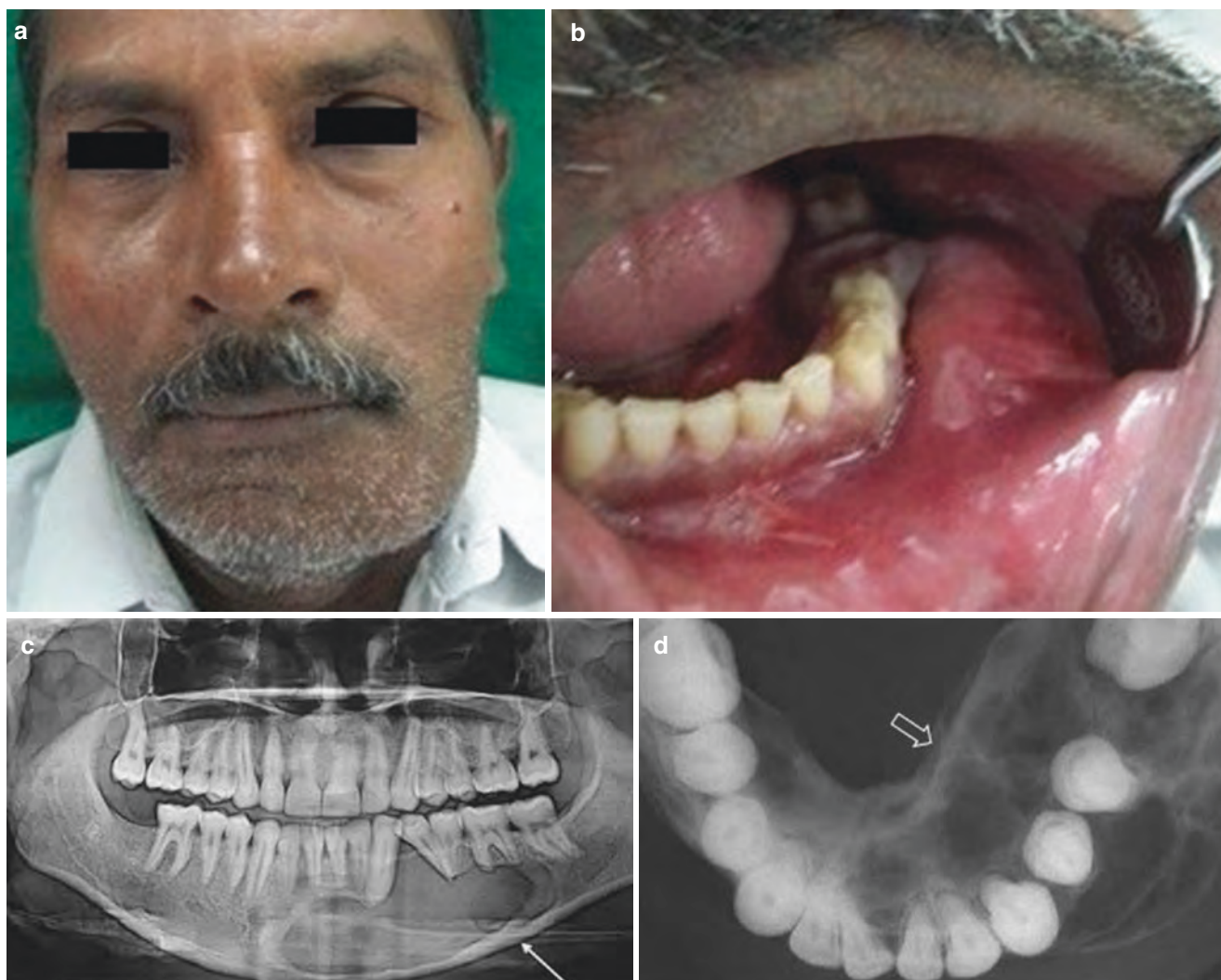The lesion can occur in any age group but, children and young adults are more commonly affected and with a female predominance [19]. The anterior mandibular region is the most frequent site of occurrence almost twice as compared to the maxilla. The most common presentation is that of an asymptomatic, slow-growing, bony hard and expansile swelling of the involved jaw [19, 20]. This can be accompanied by progressive displacement/loosening of teeth, paresthesia, nasal obstruction and secondary infection leading to pain (Fig. 29.5a, b).

29.6.3 Differential Diagnosis

Histopathologically, central giant cell granulomas and brown tumour of hyperparathyroidism are indistinguishable from each other, and this can be very misleading to the clinician and the pathologist. Hence, biochemical tests like serum calcium, phosphate and parathormone levels are to be evaluated to rule out brown's tumour. In all cases of multi-focal and/or recurrent central giant cell granulomas of jaws, the possibility of primary or secondary hyperparathyroidism is to be ruled out, so that unnecessary surgical procedures and their added morbidity can be avoided.

29.6.4 Radiological Features

The central giant cell granuloma presents as multi-locular radiolucency with scalloped margins that are usually non-corticated [19]. The cortical expansion, thinning followed by perforation, root resorption and displacement of adjacent teeth can be seen in aggressive variants [20] (Fig. 29.5c, d).



©Association of Oral and Maxillofacial Surgeons of India

Fig. 29.5 (a, b) Central Giant cell granuloma presenting as hard bony mass over the left body of the mandible with bi-cortical expansion. (c) Central Giant cell granuloma presenting as a unilocular osteolytic

lesion with sclerotic border and thinning of lower border. (d) Occlusal radiograph demonstrating bi-cortical expansile lytic lesion with incomplete septae

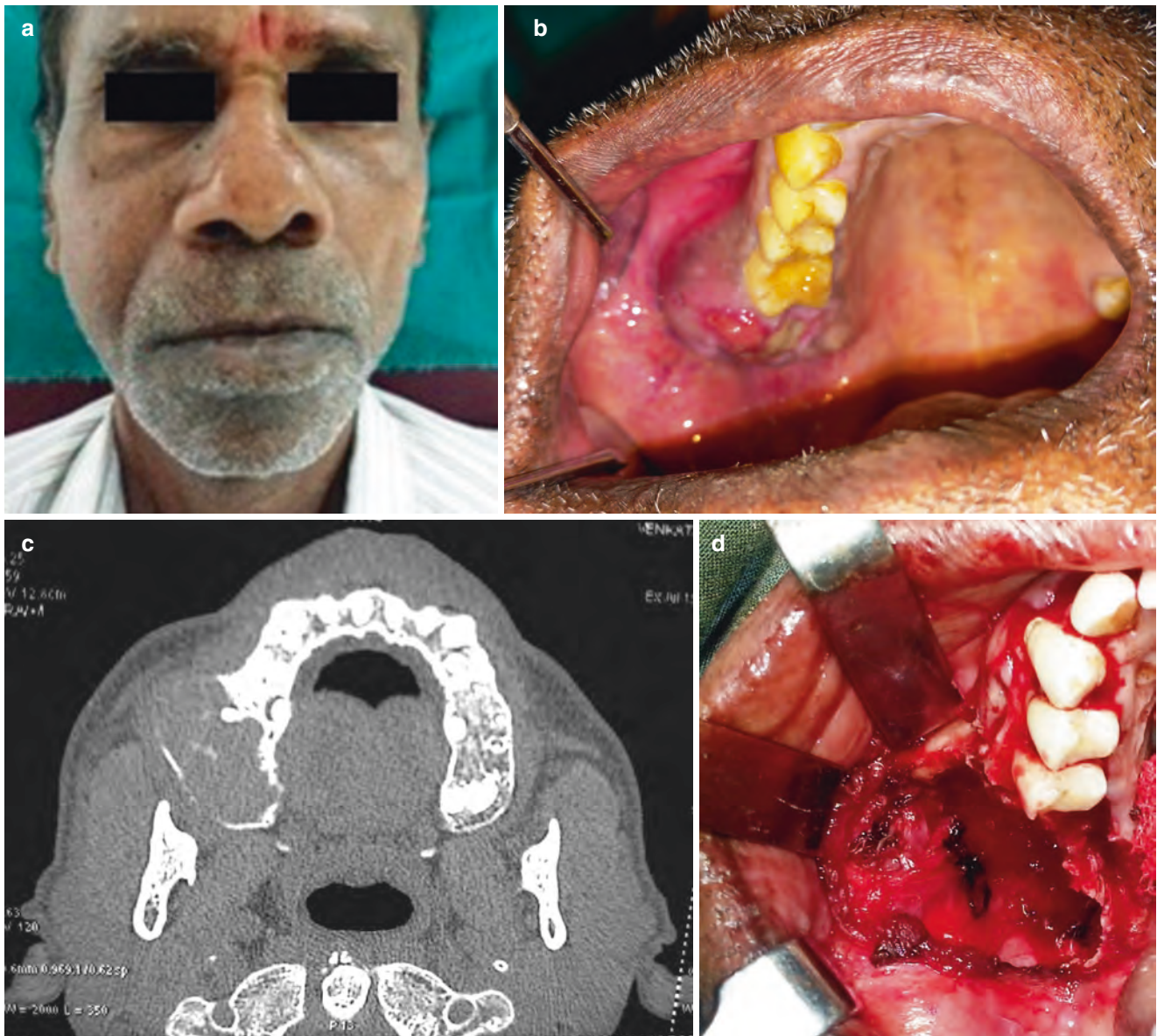29.6.5 Histopathologic Features

The lesion consists of a proliferation of spindle-shaped fibroblasts in fibrous and fibromyxoid/vascular stroma [20]. Clusters of multi-nucleated giant cells are scattered throughout connective tissue stroma especially around vascular channels. These cells are believed to originate from osteoclasts or by the fusion of mono-nuclear cells [9]. Focal deposits of metaplastic bone are seen. The histological picture is precisely identical to brown's tumour of hyperparathyroidism [1].

29.6.6 Treatment

The most commonly practised and favoured treatment for central giant cell granuloma has been aggressive surgical

curettage. Recurrence rates ranging from 20 to 50% have been reported following curettage [21]. Adjuvant treatments to curettage-like peripheral ostectomy or marginal resection have been advocated to reduce the chances of recurrence [22]. Aggressive surgical treatment options such as en bloc resection/segmental mandibulectomy/maxillectomy are presently reserved for locally advanced lesions & recurrent lesions [22, 23]. Significant vascularity and intra-operative bleeding are frequently associated with these lesions. Aggressive surgical resection with 0.5 cm margins of healthy tissue is advocated to reduce the chances of recurrence [24]. However, the morbidity associated with surgical resection such as functional, cosmetic impairment, loss of teeth, teeth buds and neurosensory disturbances questions the need for such aggressive treatments in a benign reactive lesion-like central giant cell granuloma [24].



©Association of Oral and Maxillofacial Surgeons of India

Fig. 29.6 (a) Swelling right side face. (b) Intra oral view of lesion right posterior maxilla. (c) CT axial cut showing changes in posterior right maxilla. (d) Intra operative view

Medical Methods of Treatment Based on the premise that osteoclastic activity steers the progression of the disease process, medical treatments aimed at antagonising the activity and proliferation of osteoclasts have been used with varying rates of success [25–27].

Intra-lesional Steroids Steroids have demonstrated the ability to inhibit bone resorption and induce apoptosis of osteoclasts. Weekly intra-lesional injections of triamcinolone acetonide for six weeks have shown highly variable results from partial shrinkage, in complete remission, to complete resolution leading to hypercalcification of the area [28, 29]. The protocol described involves the use of a 50% mixture of local anaesthetic

and 10 mg/ml triamcinolone acetonide. Two ml of this solution has to be used for every 1cc of the lesion visible on orthopantomogram [29, 30].

Systemic Calcitonin Therapy Based on the observations that calcitonin receptors were found in the multi-nucleated giant cells of central giant cell granuloma and the role of calcitonin in inhibiting osteoclast function, systemic administration of calcitonin has been practised to treat central giant cell granuloma [31]. Calcitonin is administered through a sub-cutaneous or intra-nasal route. Sub-cutaneous administration involves 100 units per day for a period of 18–21 months during which sequential radiographs are obtained to monitor the remission of the lesion.

Unlike sub-cutaneous administration, the intra-nasal route has better patient compliance but unpredictable absorption rates [31].

Results with calcitonin therapy have been highly variable. In some instances, they have been used to shrink the lesions first, later to be followed by curettage.

Interferon Therapy Owing to the prominent vascular component in central giant cell granuloma, the anti-angiogenic properties of interferon alpha have been used as adjuvant therapy following enucleation/curettage of the lesion. Isolated interferon therapy without prior surgical procedure led to partial resolution of lesions and is of limited value. Kaban et al. had proposed a protocol that involved treatment of aggressive central giant cell granulomas of the mandible by a staged treatment of conservative surgical enucleation (sparing the inferior alveolar nerve and teeth). This is followed by administration of interferon Alpha 2 or beta (3,000,000 units/m²) 48–72 h after surgery, given once daily by a sub-cutaneous route for a period of 6 months or till a period when CT scan showed complete regeneration of bony defect [32]. Their study was based on the hypothesis that these lesions are vascular proliferations, thus explaining the high success rate in response to anti-angiogenic therapy in their experience [32].

Bisphosphonates Bisphosphonates that have an antagonising effect on the osteoclastic activity. Owing to the virtue of this property, bisphosphonates have been used in conjunction with intra-lesional steroids in central giant cell granuloma with promising results [33].

Denosumab Denosumab is a human monoclonal antibody that binds to the RANK ligand located on the surface of osteoclasts and deactivates them. The stromal cells of giant cell tumour have been shown to secrete RANKL and upregulate osteoclast activity and development. Recent Phase-II clinical trials on the use of denosumab in giant cell tumours of long bones showed that it reduces the need for morbid surgeries [34, 35]. A single report on the use of denosumab in central giant cell granulomas of jaws in two patients was recently published and had claimed very promising results involving complete remission of jaw lesions. However, studies involving a larger sample with longer follow-up periods are awaited to know the exact risk-benefit status of this novel treatment option [36].

29.7 Aneurysmal Bone Cyst (Fig. 29.7a–f)

The aneurysmal bone cyst is a controversial lesion believed to be a non-neoplastic and exaggerated reactive response of vascular tissues of bone. It is a pseudocyst that presents as

expansile, osteolytic lesion often characterised by ballooning distension of the cortex, that consists of blood-filled cavernous spaces showing occasional osteoid material and multi-nucleated giant cells [37].

29.7.1 Clinical Features

The aneurysmal bone cyst generally occurs in patients less than 30 years of age with a reported higher incidence during the second decade of life with almost equal gender predilection. Aneurysmal bone cysts of the jaws are relatively rare comprising of only 1–3% of all aneurysmal bone cysts occurring in the skeleton. The posterior region of the mandible is the preferred site compared to maxilla (6:1).

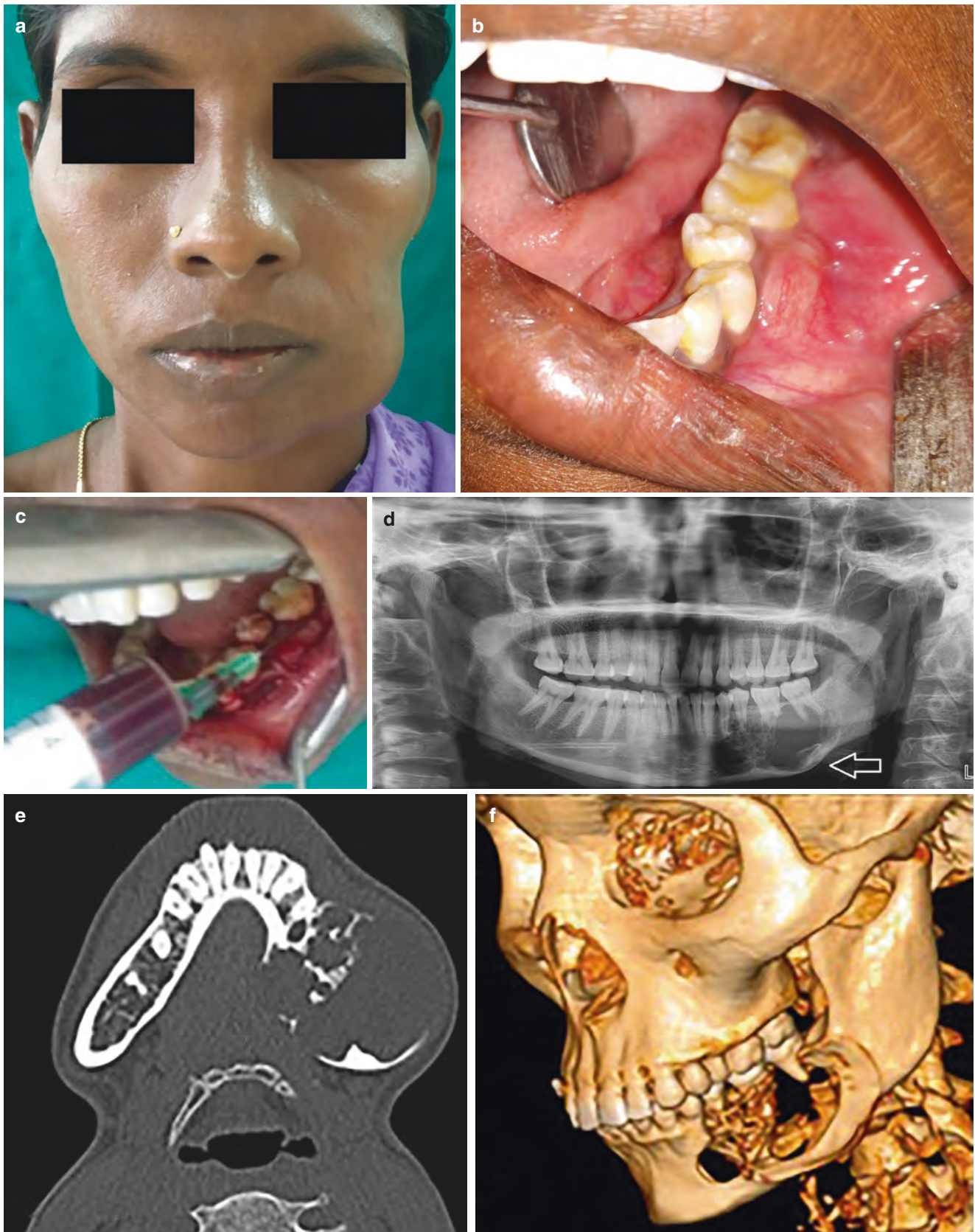Most of these lesions present as expansile swellings with or without perforation of the involved jaw bone, causing facial asymmetry or displacement of adjacent teeth and malocclusion. Pain, paresthesia and rapid progression of swelling can be seen occasionally. Dark venous blood is generally obtained on aspiration (Fig. 29.7a–c).

Pulsatile nature, thrill and bruit are generally not seen in these lesions despite the prominent vascular component associated with aneurysmal bone cysts. The presence of these signs in an expansile, osteolytic jaw lesion would rather indicate a high flow vascular malformation. The clinician should recognise this and not mistake it for an aneurysmal bone cyst, because doing an aspiration or incisional biopsy of such high flow vascular malformations can lead to disastrous bleeding and potentially fatal outcomes.

29.7.2 Aetiopathogenesis

The exact mechanism regarding the origin of aneurysmal bone cysts remains controversial. The reported hypotheses include post-traumatic, reactive malformation, genetic predisposition causing chromosomal translocation and minor vascular injury in a pre-existing bone lesion leading to pooling of blood in the stromal spaces creating bone destruction [38].

This lesion can occur de novo as a primary aneurysmal bone cyst or as a secondary phenomenon arising in pre-existing lesions like central giant cell granuloma, ossifying fibroma, fibrous dysplasia, osteosarcoma, fibrosarcoma and other lesions [38]. It has been postulated that injury to the capillary network in these lesions leads to extravasation of blood. The associated capillary blood pressure readily destroys unsupported stroma resulting in a blow out reaction thereby producing the expansile and destructive aneurysmal bone cyst.



©Association of Oral and Maxillofacial Surgeons of India

Fig. 29.7 (a) Swelling left side body mandible. (b) Intra oral view of swelling left lower posterior buccal cortex. (c) Aspirate showing blood tinged fluid. (d) OPG showing lesion left body mandible. (e) Axial CT

scan showing the expansile lesion. (f) 3D CT showing the destruction of bone

29.7.3 Radiologic Features

Owing to its osteolytic nature, aneurysmal bone cyst presents as unilocular or multi-locular radiolucency often associated with cortical thinning and perforation with resorption of roots seen occasionally. A classic sign commonly seen is the 'ballooning' distension of the thinned out cortex occurring as a result of a thin outline of reactive sub-periosteal bone formation. CT and MRI scans of such lesions often demonstrate blood and free fluid in these cavities (Fig. 29.7d, e, f).

These typical features can sometimes be masked in those aneurysmal bone cysts occurring as secondary phenomena in pre-existing bone lesions. Such aneurysmal bone cysts present as mixed radiolucent-radiopaque lesions.

29.7.4 Histopathological Features

Histopathologically, it consists of variable amounts of fibrous connective tissue stroma with blood-filled sinusoidal spaces, multi-nucleated giant cells and reactive woven bone/osteoid. Correlating the histopathological and clinical features, three variants of aneurysmal bone cysts were proposed namely, the solid type, vascular type and mixed type [39]. The solid type is associated with a dense stroma, few sinusoidal spaces and blood vessels that correlates with the absence of cortical perforation clinically and minimal bleeding observed intra-operatively. The vascular variant falls into the other end of the spectrum that shows loose fibrous tissue stroma with large blood-filled cavernous spaces causing extensive osteolysis and cortical perforation that is frequently associated with brisk intra-operative bleed. The mixed variant shows characteristics of both these sub-types.

29.7.5 Treatment

Complete Surgical curettage of the lesion is the most commonly followed treatment modality. Adjuvant therapies like cryosurgery and electrocauterisation have been used to reduce the chances of recurrence. Due to its vascular nature, brisk bleeding is often encountered during surgery that generally ceases after complete removal of the lesion. Pre-operative embolisation had been advocated in extensive, vascular variants of aneurysmal bone cysts to reduce intra-operative blood loss.

Resection is generally reserved for aggressive aneurysmal bone cysts that have extensively resorbed the lower border of the mandible or have caused a pathological fracture and lesions that have recurred following conservative therapy. The decision to perform segmental resection is also influenced by the nature and extent of primary jaw pathology in which the aneurysmal bone cyst has arisen. Segmental resection has been recommended as the treatment option for sec-

ondary aneurysmal bone cysts occurring in ossifying fibromas, giant cell granulomas and osteblastomas [40].

29.7.6 Prognosis and Complications

Aneurysmal bone cysts have relatively higher recurrence rates compared to central giant cell granuloma [38]. This has been attributed to incomplete removal of the lesion during curettage/marginal mandibulectomy. The multi-locular nature of the lesion can sometimes limit the access leading to residual pathological tissue that causes increased intra-operative bleeding and also gives rise to recurrences usually in the first year following surgery.

29.8 Brown Tumour of Hyperparathyroidism (Fig. 29.8)

Brown tumour is a misnomer as it is not a true neoplasm, but a localised area of osteolytic defect caused by increased osteoclastic activity and demineralisation of bone that is induced by excessive secretion of parathyroid hormone. It is considered to be an intra-osseous reactive lesion [4].

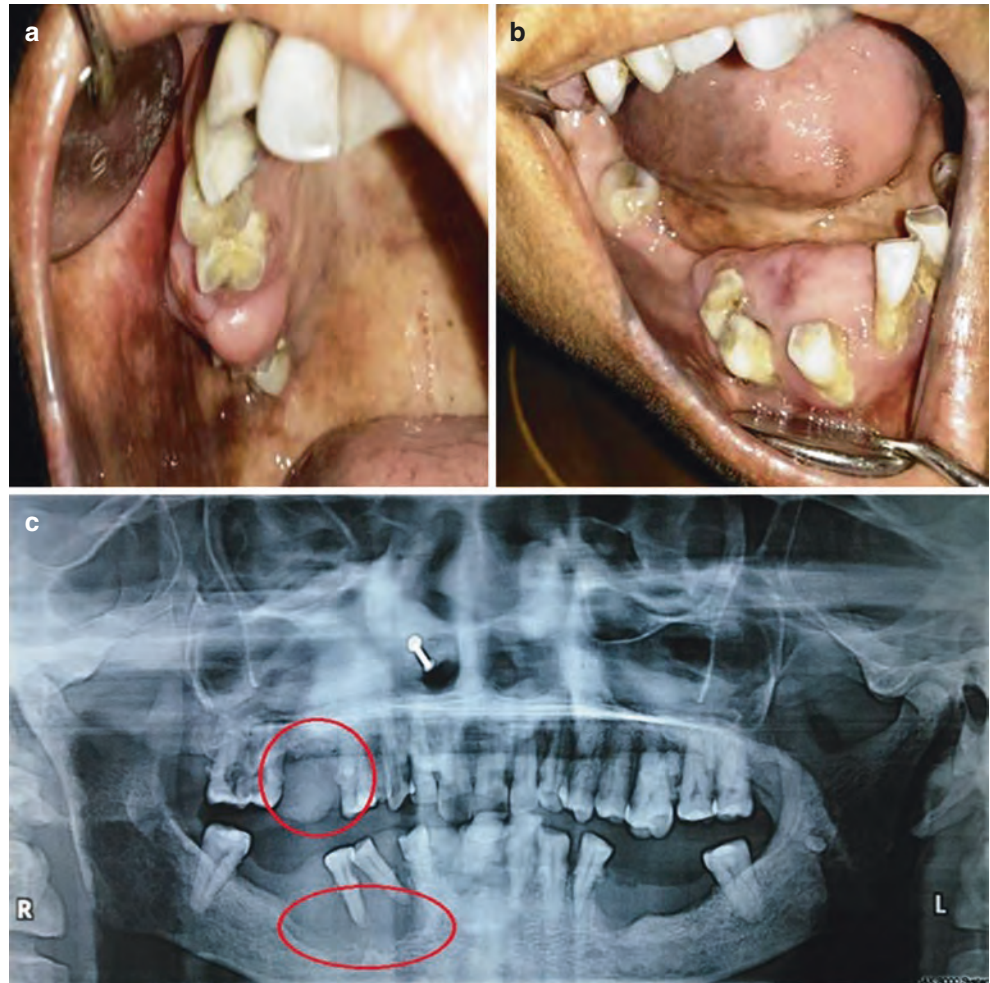
29.8.1 Etiopathogenesis

Hypersecretion of parathyroid hormone can occur due to Primary (benign/malignant adenoma of parathyroid gland), secondary (pre-existing kidney disease leads to compensatory overactivity of parathyroid) or tertiary causes (parathyroid tumours arising due to prolonged hyperactivity induced by secondary causes). Irrespective of the origin, the resultant effect is hypercalcaemia (caused by mobilisation of calcium from bone to bloodstream) and altered phosphate levels that give rise to the entire spectrum of signs and symptoms of this disease. These include disturbances in ion metabolism, demineralisation of bone, kidney stones, gastrointestinal disorders and muscle weakness. Hence, hyperparathyroidism is also referred to as the 'disease of bones, stones, abdominal groans and psychic moans' [41].

29.8.2 Clinical Features

Brown tumour is a localised, lytic bone defect characterised by a mass of reactive fibrous tissue that presents as swelling with cortical expansion, perforation occasionally associated with pain and pathological fracture. The lesion occurs in adults above 50 years of age and has a female to the male pre-dilection of 5:2 and can occur in any bone but more common sites are long bones, pelvis, ribs, maxilla and mandible [42]. Co-existing multiple synchronous lesions in the jaws and at other skeletal sites can also occur

Fig. 29.8 (a) Lesion right posterior maxilla. (b) Lesion anterior mandible. (c) OPG showing the changes (red circles)



©Association of Oral and Maxillofacial Surgeons of India

[43] (Fig. 29.8a–c). Bone manifestations usually occur in the late stages of hyperparathyroidism, and brown tumours are picked up during the diagnostic work-up for the same. Rarely, brown tumour of the jaw may be the first manifestation of primary hyperparathyroidism [44, 45]. They can cause significant bone destruction leading to facial asymmetry, displacement of teeth, malocclusion pathological fracture etc.

29.8.3 Diagnostic Workup

Since it is not possible to histopathologically distinguish brown tumour from central giant cell granuloma, biochemical tests are mandatory to confirm its diagnosis. Elevated serum calcium (>10.4 mg/dl), decreased serum phosphate level, elevated parathormone levels, ultrasonography to identify parathyroid adenomas (primary hyperparathyroidism), and renal function tests to rule out renal disease (secondary hyperparathyroidism) constitute the sequence of diagnostic work up to diagnose hyperparathyroidism [45].

29.8.4 Differential Diagnosis

- Giant cell granuloma
- Giant cell tumour
- Aneurysmal bone cyst

29.8.5 Radiographic Features

It shows a well-defined mono-locular or multi-locular well-demarcated lesion that is purely lytic. There are significant root resorption and loss of lamina dura.

29.8.6 Histopathology

Brown tumour very closely resembles central giant cell granuloma, and these two lesions are indistinguishable on histopathology. Features such as the proliferation of multi-nucleated giant cells, osteoclasts present in a rich fibro-cellular and vascular connective tissue stroma with

scattered areas of haemorrhagic foci and haemosiderin pigmentation are seen. The presence of haemosiderin renders this lesion its characteristic brown/brownish yellow colour and hence the name brown tumour.

29.8.7 Treatment

Spontaneous resolution/remission of brown tumour generally occurs after treatment of the underlying cause of hyperparathyroidism. Primary hyperparathyroidism is treated by excision of parathyroid adenoma/gland. Treatment of renal disease, vitamin D deficiency is done in the cases of secondary hyperparathyroidism. Refractory lesions that fail to resolve or incomplete remissions after treatment of underlying cause would require surgical curettage [44, 45].

29.8.8 Prognosis

Brown tumours are generally slow-growing lesions that can be locally destructive. Invasion into surrounding structures may cause a variety of symptoms. Small lesions usually resolve spontaneously once the underlying condition (hyperparathyroidism) is treated whereas large lesions take about 6–12 months to subside.

Pearls, perils and pitfalls:

1. Central Giant cell granuloma (CGCG) and brown tumour are indistinguishable histologically. An incisional biopsy report of CGCG should prompt the clinician to ask for biochemical investigations to rule out the brown tumour, that is characterised by increased serum levels of calcium, phosphate, alkaline phosphatase and parathyroid hormone.
2. It is crucial to diagnose brown tumours that are invariably reported as CGCG on incisional biopsy because treatment of hyperparathyroidism will generally lead to spontaneous resolution of brown jaw tumours, thereby avoiding unnecessary surgical procedures of jaw lesions.
3. Aneurysmal bone cysts have varied clinical, radiological and histological presentations.
4. Secondary aneurysmal bone cysts that arise in pre-existing pathologies have a higher tendency to recur if treated by conservative surgical methods like curettage.

29.9 Chronic Sclerosing Osteomyelitis and Garre's Osteomyelitis

Chronic sclerosing type of osteomyelitis occurs as a result of low-grade and long-standing infection of the marrow spaces that is characterised by areas of reactive bone sclerosis extending over a larger area (diffuse sclerosing) or localised to one or two teeth (focal sclerosing) [4].

Garre's osteomyelitis also known as proliferative periostitis is a sub-type of osteomyelitis that occurs in children. It is characterised by reactive sub-periosteal bone formation in response to chronic low-grade infection. Predominantly occurring in the posterior region of the mandible, it is best seen on an occlusal radiograph or an axial section CT scan as onion skin-layered appearance of the expanded bony cortex.

Rarely, malignancies like osteosarcoma (juxtacortical and parosteal), chondrosarcoma, fibrosarcoma and others can closely mimic Garre's osteomyelitis leading to a diagnostic dilemma and sub-optimal treatment.

These lesions are discussed in detail in other chapters of the book.

29.10 Conclusion

A variety of reactive soft tissue and bony pathologies occur in the oro-facial region that arises in response to chronic low-grade inflammation, trauma, metabolic and hormonal influences. These lesions very closely mimic benign and malignant neoplasms in their clinical, radiological and histological presentations. Knowledge about their etiopathogenesis, clinical behaviour patterns is of paramount importance for providing appropriate treatment.

Case Scenario 1 (Fig. 29.5)

A 53-year-old male patient reported with a chief complaint of bony hard swelling over the left side lower jaw of 8 month duration.

Clinical Examination

Bony hard swelling over the left body of the mandible was noted with the expansion of buccal and lingual cortical plates (Fig. 29.5a, b).

Pre-operative Diagnostic Work-up

Imaging: Orthopantomogram revealed unilocular radiolucency with a sclerotic border and x-ray occlusal view showed a bicortical expansile, osteolytic lesion at the left body of mandible, with areas of osteosclerosis (Fig. 29.5c, d).

Incisional Biopsy: Incisional biopsy done under local anaesthesia proved it to be central giant cell granuloma. Biochemical tests for assessment of serum parathormone, calcium, phosphate levels were performed, and the possibility of brown tumour of hyperparathyroidism was ruled out.

Diagnosis: Central Giant cell granuloma of mandibular body.

Surgical Plan: Considering bi cortical perforation and thinning of lower border caused by the lesion, segmental mandibulectomy through submandibular approach + mandibular reconstruction plate fixation was performed.

Postoperative Period: Post-operative period was uneventful. The patient was last seen three years after surgery and was found to be recurrence-free.

Case Scenario 2 (Fig. 29.6a–d)

A 60-Year-old male with a complaint of an asymptomatic slow-growing swelling in the upper jaw of 10 months duration.

Clinical Examination

A single firm to hard swelling measuring approximately 4 × 3 cm located over the right maxillary posterior alveolus causing buccolingual expansion, vestibular obliteration was found. It was extending from the mesial aspect of right maxillary 1st molar to the maxillary tuberosity area. The swelling was non-tender, firm to hard in consistency, with normal overlying mucosa. There was associated odontogenic focus of sepsis, but there was grade-II mobility of right maxillary 1st molar.

Pre-operative Diagnostic Work-up

Imaging: A pre-operative CT scan revealed a unilocular radiolucency with scattered areas of radio-opacity located at right maxillary posterior alveolus that was causing buccal cortical expansion, thinning and even perforation with denuding of the roots of the 1st molar. Superiorly the lesion was found to be extending till the body of the zygoma and just abutting the floor of the maxillary sinus.

Histopathological and Biochemical Evaluation: An incisional biopsy of the lesion was performed under local anaesthesia, that was reported as a central giant cell granuloma of the maxilla. A thorough biochemical evaluation was done to rule out brown tumour of hyperparathyroidism as both the lesions are indistinguishable histopathologically. Serum calcium, parathormone, and phosphate were within the normal limits.

Diagnosis: Central Giant cell granuloma—Right maxillary posterior alveolus.

Surgical Plan: Extended alveolectomy of the right posterior maxillary alveolus + nasal antrostomy + two-layered

closure of the resultant defect with oroantral communication by mobilisation of the buccal fat pad and adjacent Buccopalatal mucoperiosteum. Following excision of the lesion, since maxillary sinus was breached, the resultant defect was packed with ribbon gauzed soaked in whitehead's varnish, and a trans nasal inferior meatal antrostomy was done, through which the tip of the pack was brought outside and knotted for removal on the 12th day. A two-layered watertight closure of the wound was achieved.

Post-operative Period: The wound healed uneventfully. The patient was last seen 4 years post-operatively and was free of disease.

Case Scenario 3 (Fig. 29.7)

A 38-year-old female with a complaint of swelling at the left side lower jaw of 1-year duration.

Clinical Examination

Figure 29.7a A single firm to hard swelling was located over the left body of mandible, non-tender with normal overlying skin & mucosa. On palpation, buccal and lingual cortical plate expansion (Fig. 29.7b) with eggshell crackling sign-positive suggestive of expanded and thinned out cortical plates causing microfractures on digital pressure.

Pre-operative Diagnostic Work-up

Imaging: Orthopantomogram revealed a radiolucent lesion in the left body of the mandible with focal radio-opacities located in the anterior aspect of the lesion. The lesion was causing root resorption, thinning of mandibular lower border and was extending from lower left 2nd molar to lower left lateral incisor (Fig. 29.7d).

CT scan confirmed the presence of an expansile, lytic lesion with a characteristic 'ballooning distension of the buccal and lingual cortical plates'. It also showed scattered areas of radio-opacities & multilocularity in the anterior region of the lesion and bi-cortical perforation along its posterior aspect.

'Ballooning distension' of the cortex with scattered areas of radio-opacities within a radiolucency was suggestive of secondary aneurysmal bone cyst arising in a pre-existing lesion (Fig. 29.7e).

Reconstructed CT scan showing bi-cortical perforation and lower border thinning at the mandibular body (Fig. 29.7f).

Aspiration: Figure 29.7c Dark venous blood of about 8–10 ml could readily be aspirated from the lesion.

Incisional Biopsy: Correlating the bloody venous aspirate, clinical & radiological findings, a clinical diagnosis of the aneurysmal bone cyst was made. However, owing to the change in radiodensity in the anterior aspect of the lesion (as

evident on CT scan), an incisional biopsy was performed to rule out the presence of a hybrid lesion or co-existing pathology.

Diagnosis: A histopathological diagnosis of *secondary aneurysmal bone cyst arising in ossifying fibroma* of the mandible has been made.

Surgical Plan: Considering the hybrid nature of the lesion, bi-cortical perforation, thinning of lower border, the proposed surgical plan was segmental mandibulectomy and reconstruction.

Case Scenario 4 (Fig. 29.8)

A 40-year-old female patient reported with a complaint of swelling over the lower jaw of 18 months duration and swelling over the right side of the upper jaw of 6 months duration.

Clinical Examination

A firm to hard swelling was noted in the mandibular anterior dentoalveolar region extending from right lower 2nd premolar to lower left lateral incisor (Fig. 29.8a). There was a displacement of lower anterior teeth. Another similar firm swelling was noted in the right maxillary posterior dentoalveolar region in the region of missing right 1st maxillary molar (Fig. 29.8b). Overlying mucosa appeared normal in both the swellings.

Pre-operative Diagnostic Work-up

Imaging: Figure 29.8c Orthopantomogram revealed a unilocular radiolucency with a sclerotic border located in relation to the periapical region of right lower premolars. A poorly defined mixed lesion (radiolucent lesion with foci of radio opacities) was noted in the right maxillary posterior region.

Incisional Biopsy: An incisional biopsy of both the lesions was performed under local anaesthesia. Both the lesions were reported as central giant cell granulomas.

Biochemical Evaluation: Since synchronous giant cell granulomas are generally rare and as these lesions are histopathologically similar to brown tumour, biochemical evaluation was performed. Serum parathormone was remarkably elevated along with raised serum calcium levels, while renal function parameters were well within normal limits.

Ultrasound Evaluation of Neck: An ultrasound evaluation of neck revealed parathyroid adenoma on the left side.

Diagnosis: After correlating the biochemical and sonographic examination, a diagnosis of primary hyperparathyroidism is made. The osteolytic lesions of mandible and

maxilla were diagnosed as *Synchronous brown tumours of maxilla and mandible*.

Surgical Plan: The patient was advised parathyroidectomy for primary hyperparathyroidism followed by the wait and watch policy for synchronous brown jaw tumours to undergo self-resolution. But spontaneous resolution the jaw lesions was very slow following eight months after parathyroidectomy and the patient wanted surgical removal of the brown jaw tumours. They were treated by marginal mandibulectomy and alveolectomy of posterior maxilla.

References

Reactive Lesions of Oro-facial Soft Tissues

- Marx RE, Stern D. Oral and maxillofacial pathology: a rationale for diagnosis and treatment. Hanover Park, IL: Quintessence Publishing; 2012.
- Eversole LR, Rovin S. Reactive lesions of the gingiva. *J Oral Pathol Med.* 1972;1(1):30–8.
- Neville BW. Soft tissue tumours. In: Oral and maxillofacial pathology. London: Elsevier; 2009. p. 507–70.
- Wick MR, McDermott MB, Swanson PE. Proliferative, reparative, and reactive benign bone lesions that may be confused diagnostically with true osseous neoplasms. *Semin Diagn Pathol.* 2014;31(1):66–88. WB Saunders
- Hoch B, Montag A. Reactive bone lesions mimicking neoplasms. *Semin Diagn Pathol.* 2011;28(1):102–12. WB Saunders
- Sternberg SS, Antonioli DA, Carter D, Mills SE, Oberman H. Diagnostic surgical pathology. 3rd ed. Philadelphia, PA: Lippincott Williams & Wilkins; 1999.
- Epivatianos A, Antoniadis D, Zaraboukas T, Zairi E, Pouloupoulos A, Kiziridou A, et al. Pyogenic granuloma of the oral cavity: comparative study of its clinicopathological and immunohistochemical features. *Pathol Int.* 2005;55:391–7.
- Motamedi MH, Eshghyar N, Jafari SM, Lassemi E, Navi F, Abbas FM, Khalifeh S, Eshkevari PS. Peripheral and central giant cell granulomas of the jaws: a demographic study. *Oral Surg Oral Med Oral Pathol Oral Radiol Endod.* 2007;103:39–43.
- Katsikeris N, Kakarantza-Angelopoulou E, Angelopoulos AP. Peripheral giant cell granuloma. Clinicopathologic study of 224 new cases and review of 956 reported cases. *Int J Oral Maxillofac Surg.* 1988;17(2):94–9.
- Hernandez G, Lopez-Pintor RM, Torres J, de Vicente JC. Clinical outcomes of peri-implant peripheral giant cell granuloma: a report of three cases. *J Periodontol.* 2009;80:1184–91.
- Hirshberg A, Kozlovsky A, Schwartz-Arad D, Mardinger O, Kaplan I. Peripheral giant cell granuloma associated with dental implants. *J Periodontol.* 2003;74(9):1380–4.
- Subramanyam RV. Misnomers in oral pathology. *Oral Dis.* 2010;16(8):740–6.
- Prasad S, Reddy S, Patil SR, Kalaburgi NB, Puranik RS. Peripheral ossifying fibroma and pyogenic granuloma. Are they interrelated? *N Y State Dent J.* 2008;74:50–2.
- Buchner A, Hansen LS. The histomorphologic spectrum of peripheral ossifying fibroma. *Oral Surg Oral Med Oral Pathol Oral Radiol.* 1987;63(4):452–61.

15. Mergoni G, Meleti M, Magnolo S, Giovannacci I, Corcione L, Vescovi P. Peripheral ossifying fibroma: a clinicopathologic study of 27 cases and review of the literature with emphasis on histomorphologic features. *J Indian Soc Periodontol.* 2015;19(1): 83–7.
16. Cuisia ES, Brannon RB. Peripheral ossifying fibroma—a clinical evaluation of 134 pediatric cases. *Pediatr Dent.* 2001;23(3): 245–8.

Central Giant Cell Granuloma

17. Yamaguchi T, Dorfman HD. Giant cell reparative granuloma: a comparative clinicopathologic study of lesions in gnathic and extragnathic sites. *Int J Surg Pathol.* 2001;9(3):189–200.
18. Schlorf RA, Koop SH. Maxillary giant cell reparative granuloma. *Laryngoscope.* 1977;87(1):10–7.
19. Chuong R, Kaban LB, Kozakewich H, Perez-Atayde A. Central giant cell lesions of the jaws: a clinicopathologic study. *J Oral Maxillofac Surg.* 1986;44(9):708–13.
20. Whitaker SB, Waldron CA. Central giant cell lesions of the jaws: a clinical, radiologic, and histopathologic study. *Oral Surg Oral Med Oral Pathol Oral Radiol.* 1993;75(2):199–208.
21. Eisenbud L, Stern M, Rothberg M, Sachs SA. Central giant cell granuloma of the jaws: experiences in the management of thirty-seven cases. *J Oral Maxillofac Surg.* 1988;46(5):376–84.
22. Tosco P, Tanteri G, Iaquina C, Fasolis M, Rocchia F, Berrone S, Garzino-Demo P. Surgical treatment and reconstruction for central giant cell granuloma of the jaws: a review of 18 cases. *J Cranio-Maxillofac Surg.* 2009;37(7):380–7.
23. Bataineh AB, Al-Khateeb T, Ma'amoun AR. The surgical treatment of central giant cell granuloma of the mandible. *J Oral Maxillofac Surg.* 2002;60(7):756–61.
24. de Lange J, van den Akker HP, van den Berg H. Central giant cell granuloma of the jaw: a review of the literature with emphasis on therapy options. *Oral Surg Oral Med Oral Pathol Oral Radiol Endod.* 2007;104:603–15.
25. Pogrel AM. The diagnosis and management of giant cell lesions of the jaws. *Ann Maxillofac Surg.* 2012;2(2):102–6.
26. Suárez-Roa LM, Reveiz L, Ruíz-Godoy LR, Asbun-Bojalil J, Dávila-Serapio JE, Menjivar-Rubio AH, Meneses-García A. Interventions for central giant cell granuloma (CGCG) of the jaws. *Cochrane Database Syst Rev.* 2009;4:CD007404.
27. Vered M, Buchner A, Dayan D. Immunohistochemical expression of glucocorticoid and calcitonin receptors as a tool for selecting therapeutic approach in central giant cell granuloma of the jawbones. *Int J Oral Maxillofac Surg.* 2006;35(8):756–60.
28. Jacoway JH, Howell FV, Terry BC. Central giant cell granuloma: an alternative to surgical therapy. *Oral Surg Oral Med Oral Pathol.* 1988;66:572.
29. Terry BC, Jacoway JR. Management of central giant cell lesions: an alternative to surgical therapy. *Oral Maxillofac Surg Clin North Am.* 1994;6(3):579–600.
30. Abdo EN, Alves LC, Rodrigues AS, Mesquita RA, Gomez RS. Treatment of a central giant cell granuloma with intral-lesional corticosteroid. *Br J Oral Maxillofac Surg.* 2005;43(1): 74–6.

31. Pogrel MA. Calcitonin therapy for central giant cell granuloma. *J Oral Maxillofac Surg.* 2003;61(6):649–53.
32. Kaban LB, Troulis MJ, Ebb D, August M, Hornicek FJ, Dodson TB. Antiangiogenic therapy with interferon alpha for giant cell lesions of the jaws. *J Oral Maxillofac Surg.* 2002;60(10):1103–11.
33. Da Silva NG, Carreira AS, Pedreira EN, Tuji FM, Ortega KL, Pinheiro JD. Treatment of central giant cell lesions using bisphosphonates with intralesional corticosteroid injections. *Head Face Med.* 2012;8(1):23.
34. Thomas D, Henshaw R, Skubitz K, Chawla S, Staddon A, Blay JY, Roudier M, Smith J, Ye Z, Sohn W, Dansey R. Denosumab in patients with giant-cell tumour of bone: an open-label, phase 2 study. *Lancet Oncol.* 2010;11(3):275–80.
35. Chawla S, Henshaw R, Seeger L, Choy E, Blay JY, Ferrari S, Kroep J, Grimer R, Reichardt P, Rutkowski P, Schuetze S. Safety and efficacy of denosumab for adults and skeletally mature adolescents with giant cell tumour of bone: interim analysis of an open-label, parallel-group, phase 2 study. *Lancet Oncol.* 2013;14(9):901–8.
36. Naidu A, Malmquist MP, Denham CA, Schow SR. Management of central giant cell granuloma with subcutaneous denosumab therapy. *J Oral Maxillofac Surg.* 2014;72(12):2469–84.

Aneurysmal Bone Cyst

37. Rosenberg AE, Nielson GP, Fletcher JA. Aneurysmal bone cyst. In: CDM F, Unni KK, Mertens F, et al., editors. *WHO classification of tumours: pathology and genetics of head and neck tumours*, vol. 9. 3rd ed. Lyon: IARC; 2005.
38. Struthers PJ, Shear M. Aneurysmal bone cyst of the jaws:(II). Pathogenesis. *Int J Oral Maxillofac Surg.* 1984;13(2):92–100.
39. Motamed MH, Navi F, Eshkevari PS, Jafari SM, Shams MG, Taheri M, Abbas FM, Motahhari P. Variable presentations of aneurysmal bone cysts of the jaws: 51 cases treated during a 30-year period. *J Oral Maxillofac Surg.* 2008;66(10):2098–103.
40. Sun ZJ, Zhao YF, Yang RL, Zwahlen RA. Aneurysmal bone cysts of the jaws: analysis of 17 cases. *J Oral Maxillofac Surg.* 2010;68(9):2122–8.

Brown Tumor

41. Abdelrahman TE. Brown jaw tumors: challenges and outcomes. *Int Surg J.* 2017;4(11):3586–9.
42. Ullah E, Ahmad M, Ali SA, Redhu N. Primary hyperparathyroidism having multiple Brown tumors mimicking malignancy. *Indian J Endocrinol Metab.* 2012;16(6):1040.
43. Chami B, Benrachadi L, El Omri N, El Qatni M, El Wady W, El Mohtarim B. Brown tumor of the palate as first manifestation of primary hyperparathyroidism: a case report. *Méd Buccale Chir Buccale.* 2011;17(4):287–91.
44. Arunkumar KV, Kumar S, Deepa D. Brown tumor in mandible as a first sign of vitamin D deficiency: a rare case report and review. *Indian J Endocrinol Metab.* 2012;16(2):310.
45. Scott SN, Graham SM, Sato Y, Robinson RA. Brown tumor of the palate in a patient with primary hyperparathyroidism. *Ann Otol Rhinol Laryngol.* 1999;108:91–4.

Open Access This chapter is licensed under the terms of the Creative Commons Attribution 4.0 International License (<http://creativecommons.org/licenses/by/4.0/>), which permits use, sharing, adaptation, distribution and reproduction in any medium or format, as long as you give appropriate credit to the original author(s) and the source, provide a link to the Creative Commons license and indicate if changes were made.

The images or other third party material in this chapter are included in the chapter's Creative Commons license, unless indicated otherwise in a credit line to the material. If material is not included in the chapter's Creative Commons license and your intended use is not permitted by statutory regulation or exceeds the permitted use, you will need to obtain permission directly from the copyright holder.





Fibro-osseous Lesions in the Maxillofacial Region

30

Taranjit Kaur

Fibro-osseous lesions have posed a diagnostic dilemma since the beginning, when first case was reported in late 19th century. Since then various lesions are included in this group, yet the understanding of the lesions remains obscure for the clinician/surgeon. The main reason for this, is their histological resemblance with one another, where they all show varying degrees of healthy bone replaced by fibrous tissue and some amount of bone/cementum like tissue intermingled in between. This chapter is written with the aim of simplifying these group of bony lesions for its readers and highlighting the key idea of interdisciplinary approach in the management of these lesions where the oral pathologist along with radiologist and clinician play a pivotal role in differentially diagnosing these lesions, for the maxillofacial surgeon to chose and perform her/his duty of managing them, rightfully, for their patients. The spectrum of these lesions have seen several changes during the course of history yet there is still ample scope for ambiguity in identification and classification of the lesions, hence the authors have chosen few most commonly encountered lesions in Indian subcontinent, for the description and discussion.

30.1 Introduction

Fibro-osseous lesions (FOLs) are miscellaneous and challenging group of intra-osseous lesions posing a diagnostic dilemma for the clinician as well as the pathologist and this makes them interesting to treat and manage for the surgeon [1]. It was Boyko who first reported a case of craniofacial fibrous dysplasia, diagnosed at that time as osteofibroma, in

1936, which was called leontiasis ossea, the term first described by Virchow in 1862, for bony lesions involving upper facial bones resulting in lion-like faces. Clinicians and pathologists have gone through a drastic change in their understanding of these lesions since then yet pathogenesis and progression still needs further investigation [2].

One thing that is common in all these lesions is that normal bone is replaced by connective tissue and fibroblasts; occasional foci of mineralisation is seen, with varying degrees of bone- or cementum-like tissue. The biological behaviour of these lesions ranges from benign and indolent to aggressive, inflammatory and neoplastic [1].

The diagnosis is difficult to obtain on the basis of histopathology alone, clinical history and radiographic details have an important role to play in the decision-making of the management. Most often than not, pathologists may not be able to comment more than just benign fibro-osseous lesion in the absence of additional clinical and radiographic information [1].

Though considered as one of the most confusing and challenging pathological processes, it was the meticulous hard work of Charles A Waldron, an American Oral Pathologist, who was first to describe these lesions in a systematic way and propose the classification, in the year 1985, which was later revised by himself in the year 1993 [3, 4].

With the evolution of technology and a better clinical understanding of the lesions as well as the availability of ample literature, various other classifications have emerged from time to time [5, 6].

30.2 Classifications

Fibro-osseous lesions have undergone a turbulent phase with regard to its classification and categorisation and in this chapter, it may not be possible to include all the available classifications, but the major ones have been referred to. The major changes in classifications are seen in the publications by Waldron [5], Waldron [6], Slootweg [7], WHO [8], Speight

Electronic Supplementary Material The online version of this chapter (https://doi.org/10.1007/978-981-15-1346-6_30) contains supplementary material, which is available to authorized users.

T. Kaur (✉)
Department of Oral and Maxillofacial Surgery, Government Dental College and Hospital, Jamnagar, Gujarat, India

and Carlos [9] and Eversole et al. [1]. As all the changes in classifications have not been included in the chapter, readers are encouraged to refer the concerned publications. Some of the commonly used classifications are as follows.

30.2.1 Waldron's Classification, 1985 [5, 10]

1. Fibrous dysplasia (FD)
 - (a) Monostotic
 - (b) Polyostotic
2. Fibro-osseous (cemental) lesions' plausible origin in the periodontal ligament
 - (a) Periapical cemental dysplasia
 - (b) Localised fibro-osseous-cemental lesions (presumably reactive in nature)
 - (c) Florid cemento-osseous dysplasia (gigantiform cementoma)
 - (d) Ossifying and cementifying fibroma
3. Fibro-osseous neoplasms of uncertain or detectable relationship to those arising in the periodontal ligament
 - (a) Cementoblastoma, osteoblastoma and osteoid osteoma.
 - (b) Juvenile active-ossifying fibroma and other so called aggressive-ossifying/cementifying fibromas.

30.2.2 WHO Classification of FOLs, 2005 [8]

At the core of these classifications is the spectrum of clinicopathological entities in which the diagnosis can only be made by the correlation of clinical, radiological and histological features.

1. Ossifying fibroma (OF)
2. Fibrous dysplasia
3. Osseous dysplasia
 - (a) Periapical osseous dysplasia
 - (b) Focal osseous dysplasia
 - (c) Florid osseous dysplasia
 - (d) Familial gigantiform cementoma
4. Central giant cell granuloma
5. Cherubism
6. Aneurysmal bone cyst
7. Solitary bone cyst

30.2.3 Speight and Carlos Classification (2006) [9]

1. Fibrous Dysplasia
 - (a) Monostotic FD
 - (b) Polyostotic FD
 - (c) Craniofacial FD

2. Osseous Dysplasia
 - (a) Periapical Osseous Dysplasia
 - (b) Focal Osseous Dysplasia
 - (c) Florid Osseous Dysplasia
 - (d) Familial Gigantiform Cementoma
3. Ossifying Fibroma
 - (a) Conventional Ossifying Fibroma
 - (b) Juvenile Trabecular-Ossifying Fibroma
 - (c) Juvenile Psammomatoid-Ossifying Fibroma

30.2.4 Eversole Classification, 2008 [1]

In 2008, Eversole et al. gave a comprehensive classification by including developmental lesions, neoplastic lesions and inflammatory/reactive processes. This classification emphasised that final diagnosis can be attained by the correlation of microscopy, imaging and clinical features together and not on the basis of histopathological features alone.

1. Bone dysplasias
 - (a) Fibrous dysplasia
 - (i) Monostotic
 - (ii) Polyostotic
 - (iii) Polyostotic with endocrinopathy (McCune-Albright)
 - (iv) Osteofibrous dysplasia
 - (b) Osteitis deformans or Pagets disease
 - (c) Pagetoid heritable bone dysplasias of childhood
 - (d) Segmental odontomaxillary dysplasia
2. Cemento-osseous dysplasias
 - (a) Focal cemento-osseous dysplasia
 - (b) Florid cemento-osseous dysplasia
3. Inflammatory/reactive processes
 - (a) Focal sclerosing osteomyelitis
 - (b) Diffuse sclerosing osteomyelitis
 - (c) Proliferative periostitis
4. Metabolic disease
 - (a) Hyperparathyroidism
5. Neoplastic lesions (ossifying fibromas)
 - (a) Ossifying fibroma
 - (b) Hyperparathyroidism jaw lesion syndrome
 - (c) Juvenile-ossifying fibroma
 - (i) Trabecular type
 - (ii) Psammomatoid type
 - (d) Gigantiform cementomas

Based on the above-mentioned classification systems, author have selected few most commonly occurring BFOLs (Benign fibro-osseous lesions), which will allow a better understanding of these lesions, from a maxillofacial surgeon's point of view.

It is apparent from this wide spectrum of FOL that a diagnosis cannot be made from pathology reports alone and it has

to be correlated with the clinical and radiological findings [11]. BFOL form a wide spectrum of diseases, which occur intra-osseously and is characterised by similar microscopic pictures with hypercellular fibroblastic stroma and varying amounts of bone, cementum and other calcified structures. El Mofty stated that reactive, dysplastic, developmental and neoplastic processes are included under the broad umbrella of BFOLs and the treatment given varies from case to case [12].

30.3 Fibrous Dysplasia (FD)

Fibrous Dysplasia is a benign dysplastic disease with a well-approved genetic cause in *GNAS 1* (Guanine nucleotide-binding protein alpha-stimulating activity polypeptide 1) gene. The clinical severity of the disease depends on the stage of foetal life (prenatal/postnatal) at which gene mutation occurs. So far, the identification of *GNAS1* mutations are the most useful molecular tool to differentiate fibrous dysplasia from other fibro-osseous lesions [13].

30.3.1 Clinical Features

There are four main clinical subtypes of FD depending on the time of mutation in *GNAS 1*

- (a) Monostotic FD, which affects single bone: Post-natal life mutation.
- (b) Polyostotic FD affecting multiple bones at the same time: Mutation in the late embryonic stages of life.
- (c) McCune—Albright syndrome in which multiple bony lesions are seen along with skin pigmentations and endocrinopathies presenting itself as precocious puberty and hyperthyroidism: Due to mutation in early embryonic stages of life.
- (d) Craniofacial FD confined to bones of craniofacial complex.

Craniofacial variant will be discussed in detail, as it is the most common FD encountered in the maxillofacial region.

FD is the disease of growing bones and the majority of lesions are diagnosed in first two decades of life, without any predilection for gender or race. Though mandibular lesions are purely monostotic, but the lesions involving maxilla, which invariably involve zygoma, sphenoid and other adjoining bones of the craniofacial skeleton, are not truly monostotic and hence may be suitably referred to as Craniofacial FD. Since multiple adjoining bones are involved of the same anatomic region, term polyostotic is avoided. Craniofacial FD appears in few commonly seen patterns,

One, involving maxilla-zygoma-sphenoid-frontal-nasal bones. Another, involving frontal-temporal-sphenoid-zygoma bones

Clinically, painless expansion of the affected area with facial asymmetry is the common presentation of FD. Rarely does a lesion expand the bone to cause structural weakening. Thickening of the skull bones and obliteration of the foramina of the base of the skull occasionally can present variously as headache, proptosis, visual loss, anosmia and hearing loss.

30.3.2 Radiographic Features

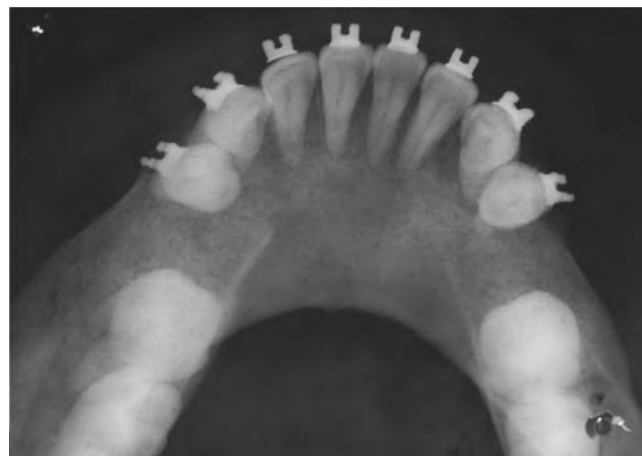Radiographic features vary depending on the stage at which the lesion is diagnosed. Early onset lesions appear radiolucent and later as they age, the classical 'ground glass appearance' (Fig. 30.1) is the identifying feature.

The lesion is ill defined and is radiologically imperceptible from the adjoining normal bone. Ground glass appearance is due to radiodensity caused by abundance of woven bone, which also leads to fuzziness of the boundaries, and strict delineation of lesion from the normal bone is difficult on the radiograph. Poorly defined borders are the diagnostic clue for FD and also differentiate it from Ossifying fibroma, which has well-defined appearance on the radiograph. Publications have stressed on the importance of CT and CBCT as investigative modalities of FOLs [14].

The clinical case scenarios 1 and 2 are provided for the readers to appreciate the difference in the CT images between early and long-standing lesions

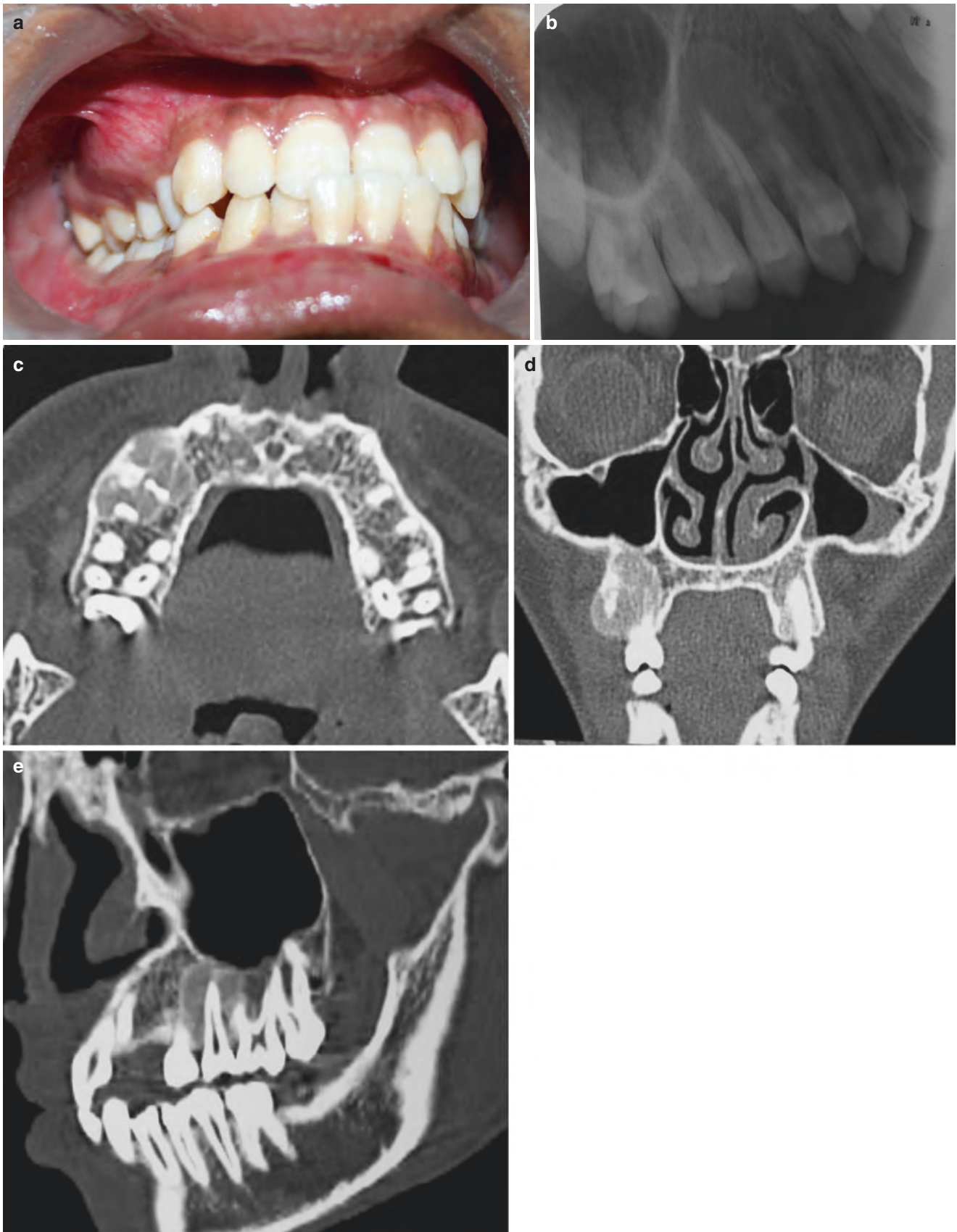
Clinical case scenario 1 (Fig. 30.2a–e)

A 17-year-old male with noted swelling in the upper right maxilla posterior vestibule region and he was aware of the swelling for about 1 month.



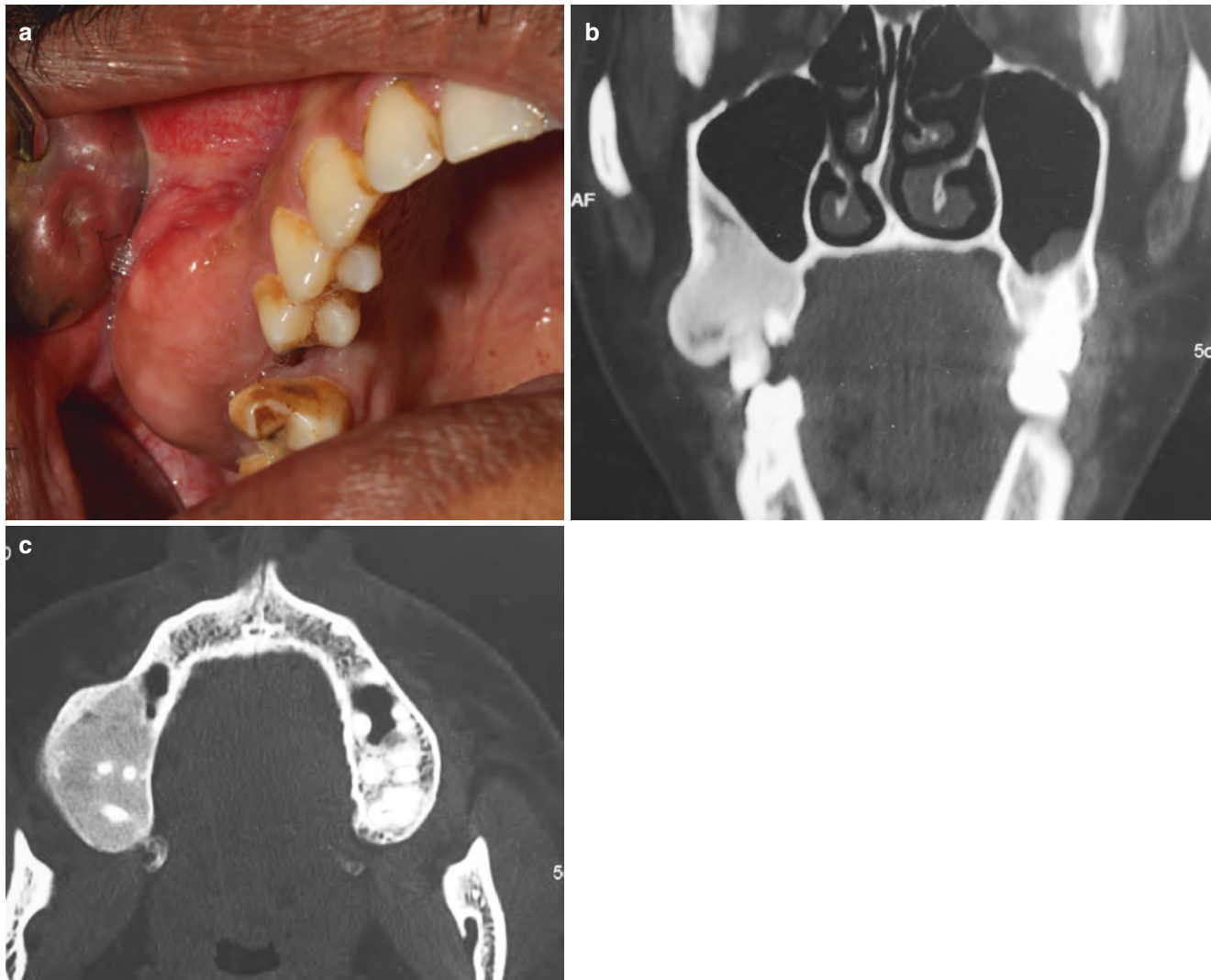
©Association of Oral and Maxillofacial Surgeons of India

Fig. 30.1 Occlusal image showing ground glass appearance in a 36-year-old female, who had asymptomatic bilateral body region mandible swelling



©Association of Oral and Maxillofacial Surgeons of India

Fig. 30.2 (a) Clinical picture of FD right upper posterior buccal sulcus. (b) Occlusal view showing ground glass appearance, no root resorption, no root displacement, hazy margins, lamina dura appeared to be lost in IOPA. (c) Axial view CT. (d) Coronal view CT. (e) Sagittal view CT



©Association of Oral and Maxillofacial Surgeons of India

Fig. 30.3 (a) Clinical image. (b) Coronal CT showing more dense/opaque appearance of the lesion. (c) Axial image

Clinically, the lesion was Ovoid, well defined, non-tender and firm with no palatal expansion, involving the buccal sulcus of tooth 13–16 (Fig. 30.2a).

Occlusal X-ray showed ground glass appearance (Fig. 30.2b), There was no root resorption, no root tilting, margins were hazy and lamina dura lost.

CT scan shows well-defined lesion (Fig. 30.3c–e—axial, coronal and sagittal views, respectively).

The Calcium and Phosphorous values were normal.

A bone incision biopsy was done and the final diagnosis was that FD. It was decided to observe the lesion till growth is completed; however, the patient was lost for follow up

Clinical case scenario 2 (Fig. 30.3a–c)

This patient in his late thirties was aware of the swelling on the right posterior upper jaw for past 5-6 years. After an initial biopsy proved it to be FD, the lesion was excised completely under GA.

30.3.3 Histological Features

Histologically, FD shows irregularly shaped trabeculae of immature woven bone dispersed in cellular fibroblastic stroma. The bone trabeculae evolve directly from stroma and assume delicate curvilinear patterns, which appear like ‘Chinese letters’ [15]. The osteoid is generally not rimmed with osteoblasts and develops into lamellar bone as the lesion matures. Such may not be the case with extra gnathic lesions.

30.3.4 Treatment and Prognosis

In a large majority of cases, lesions show the tendency of slow growth and eventually stabilise with the cessation of the growth phase. Indications for surgical treatment include functional deficits or significant cosmetic deformity. The aim of treatment is to restore function and cosmetic symmetry.

The involvement of the bone may range from minimal to functional and/or esthetic deformity being present. Based on patient's age, the presence/absence of cosmetic and functional deficits and the growth rate, the treatment is currently designed in the following way [16] (Video 30.1).

1. Observation
2. Conservative approach in the form of surgical recontouring and reshaping.
3. Radical surgical approach involving resection and reconstruction.

In the case of minimal involvement, no surgical intervention may be needed but when involvement is more significant, surface shaving of excess bone, for cosmetic reasons may be done. Radical surgical approach is preferred in the case of significant functional and aesthetic deficit.

A treatment scheme offered by Chen in 1990 [17] is helpful in determining the approach depending on the extent of conditions. The lesions are defined as per the regions, in Zone 1, i.e. frontomaxillofacial area, it is advised that they are completely excised and reconstructed henceforth. In Zone 2, i.e. hair-bearing cranium, observation and conservative or radical approach as and when needed. Whereas in Zone 3, which is central cranial base, more conservative or observational approach is required due to the difficult location of neurovascular bundle, lastly Zone 4 lesions involving dentate maxilla and mandible are advised conservative treatment in the form of surgical recontouring and shaping. Optic canal decompression was advised on patients with orbital dysplasia and decreasing visual acuity.

Riclade in 2001 in his review article stated that in craniofacial dysplasia, early treatment is advised in progressive sensory disturbances, in order to reduce the problems caused by decompression at a later stage [18].

Non-surgical treatment has a limited role, radiotherapy is contraindicated. Steroids show some effectiveness in reducing bone pain and temporary relief from symptoms due to nerve compression. Calcitonin and pamidronate have shown some promise in recent studies but the results of long term trials are awaited [16].

Monostotic lesions of the craniofacial complex need to be differentiated from other FOLs like cemento-ossifying fibroma (COF) and diffuse-sclerosing osteomyelitis of the mandible [15] while COF most commonly appears in young adults in tooth bearing areas of mandible and maxilla, it is well defined and can be separated or scooped out from the adjoining healthy bone easily.

Clinical case scenario 3 is a 14-year-old boy who reported with a recurrent lesion on upper left buccal posterior alveo-

lus. The clinical, radiological and surgical findings were suggestive of a COF; however, the pathology report was that of FD. This case is shown to highlight the varied pathology reports, which can be expected in dealing with lesions under the BFOL spectrum (Fig. 30.4a-d).

Clinical case scenario 4 (Fig. 30.5a-c) is given to show lesion, which had initial differential diagnosis of FD, but pathology report showed it to be sclerosing osteomyelitis

In 2008, eversole classification inflammatory reactive process containing focal sclerosing osteomyelitis/diffuse sclerosing osteomyelitis (DSOM) and proliferative periostitis were categorised under BFOL.

Figure 30.6 is an OPG of a 11-year-old child who presented with recurrent pain and swelling left side body mandible. OPG shows a diffuse ground glass appearance, with changes in the trabecular pattern on the whole of the left ramus and body mandible. A provisional diagnosis of DSOM can be made. Unfortunately, the patient didn't report for further investigations. OPG is included to demonstrate the alteration of the trabecular pattern.

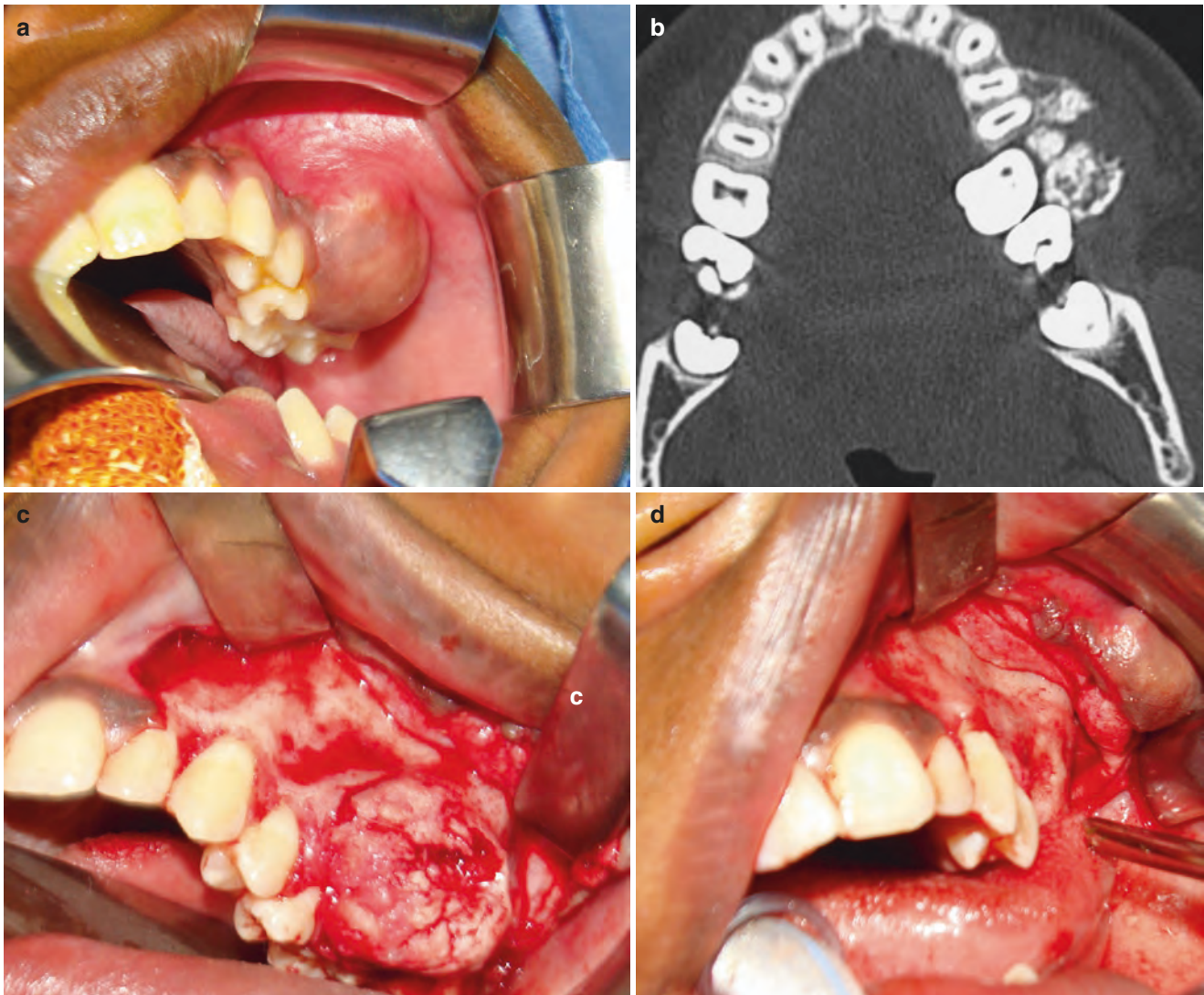
30.4 Ossifying Fibroma/Cementifying Fibroma/Cemento-Ossifying Fibroma (COF) and Juvenile (Aggressive)-Ossifying Fibroma

30.4.1 Clinical Features

These were traditionally a group of Fibro-osseous lesions with neoplastic tendencies. COF has had its own share of controversies, being included previously under BFOLs. The recent update in 2018; however, accepts COF as odontogenic in origin and had been placed under mesenchymal odontogenic tumours [19]. Another entity with a similar clinical picture is central odontogenic fibroma, which is also under benign mesenchymal tumours. Lesion that produces cementum including COF and cementoblastoma, thus, currently has found a new place.

In 2017, the consensus group felt that the term cemento-ossifying fibroma is suitably descriptive and indicates that these lesions are specific to the tooth-bearing areas of the jaws and can be distinguished from the two juvenile variants of ossifying fibroma. This clearly distinguishes it from ossifying fibromas that are non-odontogenic and are classified under benign fibro- and chondro-osseous lesions. The three variants are, therefore, defined as cemento-ossifying fibroma, juvenile trabecular-ossifying fibroma and juvenile psammomatoid-ossifying fibroma [20–22].

COF progressive painless buccal and lingual plate expansion. COF affects dentate segment of mandible and maxilla.



©Association of Oral and Maxillofacial Surgeons of India

Fig. 30.4 (a) Clinical image of swelling left upper buccal alveolus in a 14-year-old boy. (b) Axial CT image showing flecks of radiopacities. (c) Shows the lesion exposed, note the gritty nature, which could be

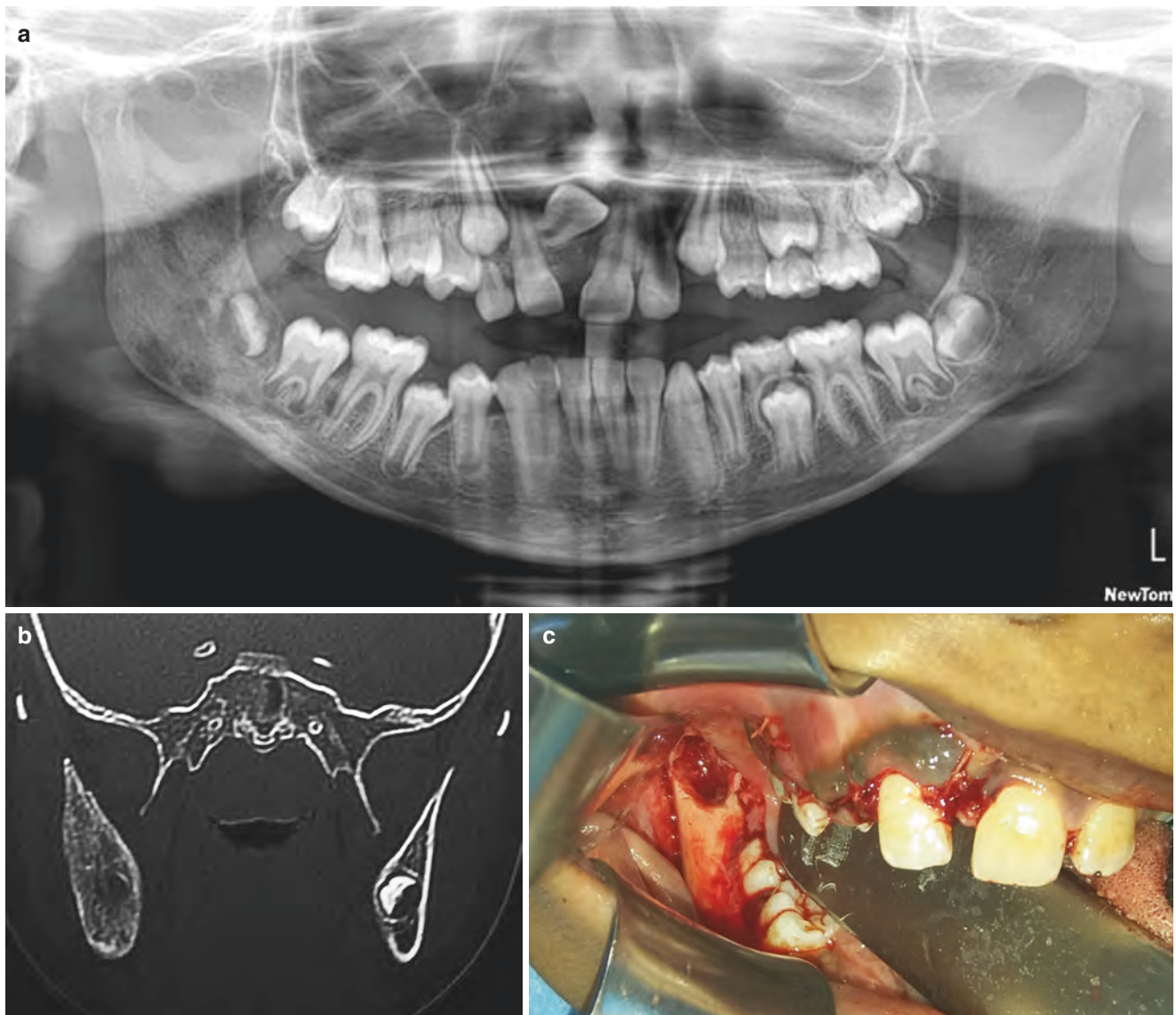
easily shelled out with relative ease, in this case. (d) Intra-operative image where the lesion was shaved out from the alveolar bone via a mucoperiosteal flap approach

They are slow growing in nature in adults, but show aggressiveness in the younger age group. The teeth are generally displaced. Ossifying Fibromas demonstrate a well delineated or encapsulated cellular fibrous connective tissue with varying amounts of osseous products like bone and cementum (spherical calcification).

Lesions are more commonly seen in mandible (77%) especially the molar region and are found exclusively in jaws. The peak age is 3rd and 4th decades of life and very strong female pre-dilection (almost 5:1). The juvenile variant (Juvenile-Ossifying Fibroma), which is also more aggressive, is seen in the younger age group [23].

30.4.2 Radiological Features

It is a well-demarcated radiolucent lesion, in the initial stages, separated from the surrounding healthy bone. Usually, a solitary lesion and is unilocular. The well-demarcated radiolucent/radiopaque appearance is the main differentiating consideration with Fibrous Dysplasia. Appearance is dependent on the maturity of the lesion, i.e. purely radiolucent (initial stages); mixed with radiopaque foci or radiopaque. The radiographic presentation of bowing of mandible with thinning and weakening of the lower border, particularly in large expansive lesions, is seen. Resorption or divergence of roots may result due to continued growth.



©Association of Oral and Maxillofacial Surgeons of India

Fig. 30.5 (a, b) OPG ant coronal CT cuts show evident changes in the right ramus of a 10-year-old girl, who presented with progressing facial asymmetry on the right side ramus region. The provisional diagnosis

was of FD, but the bone biopsy (c) report was suggestive of sclerosing osteomyelitis

30.4.3 Histologic Features

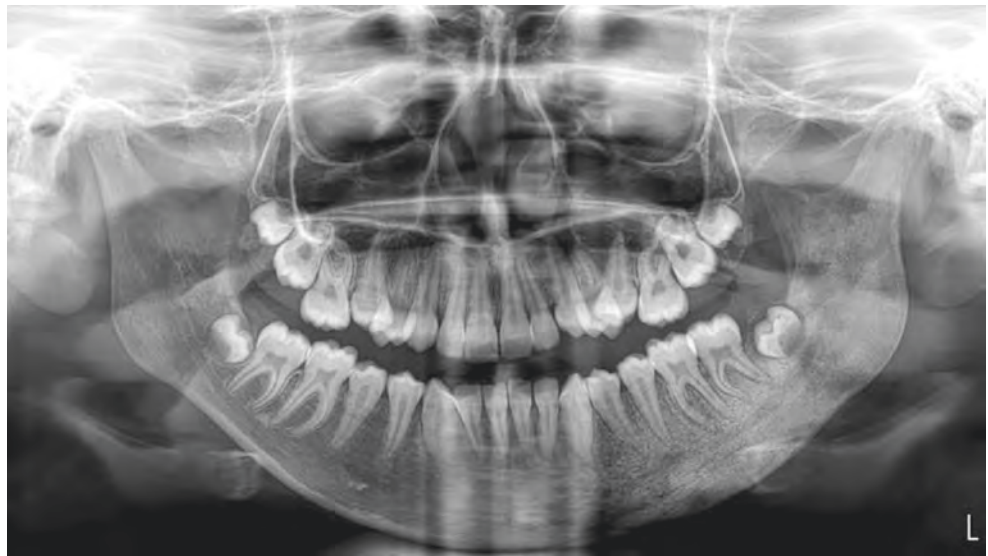Ossifying fibromas of craniofacial skeleton are divided into two categories depending on the cell of origin.

- (A) Cemento-ossifying Fibroma (COF): OF with odontogenic origin.
- (B) Juvenile (aggressive)-Ossifying Fibroma [9, 24–26]: subcategorised as (Table 30.1) (Fig 30.7)
 1. Juvenile trabecular-Ossifying Fibroma (JTOF)
 2. Juvenile Psammomatoid-ossifying fibroma (JPOF)

30.4.4 Treatment and Prognosis

COF is a slowly growing benign neoplasm commonly seen in the 3rd to 4th decades of life, if left untreated can enlarge to a significant size. Since it is radiographically as well as microscopically well circumscribed and shells out from the surrounding bone with little effort, it is curettage or enucleation a preferred initial treatment option. An important feature is, it is well defined and can be easily shelled out from the adjoining normal bone, grossly the lesion can be separated out in one piece or a few large chunks. The recurrence rate is variable and unpredictable. Surgical curettage is an

Fig. 30.6 OPG in a 11-year-old child showing the diffuse change in the trabecular pattern at the left body/ramus region of mandible



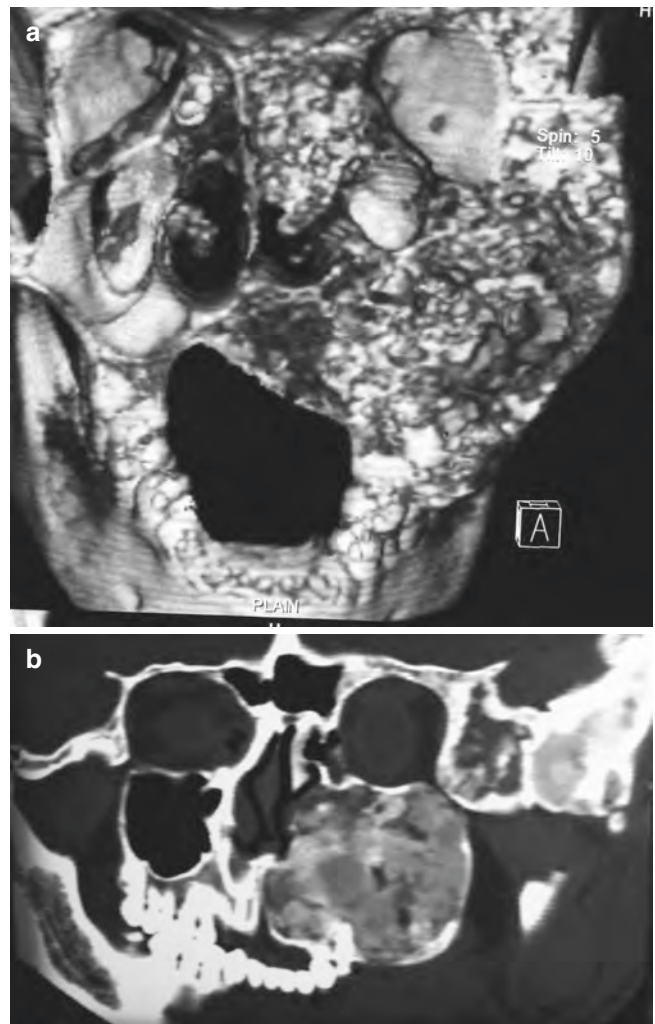
©Association of Oral and Maxillofacial Surgeons of India

Table 30.1 Comparing the main features of JTOF and JPOF (adapted from Speight and Carlos [9])

	JTOF	JPOF
Age (mean)	2–30 years (10)	3 months–72 years (20)
Female: male	1.2:1	1.3:1
site	Maxilla 50% Mandible 44% Sino-nasal 6%	Sino-nasal 62% Maxilla 20% Mandible ramus 10% Cranium 8%
Radiology	Well circumscribed Speckled calcifications	Well circumscribed, aggressive, expands and occupies the paranasal sinuses
Histopathology	Densely cellular, immature bone and osteoid in a trabecular pattern, osteoblast rimming seen	Densely cellular, spherical cementum-like psammomatoid calcifications
Clinical features	Progressive and rapid expansion of lesion, pain may not be present, in maxilla can produce nasal obstruction and epistaxis	Affects predominantly extragnathic bones of craniofacial skeleton, particularly the paranasal, orbital, frontal and ethmoid bones. Orbital extension of sino-nasal tumors may present as proptosis, visual complaints nasal stuffiness etc

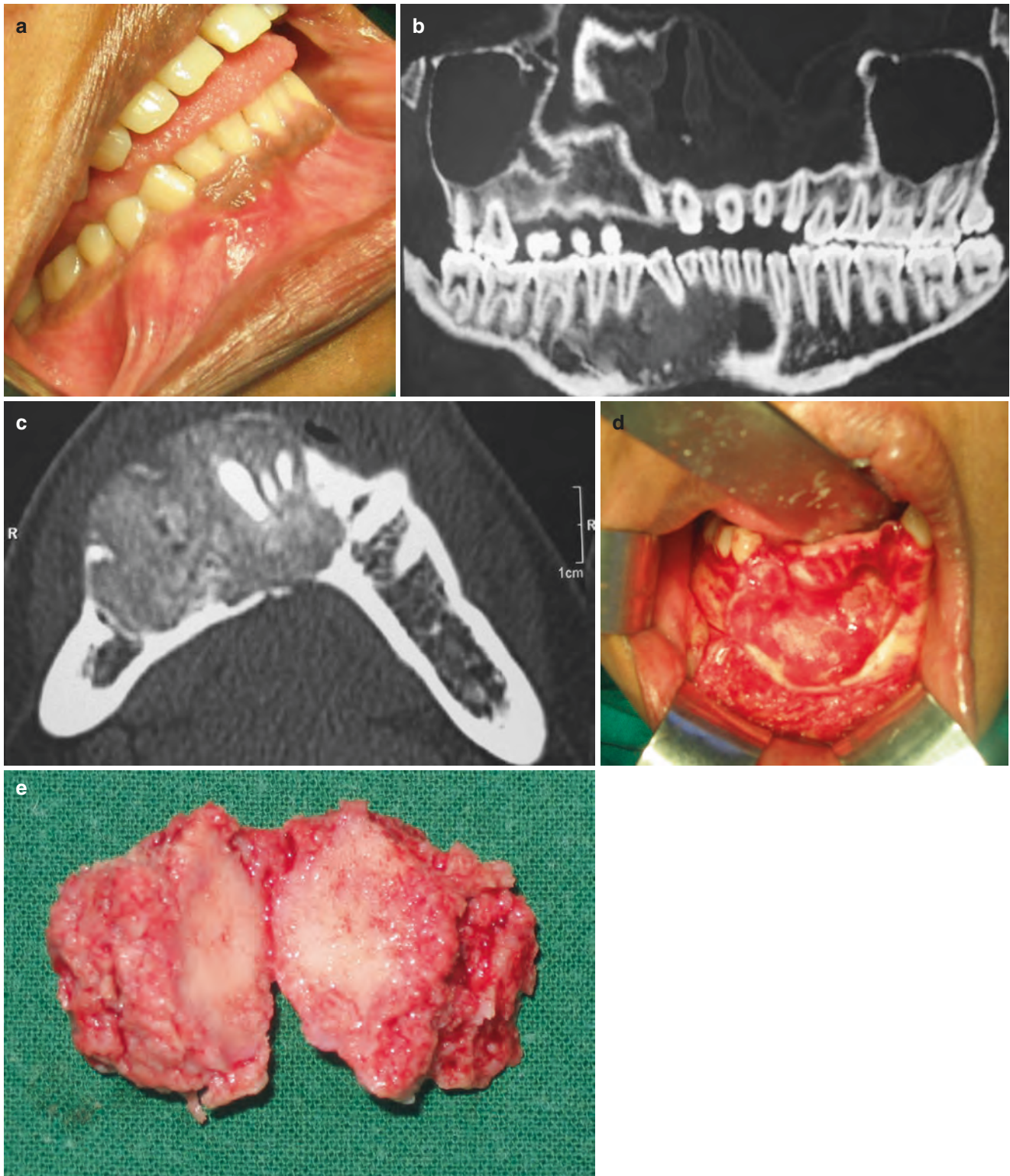
acceptable treatment [27]. Lesions exhibiting more aggressive behaviour and recurrence may need to undergo resection. The anatomical location and age of the patient and aggressiveness of the lesion have a role in deciding the treatment modality of the lesion.

Clinical case scenario 5 (a case of COF affecting the right side body of the mandible) (Fig. 30.8a–e).



©Association of Oral and Maxillofacial Surgeons of India

Fig. 30.7 (a, b) Coronal and panoramic CT views in a 26-year-old man with long-standing swelling of the left side maxilla and cheek bone—the case of JOF—lesion fills the left hand side of the nose and paranasal sinuses



©Association of Oral and Maxillofacial Surgeons of India

Fig. 30.8 (a) Swelling rt body mandible in 29-year-old female, clinical picture. (b) Panoramic image of the CT scan. (c) Axial CT image showing the bone destruction. (d) Surgical bed after excision of the lesion. (e) Cut section of the fibrous lesion

30.5 Cemento-Osseous Dysplasia (Osseous Dysplasia)

Osseous dysplasia is a non-neoplastic, commonest, least understood fibro-osseous lesion occurring in tooth-bearing areas of the jaws. The cause of misunderstanding lies at the similarities shared at the clinical and histological levels with other fibro-osseous lesions like fibrous dysplasia and ossifying fibroma and even few neoplasias [28].

Since these lesions lie in close association with the periodontal ligaments of the tooth-bearing segment of the jaws, and histopathologically as well, they bear close similarity with PDL, the strong suspicion of the origin in PDL cannot be ruled out.

Two main types are recognised, based on the clinical and radiological features.

1. Localised and
2. Generalised.

Localised variety includes

- (a) Periapical cemento osseous dysplasia (PCOD)
- (b) Focal cemento osseous dysplasia (FCOD)

Generalised variety includes

Florid cemento osseous dysplasia

Ideally, these lesions can be identified clinically and radiographically without the need for the biopsy, as the presentation is pathognomonic

Su et al. in 1997 have published a series of 316 cases to distinguish the clinical, radiological and pathological features of the cement osseous dysplasias [29, 30].

30.6 Periapical Cemento-Osseous Dysplasia

30.6.1 Clinical, Radiological and Histological Presentation

The clinical and radiographic presentation of PCOD is well established. There is a marked predilection for females (14:1) and Afro-Caribbean women [2], and commonly seen in and around the third decade of life, rarely before the age of 20.

Predominantly involves periapical region of anterior mandible, frequently involving more than one tooth at a time though solitary lesions may be occasionally seen.

These are non-expansile asymptomatic lesions and teeth in association are invariably vital and are discovered accidentally when radiographs are taken for other purposes.

Radiographically, maturation of the lesion can be appreciated, when examined at various stages.

Initially, they appear as periapical radiolucencies, which can be easily mistaken for a periapical cyst or a granuloma.

Over a period of time, the mixed radiolucent radiopaque picture may emerge and as the lesion matures further, eventually show dense periapical calcifications at the end stage, which is surrounded by a narrow radiolucent rim. The lesions seldom reach beyond 1–1.5 cm diameter and growth is self-limiting. The lesions remain separated from the periodontal ligament of the tooth throughout their growth phase.

The histological features are coincidental with radiographic findings and categorised as three stages.

Stage 1: Osteolytic stage/Radiolucent phase

Which shows ample fibrous connective tissue, highly cellular and with numerous small vessels.

Stage 2: Cementoblastic stage/radiolucent radiopaque phase

Various trabecular-woven bone and cementum-like tissues seen.

Stage 3: Mature stage/radiopaque phase

Consolidation of bone- or cementum-like tissue.

30.7 Focal Cemento Osseous Dysplasia

For several years, pathologists were aware of the lesions occurring in the mandibular posterior region, often occurring in the tooth-bearing areas and in relation with recently extracted teeth sockets. Waldron recognised them to be, localised fibro-osseous cemental lesions, supposedly reactive in nature. The present understanding of these lesions is hard work of Summerlin and Tomich, besides naming them as Focal cemento osseous dysplasia, they clinically defined them for a better understanding and differentiation from other lesions especially Ossifying Fibroma [31].

30.7.1 Clinical, Radiological and Histopathological Features

Focal osseous dysplasia is more commonly seen in Afro-Caribbean females. Male to female preponderance is 1:8. Mainly occurs in the 4th to 5th decades of life with 38 years being an average age of occurrence.

The lesion appears as painless, non-expansile, localised condition especially in posterior mandible, both tooth-bearing areas as well as edentulous mandible where tooth was extracted in the recent past. A clinical, radiographic and

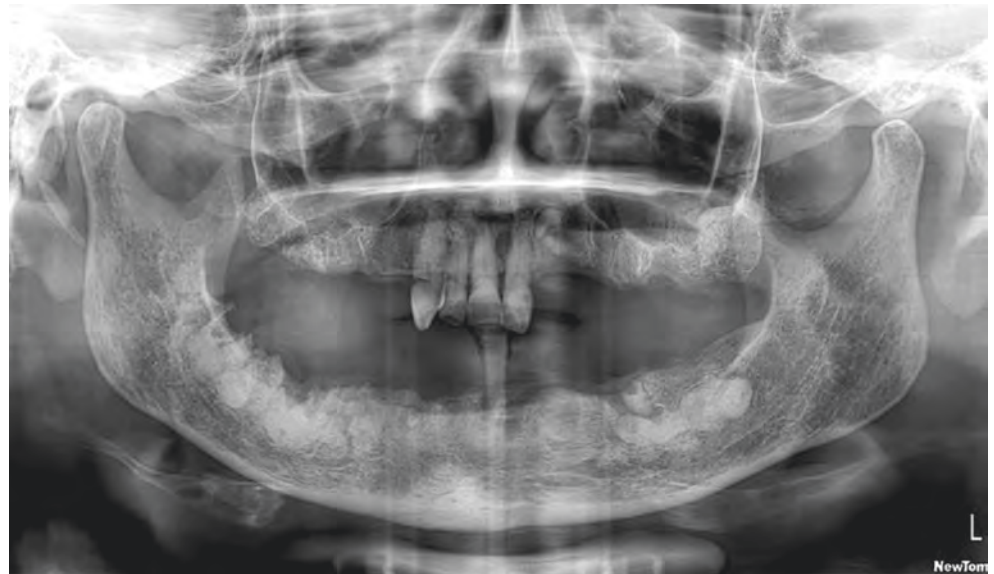histopathological differential diagnosis of Focal osseous dysplasia is Ossifying fibroma. Since both are more common in posterior mandible and may appear as radiolucent, mixed or radiopaque, well-circumscribed lesions, the clinical and radiological differentiation can be confusing provided one notices the centrifugal growth pattern of and focal osseous dysplasias barely grow beyond 1.5 cm. Radiographically, focal osseous dysplasias tend to be well defined with slightly irregular borders.

On histological examination, one finds connective tissue stroma comprising of loose collagen fibers, interspersed with irregular shaped cementoid calcifications. Free haemorrhage is noticed throughout, intermixed with collagen background.

30.8 Florid Cemento-Osseous Dysplasia

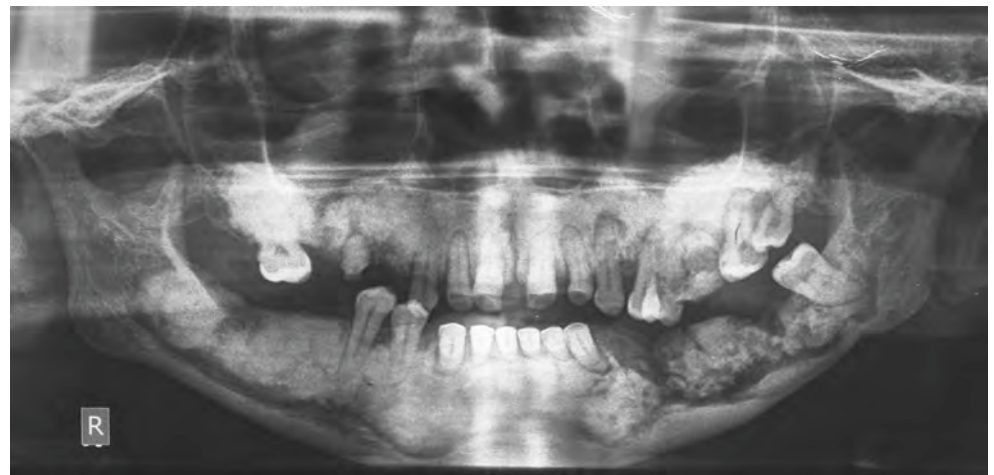When the lesions, similar in microscopic and radiographic appearance to Focal cemento osseous dysplasia, are found in more than one location in a mandible or in both the quadrants simultaneously, they are identified as Florid cement osseous dysplasia. Radiographs displayed a spectrum of sclerotic and ground-glass opacities limited to alveolar processes but not to root apices [32]. Chronic osteomyelitis may infrequently complicate the disease. These cases appear to represent the most exuberant manifestation of reactive fibro-osseous jaw disease. Many times, these diseases are an incidental finding and patient may be asymptomatic (Figs. 30.9 and 30.10)

Fig. 30.9 OPG of a 73-year-old Asian female, who had x-ray taken for removal of lower right third molar. X-ray shows diffuse florid COD-like lesions



©Association of Oral and Maxillofacial Surgeons of India

Fig. 30.10 OPG of a 55-year-old Asian female who reported for dental extractions due to pain. Xray reveals florid COD-like lesions in both jaws



©Association of Oral and Maxillofacial Surgeons of India

30.8.1 Clinical, Radiological and Histological Features

Florid cemento osseous dysplasia shows predilection for Afro-Caribbean women in the fourth to fifth decades of life, with a mean age of 42 years. The lesion has a propensity for bilateral symmetrical involvement of mandible. Occasional maxillary involvement is not rare.

The patients are usually edentulous and lesions are usually non-expansile, if cortical expansion is present then it is limited in nature.

The diagnosis of Florid OD is mainly clinical and radiographic, Melrose [32] suggests the involvement of two jaw quadrant is imperative for the diagnosis of Florid COD. Radiographically, the lesion undergoes stages of maturation as seen in the other types of OD, initially, the lesions are mainly radiolucent and with time progressively become first mixed radiolucent radiopaque and then in later stages turn into radiopaque sclerotic masses. Simple bone cyst that appears as sharply defined radiolucent areas may be intermixed with the lesional tissue, is a frequent finding in Florid OD. The most commonest radiographic presentation is of multiple sclerotic lobular opacities mixed ill defined with radiopaque radiolucent masses involving the alveolar process of mandible and maxilla sparing the lower border of the mandible and vertical rami.

Histologically, the lesion has similar features like other two forms of OD. The lesion specimen consists of cellular mesenchymal connective tissue, with numerous spindle-shaped fibroblasts and blood vessels. Multiple haemorrhagic sites are a common finding in the connective tissue background along with lamellar-, woven- and cementum-like particles. Depending on the extent of maturation of the lesion, they become more sclerotic and the ratio of fibrous connective tissue to mineralised material decreases.

30.8.2 Treatment/Management

The modified osseous tissue is prone to infection, hence any local causes of infection-like periapical pathosis, periodontal disease, ill-fitting dentures can lead to osteomyelitis of the underlying altered bone and fistula and sequestra formation. It is recommended to avoid any surgical intervention for diagnostic purposes, as the diagnosis is generally made on clinical and radiographic presentation. As for the treatment of symptomatic lesions like the presence of underlying osteomyelitis, conservative care in the form of removal of sequestra and prolonged antibiotic therapy is recommended. Extractions are not recommended for the same reason, as the socket heals by replacement with cementum-like tissue, which is mainly avascular.

Surgical intervention in terms of the debulking procedures is only recommended where there is obvious facial deformity resulting in reduced quality of life [33].

30.9 Conclusion

FOLs form a diverse wide spectrum of lesions, which are still evolving; in their classifications. Maxillofacial surgeons usually come across intra-oral lesions at various stages and many of them can be managed easily by routine surgical modalities. Certain lesions show aggressive nature and involve mid-face and sino-nasal areas. Such cases will need a multi-disciplinary approach for optimal treatment outcomes. Close interaction with the pathologist and adequate radiological investigations are needed to ascertain the diagnosis in many cases. The lack of clarity in classification and the similar radiological and histological picture of various lesions add to the difficulty in reaching a diagnosis.

Acknowledgments Suvy Manuel for Figures 30.1, 30.2, 30.3, 30.4, 30.5, 30.6, and 30.9

Oommen A Jacob-Figures 30.7, 30.8

Sooraj S- Figure 30.10

References

1. Eversole R, Su L, ElMofty S. Benign fibro-osseous lesions of the craniofacial complex a review. *Head Neck Pathol.* 2008;2:177–202.
2. Brannon RB, Fowler CB. Benign fibro-osseous lesions: a review of current concepts. *Adv Anat Pathol.* 2001;8:126–43.
3. Waldron CA. Fibro osseous lesions of the jaws. *J Oral Maxillofac Surg.* 1985;43:249–62.
4. Waldron CA. Fibro-osseous lesions of the jaws. *J Oral Maxillofac Surg.* 1993;51:828–35.
5. Rajpal K, Agarwal R, Chhabra R, Bhattacharya M. Updated classification schemes for fibro-osseous lesions of the oral & maxillofacial region: a review. *IOSR J Dent Med Sci Ver.*
6. Srichinthu KK, Yoithapprabhunath TR, Chitturi RT, Yamunadevi A, Potsangbam AD, Singh DN. Fibro osseous lesions—classifications, pathophysiology and importance of radiology: a short review. *Int Biol Biomed J.* 2016;2:11–20.
7. Slootweg PJ. Maxillofacial fibro-osseous lesions: classification and differential diagnosis. *Semin Diagn Pathol.* 1996;13:104–12.
8. Barnes L, Eveson JW, Reichart P, Sidransky D. World Health Organization classification of tumours. Pathology and genetics—head and neck tumours. Lyon: IARC; 2005. p. 319–23.
9. Speight P, Carlos R. Maxillofacial fibro-osseous lesions. *Curr Diagn Pathol.* 2006;12(1):1–10.
10. Waldron CA, Giansanti JS. Benign fibro-osseous lesions of the jaws: a clinical-radiologic-histologic review of sixty-five cases. II. Benign fibro-osseous lesions of periodontal ligament origin. *Oral Surg Oral Med Oral Pathol.* 1973;35(3):340–50.
11. Hall G. Fibro-osseous lesions of the head and neck. *Diagn Histopathol.* 2012;18(4):149–58.
12. El-Mofty SK. Fibro-osseous lesions of the craniofacial skeleton: an update. *Head Neck Pathol.* 2014;8:432–44.

13. Pereira TDSF, Gomes CC, Brennan PA, Fonseca FP, Gomez RS. Fibrous dysplasia of the jaws: integrating molecular pathogenesis with clinical, radiological, and histopathological features. *J Oral Pathol Med*. 2019;48:3–9.
14. MacDonald DS. Maxillofacial fibro-osseous lesions. *Clin Radiol*. 2015;70(1):25–36.
15. Slootweg PJ, Müller H. Differential diagnosis of fibro-osseous jaw lesions. A histological investigation on 30 cases. *J Craniomaxillofac Surg*. 1990;18(5):210–4.
16. Orten SS, Hanna E. Fibrous dysplasia: biology and indications for surgery. *Oper Tech Otolaryngol Head Neck Surg*. 1999;10(2):109–12.
17. Chen YR, Noordhoff MS. Treatment of craniomaxillofacial fibrous dysplasia: how early and how extensive? *Plast Reconstr Surg*. 1990;86(5):835–42; discussion 843–4.
18. Ricalde P, Horswell BB. Craniofacial fibrous dysplasia of the fronto-orbital region: a case series and literature review. *J Oral Maxillofac Surg*. 2001;59(2):157–67; discussion 167–8.
19. Speight PM, Takata T. New tumour entities in the 4th edition of the World Health Organization classification of head and neck tumours: odontogenic and maxillofacial bone tumours. *Virchows Arch*. 2018;472(3):331–9.
20. Zegalie N, Martin L, Speight PM. Ossifying fibromas of the jaws and craniofacial bones. *Diagn Histopathol*. 2015;2015(21):370–8.
21. Wright JM, Odell EW, Speight PM, Takata T. Odontogenic tumours, WHO 2005: where do we go from here? *Head Neck Pathol*. 2014;8(4):373–82.
22. El-Mofty SK, Nelson B, Toyosawa S. Ossifying fibroma. In: El-Naggar AK, JKC C, Grandis JR, Takata T, Slootweg PJ, editors. *WHO classification of head and neck tumours*. 4th ed. Lyon: IARC; 2017. p. 251–2.
23. Eversole LR, Leider AS, Nelson K. Ossifying fibroma: a clinicopathologic study of sixty-four cases. *Oral Surg Oral Med Oral Pathol*. 1985;60(5):505–11.
24. El-Mofty S. Psammomatoid and trabecular juvenile ossifying fibroma of the craniofacial skeleton: two distinct clinicopathologic entities. *Oral Surg Oral Med Oral Pathol Oral Radiol Endod*. 2002;93(3):296–304.
25. Slootweg PJ, Panders AK, Koopmans R, Nikkels PG. Juvenile ossifying fibroma. An analysis of 33 cases with emphasis on histopathological aspects. *J Oral Pathol Med*. 1994;23(9):385–8.
26. Slootweg PJ, Panders AK, Nikkels PG. Psammomatoid ossifying fibroma of the paranasal sinuses. An extragnathic variant of cemento-ossifying fibroma. Report of three cases. *J Craniomaxillofac Surg*. 1993;21(7):294–7.
27. Titinchi F, Morkel J. Ossifying fibroma: analysis of treatment methods and recurrence patterns. *J Oral Maxillofac Surg*. 2016;74(12):2409–19.
28. Neville BW, Damm DD, Allen CM, Chi AC. *Oral and maxillofacial pathology*. 4th ed. St Louis: Saunders; 2016.
29. Su L, Weathers DR, Waldron CA. Distinguishing features of focal cemento-osseous dysplasias and cemento-ossifying fibromas: I. A pathologic spectrum of 316 cases. *Oral Surg Oral Med Oral Pathol Oral Radiol Endod*. 1997;84(3):301–9.
30. Su L, Weathers DR, Waldron CA. Distinguishing features of focal cemento-osseous dysplasia and cemento-ossifying fibromas. II. A clinical and radiologic spectrum of 316 cases. *Oral Surg Oral Med Oral Pathol Oral Radiol Endod*. 1997;84(5):540–9.
31. Summerlin DJ, Tomich CE. Focal cemento-osseous dysplasia: a clinicopathologic study of 221 cases. *Oral Surg Oral Med Oral Pathol*. 1994;78(5):611–20.
32. Melrose RJ, Abrams AM, Mills BG. Florid osseous dysplasia. A clinical-pathologic study of thirty-four cases. *Oral Surg Oral Med Oral Pathol*. 1976;41(1):62–82.
33. Shah A, Modgill O, et al. Cemento-osseous dysplasia: to treat or not to treat? *J Oral Maxillofac Surg*. 2016;74(9):e60.

Open Access This chapter is licensed under the terms of the Creative Commons Attribution 4.0 International License (<http://creativecommons.org/licenses/by/4.0/>), which permits use, sharing, adaptation, distribution and reproduction in any medium or format, as long as you give appropriate credit to the original author(s) and the source, provide a link to the Creative Commons license and indicate if changes were made.

The images or other third party material in this chapter are included in the chapter's Creative Commons license, unless indicated otherwise in a credit line to the material. If material is not included in the chapter's Creative Commons license and your intended use is not permitted by statutory regulation or exceeds the permitted use, you will need to obtain permission directly from the copyright holder.



Vascular Anomalies of the Oro-Maxillofacial Region

Sanjiv Nair and Sunil S. Shroff

31.1 Introduction

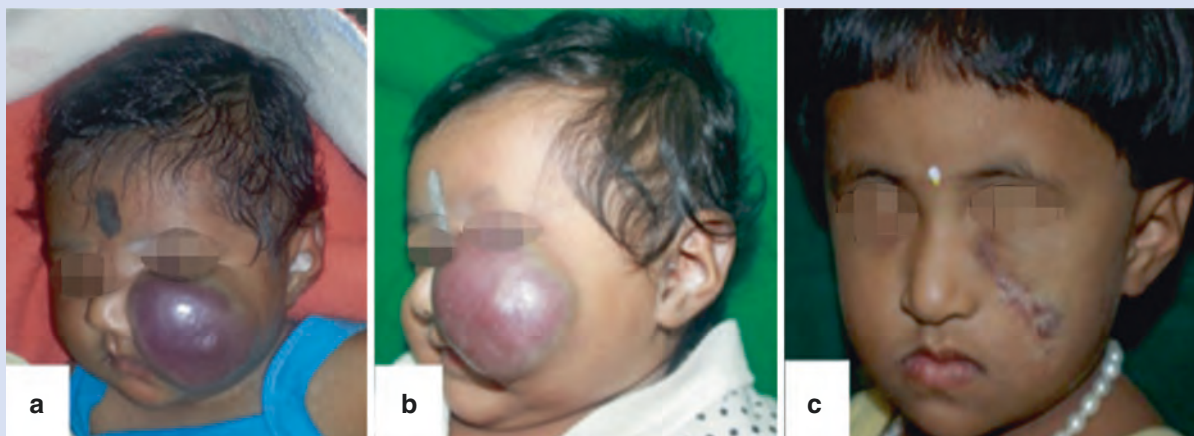
Vascular anomalies are lesions arising from the arterial and/or venous and/or lymphatic circulation. These have a wide array of histological and clinical features and constitute one of the commonest congenital anomalies in infants and children [1].

In the context of iatrogenic creation of arteriovenous fistulas by phlebotomists, William Hunter in the mid-eighteenth century first described vascular anomalies. Haemangiomas and vascular malformations are different entities of vascular

anomalies and this was first recognised by James Wardrop in 1818 [2]. In spite of Dr. Wardrop's work, subjective words like 'strawberry hemangioma' and 'salmon patch' were used for a long time. These terms only reflected the appearance and did not correlate clinically or histologically [2].

Anomalies presenting in different age groups with varying clinical behaviours needing different treatments were often given the same or overlapping names by clinicians. Commonly used terms are: haemangioma, arterial malformation, venous malformation, capillary malformation and lymphatic malformation.

Haemangioma (Figs. 31.1 and 31.20): Is a benign tumour of blood vessels comprising arterioles with endothelial cells, which are proliferative and hyperplastic in nature.



©Association of Oral and Maxillofacial Surgeons of India

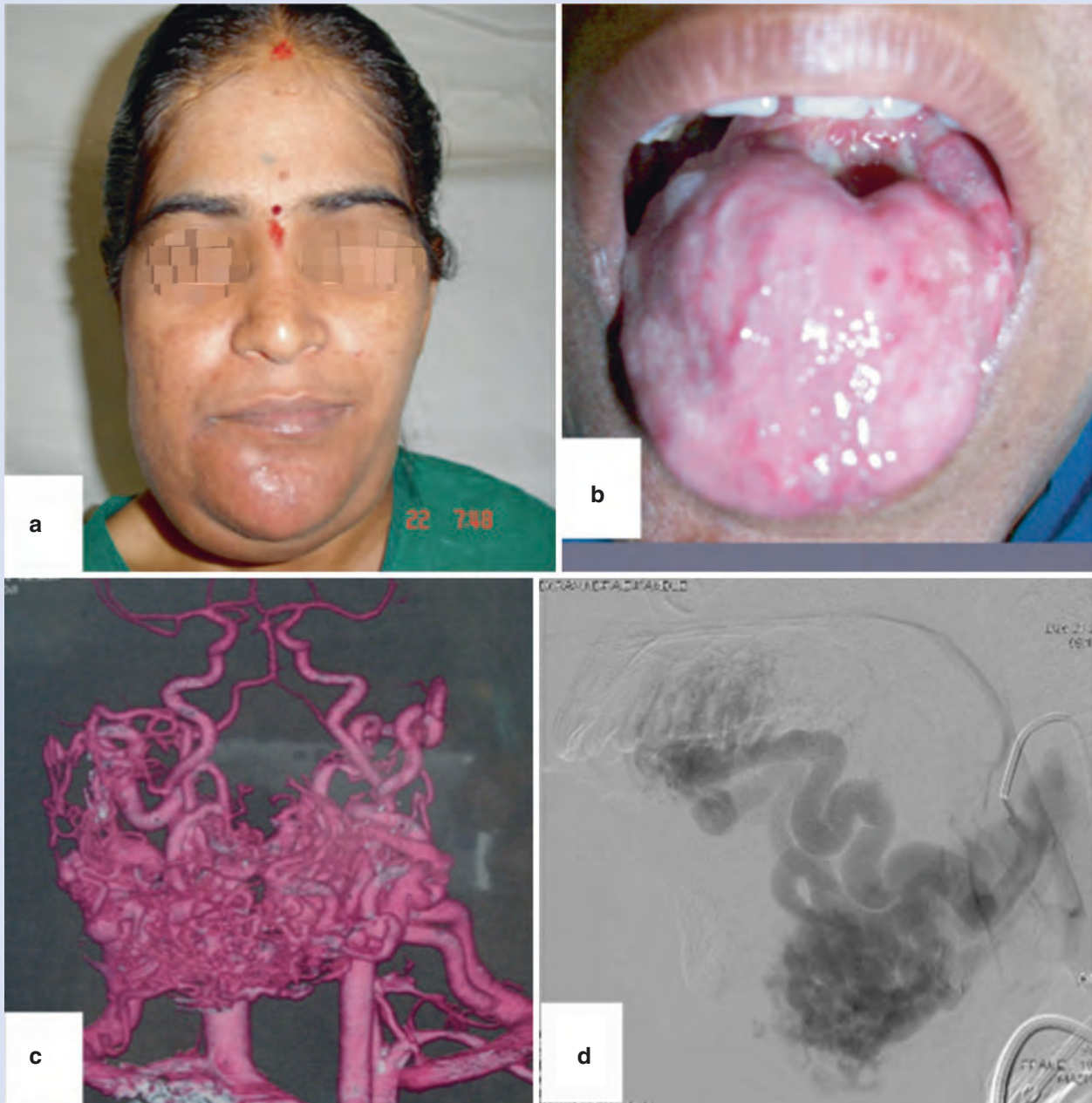Fig. 31.1 Non-involving congenital Haemangioma (NICH) of left cheek ((a) initial therapy with propranolol 10 days post-birth, (b) 6 months following propranolol therapy, (c) excision of lesion at 2 years age)

S. Nair (✉) · S. S. Shroff (✉)
 Department of Oral and Maxillofacial Surgery, Bhagwan Mahaveer
 Jain Hospital, Bengaluru, Karnataka, India

This terminology has been used by many as a common term for any vascular anomaly especially in childhood. These develop within the initial few weeks of life but

often resolve with time. It is necessary for one to be able to differentiate between haemangioma and other vascular anomalies.

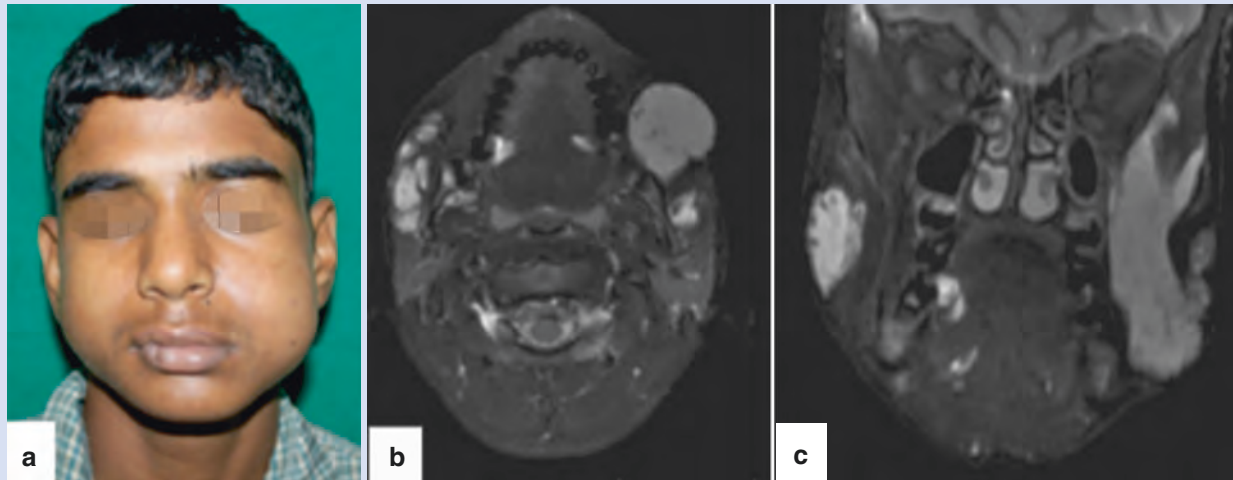
Arterial malformation (Fig. 31.2): These are dilated, overlapping and tortuous arteries having a coil-like appearance and/or a collection of arterial loops without any venous component. They are also described as 'high flow lesions'.



©Association of Oral and Maxillofacial Surgeons of India

Fig. 31.2 Arterial malformation ((a, b) tongue high flow lesion, (c) DSA, (d) embolisation)

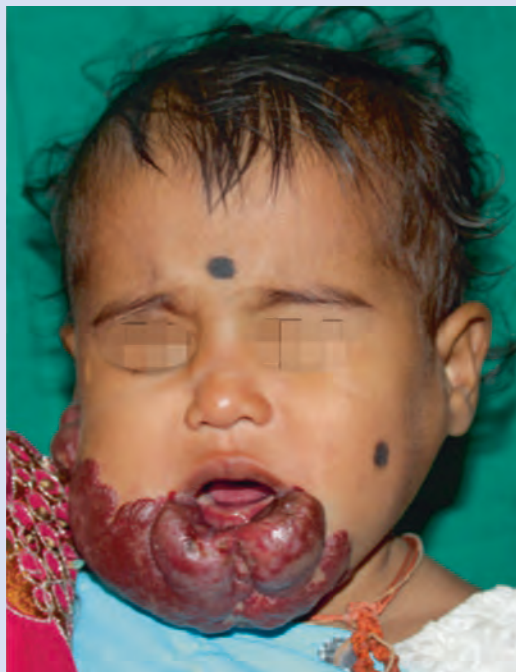Venous malformation (Fig. 31.3): These are commonest type of vascular malformations caused by ectatic venous channels, also called 'low flow lesions'.



©Association of Oral and Maxillofacial Surgeons of India

Fig. 31.3 Left cheek venous malformation ((a) pre-operative Left cheek VM, (b) axial and (c) coronal STIR sequence MRI)

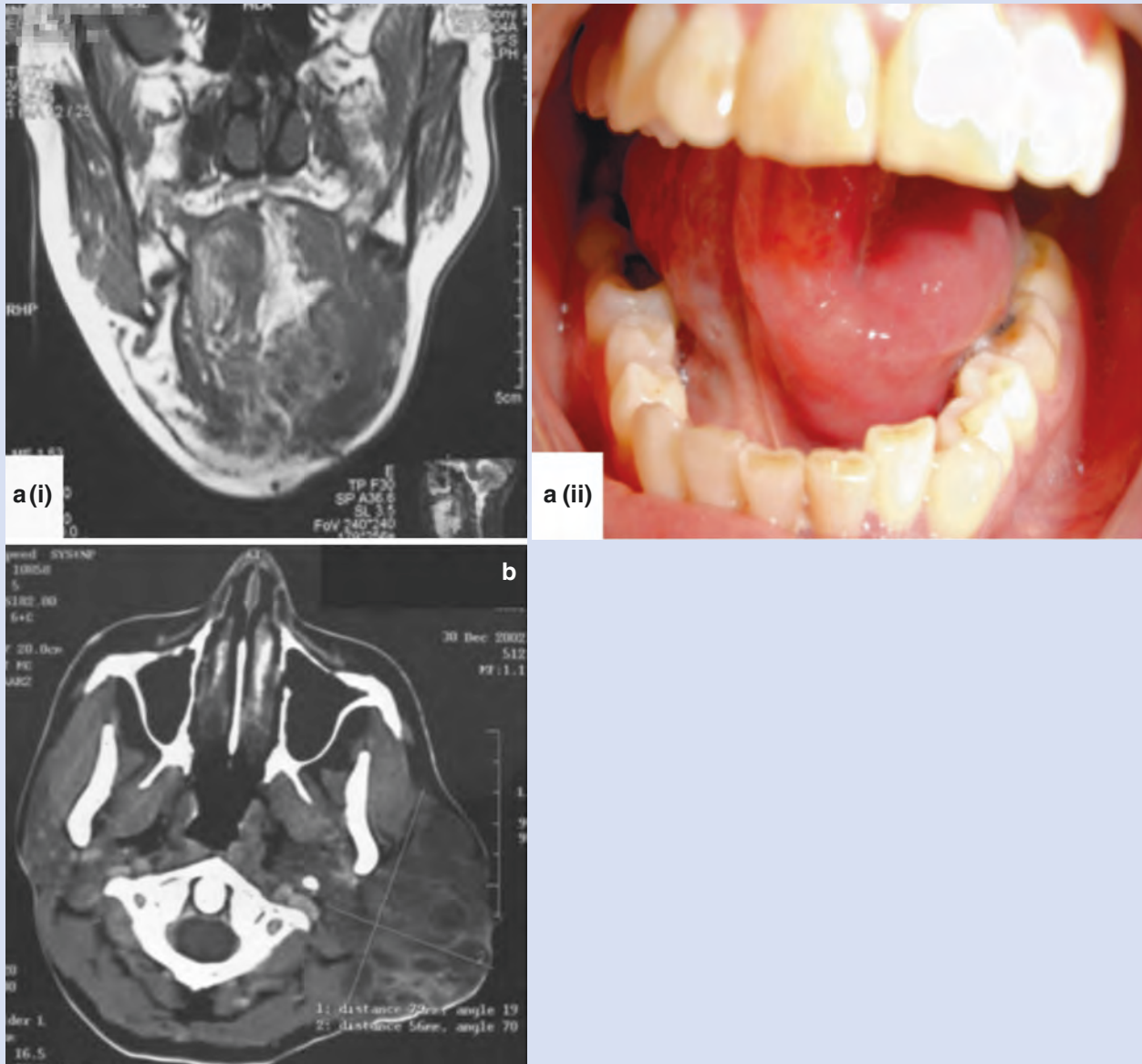
Capillary malformations (Fig. 31.4): These are commonly known as, '*port wine stain*'. It is a flat, well-defined vascular stain of skin seen early in development when vessels of skin form abnormally which can increase in size and give a nodular appearance as a late presentation.



©Association of Oral and Maxillofacial Surgeons of India

Fig. 31.4 Capillary malformation of lower lip, chin and right cheek

Lymphatic malformation (Fig. 31.5a, b): These are lesions containing fluid-filled spaces or channels, thought to be caused by abnormal development of the lymphatic system.



©Association of Oral and Maxillofacial Surgeons of India

Fig. 31.5 (a) Micro-cystic lymphatic malformation of tongue ((i) coronal T2 weighted MRI image, (ii) pre-operative clinical). (b) Axial post-contrast image of macro-cystic lymphatic malformation of left Parotid. Copyright: Authors own publication from IJOMS 2018

The above lesions in different combinations make up for ‘arteriovenous’ (Fig. 31.6) and ‘lymphovenous’ malformations.

31.2 Pathogenesis

Histologically, vascular anomalies are seen as a localised increase in vasculature with abnormal tortuosity and enlargement. This is known to be caused by defects in the formation of these vessels during vasculogenesis [3].

‘Vasculogenesis’ is defined as growth of vessels from precursor cells like, haemangioblasts that further give rise to angioblasts and haemocytoblasts.

Fusion takes place in islands of vasculature leading to the formation of primary capillary plexus, which then extends and matures during angiogenesis. This involves the proliferation of endothelial cells and the recruitment of mural cells to form fully developed and functional lymphatic and vascular trees [4].

Angiogenesis is regulated by factors like VEGFs (vascular endothelial growth factors), FGFs (fibroblast growth factors), PDGF-beta (platelet derived growth factor beta) and ANGPT-1 and ANGPT-2 (angiopoietins). These factors

cause activation of precursor cells, leading to migration, proliferation and differentiation of the primary capillary plexus [5].

VEGFs, angiopoietins, and their endothelial tyrosine kinase receptors are known to be the central regulators of vasculogenesis, angiogenesis and lymphangiogenesis [4].

Haemangiomas have currently 2 dominant theories [6], although unclear. These are:

1. Endothelial cells are formed from deranged placental tissue present in foetal soft tissues during gestation.
2. Stem cells and endothelial progenitor cells which give rise to haemangiomas, are found in circulation of patients with haemangiomas.

Abnormal levels of matrix metalloproteinases (MMP9) and proangiogenic factors (VEGF, b-FGF and TGF-beta 1) are involved in the pathogenesis of haemangioma. Genetic errors involving growth factor receptors are also known to influence the development of these lesions [6].

There are 3 stages in the life cycle of haemangiomas [7], each characterised by biological markers and processes. These stages are clinically seen and distinguished microscopically and immunohistochemically [8] as,

1. *Proliferative phase—0–1 year of age*
2. *Involuting phase—1–5 years of age*
3. *Involuted phase—more than 5 years of age*

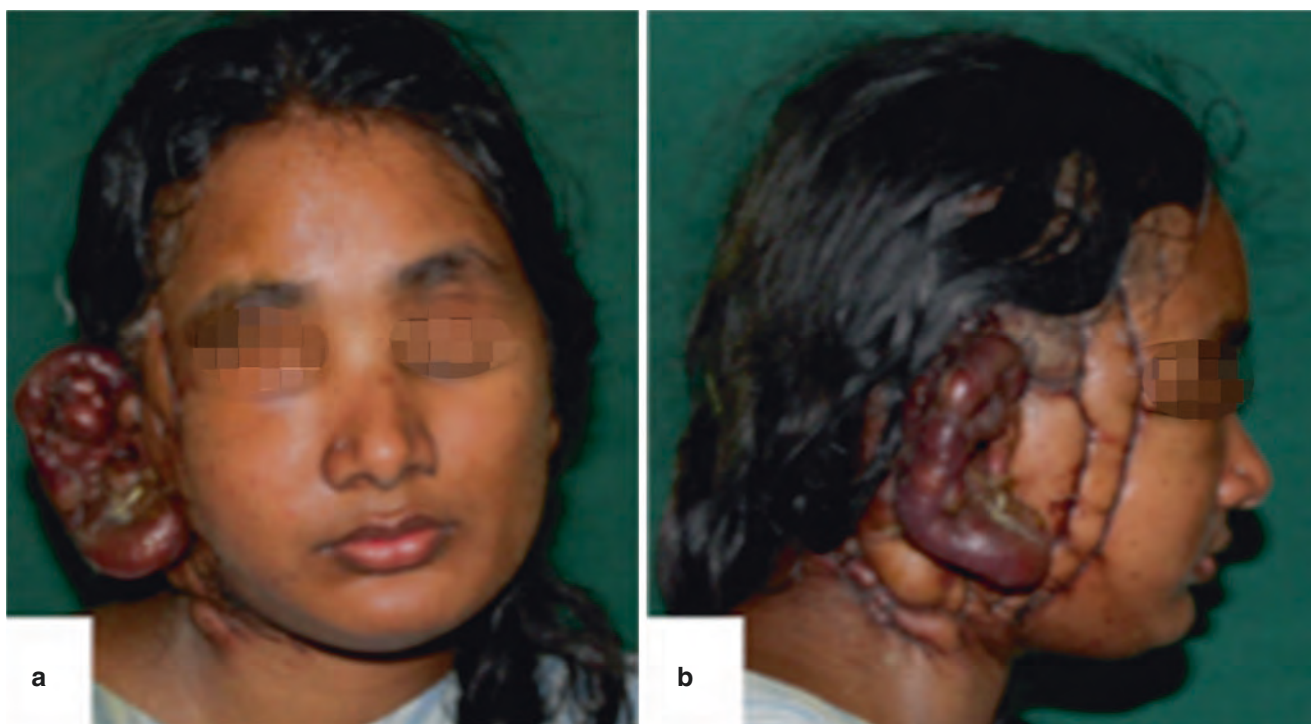
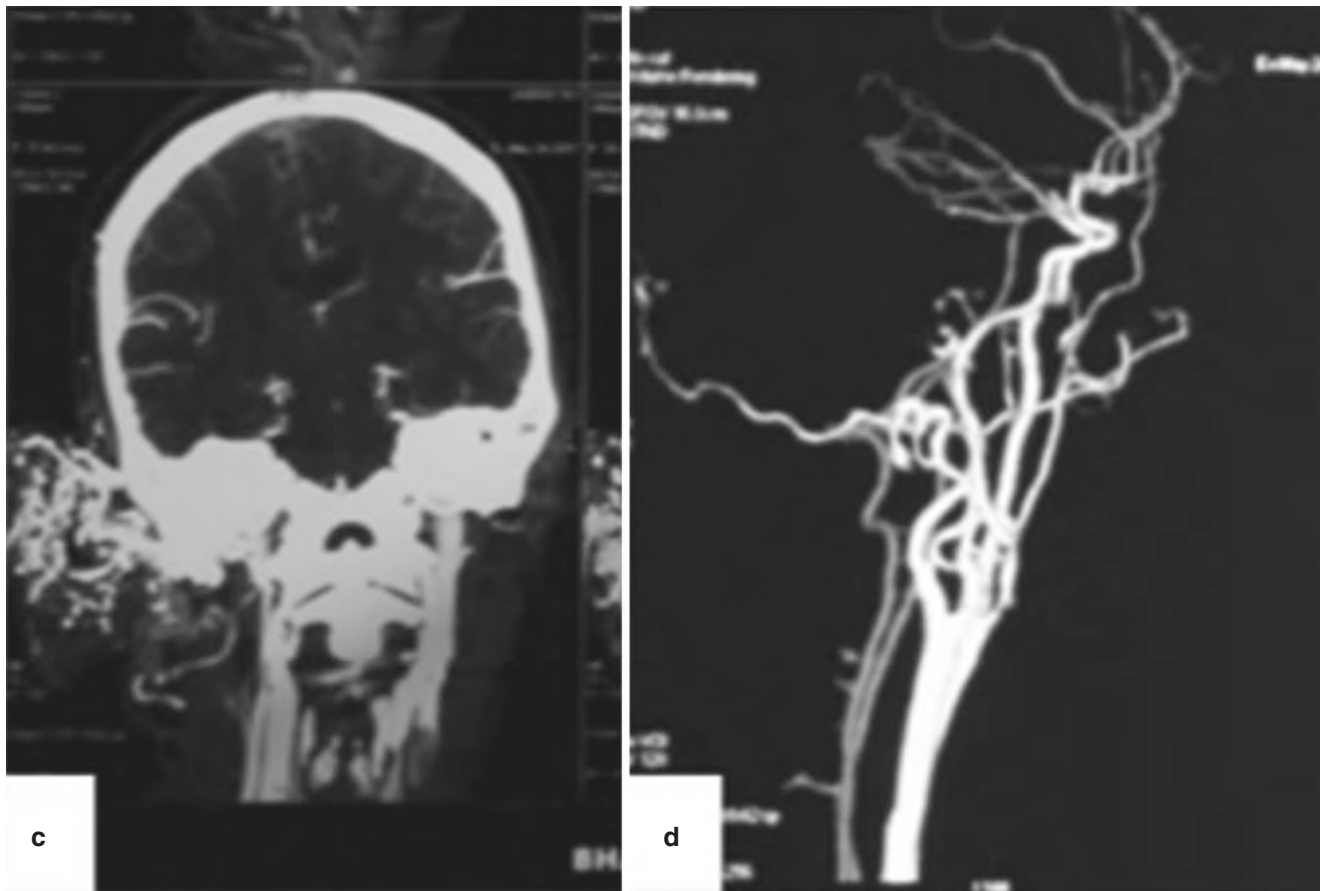
Fig. 31.6 Arteriovenous malformation of pinna of right ear ((a, b) previous Popescu suturing as reported, (c) coronal CT angiography image, (d) contrast MR angiography image). Copyright: Authors own publication from IJOMS 2018



©Association of Oral and Maxillofacial Surgeons of India

Fig. 31.6 (continued)

Venous malformations (VMs) are known to be autosomally dominant showing high penetrance. Abnormal venous connections cause venous congestion, thrombosis and slow expansion of these lesions. VMs commonly have a sporadic occurrence, but research has suspected a genetic locus to be involved in their development [6]. Chromosome 9p has been localised to cause inherited forms of VMs. The loss of functional mutation on the angioprotein-receptor gene TIE2/TEK and upregulation of many factors like tissue growth factor beta (TGF-beta) and basic fibroblast growth factor (beta-FGF) is seen [6]. Progesterone receptors are also found in VMs, which explains their propensity to enlarge rapidly during hormonal changes.

The pathogenesis of *capillary malformations (CMs)* is not clearly understood. These can be seen anywhere on the body, localised to a dermatome or extensive in nature. A familial pattern has been identified with a locus on chromosome 5q in a genome-wide linkage analysis [9].

Lymphatic malformations (LMs) show a focal pattern of occurrence. The aetiology is not clearly understood. Although most cases are congenital, there is no evidence of associated familial pattern. There have been cases of LMs following trauma or infection. Receptors like VEGFR3 and Prox-1, likely play a role in their development [10].

The pathogenesis of *arterio-venous malformations (AVMs)* is also not clearly understood. A defect in vascular stabilisation is known to potentially cause AVMs. Intracranial AVM is seen most commonly, followed by AVMs involving extracranial head and neck, extremities, trunk and viscera. These are seen at birth and are frequently misdiagnosed as a CM or haemangioma. These lesions have been seen following trauma in adults. Defects in signalling of TGF-Beta and genetic two-hit hypothesis are the existing theories [11, 12].

31.3 Classifications

Mulliken and Glowacki [13] in 1982 introduced a biological classification, which classified vascular lesions into two distinct entities: haemangiomas and vascular malformations.

Haemangiomas demonstrate endothelial hyperplasia unlike vascular malformations, which show progressive dilatation of abnormal vessels lined by flat endothelium on a thin basal lamina. A more practical classification amalgamating their biological behaviour and flow dynamics was later introduced [14] (Table 31.1).

Table 31.1 Modified Mulliken and Glowacki classification [14]

A. Haemangioma
Superficial (Capillary haemangioma)
Deep (Cavernous haemangioma)
Compound (capillary cavernous haemangioma)
B. Vascular Malformations
<i>Simple lesions</i>
Low-flow lesions
Capillary malformations (capillary haemangioma, port-wine stain)
Venous malformation (cavernous haemangioma)
Lymphatic malformation (lymphangioma, cystic hygroma)
<i>High-flow lesions</i>
Arterial malformation
<i>Combined lesions</i>
Arteriovenous malformations
Lymphovenous malformations
Other combinations

Table 31.2 International Society for the study of Vascular Anomalies classification system (ISSVA) [15]

Vascular tumors
Benign
Locally aggressive or borderline
Malignant
Vascular malformations
<i>Slow-flow</i>
Capillary malformations
Lymphatic malformations
Venous malformations
Arteriovenous malformations
Arteriovenous fistula
<i>Combined (2 or more VMs in one lesion)</i>
CVM, CLM, LVM, CLVM, CAVM, CLAVM, others (C-capillary, V-venous, L-lymphatic, AV-arteriovenous)
<i>Anomalies of major named vessels</i>
<i>Vascular malformations associated with other anomalies</i>

This system was later revised and adopted by the ISSVA [15] (*International Society for the study of Vascular anomalies*). This is currently the most widely accepted and divides vascular anomalies into: vascular tumors and vascular malformations (Table 31.2). The online version of the classification, is available on the ISSVA website (www.issva.org), contains hypertext links that facilitate the navigation in the classification and its appendices. These vascular neoplasms show an increased turnover of endothelial cells, which undergo division by mitosis, unlike vascular malformations. Vascular malformations can be capillary, venous, lymphatic and arterial, which progress in proportion to the child.

We proposed a practical classification of vascular lesions based on anatomy and depth of location in the head and neck region [1] (Table 31.3), which helped not only in understanding the extent of lesion but also in determining the surgical approach and reconstruction necessary. This classification is found to be most useful for the surgical management of these complex lesions.

Table 31.3 Anatomical classification of Vascular malformations [1] (IJOMS 2011: 40)

Type-I	Mucosal/cutaneous
Type-II	Sub-mucosal/sub-cutaneous
Type-III	Glandular
Type-IV	Intra-osseous
Type-V	Deep visceral

Type-I lesions (Fig. 31.7) are superficial involving the epidermis and dermis. These can be excised in toto and reconstructed with local flaps where necessary. Lasers have some use in such surface lesions.

Type-II lesions (Fig. 31.8) involve sub-cutaneous tissue and facial planes. These can be widespread sometimes and approached by meticulously raising a superficial skin flap. The lesion is either debulked, excised or corseted as necessary (discussed in surgical management).

Type-III lesions (Fig. 31.9) are deeper involving salivary glands, usually parotid and sub-mandibular, demand-raising flaps in sub-cutaneous and sub-dermal planes. The lesion is either debulked, excised or corseted as necessary (discussed in surgical management).

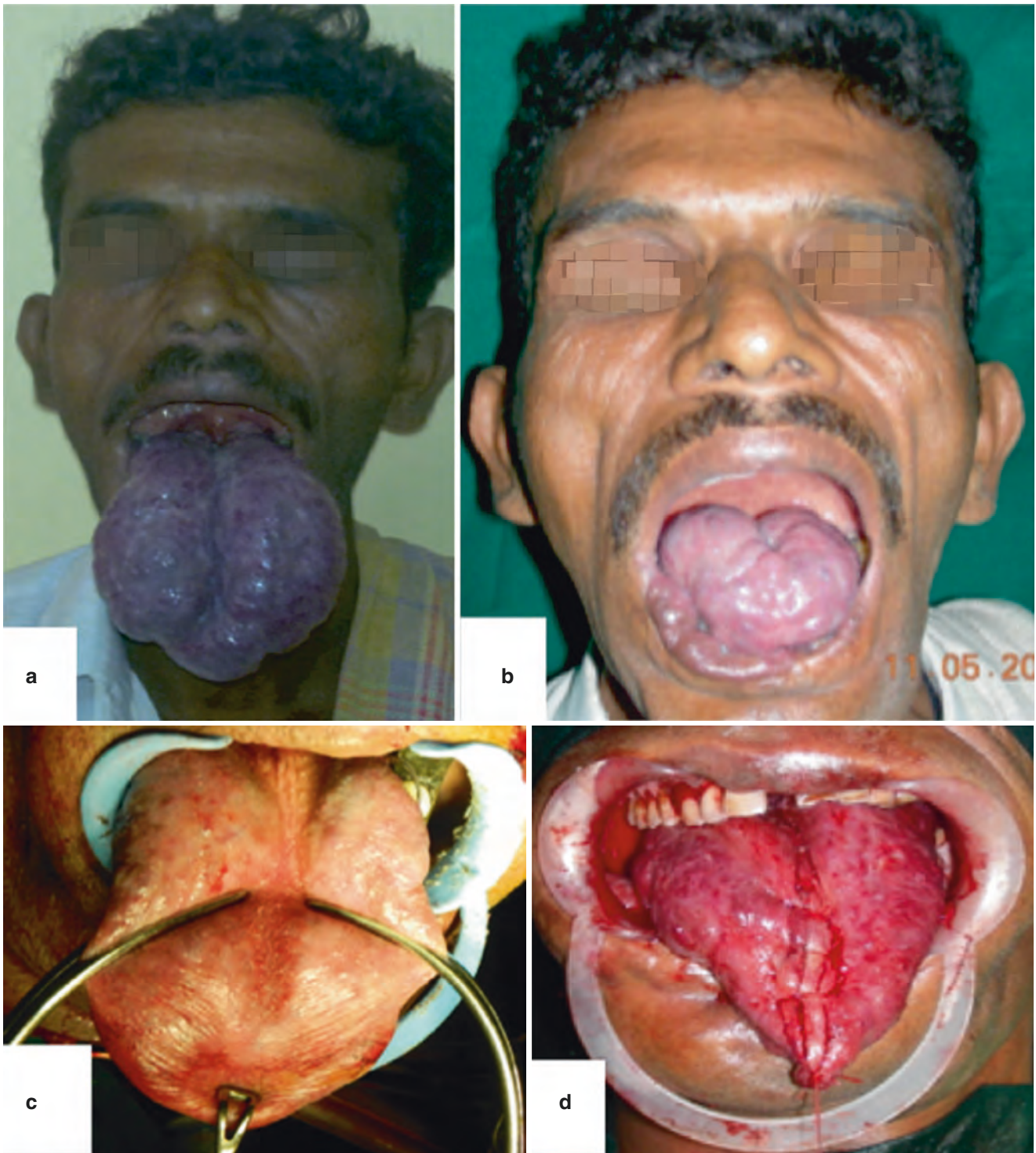Type-IV lesions (Fig. 31.10) involve bone and are either curetted or excised followed by reconstruction. These are usually high-flow lesions and require ECA control or endovascular embolisation to achieve adequate haemostasis (intra-operative dye administration in Fig. 31.10 demonstrates the efficacy of intra-operative ECA control in treating such high-flow vascular lesions).

Type-V lesions (Fig. 31.11) involve deeper visceral spaces like parapharyngeal, retropharyngeal, glottis and laryngeal. These can be rarely excised in toto and require access osteotomies of maxilla, mandible or zygoma (see Chap. 85 on access osteotomies).

31.4 Clinical Findings (Table 31.4)

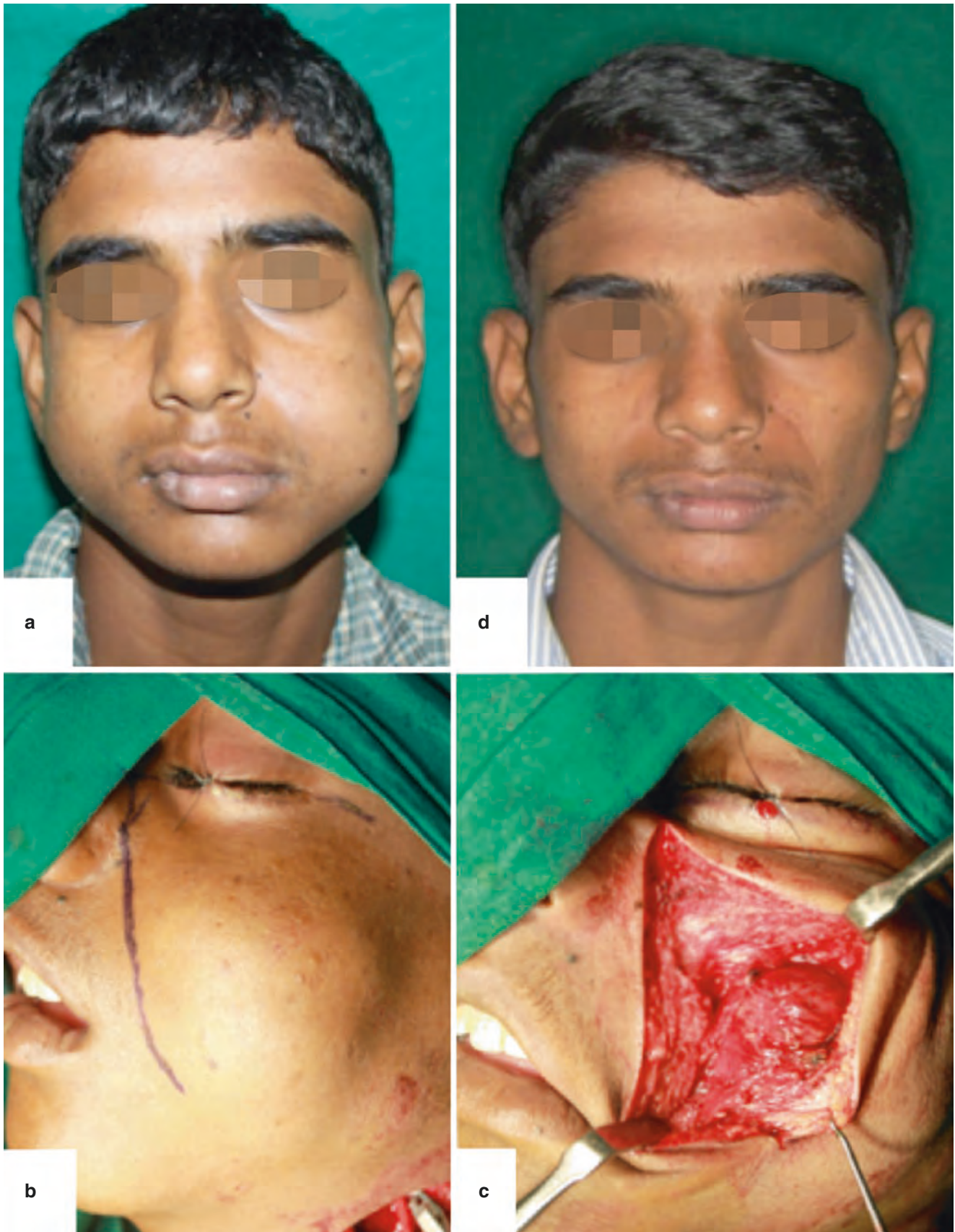A comprehensive and holistic understanding of the true nature of lesion is important to adequately manage these patients. The different types will be discussed according to the ISSVA classification for simplicity here, while the surgical management will be discussed according to the anatomical classification, as it was found to be more helpful than other available classifications.

Superficial *haemangiomas* (Fig. 31.20) can appear as raspberry-coloured birthmarks or reddish discoloration of the skin. The bright red strawberry-like classic appearance may not be seen in deeper lesions involving sub-cutaneous tissues. These deep lesions are wrongly diagnosed as vascular malformation, with normal appearing overlying skin. Superficial lesions were previously called ‘capillary hemangiomas’, and deeper lesions ‘cavernous hemangiomas’. These terms do not reflect the clinical nature or influence the



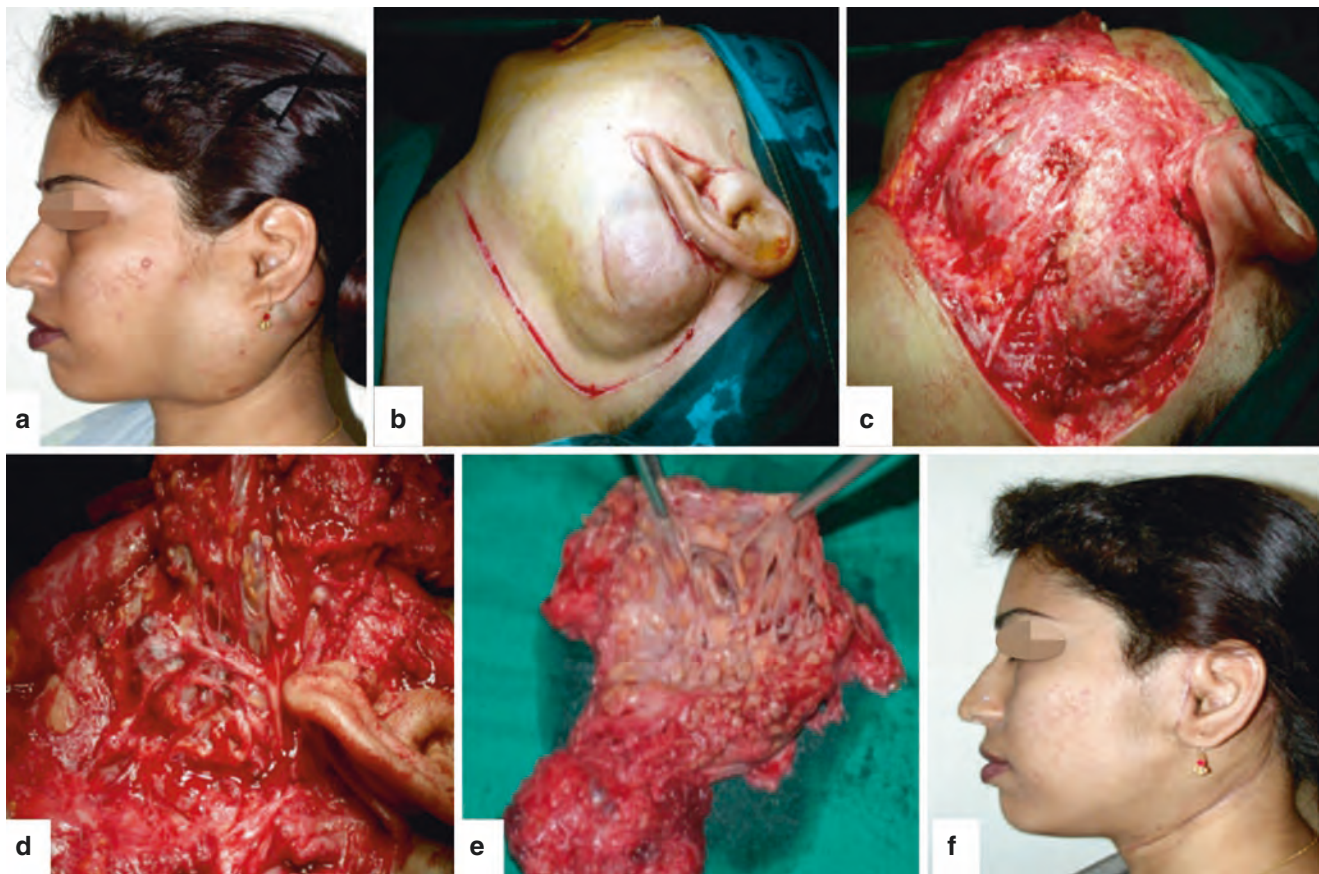
©Association of Oral and Maxillofacial Surgeons of India

Fig. 31.7 Type-I vascular lesion ((a) pre-operative tongue VM, (b) debulking, (c) closure and (d) post-operative). Copyright: Authors own publications from IJOMS 2011



©Association of Oral and Maxillofacial Surgeons of India

Fig. 31.8 Type-II vascular lesion ((a) pre-operative Left cheek VM, (b) incision, (c) exposure and excision and (d) Post-operative)



©Association of Oral and Maxillofacial Surgeons of India

Fig. 31.9 Type-III vascular lesion ((a) pre-operative Left parotid AVM, (b) incision, (c) exposure, (d) facial nerve dissection, (e) excision specimen and (f) post-operative). Copyright: Authors own publications from IJOMS 2011

treatment and should be reserved only for histological description. Compound lesions involving superficial and deeper tissues are also seen. The clinical appearance may vary depending on the depth of tumour. Growing haemangiomas can show organ involvement and cause ulcerations, bleeding, hearing problems, vision changes, difficulty in mastication, dysphagia and dyspnea.

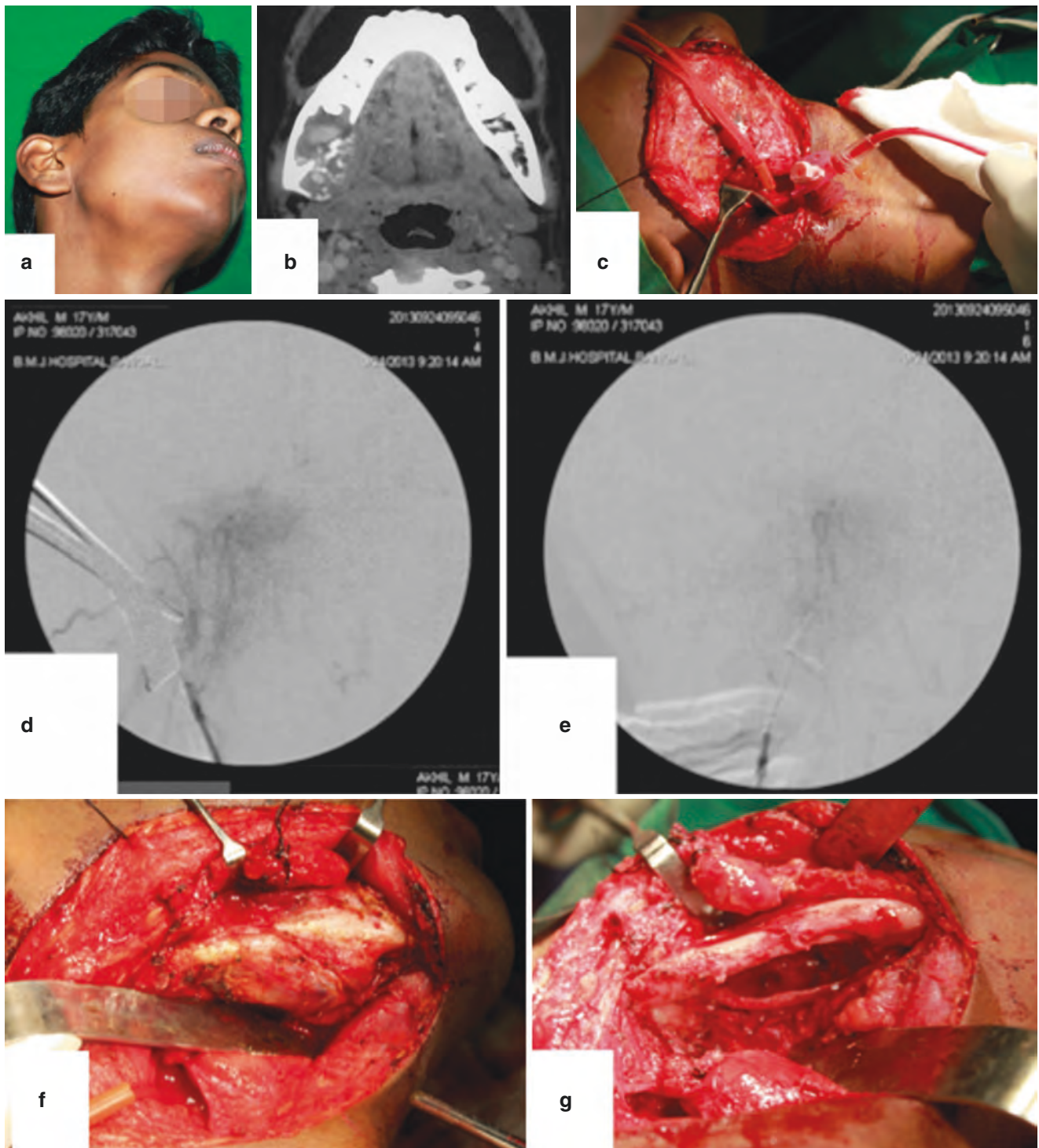
Congenital haemangiomas are further divided into infantile haemangiomas (IHs), rapidly involuting congenital haemangiomas (RICHs), non-involuting congenital haemangiomas (NICHs) and partially involuting congenital haemangiomas (PICHs) [15, 16].

IHs are commonly seen in infants and occur in 5–10% of children [17]. They appear anywhere between a few days to 3

weeks after birth. 80% of these cutaneous lesions are single and 20% are multiple. They grow rapidly and then enter an inactive phase at about 6 months of age. They then begin to shrink and involute after 1 year of age and sometimes leave behind a residual lesion. These residual lesions take longer to resolve.

RICHs (Fig. 31.20) are present at birth and involute by 6–14 months of age. Occasionally, they cause haematological irregularities like the Kasabach-Merritt phenomenon (KMP).

NICHs (Fig. 31.1) are present at birth and get larger with age. It is best to wait until 1 year of age to differentiate between RICH and NICH by looking at the involution pattern. PICHs initially present as RICH but fail to involute completely and remain as NICH.



©Association of Oral and Maxillofacial Surgeons of India

Fig. 31.10 Type-IV vascular lesion ((a) pre-operative AVM right mandible, (b) axial post-contrast CT image, (c) ECA control and injection of radiopaque dye, (d) intra-operative C-arm picture following dye

injection before occluding of ECA, (e) intra-operative C-arm picture following dye injection and occlusion of ECA, (f) lesion exposure and (g) curettage of lesion)

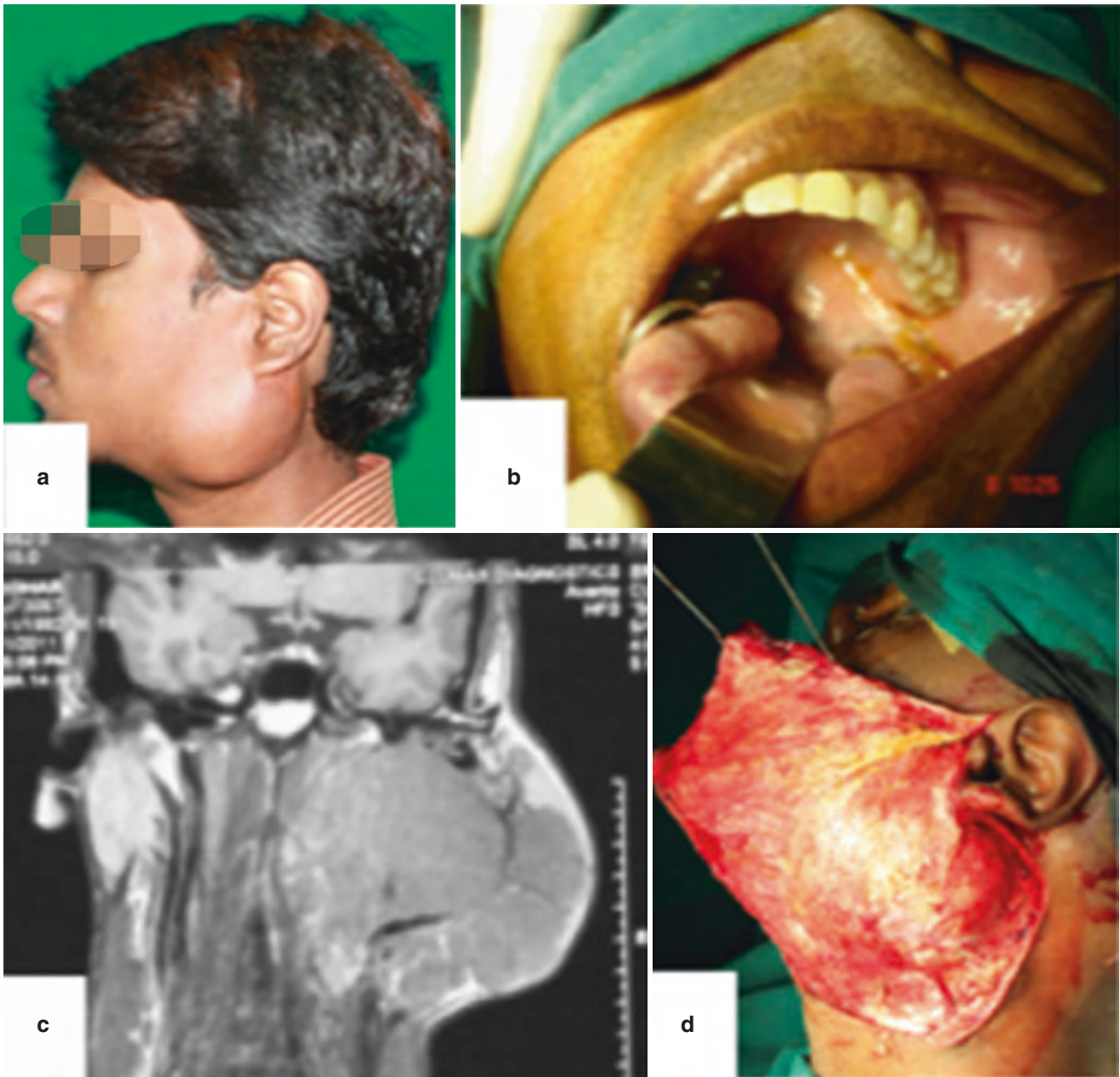
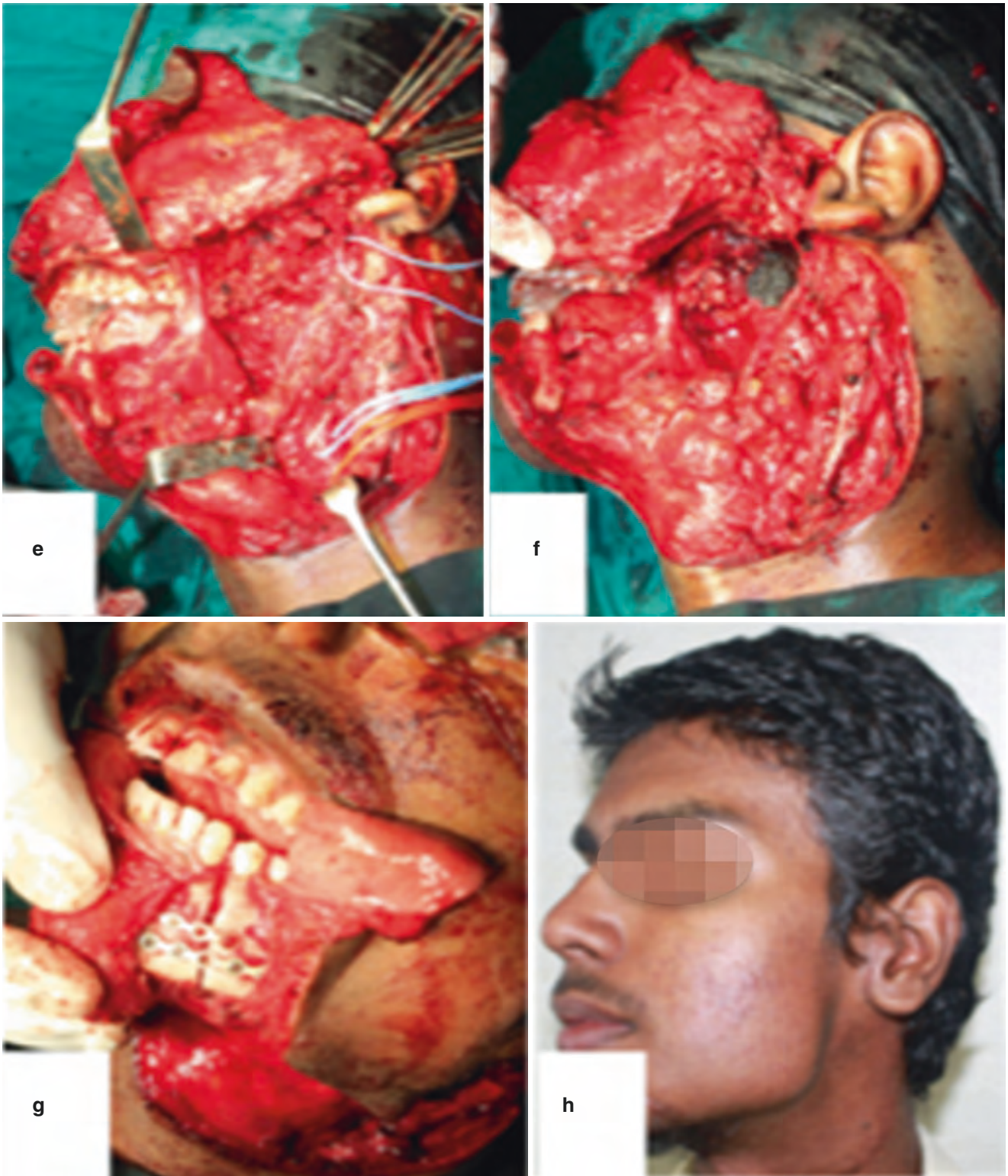

Fig. 31.11 Type-V vascular lesion ((a) pre-operative VM left parotid, (b) parapharyngeal extension, (c) coronal T1 weighted MRI image, (d) exposure, (e) lesion exposure with mandibulotomy and ECA control, (f) lesion complete curettage, (g) mandibulotomy closure and (h) post-operative). © Association of Oral and Maxillofacial Surgeons of India



©Association of Oral and Maxillofacial Surgeons of India

Fig. 31.11 (continued)

Table 31.4 Clinical findings of Vascular anomalies of Head and Neck

	Haemangioma	VM's	CM's	LM's	AVM's	KHE's
Age	Birth, few days to 3 weeks after birth	Birth	Birth	Birth, later in life	Later in life	Neonate
Appearance	Reddish discolouration of skin	Bluish	Red or purple patch	Diffuse swelling	Pink to bluish	–
Depth	Skin, subcutaneous tissues	Superficial, deep	Cutaneous only	Deep tissues	Superficial, deep	–
Types	IH, RICH, NICH	–	Medial, lateral	Macrocystic, microcystic	–	–
Behaviour	Slow growing, involute in 12–14 months	Slow growing, low flow, local blood stasis	Painless, can involve deeper structures	Expansile, infiltrative	Pulsatory, thrill	Large, more than 5 cm in size
Functional problems	Ulceration, vision/hearing/swallowing/airway issues	Painful thrombophlebitis, phlebolith formation	Cosmetic disfigurement, involve other areas like in Sturge Weber syndrome, Klippel Trenaunay syndrome	Airway problems, pain, dysphagia, difficulty in mastication	Coagulopathy LIC/DIC, throbbing pain, ulceration	Thrombocyte penia, Kasabach-Merritt phenomenon

Venous malformations (VMs) (Fig. 31.3) are most commonly seen vascular malformations, which are slow-growing, low-flow lesions present at birth and demonstrate a network of serpiginous inter-woven veins. These can grow extensively, become palpable, discoloured or bluish in colour with local blood stasis, which sometimes lead to painful thrombophlebitis. VMs can increase in size, in proportion to the increase in pressure within vessels caused by valsalva manoeuvre, dependency, exercise or agitation. VMs are usually compressible on palpation. They can demonstrate ‘phleboliths’, which are nothing but small calcifications formed due to, prolonged intra-vascular coagulation (Fig. 31.12).

Phleboliths are the commonest cause of pain in VMs. There is progressive lamellar fibrosis following intra-vascular thrombus formation. Calcium phosphate and carbonate are deposited in the core of the thrombus with peripheral mineralisation [18], which slowly increases in size. They are clinically palpable intra-orally, bi-manually in the cheek and over bony prominences. These are present as multiple oval or round laminated bodies (Fig. 31.12) with radiolucent or radiopaque corners, radiologically. Phleboliths can be areas of resistance to injecting sclerosants and should be excised separately.

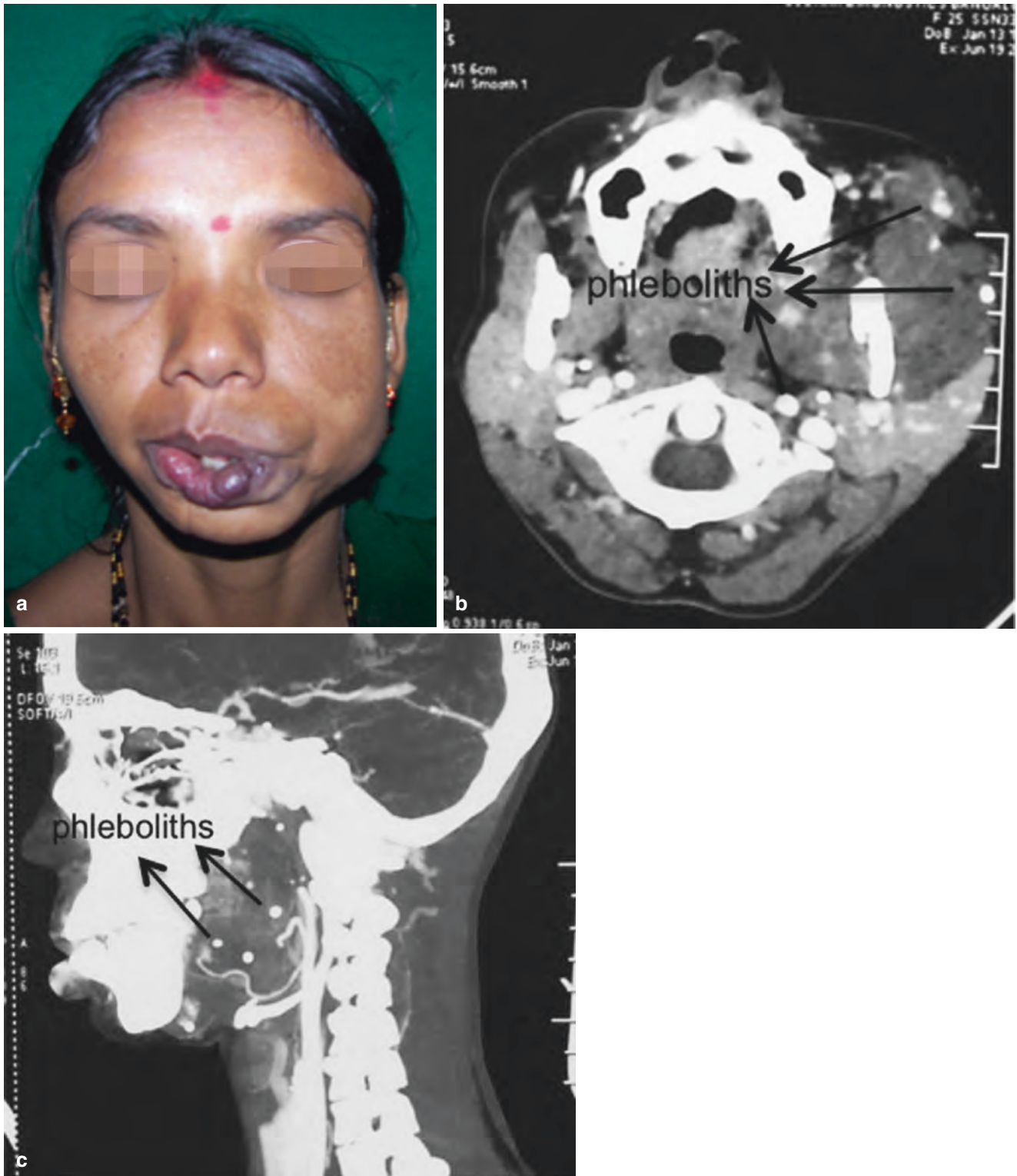
Capillary malformations (CMs) (Fig. 31.4), can be seen in the neonatal period and should not be mistaken with infantile haemangiomas (IHs). They occur in around 0.3% of children presenting with vascular anomalies. CMs usually present congenitally as a flat, red or purple cutaneous patch with asymmetric borders. They are painless and do not bleed spontaneously. They are categorised as ‘medial’ or ‘lateral’ lesions, based on their location in head and neck. Lateral lesions involve areas of face along the distribution of trigeminal nerve. They present as portwine stains, usually increase in size to involve deeper sub-cutaneous tissues causing the lesions to become darker, more raised and nodular. CMs may

be part of a syndrome, commonly the Sturge-Weber syndrome, which is characterised by CM involving the ophthalmic branch of trigeminal nerve, leptomeningeal angiomas and choroid angioma. CMs may also be seen in the Klippel-Trenaunay syndrome with multiple vascular (lymphatic, venous and capillary) abnormalities.

Lymphatic malformations (LMs) (Fig. 31.5) are usually congenital and not always detected until later in life. LMs are slow-flow lesions and can be *macro-cystic* (>2 cm) (Fig. 31.5b), *micro-cystic* (<2 cm) (Fig. 31.5a) or *mixed*, depending on the size of predominant cysts within them. Macro-cystic LMs can show expansion and compression of adjacent anatomical structures in the head and neck causing dysphagia, dyspnea and masticatory problems. Micro-cystic LMs were previously called lymphangiomas and demonstrate an infiltrative nature. LMs with local haemorrhage and infection can cause significant pain. LMs of the head and neck are further described by the *de Serres classification scheme* [19], which classifies disease severity based on the location and prognosis.

Fast-flow *arterio-venous malformations (AVMs)* (Fig. 31.6), usually present with a pulsatile local swelling. These AVMs along with some slow-flow lesions are at an increased risk of haematological complications like coagulopathies due to disturbances in haemostasis and thrombosis. Blood pools in abnormal slow-flow vessels, resulting in activation of the coagulation system, resulting in a process known as ‘localized intravascular coagulopathy’ (LIC), which shows low fibrinogen, elevated D-dimer levels and mild thrombocytopenia. This can further cause, ‘disseminated intravascular coagulopathy’ (DIC) and consumption of various coagulation factors.

AVMs are known to behave aggressively in later life, which can be stimulated by pubertal changes, pregnancy or trauma. They may present with throbbing pain, ulceration



©Association of Oral and Maxillofacial Surgeons of India

Fig. 31.12 Left cheek and lower lip VM ((a) clinical picture, (b, c) post-contrast axial and sagittal CT images showing multiple phleboliths)

and bleeding. Significant bleeding can sometimes be a cause of cardiac failure, in affected individuals.

A useful clinical staging system was introduced by Schobinger [20] in 1990. This system is widely used for describing the clinical presentation and evolution of AVMs:

Stage I (quiescence): pink-bluish stain, warmth and arterio-venous shunting by way of Doppler examination

Stage II (expansion): same as stage I, plus enlargement, pulsations, thrill, bruit and tense/tortuous veins

Stage III: the same as stage II, plus dystrophic skin changes, ulceration, (destruction) tissue necrosis, bleeding or persistent pain

Stage IV: the same as stage III, plus cardiac failure (decompensation)

Undiagnosed AVMs of bone are occasionally the cause of increased bleeding during/after extraction of teeth in a dental office, which can lead to life-threatening airway and haematological problems if not treated immediately (Fig. 31.13). These warrant urgent transfer to a hospital and embolisation or ECA control.

Hereditary haemorrhagic telangiectasia (HHT) is autosomally dominant and presents with the formation of expanding arterio-venous fistulas. These patients usually present with superficial (skin, mucosal) or deep (visceral) telangiectatic lesions. They may sometimes present with aneurysms causing epistaxis or intra-cranial haemorrhage.

Kaposiform haemangioendotheliomas (KHEs) are large lesions (greater than 5 cm), which are present in the neonatal period. They are extremely rare and have a low incidence of occurrence. Hence, there are no clear guidelines on their management. These are aggressive vascular tumours, which can be complex in their management due to thrombocytopaenia secondary to platelet trapping. This phenomenon is known as KMP (Kasabach-Merritt phenomenon). 70% of patients with KHEs demonstrate this phenomenon [21].

31.5 Radiological Assessment

Clinical and radiological assessment go hand in hand to accurately diagnose and manage these diverse groups of head and neck vascular anomalies. Selection of the imaging should be tailored according to the indication, advantages, disadvantages and availability of resources. Good knowledge of all the available radiological modalities is essential to treat these lesions.

Commonly used imaging modalities are

Ultrasound (US)

Coloured Doppler ultrasound

Computed tomography (CT) with contrast

Digital subtraction angiography (DSA)

Magnetic resonance imaging (MRI)

MRI angiogram

Multi-planar dynamic contrast enhanced MRI

US (Fig. 31.14) is the least invasive modality of imaging available for assessment of vascular anomalies. It is used as a baseline investigation for superficial head and neck vascular lesions. In addition to the above, the US has a high sensitivity in diagnosing these lesions. The disadvantages of the US are its limitation in detecting deeper soft tissue and bony lesions.

Doppler ultrasound (Fig. 31.15) is used to demonstrate high-flow lesions. Flow towards the ultrasound transducer is seen in red and away from the transducer seen in blue. The arterial feeder is usually identified by increased colour flow, high doppler shift and low resistance.

CT (Fig. 31.16) is used to diagnose bony lesions, provide cross-sectional details and detect the presence of calcifications like phleboliths in venous malformations and haemangiomas. Most scans can be done in less than a minute with quick acquisition time. Reduced imaging time and low cost compared to MRI make contrast CT widely used for diagnosing soft tissue vascular lesions. Surveillance imaging with CT is not recommended due to increased exposure to ionising radiation.

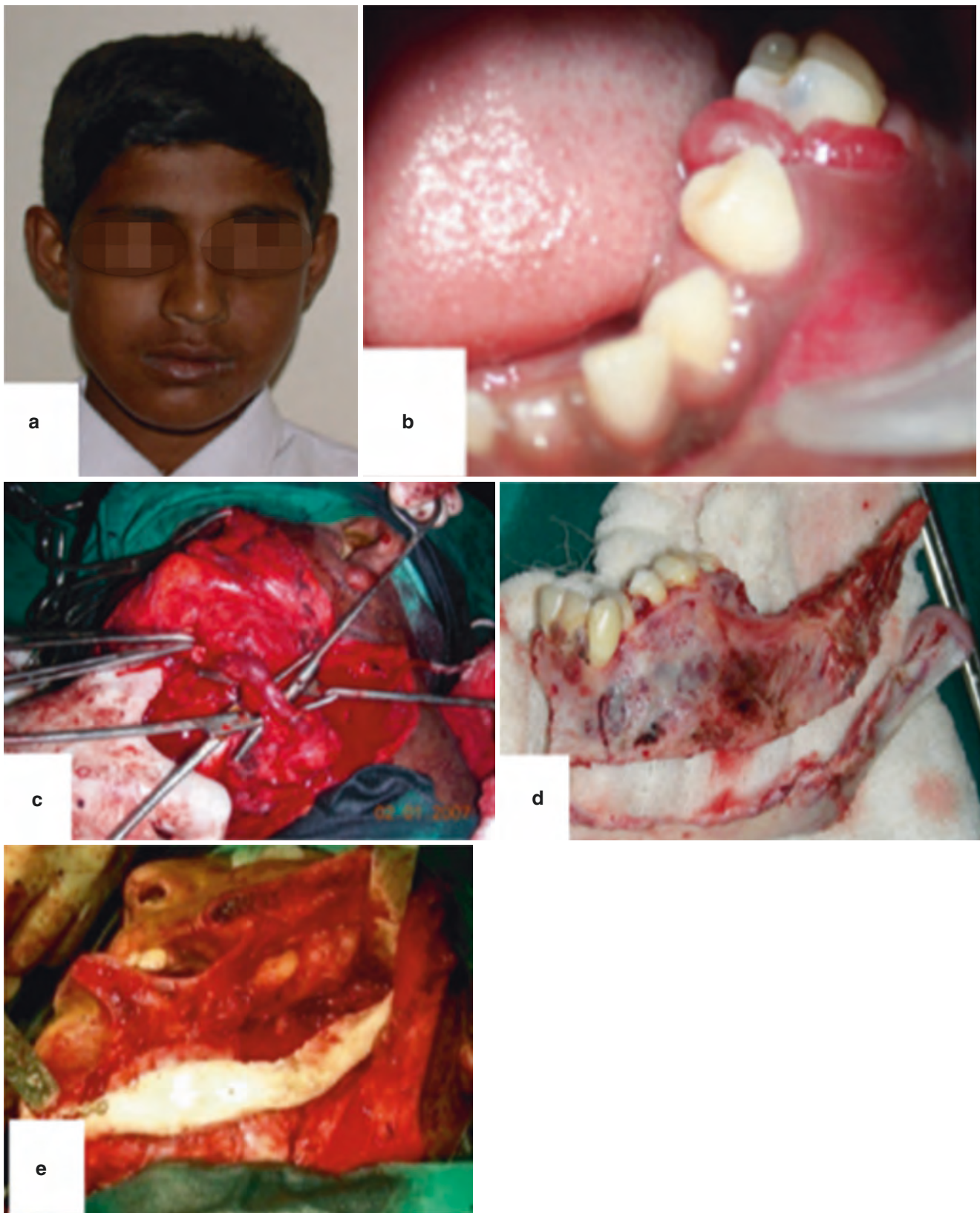
MRI (Fig. 31.17) is the most preferred and accepted imaging for diagnosing and monitoring soft-tissue vascular lesions of head and neck. Its superior contrast resolution, in-depth soft-tissue assessment and non-exposure to ionising radiation, makes it the investigation of choice for these lesions. Haemangiomas and VMs show intense enhancement with MRI. AVMs and LMs show minimal enhancement.

Fat-suppressed T2-weighted imaging is used to discriminate these lesions among each other. Intense T2-weighted signal is seen with VM's and macro-cystic LM's due to cystic spaces within them and pooling of slow-flowing blood or lymph. Moderate signal intensity is seen with haemangiomas and vascular neoplasms due to their cellular composition. Mild T2-weighted signal is seen with AVM's reflecting tissue oedema.

Long acquisition time (at least 30 min) and increased cost of imaging limit its use [22]. Use of sedation or anaesthesia is required for infants, children and uncooperative adults.

Angiography (Fig. 31.18) is usually reserved for therapeutic endovascular interventions. Angiography includes arteriography, venography and injection of direct intralésional contrast agent. This provides good resolution (spatial and temporal) of the vascularity and also permits catheter-induced percutaneous therapy. Arteriography is used for the evaluation of high-flow vascular lesions. Its use is limited due to the invasive nature and use of ionising radiation.

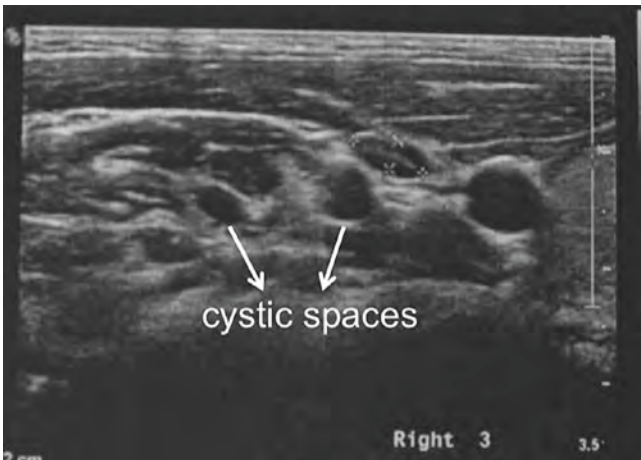
DSA (Fig. 31.19) should be reserved for patients undergoing endovascular treatment. DSA is used for diagnosis of AVM's where the feeding artery, draining vein, nidus connecting artery and vein can be clearly imaged [23] and simultaneous embolisation can be performed, by an interventional radiologist.



©Association of Oral and Maxillofacial Surgeons of India

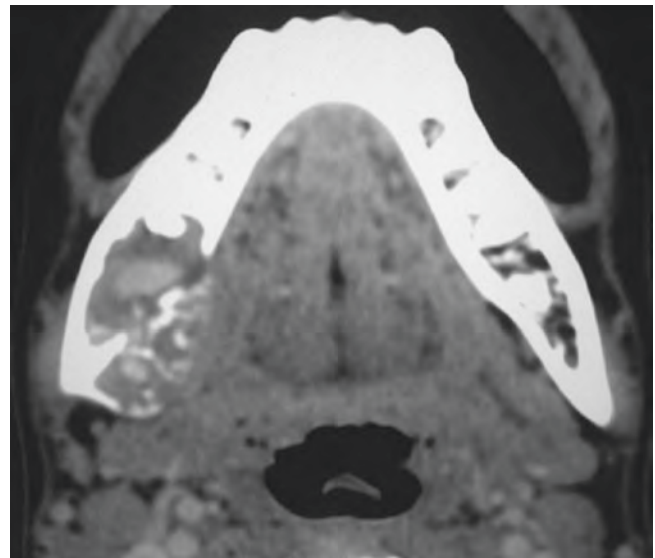
Fig. 31.13 Bleeding following dental extraction—Extracorporeal curettage of high-flow bony vascular lesion and fixation of mandible ((a) pre-operative, (b) intra-oral, (c) ligation of main feeder, (d) extra-cor-

poreal curettage and excision of diseased bone and (e) fixation of mandible as the free graft)



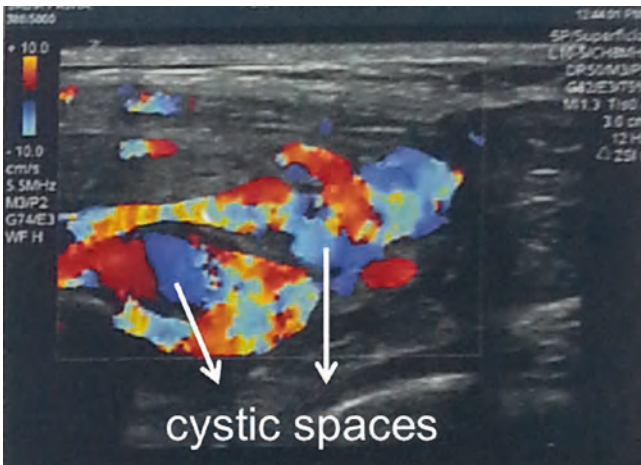
©Association of Oral and Maxillofacial Surgeons of India

Fig. 31.14 Ultrasound image-Venous malformation of submandibular region showing multiple cystic spaces



©Association of Oral and Maxillofacial Surgeons of India

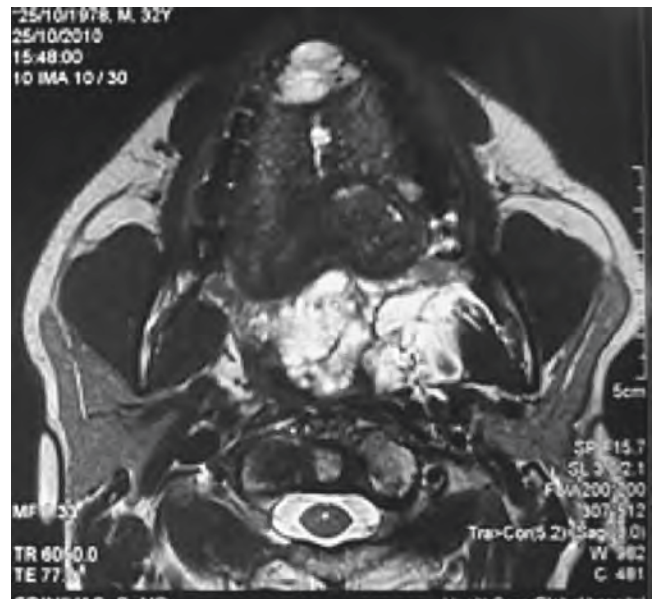Fig. 31.16 CT with contrast, Right mandible Type-IV lesion



©Association of Oral and Maxillofacial Surgeons of India

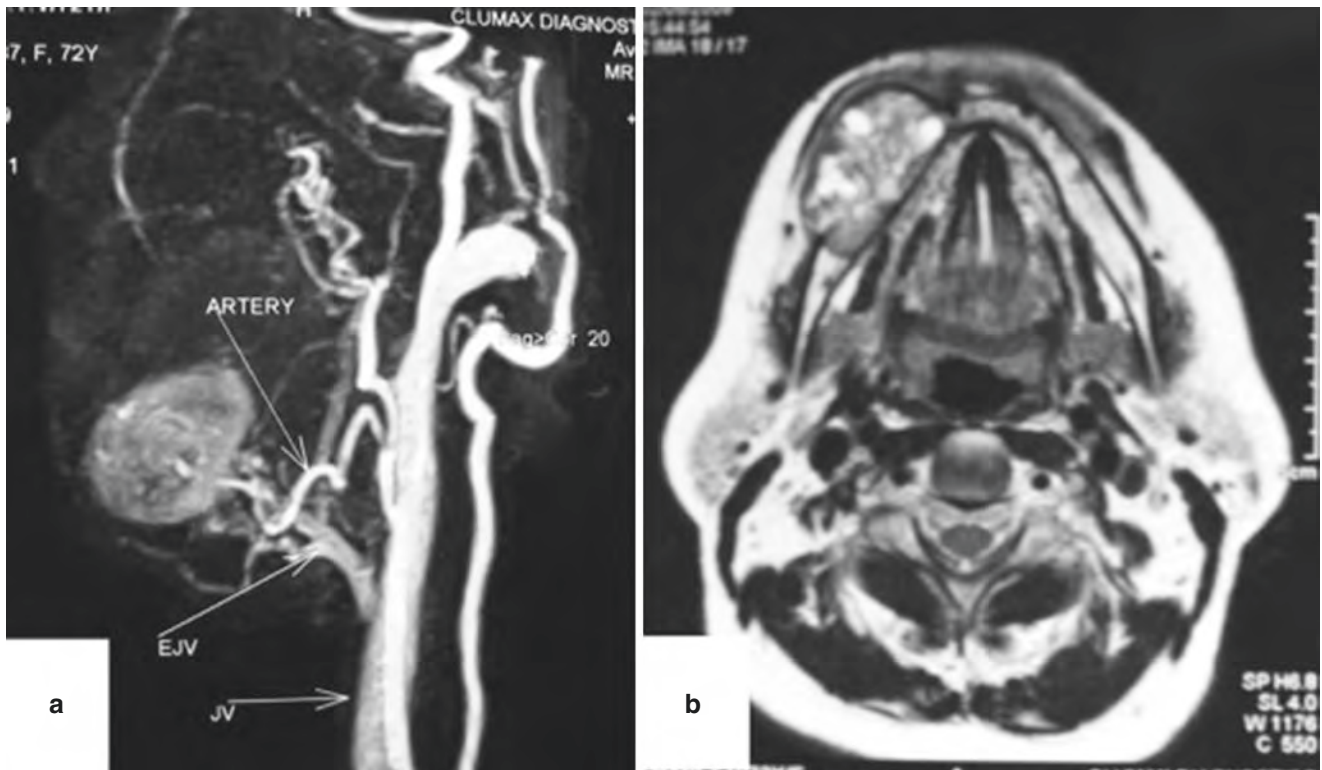
Fig. 31.15 Coloured Doppler Ultrasound image of AVM of neck showing multiple cystic spaces filled with colour (flow towards the transducer seen in 'red' and away in 'blue', lighter shades of colour depict higher velocity)

Multi-planar dynamic contrast-enhanced MRI is preferred for extensive vascular malformations of the head and neck, especially in lesions involving aerodigestive tract, neural and vascular structures.



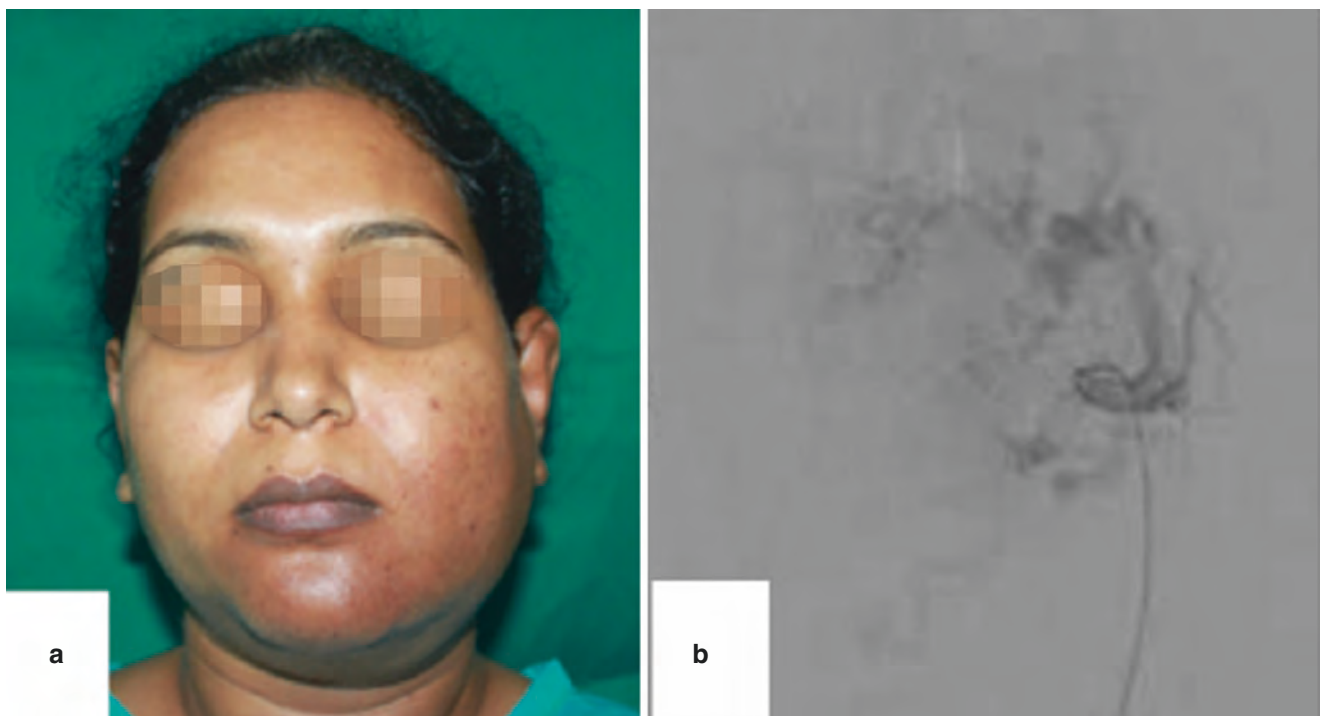
©Association of Oral and Maxillofacial Surgeons of India

Fig. 31.17 T2-weighted MRI, left parapharyngeal venous malformation



©Association of Oral and Maxillofacial Surgeons of India

Fig. 31.18 AVM of right mandible ((a) Contrast MR angiography image, (b) T2-weighted MRI image). Copyright: Authors own publications from IJOMS 2011



©Association of Oral and Maxillofacial Surgeons of India

Fig. 31.19 AVM left cheek ((a) clinical image, (b) DSA image during embolization)

31.6 Medical and Interventional Management

Correct diagnosis is important for selecting the appropriate therapy for vascular anomalies.

The aim of managing complex vascular lesions should be to relieve acute symptoms like pain, swallowing and airway problems, prevent and treat thromboembolic events and correct the cosmetic impairment caused by them.

The type of vascular anomaly and its flow characteristics, determine the mode of management.

These mostly fall into:

- Medical line of management,
- Interventional therapy and
- Surgical management.

Congenital haemangiomas, low flow venous malformations and lymphangiomas can be considered for treatment

with systemic and sclerotherapy. Residual and large lesions are usually treated with surgery. AVM's and high-flow malformations have been mostly treated using embolisation with or without surgical excision/debulking successfully.

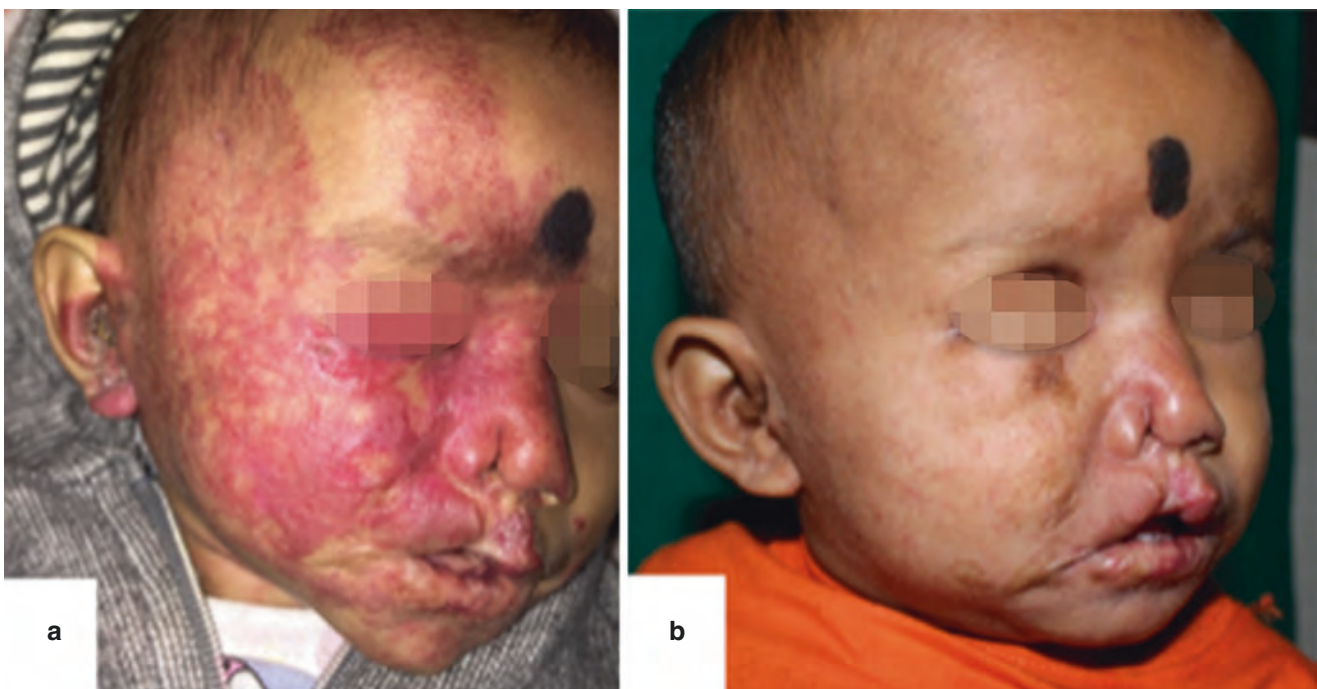The author's wide experience in the surgical management of most low- and high-flow lesions has provided acceptable and predictable results.

In *haemangiomas*, a 'wait and observe' strategy is preferred. Involution is seen in more than 85% of patients. If a malignant lesion is suspected, a biopsy with a request for GLUT-1 immunostaining is required to confirm its true nature [24]. Active intervention is considered if the lesion is

- Large in size causing obvious facial asymmetry
- Multiple with systemic changes like high-output cardiac failure.
- Adjoining or involving important structures like airway, eye and ear causing—vision, hearing, airway or swallowing problems.
- Recurrent and persisting ulcerations

Propranolol (Fig. 31.20) is the first line of treatment and is best to involve a paediatrician to monitor the dosage and systemic complications associated with it. Propranolol causes vasoconstriction and possibly reduced expression of pro-angiogenic factors of the haemangioma growth phase, leading to apoptosis of capillary endothelial cells.

Treatment during the proliferating phase is given to prevent impending functional or aesthetic complications especially



©Association of Oral and Maxillofacial Surgeons of India

Fig. 31.20 Rapidly involuting congenital Haemangioma (RICH) of right face treated with propranolol therapy ((a) pre-treatment, (b) post-treatment)

near vital areas like eyes and ear. In the absence of contra-indications to propranolol like sensitivity to beta-blockers, bronchospasm, hypotension or bradycardia and after having a routine haematological and biochemical assessment by the paediatrician, a dose of 1 mg/kg/day in three divided doses may be initiated and titrated up to 2 mg/kg/day. This is given for 12 months or longer according to the response. Meticulous dose adaptation is important to prevent adverse effects. These could be bradycardia, increased airway resistance, bronchial obstruction and hypotension. Long-term effects of propranolol are still not known and other drugs like timolol have been tried for superficial and peri-ocular lesions. Invasive therapies are almost never required to treat these lesions.

Although propranolol has replaced the use of *systemic steroids* as the first line therapy for haemangiomas, intra-lesional therapy for localised lesions with, Triamcinolone may be used with a dose of 2 mg/kg every 4–6 weeks depending on the response. It is known that one-third of patients do not respond to treatment with steroids. Systemic steroids are sometimes given in conjunction with propranolol after consulting with the paediatrician.

Rebound growth being a problem with systemic therapy using propranolol and/or steroids, the dose is always preferred to be tapered-off before discontinuing following resolution of the lesion.

Embolisation is considered in patients with high-output cardiac failure and large-aggressive lesions causing problems with haemostasis.

Surgery is considered between 2 and 4 years of age after having attempted medical treatment to minimise deformity involving eyes, nose and lips and other areas of face.

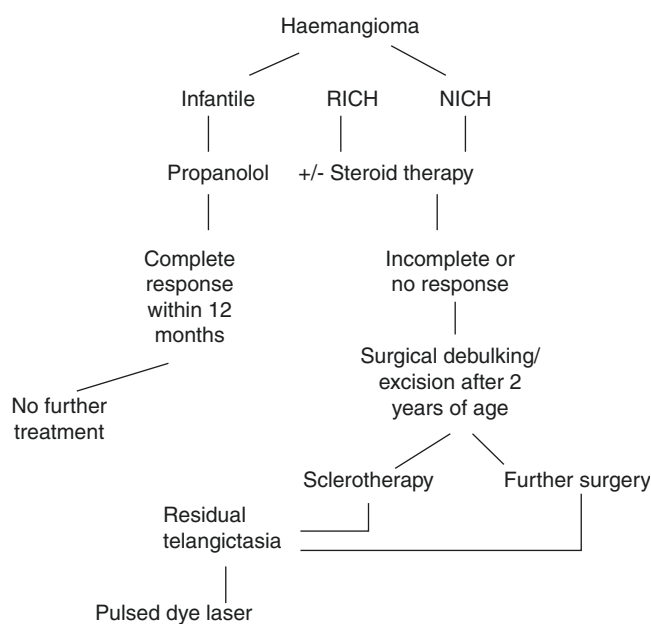
Pulsed dye laser was used in past for coagulating the surface of ulcerated lesions. This is now used for the treatment of surface residual telangiectasia, usually after 10 years of age (Algorithm 31.1).

Minimally invasive percutaneous sclerotherapy is used widely for the treatment of venous malformations. A wide range of agents are known to be used in the literature. There is no consensus on choice of sclerosant to be used. Commonly used sclerosants [25] are pingyangmycin (PYM), absolute ethanol, OK-432 (picibanil), ethanolamine oleate, bleomycin, polidocanol, doxycycline and STS (Sodium tetradecyl sulphate).

PYM [25], also known as Bleomycin A5, is the most commonly used single-drug therapy for the treatment of cervicofacial malformations. Transient fever and swelling are commonly seen side effects. Skin ulceration and subcutaneous tissue atrophy are scarcely seen complications.

Absolute ethanol [25] causes alteration in cellular proteins and hence damages the endothelium of the vascular wall leading to obliteration of its lumen. Common complications include, nerve injury, necrosis and ulceration of skin.

OK-432 [25] is a lyophilised preparation of low-virulence bacteria, group A *Streptococcus pyogenes*, incubated with



Algorithm 31.1 Management of Haemangioma

benzyl- penicillin. It causes, induction of various cytokines. The inflammatory response caused by this remains localised and causes endothelial damage. The complications include local swelling and transient facial nerve palsy.

Ethanolamine oleate [25] is an emulsion of fatty acids, which induces thrombosis and damages the endothelium. Complications like ulceration and necrosis of skin are known but infrequently observed.

Bleomycin [25] was first used in the treatment of cystic hygromas (now lymphatic malformation). It is now used widely for management of lymphatic and venous malformations. It inhibits DNA synthesis and has a non-specific inflammatory reaction on the endothelial cells. Adverse effects of bleomycin are minimal and transient, mostly being localised pain and swelling. Skin infections in the area of injection are seen less commonly. Some people report with occasionally severe nausea.

Polidocanol [25] is a non-ionic detergent, causes absorption at the cell membrane and leads to lysis of endothelial lining. Superficial necrosis of skin or mucosa is a known complication with Polidocanol.

Doxycycline [25] belongs to the tetracycline group of antibiotics. Its mode of action is not yet clear, but its effects are known to be due to inhibition of matrix metalloproteinases and cell proliferation. It also causes suppression of vascular endothelial growth factor during angiogenesis and lymphangiogenesis. This further leads to dense adhesions and fibrosis due to collagen and fibrin deposition. Macro-cystic LM's show a better response to treatment with doxycycline in comparison to micro-cystic LM's. Haemorrhage, cellulitis, pain and transient oedema are com-

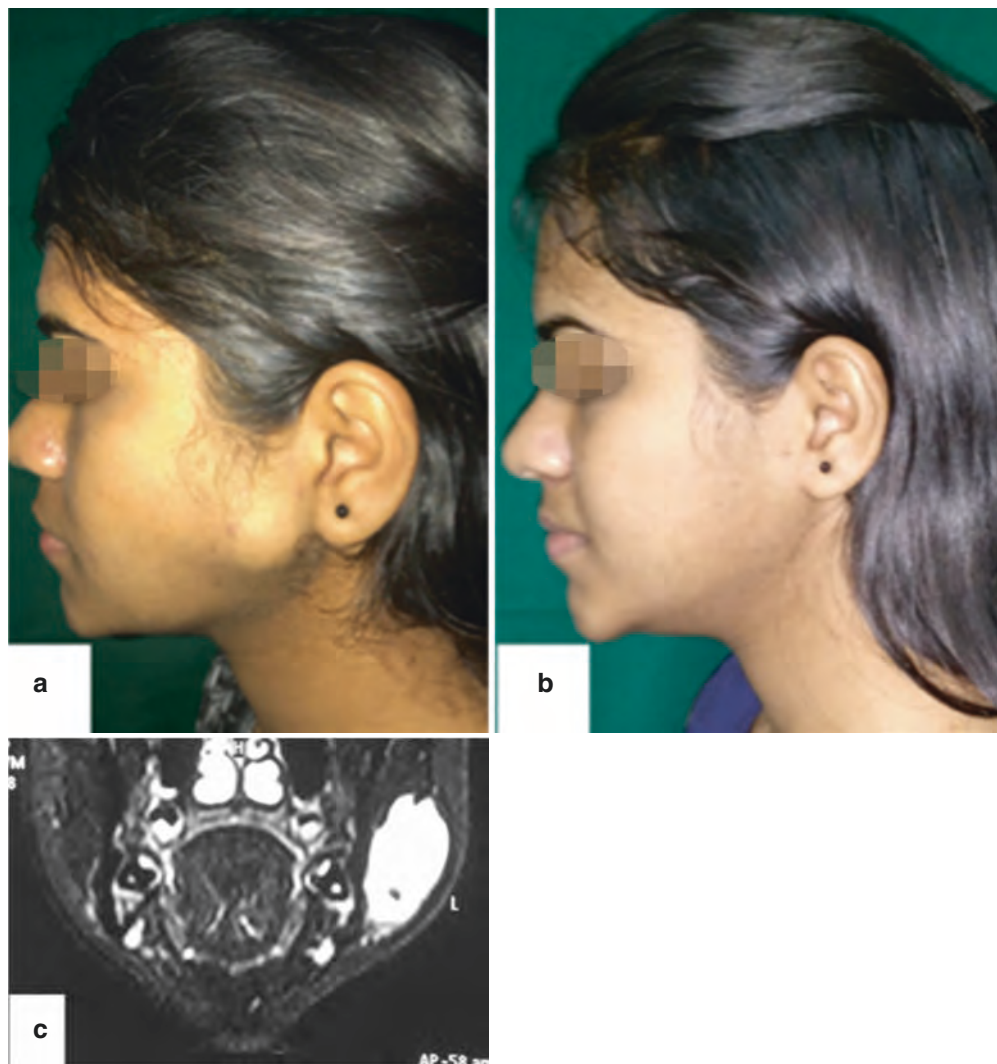monly seen complications. Scarring, skin excoriation and horner syndrome are seen less commonly. These adverse effects are self-limiting and likely to be related to the sclerosing effect rather than a side effect of the medication itself.

STS [25], also known as *sotradecol*, causes denaturation of proteins like clotting factors due to disruption of the normal architecture of the lipid bilayer in cell membranes of endothelial cells. This causes fibrosis and occlusion of vessels. It is not known to have any major complications so far.

Lymphatic malformations are treated depending on the type and location in head and neck. As mentioned previously, these lesions can cause pressure on the airway, aerodigestive tract and enlarge due to repeated infection or haemorrhage into the lesion. In the majority of patients with macro-cystic LMs, sclerotherapy with *Picibanil* (*OK-432*) has shown good results. Patients may develop inflammation at the site of injection and fever, which is managed

symptomatically. Micro-cystic LMs may require systemic therapy with *Sirolimus* or surgery as they do not always respond to *Picibanil*. *Sirolimus* is a natural macrolide secluded from *Streptomyces* genus (*Streptomyces hygroscopicus*). It causes a decrease in the vascular endothelial growth factor (VEGF) and is a key regulator in lymphangiogenesis and angiogenesis.

Bleomycin is used widely for the treatment of VMs and microcystic LMs. The mechanism of action on micro-cystic disease is not completely understood and may involve derangement of tight junctions between endothelial cells or induction of endothelial mesenchymal transition. The overall response is favourable but complete response is seen in only about 20–57% [25]. The author follows a protocol of intralesional injection of 15 IU Bleomycin in 5 ml of fresh normal saline, administered every 15 days. Most patients show a response in 3–4 sittings (Fig. 31.21). Lymphatic malformations are known to cause sec-



©Association of Oral and Maxillofacial Surgeons of India

Fig. 31.21 Venous malformation-Left cheek ((a) before sclerotherapy, (b) after sclerotherapy, (c) pre-treatment T2-weighted MRI image)

ondary skeletal deformities, which are addressed due to functional or cosmetic reasons as necessary.

AVMs are the most challenging type of vascular malformations to manage due to their aggressive nature. They tend to cause progressive facial deformity and pose a significant systemic risk. They are high-flow lesions that typically demonstrate a nidus with arterial feeders, arteriovenous connections and enlarged veins. Schobinger's class III and IV demand aggressive management with combined embolisation, surgical excision and reconstructing the residual defect. Trans-arterial and trans-venous catheter angiography are commonly used for assessment, examination of the nidus and location of arterio-venous shunting. A few lesions can be controlled with frequent embolisation. The nidus must be treated to get control over the lesion. *Catheter embolisation causes* obliteration of the nidus in order to prevent a further increase in size and haemorrhagic complications. This can be either *endovascular* (Fig. 31.22) as used for large AVM's with aberrant feeders or *percutaneous* (Fig. 31.23) used for more superficial lesions. The feeders are sequentially embolised from distant to proximal feeders. Embolisation can be used for pre-surgical occlusion of feeder vessel on the same day of planned surgery to minimise intra-operative blood loss.

Commonly used embolic agents are:

Ethanol,
Cyanoacrylate (glue),
Coils, polyvinyl particles,
Onyx—a liquid ethylene vinyl alcohol copolymer.

Kaposiform Haemangioendotheliomas (KHEs) are treated with hematological agents such as *vincristine*, *steroids* or *sirolimus*. These systemic medications help in the resolution of KHE and associated KMP (Kasabach Merritt phenomenon). Surgical management of these lesions is usually not required but small lesions can be removed in toto with early intervention.

31.7 Surgical Management

Unlike in the past, most low- and high-flow vascular anomalies are amenable to surgical management by either excision or debulking. Smaller-sized lesions are almost always excised completely. In contrast, larger-sized lesions are mostly debulked and need multiple procedures. External carotid artery (ECA) control is used to have reasonable control before and

during procedures involving high-flow lesions. This is partly because of collateral blood supply from the opposite side.

For simplicity, the author's own anatomical classification is followed as it makes the understanding of the surgical approaches and the rationale behind them more lucid and comprehensible. Also, the concept of 'Corset suturing' will be explained, which has been proved to be an asset in management of large low-flow vascular anomalies.

31.7.1 Surgical Anatomy

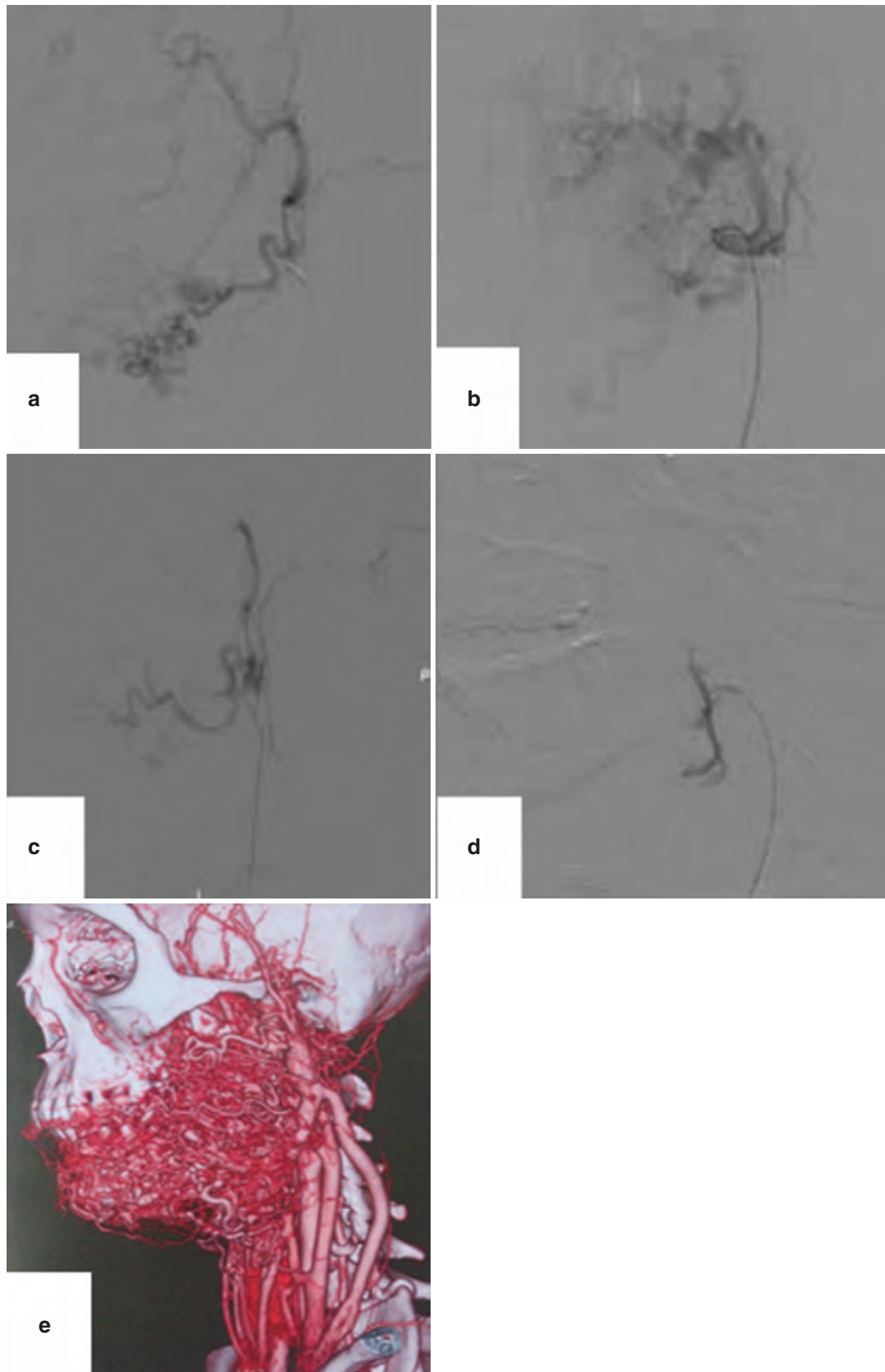
An understanding of the different layers and planes of dissection in the head and neck is important to approach and treat these vascular anomalies. The commonest areas involved in the head and neck are cheek, lower and upper lips, eyelids, pre-auricular, mandible, submandibular, submental, upper neck, posterior and lateral oropharynx. The glottis, sub-glottis and lower neck are less commonly involved. Lymphovascular malformations are seen occupying scalp and orbit commonly.

Layers of face from superficial to deep are—skin, subcutaneous tissue, SMAS layer, parotid fascia (pre-auricular)/deep cervical fascia (sub-mandibular), salivary gland (parotid and sub-mandibular regions), muscle, periosteum and bone. The scalp has a loose areolar plane and all other tissues attached. The neck has vital structures like the carotid artery, jugular vein, spinal accessory nerve, cervical plexus and other muscles superficial and deep to them.

31.7.2 Case Selection

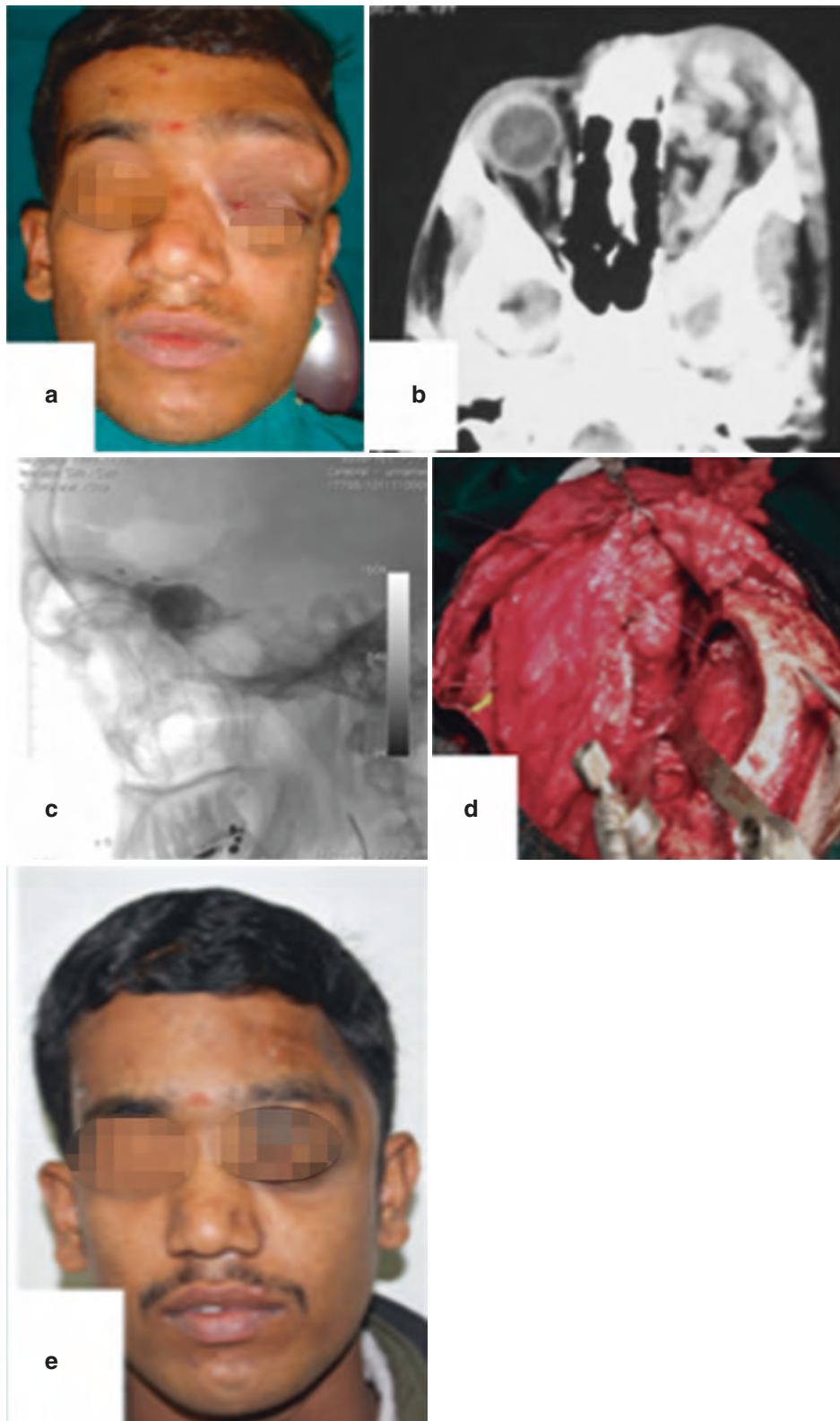
According to the author's classification, vascular malformations were categorised into five types based on their anatomy and depth of location in the head and neck. This is a good guide for selecting the type of surgical management and reconstruction.

- In type-I, superficial lesions require excision of skin or mucosa. Local or regional flaps have been used in reconstruction of the residual defect.
- Type-II, sub-mucosal lesions require complete excision after elevation of skin flaps.
- Type-III, lymphovenous malformations or venous malformations involve salivary glands and are excised along with the affected gland.
- Type-IV, intra-osseous lesions require excision with removal of involved bone and reconstruction of the residual defect as necessary.



©Association of Oral and Maxillofacial Surgeons of India

Fig. 31.22 Sequential endovascular embolisation of left cheek AVM ((a–d) progressing blockage of blood supply to AVM, (e) 3D reconstructed view of the vascular network)



©Association of Oral and Maxillofacial Surgeons of India

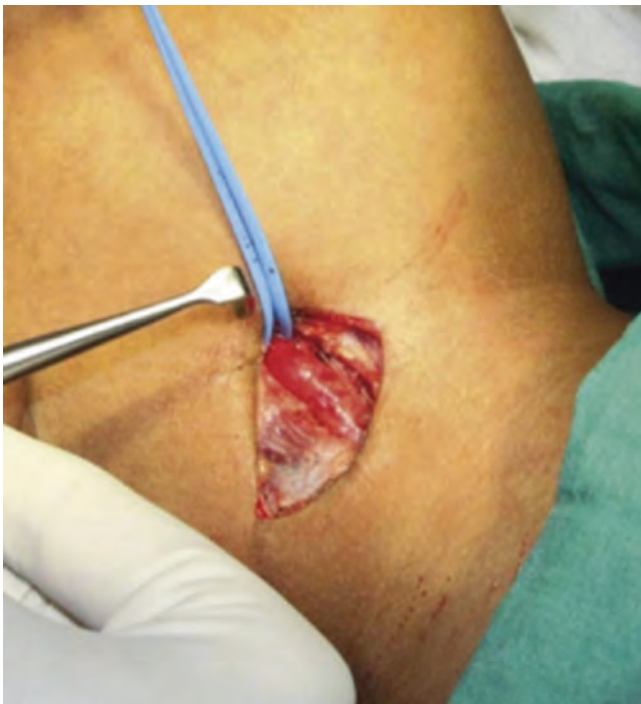Fig. 31.23 AVM of left supra-orbit ((a) pre-operative, (b) CT with contrast, (c) percutaneous embolisation, (d) Surgical excision via haemicoronal approach, (e) post-operative)

- Type-V lesions involve deep visceral spaces, such as the parapharyngeal or infra-temporal fossa and usually require mandibular access osteotomy for complete exposure and complete removal of the lesion.

The above procedures can demand either endovascular embolisation, intra-lesional embolisation or ECA control prior to attempting excision or debulking of these lesions.

31.7.3 Technique of External Carotid Artery (ECA) Control (Fig. 31.24)

The ECA of the involved side is exposed through a cervical incision, which often forms, part of the access for removal of the malformation. The sternocleidomastoid muscle is retracted posteriorly at the level of the greater cornu of the hyoid bone, exposing the carotid sheath. The external carotid distal to the carotid bifurcation is identified. The vessel is snared with a vascular sling passed through a rubber catheter. Gentle strangulation of the vessel can be accomplished by advancing the catheter. This additional compression of the vessel serves to reduce blood flow to the lesion. In demanding situations, the ECA can be ligated. Many times due to risk of collateral blood supply to these lesions, ECA control is an adjunct to achieving haemostasis along with aggressive local control.



©Association of Oral and Maxillofacial Surgeons of India

Fig. 31.24 ECA control. Copyright: Authors own publications from IJOMS 2011

31.7.4 Corset-Suturing Technique (Fig. 31.25)

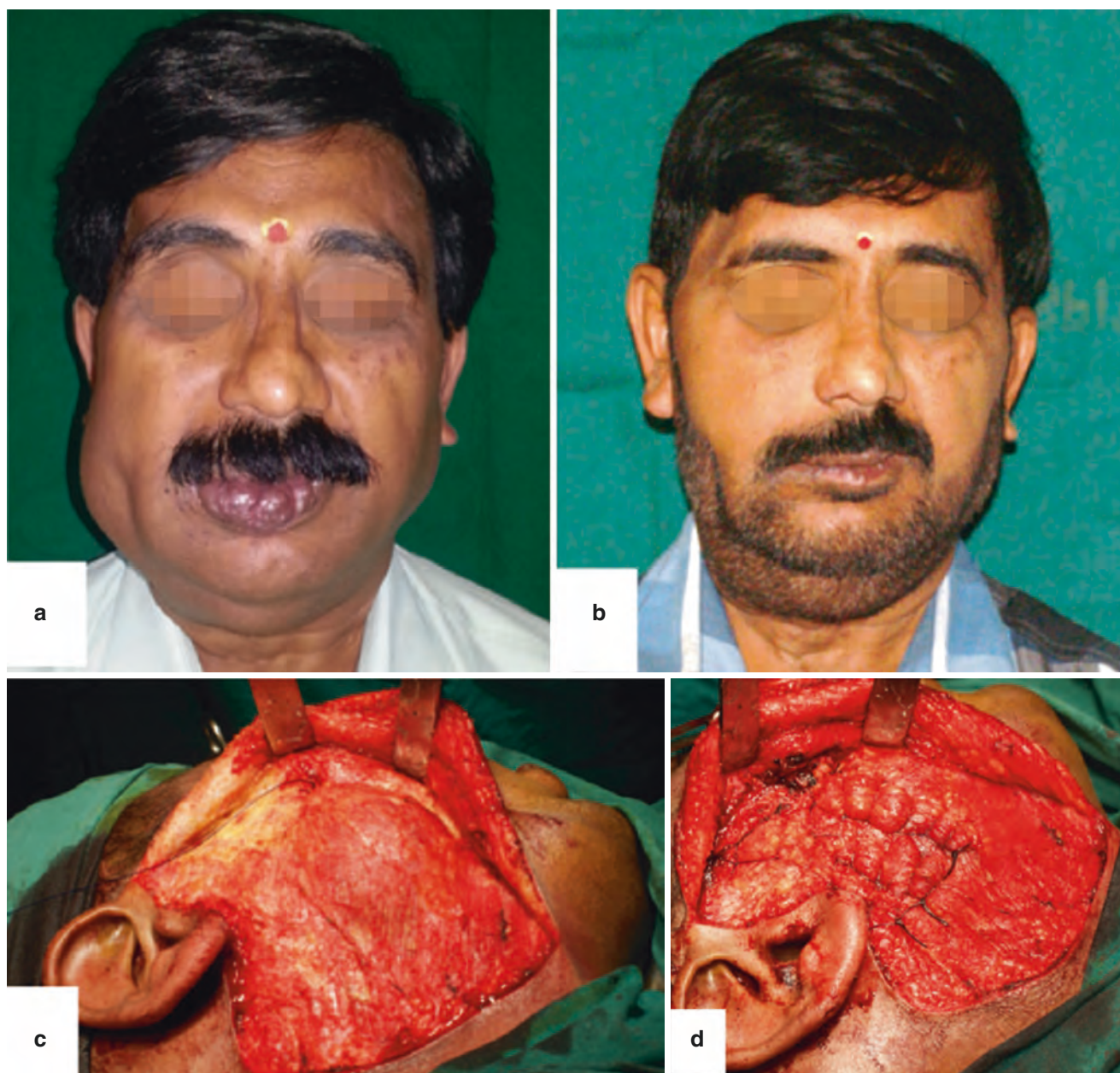
Corset suturing [26] is a proven technique in management of large low-flow venous malformations of head and neck, especially in lesions where complete excision is not practically possible and also those in close proximity to important structures like airway, facial nerve, spinal accessory nerve, internal jugular vein and in medically compromised individuals.

‘Corset’, is a garment worn to hold and train the torso in to a desired shape for aesthetic or orthopaedic purposes. The procedure employed is raising a flap in the sub-SMAS or sub-cutaneous plane depending upon the type of lesion followed by placement of a bioresorbable suture (polydioxanone) that runs in a continuous vertical looping fashion from sub-cutaneous to deep layer and from one end to another, incorporating the lesion within the suture. The suturing is advanced at regular and equidistant intervals to involve the bulk of lesion resulting in compression of the vascular spaces and causing obstruction of the afferent and efferent vessels. This reduces the risk of bleeding, swelling and size of lesion. The blood supply gets interrupted due to obstruction of afferent vessels. In large lesions, this suturing should be done parallel to each other covering the whole lesion from superior to inferior and medial to lateral, which would occlude the regional vascular channels, interrupting and obstructing the blood circulation in the tumour. These sutures must be tightened cautiously, slowly and progressively to achieve gradual and complete strangulation of vascular channels until complete closure of their lumen is assured. This procedure decompresses the lesion completely and reduces the risk of post-operative haemorrhage. The excess skin flap is excised, drains are secured followed by primary closure. The final scar is fairly acceptable, as all incisions are originally placed within the skin tension lines.

31.7.5 Approaches and Excision/Debulking

Superficial Type-I (Fig. 31.7) lesions mostly derive from the reticular dermis and is treated with direct excision and closure or local-flap reconstruction. Care is taken to place incisions along the skin tension lines of the face and neck to avoid unaesthetic results. It is challenging to select these lines in young individuals and every attempt is made to lay these incisions on prominent skin creases like nasolabial, mentolabial, pre-auricular and lower skin crease of neck.

Type-II (Fig. 31.8) lesions are approached by raising skin flaps using the following incisions, commonly—pre-auricular with either neck skin crease extension or temporal extension, neck crease incision alone, nasolabial skin crease incision, mid-face Weber-fergusson incision and coronal approach. Every attempt is made to maintain a sub-SMAS



©Association of Oral and Maxillofacial Surgeons of India

Fig. 31.25 Venous malformation right face, lower lip ((a) pre-operative, (b) post-operative, (c) lesion exposure and (d) corset suturing of lesion). (Fig. 31.25 a,b,d - copyright authors own publication IJOMS 2018)

plane but vascular anomalies being composite in nature can demand modifications. There is always a risk of thinning the skin flap excessively and care should be taken to avoid button-holing and avoiding avascular necrosis. The lesion is excised completely or debulked depending on the size. Corseting is used for large low-flow malformations as described above.

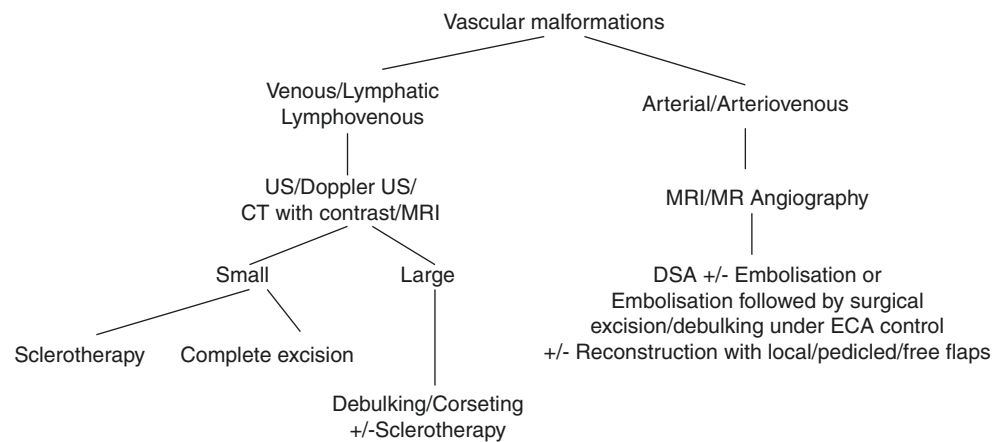
Tongue lesions are mostly excised in toto or debulked in a V shaped fashion to achieve primary closure.

Type-III (Fig. 31.9) lesions are approached the same way as Type-II. Being deeper in nature, the gland is sacrificed with some risk of permanent facial nerve damage. Use of 'corseting' in these cases has shown good results with complete recovery of facial nerve weakness over a period of 1 year.

Type-IV (Fig. 31.10) lesions like other types are rarely seen on their own and are usually in combination with Type I, II or V. These lesions are treated with curettage or segmen-

Algorithm 31.2

Management of Vascular malformations



tal resection of bone followed by reconstruction (Fig. 31.13). There are reports of extra-corporeal curettage of segmentally resected lesions and re-fixation to maintain bone continuity.

Type-V (Fig. 31.11) lesions commonly require access to osteotomies like mandibulotomy, segmental or complete Lefort-I, rhinotomy or zygomatic swing osteotomies to gain adequate access. The lesions are unencapsulated and rarely excised completely but improve the quality of life and reduce risk of mortality due to airway obstruction and haemorrhage. In the authors' experience, use of corseting has proven to be beneficial in these cases.

Excess skin flap is always excised to give a near normal appearance. Use of an adequate number of drains and meticulous haemostatic closure is imperative to achieve acceptable and aesthetic results.

Most large lesions require further excision and debulking procedures as the age advances until growth is achieved. Large low-flow lesions have potential to be excised completely secondarily, following prior corset suturing.

Algorithm 31.2 summarises the management of vascular malformations.

31.8 Complications

Vascular lesions can have complications ranging from none (like in haemangiomas) to bleeding, ulcerations and infection. Superficial lesions and ulcerations benefit with the use of pulsed-dye laser. Bleeding can usually be managed with compression dressings.

Large venous and lymphatic malformations can cause local swelling, pressure effects on trachea and oesophagus, pain and infection, demanding immediate treatment like embolisation or surgical debulking along with control of airway and infection.

The two common complications of LMs are bleeding within the lesion and infection. Bleeding can be seen spontaneously or as a result of trauma. This further causes immediate and painful enlargement of the lesion with associated ecchymosis. Analgesia and observation usually suffice for symptomatic management. Prophylactic antibiotics can be given in the case of profuse bleeding. Long-term intravenous broad spectrum antibiotics may be necessary covering pathogens of head and neck, especially in high-risk patients. Haemorrhage and infection can sometimes transform a macro-cystic lesion into a micro-cystic type with associated scarring. LMs are known to increase in size in the presence of a viral or bacterial infection. This is usually self-limiting and thought to be due to changes in the lymphatic flow. Bacterial superinfections can be fatal causing ascending cellulitis and septicaemia. Any infection in cervicofacial LMs can cause obstruction of the upper airway and oesophagus causing dyspnea and dysphagia.

Incompletely treated AVMs tend to recur and continue to grow. They should not be underestimated.

31.9 Recent Advances

Micro-cystic lymphatic malformations have always been challenging cases to be treated, especially involving extra- and intracranial areas of head and neck. Currently available treatments have limited effectiveness and high risk of complications. Techniques using lymphography and indocyanine green have been used to locate the exact location of afferent and efferent lymphatic flow and performing a lymphatic-venous anastomosis has been described in treating these lesions [27].

Vascular-disrupting agents (VDA's) [28] are a group of 'vascular targeting' agents that show selective activity against tumour vascular networks, causing severe obstruc-

tion in their blood flow and subsequent necrosis. These have been investigated for a long time but haven't yet actively been used in the treatment of vascular lesions of the head and neck. Micro-tubule-depolymerising agents are the largest group of small molecular weight VDAs, which include lead compound disodium combretastatin A-4 3-O-phosphate (CA-4-P) [28], and are under clinical development for cancer. VDAs can also interfere with angiogenesis and can be potentially used as novel drugs for the treatment of conditions with excessive angiogenesis, in addition to cancer.

3D remodelling and bioprinting of areas affected by vascular anomalies with their feeder vessels are under study, for training and familiarising one with possible complications during procedures like embolisation and surgery.

31.10 Conclusion

Vascular anomalies are a diverse group of lesions requiring knowledge and skill to identify, accurately diagnose and treat adequately. Most of these lesions present as a complex problem with a combination of different types and other systemic complicating features. This demands a multi-disciplinary team comprising maxillofacial surgeon, vascular surgeon, pediatrician, reconstructive surgeon, anaesthetist and speech and language therapist with extensive training, understanding and experience to tailor an appropriate treatment plan. Selection of sclerosants should be with caution to minimise their side effects. Surgery has an important role in achieving quicker and long-term stable results in most cases.

References

- Nair SC, Spencer NJ, Nayak KP, Balasubramaniam K. Surgical management of vascular lesions of the head and neck: a review of 115 cases. *Int J Oral Maxillofac Surg.* 2011;40:577–83.
- Mulliken JB, Young AE. *Vascular birthmarks. Hemangiomas and malformations.* Philadelphia: Saunders; 1988.
- Brouillard P, Vikkula M. Vascular malformations: localized defects in vascular morphogenesis. *Clin Genet.* 2003;63:340.
- Lohela M, Bry M, Tammela T, et al. VEGFs and receptors involved in angiogenesis versus lymphangiogenesis. *Curr Opin Cell Biol.* 2009;21:154.
- Boon LM, Ballieux F, Vikkula M. Pathogenesis of vascular anomalies. *Clin Plast Surg.* 2011;38:7–19.
- Richter GT, Friedman AB. Hemangiomas and vascular malformations: current theory and management. *Int J Pediatr.* 2012;2012:645678.
- Marler JJ, John B. Mulliken current management of hemangiomas and vascular malformations. *Clinic Plast Surg.* 2005;32:99–116.
- Takahashi K, Mulliken JB, Kozakewich HP, Rogers RA, Folkman J, Ezekowitz RA. Cellular markers that distinguish the phases of hemangioma during infancy and childhood. *J Clin Invest.* 1994;93:2357–64.
- Eerola LMB, Watanabe S, Grynberg H, Mulliken JB, Vikkula M. Locus for susceptibility for familial capillary malformation (“port-wine stain”) maps to 5q. *Eur J Hum Genet.* 2002;10(6):375–80.
- Pavlov KA, Dubova EA, Shchyogolev AI, Mishnyov OD. Expression of growth factors in endotheliocytes in vascular malformations. *Bull Exp Biol Med.* 2009;147(3):366–70.
- Corti P, Young S, Chen CY, et al. Interaction between alk1 and blood flow in the development of arteriovenous malformations. *Development.* 2011;138(8):1573–82.
- Kim H, Su H, Weinsheimer S, Pawlikowska L, Young WL. Brain arteriovenous malformation pathogenesis: a response-to-injury paradigm. *Acta Neurochir Suppl.* 2011;111:83–92.
- Mulliken J, Glowacki J. Hemangiomas and vascular malformations in infants and children: a classification based on endothelial characteristics. *Plast Reconstr Surg.* 1982;69(3):412–20.
- Ethunandan M, Mellor TK. Hemangiomas and vascular malformations of the maxillofacial region—review. *Br J Oral Maxillofac Surg.* 2006;44:263–72.
- ISSVA Classification of Vascular Anomalies ©2018 International Society for the Study of Vascular Anomalies Available at “issva.org/classification”.
- Johnson AB, Richter GT. Vascular anomalies. *Clin Perinatol.* 2018;45(4):737–49.
- Kilcline C, Frieden IJ. Infantile hemangiomas: how common are they? A systematic review of the medical literature. *Pediatr Dermatol.* 2008;25(2):168–73.
- Mohan RPS, Dhillon M, Gill N. Intraoral venous malformation with phleboliths. *Saudi Dent J.* 2011;23:161–163.
- de Serres LM, Sie KC, Richardson MA. Lymphatic malformations of the head and neck. A proposal for staging. *Arch Otolaryngol Head Neck Surg.* 1995;121(5):577–82.
- Kohout MP, Hansen M, Pribaz JJ, Mulliken JB. Arteriovenous malformations of the head and neck: natural history and management. *Plast Reconstr Surg.* 1998;102(3):643–54.
- Croteau SE, Liang MG, Kozakewich HP, et al. Kaposiform hemangioendothelioma: atypical features and risks of Kasabach-Merritt phenomenon in 107 referrals. *J Pediatr.* 2013;162(1):142–7.
- Steinklein JM, Shatzkes DR. Imaging of vascular lesions of head and neck. *Otolaryngol Clin N Am.* 2018;51:55–76.
- Baek HJ, Hong JP, Choi JW, Suh DC. Direct percutaneous alcohol sclerotherapy for venous malformations of head and neck region without fluoroscopic guidance: technical consideration and outcome. *Neurointervention.* 2011;6:84–8.
- Hoff SR, Rastatter JC, Richter GT. Head and neck vascular lesions. *Otolaryngol Clin N Am.* 2015;48:29–45.
- Horbach SER, Lokhorst MM, Saeed P, de Gouyon Matignon de Pontouraude CMF, Rothová A, van der Horst CMAM. Sclerotherapy for low-flow vascular malformations of the head and neck: A systematic review of sclerosing agents. *J Plast Reconstr Aesthet Surg.* 2016;69:295–304.
- Nair SC, Chawla JP, Shroff SS, Kumar B, Shah A. Corseting: a new technique for the management of diffuse venous malforma-

- tions in the head and neck region. *Int J Oral Maxillofac Surg.* 2018;47(12):1534–40.
27. Kato M, Watanabe S, Iida T, Watanabe A, Megumi F. Peri-orbital lymphangioma treated by lymphatic-venous anastomosis with indocyanine green lymphography analysis. *J Pediatr Surg Case Rep.* 2017;23:9e14.
28. Kanthou C, Tozer GM. Microtubule depolymerizing vascular disrupting agents: novel therapeutic agents for oncology and other pathologies. *Int J Exp Pathol.* 2009;90:284–94.

Open Access This chapter is licensed under the terms of the Creative Commons Attribution 4.0 International License (<http://creativecommons.org/licenses/by/4.0/>), which permits use, sharing, adaptation, distribution and reproduction in any medium or format, as long as you give appropriate credit to the original author(s) and the source, provide a link to the Creative Commons license and indicate if changes were made.

The images or other third party material in this chapter are included in the chapter's Creative Commons license, unless indicated otherwise in a credit line to the material. If material is not included in the chapter's Creative Commons license and your intended use is not permitted by statutory regulation or exceeds the permitted use, you will need to obtain permission directly from the copyright holder.



Part XII

**Aesthetic Procedures in Oral
and Maxillofacial Region**



Non-surgical Modalities of Facial Rejuvenation and Aesthetics

32

Arun Kumar Panda and Aarti Chowdhary

32.1 Introduction to Ageing Face

32.1.1 Facial Changes Due to Ageing

The Face is a mirror of what we are from inside. It is like an opera that reveals a person's inner self, nature, personality and health. The signs and symptoms of age, illness, deficiencies and personality traits show on our faces. A lot can be postulated by just observing the different facial expressions of a person. A minuscule defect on the face engraves an exaggerated long-lasting impression on a person's mind and soul.

Ageing is a process which cannot be defied. With the passage of time, every individual goes through a phenomenon of complex transformations which takes away the youthfulness. The various signs of ageing seen on the face include recession of hairline, wrinkles on the forehead, drooping of the upper eyelid, hollowness in the under-eye area, deepening of nasolabial fold, folds on the face, sagginess of skin at the border of mandible, etc. (Fig. 32.1). Today, with the changing cultures and requirements in the profession, every individual wants to look better than what he or she is.

As the saying goes "Beauty has no age", more and more elderly people also want to have their face rejuvenated. So, today we have a range of patients of vast age variations who want to have a more rejuvenated look. The various modalities for rejuvenating the ageing face require fine skill and artwork combined with scientific knowledge and understanding of the whole face including scalp, forehead, perior-

bital area, perioral area, neck, etc., so as to achieve a more youthful appearance.

Time and technology has evolved. For many years the standard had been chemical peels as the non-invasive procedure to facelift as the invasive modality for face rejuvenation. Today, we have a vast range of procedures and technologies to counter ageing phenomenon and provide a rejuvenated appearance. We shall discuss the various non-surgical modalities in this section which physicians are adopting to treat patients with a wide range of Facial Aesthetic concerns.

The ageing of human face is a highly complex, irreversible and progressive biologic phenomenon that occurs with the ticking of time. The main factors leading to facial ageing include gravity, bone remodelling, subcutaneous fat redistribution and loss, hormonal imbalance, chronic sunlight, pollution and smoking. Other environmental factors that allegedly affect facial appearance include mental stress, nutritional deficiencies, work habits, drug abuse and disease. This dynamic process is a synergistic effect of various factors and actually takes place at 4 distinct levels (the 4 S levels): Skin, Subcutaneous tissue, SMAS and facial Skeleton.

32.1.2 Ageing of Skin

The epidermis contains keratinocytes and dead corneocytes. The basal cells at the stratum basal divide to form keratinocytes, produce keratins and drift upwards as they mature. By the time keratinocytes reach the most superficial layer, they lose their nucleus and cytoplasmic organelles and are known as corneocytes. In a total period of 40–50 days, the keratinocytes come to the surface and corneocytes exfoliate. This time taken for the process of keratinisation, that is maturation of keratinocytes along with shedding of corneocytes, is known as the turnover time.

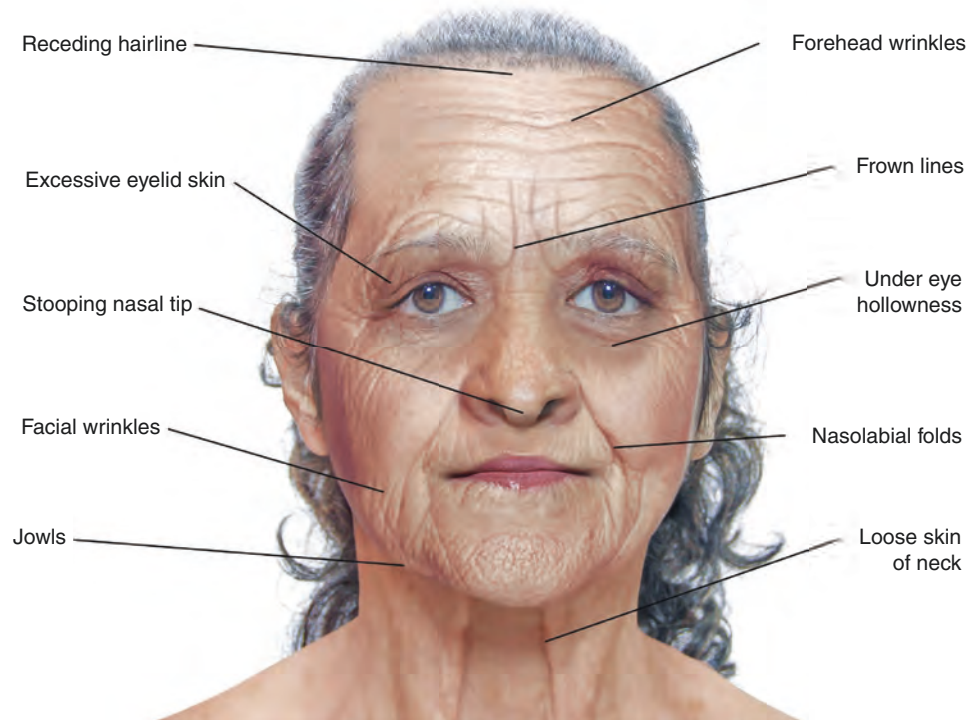
The natural process of desquamation sheds off the dry, old, hardened skin cells and gives way to the new cells to

Electronic Supplementary Material The online version of this chapter (https://doi.org/10.1007/978-981-15-1346-6_32) contains supplementary material, which is available to authorized users.

A. K. Panda (✉)
Department of Oral & Maxillofacial Surgery,
SD Dental College and Hospital, Parbhani, Maharashtra, India

A. Chowdhary
Department of Periodontology, SD Dental College and Hospital,
Parbhani, Maharashtra, India

Fig. 32.1 Various signs of an ageing face include but not limited to forehead wrinkles, droopy eyelids, under-eye hollowness, deep nasolabial folds, jowl formation, loose neck skin and thin lips



©Association of Oral and Maxillofacial Surgeons of India

come to the surface. This process also eliminates damaged and contaminated cells that carry pollutants and microorganisms from the environment.

The specialised fibroblasts in the dermal layer produce two key proteins—collagen and elastin. Collagen constitutes 80% of the dermis and provides strength and firmness to the skin. While elastin, as the name implies, provides elasticity to the skin and enables the skin to bounce back to its original shape after it is stretched, thus preventing wrinkles.

Skin ageing is a dynamic mechanism that transpires due to two basic factors:

- Intrinsic or Innate factors are insidious deteriorating elements that are influenced by internal metabolic processes, genetic programming, cellular metabolism and hormones;
- Extrinsic or Exogenous factors include Ultraviolet rays in the sunlight, cigarette smoking, environmental pollution, etc.

Intrinsic ageing is an inevitable natural ageing process which commences as early as mid-20s. It consists of internal physiological factors that cause inherent degenerative process in the body. Dead corneocytes do not desquamate as swiftly as expected and the turnover of new epidermal cells decreases somewhat. In the dermis, the production of collagen and elastin slows down. The cumulative effect which is seen in case of the inherent ageing includes fine wrinkling,

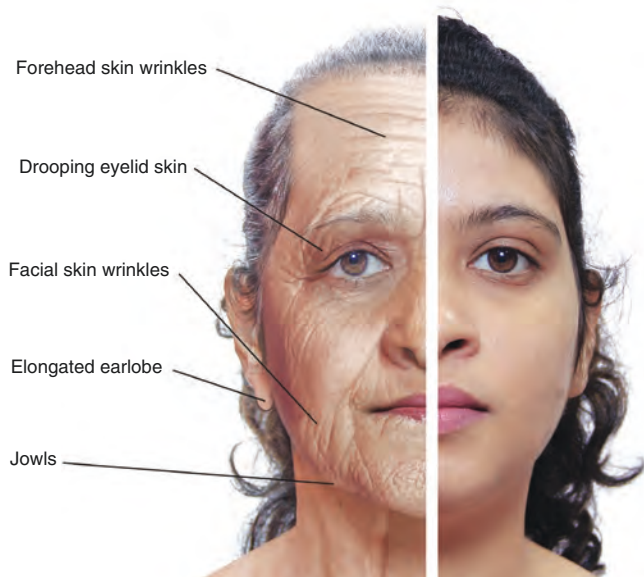parched, thin and transparent skin and depleted elastic nature of the skin.

Extrinsic ageing is because of the aggregated damage caused by environmental factors such as sun's UV radiation, gravity, sleeping posture, pollution, smoking, exposure to chemicals, etc. These exogenous factors along with the innate factors cause premature ageing of our facial skin. The face, which is most commonly exposed part of the human body to the UV radiations of the sun, undergoes ageing prematurely than any other part. Photoageing with recurrent sun exposure causes the skin to lose its capability to renovate and thereby accumulating damage. Recurrent and continual UV exposure disintegrates collagen and impedes the synthesis of new collagen. Alongside, there is a breakdown of elastin. This causes the facial skin to become slack, wrinkled and leathery much earlier than a sun-protected skin.

Gravity constantly works on different parts of our facial skin. As the skin elasticity reduces with age, the effects become evident. It precipitates jowls, nasolabial fold, drooping of eyelids, elongation of ears, etc. (Fig. 32.2).

Sleep lines are wrinkles that are etched on the facial skin of the people who sleep with the face pressed on the cushion or sleep on the sides.

Cigarette smoking over a period of time causes many biochemical alterations in our body. It has deleterious effects on skin and expedites the ageing process. The nicotine causes vasoconstriction thereby impairing the supply of oxygen and



©Association of Oral and Maxillofacial Surgeons of India

Fig. 32.2 Influence of ageing on skin. Facial wrinkling, jowls and droopy eyelids clearly demonstrate the ageing process

important nutrients, such as vitamin A to the skin. Many of the over 7000 chemicals released from the burning cigarettes cause increased production of matrix metalloproteinases (MMP) that causes degradation of collagen and causes abnormal creation of elastosis materials. These cause premature facial skin wrinkling.

32.1.3 Ageing of Subcutaneous Tissue

The subcutaneous fat gives the volume and shape to the face. As explained by Rohrich and Pessa [1], the subcutaneous fat is distributed throughout the face in a multidimensional fashion and is highly compartmentalised. A youthful face is characterised by a smooth transition between these subcutaneous compartments. The superficial musculoaponeurotic system (SMAS) divides this fat into superficial and deep layers. As explained anatomically by Rohrich and Pessa [1], the external recess is in between the skin and SMAS while the internal recess lies under the SMAS and is adherent to the periosteum. The superficial and deep fat recesses are as explained in Fig. 32.3.

Furnas in 1989 first described the osteocutaneous ligaments within the cheek that anchor the dermis to the underlying fibro-osseous structures [2]. He outlined the zygomatic ligaments (McGregor's patch), the mandibular ligament, the platysma auricular ligament and the anterior platysma-cutaneous ligament that anchor the dermis and also support the midface soft tissue. Two theories explain the character-

istic soft tissue changes that are distinguished during the mid-face ageing. The gravitational theory advocates that with the attenuation of the osteocutaneous ligaments, there is vertical descent of facial soft tissue which contributes to the deep creases of the ageing face [3]. The diminished strength of the ligaments is because the age-related elastosis and also because of the repeated animation of the muscles of facial expression.

Donofrio explained the volumetric theory in 2000. He suggested that it's the corresponding volume loss or gain in the adjoining areas of the face is what creates the deep creases of age [4]. This theory was later in 2007 reinforced by Lambros who stated that the ageing process was due to the relative deflation of certain fat pads, especially the deep fat pads [5].

32.1.4 Ageing of SMAS

The superficial musculoaponeurotic system is a multidimensional scaffold of organised fibrous tissue that connects the facial muscles with the dermis [6]. This fibromuscular layer also segregates the superficial and deep facial fat pads. Anatomically, the SMAS lies in the midface, inferior to the zygomatic arch and superior to the muscular belly of the platysma. It blends with the superficial temporal fascia and frontalis muscle superiorly, and with the platysma muscle inferiorly. Since it connects the facial muscles to the dermis, its purpose is to transmit, distribute and amplify the activity of all facial muscles [7].

As we age, and with the continuous use of the muscles of facial expression, the SMAS weakens and the strength diminishes. So, the ability to hold up the muscles, fat and the skin gets impaired. Combined with the effect of gravitational forces, the weakening causes the structures of the face to slump. The youthful appearance of the face changes as jowls are formed, the nasolabial fold deepens and the mandibular line angle becomes ill defined.

32.1.5 Ageing of Facial Skeleton

The bony skeleton serves as a framework for the soft tissues of the face including the skin, muscles and subcutaneous fat. The facial skeleton keeps changing anatomically throughout life with only degenerative and catabolic changes occurring after adolescence.

With ageing, the facial skeleton keeps resorbing in a very predictable manner and that contributes to the appearance of an aged face. Areas with strong tendency to resorb include the periorbital area, the midface, the perinasal area and the mandible (Fig. 32.4).

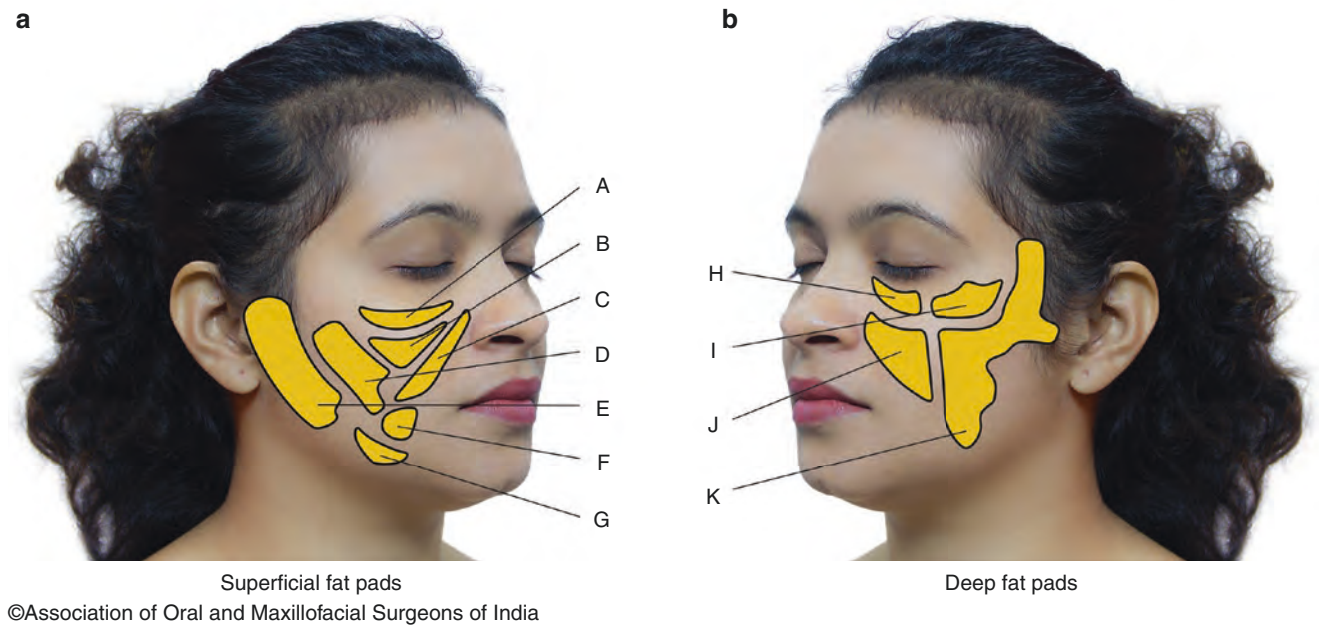
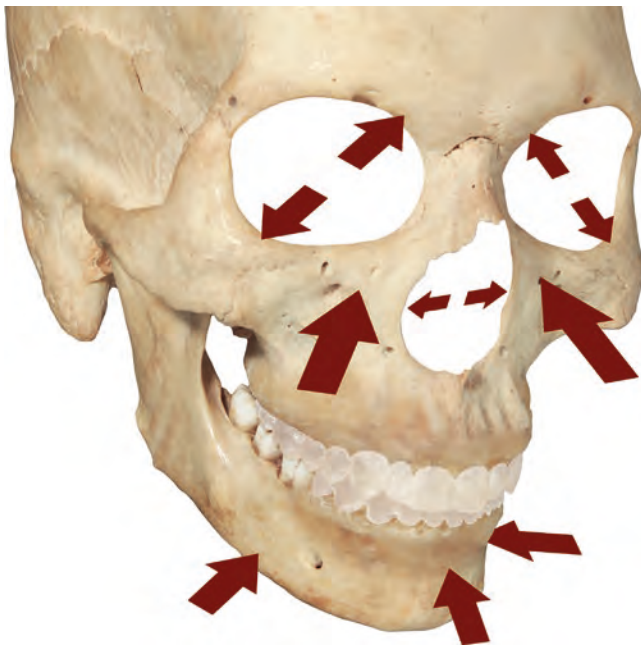


Fig. 32.3 (a, b) (A) Infraorbital fat, (B) Medial cheek fat, (C) Nasolabial fat, (D) Medial cheek fat, (E) Lateral cheek fat, (F) Superior jowl fat, (G) Inferior jowl fat, (H) Medial sub-orbicularis fat, (I) Lateral sub-orbicularis fat, (J) Deep medial cheek fat, (K) Buccal fat



©Association of Oral and Maxillofacial Surgeons of India

Fig. 32.4 Various areas of facial skeleton as marked are predominantly destined to resorb contributing to the appearance of aged face

The orbital aperture enlarges with age in all dimensions. The superomedial and inferolateral aspects tend to recede more which imparts the stigmata of periorbital ageing such as increased prominence of the medial fat pad, elevation of the medial brow and lengthening of the lid cheek junction [8].

The midface skeleton is formed by the maxilla medially and the zygoma laterally. With age, the maxilla recedes and the maxillary angle decreases by about 10° between the age of 30 and 60 years [9]. The piriform aperture enlarges with age, as the edges of the nasal bones recede [10]. The anterior nasal spine also retreats which reduces the skeletal support and thereby contributing to retraction of the columella, with a downward rotation of nasal tip and apparent lengthening of the nose [11]. In regards to the mandible, it is well established that the mandibular angle increases, the ramus height and mandibular body height and length decreases with age [12]. The above-mentioned skeletal resorption patterns contribute significantly to the appearance of an ageing face.

In the recent years, the demand for facial rejuvenation has increased exponentially. Individuals from every socioeconomic strata and from all age groups today desire a younger and rejuvenated look. Evolution of numerous surgical and non-surgical procedures has led to an increase in patient demands and expectations. Every aesthetic physician should understand the facial anatomy and the facial ageing process well so as to perform the procedures that would best suit the requirement of the individual to deliver the best of the results. The various non-surgical modalities of facial rejuvenation include the use of Botulinum toxin, dermal fillers, thread lifts, platelet concentrates and radiofrequency waves. Botulinum toxin and fillers are elaborated in the subsequent chapter. The following is a detailed description of the role of thread lifts, platelet concentrates and radiofrequency waves in achieving facial rejuvenation.

32.2 Non-surgical Facelift with Threads

Age-related changes on the face include remodelling in the facial skeleton and reorganisation of musculature, connective tissues, fat and skin. The dynamic process of ageing is unstoppable and it induces an ever-progressing slackness in the soft tissues that leads to a ptotic brow, jowl formation, ill-defined mandibular margin and deep nasolabial folds.

Gravity is an important factor that causes drooping of the upper, mid- and lower-facial soft tissue, which adds to the effect of an aged appearance. The hollowness of the midfacial and infra-orbital area is because of the downward shift of the malar fat pad. To manage this ptotic situation, surgical facelift procedures have been the most effective treatment as they not only excise the redundant tissues but also haul the soft tissue in the opposite vector of ageing process. The other non-invasive procedures cannot be as effective as the facelift procedure. But because of the significant downtime, cost and risks involved, facelift is not accepted by patients very readily. To have a way in between the surgical and non-invasive modalities, thread lift has become a popular procedure to manage drooping tissue of the face because of ageing.


32.2.1 Introduction to Thread Lift

Thread lifting modality is a minimally invasive cosmetic procedure that utilises a biocompatible implant placed into the deeper layers of face to predictably shift and realign tissues in a predetermined direction or vector. When compared to a surgical facelift procedure, this elevates the drooping tissues with least amount of risks and complications, immediate results and rapid recovery.

Historically, Ruff in Durham, North Carolina, in 1992 and Sulamanidze et al. in Moscow, Russia, in 1996 independently developed barbed sutures for correcting facial ptosis. FDA in 2004 approved Ruff's clear, barbed, unidirectional, polypropylene sutures for treating ptotic skin of face and neck [13].

32.2.2 Classification

- (A) Depending on the modality of their action (Fig. 32.5):
- Redefinition of the facial contours—Barbed threads
 - Induction of collagen production—Mono PDO threads



©Association of Oral and Maxillofacial Surgeons of India

Fig. 32.5 Various types of polydioxanone threads are mono threads for facial rejuvenation and cogs threads for redefining facial contours

- (B) Depending on pattern of resorption of implant material:
- Permanent/Non-resorbable threads—Polypropylene threads like Aptos threads, Silhouette lift threads, etc.
 - Resorbable threads—Polydioxanone threads like Alfa aqualift, and Poly-L Lactic acid threads like silhouette soft threads, etc.
- (C) Depending on mode of Fixation:
- Anchored: Wherein the thread is anchored to a proximal fixed place like the deep temporal fascia or mastoid fascia.
 - Free floating: They are not fixed and cause the pull because of the thread design.
- (D) Depending on the surface texture of the thread:
- Barbed
 - Non-barbed

The Barbed threads are of 3 types:

- Unidirectional barbed threads—these are anchored on to a fixed point like the deep temporal fascia, e.g. Contour thread
- Bidirectional barbed threads—these are placed in the treatment area by a canula and stretch the skin because of the design, e.g. Aptos threads.
- Cogged threads—these can be unidirectional, bidirectional or multidirectional and they lift the skin towards the point of entry once tissues get entangled with the cogs.

The Non-barbed threads can be:

- Plain
- Spiral or spring

32.2.3 Mechanism of Action

From a clinical point of view, the barbed sutures simply work by grasping and mechanically pulling the ptotic skin. These barbs get entangled in the subcutaneous tissues and as the thread is pulled backwards, the tissues get squeezed along the barbs and stay there as the thread outside is cut off.

From a histologic aspect, a basic mechanism of mechanical transduction happens when the polydioxanone threads are placed in the tissues. A torrent of intracellular signals in the surrounding cells through which the polydioxanone threads pass is triggered by the mechanical stresses instigated by the threads thus influencing the metabolic responses and encouraging cellular growth and survival and modulating tissue morphology and architecture [14].

There are 2 major types of collagen proteins that are found in our skin. The type 1 collagen or the fibrous collagen makes up about 70% of the total collagen while the type 2 collagen or the reticular collagen makes up to about 5–20%. Both of them provide structural support to the skin. Today, most of the aesthetic procedures are aimed at a phenomenon of biostimulation. The main intention is to improve on the plasticity, resilience, flexibility, firmness and turgor of the skin tissues that are normally lost with ageing due to the loss of proteins like collagen and elastin. This is achieved by penetrating the dermis with substances that would encourage the production of these proteins [15]. The biostimulation caused with PDO threads is due to neocollagenesis, i.e. the production of type 1 collagen which is essentially fibrotic in nature. The PDOs resorb in 6 months and till that time it keeps inducing collagen. The fibrotic collagen exhibits a retracted effect improving the skin appearance. Concurrently, the

compaction and stiffening of the collagen fibres also determine the functional damage [16].

32.2.4 Indications

There are 2 major indications for the threads treatment:

- Skin rejuvenation
- Elevating the sagging skin

Skin rejuvenation can be done with the use of plain polydioxanone threads. It also increases the volume in certain areas where there is minimal volume loss.

The barbed threads are indicated in areas where there is ptosis of the tissues. The barbs work as cogs and by engaging the tissues along its path, it mechanically pulls the tissues upwards thereby reducing the ptosis.

The plain polydioxanone threads can be used for facial rejuvenation and are mostly utilised for the following indications (Fig. 32.6):

- Fine lines and wrinkles in any part of the face like the periorbital area, malar areas, perioral areas, chin, etc.
- Skin tightening—Under the neck, cheek lifting, lines around and under the mouth.
- Crepey skin
- Acne scar filling
- Outlining of Lips to create a fuller look naturally (Fig. 32.7)

The barbed threads can be used to lift the ptotic skin and hence be utilised in the following areas (Fig. 32.8):

- Nasolabial folds
- Eyebrow lift
- Upper and lower cheeks
- Neck & Jawline
- Marionette lines

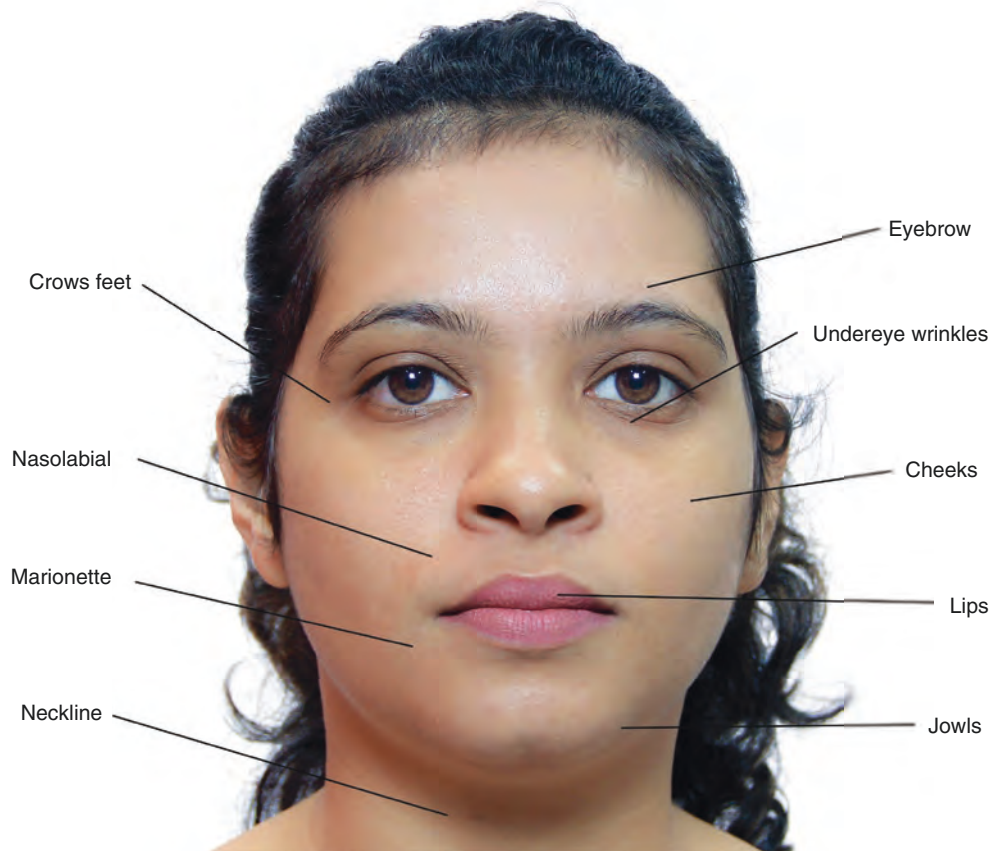
32.2.5 Treatment Protocol [4]

Choosing the ideal procedure for rejuvenation depends on the grade of skin ageing.

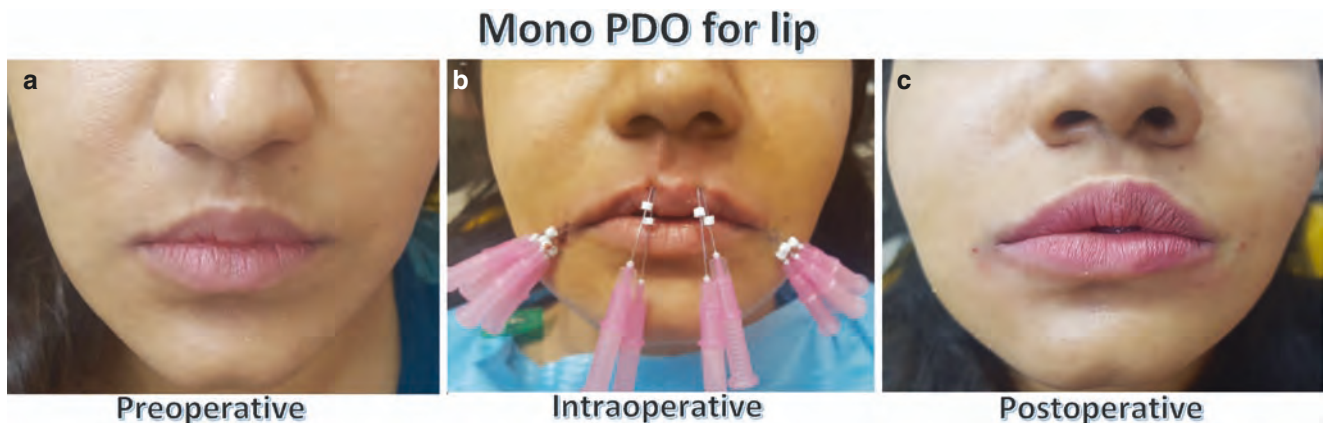(A) Mild skin ageing

- Rejuvenation—Apply Plain or screwed PDO threads (Fig. 32.9)
- Lifting
 - for a “natural look” lifting—apply PDO cogs along with plain PDO threads.

Fig. 32.6 Various indications of mono polydioxanone threads for facial rejuvenation



©Association of Oral and Maxillofacial Surgeons of India



©Association of Oral and Maxillofacial Surgeons of India

Fig. 32.7 (a, b, c) Mono polydioxanone threads can be used to create the lip borders and also to create a fuller looking lip

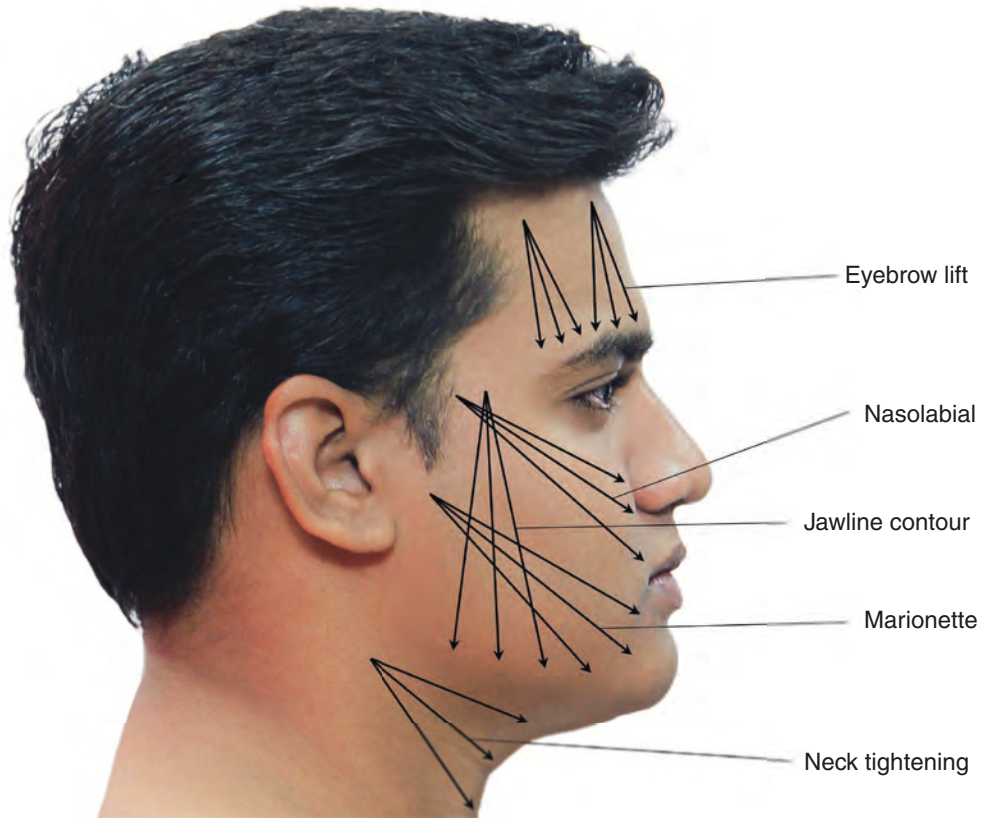
- for heavy lifting—apply anchored sutures or long suture technique.
- (B) Moderate to severe skin ageing
 - Rejuvenation—Apply short PDO cogs along with plain PDO threads (Fig. 32.10).
 - Lifting—Not recommended.

32.2.6 Procedure

The Polydioxanone thread used in facial rejuvenation are basically of 2 types: Mono PDO thread and Cogs PDO thread

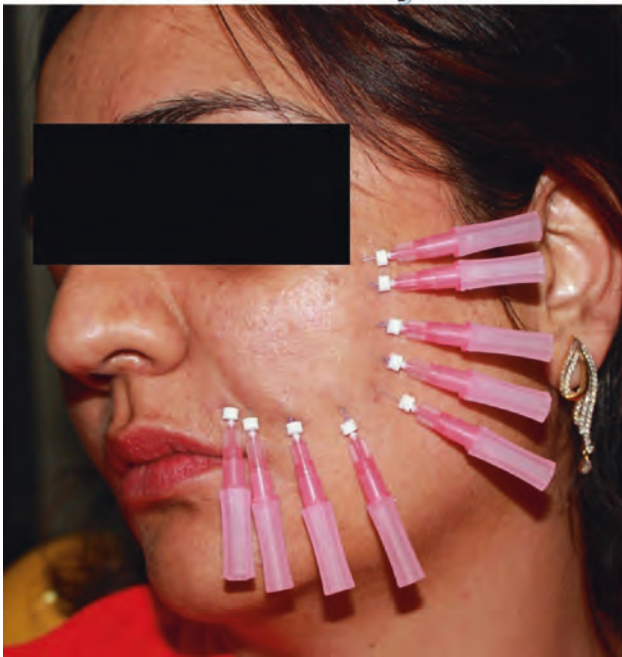(A) The Mono PDO thread—These are 5-0 or 6-0 suture materials which are essentially monofilament and

Fig. 32.8 Various indications of barbed PDO threads for redefining facial contours and lift the ptotic tissues



©Association of Oral and Maxillofacial Surgeons of India

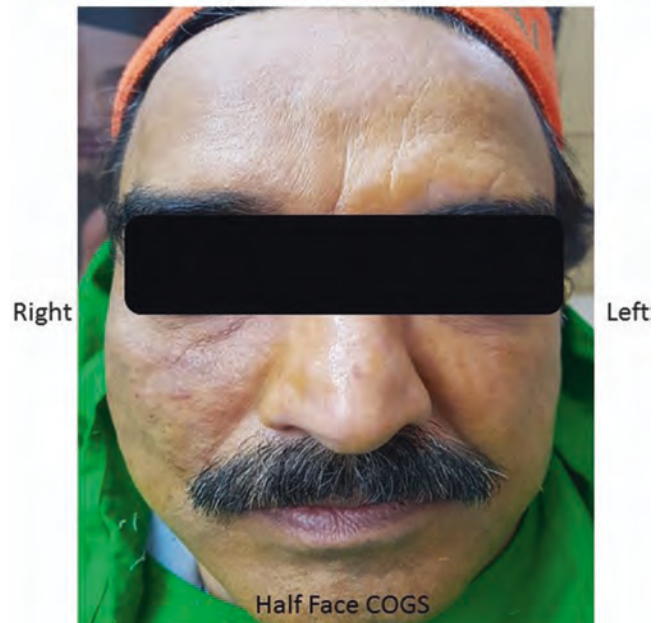Mono PDO for rejuvenation



©Association of Oral and Maxillofacial Surgeons of India

Fig. 32.9 Mono PDO threads for facial rejuvenation

COGs



©Association of Oral and Maxillofacial Surgeons of India

Fig. 32.10 Cogs thread for lifting nasolabial folds. Note the lifted up right nasolabial fold only as the thread has been applied only on that side. Left side is still untreated

non-barbed. It can also be braided to a spring to provide more tensile strength [17]. The thin suture material forms a V-shape when inserted to a needle of 26–30 g, with one half of the thread inside the calibre of the needle and the other half on the outside. Once the needle with the suture material is inserted into the dermal layer, the thread gets buried into the tissues and at the removal of the needle, the thread stays back intact.

These types of threads are placed in the dermal layer where they cause collagen formation.

EMLA cream must be applied 45 min prior to the procedure. The full face was cleansed with povidone iodine solution. Once ready, the mono PDO threads are placed in the dermal layer making up meshes in the areas of indication. One must keep observing for any threads that stay outside the skin. It must be removed immediately by grasping it with a needle holder so that it doesn't cause any infection or granuloma.

(B) The Cogs PDO thread—Cog PDO thread has small barbs or spikes all along its length, which get engaged to the tissues when inserted and lifts it once pulled back.

Depending on the direction of the spikes, cog PDO thread is classified as unidirectional, bidirectional or multidirectional.

The cog thread is actually 3-0 suture which has barbs and this thread is mounted on an 18 g canula or needle. The canula is considered safer as it does not damage the blood vessels and nerves.

The barbed threads must be placed in the subcutaneous layer so as to prevent any palpability of the implant material.

Local anaesthesia should be given with 2% lidocaine with epinephrine. The full face is cleansed with povidone iodine solution. The path of insertion of the canula is marked on the skin with a sterile marking pen. The vectors are checked by manually stretching the skin upwards. Point of insertion is marked on a line 1.5 cm in the preauricular area. A small opening is made with an 18 g needle for the insertion of the canula. The barbed thread mounted on the canula is then passed along the vector in the subcutaneous plane all the way till the nasolabial fold or the marionette line. Once in place, the end part of the thread gets hooked in the subcutaneous plane, and the canula is pulled back and taken off the skin. The thread stays entangled in the subcutaneous plane. Once all threads are positioned in the skin, the distal part of the suture is held in one hand and the skin is pushed in the opposite direction to fully engage the threads and lift the tissues. The end part of the suture is then cut very close to the skin with help of sharp scissors so that the ends go into the tissues to prevent any future granuloma formation (Figs. 32.11a–d).

Post-operatively, ice packs are applied to minimise edema and bruising. Oral antibiotics are prescribed for 5 days after the procedure.

Anti-inflammatory tablets should be avoided as the more the inflammation at the site, the better would be the results. Patients generally do not require anti-inflammatory drugs post-surgery. Within the first 3 weeks after the procedure, the patients are advised against any strenuous movements of the muscles of midface such as yawning, wide smiling and laughing.

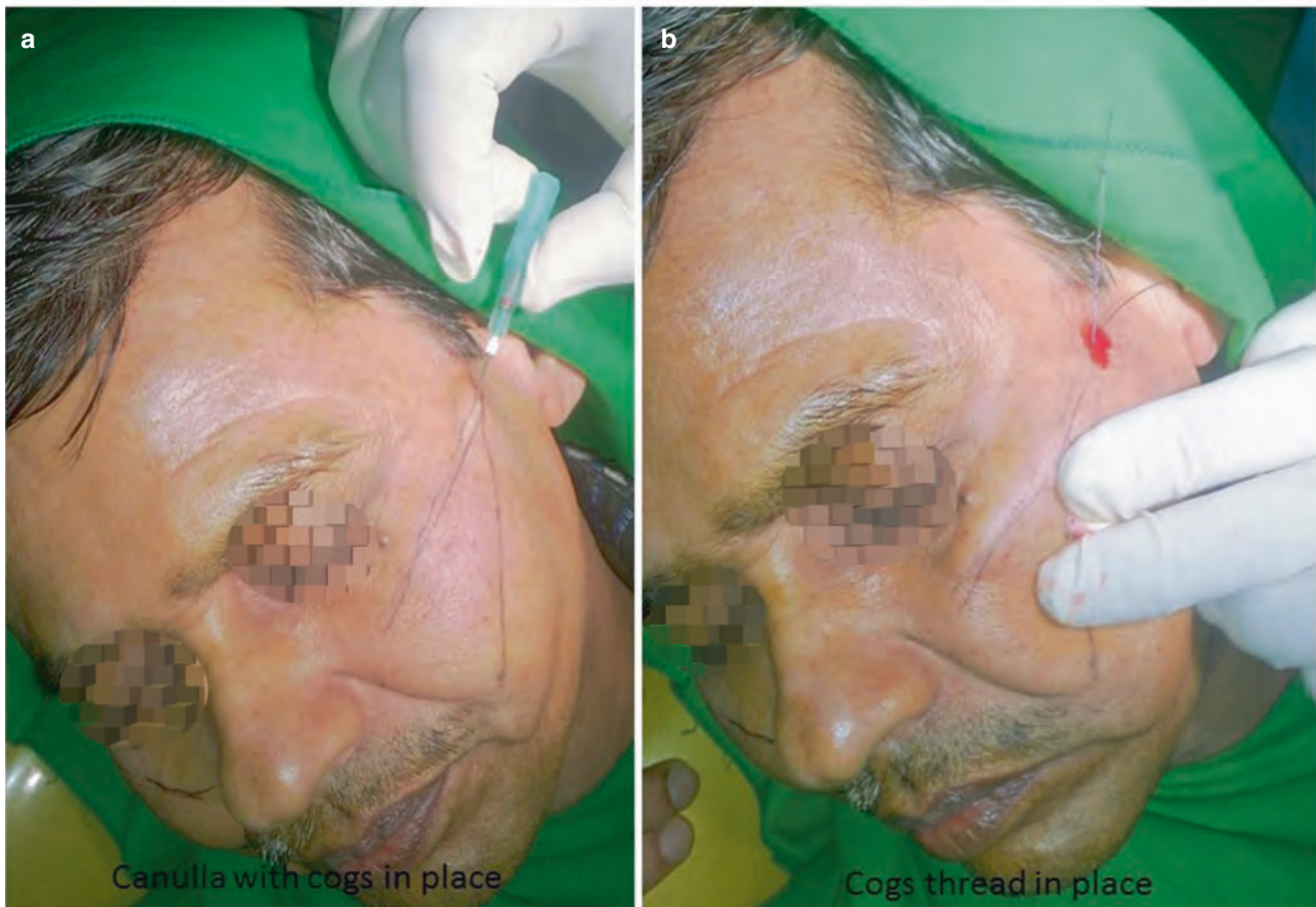32.2.7 Complications and Management

The various complications that could occur with the PDO barbed threads include:

1. Bruising—Bruising is quite common while placing the PDO threads. Post-procedure application of ice prevents further bruise.
2. Pain and Swelling—Thread lift surgery causes very mild to moderate post-operative pain and swelling. Patients are generally asked to apply ice externally to reduce inflammation and pain. If a patient complains of severe pain, anti-inflammatory may be advised. In case of serious swelling, the patient must be evaluated for hematoma and infections.
3. Infection—Proper aseptic protocol needs to be followed to prevent any type of skin infection. However, it is better to prescribe oral antibiotics for 5 days for the thread lift surgery.
4. Palpability of the thread—If the threads are placed too superficial, they become palpable from outside the skin. The barbs or cogs should always be placed in the subcutaneous layer.
5. Hematoma—Since the placement of threads is a blind procedure, the chances of damage to a blood vessel is always there. The patient should always be informed prior to the procedure regarding hematoma. Pressure application and cold compressions should be immediately given. After a period of time, the skin over the hematoma may turn bluish then brown and yellow as the blood is dissolved and absorbed. It may take 1–4 weeks for the hematoma to subside.
6. Nerve damage (Fig. 32.12)—There is always a chance of trauma to the branches of facial nerve since the placement of the threads is in close vicinity to the nerve, especially the marginal mandibular and frontal branches. Thus, the muscles of facial expression can be impaired. Fortunately, the nerve damage resolves soon and motor functions are restored.
7. Asymmetry: Pre-existing asymmetries on the face should be explained to the patient prior to treatment. It's

- always a good practice to let the patient seat vertically straight while inserting the barb threads and making the patient participate while retracting the tissues by visualising with a mirror to avoid any potential problems of asymmetry later on.
8. Dimpling: This normally would happen if the depth of the advancing thread is too superficial. A depression or an irregular contour would occur at a portion where the barb is located close to the skin. Most cases normally resolve spontaneously. But remarkable dimples need to be managed by manual reduction at that time itself.
 9. Rippling and puckering: The skin would ripple over the thread and cause visible folding if tightened too much while retracting the tissues. This typically resolves itself in a few days if the thread has been placed in the correct tissue plane.
 10. Granuloma: Higher incidences of granuloma formation are essentially seen if the threads placed in a more superficial plane and they are not cut very close to the skin.
 11. Thread loss: With mono PDO thread, if there is a protruding thread, the end should not be cut as with barbs and cogs, but grasped firmly and removed. It's safer to remove a monofilament thread than leaving it there, thus risking the formation of granuloma. Barbed and cogged threads are very difficult to retrieve and hence excessive care should be taken to place them in the right plane.
 12. Thread breakage: This can happen during the tightening of the barbs and cogs just before cutting at the skin level. Hence, careful manipulation should be done to avoid breakage during insertion and tightening.
 13. Thread exposure: Repeated inflammation and migration of the thread to superficial layers can cause thread exposure. It can be prevented by placing the threads in proper plane.

COG Threads



©Association of Oral and Maxillofacial Surgeons of India

Fig. 32.11 (a, b) Placement of cannula with cogs threads along the vectors for nasolabial folds and after removal of cannula the cogs threads in place. (c, d) Pulling the cogs threads to lift the ptotic nasolabial fold tissues and final twisting and snipping the threads just below the skin level

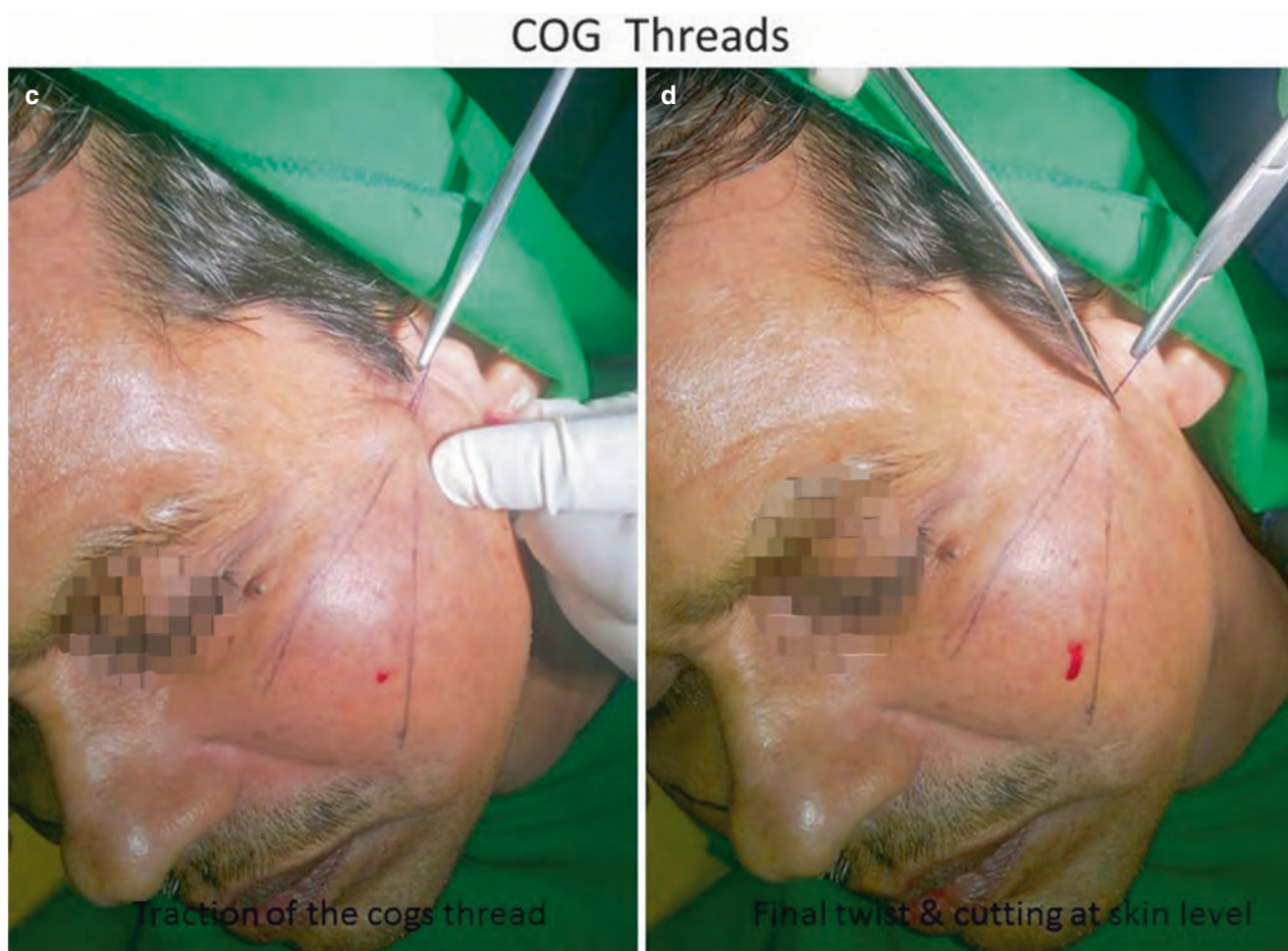

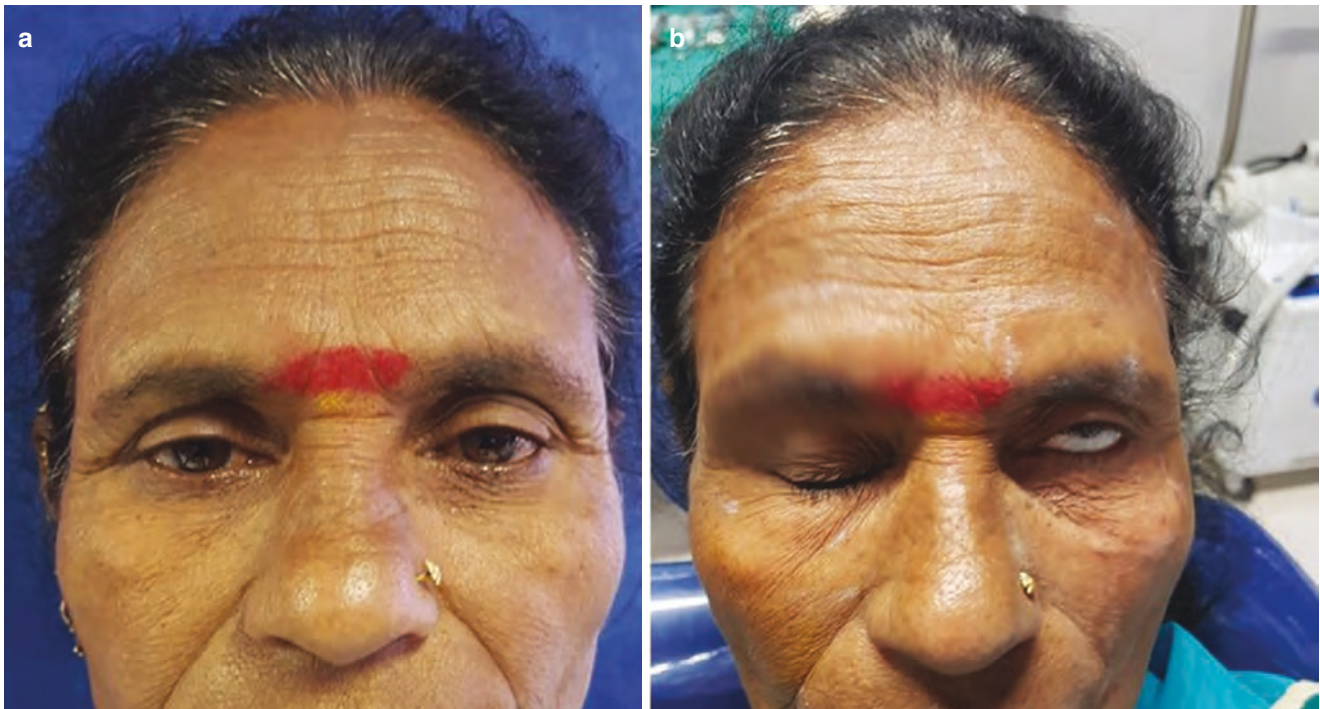Fig. 32.11 (continued)

32.2.8 Conclusion

The PDO thread lift is a non-invasive procedure that actually gives a “lifted effect” of the ptotic skin. It has been widely accepted as a standard procedure for patients who do not want to opt for a more aggressive surgical facelift. Patient selection is of prime importance. Only patients with mild to slightly moderate levels of ptosis should be selected for polydioxanone cogs thread lift. The patient should be given a realistic expectation of the lift of no more than 1 cm. Patients who are too chubby or who are too skinny should not be considered for thread lift. Overall, every aesthetic practitioner should have knowledge of thread lift as it is a simple and versatile anti-ageing procedure.

32.3 Biostimulatory Lift with Platelet-Rich Plasma

Today, Platelet-rich plasma (PRP) has been incorporated in many medical specialities including orthopaedics, general surgery, plastic surgery, dental surgery and dermatology because of its healing capabilities. Its usage in aesthetics and trichology has touched newer horizons as we have come to know about the healing cytokines present in the platelets which can be used for antiageing therapies and therapies for regenerative aesthetics.



©Association of Oral and Maxillofacial Surgeons of India

Fig. 32.12 (a, b) Damage to frontal branch of the facial nerve during placement of cogs threads

32.3.1 Platelets and Platelet Concentrates

Platelets, also called thrombocytes, are enucleated fragments of cytoplasm that are derived from the megakaryocytes of the bone marrow, which are released into the circulation. They have a fundamental role in haemostasis and wound healing.

The platelets contain various secretory granules, namely the alpha granules, dense granules and lysosomes. The alpha granules are the most abundant ones and contain the coagulation factors, growth factors, also called cytokines, adhesion molecules, and a variety of other angiogenic factors which efficiently encourage the proliferation and activation of cells required for wound healing including fibroblasts, mesenchymal stem cells (MSCs) and facilitates angiogenesis [18].

The growth factors along with their function are listed below [19]:

1. PDGF (platelet-derived growth factor)—PDGF plays a role in embryonic development, cell proliferation, cell migration and angiogenesis.
2. TGF- β 1 & β 2 (transforming growth factor)—TGF is involved in regulating and mediating processes at the cellular level, including cell proliferation, differentiation,

motility, adhesion and apoptosis as well as causes wound healing and angiogenesis.

3. VEGF (vascular endothelial growth factor)—Chemotactic and mitogenic for endothelial cells, mediates angiogenesis.
4. EGF (epidermal growth factor)—Mediates angiogenesis, causes proliferation of fibroblasts, endothelial cells and keratinocytes.
5. HGF (hepatocyte growth factor)—Mediates regeneration.
6. FGF (fibroblast growth factor)—Mediates tissue organisation and regeneration.
7. FGF-9—Aids generation of new follicles.

These growth factors or the “cytokines” are proteins, each of about 25,000 Daltons molecular weight. In response to the thrombocyte aggregation, as occurs in injury or surgery, the cell membrane activates the alpha granules which in turn unleash these growth factors via active extrusion through the cell membrane. The active secretion begins within 10 min during which 70% of stored growth factors are released and more than 95% of the presynthesised growth factors are secreted within 1 hour. Platelets then synthesise additional amount of growth factors for about 8 days till they die [20].

Platelet concentrate means plentiful amounts of platelets that are concentrated into a small volume of plasma. There are various types of platelet concentrates which can be formulated, all differing in the way they are made [21]. A general classification takes 2 key parameters into consideration: the presence of a cell content (mostly leukocytes) and the fibrin architecture.

There are 4 major families:

1. P-PRP

Pure Platelet-rich plasma is a preparation without Leukocytes. It has low-density fibrin network after activation. It is used as liquid solutions or an activated gel form and can be injected. P-PRP is commonly used in sports medicine & aesthetic medicine.

2. L-PRP

Leukocyte and PRP is a preparation with leukocytes in it. Even this has low-density fibrin network after activation. It is used as liquid solutions or an activated gel form and can be injected. L-PRP is used in aesthetic medicine, sports medicine, orthopaedics, trichology, etc.

3. P-PRF

Pure Platelet-rich fibrin is a preparation without leukocytes. It has a high-density fibrin network and exists as a strongly activated gel form. It cannot be injected, but can be handled like a real solid material. It has been very commonly used in dentistry & maxillofacial surgery today.

4. L-PRF

Leukocyte and PRF is a preparation with leukocytes. It has a high density of fibrin network and exists as a strongly activated gel form. It cannot be injected and can be handled as a real solid material. It is today used in implant dentistry, periodontal surgeries, oral surgeries, treatment of skin wound ulcers, etc.

32.3.2 Mechanism of Action of PRP

PRP can be described as a biologic product derived from autologous blood with the plasma fraction containing platelets at a concentration of more than 3–5 times above baseline.

The scientific evidence suggests that wound healing enhancement is seen using concentrates of 1,000,000 platelets/ μ l. Any concentration lower than this cannot be depended on to enhance wound healing, and concentrations far more than this has not been scientifically proved to help and enhance healing [22].

So, PRP by virtue of its increased concentration of platelets and thereby an inflated amount of growth factors or cyto-

kines have been theorised to encourage tissue repair and regeneration by neocollagenesis, neoangiogenesis and much more. It has been embraced as a frontline treatment modality for the management of facial ageing, androgenetic alopecia, acne scarring, etc.

32.3.3 Indications of PRP Therapy in Aesthetic Medicine

1. Facial rejuvenation.
2. Skin tightening and Antiageing therapy
3. Acne scar management
4. Alopecia
5. Skin lightening
6. Improvement of skin quality in under eye area.

32.3.4 Preparation of PRP

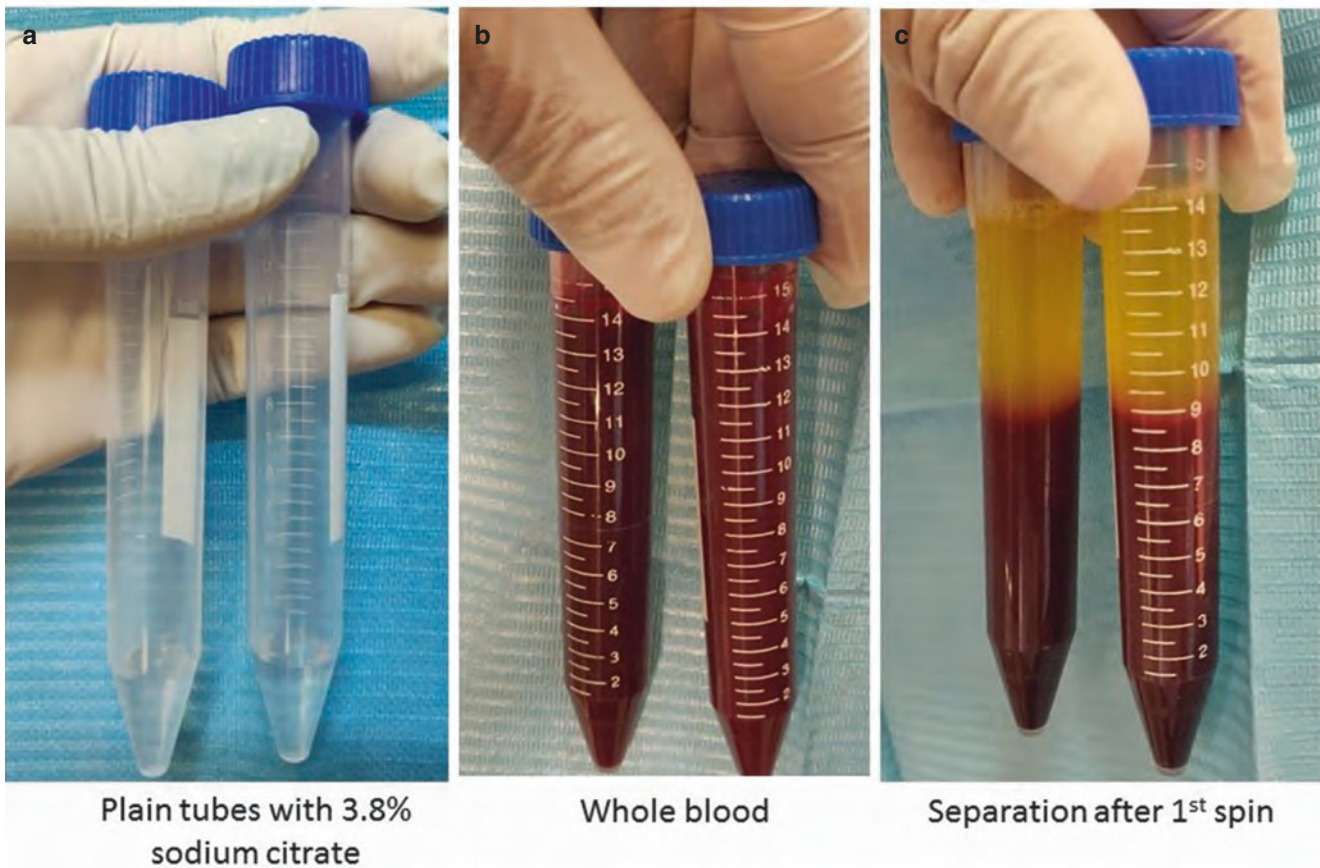
PRP is derived from autologous blood by using a centrifuge and can be performed under local anaesthesia under aseptic conditions. An anticoagulant, like citrate dextrose solution formula A (ACD-A) or sodium citrate 3.8%, is used to inhibit platelet aggregation.

Manual Double Spin Method (Figs. 32.13, 32.14, 32.15, and 32.16)

Whole blood is collected by venipuncture from antecubital vein in 15 ml polystyrene tubes under sterile conditions containing 3.8% sodium citrate as an anticoagulant. In each tube, 1 ml of sodium citrate is mixed with 12 ml of whole blood. Eight such tubes are taken to make up a volume of 104 ml. The tubes are slowly turned upside down twice to homogeneously mix the whole blood with the anticoagulant. All the 8 tubes are placed in the centrifuge (Remi 8c) and are centrifuged at 1500 rpm for 10 min. This is called the ‘soft spin’ which separates the whole blood into 3 layers. The erythrocytes settle at the bottom of the tube because of the highest specific gravity or density of about 1.090. Just above the erythrocytes, a hazy layer is seen which contains the leukocytes with a specific gravity of 1.060 and platelets with a specific gravity around 1.040. At the top, we find the clear plasma with the lowest concentration of platelets with a specific gravity of around 1.020.

The buffy coat is separated along with some amount of plasma and placed in a separate tube. At this time, if the buffy coat is separated along with the slightest superficial erythrocyte layer, it is referred to as L-PRP (leukocyte-PRP) and if it

PRP by Double centrifuge technique



©Association of Oral and Maxillofacial Surgeons of India

Fig. 32.13 (a, b, c) Primary separation of erythrocytes during the preparation of platelet-rich plasma using plain tubes containing sodium citrate 3.8%

is taken above the layer of erythrocytes, it is referred to as P-PRP (pure-PRP) depending on the kind of PRP preparation, i.e. with or without leukocytes. About 10 ml of these are taken in 2 tubes and placed in the centrifuge for a second spin called the 'hard spin' at 2500 rpm for 15 min. At the end of the spin, a platelet plug is found at the bottom of the tube. The top 3 quarter of the platelet poor plasma was discarded and the lowest quarter with the platelet plug was mixed and used as the PRP. This gives us a viable platelet count of 5 times the baseline. This was activated by mixing with calcium gluconate at a ratio of 9:1 in an insulin syringe and injected immediately.

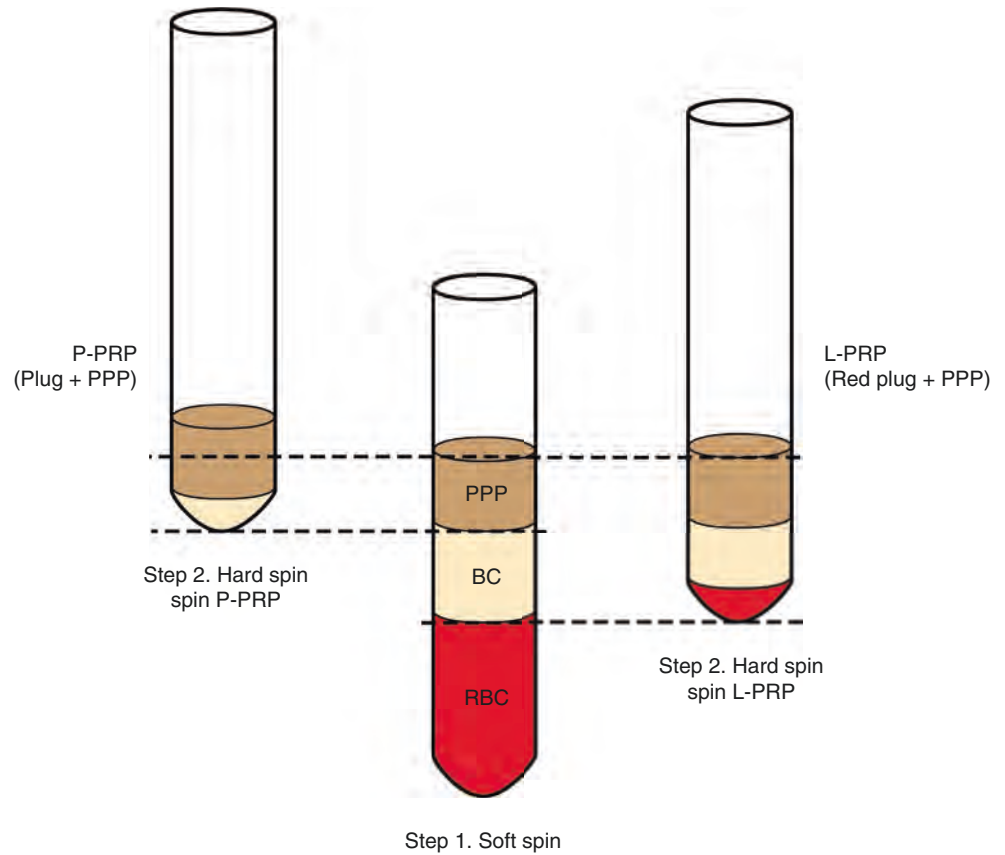
Automated Devices (Fig. 32.17)

Numerous commercial devices of varying standards are now available for the preparation of PRP. Although time saving, these adapted kits can be quite expensive as compared to the manual process.

In general, a PRP tube typically contains sodium citrate as an anticoagulant along with a separating gel. This gel has a density of about 1.070, which is in between the erythrocytes and platelets.

20 ml of Whole blood is collected by venipuncture and added into two of these PRP tubes. The blood is homogeneously mixed with the anticoagulant by gently turning the tube upside down twice. The tubes are then placed in the centrifuge and spun at 3700 rpm for 9 min. The erythrocytes because of the higher density than the separating gel settle down below the gel, while the plasma along with leucocytes and platelets segregate above the gel. The superficial platelet poor plasma is discarded leaving behind 2–3 ml of plasma above the gel. The tubes can be turned upside down to mix the platelets as they get entangled in the gel. This would give a uniform concentration of platelets throughout. It is now mixed with calcium gluconate as an activator and injected immediately.

Fig. 32.14 Difference in preparation of L-PRP and P-PRP



©Association of Oral and Maxillofacial Surgeons of India

32.3.5 PRP Injections for Facial Rejuvenation, Biostimulatory Lift and Acne Scar

Studies have shown that PRP by inducing neocollagenesis through activation of fibroblasts and by removing photodamaged extracellular matrix (ECM) components amplifies dermal elasticity via following molecular mechanisms [23, 24]:

- Encouraging proliferation of human dermal fibroblasts to induce new collagen.
- Increased expression of MMP-1 (matrix metalloproteinase-1) and MMP-3, resulting in the removal of photodamaged ECM.
- Enhanced creation of procollagen type I peptide and expression of collagen type I, alpha-I, resulting in the synthesis of fresh collagen.
- Increases expression of G1 cell cycle regulators resulting in accelerated wound healing.

PRP can be injected using an insulin syringe that has 31 g needle. Local anaesthetic in the form of nerve blocks should

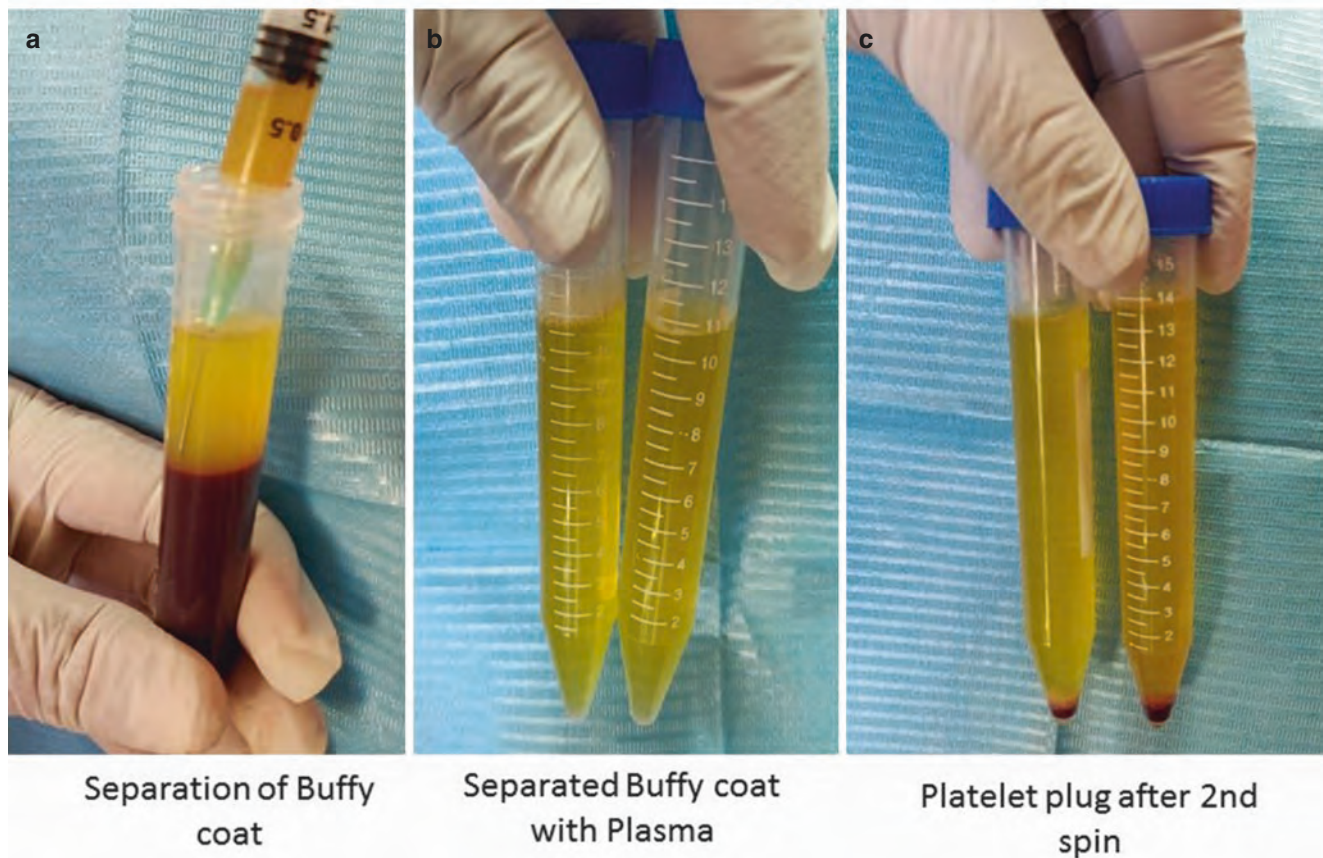
be given prior to the session. The facial skin should be cleansed with povidone iodine solution. Multiple intradermal injections of PRP after activating it are given all over the face including the infraorbital area. Three sessions each at a gap of 1 month of PRP therapy along with micro-needling (collagen induction therapy) with derma pen with a needle depth of 0.7–1 mm has been shown to give very good results for rejuvenating the aged skin and acne scars. Histologically, the treated skin showed improved length of dermo-epidermal junction, increased quantity of collagen and fibroblasts.

Post-operatively, patients are advised to apply ice on the face. Sun exposure should be avoided. Patient should be advised not to take anti-inflammatory tablets as the more the inflammation, the better the results are going to be. Most of the times, patients experience very mild post-operative discomfort.

PRP therapy can also be combined with CO2 fractional resurfacing to achieve excellent results in treating acne scars.

PRP has also shown excellent results in infraorbital rejuvenation where the skin is very thin and shows initial signs of ageing [25].

L-PRP by Double Centrifuge Technique



©Association of Oral and Maxillofacial Surgeons of India

Fig. 32.15 (a, b, c) Platelet plug formed after the second spin during the preparation of L-PRP

32.3.6 Contraindications to PRP Therapy [26]

Absolute contraindications:

- Platelet dysfunctions.
- Thrombocytopenia (low platelet counts).
- Hypofibrinogenemia.
- Local sepsis.
- Hemodynamic instability.
- Septicaemia.
- Patient unwilling to accept risks.
- Patients on long-term anticoagulant therapy (warfarin or heparin).

Relative contraindications:

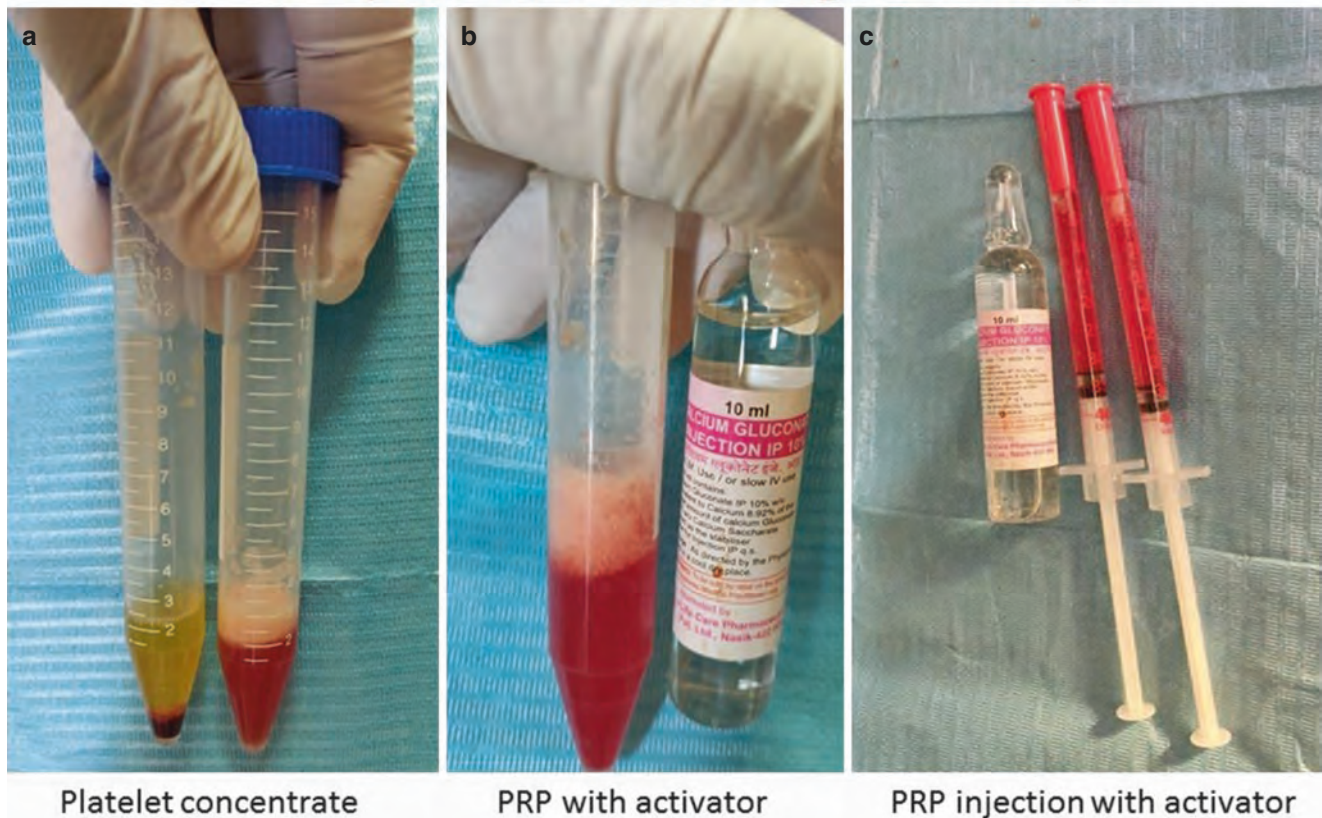
- Consistent use of NSAIDs and corticosteroids within 15 days
- Recent episode of infections, fever or illness.
- Cancer—especially hematopoietic or of bone.

32.3.7 Conclusion

The use of cytokines derived from platelet-rich plasma (PRP) is an effective modality to promote tissue regeneration and hence can be used in regenerative medicine including facial aesthetics and trichology.

PRP therapy is an inexpensive procedure as it does not require complex and voluminous equipment or extensive training for its execution. Furthermore, since the product is primarily autologous in origin, the patient's apprehension regarding the immunogenic reactions or disease transmission is abolished. Over three decades of its application to various fields and the multitude of studies with enormous positive results, PRP therapy today has become a gold standard for facial rejuvenation and hair loss therapy. The release of bioactive cytokines that help in neocollagenesis which takes care of the ageing process of wrinkle formation has made it a versatile tool for many anti-ageing therapies on the face.

L-PRP by Double Centrifuge Technique



©Association of Oral and Maxillofacial Surgeons of India

Fig. 32.16 (a, b, c) Platelet-rich plasma needs to be activated for release of cytokines from the alpha granules

32.4 Face Tightening with HIFU (High Intensity Focussed Ultrasound)

Facial wrinkles, reduced elasticity of the facial skin and sagging parts of the face are the most common concerns today an aesthetic surgeon encounters from the patients. In the present social scenario, facial skin laxity is considered highly disgraceful and has a great impact on a person's psychology and quality of life [27]. The natural process of ageing which is inevitable and the other external factors like sun's UV radiations, stress and worry, smoking, unhealthy diet, etc. are the major factors which cause the wrinkles and sagginess. We are aware that the loss of the important proteins viz collagen and elastin, which gives the strength, resilience and elasticity to the skin is the reason behind the loose skin and wrinkles.

Various treatment modalities have been utilised to manage these concerns of the face. Surgical excision of the redundant skin via facelift surgery definitely gives the best results. But with the increasing concerns over the complications and the downtime, the focus of therapeutic modalities is shifting towards non-surgical aspects.

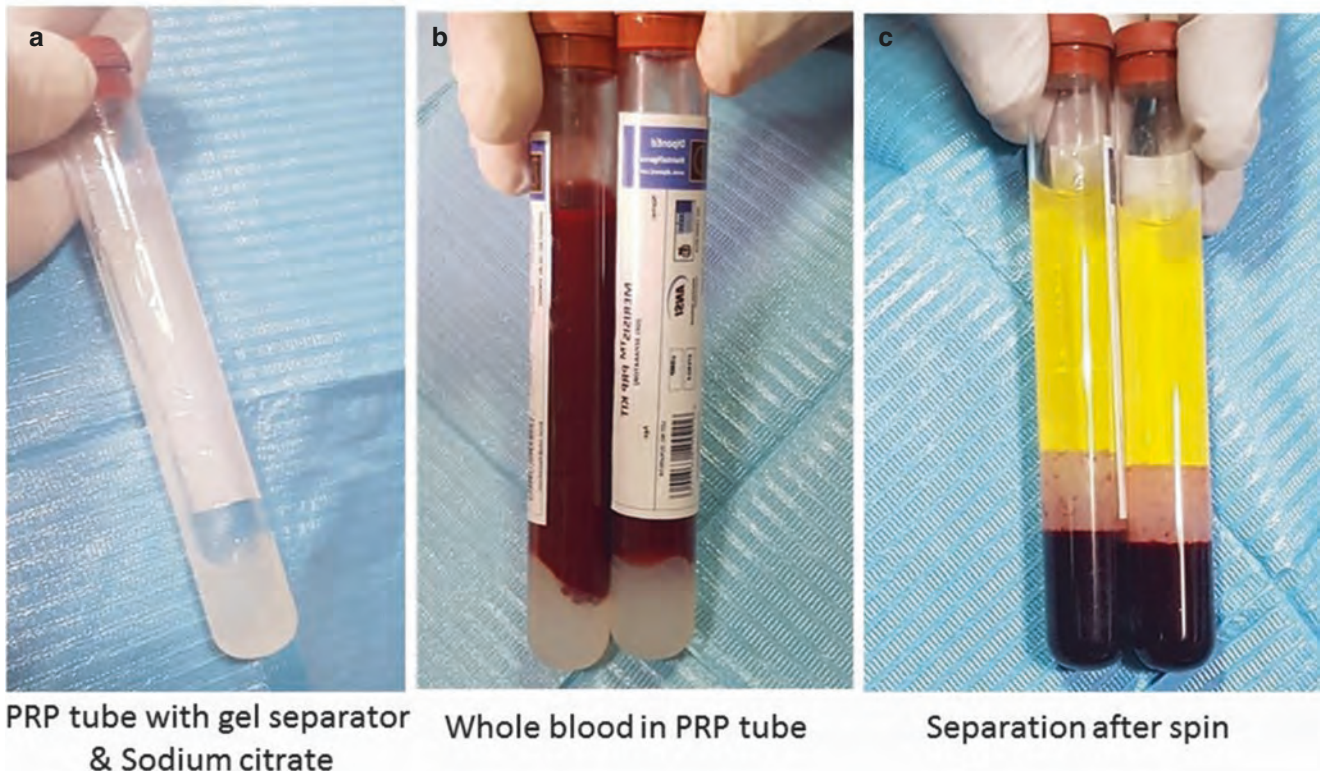
Non-surgical treatment modalities like microdermabrasion, chemical peels, fractional lasers, etc. have been advocated in the past. In recent times, newer modalities like the HIFU and RF have come into limelight due to their non-invasiveness and low or no downtime for the treatment of sagging skin.

32.4.1 Introduction to HIFU

Ultrasound was introduced for its diagnostic ability. The capability of the focussed ultrasound energy to cause tissue regression and ablation has been well utilised today as a non-invasive modality to treat solid tumours and also being used to treat both primary and metastatic tumours as these can precisely locate the mass for ablation [28].

More recently this intense focussed ultrasound has also been utilised in many painful conditions including neuropathic pain and musculoskeletal degeneration [29].

PRP preparation by using PRP tubes



©Association of Oral and Maxillofacial Surgeons of India

Fig. 32.17 (a, b, c) Preparation of Platelet-rich plasma with the help of PRP tubes containing anticoagulants and the separating gel

HIFU or high intensity focussed ultrasound was introduced into the field of facial aesthetics very recently to manage the facial wrinkles and periorbital rejuvenation.

FDA in 2009 approved the use of HIFU in brow lifting as the first dermatologic and aesthetic indication following the report by White et al. [30] in 2008. It was later in 2014 cleared as an indication to improve lines and wrinkles of the upper chest and neckline (décolletage). Currently, its use for facial rejuvenation, skin lifting and tightening and body contouring is considered 'off-label'.

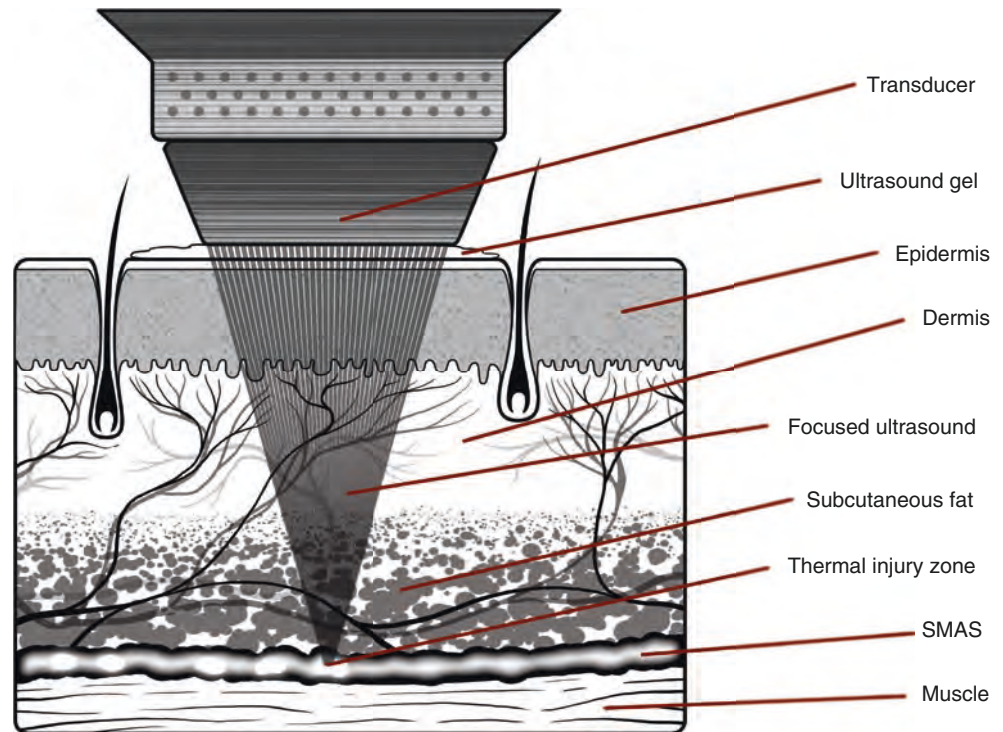
32.4.2 Mechanism of Action

High intensity focussed ultrasound or HIFU embodies a piezoelectric transducer which produces focussed ultrasound beams. This transducer releases ultrasound waves over a length of around 2.5 cm which are focussed at 1.5, 3 or 4.5 mm depth. The 1.5 mm focusses the superficial or papillary dermis, while the 3 mm focusses the deep or reticular dermis and the 4.5 mm focusses the SMAS layer. Like a magnifying glass, the transducer focusses the ultrasound to

the desired depth and at the focal spot, there is a swift rise in temperature to 60–80°C within a very short period (typically 1–20 s). This causes an immediate contraction of native collagen which is subsequently followed by cell injury and tissue shattering due to both coagulation necrosis and protein denaturation. These events occur at the deeper focussed zones, while the superficial tissues are left safe and unaffected [31] (Fig. 32.18).

The focussed ultrasound energy is absorbed by the tissues and this causes the molecules to vibrate rapidly. The friction due to molecular oscillations results in heat generation and a rapid rise of temperature at the focal zone. This thermomechanical process causes tissue injury at the site of focus. Supplemental to this, the ultrasound waves that propagate through the tissues cause continuous compressions and rarefactions that result in powerful shear forces. This microscopic but mighty shearing motion results in frictional heating [32]. Once tissue destruction is done, the inflammatory phase (in first 48 h) sets in wherein the damaged cells are removed and the WBCs, growth factors and enzymes create swelling, heat, pain and redness.

Fig. 32.18 Mechanism of high-intensity focussed ultrasound. Thermal coagulation zones are created due to the extreme heat produced by the ultrasound focussed to a particular depth



©Association of Oral and Maxillofacial Surgeons of India

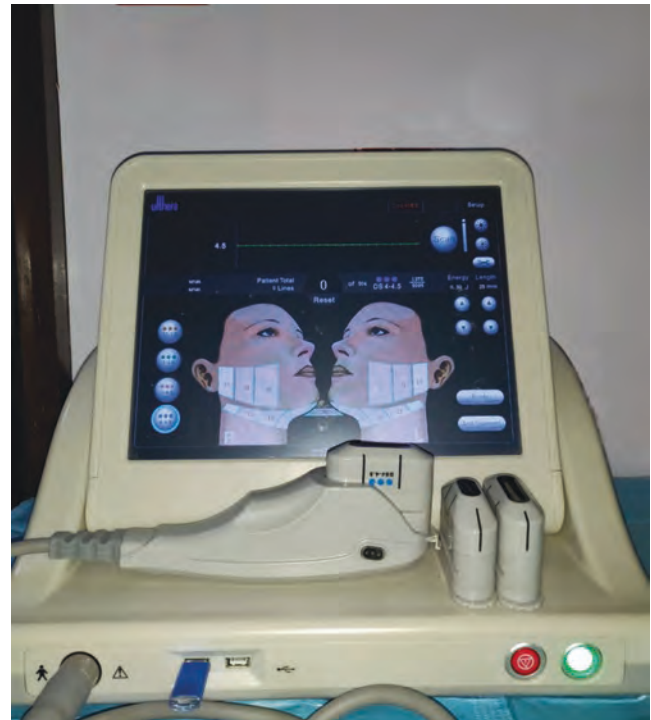In the next proliferative phase (up to 6 weeks), there is tissue contracture due to the myofibroblasts which are built. New tissues made up of collagen and extracellular matrix are formed.

The last maturation phase (from 3 weeks to 6 months) shows collagen is remodelling from type III to type I. The collagen which was laid down during the proliferative phase is now aligned along the tension lines and also there is cross-linking of the collagen. A histological evaluation post HIFU treatment exhibited significantly regenerated and proliferated quantity of dermal collagen and elastic fibres [33]. This causes skin tightening over a period of time. The results keep improving and the best final results are seen by 6 months.

32.4.3 Armamentarium

The HIFU machine basically consists of 2 parts: the body and the transducer (Fig. 32.19).

The screen in the body keeps monitoring the number of shots, depth of shots, length of release of ultrasound waves and the energy of the ultrasound in real time. The transducer releases the focussed ultrasound waves. The following are the 3 transducers usually used on the face:



©Association of Oral and Maxillofacial Surgeons of India

Fig. 32.19 High-intensity focussed ultrasound device

1. DS-4.5 4—Focussed ultrasound of 4 MHz frequency is transmitted to a depth of 4.5 mm to the SMAS layer, forming “thermal coagulation” spots. It is normally targeted to thicker skin, such as cheeks, etc. and is the most important aspect of midface tightening.
2. DS-3.0 8—High-frequency ultrasound of 8 MHz is focussed to the deep dermis layer at 3.0 mm depth and is responsible for activating the skin’s collagen. It effectively reduces the appearance of wrinkles and also ameliorates large pores.
3. DS-1.5 10—Here, 10 MHz frequency ultrasound energy is focussed to the superficial dermis. It is used in thinner tissue in the periorbital area.

32.4.4 Indications and Contraindications in Facial Aesthetics

The numerous indications of HIFU are given below.

1. Brow lifting
2. Facial rejuvenation.
3. Fine and deep wrinkles of face.
4. Infraorbital area laxity.
5. Crow’s feet.
6. Nasolabial folds (Fig. 32.20).
7. Mentolabial grooves.
8. Jowls.
9. Submental skin.
10. Double chin.

The contraindications are the following;

1. Open facial wounds or lesions in treatment region.
2. Pustular acne in the treatment region.
3. Active implants (e.g. pacemakers or defibrillators) in treatment region (no contraindications to Dental Implants).
4. Perform fillers and threads treatment after the HIFU session.
5. Pregnant or breast-feeding woman.
6. Directly over mechanical and permanent dermal implants.
7. Existing keloids in the treatment area.
8. Patients with active systemic and skin diseases like herpes, etc.
9. Unrealistic expectations of treatment.

32.4.5 Procedure for Face Tightening

32.4.5.1 Facial Rejuvenation - HIFU (Video 32.1)

The sequence for HIFU application includes the following:

1. Patient consent and explanation of the procedure, adverse effects and alternatives.
2. Removal of all makeup from face.
3. Cleansing the full face and neck area.
4. Application of local anaesthetics ointment like EMLA, Toplap, etc., and occluding it with plastic sheet for 45 min.
5. Markings of the skin for treatment.
6. Application of ultrasound gel on the skin and face and application of transducer tip at an angle perpendicular to the skin.
7. Start with 4.5 mm transducer, followed by 3 mm and then 1.5 mm with a number of shots and area as mentioned in the figures.
8. Removal of ultrasound gel and explaining post-operative instructions before discharging the patient.
9. Follow up on the next day to assess any complications and at 3 and 6 months to assess the results.

32.4.6 Adverse Effects

Severe adverse effects of HIFU are very rare and hence considered a very safe procedure to perform on an outpatient basis. The adverse effects that have been described may be:

- Pain—Transient discomfort may be experienced during the procedure which resolves within 2 h to 2 days. Tenderness is also possible and typically resolves in maximum 2 weeks.
- Erythema—May exhibit immediately after the treatment which resolves in few hours (Fig. 32.21).
- Edema—Skin may exhibit slight edema following treatment which settles in 3–72 h after treatment.
- Motor Nerve paresis—Symptoms of motor nerve paresis can be seen in the first 12 h of the treatment. It normally happens with the marginal mandibular and temporal branches of facial nerve which are pretty superficial. The HIFU could cause inflammation of these nerves and this may lead to disruption of motor function. The frontalis muscle and the muscles of perioral area are affected. The symptoms usually resolve in 2–6 weeks. Anti-inflammatory medications can be prescribed if symptoms of nerve paresis arise.

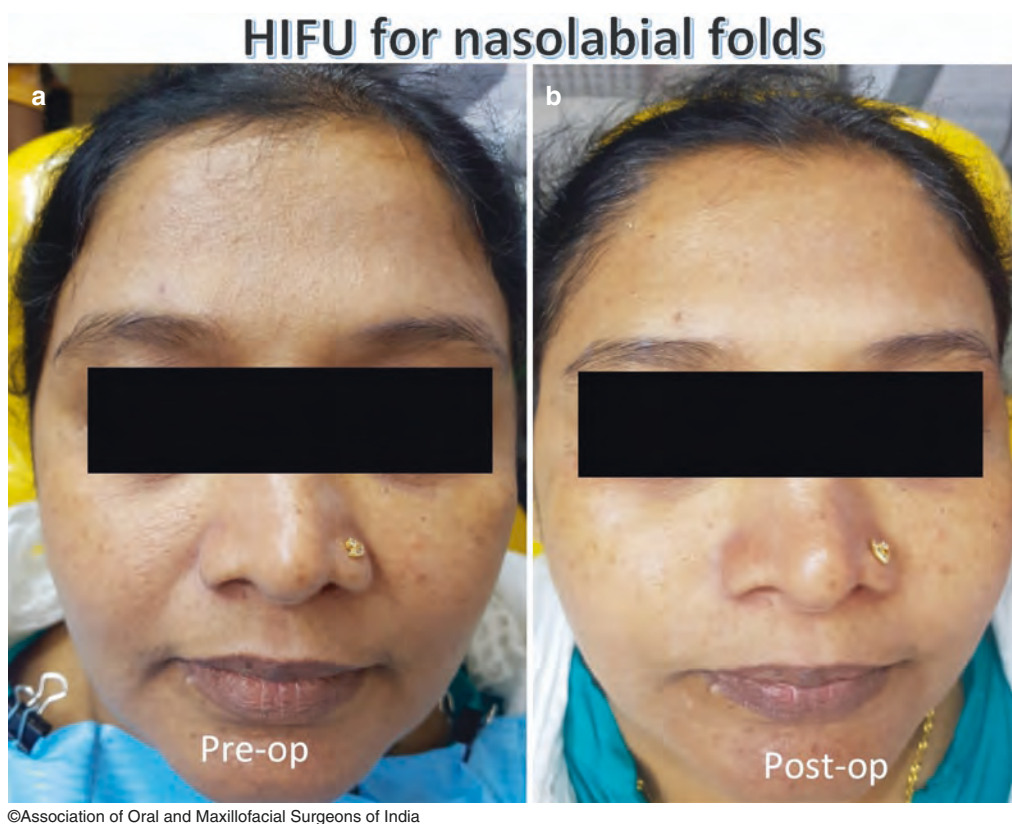

Fig. 32.20 (a, b) Lifting of nasolabial fold with HIFU

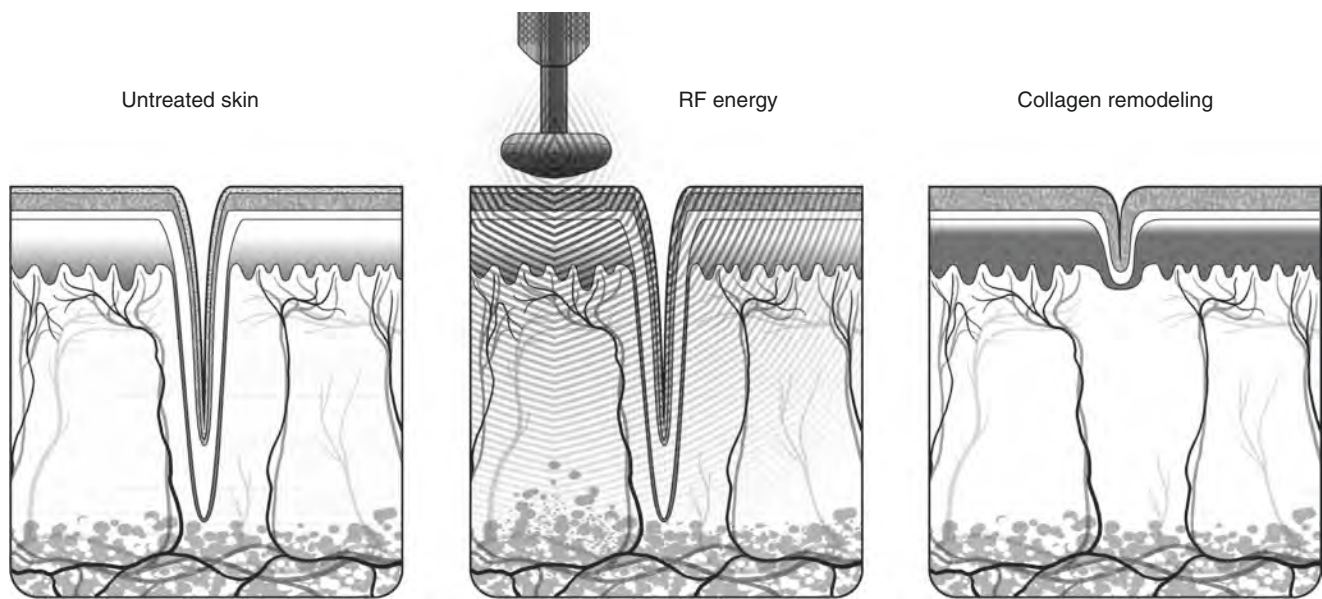
- Skin burns: This happens when inadequate ultrasound gel is not applied between the transducer and the skin. There is thus inadequate acoustic coupling and defocussing of the beam due to air entrapment and deposition of energy at the skin surface leading to skin burn (Fig. 32.21).
- Scarring: Rarely happens if correct treatment protocol and technique is not followed.

32.4.7 Conclusion

HIFU can be considered as a very effective, non-invasive and safe procedure for tightening the facial skin. The advantages over a surgical facelift are hard to deny. There are no incisions, no scarring and no downtime. Of course, it is much less expensive than a surgical facelift. If patients are chosen carefully, like patients with mild to moderate skin laxity, facial wrinkles, lower eyelid laxity, etc., HIFU can be an excellent option for facial skin tightening.

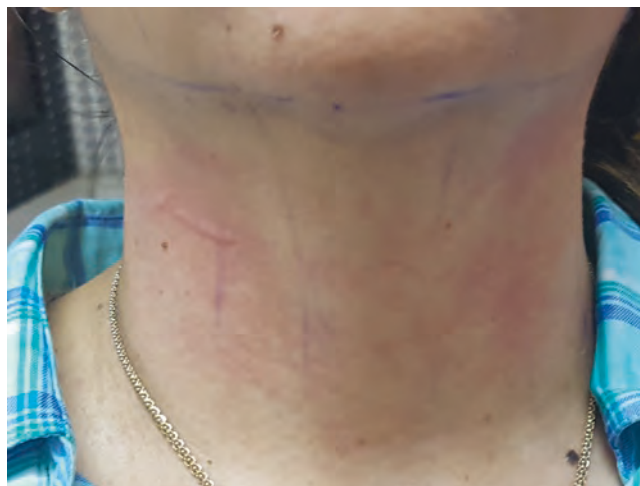

Fig. 32.21 Complication during HIFU—erythema and skin burn



©Association of Oral and Maxillofacial Surgeons of India

Fig. 32.22 Mechanism of action of non-ablative radiofrequency. Collagen remodelling takes place because of the heat generated due to the tissue resistance to radiofrequency energy

32.5 Skin Tightening with Radiofrequency

Non-ablative radiofrequency or RF is another non-surgical and non-invasive modality of skin tightening. The selective and controlled rise in tissue temperature is because of a high-frequency alternating current (0.3–10 MHz). The amount of energy applied and the tissue resistance determine the amount of temperature and the depth of heating [34].

Since electrical current produces the RF energy, the tissue damage like a laser is minimised and neither is the epidermal melanin compromised to cause hyperpigmentation.

RF therapy was first FDA approved as a non-invasive treatment modality in periorbital rhytids in 2002. Subsequently in 2004 it was cleared for full face. Since then, it has become a very popular non-invasive treatment modality for the facial skin tightening.

32.5.1 Principle of Action

High frequency (0.3–10 MHz) alternating current is utilised in a RF therapy. Intrinsic tissue resistance (impedance) to the passage of electrons converts the electric current to thermal energy causing heat generation. Ohm's Law relationships state that:

$$\text{Power } (P) = I^2 \times R \text{ and Energy } (E) = P \times T$$

Hence, Energy $(E) = I^2 \times R \times T$ (where I = current, R = tissue impedance and T = time of application). The level of energy of the alternating current and tissue resistance deter-

mines the amount of rise in temperature and the depth of heating. High tissue resistance as demonstrated by subcutaneous fat generate more heat [35]. The thermal damage thus caused stimulates the alterations in collagen configuration and produces neocollagenesis in deep layers of skin and subcutaneous tissue (Fig. 32.22).

Significant results can be observed 2 months post-application of radiofrequency energy. Histological pictures after each session demonstrated expansion of the papillary dermis due to oedema and vascular congestion, followed by accumulation of intercellular substance. Post 2 months treatment histological pictures showed escalated amount of collagen, elastic fibres and mucopolysaccharides [36].

32.5.2 Armamentarium

There are 2 major components of the RF machine: the RF generator and the handheld tips (Fig. 32.23). The membrane electrode functions by dispersing energy uniformly across the skin surface by a mechanism termed as capacitive coupling that creates a zone of raised temperature at depths of 3–6 mm [37]. The energy transmitted to the skin is by utilising the capacitive method (bipolar, tripolar or multipolar electrode). Montesi et al. (2007) described the main difference between the inductive and the capacitive method. It depends on the configuration of the electrodes that are applied to the skin that influences the energy transmission in the tissues.

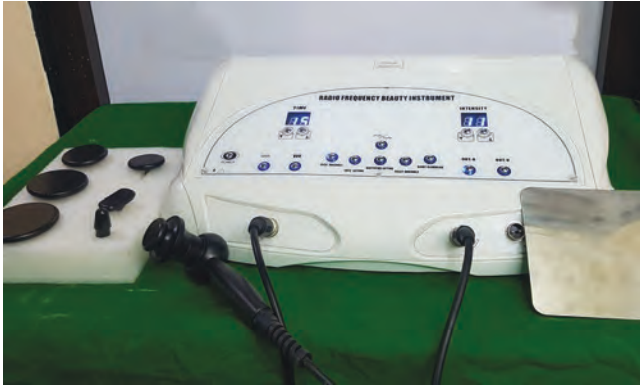The inductive method (monopolar electrode) uses an active and a passive electrode, in which the passive electrode

acts as a grounding electrode. The active electrode transmits power to the tissue via a single point of contact. This enhances the penetration of the generated current.

In the capacitive method (bipolar, tripolar or multipolar electrode), energy alternates between 2 electrodes situated at a short distance from one another. In the tripolar and multipolar devices, bipolar energy switches between dif-

ferent poles at any given point of time. The energy is concentrated at the site of treatment and the achieved depth is half of the distance between the two electrodes [38].

Parameters utilised by the device includes frequency ranging from 1 to 6 MHz and the power ranging from 40 to 240 W. All the parameters can be modified during the treatment. Throughout the procedure, the temperature of epidermis is maintained at 40 °C, whereas that of dermis rises to about 50–75 °C. This heating up of the dermis causes new collagen and elastin production.



©Association of Oral and Maxillofacial Surgeons of India

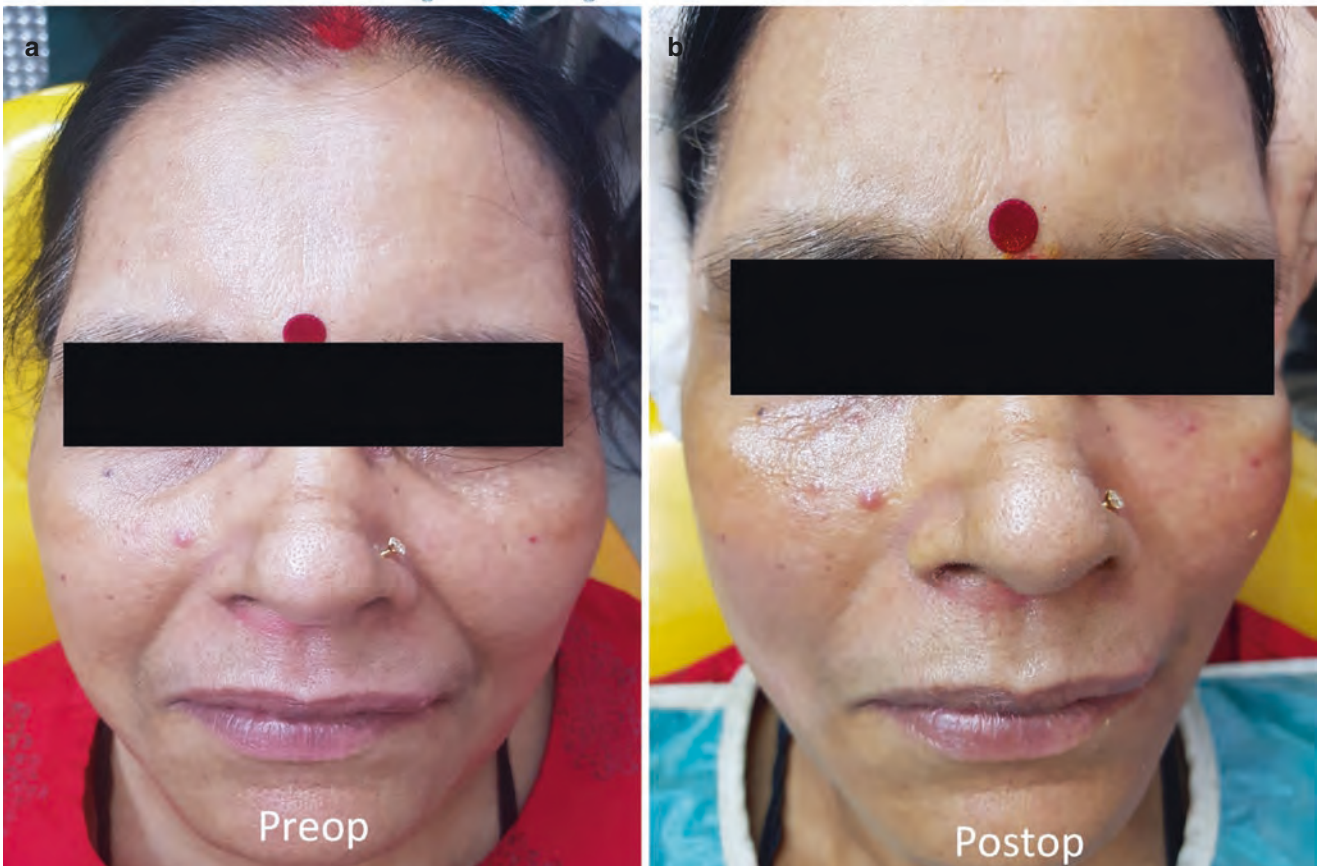Fig. 32.23 Non-ablative radiofrequency device

32.5.3 Indications

The various indications of RF include the following:

1. Complete facial rejuvenation.
2. Wrinkles around eye
3. Fine lines on forehead.
4. Jowls
5. Nasolabial folds (Fig. 32.24)
6. Perioral fine lines
7. Undefined jaw line

Radiofrequency for nasolabial fold



©Association of Oral and Maxillofacial Surgeons of India

Fig. 32.24 (a, b) Nonablative radiofrequency for tightening nasolabial folds

32.5.4 Advantages

The biggest advantage of RF is unlike lasers, the energy does not disturb the epidermal melanocytes and thus can be used for all skin types, i.e. type 1–6. The procedure can be performed frequently as per requirement without any adverse effect and different depths of tissue can be treated, allowing for ultimate collagen contraction and production of new collagen.

32.5.5 Procedure of RF for Face

Application of RF is done systematically and the various steps involved are mentioned below.

1. Patient consent for the treatment is mandatory after a detailed explanation of the procedure, side effects, benefits and alternatives.
2. Removal of all make-up from face.
3. Cleansing of the full face and neck area.
4. Application of prilocaine and lignocaine skin anaesthetic cream like toplap, prilido, etc.
5. Ultrasound gel is applied generously to the facial skin to establish uniform thermal and electrical contact between the treatment tip and the skin and to enhance proper energy conduction.
6. For each session, a total of 5–8 passes per treatment region can be given.
7. Removal of ultrasound gel and explaining post-operative instructions before discharging the patient. Post-operative instruction includes prevention of sun exposure by using sunscreen to promote healing.
8. Follow up on the next day to assess any complications and at 1, 3, 5 weeks to repeat the procedure and at 3 and 6 months to assess the results. The possible side effects of RF application are found in Box 32.1.

Box 32.1 Side Effects of RF Treatment

1. Burns
2. Permanent scarring
3. Skin pigmentations
4. Deeper skin fat loss.
5. Mild swelling of the treated skin.
6. Redness.
7. Sinking of the treated area.
8. Skin sensitivity.

32.6 Conclusion

Non-ablative radiofrequency is an effective and non-invasive modality for tightening and rejuvenating wrinkled, photo-aged facial skin and contour facial skin laxity. It works on the principle of stimulation repair process by producing new collagen and elastin and by reversing the clinical and the histopathological signs of ageing. The procedure has an added advantage of being relatively risk-free with little or no downtime.

Disclosure Authors have no financial conflicts to disclose.

32.7 Case Scenarios

32.7.1 Patient 1 (Fig. 32.25a–d)

A 48-year female approached us with complaints of sagging skin. She wasn't happy with her deepening nasolabial folds, loose skin in her neck and the fine wrinkling on her face.

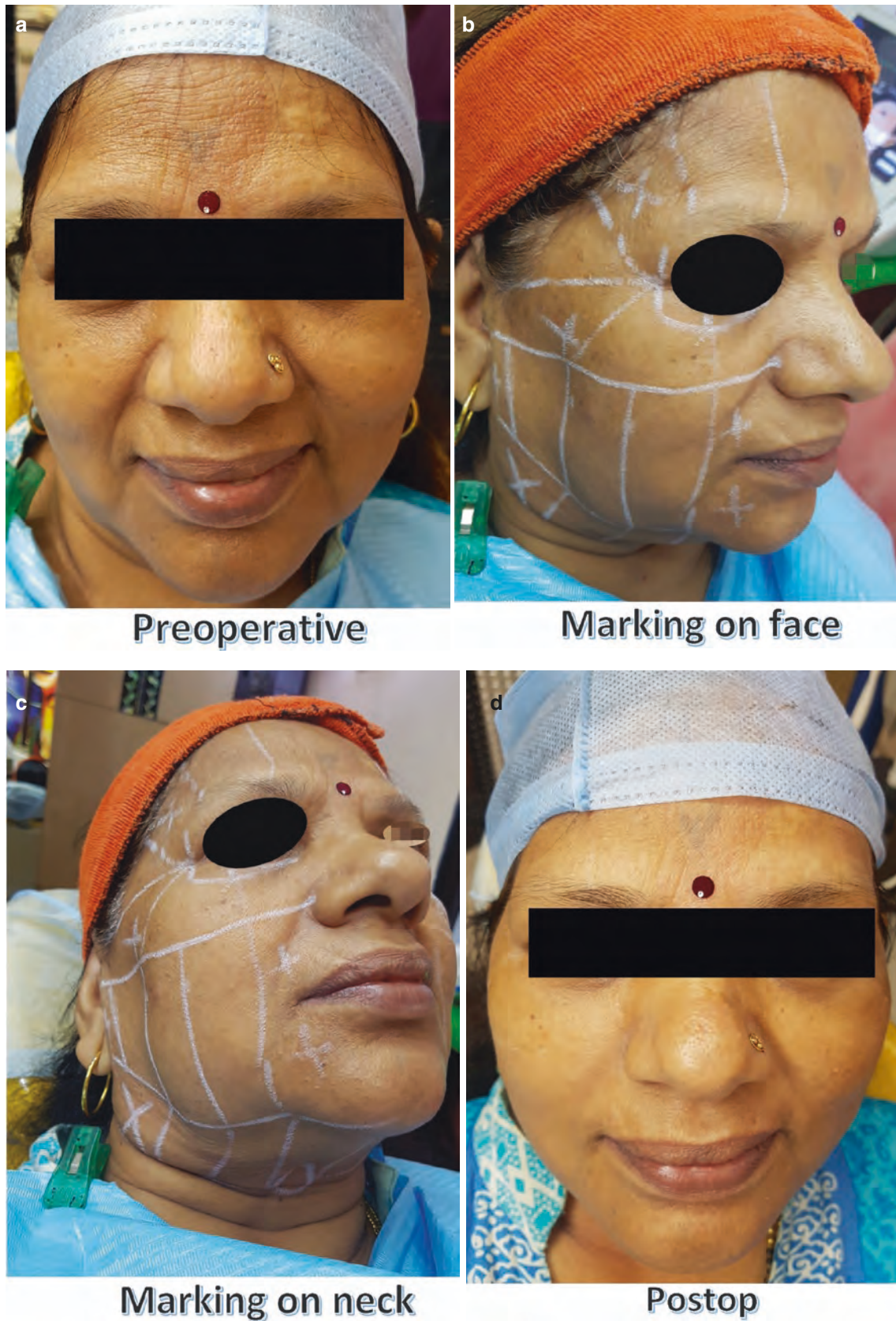Treatment options included surgical facelift, thread lift therapy and non-invasive therapies like HIFU and RF. The patient consented to undergo non-invasive treatment which included a session of High intensity focussed ultrasound (HIFU).

After cleansing the face, proper markings were made. The treatment was performed with sequential transducers of 4.5, 3 and 1.5 mm with number of shot as recommended, area wise. The patient was evaluated post-operatively and patient's satisfaction was recorded. Post-operative instructions were given before discharging. Patient was recalled for reevaluation after 1 month.

32.7.2 Patient 2 (Fig. 32.26a–g)

A 52-year male approached us with complaints of loose skin on the face. His main concern was the deepening nasolabial folds and the fine wrinkling on the face. The treatment options included surgical facelift and thread lift therapy. The patient consented to get a thread lift procedure done. It was decided to use 3 COG threads along with 20 mono PDO threads on either side.

After cleansing the face with povidone iodine, vectors were marked to lift the nasolabial folds. Lignocaine with adrenalin was used as local anaesthetic agent. The thread lift procedure with COGS thread was performed with placement of the COGS in the subcutaneous layer for the proper lift and



©Association of Oral and Maxillofacial Surgeons of India

Fig. 32.25 (a–b) Case Scenario 1. (a) Pre-op photograph. (b, c) Marking on face and neck, right side. (d) Post-op photograph

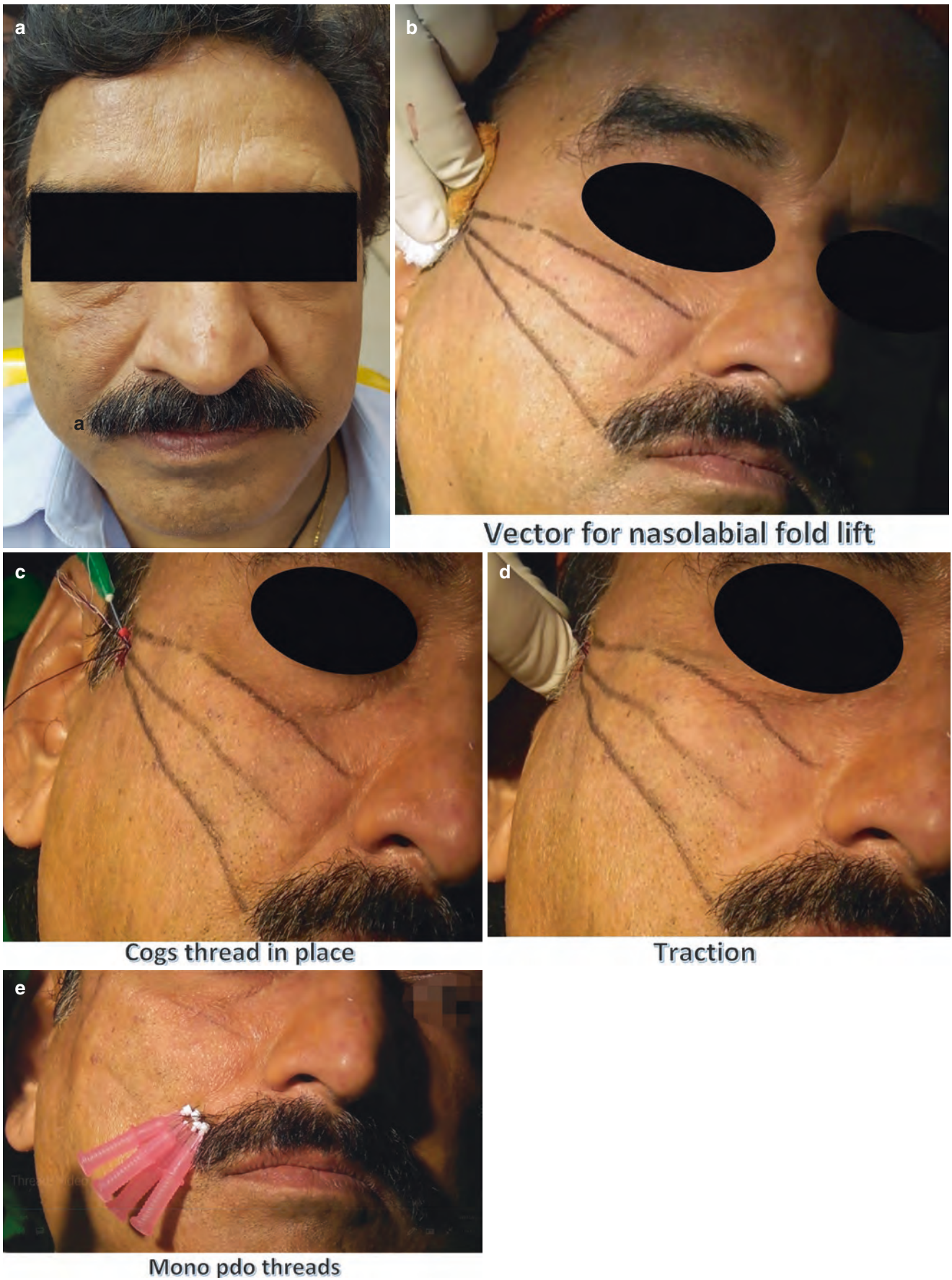
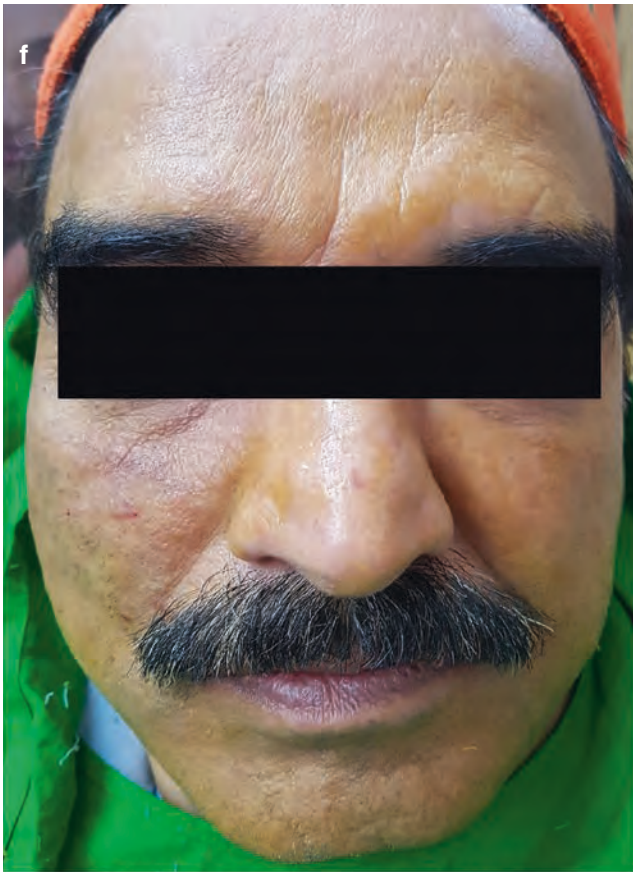
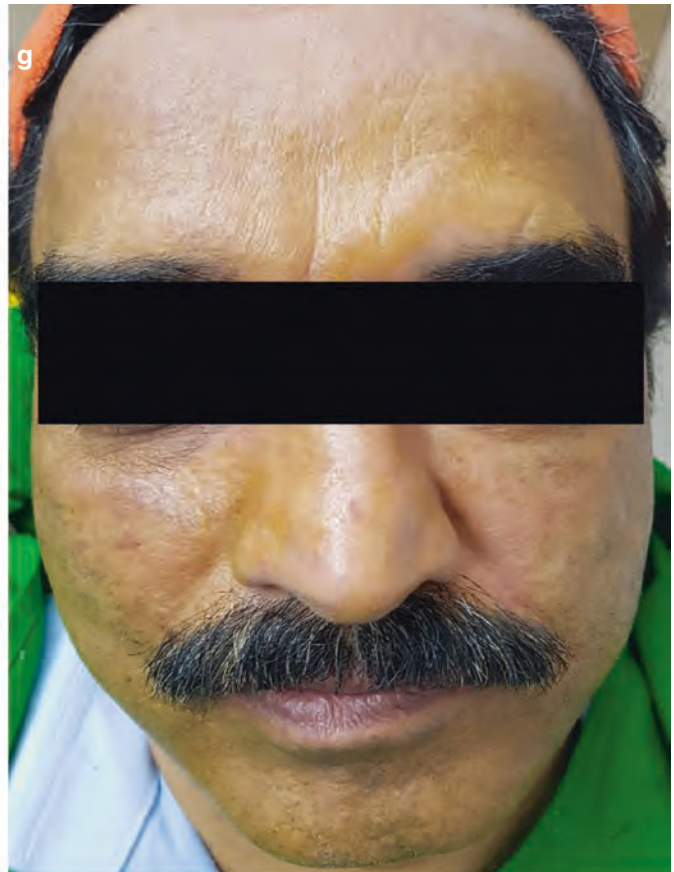Fig. 32.26 Case Scenario 2. (a) Pre-op photograph. (b) Marking of vectors. (c) 3 cogs in place at subcutaneous layer. (d) The traction on threads lifts the nasolabials. (e) Placement of mono PDOS. (f, g) Post-op photograph (also see Fig. 32.10)



Right half thread lift



Postoperative

©Association of Oral and Maxillofacial Surgeons of India

Fig. 32.26 (continued)

the mono PDO at the dermal layer for rejuvenation and fine lines.

The patient was evaluated post-operatively and patient's satisfaction was recorded. Post-operative instructions were given before discharging. Patient was recalled for reevaluation after 3 days and after 1 month.

References

- Rohrich RJ, Pessa JE. The fat compartments of the face: anatomy and clinical implications for cosmetic surgery. *Plast Reconstr Surg.* 2007;119(7):2219–27.
- Furnas DW. The retaining ligaments of the cheek. *Plast Reconstr Surg.* 1989;83(1):11–6.
- Wulc AE, Sharma P, Czyz CN. The anatomic basis of midfacial aging. In: *Midfacial rejuvenation.* New York, NY: Springer; 2012. p. 15–28.
- Donofrio LM. Fat distribution: a morphologic study of the aging face. *Dermatol Surg.* 2000;26(12):1107–12.
- Lambros V. Observations on periorbital and midface aging. *Plast Reconstr Surg.* 2007;120(5):1367–76.
- Gosain AK, Yousif NJ, Madieto G, Larson DL, Matloub HS, Sanger JR. Surgical anatomy of the SMAS: a reinvestigation. *Plast Reconstr Surg.* 1993;92(7):1254–63.
- Owsley JJ. SMAS-platysma facelift. A bidirectional cervicofacial rhytidectomy. *Clin Plast Surg.* 1983;10(3):429–40.
- Mendelson B, Wong CH. Changes in the facial skeleton with aging: implications and clinical applications in facial rejuvenation. *Aesthet Plast Surg.* 2012;36(4):753–60.
- Mendelson BC, Hartley W, Scott M, McNab A, Granzow JW. Age-related changes of the orbit and midcheek and the implications for facial rejuvenation. *Aesthet Plast Surg.* 2007;31(5):419–23.
- Shaw RB Jr, Kahn DM. Aging of the midface bony elements: a three-dimensional computed tomographic study. *Plast Reconstr Surg.* 2007;119(2):675–81.
- Rohrich RJ, Hollier LH Jr, Janis JE, Kim J. Rhinoplasty with advancing age. *Plast Reconstr Surg.* 2004;114(7):1936–44.
- Shaw RB Jr, Katzel EB, Koltz PF, Kahn DM, Giroto JA, Langstein HN. Aging of the mandible and its aesthetic implications. *Plast Reconstr Surg.* 2010;125(1):332–42.
- Garvey PB, Ricciardelli EJ, Gampper T. Outcomes in threadlift for facial rejuvenation. *Ann Plast Surg.* 2009;62(5):482–5.
- Kuang R, Wang Z, Xu Q, Liu S, Zhang W. Influence of mechanical stimulation on human dermal fibroblasts derived from different body sites. *Int J Clin Exp Med.* 2015;8(5):7641.
- Amuso D, Amore R, Iorio EL, Dolcemascolo R, Reggiani LB, Leonardi V. Histological evaluation of a biorevitalisation treatment with PDO wires. *Union of Aesthetic Medicine–UIME.* 2015;1(3):1–7.
- World Academy of Science, Engineering and Technology. *Int J Med Health Sci.* 2016;10(12).
- Suh DH, Jang HW, Lee SJ, Lee WS, Ryu HJ. Outcomes of polydioxanone knotless thread lifting for facial rejuvenation. *Dermatol Surg.* 2015;41(6):720–5.
- Nurden AT. Platelets, inflammation and tissue regeneration. *Thromb Haemost.* 2011;105(S 06):S13–33.
- Steed DL. The role of growth factors in wound healing. *Surg Clin N Am.* 1997;77(3):575–86.
- Kevy S, Jacobson M, Blasetti L, Fagnant A. Preparation of growth factor enriched autologous platelet gel. In *Proceedings of the 27th Annual meeting of Service Biomaterials; 2001 April 26.* p. 15–18.
- Ehrenfest DM, Andia I, Zumstein MA, Zhang CQ, Pinto NR, Bielecki T. Classification of platelet concentrates (Platelet-Rich Plasma-PRP, Platelet-Rich Fibrin-PRF) for topical and infiltrative use in orthopedic and sports medicine: current consensus, clinical implications and perspectives. *Muscles Ligaments Tendons J.* 2014;4(1):3.
- Marx RE. Platelet-rich plasma (PRP): what is PRP and what is not PRP? *Implant Dent.* 2001;10(4):225–8.
- CHO JW, Kim S, Lee KS. Platelet-rich plasma induces increased expression of G1 cell cycle regulators, type I collagen, and matrix metalloproteinase-1 in human skin fibroblasts. *Int J Mol Med.* 2012;29(1):32–6.
- Kim DH, Je YJ, Kim CD, Lee YH, Seo YJ, Lee JH, Lee Y. Can platelet-rich plasma be used for skin rejuvenation? Evaluation of effects of platelet-rich plasma on human dermal fibroblast. *Ann Dermatol.* 2011;23(4):424–31.
- Kang B, Lee J, Shin M, Kim N. Infraorbital rejuvenation using PRP (platelet-rich plasma): a prospective, randomized, split-face trial. *J Am Acad Dermatol.* 2013;1:68(4).
- International Cellular Medicine Society Guidelines. Section X—guidelines for the Use of Platelet Rich Plasma. Adopted 2011 (Cited 2019, May 20). Available from <http://www.cellmedicinesociety.org/icms-guidelines/guidelines>
- Mendonça RD, Rodrigues GB. As principais alterações dermatológicas em pacientes obesos. *Arq Bras Cir Dig.* 2011;24(1):68–73.
- She WH, Cheung TT, Jenkins CR, Irwin MG. Clinical applications of high-intensity focused ultrasound. *Hong Kong Med J.* 2016;22(4):382–92.
- Brown MR, Farquhar-Smith P, Williams JE, Ter Haar G, Desouza NM. The use of high-intensity focused ultrasound as a novel treatment for painful conditions—a description and narrative review of the literature. *Br J Anaesth.* 2015;115(4):520–30.
- White WM, Makin IR, Barthe PG, Slayton MH, Gliklich RE. Selective creation of thermal injury zones in the superficial musculoaponeurotic system using intense ultrasound therapy: a new target for noninvasive facial rejuvenation. *Arch Facial Plast Surg.* 2007;9(1):22–9.
- Jolesz FA, Hynynen K, McDannold N, Tempny C. MR imaging-controlled focused ultrasound ablation: a noninvasive image-guided surgery. *Magn Reson Imaging Clin N Am.* 2005;13(3):545–60.
- Fabi SG. Noninvasive skin tightening: focus on new ultrasound techniques. *Clin Cosmet Investig Dermatol.* 2015;8:47.
- Suh DH, Oh YJ, Lee SJ, Rho JH, Song KY, Kim NI, Shin MK. A intense-focused ultrasound tightening for the treatment of infraorbital laxity. *J Cosmet Laser Ther.* 2012;14(6):290–5.
- Belenky I, Margulis A, Elman M, Bar-Yosef U, Paun SD. Exploring channeling optimized radiofrequency energy: a review of radiofrequency history and applications in esthetic fields. *Adv Ther.* 2012;29(3):249–66.
- Atiyeh BS, Dibo SA. Nonsurgical nonablative treatment of aging skin: radiofrequency technologies between aggressive marketing and evidence-based efficacy. *Aesthet Plast Surg.* 2009;33(3):283–94.

36. Alvarez N, Ortiz L, Vicente V, Alcaraz M, Sánchez-Pedreño P. The effects of radiofrequency on skin: experimental study. *Lasers Surg Med.* 2008;40(2):76–82.
37. Bassichis BA, Dayan S, Thomas JR. Use of a nonablative radiofrequency device to rejuvenate the upper one-third of the face. *Otolaryngol Head Neck Surg.* 2004;130(4):397–406.
38. Montesi G, Calvieri S, Balzani A, Gold MH. Bipolar radiofrequency in the treatment of dermatologic imperfections: clinico-pathological and immunohistochemical aspects. *J Drugs Dermatol.* 2007;6(9):890–6.

Open Access This chapter is licensed under the terms of the Creative Commons Attribution 4.0 International License (<http://creativecommons.org/licenses/by/4.0/>), which permits use, sharing, adaptation, distribution and reproduction in any medium or format, as long as you give appropriate credit to the original author(s) and the source, provide a link to the Creative Commons license and indicate if changes were made.

The images or other third party material in this chapter are included in the chapter's Creative Commons license, unless indicated otherwise in a credit line to the material. If material is not included in the chapter's Creative Commons license and your intended use is not permitted by statutory regulation or exceeds the permitted use, you will need to obtain permission directly from the copyright holder.



Botulinum Toxin and Fillers for Maxillofacial Esthetics

33

Sainath Matsa

33.1 Introduction

33.1.1 Facial Aesthetics

The field of cosmetology has steadily progressed over the past decade, and cosmetic procedures are moving towards a new era [1]. People are becoming more aware of the way they look, especially the face and are turning to medical and dental professionals to improve their appearance. Attractive facial aesthetics at any age has social and psychological benefits. Facial skin constitutes a major part in contributing to facial aesthetics. The skin is a reflection of several body characteristics, of which gender is a prominent one [1]. Age, genetic, hormonal and exogenous factors can affect both skin structure and function and are responsible for differences between different men and women. This chapter gives the basics and advances in the field of facial cosmetic and functional correction using Neurotoxins (Botulinum toxin) and Dermal Fillers.

33.1.2 Facial Skin Physiology, Muscular Anatomy and Mechanical Properties

In humans, skin including the epidermis and dermis is 1.428 times thicker in men than in women across 5–90 years of age [1]. However, women tend to have thicker subcutaneous fat. It has been found that, in men, it gradually becomes thinner with advancing age (12–93 years), whereas in women, the

skin thickness remains constant till the fifth decade, after which it tends to decrease [2].

Gender plays an important role in facial wrinkling. In men, the incidence of forehead wrinkles is higher than in women. However, the incidence of upper eyelid wrinkles does not appear to be influenced by gender. Wrinkles in other parts of the face are found to be greater in men than in women, except above 65 years of age, when the incidence appears to equalise [3]. One study evaluated the skin morphology, elasticity and areas of sagging using photographs and a cutometer. The authors found that these were similar in both genders in the cheek region, but in the lower eyelids, sagging was more severe in males after middle age [4, 5].

33.1.3 Facial Muscles and Their Actions (Fig. 33.1)

A good understanding of the action of the various facial muscles is important for precise application of botulinum toxin. The muscles and their actions are tabulated (Table 33.1).

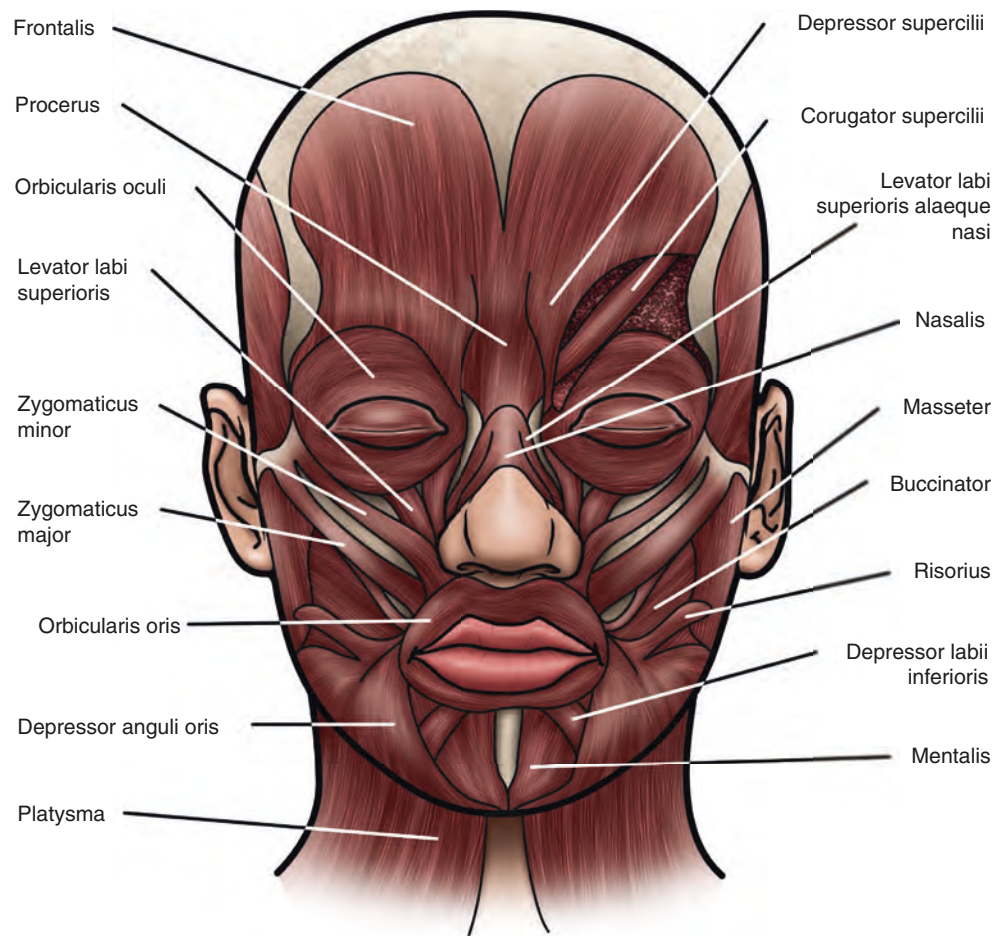
Electronic Supplementary Material The online version of this chapter (https://doi.org/10.1007/978-981-15-1346-6_33) contains supplementary material, which is available to authorized users.

S. Matsa (✉)
Praseedha Clinic for Maxillofacial Cosmetic Surgery,
Chennai, Tamil Nadu, India

33.2 Botulinum Toxin

33.2.1 Botulinum Toxin-Type A

Botulinum Toxin type A was first used on the face by Carruthers and Carruthers in the late 1980s [6]. Following studies in the 1990s about its cosmetic use, botulinum toxin was approved by the USA Food and Drug Administration (FDA). This led to a revolution in treating ageing skin in recent years [1].

Fig. 33.1 Muscles of facial expression

©Association of Oral and Maxillofacial Surgeons of India

Table 33.1 Facial Muscles and Their Actions

<i>Frontalis</i> —Raising the eyebrows; transverse wrinkling of the forehead
<i>Corrugator</i> —Vertical/oblique wrinkling of the forehead; draws the eyebrows together
<i>Procerus</i> —Pulls the glabellar skin in an inferior direction and causes transverse wrinkles
<i>Depressor Supercilii</i> —Pulls the eyebrow downwards on the medial canthal region
<i>Orbicularis Oculi</i> —Controls the sphincter of the eye
<i>Risorius</i> —Lateral movement of the corner of the mouth
<i>Orbicularis Oris</i> —Opening and closing of the mouth (sphincter action)
<i>Levator Labii Superioris</i> —Pulls the upper lip superiorly
<i>Depressor Anguli Oris</i> —Draws the corner of the mouth inferiorly
<i>Depressor Labii Inferioris</i> —Pulls the lower lip downwards
<i>Modiolus</i> —It's a union of muscles, situated lateral to the external commissure of the mouth, allowing symmetrical perioral expression.

33.2.2 Pharmacology and Mechanism of Action

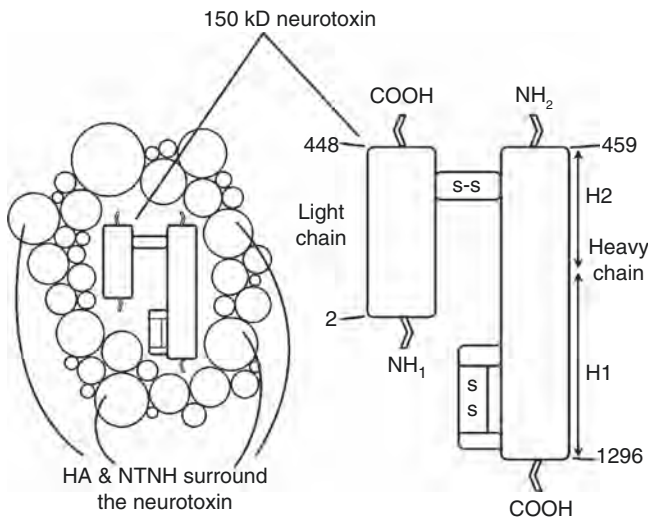
Clostridium botulinum produces an exotoxin. It is an anaerobic gram positive bacillus (Fig. 33.2) which forms spores. It

has eight types of strains which are labelled alphabetically: A, B, C, D, E, F, G, and H [7].

Two types of strains, A and B, are available currently. These result from the modification of the protein structure that has been used for a variety of medical and cosmetic purpose. Botulinum Neurotoxin causes denervation of the motor neuron temporarily, in the treated muscle and selectively inactivates the nerve terminals by blocking the release of acetylcholine and the target protein SNAP25, [8] leading to a temporary and reversible blockade of cholinergic transmission. In the neuromuscular junction, the blockade of the release of acetylcholine promotes muscle relaxation to muscular palsy [9] (Fig. 33.3a, b, c).

Reconstitution, Dilution and Dose:

Botulinum Toxin Type-A is available as lyophilised powder that must be stored frozen -4°C or lower. Reconstitution of the powder may be done using 0.9% Normal Saline solution, which is isotonic. Once reconstituted, the solution must be used within 4–8 h, after which the potency of the drug may be lost, and contamination of the vials may occur.



900kD BoNT/A complex contains:
 - 150 kD neurotoxin
 - Hemagglutinins (HA)
 - Nontoxic, non-HA proteins (NTNH)

©Association of Oral and Maxillofacial Surgeons of India

Fig. 33.2 Chemical structure

- Botulinum toxin A is marketed in two vials—50 and 100 U.
- In mice, the *Median Lethal Dose* is 1 U. The *MLD* in humans is estimated at 3000 U.
- For reconstituting 100 U, 2.5 ml of 0.9% Normal Saline may be used, which gives a concentration of 40 U/ml.

Many commercial brands are available for Botulinum Neurotoxin–A, like Siax[®], Botox[®], Xeomin[®] and Dysport[®] and every brand has variation in its dilution.

33.2.3 Indications

Botulinum toxin injections may be used in the clinical scenarios highlighted in Box 33.1.

Box 33.1 Indications of Botulinum Toxin

- Wrinkling of the face
- Facial rejuvenation of ageing face
- Gingival smile
- Masseteric hypertrophy
- Facial asymmetry
- Platysmal wrinkling and bands
- Hyperhidrotic conditions (excessive sweating)
- Blepharospasm
- Spasmodic torticollis
- Dystonia
 - cranial, lower facial, cervical, oromandibular.

33.2.3.1 Contraindications [10]

The use of Botulinum toxin injections is contraindicated in the following clinical situations:

- Pregnancy and breastfeeding.
- Individuals with an infection in the proposed area of the injection.
- Neuromuscular transmission disorders (myasthenia gravis).
- Individuals under medications that may influence neuromuscular transmission. These include Calcium channel blockers, Penicillamine, Quinine, Aminoglycosides, Pancuronium, Tubocurarine and Succinylcholine.
- Individuals under medications that interfere with coagulation like Acetylsalicylic Acid, Anticoagulants and Vitamin E.

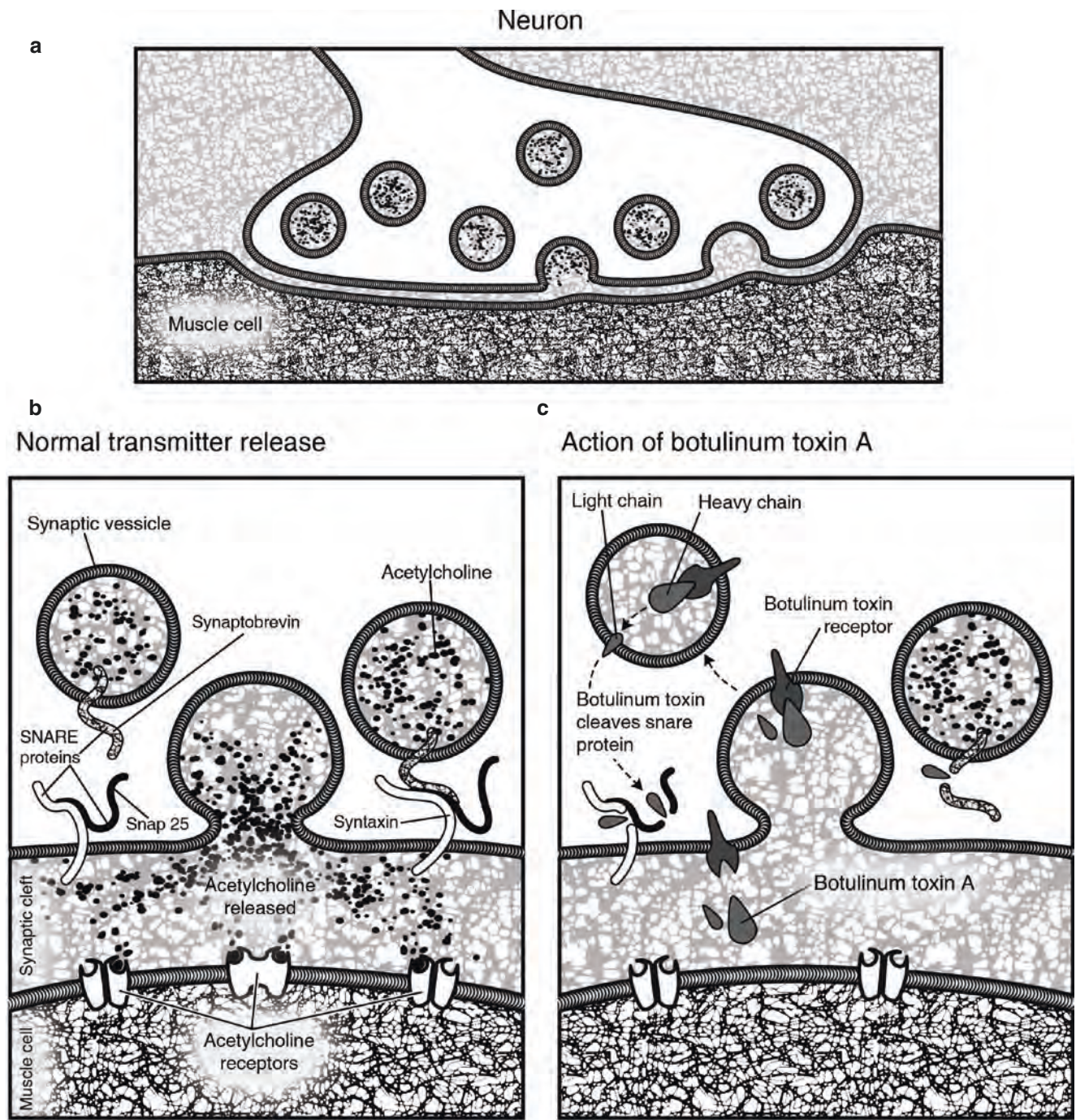
Patient Selection:

In the present era, patients have increased awareness and knowledge about their health and skin conditions. They may be very ambitious and optimistic about the procedure and are likely to expect a high level of satisfaction with their personal appearance after the treatment. The goal of treatment is to achieve a better looking and natural appearance. The patients' psychological aspects and expectations should be understood and evaluated prior to the start of any cosmetic treatment.

33.2.4 Injection Techniques (Video 33.1)

The following techniques are used for injecting botulinum toxin into various areas of the face.

- Glabella lines injection technique* (Fig. 33.4a, b): Visualise an imaginary “X” formed by two lines that join the inner brows with the contralateral inner canthus [11]. The injection must be given at the midpoint of the ‘X’. Conventionally, the Corrugator Supercilii muscle is visualised by observing the medial part of the eyebrow when the patient frowns. Botulinum Toxin is then slowly injected into the belly [11] of the muscle on either side. The needle must be maintained at 0.5 cm from the upper orbital rim, and lie internal to the mid-pupillary line. The total dose for glabellar line ranges from 10 to 15 U and can be increased to a maximum of 40 U based on the severity of the wrinkles.
- Forehead lines Injection technique* (Fig. 33.5): The frontalis muscle is superficial and may be easily identified by asking the patient to raise and lower the brow. The extent of muscle movement is then assessed. Injections must be done in the superficial subcutaneous tissue, over the entire forehead from medial to lateral. The typical dose ranges from 2 to 3 U in each point of small dots represented on the upper and lower aspects of the forehead or



©Association of Oral and Maxillofacial Surgeons of India

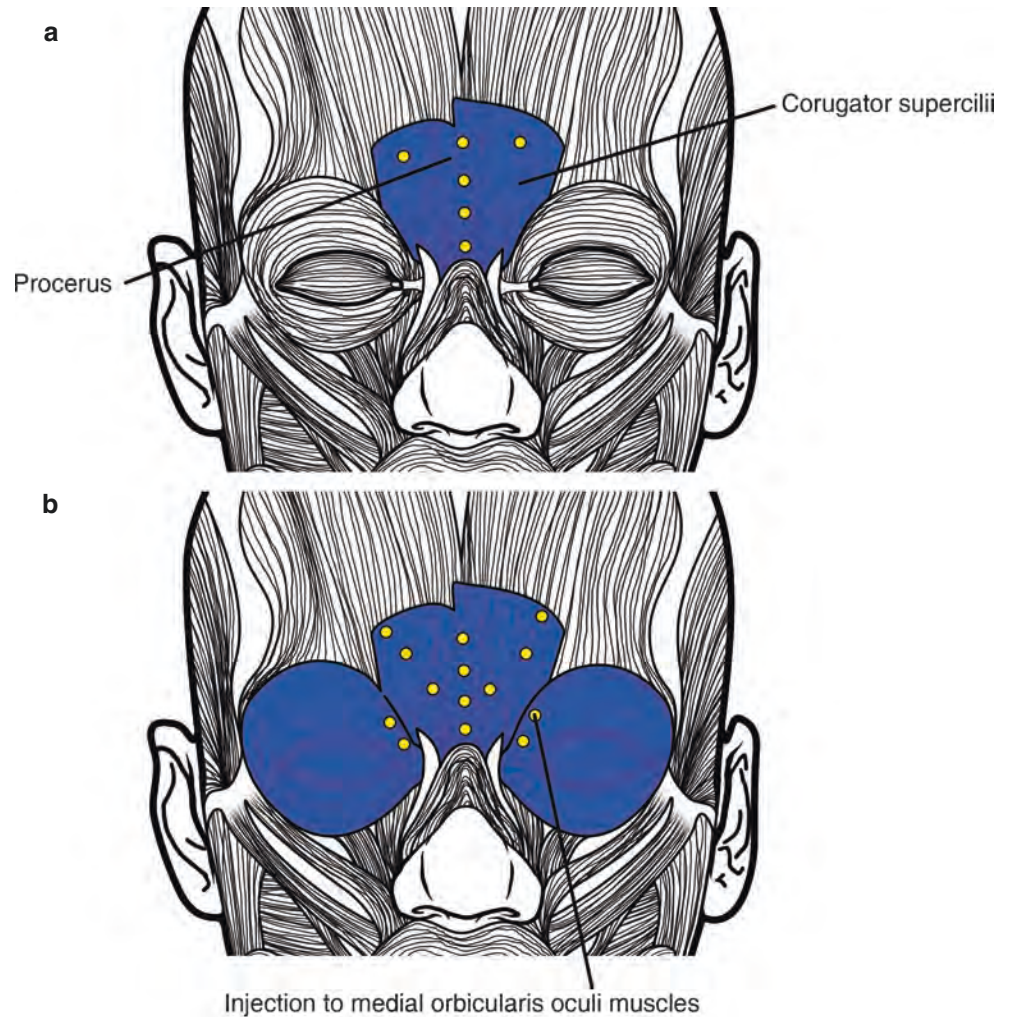
Fig. 33.3 (a–c) Action at the neuromuscular junction

5 U per point of the middle aspect of the muscle, represented in a big dots as given below in the figure. Frontal injections and glabellar injections must preferably be done together, to avoid increased compensatory use of glabellar muscle, which are mainly depressors [12, 13]. The dose of the injections must be kept small enough to just weaken the muscle instead of producing total paral-

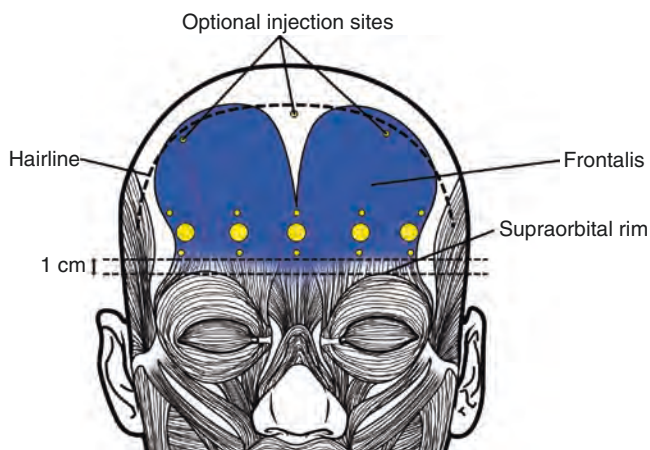
ysis. This is because the frontalis is responsible for facial expressiveness, and total paralysis would cause brow ptosis [14, 15]. It is also important to preserve at least some frontal is muscle movement, responsible for facial expression and lift of the eyelids and brows.

(c) *Crow feet wrinkles Injection technique* (Fig. 33.6a, b): Three to four injections of Botulinum toxin-A may be

Fig. 33.4 (a, b) Glabellar lines injection technique



©Association of Oral and Maxillofacial Surgeons of India



Do not inject within 1 cm of the supraorbital rim

©Association of Oral and Maxillofacial Surgeons of India

Fig. 33.5 Forehead lines injection technique

administered lateral to the eye, in the ‘crow’s feet’ region that radiates out from the lateral canthi. Around 8–20 U may be administered on each side [16]. The injection must be placed 1 cm lateral to the orbital rim and must be above the canthal angle, to avoid upper lateral lag. To achieve this, one can place a guiding finger of the other hand at the lateral orbital rim. Owing to the superficial location of the muscle, the needle need not be advanced deep into the subcutaneous tissue. Botulinum Toxin has a wide zone of effect, and therefore a superficial dermal injection will minimise bruising, but will still give good clinical results [16].

- (d) *Elevating Oral commissures and Smile line Injection technique* (Fig. 33.7): Depressor anguli oris is the muscle to be elevated for improving the smile lines. It is indicated in patients with inverted smile line (reverse smile line), which is caused by pulling the corner of the mouth inferiorly. To identify the depressor anguli oris muscle, the patient must frown and the muscle must be simultaneously palpated 1 cm lateral and inferior to the oral

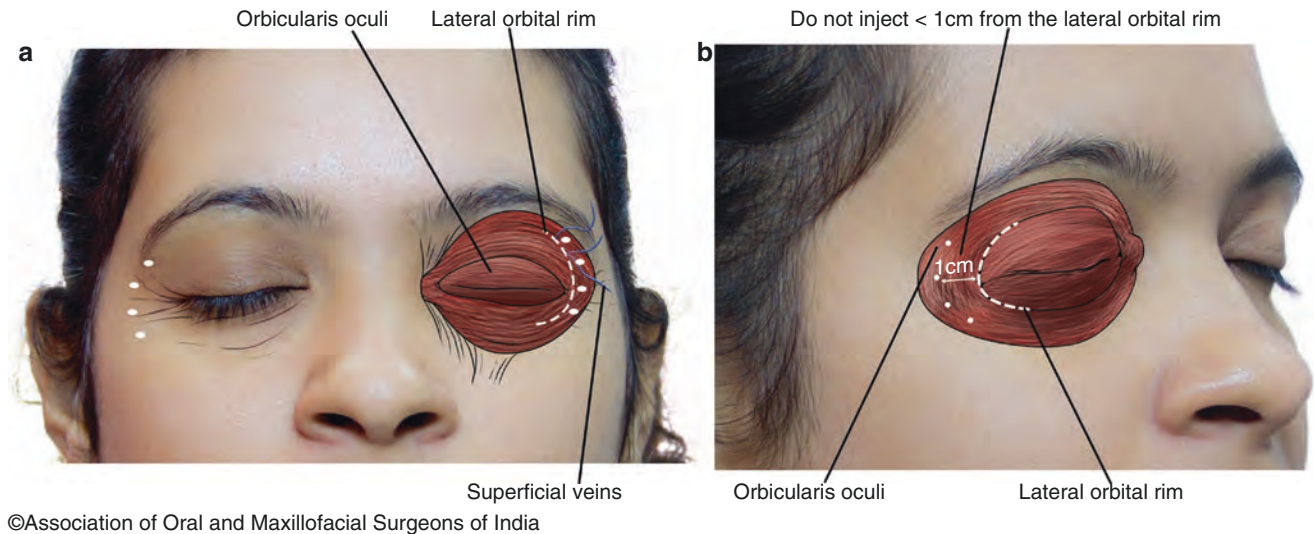


Fig. 33.6 (a, b) Crow feet wrinkles injection technique

commissure. Inject approximately 2–5 U deeply into the muscle on either side [16].

- (e) *Gummy smile or Gingival show correction Injection technique* (Fig. 33.8): In some patients, while smiling, their upper lip is pulled up, which reveals some amount of gingival tissue. If this is >1 cm, it is referred to as a “Gummy smile or Gingival Show”. The levator labii superioris alaeque nasi elevates the upper lip during smile. These muscles have their origin on the frontal process of the maxilla, and insert into the skin of the lateral aspect of the nose and upper lip. If only one muscle contracts, it results in a ‘snarl’, and this muscle has been referred to as the “Elvis” muscle [16]. Normally, 1–2 U of the Botulinum neurotoxin is injected on each side in the muscle. Care should be taken because this injection can produce elongation of the upper lip.
- (f) *Platysmal wrinkles Injection technique* (Fig. 33.9): The platysma forms horizontal lines or wrinkles. Into every horizontal crease, an intradermal injection of 1–2 U may be injected for every 1.0–1.5 cm [16]. There may be several creases, but each treatment session must not use more than 15–20 U. In these areas, careful injections are absolutely essential, as these muscles are cholinergic, and deep injections may affect swallowing. If the injections are placed at deeper levels, or high volumes are used, a weak or diminished swallow may result.
- (g) *Masseteric Hypertrophy Injection technique* (Fig. 33.10): The masseter can give masculine characteristics, such as square jawlines and wide mandibular borders. This is enhanced when the muscle hypertrophies, and may not be attractive in women. Bruxism and clenching of teeth can lead to hypertrophy of the masseter muscle, which in turn increases the horizontal width of the mandible [16]. While injecting into the masseter, one finger may be

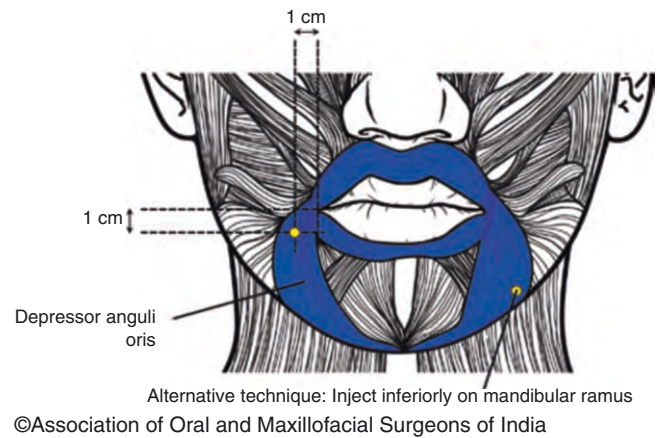


Fig. 33.7 Smile line correction

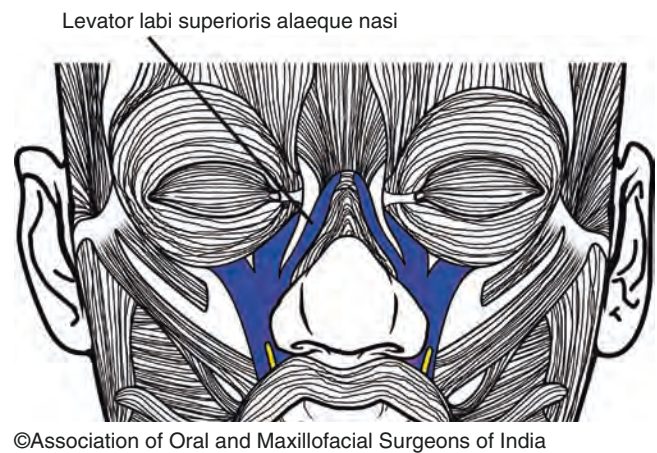
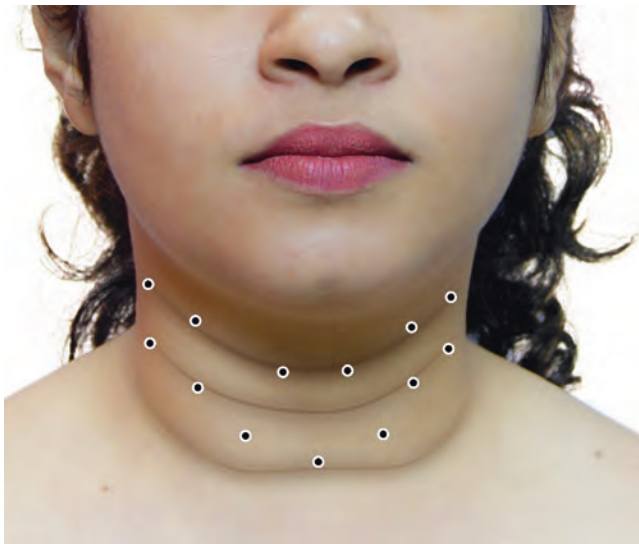

Fig. 33.8 Gummy smile correction

placed along the lower border of the mandible, one finger along the posterior border and one at mandibular angle. This may be done with the patient clenching, as



Intradermal injection

©Association of Oral and Maxillofacial Surgeons of India

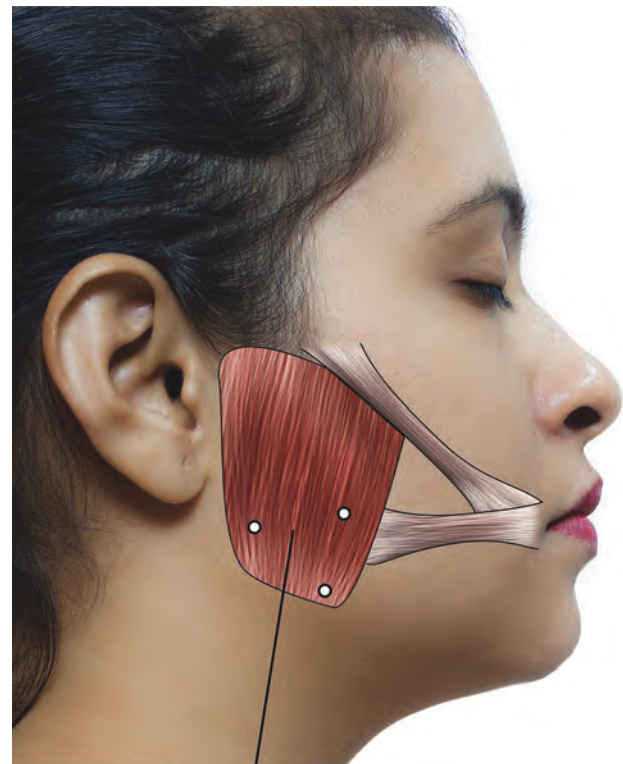
Fig. 33.9 Platysmal banding

this marks the perimeter of the muscle. While injecting bone should be felt by the needle and withdrawn slightly just above the bone and deposit 4–5 U along the marked lines. Depending on the volume of hypertrophy, around 20 U may be injected [16]. Over-injection at the masseter region may result in problems with bite or chewing.

- (h) *Frey's Syndrome or Gustatory sweating Injection Technique* (Fig. 33.11): This is a condition in which mild to profuse sweating occurs in the cheek or malar area while eating. A diagnostic test called “*starch-iodine test*” [16] can be performed prior to injection of Botulinum toxin. Povidone iodine is applied over the cheek and corn starch is sprinkled. The patient is advised to eat, to stimulate the salivary gland and left to dry for a few minutes. The corn starch turns black in the area of sweating [16], and a grid is drawn along this area. Once the test is confirmed, usually 30–50 U is injected along the grid as shown. The botulinum toxin blocks acetylcholine, which is the neurotransmitter that stimulates sweating.

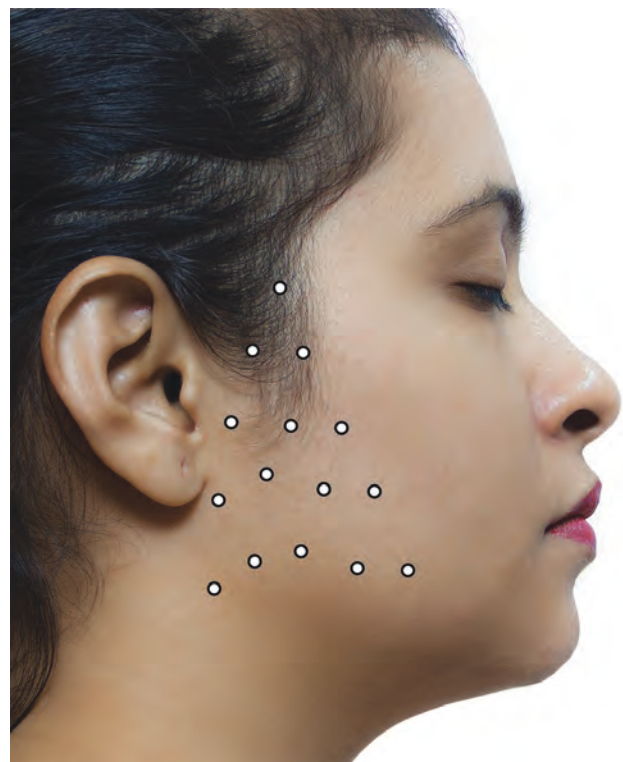
33.2.5 Complications and Recommendations While Using Botulinum Toxin

- Apply pressure at the site before and after treatment. Cold packs may also be used.
- The use of small syringes and fine-gauge (30 g) needles can reduce pain and bruising at the injected site.
- Using topical anaesthesia (EMLA—Eutectic Mixture of Local Anaesthesia) reduces pain while injecting.



Masseter

©Association of Oral and Maxillofacial Surgeons of India

Fig. 33.10 Masseteric hypertrophy

©Association of Oral and Maxillofacial Surgeons of India

Fig. 33.11 Frey's Syndrome

- Injections should be symmetrical regarding doses, muscles and areas. This is important for the natural balance of the facial structures and to avoid asymmetries.
- Since the results are expected for 4–6 months, treatments are usually repeated twice a year, for maintenance of the results.
- There are isolated few reports of systemic adverse effects after injections with the use of doses larger than those usually recommended for cosmetic purposes [17].
- The most common injection-related side effects are pain, transient edema at the injected site, erythema, haematomas and ecchymosis [13, 17].
- Common technique-dependent complications include eyelid ptosis, asymmetries and excessive brow elevation.
- In the lower face, complications are related to high doses can cause undesirable paralysis of the musculature, resulting in asymmetric smiling and complications due to the incompetence of the sphincter function of the mouth.
- In the neck, complications can be dysphagia and difficulty in the movements.

33.3 Dermal Fillers

33.3.1 Role of Fillers in Facial Aesthetics

Throughout the past decades, there have been major changes and advancements in the injectable preparations used for soft tissue augmentation. Introduced by Dr. Arnold Klein [1] in the 1980s, for lip augmentation, collagen has progressed to the broader concept of volumising the face and to correct the subcutaneous atrophy due to ageing and fat loss.

Following extensive clinical trials in the late 1970s, the FDA first approved the use of bovine collagen in 1981, which greatly advanced the field of soft-tissue augmentation. Over the past 10 years, several types of facial fillers have been approved in the United States and Europe, and there is a constantly evolving and expanding assortment of the dermal filler materials and devices for soft tissue augmentation [18].

Hyaluronic Acid (HA), which was introduced as a facial filler in 2003, brought about a much needed change from the allergies being reported due to bovine collagen [18]. Hyaluronic Acid is a member of the glycosaminoglycan family and a natural component of human connective tissue. The HA molecule is identical across all species and lacks a protein component, thus it has little to no potential for immunologic reaction in humans. It is composed of repeating disaccharide units, stabilised with cross-linked hydroxyl groups that bind water to create volume. This gives a plumped appearance to the skin. HA in the skin decreases with age and sun exposure, reducing the skin's water-binding capacity and turgor, ultimately leading to skin wrinkling and sagging [19]. HA can absorb up to 1000 times its molecular weight of water, and Hyaluronic Acid fillers volumise the face by replacing body Hyaluronic Acid and restoring hydration [5].

Studies have shown that hyaluronic acid requires less injection volume as compared to bovine collagen for optimal cosmetic results, and HA is also found to be more effective at maintaining the cosmetic correction [20, 21].

The U.S. Food and Drug Administration (FDA) has now approved various types of Hyaluronic acids, bio-stimulatory products like calcium hydroxyapatite and poly-L lactic acid, as well as polymethylmethacrylate as a substitute for fillers.

Fillers are categorised as permanent, semi-permanent and temporary. The majority of injectable fillers are temporary, lasting from several weeks to several months, although some reportedly last 9–12 months. Many of these processes require ongoing treatment to maintain the desired appearance [22].

33.3.2 Classification of Fillers

Based on their duration of action, fillers may be classified as follows:

Temporary (3–12 Months) These are mainly used to replace collagen in the skin, which weakens with age and loses its elasticity. Collagen has three main sources—bovine, porcine and human. Bovine collagen is very similar to the human molecule and is widely used. It only has specific differences in the end peptides (telopeptides), which are removed in processing, leaving a core protein similar to that of a humans [23]. Hyaluronic acid is the most commonly used Filler material of this category.

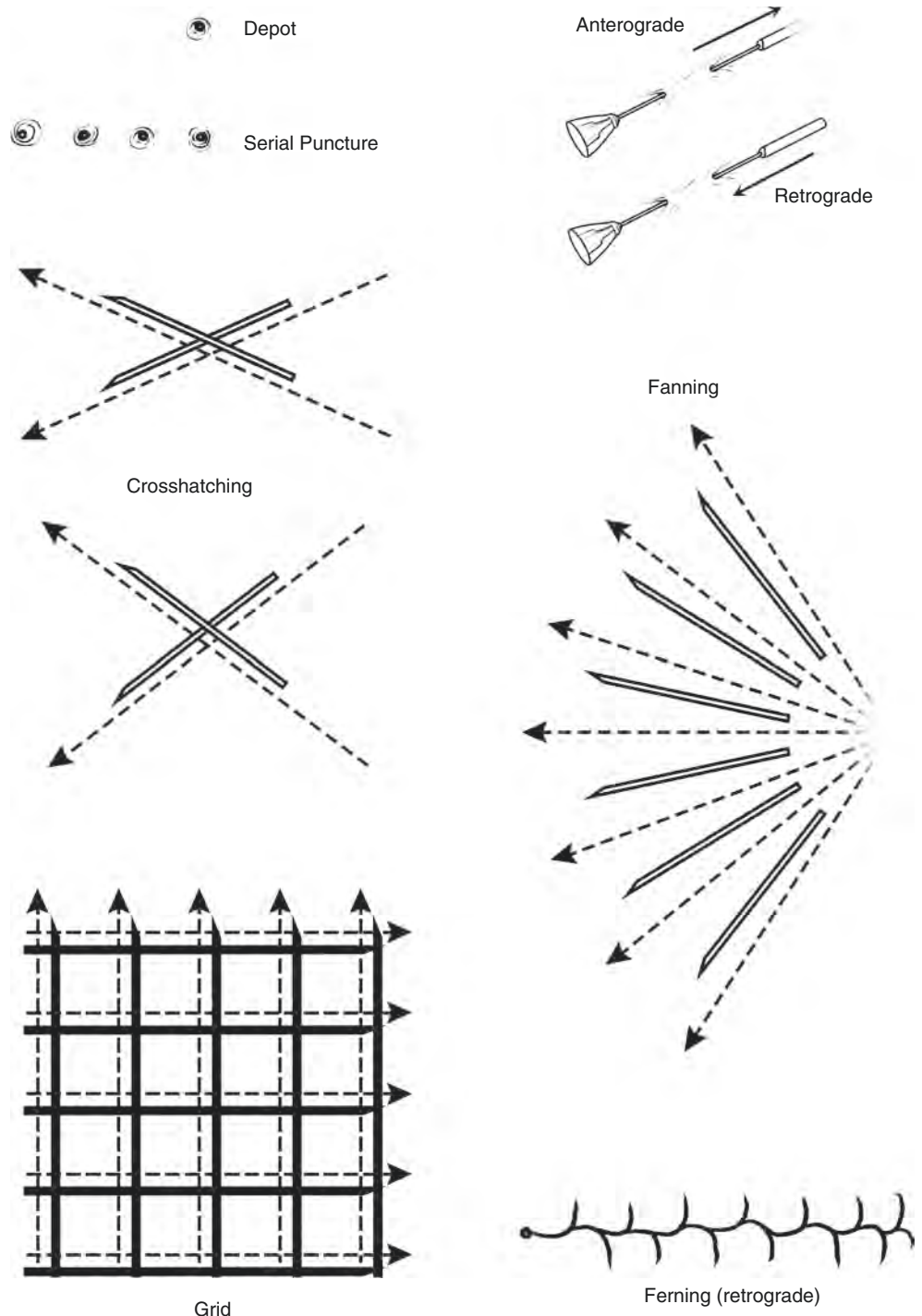
Semi-Permanent (1–5 Years) Calcium hydroxyapatite is one of the commonest semi-permanent fillers. It creates a stable scaffold for soft tissues to grow. Calcium hydroxylapatite may be injected into the deep dermis, where the microspheres are held in place until they are resorbed and collagen deposition occurs. This results in formation of non-scar-tissue type of collagen, which provides volume in the area under treatment [24].

Permanent (>5 Years) These are mostly synthetic implants, which are made of Polymethylmethacrylate (PMMA) microspheres. PMMA microspheres may be mixed with denatured bovine collagen and lidocaine, and suspended in a phosphate-buffered saline solution. Since PMMA is inert, it is well tolerated by the body and does not induce allergic reactions [25, 26].

Preparation of the Patient before Injection of Fillers:

The patient's face is washed gently to dry and disinfect the skin. This is done using propanol solution. Since the dermal fillers are very painful while injecting, application of the topical anaesthesia around the area of injection using EMLA (Eutectic Mixture of Local Anaesthesia) for 30–45 min prior or particular branch of Maxillary division or Mandibular division of the trigeminal nerve is anaesthetised using 2% Lignocaine as a local anaesthetic injection.

Fig. 33.12 Various patterns in Injection technique



©Association of Oral and Maxillofacial Surgeons of India

33.3.3 Dermal Filler Injection Methods (Fig. 33.12)

Hyaluronic acid is available in syringes in a sterile packed container. These have 26–30 gauge needle, with a length of 1–1½ inches.

These are injected at the subdermal planes in various fashion which are mentioned in Box 33.2.

The following is a description of various techniques.

Linear Threading: In this technique, fillers are injected in a needle and thread fashion. The needle is inserted and withdrawn repeatedly along a straight line. It has two types.

1. *Anterograde Injection:* The filler is injected while the needle is being advanced, and the filler is therefore easily tracked in the front of the needle.

Box 33.2 Dermal Filler Injection Methods

- Linear threading,
- Depot injection,
- Fanning method,
- Serial puncture,
- Cross hatching,
- Grid and Ferning

2. **Retrograde Injection:** The filler is not injected simultaneously during needle advancement. Once the needle is slowly withdrawn, the filler is injected.

Depot: In this technique, a small amount of the filler is deposited in the correct plane.

Serial Puncture: In a single wrinkle or fold, multiple closely spaced depot injections are placed.

Fanning: It is done through one point of entry and the needle is rotated like a fan in multiple directions, and the fillers are deposited in a retrograde way. It is important to stop injecting as the needle comes close to the insertion site in order to avoid build-up of fillers at the point of entry.

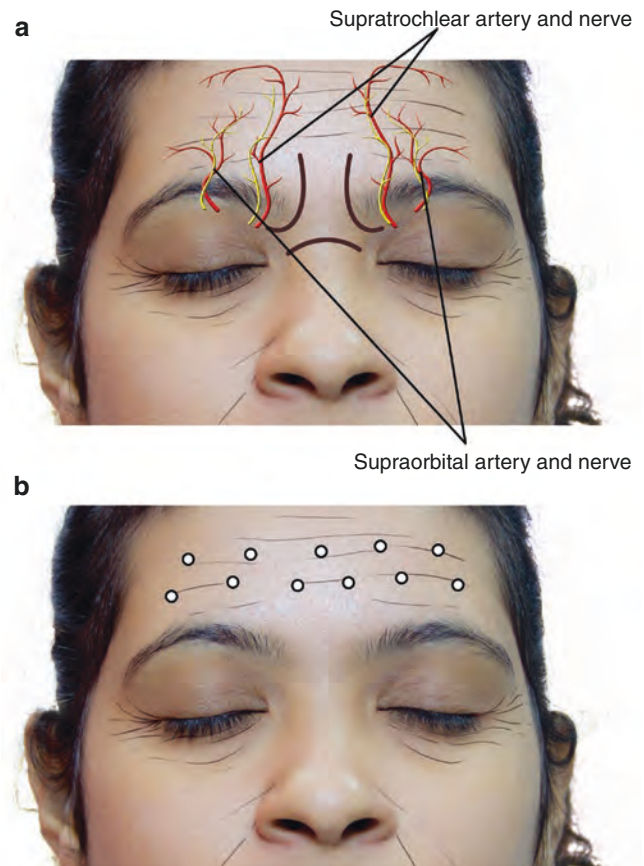
Cross Hatching: Injecting as multiple linear thread deposited in an X-shaped fashion.

Grid: It is injected as linear threads intersecting perpendicular to each other point of entry.

Ferning: [16] This is similar to retrograde injection. The needle is inserted on either side of the central tract, and the fillers are deposited in a branch-like fashion almost like the branches of a fern.

33.3.4 Injection Techniques

(a) **Glabella and Forehead region** (Fig. 33.13a,b): The Glabellar region is the most prominent site for wrinkling and very well shown even in a mild expression. There are vertical lines of wrinkling, which result from contraction of the corrugator supercilii muscles, and horizontal lines which occur due to contraction of the procerus muscle. Before injecting, the patient should frown the brow and the needle is inserted at the subdermal plane and injected in a linear fashion and it is also deposited deep and parallel to the wrinkle. Small depots or serial puncture fashion of fillers are injected along the line of the wrinkles throughout its entire length. Gentle

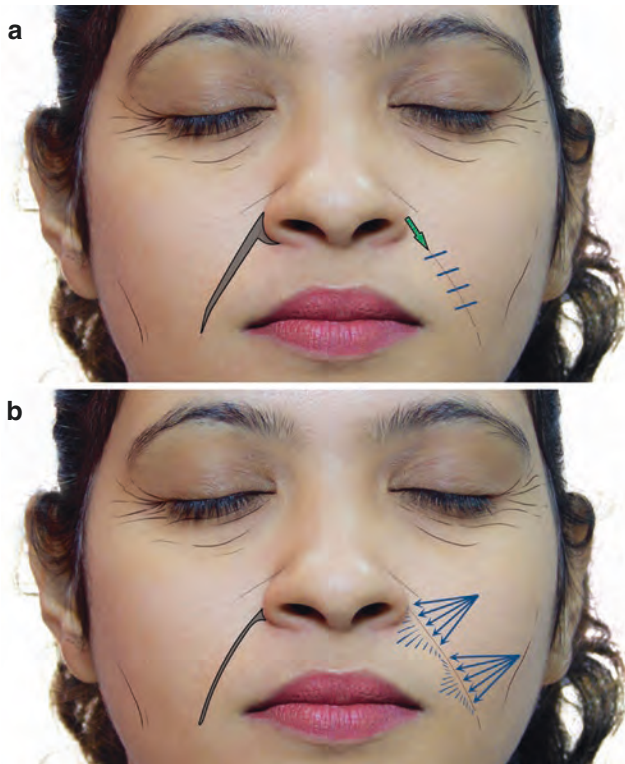


©Association of Oral and Maxillofacial Surgeons of India

Fig. 33.13 (a, b) Glabellar & forehead wrinkles

rub or massaging to be done to distribute the filler uniformly. In the case of bruising, icepacks can be used. Injecting into a vessel must be avoided as this can lead to the formation of emboli.

- (b) **Nasolabial Fold** (Fig. 33.14a,b): The nasolabial fold is defined as the groove from corner of the alar base to the margin lateral to the angle of the mouth. The nasolabial groove must never be eliminated completely as this can result in an unaesthetic appearance. Injection may be done using serial puncture, linear threading, cross-hatching, or fanning. Only the medial part of the fold must be augmented, with injections perpendicular to this. This is best done by imagining a tall, thin, triangular deficit in front of the fold that needs to be filled. To prevent bruising, ice and pressure may be applied. Initially, hyaluronic acid swells and may appear as a firm mass on palpation but gradually blends in after the first week.
- (c) **Lip Augmentation** (Fig. 33.15): This is one of the most common cosmetic procedures done using Hyaluronic acid filler for augmenting or everting the lips. The areas to be augmented are the outline of the lip, body of the lip or both. There is a potential space in the body of the vermilion, which, if correctly entered, will allow the filler to



©Association of Oral and Maxillofacial Surgeons of India

Fig. 33.14 (a, b) Nasolabial fold injection technique

move within it along the entire lip margin. Dermal fillers injected in the body of the lips can augment, rejuvenate and improve the symmetry of the lips. Philtral columns can get flattened with age. These can be accentuated by injecting along the border of the vermilion and philtral region to give a more prominent philtrum and cupid's bow with eversion of the lip. The philtrum may be pinched after injection to accentuate the ridges. Injections are generally placed superficially in to the subcutaneous plane. Massaging or a gentle rub after injection helps to distribute the filler evenly. Injection may be performed in an anterograde fashion, from lateral to medial, and the filler can be tracked along the vermilion.

- (d) *Tear Trough Deformity* (Fig. 33.16): Tear Trough is usually referred to as the crease at the medial segment of the inferior orbital region. As ageing occurs, the infraorbital rim becomes more skeletonised and depressed. To correct this sunken appearance, HA may be injected into the semicircular depression under the eyes. Normally a 30-gauge needle, 2.5 cm long, is used to inject in the dermal layer of the lower eyelid to avoid bruising, as this area is highly vascularised. The needle is then inserted upwards at an angle, till it reaches the top of the orbital rim. The finger of the opposite hand may be used to direct the needle by positioning it at this point. The tip of the needle must touch the bone and its precise location must

be verified prior to injection. The filler is injected slowly and deeply into this area. Massaging may be done at the injected area to avoid irregularities. If the HA is deposited too deep, a “Tyndall effect” [16] may be observed. Hyaluronic Acid can occasionally increase fluid retention around the periocular area, and lead to infraorbital swelling, edema or discolouration in the medial portion of the orbicularis muscle. If this occurs, subcutaneous hyaluronidase injections may lyse the Hyaluronic Acid and reduce the swelling.

- (e) *Injection technique to increase the cheek volume* (Fig. 33.17): In some patients, fat loss or volume deficit can cause cheek hollowing. The loss of buccal pad of fat causes wrinkled cheeks, exaggeration of nasolabial folds and jowling of the skin at the lower border of the mandible. The submalar region (below the zygomatic arch) and buccal region (lateral to the nasolabial fold) are areas that need attention. The injection technique should be administered in a grid or fanning pattern. The injections must be administered at the dermal–subcutaneous plane. Massaging after injection can help smoothen irregularities.

33.3.5 Contraindication [22]

Some of the most common conditions to be avoided for fillers include:

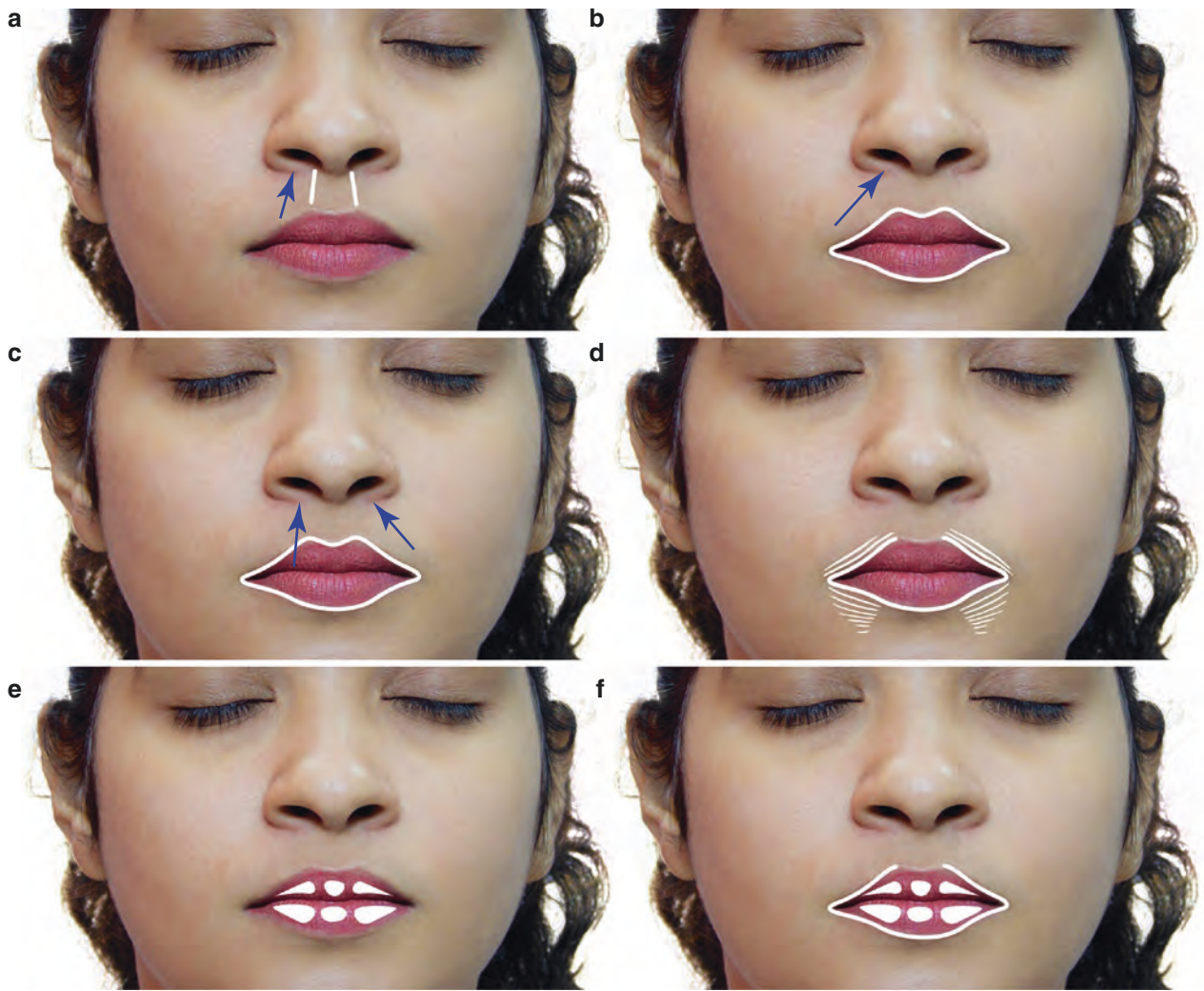
- Scarring and collagen/connective tissue disorders
- Diabetes
- Infections—e.g.: Viral Herpes
- Coagulation problems
- Pregnant or Lactating women
- Psychological conditions

33.4 Conclusion

Botulinum Toxin Type A and Hyaluronic acid dermal fillers are very safe and effective under a trained physician or surgeon for therapeutic and cosmetic use. Wrinkles especially those which are located in the face and some asymmetries, mainly caused or worsened by the repeated contraction of facial muscles and ageing process can be effectively treated by these methods.

Proper knowledge of the anatomy of facial muscles and proper techniques are important to achieve predictable results and avoid complications. Informed consent for the procedure must be obtained from the patient after explaining the risks and the outcome, before commencing the treatment. Though Botulinum toxin and dermal Fillers give temporary results, they are safe and very effective in achieving aesthetic outcome.

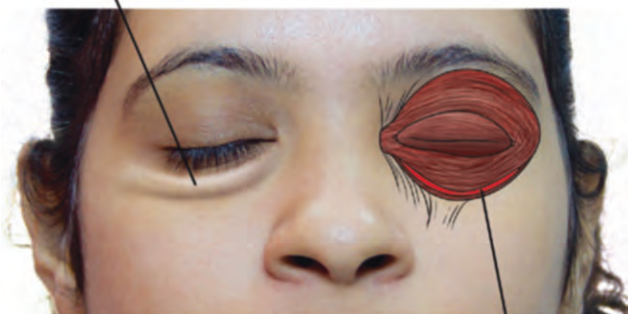Disclosure Author has no financial conflicts to disclose.



©Association of Oral and Maxillofacial Surgeons of India

Fig. 33.15 Injection technique for philtrum, lip line and the body of the lip. (a) anterograde filling (b) retrograde filling (c) both anterograde and retrograde filling (d) antero retrograde with fanning if necessary (e) depot and serial puncture filling (f) anterograde retrograde serial and depot filling

Pre periosteal filler along orbital rim

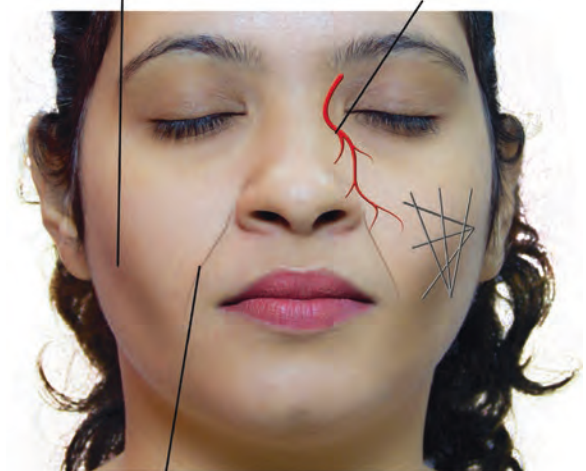

Tear trough deformity

©Association of Oral and Maxillofacial Surgeons of India

Fig. 33.16 Tear trough deformity

Submalar buccal hollow Angular artery



Nasolabial fold

©Association of Oral and Maxillofacial Surgeons of India

Fig. 33.17 Injection technique for hollowing cheeks

Case Scenarios

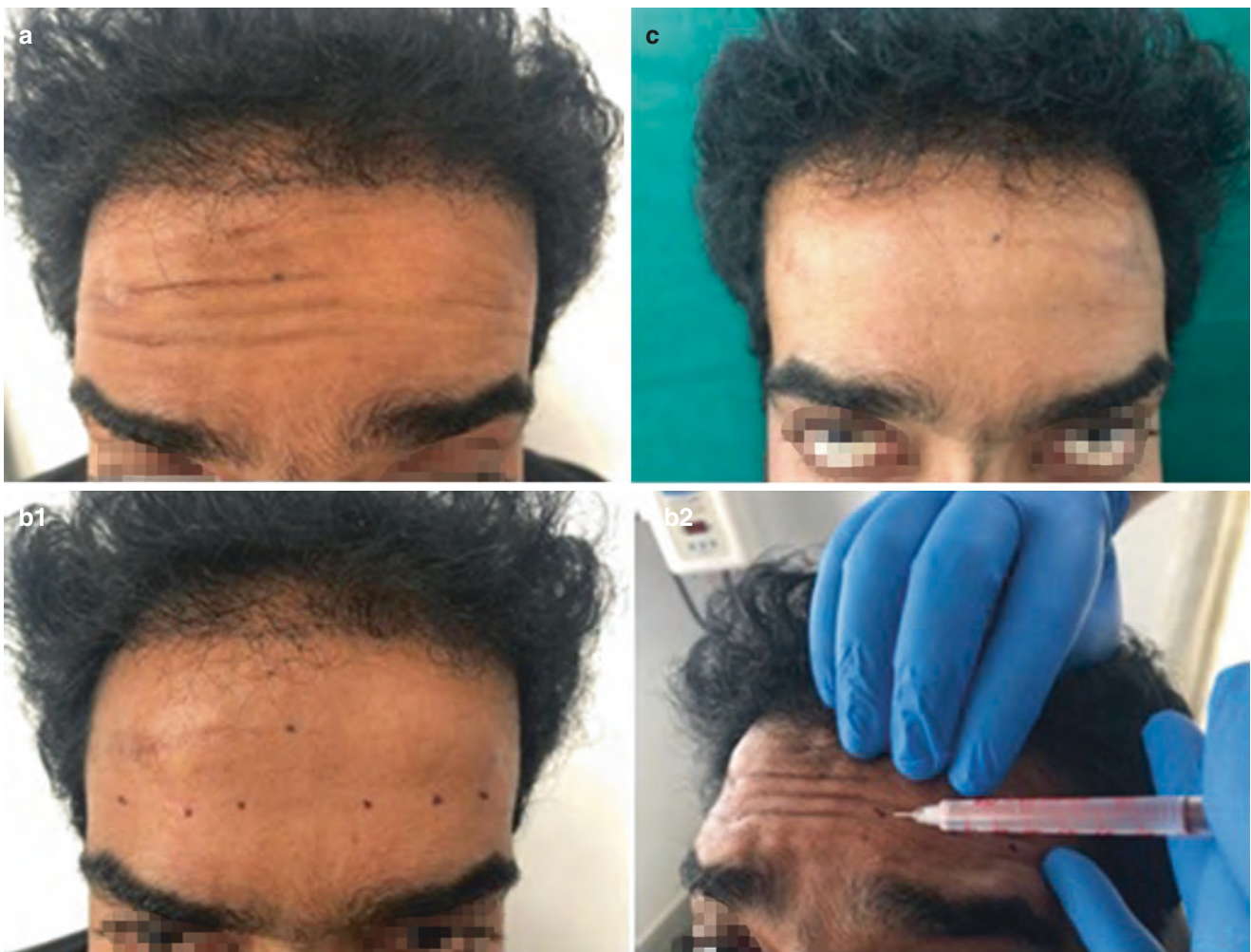Case 1 (Fig. 33.18a,b,c)

A 43-year-old female complaining of excessive tooth and gingival exposure on smiling. Clinical features (Fig. 33.18a): excessive gingival show on smiling normal lip length and

normal size of the tooth. Treatment Plan (Fig. 33.18b1, b2, b3 and b4): locating the levator labii superioris muscle and injecting Botulinum toxin Type A with a dose of 5 U on both the sides. The injection point is located at the junction between lip and the ala of the nose. Post-operative findings (Fig. 33.18c): no gingival show on smiling.



Fig. 33.18 (a) Clinical features with excessive Gingival show. (b1, b2, b3, b4) Intraoperative. (c) Postoperative, absence of Gingival show



©Association of Oral and Maxillofacial Surgeons of India

Fig. 33.19 (a) Clinical feature with forehead wrinkling. (b1, b2) Intraoperative. (c) Post-operative, absence of Wrinkling

Case 2 (Fig. 33.19a,b,c)

A 47-year-old male, complaining of excessive wrinkling in the forehead on looking upwards and frowning with ageing appearance. Clinical features (Fig. 33.19a): wrinkling and folds found on the forehead on upward staring and frowning. Treatment Plan (Fig. 33.19b1, b2): locating the frontalis muscle and injecting Botulinum toxin Type A with a dose of 5 U on both the sides at 3 different points marked and above 1 cm from the supraorbital margin. The injection point is located midway between supraorbital margin and frontal hairline. Post-operative findings (Fig. 33.19c): absence of wrinkling.

References

1. Baran R, Maibach HI. *DorisHexel Textbook of cosmetic dermatology*. 5th edn; Chap 1,50,51—Skin size and Parameters, Botulinum Toxin, Soft tissue Augmentation Chap; Pg – 3,459,473.
2. Shuster S, Black MM, McVitie E. The influence of age and sex on skin thickness, skin collagen and density. *Br J Dermatol*. 1975;93:639–43.
3. Tsukahara K, Hotta M, Osanai O, et al. Gender-dependent differences in degree of facial wrinkles. *Skin Res Technol*. 2013;19(1):e65–71.
4. Ezure T, Yagi E, Kunizawa N, et al. Comparison of sagging at the cheek and lower eyelid between male and female faces. *Skin Res Technol*. 2011;17(4):510–5.
5. Gerhardt LC, Strassle V, Lenz A, et al. Influence of epidermal hydration on the friction of human skin against textiles. *J R Soc Interface*. 2008;5:1317–28.
6. Carruthers JDA, Carruthers JA. Treatment of glabellar frown lines with C botulinum-A exotoxin. *J Dermatol Surg Oncol*. 1992;18:17–21.
7. Dover N, Barash JR, Hill KK, Xie G, Arnon SS. Molecular characterization of a novel botulinum neurotoxin type H gene. *J Infect Dis*. 2014;209:192–202.
8. Lebeda FJ, Hack DC, Gentry MK. Theoretical analyses of the functional regions of the heavy chain of botulinum neurotoxin. In: Jankovic J, Hallett M, editors. *Therapy with botulinum toxin*. New York: Marcel Dekker; 1994. p. 51–61.
9. Hexsel D, Hexsel CL, Bohn J. Long, mid, and short term effects of botulinum toxin on the musculature. In: Hexsel D, Almeida AT,

- editors. *Cosmetic use of botulinum toxin*. Porto Alegre: AGE; 2002. p. 99–103.
10. Wollina U, Konrad H. *Am J Clin Dermatol*. 2005;6(3):141–50.
 11. Ascher B, Talarico S, Cassuto D, Escobar S, Hexsel D, Jaén P, et al. International consensus recommendations on the aesthetic usage of botulinum toxin type A (Speywood Unit)—part II: wrinkles on the middle and lower face, neck and chest. *J Eur Acad Dermatol Venereol*. 2010;24(11):1285–95.
 12. Carruthers A. Botulinum toxin type A: history and current cosmetic use in the upper face. *Dis Mon*. 2002;48:299–322.
 13. Hexsel D, Mazzuco R, Zechmeister M, Hexsel CL. Complications and adverse effects: diagnosis and treatment. In: Hexsel D, Almeida AT, editors. *Cosmetic use of botulinum toxin*. Porto Alegre: AGE; 2002. p. 233–9.
 14. Benedetto AV. The cosmetic uses of botulinum toxin type A. *Int J Dermatol*. 1999;38:641–55.
 15. Lorenc ZP, Smith S, Nestor M, Nelson D, Moradi A. Understanding the functional anatomy of the frontalis and glabellar complex for optimal aesthetic botulinum toxin type A therapy. *Aesthet Plast Surg*. 2013;37(5):975–83.
 16. Kontis TC, Lacombe VG. *Cosmetic injection technique*. New York: Thieme; 2013. p. 23–4.
 17. Klein AW. Complications with the use of botulinum toxin. *Dermatol Clin*. 2004;22(2):197–205.
 18. Narins RS, et al. A randomized double-blind multicenter comparison of the efficacy and tolerability of Restylane versus Zyplast for the correction of nasolabial folds. *Dermatol Surg*. 2003;29(6): 588–95.
 19. Donofrio L. Fat distribution: a morphologic study of the aging face. *Dermatol Surg*. 2000;26:1107–12.
 20. Guttman C. A generation speaks: dermatology answers growing desire to fight aging skin. *Dermatology Times*, pp. 56–60; 2004.
 21. Guttman C. Advances in anti-aging: new techniques technology should match demand. *Dermatology Times*; 2004.
 22. Burgers CM. *Cosmetic dermatology, 2005*; Chapter 6—Soft tissue Augmentation; Pg 103.
 23. Glogau R, Narins R, Weiss R. Advances in cosmetic procedures. In *Fall clinical dermatology conference supplement proceedings. Supplement to skin and aging*, pp. 20–27; 2004.
 24. Bisaccia D, Scarborough D. The esthetic correction of the aging mouth. *Cosmet Dermatol*. 1992;11:8–11.
 25. Elson M. Soft tissue augmentation techniques: update on available materials. *Cosmet Dermatol*. 1999;13–5.
 26. Lemperle G, Romano JJ, Busso M. Soft tissue augmentation with Artecoll: 10-year history indications techniques and complications. *Dermatol Surg*. 2003;29(6):573–87.

Open Access This chapter is licensed under the terms of the Creative Commons Attribution 4.0 International License (<http://creativecommons.org/licenses/by/4.0/>), which permits use, sharing, adaptation, distribution and reproduction in any medium or format, as long as you give appropriate credit to the original author(s) and the source, provide a link to the Creative Commons license and indicate if changes were made.

The images or other third party material in this chapter are included in the chapter's Creative Commons license, unless indicated otherwise in a credit line to the material. If material is not included in the chapter's Creative Commons license and your intended use is not permitted by statutory regulation or exceeds the permitted use, you will need to obtain permission directly from the copyright holder.





34.1 Introduction

In the past few decades, maxillofacial surgeons have played a pivotal role in enhancing the aesthetic value of the face through many surgical and non-surgical procedures, with hair transplantation being one of the popular choices which has seen an exponential demand in the last decade. Though hair restoration procedures were being performed for many decades ever since Dr. Norman Orentreich in 1959 published them in the annals of the New York Academy of Sciences, there has been many advances to the originally described punch grafting which has become obsolete and has been replaced by the so-called micrografts via the two basic techniques of follicular unit transplantation (FUT) and follicular unit extraction (FUE). The success of the above techniques is in part attributed to the theory of donor dominance which postulates that the hair taken from the donor area of the posterior scalp will continue to grow without getting hit by factors which were responsible for the thinning out of hair in the frontal areas [1].

Apart from hair transplant being a promising procedure for male pattern and female pattern alopecia, it has been applied to other causes of hair loss too; traumatic and burn scars on hair bearing areas, alopecia following surgical procedures (i.e. Craniotomy, rhytidectomy procedures), redo hair transplantation, congenital reasons like cleft lip scenario. Currently the scope for hair transplantation is expanding with the demand from patients who want to strengthen a

weak hairline, desire to lower the hairline or fix missing facial hair on the moustache, beard, eyebrow or eyelashes.

As the field of hair transplantation continues to evolve at a breakneck speed with specialists from multiple specialities performing this scientific artistry, it's all the more pertinent that we as maxillofacial surgeons are abreast of the current principles and practice of this hair restorative surgery.

34.2 Surgical Anatomy

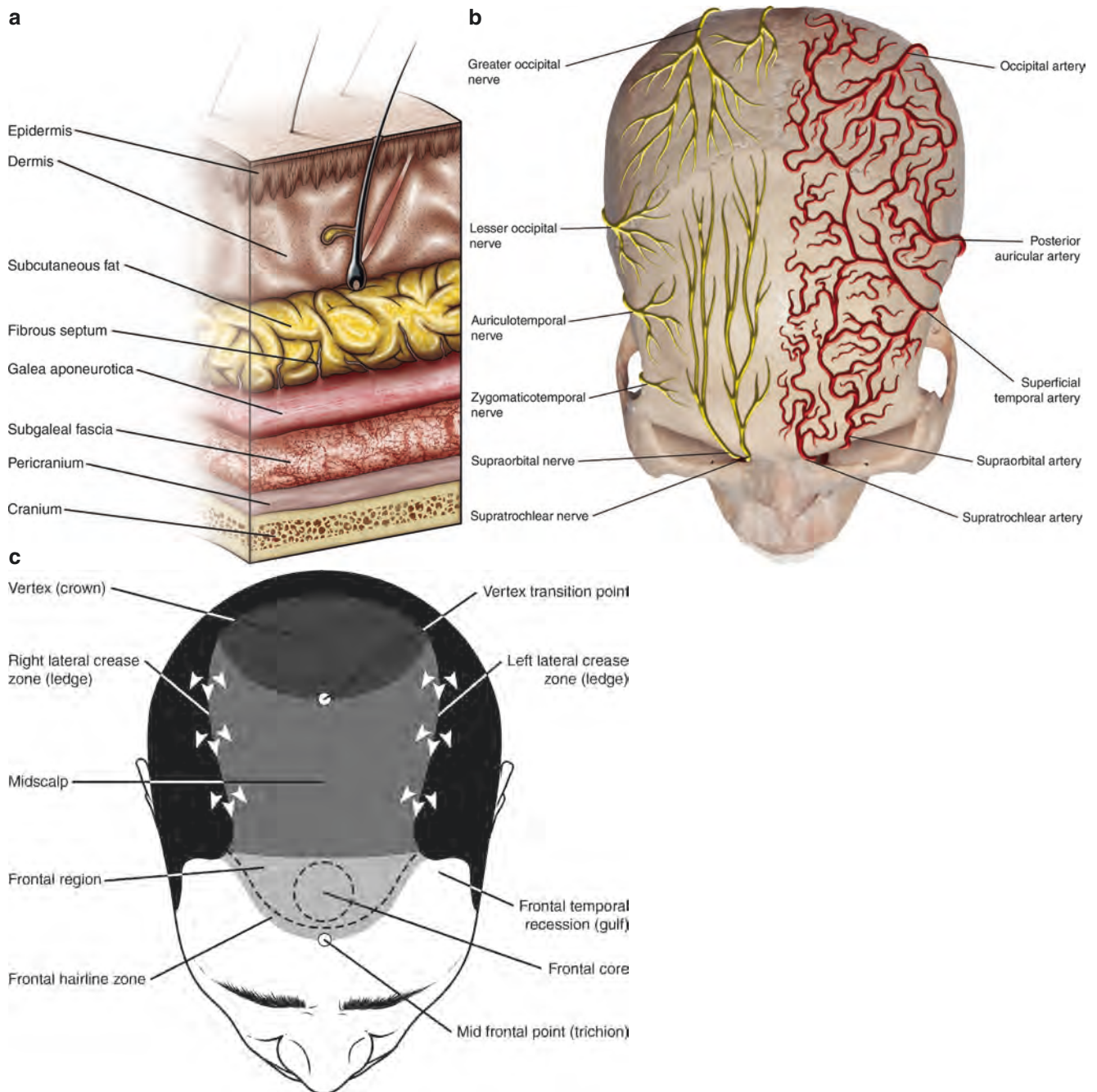
An understanding of the surgical anatomy of the scalp is necessary to avoid complications and to optimise your performance for hair transplantation.

Scalp consists of five distinct layers with the most superficial layer being the skin which comprises of epidermal and dermal layers. These layers contain hair follicles, sebaceous and sweat glands with rich vascular supply. The second layer of scalp is made up of connective tissue, which is well vascularised and heavily innervated by sensory nerves. The deepest portion of the hair follicle, bulb and papilla, may extend through the skin into this layer (Fig. 34.1a). Thus, when obtaining donor grafts, effort should be made to incorporate the upper part of dermal layer to obtain the entire hair follicle. The third layer also called galea aponeurotica is a tendinous tissue connecting the two bellies of the occipitalis and frontal muscles. Loose areolar connective tissue is the next layer which contains numerous potential spaces, capable of great distension thus allowing for exceptional mobility of scalp. Unfortunately, these spaces are also capable of potential space for haematoma collection and spread of infections. The deepest layer of the scalp defines the pericranium, which is analogous to periosteum throughout the body.

Electronic Supplementary Material The online version of this chapter (https://doi.org/10.1007/978-981-15-1346-6_34) contains supplementary material, which is available to authorized users.

S. R. Pothula (✉)
Oral and Maxillofacial Surgery, Pioneer Advanced Hair Transplant
Centre, Bengaluru, Karnataka, India

B. S. Jayanth (✉)
ABMSS, Bengaluru, Karnataka, India



©Association of Oral and Maxillofacial Surgeons of India

Fig. 34.1 (a) Hair follicle extending into dermis; note the layers of the scalp. (b) Arteriovenous supply of the scalp with sensory innervation. (c) Zones of the scalp

34.2.1 Blood Supply and Sensory Innervation

The arterial supply to the scalp arrives from branches of both external and internal carotid arteries. Branches of the external carotid artery in order from posterior to the anterior include the occipital, posterior auricular and superficial temporal arteries. The supratrochlear and supraorbital arteries

are branches of the internal carotid artery. The veins of the scalp follow the same basic network of the arteries and drain into the jugular veins (Fig. 34.1b). All of these vessels freely anastomose in the connective tissue layer of the scalp. Awareness and approximate location of the main branches are very important during the hair transplant surgery not only to avoid haemorrhage or haematoma but also to prevent isch-

emia to the follicles. Occipital artery which enters the scalp immediately above the external occipital protuberance at the superior nuchal line can easily be injured if depth control is not maintained. If arterial haemorrhage is encountered, electrocautery and suture ligation are adequate to secure homeostasis. Damage to vessels could likely lead to the formation of donor area scar.

Sensory innervation of the scalp arises from all three branches of trigeminal nerve antero-laterally with the forehead getting its supply from the supraorbital and supratrochlear branches of the ophthalmic division, while the anterior temporal scalp is supplied by the maxillary division and the mandibular division goes onto supply the temporoparietal zone of the scalp through its auriculotemporal nerve. The spinal cutaneous nerves of the cervical plexus (c2 and c3) come to supply the area posterior to the auricle via the greater and lesser occipital nerves. These nerves are found in the connective tissue just superior to the galea.

34.2.2 Zones of the Scalp

Typically, the areas of male pattern hair loss are horseshoe shaped and are divided into three zones [2] (Fig. 34.1c)

1. Frontal—extends from the hairline to the mid-scalp and is curvilinear. Has a frontal hairline zone anteriorly with the line being irregular like coastline of the sea with mounds and recessions. The follicles in this zone is mainly single hair follicle for the first two to three rows generally blending into multiple follicular units posteriorly giving rise to the density effect known as shingling. The frontal core zone is a small area in the central aspect of the frontal region which is circular to oval and is very important in framing the face receiving the highest density of grafted hairs.
2. The mid-scalp—is at the top of the head. This horizontal area is bordered on both the sides by the temporal parietal fringes and is sandwiched between the frontal zone anteriorly and the vertex posteriorly.
3. Vertex or crown—the most posterior area being rounded and characterised by whorl arrangement of hair is the toughest area to transplant.

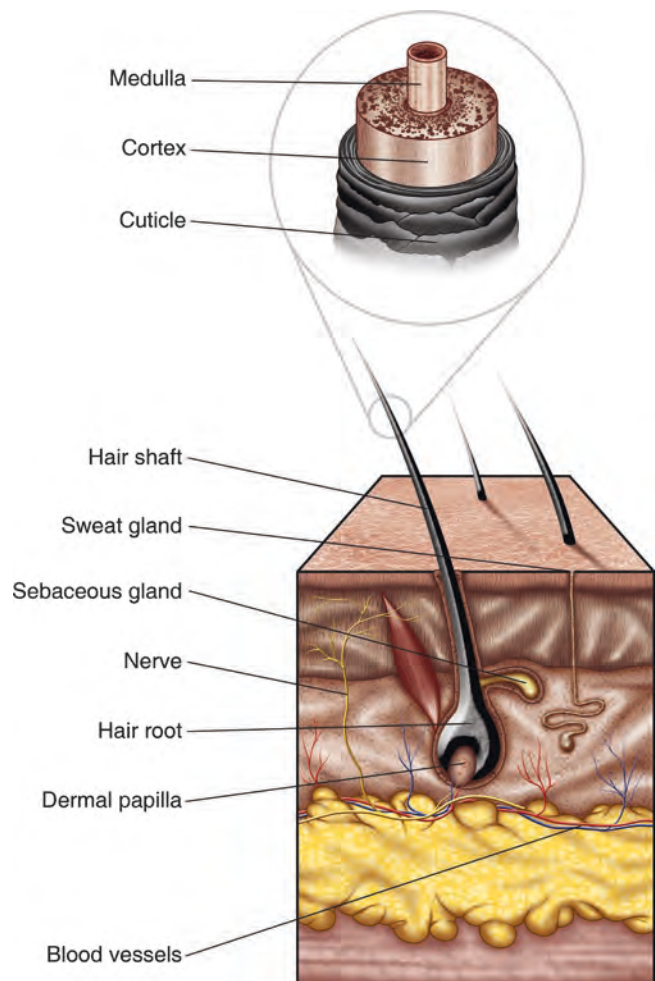
The temporal fringe is the lateral hair zone present on the sides of the scalp anterior to the tragus of the ear and posterior to this is the parietal fringe.

The frontotemporal apex is the area usually devoid of hair at the junction of the lateral frontal hairline and temporal fringe. This coincides with the deepest point of the recession on the forehead and is aligned with the lateral canthus of the eye.

34.2.3 Microanatomy of Hair

Hair consists of a living part under the skin extending into the dermis known as follicle and a non-living keratinised part above the skin, the so-called hair shaft (Fig. 34.2). The shaft has three further layers namely the outer protective cuticle, inner cortex and in certain cases the medulla forms the core, and they mainly help in protection and anchorage of the hair.

The growing structure of the hair is the follicle with the upper part being constant and consists of the top infundibulum at the opening of sebaceous gland and isthmus in the middle where the piloerector muscle comes to insert. The lower part of the follicle known as the bulb is very vital as it's the one involved with regeneration and most of the stem cells are located here. Hence, while implanting holding, the graft above or beside the bulb is vital to ensure sustenance of regenerative potential.



©Association of Oral and Maxillofacial Surgeons of India

Fig. 34.2 Microanatomy of the hair

34.3 Terminology

The unique language of hair transplant surgeons consist of a few common words to communicate within the speciality [3] (Box 34.1).

Box 34.1 Hair Transplant Surgery: Terminology

Follicular unit graft (FU): The natural Bundle of hair strands consisting of one, two or three hairs woven within a single unit and held by connective tissue elements as the follicle. The graft containing two or three follicular units becomes a multi follicular unit graft.

Micrograft: The follicular unit which has single hair graft within it is referred to as a micrograft, and the same is preferred for frontal hairline implantation.

Minigraft: The follicular unit which has more than a single hair graft and houses four to six hair grafts prior to cutting with microscopes are minigrafts.

Follicular unit density: It's the number of follicular units per cm².

Hair density: It's the number of hairs per cm².

FUT: The grafts are obtained from the harvested strip through slivering and dissection of individual follicles under magnification.

FUE: The grafts are obtained individually in the donor area one at a time utilising a punch and handheld extractor.

Stick and place implantation: Refers to implantation made immediately as the recipient site slit is made with a needle or blade.

Pre slit implantation: Refers to implantation made after all the recipient site slits are made with a blade or needle.

Coronal slits: Refers to slits oriented along coronal from side to side.

Sagittal slits: Refers to slits oriented along sagittal plane from front to back.

evenly but grows in phases and in cycles which are reproducible. Anagen is the growing phase of hair that accounts for 85% of the hair growth, during which hair grows at 0.5 inch per month for up to 10 cm per year with adequate blood supply providing nutrients and minerals to the hair. This phase lasts for anywhere between 3 and 6 years. As long as this phase persists, the hair stays on the scalp and is genetically determined. Anagen is followed by catagen and the later phase onset signals the end of active hair growth. During this transitional phase which lasts for 1–2 weeks, the production of hair stop and hair follicle start to shrink in size and nearly 2–3% of the hairs are in this phase. Telogen is the final phase of the hair cycle where the aged hair fall out and new ones push themselves out of the skin. This final phase lasts for nearly 3 months with around hundred hairs being shed per day and nearly 10–15% of the hairs are in this phase at any point in time (Fig. 34.3).

People often confuse with hair fall to hair loss. Hair fall is common in every individual. Around 10–20% of total hair will be under shedding process. That hair will grow back in 3 months. On average 80–60 hair strands fall is considered as normal.

Male pattern hair loss or androgenetic alopecia as the word suggests is a result of both androgens and genetic factors which work together causing the clinical effect of baldness [4]. Though there are many reasons for hair loss, androgenetic alopecia is the most common reason and accounts for 95%. Fortunately, it can be treated with hair transplant surgery. The diagnosis of androgenetic alopecia is supported by a family history of hair loss, although a positive history is not always identified. There is a slightly greater incidence of having a positive history on the mother's side but the inheritance of male pattern hair loss can come from either side of the family.

In androgenetic alopecia, there is change of hair from terminal hair to vellus hair. There happens to be a gradual evolution of this pattern, with each subsequent cycle of the new hair being fine and thin leading eventually to various grades of alopecia. It initially starts with the frontal hairline recession and regression, followed by loss of more temporal hair and simultaneous thinning of the vertex hair. Norwood classified approximately 7 different types of male pattern hair loss. Identification of these types is key to an understanding of proper planning of hair transplant surgery.

Testosterone gets converted to dihydrotestosterone (dht) both systemically and in the process of intrafollicular conversion under the influence of the enzyme 5-alpha reductase leading to its binding with androgen receptors of the follicular cells in genetically predisposed men leading to inhibition of protein synthesis by shortening the anagen phase, thereby producing finer hairs with shaft becoming thinner; this stunted hair follicle growth leads to miniaturisation of follicles till they become extinct establishing balding [5].

34.4 Growth Cycle and Hair Loss

Hair is cylindrical, outgrowths on the skin made up of keratinous filaments. The normal human scalp contains between 100,000 and 140,000 follicles with hair being arranged in follicular units, small groups of 1–4 hairs each. There are approximately 50,000–60,000 follicular units on the human scalp.

Testosterone is the main regulator of hair growth with the androgens binding to receptors in the dermal papilla influencing the growth. Human hair does not grow constantly and

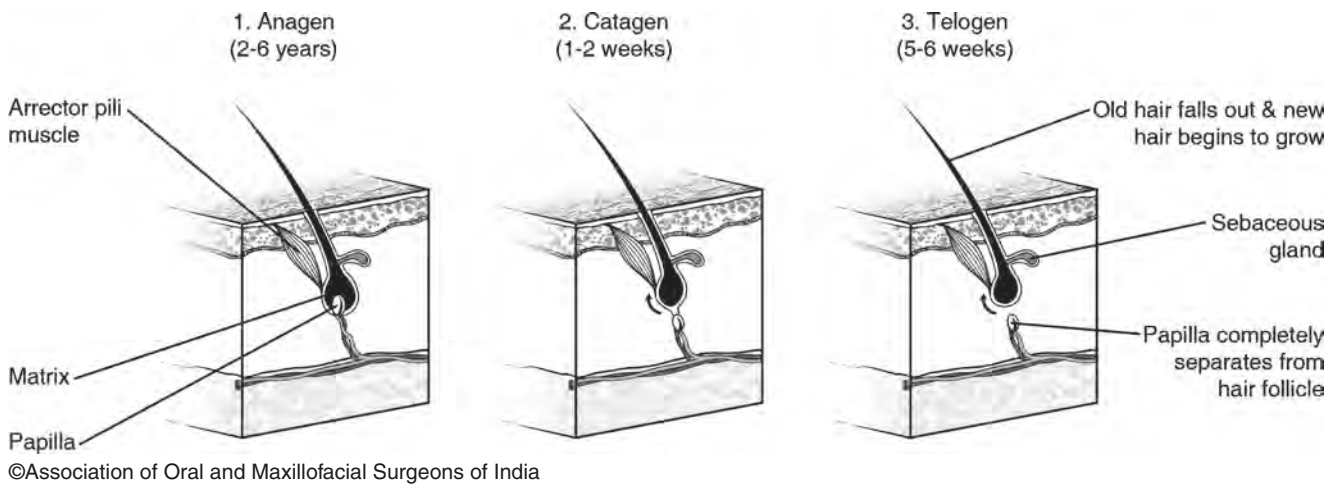


Fig. 34.3 Hair growth cycle

Box 34.2 Basic Requirements for Hair Regrowth

1. Regulating dihydrotestosterone levels in the blood
2. By ensuring normal supply of balanced nutrients to the hair roots
3. Proper blood circulation to carry the nutrients to the roots in the scalp
4. Maintaining good health through general well-being of the individual

Clinical studies have given us an understanding that hair can be grown back if the following four things are ensured (Box 34.2):

Hair loss is not a disease but a condition where anagen or the growth phase reduces and the telogen or fall phase is extended. This forms the basis of hair loss in alopecia conditions other than androgenetic alopecia. The factors leading to hair loss could stem from internal/external factors.

Internal Factors There are many factors which internally lead to deficient states harming the hair growth. A few of them which are relevant today are iron deficiency, calcium deficiency, zinc deficiency, general debility, anaemia, hypothyroidism, deficiency of the fat soluble vitamins, thyroid problems, insulin resistance, metabolic disorders like gout and PCOD, prolonged illness, emotional turmoil following surgery and individuals with seborrheic scalp.

External Factors The lifestyle and environmental factors do influence the hair health and growth cycle. The common causes are smoking including passive smoking, stress, alcohol intake, lack of sleep, crash dieting, fad diets, high-protein diet, exposure to extremes of heat or cold, less intake of fluids, poor scalp hygiene, dust, pollution, fumes and exposure to endocrine disrupting chemicals.

34.5 Classification

The most popular classification of the male pattern hair loss is the Norwood classification system (1975) which is a refined version of the original Hamilton system (1941) [6].

34.5.1 Norwood Classification (Fig. 34.4)

Type 1 presents the normal hairline with minimal recession of the frontotemporal area.

Type 2 patients present a symmetrical and mild recession of the frontotemporal area along with thinning of the hair.

Type 3 patients define balding with minimal or no in the frontal areas and a deep recession.

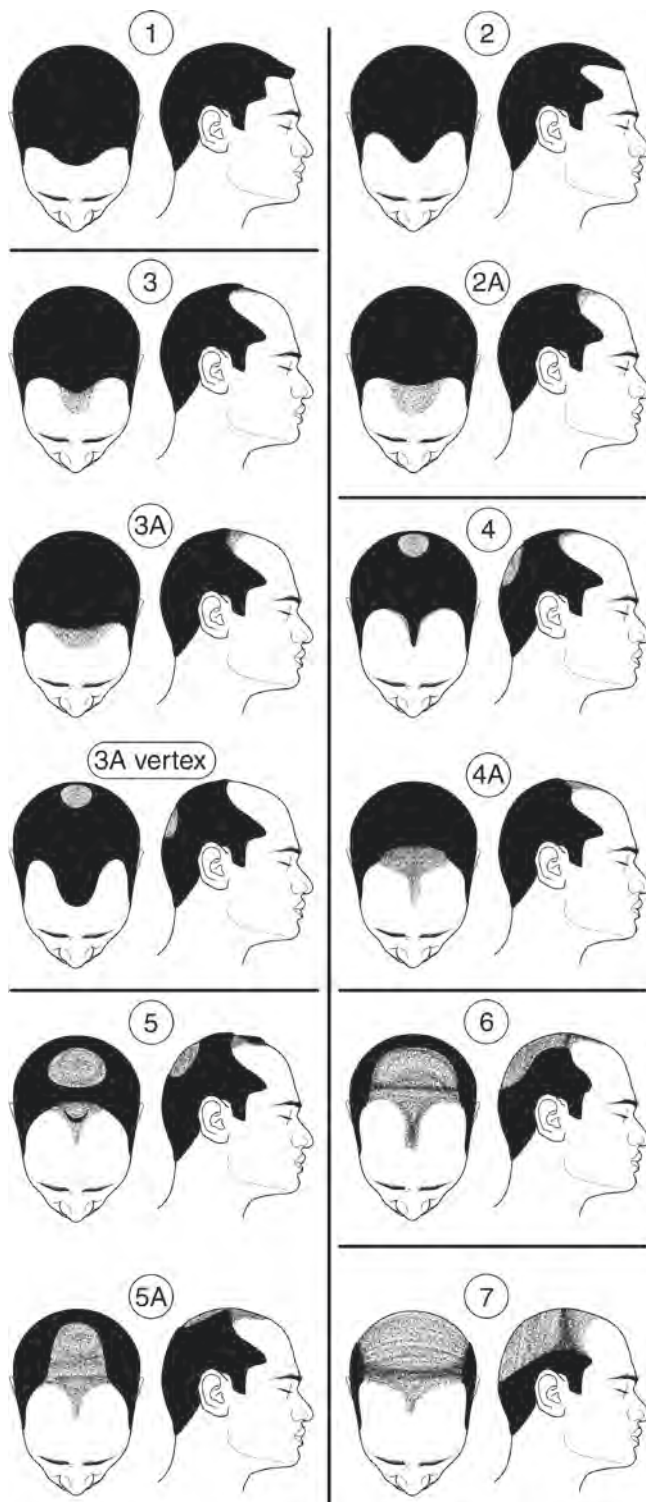
Type 4 patients present with significant recession and loss of both frontal and vertex hair with a bridge of hair between the two still retained.

Type 5 category patients present a progression of the type four category with only thin and narrow bridge of hair between the frontotemporal and the vertex areas.

Type 6 represents the loss of hair that separates the frontal and the posterior vertex areas with further progression in lateral and posterior zones.

Type 7 represents the most severe form of balding with only a band of hair remaining in the low occipital and temporal areas with extensive miniaturisation of the hair.

Basically, in the above classification, the two areas of hair loss—a bitemporal recession and thinning crown gradually enlarge and coalesce until the entire front, top and crown of the scalp are bald.



©Association of Oral and Maxillofacial Surgeons of India

Fig. 34.4 Norwood classification of male pattern alopecia

To regain the crowning glory, medical treatment gives good results up to type 3 patients while hair transplantation is the only choice for patients between types 4 and 6.

Routinely, clinicians come across variations of the classification which fall outside the Norwood classification, they are as follows: Differential use pattern alopecia, diffuse and patent alopecia.

34.5.2 Classification of Hair Loss in Women

The Ludwig classification (1977) uses three stages to describe female pattern genetic hair loss (Fig. 34.5).

Type I (mild), type II (moderate) and type III (extensive). In all three Ludwig stages, there is hair loss on the front and top of the scalp with relative preservation of the frontal hairline. The back and sides may or may not be involved.

In Ludwig type I, there is early thinning that can be easily camouflaged with proper grooming. Type I patients have too little hair loss to consider surgical hair restoration.

Women with type II hair loss have significant widening of the midline part and noticeably decreased volume. Hair transplantation may be indicated if the donor area in the back and sides of the scalp is stable.

In Ludwig type III, there is a thin, see-through look to the top of the scalp. This is often associated with generalised thinning over the entire scalp. Often patients that have progressed to this stage have too little donor hair to make surgical hair restoration worthwhile.

All women experiencing hair loss should have an accurate diagnosis made, preferably by an experienced dermatologist. This is particularly important since the diffuse hair loss that women typically develop, can occasionally be caused by a number of treatable medical conditions. Regardless of the extent or cause of hair loss, only women with stable hair on the back and sides of the scalp are candidates for hair transplantation.

Other infrequent alopecias observed among the patients visiting hair clinics are as follows:

Alopecia areata: it's an autoimmune disorder which starts with small round and punched out areas with no hair.

Lesion has very smooth skin and not even a single hair is present in the lesion.

Alopecia totalis: there is total loss of scalp hair.

Alopecia universalis: there is total hair loss in the body including the eyebrows.

Fig. 34.5 Ludwig classification for hair loss in women.



Ludwig scale

©Association of Oral and Maxillofacial Surgeons of India

Turban alopecia: caused due to tight turban usage. It affects frontal and parietal areas mainly and is seen among Sikhs.

Trichotillomania: a psychiatric disorder where the individuals deliberately pull their hair every day leading to hair loss in those areas.

34.6 Medications for Hair Loss

Only 2 drugs have been approved by FDA and have proven their efficacy in the management of hair loss with good success.

34.6.1 Minoxidil

This is a direct hypertrichotic drug, which was initially approved as an antihypertensive agent and was found to have side effect of hypertrichosis. Today, it is available as an over the counter drug with 2% formulation for women and 5–10% formulation for men as topical solution and gel. It improves hair count, weight and growth of hair. Post transplantation too it has been found to decrease the shedding of hair and enhanced the time to onset for hair growth. According to few studies, minoxidil acts as a vasodilator by opening up the potassium channels and thereby enhances the vascularity of the hair bulb which in turn promotes hair growth. However, the exact mechanism is unknown. This topical product needs to be applied to the scalp and not the hair and patients need to be informed about the initial increased shedding of weak hair in the first 4–8 weeks. Further, the patients need to be counselled to apply the product twice a day to maximise the efficacy and to wait for a timeframe of at least 4–5 months prior to seeing the results.

34.6.2 Finasteride

Finasteride is a drug which is used only in men for reversal of miniaturised hair follicles. This drug is a competitive inhibitor of the enzyme 5-alpha reductase which blocks the conversion of male hormone testosterone to dihydrotestosterone, and thereby works on the pathogenesis of androgenetic alopecia. It is to be taken orally once a day daily at 1 mg. Finasteride can cause loss of libido and oligospermia in few individuals. However, this side effect is reversible once the drug is discontinued.

Other medicines like Dutasteride though being a potent inhibitor of 5-alpha reductase is not that popular in the market as it has got adverse effects. Few natural products like saw palmetto can be used in young individuals who refuse to take finasteride.

34.6.3 Cyclical Therapy

It entails giving vitamins with calcium supplements on a single day, followed by iron and mineral combination product on one other day of the week and finally amino acid blend; the three regiments are also advocated that their intake be on alternative days as different nutrients and the daily dosing is avoided. The basis of this therapy is that hair requires nutritional support during their anagen growth phase and also for its maintenance; without nutrients, hair cannot get support and the stimulated hair growth to demonstrate disappointing outcomes. This therapy is the result of pioneering work on the role of nutritional supplements in hair growth.

Platelet-rich plasma (PRP) is an autologous biological modifier which has many concentrated growth factors in it and has demonstrated good results in reducing hair loss and has shown to enhance hair counts. It is prepared in a three-

step process where blood is drawn, processed and injected into the scalp. It is injected into the scalp once every fortnight for 4–6 sittings and this can be combined with the standard therapy.

34.7 Clinical Consultation

It is important to begin the consultation by knowing the general health of the patient with a focus on endocrinal conditions affecting hair namely the thyroid disease, any uncontrolled diabetes, polycystic ovarian disease in the case of females and also enquiring specifically about family history of hair loss, past medical management, understanding personal hair care regimen and any past hair transplants done.

The next focus of the clinician during consultations should be on the expectations and motivation levels of the patient trying to drive home the message that it's a progressive condition especially in younger patients who are demanding and want a low hairline. It's important to have a family member during consultation and ensure that they understand that any future hair loss is understood and you are only trying to frame the face. The pattern of the hair loss also needs to be well documented.

The donor site assessment will verify the presence of any white hair, check the elasticity of the scalp, the density of the hair follicles per square centimetre, note the calibre of the hair (thick vs. thin), presence of curly or straight hair, rule out any existing scars and skin pathology including dandruff and infections.

The assessment of the recipient site will focus on the quality and quantity of remaining hair, ascertaining the grade of balding and the pattern of hair loss, previous results of hair transplantation, the skin to hair contrast, direction of the existing hair and existing skin condition. Based on the priorities of the case and having assessed the areas requiring hair transplantation, the number of follicular units required per square centimetre (around 30/cm²) is calculated to arrive at the number of follicular units to harvest.

34.8 Concept of Hair Transplantation

Hair transplantation as performed today is basically micro-follicular unit transplantation and few clinicians call it as hair restoration as there are many methods to achieve the results.

In the early days, hair transplant concept started with flap rotation techniques requiring procedures to be performed under general anaesthesia. These invasive techniques did not gain popularity as the results were not satisfying and the procedures left disfigurement in few individuals. Later on dur-

ing the evolution of techniques, macro and micrografts being 5–6 mm in size were introduced which were harvested with biopsy punches and the resulting grafts were implanted. These plug like grafts being unnatural in appearance gave a classical doll's hair appearance after growth and got phased out with further refinement of hair transplant procedures.

By around 1963, follicular unit transplantation or strip technique was introduced which became a workhorse of hair transplantation until recently and is still considered to be the gold standard method for hair restoration. In the year 2002, Rossman and Bernstein refined the punch method of harvesting the follicles and named it follicular unit extraction which has seen an exponential growth in the recent years and is today the most popular technique of hair transplantation.

The principle behind hair transplantation is quite simple. The hair that grows on the back and sides of the scalp tends to be permanent in most of the individuals. These occipital and parietal hairs are resistant to androgenic alopecia and are used to implant into the frontal or vertex area which will continue to grow as long as occipital hair grow, but in few individuals with advanced grades even these donor hairs can be miniaturised and lost. That's the reason as to why anticipating the future hair loss is most important factor while planning hair transplant procedure.

Hair transplant as a procedure is successful only when hair loss is stabilised, as it will not stop further hair loss. We as surgeons can only relocate and transfer few strong follicles from donor area to recipient area without increasing any new follicle per se. Many young patients who are frustrated by taking medicines over a period of time will seek hair transplant procedure as a remedy, which is an absolutely wrong decision for the clinicians to encourage. It is imperative on the part of the clinician to stabilise any ongoing hair loss before embarking on the hair transplantation, with individuals below the age of 25 years being denied the scope of the procedure.

Hair transplant surgery demands good planning, great surgical skill and good aesthetic sense on the part of the clinician, as hairs grow in specific direction and angulations for the given area of the scalp, and grafts should be placed in a way which should look natural and cover the scalp gaps thus achieving good density.

Most of the patients would like to know if the results are permanent with guaranteed results. Here, it's the astute clinician who should make all efforts to ensure that patient understands the concept of the hair transplant and the future consequences too, rather than simply promising the results.

The basic concept in hair transplant surgery is one of camouflaging technique which makes them look better rather than taking them back to their crowning glory days of their past during their younger days.

Patient should understand that he may still loose hair further and get worse with his genetic predilection to go bald

and it's a progressive process. Hair transplant will only help him to maintain hairs which are aesthetically acceptable for his age and few individuals may require future sessions too.

Preparation Prior to Hair Transplantation

Routine blood test consisting of Complete blood count, glycaemic levels, prothrombin time and serology are done for every case. In patients with any underlying medical conditions, further investigations as deemed necessary for the case are done and a medical fitness is obtained from the physician.

All patients are advised to stop topical minoxidil at least a week prior to transplant to avoid bleeding hampering the progress of the case.

Photographs and consent for the procedure are obtained as a part of standard operating procedure for hair transplantation.

Consenting for the procedure should focus on detailed information of the procedure with clarity given on the results that can be obtained explaining the pros and cons of the procedure, their complications and outcomes. Alternative suggestions should also be given including no surgery, use of camouflage techniques and patients being on only medicines. Adequate time should be given to discuss and understand the proposed procedures. Finally, the proposed treatment plan with the fees proposed should be mentioned in the consent along with written preoperative and post-operative instructions.

The treatment plan formulated needs to account for the quantum of hair to be transplanted, the hairline design, the areas of high priority on the scalp, patient commitment and compliance.

34.9 Techniques and Description

34.9.1 Follicular Unit Transplantation (FUT) (Box 34.3) (Video 34.1)

FUT is also called strip method or stitch method. It's a gold standard method in hair transplant procedures till date though it's an old method [7]. The modern-day FUT is mainly harvesting a single strip, though earlier few doctors practised with multiple blades to obtain multiple strips which are obsolete now.

Strip method includes taking or harvesting a strip of the skin layer from the donor area usually from the occipital area of the head below the occipital protuberance and above the nape of the neck in the so-called safe zone for harvesting.

Strip measurements are variable with 30 cm being the maximum length and 1–2 cm width depending on skin laxity of the patient. However, the length and width are variable according to planning arrived at during the consultation with

the patient as per the indication of the case. At times we have to limit strip width to 1 cm if the skin laxity is limited. Usually a strip of 30 cm in length and 1.5 cm in width will give around 2000–3000 grafts depending on the hair density of the individual.


Box 34.3 FUT

- Linear scar in donor area.
- Healing time is more in donor area.
- Little post-op discomfort in donor area.
- Difficult in tight scalp, with risk of scarring.
- Can't use in non-scalp hair like beard or body hair.
- Quality of graft is good
- Less time
- No need for shaving entire donor area.
- We can harvest up to 4000 follicular units in a single session.
- Less expensive
- Follicles Transection rate is very less.

34.9.1.1 Assessment of the Donor Hair

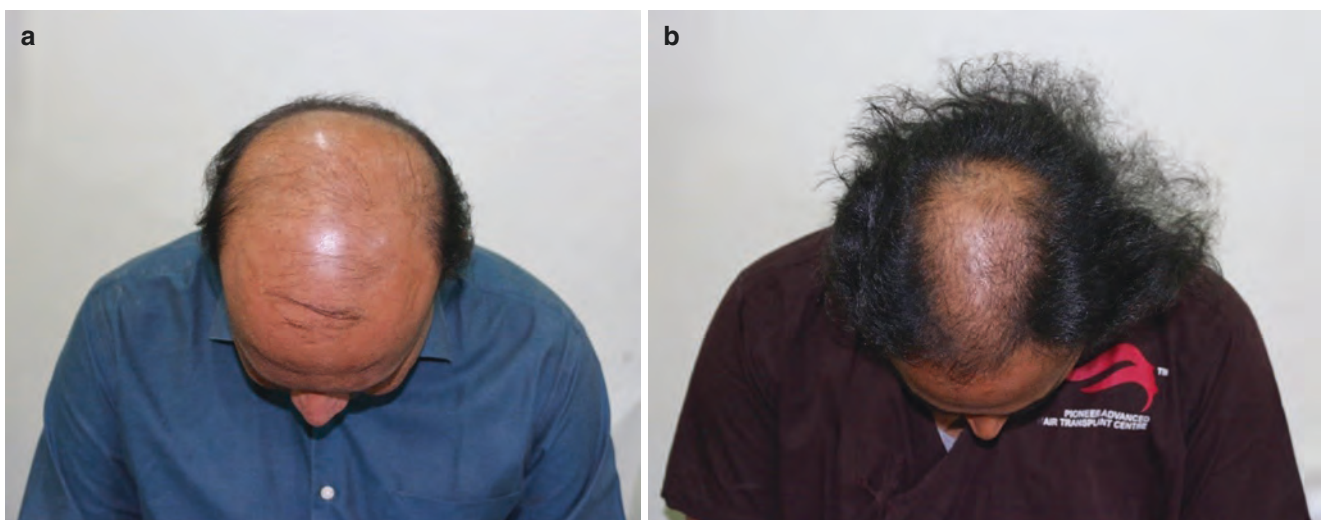Hair transplant outcomes will greatly depend on the donor hair quality and quantity [8]. The important factors that the clinician has to bear in mind are as follows:

1. The number of grafts that are present per square centimetre
Few individuals have thick density being good or best donors (Fig. 34.6a) while a few have sparse density being poor donors (Fig. 34.6b) with the number of grafts per sq cm varying between 25 and 65 grafts on an average in healthy Indian adults. It further varies from person to person and sometimes from area to area in the same individual. Usually, occipital area has thick density whereas parietal area has less density. Good observation of the grafts in the donor area is most important for the surgeon to achieve good results.
2. Number of follicles present per graft
This is highly variable with 2, 3 or 4 follicles being present in Indian adults whereas a few have only one or two follicles per graft. The presence of reducing follicles per graft is a sign of the progressive nature of the blading process.
3. Donor skin area
Few individuals have large donor area as their scalp size is larger while a few individuals have donor bearing area which is smaller (Fig. 34.7a, b). This entity will decide the number of grafts that is available for harvesting.



©Association of Oral and Maxillofacial Surgeons of India

Fig. 34.6 (a) Good/best donor area based on hair follicular density. (b) Poor donor area based on hair follicular density. (c) Donor area skin laxity testing to ascertain the strip width planned for FUT



©Association of Oral and Maxillofacial Surgeons of India

Fig. 34.7 (a) Large head with more surface area at donor zone. (b) Small head with lesser surface area at donor zone

4. Shaft diameter

Individuals with thick shaft diameter will have better density and the outcome of the results is enhanced.

5. Skin laxity (Fig. 34.6c)

In individuals with better skin laxity, we can harvest more grafts by FUT method by going for wider strips in a single session, whereas the same skin laxity may not have any significance with the FUE method.

Patients who present with straight hair end up optically having less density because light can pass through hair strands and skin becomes visible especially if the hair is black and is contrasting against a fair skin background. Whereas presence of curly and course hair in an individual with dark complexion can give the illusion of thick density.

34.9.1.2 Donor Site Preparation and Anaesthesia

Trimming is essential in the donor site to harvest the strip and the team member in charge of the preparation can ensure trimming the hair to 3 mm all over the scalp. Few surgeons prefer the procedure without trimming so as to reduce the downtime for the patient's social acceptability. But trimming will ensure better visibility and accessibility to the surgeon while performing the suturing with attention to detail to ensure minimal scarring along the strip harvest. Following the trimming, the next step is to wash the scalp with betadine solution. The clinician should ensure that preoperative photos, consent for the procedure, recording of baseline vitals of the patient and his weight is recorded prior to the preparation of the donor site.

The harvesting of the strip is done with the patient in prone posture following the standards of care with an iv line, monitoring of the vitals with a 3 parameter monitor, and following a dose of prophylactic antibiotic under aseptic conditions. Next, the donor area strip length and width to be harvested are marked out based on the skin laxity tests and depending on the individual's follicular density per square cm.

Once the marking is done, local anaesthesia is administered to the donor area, usually preferring field block in that area. Injecting the local anaesthetic in the lower border of the strip would provide sufficient anaesthesia to the field above.

34.9.1.3 Preparation of Local Anaesthesia

Hair transplant procedure is time taking and lasts around 6–8 h. Lidocaine usually is a very safe anaesthetic with a duration of action lasting between 90 and 120 min and therefore we need to add a long-acting drug-like bupivacaine for hair transplant procedure. Combination of the above would work better for 8–10 h and the overall dosage should not exceed the maximum permissible as per the weight of the

individual. The local anaesthetic solution used is typically as follows:

Lidocaine 2% 30 ml + bupivacaine 0.5% 4 ml + ns 60 ml.

The above combination gives 64 ml of local anaesthesia, which is of lidocaine 1%.

Tumescence is widely used in hair transplant surgery to raise neurovascular bundles away from the hair follicles which will reduce the trauma to nerves and vessels during the procedure. Another important role for the use of tumescence is in reducing the bleeding during the procedure since scalp bleeds more.

Tumescence solution consists of 500 ml ns + 1 ampule of 1:1000 epinephrine and this is injected into the strip area following the local anaesthesia at least 15 min before the strip harvesting.

34.9.1.4 Instruments for the Strip Procedure

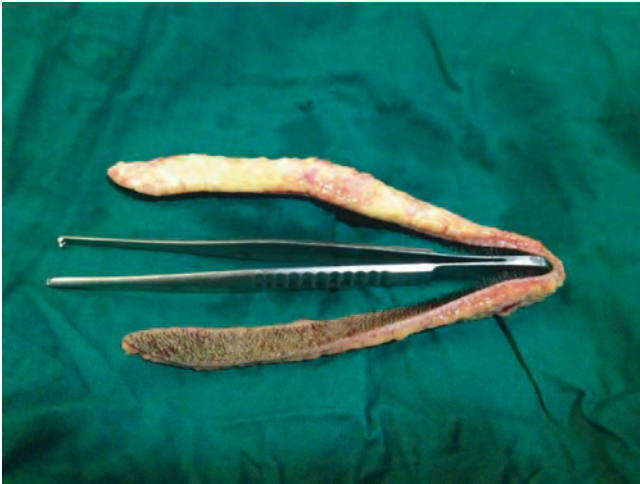Variscore blade (Fig. 34.8) is useful to have control on the dimensions of the strip and it gives the option to adjust the strip width by adding or reducing the metal spacer plates. Each metal spacer plate comes with thickness of 2 mm and 1 mm and, for example, if we need a strip with width of 1.3 cm, then we need to add 6 plates of 2 mm and 1 plate of 1 mm. The variscore blade has added advantage of depth control while making incision and can accommodate two surgical blades. Usually, for scalp, we can use number 15 surgical blades.

Prior to the incision marking, the strip dimensions are done. Most of the surgeons make straight incision, which may lead to scar. It's always better to follow Langer lines of the skin which ensures less scars with the strip incision looking like a crescent shape with the end tapering off. Strips which are as long as 30 cm (Fig. 34.9) in length run from above one ear to the other ear. It's always recommended to

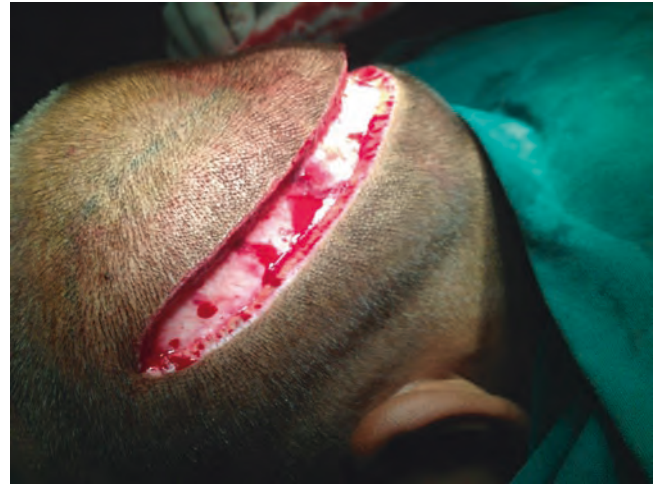

©Association of Oral and Maxillofacial Surgeons of India

Fig. 34.8 Variscore blade -popular blade handle for FUT



©Association of Oral and Maxillofacial Surgeons of India

Fig. 34.9 Strip harvested prior to slivering

©Association of Oral and Maxillofacial Surgeons of India

Fig. 34.10 Wound margins prepared for trichophytic closure

place the incision at or just below the external occiput area as the follicles here are considered permanent. It is indeed not good to go too low below the external occiput as we may end up in big blood vessels. After the initial indentation of the incision is done with variscore blade, it is later followed up by the use of BP blade number 15 and the incisions are made very carefully to reach up to 3 mm beneath the follicular depth with some amount of subcuticular fat around it, while we ensure that we do not cut the galea. While making the incisions, care is taken to prevent slicing of the follicles at the skin margins and the flap is raised from one end to the other using gentle yet deft strokes with the blade.

Good illumination and haemostasis can help to raise strip with minimal damage to both the follicles and vessels in the vicinity. Damage to the vessels is most common if proper tumescence is not attained and can lead to bigger scar and shock loss of hair in the donor area. Any adventure into the galeal layer can lead to haematoma and chances of spreading infections through emissary veins.

Haemostasis is achieved prior to closure by using bipolar diathermy; the scalp wound is irrigated with nor-

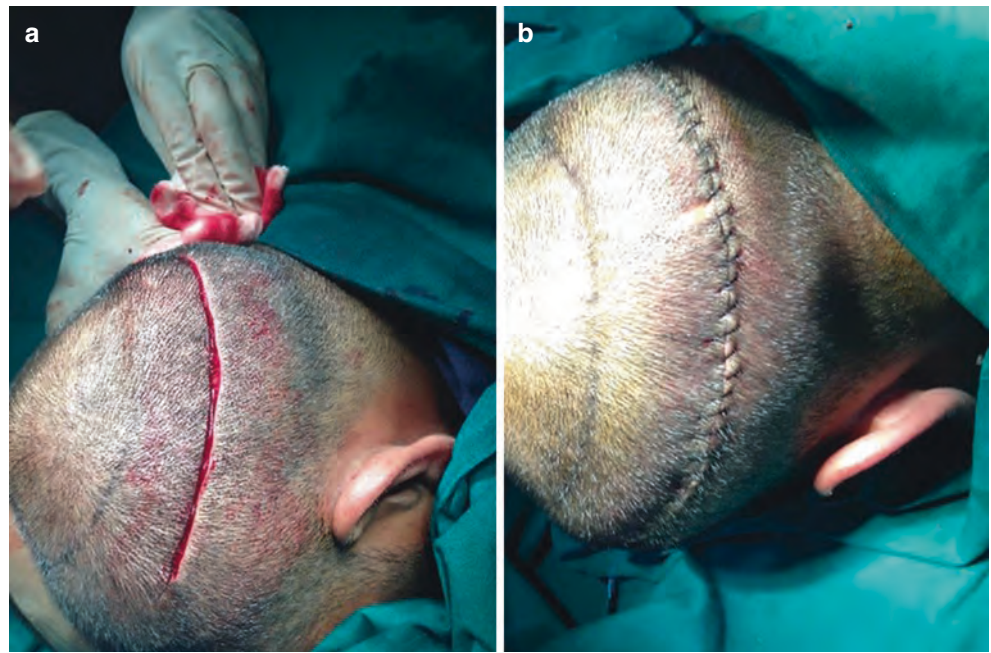
mal saline and a double layer closure is performed with vicryl 2.0 (TS 2404, 3/8 circle, cutting edge) for the inside and a prolene 3.0 (nw800, 3/8 circle cutting edge) for the outer skin (Fig. 34.11a, b). The strip that is harvested is preserved in cold saline on a petri dish at 4 °C.

34.9.1.5 Trichophytic Closure

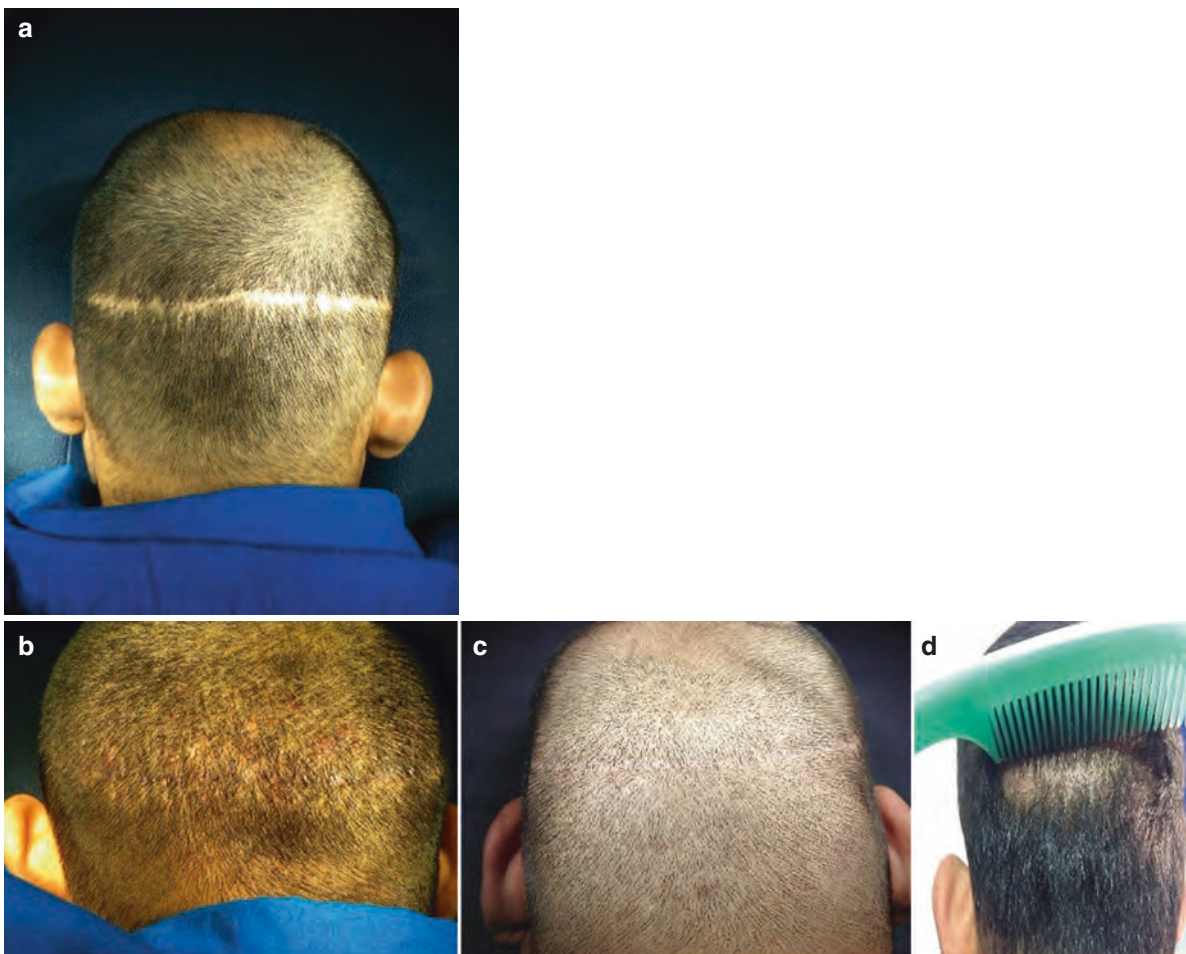Trichophytic closure (Fig. 34.10) involves trimming of the upper and lower edges of the skin which facilitates the hair to emerge through the scar ensuring that we will give aesthetically acceptable scar to the patient (Fig. 34.12b) Wound closure done without the above clinical manoeuvre leads to poor scar (Fig. 34.12a), which is quite obvious.

Post-operative care of the wound is important. Antiseptic creams are optional if the donor site wound is washed with clean water or ns on a daily basis. In our experience, suture removal is recommended on 11th post-operative day to avoid wound gaping or wound dehiscence.

Fig. 34.11 (a, b) Wound closure in layers after Haemostasis



©Association of Oral and Maxillofacial Surgeons of India

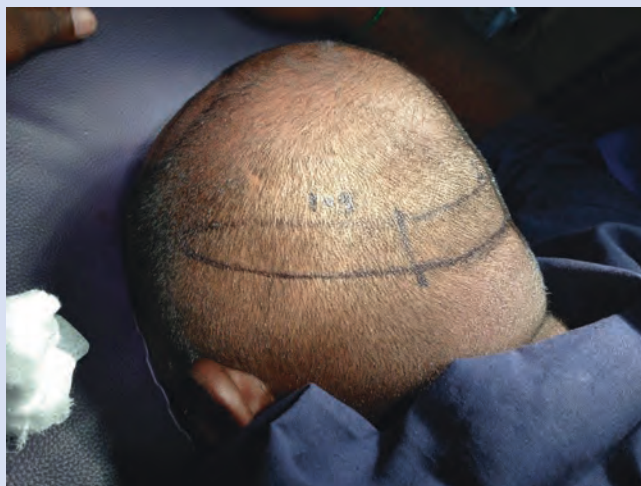

©Association of Oral and Maxillofacial Surgeons of India

Fig. 34.12 (a) Poor scar resulting from normal wound closure (b–d) post operative scar following trichophytic closure

Variable Strip Technique

This will help us to get maximum grafts with less tension along the scar leading to a better scar. Most of the individuals have thick density in the occipital area and lesser density in the parietal area and any misjudgement will lead to poor wide scar in the parietal areas. Here, by using variable dimensions of the strip technique (Fig. 34.13), we can target for more grafts with least possible scar. In this technique, the strip width is more in the occipital area than compared to the parietal area as illustrated in the image below.



©Association of Oral and Maxillofacial Surgeons of India

Fig. 34.13 Variable dimensions of the strip marked out for harvesting

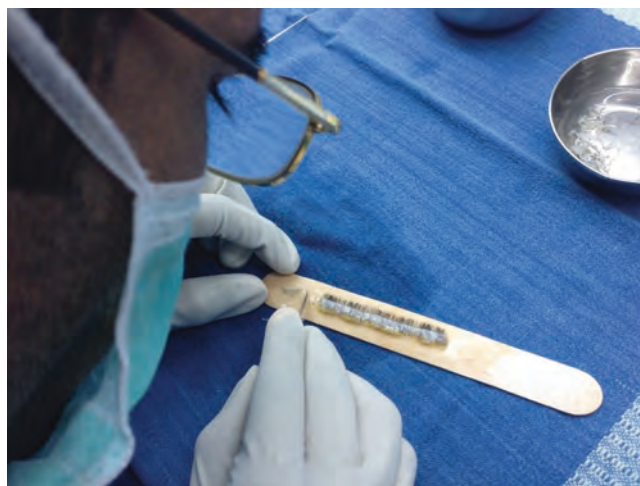34.9.1.6 Slivering

Slivering is a process where the strip is sliced into small bits of tissues with rows of hair follicles in them, through meticulous deft handwork akin to the baker slicing the bread loaf into thin slices. It is the first step of the separation of grafts from the strip while avoiding any transection of the graft. Higher magnifications should be used to perform this important step for which a few clinics are using stereoscopic microscopes while the others manage with normal 10× magnification. It should be done simultaneously while the surgeon performs the wound suturing to save the crucial graft holding time of around 6 h.

At the end of this step, we get slivers which are ready for the separation process (Fig. 34.14). The separation process is separating individual grafts from the sliver. For the separation process, we need more trained technicians as it is cumbersome exercise and needs great attention to detail to avoid any form of trauma to the graft being obtained with an obvious fight against time.

For the separation process, we need to use 3× magnification which can be done on a sterilised wooden spatula or an acrylic illuminated sheet.

Wooden spatula would give us good resistance to cut the grafts whereas acrylic sheets will be slippery. Advantage of the acrylic sheet is we can illuminate from below, which is easy for separating the grafts. The separation process is noth-



©Association of Oral and Maxillofacial Surgeons of India

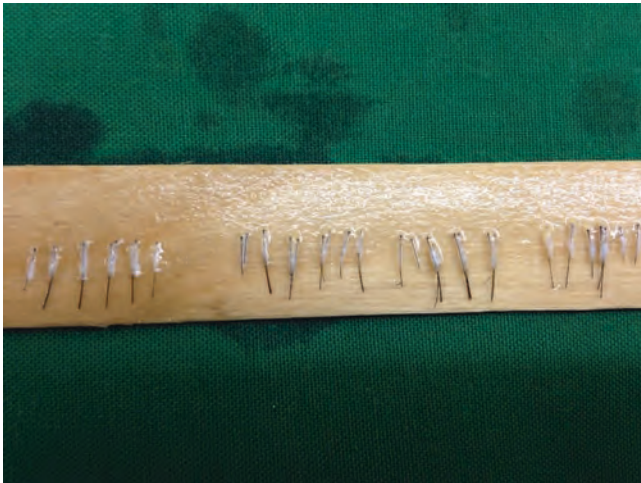Fig. 34.14 Slivering and separation of grafts from the strip in FUT

ing but getting rid of the excess fat around the grafts and making the grafts slender in a pear shape or tear drop shape. Care is to be taken to ensure that we do not denude the roots and little fat is left behind for survival of the graft through plasma imbibition. All skin has to be trimmed and removed from the graft and finally these prepared grafts are preserved in cold normal saline around 4–8 °C temperature.

While separating the grafts, we would get single, double, triple follicular unit grafts, and care is exercised to maintain the follicular unit (Figs. 34.15 and 34.17a), as it is natural to ensure better survival. These are segregated further in different bowls and are used up for implanting starting with single units for the frontal hairline and progressing onto multiple follicular units as we go posteriorly in a progressive manner.

34.9.2 Follicular Unit Extraction (FUE) (Box 34.4) (Video 34.2)

In this technique, we extract the individual follicles one graft at a time with the help of small punches. Also known as no stitch and no cut method, it's minimally invasive procedure



©Association of Oral and Maxillofacial Surgeons of India

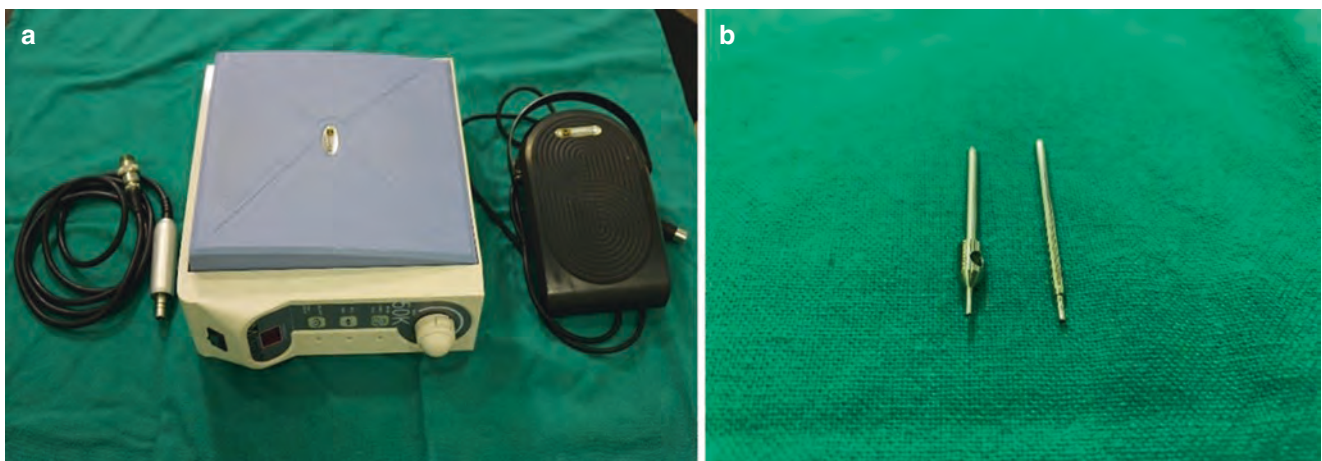
Fig. 34.15 Separated follicular units

compared to the FUT. FUE gained popularity in recent years because of its ease of doing and being less invasive with minimal downtime for the patient. Initially, FUE was introduced with manual punches which was more tedious and time consuming limiting the number of grafts that could be done in a session [9]. Current advances with motorised punch have improved the pace and its effectiveness in harvesting more grafts. Though many different motors and punches are available in the market, normal dental micromotor with straight hand piece would suffice to perform FUE (Fig. 34.16a, b).

Punches are made up of either titanium or stainless steel with the diameter of the punch ranging from 0.6 to 1 mm, with 0.9 mm being suitable for Indian scalp. The advent of FUE has expended the scope of harvesting follicles from other sites of the body wherein 0.6 or 0.7 mm punches are useful for beard site and 0.8 or 0.9 mm punches have been suitable for chest hair harvesting, respectively.

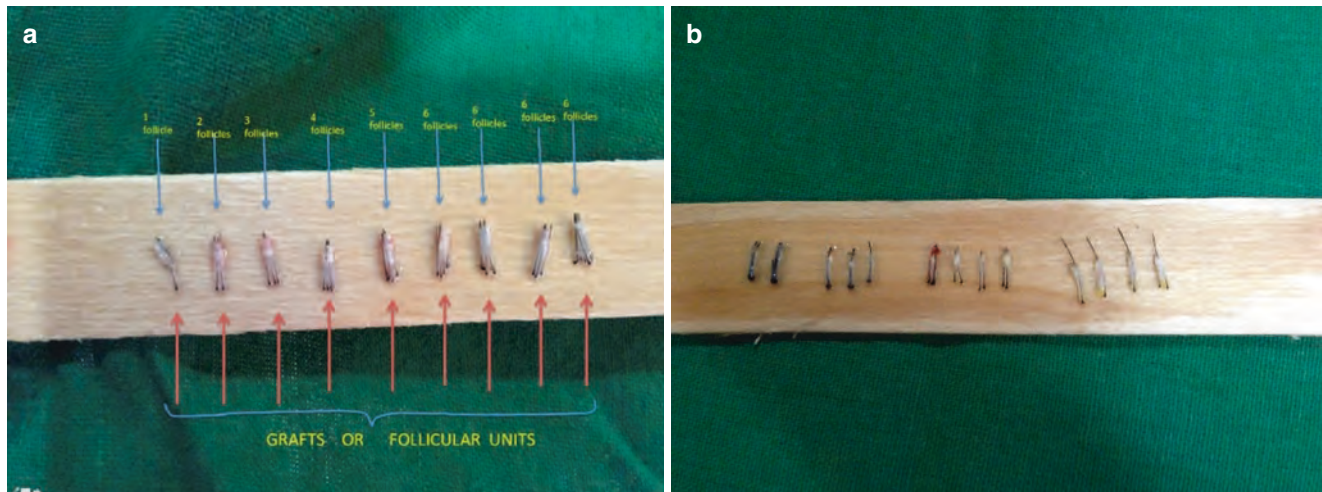
Box 34.4 FUE

- No linear scar, small round dots in donor area.
- Decreased healing time in donor area.
- No post-op discomfort in donor area.
- Useful for those with risk of donor scarring. Like young pt, very muscular, very tight scalp.
- Useful in Body hair transplant
- Graft quality is not as good as FUT.
- Procedure is time consuming.
- Large sessions required to shave the entire donor area.
- More expensive.
- Follicles transection rate is more



©Association of Oral and Maxillofacial Surgeons of India

Fig. 34.16 (a, b) FUE instruments: micromotor, straight handpiece and punches



©Association of Oral and Maxillofacial Surgeons of India

Fig. 34.17 (a) Follicular units and their natural arrangements. (b) Comparison – FUE grafts on the left which are lean and slender versus FUT grafts on the right which are bulkier

Punches are available as dull, sharp, serrated and oscillating type. Normal dull or sharp punched would be sufficient to perform FUE. On an average one punch can be used to harvest around 1000–1500 grafts.

This latest motorised technology has made surgeons' job easy and in experienced hands we can harvest around 800–1000 grafts in 1 h, provided patient's skin is favourable.

Being a blind procedure, this is technique sensitive and is associated with a steep learning curve requiring more concentration. It is performed under 3× magnification controlling the punching around the hair graft while maintaining depth and angulation which is very vital to harvesting the grafts. The punch should get down to epidermis and dermis junction not going beyond 4 mm from the skin. Surgeon should always analyse the angle of exit of the hair and be parallel it prior to the punching. Acute angles of the grafts would lead to difficulty in punching and lead to not only bigger punch holes but higher transaction rates. Most of the Indian skin is favourable for FUE procedure because of thicker skin types. The follicles obtained by FUE are comparatively slender and devoid of extra adventitious tissue in comparison to the FUT follicles (Fig. 34.17b).

34.9.2.1 Blades

They can vary in size and shape from being thin sharp blade to having a pointed chisel as in the case of sp90 which is one of the popular blades for pre slit technique. Today, the surgeons have a choice of customising the blade with commercially available tools and can use a square or tapered blade as per their choice.

34.9.2.2 Needles

Standard 19 gauge hypodermic needle is preferred for making the graft recipient sites while the same can be achieved with solid core needles eliminating epidermal implantation.

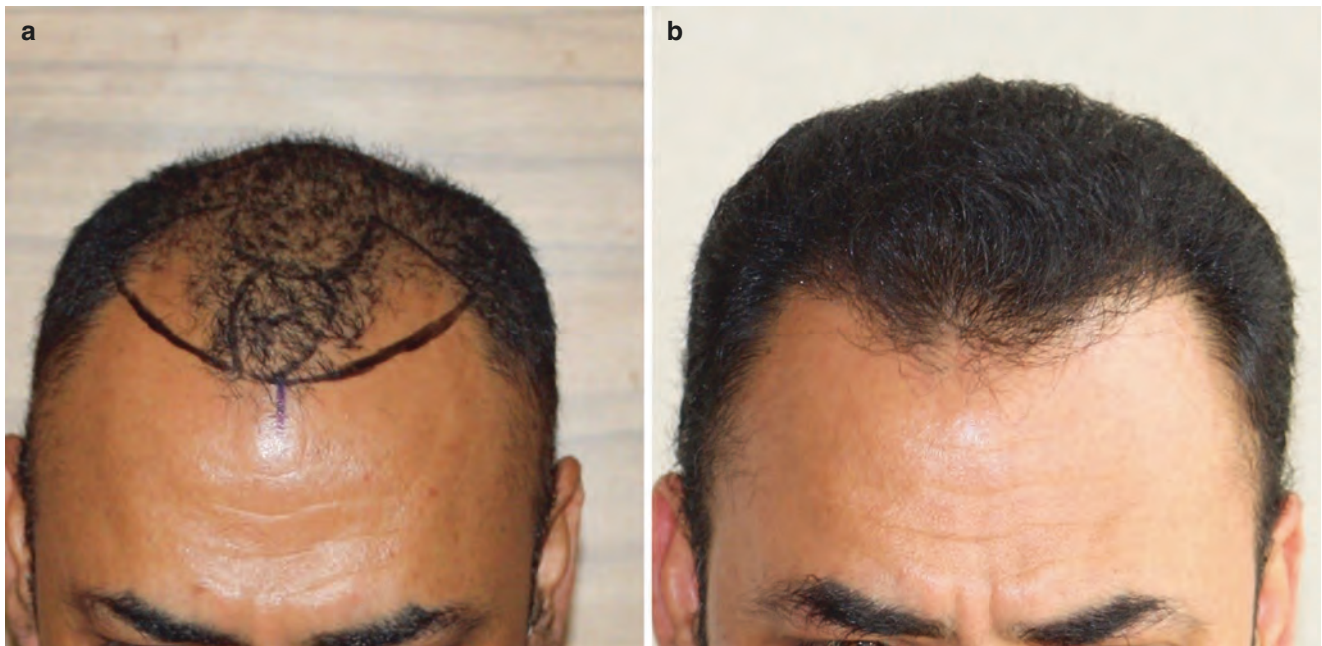34.9.2.3 Limitations of Follicular Unit Extraction

FUE has an important role to play in hair transplant because it can reach the areas where strip cannot reach to harvest grafts. When we plan second session, FUT may not be possible in unyielding skin types. In poor candidates where donor areas of the scalp have poor hair quality, FUE can be used to target beard and body hairs. FUE like any other procedure is associated with a few disadvantages like comparatively more GTR (graft transection rate), especially in curly hair types and in these few cases graft yield is abysmally low wherein the surgeon will have to convert the case to strip technique. Follicular splay is another situation where hair roots are placed apart which causes difficult extraction. In case of scattered grafts too, the punch may tend to damage more grafts while harvesting and would not be an ideal situation to continue harvesting with high graft transection.

34.9.2.4 Hairline (Fig. 34.18a, b)

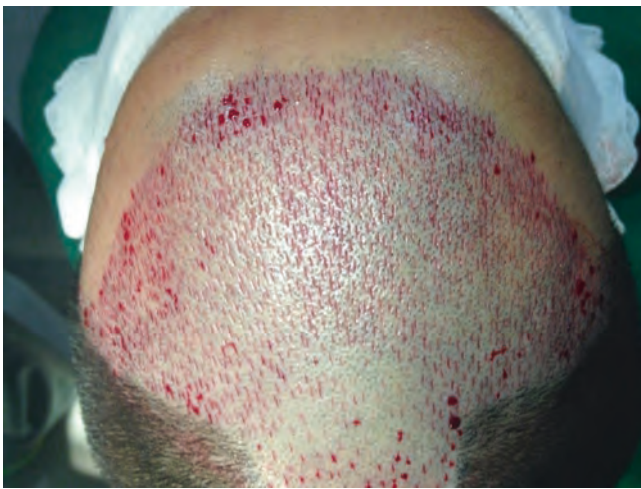The hairline design and location are the most critical factors in the success of hair transplantation, for which one should understand the concept of facial thirds. Till the age of third decade of life, the anterior hairline at the midline is located at a distance equal to the middle third height of the face from the glabella, adding additional 1 cm in length to it with each passing decade of life to take the hairline upwards and backwards to give a matured look to face considering the progressive nature of hair loss. The frontotemporal apex is the deepest point of the anterior hairline laterally as it merges with the temporal hairline and is located along the lateral canthus of the eye [10].

It is to be borne in mind that the hairline anteriorly is not a straight line but an irregular one having peaks and troughs making it look like a coastline with the front two rows made



©Association of Oral and Maxillofacial Surgeons of India

Fig. 34.18 (a, b) Hairline design and natural looks



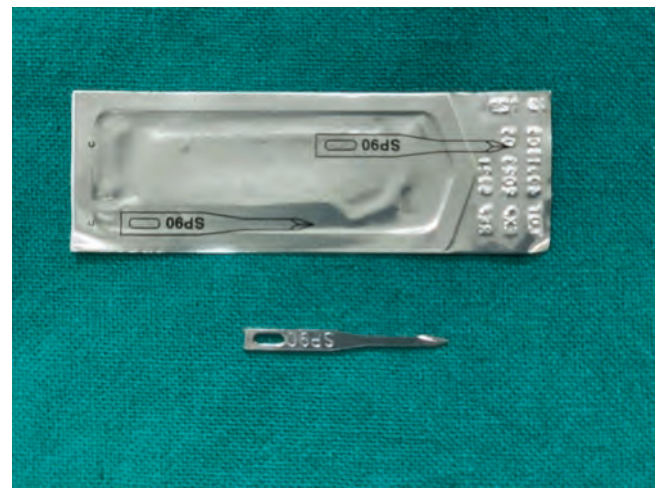
©Association of Oral and Maxillofacial Surgeons of India

Fig. 34.19 Recipient site slits

up of single follicular units and gradually it progresses to double and triple follicular units to give the density. The central core or frontal tuft area gets the maximum density of hairs implanted to enhance the strength and aesthetic value of the hairline thus created.

34.9.2.5 The Recipient Sites Preparation and Implantation

Recipient sites are prepared (Fig. 34.19) to receive the grafts by making slits in the skin with either 19 gauge hypodermic needles or sp 90 blades (Fig. 34.20) or other microblades which are of 1–1.1 mm in width. This step could be done



©Association of Oral and Maxillofacial Surgeons of India

Fig. 34.20 sp 90 blade used for recipient site preparation

prior to implantation for all the grafts (pre-slit method) or individually for each graft while simultaneously implanting it (stick and place method).

Slits made with blades tend to give more natural looks when compared to needle implantation (Table 34.1). As a prerequisite to facilitate implantation, the site needs to be trimmed short while the remaining hairs guide us in the direction and angulation of the implantation. Proper tumescence will allow us to expand scalp so that we can place more grafts in the given area while also reducing any damage to the neurovascular bundle and enhances visibility.

The slits are performed in the area with proper direction (converging forwards), depth (follicular length for the given patient) and angulation (15° in the front -45° as we approach the crown part of the scalp).

Once the slits are done, implantation is done by using jeweller's forceps (Fig. 34.21), which are pressure graded. This is also called 2 forceps technique as one forcep is used to locate the slit while the other one is used to implant the graft into the slit. The grafts are to be held above the bulb or beside it where the dermal fat is held.

Implantation of 3000 grafts by forceps would need around 3–3.5 h approximately (Fig. 34.22a).

34.9.2.6 Implanters

Few surgeons use implanters (Fig. 34.22b) which can hold the graft in it and all you have to do is to eject them into the site at the desired direction and angulation. Technicians will preload the graft into the implanter. Implanter can be used

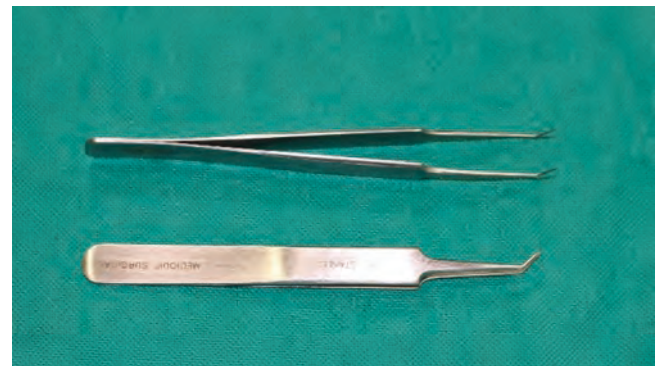with pre slits or without pre slits made in the scalp. However, implanters tend to create a circular slit which may lead to pitting kind of scars at the base of the graft after growth. They need extra hands for the procedure and come at an extra cost too.

34.9.3 Combi Technique (Fig. 34.23)

This is a combination of FUT and FUE in a single session. Combi technique is recommended when we need more grafts as in anything over and above 3500 follicles in a single session. In this technique, the strip is first harvested

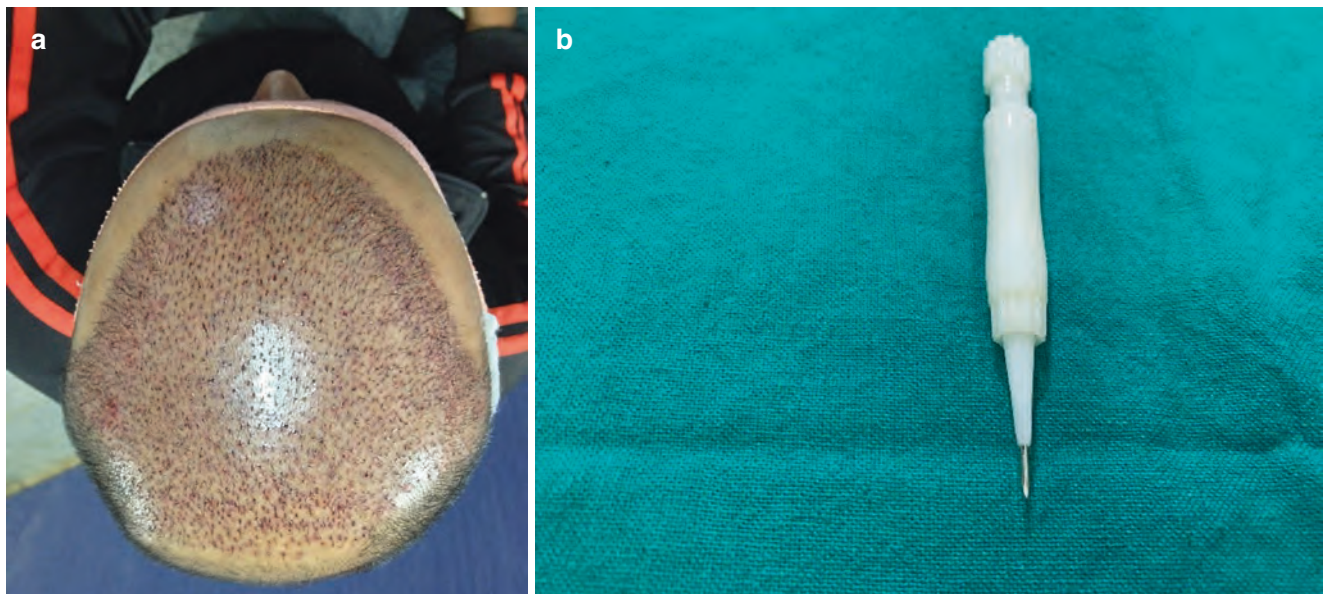
Table 34.1 Advantages and disadvantages of blade versus needle for slit creation

	Blades	Needle
Distribution	Uniform	Variable
Bleeding	More	Less
Direction and angulation control	Better	Possible in few trained hands
Time taken	Less	More
Aesthetic appearance	More likely	Less likely
Healing	Without marks	Leaves pitting/embossed scars



©Association of Oral and Maxillofacial Surgeons of India

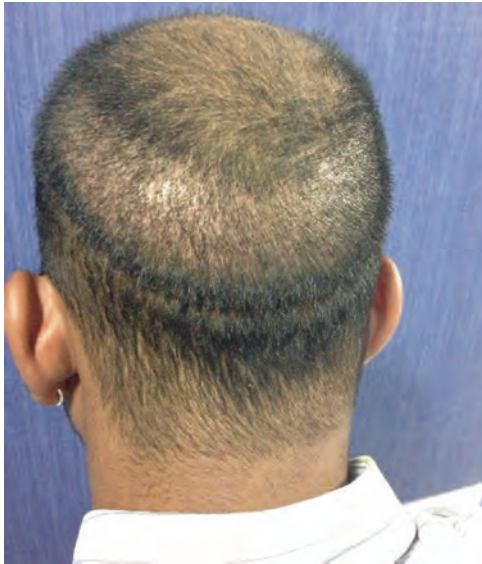Fig. 34.21 Jeweller's forceps used for implantation



©Association of Oral and Maxillofacial Surgeons of India

Fig. 34.22 (a) Immediate view of a case post-implantation. (b) Implanters used for implantation

and then the FUE is performed above and below the strips in the same sitting before implanting. Advantages of this procedure are that the surgeon can reduce the strip length and still can obtain more grafts thereby reducing the strip length and the resulting scar. However, it requires an experienced surgeon and well-trained team to execute the procedure.



©Association of Oral and Maxillofacial Surgeons of India

Fig. 34.23 Combi technique post-operative view

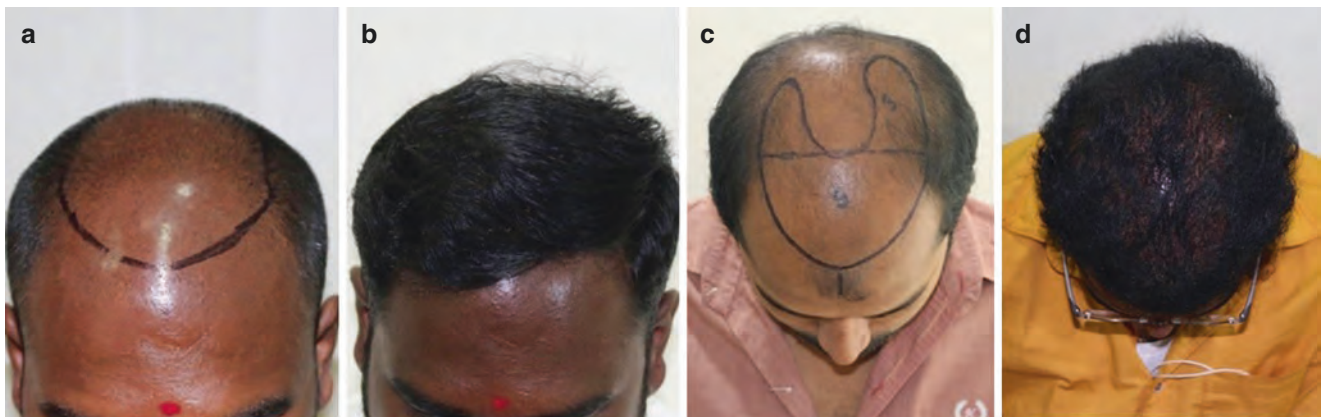34.10 Post-operative Care

Immediately after the procedure, the heaviness, numbness or tightness may be there for a few hours. There is also some swelling on the forehead and temple area due to the tumescence and surgical insult and the resulting swelling is normal. Patients are allowed to sleep on the back or on the sides but are not allowed to sleep on their tummy as otherwise the swelling tends to gravitate onto face and eyes. Patients should be asked to massage the forehead from the middle to the sides for 5 min every hour for first few days. Rarely some patients may feel momentary dizziness especially while standing up from the lying down position on the procedure table.

There is some oozing of blood-stained fluid from grafted site as well as in donor area (both in case of strip or FUE). Bending forward of the neck can stretch the stitches and can initiate some more oozing from the stitches therefore keeping the chin up is recommended.

Patients are restricted to perform any contact sports/gymming for a period of 12 days and should avoid swimming for up to 3 weeks. They should also not get to field work under the sun for first 3 weeks. Patients who ride a bike are allowed to wear a helmet after a period of 4 weeks. Topical minoxidil can be restarted in the transplanted site after a waiting period of about 15 days post-operatively. Patients are also forbidden from riding a bike or driving in an open vehicle for up to 2 weeks.

After the procedure, antibiotics and analgesics are provided for 5 days. The donor and recipient sites may or may not be bandaged. If bandaging is preferred, a non-adhering betadine pad is placed over the operative sites with several layers of flattened gauze sponges over them to hold the betadine pad in place as the scalp is wrapped with clean bandage using two to three 4-inch gauze rolls. Crepe bandage can



©Association of Oral and Maxillofacial Surgeons of India

Fig. 34.24 (a–d) Outcome following hair transplantation

be used over it. The dressing is removed the following morning, and the scalp and each graft are clean meticulously by gently dabbing with a cotton swab with normal saline. Patients are advised to sprinkle or spray normal saline over the grafts every 3–4 h for 8–10 days. Suture removal is performed on 11th day and is not applicable for FUE. Initially for 10 days the grafted area should be washed without rubbing the grafts. Whereas after the above period, grafted area can be washed and patients can rub the grafts. Most of the grafts will be shed by 12–20 days which is a common phenomenon, one need not to worry about it falling off.

Regrowth and Results (Fig. 34.24a–d)

Summary of events following a hair transplant.

Immediate after a hair transplant, there will be mild blood excretion and oozing.

1st day scabs (nothing but dried blood) will form and continue forming for the next few days.

After 4 to 10 days you will notice itching. This is normal, but do not scratch or pick on the transplanted areas.

After 10 days your scalp will be cleared of all scabs.

After 11–20 days your new implanted hair will shed. Now your new follicles are in its dormant (sleeping) stage. It's time to watch and wait.

Pt must be aware that a lag phase exists before hair growth is initiated. After approximately 4 months, the telogen phase to the implanted grafts ends and anagen begins. Complete growth can be seen only after 8 months and hair continue to grow until 12–14 months.

34.11 Complications

Able professionals should manage any adverse outcomes by minimising the damage and help achieve the desired outcomes with low morbidity. Fortunately, today the follicular unit hair transplantation is a safe procedure with low rates of complication when performed with care [11].

34.11.1 Complications in Preoperative Phase

Overexpectations of the patients are the major cause of complications and arise due to hasty or incomplete consultation and is better addressed with more than one consultation to assimilate the requisite information with the help of informative brochures, websites and discussions with the clinician to arrive at realistic outcomes especially in the younger patients who happen to be unclear and lack maturity for comprehending the results; in such cases, it's better to keep them on medical line of treatment till they become practical in accepting the results. Any individual with body dysmorphic disorder and Norwood vii patients where you

would not make much difference would count as poor patient selection by the clinician. In case of ongoing hair loss, the clinicians should not be tempted to promise full coverage or high density influenced by the advent of current medicines as the patients may change their minds and stop the intake of medicines over a long period of time, eventually resulting in inappropriate placement pattern and lack of donor site for harvesting. Clinicians should not be further influenced by the patients' demand for low unaesthetic hairline, or be drawn into performing mega sessions arising out of patients' demand and be careful in choosing the donor material in the middle of the back and sides of the permanent fringe avoiding any slanted scars or scars visible in scanty donor hair bearing areas.

34.11.2 Complications in Surgical Phase

1. Pain:

Patients who are counselled appropriately and are provided with a relaxing ambience generally experience minimal discomfort. In-depth local anaesthesia achieved through precise nerve blocks and ring blocks administered with a long-acting drug-like sensorcaine and taking help of vibrating devices while injecting the solution slowly will go a long way in enhancing the comfort levels. Anxiolytics should be prescribed by the clinicians to patients who are apprehensive about the procedure.

2. Bleeding and popping:

Optimising the health of the patient prior to the surgery results in blood pressures being within normal limits. Adequate tumescence consisting of saline and epinephrine has to be injected below the dermis to allow the surgical field to be lifted away from the bleed vessels and then the clinician has started the procedure after 15 min will have minimal bleeding. Too much of tumescent in the recipient site can be a cause of popping, though clinician cannot eliminate popping as pre slit technique can minimise the issue.

3. Bad hair direction:

Clinicians should plan appropriately to maintain the direction and exit angle of the hair that mimics the natural growth. Keeping the grafts with a few millimetres of hair will allow the clinician to ascertain the angle during implantation.

4. Hiccups:

Due to the irritation of the aberrant branch of the vagus nerve, patients can have hiccups through the procedure.

5. Poor graft quality:

A good team leader will constantly supervise to ensure proper handling of the follicles, which will minimise trauma to the follicle resulting from transaction, manipulation, desiccation, oxygen starvation and crushing of the graft [12].

34.11.3 Post Surgical Complications

1. Donor site effluvium:

Hair in the growth phase can fall rapidly post transplantation due to temporary lack of oxygen during surgery resulting in loss of hair variably along to suture line when significant blood vessels are cut. Any such hair loss will be noticeable around the third week post-operatively and leads to embarrassment to the surgeon. If the donor area can be raised above the blood vessels with good volume of tumescence, the above complication is rarely encountered.

2. Infection:

This is a very rare complication seen today given the standard asepsis precautions followed and is rarely encountered where the patients are not given adequate post-operative instructions especially in cases of tight donor area closure and in patients with compromised immunity.

3. Dehiscence:

A poor surgical technique associated with bad suturing, harvesting wide strips, performing tight closures or resulting infections and necrosis can lead to dehiscence.

4. Dysesthesias:

Today it's no longer a complication thanks to adequate use of tumescence which will lift the hair follicles above the neurovascular bundles.

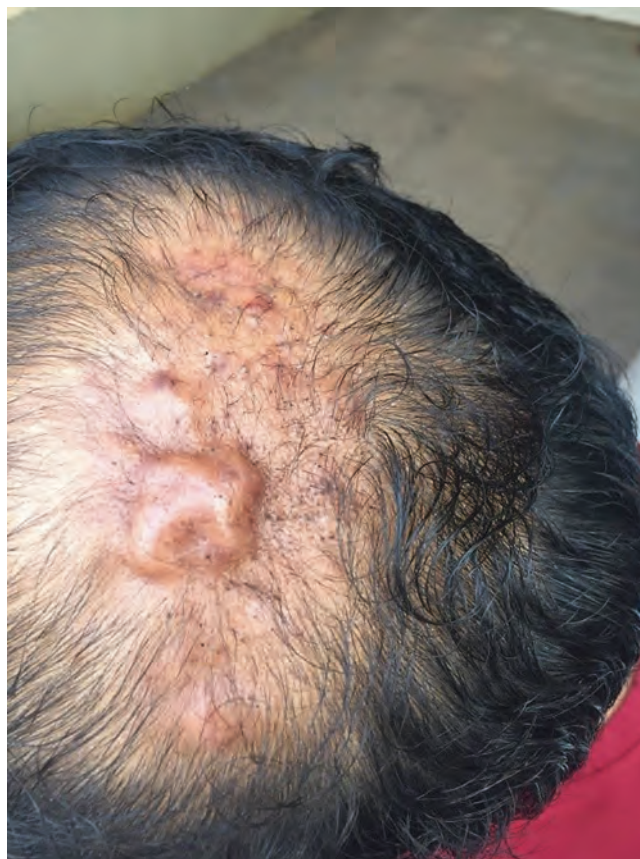5. Scars:

This unavoidable outcome can be prevented by following the basic principles of surgery with accurate approximation, closure without tension, by using double layered closure, trichophytic technique and avoiding resolvable suture for closing the skin. Donor scars also occur due to improper donor assessment prior to the surgery. Skin laxity test will help us to evaluate the skin laxity so that we can limit the strip width. At times we may need to consider variable width dimension to reduce the tension in the wound, usually where occipital area skin laxity is more and parietal area skin laxity is less. So we can consider more width at occipital area and less width at parietal area. If skin has less laxity, we can consider FUE.

Any hypertrophic scar can be managed with steroid or injection and later implanting hairs with FUE.

6. Forehead swelling and ecchymosis:

Based on the laxity of the skin in the frontal area and the trauma induced by the slit making process, swelling occurring at 3–4 days post hair transplantation can be mitigated by including some steroids in the la solution, applying pressure bandage and some digital massage across the forehead.



©Association of Oral and Maxillofacial Surgeons of India

Fig. 34.25 Folliculitis post hair transplantation

7. Surgical effluvium:

This is similar to the donor site effluvium which results in the anagen hairs going into telogen phase and falling out around the second or third post-operative week and regrowing with the grafts. Preoperative use of minoxidil solution tried 1 month prior to the procedure is recommended to prevent the above complication.

8. Cysts, pustules, pimples and folliculitis: (Fig. 34.25)

The above sequelae following hair transplantation can be avoided by preventing deep implantation of grafts, transacting hair during site creation and piggybacking of one follicle up on another. Most of them do settle down with time; however, acne like therapy can be offered to resolve the lesions faster.

9. Pitting and tenting:

It's very important to avoid the above complication in the frontal hairline which could otherwise be unacceptable and are easily preventable by avoiding deep placement of the grafts as in the case of pitting and too superficial placement of the grafts as in the case of tenting.

10. Poor growth:

This can be attributed to poor handling of the grafts resulting in physical and biological trauma to the grafts associated with dehydration of the follicle, crushing of the follicle during implantation, thermal insult and prolonged holding time outside the body.

The incidence of complications may be reduced by avoiding mistakes by the team in general (Box 34.5) and those related to the technique, specifically graft survival (Box 34.6).

Box 34.5 Frequently Made Mistakes Made by Team

- Too much cross talk between team members annoying the patient.
- Members do not address patient by name.
- Grafts prepared either too chubby or skinny.
- Too many single grafts prepared.
- Photography not taken properly.
- Consent not taken properly.
- Grafts allowed to dry.
- Not interested in routine work.

Box 34.6 Factors Affecting Graft Survival

- Proper donor tumescence
- Temperature of holding solution
- Dehydration of follicle
- Crush injury of follicle
- Transection of follicle
- Adequate dermis and fat around follicle
- Smoking
- Biological modifiers

34.12 Current Advances

Futuristic developments in the field of hair transplant need to focus on the current lacunae in the procedure and revolves around the availability of limited donor supply and the duration of the procedure.

Low-level laser light therapy has been approved by FDA as a device to stimulate the hair growth in the 650–800 nm spectrum. Home-use scalp brush or helmets with laser technology are available which use the pain-free technology to stimulate epidermal stem cells in the hair follicle to move the follicles into anagen phase.

Automation of the FUE process with the use of robotics has shown to reduce the follicular transaction rates and improve the harvest speed, resolving the issue of skills possessed by practitioners. Artas and neo-graft are devices which have glamorised the field by involving robotic technology, but the running expenses and need to create sites and manually implant follicles need to be solved in the coming days.

If hair can be cultured from the scalp biopsy, then the patient would not need to donate hair by going through a painful procedure, by cloning hair we can create unlimited supply of follicles and avoid ration of hair. Current state-of-the-art research promises that the technology would get transferred from bench side to the bedside in a few years from now.

34.13 Role of a Maxillofacial Surgeon

A maxillofacial surgeon makes a good hair transplant surgeon as they are well trained in surgical anatomy of the head and neck with a detailed knowledge of flap design and through in-depth working knowledge of the local anaesthesia management. They have a great aesthetic sense with artistic hands and are well versed with cephalometric analysis which comes handy in judging facial proportions and hairline placements, further most of them are very well adapted to handling the rotary handpiece from their formative training. Maxillofacial surgeons are well trained exclusively in head and neck surgery for 3 years and are competent at managing wounds and infections, thus justifying their qualifications to perform hair transplantation alongside plastic surgeons and dermatologists.

34.14 Conclusion

Surgeons who deal with aesthetic surgeries on the face need to have a good range of skills to deal with all aspects of beauty which are defined by the individual elements. The most important of them all being framing of the face like a photo frame with hair transplantation which will allow us to focus our vision on the finer elements of the facial beauty be it the nose, lips, eyes, teeth, jawline or a good smile. If surgeons follow the principles of hair transplantation surgery, they will create patients with high degree of satisfaction using the micrografts of FUE or FUT procedure. This sophisticated form of art will bring a sense of gratification to oral and maxillofacial surgeons by embracing it as a tool along with all other tools at his disposal.

34.15 Case Scenarios

Case Scenario 1 (Fig. 34.26)

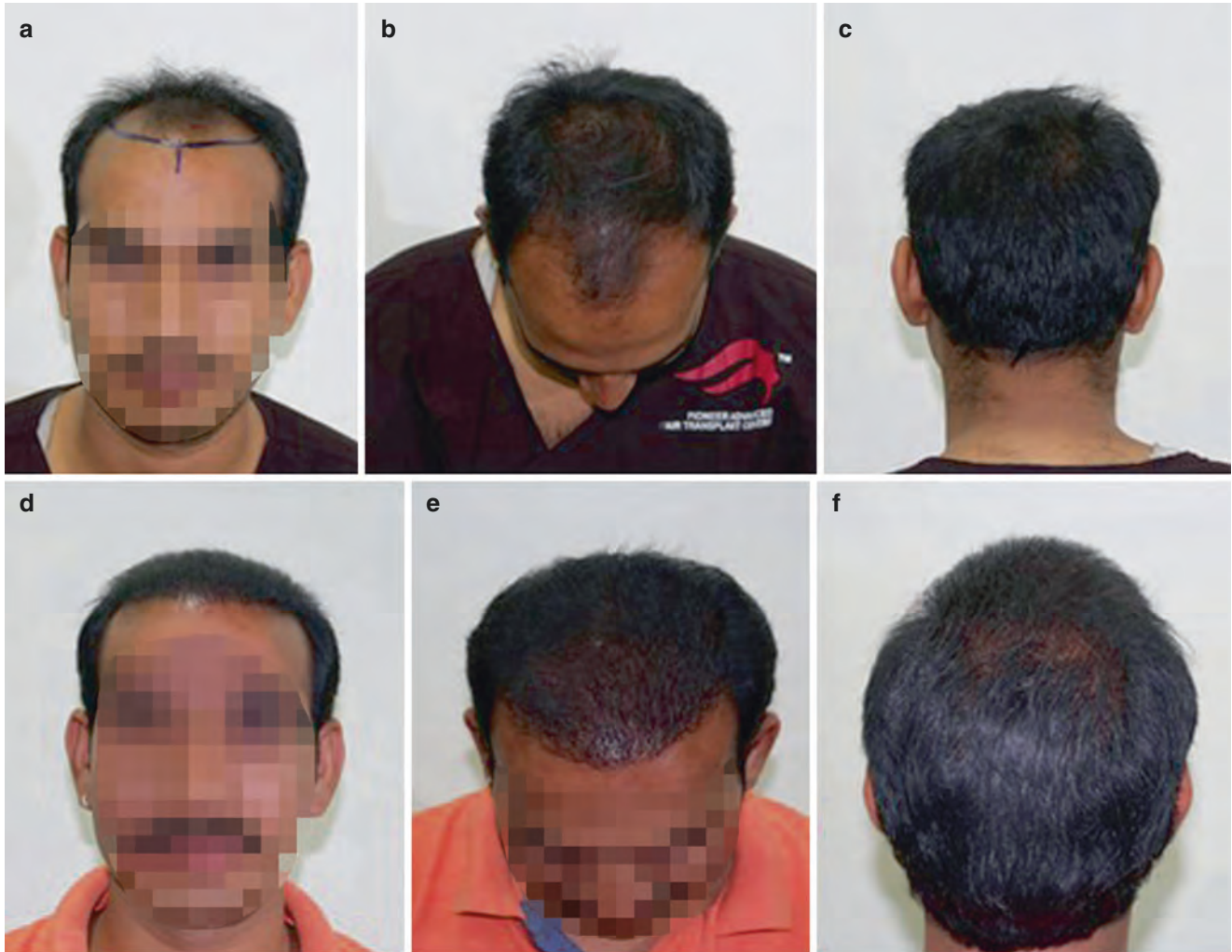Figure 34.26: male pattern baldness—Norwood classification 4.

Treatment: FUT method with 2850 plus microfollicular grafts transplanted.

Case Scenario 2 (Fig. 34.27)

Figure 34.27: male pattern baldness class 5.

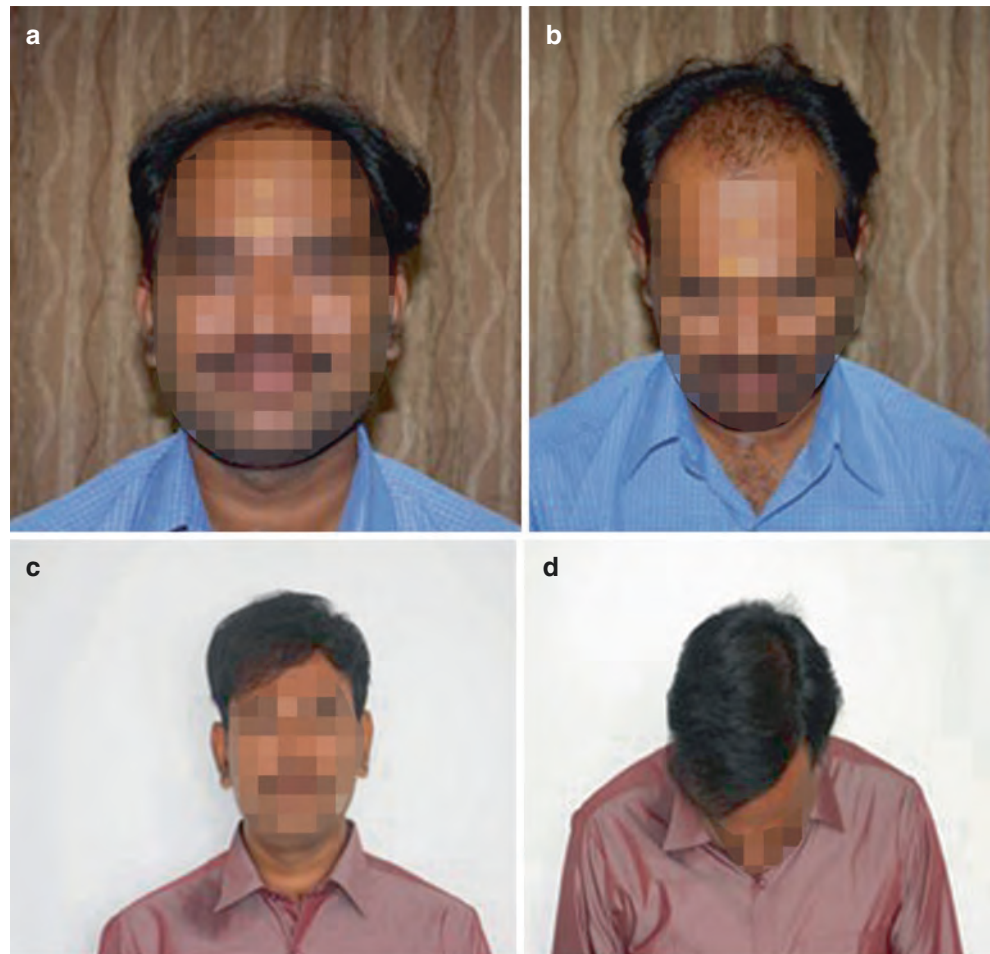Treatment: 4000 follicular units transplantation done through Combi technique involving both FUT and FUE in the same session.



©Association of Oral and Maxillofacial Surgeons of India

Fig. 34.26 (a-f) Case scenario 1

Fig. 34.27 (a–d) Case scenario 2



©Association of Oral and Maxillofacial Surgeons of India

References

- Orentreich N. Autografts in alopecias and other selected dermatological conditions. *Ann N Y Acad Sci.* 1959;83:463–79.
- Beehner M. Nomenclature proposal for the zones and landmarks of the balding scalp. *Dermatol Surg.* 2001;27:375–80.
- Bernstein R, Rassman WR, Seager D, et al. Standardizing the classification and description of follicular unit transplantation and mini-micrografting techniques. *Dermatol Surg.* 1998;24:957–63.
- Haber RS. Pharmacologic management of pattern hair loss. *Facial Plast Surg Clin North Am.* 2004;12:181–9.
- Price VH. Treatment of hair loss. *N Engl J Med.* 1999;341:964–73.
- Unger W, Shapiro R. Hair transplantation. New York: Marcel Dekker; 2004. p. 49–56.
- Bernstein RM, Rassman WR. Follicular transplantation: patient evaluation and surgical planning. *Dermatol Surg.* 1997;23:771–84.
- Bernstein RM, Rassman WR. The logic of follicular unit transplantation. *Dermatol Surg.* 1999;17:277–95.
- Rassman WR, Bernstein RM. Follicular unit extraction—minimally invasive surgery for hair transplantation. *Dermatol Surg.* 2002;28:720–8.
- Shapiro R. Principles and techniques used to create a natural hairline in surgical hair restoration. *Facial Plast Surg Clin North Am.* 2004;12:201–17.
- Cooley JE. Complications of hair transplantation. In: Unger WP, Shapiro R, editors. *Hair transplantation.* 4th ed. New York: Marcel Dekker; 2004. p. 568–73.
- Bernstein RM, Rassman WR, Rashid N, Shiell RC. The art of repair in surgical hair restoration. Part 1: basic repair strategies. *Dermatol Surg.* 2002;28:738–94.

Open Access This chapter is licensed under the terms of the Creative Commons Attribution 4.0 International License (<http://creativecommons.org/licenses/by/4.0/>), which permits use, sharing, adaptation, distribution and reproduction in any medium or format, as long as you give appropriate credit to the original author(s) and the source, provide a link to the Creative Commons license and indicate if changes were made.

The images or other third party material in this chapter are included in the chapter's Creative Commons license, unless indicated otherwise in a credit line to the material. If material is not included in the chapter's Creative Commons license and your intended use is not permitted by statutory regulation or exceeds the permitted use, you will need to obtain permission directly from the copyright holder.



Paritkumar Ladani

35.1 Introduction

The human ear is a vital and distinctive feature of the face, and therefore, its deformity confers a significant impact on self-esteem and mental development in affected patients. Microtia is the commonest congenital ear malformation. The management of ear malformations can be challenging, because of its complex 3D structure. To achieve proper reconstructive results, it is first essential to understand the basic anatomy and architecture of the ear [1]. Materials used for reconstruction of the ear include autogenous cartilage, alloplasts like silicone, Medpor, and osseointegrated materials. Surgical reconstruction of the ear with autogenous grafts is a unique marriage of science and art [2]. Good results depend not only on surgical skill but also on conforming to the basics of plastic surgical principles and tissue transfer. The gold standard for external ear reconstruction even today is the use of autogenous cartilage frameworks.

35.2 Incidence and Etiology

The incidence of microtia is around 1 in 10,000 live births. It appears to be more frequent at higher altitudes, especially above 2000 m, due to the low oxygen levels. The condition is 2.5 times more common in boys than in girls and more commonly affects the right ear. Unilateral cases are four times as common as bilateral ones. Aural atresia is found with microtia in 75% of cases. Microtia usually occurs if there is an abnormality in the embryologic development of the six auricular hillocks. These develop at 4–12 weeks of

gestation. Microtia may be associated with other birth defects. The exact cause behind the abnormal embryologic development remains unknown. However, certain teratogens like isotretinoin and thalidomide have also been implicated in this [3].

Microtia may occur in association with other malformations, including facial nerve weakness, cardiac defects, urogenital defects, hemifacial macrosomia, and spine defects. It has also been associated with syndromes like Goldenhar syndrome and Treacher-Collins syndrome [4].

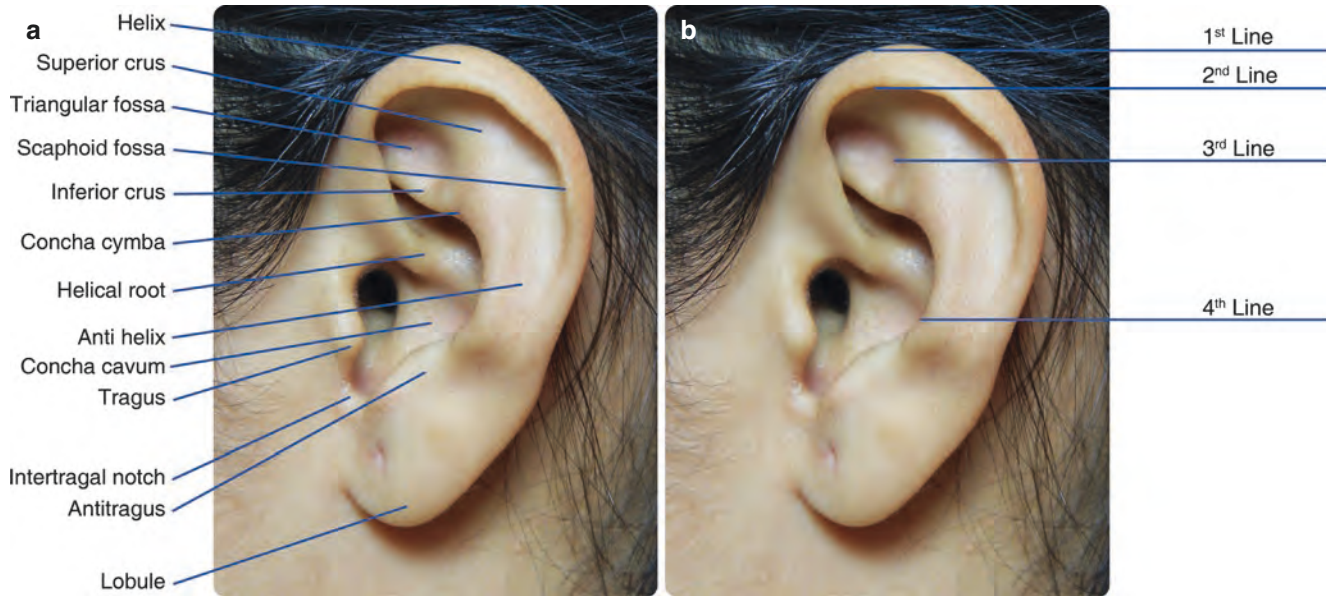
35.3 Surgical Anatomy

It is crucial to understand the external auricular anatomy and architecture before proceeding with reconstruction (Fig. 35.1a). The ear has certain definite structural elements. The overall outline of the ear is oval shaped and is slightly flattened posteroinferiorly. A distinct line can be made out that defines the helical rim, arising from its root and ending at the crus helicis. Another line forms the concha, which consists of the tragus and antitragus. The fossa triangularis is the final defining structure that defines the ear (Fig. 35.1b). A complete understanding of these structures allows the microtia surgeon to use these basic components to reconstruct the complex three-dimensional structure.

When viewed in the horizontal plane, the ear is divided into three parts. The superior portion starts at the top of the helical rim and ends at the helical root at the superior border of the concha cymba. The midportion starts at the upper border of the concha cymba and ends at the upper aspect of the antitragus. The lowest portion extends from the tip of the lobule to the superior border of the antitragus. The length of the ear is defined as the distance between the highest point (supra-aurale) and the lowest point (subaurale). This may vary between patients in accordance with the differences in the shape of the patient's face and their lobule characteristics. For instance, the ear lengths vary from 55 mm to 65 mm, with a

Electronic Supplementary Material The online version of this chapter (https://doi.org/10.1007/978-981-15-1346-6_35) contains supplementary material, which is available to authorized users.

P. Ladani (✉)
Oral and Maxillofacial Surgery, Swiss Cleft and Craniofacial
Centre, BSES MG Hospital,
Mumbai, India



©Association of Oral and Maxillofacial Surgeons of India

Fig. 35.1 Normal external auricular anatomy and architecture



©Association of Oral and Maxillofacial Surgeons of India

Fig. 35.2 Relation of ear to nose and facial plane

mean of 62.4 mm in males and a mean of 58.4 mm in females. The width is approximately 55% of the ear length and is around 35.5 mm in males and 33.4 mm in females. The protrusion of the ear, also called the auriculocephalic angle, ranges from 15° to 20°. This is the angle between the mastoid skin and the posterior surface of the auricle. Again, this may show variation between patients. However, this angle should remain the same in both the normal and the reconstructed ears [3]. The angle between the vertical axis of the face and the longitudinal axis of the ear is referred to as the ear inclination. It must be measured with the patient oriented to the Frankfort

horizontal position. This is around 24° with the face, but is 32° in relation to the nasal dorsum (Fig. 35.2).

35.4 Classification

There are four grades of microtia, depending on the severity. These are as follows:

Grade 1: The ear has anatomically normal characteristics, but may be slightly smaller than normal. An external auditory canal is usually present, but may demonstrate atresia.

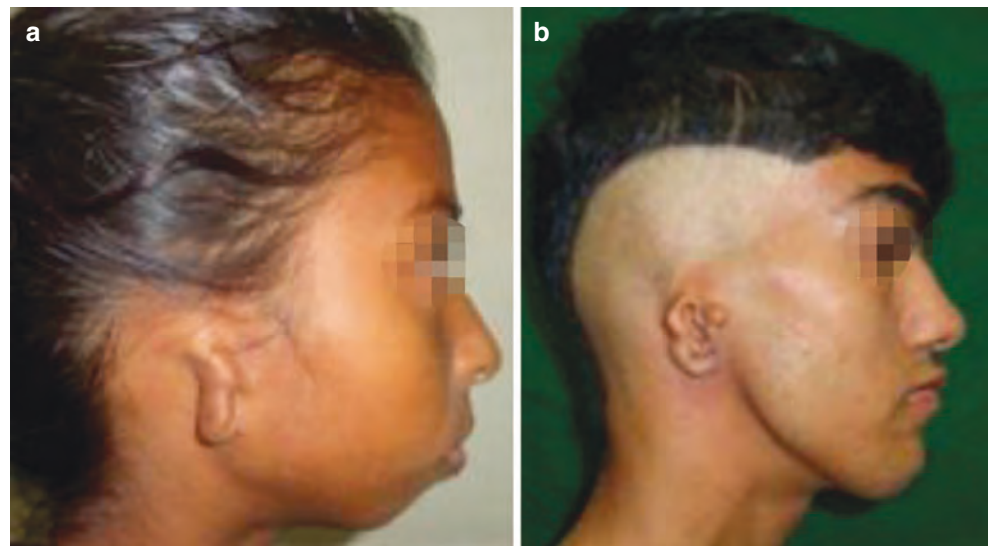Grade 2: The size of the ear is than in grade 1, and it may be less developed. Although a part of the helix may be formed, the triangular fossa, scaphae, and antihelix are under-developed. Atresia of the external auditory canal may or may not be an associated feature.

Grade 3 or classic: This is the commonest grade seen and usually consists of a vertical remnant of skin. There is a superior component that contains the malformed cartilage, and an inferior component that forms the displaced earlobe. This grade is almost always associated with atresia.

Grade 4 or anotia: The outer ear structure is completely absent, and atresia is always present.

There is another simplified classification, in which microtia is divided into the lobular type (ear remnant and lobule

Fig. 35.3 (a) Lobule-type and (b) conchal-type microtia



©Association of Oral and Maxillofacial Surgeons of India

are present) or conchal type (presence of concha, external canal, and tragus with lobule) (Fig. 35.3).

35.5 Evaluation and Management

The management of a child with microtia should ideally be discussed with parents shortly after birth, to reduce parenteral stress and offer them reassurance. The audiologic testing should be performed before discharge. In cases of unilateral microtia, treatment is not urgent because the other side will have normal hearing. Treatment can be thoughtfully planned after consulting with relevant specialists. However, in bilateral cases, brainstem auditory-evoked response testing must be performed as soon as possible so that the child can be fitted with a bone-conduction headband. The microtia surgeon can discuss about all the possible option with the family, including observation, autologous costal cartilage, alloplasts, and prosthetics. Each method of management has a different timing, and therefore, all options must be discussed at an early stage. In addition, the microtia surgeon must also coordinate ear reconstruction with auditory management, so that the timing of the hearing correction may be optimized [4].

35.6 Timing

Timing of repair is governed by both physical growth and psychological consideration. The ears reach much of their mature size by age 7. Generally, by the age of 6, cartilage is sufficiently developed to provide an optimal primary framework. However, the older the child, the more cartilage is available for reconstruction. On the other hand, waiting for cartilage growth must be weighed against the psychological

and social effects of the missing ear on the child. Studies show that psychological effects usually manifest only around the age of 7–10. However, by age 6, most children are aware of the problem and want to get it corrected [3]. The timing can also depend on the method of reconstruction chosen. The Brent method, which requires less cartilage, may be performed as early as 6–7 years of age. On the other hand, the Nagata method can be done only after 10 years of age, when the chest measures at least 60 cm at the xiphisternum. This is because it needs larger amounts of cartilage [1].

35.7 History

Tanzer et al. first established the technique for total auricular reconstruction. The technique was modified by Brent, who utilized more defined surgical techniques such as fabrication of the framework and reconstruction of the tragus using composite chondrocutaneous grafts. These techniques were three stages and four stages, respectively. Nagata and Park outlined techniques that involved just one or two stages for ear reconstruction [5]. Alloplastic implants were tried since the 1960s. Initially, silicone implants were used, but these were associated with complications such as implant failure following minor trauma or abrasions. In 1993, Wellisz reintroduced the prefabricated alloplastic implant for microtia reconstruction. This was constructed from PHDPE [6].

35.8 Principle and Planning (Video 35.1)

The Microtia surgeon should begin with proper planning and achievable goals for successful auricular reconstruction. It is important to discuss the details of surgical procedure and

limitation of surgical repair with the family during preoperative consultation. The surgeon must prepare the family for multiple stages, long preoperative and postoperative care, and complications. The reconstructed ear will possess some deficits as compared to the normal ear and will be less flexible and elastic. The reconstructed ear can also be prone to complications, including hematoma, poor healing, infection, or skin breakdown. These complications can compromise the definition and contour of the reconstructed ear [3].

If the patient has coexisting anomalies, such as clefts, early surgery must be done first to correct these. For instance, in cases of Treacher Collins syndrome and other first and second branchial arch defects (craniofacial microsomia, Goldenhar's syndrome, etc.), the bone reconstruction must be achieved first, with scars peripheral to the proposed ear [7].

The precise positioning and dimensions of the reconstructed framework will define the end result of the surgery. The reconstruction must be symmetrical to the contralateral ear in the unilateral case. In bilateral cases, the parent's ear is used as a reference. Visual examination may not be reliable, and it is essential to make exact measurements, after properly positioning the patient. For an ideal position, the superior extent of the ear must be placed parallel to the Frankfort's horizontal plane, at the level of the lateral brow (Fig. 35.4). The root of the helix may be positioned at the level of the subnasale, approximately one ear-length behind the lateral brow. Measurements must be taken carefully, particularly from the lower one-third of the face, in cases of facial asymmetry (seen in about 88% of patients with microtia). The asymmetries can range from mild differences in gonial posi-

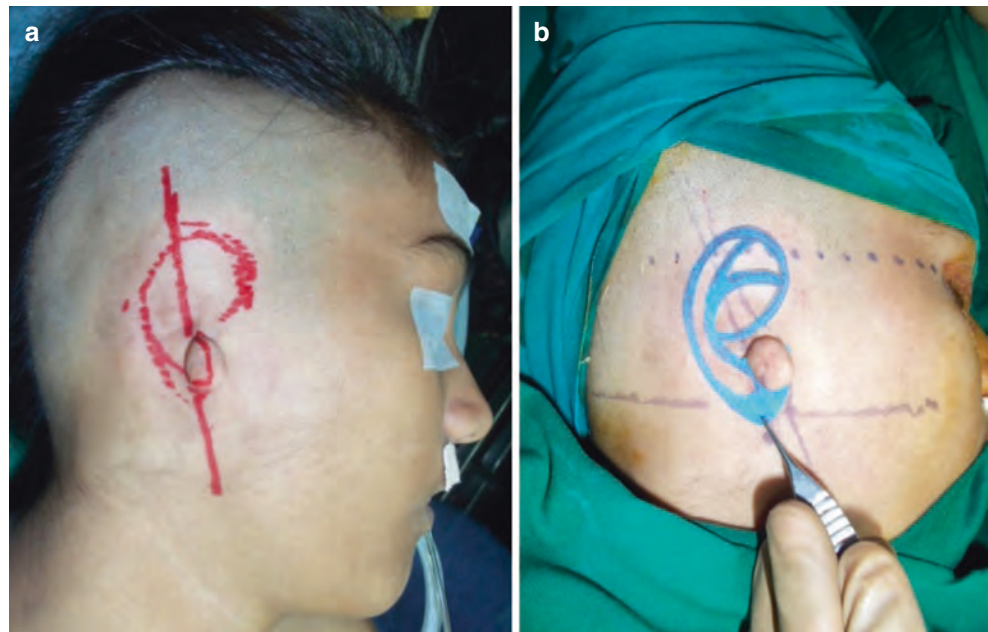
tion to full-blown hemifacial macrosomia and can lead to inaccuracies in measurement [3].

The final outcome also depends on the skin quality around the ear area. If the skin is scarred, natural expansion cannot take place, and the final ear may have a poor definition. In such cases, supplemental tissue in the form of flaps (e.g., temporoparietal fascia flap) may be considered to augment the supple skin envelope. In general, skin elasticity varies for each individual, and this can influence the final definition of the ear [8]. In cases of tight skin, a lower-profile 3D framework (1 mm) may be created, to avoid strain on the skin.

35.9 Simulation Training

The surgeon must obtain enough training in plastic and reconstructive surgery, including skills such as gentle flap dissection, delicate wound closures, and skin grafting, to achieve optimal outcomes. In addition, surgeons must be familiar with precise carving that is required for forming the 3D framework for the ear. Potato, carrot, or pumpkin can be used to learn and perfect the art of sculpting a framework [8]. Silicone dental impression material provides a convenient replica of costal cartilage, as it has the same consistency and texture. An exact replica of the rib cartilage and a precise template of the ear will allow the simulation to mimic the clinical situation. Creating the framework can be done using wood carving instruments. These techniques aid the novice surgeon in improving their results during the actual surgery [9].

Fig. 35.4 Future position and size of ear



35.10 Template

Preoperative photographs should be obtained, and measurements of the normal ear must be obtained when the patient is awake. The surgical template is prepared from radiograph film using normal ear as a guide. In the beginning, an outline of the helical rim, lobule, antitragus, tragus, and conchal bowl is created from the opposing ear as the first template [3]. This template needs to be reversed to plan the ipsilateral ear. Another mirror image template is created based on the first one, which is smaller in dimension. This would allow for the extra thickness following insertion of cartilage under the skin (Fig. 35.5). The inferior pole on the framework is created much smaller in size, to accommodate the transposition of the earlobe. If the patient does not have usable earlobe tissue, this can be carved into the lower end of the framework. A second template is created, this time minus the helical rim. This template is used as a guide for creating the base of the framework from the sixth and seventh ribs, after which



©Association of Oral and Maxillofacial Surgeons of India

Fig. 35.5 Final surgical template of ear made from x-ray film

the rim of the helix can be added. The templates must be chemically sterilized prior to intraoperative use. A third template, made along with the first, has markings at the lateral canthus of the eye and commissure of the mouth. This allows ideal framework positioning and orientation. The distances marked on the template must be verified by measuring the distance between the lateral canthus and the root of the helix [3].

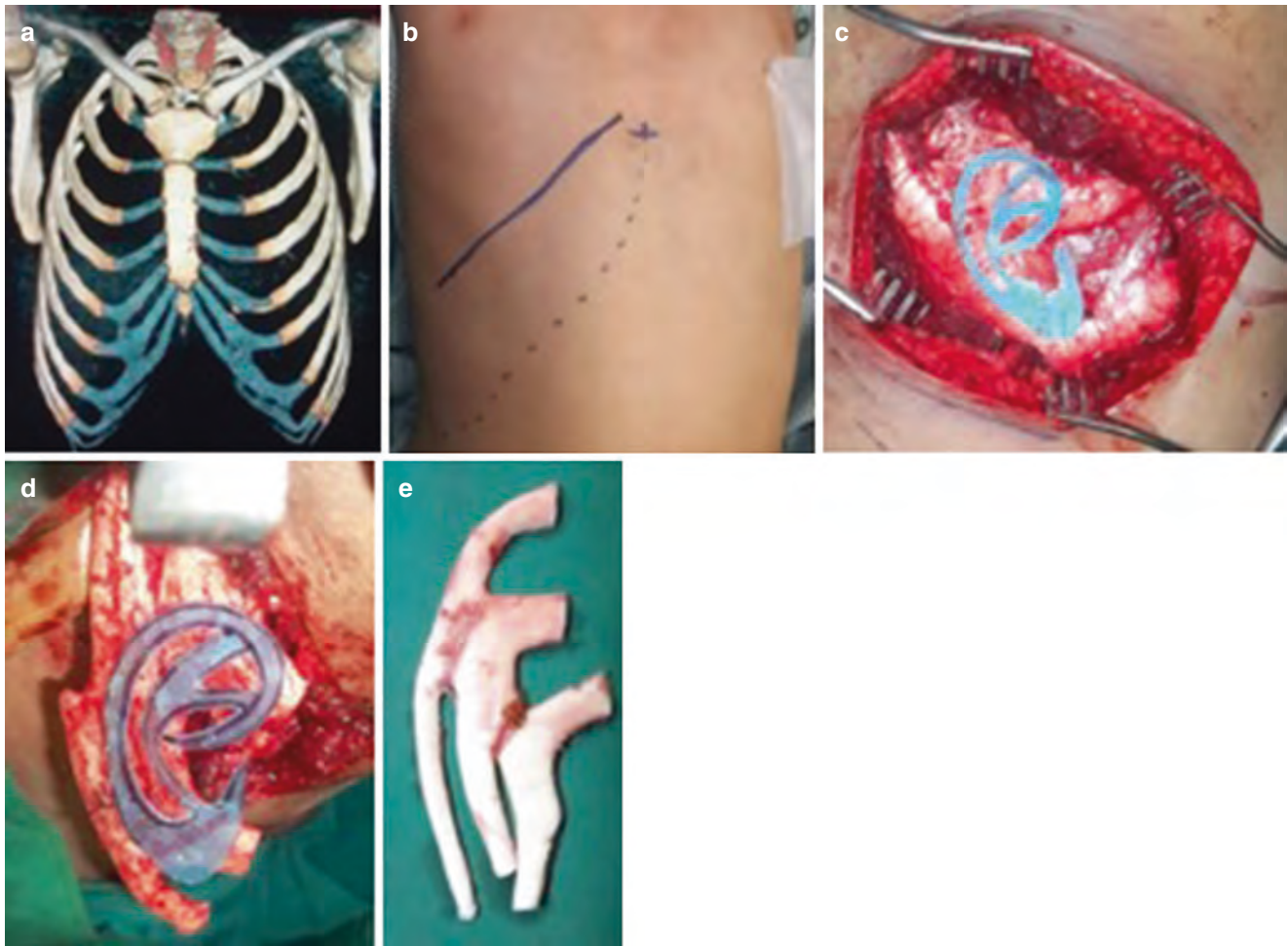
35.11 Auricular Reconstruction Using Autologous Rib Cartilage

35.11.1 Harvesting Rib Cartilage

For harvesting the rib cartilage, an incision, 4–5 cm long, is placed obliquely on the ipsilateral side, at the level of the synchondrosis of the sixth and seventh ribs [10]. The incision is carried down through the muscle, to expose the costal cartilages. It is safer to harvest the cartilage without perichondrium because leaving the perichondrium behind offers one more layer of protection to pleura. The perichondrium also allows for the regeneration of the cartilage/bone matrix. Removing perichondrium can not only offer less protection but also lead to significant depressive chest deformities [8]. After harvesting is complete, intercostal nerve blocks may be administered. Closure of the muscle and deep fascial layers is done, and a large piece of cartilage may be banked in a subcutaneous pocket for the second stage [10]. Smaller cartilage pieces may be diced and placed inside the sutured perichondrial pocket, where it can aid in cartilage regeneration (Fig. 35.6).

35.11.2 Framework

The supporting framework is a living sculpture that serves as the foundation for the repair. Rather than carving the framework to exactly mimic auricular cartilage, the surgeon must make allowances for the abnormal skin coverage that is present. These limitations include skin-volume shortage and greater skin thickness, both of which produce excess skin tension. To prevent the flattening of the ear's rim that this tension might cause, one must carve a somewhat thicker and more substantial helix. This exaggeration of the cartilaginous framework will compensate for the thickness of the overlying skin. The 3D framework must be at least 9.5–10.0 mm high in the case of primary reconstruction and further augmented by 1.0–2.0 mm for secondary reconstruction [8].

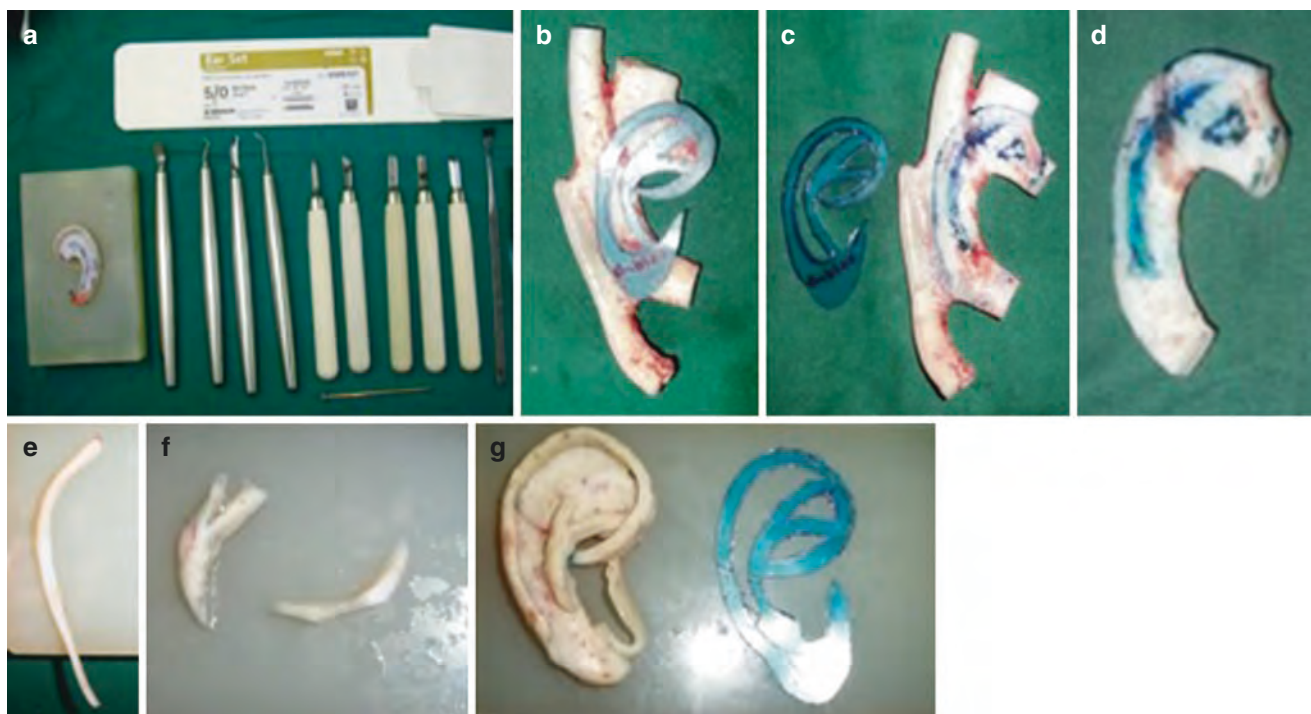


©Association of Oral and Maxillofacial Surgeons of India

Fig. 35.6 (a) 3D CT scan of Rib cage. (b) Incision for cartilage harvest. (c) Exposure of rib cartilage. (d) Template used to harvest cartilage. (e) Harvested cartilage

The cartilaginous framework is constructed from the synchondrosis of the sixth and seventh ribs (Fig. 35.7b, c, d). Cartilage wedges from these ribs are used to create the helical sulcus and the triangular fossa. The helix itself is formed from the eighth rib because it is longer. If additional length is required, the ninth rib can also be harvested (Fig. 35.7e) [10]. While carving the helix, it must be ensured that superior portion is higher than the inferior portion. The part of the helix that will be continuous with the lobule must be trimmed at the lower end, until it is long enough to receive the lobule attachment. The constructed helix is then affixed to the basal cartilage. On doing this, an outward inclination of 10–15° is maintained, at the middle one-third of the ear. The entire length of the lower part of the basal cartilage, at the outer end, is trimmed [5]. The floating rib cartilage that is used to create the helix must be thinned on its outer convex surface. This causes the cartilage to warp in a favorable direction and creates an acute angle that resembles the helix. This cartilage is then fastened to the body of the framework with 5-0

Stainless steel suture. The thickest parts of the remaining segments of cartilage are used to create the rest of the auricle, namely, the antihelix and antitragus-tragus complex, which surround the conchal bowl (Fig. 35.7f). The highest point of the antihelix is the middle, and this slowly tapers down to the helix. The superior and inferior crura are created, at the slope toward the lowest portion of the base frame. Enough space must be secured between the upper helix and superior and inferior crura, in order to accommodate the skin envelope. Otherwise, an effect of continuity between 2 crura and helix is created, which is undesirable [8]. The components of the framework are then assembled and secured together using 5-0 stainless steel wires. To achieve a snug fit, a small incision is placed in the cartilage and the wire is pulled gently toward the incision without burying it [10]. The position of the antihelix within the antitragus must be high, and trimming must be done at a lower level toward the superior and the inferior crura. In order to augment the antihelix, cartilage may be added in a vertical manner near the conchal area.



©Association of Oral and Maxillofacial Surgeons of India

Fig. 35.7 (a) Armamentarium for carving, (b–d) preparation of base of the cartilaginous framework from the synchondrosis of the sixth and seventh ribs, (e) helix prepared from eighth rib cartilage, (f) antihelix and tragus, and (g) Final framework

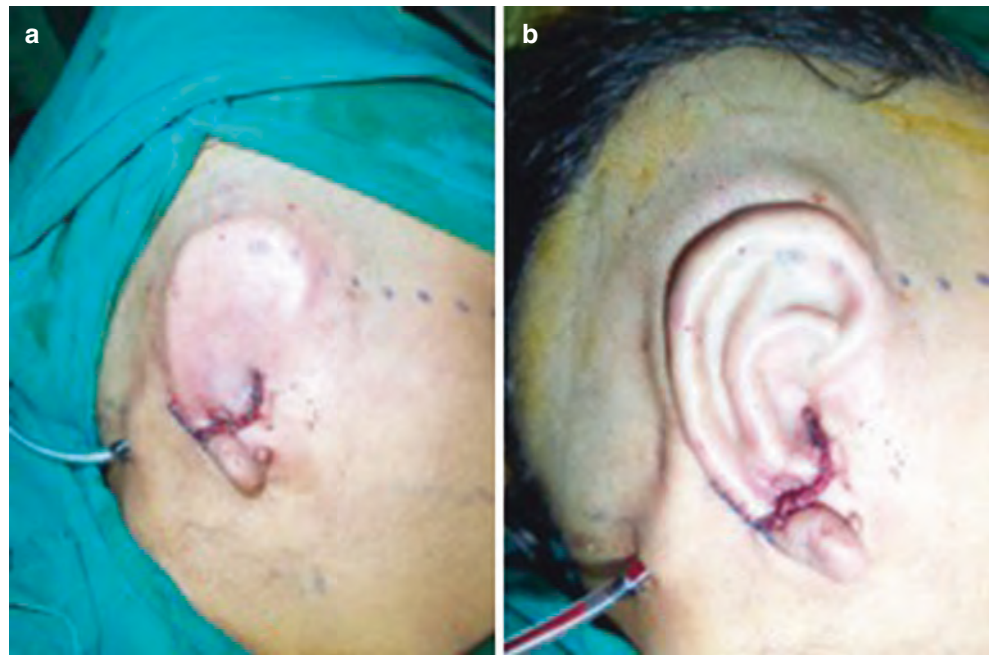This gives an effect of deepening of the concha. The antihelix is also trimmed in the region of the scaphoid fossa, so that it develops a slight inclination that resembles the natural convolution. Finally, the surfaces of the entire framework must be tapered smoothly tapered, and block-like corners must be removed, to ensure that the covering skin fits on smoothly (Fig. 35.7g). Throughout the process, isotonic saline solution is used to irrigate the cartilaginous framework. This helps preserve chondrocytes. The use of rotary and power tools must be avoided to prevent chondrocyte damage [7].

35.11.3 Skin Pocket

A pocket must be created within the skin in a meticulous fashion. This will provide proper vascular covering to receive the framework. As per the level of the lobular remnant, the level of the incision line for rotating the lobule may be determined. A small part of the lobular remnant is transposed posteriorly and separated from the microtic remnant. Then, the lobule is dissected and rotated to create a pocket that will accommodate the caudal end of the cartilage framework. This causes the lobule to be brought down and results in a smooth interface between the lobule and the framework. Creation of the skin pocket preserves the subdermal vascular plexus. The amount of dissection (at least 2 cm beyond the outline) must be wide enough to allow proper draping of the

skin flaps over the framework with minimal tension. Any cartilage, if present in the vestigial remnant, is removed. Meticulous hemostasis must be achieved [5]. An incision is placed at the posteroinferior border of the vestigial remnant, and the cartilaginous framework is placed in the subcutaneous pocket. The tail end of the framework is inserted into the lobule first, followed by suturing of the outer incision. In order to let the skin adhere to the framework, two polyethylene drains with multiple perforators must be inserted beneath the framework. These are secured to the skin using 5/0 nylon sutures. A syringe (50-cc) may be connected to the drain. After final suturing of the subcutaneous pocket, the skin flap is approximated, and the piston of the syringe may be fixed in activated position using two wooden tongue depressors (Fig. 35.8) [5]. If skin blanching is noticed at this stage, the pocket must either be enlarged or the framework must be inserted at a lower position. The use of pressure dressings must be avoided as these can compromise the vascular supply. The entire reconstructed ear must be layered in petrolatum gauze, which must be placed loosely and left in place for 3 days [3]. The syringe with the activated piston may be changed frequently in the postoperative period, ensuring that proper tension is maintained. The drains may be removed on the fourth or fifth postoperative day, provided that the volume of fluid drained is less than 1-cc. Petrolatum gauze may be left in place until suture removal, on the sixth postoperative day [5].

Fig. 35.8 (a) Before activation of suction and (b) after activation of suction



©Association of Oral and Maxillofacial Surgeons of India

35.11.4 Second Stage

The second stage of surgery involves elevating the auricle from the head, which creates the auriculocephalic angle. This procedure should ideally be performed 6–9 months following the first stage. In the conventional method, the incision lies several millimeters away from the margin, and reconstructed ear is gently lifted from the base. Care must be taken to preserve connective tissue on the undersurface of the ear, as well as on the bony floor. The posterior part of the auricle and the skin defect overlying the mastoid are grafted with skin. Since the ear lacks skeletal support, it contacts the mastoid skin and is not elevated. This creates a narrow space, which may be difficult for the patient to clean [8].

In the Nagata technique, the second stage is more complex than the conventional one. This involves the following steps: (1) separation of the auricle from the mastoid, (2) The banked subcutaneous rib cartilage or an alloplast is used to create a wedge-shaped block, which is placed underneath the auricle, (3) A temporoparietal fascia (TPF) flap is then harvested to cover the posterior part of the auricle, and (4) A split skin graft harvested from the scalp to cover the fascial flap. Scalp skin is preferred as it has better color match as compared to groin skin (Figs. 35.9 and 35.10) [8].

35.11.5 Complications

- During the harvest of Rib Cartilage

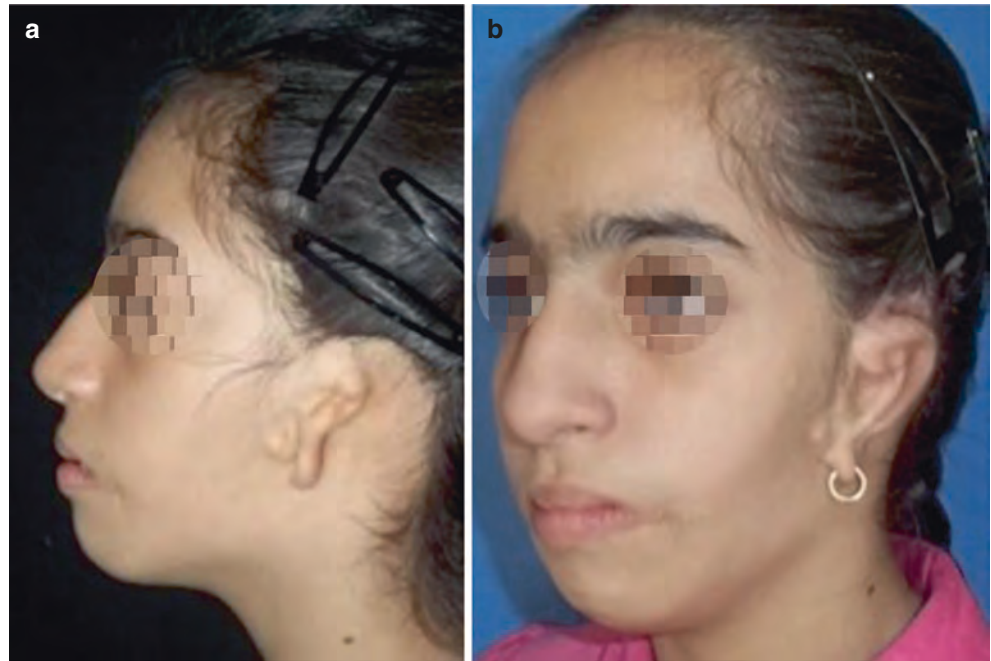The two commonest complications at this stage are pneumothorax and atelectasis. If detected intraoperatively, pneu-

mothorax can be easily treated and may not require chest tube placement. Positive pressure ventilation is used after irrigating the wound to see if there is any leak. If there is no leak, the wound is closed in layers. If a leak is seen, it indicates the presence of pneumothorax. In this case, a red rubber catheter is inserted into the pleural opening to which a syringe is attached to this to evacuate residual air. Following this, the chest may be closed and an intraoperative chest radiograph is asked for to rule out residual pneumothorax. If this is absent, the wound may be closed, the catheter may be removed and follow-up may be done with serial films [3]. Atelectasis is best prevented by frank preoperative preparation of the patient and vigorous postoperative respiratory therapy.

- Skin Flap Necrosis

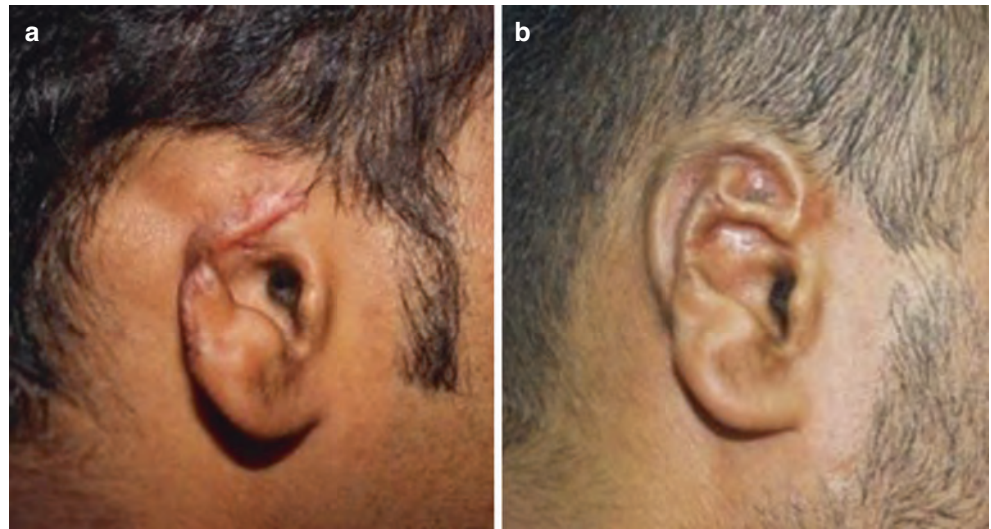
The first 10 postoperative days are critical to check for any skin flap necrosis. It is essential to achieve a balance between the thickness of the skin flap and the size of the pocket with the contouring of the cartilage framework. To prevent skin necrosis, it is advisable to minimize or completely avoid the use of epinephrine in the flap. The status of vascular supply can be tested by placing the framework in the pocket, activating the suction drain, and observing any for blanching along the rim of the helix. If blanching is present (indicating vascular compromise), the size of the pocket may be enlarged until blanching disappears. If needed, the skin supply may be increased by placing a tissue expander 2 months prior to insertion of the framework and skin adhesion [1]. If skin necrosis is observed, it must be attended to immediately, as it can cause infection of the underlying cartilage

Fig. 35.9 Ear reconstruction in hemifacial microsomia associated with microtia. (a) Preop and (b) Postop



©Association of Oral and Maxillofacial Surgeons of India

Fig. 35.10 Ear reconstruction after traumatic amputation of upper half of ear. (a) Preop and (a) Post op



©Association of Oral and Maxillofacial Surgeons of India

and framework resorption. The damage can be minimized by covering with a local skin flap or fascial flap (Fig. 35.11).

- Infection

This is uncommon in the autologous reconstruction. If it occurs, along with appropriate systemic antibiotics, vigorous irrigation of the surgical site must be done.

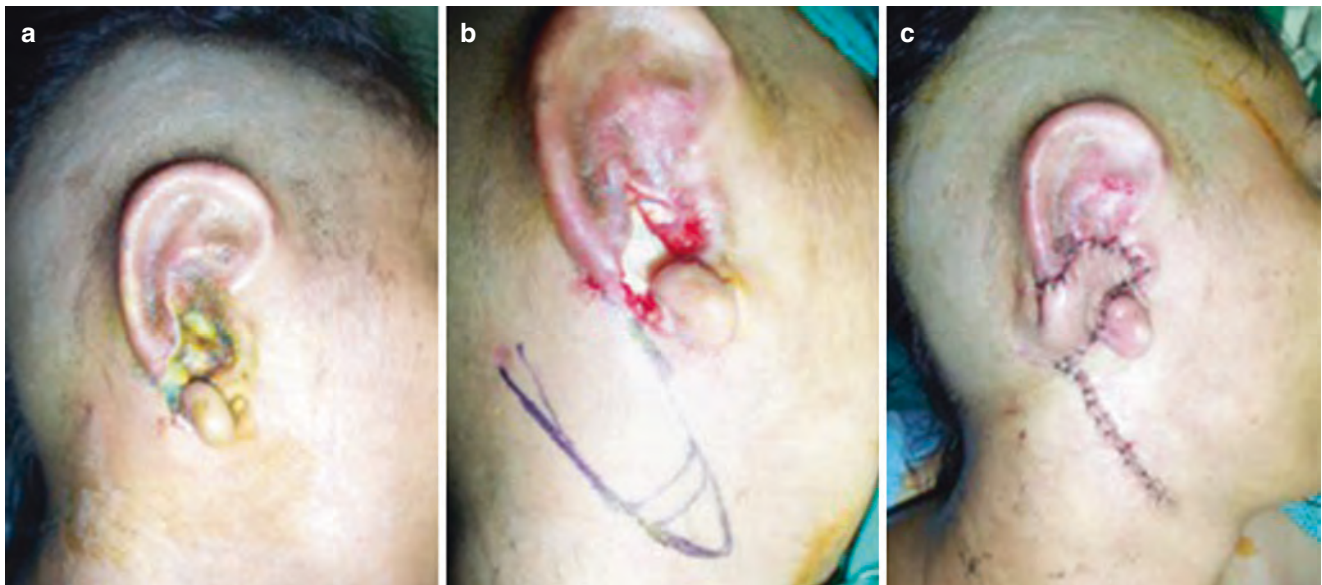
- Cartilage Resorption

If there is either ischemia or infection, there are chances that the cartilaginous framework can get resorbed or deformed.

This can also occur if the skin envelope is too tight, especially at the hairline border. To avoid this, dissection of the skin pocket around the hairline must be done carefully. Any tight fibrous band that exists along the hairline must be released.

- Wire Extrusion

If any wires extrude from the framework, they can easily be removed at the outpatient facility. It is necessary that the wire must be removed as soon as extrusion is noticed, and the patient/family must be educated accordingly. Otherwise, there are chances that the exposed wires can cause resorption of cartilage around the wire.



©Association of Oral and Maxillofacial Surgeons of India

Fig. 35.11 (a) Necrosis of skin at near suture line, (b) debridement and marking for local flap, and (c) flap in situ

35.12 Auricular Reconstruction Using Alloplast

The material used for creating framework has been a subject of debate and research. Autologous costal cartilage is still the most preferred material in microtia repair. However, some surgeons consider using alloplasts because of the following advantages.

1. Donor site morbidity is avoided,
2. Reconstruction can be done at a younger age,
3. Reduction in the number of interventions,
4. More predictable outcome,
5. The structural limitations associated with the use of autologous rib may be avoided
6. The ability to tailor reconstruction to individual patient needs (such as low hairline and bilateral malformations) [11].

The ideal alloplast for auricular reconstruction should have the following features: cost-effectiveness, ability to be implanted safely, ability to resist infection, and capability to undergo customization to resemble the contralateral normal ear. To date, more than 40 different materials have been used for creating the auricular framework. These include ivory,

nylon, wire mesh, and silicone. Silicone was thought to show good results since it could mimic the flexibility and form of the native ear cartilage. However, it had a high rejection rate, especially when placed under thin skin flaps. pHDPE (Fig. 35.12) is a modestly flexible, robust enough to withstand microtrauma, and easily shapable and allows soft tissue ingrowth. This permits it to be protected against extrusion and infection. It also allows targeted drug delivery to the implant [11].

35.12.1 Technique

It is crucial to assess the age of patient, dimension of contralateral ear in the case of unilateral microtia, and the dimensions of their gender-matched parent's ear preoperatively for achieving equal dimensions between the normal ear and the reconstructed pHDPE ear. The ear created must be adult sized as the alloplast does not increase in size.

The vascular Doppler is used for marking superficial temporal artery. The incision is given in the postauricular area few millimeters behind the new helical rim of the microtic ear to approach TPF flap. Incision is extended in a curvilinear fashion over the TPF flap to improve the exposure and also helps to harvest the distal flap of recommended length. Other approaches may be used, including an Y incision (Fig. 35.13a), which extends superiorly from the mastoid area, and the Z incision, (Fig. 35.13b) which exposes the TPF. These approaches also allow better access to the fascia.



©Association of Oral and Maxillofacial Surgeons of India

Fig. 35.12 Porous high-density polyethylene (PHDPE) framework for auricular reconstruction

However, they increase the risk of alopecia at the incision lines and at the apex of a triangular flap.

An anteriorly based skin flap of minimum thickness is elevated meticulously, and microtic cartilage is excised. Usually, the inferior portion of the flap is attached initially to the lobular remnant. If this is malpositioned, this skin flap may be removed and used as a free graft to improve skin coverage. A TPF flap, based inferiorly, of approximately 10.5 by 13.0 cm is raised off the deep temporal fascia and periosteum beneath, superior to the level of the temporal line. The base of the flap is made wide (around 6 cm) to include additional vascular supply (branches of the occipital artery, postauricular artery, and the mastoid emissary vein), and the base of the flap is made wide, around 6 cm. The flap must be made as robust as possible, and loose areolar tissue on the deep surface of the TPF must be included in it. This tissue, which lies deep to the skin graft, allows the skin to slide over the underlying tissue. This resists surface trauma and implant exposure. The PHDPE framework is then sculpted, fused, and matched to contralateral ear. Prior to implant placement, two flat suction

drains are inserted through the skin of the mastoid. One drain lies deep to the PHDPE, while the second lies in the posterior part of the donor site on the scalp. The implant is placed over the mastoid area and covered with the TPF flap after checking its anatomic orientation, projection, and axis. The flap is made to wrap tightly around the implant by the negative pressure generated by the first drain. The second drain functions to remove any serous exudate from the donor site. The skin flap, which is based anteriorly, is draped over the TPF. It may also be removed and used as a free skin graft. Sometimes, the skin at the ipsilateral mastoid may not be sufficient to cover the surface of the reconstructed ear entirely. In such cases, a full-thickness skin graft may be harvested from the opposing side postauricular region. A graft taken from this region would provide the best color and texture match. To cover the back of the ear, a larger skin graft may be required, which can be harvested from the inguinal region. After activating the drains, the ear may be coated with a layer of antibiotic cream and the concave regions may be dressed with gauze. The entire ear is then covered in a customized cast made of silicone. This cast prevents seroma, hematoma, or shearing trauma, which may compromise the viability of the skin graft. This cast should not be under pressure. A pressure dressing to prevent seromas can be applied over the donor site. All suction drains may be removed following extubation [11].

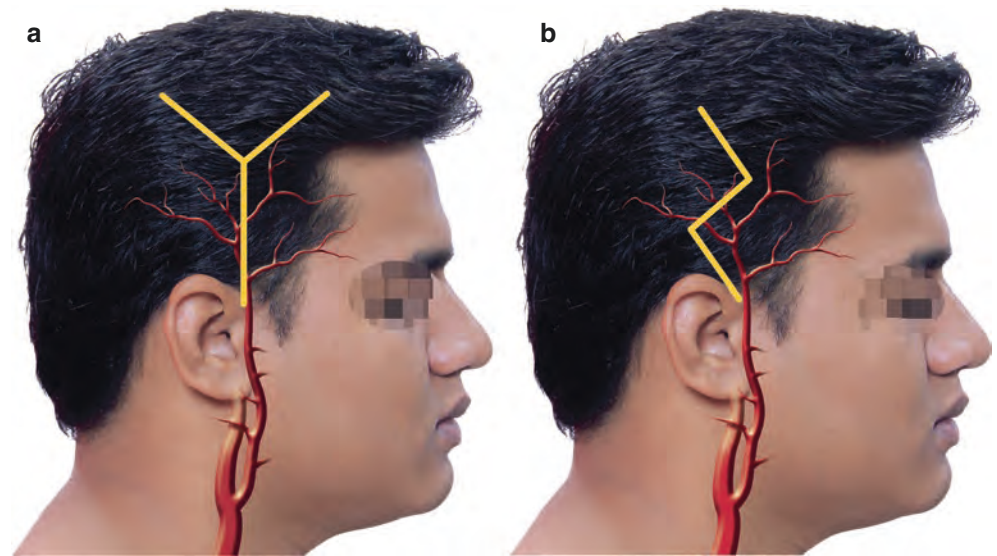
35.12.2 Complications

The complications of this procedure may be minor, such as a simple wound infection, or major, such as total flap necrosis with exposure of the Medpor framework beneath. In case the implant is exposed or infected, removal may rarely be required. Late complications include traumatic excoriations to the re-constructed ear, which should be managed with good wound toileting or with local skin flaps if required.

35.13 Prosthetic Ear

Certain traumatic, congenital, or surgical defects may benefit from auricular prostheses. The choice between surgical and prosthetic reconstruction is controversial, particularly for patients. The ideal age for prosthetic treatment is the same as the age for surgical reconstruction, namely, between 6 and 9 years. The child must be capable of caring for the prosthesis. In cases of unsuccessful surgical outcome, the prosthetic ear is one of the options. Prosthetic ear is a suitable option for the ear defects caused by trauma and disease in adult populations.

Fig. 35.13 Approach for temporoparietal flap. (a) Y shape Incision. (b) Large Z incision



©Association of Oral and Maxillofacial Surgeons of India

35.13.1 Retention of the Prosthesis

Tissue adhesives are used conventionally for ear prosthesis retention because of their low cost and quick results. Tissue adhesive is an old method and causes skin reaction. It is difficult to wear and take off adhesive while bathing and swimming. Osseointegrated implant is superior option for retention, and because of nature sense of prosthesis, ease of use, long lifetime and retention during daily activities, it is accepted by patients. An implant-retained prosthesis is preferred when there is hair on the surface of the defect or when the patient has excessively oily and perspiring skin. The prosthesis may be attached to the implant screws using precision attachments or magnets. Osseointegrated implants are contraindicated during radiation therapy, as the bone is demineralized and prone to hard tissue vasculitis, fibrosis, persistent infections, reduced tissue perfusion, and oxygenation. Osseointegration in such patients is difficult, but may be attained with hyperbaric oxygen treatment [12].

35.13.2 Prosthetic Technique

Impressions are made of both the defect and contralateral normal ear. Usually, rubber silicone material is used and plaster models are prepared. The plaster models of contralateral side are used as a reference to sculpt the framework. This is done using wax or clay. Next, a negative mold is obtained when the wax is removed, leaving behind a void. Medical-grade silicone usually of clear shade is mixed with pigments to create the skin colors of the individual patient. This silicone is packed into the void and cured. After removal from the mold, the texture and the color of the skin can be reproduced to match the contralateral side and adjacent skin [12].

35.14 Future

Regardless of the method used, ear reconstruction cannot provide an appearance that equals auricular prostheses. Future techniques must focus on emerging tissue engineering technologies that can create bone, cartilage, skin, and blood vessels. This can provide a novel direction for the treatment of patients with microtia. The creation of a natural ear using cultured chondrocytes on a prefabricated cartilaginous framework is an area of active research, but still holds some challenge [1]. Creating functional and durable tissue through tissue engineering can remove the need for donor sites and revolutionize reconstructive surgery.

35.15 Conclusion

The human ear is a unique structure that is difficult to replicate owing to its complex cartilaginous structure and thin overlying skin. The ultimate goal of total ear reconstruction should be creation of an auricle that closely matches the normal ear in appearance. Several surgical techniques are available for ear reconstruction. Since microtia is a rare condition, cases are limited, but at the same time, only a high case volume can improve success rates. The learning curve is long and might be at the expense of the patient. Although this learning curve is unavoidable, it is imperative to curtail its steepness. Prior to embarking on ear reconstruction, surgeons must be familiar with the principles and techniques involved. It is important to remember that repetition helps us master the technique.

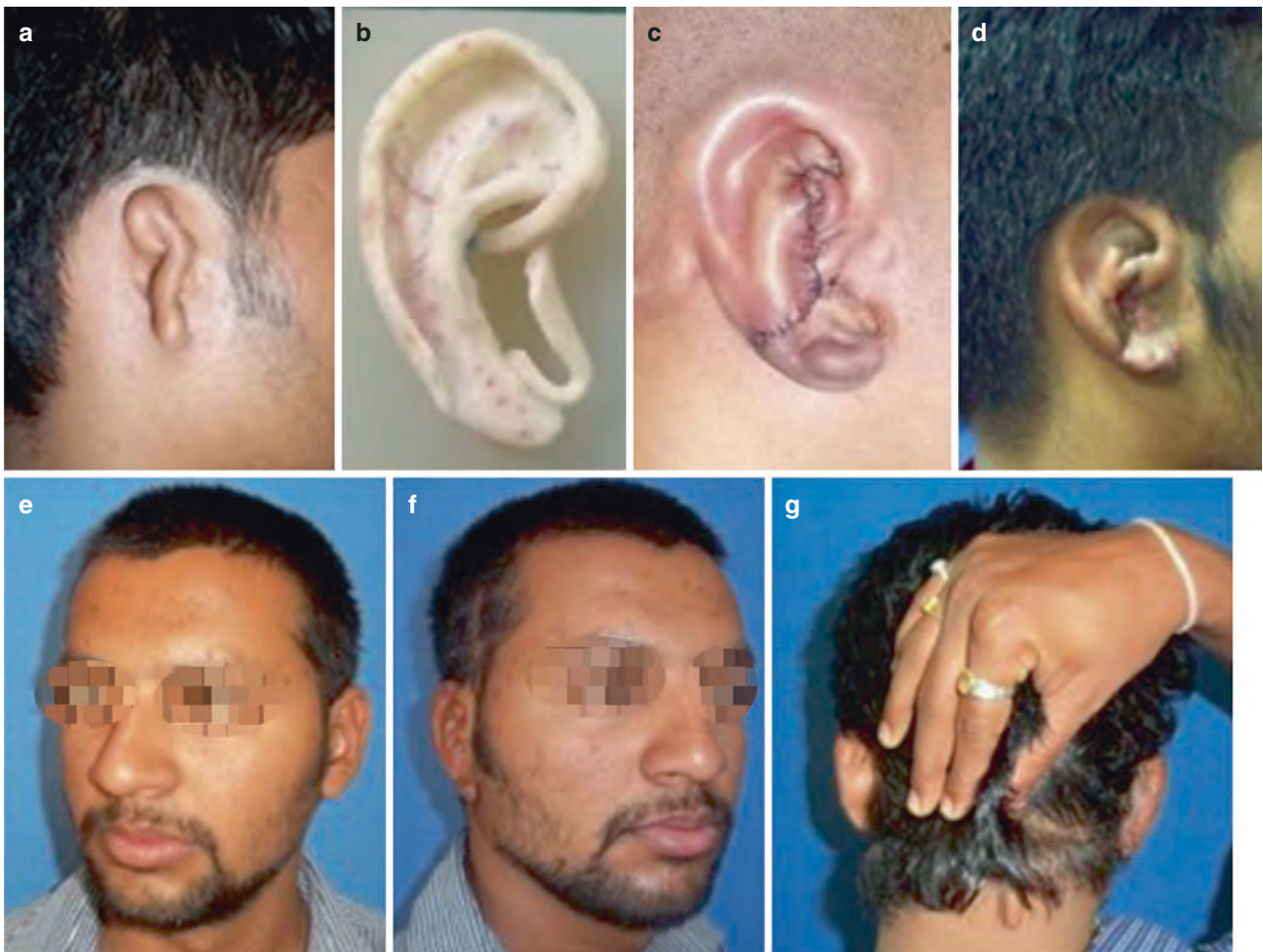Disclosure Authors have no financial conflicts to disclose.

35.16 Case Scenarios

Case 1 (Fig. 35.14a–g)

24 year-old male with Unilateral Left side Grade 3 or Lobule type microtia. On audiometry testing, hearing was normal with conductive hearing on left side. External auditory meatus is absent. He was planned for auricular reconstruction using autologous costal cartilage. Costal cartilage was harvested from ipsilateral side. Synchondrotic junction and

floating rib were harvested from the seventh, eighth, and ninth rib. Framework was prepared as shown in photo (b). Tragal component is added in framework. Skin pocket was prepared, and lobule was transposed posteriorly. Framework was inserted in pocket, and suction was applied for close adaptation of skin to framework. Stage II surgery was done after 1 year. Ear was elevated, and cartilage graft was placed for support. Graft was covered with temporoparietal fascia flap and skin grafting done. 6 months postop shows symmetric projection of both ears.



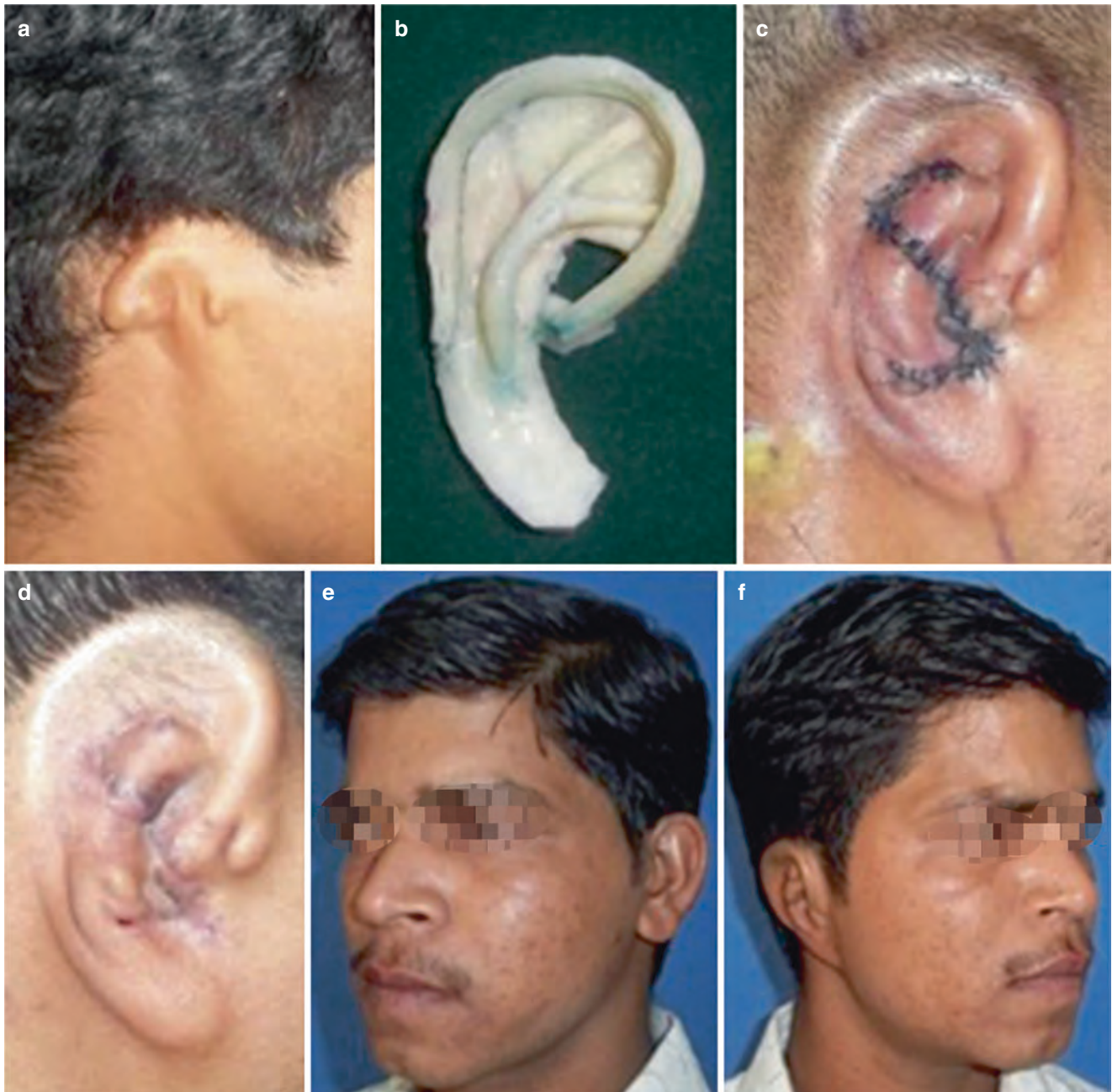©Association of Oral and Maxillofacial Surgeons of India

Fig. 35.14 (a) Preop, (b) Framework, (c) Postop, (d) 3 months postop, (e) and (f) Comparison between normal and reconstructed ear after elevation of ear, and (g) Projection of reconstructed ear

Case 2 (Fig. 35.15a–f)

21 year-old male with Unilateral Left side Grade 4 or Anotia. On audiometry testing, hearing was normal with conductive hearing on left side. He was planned for auricular reconstruction using autologous costal cartilage. Costal cartilage was harvested from ipsilateral side. Synchondrotic junction and floating rib were harvested from seventh, eighth, and ninth

rib. Simple Framework was prepared as shown in photo (b). Skin pocket was prepared using Z-plasty incision. Framework was inserted in pocket, and suction was applied for close adaptation of skin to framework. Stage II surgery was done after 1 year. Ear was elevated, and cartilage graft was placed for support. Graft was covered with temporoparietal fascia flap and skin grafting done. 8 months postop shows symmetric projection of both ears.



©Association of Oral and Maxillofacial Surgeons of India

Fig. 35.15 (a) Preop, (b) Framework, (c) Postop, (d) 3 months postop, (e) and (f) Comparison between normal and reconstructed ear after elevation of ear

References

1. Tollefson TT. Advances in treatment of microtia. *Curr Opin Otolaryngol Head Neck Surg.* 2006;14:412–22.
2. Brent B. Microtia repair with rib cartilage grafts. *Clin Plast Surg.* 2002.
3. Quatela V, Thompson S, Goldman T. Microtia reconstruction. *Facial Plast Surg Clin North Am.* 2006.
4. Bonilla A. Pediatric microtia reconstruction with autologous rib. *Facial Plast Surg Clin North Am.* 2018.
5. Cho BC, Kim JY, Byun JS. Two-stage reconstruction of the auricle in congenital microtia using autogenous costal cartilage. *J Plast Reconstr Aesthet Surg.* 2007;60:998–1006.
6. Wellisz T. Clinical experience with the Medpor porous polyethylene implant. *Aesthetic Plast Surg.* 1993;17(4):339–44.
7. Kobus K, Szczyt M, Latkowski I, Wojcicki P. Reconstruction of the auricle. *Br J Plast Surg.* 2002;55:645–51.
8. Yamada A. Autologous rib microtia construction. *Facial Plast Surg Clin North Am.* 2018.
9. Thadani S, Ladani P. A new method for training of ear framework creation by silicon dental impression material. *Indian J Plast Surg.* 2012;45(1):134–7.
10. Ladani P, Valand R, Sailer HF. Ear reconstruction using autologous costal cartilage: a steep learning curve. *J Maxillofac Oral Surg.* 2018.
11. Stephan S, Reinisch J. Auricular reconstruction using porous polyethylene implant technique. *Facial Plast Surg Clin North Am.* 2018.
12. Tanner PB, Mobley SR. External auricular and facial prosthetics: A collaborative effort of the reconstructive surgeon and anaplastologist. *Facial plastic surgery clinics of North America.* 2006;14(2):137–45.

Additional Reading

- Tanzer RC. Microtia- a long term follow up of 44 reconstructed auricles. *Plast Reconstr Surg.* 1978;61:161–6.
- Brent B. The correction of microtia with autologous cartilage graft: I. The classic deformity. *Plast Reconstr Surg.* 1980;66:1–12.
- Brent B. Technical advances in ear reconstruction with autogenous rib cartilage graft: personal experience with 1200 cases. *Plast Reconstr Surg.* 1999;104:319–34.
- Nagata S. A new method of total reconstruction of the auricle in microtia. *Plast Reconstr Surg.* 1993;92:187–201.
- Nagata S. Secondary reconstruction for unfavourable microtia results utilizing temporo-parietal and innominate fascia flaps. *Plast Reconstr Surg.* 1994;94:254–65.
- Nagata S. Modification of the stages in total reconstruction of the auricle: part I. Grafting the three-dimensional costal cartilage framework for lobule-type microtia. *Plast Reconstr Surg.* 1994;93:221–30.
- Nagata S. Modification of the stages in total reconstruction of the auricle: part II. Grafting the three-dimensional costal cartilage framework for concha-type microtia. *Plast Reconstr Surg.* 1994;93:231–42.
- Nagata S. Modification of the stages in total reconstruction of the auricle: part III. Grafting the three-dimensional costal cartilage framework for small concha-type microtia. *Plast Reconstr Surg.* 1994;93:243–53.
- Nagata S. Modification of the stages in total reconstruction of the auricle: part IV. Ear elevation for the constructed auricle. *Plast Reconstr Surg.* 1994;93:254–66.
- Firmin F. La reconstruction auriculaire en cas de microtie. Principes, methods et classification. *Ann Chir Plast Esthet.* 2001;46:447–66.
- Firmin F. Ear reconstruction in cases of typical microtia. Personal experience based on 352 microtic ear corrections. *Scand J Plast Reconstr Surg Hand Surg.* 1998;32:35–47.

Open Access This chapter is licensed under the terms of the Creative Commons Attribution 4.0 International License (<http://creativecommons.org/licenses/by/4.0/>), which permits use, sharing, adaptation, distribution and reproduction in any medium or format, as long as you give appropriate credit to the original author(s) and the source, provide a link to the Creative Commons license and indicate if changes were made.

The images or other third party material in this chapter are included in the chapter's Creative Commons license, unless indicated otherwise in a credit line to the material. If material is not included in the chapter's Creative Commons license and your intended use is not permitted by statutory regulation or exceeds the permitted use, you will need to obtain permission directly from the copyright holder.



36.1 Introduction

When the body sustains injury, the process of wound healing will commence. Scar formation is a part of wound healing. These are described as primary, secondary and tertiary intention processes [1]. In primary, there is close approximation of the wound edges, and in the secondary, the edges could not be approximated. The wound is left open, and the defect is slowly filled with connective tissue. In the tertiary, however, there is infection or contamination and there is a delay until the offending items are removed. This is followed by primary intention healing.

An ideal scar is a thin line or lines in parallel to the relaxed skin tension lines (RSTLs) described by Borges [2]. This should have a natural contour, colour and no distortion of the surrounding structures.

The scar particularly the facial is not aesthetically pleasing and can cause psychological distress to patients, resulting in poor body image, reduced self-esteem, generally loss of confidence and at times certain social stigma.

Prevention of an unsightly scar is primarily important requirement to any Surgeons but particularly important to Facial Plastics and Aesthetic Surgeons.

The origin of the word scar comes from Greek termed “iskharo” and in French “eschori” and interestingly was first used in the English language in the fourteenth century.

The primary aim in the management of scar is to produce an invisible line.

Less than ideal scars demonstrate features that are highlighted in Box 36.1.

Multiple causes can play a role in unsightly scar formation. Non-clear wound edges cannot give an aesthetically pleasing outcome. Nutritional status, co-morbidities such as diabetes, previously radiotherapy field and habits such as smoking have a detrimental effect in wound healing and thus

Box 36.1 Characteristics of less than ideal scars

- wide
- raised
- depressed
- pigmented
- hypo-pigmented
- and erythematous
- may transect natural creases, folds and junctions

imperfect scars. The most important factor is also the surgical competence of the operator.

36.2 Pathophysiology

The pathophysiology of wound healing and scar formation is very complicated [3].

The wound healing is characterised by four separate but overlapping phases (Box 36.2).

Haemostasis and inflammation occur during the first 4–6 days. During the first few minutes after surgery, there are vascular contraction and formation of fibrin clot. The ruptured cell membranes result in the release of inflammatory factors in order to cause vasoconstriction, which will last for 5–10 min, and then the vessel dilatation starts. This process can take up to 20 min. The vessel dilatation is caused by histamine, which, in turns, allows inflammatory cells to arrive at the wound site. The platelets also adhere to the site of injury. Subsequently, the coagulation cascade will be activated. The structure of the clot will be a fibrin protein network filled with platelets and its contents. The main inflammatory mediators released by the platelets are the prostaglandins, leukotrienes, interleukins, growth factors and cytokines. During the inflammatory phase, there is also the arrival of neutrophils, macrophages and lymphocytes. The main function of the neutrophils is the removal

V. Ilankovan (✉) · A. Sayan
Oral and Maxillofacial Surgery, Poole Hospital NHS Foundation
Trust, Poole, UK

Box 36.2 Phases of wound healing

- haemostasis
- inflammation
- proliferation
- remodelling

of the invading materials such as the microbes and products from the cell death. The macrophages are, however, responsible for inducing and clearing dying cells, which will result in improvement of inflammation. The apoptotic cells are cleaned by the macrophages, and the reparative stage begins. During this stage, there is migration of the epithelial cells usually after 48 hours and this process continues until the tenth day. Fibroblasts promote collagen synthesis. The epidermis is thickened in layers, and the collagen fibres promote dermal strength. The collagen deposition takes 2–3 weeks, and at this time, the remodelling phase begins. The collagen fibres will become rearranged during this period, and the cross-linked will be aligned along the tension lines. Largely, the maturation phase can take up to a year or longer depending on the type and site of wound. Therefore, the inflammatory process plays a major role in scar formation with the resultant fibroblast proliferation migration and differentiation.

The formal scar can be made better by using scar and scar reducing agents such as non-steroidal anti-inflammatory drugs (NSAIDs), minocycline and gene therapy. The main recognised scar reducing agents are transforming growth factor (TGF), TGF beta 3, COX-2 inhibitors and angiotensin receptor blockers [4]. The TGF beta modulating agents are still undergoing phase 2 trials in order to find out ideal scar modulating topical or intralesional agents.

Microfat grafting [5] is a technique with great potential in scar management where fat can be used intralesionally using a small 0.7 mm diameter cannula. It has been shown to be even more effective in placing fat in deep dermal layer of the skin using a 23-gauge needle in a treatment called sharp needle intradermal fat (SNIF) grafting. However, the work carried out by Tonnard et al. [6] in emulsifying the fat filtered until a liquid suspension was obtained, called Nanofat, which is injected using a 27-gauge needle, which conveys excellent outcome.

The ideal scar is an invisible line. There was increased interest in the recent past on intrauterine surgery to improve craniofacial clefts with some success and large failures. The extrauterine scars can present as stretched to depressed, hypertrophic or at times keloid. The stretched and depressed scars are as a result of inadequate primary intention management. The differences between a hypertrophic scar and keloid scar are highlighted in Box 36.3.

Box 36.3 Hypertrophic scar vs Keloid

Hypertrophic scar	Keloid
do not grow beyond the boundaries of the original wound	grow horizontally and outgrowing wound boundaries
occur when there are skin wounds of any aetiology	can arise from small injuries such as piercing of ears
Not genetic	genetic
Not related to any race	More in dark skinned
Equal sex predilection	More in females

36.3 Scar Management**36.3.1 General Principles**

Scar management includes prevention, pre-injury treatments during the healing period and definitive treatment once the scar is established.

It is essential to take accurate history about any previous scar formation. If it is known, extra precautions should be taken, patients should be alerted and incisions along the susceptible sites should be omitted.

For example, when doing blepharoplasty with a history of previous hypertrophic scar, we should avoid a subciliary incision and the treatment should be carried out via a trans-conjunctival approach. Avoidance of treatment should be practised, for example, a patient who had keloid on previous ear-piercing episodes.

Limiting skin stretching during wound healing, facilitating appropriate wound resting and preventive exercises in certain sites such as chest and suprapubic areas are observed. Atkinson et al. [7] reported a randomised control trial of the effect of tape fixation and the prevention of hypertrophic scars post-caesarean section with significant scar reduction.

Therefore, scar reduction therapies are classified into:

- topical,
- intralesional,
- radiation and
- scar revision with Z plasty, local flaps and skin grafts.

The latest progress in scar management includes treatment with lasers to reduce angiogenesis, subcision and intra-

dermal fillers. The emulsified fat (NanoFat) with stromal vascular fraction (SVF) and plasma rich protein (PRP) usage is the current trend in the non-surgical outcome of scar management.

Box 36.4 Non-surgical remedies

- *Steroid*
- *5FU*
- *Bleomycin*
- *Lasers*
- *Dermabrasion*
- *Subcision*
- *Fillers*
- *Silicone gel sheets*
- *Pressure therapy*
- *Cryotherapy*
- *Radiation*
- *Emulsified fat for scar rejuvenation*

36.3.2 Non-surgical Remedies

The non-surgical modalities of scar management are highlighted in Box 36.4, and the description of each is as follows:

- *Steroid*

Triamcinolone is the mostly used steroid for scars. The mode of action when used as an intralesional therapy is in inhibition of the inflammatory mediators, inhibition of fibroblast proliferation, collagen synthesis and inhibition of TGF—BETA 1 and BETA 2—and enhancement of collagen degradation and collagenase action in keratinocytes [8].

The published reports, however, give varying outcomes with dose-dependent side effects such as hypopigmentation, telangiectasia and dermal atrophy [9]. There is an encouraging outcome, however, in combination therapy when the dosage is reduced.

- *5FU*

The suggested mode of action is an inhibition of fibroblast proliferation and TGF-BETA 1-induced collagen synthesis [10]. Anecdotal results are positive; however, trials lack adequate controls. Nonetheless, the effect is encouraging in combination therapy with steroid and pulse dye lasers. Much work is required in controlled studies.

- *Bleomycin*

It is an antibiotic and has been used intralesionally in vascular malformation with good outcome [11].

The mode of action is in reduction of collagen synthesis and increased destruction of collagen by inhibiting Lysyl Oxidase such as TGF-B1 [12]. Much work is needed in its definitive usage.

- *Lasers*

Lasers target three chromophores such as water, melanin and haemoglobin. Laser-induced tissue hypoxia results in the breakdown of disulphide bonds of the collagen fibrils. Pulse Dye Laser (PDL), KTP laser and Nd YAG lasers have affinity to haemoglobin, leading to collagen necrosis, and results in reduction of proliferation of fibroblast and deposition of collagen type 3. Ablative lasers remove the scar layer by layer with minimal thermal injury [13].

- *Dermabrasion*

This technique is still used in treating irregular scars such as ice pick scars of acne. The aim is to abrade up to the reticular dermis, allowing epithelialisation to take place. This treatment causes erythema for a long time, and the symmetrical outcome is not guaranteed.

Microdermabrasion is an advancement where there is high-speed pressurised aspiration-compression system. The benefit is that it minimises deep thermal injury [14].

Carbon Dioxide (CO₂) and Erbium laser resurfacing supersedes microdermabrasion with minimal thermal damage. Laser resurfacing acts in a different way compared to the vascular lasers. The vascular laser action is as a non-ablative principle, whereas CO₂ and Erbium cause ablation.

Vascular lasers decrease the prominence by destroying the blood vessels and stimulating collagen remodelling, thus softening the scar, whereas the ablative lasers such as CO₂ and Erbium ablate or vaporise the excessive tissues. CO₂ can induce more collagen remodelling and promote wound contraction [15].

The vascular lasers are used in hypertrophic and keloid scars. CO₂ and Erbium are useful in stretched, asymmetric and irregular scars. There is a restriction as it is not effective in all skin types as resurfacing can result in excessive pigmentation in dark, Asian and African skins.

- *Subcision*

It is a technique where depressed scars are elevated, and the controlled trauma can aid in formation of new connective

tissue. This is carried out by custom-made subcision knives or 20 gauge needles. It can be combined with autologous fat injection to the subcised areas filling in the space and simultaneous laser resurfacing [16].

- *Fillers*

Synthetic Hyaluronic acid, calcium hydroxylapatite and bovine collagen are used in aesthetic surgery for voluminisation. They can be used in treating depressed scars. However, these agents cannot be used in a larger quantity as they will cause subcutaneous nodules and inflammation, and in bovine collagen, there is 3% incidence of allergic history. There is also a need for repeat injection. Autologous fat has taken over as a material of choice for filling in scar management.

- *Silicone gel sheets*

These sheets are used prophylactically in known patients for bad scars as well as therapeutically. However, the outcome for hypertrophic scars is still questionable and inconclusive.

It appears that controlled studies have shown significant beneficial outcome in scar volume when the silicone sheets are used or not used in mirror image wounds. A Cochrane review of 13 trials involving 559 patients, however, con-

cludes weak evidence in preventing hypertrophic scars in susceptible patients [17].

The mechanism of action is in producing hydration to the scars by occlusion.

- *Pressure therapy*

It is a perceived therapy that there is positive evidence in the literature. The largest randomised trial showed no significant difference in scar reduction with pressure therapy when compared to the controlled group [18].

- *Cryotherapy*

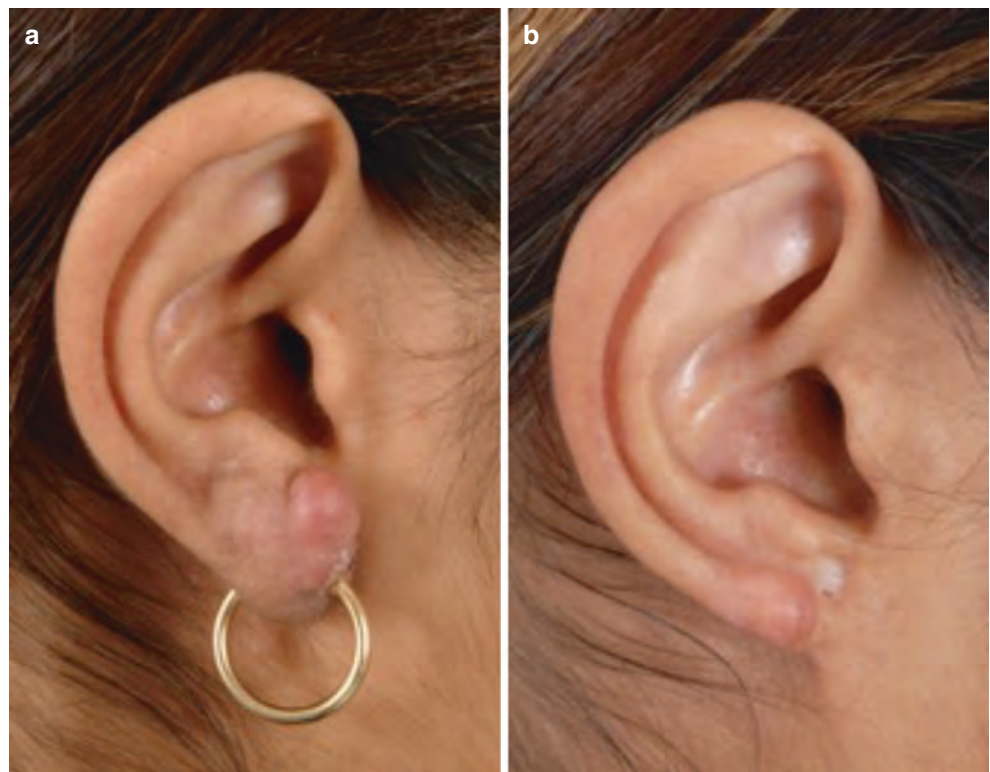A large uncontrolled study of 135 patients with 166 keloids demonstrated 79.5% response rate with 80% reduction in scar volume. However, the results are not reproducible. This treatment causes atrophic, depressed scars with residual hypopigmentation [19].

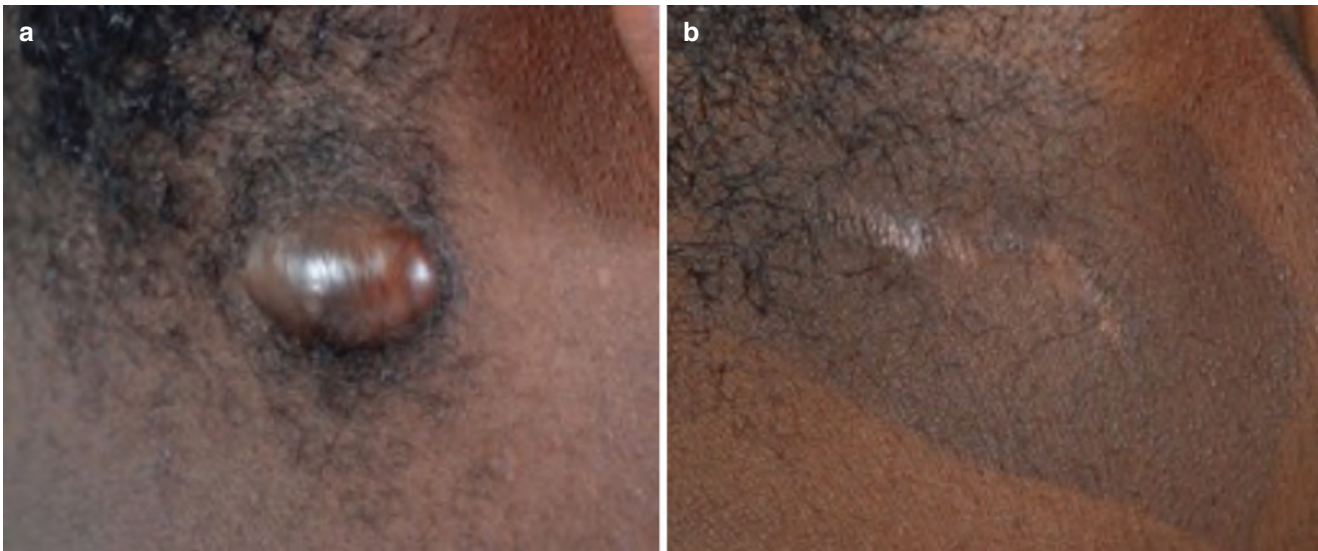
Therefore, the usage of cryotherapy particularly on the face should be discouraged as a modality.

- *Radiation*

It is an effective adjuvant to surgical excision particularly to keloid. The effect is caused by inhibition of proliferation

Fig. 36.1 (a) Keloid Scar right ear lobule. (b) Post-operative photograph following scar excision and one dose of radiotherapy





©Association of Oral and Maxillofacial Surgeons of India

Fig. 36.2 (a) Keloid Scar post-auricular region. (b) Post-operative photograph following scar excision and one dose of radiotherapy

of fibroblasts and neo-vascular blood formation, resulting in decreased collagen production [20].

The highest cure rate is described in a single dose within 24 hours after surgical excision; however, further studies are needed to evaluate the dosage and to obtain optimum results (Figs. 36.1 and 36.2).

- *Emulsified fat for scar rejuvenation*

The fat tissue is accepted not only as a simple layer of insulation and as a storage for energy but also as a complex endocrine organ, which is intrinsically involved in metabolism and immunomodulatory activities and can provide multi-source resources for stem cells and other undifferentiated cell population, which is essential for regeneration.

In addition to the adipocytes in the fat tissue, there are other cell groups that are functionally very important such as stromal vascular fraction (SVF) and cell-assisted lipotransfer (CAL). The SVF of adipose tissue is a rich source of epithelial progenitor cells, T cells, B cells and adipose tissue macrophages [21]. Separation of SVF is a time-consuming and expensive process requiring collagenase treatment and centrifugation. The recent clinical results obtained with Nanofat grafting where the cells are emulsified show greater value than the components of SVF used separately.

In Nanografting, a 23 gauge needle is used as a sharp needle for subdermal fat injection technique (SNIF) followed by a 27 gauge needle to superficial layers. In order to do this, the fat should be emulsified and takes the name, thus, Nanofat [6].

This now emerges to the forefront in regenerative medicine due to its ability to differentiate into a variety of

different cells of cell lineage and the anti-apoptotic, anti-inflammatory, pro-angiogenic immunomodulators and anti-scarring properties.

Nanofat has shown to improve the aesthetics of hypertrophic and keloid scars by improving the texture of the scars in addition to improving the symptoms of pain and itching [22].

Fat is used in voluminisation initially as foundation micrograft just above the periosteum. The second layer is subdermal graft followed by subcision and lastly Nanofat injection using SNIF technique with 23-gauge needle followed by superficial needle injection using 27-gauge needle. This process is to treat depressed scars. Intralesional Nanofat injection improves hypertrophic and keloid scars. This can be combined with other modalities such as laser resurfacing.

36.4 Surgical Scar Management

36.4.1 Basic Principles

As described above, an ideal scar should be an imperceptible line parallel to RSTL. The only exception is scar along the lower lid due to the possibility of ectropion, if incisions are made in parallel to RSTL.

The aim of scar revision is to re-orientate the scar to follow the RSTLs and correction of adjacent structure distortion.

Patient understanding, nutrition, expectation and the psychological stability are paramount factors to implement pre-operatively prior to any scar revision exercises particularly in burn scars. The timing of the revision is also important as the remodelling may take up to 12 months.

Nutritional status and the medical history are important pre-operative considerations. It has been described with certain evidence that the use of vitamins A, C and E and zinc have beneficial effects and, at the same time, some herbal supplements such as arnica, garlic, ginseng and saw palmetto can impair wound healing [22]. Systemic conditions such as diabetes and immunosuppression can adversely affect wound healing. Smoking has proven to cause perilous effect on healing and wound repair.

Vitamin E refers to a group of ten lipid soluble compounds that include both Tocotrienols and Tocopherols as a fat soluble antioxidant; it stops the production of reactive oxygen species formed when fat undergoes oxidation [23]. It has been identified that alpha-tocopherol, the most biologically active form of vitamin E, has anti-inflammatory effects by decreasing plasma C-reactive protein (CRP) levels and release of pro-inflammatory cytokines. The CRP, a downstream marker of inflammation in addition to being a risk marker for cardiovascular disease, could contribute to atherosclerosis. Alpha-Tocopherol has been shown to decrease CRP level in patients and has a positive effect in scar reduction. Topical vitamin E application has been practised in managing scar 10 days post-suture removal. Anecdotally, in the last 25 years, good scar outcome has been observed.

36.4.2 Surgical Technique

In most circumstances, incisions should be made parallel to the skin surface. A number 11 or 15 blade is ideal. Tissue handling must be atraumatic. The skin flaps should be held with non-toothed forceps, and the tooth forceps should only be used to handle tissues subdermally. Undermining and constant hydration of edges are essential. In stretched scars, preservation of the dermis by de-epithelialisation will provide extra support in correcting the depression. Haemostasis

should be achieved using a bipolar diathermy again minimising thermal injury to the surrounding areas.

Suturing is done in layers. In areas where supportive tension is required, resorbable round body needle sutures are useful. Depending on the site and the extent of the scar, short- or long-term resorbable sutures could be selected. With deep suturing as much as possible, the knot should be buried with skin approximation to achieve 'eversion'. Simple-interrupted sutures are preferable in a majority of areas; however, subcutaneous running sutures could be used where only gentle approximation is needed.

1. Z plasty (Fig. 36.3)

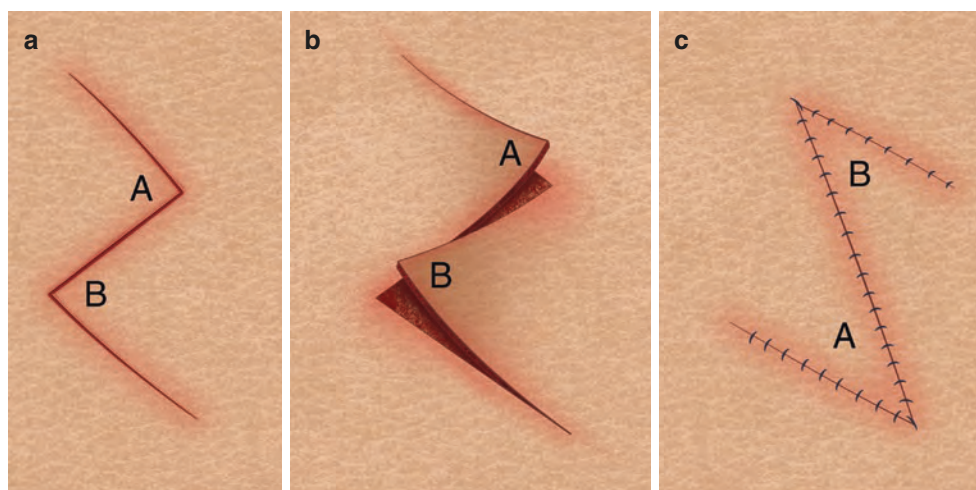
This is a common technique used in scar revision to either change the direction of the scar or lengthen the scar. Contracted scars can be corrected by plating multiple simultaneous Z plasties.

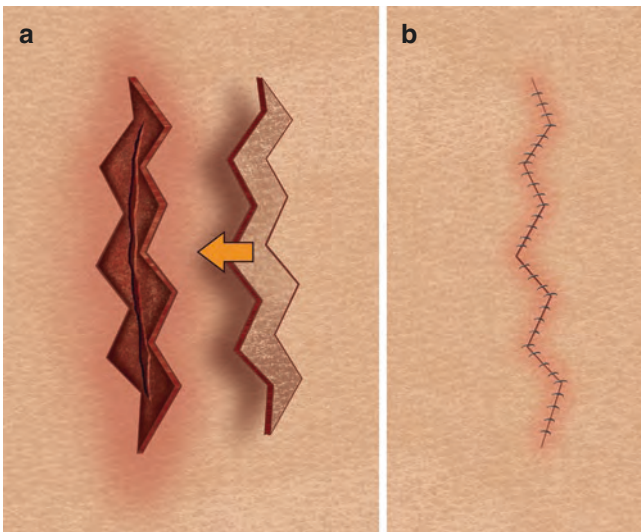
The Z plasty is created by using the original scar as a central portion, and triangular flaps are raised. Multiple variations are in Z plasty. In the classical Z plasty, all the limbs are of equal length and the angle between the flaps is 60°. The scar will lengthen by 75%. A 30° angle will lengthen by 25%, and 45° will lengthen by 50%. Multiple Z plasties are useful in long scars, which can be divided into separate segments, and the angles are contoured or modified depending on the sites.

2. W plasty (Fig. 36.4)

This technique is used to irregularise scars so that dimensions of the scar are not perceived by the naked eye. A series of consecutive triangles are made. It is mirror image on the opposite side. The arm length should be around 5 mm, and the angle in-between the flap should be maximum 90°. One side of the triangle should be in parallel to our RSTL. The

Fig. 36.3 Z plasty (a) scar revision. (b) triangular flaps raised. (c) interposition of triangular flaps





©Association of Oral and Maxillofacial Surgeons of India

Fig. 36.4 W plasty— (a) scar revision. (b) post-operative

triangle are excised, undermined and closed with interdigitation. This technique is very useful in correcting unsightly hairline scars such as revision of face lift.

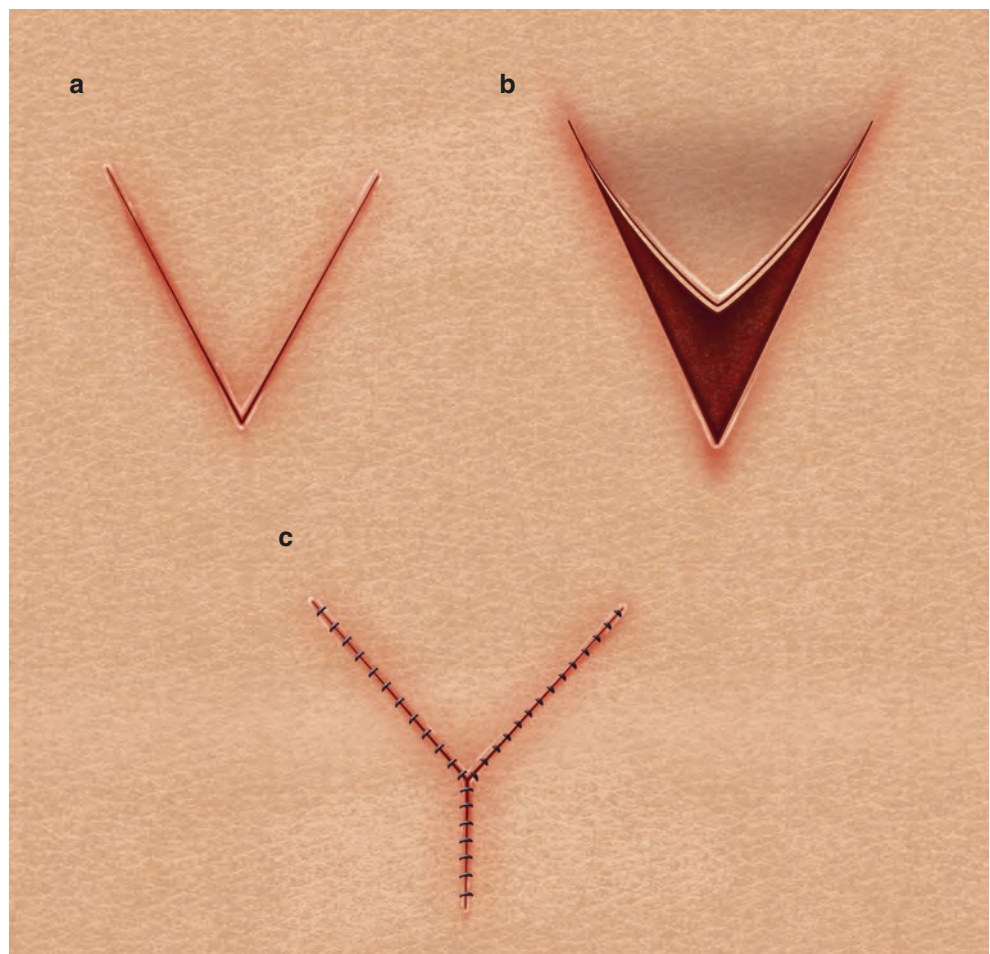
3. *Geometric broken line closure (GBLC)*

This is another technique to minimise the perception of a long scar. Here, random geometric designs are planned with corresponding mirror images. The length of the limbs should be 3–6 mm and at the angle near to 90°, and a W plasty could be done at the end of the design.

4. *V-Y and Y-V advancement*

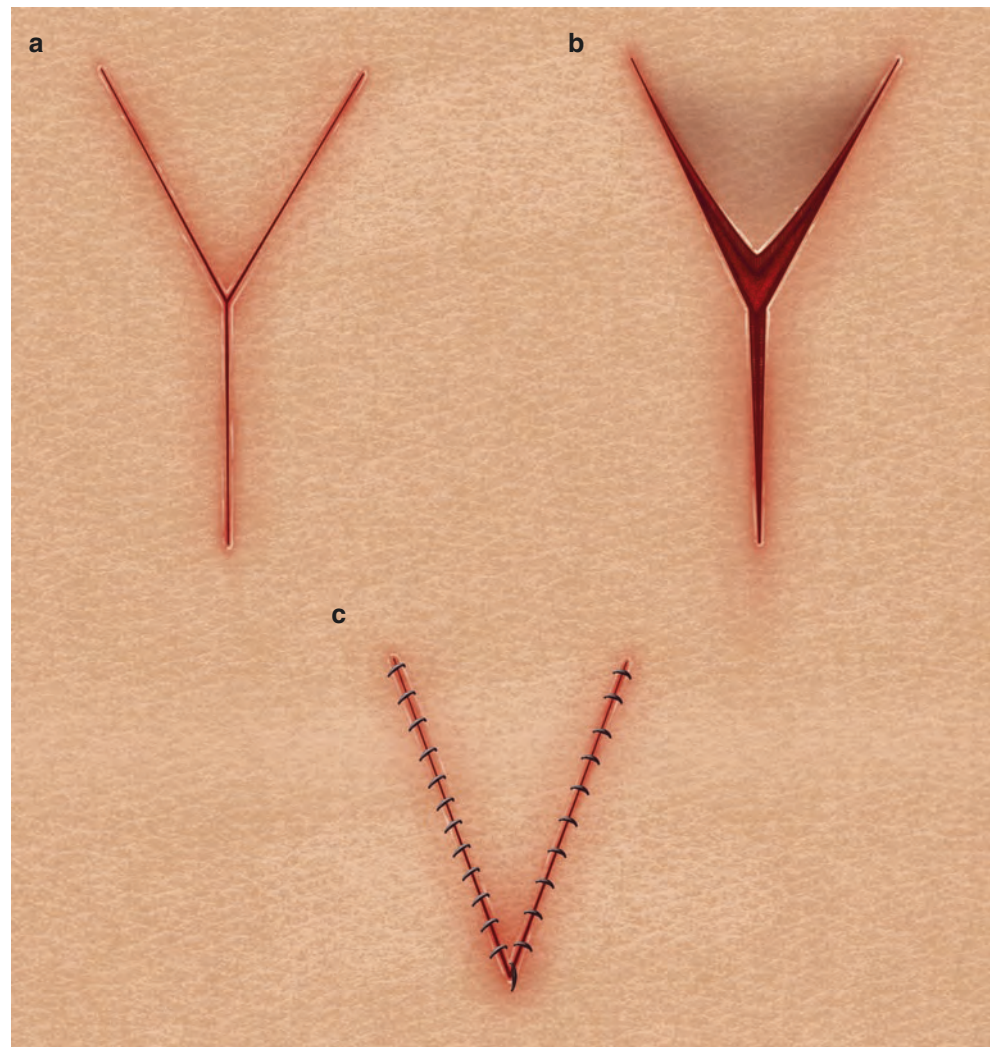
V-Y scar correction (Fig. 36.5a–c) is utilised when there is an indication on scar lengthening in contracted scars with ‘trap door deformity’. In contrast, Y-V technique is utilised where the scar is shortened, removing the ‘Y’ ‘extension’ (Fig. 36.6a–c).

Fig. 36.5 V-Y scar lengthening correction. (a) V incision. (b) Triangular flaps raised. (c) Y closure



©Association of Oral and Maxillofacial Surgeons of India

Fig. 36.6 Y-V scar shortening correction. (a) Y incision. (b) Triangular flaps raised. (c) V closure



©Association of Oral and Maxillofacial Surgeons of India

Flaps can be used to revise large scars. “Doggy ear” and “trap door deformities” could be improved by excising the excess. For passive scar settlement, selective bulking and simultaneous multiple ‘Z’ and ‘W’ plasties are useful adjuncts.

Clinical tip

When repairing wounds in patients who are prone to develop hypertrophic scars, deep sutures should be placed using round bodied needles. The suture removal is delayed by an extra 3–4 days. Applying steri strips after removal of the sutures adds extra support, and this should be incorporated to achieve the best result.

Prophylactic intralesional steroids in patients prone to hypertrophic scars should be considered. Obliteration of the dead space by appropriate sutures or pressure dressings with or without drains should be considered to prevent haema-

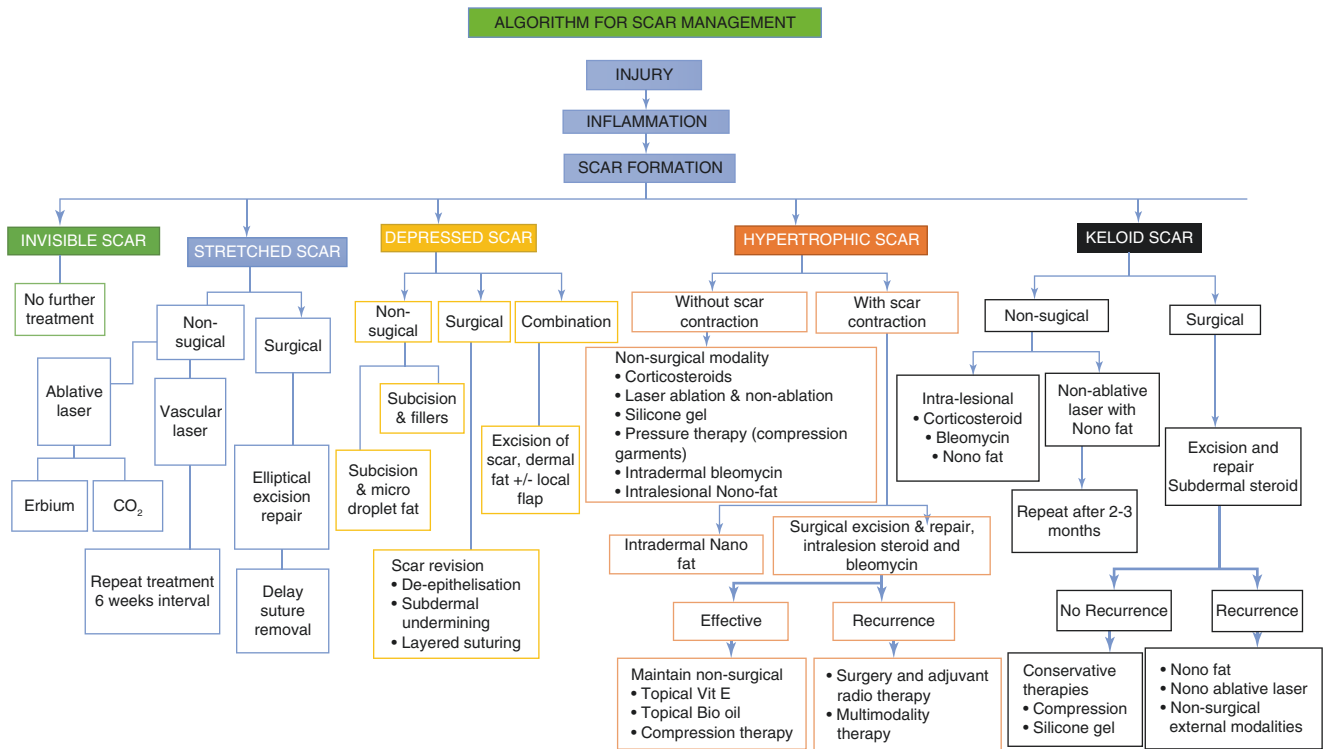
toma formation. If not, haematoma on its own will spoil the good work of scar revision.

36.5 Future

Extrauterine scarless surgery is not possible. Therefore, careful patient factor and scar characteristics should be studied to prevent unsightly scar formation and to correct perceptible scars.

General health and optimising comorbidities are important requirements to achieve good scars. Both non-surgical and surgical options should be available in the armamentarium to the Surgeon.

Nanofat has very positive potential in scar management. The research on gene therapy using adenovirus as a mediator to deliver dermal fibroblast is encouraging [24].



©Association of Oral and Maxillofacial Surgeons of India

Fig. 36.7 Algorithm for scar management

Although inflammatory response is traditionally believed to be a key event for wound healing in adult skin, studies of foetal wound healing suggest that a high level of inflammation might prevent good scar formation rather than enhancing the wound healing process. Therefore, further studies are needed to confirm if really inflammation is necessary for wound healing in adult skin. However, at present, we need to follow the inflammatory process and available evidence of therapeutic modulators of scar formation.

Furthermore, it is paramount to consider that there are clinical, histological, biochemical and molecular differences between hypertrophic and keloid scars. There is marked difference in the proliferative and apoptotic cell deaths between the scars, resulting in variable response of different treatments. This should be taken into account in treatment planning process.

It is also essential to avoid excessive movements that can stretch the wound and for avoidance of the scar to direct mechanical forces such as friction and scratching and particularly earlobe wounds, to minimise the contact with pillows and wound hygiene.

Not least the patient's involvement plays a vital role in the management of scars. Variable scales in the literature exist for reliable and reproducible scar management, for both the observer, i.e. surgeon, and the patient. The observer opinion

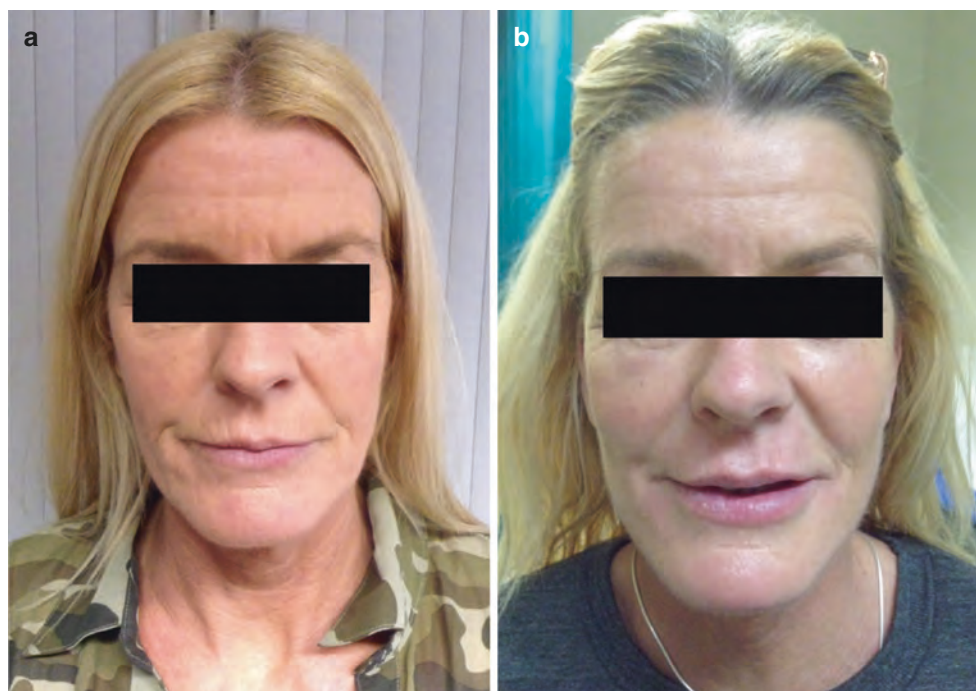is always influenced by vascularisation, thickness and pigmentation. The patient opinion, on the other hand, is influenced by action of itching sensation and thickness of the scar. Out of the available assessment scales, the patient and observer scar management described by Draaigers L et al. is an informative tool in documentation of the progress in the management of scar, which should be addressed [25].

In summary, a surgeon should have an algorithm to follow on how to manage scars in normal patients as well as patients who are prone for hypertrophic and keloid scars (Fig. 36.7).

36.6 Conclusion

Scar formation is a part of wound healing process. Facial scars can be aesthetically detrimental and affect social stigma. As facial surgeons, we need to achieve ideal scars with natural contour, colour and limited distortion. It is paramount to remember that scar management includes prevention, treatments during the healing period and definitive management once the scar has been established. We have, in this chapter, included all the different available treatments separating them into non-surgical remedies and surgical techniques. The algorithm, in this chapter, allows a very easy review process for surgeons who manage stretched,

Fig. 36.8 (a) Pre-operative. (b) Post-“microfat grafting” and laser resurfacing



©Association of Oral and Maxillofacial Surgeons of India

depressed, hypertrophic and keloid scars. Disclosure Authors have no financial conflicts to disclose.

36.7 Case Scenarios

Case Scenario 1 (Fig. 36.1)

A 27-year-old female patient of Asian ethnicity had an extra ear piercing to the right earlobe. Within 4 months, she started to develop a very painful hard lump at the pierced site. Within the following 6 weeks, it developed into an irregular mass involving the whole of the earlobe.

Her medical history was unremarkable, and she was not on any medication.

On examination (Fig. 36.1a), there was an unsightly thick lumpy scar along the right earlobe. A diagnosis of keloid was made.

Under a local anaesthetic, the keloid scar was excised and the earlobe was reconstructed. The next post-operative day she underwent single dose of radiotherapy (10 Gy) as an outpatient.

On review, 6 months post-treatment (Fig. 36.1b), she had no recurrence and on palpation, the skin was soft and non-tender.

Case Scenario 2 (Fig. 36.8)

A 48-year-old Caucasian patient who had a considerable amount of sun exposure presented with an unhappy peri-oral aesthetics (Fig. 36.8a).

Her medical history was unremarkable, and she was not on any medication.

In one examination, she had loss of volume along the peri-oral site mainly along the upper lip. The vermillion border had lost its definition. She had multiple small vertical subdermal lines, which were crossing the vermillion border. She also had epidermal thinning.

A diagnosis of aging of the peri-oral area, particularly upper lip, was made. She, in fact, had epidermal thinning, subdermal scarring and loss of inter- and intramuscular fat.

She underwent “microfat” grafting to restore the volume, subdermal “emulsified fat” to restore the subdermal structure and an “erbium laser resurfacing” (fluence 500 mJ, mode: SP, spot 3 mm, frequency 20 Hz).

The post-operative appearance 4 months later (Fig. 36.8b) showed excellent volume restoration, much improvement in the subdermal scarring, better vermillion definition and a new regenerative skin.

This combination technique is very useful in burn scar management.

References

- Beldon P. Basic science of wound healing. *Sci Direct*. 2010;28:409–12.
- Borges AF. Relaxed skin tension lines. *Dermatol Clin*. 1989;7:169–77.
- Broughton G, Janis JE, Attinger CE. The basic science of wound healing. *Plast Reconstr Surg*. 2006;117:12S–34S.
- Reish RG, Ericksson E. Scars: A review of emerging and currently available therapies. *Plast Reconstr Surg*. 2008;122:1068–78.
- Collet C, Laversanne S, Haen P, et al. Micro-re-injection of autologous fat. *Rev Stomatol Chir Maxillofac Chir Orale*. 2013;114:381–6.
- Tonnard P, Verpaele A, Peeters G, Hamdi M, Cornelissen M, Declercq H. Nanofat grafting: basic research and clinical applications. *Plast Reconstr Surg*. 2013;132:1017–26.
- Atkinson JA, McKenna KT, Barnett AG, et al. A randomised controlled trial to determine the efficacy of paper tape in preventing hypertrophic scar formation in surgical incisions that traverse Langer's skin tension lines. *Plast Reconstr Surg*. 2005;116:1648–56.
- Roques C, Teot L. The use of corticosteroids to treat keloids. A review. *Int J Lower Extremity Wounds*. 2008.
- Niessen FB, Spauwen PH. On the nature of hypertrophic scars and keloids: a review. *Plast Reconstr Surg*. 1999;104:1435–58.
- Fitzpatrick RG. Treatment of inflamed hypertrophic scars using intralesional 5-FU. *Dermatol Surg*. 1999;25:224.
- Sindel A, Sayan A, Ilankovan V, et al. Percutaneous treatment of orofacial vascular malformations. *Br J Oral Maxillofac Surg*. 2018;56:206–11.
- Crooke ST, Bradner WT. Bleomycin, a review. *J Med*. 1976;7:333–428.
- Lupton JR, Alster TS. Laser scar revision. *Dermatologic Clin*. 2002;20:55–65.
- Tsai RY, Wang CN, Chan HL. Aluminium oxide crystal microdermabrasion. A new technique for treating facial scarring. *Dermatol Surg*. 1995;21:539–42.
- Bowes LE, Nouri K, Bernam B, et al. Treatment of pigmented hypertrophic scars with the 585 nm Pulsed Dye Laser and the 532 nm Frequency Doubled Nd: YAG laser in the Q-Switched and variable pulse modes: a comparative study. *Dermatol Surg*. 2002;28:714–9.
- Orientreich DS, Orientreich N. Subcutaneous incisionless (subcision)surgery for the correction of depressed scars and wrinkles. *Dermatol Surg*. 1995;21:543–9.
- Neissen FB, Spauwen PH, Robinson PH, Fedler V, Kon M. The use of silicone occlusive sheeting (Sil-K) and silicone occlusive gel (Epiderm) in the prevention of hypertrophic scar formation. *Plast Reconstr Surg*. 1998;102:1962–98.
- Chnag P, Laubenthal KN, Lewos R, et al. Prospective, randomized study of the efficacy of pressure garment therapy in patients with burns. *J Burn Care Rehabil*. 1995;16:473.
- Rusciani L, Paradisi A, Alfano C, et al. Cryotherapy in the treatment of keloids. *J Drugs Dermatol*. 2006;5:591.
- Ragoowansi R, Cornes PG, Moss AL, et al. Treatment of keloids by surgical excision and immediate postoperative single-fraction radiotherapy. *Plast Reconstr Surg*. 2003;111:1853.
- Zhu X, Du J, Liu G. The comparison of multilineage differentiation of bone marrow and adipose-derived mesenchymal stem cells. *Clin Lab*. 2012;58:897–903.
- Broughton G, Crosby MA, Coleman J, et al. Use of herbal supplements and vitamins in plastic surgery: a practical review. *Plast and Reconst Surgery*. 2007;119:48–66.
- Devaraj S, Leonard S, Traber M, Jialal I. Gamma-tocopherol supplementation along and in combination with alpha-tocopherol alters biomarkers of oxidative stress and inflammation in subject with metabolic syndrome. *Free Radic Biol Med*. 2008;44:1203–8.
- Liu W, Chua C, Wu X, Want D, Ying D, Cui L. Inhibiting scar formation in rat wounds by Adenovirus-Mediated overexpression of truncated TGF- β Receptor II. *PRS*. 2005;115:860–70.
- Draaijers LJ, Templeman FR, Botman YA, Tuinebreijer WE, Middelkoop E, Kreis RW. The patient and observer scar assessment scale: a reliable and feasible tool for scar evaluation. *PRS*. 2004;113:1960–5.

Open Access This chapter is licensed under the terms of the Creative Commons Attribution 4.0 International License (<http://creativecommons.org/licenses/by/4.0/>), which permits use, sharing, adaptation, distribution and reproduction in any medium or format, as long as you give appropriate credit to the original author(s) and the source, provide a link to the Creative Commons license and indicate if changes were made.

The images or other third party material in this chapter are included in the chapter's Creative Commons license, unless indicated otherwise in a credit line to the material. If material is not included in the chapter's Creative Commons license and your intended use is not permitted by statutory regulation or exceeds the permitted use, you will need to obtain permission directly from the copyright holder.



37.1 Introduction

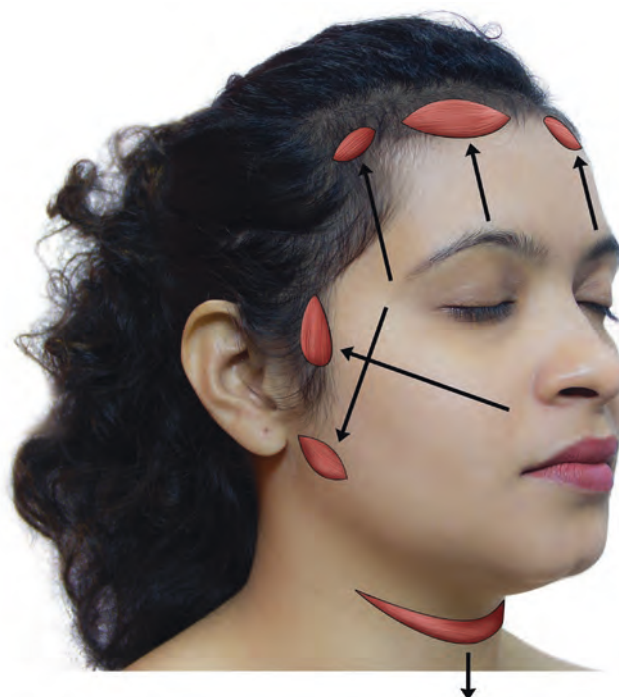
An ancient Chinese proverb “岁月不饶人” observed that “no one is spared from the ravages of ageing”. A combination of age, gravity, physiologic contraction of facial muscles and solar (sun) and chemical (smoking) insults results in intrinsic and extrinsic changes to the skeleton, muscles and skin [1]. Preservation of one’s youthful looks has been a goal of humans regardless of cultures and ethnicities. The search for this elixir of youth was found unexpectedly in the hands of cosmetic surgeons. Even with the recent advent of skin peels, botulinum toxin injections, lasers and injectable filler injections, the century-old facelift still possesses the most dramatic improvement to the moderate to severe ageing lower face when done well.

Facelift or rhytidectomy as its name suggests is a procedure to partially eliminate folds, creases and wrinkles (rhytids) caused by gravity and degeneration. In effect, the creation of two large cervicofacial flaps, which, after suspension and trimming, produces an overall tightening of the skin and the fascial envelope of the face and neck, results in restored anatomical structure. Facelift can help to negate some of these gravitational problems and produce some intrinsic improvement.

37.2 Historical Perspective

Historically, rhytidectomy was limited to skin elliptical excisions and tightening. The German surgeon, Eugen Höllander, first described being persuaded by his patient to remove excessive skin in the temporal, preauricular and postauricular regions in 1901. With cosmetic surgery frowned upon in

those times, he did not report his surgery immediately but only recounted retrospectively that the iatrogenic wounds when approximated resulted in some tightening in 1912 [2]. The initial reports of rhytidectomy were dominated by a slew of American surgeons such as Cantrell (1902), Miller (1907) and German surgeons, Lexer (1906) and Joseph (1912) [3]. The French surgeon Passot wrote an important paper “La chirurgie esthétique des rides du visage” in 1919 where he illustrated strategically placed forehead, malar, cheek and submental elliptical incisions to tighten the face for aesthetic purposes, thus heralding the concept of short scar rhytidectomy (Fig. 37.1).



©Association of Oral and Maxillofacial Surgeons of India

Fig. 37.1 Illustration showing Passot’s principles on facelift through elliptical excisions

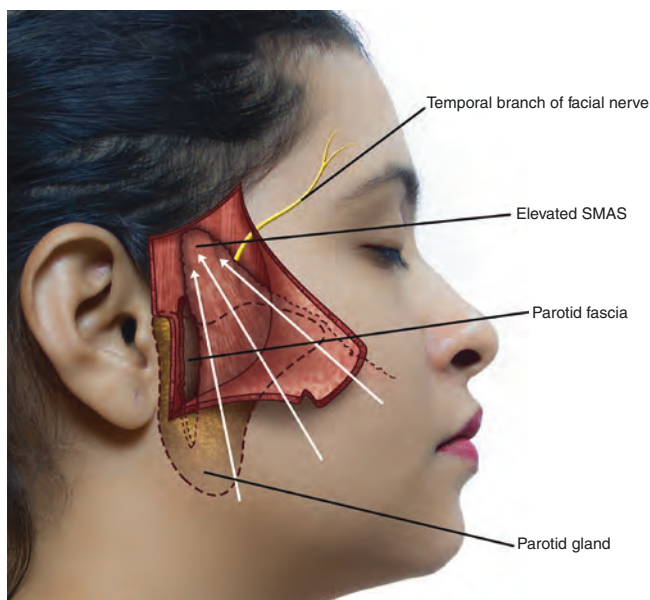
V. Ilankovan (✉)
Oral and Maxillofacial Surgery, Poole Hospital NHS Foundation
Trust, Poole, UK

T. E. Seah
TES Clinic for Face and Jaw, Singapore, Singapore

However, with limited undermining, wounds were closed under tension, resulting in unsightly scarring. To circumvent this problem, skin flap only procedures during which only the skin was raised, undermined for a short distance and tightened were introduced (Barnes 1927) [4].

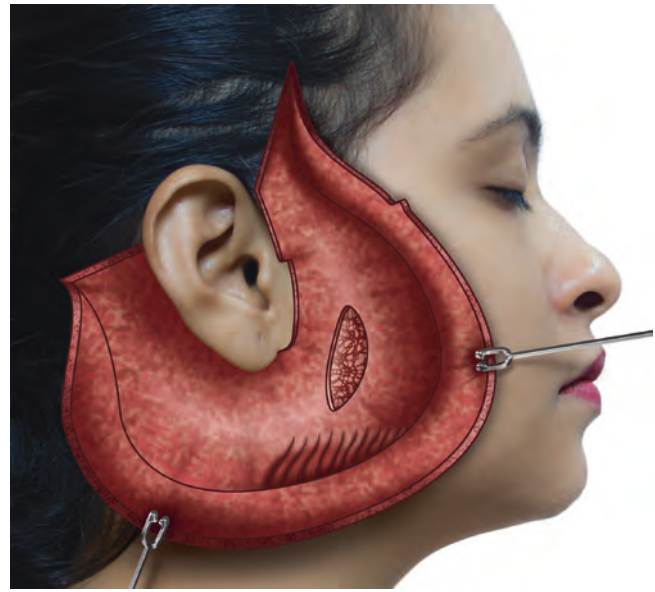
The results of skin flap only facelift were short term with limited correction of the ageing face, forcing surgeons to search for better alternatives. In 1974, Tord Skoog, a Swedish surgeon, revolutionized facelift concepts by describing the dissection, elevation and tightening of the superficial fascia of the face in addition to removing excess skin. He expounded the importance of retro-positioning the “buccal fascia” and the platysma for better results. The importance of this technique was later cemented when the superficial fascia of the face was clarified as the “superficial muscular aponeurotic system” (SMAS) by Mitz and Peyronie in a landmark paper in 1976 [5]. Manipulation of the SMAS layer in a superior or superolateral vector became an important part of modern facelift. Soon, a flurry of papers on the modifications to facelift procedures concentrated on the management of the SMAS.

Treatment of the SMAS layer could be broadly categorized into three methods. They were plication, elevation, imbrication and SMASectomy [6]. The most conservative of these methods was plication of the SMAS layer, as it did not actually involve dissecting the SMAS layer but instead used sutures to fold the SMAS and achieve a tightening effect [7]. More aggressive management of the SMAS included imbrication, which involved the elevation and repositioning of the SMAS in a superior or superolateral vector [8]. In standard SMAS elevation, the SMAS was dissected, lifted off the parotid fascia and secured to the underlying zygomatic soft tissues or the deep temporal fascia (Fig. 37.2).



©Association of Oral and Maxillofacial Surgeons of India

Fig. 37.2 SMAS imbrication



©Association of Oral and Maxillofacial Surgeons of India

Fig. 37.3 SMASectomy. 1–2 cm of the SMAS is excised superficial to the anterior border of the parotid

SMASectomy was later described [9]. This required excision of approximately 1–2 cm strip of the SMAS, superficial to the underlying parotid fascia, and then tightening were carried out by suturing the opposing two cut SMAS margins [6] (Fig. 37.3).

It soon became obvious to the surgeons that skin excision and SMAS manipulation were only effective in treating the lower face but not as effective in treating midface ageing. In particular, the nasolabial fold proved to be a stubborn adversary. The spotlight turned towards the high density, retaining ligaments such as the zygomatic retaining ligaments, which prevent effective rejuvenation of the midface using the aforementioned procedures.

The deep plane facelift was described by Hamra to include the malar fat pad [10]. In this, the dissection and elevation of the SMAS layer were carried out further to release the zygomatic retaining ligaments so that more traction could be obtained from the midface. The orbicularis oculi and later septal reset were included to improve midface aesthetics, and the term composite facelift was coined by Hamra [11].

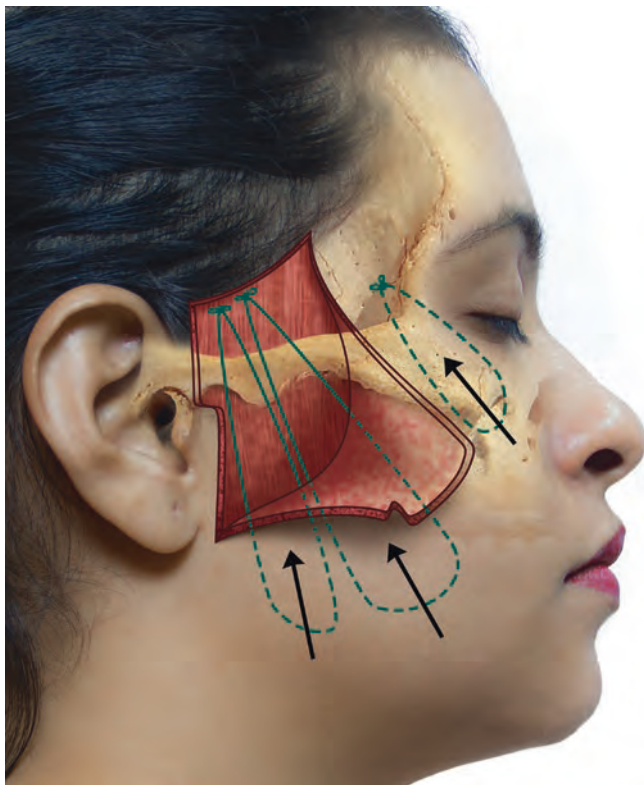
As the facelift landscape progressed, efforts turned almost full circle towards smaller incisions. Comparisons of different published facelifts were unable to reveal an optimal technique [12] although complications were significant higher in extensive SMAS procedures.

Attention turned towards having minimal excision, limited dissection and SMASectomy with imbrication, and in 2001, Saylon and later Fulton et al. described the S-lift [13]. In this technique, the preauricular skin was excised in a pre-determined S-shape followed by purse-string plication of the

mobile SMAS using a U-shaped purse string suture and an O-shaped purse string suture. Both sutures were anchored into the periosteum of the zygoma.

Tonard et al. later introduced the minimal access cranial suspension (MACS) as a modification to the S-lift [14] (Fig. 37.4).

In this procedure, he described suspending the sagging SMAS tissues with cranially directed purse string sutures via limited incisions that extend from the sideburn to the inferior helical attachment. Four main differences lie between the ‘S’ lift and the ‘MACS’ lift. First, the S-Lift pre-empted the amount of excess skin and excised it via an S-shaped incision. The MAC lift redraped the excessive skin and removed it according to the margin. The second difference lies between point of anchorage as the ‘S-lift’ anchored to the periosteum of the zygoma, while the ‘MACS lift’ anchors to the superficial layer of the deep temporal fascia. Third, during the S-lift, SMASectomy and imbrication were carried out, while during the MACS lift, only plication was performed. Fourth, besides the two O and U-shaped sutures, the MACS lift utilizes a third vertical suspension suture that suspended the malar fat pad, thus reducing the depth of the nasolabial fold. This area is accessed by extending the temporal hairline incision, and Tonard and Verpaale called this the extended MACS lift.



©Association of Oral and Maxillofacial Surgeons of India

Fig. 37.4 MACS Lift

37.3 Anatomy of Ageing Face

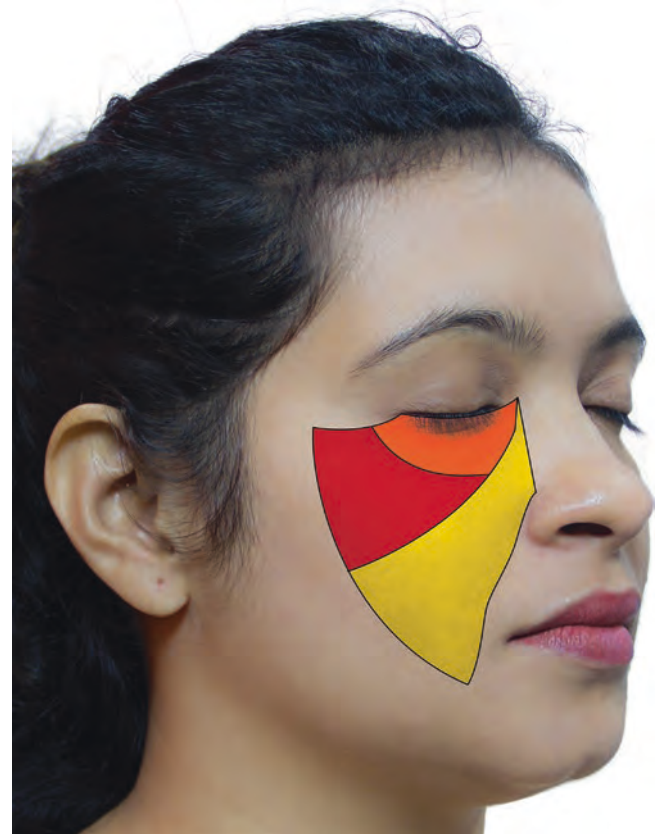Some of the gravitational changes include lateral brow ptosis, tear trough, malar palpebral groove, SOOF descent, malar fat descent, deepening of the nasolabial groove, buccal fat pad herniation, marionette lines, jowls, loss of neck definition, submental fat and excess skin [1].

With ageing, a combination of gravitational forces, laxity of the skin due to loss of elasticity, decreased dermal thickness and loss of dermal appendages results in ptotic, hanging skin.

The mid cheek’s fat is divided into three compartments [15] (Fig. 37.5). It is thinnest at the lid-cheek segment and is thickest in the nasolabial region. The malar fat is also moderately thick although not as thick as the nasolabial region.

Accumulation of fat in the cervical region results in loss of neck definition and submental fat.

Superficial fat and deep fat are separated by SMAS layer. The superficial fat is separated into five compartments, namely, the nasolabial, medial cheek, middle cheek,



©Association of Oral and Maxillofacial Surgeons of India

Fig. 37.5 Cheek fat is divided into three compartments. They are lid-cheek segment (Orange), Malar segment (red) and nasolabial region (yellow). (Figure adapted and redrawn from *Aesthetic Plastic Surgery* 2009, Chapter 6 by Mendelson BC)

lateral temporoparietal and inferior orbital fat. Deep fat is divided into the deep medial fat and suborbicularis oculi fat (SOOF) [16].

The superficial musculoaponeurotic system (SMAS) is a fibrous sheath, which was described in a classical paper by Mitz and Peyronie [5] in 1976, and starts from the galea superiorly. Superolaterally, it is continuous with the superficial temporal fascia also known as the temporoparietal fascia. In the central upper face, deep into the superficial fat, the SMAS layer is invested by the muscles of facial expression, derived from the embryonic second branchial arch: frontalis, orbicularis oculi, corrugator supercilii, depressor supercilii and the procerus. In the middle third, the SMAS is invested by the nasalis muscles, zygomaticus major, minor, levator labii superioris alaeque nasi and levator labii superioris. Laterally, the SMAS is superficial to the parotid fascia and extends inferiorly to include the platysma muscles. Inferomedial, the SMAS is invested by the orbicularis oris, risorius, depressor anguli oris, depressor labii inferioris and mentalis and is continuous with the platysma.

With the exception of the levator anguli oris and mentalis, the facial nerve travels deep into the SMAS layer and innervates the muscles of facial expression, making dissection above the SMAS during facelift safe [16].

An analogy of the retaining ligaments is that they are rooted in a tree into the periosteum and deep fascial thickening, and as it approaches the SMAS, it divides into numerous branches and inserts into the dermis called retinacular cutis [15] (Fig. 37.6).

Stuzin [17] and Furnas et al. [18] described the retaining ligaments [17]. The partitioning of separate fascial spaces and compartments is caused by these retaining ligaments, which are classified into osteocutaneous and fasciocutaneous retaining ligaments.

Osteocutaneous retaining ligaments originate from the periosteum and include the zygomatic and mandibular cutaneous ligaments. Stout zygomatic retaining ligaments originate from the inferior border of the zygomatic arch towards the junction between the arch and the body and insert into the dermis of the skin as fibrous septa. It is posterior to the zygomaticus major muscle, approximately 3 mm in width, 0.5 mm in thickness and 4.5 cm anterior to the tragus [18]. Loss of support results in malar fat descent.

The mandibular ligament originates from the periosteum 10 mm above the mandibular border, extends along the anterior one third of the mandibular body and inserts into the dermis [19] (Fig. 37.7). It coincides with the anterior margin of the jowl.

Fasciocutaneous retaining ligaments include the masseteric and parotid cutaneous ligaments also known as the platysma auricular ligament and coalesce between the superficial and deep fascia of the face [1].

Masseteric ligaments originate from the parotidomasseteric cutaneous ligaments, and: loss of support results in

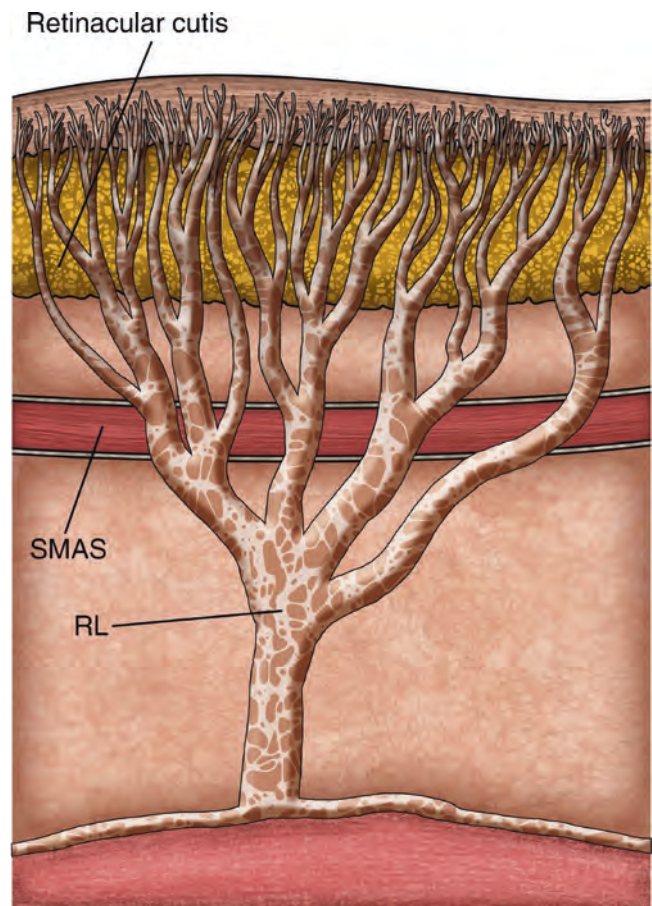
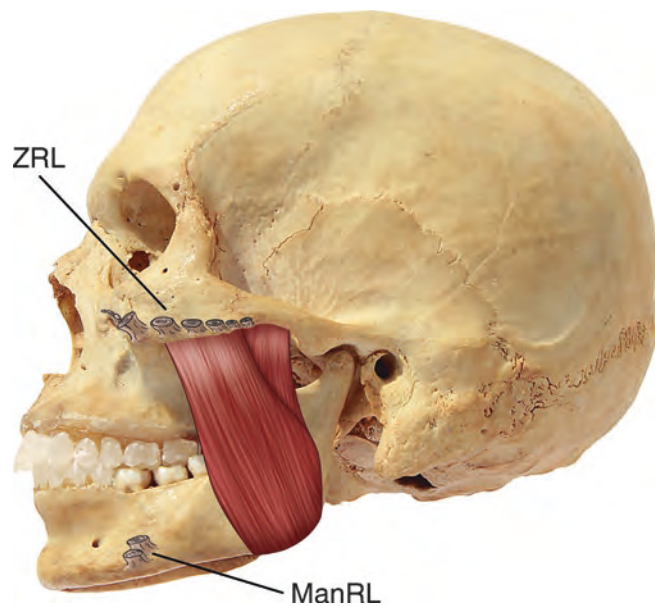
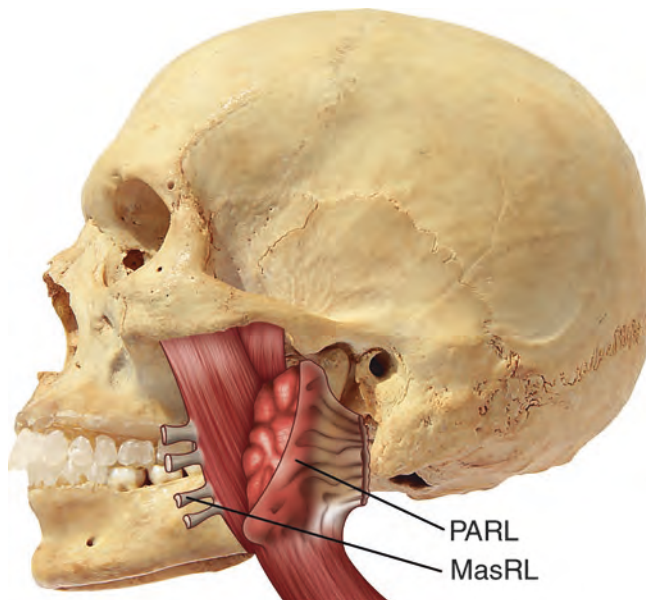


Fig. 37.6 Retaining ligaments (RLs) insert into the subcutaneous layer as retinacular cutis. It is likened to a tree by Mendelson BC [15]. (Figure adapted and redrawn from *Aesthetic Plastic Surgery* 2009, Chapter 6 by Mendelson BC)



©Association of Oral and Maxillofacial Surgeons of India

Fig. 37.7 Osteocutaneous ligaments comprising the zygomatic retaining ligaments (ZRLs) and the mandibular retaining ligaments (MRLs)



©Association of Oral and Maxillofacial Surgeons of India

Fig. 37.8 Fasciocutaneous retaining ligaments comprising the masseteric retaining ligaments (MasRLs) and the parotid cutaneous ligaments also known as platysma auricular retaining ligaments (PARLs)

facial jowling. Parotid cutaneous ligaments are formed by the posterior border of the platysma, which had receded into fascial condensation. It is fused with the parotid fascia, is attached to the overlying skin and provides firm anchorage between the platysma and the dermis in the inferior auricular region (Fig. 37.8).

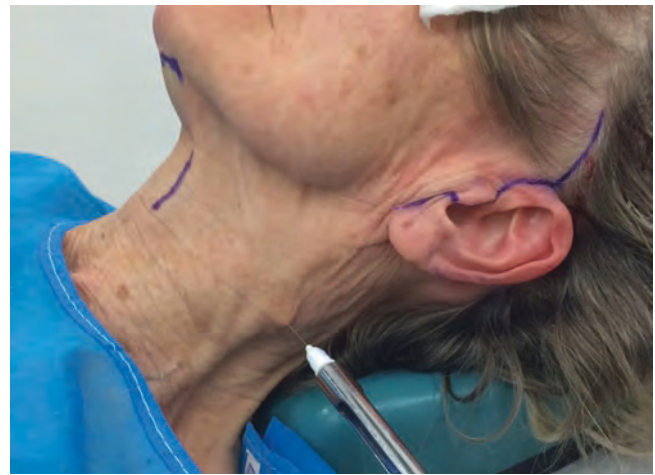37.4 Standard Facelift

Surgery can be carried out either under general anaesthesia or under local anaesthetic with or without sedation.

Local anaesthesia comprising Lidocaine 2% with adrenaline 1:80,000 is infiltrated in the zygomaticofacial region, infraorbital, mental, greater auricular (Fig. 37.9) and the lesser occipital nerves.

Tumescent solution reconstituted with 1 L of saline, 50 mL of 1% lidocaine, 1 mL of adrenaline 1:1000 and 6 mL of 8.4% Sodium Bicarbonate is then injected subcutaneously after stab incisions are placed in the temporal, preauricular, postauricular and submental regions. Approximately 300 mL of tumescent solution in all is injected.

In both approaches, infiltration of Tumescent solution in a subcutaneous plane is essential to carry out atraumatic dissection. In our practice, 95% of standard facelift are carried out with simultaneous neck lift, as we feel it would be impossible to mobilize the attenuated soft tissue to achieve symmetry and an unoperated look of the midface without bringing attention to the neck aesthetics.



©Association of Oral and Maxillofacial Surgeons of India

Fig. 37.9 Greater auricular nerve block

37.4.1 Incision

The incision lines are divided into four sections: temporal, preauricular, postauricular and scalp extension. The temporal component is either into the hairline or just at the hairline/sideburn border. The latter has the advantage of not moving the sideburn position; however, it would give a telltale sign of a visible scar. In the former approach, the sideburn area may get lifted into the temporal area and the scar will be hidden. This position should be made in conjunction with discussion with the patient, and suitability of the incision should be selected.

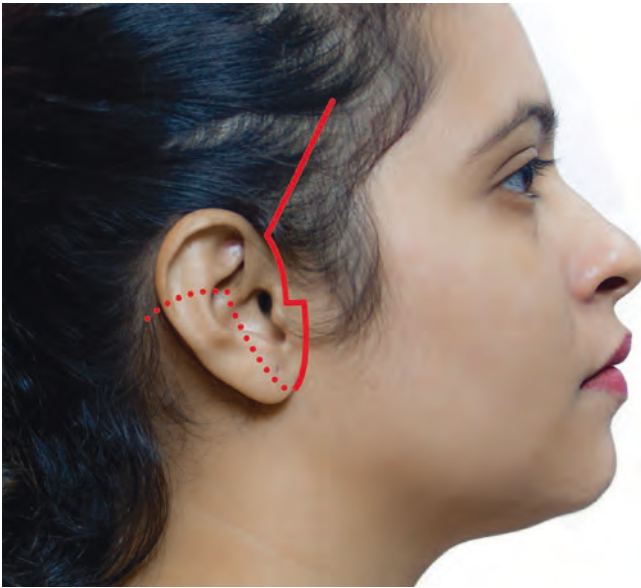
The preauricular marking could be a pre-tragal, intra-tragal or post-tragal. The latter can distort the tragal projection, and the pre-tragal will give a visible scar. We prefer an intra-tragal approach and obtain the tragal projection by placing a subcutaneous anchor suture before the final closure in order to maintain the natural concavity and simultaneously achieve an invisible scar (Figs. 37.10 and 37.11).

The postauricular incision should be a few millimetres into the postauricular area from the sulcus so that post-operatively the scar will settle down comfortably into the sulcus. The scalp extension is carried out by multiple W or Z plasty type incisions in a trichophytic fashion to minimize hair loss and to have an invisible scar (Fig. 37.12).

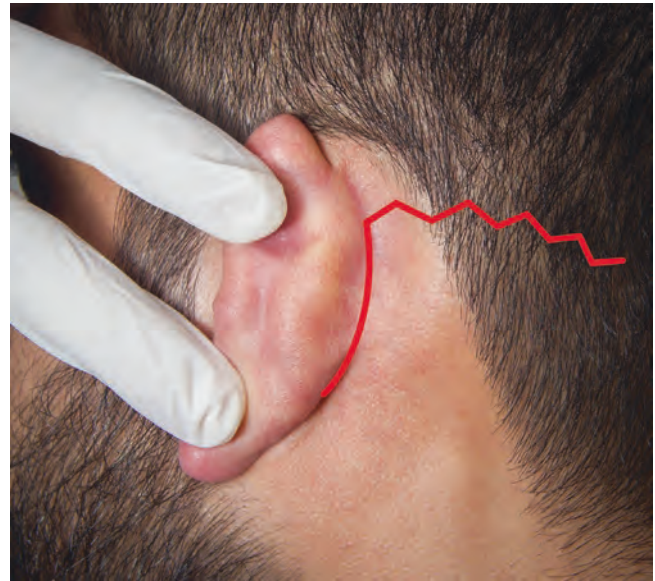A 2.5 cm curvilinear incision parallel to the mandibular contour is the submental incision to the neck lift section in order to expose the anterior border of the platysma and the platysmal dissection.

37.4.2 Dissection

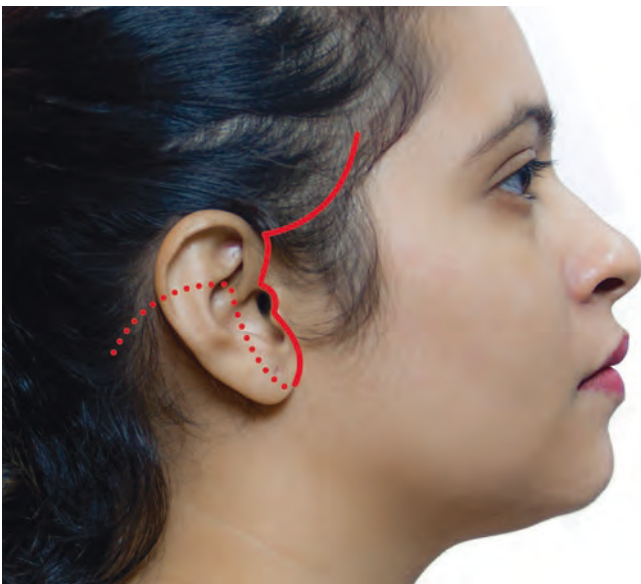The submental flap dissection is carried out at first to expose the platysma muscle as much as possible (Fig. 37.13).



©Association of Oral and Maxillofacial Surgeons of India

Fig. 37.10 Temporal to preauricular incision (red). Occipital or scalp extension (broken line)

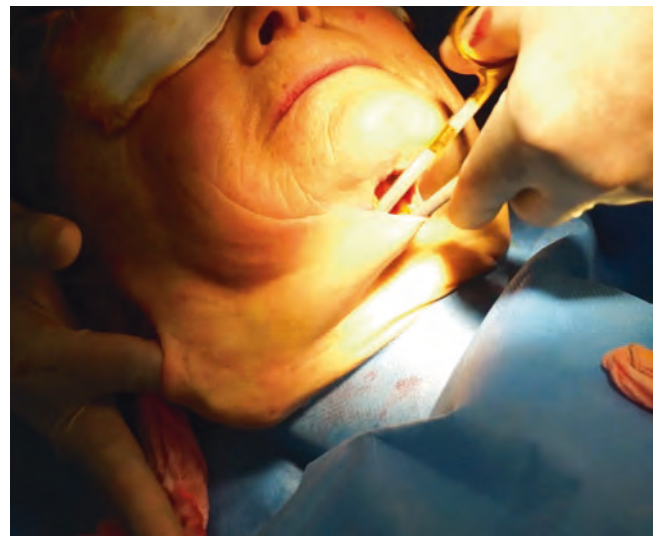©Association of Oral and Maxillofacial Surgeons of India

Fig. 37.12 Illustration showing the postauricular and occipital or scalp extension

©Association of Oral and Maxillofacial Surgeons of India

Fig. 37.11 Hairline to tragal incision (red). Occipital or scalp extension (broken line)

Next, the scalp and postauricular dissection is carried out. The anterior border of the sternocleidomastoid muscle and posterior border of the platysma are exposed, and a cavity of the neck is connected anteriorly and posteriorly (Fig. 37.14). The next step is to focus on the temporal and preauricular dissection. In the temporal, the deep part of deep temporal

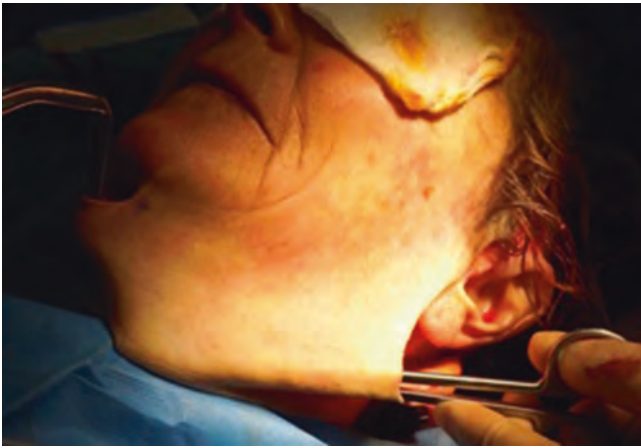

©Association of Oral and Maxillofacial Surgeons of India

Fig. 37.13 Dissection is in the supraplatysma plane

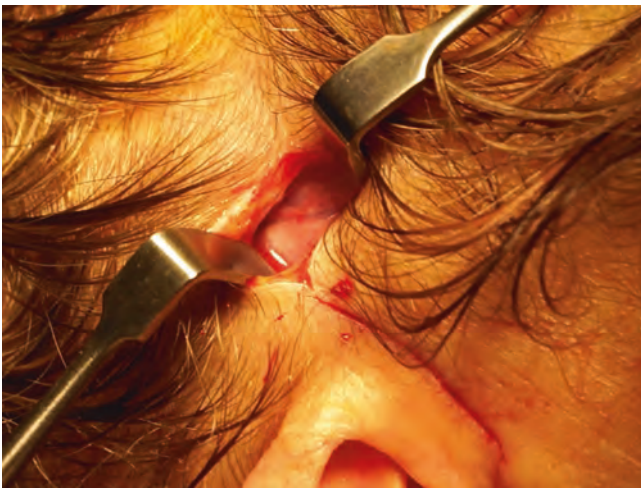fascia is exposed, which we use as an anchor point to the SMAS suturing (Fig. 37.15). The preauricular dissection will expose the zygomatic ligaments, lateral end of the orbicularis oculi and the anterior border of the parotid–masseteric fascia with careful attention towards the buccal branch of the facial nerve (Fig. 37.16).

The preauricular, neck and postauricular dissection should now be in one cavity.



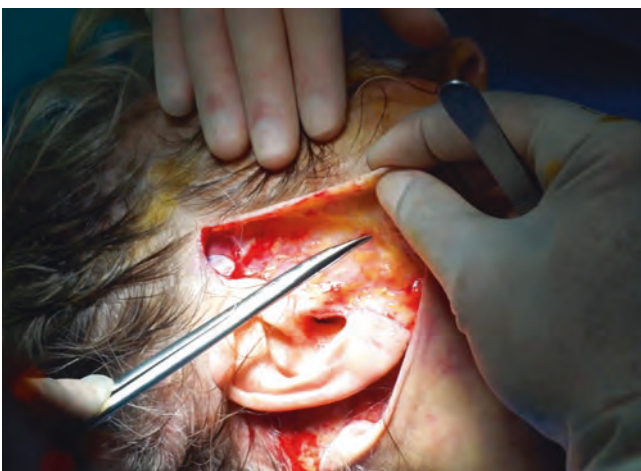©Association of Oral and Maxillofacial Surgeons of India

Fig. 37.14 The postauricular flap is then connected to the cervical flap and the submental region made previously



©Association of Oral and Maxillofacial Surgeons of India

Fig. 37.15 Deep layer of the deep temporal fascia exposed

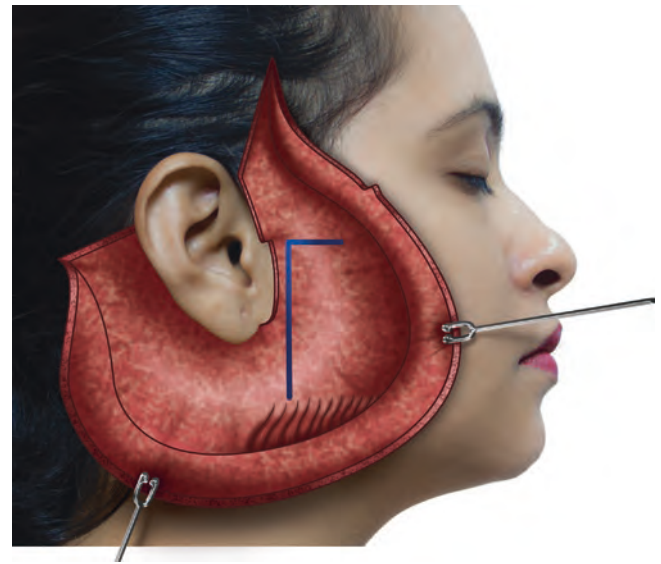


©Association of Oral and Maxillofacial Surgeons of India

Fig. 37.16 After the deep temporal fascia is exposed, dissection is carried out in a different plane subcutaneously to raise a skin flap

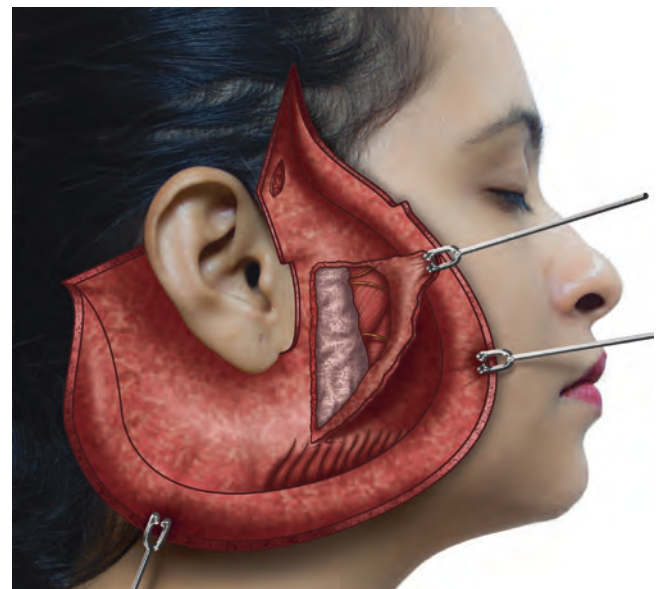
37.4.3 SMAS and Platysmal Elevation and Plication

SMAS elevation and management are carried out in various forms. We elevate the SMAS in an inverted L fashion (Fig. 37.17) starting at the preauricular plane, and the superior limit is at the lateral end of the zygomatic arch. The anterior dissection passes to the parotid-masseteric fascia (Fig. 37.18). The inferior dissection is to join the subplatys-



©Association of Oral and Maxillofacial Surgeons of India

Fig. 37.17 An inverted L shape incision (blue lines) is made on the SMAS stopping short of the parotid fascia. The shorter limb is just below the zygomatic arch, while the longer limb is in the preauricular region

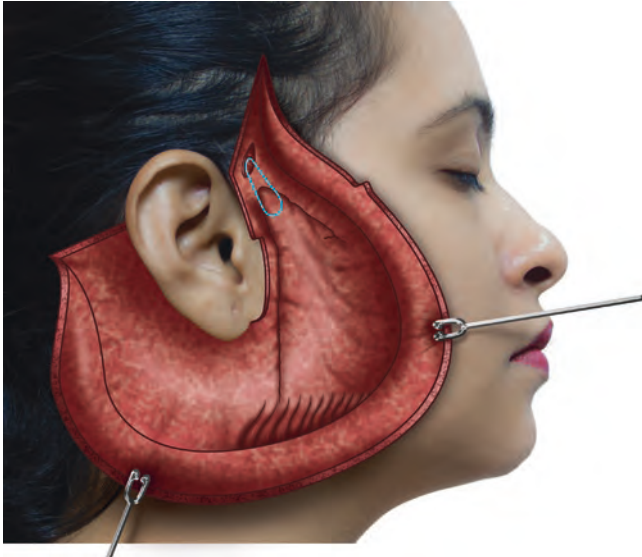

©Association of Oral and Maxillofacial Surgeons of India

Fig. 37.18 Cut SMAS peeled anteriorly to show underlying parotid. Facial nerve exits the parotid deep into the SMAS. Deep into these are the masseter muscles followed by the buccinator muscles with horizontal muscle striations

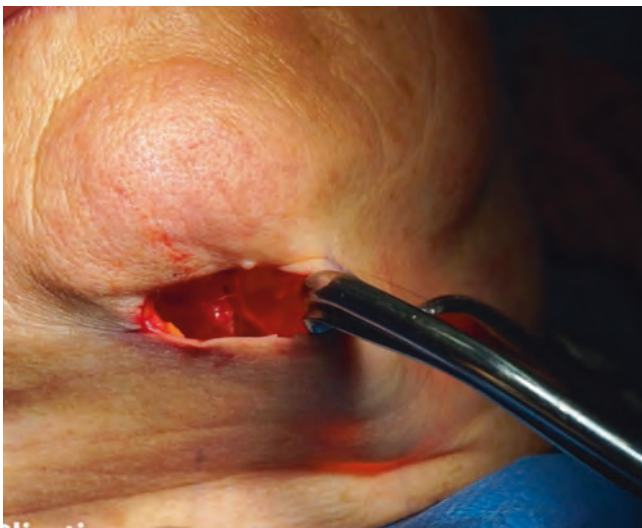
mal plane at the angle of the jaw with consideration to avoid damage to the two or three cervical branches. In our practice, the elevated SMAS is anchored in a superior direction to the deep part of the deep temporal fascia (Fig. 37.19).

Our platysma dissection and plication are in four steps. The anterior border of the platysma is sutured in the midline [20] (Fig. 37.20). In some patients with short neck, the platysmal suturing needs to be hitched to the body of the hyoid bone. In some patients, a release of the inferior border of the platysma muscle at this area could also be considered. Then,



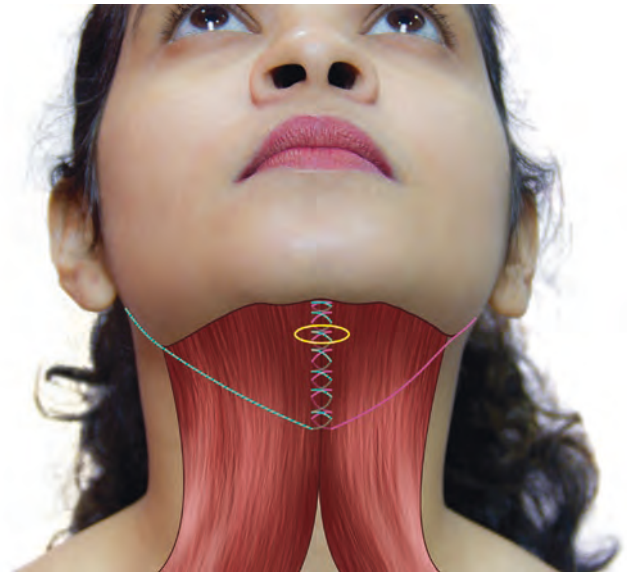
©Association of Oral and Maxillofacial Surgeons of India

Fig. 37.19 The cut SMAS is then advanced superiorly and sutured to the deep temporal fascia with 3/0 Polygluconate (Maxon, Tyco Health UK Ltd., Gosport PO130AS, UK) (blue line)



©Association of Oral and Maxillofacial Surgeons of India

Fig. 37.20 The medial edges of the platysma are sutured to each other at the midline in a corset manner



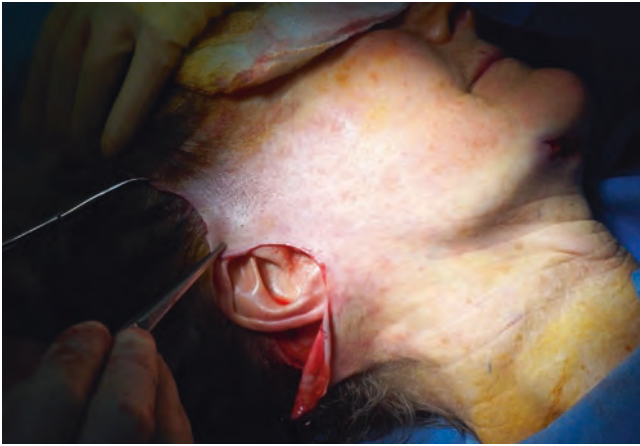©Association of Oral and Maxillofacial Surgeons of India

Fig. 37.21 A submental incision is made (white outline). Corset sutures are done twice, and the suture is plicated to the mastoid fascia on both sides

the lateral border of the platysma muscle is sutured to the anterior border of the sternocleidomastoid muscle. The third step in platysmal plication is placing a cinch suture, which is placed joining the two anterior borders of the muscles in the midline and, after catching the platysma muscle in two or three areas, hitched the sternocleidomastoid muscle and the final anchor into the mastoid periosteum (Fig. 37.21). Depending on the neck anatomy, we sometimes place a second cinch suture about 5–6 mm below the first to avoid bulging of the submandibular gland.

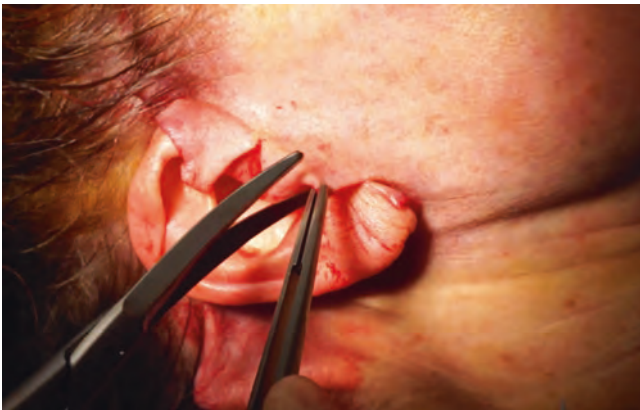37.4.4 Closure

Meticulous haemostasis is done with bipolar electrocautery throughout the procedure. The cervicofacial flaps are draped over the margins in a superolateral vector with much emphasis on the superior than the lateral direction (Fig. 37.22). Final anchoring is done with two key sutures that are placed along the helical attachment and the superior aspect of the postauricular incision. Cuts are made on the excess skin, perpendicular to the flap margin, stopping just short of it (Fig. 37.23). This allows the margins to be visualized when trimming the excess skin. If a tragal incision was made, the skin can be thinned and trimmed to mimic tragal shape and skin during closure at the tragus. Dog ears are preferably removed at the apex rather than in the ear lobe region. The ear lobe is then replaced 15° posterior to the vertical position. Layered repaired is then carried out in the final closure.



©Association of Oral and Maxillofacial Surgeons of India

Fig. 37.22 Excess skin is draped in a superolateral vector over the margins and excised



©Association of Oral and Maxillofacial Surgeons of India

Fig. 37.23 Cuts are made perpendicular to the flap margin stopping short of the margins and then excised accordingly

37.4.5 Support Dressings

There are different ways of providing this final exercise. We apply antibiotic topical ointment followed by non-sticky dressing to the pre- and postauricular area and an adjustable Velcro band. In the literature, however, various pressure dressings are applied.

37.5 Post-operative Management

Velcro bands are removed on a daily fashion. Wounds are cleaned followed by topical ointment and reapplication of the Velcro band.

The medications are taken on a prescribed fashion.

The patient is placed on antibiotics and painkillers for a week. Sleeping is done with the head elevated by 2–3 pillows. The patient is seen on the day after the surgery to ensure that there is no haematoma. If drains are placed, they are removed during this time.

Facial bandages are placed between 2 and 5 days. Sutures are removed 7–10 days later. The wounds are kept moist with antibiotic ointment such as Tetracycline 3% or Mupirocin ointment 2% (Figs. 37.24a, b and 37.25a, b).

37.6 Complications and Management

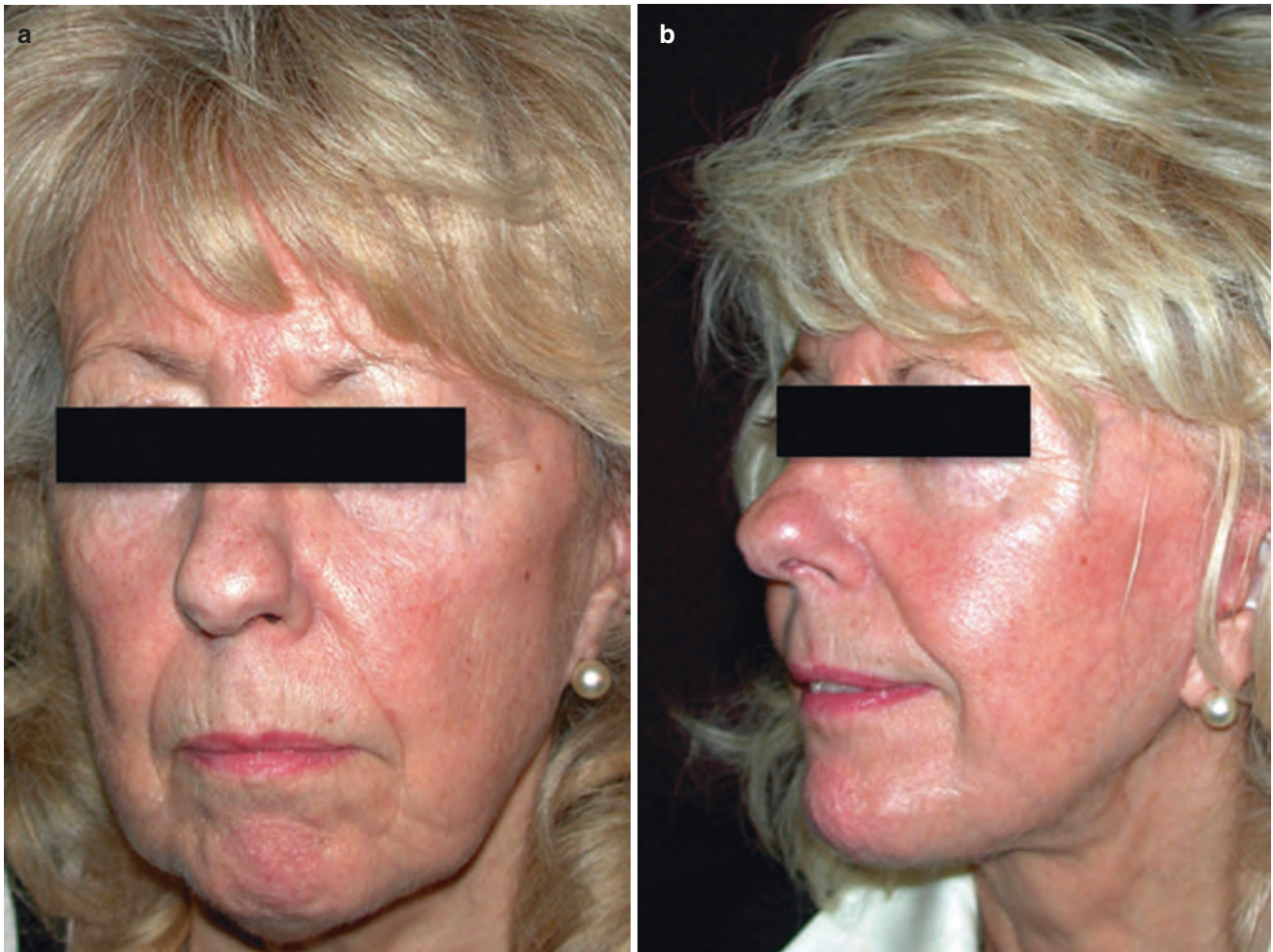Post-operative complications of facelifts include post-operative haematoma, skin necrosis, sensory and motor disturbances, obvious scarring, seroma, alopecia, auricular deformity and dyspigmentation [21]. Detailed informed consent should be obtained from patients prior to the surgery.

37.6.1 Haematoma

A thorough medical history is needed prior to surgery. Antiplatelet medications such as Aspirin, Clopidogrel, Dipyridamole and powerful anticoagulation drugs such as warfarin will have to be stopped after consultation with the patient's prescribing physicians. Patients on herbal or traditional Chinese medications such as ginkgo biloba and Cordyceps will also need to be stopped before surgery.

Haematoma formation is by far the most common complication with some papers reporting up to 15% [21]. Expanding haematoma usually happens in the first 24 hours and must be evacuated. Smaller haematoma can be aspirated, and pressure bandage is placed for pressure haemostasis. Meticulous haemostasis with bipolar diathermy is mandatory for facelift procedures. The flap and the underlying bed should be scrutinized for bleeding spots with a good head light or fibre optic light attached to a retractor. Brisk bleeding from larger vessels should be ligated. Adjunctive measures including fibrin glue [22, 23] and platelet gel and facelift bandages have been explored.

Large haematoma are a cause for concern and need to be evacuated. They can cause problems in healing including skin ischaemia.



©Association of Oral and Maxillofacial Surgeons of India

Fig. 37.24 (a) Pre-operative profile view showing excess loose skin, jowling, submental fat and deep nasolabial fold. (b) Post-operative profile view after facelift and platysma plication. Excessive skin had been

resected, jowls had been corrected and there was improved cervicomenatal definition

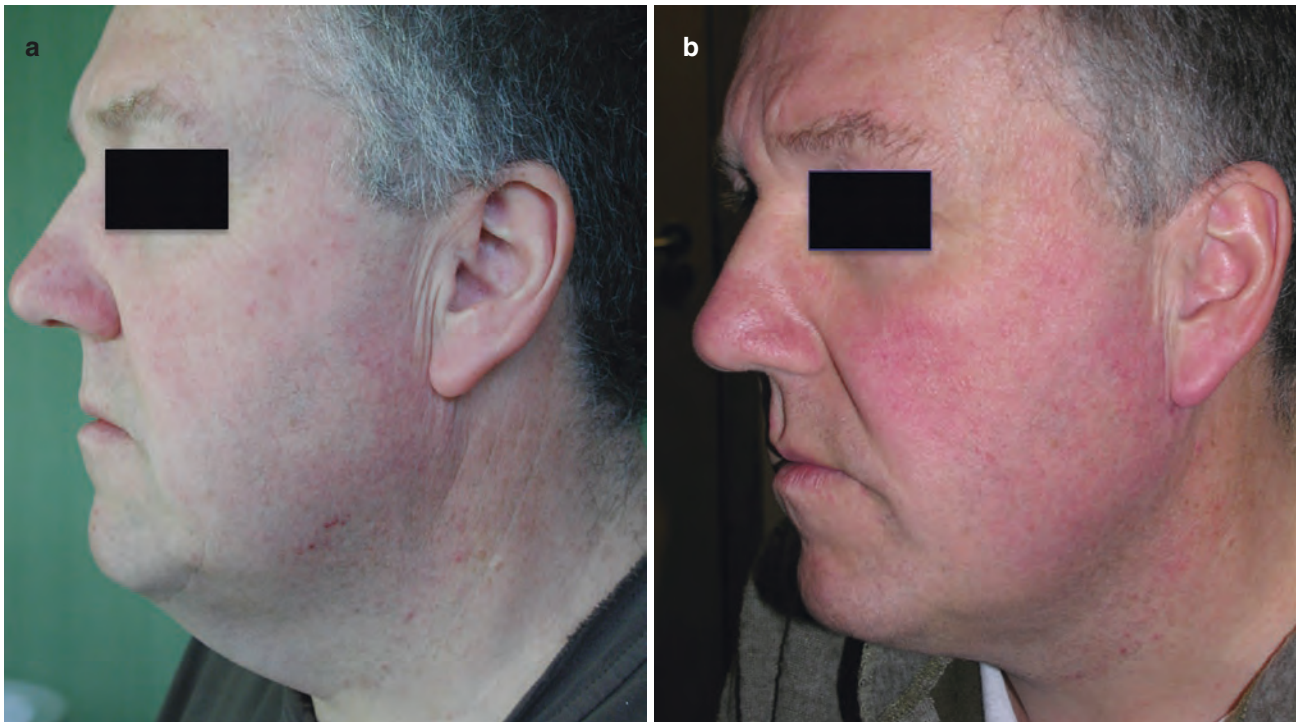
37.6.2 Skin Ischaemia and Necrosis

Ischaemic changes and flap necrosis can occur due to circulatory disturbances. This can happen when the flap is too thin or had undergone extensive undermining and exuberant cautery, closed under excessive tension or compromised by excessively tight bandage compression. The incidence ranges between 1.1 and 3% [24]. Venous congestion or arterial obstruction can result in skin ischaemia and necrosis. Large unevacuated haematoma separates the flap off the underlying

bed during which perfusion is only by the vessels supplying the flap. This causes the areas furthest away from the perfusing vessels to be at risk of ischaemia.

Necrosis of the skin is more common in the postauricular than the preauricular region.

Application of nitroglycerin paste may help to encourage vasodilation when done in the early stages [25]. Conservative treatment to allow healing via secondary intention followed by laser, excision of the scar with repair via rotation flaps can be carried out at a later stage.



©Association of Oral and Maxillofacial Surgeons of India

Fig. 37.25 (a) Pre-operative profile view showing excess skin, slight jowling, submental fat and severe loss of neck definition. (b) Post-operative profile view after facelift and platysma plication

37.6.3 Obvious Scarring

Scarring can occur when the wounds are closed under excessive tension or if the incisions are placed at an inappropriate position due to poor design. Skin slough and necrosis of the flap can lead to severe scarring. Patients who are more prone to hypertrophic scarring or keloids should be warned. Wound tension can develop and cause scarring if there is excessive removal of skin or if undermining of the flap is inadequate.

Treatment of scarring includes conservative treatment with antibiotic ointment such as Tetracycline cream 3% or Bactroban cream. This is followed by steroid injections such as triamcinolone acetate, application of silicone sheet or gel dressing. As the scar improves and stabilizes, it can be lasered, excised and revised.

37.6.4 Sensory Disturbances

Sensory disturbances occur invariably due to the dissection and separation of the facial planes during the facelift procedure,

but this usually occurs temporarily and resolves in 1 year.

The most common sensory disturbance occurs to the great auricular nerve. The greater auricular nerve crosses the sternocleidomastoid muscle at approximately 6.5 cm inferior to the external auditory meatus and travels superiorly to supply the postauricular region.

Injury to this nerve can be temporary or permanent due to dissection over the postauricular, mastoid region and to a lesser extent in the cervical region. This results in numbness of the ear lobe and postauricular area.

Other forms of numbness can be found in preauricular region.

37.6.5 Motor Nerve Disturbances

Keeping away from the planes that the facial nerve travels in is the safest method to avoid motor nerve problems. The facial nerve branches course through the parotid gland and exits the parotid gland to travel deep to the SMAS layer before innervating the muscles of facial expression. Care

should be taken when dissecting beyond the parotid or when dissecting deep into the SMAS layer.

Facial nerve injury ranges from 0.4 to 2.6% [21]. The most common motor nerve damage is the marginal mandibular nerve followed by the temporal nerve and then the buccal branch. Neuropraxia from exuberant retraction, cautery heat and compression can result in temporary or permanent loss of the motor function. The marginal mandibular branch courses in the superficial layer of the deep cervical fascia, deep into the platysmal layer, and may be damaged when dissecting in this region. The temporal branch of the facial nerve courses just deep to the superficial temporal fascia and travels 0.5 cm anterior to the tragus and then obliquely to 1.5 cm above the lateral edge of the eyebrows.

37.6.6 Ear Lobe Irregularities

“Pixie or elf-like” ear is a stigma of facelift. The ear lobe should be repositioned in a tensionless fashion, and the ear lobe should be placed 15° posterior to the vertical axis of the pinna [6]. Over resection of the flap at the base of the auricle as well as failure to place subcutaneous stay sutures on the facial flap at the ear base can result in the ear being pulled inferiorly.

Pixie ears can be revised by releasing the base of the auricle and creating a new ear lobe.

37.7 Conclusion

The facelift remains the single most powerful method in facial rejuvenation for the moderate to advanced ageing face. It has developed from small elliptical incisions and closure to full facelift with simultaneous neck lift. A variety of techniques have been described contributing to its evolution including SMAS layer management, standard facelifts, composite facelifts, platysmal plication and smaller flaps such as the MACS lift and S-lifts. The standard face and simultaneous neck lift can treat most of the problems of the mid and lower face as well as the neck. An intimate understanding of the anatomy of the face, appropriate choice of the facelift design and meticulous execution are paramount in giving the patient an ideal outcome while avoiding the possible complications.

Disclosure Authors have no financial conflicts to disclose.

37.8 Case Scenarios

Case Scenario 1 (Fig. 37.26)

A 67-year-old Caucasian lady presented with unhappy aesthetics of her face. She had had a considerable amount of sun exposure over the years. Her medical history was unremarkable.

Clinical features:

On examination she had multiple minor and major wrinkles on her face. On examination of the mid face, she showed descending SOOF and malar fat pads. She had prominent folding of the nasolabial fold and loss of mandibular border definition. Her neck was a good shape for her age (Fig. 37.26a, b).

Treatment:

She underwent a standard facelift without a neck lift and simultaneous autologous fat augmentation malar, chin and perioral areas.

Post-operative findings:

The post-operative profile shows aesthetically pleasing contour with an unoperated look (Fig. 37.26c, d). A majority of ageing changes have been removed. She ideally should undergo perioral laser resurfacing to improve the skin quality.

Case Scenario 2 (Fig. 37.27)

A 73-old lady presented with ageing changes and was unhappy with the mid and lower face. She was concerned about the aesthetics of her neck (Fig. 37.27a, b).

She is an insulin-dependent diabetic and takes medication for hypertension.

Clinical features:

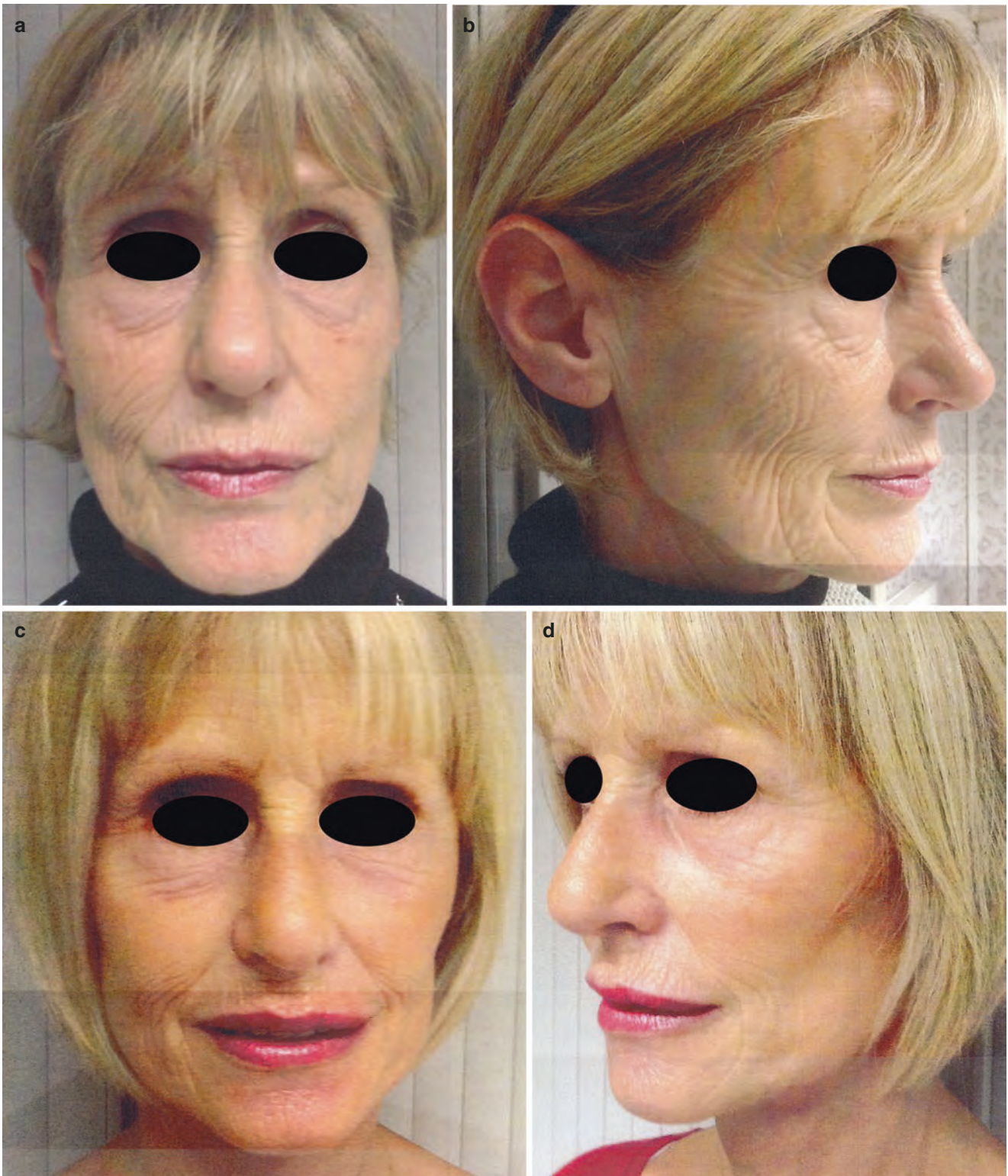On examination, the mid face showed malar fat descent with prominent nasolabial fold. She had marked marionette lines, pre-jowl sulcus and prominent jowls. Examination of the lower face showed platysmal bands and loss of mandibular neck definition with submental fat projection.

Treatment:

She underwent a standard face and neck lift with platysmal and SMAS plication.

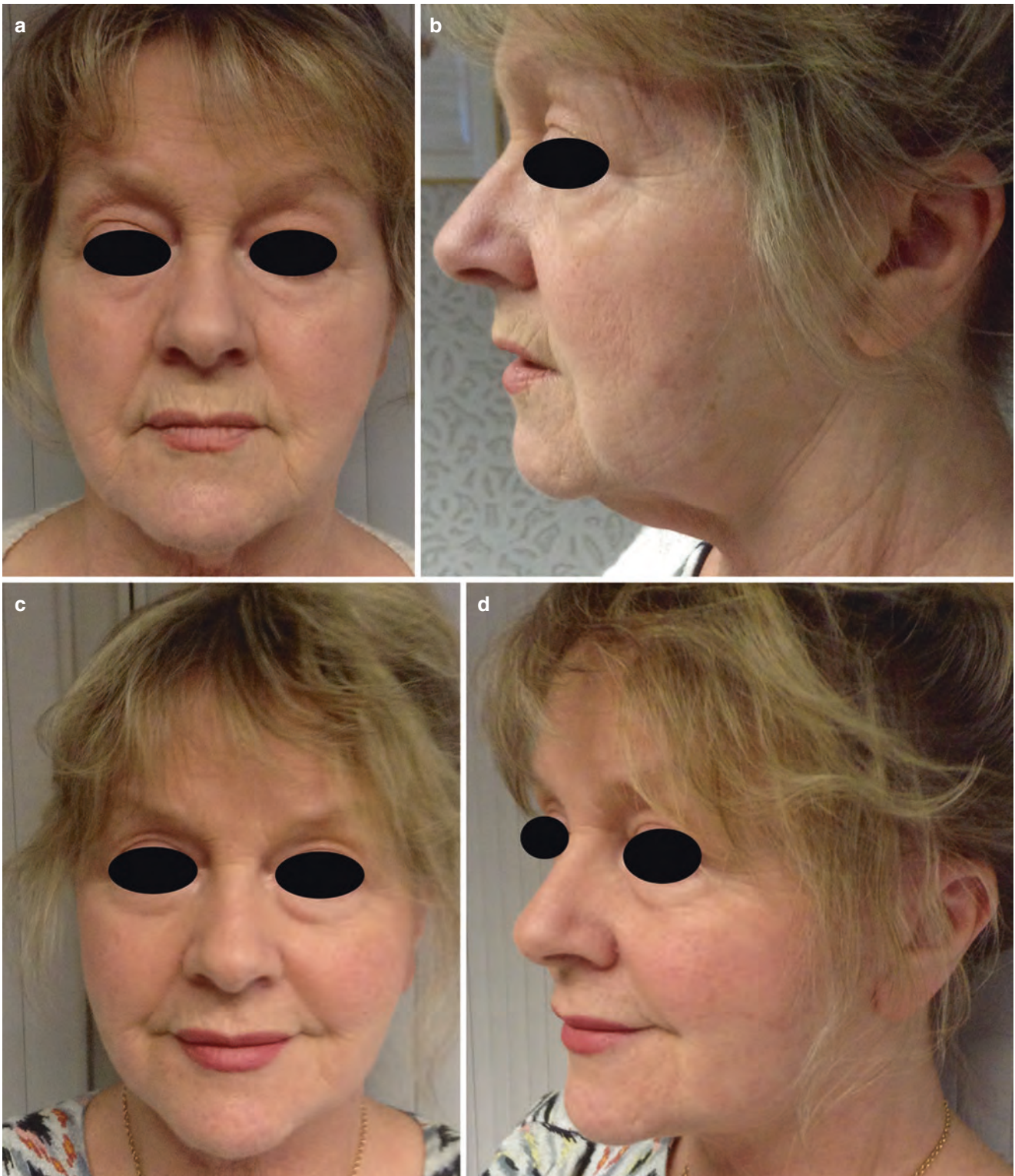Post-operative findings:

Three month post-operative photograph shows correction for the ageing changes and a pleasing facial and neck profile (Fig. 37.27c, d).



©Association of Oral and Maxillofacial Surgeons of India

Fig. 37.26 Standard face and neck lift with platysmal and SMAS plication. (a, b) Pre-operative appearance demonstrating wrinkles in frontal and profile view. (c, d) Post-operative appearance demonstrating wrinkles in frontal and profile view



©Association of Oral and Maxillofacial Surgeons of India

Fig. 37.27 Standard face and neck lift with platysmal and SMAS plication. (a, b) Pre-operative appearance demonstrating wrinkles in frontal and profile view. (c, d) Post-operative appearance demonstrating wrinkles in frontal and profile view

References

1. Ilankovan V. Anatomy of the aging face. *Br J Oral Maxillofac Surg.* 2014;52:195–202.
2. Hollander E. Die kosmetische chirurgie. In: Joseph M, editor. *Handbuch der Kosmetik.* Leipzig: Von Veit; 1912. p. 688.
3. Mangat DS, Frankel JK. The history of rhytidectomy. *Facial Plast Surg.* 2017;33(3):247–9. Epub 2017 Jun 1.
4. Tonnard PL, Verpaele AM. *The MACS-lift short-scar rhytidectomy.* Quality Medical Publishing; 2004. p. 4.
5. Mitz V, Peyronie M. The superficial musculoaponeurotic system (SMAS) in the parotid and cheek area. *Plast Reconstr Surg.* 1976;58(1):80–6.
6. Ilankovan V. Recent advances in face lift to achieve facial balance. *J Maxillofac Oral Surg.* 2017;16(1):3–12.
7. Webster RC, Smith RC, Papsidero MJ, Karolow WW, Smith KF. Comparison of SMAS plication with SMAS imbrication in face lifting. *Laryngoscope.* 1982;92(8):901–12.
8. Lemmon ML, Hamra ST. Skoog rhytidectomy: a five year experience with 577 patients. *Plast Reconstr Surg.* 1980;65:283–97.
9. Baker DC. Lateral SMA Sectomy. *Plast Reconstr Surg.* 1997;100:509–13.
10. Hamra ST. Approaches to rejuvenation of the upper face. *Aesthet Surg J.* 2000;20(1):47–52.
11. Hamra ST. The role of the septal rest in creating a youthful eyelid-cheek complex in facial rejuvenation. *Plast Reconstr Surg.* 2004;113(7):2124–41.
12. Antell DE, Orseck MJ. A comparison of face lift techniques in eight consecutive sets of identical twins. *Plast Reconstr Surg.* 2007;120:1667–73.
13. Fulton JE, et al. The S-Lift facelift featuring the U-Suture and O-Suture combined with skin resurfacing. *Dermatol Surg.* 2001;27(1):18–22.
14. Tonnard P, et al. Minimal access cranial suspension lift: a modified S-Lift. *Plas Reconstr Surg.* 2002;109(6):2075–86.
15. Mendelson BC. *Aesthetic plastic surgery.* Saunders Elsevier; 2009. Chapter 6, pp. 53–71.
16. Warren RJ, et al. Face lift. *Plast Reconstr Surg.* 2011;128:747e–64e.
17. Stuzin JM, Baker TJ, Gordon HL, Baker TM. Extended SMAS dissection as an approach to midface rejuvenation. *Clin Plast Surg.* 1995;22(2):295–311.
18. Furnas DW. The retaining ligaments of the cheek. *Plast Reconstr Surg.* 1989;83:11–6.
19. Alghoul M, Codner MA. Retaining ligaments of the face: review of anatomy and clinical applications. *Aesth Surg J.* 2013;33(6):769–82.
20. Sebasan T, Ilankovan V. Plication of the platysma. *Br J Oral Maxillofac Surg.* 2006;44(4):325.
21. Bloom JD, et al. Face-lift complications. *Facial Plast Surg.* 2012;28:260–72.
22. Griffin JE, Jo C. Complications after superficial plane cervicofacial rhytidectomy: a retrospective analysis of 178 consecutive facelifts and review of the literature. *J Oral Maxillofac Surg.* 2007;65(11):2227–34.
23. Zoumalan R, Rizk SS. Hematoma rates I drainless deep-plane face-lift surgery with and without the use of fibrin-glue. *Arch Facial Plast Surg.* 2008;10:103–7.
24. Baker DC. Complications of cervicofacial rhytidectomy. *Clin Plast Surg.* 1983;10:543–62.
25. Niamtu J. *Cosmetic facial surgery:* Elsevier Mosby; 2011. p. 354.

Open Access This chapter is licensed under the terms of the Creative Commons Attribution 4.0 International License (<http://creativecommons.org/licenses/by/4.0/>), which permits use, sharing, adaptation, distribution and reproduction in any medium or format, as long as you give appropriate credit to the original author(s) and the source, provide a link to the Creative Commons license and indicate if changes were made.

The images or other third party material in this chapter are included in the chapter's Creative Commons license, unless indicated otherwise in a credit line to the material. If material is not included in the chapter's Creative Commons license and your intended use is not permitted by statutory regulation or exceeds the permitted use, you will need to obtain permission directly from the copyright holder.



38.1 Introduction

The nose occupies the centre of the face and receives enormous attention as a key aesthetic element. It is also an important organ contributing to vital functions of breathing and olfaction. A nose with ideal proportions creates a harmonious balance of aesthetic and psychological wellness. Whilst a rhinoplasty can significantly improve the quality of life of patients, there may be associated complications and undesirable outcomes. It is imperative that the surgeon desiring to practise the art and science of rhinoplasty should be familiar with the essential basics before embarking on this journey.

The aim of this chapter is to provide a clinical overview of the spectrum of rhinoplasty in an easily comprehensible manner. The primary section is focussed on the key elements of anatomy, diagnosis and documentation prior to any surgical procedure on the nose. Basic operative techniques including approaches, septoplasty, osteotomies and grafts are described in the next section. The management of most common nasal deformities is covered in the last section.

38.2 Surgical Anatomy of the Nose

The nose is a complex anatomic unit composed of skin, subcutaneous tissue and fibro-fatty tissue draped over a complex osteocartilaginous framework [1]. Understanding its overall morphology along with other characteristics helps in accurate diagnosis and management of various deformities. Based on the framework, the nose can be divided into exter-

Electronic Supplementary Material The online version of this chapter (https://doi.org/10.1007/978-981-15-1346-6_38) contains supplementary material, which is available to authorized users.

N. A. Nasser (✉)
Barts & London NHS Trust, Whipps Cross University Hospital,
London, UK

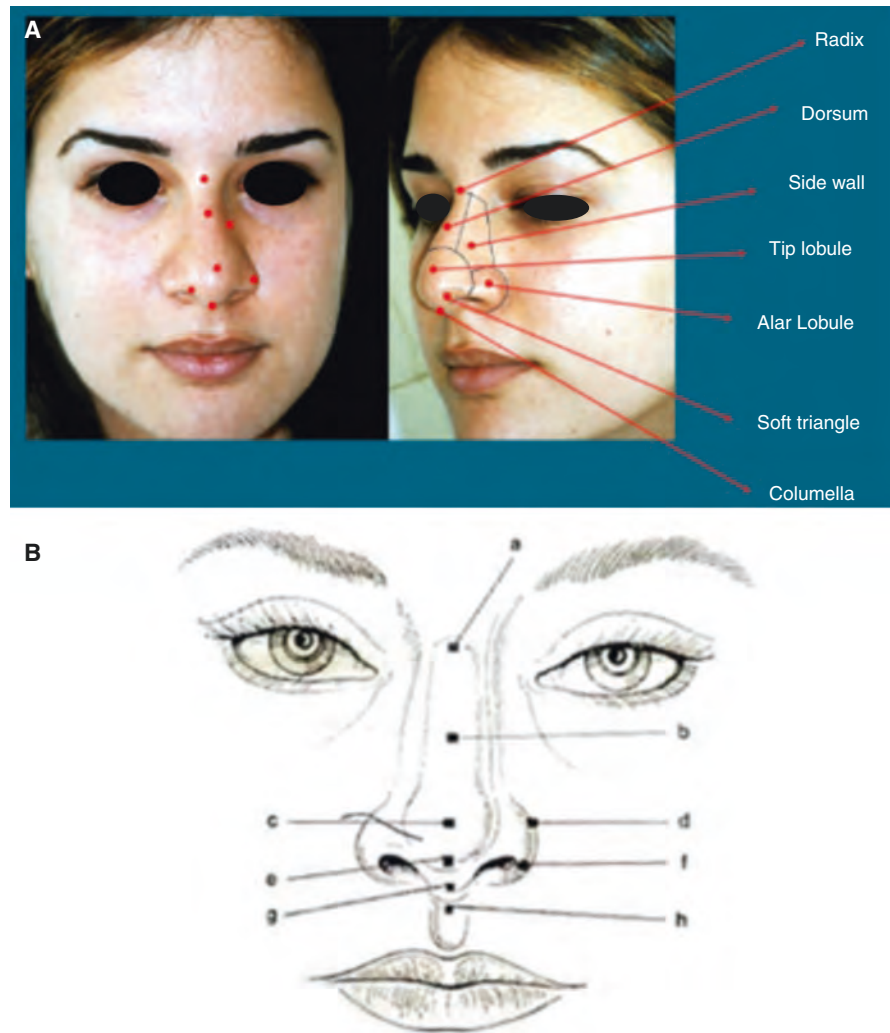
nal nose and internal nose. The important landmarks (Figs. 38.1A, B and 38.2) related to nasal anatomy are highlighted in Box 38.1.

38.2.1 External Nose

A. Skin and underlying tissues: The features of nasal skin including color, consistency and thickness can vary between patients and are important determinants of outcome of rhinoplasty. Skin thickness varies in different parts of the nose and at different stages of life. The average skin thickness is the greatest at the radix (measuring 1.25 mm) and the least at the Rhinion (0.6 mm) [2]. The supratip area has abundant sebaceous glands especially in adolescent males. Skin thickness is reduced in the columella and mid-alar area and increased in the alar base area. Both the thickness of the skin and the presence of sebaceous glands in the caudal half of the nose make it difficult to achieve an ideal result in a predictable manner.

Beneath the skin and above the underlying osseocartilaginous framework are the layers of the superficial musculoaponeurotic system (SMAS), fibromuscular layer, deep fatty layer, and periosteum/perichondrium [3]. The SMAS of the nose is the continuation of the sheath that extends across the entire upper half of the face with adipose tissues, vertical fibres and septi, extending to the skin. Under the SMAS is a layer of thin fibrofatty tissue that divides the superficial and deep muscles of the nose [4]. The deep fatty layer separates the fibromuscular layer from the underlying nasal framework. Major blood vessels, lymphatics and nerves run within it. Deep to this layer is the periosteum of the nasal bones and the perichondrium of the cartilaginous frame. The avascular plane of dissection is in the supra perichondrial plane just below the fibrofatty SMAS layer.

Fig. 38.1 Nasal anatomy landmarks—frontal view. (A) Clinical picture, (B) Line diagram: (a) Radix, (b) Dorsum, (c) Tip lobule, (d) Alar lobule, (e) Tip, (f) Alar base, (g) Columella, (h) Philtrum



©Association of Oral and Maxillofacial Surgeons of India

B. External Vault

The nose is divided topographically into thirds as shown in Figs. 38.3 and 38.4.

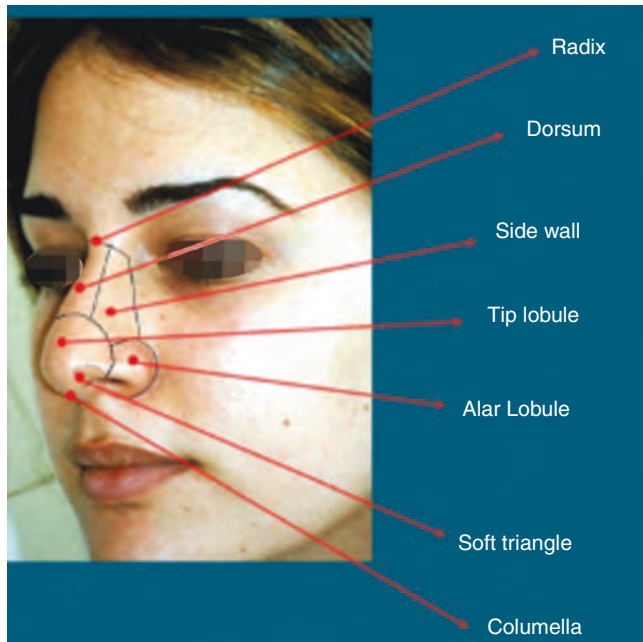
Upper third: The nasal bones constitute the upper one third. This part of the nose is pyramidal in shape, the narrowest portion being at the intercanthal line. Nasal bones vary in length and become thinner as they extend caudally toward the Rhinion. The nasal bones are attached to the frontal bone above at the radix which forms the frontonasal angle. They articulate with the ascending process of the maxilla. Caudally, the nasal bones overlap the upper lateral cartilages [Keystone area] [5].

Middle third: This contains the paired upper lateral cartilages (ULCs) and is referred to as the cartilaginous vault. The ULCs are fixed above to the under-surface of the nasal bones and fused with the septum, and they separate from the septum as they extend inferiorly. An important surface landmark in this region is the external lateral triangle; bounded above by the upper lateral cartilages, laterally by the frontal process of the maxilla, and caudally the cephalic border of the lower lateral cartilage.

The angle between the caudal border of the upper lateral cartilage and the septum is usually 10–15° and constitutes the internal nasal valve (Fig. 38.5a, b).

Lower Third: The lower third or lobule of the nose is further subdivided into the tip, supra tip and infra tip regions. These specific areas of the lobule are formed by variations in the shape, size, and angles of the lower lateral cartilages (LLCs). The form of the lobule is defined by the tip or apex of the nose. The area defining the overlap of the LLC and the caudal aspect of the ULC is called the “scroll” area and has a fibrous attachment. The size of the scroll area along with the slope of the lateral crus contributes to the bulbosity of the lobule.

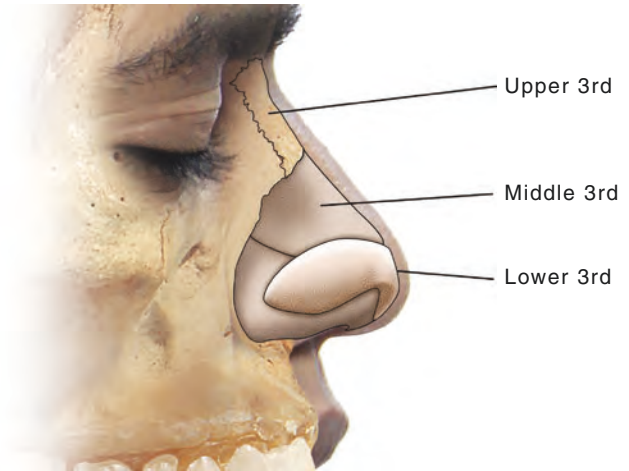
The lower lateral cartilages have four essential components: the medial crus, intermediate crus, dome and the lateral crus (Fig. 38.6a, b, c): The cephalic edge of the domal segment of the intermediate crus is responsible for the aesthetic point known as the pronasale. The supra tip is immediately cephalic to the pronasale. The infra tip is located between the pronasale and the apex of the nostrils. The infra tip region should have a gentle curve that



©Association of Oral and Maxillofacial Surgeons of India

Fig. 38.2 Nasal anatomy landmarks—lateral view

Landmark	Definition
14. Supra-alar crease	Groove immediately cephalad to the alar crease
15. Sub-nasale	Junction of columella with the lip



©Association of Oral and Maxillofacial Surgeons of India

Fig. 38.3 External vault—lateral view

Box 38.1 Rhinoplasty landmarks

Landmark	Definition
1. Nasion	Depression at the junction of the nose with the forehead Deepest point at the root of the nose
2. Radix	Area centred around the nasion.
3. Nasal pyramid	Part of the nasal frame made up of the bilateral nasal bone and frontal process of the maxilla
4. Keystone area	Junction of the perpendicular plate of the ethmoid with the septal cartilage at the dorsum of the nose
5. Rhinion	The point located at the osseocartilaginous junction over the dorsum of the nose
6. Nasal tip lobule	Caudal part of the nose bounded posteriorly by the anterior nostril edge, superiorly by the supra tip area and laterally by the alar grooves
7. Nasal tip	The most anterior point of the lobule
8. Anatomic dome	Most anterior projected portion of the lower lateral cartilages between the medial and lateral crus
9. Tip defining points (TDP)	Summit of the domes. Most projecting area on each side of the tip that produces external light reflection
10. Supratip area	Area just cephalad to the nasal tip at the caudal portion of the nasal dorsum
11. Infratip lobule	Portion of the tip between the tip defining points and apex of nostrils
12. Tip projection	Distance from the most projected portion of the tip to the most posterior point of the nasal-cheek junction
13. Alar groove	Oblique skin depression between the tip and the ala

slightly projects inferiorly to the alar margins. The medial-lateral crura complex forms a tripod that is an essential concept to understand for correction of tip deformities. The lateral crura form the two cephalic lateral legs while the medial along with the intermediate crus form the caudal leg of the tripod (Fig. 38.7a, b, c).

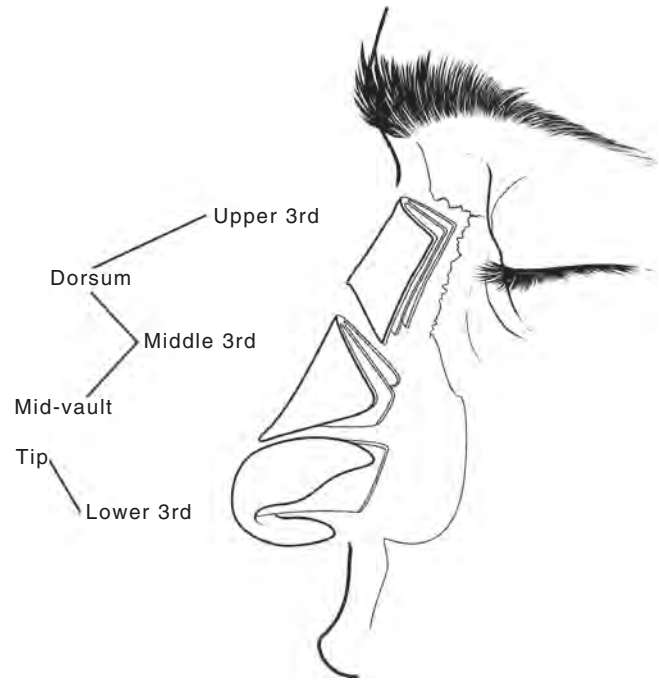
Medial crus: The medial crus has two distinct segments: the footplate and the columella. The footplate varies in size and in the degree of lateral angulation, which governs the width of the columellar base.

Intermediate crus: It extends between the medial crus and the lateral crus. The length and width of the intermediate crus control the configuration of the infra-tip lobule.

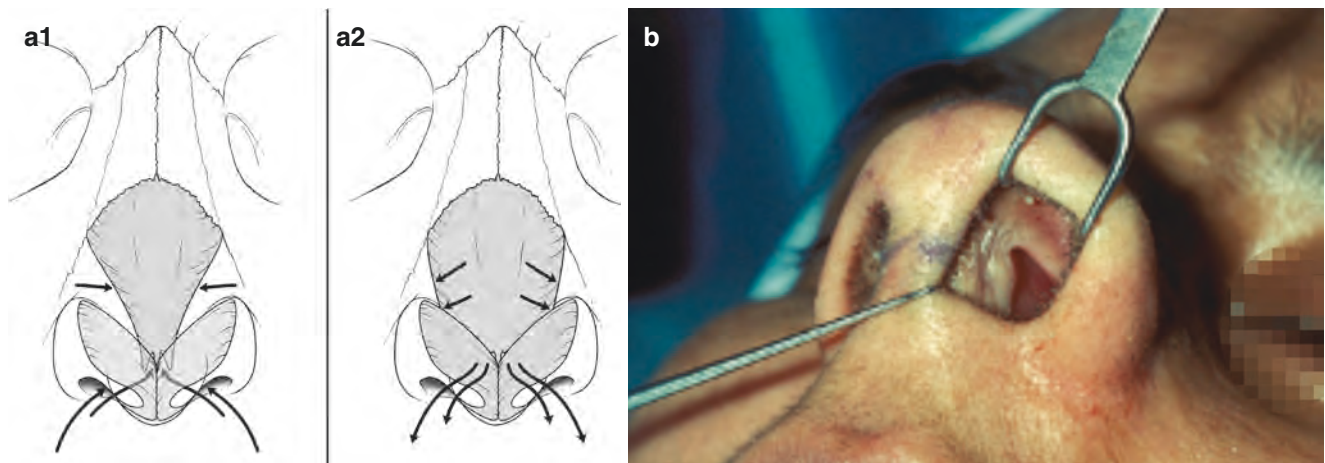
Dome: The domal segment is the narrowest and thinnest portion of the lower lateral cartilage, yet is the most important in relation to the tip shape. In an ideal nose, the cephalic edges of the paradomal segments are in close approximation and the caudal portions are divergent. Whenever the cephalic margins diverge, they result in widening of the nasal tip. A wide domal angle with increased interdomal width results in a boxy tip.

Lateral Crus: It constitutes the larger component of the nasal lobule. It is narrow anteriorly, widens in the mid-portion and narrows again laterally. The anterior portion of this cartilage can curve with different angulations and controls the convexity of the ala. The lateral crus also provides support to the anterior half of the alar rim. This cartilage is usually oriented at a 45° angle to the vertical facial plane. Narrowing of the angle between the dorsum and the long axis of the lower lateral cartilage

Fig. 38.4 External vault—lateral view. Line diagram showing the three divisions



©Association of Oral and Maxillofacial Surgeons of India



©Association of Oral and Maxillofacial Surgeons of India

Fig. 38.5 Nasal valve; (a1, a2) line diagram, (b) clinical photograph

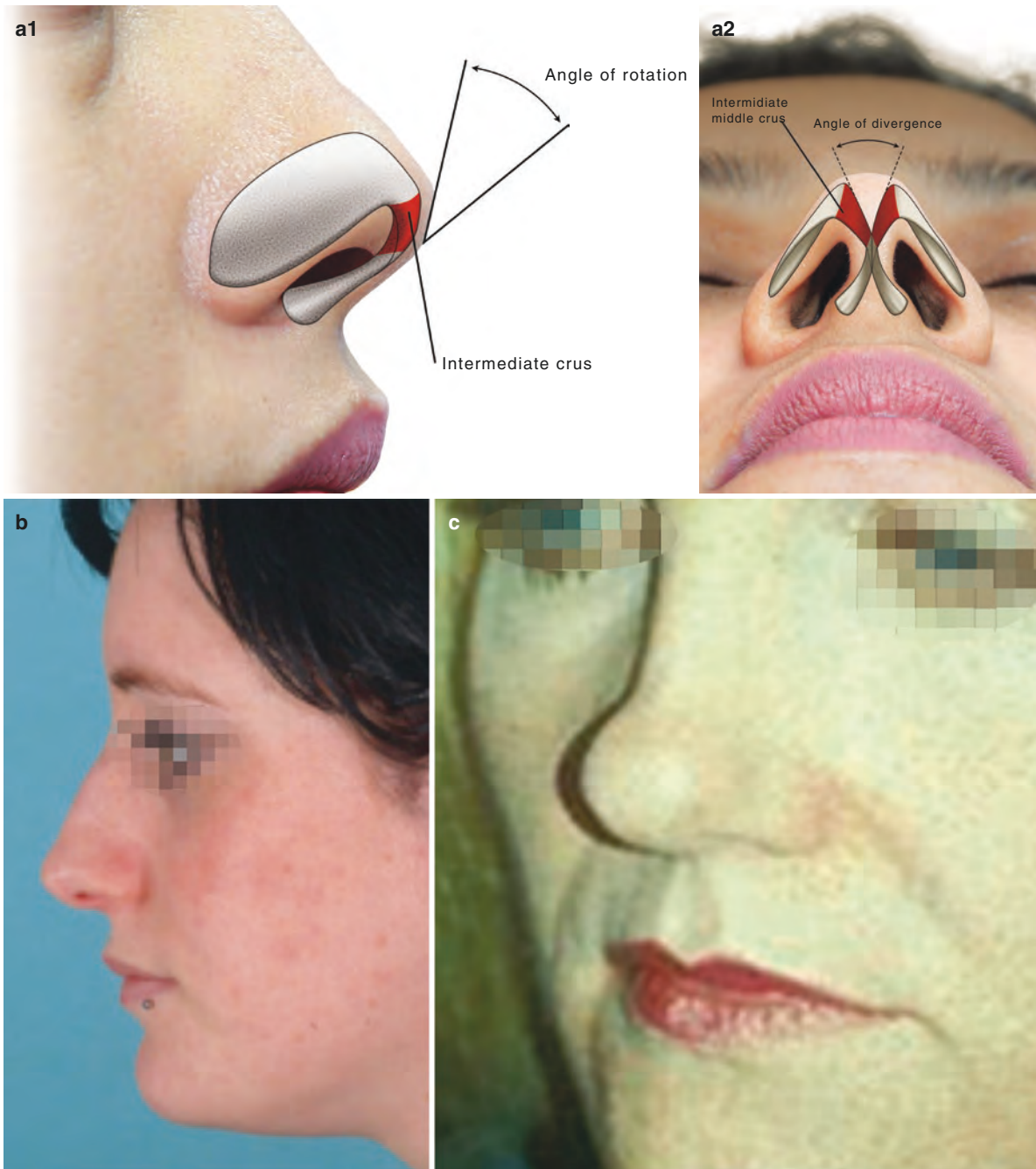may cause dysmorphology of the tip called cephalic malposition or ‘parenthesis deformity’.

Several fibrous attachments exist joining the cartilages to each other, namely, lower lateral cartilages to the upper lateral cartilage, from one lateral crus to the opposite in the supratip area (the Pitanguy ligament), dense fibrous bands between the caudal septum & the medial crura and between the medial crura themselves [6].

Muscles (Fig. 38.8): The muscles of the nose are divided by their functions into four categories; elevators, depressors, com-

pressors, and dilators. The procerus, levator labii superioris alaeque nasi, elevates and shortens the nose. These muscles are important because they assist in opening the nasal valves. The depressor muscles consist of the nasalis and depressor septi. On contraction, this group of muscles adversely affect the tip rotation by displacing it inferiorly and elevating the lip superiorly [5]. The transverse nasalis muscle forms the compressor, while the dilator naris has the opposite function.

Blood Supply and innervation: Both external and internal carotid arteries contribute to the vasculature of the external nose (Fig. 38.9). The major blood supply is from



©Association of Oral and Maxillofacial Surgeons of India

Fig. 38.6 Lower lateral cartilage (a1, a2) Diagrammatic representation and (b, c) clinical pictures

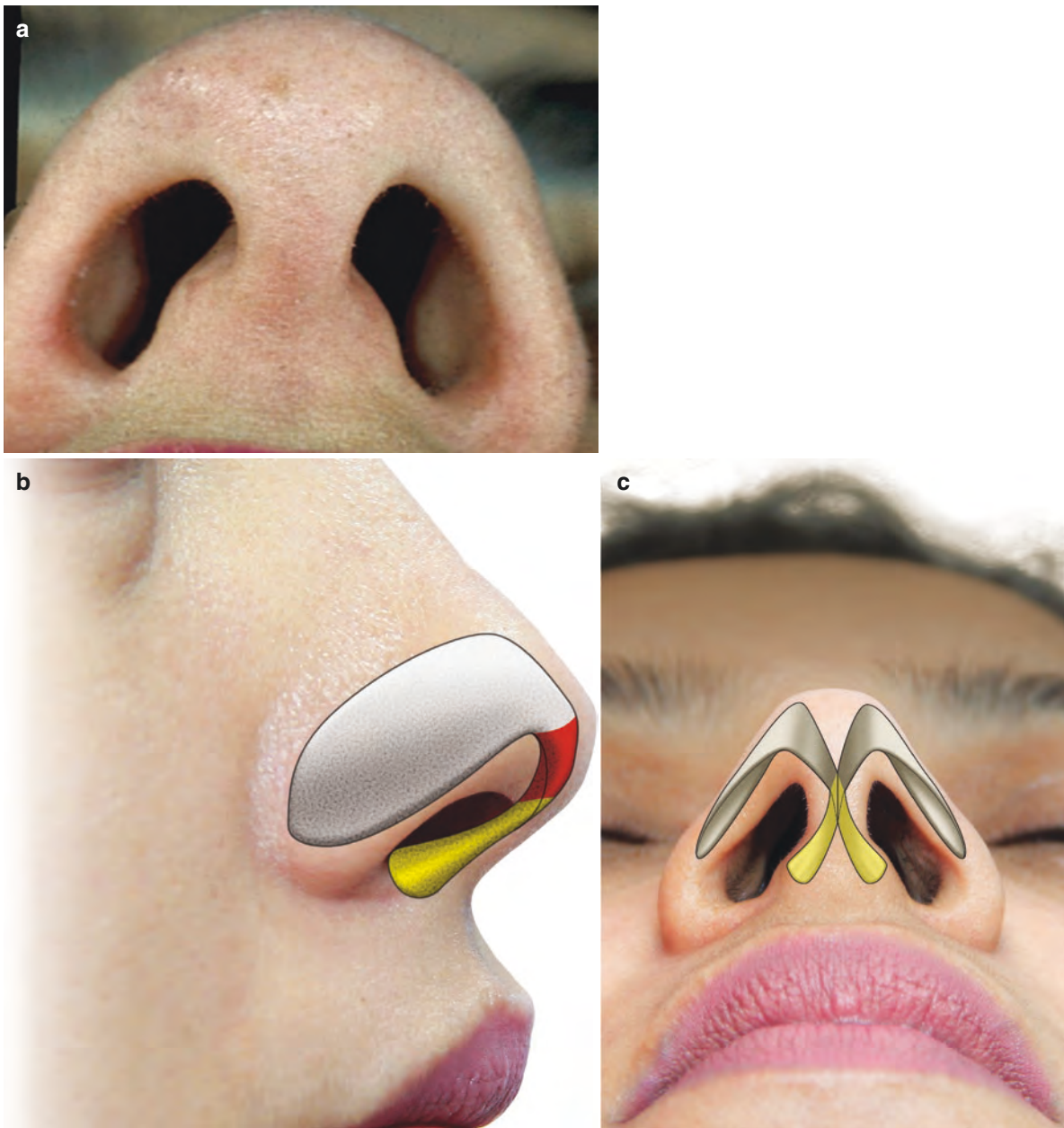
three vessels: the dorsal nasal artery—a terminal branch of the ophthalmic artery, the angular and superior labial arteries from the facial artery. The lateral nasal artery (branch of the angular artery) forms a plexus with the dorsal nasal artery, branches of infra-trochlear artery, and the external branches of the anterior ethmoidal artery. A small contribution is also received from the lateral branches of the infra-orbital artery.

Sensory innervation to the nose is provided by the maxillary and ophthalmic branches of the fifth cranial nerve [7].

38.2.2 Internal Anatomy

The internal nose is divided by the “midline” nasal septum. Anteriorly, the septum forms the medial boundary of the nasal vestibule whose lateral wall is formed by the lower lateral cartilages and their attachment to the pyriform rim.

The deeper part of the nasal cavity is bounded laterally by the medial wall of the antrum, medially by the osseocartilaginous septum, superiorly by the ethmoid and the sphenoid bones and inferiorly by the palatal process of the maxilla and



©Association of Oral and Maxillofacial Surgeons of India

Fig. 38.7 Nasal tripod; (a) clinical photograph, (b) line diagram showing medial crus (yellow), intermediate crus (red) and lateral crus (grey) (c) line diagram showing basal view

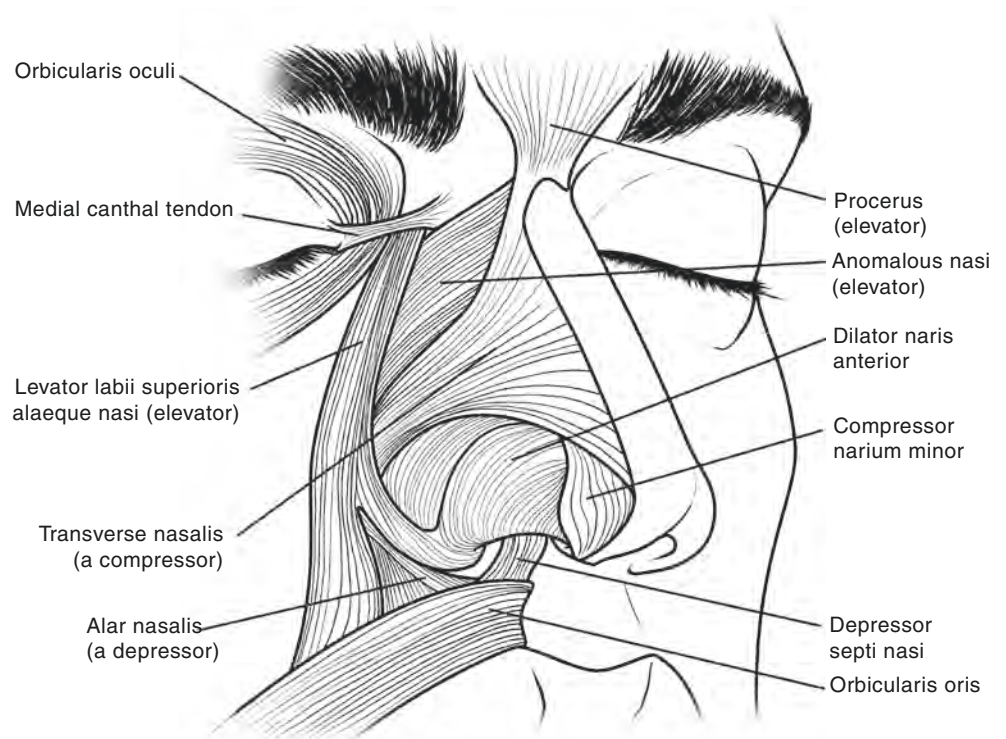
the palatine bones. There are thin, curved, bony prominences in the lateral wall called the inferior, middle, and superior concha. The cephalic portion of the lateral nasal wall is bound with the ethmoid cells, interposed between the lateral wall of the nasal cavity and the medial wall of the orbit.

38.2.3 Nasal Septum

The septum is partly cartilaginous and partly bony. The ethmoid perpendicular plate forms the upper bony septum and is continuous with the frontal bone and the cribriform plate. The lower bony septum is composed of the vomer and nasal crest of the maxilla (Fig. 38.10a, b).

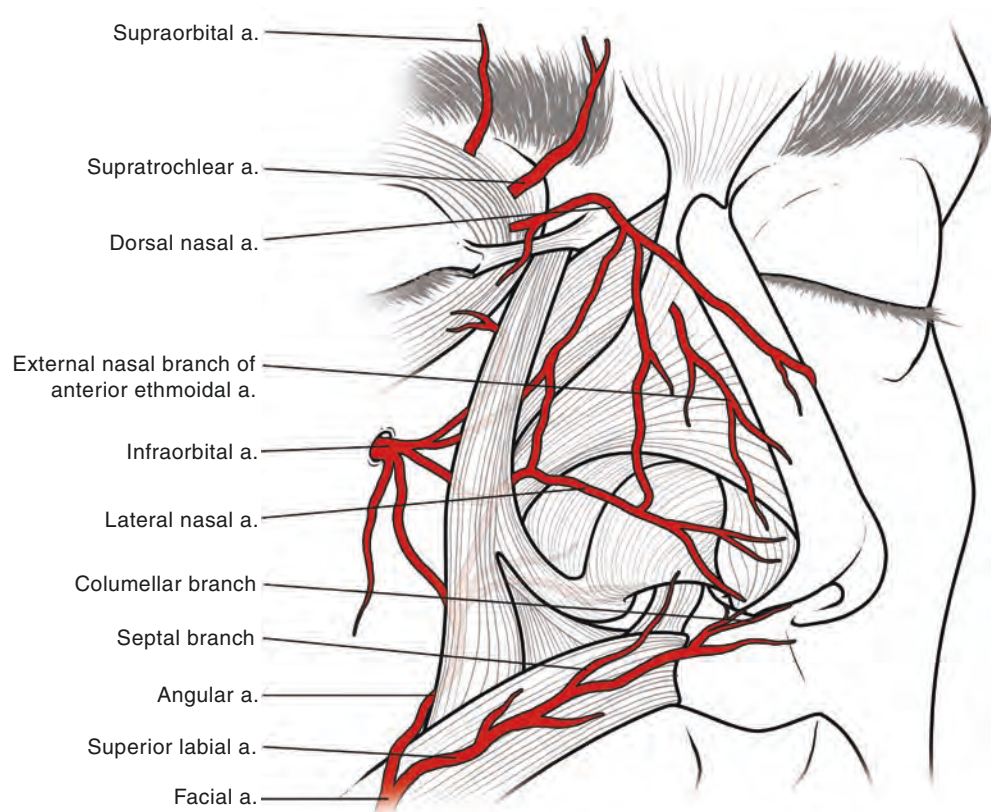
The cartilaginous septum is formed by the quadrangular cartilage that extends from Rhinion to the supratip area and supports the dorsum and the tip complex. Inferiorly, the cartilaginous septum is attached firmly to the anterior nasal spine and the maxillary crest. The junction between the dorsal and caudal portion of the cartilaginous septum is called the “anterior septal angle”. There is tenuous attachment of the perichondrium and periosteum at the junction of the bony and cartilaginous septum. The membranous septum lies above the cephalic margins of the paired medial crura. It encases fibrous bands between two layers of soft tissue covering and the depressor septi muscle.

Fig. 38.8 Muscles of the nose

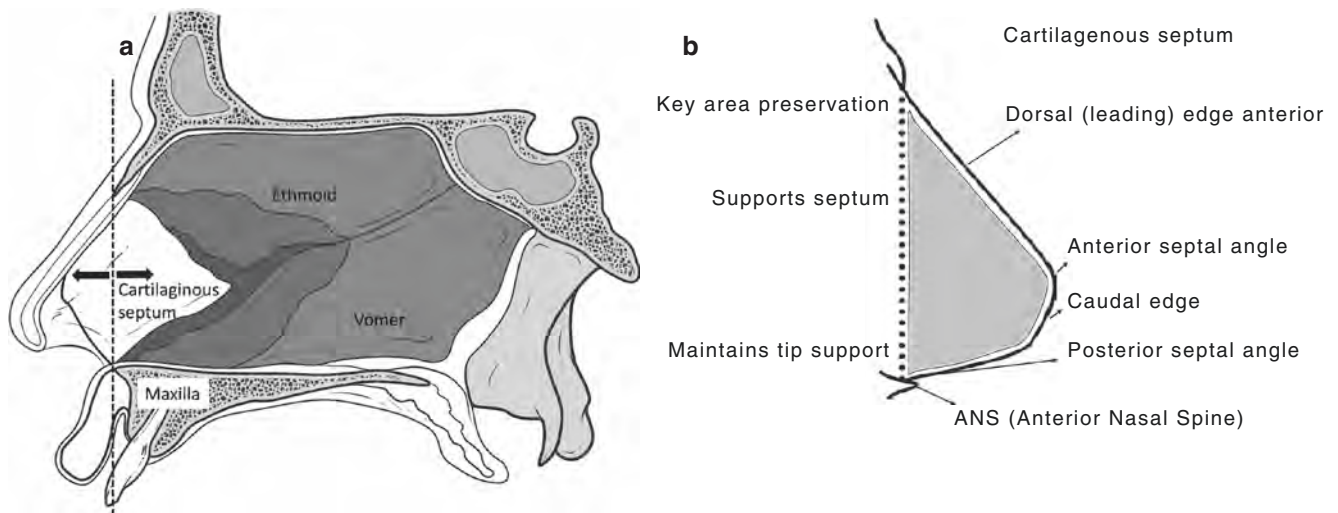


©Association of Oral and Maxillofacial Surgeons of India

Fig. 38.9 Vascularity of the nose



©Association of Oral and Maxillofacial Surgeons of India



©Association of Oral and Maxillofacial Surgeons of India

Fig. 38.10 (a) Anatomy of nasal septum, (b) line diagram with landmarks

Box 38.2 Clinical examination for Rhinoplasty

General/Systemic	Local	
	Facial	Nose
Airway/breathing Mouth breathing	Intercanthal distance	Skin quality
Bleeding disorders	Inter-eyebrow distance	Nasal bone—width, length and symmetry
Hypertension	Frontal-bossing/glabellar projection	ULC (Upper Lateral Cartilage)—width and symmetry
Diabetes/ immunosuppression	Upper lip position	LLC (Lower Lateral Cartilage) <ul style="list-style-type: none"> • Cephalic malposition • Interdomal distance • Asymmetry of light reflecting points • Lobule position • Nostril-columellar relation
Psychological assessment	Chin position	Alar base <ul style="list-style-type: none"> • Vertical and horizontal position (in repose and smile) • Inter alar distance (should be 2 mm wider than intercanthal distance) • Insertion of the alar base

38.2.4 Lateral Nasal Wall

The lateral aspect of the nasal cavity is composed of three anatomic structures: the inferior, middle, and superior turbinates. The inferior turbinate forms a boundary of the internal nasal valve, where its specially adapted erectile tissues regulate the air flow and facilitate heat and moisture exchange.

Branches of the anterior ethmoidal artery accompany the external nasal branch of the anterior ethmoid nerve, passing between the nasal bone and upper lateral cartilages, and supply the soft tissues of the dorsum and tip of the nose. The posterior ethmoidal branches supply the smaller area above the superior concha on the lateral wall and a corresponding area high on the septum [8]. The posterior part of the internal nose is supplied by branches of the sphenopalatine ganglion of the second division of the trigeminal nerve (the long sphenopalatine, the nasopalatine and part of the greater palatine nerves).

38.3 Clinical Examination

Clinical examination should be comprehensive and include the assessment of systemic diseases (Box 38.2) [9].

General examination would include ruling out any syndromic deformities [9]. Obtaining correct history of systemic disease and bleeding disorders are of paramount importance. The extensive vascular network in the nose, in the presence of a coagulation disorder, may predispose the patient to severe haemorrhage in the intra- or post-operative period.

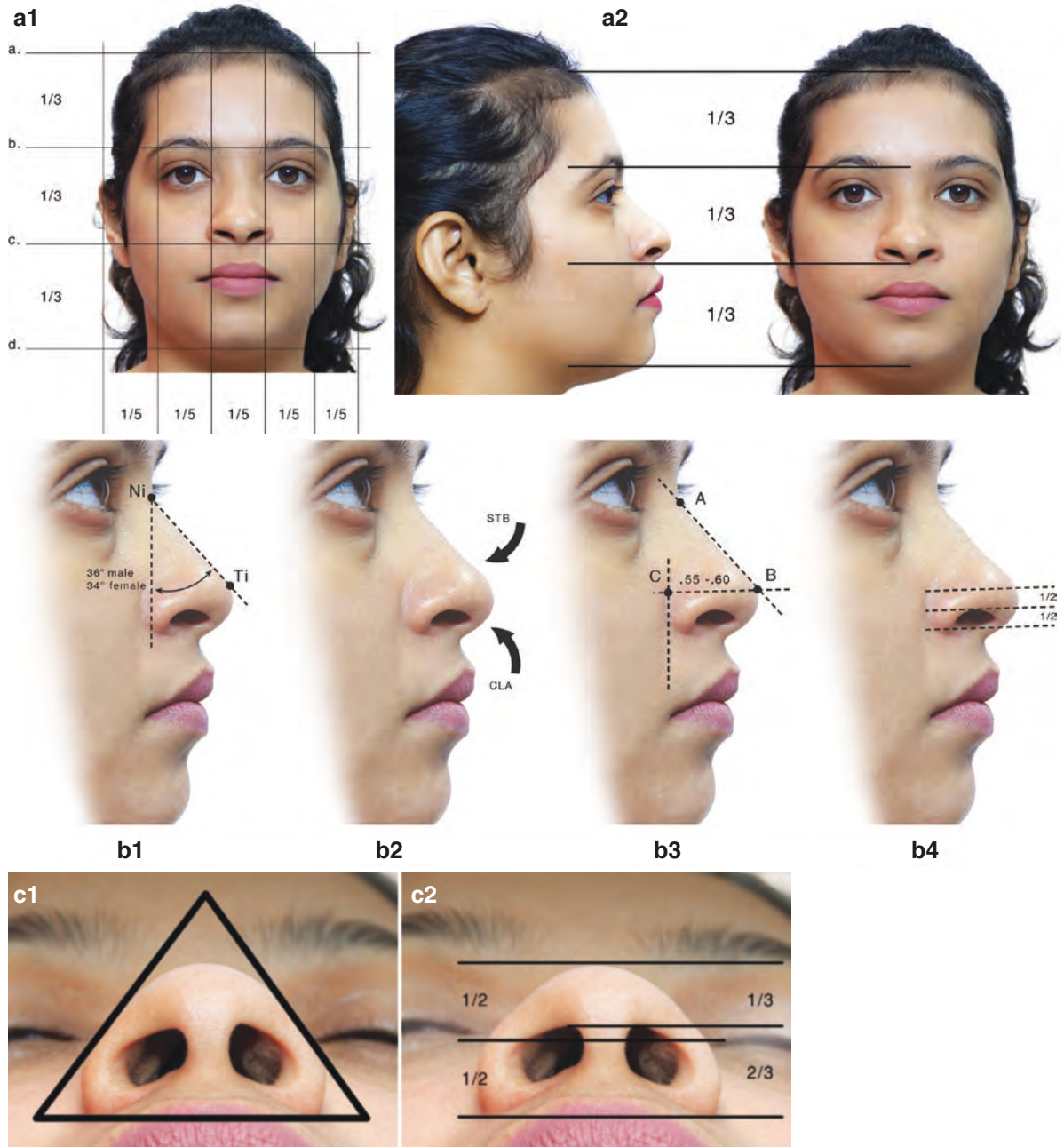
Existing breathing difficulty or any allergy-related symptoms such as rhinorrhea, sneezing, watery eyes, itching and loss of sense of smell and taste are observed. Majority of successful rhinoplasties are reductive in nature; an undetected or uncorrected underlying airway compromise may cause further deterioration and convert an aesthetic concern to a functional predicament. If the presence of any sinus

infections and headaches is not recorded preoperatively, the patient may attribute these conditions to rhinoplasty [10].

38.3.1 Examination of the Face

The face in the frontal view is divided into thirds and fifths for assessment of proportion and harmony of various structures (Fig. 38.11a, b, c). In the upper third, the intercanthal distance

and interpupillary distance is important in assessing the nasal bones, dorsum and radix. For a proper facial balance, the malar bone, maxilla, mandible and the nasal bones should be in an optimum spatial relationship. The length of the upper lip, its position during rest and smile, upper incisor show and its proportion in relation to the rest of the face are also assessed. The nose and chin may have a paradoxical relationship whereby a patient may have an overprojected nose and at the same time an underprojected chin and vice versa.



©Association of Oral and Maxillofacial Surgeons of India

Fig. 38.11 (a)–(c) Examination of face and nose; frontal, lateral, basal. (b1) Ni - Ideal nasion, Ti Ideal tip. (b2) STB - Supra Tip Break, CLA - Columella Labial Angle. (b3) Nasal Length is measured from nasal radix to nasal tip (A–B), Nasal projection (C–B) is length from Naso-labial junction to nasal tip. The ratio between AB and CB (Goode’s Ratio) should be ideally 0.55 to 0.60

38.3.2 Examination of the Nose

Visual analysis of the nose along with careful palpation allows the surgeon to assess the morphology and thickness of the skin and soft tissue envelope.

Frontal, profile and basal views should be used to assess the various components of the nose discussed above, individually.

38.3.3 Photographic Assessment

Patient's photographs are an important component of preoperative analysis and planning of the procedure. In addition, pre- and post-operative photographs are crucial for outcome monitoring and are indispensable from a medicolegal point of view [11]. With the advent of 3D imaging, image fusion and photogrammetry, preoperative and postoperative features can be compared in all dimensions [12].

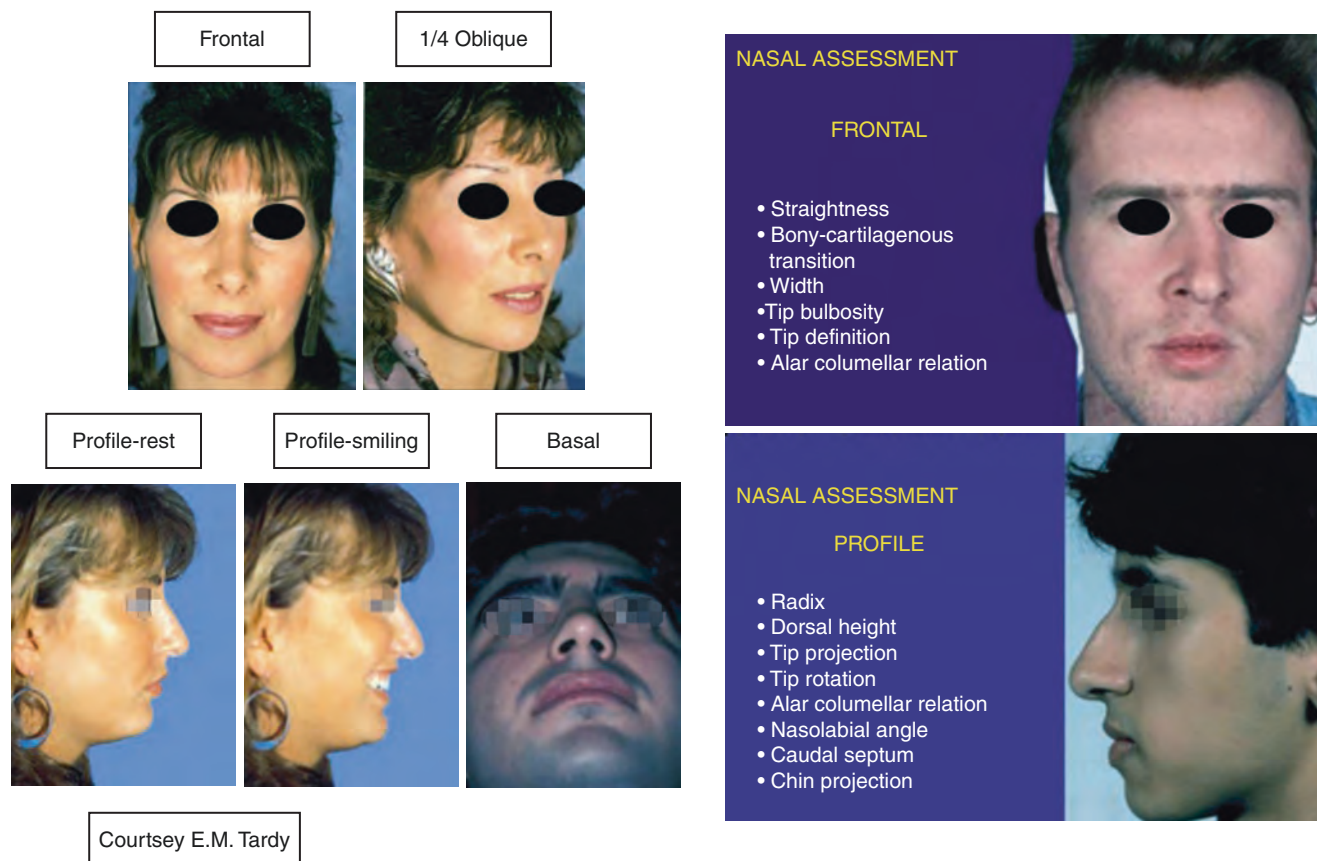
There are four important photographic views that are used for analysis of the nose, namely, frontal, basal, lateral (at rest and smiling) and oblique views (Fig. 38.12). Photographs

are standardised in relation to the Frankfurt horizontal plane. All four views are evaluated for the assessment of the facial horizontal thirds and vertical fifths. The quality of skin (thickness and Fitzpatrick type) and facial symmetry are also studied using all the views. The basic focus lies in the study of the loco-regional anatomy and the inter-relationships of the structures. The pictures are evaluated to assess any discrepancies in size, deviations or dorsal hump that may be immediately evident and recordable.

• Frontal view

The length, width and the tip characteristics are well observed on the frontal views. The width is individually assessed in the upper, middle and lower thirds of the nose. Frontal views also show a straight or a crooked nose. The presence of a dorsal hump or a saddle deformity is noted as these may provide an illusion of the nose being narrow or wide, respectively. The presence of a truly wide nose may also demonstrate features of pseudo/true hypertelorism.

The dorsal aesthetic lines should be studied in detail. They follow the eyebrows across the radix and along the dorsum to end at the tip defining points on either side.



©Association of Oral and Maxillofacial Surgeons of India

Fig. 38.12 Photographic analysis

The lines should be almost parallel with a smooth divergence at the brow but without any visible or perceptible breaks.

The nasal tip is assessed for symmetry and definition. The tip is also assessed for features of boxy appearance, bulbosity or bifidity. The alar base, ala and columella are also evaluated. The formation of a gentle “gull in flight” form should be appreciated for the relationship of the ala and the infratip lobule. An exaggerated curve may be indicative of a retracted ala or a plunging lobule. The position and insertion of both ala and their symmetry and direction are also noted.

- **Basal view**

Assessment should include the study of lobule, columella, ala and the alar base. Emphasis should be placed on the evaluation of the triangular shape of the nasal base, symmetry and the ratios, namely, the columella/lobule ratio and the lobule to ala ratios. The nasal base should present as an isosceles triangle with a rounded apex. The alar sidewalls should demonstrate a gentle flare. Poor triangular form or a trapezoidal form is indicative of a broad dome. Nostril symmetry and the angulations are studied next. The nostrils are angulated at 30–45° to the midline and are pear shaped. The caudal septum is assessed for straightness and its position in relation to the maxillary crest and anterior nasal spine. The alar base width, flare and insertions are also assessed in this view.

- **Profile view**

Key points that need to be evaluated from the lateral view include (1) a dorsal profile that may demonstrate a saddle/hump and the supratip break, (2) evaluation of the chin and mentolabial sulcus, (3) projection and rotation of the nasal tip, (4) nasal length, (5) assessment of the radix and (6) columellar show with double break.

The ratio of nasal projection is evaluated by the method of Goode. The ideal ratio between the line joining the tip defining point and alar-facial groove tangent, to the line dropped from the nasion to the alar facial groove should be between 0.55 and 0.60. Rotation of the nasal tip is approximately considered 90° in Caucasian males and between 90 and 95° in Caucasian females.

The length of the nose is relative to the person’s facial profile and general stature. It may be categorized as the central nose length from the nasion to the nasal tip and lateral length from the nasion to the alar rims. A short or long lateral length may reflect as retracted or hooded ala, respectively. The nose may also show a relative increase or decrease in length depending on the depth of the radix. A deep radix may make the nose look short while a shallow radix makes the nose appear long.

The columella is also assessed for over- and undervisibility with the evaluation of a columellar double break that is formed by the junction of the medial and intermediate crus.

- **Oblique view assesses the volume of the tip lobule and Brow tip aesthetic line.**

Assessment of the oblique view may not provide objective details. However, the nose is most viewed at this angle thus making it an important view to assess the aesthetic balance of the face and nose. Important features that need to be assessed in this view include soft tissue facets, lateral aspect of the nasal bones, nasal length, dorsal contour and tip projection.

38.3.4 Investigations

- Inspection with speculum will demonstrate any septal curvatures, angulations or spurs.
- *Computed tomography* is helpful if sinus pathology is suspected.
- *Endoscopy* of the middle meatus should be done to rule out clinical evidence of sinus disease.
- *Tests for functions of internal nasal and external nasal valves* should be done. Careful observation of the nasal valves while the patient is asked to inspire will provide a significant amount of information. A speculum or Q tip facilitates proper examination. Cottle’s Maneuver helps in localizing obstruction due to nasal valve dysfunction.
- *Acoustic rhinometry* is a recently developed objective technique for assessment of geometry of the nasal cavity. The technique is based on the analysis of sound waves reflected from the nasal cavities. It measures cross-sectional areas and nasal volume.
- *Rhinomanometry* has also been widely accepted and used as an objective method to assess nasal patency. However, these tools may not necessarily show clinical correlation [13].

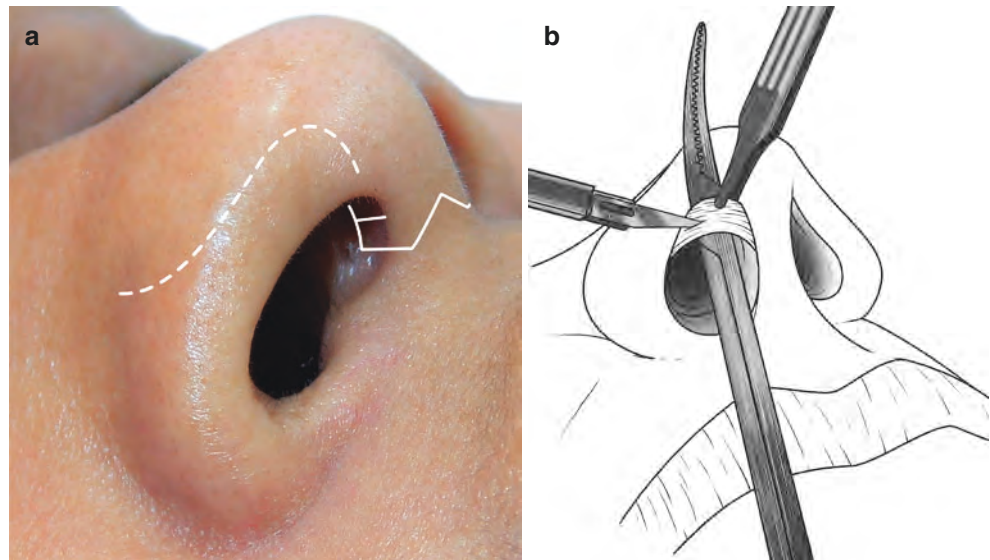
38.4 General Operative Techniques

38.4.1 Surgical Approaches for Rhinoplasty

Rhinoplastic approaches: (1) open approach or the open structure rhinoplasty approach and (2) closed or the endonasal approach.

Open approach involves an external cutaneous incision while the closed approach involves intranasal incisions only (Fig. 38.13a, b).

Fig. 38.13 Open (a) Vs Closed (b) approach



©Association of Oral and Maxillofacial Surgeons of India

Choice of incision is based on the clinical problem to be corrected and the exposure required. The ideal incision must enable adequate and easy access to the nasal architecture without compromising the nasal structures. The differences between the different types of incisions are highlighted in Table 38.1.

A. Open structure rhinoplasty

The open structure approach is employed when extensive reconstruction is required. There is more emphasis on the preservation and realignment of structures of the lower third of the nose and also achieving balance of the nasal “tripod”.

The open approach involves the use of a marginal and mid-columellar incision (Fig. 38.14b)

- *Marginal incision*
- The incision is placed along the caudal margins of the LLC, starting at the caudal margin of the medial crus, running along the entire dome and extended laterally along the caudal margin of the lateral crus.
- *Columellar incision*
- This is a transverse mid-columellar incision extending across to connect the marginal incisions on either side. Numerous modifications of the columellar incision have evolved over a long period (Fig. 38.15a, b, c).
 - Rethi transcolumellar incision 1931 (across the apex of the nostril aperture)
 - Sercer “nasal decortication” approach—1957
 - Bardach columellar base incision extending into prolabium (reserved for cleft rhinoplasty)

- Goodman modification mid columellar ‘V’ facing upwards 1952
- Johnson & Toriumi inverted ‘V’ midcolumellar incision
- Stair-step mid columellar incision (Bahman Guyuron)

The **indications** for the open structure approach are highlighted in Box 38.3.

B. The endonasal approach (Fig. 38.14a)

Nondelivery/Partial delivery and delivery approaches (Fig. 38.16a, b).

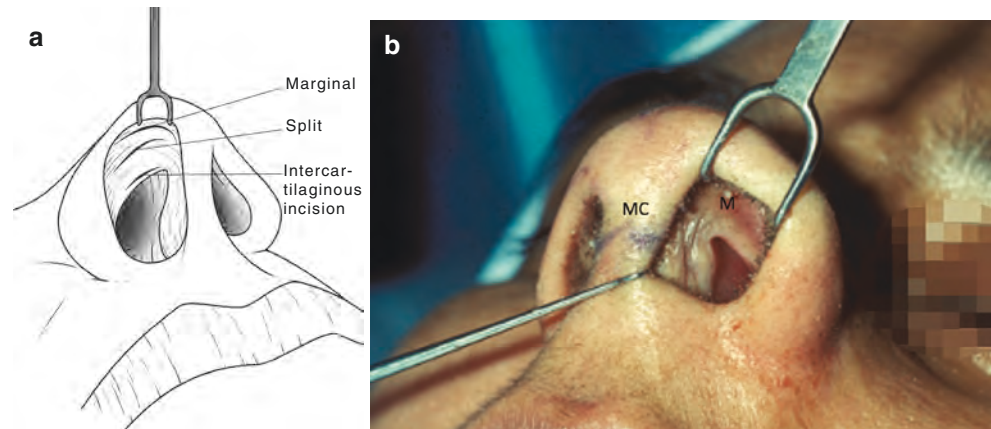
1. **Nondelivery approaches are employed when** minimal reduction of the lateral crus or mild cephalic rotation of the tip complex is indicated.

The technique in turn may involve either the cartilage splitting approach or the retrograde eversion approach.

- The *cartilage splitting method* involves a transcartilaginous incision through the most cephalic portion of the lower lateral cartilage that needs to be resected. However, extreme care is taken to preserve at least 8 mm of sound LLC to prevent structural compromise.
 - The *retrograde eversion method* is difficult for beginners and hence not favoured in current practise, and most surgeons today prefer to use the delivery method.
2. The technique for the **delivery method** encompasses two incisions: the first inter-cartilaginous incision and the subsequent marginal incision to mark the chondrocutaneous unit of the LLC. The nonvestibular side of the LLC is

Table 38.1 Differences between the different types of incisions

	Open/external	Closed/endonasal	
		Nondelivery Cartilage splitting Retrograde eversion	Delivery
Incision	<ul style="list-style-type: none"> • Marginal • External (columellar) 	<ul style="list-style-type: none"> • Transcartilaginous (Cartilage splitting) or • Intercartilaginous (Retrograde eversion) 	<ul style="list-style-type: none"> • Marginal • Intercartilaginous
Exposure	Extensive	More of LLC exposure Less of tip exposure	Increased dome and interdomal visibility
Indications	<ul style="list-style-type: none"> Marked asymmetry Secondary rhinoplasty Need for structural grafting Post traumatic nasal deformity Nasal valve correction 	<ul style="list-style-type: none"> Minimal tip correction Access to dorsum and middle vault Volume reduction of LLC Septal surgery Bony and cartilaginous hump removal 	Allows more delicate tip work than the nondelivery approach septal surgery
Advantages	<ul style="list-style-type: none"> • Excellent visual control of entire nasal framework • Enhanced surgical access • Accurate structural grafting under direct vision • Ideal for demonstration and teaching • Predictable results 	<ul style="list-style-type: none"> Less invasive Less disruption of support mechanisms of nasal tip May be used for septal cartilage harvesting 	
Limitations	<ul style="list-style-type: none"> • External (transcolumellar) scar • Destabilization of tip support • Protracted edema • Risk of columellar necrosis (poor operative technique) • Sensory disturbances at the tip area 	<ul style="list-style-type: none"> Steep learning curve No binocular vision Essential ENT experience Limits assistant's view of exposure Difficult to perform complex nasal tip surgery Spreader-grafts are difficult/impossible 	

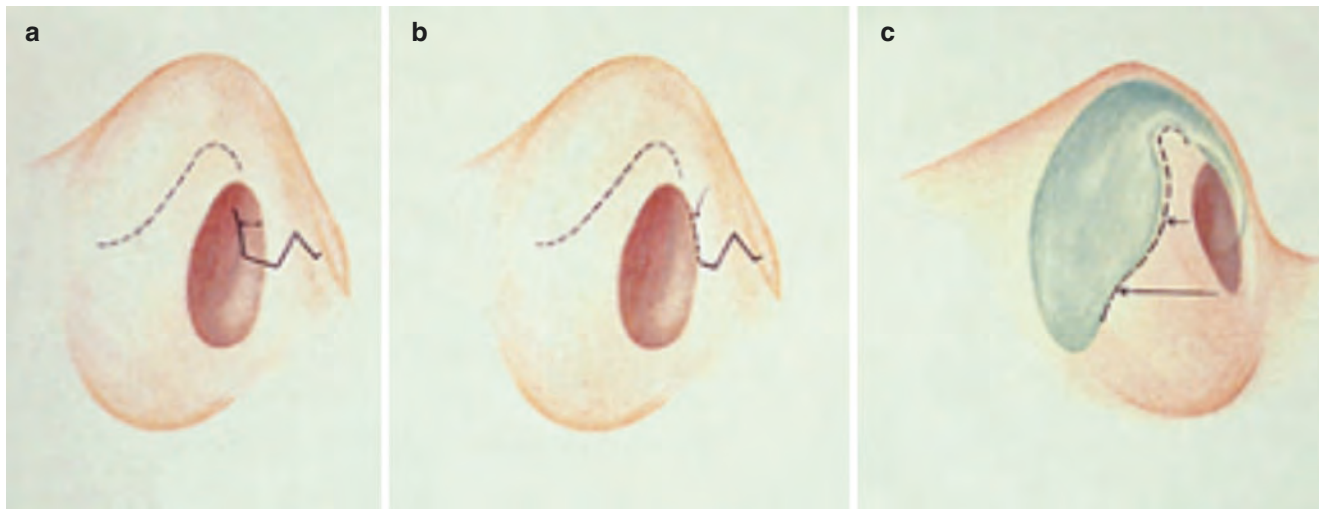
Fig. 38.14 Incisions for rhinoplasty: (a) closed and (b) open approach (MC- mid columellar, M- Marginal)

©Association of Oral and Maxillofacial Surgeons of India

then dissected off the overlying SSTE permitting the delivery of the LLC chondrocutaneous unit as a bipediced flap. Improperly positioned intercartilaginous incision may predispose to scarring at the valve area.

Incisions for the endonasal approach

- Intercartilaginous (limen-vestibular) incision
- Intracartilaginous (trans-cartilaginous/cartilage splitting) incision
- Infracartilaginous (alar marginal) incision
- Septal transfixion incision
 - Hemi-transfixion
 - Bilateral transfixion—partial/full
- Pyriform rim incisions for access to the lateral nasal wall
- Lateral nasal vestibular incisions for access to the paranasal premaxillary area
- Endonasal transmucosal medial osteotomy facilitated high up in the nasal vault.



Courtesy Rollin Daniel

©Association of Oral and Maxillofacial Surgeons of India

Fig. 38.15 (a–c) Modifications of columellar incision

Box 38.3 Indications for open Rhinoplasty

- Secondary/revision rhinoplasty
- Post-traumatic nasal deformity
- Cleft nasal deformity
- Need for structural grafting
- Septal reconstruction
- Nasal valve surgery
- Dermoid cyst excision

Indications for the endonasal approach

- Symmetrical anatomy
- Good size nostrils
- Principal deformity at the nasal vault
- Ability to insert cartilage grafts

The endonasal approach is, however, unsuited for the novice surgeon and does depend on the surgeon's experience and prior training in Rhinoplasty for optimal outcomes.

38.4.2 Grafting in Rhinoplasty

Reduction rhinoplasty can weaken the underlying nasal tip framework with subsequent buckling and late structural deformity. Cartilage grafting during primary and revision

procedures helps to prevent such a secondary deformity [14–17]. An open technique is preferred as it offers better visualization for placement of grafts. The grafts used in rhinoplasty can be summarised as follows (Fig. 38.17a, b) (Tables 38.2 and 38.3):

38.4.3 Septoplasty

38.4.3.1 Deformities of Nasal Septum

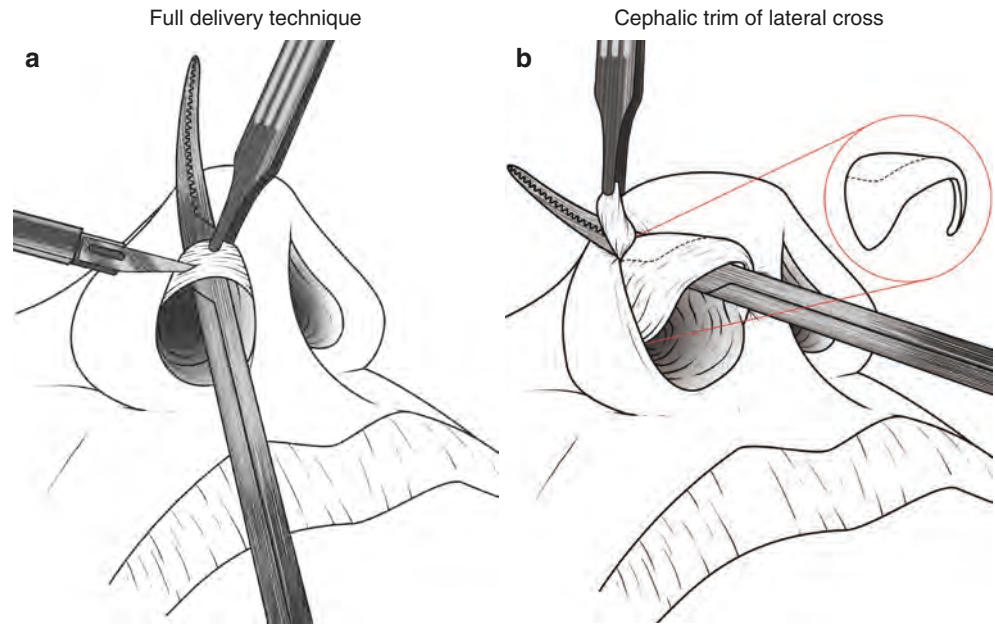
Deformities of the nasal septum may either be congenital or acquired. They are classified as shown in Box 38.4.

Septal deformities depend on alterations in the growth and direction of growth of the septal cartilage.

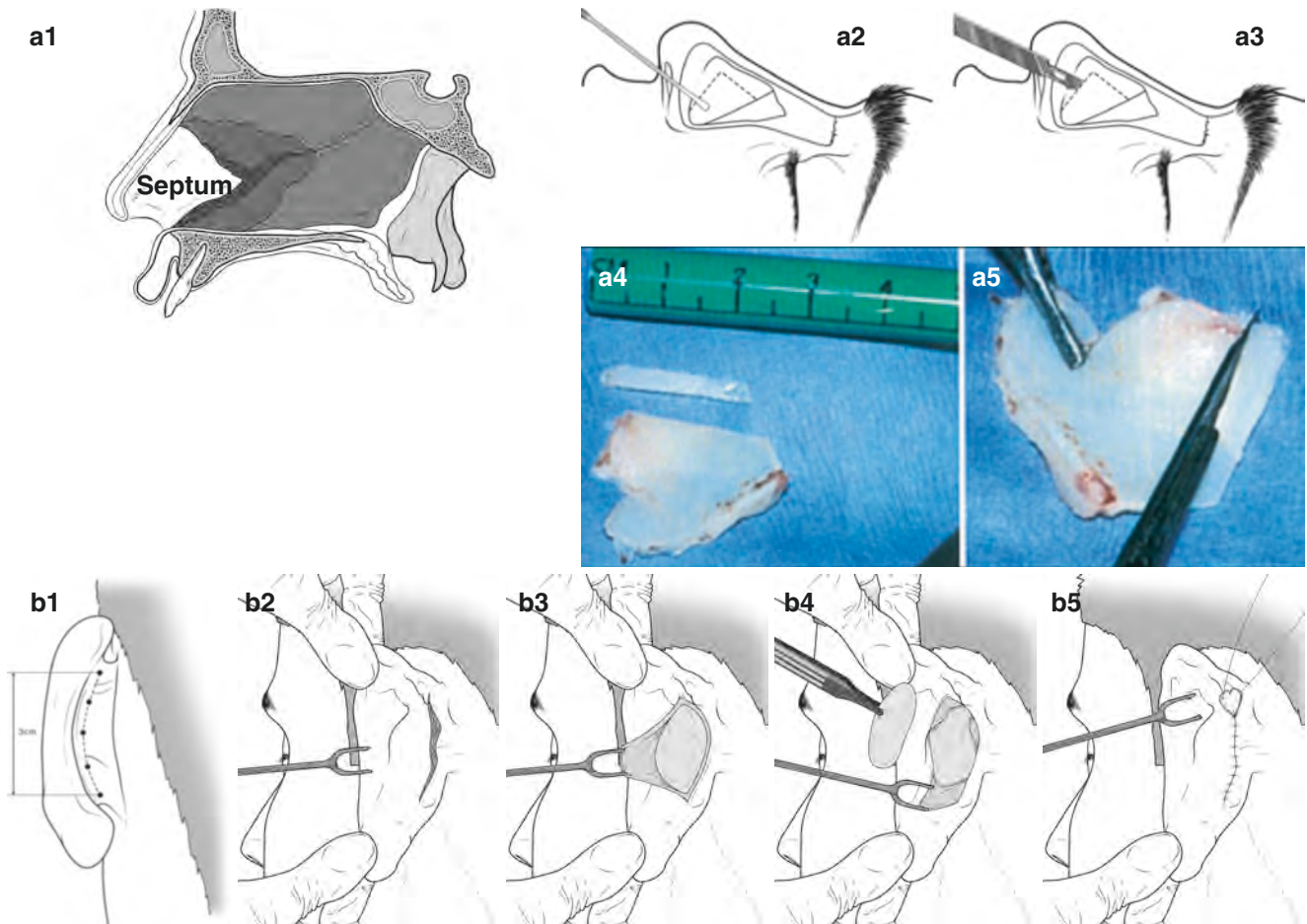
Deformities of the nasal septum may present clinically (Fig. 38.18a, b).

1. Dorsal excess may present as a tension nose
2. Dorsal deficiency causes concave or Saddle nose
3. Caudal excess causes increased columellar show
4. Caudal deficiency leads to columellar retraction
5. Lateral angulation of the septum is seen as a bent nose
6. Both lateral & AP curvatures give a twisted nose/ crooked nose
7. Septal perforations and collapse may lead to a variety of deformities

Fig. 38.16 (a, b) Nondelivery vs. delivery method



©Association of Oral and Maxillofacial Surgeons of India



©Association of Oral and Maxillofacial Surgeons of India

Fig. 38.17 Sources of cartilage graft; (a) septal cartilage graft (a1) anatomy of septum (a2) marking for cartilage harvest preserving L shaped dorsal strut (a3) incision for cartilage harvest (a4) harvested cartilage (a5) carving of harvested cartilage and (b) Harvest of auricular cartilage; (b)- marking on the ear (b2)- incision (b3)- reflection of sub perichondrial flap to expose cartilage (b4) cartilage harvest (b5) closure of donor site

Table 38.2 Autologous graft materials

<i>Autogenous grafts</i> —Donor site morbidity, increased operating time, predictable long-term results, minimal risk for extrusion and infection	
Nasal septal cartilage	Considered to be the best grafting material as it is easy to harvest and contour
	Intrinsic anatomy of septal cartilage [firmness, resiliency, flatness] provides optimal aesthetic results
	Sufficient rigidity to provide structural support
	No donor site morbidity with excellent long-term results
	Insufficient when large volumes are needed/previous septal surgery
Auricular/conchal cartilage	Easy to harvest but difficult to contour due to its brittle nature
	Low strength and hence provides poor structural support
	Low donor site morbidity and with good long-term results
	Intrinsic anatomy [curved shape with elastic memory] of auricular cartilage makes it difficult to provide optimal aesthetic results
	Used if nasal septal cartilage is not adequate e.g. extensive revision cases and simultaneous multiple grafting procedures
	Useful when elasticity is needed e.g. lateral crus reconstruction
Costochondral grafts	Insufficient when large volumes are needed
	Abundant supply
	Sufficient rigidity to provide structural support
Temporalis fascia	Can be reharvested
	Used for cartilage-fascia grafts in primary and revision rhinoplasty. For smoothing contour defects and irregularities on the nasal dorsum.
	Easy to harvest
	Adequate size available
	Shows minimal resorption and is stable in followup
Perichondrium over rib	Used for repair of septal perforations and for smoothing irregularities over the dorsum
	Easily available and harvested contiguous with rib cartilage which is a commonly used graft in rhinoplasty

Table 38.3 Alloplastic graft materials

<i>Alloplastic grafts</i> —No donor site morbidity, reduced operating time, unpredictable long-term results and increased risk of extrusion and infection	
Silicone	Pliable, elastic solid that causes little tissue reaction
	Easy to handle, comes in prefabricated shapes—most commonly used alloplastic graft material
	Increased risk of displacement/extrusion as its nonporous nature prevents surrounding tissue in-growth, instead, leading to the formation of a fibrous capsule
	Easy to remove even after a long time as a fibrous capsule will form around the implant, without ingrowth in to the graft
	Asymmetric contracture of the capsule around the implant can deform the implant over time
	Low strength and hence provides poor structural support
	Preferred in Asians with thicker dorsal nasal skin
Medpor [high density polyethylene]	Easy to carve and bend due to thermoplastic property
	Poor aesthetic results and comfort due to its stiffness
	Sufficient rigidity to provide structural support
	Minimal risk for displacement due to its porous nature with subsequent ingrowth of surrounding fibrovascular tissue
	Difficult to remove in the long term as there will be extensive tissue ingrowth
Gore-tex [expanded poly-tetra-fluoro-ethylene (PTFE)]	Tends to shed particles, when implanted in stress-bearing and mobile areas may cause a chronic inflammatory response
	Porous implant composed of carbon and fluorine molecules with pores
	Second most widely used alloplastic implant, after silicone
	Better comfort and aesthetics due to its softness
	Minimal risk for displacement due to its porous nature with subsequent ingrowth of surrounding fibrovascular tissue
	Poor long-term aesthetics as it decreases in volume over time
<i>Injectable filler materials</i> —No donor site morbidity; reduced operating time; unpredictable long-term results and increased risk of extrusion, infection and embolization	Difficult to remove in long term owing to extensive tissue ingrowth
	Low strength and hence provides poor structural support
	Bovine collagen, human-derived collagen, hydroxyapatite microspheres, hyaluronic acid
	Mainly used for minor augmentations
	Necessary to overaugment by 20–30% to compensate for long-term absorption
	Provides poor structural support
	High complication rate including persistent redness, contour irregularity, swelling and necrosis of surrounding dermis or soft tissue, hypersensitivity reactions, extrusion
	Patients may object on religious grounds

Box 38.4 Classification of septal deformities**Congenital:**

- Syndromic
 - Cleft lip and palate
- Congenital syphilis

Acquired:

- Developmental: midline dermoid cyst, short nose/long nose
- Post traumatic: bent nose/crooked nose
- Iatrogenic
 - Incorrect or aggressive rhino/septal surgery. Lefort I maxillary impaction with inadequate trimming of septum
- Cocaine misuse: destruction of cartilage and bony septum

38.4.3.2 Sequencing for Treatment

The sequence to be followed for planning a proper septoplasty includes

1. Establishing an accurate diagnosis. Apply Mladini classification for septal deformities (See additional Reading)
2. A thorough external and internal examination of the nose
3. Internal examination should include (1) anterior rhinoscopy and (2) nasendoscopy
4. Imaging of the nose, septum and the paranasal sinuses is mandatory. This should include CT scans with both soft tissue and bony windows [18].
5. It is preferable to perform the surgery “in conjunction with ENT colleagues”
6. Gross iatrogenic nasal deformities need careful evaluation of previous surgical records before treatment planning
7. Informed consents to be obtained for the harvest and use of grafts (Septum, Concha or Rib cartilage)
8. Care should be exercised to preserve the integrity of the turbinates and the internal nasal valve.

38.4.3.3 Surgical Approaches

Septoplasty may be performed in conjunction with a formal rhinoplasty using an open or closed approach.

Closed approaches for septoplasty include;

1. Endonasal caudal vestibular access via a right or a left hemi-transfixion incision or
2. Bilateral septal transfixion incision [19, 20].

38.4.3.4 Surgical Technique (Fig. 38.19a, b, c)

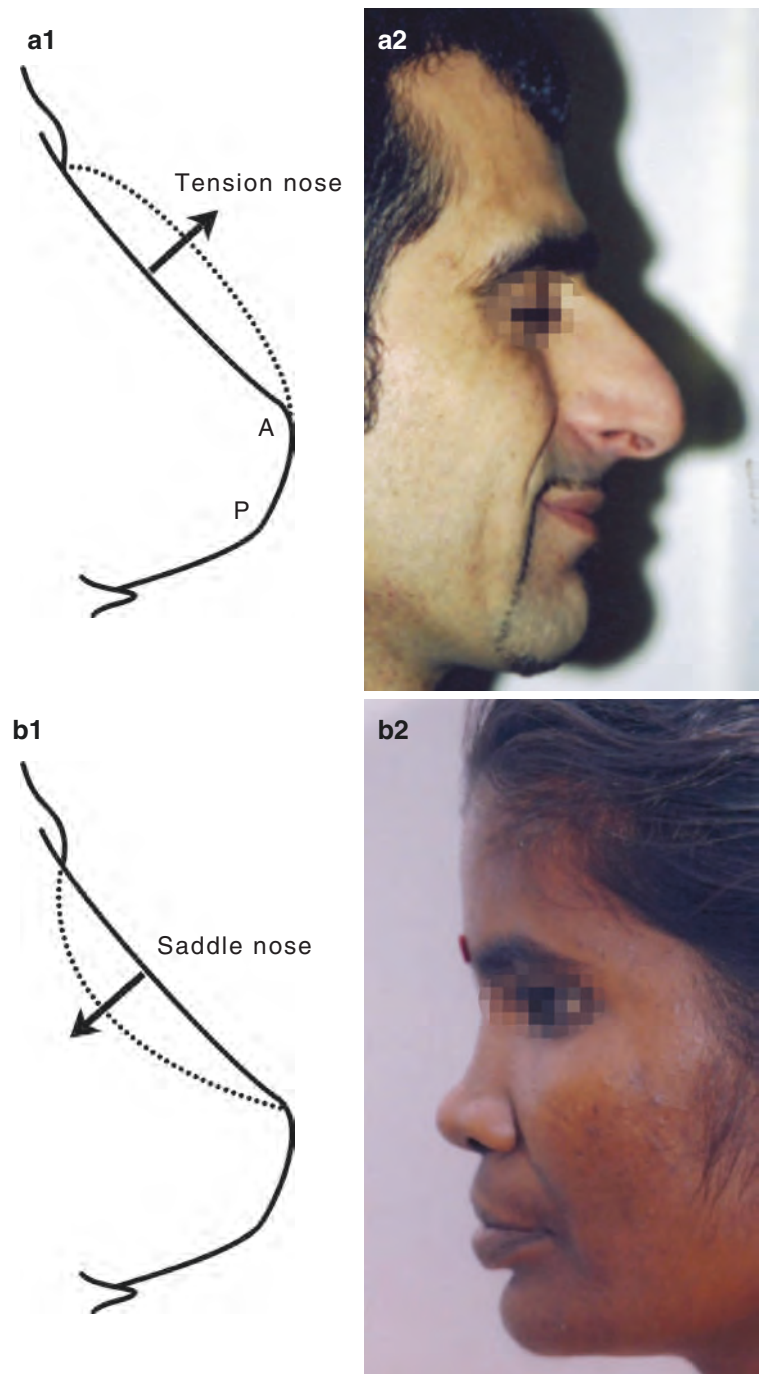
The local anaesthetic solution is infiltrated with adrenaline for optimal haemostasis. This not only provides a clear field for surgery but also aids in developing planes by the process of hydrodissection. An incision is made at the caudal margin of the septal cartilage, which may be unilateral or bilateral. Cautious, careful, unhurried dissection in the correct anatomical plane is done, using sharp precise instrumentation (Cottle/Masing, Freer or Joseph’s elevator). It is imperative to identify and stay in a bloodless sub-mucoperichondrial plane. The light blue colour of the septal cartilage ensures the correct plane of dissection. An anterior tunnel is first made, followed by an inferior tunnel to expose the entire septum. The plane is then expanded and separated further with a Killian forceps. This offers bilateral exposure of the dissected tunnel and the septum. Sharp curvatures, angles and fracture lines are negotiated carefully also bearing in mind that the transition zone between the mucoperichondrium and the mucoperiosteum is an area vulnerable to tears. Tears over the mucoperichondrium require careful repair with vicryl sutures on a round body needle. However, tears in the inferior tunnel overlying bone need not be sutured and may act as drains. The flap elevation is extended posterior to chondrovomerine and chondroethmoid junctions for complete exposure of the bony septum.

Bony spurs or angulations and bends are identified, which may contribute to airway block. The osteocartilaginous junction is then separated to free the septum in the posterior aspect. Takayashu forceps are used to nibble away any bony/cartilage spurs. This may also be performed using thin chisels and osteotomes. Buckling of the septum may be corrected by resection of overhanging cartilage in the caudal aspect. Adequate relief thus allows the passive return of the septum to midline. Measures such as scoring, suturing or the use of PDS sheets/cartilage grafts may be required to correct and straighten residual curvatures. Harvest of septal cartilage may be performed at this juncture and should be done posterior to the key area (imaginary vertical line joining the tip of the nasal bone and the anterior nasal spine). Stabilisation to the midline is achieved by the use of a PDS suture anchoring the dissected septum to the anterior nasal spine. The flaps are reapposed with one or two transfixion sutures to prevent septal haematoma. Nasal packing is outdated and has been replaced by silastic sheets and intra-operative control with Merocel packs.

Advantages of the endonasal approach include

1. Minimal trauma to local tissues
2. Reduced post-surgical oedema and
3. A-faster-recovery-to-normalcy

Fig. 38.18 Deformities of nasal septum; (a) tension nose and (b) saddle nose



©Association of Oral and Maxillofacial Surgeons of India

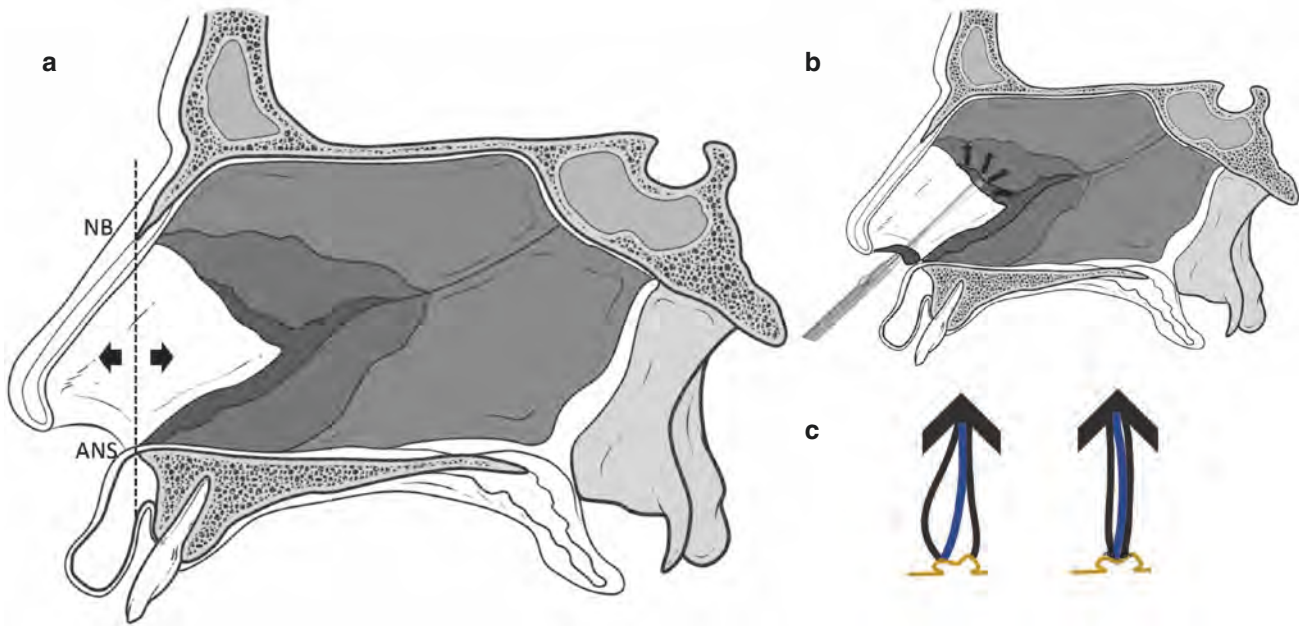
Disadvantages of the endonasal approach are

1. Steep learning curve
2. Limited exposure & visualisation (headlight required)
3. Limited visualisation for the assistant
4. Difficult to place spreader grafts
5. Contour irregularities at the dorsal edge
6. Septal malposition/perforation

7. Increased risk for secondary deformities like saddling

38.4.4 Nasal Osteotomies

Nasal osteotomies are often required during correction of deformities of the nose as well as an adjunct to procedures which involve correction of the osseocartilaginous vault.



©Association of Oral and Maxillofacial Surgeons of India

Fig. 38.19 Septoplasty intra-operative steps. (a) the part of the septum anterior to the line dropped from the tip of nasal bone (NB) to the anterior nasal spine (ANS) has to be preserved. (b) Dysjunction of the cartilaginous septum from the bony septum. (c) Septal repositioning with sutures to the midline crest of the maxilla

38.4.4.1 Indications for Nasal Osteotomies

1. Close an open roof after dorsal hump removal
2. Correction of a deviated bony nasal vault (crooked nose/bent nose)
3. Correction of concave or convex nasal bones
4. Reduce or narrow bony base width
5. Mobilise malunited fractured nasal bones prior to reduction

Different types of nasal osteotomies (Fig. 38.20a, b) are utilised for a variety of clinical indications [21, 22]. They are enumerated in Box 38.5.

38.4.4.2 Armamentarium for Nasal Osteotomies

- Chisels/Osteotomes
 - Straight osteotomes—2 mm microosteotome
 - Curved osteotomes
 - Guarded osteotomes—Nievert, Silver
 - Angled blade osteotomes—Murray-Parkes
 - Notched osteotomes—Walter
- Power instruments
 - Oscillating/reciprocating saws
 - Piezo saw

38.4.4.3 Surgical Technique

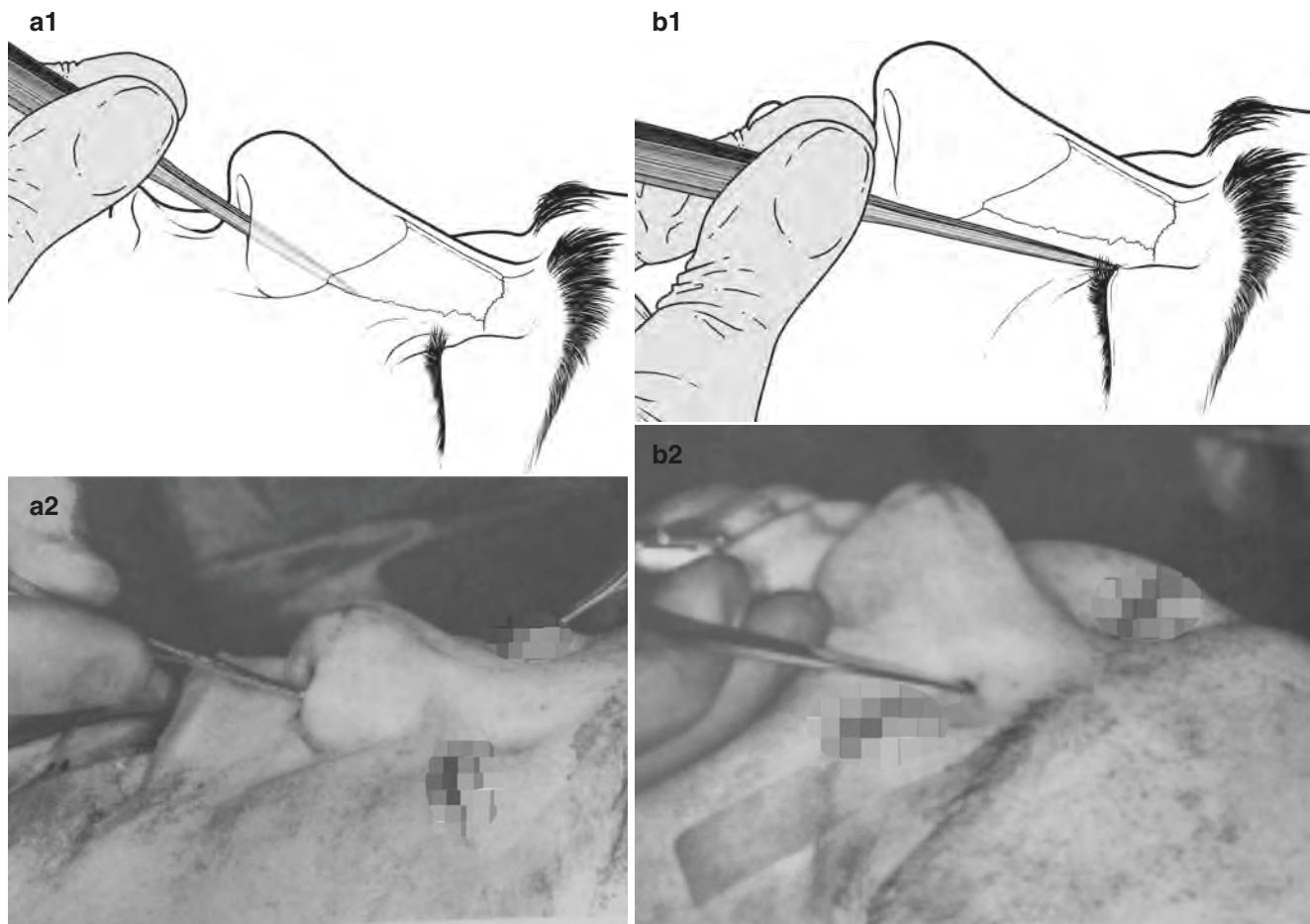
The different techniques for performing nasal osteotomies are (1) endonasal, (2) percutaneous, (3) endoral and (4) nasofrontal

Percutaneous technique (Fig. 38.21a, b, c)

The percutaneous technique involves the completion of a lateral osteotomy and a transverse root(superior) osteotomy. The local anaesthetic solution is infiltrated with adrenaline 10–15 min earlier for good haemostasis.

The sites of the lateral and superior osteotomies are marked on the skin. The cephalic end of the cross-over of these two osteotomies should be kept no higher than the level of the intercanthal line.

A small 2–3 mm stab incision is made on the skin at the middle of the lateral osteotomy marking. The incision is deepened down and to bone. The osteotome is swept along the entire length of the marking to provide good release of the skin and subcutaneous tissue and keep the angular artery away from the line of osteotomy. The osteotome is then positioned supraperiosteally at 2 mm intervals and struck with a mallet to produce an interrupted line of punch holes. The osteotomies are started at the pyriform rim and continued superiorly to the nasofrontal junction. The same technique is followed for the transverse root(superior) osteotomy. The contra-lateral nasal wall is osteotomised in a similar



©Association of Oral and Maxillofacial Surgeons of India

Fig. 38.20 Types of osteotomies. (a) Endonasal and (b) Percutaneous

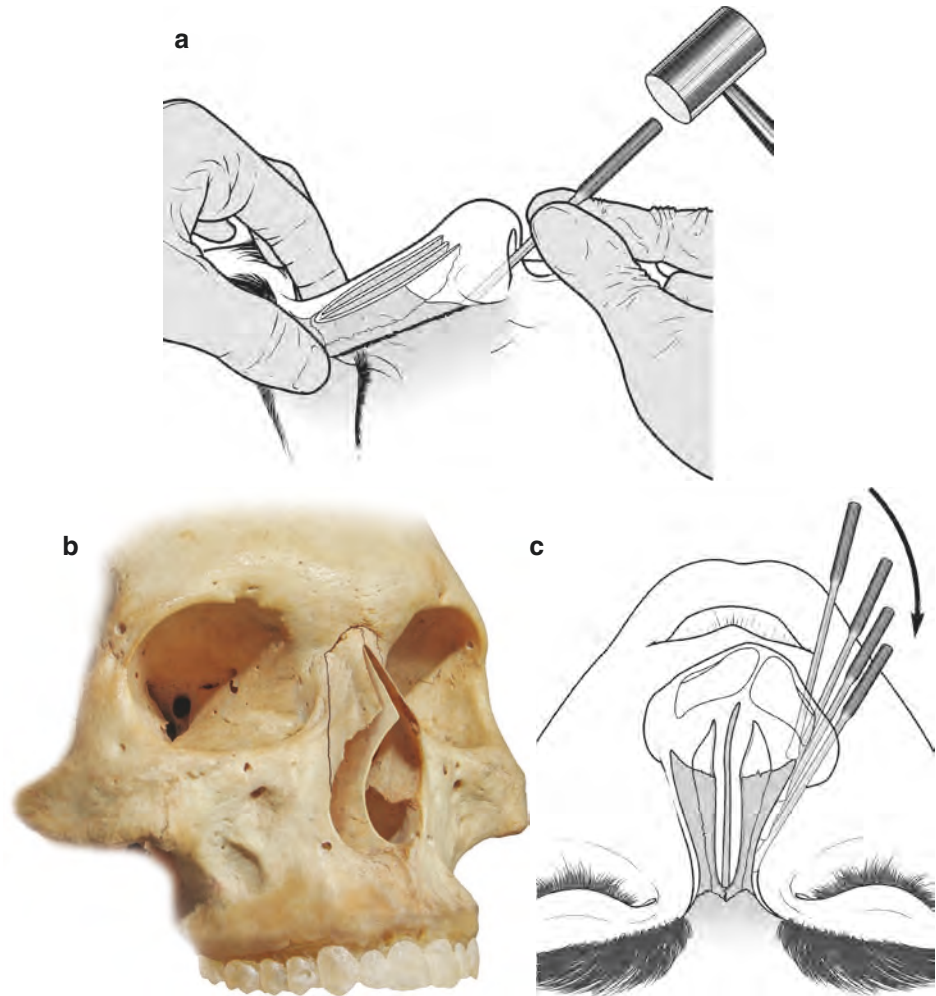
Box 38.5 Osteotomies types

- Lateral osteotomy
 - Low to high
 - Low to low
- Medial osteotomy
 - Fading paramedian
 - True median
- Superior osteotomy
 - Transverse root
- Intermediate osteotomy
 - Vertical
 - Horizontal
- Fragmentation/comminution (largely outdated)

fashion. Once this is completed, the nasal bones are held with firm/controlled pressure between the thumb and the fore-fingers of both hands over a gauze square and then fractured along the already osteotomised punch holes. Moderate pressure over the wound helps with haemostasis and prevention of ecchymosis. No sutures are required and the skin is dressed with a Steri-Strip.

Complications include comminution, unpredictable fracture line, loss of lateral wall support, avulsion/displacement of upper laterals, step deformity, residual deformity and failure to fracture/mobilise nasal bones.

Fig. 38.21 Steps in nasal osteotomy. (a) Start of the lateral osteotomy. (b) Osteotomy marking on skull. (c) Movement of the osteotome for lateral osteotomy



©Association of Oral and Maxillofacial Surgeons of India

38.5 Surgical Management of Basic Nasal Deformities

38.5.1 Dorsal Hump Deformity

The dorsal hump is the most common problem for which a patient may seek rhinoplasty. Based on the anatomical units involved, three main types of dorsal hump may be identified [23, 24];

1. Osseous/bony hump that exclusively involves the bony vault,
2. cartilaginous hump that involves the cartilaginous middle vault with septal and upper lateral cartilages and
3. the osseocartilagenous hump that is a combination of the two.

38.5.1.1 Types of Dorsal Humps

Dorsal humps can also be categorised as true and pseudo-humps. True humps may occur isolated or may occur in con-

junction with other nasal deformities. The pseudohump may produce a relative appearance of a dorsal hump, while in reality, the appearance may be due to a high anterior septal angle, supratip prominence or tip ptosis (Box 38.6).

38.5.1.2 Clinical Assessment of a Dorsal Hump

(Fig. 38.22a–d)

- Palpation of nasal bones, normal, long or short
- Ascertain area of hump requiring reduction
- Dorsal line—imaginary line from the radix extended along the nasal dorsum
- Assess if tip projection is adequate; reduced or increased, prior to hump reduction
- Assess if tip support is adequate; weak or strong, prior to hump reduction

38.5.1.3 Armamentarium for Dorsal Hump Reduction

The armamentarium required for dorsal hump reduction are shown in Box 38.7.

Box 38.6. True vs. Pseudo humps

True dorsal hump	Pseudo hump
Hump associated with the following clinical situations <ul style="list-style-type: none"> • high dorsum • low dorsum • short nasal bones • wide bony base • narrow bony base • deviated nasal bones • cleft nose deformity • under-projected nasal tip • over-projected nasal tip • short nose • long nose 	<ul style="list-style-type: none"> • High anterior septal angle • Supra-tip prominence • Loss of tip projection

38.5.1.4 Dorsal Hump Reduction (Profile Lowering)

The procedure for dorsal hump reduction (profile lowering) is facilitated by two important steps, namely, (1) bony hump removal and (2) cartilaginous hump removal.

Bony hump removal (Fig. 38.23A–K)

En-bloc bony or cartilaginous hump removal requires experience as there is a high risk of excessive reduction when the surgeon may be inexperienced. The procedure begins with infiltration of lidocaine 2% with 1 in 100,000 adrenaline.

After exposure of the osteocartilaginous vault is completed, the osteotome is engaged at the caudal edge of the nasal hump (osteocartilaginous junction) and the bone is removed using an osteotome and mallet (18 oz Heath mallet) with firm blows to follow a careful alignment. It is better to always under-reduce, rather than over-reduce as it may cause severely compromised results. The dorsal edges can then be rasped down to the desired extent. Care is taken not to rasp the cartilage as it may produce irregularities, tears or avulsions.

When separation of a large hump is desired, placement of a superior stop-cut as described by Tardy allows precise and clear separation at the desired level. Diamond rasps are used to smooth irregularities at the dorsal edge of the nasal bones. Removal of an osteocartilaginous hump results in an open roof deformity of the nasal dorsum, which needs to be closed with an osteotomy [23].

38.5.1.5 Complications

- Unpredictable hump reduction
- Avulsion of upper lateral cartilages
- Fenestration of the skin envelope
- Residual irregularities
- Excessive overzealous hump reduction
 - Bony saddle
 - Loss of support to ULC

Box 38.7. Bony vs. Cartilaginous hump, (Armamentarium)

Bony hump	Cartilaginous hump
Manual nasal saw. <ul style="list-style-type: none"> • Joseph saw • Bull saw (guarded tip) <ul style="list-style-type: none"> Osteotomes. • Rubin (dorsal fin) • Cinnelli (guarded edges) • Aiach (wire guide) • McIndoe grooved chisel (not recommended) <ul style="list-style-type: none"> Bone cutters/nibblers • Sulsenti • Heanley Rasps <ul style="list-style-type: none"> • Graded two way tungsten carbide rasps (Rees) • Pull rasp/push rasp (Daniel) • Diamond rasps Power saw <ul style="list-style-type: none"> • Rhinobur (Toriumi) • Piezoelectric saw 	<ul style="list-style-type: none"> • Scalpel (11 bard Parker) • Fomon scissors (angled on flat) • Turbinate scissors (angled on side) • Kaplan scissors (double action) • Cautious, conservative reduction at osteocartilaginous junction only • Preserve leading edges of ULC to create spreader flaps (prevent middle vault narrowing)

- Loss of key area support to septum
- Inadequate hump reduction
 - Residual hump
 - Failure to follow dorsal line: superior bony spur

38.5.1.6 Preservation Technique of Hump Removal (Regnault & Daniel)

This technique advocates aggressive removal of the large hump with osteotome. The under-surface of the hump is then reduced extracorporeally with a bur. The reduced hump is replaced in the dorsal defect. This obviates the need for nasal osteotomy and provides optimal results of a corrected dorsum.

38.5.2 Saddle Nose Deformity

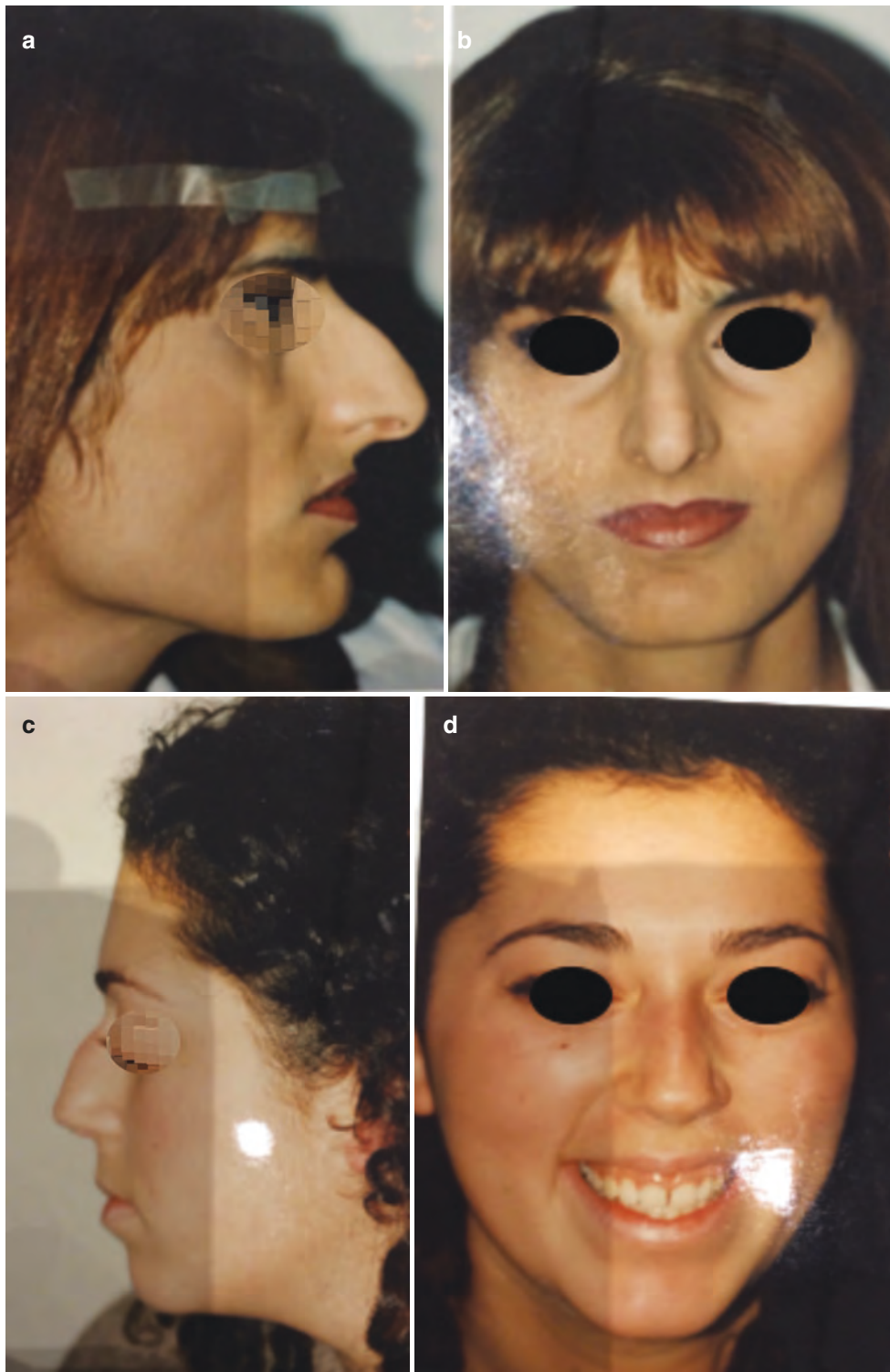A saddle nose deformity is defined as a wide and flat nose with a concavity on the nasal dorsum.

Classical clinical presenting features of this deformity are

- Loss of height of the nasal dorsum (appearance of a shortened nose)
- Increased width of the nasal dorsum (wide nose)
- Underprojected tip due to inadequate septal support to the tip complex

38.5.2.1 Classification

Saddle nose deformity can be classified based on the underlying structural problem into

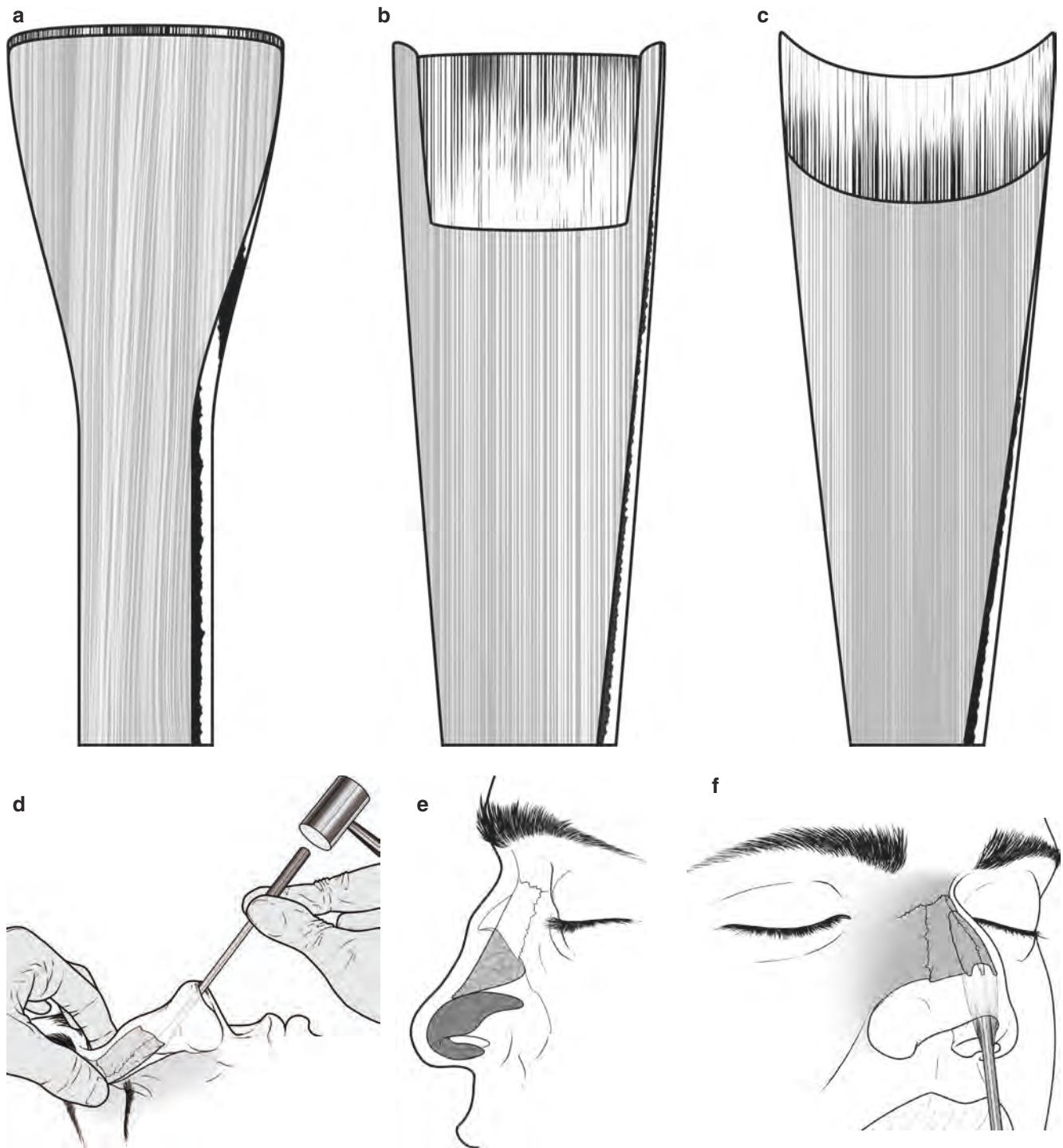


©Association of Oral and Maxillofacial Surgeons of India

Fig. 38.22 Dorsal hump - clinical presentation. (a) Profile and (b) frontal pictures of patient 1. (c) Profile and (d) frontal pictures of patient 2

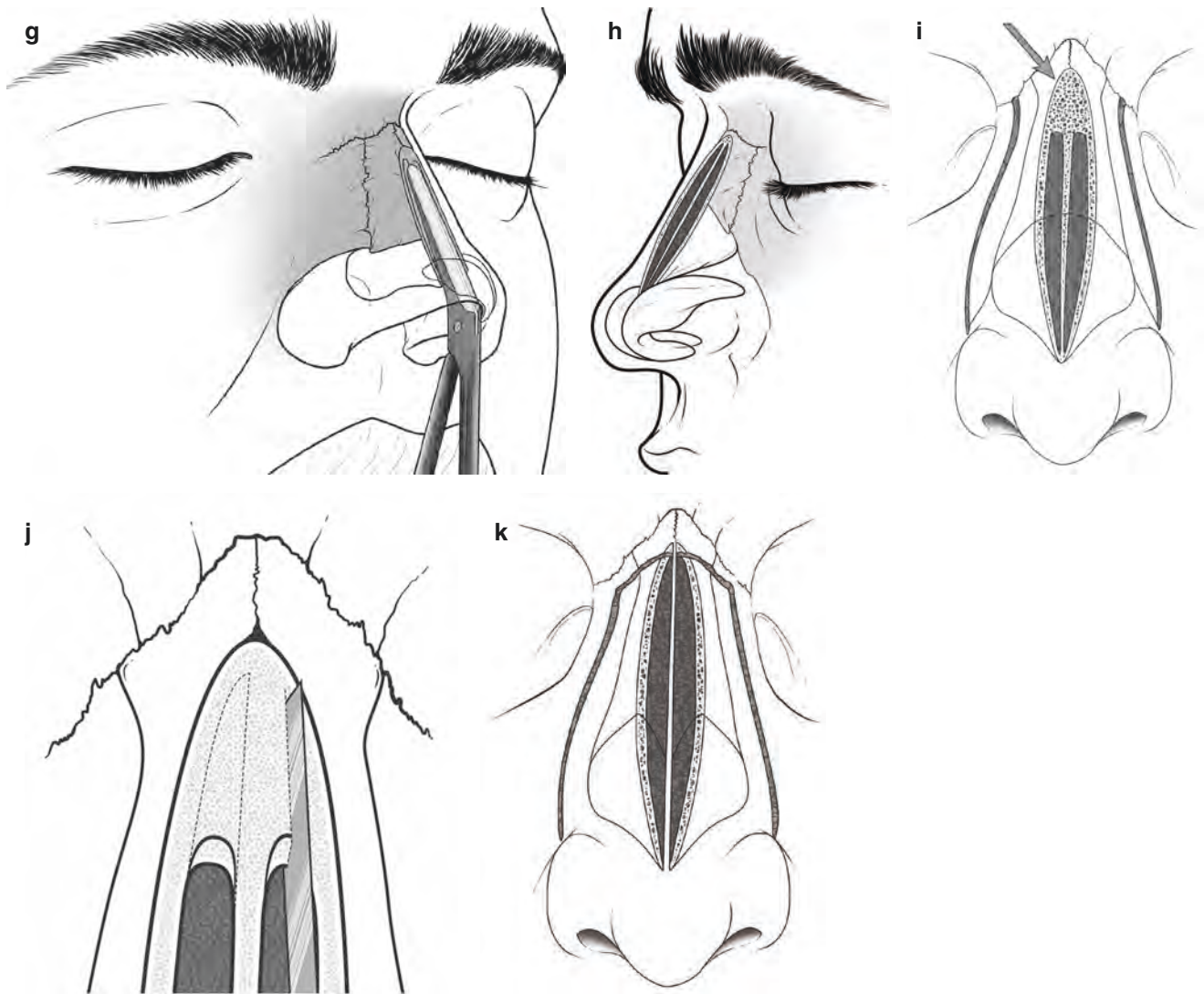
1. Bony saddle
2. Cartilaginous saddle
3. Combination of bony and cartilaginous elements

The causes responsible for saddle nose deformity are many, namely, septal hematoma following trauma, iatrogenic—inappropriate surgery to the septum, bony vault &



©Association of Oral and Maxillofacial Surgeons of India

Fig. 38.23 Hump reduction technique: Armamentarium (A, B & C). Surgical technique (D, E & F) Removal of the dorsal hump with the osteotome, (G–K) Preparation of the “open roof” deformity for closure



©Association of Oral and Maxillofacial Surgeons of India

Fig. 38.23 (Continued)

middle vault and substance abuse (cocaine), diseases like congenital syphilis/leprosy and racial predisposition—African, Afro-American, and Asian.

38.5.2.2 Clinical Features

The salient features (Fig. 38.24) demonstrable on a patient with saddle nose deformity are enumerated in Box 38.8.

The septum may exhibit deformity with twisting/deficiency or at times may be totally absent.

The skin and soft tissue envelope may show a “concertina” effect due to loss of structural support.

38.5.2.3 Surgical Management (Fig. 38.25a, b)

Surgery for the correction of saddle nose deformity may be planned in a staged manner with the first stage involving the correction of the foundation of the nose and the second stage involving the aesthetic makeover [25, 26]. The aim of the procedure is to re-establish the tension between the nasal tip

Box 38.8 Features of saddle nose deformity**Frontal:**

- Wide nasal dorsum
- Loss of dorsal lines
- Epicanthal folds due to the lateral movement of dorsal skin
- Loss of tip definition
- Increased tip width
- Presence of a flat alar-columellar line

Profile:

- Loss of dorsal height
- Marked concavity of the nasal dorsum
- Loss of tip support and projection
- Tip rotation may be increased or decreased
- Retraction of the columella
- Relative increase of the upper lip length (columellar skin migrates downward)

Basal:

- Wide alar base
- Shortened and deformed columella
- Loss of nostril orientation
- Ballooning of the internal nasal valve



©Association of Oral and Maxillofacial Surgeons of India

Fig. 38.24 Saddle nose clinical photo

complex and the dorsum, which has been lost due to the concertina effect.

Surgical correction involves three essential steps that are independent of each other.

- Establish the height and length of the septum to restore structural support to the entire nose. This involves the use of a robust septal extension graft, fashioned from harvested rib cartilage (preferably the eighth rib).
- Correction of the dorsal deficiency using a dorsal strut graft that extends from nasion to under the domes.
- Provision of support for the tip complex. This is achieved with the use of a columellar strut graft to restore tip projection.

This procedure involves the use of strong and robust cartilage grafts. The eighth rib provides an adequate amount of cartilage which is ideal for this situation. Ear cartilage lacks rigidity, while banked cartilage tends to undergo resorption.

38.5.3 Correction of the Deviated Nose

Deviated noses can be of two types

1. “Bent” nose where the nasal bones and the upper lateral cartilages point to the same side, and
2. “Crooked” nose where the nasal bones and the upper laterals face in opposite directions

38.5.3.1 Aetiology

The most common causes of a deviated nose

1. Developmental—unilateral cleft nasal deformity
2. Post trauma to the face and nose—following road traffic accidents, sports injuries or interpersonal violence
3. Iatrogenic—as a result of earlier surgical procedures; Maxillary impaction by a LeFort 1 osteotomy without addressing the septum or septoplasty with excessive scoring, resection and weakening

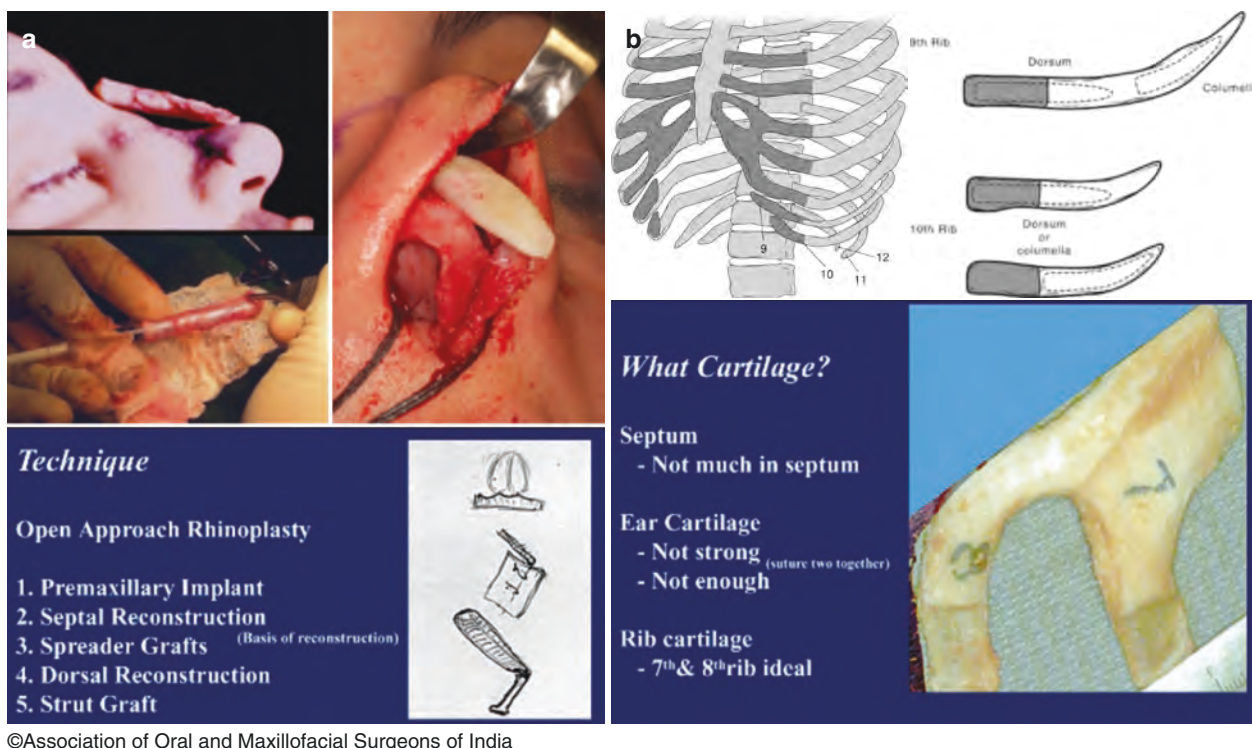


Fig. 38.25 Saddle nose-intra op. (a) intra-operative pictures demonstrating use of rib cartilage for dorsal nasal reconstruction. (b) Landmarks for rib harvest

38.5.3.2 Clinical Features

Clinical features of a deviated, bent or crooked nose include both functional and aesthetic issues

1. Blockage of the nasal airway, unilateral or bilateral
2. Visible deformities affecting the upper, middle and lower thirds of the nose

(a) Frontal

- Deformity of the nasal pyramid
- Twisting or angulation of the nose
- Constriction or bulge at the middle vault
- Bending of the nose showing midline discrepancy
- Unequal height of the nasal bones
- Tip deformity secondary to the loss of septal support/angulation

(b) Profile

- Patient may present with a dorsal hump or a saddle deformity
- Loss of tip projection
- Nasal tip ptosis
- Retraction of the columella

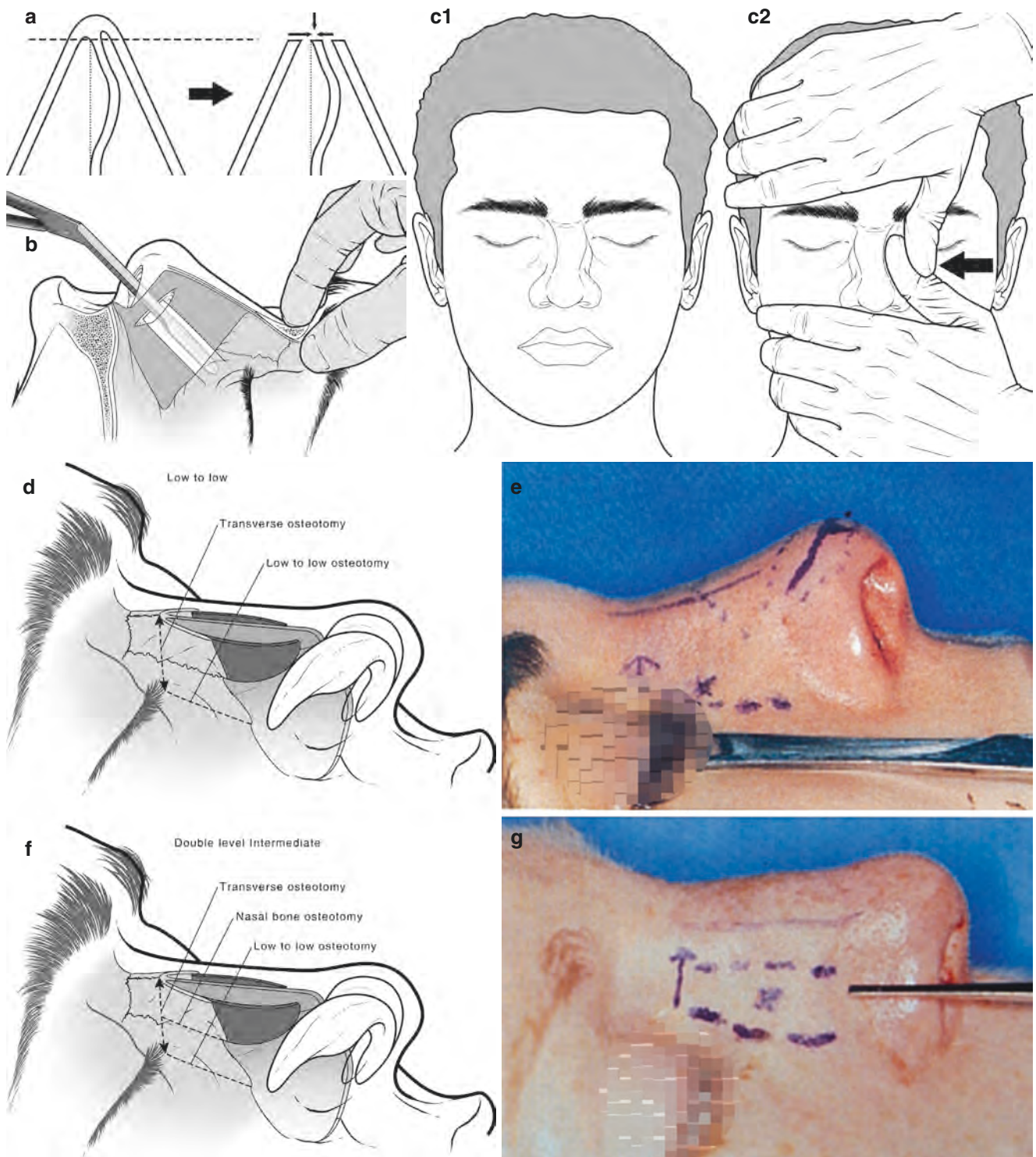
(c) Basal

- Deviation of the nasal tip or middle vault
- Angulation or shortening of columella
- Displacement of the caudal septum from the maxillary crest into the nasal vestibule
- Nasal valve obstructions

(d) Varied presentations of septal deformities (Mladini classification)

38.5.3.3 Treatment (Fig. 38.26a–g)

Septorhinoplasty is required to correct the deformity. Some prefer single-stage correction, while others may choose staged procedures (first stage septoplasty followed by a second stage external deformity correction). However, a single-stage correction is preferred. This is usually performed using an open structure approach with exposure and separation of the septum from the upper lateral cartilages. Straightening of the septal cartilage is performed by excision and/or partial division of the cartilage and may be followed by scoring or sutures as indicated. Some surgeons prefer the use of a PDS sheet to splint the corrected septum. However, costal cartilage may be harvested for reinforcement of the straightening



©Association of Oral and Maxillofacial Surgeons of India

Fig. 38.26 Techniques of reduction of crooked nose deformity with twisting/angulation of septum, (a) differential reduction of hump prior to osteotomy, (b) septal repositioning, (c) digital reduction/manipulation after osteotomy, (d) line diagram of “low-to-low” osteotomy, (e) intra-operative picture with osteotome positioning (low-to-low), (f) line diagram of “nasal bone osteotomy”, (g) intra-operative picture with osteotome positioning (nasal bone osteotomy)

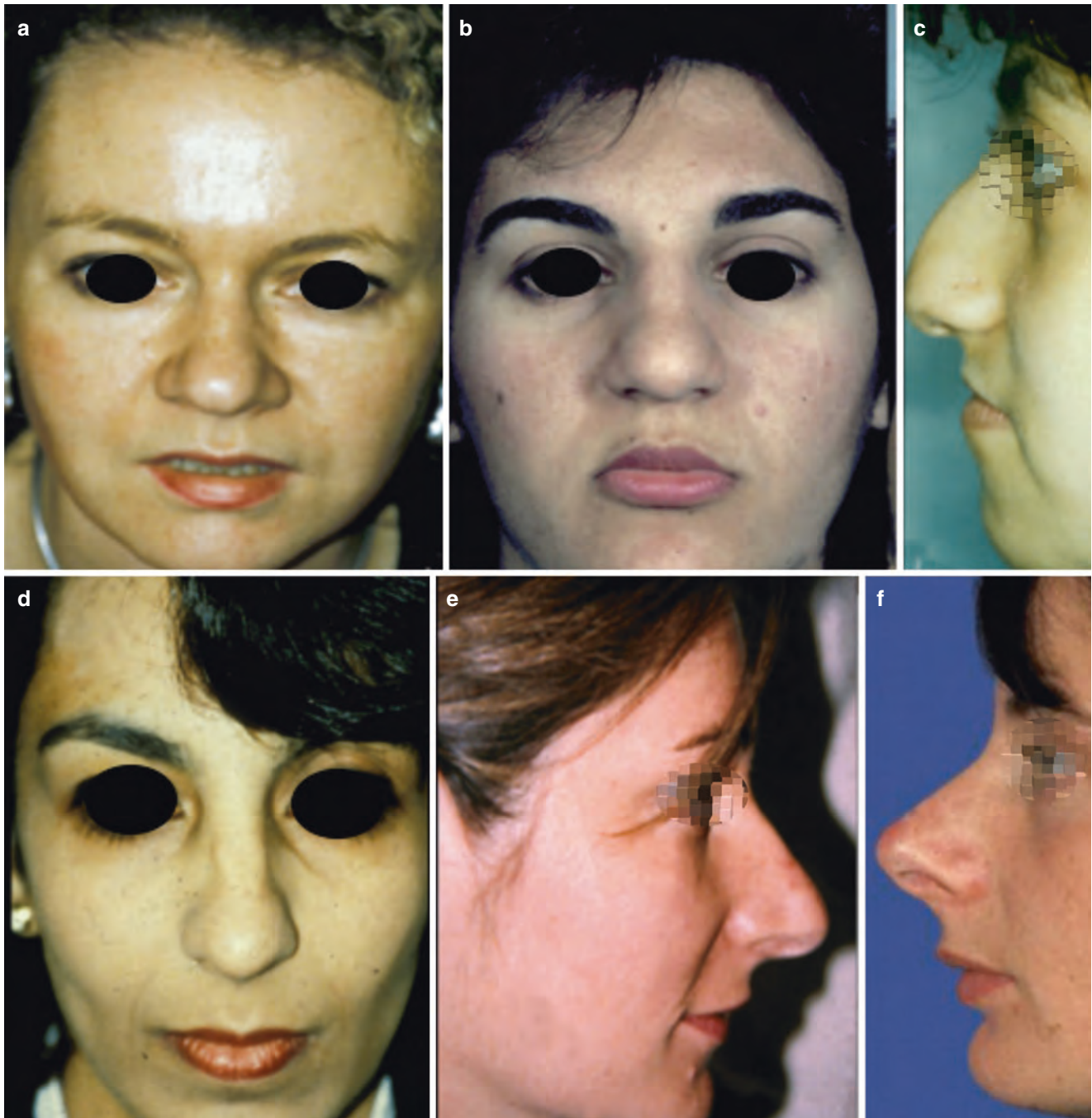and to provide a spreader effect to correct the nasal valve simultaneously. Osteotomy of the nasal bones is often required to correct the angular deformity of the bony vault. A tip plasty may be necessary in most cases to correct the nasal tip tripod deformity secondary to nasal deviation.

It is to be borne in mind that the results for the correction of deviated noses are not always satisfactory. There is a possibility of residual deformity, recurrent deformity, loss of tip support and saddling.

38.5.4 Tip Plasty

The nasal tip is the centre of focus for both nasal anatomy and aesthetics. It is a very important anatomical subunit and can be most challenging to refine surgically.

Nasal tip deformities may show varied morphology and diverse clinical presentations (Fig. 38.27a–f). They may occur in isolation or concomitant with deformities of the dorsum or septum.



©Association of Oral and Maxillofacial Surgeons of India

Fig. 38.27 Types of tip deformity. (a) Wide bulbous tip, (b) ball-ended amorphous tip, (c) plunging infra-tip lobule, (d) amorphous bulbous tip with deviation and constriction of right lower middle vault, (e) over-projection of nasal tip owing to prominent ANS & overtly long lower lateral cartilage with normal naso-labial angle, and (f) nasal tip over-projection with upward over-rotation

Tip deformities can be enumerated as follows as in Box 38.9.

38.5.4.1 Wide Nasal Tip

A tip is considered abnormally wide when the width of the tip is greater than the width of the dorsum. Normally, the tip width is equal to the width of the dorsum.

This can be further subclassified as mild, moderate or severe.

A wide nasal tip may be caused due to three morphological alterations:

1. increased interdomal width (wide interdomal angle)
2. increased intradomal width, where the domal angle is wide, and
3. increase in both intradomal width and interdomal width

Box 38.9 Types of tip deformities

- Wide
- Bulbous
- Over projected
- Under projected
- Over-rotated (piggy nose/toffee nose)
- Under-rotated (ptotic tip)
- Asymmetric

Surgical management

Surgery for the nasal tip can be performed either through a closed or open structure rhinoplasty approach. This may depend on the clinical indications involved as well as the skill and experience of the operating surgeon. Steps for correction of a wide nasal tip include reduction of the interdomal width by placing a permanent interdomal suture with 5-0 prolene or 5-0 PDS (semipermanent). This is followed by the creation of a new domal angle (transdomal suture followed by the interdomal suture). One should also consider surgical removal/excision of a segment of the intermediate crus for better tip definition (Fig. 38.28a, b).

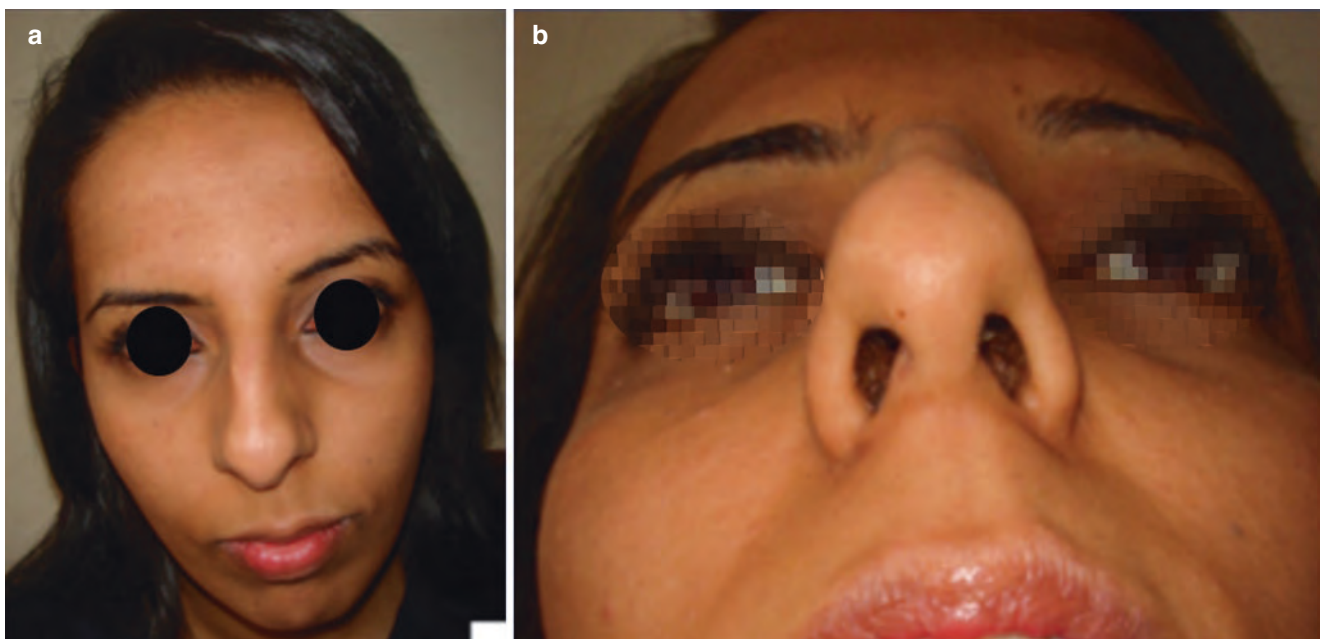
38.5.4.2 Bulbous/Boxy Tip (Fig. 38.29)

Bulbous tips have problems associated with thick SSTE (skin & soft tissue envelope), excessive subcutaneous fat, strong convex and bulky lateral crura and a concertina effect of a shortened nose in general.

Surgical management

This involves careful degloving of the SSTE leaving the subcutaneous fibrofatty tissue on the lateral crura. Careful defatting and thinning of the subcutaneous plane should be performed. A modest cephalic trim is performed to correct the large and bulky lateral crura. As this is a more general deformity involving not only the tip but also the associated SSTE, a careful distribution of volume to produce balance may be required. This helps camouflage the deformity to a great extent while improving outcomes.

Excessive or injudicious defatting of the nasal tip may cause ischemia/necrosis of the skin of the nasal tip,



©Association of Oral and Maxillofacial Surgeons of India

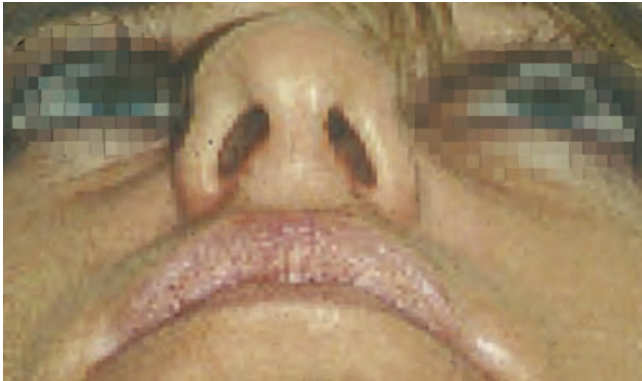Fig. 38.28 (a, b) Wide nasal tip clinical

blanching of the tip skin with exposure to cold, contour irregularities of the underlying cartilage to become visible and may also lead to the skin pores communicating to the underlying tissues.

38.5.4.3 Overprojected Nasal Tip (Fig. 38.30a–c)

Nasal projection is defined as the distance along a perpendicular line from the vertical facial plane to the anterior most point on the nasal tip. The nose when not in normal facial balance can either be overprojected or underprojected.

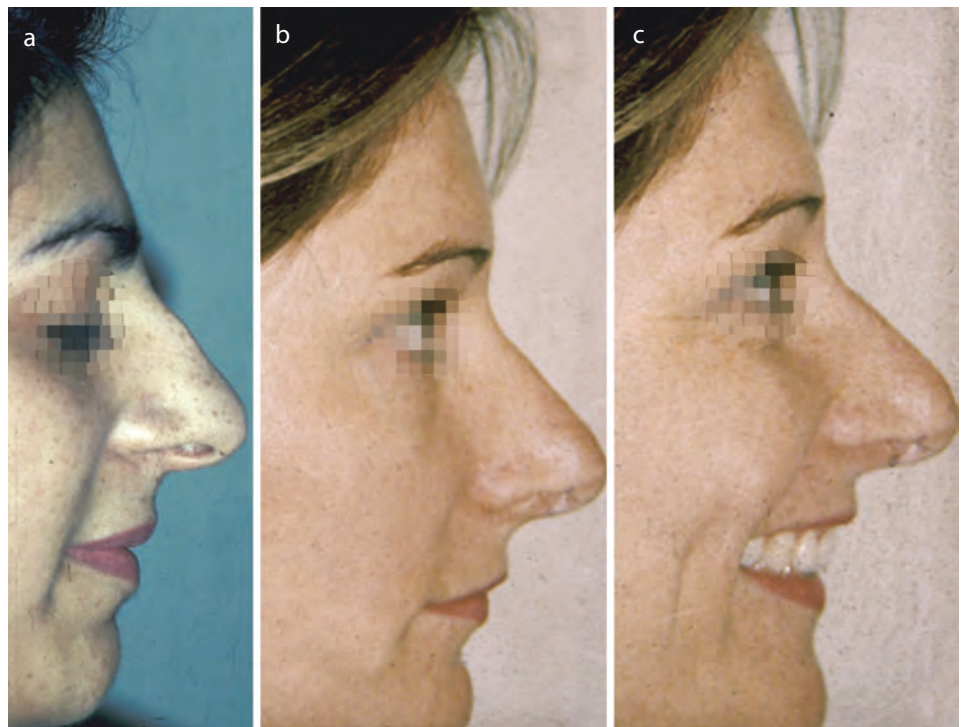The key to correction of the overprojected nasal tip is to establish the cause. This may be due to the increased length



©Association of Oral and Maxillofacial Surgeons of India

Fig. 38.29 Bulbous tip clinical

Fig. 38.30 Overprojected nasal tip (a) profile of patient 1, (b) profile of patient 2 at repose and (c) profile of patient 2, smiling



©Association of Oral and Maxillofacial Surgeons of India

of the anterior nasal spine, excess caudal septal height or overtly long alar cartilages.

Surgical management

Surgery for the overprojected nose should be performed through a full bilateral septal transfixion incision with the aim of deprojecting the nose by 4–5 mm. The anterior nasal spine is reduced judiciously followed by the resuspension of the upper lip to the ANS. The anterior septal angle is lowered to achieve further deprojection. Deformities of the alar cartilage may be varied and may require division and overlap of the medial crura, division or resection of the medial footplates. A lateral crural overlap with resection of a segment is performed 1 cm from the dome. Domal resections are to be avoided as they may produce secondary deformities: irregularities, angulation, and bossa formation. They may produce a sharp angulation with a pointed tip (pinched nose), which may require a shield graft for tip camouflage. Care should be taken to avoid/prevent loss of tip support during these manoeuvres.

38.5.4.4 Underprojected Tip (Fig. 38.31a, b)

It is important to establish the cause for underprojection prior to treatment. Causes of underprojection may include

- Short medial crura (short columella)
- Underdeveloped lower lateral cartilages e.g. binders
- Deficient height of caudal septum

- Deficient or absent anterior nasal spine/premaxilla
- Bilateral cleft lip nose

Surgical management

Surgery for the underprojected nose should follow the sequence provided below: the columella is strengthened with a strut graft, a transdomal suture is placed to project the dome. A shield, cap or an umbrella graft may be used to increase tip projection. A caudal septal extension graft is added to strengthen the septal support and increase projection. Finally, a transcolumellar suture is performed through the medial foot-plates. In patients with the deficiency of the premaxilla or the total bony maxilla (cleft maxillary hypoplasia) where loss of bone support contributes to the loss of nasal projection, advancement of the maxilla or Onlay grafting of the premaxillary segment may offer the correct solutions.

38.5.4.5 Over-Rotated Tip (Piggy Nose) (Fig. 38.32b)

Tip rotation denotes the angle formed by the columella to the upper lip. The point of reference here is the nasolabial angle. Deformities of the nasal tip related to the rotation can be either over-rotation or under-rotation (ptotic nose).

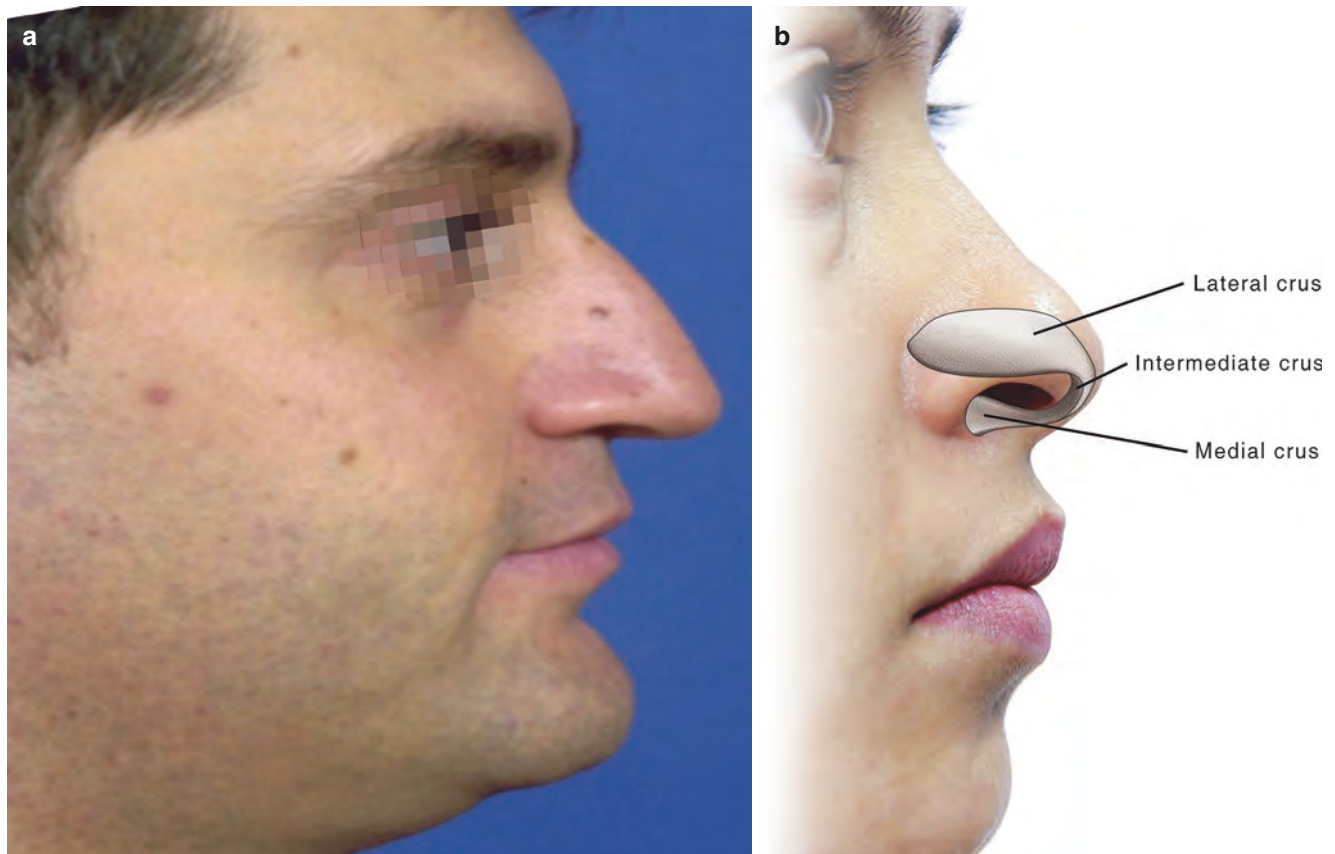
Over-rotation of the nose may arise due to various causes: post-traumatic (caudocephalic impact to the nose) or an inherently short nose. Over-rotation may also be a complication of prior rhinoplastic procedures due to over-zealous caudal septal reduction, excessive cephalic trim of the lateral crura or injudicious lowering of the anterior septal angle.

Surgical management

Surgery for the correction of over-rotation of the nasal tip should include techniques for de-rotation of the nose like placement of a caudal septal extension graft and/or extension of the dorsal graft beyond the domes. These procedures require extensive cartilage grafting to lengthen the shortened nose.

38.5.4.6 Under-Rotated Tip (Ptotic Nasal Tip) (Fig. 38.32a)

Under-rotation denotes cephalocaudal rotation of the nasal tip, which makes the tip point downward. This needs to be differentiated from an underprojected tip. However, occasionally both problems may co-exist. It is also important to identify the presence of pseudo-ptosis in which the tip is normal but a more prominent anterior septal angle makes the tip appear ptotic.



©Association of Oral and Maxillofacial Surgeons of India

Fig. 38.31 Underprojected tip. (a) Clinical picture and (b) diagrammatic representation

Ptotic tips need to be examined both at rest and dynamically. The dynamic inferior movement of the nasal tip may occur due to the downward pull of a strong depressor septi muscle. Care should also be taken to look for any other associated deformities.

Causes for an under-rotated or ptotic tip may be hereditary as in the noses of people from the Mediterranean countries, developmental due to heavy SSTE and weak cartilages or the presence of excessive skin in the membranous columella. Patients with bilateral cleft lip deformities are predisposed to have underprojected and under-rotated noses due to columellar deficiency.

Iatrogenic causes for tip ptosis include: poorly planned and executed septorhinoplasty with loss of septal support, inadequate maintenance of tip support or reattachment of the tip support structures. It may also be a complication following (1) prolonged intubation with the nasotracheal tube not anchored well and (2) tumour ablations with inadequate reconstruction.

Surgical management

Correction of the ptotic tip should be based on the anatomy involved. It is best to follow an algorithm for planning the

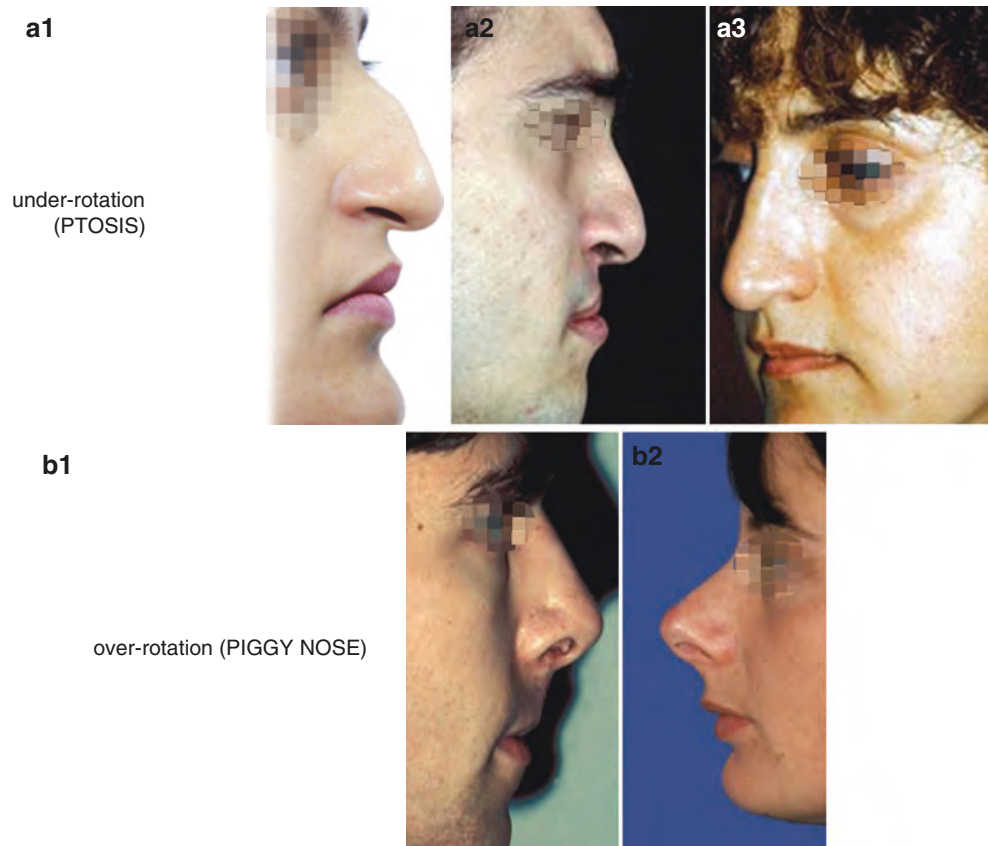
surgical procedure. The structures contributing will enable us to plan and perform the correct procedure.

- An elongated septum producing the ptosis is corrected by a wedge excision of the excessive septum and the overlying mucosa (Fred technique).
- Elongated lower lateral cartilages can be managed by two methods depending on the tip projection; in underprojected tips, a columellar strut is provided for enhancing support and augmented with the tip rotation suture, while in the case of an overprojected tip, transection of the LLC is performed with overlapping and suturing. The tip rotation suture may be optional depending on the clinical indication.
- In the case of a shortened medial crura, a columellar strut or a medial crural anchor suture is placed with the tip rotation suture again being optional.

38.5.5 Managing the Wide Ala

The normal width of the ala falls within or just beyond an imaginary vertical line dropped from the medial canthus to the upper lip. The ala may be either narrow or wide. A wide

Fig. 38.32 Nasal tip rotations clinical. (a1, a2, a3) Under-rotation of tip and (b1, b2) Over-rotation of tip



ala compromises facial aesthetics and is often a complaint for which the patient seeks help.

38.5.5.1 Causes of Variations in Alar Base Width

A wide alar base may be a characteristic of racial variations, for example, African and Asian races exhibit increased width of the alar base. It may also be wide in patients with congenital anomalies like cleft lip and palate. Wide alar base may also be due to iatrogenic causes like

1. after a Le Fort 1 maxillary advancement or impaction surgery,
2. injudicious rhinoplasty with loss of tip projection due to loss of septal support

38.5.5.2 Clinical Features

Patients with a wide alar base exhibit a nose that looks flat and broad; the alar columellar line may be straight and they may have an associated wide nasal tip. In the basal view, the nose presents with reduced tip projection and short or distorted columella. The alar side walls show increased bulk and increased flare, and the alar insertion into the nasolabial area may be horizontal or oblique. The alar sill

width may also show an increase. The premaxillary base that supports the alar complex may be normal, deficient or asymmetric.

38.5.5.3 Evaluation

The nose should be evaluated for the cause of alar widening. This is the basis on which the treatment may be planned. When there is a doubt regarding the width of the ala, it may be wise to abandon the idea during a primary rhinoplasty and perform the alar correction as an isolated secondary procedure.

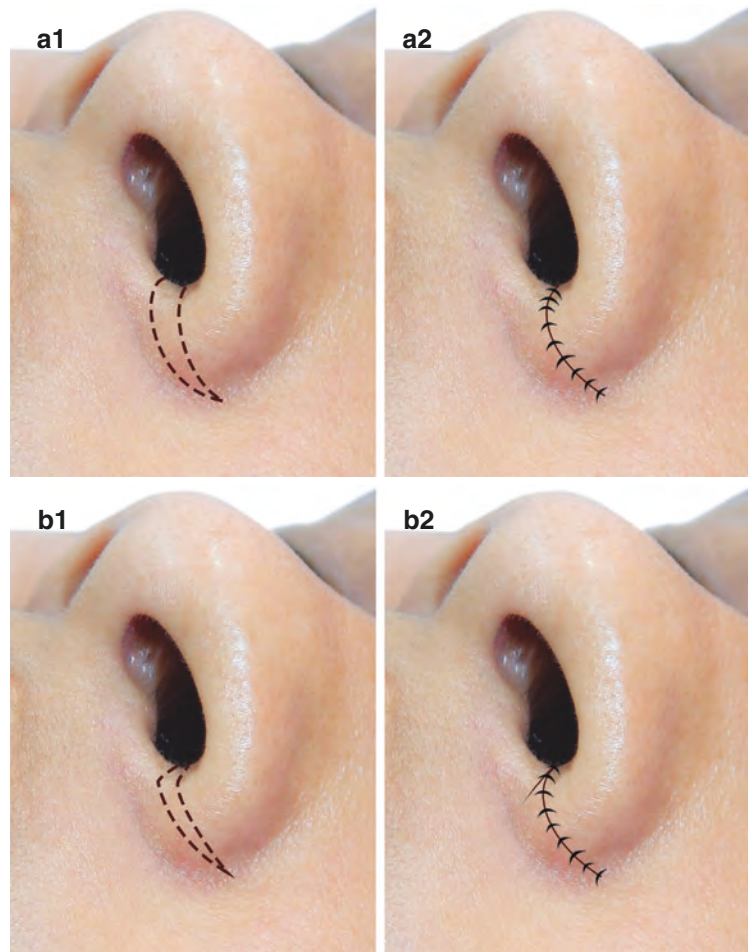
38.5.5.4 Surgical Treatment (Fig. 38.33a, b)

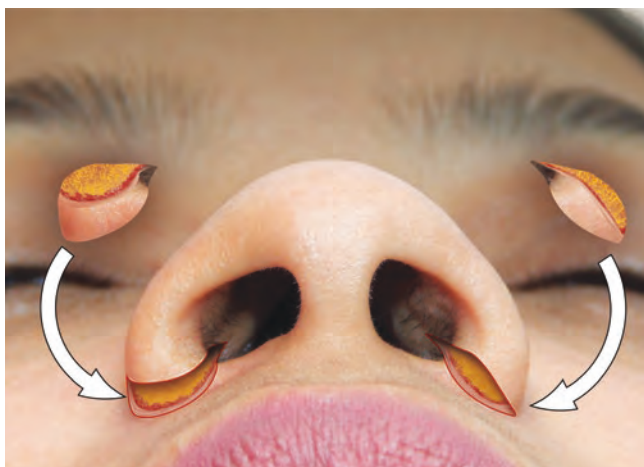Surgery for the wide ala needs to be sequenced after assessment of the cause; this may be a wide ala demonstrating

1. significant flaring,
2. flaring with increased sill width,
3. rarely isolated increase of sill width and
4. presence of a lateral insertion of ala on the face.

- The treatment of choice for the flaring ala is wedge excision (Weir) (Fig. 38.34), which helps to preserve the natural contour of the ala as well as provide a good camouflage

Fig. 38.33 Wide ala surgery techniques. (a) Traditional Weir excision (leaves a notch deformity) and (b) modified excision incorporating a lateral advancement which prevents notch deformity and restores continuity of alar rim





©Association of Oral and Maxillofacial Surgeons of India

Fig. 38.34 Wedge technique for alar base reduction

of the scar. A medial flap excision technique as described by Sheen may also be a good alternative to this. The decision regarding medial repositioning of the alar base should be in accordance with Sheen, who recommends it only in cases of extreme lateral divergence.

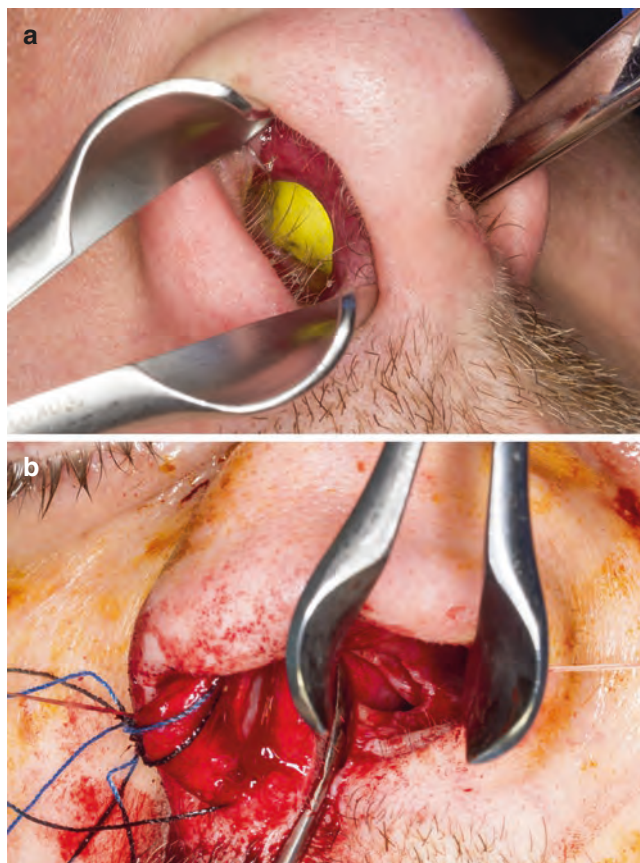
- When flaring is associated with a wide sill then a wedge with a sill excision may be preferred to correct the deformity. In rare instances an isolated sill excision may be indicated for a problem of increased sill width alone.
- When the nose demonstrates a lateral insertion of the alar base on to the face, then a “V to Y” plasty is performed as described by Bernstein, which helps relocate the alar base medially.

38.5.6 Septal Perforations

Septal perforations are pathological defects in the nasal septum which form communications between the right and the left sides of the nasal cavity. These may present as anterior, mid-septal or posterior perforations (Fig. 38.35a, b).

The most common aetiological factors producing septal perforations are

1. Cocaine misuse
2. Trauma to the face and nose—e.g. NOE fractures
3. Iatrogenic—injudicious septal surgery or poor techniques during septorhinoplasty
4. Self induced—obsessional nasal toileting or habitual nose picking
5. Granulomatous diseases
6. Malignancy



©Association of Oral and Maxillofacial Surgeons of India

Fig. 38.35 Septal perforation; (a) clinical presentation, (b) intra-operative picture

38.5.6.1 Clinical Features

The occurrence of septal perforations also leads to a variety of sequelae that produce secondary deformities of not only the nose but also significantly affect the face and the oral structures. The nose may show a saddle deformity, columellar retraction and narrowing of the nasal valve. Furthermore, the loss of nasal cartilage and bony framework may lead to a concertina deformity of the skin envelope. Perforations may expand in an inferior direction with associated necrosis of the vomer and maxillary crest, thus causing a palatal fistula. Other symptoms include nasal airway block, nasal discharge, crusting, epistaxis, midfacial pain, and a characteristic whistling noise.

38.5.6.2 Investigations

Investigations for perforations of the nasal septum include a thorough clinical evaluation of the nasal cavity, oral cavity and the face for accurate diagnosis. The patient is also subjected to a rhinoscopy and a nasendoscopy for assessment of the intra-

nasal deformity. This is followed by a biopsy from the margins of the perforation. A swab may also be performed for culture and sensitivity when there are signs of acute infection of the region.

38.5.6.3 Treatment

Treatment is initiated in a conservative form with counselling, wound care and topical medication. This involves abstinence from cocaine use with rehabilitation under supervised care. Regular inspection of the nasal cavity and nasal toileting with seawater douches. Topical administration of Naseptin cream alternating every 2 weeks with Bactroban (Mupirocin) ointment is mandatory prior to surgical intervention.

Surgical management (Fig. 38.36a, b, c) for septal perforations is extremely challenging and often give disappointing results. Any treatment is bound to be compromised due to resurgence of the cocaine addiction and poor vascular status of the involved anatomy resulting in a high incidence of residual defects after surgery.

There are also risks of total failure of procedures with secondary donor site deformities, adding to the post-surgical morbidity in these patients.

38.5.7 Nasal Valve Problems

To understand the problems associated with the nasal valve, it is important to see the distinction between the “nasal valve area” or the internal nasal valve, the “nasal valve” and the external nasal valve: The nasal valve area is the empty triangular space that is bounded medially by the nasal septum, laterally and superiorly by the caudal margin of the upper lateral cartilage and its attachment to the pyriform rim and inferiorly by the bony nasal floor. The nasal valve specifically denotes the slit that is seen between the caudal end of the upper lateral cartilage and the nasal septum. Physiologically, the internal nasal valve is the area offering

the highest resistance to airflow, and any deformities of this region may compromise the air-flow dynamics.

38.5.7.1 Anatomy of the Nasal Valves

The components of internal and external valves are projected in Box 38.10.

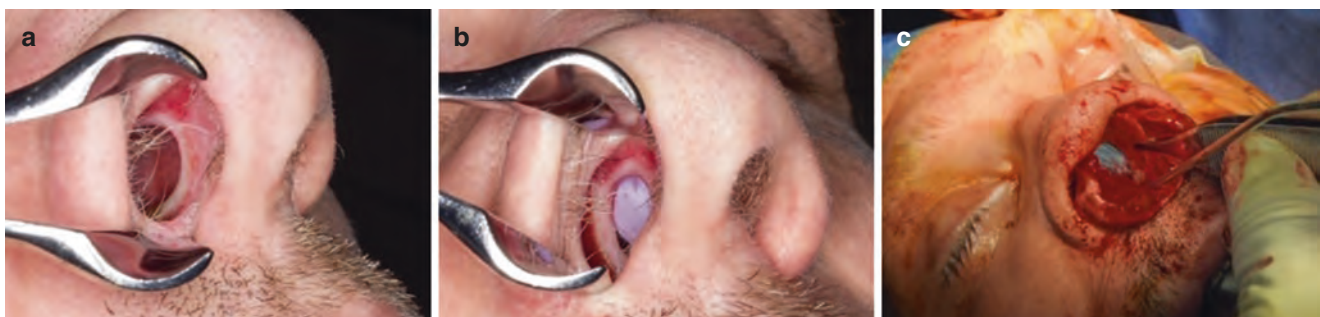The aetiology of nasal valve problems are enumerated in Table 38.4.

Box 38.10. Components of nasal valves

Components of the external nasal valve	Components of the internal nasal valve
<ul style="list-style-type: none"> • Alar rim and alar side wall • Columella • Caudal septal margin • Nasal sill 	<ul style="list-style-type: none"> • Caudal septum • Caudal margin of the upper lateral cartilage • Floor of the nose • Head of the inferior turbinate

Table 38.4 Etiology of nasal valve problems

External nasal valve	Internal nasal valve
<ul style="list-style-type: none"> • Inherently weak alar sidewall (collapsing on inspiration) • Caudal septal deflection • Deviated footplate of the medial crus • Narrow/scarred nasal sill • Wide columellar base • Iatrogenic causes (knock-knee deformity of the alar sidewall due to excessive cephalic trim) • Medialisation of lateral crus following domal suture 	<ul style="list-style-type: none"> • Caudal septal deviation • Mid-septal bulge impinging on the upper lateral cartilage • Inferior turbinate hypertrophy • Iatrogenic causes <ul style="list-style-type: none"> – Misplaced intercartilagenous incisions – Medialisation of the inferior turbinate due to an injudicious lateral osteotomy – Narrowing of the middle vault due to closing of an open roof deformity



©Association of Oral and Maxillofacial Surgeons of India

Fig. 38.36 (a–c) Septal perforation surgical technique

38.5.7.2 Clinical Examination of Nasal Valve Problems

It is extremely important to identify the exact location of the nasal obstruction to obtain the best surgical outcomes. This can be accomplished using

1. Clinical testing using “Cottle’s sign”
2. Endonasal examination and rhinoscopy
3. Dynamic photographs or video recordings of the “external valve flutter”
4. Air-flow studies using CT scans and computer simulation models

38.5.7.3 Surgical Management

Sequencing of treatment for the management of nasal valve problems should include certain empirical steps. The first step is to perform an optimal septoplasty to relocate the septum to the midline. This is followed by straightening and strengthening of the alar sidewall using alar batten grafts and rim grafts. Narrowing of the columellar base may be performed in cases of true columellar widening. Collapse of the nasal valve can be corrected by the use of spreader grafts that help in widening. In certain cases, there may be webbing or scarring along the nasal valve area. This may need a “Z” plasty for release and correction. Finally, judicious removal of the inferior turbinate may be contemplated in indicated patients after due consultation with the ENT surgeon.

38.6 Complications Following Rhinoplasty

A sequela may be defined as a natural consequence following a disease process or a surgical procedure while a complication implies undesirable sequelae or process following surgery.

This section will dwell on the common sequelae and complications that may occur following rhinoplasty and will help providing tips for reducing or preventing complications.

Common sequelae following rhinoplasty may be tabulated as early and late in Box 38.11.

Box 38.11. Complications of Rhinoplasty

Early sequelae	Late sequelae
Swelling	Infra-orbital discoloration
Bruising	Loss of tip-lobule definition
Paraesthesia	Lateral shortening
Swelling of the tip and supratip area	False “polly-beak” deformity

Most sequelae are self-limiting and may not require any active intervention. However, it is imperative to follow certain steps to minimise or avoid complications as discussed below.

The key to minimising or preventing unfavourable outcomes depends on proper case selection after a thorough evaluation of the patient both physically and psychologically (perceived complaint vs objective deformity). A good clinical examination should follow with optimal documentation (clinical analysis and photographs). The subsequent consultation should include obtaining informed consent from the patients after discussion of the indications and anticipated complications associated with the surgical procedure. It is important to understand our limitations and accept them while not refraining from seeking professional help/support when needed.

Complications in rhinoplasty may depend on the area of surgery and the procedure performed as indicated below:

1. *Complications associated with the nasal dorsum* include loss of dorsal height, concavity or saddle deformity (due to over-resection), residual hump, supratip prominence or a true “polly-beak” deformity due to under-resection. There may be bony or cartilaginous irregularities (inadequate removal). An open roof deformity may present if the nasal bones are not fractured after hump reduction. An incomplete lateral osteotomy may result in a lateral wall step deformity, while medialisation of the upper lateral cartilages may result in an inverted “v” deformity. Another complication is the appearance of a visible dorsal septal edge.
2. *Complication of tip deformities* may present as a “pinched tip” or a “knock-knee” alar deformity (over-resection of the lateral crus). It may also show tip changes like “button-tip” deformity, tip/domal asymmetry, supra-alar concavity or alar retraction. Loss of tip support produces ptosis of the tip, loss of tip projection may produce infratip slip below the anterior septal angle and excess resection of the caudal septum may lead to over-rotation of the tip complex.
3. *Alar base reduction complications* may include narrowing of the nostril circumference, which may contribute to increased nasal airway pressure. The surgery by itself may cause a web scar at the alar-facial junction. It may also result in distortion and secondary deformity of the nose, cheek and lips.
4. *Complications following septal surgery* include failure to straighten, midline deviation, tip deviation secondary to caudal septal displacement and septal collapse leading to a saddle nose deformity. The columella may develop retraction or scarring and rarely necrosis.

The skin and soft tissue envelope may also show scarring, ischemia/dyscolouration and at times telangiectasia.

Management of complications may be necessary when the deformity is visible to both the surgeon and the patient. This necessitates revision or secondary surgery which may be indicated in about 5–8% of the patients. Even when indicated, it is better to wait for a year prior to attempting revisions or secondary interventions. This is to facilitate a careful assessment of long-term changes following the procedure and the final outcome prior to intervention.

38.7 Conclusion

Rhinoplasty in most realms is considered as the epitome of aesthetic surgical skill. This burdens the surgeon with the responsibility of performing the surgery with accurate planning and prediction of outcomes. It is also important for both the young surgeon and the patient to understand that the final outcome of the surgery is not in the immediate future but is a culmination of all the surgical manoeuvres and their response over a period of time. This is the same fact that makes rhinoplasty among the most difficult to master. Rhinoplasty has transgressed from the early procedures of sole nasal reduction to encompassing not only the aesthetics of the nasal complex but also improvement of the function and establishing a balance for today's patient. This chapter is aimed to provide the reader with the basics of surgical techniques. Perhaps, this is one surgical skill where the surgeon still holds all the cards while the others are losing the battle to technology.

References

1. Oneal RM, Beil RJ. Surgical anatomy of the nose. *Clin Plast Surg.* 2010;37(2):191–211.
2. Lessard ML, Daniel RK. Surgical anatomy of septorhinoplasty. *Arch Otolaryngol.* 1985;111(1):25–9.
3. Gonzalez-Ulloa M, Castillo A, Stevens E, et al. Preliminary study of the total restoration of the facial skin. *Plast Reconstr Surg* (1946). 1954;13(3):151–61.
4. Letourneau A, Daniel RK. Superficial musculoaponeurotic system of the nose. *Plast Reconstr Surg.* 1988;82(1):48–57.
5. Wright WK. Surgery of the bony and cartilaginous dorsum. *Otolaryngol Clin North Am.* 1975;8(3):575–98.
6. Pitanguy I. Surgical importance of a dermocarilaginous ligament in bulbous noses. *Plast Reconstr Surg.* 1965;36:247–53.
7. Guyuron B. Soft tissue functional anatomy of the nose. *Aesthetic Surg J.* 2006;26(6):733–5.
8. Hollingshead WH, editor. *Anatomy for surgeons*, vol. 1. 3rd ed. Philadelphia, PA: Harper and Row; 1982.
9. Khan HA. Rhinoplasty: initial consultation and examination. *Oral Maxillofac Surg Clin North Am.* 2012;24(1):11–24. Review.
10. Patient assessment for Rhinoplasty. In: Guyuron B, editor. *Rhinoplasty*. Edinburgh: Elsevier/Saunders; 2012.
11. Guyuron B. Precision rhinoplasty. Part I: The role of life-size photographs and soft tissue cephalometric analysis. *Plast Reconstr Surg.* 1988;81(4):489–99.
12. Moscatiello F, Herrero J, González Ballester MÁ, Carreño Hernández E, Piombino P, Califano L. Preoperative digital three-dimensional planning for rhinoplasty. *Aesthet Plast Surg.* 2010;34:232–8.
13. Andre RF, Vuyk HD, Ahmed A, Graamans K, Nolst Trenite GJ. Correlation between subjective and objective evaluation of the nasal airway. A systematic review of the highest level of evidence. *Clini Otolaryngol.* 2009;34(6):518–25.
14. Sajjadian A, Naghshineh N, Rubinstein R. Current status of grafts and implants in rhinoplasty: Part II. Homologous grafts and allogenic implants. *Plast Reconstr Surg.* 2010;125(3):99e–109e.
15. Sajjadian A, Rubinstein R, Naghshineh N. Current status of grafts and implants in rhinoplasty: Part I. Autologous grafts. *Plast Reconstr Surg.* 2010;125(2):40–9.
16. Koehler J, McLain L. Grafting in cosmetic rhinoplasty. *Oral Maxillofac Surg Clin North Am.* 2012;24(1):59–66.
17. Jang YJ, Moon BJ. State of the art in augmentation rhinoplasty: implant or graft? *Curr Opin Otolaryngol Head Neck Surg.* 2012;20(4):280–6.
18. Wotman M, Kacker A. What are the indications for the use of computed tomography before septoplasty? *Laryngoscope.* 2016;126(6):1268–70.
19. Shah J, Roxbury CR, Sindwani R. Techniques in septoplasty: traditional versus endoscopic approaches. *Otolaryngol Clin North Am.* 2018;51(5):909–17.
20. Most SP, Rudy SF. Septoplasty: basic and advanced techniques. *Facial Plast Surg Clin North Am.* 2017;25(2):161–9.
21. VanKoeveering KK, Rosko AJ, Moyer JS. Osteotomies demystified. *Facial Plast Surg Clin North Am.* 2017;25(2):201–10.
22. Wayne I. Osteotomies in rhinoplasty surgery. *Curr Opin Otolaryngol Head Neck Surg.* 2013;21(4):379–83.
23. Bohluli B, Moharamnejad N, Bayat M. Dorsal hump surgery and lateral osteotomy. *Oral Maxillofac Surg Clin North Am.* 2012 Feb;24(1):75–86.
24. Barrett DM, Casanueva F, Wang T. Understanding approaches to the dorsal hump. *Facial Plast Surg.* 2017;33(2):125–32.
25. Suh MK. Dorsal augmentation using autogenous tissues. *Facial Plast Surg Clin North Am.* 2018;26(3):295–310.
26. Kim CH, Park SC. Homologous tissue for dorsal augmentation. *Facial Plast Surg Clin North Am.* 2018;26(3):311–21.

Additional Reading

- Mladina R. The role of maxillar morphology in the development of pathological septal deformities. *Rhinology.* 1987;25(3):199–205.

Open Access This chapter is licensed under the terms of the Creative Commons Attribution 4.0 International License (<http://creativecommons.org/licenses/by/4.0/>), which permits use, sharing, adaptation, distribution and reproduction in any medium or format, as long as you give appropriate credit to the original author(s) and the source, provide a link to the Creative Commons license and indicate if changes were made.

The images or other third party material in this chapter are included in the chapter's Creative Commons license, unless indicated otherwise in a credit line to the material. If material is not included in the chapter's Creative Commons license and your intended use is not permitted by statutory regulation or exceeds the permitted use, you will need to obtain permission directly from the copyright holder.



Part XIII

Advances in Oral and Maxillofacial Surgery



39.1 Introduction

The first successful demonstration of laser was performed by Maiman in 1960 who also predicted one of its uses to be in medical science [1, 2]. Decades after the first medical use in the oral cavity and face, lasers are not just an adjunctive tool today but are an integral part of an Oral and Maxillofacial Surgeon's (OMS) armamentarium. Although CO₂ laser has been the traditional workhorse for an OMS, advancement in the capabilities of CO₂ lasers, as well as the development of other types of lasers, has helped grow their utility. Increasing use of lasers in turn has created greater evidence of its efficacy and safety record. Use of lasers has not only added advantages to conventional OMS procedures, as opposed to a scalpel, it has also given rise to newer procedures, which were not possible with conventional tissue-cutting tools.

39.2 Laser Physics

Modern lasers are simple to use but a lack of knowledge on the physics of lasers, inadequate training and caution in handling lasers, can give rise to potential adverse outcomes and unwanted complications. The term "laser" stands for light amplification by stimulated emission of radiation and was first used by Gordon Gould in 1957 [3]. The laser, as opposed to a regular light source, is composed of monochromatic, coherent and collimated beams, which, when they strike a suitable target, create photoacoustic, photochemical, phototablative, and photothermal effects. Laser light energy can undergo absorption, reflection, transmission, and scattering based on the optical properties of the target tissue or matter. For surgeons, the most desirable action is absorption into the

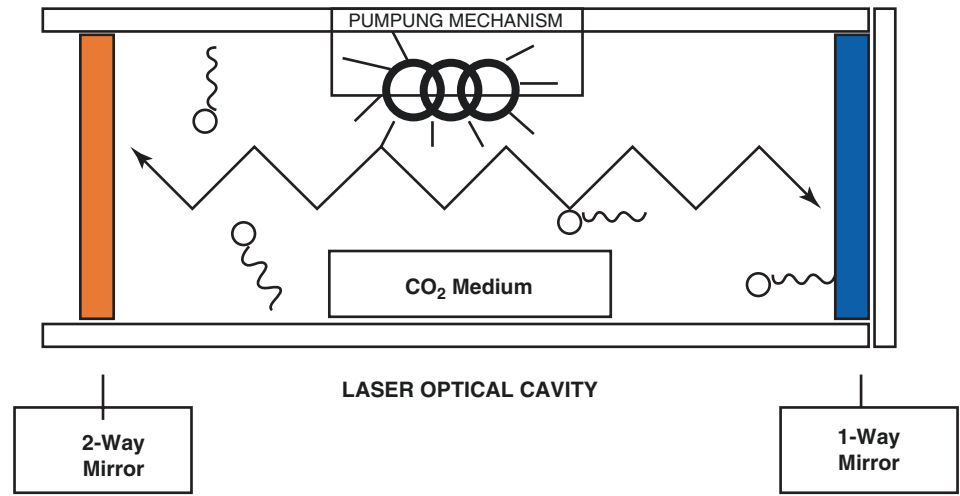
tissue, which creates the predictable photothermal outcome of coagulation and then vaporization of tissues [4].

The basic component of a laser unit includes a "laser cavity" where the laser beam is produced via the phenomenon of stimulated emission as postulated by Albert Einstein. The laser cavity is composed of an active medium, an excitation source acting as a pumping mechanism, and an optical resonator (Fig. 39.1). The active medium is the chemical (gas/liquid/solid) that the type of laser is named after and is the material that undergoes stimulated emission. The photons of energy produced are collimated and amplified to produce the laser beam, which is then delivered to the target tissues via an appropriate delivery mechanism, either a flexible fiberoptic system, semiflexible hollow waveguides, or articulated mirrored arms (Fig. 39.2a–c). Lenses focus the active laser beam to create a "focal point," the point at which the energy is condensed to the smallest area to create the maximum effect. Some fiberoptic laser systems utilize a quartz or sapphire crystal at the tip of the fiber to enable the beam to be absorbed by this crystal and allow contact with tissues at the tip of the fiber, while others are used in a noncontact mode. A laser beam is an electromagnetic beam of radiation, which can fall anywhere in the spectrum of visible or invisible light. Nd:YAG, CO₂, and erbium lasers fall into the infrared invisible spectrum; hence, they are often accompanied by a visible aiming beam, which helps the surgeon to know the point in the tissues where laser beam hits the target tissues. Aiming beams can be another low power laser or a regular light source [4] (Fig. 39.3).

The factors related to the use of lasers that are under control of the surgeon include the spot size, power, and time on target. The spot size of the laser is the width of the laser beam on target. At the focal point, the maximum energy is focused to produce the smallest spot size or the thinnest possible incision but to the greatest depth. When the tip of the laser delivery system is moved away from the tissues, the laser beam diverges causing a bigger spot size and the energy is then distributed over a larger area and the related depth is

S. Renapurkar (✉) · R. A. Strauss
Department of Oral and Maxillofacial Surgery, Virginia
Commonwealth University Medical Center, Richmond, VA, USA
e-mail: srenapurkar@vcu.edu; rastrauss@vcu.edu

Fig. 39.1 Components of laser tube



©Association of Oral and Maxillofacial Surgeons of India

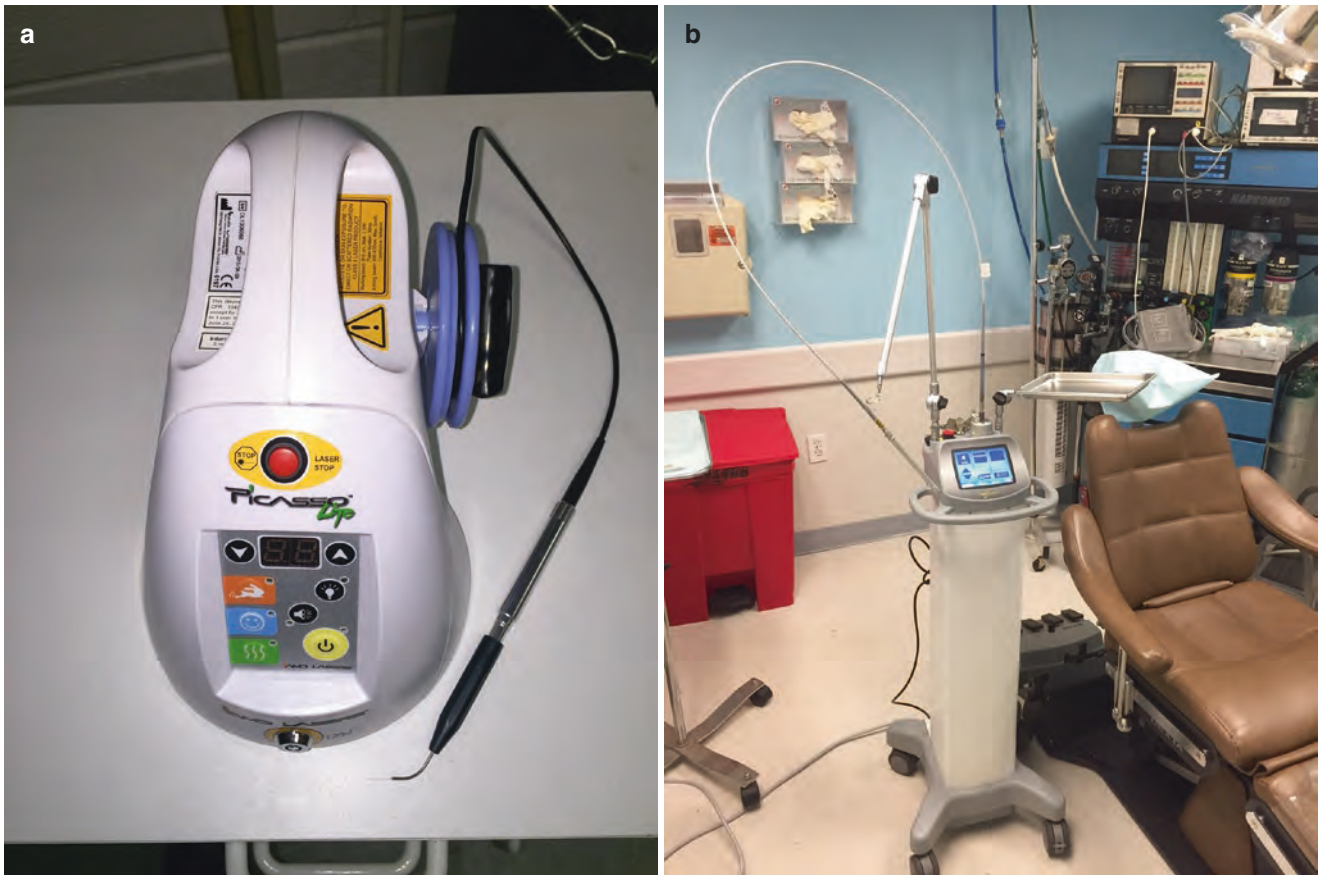
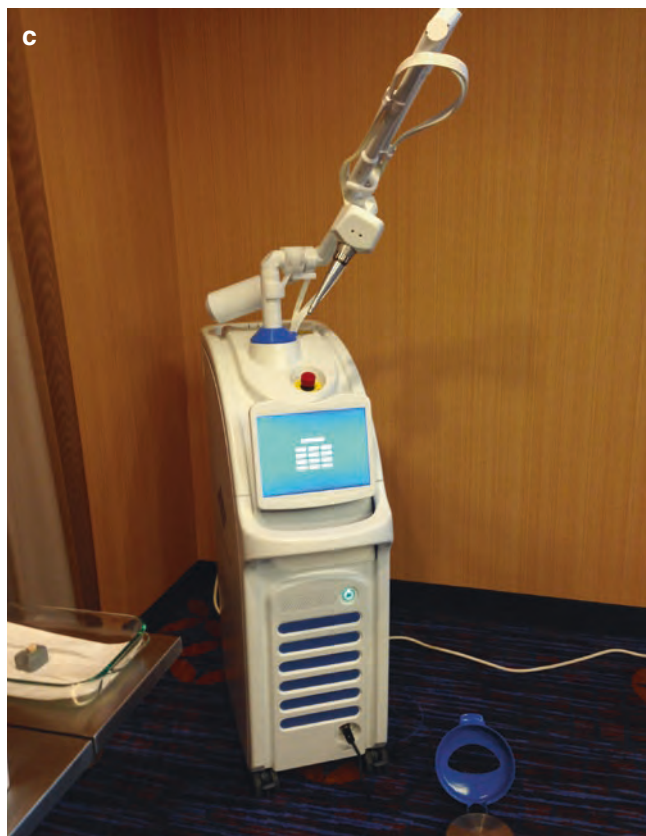
Fig. 39.2 (a) Fiberoptic laser. (b) Hollow waveguide laser. (c) Articulated arm laser



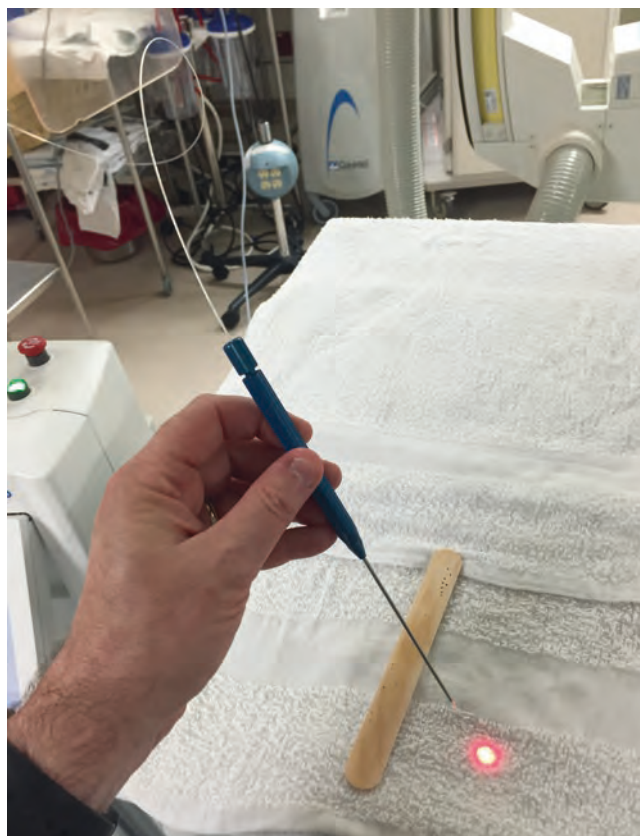©Association of Oral and Maxillofacial Surgeons of India

Fig. 39.2 (continued)

decreased [5]. Laser emission modes and the surgeon's hand speed can affect the temperature rise and effect in the tissues. Lasers can be emitted in "continuous-wave" mode or in a "pulsed mode." Lasers used in pulsed mode allow time for tissues to cool before the next pulse of laser radiation is started while continuous wave mode of laser must be stopped manually to allow the tissues to cool. The time between pulses can help avoid thermal effects on surrounding tissues or excessive thermal effect on target tissues. The lasers with pulsed mode of emission can be of two types, "gated pulsed" or "true pulsed." True-pulsed lasers are pulsed by a mechanism within the laser cavity, while the gated-pulsed lasers have a shutter-like mechanism outside the laser cavity [4].

39.2.1 Advantages of Laser

Lasers have obvious advantages, which make them superior to conventional cutting tools. An ability to provide better hemostasis is a great advantage for surgeons to maintain visibility and reduce blood loss. Since spot size, power, and time on



©Association of Oral and Maxillofacial Surgeons of India

Fig. 39.3 Low-level laser-aiming beam

target are regulated by the surgeon, lasers provide better control of desired tissue changes, which enhances the precision of surgery. Increased precision of the depth of tissue damage along with fewer myofibroblasts in laser wounds compared to scalpel wounds, allow for improved tissue healing and decreased scarring. The mentioned advantages are presumed to decrease postoperative pain with the use of lasers, although the pathophysiology for this effect is not well understood.

39.2.2 Disadvantages of Laser

Despite several advantages of lasers in surgery, the provider should make sure the benefits outweigh the risks and disadvantages. Hard-tissue lasers such as Er:YAG and Er:CR:YSGG do not match the speed of bone or tooth cutting as do conventional tools such as burs or saws. Soft-tissue healing after laser-assisted incision or excision is slower (although with decreased scarring) than tissue healing using scalpels. The associated learning curve and costs of the laser equipment add to the drawbacks of using lasers.

39.3 Selection of Lasers

The type of laser to be used is based on the laser's physical characteristics, interaction with the target tissues, and the goals of the procedure. For example, CO₂ laser's excellent affinity for water, which is the main component of soft tissues, makes it the most widely used laser for soft-tissue surgical applications. The most commonly used CO₂ laser is the 10,600-nm wavelength, although 9600-nm and other wavelength variants of this laser exist. The CO₂ laser is currently the most ideal laser used for most intraoral and extraoral soft-tissue procedures. The absorbed energy causes vaporization of the intracellular fluid causing tissue vaporization, while lateral heat conduction causes contraction of collagen and closure of blood vessels of approximately 500 μ or less in diameter. High-power CO₂ lasers are generally delivered via articulating arms, but new hollow waveguide systems suitable for office use provide increased accessibility intraorally along with their ease of use [6, 7].

Other lasers include the Nd:YAG (a crystal of Yttrium, Aluminum, and Garnet doped with the rare earth element Neodymium) laser, which functions in the near-infrared electromagnetic spectrum at 1064 nm, and has minimal water and superficial tissue absorption leading to deeper tissue penetration. Hence, the Nd:YAG can be used for coagulation of deeper and larger (2–3 mm) diameter vessels. These qualities of Nd:YAG have led to its use in treating angiomatous or vascular tissue lesions, although this same lack of water absorption limits its utility for the OMS. Depending on the desired effect, the Nd:YAG laser can be used both in contact and noncontact modes [8–10].

The Er:YAG laser works at a 2940-nm wavelength and is even more highly absorbed in water than the CO₂ laser leading to rapid absorption by the superficial layers of tissue and minimal penetration. This can be an advantage in some cases but also means that this laser is less effective on tissue than the CO₂ laser. As an example, when used for cosmetic skin resurfacing it shows much more superficial effects, which heal quite quickly, but also shows much less of a result than CO₂ laser does. For this reason, it has fallen somewhat out of favor for this purpose [11–15]. Owing to limitation of its thermal effects mostly in superficial layers of soft and hard tissue, Er:YAG laser has become popular in implant dentistry. It can be used on both soft and hard tissues and finds its application in bone preparation, second-stage surgery, treatment of peri-implantitis. Being reflected off the surface, it has minimal or no apparent adverse effects on dental implants [16].

The Holmium:YAG laser is generated at a 2100-nm wavelength, which enables it to be delivered in contact mode via fiberoptic cable also demonstrates very little water absorption but is well absorbed by other tissue components [17]. This allows it to be transmitted through water-rich environments while having similar tissue effects as the CO₂. Minimal lateral thermal damage, precise depth of cut, and good coag-



©Association of Oral and Maxillofacial Surgeons of India

Fig. 39.4 Diode laser

ulation combined with its ability to be used in presence of saline/lactated Ringer's solution makes it the preferred laser for operative TMJ arthroscopy [18].

Diode lasers at wavelengths between 805 and 980 nm have been reported to be compact, inexpensive, and easy to use in OMS procedures (Fig. 39.4). These can be used in continuous or pulse modes with contact or noncontact handpieces. However, it should be understood that these wavelengths are not well absorbed by soft tissues (although pigmented tissue will absorb it the most), the use of this laser wavelength would lead to very limited effects on surface tissue and very deep, poorly controlled, and undesirable tissue penetration. This is bypassed by using a material on the tip of the fiber that absorbs these wavelengths (either pigmented material such as ink paper or a suitable crystal material) and creates a red hot thermal tip, which is then used in surgery. In reality, the laser wavelength produced is not actually used for surgery; it is only absorbed by the fiber tip to essentially produce a thermal cautery. Although diodes are cheap and easy to use due to their fiberoptic contact tip, this thermal cautery effect rather than the use of the actual laser beam is very inefficient for surgery and severely limits its use by the OMS [19].

39.4 Applications of Lasers in Oral and Maxillofacial Surgery

Three basic categories of application of lasers in OMS can be classified as follows:

1. Incisional/excisional procedures
2. Vaporization (tissue ablation)-based procedures
3. Surgical hemostasis

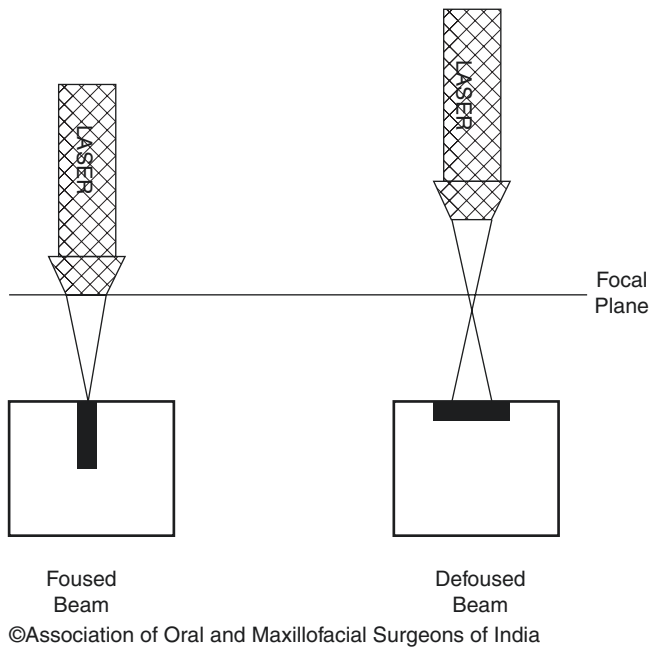


Fig. 39.5 Focused vs. defocused beam

Incisional procedures require a precise thin cut with careful control of the depth of the cut. The thickness or thinness of the cut with a laser is controlled by the spot size (usually 0.1–0.4 mm). The laser beam's focal length is usually between 1 mm and 1 cm, depending on the delivery system, and is where the smallest spot size can be achieved with maximum power density. This is called “focused mode” (Fig. 39.5). The laser can be controlled by a foot pedal, but it is often useful to limit time on tissue to speeds faster than a foot control allows. Hence, a “gated/pulsed mode” can be used to generate 2–20 pulses per second to create or mark a dotted outline with lesser depth and allow careful delineation of the margins of the excision. This is then followed by a continuous mode (using the foot pedal) to “connect the dots” and complete the excision. The settings to obtain a desired depth of cut vary from one tissue to another due their different water content and absorption coupled with the surgeon-controlled factors as mentioned earlier. It is not possible to have standard laser parameters for all types of tissues or lesions. The smallest spot size possible with 4–10 W power can be a good initial setting. The initial cut then gives the surgeon ability to observe the clinical effect and depth of incision, which then can be used to lead to adjustments of the power and time on target to achieve the desired changes. Common soft-tissue lesions that can be incised or excised using lasers include fibromas, mucoceles, epulis fissuratum, mucosal or gingival lesions, papillomas, etc. Wound closure after a laser-assisted incisional biopsy or excisional procedure is often unnecessary due to the limited scarring and excellent hemostasis and is up to the surgeon's discretion, as healing is excellent regardless of closure. Closure does not usually effect hemostasis or pain relief (Fig. 39.6a–c) [5].

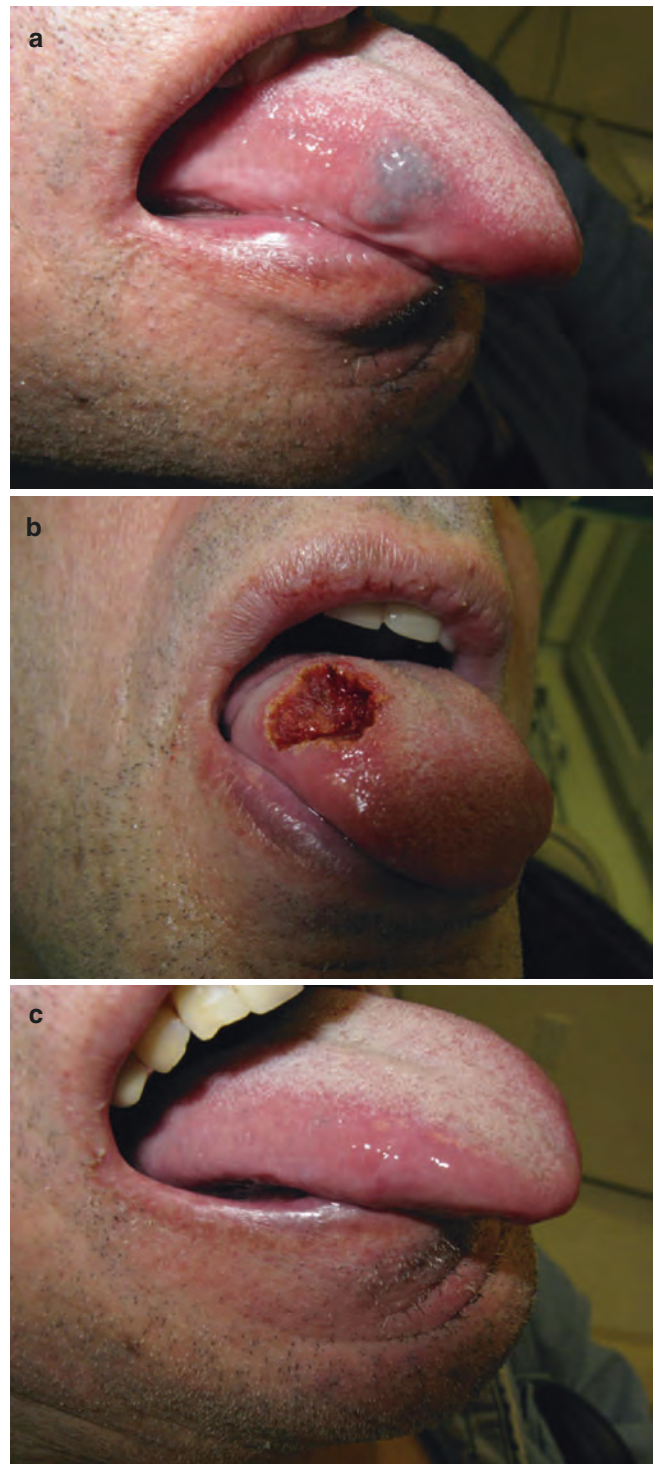


Fig. 39.6 (a) Lesion of tongue. (b) Tongue after laser excision with no closure. (c) Excellent healing

Ablative or vaporization procedures are done when the surgeon wants to remove only a superficial layer of the tissue. Lasers, cryotherapy, chemical peeling, and scalpel can be used for this purpose, but the precision of cut and control of the depth of tissue changes along with excellent hemo-

stasis make lasers the preferred tool for vaporization procedures. Lasers, when used for vaporization procedures, are used defocused so as to decrease the power density (the energy per unit area) and limit the depth of effect while increasing the area of the tissue ablation. The spot size used for vaporization ranges from 1.5 to 3 mm and allows large surface areas to be removed very superficially (literally cell layers at a time if desired). This is ideal for large but flat and superficial lesions such as hyperkeratosis, dysplasia, lichen planus, etc. The laser is again used in gated mode to carefully and precisely outline the margins. This is followed by passing the laser in overlapping “U”-shaped patterns to cover the entire area. The parameters can be adjusted by the surgeon, just as in incision cases, after the first pass is done at 4–10 W power. As implied by vaporization, there is no tissue available for biopsy in these cases. Hence, a definitive diagnosis should be established prior to performing ablative or vaporization procedures on mucosal lesions (Fig. 39.7a–c).

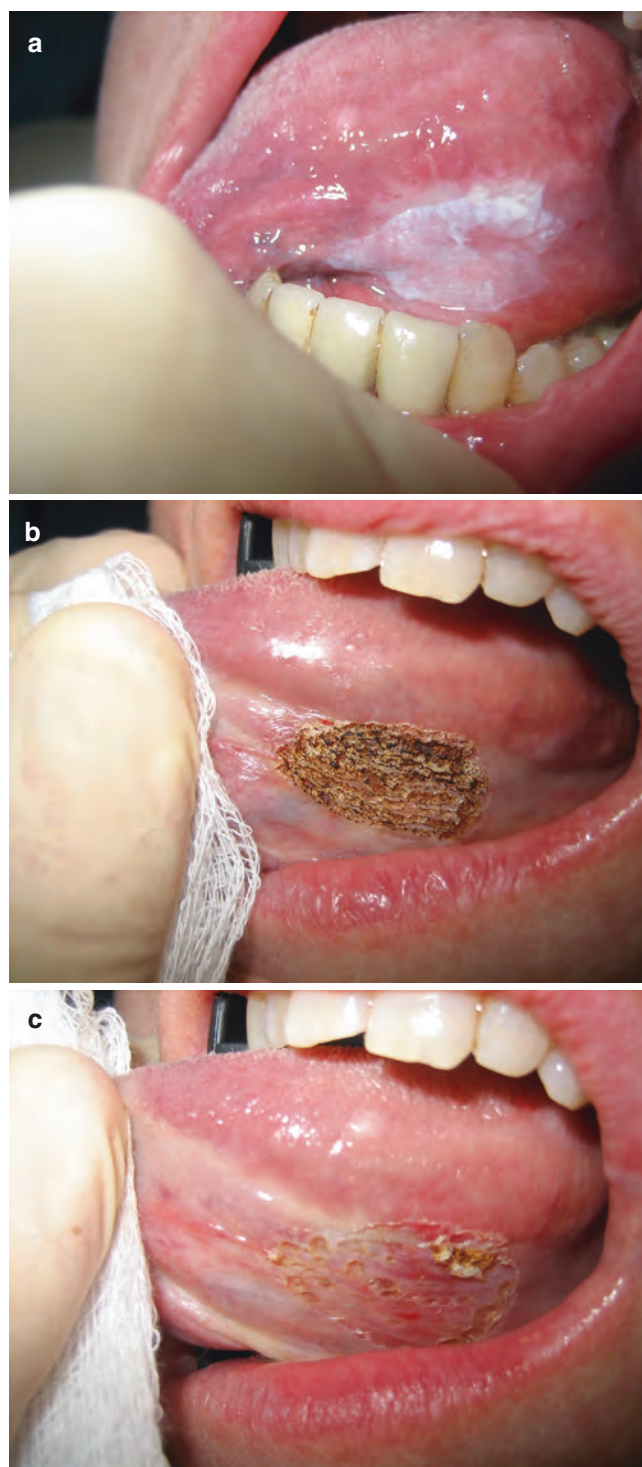
Due to the ability of CO₂ lasers to constrict blood vessels rather than coagulate blood, it can be an excellent tool to obtain hemostasis in most surgical wounds where the vessels are smaller than the thermal effect of the laser in tissue (about 500 μ). The lateral thermal effect of the laser beam should be equal to or greater than the diameter of the bleeding vessels. If the vessel is of larger diameter, conventional hemostatic techniques should be used. For small superficial vascular lesions, the CO₂ laser can be used to excise the lesion (since the feeding vessels are usually smaller than 500 μ), while deeper or larger vascular lesions are best treated using lasers that are specifically absorbed by hemoglobin, leading to true coagulation of the lesion itself [6].

39.5 Specific Examples of Application of Lasers in Oral and Maxillofacial Surgery

1. *Cosmetic facial surgery:*

The use of lasers in cosmetic surgery has changed these procedures significantly over the years. The advantages of lasers as previously described, including the capability of lasers to only affect the superficial layers of skin with precise depth control, turned out to be its critical advantage. Lasers in cosmetic facial surgery can be used both for incisional or ablation procedures based on indication [20].

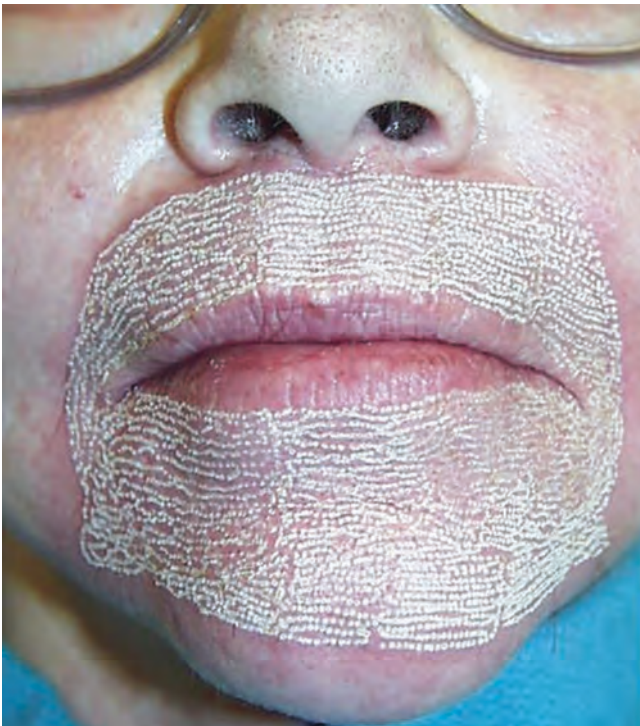Lasers used for laser skin resurfacing (removal of superficial skin wrinkles from the face) are an example of ablation or vaporization procedure. In skin resurfacing procedures, the superficial layers of the epidermis and



©Association of Oral and Maxillofacial Surgeons of India

Fig. 39.7 (a) Hyperkeratosis of lateral tongue. (b) Laser ablation of tongue. (c) Healing after laser ablation

papillary dermis are removed while leaving behind the reticular layer of the dermis with its adnexal structures. This layer, if intact, provides epithelial cells that are required for rapid re-epithelialization of skin in a uniform



©Association of Oral and Maxillofacial Surgeons of India

Fig. 39.8 Laser cosmetic skin resurfacing of face

manner. As opposed to chemical peels or dermabrasion, lasers offer more precise depth control, which is crucial in uniform healing and improved outcomes. CO₂ and the Er:YAG are the commonly used lasers for skin resurfacing, although recent improvements in the way CO₂ is used to improve results with lessened postoperative healing time, have severely diminished the use of the Er:YAG. Although the CO₂ laser is most commonly used and is more effective, it can be associated with long-term erythema and greater risk of scarring if exposure is done too deeply. Since CO₂ is a continuous-wave beam, which means that even at a short “pulse” the laser would be on tissue too long and lead to scarring, it must be electronically “pseudopulsed” at high powers to obtain the short times needed to reduce risk from lateral thermal damage to the unintended underlying dermis (roughly less than 1000 μs). On the contrary, the Er:YAG laser has less penetration in skin owing to its higher affinity to water in tissue. It is also a true pulsed laser and hence it allows higher power with shorter pulse duration. Although this is an advantage of Er:YAG laser, which helps reduce risk of excessive ablation and scarring, as mentioned before, it also decreases the effectiveness and results of the Er:YAG laser and most surgeons have abandoned its use in favor of newer CO₂ lasers that create very deep but thin vertical columns in the skin, allowing for tissue contraction with quick healing and less chance of scarring [21].

In skin resurfacing, as opposed to ablation of intraoral mucosal pathology, the passes of laser should not be overlapping to avoid excessive tissue ablation (Fig. 39.8). Computer pattern generator handpieces (CPG) can be used, which automatically create a uniform pattern of coverage on the skin (Fig. 39.9a, b) [22].

Skin resurfacing principles are also used in scar revision procedures. The prominence or visibility of a scar is mainly affected by the surface depression or elevation. The CO₂ and Er:YAG lasers can be used to reduce the elevation of the scar tissue or decrease the elevation of the surrounding skin to make a depressed scar tissue blend well with it (Fig. 39.10a–c). Healing scars can also have hypervascularity as evidence by prolonged erythema. This can be managed by decreasing the vascularity within the scar by use of vascular-specific lasers such as 532-nm KTP:YAG or Pulsed Dye Lasers (PDL) lasers [23].


In blepharoplasty, the CO₂ laser can be used to make a transconjunctival incision on the lower eyelid as well as the skin incision for the upper eyelid blepharoplasty. The use of laser to then excise muscle or fat with excellent hemostasis provides great visualization and tissue control (Fig. 39.11).

In endoscopic brow lift techniques, lasers are passed through either flexible fiberoptic cables or through small diameter hollow waveguide extensions in order to be used for incisions made within the optic cavity. The advantage of using lasers in endoscopic procedures is to provide precise incisions with excellent hemostasis, which aids in better visualization. Laser is used to incise the periosteum and/or muscle attachments. CO₂ laser is a commonly used laser for this purpose.

2. *Intraoral mucosal surgery:*

Lasers have been extensively used in intraoral mucosal surgeries. Common applications include incisional/excisional biopsy of intraoral soft-tissue lesions (Fig. 39.12a–c), frenectomy (Fig. 39.13a, b), ablation of premalignant lesions, preprosthetic procedures such as vestibuloplasty and excision of epulis fissuratum (Fig. 39.14a–d). As mentioned previously in this chapter, advantages of lasers stand superior compared to traditional scalpels in terms of wound healing, tissue handling, and hemostasis, which ultimately help improve patient experience when used for intraoral procedures as well. Vaporization or ablation of tissues intraorally is usually performed on premalignant lesions, commonly for white lesions such as hyperkeratosis or mild epithelial dysplasia. More severe dysplasias are best excised with the laser to allow for margin control. Definitive diagnosis with the help of a biopsy is a precursor for management of premalignant lesions with laser vaporization since there will be no specimen to biopsy [24].

Although diode, ND:YAG, Er:YAG and CO₂ lasers can be used for intraoral mucosal surgeries CO₂ lasers stand out as the workhorse and most studied laser over the



©Association of Oral and Maxillofacial Surgeons of India

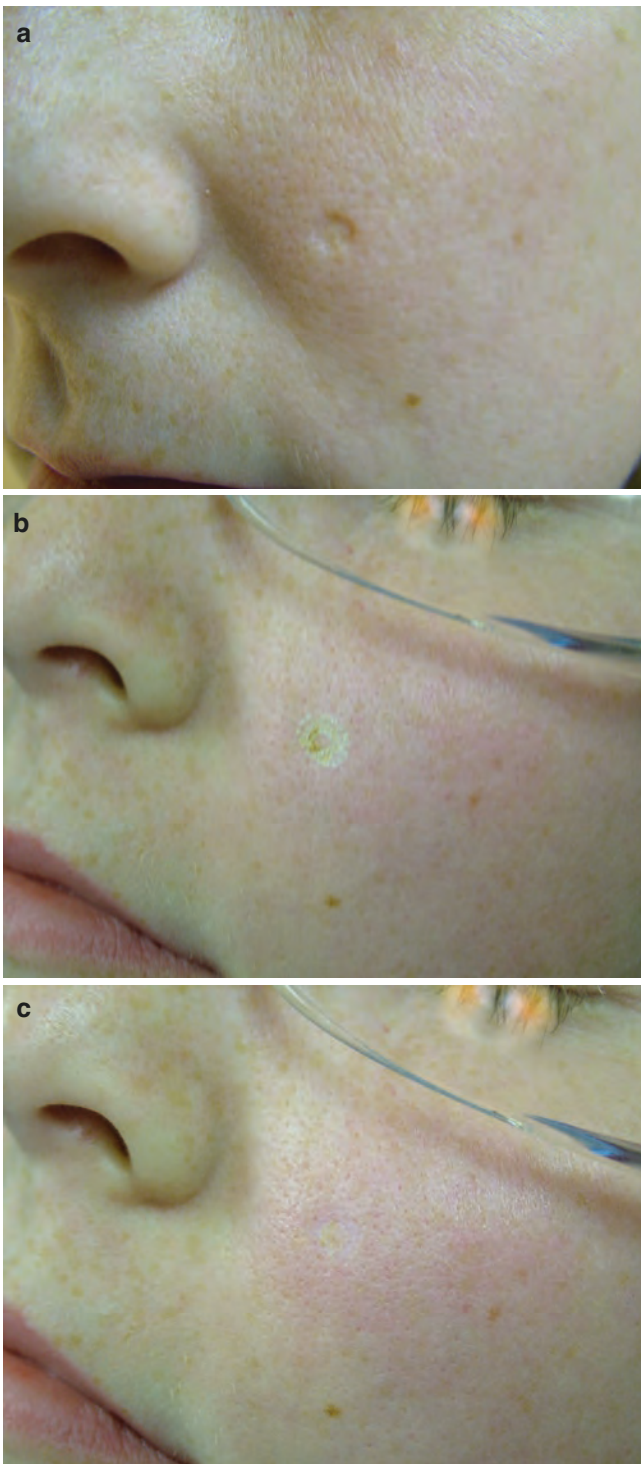
Fig. 39.9 (a) Computerized pattern generator (CPG) for laser skin resurfacing. (b) Optional patterns for CPG

past four decades. When using lasers intraorally on intended soft tissues, care must be exercised to protect adjacent hard/soft tissue from inadvertent damage or devitalization due to pulpal damage. This is done with either a moist gauze, a mouth guard, a wet tongue blade, or nonreflective plastic instrumentation [25]. The use of lasers as compared to scalpel is presumed to also provide a decreased chance for lymphatic and hematogenous seeding as an added advantage in the management of pre-malignant or malignant lesions. Principles and technique of incision and ablation have been detailed elsewhere in the chapter.

3. *Implant surgery:*

Lasers are also useful in the management of peri-implant soft tissues. 10,600-nm wavelength CO₂ laser and 980-nm diode are the commonly used soft-tissue lasers in implant surgery. ND:YAG laser, due to its inherent high depth of penetration and risk for damage to adjacent tissue and implant surface, is considered unsafe for use on implants. Er:YAG laser, which has been approved for use

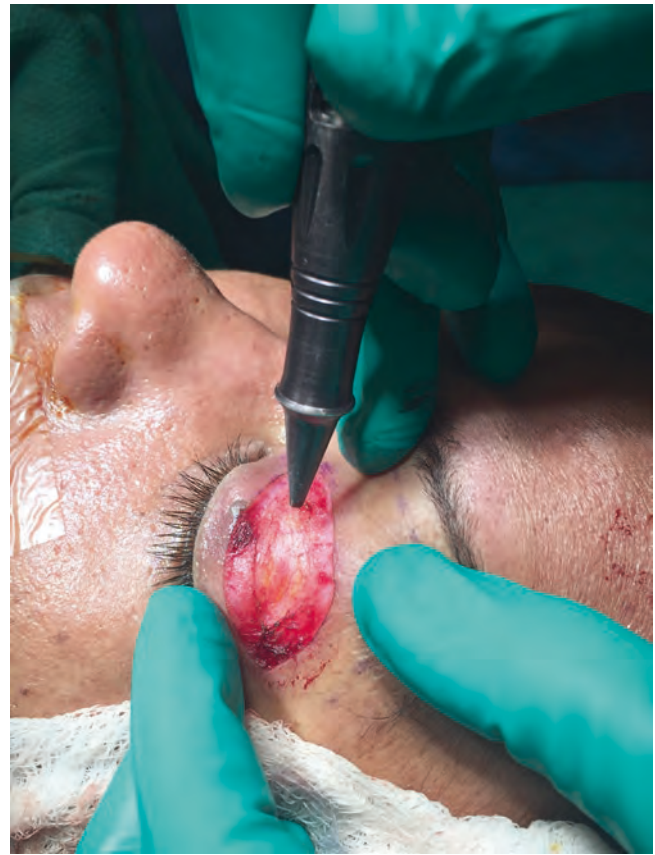on hard tissues, has been used in uncovering a thin layer of bone in second-stage implant uncovering and initiating the implant osteotomy, but there is need for further data on the use of Er:YAG for complete preparation of implant osteotomy. 9300-nm CO₂ laser has been used for hard-tissue applications, but more data on its safety and efficacy are needed. Advantages of using lasers in implant surgery include the precision, atraumatic tissue handling, bloodless field of view, and decreased bacterial contamination. Lasers have been used for several indications in implant surgery, including implant site preparation procedures such as the release of frenal attachment, excision of redundant tissue, and incision placement prior to bony osteotomy. Placement of incisions with lasers as opposed to scalpel creates less inflammation, swelling, and post-operative discomfort to the patient as well as added property of tissue sterilization from antibacterial effect. They can also be used for second-stage surgery, including removal of soft tissue and, in the case of Erbium lasers and 9300 nm CO₂ lasers, bone covering the implant [26].



©Association of Oral and Maxillofacial Surgeons of India

Fig. 39.10 (a) Depressed scar of face. (b) Blending of scar using CO₂ laser. (c) Results of laser scar revision

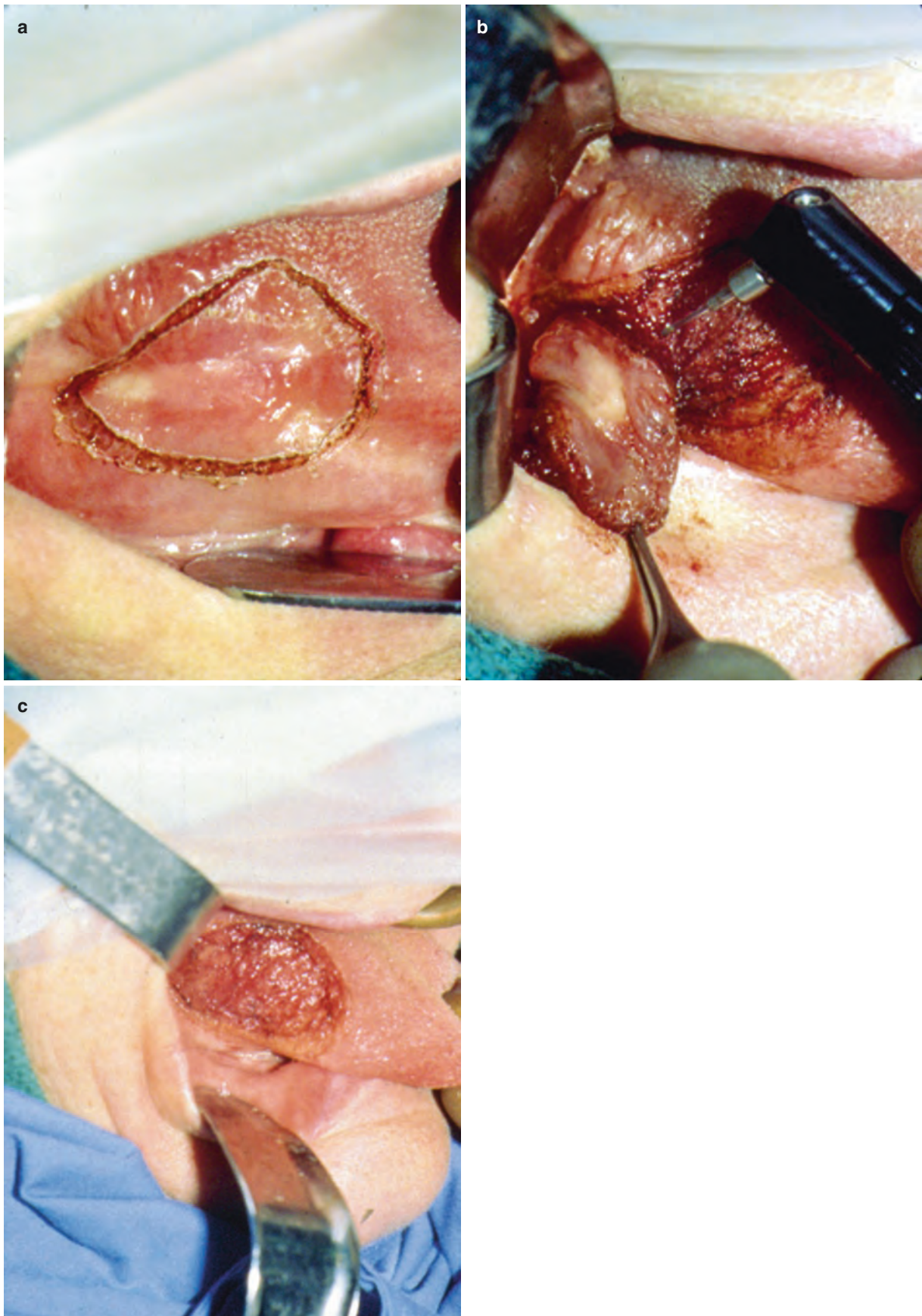
Treatment of mucositis and peri-implantitis around implants is a challenging problem in implant surgery with limited efficacy when managed via conventional treatment protocols. If an implant with signs of peri-implanti-



©Association of Oral and Maxillofacial Surgeons of India

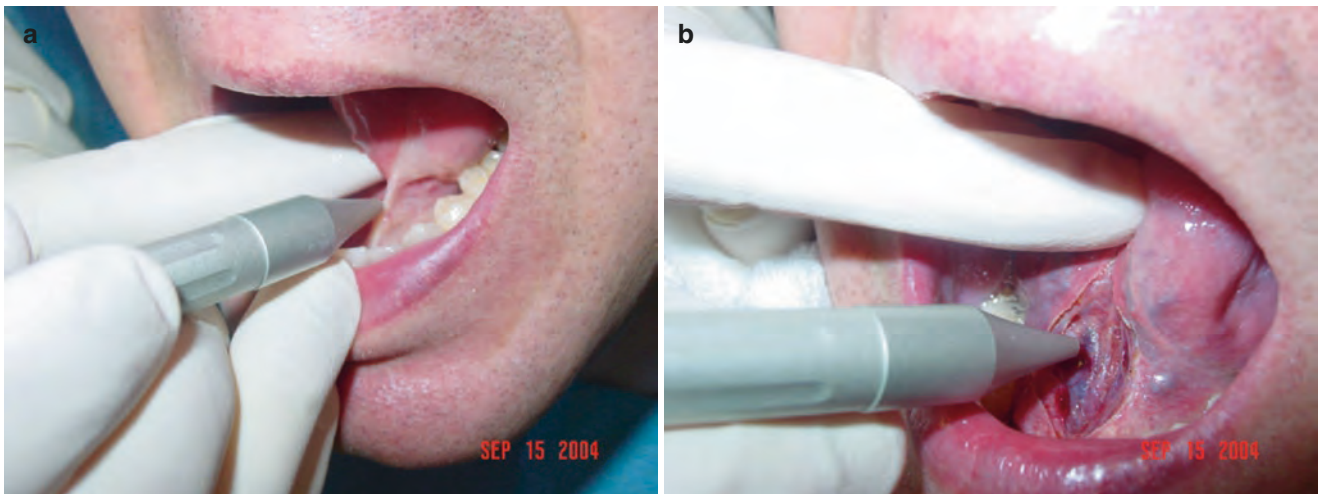
Fig. 39.11 Laser blepharoplasty

tis is deemed stable without severe bone loss and/or mobility, then treatment is attempted to salvage. Treatment of choice includes debridement of the granulation tissue accompanied by the administration of antibiotics around the implant for the eradication of as much bacteria as possible followed by bone graft of any defect created. Traditional tools include plastic instruments, citric acid, chlorhexidine, and topical Tetracycline. A laser-assisted algorithm for management of peri-implantitis includes obtaining access to the implant in question via a laser incision and reflection of flap leading to exposure of implant and surrounding bone. Then, the pathologic tissue is vaporized by laser energy and the implant surface and bony defect are decontaminated by the laser, which is accomplished by ablating the surface at low energies to kill off any bacteria on the surface as well as any attached soft tissue. Bone grafting, if necessary, can then be performed. Data have shown significantly better outcomes in cases of peri-implantitis as compared to conventional tools. As in other laser-assisted surgeries, healing is enhanced because of reduced inflammation and decreased postoperative pain as opposed to conventional tools [26] (Fig. 39.15a, b).



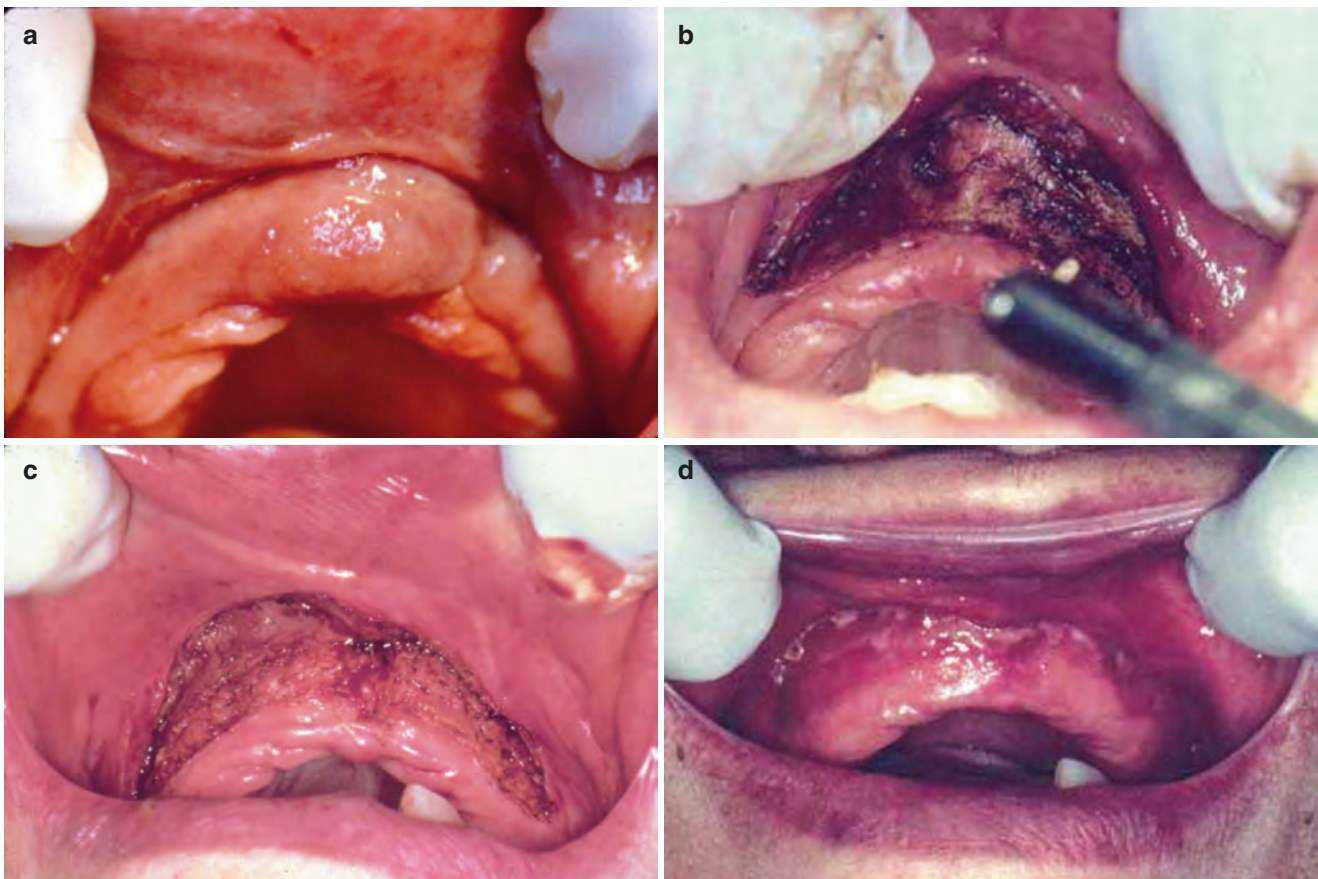
©Association of Oral and Maxillofacial Surgeons of India

Fig. 39.12 (a) Outlining a small tongue cancer for laser excision. (b) Excision of lesion with CO₂ laser. (c) Lesion excised and allowed to heal with no closure



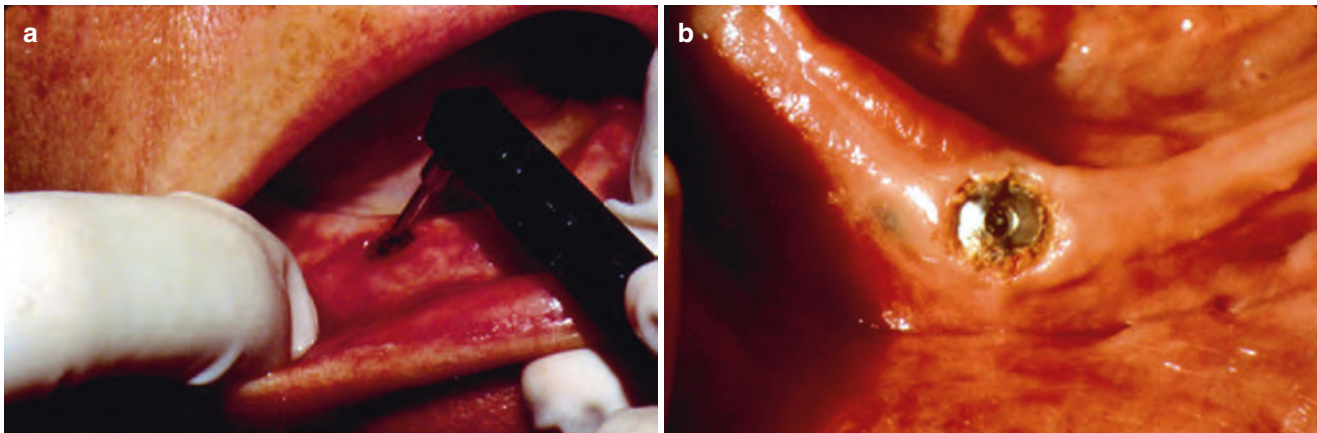
©Association of Oral and Maxillofacial Surgeons of India

Fig. 39.13 (a) Laser frenectomy with CO₂ laser. (b) After laser frenectomy



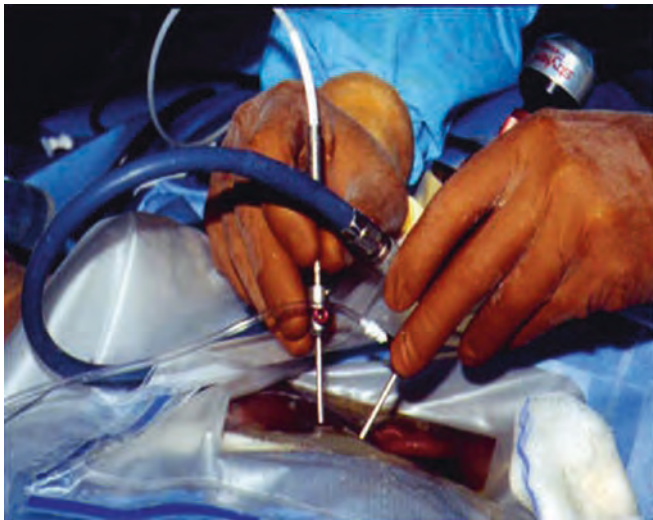
©Association of Oral and Maxillofacial Surgeons of India

Fig. 39.14 (a) Epulis fissuratum of maxilla. (b) Excision of epulis with CO₂ laser. (c, d) Supraperiosteal dissection allowed to secondary heal



©Association of Oral and Maxillofacial Surgeons of India

Fig. 39.15 (a, b) Implant uncovering with CO₂ laser



©Association of Oral and Maxillofacial Surgeons of India

Fig. 39.16 TMJ arthroscopy with Holmium YAG laser

4. *Temporomandibular joint surgery (TMJ):*

Arthroscopic TMJ surgeries have been proven to be efficacious, minimally invasive, and efficient procedures to treat and manage several aspects of temporomandibular joint disorders. Arthroscopic surgery utilizes various modified cutting instruments, which are passed through a narrow trocar to be able to release the disc attachments, remove redundant inflamed tissues, and/or perform synovial biopsies. These conventional cutting tools are difficult to maneuver, increase the risk of bleeding, which creates a poor visual field and a higher risk of complications. Use of lasers administered via narrow-diameter fiberoptic cables adds advantages in maneuverability, which makes it easier to sweep through the small-sized TMJ and make precise incisions and ablation with better hemostasis in a noncontact mode. Due to their high water absorption, CO₂ and Er:YAG lasers

cannot be used for this purpose. Ho:YAG is the commonly used laser for the purpose of TMJ arthroscopy. With low water absorption, it is less affected by the presence of the synovial and lavage fluids, while low penetration (~0.5 mm) decreases the risk of damage to adjacent tissues. Other TMJ procedures such as disk repositioning and removal have been described with the use of arthroscopic techniques and laser assistance with significant success (Fig. 39.16) [17, 18].

39.6 Safety Concerns with Use of Lasers

Efficient and safe use of lasers starts with operator's familiarity with details of the laser system in use. All laser systems come with a user's manual, which lists all required technical details as well as recommended indications for use of that laser system. Common safety issues with lasers happen with accidental exposure of surrounding tissues.

1. *Personnel protection:*

Patients, providers, and the assistants are all at risk of inadvertent irradiation with lasers. Any reflective surface in the area of laser target can divert the beam away from the intended area and potentially cause harm. Use of special protective glasses (that are matched to the specific wavelength of the laser) can help avoid injury to eyes of patients or personnel in the operatory. Everyone in the operatory should be familiar with the basic functioning of the laser equipment and nonreflective tools should be used and reflective surfaces intraorally such as crowns be protected with a wet sponge or nonreflective retractors. Posting a "danger" sign for use of laser on the door of the operatory in order to avoid unprotected personnel from entering the room, while laser is in use could avoid accidental injuries as well (Fig. 39.17a, b) [6].



©Association of Oral and Maxillofacial Surgeons of India

Fig. 39.17 (a) Wavelength-specific eyewear for protection of operator, patient, and assistants. (b) “Danger” sign outside the operatory along with closure of any see-through glass panels on the door

2. Fire hazard:

Lasers in an oxygen-rich environment such as the oral cavity of a patient being provided supplemental oxygen, or inside an endotracheal tube, can pose a significant fire risk. To avoid fire, supplemental O₂ concentration should be kept to a minimum required level or use of room air is recommended. For endotracheal tubes, compressed air can be substituted for oxygen to keep the inspired concentrations of oxygen to below 30% [6].

3. Laser plume:

When a laser is used for incision or vaporization procedures, the tissue that is being handled will create a “plume,” which consists of potentially hazardous particulate debris, which is considered infectious. There are studies, which showed the presence of viral DNA in the plume, but to date there hasn’t been any clinical significance or transmission proven. Nevertheless, for protection of the provider/staff, high flow suction made of a nonreflective material such as plastic should be used to remove the plume. Wearing masks and other personal protective barriers such as eyeglasses will help avoid infection transmission as well [27–29].

39.7 Conclusion

Lasers have changed the OMS practice significantly to a point that it is today an essential surgical tool in many ways. Development of lasers in future may overcome current disadvantages and increase utility and safety. Use of lasers in hard tissue is still somewhat limited in comparison to soft-tissue applications. Further research and development could help improve this aspect of laser. Disclosure Authors have no financial conflicts to disclose.

References

1. Hecht J. Beam the race to make the laser. Oxford: Oxford University Press; 2005.
2. Maiman T. Comments on his precocious five-year-old [editorial]. *Laser Focus*. 1965;1:2–4.
3. Sulewski JG. Einstein’s “Splendid Light”: origins and dental applications. In: Convissar R, editor. *Principles and practice of laser dentistry*. 2nd ed: Elsevier Health Sciences; 2016. p. 1–11.
4. Coluzzi DJ, Convissar RA, Roshkind DM. *Laser fundamentals*. In: Convissar R, editor. *Principles and practice of laser dentistry*. 2nd ed: Elsevier Health Sciences; 2016. p. 12–26.

5. Strauss RA, Fallon SD. Lasers in contemporary oral and maxillofacial surgery. *Dent Clin N Am.* 2004;48(4):861–88.
6. Strauss RA, Coleman M. Lasers in major oral and maxillofacial surgery. In: Convissar R, editor. *Principles and practice of laser dentistry.* 2nd ed: Elsevier Health Sciences; 2016. p. 234–50.
7. Barak S, Kaplan I, Rosenblum I. The use of the CO2 laser in oral and maxillofacial surgery. *J Clin Laser Med Surg.* 1990;10:69–70.
8. Bradley P. A review of the use of the neodymium YAG laser in oral and maxillofacial surgery. *Br J Oral Maxillofac Surg.* 1997;35(1):26–35.
9. Romanos G. Clinical applications of the Nd:YAG laser in oral soft tissue surgery and periodontology. *J Clin Laser Med Surg.* 1994;12:103–8.
10. White J, Goodis H, Rose C. Use of the pulsed Nd:YAG laser for intraoral soft tissue surgery. *Lasers Surg Med.* 1991;11:455–61.
11. Khatri KA, Ross V, Grevelink JM, Magro CM, Anderson RR. Comparison of erbium:YAG and carbon dioxide lasers in resurfacing of facial rhytides. *Arch Dermatol.* 1999;135:391–7.
12. Li Z, Reinisch L, Van de Merwe W. Bone ablation with Er:YAG and CO2 laser: study of thermal and acoustic effects. *Lasers Surg Med.* 1992;12:79–85.
13. Arnabat-Dominguez J, Espana-Tost AJ, Berini-Ayres L, Gay-Escoda C. Erbium:YAG laser application in the second phase of implant surgery: a pilot study in 20 patients. *Int J Oral Maxillofac Implants.* 2003;18:104–12.
14. El-Montaser M, Devlin H, Dickinson MR, Sloam P, Lloyd RE. Osseointegration of titanium metal implants in erbium-YAG laser-prepared bone. *Implant Dent.* 1999;8:79–85.
15. Walsh L. The use of lasers in implantology: an overview. *J Oral Implantol.* 1992;18:335–40.
16. Kreisler M, Kohnen W, Marinello C, Gote H, Duschner H, Jansen B, dHoedt B. Bactericidal effect of the Er:YAG laser on dental implant surfaces: an in vitro study. *J Periodontol.* 2002;73:1292–7.
17. Hendler BH, Gateno J, Moar P, Sherk HH. Holmium:YAG laser arthroscopy of the temporomandibular joint. *J Oral Maxillofac Surg.* 1992;50:931–4.
18. Koslin M. Laser applications in temporomandibular joint arthroscopic surgery. *Oral Maxillofac Surg Clin N Am.* 2004;16(2):269–75.
19. Romanos G, Nentwig G. Diode laser (980 nm) in oral and maxillofacial surgical procedures: clinical observations based on clinical applications. *J Clin Laser Med Surg.* 1999;17:193–7.
20. Mitchell O, Blackhall K, Lister T, Downie I. The use and application of lasers in oral and maxillofacial surgery. *Br J Oral Maxillofac Surg.* 2017;55(10):E155.
21. Guttenberg SA, Emery RW III. Laser physics and tissue interaction. *Oral Maxillofac Surg Clin N Am.* 2004;16(2):143–7.
22. Watson SW, Sawisch TJ. Cosmetic ablative skin resurfacing. *Oral Maxillofac Surg Clin N Am.* 2004;16(2):215–30.
23. Boyden DK. A brief overview of noninvasive lasers in cosmetic maxillofacial surgery. *Oral Maxillofac Surg Clin N Am.* 2004;16(2):231–7.
24. Wlodawsky RN, Strauss RA. Intraoral laser surgery. *Oral Maxillofac Surg Clin N Am.* 2004;16(2):149–63.
25. Stephen Brandon M, Strauss RA. Complications of CO2 laser procedures in oral and maxillofacial surgery. *Oral Maxillofac Surg Clin N Am.* 2004;16(2):289–99.
26. Julian J. Lasers in implant dentistry. In: Convissar R, editor. *Principles and practice of laser dentistry.* 2nd ed: Elsevier Health Sciences; 2016. p. 107–30.
27. Bellina JH, Stjernholm RL, Kurpel JE. Analysis of plume emissions after papovavirus irradiation with the carbon dioxide laser. *J Reprod Med.* 1982;27:268–70.
28. Mullarky MB, Norris CW, Goldberg ID. The efficacy of the CO2 laser in the sterilization of skin seeded with bacteria: survival at the skin surface and in the plume emission. *Laryngoscope.* 1985;95:186–7.
29. Walker NPJ, Matthews J, Newson SWB. Possible hazards from irradiation with the carbon dioxide laser. *Lasers Surg Med.* 1986;6:84–6.

Open Access This chapter is licensed under the terms of the Creative Commons Attribution 4.0 International License (<http://creativecommons.org/licenses/by/4.0/>), which permits use, sharing, adaptation, distribution and reproduction in any medium or format, as long as you give appropriate credit to the original author(s) and the source, provide a link to the Creative Commons license and indicate if changes were made.

The images or other third party material in this chapter are included in the chapter's Creative Commons license, unless indicated otherwise in a credit line to the material. If material is not included in the chapter's Creative Commons license and your intended use is not permitted by statutory regulation or exceeds the permitted use, you will need to obtain permission directly from the copyright holder.





Piezosurgery in Oral and Maxillofacial Surgery

40

Shravan Renapurkar and Sowjanya Nagamalla

40.1 Introduction

The term “piezo” has been derived from the word “Piezien,” which implies pressure in the Greek language. Piezoelectric effect was first described by Jacques and Pierre Curie in 1880 and involves the appearance of an electric charge across certain crystals when they are under mechanical pressure. Inversely, when an electric current is applied across them, they deform. This phenomenon of deformation when under alternating current creates microvibrations or oscillations of ultrasonic frequency [1]. Although ultrasonic microvibration technology was experimentally used earlier, it was in 1988 that Italian oral surgeon Tomaso Vercellotti developed the first commercially available Mectron® piezoelectric bone surgery unit to cut bone tissue while minimizing the limitations of conventional tools [2, 3]. The first use of piezoelectric surgery was for osteotomies by oral and maxillofacial surgeons and later on used for neurosurgical and orthopedic procedures. This revolutionary tool not only lowers the chance of damage to adjacent vital soft-tissue structures such as nerves and vessels during osteotomies, but also preserves osteocytes, which in turn complements bone healing [4, 5].

40.2 Equipment and Principles of Use

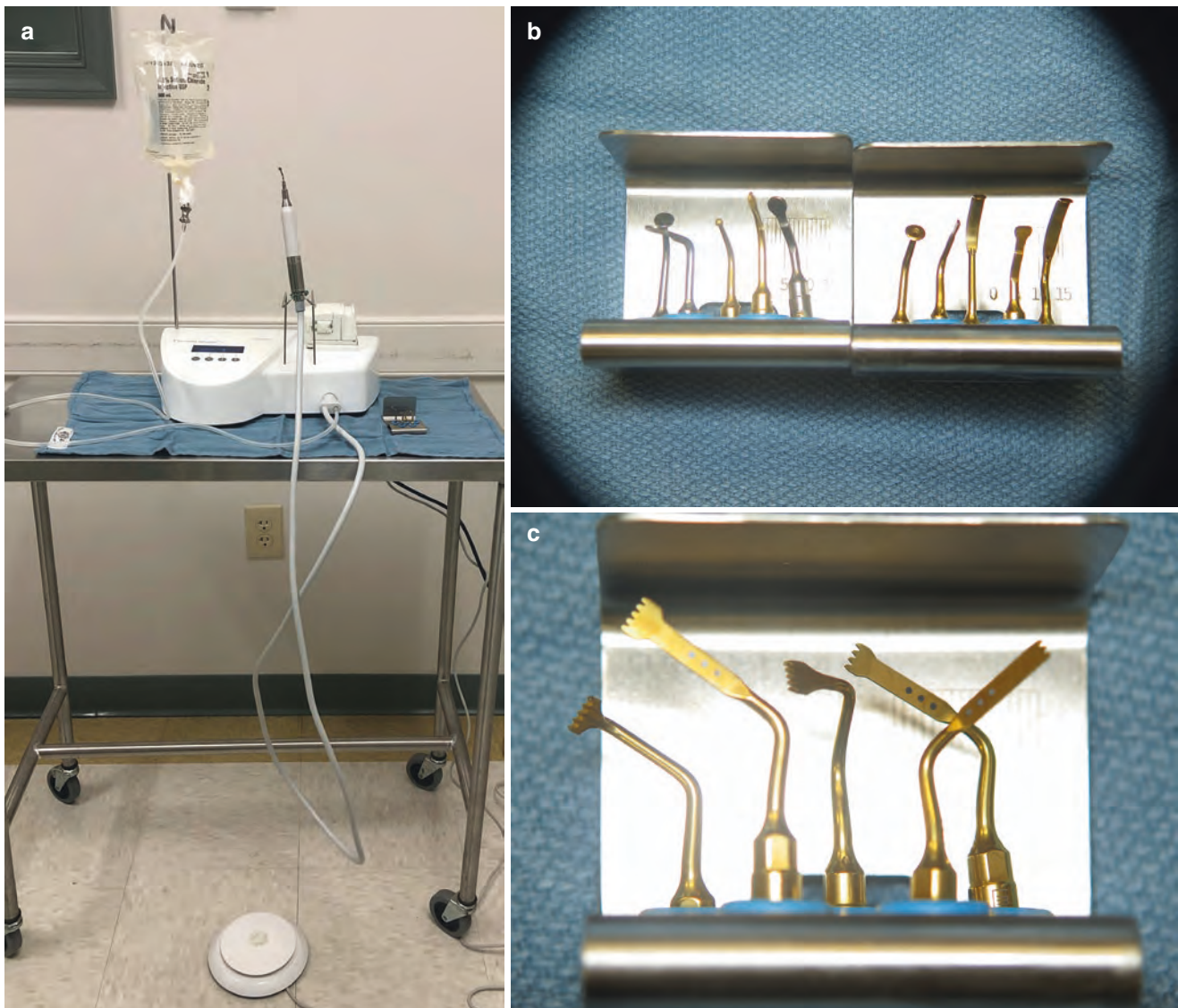
Piezoelectric surgery devices are generally small portable units comprising a handpiece with a working tip and a foot control switch, which are connected to the main power-generating unit. The main power unit also features holders for the handpiece and irrigating/cooling fluid (Fig. 40.1a–c). The handpiece is the critical part of this device, containing within it the ceramic chips where the microvibrations are created and later transmitted to the working tip. Commonly

used ceramic chips in Piezoelectric surgery units are Barium Titanate or an equivalent material. The amount of deformation in the crystals within the handpiece and resultant vibrations in the insert depend on the power applied [6].

The working tips of a piezoelectric system used for surgical purposes are interchangeable inserts, which can be of different shapes, sizes, and cutting edges based on the intended clinical applications. These inserts can be made of different materials and be coated with titanium or a diamond layer to improve the cutting efficiency. To create a cutting effect rather than a debriding effect, the vibrations of the insert enter into a resonance with the ceramic chips, which increases the energy output. This, combined with the form of the insert, acts like a micrometric oscillating saw. The main energy unit has an interactive touchpad, which allows the operator to control the frequency of vibrations, power of the unit, and the amount of irrigating or coolant fluid. The pressure applied on the insert can also be manually controlled by the operator and can affect the frequency delivered to the target tissue, which in turn affects the cutting efficiency. When higher pressure is applied at the tip, it impedes the cutting efficiency of the insert and releases the energy as heat, which is detrimental to the bone as well as adjacent soft tissue [6, 7].

The Piezoelectric unit also allows for election of modes of operation, which are preset power modes with varying frequencies to match the clinical application. The frequency is usually set between 25 and 29 kHz, which can create micro-oscillations of 60–210 μm amplitude, providing the handpiece with power exceeding 5 W. The vibrations produced in the “Low mode” result from average ultrasonic powers, without frequency overmodulation, and allow the operator to perform endodontic procedures. On the contrary side, the “high mode” and the “boosted mode” are characterized by vibrations with higher ultrasonic power and frequency overmodulation, which allows cutting of mineralized tissue. The “boosted mode” has frequency overmodulation with an increased rate that is most efficient for osteotomy and osteoplasties in surgical procedures, while the “high mode” is less

S. Renapurkar (✉) · S. Nagamalla
Department of Oral and Maxillofacial Surgery, Virginia
Commonwealth University Medical Center, Richmond, VA, USA
e-mail: srenapurkar@vcu.edu; nagamallas@vcu.edu



©Association of Oral and Maxillofacial Surgeons of India

Fig. 40.1 (a) The Piezosurgery® unit from Mectron® is made of a power supply unit, a handpiece, its holder, an irrigant solution holder, foot control switch. (b, c) Inserts or working tips of a piezosurgery unit. (b) shows working tips for Sinus lift and (c) shows osteotomy tips

efficient but more helpful in periodontal procedures and bone smoothing [6–8].

The device includes an irrigating system for cooling that creates an adjustable jet of coolant solution through a peristaltic pump at rates between 0 and 60 ml/min and helps remove debris from the cut surface and helps maintain hemostasis because of its cavitation effect. This enhances visibility, particularly in difficult-to-reach anatomical zones, by scattering coolant liquid as an aerosol. The irrigation liquid should be refrigerated at 4 °C for effectual cooling [6, 8, 9].

For optimal use and maximum efficiency, the operator could select the proper power based on the surgical tissue, apply light pressure with the tip, and adjust the rate of deliv-

ery of the irrigating solution to avoid overheating the tissue and decrease the chance of damage to soft tissues. Although the device has a safe frequency range along with the cooling irrigation liquid, there is a possibility of damage to soft tissues due to high pressure and overheating [10].

40.3 Advantages

Used in many therapeutic surgical procedures, piezosurgery has several advantages when compared to traditional methods of surgical instrumentation used for osteotomies or osteoplasty. These are as follows:

- *Decreased risk of damage to adjacent soft tissues:* This is the major advantage with use of a piezoelectric surgical unit. When used as recommended, at the appropriate frequency, the micrometric oscillating motion decreases the chance of damage or cutting of adjacent soft tissue while cutting through hard tissues. For example, it allows improved Schneiderian membrane preservation during osteotomy of the maxillary lateral wall during a sinus lift and preservation of the inferior alveolar nerve (IAN) during mandibular osteotomy.
- *Improved visibility:* With use of piezosurgery, better visibility is secondary to the decreased amount of bleeding and the phenomenon of cavitation. Cavitation refers to the phenomenon of “microboiling” occurring in liquids in a solid-liquid interface at intermediate frequencies of vibration secondary to the creation of imploding bubbles when the irrigating solution contacts the insert. Improved visibility helps the operator to place the osteotomy in the preferred location with increased accuracy [6].
- *Increased patient comfort:* Due to the micrometric nature of the vibrations and decreased noise, use of a piezosurgery device improves patient comfort and decreases anxiety during procedures done under local anesthesia. When used for bone harvesting, it also reduces the need for use of chisels, which can help improve the patient experience and reduce stress.
- *Improved survival of osteocytes:* Bone harvested with various techniques, including rotary instruments, chisels, rongeurs, and a piezosurgery device, was studied with histomorphometry evaluation by Berengo et al. The piezosurgery device was shown to be one of the best methods of harvesting bone along with gouge chisels, back action chisels, and rongeurs in terms of the viability of the harvested bone and number of osteocytes. Bone harvested with rotary instruments, including burs and safe scrapers, was noted to be completely nonvital with an absence of osteocytes. In another histomorphological study done with the placement of porous titanium implants in minipig tibias, neo-osteogenesis was noted to be consistently more active in bony samples from implant sites that were prepared using piezoelectric surgery, and there was an earlier increase in BMP-4 and TGF-2 proteins and fewer proinflammatory cytokines in bone around the implants [5, 11].

40.4 Disadvantages/Limitations

Although piezosurgery has numerous advantages as listed here, it is associated with some drawbacks as follows:

- *Low efficiency/increased operating time:* One of the major drawbacks with ultrasonic/piezo surgery osteotomes is the increased time required for the procedure. The cutting

efficiency of a piezosurgery device has been reported to be 3–4 times less than that of conventional osteotomes for some procedures [12, 13]. For example, in a randomized prospective crossover clinical study done by Stefano Sivolella, piezoelectric osteotomy of a lower third molar took 9.4 min longer than rotary tools to complete [14].

- *Expense:* The cost of equipment is sometimes an additional burden to the provider. Each individual cutting tip in a piezosurgery equipment setup is generally more expensive than traditional cutting tools such as burs, chisels, or saw blades. These tips can also potentially break or fracture when improperly used, which can again increase the need for more equipment.
- *Learning curve:* Use of piezo requires a short learning curve to attain maximum efficacy, which could be frustrating to the operator. The digital pressure applied by the surgeon while using conventional tools such as saws and drills is quite different from piezoelectric surgery as it mandates less pressure and failing to calculate the pressure according to the speed of the insert prevents microvibrations of the insert. When the microvibrations are prevented due to excessive pressure on the working tip, energy not used for cutting will be transformed into heat, which, if it continues for long time, would damage the tissue.
- *Pacemakers and defibrillators:* Piezosurgery is *relatively* contraindicated for use in patients with pacemakers, although there is no evidence of electromagnetic interactions produced by piezoelectric devices according to one in vitro study [15].

40.5 Applications for Piezosurgery

40.5.1 Dentoalveolar Procedures

Piezosurgery can be applied toward multiple dentoalveolar procedures where there is a requirement for meticulous bone preparation, atraumatic tooth extraction/exposure, and when the location of the surgical site is in proximity to vital anatomical structures. Example of applications in dentoalveolar surgery include ankylotic tooth root extraction, impacted third molar extraction, surgical exposure of impacted teeth, and extractions in patients with a thin periodontal biotype. In all of these indications, piezosurgery has the potential to limit bone loss and maximize maintenance of alveolar bone integrity, especially when the alveolar bone is thin and the procedure requires a high degree of precision. A split-mouth design, randomized, clinical trial conducted by Mantovani et al. studied differences in postoperative pain, orofacial swelling and duration of the procedure when using a rotary bur for third molar osteotomy versus a piezosurgery device. They found that, although the duration of the procedure was longer, the postoperative pain and swelling were less in the piezosurgery group [16].

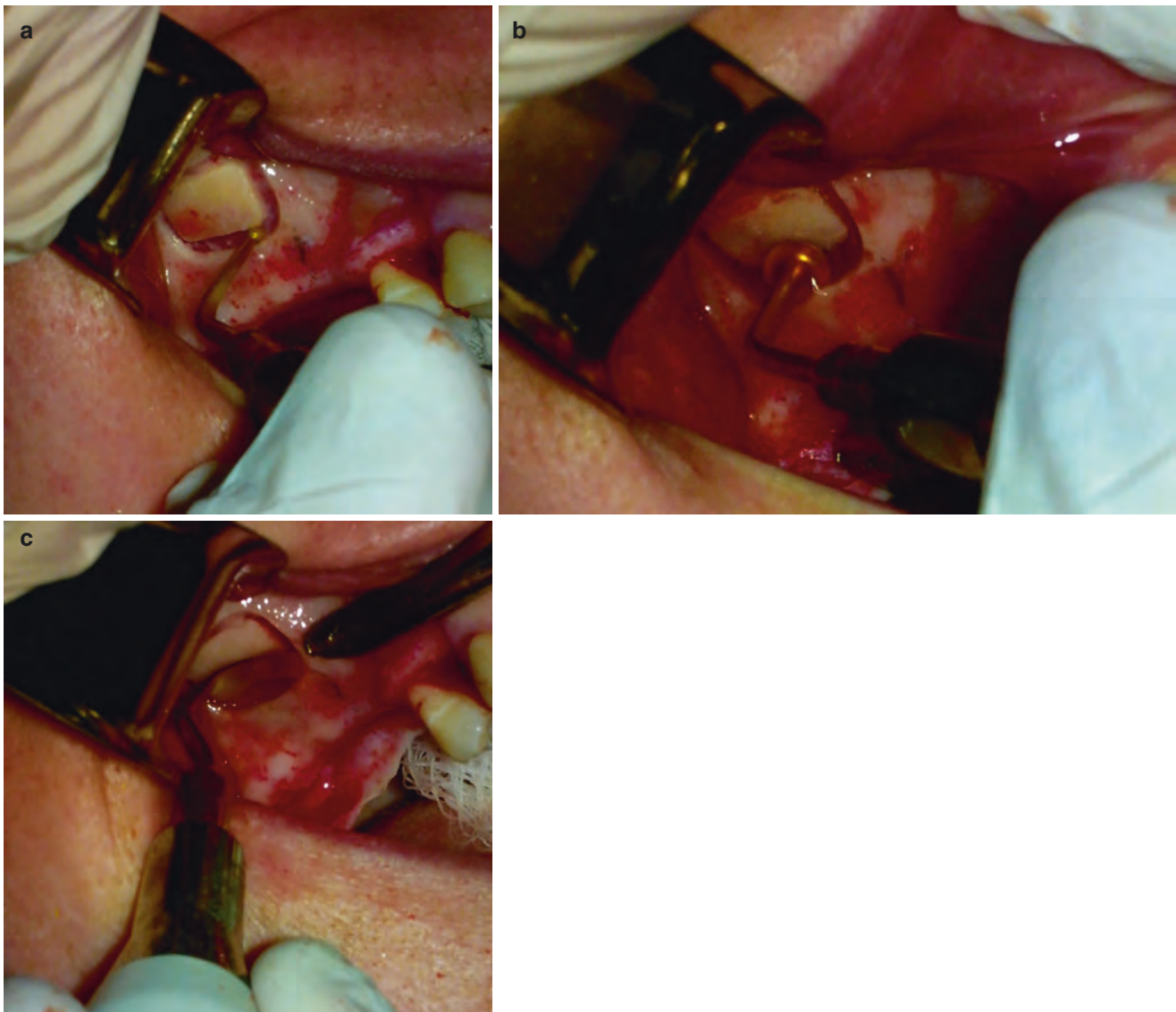
40.5.2 Dental Implant Surgery

40.5.2.1 Sinus Floor Elevation

Perforation of the Schneiderian membrane during lateral wall osteotomy, and/or while raising the maxillary sinus floor manually, is a common complication, which can affect the bone grafting procedure. Use of piezosurgery in sinus lift procedures not only minimizes the chance of perforation during osteotomy but also eases the separation of the membrane as well (Fig. 40.2a–c). In the commonly used lateral approach technique for sinus lift, piezoelectric devices have a superior action in each technique or step compared to

traditional instruments. The chance of membrane perforation with conventional techniques is reported to be 14–56%, while studies on the use of piezosurgery devices report it to be 5–7% [8, 17, 18].

- **Thinning buccal wall:** With traditional instruments, it is difficult to thin the buccal wall with good control. Piezoelectric device makes precise osteoplasty easy and the bone fragments produced during osteoplasty can be used as grafting material.
- **Bony window/osteotomy:** Piezosurgery makes the frame of the bony window optimal with respect to the sinus



©Association of Oral and Maxillofacial Surgeons of India

Fig. 40.2 (a) Piezosurgery insert used to perform outline of the lateral wall osteotomy to thin the wall. (b) Blunt piezosurgery insert used to infracture the window wall and initiate the separation of the Schneiderian membrane from the sinus wall. (c) After the lateral sinus wall oste-

otomy completed, membrane separation initiated a third insert shaped as an elevator used to continue the separation of the membrane to create required space for the bone graft for augmentation

anatomy with decreased chance of membrane perforation.

- Sinus membrane separation: Most commercially available piezosurgery devices have special inserts that make the separation around the perimeter of bony window easier and decrease chance of tear or perforation during the manual lifting process.

40.5.2.2 Implant Site Preparation

Implant site healing and ultimate osseointegration of implants is negatively influenced by the high temperatures created during site preparation. Results of an in vitro study done by Heinemann et al. in 2012 on porcine jaws comparing piezosurgery, Sonicflex®, and rotary instruments showed the highest temperature rise with use of piezosurgery, although the trabecular bone and osteocytes were still intact [19]. On the contrary, a recent randomized, controlled clinical trial by Da Silva Neto et al. in 2014 compared implant stability at various times postoperatively in osteotomies performed by conventional rotary instruments versus piezosurgery devices, and found implant stability to be higher with Piezosurgery [20]. The use of piezoelectric devices facilitates the use of selective enlargement of only one socket wall and Vercellotti called this: “differential ultrasonic socket preparation.” [4].

40.5.2.3 Alveolar Ridge Splitting

Ridge-splitting techniques for alveolar augmentation is indicated when there is adequate height of bone for implant placement but inadequate ridge thickness. The conventional ridge-splitting procedure uses chisels, rotary instruments, or saws, all of which have a high risk for damage to soft tissue, undesired propagation of the osteotomy and bone fracture, as well as prolonging treatment time due to the need for second-stage surgery to place the implants. (Fig. 40.3a, b) With use

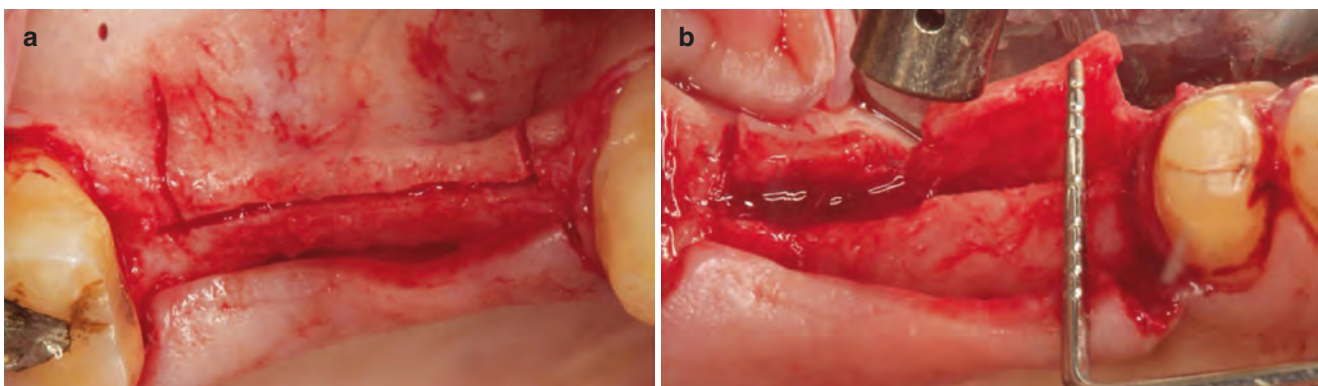
of piezosurgery, one can decrease the chance of the damage to adjacent structures during the osteotomy as well as reduce the risk of bone thermonecrosis, while simultaneously providing better control of propagation of the ridge split osteotomy. Although ridge splitting was traditionally used in the maxillary arch, piezoelectric bone surgery allows ridge expansion even in highly mineralized tissues like the mandible with ease [21, 22]. Blus et al. conducted a study on ridge splitting for more than 200 implants placed in 57 patients and reported 96.5% success rate with a 36-month follow up [23].

40.5.2.4 Lateralization of the Inferior Alveolar Nerve

In order to place implants in atrophic edentulous mandibles, IAN lateralization can be used as an alternative to bone augmentation procedures (Fig. 40.4a–c). Bovi, in 2005, first reported a technique for IAN mobilization with simultaneous implant placement utilizing a piezoelectric device. He reported that IAN mobilization with a piezoelectric device minimizes the risk of irreversible damage to the IAN and enables the surgeon to make a smaller bony window, which, in turn, decreases overstretching of the mental nerve [24]. In an in vitro study, Metzger compared transposition of the IAN with use of a piezoelectric device versus conventional burs. His study also supported the lower rate of nerve injury from use of piezosurgery [25].

40.5.3 Bone Graft Harvesting

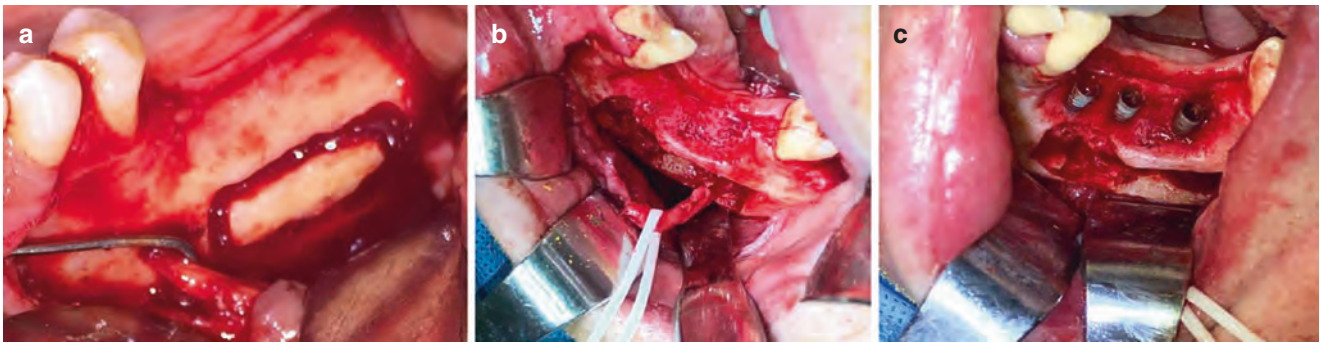
For bone augmentation, bone grafts in the form of chips or blocks can be used. Bone chips are primarily indicated in guided bone regeneration where the stabilization of the graft is not an issue, such as multiwalled defects. On the other hand, when the bony defect is large or stabilization is diffi-



©Association of Oral and Maxillofacial Surgeons of India

Fig. 40.3 (a, b) Ridge split technique with piezo surgery. Bony osteotomies performed with piezoelectric device then ridge expanded to desired dimensions. From: Tarun Kumar, A., Triveni, B., Priyadarshini,

M., & Mehta, G. (2016). Staged Ridge Split Procedure in the Management of Horizontal Ridge Deficiency Utilizing Piezosurgery. *Journal of Maxillofacial and Oral Surgery*, 15(4), 542–546 (Springer)



©Association of Oral and Maxillofacial Surgeons of India

Fig. 40.4 (a–c) Inferior alveolar nerve (IAN) lateralization for placement of implant

cult, block grafts must be utilized to augment vertical or horizontal dimension. Piezosurgery is used for harvesting all types of bone grafts, including autologous free block grafts, microvascular free flaps, and bone chips.

For example, piezosurgery is commonly used to harvest mandibular ramus block grafts. This requires use of two types of piezosurgery inserts. One is the standard saw-shaped right angle insert, which is used in an area, which can be viewed directly to make the depth cut and vertical cuts, while a second, dual-angled, insert is used specifically to make the inferior horizontal bone cut. In bone graft harvesting, piezosurgery allows better visibility, precise cuts, and good adaptation of the grafts along with better survival of bone cells. In a study by Happe in 2007 on 40 patients, bone grafts harvested from the mandibular ramus by piezosurgery resulted in 93% uneventfully healed donor sites and 96% uneventfully healed graft sites [26]. There was also minimal resorption of the graft. Shaping of block grafts can be better controlled with piezosurgery, although this can take longer than rotary instruments. In microvascular free bone flaps harvested with piezosurgery, the surgeon can decrease the chance of injury to the vascular bundle along the surface of bone. With the use of piezoelectric surgery, the clinician can cautiously osteotomize the fibula or other bone without any periosteal/pedicle dissection. In addition, the piezoelectric method also allows shaping and handling the pedicle while it is still attached to the donor site.

40.5.4 Orthognathic Surgery

Piezoelectric devices are increasingly being used in orthognathic surgery due to its precise cutting and lower risk of damage to adjacent teeth and nerves. Landes et al. performed a large study on 90 patients in whom orthognathic surgery was performed with piezosurgery. This study demonstrated decreased


blood loss compared to conventional surgery but no significant difference in surgical times. Lefort I osteotomy only required the use of chisels in about 33% of cases [5, 27, 28]. In the same study, among patients who underwent bilateral sagittal split osteotomy (BSSO), inferior alveolar nerve sensitivity at 3-month follow up was retained in 98% of the cases, compared with 84% after conventional BSSO (Fig. 40.5). When performing surgically assisted rapid maxillary expansion (SARME), the advantage of using piezoelectric surgery is that it minimizes potential damage to the descending palatine artery while separating the pterygomaxillary junction, the nasopalatine artery while making the midline maxillary cut, and it lowers indirect thermal damage to the bony surfaces and adjacent structures, including teeth [29].

40.5.5 Aesthetic Facial Surgery

Conventionally, chisels are used for osteotomy of the lateral nasal bone during rhinoplasty, which transmit significant force to the surrounding soft tissues in a blind manner, and increases the risk for bleeding from injury to the adjacent vasculature. A study done by Robiony et al. assessed use of chisels versus piezosurgery and found a decreased risk of injury to adjacent soft tissues with use of piezosurgery. Use of chisels also may create inaccuracy due to blind use and the unguarded nature of the instrument. On the other hand, use of piezo will not incur this issue and gives the operator more control and accuracy [30].

40.5.6 Distraction Osteogenesis

Distraction osteogenesis (DO) is indicated when there is a need for significant amounts of bone augmentation or lengthening, or when the soft tissues that cover the bone will not



©Association of Oral and Maxillofacial Surgeons of India

Fig. 40.5 (a, b) Orthognathic surgery using Piezo. Figure shows steps in a BSSO. Variations in the blade design can be used based on desired osteotomy

allow for osseous augmentation. The use of piezosurgery permits the initial osteotomy to be made delicately and accurately while minimizing injury to the soft-tissue flap and surrounding hard tissue, allowing maintenance of the vascularity needed for successful new bone formation [31]. Distraction Osteogenesis (DO) can be used for distraction of either the alveolar bone or the basal jawbone. DO with a piezoelectric device ensures the preservation of original bone structures, specifically the cancellous bone, which favors the healing process due to its high healing potential. In a recent article, DO with microdistactors using a piezoelectric device has shown favorable results in patients with Pierre Robin Sequence [32].

40.5.7 Temporomandibular Joint Surgeries

Osteotomies and osteoplasty in the temporomandibular joint (TMJ) region involves risk to the facial nerve as well as major vessels such as the internal maxillary artery and the masseteric artery. Due to anatomical complexity, the use of conventional bone-cutting tools such as burs and saws may put these vital structures at risk of injury or permanent damage. Given the advantages of piezosurgery as discussed previously in the chapter, its use in this specialized surgery is reasonable and advisable. In 2014, Anson Jose observed less

bleeding along with minimal postoperative complications while treating TMJ ankylosis with piezosurgery [33].

40.5.8 Inferior Alveolar Nerve Preservation

The IAN is at risk whenever there is the need to extract impacted mandibular molars, enucleate large cysts, or remove benign mandibular tumors. In 2009, Dr. Kagan Degerliyurt presented an article describing a procedure called the “bone lid technique,” which is performed by using a piezosurgery device when there is a definitive risk of damage to IAN [34, 35].

40.5.9 Trauma

Piezoelectric devices can be used for reconstruction in multiple trauma cases, such as comminuted frontal bar fractures, to cut and shape the inner table of a calvarial bone graft, to osteotomize a healing fracture while reducing the chance of adjacent tissue injury. Using piezosurgery in post-traumatic cases can help preserve bone, protect adjacent soft tissues, decrease blood loss, improve visibility, and ensure a better overall outcome [36].

40.6 Conclusion

Piezosurgery is a promising surgical tool for safe and effective use in various surgeries. For an oral and maxillofacial surgeon, piezosurgery allows safer and effective osteotomy or osteoplasty compared to conventional rotating instruments such as burs and saw blades, even in complex anatomical areas. Over the past decade, it has not only been increasingly used in OMFS but has been adapted for use in neurosurgery, orthopedic surgery, and otorhinolaryngology. In addition to the surgical advantages, it helps the patient by reducing procedural stress, postoperative swelling, pain and overall improves the surgical experience. The major drawback of piezosurgery is the lack of efficiency or cutting speed, which can be balanced by improved clinical outcomes. Future generations of ultrasonic devices may bring about better efficiency and ultimately replace all conventional cutting tools.

References

- Curie J, Curie P. Contractions et dilatations produites par des tensions dans les cristaux hémihédres à faces inclinées. *C R Acad Sci Gen.* 1880;93:1137–40.
- Vercellotti T. Technological characteristics and clinical indications of piezoelectric bone surgery. *Minerva Stomatol.* 2004;53:207–14.
- Aly L. Piezoelectric surgery: applications in oral & maxillofacial surgery. *Future Dent J.* 2018;4(2):105–11.
- Vercellotti T. Essentials in piezosurgery: clinical advantages in dentistry. Milan: Quintessence; 2009.
- Berengo M, Bacci C, Sartori M, et al. Histomorphometric evaluation of bone grafts harvested by different methods. *Minerva Stomatol.* 2006;55(4):189.
- Leclercq P, Zenati C, Amr S, Dohan D. Ultrasonic bone cut. Part 1: State-of-the-art technologies and common applications. *J Oral Maxillofac Surg.* 2008;66(1):177–82.
- Labanca M, Azzola F, Vinci R, Rodella LF. Piezoelectric surgery: twenty years of use. *Br J Oral Maxillofac Surg.* 2008;46(4):265–9.
- Schlee M, Steigmann M, Bratu E, Garg A. Piezosurgery: basics and possibilities. *Implant Dent.* 2006;15(4):334–40.
- Claire S, Lea SC, Walmsley AD. Characterisation of bone following ultrasonic cutting. *Clin Oral Invest.* 2013;17(3):905–12.
- Schaeren S, Jaquier C, Heberer M, Tolnay M, Vercellotti T, Martin I. Assessment of nerve damage using a novel ultrasonic device for bone cutting. *J Oral Maxillofac Surg.* 2008;66:593–6.
- Preti G, Martinasso G, Peirone B, et al. Cytokines and growth factors involved in the osseointegration of oral titanium implants positioned using piezoelectric bone surgery versus a drill technique: a pilot study in minipigs. *J Periodontol.* 2007;78:716–22.
- Leclercq P, Charlotte Z, Dohan DM. ultrasonic bone cut. Part 2: State-of-the-art specific clinical applications. *J Oral Maxillofac Surg.* 2008;66(1):183–8.
- Beziat JL, Bera JC, Lavandier B, Gleizal A. Ultrasonic osteotomy as a new technique in craniomaxillofacial surgery. *Int J Oral Maxillofac Surg.* 2007;36:493–500.
- Sivolella B, Bressan DF, Stellini E. Osteotomy for lower third molar germectomy: randomized prospective crossover clinical study comparing piezosurgery and conventional rotary osteotomy. *J Oral Maxillofac Surg.* 2011;69(6):E15–23.
- Gómez J, Sánchez R, Ferrer R, Duran-Sindreu F. Safety concerns of piezoelectric units in implantable cardioverter defibrillator. *J Oral Maxillofac Surg.* 2017;76(2):273–7.
- Mantovani A, Schierano F, Gallesio M, Russo S, Carossa S. A split-mouth randomized clinical trial to evaluate the performance of piezosurgery compared with traditional technique in lower wisdom tooth removal. *J Oral Maxillofac Surg.* 2014;72(10):1890–7.
- Pavlíková G, Foltán R, Horká M, Hanzelka T, Borunská H, Šedý J. Piezosurgery in oral and maxillofacial surgery. *Int J Oral Maxillofac Surg.* 2011;40(5):451–7.
- Wallace SS, Mazor Z, Froum SJ, Cho SC, Tarnow DP. Schneiderian membrane perforation rate during sinus elevation using piezosurgery: clinical results of 100 consecutive cases. *Int J Periodontics Rest Dent.* 2007;27:413–9.
- Heinemann F, Hasan I, Kunert-Keil C, Götz W, Gedrange T, Spassov A, Schweppe J, Gredes T. Experimental and histological investigations of the bone using two different oscillating osteotomy techniques compared with conventional rotary osteotomy. *Ann Anat.* 2012;194(2):165–70.
- Da Silva Neto UT, Joly JC, Gehrke SA. Clinical analysis of the stability of dental implants after preparation of the site by conventional drilling or piezosurgery. *Br J Oral Maxillofac Surg.* 2014;52(2):149–53.
- Vercellotti T. Piezoelectric surgery in implantology: a case report—a new piezoelectric ridge expansion technique. *Int J Periodont Rest Dent.* 2000;20:358–65.
- Enislidis G, Wittwer G, Ewers R. Preliminary report on a staged ridge splitting technique for implant placement in the mandible: a technical note. *Int J Oral Maxillofac Surg.* 2006;21:445–9.
- Blus C, Szmukler-Moncler S. Split-crest and immediate implant placement with ultra-sonic bone surgery: a 3-year life-table analysis with 230 treated sites. *Clin Oral Impl Res.* 2006;17:700–7.
- Bovi M. Mobilization of the inferior alveolar nerve with simultaneous implant insertion: a new technique. Case report. *Int J Periodont Rest Dent.* 2005;25(4):375–83.
- Metzger M, Bormann K, Schoen R, Gellrich N, Schmelzeisen R. Inferior alveolar nerve transposition—an in vitro comparison between piezosurgery and conventional bur use. *J Oral Implantol.* 2006;32(1):19–25.
- Happe A. Use of a piezoelectric surgical device to harvest bone grafts from the mandibular ramus: report of 40 cases. *Int J Periodont Rest Dent.* 2007;27:241–9.
- Landes CA, Stubinger S, Ballon A, Sader R. Piezoosteotomy in orthognathic surgery versus conventional saw and chisel osteotomy. *J Oral Maxillofac Surg.* 2008;12:139–47.
- Spinelli G, Lazzeri D, Conti M, Agostini T, Mannelli G. Comparison of piezosurgery and traditional saw in bimaxillary orthognathic surgery. *J Craniomaxillofac Surg.* 2014.
- Olate S, Pozzer L, Unibazo A, Huentequeo-Molina C, Martinez F, De Moraes M. LeFort I segmented osteotomy experience with piezosurgery in orthognathic surgery. *Int J Clin Experiment Med.* 2014;7(8):2092–5.
- Robiony PF, Costa F, Toro C, Politi M. Ultrasound piezoelectric vibrations to perform osteotomies in rhinoplasty. *J Oral Maxillofac Surg.* 2007;65:1035–8.
- Deepa D, Jain G, Bansal T. Piezosurgery in dentistry. *J Oral Res Rev.* 2016;8(1):27–31.
- Galié M, Candotto V, Elia G, Clauser L. Piezosurgery: a new and safe technique for distraction osteogenesis in Pierre Robin sequence review of the literature and case report. *Int J Surg Case Rep.* 2015;6C(1):269–72.
- Jose A, Nagori S, Virkhare A, Bhatt K, Bhutia O, Roychoudhury A. Piezoelectric osteoarthrectomy for management of ankylosis of the temporomandibular joint. *Br J Oral Maxillofac Surg.* 2014;52(7):624–8.

34. LaBanc JP. Inferior alveolar nerve repair after treatment of benign cysts and tumors of the mandible. *Oral Maxillofac Surg Clin N Am.* 1991;3:209–22.
35. Degerliyurt K, Akar V, Denizci S, Yucel E. Bone lid technique with piezosurgery to preserve inferior alveolar nerve. *Oral Surg Oral Med Oral Path Oral Rad Endodontol.* 2009;108(6):E1–5.
36. Kane S, Balasundaram I, Rahim I, Kanzaria A, Bridle C, Holmes S. Indications of Piezoelectric surgery in trauma oral and maxillofacial surgery. *Brit J Oral Maxillofac Surg.* 2014;52(8):E54–5.

Open Access This chapter is licensed under the terms of the Creative Commons Attribution 4.0 International License (<http://creativecommons.org/licenses/by/4.0/>), which permits use, sharing, adaptation, distribution and reproduction in any medium or format, as long as you give appropriate credit to the original author(s) and the source, provide a link to the Creative Commons license and indicate if changes were made.

The images or other third party material in this chapter are included in the chapter's Creative Commons license, unless indicated otherwise in a credit line to the material. If material is not included in the chapter's Creative Commons license and your intended use is not permitted by statutory regulation or exceeds the permitted use, you will need to obtain permission directly from the copyright holder.



Computer-Assisted Navigation Surgery in Oral and Maxillofacial Surgery

41

Shintaro Sukegawa and Takahiro Kanno

41.1 Introduction

The anatomy of the oral and facial region is complex, having many vital organs and structures, including an intricate network of blood vessels and nerves as well as the brain, eyes, nose, and vital teeth. Plain radiography can be used for screening because of its simplicity, but it cannot characterize detailed anatomical relationships. Currently, imaging diagnosis must be performed with computed tomography (CT) and/or magnetic resonance imaging (MRI) before surgery to characterize the surgical area and surrounding anatomical structures. Recent developments in imaging technology have allowed for rapid processing and visualization of significant amounts of data yielded from a variety of digital imaging modalities. Prerequisites have been established for three-dimensional (3D) visualization as well as programs for the computer-assisted 3D planning of surgical procedures, and these image sources are now available to assist the surgeon in the operating room [1].

Today, surgeons can use computer-aided design and computer-aided modeling (CAD/CAM) software to assist with the planning and implementation of complex maxillofacial surgical procedures [2]. CAD/CAM software allows the clinician to import two-dimensional (2D) CT data in DICOM format (Digital Imaging and Communications in Medicine) to a computer workstation and create accurate 3D representations of the facial skeleton and related soft tissues. The data can then be used either to print a stereolithographic (STL) model or for virtual manipulation of the generated 3D model by segmentation, reflection (mirroring), insertion, or repositioning of 3D objects for treatment planning [3].

S. Sukegawa
Division of Oral and Maxillofacial Surgery, Kagawa Prefectural
Central Hospital, Takamatsu, Kagawa, Japan

T. Kanno (✉)
Department of Oral and Maxillofacial Surgery, Shimane University
Faculty of Medicine, Izumo, Shimane, Japan
e-mail: tkanno@med.shimane-u.ac.jp

Stereolithographic 3D models are useful for maxillo-mandibular reconstruction indicators such as

1. A guide for plate adaptation.
2. Planning bony osteotomies.
3. Planning for graft or flap placements.
4. Surgeries involving jaw repositioning.
5. Construction of patient-specific custom implants (PSI).

Not only are they useful in visualizing and planning, but also for providing haptic support to the surgeon for perceived excellent tactile feedback during virtual surgery. They also prove to be very useful in creating a more predictable workflow for the intended surgical intervention. Unfortunately, there is no single prediction method where the surgical plan as performed on the model can be directly transferred to the patient.

Computer-assisted surgery (CAS) uses data from image processing, and can be divided into two major categories:

1. Computer-assisted presurgical planning.
2. Intraoperative navigation.

Computer-assisted presurgical planning involves preoperative surgical simulation using physical or virtual 3D images or models, and helps the surgeon to appreciate the underlying skeletal anatomy in a more precise manner. The application of preoperative surgical simulations is being used in the field of dental implantology for determining the appropriate positions and sizes of implants as well as evalu-

ating and planning for bone augmentation when needed, and in the field orthognathic surgery for assessing the amount and direction of movement of the jaws.

The process of intraoperative navigation was developed to improve the sequence of “diagnosis-surgical planning-surgery,” allowing surgeons to accurately visualize the positions of surgical instruments and guides in real time on a display of patient CT and/or MRI data. Intraoperative navigation systems integrate diagnostic imaging with the actual surgical field, allowing simultaneous visualization of the surgical site and the analogous image counterpart with the help of a sensor that enables more precise access and manipulation for areas with sensitive anatomy. These navigation systems have now evolved greatly to minimize invasiveness while improving accuracy. The development of intraoperative navigation surgery has enabled improvement in execution and predictability for greater precision during oral-maxillofacial surgery.

This section presents an overview of currently available navigation systems and their applications, focusing on clinical utility and solutions they offer for problems and challenges in the field of oral and maxillofacial surgery.

41.2 Medical Navigation Technology

“Navigation-assisted surgery” is a broad term and can be interpreted in various ways.

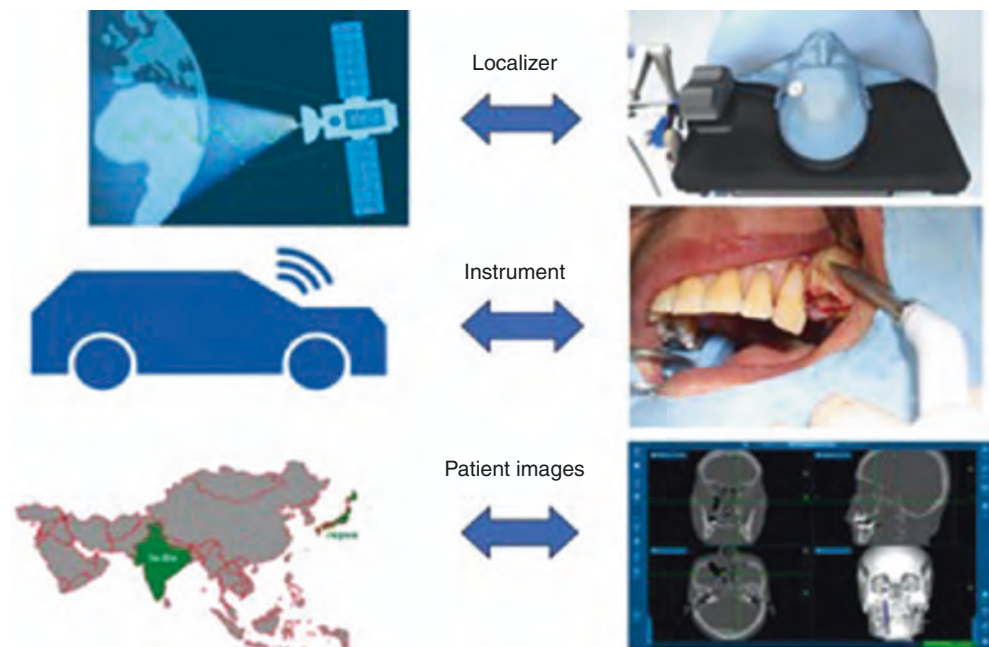
This is most usefully represented by three questions: “Where is the anatomical target in our patient?”, “How can we reach our target safely for our patient?”, and “What is our current anatomical location?”.

Besides these questions, navigation-assisted surgery may also be used as an “information center” to provide surgeons with accurate and efficiently retrievable information. Navigation systems used for surgery are very similar to a global positioning system (GPS), as is commonly found in automobiles.

It comprises three principal components: (1) a localizer, which is analogous to a satellite; (2) a “hand-held” probe, which corresponds to the track waves emitted by the GPS unit in the vehicle; and (3) the CT scan data of the patient, which is analogous to a road map.

Intraoperative navigation systems were initially developed for use in neurosurgery, but they are now commonly used in surgery of the craniomaxillofacial region due to their high accuracy and reliability [1, 4] (Fig. 41.1).

Fig. 41.1 Components of a surgical navigation system. A surgical navigation system is comparable to a global positioning system (GPS) as is commonly used in automobiles, and is composed of three primary components: a localizer, which is analogous to a satellite in space; an instrument or surgical probe, which represents the track waves emitted by the GPS unit in the vehicle; and a CT scan data set, which is analogous to a road map



41.2.1 Differences Between Optical and Electromagnetic Tracking Systems

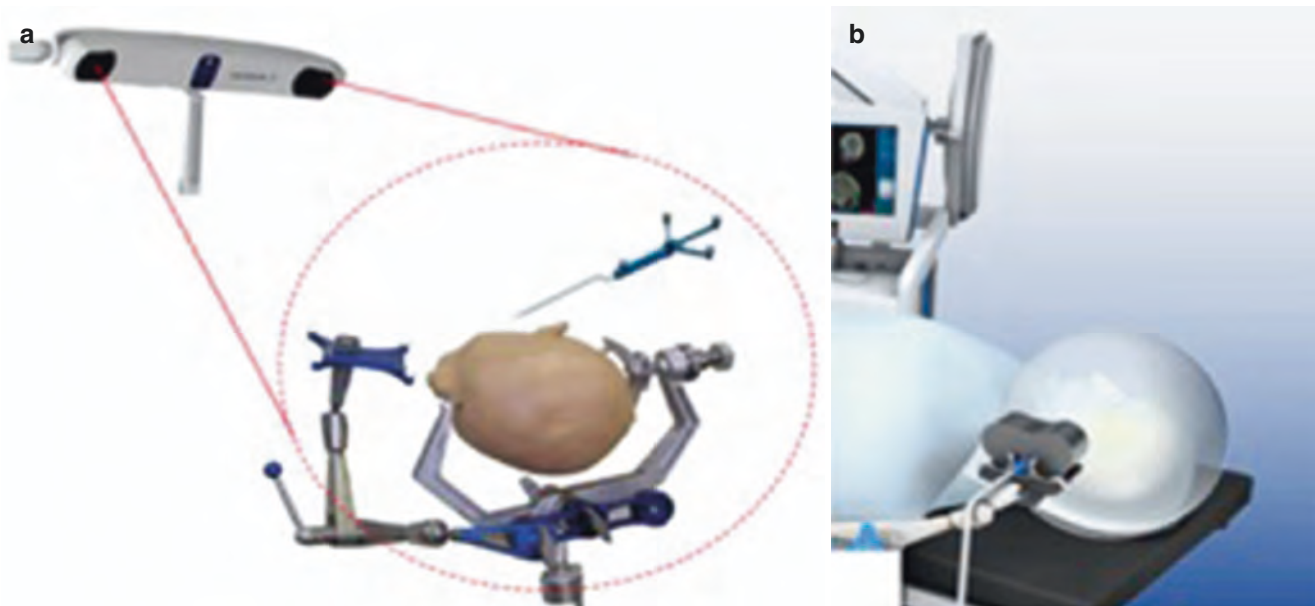
Two main technologies are currently available for intraoperative navigation, including optical and electromagnetic (Fig. 41.2), and they share the same function. However, they use very different technologies to relay position information to the surgeon. Two major components of the optical navigation system are measured using an infrared camera. These include the position of the reference frame, which is the optical point of reference for navigation and is also called the patient tracker, and a surgical probe with light reflectors. This enables the position of the surgical probe to be displayed on the CT or MRI image in real time. Care should be taken to ensure that both the tracker and the probe are detected by the infrared camera of the navigation system to track the instrument position within the surgical field [5]. By contrast, the electromagnetic system utilizes electromagnetic fields and reference points on a patient borne device, along with a wired instrument for the surgeon to manipulate within the surgical field. The system functions by creating a magnetic field of known intensity and then using microsensors in key instruments to allow the system to determine where the instrument is located relative to the patient's anatomy [6]. In contrast to an optical system, an electromagnetic system does not require a clear line of vision between the IR camera and the sensors, allowing equipment and objects to be placed between the sensors and the IR camera. However, the accuracy of this system is compromised when using ferromagnetic instruments.

41.2.2 Registration Techniques

Registration is the task of obtaining the mutual transformation matrix by calculating the relationship between the coordinates of the actual patient space and the coordinates of the medical image. In other words, this procedure involves the alignment of the patient and the image, and it is the most important process when performing surgical navigation.

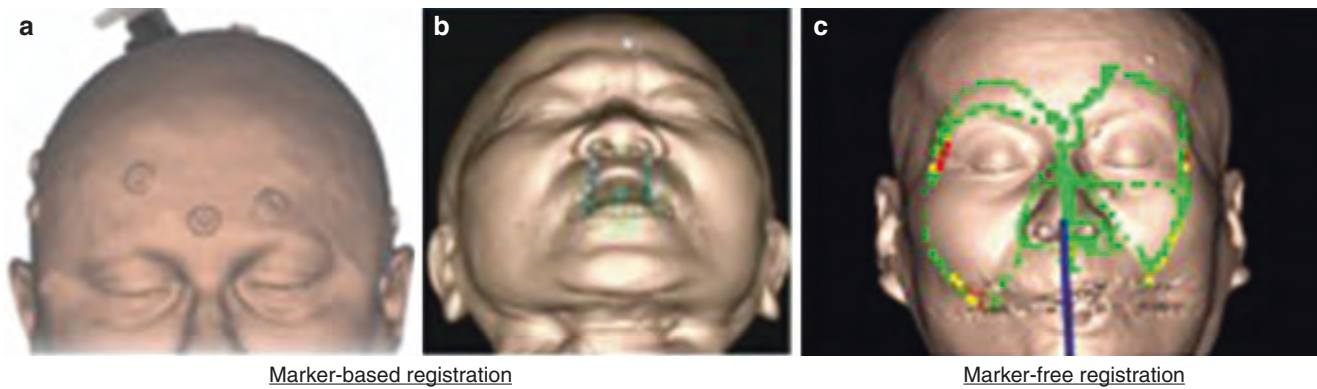
Registration techniques are categorized into two major types: (1) marker-based [7] and (2) marker-free [8] (Fig. 41.3).

In the marker-based technique, registration requires identifiable markers to be placed within preoperative images that can be easily detected on the patient during the surgery. These markers include dental splints [9], skin adhesive reference markers, and bone-implanted screws [10]. In contrast, the marker-free technique is based on the patient's regional anatomy. This can be performed by registering easily identifiable soft tissue or bony structures on the patient's preoperative scans. Another technique for marker-free registration is laser surface scanning, which is used to match random points on the surface of facial skin to corresponding points on CT or MRI images. More recently, hybrid registration combining methods have been used that combine point registration and surface registration [11].



©Association of Oral and Maxillofacial Surgeons of India

Fig. 41.2 There are two main types of navigation systems currently available: (a) optical and (b) electromagnetic systems



©Association of Oral and Maxillofacial Surgeons of India

Fig. 41.3 Registration techniques for navigation preparation can be categorized into two main groups: marker-based and marker-free. Marker-based registration requires markers that are apparent on preoperative images and that are easily detectable on the patient during the procedure, such as (a) skin adhesive reference markers or (b) a referencing dental splint (c) Marker-free registration relies on the patient's

craniomaxillofacial anatomy. Laser surface scanning is applied in a distinct marker-free registration technique, where random points on the facial skin surface are matched to corresponding points on the soft tissues in preoperative computed tomography/magnetic resonance imaging (CT/MRI) images

41.2.3 Application to Oral-Maxillofacial Surgery

41.2.3.1 Application to the Maxilla and Midface

The use of navigation systems significantly improves the degree of intraoperative precision and accuracy that can be predictably transferred from the planning stages to the actual surgery. However, navigational accuracy is limited by the type of system used, the method of procuring imaging data, and the intraoperative synchronization of the imaging data with the patient's actual position. The systems currently in use for maxillary and midface surgery are relatively reliable, as most have been modified from their neurosurgical counterparts [12]. Because the maxilla and midface are immovable, unlike the mandible, the position of the skull relative to the reference is stable, and the registration procedure directly reflects this. Therefore, navigation-assisted surgery is the best option at the maxilla and midface.

41.2.3.2 Application to the Mandible

The use of navigation systems is not currently approved for mandibular surgery. This is due to the nature of the mandible to move on its joint (Fig. 41.4), resulting in the registration not being reflected accurately in the navigation of the mandible. However, it may be possible if the position of the mandible is held identical to its intraoperative position during image acquisition.

At present, solutions exist for the application of navigation systems to mandibular surgery. One such option is the use of a dynamic reference frame mounted to the mandible that enables the continuous tracking of mandibular movement during surgery [13]. This method utilizes a sensor frame and mandible/teeth supported markers for the direct tracking of the mandible during surgery. This permits free intraoperative

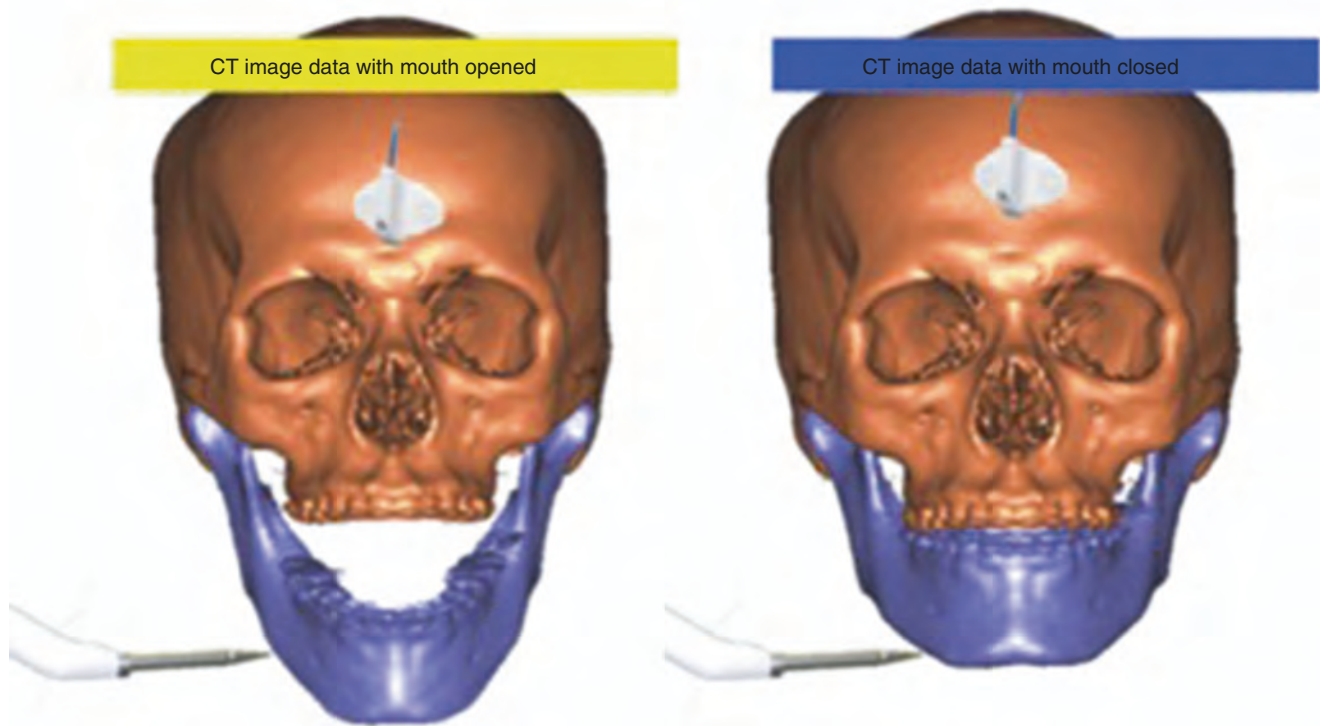
movement of the mandible. The second option is to maintain an immobile intercuspatation position, such as using a maxilla-mandibular fixation to maintain intraoperative synchronization [14]. Unfortunately, this is impossible to achieve in most intraoral procedures. Therefore, a third strategy has been developed in which the mandible is placed in a reproducible position against the maxilla using an occlusal splint. This method appears to produce no additional error.

41.3 Clinical Significance in Oral and Maxillofacial Surgery

There are numerous clinical applications for CAS and intraoperative navigation in oral and maxillofacial surgery. This is reiterated by literature support available over the last decade supporting its use.

41.3.1 Application for Oral-Maxillofacial Trauma

Computer-based surgery is a rapidly emerging approach used in some surgical disciplines, and can be used both as a research tool and to improve healthcare. Computer-based surgery, in combination with the use of a navigation system, has been shown to reduce overall operation time in complex anatomic areas, such as maxillofacial trauma surgery (e.g., orbital trauma reconstruction surgery), making surgery more reliable. Using 3D models based on CAS is suitable for preoperative preparation of reconstruction material for bone defects caused by trauma. On the other hand, navigation surgery is most suitable for intraoperative anatomical evaluation [15]. By combining these techniques, safer and minimally



©Association of Oral and Maxillofacial Surgeons of India

Fig. 41.4 The positional relationship between the reference and the target becomes unstable due to the free mobility of the mandible. If the mandible were maintained in an identical position during image acquisition

and the surgical procedure, then all structures within the image could be fixed in an identical position, thereby ensuring the accuracy of the navigation surgery

invasive surgery is possible. Maxillofacial trauma may be an important indicator suggesting the use of navigation systems (Figs. 41.5, 41.6, 41.7 and 41.8). Unilateral midfacial and orbital trauma surgery may also be indicators, and are normally treated with open reduction and fixation with navigation assistance.

The largest sample sizes for navigation surgery were found in the field of craniomaxillofacial trauma, offering significant positive results for orbital fracture treatment through navigation-assisted surgery. Midfacial trauma, and particularly unilateral midfacial trauma, was most common example of maxillofacial trauma available in the literature. Some of these reports described the treatment of patients with delayed zygomatic fractures requiring osteotomies to reposition the abnormally healed bones. This results in added complexity for the surgeon due to the lack of known anatomical landmarks. He et al. presented a protocol for the creation of artificial landmarks on the surface of the zygoma [16]. The technique involved the registration being performed with rigidly fixed, light-reflecting spheres placed on the patient's skull. Subsequent soft tissue surface scanning was performed using a laser pointer to complete the process.

Another challenging facet of oral and maxillofacial surgery is the management of orbital fractures. This can prove

to be demanding even for the most experienced of surgeons. Literature indicates that intraoperative navigation is a very useful tool in post-traumatic orbital reconstruction. Another rising trend is the use of patient-specific implants (PSIs). A recently published literature also discusses the use of PSIs with navigation guidance [17]. A control group was treated with navigation using prebent titanium mesh. Several significant factors were reported favoring the study group. PSIs are poised to make a significant change in the management of orbital trauma.

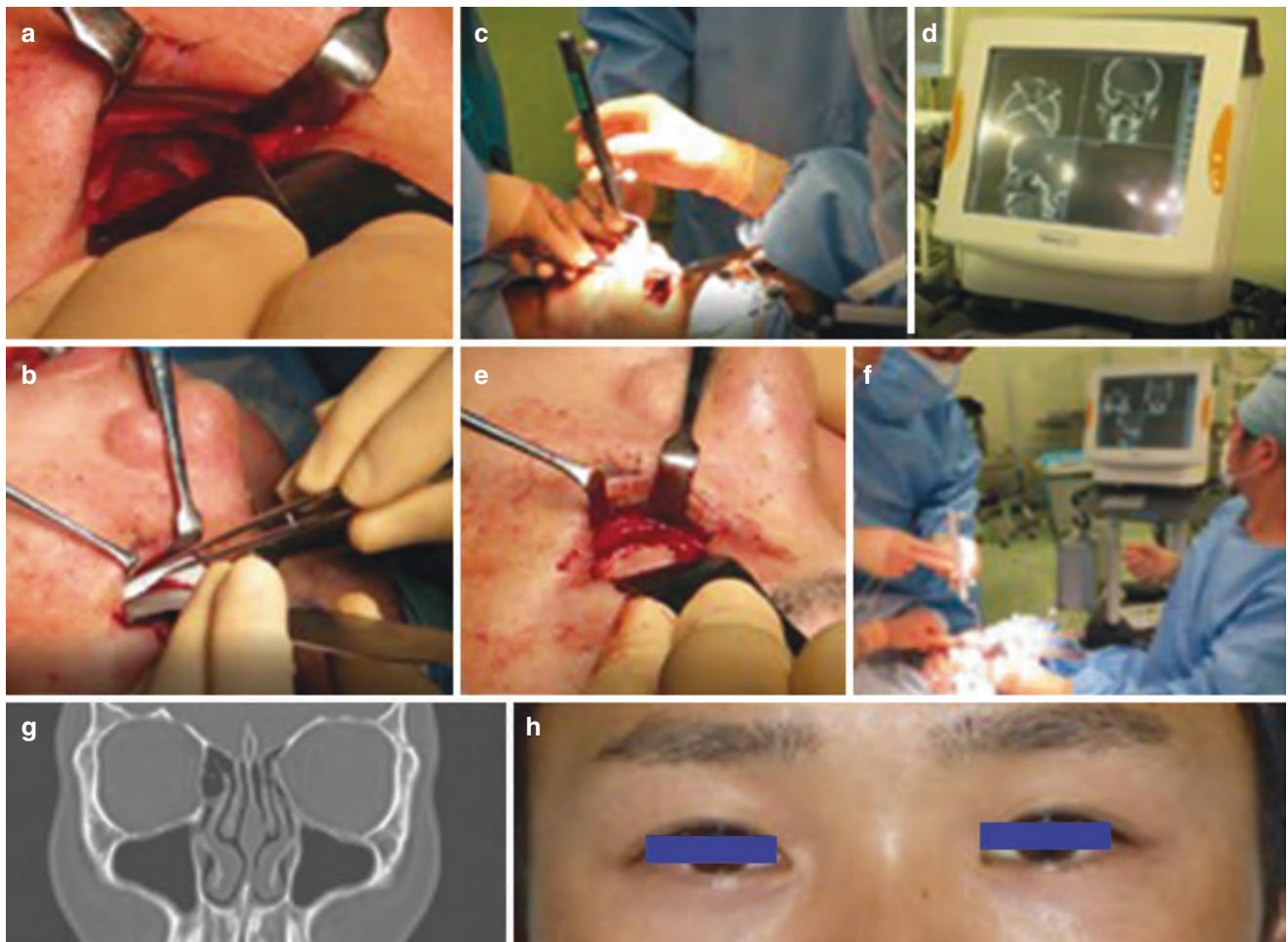Innovations such as intraoperative navigation and computer-assisted surgical planning have been shown to improve the efficacy, accuracy, and predictability of surgical procedures. The 3D reconstruction abilities of software could be used to virtually display the patient's anatomy throughout the case, allowing for stereotactic navigation. During the surgery, the intraoperative navigation system helps surgeons to control the positions of implants or of repositioned bone, and assists in verifying the final location. A navigation system enhances the surgeon's ability to measure the extent of resection and to confirm the orientation of bone grafts used for reconstruction. Using this approach, it is possible to minimize the human error factor by increasing the adherence to a pre-



©Association of Oral and Maxillofacial Surgeons of India

Fig. 41.5 A 17-year-old male undergoing a large orbital floor to medial orbital fracture reconstruction. Surgeons first created a three-dimensional model that was mirrored by CAS, and determined the angle and form of reconstruction material using third-generation bioac-

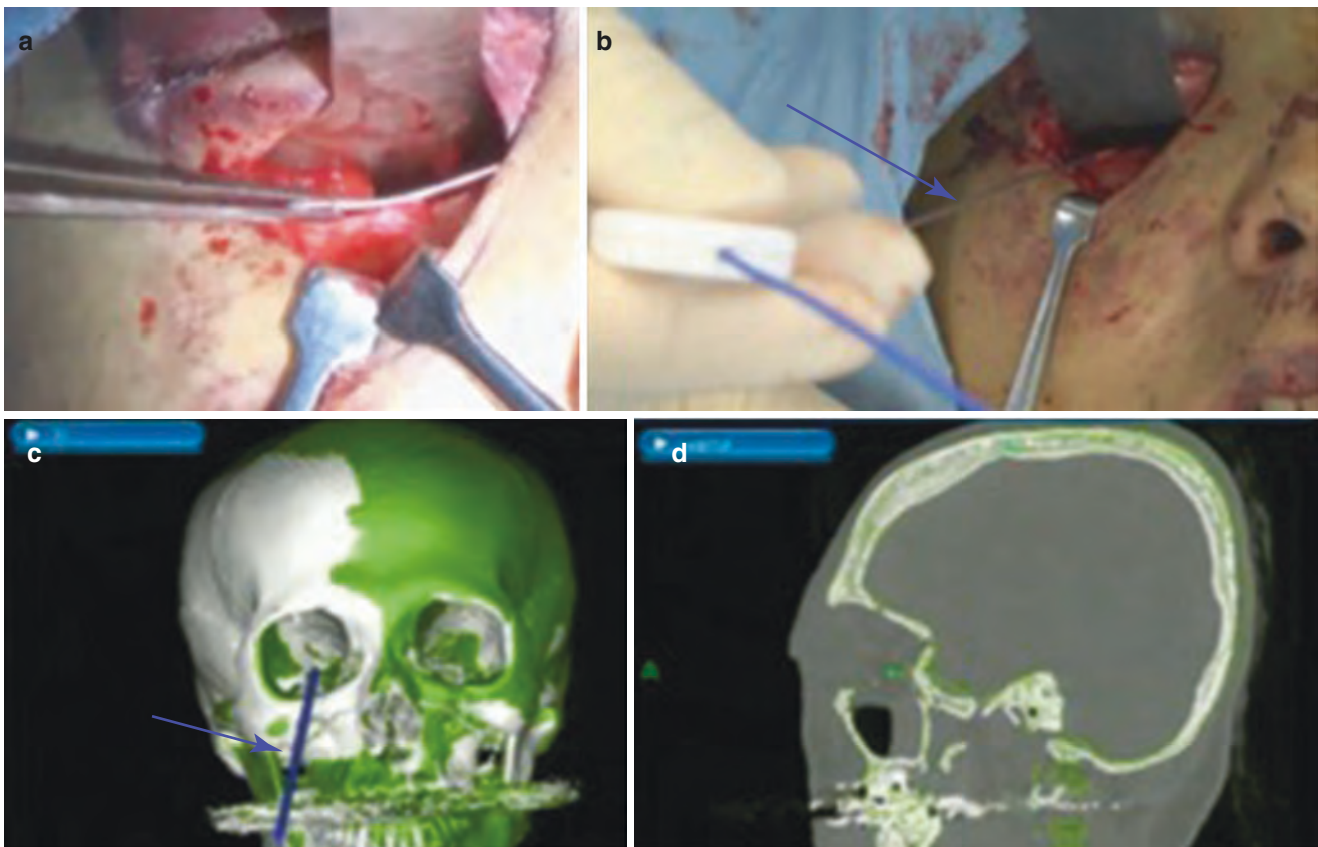
tive/bioresorbable materials, the SuperFIXORB-MX® (OsteotransMS®) system; TEIJIN Medical Technologies Co., Ltd, Osaka, Japan, according to the shape of the orbits to be reconstructed



©Association of Oral and Maxillofacial Surgeons of India

Fig. 41.6 (a–h) A 17-year-old male undergoing a large orbital floor to medial orbital fracture reconstruction. Navigation will determine the exact intraoperative anatomical form. Reconstruction material before

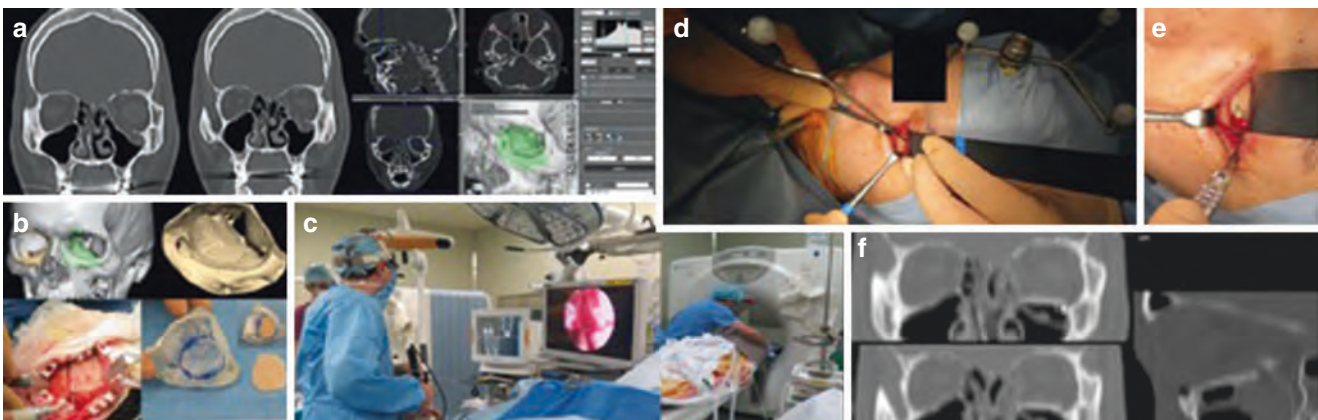
CAS was positioned at the reconstruction site. We then confirmed the exact position of the reconstruction material and reconstructed the orbital shape using the navigation system



©Association of Oral and Maxillofacial Surgeons of India

Fig. 41.7 (a) The bioresorbable mesh plate was positioned to support the orbital globe. (b) The reconstructed site was confirmed to match the mirror image using a tip pointer with a navigation system. (c) Intraoperative navigation system screenshot showing a multiplane view

of the position of the surgeon's navigation probe in relation to the orbital floor defect region at the time of localization. (d) Shows the reconstruction plan image, created using the mirroring technique



©Association of Oral and Maxillofacial Surgeons of India

Fig. 41.8 (a, b) A 33-year-old male undergoing a naso-orbitoethmoidal (NOE) and maxillary fractures open treatment, including a large orbital floor to medial orbital walls fractures reconstruction. We, maxillofacial surgeons, first created a three-dimensional (3D) precise preorbit to orbital groove model that was mirrored by computer-assisted simulation, and determined the anatomical form of reconstruction for autogenous bone harvested from calvaria using Piezosurgery® according to the 3D shape of the orbits to be reconstructed (produced by Yasojima Proceed Co., Ltd. Osaka, Japan). Navigation will determine the exact

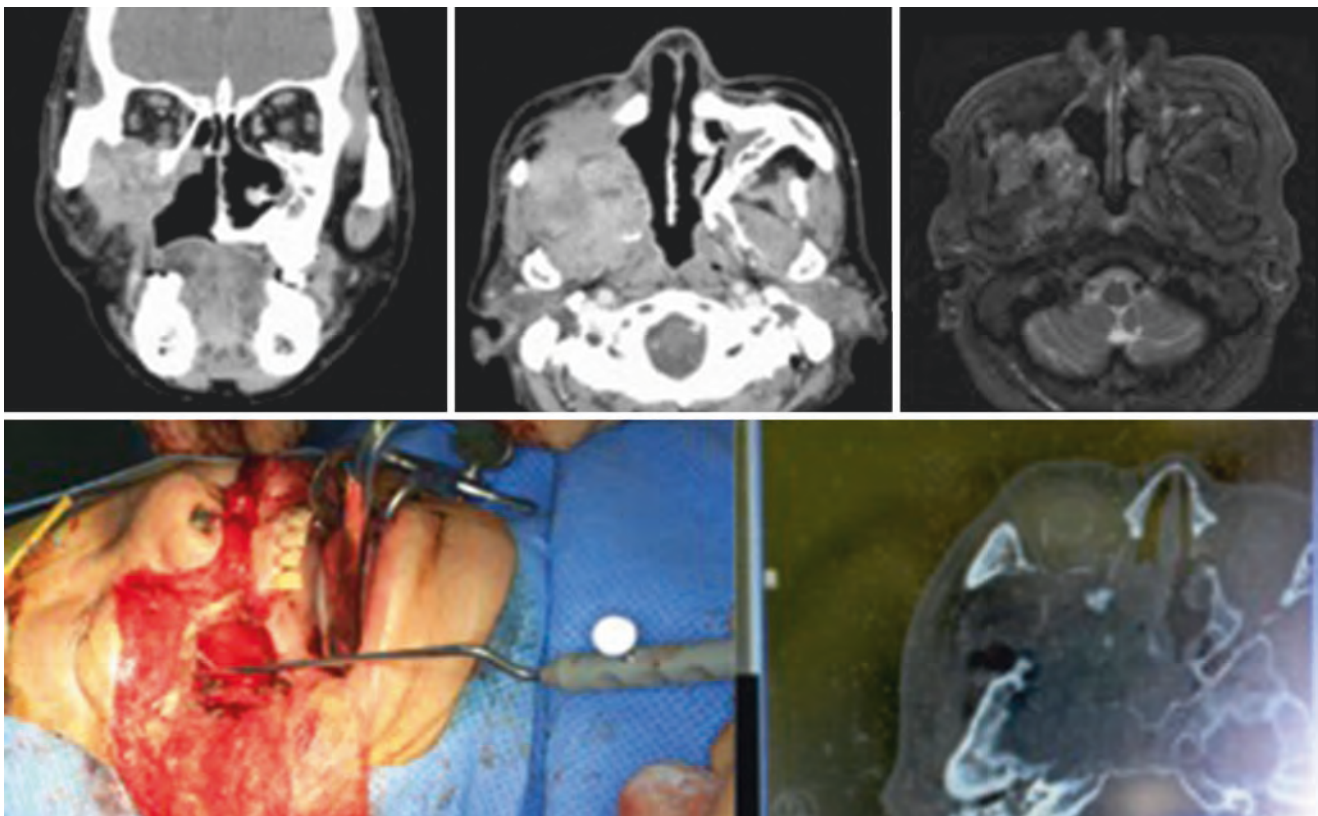
intraoperative 3D anatomical form. (c) The fractured deep medial orbital wall was precisely reduced under an endoscopic-assisted navigation-guided surgery by otorhinolaryngology-head and neck surgeons. (d, e) We then reconstructed the large orbital floor and confirmed the exact position of the autogenous calvarial bone for accurate reconstruction of the orbit using the navigation system, followed by fixation using titanium screws. (f) The use of intraoperative CT in the hybrid operation room can provide rapid CT data during surgery for the final 3D confirmation of complex orbital reconstruction cases

operative plan. Furthermore, this also helps in reducing the incidence of postoperative complications due to improperly positioned or oriented bone grafts, plates, or fixation screws. Virtual surgical planning (VSP) combined with 3D printing technology has improved surgical efficiency and precision through the generation of 3D surgical models, implants, and guides [18]. This increases the number of indicators suggesting the use of VSP by the surgeon, as it offers additional tools in preoperative planning and intraoperative decision making. Both VSP and 3D models may be used to plan the optimal reconstruction material in terms of the volume, shape, and dimensions required. They can also be used to produce templates for resective surgery to accurately demarcate the boundaries for resection and/or to plan more efficient and accurate reconstructive strategies. A further advantage of using 3D models is a reduction in total operative time and the elimination of potential complications from prolonged surgery.

41.3.2 Application for Oral-Maxillofacial Tumor/Cancer

Computer-assisted navigational surgery is a proven method for reducing operating time and increasing reliability in complex surgical procedures of the infratemporal fossa and the periorbital region [19] (Fig. 41.9). Navigation-assisted surgery was introduced in the field of oral, head, and neck tumors more than 20 years ago. The use of navigation in the management of benign and malignant lesions is discussed later.

Malignant lesions of the head and neck have a high rate of recurrence (25–48%). Tumor control essentially depends on the extent of the tumor, its location, and the margins of resection, with the latter being a very important prognostic factor in cancer surgery. Feichtinger et al. [20] used navigation systems to evaluate the resection margins in the treatment of six patients with carcinomas in the nasal cavity, maxillary sinus, and oral cavity. In four patients, further resection had to be performed after an assessment with a navigation system



©Association of Oral and Maxillofacial Surgeons of India

Fig. 41.9 A 79-year-old male with recurrent ameloblastoma of maxilla-infratemporal fossa. Because of the complexity of the local anatomy, tumors in the infratemporal fossa present a challenge to oral and maxillofacial surgeons. Recurrent malignant tumors in this area are particularly difficult to resect because scars from previous operations

may dislocate important structures. A navigation technique has been introduced to resect infratemporal fossa tumors and was successfully applied for the resection of recurrent malignant tumors. The visible navigation during surgery could increase the accuracy and safety of the operations and enhance surgeon confidence

using positron emission tomography (PET)-CT scans proved the initial resection to be unsatisfactory. This demonstrates that navigation surgery based on PET-CT image fusion is an excellent tool for improving the local control of advanced head and neck cancer.

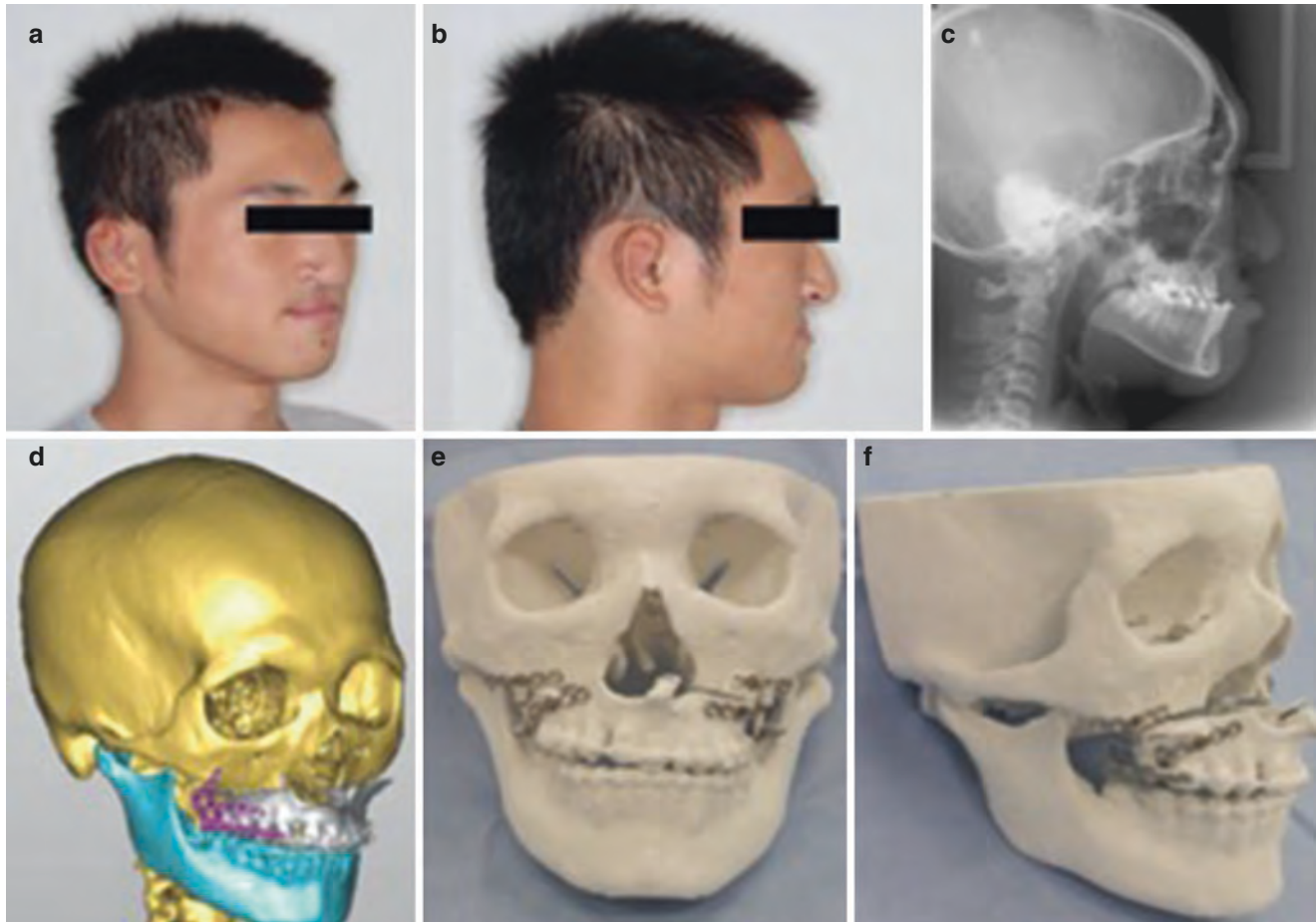
Navigation-assisted surgery has also been successfully used in the management of benign tumors of the maxillofacial region [21]. This was performed with features such as mirroring and side-to-side comparisons, and was applied with successful results. Use of customized hydroxy-apatite prosthesis with pre-embedded titanium implants was used for reconstruction. Optimal positioning is secured using navigation. Some interesting techniques for reconstruction are discussed now.

It is important to remember that navigation is an excellent tool when it comes to its use in the skull base [22], the mid-face [23], and the neck [24]. However, its use in mandibular

tumors is limited due to the possibility of changes in the spatial orientation of the lower jaw, as described earlier.

41.3.3 Application for Orthognathic Surgery

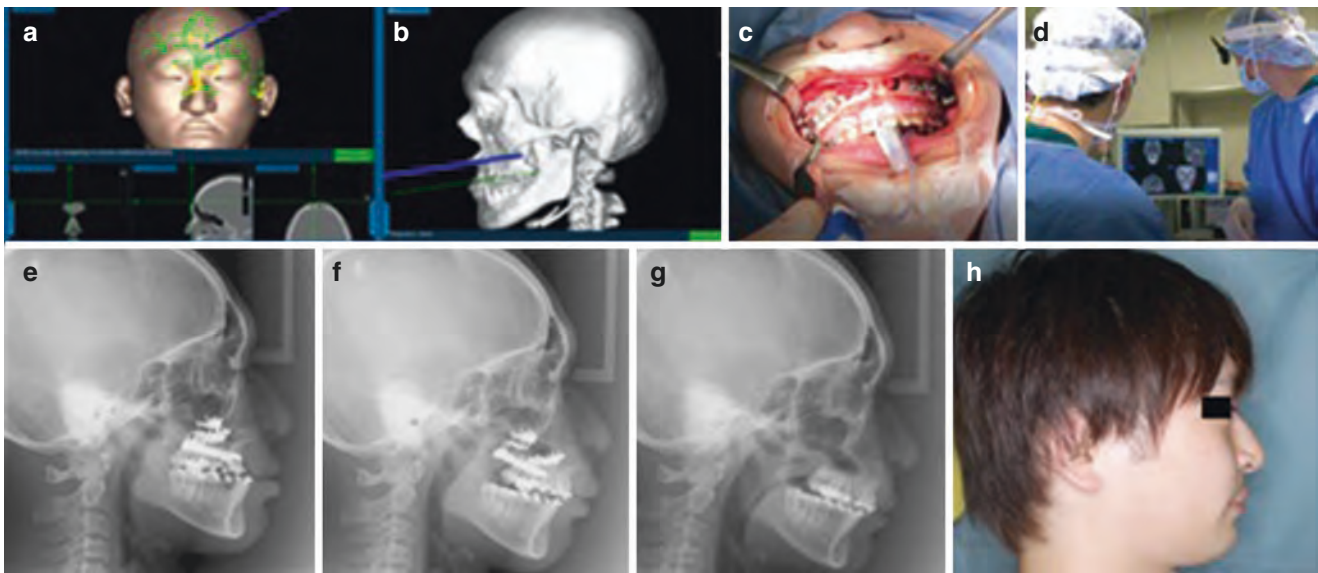
The primary determinants of success in orthognathic surgery include an accurate diagnosis, meticulous treatment planning, and the ability to transfer the plan precisely to the patient intraoperatively. In earlier years, this was performed by a process of model surgery in a laboratory using articulators on plaster casts, which were then transferred to the patient using acrylic splints during the surgical procedure (Figs. 41.10 and 41.11). The procedure was error prone at multiple levels within the sequence. Literature reports an error of up to 5 mm using this type of treatment sequence. With the advent and routine usage of CAD/CAM technology



©Association of Oral and Maxillofacial Surgeons of India

Fig. 41.10 Optimal treatment planning and preparation using 3D models. CAS for cleft lip and palate-related severe maxillary hypoplasia deformity patients using maxillary distraction osteogenesis. (a–c) A 17 year old male undergoing maxillary distraction for cleft-related mid-facial retrusion. (d) Detailed computer simulation for maxillary distraction

surgery in a patient with severe maxillary hypoplasia deformity was used to determine the optimal treatment plan, such as the distraction direction and degree of advancement. (e, f) A 3D printed skeletal model was used to prepare for a maxillary semi-custom-made distractor setting with fabrication



©Association of Oral and Maxillofacial Surgeons of India

Fig. 41.11 A 17-year-old male undergoing maxillary distraction for cleft-related midfacial retrusion. (a–d) Accurate transfer of the treatment plan to the patient in the operating room was achieved. Using the navigation system, precise placement of the maxillary distraction planned pre-

operatively at the set position was performed. The surgeon then confirmed the same distraction direction that was preoperatively planned by the intraoperative navigation. (e–g) Shows the radiographs during and post treatment. (h) Shows the final post surgical result of the patient

and virtual surgical planning, the workflow of treatment planning in orthognathic surgery has undergone a paradigm shift. The conventional workflow of model surgery and splint fabrications is slowly paving the way for VSP and custom printed 3D splints and guides.

Although the degree of inaccuracies associated with treatment planning is reduced using this approach, certain drawbacks such as autorotation of the mandible and lack of control on the vertical position of the maxilla are still prevalent.

There are three methods by which CAS is used in the practice of orthognathic surgery: (1) using real-time intraoperative guidance with surgical navigation for the repositioning of the maxilla and mandible; (2) use of 3D printed cutting guides for precise osteotomy and repositioning, with or without customized 3D printed osteosynthesis plates; and (3) the use of wafer-less surgical planning where the printed implant doubles as both a cutting guide for the osteotomy and as the fixation devices. Many clinical studies have evaluated the efficacy of these methods with promising results.

Mazzoni et al. were the first to report the use of intraoperative navigation in orthognathic surgery, in 2010 [25]. They calculated the overlap error to assess the accuracy of

the technique after surface matching the virtually planned model and the postoperative CT scan. The accuracy was reported for the entire facial skeleton, rather than for each component individually (maxilla, mandible, chin), with a mean match error for each patient ranging from 0.28 to 1.99 mm. Repeatability (<2 mm) in the face area ranged from 77.5% to 96.2% between patients, with a mean reproducibility of 86.5%.

Zinser et al. published a clinical controlled trial study in 2013 that compared the navigation technique with conventional technique, using 3D surgical guides and intermaxillary splints [26]. The highest accuracy for transfer of the maxillary plan to the patient was observed when a 3D surgical guide was used, and no significant linear differences between the planned virtual model and the postoperative results were present in any direction. The navigation technique only showed a significant mean linear difference in the vertical dimension, and differences in angulation were not significant in either group. In contrast, significant linear differences were shown for the classic intermaxillary splints between the planning results and the actual results in the sagittal and vertical dimensions. Differences in plane angulations when using an interocclusal splint were also significant. The usefulness of navigation-assisted surgery for orthognathic surgery was supported based on previous reports.

Published literature demonstrates that all studies have met the 2-mm success criterion, which refers to a maximum difference of 2 mm between the virtual planning performed and

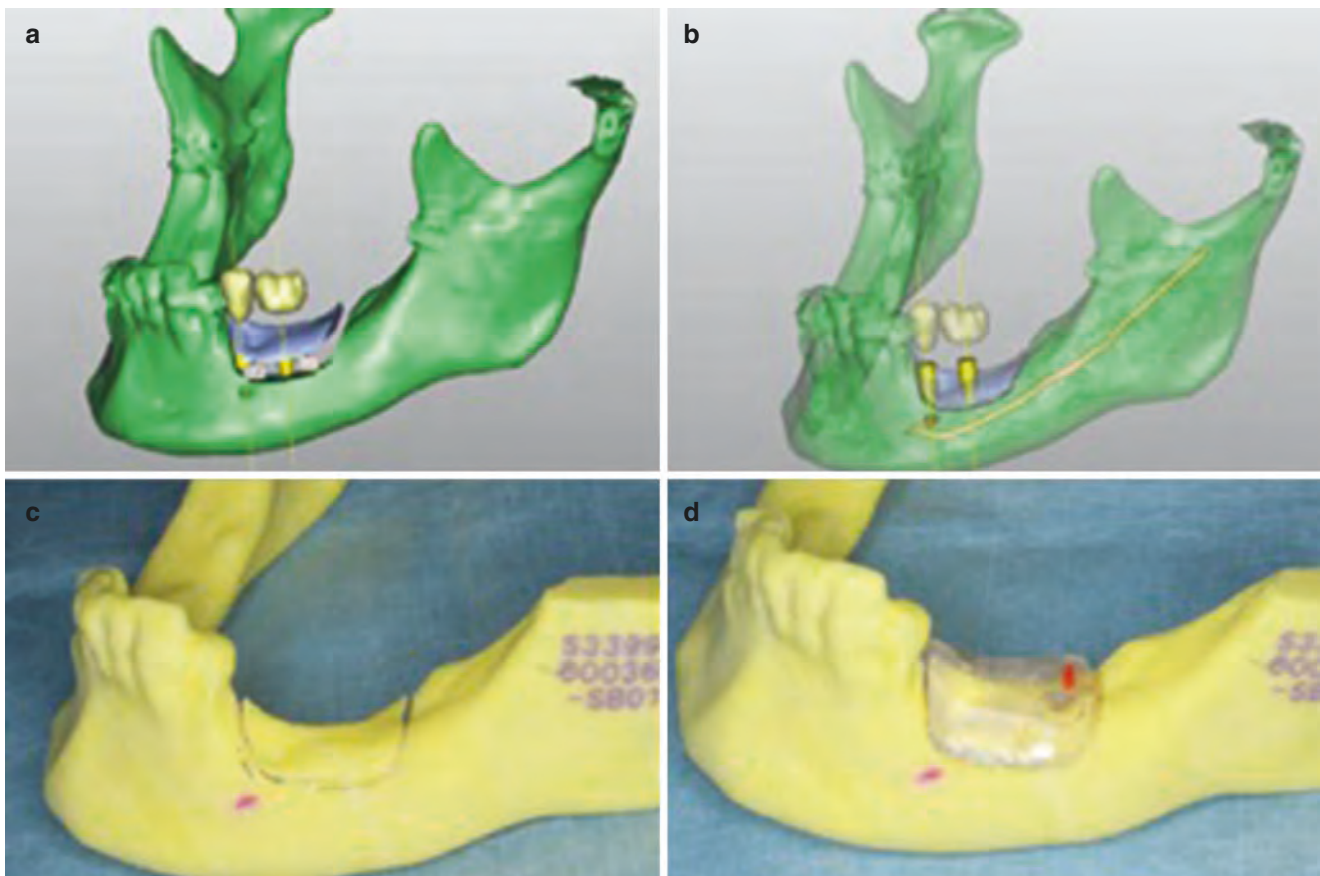
the actual surgical outcome. Zinser et al. reported the only prospective controlled clinical trial comparing CAD-CAM splints, navigation surgery, and intermaxillary splints for the transfer of maxillary planning [26]. The CAD-CAM splints, patented by the authors, were used for maintaining the mandibular condyles (TMJ) in their centric relation. Mandibular positioning still poses a challenge during orthognathic surgery, with none of the solutions having attained “gold-standard” status.

An important clinical limitation for the use of navigation is the increase in operating time [27]. Though there is ample support for increased accuracy levels with the use of navigation, the prolonged operating time still remains a deterrent for the routine use of intraoperative navigation in orthognathic surgery. A recent study indicates that dynamic navigation systems have an entry error of approximately 0.4 mm [28] and an angular deviation error of approximately 4° [29]. Further technological developments can be expected in the field of orthognathic surgery, and an appropriate update for surgeons is required.

41.3.4 Application for Preimplant Bone Augmentation/Dental Implants

Loss of teeth and supporting structures is a common occurrence in the field of oral and maxillofacial surgery for patients who have suffered extensive alveolar bone defects caused by cysts, tumors, facial trauma, or severe periodontal disease [30]. Comprehensive reconstruction methods, including rehabilitation with multiple dental implants, are commonly required to restore function in these patients.

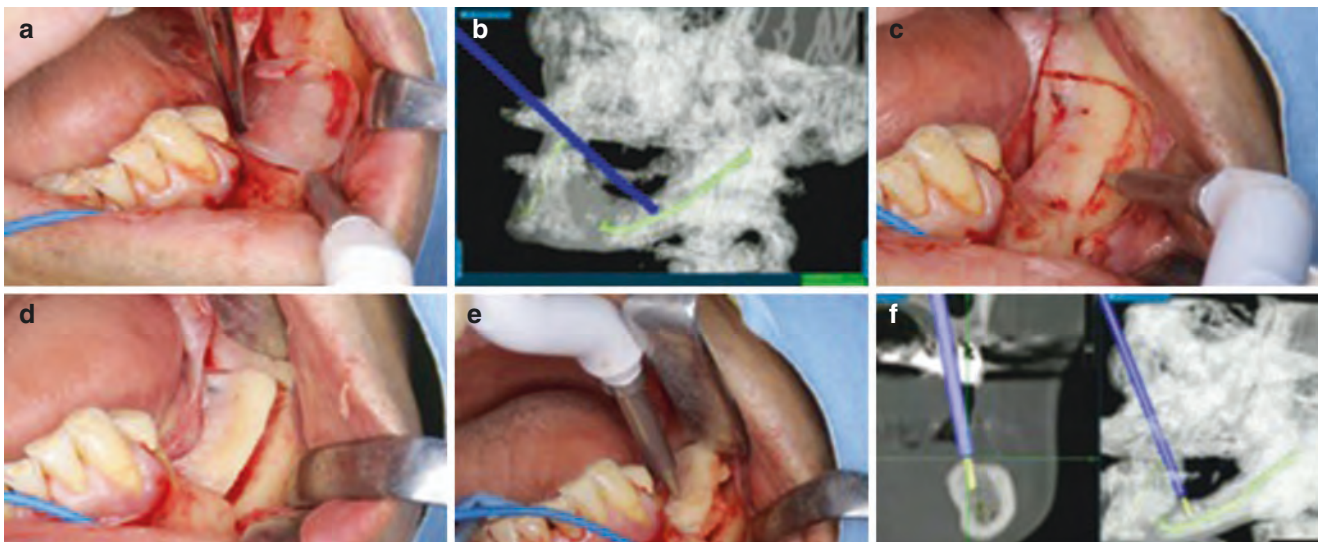
Issues like atrophic jaws, where dental implants cannot be placed due to the loss of bone corpus, are managed by regenerative procedures. Although bone augmentation at the mandibular posterior area is important for occlusion reconstruction using dental implants, it is difficult due to anatomical limitations arising from the inferior alveolar nerve (IAN) and the mandibular bone. However, bone augmentation at the mandibular posterior area can be performed safely and reliably using CAS with 3D modeling and navigation systems (Figs. 41.12 and 41.13).



©Association of Oral and Maxillofacial Surgeons of India

Fig. 41.12 (a–d) Computer simulation based on preoperative CT data will determine the bone augmentation method for implantation. In this case, we chose bone augmentation using the sandwich technique. The necessary bone augmentation volume and position of the anatomically

important inferior alveolar nerve (IAN) were confirmed using computer simulation. Based on this information, we will determine a safe bone cutting line. Surgeons then created a surgical guide using a 3D model based on simulation



©Association of Oral and Maxillofacial Surgeons of India

Fig. 41.13 (a–d) This is a continuation of Fig. 41.12. While confirming the position of the IAN in real time based on intraoperative navigation, the surgeon cut the alveolar bone with reference to the surgical guide created before surgery. (e) The surgeon then inserted autologous

bone taken from the donor and increased the alveolar bone vertically. The most important goal in this surgery is to acquire alveolar bone height as planned before surgery. (f) The bone height can be confirmed in real time based on intraoperative navigation

Traditionally, implants have been placed freehand or with the use of laboratory-fabricated guidance stents. The use of CT-guided 3D printed stents with coordinated drill sequencing has minimized errors to a level of less than 2 mm for crestal and apical deviations, and to less than 5° in angulations. Dynamic navigation systems use a time-effective method to accurately place implants with equivalent implant placement error. Currently the Image-Guided Implantology system (Navident; HERMANS Corp., Tokyo, Japan) is the only dynamic image navigation system (DINS) available for in-office dental procedures in Japan. Its counterpart in the United States is the passive optical dynamic navigation in implantology (X-Nav Technologies, Inc., Lansdale, PA, USA).

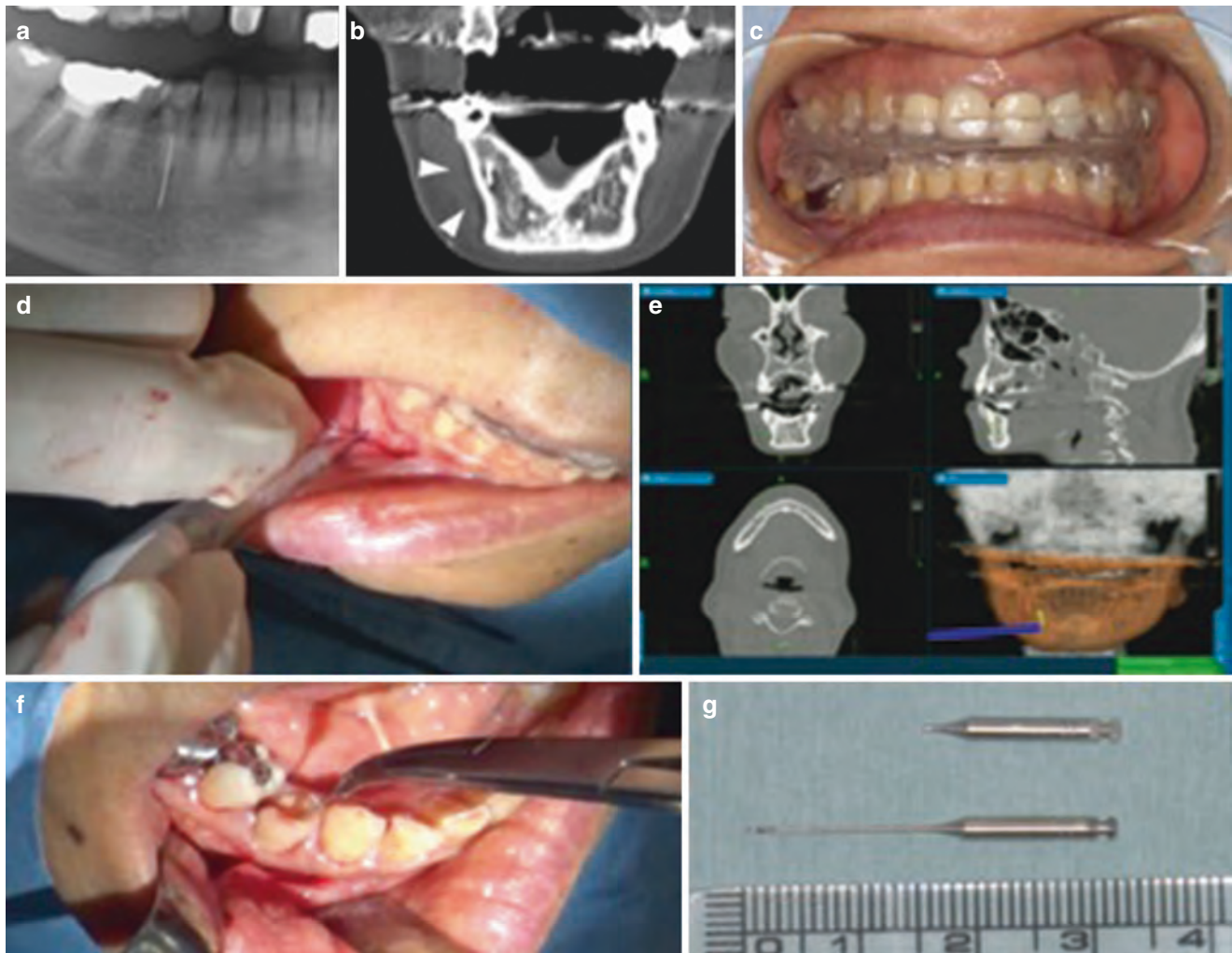
Navigation in dental implantology can add the following advantages: (1) precise depth control and reduced risk of IAN damage [31]; (2) help in planning for flapless surgery or limited flap elevation surgery with reduced postoperative morbidity [32]; and (3) accurate spacing and implant angulation compared to using a freehand approach.

The use of virtual implant planning and intraoperative navigation allows for prosthodontic and surgical coordination due to its planning accuracy and implementation in actual surgical scenarios.

Dynamic navigation methods have similar advantages, including high accuracy, time- and cost-effectiveness, minimally invasive techniques, and flexibility in changing the implant size, system, and location during the surgical procedure [33]. An additional advantage is comfort provided the surgeon in the form of posture, facilitating reduced bending of the neck and back. For example, dynamic navigation allows implant placement for patients with a limited mouth opening, or requiring an implant at a second molar site with reduced access, by relying on a navigation screen to guide the drill sequence without direct visualization of the patient's mouth.

41.3.5 Clinical Applications for the Removal of Foreign Bodies

Retrieval of foreign bodies in the craniomaxillofacial region is often extremely dangerous due to the proximity to various vital structures within a limited anatomical space [34]. This may be made more complex by the presence of deep foreign bodies secondary to severe trauma such as gunshot wounds or blast injuries, which significantly alter the anatomy. Precise location of the foreign body is the first step in the retrieval process, and this may be accomplished with preoperative scans and 3D image rendering. The intraoperative step is next, and is more challenging, as the exact location of the foreign body within the surgical field must be ascertained. Traditional methods utilize a stereotactic “double needle” method with venipuncture needles for triangulation



©Association of Oral and Maxillofacial Surgeons of India

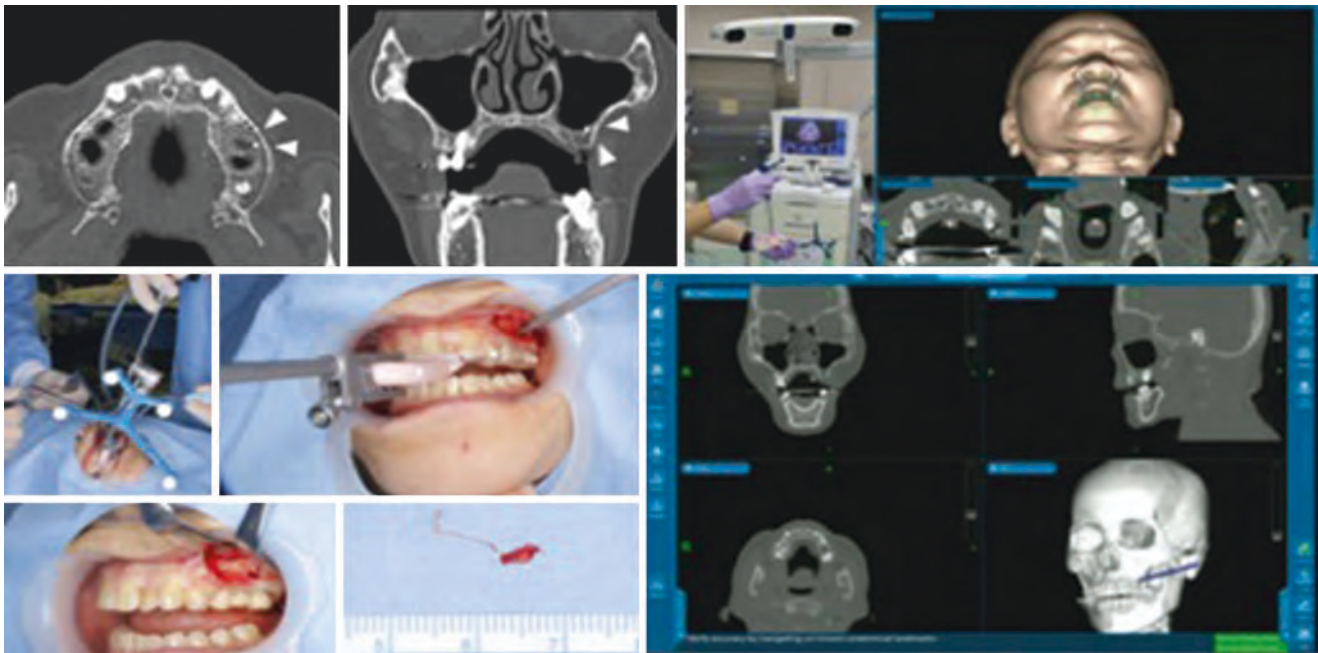Fig. 41.14 (a–g) A 65-year-old female with a foreign body due to dental instrument breakage in the mandible, occurring during an endodontic treatment for a restorative dental procedure. (a, b) Fracture of root canal instruments, with a fractured piece protruding beyond the apex, is a troublesome incident during endodontic treatment. Locating and retrieving these objects represents a challenge for maxillofacial surgeons because they are difficult to access due to the proximity between the foreign body and vital structures. Using the navigation system for mandible treatment is difficult as the mobile nature of the mandible complicates its synchronization with the preoperative imaging data during surgery. (c) The broken dental instrument was removed using a

minimally invasive approach with a surgical navigation system and an interocclusal splint for stable, identically repeatable positioning of the mandible. (d, e) Based on the 3D position of the navigation probe, a location that best approximated and the most anterior extent of the fragment was selected. (f) A minimal vestibular incision was made at this location, a subperiosteal reflection was performed, and the foreign body location was confirmed using the navigation system. (g) The instrument was carefully visualized and extruded from the apical to the tooth crown side and was then removed using mosquito forceps through the medullary cavity of the crown side of the tooth

of the foreign body using plain radiographs [35]. This involved the two reference needles being sequentially placed until both met the foreign body on radiographs. Through blunt dissection, one of the needles is made to contact the foreign body and locate it. It is important to understand that it may be difficult to distinguish small changes in position on plain radiographs. The use of C-arm digital fluoroscopy was a significant advancement for this method, providing rapid radiography [36]. However, as with plain films, fluoroscopic images are 2D, which imposes limitations when locating

objects in a 3D space. The use of intraoperative ultrasound imaging has also been proposed to localize foreign bodies. However, the precision involved in positioning may be questionable, and its use in the oral cavity may also be limited by the size of the instrument.

Intraoperative navigation systems could allow a foreign body to be accurately located in 3D space; these systems are very effective for removing a foreign body during facial surgery [37] (Figs. 41.14 and 41.15). One limitation of navigation is the incapability of the system to account for



©Association of Oral and Maxillofacial Surgeons of India

Fig. 41.15 A 78-year-old female with a small foreign body in the maxilla. Accurate determination of the position of the foreign body in the maxillofacial region can be challenging. This may be due to a small-sized foreign body or a limited inflammatory response. Navigation systems are helpful in identifying the location of the foreign body, determining the optimal approach, and performing the surgical proce-

dures using a minimally invasive surgical strategy. In this case, registration could be reliably performed before surgery using an optical navigation system that facilitates the process, utilizing splints with embedded reference points. This method can decrease the operation time

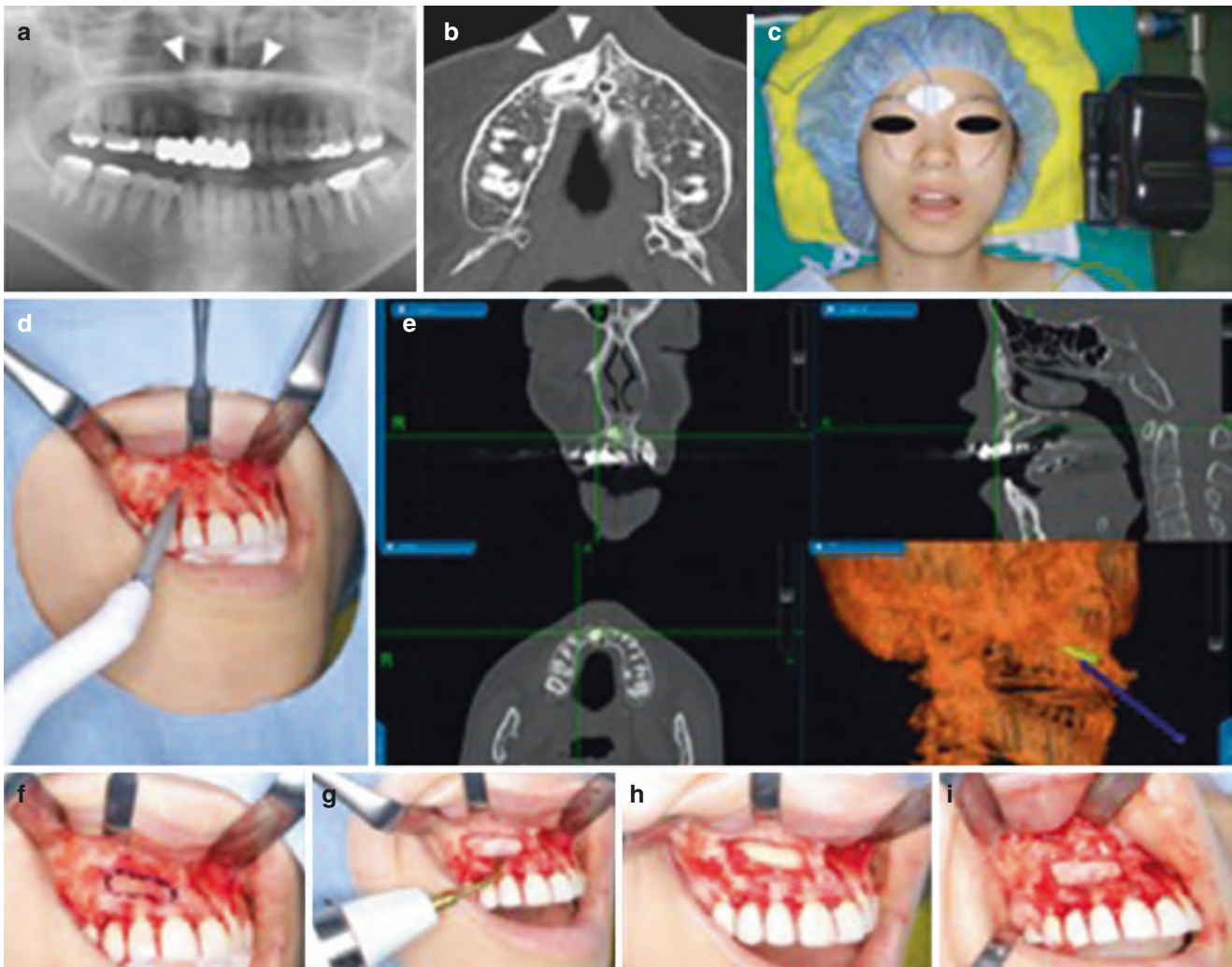
intraoperative soft-tissue changes. The use of navigation techniques superficial tissues or to minimize soft-tissue manipulation may help us overcome this to an extent.

41.3.6 Application for Dentoalveolar Surgery

Dynamic computer-based image navigation technology is a good method for increasing accuracy while minimizing the invasiveness of surgery. It has the additional advantage of real-time access to intraoperative radiographs, which enable us to perform complex dentoalveolar procedures with relative ease. Currently, the Image-Guided Implantology system (Navident; HERMANS Corp.) is the only dynamic image navigation system (DINS) available for in-office dental procedures in Japan. This is an ultraviolet-based optical system, which was approved by the US Food and Drug Administration for the placement of dental implants. However, its use for other dentoalveolar procedures is not approved. Its advantages in the field of dental implantology have already been discussed earlier. The use of dynamic navigation when applied to complex dentoalveolar procedures, such as the surgical removal of third molars, is similar to its use for dental

implants, helping the surgeon prevent inadvertent damage to key structures like the IAN, roots of adjacent teeth, or the lingual plate of the mandible [38]. Common indications for the use of navigation in dentoalveolar surgery include third molar extractions and the location and extraction of supernumerary [39] or malposed teeth (Fig. 41.16), as well as teeth, which get iatrogenically displaced into the sinus, the sublingual pouch, or even the infra temporal fossa.

The use of CAS in oral and maxillofacial surgery has been enhanced with the increasing availability of CBCT. This in turn has promoted the use of Dynamic Image Navigation. As described earlier, the use of DINS during surgical extraction improves visualization of the regional anatomy, preventing or minimizing complications secondary to dentoalveolar surgery. In addition, improved instrument control allows for reduced bone removal, minimization of the surgical access size, and an overall reduction in the morbidity of the procedure. As discussed earlier, this technology also allows for improvement of the ergonomics involved during the surgery. Lastly, dynamic guidance can serve as an effective teaching tool for young surgeons by displaying the surgery and the locations of vital structures on screen.



©Association of Oral and Maxillofacial Surgeons of India

Fig. 41.16 (a–i) A 24-year-old female with an impacted maxillary canine tooth. Bone lid surgery involves cutting a window into the cortical bone and removing a portion thereof; this portion is subsequently returned to its original position at the end of surgery. Bone lid surgery is a minimally invasive technique designed to avoid secondary large bone defects during osteotomies. However, because jaw bone lesions are completely covered with cortical bone, it can be difficult to accurately determine the position of the lesion from the outside. As a potential solution, we used navigation-assisted bone lid surgery. Using navigation, surgeons could

confirm the state of the impacted tooth and surrounding tissue from above the covered bone. We were also able to establish a safe and reliable bone cutting line. In addition, the removed cortical bone was returned to the same (i.e., presurgical) position. Navigation-assisted bone lid surgery for the removal of impacted teeth increases surgical accuracy, minimizes invasion, and allows the bone to be returned to its original position (a, b)–pre operative OPG and CT (c–e)–shows intra operative navigation. (f) outline of canine marked (g, h) impacted canine being removed (i) the bone lid placed back in position

Wang reported the following advantages of surgical navigation in complicated extractions: (1) localization of teeth for accurate access planning and minimal bone removal; (2) differentiation of impacted teeth from erupting tooth germs; (3) ensured transfer of the preoperative plan to the surgical procedure; and (4) the marking of safety margins while preserving adjacent structures, to avoid complications [40].

41.3.7 Application for Temporomandibular Joint and Skull Base Surgery

The TMJ and surrounding anatomy, including the skull base, are extremely complex and require a cautious approach during surgery. Intraoperative navigation can play an important role for surgeries such as the removal of an ankylotic bony mass, tumor resection, and gap arthroplasty [41]. Successful treatment outcomes have been reported by studies for the use

of navigation assistance in unilateral surgery for the TMJ. Other publications report that navigation is helpful and increases safety in TMJ surgery. A recent publication used navigation to compare prospectively treated groups of patients with recurrent malignant tumors of the infratemporal fossa. Although the results are not independently significant, they yielded a benefit to the navigation cohort. The authors concluded that surgeon confidence and safety during the operations improved, but the navigation system alone did not determine patient outcomes.

Management of tumors at the skull base or of end-stage degenerative TMJ disorders requires thorough knowledge of the regional anatomy and precise 3D planning of the resection margins with attention of vital structures in the immediate vicinity (Fig. 41.17). The location, invasion, and extent of the tumor are key determinants in deciding the surgical approach. In the past, malignant tumors that had infiltrated into the infratemporal fossa or the middle of the skull base were considered inoperable due to the compromised access and inability to achieve predictable tumor control or hemostasis.

The use of surgical navigation for skull base surgery offers the following advantages: (1) ensuring safer and quicker skull base access through a dynamic display of the precise operating site and the extent of bone drilling, thereby significantly reducing intraoperative risk; (2) mapping the anatomical structures and important landmarks such as the foramen ovale and rotundum; and (3) the incorporation of allied imaging modalities, such as 3D CT angiography and MRI, into the intraoperative navigation planning, increasing our understanding of the skull base anatomy and the internal carotid artery region.

As surgery of the skull base is not affected by the shifting brain, use of navigation in this field is more precise than in other neurosurgical procedures. The use of a navigation system for the resection of tumors of the skull base or of TMJ lesions increases surgical predictability while reducing the surgical duration.

41.3.8 Other Applications

Another application of intraoperative navigation is in surgery for the management of Eagle's syndrome, which may be due to the elongation of the styloid process or calcification of the stylo-mandibular ligament [42]. This condition involves a group of symptoms, including throat pain and foreign body sensation on

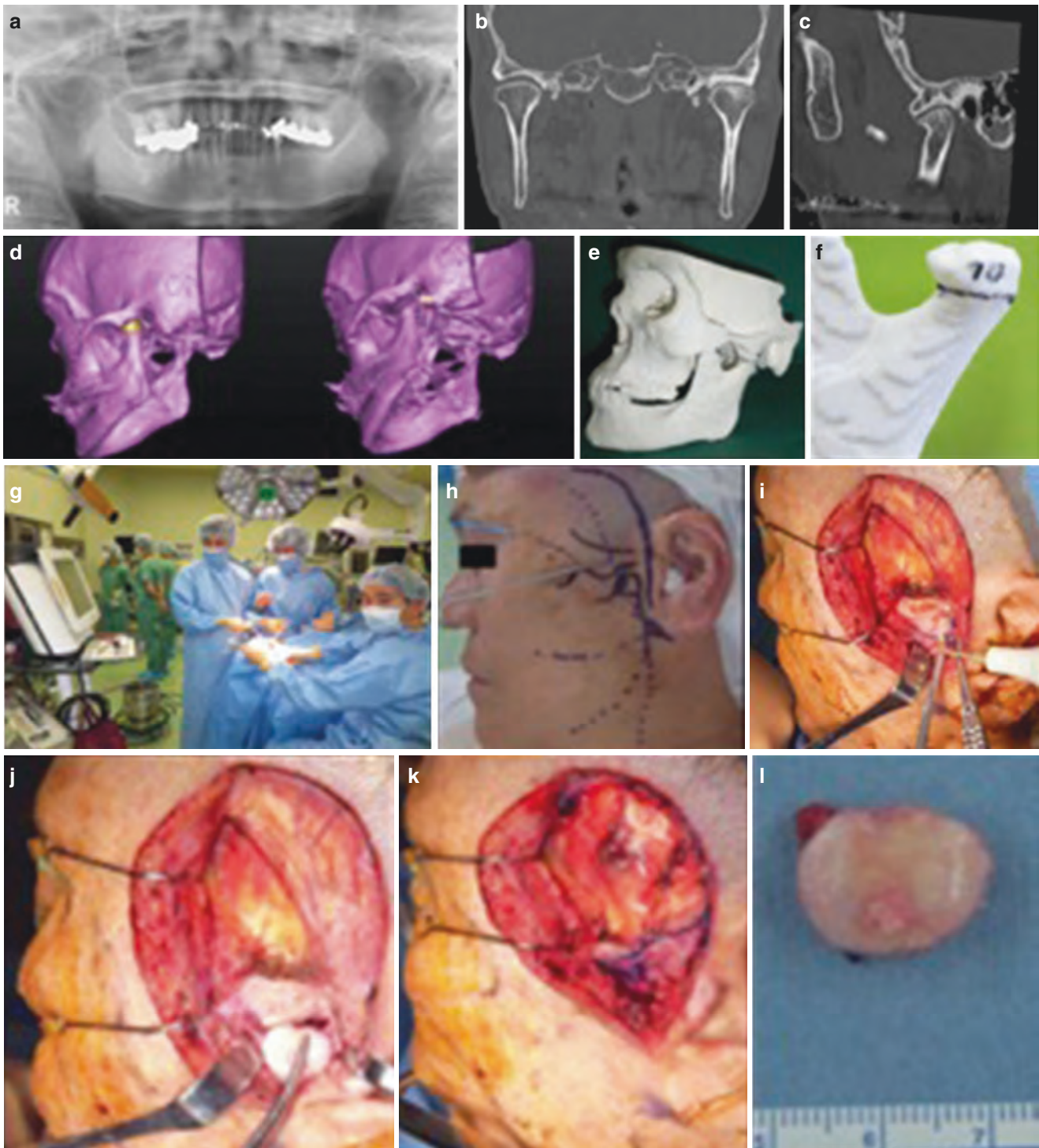
the affected side, reflex otalgia, head and neck pain, and hyper-salivation. Surgical treatment was indicated for patients with no symptomatic improvement following conservative treatment.

The surgery may be performed by two different approaches: (1) transcervical and (2) transoral. The cervical approach provides better surgical exposure of the area, but has the major disadvantage of an external incision. The transoral approach is cosmetically favorable, and is more commonly used. However, this approach offers very limited access. This may affect the management of intraoperative complications, including hemorrhage or difficulty in identifying the styloid process. Several methods have been advocated recently to overcome these problems. One report suggests an endoscopically assisted transoral approach for achieving better exposure and visibility of the field. Another method proposes a combination of piezoelectric surgery and surgical navigation for a transcervical approach to remove the styloid. This technique offers a safe and effective method for the treatment of Eagle's syndrome (Fig. 41.18).

41.4 Recent Advances

41.4.1 Navigation Using Intraoperatively Updated Images

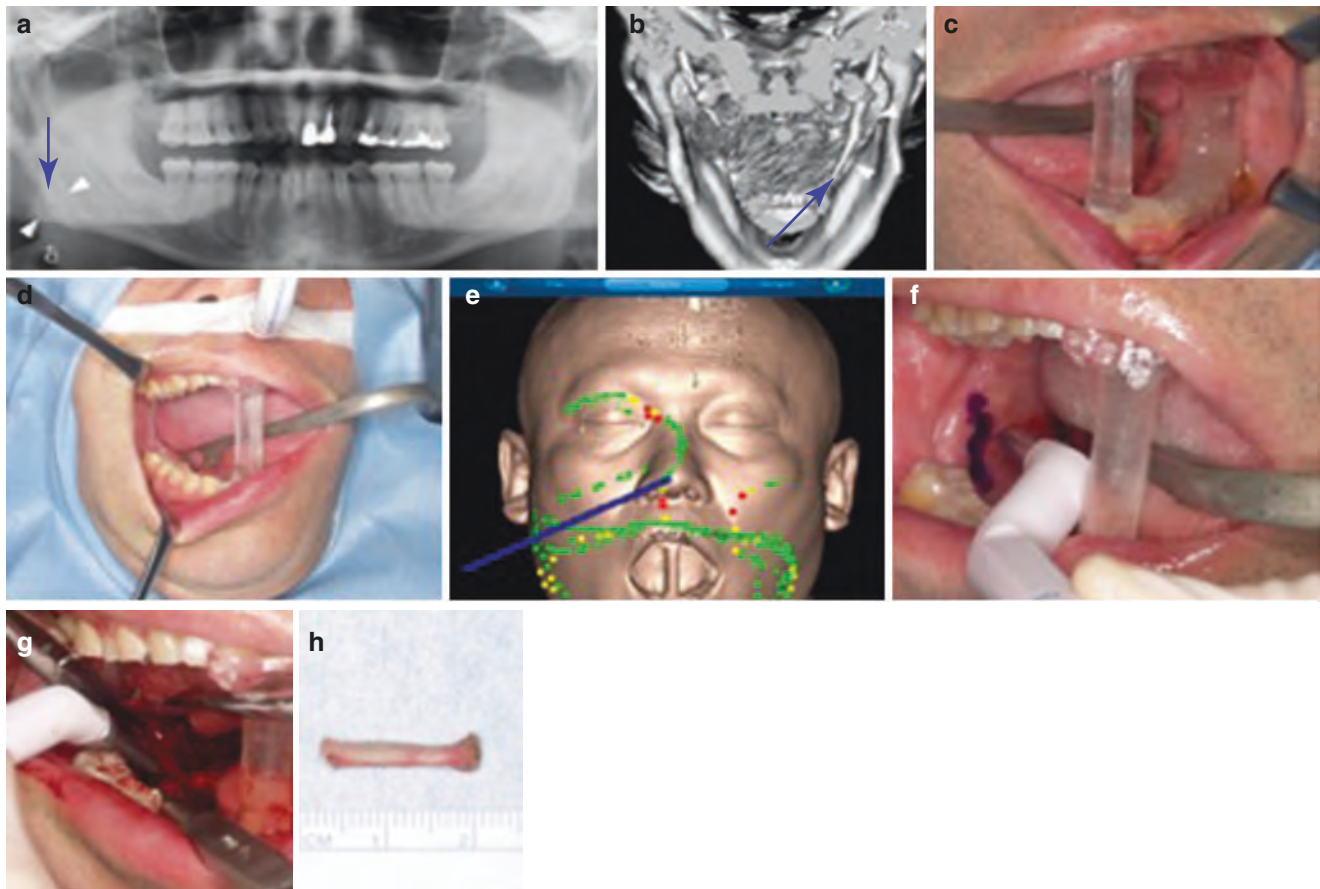
The accuracy of surgical navigation in recent years has been augmented by the induction of intraoperative imaging modalities like the intraoperative CBCT, C-arm, and O-arm systems [43]. These offer intraoperative multiplanar reconstruction capabilities, which enable the improvement of surgical outcomes in demanding surgeries such as surgery of the orbital walls. Furthermore, the popularization of hybrid operating rooms (Fig. 41.19) equipped with both intraoperative imaging and navigation systems has revolutionized surgery of the maxillofacial region. It is now possible to continuously update intraoperative images to determine the best sequence to follow during surgeries (Fig. 41.20). The effectiveness of a navigation system using intraoperative CT images has been already demonstrated in orthopedic surgery and maxillofacial operations, which involve bone movement, such as trauma surgery and orthognathic surgery. Intraoperative CT images have allowed for rapid intraoperative evaluations, which when coupled with surgical navigation, may allow for performing more complicated maxillofacial surgery with increased accuracy.



©Association of Oral and Maxillofacial Surgeons of India

Fig. 41.17 A 70-year-old female with temporomandibular joint (TMJ) ankylosis. Ankylosis surgery is used for gap arthroplasty and mobilization of the joints. (a–c) However, removal of the bony ankylosis and creation of a gap between the ramus of the mandible and the base of the skull can be difficult because of the size of the ankylosis and the anatomy on the inner aspect of the mandible. Virtual planning is useful in conjunction with surgical navigation to remove the ankylosis. (d) First, a computer simulation based on preoperative CT data was performed for the virtual surgery. (e, f) Once the virtual surgery was completed,

templates were constructed using rapid prototyping techniques from the virtual plan and applied at the time of surgery to facilitate the bony cuts. (g, h) Using the intraoperative navigation system, the surgeon can see the medial aspect of the mandible on the navigation station CT and protect important structures on the medial side. (i–l) This visualization prevents significant bleeding from the vessels on the medial side of the mandible and prevents penetration into the middle cranial fossa during release of the ankylosis. The temporalis flap was used for prevention of reankylosis



©Association of Oral and Maxillofacial Surgeons of India

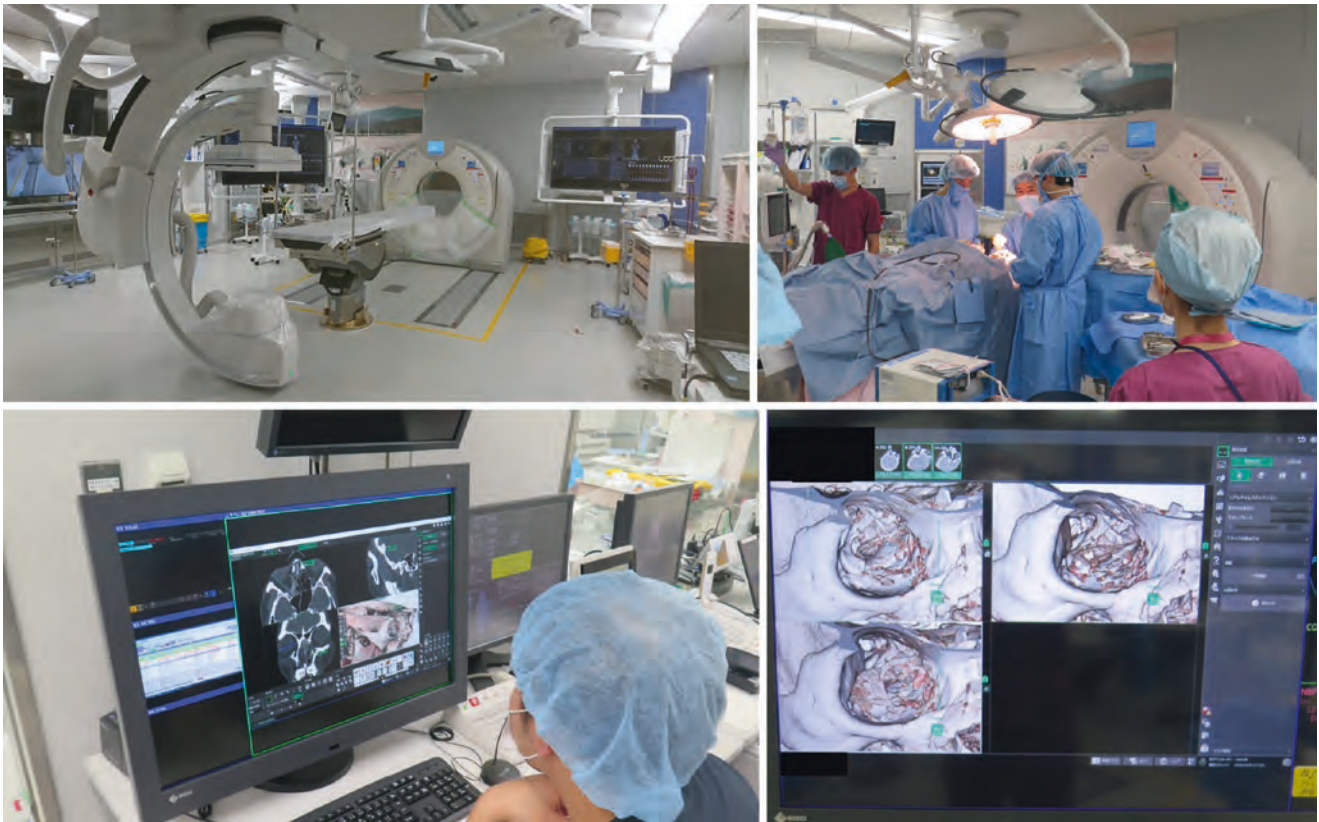
Fig. 41.18 (a, b) A 45-year-old male with elongated styloid process syndrome (Eagle's syndrome). A minimally invasive approach with an intraoperative navigation system was used. (c) Preoperative preparation involved a custom interocclusal splint to produce the mouth opening conditions required during surgery. In this case, since the transoral approach was employed, it was important to reproduce the same mouth-opening conditions when obtaining the preoperative images required during surgery, because the position of the styloid process and the blood vessels may change depending on the position of the mandible during the mouth opening. Since it is difficult to implement the locational findings from the preoperative imaging data while performing surgery owing to the mobile nature of the mandible, a custom interocclusal splint for repeated maximum opening in the same mandibular position,

while enabling surgical access, was used. (d) The patient was taken to the operating room, where the custom interocclusal splint was reinserted. (e) To perform patient-to-CT and MRI data registration, the instrumentation navigation probe was used to trace the reference array and soft tissue landmarks of the face. (f) Using the 3D position of the navigation probe, the location of the elongated styloid process was identified. (g, h) After confirmation of the resection location via the transoral approach, the styloid process was dissected using piezoelectric surgery. Follow-up examination showed an uneventful recovery with no associated complications. (The resection of the styloid process using an intraoperative navigation system and a custom interocclusal splint during a transoral approach, together with a piezoelectric cutting device, is safe and effective for the treatment of Eagle's syndrome)

41.4.2 Wearable Mount Display for Navigation-Assisted Surgery

Although intraoperative navigation yields helpful information on anatomical features, it is used in conjunction

with a monitor. Generally, the direction of the monitor from the surgeon and operator is different from that the surgical field. Therefore, to see the navigation image, the surgeon and the operator must look up, which is stressful for the operator. It is important to minimize muscle tension and allow the surgeon to perform the operation in a



©Association of Oral and Maxillofacial Surgeons of India

Fig. 41.19 A hybrid operating room is a surgical theater equipped with advanced medical imaging devices, such as fixed C-arm and angiographic systems. Intraoperative CT imaging is convenient because the

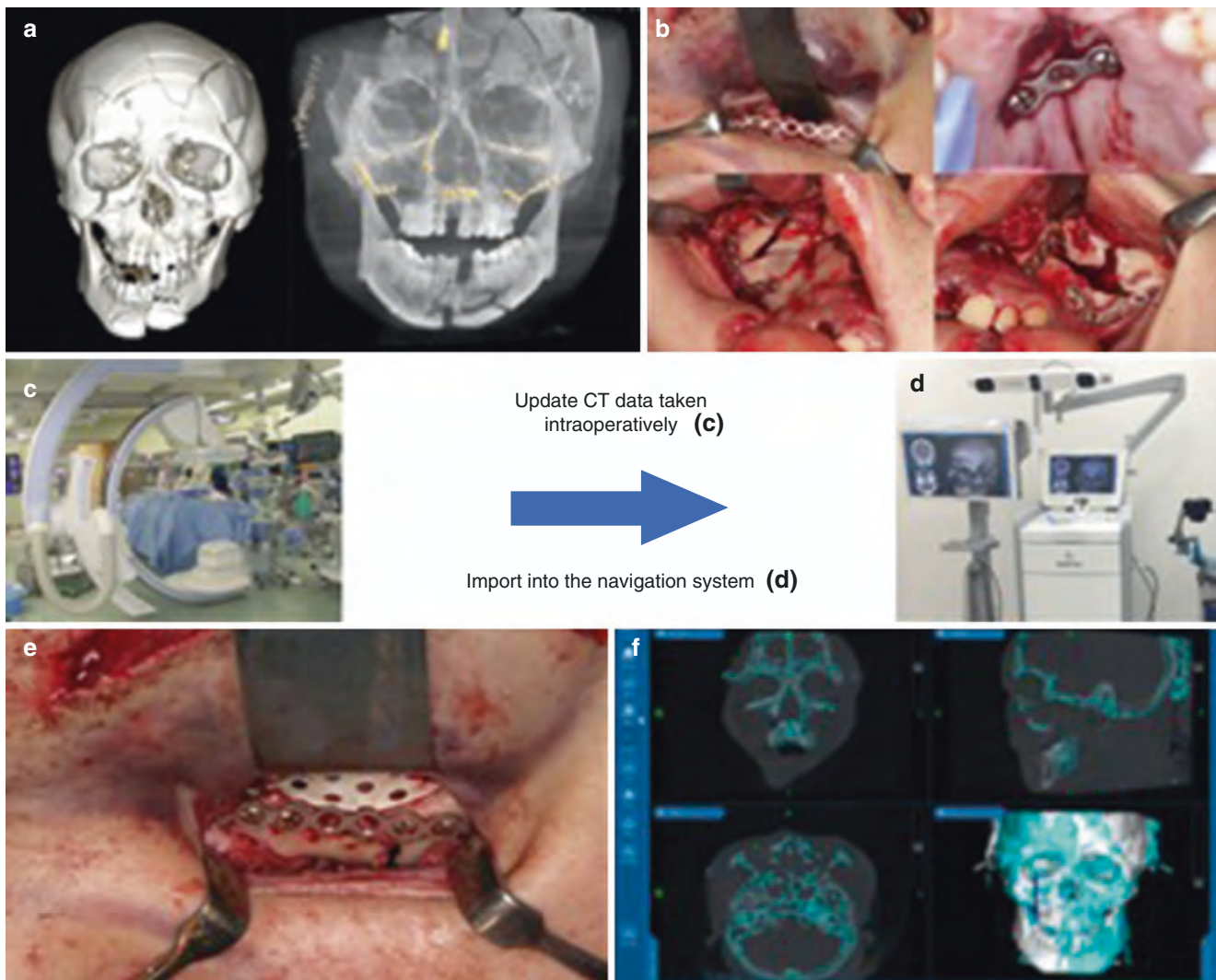
CT is installed in the hybrid operating room. Furthermore, recent advances in technology have made it possible to edit and use images simultaneously with intraoperative CT imaging

relaxed position. Moving the head to look at the monitor can result in considerable misalignment of the eye-hand-target axis during task execution, significantly affecting postural comfort and interventional safety. In recent years, head-mounted display monitors have been developed to address this problem. Such wearable displays can provide high-quality images [44]. Using a head-mounted display monitor, surgeons can finish the surgery without moving their head to check the navigation image. The head-mounted device also allows both the surgeon and the assistant to view both the navigation image and the surgical field without interrupting the flow of surgery. This contributes to rapid surgical operation, resulting in

minimally invasive surgery. Navigation-assisted surgery with a head-mounted display is a revolutionary technique. In the future, head-mounted displays will be wearable devices that promote the use of navigation (Fig. 41.21).

41.5 Conclusions and Perspectives

CAS and navigation offers significant improvements in patient orientation and safety in every facet of maxillofacial surgery. Ranging from precisely planned orthognathic procedures to the removal of foreign bodies requiring



©Association of Oral and Maxillofacial Surgeons of India

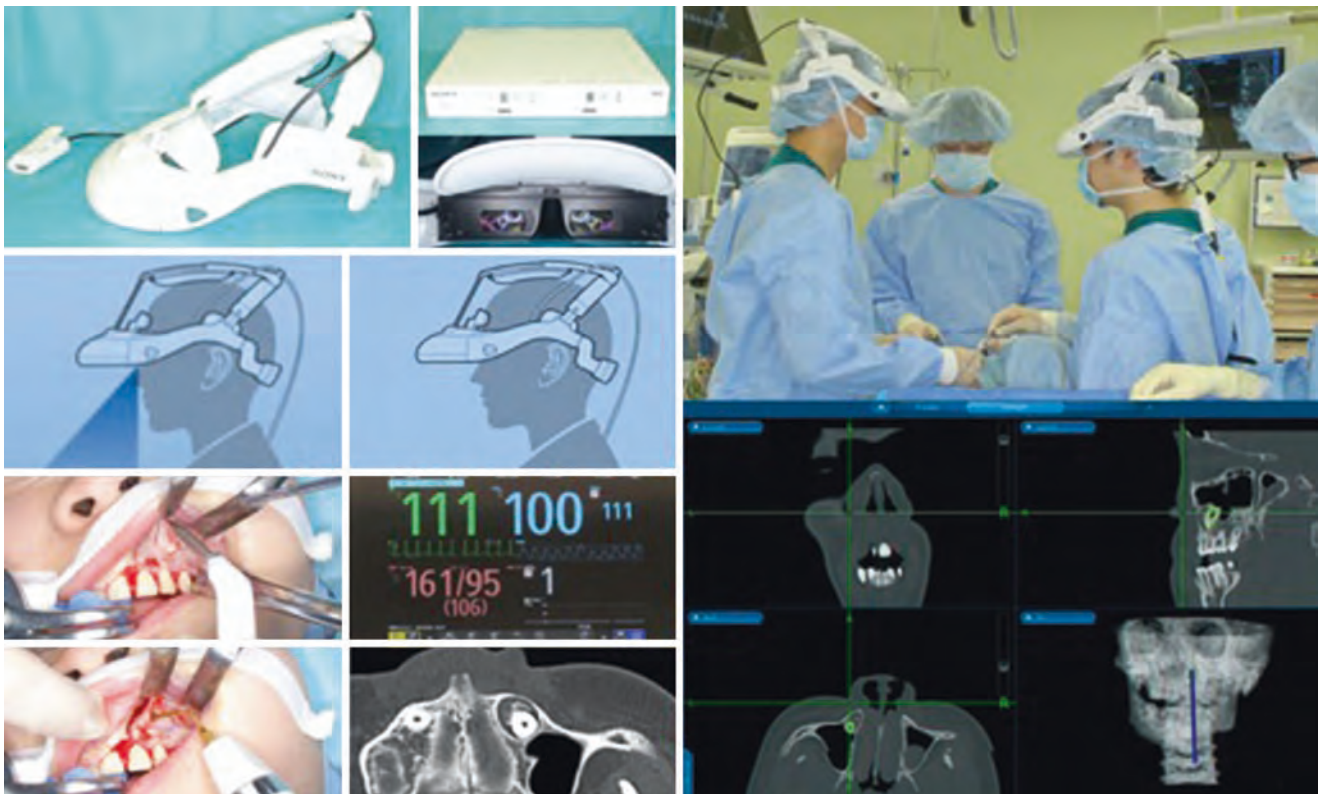Fig. 41.20 (a) A 19-year-old male with a complex facial fracture and orbital fracture. Navigation surgery is difficult to apply for treating a complex facial fracture with orbital fracture. (b) Since reconstruction of the buttress of the facial bone is performed prior to the treatment of the orbital fracture, preoperative CT data and the actual state of the facial bone are different. Therefore, a navigation system using preoperative

CT data cannot be employed. (c) Using CT data obtained after facial fracture reduction, (d) it is possible to use a navigation system reflecting the updated patient condition. The use of CT in the hybrid room can provide rapid CT data during surgery. (e) The orbital floor defect has been repaired. (f) Post operative CT showing the accurate reduction of fractures

extremely flexible surgical options, and from minimally invasive dental implantology procedures to radical tumor resections of the skull base, they have made their mark improving procedure safety, predictability, and accuracy of surgery while also improving options for intraoperative adaptations. In the future, the application of CAS is expected to further reduce operative risks and surgery

time, accompanied by a considerable decrease in patient stress.

Navigation systems are effective for delicate and accurate oral and maxillofacial surgery and neurosurgery, as well as for otolaryngology and orthopedic surgery. In the future, we expect to develop more convenient and reliable navigation systems using new technologies and devices.



©Association of Oral and Maxillofacial Surgeons of India

Fig. 41.21 The head-mounted display can provide high-quality images with wearable technology. The head-mounted display unit was composed of a head-mount image processor unit (HMM-3000MT; Sony Corporation, Tokyo, Japan) and a head-mounted display monitor. Although the navigation system provides helpful information, it is used in conjunction with a monitor. Generally, the direction of the monitor differs from the surgical field. Therefore, to see the navigation image, the surgeon and the operator have to look up, which is stressful for the operator. Using a head-mounted display monitor, we could finish surgery without moving the head position. The surgeon must perform not

only the surgery but also intraoperative systemic management. Multimodality patient information is important in such cases. Multimodality medical information fusion and processing have been developed in recent years. This head-mounted display system allows the integration of preoperative radiological findings with monitoring of navigation images and patient vital signs. Using the head-mounted display system, the surgeon can see multiple images in one view using a split screen, regardless of the head position. This technology facilitates safe surgical management with the navigation system

References

1. Sukegawa S, Kanno T, Furuki Y. Application of computer-assisted navigation systems in oral and maxillofacial surgery. *Jpn Dent Sci Rev.* 2018;54:139–49.
2. Rodby KA, Turin S, Jacobs RJ, Cruz JF, Hassid VJ, Kolokythas A, Antony AK. Advances in oncologic head and neck reconstruction: systematic review and future considerations of virtual surgical planning and computer aided design/computer aided modeling. *J Plast Reconstr Aesthet Surg.* 2014;67:1171–85.
3. Bell RB. Computer planning and intraoperative navigation in cranio-maxillofacial surgery. *Oral Maxillofac Surg Clin N Am.* 2010;22:135–56.
4. Kanno T, Sukegawa S, Karino M, Furuki Y. Navigation-assisted orbital trauma reconstruction using a bioactive osteoconductive/bioresorbable u-HA/PLLA system. *J Maxillofac Oral Surg.* 2019;18:329–38.
5. Li L, Yang J, Chu Y, Wu W, Xue J, Liang P, Chen L. A novel augmented reality navigation system for endoscopic sinus and skull base surgery: a feasibility study. *PLoS One.* 2016;11:e0146996.
6. Samarakkody ZM, Abdullah B. The use of image guided navigational tracking systems for endoscopic sinus surgery and skull base surgery: a review. *Egypt J Ear Nose Throat Allied Sci.* 2016;17:133–7.
7. Hassfeld S, Mühling J, Zöller J. Intraoperative navigation in oral and maxillofacial surgery. *Int J Oral Maxillofac Surg.* 1995;24:111–9.
8. Marmulla R, Lüth T, Mühling J, Hassfeld S. Markerless laser registration in image-guided oral and maxillofacial surgery. *J Oral Maxillofac Surg.* 2004;62:845–51.
9. Bettschart C, Kruse A, Matthews F, Zemmann W, Obwegeser JA, Grätz KW, Lübbers H-T. Point-to-point registration with mandibulo-maxillary splint in open and closed jaw position. Evaluation of registration accuracy for computer-aided surgery of the mandible. *J Cranio-Maxillofac Surg.* 2012;40:592–8.
10. Šiniković B, Kramer F-J, Swennen G, Lübbers H-T, Dempf R. Reconstruction of orbital wall defects with calcium phosphate cement: clinical and histological findings in a sheep model. *Int J Oral Maxillofac Surg.* 2007;36:54–61.
11. Jeon S, Park J, Chien J, Hong J. A hybrid method to improve target registration accuracy in surgical navigation. *Minim Invasive Ther Allied Technol.* 2015;24:356–63.

12. Gumprecht HK, Widenka DC, Lumenta CB. Brain lab vector vision neuronavigation system: technology and clinical experiences in 131 cases. *Neurosurgery*. 1999;44:97–104.
13. Casap N, Wexler A, Eliashar R. Computerized navigation for surgery of the lower jaw: comparison of 2 navigation systems. *J Oral Maxillofac Surg*. 2008;66:1467–75.
14. Li P, Li Z, Tian W, Tang W. A strategy for removal of foreign body in mandible with navigation system. *Int J Oral Maxillofac Surg*. 2015;44:885–8.
15. Dong QN, Karino M, Koike T, Ide T, Okuma S, Kaneko I, Osako R, Kanno T. Navigation-assisted isolated medial orbital wall fracture reconstruction using an U-HA/PLLA sheet via a transcaruncular approach. *J Invest Surg*. 2019;1–9.
16. He D, Li Z, Shi W, Sun Y, Zhu H, Lin M, Shen G, Fan X. Orbitozygomatic fractures with enophthalmos: analysis of 64 cases treated late. *J Oral Maxillofac Surg*. 2012;70:562–76.
17. Baumann A, Sinko K, Dorner G. Late reconstruction of the orbit with patient-specific implants using computer-aided planning and navigation. *J Oral Maxillofac Surg*. 2015;73:S101–6.
18. Azarmehr I, Stokbro K, Bell RB, Thygesen T. Surgical navigation: a systematic review of indications, treatments, and outcomes in oral and maxillofacial surgery. *J Oral Maxillofac Surg*. 2017;75:1987–2005.
19. Schmelzeisen R, Gellrich N-C, Schramm A, Schön R, Otten J-E. Navigation-guided resection of temporomandibular joint ankylosis promotes safety in skull base surgery. *J Oral Maxillofac Surg*. 2002;60:1275–83.
20. Zrnc TA, Wallner J, Zemann W, Pau M, Gstettner C, Brcic L, Assaf AT, Hassanzadeh H, Feichtinger M, Schwenzler-Zimmerer K. Assessment of tumor margins in head and neck cancer using a 3D-navigation system based on PET/CT image-fusion – a pilot study. *J Cranio-Maxillofac Surg*. 2018;46:617–23.
21. Sukegawa S, Kanno T, Shibata A, Matsumoto K, Sukegawa-Takahashi Y, Sakaida K, Furuki Y. Intraoperative navigation-assisted accurate bone lid surgery to remove a mandibular lesion: a case report. *Oral Maxillofac Surg Cases*. 2017;3:15–9.
22. Wei B, Sun G, Hu Q, Tang E. The safety and accuracy of surgical navigation technology in the treatment of lesions involving the skull base. *J Craniofac Surg*. 2017;28:1431–4.
23. Ricotta F, Cercenelli L, Battaglia S, Bortolani B, Savastio G, Marcelli E, Marchetti C, Tarsitano A. Navigation-guided resection of maxillary tumors: can a new volumetric virtual planning method improve outcomes in terms of control of resection margins? *J Cranio-Maxillofac Surg*. 2018;46:2240–7.
24. Luna-Ortiz K, Villa-Zepeda O, Carrillo JF, Molina-Frias E, Gómez-Pedraza A. Parapharyngeal space tumor: submandibular approach without mandibulotomy. *J Maxillofac Oral Surg*. 2018;17:616–24.
25. Mazzoni S, Badiali G, Lancellotti L, Babbì L, Bianchi A, Marchetti C. Simulation-guided navigation. *J Craniofac Surg*. 2010;21:1698–705.
26. Zinser MJ, Sailer HF, Ritter L, Braumann B, Maegele M, Zöller JE. A paradigm shift in orthognathic surgery? A comparison of navigation, computer-aided designed/computer-aided manufactured splints, and “classic” intermaxillary splints to surgical transfer of virtual orthognathic planning. *J Oral Maxillofac Surg*. 2013;71:2151.e1–2151.e21.
27. Holly LT, Foley KT. Intraoperative spinal navigation. *Spine (Phila. Pa. 1976)*. 2003;28:S54–61.
28. Block MS, Emery RW. Static or dynamic navigation for implant placement-choosing the method of guidance. *J Oral Maxillofac Surg*. 2016;74:269–77.
29. Chao AH, Weimer K, Raczkowsky J, Zhang Y, Kunze M, Cody D, Selber JC, Hanasono MM, Skoracki RJ. Pre-programmed robotic osteotomies for fibula free flap mandible reconstruction: a preclinical investigation. *Microsurgery*. 2016;36:246–9.
30. Sukegawa S, Kawai H, Nakano K, Kanno T, Takabatake K, Nagatsuka H, Furuki Y. Feasible advantage of bioactive/bioresorbable devices made of forged composites of hydroxyapatite particles and poly-L-lactide in alveolar bone augmentation: a preliminary study. *Int J Med Sci*. 2019;16:311–7.
31. Gaggl A, Schultes G, Kärcher H. Navigational precision of drilling tools preventing damage to the mandibular canal. *J Cranio-Maxillofac Surg*. 2001;29:271–5.
32. Stefanelli L, DeGroot B, Lipton D, Mandelaris G. Accuracy of a dynamic dental implant navigation system in a private practice. *Int J Oral Maxillofac Implants*. 2019;34:205–13.
33. Emery RW, Merritt SA, Lank K, Gibbs JD. Accuracy of dynamic navigation for dental implant placement—model-based evaluation. *J Oral Implantol*. 2016;42:399–405.
34. Shuker ST, Satta R. Craniomaxillofacial falling bullet injuries and management. *J Oral Maxillofac Surg*. 2010;68:1593–601.
35. Bedrock RD, Skigen A, Dolwick MF. Retrieval of a broken needle in the pterygomandibular space. *J Am Dent Assoc*. 1999;130:685–7.
36. Park S-S, Yang H-J, Lee U-L, Kwon M-S, Kim M-J, Lee J-H, Hwang S-J. The clinical application of the dental mini C-arm for the removal of broken instruments in soft and hard tissue in the oral and maxillofacial area. *J Cranio-Maxillofac Surg*. 2012;40:572–8.
37. Sukegawa S, Kanno T, Shibata A, Matsumoto K, Sukegawa-Takahashi Y, Sakaida K, Furuki Y. Use of an intraoperative navigation system for retrieving a broken dental instrument in the mandible: a case report. *J Med Case Rep*. 2017;11:14.
38. Emery RW, Korj O, Agarwal R. A review of in-office dynamic image navigation for extraction of complex mandibular third molars. *J Oral Maxillofac Surg*. 2017;75:1591–600.
39. Retana A, Emery RW, Keir V. Removal of impacted supernumerary teeth using a dynamic surgical navigation system: a case report. *J Oral Maxillofac Surg*. 2019;77:1130–4.
40. Wang H, Yang C-Y, Li Z. Traumatic displacement of teeth into maxillary sinus and the retrieval assisted by computer-assisted navigation. *Medicine (Baltimore)*. 2018;97:e13865.
41. He Y, Huang T, Zhang Y, An J, He L. Application of a computer-assisted surgical navigation system in temporomandibular joint ankylosis surgery: a retrospective study. *Int J Oral Maxillofac Surg*. 2017;46:189–97.
42. Sukegawa S, Kanno T, Yoshimoto A, Matsumoto K, Sukegawa-Takahashi Y, Masui M, Furuki Y. Use of an intraoperative navigation system and piezoelectric surgery for styloidectomy in a patient with Eagle’s syndrome: a case report. *J Med Case Rep*. 2017;11:322.
43. Wikner J, Riecke B, Gröbe A, Heiland M, Hanken H. Imaging of the midfacial and orbital trauma. *Facial Plast Surg*. 2014;30:528–36.
44. Matsuo A, Hamada H, Oba H, Shibata K. Virtual reality head-mounted display for endoscopically-assisted implant surgery. *Br J Oral Maxillofac Surg*. 2018;56:636–7.

Open Access This chapter is licensed under the terms of the Creative Commons Attribution 4.0 International License (<http://creativecommons.org/licenses/by/4.0/>), which permits use, sharing, adaptation, distribution and reproduction in any medium or format, as long as you give appropriate credit to the original author(s) and the source, provide a link to the Creative Commons license and indicate if changes were made.

The images or other third party material in this chapter are included in the chapter's Creative Commons license, unless indicated otherwise in a credit line to the material. If material is not included in the chapter's Creative Commons license and your intended use is not permitted by statutory regulation or exceeds the permitted use, you will need to obtain permission directly from the copyright holder.



Part XIV

**Practice Management in Oral
and Maxillofacial Surgery**

Human Factors Recognition to Enhance Team Working and Safer Patient Care

42

Peter A. Brennan and Rachel S. Oeppen

42.1 Introduction

Human error and organisational mistakes are a significant cause of morbidity for patients. It is important to recognise and address human factors (HF) in the context of our own performance optimisation, enhancing team working to improve patient safety, and better working lives for clinicians across surgery and medicine.

Medical errors are usually multi-factorial rather than the direct fault of any one individual. Organisational issues, poor team working and other HF are often at the root of many incidents and errors. The Surgical Checklist produced by the World Health Organization (WHO), and aviation-styled communication training initiatives have been advocated to optimise surgical performance by reducing human fallibility and misinterpretation between team members. Brief and debriefing processes and other performance improvement practices have been positively rated when incorporated into healthcare. Ergonomics and other factors such as stress and fatigue, emotional status, hunger, dehydration and situational awareness can all lead to human error, but these are often under-appreciated and in some cases even disregarded.

The aims of this chapter are to raise colleague awareness of both individual human factors and those relevant to organisations and to highlight relatively simple methods to actively reduce error in healthcare.

P. A. Brennan (✉)
Maxillofacial Unit, Queen Alexandra Hospital, Portsmouth, UK
e-mail: peter.brennan@porthosp.nhs.uk

R. S. Oeppen
Consultant Radiologist, University Hospital Southampton,
Southampton, UK
e-mail: Rachel.oeppen@uhs.nhs.uk

42.2 The Scale of the Problem

Over 70% of plane crashes are due to a human mistake rather than a failure of the aircraft itself. Issues with communication can occur in up to 80% of air disasters. Recognition of factors leading to human error, including tiredness, stress, and repetitive tasks, and an acceptance that a certain degree of failure is almost inevitable, has improved air safety. These factors are being increasingly recognised by healthcare professionals [1]. The American Institute of Medicine report entitled “To Err Is Human” published in 1999 and subsequent work has found death from preventable medical errors, with those in surgery second only to medication errors as the most common reasons for death from medical error [2]. Recent estimates place avoidable patient deaths in USA hospitals at over 400,000 per year, with preventable harm in the top three causes of death [3].

While the authors were not able to source any statistics for the Indian sub-continent, death in UK hospitals from medical error is estimated to be about 4000 per year, with a disproportionate amount of harm caused by errors in surgery. To put this into context, this would be the equivalent of more than one A320 fatal airbus (Fig. 42.1) crashes occurring twice a month. Incidentally, the A320 is the aircraft involved in the widespread media coverage after an emergency landing on the River Hudson in January 2009 by Captain ‘Sully’ Sullenberger, subsequently dramatized in the well-known movie, *Sully*. Despite the WHO checklist, which is widely used throughout the modern world, the number of ‘never events’—those that should never happen, including wrong site surgery and retained instruments or swabs—is increasing [4]. Although doctor-induced mistakes are quite rare, a near miss occurs far more commonly in the hospital environment. An investigation and detailed cause analysis following any incident can help organisations learn, prevent and reduce the chance of such errors occurring again in the future.



©Association of Oral and Maxillofacial Surgeons of India

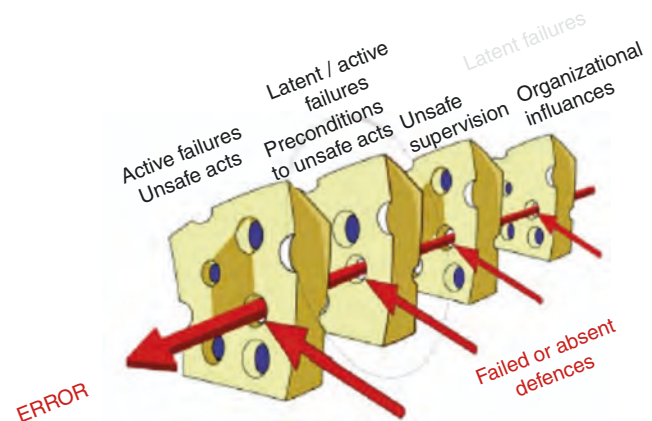
Fig. 42.1 The flight deck of an Airbus A320 being configured for departure

42.3 How Do Human Errors Arise?

Recognition and understanding of those relevant HF involved in potential error is vital for improving patient safety. These factors include fatigue and tiredness, stress, communication style, effective team working, and good leadership. The well-known ‘Swiss cheese model’ of error (Reason [5]) is illustrated in Fig. 42.2. Organisational failures contributing to medical error could include pressures on individuals to meet hospital targets, having too many patients on an operating list than is deemed safe, too many patients in an outpatient clinic, working very long hours without taking a break or being expected to operate the following day after having been disturbed overnight with on-call emergencies.

42.3.1 Senior Management Support Is Essential in Helping to Reduce Medical Error

Senior management commitment is essential in ensuring safety across any organisation. An open culture has to be key in any hospital agenda and strategy. Poor leadership together with a ‘blame culture’ led to more than 35 deaths in the Bristol paediatric cardiac surgery service. As a result, a large number of changes were implemented to limit future preventable surgical incidents. Pilots, aircraft ground engineers and other aviation safety staff are encouraged to actively question any safety issues related to their aeroplane, and their employer must investigate concerns, even if this means stopping a flight from taking off. In healthcare, we should be following this safety model with higher hospital management and surgical team leaders creating a safe environment



©Association of Oral and Maxillofacial Surgeons of India

Fig. 42.2 Schematic representation of the Swiss cheese model of human error. Each of the cheese slices acts as a barrier to an error occurring with the final chance for stopping the error being the elimination of the unsafe act itself. Error has its origin in organisation influences (latent failure) and those caused by individuals and teams (active failures)

Table 42.1 Avoiding human error traps

- Read out WHO Checklist with active participation of all team members. Engage with it as if your own life or limb depended on getting it right
- Ensure staff communicate well with each other
- Use briefing/debriefing to improve team working
- Limit avoidable distractions and any interruptions during essential parts of an operation (same as sterile cockpit in aviation).
- Promote use of positive two-way communication.
- Ensure 6–8 h of sleep, regular physical activity and adequate nutrition and hydration before starting surgery.
- Look out for each other as part of the team.
- Ensure you take regular breaks and eat and drink often during the day.
- Recognise when something doesn't seem right in yourself.
- Do not assume physically uncomfortable postures unless absolutely necessary. Adjust equipment, table for the comfort of you and your team.

Table 42.2 Take special care—recognise situations in which error/harm is more likely

- Site- and side-specific procedures
- Staffing limitations high turnover rates
- Changes in physical environment
- Changes in staff/scheduling
- Staffing limitations
- High staff turnover
- Significant changes in life situation of team members—divorce, death in family
- Special patient factors, e.g. Jehovah witness unable to accept transfusion, obesity

to report and action possible error. The surgical team has to endorse the use of evidence-based best practices, including use of the WHO Surgical Checklist, avoiding human error traps (Table 42.1) and early identification of those situations in which harm or error is more likely to occur (Table 42.2).

While a surgeon's life or limb is not at stake during an operation (unlike an air disaster when a mistake made by an airline pilot might result in the death of all those on board, including the crew), the psychological effects of a major surgical incident or error can be devastating to both individuals and teams [6].

42.3.2 Human Factors That We Should Be Thinking About

There are many personal human factors that can cause error, including tiredness and fatigue, nutritional status, anger and stress, multitasking and loss of our own situational awareness. However, all too often as individuals we sometimes imagine that these factors do not apply to us, and therefore we might choose to ignore them (such as missing lunch, working for many hours without taking a break) significantly raising the risk of patient harm and potentially damaging our own health and well-being.

42.3.2.1 Fatigue and Tiredness

These are known in aviation and other high-risk organisations (HROs) as significant factors that can cause human error. As a result, strict guidelines have been put in place in these HRO, with for example flight crews only being working a defined number of hours in any given month. Many airlines have a policy in place to make sure that one pilot is as refreshed as possible for the most dangerous aspects of flying such as the landing. Intense concentration can only be maintained for about 20–30 min. For example, one pilot will take over the actual landing when the other has done the first-stage descent. The effect of these personal factors in surgical performance is less understood than in aviation though tiredness will affect decision making, as well as doing complex tasks. Situational awareness will also be affected even if surgeons behave as if they are immune and operate for many hours without taking a break. The ability for sleep deprivation to degrade performance is dramatically under-estimated by healthcare providers [7].

With reference to the Swiss cheese analogy, tiredness, emotional factors and stressful surgery can all align together to raise the risk of serious error. Table 42.2 shows some of these high-risk situations. Good communication and team working and the ability to question decisions with a phrase such as 'can I check that I've got this correct' can be useful. Other phrases like 'I am not happy' and 'I am going to take over' can also be used in situations where an error might happen.

42.3.2.2 Nutritional Status and Hydration

These factors significantly affect HF and our performance in a demanding operating room setting. Even modest levels of

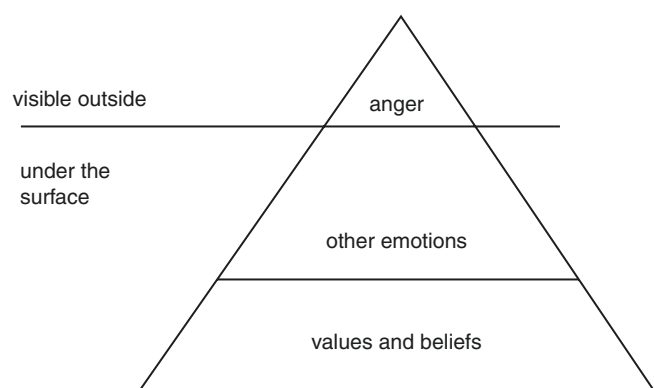
dehydration are known to impair cognitive function and performance [8]. Meals that contain protein, carbohydrates and fats such as those derived from olive oil, fish and avocado as well as certain nuts are considered to be best for optimal nutrition. Simple sugars (such as chocolate bars) and processed food do not readily support long-term concentration and the endurance that is needed in the operating theatre [8].

The authors recommend taking a short break of 10–15 min every 2–3 h when at work, especially if performing complex tasks or surgery. Of course, the procedure can continue if there is suitable expertise within the team, but each team member should plan to take a regular break, which can be staggered. Even a short time spent away from operating can help provide a fresh outlook, improve morale, and enable a toilet and food/water break. Recovery is aided through regular sleep, which is positively linked to healthy eating and drinking. Certain nutritional supplements may also support performance [9].

42.3.2.3 Stress and Emotions While We Are Working

Emotional and psychological issues can affect performance. While these emotions can often be hidden, a trigger or so-called sentinel event that results in upset or even anger can occur, during times of high mental workload or in those stressful situations that we all will be familiar with. Many of us will have witnessed others (or ourselves) having an emotional outburst, including shouting at other team members. During these events, error is much more likely to occur. In these situations, visible anger usually results from additional hidden factors that others do not see in the so-called anger triangle (Fig. 42.3).

A simple thing to remember, **HALT** (Table 42.3), reminds us of sometimes overlooked personal issues and to ensure we stop to take a break. The importance of a short rest cannot be emphasised enough if it is safe, especially when these HALT



©Association of Oral and Maxillofacial Surgeons of India

Fig. 42.3 Anger triangle: many emotions may be hidden from others until a sentinel event causes an outburst of anger. During this time, error is much more likely

Table 42.3 Try to stop or inform a member of the team when experiencing or witnessing these HALT factors

H	Hungry
A	Angry or anxious
L	Lonely or late
T	Tired

issues becomes apparent, and may prevent something serious from occurring.

Management strategies such as increasing our own emotional awareness and learning how to deal with personal stress may also be useful.

Effective communication with the rest of the team and questioning decisions where there might be some doubt by saying something like ‘can I check that I have got this right?’ is paramount. Other words such as ‘I’m not happy’ and ‘I’m going to take over’ can also be used in situations where potential errors are deemed more likely.

42.4 What About WHO and Other Checklists and Team Working Dynamics on Surgical Performance?

The WHO Surgical checklist has resulted in significant decreases to post-operative mortality and morbidity on a worldwide scale, yet errors persist and recur. While checklists, including WHO’s, cannot address all aspects of medical and surgical practice, good team working with effective briefing can help to optimise team performance. There are many situations in surgery and other medical specialities when mental or physical workloads increase suddenly or dramatically (for example, during complex microvascular reconstruction) and these can have an adverse effect on performance. In such cases, team dynamics and an understanding of each individual’s role within the wider team are crucial. Airlines enforce a ‘sterile cockpit’ policy in which noise is kept to only essential conversation below 10,000 ft (during high-risk procedures such as landing and take-off) and only essential conversation relating solely to procedure is permitted. The sterile flight deck concept is being advocated for reducing error in anaesthesia and surgery [10]. This should be discussed with all team members at the pre-operative briefing so that all know the need to stop non-essential communications at certain times. Poor team working has had tragic consequences on many occasions. In one well-known UK case (Elaine Bromiley), the airway was lost following induction of anaesthesia for a routine ENT procedure. The anaesthetists made repeated attempts to secure an airway, and had ‘tunnel vision’ about this rather than seeking assistance from surgeons or others for an emergency needle cricothyroidotomy.

Ancillary staff were well aware of the patient’s prolonged hypoxic state but felt reluctant to assert themselves or state the need for alternative intervention. No individual took a leadership decision role and the team did not have designated roles during a difficult airway situation. As a result, the patient died when she could so easily have been saved. Lack of leadership, poor communication, inability to challenge hierarchy, and many other HF failings were to blame for this tragedy.

Effective team working is also valuable in promoting a sense of shared responsibility for patient safety. Team performance is often improved when front line staff actively monitor important performance criteria such as blood loss, regular swab counts, and needle and instrument checks.

The WHO checklist and other team tools have helped with theatre safety; however, never events still continue to occur [4]. Much more is needed around safer team interactions. The team brief, coupled to a debriefing after the day’s operating, can enhance patient care, team working and feeling valued by all.

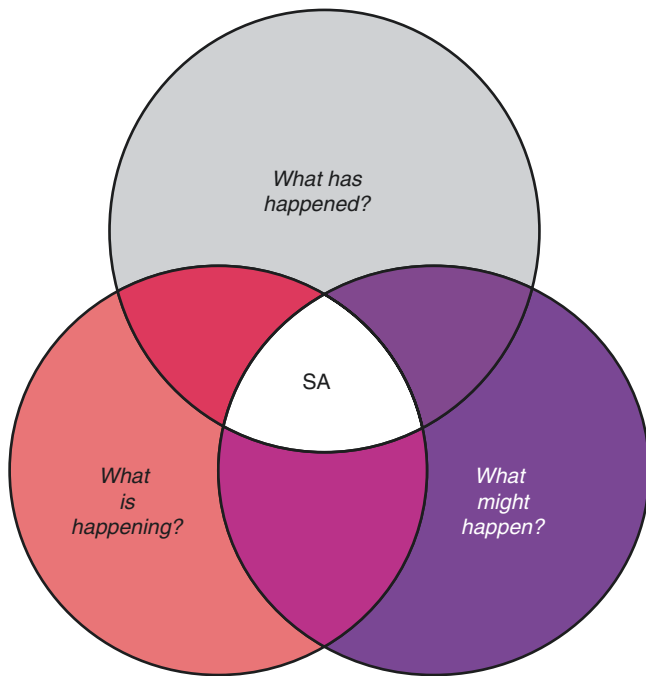
Airline pilots discuss the ‘what if?’ scenario in pre-flight briefings and know who will be doing what if something doesn’t go well (Fig. 42.4). Some clinicians even go as far as to ask team members ‘how could we kill this patient today?’ Table 42.4 summarises items that could be included in a good briefing and debriefing. The nominated team leader can summarise what has been discussed and repeat back as necessary to confirm to everyone that there is shared understanding. We also suggest monitoring each other for signs of loss of situation awareness as well as looking for features of tiredness and fatigue.

An open culture and respect by all team members are crucial for better team working and enhancing patient safety. Even the most inexperienced pilot will question decisions of senior Captains without fear. While a hierarchal gradient between trainees and their boss is needed, this should be sufficiently flat to allow and encourage them to speak up when something does not seem right. At all times, this needs to be done in an environment where there is no fear of retribution for speaking up about something that may appear trivial.

This concept is important in the team brief so that students, trainees, and nurses all feel valued. We need to be aiming for a ‘smooth and enjoyable flight’ in our workplaces, even if the view isn’t as exciting as from the flight deck.

42.5 Situational Awareness

An important HF principle is recognising and understanding how we relate and behave and how changes over time. Surgeons can sometimes develop tunnel vision during long procedures. This can be confounded by indicators that they recognise confirm their behaviour, and thus may need to rely



©Association of Oral and Maxillofacial Surgeons of India

Fig. 42.4 The three key elements that comprise situational awareness (SA)

Table 42.4 Things to consider at a team brief

A well-prepared team knows their role, looks out for each other and helps all to feel valued.
<i>Briefing</i>
Introductions, transparent culture, ‘anyone can speak if concerned’
Team working and leadership
Identify major parts of surgery and who is going to do what
Ask ‘What am I going to do if something goes wrong?’
Situation awareness—how can I intervene when something doesn’t seem quite right
Decision-making skills
<i>Debriefing</i>
<ul style="list-style-type: none"> • What went well today? • One thing I (we) could do more of? • One thing I (we) could do less of? • What will I (we) do differently next time? • Saying ‘Thank you’ to everyone

on other team members to identify a problem. Losing track of time is one factor, which can lead to catastrophic consequences as highlighted by the Elaine Bromiley incident mentioned earlier. An otherwise competent team lost their situational awareness as critical minutes passed by during failed intubation attempts. Her husband Martin (airline pilot) knew about the same tunnel vision from a fatal plane crash, where a prolonged attempt to troubleshoot a landing light warning and a crew member’s failure to assertively communicate led to the plane running out of fuel.

A lack of situation awareness causes many diving accidents. Recognising it for ourselves is important for develop-

ing surgical skill and where possible stopping what we are doing when things do not seem quite right. A well-briefed team will be able to recognise at a much earlier stage when something is not quite right [11].

A simple diagram showing the three key components of situational awareness is shown in Fig. 42.4.

42.6 HF Training When Not in the Operating Theatre

Technology developments have led surgeons to perform increasing minimally invasive procedures. Physicians also do more invasive procedures such as interventional radiology (IR), percutaneous coronary techniques and gastrointestinal endoscopic surgery. The lessons learnt from surgery and team briefs, WHO checklists and other HF training initiatives should be applied to other parts of the hospital.

Medicine is a challenging activity and patients are far more complex than aircraft. Greater control is needed wherever possible to minimise the risk of harm to others as a result of human error. HF training can readily be taught across medical practice leading to widespread improvements in safety. It is clear that any HF training includes important safety concepts, including better communication in teams, a culture of open reporting without blame, regular safety briefings and leadership skills. Aviation-based ‘Crew Resource Management CRM’ training has improved reduction in wrong site surgery. Hospitals need to recognise that they can influence attitudes, culture and values towards patient safety. HF training is simple, cost-effective and deliverable way of getting all staff members involved.

42.7 Conclusion

HF and better team working, as well as commitment towards continual performance improvement, are increasingly recognised as essential aspects of patient safety. Despite this, serious medical errors have not been abolished. Many errors can be prevented by recognising and using simple measures in our clinical practice. An appreciation of those factors that affect each of us as being potential contributors to error is a great step towards improving safety for our patients.

We believe and advocate that HF training is essential for medical staff as it is for airline employees. Since the introduction of compulsory HF training in the early 1990s, there has not been a single death on a UK-based airline due to human error in more than 3 billion passenger journeys. An individual would have to fly every day for 38,000 years before experiencing a human error-related aviation catastrophe. Surely we owe it to our patients to do everything we can to improve their safety too?

References

1. O'Connor T, Papanikolaou V, Keogh I. Safe surgery, the human factors approach. *Surgeon*. 2010;8:93–5.
2. Leape LL, Berwick DM. Five years after To Err Is Human: what have we learned? *JAMA*. 2005;293:2384–9.
3. Makary MA, Daniel M. Medical error—the third leading cause of death in the US. *BMJ*. 2016;353:i2139.
4. Reid JH. Surgical never events should never happen. *J Perioper Pract*. 2011;21:373–8.
5. Reason J. A system approach to organizational error. *Ergonomics*. 2005;38:1708–21.
6. Abd Elwahab S, Doherty E. What about doctors? The impact of medical errors. *Surgeon*. 2014;12:297–300.
7. Parry DA, Oeppen RS, Amin MSA, Brennan PA. Sleep: its importance and the effects of deprivation on surgeons and other health-care professionals. *Br J Oral Maxillofac Surg*. 2018;56:663–6.
8. Parry D, Oeppen RS, Gass H, Brennan PA. Impact of hydration and nutrition on personal performance in the clinical workplace. *Br J Oral Maxillofac Surg*. 2017;55:995–8.
9. Parry DA, Oeppen RS, Amin M, Brennan PA. Can dietary supplements improve a clinician's well-being and health? *Br J Oral Maxillofac Surg*. 2018;56:85–9.
10. Wadhwa RK, Parker SH, Burkhart HM, et al. Is the “sterile cockpit” concept applicable to cardiovascular surgery critical intervals or critical events? The impact of protocol-driven communication during cardiopulmonary bypass. *J Thorac Cardiovasc Surg*. 2010;139:312–9.
11. Mishra A, Catchpole K, Dale T, McCulloch P. The influence of non-technical performance on technical outcome in laparoscopic cholecystectomy. *Surg Endosc*. 2008;22:68–73.

Open Access This chapter is licensed under the terms of the Creative Commons Attribution 4.0 International License (<http://creativecommons.org/licenses/by/4.0/>), which permits use, sharing, adaptation, distribution and reproduction in any medium or format, as long as you give appropriate credit to the original author(s) and the source, provide a link to the Creative Commons license and indicate if changes were made.

The images or other third party material in this chapter are included in the chapter's Creative Commons license, unless indicated otherwise in a credit line to the material. If material is not included in the chapter's Creative Commons license and your intended use is not permitted by statutory regulation or exceeds the permitted use, you will need to obtain permission directly from the copyright holder.





De Novo Practice of Oral and Maxillofacial Surgery

43

Srinivas Gosla Reddy and Avni Pandey Acharya

43.1 Introduction

The exhilarating and exciting emotion of starting your own practice can also be a daunting experience to a freshly passed out maxillofacial surgeon. Student loans taken during the course of one's studies also play a significant role in determining one's ability to take on any additional financial burden.

As oral and Maxillofacial surgery is a bridge between medicine and dentistry, there is a continual national debate regarding the need to pursue a dual degree. The option to pursue a condensed medical degree as part of the current syllabus is still not available in India. Thus, new residents should always strive to do additional training [residency, fellowship and diplomas] in their fields of interest to expand their expertise prior to starting their own set-ups [1]. It is a well-known fact that it is easier to gain knowledge and skills during the starting of one's career rather than later in life. The goal is to aim high by keeping one's feet grounded in the soil of academics.

The fire of determination and passion should always be kept alive in order to truly succeed and excel in our field. The truly successful surgeon is the one who has thrived against all the odds and taken advantage of every opportunity that has come his or her way. This chapter aims to guide the freshly passed out maxillofacial surgeon regarding further avenues of learning and about the establishment and expansion of one's surgical practice.

43.2 Professional Skill and Learning

For the freshly passed out maxillofacial surgeon, the option of acquiring financial stability always appears alluring. However, it is a well-known fact that enhanced surgical skills

and strong academic knowledge cannot be traded for the financial gains obtained by prematurely starting one's surgical practice. Thus, it is always advisable to pursue additional training in the form of a fellowship, residency or diploma in one's area of interests [2, 3]. This trend will help the surgeon establish a niche practice where they specialize in a particular domain of oral and maxillofacial surgery, which eventually leads to improved surgical results and credibility for our profession. This kind of surgical practice will also help to create an edge over the plastic surgeon and the otolaryngologist and establish a distinguishable specialty offering an unequivocal service to patients. Despite the prevailing circumstances governing one's decision to enter practice immediately or continue training, everyone will eventually contribute to the OMFS field with their skills and knowledge.

Laskin [4] made an organized attempt to tackle this problem by dividing the scope of oral and maxillofacial surgery into three categories: areas of expertise, competence, and familiarity. To be addressed as an oral and maxillofacial surgeon, one needs to include the areas of expertise and competence in their work profile.

- Areas of expertise include oral pathology/oral medicine, dentoalveolar surgery, implantology, pre-prosthetic surgery, and maxillofacial traumatology.
- Areas of competence involve orthognathic surgery, temporomandibular joint surgery, and local reconstructive surgery.
- Areas of familiarity are cleft lip and palate surgery, regional reconstructive surgery, oncologic surgery, craniofacial surgery, and cosmetic surgery.

The first step in learning a skill is to know how a skill is learned. Educationists have constructed many models attempting to outline the learning process. The most widely accepted was first documented by Noel Bunch and was subsequently re-worked by Abraham Maslow (Figs. 43.1 and

S. G. Reddy (✉) · A. P. Acharya
GSR Institute of Cranio-maxillofacial & Facial Plastic Surgery,
Hyderabad, Telangana, India

43.2). In the beginning, a student is in the ‘unconsciously incompetent’ phase. An undergraduate dental student in their third year would have no idea about administering local anaesthesia. After working on the skill for some time, they move on to the ‘consciously incompetent’ phase. Here, they have attempted different ways of anaesthetizing teeth and are now keenly aware of the various ways to give local anaesthesia along with their shortcomings in certain regional nerve blocks.

Most of our trainees will arrive somewhere between these two steps of knowing what they can and cannot perform. Educators must help them overcome their limitations. Once they are aware of their shortcomings, they can actively

begin to correct them. With practice and appropriate teaching, they move to the third level of being ‘consciously competent’. Here, the trainee can perform every step of local anaesthesia along with variations of different techniques. However, the steps require focus and assiduousness. Now, he or she would be considered as a competent surgeon who can practice independently although lacking in instinctiveness. As learning advances, with years of handwork and practice, they will reach to the concluding stage, ‘unconsciously competent’. Now the local anaesthesia can be given while listening to music or talking to patients or colleagues [5].

The obstacle to a meticulous ‘ability preparation’ is that most of our instructors perform numerous components at an unknown and advanced skilled dimension, while the students are frequently unmindful of numerous components of what they have to learn. The individuals who have overlooked the subtleties of an expertise are entrusted with showing people who don’t know about what abilities they are unequipped for performing. The initial step for an ace instructor is to perceive that the educator and understudy live at inverse finishes of the authority. Perception, readiness, practice and tolerance are the key components of learning in any skill [6].



Fig. 43.1 Gradation of maxillofacial surgery and importance of super specialization

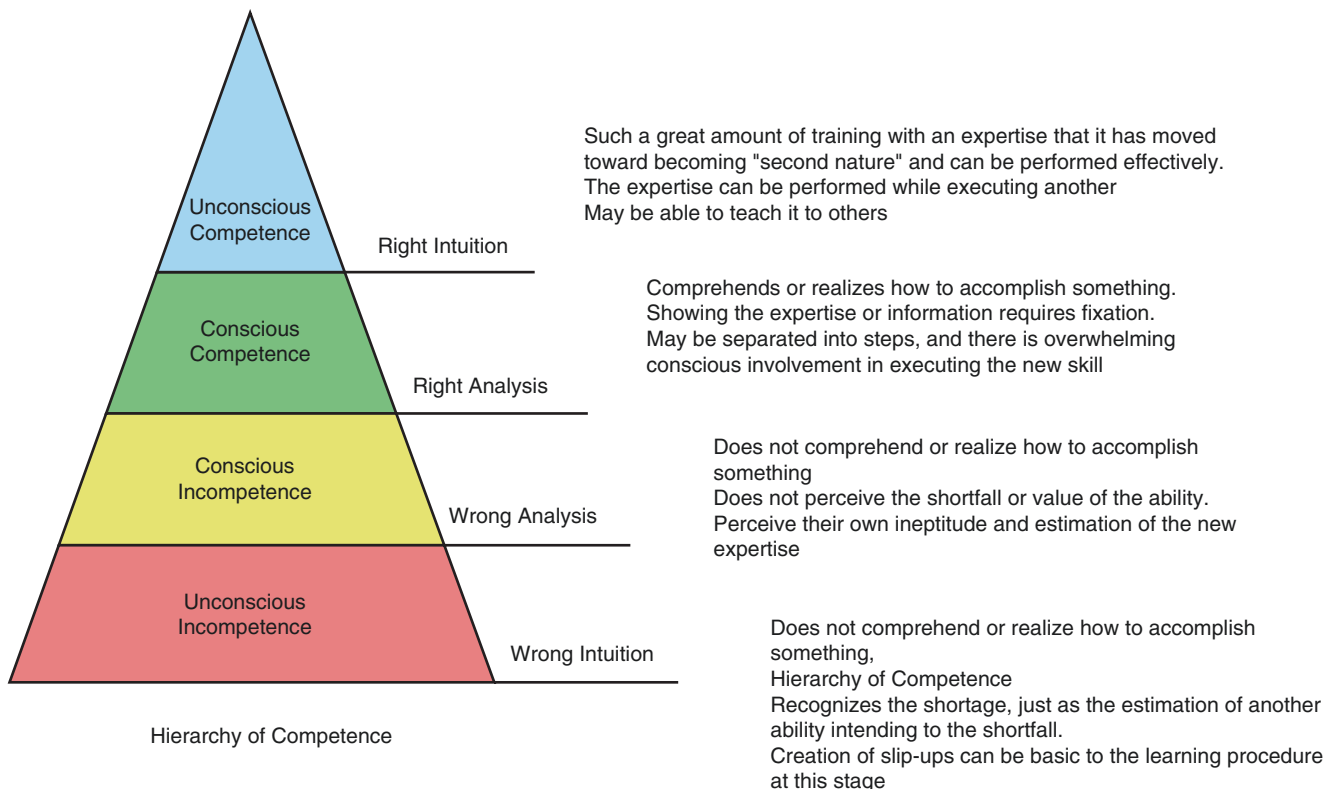


Fig. 43.2 Competence hierarchy

43.2.1 Kolb's Learning Cycle [7]

David Kolb is renowned in educational circles for his Learning Style Inventory. In Kolb's speculation, the drive for the headway of new thoughts is given by new experiences. "Learning is the technique whereby data is made through the difference in comprehension" [7]. Kolb's experiential learning style theory is conventionally addressed by a four-stage learning cycle in which the understudy contacts all of the bases (Fig. 43.3). Along these lines, everyone responds to and needs the improvement of a wide scope of learning styles.

Here are brief depictions of the four Kolb learning styles:

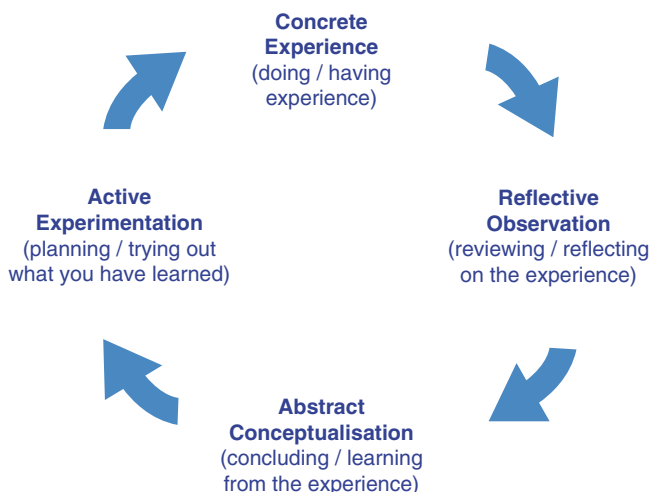
- *Diverging (feeling and watching—CE/RO)*

These individuals can take a gander at things from alternate points of view. They are touchy. They want to observe as opposed to doing, tending to accumulate data and use creative ability to tackle issues. They are best at reviewing solid circumstances from unique perspectives.

Kolb called this style 'separating' in light of the fact that these individuals perform better in circumstances that require thoughts, for instance, conceptualizing. Individuals with a wandering learning style have wide social premiums and like to assemble data.

They are keen individuals, will in general be inventive and enthusiastic, and will be solid in expressions of the human experience. Individuals with the veering style like to work in gatherings, to tune in with a receptive outlook and to get individual criticism.

- *Assimilating (watching and thinking—AC/RO)*



©Association of Oral and Maxillofacial Surgeons of India

Fig. 43.3 Kolb's Experiential learning cycle

The Assimilating learning inclination is for a compact, sensible methodology. These individuals require clear clarification as opposed to pragmatic chance. They exceed expectations at seeing wide-going data and sorting out it in a reasonable coherent configuration.

This learning style is essential for viability in data and science vocations. In formal learning circumstances, individuals with this style incline toward readings, addresses, investigating diagnostic models, and need room to thoroughly consider things.

- *Converging (doing and thinking—AC/AE)*

Individuals with this combining learning style can tackle issues and will utilize their figuring out ability to discover answers for reasonable issues. They lean toward specialized assignments and are less worried about individuals and relational angles.

Individuals with a combining learning style are more pulled into specialized errands and issues than social or relational issues. A meeting learning style empowers expert and innovation capacities. Individuals with a meeting style like to try different things with new thoughts, to recreate, and to work with handy applications.

- *Accommodating (doing and feeling—CE/AE)*

The Accommodating learning style is 'hands-on' and depends on instinct as opposed to rationale. These individuals utilize other individuals' examination and want to take a viable, experiential methodology. They are pulled in to new difficulties and encounters. They usually follow up on 'gut' nature as opposed to sensible examination.

Individuals with an obliging learning style will in general depend on others for data than complete their own examination. This learning style is common inside the all-inclusive community. To become familiar with specific, careful abilities, an understudy needs to go intensively through every one of the styles of learning. First, we have to observe, think and feel pursued by experimentation on models to learn the aptitude to do medical procedure on humans.

43.2.2 Transformative Learning Way

Transformative learning is the procedure by which we digest and decipher data based on our own encounters to date, to deal with ace Surgical aptitudes. This can be seen in a case of a boss helping a careful student with his or her first case. One of the key issues is for the chief to be accessible if for no other explanation other than to counsel, whenever required, and guarantee that things go easily. Grown-up students need to realize that they have the director's certainty and support

and that they will be permitted to extend their range of abilities to attempt to take care of any issues they may experience, before the chief strides in.

The following enquiries of destinations and points can give understanding into the learner's self-appraisal capacity or trainee's self-assessment:

- Pre-employable appraisal or Pre-operative assessment
- Discourse of case, history, examination and examinations to date.
- Discourse of the means of the activity and who will attempt which part—the director ought not to set suddenly exclusive requirements, just what is sensible to accomplish for the dimension of the student.
- Conceivable complexities and their goals
- Armamentarium.
- Consent
- Break process

43.2.3 Intra-operative Educating

- The student endeavours to pursue the pre-operative plan and, if there is a deviation, guarantees to take assent from the supervisor.
- The supervisor controls through the central specialized advances and focuses on technical steps and gives assertion for leading following the next stage, simply after fruitful fulfilment of past advances.
- The teacher gives prompt input on what is being progressed admirably and what should be possible in an unexpected way.
- The chief considers enabling the student to accomplish more on the off chance that they are advancing admirably and exhorts them in like manner.

The teacher must attempt to 'dominate', if important to help the patient yet this positively doesn't imply that boss should hinder in each progression and make the student uncertain.

Post-operative questioning

This can begin to happen as the student is concluding the case; however, a few learners may discover this diverting, which may hamper their execution.

The chief should plan to question in a peaceful domain.

- Ask the student how they think they went, invigorate reflection and show general tenets; help them survey their execution; investigate ways they can set a few objectives to help address insufficiencies
- Provide explicit instances of how the student could have performed better. An administrator may figure the learner

progressed nicely, yet on the off chance that they don't convey, the student may feel that some perspective was not progressed admirably. Strong correspondence is critical [8].

43.3 Career Goals

Oral and maxillofacial surgery gives a wide range of alternatives from a conventional private minor oral surgery practice to specialist maxillofacial surgery in trauma, temporomandibular surgeries, orthognathic surgeries, implantology, oncology, aesthetic surgery and cleft and craniofacial surgery [9]. The following are the alternatives, which can be taken by a newly passed oral and maxillofacial surgeon:

- *Associateship*—The possibility of associateship with an officially settled practice is by all accounts extremely appealing. By joining a specialist set-up, one stays away from the numerous costs and unpleasant circumstances involved in setting up one's own practice. However, one should make sure to join the right specialist practice. There is a lot of contrast between a specialist that genuinely needs a partner and a specialist that may need a partner for increasingly narrow-minded reasons. The practice may not have enough volume to support two specialists and the senior associate may. In this situation, the new specialist may be in charge of creating the new referrals. This can be a troublesome circumstance. In addition, one may anticipate that as the new associate one should take an excessive measure of call, see all patients with insurance formalities and not take an interest in the 'great cases'. Additionally, the desires of the senior associate might be farfetched and a lot of additional fault may be put on the new junior associate. Before getting engaged with any of the associateship, the term and conditions ought to be clear in the pre-legally binding stage [10].
- *Scholastics and Research*—Teaching is one of the alternatives for a specialist who has the enthusiasm to educate the new batch of upcoming surgeons. It is one of the best ways to remain connected with your field. There are many institutes looking for youthful surgeons with a keen interest in academics, research and administrations [11].
- *Organization*—Being a manager includes leading, managing, overseeing and supporting health care departments or associations to accomplish their pre-set goals. With the opening of a several corporate hospitals, administrators with a medical background are most desirable for such roles. The size, intricacy and mission of various health-care organizations (hospital systems, academic medical centres, practice groups, insurance companies) require assistance from experienced specialists with fluctuating roles [12].

- *De novo Practice*—Opening one’s own OMFS office from the ground up is an extremely tough task that is not for the weak hearted. It has been rightly said the war field ought not be entered without a weapon and thus one need to be confident in their surgical skills and also have a basic understanding of the administration involved with running one’s own practice [10].

43.4 De Novo Practice

43.4.1 Requirements

- *Surgical Skills*: Never accept surgery as an easygoing endeavour and always keep the patient’s prosperity over any of your own advantages. It is important to develop surgical skills early on in one’s career as it is these skills that will carry you forward throughout life. However, one should also make an effort to get the right opportunity
- *Site or place of your practice*: Selection of the place where you will set up your centre is the first and most basic decision that one comes across. Choosing a location that has a geographic advantage [as in easily accessible via adequate public and private transport] and has an adequate population to support your practice is essential. Demand and supply also needs be considered when choosing your location. Too many competing specialists in the vicinity will definitely make attracting patients difficult. However, it must be said that the eventual fate of a practice depends on the surgical skills and services offered by the surgeon in charge. Lastly, the spot ought to be close to the living arrangement of the surgeon in case of a medical emergency [13].
- *Accounts or Finances*: It is prudent to begin a project of such magnitude with your financial capacity in mind. Very few specialists manage to acquire stipends during their residency programs and hence are not well acquainted with handling funds. One should avoid large and unnecessary expenses in the beginning. However, this does not mean that one should skip on the basic requirements for starting a well-equipped practice. Expansion, modernizing and incorporation of advanced technology into the practice must be kept as a long-term step wise plan. The computations of property expenses [rent/lease/loan], staff salaries, equipment costs, sterilization and biomedical waste management ought to be dependably considered in evaluating the finances [14].
- *Framework*: The rooms required in an OMFS workspace are as follows: reception room, business zone, financial zone, exams rooms, operatories, x-ray zones, research centre space, staff lounge, specialist’s private office, rest-rooms, medicinal gas space, mechanical space, sterilization space, recovery space and storage space [10].

- *Marketing strategy*: Health care associations actualize business techniques through projects and administrations, and achievement relies upon program structure and execution. Beginning a business adventure without an arrangement is out and out welcoming a fiasco and human services is no exemption for this standard. Since we are specialist co-ops, we ought to dependably remember that this field is certifiably not a “high pay” creating field except if we are managing corporate divisions. That is the reason why practical objectives ought to be set to keep ourselves as well as other people away from the rat race of cash. This positively doesn’t imply that you ought not dream about a sensible way of life.

43.4.2 Types of Practice

There are four different ways by which medical practices can be organized:

- (a) *Sole Proprietor*—This is for the specialist who already has a foundation of maxillofacial surgical or other medical service organizations running in the family. The choice appears to be practical for the surgeon who has full control of his financial assets and is as of now experienced in the field [15].
- (b) *Organization or associateship*—If you have fellow medics who are of the same or diverse fields and are prepared to create a combined practice with you, then it is the most reasonable choice. Always scrutinize your colleagues before entering into such arrangements. The success of this arrangement relies upon mutual trust for each other. It is also necessary to discuss all the terms and conditions [expenses and division of profits] before entering such an arrangement.

Additionally, you can work under the umbrella of some settled specialist and eventually move toward becoming a partner in the not-so-distant future [15].

- (c) *Corporate segment*. Joining corporate hospitals or chains is also an alternative. The hustles of marketing, equipment, and location can be obliterated. However, corporate hospitals today are keen on hiring well-settled specialists as patients are hesitant being treated by novice surgeons [15].
- (d) *Trust or NGOs*—These organizations are created to help unaffording individuals for treatment. One cannot expect great monetary benefits from a trust or NGO. However, there is a feeling of fulfilment of helping other people. There are a few associations in and outside India, which raise funds for such organizations. A point worth noting is that there are numerous specialists who are working free of charge under such associations while simultaneously obtaining their standard pay elsewhere [15].

43.4.3 Qualities Needed

43.4.3.1 Strategic Planning

Due to the contingent nature of the decision of essential structure be it sole owner or in affiliation, Strategic arranging is required. It is a definite methodical report demonstrating the manner in which it intends to advance from its present circumstance to the ideal future situation [16].

The SP procedure is isolated into progressive stages. The writing gives diverse names to unmistakable stages yet we are adopting established strategy, distinguishing five values simultaneously. The Mission, Vision and Values ought to be institutionalized amid the underlying stages.

- Mission
- This mission characterizes the general motivation behind the association, the objective customers, the administrations offered, its distinctive highlights, the geographical territory in which the centre works, and occasionally the manner in which it works (quality, morals, productivity, and so forth.).
- Vision
- The vision displays the future picture. The substance of the vision ought to uncover what the human services association explicitly tries to be later on.
- Qualities
- Qualities are the arrangement of standards, rules and social viewpoints administering the Hospital Organization (HO) and deciding their institutional conduct. They comprise the association's moral code that gives it its 'spirit' and 'character'. These qualities foresee a particular reaction by the HO when a circumstance emerges that must be quickly settled.

43.4.3.2 Technique Formulation

The accompanying five phases ought to be considered

- *First Stage: Analysing the External Environment*
- This examination generates data on those difficult to change external variables that can affect the association. This involves patients and contenders.
- Patients: The place that you will eventually set up should have a geographic advantage with the right patient demographic. All too often, a specialist will begin their facility in a distant, underdeveloped and immature zone due to the dread of rivalry. It is a well-known fact that a specialist practice survives on referrals and not only on walk-in patients.
- Contenders: Good work and identity are significant in keeping an edge over your rivals. Endeavour to build up your individual character, as far as work and morals are concerned, should be made.

- *Second Stage: Analysing the Internal Environment*
- This investigation generates data on everything pertinent that has/can and is happening inside the set-up. This investigation centres around three distinct angles:
 - Resources: It incorporates individuals, monetary spending plans, consumable and non-consumable supplies and their level of obsolescence.
 - Licensure—Legal parts of drug store, radiations, and different licenses with respect to specific region ought to be taken already relying upon the standards of the region.
 - Analysis of clinical and research work, action and spending plan ought to dependably be kept aside [16].
- *Third Stage: The SWOT matrix*
- When the outside and inside examinations have been finished and coordinated, the vital arrangement directing gathering will have an abundance of thoughts regarding conceivable vital activities that could be tended to in the arrangement. Then, the issues distinguished in the examination are characterized into four classifications to comprehend what to do and in what request. This is the SWOT investigation, an abbreviation framed from qualities (S), shortcomings (W), openings (O) and dangers (T), which orders the consequences of the examination.
- Every one of the outcomes, notwithstanding grouping them with SWOT criteria, can be weighted as far as significance or relative power (high, medium, and low; +, ++ or +++, and so on.). It permits the arranging group to build up a positioning, with the most vital components positioned in the principal position, situated to key priorities [17, 18].

TOWS Matrix Analysis

The TOWS Matrix is aimed at developing strategic options from an external-internal analysis. TOWS idea is firmly identified with SWOT investigation. Whereas SWOT Analysis starts with an internal analysis, the TOWS Matrix starts the other way around, with an external environment analysis; the threats and opportunities are examined first. As indicated by H. Wehrich (1982) [19], Dangers, Opportunities, Weaknesses, Strengths (of the association) ought to be examined in a specific order, as a critical thinking succession during the time spent on the procedure plan. To streamline, let's use TOWS examination in beginning an oral and maxillofacial medical procedure set-up:

Inner Strengths: The accompanying could be qualities of the endeavour:

- Proficient abilities of the head picked up by changed associations, confirmations and courses
- Focal Location of the set-up
- Access to demonstrated plan of action

- Relationship with other dental and restorative fields to give all administrations under one rooftop
- The individual variables of the specialist like family foundation, past experience, unique intrigue, administrative and specialized abilities, self-assurance, inventiveness, creativity and eagerness to go for broke

Inward Weaknesses

- less familiarity with the field of Oral and maxillofacial medical procedure
- Constrained patient base if there should arise an occurrence of elite oral and maxillofacial practice
- Understanding paying limit
- Issue of staff wear out

Individual shortcomings (inside negative factors or challenge) like deficient abilities, terrible work propensities or attributes like poor relational abilities, poor systems administration, ineffectual authority characteristics, absence of specialized mastery, absence of IT information, absence of comprehension of statistical surveying, absence of promoting skill and so on because of which wrong choices are generally taken.

The following stage is the planning of TOWS 'Matrix of key' choices, which empowers determination of supportable, open door, simpler, and quantifiable results. 'Inward' are the shortcomings and qualities and 'outer' are the dangers and shortcomings. Four quadrants with various vital circumstances are created as pursued:

S-O—How can the organization employ the expertise of its own professionals to respond to the needs of centres? By partnering up, the organization can convince the institutions that there is enough capacity, knowledge and experience to train young people to independent professionals at all levels of surgery.

- *SO circumstance—maxi-maxi system.* This circumstance compares to the maxi-maxi methodology whereby it is conceivable to have solid extension and broadened advancement. In such cases, if the cost is utilized as to prepare individuals and keep them on minimal effort at first to give complete consideration by the prime specialist will prompt bringing down of beginning costs. Along these lines, more income is produced amid starting days just to have the capacity to rise as market pioneer.

S-T—How can the organization use its skilled staff to compete with cheaper workers employed by competitors? A smart approach for the organization would be to communicate to the outside world that their staff has accredited diplomas and that it's important for health care centres to comply with legal requirements and safety standards.

- *ST circumstance—maxi-little system.* The wellspring of troubles in development and improvement are ominous outer conditions (predominance of dangers) like a lot of swarming of good oral specialists in the zone, or patients paying limit is low, and so on. The procedure should utilize vast interior qualities in endeavour to defeat dangers from environment. The technique of reaching and catching patient ought to be connected through free camps, minimal effort medications contrasted with encompassing zones and catching exchange out specialists. On the off chance that the ability of the prime specialist is awesome, settle on troublesome cases left by different specialists with the dread of disappointment. In addition more up-to-date methods and medical procedures ought to be aced by the specialist in such cases.

W-O—How can partnerships with other centres help the organization to improve itself and put more effort into patient acquisition? By presenting itself as an accredited apprenticeship provider, the organization will put itself on the market again and its shows that adapt to changing times and wants to offer different kinds of treatments.

- This circumstance has more vulnerabilities—shortcomings, yet its condition gives more open doors like less number of oral specialists in the town and so forth. The procedure ought to incorporate the utilization of these chances while decreasing or amending shortcomings inside. Executing the arrangement step by step is required in such cases. The emphasis ought to be on improving the patient experience by great work by prime specialist, less staff and nearly not all that extravagant set-up amid introductory stage. Along these lines, cost cutting should be possible successfully without settling on the treatment plan. As the patient information and OPD increments, further advances can be taken for extension.

W-T—How can the organization better position itself in the market and thus reduce the threat posed by competitors? By presenting itself as an accredited apprenticeship provider, the organization can claim that they are a serious competitor and can possibly offer healthcare services by apprentices at reduced rates, with the work still being done by the prime specialists.

- *WT circumstance—smaller than usual little methodology.* This circumstance is without any advancement openings. It works in antagonistic situations, and its potential for change is little. It doesn't have huge qualities, which could withstand dangers. Scaled-down smaller-than-expected technique comes down to a negative rendition of the shut down or in idealistic circumstance—to take a stab at survival keeping in mind the

desire of restoration. Advertising is the key in such cases alongside advancement of uncommon careful just as relational abilities of the prime specialist. Additionally, creating specialty brands are of significance as the abilities are not present with basic maxillofacial specialists. These brands include clefts, oral oncology, all out TMJ substitution and so on [17].

- *Fourth Stage: Strategic Alternatives*
- Equipped with this arrangement of recommendations, the vital arrangement controlling gathering starts a procedure, which orders them into characterized territories of activity. These zones of activity are additionally at the same time distinguished and named relying upon the kind of recommendations they contain [16].
- *Fifth Stage: Strategic Areas and Objectives*
- Now, it is prudent to adjust the procedure definition created, to check whether in reality a methodology exists by asking the accompanying inquiries:
 - Does the plan give a key suggestion that will lead the setup to a truly remarkable position thinking about the challenge?
 - Does it offer an incentive in an alternate manner?
 - Are the key decisions that have been made substantial in the long haul?

On the off chance that there are negative answers, the detailing ought to be looked into to check whether, rather than shaping a key arrangement, an arrangement has been made with a progressively restricted scope [16].

43.4.3.3 Operational Planning

The point of operational arranging is to make the arrangement totally explicit, viable and unmistakable. The Operation destinations unite the accompanying attributes:

- They must have a fixed length, in every case under 1 year. Middle-of-the road objectives can be built up to be completed in various stages after some time.
- They ought to be evaluated. To follow their level of consummation, pointers that measure this are oftentimes required.
- They ought to challenge and keep the association in a condition of alarm so as to accomplish them.
- As a capability to the previous, the Operational goals ought to be feasible.
- Each objective must have an assigned individual in control, who truly has the ability to change the execution of the unit or subunit.
- Each Objective must have a cost doled out to its usage, with the end goal that the all-out expense of all the goals is equivalent to the absolute expense of the key arrangement.

- Each Objective must have the financing and different assets (staff time, gear and so forth.) important to accomplish the goals.

When all the OOs are detailed, the execution has to be incorporated with that of the others inside a course of events of activities that incorporates every one of them and gives an outline of the connections, timing and succession of errands, just as the joined endeavours that the HO needs to perform at each stage.

43.4.3.4 Assessment of Results

Auspicious evaluation of results ought to be done, which is dependent on development of number of patients, nature of administrations, nature of medical procedure, income age and work fulfilment. This should be possible by figuring the development charge. Arbitrary overviews on the web or discontent ought to be finished with the assistance of patients to keep up the pace of association and know the dimension of fulfilment of the patient with the health care providers, i.e. the head and the staffs. Likewise, number of patient waiting ought to dependably increase steadily for a feasible growth [16].

43.4.3.5 Marketing Oral and Maxillofacial Surgery [20]

- It is a must that both the specialist and the staff also show consideration for the patient's needs and have a humble attitude. This will go a great length in gaining the good will of the patient and word-of-mouth referrals.
- Utilizing online marketing tools through advertisement and social networking are slowly becoming a must for every new practice.
- Showcasing your work in study clubs, get-togethers and association conferences will also make fellow medicos aware about your abilities.
- You can publish in the neighbourhood newsletters through knowledgeable articles with respect to your field.
- Conducting free camps for check-ups with the neighbourhood non-profit associations can also help showcase your aptitudes.

43.4.3.6 Staff Hiring

The staff should be skilled in their work and maintain a humble and empathetic attitude. Always hire and maintain the correct staff

- Make clear what is expected of them through a detailed manual
- Train them to be focused in their specific roles and reward them for their endeavours

- Hold meetings at frequent intervals to address problems and figure out solutions
- Always be an instructor and a student [21]
- Know when to fire an employee

43.4.3.7 Communication

Communication or Correspondence is most imperative for achieving the great name as an expert. Thinking from the patients' point of view and attempting to clarify in straightforward however non-phobic words about the method will help in building up the trust of patient for the specialist. This will likewise spare the legitimate ramifications if there should be an occurrence of adversity, which can emerge by not disclosing the intricacies appropriately to the patients. The way toward relieving a patient requires an all-encompassing methodology, which includes contemplations post treating a malady. It warrants a few aptitudes in a specialist along with the specialized ability. Studies have showed great correspondence ability in a specialist improves patient's consistence and general fulfilment. There are fundamental standards of rehearsing great correspondence. Persistent tuning in, compassion, and focusing on the para verbal and non-verbal parts of the correspondence are the essential steps that are often disregarded. Appropriate data about the nature, course and forecast of the infection are essential. Additionally, patients and orderlies ought to be clarified about the need and yield of costly examinations and dangers/benefits engaged with obtrusive strategies. One ought to be mindful while overseeing troublesome experiences and breaking awful news. Formal preparation of the specialists in improving relational abilities is vital and has demonstrated to improve outcomes. Furthermore, it is additionally helpful in overseeing difficult clinical experiences. This way diminishes the disappointment of both the specialist and the patient or chaperon in circumstances of enthusiastic upheavals. It has also appeared to diminish work pressure and increase work fulfillment [22].

43.4.3.8 Record Keeping

Record keeping is vital to a successful practice especially in view of the legal implications that come along with a failure to maintain the same. One should maintain both a hard copy and a virtual copy of their records as backups are most essential. Informed consent forms should clearly record possible complications in a language understood by the patient. Photographic records at the preop, intraop, and postop phases need to be maintained and become especially important when a patient has unrealistic expectations. It is also important to maintain well-documented out-patient records and operative notes. Never forget the seventh principle of the Caldicott report, an NHS report on patient information, which says '*the duty to share*

information can be as important as the duty to protect patient confidentiality' [23].

43.4.3.9 Reformulating the Strategy

If at any point of time you come to realize that your practice is unable to achieve patient needs or financial goals, it is time to reconsider your strategy [16].

43.4.3.10 Professional and Financial Growth in Career

Nothing is permanent in life and in one's career. You can run your profession for a particular timeframe to be trailed by slow decrease in the training with age. Wellbeing and prosperity play a vital depiction to build the life span of the training (Fig. 43.4a). Till 45 years, there is a tendency to achieve followed by continuous decrease in the field. The thought is to augment the achievement with slow decrease. A specialist can viably work till the age 55–60, which can be expanded till 65–70 with great wellbeing and consistent learning. It is the duty of old specialists to offer approach to novel specialists for the improvement of field. Supportable model can be made to prepare novice specialists followed by naming them as partners.

43.4.3.11 Time Management (Fig. 43.4b)

Time is the most essential commodity that we have in our lives. Digitalization of many facets of hospital management has helped save time. This time can be re-invested in various other aspects of your clinical practice like discussion regarding treatment planning and discussion of various cases. Make sure you plan your day daily and weekly so that you are aware of the time that you have and be able to invest it wisely [24].

43.4.3.12 Management of Finances (Fig. 43.4c)

One must learn how to handle finances appropriately; unnecessary and exorbitant spending at the earlier stages is not a wise idea and can lead to a sudden financial crisis, which can even lead to the premature end of one's career. As mentioned before, expansion and modernization of the practice should follow a well-thought-out long-term incremental approach. Similarly, it is wise to slowly create an alternate source of income to help tide over any financial crises that one may face throughout the course of their career [25].

43.5 Conclusion

Oral and maxillofacial surgery is gaining popularity as a field and general awareness is increasing in India. It is the responsibility of new surgeons to contribute their best to the field in order to get the maximum out of their careers

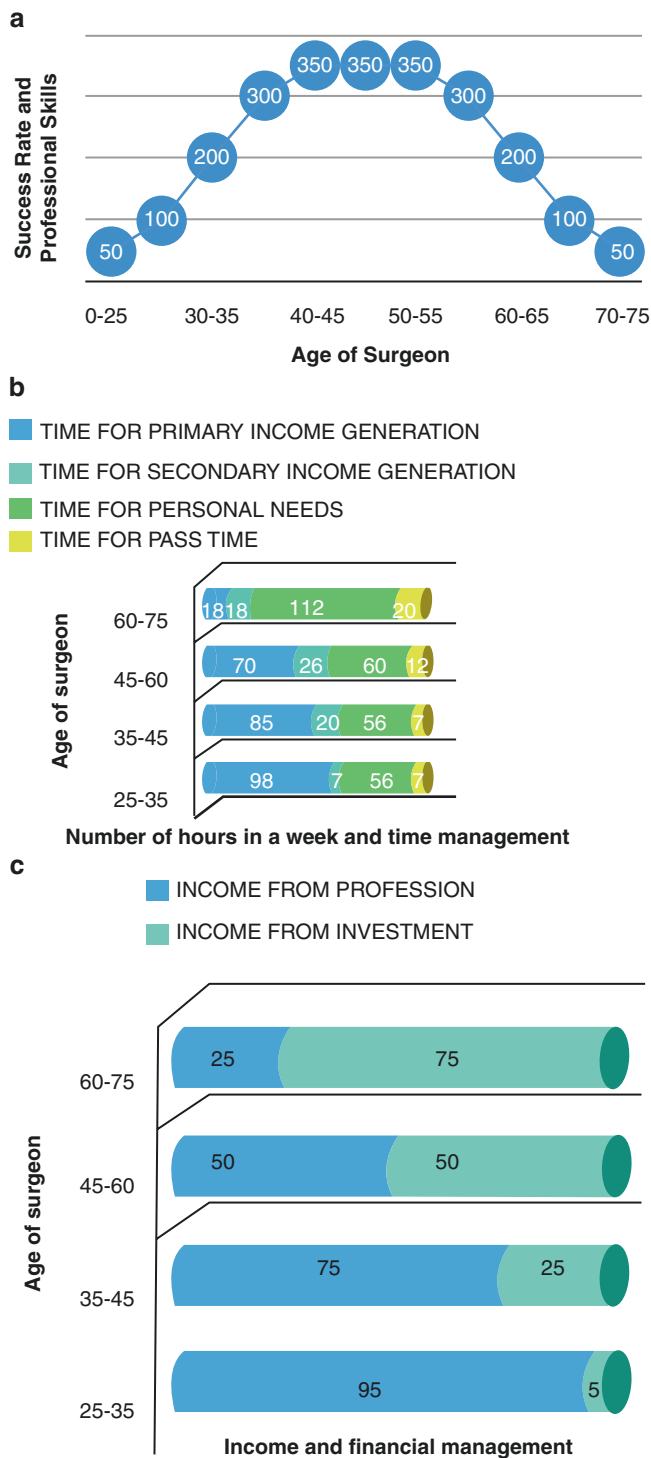


Fig. 43.4 (a) Professional life cycle of oral and maxillofacial surgeon. (b) Time management in the life of a maxillofacial surgeon. (c) Finances management in the life of a maxillofacial surgeon

and life. As is said ‘Do good and it will come back in unexpected ways to you’. Never lose your principles and ethics in this competitive world as it will only tarnish your reputation. Everyone has a specific purpose in this world. The aim is to find that purpose and work upon it with the help of the skills and knowledge you have gathered. These were my rules for success that I stumbled up on while achieving my goals. The newer generation is getting smarter and sharper and will surely contribute to a new set of rules and redefine success.

‘Those are my principles, and if you don’t like them, well, I have others’—Groucho Marx

Disclosure Authors have no financial conflicts to disclose.

References

1. Samman N. The modern specialty of oral and maxillofacial surgery. 2009;14(6). Dental Bulletin, The Hong Kong Times.
2. Kumar S. Training pathways in oral and maxillofacial surgery across the globe—a mini review. *J Maxillofac Oral Surg.* 2017;16(3):269–76.
3. Clark PK, Markiewicz MR, Bell RB, Dierks EJ. Trends and attitudes regarding head and neck oncologic surgery: a survey of United States oral and maxillofacial surgery programs. *J Oral Maxillofac Surg.* 2012;70:717–29.
4. Laskin DM. The past, present, and future of oral and maxillofacial surgery. *J Oral Maxillofac Surg.* 2008;66:1037–40.
5. Smith M. Aristotle and education. 2001. <http://infed.org/mobi/aristotle-and-education/>
6. Sadideen H, et al. Surgical experts: born or made? *Int J Surg.* 2013;11:773–8.
7. Kolb DA. *Experiential learning: experience as the source of learning and development*, vol. 1. Englewood Cliffs, NJ: Prentice-Hall; 1984.
8. Knowles MS. *The modern practice of adult education: Andragogy versus pedagogy* (Revised edition). Prentice Hall/Cambridge: Englewood Cliffs; 1988.
9. Haider SM, et al. Oral & maxillofacial surgery; A historical review of the development of the surgical discipline. *Int J Surg.* 2018.
10. Niamtu J. Beginning a new oral and maxillofacial surgery practice.
11. Walker TW, et al. Educational paper: research in oral and maxillofacial surgery. *Br J Oral Maxillofac Surg.* 2010;48(8):629–32.
12. Ghosh R, et al. Management and leadership skills for doctors. *BMJ.* 2008;336
13. McDonald S, et al. Where to put an OMS practice, A supplement to the AAOMS. *Today Newsletter.* March/April 2007.
14. Pollock SL, et al. Financial arrangements in an oral and maxillofacial surgery practice, Part II, A supplement to the AAOMS. *Today Newsletter.* March/April 2009.
15. Miron-Shatz T, et al. Promoting business and entrepreneurial awareness in health care professionals: lessons from venture capital panels at Medicine 2.0 Conferences. *J Med Internet Res.* 2014;16(8):e184.

16. Rodríguez Perera Fde P, et al. Strategic planning in healthcare organizations. *Rev Esp Cardiol (Engl Ed)*. 2012;65(8):749–54. Epub 2012 Jun 13.
17. Watkins M. From SWOT to TOWS: answering a reader's strategy question. *Harv Bus Rev*. 2007;27.
18. Wiley Encyclopedia of management, SWOT analysis.
19. Weihrich H. The TOWS Matrix: A tool for situational analysis, Long range planning. 1982;15(2):54–66. [https://doi.org/10.1016/0024-6301\(82\)90120-0](https://doi.org/10.1016/0024-6301(82)90120-0).
20. Bhangale V. Marketing of healthcare services in India: a study on factors influencing patients' decision making on choice of a hospital. *J Manag Market Healthcare*. 2011;4(4).
21. Mamoon Z, et al. Hiring the right people for your organization. *Glob J Manag Bus Res Admin Manag*. 2013;13(8).
22. Ranjan P, et al. How can doctors improve their communication skills? *J Clin Diagn Res*. 2015;9(3):JE01–4.
23. Mathioudakis A, et al. How to keep good clinical records. *Breathe (Sheff)*. 2016;12(4):369–73.
24. Christie S, et al. How to improve your time management skills. *BMJ*. 2012;344
25. Halvorson GC. Healthcare tipping points. *Healthcare Financ Manag*. 2005;74:80.

Open Access This chapter is licensed under the terms of the Creative Commons Attribution 4.0 International License (<http://creativecommons.org/licenses/by/4.0/>), which permits use, sharing, adaptation, distribution and reproduction in any medium or format, as long as you give appropriate credit to the original author(s) and the source, provide a link to the Creative Commons license and indicate if changes were made.

The images or other third party material in this chapter are included in the chapter's Creative Commons license, unless indicated otherwise in a credit line to the material. If material is not included in the chapter's Creative Commons license and your intended use is not permitted by statutory regulation or exceeds the permitted use, you will need to obtain permission directly from the copyright holder.





Medicolegal Issues in Maxillofacial Surgery

44

George Paul and Manjunath Rai

44.1 Introduction

In the modern world, human activity is governed by a set of rules and regulations collectively referred to as law. All professions must follow legal requirements and this is especially important while practising health care, including maxillofacial surgery. Doctors must be aware of their duties, rights and scope of practice within the framework of the laws governing their respective countries or states. This is especially important for maxillofacial surgeons, who straddle the line between medicine and dentistry. This chapter aims to outline the various legal issues that pertain to the maxillofacial surgeon. The laws referenced are mostly India centric, but the general principles are not very different from international laws.

44.2 What Are the Legal Issues That Must Concern the Maxillofacial Surgeon?

Since the role of a maxillofacial surgeon acts as a link between the medical and dental professions, the scope of practice has always been controversial. Maxillofacial surgeons have moved from beyond the oral cavity to the head and neck region, and even to distant body parts for procedures such as flap harvesting. All maxillofacial surgeons must be aware of what procedures they are allowed to practice under the law and what they must avoid.

During any procedure, legal documentation is of utmost importance. These include informed consent and filing medico-legal reports. Informed consent is a legal necessity to prove that a patient is willing to undergo a procedure.

G. Paul (✉)
Kerala University of Health Sciences, Thrissur, Kerala, India
Dr MGR Medical University, Chennai, Tamil Nadu, India
M. Rai
Department of OMFS, A. J. Institute of Dental Sciences,
Mangalore, Karnataka, India

Medico-legal reports must be filed when one treats a case that could potentially become a legal issue. Maxillofacial surgeons may be called upon to testify as expert witnesses in legal cases such as assault and road traffic accidents. They should therefore be aware of procedures required to document evidence in these cases.

Finally, all medical professionals are vulnerable to malpractice suits. The surgeon must be aware of what actions could put them at risks for facing such suits and what procedure must be followed if one ever faces a malpractice litigation.

44.3 Scope of Practice of Maxillofacial Surgery as per the Indian Law

44.3.1 Historical Perspective

Oral and Maxillofacial Surgery has a unique place in the health care systems around the world. It is a stand-alone speciality in modern medicine that has its provenance in dentistry. However, when one realizes that modern medical systems are barely more than a century old, it is not long ago that the treatments of dental and oral diseases were a part of an integral system that encompassed holistic health care.

Dentistry as a separate autonomous speciality is an accident and an aberration in the history of modern medicine. In fact, the first dentists were medical doctors or surgeons like Pierre Fauchard in France who had a special interest in treating dental and oral conditions [1] and John Hunter [2] in England.

In the late nineteenth and early part of the twentieth centuries, dental schools and curriculums were established as courses separate from medical courses and the bifurcation became an established practice in different countries in almost all continents [3, 4].

It is through this prism that we need to view the speciality of OMFS and its future as a complex and distinct part of health care. In fact, training to become a maxillofacial

surgeon through the route of dental surgery is unique when compared to other distinct regional specialties, which emerge as a post-medical qualification, e.g. ophthalmology, otolaryngology, or gastroenterology.

Realizing the need for adequate training in surgery, substantial additions were made to the dental and oral and maxillofacial surgery curricula by including several basic medical sciences and clinical medical subjects in the undergraduate and post-graduate level, to help meet the medical training requirements of a surgeon.

The impetus for the evolution of OMFS was provided by the two World Wars of the twentieth century and other armed conflicts, where dental and oral surgeons were found to be invaluable in the treatment of facial bone fractures. Thus, Oral and Maxillofacial Surgery was born as a speciality of dentistry and went on to encompass a wide range of surgical work, including pathologies of the mouth and jaws, TMJ surgeries, surgical corrections of dento-facial deformities and cosmetic surgery of the face.

In many countries, including those in Europe, this resulted in the concept of dual degrees (medical as well as dental degrees) to better address surgery in a complicated region of the body where one needed a clear understanding of surgical principles as well as sound dental concepts. Duality is often mistaken for an additional medical degree. In fact, duality includes the need for a dental degree for those with a medical background. In countries like USA, India and several Asian countries, oral and maxillofacial surgery continues to be a surgical speciality of dentistry, although some surgeons chose to do medicine as additional qualification to further their interests and knowledge [5]. Similarly, dentistry was offered as an additional degree for those with medical qualifications only. Dentistry was however an essential pre-qualification to become a maxillofacial surgeon. It must be remembered that 90% of the world population is still serviced by OMFS with a single dental qualification re-enforced by rigorous surgical training as part of their post-graduate curriculum. This includes the USA, Canada, Latin America and the Caribbean, Africa, China, Russia, Central Asia, South Asia, Middle East Asia, South West Asia, Japan, and Far East Asia [6–12]. Starting in the 1970s, several countries also offered integrated 6–7 year residencies leading to OMFS that provide an additional Medical or Dental degree depending on their original background.

The curriculum for Oral and Maxillofacial Surgery in India and several other countries has been suitably modified for patient safety and competence. In India, the speciality of OMFS is regulated by the Dentist Act of 1948 as more than 90% of OMFS are dental-qualified surgical specialists [13]. OMFS has been included as a recognized speciality with distinct privileges in the medical health care system and has been included in significant legislations at the national and state levels, including the Clinical Establishment Act of 2012.

44.3.2 Current Legal Privileges

Oral and Maxillofacial Surgery is a recognized department in most multi-specialty hospitals and they are given privileges such as admissions and autonomous departments within the surgical or dental services.

The Dentist Act has defined Oral and Maxillofacial Surgery as a surgical branch of dentistry dealing with diseases affecting the mouth, jaws, and face. The updated curriculum of OMFS is a focused training in surgical management of diseases, injuries and deformities of the face and gnathic system. Training includes interdisciplinary rotation with allied surgical specialties and standard competence in dealing with complex surgical situations in the mouth, jaws and face.

In an increasingly competitive surgical arena, different surgical specialties compete for ownership of procedures based on their diverse backgrounds. It is therefore expected that OMFS, as an emerging surgical specialty, is sometimes in conflict with other specialties.

The legal competence to perform procedures is dictated by the qualification and training received as part of the curriculum set up by the respective statutory bodies through due process of law.

The legal remit and privileges of OMFS in India are based on the training received as part of the curriculum of the master's degree in Oral and Maxillofacial Surgery as outlined by the Dental Council of India in its regulation issued from time to time. The current syllabus, curriculum and training equip the specialist to deal with a wide range of surgical procedures in the face, jaws, oral cavity and teeth. This includes comprehensive management of defects or deformities of dento-facial region caused by congenital anomalies, injuries or surgical ablation. However increased competence, like in any other surgical speciality, is achieved through experience and continuous training in the form of fellowships and structured courses.

Oral and Maxillofacial Surgery falls into a grey area, overlapped by several other surgical specialties. However, competence is defined by the scope offered by legally approved training within the framework set out by the statutory bodies in the respective countries. In India, OMFS is an advanced surgical specialty of dentistry and its remit is regulated by the Dental Council of India.

44.4 Legal Requirements to Be Followed When Dealing With a Patient

44.4.1 Informed Consent

Consent to medical treatment as an ethical and moral principle is probably as old as medical science. It is inconceivable

that a medical practitioner at any point in history would have treated or operated on a patient without his or her permission. However, consent to treat as a legally binding entity is of recent origin. Today, it is validated by multiple principles drawn from social and behavioural sciences, moral philosophy, human rights, ethics and laws of a particular country. One of the main guiding principles of Informed consent involves the rights of patients to make clear assertions of what can or cannot be done to their bodies based on unbiased and full disclosure of the benefits and risks that will ensue from treatment. While most diagnostic treatment procedures are today performed only with a clear informed consent, there are some which attract particular attention in the matter of informed consent, e.g., HIV testing and high-dose radiation in vulnerable patients.

44.4.1.1 Definition and Principles of Informed Consent

Farlex's free online dictionary [14] has a simple definition of Informed Consent. It is "Consent by a patient to a surgical or medical procedure or participation in a clinical study after achieving an understanding of the relevant medical facts and the risks involved." A more descriptive definition is sometimes employed to capture the nuances of informed consent. It may thus be defined as "Consent given by a patient after understanding his/her condition, procedure, risks and alternatives based on unbiased information by the medical professional in a language and manner which is unambiguous, lucid."

44.4.1.2 History and Theory of Informed Consent [15]

The key historical signposts in the evolution of the Informed Consent as a valid legal document can be traced to cases from the US judicial system, though the basic principles find their roots in English Common law.

- While consent has been a well-known moral requirement before treatment, it gained legal sanctity only in 1914 with the case of *Schloendorff Vs Society of New York Hospitals*. It set the tone for a legally acceptable premise of self-determination [15]. Justice Benjamin Cardozo summarized the basic philosophy in his judgment thus "Every human being of adult years and sound mind has a right to determine what shall be done with his own body and a surgeon who performs an operation without his patients consent commits an assault for which he is liable."
- However, it was with a series of case in the 1960s and 1970s that self-determination came to be legally binding as a legal principle and more importantly the importance of full divulgence by the doctor based on which a consent can be made became a dictum. Important cases include the *Salgo Vs Le Land Stanford Jr Case (1972)* and the

Canterbury Vs Spence Case (1972) [16]. Thereafter, not obtaining informed consent became legal violation, equivalent to assault or "battery".

- With the advent of new technology and emergence of new diseases like HIV, Informed Consent documents are constantly being upgraded to include new medical procedures.
- Informed Consent Document (ICD) in research was largely evolved due to the World War II atrocities in Nazi Concentration camps. ICDs in research have been formulated and reviewed by the Nuremburg conference and the Helsinki declaration. They are closely monitored for content by organizations such as the WHO, FDA, and the ICMR in India.

44.4.1.3 Types of Informed Consent [17]

Informed consent may be of two types:

1. Implied and
2. Oral or written Consent
 - Implied Consent: It is given by the behaviour of the patient, such as entering the clinic and opening the mouth to be examined, etc.
 - Oral Consent: It is acceptable for inconsequential procedures such as examination, taking of impressions, or even routine low-exposure X Rays, etc.
 - Written Consent: While oral consent is an acceptable consent, it can often be challenged and the consent cannot often be proved or validated. It is therefore more binding to give a written informed consent.

44.4.1.4 Informed Consent in Oral and Maxillofacial Surgery

Informed Consent for orthognathic surgery is particularly important because of the nature of the procedure. It is an elective procedure and the patient often seeks treatment for enhancement of aesthetics and function. The expectations are high and therefore the scope for disillusionment as well.

Orthognathic surgery is a highly skilled procedure in a complex anatomical area. Treatment often involves multiple specialists, including orthodontists, anaesthetists, general dentists, and other surgical specialists like neurosurgeons, otolaryngologists, or plastic surgeons. In addition to results falling below expectations, which are largely subjective, patients may also have morbidity in the form of neurological deficit, infections, occlusal discrepancy, TMJ problems, and in rare situations excessive exsanguinations and even death.

Maxillofacial Surgery is a unique speciality of dentistry and medicine and involves complex procedures and outcomes. Some of the procedures are cosmetic whereas others are ablative. Being a surgical procedure involving the mouth, jaws and face, there are several issues of deformity and disability.

The informed consent should include the following (Box 44.1):

Box 44.1. Components of Informed consent for surgery

1. the purpose of the proposed procedure;
2. a summary of the surgical approach;
3. expected benefits and limitations;
4. a description of postoperative recovery; possible complications and known side effects, including those that are rare.
5. risks associated with the procedure and/or medications should include alternatives, including the option of no treatment or surgery at all.

Irrespective of whether the surgery is a minor dento-alveolar extraction or major reconstructive procedure, it may be cautious to take an informed Consent, which includes chance of injury or consequences that have disutility for the patient. While operating as a team there are decisions that can be taken jointly by the other members in the treatment process, e.g., Neurosurgeons or orthodontists. For instance, in orthognathic surgery, the Informed Consent Document may have several distinct parts. Gasparini G, Boniello R et al. suggest a three-part informed consent to include pre-op orthodontics, orthognathic surgery and post-op orthodontic treatment [17].

The informed Consent document may need to include the following principles and the surgeon and his team can make appropriate changes to accommodate them. These have been enunciated by Lord Scarman in the case of Sidaway v Board of Governors of Bethlehem Royal Hospital [18].

1. The individual should be of adult years (18 years in India) and sound mind and should have the legal mental capacity to choose what happens to his body.
2. It should offer a choice that entails an opportunity to evaluate knowledgeably the options available and the risks attendant on each (including no surgery option)
3. The doctor should therefore disclose all material risks. The material risks are determined by the “prudent patient test,” which determines what a “reasonable” patient in a position of a plaintiff (complainant) would attach significance to, in coming to a decision on the treatment given.

In addition to this, in the Indian context:

4. All informed consent must be in a language understood by the patient (vernacular languages like Tamil, Malayalam, Bhojpuri, Kannada, etc.)
5. In case of illiterates, the informed consent must be read to them in the presence of an independent witness who must sign on the space provided.
6. In children below 18, a parent or guardian can sign on behalf of the child.

Recent concerns have suggested that informed consent should also cover diagnostic tests. It is a common practice in some countries, including India, to do a routine HIV testing. These can be undertaken only with an informed consent, including pretesting counselling. Many countries also insist on informed consent for multiple high-dose radiation, especially with the use of CT scan.

**A standard Informed Consent form is attached and can be used as a template. Any change depending on local conditions can be added (addendum).

44.4.1.5 Informed Consent and Negligence in Oral and Maxillofacial Surgery

Informed consent regulations today are largely governed by the principles of medical negligence rather than the tort of battery as in the early days. Any injury, even expected, may be considered a negligent act if there is no informed consent, e.g., paresthesia following Impactions or BSSO. The situation can be defended if the patient was informed and consent obtained. The civil liability for the same will be similar to the liability for medical negligence.

Similarly, Informed consent does not absolve the surgeon from liability for negligence, if it is proved that it could have been avoided if the surgeon had exercised reasonable care.

In short, liability for negligence can be mitigated by an informed consent, but informed consent cannot totally absolve a surgeon for an obvious negligent act.

Defence for non-information

Sometimes, the surgeon may encounter a non-reported or rarely reported complication despite reasonable care. In these situations, they can take defence in the principle of “Act of God!!” These are complications or sequels that may not have been anticipated by a reasonable surgeon.

Exceptions for the use of Informed consent

- Life-threatening situations, e.g., Carotid Ligation, Tracheostomy, etc.
- Incapacity of patient by virtue of age or mental status (It is taken from the guardian/parent).

44.4.1.6 Informed Consent for Clinical Trials and New Techniques

Informed consent has to be obtained if the patient undergoing the surgery is the subject of a new device, implant, or technique which is not a standard one. In India, devices are not covered by the DCGI (Drug Controller General of India). New techniques on an experimental basis, particularly in teaching institutions, must be communicated to the patient and should be cleared by an Institutional Review Board (IRB) or

Independent Ethics Committee (IEC). The ICD requirements for research are clearly enunciated in India by the ICMR.

In conclusion, Informed Consent Documentation is an important and critical part of all treatment plans and often includes invasive or potentially harmful investigations. A proper informed consent that is realistic and involves full disclosure, if the patient is exposed to a chance of injury for which he has no utility, is a necessary part of all treatment protocols. Informed consent documents respect the right of patients to take a decision on how their body is treated based on all available information. It is a moral, ethical and legal obligation to obtain a consent based on credible information. It also provides a safety net for the surgeon when unexpected adverse complications occur.

44.4.2 Dentist/Maxillofacial Surgeons as Expert Witnesses

Dentists and maxillofacial Surgeons are often called upon to give evidence in case of civil or criminal cases. When surgeons are called upon to give evidence as part of forensic evidence, they need to have a grasp of the subject. Forensic medicine and odontology have been used in many sensational cases in India, the Rajiv Gandhi assassination being one of the better-known ones.

Surgeons are often called upon in other more common situations as well.

1. Evaluation of disability after dental or maxillofacial injuries.
2. For opinions regarding the procedures adopted by other doctors/dentists in cases of alleged negligence.

Expert witnesses are issued summons as discussed earlier in the chapter. The surgeon is obliged to present himself before the court at the appointed time. He may be questioned by the lawyers of the prosecution, defence or the insurance company, as to the nature of injury and the quantum of disability. The surgeon is to clearly state his/her opinion without ambiguity and should remain non-committal about subjects that they are not sure about. If the surgeon has issued a wound certificate, the copy of the same will be given to him for reference at the time of testifying. The witness is to merely state the facts. They are not expected to involve themselves with the law on the subject, e.g., Loss of teeth, fracture of jaw, etc. They may answer truthfully to any other question pertaining to the same.

Today, there are only a few quantified disability criteria for dental and maxillofacial impairment in India. They include “The Manual for Permanent Disability” brought out by the CGHS, WHO, and AIIMS in 1981. A compendium of suggested dental and maxillofacial deformities/disabilities has been suggested by Paul G and Thomas S in the published book *Medical Law for the Dental Surgeon* [19]. It has been extensively used in courts of law. If unsure, the surgeon may

state if the injury is grievous or not. He may also elaborate on the actual disability that the defect might cause.

Examples of grievous injuries are:

1. Fractures and loss of teeth.
2. Fractures of jaw.
3. Extensive soft-tissue injuries and scarring
4. Neurosensory or motor disturbances
5. Restricted function, e.g. limited mouth opening

Duties of Witness

Failure to appear in court without valid reasons after warrant has been issued can invite contempt of court.

Exaggeration or false statements given under oath are not only unethical, but can invite punishment under sec.181, sec.193.

44.5 Medical Negligence in Maxillofacial Surgery

44.5.1 What Is Negligence?

Negligence is usually a civil wrong or tort. It is the single most important issue in medical law pertaining to litigation for damages.

By definition, negligent torts (civil wrongs) are not deliberate but rather a failure to act as a reasonable person should in the conduct of duties to someone whom he or she owes a duty to.

The liability for negligence can however also be criminal or statutory.

Negligence as Tort (Civil liability)

It has several formal definitions, but a convenient one by Alderson explains it rather lucidly as “the omission to do something which a reasonable man, guided upon those considerations which ordinarily regulate the conduct of human affairs, would do, or doing something which a prudent and reasonable man would not do.”

For an act to be considered negligent, the following aspects must be present, in regard to a surgeon (Box 44.2).

Box 44.2. Features of a Negligent act

1. That the surgeon owed a certain standard of care.
2. That the doctor/surgeon did not maintain that standard.
3. That there was an injury resulting from the lack of care.
4. There should be a proximate or causal relationship between the negligent act and the resultant injury.

Exceptions to negligence

Normally, carelessness is neither culpable nor a ground for legal liability, as there is no wrongful intention. However, in medical negligence, the outcomes have serious implications on the patient in particular and the public in general. The consequences of negligence by a surgeon who owes a duty of care are enormous and the law has imposed a duty of carefulness on the doctor or health worker in the interest of safe practices. However, there are several situations, which do not conform to the strict definition of negligence. In India, several judicial orders have placed many actions by doctors outside the ambit of negligence.

A review of Consumer cases (Under the Consumer Protection Act) shows that some of the situations mentioned here do not come under medical negligence.

- Not providing an ambulance, due to non-availability of the service does not constitute a negligent act.
- Any adverse outcome for a procedure done in good faith, in an emergency, beyond the call of duty, is not considered a negligent act. It is also called the Good Samaritan Act in some countries.
- Mere patient dissatisfaction with progress of treatment or desired relief cannot be construed as negligence.
- Non-availability of beds in an ICU is not negligence.
- Giving precedence of one patient over the other based on clinical risks or emergencies is not negligence.
- A fee, being perceived as exorbitant by the patient, is not negligence.
- Non-availability of a doctor outside his or her working hours may not constitute negligence.

44.5.2 Duty of Care

Minimum standard of care

The degree of carelessness for a particular profession depends on the risk that it poses to the person who is exposed to it.

Professional standard of care is therefore that standard of care or skill that is laid down by a body of professionals on behalf of the medical profession and which a surgeon or physician is expected to bring to his duty.

If skill and knowledge fall below this established standard, it will be considered to be negligent. A body of professionals can establish this standard by publication in books, reports of scientific studies, or by protocols established by them, e.g., text books, journals and protocols created by professional associations. Today, evidence-based science is the hallmark of best practices and is defined by the quality of evidence established through Randomized Clinical Trials (RCT) and meta-analysis of peer-reviewed publications.

When there is a difference of opinion on technical matters, an alternate method recognized by another body of pro-

fessionals will be acceptable as a valid procedure and will not be considered as negligence. This is ascertained by the application of Bolam's law [20], which recognizes reasonable difference of opinion based on credible evidence or experience among peer professional groups.

The Bolitho test uses a different legal parameter and has undermined the usual dependence on the Bolam test. The Bolitho test goes beyond dependence on just two opinions and looks at credible scientific evidence as more important than mere difference of opinions.

In this context, it is important to discuss the semantics of customary and acceptable.

A professional cannot adopt a procedure merely because it is customary. Customary standards have been looked at critically because it does not provide incentive to adopt better practices. Because a particular procedure has been done for many years does not make it an acceptable practice. An acceptable practice, on the other hand, is not only time tested but also scientifically sound. An acceptable practice is usually the product of evidence-based science as opposed to customary practice, which is either anecdotal or proven to be inadequate or irrelevant by scientific scrutiny.

An often-quoted legal principle is that "The skill, diligence, knowledge, means and methods are not those that are ordinarily or generally or customarily exercised or employed, but those that are reasonably exercised or applied, negligence cannot be excused on the ground that others practice the same kind of negligence."

It may therefore be said that a "health worker is under a duty to use that degree of skill which is expected of a reasonable competent practitioner in the same class to which he belongs, acting in the same or similar circumstances." The Supreme Court has defined this duty in the case of Indian Medical Association Vs V.P. Shanta [21] as "In general a professional man owes to his client a duty in tort (civil wrong) as well as in contract to exercise reasonable care in giving advice or performing services."

Importantly, the court held that this standard should be outlined by the medical profession and it is not the duty of the "lay courts" to decide on what constitutes "standard" care. Negligence, in these situations, may be dependent on the locality, availability of facilities, specialization of the doctor, proximity to specialists and advanced technology. However, it is important to remember the dictum "no man is bound in law to be a good surgeon, but all men are bound *not to act* as a surgeon until he is good and capable as such."

The foregoing dictum indicates that a physician or surgeon should not venture to do a procedure unless he is trained and competent in performing it. Merely admitting that he had inadequate experience is no legal remedy. In other words, it is not legally wrong to be ignorant, but it is legally wrong to act in ignorance.

44.5.3 The Test of Negligence

The Bolam Test

This is a classical test widely used in the United Kingdom. The Bolam test is an acceptable test used by the National Health Service of the U.K. when a situation of negligence presents itself as observed in the landmark case of *Bolam Vs Friern Hospital managing committee. (1957) 2 AllER 118*.

The Bolam test establishes that standard procedures be the basis of treatment. Importantly, it provides for alternate management protocols. If there is more than one school of thought, both alternates will be acceptable as a standard.

Bolitho Test

In a minority judgment comments in Bolitho, it was emphasized that the word “responsible” in the traditional formulation of the Bolam test meant that responsible practice is that which withstands the scrutiny of “logical analysis” from a judicial perspective. Today, courts are increasingly scrutinizing risk analysis from a patient view point, which undermines the traditional view point of only the care giver.

Negligence—Carelessness vs. Recklessness

While both words have almost the same meaning, there is a small difference. A careless person may not think of the eventuality while being careless. On the other hand, the reckless person is fully cognizant of the injury that his act may cause, but still takes the risk of possible injury. The former is passive, whereas the latter is an active act. Both acts are however are *not intentional* and is therefore often used to describe negligence.

Standards of Care in Hospitals

Legal standards applicable to hospitals are somewhat similar to those required of doctors or other health workers.

The hospitals are bound to maintain standards in two ways.

1. The facilities of a hospital should be that of a reasonable hospital engaging in similar type of health care.
2. The Hospitals should maintain standards laid down by statutory provisions (if available). In India, there are now basic standards for all medical establishments, which are defined by a legislated statute called the Clinical Establishment Act. It provides for the basic requirements of different categories of hospitals and the role of personnel in providing standard care.

In addition, the hospitals may be answerable for the negligence of their doctors, nurses and other health workers through what is called vicarious liability.

44.5.4 Contributory Negligence

In some situations, negligence arises fully or in part due to the patients or the complainant’s fault. As the patient, wholly or partly, contributes to the negligent act, it is called contributory negligence.

The standard to be adopted to assess contributory negligence is somewhat similar to the standard adopted for the doctor. It may be said that ‘contributory negligence is when a competent adult (patient) may be negligent by contribution when his conduct falls short of the degree of care that society expects a reasonable person to do or not to do for his own safety’. This would obviously preclude children and mentally incapacitated adult.

Examples

1. When a patient refuses to take a prescribed medication resulting in postoperative infection.
2. A patient who removes inter-maxillary wiring on his own resulting in non-union.

44.5.5 Remedy for Negligence Under the Indian Legal Systems

Negligence can be

1. Tortious (Civil wrong)
2. Contractual (Breach of contract)
3. Criminal
4. Vicarious (Liability passed on to hospital or employer)

Negligence can be remedied depending on what legal provision the complainant wishes to seek remedy.

The punishment under the law of Tort (Tortious liability) is unliquidated damages, i.e. whatever damages the judge wishes to award depending on injury, circumstances and other considerations like age, earning potential, profession, etc.

If an implied agreement was made between doctor and patient, then the remedy would be as specified in the contract. The judge may order a specific performance to do or not do something he has agreed to. However, guarantees for treatment are against ethical guidelines for treatment and it is not applicable in medical law.

If the complainant seeks punitive action against the doctor, he may file a criminal case under the relevant statutes. The Indian Penal Code for example, has provisions to punish doctors for death or disability. The remedy under criminal law is always in the form of a punishment (Penal). It may involve imprisonment or fine or both. Rarely, the court can order compensation or specific performance as well. Criminal law sees negligence as a crime against the state and not just against the plaintiff.

Doctors may also be liable under professional statutory laws governing the practice of the profession. In India, statutory bodies such as the Medical Council of India or the Dental Council of India can prescribe punitive action in accordance with laid down laws. The laws can be initiated only against persons registered under the particular statutory body. The Medical Council of India, for instance, cannot take action against a dental-qualified maxillofacial surgeon.

In some instances, a doctor may not have to answer for his negligence directly. The hospital or establishment employing him may have to answer to the allegation to negligence. This is called vicarious liability and is usually relevant to salaried employees who work for a contract of services and not a contract for services.

However, in practice, for the sake of regularity, it may be said that all permanently or part-time employed doctors are only vicariously liable. However, if the patient is admitted by a doctor in his personal capacity, then the doctor will be personally liable.

Contractual nature of liability

In a doctor patient relationship, an implied contract is established when a doctor accepts a patient for treatment. A breach of any aspect of this implied contract may amount to negligence when the doctor is under duty to

1. Treat with care
2. Continue to treat and not terminate until patient is cured or the patient discontinues treatment.

This may be considered the contractual nature of medical liability. However, Medical ethics does not provide for a written contract, which can be violated as in the case of a commercial transaction. So any liability based on breach of an implied contract will essentially lie within the realm of tortious liability.

Written contracts with promise to cure, failing which a refund is assured is against the ethics of medical or dental practice. It is this author's view that such contracts can be technically void, considering the ethical and legal issues involved.

Tortious Liability is usually dealt with in Civil Courts. In India, medical negligence comes within the ambit of the Consumer Protection Laws established to provide speedy relief to plaintiffs seeking redressals for goods and services that fall short of standards. The Consumer Protection Act defines medical care as contract for services, which makes doctors and hospitals liable under the Consumer Protection Act of 1986. The Consumer Courts are quasi-judicial legal redressal forums established for speedy justice. They are tiered under the District, State and National Forums depending on the place of the cause

of action and the pecuniary jurisdiction (amount claimed as damages).

Criminal Liability

This liability normally lies with an identifiable individual or groups of individuals. However, recent trends indicate that Hospitals also may be held vicariously liable just as in civil liabilities.

Criminal liability is penal and involves punishment in the form of imprisonment or fine or both. Criminal negligence is considered to be a crime against society and not just the aggrieved party and is in violation of penal codes of countries. In India, it is a violation of various sections of the Indian Penal Code 1868 (amended several times).

The important offences inviting criminal liability with regard to negligence are:

1. Sec 304 A (IPC)—negligent homicide. A rash or negligent act resulting in Death, e.g. death on the dental chair or hospital or operating room.
2. Sec 336 (IPC) An act endangering the life of a person (even if there is no injury), e.g. conscious sedation without essential monitors or oxygen, even if no harm is caused.
3. Sec (337) (IPC) A rash or negligent act causing a simple injury, e.g. mild reversible thermal burns caused by bone-sectioning equipment.
4. Sec (338) (IPC) A rash or negligent act resulting in grievous injury, e.g. fracture of jaw during extraction due to excessive or improper force or avascular necrosis following osteotomy.

While these are the common sections under which a doctor may be liable, other sections also apply. Any offence against the human body (Sec 299 to Sec 377) or offences against property (Sec 378–462) can be used against doctors, e.g. abetting suicide, causing miscarriage sec 312–316 (subject to exemption from the Medical Termination of pregnancy Act 1971), etc.

Sections 78, 80, 81, 87, 88 are directly or indirectly relevant to the medical practitioner. Some can be used in defence of the doctor accused of negligence. Section 88 for instance is an act done in good faith not intended to cause death. It is a good defence in emergency care. Sections 86 and 87 IPC are in respect to harm or death caused by an act not intended to cause harm or death and is done with consent in the best interest of patients. Section 499 deals with defamation. It can be used by doctors to counter malicious charges by patients intending to spoil the good name of the doctor by frivolous or vexatious charges. It can also be used by patients as a criminal violation of confidentiality statutes. For example, revealing HIV status when the patient is not likely to be a public health hazard.

It is important to understand some terms in connection with criminal liability (Box 44.3).

Box 44.3. Terms related to criminal liability

- *Cognizable Offence*: A police officer can arrest without a judicial warrant based on his investigation.
- *Non-Cognizable*: An arrest can only be made by a judicial warrant.
- *Bailable*: the arresting officer can provide bail. Bail is a matter of right and has to be given unless the officer apprehends that the accused may abscond or tamper with evidence.
- *Non-Bailable*: Bail can be secured only from a magistrate. Heinous and violent crimes fall in this category, e.g., if there is a significant risk that the offender may commit further crimes, abscond or tamper with evidence.
- *Compoundable*: A crime in which a compromise between the suspected offender and the victim or his attendant can be worked out it is said to be compoundable
- *Non-Compoundable*: If the crime is against society and is of a serious nature, no compromise can be made between the accused and the victim. These cases are said to be non-compoundable.
- *Sec 304 A* is cognizable, bailable and non-compoundable. It can be punished with imprisonment of either description for a term of 2 years or fine or both.
- *Sec 337 and 338* are cognizable, bailable and compoundable. Sec 337 may attract an imprisonment up to 3 months and a fine up to Rs 250/ or both. Sec 338 can involve imprisonment up to 2 years and a fine up to Rs 1000/ or both.

It is important for the surgeon to be aware of these liabilities. It is also important for him to understand his rights. For example, bail is a matter of right in the foregoing situations and it is to be given by the police officer attempting to arrest a medical professional. Bail is granted on the surety given by the doctor or a colleague. A doctor can give surety on his own reputation. The burden of providing reasons for refusing bail rests on the police officer and he will have to give convincing reasons for *not granting bail*.

Representations to amend Criminal procedures for arresting Doctors

Doctors cannot be arrested arbitrarily.

In a landmark case referred to as the Jacob Mathew Case (2002), the Supreme Court of India has prevented arbitrary arrest and detention of doctors even in case of death or serious

disability, as a part of treatment. Criminal liability and arrest can only be made on the basis of a credible Medical Board opinion duly constituted or recognized by the Government.

Statutory Liability

A doctor or nursing home is liable if there is any infringement of Statutes (rules). They then become accountable to a statutory body. The liability depends on the kind of infringement and the provisions in the statute to deal with it. There are many statutes dealing with practice of Doctors and Dentists, as well as Hospitals. Recently, the newly legislated Clinical Establishment Act provides guidelines for the whole of India.

Doctors and dentists may also be liable to other statutory laws such as The Pollution Control Board and the Drugs and Cosmetics Act, etc.

44.5.6 Legal Procedure and Evidentiary Requirements

(With special reference to medical/dental Negligence)

Legal Procedure (Procedural Law) Relevant to Medical/ Dental Negligence.

It is important for the doctor/dentist to know the legal procedure involved in medical negligence. The legal procedure is slightly different for civil negligence, criminal negligence, and negligence under the Consumer Protection Act.

To understand legal procedures, one must be familiar with some of the procedural laws. They are,

1. Civil Procedure Code.
2. Criminal Procedure Code
3. The Indian Evidence Act
4. The Limitation Act
5. The Court fees Act
6. Procedure under CPA.

The Evidence Act

It is a very important procedural law. There are three concepts in Evidentiary Law.

1. Facts
2. Facts in Issue
3. Relevant Facts.

The facts are the material evidence.

The “facts in issue” are those that have to be explicitly proved. The facts in issue are proved by bringing into evidence the relevant facts. Sections 6–55 deal with these relevant facts.

There are also other rules in Evidence Law.

- *Who needs to bring in Evidence?*

The person who has to legally bring in evidence to prove or disprove a fact is said to have the ‘burden of proof’”. When one has the burden of proof he has:

1. The burden of establishing a case
2. The burden of introducing evidence.

The general rule (with some exception) is that the onus of proving any particular fact lies with the party who alleges it and not with the party who denies it. In other words, the onus of proof lies with the complainant and not with the defendant.

Negligence can be proved by

1. Direct Evidence
2. Circumstantial Evidence
3. Res ipsa loquitor (The matter speaks for itself)
 - Another aspect of evidentiary law is *standard of proof*.

The standard of proof in civil cases can be based on probability and circumstantial evidence. However in a criminal case, the standard of proof is more stringent and should be beyond reasonable doubt as sanction in criminal law is more severe and penal in nature.

- The limitation act (1963)

It is the statute dealing with the time limit for various suits, appeals, bail application and other legal actions.

- *Cause of Action:*

This refers to the incident, which has necessitated a legal process. Limitation period begins as soon as the cause of action takes place. The period of time varies according to the suit and it is given in the schedule of limitations.

Appeals/Application for leave of appeals

For appeals, the day of judgment marks the beginning of limitation period after giving time for obtaining the copy of decree (Judgment Order). This will not include ‘writs’ as the limitation Act does not apply to them.

If a suit or appeal is made after the statutory limitation period, the court may reject the petition on grounds of being barred by limitation. The court may however accept a petition even if it is barred by limitation, if it is satisfied that the

delay was unavoidable. However, in criminal cases, the Act does not provide a period of limitation. Criminal proceedings can be instituted at any time after the offence has been committed. However, as per the guidelines given in Section 468 of CrPC, the limitation periods run thus:

- (a) 6 months for offences punishable with fine only.
- (b) 1 year for offences punishable with imprisonment up to 1 year.
- (c) 3 years for offences punishable with imprisonment up to 3 years (not less than 1 year).

If the limitation period ends on a day when the court is closed, then the next working day is included as the limitation period. It may therefore be said that a suit should be filed as soon as the cause of action occurs.

Court Fees Act (Varies from State to State)

Any party who wishes to approach a court with litigation has to pay a court fees with some exceptions like the Consumer Court. Each state may have a different court fee structure. In a suit for money, the fee is usually computed based on the amount claimed by the plaintiff. Court fees are paid in the form of Stamps, which may be adhesive or impressed or both.

44.6 Conclusion

This chapter is unique as most textbooks do not address issues pertaining to law and ethics in practice.

The maxillofacial surgeon is often confronted with questions on their remit and scope of work as it overlaps with several other specialties and is constantly in conflict with issues of qualification and areas of competence. The sections on these issues will throw light on their practice privileges in addition to dealing with litigation for medical negligence, which has become all pervasive.

Disclosure Authors have no financial conflicts to disclose.

Annexures

A.1 AOMSI—Informed Consent Forms for All Procedures <https://www.aomsi.com/WebPages/downloads.aspx>

1. Health questionnaire

ORAL & MAXILLOFACIAL SURGERYHEALTH QUESTIONNAIRE

Patient's Name

Age/Sex

Date

Please initial on each page after reading. If you have any questions, please ask your doctor **BEFORE** initialing.

Have you had any of the following Problems? Please tick **YES** or **NO**

GENERAL PROBLEMS:

- Cold , cough -----Yes \ No
 - Fever. -----Yes \ No
 - Sinusitis -----Yes \ No
- (If Yes, when was the last episode_____)

RESPIRATORY PROBLEMS:

- Nasal obstruction
 - Asthma
 - Shortness of breath
 - Tuberculosis (TB).
 - Bronchitis.
 - Emphysema
 - Lung diseases.
- (If Yes, when was the last episode_____)

HEART PROBLEMS:

- High blood pressure
- Chest pain

- Heart attack
- Heart murmur
- Pacemakers
- Rheumatic fever
- Irregular heart beat
- Infective endocarditis .
- Angioplasty / Angiogram.
- Bypass surgery.

Signature -----

(If Yes, mention the details of medication, Procedure date & last visit to the Physician _____

_____)

CNS PROBLEMS:

- Seizures/ epilepsy
- Stroke
- Paralysis
- Brain tumor
- Muscle weakness
- Neuralgia

(If Yes, mention the details of medication, Procedure date & last visit to the Physician _____

_____)

GIT PROBLEMS:

- Acidity
- Peptic ulcers
- Gall bladder stones
- Colitis
- Appendicitis

- Piles
- Fistula and fissure

Signature -----

(If Yes, mention the details of medication, Procedure date & last visit to the Physician _____)

LIVER AND KIDNEY PROBLEMS:

- Cirrhosis
- Liver failure
- Kidney stones
- Kidney failure
- Prostate obstruction
- Urinary obstruction

(If Yes, mention the details of medication, Procedure date & last visit to the Physician _____)

BLEEDING PROBLEMS:

- Anemia
- Clotting and bleeding time
- Platelet count
- Haemophilia

(If Yes, mention the details of medication, Procedure date & last visit to the Physician _____)

ENDOCRINE PROBLEMS:

- Diabetes

- Thyroid
- Steroids.

Signature -----

(If Yes, mention the details of medication, Procedure date & last visit to the Physician _____

_____)

PSYCHAITRIC PROBLEMS & COUNCILLING

(If Yes, mention the details of medication, Procedure date & last visit to the Physician _____

_____)

ARTHRITIS:

(If Yes, mention the details of medication, Procedure date & last visit to the Physician _____

_____)

RADIOTHERAPY:

(If Yes, mention the details of Procedure date & last visit to the Physician _____

_____)

PREVIOUS SURGERIES:

(If Yes, mention the details of medication, Procedure date & last visit to the Physician _____

_____)

ACQUIRED DISEASES:

- AIDS
- HEPATITIS – B & C

(If Yes, mention the details of medication, Procedure date & last visit to the Physician _____)

Date of last physical exam:

Date of last ECG:

Signature -----

Are you pregnant: YES/ NO**(If yes specify the trimester _____)**

Are you breast feeding: YES/ NO**(If Yes, since how long _____)**

Have you been under the care of physician during last 2 years?

(If yes, why & when _____)

Have you undergone general anesthesia for an operation?

(If Yes, Operation details & any anesthesia complications noted _____)

Are you taking medicine of any kind: YES/NO

(If Yes, For what & since how long _____)

Do you smoke YES/NO **(If yes, How long _____ how many _____)**

Do you consume alcohol YES/NO **(If yes, How long _____ how much _____)**

Do you chew Tobacco/ Areca nut YES/NO **(If yes, How long _____ how much _____)**

Are you allergic to any drugs: YES / NO

Pencillin... YES/NO

Codeine...YES/NO

Local anesthetic...YES/NO

Aspirin....YES/NO

General anesthetic....YES/NO

Barbiturates....YES/NO

Any other allergies in specific _____

Do you wear dentures...YES/NO

Do you wear lenses...YES/NO

Any other medicines...YES/NO

(If yes specify the medicine _____)

PATIENT SIGNATURE \ DATE _____

WITNESS SIGNATURE \ DATE _____

2. Medication questionnaire

**HEALTH QUESTIONNAIRE**

Patient Name: _____

Date _____

Primary care Physician

Primary care dentist

Phone _____

Phone _____

Address _____

Address _____

Have you had any of the following ? Please check **YES** or **NO****Yes No**

Recurrent illness(Within one year)

Cough, cold , flu(Within 2 months)

Nose obstruction

Shortness of breath

Lung disease

Asthma

Bronchitis

Emphysema

Heart trouble

Chest pain

Heart attack

Irregular heart heat

Yes No

Heart murmur

Rheumatic fever

Scarlet fever

Arthritis

Artificial joints

Cortisone

High blood pressure
 Pacemaker
 Heart Surgery
 Excessive bleeding
 Anemia
 Treatment of Tumor

Yes No
 seizures/ epilepsy
 psychiatric disorder
 liver disease
 stroke
 hepatitis
 Stomach ulcer
 Diabetes
 Kidney disease
 HIV
 AIDS
 Others serious illness

Date of last physical exam _____ Date of last ECG

Yes ___ No ___ Are you pregnant?

Yes ___ No ___ Have you been under the care of physician during the last two years?

Yes ___ No ___ Have you been made unconscious for an operation?

List anesthesia complications _____

Yes ___ No ___ Are you taking medicine of any kind? List _____ --

Yes ___ No ___ Do you smoke? _____ How long? _____ How
 much? _____

Are you allergic to any drugs : if Yes _____

Yes ___ No ___ Pencillin. Yes ___ No ___ Codeine

Yes ___ No ___ Novocain Local Anesthetic. Yes ___ No ___ Aspirin

Yes ___ No ___ General Anesthetics Yes ___ No ___ Barbiturates

Yes ___ No ___ Do you wear dentures?

Yes ___ No ___ Do you wear contact lenses

Yes ___ No ___ Other medicines.

Signature of persons completing this form

Age _____ Weight _____ -BP _____

Reviewed by _____ - _____ Date Reviewed _____

3. Consent for Minor oral surgery



CONSENT FOR MINOR ORAL & MAXILLOFACIAL SURGERY

PATIENT'S NAME :
 DATE :
 PLACE :
 DIAGNOSIS :
 TREATMENT PLAN :

- My doctor has explained to me that there are certain inherent and potential risks and side effects associated with my proposed treatment and in this specific instance they include, but are not limited to :
 1. Post-operative swelling and discomfort that may require several days of recovery.
 2. Prolonged or heavy bleeding that may require additional treatment.
 3. Injury or loosening of adjacent teeth or fillings.
 4. Post-operative infection that may require additional treatment.
 5. Stretching of the corners of the mouth that may cause cracking or bruising and may heal slowly.
 6. Restricted mouth opening during healing sometimes related to swelling and muscle soreness and sometimes related to stress on the jaw joints(TMJ),especially when TMJ problem already exists.
 7. A decision to leave a small piece of root in the jaw when its removal would require extensive surgery or risk of other complications.
 8. Fracture of the jaw (usually only in more complicated extraction or surgery)
 9. Injury to the nerve adjacent to teeth, resulting in pain numbness tingling or sensory disturbances on the chin, lip, cheek, gums or tongue and which may persist for several weeks, months, or in rare instances permanently.
 10. It has been explained that during the course of treatment unforeseen conditions may result that may require change in the procedure, I authorize my Doctor to use professional judgement to perform such additional procedures that are necessary to complete my surgery.

The Anaesthetic I have chosen for my surgery is

- Local anaesthesia
- Local with oral premedication
- Local with intravenous sedation
- General anaesthesia

It has been explained to me and I fully understand that a perfect result is not or cannot be guaranteed.

I have read and fully understood the above and discussed this operation and alternative treatment with _____. He has given me ample opportunity to ask questions about specific points and has answered those questions to my satisfaction.

PLEASE ASK YOUR DOCTOR IF U HAVE QUESTIONS CONCERNING THIS CONSENT FORM

PATIENTS (OR LEGAL GUARDIANS) SIGNATURE

DATE

SURGEON's NAME:

4. Consent for Implant



ORAL & MAXILLOFACIAL SURGERY

CONSENT FOR DENTAL IMPLANT SURGERY

Patients Name Age/Sex _____

Date _____

Please initial on each page after reading. If you have any questions, please ask your doctor BEFORE initialing.

1. I hereby authorize Dr. _____ and assistants to treat the condition described as _____.

2. The procedure offered to treat the condition has been explained to me and I understand the nature of the procedure to be: _____.

3. I understand that incisions will be made in my mouth for the purpose of placing one or more endosteal root form structures (implants) in my jaw to serve as anchors for a missing tooth or teeth replacement or to stabilize a crown (cap), bridge, or denture. I acknowledge that the doctor has explained to me the procedure, including the number and location of the incisions and the type of implant to be used. I understand that the crown, bridge or denture that will be attached to this implant(s) will be made and attached by Dr. _____ and that a separate charge will be made by the office.

4. I understand that the implant(s) may need to remain covered by gum tissue for at least three months before being used and that a second surgical procedure may be needed to uncover the top of the implant. No guarantee can be or has been given that the implant(s) will last for a specific time period. It has been explained to me that once the implant is inserted, the entire treatment plan must be followed and completed on schedule. If the planned schedule is not carried out, the implant(s) may fail.

5. I have been informed of possible alternative methods of treatment (if any), including _____

I understand that other forms of treatment or no treatment at all are choices that I have and the risks of those choices have been presented to me.

6. My doctor has explained to me that there are certain inherent and potential risks and side effects of any surgical procedure and in this specific instance such risks include but are not limited to:

- A. Post-operative discomfort , Pain and swelling that may require several days of at- home recuperation.
- B. Prolonged or heavy bleeding that may require additional treatment.
- C. Injury or damage to adjacent teeth and soft tissue.

Signature -----

- D. Post-Operative infection and inflammation of soft tissues around the implant that may require additional treatment.
- E. Stretching of the corners of the mouth that may cause cracking and bruising and may heal slowly.
- F. Restricted mouth opening for several days; sometimes related to swelling and muscle soreness and sometimes related to stress on the jaw joints (TMJ).
- G. Injury to nerve branches in the lower jaw resulting in numbness, pain or tingling of the chin, lips, cheek, gums or tongue on the operated side(s). These symptoms may persist for several weeks, months or, in rare instances may be permanent.
- H. Opening into the sinus (a normal bony chamber above the upper back teeth) requiring additional treatment. If the sinus is intentionally entered (sinus-lift procedure with grafting), there may be several weeks of sinusitis symptoms requiring certain medications and additional recovery time.
- I. Fracture of the jaw or perforation of thin bony plates.
- J. use of other materials which may have to be removed at a later date: _____
- K. Bone loss around implants and loosening of implants.
- L. implant or prosthesis fracture, or loss of the implant due to rejection by the body.
- M. Allergic or adverse reactions to any medications.
- N. Accidental swallowing of foreign material.
- O. other _____

7. It has been explained to me that during the course of surgery unforeseen conditions may be revealed which will necessitate extension of the original procedure or a different procedure from that set forth in paragraph 2 above. I authorize my doctor and his staff to perform such additional procedures as are necessary and desirable in the exercise of professional judgment.

8. I understand smoking is extremely detrimental to the success of my implant surgery. I agree to cease all forms of use of tobacco for 2-3 weeks after surgery, including the later uncovering procedure (when necessary), and to make a strong efforts to give up smoking entirely.

9. I consent to the administration of anesthesia I have chosen, which is:

- Local
- Local with Nitrous Oxide / Oxygen Analgesia
- Local with oral Premedication
- Local with Intravenous Sedation
- General Anesthesia

10. **ANESTHETIC RISKS** include: discomfort, swelling, bruising, infection, prolonged numbness and allergic reactions. There may be inflammation at the site of an intravenous injection (phlebitis which may cause prolonged discomfort and / or disability, and may

require special care. Nausea and vomiting, although rare, may be unfortunate side effects of IV anesthesia. Intravenous anesthesia is a serious medical procedure and, although considered safe, carries with it the risk of heart irregularities, heart attack, stroke, brain damage or death.

Signature -----

10. YOUR OBLIGATIONS IF IV ANESTHESIA IS USED

A. Because anesthetic medications cause prolonged drowsiness, you **MUST** be accompanied by a responsible adult to drive you home and stay with you until you are recovered sufficiently to care for yourself. This may be up to 24 hours.

B. During recovery time (24 hours) you should not drive, operate complicated machinery or devices or make important decisions such as signing documents, etc.

C. you must have a completely empty stomach. It is vital that you have nothing to eat or drink for eight (8) hours prior to your anesthetic. To do otherwise may be life-threatening.

D. However, it is important that you take any regular medications (high blood pressure, antibiotics, etc.) Or any other medications provided by this office, using only a small sip of water.

11. I understand that no guarantee can be promised and I give free and voluntary consent for treatment.

My signature below signifies that all questions have been answered to my satisfaction regarding this consent and I fully understand the risks involved of the proposed surgery and anesthesia. I certify that I speak, read, and write English.

BEFORE SIGNING, PLEASE ASK YOUR DOCTOR IF YOU HAVE ANY QUESTIONS CONCERNING THIS CONSENT FORM.

Patient's (or Guardian's) Signature & Date

Witness Signature

1)

2)

Doctor's Signature

5. Consent for Orthognathic surgery



ORAL AND MAXILLOFACIAL SURGERY

CONSENT FOR ORTHOGNATHIC SURGERY

Patient's Name _____ Age /sex _____ Date _____

Please initial on each page after reading. If you have any questions, please ask your doctor BEFORE initialing.

Orthognathic surgery is being planned for you, and it is important that you understand the benefits and risks of such surgery. This is NOT minor surgery and you have the right to be fully informed about your condition and the recommended treatment plan. The disclosures in this consent are not meant to alarm you, but rather to provide information you need in order to give or withhold your consent to the planned surgery.

1. I hereby authorize Dr. _____ and staff to treat the condition described as: _____

2. The surgical procedure planned to treat the above condition has been explained to me and I understand the nature of the treatment to be: _____

3. I have been informed of possible alternative forms of treatment (if any), including: _____

4. My doctor has explained to me that there are certain potential risks and side effects of the surgery planned, some of which may be serious. They include, but are not limited to:
 - A. Facial and jaw swelling after surgery, usually lasting several days.
 - B. Bleeding, both during and after surgery, which may sometimes be severe enough to require blood transfusion. I have been informed about the opportunity for blood donation before surgery so that, my own blood may be transfused back to me (auto transfusion) if necessary.
 - C. Allergic reaction to any of the medications given during or after surgery.
 - D. Delayed healing of the bony segments; rarely requiring a second surgery and/or bone graft to repair.

- E. Relapse: the tendency for the repositioned bone segments to return to their original position, which may require additional treatment, including surgery and/or bone grafting.
- F. Bruising and discoloration of the skin around the jaws, eyes and nose. Possible Hematoma at injection site .
- G. Diminished sense of smell (anosmia) in the upper jaw surgery.

- H. A change in cosmetic appearance. Although this is primarily a procedure to restore jaw function, I am aware of some expected change in my appearance. I understand that certain cosmetic changes may not be totally predictable. There may also be changes in speech patterns which may require additional treatment.

- I. Loss of feeling, pain or a tingling numbness in my chin, lips, tongue, gums, or teeth which occurs in a significant number of patients. Loss of taste sensation in tongue and palate . These symptoms may last for several days, weeks or months. I have been told that there is some chance that it may be permanent.
- J. Possible decreased function of muscles of facial expression.
- K. Scarring from external skin incisions if certain rigid fixation methods are used.
- L. Malfunctioning or breakage of hard ware. Possible need for additional procedures to remove fixation devices, pins, screws, plates or splints.
- M. In certain cases where bone cuts may be made in the marrow space between teeth, there is the possibility of devitalization of those teeth which may require later root canal procedures, and may result in the loss of these teeth.
- N Fracture of the maxilla and mandible due to improper mobilization or incomplete osteotomies
- O. In upper jaw surgery, the sinus will be affected for several weeks, and there may be bleeding from nose in postoperative period. There may be a need for further sinus surgery to remedy any lingering problems.
- P. Post-operative infection which may cause loss of adjacent bone and/or teeth and which may require additional treatment for a prolonged period of time.
- Q Change in position of the jaw joints (TMJ) which may cause post-operative discomfort, bite change and chewing difficulties. If TMJ symptoms existed before surgery, there may be no improvement and even some worsening of these symptoms after surgery.
- R. Stretching of the corners of the mouth with resulting discomfort and slow healing.
- S. Inflammation of veins (phlebitis) that are used for IV fluids and medications, sometimes resulting in pain, swelling, discoloration and restriction of arm or hand movement for some time after surgery.
- T. Hypernasality of voice due to swelling of nasal mucosa in immediate post operative period. Difficulty in swallowing and speech in cases of cleft patients due to velopharyngeal incompetence.

U I consent to being photographed (head and neck region only) before and After surgery and during the operation to be performed. .

These photographs may be used for medical, scientific or educational purposes, provided my name is not revealed by the pictures

V Airway compromise and fall back of tongue in cases of set back surgeries of mandible.

5. **General anesthesia** will be used for this surgery and I have been told of the risks, including bronchitis, pneumonia, hoarseness or voice changes, cardiac irregularities, heart attack or death. I am aware of the importance of not having anything by mouth (including clear liquids unless specifically authorized by my doctor or anesthesiologist) FOR EIGHT (8) HOURS PRIOR TO AND (8) HOURS AFTER SURGERY . TO DO OTHERWISE MAY BE LIFE-THREATENING!

6. I realize the importance of providing true and accurate information about my health, especially concerning possible pregnancy, allergies, medications and history of drug or alcohol use. If I misinform my doctor I understand the consequences may be life-threatening or otherwise adversely affect the results of my surgery.

ABOUT WIRING OF TEETH

If my teeth are wired together after this surgery, I understand there are certain associated risks and complications: oral hygiene will be diminished, there may be resulting gum disease, my teeth will feel slightly loose for some time after the wiring, compromised nutrition and there is always some concern about airway obstruction. I agree to carry wire cutters with me at all times when my jaws are wired and to avoid the use of alcohol and other activities that may cause nausea or airway problems.

Signature -----

INFORMATION FOR FEMALE PATIENTS

I have informed my doctor about my use of birth control pills. I have been advised that certain antibiotics and other medications may neutralize the preventive effect of birth control pills, allowing for conception and pregnancy. I agree to consult with my personal physician to initiate additional forms of birth control during the period of my treatment, and to continue those methods until advised by my personal physician that I can return to the use of oral birth control pills.

Signature -----

By signing this consent form, I acknowledge that I have read it completely and understand the procedure to be performed, the risks, and the alternatives to surgery. I have had all my questions answered to my satisfaction. I was under no pressure to sign this form and have made a voluntary choice to proceed with surgery. The fee for services has been explained to me and is satisfactory and I understand there is no warranty or guarantee as to the result and/or cure and that my condition may return or become worse. I certify that I speak, read and write English.

Patients (or guardian`s) signature & Date

Witness signature:

1.

2.

Doctor`s signature

6. Consent for TMJ**ORAL AND MAXILLOFACIAL SURGERY****CONSENT FOR TREATMENT FOR REPAIR OF TEMPORO-MANDIBULAR JOINT**

Patient's Name

Age/Sex

Date

Please initial on each page after reading. If you have any questions, please ask your doctor BEFORE initialing.

Dr. _____ has explained to me about the pathology (disease) that exists in my right and/or left temporomandibular joints (lower jaw joint).

I understand that my condition of limited or compromised function and/or pain may be secondary to a number of possible processes including, but not limited to

- | | Mark the symptoms |
|---|--------------------------|
| 1. Traumatic injury | <input type="checkbox"/> |
| 2. Malocclusion | <input type="checkbox"/> |
| 3. Articular displacement (cartilage dislocation) | <input type="checkbox"/> |
| 4. Degenerative joint disease, inflammation | <input type="checkbox"/> |
| 5. Infection | <input type="checkbox"/> |
| 6. Arthritis | <input type="checkbox"/> |
| 7. Vascular injuries(hematoma formation) | <input type="checkbox"/> |

-
- 8. Instrument breakage during arthroscopy
 - 9. Ankylosis(fibrous union / bony union of joint)

 - 10. Chronic pain
 - 11. Material failure (foreign body reaction)
 - 12. Frey`s syndrome (sweating over temporal region on operated side)
 - 13. Neruosensory disturbances (numbness over skin and adjacent area of operated site)
 - 14. Otology complications (ear related)
 - 15. Intracranial injuries (Dural tear, cerebrospinal fluid leak)
 - 16. Post operative maxilla-mandibular fixation
 - 17. Objectionable scar formation.
 - 18 Facial swelling lasting for longer period of time

I understand that the surgery to be performed is an exploratory procedure and the treatment rendered at that time will be based on the findings during surgery.

Surgical treatment may includes

mark the procedure

- 1. Meniscus repair
- 2. Meniscectomy (removal of cartilage)
- 3. Placement of an implant

- | | |
|---|--------------------------|
| 4. Eminectomy | <input type="checkbox"/> |
| 5. Condylectomy. | <input type="checkbox"/> |
| 6. Arthroscopy | <input type="checkbox"/> |
| 7. Arthrocentesis | <input type="checkbox"/> |
| 8. Gap arthroplasty(release of ankylotic mass) | <input type="checkbox"/> |
| 9.Ligament Plication | <input type="checkbox"/> |
| 10.Interpositional Arthroplasty | <input type="checkbox"/> |
| 11.TMJ Reconstruction | <input type="checkbox"/> |

I (we) understand that my surgeon may discover other or different conditions which require additional or different procedures than those planned.

I (we) understand that no warranty or guarantee has been made to me as to a result or cure. I (we) also realize that the following risks and hazards may occur in connection with this particular procedure:

1. Facial nerve paralysis with inability to close eyelid on the affected side.
2. Inability to wrinkle the forehead.
3. Inability to blow air from mouth
4. burning sensation of eye due to inability to close eyelids
5. drooling of saliva from corner of mouth
6. Infection.

7. Resultant malocclusion (incorrect bite) and limited opening of jaw.
8. Lack of improvement or worsening of pain and jaw dysfunction.
9. Further degenerative changes with the temporomandibular joint (TMJ).

Patients (or guardian`s) signature & Date

Witness signature:

1.

2.

Doctor`s signature

7. Consent for Trauma



ORAL & MAXILLOFACIAL SURGERY

CONSENT FOR TREATMENT FOR REPAIR OF FACIAL BONE FRACTURES

Patient's Name

Age/Sex

Date

Please initial on each page after reading. If you have any questions, please ask your doctor BEFORE initialing.

My doctor has explained to me that there are inherent and potential risk and side effects associated with my proposed treatment and in this specific instance, but they are not limited to

1. Damage to or loss of teeth in the area of trauma or fracture, loss of vitality of those teeth with requirement for future root canal therapy, loss of dental restoration, accidental swallowing or aspiration of tooth or foreign object, devitalization of bone and soft tissue in the area of trauma which may result in some loss of tissue.
2. Unusual procedures required during surgery such as incomplete removal of tooth, which endanger adjacent vital structures.
3. Post operative swelling, discomfort, bruising, bleeding, hematoma (blood clot), wound infection or dehiscence, sinusitis and limitations of function, any of which require further care.
4. Adverse or allergic reactions to medications or anesthesia causing multiple side effects, some of which may be serious and require additional care or hospitalization.
5. Reaction to foreign material which may have been introduced into the wound by the trauma, or "tattooing" of the skin or mucosa from particles of foreign material
6. Change in occlusion (bite) and jaw function after treatment; secondary problems of the jaw joint (TMJ) which may be prolonged, or even permanent, and which may require future treatment.
7. Possibility of otologic (ear related) complications such as perforation, infections, decrease in function of parotid gland(one of the gland responsible for saliva secretion), formation of fistula over preauricular& retromandibular region(areas of lateral

- surface of face), mandibular hypomobility in long term experience, ankylosis of TMJ during surgeries of TMJ joint.
8. Scarring either inside or outside of the mouth, depending on the nature and force of the trauma and the locations of certain incisions required in treatment.
 9. Facial muscle weakness particularly of the lip, eyelid or other muscles of expression caused by injury to motor nerves in the area of the trauma. Such weakness may be partial or total and may be temporary or permanent.
 10. Sensory nerve injury causing pain, numbness, or other sensory alterations anywhere in the mouth, tongue, cheek, lip, and areas of facial skin which may be temporary or permanent.
 11. Wiring the teeth together during the time required for healing of bone fractures will significantly reduce oral hygiene effectiveness, which may then lead to or worsen periodontal (gum) disease, bleeding gums, discomfort and loosening of teeth. Following treatment for facial injury, any such conditions must be treated. Jaw wiring will decrease normal diet and cause temporary weight loss.
 12. Certain wires, screws, plates, splints or other fixation devices may be introduced, and some may require later removal.
 13. Unusual effects related to hardware used such as metal sensitivity, Infection ,screw fracture, plate fracture or plate exposure.
 14. Non-union or malunion of bony fractures, possibly requiring re-treatment. Some cosmetic or functional deformity may occur in areas adjacent to the trauma or repair

I understand that additional injury may be discovered during treatment that might necessitate a change in approach or a different procedure from those explained above and I authorize my doctor to perform such procedures that are necessary and advisable in the exercise of professional judgment.

I understand that this is complex treatment and there can be no guarantee of complete resolution of my present symptoms or jaw/teeth/facial bone injury. Occasionally there may be increased symptoms post-operatively (for example, numbness). I also understand that additional treatment may be necessary post-operatively, including (but not restricted to) physical therapy, reconstructive dentistry, orthodontics, retreatment of bone fractures including bone grafting, removal of certain fixation devices, or TMJ treatment. I agree to cooperate with my doctor's recommendations during treatment, realizing that lack of cooperation will result in a less-than-optimal result.

I have discussed my past medical history with my doctor and have disclosed all diseases and medications, including alcohol and drug use (past and present).

Signature -----

I have had an opportunity to have all my questions answered by my doctor that all blanks on this form were filled in prior to my signing, and I certify that I understand English. My signature below signifies that I understand the surgery and anesthetic that is proposed for me, together with the known risks and complications associated. I hereby give my consent for such surgery and anesthesia I have chosen.

Patients(or guardian`s) signature &Date

Witness signature:

- 1.
- 2.

Doctor`s signature

8. Requisites for translation of “informed consent” to vernacular languages



Here is the Consent for informed consent and illiterates. This as per the standard requirement. You can dilute it or modify it.

1. All consent forms should be in the language of the majority of the population. Therefore it must be in the Vernacular of that region plus English or any other popular language. The English Consent form should be translated to the local language. There are two ways of doing it so that the essence and meaning are not lost.

A. Ethical committee approved consent forms in order to remain valid will need 'back translation'. The suggested or approved consent form must be translated into the vernacular. The thus translated matter must then be translated back to the original English by another person. Then the original and the 'back translated versions are compared. If the meaning remains unchanged then the translation is accepted. Please note that this is required only in approved consent forms in research etc. In the clinical setting the AOMSI consent for is only a template and such rigorous measures may not be necessary.

B. Alternately the approved consent in English can be translated by a Government approved translator (usually a University translation department). E.g. The Tamil University in Tanjore does approved translations.

2. For obtaining Informed Consent of illiterate persons the Consent form can be read out to the person giving consent in the language he/ she understands in the presence of an independent third party or relative of patient who should be literate. The consent form is then signed and attested by the independent witness in addition to signature or thumb impression of the consenting person.

3. In case of children below 18 years, the parent or legal guardian can sign on behalf of the children. However, child rights activists and the new law in several countries may require a consent (particularly in older children who can comprehend issues). Technically, in India, children below 18 are considered to be 'not legally competent'.

4. In mentally retarded or persons incapable of consenting due to mental incapacity, the parent or legal guardian (if unavailable -institutional heads of organizations taking care of them can sign on their behalf).
5. In hearing impaired illiterates the consent must be explained by sign language or any means that is used for communication to translate the document. It needs third party attestation. Similarly, in visually impaired persons the consent can be obtained through Braille or by oral communication with third party attestation.

Today, in many countries video recorded informed consent procedures are utilised. It may become mandatory in India too.

Caveat: informed consent, however carefully taken can be challenged on the grounds of being an unequal contract influenced by fiduciary relationship in doctor- patient relationship.

The above is my personal opinions based on experience and the use of consent approved by Ethiconsult Services of which Dr George Paul was a member secretary. It can be modified as per personal perception of what constitutes adequate consent.

9. Informed refusal of treatment



Informed refusal of treatment.

This form is primarily used when any recommended treatment is refused by a patient. (It may also be used for patients with TMJ implants who remain both asymptomatic and without imaging changes in joints and who, contrary to FDA and AAOMS guidelines, do NOT wish to have TMJ implants removed)

I have been informed by DR of my condition and the recommended treatment consisting of :

I have also been offered alternative treatment which include:

After considering the treatment possibilities offered, and having the benefits and risks of each explained to my satisfaction, I have voluntarily chosen to :-

I understand that my decision is contrary to my doctor's recommendation and that my condition may significantly worsen as a result, may require additional therapy additional therapy/ or hospitalization, and in rare circumstances may be life threatening. I AGREE TO RETURN TO THIS OFFICE FOR PERIODIC MONITORING OF MY CONDITION AS scheduled by my doctor.

I realize that I may consider my decision at any time by notifying my doctor.

Patient 's(or Guardian) signature

Date

Witness's Signature

Date

Doctor's Signature

Date

A.2 Quantification of Disability

A.2.1 Quantification of Dento-facial Disability/Deformity: A Proposal [19]

Form and function are the quintessence of human life. Disability and deformity are interruptions to this harmony. Disability/deformity may be congenital or acquired. Governments have a social responsibility to mitigate such afflictions by creating an environment for re-integrating them into normal social life. Most welfare states provide benefits for persons with disability.

Disability can also be caused by accidents, interpersonal violence and iatrogenic causes. These situations have legal overtones and often require compensation in some form. Benefits and compensation can only be calculated if the disability is quantified. Orthopedic disabilities in Civil and Military life have been calibrated and quantified. Similarly other disabilities involving loco motor, neurological, visual and hearing deficit have also been quantified. Unfortunately the maxillofacial region has not been adequately addressed in any of these quantification charts.

Quantification of the maxillofacial region is unique on account of the fact that there are two criteria to be evaluated—Disability and Deformity. While disability is more readily calculated, deformity is highly subjective and therefore any award for the latter is bound to be arbitrary. However it is not possible to ignore the importance of deformity to the face, and an attempt is made to establish a broad parameter in which it can be assessed.

Review of Quantification Criteria

Quantification of orthopedic disability is well established and has been in use for social benefits, rehabilitation, assistance and percentage reservations in labour market placement of disabled people. It has also been in use for legal and insurance compensations due to accidents, interpersonal violence and occupational diseases. The Phulhems profile by the Canadian Army was established as early as 1943. The McBrides criteria was the established reference in India till 1980. It did cover some aspects of the maxillofacial region and was generally accepted for dental injuries and dental loss. The McBrides criteria (1955) was replaced in India by the “Manual for Doctors to Evaluate Permanent Physical Impairment” (1981). Unfortunately the impairment and disability of the face is covered rather incomprehensively and inadequately, relegating the whole area of the face to one half of a chapter, with hardly 30 points being allocated to the face. Not one maxillofacial surgeon sat on the expert committee of 45 advisors. In the realm of physical rehabilitation and orthopedics, numerous references are available. Kessler (1970) covered various aspects of upper and lower extremity disabilities. The American Academy of Orthopedic Surgeons Manual (1966) discusses the concept of permanent impair-

ment through a series of questions that reveal the permanency of the deficit. The Govt. of India notification (1986) covers visual disabilities, locomotor disabilities and hearing and speech disabilities. It recommends that Kessler’s formula can be taken as a general guideline.

Significantly the only other Indian guideline for Maxillofacial region comes through a Government of Tamilnadu notification (1974) where complete facial disfigurement is dealt with. It simply awards a 50% for total facial disfigurement. No break up figures is given for type or severity of disfigurement.

The American Association of Oral and maxillofacial Surgeons and American Medical Association have given guidelines for assessment of maxillofacial injuries and disabilities. They however need modification to suit our population and needs.

The authors have depended on two major sources while making this evaluation.

1. Objective Evaluation of Impairment and Ability in Locomotor Handicapped by Sabapathyvinayagam Ramar. An excellent reference book on Physical Medicine and Rehabilitation.
2. Guidelines to the Evaluation of Impairment of The Oral and Maxillofacial Region—issued by the American Association of Oral and Maxillofacial Region.

The authors have modified the guidelines of the above sources to arrive at the recommendations.

The general aim of the exercise was to evolve quantification criteria for disabilities and deformities of the Maxillofacial region taking into account the special features of the problems encountered in India. It also endeavours to simplify the percentages awarded by eliminating complex variables. **The evaluation adopts a position of awarding a 100% to the face to be divided between deformity (50%) and disability (50%). It does not try to evaluate facial impairment as a part of the total body as it would significantly reduce the quantum of impairment and thus defeat the purpose of this exercise.** Consider a situation where 100% has to be divided between cardiovascular, alimentary, central nervous and locomotor systems in addition to sexual dysfunction, liver dysfunction, renal, endocrine and metabolic dysfunctions. Further distribution amongst visual, hearing, etc. will certainly minimize any help of giving value to the face.

The evaluation has also eliminated the need to go into variables like age, sex and occupation, which will modify the award percentages. These will rest within the realm of the government agencies, judiciary or insurance agents.

The criteria formulated shall simply make a statement of disability/deformity based on standards established within the purview of the 100% for the face—equally divided

amongst the various structures and functions. **The total of these shall remain within hundred utilizing the formula**

$$A + \frac{B(100 - A)}{100}$$

where, **A = higher value and
B = lower value.**

Definitions

Based on Govt. of India Gazette Part I section 1 No. 4-2/83—
HW III Ministry of Welfare, 1986.8

- **Impairment:** is defined as any loss (or) abnormality of psychological, physiological (or) anatomical structure (or) function.
- **Disability:** WHO defines disability in the context of health experience as any restriction or lack (resulting from an impairment) of ability to perform an activity in the manner (or) within the range considered normal for a human being.
- **Deformity:** facial disfigurement involving soft and hard tissues arising from multiple genetic factors, environment influences, acquired defects, neoplastic processes and trauma.

Recommended Quantification for the Dento-facial Region
Areas of Deformity Evaluation—Hard Tissues:

A. Loss of Teeth:

<i>Anteriors</i>	<i>Deformity/Disability</i>
All anteriors (upper and lower)	: 25%
Between 8 and 11	: 20%
Between 4 and 7	: 15%
Between 2 and 3	: 10%
One tooth	: 05%

Though these are disabilities and deformities that can be replaced, it deserves the above percentile as the strength and function of false teeth are not considered equal to natural teeth. Orthopedic deformities are evaluated even if prosthesis is given.

Posteriors Disability

– Excluding third molars and including premolars.

All posteriors (16)	: 25%
Between 10 and 14	: 20%
Between 6 and 9	: 15%
Between 2 and 5	: 10%
Occlusal discrepancy	: 10–20%
One tooth	: 05%

Loss of teeth due to progressive dental pathology (e.g. Periodontitis, caries) are not considered. The dental surgeon will have to make an assessment based on the condition of remaining teeth or preexisting records.

B. Loss of Bone (Disability/Deformity)

Significant loss of bone causing
Deformity/Disability : 10–25%
Small bony fragment : 5%

C. Mal-united Facial Bones: (Depending on extent of Disability/Deformity)

Malunited facial bones : 10–20%
– Occlusion to be combined whenever affected.

This is an incomplete quantification and will have to be assessed by the surgeon on the basis of the degree of disability/deformity caused by the malunion.

D. Orbital Deformity (excluding visual field assessment)

Subjective evaluation based on:
Bony orbit : 5–10%
Soft tissue e.g.) etropian, scar etc : 5–10%
Composite deformities including
Telecanthus etc : 15–25%

Areas of Deformity Evaluation—Soft Tissue

A. Soft Tissue—Non-reversible

Single linear scar : 5%
Multiple or deforming scars
Including Keloids : 10–30%
Significant loss of soft tissue
E.g. Loss of nose, ear, lips etc : 20–50%

B. Facial Sensory Impairment (Ramar)

Face has 34% sensory innervations of whole body.
Ophthalmic : 8%
Maxillary : 8%
Mandibular : 8%
Tongue : 10%

C. Impairment Rate for Mouth Opening (Ramar)

Impairment rate for interincisor distance of 4 cm : 0%
Impairment rate for interincisor distance of 3 cm : 10%
Impairment rate for interincisor distance of 2 cm : 20%
Impairment rate for interincisor distance of 1 cm : 30%
Impairment rate for interincisor distance of 0 cm : 50%

D. Motor Disability (RAMAR)

Jaw muscles (masticatory) : 5% right side, 5% left side
Tongue muscles : 15% either side.

E. Facial Nerve Impairment

Single branch : 05%
Five branches : 25%
Zygomaticotemporal : 10%

Bilateral problems are not addressed.

F. Disfigurement criteria (AAOMS and AMA guidelines 1997 and 2002)

- Class 1—(0–5%) Disorder of cutaneous structure e.g. visible scars
- Class 2—(5–10%) Loss of supporting structure with or without cutaneous disorder e.g. Depressed cheek and nose.
- Class 3—(10–15%) Absence of normal anatomical area of face. E.g. Loss of eye or part of nose. Visual or hearing loss will have to be separately evaluated.
- Class 4—(15–35%) Impairment of whole person. Facial disfigurement is so severe that it precludes social acceptance.

This criteria appears logical and it significantly simplifies an otherwise complex quantification of facial disfigurement. However we would encourage its use with the other mentioned parameters. The multiple percentages can be resolved with the Kessler's formula.

In multiple disabilities and deformities or when there is a combination of the two the Kessler's Formula $A + \frac{B(100-A)}{100}$ can be used, where A= the higher and B= lower value

Another formula has also been used by Ramar as per the Government of India notification: $A + \frac{B(90-A)}{90}$ again A being the higher value and B being the lower value.

The formula can be used in a few mock situations.

1. X has an injury resulting in the fracture of the mandible and loss of four incisors. He also develops a paresthesia of the marginal mandibular nerve following surgery. His total percentile may be calculated thus: A = 15% and B = 5%.
 $15 + \frac{5(100-15)}{100} = 19.25$, whereas the sum of both would have been 20%.
2. Y has an injury resulting in the fracture of both condyles causing subsequent total bony ankylosis. He also has a large scar with keloid on his right cheek. His percentage is calculated thus:
 $50 + \frac{20(100-50)}{100} = 60$ whereas the sum of two injuries would have been 70. Please note that the value adjusts itself as the percentiles go up.

Discussion

Quantifying all kinds of disabilities/deformities is an enormous task. This paper attempts to deal with only those disabilities resulting from accidents. Congenital disabilities/deformities such as those found in cleft—craniofacial anomalies will require a more extensive analysis. Similarly disabilities and deformities caused by aggressive tumours and cancers of the head and neck comprise a wide range of

problems, which are not necessarily regional. Cancer in particular may have numerous associated problems ranging from donor site morbidity to psychological impact affecting quality of life and mental depression.

Dental injuries and their resultant disability/deformity are closely linked to aesthetics and mastication. For the purpose of awarding percentiles, the anterior teeth were considered for aesthetics and the posterior teeth for masticatory function. The awards are arbitrary and based on the relative dysfunction caused by the absence of teeth in the masticatory apparatus. The American Association of Oral and Maxillofacial Surgery (AAOMS) guidelines award percentages for the complete masticatory apparatus. It awards 24% for a person who is restricted to liquid diet (40–60% if tube feeding is necessary) and 5–19% if person is restricted to semisolids (includes those with ability to wear dentures). We have taken the liberty of awarding points for individual teeth. However if the whole masticatory apparatus is to be evaluated, one may separately evaluate absence of teeth, occlusal disharmony, TMJ movement (craniomandibular articulation), muscle power etc and arrive at a figure by using the Kessler's formula of $A + \frac{B(100-A)}{100}$.

This appears as a reasonable formula, which accounts for individual disabilities within the framework of the masticatory apparatus.

Further the AAOMS guidelines classifies the percentiles into two categories (1) Percentage of normal. (2) Percentage impairment of whole person. The dichotomy does not seem reasonable and is likely to cause further confusion. Finer details such as lateral excursion etc which, have been dealt with in the AAOMS guidelines have been ignored.

Similarly the concept of deformity and disfigurement has been dealt with differently in the AAOMS and the AMA guidelines. The matter of disfigurement is complicated by issues such as personality crisis and the impact of social acceptance. As suggested earlier this criteria can be incorporated into Kessler's formula, thus resolving the issue of multiple disabilities and deformities.

Finally the question of who can give a disability certificate. The Indian sources are silent in the matter of maxillofacial injuries. However the law in many American states clearly provides for the role of a Board qualified Oral Surgeon or maxillofacial Surgeon to issue disability certification for the maxillofacial region.

Contrary to general perception, it is not necessary that these criteria need to be made by statutory bodies. General usage can give legal legitimacy. It would of course be in the best interest of the Surgeon, patient and the public if these suggestions can be scrutinized, amended and enlarged to accommodate a larger spectrum of disabilities and deformities.

A.2.1.2 Duties of Witness

Failure to appear in court without valid reasons after warrant has been issued can invite contempt of court.

Exaggeration or false statements given under oath is not only unethical, but can invite punishment under sec. 181, Sec. 193.

References

- Bernhard Wolf Weinberger. Pierre Fauchard, Surgeon-dentist: a brief account of the beginning of modern dentistry, the first dental textbook, and professional life two hundred years ago. 1941.
- Moore W. The knife man. Transworld; 2010. pp. 223–4. ISBN 978-1409044628. Retrieved 8 Mar 2012.
- <https://www.dental.upenn.edu/admissions-academics/graduate-dental-education-programs/oral-maxillofacial-surgery-residency-m-d/>
- <http://dental.nyu.edu/academicprograms/advanced-education-programs/oms6.html>
- Martin-Granizo R. Double degree in oral and maxillofacial surgery — is it necessary? *IJOMS*. 2017;02:126.
- Amin M, Ahmed B. Dental education in Pakistan: current trends and practice. *J Coll Physicians Surg Pak*. 2010;20(8):497–8.
- Mawatha NK. Prospectus, MD oral and maxillofacial surgery and board certification. Postgraduate Institute of Medicine, University of Colombo. 2011.
- Zheng J, Fang B, Zhang S, Yang C, Shen G, Qiu W, et al. Oral and maxillofacial surgery in China: past, present and future. *Open J Stomatol*. 2013;03:354–8.
- Fiehn N-E. Perspectives on dental education in the Nordic Countries. *J Dent Educ*. 2002;66(12):1374–80.
- EACMFS. White book. Russia. 1st ed. 2017. <http://beta.jointogethergroup.com/Society/members/whitebook/export.asp?wb=31>
- Kumar S. Training programmes in oral and maxillofacial surgery across the globe – a mini review. *J Maxillofac Oral Surg*. 2017;16(3):269–76.
- Revised Dentists (Code of Ethics) Regulations – 2014, Part II, Section 3, Sub-sec (1) of the Gazette of India.
- <http://www.thefreedictionary.com/informed+consent>
- Faden RR, Beauchamp TL. A history and theory of informed consent. Oxford University Press; 1986. p. 28, 123.
- Faden RR, Beauchamp TL. A history and theory of informed consent. Oxford University Press; 1986.
- Gasparini G, Boniello R, Moro A, Di Nardo F, Pelo S. Orthognathic surgery: a new preoperative informed consent model. *J Craniofac Surg*. 2009;20(1):90–2.
- Krishnan NR, Kasthuri AS. Informed Consent MFAJL. 2007;63:164-166.
- <http://www.surgery.org/press/news-release.php?iid=125>
- Paul G. Medical law for the dental surgeon. Jaypee Publishers; 2004. p. 30.
- Bolam Vs Friern Hospital managing committee. (1957) 2 AIIER 118.
- IMA v VP Shantha and Oths 111 (1995) CPJ (SC).

Open Access This chapter is licensed under the terms of the Creative Commons Attribution 4.0 International License (<http://creativecommons.org/licenses/by/4.0/>), which permits use, sharing, adaptation, distribution and reproduction in any medium or format, as long as you give appropriate credit to the original author(s) and the source, provide a link to the Creative Commons license and indicate if changes were made.

The images or other third party material in this chapter are included in the chapter's Creative Commons license, unless indicated otherwise in a credit line to the material. If material is not included in the chapter's Creative Commons license and your intended use is not permitted by statutory regulation or exceeds the permitted use, you will need to obtain permission directly from the copyright holder.





George Dimitroulis

45.1 Introduction

We have all been too quick to make up our minds and too slow to change them. In Oral and Maxillofacial Surgery, our opinions are slaves to our prior experience. Ignorant confidence is what defined early Surgery as there was a distinct lack of interest in proving and promoting what was effective. The “God complex” among early Surgeons meant that what they thought was true did not need scientific evidence. It is only in more recent times that Surgical practice has embraced evidence to guard against rumour, bias, misconceptions and misunderstandings. Indeed, just in the last few decades we have witnessed the gradual evolution of Surgery from eminence-based practice, the idea that senior experienced Surgeons held all the knowledge, to evidence-based practice, where fair tests are employed to compare one treatment against the other in order to find what works best. History has taught us that clinical research leads to reforms in the practice of Surgery while basic research leads to revolutions in Medicine.

Like in most other scientific disciplines, Surgical research is used to confirm facts, reaffirm the results of previous work, solve existing problems and ultimately develop new ideas of practical value. If you can understand more, you can make better decisions rather than blind guesses which is the hallmark of successful clinical practice. Judgements, predictions and plans are based on the latest available information and should be constantly updated in the light of new information derived from good research. The late British Economist John Maynard Keynes once said “when the facts change, I change my mind”. So too, a good Surgeon must be open to new ideas and techniques which are essential to the progress and evolution of each surgical specialty, as change is only possible when key opinion leaders lead the charge.

G. Dimitroulis (✉)
Maxillofacial Unit, St. Vincent’s Hospital – University of
Melbourne, Melbourne, Australia

Essentially, the greatest discoveries in Surgery are those that force us to rethink our beliefs about human disorders and our role in managing it. Research builds our core knowledge, and the most useful knowledge is one that changes the behaviour and practice of Surgeons. The simple idea of washing your hands before handling patients met with immense resistance from the established medical community in the nineteenth century until the scientific evidence supporting microbial infection became too overwhelming to ignore. Knowledge increases your ability to predict the outcomes, and the knowledge of bacterial infections was one of the greatest breakthroughs in modern medicine that significantly reduced the mortality and morbidity of even the simplest of surgical procedures. Research has been pivotal to the success of surgery over the last two centuries and will continue to be an integral part of all future progress, especially in the rapidly expanding field of Oral and Maxillofacial Surgery.

Progress doesn’t occur in a vacuum; it almost always builds on existing ideas with a series of incremental improvements. That is why most research is used to develop further knowledge on a topic by reaffirming the results, theories and problems of past work in the field. Occasionally, when trying to solve an existing problem, research may lead to the discovery of new problems, ideas and theories which makes the science of Surgery a dynamic process of knowledge acquisition that has no endpoint.

45.2 The Science of Research

The word Science comes from the Latin “scientia” which means knowledge or skill. Science is about new ideas and testing these in the most transparent way. What launched the Scientific revolution was the realization that we do not have the answers to their most important questions. To find the answers, experiments are what people devised when they weren’t sure of the truth. Ignorance is the starting point of all

science, and curiosity about the world around us is what drives science. The more that is unknown, the greater the opportunity to discover, and that is how research has become an essential tool of discovery.

The word Research is derived from an old French term referring to seeking or searching. Research is all about the ability to test, reproduce, quantify and falsify an idea before it can be fully accepted as scientific fact. In research we learn more from the unexpected results than from those we anticipate. Understanding the research process helps generate new research questions. The trick is to ensure the right methods are used to answer the right questions. For example, when we are seeking verification, we must ask ourselves “Did I build the system right?”, while if we want to validate something, we then ask “Did I build the right system?”.

Scientific research is a systematic way of explaining things by collecting evidence which make practical applications possible. The goal of research is not only to yield new knowledge but also to make us better understand existing issues or topics. There are three main forms of Research; Exploratory research helps to identify a problem, while Constructive research proposes solutions to the problem. The third is Empirical research which tests the feasibility of the solution using either qualitative or quantitative methods. Qualitative research collects data in the form of words, images and video which is largely confined to the social sciences but may also have applications in Surgical techniques. The difference between quantitative (numbers) and qualitative (descriptions) research is well summarized by the famous scientist, Albert Einstein, who once said that “Not everything that matters can be measured, and not everything that can be measured matters”. The world cannot be understood without numbers, and equally, it cannot be understood with numbers alone.

In Surgery, quantitative research is most often used to establish the existence of causal relationships between variables by collecting and analysing numerical data. By relying on random sampling, the quantitative research method allows for experimental, correlational and descriptive (i.e. survey) results that are easy to summarize, compare and generalize using statistics to determine the relationship between variables. For example, if the research question is about best mandibular reconstruction following tumour resection, the patients may be randomly assigned to different groups, each representing a different mode of reconstruction. If this is not feasible, the researcher may collect data related to the patient’s demographics and situational characteristics to statistically control for their influence on the degree of morbidity following their particular mandibular reconstruction. Often the intent of the surgical research is to generalize from the study participants to a larger population which will require the researcher to employ probability sampling to select the study participants.

Table 45.1 The scientific research method

- a. Identifying problem through observation
- b. Review the literature—look for gaps in knowledge
- c. Specify aims/purpose of research
- d. Determine specific question or hypothesis
- e. Define the variables being measured
- f. Choose method of data collection—avoid bias
- g. Data analysis—choose your statistical method
- h. Data interpretation—keep an open mind
- i. Test/revision of hypothesis
- j. Conclusion/recommendations for surgical practice
- k. Reporting/communicating/publishing findings

45.3 The Scientific Research Method (Table 45.1)

Scientific research follows a structured process. Successful research is only possible when asking the right questions, engaging in the right observations, running the right experiments and networking with the right people to elicit ideas and feedback. The core principle of science and research are precision and transparency—being clear about your methods and honest with your results. Transparency is what gives science credibility. World-changing ideas and technology were built from a protracted process of trial and error. Experiments are designed to show what does work and what doesn’t. It is by testing that we gain access to the feedback that drives progress. Formal research has a well-established pathway that follows the basic steps set out below.

45.3.1 Observation

Many people simply watch the world around them (on auto-pilot). Few people observe. An astute observer will see the problem only when they’re not vested in the way things have been. Their ability to imagine how things should be is what drives change and progress. The hardest part of solving a problem is seeing it, and many surgeons blindly follow procedures that do more harm than good for the patient because they have failed to question the surgical technique they have been taught. In surgery, very few surgeons have ever asked the pivotal question—“Is there a better way?” Curiosity and an open mind is what drives progress, and unfortunately, most surgeons have achieved their chosen profession by not rocking the boat and adhering to conventional practices.

Many of the things we accept as objective truths are themselves assumptions based on uncertainty, even in the world of Surgery. No surgical concept or technique has an absolute and permanent value. Time, experience and better experimental tools give rise to new ideas that supplant the old ideas. In other words, all existing surgical ideas and techniques are sooner or later supplanted by new ideas and techniques which means surgery is a never ending marvel of evolution.

Before embarking on any kind of research, the first step is to look for any idea or technique that has not been adequately explained or supported by evidence. When looking to a topic or issue as a potential subject for research, the hierarchy of deliberation begins with (1) “Where is the evidence?”, (2) “How sound is the evidence?” and (3) “Has the evidence been properly interpreted?”. Once you have selected the appropriate subject or topic you would like to explore, the next step is to find out what the literature has to say and look for gaps in the existing knowledge.

45.3.2 Literature Review

All the world’s information is now at our fingertips, and to access scientific publications is a matter of a few keystrokes. Search engines like Google Scholar and PubMed have opened up a whole new digital world of scientific literature that even the largest University libraries could never hope to subscribe to. Access to the world’s scientific literature has never been simpler than it is today, and subscriptions to University libraries also allow students digital access to a wide range of local and international journals.

Once the research topic has been selected, a thorough review of the literature is required to establish what is already known. It is best to begin with the most recent peer-reviewed articles on the topic which will often summarize the existing body of knowledge. Meta-analysis papers, especially those that follow the PRISMA guidelines, are becoming more common, and these papers can form the foundation of your research topic. Good journal papers will commonly highlight the gaps in our knowledge, the weakness in the current evidence available, and what further research is required that will conveniently point you in the right direction.

45.3.3 Purpose of Research

Once you have gathered all the pertinent information from the literature review, the next step is to crystalize in your own mind why you are embarking on this research. The flaws or holes in previous research are identified so that the gaps in the literature will provide justification for the new research being proposed. Look for clues in the literature where there may be a deficiency in the evidence surrounding published statements, particularly those that make generalizations that are not adequately backed by evidence. Indeed, many Cochrane reviews have consistently concluded that the vast majority of clinical papers fail to provide the level of evidence required to make any firm conclusions. The aim or purpose of the research is pivotal to the whole project as it dictates the methodology required to adequately address the aims. It is also the main driver in funding applications and recruiting study participants.

45.3.4 Hypothesis

Science grows with every new piece of evidence with the hypothesis as the compass that directs the inquiries. Scientific theories have to make testable predictions that can be validated in experiments. Science is not just about confirmation; it is also about falsification. If a theory cannot be tested, then it’s logically impossible to ever falsify it. Karl Popper said “if it is not falsifiable, it’s not scientific”. If a theory cannot be tested with experiments, then it falls in the realm of religion or philosophy or pure speculation. Questions that generate the greatest emotional response are a great indicator of challenging the way things are.

The gap in the literature creates a research question which is otherwise referred to as the Hypothesis. The Hypothesis is a prediction which is set out as a statement that defines the relationship between two or more variables. In research, it is the hypothesis that is being tested as to whether it is true or false. If the hypothesis turns out to be consistent with the observations, then it is said to be supported rather than proven as it is still subject to further scrutiny. But if it is rejected, then support is claimed for an alternative hypothesis. The Null hypothesis is when there is no relationship between the variables being investigated.

45.3.5 Define the Variables

In the hypothesis statement, there will be two or more variables that will be the focus of the study. The study is designed to establish the relationship between the variables. However, before commencing the study, the variables must be clearly defined so that there is no doubt as to what each variable represents. Without clear definitions of the variables, studies cannot be repeated and hence impossible to validate.

45.3.6 Data Collection

What isn’t measured can’t be managed. Without data, we cannot make informed decisions. We gather data to collect information that becomes knowledge which is finally displayed as wisdom. Data has to be collected, processed and analysed for it to become information which can be used to make better decisions. Ultimately, the answer is only as good as the quality of the data fed into it.

Apart from field studies such as surveys and clinical audits, OMF Surgeons also conduct experiments that involve laboratory controlled conditions, often by recruiting the resources of other medical specialities such as pathology, microbiology, radiology, biochemistry, pharmacology and haematology. Data collection is easiest when data points can be quantified or represented with numerical figures. Even

descriptive surveys can be quantified provided the responses can be listed on a sliding scale ranging from good to bad, high to low or positive to negative. A typical example is the visual analogue scale used by OMF Surgery researchers to quantify pain scales, chewing ability and quality of life outcomes before and after jaw surgery.

In Medicine, randomized trials where the patients and experimenters are blinded are least vulnerable to bias than observational studies, which are most prone to bias. Unfortunately, randomized trials are more expensive than observational studies and require a lot more manpower and resources to properly execute. In surgery, we most commonly rely on observational studies as the best evidence we have to go on for two reasons. Firstly, control groups with which to compare treatment outcomes, unlike a placebo sugar drug, are rare as it is ethically impossible to undertake sham operations. And secondly, it is practically impossible to blind surgeons and patients when it comes to evaluating surgical procedures. Evidence in the field of Oral and Maxillofacial Surgery therefore relies largely on observational studies derived from surveys and clinical audits of case series.

45.3.7 Data Analysis

Data science is about understanding the world by spotting patterns and predicting how one variable will affect another. While our instincts may give us a reasonable sense of how the world works, we need data to sharpen the picture as we can be easily blinded by our own experiences and prejudices.

Data shows us there is more to OMF Surgery than we think we see. Good data science can often demonstrate counterintuitive results—what you least expected to see. Selection biases are distortions of the results introduced either by the data collecting tools or by the method of data accumulation.

Statistics is a valuable tool that helps determine whether the results you have found are likely to be due to a chance rather than a true finding. Make sure the data is collected on an Excel spreadsheet, and work out what level of confidence you will accept as statistically significant which, in clinical research, is often the 95% confidence level (i.e. P value <0.05). In statistics, the smaller the sample, the lower the likelihood that it would mirror the broader population. Large samples yield more precise results, while small samples are more susceptible to extreme results. As sample sizes get larger, the statistical calculations from that sample get more precise. Small differences (1%) between two populations being measured require bigger sample numbers than large differences (25%) for the true value to emerge. This is called the power calculation which is an important measure to con-

sider before embarking on any study. Statistics is a complex affair and beyond the scope of this chapter, so the services of an expert statistician may well be useful when it comes to crunching the data.

45.3.8 Data Interpretation

Information is interpreted by different people in different ways. People can look at the same set of facts and disagree. Data can be manipulated to support any argument. You don't always need a ton of data to find important insights. What you need is the right data. Numbers can be seductive. We can grow fixated with them, and in doing so, we can lose sight of more important considerations. When looking at data, it is not the raw crunching power you have that matters most, but what you do with it that is most important. Behind every statistic there is a certain set of assumptions and prejudices. Minds crave certainty, and when they don't find it, they impose it so we must keep an open mind when the data does not yield the results we expected to see.

45.3.9 Test or Revision of Hypothesis

Your judgement call about how the results support your hypothesis is essential to your conclusions. If the data does not support your hypothesis, then it is essential to state an alternate hypothesis that fits with what has been observed. The scientific method is tailor-made for cherry picking because of its hypotheses and caveats and refusal to embrace certainty. Even in Science, certainty still relies on the assumptions, interpretations and theories of researchers based on what they see. Nothing is definite, for doubt is an essential operating principle of science. This means that doubt still has a place in all scientific proofs, so that all evidence is provisional and not final. In other words, what you have ascertained in your research is not definite proof but rather tacit support for an idea.

45.3.10 Conclusions and Recommendations

The conclusion is a summary of the entire experiment or study that simply states the outcomes observed which must be clear, concise and to the point. Any ambiguity should be highlighted and recommendations made as to how future studies should be conducted to minimize the uncertainty. It may simply be a numbers game where more patients are required, or additional groups such as control patients which may provide a clearer outcome. For example, the effective-

ness of Botox in Myofascial Pain (TMD) can never be properly evaluated if there are no control groups (i.e. that have normal saline injected) with which to compare.

The conclusion is the most sought after piece of information that others will first look at when reviewing your research. Although it sounds rather obvious, the conclusion(s) must be supported by the data; otherwise, the research makes no sense. The onus is on the researcher to make sure the conclusions also fulfil the goals and aims of the study. Recommendations based on the conclusions are essential in providing a practical guide to surgical practice. Research is what drives clinical advances in Surgery, and the change in behaviour of Surgeons can only be achieved with evidence.

45.3.11 Reporting/Communicating/ Publishing Findings

Research is useless if it is not shared with the outside world. All humanity is now connected by digital technology which has rendered distance, time and costs irrelevant to the distribution and exchange of ideas. The digital world has made recording, storage and dissemination of information, research and ideas virtually free with costless reproduction and instantaneous global distribution. Reporting and publishing research findings is described in detail in Sect. 5.

45.4 Constraints in Surgical Research

Cultures that fail to encourage questioning also fail to come up with new ideas. Great institutions should teach us how to ask hard questions and where to look for answers. Knowing all the answers does not distinguish someone's intelligence—rather, the ability to ask the right questions and linking the unconnected is the mark of a true genius. Generally, it is considered a weakness and a sign of vulnerability for clinicians to appear unsure. Confidence in medicine is valued over uncertainty, but science is all about uncertainty which drives progress. If we knew it all, there would not be a need for research.

Nothing is as powerful as an idea whose time has come. New ideas are what drive behavioural change and innovation. A new behaviour needs social approval before others are likely to pick up the habit as their own. Only the curious, who are open to learning, have a much greater chance of creating a truly novel solution. Unfortunately, originality is not always embraced by the surgical profession who are generally conservative by nature.

It is much easier for Surgeons to accept familiar ideas than totally original ones because if the ideas are too original, then it may be too hard for the Surgeon to accept or

understand. The goal is to push the envelope, not to tear the envelope. Radical ideas are best presented in a way that is less shocking and more appealing to mainstream surgical practice by planting the seeds of a simple idea before revealing the larger idea. If you want your ideas to be accepted by your peers, make your ideas more appealing by connecting it with other ideas that are already understood by your colleagues. Other constraints related to research involve ethics, funding and bias which are discussed below.

45.4.1 Ethics

There has been a push in recent years by institutions and clinical journals to have all animal and human research activities sanctioned by appropriate ethics review boards or panels attached to hospitals or Universities. Without ethics approval or clearance, it may be impossible to conduct even the simplest of clinical studies, including basic surveys. Some Journals now request a copy of the ethics clearance letter before the paper can even be put out to review.

Unlike pharmaceutical research, the level of evidence in clinical surgery is hampered by the fact that control subjects are often missing because you cannot ethically perform sham operations in humans. Therefore, when designing surgical experiments, consider whether animal, laboratory or cadaver studies may be useful instead. Otherwise, you are limited to clinical audits which provide useful information which may not be scientifically valid. For example, a hospital which boasts 100% survival of its patients achieves this by turning away the sickest patients. Or a hospital which has the worst outcomes may well be a tertiary referral centre that only treats the most complex of cases that other hospitals turn away. So, while clinical audits provide a snapshot of the Hospital Unit's activities, it tells us very little else as far as science, progress and innovation is concerned.

We must be suspicious of therapeutic claims that have not been properly tested. Equally, we must be even more suspicious of research results that cannot be replicated. Many people are driven by a deep human desire for recognition and affirmation of work well done. Sometimes it is possible to build an academic career by sounding clever, rather than being clever. Most academics chase large numbers of trivial publications instead of investing their energies in new frontiers. In other words, why search for something new when you can collect rents on everything that has already been done. Sadly, there are small numbers of academics and researchers who have built their careers on falsification and plagiarism. The desire for recognition and the need for promotion when combined with the pressure to publish can tip some academics, clinicians and scientists towards fraudulent activities where data is made up and text is plagiarized in

order to churn out the maximum number of “scientific” papers. In science and surgery, reputation takes many years of hard dedication to build up and an instant to destroy when you’re suspected of scientific fraud.

45.4.2 Funding

Scientists have an innate desire to innovate, share, collaborate and be recognized for it regardless of the financial incentives. Hence, good research requires funding from external sources. Unfortunately, the spirit of open scientific enquiry can sometimes be hijacked by the combination of self-interest and money, especially when industry offer to bankroll the study. Industry rely on profitable enterprises which grow shareholder value. Scientific support behind a product is perhaps the ultimate value-adding marketing tool, so industry are always looking out for research that shows positive outcomes related to their products. Furthermore, industry never leave anything to chance so they want control of scientific research through financial rewards to various research institutions. By directly funding research, industry have control over what is published (i.e. the positive results) and what stays buried in a locked cupboard (i.e. the negative results).

Therefore, the most respectable research is that which is funded by government or not-for-profit organizations such as Medical Societies and disease interest groups like the Heart Foundation or the Cancer Council and so on. Funding from non-industry groups are much more competitive as there is always a limited amount of money available for research so applications must be of high quality. Furthermore, the non-industry funding bodies give free reign to the scientists on how the data is used and published. Industry funding, on the other hand, have simpler applications but more control of the data which remains their property. Most importantly, industry insist on the final veto on whether or not the results are published.

45.4.3 Confirmation Bias

Confirmation bias is one of the shortcomings of science because the human mind is bad at seeing things it did not expect to see and a bit too eager to see what it expected to see. It is basically seeing what you want to see and ignoring everything else. In essence, confirmation bias is when you filter reality through biases by eagerly accepting evidence that confirms what you believe and ignoring evidence that refutes or challenges what you believe. Once we adopt a particular hypothesis or interpretation, we find it difficult to see things any other way. People will accept any explanation as long as it fits with their own understanding of the facts.

45.4.4 Cognitive Dissonance

Cognitive dissonance is another impediment to scientific progress that affects many people. It is simply a feeling of discomfort that people experience when presented with information that is inconsistent with their beliefs. When we are confronted with evidence that challenges our deeply held beliefs, we are more likely to reframe the evidence than we are to alter our beliefs. In most cases, instead of acknowledging an error in judgement, people tend to reformulate their views in a way that justifies their old opinions. We simply invent new reasons, new justifications, or new explanations or ignore it altogether. Some people go to absurd lengths to justify their beliefs or judgement even when confronted with clear contrary evidence. The more committed we are to a certain opinion, the less likely we are to relinquish it, even when confronted with massive or overwhelming contradictory evidence. As an example, the introduction of microvascular venous couplers in microsurgery was developed by those who could see the obvious benefits of speed and patency of the anastomosis, and yet was resisted by those who felt the skill of micro-suturing tiny veins would be lost, regardless of the benefits of reduced thrombosis and improved flap survival.

45.5 Publishing

Research cannot thrive without publishing. All research projects are conceived with publication as the end game. The excessively competitive field of research creates a tendency to rush to conclusions and publish results that have not been properly validated. Valid conclusions can only be drawn from reproducible data sets because results that initially look promising aren’t always repeatable. It is little wonder that remarkably few published breakthroughs have ever led to any useful treatments.

There are numerous media that researchers can use to propagate their experimental findings which are discussed below.

45.5.1 Electronic Media

Digital technology has not only transformed but has revolutionized the way we live. The merger of the personal computer and the Internet allowed networking to blossom on a massive scale, and so surgeons and scientist are not wholly reliant on print media to propagate their ideas. Websites like ResearchGate encourage scientists and clinicians to upload their research, both published and unpublished, onto a digital platform for all to see and to foster collaboration between research groups across the world.

Digital media platforms like YouTube are fast becoming a quick, easy and virtually cost-free way of publishing your novel ideas and surgical techniques on the Internet for all to see. More and more Surgeons are bypassing the heavily fortified realm of print media for the highly accessible digital media which not only offers a global audience but also facilitates immediate upload of content with virtually no delay. The disadvantage is of course the lack of scrutiny which suggests the content has not been vetted by experts. Hence, the scientific value of the video post is virtually zero. While you may have a wide audience, it may not necessarily be the people you want to impress.

45.5.2 Magazines

Glossy magazines that specifically target general medical/dental practitioners are supported by lots of industry advertising which is interspersed with clinical articles that have not been peer-reviewed, but rather submitted on the invitation of the magazine editor. The articles, which often have more clinical pictures than text, are written by clinicians and academics as a general interest piece that provides the reader with an update of what is current clinical practice that is aimed at the non-specialist practicing clinician. Authors are generally paid for their contributions. These articles are of little value to the specialist trainee or clinician wanting to find out more about their own specialty.

45.5.3 Textbooks

Textbooks contain information that is current practice and accepted by the profession. Unfortunately, by the time a textbook is commissioned, written, published and finally released, the information is often about 2 years out of date. Therefore, the strength of textbooks is in the basic principle of surgical practice, and the weakness lies in the distinct lack of new information. Digital technology is gradually changing the need for printed textbooks as students are gravitating to knowledge that is presented in discrete digital packages with hyperlinks that cross-reference important concepts similar to “Wikipedia”. While university and hospital libraries still purchase textbooks for student consumption, today’s students are finding the expense of textbooks prohibitive and so seek other means of accessing surgical information and knowledge through the Internet, which is often up to date as long as they know what to look for and are able to critically evaluate the credibility of the information source.

45.5.4 Peer-Reviewed Journals

There are over 1 million academic papers published every year in over 24,000 academic journals where gaps in our knowledge are discussed and new experiments are conducted that might resolve these gaps. Unfortunately, published scientific papers tend to be biased towards reporting positive results. Negative results do not make headlines so they are rarely published. Publication in a journal is not a mark of truth but merely that the research has passed a certain standard that warrants entering the formal literature and further discussion.

Scientific journals sell scholarship back to the same universities whose scientists had produced, written, peer reviewed and edited largely for free. Hence the cost of producing scientific journals is kept as low as possible in order to facilitate as wide a distribution as possible. Unlike magazines, peer-reviewed journals with few exceptions keep industry advertising to a minimum as they are supposed to be impartial to avoid conflict of interest when reporting studies that may conflict with the interests of a big advertiser.

Peer-reviewed journals are the platform we use to announce new discoveries, to comment on or criticize the discovery of others and to synthesize and seek to build consensus about what is known. In Oral and Maxillofacial Surgery, case reports and technical notes account for about one-third of journal publications, while less than one in ten are randomized control (Level 2 evidence) or non-randomized control (Level 3 evidence) studies (Table 45.2). Because of the difficulty in performing high-level randomized control trials in surgery, Surgeons are more accepting of lower-level evidence which is based on observation. Indeed, it is unlikely to extract any high-level evidence research from surgical departments who rely on surgical trainees for their research output.

Table 45.2 Levels of evidence (Oxford Centre for Evidence-Based Medicine)

<i>Level 1: Randomized control trials (RCT)</i>
High-quality, properly powered and conducted studies with reduced bias when double blinded and multicentred
<i>Level 2: Cohort clinical studies</i>
Prospective, comparative clinical study without randomization
<i>Level 3: Case-controlled studies</i>
Retrospective clinical study
<i>Level 4: Case series studies</i>
Cross-sectional study (clinical audit) with or without intervention
<i>Level 5: Case-based reasoning</i>
Includes case reports, expert opinions and bench research

Note: The strength of systematic reviews and meta-analysis depends on the evidence levels of the papers being reviewed. If all the papers are Level 3 evidence, the systematic review will also be Level 3 evidence

Table 45.3 Factors to consider in the design of a clinical study

1. Where is the study being conducted? (field, hospital, clinic, laboratory, etc.)
2. Are there ethical issues? (animal or human studies)
3. Define your study groups or variables being investigated
4. Selection criteria (inclusion/exclusion)
5. Are there matched controls?
6. Describe the surgical or technical details
7. Method of data collection (randomized or blinded)
8. Method of data handling (statistical method)

Table 45.4 Criteria for a good surgical manuscript

1. Short, succinct title
2. Original ideas with practical or pragmatic applications
3. Clear purpose/aim(s)
4. Good grammar—clear and concise wording/short sentences
5. Methods described in adequate detail to allow independent verification
6. Results set out in clearly labelled tables, graphs, figures, photos, diagrams
7. Focused discussion with balanced literature that both support and refute results
8. The most recent references that adequately support discussion
9. Conclusion supported by the results of the study

Table 45.5 Anatomy of a poor surgical manuscript

1. Long, convoluted and ambiguous title
2. Wild, unusual, unethical or dangerous ideas of little practical value
3. No clear aims or purpose stated
4. Plagiarism and duplication (study previously published elsewhere under different title)
5. Poor grammar—incorrect wording/long convoluted sentences/emotive language
6. Methods inadequately or poorly described that cannot be repeated
7. No data, tables, figures, graphs, photos or diagrams provided
8. Convoluted discussion without clear direction and biased to supportive literature
9. Old or antiquated references
10. Conclusion not supported by the results of the study

All journals subscribe to the IMRD layout which means all submissions must have an Introduction, Methods, Results and Discussion sections. The introduction builds the case for why you pursued the line of research and the final sentence is always the statement of the aim(s) of your study. The Methods section describes how the study was performed in terms of setting (e.g. Hospital or Laboratory), subjects (i.e. animals or humans), recruitment (e.g. inclusion/exclusion criteria), data collection (e.g. Surveys, measurements), variables being compared (experimental vs. control) and data analysis (statistics used) (Table 45.3). The Results section simply states the summary of the outcomes as depicted in the tables and graphs, while the Discussion critically analyses and compares the results in light of what has already been previously published on the topic. The discussion must include references that both agree and disagree with your findings so that a balanced argument can be presented which will add weight to the study.

Table 45.6 Guidelines for formatting papers for publication

1.	Randomized control studies:	www.consort-statement.org
2.	Observational studies:	www.strobe-statement.org
3.	Systematic reviews:	www.prisma-statement.org
4.	Case series:	www.processguideline.com
5.	Case reports:	www.scareguideline.com

The final paragraph in the discussion is a summary of the research results with mention of any practical clinical applications that may arise from the study.

Authors must keep in mind that originality and a clear message are essential in getting their papers published in the highly competitive world of scientific journal publishing (Table 45.4). The high impact factor journals generally attract articles with high evidence levels so it is imperative to select a journal that caters to the subject and evidence levels of your particular study to avoid rejection and delays in publication of your paper. Original contributions that add new information to the existing body of knowledge are more likely to be considered for publication. However, wild or fanciful ideas are unlikely to garner support from journal editors who are looking for papers that lend respectability to their journal.

Unlike works of fiction, good scientific communication is based on clear and concise wording with short titles and tightly controlled sentences that describe complex ideas in the simplest language possible. Poor grammar, emotive language and long-winded descriptive wording must be avoided so that the ideas being conveyed are not buried in a convoluted tangle of discourse (Table 45.5). When evaluating the importance and relevance of published articles, surgeons and scientists look for the facts, not fancy prose.

To improve the acceptability of your paper for publication in a peer-reviewed journal, there are general guidelines available online that help you set out your paper in a format that is recognized and accepted throughout the world (Table 45.6). By following the guidelines, you improve the chances of your paper being accepted for publication. For instance, if you want to submit an observational case cohort study, then the “STROBE” statement will guide you in how to properly format your paper. If it is a case report then it is worth checking out the “SCARE” guidelines. Alternatively, if you want to undertake a systematic review of a topic, the “PRISMA” statement is essential.

45.6 Conclusion

In Surgery there is no greater accomplishment than being the first to successfully implement a successful treatment that changes the history of medicine. However, the person with the first idea is usually not the one recognized by history. Credit often goes to the person who convinces the world, not to the one with the original idea, because the credibility of all new ideas requires convincing evidence. If you make a claim

about something, you provide the evidence, or at least a reference to the evidence that backs your claim. Research is the essential tool that builds the evidence which provides a better understanding of how and why things worked or failed. Good surgical practice must be based on evidence.

Surgical innovation is a constant work in progress because any new ideas or techniques are quickly supplanted by an even better ideas and techniques. Gaps in the literature are what fuel research, and the journey of discovery is paved with potholes that need to be filled. To paraphrase the great scientist Sir Isaac Newton, if you want to see further than anyone else has seen before, you need to stand on the shoulders of giants. Your voyage of discovery begins once you have secured your footing on the shoulders of the surgeons and scientists who have gone before you, so you can see the path they have built for you to follow.

Further Reading

- Dimitroulis G. EDITORIAL – Getting published in peer-reviewed journals. *Int J Oral Maxillofac Surg.* 2011;40:1342–5.
- Dimitroulis G. EDITORIAL – Research – why bother? *Int J Oral Maxillofac Surg.* 2011;40:1346.
- Hardicre J. An overview of research ethics and learning from the past. *Br J Nurs.* 2014;23:483–6.
- Knottnerus JA, Tugwell P. EDITORIAL – Evidence-based medicine: achievements and prospects. *J Clin Epidemiol.* 2017;84:1–2.
- Lau SL, Samman N. Levels of evidence and journal impact factor in Oral & Maxillofacial Surgery. *Int J Oral Maxillofac Surg.* 2007;36:1–5.
- Mohan M, Shetty D, Shetty T, Pandyak K. Rising from plagiarising. *J Maxillofac Oral Surg.* 2015;14:538–40.
- Sollaci LB, Pereira MG. The introduction, methods, results, discussion (IMRAD) structure: a fifty year survey. *J Med Libr Assoc.* 2004;92:364–7.
- Szklo M. Impact factor: good reasons for concern. *Epidemiology.* 2008;19:369.

Open Access This chapter is licensed under the terms of the Creative Commons Attribution 4.0 International License (<http://creativecommons.org/licenses/by/4.0/>), which permits use, sharing, adaptation, distribution and reproduction in any medium or format, as long as you give appropriate credit to the original author(s) and the source, provide a link to the Creative Commons license and indicate if changes were made.

The images or other third party material in this chapter are included in the chapter's Creative Commons license, unless indicated otherwise in a credit line to the material. If material is not included in the chapter's Creative Commons license and your intended use is not permitted by statutory regulation or exceeds the permitted use, you will need to obtain permission directly from the copyright holder.



Part XV

Salivary Gland Pathologies

46.1 Introduction

The salivary glands secrete saliva which has lubricating, immunologic, digestive, and cleansing functions. They are affected by systemic and local inflammatory conditions, obstructive pathologies, as well as neoplasms. Most of the tumors are parenchymal in origin, whereas few could be interstitial. Majority of tumors affecting major glands are benign, but those affecting minor salivary glands are more often than not, malignant. The disorders that involve these glands can either be acute or chronic inflammatory lesions, congenital abnormalities, systemic disorders, or benign and malignant tumors. However the most, common disorders affecting salivary glands are tumors and infections.

46.2 Surgical Anatomy

46.2.1 Parotid Gland

The gland lies in the retromandibular fossa bound medially by the styloid process and superiorly by external acoustic meatus and mastoid process, and it touches the medial pterygoid muscle and mandibular ramus (Fig. 46.1). A part of the gland may also cover the TMJ in front of the ear but never extends beyond the zygomatic arch. The parotid capsule is a dense, adherent fibrous condensation of deep cervical fascia which is tough and unyielding. Hence parotid space infections show minimal swelling but are severely painful. Incision and drainage is needed early on, without a frank fluctuant abscess to relieve the pressure within the capsule to

prevent pressure necrosis of the parenchyma. Due to weakness in the capsule covering the deep surface of the gland, parotid abscess may spread into the lateral pharyngeal space, if not drained promptly [1]. Benign tumors grow slowly and hence take a longer time to manifest as external bulges. Parotid gland has a superficial lobe (80%) and a deep lobe (20%) connected by an isthmus with the facial nerve passing between the two lobes.

The facial nerve is related to the parotid gland in a number of ways [2].

1. (a) Superficial and deep lobes are united above, so that the gland is essentially folded over the nerve.
(b) An isthmus uniting the two lobes.
(c) Combination of (a) and (b)
2. The gland and nerve can also lie intertwined within superficial and deep lobes; relation will vary according to plane of section.

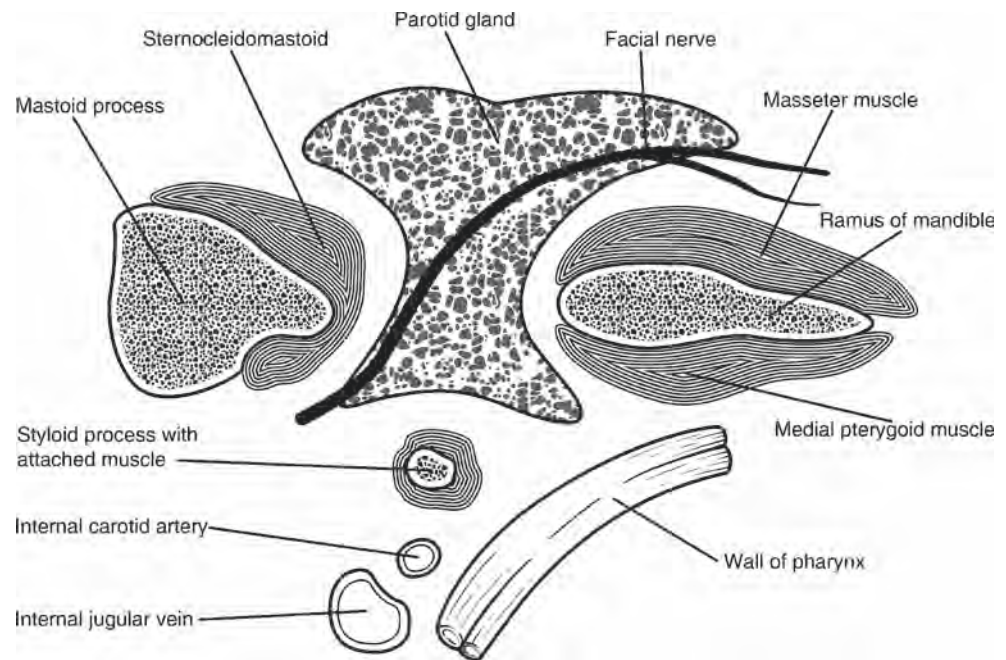
The intratemporal and intraparotid facial nerve has varied pattern of branching which is of immense surgical importance and might show bifurcation and trifurcation of the main trunk within the mastoid segment (Fig. 46.2). This intratemporal division of the facial nerve is associated with congenital abnormalities of the pinna or inner ear (Table 46.1).

Parotid duct or the Stensen's duct crosses the masseter about a finger breadth below the zygomatic arch. It then takes a sharp turn medially at the anterior border of the masseter further traversing through the buccal fat pad and buccinator muscle. It then runs obliquely between the buccinator and oral mucosa to open on the parotid papilla, opposite the second maxillary molar. The obliquity of the duct in between the buccinator and mucosa acts like a valve to prevent inflation of the duct while blowing air. The duct lies between the upper and lower buccal branches of the facial nerve. Its caliber is about 3 mm, but at the point where it penetrates the buccinator muscle, an isthmus narrows down the duct to 1.2 mm, and at the orifice (ostium), it is 0.5 mm.

Electronic Supplementary Material The online version of this chapter (https://doi.org/10.1007/978-981-15-1346-6_46) contains supplementary material, which is available to authorized users.

N. A. Agni (✉)
Department of Oral and Maxillofacial Surgery, SMBT Institute of Dental Sciences and Research, Nashik, India

Fig. 46.1 Transverse section of parotid gland



©Association of Oral and Maxillofacial Surgeons of India

Structures traversing the parotid gland from lateral to medial (superficial to deep) include the facial nerve, retro-mandibular vein, and external carotid artery. Few parotid lymph nodes are also present within the gland.

Parasympathetic secretomotor fibers from the inferior salivary nucleus of the ninth cranial nerve supply the gland. Nerve fibers pass to the otic ganglion via the tympanic branch of the glossopharyngeal nerve and the lesser petrosal nerve. Postganglionic parasympathetic fibers reach the parotid gland via the auriculotemporal nerve, which lies in contact with the deep surface of the gland. Postganglionic sympathetic fibers reach the gland as a plexus of nerves around the external carotid artery [4].

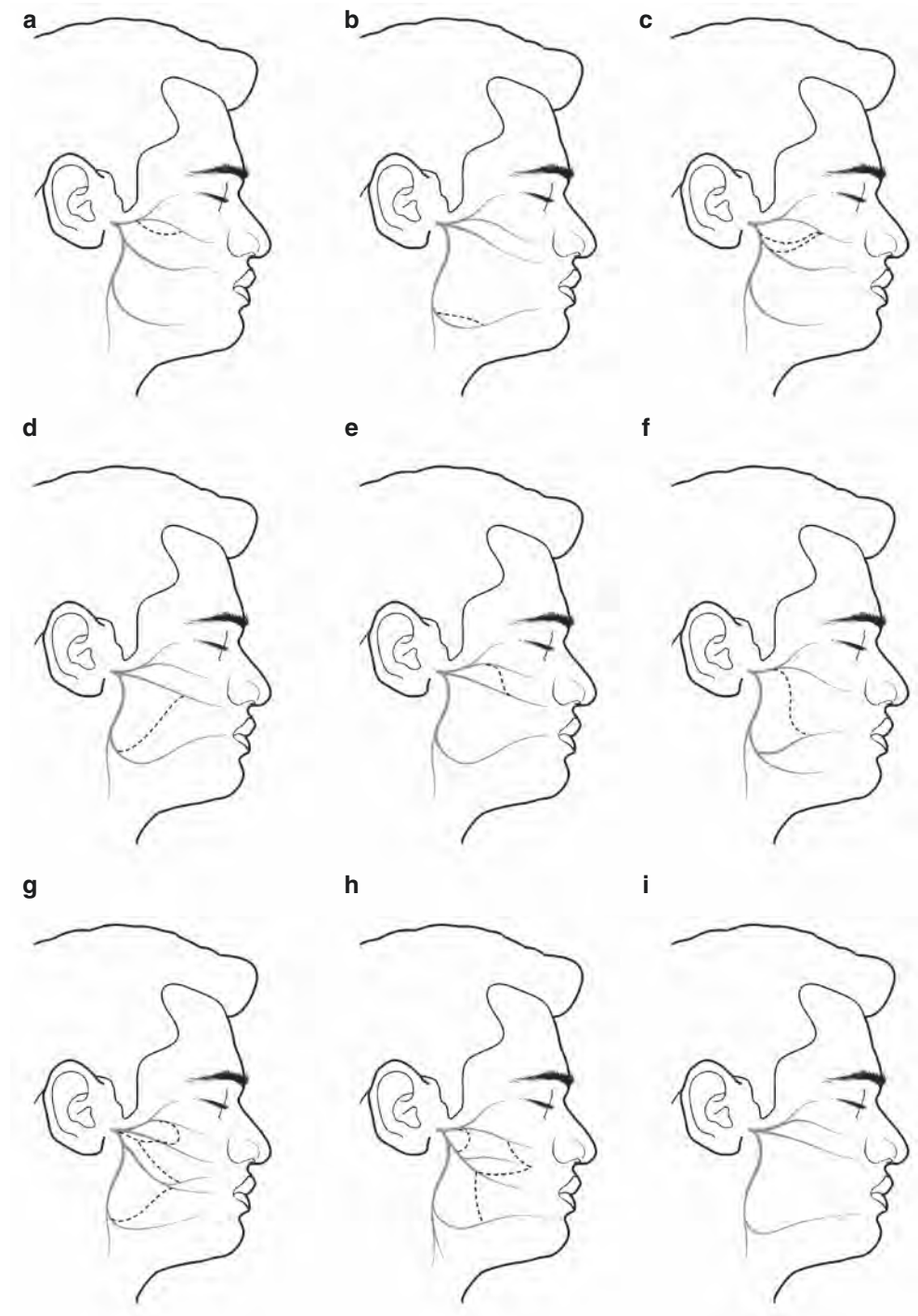
46.2.1.1 Identification of the Facial Nerve [5, 6]

The facial nerve identification can be done either proximally or distally. Proximally the main trunk of the nerve is identified before it enters the gland. Distally it is identified as branches after the nerve leaves the gland (Table 46.2).

There are four facial nerve pointers at the stylomastoid foramen. However more techniques have been added later on by various authors. They are as follows:

1. The cartilaginous pointer of Conley (1978) is created at its anterior inferior border and is the least reliable one. The backward pull on the cartilage causes the meatus to assume the shape of a horn, the curved extremity of which allegedly points to the position of the facial nerve. The nerve is located medial and inferior to the pointer (Fig. 46.3).
2. A short segment of the facial nerve lies in between the stylomastoid foramen and parotid gland and is an ideal location to identify it. It can be located in the tympanomastoid sulcus which is formed by the edge of the bony external meatus and anterior face of the mastoid process. The nerve emerges from the stylomastoid foramen some 3–4 mm deep to the outer edge of the bony external canal. The tympanomastoid sulcus is filled with fibrofatty lobules that mimic the facial nerve trunk which may lie as deep as 1 cm to this landmark.
3. The anterior superior aspect of the posterior belly of the digastric muscle is inserted just behind the stylomastoid foramen. The posterior belly of the digastric muscle lies just inferior to the nerve and is the most reliable landmark to identify the nerve (Fig. 46.4).
4. The styloid process is a confirmatory landmark. The facial nerve lies lateral to the styloid process near the styloid base. The posterior auricular artery bleeds frequently while looking for the facial nerve since it lies below and just lateral to the nerve, and hence it cannot be relied upon for identification of the nerve.
5. Borle's triangle has been recently introduced to locate the facial nerve trunk. Lines are drawn from the tip of the mastoid process, running along the superior border of the posterior belly of digastric muscle and posterior border of the ramus of the mandible. These two lines intersect with each other anteriorly, forming the apex of the triangle (angle a). The base of the triangle is marked by drawing the third line starting from the tip of the mastoid process (angle b), running anteriorly till it joins

Fig. 46.2 (a)–(i) Katz-Catalano classification based on operative findings



©Association of Oral and Maxillofacial Surgeons of India

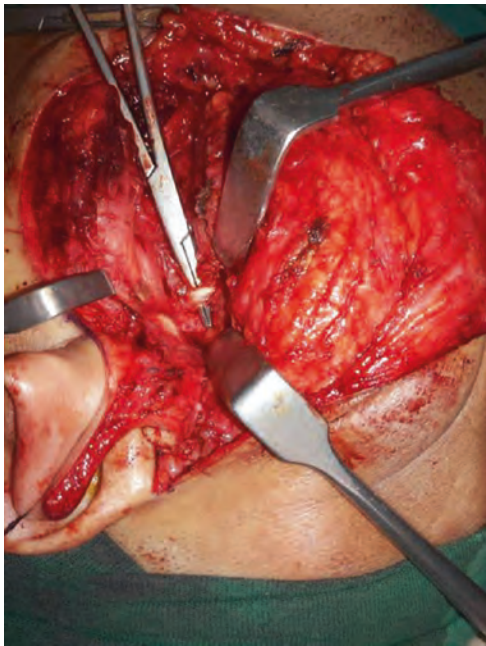
Table 46.1 Katz-Catalano classification

Type 1	25%	Branches are separate
Type 2	14%	Buccal branch fuses with zygomatic branch
Type 3	44%	Major communicating, buccal, and other branches
Type 4	14%	Complex branching between all branches
Type 5	3%	More than one major trunk

Katz and Catalano [3], 1987

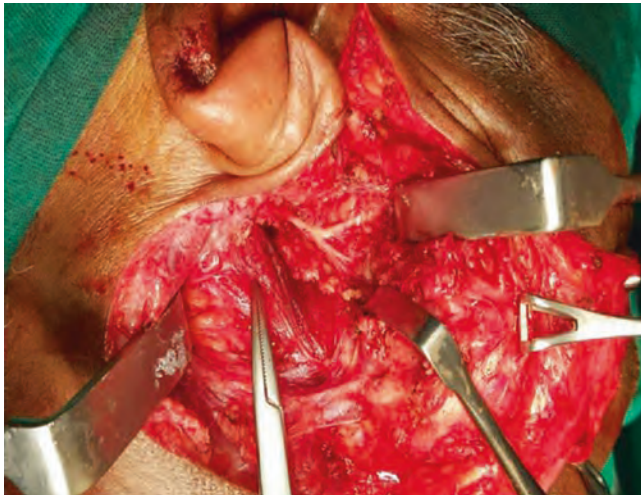
Table 46.2 Facial nerve identification

1	Anterograde approach—Direct identification of main trunk at stylomastoid foramen
2	Retrograde approach—Early identification of mandibular branch over posterior facial vein or other branches along the parotid duct
3	Supravital staining of parotid—gland is stained blue, tumor is unstained, and facial nerve is gleaming white



©Association of Oral and Maxillofacial Surgeons of India

Fig. 46.3 Showing relation of cartilaginous pointer and facial nerve main trunk



©Association of Oral and Maxillofacial Surgeons of India

Fig. 46.4 Showing relation of the posterior belly of the digastric muscle and main trunk of the facial nerve (muscle pointed by mosquito forceps)

the second drawn line along the posterior border of the ramus (angle c). The facial nerve trunk is often found within this triangle just above the angle b formed by the first and the third line if gentle and blunt dissection is carried out at this point. The mean distance of nerve trunk from the angle b is 12.18 ± 2 mm within a range of 9–15 mm [7] [Fig. 46.5—<https://www.ncbi.nlm.nih.gov/pmc/articles/PMC6126203/>. doi: <https://doi.org/10.1016/j.jobcr.2018.08.004>. (open access)].

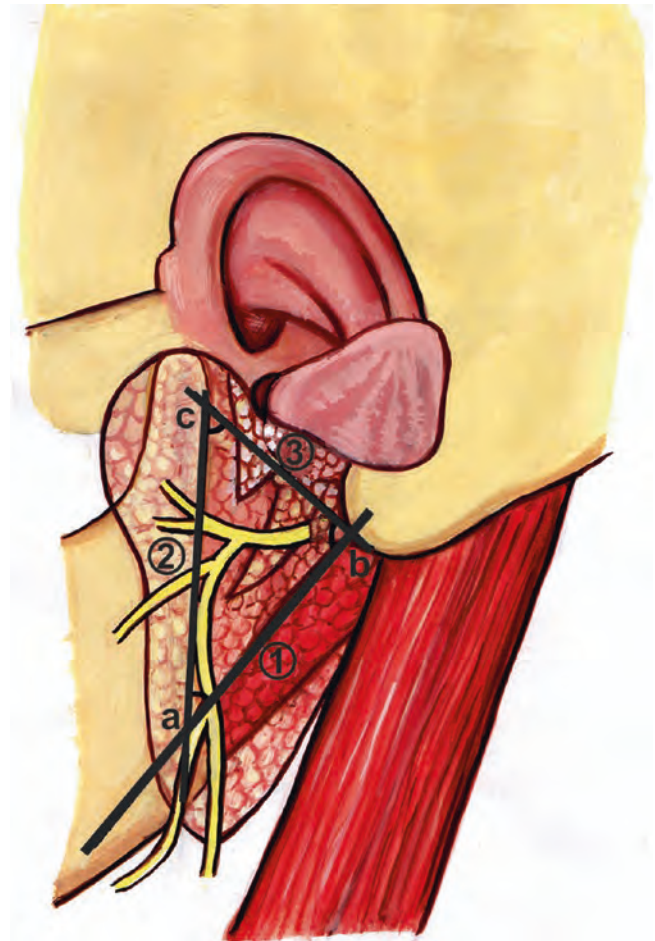


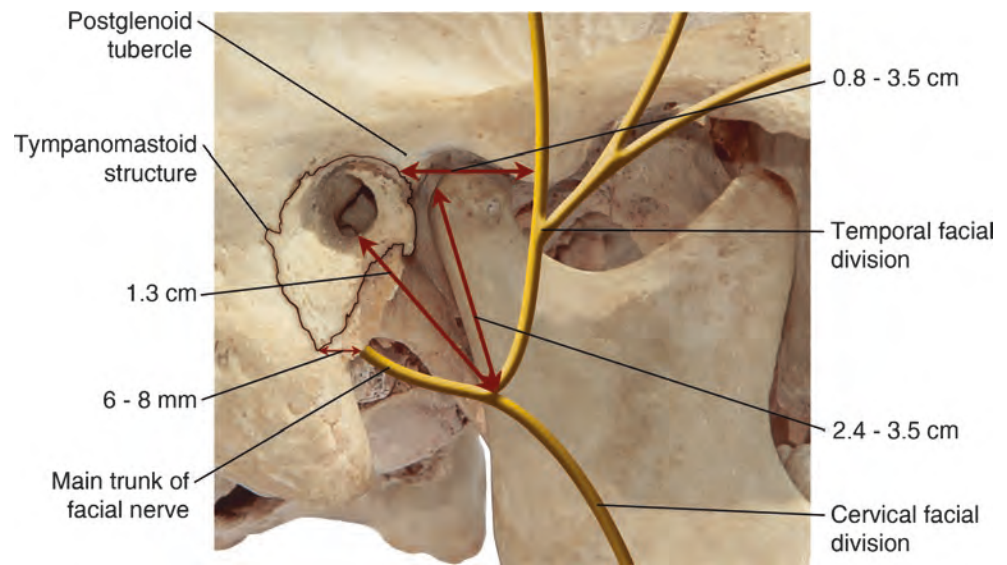
Fig. 46.5 Borle's triangle. Line 1: Started from mastoid process tip and running along the superior border of posterior belly of the digastric muscle. Line 2: At the posterior border of ramus of the mandible. Line 3: Starts from the tip of the mastoid process running anteriorly till it joins the second line. Angle a: Lines 1 and 2 intersect with each other forming the apex of triangle. Angle b: Is the base of the triangle. Angle c: Is the angle where third line meets second line

When identification of facial nerve trunk is difficult using the above said pointers due to distorted anatomy due to the tumor, a retrograde approach can be used by identifying a peripheral branch of the nerve and tracing it proximally. The easiest branch to locate is the marginal mandibular nerve. Baker et al. have reported that the marginal mandibular nerve is located 1–2 cm below the inferior border of the mandible. The marginal mandibular branch can be used to trace the facial nerve in a retrograde direction by identifying it at the point of emergence of the retromandibular vein and then carrying out a proximal dissection. By working backward along the nerve, the two divisions, the other branches, and the main trunk can be found [8].

Figure 46.6 represents the average distance of facial nerve pointers from the surrounding landmarks (Table 46.3).

Intraoperative facial nerve monitoring using electromyographic techniques can also be used for identification of the main branch or the peripheral branches in centripetal or retrograde approach. In pediatric population the facial nerve trunk

Fig. 46.6 Distance from facial nerve pointers



©Association of Oral and Maxillofacial Surgeons of India

Table 46.3 Distance of the facial nerve pointers from the surrounding landmarks [10]

Sr. no.	Pointer	Distance in mm	Mean in mm
1	Tragal pointer	24.3–49.2	34
2	Posterior belly of the digastric muscle	9.7–24.3	14.6
3	External auditory canal	7.3–21.9	13.4
4	Tympanomastoid suture	4.9–18.6	10.0
5	Styloid process	4.3–18.6	9.7
6	Transverse process of axis	9.7–36.8	16.9
7	Angle of the mandible	25.3–48.69	38.1

exits the stylomastoid foramen and is found approximately 1 cm anterior to mastoid process and 1.5 cm posterior to the ramus of the mandible. The parotid does not extend posterior to the ramus of the mandible in the newborn infant and consequently covers only the lower distal branches of the nerve [9].

46.2.1.2 Facial Nerve Monitoring

There are two types of facial nerve monitoring:

- Electromyography
- Pressure or strain gauge sensor

Facial nerve monitoring is performed with a nerve stimulator which can either be monopolar or bipolar. The monopolar stimulator is more useful for identifying the nerve, while the bipolar is more useful if the nerve course is evident. However, a bipolar stimulator is more precise.

46.2.2 Submandibular Glands

It is a U-shaped gland with a smaller deep lobe and larger superficial lobe enveloping the mylohyoid muscle. Hence

during surgical removal, the mylohyoid has to be retracted anteriorly to expose the deep lobe and the Wharton's duct. The capsule is loosely attached to the gland substance, and hence the gland can be shelled out easily.

Since the submandibular group of lymph nodes are in contact with the gland or embedded in it, it is essential to clear the nodes along with the gland during a neck dissection.

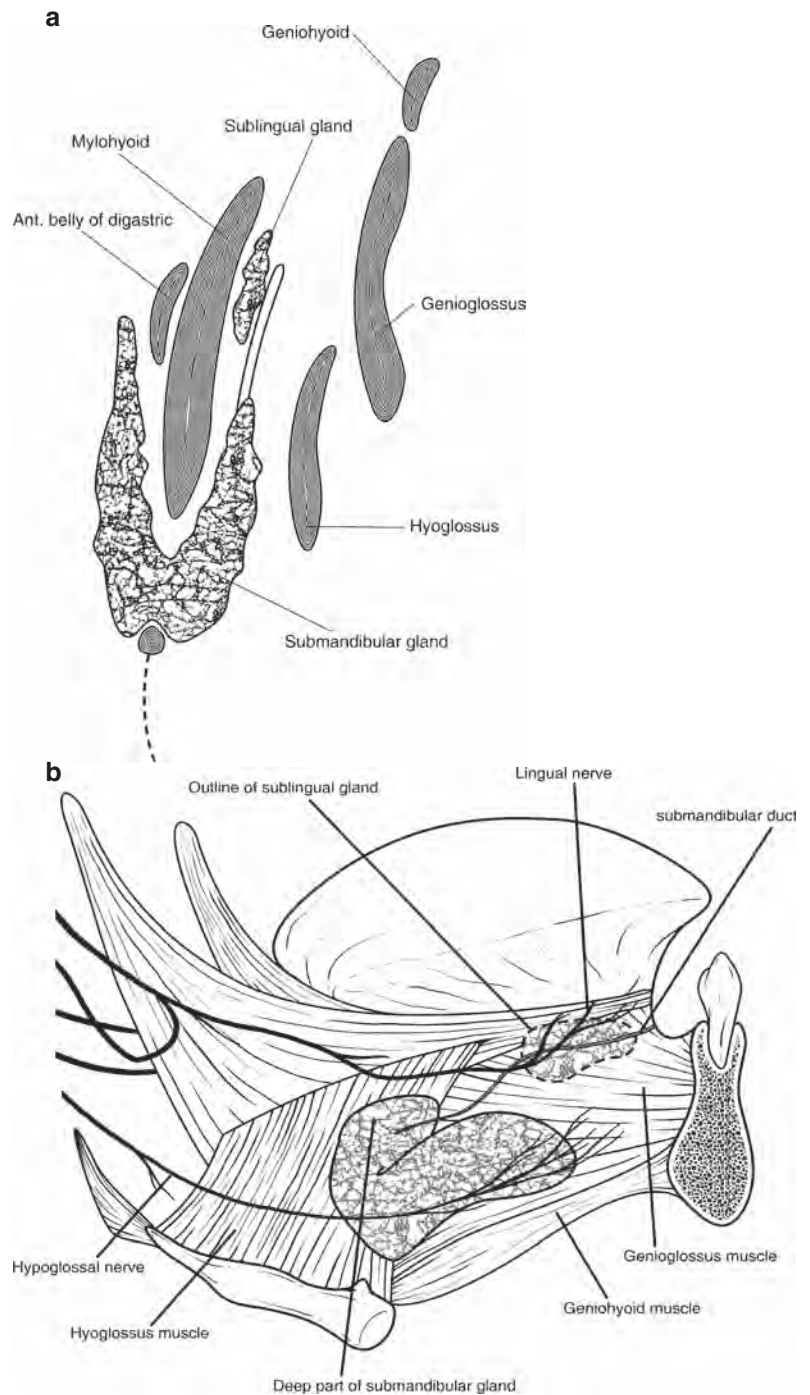
The facial artery loops around the submandibular gland. The facial artery is visualized by retracting the posterior belly of the digastric muscle inferiorly. Hence, during excision of the submandibular gland, the facial artery and vein were customarily ligated. However, during neck dissection, the current standard is to try and save it so that it can be used for anastomosis during a free flap reconstruction.

The facial artery is ligated away from the external carotid artery, so that in case the vessel retracts into the tissue, it can be located and religated and bleeding can be controlled. In case the ligature slips and the facial artery retracts, the posterior belly of the digastric muscle is divided for easy location of the bleeding vessel.

The lingual nerve passes below the duct and forms a loop around its outer aspect before inserting into the tongue mucosa. It is at risk when the deep part of the gland is being mobilized. The submandibular duct or Wharton's duct is longer and has a tortuous, uphill course. Thus the secretions have to be emptied against gravity, and there are increased chances of retention. Also, the mineral content of the secretion is high, especially calcium content which along with increased retention of secretions results into higher incidence of calculus formation and inflammatory pathologies in the submandibular gland and duct.

Figure 46.7a, b shows the relations of the submandibular gland.

Fig. 46.7 (a, b) Relations of submandibular gland



©Association of Oral and Maxillofacial Surgeons of India

46.2.3 Sublingual Glands

They are located beneath the mucosa of the floor of the mouth and appear as an elevation in the floor of the mouth. The excretory ducts of the sublingual glands are very superficially located and open in the floor of mouth at a superior

level than the gland. Hence, they easily get damaged, and any trauma or infection of the ducts leads to salivary retention and formation of a mucous retention cyst which is called “ranula” due to its bluish color resembling the belly of a frog. The international statistical classification of diseases and related health problems shown in Table 46.4.

Table 46.4 International statistical classification of diseases and related health problems

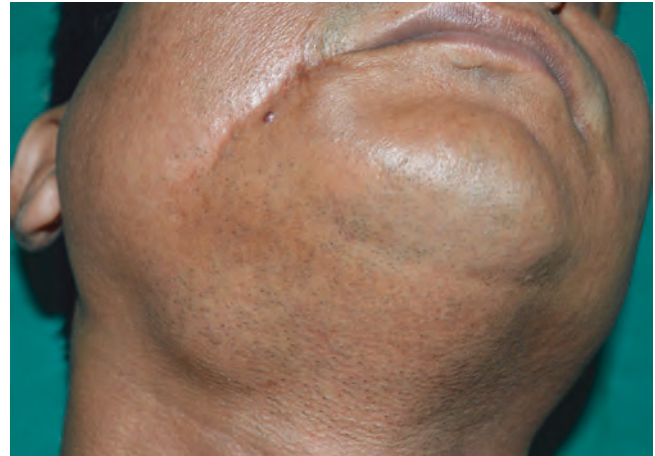K 11	Diseases of salivary glands
K 11.0	Atrophy of the salivary gland
K 11.1	Hypertrophy of the salivary gland
K 11.2	Sialadenitis
	Excludes epidemic parotitis and uveoparotid fever
K 11.3	Abscess of the salivary gland
K 11.4	Fistula of the salivary gland
	Excludes congenital fistula of the salivary gland
K 11.5	Sialolithiasis
	Calculus/stone of salivary gland or duct
K 11.6	Mucocele
	Mucous extravasation cyst/retention cyst
	Ranula
K 11.7	Disturbances of salivary secretion
	Hypoptyalism
	Ptyalism
	Xerostomia
	Excludes dry mouth NOS
K 11.8	Other diseases of the salivary glands
	Benign lymphoepithelial lesion of the salivary gland
	Mikulicz' disease
	Necrotizing sialometaplasia
	Sialectasia
	Stenosis/strictures of salivary ducts
	Excludes Sicca syndrome (Sjögren's syndrome)
K 11.9	Diseases of the salivary glands unspecified
	Sialoadenopathy NOS

10th Revision (Version for 2003) [11]

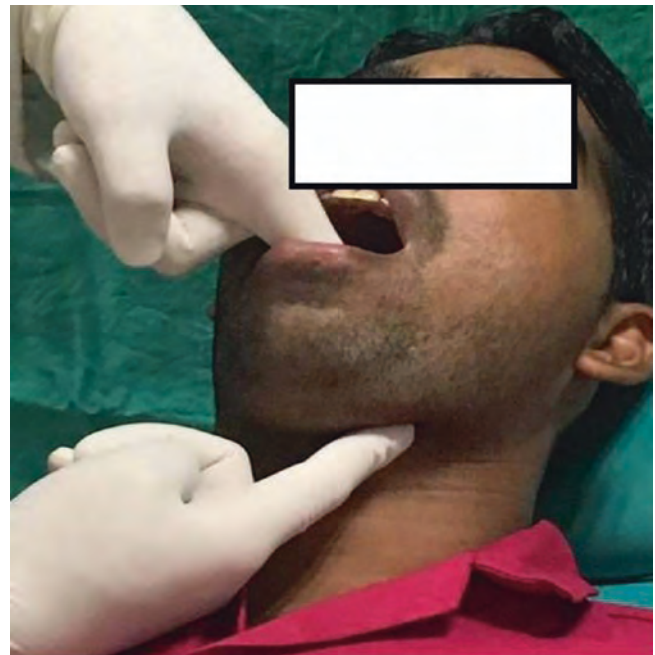46.3 Diagnosis and Diagnostic Aids

A thorough history followed by meticulous examination holds the key to proper diagnosis of salivary gland pathologies. Salivary gland neoplasms are usually slow growing and non-tender. A slow-growing swelling of the salivary gland is suggestive of a neoplasm, whereas a sudden, painful swelling is suggestive of an infective pathology although it can sometimes indicate a malignant tumor with secondary infection. Nerve weakness and skin infiltration are always associated with malignant tumors which have already infiltrated the nerve or skin although the vice versa is not always true.

Major salivary glands are palpated, and secretions milked out to check flow, quantity, and quality of secretion. A turbid salivary discharge may indicate an infection, whereas reduced salivary flow could indicate either less secretion or obstruction to flow. Function of facial nerve should be checked and documented during parotid examination. On inspection submandibular gland swelling can be easily identified and compared with the contralateral side; however the submandibular glands are bimanually palpated (Figs. 46.8 and 46.9).



©Association of Oral and Maxillofacial Surgeons of India

Fig. 46.8 Clinical photo showing submandibular gland enlargement, right side

©Association of Oral and Maxillofacial Surgeons of India

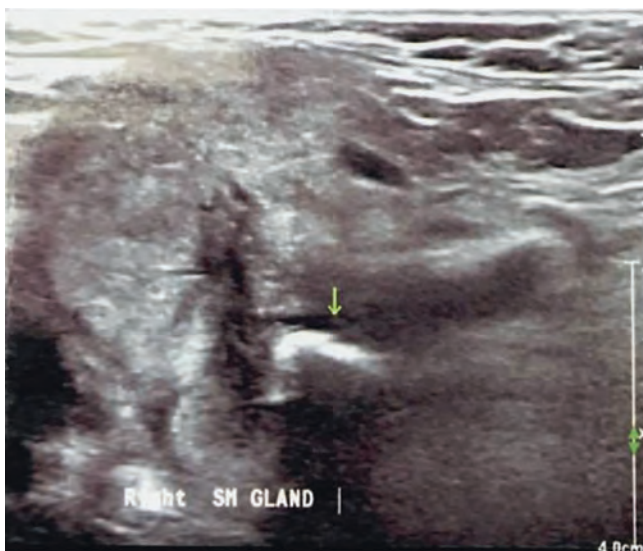
Fig. 46.9 Bimanual palpation

Various diagnostic aids for investigating salivary gland diseases are as follows:

1. Diagnostic imaging

- (a) Routine radiographs: It is useful only for diagnosing sialoliths and parenchymal calcifications. Radiopaque salivary calculi in the gland or duct can be picked up on plain films such as occlusal X-ray for submandibular gland and duct and a posteroanterior (PA) skull with blown-out cheeks for parotid calculi.

- (b) **Ultrasonography:** Ultrasonography (USG) is a noninvasive modality that utilizes non-ionizing radiation, gives good soft tissue discrimination, has excellent sensitivity for mass lesions, and can be repeated as frequently as required. Normal gland is relatively homogeneously hyperechoic than adjacent muscle, and so is cyst and tumor from parenchyma [12, 13]. It helps to distinguish a cystic lesion from a solid mass in space-occupying lesion (Fig. 46.10). USG with color Doppler is useful to rule out vascular lesions and also aids in assessing vascularity of lesions.
- (c) **Sialography:** It assesses obstructive pathology by instillation of radiopaque contrast medium to locate obstruction in the ductal system. The technique is more or less obsolete now with the advent of MRI imaging. It is a technique which involves injection of a radiopaque dye into the ductal system of the major salivary glands and taking plain X-rays to see the pattern of the dye into the ductal systems. Most commonly the contrast dyes used are iodine based. They can either be lyophilic (oil based) or aqueous (water based or water soluble). Lyophilic (oil-based) contrast dyes include Lipiodol (iodized poppy seed oil) and Pantopaque (organic iodine compound). Aqueous contrast dyes include iothalamate (Conray) and metrizoate (Triosil). Aqueous-based dyes are most commonly preferred. Sialography is indicated to diagnose obstructive pathologies and duct anomalies, degenerative changes in the gland, chronic inflammatory conditions, and intra- and extraglandular tumors. It is contraindicated in acute infections of the gland and in case of allergies to the dye.



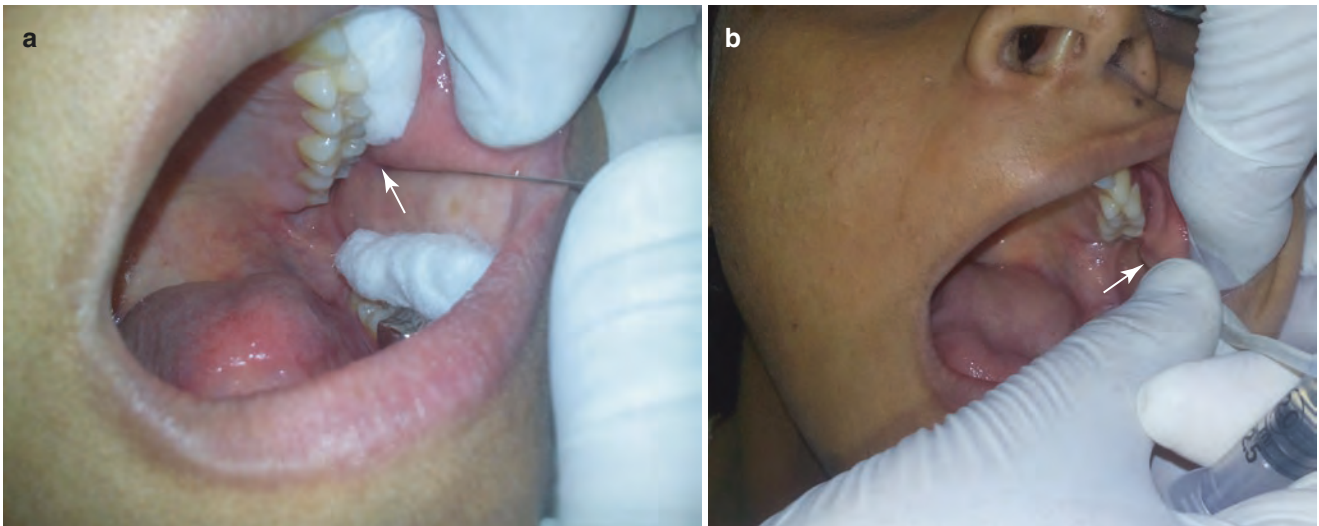
©Association of Oral and Maxillofacial Surgeons of India

Fig. 46.10 USG of submandibular gland

Procedure: The duct orifice is enlarged using a lacrimal probe and cannulated with a 22 gauge cannula after infiltrating local anesthetic (Fig. 46.11a, b). The selected dye is injected into the ductal system using a Luer lock syringe with gentle continuous pressure with simultaneous massage of the gland. Once the patient feels some discomfort, dye injection is stopped. X-rays are taken during the filling phase and emptying phase as well.

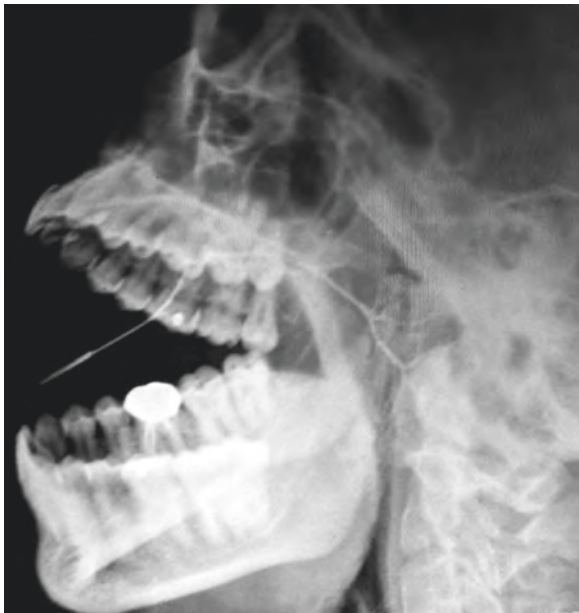The X-rays show different patterns:

- (i) The normal parotid gland shows “tree in winter” or “leafless tree” pattern, and submandibular gland shows “bush in winter” appearance. This is because the normal acini do not allow dye to enter and it is seen only in the ducts and ductules (Fig. 46.12—normal sialography: leafless tree).
 - (ii) In chronic inflammation the dye enters the ductules, and the empty acini give a “blossom tree” or “leafy tree” appearance.
 - (iii) Sjögren’s syndrome and Mikulicz’ disease show a “snow storm” or “branchless fruit-laden” appearance.
 - (iv) Stricture in a duct is seen as a filling defect, whereas multiple strictures show a sausage string appearance.
 - (v) “Cannon ball” appearance is seen in intraglandular tumors, whereas extraglandular tumors show a “ball in hand” appearance.
 - (vi) Duct perforation and sialocele show dye spillage in the soft tissues.
- (d) **Radionucleotide scanning:** It is used to distinguish between obstructive and nonobstructive sialadenitis. It involves both dynamic and static scanning. Radionuclide scanning is useful when a sialogram is contraindicated to distinguish between acute obstructive and nonobstructive sialadenitis [14].
- (e) **CT scan:** It is used to evaluate masses in parotid glands and surrounding structures as it gives excellent soft tissue details (Fig. 46.13) especially when used with a contrast dye. Bony changes in the course of facial nerve like erosions, sclerotic margins, and widening of stylomastoid foramen or fallopian canal suggest involvement of nerve. Plain computed tomography (CT) scans have a major role to play for diagnosis of obstructive pathologies like a calculus.
- (f) **MRI scan:** It allows assessment of salivary masses and early diagnosis of perineural spread due to excellent soft tissue contrast. In the case of neoplasms, it helps in demonstrating involvement of the facial nerve (Fig. 46.14).
- (g) **Arteriography:** It assesses the vascularity and source of vascular supply of the tumors.



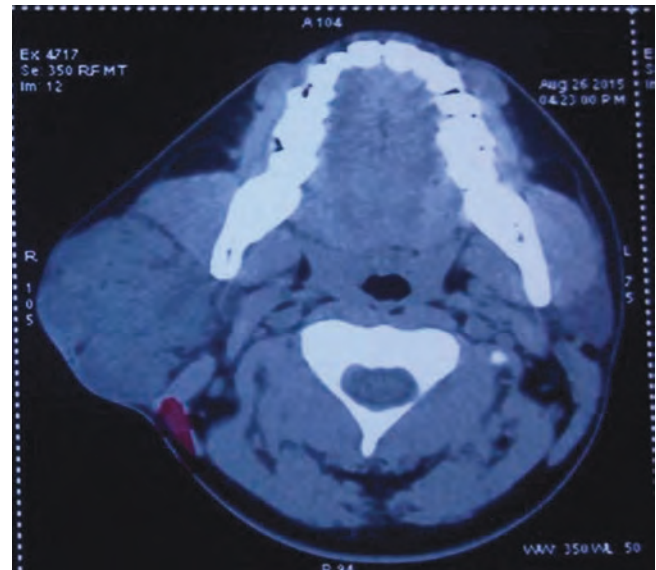
©Association of Oral and Maxillofacial Surgeons of India

Fig. 46.11 (a, b) Sialography technique



©Association of Oral and Maxillofacial Surgeons of India

Fig. 46.12 Normal parotid gland in sialography

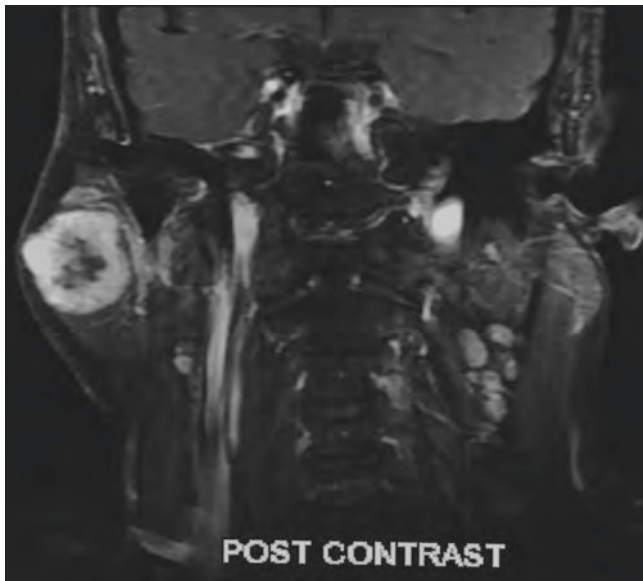

©Association of Oral and Maxillofacial Surgeons of India

Fig. 46.13 CT scan showing parotid tumor

(h) Positron emission tomography (PET): Uptake of radiotracer fluorodeoxyglucose used with PET scans by salivary glands makes this diagnostic technique useful for salivary gland tumors. Although this is an expensive technique, measurement of metabolic activity makes it more reliable than CT and MRI scans. It can be used to diagnose recurrences, tumor hypoxia, and proliferation rates [15].

2. Histopathology: The gold standard of diagnosis for neoplasms will always be histopathology (HPE). However, as the major salivary glands are deeper structures, an FNAC (fine-needle aspiration cytology) is considered as a standard of care for diagnosis to avoid tumor seeding, which might follow an open biopsy. An open biopsy can be considered for minor salivary gland tumors or malignant tumors affecting major salivary glands with skin infiltration, needing skin excision to achieve surgical clearance. HPE for salivary gland



©Association of Oral and Maxillofacial Surgeons of India

Fig. 46.14 MRI showing parotid tumor, right side

pathologies is very challenging, and hence diagnosing lesions on FNAC is more difficult. It is important to distinguish benign and malignant pathologies on FNAC even if the exact malignant variant is missed, because except adenoid cystic carcinoma which has perineurial spread, the surgery doesn't change for any other malignant tumor variant.

- (a) Fine-needle aspiration cytopathology (FNAC): It shows high diagnostic accuracy both for benign and malignant tumors. Complete histological features and status of invasion can't be revealed by this technique.
 - (b) Incisional biopsy: It is not a reliable technique as there is high possibility of seeding of tumor cells as well as fungation through skin.
3. Frozen sections: These help in diagnosing the nature of tumor, but accurate histopathologic features can't be diagnosed.

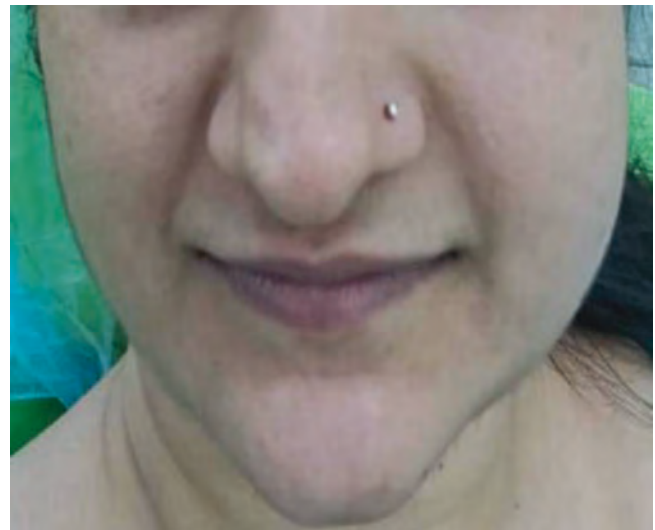46.4 Non-neoplastic Diseases (Table 46.5)

46.4.1 Acute Bacterial Sialadenitis

Parotitis (Fig. 46.15) occurs secondary to decreased salivary secretions, and various reasons are attributed.

Table 46.5 Important terminologies in relation to salivary gland diseases

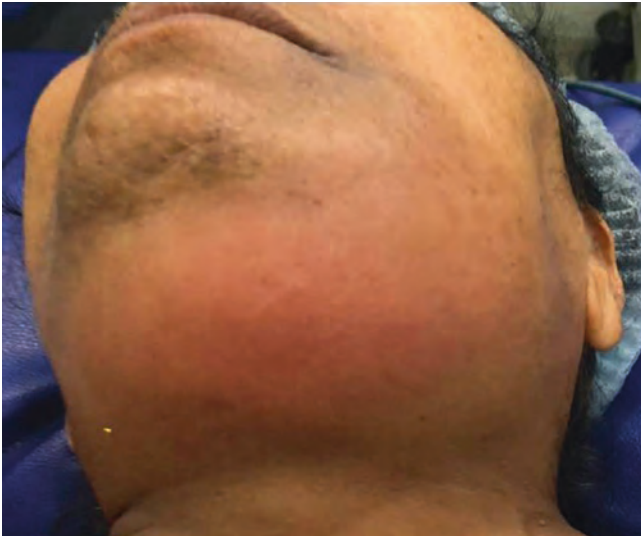<p><i>Sialadenitis</i>: Sialadenitis is inflammation of the gland parenchyma. It could either be suppurative (with pus) or nonsuppurative (without pus). It can also be classified as acute, subacute, or chronic.</p>
<p><i>Sialodochitis</i>: This refers to inflammation of the salivary gland duct. It may be associated with duct strictures and/or sialoliths.</p>
<p><i>Sialectasis</i>: This refers to cystic dilatation of the ducts due to either a sialolith or ductal strictures. It is most commonly seen in parotid gland infections. It can occur due to any condition causing chronic inflammation of the gland.</p>
<p><i>Sialorrhoea</i>: This refers to excessive secretion of saliva or drooling of saliva. It is most commonly seen in patients with cerebral palsy and neuro-degenerative disorders.</p>
<p><i>Sialosis</i>: It is defined as an asymptomatic, non-neoplastic, non-inflammatory parenchymal salivary gland disease which manifests as persistent painless bilateral salivary gland swelling, most commonly involving the parotid gland [16].</p>
<p><i>Sialodochoplasty</i>: It is repair of the salivary gland duct usually by translocating the ductal opening.</p>



©Association of Oral and Maxillofacial Surgeons of India

Fig. 46.15 Parotitis left side

The common etiologic factors for parotitis are reduced salivary flow due to severe dehydration, in patients with debilitating diseases, old age, post-operative patients, post radiotherapy for head and neck cancers, poor oral hygiene leading to recurrent infection, mechanical obstruction to flow, compromised host resistance due to systemic illnesses like Diabetes Mellitus, renal failure, HIV, post transplant immunosuppressants. The drugs which induce systemic dehydration such as antihypertensives, diuretics, tricyclic antidepressants, phenothiazines, barbiturates, anticholinergics and betablockers also lead to reduced salivary flow rate [17].



©Association of Oral and Maxillofacial Surgeons of India

Fig. 46.16 Submandibular sialadenitis left side

It may be retrograde contamination of salivary ducts and parenchymal tissues by oral microflora providing a bacterial source of infection. Stasis of salivary flow through the ducts and parenchyma may also promote acute suppurative infection. There is a higher risk of sialolith in the submandibular duct causing secondary suppurative sialadenitis (Fig. 46.16 showing submandibular sialadenitis).

46.4.1.1 Clinical Features

- Sudden onset of pain and swelling, exacerbates with food sighting or smelling
- Generalized malaise, fever, body ache, and sometimes signs of dehydration.
- Diffuse inflammatory swelling, induration, erythema, edema, and extreme tenderness over the affected gland.
- Tense, glossy, and erythematous skin.
- Raised ear lobule is pathognomonic sign of parotid swelling.
- The duct orifices are inflamed, and milking of gland may exhibit lesser salivation or purulence.
- Systemic sepsis occurs more commonly in parotid sialadenitis as compared to submandibular sialadenitis.
- Parotid swellings are not fluctuant due to fixity of overlying investing parotidomasseteric fascia and are extremely painful due to the mounting pressure as the fascia is nonyielding. This mounting pressure leads to ischemic necrosis of the gland, and the abscess may spontaneously burst in the external auditory canal.

Routine blood count to rule out impending sepsis in addition to a plain radiograph or USG to rule out a sialolith in the duct is indicated. Sialography is contraindicated in cases of acute infections and also sialoliths. Aspiration might not yield frank pus.

46.4.1.2 Management

Treatment is managing underlying cause and adequate hydration and systemic antibiotics. If swelling doesn't subside with medical management in 2 days or shows an increasing trend, an incision and drainage is indicated. The cellulitic phase may not yield any frank pus, but toxic fluid is drained and it releases the pressure over the gland and prevents pressure necrosis of the gland parenchyma. Parotid space abscess has the tendency to spread into the pharyngeal spaces and cause respiratory distress and descending mediastinitis or burst into the auditory canal or TMJ and cause septic arthritis of the TMJ.

46.4.2 Chronic Bacterial Sialadenitis [18]

It is a recurrent sialadenitis with episodic relapsing swellings of the salivary glands, most commonly seen in the parotid gland. Salivary retention and stasis are the main predisposing factor. It might be preceded by an acute sialadenitis. Strictures may also form in the ducts leading to salivary stasis and eventually chronic sialadenitis. Generalized constitutional symptoms may be low grade, and salivary gland milking may yield scanty saliva. MRI is more specific than CT scan.

46.4.2.1 Management

Management consists of short-term corticosteroids to eliminate glandular inflammation followed by use of sialogogues to increase salivation and flush the debris. Sialoendoscopy can play a role in increasing the salivary flow.

The sialoendoscope is advanced slowly into the duct with continuous saline irrigation to help visualize the system and also dilating the strictures with help of the sialoballoon. This is followed up by placing a stent into the duct for 4 weeks.

Superficial parotidectomy with facial nerve preservation can also be considered in case of chronic pain, provided imaging studies determine the involvement of superficial lobe.

Chronic recurrent parotitis if left untreated may lead to benign lymphoepithelial lesion which can progress to lymphoproliferative disorders like non-Hodgkin's lymphoma, carcinoma, or pseudolymphoma.

46.4.3 Obstructive Disorders (Video 46.1)

Sialolithiasis or salivary calculi are most commonly seen in the submandibular gland and duct (Fig. 46.17a, b). Symptomatic calculi are much lesser in occurrence. Only those cases with superadded infection and inflammation of the gland and duct result into pain.

46.4.3.1 Etiology

Salivary stasis is a major etiologic factor for formation of sialolith. The right-angle bend of the Stenson's duct where it pierces the buccinator and the 90° bend of the Wharton's duct at the border of the mylohyoid is the common location for sialoliths. They can also result from chronic sialadenitis. Systemic abnormalities of calcium metabolism are not associated with any increased risk of salivary stone formations. Gout is the only systemic illness known to predispose to salivary stone formation [19].

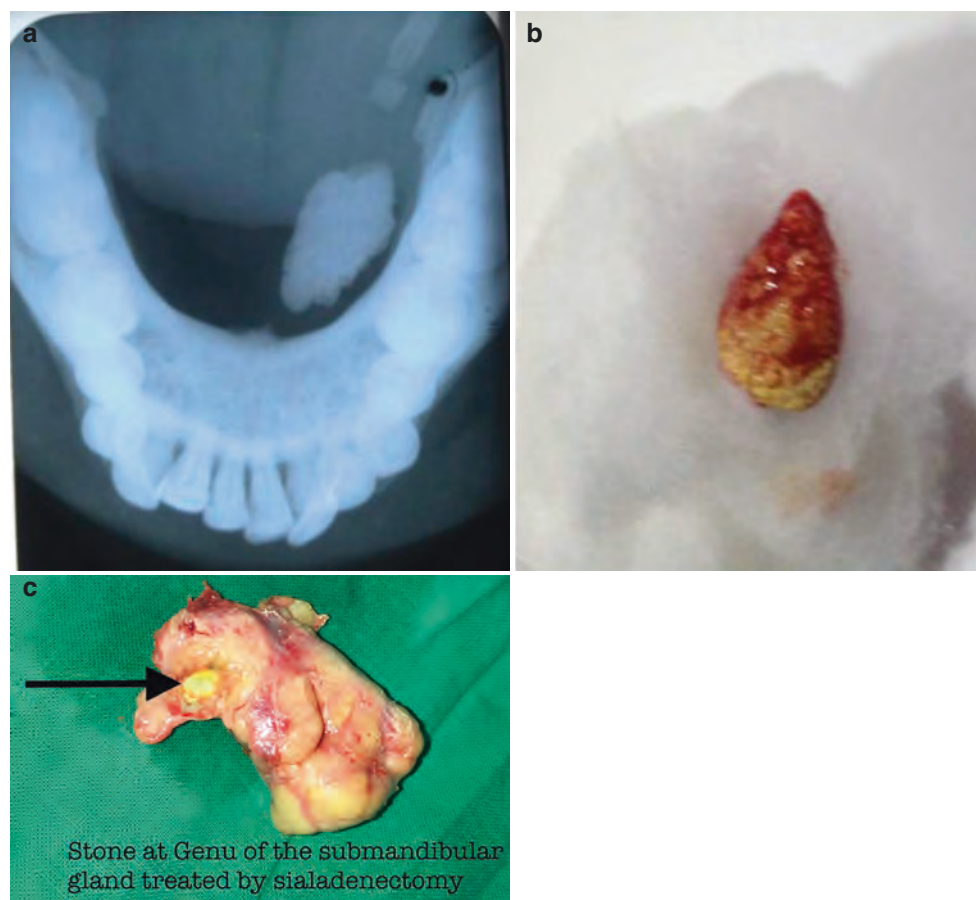
Salivary stasis changes the mucoid element of saliva to a gel framework for deposition of salts and organic substances

creating a stone. Unknown metabolic phenomenon increases salivary bicarbonate content altering the calcium phosphate solubility and leading to precipitation of calcium and phosphate ions [20]. Wharton's duct is longer than the Stenson's duct, and the submandibular gland is situated at a lower level than the opening of the duct. Hence the duct has to follow an uphill, tortuous course and drain against gravity. So stagnation of secretions is more common than parotid gland.

In the submandibular gland, the calculus results in sialadenitis, whereas in the parotid gland, sialadenitis causes calculus formation. In the parotid gland, stones are most commonly located at the hilum or parenchyma, whereas submandibular sialoliths develop in the duct [21]. Sometimes typically the sialolith is expelled out of the gland through the duct and is seen at the duct orifice.

46.4.3.2 Diagnosis and Management

Sialography can be used for diagnosis of sialoliths but is contraindicated if the calculus is already diagnosed on plain radiographs. Smaller stones can be expelled out through the



©Association of Oral and Maxillofacial Surgeons of India

Fig. 46.17 (a, b) Left—Submandibular duct calculus (a). Right—Calculus after surgical removal (b). (c) Submandibular gland specimen showing calculus at the genu

duct opening using local massage, sialogogues, and adequate hydration. Larger stones are managed surgically according to its location in the duct and gland.

If the stone is palpable in the oral course of the duct, the duct is dilated with a lacrimal probe and cut open to retrieve the stone. The duct margins are sutured to the adjacent mucosa to avoid stricture formation. A stay suture can be placed around the duct proximal to the stone to avoid accidental pushing of the stone into deeper inaccessible part of the duct. In submandibular stones which are at the genu of the duct or deeper into the gland, a sialadenectomy is needed (Fig. 46.17c).

If the sialolith is posterior in the duct, a suture is placed behind the stone to prevent slippage of stone into the duct. The incision is placed over the duct to extract the stone, and the duct is left without suturing (Fig. 46.18a, b).

Sialodochoplasty is a procedure wherein the incised duct margins are sutured with adjacent mucosa leading to a translocation of duct orifice [22, 23].

In the case of parotid sialoliths, only those in the duct distal to the masseter muscle can be accessed transorally and removed. All deeper stones warrant a parotidectomy.

Extracorporeal shock wave lithotripsy and use of sialoendoscopy are newer modalities to manage sialoliths. Lithotripsy reduces calculi to small fragments that are then

flushed out of the duct with spontaneous salivation or use of sialogogue [24]. The primary requirement for salivary stone lithotripsy is a functional gland which produces saliva which will clear the fragmented stone. A “gum test” which involves chewing of a sour gum can be done to test the functionality of the salivary gland. If the salivary secretions are normal, a visible swelling in the region of the gland will be noticed. If the test is negative, the patient cannot be taken up for lithotripsy.

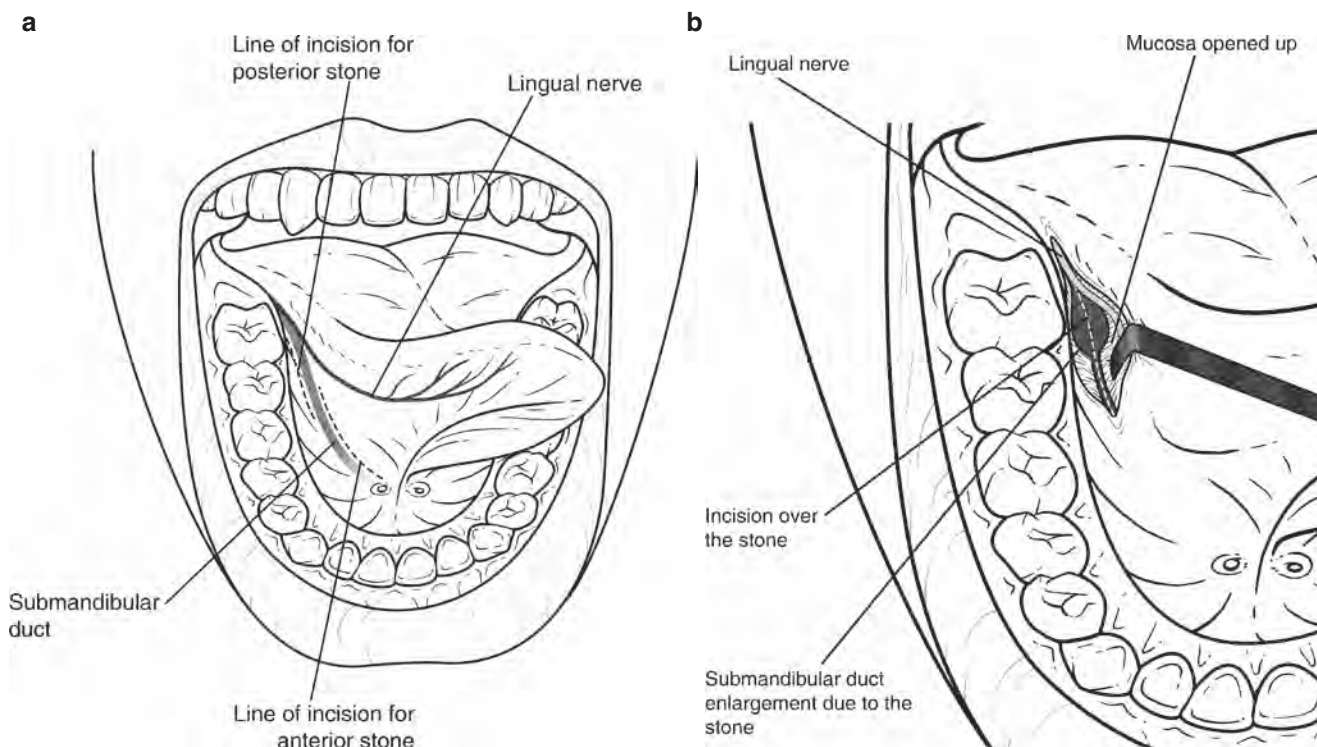
46.5 Viral Infections of Salivary Glands

46.5.1 Mumps

Mumps is an acute nonsuppurative viral parotitis caused by paramyxovirus also known as epidemic parotitis. The term “mumps” is derived from the Danish word “Mømpen” which means mumbling (like an old man) and describes the difficulty with speech because of inflammation and trismus [17].

46.5.1.1 Pathogenesis

It is an endemic disease and spreads by airborne droplet dissemination. It has an incubation of 2–3 weeks followed by 3–5-day viremia. The virus localizes to the salivary glands,



©Association of Oral and Maxillofacial Surgeons of India

Fig. 46.18 (a, b) Technique of sialolith removal from submandibular duct

germinal tissues, and CNS [25]. The infection has a strong predilection for the parotid gland. It is highly contagious and occurs in children below 15 years of age with peak incidence being in the 4- to 6-year-old group of children [26]. Adults are rarely infected due to the immunity because of childhood exposure or due to the MMR vaccine [17].

46.5.1.2 Clinical Features

Prodromal symptoms include headache, myalgias, arthralgias, anorexia, and malaise prior to development of parotitis. It starts with an earache, pain around the gland, trismus, and dysphagia. Pain is exacerbated by salivary stimulation during meals. The parotid papilla may be inflamed and puffy. Palpation of the gland reveals a swelling of the gland which may be tense, rubbery, and firm with non-pitting-type edema. The overlying skin is tensed and shiny without erythema or increased local temperature. Swelling lasts for 1–5 days and can displace the pinna. Seventy-five percent cases result in bilateral involvement of parotid gland. However, it begins as a unilateral swelling and involves the contralateral gland after a period of 1–5 days [25].

Diagnosis is primarily clinical, but a blood count shows leukocytopenia with relative lymphocytosis. Serum amylase levels are also raised. It peaks during the first week and starts declining in the second or third week and comes back to normal later [25].

“S” or soluble antibodies directed against the nucleoprotein core of the virus appear within the first week of infection and peak within 2 weeks and disappear within 8–9 months. “V” or viral antibodies directed against the outer surface hemagglutinin appear several weeks after the “S” antibodies and persist at low levels for approximately 5 years following exposure. A fourfold rise in antibody titer is diagnostic of active infection. Mumps skin test is not useful in the diagnosis of acute infection because dermal hypersensitivity does not develop until 3 or 4 weeks following viral exposure.

46.5.1.3 Treatment

The disease is self-limiting, and treatment is primarily supportive such as rest, adequate hydration, antipyretics, and anti-inflammatory medicines.

Live attenuated Jerry Lynn vaccine is given combined with measles and rubella as MMR vaccine after 12 months of age. Immunized population is less likely to get the disease but may be infected with a nonparamyxovirus.

46.5.1.4 Complications

Orchitis and oophoritis can occur as systemic manifestations and rarely lead to complete sterility. Mastitis has been associated with decreased lactation. Aseptic meningitis occurs in

10% of cases, and asymptomatic meningeal inflammation is more common. Five percent patients are affected by acute pancreatitis, wherein serum lipase levels are also increased. Sensorineural hearing loss complicates 0.05–4% of patients and may be permanent and profound [26]. Tinnitus, aural fullness, and vertigo are associated symptoms, but they resolve over a period of few weeks. Additional complications include myocarditis, polyarthritides, hemolytic anemia, plasmacytosis, lymphocytic leukemoid reactions, and thrombocytopenia [12]. These conditions are self-limiting or resolve with or without steroid therapy.

46.5.2 HIV Parotitis

HIV-associated salivary gland disease is the term used to describe the diffuse enlargement of the salivary glands that affects HIV patients throughout all stages of the disease. In fact, HIV-SGD may be the first presenting sign of HIV. Like most of the salivary diseases, the parotid gland is the most frequently affected. Clinically, HIV-infected individuals show reduced salivary flow rates. Parotid gland enlargement is reported to occur in 1–10% of the HIV-infected population. It is usually secondary to development of benign lymphoepithelial cysts within the parotid gland [25].

46.5.2.1 Management

Antiretroviral therapy with zidovudine, maintenance of oral hygiene, and use of sialogogues form the mainstay of management.

46.6 Noninfectious Inflammatory Diseases

Mikulicz’ disease and Sjögren’s syndrome are closely related to each other and are autoimmune in origin, wherein the salivary tissue itself becomes antigenic [27].

46.6.1 Mikulicz’ Disease

46.6.1.1 Clinical Features [28]

Middle-aged females are affected commonly. It behaves like an inflammatory as well as a neoplastic disease. Presenting symptoms may be diffuse, poorly outlined, unilateral or bilateral enlargement of the parotid or submandibular glands with an occasional increase or decrease in size of the swelling. There is mild local discomfort, occasional pain, and xerostomia. Fever, upper respiratory tract infection, tooth extraction, or some other local inflamma-

tory disorder may precede the disease. Sometimes the lacrimal glands may be enlarged. FNAC can help diagnose the condition.

46.6.1.2 Management

Mild cases once diagnosed do not warrant any treatment. In some cases, the swelling might regress spontaneously. Persistent cases can be managed by sialadenectomy [28].

46.6.2 Sjögren's Syndrome

Sjögren's syndrome or Sicca syndrome is a chronic autoimmune disorder of the exocrine glands involving multiple extraglandular sites and can even evolve into a lymphoid malignancy. Sjögren's syndrome shows a triad of symptoms—keratoconjunctivitis sicca, xerostomia, and a systemic disease, usually but not always rheumatoid arthritis. Primary Sjögren's syndrome also known as Sicca complex presents with only dry eyes and dry mouth. Secondary Sjögren's syndrome has in addition to the above features systemic manifestations such as systemic lupus erythematosus, polyarteritis nodosa, polymyositis or scleroderma, and rheumatoid arthritis [28].

Arthritis is the most frequent first complaint, followed by ocular complaints and then xerostomia which leads to difficulty in chewing and swallowing, sore mouth, recurrent dental caries, and fungal infections in the oral cavity. The tongue appears bald with loss of filiform papillae and fissuring of tongue. The saliva is usually cloudy due to pus and abnormally viscous due to gel-like consistency. Parotid gland enlargement is seen in 25–66% cases of primary Sjögren's syndrome but is uncommon in secondary cases. Xerophthalmia leads to chronic irritation and destruction of the corneal and bulbar conjunctival epithelium, referred to as keratoconjunctivitis sicca. The patient complains of redness, itchiness, or burning sensation in the eye, rope-like secretions, dryness, and a foreign body sensation in the eye and may not be able to tolerate smoke, air draft, or light [27].

Schirmer's test is used to confirm lacrimal secretions. Patients complain of easy fatigue, general malaise, low-grade fever, myalgias, and arthralgias. Respiratory tract symptoms range from dry cough due to xerotrachea to dyspnea due to interstitial disease or even airway obstruction. High-resolution CT scan shows bronchial and peribronchial thickening, whereas transbronchial biopsies show bronchiolar lymphoid infiltrates and follicular bronchiolitis [29]. Sensorineural hearing loss is associated with Sjögren's syndrome in 21–46% of cases [30]. Dysphagia results from drying of the pharynx and esophagus. Other complications

include renal disease, Raynaud's disease, inflammatory vascular disease, peripheral sensory or sensorimotor polyneuropathy or mononeuritis multiplex, skin dryness, vasculitis, and frequent allergic reactions. Labial salivary gland biopsy is used as a means of assessment of salivary pathology in Sjögren's syndrome.

46.6.2.1 Management

Xerostomia and keratoconjunctivitis sicca are managed by use of 0.5% methylcellulose artificial saliva and tears. Preventive dental care and fluoride application and maintenance of general hygiene are necessary. Eye patching and boric acid ointment can be used for corneal ulcers. Pilocarpine hydrochloride can be used as a secretagogue for management of xerophthalmia and xerostomia. Systemic corticosteroids can be used for systemic complications such as vasculitis, glomerulonephritis, and interstitial lung disease.

46.6.3 Mucoceles (Video 46.2)

Mucous retention cyst arises from ductal obstruction in a minor or accessory salivary gland due to traumatic severance of the duct due to biting of the lips, cheeks, and tongue or due to injury due to lip pinching during extraction. Majority of cases are an extravasation type of cysts which result from collection of salivary secretions in the soft tissues due to traumatic injury to the gland or duct. Lower lip was affected in 44–79% of cases. It occurs in any age with no gender predilection [31].

46.6.3.1 Clinical Features

Superficial lesions appear like a circumscribed, raised vesicle with a bluish translucent hue due to the thin overlying mucosa. However, deeper lesions being covered by normal mucosa have a normal color and texture. Mucoceles may get traumatized and rupture spontaneously and may recur later.

46.6.3.2 Management

Surgical excision of the mucocele along with a few normal minor salivary glands is the procedure of choice. Care should be taken to avoid creation of any other partially transected minor salivary glands which might give rise to the recurrent mucocele.

Mucocele can be excised by giving an elliptical incision around the lesion and closure (Fig. 46.19a–d), [32] or as the case requires, an incision may be given over the mucocele; lesion can be excised carefully without rupture and closure attained (Fig. 46.19e–h).

Huang I et al. [33] recommended use of carbon dioxide laser vaporization to treat the lower lip mucocele with good results and less complications.

46.6.4 Ranula

Ranula is a mucocele arising from the sublingual salivary gland in the floor of the mouth (Fig. 46.20). It presents as a large blue, tense vesicle in the floor of the mouth. The appearance is of that of a frog's belly, hence the term ranula (frog belongs to genus *Rana*). It is firm on palpation. The cyst is usually present above the mylohyoid curtain, but when it presents in the upper part of the neck, it is called as a "plunging ranula." Plunging ranulas may grow to a sufficient size so as to compromise respiration and swallowing and may also extend into mediastinum [32].

46.6.4.1 Management

Excision of the ranula and entire sublingual gland through a transoral approach is management of choice taking care to avoid damage to the lingual nerve. The incision is made through the mucosa in the lingual fold from the second molar to canine tooth. Blunt dissection is done up to the mylohyoid muscle. The gland is dissected free from the surrounding soft tissues and the Wharton's duct. The gland can be retracted using holding sutures, and blunt dissection is carried out till the lingual nerve is identified as it crosses the Wharton's duct. The gland is delivered once it is dissected free from the entire surrounding soft tissues taking care to prevent damaging the submandibular duct and lingual nerve [34].

Marsupialization can be used as an alternative modality wherein the ranula is deroofed and the mucosa sutured to the cystic lining followed by open packing of the cyst and sequentially reducing the size of the pack till it heals completely.

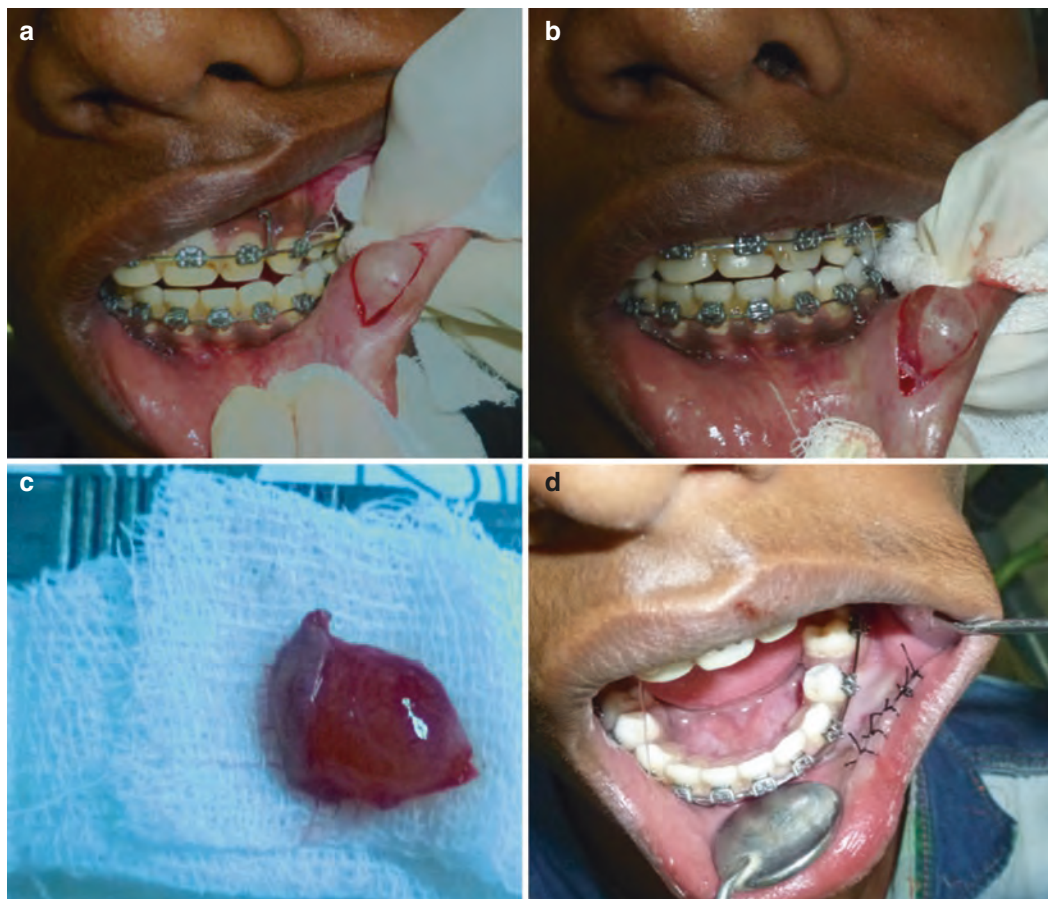
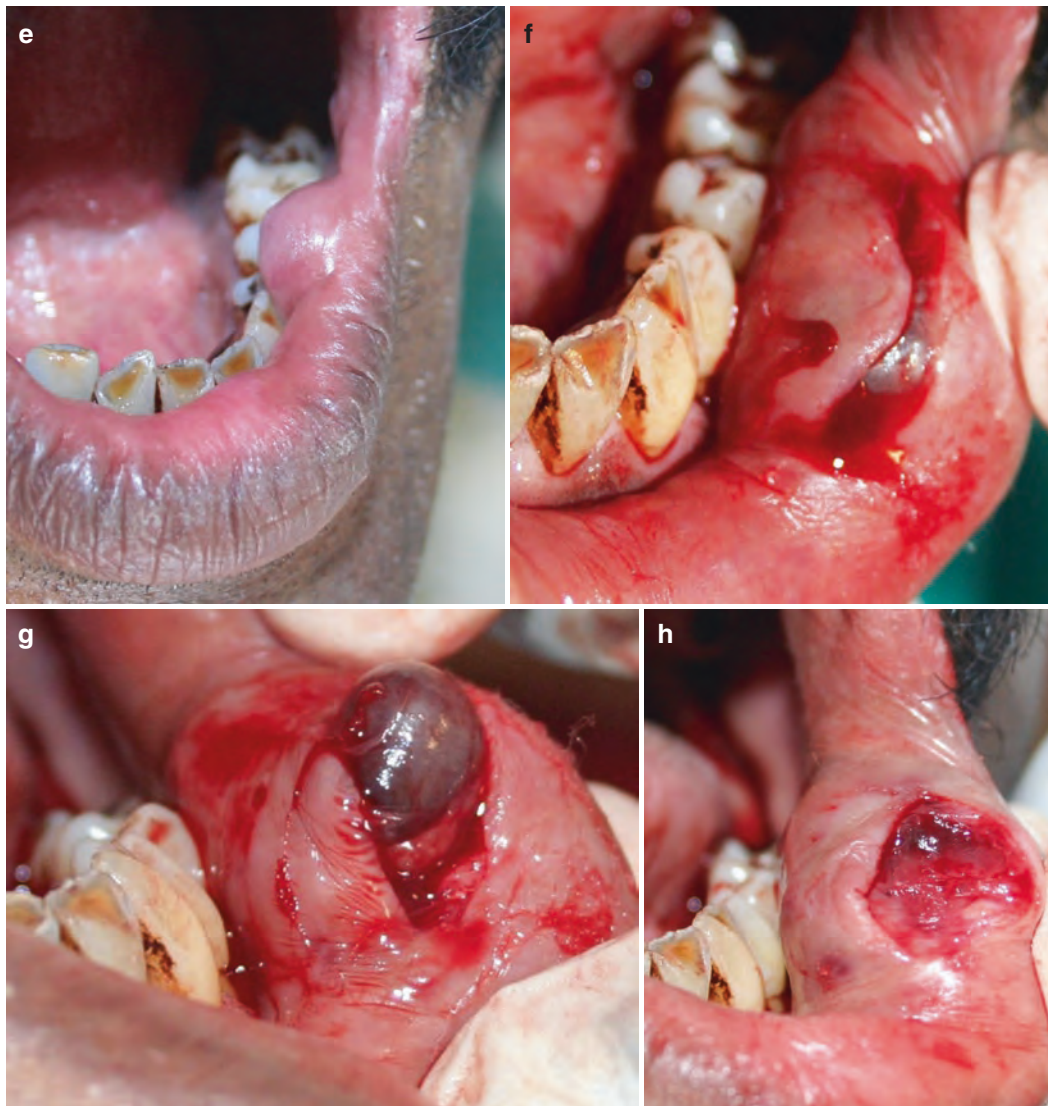

Fig. 46.19 (a)–(d) Figure showing surgical removal of mucocele by elliptical incision. (e)–(h) Figure showing excising mucocele by incision directly over the lesion



©Association of Oral and Maxillofacial Surgeons of India

Fig. 46.19 (continued)

Higher recurrence rate (61–85%) has been reported with simple marsupialization and ranula excision. To lower the rate of recurrence, total sublingual excision is the treatment of choice [35].

Kono et al. [36] recommended an injection of sclerosing agent, OK-432 (Picibanil), as a safe and effective method of treating intraoral ranulas. The number of injections used was 1–4 (mean 1.70) in their study.

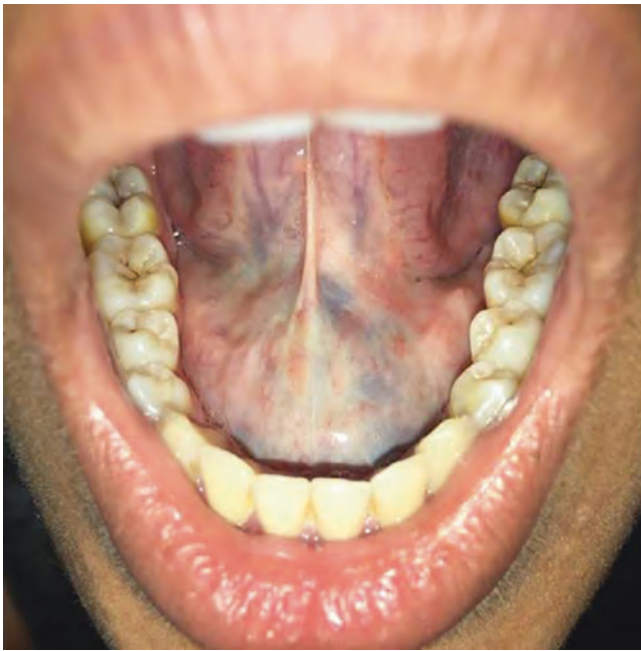46.7 Salivary Gland Tumors

46.7.1 Etiology

Although no specific etiology has been attributed to occurrence of salivary gland tumors, its association with radia-

tions, viruses, hormones, lifestyle, or occupation and like factors can't be denied.

- **Radiation:** Evidence exists regarding susceptibility of lymphoid component rather than parenchymal component of gland to low radiation and UV ray damage (140 rad) [37–39].
- **Viruses:** It is believed that genetic component, environment, and immunity of host play a key role in malignant transformation of salivary gland tumors. Viruses like human papillomavirus, Epstein-Barr virus, cytomegalovirus, and polyomavirus have been speculated to be responsible for occurrence of salivary gland tumors.
- **Hormones:** Endogenous hormones play an important role in carcinogenesis of these tumors. Patients of breast cancer are more prone to salivary gland neoplasms.



©Association of Oral and Maxillofacial Surgeons of India

Fig. 46.20 Ranula in the floor of the mouth

- Lifestyle: Tumors like Warthin's tumor or epidermoid carcinoma have been associated with cigarette smoking. Salivary gland enlargements are observed in nutritional deficiencies, but there are no reports of malignancies [40].
- Occupation: Those who engage in occupations which involve manufacturing and use of rubber products, asbestos mining, and plumbing are at increased risk of developing salivary gland tumors [37].

46.7.2 Incidence

Salivary gland tumors occur rarely both among Indian population and around the world. Incidence of benign and malignant salivary gland tumors in major portion of the world ranges from 1 to 2 cases per 100,000 people per year [41]. There is no specific predilection of occurrence of these tumors in any particular gender, although Warthin's tumor is more common in males and acinic cell tumor in females. Site wise incidence varies for both benign and malignant tumors. Seventy-five to eighty percent of benign tumors occur in the parotid glands, 5–10% in submandibular glands, and only 1–2% in sublingual glands. Malignant tumors are more common in sublingual glands (80%) and least in parotid glands (17–20%). Benign tumors affect a mean age group of 40 years, and malignant tumors affect an age group of 55 years. Both benign and malignant tumors

by large resemble each other clinically. Hence, histopathologic examination is pivotal to establish a correct diagnosis.

46.7.3 TNM Staging of Salivary Gland Tumors According to American Joint Commission on Cancer (AJCC) 2002 [42]

Tumor (T): T with a letter/number describes the location or size of the tumor

TX: Indicates the primary tumor cannot be evaluated.

T0 (T plus zero): No evidence of a tumor was found.

T1: Describes a small, noninvasive (has not spread) tumor that is 2 centimeters (cm) at its greatest dimension.

T2: Describes a larger, noninvasive tumor between 2 cm and 4 cm.

T3: Describes a tumor that is larger than 4 cm but not larger than 6 cm and has spread beyond the salivary glands but does not affect the seventh nerve, the facial nerve that controls expression, such as smiles or frowns.

T4a: The tumor has invaded the skin, jawbone, ear canal, and/or facial nerve.

T4b: The tumor has invaded the skull base and/or the nearby bones and/or encases the arteries.

Nodes (N): N is for lymph nodes. Lymph nodes of the head and neck region are regional lymph nodes, and those away from this region are distant nodes.

NX: The regional lymph nodes cannot be evaluated.

N0: There is no evidence of cancer in the regional nodes.

N1: Cancer has spread to a single node on the same side as the primary tumor, and the cancer found in the node is 3 cm or smaller.

N2: Describes any of these conditions:

- N2a: The cancer has spread to a single lymph node on the same side as the primary tumor and is larger than 3 cm but smaller than 6 cm.
- N2b: The cancer has spread to more than one lymph node on the same side as the primary tumor, and none measures larger than 6 cm.
- N2c: The cancer has spread to more than one lymph node on either side of the body, and none measures larger than 6 cm.

N3: The cancer found in the lymph nodes is larger than 6 cm.

Metastasis (M): Describes the cancer that spreads to different body parts.

MX: Indicates distant metastasis cannot be evaluated.

M0: Indicates the cancer has not spread to other parts of the body.

M1: Describes cancer that has spread to other parts of the body.

46.7.4 Classification of Salivary Gland Tumors

Salivary gland tumors were first classified by WHO in 1972. It was later modified in 1991 wherein the term “tumor” was replaced by “carcinoma” to denote acinic cell carcinoma and mucoepidermoid carcinoma [43]. It was further revised in 1997, and a greater number of entities of adenomas (myoepithelial adenoma, basal cell adenoma, canalicular adenoma) and carcinomas (acinic cell carcinoma, mucoepidermoid carcinoma, polymorphous low-grade adenocarcinoma, salivary duct carcinoma, myoepithelial carcinoma) were redefined with emphasis on the prognosis and therapy [44]. A revised classification was put forth by WHO in 2005 also. The latest classification of WHO which was given in 2017 consisted of the following changes:

- Secretory carcinoma, borderline tumor—sialoblastoma—and sclerosing polycystic adenosis were added as new entities under malignant tumors.
- Simplification of terminologies of polymorphous adenocarcinoma, clear cell carcinoma, and intraductal carcinoma was done.
- Rare entities like adenocarcinoma, NOS, canalicular adenoma, and poorly differentiated carcinoma were regrouped (Table 46.6).

46.7.5 Pleomorphic Adenoma

“Pleomorphic adenoma” suggested by Willis closely resembles the unusual histologic pattern of the lesion [28]. The tumor derives its name from the Greek words Pleos = many and morphus = form because of the heterogeneous nature of its histologic appearance [46].

46.7.5.1 Clinical Features

Most frequently found in the superficial lobe of the parotid gland, it presents as a firm, slow-growing asymptomatic mass which is smooth, rounded, lobular, and mobile with a rubbery consistency causing ear lobule to be raised (Fig. 46.21a). If the tumor involves both the superficial and deep lobes of parotid, it is classically referred to as dumbbell tumor. Incidence of the tumor except those found in the pharynx is more in females than males, and they are often seen in the fourth and fifth decade. A bilateral tumor occurrence rate is estimated at 1 in 40,000 [47].

Table 46.6 Revised classification of salivary gland tumors (2017) [45]

<i>Malignant Tumors</i>	<i>Benign Tumors</i>
Mucoepidermoid carcinoma	Pleomorphic adenoma
Adenoid cystic carcinoma	Myoepithelioma
Polymorphous adenocarcinoma	Basal Cell Adenoma
Epithelial-myoepithelial carcinoma	Warthin’s tumor
Clear cell carcinoma	Oncocytoma
Basal cell adenocarcinoma	Lymphadenoma
Sebaceous adenocarcinoma	Cystadenoma
Intraductal carcinoma	Sialadenoma papilliferum
Cystadenocarcinoma	Ductal papillomas
Adenocarcinoma, NOS	Sebaceous adenoma
Myoepithelial carcinoma	Canalicular adenoma and other ductal adenomas
Carcinoma ex pleomorphic adenoma	<i>Other Epithelial Lesions</i>
Carcinosarcoma	Sclerosing polycystic adenosis
Poorly differentiated carcinoma	Nodular oncocytic hyperplasia
1) Neuroendocrine and non-neuroendocrine	Lymphoepithelial lesions
2) Undifferentiated carcinoma	Intercalated duct hyperplasia
3) Large cell neuroendocrine carcinoma	<i>Soft Tissue Lesions</i>
4) Small cell neuroendocrine carcinoma	Hemangioma
Lymphoepithelial carcinoma	Lipoma/sialolipoma
Squamous cell carcinoma	Nodular fasciitis
Oncocytic carcinoma	<i>Hematolymphoid Tumor</i>
<i>Borderline Tumors</i>	Extranodal marginal zone lymphoma of MALT
Sialoblastoma	

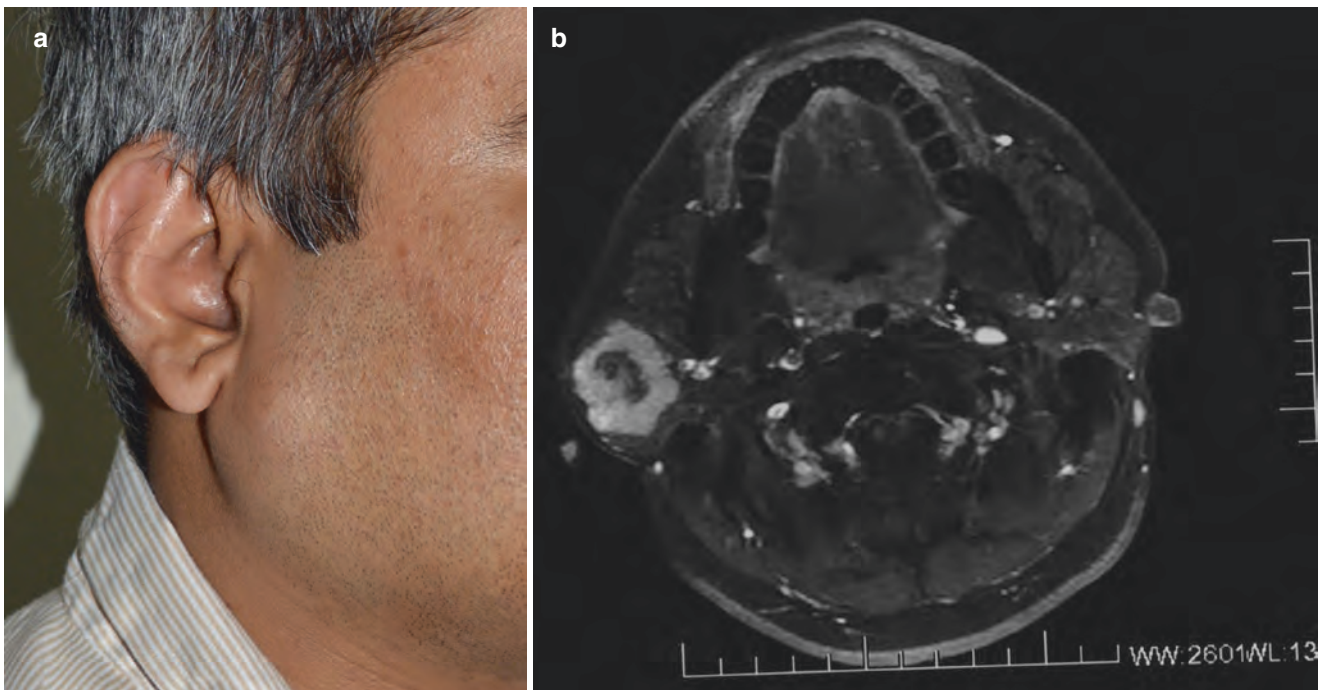
They are encapsulated and do not show fixity to the deeper tissues or the overlying skin in major salivary gland tumors, which can be confirmed on an MRI (Fig. 46.21b), but in the case of the minor salivary glands of the palate, it may appear to be fixed to the underlying palatal bone but does not invade or erode the bone. Pain is uncommon but 50% patients experience a pressure sensation. Accumulation of mucus can occur so that elastic swellings or frankly fluctuant cysts may form in the tumors.

In the case of the submandibular gland, palpation of the mass both extraorally and bimanually helps in localizing it and differentiating it from a lymph node, but FNAC is always needed to differentiate it from sialadenitis.

46.7.5.2 Histopathology [48]

On light microscopy morphologically complex and diverse cellular elements are seen. Both epithelial and myoepithelial elements are present. Based on cellular types, Foote and Frazel [49] have classified pleomorphic adenomas as follows:

- Principally myxoid (36%)
- Equally myxoid and cellular (30%)
- Predominantly cellular (22%)
- Extremely cellular (12%)



©Association of Oral and Maxillofacial Surgeons of India

Fig. 46.21 (a) Parotid tumor showing elevation of ear lobule (pathognomonic sign). (b) MRI axial view showing the tumor

46.7.5.3 Management

Surgical excision is the treatment of choice. Historically, enucleation was practiced which resulted in inadequate surgery and recurrences [50]. Superficial parotidectomy is the most widely accepted technique in the treatment of pleomorphic adenomas in the superficial lobe of the parotid gland, and total gland excision with facial nerve preservation is carried out. Tumors of the submandibular gland are usually contained within the gland, and their resection is usually confined to the gland and surrounding fat or lymph nodes until the neoplasm is a malignant and invasive tumor. As with the parotid gland, most neoplasms are asymptomatic. Small palatal pleomorphic adenomas usually cause pressure resorption of the palate but do not invade the bone. A disk of palatal mucosa is outlined well clear of the visible swelling because the tumor is flattened owing to the toughness of the palatal tissues. The tumor along with the periosteum of the palate is excised in continuity with each other. In case the pleomorphic adenoma invades the palate or proliferates into the floor of the maxillary sinus, a partial maxillectomy or total maxillectomy depending on the extension of the tumor has to be performed.

Although pleomorphic adenoma is a benign tumor, it may cause problems in clinical management due to its tendency to recur and risk of malignant transformation.

46.7.6 Monomorphic Adenoma

The WHO classification subdivides the monomorphic adenomas into three groups [45]:

- Adenolymphoma (Warthin's tumor)
- Oxyphilic adenoma (oncocytoma)
- Others

A number of other classifications of monomorphic adenomas have been put forth, but there is no unanimity. Two main histologic patterns have evolved:

- Basal cell adenoma
- Canalicular adenoma

46.7.7 Warthin's Tumor

Warthin's tumor, also known as papillary cystadenoma lymphomatosum and adenolymphoma, is the second most common benign tumor of the salivary glands, around 5% of neoplasms [51].

It was first described by Hildebrand in 1895 as a form of congenital cyst of the neck. It is known as Warthin's tumor in

recognition of the pathologist who first described it in the USA in 1929. He described two cases and also coined the term papillary cystadenoma lymphomatosum [52].

46.7.7.1 Clinical Features

The majority of the tumors arise in the parotid gland, more often bilaterally, in the elderly and occurs in the fifth and sixth decades of life. A predilection for male sex is seen, more in Caucasians. Both tumors do not occur simultaneously but are metachronous in their manifestation. A concept of multicentric and multifocal disease has been put forth to explain this. It is a solitary, nodular, slowly enlarging swelling, most commonly located in the inferior pole of the parotid next to the angle of the mandible. It varies from moderately firm to fluctuant on palpation and is asymptomatic. It is not as discrete as the mixed tumor. Very few patients present with complain of pain, pressure, or rapid increase in the tumor size. Scintigraphy may be helpful due to its increased uptake of technetium-99m pertechnetate. It appears as a smooth-margined, radiopositive “hot” nodule in contrast to the mixed tumors, nonfunctioning malignant tumors, and metastatic tumors which appear as a “cold” nodule in scintigraphy. Positive scintigraphy with ^{123}I is indicative of Warthin’s tumor but may also signify presence of ectopic thyroid or metastatic thyroid tumor.

46.7.7.2 Management

Surgical removal is the established treatment for Warthin’s tumor. As the tumor is superficial in the parotid gland, it is easily removed with minimal loss of glandular function and with preservation of the facial nerve.

Treatment philosophies given are:

- Tumor enucleation with resection of minimal amount of surrounding normal tissue
- Superficial parotidectomy, which is more aggressive than enucleation
- Local excision of parotid gland

Local excision of the tumor is preferred to enucleation of the tumor because lymph nodes at the posteroinferior part of the gland cannot be cleared by enucleation. Preoperative diagnosis of Warthin’s tumor must be confirmed by coordinating the clinical findings with imaging and fine-needle aspiration biopsy reports before local excision is carried out. If there is associated chronic obstructive parotitis, superficial parotidectomy is essential. Similarly, if the tumor is located in front of the ear, a superficial parotidectomy is the treatment of choice.

46.7.8 Oncocytoma

An oncocytoma is a tumor characterized by large epithelial cells, i.e., oncocytes that contain a brightly eosinophilic, granular cytoplasm. The oncocyte is derived from the Greek word “onkousthai” meaning swollen or enlarged and was described in 1897 by Schaffer who observed this tumor in ductal and acinar elements of salivary glands in the tongue, pharynx, and esophagus. Jaffe was the first to introduce the term oncocytoma [53]. However, he had termed Warthin’s tumor as oncocytoma. The other terminologies used to describe this tumor are oxyphilic adenoma and acidophilic adenoma.

46.7.8.1 Clinical Features

There is no race predilection for occurrence of this tumor. Oncocytoma is predominantly a tumor of the major salivary glands, parotid being the most common. Bilateral occurrence is also known. Among minor salivary glands, which are rarely affected, palatal mucosa followed by buccal mucosa and tongue is affected.

The oncocytoma is a small benign lesion which generally does not attain a great size. It most frequently presents as an indolent, single, often multi-lobulated, firm, solid, and mobile mass in the superficial lobe of the parotid gland. It can also be located in the deep lobe of the parotid gland and may be insinuated between the branches of the facial nerve. However, it does not cause any symptoms of pain or paresthesia unless the branches of the facial nerve are compromised. Tumor size varies with the duration of the lesion but generally does not increase beyond 4.0 cm. Intraoral tumors do not exhibit any special characteristic diagnostic features. However, their overlying mucosa may become ulcerated due to trauma [53].

46.7.8.2 Management

Partial parotidectomy with facial nerve preservation whenever possible is the treatment of choice. It ensures complete removal of the tumor and reduces the rate of recurrence. Curettage or simple enucleation of the tumor is to be avoided to avoid recurrence. Complete sialadenectomy is the treatment of choice in cases of submandibular gland oncocytomas. In the case of minor gland tumors, local excision of the tumor with a margin of normal tumor-free tissue is carried out. Radiation therapy after surgery has been tried but it has shown to be ineffective.

46.7.9 Basal Cell Adenoma

It was first reported as a separate entity by Kleinsasser and Klein in 1967 [28].

46.7.9.1 Clinical Features

Basal cell adenomas occur between the third and ninth decade, but the peak incidence is in the sixth decade with a slight male predilection of 5:1 [28]. They are clinically indistinguishable from mixed tumors and occur in the superficial portion of the parotid gland. They are slow-growing, painless, round or ovoid, well-circumscribed, and freely mobile masses with a smooth-surfaced capsule and a soft to moderately firm consistency. They may be mistaken for a hyperplastic lymph node because of their encapsulation, size, and color.

Clinically basal cell carcinoma of skin, ameloblastoma, pleomorphic adenoma, and adenoid cystic carcinoma can be considered in the differential diagnosis.

On the basis of histopathologic appearance, they may be divided into four subtypes:

- Solid
- Trabecular
- Tubular
- Membranous

46.7.9.2 Management

Surgical excision with a sufficient clear margin of normal tissue is the treatment of choice.

46.7.10 Canalicular Adenoma

46.7.10.1 Clinical Features

It is seen between the fourth and ninth decade, highest incidence being in the seventh decade with a female/male ratio of 1.7 to 1.0 and a higher incidence in Caucasians. It is seen more commonly in the minor salivary glands of the lip and cheek and rarely affects the major salivary gland [54].

It presents as a non-ulcerated, painless, mobile nodule that exhibits slow growth unless it is traumatized, wherein there is presence of ulceration. Clinical appearance is similar to that of a mucocele [54]. The overlying mucosa may be normal colored or bluish.

In the case of upper lip lesion, a sialolith, mucocele, mucous retention cyst, and pleomorphic adenoma can be considered in the differential diagnosis.

46.7.10.2 Management

Surgical excision, enucleation, or limited extracapsular excisions have been used as treatment modalities in these tumors with success.

46.7.11 Sialadenoma Papilleferum

First described by Abrams and Finck in 1969, it was termed sialadenoma papilleferum because of its histologic similarity

to syringocystadenoma papilleferum of skin adnexal origin [55].

46.7.11.1 Clinical Features

Sialadenoma papilleferum presents as a subcentimetric, asymptomatic, exophytic, papillary surface lesion which can be confused with squamous papilloma. The most common site of occurrence is the minor salivary glands at the junction of soft and hard palate with the tumor located on one side of the midline. This tumor occurs at an average age of 56 years, cases being reported from 2 years to 87 years. Male predilection is seen in the ratio of 1.5 to 1. However, there is no racial predominance [55].

Clinically it resembles a squamous papilloma, and a differential diagnosis of verrucous carcinoma or a warty dyskeratoma needs to be considered.

46.7.11.2 Management

Being small, these tumors are easily excised usually with a clinical diagnosis of a squamous papilloma. However, recurrence is rare.

46.7.12 Inverted Ductal Papilloma

Inverted ductal papilloma is a rare tumor and was first described by White et al. in 1982 when they reported four cases [56].

46.7.12.1 Clinical Features [56]

It occurs as a firm, asymptomatic, discrete nodule of 1–1.5 cm beneath the normal mucosa which in some cases may be contiguous with a small surface pore. The mean age of occurrence is 50 years without any sex predilection. The sites usually involved are the lower lip and buccal vestibular mucosa in descending order with occasional cases reported in the upper lip, floor of mouth, and soft palate.

46.7.12.2 Treatment and Prognosis

It is treated by simple surgical excision as it is not known to recur.

46.7.13 Intraductal Papilloma

It is a rare tumor. These tumors present as asymptomatic, submucosal swellings that vary in size from less than 1 to 1.5 cm in the minor salivary glands. The ages of patients range from 29 to 77 years, with a mean age of 54 years. Men and women are equally affected.

46.7.13.1 Treatment and Prognosis

Excision is curative, and these tumors are not known to recur. In case the tumors are small, all types of papillomas of the

minor salivary glands, including intraductal, inverted, and sialadenoma papilliferum, can be excised in the dental office or the clinic under local anesthesia [55].

46.7.14 Mucoepidermoid Carcinoma

Mucoepidermoid carcinoma is the most common malignant salivary gland neoplasm. They are classified as grade I (low grade) which are well differentiated, grade II (intermediate grade) which are moderately differentiated, and grade III (high grade) which are poorly differentiated tumors.

46.7.14.1 Clinical Features

Mucoepidermoid carcinomas occur more commonly in the minor salivary glands with a female predilection [57]. It occurs as a painless, circumscribed, mobile solitary enlargement of the body or tail of the parotid or the submandibular region with over a year duration generally. Pain, facial paralysis, and fixation to the overlying skin are usually suggestive of high-grade lesions [57]. Minor salivary gland lesions present as a bluish or red-purple, fluctuant, smooth-surfaced mass that is often clinically mistaken for a mucocele or hemangioma [57]. Large lesions at the base of the tongue or in the oropharynx may cause dysphagia. Aggressive tumors show ulceration. Numbness of the teeth may occur when the bone is involved. Histopathologically, mucoepidermoid carcinomas are graded as low-grade, intermediate-grade, and high-grade carcinomas. They are generally partially encapsulated and don't show adequate circumscription.

46.7.14.2 Management

Complete, adequate, and radical surgical excision is the treatment of choice for all grades of mucoepidermoid carcinomas [58]. In the case of stage I and stage II mucoepidermoid carcinomas of the parotid gland, conservative excision with preservation of the facial nerve, if possible, is recommended. The affected submandibular gland should be removed entirely. Radical neck dissection is performed in patients with clinical evidence of cervical node metastasis and is considered in any patient with a T3 lesion. In the case of facial nerve involvement, total parotidectomy with facial nerve sacrifice up to histologically tumor-negative nerve trunk is done. The 5-year disease-free rate in patients receiving this aggressive treatment was about 60% [58].

Treatment of minor salivary gland mucoepidermoid carcinomas entails a wide surgical excision with the bone if involved, to achieve a negative margin, and the wound is left to heal secondarily [59]. For small low-grade tumors in the absence of bone involvement, wide excision down to periosteum with 1 or 2 cm tumor-free lateral margins is

adequate therapy [59]. High-grade and advanced stage tumors must be treated aggressively at any site. The overall recurrence rate of mucoepidermoid carcinomas is approximately 25%. Better survival is seen among younger patients and among females. Tumors in the submandibular gland and in the base of the tongue generally have a poorer outlook than those at other major and minor salivary gland sites. Also invasion into bone signifies a poorer prognosis. Survival is closely related to the clinical stage and the histologic grade.

46.7.15 Adenoid Cystic Carcinoma

Adenoid cystic carcinoma (ACC) is a highly aggressive, destructive, and clinically unpredictable tumor of the head and neck region [60]. The other terms used for ACC used in the past are cylindroma and adenomyoepithelioma. Foote and Frazell [49] proposed the currently accepted term adenoid cystic carcinoma in their classic paper in 1953 and in their fascicle on major salivary gland tumors in 1954.

46.7.15.1 Clinical Features

Adenoid cystic carcinoma occurs in adults between 50 and 70 years of age with equal prevalence in males and females [61]. The most frequent locations of this tumor are the parotid, submandibular, and palatal salivary glands [62]. They are only rarely observed in the sublingual gland [61].

Clinically adenoid cystic carcinoma manifests in the major and intraoral accessory salivary glands as a slow-growing swelling or mass. Pain and fixation to skin as well as surrounding deeper structures generally occur during the course of tumor growth. An ominous feature of adenoid cystic carcinoma of the parotid gland is paralysis of the facial nerve. Radiographic examination is valuable in assessing the extent of osseous destruction. Symptoms may have been present for months or years and are generally of longer duration than those associated with squamous carcinoma, which is the most frequent malignancy of this location. Adenoid cystic carcinomas of the maxillary antrum, nasal cavity, and ear canal produce symptoms of pain, obstruction, and deafness, respectively.

Histopathologically, ACC are classified into cribriform pattern, tubular pattern, and solid pattern. A major microscopic feature in most adenoid cystic carcinomas is the propensity for the tumor to involve peripheral nerves, reported to occur in 20–80% of the patients. Although perineural invasion is characteristic of adenoid cystic carcinoma, it is not unique to the tumor.

46.7.15.2 Management of Adenoid Cystic Carcinoma

Complete excision like all other tumors is the treatment of choice. Elective regional lymph node dissection is not indicated, because distant metastasis is more common than cervical (regional) node involvement. According to Maciejewski et al., radical surgical excision with histologically proven negative margins with postoperative radiotherapy for all cases should be the treatment of choice. Lymph node dissection is recommended only in cases of histologically proven positive lymph nodes [60]. A frozen section diagnosis to achieve tumor-free safe margins is necessary to specifically look for safe perineural margins because ACC is known to spread quickly along the nerve.

The slow biologic growth of adenoid cystic carcinoma along with a late metastasis of the disease results in relatively favorable 5-year survival rates. Factors that indicate a poor prognosis include failure to achieve clear margins at first surgery, a solid pattern histologically, recurrent disease, and distant metastasis [63].

In a study by Witten et al., local recurrences have been seen in almost 32% of the cases [63]. The risk of distant metastasis is also high, approximately 40%, and can occur in less than 8 years after treatment.

46.7.16 Clear Cell Carcinoma

Clear cell neoplasms of salivary glands have been classified as both adenomas and carcinomas [64].

46.7.16.1 Clinical Features

It occurs predominantly in the palatal minor salivary glands followed by parotid and submandibular glands without any sexual or racial predilection. It occurs between the ages of 18 and 86 years, mean 56 years. Clinical manifestation is of a swelling similar to other tumors. It may be confused with mucoepidermoid and acinic cell carcinoma as well as metastatic renal cell carcinoma. A positive reaction to mucicarmine would preclude the possibility of renal cell carcinoma.

46.7.16.2 Management

Due to their infiltrative growth and the incidence of recurrence and regional lymph node metastases, it is appropriate to consider them low-grade adenocarcinomas. Hence surgical treatment is the mainstay of management.

46.7.17 Epithelial-Myoepithelial Carcinoma

The epithelial-myoepithelial carcinoma of intercalated duct origin is a rare biphasic type of low-grade salivary gland car-

cinoma that constitutes less than 1% of salivary gland neoplasms.

46.7.17.1 Clinical Features

It occurs more commonly in females around 60–70 years of age. Parotid gland is the most frequently affected [65]. Patients present with an asymptomatic or painful salivary gland swelling with a history of steady increase in size over an extended period of time and may also present with facial paralysis [66]. In patients with maxillary involvement, nasal obstruction and facial deformity may be the presenting complaints. Differential diagnosis includes pleomorphic adenoma, acinic cell adenocarcinoma, adenoid cystic carcinoma, mucoepidermoid carcinoma, sebaceous carcinoma, and oncocytoma.

46.7.17.2 Management

Surgery is considered the primary mode of treatment. Total parotidectomy with facial nerve preservation is advocated for tumors in the parotid gland unless the nerve is involved by the tumor. Recurrences and distant metastasis are a known complication.

46.7.18 Carcinosarcoma

Carcinosarcoma, also known as true malignant mixed tumor, shows malignant cells in both the stromal and epithelial components [67]. When these tumors metastasize, both components metastasize together.

46.7.18.1 Clinical Features

Carcinosarcomas are rare tumors with an average incidence of 0.4% in major salivary glands and 1% in minor salivary glands. It occurs between 25 and 85 years of age (average 58.5 years) with the frequency of occurrence being more in parotid than submandibular gland and then minor glands in palate and tongue [67].

It presents as an enlarging mass with a rapid increase in size and may be associated with pain and facial nerve paralysis. Rarely, patients present with metastases or experience difficulty in swallowing or breathing. A patient with a central nervous system metastasis has been reported to present with headaches [67].

46.7.18.2 Management

The data available is insufficient to recommend one type of therapy as definitive. However radical surgical excision, together with radiation therapy and lymph node dissection for palpable disease, seems to be the most prudent form of therapy. Radiotherapy as the only means of therapy has not proved effective. Tumor metastasis is most frequent to the lungs followed by hilar and cervical lymph nodes. Distant metastasis is also rarely found [67].

46.7.19 Undifferentiated Carcinomas

This group includes three distinct entities:

1. *Lymphoepithelial carcinomas (malignant lymphoepithelial lesion)*: It is more prevalent in females and occurs between fourth and fifth decade of life. The parotid gland is most commonly involved followed by submandibular gland. Painful indurated mass and occasional facial paralysis are the presenting symptoms. It might be preceded by benign lymphoepithelial lesion for many years. It is managed by wide surgical excision with or without neck dissection and may be supplemented with radiotherapy.
2. *Undifferentiated large cell carcinomas*: It occurs predominantly in older population with a male predilection. It most commonly affects the parotid followed by submandibular and minor salivary glands. Histologically it shows predominantly poorly differentiated large cell components. It carries a poor prognosis and has a higher risk of locoregional as well as distant metastasis and recurrences. The worst prognostic factor is the size of the lesion. Less than 4 cm, mean survival time was 46 months, and more than 4 cm it was reduced to 7.7 months [51].
3. *Undifferentiated small cell carcinomas*: It rarely affects the salivary glands and is primarily a pulmonary tumor. When it occurs, it shows a male preponderance and occurs between fifth and seventh decade, in the parotid mainly followed by submandibular gland. It presents as a rapidly growing mass which may or may not be painful. Management is primarily wide surgical excision with neck dissection for clinically positive neck node involvement. Chemoradiotherapy may be used as an adjunctive modality for treatment. It tends to metastasize via the hematogenous route, and hence a distant metastasis needs to be ruled out.

46.7.20 Squamous Cell Carcinoma

The diagnosis of primary squamous cell carcinoma is limited to the major glands because distinction between possible minor salivary gland primary tumors and those originating from mucosal surface epithelium is generally not possible.

46.7.20.1 Clinical Features

It occurs between 7 and 95 years of age, the mean age being 60.5 years with a male predilection of 2:1. Parotid gland is the most commonly involved followed by submandibular and sublingual glands [68]. It presents as an asymptomatic mass with occasional pain and facial nerve palsy. This tumor often replaces the entire gland with fixation to underlying structures and skin.

Ductal squamous metaplasia, high-grade mucoepidermoid carcinoma, and lymphoepithelial carcinoma should be considered in the differential diagnosis of squamous cell carcinoma of the salivary gland.

46.7.20.2 Management

Surgical management is the mainstay of treatment. Parotidectomy with or without facial nerve preservation depending on the case is needed for parotid tumors. Submandibular sialadenectomy is needed for submandibular gland tumors. A neck dissection is done in clinically positive necks at the slightest suspicion. Locoregional failure is the most significant problem, and hence a composite resection in larger submandibular malignancies might be needed. Postoperative radiotherapy when combined with surgery may improve the locoregional control [68].

46.8 Surgical Management of Parotid Tumors (Video 46.3)

The following procedures are performed:

- Local excision of the parotid gland
- Superficial parotidectomy
- Functional superficial parotidectomy
- Complete parotidectomy with facial nerve preservation
- Radical parotidectomy with or without neck dissection
- Parotidomandibulectomy
- Temporoparotidectomy

46.8.1 Skin Incisions for Parotidectomy [69]

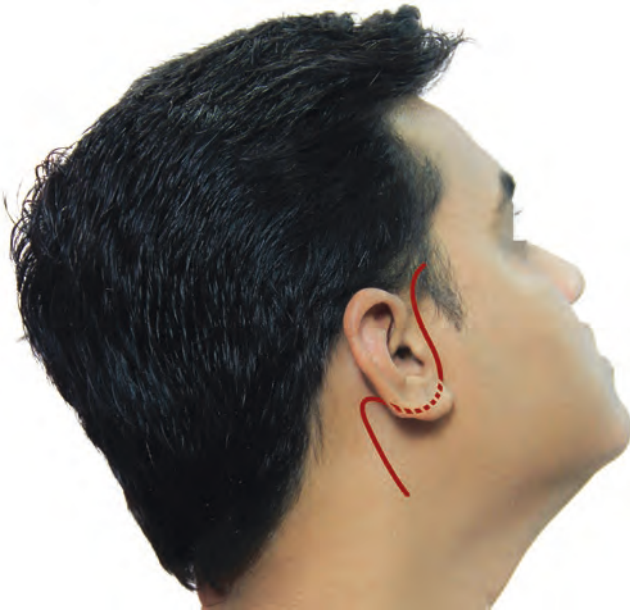The ideal incision should combine good exposure with the best ultimate cosmetic result. This part of the procedure is common to all the resection procedures unless skin is being excised because it is involved by the tumor.

Gutierrez (1903)—The incision had a temporal extension, a preauricular component, and a limb extending onto the neck in one of the skin creases (Fig. 46.22). The chief drawback of this incisions was esthetics in case of development of a keloid.

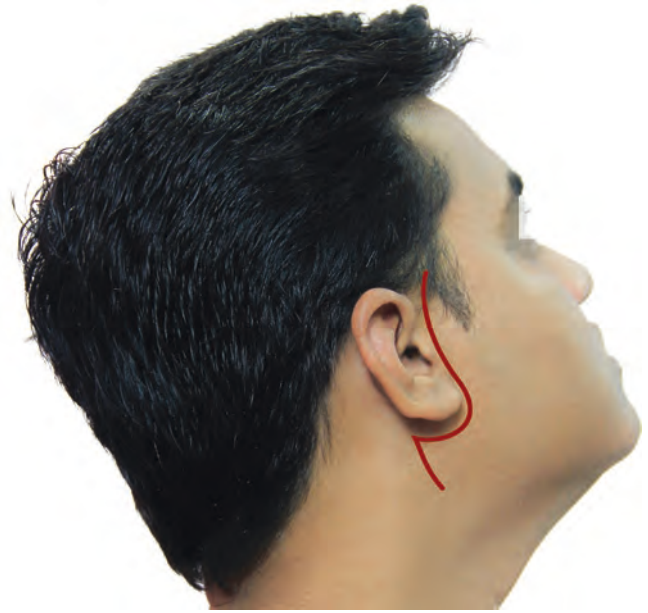Redon and Vaillant and Laudenbach—The incision line is similar to that proposed by Adson (Fig. 46.23).

Adson and Ott have described a “Y”-shaped incision with a preauricular part, a postauricular part, and a cervical incision line that splits off from the site of union of the first two branches (Fig. 46.24). The advantage of this incision is improved esthetics because it lacks a temporal incision line, but the drawback is that it impairs dissection. Also, one section of the incision is located in the carotid region.

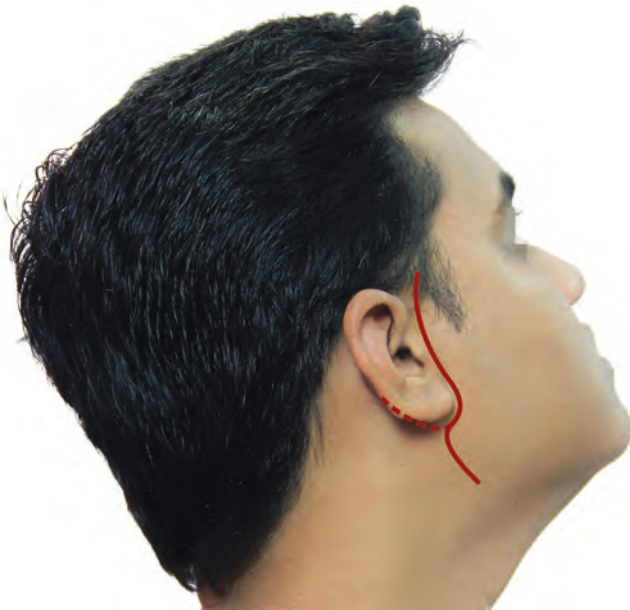Samengo (1961)—The incision has a preauricular, a postauricular, and a neck extension in the incision line (Fig. 46.25).



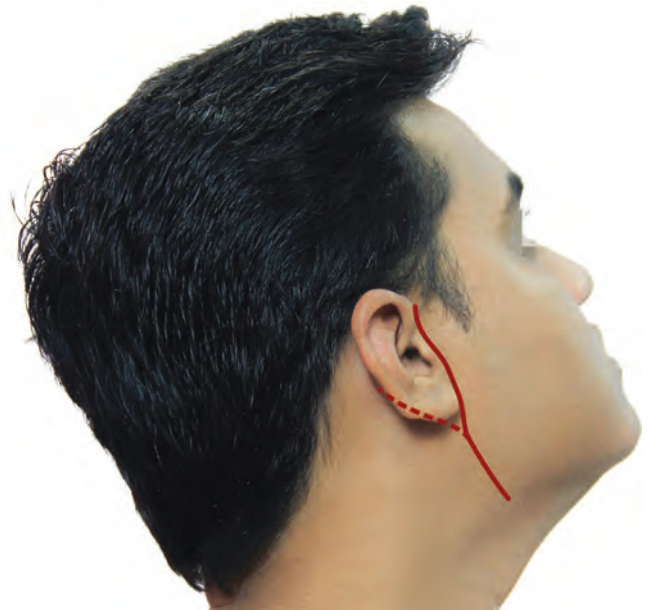©Association of Oral and Maxillofacial Surgeons of India

Fig. 46.22 Gutierrez incision

©Association of Oral and Maxillofacial Surgeons of India

Fig. 46.23 Redon and Valliant and Laudénbach incision

©Association of Oral and Maxillofacial Surgeons of India

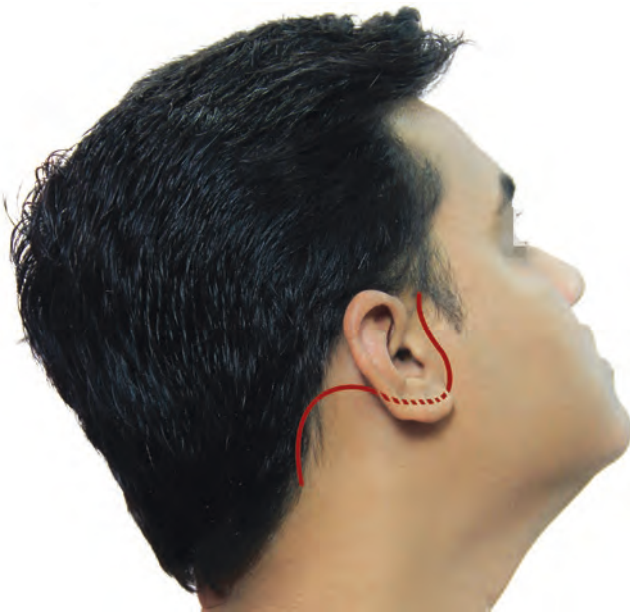Fig. 46.24 Adson and Ott incision

©Association of Oral and Maxillofacial Surgeons of India

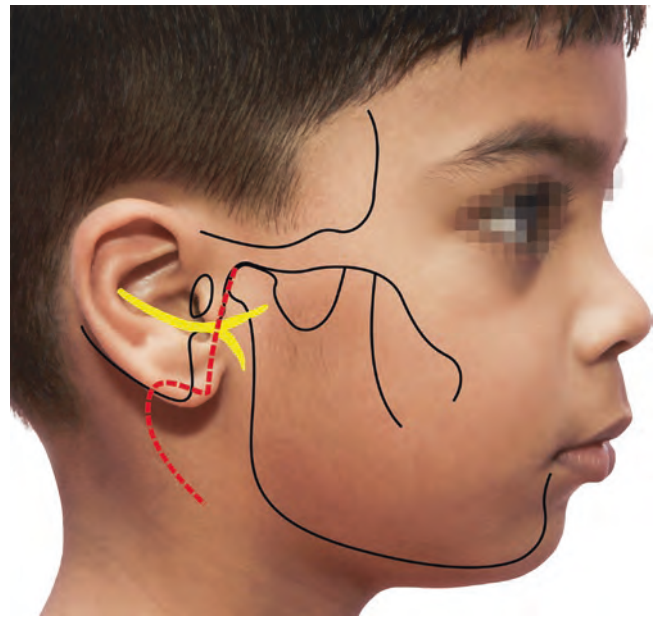
Fig. 46.25 Samengo incision

Appiani (1967)—The incision within the lower portion of the scalp is hidden by the hair instead of the vertical incision line. The benefit of this incision is better esthetics. However, the temporal extension of this incision is short, and this impairs access to the anterior portion of the gland (Fig. 46.26).

Ferreria JL et al. [69] modified Appiani's incision by extending the temporal incision line but not beyond the hair-line. It provides a better access to the anterior portion of the parotid gland without compromising esthetics. Also, the angles are rounded off where the incision line changes direction reducing dehiscence and salivary fistula formation.



©Association of Oral and Maxillofacial Surgeons of India

Fig. 46.26 Appiani's incision

©Association of Oral and Maxillofacial Surgeons of India

Fig. 46.27 Modified Blair incision in pediatric patient

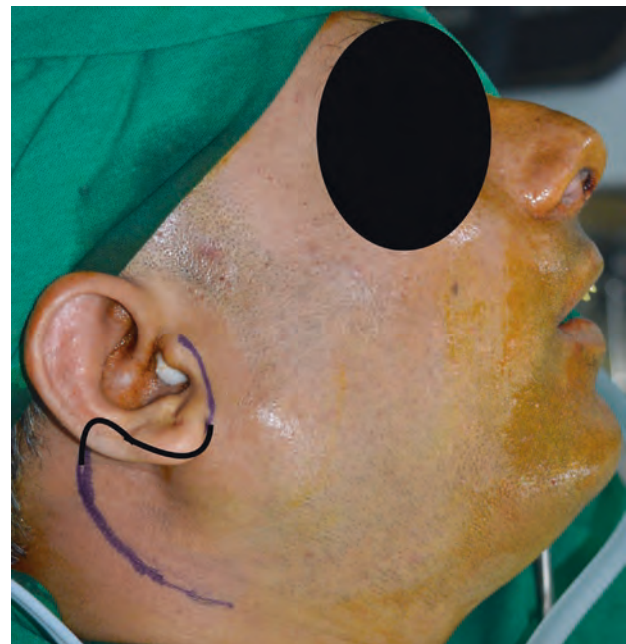Farrior et al. recommended a single curved incision 1.5–2.0 cm below the mandible and extending over the mastoid region 1.5 cm behind the postauricular crease in children. The preauricular crease used in adults is avoided because of the superficial location of the facial nerve and possibility of facial nerve damage during flap elevation [68] (Fig. 46.27).

The Blair incision is an S-shaped incision that starts from the preauricular region and extends in the neck. The major disadvantage of the Blair incision is a visible scar in the neck that may cause facial or cervical disfigurement causing patients dissatisfaction [70].

The standard incision is a modified Blair incision (Fig. 46.28) wherein the skin incision is placed in a preauricular crease and doesn't extend beyond the level of the root of the helix. It extends inferiorly around the ear lobule over the mastoid tip. It gently curves down along the sternocleidomastoid muscle and then slightly forward in a natural crease in the upper neck [71].

A facelift incision can be used to avoid the hollowing after parotidectomy, and the defect can be filled with SMAS advancement flap (Bananno and Casson [72], 1992). However, the SMAS-lifting technique is not a routine procedure for many surgeons [73].

Rai A et al. [74] advocated use of posterior belly of the digastric muscle flap (PBDMF) for reconstruction of the surgical defect after superficial parotidectomy. PBDM inserts very close to stylomastoid foramen, and it is considered as an



©Association of Oral and Maxillofacial Surgeons of India

Fig. 46.28 Modified Blair incision in adults

important landmark in the identification of facial nerve main trunk. The harvesting and dissection of PBDMF becomes easier as it lies in the surgical site, and no extra incision is required to harvest it. It can be used in thin and young patients with good esthetic results.

46.8.2 Identification of the Facial Nerve

This has been previously described in the section on applied anatomy of the parotid gland.

46.8.3 Surgical Management

The selection of type of procedure for surgical management of parotid tumors depends on the site, size and clinicohistopathologic features. The various procedures are described briefly as under:

46.8.3.1 Local Excision of Parotid Gland

This technique is used for management of a small tumor in the tail of the parotid gland less than 3.5 cm. Due to small tumor size, most of the functional gland along with the duct can be preserved.

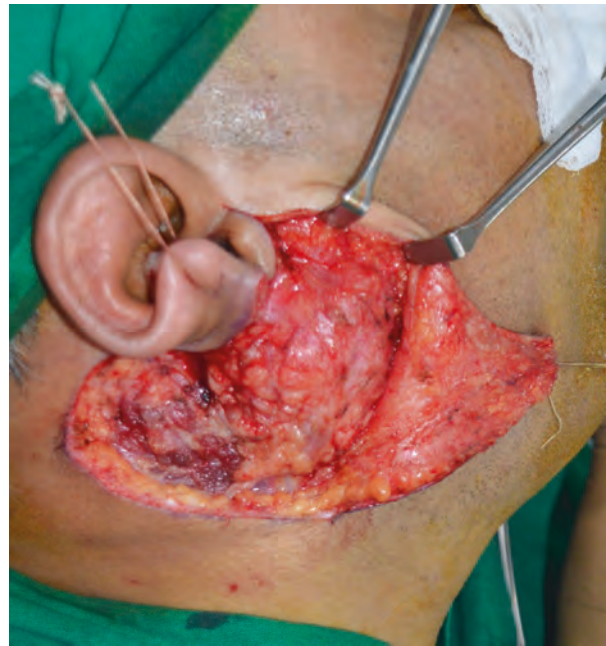46.8.3.2 Parotidectomy with Preservation of the Facial Nerve [75]

After marking the incision, infiltration is usually done with Saline Plus 1 in 200,000 parts adrenaline instead of lignocaine with adrenaline to avoid blocking the facial nerve fibers. In case lignocaine is used, care should be taken to avoid deep injections. Care should be taken to avoid extending the incision too far posterior beneath the ear lobe to avoid persistent edema [75].

The incision in the neck crease is deepened to raise a flap in the subplatysmal plane (Fig. 46.29). The greater auricular nerve is identified and preserved. It branches over the surface of the gland where two or more branches should be followed and then divided.

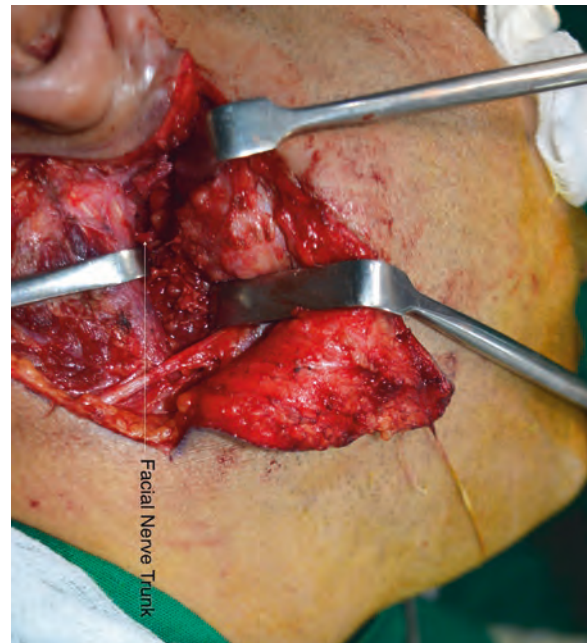
Once the deep fascia has been identified, rest of the wound is deepened to this level and skin reflected forward from it. At the zygomatic bone, some subcutaneous fat should be left on the fascia to avoid damaging the branches of facial nerve which lie more superficially as they emerge from the upper part of the parotid. The main trunk of the nerve is found by first separating the lower pole of the gland from the anterior border of the sternomastoid and then from the mastoid process and the cartilaginous part of the external auditory meatus (Fig. 46.30). The wound is deepened anterior to the margin of the sternomastoid, and the lower pole is dissected free as far forward as the external jugular, uncovering the posterior belly of the digastric muscle. The vein should not be divided and tied at this stage because this will increase the venous engorgement of the parotid and the ooze from its divided tissues.

Neither should the lower pole be raised further forward because the branches of the facial nerve often pass superficial to the vein and emerge from the gland anterior to it. The parotid is retracted forward as the dissection proceeds and



©Association of Oral and Maxillofacial Surgeons of India

Fig. 46.29 Flap raised in the sub platysmal plane exposing the superficial surface of tumor



©Association of Oral and Maxillofacial Surgeons of India

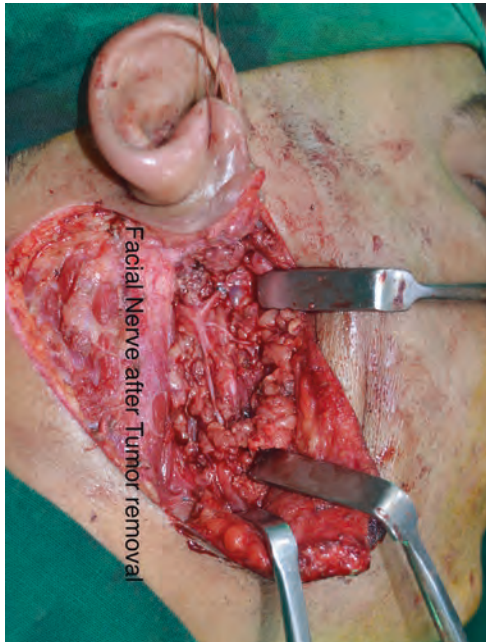Fig. 46.30 Representing facial nerve main trunk

the pointed, lower extremity of the tragal cartilage (pointer) will be uncovered. Where possible, the edge of the fascia should be raised and the underlying tissue separated by blunt dissection until the nerve is seen as white cords some 2–3 mm thick.

The stylomastoid branch of the posterior auricular artery passes superficial to the nerve to enter the stylomastoid foramen. Damage to this vessel should be avoided as bleeding may hamper vision, and also it supplies a nutrient branch to the nerve. The curved mosquito forceps are used for dissection by opening the blades a little at a time to stretch the tissues and raise it, so as to lift the gland substance off the surface of the nerve, and then expose it by cutting through the gland with scissors. At all times when a cut is made, the adjacent nerve must be seen clearly.

Almost immediately the nerve trunk starts to travel laterally within the parotid, and just below the neck of the condyle, it splits into an upper temporofacial and a lower cervicofacial division. Follow the lower division first, and trace the cervical or the marginal mandibular branch anteriorly to a point in front of the parotid to mobilize the lower pole completely. Then by progressing upward, branch by branch further mobilization can be achieved (Fig. 46.31). Some tissue should always be left on the tumor to ensure complete removal.

In general, the nerves pass superficial to the retromandibular vein, but some may pass deep to it. Careful mobilization of both nerve and vein with division and ligation of the latter is necessary. Tiny vessels should be sealed with bipolar diathermy avoiding damage to adjacent nerves.



©Association of Oral and Maxillofacial Surgeons of India

Fig. 46.31 Parotidectomy with preservation of the facial nerve

46.8.3.3 Functional Superficial Parotidectomy [76]

This is superficial parotidectomy where gland function is preserved by preservation of the Stenson's duct. If the duct is superficial to the buccal branch, its preservation is contraindicated as it will obstruct the surgical procedure. After raising the skin flap and exposing the parotid gland, the duct is identified passing on the masseter muscle. Stenson's duct is located; dissection and ligation of the duct are avoided unless it is located superficial to the buccal branches of the facial nerve. Rest of the procedure is similar to superficial parotidectomy.

Advantages

- It is a simpler surgery than conservative superficial parotidectomy.
- It preserves partial function of the parotid gland.
- It avoids the influence of subsequent gland atrophy on facial contour.

It decreases postoperative complications.

46.8.3.4 Partial Superficial Parotidectomy

This is similar to local excision of parotid gland. Maximum healthy tissue is left behind without compromising on the clearance. The advantage of this procedure over superficial parotidectomy is relatively low incidence of Frey's syndrome. The reported incidence of this complication is 4.8% [77]. In addition, better gland function is preserved due to more parenchyma that is left back [78].

46.8.3.5 Intraoral Deep Lobe Tumor Excision [79]

It is a transoral approach used in removal of few benign tumors of the deep lobe, which are easily visible displacing the superior portion of the tonsil and soft palate medially. An incision is made with cautery or knife over the most prominent aspect of the swelling in the tonsil and palate area, extending above and below the apparent location of the tumor. The constrictor muscle is identified, and dissection is continued through thinned constrictor muscle by dividing it above and below the tumor. Pressure on the neck often assists in removal of the tumor. Fascial connections from the tumor into the adjacent bed are removed with blunt dissection, and the tumor is delivered into the mouth. Any vascular connections to the tumor should be cauterized, and meticulous hemostasis should be achieved. The superior and inferior portions of the wound are closed with interrupted sutures. The middle portion of the wound is left open to heal secondarily.

Complications

- Tumor rupture
- Incomplete removal
- Uncontrolled hemorrhage

46.8.3.6 Total Parotidectomy with or Without Facial Nerve Preservation

It is usually indicated in tumors affecting the deep lobe. A neoplasm of the deep part of the parotid enters the soft palate through the interval between the styloid process and the back of the mandible and is often of dumbbell shape with the isthmus lying in this gap. After raising a skin flap, the facial nerve is identified and dissected out leaving a layer of glandular tissue on it. An access osteotomy either in the form of vertical subsigmoid or mandibular body distal to the mental foramen is used to open up the interval between the mandible and the styloid process through which the tumor has passed. The stylohyoid muscle may be divided close to the styloid process and turned forward. The external carotid artery will be encountered emerging above the muscles and should be divided. The origin of the facial artery should be identified to check the identity of the vessel.

As the parotid gland and the tumor are freed, it may be raised up between the two nerve bundles or below both bundles. Next entry is made intraorally over the tumor, and under direct vision tissues are divided to deliver the mass. Care is taken to avoid damaging the internal jugular vein and internal carotid artery which lie deep to styloid process. Following removal of the mass, the wound is irrigated, and the oral tissues closed with care using resorbable suture. The drapes are replaced over the mouth, gloves changed, and the mandibular fragments fixed together and the wound closed in the normal way.

46.8.3.7 Parotidectomy Using SMAS Plane for Dissection [73]

The advantages of this flap are that exposure of the gland is sufficient and the dissection is easy to perform. There is no donor-site morbidity, minimum additional operating time, and no extra cost. It seems to decrease the incidence of Frey's syndrome. The speed of the recovery of the facial nerve has been highlighted in the literature. It is more satisfactory from the patient's point of view.

46.8.3.8 Parotidomandibulectomy and Temporoparotidectomy [80]

Parotidomandibulectomy is indicated where there is invasion of the mandible by a malignant neoplasm.

In temporoparotidectomy, small-scale resection of the external auditory canal may be included with the excision of the

pinna and overlying skin of the parotid where these structures are involved. The deficiency may be made good with a deltopectoral or other suitable flap.

46.8.4 Parotidectomy in Continuity with Neck Dissection

In the case of lymph node metastasis as stated in surgical pathology, neck dissection can be done in continuity with parotidectomy by increasing the neck skin crease incision and clearing the lymphatic structures.

46.8.5 Complications of Parotid Surgery

- Facial paresis or paralysis often results from poor technique and failure to preserve small nerve branches.
- Bleeding and hematoma formation, which can significantly compromise the airway.
- Rarely, persistent salivary leakage or sialocele formation occurs.
- Frey's syndrome.
- Skin flap necrosis.

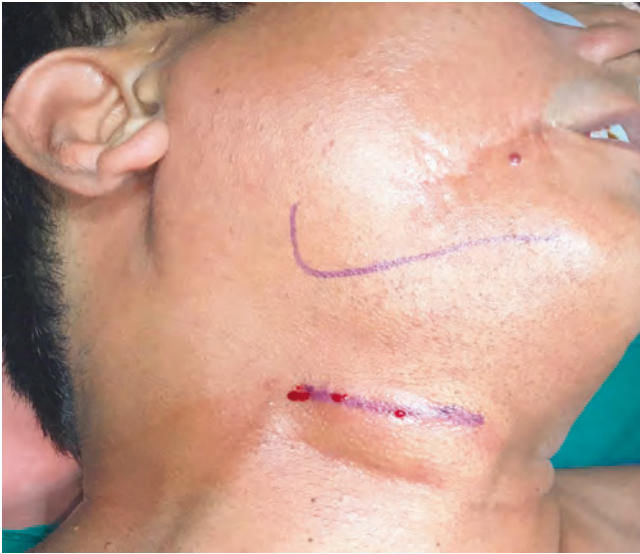46.9 Surgical Management of Submandibular and Sublingual Gland Tumors

Small tumors confined to the gland are treated by sialadenectomy, and tumors spreading beyond the confines of the gland are treated with a wider en bloc excision, which may include resection of the floor of mouth and mandible depending on extent of tumor. The neurotropic tumors might involve the lingual, hypoglossal, mylohyoid, and marginal mandibular nerve leading to a perineurial spread which can be confirmed on frozen section. Thickening and nodularity of the nerves may indicate perineurial involvement [81].

46.9.1 Incision

For submandibular sialadenectomy, a skin crease incision below 3 cm from the lower border of mandible is taken to avoid damaging the marginal mandibular nerve which loops below the lower border of the mandible (Fig. 46.32).

For simple excision of the sublingual gland, an incision is made in the floor of the mouth lateral to the submandibular



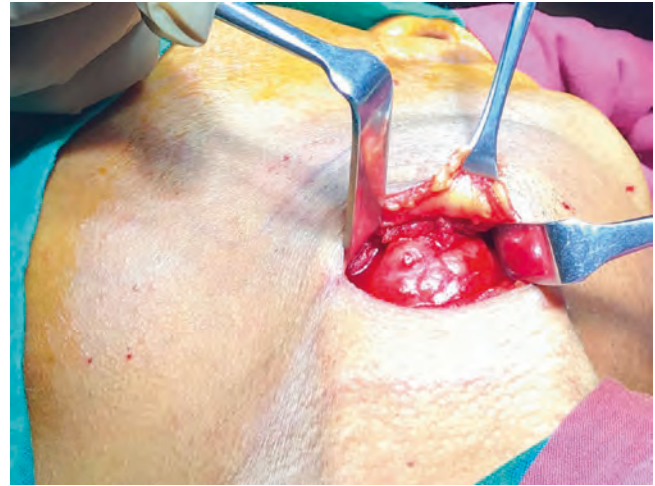
©Association of Oral and Maxillofacial Surgeons of India

Fig. 46.32 Submandibular incision

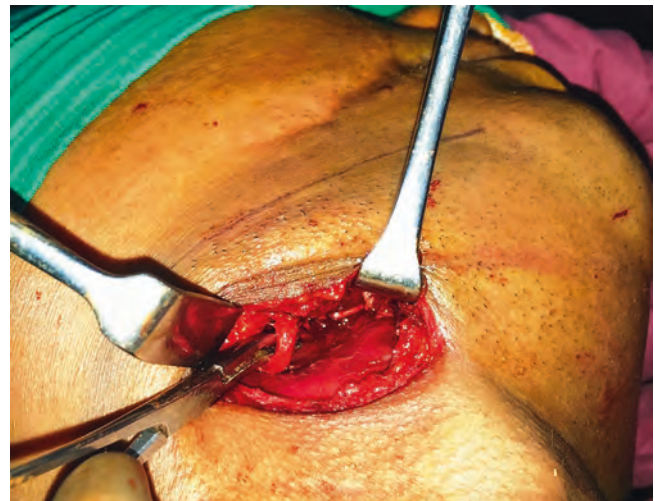duct taking care to limit it up to premolar region, as at the molar region, there is a chance to damage the lingual nerve. When sublingual gland excision is necessary for a tumor, it should be removed with a wide margin including a rim resection of the mandible.

46.9.2 Extracapsular Excision of the Submandibular Salivary Gland [82]

After making an incision in the neck crease, skin flap is raised in the subplatysmal plane (Fig. 46.33). The capsule of the gland should be left intact when the sialadenectomy is being done for a tumor, which might compromise the marginal mandibular nerve. The facial artery and nerve are identified as close to the gland as possible. After transection, they are elevated superiorly to identify and reflect the marginal mandibular nerve. Nowadays the facial artery is spared during surgery to allow free flap anastomosis during oncosurgeries (Fig. 46.34). The investing fascia is then divided at the lower border of mandible, and the gland is delivered out from between the anterior and posterior bellies of the digastric muscle. Anteriorly the gland is separated from the mylohyoid muscle, and lingual nerve, hypoglossal nerve, and Wharton's duct are identified. The lingual nerve shares the same facial sheath as the gland at the upper pole. This attachment of the lingual nerve to the gland represents its parasympathetic supply. The Wharton's duct is inferior to lingual nerve and is often surrounded by sublingual glands. As fascia and gland are mobilized upward from the surface of the hypoglossus, the hypoglossal nerve is identified more inferiorly. It is accompanied by ranine vein. Posteriorly the angular tract



©Association of Oral and Maxillofacial Surgeons of India

Fig. 46.33 Submandibular gland exposure with subplatysmal dissection

©Association of Oral and Maxillofacial Surgeons of India

Fig. 46.34 Facial artery preservation in submandibular sialadenectomy

of fascia has to be cut with scissors to allow the gland in its fascial envelope to be drawn down without grasping the gland with instruments. Where necessary the upper pole may be mobilized via the mouth. An assistant can then depress the gland toward the submandibular wound to enable the operation to be concluded.

The duct and the branch of the lingual nerve supplying the submandibular gland are ligated and transected. The duct is divided close behind the papilla. During excision for inflammatory disease, the nerve is always separated from the gland with knife or scissors. However, if the nerve appears to be involved in a tumor, it is sectioned in front of and behind the gland and the cut ends sutured. The wound is closed in layers with drainage in the usual way.

46.10 Management of Minor Salivary Gland Tumors

Surgical resection of minor salivary gland tumors depends on the site of origin and extent of disease. This may range from a wide local excision of localized low-grade tumors to more radical excision, including marginal or segmental mandibulectomy and/or partial or total resection of the hard or soft palate, partial or total maxillectomy, infratemporal fossa dissection, and/or anterior craniofacial resection for larger and/or high-grade tumors. The V2 and V3 divisions of the trigeminal nerve are at potential risk for perineural spread of minor salivary gland malignancy and may facilitate an early skull base metastasis. Resection of the cranial base may be required in some cases to eradicate the tumor and obtain negative surgical margins [81].

46.10.1 Excision of Palatal Pleomorphic Adenomas [83]

Small pleomorphic adenomas on the palate can cause pressure resorption of the bone but do not cause true bony invasion. They are managed by local excision along with the periosteum. In the case of involvement of greater palatine foramen area, the lesion is freed until it can be drawn down, and the vessels clamped and cauterized under direct vision. If not, the vessel retracts into the canal and causes irritating bleeding. The wound is left to granulate secondarily.

46.10.2 Excision of Palatal Mucoepidermoid Carcinoma [83]

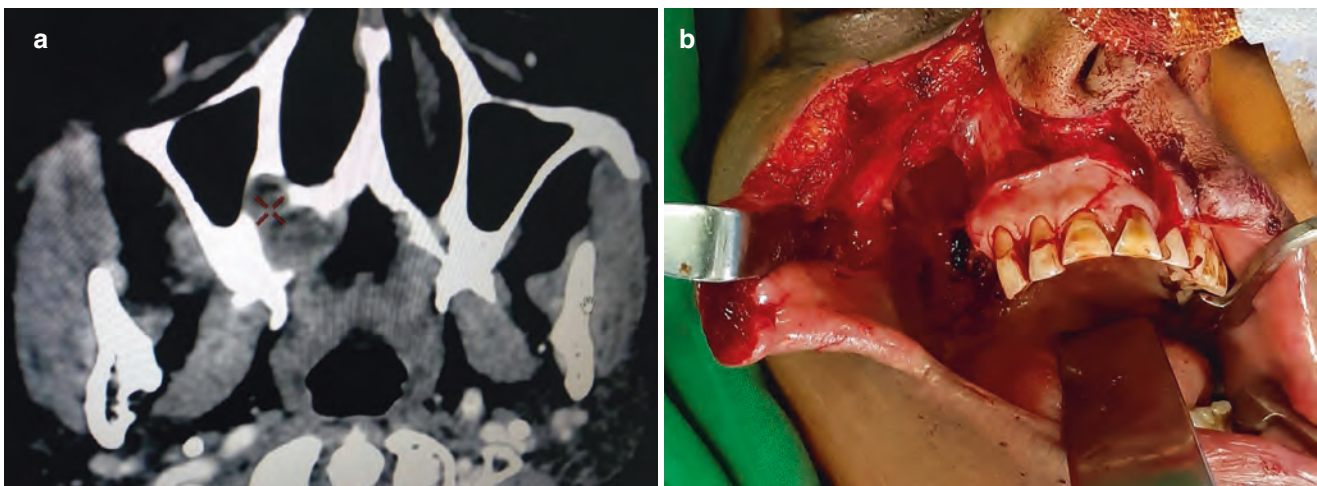
Low-grade mucoepidermoid carcinomas may be treated by the excision of a full-thickness disk of palate, including palatal and alveolar bone. Nasal and oral mucous membranes are sutured together around the defect in the soft palate. Primary reconstruction is avoided and an obturator is used instead (Fig. 46.35a, b).

46.10.3 Excision of Palatal Adenoid Cystic Carcinoma [83]

Spread along the perineurial tissues makes an inadequate surgical margin very likely after surgical management of ACC. A combination of surgery and radiotherapy is best. Surgical excision should be generous. Hemimaxillectomy including the orbital floor is a minimum, unless there is very good evidence that less will be sufficient. Where the soft palate and pterygoid region are involved, extended maxillectomy approach is essential to ensure adequate excision under direct vision.

46.10.4 Excision of Neoplasms of the Cheek and Lips

A primary excision with a margin of normal adjacent tissue can be used, but if there is any doubt, it can be preceded by a biopsy. Re-operation following incomplete extirpation



©Association of Oral and Maxillofacial Surgeons of India

Fig. 46.35 (a) CT scan showing mucoepidermoid carcinoma of palate (red arrow). (b) Surgical excision of tumor using standard Weber-Ferguson incision

could mean the unnecessary sacrifice of tissue to ensure an adequate margin on the second occasion. Clinically aggressive neoplasms must be biopsied, since adequate treatment may involve radiotherapy and full-thickness excision and repair.

More aggressive tumors affecting the palatal salivary glands are managed by partial maxillectomy or total maxillectomy or extended maxillectomy based on the extent of disease.

46.10.5 Complications

- A hematoma may develop in the dead space after gland excision. It can be avoided by meticulous hemostasis and placement of suction drain to clear out any collection. In case a hematoma develops, it can be aspirated or sucked under aseptic precautions. However, it may not be completely effective. The patient can be just put on good antibiotic coverage, and it will resolve without getting infected.
- Trismus occurs due to masseter muscle spasm or inflammation in the TMJ. It generally resolves spontaneously and hence should be just managed symptomatically.
- Salivary fistula occurs uncommonly due to discontinuity between the residual salivary gland parenchyma and the salivary duct. In majority of cases, the problem is self-limiting. Management includes repeated aspiration, pressure dressings, wound care, an antisialogogue medication (glycopyrrolate), and patience.
- Facial nerve dysfunction results from traction injury to the facial nerve (neuropraxia) during dissection in parotid surgery. Complete recovery within a few months can be expected if nerve integrity has been maintained. In case the nerve is transected, it should be followed by immediate nerve grafting repair.
- Auriculotemporal syndrome of Frey is also called gustatory sweating. It manifests as flushing and sweating of the skin of upper cheek, temporal region, and forehead coincident with eating and smelling of food. Following damage to the auriculotemporal nerve or to communicating branches to the facial nerve, secretomotor parasympathetic nerves from the otic ganglion and also sympathetic fibers to the sweat glands traveling in the same nerve are divided. Following regeneration, fibers from otic ganglion come to supply the sweat glands. Minor's starch-iodine test is used for diagnosis [78]. It can be managed by simple treatment of antiperspirant application; 1% local application of glycopyrrolate is effective. The only effective cure is to divide the parasympathetic fibers from the glossopharyngeal nerve.

Sensory abnormalities associated with greater auricular nerve sacrifice, reflect as sensory deficit in the lower third of

pinna including earlobe as well as adjacent preauricular and postauricular skin.

46.11 Recent Advances [84]

Robotic sialadenectomy of the submandibular gland has been done via a modified face lift approach. Virgilio et al. performed robotic sialadenectomy of the submandibular gland in five patients (two patients each with sialolithiasis and pleomorphic adenoma and one patient of ranula) with success. They used three robotic arms, two operative arms, and a facedown 30° endoscopic arm. The operative left arm is equipped with Maryland forceps and right arm with harmonic scalpel.

46.12 Conclusion

Salivary gland pathologies may be neoplastic, non-neoplastic, inflammatory, or non-inflammatory. Early surgical intervention after a good clinical, radiological, and histopathological diagnosis is need of an hour to minimize the postoperative complications. Early diagnosis and management with recent advanced technologies is the key factor in achieving excellent prognosis of the disease.

Acknowledgment Author wishes to thank Dr. Anshul Rai for Figs. 46.3, 46.4, 46.9, 46.13, 46.17a, b, and 46.20.

Author wishes to thank Dr. Kedar Saraf, Professor, Dept. of OMDR, SMBT Institute of Dental Sciences, Sangamner, Maharashtra, for Figs. 46.11a, b, and 46.12.

References

1. Saunders PR, Macpherson DW. Acute suppurative parotitis: a forgotten cause of upper airway obstruction. *Oral Surg Oral Med Oral Pathol.* 1991;72:412–4.
2. Hollinshead WH. The face. *Anatomy for surgeons: Vol I. The head and neck.* 3rd ed. Philadelphia: Harper and Row Publishers; 1982. p. 291–324. Chapter 6.
3. Cawson R, Gleeson M. Anatomy and physiology of the salivary glands. In: Gleeson M, editor. *Scott-Brown's otolaryngology. Basic sciences.* 6th ed. Great Britain: Butterworth Heinemann; 1997. Chapter 9, p. 1/9/1–1/9/18.
4. Snell RS. The head and neck. *Clinical anatomy.* 7th ed. Philadelphia: Lippincott Williams and Wilkins; 2004, Chapter 11, p. 719–922.
5. McGregor IA, McGregor FM. Salivary glands. *Cancer of the face and mouth. Pathology and management for surgeons.* Edinburgh: Churchill Livingstone; 1986. Chapter 25, p. 569–606.
6. Rankow RM, Polayes IM. *Surgical anatomy and diagnosis. Diseases of Salivary glands.* Philadelphia: W.B. Saunders; 1976. Chapter 7, p. 156–84.
7. Borle RM, Jadhav A, Bhola N, Hingnikar P, Gaikwad P. Borle's triangle: a reliable anatomical landmark for ease of identification of facial nerve trunk during parotidectomy. *J Oral Biol Craniofac Res.* 2019;9(1):33–6.

8. Wetmore SJ. Surgical landmarks for the facial nerve. *Otolaryngol Clin N Am.* 1991;24(3):505–30.
9. Farrior JB, Santini H. Facial nerve identification in children. *Otolaryngol Head Neck Surg.* 1985;93:173.
10. Pather N, Osman M. Landmark of facial nerve: implication for parotidectomy. *Surg Radiol Anat.* 2006;28(2):170–5.
11. <http://apps.who.int/classifications/apps/icd/icd10online2003/fr-icd.htm>
12. Norman JE, McGurk M. Salivary gland imaging. In: Morse MH, editor. *Color atlas and text of Salivary glands – diseases, disorders and surgery.* Wolfe, Spain: Mosby; 1995. p. 105–27.
13. Lowman RM, Cheng GK. Diagnostic roentgenology. In: Rankow RM, Polayes IM, editors. *Diseases of salivary glands.* Philadelphia: W.B. Saunders; 1976. Chapter 4, p. 54–98.
14. DelBalso A. Salivary imaging. *Oral Maxillofac Surg Clin N Am.* 1995;7(3):387–422.
15. Taylor & Francis. *Acta Oto-Laryngologica.* 1998;118 Suppl 538:214–20.
16. Kim D, Uy C, Mandel L. Sialosis of unknown origin. *N Y State Dent J.* 1998;64(7):38–40.
17. McQuone SJ. Acute viral and bacterial infections of the salivary glands. *Otolaryngol Clin N Am.* 1999;32(5):793–811.
18. Nahlieli O, Bar T, Shacham R. Management of chronic recurrent parotitis: current therapy. *J Oral Maxillofac Surg.* 2004;62:1150–5.
19. Work WP, Hecht DW. Inflammatory diseases of the major salivary glands. In: Papparella MM, Shumrick DF, editors. *Otolaryngology, vol. 3.* Philadelphia: WB Saunders; 1980. p. 2235–43.
20. Williams MF. Sialolithiasis. *Otolaryngol Clin N Am.* 1999;32(5):819–34.
21. Lustmann J, Regev E, Melamed Y. Sialolithiasis: a survey on 245 patients and a review of literature. *Int J Oral Maxillofac Surg.* 1990;19:135–8.
22. Kawaguchi K, Yamada H, Iida N, Horie A, Sato J, Seto K. Sialodochoplasty to treat sialoliths using a microsurgical technique. *Br J Oral Maxillofac Surg.* 2008;46(7):607–8.
23. Park JH, Kim JW, Lee YM, Oh CW, Chang HS, Lee SW. Long-term study of sialodochoplasty for preventing submandibular sialolithiasis recurrence. *Clin Exp Otorhinolaryngol.* 2012;5(1):34–8.
24. Arrieta AJ, McCaffrey TV. Inflammatory disorders of Salivary glands. In: Cummins *Otolaryngology – head and neck surgery.* 4th ed. Mosby; 2005. Part 5. Chapter 58, p. 1323–38.
25. Agni N, Borle R. Non neoplastic diseases. In: *Salivary gland pathologies.* Jaypee; 2013. Chapter 7, 54–89.
26. Rice DH. Salivary gland disorders: neoplastic and nonneoplastic. *Med Clin N Am.* 1999;83(1):197–217.
27. Mandel L. Inflammatory disorders – clinicopathologic considerations. *Diseases of salivary glands.* In: Rankow RM, Polayes IM, editors. Philadelphia: W.B. Saunders; 1976. Chapter 9, Part 1, p. 202–38.
28. Shafer WG, Hine MK, Levy BM. Tumors of salivary glands. A textbook of oral pathology. 4th ed. Singapore: Harcourt Asia PTE Ltd.; 1993. Chapter 3, p. 231–57.
29. Manoussakis MN, Moutsopoulos HM. Sjögren's syndrome. *Otolaryngol Clin N Am.* 1999;32(5):843–60.
30. Trott MS, Hughes GB, Calabrese LH. Hearing and Sjögren's syndrome. *Ear Nose Throat J.* 1996;75:666.
31. Yamasoba T, Tayama N, Syoji M, et al. Clinicostatistical study of lower lip mucoceles. *Head Neck.* 1990;12:316.
32. Marx DE, Stern D. Non-neoplastic salivary gland disease. In: *Oral and maxillofacial pathology: a rationale for diagnosis and treatment.* New Delhi: Quintessence Publishing; 2003. Chapter 11, p. 497–527.
33. Huang I, et al. Treatment of mucocele of the lower lip with carbon dioxide laser. *J Oral Maxillofac Surg.* 2007;65:855–8.
34. Baumash HD. Mucoceles and ranulas. *J Oral Maxillofac Surg.* 2003;61:369–78.
35. Harrison JD. Modern management and pathophysiology of ranula: literature review. *Head Neck.* 2010;32:1310.
36. Kono M, et al. Evaluation of OK-432 injection therapy as possible primary treatment of intraoral ranula. *J Oral Maxillofac Surg.* 2017;75:336–42.
37. Schneider AB, Favus MJ, Stachura ME, et al. Salivary gland neoplasms as a late consequence of head and neck irradiation. *Ann Intern Med.* 1977;87(2):160–4.
38. Tsai CC, Chen CL, Hsu HC. Expression of Epstein-Barr virus in carcinomas of major salivary glands: a strong association with lymphoepithelioma-like carcinoma. *Hum Pathol.* 1996;27(3):258–62.
39. Sadetzki S, Oberman B, Mandelzweig L, et al. Smoking and risk of parotid gland tumors: a nationwide case-control study. *Cancer.* 2008;112(9):1974–82.
40. Spitz MR, Batsakis JG. Major salivary gland carcinoma. Descriptive epidemiology and survival of 498 patients. *Arch Otolaryngol.* 1984;110(1):45–9.
41. Van Der Waal I. Salivary gland neoplasms. In: Van Der Waal I, Prabhu SR, Wilson DF, Daftary DK, Johnson NW, editors. *Oral diseases in the tropics.* Delhi: Oxford University Press; 1993. Chapter 41, p. 478–86.
42. Amin MB, Edge SB, Greene FL, et al., editors. *AJCC cancer staging manual.* 8th ed. New York: Springer; 2017.
43. Seifert G, Sobin LH. The World Health Organization's histological classification of salivary gland tumors. A commentary on the second edition. *Cancer.* 1992;70(2):379–85.
44. Seifert G. Diagnosis and prognosis of salivary gland tumors. An interpretation of new revised WHO classification. *Mund Kiefer Gesichtschir.* 1997;1(5):252–67.
45. Seethala RR, Stenman G. Update from the 4th edition of the World Health Organization classification of head and neck tumours: tumors of the salivary gland. *Head Neck Pathol.* 2017;11(1):55–67.
46. Ord RA. Surgical management of Parotid tumors. *Oral Maxillofac Surg Clin N Am.* 1995;7(3):529–64.
47. Cornog JL, Gray SR. Surgical and clinical pathology of salivary gland tumors. In: Rankow RM, Polayes IM, editors. *Diseases of salivary glands.* Philadelphia: W.B. Saunders; 1976. Chapter 5, p. 99–142.
48. Waldron CA. Mixed tumor (Pleomorphic adenoma) and Myoepithelioma. In: Ellis GL, editor. *Surgical pathology of the salivary glands.* Philadelphia: W.B. Saunders; 1991. Chapter 10, p. 165–86.
49. Foote FW, Frazell EL. Tumours of the major salivary glands. *Cancer.* 1953;6:1065–133.
50. Papadogeorgakis N, Skouteris CA, Mylonas AI, Angelopoulos AP. Superficial parotidectomy: technical modifications based on tumor characteristics. *J Cranio Maxillofac Surg.* 2004;32:350–3.
51. Batsakis JG. Tumors of the head and neck – Clinical and pathological considerations. 2nd ed. Baltimore: Williams and Wilkins; 1979. Chapter 1.
52. Warnock GR. Papillary cystadenoma lymphomatosum (Wharton's tumor). In: Ellis GL, editor. *Surgical pathology of the salivary glands.* Philadelphia: W.B. Saunders; 1991. Chapter 11, p. 187–201.
53. Goode RK. Oncocytoma. In: Ellis GL, editor. *Surgical pathology of the salivary glands.* Philadelphia: W.B. Saunders; 1991. Chapter 13, p. 225–37.
54. Kratochvil FJ. Canalicular adenoma and Basal cell adenoma. In: Ellis GL, editor. *Surgical pathology of the salivary glands.* Philadelphia: W.B. Saunders; 1991. Chapter 12, p. 202–24.
55. Ellis GL, Auclair PL. Ductal papillomas. In: Ellis GL, editor. *Surgical pathology of the salivary glands.* Philadelphia: W.B. Saunders; 1991. Chapter 14, p. 238–51.
56. White DK, Miller AS, McDaniel RK, Rothman BN. Inverted ductal papilloma: a distinctive lesion of minor salivary gland. *Cancer.* 1982;49:519–24.

57. Auclair PL, Ellis GL. Mucoepidermoid carcinoma. Surgical pathology of the salivary glands. Philadelphia: W.B. Saunders; 1991. Chapter 16, p. 269–98.
58. Healey WV, Perzin KH, Smith L. Mucoepidermoid carcinoma of salivary gland origin: classification, clinical-pathologic correlation, and results of treatment. *Cancer*. 1970;26:368–88.
59. Olsen KD, Devine KD, Weiland LH. Mucoepidermoid carcinoma of the oral cavity. *Otolaryngol Head Neck Surg*. 1981;89:783–91.
60. Maciejewski A, Szymczyk C, Wierzgon J. Outcome of surgery for adenoid cystic carcinoma of head and neck region. *J Cranio-Maxillofac Surg*. 2002;30:59–61.
61. Tomich CE. Adenoid cystic carcinoma. In: Ellis GL, Auclair PL, Gnepp DR, editors. *Surgical pathology of the salivary glands*. Philadelphia: W.B. Saunders; 1991. Chapter 19, p. 333–49.
62. Kim KH, Sung MW. Adenoid cystic carcinoma of the head and neck. *Arch Otolaryngol Head Neck Surg*. 1994;120:721–6.
63. Witten J, Hybert F, Hansen HS. Treatment of malignant tumors in the parotid glands. *Cancer*. 1990;65:2515–20.
64. Auclair PL, Ellis GL. Clear cell carcinoma. In: Ellis GL, Auclair PL, Gnepp DR, editors. *Surgical pathology of the salivary glands*. Philadelphia: W.B. Saunders; 1991. Chapter 22, p. 379–89.
65. Corio RL. Epithelial – myoepithelial carcinoma. In: Ellis GL, Auclair PL, Gnepp DR, editors. *Surgical pathology of the salivary glands*. Philadelphia: W.B. Saunders; 1991. Chapter 24, p. 412–21.
66. Corio RL, Sciubba JJ, Brannon RB, Batsakis JG. Epithelial-myoepithelial carcinoma of intercalated duct origin. *Oral Surg Oral Med Oral Pathol*. 1982;53:280–7.
67. Gnepp D, Wenig B. Malignant mixed tumors. In: Ellis GL, Auclair PL, Gnepp DR, editors. *Surgical pathology of the salivary glands*. Philadelphia: W.B. Saunders; 1991. Chapter 20, p. 350–68.
68. Speight PM, Barrett AW. Salivary gland tumours. *Oral Dis*. 2002;8(5):229–40.
69. Ferreria JL, Maurino N, Michael E, Ratnoff M, Rubio E. Surgery of the Parotid region: a new approach. *J Oral and Maxillofac Surg*. 1990;48:803–7.
70. Blair VP, editor. *Surgery and diseases of the mouth and jaw*. 3rd ed. St Louis: Mosby; 1918.
71. Hanna EY, Lee S, Fan CY, Suen JY. Benign neoplasms of the salivary glands. In: Haughley BH, editor. *Cummings otolaryngology head and neck surgery*. vol. II, 4th ed. Elsevier Mosby; 2005. Chapter 60, p. 1348–77.
72. Bananno PC, Casson PR. Frey's syndrome: a preventable phenomenon. *Plast Reconstr Surg*. 1992;89(3):452–6.
73. Meningaud JP, Bertolus C, Bertrand JC. Parotidectomy: assessment of a surgical technique including facelift incision and SMAS advancement. *J Cranio-Maxillofac Surg*. 2006;34:34–7.
74. Rai A, et al. Posterior belly of digastric muscle flap for contour deformity correction after superficial parotidectomy. *J Stomatol Oral Maxillofac Surg*. 2018;119(4):304–6.
75. Johns M, Nachlas N. Salivary gland tumors. In: Paperella M, Shumrick D, Gluckman J, Meyerhoff W, editors. *Otolaryngology*. vol. 3, 3rd ed. Philadelphia: W.B. Saunders; 1991. Chapter 20, p. 2099–127.
76. Kun Z, Dao-Yi Q, Li-Min W. Functional superficial parotidectomy. *J Oral Maxillofac Surg*. 1994;52:1038–41.
77. Papadogeorgakis N, Skouteris CA, Mylonas AI, Angelopoulos AP. Superficial parotidectomy: technical modifications based on tumor characteristics. *J Cranio Maxillofac Surg*. 2004;32:350–3.
78. Yamashita T, Tomoda K, Kumazawa T. The usefulness of partial parotidectomy for benign parotid gland tumors. *Acta Otolaryngol*. 1993;500:113–6.
79. Olsen KD. Intraoral salivary gland tumor removal. Section I. Head and neck. In: Bailey BJ, Calhoun KH, Friedman NR, Newlands SD, Vrabec JT, editors. *Atlas of head and neck surgery – Otolaryngology*. 2nd ed. Philadelphia: Lippincott Williams & Wilkins. p. 6–7.
80. Shah JP. Color atlas of operative techniques in head and neck surgery. England: Wolfe Medical. p. 117–33.
81. Hanna EY, Suen JY. Malignant tumors of the salivary glands. In: Myers EN, Suen JY, Myers JN, Hanna EY, editors. *Cancer of the head and neck*. 4th ed. Saunders; 2003. Chapter 21, p. 475–510.
82. Seward GR. Nodular enlargement of a salivary gland. In: Moore J, editor. *Surgery of the mouth and jaws*. London: Blackwell Scientific; 1985. Chapter 38, p. 676–99.
83. Hanna EY, Suen JY. The Parotid neoplasm. Section 22. Controversies in otolaryngology. In: Pensak ML, editor. *New York: Publication Thieme*; 2001. Chapter 66, p. 348–54.
84. Virgilio DA, et al. Robotic sialoadenectomy of the submandibular gland via a modified face-lift approach. *Int J Oral Maxillofac Surg*. 2012;41:1325–9.

Additional Reading

- Barnes L, Eveson JW, Reichart P, Sidransky D. World Health Organization classification of tumours. Pathology and genetics of head and neck tumours. vol. 9. Lyon: IARC; 2005.
- Kennedy RA. WHO is in and WHO is out of the mouth, salivary glands, and jaws sections of the 4th edition of the WHO classification of head and neck tumours. *Br J Oral Maxillofac Surg*. 2018;56(2):90–5.
- McGurk M, Combes J. *Controversies in the management of salivary gland disease*. 2nd ed. Oxford University Press; 2013.

Open Access This chapter is licensed under the terms of the Creative Commons Attribution 4.0 International License (<http://creativecommons.org/licenses/by/4.0/>), which permits use, sharing, adaptation, distribution and reproduction in any medium or format, as long as you give appropriate credit to the original author(s) and the source, provide a link to the Creative Commons license and indicate if changes were made.

The images or other third party material in this chapter are included in the chapter's Creative Commons license, unless indicated otherwise in a credit line to the material. If material is not included in the chapter's Creative Commons license and your intended use is not permitted by statutory regulation or exceeds the permitted use, you will need to obtain permission directly from the copyright holder.



Obstructive Salivary Gland Disease and Sialendoscopy

Prithvi S. Bachalli and Aditya Moorthy

47.1 Introduction

Salivary gland diseases have been described in the literature for centuries. From the time of Hippocrates to the descriptions of parotid tumours in the sixteenth century and the anatomical descriptions of the ductal systems of the major salivary glands in the seventeenth century, we have assimilated knowledge of anatomy and pathology of these glands [1].

The conventional approach to infections of the salivary glands is medical management, occasional expression of the stone through the papilla, marsupialisation of the duct following removal of sialolith. Failing all, removal of the involved gland [2].

Minimally invasive surgery especially those in which endoscopes are utilized has gradually become popular over the last three decades. As a whole, the trend in surgery is to improve function and hasten recovery. To achieve these ends, a combination of technology and smaller incisions has been crucial. Hence there is an increasing interest to manage salivary gland diseases endoscopically [3].

Sialendoscopy is the endoscopic management of obstructive salivary ductal disease and has rapidly become the procedure of choice for such conditions.

47.2 Obstructive Salivary Diseases

Salivary gland diseases can broadly be classified into ductal and parenchymal disorders.

Electronic Supplementary Material The online version of this chapter (https://doi.org/10.1007/978-981-15-1346-6_47) contains supplementary material, which is available to authorized users.

P. S. Bachalli (✉) · A. Moorthy
Department of Oral and Maxillofacial Surgery, Rangadore Memorial Hospital, Apollo Hospitals,
Bangalore, Karnataka, India

Some conditions, such as Sjögren's syndrome and juvenile recurrent parotitis, tend to have an overlapping component and thus are difficult to segregate.

Ductal obstructions can be commonly attributed to-

- Sialoliths,
- Strictures within the duct or at the punctum,
- Presence of mucous plugs, and
- Retrograde bacterial infection.

The majority of obstructive salivary gland disease can be attributed to the presence of stones or sialoliths. Almost 60–70% of reported obstructive salivary disease comprises of sialolithiasis [4], which occurs in about 1.2% of the population. Amongst the major salivary glands, the submandibular is most affected (87%), then the parotid (10%), and the sublingual (3%) to a much lesser extent [5].

Although sialolithiasis has been reported as the most common cause of salivary ductal obstructions, strictures, mucous plugs and the rare foreign body can cause significant obstruction to ductal flow.

47.3 Sialendoscopy

Sialendoscopy is a minimally invasive technique which makes use of miniature endoscopes to diagnose and treat salivary gland pathologies, including sialolithiasis, sialadenitis and strictures.

It is fast becoming the investigating procedure of choice for such conditions. Sialendoscopy has grown as a subspeciality in the last three decades, since the first attempts to retrieve salivary stones endoscopically were carried out. It is slowly gaining popularity and awareness in the last decade and a half.

47.4 Evolution of Sialendoscopy

It took a few centuries, after the discovery of the ductal systems, for the first endoscopy to be reported. In 1990, Konigsberger et al. reported the first successful salivary endoscopy using a 0.8-mm flexible endoscope. Katz removed a stone with a flexible scope using blind passage of a basket in 1991, and for over a decade, both Nahlieli et al. and Marchal described various types of sialendoscopy instruments and approaches [3].

The last decade and a half has witnessed significant development of minimally invasive techniques for diagnosing and treating salivary ductal obstructions. Like with other surgical fields, this has led to a paradigm shift from open procedures to minimally invasive and endoscopic techniques with the emphasis on gland preservation and restoration of function. The miniaturization of endoscopes and advancing technology have made exploration and visualization of salivary ductal system possible using sialendoscopes [4].

47.5 Indications and Contraindications

As mentioned previously, sialolithiasis is the most common obstructive condition affecting the salivary duct and therefore is where sialendoscopic/sialendoscopy-assisted retrieval of sialoliths is most indicated.

Ductal strictures which may be secondary to calculi or those at the papilla opening can be very effectively treated by serial dilatation with sialendoscopes of increasing diameter [4].

Juvenile recurrent parotitis (JRP) is an inflammatory condition affecting the parotid gland and is the second most common condition in children after mumps [6, 7]. The condition affects the paediatric population primarily especially the ages between 3 and 6 years and occasionally persists in adolescence [8]. As the cause is unknown, management has generally been conservative. Anatomical aberrations, such as kinks in the duct, dehydration and possible ascending bacterial infection, have been hypothesised as causes.

Dilatation and lavage as a consequence of performing sialendoscopy has provided relief from symptoms and reduction in the frequency of attacks, even though the mechanism is not fully understood. This condition has a tendency of spontaneous cessation at puberty.

Although in Sjogren's syndrome, where the parenchyma of the parotid gland is primarily affected, there is also an associated ductal pathology, namely, strictures. Here too dilatation via sialendoscopy can provide symptomatic relief.

Acute inflammation of salivary glands and ducts is a contraindication to performing sialendoscopy. The duct is essentially a condensation of surrounding epithelium and not a rigid

structure. In such an inflamed state, the risk of creating a false passage or perforating the duct is significantly higher [4].

Management in such situations is conservative, mainly with the use of appropriate antibiotics and analgesics, incision and drainage of a collection, and removal of cause, such as a sialolith, if easily visible or accessible, to allow acute symptoms to settle before a formal sialendoscopy is carried out.

Trismus is a relative contraindication to performing sialendoscopy, as naturally, reduction in mouth opening makes it both difficult to introduce and manoeuvre the scopes.

47.6 Investigations

A simple ultrasound in the hands of an experienced sonologist usually provides adequate information prior to sialendoscopy. It is a non-invasive, economical investigation which can determine the presence and size of sialoliths, strictures, dilatation or fibrosis of the duct. Alternatively a CT scan can be considered to achieve the same result.

MR sialograms are particularly useful in identifying strictures or areas of stenosis. However, like conventional sialography the papilla needs to be dilated and cannulated to inject the dye. In the hands of an inexperienced operator, damage to papilla might make performing sialendoscopy impossible.

47.7 Armamentarium

The sialendoscope can be divided very simply into two systems: the Marchal All-in-one (Fig. 47.1) and the Modular system (Fig. 47.2).

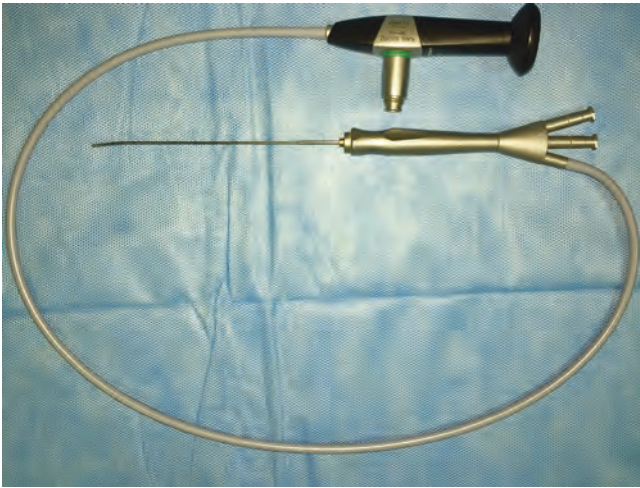
As the name suggests, the all-in-one has an irrigation port, a working channel through which various instruments can be introduced, and fibre optics in the same unit. This scope serves as both diagnostic and as an interventional tool.

The modular sialoendoscope consists only of a telescope, attached fibre-optic cable and an eyepiece. Interchangeable sheaths of various diameters are available which fit onto the basic telescope [6]. This scope with the appropriate sheaths can be used for both diagnostic and interventional purposes.

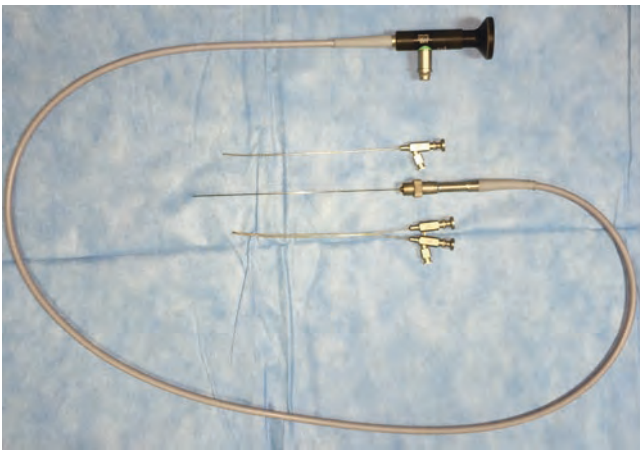The sheaths used in the modular system make it rigid and unfortunately also bulky; thus significant dilatation of the papilla is required to introduce the scope [6].

Unlike other endoscopes, sialendoscopes come with only a zero-degree viewing angle. The all-in-one is semirigid, with a 5–15-degree angulation at the tip to facilitate manoeuvrability especially while exploring branches of the duct.

Diagnostic scopes come with only an irrigation port, whereas a working channel is also provided in therapeutic scopes to introduce instruments such as wire baskets and graspers for entrapping stones, balloons for stricture dilation



©Association of Oral and Maxillofacial Surgeons of India

Fig. 47.1 Marchal All-in-one sialendoscope

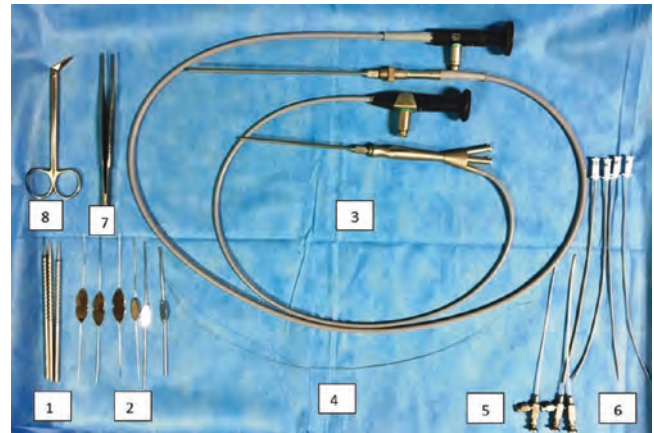
©Association of Oral and Maxillofacial Surgeons of India

Fig. 47.2 Modular sialendoscope with sheaths

and a holmium laser fibre or a micro drill to fragment sialoliths [6].

Diameter of available scopes range from 0.9 to 1.6 mm, the smallest purely diagnostic and others having various sizes of the working channel to allow certain instruments only. This is a disadvantage of the all-in-one system in that the entire scope has to be changed if a larger instrument is required, whereas in the modular only the sheath can be changed [6].

Preliminary instruments, those that are used to dilate the papilla to facilitate the introduction of the scope, are also available. These include two types of dilators, papillotomy scissors, guide wires and hollow dilators [6] (Fig. 47.3).



©Association of Oral and Maxillofacial Surgeons of India

Fig. 47.3 Armamentarium. (1) Conic dilators, (2) Lacrimal probes, (3) Sialendoscopes, (4) Guide wire, (5) Sheaths for Modular sialendoscope, (6) hollow dilators, (7) vascular forceps, (8) papillotomy scissors

47.8 Anaesthesia and Technique

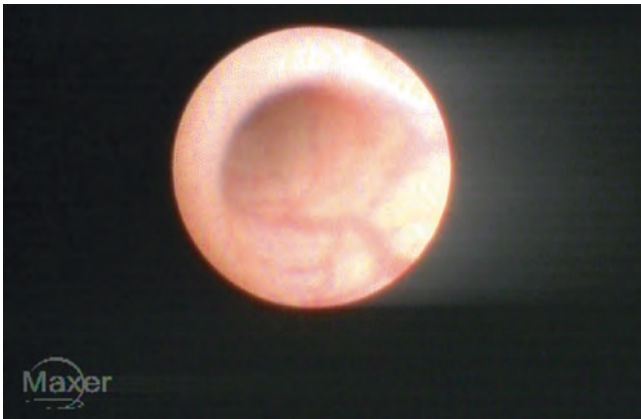Anaesthetic of choice depends on the clinical and radiologically findings and the anticipated difficulty of the procedure. Local anaesthetic, with or without sedation, is usually adequate for a diagnostic procedure. In cases where sialolith retrieval is planned, either endoscopically or with a combined approach, general anaesthetic is usually preferable. Antisecretory agents like atropine and glycopyrrrolate are avoided [6].

47.8.1 Positioning

Patient is placed supine with head fixed on a head rest and turned towards the surgeon. Shoulder extension is preferable. The monitor is placed opposite the surgeon. The assistant is next to the surgeon [6].

47.8.2 Identification, Cannulation and Dilatation of Punctum

The Wharton's duct punctum is comparatively more difficult to locate given the position is quite variable. There may even be a 'hood' of tissue obscuring the opening. In such situations, local anaesthetic can be infiltrated around the area which stiffens the opening, thereby aiding in location. Occasionally an incision might need to be placed on the floor of the mouth accompanied by minimal dissection to locate the duct. The Stensen's duct opening is far easier to identify. It is located on the buccal mucosa opposite upper second molar. Once the punctum is identified, the opening is serially dilated with conical dilator and probes of various sizes [6].



©Association of Oral and Maxillofacial Surgeons of India

Fig. 47.4 Normal duct with vascular markings

47.8.3 Sialendoscopic Evaluation

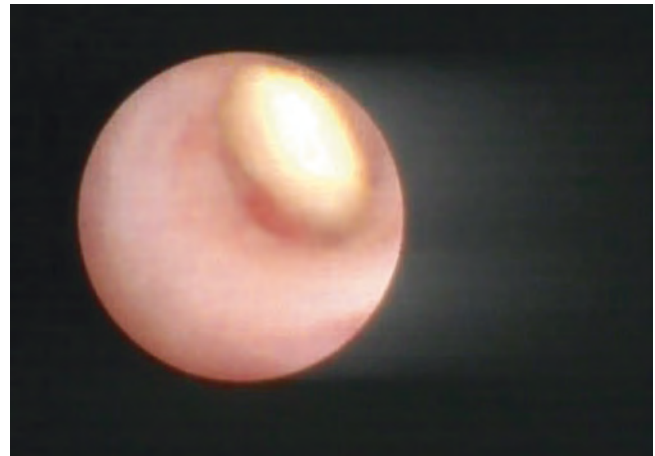
Once the punctum is adequately dilated, the appropriate sialendoscope is introduced into the duct. The duct is normally a collapsed structure, and irrigation fluid is required to keep the lumen open to visualise the duct and to advance the scope (Fig. 47.4). Normal saline is the preferred choice of irrigant solution and is diluted with local anaesthetic if the patient is awake for the procedure.

The irrigant also serves an additional purpose as this also performs lavage of the duct, thereby washing out debris and mucous plugs which might be accumulated [6].

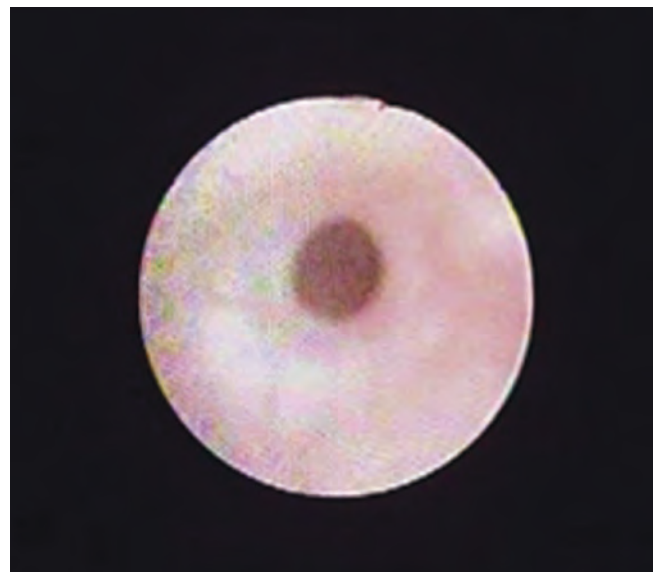
The endoscope is slowly and gently passed from the punctum till branches are identified and explored if possible. This point of division of the duct is known as the hilum and is considered the end point of sialendoscopy. Alternatively, the presence of pathology such as a sialolith or stricture may prevent complete exploration of the duct (Figs. 47.5 and 47.6). It is important to note that once the pathology has been treated, the entire duct must be explored so as to ensure there are no further causes of obstruction, including the withdrawal of the scope under vision [6].

As the scope is guided through the primary and secondary ducts, the colour and texture of the mucosa are noted which are an indicator of the presence of inflammation. In relation to sialoliths, the size, shape and position need to be assessed as these will determine the method of retrieval [6].

Between the submandibular and the parotid duct, the Stensen's duct is comparatively more difficult to navigate due to the presence of the masseteric bend.



©Association of Oral and Maxillofacial Surgeons of India

Fig. 47.5 Sialolith

©Association of Oral and Maxillofacial Surgeons of India

Fig. 47.6 Stricture

47.9 Diagnostic vs. Interventional Sialendoscopy

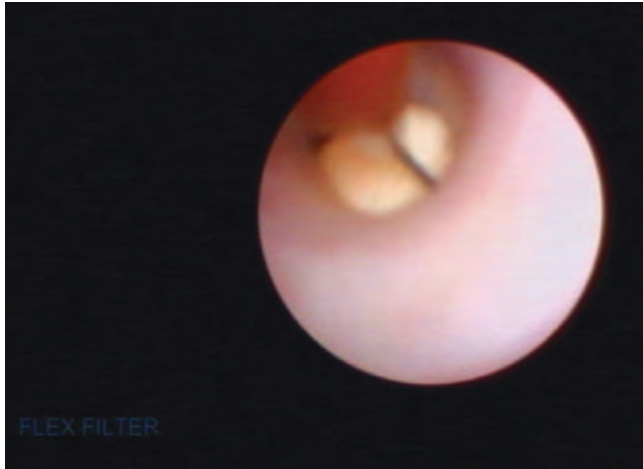
Indications for a diagnostic procedure include clinical symptoms, yet an unremarkable ultrasound and stricture at the papilla opening, to assess size and position of sialoliths.

Diagnostic sialendoscopy is a low morbidity, minimally invasive technique, which becomes the investigational procedure of choice for salivary duct pathologies in all age

groups. Sialendoscopy has the advantage of offering a real-time ductal view. Diagnostic endoscopy is occasionally therapeutic, in minor obstructions caused by mucous plugs which can be relieved by lavage.

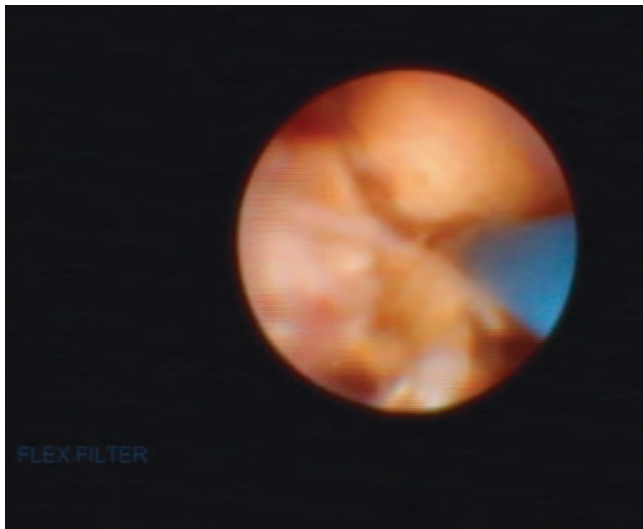
Interventional sialendoscopy makes use of a wide array of armamentarium including wire baskets (Fig. 47.7), balloon catheters and holmium laser to assist in sialolith retrieval (Fig. 47.8).

Sialoliths with sizes ranging between 3 and 4 mm are amenable for endoscopic retrieval. Here they may be



©Association of Oral and Maxillofacial Surgeons of India

Fig. 47.7 Sialolith entrapped within wire basket



©Association of Oral and Maxillofacial Surgeons of India

Fig. 47.8 Laser lithotripsy

entrapped and retrieved by use of a wire basket or dragged to the punctual opening where a small incision is placed to facilitate removal.

Larger stones require a combined approach, whereby the position of the sialolith is identified and marked endoscopically and retrieved with an open surgical approach. The open approaches for submandibular sialoliths may be as small as a papillotomy or an extensive dissection of the floor of the mouth. The lingual nerve and iatrogenic ranula formation are important considerations when operating in this region. Large parotid stones require a SMAS flap, for the identification and protection of facial nerve branches and the duct, as well as reconstruction post-retrieval. Sialocele formation is an important consideration.

Hollow bougies of increasing diameter can be threaded over a guide wire to widen strictures at the papillae. Balloons are another means of treating ductal strictures and once introduced through the working channel of the sialendoscope are inflated to dilate narrowed areas of the duct wall.

Stents are placed to maintain the patency of the duct and also to allow an incised duct to heal over with the aim of preventing stenosis. These stents are generally kept in place for up to 3 weeks. The authors have devised a salivary stent (Moorthy-Bachalli stent), made of polyurethane. These stents are available in sizes ranging from 3.5 French (diameter, 1 Fr = 0.3 mm) to 8 French and lengths from 5 to 7 cm with markings every centimetre. The stents also have a flange with prefabricated suture holes to facilitate suturing to the surrounding mucosa. An Ethilon 4-0 suture is preferred by the authors.

47.10 Complications

Like any other surgical procedure, open or endoscopic, sialendoscopy has its fair share of complications (Table 47.1).

Table 47.1 Complications of sialendoscopy

Complications	Management
Inability to locate papilla	Abort procedure/open approach to submandibular/parotid duct
False passage	If possible to locate duct-proceed, and abort procedure otherwise
Duct perforation	If possible to navigate beyond-proceed In case of floor of mouth or cheek oedema, then abort
Duct avulsion	Gland excision

47.11 Summary

When compared to other medical specialities, particularly otorhinolaryngologists, maxillofacial surgery is still in a primitive stage as far as the use of endovision is concerned. Hopefully an interest in areas like endoscopic management of salivary gland and temporomandibular joint diseases will narrow this gap.

Sialendoscopy is still in its infancy, in many parts of the world. Despite the challenges, growing awareness and the added attraction of minimally invasive surgery is steadily making it a popular choice for managing salivary ductal disease.

References

1. Marchal F. Sialendoscopy: the endoscopic approach to salivary gland ductal pathologies. Endo Press: Tuttlingen; 2012. pp 8.
2. Al-Abri R, Marchal F. New era of endoscopic approach for sialolithiasis: sialendoscopy. *SQU Med J*. 2010;10(3):382–7. Epub 14th Nov 10.
3. Erkul E, Gillespie MB. Sialendoscopy for non-stone disorders. *Laryngoscope Investig Otolaryngol*. 2016;1:140–5.
4. Singh PP, Gupta N, Goyal A, Tomar S. Interventional sialendoscopy for parotid ductal calculi: our preliminary experience. *Indian J Otolaryngol Head Neck Surg*. 2012;64(3):252–6.
5. Kopeć T, Szyfte W, Wierzbicka M. Sialoendoscopy and combined approach for the management of salivary gland stones. *Eur Arch Otorhinolaryngol*. 2013;270:219–23.
6. Singh PP, Gupta V. Sialendoscopy: introduction, indications and technique. *Indian J Otolaryngol Head Neck Surg*. 2014;66(1):74–8.
7. Harold D. Baurmash: chronic recurrent parotitis: a closer look at its origin, diagnosis, and management. *J Oral Maxillofac Surg*. 2004;62:1010–8.
8. Canzi P, Occhini A, Pagella F, Marchal F, Benazzo M. Sialendoscopy in juvenile recurrent parotitis: a review of the literature. *Acta Otorhinolaryngol Ital*. 2013;33:367–73.

Open Access This chapter is licensed under the terms of the Creative Commons Attribution 4.0 International License (<http://creativecommons.org/licenses/by/4.0/>), which permits use, sharing, adaptation, distribution and reproduction in any medium or format, as long as you give appropriate credit to the original author(s) and the source, provide a link to the Creative Commons license and indicate if changes were made.

The images or other third party material in this chapter are included in the chapter's Creative Commons license, unless indicated otherwise in a credit line to the material. If material is not included in the chapter's Creative Commons license and your intended use is not permitted by statutory regulation or exceeds the permitted use, you will need to obtain permission directly from the copyright holder.



Part XVI

Maxillofacial Traumatology

Primary Assessment and Care in Maxillofacial Trauma

Saurabh Saigal and Manal M. Khan

48.1 Introduction [1, 2]

Maxillofacial injuries are common in polytrauma patients, and spectrum can be minor to life-threatening injuries. Primary assessment and management can be very important. They can involve facial soft tissues, facial bones, or both. Maxillofacial injuries can be due to various causes including road traffic accidents, assaults, and fall from height, industrial injuries, animal bites, sports injuries, burns, and war injuries. Life-threatening maxillofacial injuries can complicate the initial management of a trauma patient due to presence of concomitant injuries to airway, head, or cervical spine.

The mechanism for this injury is exemplified by an unbelted automobile passenger who is thrown into the windshield and dashboard. Trauma to midface can produce fractures and dislocations that compromise the nasopharynx and oropharynx. Facial fractures can be associated with hemorrhage, increased secretion, and dislodged teeth. Fractures of mandible, especially bilateral body fractures, can cause loss of normal airway and structural support. Airway obstruction can result if the patient is in supine position.

The term “golden hour” has to be kept in mind while handling the trauma patient which indicates that the injured patient has 1 h (60 min) from the time of injury to receive definitive care. After that there will be significant increase in the morbidity and mortality of the patient. “Chances of survival of the critically injured patient will largely determine after the first hour” [3].

Electronic Supplementary Material The online version of this chapter (https://doi.org/10.1007/978-981-15-1346-6_48) contains supplementary material, which is available to authorized users.

S. Saigal (✉)
 Department of Anaesthesiology, AIIMS Bhopal,
 Bhopal, Madhya Pradesh, India
 e-mail: saurabh.criticalcare@aiimsbhopal.edu.in

M. M. Khan
 Department of Burns and Plastic Surgery, AIIMS Bhopal,
 Bhopal, Madhya Pradesh, India

48.2 Triage [4]

Sorting of patients based on their need for treatment and the available resources to provide the treatment is triage. This sorting may be carried out by the paramedic team at the accident scene or receiving hospital who decides what level of care is required. It may be based on which patients need immediate, lifesaving interventions, which can wait and which are, in fact, beyond saving. Depending on the urgency of treatment required, maxillofacial injuries can be broadly placed into one of four groups (Table 48.1).

Appropriate triage and prompt evaluation, using the Advanced Trauma Life Support (ATLS) system, benefit patients [5].

Box 48.1 Step-by-Step Management of a Trauma Patient in Emergency Unit

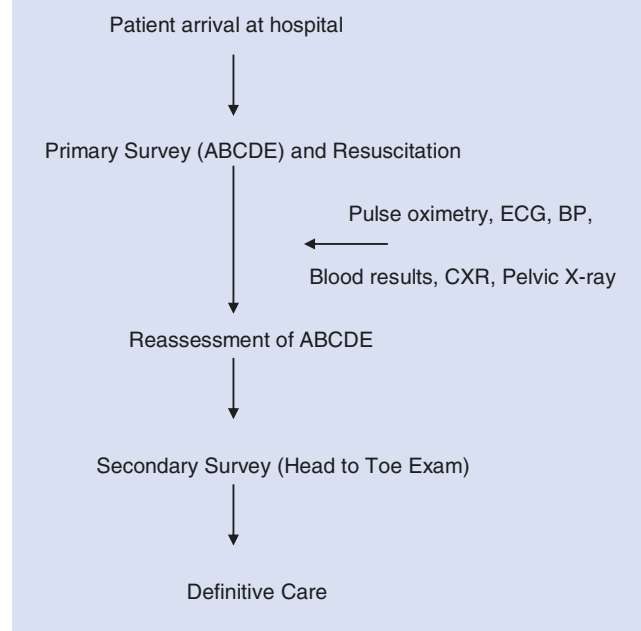



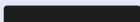


Table 48.1 Triage color coding

Group	Color coding	Description
Group 1	Red 	Intervention required within few minutes. Immediate lifesaving management needed (airway compromise, severe uncontrolled blood loss)
Group 2	Yellow 	Intervention required within few hours. Patient stable but urgent management needed (cranial fractures with open dura, contaminated wounds, and open fractures)
Group 3	Green 	Intervention required within few days. Can wait a day or two (clean laceration and some fractures)
Group 4	Black 	Intervention required within few weeks. Can wait for more days (most fractures)

48.2.1 Glasgow Coma Scale (Please Refer Table 7.5 in Chap. 7 of this book)

There are three variables used with the scale:

Best motor response (level of central nervous system function)
Best verbal response (ability of CNS to integrate information)
Eye opening (brainstem activity)

48.3 Primary Survey and Resuscitation [6]

The primary survey is a rapid, reproducible physical examination to evaluate every trauma patient and is designed to diagnose and treat immediately life-threatening conditions first. All patients are evaluated for physiologic or anatomic derangements that could lead to early mortality and morbidity. Treatment of problems identified during the primary survey begins without delay, before the survey is completed.

The sequence of primary survey is ABCDE:

1. **A**irway with cervical spine control
2. **B**reathing with ventilation
3. **C**irculation and hemorrhagic control
4. **D**isability management (neurological)
5. **E**xposure with environment control

Patient monitoring (pulse oximetry, electrocardiogram (ECG), blood pressure (BP), blood results, chest and pelvic radiographs) should run in parallel with the primary survey. Team approach is crucial for primary survey.

48.3.1 Airway with Cervical Spine Control

Airway assessment is first and foremost priority of primary survey. Patients with maxillofacial and head injuries are at high risk of compromised airway.

Causes of upper airway obstruction

1. Foreign body aspiration
2. Tongue fall position
3. Tracheal, laryngeal, facial, and mandibular fractures
4. Regurgitation of stomach contents

Maxillofacial injuries can cause airway obstruction because of:

- Bilateral anterior mandible fracture allows the tongue to fall posteriorly
- Downward and backward displacement of maxilla into nasopharynx, after midface fracture
- Blood clots and secretions
- Foreign bodies in the form of avulsed teeth or dentures

The chin lift or jaw-thrust maneuver is recommended to achieve patency of airway. The patient's head and neck should not be hyperextended, hyperflexed, or rotated to establish and maintain the airway. There may be associated cervical spine injury; all the cases are treated as they are having cervical spine injury unless diagnosed otherwise. Hence, cervical spine stabilization should be done.

48.3.2 Airway and Ventilatory Problems in Maxillofacial Trauma (Please Refer Chap. 7 of this book)

Early preventable deaths from airway problem after maxillofacial trauma often result from:

- Failure to identify the need for an airway intervention
- Inability to establish an airway
- Lack of backup or alternative airway plan in the setting of failed intubation attempts

- Failure to recognize an incorrectly placed airway
- Displacement of a previously established airway
- Failure to identify the need for ventilation
- Aspiration of gastric contents during dealing with airway

48.3.3 Airway and Ventilation Are the First Priorities

Airway compromise may be sudden and complete, insidious and partial, and/or progressive and recurrent. The early sign of airway or ventilator compromise is tachypnea or inability to speak words or sentences. “Talking patient” provides reassurance for that period of time that the airway is patent and not compromised. Failure to respond or an inappropriate response suggests an altered level of consciousness, airway and ventilator compromise, or both. Patient with the altered level of consciousness is at particular risk for airway compromise and aspiration, so he requires definite airway.

48.3.4 Objective Signs of Airway Obstruction

1. Observe the patient for agitation and obtundation, suggest hypercarbia, and cyanosis indicates hypoxemia due to inadequate oxygenation which can be identified by inspection of nail beds and circum-oral skin. However, cyanosis is a late finding of hypoxia. Pulse oximetry is used early in the airway assessment, to detect inadequate oxygenation prior to development of cyanosis. Look for retractions and use of accessory muscles of ventilation that, when present, provide additional evidence of airway compromise.
2. Listen for abnormal, noisy sound breathing which is usually snoring, gurgling, and crowing sound (stridor) and can be associated with partial obstruction of the pharynx or larynx. Hoarseness (dysphonia) implies functional, laryngeal obstruction.
3. Feel for location of trachea, and quickly determine whether it is in the midline position.
4. Evaluate patient behavior. Abusive and belligerent patient may in fact have hypoxia and should not be presumed to be intoxicated (suggestive of hypoxia, then only presume intoxication).

48.3.5 Airway Management [7, 8]

To assess airway patency and adequate ventilation quickly and accurately, pulse oximetry and end-tidal CO₂ measurement are essential. There are some measures to improve the oxygenation including airway maintenance techniques, definitive airway measures, or surgical airways. Because abovementioned measures include some movement of the neck, it is important to maintain cervical spine protection in all patients of trauma.

High-flow oxygen is required both before and immediately after airway management measures are instituted. A rigid suction device is essential and should be readily available. Nasal route for endotracheal route should not be chosen in patients with facial injury and midface injury. Patients who are wearing helmet and require airway management need their head and neck held in a neutral position. For this two-person procedure, one person provides manual inline stabilization from below, while the second person expands the helmet laterally and removes it from above. Then inline stabilization is re-established from above. And patient’s head and neck are secured during airway management. Removal of the helmet using a cast cutter while stabilizing the head and neck can minimize cervical spine (C spine) motion in patients with known C spine injury [9].

Tracheostomy - Video 48.1.

Box 48.2 Need for Airway Protection

1. Severe maxillofacial fractures
2. Risk for obstruction
 - Neck hematoma
 - Laryngeal or trachea
 - Stridor
3. Risk for aspiration
 - (i) Bleeding
 - (ii) Vomiting
4. Unconscious

Box 48.3 Need for Ventilation or Oxygenation

1. Inadequate respiratory efforts
 - Tachypnea
 - Hypoxia
 - Hypercapnia
 - Cyanosis
2. Massive blood loss and need for volume resuscitation
3. Severe closed injury with need for brief hyperventilation if acute neurologic deterioration occurs
4. Apnea
 - Neuromuscular paralysis
 - Unconscious

48.3.6 Breathing with Ventilation

Next, the patient’s breathing, ventilation, and oxygenation should be assessed, and any life-threatening derangements must be treated. Physical examination, pulse oximetry, and continuous end-tidal carbon dioxide monitoring should be used. For proper ventilation the lungs, chest wall, and diaphragm must all function adequately.

The most common interventions performed during the primary survey to support breathing are supplemental oxygen delivery, assisted or mechanical ventilation, and tube thoracotomy or chest tube insertion.

48.3.7 Ventilation

Sometimes it will happen that airway of the patient will be patent but ventilation will be inadequate, so look for the objective signs of inadequate ventilation. Ventilation may be compromised by airway obstruction, altered ventilatory mechanics, and central nervous system depression.

Following are the conditions where the ventilation may be compromised:

1. Direct trauma to the chest, like rib fractures, leading to severe pain during breathing and leads to shallow breathing and hypoxemia.
2. Elderly patients and other individual with pulmonary dysfunction are at significant risk for ventilator failure.
3. Intracranial injury can cause abnormal breathing patterns and compromised adequacy of ventilation.
4. Cervical spinal cord injury can result in diaphragmatic breathing and interfere with the ability to meet increased oxygen demands.
5. Complete cervical cord transection, which spares the phrenic and results in abdominal breathing paralysis of the intercostal muscles, and assisted ventilation may be required.

48.3.8 Objective Signs of Inadequate Ventilation

1. Symmetrical rise and fall of the chest and adequate chest wall excursion indicate the adequate ventilation, but asymmetrical rise and fall suggests splitting of rib cage or flail chest. Labored breathing may indicate an imminent threat to the patient's ventilation.
2. Listen for movement of air on both sides of the chest. Decreased or absent sounds over one or both hemithoraces should alert examiner to the presence of thoracic

injury. Beware of rapid respiratory rate—tachypnea can indicate respiratory distress.

3. Use a pulse oximeter: This device provides information regarding patient's oxygen saturation and peripheral perfusion.

48.3.9 Circulation and Hemorrhage Control

Circulation must be assessed to determine the presence or absence of shock after addressing the highest priorities in the primary survey (airway and breathing). Shock is defined as inadequate organ perfusion and tissue oxygenation. In the trauma patient, shock is assumed to be hypovolemic/hemorrhagic, and resuscitation begins as soon as vascular access can be obtained. The possibility of neurogenic shock (e.g., spinal cord injury) or cardiogenic shock (e.g., pericardial tamponade) should also be considered. The focus of this segment of the primary survey should be assessing for the presence of shock, determining the cause (usually blood loss), and beginning resuscitation.

Signs of poor perfusion include a weak pulse, cool or clammy extremities, dry mucous membranes, pale skin, and confusion. A normal mental status examination confirms the presence of acceptable cerebral perfusion. The goal of resuscitation is to maintain tissue perfusion and homeostasis.

48.3.10 Bleeding

External or internal bleeding source should be identified. External hemorrhage is identified and controlled during the primary survey. Rapid external blood loss is managed:

- By direct manual pressure on the wound
- Tourniquets which are effective in massive exsanguinations from an extremity

Internal hemorrhage areas are chest, abdomen, retroperitoneum, pelvis, and long bones. Chest X-ray, pelvic X-ray, or focused assessment sonography in trauma (FAST) can be done to identify the source of bleeding.

48.3.11 Disability Management

The primary focus is on rapidly determining a patient's mental status and neurologic function via physical exami-

nation. The Glasgow Coma Scale (GCS) is a rapid and reliable way to quantify a patient's level of consciousness (Table 7.5). The GCS score allows for quick communication among clinicians about a patient's current mental status and can be important for decision-making. The neurologic assessment also includes an examination of the cranial nerves, pupils, and sensory and motor function.

48.3.12 Exposure with Environment Control

Exposure and environment are the final components of the primary survey. While lowering priority, they are still vital to the successful management of the trauma patient. The patients should be completely exposed so that injuries can be fully assessed. Decontamination may also be needed, depending on the nature of the trauma. Protection from hypothermia and continuous temperature monitoring are essential.

48.3.13 Monitoring of Adequacy of Oxygenation

Oxygenated inspired air is best provided via tight-fitting oxygen reservoir face mask with a flow rate of at least 11 L/min. Other methods (e.g., nasal catheter and non-breather mask) can improve the inspired oxygen concentration. Pulse oximetry is a noninvasive method of continuously measuring the oxygen saturation (O_2 sat) of arterial blood. It does not measure the partial pressure of oxygen (PaO_2), and depending upon the position of oxy-hemoglobin dissociation curve, the PaO_2 can vary widely. However a measured saturation of 95% or greater by pulse oximetry strongly suggests adequate peripheral artery oxygenation ($PaO_2 > 70$ mmHg).

Pulse oximetry requires intact peripheral perfusion and can't distinguish oxy-hemoglobin from carboxy-hemoglobin or methemoglobin, which limits its usefulness in patients with severe vasoconstriction and those with carbon monoxide poisoning. Profound anemia ($Hb > 5$ g/dL) and hypothermia (<30 °C) decrease the reliability of the technique. However, in most patient pulse oximetry is useful as the continuous monitoring of oxygen saturation provides an immediate assessment of therapeutic intervention.

48.3.14 Electrocardiographic (ECG) Monitoring

ECG monitoring of trauma patient is important.

Box 48.4

Injury indication	ECG changes
Blunt cardiac injury	Dysrhythmias including unexplained tachycardia, atrial fibrillation, premature ventricular contractions, and ST segment changes
Cardiac tamponade Tension pneumothorax Profound hypovolemia	Pulseless electrical activity (PEA)

48.3.15 Fluid Resuscitation

Warm resuscitation fluids should be given. IV fluid therapy with crystalloids should be initiated. A bolus of 1–2 L of an isotonic solution may be required to achieve an appropriate response in adult patient.

48.3.16 Urinary and Gastric Catheters

Urine output monitoring is important to manage the fluid therapy. Urine output reflects renal perfusion, and it is accomplished by insertion of indwelling bladder catheter.

Contraindications to the placement of Foley catheter and urethral injury should be suspected in the presence of:

1. Blood at the urethral meatus
2. Hemorrhage into the scrotum
3. High-riding prostate

A gastric tube is indicated to:

1. Reduce stomach distension
2. Decrease risk of aspiration
3. Assess for upper gastrointestinal hemorrhage from trauma

48.4 Secondary Survey [10–12]

Once the primary survey is completed, secondary survey is started. If additional personnel is available, then part of secondary survey can be conducted along with primary sur-

vey; however, it should be made sure that it does not interfere with primary survey, as primary survey is the first priority.

Secondary survey is a complete head to toe examination of the trauma patient which includes complete history taking and physical examination. During secondary survey, a complete neurologic examination is conducted. Patient's GCS score is identified, radiographs are obtained, and laboratory studies are conducted as indicated.

48.4.1 History Taking

A complete medical assessment includes history taking and understanding the mechanism of the injury. Often, patient is not in a condition to provide this history. In such cases, it should be obtained from the family members. The history taking involves identification of various allergies, present medications, past history of any illness, pregnancy, last meal taken, and the event of trauma. The mechanism of injury must be understood whether it's inflicted by a penetrating or blunt trauma or if the injury is thermal injury or due to hazardous environment.

48.4.2 Physical Examination

During physical examination in secondary survey, a sequence has to be followed, which is examination of head, maxillofacial structures, cervical spine and neck, chest, abdomen, perineum/rectum/vagina, musculoskeletal system, and neurologic system.

48.4.3 Four-Person Logroll

To examine the patient's back and remove the spine board, at least four persons are required for logrolling:

- (a) Person one stands at the patient's head to control the head and C spine and two persons along the patient's sides to control the body and extremities.
- (b) Three persons maintain the alignment of spine, as the patient is rolled.
- (c) Fourth person examines the back and removes the board.
- (d) Once the board is removed, patient is returned into the supine position while maintaining the alignment of spine.

48.4.4 Head

Secondary survey starts with examination of head which involves identification of injuries. The complete scalp should be examined for lacerations, contusions, and evidence of fractures. Other than these injuries, visual acuity, pupillary size, hemorrhage of conjunctiva and/or fundi, and ocular entrapment must be examined. These aspects must be re-evaluated once the periocular edema subsides.

Visual acuity examination must be done by asking the patient to read printed material such as handheld Snellen chart. To exclude ocular entrapment, ocular movement must be checked.

48.4.4.1 Classification of Brain Injury

Box 48.5

Severity	GCS score
Minor	13–15
Moderate	9–12
Severe	3–8

Intracranial lesions may be classified as diffuse or focal. The focal lesions include epidural hematomas, subdural hematomas, contusions, and intracerebral hematomas.

Signs of skull base fracture:

1. Hematoma or ecchymosis over the mastoid (Battle's sign)
2. CSF otorrhea or rhinorrhea
3. Hemotympanum
4. Subscleral hemorrhage

Computed tomography (CT) scan of the head should be carried out to accurately assess the neurologic injuries and detect mass lesions. CT scan helps in diagnosing:

- Intracranial hemorrhage
- Contusion
- Skull fractures
- Foreign bodies
- Brain shift
- Hydrocephalus

In a comatose patient, motor responses may be elicited by pinching the trapezius muscle or with nail bed or supraorbital pressure. Testing for doll's eye movements (oculocephalic) the caloric test with ice water (oculovestibular) and testing of corneal responses are deferred to a neurosurgeon.

48.4.5 Maxillofacial Structures

Maxillofacial examination includes examination of soft tissue, palpation of all the bony structures, checking of occlusion, and intraoral examination. Trauma to the maxillofacial region not associated with airway obstruction should be treated once the patient is stabilized after the management of life-threatening injuries.

48.4.6 Cervical Spine and Neck

Patients with maxillofacial trauma must be presumed to have an unstable cervical spine injury unless it is proven otherwise. The absence of any neurologic deficit does not exclude the presence of any C spine injury. A complete cervical spine radiographs and CT scan should be done to evaluate C spine injury. The patient wearing any kind of helmet must be removed with extreme care.

C spine injuries can result from one or a combination of the following mechanism of injury:

- Flexion
- Axial loading
- Extension
- Rotation
- Lateral bending
- Distraction

A complete examination of neck includes inspection, palpation, and auscultation. Inspection should be done to note any blunt injury over the neck. Carotid arteries should be palpated and auscultated for bruits. Penetrating injuries of neck are potentially fatal. If the wound is deep, they should not be explored in emergency department [13].

A cervical collar can be applied to the patients suspecting the cervical spinal injury. Its role is to immobilize the C spine. Cervical collars are divided into two groups: soft and rigid collars. Soft collars are generally used for whiplash injury; some surgeons prefer rigid collars. Rigid collars provide excellent immobilization in transverse and sagittal planes compared with soft collars. However patient's comfort is to be taken into consideration in selecting the collars. The Philadelphia collar is available in two pieces having front and back pieces; it is held together by Velcro straps to support the neck [14].

48.4.7 Chest

Chest examination includes inspection, palpation, percussion, and auscultation. Inspection of anterior and posterior chest can identify conditions like open pneumothorax and large flail segments. Contusions and hematoma over chest suggest occult injury. Palpation of entire rib cage, clavicle, and sternum helps in diagnosing fractures. Significant injury may present with pain, dyspnea, and hypoxia.

Auscultation of high anterior chest helps in diagnosis of pneumothorax, whereas posterior base auscultation reveals hemothorax. Cardiac tamponade can be identified by the presence of distant heart sounds and decreased pulse pressure. Presence of distended neck veins suggests cardiac tamponade and tension pneumothorax. A chest radiograph may confirm the presence of hemothorax or simple pneumothorax.

48.4.7.1 Classification of Chest Trauma

Immediate life-threatening chest injuries are to be identified and treated during primary survey.

These six life-threatening chest injuries include:

1. Open pneumothorax
2. Tension pneumothorax
3. Open pneumothorax
4. Flail chest and pulmonary contusion
5. Massive hemothorax
6. Cardiac tamponade

48.4.7.2 Managing Chest Trauma [15]

The basic principles of management remain the same with the universal sequence of airway, breathing, and circulation to be treated in that sequence.

48.4.7.3 Airway

It is necessary to recognize and address major injuries affecting the airway during the primary survey. Airway patency and air exchange should be assessed by listening for air movement at the patient's nose, mouth, and lung fields; inspecting the oropharynx for foreign body obstruction; and observing for intercostal and supraclavicular muscle retractions. Laryngeal injury can accompany major thoracic trauma. Although the clinical presentation is occasionally delayed, acute airway obstruction from laryngeal trauma is a life-threatening injury. Injury to the upper chest can create a

palpable defect in the region of the sternoclavicular joint, with posterior dislocation of the clavicular head, which causes upper airway obstruction. Identification of this injury is made by listening for upper airway obstruction (stridor) or a marked change in the expected voice quality, if the patient is able to talk. Management consists of a closed reduction of the injury, which can be performed by extending the shoulders or grasping the clavicle with a pointed instrument, such as a towel clamp, and manually reducing the fracture. Once reduced, this injury is usually stable if the patient remains in the supine position.

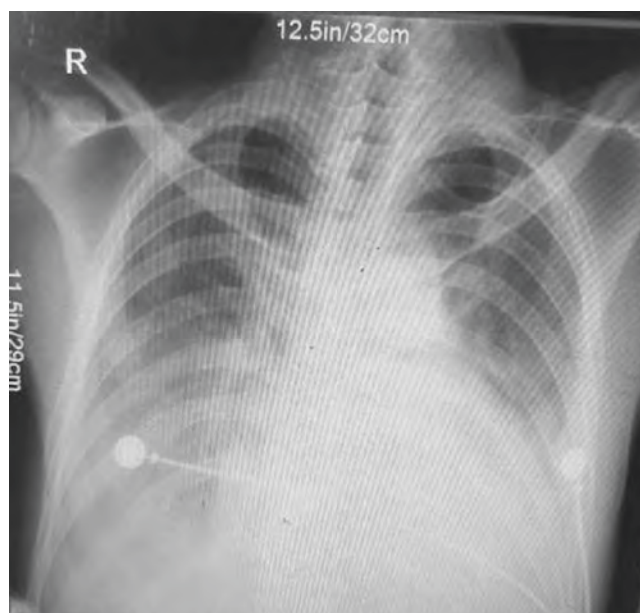
48.4.7.4 Breathing

The patient's chest and neck should be completely exposed to allow for assessment of breathing and the neck veins. This may require temporarily releasing the front of the cervical collar following blunt trauma. In this case, cervical spine immobilization should always be actively maintained by holding the patient's head while the collar is loose. Respiratory movement and quality of respirations are assessed by observing, palpating, and listening. Important, yet often subtle, signs of chest injury or hypoxia include an increased respiratory rate and change in the breathing pattern, which is often manifested by progressively shallower respirations. Cyanosis is a late sign of hypoxia in trauma patients. However, the absence of cyanosis does not necessarily indicate adequate tissue oxygenation or an adequate airway. The major thoracic injuries that affect breathing and that must be recognized and addressed during the primary survey include tension pneumothorax, open pneumothorax (sucking chest wound), flail chest and pulmonary contusion, and massive hemothorax.

Important: After intubation, one of the common reasons for loss of breath sounds in the left thorax is a right mainstem intubation. During the reassessment, be sure to check the position of the endotracheal tube before assuming that the change in physical examination is due to a pneumothorax or hemothorax.

48.4.7.5 Tension Pneumothorax

A tension pneumothorax develops when a "one-way valve" air leak occurs from the lung or through the chest wall. Air is forced into the pleural space without any means of escape, eventually completely collapsing the affected lung. The mediastinum is displaced to the opposite side, decreasing venous return and compressing the opposite lung. Shock results from the marked decrease in venous return causing a reduction in cardiac output and is often classified as obstructive shock (Fig. 48.1). The most common cause of tension pneumothorax is mechanical ventilation with positive-pressure ventilation in patients with visceral pleural injury. However, a tension pneumothorax can complicate a simple pneumothorax following penetrating or blunt chest trauma in which a parenchymal lung injury fails to seal or after a mis-



©Association of Oral and Maxillofacial Surgeons of India

Fig. 48.1 Tension pneumothorax

guided attempt at subclavian or internal jugular venous catheter insertion. Occasionally, traumatic defects in the chest wall also can cause a tension pneumothorax if incorrectly covered with occlusive dressings or if the defect itself constitutes a flap-valve mechanism. Tension pneumothorax rarely occurs from markedly displaced thoracic spine fractures. Tension pneumothorax is a clinical diagnosis reflecting air under pressure in the affected pleural space. Treatment should not be delayed to wait for radiologic confirmation.

Tension pneumothorax is characterized by some or all of the following signs and symptoms:

- Chest pain
- Air hunger
- Respiratory distress
- Tachycardia
- Hypotension
- Tracheal deviation away from the side of injury
- Unilateral absence of breath sounds
- Elevated hemithorax without respiratory movement
- Neck vein distention
- Cyanosis (late manifestation)

Because of the similarity in their signs, tension pneumothorax can be confused initially with cardiac tamponade. Differentiation is made by a hyper-resonant note on percussion, deviated trachea, and absent breath sounds over the

affected hemithorax, which are signs of tension pneumothorax. Tension pneumothorax requires immediate decompression and may be managed initially by rapidly inserting a large-caliber needle into the second intercostal space in the midclavicular line of the affected hemithorax. However, due to variable thickness of the chest wall, kinking of the catheter, and other technical or anatomic complications, this maneuver may not be successful [16].

When successful, this maneuver converts the injury to a simple pneumothorax; however, the possibility of subsequent pneumothorax as a result of the needle stick now exists, so repeated reassessment of the patient is necessary. Chest wall thickness influences the likelihood of success with needle decompression. Recent evidence suggests that a 5 cm needle will reach the pleural space >50% of the time, whereas an 8 cm needle will reach the pleural space >90% of the time. Even with a needle of the appropriate size, the maneuver will not always be successful. Definitive treatment requires the insertion of a chest tube into the fifth intercostal space (usually at the nipple level), just anterior to the midaxillary line.

In a tension pneumothorax, air from a ruptured lung enters the pleural cavity without a means of escape. As air pressure builds up, the affected lung is compressed, and all of the mediastinal tissues are displaced to the opposite side of the chest.

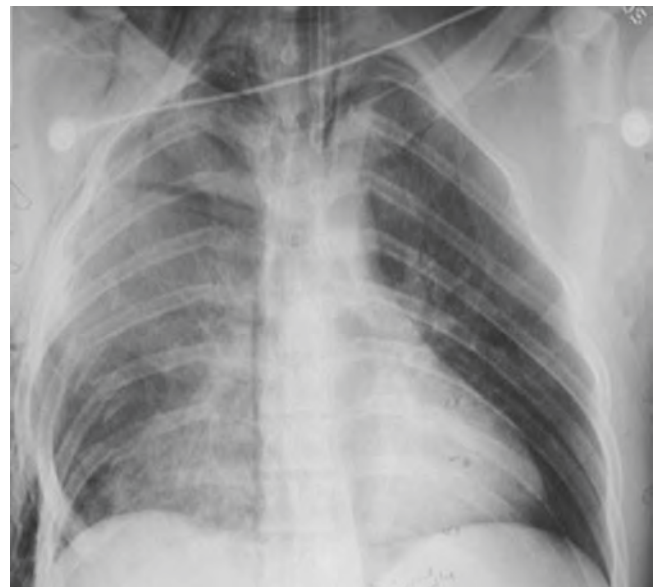
48.4.7.6 Open Pneumothorax (Sucking Chest Wound)

Large defects of the chest wall that remain open can result in an open pneumothorax, which is also known as a sucking chest wound. Equilibration between intrathoracic pressure and atmospheric pressure is immediate. Air tends to follow the path of least resistance; as such, if the opening in the chest wall is approximately two-thirds of the diameter of the trachea or greater, air passes preferentially through the chest wall defect with each respiratory effort. Effective ventilation is thereby impaired, leading to hypoxia and hypercarbia. Initial management of an open pneumothorax is accomplished by promptly closing the defect with a sterile occlusive dressing. The dressing should be large enough to overlap the wound's edges and then taped securely on three sides in order to provide a flutter-type valve effect. As the patient breathes in, the dressing occludes the wound, preventing air from entering. During exhalation, the open end of the dressing allows air to escape from the pleural space. A chest tube remote from the wound should be placed as soon as possible. Securely taping all edges of the dressing can cause air to accumulate in the thoracic cavity, resulting in a tension pneumothorax unless a chest tube is in place. Any occlusive dressing (e.g., plastic wrap or petrolatum gauze) may be used as a temporary measure so that rapid assessment can continue. Subsequent definitive surgical closure of the defect is frequently required [17].

48.4.7.7 Flail Chest and Pulmonary Contusion

A flail chest occurs when a segment of the chest wall does not have bony continuity with the rest of the thoracic cage. This condition usually results from trauma associated with multiple rib fractures, that is, two or more adjacent ribs fractured in two or more places (Fig. 48.2). The presence of a flail chest segment results in disruption of normal chest wall movement. Although chest wall instability can lead to paradoxical motion of the chest wall during inspiration and expiration, this defect alone does not cause hypoxia. The major difficulty in flail chest stems from the injury to the underlying lung (pulmonary contusion). If the injury to the underlying lung is significant, serious hypoxia can result. Restricted chest wall movement associated with pain and underlying lung injury is major causes of hypoxia. Flail chest may not be apparent initially if a patient's chest wall has been splinted, in which case he or she will move air poorly and movement of the thorax will be asymmetrical and uncoordinated. Palpation of abnormal respiratory motion and crepitation of rib or cartilage fractures can aid the diagnosis. A satisfactory chest X-ray may suggest multiple rib fractures but may not show costochondral separation. Initial treatment of flail chest includes adequate ventilation, administration of humidified oxygen, and fluid resuscitation. In the absence of systemic hypotension, the administration of crystalloid intravenous solutions should be carefully controlled to prevent volume overload, which can further compromise the patient's respiratory status.

The definitive treatment is to ensure adequate oxygenation, administer fluids judiciously, and provide analgesia to improve ventilation. The latter can be achieved with intravenous narcotics or local anesthetic administration, which



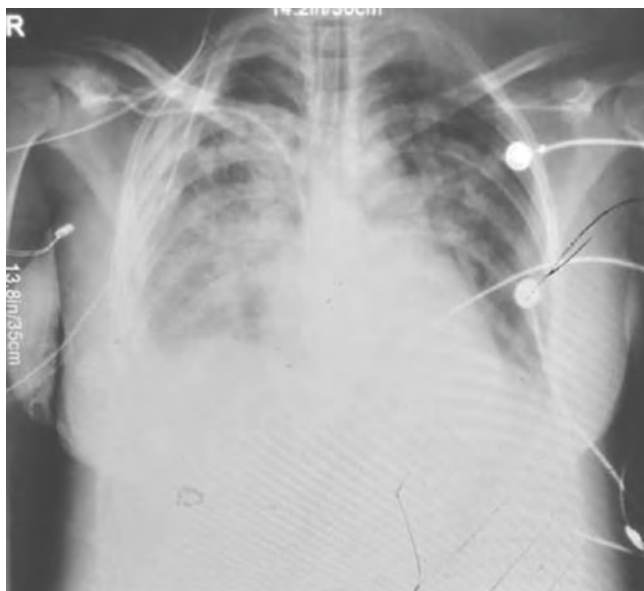
©Association of Oral and Maxillofacial Surgeons of India

Fig. 48.2 Flail chest with pulmonary contusion

avoids the potential respiratory depression common with systemic narcotics. The options for administration of local anesthetics include intermittent intercostal nerve block(s) and intrapleural, extrapleural, or epidural anesthesia. When used properly, local anesthetic agents can provide excellent analgesia and prevent the need for intubation. However, prevention of hypoxia is of paramount importance for trauma patients, and a short period of intubation and ventilation may be necessary until diagnosis of the entire injury pattern is complete. A careful assessment of the respiratory rate, arterial oxygen tension, and work of breathing will indicate appropriate timing for intubation and ventilation [18].

48.4.7.8 Massive Hemothorax

Massive hemothorax results from the rapid accumulation of more than 1500 mL of blood or one-third or more of the patient's blood volume in the chest cavity (Fig. 48.3). It is most commonly caused by a penetrating wound that disrupts the systemic or hilar vessels. However, massive hemothorax can also result from blunt trauma. In patients with massive hemothorax, the neck veins may be flat as a result of severe hypovolemia, or they may be distended if there is an associated tension pneumothorax. Rarely will the mechanical effects of massive intrathoracic blood shift the mediastinum enough to cause distended neck veins. A massive hemothorax is suggested when shock is associated with the absence of breath sounds or dullness to percussion on one side of the chest. This blood loss is complicated by hypoxia. Massive hemothorax is initially managed by the simultaneous restoration of blood volume and decompression of the chest cavity.



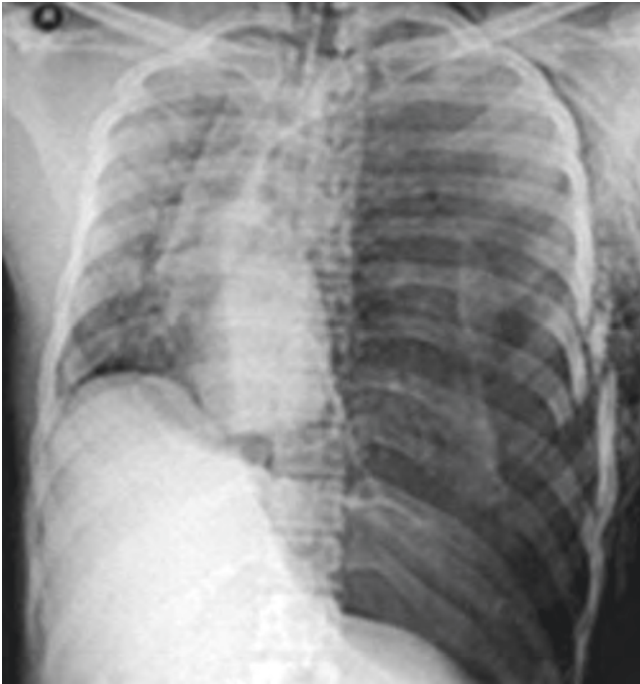
©Association of Oral and Maxillofacial Surgeons of India

Fig. 48.3 Hemothorax

Large-caliber intravenous lines and a rapid crystalloid infusion are begun, and type-specific blood is administered as soon as possible. Blood from the chest tube should be collected in a device suitable for autotransfusion. A single chest tube (36 or 40 French) is inserted, usually at the nipple level, just anterior to the midaxillary line, and rapid restoration of volume continues as decompression of the chest cavity is completed. When massive hemothorax is suspected, prepare for autotransfusion. If 1500 mL of fluid is immediately evacuated, early thoracotomy is almost always required. Patients who have an initial output of less than 1500 mL of fluid, but continue to bleed, may also require thoracotomy. This decision is not based solely on the rate of continuing blood loss (200 mL/h for 2–4 h) but also on the patient's physiologic status. The persistent need for blood transfusions is an indication for thoracotomy. During patient resuscitation, the volume of blood initially drained from the chest tube and the rate of continuing blood loss must be factored into the amount of intravenous fluid required for replacement. The color of the blood (indicating an arterial or venous source) is a poor indicator of the necessity for thoracotomy. Penetrating anterior chest wounds medial to the nipple line and posterior wounds medial to the scapula should alert the practitioner to the possible need for thoracotomy because of potential damage to the great vessels, hilar structures, and the heart, with the associated potential for cardiac tamponade. Thoracotomy is not indicated unless a surgeon, qualified by training and experience, is present.

48.4.7.9 Cardiac Tamponade

Cardiac tamponade (Fig. 48.4) most commonly results from penetrating injuries. However, blunt injury also can cause the pericardium to fill with blood from the heart, great vessels, or pericardial vessel. The human pericardial sac is a fixed fibrous structure; a relatively small amount of blood can restrict cardiac activity and interfere with cardiac filling. Cardiac tamponade may develop slowly, allowing for a less urgent evaluation, or may occur rapidly, requiring rapid diagnosis and treatment. The diagnosis of cardiac tamponade can be difficult in the setting of a busy trauma or emergency room. Cardiac tamponade is indicated by the presence of the classic diagnostic Beck's triad: venous pressure elevation (distended neck veins), decline in arterial blood pressure, and muffled heart sounds. However, muffled heart tones are difficult to assess in the noisy examination area, and distended neck veins may be absent due to hypovolemia. Additionally, tension pneumothorax, particularly on the left side, can mimic cardiac tamponade. Kussmaul's sign (a rise in venous pressure with inspiration when breathing spontaneously) is a true paradoxical venous pressure abnormality associated with tamponade. Pulseless electrical activity (PEA) is suggestive of cardiac tamponade but can have other causes, as listed above [19]. Insertion of a central venous line with measurement of central venous pressure (CVP) may aid diagnosis, but CVP can be elevated for a



©Association of Oral and Maxillofacial Surgeons of India

Fig. 48.4 Cardiac tamponade

variety of reasons. Additional diagnostic methods include echocardiogram, focused assessment sonography in trauma (FAST), or pericardial window. In hemodynamically abnormal patients with blunt or penetrating trauma and suspected cardiac tamponade, an examination of the pericardial sac for the presence of fluid should be obtained as part of a focused ultrasound examination performed by a properly trained provider in the emergency department (ED). FAST is a rapid and accurate method of imaging the heart and pericardium. It is 90–95% accurate for the presence of pericardial fluid for the experienced operator. Concomitant hemothorax may account for both false-positive and false-negative ultrasound exams. Prompt diagnosis and evacuation of pericardial blood are indicated for patients who do not respond to the usual measures of resuscitation for hemorrhagic shock and in whom cardiac tamponade is suspected. The diagnosis can usually be made with the FAST exam. If a qualified surgeon is present, surgery should be performed to relieve the tamponade. This is best performed in the operating room if the patient's condition allows. If surgical intervention is not possible, pericardiocentesis can be diagnostic as well as therapeutic, but it is not a definitive treatment for cardiac tamponade. However all patients with acute tamponade and a positive pericardiocentesis will require surgery to examine the heart and repair the injury. Pericardiocentesis may not be diagnostic or therapeutic when the blood in the pericardial sac has clotted. Preparation to transfer such a patient to an appropriate facility for defini-

tive care is always necessary. Pericardiectomy via thoracotomy is indicated only when a qualified surgeon is available.

48.4.8 Abdomen [20]

Abdominal injuries must be identified and managed aggressively. It is not as important to arrive at a specific diagnosis as it is to recognize the injury which requires a surgical intervention. It is important to closely observe and re-evaluate the abdomen to identify the blunt injury. The safest management of penetrating wounds is a laparotomy.

Abdominal Trauma	
Blunt trauma	Penetrating trauma [21]
Direct blow, e.g., crushing injury to abdominal viscera and pelvis	Stab wounds commonly involve liver (40%), small bowel (30%), diaphragm (20%), and colon (15%)
Shearing injuries, e.g., laceration of the liver and spleen	Gunshot wounds commonly involve small bowel (50%), colon (40%), liver (30%), and abdominal vascular structures (25%)

The diagnostic peritoneal lavage (DPL) was used to diagnose blunt and occasionally penetrating abdominal trauma, but its use was decreased with the advancement of CT and USG. Focused assessment sonography in trauma (FAST) is very helpful to detect the presence of hemoperitoneum.

48.4.8.1 Focused Assessment Sonography in Trauma (FAST) [22]

The ultrasound machine and water-based gel are necessary to perform FAST.

Fast includes the following views:

1. **Pericardial view:** fluid within the heart should be black.
2. **Right upper quadrant view (RUQ):** diaphragm-liver interface and Morison's pouch.
3. **Left upper quadrant view (LUQ):** diaphragm-spleen interface and spleen-kidney interface
4. **Suprapubic view:** to see bladder

48.4.9 Perineum/Rectum/Vagina

Contusions, hematomas, lacerations, and urethral bleedings should be examined in the perineal area. The presence of blood at urethral meatus suggests urethral injury. Inspect the scrotum and perineum for ecchymosis or hematoma, also suggestive of injury to the urethra. In patients with perineal hematoma or high-riding prostate, Foley catheters should be avoided.

Rectal examination can be done to evaluate the presence of blood within the bowel lumen. In patients with the risk of

vaginal injury, vaginal examination should be carried out. Pelvic compressions should be carried out to identify any pelvic fractures. Pelvic fractures can be suspected by the presence of ecchymosis over iliac wings, pubis, scrotum, or labia. The pelvic fracture can be divided into closed, open book, and vertical shear fracture. Hemorrhage control and fluid resuscitation will be in the initial management of major pelvic disruption associated with hemorrhage. Pelvic binder or sheet can apply sufficient stability for the unstable pelvis at the level of greater trochanters of the femur bone.

48.4.10 Musculoskeletal System

The patient must be completely undressed for adequate examination. Extremities should be inspected for deformities, abrasion, and contusions. Presence of tenderness on palpation of bones and abnormal movement helps in identification of occult fractures. Significant injuries of extremities can exist without fracture being evident. Ligament ruptures and a muscle tendon unit injury interferes with active motions. The musculoskeletal examination is incomplete without examination of the back of the patient.

Musculoskeletal injuries are a potential source of blood loss in patients with hemodynamic abnormalities. The proper splint application helps in blood loss control, reducing pain, and preventing further soft tissue injury. Splinting is required in the patients with joint dislocations.

Crush syndrome: it refers to the injured muscle which if left untreated can lead to acute renal failure. Traumatic rhabdomyolysis ranges from asymptomatic illness with elevation of creatine kinase level to a life-threatening condition associated with acute renal failure and disseminated intravascular coagulation (DIC). Early and aggressive fluid therapy protects the kidneys and prevents renal failure in patients with rhabdomyolysis.

Compartment syndrome: develops when the pressure within an osteofascial compartment of muscle causes ischemia and subsequent necrosis. Sometimes fasciotomy is required to manage the condition.

48.5 Conclusion

Management of airway is challenging in patients with maxillofacial trauma. Securing airway in these patients is dependent on the clinical status and the features of trauma. Before initiation of airway management, a series of steps are to be planned. For optimal care, one must have adequate knowledge of the specific

attributes of difficult airway. Also, the expertise in techniques for managing the difficult airway, familiarity with devices, and recognition of failed airway are necessary. A multidisciplinary approach involving anesthesiologist, maxillofacial surgeon, and a trauma expert must be a practice for better outcome (please refer Chap. 7 for further reading).

References

1. Perry M. Advanced trauma life support (ATLS) and facial trauma: can one size fit all? Part 1: dilemmas in the management of the multiply injured patient with coexisting facial injuries. *Int J Oral Maxillofac Surg.* 2008;37:209–14.
2. Perry M, Morris C. Advanced trauma life support (ATLS) and facial trauma: can one size fit all? Part 2: ATLS, maxillofacial injuries and airway management dilemmas. *Int J Oral Maxillofac Surg.* 2008;37:309–20.
3. Cowley RA. A total emergency medical system for the state of Maryland. *Md State Med J.* 1975;45:37–45.
4. Johnson G. Trauma triage and trauma system performance. *West J Emerg Med.* 2016;17:331–2.
5. Ray JM, Cestero RF. Initial management of the trauma patient. *Atlas Oral Maxillofac Surg Clin North Am.* 2013;21(1):1–7.
6. Gondek S, Schroeder ME, Sarani B. Assessment and resuscitation in trauma management. *Surg Clin North Am.* 2017;97:985–98.
7. Kovacs G, Sowers N. Airway management in trauma. *Emerg Med Clin North Am.* 2018;36:61–84.
8. Barak M, Bahouth H, Leiser Y, Abu El-Naaj I. Airway management of the patient with maxillofacial trauma: review of the literature and suggested clinical approach. *Biomed Res Int.* 2015:724–32.
9. Rocca F, Cassarino E, Boccaletti R, Stura G. Cervical spine fractures associated with maxillofacial trauma: an 11-year review. *J Craniofac Surg.* 2007;18:1259–63.
10. Galvagno SM, Nahmias JT, Young DA. Advanced Trauma Life Support® Update 2019: Management and applications for adults and special populations. *Anesthesiol Clin.* 2019;37:13–32.
11. Sidwell R, Matar MM, Sakran JV. Trauma education and prevention. *Surg Clin North Am.* 2017;97:1185–97.
12. Rodrigues IFDC. To log-roll or not to log-roll—That is the question! A review of the use of the log-roll for patients with pelvic fractures. *Int J Orthop Trauma Nurs.* 2017;27:36–40.
13. Rogers WA. Fractures and dislocations of the cervical spine: An end-result study. *J Bone Joint Surg Am.* 1957;39-A:341–76.
14. Whitcroft KL, Massouh L, Amirfeyz R, Bannister GC. A comparison of neck movement in the soft cervical collar and rigid cervical brace in healthy subjects. *J Manipulative Physiol Ther.* 2011;34:119–22.
15. Saillant NN, Sein V. Management of severe chest wall trauma. *J Emerg Crit Care Med.* 2018;2:41.
16. Eckstein M, Suyehara D. Needle thoracostomy in the prehospital setting. *Prehosp Emerg Care.* 1998;2:132–5.
17. Butler FK, et al. Management of open pneumothorax in tactical combat casualty care: TCCC guidelines change 13-02. *J Spec Oper Med.* 2013;13:81–6.
18. Pettiford BL, et al. The management of flail chest. *Thorac Surg Clin.* 2007;17:25–33.

19. Spodick DH. Pathophysiology of cardiac tamponade. *Chest*. 1998;113:1372–8.
20. Matar ZS. The clinical profile of poly trauma and management of abdominal trauma in a general hospital in the central region of the Kingdom of Saudi Arabia. *Internet J Surg*. 2008;14:11.
21. Demetriades D, et al. The management of penetrating injuries of the back: a prospective study of 230 patients. *Ann Surg*. 1988;207:72–4.
22. Chaudhry R, Galagali A, Narayanan RV. Focused abdominal sonography in trauma (FAST). *Med J Armed Forces India*. 2007;63:62–3.

Open Access This chapter is licensed under the terms of the Creative Commons Attribution 4.0 International License (<http://creativecommons.org/licenses/by/4.0/>), which permits use, sharing, adaptation, distribution and reproduction in any medium or format, as long as you give appropriate credit to the original author(s) and the source, provide a link to the Creative Commons license and indicate if changes were made.

The images or other third party material in this chapter are included in the chapter's Creative Commons license, unless indicated otherwise in a credit line to the material. If material is not included in the chapter's Creative Commons license and your intended use is not permitted by statutory regulation or exceeds the permitted use, you will need to obtain permission directly from the copyright holder.





Management of Soft Tissue Injuries in the Maxillofacial Region

49

Abhay Datarkar and Shikha Tayal

49.1 Introduction

Soft tissue injuries are one of the most commonly encountered injuries in head and neck region and present especially in the emergency department or surgical casualty. They can be isolated soft tissue injuries, or injuries having concomitant skeletal trauma. The frequent facial soft tissue injuries include simple lacerations, abrasions, contusions, bites, avulsions, and burns. These injuries are complicated by presence of vital anatomical structures like vessels, ducts, nerves, and muscles. Presence of foreign debris and hematoma further complicates the soft tissue injuries. The face is a region of high esthetics and functional importance. Hence, there are many factors that help to manage such injuries.

Factors that guide facial soft tissue injury management are:

- (i) **Recognition of nature of the injury**—Helps in logical treatment planning that ultimately results in better esthetic and functional outcomes.
- (ii) **Extent of injury**—Many facial soft tissue injuries that are relatively minor are treated in emergency department by the oral and maxillofacial surgeons. These wounds are managed by thorough cleaning, irrigation, debridement, primary suturing, and cleaning whenever needed. More complex wounds require special intervention by taking the patient into operation theatre and reconstructing using various grafts and flaps.
- (iii) **Timing of the injury**—Any type of injury, by default, should be attended at the earliest to maximize the prognosis. The bottom line of many past and present literature is that the wounds of face and scalp should be

primarily closed as soon as they are seen and as long as active infection is not present.

To achieve this, the surgeon needs to understand the etiopathogenesis, surgical anatomy, biomechanics of tissue wound, biology of wound healing, and the art of soft tissue repair.

49.2 Etiology

The most common etiology of facial soft tissue injuries varies according to the age, sex, and geographical distribution of the population. Facial soft tissue trauma tends to occur in certain areas of the head depending on the causative mechanism. It typically includes the T-shaped area that includes forehead, nose, lips, and chin, followed by the occiput and anterior temporal areas.

- (a) **Falls** are by far the most common cause, accounting for 48–51% of the injuries [1, 2]. This etiology has a trimodal distribution. The first peak is 2–3 years, when toddlers begin to walk and fall into objects. There is smaller peak during the second and third decades and then a steady rise after age of 50 years. Alcohol consumption is a major factor for soft tissue injuries due to fall between 30 and 50 years. Medical comorbidities such as epilepsy are also the causative factor for falls in old age group.
- (b) **Non-fall impacts**. Approximately 16% of facial soft tissue trauma is the result of a non-fall impact with structural element such a door, wall, or window frame. Other collisions with furnishings such as tables also counted. These types of injuries peak in children younger than 5 years. The common areas include the forehead, nose, and anterior temples.
- (c) **Assaults** account for 16–32% of facial soft tissue injuries [1]. The assaults are most commonly caused by fists, kicks, and blunt instruments. The injuries due to assault occurs more frequently among young men on left side of face. Alcohol consumption is a factor in two-thirds of these patients.

Disclosure: Authors have no financial conflicts to disclose.

A. Datarkar (✉) · S. Tayal
Department of Oral and Maxillofacial Surgery, Government Dental College and Hospital, Medical College Premises, Nagpur, Maharashtra, India

- (d) **Road traffic accidents** cause 6–13% of facial trauma [2] where soft tissue injuries may occur alone or in combination with other fractures. The peak incidence is seen in young men at 15–24 years of age [3]. Impact from steering wheel, dashboard, and windshields results in most lacerations.
- (e) **Sporting injuries** account for about 8% of facial soft tissue trauma [1], commonly occurring in young men. The forehead, nose, and teeth are the most likely areas to be injured. Concomitant facial fractures like nasal fractures, avulsive teeth injuries, and mandibular fractures are also common among these group of patients.
- (f) **Others include occupational injuries, bites from humans or animals**, and other miscellaneous causes. Occupational injuries [3] account for 5% of facial trauma and are primarily seen in young men. The risk of dog bites is higher for children aged 5–9 years and decreases with age. The frequency of facial injuries is highest in children younger than 4 years, in whom nearly 65% of dog bite injuries involve the face. In adults, it is about 9%. Most dog bite injuries are from dogs known to person or occur near home. These injuries typically involve the cheek, lips, forehead, and nose.

1. Abrasions
 2. Contusions
 3. Lacerations
- When injury is caused due to sharp force:
 1. Incised wounds
 2. Chop wounds
 3. Stab/punctured wounds
- (II) Thermal injuries:
- Due to excessive cold: e.g., frostbite
 - Due to moist heat: e.g. burns and scald wounds
- (III) Chemical injuries: Due to corrosive acids and alkalis
- (IV) Miscellaneous: Electricity, lightning, etc.
- (V) Explosions: Blast injuries

(B) Legal classification

1. **Simple**—soft tissue injuries without much tissue loss and can be managed conservatively. Heals rapidly without any permanent deformity.
2. **Grievous injuries**—described under Section 320 of Indian Penal Code as any injuries that endanger life and cause severe disfigurement or deformities like permanent hearing loss, vision loss, and severe head injuries. Tooth fracture or tooth loss following a blow in an interpersonal violence is also considered a grievous injury and penalized by the court of law. These injuries heal slowly and incompletely.
3. **Dangerous**—the grievous injuries that endanger life immediately after impact (Box 49.1).

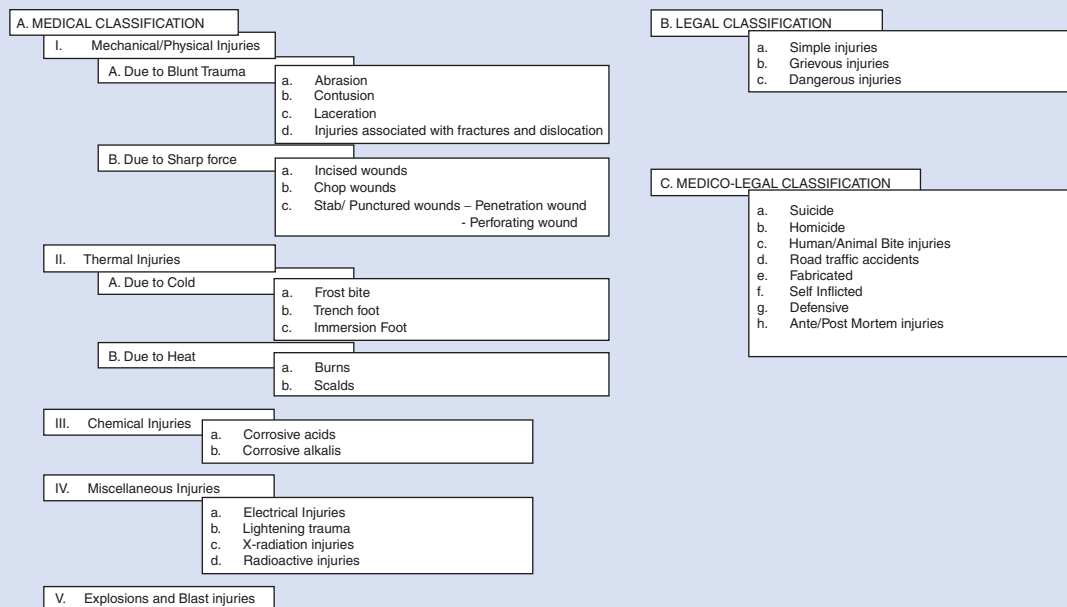
49.3 Classification of Soft Tissue Injuries

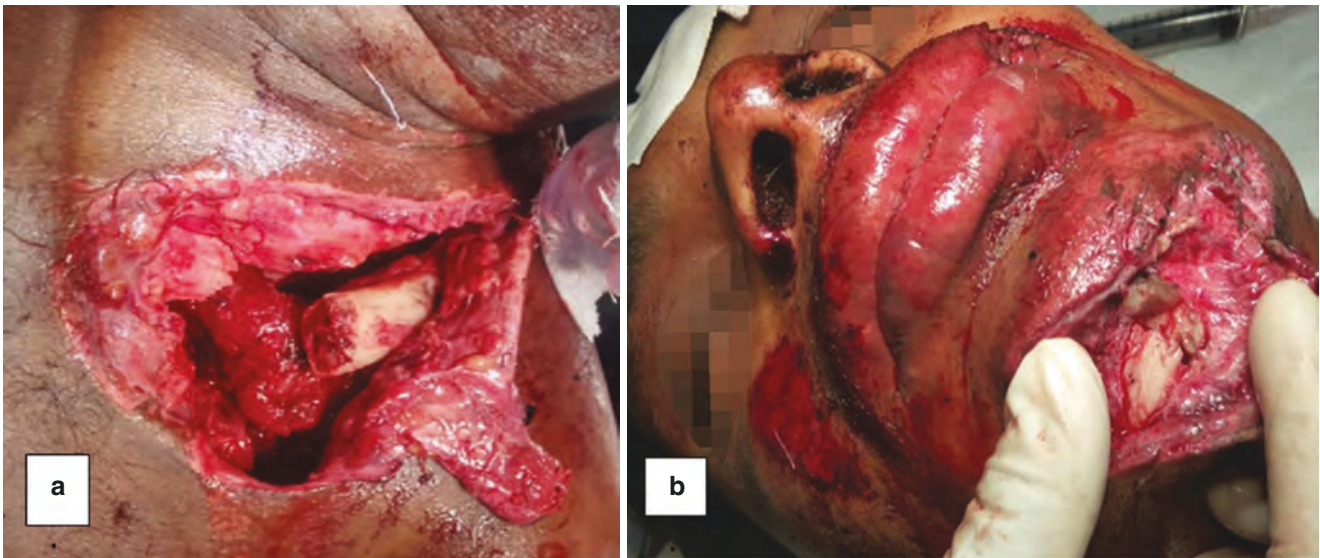
Soft tissue injuries can be classified into multiple categories:

(A) Based on mechanism of injuries

- (I) Mechanical or physical injuries:
- When injury is caused due to blunt force:

Box 49.1 Classification of Soft Tissue Injuries





©Association of Oral and Maxillofacial Surgeons of India

Fig. 49.1 (a) Showing open wound where fractured left clavicle is visible from the wound surface. (b) Open wound of maxillofacial region where underlying mandible is visible

(C) **Based on the communication of the injury with the external environment**

Closed wound: Only the underlying tissue and/or structures are damaged without breaking the skin. Examples of closed wounds include hematomas, contusions, and crush injuries. These types of wounds are not contaminated and, hence, heal on their own without any sequelae.

Open wounds: There is a break in the skin, which exposes the underlying structures to the external environment. Open wounds include simple and complex lacerations, avulsions, punctures, abrasions, accidental tattooing, and retained foreign body with a tendency to heal with scarring. These injuries require extensive exploration and debridement followed by a course of antibiotic regimen for uneventful healing (Fig. 49.1).

(D) **According to the facial subunit(s) involved.** The major esthetic subunits on the face are the scalp, forehead, nose, periorbital region, cheek, perioral region, auricle, and neck [4].

These major facial esthetic subunits are further divided into smaller subunits by location. The individual subunits must be reconstructed individually one by one in order to attain good esthetics (Fig. 49.2).

(E) **Based on additional injuries to the related structures**

(a) **Injuries to nerve**—The nerve injuries are most commonly encountered in cases of open wounds.

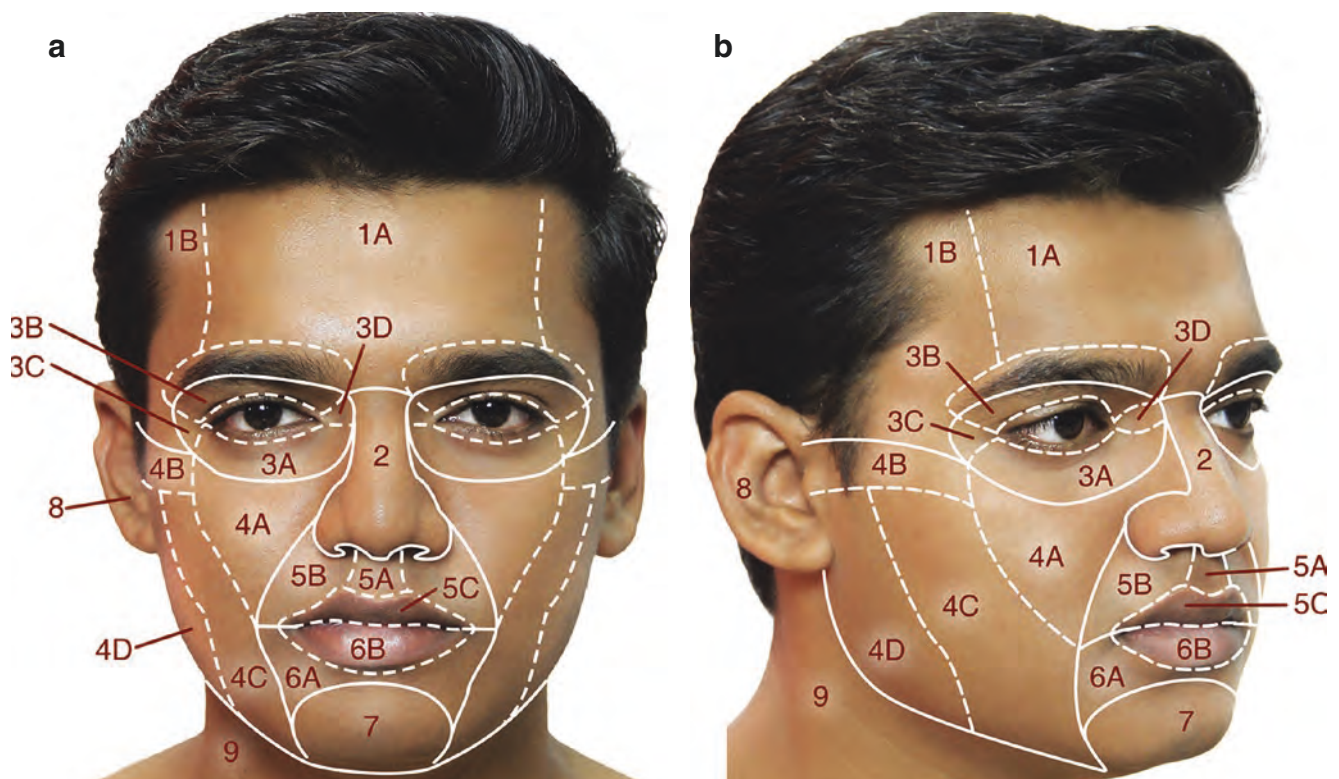
The nerve injuries are further classified into neuropraxia, axonotmesis, and neurotmesis (Seddon's classification of nerve injuries [5]). Sunderland [6] further revised this classification of nerve injuries based on the histologic degree of nerve damage. There should be careful evaluation of sensory and motor components of the nerves in the involved region for proper treatment. The most commonly encountered nerve injuries in maxillofacial region are the facial nerve and trigeminal nerve.

(b) **Injuries to arteries and veins**—The face is a highly vascular region where even a small injury leads to significant bleeding. Any wound in maxillofacial region should be attended in emergency setting at the earliest due to chances of injury to the extensive vascular network which necessitates hemostasis.

(c) **Injuries to parotid duct**—Seen in cases of deep lacerations on cheek at the region of parotid duct. If undiagnosed and untreated, this injury can lead to cumbersome sequelae of parotid fistula. Parotid duct injury is suspected if the laceration involves an imaginary line joining the tragus of the ear to the upper lip. In such cases, exploration is performed to evaluate the injury, and suturing should be done using a stent to establish patency of the duct.

(F) **Rank and Wakefield classification [7] of wounds**

(a) **Tidy wounds**—The wounds that are inflicted by sharp instruments like surgical blades and contain



©Association of Oral and Maxillofacial Surgeons of India

Fig. 49.2 Various facial esthetic subunits (Also see Fig. 86.3 in this book)

no devitalized tissue are called tidy. These wounds are closed primarily. Examples are surgical incisions, cuts from glass, and knife wounds.

- (b) **Untidy wounds**—Untidy wounds result from crushing, tearing, avulsion, vascular injury, or burns and contain devitalized tissue. Such wounds must be managed by wound excision. The devitalized tissue is excised, and the untidy wound is converted into the tidy wound before proper closure is achieved. The chances of infection are high if inadequately managed.

(G) CDC classification of surgical wounds

A **surgical wound** is a wound created by incisions and placement of drains during surgeries.

Surgical wounds can be classified into four different categories depending on the bacterial load, the risk of infection, and where the wound is located on the body.

Class I: Clean wounds. They show no signs of infection or inflammation. They often involve the eye, skin, or vascular system. It is often due to non-penetrating (blunt) trauma.

Class II: Clean-contaminated wounds. Although the wound may not show signs of infection, it is at an increased risk of becoming infected because of its

location. For example, surgical wounds in the respiratory tract like oropharynx and gastrointestinal tract may be at a high risk of becoming infected.

Class III: Contaminated wound. A surgical wound in which an outside object has come into contact with the skin and has a high risk of infection. For example, a gunshot wound may contaminate the skin around where the surgical repair occurs.

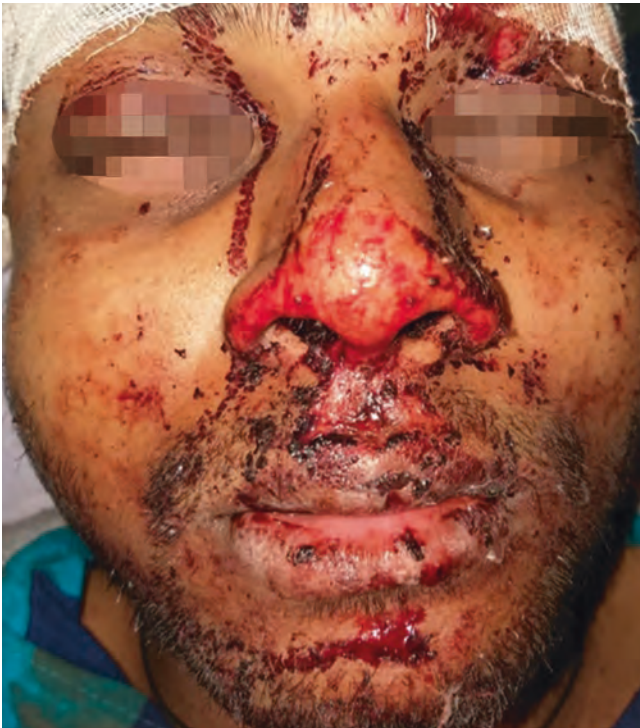Class IV: Dirty-contaminated or infected wounds. The wounds that have been exposed to fecal material and have a high bacterial load.

This wound classification guides in choosing appropriate treatment as well as helps in predicting post-repair form and function.

49.3.1 Common Soft Tissue Injuries

The common clinical presentation of soft tissue injuries included abrasions, contusions, and lacerations.

1. **Abrasions**—(also known as gravel rash) (Fig. 49.3)—It is destruction of the superficial layer of skin only. It is caused by frictional forces that are light enough to erode only the superficial layer of epidermis. It can be scratches



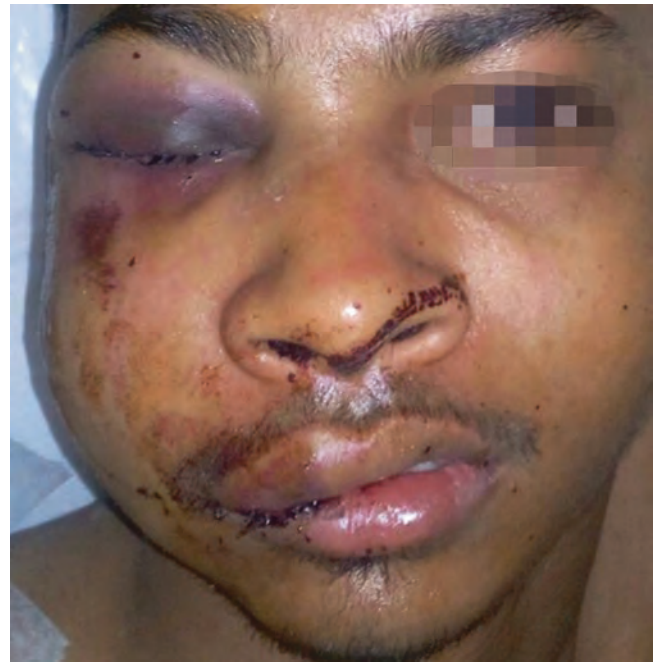©Association of Oral and Maxillofacial Surgeons of India

Fig. 49.3 Showing multiple abrasions over face involving the supra-orbital region, nose, upper lip, and chin

or linear type of abrasion, graze or sliding abrasion, pressure abrasions, and impact abrasions.

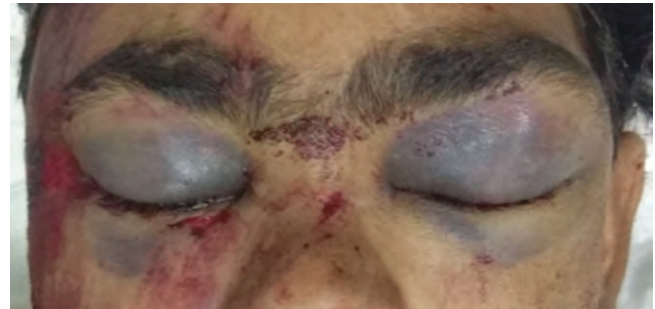The healing of abrasions takes place from the periphery of the wound towards the center by new growth of epithelial cells. The wound is bright red in color for the first 12–24 h due to extravasation of blood which dries up to form a red scab. After 2–3 days, a reddish-brown scab is formed. After 4–7 days, epithelium grows and covers the defect under the scab, which gives it a dark brown to brownish-black appearance. After 7 days, the scab dries and ultimately falls off, leaving depigmented bright pinkish area underneath, which attains its normal pigmentation gradually over a period.

2. **Contusions (bruising)** (Figs. 49.4 and 49.5)—This is effusion of blood into the tissues, due to the rupture of small blood vessels at the site of impact. There is no destruction of the superficial layer of skin. The subtypes are (a) intradermal, (b) subcutaneous, and (c) deep. A bruise heals by disintegration of extravasated blood. The red cells in the wound are hemolyzed, and the hemoglobin molecule is broken down into hemosiderin, hematin, and bilirubin by the action of enzymes. This type of injury demonstrates a change in the color of the wound according to the time lapsed after injury: red at the time of injury, blue within few hours to 3 days, and



©Association of Oral and Maxillofacial Surgeons of India

Fig. 49.4 Showing contusion wound over right cheek and periorbital ecchymosis of the right eye. The color changes can be appreciated intraorally

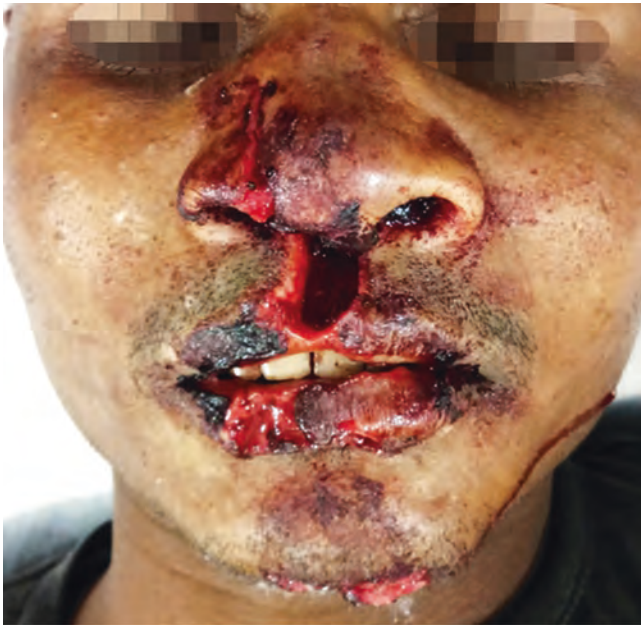

©Association of Oral and Maxillofacial Surgeons of India

Fig. 49.5 Showing bilateral periorbital ecchymosis (raccoon eyes)

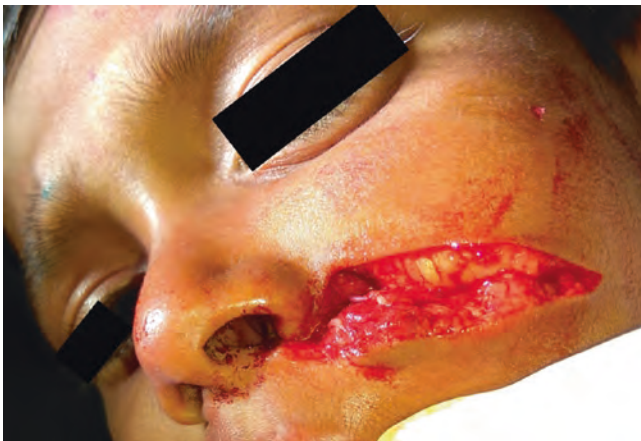bluish-black to brown color due to deposition of hemosiderin from the extravasated RBCs, by the 4th day. In 5–6 days, the wound appears greenish due to disintegration of hemoglobin to hemosiderin. Between 7 and 12 days, the wound appears yellow due to the presence of bilirubin which is the final disintegrated product from hemoglobin. The wound appears normal by 2 weeks. The various factors affecting the color of contusion include the depth of the bleeding, amount of extravasated blood, and overlying skin color.

3. **Lacerations**—It is the tear or split of skin, mucous membrane, muscle, or internal organs produced by the application of blunt force to a broad surface area, which



©Association of Oral and Maxillofacial Surgeons of India

Fig. 49.6 Showing split lacerated wound over the nose, columella, lower lip, and chin



©Association of Oral and Maxillofacial Surgeons of India

Fig. 49.7 Cut laceration having sharp clean cut edges

crushed or stretched tissues beyond the limits of their elasticity. They can be split lacerations (Fig. 49.6), stretch lacerations, shearing lacerations, and cut lacerations (Fig. 49.7).

4. **Incised wounds**—The wound is longer than it is deep. It is caused by the pressure and friction of any sharp object against the soft tissues (Fig. 49.8).
5. **Chop wounds (slash wounds)**—They are deep bigger wounds with gaping caused by a blow with the sharp-cutting edge of a heavy weapon, like an axe or chopper.
6. **Stab or punctured wounds**—Produced when the force is delivered along the long axis of a narrow or pointed

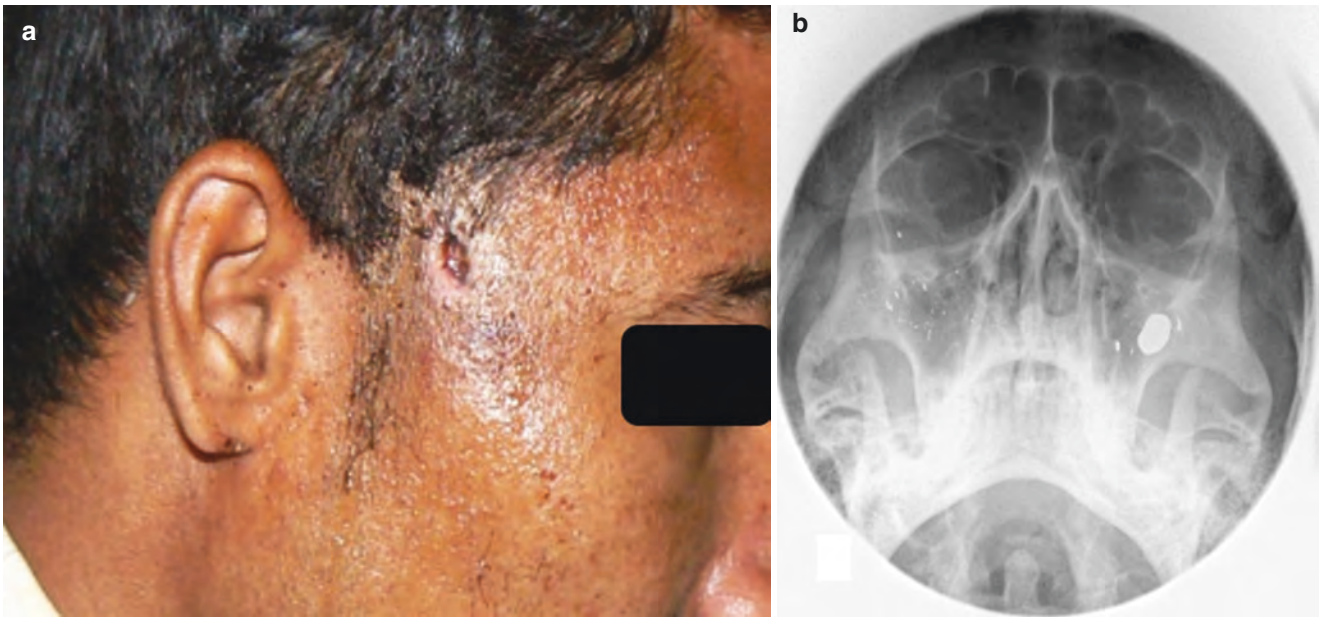


©Association of Oral and Maxillofacial Surgeons of India

Fig. 49.8 Showing incised wound extending from dorsum of the nose till pre-auricular region; caused by knife in a case of assault

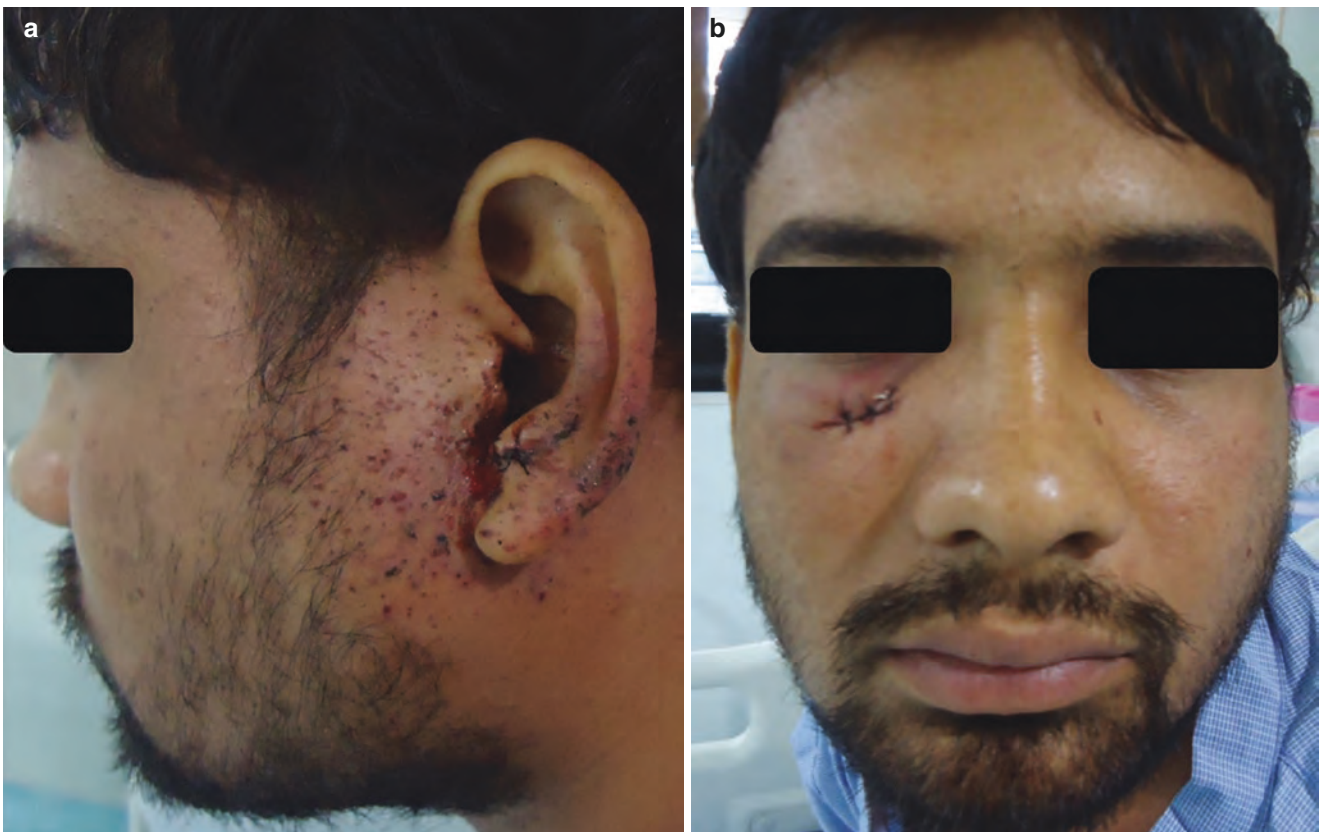object, such as knife, sword, chisel, scissors, nail, needle, spear, arrow, screw driver, etc. into the depths of the body. This type of wound is deeper than its length and width. These can be of the following types:

- (a) **Penetrating wounds**—When an object pierces the skin and enters a cavity of body or a viscus creating a localized path of entry leaving it an open wound (Fig. 49.9). In head and neck region, this type of injuries should be assessed for upper airway and bleeding as direct trauma to vital structures occurs along with facial bone fractures. Careful exploration of the wounds should be performed, and any impacted debris should be removed before closure.
 - (b) **Perforating wounds or through-and-through puncture wounds**—Produced when the object enters the body at one surface and exits at another surface without causing much tissue loss. The wound of entry is larger with inverted edges, and the wound of exit is smaller with everted edges. They are considered to be sterile wounds (Fig. 49.10).
7. **Crush injury**—A crush injury typically occurs when the body part is crushed between two heavy blunt objects. Most severe trauma cases will have this type of injury. Crush injuries have ragged edges, varying amounts of devitalized tissue, and, sometimes, tissue loss.
 8. **Avulsion injuries**—These involve significant tissue loss. Avulsion can be considered a very severe form of abrasion, wherein all layers of skin are torn off and the underlying structures are grossly exposed. The term avulsion can also mean complete loss of a small body part such as eyelid, fingertip, part of ear, etc.



©Association of Oral and Maxillofacial Surgeons of India

Fig. 49.9 Showing penetrating wound. (a) Only the entry site is seen over the right temporal region. (b) The object remains dislodged within the body cavities



©Association of Oral and Maxillofacial Surgeons of India

Fig. 49.10 Showing gunshot wound injuries. (a) Picture showing entry wound over pre-auricular region. (b) Showing exit wound over right infraorbital region on opposite side

9. **Burn injuries**—Burns are injuries to tissues caused by heat, friction, electricity, radiation, or chemicals. Most burns are from hot objects (including fluids) and fire. Burns cause severe skin damage where the cells die. Burns are highly painful injuries which require specific treatment as distinct from other injuries depending on the degree of burn.

The clinical presentation of burns depends largely on the depth of injury. Superficial burns (first degree) are confined to the epidermis. They are characterized by severe pain, dryness, and redness of skin. Superficial partial-thickness (second degree) burns extend into the papillary dermis. The skin is moist and red and blanches with pressure. Blisters are common in this type of injury. Deep partial-thickness burns extend into the reticular dermis. The skin is dry and appears yellow or white with minimal blistering. Full-thickness burns extending to the entire depth of dermis are classified as 3rd degree. These are very severe injuries. The skin is stiff, leathery, and brown, but pain is not a common feature. Fourth-degree burns involve charring of skin and affect the deeper structures like fat and muscle. The skin is dry, black, and painless.

49.4 Initial Evaluation and Assessment

All trauma patients should be assessed and managed initially according to the principles of Advanced Trauma Life Support. Soft tissue injuries of the head and neck region can be accompanied by significant swelling and bleeding leading to airway compromise. The patient also should be assessed for associated ophthalmologic, intracranial, and cervical spine injuries.

49.5 History and Examination

Once the patient has been evaluated for life-threatening injuries and stabilized as necessary, a thorough and focused history and physical examination of the head and neck should be performed. History includes timing and mechanism of injury.

Early treatment of soft tissue injuries is associated with optimal esthetic outcomes. Determining the mechanism of injury may help the surgeon in managing the wounds with special consideration. For example, crush injuries may result in a larger area of compromised tissue than appreciated on initial examination. Tissue that appears healthy initially may subsequently necrose and may require serial debridement.

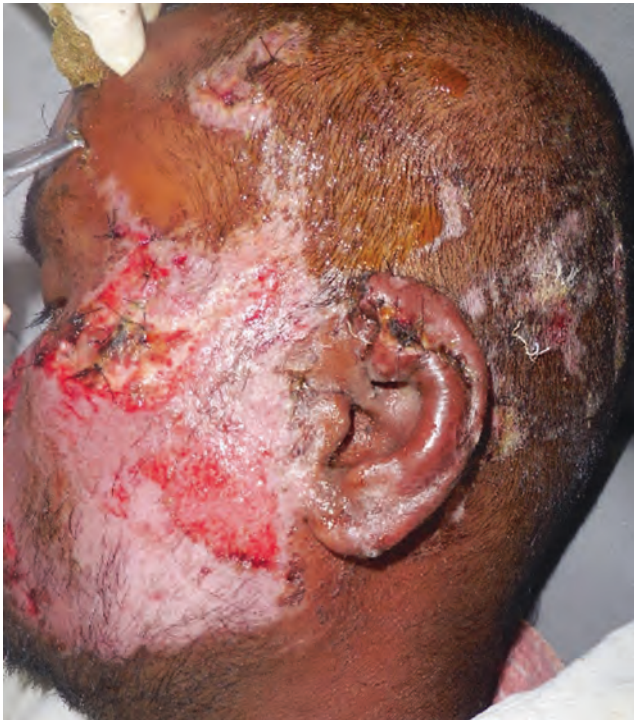The site(s), depth, and nature of all wounds should be noted. Presence of nonviable tissue, gross contamination, and any foreign body like dirt and debris are important to discern.

Palpation helps to identify the presence of underlying bony injuries. Palpation can be done through the open wound itself.

49.6 Management of Soft Tissue Injuries

The principles of management of soft tissue injuries include the control of bleeding, copious irrigation of the wound, debridement of devitalized tissue, and removal of foreign bodies before closure.

- (a) **Control of bleeding**—Blood loss is minimized by applying local pressure using hands and pressure dressings. The wound should be examined thoroughly with suction, irrigation, and meticulous dissection to identify the offending vessel, if any. If local pressure fails to achieve hemostasis, local hemostatic agents can be used. Local anesthesia with adrenaline helps in control of pain as well as bleeding through its vasoconstrictive action. If generalized oozing is still present which is hampering the ability of a surgeon to close the wound, systemic measures like injectable vitamin K, tranexamic acid, or ethamsylate can be given, provided the blood investigations (INR, BT, CT) are within normal limits.
- (b) **Copious irrigation** serves to dilute and wash out the contamination present in a wound. All grossly contaminated wounds should be copiously irrigated with sterile saline. The fluids may be warmed to 37 °C to promote cellular activity. The cleanser should be nontoxic and have a neutral pH. Alkaline soaps are best avoided. Antiseptics are generally not recommended for cleansing. They are applied on the wound after wound cleansing. The most commonly used antiseptic is Povidone-iodine 10% solution. An alternative solution for this purpose is Cetrimide 15% in combination with chlorhexidine gluconate 1.5%.
- (c) **Broad-spectrum antibiotic prophylaxis** is warranted in grossly contaminated wounds and bite wounds and in immunocompromised patients.
- (d) **Tetanus vaccination** [8]—Prevention of the local wound infection especially in crushed injuries, contaminated wounds, and bite wounds is a main concern. Tetanus prophylaxis in wound management is required as per the accepted international protocols.
- (e) **Wound excision** (also known as **wound debridement** or **toileting of the wound**)—Serial debridement of contaminated and untidy wounds done to remove all the necrotic tissues like devitalized muscles, tendons, and fascia and comminuted bony fragments that have lost the soft tissue cover of periosteum and are hanging within the wound, in order to aid in uneventful and optimum healing. The blunt contused margins of skin are also



©Association of Oral and Maxillofacial Surgeons of India

Fig. 49.11 Showing wound excision and serial debridement of an extensive untidy wound gradually healing secondarily

excised using sharp scissors, and the wound margins are freshened up. The toilet of any wound should be done in a systematic layer-wise manner from superficial to deep (Fig. 49.11).

- (f) **Closure**—Ideally, facial soft tissue injuries should be closed as early as possible. Primary closure of a wound should be completed within 8 h of injury when possible [9]. Early intervention and closure decreases the risk of infection as well as optimizes the functional and cosmetic result. Basic principles of suturing should be met, which include precise approximation and eversion of the skin edges, avoidance of excessive tension, and layer-wise closure to prevent dead space and fluid accumulation.

If gaping of the lacerated margins or tissue loss is present that cannot be closed primarily, the tissue can be managed by regular dressing and allowed to heal secondarily. Revision surgeries to improve esthetics and function are performed after minimum of 9 months.

- (g) **Reconstruction** [10]—Done in cases of extensive degloving injuries. There are several options for soft tissue reconstruction using flaps. Starting from local, regional, distant flaps and free microvascular flaps, depending on the type, location, and extent of the injury (Box 49.2).

Box 49.2 Reconstructive Options for the Head and Neck Region

CLASSIFICATION SCHEME OF VARIOUS RECONSTRUCTIVE FLAPS

Based on CIRCULATION	According to SOURCE OF HARVEST	Based on the MODE OF TRANSFER of flap	According to THE THICKNESS of the flap
<p>a. Axial – flap with one blood vessel. Further classified as fasciocutaneous, musculocutaneous, venous and direct. E.g. – Radial forearm flap, nasolabial flap, submental flap etc.</p> <p>a. Random – multiple random tributes of small vessels.</p>	<p>a. Local – area adjacent to the wound</p> <p>b. Regional – Same region e.g. – head and neck</p> <p>c. Distant – Region away from the wound</p> <p>d. Free Flaps – Flaps having their own blood supply, connected to the defect using microvascular technique.</p>	<p>a. Rotational – a semicircular type of flap pivoting onto the defect.</p> <p>b. Transpositional – flap that moves laterally around the adjacent defect.</p> <p>c. Advancement – Flap moved forward into the wound defect. E.g., –VY flap</p> <p>d. Interpositional – the flap moved laterally into the defect but not adjacent. Undermined to reach the area.</p>	<p>a. Full thickness flap – offers better esthetics</p> <p>a. Partial thickness flap</p>
Based on COMPOSITION of the flap			
<p>a. Dermal</p> <p>b. Muscle</p> <p>c. Fascia</p> <p>d. Tendon</p> <p>e. Bone</p> <p>f. Various combinations</p>			

49.7 Wound Dressings

Wound dressings are sterile pads used to cover the wounds. Lister [11] introduced antiseptic dressings by soaking gauze in carbolic acid. The dressings should be clean and provide a warm and moist environment for the successful wound healing. The dressings should be frequently

changed in order to keep the wound free from bacterial load. Antibacterial ointments must be applied over the wound to keep it lubricated and free from bacteria. The dressings are selected on the basis of two concepts: occlusion and absorption. The reasons for placing a wound dressing are enumerated in Box 49.3.

Box 49.3 Purposes of Dressings*Purposes of applying dressings over wounds*

- (i) Protection the wound from elements of nature
- (ii) Prevention of bacterial contamination
- (iii) Application of compression where required
- (iv) Absorption of exudate
- (v) Facilitation of hemostasis
- (vi) Prevention of further inadvertent trauma to wound site

In selected cases, the dressing is modified to achieve additional purposes such as

- (vii) Relief of pain
- (viii) Application of topical antibiotic
- (ix) Removal of slough and foreign bodies from the wound

Studies [12] have demonstrated that the rate of epithelialization under a moist occlusive dressing is twice that of a wound that is left uncovered and allowed to dry. An occlusive dressing provides a mildly acidic pH and low oxygen tension on

the wound surface, which is conducive for fibroblast proliferation and formation of granulation tissue.

However, wounds that produce significant amounts of exudate or have high bacterial counts require a dressing that is absorptive and prevents maceration of the surrounding skin. These dressings also need to reduce the bacterial load while absorbing the exudate produced. Placement of a pure occlusive dressing without bactericidal properties would allow bacterial overgrowth and worsen the infection.

The various types of dressings [13] can be enumerated as in Table 49.1.

49.8 Other Therapies

1. **Hyperbaric oxygen therapy**—uses oxygen as a drug and the hyperbaric chamber as a delivery system to increase PO₂ at the target area. It involves inhalation of 100% oxygen at 1.9–2.5 atm, for sessions of 90–120 min each. Treatments are given once daily, five to six times per week and should be given as an adjunct to surgical or medical therapies. Clinical evidence of wound improvement should be noted after 15–20 treatments.

Table 49.1 Types of wound dressing materials

Kind of dressing	Examples	Properties	Indications
Protective	Gauze	Inexpensive, readily available Highly permeable and nonocclusive Dry dressing—can stick to the wound if used primarily	As secondary dressing over another material
	Polymeric films (Opsite, Tegaderm)	Transparent, waterproof dressing Semi-permeable, thin, highly elastic	Surgical incisions
Absorbent	Hydrogels	Mostly contain water Provide a moist and cool environment	Wounds with mild exudates Not for heavily exuding or infected wounds
	Hydrocolloids	Composed of methylcellulose, pectin, and gelatin Absorb fluids and convert them into a gel that covers the wound Provides pain relief as the gel covers nerve endings	Light to heavily exuding wounds such as burns Must not be used on infected wounds
Bioactive	Antimicrobial dressings	Soft, paraffin dressing impregnated with chlorhexidine (Bactigras) or framycetin (Sufratulle) Actively prevent bacterial contamination Require a secondary dressing over it	Flat, shallow wounds such as skin graft donor sites, superficial burns, and abrasions
		Scarlet Red , a relatively nonocclusive dressing that is impregnated with <i>O</i> -tolylazo- <i>O</i> -tolylazo- β -naphthol Xeroform—hydrophobic dressing containing 3% bismuth tribromophenate in a petrolatum base, which helps mask wound odors and has antimicrobial activity against <i>Staphylococcus aureus</i> and <i>Escherichia coli</i>	Skin graft harvest sites in burn care
	Collagen dressings	Activate matrix metalloproteinases and promote new collagen formation	Chronic non-healing wounds Burn wounds

Mechanism of action—HBO therapy can increase tissue PO₂ ten times higher than usual. The higher PaO₂ is sufficient to supply the tissue with all its metabolic requirements even in the absence of hemoglobin. This elevated level lasts for 2–4 h after termination of HBO therapy and induces synthesis of endothelial cell NO synthase as well as angiogenesis. Oxygen stimulates angiogenesis, enhances fibroblast and leukocyte function, and normalizes cutaneous microvascular reflexes, thus aiding in healing of chronic, complicated, non-healing wounds.

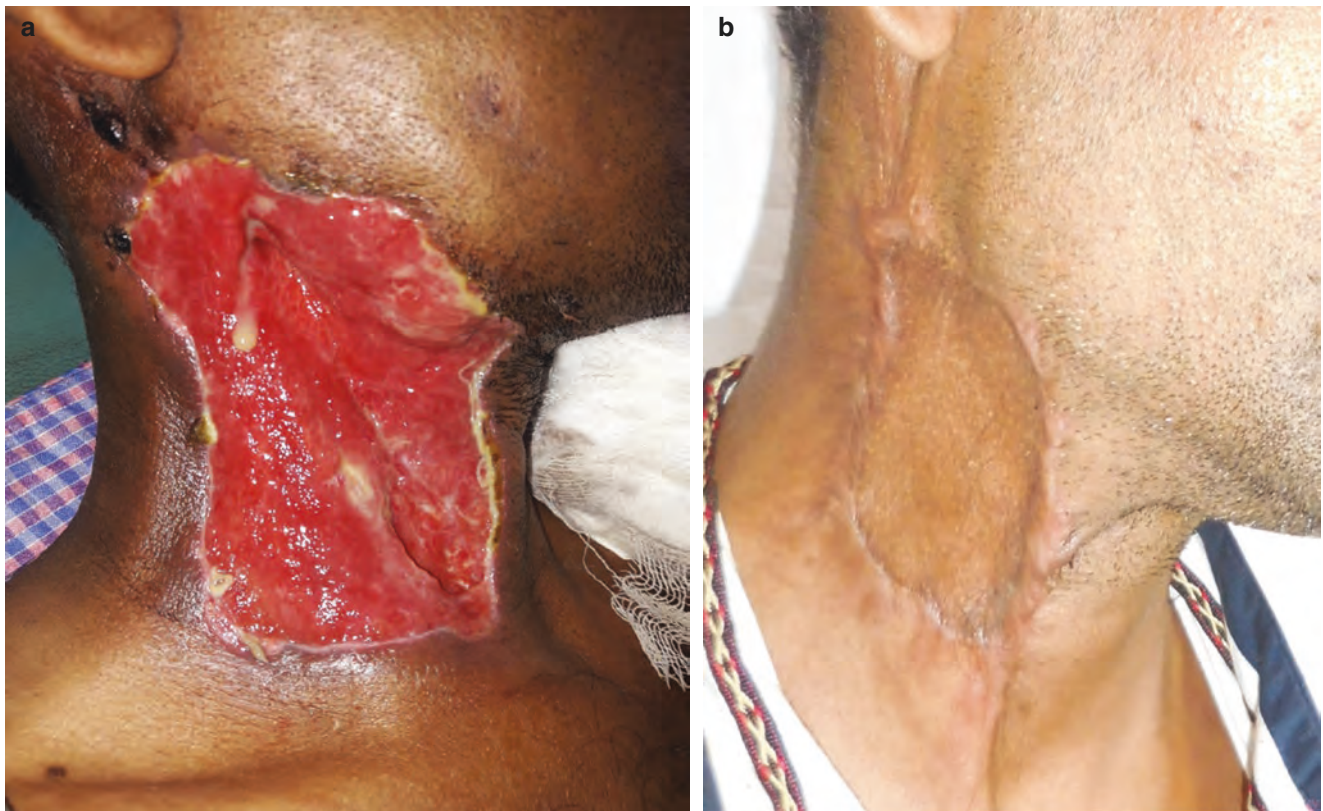
2. **Negative pressure-assisted wound therapy**—Argenta [14] and associates originally described the use of negative pressure to assist in wound closure in 1997. By applying subatmospheric pressure to wounds, they demonstrated removal of chronic edema, an increase in local blood flow, and stimulation of granulation tissue. This technique may be used on acute, subacute, and chronic wounds. The wound is filled with a foam substance. A drainage tube is inserted into, or laid on, the foam, and the part is then covered with impermeable film. Suction is applied at around 125 mmHg between changes of dressing.

49.9 Necrotizing Fasciitis

It is a rapidly spreading necrotizing soft tissue infection, also known as flesh-eating disease. It is one of the most challenging infections faced by the maxillofacial surgeons due to its diagnosis and management. The most common bacteria responsible for the fascial necrosis are hemolytic *Streptococcus* and *Staphylococcus*.

It is foul-smelling with loss of skin and superficial subcutaneous tissue, having patchy blackish necrosis and frank pus along with the raw surface of the wound, margins of which are pale and spreading in nature. If it involves the skin of scrotum, it is known as Fournier's gangrene.

The prompt diagnosis and aggressive treatment is the key to manage this complicated condition. Removal of the offending factors like carious tooth and infected foreign material is the prime step followed by aggressive debridement and desloughing involving the normal tissue margins under the antibiotic coverage and adequate anesthesia. Once the wound is free of the active infection, showing healing margins with no evidence of pus, it is reconstructed with the skin grafts (Fig. 49.12).



©Association of Oral and Maxillofacial Surgeons of India

Fig. 49.12 Depicting a case of necrotizing fasciitis of the right side of the neck due to infection from right mandibular third molar. The patient was promptly and aggressively managed by sequential debridement followed by anterolateral thigh skin graft

Table 49.2 Phases of wound healing

Phases of wound healing	Time period	Mechanism of healing
Inflammatory phase	Immediate till 5th day	<ul style="list-style-type: none"> • Immediate vascular response • Cellular infiltration—Polymorphonuclear leukocytes initially, followed by monocytes within 24 h, which become dominant by the 5th day and actively engaged in phagocytosis • Formation of new blood vessels at the edges of wound (neovascularization) • Synthesis of granulation tissue
Proliferative phase	Established by 5th day	<ul style="list-style-type: none"> • Cellular proliferation—Macrophages are preponderant • With time, the number of fibroblasts increases that are active in synthesis of extracellular collagen and proteoglycans (collagen synthesis) • The fibroblasts in the wound are closely followed by the endothelial buds of capillaries. The wound is filled with vascular granulation tissue containing new capillaries, fibroblasts, macrophages, and mast cells • An intrinsic increase in the mechanical strength of the wound at the end of this phase
Maturation phase		<ul style="list-style-type: none"> • Extensive remodeling as a result of a decrease in the numbers of fibroblasts and macrophages concurrent with a decrease in vascularity • Increase in wound strength • Formation of scar tissue

49.10 Principles of Soft Tissue Healing

The three phases of repair in soft tissue wounds are overlapping and include

- The inflammatory phase
- The proliferative phase
- The maturation phase (Table 49.2)

Any alteration in the local environment of the wounds or the systemic status of the patients can influence the normal process of wound healing.

49.11 Types of Wound Healing

The various types of wound healing include:

1. Primary intention
 2. Delayed primary closure
 3. Secondary intention
1. **Primary intention**—occurs when full-thickness wound edges are approximated shortly after the primary wound has been created. This type of closure is generally avoided in grossly contaminated wounds, in wounds that cannot be completely debrided, and in wounds where further tissue loss is anticipated as in blast injuries.
 2. **Delayed primary closure**—Primary closure is delayed to allow host inflammatory and immune responses to control contamination. It is typically completed 3–4 days after the initial injury but depends on the particular characteristics of the wound. Serial debridements may be performed until the full extent of tissue devitalization is determined.

Table 49.3 Factors that negatively influence wound healing

Local factors	Systemic factors
Presence of foreign bodies	Smoking
Venous insufficiency	Comorbidities like diabetes
Ischemia/ hypoxia to tissues	Systemic condition—malnutrition, chronic illness, deficiency of vitamins
Radiation	Prolonged drug use—corticosteroids, cytotoxic chemotherapy
Salivary contamination	
Scarring	
Hematoma	

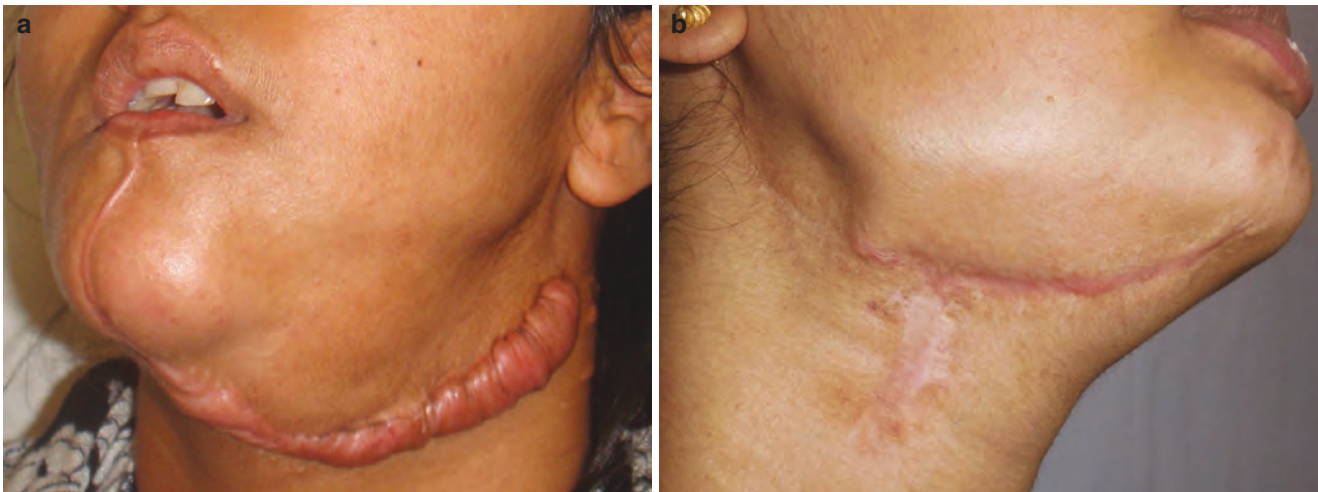3. **Secondary intention**—healing is by natural biologic processes without surgical intervention, and it usually occurs in large wounds associated with soft tissue loss or avulsion. It involves epithelialization and collagen deposition for wound healing. Contraction is the most important phenomenon in the spontaneous closure of large open wounds.

49.12 Complications in Wound Healing

Complications in the normal process of wound healing may occur due to presence of various local and systemic factors which exert a negative impact (Table 49.3).

One of the frequently observed complications is “abnormal wound healing” which presents in different forms such as keloids and hypertrophic scars. These are proliferative scars characterized by excessive net collagen deposition. Keloids and hypertrophic scars (Fig. 49.13) differ histologically from normal scars. The clinical appearance of the two types of scar is described in Table 49.4.

Keloids and hypertrophic scars contain collagen bundles aligned in the same plane as the epidermis. Tension



©Association of Oral and Maxillofacial Surgeons of India

Fig. 49.13 Showing. (a) keloid type of scar and (b) hypertrophic scar healing

Table 49.4 Difference between keloids and hypertrophic scar

Keloids	Hypertrophic scar
Contain disorganized type I and type III collagen bundles	Primarily contain well-organized type III collagen fibers
The collagen bundles are thicker and form a nodelike structure in the deep layer of skin	Contain islands of aggregates of fibroblasts, small vessels, and collagen fibers throughout the dermis
Cannot be prevented and are often refractory to medical and surgical intervention	Often preventable
Occur above the clavicles, on the trunk, on the upper extremities, and on the face	Prolonged inflammation and insufficient resurfacing (e.g., burn wounds) promote hypertrophic scarring
Grow beyond the borders of the original wounds and rarely regress with time	Raised scars within the confines of the original wound and frequently regress spontaneously
Appear to be genetically predisposed	Represent a reversible hyperproliferative scar phenotype that regresses when the original stimulus (skin tension, stimulatory growth factors) are removed
First-line treatments include pressure therapy and intralesional corticosteroid injections. Intralesional 5-fluorouracil, bleomycin, and verapamil used according to the established treatment protocols. Refractory cases after 12 months of therapy should be considered for surgical excision in combination with adjuvant therapy. Excision alone results in a high recurrence rate of 50–100% and enlargement of the keloid. Immediate postoperative electron beam irradiation or brachytherapy with iridium-192 reduces recurrence rates.	Pressure and silicone therapy combined with selective localized corticosteroid injections in resistant areas. Bleomycin, 5-fluorouracil, and verapamil can be used as adjuncts to corticosteroid therapy. Laser therapy to reduce scar thickness, resurface scar texture, and treat residual redness, telangiectasias, or hyperpigmentation. Early surgery is indicated if the scar causes functional impairment. Scar contracture release procedures in the neck and axilla are best performed with flaps to improve functional and cosmetic outcomes. Widespread large hypertrophic scars may require serial excision or tissue expansion.

over the edges of the wound signals the formation of activated fibroblasts resulting in excessive collagen deposition.

Scars perpendicular to the underlying muscle fibers tend to be flatter and narrower, with less collagen formation than when they are parallel to the underlying muscle fibers. As muscle fibers contract, the wound edges become reapproximated when they are perpendicular to the underlying muscle and tend to gape if placed parallel to it, leading to greater wound tension and scar formation.

49.12.1 Prevention of Hypertrophic or Keloid Scars

The four strategies that reduce adverse scarring immediately after wound closure are:

- Layer-wise closure as to avoid gaping within the layers of the wound
- Closure without tension
- Hydration of the wound with clean dressing
- Use of pressure garments

Postsurgical taping of the wound for 3 months can reduce scarring. Moisturizing lotions and moisture-retentive dressings (silicone sheets and gels) can reduce the thickness, discomfort, and itching and improve the appearance of the scar.

49.13 Recent Advances in Soft Tissue Management

1. Use of **growth factors**—intimate role in the regulation of all phases of wound healing, i.e., chemotaxis, proliferation, matrix synthesis, inflammation, and angiogenesis. The enhancement of soft tissue wound healing can be done by various methods. Topical application of growth factors in a vehicle or by direct seeding of cells topically on the wound can enhance healing. Placement of growth factors or cells can also be done with a fibrin sealant or glue. Use of platelet-rich plasma (PRP) by degranulation of platelets with the secretion of its contents of growth factors into the surrounding fibrin matrix or, more recently, use of tissue-engineered equivalents of skin or mucosa can provide a scaffold that enhances healing.
2. **Gene and stem cell therapy**—in which the gene encoding for the therapeutic growth factor or protein is directly transfected into host cells. This is a promising approach for the treatment of acute and chronic wounds.
3. **Tissue engineering**—In 1987, the National Science Foundation bioengineering panel defined tissue engineering as “the application of the principles and methods of engineering and the life sciences toward the development of biologic substitutes to restore, maintain, or improve function.”
They include—*Bioengineered Skin substitutes vis* [15]

- (a) *Epidermal substitutes*—These are autografts taken from split-thickness skin grafting or from cell line bioreactor expansion and grown in laboratory until enough tissue is produced to be transferred to the wound later.
- (b) *Dermal substitutes*—When the wound is deep and the dermis is destroyed, epidermal substitutes are not enough to ensure wound healing. The dermis is replaced by the one manufactured in the laboratory from the patient-specific cells. This dermis is essential to maintain mechanical resistance and occlude the surface of the wound.

- (c) *Bilayer substitutes*—Integra, developed in 1981, was the first acellular bilayer and has been used successfully to treat burns and chronic wound patients.

49.14 Conclusion

Proper assessment and classification of soft tissue injuries is the primary step in management. Early intervention and closure of soft tissue injuries is associated with optimal functional and esthetic outcomes as well as decreases the risk of complications. The basic principles of management of soft tissue injuries include the control of bleeding, copious irrigation of the wound, debridement of devitalized tissue, and removal of foreign bodies before closure. Administration of antibiotics and tetanus prophylaxis play a vital role in management of contaminated wounds. Wound dressings are mandatory to protect wounds postoperatively and facilitate ideal healing. Soft tissue injuries resulting in loss of tissue must be reconstructed using flaps which may be local, regional, distant, or free microvascular flaps, depending on the type, location, and extent of the injury. Innovative options such as growth factors, stem cell therapy, and bioengineered skin substitutes may be considered.

49.15 Case Scenarios

Case Scenario 1

A 23-year-old male patient met with a road traffic accident and suffered from a perforating injury over the nose, extending to right infra-orbital region. After initial resuscitating of the patient and ruling out the head injury component, the patient was taken up for the management of soft tissue and hard tissue injuries under general anesthesia. Through the existing lacerated wound, open reduction and internal fixation was done within 48 h of the trauma. Simultaneously, the soft tissue closure was performed layer-wise. Closure of the muscle layer was performed followed by the subcutaneous tissue and finally the skin (Fig. 49.14a–e).

Case Scenario 2

A case scenario of a 67-year-old male patient who reported to the department of Oral and Maxillofacial Surgery. He was a victim of ballistic injury while he was working in a marketplace. The penetrating pathway of the bullet could be traced

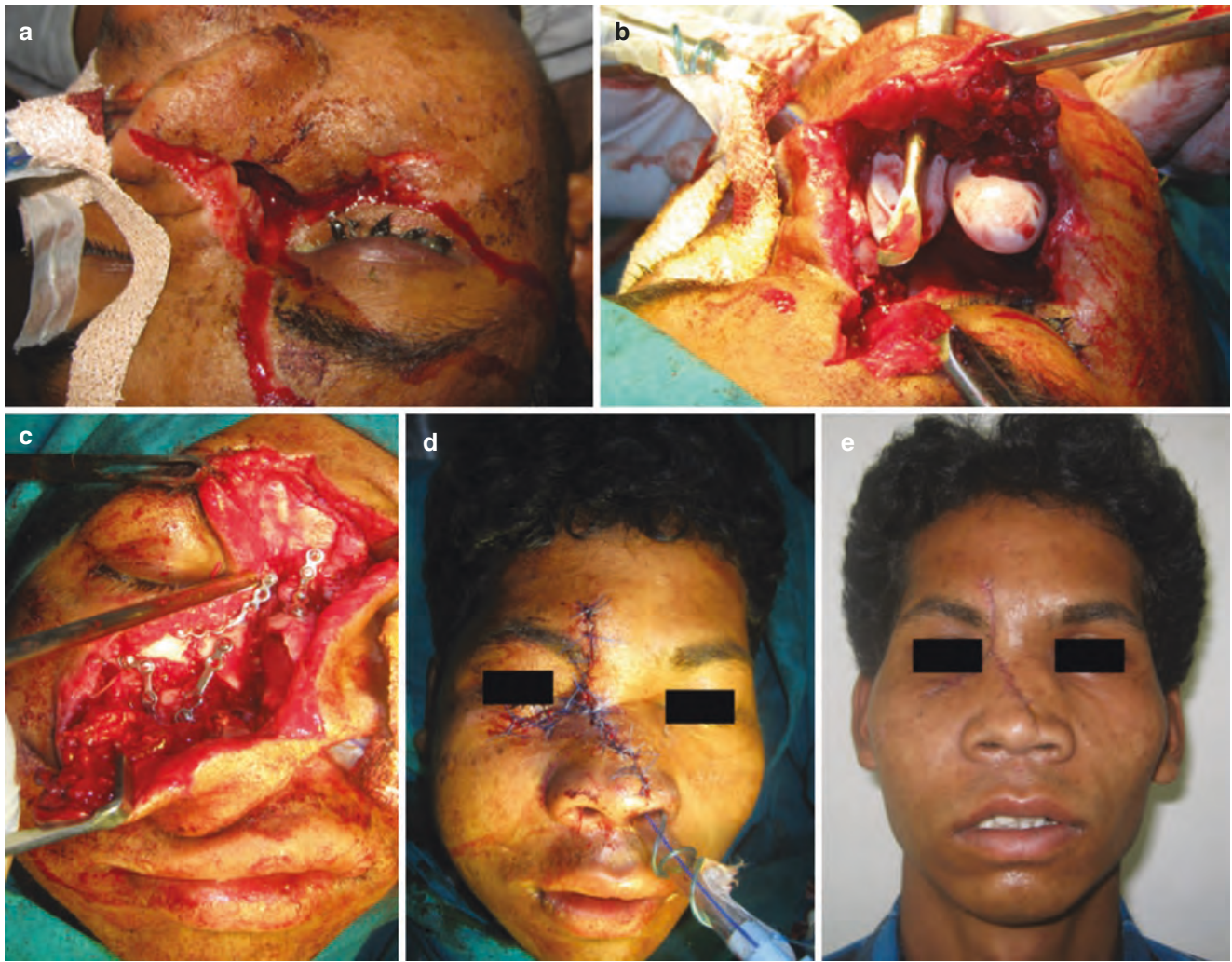

Fig. 49.14 Case scenario 1(a-e): Soft tissue management of a road traffic accident victim

having an entry site over left cheek. An extensive and careful exploration was performed in the OT under general anesthesia after the sections of 3D CT face were obtained (Fig. 49.15a-g). The comminuted fracture of the mandible was reconstructed using reconstruction plate. The bullet was found to be lodged in the carotid triangle just above the bifurcation of the common carotid artery.

Soft tissue management in such type of ballistic injuries becomes very critical. Since the bullet is a foreign material, it has to be removed from the soft tissues. The approach could either be through the entry wound but due to deep seat-

ing of the bullet into the neck and proximity of vital structures, one should always think of an extensive approach. The neck dissection was carried out in this case to remove the bullet from the bifurcation of common carotid artery in as atraumatic manner as possible. Bidigital palpation is a crucial step to locate the foreign body in this region. One interesting fact about such injuries is that though they are extensive with crushed and comminuted fractures and they are sterile due to the heat generated by the velocity of the bullet along its path. Such injuries are less prone to infection.

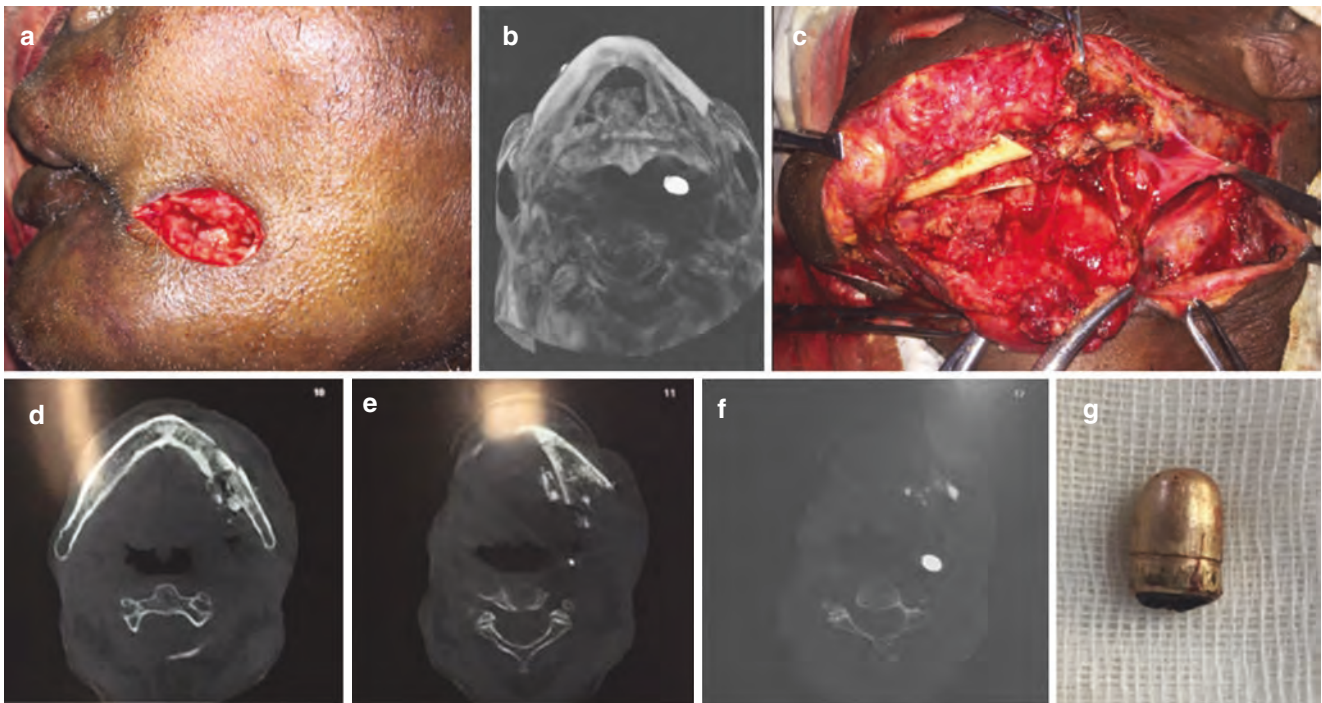


Fig. 49.15 (a–g) Case Scenario 2: Soft tissue management in a ballistic injury

Proper surgical toilet with wound irrigation followed by careful debridement remains the mainstay of treatment of all types of soft tissue injuries.

References

- Hussain K, Wijetunge DB, Grubnic S, et al. A comprehensive analysis of craniofacial trauma. *J Trauma*. 1994;36:34.
- Key SJ, Thomas DW, Shepherd JP. The management of soft tissue facial wounds. *Br J Oral Maxillofac Surg*. 1995;33(2):76–85.
- Karlson TA. The incidence of hospital-treated facial injuries from vehicles. *J Trauma*. 1982;22:303.
- Fattahi TT. An overview of facial aesthetic units. *J Oral Maxillofac Surg*. 2003;61(10):1207–11.
- Seddon HJ, Medawar PB, Smith H. Rate of regeneration of peripheral nerves in man. *J Physiol*. 1943;102:191–215.
- Sunderland S. A classification of peripheral nerve injuries producing loss of function. *Brain*. 1951;74:491–516.
- Rank BK, Wakefield AR. *Surgery of repair as applied to hand injuries*. London: Livingstone; 1960.
- Stefanopoulos PK, Tarantzopoulou AD. Facial bite wounds: management update. *Int J Oral Maxillofac Surg*. 2005;34(5):464–72.
- Janis JE. *Essentials of plastic surgery*. 2nd edn. Boca Raton, FL: Quality Medical; 2014. p. 316–21, 382–5, 390, 480.
- Frodel JL, Holt GR, Larrabee WF Jr, et al. Facial plastic and reconstructive surgery. In: Papel ID, editor. 4th edn. New York: Thieme; 2016. p. 754–65.
- Pitt D, Aubin JM. Joseph Lister: father of modern surgery. *Can J Surg*. 2012;55(5):E8.
- Morin RJ, Tomaselli NL. Interactive dressings and topical agents. *Clin Plast Surg*. 2007;34(4):643–58.
- Lionelli GT, Lawrence WT. Wound dressings. *Surg Clin*. 2003;83(3):617–38.
- Argenta LC, Morykwas MJ. Vacuum-assisted closure: a new method for wound control and treatment: clinical experience. *Ann Plast Surg*. 1997;38:563–77.
- Greaves NS, Iqbal SA, Baguneid M, Bayat A. The role of skin substitutes in the management of chronic cutaneous wounds. *Wound Repair Regen*. 2013;21(2):194–210.

Open Access This chapter is licensed under the terms of the Creative Commons Attribution 4.0 International License (<http://creativecommons.org/licenses/by/4.0/>), which permits use, sharing, adaptation, distribution and reproduction in any medium or format, as long as you give appropriate credit to the original author(s) and the source, provide a link to the Creative Commons license and indicate if changes were made.

The images or other third party material in this chapter are included in the chapter's Creative Commons license, unless indicated otherwise in a credit line to the material. If material is not included in the chapter's Creative Commons license and your intended use is not permitted by statutory regulation or exceeds the permitted use, you will need to obtain permission directly from the copyright holder.





Dentoalveolar Injuries and Wiring Techniques

50

Omkar Anand Shetye

50.1 Definition

Dentoalveolar fracture is defined as a fracture in the bone surrounding the teeth without any extension to the basal bones of the maxilla or mandible [1, 2].

50.2 Incidence

Dentoalveolar injuries commonly occur in the age group of 8–12 years. They generally involve teeth, soft tissues, and/or associated bone. Traumatic dental injuries account for a total of 92% of maxillofacial injuries of which 92% involves only the soft tissues and 8% involve the maxillofacial bones [2].

50.3 Introduction

Trauma is the foremost etiological factor that leads to a loss of significant number of teeth annually. The recent advancements in the field of preventive dentistry as well as the development of myriad evidence-based techniques to restore the lost form and function of teeth have made it possible for the dental surgeon to successfully facilitate the improvement in the quality of life of trauma-afflicted patients. Time elapsed post-trauma plays a major factor in determining the outcome of the intervention. Apart from reestablishing the premorbid position of the traumatized tooth in its socket, the goal of the treatment is directed toward achieving the pre-traumatic occlusion and intra-arch contour [3].

Electronic Supplementary Material The online version of this chapter (https://doi.org/10.1007/978-981-15-1346-6_50) contains supplementary material, which is available to authorized users.

O. A. Shetye (✉)
Department of Oral and Maxillofacial Surgery, Goa Dental College and Hospital, Bambolim, Goa, India

50.4 Diagnosis and Treatment Planning

The foundation of diagnosis and management of traumatic dental injuries solely lies on the pillars of a detailed patient history and a clinical examination. **When, Where, and How** forms the “Trauma Triad” of history taking in traumatic dental injuries [4].

When—Time interval between injury and treatment may significantly affect the prognosis for cases of pulp exposure, displacement, and avulsion type of injuries.

Where—The place of injury. The chances of the injury getting infected on a playground compared to an injury that has occurred at home in relatively cleaner surroundings. The place of injury has medico-legal repercussions if the assault or accident has occurred at the place of work. Depending on the cleanliness of the wound, the clinician can also consider protection against tetanus.

How—This may give an indication of concomitant injuries like soft tissue injuries secondary to the trauma [5].

History of immediate local measures employed to reduce the severity of injury helps in eliciting information regarding the original condition of the injured area [6].

History of any systemic disorders that may interfere with treatment or post-operative healing including a history of tetanus vaccination has to be obtained before starting the treatment [7].

“Outside-in” examination (examining the facial structure in three concentric rings paying more attention to the innermost ring) helps in achieving the desired management protocol. Level of consciousness should be assessed prior to the clinical examination [6].

The potential for aspiration, airway compromise, and neurosensory deficit warrants the need for a thorough evaluation of all maxillofacial injuries before managing dental injuries [3].

In a patient with missing tooth fragment or prosthesis, a chest radiograph and abdominal radiograph may be helpful in locating the missing structures and their management. Owing to its anatomic position, the right bronchus is often the site of foreign body dislodgement [3, 6].

50.5 Clinical Examination

Clinical examination of the patient has to be divided into the following subsets [8]:

- Extra-oral soft tissue
- Intra-oral soft tissue
- Jaws and alveolar bone
- Teeth (displacement and mobility)
- Percussion and pulp testing [3]

50.5.1 Extra-oral

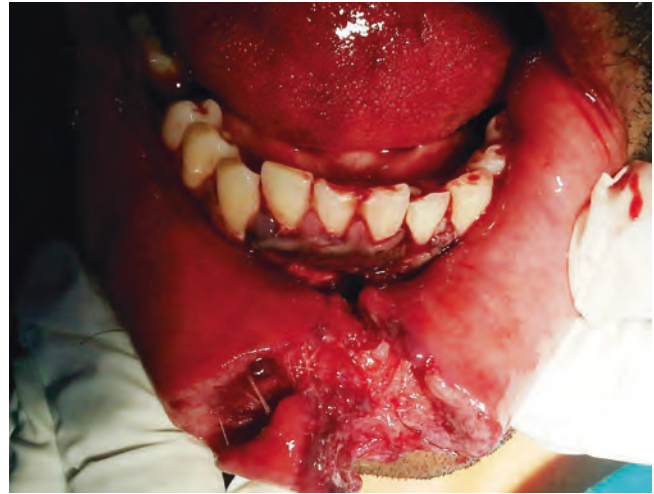Asymmetry of the face following trauma could be due to injury to the facial skeleton or swelling. Areas of ecchymosis and hematoma may indicate fracture of the underlying osseous structure. Laceration, contusion, and abrasion of the overlying skin are common with dentoalveolar injuries (Figs. 50.1, 50.2, and 50.3). Mild antiseptic soap should be used to clean the extra-oral abrasions or a saline wash can be used while being careful to not inoculate injury site further with debris or foreign body [4, 8].

50.5.2 Intra-oral

Buccal mucosa lacerations should raise suspicion for a Stensen's duct injury. The lips, floor of the mouth, and tongue are areas which are at a risk of being penetrated or sites for secondary injuries [3].

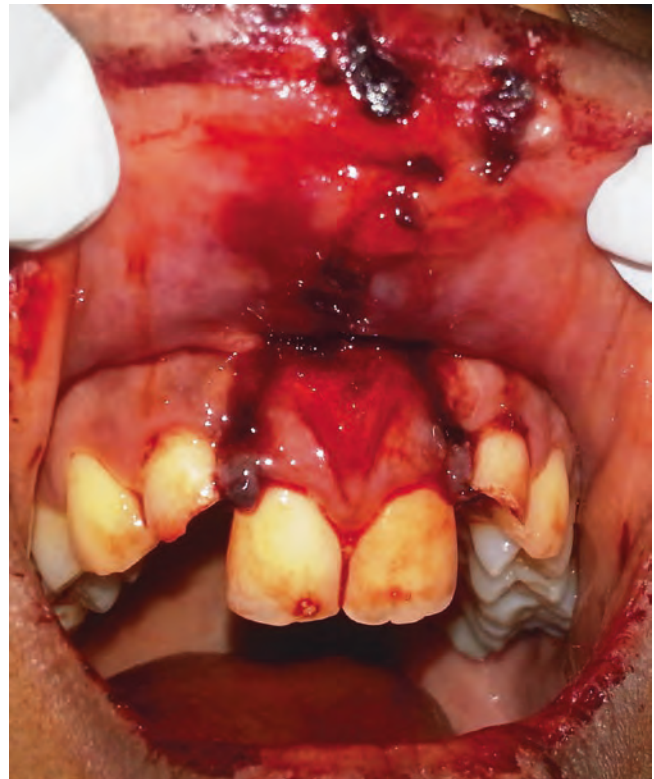50.5.3 Jaws and Alveolar Bone

Bimanual palpation of the maxillary and mandibular dentition and evaluation of occlusion should reveal areas of discrepancy or mobility. The direction of dislocation of the apex of primary tooth should be diagnosed since these teeth are in close approximation to the succedaneous teeth. Palpating from the vestibular approach makes this diagnosis easier. Sublingual ecchymosis/hematoma (Coleman's sign) at the floor of the



©Association of Oral and Maxillofacial Surgeons of India

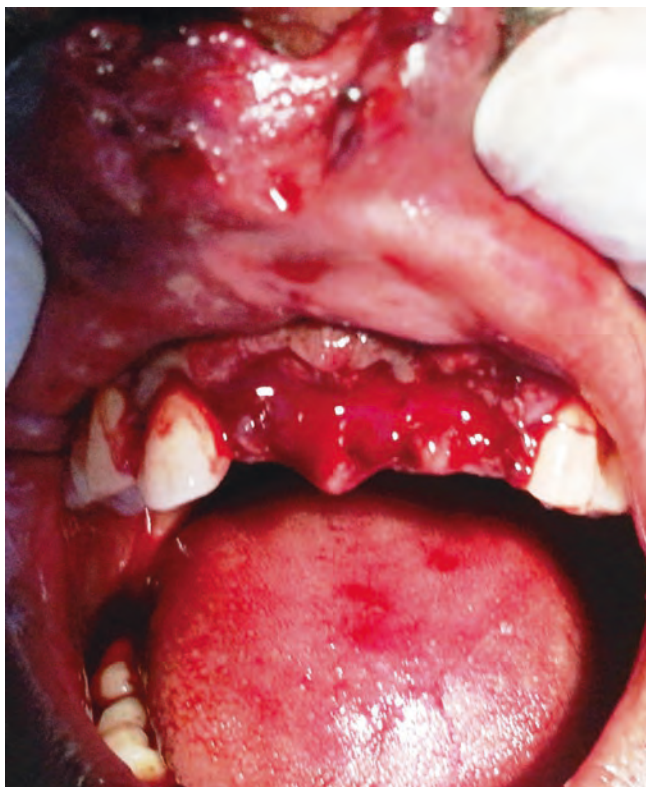Fig. 50.1 Mandibular anterior lingually displaced dentoalveolar fracture with degloving vestibular wound and ragged lip lacerations



©Association of Oral and Maxillofacial Surgeons of India

Fig. 50.2 Maxillary anterior palatally displaced and extruded dentoalveolar fracture with associated upper lip injury. Note incisal fractures of the upper lateral incisors (see also Fig. 50.8)

mouth is suggestive of underlying mandibular fractures. Step deformity, crepitation, malocclusion, and gingival lacerations raise suspicion for possible bone defects [7, 9].



©Association of Oral and Maxillofacial Surgeons of India

Fig. 50.3 Maxillary anterior teeth complete avulsion with associated upper lip injury

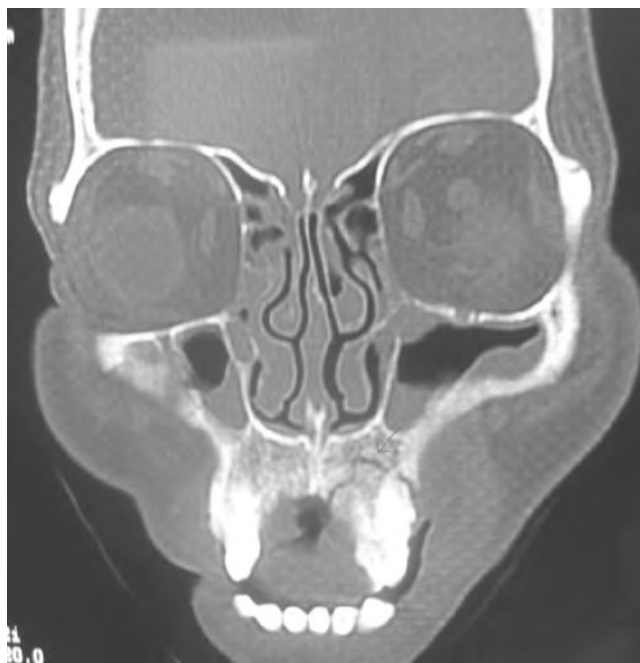50.5.4 Percussion and Pulp Testing

Percussion test is performed with the end of the handle of an examination mirror. Pain to percussion of a tooth is indicative of damage to the periodontal ligament. Dullness to percussion in one or several adjacent teeth can be indicative of partially luxated teeth or en bloc fracture of tooth or alveolar bone. The percussion test should be started on a non-injured tooth to ensure a reliable response through visual analogue scale [6, 8].

To evaluate the tooth injury thoroughly, pulp vitality is a must. A positive response indicates that the pulp is alive, whereas a negative response indicates that the pulp is dead. Following injury, the tooth may be in a state of shock and may give a false response. Hence pulp testing should also be performed during the subsequent visits to acknowledge the change in response [5].

Electric vitality testing depends on a number of factors including the stage of eruption of tooth, the presence of a restoration or decay, and the ability to isolate the tooth and keep the area clear of blood and saliva [8].

Laser Doppler flowmetry (LDF) is a relatively new pulp testing apparatus. It employs a laser beam directed at the



©Association of Oral and Maxillofacial Surgeons of India

Fig. 50.4 Coronal CT image showing left maxillary high dentoalveolar fracture

coronal-labial aspect of the pulp which is scattered by pulp blood cells that in turn produce a Doppler frequency shift. The fraction of light scattered back is detected and processed to elicit a signal. The basic theory is that the pulp revascularization process can be monitored. Studies have shown that in cases in which electrometric tests were negative and LDF displayed vascular perfusion, the LDF accuracy of pulp vitality reached 100% [3].

All the teeth should be tested for abnormal mobility both horizontally and vertically. It should be remembered that primary teeth undergoing physiologic root resorption and therefore always exhibit a certain degree of mobility. The typical sign of an alveolar fracture is the movement of adjacent teeth when the mobility of a single tooth is tested [6].

50.6 Radiographic Examination

Radiographic techniques are available to evaluate dentoalveolar trauma.

Radiographic examination is essential to determine damage to underlying structures and should include intraoral periapical (IOPA), occlusal, panoramic radiographs (OPG), and cone-beam computed tomography (CBCT) imaging [3, 4].

If conventional CT imaging is done as part of the trauma series, fine axial and coronal cuts will also show the dentoalveolar injuries (Fig. 50.4)

IOPA radiograph provides vital information about root fracture and dislocation of teeth. At times it is difficult to adequately evaluate a fracture on an IOPA radiograph, due to variations in tube-tooth-film geometry. Post-treatment radiographs can confirm the proper repositioning of avulsed or luxated tooth into alveolar bone.

Occlusal radiographs provide a larger field of view, and a steep occlusal exposure is of special value in the diagnosis of root fracture and lateral luxations with displacement of crown [8].

OPG is a useful screening tool and can demonstrate fractures of the mandible and maxilla as well as fractures of alveolar ridges and teeth.

Radiographic evaluation of foreign bodies within soft tissues of the lips and cheeks is done by taking radiographs with the film placed labial to the alveolus. A reduced radiographic exposure time (approximately 1/3rd of the normal) is used.

CBCT scanning is extremely useful in diagnosis of maxillofacial, alveolar bone, and teeth fractures with the advantage of high-resolution three-dimensional images with low radiation.

The etiology of pediatric and adult dentoalveolar injuries were shown in Box 50.1 and Box 50.2 respectively. Box 50.3 and Box 50.4 represents the classification of alveolar bone fracture and classification of alveolar bone fracture based on location and displacement respectively.

Box 50.1: Etiology of Pediatric Dentoalveolar Injuries
Pediatric patients [9]

- Bicycle injuries
- Falls
- Sports injuries
- Car crashes
- Child abuse
- Iatrogenic injuries(dental extractions, endoscopy, oral intubation)
- Industrial accidents

Box 50.2: Etiology of Adult Dentoalveolar Injuries

Adult patients

- Motor vehicular accidents
- Interpersonal violence
- Sports injuries(contact injuries)
- Falls
- Work-related trauma

Box 50.3: Classification of Alveolar Bone Fracture:
Traumatic alveolar bone [9]

Type I: Areas surrounding a single tooth

Type II: Entire dentoalveolar segment dislocation

Box 50.4 Alveolar fracture can be classified by their specific location and movement of displacement [10]

Class I: Edentulous segment fracture

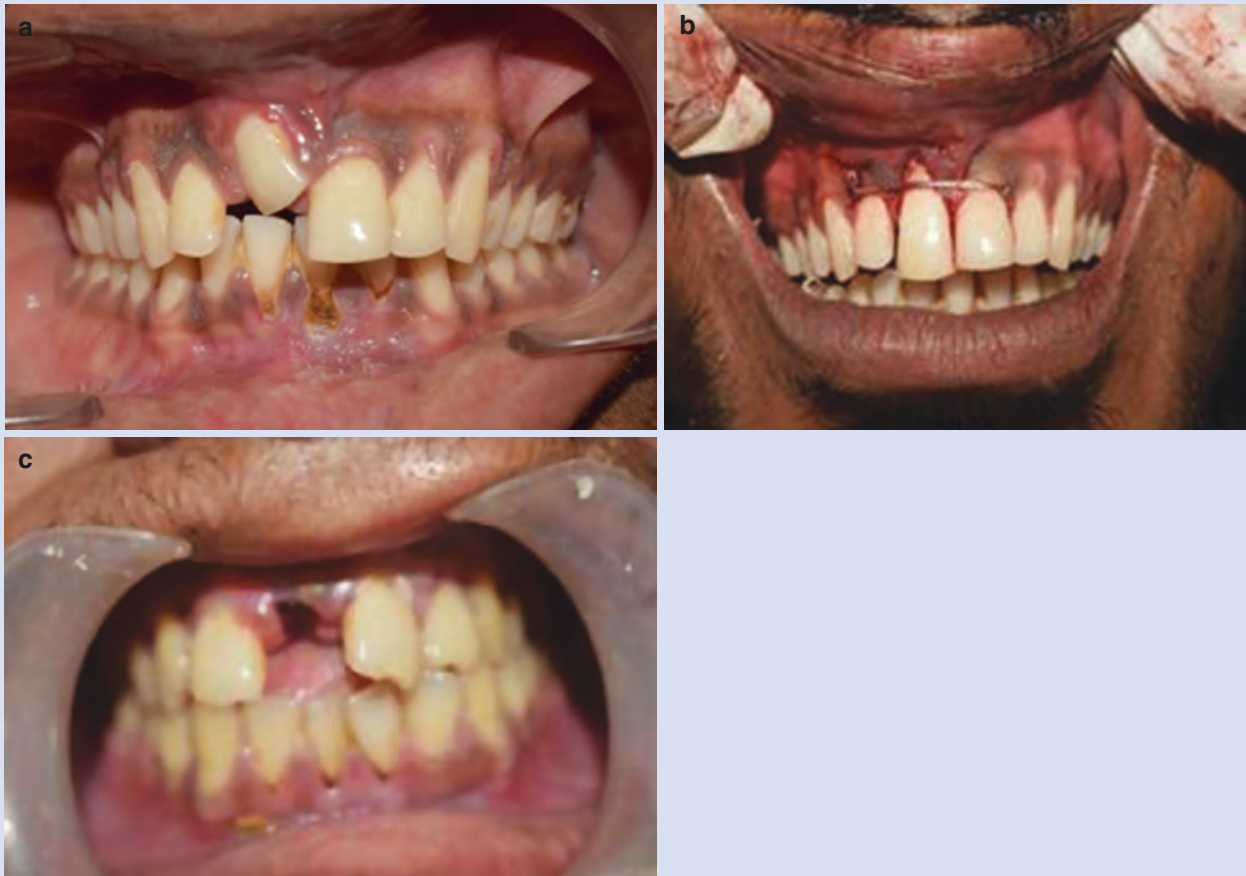Class II: Little or any displacement of fractured dentulous segment

Class III: Moderate to severe displacement of fractured dentulous segment

Class IV: Multiple fracture lines with combination of fracture of the dentulous segment

Box 50.5: Classification of Dental Injuries and Surrounding Structure**Classification based on level of involvement [11]**

1. Fracture involving enamel
2. Fracture involving enamel and dentin
3. Fracture involving enamel, dentin and pulp
4. Fracture involving enamel, dentin, cementum
5. Crown/ root fracture
6. Luxation of tooth
7. Intrusion and extrusion (Fig. 50.5a,b) (Box 50.6)
8. Avulsion (Fig. 50.5c) (Boxes 50.7 and 50.8)

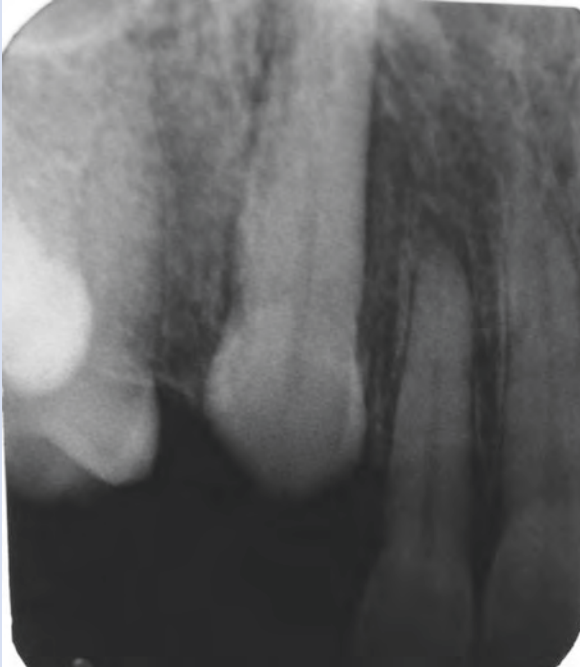

©Association of Oral and Maxillofacial Surgeons of India

Fig. 50.5 (a–c) Clinical images showing tooth (a) intrusion, (b) extrusion, and (c) avulsion

Box 50.6: Management of Intruded Tooth (Fig. 50.6)

Diangelis et al. [12, 13]



©Association of Oral and Maxillofacial Surgeons of India

Fig. 50.6 IOPA showing an intruded upper right canine**Permanent Teeth**

1. In closed apex
 - Intrusion <3 mm—allow eruption
 - Intrusion between 3 and 7 mm—surgical or orthodontic repositioning
 - Intrusion >7 mm
 - (a) Surgical extrusion with flexible splint for 4–8 weeks
 - (b) RCT using Ca (OH)₂ medicament 2–3 weeks after surgical extrusion
2. In open apex
 - (a) Wait till the tooth erupts for 3 months
 - (b) Place an orthodontic extruding appliance

Primary Teeth

Treatment is debatable

Immediate extraction of the involved tooth
or

More conservative approach

Box 50.7: Principle of Avulsion

- Primary should not be replanted
- Permanent teeth should be replanted as soon as possible and stabilized for 7–10 days up to 2 weeks [14, 15].

Box 50.8: Primary Management of Avulsion by the Patient

What the patient can do:

- To hold the tooth by its crown and not to touch the root surface.
- To rinse the tooth immediately with saliva, tap water or saline solution and reimplant the tooth.
- If the patient cannot replace the tooth, it should be held in the buccal vestibule (only if patient is fully conscious).
- Gentle irrigation with saline or gauze soaked with saline may be employed to remove blood clots or foreign objects from the surface of the root.

What the patient should not do:

- No effort should be made to mechanically cleanse the root of the tooth because this would damage the remaining periodontal ligament.

Transportation media for avulsed teeth include

1. Viaspan: a specialized tissue storage media used when transporting liver for transplantation.
2. Hanks balanced salt solution: both hanks solution and viaspan are physiologic with compatible pH and osmolality. The relative availability and cost-effective hanks solution makes it medium of choice in storage of avulsed teeth.

Commercial products are designed especially for storing avulsed teeth. It has shelf life of 2 years without refrigeration (Box 50.9).

3. Milk: is a readily available medium. It is the medium of choice in the absence of hanks balanced salt solution or viaspan. Milk will only prevent further cellular demise and is used specifically when the teeth has been outside the oral cavity for less than 20 min.

50.6.1 Storage and Transportation Media

If the tooth cannot be reimplanted within 5 min, it should be stored in a medium that will maintain its vitality and periodontal ligament fibers [14–16].

Box 50.9: HBSS Contents

Contents of Hanks balanced salt solution [19]

- Sodium chloride
- Glucose
- Potassium chloride
- Sodium bicarbonate
- Sodium phosphate
- Calcium chloride
- Magnesium chloride
- Magnesium sulfate

Box 50.10: Reagent for Root Surface Therapy

Agents used for root surface treatment to prevent resorption

- Citric acid
- Doxycycline
- Tetracycline
- Fluorides
- Enamel matrix derivative (emdogain)
- Diphosphonates

4. Saliva: is an excellent transport medium and is as effective as saline. It does not matter if the tooth is stored in another person's saliva.
5. Tap water: has been commonly recommended storage solution but due its hypotonicity, it leads to rapid cell lysis and increased inflammation on replantation.
6. Contact lens solution: a compilation of information from a study Blomlof et al. [17] indicates that Hanks buffered saline, isotonic saline, and pasteurized bovine milk may be the most favorable known storage media. If none of these are available, human saliva or contact lens solution is acceptable short-term substitute storage liquid.
7. Culture mediums like minimum essential eagles medium and Dulbecco's storage media [18] have been used as they contain amino acids, vitamins, and bicarbonates that help to maintain the vitality of cells.
8. Propolis: a beehive product which has an excellent anti-inflammatory and anti-bacterial effect has been used as a storage medium.
9. Green Tea: its polyphenol derivative have antioxidative, anti-carcinogenic, anti-mutagenic, anti-inflammatory, antimicrobial, and antiviral effect.
10. Patients own serum have shown to maintain the vitality of periodontal ligament cells up to 1 h.
Morus rubra (red mulberry), egg white, coconut water, rehydrating solution like Gatorade and ricetral, lens solution, probiotic solutions, saliva officinalis, honey milk, and ascorbic acid have been used as a transportation medium for avulsed tooth.

50.7 Treatment at the Clinic

Traumatically avulsed teeth when out of the mouth for a short period should be reimplanted as soon as possible.

After normal reattachment, survival is prolonged. Avulsed teeth which remain out of the mouth for more than 2–3 h generally resorb rapidly and should not be reimplanted indiscriminately.

The outcome of replantation depends on the stage of root development and extra-oral time. If the avulsed tooth has a closed apex and extra-oral time is less than 60 min (early replantation), the reimplanted tooth will have the best prognosis. The ideal time to begin root canal treatment is within 10–14 days post-replantation and before splint removal.

There is a statistically significant association between extirpation within 14 days and an increased likelihood of successful periodontal healing and prevention of external inflammatory root resorption.

It is generally agreed that Ca (OH)₂ has a beneficial effect in the outcome because of its antibacterial properties, ability to dissolve necrotic tissue, and its ability to prevent or control inflammatory resorption. The anti-inflammatory and antibacterial action may decrease root resorption by directly inhibiting resorptive cells (Box 50.10).

50.7.1 Delayed Replantation (more than 60 min)

Delayed replantation of avulsed tooth with closed apex has a poor long-term prognosis. The periodontal ligament gets necrotic and healing is delayed. The goal of delayed replantation is to promote alveolar bone growth so as to encapsulate the reimplanted tooth. The eventual outcome is ankylosis.

In children below age of 15 years, if ankylosis occurs and when the infra position of the tooth crown is more than 1 mm, decoronation is recommended to preserve the contour of the alveolar bone.

Root canal treatment (RCT) can be carried out on a tooth prior to reimplantation or it can be carried out within 14 days of reimplantation. The tooth is immersed in 2% sodium fluoride solution for a minimum of 5 min up to 20 min.

Avulsed teeth having open apices and extra-oral time less than 60 min are also reimplanted and stabilized for 7–10 days and up to 2 weeks. The goal of reimplanting developing (immature) teeth in children is to allow for possible revascularization of the tooth pulp.

If there is evidence of the pulpal infection or inflammatory response, the pulp should be removed and Ca (OH)₂ placed immediately, aiming to stimulate apexification and halt the inflammatory process.

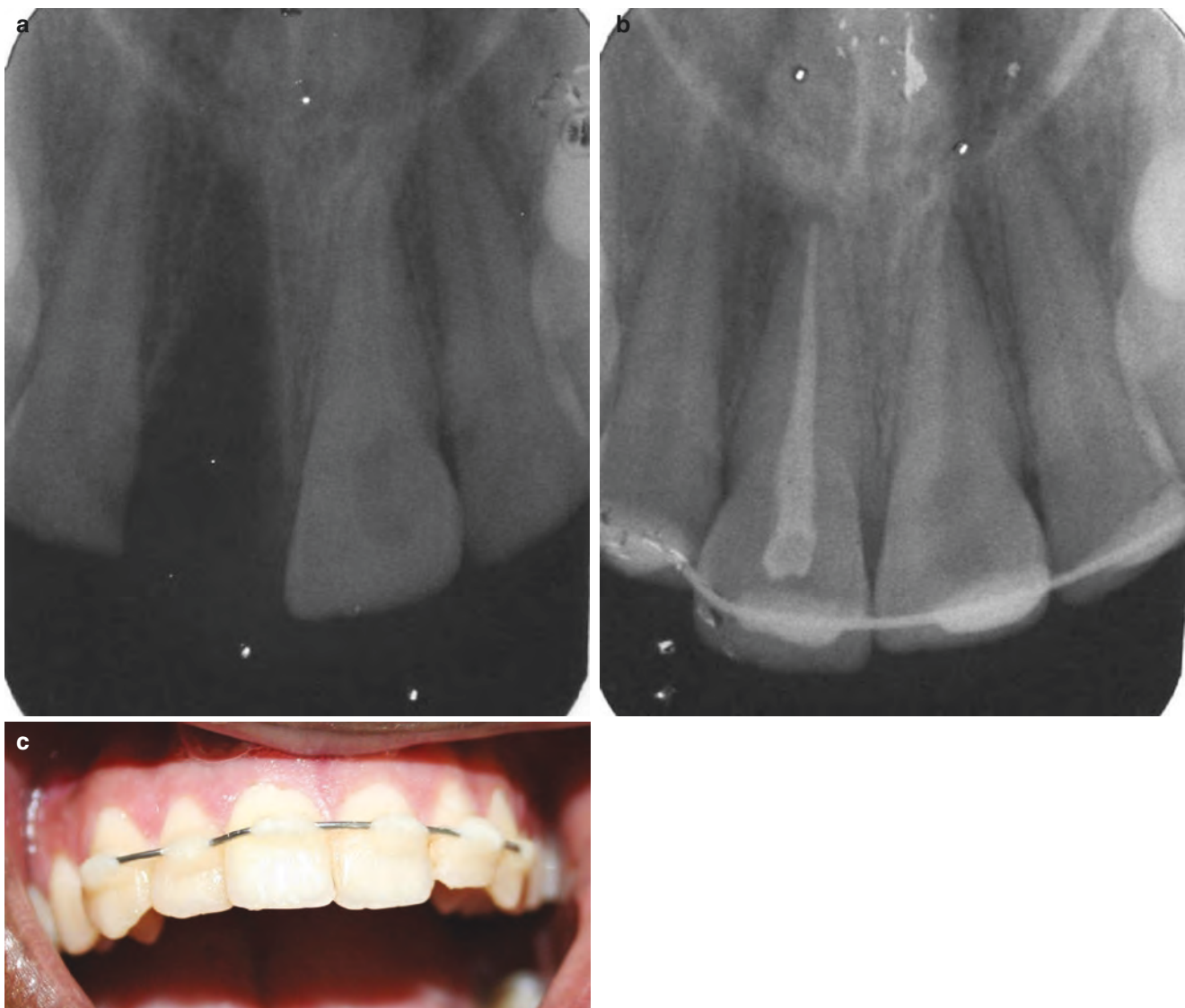
It is believed that delayed replantation of avulsed teeth with open apices have a poor long-term prognosis. The peri-

odontal ligament gets necrotic and is not expected to heal. Osseous replacement, resorption, or ankylosis will occur. Therefore some authors have concluded that such teeth should not be reimplanted.

The recent guidelines recommend replantation to maintain alveolar ridge contour as ankylosed roots get transformed to bone during the remodeling process. RCT can be performed on the tooth prior to replantation through an open apex (Fig. 50.7a–c).

50.7.2 Stabilization

Stabilization of an avulsed tooth can be achieved using a variety of materials like wires, arch bar wired to the teeth,



©Association of Oral and Maxillofacial Surgeons of India

Fig. 50.7 (a–c) Shows a case of avulsed upper right central incisor in a 24-year-old man, which presented after few hours of avulsion. The tooth was transported in milk by the relatives. A RCT was carried out

and the tooth reimplanted and stabilized with wire and composite splint (a, IOPA showing avulsed incisor; b, IOPA with tooth reimplanted; c, shows the clinical image after splinting)

orthodontic band and brackets attached by acid etch technique, combined with orthodontic band and acrylic appliance, or periodontal pack.

They are generally maintained for 7–10 days after replantation to allow gingival reattachment.

Studies by Andreason [20] (1985) have shown that prolonged splinting may be inadvisable because it enhances ankylosis.

The socket should be left undisturbed before replantation. If the alveolar bone has collapsed, a blunt instrument should be inserted carefully into the socket in an attempt to reposition the wall. It should be lightly aspirated if a blood clot is present.

In general, stabilization for reimplanted teeth is required for 7–14 days. The periodontal ligament fibers should have healed sufficiently after the first week to remove the splint. However, the patient should be advised not to bite directly on the reimplanted tooth for 3–4 weeks after injury.

50.7.3 Technique

50.7.3.1 Wire Acid Etch Composite Splint

A wire of moderate stiffness (round 0.030 in. stainless steel) is adapted to the facial surface at least one or more stable teeth on either side of the reimplanted teeth.

The physiologic movement imparted to the reimplanted tooth during function is increased when fewer teeth are included in stabilization of the avulsed tooth.

The facial surface of the avulsed and adjacent teeth is acid etched, and wire is cemented to them with composite.

The wire is generally curved along the middle third of the labial surface of the teeth. 90° terminal bends toward the gingiva are made at the labiodistal angles of the most posterior teeth to be splinted in order to avoid sharp edges and stability. The terminal ends should be about 2 mm long to reduce the possibility of lateral displacement of the wire [21, 22].

Splinting periods for traumatic dental injuries [6]

Traumatic dental injuries	Splinting period
Subluxation	2 weeks
Extrusive luxation	2 weeks
Avulsion	2 weeks
Lateral luxation	4 weeks
Intrusion(if surgically repositioned)	4–8 weeks
Root fracture(middle third)	4 weeks
Root fracture(cervical third)	4 months

50.7.4 Complications

1. Pulp necrosis
2. Pulp chamber or root canal obliteration
3. Internal resorption
4. External resorption—three types:
 - (a) Surface replacement
 - (b) Replacement resorption (ankylosis)
 - (c) Soft tissue replacement [23]

50.8 Alveolar Process Fracture

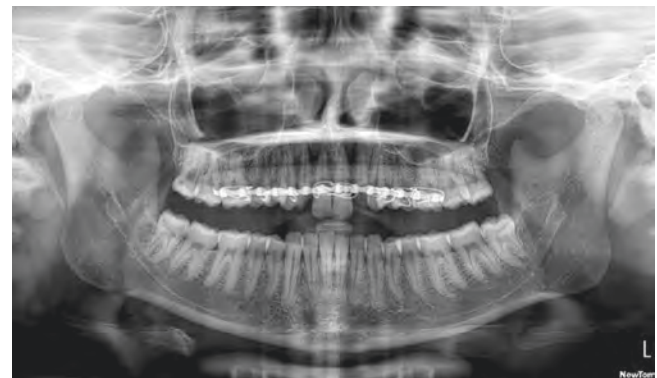Fracture of the alveolar process usually involves the teeth.



Place the segment into position (closed reduction) (Fig. 50.8)

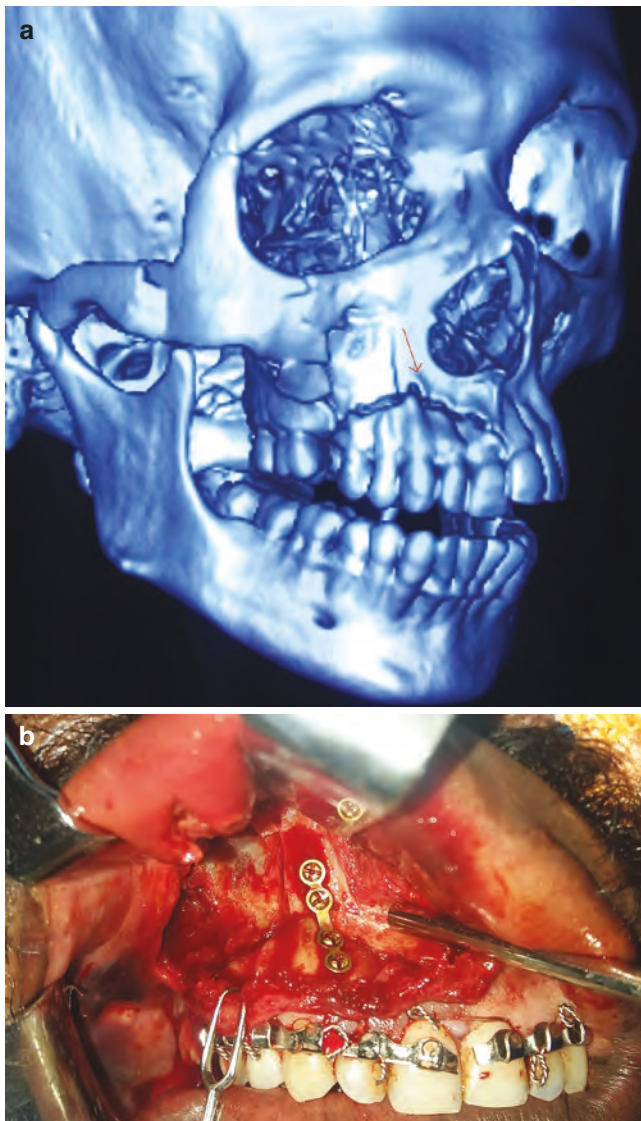

Open reduction/ raise the flap if reduction not possible (Fig. 50.9 a, b)



©Association of Oral and Maxillofacial Surgeons of India

Fig. 50.8 Shows the case in Fig. 50.2, which has undergone closed reduction and fixation by arch bar. Full intrusion and reduction was not achieved. The occlusal discrepancy was planned to be corrected later by RCT and necessary prosthetic work



©Association of Oral and Maxillofacial Surgeons of India

Fig. 50.9 (a, b) Shows a case of high alveolar process fracture segment in the maxillary right side with associated split between central incisors. Under GA, the extruded displaced alveolar segment was repositioned after placement of split arch bars and bridle wiring between the central incisors. The segment was fixed with mini plate and screws, taking care not to injure the tooth roots. Due to root anatomy, only a single plate was fixed after reduction. Post-operative IMF was given for 2 weeks, for additional stability and to help the healing process

50.9 Management of Dentoalveolar Fracture

The goals of treatment should be:

- (a) Anatomic reduction
- (b) Re establishment of premorbid occlusion
- (c) Early return of function
- (d) Preservation of premorbid arch form and facial contour [24]

50.9.1 Treatment Options

1. Arch bars (Fig. 50.8)
2. Loop wiring
3. Orthodontic bands
4. Acrylic/metallic splints
5. Acid etch composite

Model surgery on the plaster models is performed to recreate the normal anatomic relationship of the fractured segment and allow fabrication of accurate splint [9].

50.9.2 Specific Treatment Options

Class I fractures that involve a non-displaced, edentulous alveolar segment often do not require treatment other than a soft diet and observation. If there is concern about the stability of the fracture during the healing process, stabilization may be used.

Class II fractures that involve a displaced dentulous segment and need reduction may require a great deal of force to realign the fractured segment. Posterior fragments are always displaced to the lingual area. Large forceps may be helpful to apply a force suitable to reduce the bony fragment. Reduced fragments are held in place by MMF or splints.

Class III fractures of a moderately or severely displaced dentulous segment may be too difficult to reduce adequately. There may be scant room into which the irregular, displaced segment needs to be replaced. It may be necessary to burr or rasp down the displaced segment or the opening in the remaining bone to successfully reduce the fracture. This is usually accomplished by use of a power drill with a suitable size bur or a fine rhinoplasty rasp. The amount of tissue that is removed should be limited so that the sufficient bone to bone contact remains for bony union as the fracture heals. Maintenance of class III fractures in a reduced fashion may be accomplished with arch bars, MMF, and/or variety of splints.

Class IV fractures that extend into one or more non alveolar fracture lines are usually less challenging than class III fractures because (1) the bone segments are larger, (2) the treatment of the associated fractures gives excellent exposure, and (3) usually no barrier exists to reduction. Plates, screws, arch bars, MMF, and/or variety of splints may be used [7].

50.9.3 Wiring Techniques

In MMF, wires are passed interdentially between teeth in both the jaws followed by tightening of these wires together in a cross arch fashion which serves to stabilize the fracture segments.

Over the period of last century, MMF techniques have evolved dramatically, and more recently, many more easier and effective methods have been introduced like MMF screws, eyelet wiring, and Erich arch bars to name a few. Although it is a quick and efficient way of securing MMF, yet, this technique is criticized for extended periods the patient needs to be closed mouth, difficulty in maintaining oral hygiene, lack or deficient nutritional support via oral route and inability to use this treatment modality in medically compromised patients like epileptics or in immediate post-operative period due to increased risk of aspiration.

50.9.4 Armamentarium and Principles (Fig. 50.10)

A soft stainless steel wire of 0.35–0.5 mm diameter is utilized and pre-stretched to 10% of its original length to prevent loosening of wire once tightened. Overstretching beyond this point should be avoided as this will make the wire brittle and susceptible to breakage.

50.9.5 Principles

Basic principles to be followed are [25]:

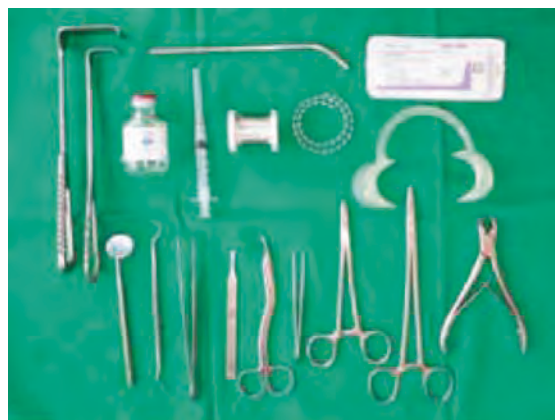1. Continuous tension on the wire while twisting and tightening.
2. Force should be apically directed while tightening.
3. Utilizing a clock wise direction for all tightening/ twisting.
4. Only half a turn to be given at a time at the end.
5. Once the tail is cut, it is turned and placed into the inter-proximal embrasures.
6. Once all the wires are in place, move the finger around the arch bar/wire to check for any sharp edge/margin/ wire ending.

50.9.6 Technique

50.9.6.1 Bridle Wire [26, 27]

First advocated by Hippocrates, bridle wire remains one of the oldest yet a conventional method of treating mandibular fractures. This technique represents a temporary way of stabilizing the fractured segments, preventing them from flaying apart.

Advantages include stabilization of the two fractured segments preventing further damage to the adjacent soft tissues, maintenance of the airway patency (especially advan-



©Association of Oral and Maxillofacial Surgeons of India

Fig. 50.10 Armamentarium for wiring

tageous for the fractures of the anterior mandible), decrease pain, and reducing damage to the neurovascular bundle from immobilizing the fractured fragments, thereby preventing gross movements and also decreasing muscle cramping.

Technique

Following administration of local anesthesia, a 24–26 gauge wire is passed around the neck of the teeth adjacent to the fracture site on either side (Fig. 50.11a). With both ends being secured in the wire holder (Fig. 50.11b), the fractured segments are manually reduced anatomically, and the wire is tightened in a clockwise fashion till further reduction is achieved (Fig. 50.11c), and the fracture is stabilized.

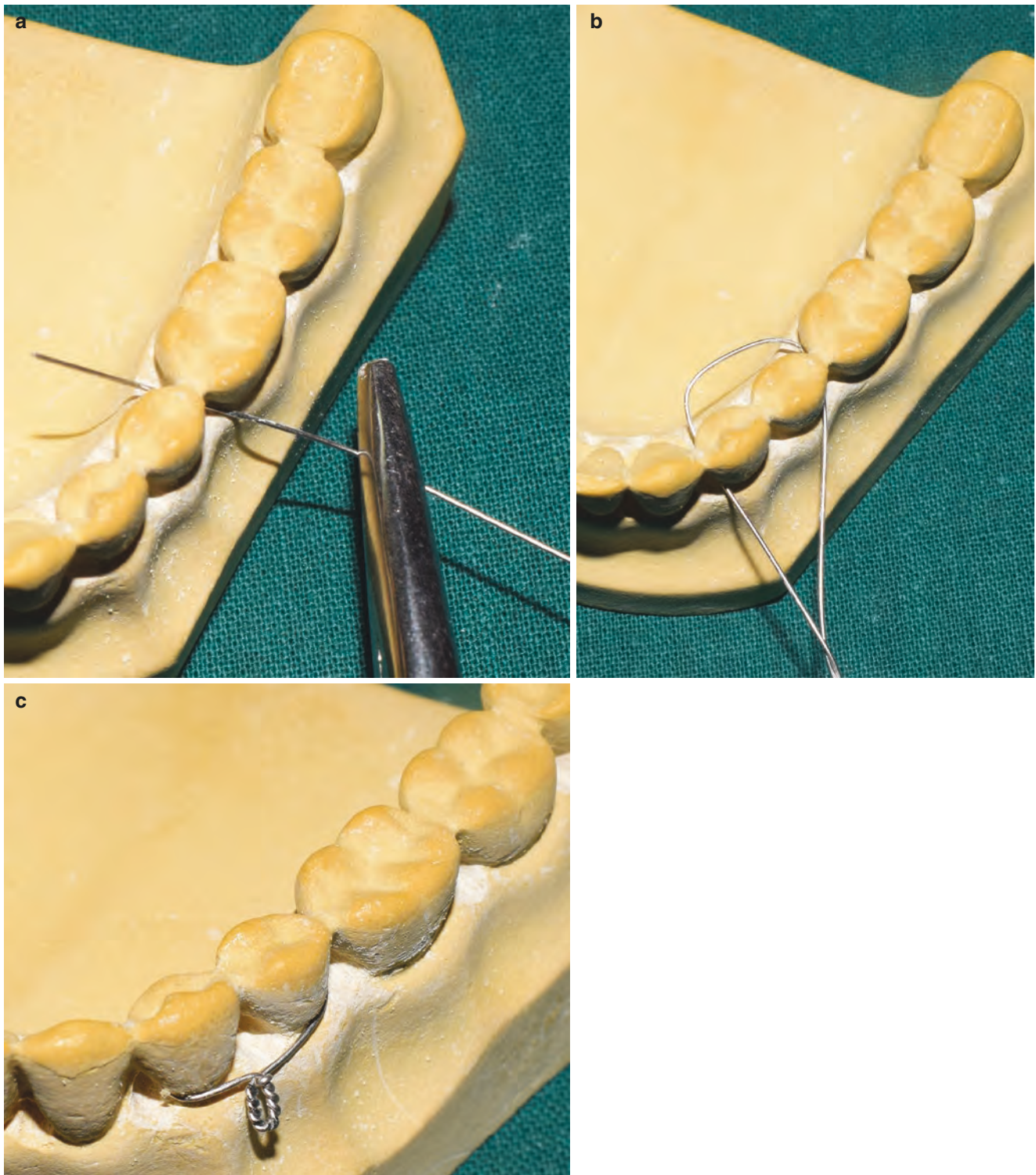
50.9.6.2 Gilmer's Direct Interdental Wiring [26, 27]

This technique represents an easy and fastest method of immobilization.

Technique

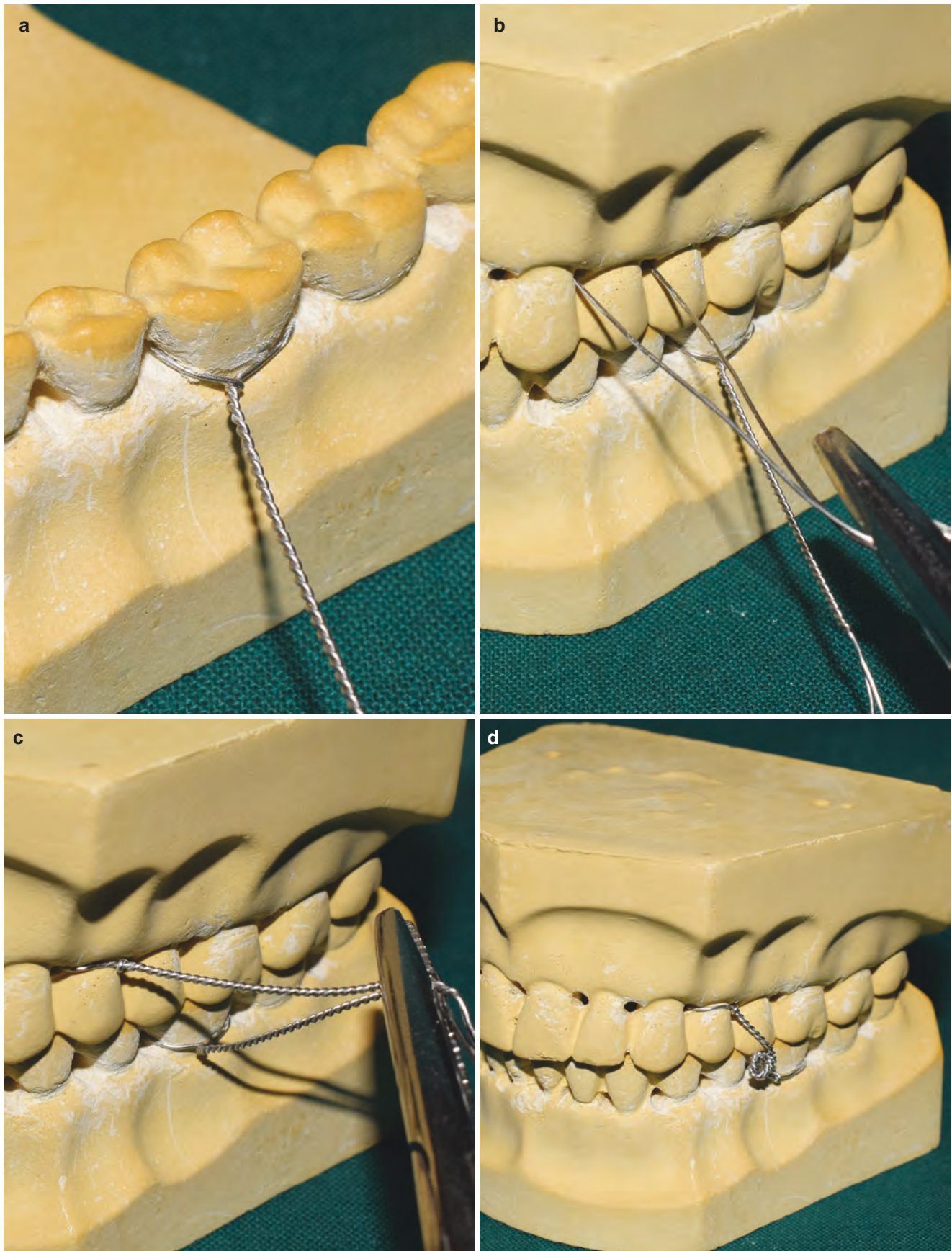
A 15 cm pre-stretched wire is passed through the interdental embrasure of the tooth on one side from buccal to lingual. This wire will pass around the tooth and emerge out buccally through the interdental embrasure from the other side. Both ends are held together and twisted to achieve a 3 cm tail (Fig. 50.12a–c). Multiple teeth (at least 5–6) in either jaw are utilized. Following manual fracture reduction and placement of teeth with pre-morbid occlusion, the tails from opposite arch are twisted together in a cross arch or zigzag fashion to achieve immobilization (Fig. 50.12d). The cut ends of the tail are secured into the interdental spaces. Once all the wires/tails are twisted, complete immobilization is achieved.

The only drawback of this technique is that, in cases of broken /loose wire, all the cross arch wires will have to be removed and redone post placement of twisted wire.



©Association of Oral and Maxillofacial Surgeons of India

Fig. 50.11 Shows sequential steps bridel wiring. (a) Passing of the wire through the tooth embrasure. (b) Formation of the wire loop assuming the fracture line is between the two premolars. (c) Twisting of both the ends to stabilize the fracture



©Association of Oral and Maxillofacial Surgeons of India

Fig. 50.12 (a–d) Shows technique of direct Gilmer wiring. Formation of the loop around the tooth in the lower and upper arch followed by twisting both the wires together in order to achieve MMF

50.9.6.3 Interdental Eyelet Wiring (Ivy Loop Method) [26, 27] (Video 50.1)

Yet another easy and quick method of securing MMF was advocated and popularized by Dr. Robert H. Ivy, Philadelphia, USA.

Technique

A pre-stretched 26 gauge/0.35 mm diameter wire was made into an Ivy loop utilizing the middle segment of the wire by twisting it around a metallic rod of 3 mm diameter. 3–4 turns are given to achieve adequate stability to the loop. Both the ends of the wire are then cut in an oblique fashion (Fig. 50.13a).

Both the ends are passed through the interdental space to emerge lingually/palatally so that the loop lies buccally (Fig. 50.13b). Following this, one end of the wire is passed from distal interdental space of the same tooth to emerge buccally. This same wire is passed through the loop and secured to the other end of the wire which is passed mesially from the lingual/palatal side to the buccal side of the adjacent tooth side (Fig. 50.13c,d). Both the ends are tightened (Fig. 50.13e), and the tail end cut short and secured into the dental space mesially to prevent damage to the adjacent soft tissues.

Stability of the MMF is based on the adequate number of Ivy loops placed in both the arches and secured.

In the maxillary arch, loops can be placed between two molars, two premolars, or between lateral incisor and canine or two central incisors. In the mandibular arch, loops are best placed between two molars, two premolars, or between lateral incisor and canine.

Modifications

1. In 1975, Hallam modified the Ivy loop by addition of another loop proximal to the first for the purpose of ligature/tie wire (Fig. 50.14)

Although an interesting modification yet the disadvantage observed was that due to increase in length and in patients with short vertical dimension, both the proximal loops would meet one another making the placement of MMF extremely difficult.

2. **Clove hitch**

This technique helps in placement of an Ivy loop in cases of missing teeth or a single isolated tooth. It is the easiest way to secure MMF where placement of an arch bar or any other technique of securing MMF is difficult due to lack of supporting teeth.

Technique of Clove Hitch

The one end of the wire that has an Ivy loop forms a loop around the lone-standing tooth (Fig. 50.15a). Continue the wire around the tooth forming another loop for the second time (Fig. 50.15b). The end of the wire is under the first loop

(Fig. 50.15c), and both the ends of the wire are pulled together and tightened (Fig. 50.15d).

50.9.6.4 Continuous or Multiple Loop Wiring [26, 27]

It was first described by Col. Stout in 1943. It represents an easy and simple technique which requires minimal instrumentation. This technique utilizes multiple loops on the buccal surface of the tooth which can be used for both MMF using wire as well as elastic traction for the purpose of fracture reduction. One major advantage of this technique is the use of differential traction force that can be achieved and applied for fracture reduction before securing it with wires for MMF.

Technique

A 30 cm-long pre-stretched wire is placed on the buccal side of the teeth with the anterior end placed as anteriorly as possible while the posterior end extending up to the last tooth to be used. The wire is passed through the interdental space of the posterior most teeth and emerged through its mesial side. The wire is then passed over the buccal wire and passed back into the same interdental space. A 3 mm diameter rod can be used parallel to the buccal wire for adequate loop diameter as well as uniformity of the loop (Fig. 50.16a). Once the wire is passed back through the same interdental space, it then emerges out from the mesial interdental space of adjacent tooth (Fig. 50.16b). This continues till the anterior most teeth where both the ends of the wire are twisted together, cut, and placed into the interdental space (Fig. 50.16c,d). Each loop is then twisted, and loops are made of uniform diameter. In cases of securing MMF, the loops are turned toward the occlusal surfaces of the teeth, but in cases of elastic traction, they are turned in the opposite direction toward the gingiva [27].

Modification

This technique needs modification when some teeth are missing. Herein, once the loop at the mesial end of the tooth adjacent to the missing tooth is formed, both of the free ends of the wires are held together and twisted till the distal end of the next tooth. Once the desired length is achieved, the loop is again formed at the distal end, and the looping continues till the anterior most teeth.

50.9.6.5 Risdon's Wiring [26, 27]

Indications

It is an alternative to an arch bar for a fractured mandible that needs fixation.

Technique

A 25 cm-long wire is passed through the posterior most tooth in the quadrant to emerge buccally, followed by twist-

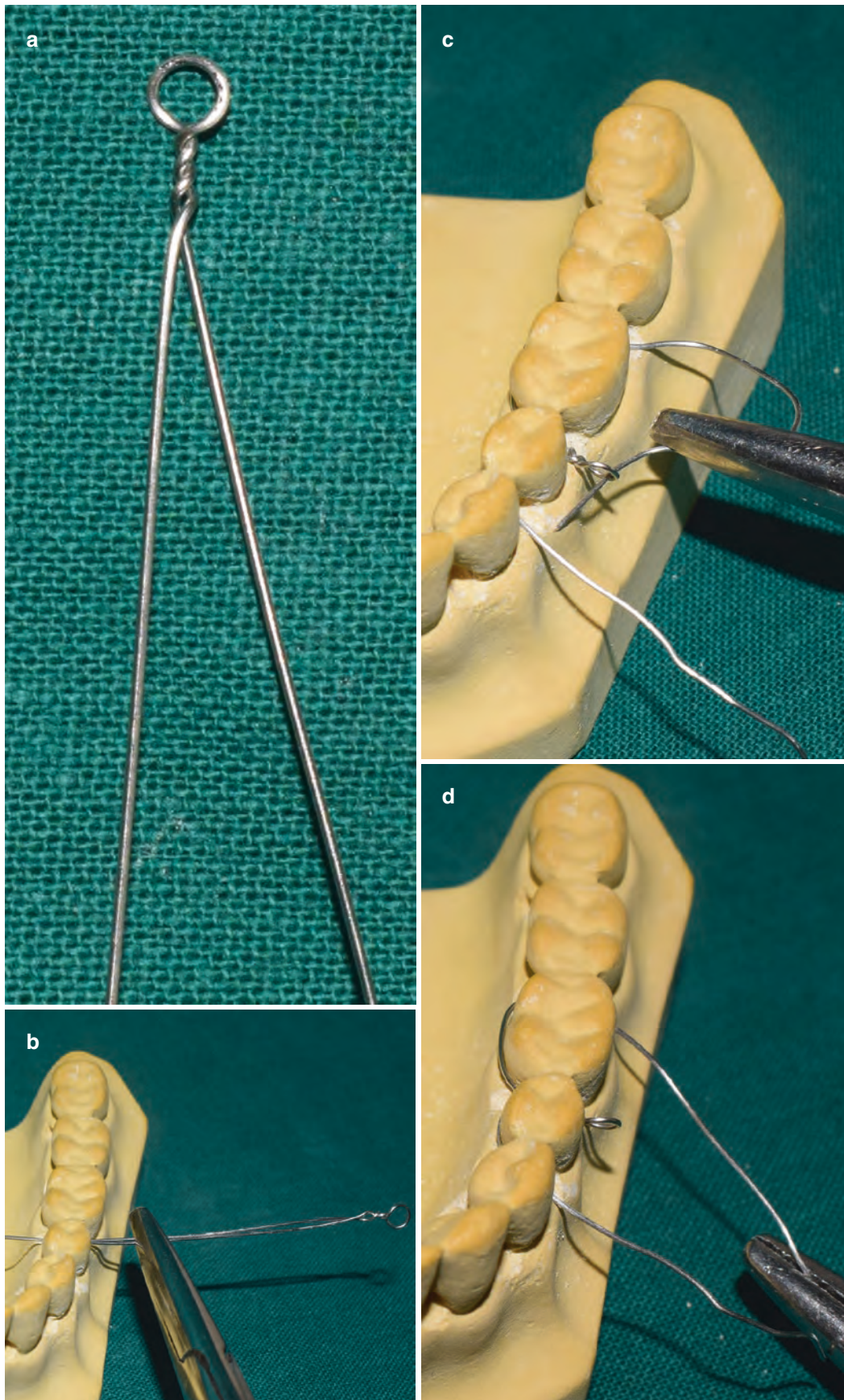
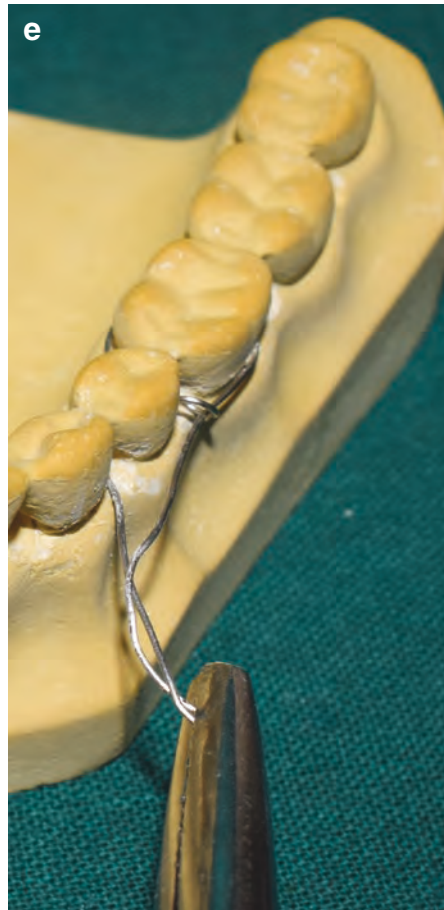

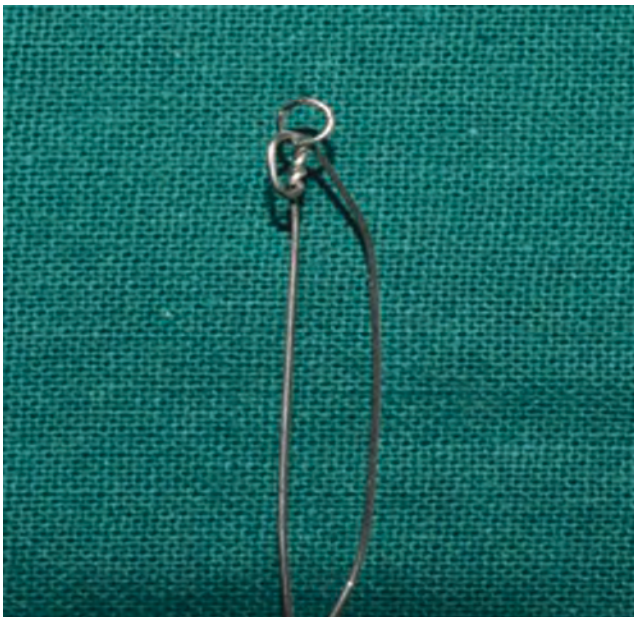
Fig. 50.13 Shows steps in Ivy loop technique. (a) Photograph of an Ivy loop. (b) Both the ends are held together and passed through the tooth embrasure of the premolar and molar. (c) One end passed is through the mesial of premolar and other through the distal of

molar to emerge buccally. (d) Distal end is passed through the loop on the buccal side to emerge mesially. (e) Both the ends of the wire are held together and twisted



©Association of Oral and Maxillofacial Surgeons of India

Fig. 50.13 (continued)



©Association of Oral and Maxillofacial Surgeons of India

Fig. 50.14 Shows a modification of Ivy loop

ing the wire up to its full length till the midline (Fig. 50.17a). Another wire is passed from the opposite quadrant of the same arch and twisted in a similar manner. Both the ends of this twisted wire are tightened at the midline after reducing the fracture segments (Fig. 50.17b,c). Once anatomic reduction is achieved, additional wires are used to stabilize this long wires by passing around the embrasures of the teeth and looping around the wire segment (Fig. 50.17d) [26, 27].

50.9.6.6 Obwegeser Wiring [26, 27]

Technique

This technique utilizes a 30 cm-long wire that is bent into a continuous “W” arcade form as depicted in Fig. 50.18a. The elevated portion of the arcade acts to form the loop, whereas the depressed portion adapts to the contour of the teeth palatally or lingually. The distal end of the wire arcade is kept long enough so that it will follow the buccal contour of the arch, when it is passed through the interdental space of the most posterior tooth from lingual/palatal to buccal side. The elevated ends of the

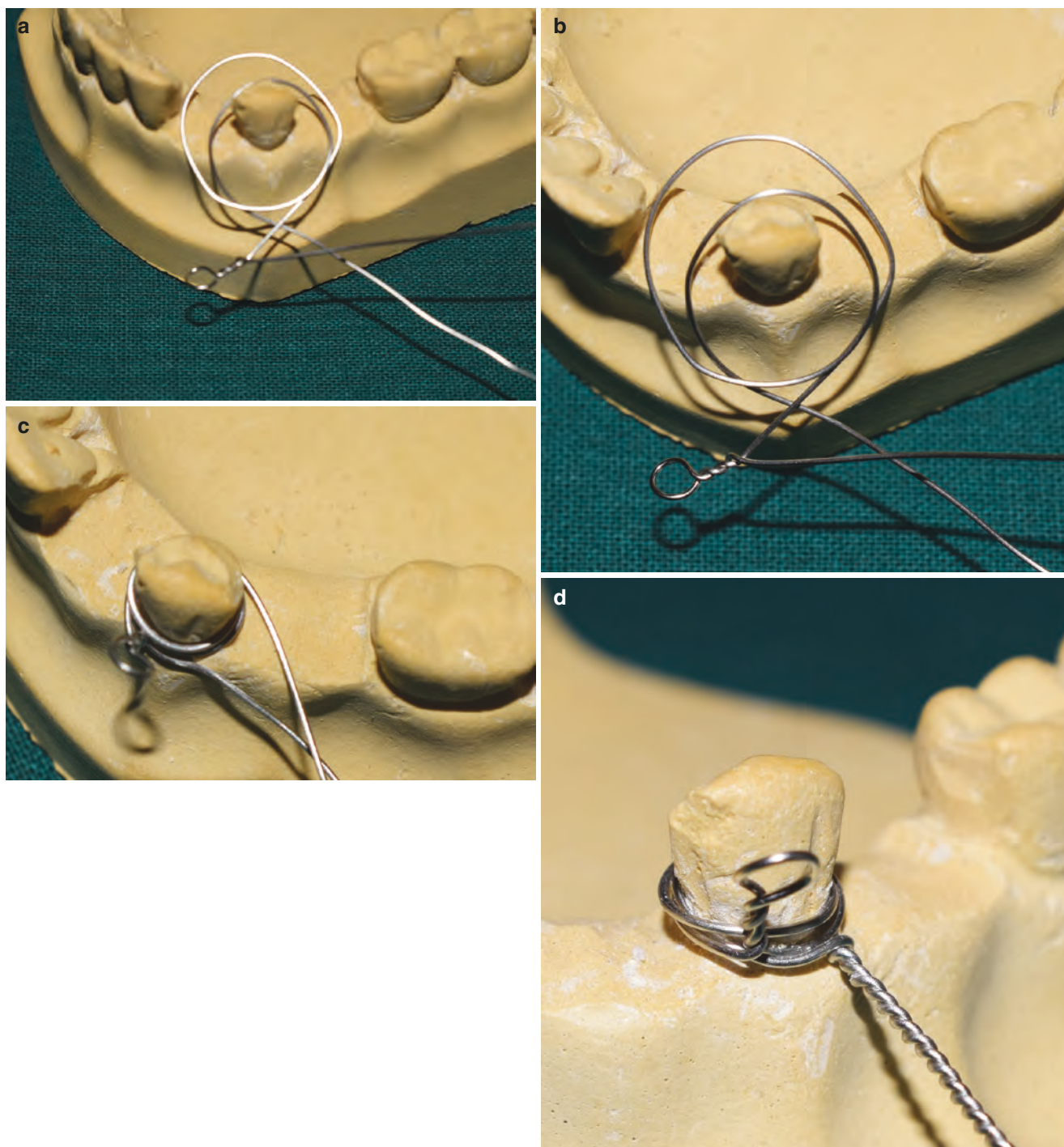
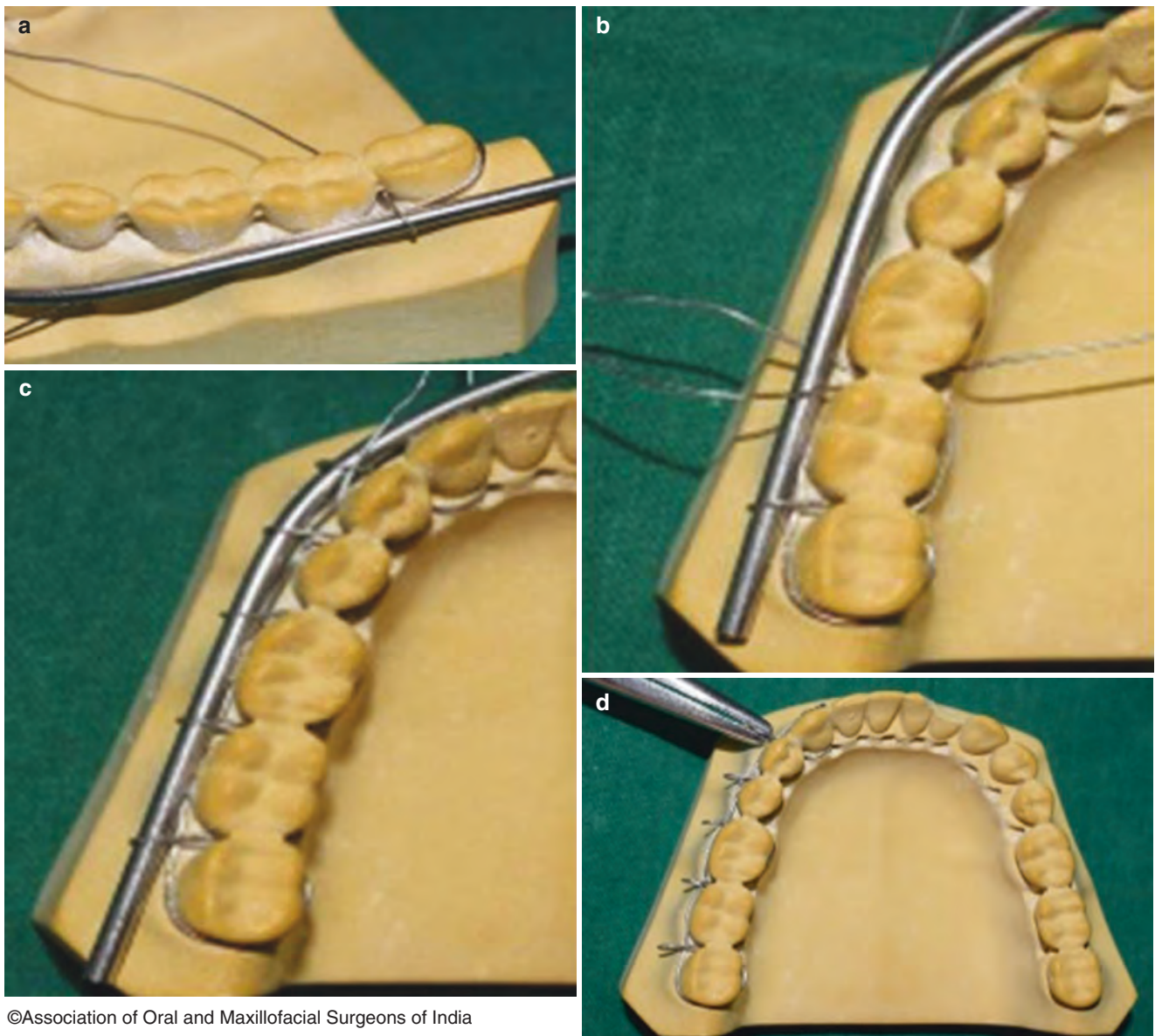


Fig. 50.15 Showing clove hitch technique. (a–c) Single loop is passed around the lone-standing tooth followed by second loop under the first one, pulling both the ends together. (d) Showing clove hitch wiring technique

arcade have a ligature wire attached to it (Fig. 50.18b), which only suffices the arcade to be pulled through to the interdental space to emerge buccally (Fig. 50.18c,d). The long wire is then passed through this loop (Fig. 50.18e), and a modified hemostat is used to twist this wire to form uniform loops. At the mesial end, both the ends of the

wire are held together and twisted (Fig. 50.18f). The loops can be used for both elastic traction and wires for securing MMF.

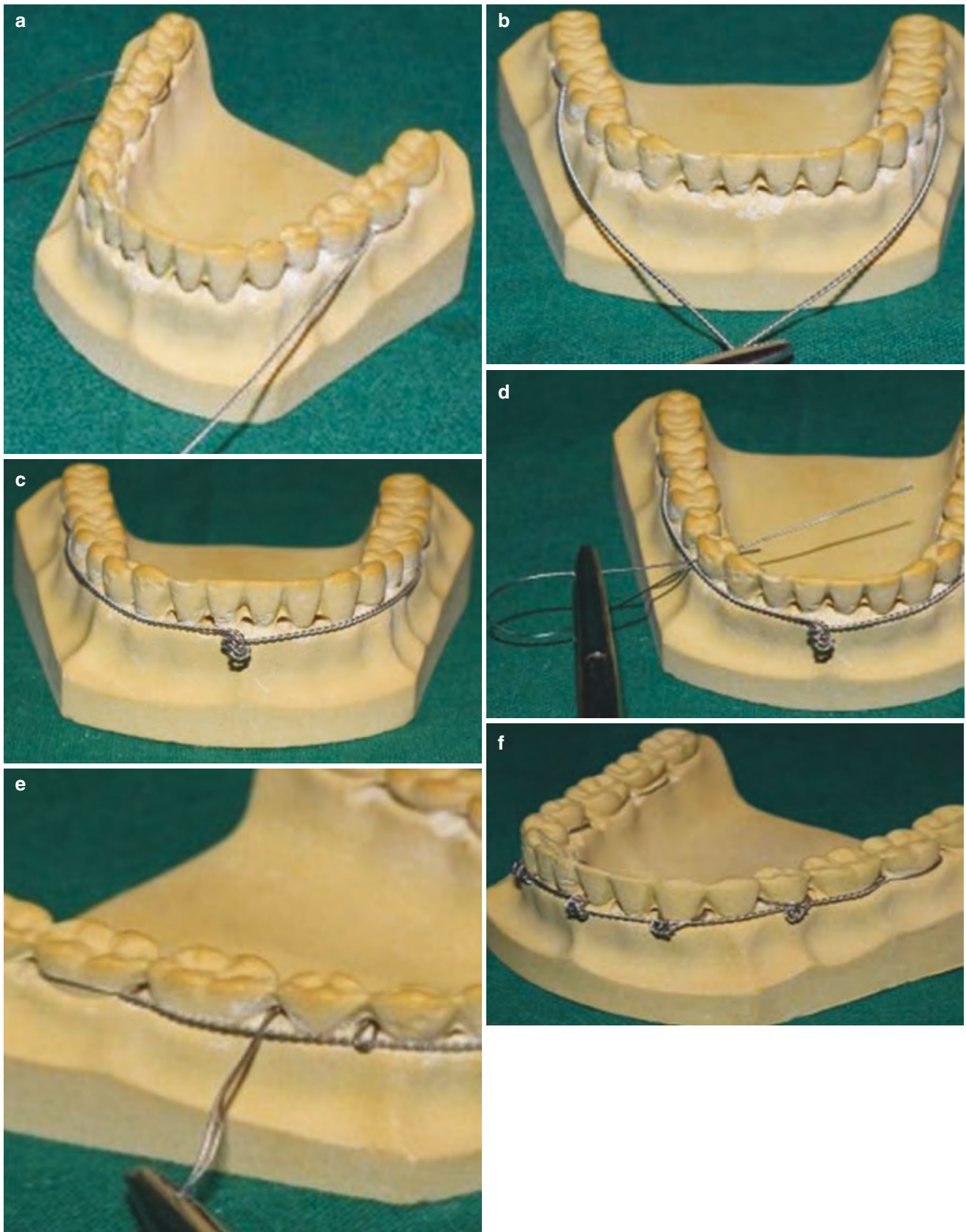
The disadvantage of this technique is that it is very cumbersome and adequate expertise is needed to carry out this technique.



©Association of Oral and Maxillofacial Surgeons of India

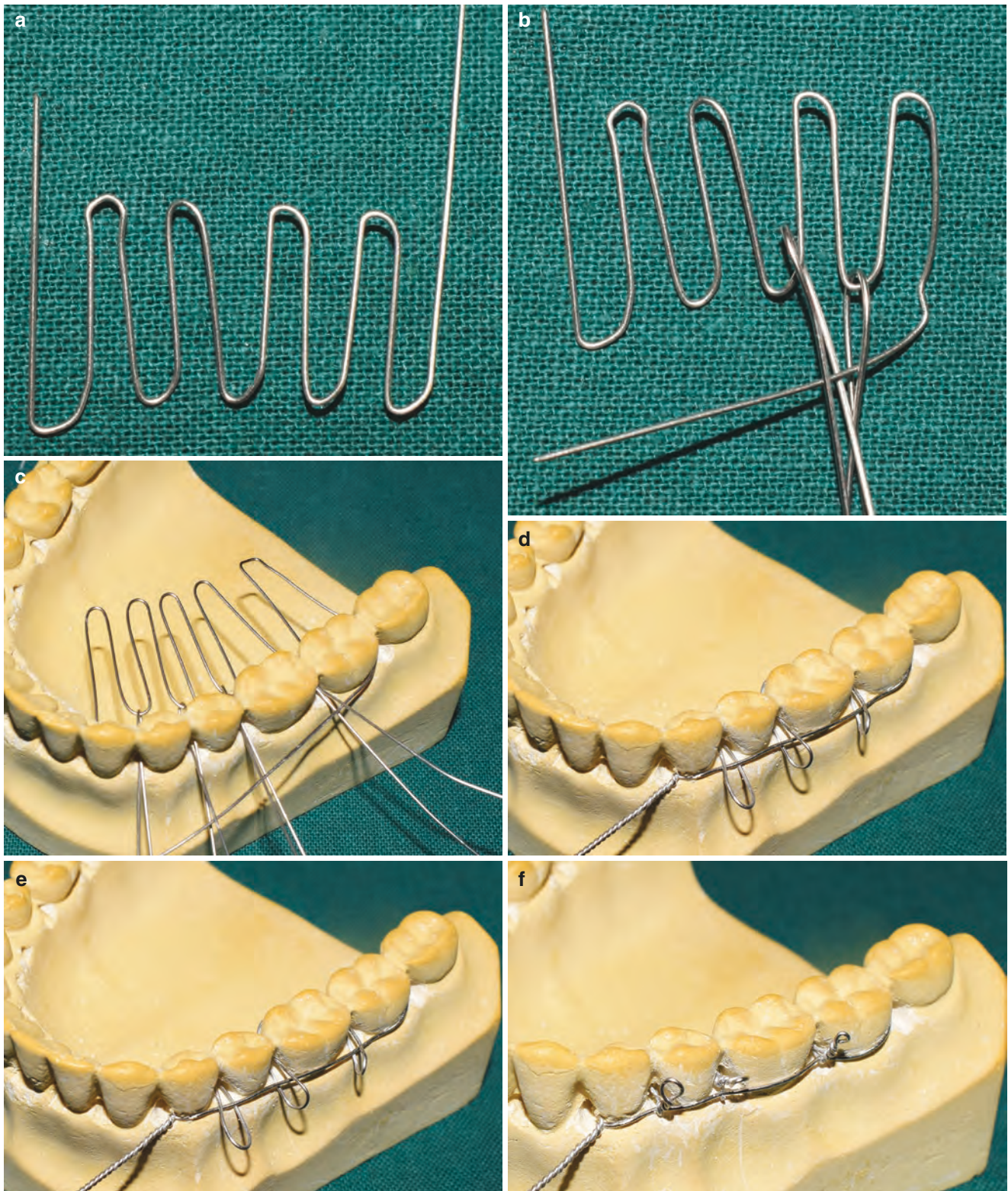
Fig. 50.16 (a, b) Showing continuous or multiple loop wiring technique, a rod is held parallel to the buccal surface of the teeth, and the wire is passed through the distal most tooth embrasure to emerge buc-

cally and looping around the rod. (c, d) Continuous loops till the midline are made followed by pulling the buccal rod out to achieve loops



©Association of Oral and Maxillofacial Surgeons of India

Fig. 50.17 (a, b) Showing steps in fabrication of Risdon wiring. Distal most tooth is used to loop the wire and twist it. (17c) Showing twisted wire in the midline. (d, e) Showing wires passed through teeth embrasure to loop around the main wire. (f) Alternate method of securing the long wire



©Association of Oral and Maxillofacial Surgeons of India

Fig. 50.18 (a, b) Showing fabricated W arcade used in Obwegeser technique. (c) Showing ligature wire pulled from the palatal/lingual side to buccal side. (d–f) Showing wire from the distal most end passing through the loops to be twisted at the most medial end of the arcade

50.9.6.7 Arch Bar [26, 27] (Video 50.2)

Commercially available arch bars are usually customized or prefabricated. In most clinical scenarios, prefabricated arch bars like Erich's, Jelenko, Winter's, or Schuchardt's suffice the need for placement.

Indications

1. Partially edentulous patients where placement of eyelets is not an option due to insufficient number of teeth.
2. The teeth present are far apart making MMF impossible.
3. For alignment of avulsed teeth/displaced dentoalveolar fracture into proper arch form.
4. Reduction and immobilization of dentoalveolar component/ fracture.
5. As a part of integrated treatment for suspension for treatment of maxillofacial fractures.

Technique

Ideal placement is as close to the interdental spaces, which are then secured with 26 gauge wire. This close placement helps to reduce the arch bar to tooth contact and allows for better adaptability of the arch bar to the arch contour, thereby reducing loosening of arch bar.

In most cases, arch bars are placed from distal of first molar, in one quadrant to the other, maintaining a minimum of two teeth on either side of the fracture line in a dentate patient.

The wire is passed from one interdental space and moved around the tooth to emerge buccally from the other side (Fig. 50.19a). Placement of arch bar by securing it with wire begins (Fig. 50.19b) usually at the midline and proceeds posteriorly or from one end (molar) to another (Fig. 50.19c,d) in order to avoid excess in the center and to achieve uniformity throughout the length of the arch bar. The wires are usually twisted in between the cleats and placed into the interdental space to avoid damage to surrounding soft tissues.

The cleats of the arch bar always face gingivally. MMF is usually secured using 24 gauze wires in box pattern.

Figure 50.19e is showing a model with upper and lower arch bar placement secured with wires, while Fig. 50.19f is showing a clinical photograph of arch bar placement.

Advantages

- Easier to manipulate and maintain the intra-arch form.
- Acts as a tension band, resisting forces acting at the alveolar level of the fractured component.
- Multiple vectors can be provided by using elastics and VW cross bracing in reducing the fracture displacement to achieve premorbid occlusion.

Disadvantages

- One of the major drawbacks is the lack of vertical stop in the anterior region when an arch bar is used. In the posterior region, the opposing teeth act as a vertical stop for occluding teeth which isn't the case with anterior region as the anterior upper teeth may slide over the lower when elastics are stretched between the maxillary and mandibular teeth resulting in extrusion of anterior teeth. This problem can be circumvented, by drilling a hole using a bur in the gingival area apical to the mucogingival junction through the buccal and lingual cortices.

An additional 24 gauze wire is passed from the buccal side of this hole to emerge lingually. The lingual end of the wire is then passed through the interdental space of the tooth to emerge buccally. Both the ends of the wire are then twisted to prevent extrusion.

In the anterior maxilla, anterior nasal spine can be used for additional suspension of the arch bar to prevent downward pull exerted by the elastics.

- Increased operating time.
- High probability of penetrating injuries to the operator.
- Compromised oral hygiene and periodontal tissue damage.
- Post-treatment removal is a traumatic experience.

Complications

Post reduction of the dentoalveolar fracture, the incisal edges of the fractured teeth bearing segment will remain above the normal occlusal plane. This discrepancy can be corrected by application of apical pressure to this segment through MMF, circummandibular wiring, suspension from ANS, lateral piriform, buttress, or using the eye of the maxillomandibular fixation screw.

50.10 Maxillomandibular Fixation (MMF) Screws [28] (Video 50.3)

50.10.1 Introduction

A self-drilling or tapping maxillomandibular fixation screws by Arthur et al. [29] in 1989 reduced the intra and post-operative problem associated with the arch bars.

50.10.2 First Generation

Screws were modified monocortical self-tapping screws that were kept at 4–5 mm above the mucosa for subsequent wire

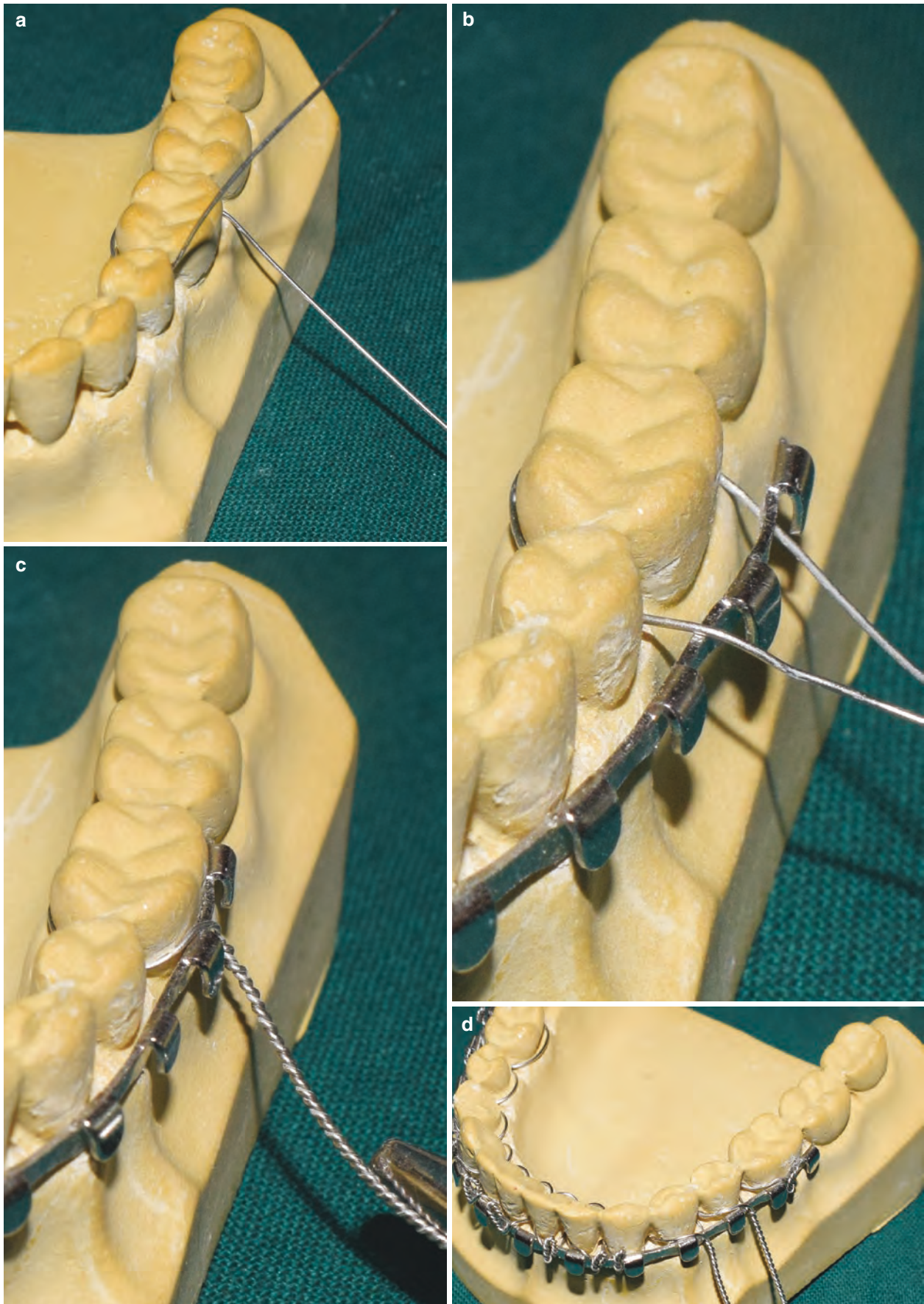
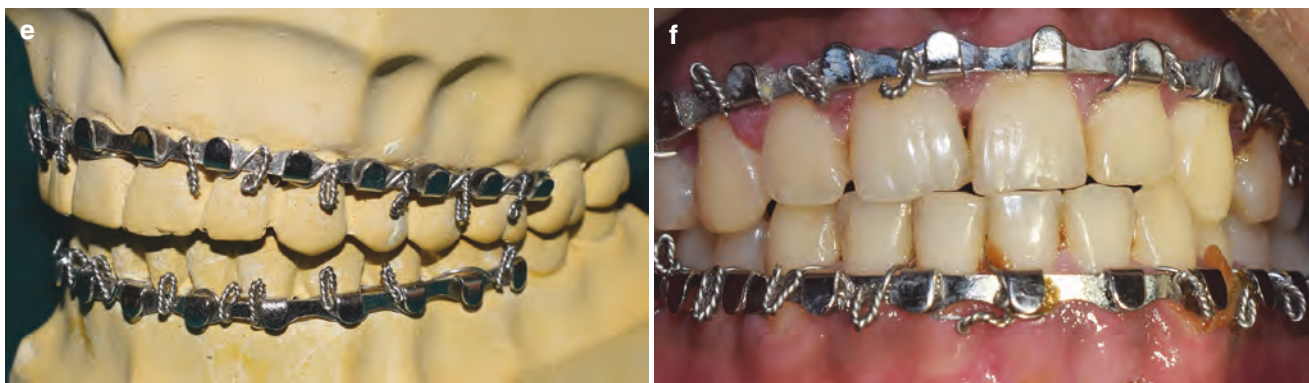


Fig. 50.19 (a–d) Showing technique of arch bar placement. The wire is passed through the embrasure or emerge buccally. The wire on the mesial side of the tooth is passed above the arch bar, whereas the distal end wire

is passed below the arch bar to secure it by twisting. (e) Showing a model with upper and lower arch bar placement secured with wires. (f) representing a clinical photograph of arch bar placement



©Association of Oral and Maxillofacial Surgeons of India

Fig. 50.19 (continued)

splinting. Surgical preparation of the site needed prior to insertion. They were usually wider in diameter with grooves/flutes.

50.10.3 Second Generation

Screws were self-drilling or self-tapping screws which were spool shaped. The central part of the screw head is perforated with one of two channels perpendicular to its axis aiding in the passage of ligature wires. The top of the screw heads is smoothly finished at the contact zone with overlying mucosa.

Clinician should consider fracture location, dentition, surgical exposure, and the quantity of bone for placement of these IMF screws.

Ideal radiographic images obtained are orthopantomogram and CT axial scan to analyze and plan placement of these screws.

Sites include anterior vestibule and anterolateral (canine and premolar regions) as they provide sufficient bone depth, clearance from adjacent tooth, and easy accessibility. Screws should be placed above the root apices as subapical placement leads to mucosal overgrowth (Fig. 50.20a–d).

Ideally one screw should be placed on either side of the fracture line. However, in severely displaced cases, it is

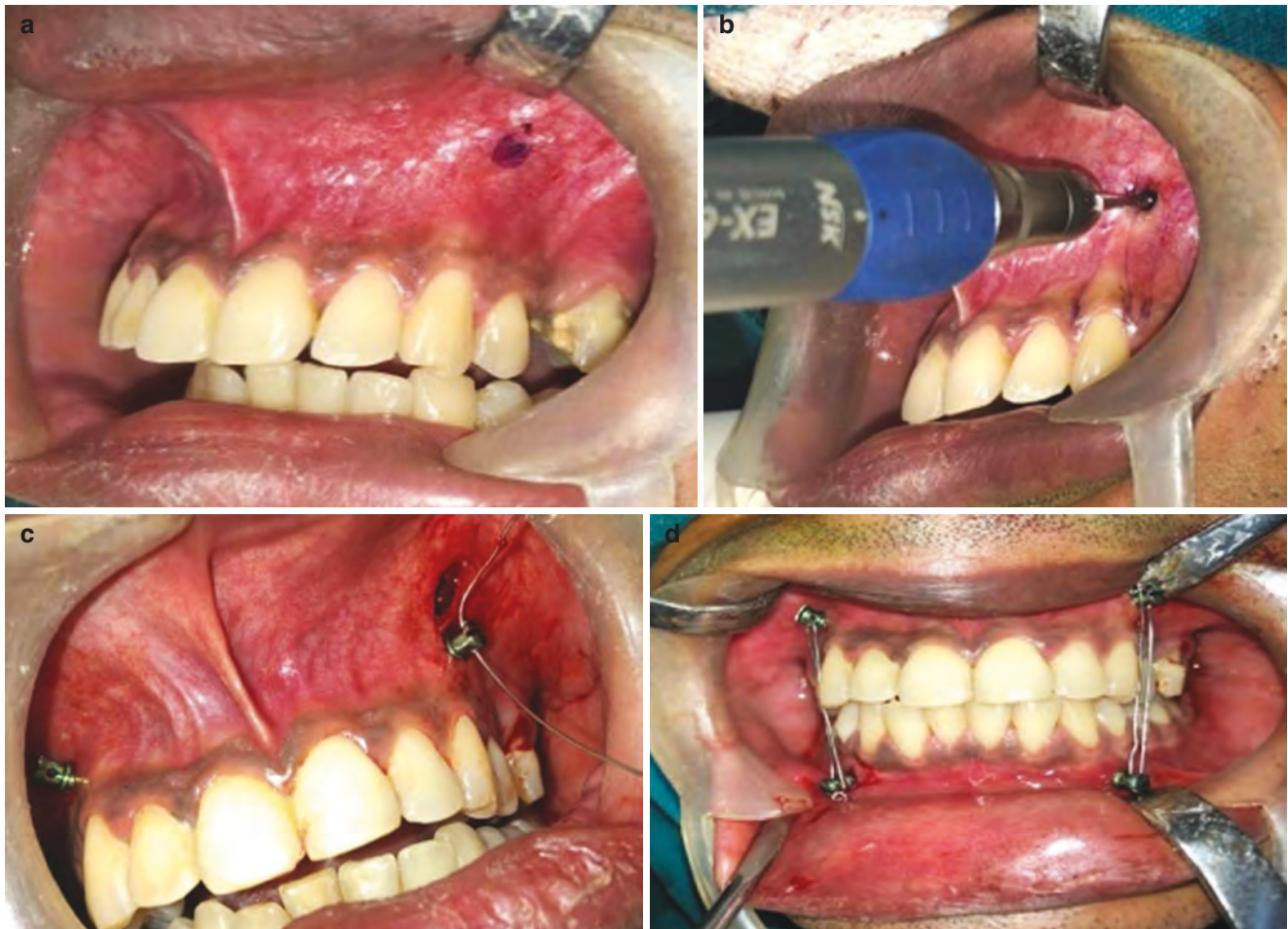advisable to use multiple screws on either side to achieve vectors in different directions.

50.10.4 Advantages

1. Cost-effective
2. Easy placement
3. Lesser operating time
4. Less incidences of penetrating injuries
5. Lesser appliances inside the oral cavity
6. Minimum damage to periodontium
7. Easy maintenance of oral hygiene

50.10.5 Disadvantages

1. Iatrogenic damage to tooth roots
2. Root fracture
3. Ingested hardware
4. Screw loosening resulting in malocclusion [30]
5. Pulpal necrosis
6. Root resorption
7. Tooth loss
8. Soft tissue growth over the screw head [31]



©Association of Oral and Maxillofacial Surgeons of India

Fig. 50.20 (a–d) Showing clinical steps in placement of MMF screw. Technique for placement of MMF screws. Marking is done between the root apices followed by drilling and placement of MMF screw, one in

each quadrant. The wire is passed through the eye of the opposing arch and secured to achieve intermaxillary fixation

50.11 Conclusion

Dentoalveolar fracture mostly involves teeth, soft tissues, and associated bones. With the recent advancements in the field of dentistry, the oral and maxillofacial surgeon can restore the lost form and function of teeth to facilitate the improvement in quality of life in trauma-afflicted patients.

Acknowledgments For Figs. 50.1, 50.2, 50.3, 50.4, 50.6, 50.7, 50.8 and 50.9 to Suvy Manuel.

References

1. Nyarady Z, Orsi E, Nagy K, Olasz L, Nyarady J. Transgingival lag screw osteosynthesis of alveolar process fracture. *Int J Oral Maxillofac Surg.* 2010;39:779–82.
2. Hale ML. Traumatic injuries of the teeth and alveolar process. In: *Kruger textbook of oral and maxillofacial surgery.* 6th edn. Jaypee; 1968. p. 357–63.
3. Leathers RD, Gowans RE. Management of alveolar and dental fractures. In: *Peterson's principles of oral and maxillofacial surgery.* Vol 1, 3rd edn. New York: McGraw Hill; 2004. p. 383–405.
4. Ellis E III, Assael LA. Soft tissue and dentoalveolar injuries. In: *Contemporary oral and maxillofacial surgery.* 2nd edn. Elsevier p. 557–86.

5. Sivakumar, Muthu MS. Traumatic injuries of teeth and supporting structures. In *Pediatric dentistry principles and practice*. 2nd edn. Elsevier; p. 305–26.
6. Pogrel MA, Kahnberg K-E, Andersson L. Traumatic dental injuries. In: *Essentials of oral and maxillofacial surgery*. 1st edn. Wiley Blackwell; 2014. p. 257–87.
7. Taub PJ, Patel PK, Buchman SR, Cohen MN. Ferraro's fundamentals of maxillofacial surgery. 2nd edn. Springer; 2015. p. 169–73.
8. Margarone JE, Hall R. Management of alveolar and dental fractures. In: *Principles of oral and maxillofacial surgery*. Vol 1. Philadelphia, PA: J.B. Lippincott; 1992. p. 381–405.
9. Gutmacher Z, Peled E, Norman D, Lin S. Alveolar bone fracture: pathognomonic sign for clinical diagnosis. *Open Dent J*. 2017;11:8–14.
10. Costello BJ, Martin B. Dentoalveolar trauma. In: *Operative oral and maxillofacial surgery*. 2nd edn. 2010; p. 475–8.
11. Pagadala S, Tadikonda DC. An overview of classification of dental trauma. *IAIM*. 2015;2(9):157–64.
12. Faus-Matoses V, Martinez-Vinarta M, Alegre-Domingo T, Faus-Matoses I, Faus-Liacer VJ. Treatment of multiple traumatized anterior teeth associated with an alveolar bone fracture in a 20 year old patient: a 3 year follow up. *J Clin Exp Dent*. 2014;6(4):e425–9.
13. Diangelis AJ, Andreasen JO, Ebelesder KA, Kenny DJ, Trope M, et al. Guidelines for the management of traumatic dental injuries: fractures and luxations of permanent teeth. *Dent Traumatol*. 2012;28:2–12.
14. Shulman LE. Transplantation and replantation of teeth. In: *Oral and maxillofacial surgery*. Vol. 2. St Louis, MO: C V Mosby; 1985. p. 118–42.
15. Turkistani J, Hanno A. Recent trends in the management of dentoalveolar traumatic injuries to primary and young permanent teeth. *Dent Traumatol*. 2011;27:46–54.
16. Camp JH. Replantation of teeth following trauma. In: McDonalds RE et al., editors. *Current therapy in dentistry*. Vol 7. St Louis, MO: Mosby; 1980.
17. Blomlof L, et al. Effect of storage in media with different ion strength and osmolities in human periodontal ligament cells. *Scand J Dent Res*. 1981;89:180–7.
18. Bag I, Yildirim S. Effect of avulsion storage media on periodontal ligament fibroblast differentiation. *Dent Traumatol*. 2017;33(6):458–64.
19. William Cornell R. Management of the avulsed tooth. In: *Clinical transplantation in dental specialities*. 2nd edn. St Louis, MO: C V Mosby; 1980. p. 89–106.
20. Andreasen JO. Periodontal healing after replantation of avulsed human teeth. Assessment by mobility testing and radiography. *Acta Odontol Scand* 1975;35:325–35.
21. Abu Samra FM. Dentoalveolar injuries classification—management—biological consequences. *J Dent Health Oral Disord Ther*. 2014;1(4):00025.
22. De Rossi M, De Rossi A, De Queiroz AM, Nelson-Filho P. Management of a complex dentoalveolar trauma: a case report. *Braz Dent J*. 2009;20(3):259–62.
23. Yamashita D, Cho N. Techniques for maxillomandibular fixation. In: *Atlas of oral and maxillofacial surgery*. Vol 1. 2nd edn. Elsevier; 2016. p. 638–44.
24. McDonald RE, Avery DR, Dean JA, Jones JE. Management of trauma to the teeth and supporting tissues. In: *McDonald and Avery's dentistry for the child and adolescent*. 9th edn. 2010. p. 403–42.
25. Coletti DP. Contemporary maxillofacial fixation technique. In: *Operative oral and maxillofacial surgery*. 2nd edn. Medical; 2010. p. 453–61.
26. Williams JL, Rowe NL. Mandibular fractures: closed reduction. In: *Rowe and Williams maxillofacial injuries*. Vol. 2. 2nd edn. Churchill Livington; 1995. p. 234–66.
27. Marunick MT. Closed reduction and Immobilization of condylar fractures with intermaxillary fixation alternative techniques of Ivy Loops and Molar wafers. In: *Atlas of craniofacial trauma*. Lippincott Williams and Wilkins; 2012. p. 36–43.
28. Manjrekar S, Joshi A. Use of mandibulo-maxillary fixation screws for the treatment of maxillofacial fractures. *Dentistry*. 2017;7(12):467.
29. Arthur G, Berardo N. A simplified technique of maxillomandibular fixation. *J Oral Maxillofac Surg*. 1989;47(11):1234.
30. Rai A et al. Are maxillomandibular fixation screws a better option than Erich arch bars in achieving maxillomandibular fixation? A randomized clinical study. *J Oral Maxillofac Surg* 2011;69:3015–3018.
31. Rai A et al. Customised screw for intermaxillary fixation of maxillofacial injuries. *Br J Oral Maxillofac Surg*. 2009;47: 325–26.

Open Access This chapter is licensed under the terms of the Creative Commons Attribution 4.0 International License (<http://creativecommons.org/licenses/by/4.0/>), which permits use, sharing, adaptation, distribution and reproduction in any medium or format, as long as you give appropriate credit to the original author(s) and the source, provide a link to the Creative Commons license and indicate if changes were made.

The images or other third party material in this chapter are included in the chapter's Creative Commons license, unless indicated otherwise in a credit line to the material. If material is not included in the chapter's Creative Commons license and your intended use is not permitted by statutory regulation or exceeds the permitted use, you will need to obtain permission directly from the copyright holder.





Principles of Internal Fixation in Maxillofacial Surgery

51

Abhilasha Yadav

51.1 Introduction

Road traffic accidents (RTA) are one of the primary etiologies of craniomaxillofacial fractures. Open reduction and internal fixation (ORIF) is the most important treatment modality to restore the compromised form and function. Adequate reduction and fixation with miniplate osteosynthesis is the essential component of management.

51.1.1 Association of Osteosynthesis (AO Principles)

The following are guidelines for internal fixation based on the four basic principles formulated by AO in 1958.

- (A) **Anatomic reduction:** Fracture reduction and fixation to restore normal anatomy
- (B) **Stable fixation:** Fracture fixation with relative or absolute stability, as required by the patients injury and type of fracture
- (C) **Preservation of blood supply:** By gentle reduction and careful handling along with preservation of vascularity of soft tissues and the bone
- (D) **Early and active mobilization:** Rehabilitation of the injured part and the patient as a whole with early and safe mobilization

A. Yadav (✉)
Department of Oral & Maxillofacial Surgery, Awadh Dental
College & Hospital, Jamshedpur, Jharkhand, India

51.2 History

1. Plating of fractures can be traced back to 1895 when a metal plate was first introduced by Lane for internal fixation. It was abandoned due to its drawback of corrosion [1].
2. Subsequently Lambotte in 1909 and Sheman in 1912 introduced plates for fixation, but due to insufficient strength, their designs were abandoned [1].
3. Eggers in 1948 developed a plate which was structurally weak resulting in instability of fixation [1].
4. In maxillofacial surgery, the interest in rigid fixation began with the treatment of fractures of edentulous mandible, as the fractures located in edentulous mandibular segments were easier to manage.
5. Keys to fast and economic bone healing are optimal reduction of fracture ends and maximum stabilization of fracture area. Simplest way to achieve these goals is to apply the principles of axial compression of fracture ends. This principle was first advocated by Belgian Surgeon Davis in 1994 and later adopted by ASIF (association for the study of internal fixation).
According to him, there was a need for compression between the fragments of fractures. He used a plate called coaptens to achieve this goal, which increased stability and suppressed interfragmentary motion. The mode of healing initiated by this is called soudure autogene (autogenous welding) now known as primary bone healing.
6. In 1967, mandibular compression screw (MCS) was used in oral and maxillofacial surgery (OMFS) in edentulous fractured mandible while performing first compression osteosynthesis. Self-tightening/automatic MCS plate was developed by Luhr in 1968. Later, dynamic plates were advocated for surgery of long bones with subsequent application in mandibular fractures.

Table 51.1 History of development of fracture management modalities

1881	Glimer	On either sides of the fracture, two heavy rods
1886	Hansmann	Retrievable bone plates
1945	Christiansen	In mandibular fracture-tantalum plates
1956	Bagby	First compression plate
1960	Luhr and Mittlmeir	Improved mandibular compression plates
1969	AO/ASIF	Dynamic compression plates (DCP)
1970s	Brons and Boering	Lag screws
1973	Schmoker and Spiessel	(EDCP) eccentric dynamic compression plates
1973	Michelete	Miniplates
1975	Champy	Monocortical screws principal for fixation
1977	Luhr	Compression plates for the first time in management of fracture mandible
1977	Spiessel	For mandible fracture advocated AO/ASIF principle
1989	Bos	Resorbable plates and screws
1994		Dynamic compression plate with locking compression plate
2011		Development of locking compression plate with combination holes

51.2.1 Evolution of Fixation Methods

History of development of fracture management modalities [2–4] (Table 51.1)

51.3 Concept of Bone Healing

51.3.1 Secondary Bone Healing (Fig. 51.1)

51.3.1.1 Stage I: Inflammation Induction

Immediately after fracture, hematoma formation occurs; hematoma plays a vital role in the angiogenesis of the healing fracture. Subsequently, inflammatory cells, stem cells, and fibroblasts initiate inflammatory response and enhance angiogenesis. Cytokines which helps in bone repair are released in this phase and hematoma is removed. Within 3 days, thin layer of fibrous tissue covers the periosteal surface of fractured bone. The cortical bone adjacent to fracture site becomes necrotic which later gets remodeled by multinucleated osteoclast.

51.3.1.2 Stage II: Fibrocartilaginous (Soft) Callus Formation

Dense fibrous tissue, cartilage, and fibrocartilage formation occurs due to organization of subperiosteal hematoma; soft callus is composed of internal (endosteum of marrow cavity and lining of Haversian canal) and external components (periosteum and organizing hematoma) and continued proliferation of osteoblasts; fibrocartilaginous tissue begin to

calcify as the periosteal and endosteal circulation develops. The conversion of chondrocytes to osteocytes occur and the entire callus is converted to immature woven bone.

51.3.1.3 Stage III: Hard Callus Formation

After 3–4 weeks of fracture, the hard callus begins to form and osseous union of the fractured cortical bone starts.

51.3.1.4 Stage IV: Remodeling

The trabeculae orient themselves in the direction of functional pressures after bone formation.

51.3.2 Primary Bone Healing (Contact and Gap Healing)

Healing without callus formation is called as primary bone healing. When there is direct apposition of cortical bone surfaces, contact healing occurs. Osteoclasts widen the Haversian canals on either side of the fracture and move toward each other. The cortical bridging occurs in 8 weeks and is usually completed in 16 weeks. In gap healing also primary bone healing occurs; gap as wide as 100 μm can be filled with mature lamellar bone (Fig 51.2).

51.4 Biomechanics of Facial Skeleton [5]

51.4.1 Mandible Fractures

The mandible is a class III lever with:

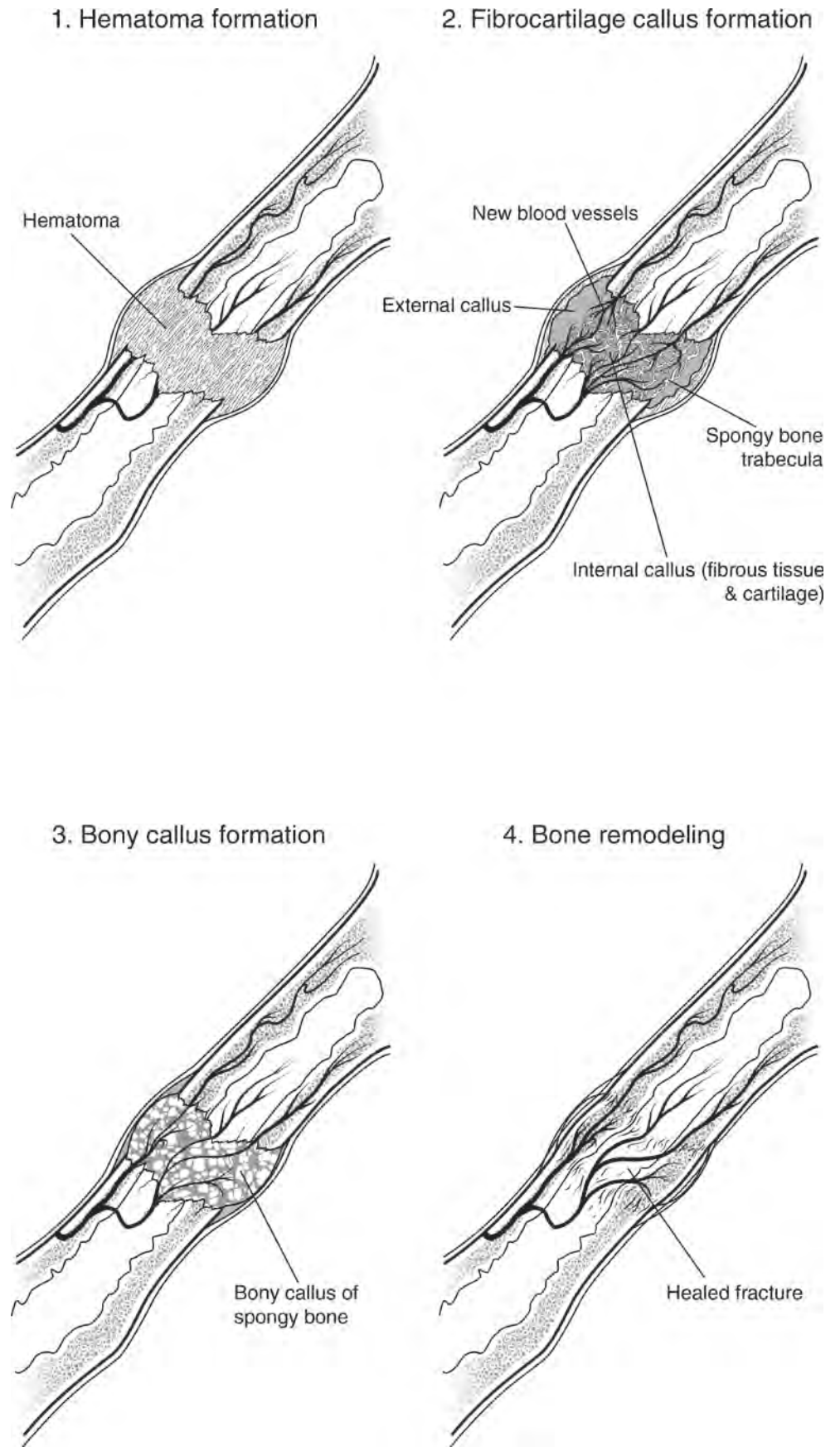
- Condyle as fulcrum.
- Bite load as a resistance force.
- Masticatory muscles as applied force.

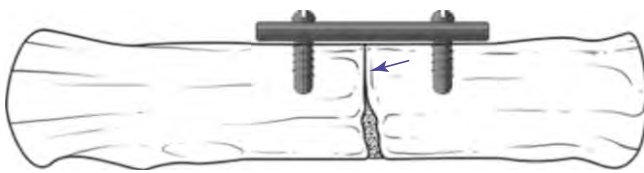
Simple beam mechanics described the traditional biomechanical properties of mandible, which represents compression at inferior border and tensile forces on the superior border with an applied anterior load (Fig. 51.3). The “neutral axis” is the line of zero stress where the tensile forces become compressive, and it is approximately at the level of the inferior alveolar canal. Compression and tension will be produced in symphysis region due to torsional forces.

The muscles inserting on the mandible and forces exerted by these muscles during function, determine the tension and compression zone in cases of fracture mandible.

The direction of the muscular forces acting on the mandible by temporalis, lateral pterygoid, pterygomasseteric sling, and suprahyoid musculature is shown by arrows in Fig. 51.4. For successful treatment of facial fractures in the form of rigid fixation, the understanding of biomechanics of facial injury is very important.


Fig. 51.1 Fracture healing





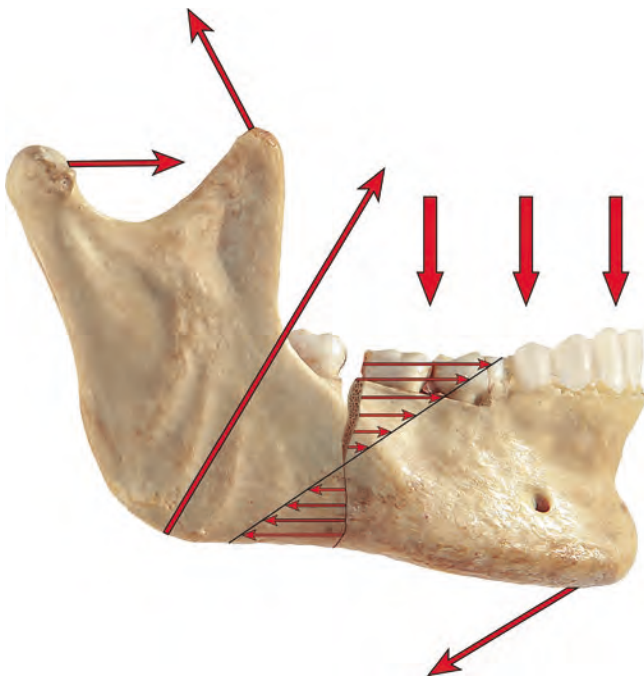
©Association of Oral and Maxillofacial Surgeons of India

Fig. 51.2 Contact and gap healing (arrow denotes contact healing)



©Association of Oral and Maxillofacial Surgeons of India

Fig. 51.3 Tensile and compressive force mechanism



©Association of Oral and Maxillofacial Surgeons of India

Fig. 51.4 Direction of muscular forces

51.4.2 Midface Fractures

Midface generally does not show muscle forces acting on them except for zygomatic bone, on which masseter exerts the primary force which can create notable bony displacement causing inferior and medial displacement especially in the presence of temporalis fascia disruption (Table 51.2).

Table 51.2 The four articulations of zygoma with their functions in management of fracture

Frontozygomatic suture	Received greatest tensile forces and is the important site for fixation
Infraorbital rim	Thin bone, least important site for fixation
Zygomaticomaxillary buttress	Best site for fixation to counter the force of masseter muscle
Zygomaticotemporal suture	Least important site for plating

51.5 Functions of Plates

51.5.1 Compression

Compressing together the main fragments of a single plane fracture can result in absolute stability, i.e., the complete abolition of interfragmentary movement. Interfragmentary compression in single plane, as in diaphyseal fractures, can be achieved by exploiting the eccentric loading capabilities of the dynamic compression family of plates.

The screw is inserted in a neutral mode, and plate was fixed to the right-hand fragment. In an eccentric (load) mode, a screw is then inserted into the left-hand fragment. As the load screw is fully inserted, it engages and slides down the sloping surface of the plate hole, and the screw and bone move toward the fracture, compressing it.

If the plate that exerts axial compression is exactly contoured to the anatomically reduced fracture surface, there will be some gapping of the opposite cortex when the plate is tensioned by tightening the load screw. This is due to the compression being maximal immediately beneath the plate and not evenly distributed over the whole area of the fracture plane. The solution to this problem is to “overbend” the plate so that its center stands off 1–2 mm from the anatomically reduced fracture surface. Slight gapping of the cortex will occur directly underneath the plate when the neutral side plate is applied to the bone. The tightening of load screw causes tension in the plate and compresses the fracture evenly across the full diameter of the bone.

51.5.2 Neutralization

A primary lag screw fixation, exerting interfragmentary compression, can be vulnerable to disruption by physiological bending and/or rotational forces. Such a primary fixation is usually protected by the use of a plate, spanning from one main fragment to the other—this “neutralizes” the disruptive forces. All such forces are then transmitted via the plate and bypass the primary lag screw fixation.

51.5.3 Tension Band

If a body with a fracture is loaded at each end, over a bending point (fulcrum), tension (distraction) forces are generated, maximal on the side opposite the fulcrum, and angulation occurs. However, if an inelastic band, such as a plate, is anchored to the tension side of the body, same load will generate compression across the fracture interface. This is known as the tension band principle.

51.6 Fixation Methods and Devices [6] (Table 51.3)

Commonly used devices used for fixation are wires, staples, pins, and screws [6].

51.6.1 Material

Most commonly used materials are titanium (Ti-6Al-4V) and stainless steel (316L). Stainless steel has been used because of its greater biocompatibility and corrosion resistance. Since 1980 titanium was used in maxillofacial surgery.

51.6.2 Rigid Fixation

The internal fixation is defined as the placement of wires, plates, screws, rods, pins, and other hardware to stabilize the fracture fragments.

51.6.2.1 Rigid Internal Fixation (RIF)

RIF is defined as “bone fixation of any form in which biomechanical forces are either countered or used to stabilize the fragments of fracture and permits loading of bone to permit active action” [7].

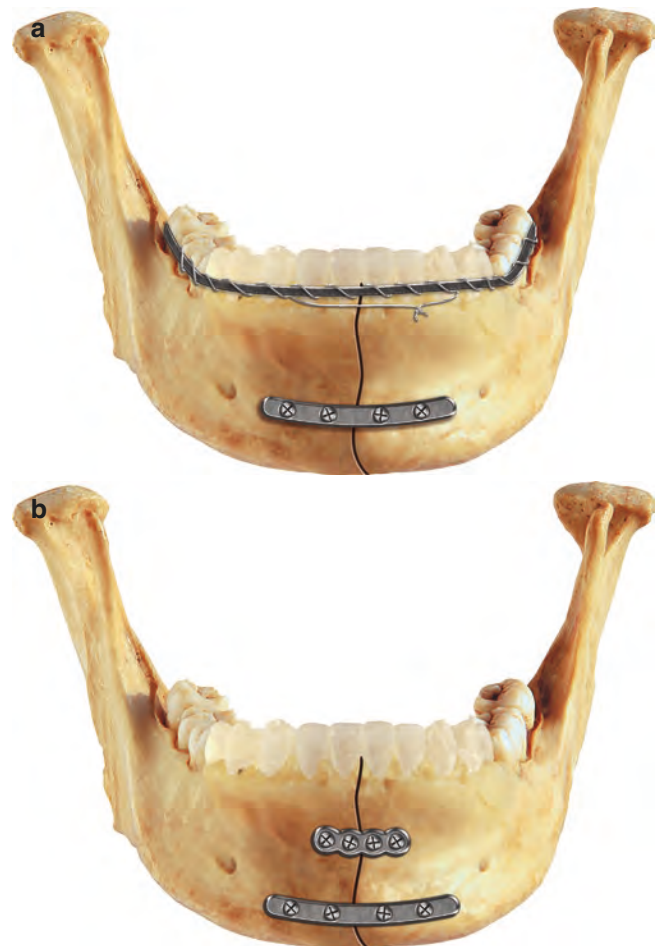51.6.2.2 Examples of RIF

Examples of RIF are the use of bone plates and screws, two lag screws, and use of reconstruction plate with three screws on each side of the fracture fragment. Use of long compression plate is also included in the rigid internal fixation examples.

Healing: In the rigid internal fixation, no callus formation is formed during bone healing. The fracture bones heal by a process of Haversian remodeling. This primary or direct bone union requires immaculate immobilization between osseous fragments, i.e., minimum gap between the rigid fixation. Examples of rigid fixation for fracture mandible are shown in Fig. 51.5a,b.

51.6.3 Nonrigid Internal Fixation

It is a kind of fixation that is not strong enough to prevent interfragmentary motion completely. Thus interfragmentary motion is the differentiating factor between rigid and non-rigid fixation. Any mobility between fragments stabilized through internal fixation on active usage of skeletal structure signifies nonrigid fixation.



©Association of Oral and Maxillofacial Surgeons of India

Fig. 51.5 (a, b) Techniques of rigid fixation for mandibular fracture. (a) Fixation with single miniplate and tension band; (b) fixation with two miniplates

Table 51.3 Fixation methods and devices

Fixation methods			
Wires	Staples	Pin	Screws
	Pneumatically driven staples	Kirschner wires	Cancellous screw
	Prebent staple legs		Cortical screw

Transosseous wiring across a fractured mandible is a good example of nonrigid fixation. The wire is unable to neutralize torsion/or shear forces and requires other fixation methods like MMF (maxillomandibular fixation).

Healing: The bone healing that occurs under the condition of mild mobility between fragments is called as secondary bone healing. There is deposition of periosteal callus in such circumstances, followed by resorption of fragment peripheries and tissue differentiation through various stages from fibrous to osseous healing.

51.6.4 Semirigid Fixation

Semirigid fixation is based on load-sharing osteosynthesis. Semirigid fixations include the use of:

- Lag screw
- Miniplates and microplate
- Locking plates
- Resorbable plates
- Three-dimensional plates

51.6.5 Load-Bearing Versus Load-Sharing Fixation (Table 51.4)

Table 51.4 Load-bearing versus load-sharing fixation

	Load-sharing fixation	Load-bearing fixation
Definition/explanation	Internal fixation of inadequate stability to withstand the functional loads across the fracture	Fixation that is capable of withstand the entire load applied during the functional activities to the mandible
Indication	1. Simple linear fractures 2. Mandibular fractures	1. Mandibular comminuted fractures 2. Loss of segment of mandible due to injury 3. Fracture with very less bony interface because of atrophy
Material used	Stainless steel, titanium 2.0 mm miniplating systems	Stainless steel, titanium 2.3 mm, 2.4 mm, 2.7 mm diameters, mandibular reconstruction bone plate
Complications	Due to inadequate bone stock adjacent to comminuted fractures, load-sharing plates should be avoided	Failure by either screw loosening or plate fracture

51.7 Classification of Plating System [8]

- (A) Luhr vitallium maxillofacial systems
 - (I) Mandibular compression screw system
 - (II) Mini system
 - (III) Micro system
 - (IV) Mandibular reconstruction system
- (B) Champy's system
- (C) AO/ASIF maxillofacial implant system
 - (I) DCP, EDCP
 - (II) Reconstruction plates
- (D) The Würzburg titanium system for rigid fixation

51.7.1 Locking Plate-Screw Systems

In the late 1950s, AO group put forth the tenets which are followed in traditional plates and screws. This included exposure of fracture with anatomic reduction and internal fixation of fracture fragments with the desired result of anatomic bone union [9]. The stability of these plates is achieved by locking the plates by the screws.

Conventional screw – bone plates system requires plate to adapt precisely. In the absence of this contact, the tightening of screw will draw the segments of the bone toward the plate which results in change of the occlusion and bony segments.

On the other hand, the locking plate-screw system does not require the intimate contact of plate to the underlying bone in all the areas. The screw tightening locks the plate and thus stabilizes the bone segments without compressing the bone to the plate. Alteration in reduction is impossible after screw insertion.

According to Herford and Ellis [10], the locking plate and screw system are simple to use. Like compression plate it does not require plate to be compressed to the bone.

Klotch et al. [11] also concluded that the locking plates require less time due to less bending and faster application with good results.

Locking plate and screw come in two designs, i.e.:

- Threaded locking plate and screw (Conventional)
- Tapered locking screw and plate (New generation)

The threaded locking plate - screw system features corresponding machined threads incorporated in both the screw and plate. Whereas, the tapered locking screw - plate system has a screw head which is tapered in shape with machined threads, with the plate either having no machined threads or a single machined thread incorporated into its design. This facilitates a more flexible locking mechanism which allows for screw angulation of upto 10 degrees, in comparison to the threaded locking system which needs absolute perpendicular screw placement [12].

51.7.2 Reconstruction Plates

The rigid plates with 2.7 mm bicortical screws were introduced by AO/ASIF in 1972 [13].

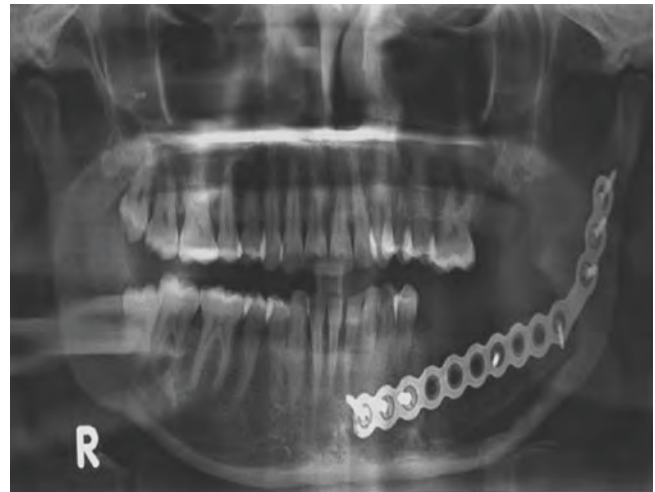The main advantage attributed to the non-locking reconstruction plate, is its “load bearing” principle. Scolozzi and Richter [14], used the 2.4 mm AO Titanium plates for the management of mandible fractures, with good outcomes and very less complications.

They are available in different shapes for specific areas like angle reconstruction plate (Fig. 51.6), condylar reconstruction plate (Fig. 51.7), and straight reconstruction plate with different lengths.

Indications

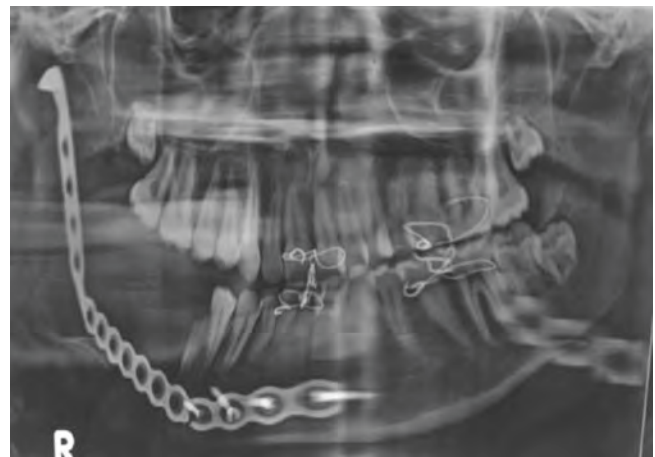1. Large defect of mandible after massive trauma
2. After mandible resection due to tumors or osteoradionecrosis
3. Commonly used in comminuted fractures of mandible, sometimes in combination with miniplates
4. To support the bone grafts in mandibular reconstruction

The advantages of rigid fixation with grafting include immediate jaw function and excellent stabilization of graft. The main disadvantage at the graft site is disuse osteoporosis or “stress shielding.” This phenomenon occurs when rigid plates absorb the mandibles functional stress. To protect the long bones from stress, the plate’s modulus of elasticity will have to exceed in comparison with the bone to which it is attached. Osteoporosis and reduction in bone strength are the result of protection from stress or shielding in long bones [15].



©Association of Oral and Maxillofacial Surgeons of India

Fig. 51.6 Angle reconstruction plate



©Association of Oral and Maxillofacial Surgeons of India

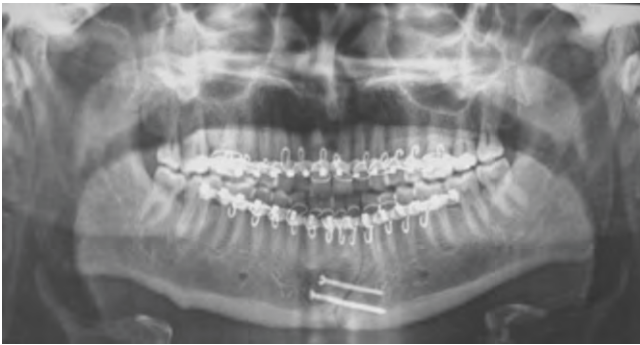Fig. 51.7 Condylar reconstruction plate

51.7.3 Lag Screw Fixation

In oral and maxillofacial surgery, Brons and Boering introduced lag screw fixation for the first time in 1970. According to them two lag screws prevent rotational movements of the fracture fragments in oblique mandibular fractures [16].

51.7.3.1 The Principle of Lag Screw

The lag screw principle is used whenever two wide contact surfaces of the bone should be pressed together (for mandibular oblique sagittal fractures or onlay graft fixation).



©Association of Oral and Maxillofacial Surgeons of India

Fig. 51.8 Orthopantomogram showing fixation with lag screws

Through the outer cortex or onlay graft, the drilling of the hole was carried out of the identical diameter to that of screw so that the screw slips through the outer cortex. The lag screw drill, which is of the same diameter as the screw, will simultaneously create a conical countersink to provide an optimal fitting of the screw head. The inner cortex is then perforated with the normal surgical drill, and the screw is inserted. It grips the inner cortex and, when tightened, exerts great force to pull the outer segment into close contact with the inner one. This principle can be used in oblique sagittal mandibular fractures, with the placement of at least three screws, or in combination with the plate, lagging only one or two of the total minimum number of screws (Fig. 51.8).

51.7.3.2 Absolute Rigid Fixation Provided by Lag Screw

Lag screw should be selected in patients having sufficient bone available for placement of two screws; dissolution of the bone around the screws results in cases of micromotion. The lag screw should be placed in the direction perpendicular to the line of fracture to avoid displacement or overriding during tightening of the screws.

Advantages of lag screws over bone plates:

1. Lag screws require less hardware hence cost-effective.
2. Absolute rigid fixation.
3. Quick and easy to use.
4. Accurate reduction.

Disadvantages

As the lag screw fixation relies on compression of bone fragments and if intervening bone is unstable due to comminution or missing, there will be segment overriding or fracture gap shortening, resulting in malocclusion.

51.7.4 Comparison of Lag Screw Fixation Methods with Different Methods of Fixations [17–19]

1. Single lag screw with arch bar, without MMF is sufficient enough in the treatment of anterior mandible indirectly reducing the cost and requiring less hardware and time of healing [17].
2. Lag screw fixation and plating showed excellent outcome in anterior mandible fracture; lag screws technique is difficult but associated with less postoperative complications [18].
3. In mandibular angle fracture, the lag screw demonstrates smaller inter-fragmentary gap in comparison with mini-plate fixation [19].
4. Lag screw osteosynthesis is more advantageous for ramus height restoration in comparison with miniplates and Kirschner wires, in patients with condylar process fractures [20].

51.7.5 Champy's System [21]

Different treatment principles using monocortical miniplates without axial compression for treatment of mandibular and midface fractures were introduced, namely, by Michelet et al. in the late 1960s, which they published in 1973.

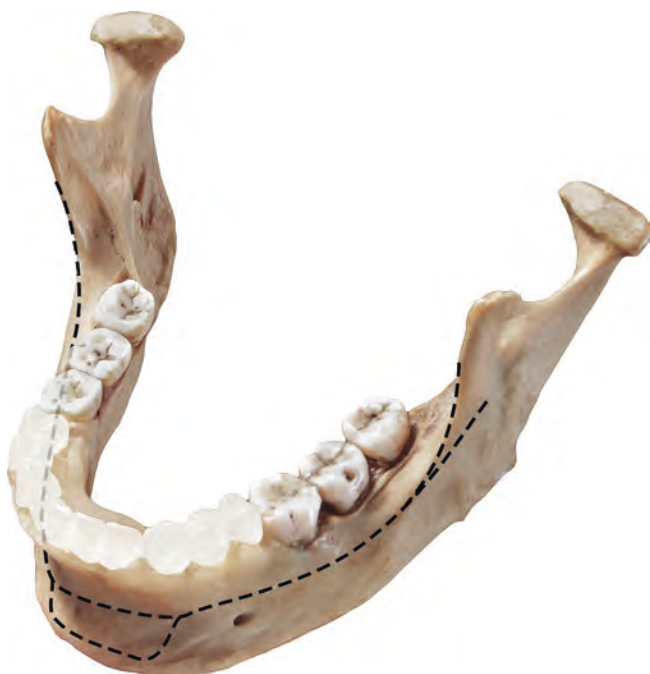Michelet's work has been elaborated by Champy et al. for the management of mandibular angle fracture by the use of intraoral monocortical miniplates. The ideal line of osteosynthesis has been followed by Champy for plates fixation (Fig. 51.9).

It is based on the principle of neutralizing unfavorable traction strains while at the same time allowing transmission of favorable compression forces. The biomechanical validity of Michelet principles was confirmed in a series of multidisciplinary experiments performed in Strasbourg, France, between 1971 and 1974 [21].

Advantages

1. Smaller incision required
2. Less soft tissue dissection
3. Less palpable
4. Decrease stress shielding effect
5. Less chance of dental injury because of monocortical screws
6. Less chances of infection

With this type of fixation, there is adequate stability to allow direct bony union and is called as functionally stable fixation. There are many fixation techniques used in oral and maxillofacial surgery (OMFS) which are not rigid fixation truly but classified as functionally stable fixation.



©Association of Oral and Maxillofacial Surgeons of India

Fig. 51.9 Champy's ideal line of osteosynthesis

51.7.5.1 Materials

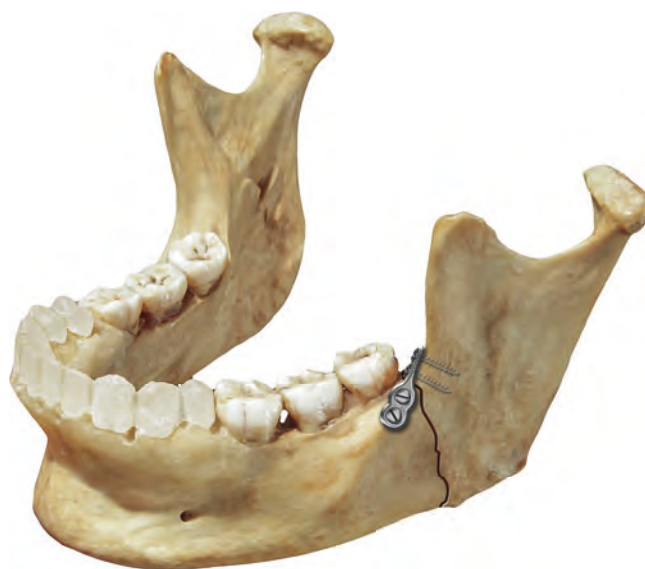Plates and screws are made up of pure titanium. The miniplates are 2 cm long, 0.9 mm thick, and 6 mm wide. They had an elastic limit of flexibility between 70 and 80 per square millimeter, and their rupture point lies between 95 and 110 decanewton (daN) per square millimeter (Fig. 51.10).

51.7.5.2 Miniplates (Fig. 51.11)

- The miniplates vary in length from 2 to 9 cm with a thickness of 0.9 mm. They come in different lengths such as 2 holes with gap, 3 holes, 4 holes, 6 holes, and 8 holes to 16 holes with gap or continuous plates.
- The four-hole and six-hole plates are available with intermediate spacing.
- A wide variety of pre-shaped plates like L, X, Y, T, and K, delta shaped, and 3D- and H-shaped plates are also available. 2.1 mm is the minimum diameter of the hole in the plate and has a bevel of 30°.

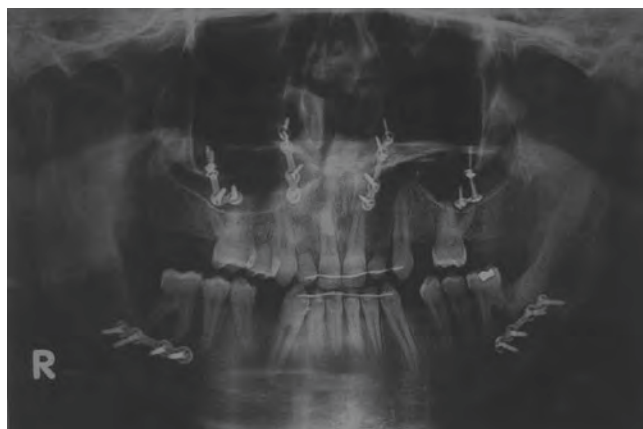51.7.5.3 Screw

- All screws are cortical and self-tapping and have cruciform head.
- Available in lengths of 5, 6, 7, 9, 11, 13, and 15 mm.
- 2 mm is the diameter of the screw with 1.6 core diameter of thread.



©Association of Oral and Maxillofacial Surgeons of India

Fig. 51.10 Champy's miniplate



©Association of Oral and Maxillofacial Surgeons of India

Fig. 51.11 OPG showing fixation with the help of miniplates after Leefort I and bilateral sagittal split osteotomy

- The screw thread is 10/10, so that one turn of the screw corresponds to 1 mm penetration into the bone.
- 2.8 mm is the screw head diameter, and it is designed such that it allows insertion at 30-degree angle with respect to the plate surface.

The drill has the same diameter as the core of the screws—1.6 mm. This ensures firm anchorage of the self-tapping screws.

51.7.5.4 Biomechanical Properties of Screw

(Fig. 51.12) [22]

- The external or the outer diameter ranges from 0.8 to 2.0 mm. Core diameter of the screw is its internal diameter. The surgical bone screws act by clamping the bone plate and bone together.

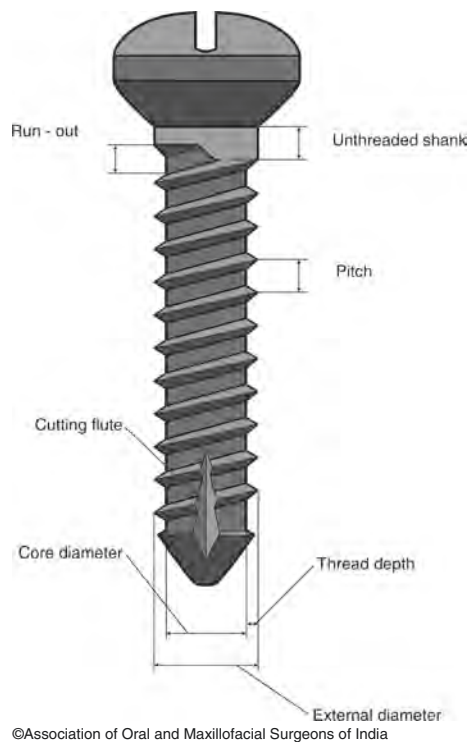


Fig. 51.12 Biomechanical properties of screw

- The pitch of the screw is calculated parallel to the screw axis from a point on one thread to corresponding point on the adjacent thread.
- The difference between core and external diameter is the thread depth.
- The distance between screw runout and screw head is the length of the unthreaded shank.
- The distance between screw runout and plate is the length of the unthreaded shank with plate.

51.7.5.5 Self-Tapping and Drilling Screws

[23, 24, 25]

Self-tapping screw: The screw which is inserted into a pre-drilled hole without tapping a screw head is the self-tapping screw.

Self-drilling screw has a drilled-shaped point to cut and does not require predrilling. Self-drilling screws have several advantages over the self-tapping such as it does not require drilling the hole and prevents thermal damage leading to infection, screw loosening, osteomyelitis, and nonunion. It also prevents damage to tooth roots and nerves by the use of drills and also avoids the complications associated with drill bit fracture.

51.7.5.6 Monocortical vs. Bicortical Screws

The monocortical screws are generally used for fixation of mandibular fractures and after sagittal split osteotomy. Chug H-IJ et al. [26] also concluded that monocortical screws provide stable fixation. Also chances of damage to the vital structure like inferior alveolar and lingual nerve are less with monocortical screws. Bicortical screws are usually used at the lower border of the mandible for fixation.

51.7.6 Microplates

The microplate fixation concept was introduced by Luhr in 1988. They are composed of cobalt, vitallium alloy, and molybdenum in the percentage of 68%, 27%, and 5 %, respectively. It has got excellent physical strength and corrosion resistance.

The thickness of plate is 0.5 mm, and the diameter of the screws is 0.8 mm. In all the three dimensions, they can be contoured and maintained an excellent degree of rigidity for osseous segment stabilization. They are used in:

1. Nasoethmoidal fractures
2. Fractures of infraorbital area
3. Fracture of frontal sinus wall
4. Reconstruction of the skull
5. Infant craniofacial surgery

51.7.6.1 Micromesh

In spite of its reduced thickness (0.3 mm), micromesh is remarkably strong. It is available in sizes of 40 by 60 and 60 by 100 mm. Template made of a soft, malleable tin alloy comes in various sizes. The template is cut to the shape and size required in the individual case, and then it is contoured to the bone surface. The actual titanium micromesh is then cut out with a wire cutter and contoured on the instrument table reduplicating the individual shape of the template.

51.7.7 AO/ASIF System [27]

The association of osteosynthesis/association for the study of internal fixation (AO/ASIF) were founded by a group of 15 Swiss surgeons in 1958. The group was led by Maurice E. Muller; AO/ASIF investigators have documented the biologic basis for the concepts on which rigid fixation techniques are based.

Spießl applied AO/ASIF concepts of long bone healing and modified AO/ASIF instrumentations for use in mandible in the late 1960s and early 1970s.

Compression can be achieved through static or dynamic means. The two devices that produce static compression are the self-compression plate and lag screw.

1. The self-compression plate designed by Perren for the ASIF has been called the dynamic compression plate (DCP). It generates interfragmentary compression by spherical guiding principle. The DCP principle causes the movement of screw in both vertical and horizontal direction which compresses the fracture segments.
2. Lag screw principle—when the screw is tightened, it compresses the surface when the screw glides through the cortex of one fragment and engages the cortex of the opposite fragment.

The EDCP (eccentric dynamic compression plate) has outer hole which is oblique causing compression on alveolar side and longitudinal inner holes creating basal side interfragmental compression. EDCPs eccentric action eliminates the need for tension band. This plate has most utility for simple fracture of the posterior region where there are no teeth available for splinting.

The reconstruction plate is a load-bearing plate and absorbs the entire functional load. They are designed for use without the tension band. It is large and reinforced version of basal stabilization plate. They can be adapted to local bony contours and are malleable. Depending on the placement of drill hole, it has two-way DC holes that enable compression to be applied in either longitudinal direction.

51.7.7.1 Plates

- (I) Linear system (compression plates)
 - (a) DCP plates
 - (b) EDCP plates
- (II) Universal systems (reconstruction plates)

51.7.7.2 Dynamic Compression Plate (DCP)

These are designed to withstand tensile loading force in the mandible. In mandibular angle, body, and symphysis regions, they can be used comfortably. It can be applied intraorally or through an extraoral incision. It is used with a tension band. The dynamic compression plate was developed in 1969.

The DCP has a self-compressing hole design. The holes are oblong, and the portion of each hole distant from the fracture has a sloping form or “shoulder.”

Experimental work showed that the flat undersurface of the DCP interfered with the vascular supply of the underlying cortex onto which it was compressed by the screws. The concept of “footprint” is the area of undersurface of the plate in contact with the underlying bone cortex.

Principles of DCP—The sloping shoulder of the DCP hole has the form of part of an angled cylinder. If a screw is inserted eccentrically, so that its head on final tightening slides down the sloping profile of the hole, the screw/bone unit will be shifted toward the fracture, and the fracture plane will thereby be compressed. Such a screw is often referred to as a load screw.

51.7.7.3 Eccentric Dynamic Compression Plate (EDCP) [27]

It produces a compressive force via arrangement of eccentric and centric (axial) plate holes. EDCP are 8 mm wide and come in four-hole (36 mm long) and six-hole (42 mm long) lengths. The stainless steel plates are 2 mm thick, and the titanium plate is 2.2 mm thick. At the fractures alveolar side, the compression has been provided by the 75° angulation. It is important to place the sloped edge of the angled hole at the mandibular lower border (if the plate is placed upside down, it will tend to distract bone edges at the alveolar border). First central screws are inserted in EDCPs (longitudinal hole eccentrically away from the fracture) than at the lower border; screws are placed in the 75-degree oblique holes eccentrically and in the last rest of the screws inserted in a neutral position. When the plates and tension band splint cannot be used, in those situations EDCP plates are used. The reduction forceps with pressure splinting are useful initially to reduce and compress the fragments when applying the EDCP plate.

51.7.8 Bioresorbable Fixation Systems

Use of titanium plates and screws is time-tested for their use in management of craniofacial fractures. However, it has many drawbacks including infection, hardware palpation and visibility, hypersensitivity to temperature changes, and stress shielding effect. They also interfere with radiographic examination. Sometimes, metal ions leach out into soft tissues. In view of these complications, bioresorbable implants were developed hoping to reduce hardware-associated complications as well as the necessity for hardware removal.

The use of bioresorbable fixation devices must be limited as their mechanical strength is inferior as compared to the titanium hardware. They can be effectively used in low load-bearing areas of maxillofacial skeleton like maxilla, zygoma, and upper regions of face. The bioresorbable system may not be strong enough to provide adequate stability in mandible fractures which are comminuted, as it is a load-bearing bone. It can be used in simple mandibular fractures.

Bioresorbable fixation systems stabilize fracture segments long enough for fracture healing and union to occur then dissolve, thereby reducing complications frequently

encountered with metallic hardware such as palpability, visibility, cold sensitivity, and need for removal. Most commonly polylactic acid (PLA) is used in bioresorbable plates.

Complications [28]

1. For allowing the polymer chains to bend without breaking, a heat source is required. Also, the working time is limited to 8–10 s.
2. Screw insertion requires pretapping the screw.
3. Increased operative time.
4. More expensive.
5. PLA decreases stress shielding compared to LD-DC plates.

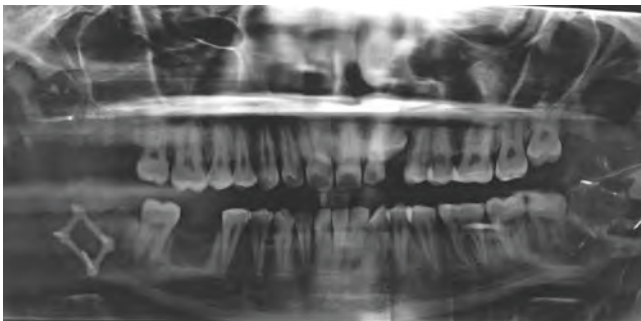
51.8 Recent Developments

To reduce the stress shielding, reduction in modulus is the answer to correct the disadvantages of internal fixation. To improve the healing of the fracture under the plates, the only solution is to allow micromotion through the fracture site; the design should be made in such a way that it resists torsional, bending, and shear movements.

51.8.1 Three-Dimensional (3D) Plates

(Fig. 51.13)

The two miniplates are connected by interconnecting cross-bars which are used as 3D plates. Technically, they are not three-dimensional structures, but their closed quadrilateral shape provides stability in all three dimensions.



©Association of Oral and Maxillofacial Surgeons of India

Fig. 51.13 Orthopantomogram showing fixation with three-dimensional plate

51.8.2 Virtual Surgical Planning, Computer-Assisted Design, and 3D Modelling

The management of the facial fracture is very challenging due to its unique three-dimensional contours and nonlinearity of facial skeleton. The recent development in the software technology and 3D modeling has revolutionized the treatment. They can be used as an adjunct to the standard preoperative preparation.

To reduce the operating time in the operation theater, the 3D models can serve as a template on which pre contouring of the fixation plates can be done. Custom-designed titanium implants can be made with the help of 3D printers to get the accurate fit. They can be preferred over the conventional implants and reduce the surgical time. The model design and virtual surgical planning help in constructing the guides which can be used perioperatively, can design the optimal approach preoperatively, and can compare the actual outcome to the virtual design. To reconstruct the multitude of craniomaxillofacial defects of mandible, zygoma, midface, and orbit, these technologies are very helpful. 3D modeling and computer-assisted surgical planning have been very helpful in managing the complications associated with these injuries.

51.8.3 Intraoperative Imaging [29]

Intraoperative imaging is very important in assessing the reduction and fixation of all maxillofacial fractures, and according to its feedback, the surgeons can immediately make corrections of any error that occur during reduction and fixation, which indirectly reduces the complications and avoids potential resurgeries. Computed tomography (CT) is commonly used for the same purpose.

51.9 Conclusion

For the treatment of maxillofacial fractures, many fixation methods have been used with great success. To reestablish the pre-injury esthetics, the normal masticatory function and the proper occlusion in cases of such fractures are the main objectives of the treatment. Maxillomandibular fixation can be done for the conservative management of such fractures which can be carried out with the help of arch bars, wiring, and cap splints and in edentulous patients by gunning splints. The open reduction and internal fixation can be carried out

with the help of miniplates, microplates, 3D plates, and reconstruction plates. Different plating systems and wiring techniques make the management of these maxillofacial fractures predictable with high success rate.

Acknowledgment Author wishes to thank Dr. Anshul Rai for providing Figs. 51.6, 51.7, 51.11, and 51.13.

References

- Uhtoff HK, Poitras P, Backman DS. Internal plate fixation of fracture: short history and recent developments. *J Orthop Sci.* 2006;11:118–26.
- Fonseca RJ, Walker RV, Barber HD, Powers M, Frost DE. *Oral and maxillofacial trauma.* China: Saunders; 2013.
- Ehrenfeld M, Manson PN, Prein J, AOCMF. *Principles of internal fixations of craniomaxillofacial skeleton, trauma, & orthognathic surgery.* Basel: Thieme; 2012.
- Rowe NL, William JL. *Maxillofacial injuries.* 1st edn. New York: Churchill Livingstone. ISBN: 978-81-312-1840-2.
- Rudderrnan RH, Mullen RL. *Biomechanics of the facial skeleton.* *Clin Plast Surg.* 1992;19:11.
- Greenberg AM, Prein J. *Craniomaxillofacial reconstructive and corrective bone surgery. Principles of internal fixation using the AO/ASIF technique.* New York: Springer. p. 101–3.
- Allgöwer M, Spiegel PG. Internal fixation of fractures: evolution of concepts. *Clin Orthop.* 1979;138:26–9.
- Uhtoff HK, Poitras P, Backman DS. Internal plate fixation of fractures: short history and recent developments. *J Orthop Sci.* 2006;11:118–26.
- Egol KA, Kubiak EN, Fulkerson E, Kummer FJ, Koval KJ. *Biomechanics of locked plates and screws.* *J Orthop Trauma* 2004;18:488–93.
- Herford AS, Ellis E. Use of a locking reconstruction bone plate/screw system for mandibular surgery. *J Oral Maxillofac Surg.* 1998;56:1261.
- Klotch DW, Gal TJ, Gal RL. Assessment of plate use for mandibular reconstruction: Has changing technology made a difference? *Otolaryngol Head Neck Surg.* 1999;121:388.
- Coletti DP, et al. Comparative analysis of the threaded and tapered locking reconstruction plates. *J Oral Maxillofac Surg.* 2007;65:2587–93.
- Spiessl B. Rigid internal fixation of fractures of lower jaw. *Reconstr Surg Traumatol.* 1972;13:124–40.
- Scolozzi P, Richter M. Treatment of severe mandibular fractures using AO reconstruction plates. *J Oral Maxillofac Surg.* 2003;61:458–61.
- Waris P. Torsional strength of cortical and cancellous bone grafts after rigid plate fixation. *Acta Orthop Scand.* 1981;52:249.
- Bansal P, Kumar S, Mishra V, Jaiswal Y, Das G. Evaluation of titanium lag screw osteosynthesis in the management of mandibular fractures. *World J Dent.* 2017;8(4):315–20.
- Emam HA, Stevens MR. Can an arch bar replace a second lag screw in management of anterior mandibular fractures? *J Oral Maxillofac Surg.* 2012;70(2):378–83.
- Ellis E. Is lag screw fixation superior to plate fixation to treat fracture of mandibular symphysis? *3rd J Oral Maxillofac Surg.* 2012;70(4):875–82.
- Schaaf H, et al. Comparison of miniplate versus lag screw osteosynthesis for fractures of mandibular angle. *Oral Surg Oral Med Oral Pathol Oral Radiol Endod.* 2011;111(1):34–40.
- Sugiura T, et al. A comparative evaluation of osteosynthesis with lag screws, miniplates, or Kirschner wires for mandibular condylar process fractures. *J Oral Maxillofac Surg.* 2001;59(10):1161–8, 1169–70.
- Michelet FX, Deymes J, Dessus B. Osteosynthesis with miniaturized screwed plates in maxillo-facial surgery. *J Maxillofac Surg.* 1973;1(2):79–84.
- You Z-H, et al. Biomechanical properties of small bone screws. *J Oral Maxillofac Surg.* 1994;52:1293–302.
- Champy M, Lodde JP, Schmitt R, et al. Mandibular osteosynthesis by miniature screwed plates via the buccal approach. *J Maxillofac Surg.* 1978;6:14.
- Baumgart FW, Cordey J, Morikawa K, et al. AO/ASIF self-tapping screws (STS). *Injury.* 24 (suppl 1):S1.
- Heidemann W, Gerlach KL, Gröbel KH, et al. Drill free screws: A new form of osteosynthesis screw. *J Craniomaxillofac Surg.* 1998;26:163.
- Chung H-IJ, et al. Postoperative stability after sagittal split ramus osteotomies for a mandibular setback with monocortical plate fixation or bicortical screw fixation. *J Oral Maxillofac Surg.* 2008;66:446–52.
- Yaramchuk MJ, Gruss JS, Manson PN. Rigid fixation of the craniomaxillofacial skeleton: Part II: Implant system for rigid fixation of craniomaxillofacial skeleton.
- Cutright DE, Hunsuck EG. The repair of fractures of orbital floor using biodegradable polylactic acid. *Oral Surg.* 1972;33:28–34.
- Meaike JD, Hollier LH. Updates in facial fracture management. *J Trauma Treat.* 2015;4:4

Open Access This chapter is licensed under the terms of the Creative Commons Attribution 4.0 International License (<http://creativecommons.org/licenses/by/4.0/>), which permits use, sharing, adaptation, distribution and reproduction in any medium or format, as long as you give appropriate credit to the original author(s) and the source, provide a link to the Creative Commons license and indicate if changes were made.

The images or other third party material in this chapter are included in the chapter's Creative Commons license, unless indicated otherwise in a credit line to the material. If material is not included in the chapter's Creative Commons license and your intended use is not permitted by statutory regulation or exceeds the permitted use, you will need to obtain permission directly from the copyright holder.



Anshul Rai

52.1 Definition

A fracture is defined as “A breach in the continuity of bone.”

52.2 Introduction

The mandible which is the only mobile bone of the maxillofacial region forms the lower third of the face. Owing to the prominence of the symphysis of the mandible, it is most vulnerable site to be traumatized during the road traffic accidents and, at the same time, most tempting site to be hit during the assault. Thus, the fractures of the mandible are one of the most common in maxillofacial area. It also affects the social life of the patients (Box 52.1).

The word “mandible” derives from the Latin word *mandere* “to chew” and *-bula* (instrument) which literally translates to *mandibulae* “instrument used for chewing.”

The bone is formed in the fetus from a fusion of the left and right mandibular prominences and the point where these sides join, the mandibular symphysis. Like other symphysis in the body, this is a midline articulation where the bones are joined by fibrocartilage, but this articulation fuses together in early childhood.

Box 52.1: General Effect of Mandible Fracture on Social Life [1]

1. Absence from work.
2. Hospital and ICU stay results in separation from family members and friends.
3. Financial loss.
4. Difficulty in feeding.
5. Weight loss (average 5% of total body weight).
6. Increased mental stress.
7. Delayed recovery in medically compromised and mentally challenged patients.

52.3 Surgical Anatomy

The mandible is a horseshoe-shaped only mobile bone of the facial skeleton. It is the strongest bone with thick cortices. Symphysis is the most prominent part of mandible, and the condyles articulate with glenoid fossa of temporal bone. The inferior alveolar neurovascular bundle passes through the bone, and in the case of fracture, it may get traumatized and can lead to hematoma and neurological deficit.

52.3.1 Angle of the Mandible

By definition, there are three types of angle as described below:

1. **Clinical angle:** It is the junction between the alveolar bone and ramus at the origin of internal oblique ridge.
2. **Surgical angle:** It is the junction between body of the mandible and ramus at the origin of the external oblique ridge.
3. **Anatomical angle or (gonion):** It is the junction where the lower border meets the posterior border of ramus.

Electronic Supplementary Material The online version of this chapter (https://doi.org/10.1007/978-981-15-1346-6_52) contains supplementary material, which is available to authorized users.

A. Rai (✉)
 Department of Dentistry, All India Institute of Medical Sciences,
 Bhopal, Madhya Pradesh, India
 e-mail: anshul.dentalsurgery@aiimsbhopal.edu.in

Anatomically, mandibular angle is a weaker structure compared to other anatomic subsites.

- The ramus of the mandible is thin as compared to the body. Whenever a thick portion of the bone unites with the thin portion, it constitutes a line of weakness.
- Further the third molars are located in the angle region, and when they are impacted, they occupy lot of space in the bone and undermine it.
- In the case of mesio-angular impaction, the impacted third molar tooth acts as a wedge and predisposes the fracture of angle of mandible, if the direction of force is perpendicular to it.
- The bone grains which are oriented vertically in the ramus change their course at the angle of mandible as they enter the body of mandible. This abrupt change in the course of the bone grains also makes the bone weak. All these factors make the mandible vulnerable for fracture at this site.

52.3.2 Canine Region of the Mandible

In the canine area, also the mandible is weaker as the canine has the longest and the strongest root, and it occupies lot of space in the bone and undermines and weakens it. Thus, the mandible has a tendency to fracture at this site.

52.3.3 Symphysis and Parasymphysis of Mandible

- The symphyseal area is most prominent and most vulnerable to trauma. There is a compression of the outer cortex and expansion of the inner cortex, and the fracture will result when the forces are beyond the limits of the capacity of the bone to withstand them.
- There is a pair of genial tubercles on the lingual cortical plate in the midline, situated supero-inferiorly, which give origin to the genioglossus and geniohyoid muscles, respectively. Whenever there is a bilateral fracture at the parasymphysis area, the tongue tends to lose its anchorage on the bone, and the patient loses control and the tongue tends to fall back. It is especially true for the unconscious patient, where the tongue fall blocks the airway, and it could be fatal if not prevented.

52.4 Classification

The general classification of fractures of bone is described in Table 52.1.

Table 52.1 General classification of fracture of bone

Simple fracture	This type of fracture is not exposed to the external environment as the overlying soft tissue cover is intact
Compound fracture	In such type of fractures, the fracture line is exposed to the external environment. All dentate fractures are compound fracture as they communicate with the oral cavity
Comminuted fracture	Comminuted fractures have multiple fracture lines and more than two bony fragments
Simple comminuted fracture	It is a comminuted fracture not exposed to the external environment
Compound comminuted fracture	This type of fracture is a comminuted one which is exposed to the external environment
Complicated fracture	This fracture involves vital structures like adjacent nerves, vessels, or joint, directly or indirectly
Impacted fracture	The fractured fragments inter-digitate to an extent that there is no appreciable clinical movement. Such a fracture is unusual in the mandible and is commonly seen in the maxilla
Greenstick fracture	It is an incomplete fracture presenting as cortical bending rather than breaking. It is commonly seen in children as their bones are more elastic in nature. This elasticity allows the bone to bend. This type of fracture is commonly seen in long bones and mandibular condyle of children
Pathological fracture	This fracture occurs readily with minimal trauma or sometimes even during normal physiological function as the bone is significantly weak due to existing undermining pathology

52.4.1 Classification of Mandibular Fracture According to Site (Fig. 52.1)

Figure 52.1 highlights the mandibular fracture according to site of fracture with its incidence [2].

52.4.2 Classification of Mandibular Fracture According to the Impact

According to the impact on bone, fracture can be classified as direct fracture and indirect fracture.

During an impact, the force on the cortex results in compression, and the other cortex undergoes tension. If the force of the impact is more than the compressive and tensile strength of the bone, the bone fractures.

In a similar fashion, when there is an impact, the point of application of force gets compressed, and the resultant vector travels along the bone and applies tensor force on the point intersected by this vector. The fracture at the site of impact is called **direct fracture**, and the fracture at the site of intersection with the vector is **indirect fracture**.

For instance, the force applied to the symphysis menti results in a direct fracture at the symphysis. The vector travels to the condylar necks bilaterally and induce indirect fractures

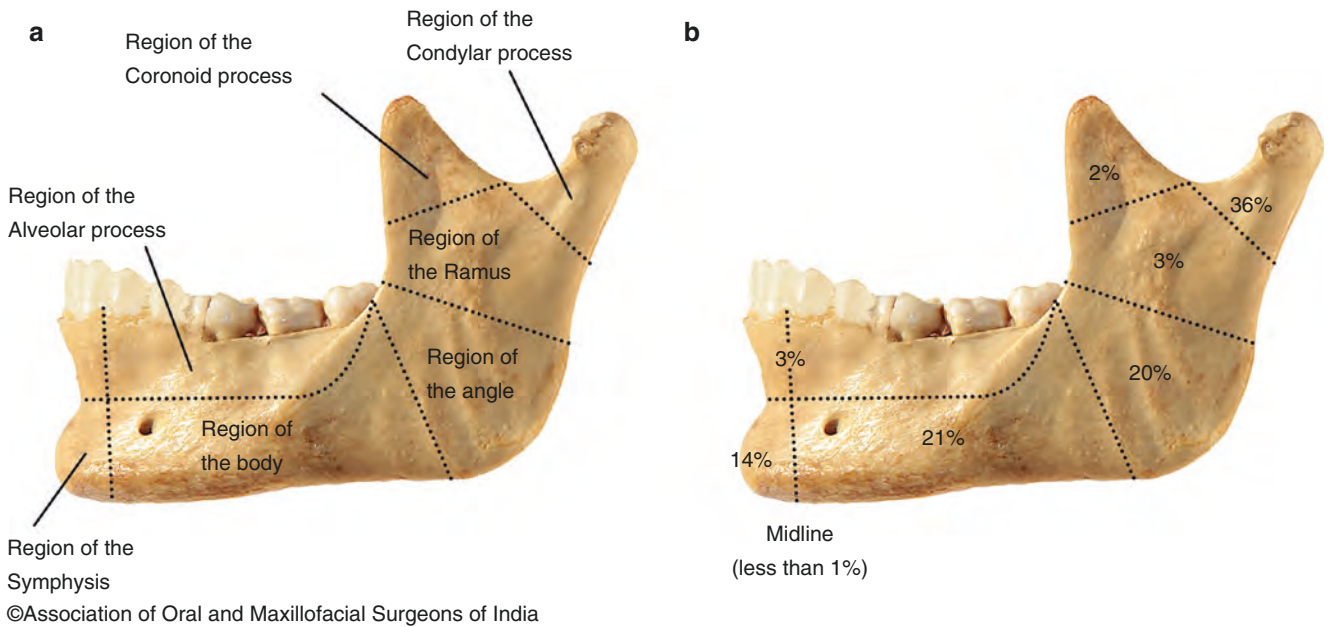
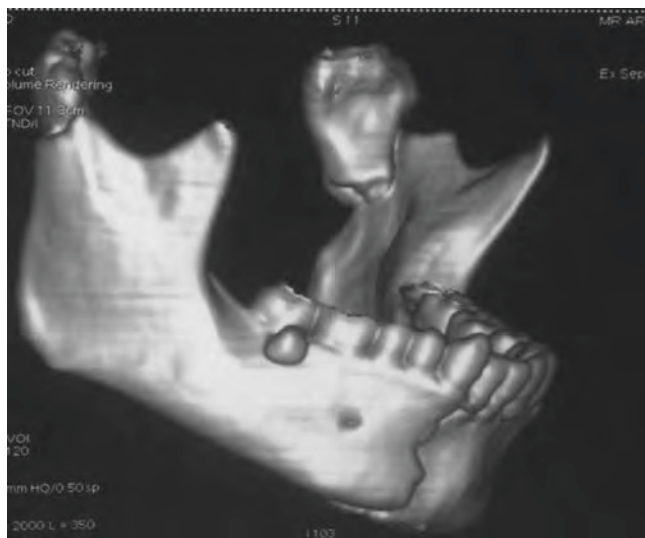

Fig. 52.1 (a, b) Highlights the mandibular fracture according to site of fracture with its incidence



©Association of Oral and Maxillofacial Surgeons of India

Fig. 52.2 3D CT showing parasymphysis and bilateral condyle fracture

Table 52.2 Combination of mandibular fractures

Direct fracture	Indirect fracture
Symphysis fracture	Bilateral subcondylar fracture
Parasymphysis fracture	Contralateral subcondylar fracture
Body fracture	Contralateral angle fracture

of subcondylar areas bilaterally, as the condylar necks are weak. This is called a “tripod fracture” (as the fracture is at 3 points) or “parade ground fracture” or “guardsman’s fracture.” The later terms are used because these fractures are commonly seen among soldiers who stand upright on the parade ground for a long time. When they faint, they fall on their chin resulting in symphysis and bilateral condylar neck fractures.

52.4.3 Combination of Fracture

The most common mandible fracture seen in the developed countries is angle fracture combined with contralateral body or symphysis of the mandible [3]. Table 52.2 and Figs. 52.2, 52.3, and 52.4 highlight various combinations of direct and indirect fractures in the mandible.

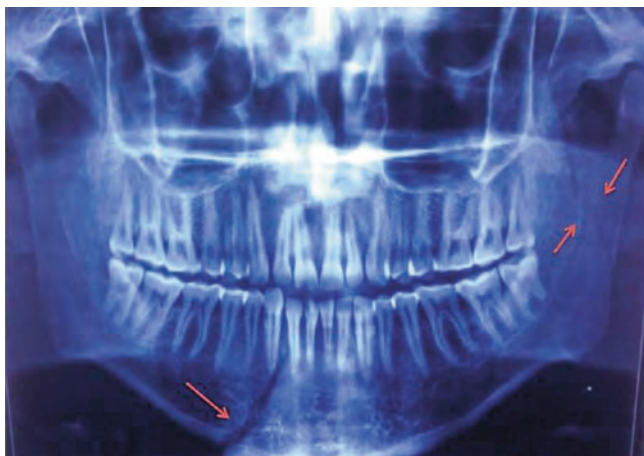
52.4.4 Classification of Mandibular Fracture According to Displacement

The fracture fragments are liable to displacement according to unfavorable muscle pull leading to difficulty in the management of these displaced fractures. Table 52.3 highlights various muscles attached to the mandible with their actions.

According to the displacement of fracture fragments due to muscle pull, the fracture can be classified as:

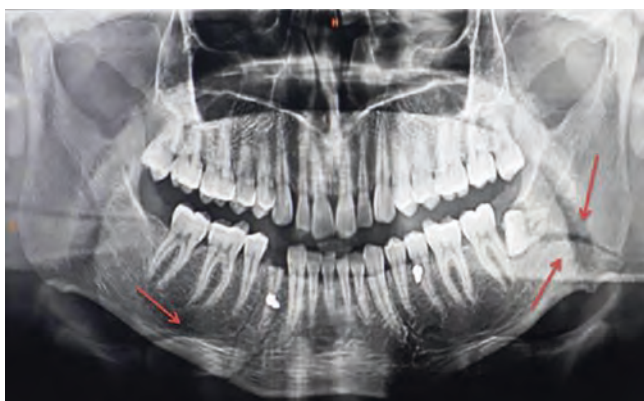When viewed from superior aspect:

1. Vertically favorable: When the fracture line is passing from buccal cortical plate to the lingual cortical plate with the buccal end lying mesially and the lingual end of the line lying distally. In such situation the distal fragment will be drawn closer to the proximal fragment due to the pull of the medial pterygoid muscle, and the fracture segments will come closer rather than getting separated in buccolingual plane, and thus the fracture is called as vertically favorable (Fig. 52.5a).
2. Vertically unfavorable: In this case, the fracture line passes buccolingually with the buccal end lying mesially. The distal fragment in this case will be easily viewed from superior border. The distal fragment in this case will easily get drifted



©Association of Oral and Maxillofacial Surgeons of India

Fig. 52.3 Showing right parasymphysis and left condyle fracture



©Association of Oral and Maxillofacial Surgeons of India

Fig. 52.4 Showing right body and left angle fracture

lingually due to the pull of the medial pterygoid muscle; thus there will be separation of the fragments in the buccolingual plane due to the unfavorable muscle pull, and the fracture is said to be vertically unfavorable (Fig. 52.5b).

When viewed from buccal aspect:

1. Horizontally favorable: The fracture line runs supero-inferiorly with its superior end lying posteriorly than its inferior end. In this situation, the muscle pulls from the temporalis, masseter muscle will pull the distal segment superiorly, and the suprahyoid muscles will put the proximal segment inferiorly, thus drawing both the segments closer to each other. This type of fracture is called as horizontally favorable fracture (Fig. 52.6a).
2. Horizontally unfavorable: The fracture line runs supero-inferiorly with its superior end lying anteriorly and the inferior end lying posteriorly; thus, the muscle pull becomes unfavorable and drifts the proximal and distal fracture segments apart. This is described as a horizontally unfavorable fracture (Fig. 52.6b).

Table 52.3 Muscle attachments over the mandible with their actions

Muscle	Action	Attachment
Masseter-medial pterygoid	Elevators of the mandible	Ramus of the mandible
Temporalis	Elevators of the mandible	Coronoid process of mandible
Lateral pterygoid	Depressors of the mandible, lateral movements	Pterygoid fovea
Suprahyoid muscles (digastricus, geniohyoid, mylohyoid)	Depressors of the mandible	Body and the genial tubercles

52.5 Clinical Features

The clinical features of the fractures are described in Table 52.4 (Figs. 52.7, 52.8, 52.9, 52.10, 52.11, 52.12, 52.13, and 52.14).

52.6 Clinical Examination

52.6.1 Bimanual Palpation

The abnormal mobility at the fracture site can be elicited by the bimanual palpation. The mandible is grasped on either side of the suspected fracture line in such a way that the index finger is on the occlusal surface of the teeth and the thumbs are on the inferior border. The proximal and distal segments are moved in supero-inferior and antero-posterior direction, to elicit abnormal mobility (Fig. 52.15).

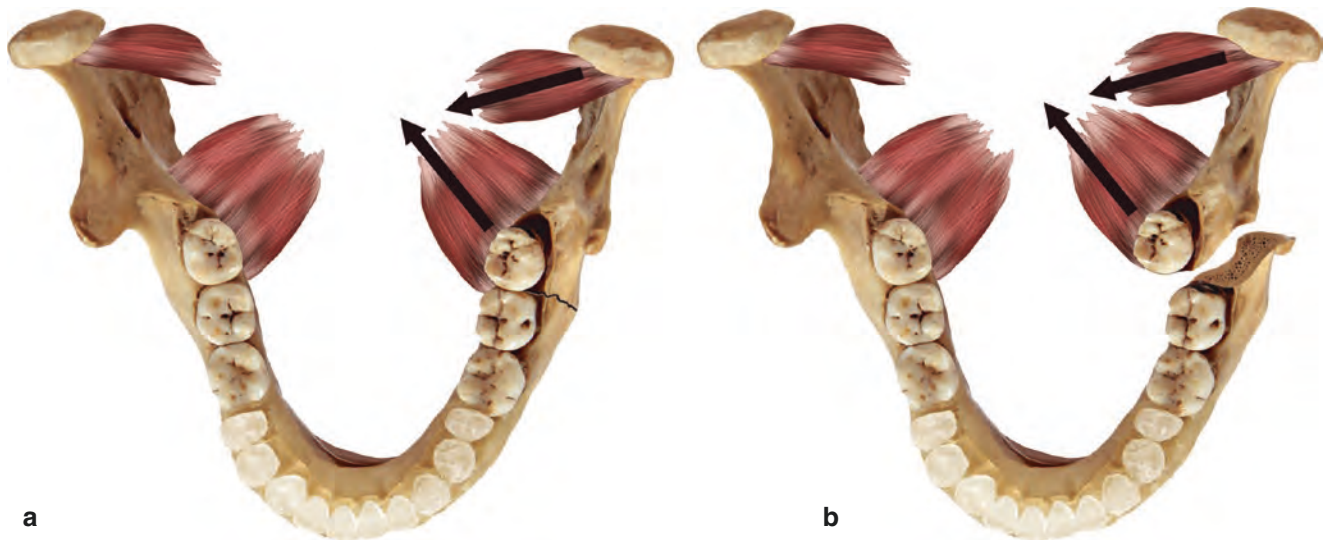
52.6.2 Compression Test

When there is a hairline, undisplaced fracture of the mandible especially at the symphysis or angle or in the subcondylar areas and it is not conspicuous clinically and radiologically, a compression of the mandible at the symphysis area and both the sides over the body, using both the palms by the operator, elicits tenderness which may suggest the fracture (Fig. 52.16a, b).

52.7 Radiographic Examination

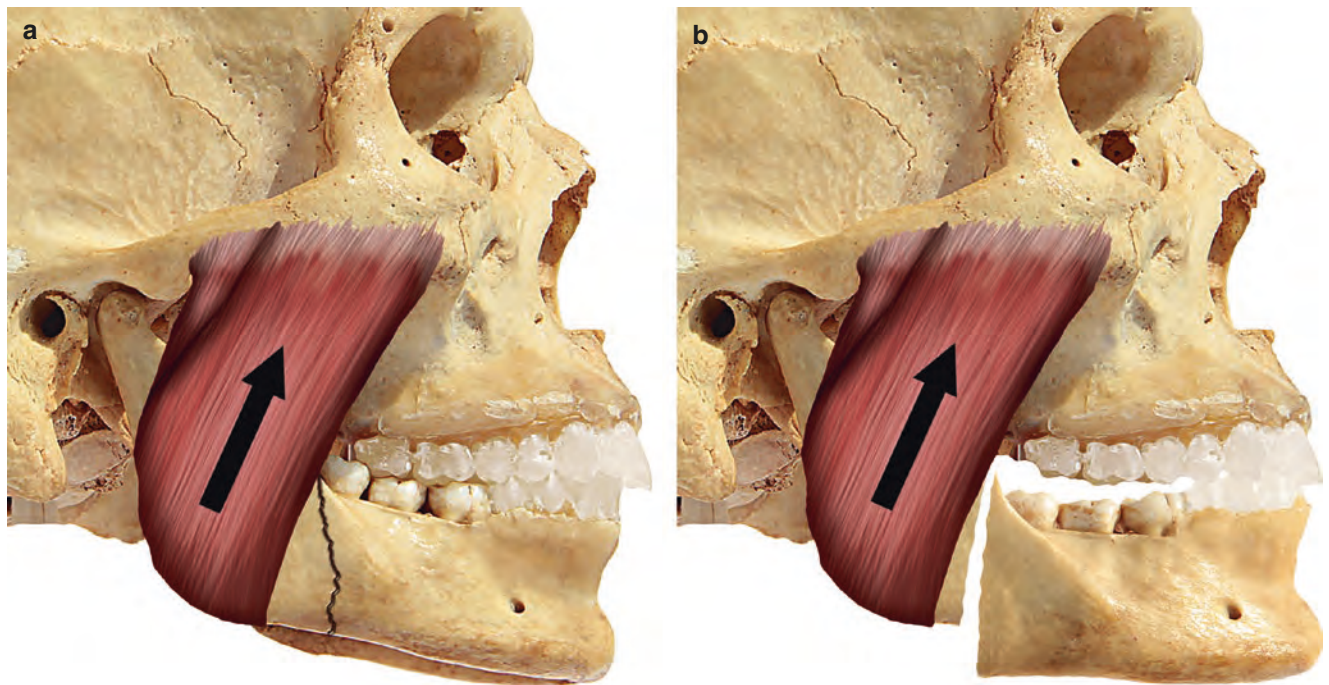
As a rule, in orthopedics, the X-ray must be taken in two planes perpendicular to each other, i.e., in the anteroposterior and mediolateral. The most common radiographs to detect fracture of the mandible are:

1. Orthopantomogram (OPG) (Fig. 52.17)
2. Postero-anterior view of the mandible (PA mandible) (Fig. 52.18)
3. Lateral oblique view is taken for body, angle, ramus, and subcondylar fractures.



©Association of Oral and Maxillofacial Surgeons of India

Fig. 52.5 (a) Vertically favorable. (b) Vertically unfavorable



©Association of Oral and Maxillofacial Surgeons of India

Fig. 52.6 (a) Horizontally favorable. (b) Horizontally unfavorable

4. Computed tomography (CT) scan (Fig. 52.19)

5. Digital visual tomography (DVT) (Fig. 52.20)

6. Cone beam computed tomography (CBCT) (Fig. 52.21)

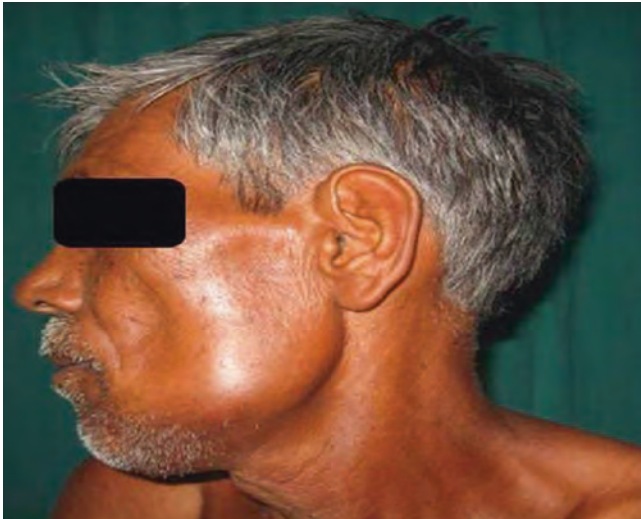– CT, DVT, and CBCT are the most commonly performed radiographs for the accurate diagnosis of mandibular fracture.

– Radiographs should not be advised unnecessary, and they should always be performed after clinical examination and after making provisional clinical diagnosis.

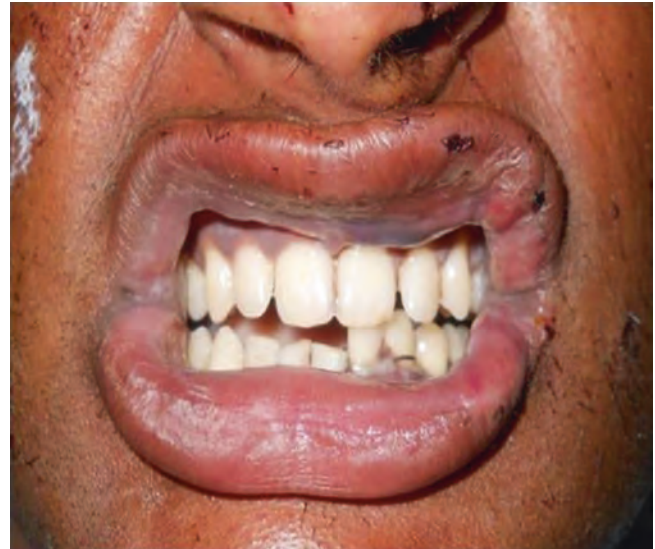– Surgeons should not depend on the radiologist's report for their diagnosis; radiographs should help in confirming the clinical diagnosis and for the medicolegal record-keeping purpose as much as possible.

Table 52.4 Clinical feature of mandibular fracture

General symptoms	Signs on inspection	Signs on palpation
Pain	Presence of hematoma (Fig. 52.9)	Crepitus over fracture site
Swelling (Fig. 52.7)	Facial asymmetry	Abnormal mobility across fracture site
Difficulty in opening mouth (Fig. 52.8)	Presence of abrasion, contusion, or laceration (Fig. 52.10)	Fracture/mobility/extrusion/intrusion/avulsion of teeth
Tenderness over fracture site	Discoloration of the skin/echymosis (Fig. 52.11)	Tenderness over fracture site
Inability to chew	Trismus due to protective myo-spasm	Intersegmental mobility on bimanual palpation
Inability to swallow	Limited excursive movements of mandible	Positive compression test
Bleeding from the ear/mouth	Visible step deformity in cases with displacement of fractured segments (Fig. 52.12)	
	Malocclusion (Fig. 52.13)	
	Sublingual hematoma (Fig. 52.14) Coleman's sign	
	Tongue fall back in bilateral anterior mandible fracture	



©Association of Oral and Maxillofacial Surgeons of India

Fig. 52.7 Swelling in angle region after fracture

©Association of Oral and Maxillofacial Surgeons of India

Fig. 52.8 Difficulty in mouth opening due to displacement and deviation of fracture

52.7.1 Are Postoperative Radiographs Necessary?

The answer is no. The reasons behind this is:

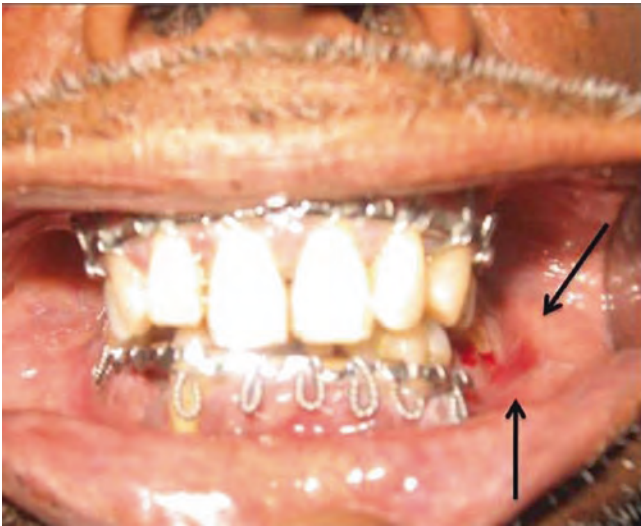
1. More than 100–250 deaths occur worldwide from cancer due to unnecessary radiation from diagnostic radiology as suggested by Royal College of Radiologists [4]
2. If somehow retreatment is required for the patient, it generally depends most commonly on the clinical findings rather than radiographic

However, the postoperative radiographs are required in few cases of:

- Mandibular fracture treated with closed reduction
- In medicolegal cases to prevent judicial complications [5]
- Patients who enrolled in the research activities

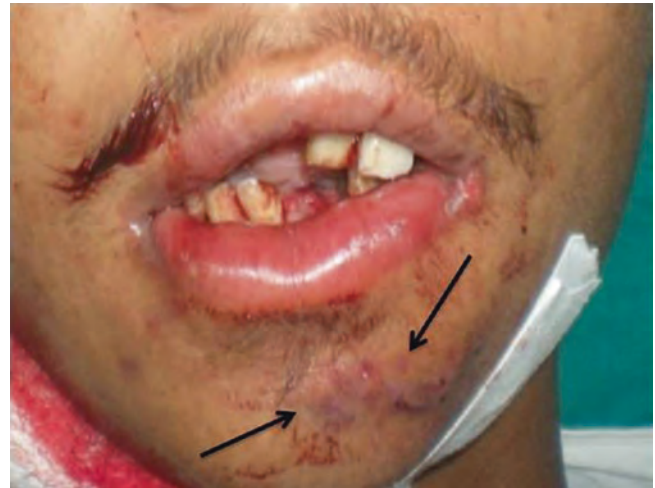Bergh van den et al. [6] also suggested that postoperative radiography is not necessary. The advantages of avoiding postoperative radiographs are:

1. Exposure reduction of patients to ionizing radiation
2. Reduced cost
3. More efficient discharge



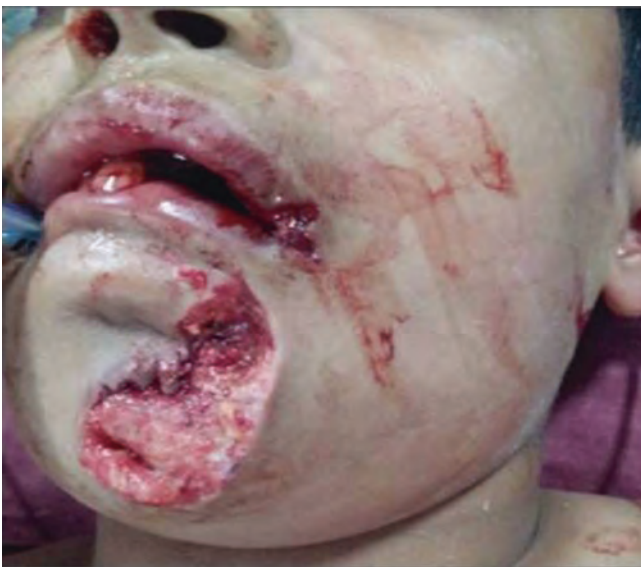©Association of Oral and Maxillofacial Surgeons of India

Fig. 52.9 Hematoma in the angle region



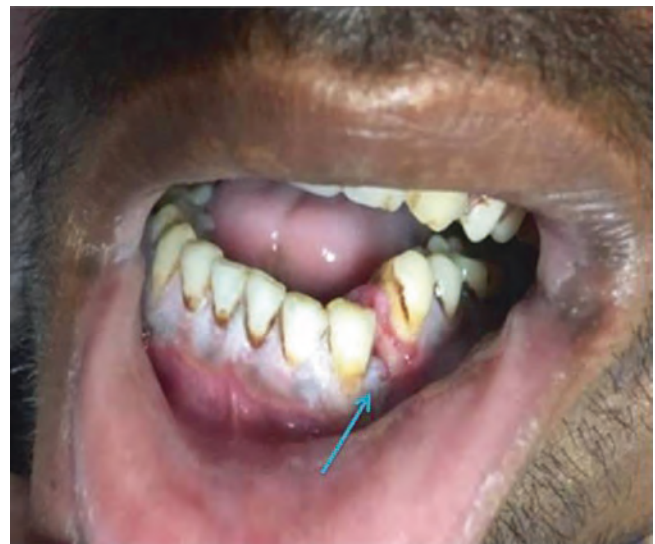©Association of Oral and Maxillofacial Surgeons of India

Fig. 52.11 Discoloration of skin



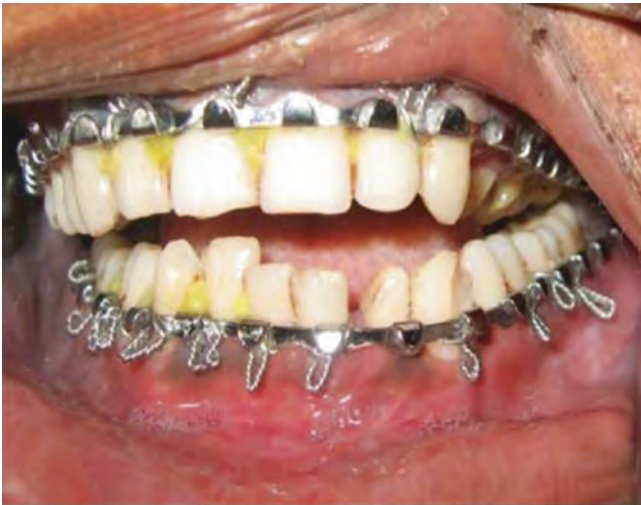©Association of Oral and Maxillofacial Surgeons of India

Fig. 52.10 Presence of abrasion, contusion, or laceration



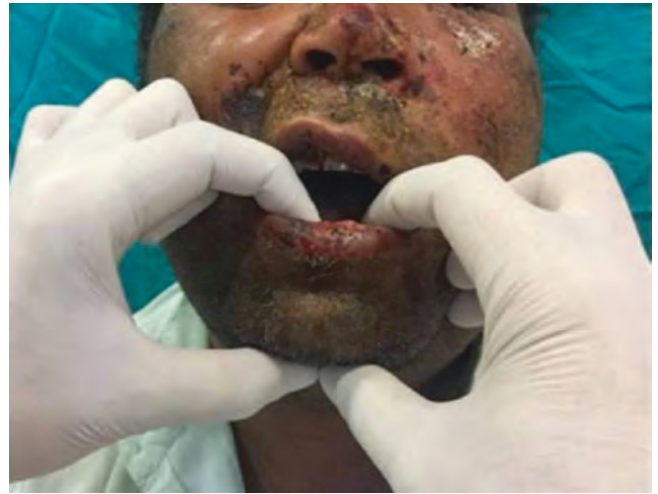©Association of Oral and Maxillofacial Surgeons of India

Fig. 52.12 Visible step deformity in cases with displacement of fractured segments



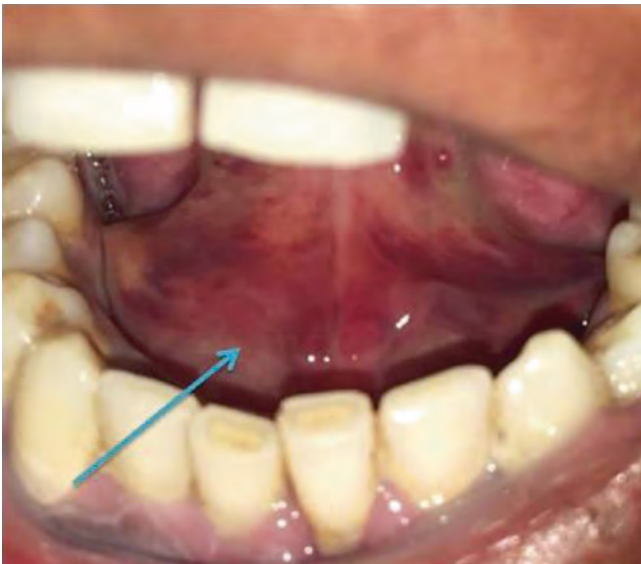
©Association of Oral and Maxillofacial Surgeons of India

Fig. 52.13 Malocclusion



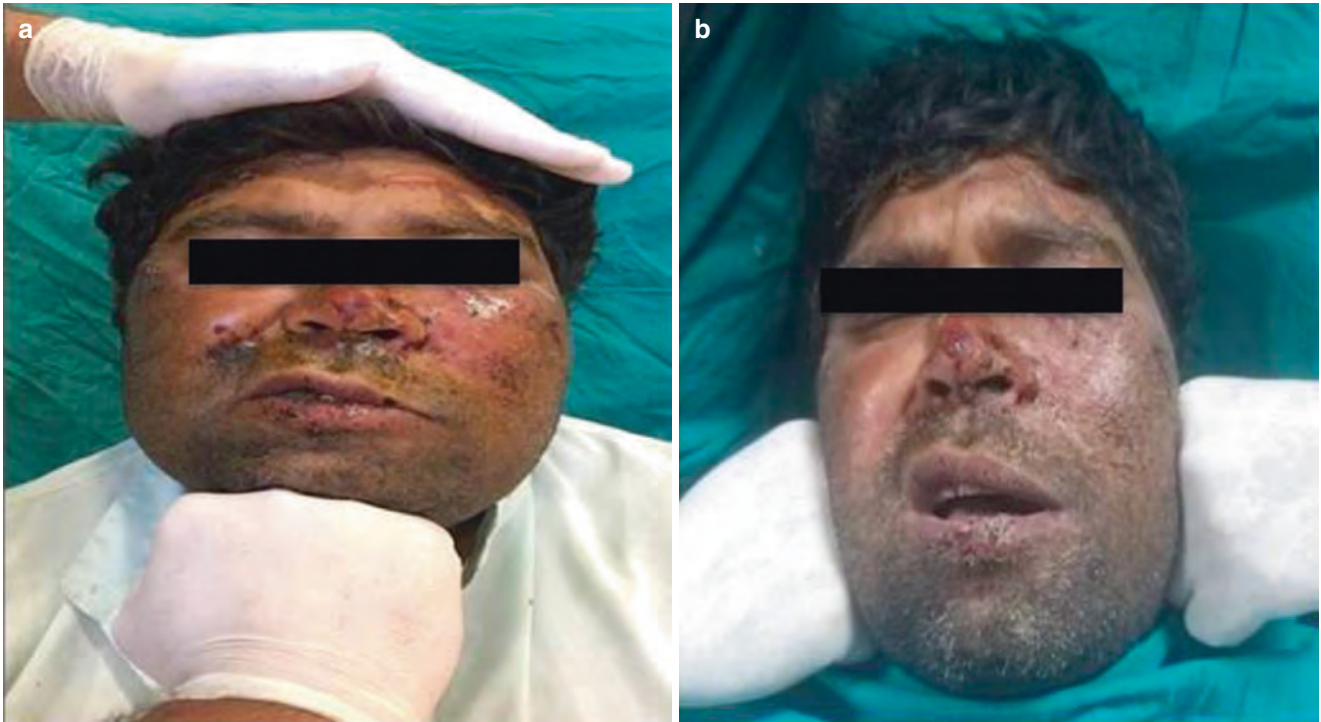©Association of Oral and Maxillofacial Surgeons of India

Fig. 52.15 Bimanual palpation



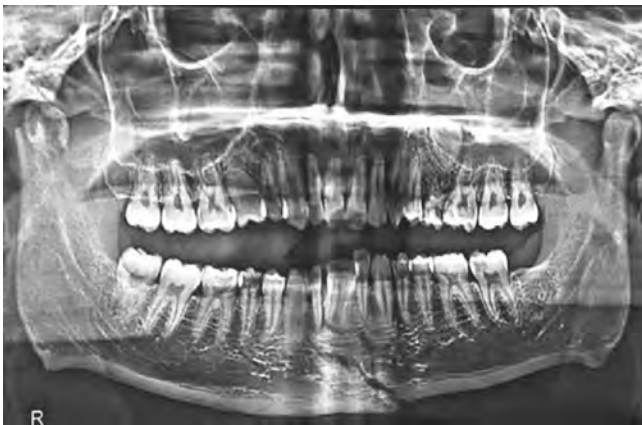©Association of Oral and Maxillofacial Surgeons of India

Fig. 52.14 Sublingual hematoma (Coleman's sign)



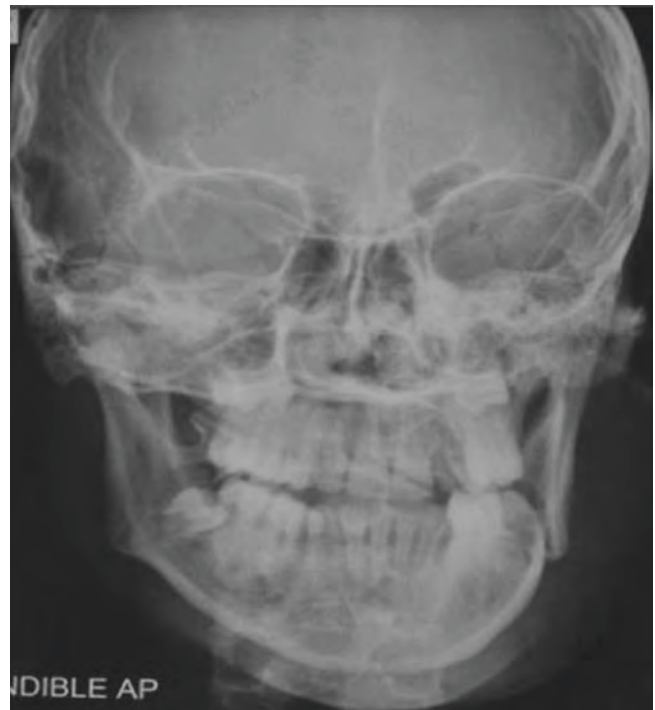©Association of Oral and Maxillofacial Surgeons of India

Fig. 52.16 (a, b) Vertical and horizontal compression test



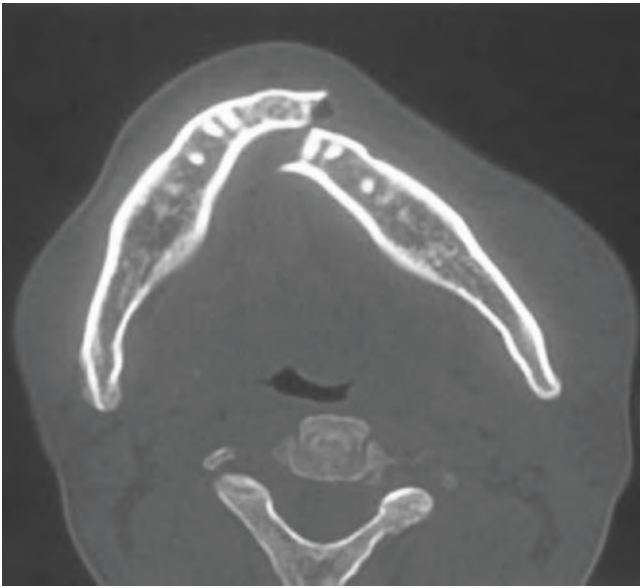
©Association of Oral and Maxillofacial Surgeons of India

Fig. 52.17 OPG demonstrating parasymphysis and contralateral condylar fracture



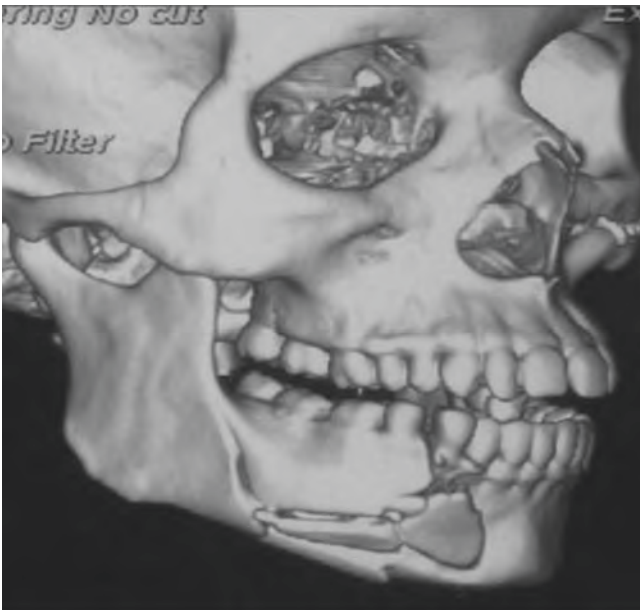
©Association of Oral and Maxillofacial Surgeons of India

Fig. 52.18 PA view mandible showing left mandibular angle fracture



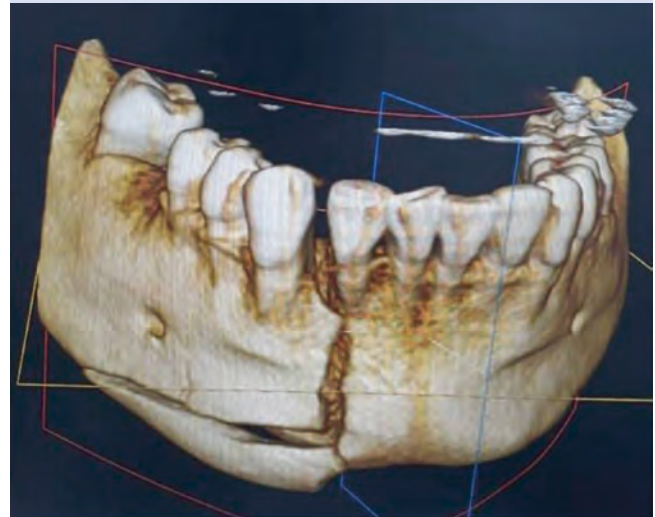
©Association of Oral and Maxillofacial Surgeons of India

Fig. 52.19 Computed tomography (CT) scan demonstrating displaced left para median fracture



©Association of Oral and Maxillofacial Surgeons of India

Fig. 52.20 Digital visual tomography (DVT) demonstrating comminuted right body fracture



©Association of Oral and Maxillofacial Surgeons of India

Fig. 52.21 Cone beam computed tomography (CBCT) demonstrating displaced right para median fracture mandible

52.8 Emergency Management (refer Chap. 48 of this book)

Once the basic Airway, breathing, circulation (ABC) in the emergency management has been secured, the suturing of the extra-/intraoral wounds and initial stabilization and immobilization of the fracture fragments are important. Box 52.2 shows advantages of immobilization of fracture fragments.

Initial stabilization and immobilization is done by:

1. Bridle wiring (refer Chap. 50 of this book)

It is a type of temporary stabilization and reduction of the fracture fragments of the dentate segment with the help of 24- or 26-gauge wires under local anesthesia.

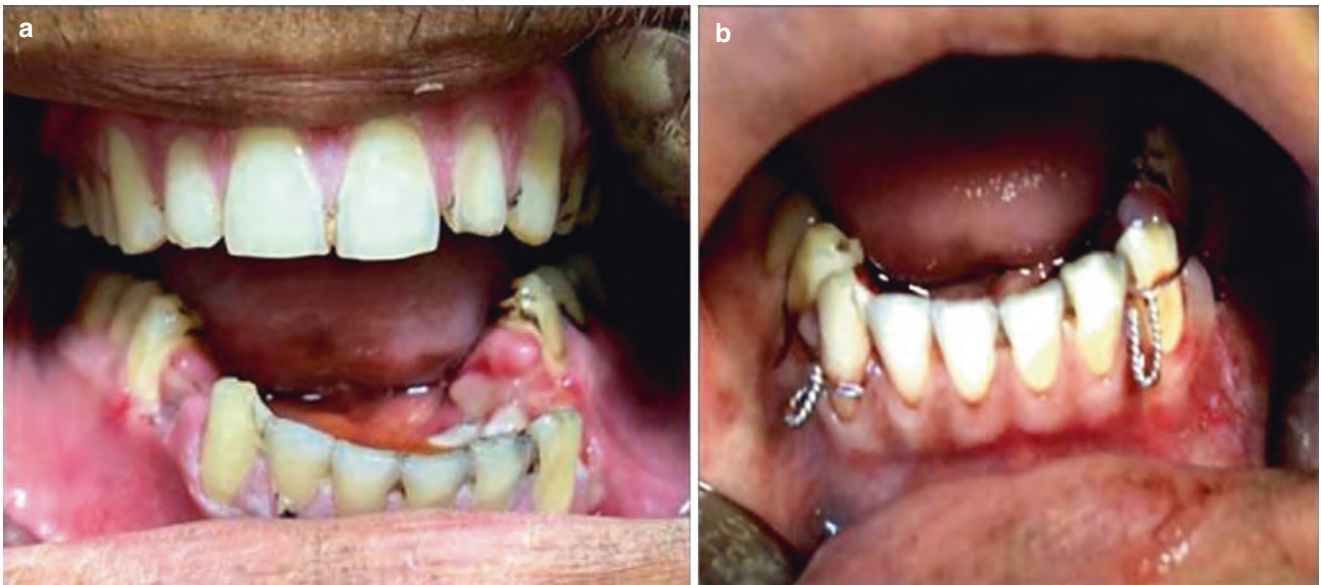
The wire should be wrapped around two healthy teeth adjacent to the fracture line; if the tooth adjacent to the fracture are mobile, the wire should be wrapped around the second tooth adjacent to the fracture (Fig. 52.22a, b).

2. Supportive bandage

These bandages are commonly used to temporarily stabilize the fracture of the lower jaw. Small crepe bandages can be used for mandible fracture.

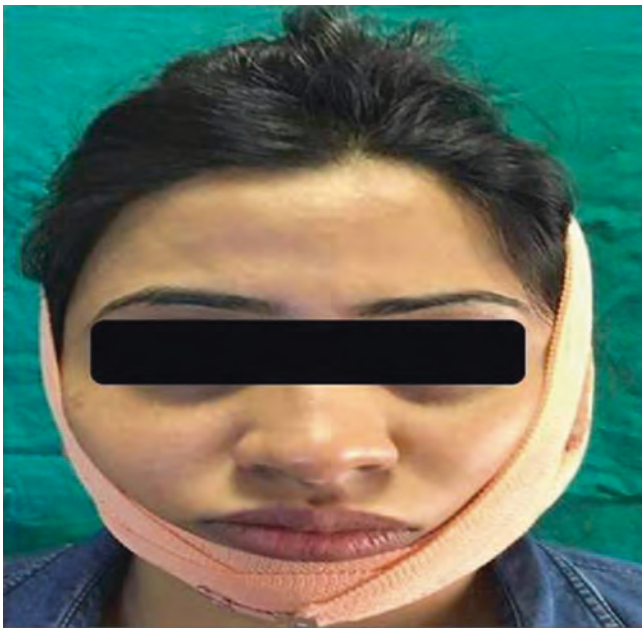(a) Barrel bandage (Fig. 52.23)

(b) Four-tailed bandage (Fig. 52.24)



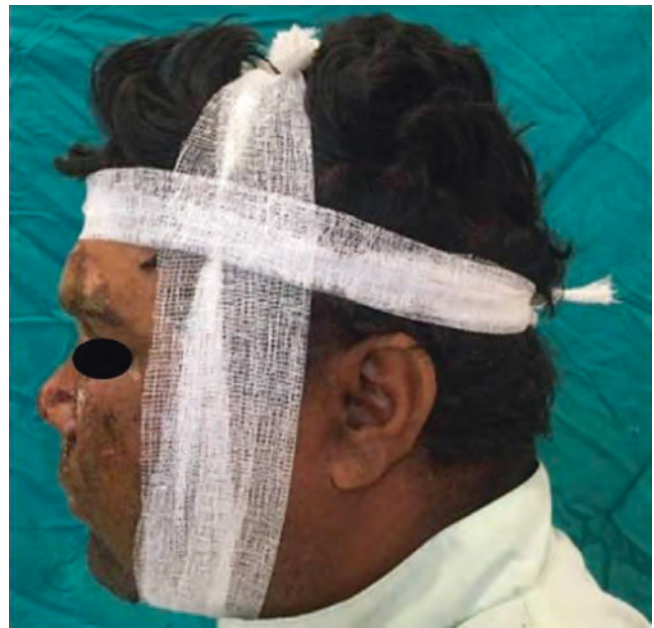©Association of Oral and Maxillofacial Surgeons of India

Fig. 52.22 (a, b) Temporary stabilization of a grossly displaced bilateral body fracture by bridling wiring



©Association of Oral and Maxillofacial Surgeons of India

Fig. 52.23 Barrel bandage



©Association of Oral and Maxillofacial Surgeons of India

Fig. 52.24 Four-tailed bandage

52.9 Goals of Treatment of Mandibular Fracture (Table 52.5)

52.10 Treatment Options for Different Sites

52.10.1 Closed Reduction (Table 52.6)

52.10.2 Clinical Tip

Wiring techniques required use of multiple wires. These wires cause inadvertent finger puncture to the operator's fingers and increases the risk of spread of blood-borne diseases like HIV and hepatitis. To avoid such complication, Rai [7] recommended the use of dynaplast adhesive tape over all fingertips before wearing sterile gloves while doing Maxillomandibular Fixation (MMF) (Fig. 52.25).

52.10.3 Open Reduction (Table 52.7)

52.10.4 Steps in Open Reduction Internal Fixation (ORIF) of Mandible Fracture

1. Incision (extra-/intraoral) (Fig. 52.26a, b).

Table 52.5 Treatment goals for mandibular fracture

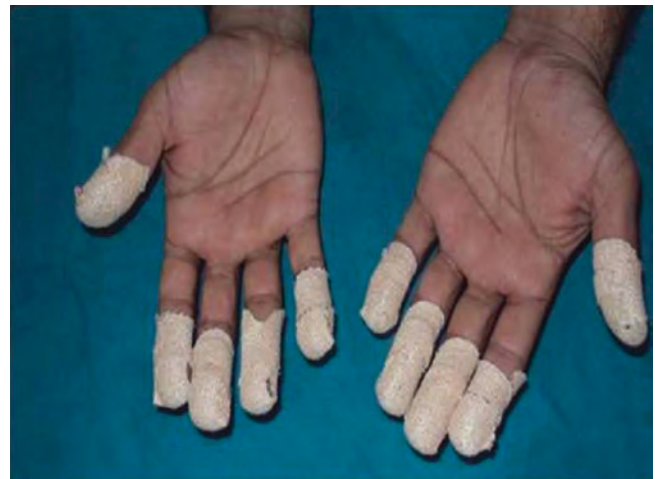1.	Anatomical restitution
2.	Immobilization
3.	Prevention of postoperative complications
4.	Rehabilitation of Functions

Table 52.6 Advantages and disadvantages of closed reduction

Advantages	Disadvantages
1. Day-care procedure, not require hospitalization	1. Restriction of mouth opening for minimum of 4 weeks
2. Cost-effective and safe	2. Patients can take only liquid diet
3. Avoid damage to the vital structures	3. Difficult to maintain oral hygiene
	4. Challenging in partially edentulous patients
	5. Weight loss
	6. Partial trismus for few weeks
	7. Contraindicated in asthmatic, in parkinsonism, mentally challenged patients

Table 52.7 Advantages and disadvantages of open reduction

Advantages	Disadvantages
1. Early return to function	1. Requires hospitalization
2. Exact anatomic reduction under direct visualization	2. Risk of general anesthesia
3. No need of MMF in most of the cases	3. Extra oral scarring
4. Less chances of postoperative complications	4. Risk of injuries to the vital structures
	5. Expensive to patients when compared to closed reduction



©Association of Oral and Maxillofacial Surgeons of India

Fig. 52.25 Finger protection before wiring

2. Exposure of the fracture site (Fig. 52.27).
3. Curettage to remove the granulation tissues and irrigation with normal saline.
4. Reduction of the fracture (with the help of bone-holding forceps) (Fig. 52.28a–c). Chin retractor is also helpful in reduction of fracture fragments (Fig. 52.29a, b).
5. Immobilization with MMF.
6. Fixation with plates and screws.
7. Closure of the incised site.
8. Pressure bandage over the surgical site to avoid postoperative hematoma formation in required cases (Fig. 52.30).

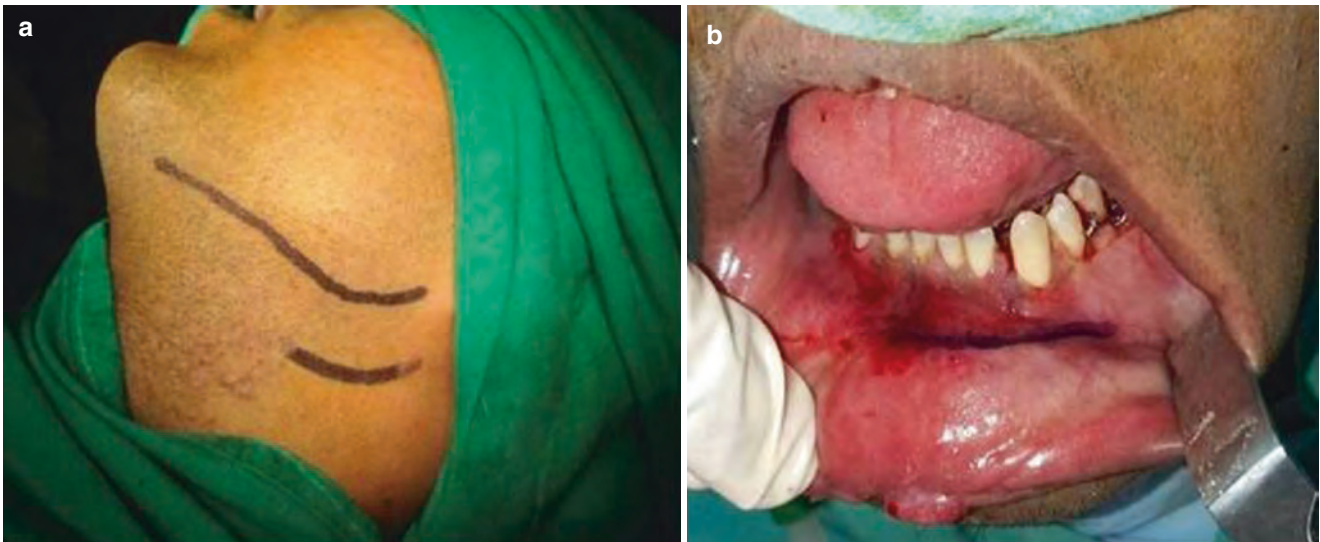
According to Dimitroulis [8] MMF is unnecessary in undisplaced angle fracture if there is a skilled assistant present to assist and help manually reduce the fracture fragments for plating. Author also believes that many undisplaced, single fracture of mandible can be fixed without MMF when two skilled surgeons operate the case.

52.10.5 Symphysis and Parasymphysis Fracture (Video 52.1)

Various internal fixation techniques were mentioned in the literature for both symphysis and parasymphysis fractures [9]. They are enumerated in Table 52.8.

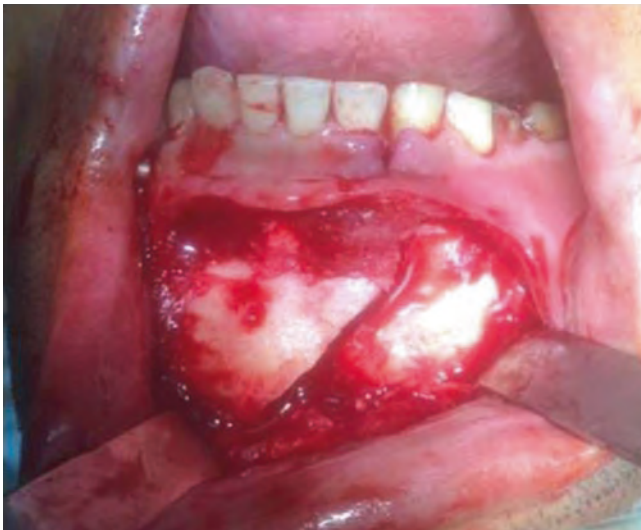Note: Readers has to refer Chap. 51 on plating systems to know the principles of osteosynthesis, tension banding, zone of compression/tension, etc.

Fixation with two miniplates is widely used for the fixation of symphysis and parasymphysis fractures (Fig. 52.31). Some authors preferred use of two lag screws (Fig. 52.32a, b) for the fixation of symphysis fractures, but their uses are less in comparison to two miniplates because they are technique sensitive. Three-dimensional plates require less manipulation and adaptation which indirectly reduce the operating time



©Association of Oral and Maxillofacial Surgeons of India

Fig. 52.26 (a, b) Extraoral sub mandibular incision and intraoral vestibular incision



©Association of Oral and Maxillofacial Surgeons of India

Fig. 52.27 Exposure of the fracture site (left paramedian mandible) via vestibular incision)

(Fig. 52.33), but use of it is questionable when fracture fragments are multiple even in isolated symphysis fractures.

Usually, an intraoral approach is preferred for management of symphysis and parasymphysis fractures. However, if an existing laceration or scar is present, it should be utilized for exposure of fractured segments and subsequent management (Fig. 52.34).

52.10.6 Parasymphysis Fracture

1. Mental nerve: The anatomic challenge in ORIF.
2. Plating should be done after the blunt dissection and retraction of the neurovascular bundle.

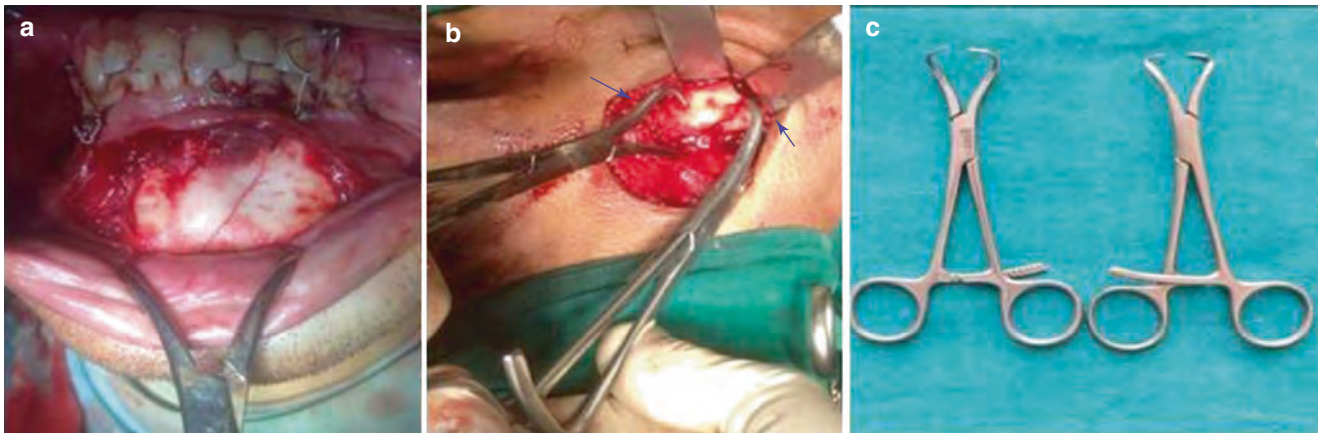
3. One miniplate above and another below the mental nerve used for fixation of parasymphysis fracture (Fig. 52.35).

52.10.7 Mandibular Angle

The prevalence of angle fractures ranges from 16.5 to 37 % in the literature. Presence of third molar (3M) increases the chance of angle fracture by 3.27 times, and class II-B positions of 3M are the most favorable for angle fracture, while class I-A act as protective factors [10].

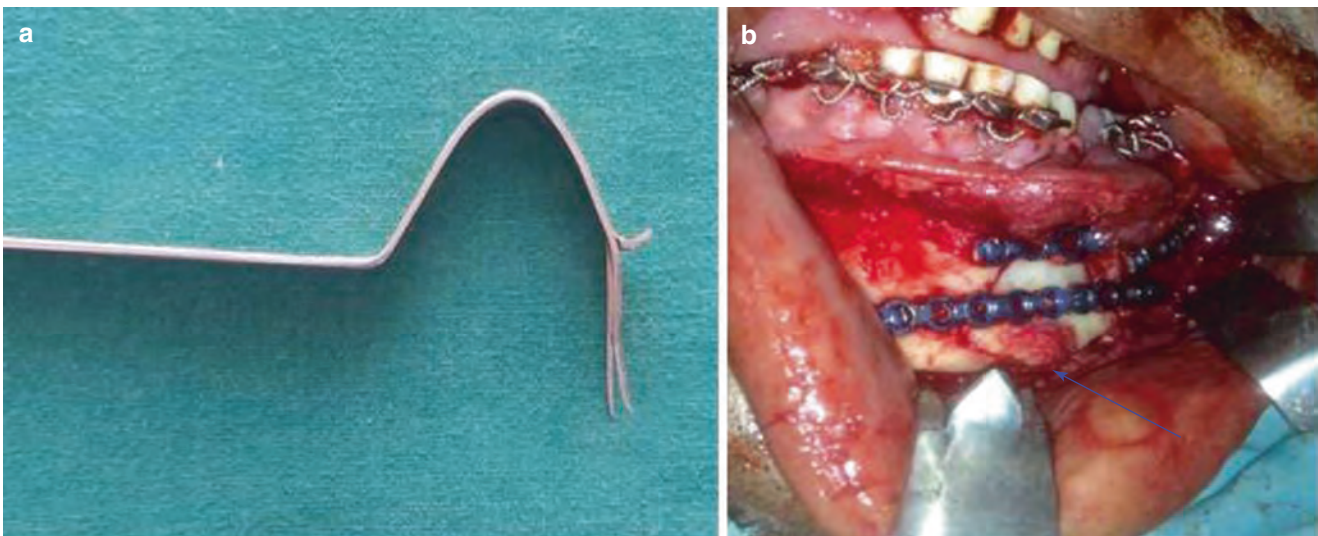
52.10.7.1 Impact of Presence or Absence of Impacted Mandibular Third Molar (IM3M) on Angle and Condylar Fracture

- Presence of IM3M generates a weak area in the mandibular angle and predisposes the angle region to fracture after injury; on the other hand, IM3M can decrease the occurrence of condylar fracture which is supposed to be the weakest area of mandible [11].
- Angle fracture is seen most commonly in patients having superficially impacted (vs deeply impacted) third molars (M3s) [12]. The reason behind this is that the mandibular strength is derived from maintenance of cortical and not the medullary bone integrity; this cortical integrity of the external ridge is disrupted by the presence of superficial impacted M3s which produce the point of weakness in the mandible and make it more prone to fractures [13].



©Association of Oral and Maxillofacial Surgeons of India

Fig. 52.28 (a–c) Reduction of the fracture (with the help of bone holding forceps)



©Association of Oral and Maxillofacial Surgeons of India

Fig. 52.29 (a, b) Use of chin retractor in reduction of fracture fragments

52.10.7.2 Open vs. Closed Reduction

Closed reduction is advisable for patients who are medically unfit for surgery (due to any reasons) or those who did not give consent for open reduction internal fixation (ORIF).

52.10.7.3 Approaches for ORIF

1. Intraoral (Fig. 52.36)
2. Extraoral (Fig. 52.26a)
3. Transbuccal (Fig. 52.37)

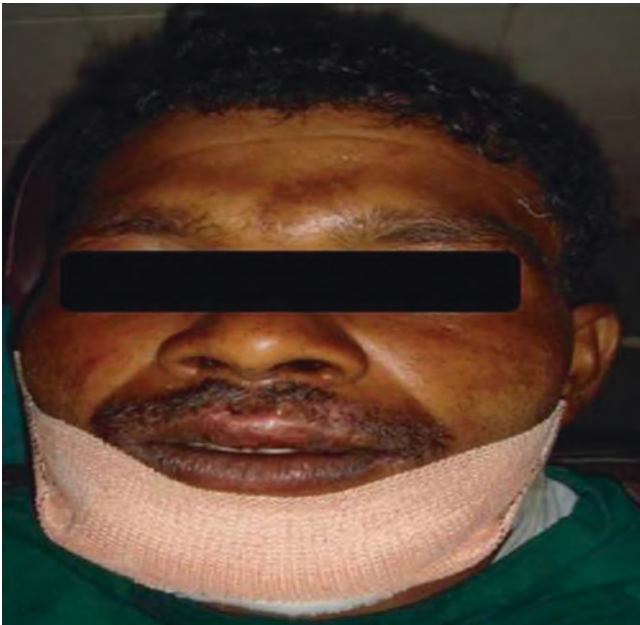Intraoral incision is advocated for ORIF with single mini-plate, but higher infection rate of 13% was reported in comparison with 2% when extraoral incision was used for plating. Marginal mandibular nerve showed weakness in 8% of cases,

and it sometimes has prominent extraoral scarring in patients treated with extraoral approach [14].

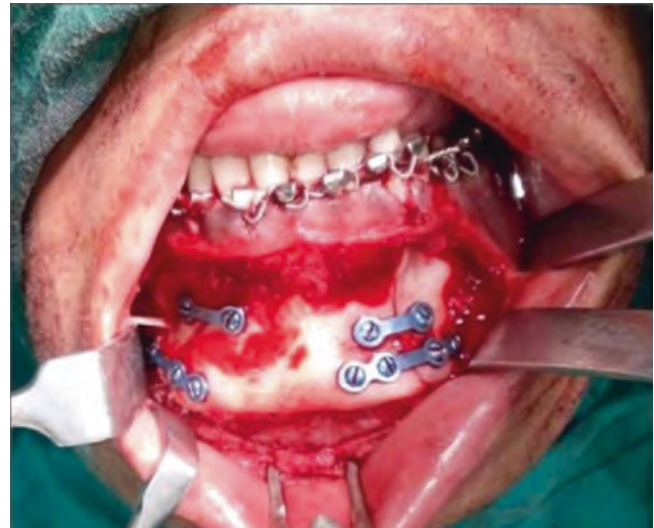Sugar [15] concluded that the combined use of transbuccal and intraoral approach is safe and effective than the intraoral approach alone for ORIF. Author too prefers the same approach.

52.10.7.4 Advantages of Transbuccal Approach [16]

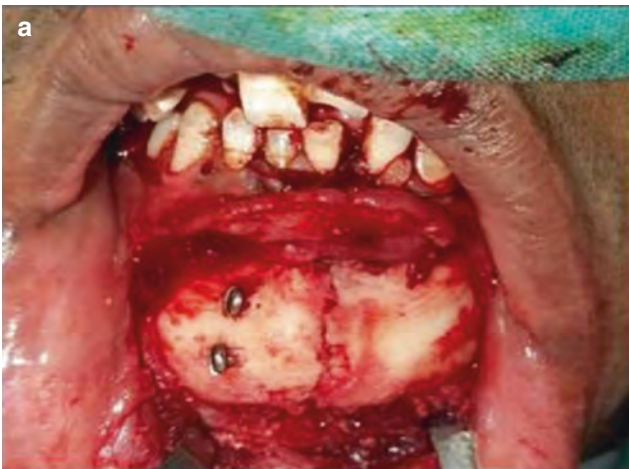1. Less operative time
2. Minimal scar formation
3. At the time of plating, direct visualization of the occlusion
4. Low risk of injury to facial nerve



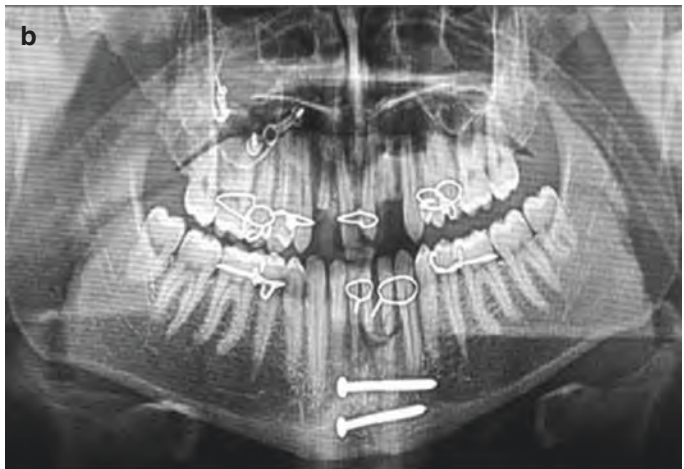
©Association of Oral and Maxillofacial Surgeons of India

Fig. 52.30 Application of pressure bandage

©Association of Oral and Maxillofacial Surgeons of India

Fig. 52.31 Fixation bilateral paramedian fracture mandible with 2 miniplates each on either side

©Association of Oral and Maxillofacial Surgeons of India

**Fig. 52.32** (a, b) Fixation left para median fracture mandible with lag screws**Position of Trocar Placement [17] (Fig. 52.37)**

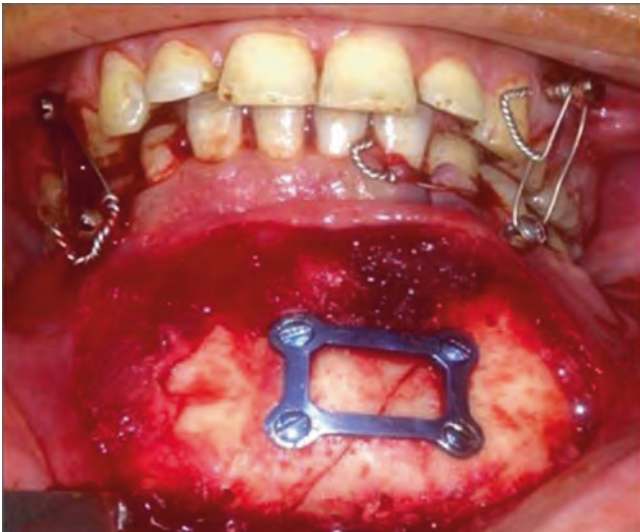
Gulses et al. described a safe zone to place the trocar in the form of a triangle created by drawing three lines on the face.

- Line 1: At the lower border of mandible (mandibular line)
- Line 2: Gonial-canthal line which ran from the gonion to the outer canthus of the eye
- Line 3: Trago-basal line which ran from tragus to the groove over the body of the mandible at infero-anterior angle of the masseter (at the point of entry of the facial artery over the body of the mandible)

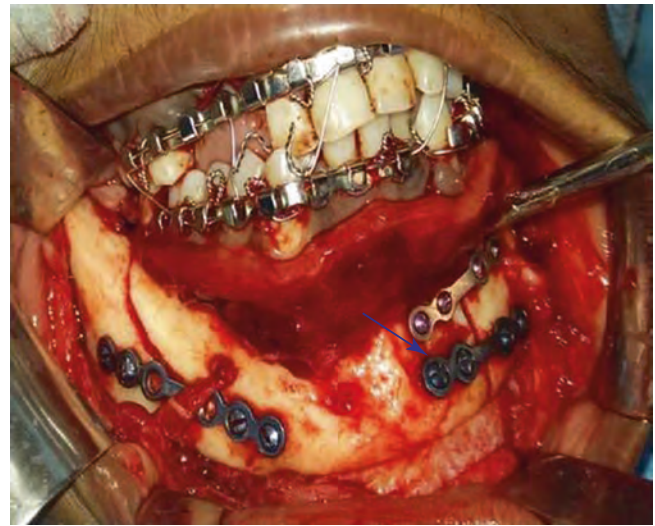
Table 52.8 Various fixation techniques for anterior mandibular fracture

1.	Reconstruction bone plates
2.	Single strong nonreconstruction bone plate
3.	Double miniplates
4.	Two lag screws
5.	Three-dimensional (3D) plate
6.	Segmental arch bar with single large and stronger bone plate

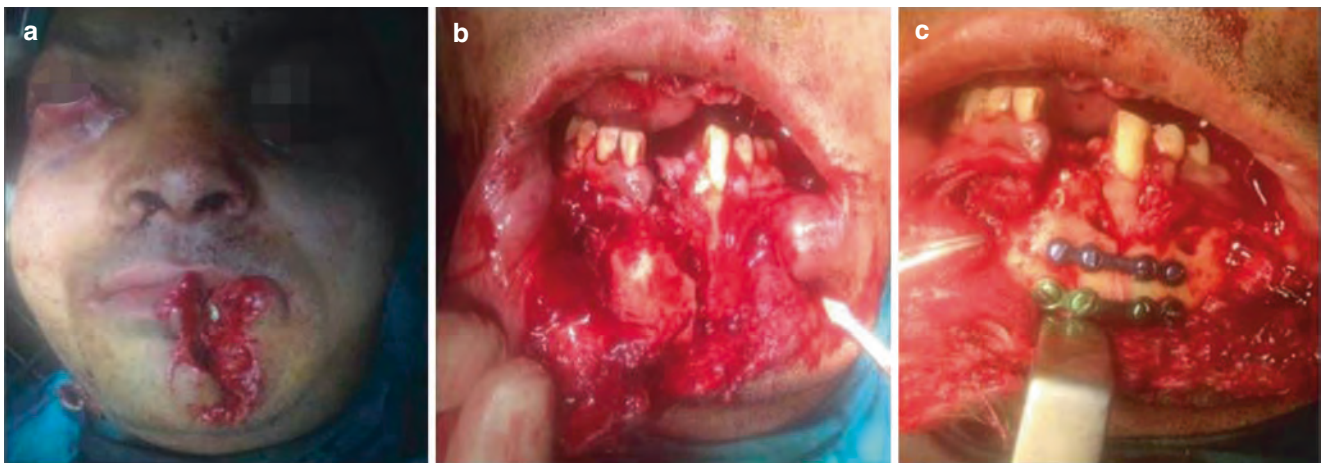
Through a small stab incision, a blunt dissection is performed with dissecting scissors till the mandibular periosteum is torn and the trocar is placed through the dissected channel.



©Association of Oral and Maxillofacial Surgeons of India

Fig. 52.33 Fixation of anterior mandible with three-dimensional plate

©Association of Oral and Maxillofacial Surgeons of India

Fig. 52.35 One miniplate above and another below the mental nerve used for fixation of parasymphysis fracture

©Association of Oral and Maxillofacial Surgeons of India

Fig. 52.34 (a–c) Existing laceration has been used as access for fixation of the anterior mandible fracture

Various techniques are mentioned in the literature for internal fixation of angle fracture (Box 52.3) [18]:

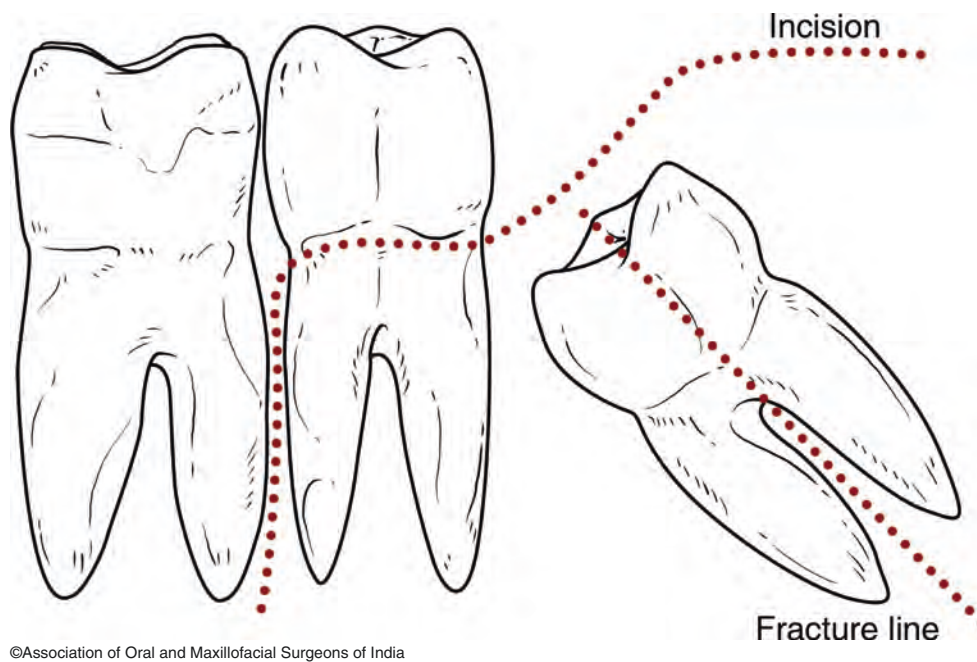
52.10.7.5 Single vs. Two Plates vs. 3D Plates

Al Moraissi [19] in a meta-analysis showed that the incidence of wound infection, dehiscence, hardware failure, and overall complications were less in patients treated with one miniplate on external oblique ridge in comparison to two.

Ellis III [20] also advocated use of single miniplate on superior border because:

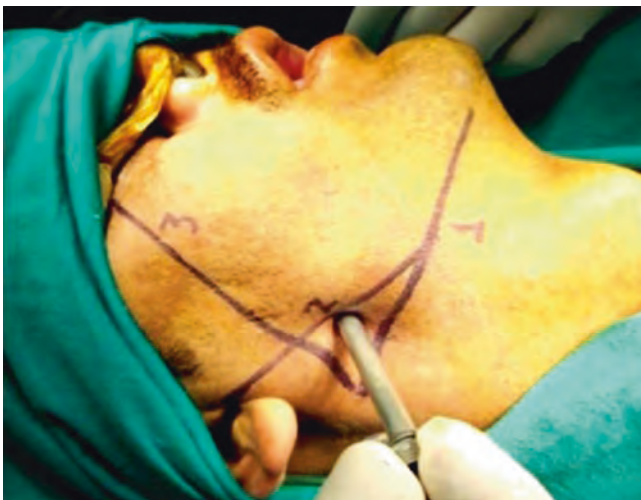Box 52.3: Fixation Techniques for Angle Fracture

1. Wire osteosynthesis (obsolete)
2. Single miniplate on the superior border (Fig. 52.38)
3. Single plate on inferior border
4. Two plates, one at superior and another on inferior border (Fig. 52.39a, b)
5. Lag screws
6. Three-dimensional plates (Fig. 52.40)



©Association of Oral and Maxillofacial Surgeons of India

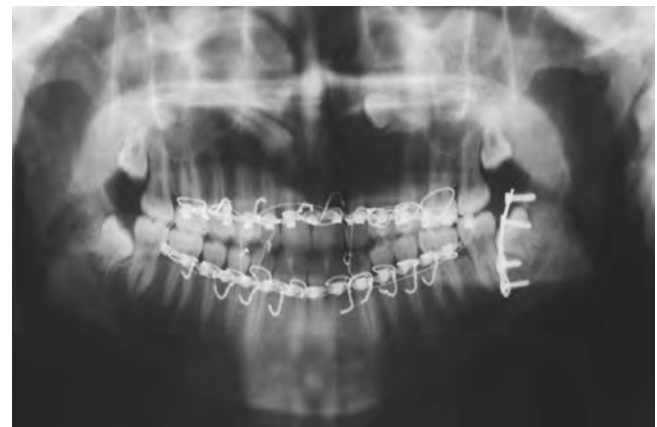Fig. 52.36 Intraoral incision for exposure



©Association of Oral and Maxillofacial Surgeons of India

Fig. 52.37 Transbuccal approach used for fixation of angle fractures

- High rate of sequestrectomy, infection, and subsequent second surgery was more in two-plate technique.
- Fixation with two plates took more time, i.e., average 37 min in comparison to an average of 23.5 min in single miniplate fixation from incision to suturing.
- Second plate fixation at inferior border is more difficult and requires more experience.

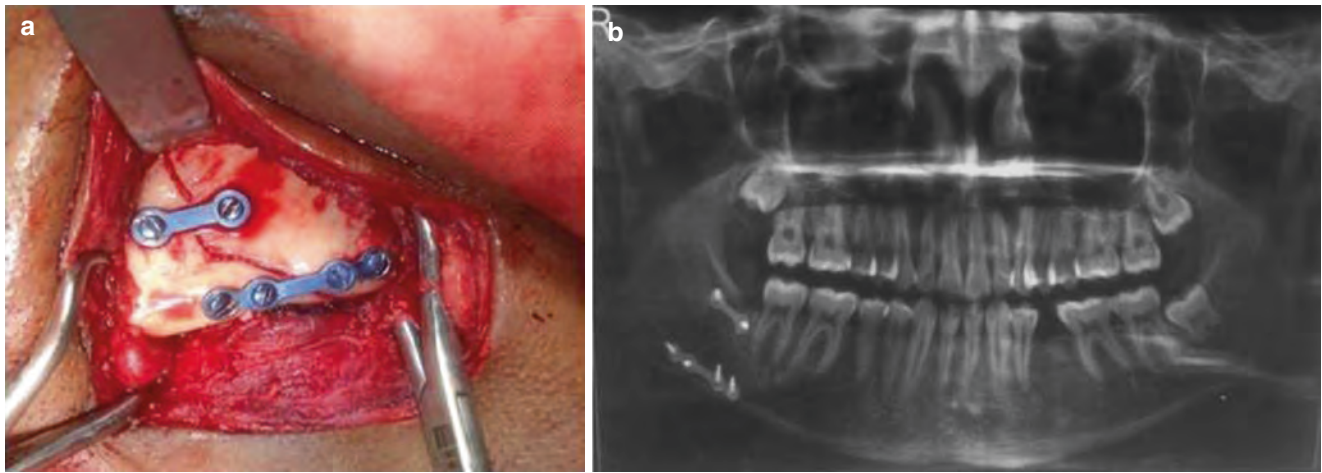


©Association of Oral and Maxillofacial Surgeons of India

Fig. 52.38 Fixation of mandibular angle fracture using single miniplate

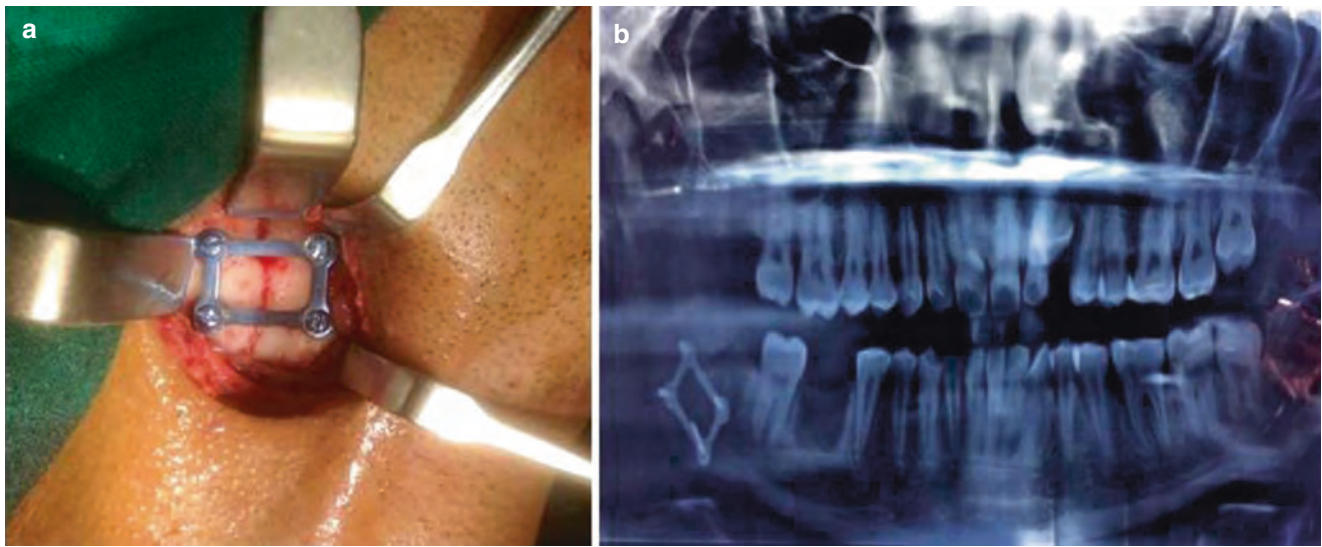
- If infection occurs, retrieval of single miniplate can be done under local anesthesia in a clinic, but two plates commonly required general anesthesia which indirectly increases the cost and prolonged the hospital stay.

Rai et al. [21] also conclude better results with two-plate fixation. Second miniplate is supposed to increase stability and protects the fracture site against torsion and bending.



©Association of Oral and Maxillofacial Surgeons of India

Fig. 52.39 Fixation of mandibular angle fracture using two miniplates. (a) Clinical picture, (b) orthopantamogram



©Association of Oral and Maxillofacial Surgeons of India

Fig. 52.40 Fixation of mandibular angle fracture using 3D plate. (a) Clinical picture, (b) orthopantamogram

Theoretically second plate establishes a second line of osteosynthesis.

Levy et al. [22] advocated two-plate fixation superior for ORIF of angle fracture. According to them two miniplates provide better stabilization and have reported lowest complication rate in comparison to any other plating technique.

Wusiman et al. [23] demonstrate that three-dimensional (3D) miniplates provide better fixation than standard miniplates. It also provides simultaneous stabilization of tension and compression zones with lower incidence of postoperative complications and good results. According to Zix et al. [24] 1-mm-thick 3D plate is as stable as 2 mm miniplates,

and it offers better bending stability and more resistant to out of plane movement or torque.

Ellis III and Ghali [25] used lag screws for treating mandibular angle fractures but reported very high incidence of postoperative infection and bone exposure. Also the fixation of angle with lag screws is technique sensitive and requires expertise.

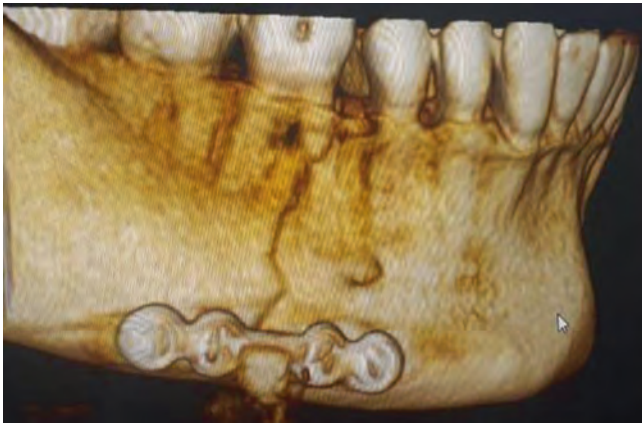Kang and Zide used seven-hole angle plate when Champy technique is ineffective and more rigid or semirigid fixation is required [26]. According to them seven-hole angle plate is fixed through transfacial trocar and stabilized intraorally. On the other hand, Champy plate required bending, lacks rigidity, difficulty in screw hole drilling, inaccurate centric placement of screws.

52.10.7.6 Extraction vs. Retention of IM3M in Angle Fracture

The use of postoperative MMF and extraction versus retention of teeth in the line of fracture did not influence any of the outcomes [27]. Increase rate of infection by extraction of a tooth was found in the study by Ellis and Walker in 1994 [28]. However, in another study published in 2002, Ellis [29] reported an increased incidence of infection if teeth were left in the line of fracture. Author advocates extraction of 3Ms at the time of ORIF for better results.

52.10.8 Body Fracture

A single four hole with gap miniplate (Fig. 52.41) below the root apex and the inferior alveolar canal is sufficient for fixation of body fracture of mandible through the intraoral approach most of the times, except when a patient is having



©Association of Oral and Maxillofacial Surgeons of India

Fig. 52.41 Fixation of body fracture with single miniplate

extraoral soft tissue injury/scar or having severely comminuted fracture fragments.

52.10.9 Ramus Fracture

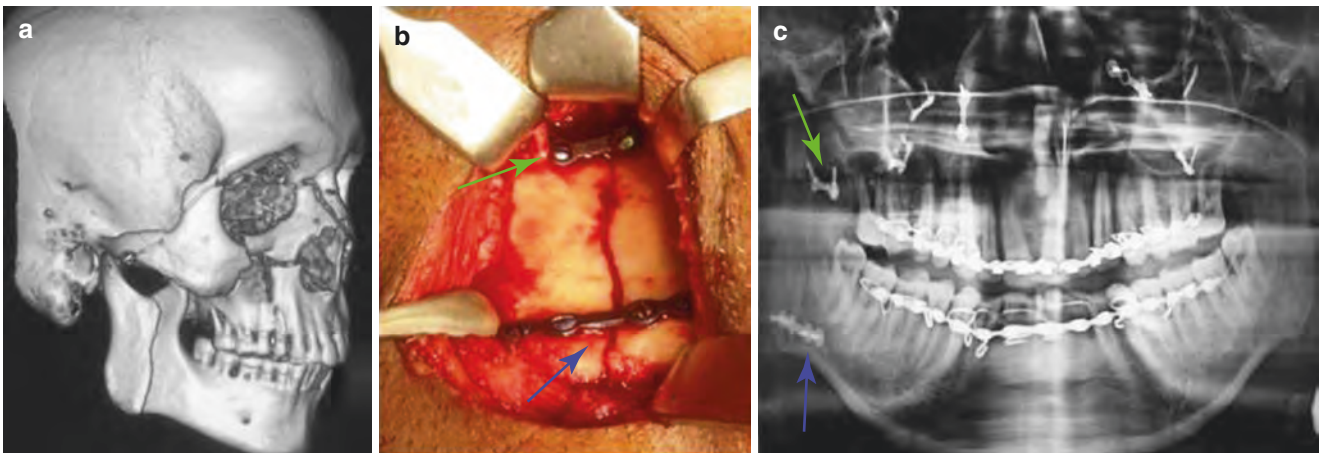
Mandibular ramus (MR) fracture occurs rarely and ranked third least common fracture after alveolar and coronoid fracture [30]. MR fractures are very rare in isolation. It can be horizontal or vertical. Its incidence ranges from 0.9 to 5.5% [31]. Isolated ramus fracture can be managed by closed reduction, but ORIF is the treatment of choice when it is associated with other maxillofacial fractures. To correct the facial height when midface is also fractured, the vertical rami become the only determinant, and re-establishment of these buttresses is very important before repositioning the crushed midfacial bones [32] (Fig. 52.42a–c).

52.10.9.1 Management of Triangular Fragments (TF) at the Lower Border

Heslop et al. [33] advocated repositioning of TF if they are attached to the muscle or periosteum and remove them if they are very small or detached from the periosteum.

According to Blinder et al. [34] to prevent infection and preserve vascularization, TF should be unexposed and unreduced. TF should be sandwiched between the two fracture lines by rigid fixation without exposure, and preserving vascularization may be the treatment of choice

TF of bone at the angle region were more often shown to get infected in comparison to body, symphysis, or parasymphysis because thick, better vascularized, and more cancellous bone presents in these areas as compared to angle region. It's better to remove small fragments in the angle region to avoid postoperative discomfort.



©Association of Oral and Maxillofacial Surgeons of India

Fig. 52.42 Management of mandibular ramus fracture. (a) DVT showing mandibular ramus fracture, (b) fixation using two miniplates, (c) postoperative orthopantomogram showing fixation of mandibular

ramus and midface fractures (blue arrows point to lower border plates and green arrows point to upper border plates)

52.10.10 Coronoid Fracture

It generally occurs in combination with other fracture of the mandible (Fig. 52.43a), and with zygomatic complex fracture (commonly with arch) (Fig. 52.43b), rarely does it occur in isolation. It can be treated by extraoral or intraoral approaches. Later, having low incidence of facial nerve injury and no facial scar. Coronoid fracture ranges from 0.6 to 4.7% of all facial fractures and 1–2.9% of all mandibular fractures [35].

It manifests as [36, 37]:

- Swelling below the zygomatic arch
- Ecchymosis in the retromolar trigone area
- Restricted mouth opening, malocclusion, and facial collapse when occurs in association with other facial fractures

52.10.10.1 Indications for Conservative or Open Reduction of Coronoid Fractures (Table 52.9)

Conservative management in the form of soft diet and mouth opening exercises to avoid bony adhesions to the surrounding structures [38]. If patients are treated with MMF and trismus occurs, it can be managed by removal of the coronoid process [39].

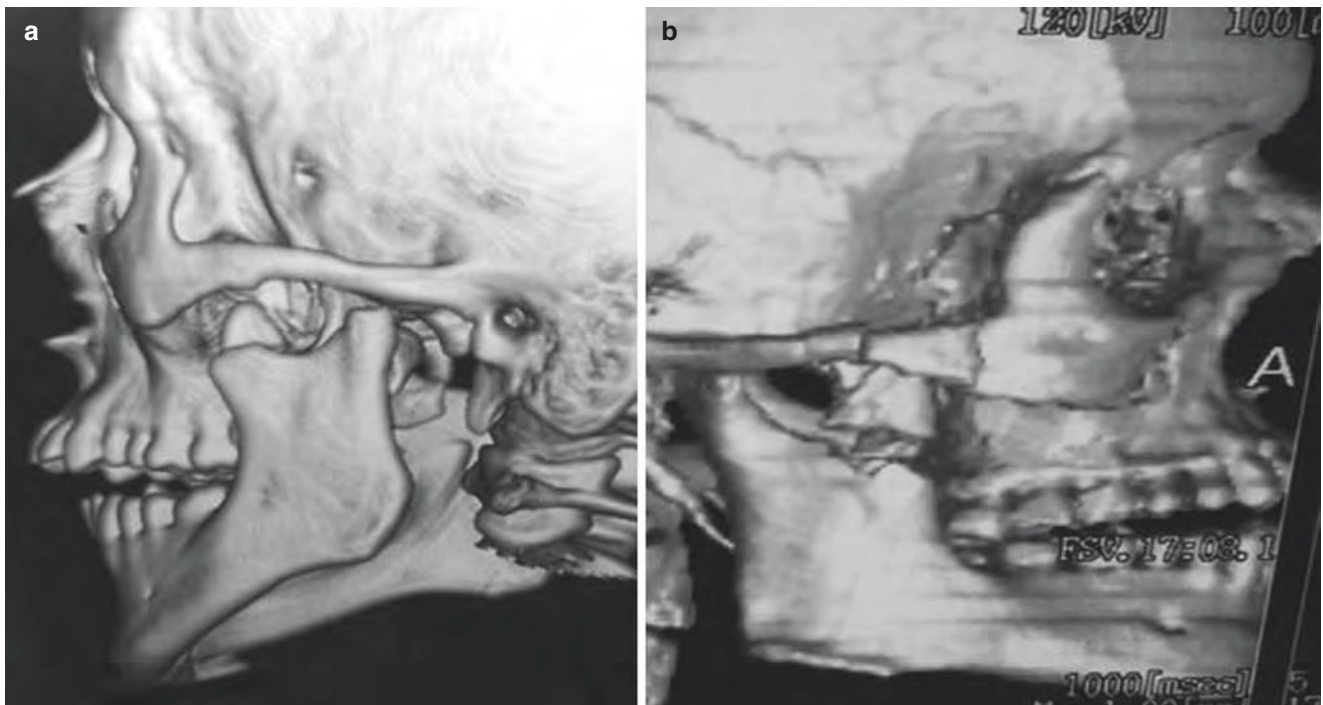
52.10.11 Bilateral Fracture of Mandible

Over half of the mandibular fractures are bilateral; in the case of angle fracture, most of the times, it occurs in combination of contralateral mandibular body and symphysis [40]. ORIF is the treatment of choice most of the times.

Clinical Tip: An MMF screw can be effectively used for reduction of a bilateral mandibular fracture by placing the screw in the symphysis region. A wire is passed through the screw, and the fracture segment can be manipulated for reduction (Fig. 52.44).

Table 52.9 Indications of closed and open reduction for coronoid fractures

Conservative	ORIF
Minimal displacement	Significant fracture displacement and Limited mouth opening
	Associated with zygoma, zygomatic arch, mandibular ramus
	Patients who are bad candidates for MMF

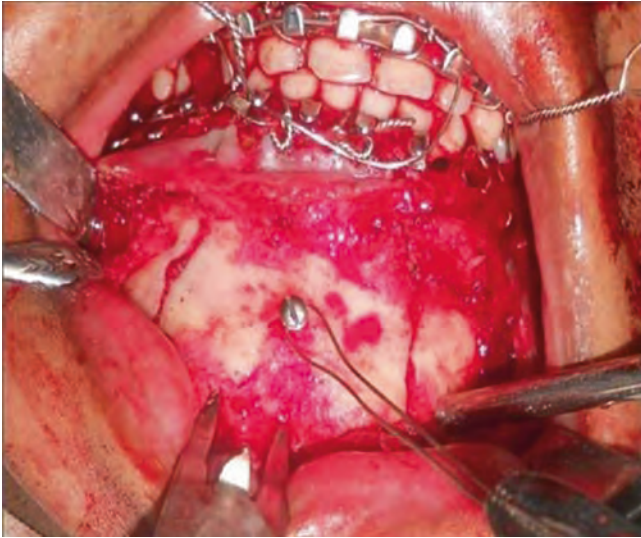


©Association of Oral and Maxillofacial Surgeons of India

Fig. 52.43 Coronoid fracture (a) associated with condylar fracture, (b) associated with zygomatic arch

52.10.12 Comminuted Mandible Fractures

Comminution is defined as presence of multiple fracture lines in many small pieces within the same area of mandibular angle, body, ramus, and symphysis [41]. This type of fracture rarely occurs in the condyle region. In a comminuted fracture, bone is “crushed, broken, splintered” into number of pieces, creating multiple small fragments (at least two free segments of bone) (Fig. 52.45a, b).



©Association of Oral and Maxillofacial Surgeons of India

Fig. 52.44 Use of MMF screw in reduction of bilateral parasymphysis fracture

To fix small fragments, multiple options are mentioned in the literature like miniplate, microplate, screws, steel wires, and absorbable sutures. A fragment larger than 1 cm should be conserved, reduced, and fixed [42].

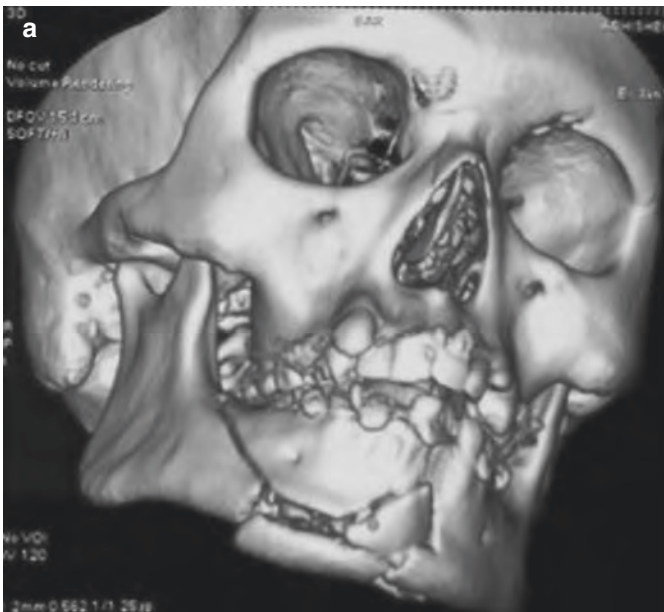Ellis et al. [43] advocated that more complications are associated with multiple fragment fractures in comparison to fractures having few segments. Therefore, comminuted fractures need load-bearing fixation.

The bone fragments will not provide buttressing to help stabilize the fracture; therefore surgeons operating comminuted mandibular fractures having two or more free bone fragments and/or requiring bone fragment removal should opt for reconstruction plates. Miniplates can be used when comminuted mandibular fractures have only one free bone fragment. Combination of reconstruction and miniplates can be used when multiple small fragments are there in comminuted mandible fracture (Fig. 52.46). Implants used for fixation of comminuted fractures are mentioned in Box 52.4.

Use of reconstruction plates required expertise and it is time-consuming. Sometimes contour is also not favorable

Box 52.4: Implants Used for Fixation of Comminuted Fractures

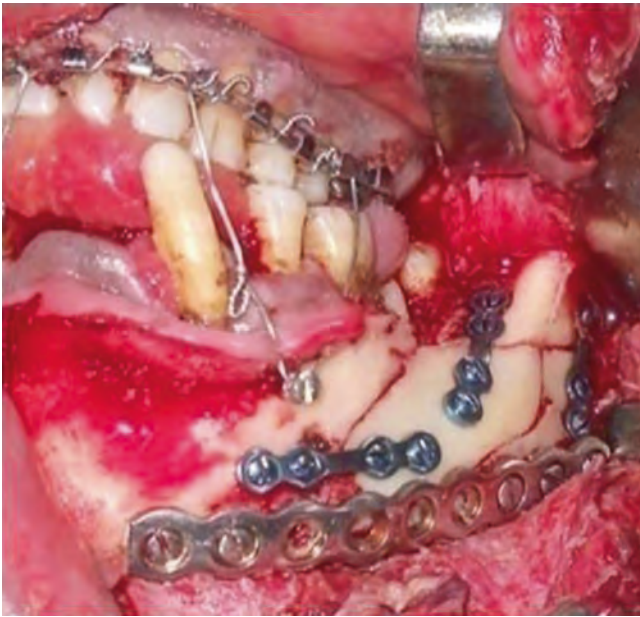
1. Multiple miniplates
2. Reconstruction plates
3. Combination of mini- and reconstruction plates
4. Titanium Mesh



©Association of Oral and Maxillofacial Surgeons of India

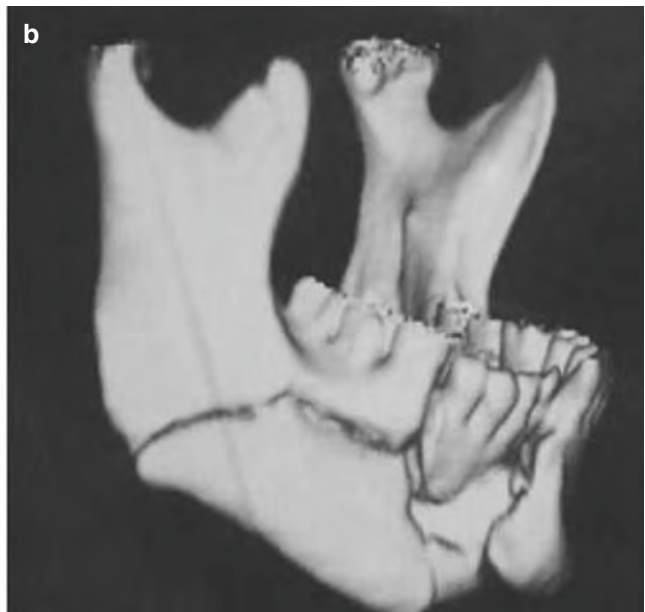

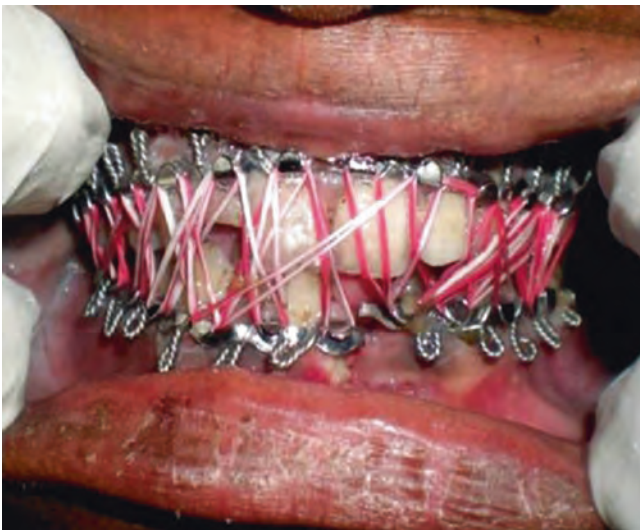Fig. 52.45 (a, b) Comminuted fractures



©Association of Oral and Maxillofacial Surgeons of India

Fig. 52.46 Combination of reconstruction and miniplates in management of comminuted fractures



©Association of Oral and Maxillofacial Surgeons of India

Fig. 52.47 Postoperative elastics for correction of minor occlusal discrepancies (Inter maxillary elastics- IME)

which can create slight malocclusion but can be managed by postoperative elastics and selective occlusal adjustments (Fig. 52.47).

Dia et al. [44] used titanium mesh for the treatment of comminuted mandible fracture with successful results. According to them mesh required little soft tissue exposure, had low infection rate, and provides favorable mandibular morphology.

52.11 Inferior Alveolar Nerve (IAN) Injury in Mandible Fracture

According to the literature, the incidence of IAN injury was [45]:

1. 5.4–81.4% before treatment
2. 0.4–91.3% after intervention
3. 0–46.6% after 1 year

The neurosensory testing was done both before and after the treatment of mandibular fracture in which nerve injury is suspected. Two-point discrimination and pinprick testing can be used to assess the level of IAN injury. Preoperative knowledge of the patient's IAN position (based on CT/CBCT) is very important in decision-making regarding fixation position of the fracture fragments with miniplates. Plating should be done above or below the course of IAN. ORIF in the area of IAN takes longer duration to normalization of sensation, and it ranges from 1 week to 12 months. Postoperative CT/CBCT is mandatory if operating surgeon suspected the impingement of screw on the IAN or no relief of sensation after 6 weeks of ORIF for further management. Surgeons should not hesitate to redo the surgery in cases of IAN injury by miniplates and screws.

52.12 Geriatric Mandibular Fracture

With old age, the incidence rate of maxillofacial fracture increases, with mandibular fracture appearing with a greater frequency. As the age advances, the weakening of the mandible occurs due to:

- Loss of teeth
- Reduced vascularity or decreased blood flow in elderly
- Loss of bone mass

The most common mechanisms of injury in geriatric patients are [46]:

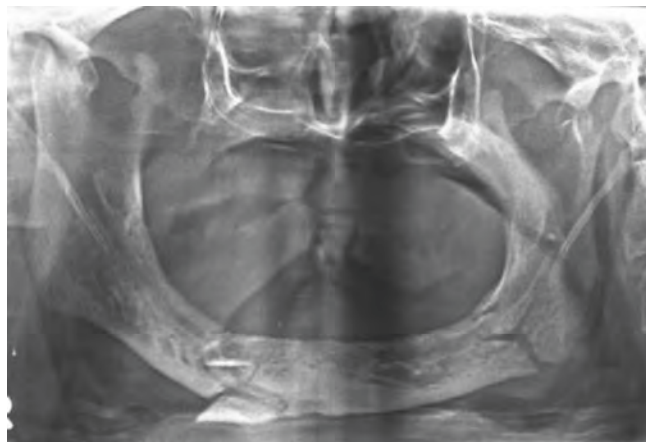
1. Fall
2. Assaults
3. Motor vehicle accidents

Fractures of the edentulous mandible pose unique challenges. Old age itself is a risk factor for poor outcomes following trauma. There are associated comorbidities like hypertension, diabetes mellitus, dementia, or stroke which limit the functional capacity of the patient to bear the stress of surgery and postoperative recovery. Also, the atrophic mandible has compromised blood supply with little osteo-

genic potential resulting in delayed bone healing. Bilateral mandibular fracture (bucket handle fracture) occurs most commonly in elderly (Fig. 52.48).

52.12.1 Management

Controversy exists in the treatment of edentulous mandibular fracture. One school of thought advocated closed reduction, and another school is in favor of open reduction and internal fixation. According to Bradley [47] the major blood supply to the mandible is “sub periosteal Plexus,” and reflection of periosteum in ORIF may seriously impair vascular supply to the bone resulting in non-union.



©Association of Oral and Maxillofacial Surgeons of India

Fig. 52.48 Bilateral mandibular fracture (bucket handle fracture) in edentulous patients

Controversy again exists in the use of bone grafts in edentulous mandible. Are bone grafts necessary? Answer is not always. Reconstruction plates (load-bearing plates) can be used for comminuted fractures and with large defects. Bone morphogenic proteins and tricalcium phosphate can be used as alternative to autogenous grafts in patients whom multiple comorbidities may influence local or systemic outcomes [48].

Few authors advocated extramucosal intraoral plating for the ORIF of the edentulous mandibular fracture. It preserves the blood supply to the mucosa and bone, at the same time provides adequate stability [49, 50].

The techniques of edentulous atrophic mandible fracture management are:

1. Closed reduction (CR)

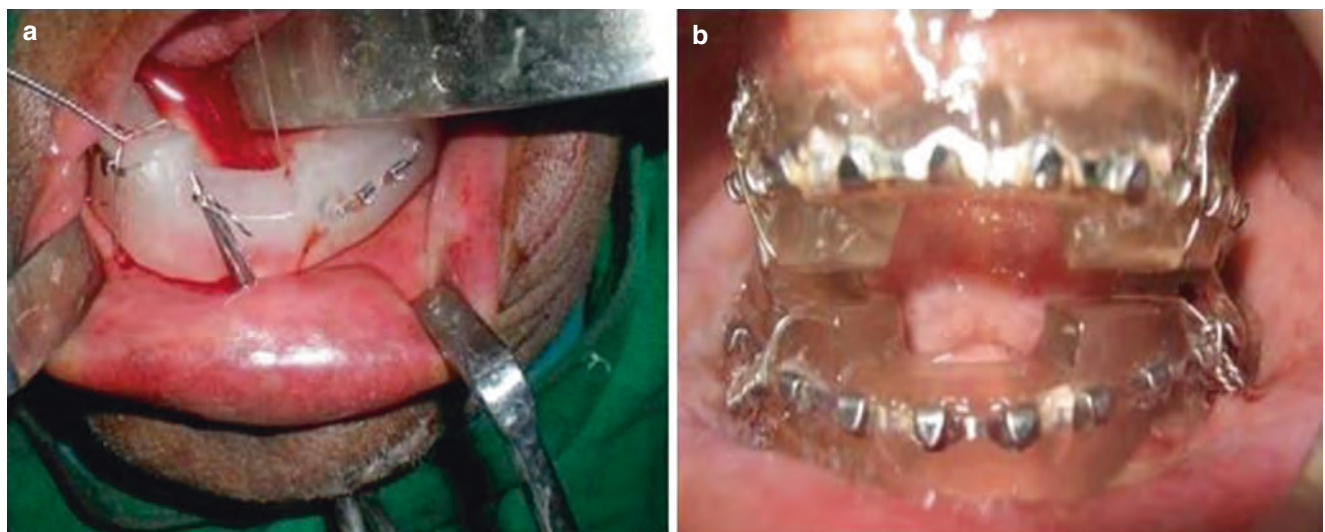
This technique is opted when the patient’s systemic condition does not allow for an open surgery. CR can be accomplished if the mandibular height is at least 30 mm. It is difficult to achieve CR if the mandibular height is <10 mm. CR can be accomplished using a preexisting denture. If there is no denture, gunning splint can be prepared. The denture/splint is used for immobilization and fixed to the mandible with circum-mandibular wiring (Fig. 52.49a, b).

Advantages: Periosteal supply to the bone is maintained.

Disadvantages: Chances of infection and pulmonary issues

2. Open reduction and internal fixation (ORIF)

This involves use of plates and screws for fixation of fractures. Options for ORIF include use of miniplates or larger reconstruction plates. Miniplates are small and



©Association of Oral and Maxillofacial Surgeons of India

Fig. 52.49 (a) Securing gunning splint by circum-mandibular wiring, (b) MMF with gunning splint in situ

hence require smaller incision. Screws of miniplates are also small which can easily involve thin fragments. However, in cases of larger fractures, a load-bearing reconstruction plate is preferred.

Advantages: Adequate fixation with no/minimum MMF

Disadvantages: Delayed healing with periosteal blood supply loss

52.13 Pediatric Mandibular Fractures

Among all the maxillofacial fractures, the incidence of pediatric facial fracture is 1–15%. After nasal bone fracture, the second most common fractures in children are mandibular fracture with an incidence of 5–50% [51]. In mandible, the condyle is the commonest site of fracture in pediatric patients followed by symphysis and parasymphysis. The most common mechanisms of injury in children are [52]:

1. Fall from height
2. Bicycle falls
3. Automobile and sports accidents
4. Violence

In children, the developing tooth buds of canine approximate the lower border of mandible. This creates a stress point making the mandible susceptible to fracture in this location. Once the canine erupts, this weak point is reinforced with the bone and is not weaker than any other regions of the mandible. This is the reason probably why parasymphysis fracture is more common in children than adolescents.

With increasing age, the skull-to-face ratio decreases. The larger cranium shields the smaller middle and lower thirds of the face from injuries. This prevents mandibular fracture in small children; however, with increasing age the mandible becomes more prominent resulting in more injuries to this region.

52.13.1 Management

The management of pediatric mandibular fractures is different in comparison to adults due to [53]:

1. Relatively small size of maxillofacial bones
2. Presence of tooth germs
3. Soft bone with good elasticity
4. Instability of deciduous or mixed dentition
5. Rapid repair process
6. Difficulties in cooperation and acceptance

Pediatric mandibular fractures are treated in the following ways:

1. Undisplaced fractures: Managed conservatively with close observation, soft diet, analgesics, and activity prevention
2. Fractures with minor malocclusions: A short period of MMF with the help of bondable buttons and wires for 7–14 days
3. Malocclusion with displacement of segments: Closed reduction using cap splint secured to mandible by circum-mandibular wiring (Fig. 52.50a–c)
4. Malocclusion with severe displacement requiring three-dimensional stabilizations: open reduction and internal fixation

However the absence of teeth due to exfoliation and poor retention of wires on the deciduous teeth crowns makes the ligature wire and traditional use of arch bars difficult or sometimes impossible [54]. In such cases splinting with acrylic splint retained with circum-mandibular wires remains a viable option in treatment of pediatric mandibular fractures.

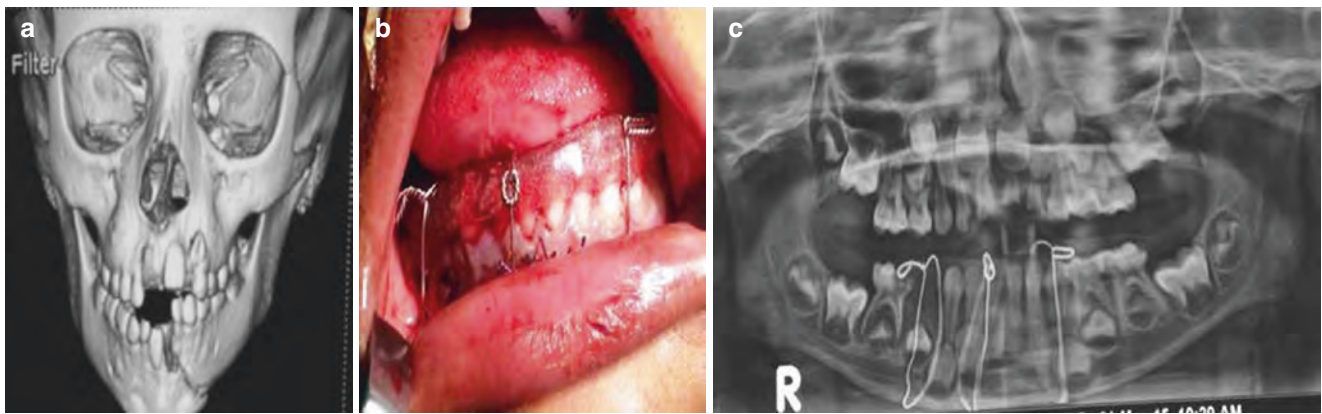
Cap splints are secured to mandible by circum-mandibular wiring. Kelsey Fry bone awl is used for this purpose. A wide-bore needle can also be used for the same (Fig. 52.51a, b). Intravenous cannula stillete (IVCS) is also mentioned in the literature for performing circum-mandibular wiring. The 16-gauge IVCS was used instead of conventional awl [55].

However, management of pediatric mandibular fracture with ORIF is controversial as the fixation of plates may hamper the growth and development of jaw. Titanium miniplates have been successfully used for ORIF, but the implants are to be removed within 3- to 12-month period [56].

Yerit et al. [57] proposed use of biodegradable plates for ORIF. These plates should be mechanically strong and must undergo resorption within a predictable time frame.

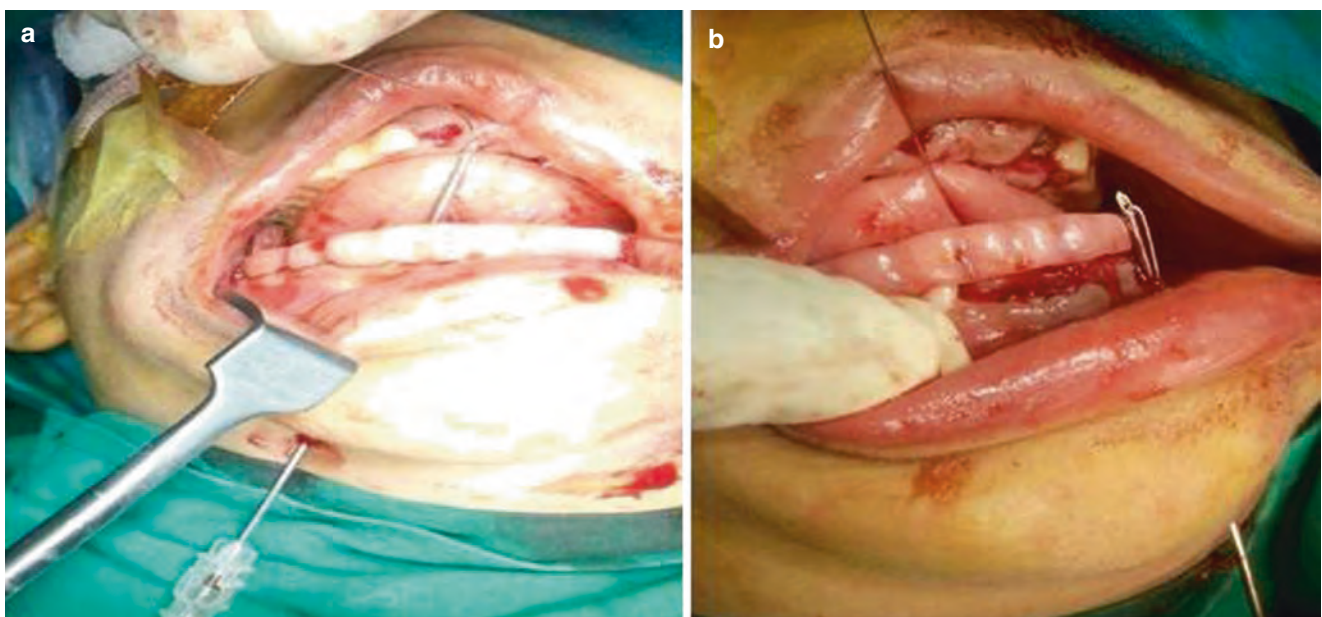
The advantages of biodegradable plates (polyglycolic and poly-L-lactic acid plating system) in comparison to titanium plates are [58]:

1. Does not require second operation for removal, indirectly becoming cost-effective and requiring less hospital visit.
2. Does not cause growth disturbances.
3. Monocortical plates and screws do not cause damage to the tooth buds.



©Association of Oral and Maxillofacial Surgeons of India

Fig. 52.50 (a) Pediatric mandibular fracture, (b) cap splint secured using circum-mandibular wiring, (c) postoperative orthopantomogram



©Association of Oral and Maxillofacial Surgeons of India

Fig. 52.51 (a, b) Securing cap splint by circum-mandibular wiring using wide-bore needle

52.14 Use of Bone Grafts in Mandible Fracture Treatment

Anterior iliac crest (cancellous or cortico-cancellous) and fibula (free microvascular reconstruction) are the most commonly used sites from where the bone grafts are used for mandibular reconstruction. All the cases required bone grafting in cases of mandibular fracture treated with ORIF should be kept in MMF of 4 weeks postoperatively.

Bone grafts are indicated in some cases of:

1. Severely comminuted fractures
2. Gunshot wounds
3. In non-union
4. Atrophic mandibular fractures

Rachmiel et al. [59] advocated two-stage reconstruction of mandibular bone defect after trauma by bone grafting followed by alveolar distraction osteogenesis (ADO). This modality helps in correction of intermaxillary vertical relationship and provides sufficient amount of bone for the placement of dental implants and prosthesis.

52.15 Postoperative Care

- Pressure dressing over the site to avoid postoperative hematoma in required cases.
- Elastic traction for correction of minor discrepancies in occlusion (Fig. 52.47).
- Soft and liquid diet.
- Maintenance of oral hygiene by oral rinses.
- Recall visit for review.
- Follow-up appointments and if results are not satisfactory frequent follow-up required.
- If patient is not satisfied, plan for retreatment.

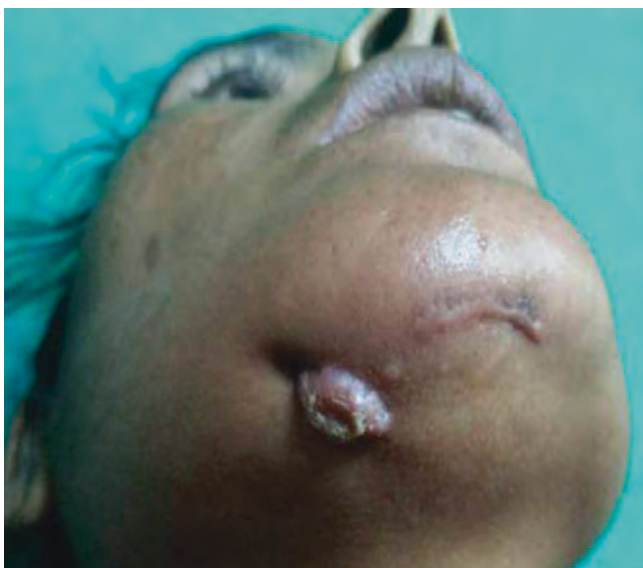52.16 Complications of Mandible Fracture

Immediate

- Pain
- Swelling

Delayed

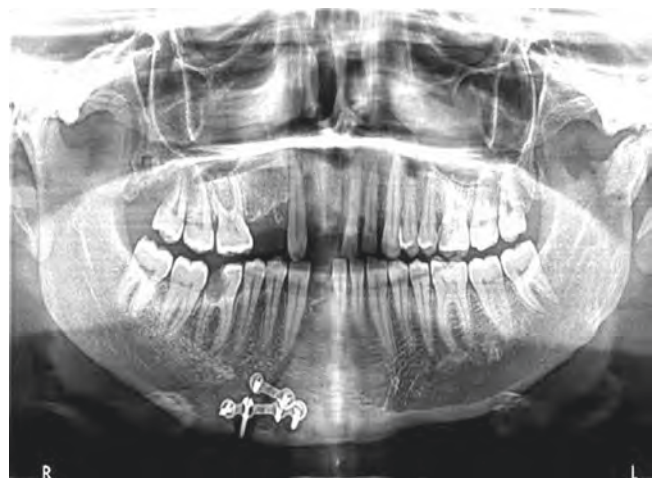- **Infection:** Found to be the most common complication (Fig. 52.52)



©Association of Oral and Maxillofacial Surgeons of India

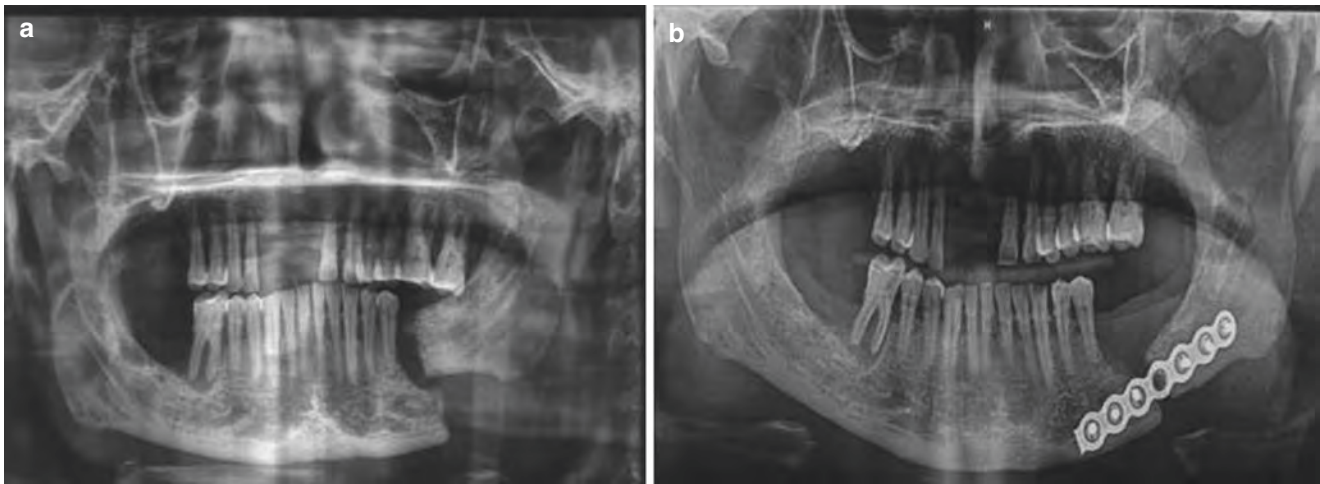
Fig. 52.52 Postoperative infection

- Predisposing factors:
 1. Preoperative oral sepsis
 2. Tooth in the line of fracture
 3. Improper reduction and fixation (Fig. 52.53)
 4. Alcoholic or metabolic disturbances
 5. Prolonged time before treatment
 6. Poor patient compliance
- **Malunion**
 - It indicates that a fracture has healed but in less than an optimal position.
 - It may result when bone is shorter than normal, rotated or twisted in a bad position, or bent.
 - It may cause pain, joint degeneration, posttraumatic arthritis, or catching episodes resulting from instability.
- **Non-union**
 - It is a type of uncommon complication of mandibular fracture, with reported incidence of 2.8–3.9% [60].
 - It is failure of fracture hematoma to become transformed into an osteogenic matrix so that it is converted into non-osteogenic fibrous tissue.
 - Non-union identified by mobility in all planes after interval of minimum 10 weeks.
 - Histologically there is absence of identifiable osteogenic tissue.
 - Radiographically no evidence of progressive decrease in radiolucency at the fracture site and rounding off of the bones' end in the later stages. It can be treated by ORIF by rigid fixation (load-bearing reconstruction plate and sometimes in combination with bone graft) (Fig. 52.54a, b).



©Association of Oral and Maxillofacial Surgeons of India

Fig. 52.53 Postoperative infection due to improper reduction and fixation

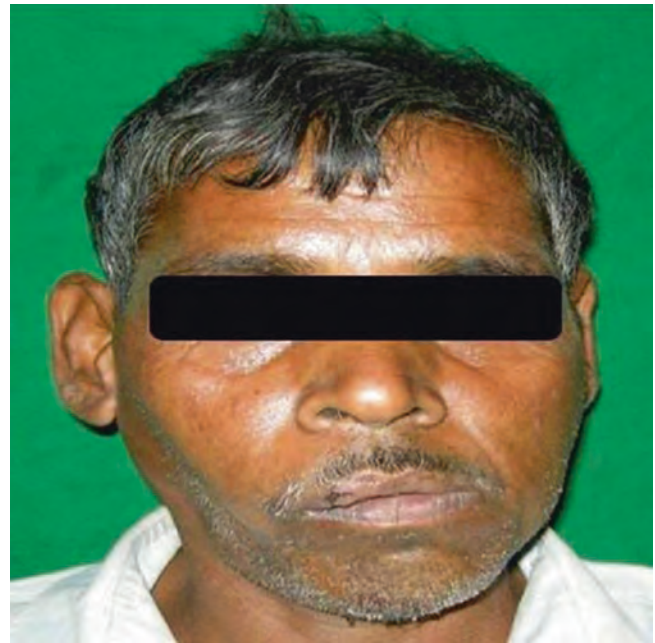

©Association of Oral and Maxillofacial Surgeons of India

Fig. 52.54 (a) Non-union due to closed reduction, (b) management of fracture non-union by load-bearing reconstruction plate

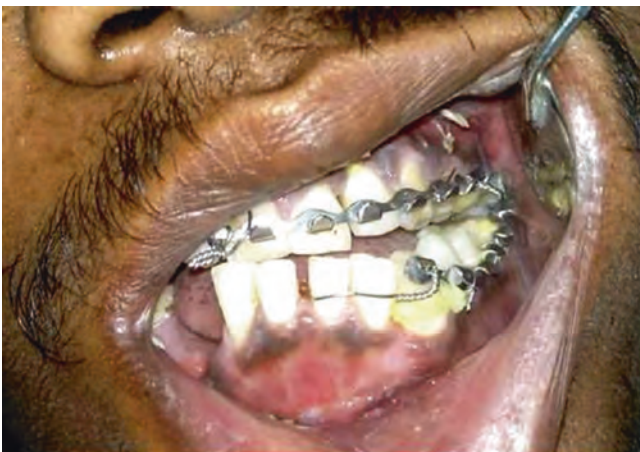Table 52.10 Management of mandibular non-union

If the defect is <1 cm	Defect size: 1–6 cm		Defect > 6 cm
Rigid internal fixation in single stage	<i>If adequate soft tissue present</i>	<i>If adequate soft tissue absent</i>	Reconstruction with vascularized bone flap in single stage
	Reconstruction with bone graft in single stage	Reconstruction with bone graft at a later stage Reconstruction with vascularized Bone flap in single stage	



©Association of Oral and Maxillofacial Surgeons of India

Fig. 52.56 Facial asymmetry



©Association of Oral and Maxillofacial Surgeons of India

Fig. 52.55 Showing malocclusion

- Mandibular growth disturbances
- Disruption of permanent teeth
- TMJ dysfunction

52.16.1 Management of Mandibular Non-union Depending upon the Size of the Defect (Table 52.10) [61]

- Malocclusion (Fig. 52.55)
- Facial asymmetry (Fig. 52.56)

52.17 Recent Advances

Kokosis et al. [62] advocated use of virtual surgical planning (VSP) with subsequent computer-aided design and manufacturing in management of acute mandibular trauma patients.

The advantages of the use of custom titanium plate in mandibular trauma are:

1. Avoid need for in situ bending.
2. Serving as a guide and confirming accurate reduction.
3. Customized titanium plates are much stronger than conventional plates.
4. Less palpable.

Computer-assisted surgery (CAS) including computer-aided design and manufacturing, surgical navigation techniques, and rapid prototyping (RP) has been used with lot of success in mandibular reconstruction (refer Chap. 41 of this book). CAS helps in [63]:

1. Preoperative planning
2. Preparation of stereolithographic (STL) models or accurate implantation material
3. Implementation of complex design through intraoperative navigation

Some Important Facts from Review of Literature Regarding Mandible Fracture [64, 65]

1. Injuries caused by assaults were more prone to develop postoperative infection, nerve damage, and malocclusion.
2. 11.8-fold more likely to have poor radiographic outcome in patients with comminuted fracture.
3. Dehiscence, nerve injury, and malocclusion occur more commonly in surgeries taking longer duration.
4. Patients with three or more fractures were 13.8-fold more likely to develop postoperative trismus in comparison to single fracture.
5. Chances of complications are more in patients who took discharge against medical advice.
6. Treatment of isolated mandible fracture can be safely delayed to allow for more improved resource distribution and prioritization of more time-dependent interventions.

52.18 Case Scenarios

Case Scenario 1

A male patient reported with a gunshot injury over right side of face. Patient's Glasgow coma scale (GCS) was 15/15 with stable vital signs, but the patient has difficulty in breathing. On maxillofacial examination, a gunshot wound was present over right side of face at the right mandibular angle region. Deviation of mandible was present on right side with cross bite on right side and open bite on left side. Tenderness was present over right mandibular angle region. On palpation, intersegmental mobility was present over right angle region.

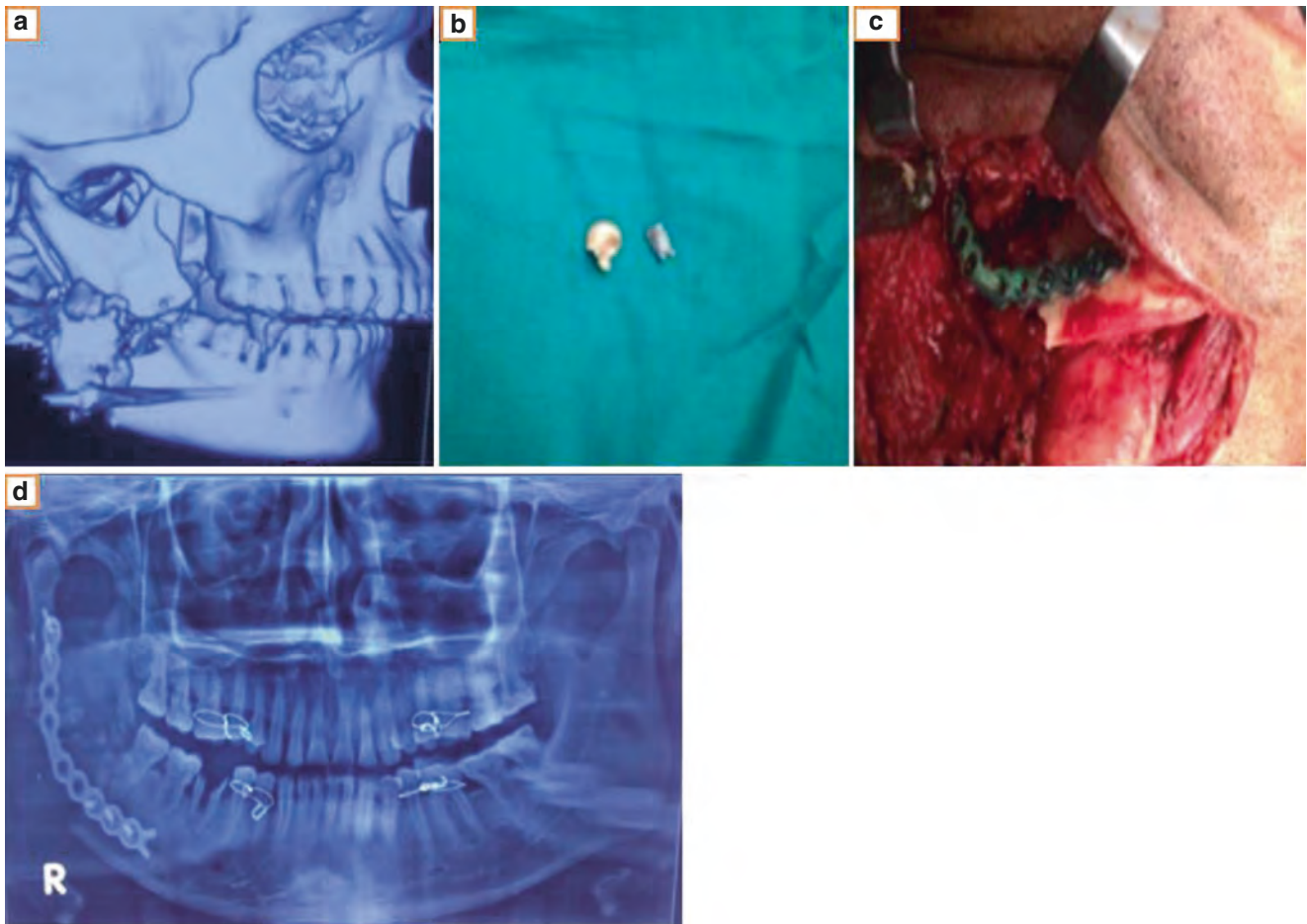
Provisional diagnosis: Right mandibular angle fracture following gunshot

Investigation: Apart from blood investigation, a CT scan was performed, and a final diagnosis of comminuted right mandibular ramus and angle fracture with bullet in situ was made (Fig. 52.57a).

Management: Patient was subjected to emergency surgery under general anesthesia with a treatment plan of bullet retrieval, debridement, and open reduction and internal fixation of fracture. After the anesthesia was induced, patient preparation was done; the fracture site was exposed through an extraoral approach. Thorough debridement was done, and bullet was retrieved in multiple pieces (Fig. 52.57b). The bone segments which were detached were removed, and the fracture segments were fixed using a reconstruction plate following achieving occlusion (Fig. 52.57c). The use of bone graft was eliminated considering the risk of postoperative infection due to scattering of bullet particles. Moreover, the fracture site was a nondentate site; hence bone grafting was not mandatorily indicated for postoperative dental rehabilitation. Figure 52.57d shows postoperative OPG and fixation of fracture with reconstruction plate (refer Chap. 59 on Gun shot injuries).

Case Scenario 2

A female patient reported with the chief complaint of difficulty in chewing following operation to treat mandibular fracture. Patient gave a history of fall from height following which she was operated for ORIF elsewhere. The general condition of patient was good. On maxillofacial examination, mandible was deviated on right side with cross bite on right



©Association of Oral and Maxillofacial Surgeons of India

Fig. 52.57 Case Scenario 1 (a) DVT showing comminuted right mandibular angle and ramus fracture with bullet in situ; (b) retrieved bullet; (c) bullet retrieval, debridement, and fixation of fracture with recon-

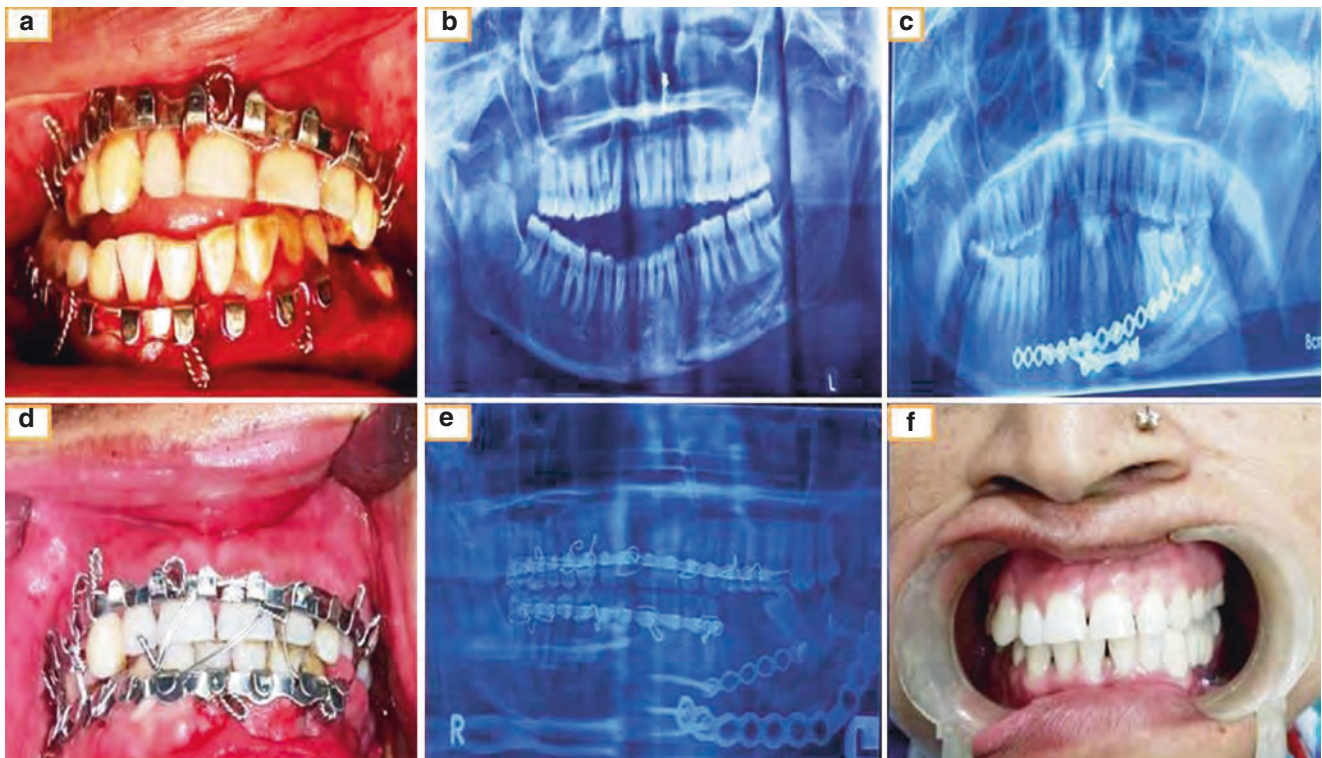
struction plate; (d) postoperative OPG showing fixation of fracture with reconstruction plate

side and open bite with lingualized occlusion on left side (Fig. 52.58a). Patient provided us with a pretreatment OPG which revealed right subcondylar with left side mandibular comminuted body and angle fracture (Fig. 52.58b). We subjected the patient to another OPG which revealed improper fixation of left mandibular body fracture and no fixation of left angle and right subcondylar fracture (Fig. 52.58c).

Diagnosis: Malunited left mandibular body, left angle fracture, and right subcondylar fracture

Management: Patient was subjected to general anesthesia. Once the anesthesia was induced, patient preparation was

done, and fracture site was exposed through extraoral incision for all the fractures. Existing implants were removed which resulted in removal of few small bone fragments. The fractured and carious teeth were extracted and reduction was done by MMF. Occlusion was achieved (Fig. 52.58d), and fixation was performed using two miniplates at subcondylar site and load-bearing reconstruction plate at the body-angle unit. A postoperative OPG was done (Fig. 52.58e). Patient was discharged in stable condition. After 6 months, dental rehabilitation was performed for missing teeth by delivering dental bridge (Fig. 52.58f).



©Association of Oral and Maxillofacial Surgeons of India

Fig. 52.58 Case scenario 2 (a) Deranged occlusion when patient reported to us, (b) pretreatment OPG, (c) improper fixation of left mandibular body fracture and no fixation of left angle and right subcondylar

fracture at other centre, (d) intraoperative occlusion achieved, (e) post-operative OPG, (f) postoperative accurate occlusion

References

- Christensen BJ, et al. How much weight loss can be expected after treating mandibular fractures? *J Oral Maxillofac Surg.* 2019;77:777–82.
- Dingman RO, Natvig P. *Surgery of facial fractures.* Philadelphia, PA: Saunders; 1964. p. 193.
- Ellis III E. Open reduction and internal fixation of combined angle and body/symphysis fractures of the mandible: how much fixation is enough? *J Oral Maxillofac Surg.* 2013;71:726–33.
- National Radiologic Protection Board. *Patient dose reduction in diagnostic radiology.* London: National Radiologic Protection Board; 1990.
- Durham JA, Paterson AW, Pierse D, Adams JR, Clark M, Hierons R, Edwards K. Postoperative radiographs after open reduction and internal fixation of the mandible: are they useful? *Br J Oral Maxillofac Surg.* 2006;44:279–82.
- Bergh van den B. Postoperative radiographs after maxillofacial trauma: sense or nonsense? *Int J Oral Maxillofac Surg.* 2011;40:1373–6.
- Rai A. A simple method of preventing needle stick type injury to the operator's finger while performing intermaxillary fixation. *J Maxillofac Oral Surg.* 2014;13(2):215–6.
- Dimitroulis G. Management of fractured mandibles without the use of intermaxillary wire fixation. *J Oral Maxillofac Surg.* 2002;60:1435–8.
- Meram AT, Olate S, Palmieri CF Jr. Is the three-dimensional strut plate an adequate fixation technique for mandibular symphysis fractures? *J Oral Maxillofac Surg.* 2018;76:140–5.
- Armond ACV, et al. Influence of third molars in mandibular fractures. Part 1: mandibular angle—a meta analysis. *Int J Oral Maxillofac Surg.* 2017;46:716–29.
- Mah D-H, et al. Relationship between mandibular condyle and angle fractures and the presence of mandibular third molars. *J Korean Assoc Oral Maxillofac Surg.* 2015;41:3.
- Samieirad S, et al. Correlation between lower third molar impaction types and mandibular angle and condylar fractures: a retrospective study. *J Oral Maxillofac Surg.* 2019;77:556–64.
- Meisami T, et al. Impacted third molars and risk of angle fracture. *Int J Oral Maxillofac Surg.* 2002;31:140.
- Kuriakose M, et al. A comparative review of 266 mandibular fractures with internal fixation using rigid (AO) plates or miniplates. *Br J Oral Maxillofac Surg.* 1996;34:315–21.
- Sugar AW, et al. A randomised controlled trial comparing fixation of mandibular angle fractures with a single miniplate placed either transbuccally and intra-orally, or intra-orally alone. *Int J Oral Maxillofac Surg.* 2009;38:241–5.
- Kale TP, Baliga SD, Ahuja N, Kotrashetti SM. A comparative study between transbuccal and extra-oral approaches in treatment of mandibular fractures. *J Maxillofac Oral Surg.* 2010;9:9–12.
- Gulses et al. Determination of a safety zone for transbuccal trocar placement: an anatomical study. *Int J Oral Maxillofac Surg.* 2012;41:930–3.

18. Braasch DC, Abubaker AO. Management of mandibular angle fracture. *Oral Maxillofac Surg Clin North Am.* 2013;25:591–600.
19. Al Moraissi EA. One miniplate compared with two in the fixation of isolated fractures of the mandibular angle. *Br J Oral Maxillofac Surg.* 2015;53:690–8.
20. Ellis E III. A prospective study of 3 treatment methods for isolated fractures of the mandibular angle. *J Oral Maxillofac Surg.* 2010;68:2743.
21. Rai A, Jain A, Datarkar A. Comparison of single versus two non-compression miniplates in the management of unfavourable angle fracture of the mandible: a prospective randomized clinical study. *Oral Maxillofac Surg.* 2018;22:157–61.
22. Levy FE, Smith RW, Odland RM, Marentette LJ. Monocortical miniplate fixation of mandibular angle fractures. *Arch Otolaryngol Head Neck Surg.* 1991;117:149–54.
23. Wusiman P, et al. Management of mandibular angle fractures using 3-dimensional or standard miniplates: A systematic review and meta-analysis. *J Cranio Maxillofac Surg.* 2019;47:622–8.
24. Zix J, Lieger O, Iizuka T. Use of straight and curved 3-dimensional titanium miniplates for fracture fixation at the mandibular angle. *J Oral Maxillofac Surg.* 2007;65:1758–63.
25. Ellis E III, Ghali GE. Lag screw fixation of mandibular angle fractures. *J Oral Maxillofac Surg.* 1991;49:234–43.
26. Kang DR, Zide M. Treatment of mandibular angle fractures using one non compression miniplates. *J Oral Maxillofac Surg.* 2013;71:327–34.
27. Patel N, Kim B, Zaid W. Analysis of mandibular angle fractures: epidemiology, patterns, treatments, and outcomes. *J Oral Maxillofac Surg.* 2016;74:1792–9.
28. Ellis E, Walker LR. Treatment of mandibular angle fractures using two non-compression miniplates. *J Oral Maxillofac Surg.* 1994;52:1032.
29. Ellis E. Outcomes of patients with teeth in the line of mandibular angle fractures treated with stable internal fixation. *J Oral Maxillofac Surg.* 2002;60:863–6.
30. Subhashraj K, Nandakumar N, Ravindran C. Review of maxillofacial injuries in Chennai, India: a study of 2748 cases. *Br J Oral Maxillofac Surg.* 2007;8:637–9.
31. Barde D, Madan R, Mudhol A. Prevalence and pattern of mandibular fracture. Central India. *Natl J Maxillofac Surg.* 2014;5:153.
32. Shaaban I, Gowen GF, Looby JP. Vertical fracture of the ascending ramus of the mandible. *Oral Surg Oral Med Oral Pathol.* 1967;24:594–97.
33. Heslop IH, Clarke PB, Becker R, et al. Mandibular fractures: treatment by open reduction and direct skeletal fixation. In: Rowe NL, Williams JL, editors. *Maxillofacial injuries.* London: Churchill Livingstone; 1985. p. 305.
34. Blinder D et al. Management of triangular fragments of the inferior border of the mandible. *Oral Surg Oral Med Oral Pathol Oral Radiol Endod.* 1995;80:398–400.
35. Delantoni A, Antoniadis I. The iatrogenic fracture of the coronoid process of the mandible. A review of the literature and case presentation. *Cranio.* 2010;28:200–4.
36. Philip M, Sivarajasingam V, Shepherd J. Bilateral reflex fracture of the coronoid process of the mandible. A case report. *Int J Oral Maxillofac Surg.* 1999;28:195–6.
37. Johnson RL. Unusual (coronoid) fracture of the mandible: report of a case. *J Oral Surg.* 1958;16:73.
38. Rankow RM, Mignogna FV. Ankylosis of the temporalis–coronoid complex of the mandible. *Ann Plast Surg.* 1978;1:280–5.
39. Shen L, et al. Mandibular coronoid fractures: Treatment options. *Int J Oral Maxillofac Surg.* 2013;42:721–6.
40. Ellis E 3rd, Walker LR. Treatment of mandibular angle fractures using one noncompression miniplate. *J Oral Maxillofac Surg.* 1996;54:864–6.
41. Finn RA. Treatment of comminuted mandibular fractures by closed reduction. *J Oral Maxillofac Surg.* 1996;54:320–7.
42. Li Z, Li Z-B. Clinical characteristics and treatment of multiple site comminuted mandible fractures. *J Cranio Maxillofac Surg.* 2011;39:296–9.
43. Ellis E, Muniz O, Anand K. Treatment considerations for comminuted mandibular fractures. *J Oral Maxillofac Surg.* 2003;61:861–70.
44. Dai J, et al. Titanium mesh shaping and fixation for the treatment of comminuted mandibular fractures. *J Oral Maxillofac Surg.* 2016;74:337–40.
45. Tay Guan AB, et al. Inferior alveolar nerve injury in trauma-induced mandible fractures. *J Oral Maxillofac Surg.* 2015;73:1328–40.
46. Cillo JE and Holmes TM. Interpersonal violence is associated with increased severity of geriatric facial trauma. *J Oral Maxillofac Surg.* 2016;74:1023.e1–7.
47. Bradley JC. A radiological investigation into the age changes of the inferior dental artery. *Br J Oral Surg.* 1975;13:82.
48. Nunez JC, et al. Atrophic mandible fractures: are bone grafts necessary? An update. *J Oral Maxillofac Surg.* 2017;75:2391–8.
49. Benech A, et al. Intraoral extra-mucosal fixation of fractures in the atrophic edentulous mandible. *Int J Oral Maxillofac Surg.* 2013;42:460–3.
50. Wood GA, et al. Transmucosal fixation of the fractured edentulous mandible. *Int J Oral Maxillofac Surg.* 2011;40:549–52.
51. Iatrou I, Theologie-Lygidakis N, Tzermpos F. Surgical protocols and outcome for the treatment of maxillofacial fractures in children: 9 years’ experience. *J Craniomaxillofac Surg.* 2010;38:511–6.
52. Smith DM, Bykowski MR, Cray JJ, Naran S, Rottgers SA, Shakir S, et al. 215 mandible fractures in 120 children: demographics, treatment, outcomes, and early growth data. *Plast Reconstr Surg.* 2013;131:1348–58.
53. Iatrou I, Theologie-Lygidakis N, Tzermpos F. Surgical protocols and outcome for the treatment of maxillofacial fractures in children: 9 years’ experience. *J Craniomaxillofac Surg.* 2010;38:511–6.
54. Kocabay C, Ataç MS, Oner B, Güngör N. The conservative treatment of paediatric mandibular fracture with prefabricated surgical splint: a case report. *Dent Traumatol.* 2007;23:247–50.
55. Thomas S, Yuvaraj V. Atraumatic placement of circummandibular wires: A technical note. *Int J Oral Maxillofac Surg.* 2010;39:83–5.
56. Iatrou I, Theologie-Lygidakis N, Tzermpos F, Kamperos G. Internal fixation of mandibular angle fractures using one miniplate in Greek children: a 5-year retrospective study. *J Craniomaxillofac Surg.* 2015;43:53–6.
57. Yerit KC, Hainich S, Enislidis G, Turhani D, Klug C, Wittwer G, et al. Biodegradable fixation of mandibular fractures in children: stability and early results. *Oral Surg Oral Med Oral Pathol Oral Radiol Endod.* 2005;100:17–24.
58. Stanton DC, Liu F, Yu JW, Mistretta MC. Use of bioresorbable plating systems in paediatric mandible fractures. *J Craniomaxillofac Surg.* 2014;42:1305–9.
59. Rachmiel A, et al. Two-stage reconstruction of the severely deficient alveolar ridge: bone graft followed by alveolar distraction osteogenesis. *Int J Oral Maxillofac Surg.* 2018;47:117–24.
60. Mathog RH, Toma V, Clayman L, et al. Nonunion of the mandible: An analysis of contributing factors. *J Oral Maxillofac Surg.* 2000;58:746.

61. Ostrander BT, et al. Contemporary management of mandibular fracture nonunion—a retrospective review and treatment algorithm. *J Oral Maxillofac Surg* 2018;76:1479–93.
62. Kokosis G, et al. The use of computer-aided design and manufacturing in acute mandibular trauma reconstruction. *J Oral Maxillofac Surg*. 2018;76:1036–43.
63. Bell RB. Computer planning and intraoperative navigation in cranio-maxillofacial surgery. *Oral Maxillofac Surg Clin North Am*. 2010;22:135.
64. Hurrell MJ, Batstone MD. The effect of treatment timing on the management of facial fractures: a systematic review. *Int J Oral Maxillofac Surg*. 2014;43:944–50.
65. Hurrell MJL. A prospective study examining the effects of treatment timing in the management of mandible fractures. *Int J Oral Maxillofac Surg*. 2018;47:1126–31.

Open Access This chapter is licensed under the terms of the Creative Commons Attribution 4.0 International License (<http://creativecommons.org/licenses/by/4.0/>), which permits use, sharing, adaptation, distribution and reproduction in any medium or format, as long as you give appropriate credit to the original author(s) and the source, provide a link to the Creative Commons license and indicate if changes were made.

The images or other third party material in this chapter are included in the chapter's Creative Commons license, unless indicated otherwise in a credit line to the material. If material is not included in the chapter's Creative Commons license and your intended use is not permitted by statutory regulation or exceeds the permitted use, you will need to obtain permission directly from the copyright holder.



Vikas Dhupar

53.1 Introduction

Maxillofacial surgeons commonly come across a high incidence of condylar fractures in their practice. A French surgeon [1] in the eighteenth century described a high propensity for a narrow portion in the subcondylar region to fracture, which is a common occurrence even today. In spite of a common occurrence, the management has been controversial as there is no established consensus in the treatment of condylar fractures. Traditionally closed reduction has been the treatment of choice for condylar fractures and have been treated by various forms of intermaxillary fixation. With the improvement in radiographic imaging and biomaterials used in the fixation, surgical management has gradually found acceptance as it restores early function.

53.2 Surgical Anatomy

The mandibular condyle forms a part of the temporomandibular joint which is unique (Box 53.1), and it is made of the following structures:

- Condyle of the mandible
- Squamous portion of the temporal bone
- Articular disc (contained within the TMJ)
- Ligaments

Electronic Supplementary Material The online version of this chapter (https://doi.org/10.1007/978-981-15-1346-6_53) contains supplementary material, which is available to authorized users.

V. Dhupar (✉)
Department of Oral & Maxillofacial Surgery,
Goa Dental College & Hospital, Bambolim, Goa, India

Box 53.1. TMJ—Unique Characteristics

- It is a ginglymoarthrodial joint, having both a hinge and a gliding action
- It has an end point closure
- It has a fibrocartilage disc

53.2.1 Condyle

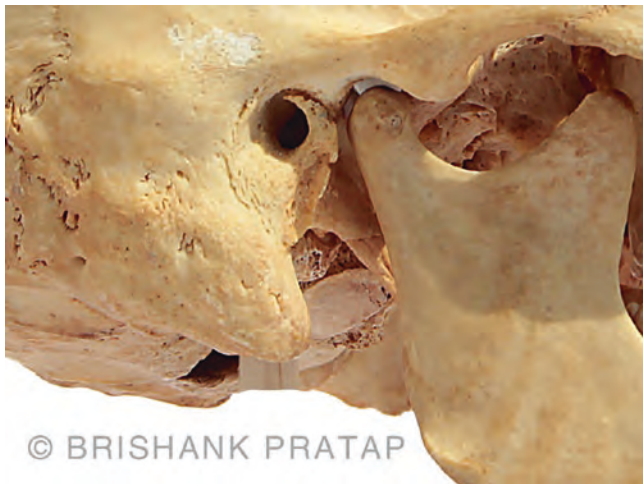The condyle is one of the two processes of the mandible present on the superior portion of the ramus. The condylar head is ovoid in shape measuring approximately 15–20 mm mediolaterally and 8–10 mm anteroposteriorly in dimension [2]. The mandibular condyle articulates with the glenoid fossa present in the squamous portion of the temporal bone to form the temporomandibular joint (Fig. 53.1). Squamous portion of the temporal bone is as thin as 2 mm as a result; the condylar processes maybe driven into the middle cranial fossa following trauma.

53.2.2 Articular Disc

The squamous portion of the temporal bone and the condyle is separated by a dense fibrous connective tissue called the articular disc. The disc is firmly anchored to the condyle by the medial and lateral collateral ligaments, and it merges with the capsule in the periphery. The joint space is divided into superior and inferior compartments by the disc.

53.2.3 Capsule and Ligaments

The capsule surrounds the TMJ and is reinforced by the medial and lateral ligaments which connect the mandible to the temporal bone. The synovial membrane lines the capsule.



©Association of Oral and Maxillofacial Surgeons of India

Fig. 53.1 Bony structures of TMJ

This membrane produces synovial fluid which aids in the lubrication and nourishment of the joint. The lateral ligament also known as temporomandibular ligament has a horizontal and an oblique component which stabilizes the joint. The strength of the lateral ligament may be partly responsible for the fracture at the neck of condyle just below the insertion of the ligament [3]. The medial and lateral discal ligaments which are present inside the capsule are also called collateral ligaments. These ligaments connect the disc to the poles of the condyle. In addition to these ligaments, there are two non-capsular ligaments, namely, sphenomandibular and stylo-mandibular which may have a limited function.

53.2.4 Muscles of Mastication

There are four muscles of mastication, namely, the medial and lateral pterygoid, masseter, and the temporalis. Lateral pterygoid is attached to the pterygoid fovea at the condylar neck and is responsible for the displacement of the condylar fractures. Change in the direction of resultant forces post fracture will alter the function of the mandible during various excursion movements.

53.2.5 Vascularisation

The arterial blood supply to the TMJ is derived from the two terminal branches of the external carotid artery, namely:

- Superficial temporal artery
- Maxillary artery

It may be noted that the condyle receives blood supply from three sources

1. Medullary bone supplied by inferior alveolar artery
2. Overlying periosteum of the condyle
3. Attachment of lateral pterygoid muscle

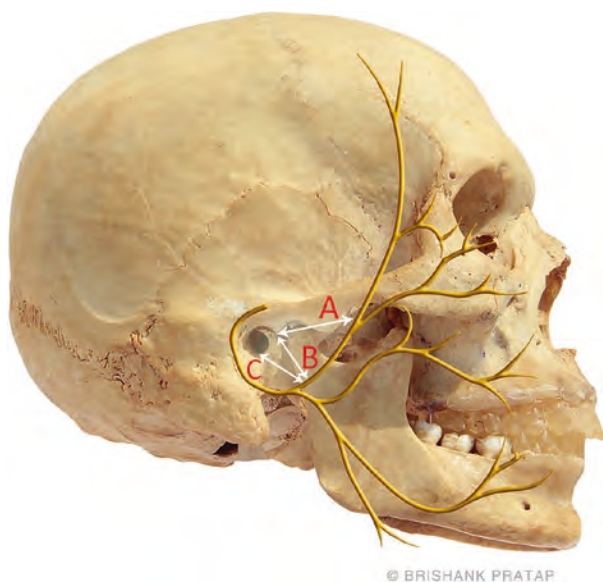
This may explain the reason for the fractured condyle to remain viable even after stripping of the periosteum during the surgical procedure as the lateral pterygoid muscle remains attached to the fractured fragment [4]. The venous drainage starts in the retrodiscal plexus which drains into the superficial temporal and maxillary veins that join to form the retromandibular vein, which in turn drains into the external jugular vein.

53.2.6 Innervation

It is imperative to understand the innervation of the joint so as to minimize the complications following fracture of the mandible and its management. Both the sensory and motor innervation is encountered while approaching the joint. The sensory nerves are auriculotemporal, masseteric, and posterior deep temporal. Auriculotemporal nerve crosses the condyle medial to it and lies in contact with the condylar neck and capsule [5]. It is encountered in the preauricular incision and may result in postoperative complications.

53.2.7 Facial Nerve

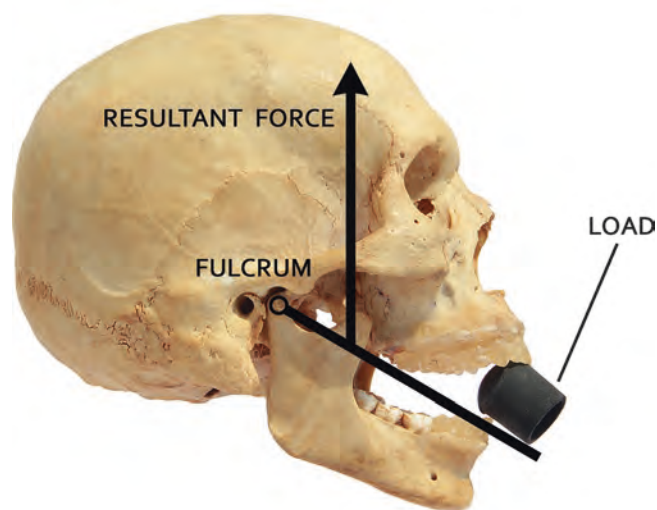
It is the key nerve that transverses the face, and it is liable for the motor function of the muscles of facial expression. This nerve transverses the temporo-parietal fascia and finally divides into five terminal branches in the parotid gland (Fig. 53.2). Hence all the extraoral approaches for the condylar fractures are designed keeping the facial nerve in mind. Al-Kayat and Bramley [6] found the nerve was at an average distance of 20 mm with a range of 8–35 mm from the anterior margin of the auditory canal. This is the reason the preauricular incision is given in the skin crease near the tragus or placed endurally. The neck of the condyle can be exposed via the transparotid approach. In this approach the condyle is reached through the space between the temporozygomatic and buccocervical trunks of the nerve. This results in a direct and safe approach to the neck of the condyle. The marginal mandibular nerve is encountered in the submandibular or periangular approach. This branch may further subdivide into two or more branches [7]. As a rule, the submandibular incision is given 2 cm below the lower border of the mandible to prevent paresis of the lower lip.



©Association of Oral and Maxillofacial Surgeons of India

Fig. 53.2 Terminal branches of facial nerve with Al Kayat and Bramely's [6] measurements for trunk of facial nerve. (A) .8–3.5 cm, (B) 2.4–3.5 cm, (C) 1.3 cm

CLASS III LEVER



© BRISHANK PRATAP
©Association of Oral and Maxillofacial Surgeons of India

Fig. 53.3 Function of mandible as class III lever

53.3 Biomechanics of Condylar Fracture

U-shaped mandible supports the condyles on either side. There are two major movements while opening the mouth, rotational, and translational which occur in the inferior and superior compartments, respectively. Mandibular function is characterised as a class III lever with the joint being the fulcrum [8]. The musculature applies the force between the joint and the masticatory load (Fig. 53.3).

53.3.1 Mechanism of Injury

Trauma causing condylar fracture was explained by Lindahl [9]. It is important to understand the pattern as it gives the type of injury sustained (Fig. 53.4).

1. Kinetic energy derived from the momentum created by the subject falling on a static object. This is an axial force which is transmitted to the condyle from the lower border of the mandible. Fracture can occur at the site of injury and at the condyles at a higher level. Occluding teeth cannot reduce the force. May also result in fracture of teeth.
2. Kinetic energy derived from the momentum created by a moving object against a static subject. Generally noted in assaults or sport injuries. More or less horizontal forces will result in a fracture both at the site of impact and at the

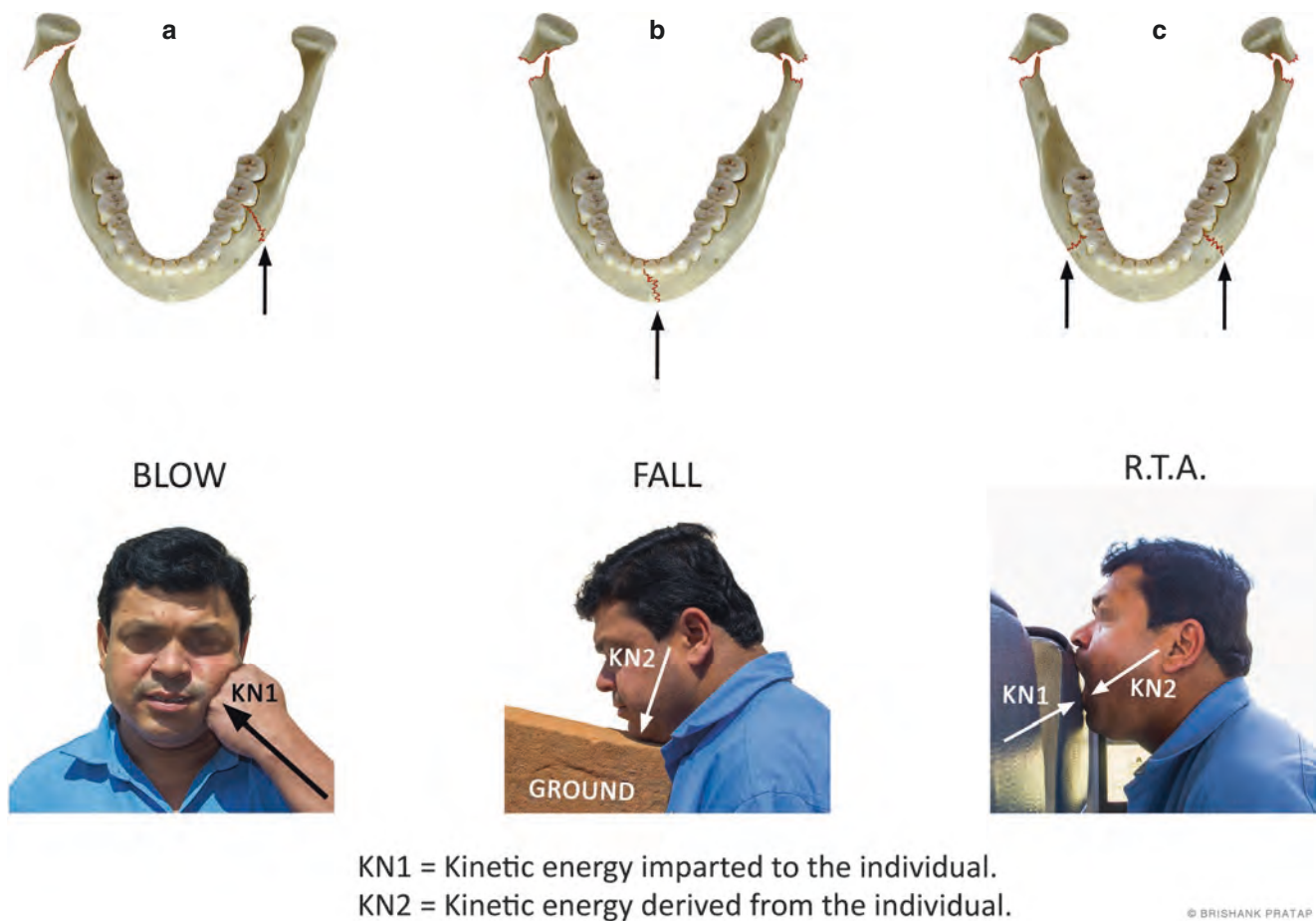
condyle on the opposite side. Fracture is usually at the base of the condyle.

3. Combination of the above two is seen in a road traffic accident and may result in more severe injuries.

An external force applied generally gets distributed over the entire mandible. However these forces result in the fracture of the subcondylar region which is weak and are subject to tensile stresses. A counter-coup injury is often noted in the condylar region. This prevents displacement of the condyles into the middle cranial fossa especially in bilateral fractures resulting from injuries over the chin.

53.3.2 Effect of Condylar Fracture

The signs and symptoms seen following trauma are due to the functional loss resulting from the disruption of the local anatomy. Following trauma a protective mechanism is triggered. It is generally expected that due to premature contact on the fractured side, excessive forces would be generated during loading of the non-fractured site on mastication. However, it is noted there is a shift of mean force vector towards the non-fractured site which results in protecting the fractured site during biting [10]. This results in neuromuscular adaptation. An increase in the muscle activity on the non-fractured side and a decrease of active force on the opposite



©Association of Oral and Maxillofacial Surgeons of India

Fig. 53.4 Mechanism of fracture of condyle

side results in this process. Hence most of the masticatory forces are directed towards the non-fractured site and resulting in less neuromuscular adaptation on the fractured site. Refer to the article by Ellis et al. [8] for a comprehensive understanding of the biological considerations of fractures of mandibular condyle.

53.3.3 Adaptation to Fracture

Following condylar fracture of the mandible, patients adapt to the injury by compensation mechanism which is divided as follows:

- Skeletal
- Neuromuscular
- Dental

Intervention by the surgeons either by open or closed reduction minimizes the dental compensation. It is noted that

there is a decreased masseter activity on the fractured site transferring load to a non-fractured site. This results in neuromuscular adaptation which may also be a protective phenomenon [8]. In case of an open reduction, there is minimum amount of neuromuscular adaptation. Usually a closed reduction results in an articulation which is inferior and anterior to the articular eminence which may limit the transitional movement. This can be avoided by open reduction and fixation. Minimum complications have been reported in the studies evaluating closed reduction in treatment of condylar fractures as pain and mouth opening were the only criteria which were evaluated. A statistically significant reduction in the incidence of malocclusion and lateral deviation on opening, along with an improved protrusive and laterotrusive movements, were noted in patients treated with surgical therapy vis-à-vis closed therapy in a recent meta-analysis report [10]. Compared to closed reduction where skeletal and neuromuscular adaptation is seen, in open reduction only neuromuscular adaptation will take place following treatment.

53.4 Classification of Condylar Process Fractures

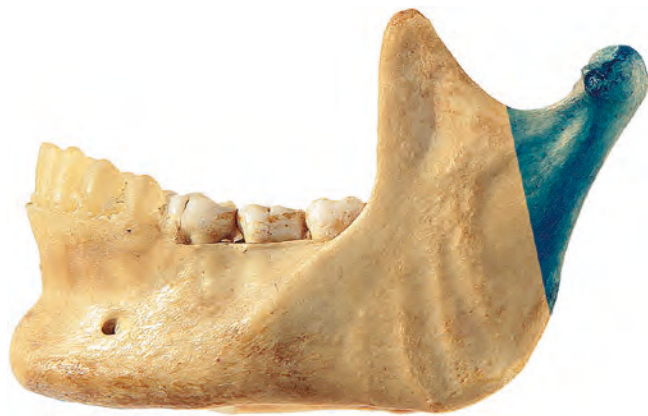Condylar fractures can be described as a fracture line above the mandibular foramen that runs from the posterior border of the ramus to sigmoid notch or the condylar head (Fig. 53.5). Literature mentions numerous classifications of condylar fractures. Most classifications described the fracture based on the anatomical site, displacement, and fracture level, inclined towards close reduction. With the advancement of imaging modalities and better understanding of open reduction procedures, classifications which are relevant are discussed.

Various terms describing the condylar fractures have appeared in the English literature (Fig. 53.6):

- No displacement—Fracture maintains anatomic position
- Deviation—Fragments are in primary contact
- Displacement—There is no contact of the fracture fragments
- Dislocation—Extra articulation of the joints

In 1927 **Wassumund** [11] differentiated between the head and neck fractures of the condyle. Early classification only described anatomical position but had no relevance in treatment as it did not document the angulation of displacement or dislocation. Condylar fractures were classified as:

- Base fracture
- Neck fracture
- Head fracture (diacapitular)



© BRISHANK PRATAP
©Association of Oral and Maxillofacial Surgeons of India

Fig. 53.5 Area of condylar fracture

MacLennan [12] was the first to differentiate between simple bending, displacement, and dislocation fractures of the condylar process.

Class I: no deviation (bending)

Class II: deviation (bending) at the fracture level

Class III: displacement (condylar head remains within fossa)

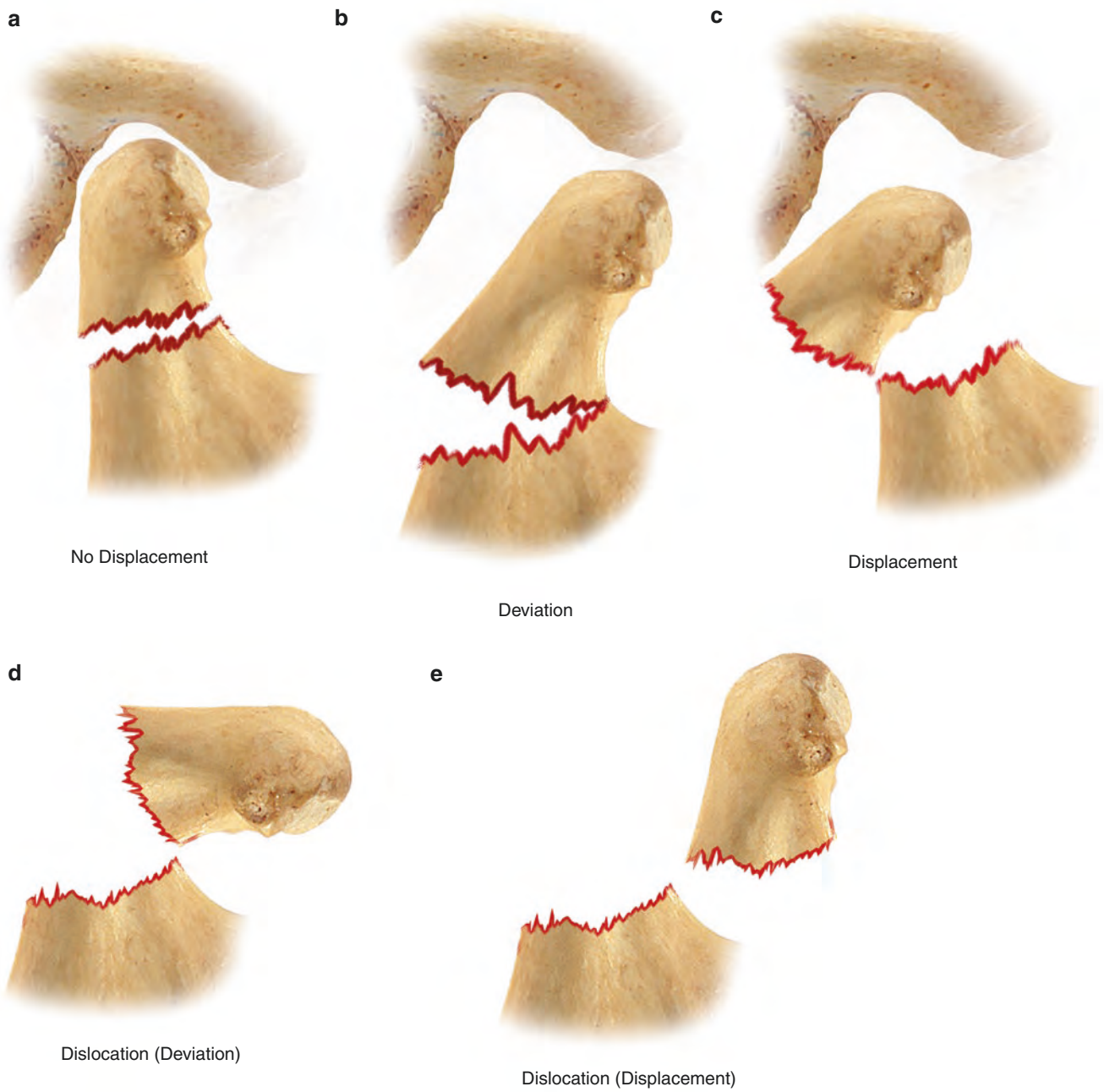
Class IV: dislocation (condylar head outside of fossa)

Spießl and Schroll [13]. A classification well accepted in the European literature, which differentiated between fractures of the base and neck of the condyle, it also noted the range of angulation with deviation, displacement, or dislocation (Fig. 53.7).

- Type I: condylar neck fracture with no associated deviation/displacement
- Type II: low condylar neck fracture with deviation/displacement
- Type III: high condylar neck fracture with deviation/displacement
 - IIIa: ventral
 - IIIb: medial
 - IIIc: lateral
 - IIId: dorsal
- Type IV: low condylar neck fracture with dislocation
- Type V: high condylar neck fracture with dislocation
- Type VI: intracapsular fracture of the condylar head

There are numerous modifications of Spiessl and Scholl classifications and were given over a period of time as a result subtypes has evolved especially in type V and VI fractures. Modifications included Rasse [14], Neff et al. [15], Hlawitschka and Eckelt [16], and Loukota et al. [17].

- Type A: There is a continuous bony contact within the glenoid fossa, with a component of the remaining condylar head and the fracture supported with no loss of ramal height (Fig. 53.8a).
- Type B: Loss of support within the articulating fossa and with the loss of mandibular ramal height (Fig. 53.8b).
- Type C: The highest portion of the fracture is below the level of the lateral ligament, as a result there is a loss of ramal height (Fig. 53.8c).



© BRISHANK PRATAP

©Association of Oral and Maxillofacial Surgeons of India

Fig. 53.6 (a) No displacement. (b) Deviation. (c) Displacement. (d) Dislocation (deviation). (e) Dislocation (displacement)

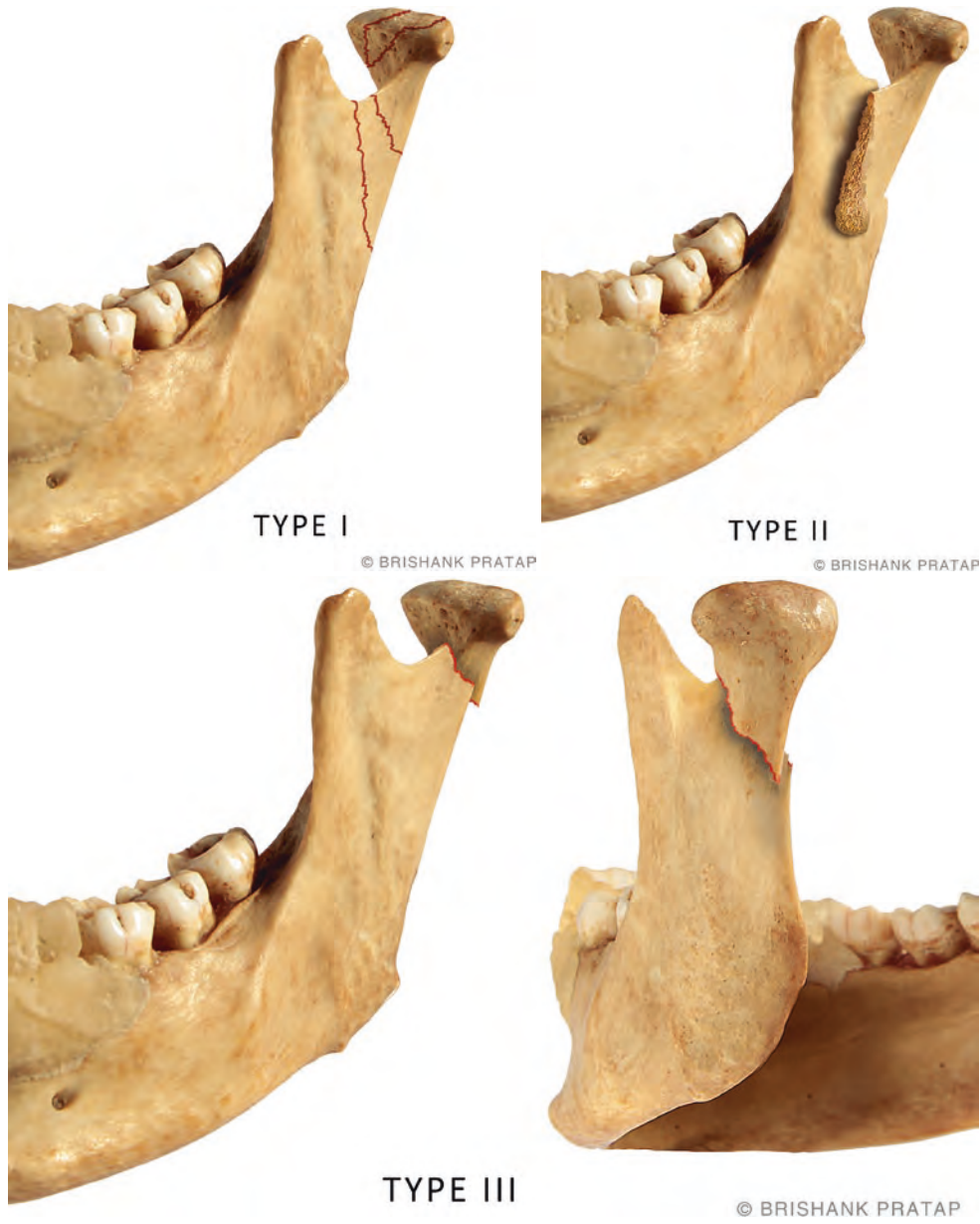
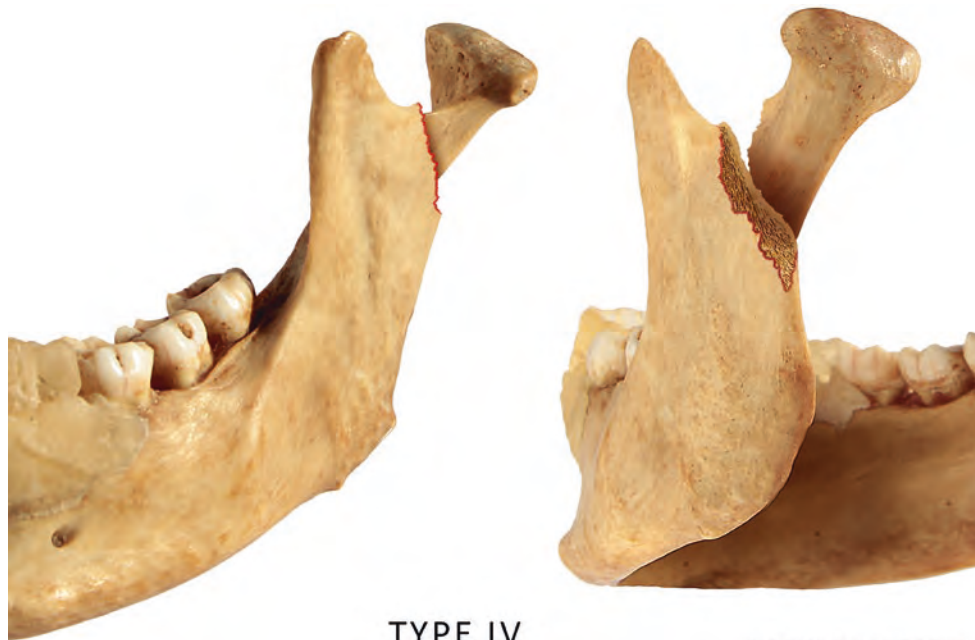
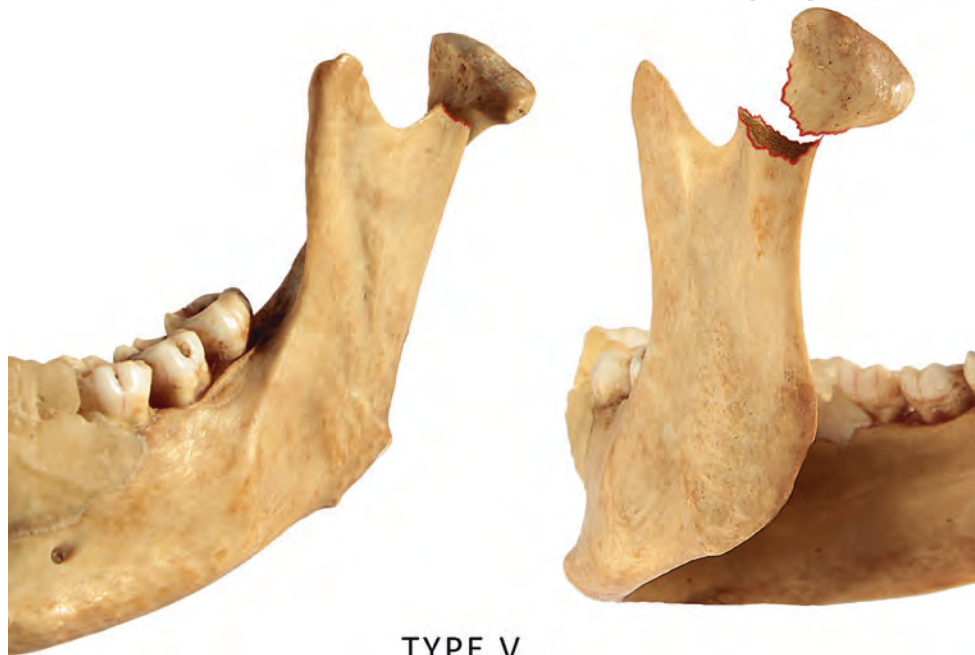Fig. 53.7 Types I–VI: Spiessl and Schroll classification



TYPE IV

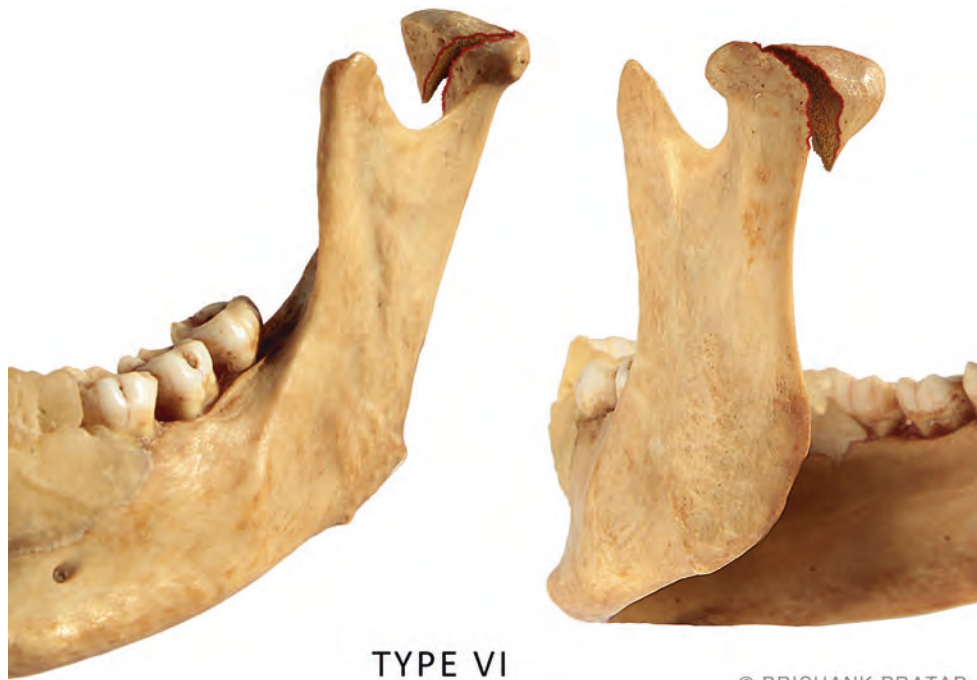© BRISHANK PRATAP



TYPE V

© BRISHANK PRATAP

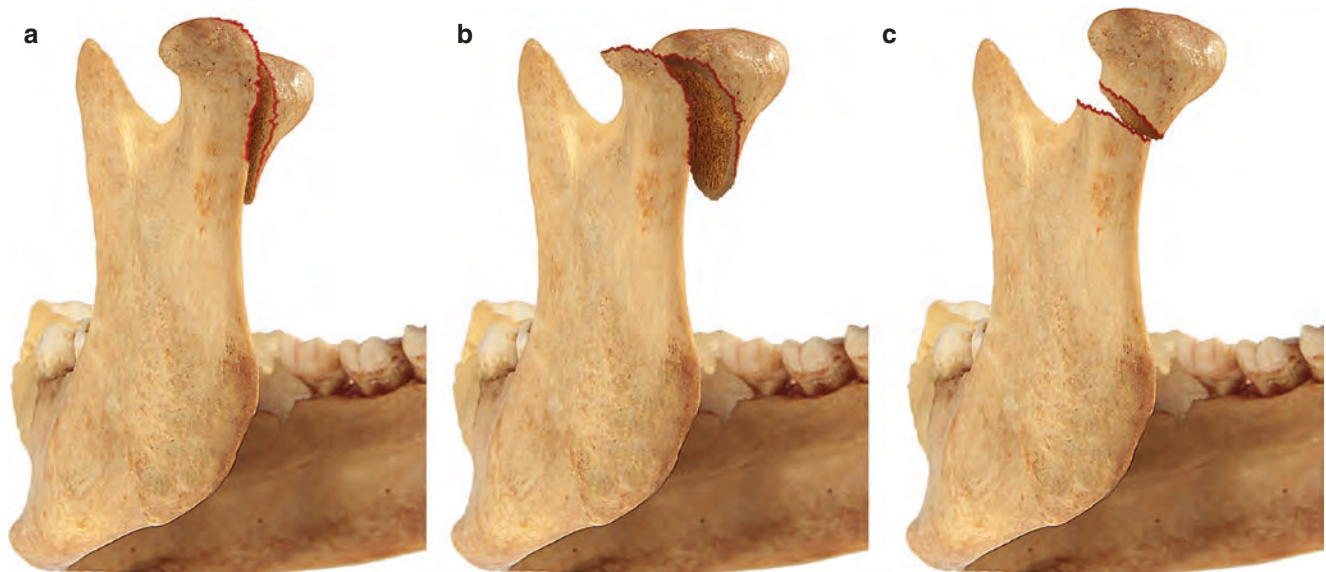
Fig. 53.7 (continued)



©Association of Oral and Maxillofacial Surgeons of India

© BRISHANK PRATAP

Fig. 53.7 (continued)



©Association of Oral and Maxillofacial Surgeons of India

© BRISHANK PRATAP

Fig. 53.8 Modified classification Type A, B, C

Lindahl [9] gave the most comprehensive classification. Although descriptive, it is a complicated classification [9].

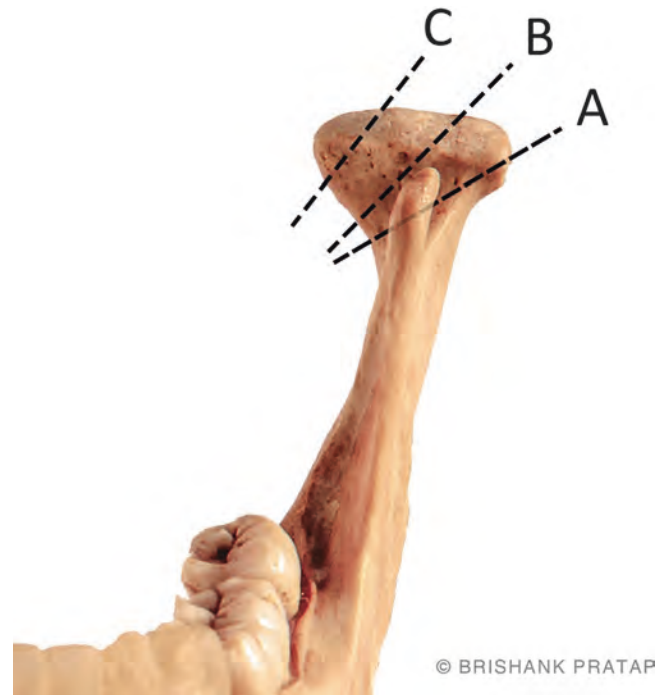
1. Fracture level
 - (a) Condylar head
 - (b) Condylar neck
 - (c) Subcondylar/condylar base
2. Deviation and displacement
 - (a) Bending/deviation with medial overlapping segments
 - (b) Bending/deviation with lateral overlapping segments
 - (c) Bending/displacement without overlapping
 - (d) Nondisplaced fracture without deviation
3. Relation between condylar head and fossa
 - (a) No dislocation
 - (b) Slight dislocation
 - (c) Moderate dislocation
 - (d) Severe and/or complete dislocation
4. Condylar head fracture
 - (a) Horizontal
 - (b) Vertical
 - (c) Compression fracture

Lindahl's Definition

- **Subcondylar fracture:** The fracture line starts at the sigmoid notch and extends to the posterior border of the mandible.
- **Condylar neck fracture:** It is located at the condylar process which is below the level of the condylar head.
- **Condylar head fracture:** The majority of the fracture components or the whole fracture is contained within the TMJ capsule.

A most common classification of diacapitular fractures was given by He et al. [18]. The types of fractures that can be recognized are (Fig. 53.9):

- Type A—Lateral third portion of the condylar head has the fracture line, and there is reduction of the ramus height.
- Type B—Central third portion of the condylar head has the fracture line, and there is no reduction of the ramus height.
- Type C—Medial third portion of the condylar head has the fracture line, and there is no reduction of the ramus height.
- Type M—It is a fracture which is comminuted with multiple fragments, usually more than three, of the condylar head.



©Association of Oral and Maxillofacial Surgeons of India

Fig. 53.9 Classification of diacapitular fractures (Type M not shown in figure)

Loukota et al. [19] proposed a system of classification for condylar processes fractures of the mandible. This classification was adopted by SOR group which is based on a line A drawn perpendicular from the lowest portion of the sigmoid notch to the posterior border of the mandible. This helps in identifying the anatomy of the mandibular ramus even in cases following severe trauma. A clarification is also given on the condylar head fracture, and it clearly defined the term minimal displacement.

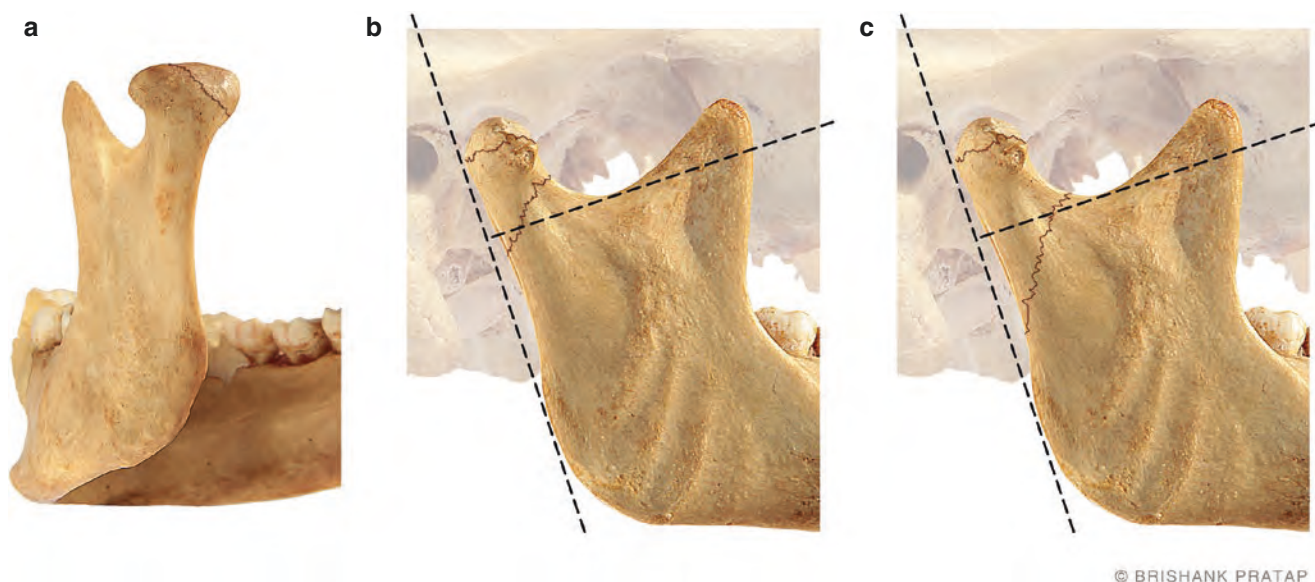
Diacapitular fracture: Starting in the articular surface the fracture line may extend outside the TMJ capsule (Fig. 53.10a).

Condylar neck: Major portion of the fracture line which starts above the line A remains above it (Fig. 53.10b).

Condylar base: Major portion of the fracture line remains below the line A, and it extends behind the mandibular foramen (Fig. 53.10c).

Minimal displacement: Less than 10° displacement or 2 mm overlap of the bone edges or both.

AO Foundation in 2010 expanded on Ellis [20] classification with the determination of “high-neck” and “low-neck” fractures in the online AO Surgery Reference, which pro-



©Association of Oral and Maxillofacial Surgeons of India

Fig. 53.10 (a) Dicapitular fracture. (b) Condylar neck. (c) Condylar base

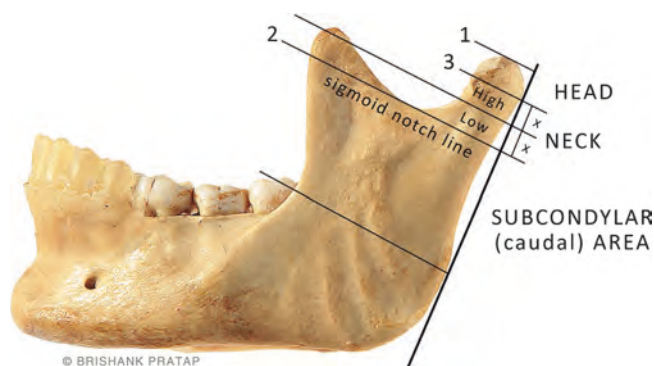
vided a great detail to the location of “high and low” fractures as explained by Loukota:

- **Line 1** runs parallel to the posterior border of the mandible line.
- **Line 2** as called the sigmoid notch line runs perpendicular to line 1 at the deepest portion of the sigmoid notch.
- **Line 3** is perpendicular to the first line and is below the lateral pole of condylar head.
- A line is also drawn half way between the line 2 and line 3 which differentiates between high- and low-neck fractures (Fig. 53.11).

Neff et al. [21] published the Comprehensive AOCMF Classification System: Condylar Process Fractures. It is a system that highlights fracture location, identification, displacement, comminution, and dislocation. Location of the condylar fracture is clearly identified:

- *Condylar head*: the condylar head reference line runs perpendicular to the posterior ramus below the lateral pole of the condylar head.
- *Condylar neck*: the sigmoid notch line running through the deepest point of the sigmoid notch perpendicular to the ramus line extending superiorly to the condylar head.
- *Base of the condylar process*: the sigmoid notch line running through the deepest point of the sigmoid notch perpendicular to the ramus line extending inferiorly.

In the early days classification systems for the condylar fractures were entirely focused in locating the fracture. This was followed by systems which added the relation of the condyle with the adjacent structure. Loukota [19] gave a



©Association of Oral and Maxillofacial Surgeons of India

Fig. 53.11 AO foundation classification

classification which accurately locates the fracture with reference to treatment which is a simple classification to follow.

The aim of classifying the condylar fractures of the mandible is to locate the type and nature of the fracture which in turn will give a clear understanding of the nature of injury. This in turn will help the surgeon make a decision on the modality of treatment which may be open or closed.

53.5 Incidence and Pattern

In the facial skeletal, one of the most common bones to fracture is the mandible. Analysis of the fracture of different anatomical sites of the mandible revealed that there was a 10–40% incidence of condylar fractures [22–24]. Ellis et al. [25] published a study that showed condyle fractures repre-

sented 29.3% of all mandibular fractures. Zachariades et al. [26] stated that 72% of the condylar fractures were associated with other mandibular fractures. Isolated condylar fractures were rare, and occurrence of malocclusion was more dependent on the site of fracture. Incidence of fractures of condylar base were 57%, neck 31%, and head 12% as reported by MacLennan [27]. Incidence of condylar head was the least with the majority fractures at the condylar base. Frequency of unilateral fractures is higher than the bilateral fractures.

The highest incidence of mandibular fractures in males was 20–30 years and females 30–40 years [25] with the male-to-female ratio 3:1 [26]. Condylar fracture can result from direct or indirect trauma. The degree, direction, magnitude, and point of application of force determine the severity of displacement [27]. Personal violence [28] followed by fall [29–31] is the most common aetiology of condylar fractures.

53.6 Clinical Features

The patient may show mild to severe signs and symptoms following a condylar fracture. These are entirely dependent on the amount of displacement of the fractured fragments. Condylar fractures infrequently occurred in isolation and are generally associated with fractures of other sites of the facial bones. Surgeons may overlook subtle clinical features.

Signs and symptoms:

- Pain and swelling over the preauricular region
- Ecchymosis over the mastoid region
- CSF otorrhea
- Hollowness over the condylar region
- Restricted incisal opening
- Locked mandible

53.6.1 Condylar Fractures: Unilateral

- Premature occlusion on the ipsilateral side (Fig. 53.12a).
- Open bite due to the loss of vertical height on the contralateral side.
- Affected side deviates on opening and is common because of the interruption of the action of the lateral pterygoid muscle.
- Limited laterotrusive movements away from the fractured side but may be maintained towards the fracture.

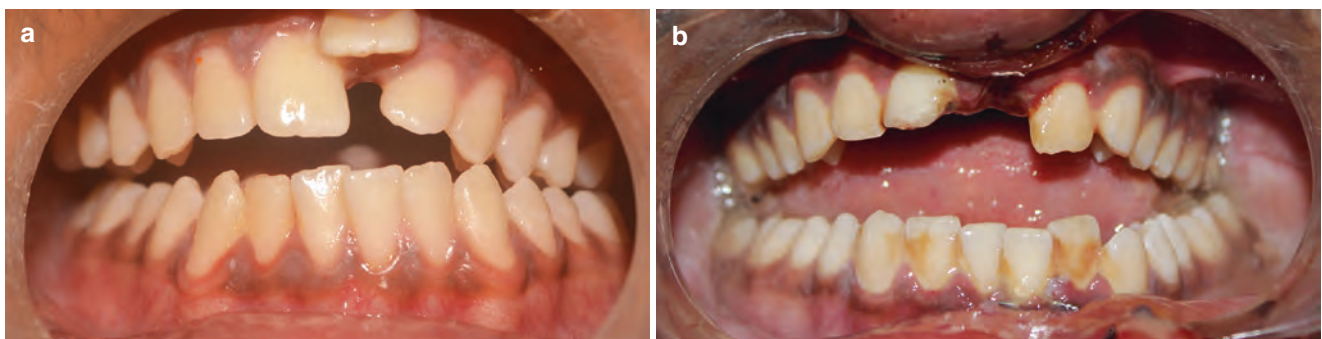
53.6.2 Condylar Fractures: Bilateral

- Bilateral loss of vertical height results in anterior open bite with posterior gagging (Fig. 53.12b).
- Restricted mouth opening
- May be associated with other fractures

53.6.3 Radiographic Assessment

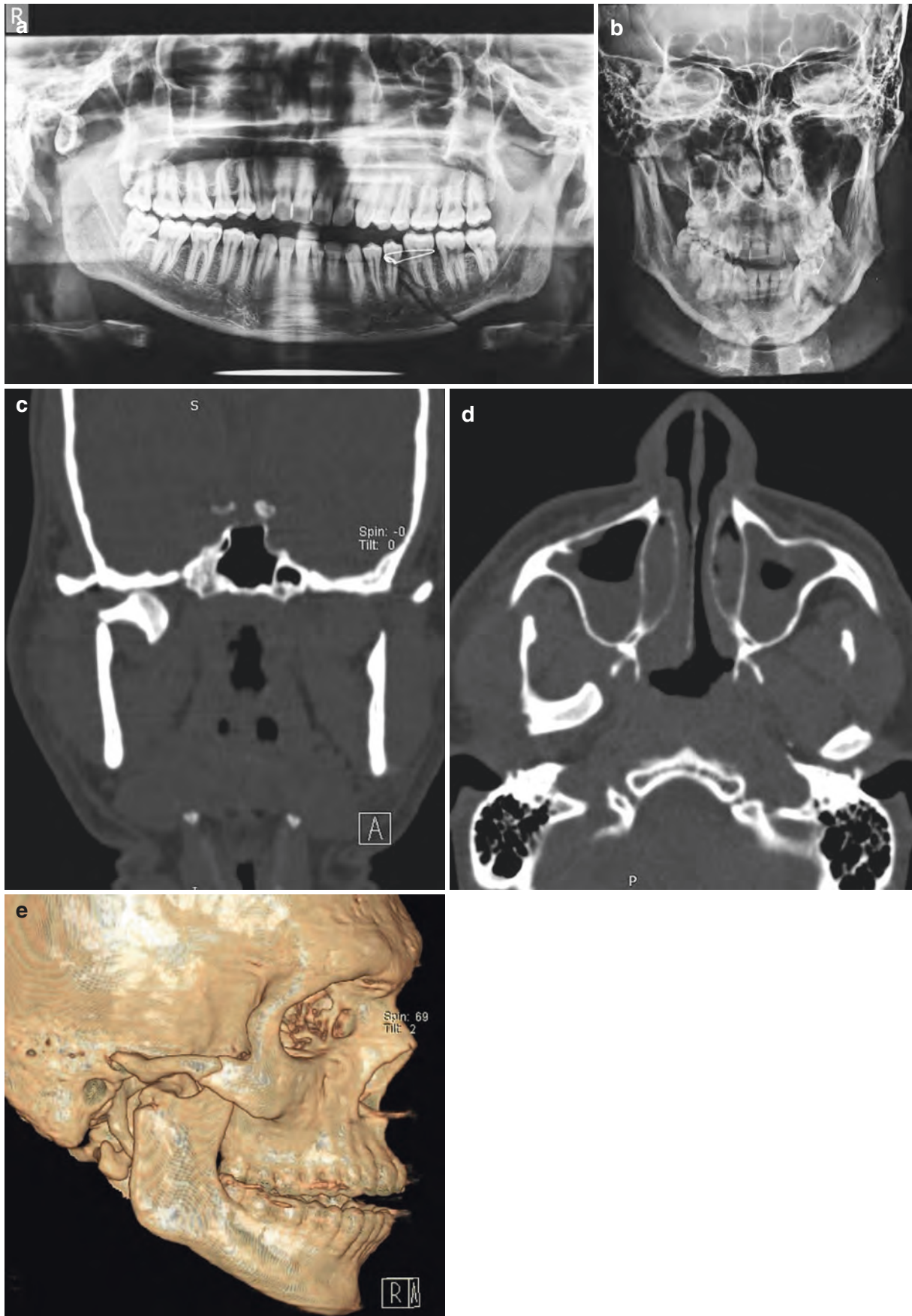
Condylar fractures can be evaluated by a number of conventional views. A set of two radiographs are usually taken perpendicular to each other for optimum evaluation. However the assessment has become more descriptive with availability of specialized radiographs. Various views which can be taken to evaluate the condylar fracture are as follows (Fig. 53.13):

- Towne's view
- AP mandible coronal position
- Panorex
- CT scan
- MRI



©Association of Oral and Maxillofacial Surgeons of India

Fig. 53.12 Occlusion post condylar fracture. (a) Unilateral condylar fracture of the left. (b) Bilateral condylar fracture



©Association of Oral and Maxillofacial Surgeons of India

Fig. 53.13 A case of unilateral fracture of the right side of condyle with a left body of mandible. (a) OPG. (b) PA mandible. (c) Coronal view. (d) Axial view. (e) 3D view of the CT scan

However it may be noted that with conventional radiography, very limited information is available. CT scans in the three planes, namely, coronal, axial, and sagittal, with volumetric studies can reveal the true picture of the fracture both for the terms of evaluation and treatment planning. MRI are essential to evaluate the disc injuries specially in dislocation and intracapsular condylar fractures; however MRI are not taken as a routine practise

53.7 Management

Historically there has been no clear agreement among the surgeons on the line of management of the fractures of the condyle. The goals of treatment which were enumerated by Walker [32] (Box 53.2) are well accepted.

Box 53.2. Treatment Goals [32]

- No pain and minimum interincisal distance of 40 mm on opening the mouth.
- On excursions movements are good.
- Restore pre-injury occlusion.
- Good stable temporomandibular joints.
- Good symmetry of face and jaw.
- Good facial and jaw symmetry

Box 53.3. Indications for Open Reduction Zide and Kent's [33]

Absolute

- Condyle displaced into middle cranial fossa
- Not possible to obtain adequate occlusion by closed reduction
- Lateral capsular displacement of condyle
- Presence of foreign body

Relative

- Bilateral condylar fracture in an edentulous patient without splint
- Comminuted midface fracture, prognathic or retrognathic jaws having associated bilateral condylar fractures
- Generalized periodontal conditions
- Jaws—totally or partially edentulous
- Unilateral condylar fractures with lack of base

Box 53.4. American Association of Oral and Maxillofacial Surgeons [34]

- Evidence of fracture—clinical
- Evidence of fracture—radiographic
- Malocclusion associated with fractures
- Mandibular dysfunction
- Abnormal maxillo-mandibular relationship
- Foreign body invasion
- Lacerations and/or haemorrhage in external auditory canal
- Cases having hemotympanum, CSF otorrhea, effusion, or hemartorisis

Literature has indicated that closed reduction has been the treatment of choice. This may be due to the complexities involved with open reduction. Surgical approach is technically demanding and associated with complications in inexperienced hands. As a result, some centres have exclusively treated condylar fractures by closed reduction. However as opposed to closed reduction, a few centres follow a protocol for management where open reduction is treatment of choice. Patients managed by surgical treatment have a superior outcome in term of post-treatment malocclusion, protrusion, laterotrusion, and lateral deviation during mouth opening. However, there was a higher infection rate as compared to non-surgical treatment. However, there is no statistical difference in post-treatment pain and maximum mouth opening in the two modalities of management [10]. Management can be divided as non-operative and operative (Box 53.6).

53.7.1 Non-operative

Some patients can be managed by observations provided they have a minimal nondisplaced fracture, dentate with a stable occlusion and having minimum pain. An important factor is that the patient must be compliant. At the onset of the treatment, patient must be explained about the possibility of additional treatment in the form of closed reduction which may be required.

Protocol followed is as follows:

1. Diet: There is no restriction on the diet; generally a patient would be restricted to a soft diet in order to avoid pain.
2. Rehabilitation: Patient is instructed to perform exercises of the jaw such that all the excursion movements are carried out. Goals of rehabilitation are mentioned in the (Box 53.8).

Box 53.5. Indication for Open and Closed Reduction
Fonseca [35] adapted from references [36–43]

Absolute

- Condyle displaced into middle cranial fossa
- Presence of foreign body
- Extracapsular displacement of condyle laterally
- Malocclusion not amenable to closed reduction (e.g., functional reduction of ramus height)

Strong evidence for open reduction

- Bilaterally fractured condyles
- Condyle displacement grossly $>45^\circ$ (severely displaced)
- Anatomic reduction of ramus height ≥ 2 mm
- Condylar fractures with an unstable base (associated midface fractures)
- Unstable occlusion generally seen in periodontal disease, less than three teeth per quadrant
- Condylar fractures for which adequate physiotherapy is impossible

Mixed evidence for open reduction

- Moderate condylar displacement, $10\text{--}45^\circ$

When to treat with closed reduction

- Nondisplaced or incomplete fractures
- Isolated intracapsular fractures
- Condylar fractures in children (except for absolute indications)
- Reproducible occlusion without dropback or with dropback that returns to midline on release of posterior force
- Medical illness or injury that inhibits ability to receive extended general anaesthesia

Box 53.6. Management of Condylar Fractures

Non-operative:

- Observation, physiotherapy, etc.

Operative:

- Closed procedures:
- MMF (arch bars or screws—elastic or wire)
- Open reduction and internal fixation (ORIF)
 - Approach is determined by:
 - (i) Surgeon preference
 - (ii) Fracture location
 - (iii) Type of fixation

Box 53.7. Factors Taken into Consideration for Treatment

- Location of the fracture
- Amount of vertical reduction in height of the ramus
- Degree of angulation
- Relation of condylar head to the glenoid fossa
- Fragmentation pattern (simple versus complex)
- Association with other mandibular injuries
- Dental occlusion/status of dentition
- Association with other facial bone injuries
- Association with systemic injuries
- Association with the condition of the patient (comorbidity factors)
- Foreign body in temporomandibular joint (TMJ)

Box 53.8. Closed Reduction

Advantages

- Relatively safe procedure
- No injuries to vital structures
- Hospitalization may not be required

Disadvantage

- Long period of intermaxillary fixation
- Growth disturbances can occur in children
- Success depends on patients cooperation
- Long-term follow
- Contraindicated in medically compromised
- Challenge in partially or totally edentulous patients

3. Follow-up: Recall visit is scheduled after 1 week. At this visit progress is recorded. Next visit is scheduled after 2 weeks if the patient is compliant. In case the progress is not satisfactory frequent follow-up would be required or a change in treatment plan.

53.7.2 Closed Reduction

Closed reduction is a misnomer. It is never possible to achieve anatomic reduction as seen in management of other fractures. Closed reduction relies on the functional adaptation where a stable occlusion is achieved. Advantage of this technique is that it is minimally invasive and may not require hospitalization. It is entirely possible to carry out the procedure under local anaesthesia. However adaptation is never complete in adults as opposed to children. It may be possible to treat all types of condylar process fractures by this technique, but the surgeon must

exercise his judgement based on the case and patient requirements. Closed reduction may involve the following:

1. Maxillomandibular fixation (MMF): Some surgeons prefer period of MMF which may range over 2–6 weeks. MMF can be obtained by using arch bars, Ivy loops, IMF screws or any other method a surgeon is comfortable; however method used will depend on the use of elastics or wires, and MMF may entirely be based on the level of fracture. The reader is advised to refer Chap. 50 of this book for details on various wiring and IMF techniques. The lower the fracture, the longer the period of immobilization. In children immobilization may range from 7 to 10 days as there are high chances of developing ankylosis. This is followed by functional treatment.
2. Functional treatment: At times only, functional treatment may be followed. This treatment relies on guiding elastics and active movements. Elastics are given to achieve repeatable occlusion. Initially heavy elastics are placed and then slowly shifted to light elastics. During the meals elastics are removed. After an initial period of 2–4 weeks, elastics are placed only during the night. Minimum elastics must be used as the aim is to permit maximum mobility of the jaw. Functional treatment can be supported by myofunctional orthodontic treatment employing activator therapy. Myofunctional therapy should be started as soon as the mouth opening enables taking dental impressions.

53.7.3 Open Reduction and Fixation

This modality is technically challenging due to the complexities in terms of anatomy, approach, and fixation. It has been observed that by achieving anatomical reduction irrespective of the type of fixation used, it will result in restoring back the skeletal architecture. This in turn would require only neuromuscular adaptation for full recovery of the patient. According to the reports, this may be the reason for open management to be superior to the closed [36].

Surgical approaches to the condylar fracture are entirely dependent on the following factors (Fig. 53.14):

1. Location of the injury
2. Type of osteosynthesis

Incisions used to approach the fractures are divided as

1. Intraoral
2. Retromandibular
3. Submandibular/ periangular
4. Preauricular/ retroauricular

Box 53.9. Open Reduction and Fixation

Advantages

- Anatomic reduction of fractures
- Short or no intermaxillary fixation
- Early function

Disadvantage

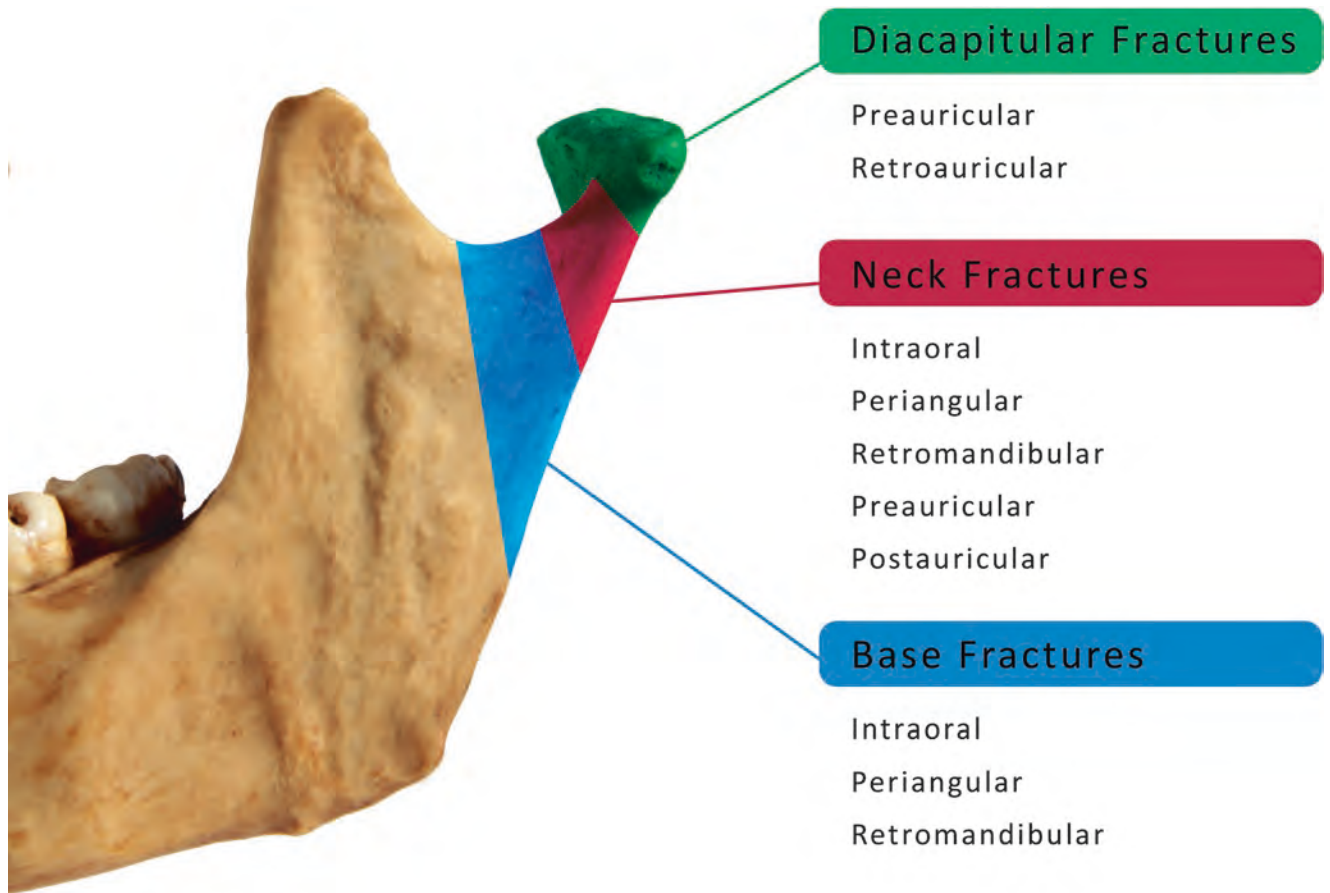
- Complications such as scar and injuries to neurovascular structures
- Infections
- Hospitalization required
- High cost of treatment
- Steep learning curve for surgeon

53.7.3.1 Submandibular/Periangular

(Fig. 53.15a, b) (Video 53.1)

This is an approach most maxillofacial surgeons are familiar with in their practise popularly known as Risdon approach. It exposes the base along with the neck of the condyle. Incision can either be parallel to the lower border or placed in a skin crease for maximum cosmetic results. For the condylar, fracture's incision is extended backward and upward to give a maximum exposure hence also referred to as periangular incision. The marginal mandibular nerve is protected by marking the incision 2–3 cm below the lower border of the mandible. Incision transverses through the skin, subcutaneous fat, and platysma. A superior platysmal dissection will expose the marginal mandibular nerve; however this may not be necessary. After dissection of the platysma, superficial layer of deep cervical fascia is transected; this may expose the facial artery and vein. These may be required to be ligated and reflected superiorly. This will protect the marginal mandibular nerve. Then pterygomasseteric sling is divided and periosteum reflected to expose the lower border of the mandible. This gives an adequate exposure for osteosynthesis.

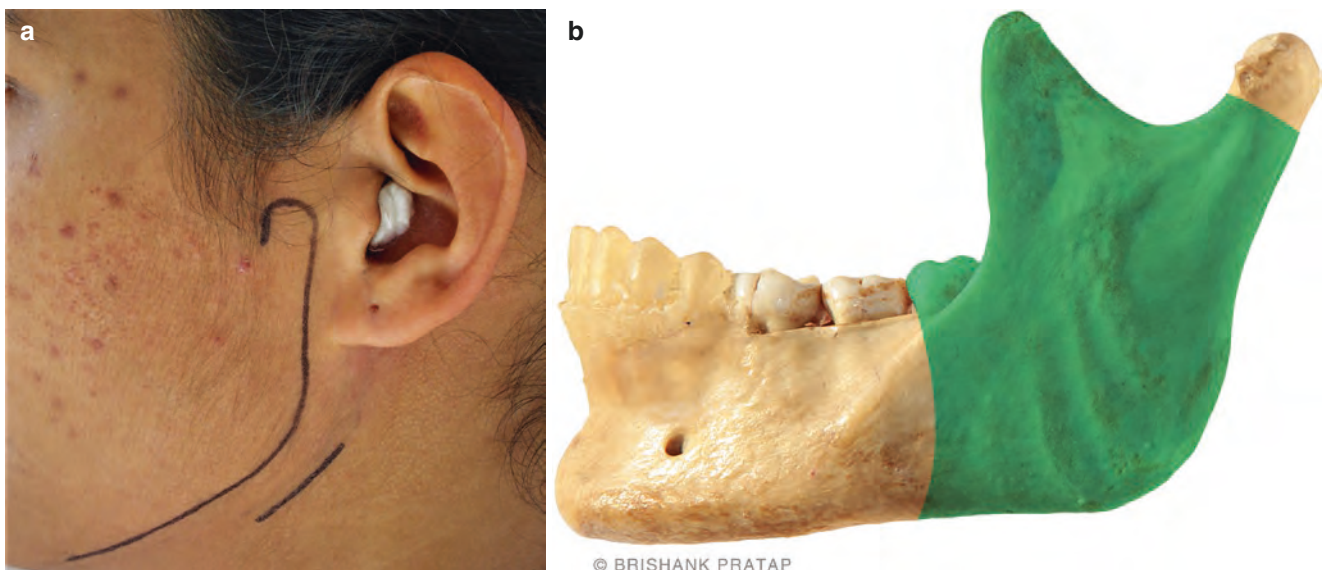
A modification of the submandibular/periangular approach known as the high submandibular approach or the high cervical transmasseteric anteroparotid approach provides good aesthetics and reduces the chances of damage to the facial nerve [44]. A curved incision measuring three to five cm in length is placed about 1 cm from the angle of mandible [45]. This is followed by layered dissection. An avascular pouch is created superiorly, and the pterygomasseteric sling is identified. Stripping the masseter muscles of its attachments will lead to the exposure of the fracture [46] (Video 53.2).



© BRISHANK PRATAP

©Association of Oral and Maxillofacial Surgeons of India

Fig. 53.14 Various incisions possible for condylar fractures based on location



© BRISHANK PRATAP

©Association of Oral and Maxillofacial Surgeons of India

Fig. 53.15 (a) Incision for submandibular/periangular approach. (b) Area exposed marked green in the mandible

53.7.3.2 Retromandibular (Fig. 53.16a, b) (Video 53.3)

Entire posterior border can be exposed via the retromandibular approach [47]; hence this approach is useful in treating fracture of the condylar neck and the base. The anatomic structures encountered in this approach are the main trunk of the facial nerve and retromandibular vein. It has two main variations transparotid and retroparotid. In both the variation marking of the incision is 5–10 mm below the lobule of the ear, parallel to the posterior border usually 3–4 cm long.

Transparotid Approach

In this approach incision extends from the skin to the subcutaneous tissue, and it is undermined to reach the parotid capsule which is divided horizontally between the path of the buccal and zygomatic branches of the facial nerve. Dissection is carried out parallel to the direction of the facial nerve branches, and it is not important to locate the branches. Pterygomasseteric sling is sectioned, and periosteal flap elevated to expose the posterior border of the mandible.

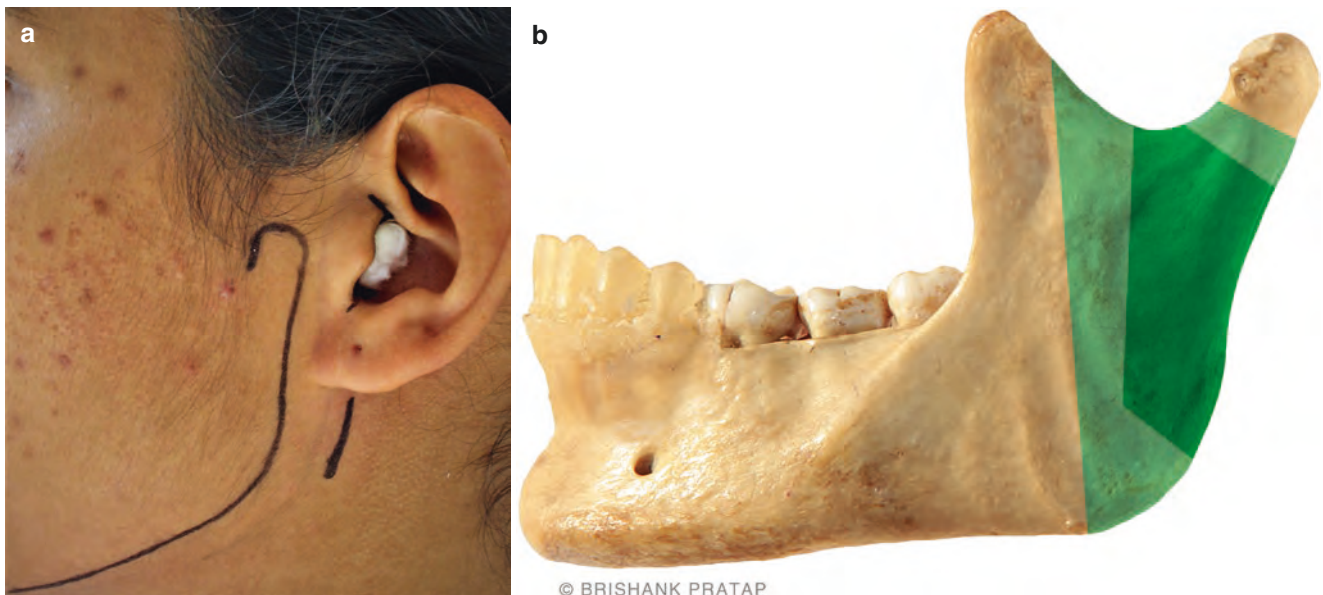
Retroparotid Approach

In this approach parotid gland is lifted rather than transected to approach the posterior border of the mandible. Incision in this approach is placed more posterior as compared to transparotid approach as a result exposure is also restricted. After the parotid fascia is identified, dissection is carried out behind the gland. The gland is lifted to expose the posterior border; from here the dissection carried out is the same as the transparotid approach.

The wound is closed in layers to avoid dead space. Also, the parotid fascia should be sutured tightly to prevent sialocele or parotid fistula. Drains can also be placed.

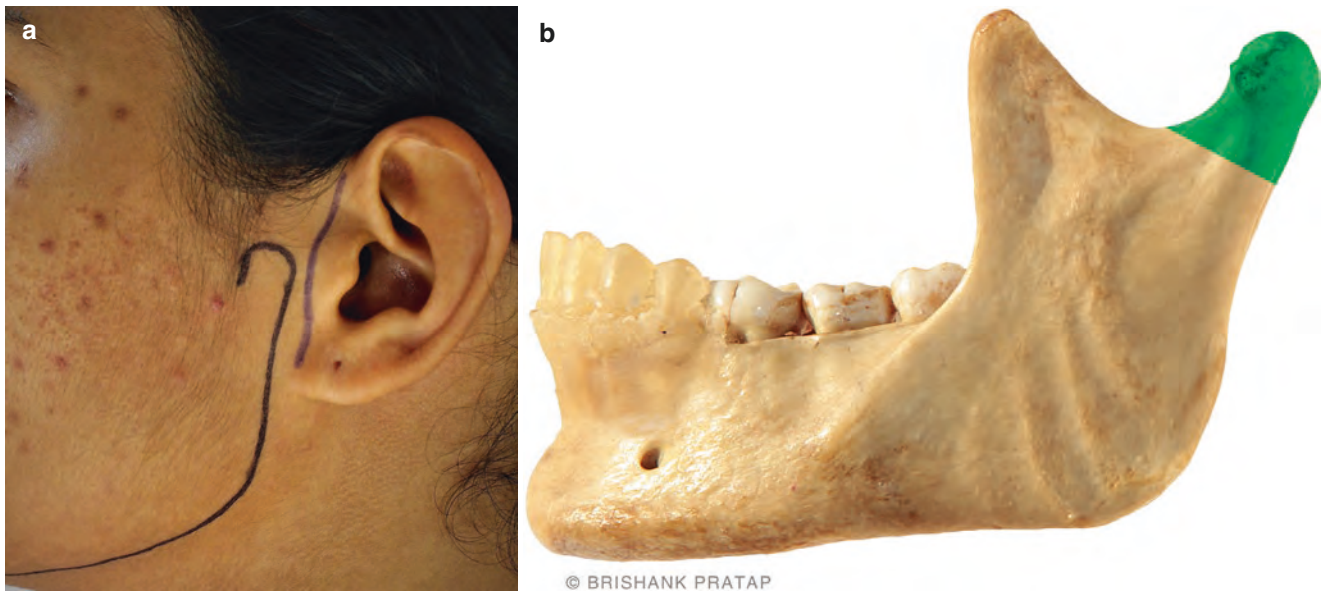
53.7.3.3 Preauricular Approach (Fig. 53.17a, b) (Video 53.4)

This incision is most commonly used by the surgeons in the TM joint surgeries. Diacapitular fractures are approached via this approach [48]. Branches of facial nerve are involved in this approach along with the superficial temporal artery and vein. Incision is placed along the crease of the skin following the tragus and helix of the ear which can be extended in the temple region. This extension on the temple minimizes traction and prevents weakness of facial nerve. Incision is carried from the skin to the subcutaneous tissue till the white glistening temporal fascia is reached. Root of the zygoma is palpated, and an oblique incision is given parallel to the frontal branch of facial nerve. Superficial temporal fascia is incised, and a periosteal elevator is inserted below the fascia to strip the periosteum of the zygomatic arch. This will expose the capsule of the temporomandibular joint. Capsule is incised in an open method to expose the head of the condyle. The neck is exposed by doing a subperiosteal dissection. Closure is done in layers first being the capsule followed by temporalis fascia, subcutaneous tissue, and the skin. The main disadvantage of this approach is an unaesthetic scar. This can be overcome by placing the incision endurally. The scar hides behind the tragus, but it can cause perichondritis.



©Association of Oral and Maxillofacial Surgeons of India

Fig. 53.16 (a) Incision for retromandibular approach. (b) Area exposed marked in mandible (dark green, retro parotid exposure; light green, transparotid exposure)



©Association of Oral and Maxillofacial Surgeons of India

Fig. 53.17 (a) Preauricular approach incision. (b) Area exposed marked in the mandible

53.7.3.4 Retroauricular Approach

This is an approach which will provide best cosmetic results. However major disadvantage is that it can result in stenosis of the external auditory canal. Also, the closure takes a longer time. Incision runs parallel to postauricular flexure approximately 3 mm behind it. Skin followed by postauricular muscles and fascia overlying mastoid are incised. External auditory canal is identified and completely transected at bony cartilaginous junction. Temporalis fascia is identified, and from here dissection followed is similar to preauricular approach to expose the condylar head. Closure is done in layers with a special attention given to the external auditory canal.

53.7.4 Reduction

After the adequate exposure of the fractured fragments reduction is achieved under direct vision. If the distal fragment is placed laterally, reduction tends to be easy. However, in most of the cases, the fragments tend to be displaced medially resulting from the pull of lateral pterygoid muscle. A medially displaced fragment must be lateralized before an attempt is made to reduce the fracture. For easy manipulation, a plate with a single screw is fixed on the distal fragment. This will help in easy lateralization of the distal fragment and prevent the fragment from slipping back as the lower end of the plate acts as a rest on the proximal segment. Before an attempt is made to reduce the fracture, manual traction is applied to the mandible so that the vertical height

of the posterior mandible is restored. This can be achieved as follows (Fig. 53.18a–d):

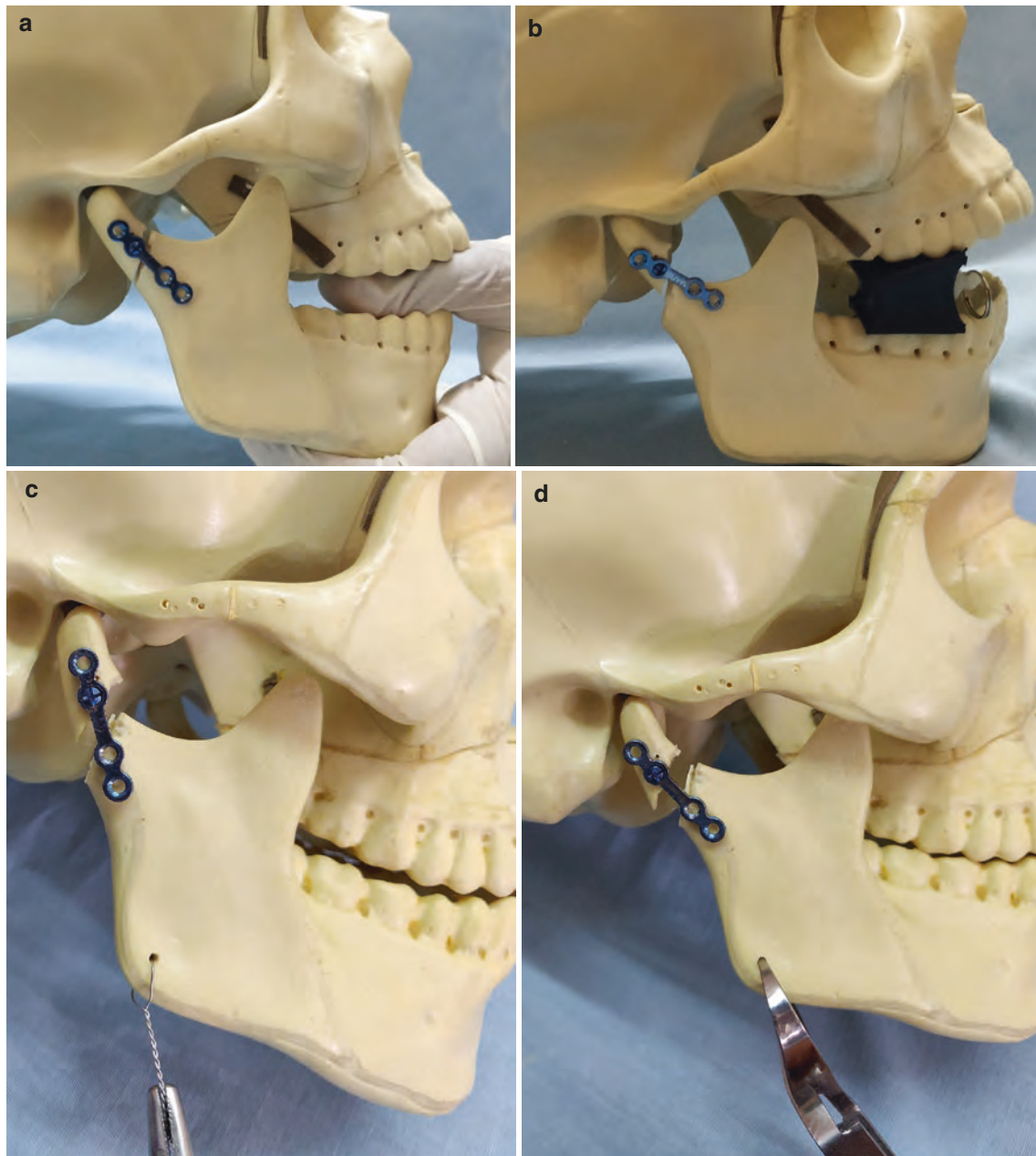
1. Manual digital traction: Thumb is placed on the lower teeth and fingers support the lower border. Mandible is pulled in inferior and anterior direction.
2. Bite block: A bite block is placed on the same side of the condylar fracture in the molar region. This will result in inferior distraction of the mandible with rotation.
3. Transosseous wire: A transosseous wire can be passed along the posteroinferior border of the mandible. A traction is applied on this wire in an inferior and anterior direction.

Once the fracture is reduced with the help of a clamp in the lowermost hole of the plate, pressure is applied to keep the fractured end in place. Figure 53.19a–d shows the reduction and fixation of a medially displaced condyle fracture.

In a case where two plates are planned for fixation, the smaller plate along the anterior border of the condyle is fixed first with a screw. Once the anterior plate is fixed on the distal segment, similar steps are followed as mentioned earlier for single plate for reduction and fixation.

Sequencing the case of multiple fractures is as follows:

1. Fractures with contralateral condylar fractures—Fractures in the tooth bearing anterior segment are fixed before the condyle is fixed.



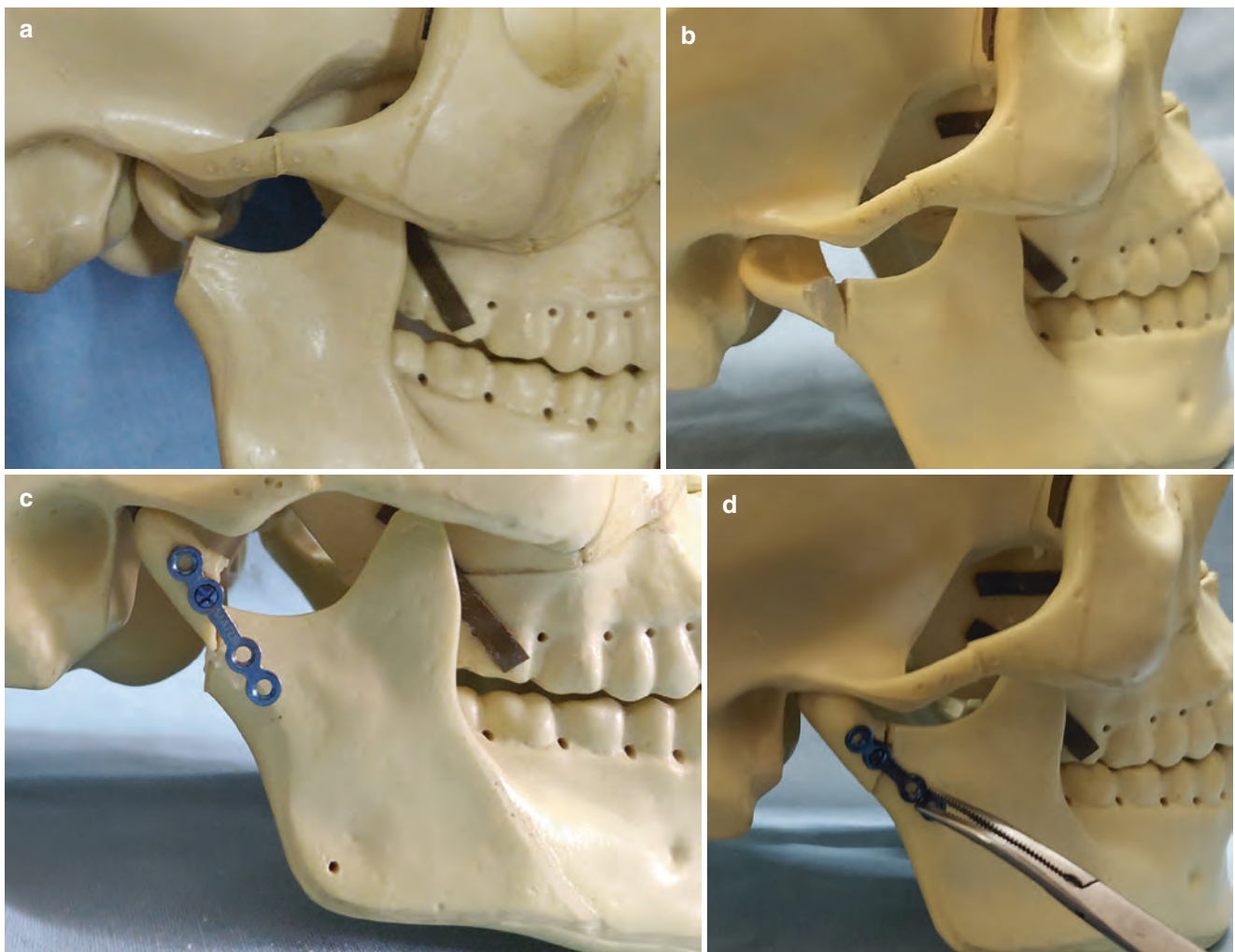
©Association of Oral and Maxillofacial Surgeons of India

Fig. 53.18 (a) Manual digital reduction. (b) Traction using bite block. (c) Transosseous wiring. (d) Towel clip

2. Bilateral condylar fracture with anterior mandible—In these cases there can be flaying of the mandible resulting in increase of transverse dimension of mandible. Anterior fractures are reduced and fixed taking into consideration into the lingual reduction. Anterior fractures are fixed before the posterior.
3. Panfacial trauma—Principal remains the same, mandible is fixed as mentioned above before the midface fractures are reduced and fixed. This may change depending on the sequence followed for fixation of panfacial fractures

53.7.5 Fixation Techniques (Fig. 53.20a–d),
 (Case 1: Fig. 53.21a–b),
 (Case 2: Fig. 53.22),
 (Case 3: Fig. 53.23a–e),
 (Case 4: Fig 53.24a–d)

The most significant advances that have taken place in the management of fracture of condylar process include the osteosynthesis material and the technique. Fixation with titanium plates and screws has given optimal results when adequate bone, proper site selection with proper techniques



©Association of Oral and Maxillofacial Surgeons of India

Fig. 53.19 (a) Medially displaced condylar fracture. (b) Fracture lateralized. (c) Distal segment secured with a plate. (d) Fracture reduced

followed [49]. At the time of surgery fixation, technique is selected based on the following parameters:

1. Fracture morphology
2. Amount of bone available
3. Surgeon preference

Fixation can be in the form of one plate, two plates, hybrid plates, lag screws, or restorable plates. Studies have shown that use of two plates is superior to one plate [40, 50]. Two plates must be used for lower level fractures to overcome tension and stress in the neck region by placing plates along the anterior and posterior border in a triangular fashion (Fig. 53.20a–d). In cases where there is limited bone, available fixation can be done with heavier single plate. Single plate is fixed along the long axis of the condyle. There are many types of hybrid plates available. These are designed to incorporate the principle of two plates in a single plate. However, this

makes the plates bulky as a result it may be at times difficult to fix them especially when there is limited bone available. Irrespective of the type of plate used, there should be at least two screws on either side of fracture.

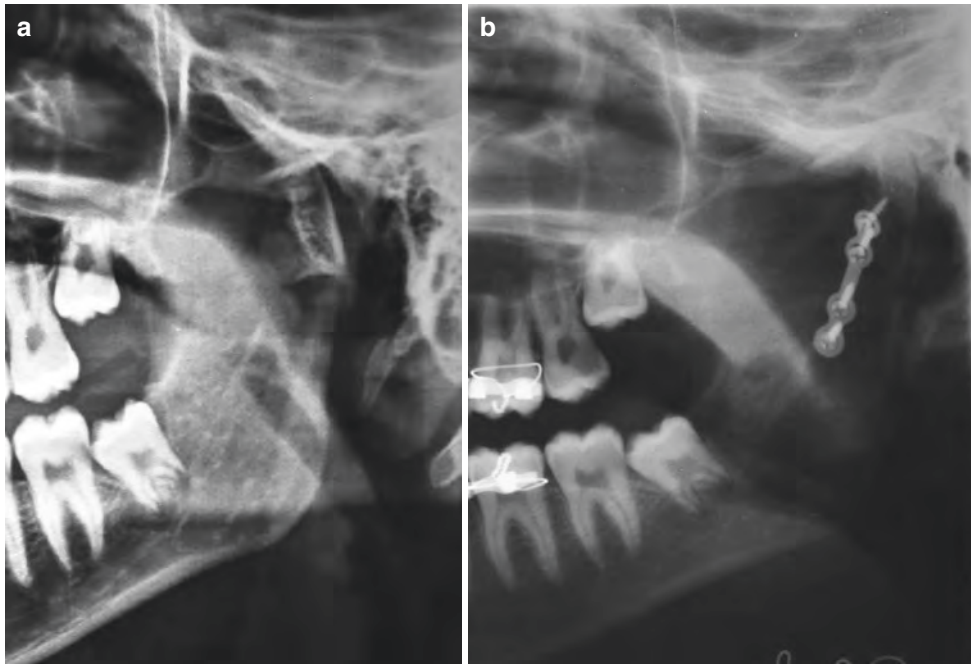
Fixation of condylar head is a challenge because of the limited space available and the fractures are intracapsular. In addition, there could be multiple small fragments and associated injury to the disc and the capsule which may be required to be repaired. Several osteosynthesis techniques are available for fixation like the mini plates, stainless steel wire, standard lag screws, resorbable screws, resorbable pins, and cannulated lag screws (Fig. 53.25). Reduction and fixation of the condylar head is technically challenging as the small fragments can easily necrose if stripping of the muscle is done. Use of two lag screws would be idle as it will prevent the reduced fragments from displacement during function, but times it may not be possible to fix two screws due to limited space Table 53.1 [51].

Intraoral endoscopic approach for treatment of condylar fractures is given in detail in Chap. 54 of this book.

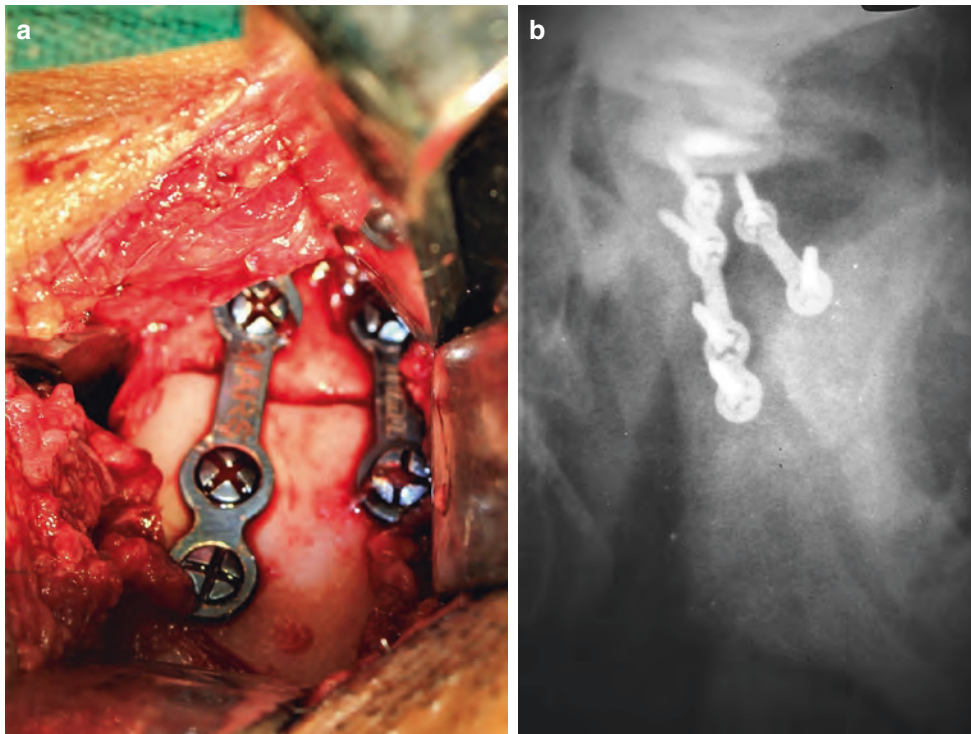


©Association of Oral and Maxillofacial Surgeons of India

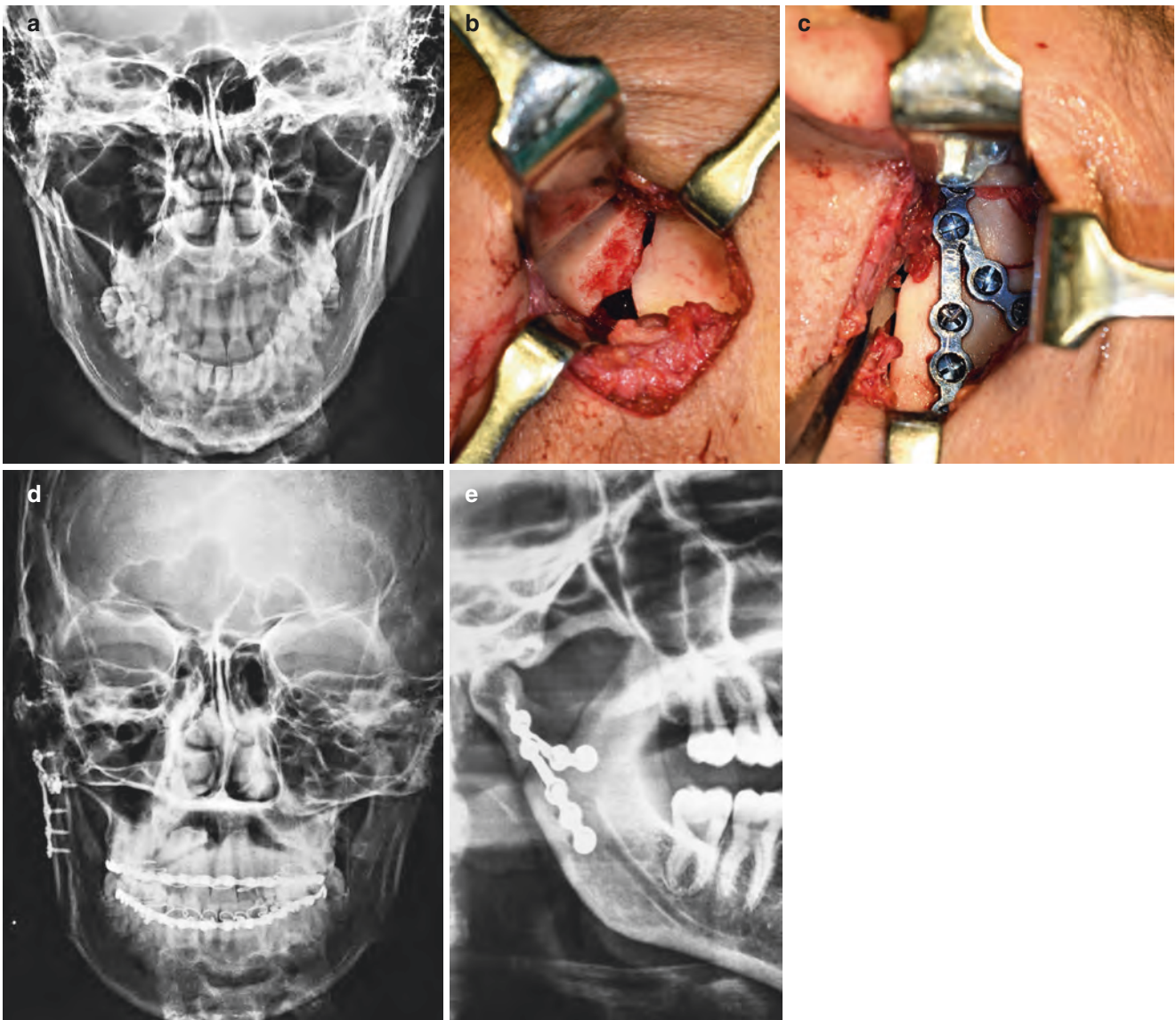
Fig. 53.20 (a) Single plate. (b) Two plates. (c) Lambda plate. (d) Delta plate



Case 1: Fig. 53.21 (a) OPG view showing left condyle fracture (b) Post operative OPG showing single plate fixed via retromandibular transparotid approach



Case 2: Fig. 53.22 (a) Intra operative view showing two plates fixed for condyle fracture via retromandibular transparotid approach. (b) Post operative radiograph of showing fixation with two plates



Case 3: Fig. 53.23 (a) PA view showing right condyle fracture. (b) Intraoperative view via retromandibular transparotid approach shows the displaced condyle. (c) Reduction and fixation done with Lambda plate. (d, e) Post operative PA view and OPG showing the fixed Lambda plates

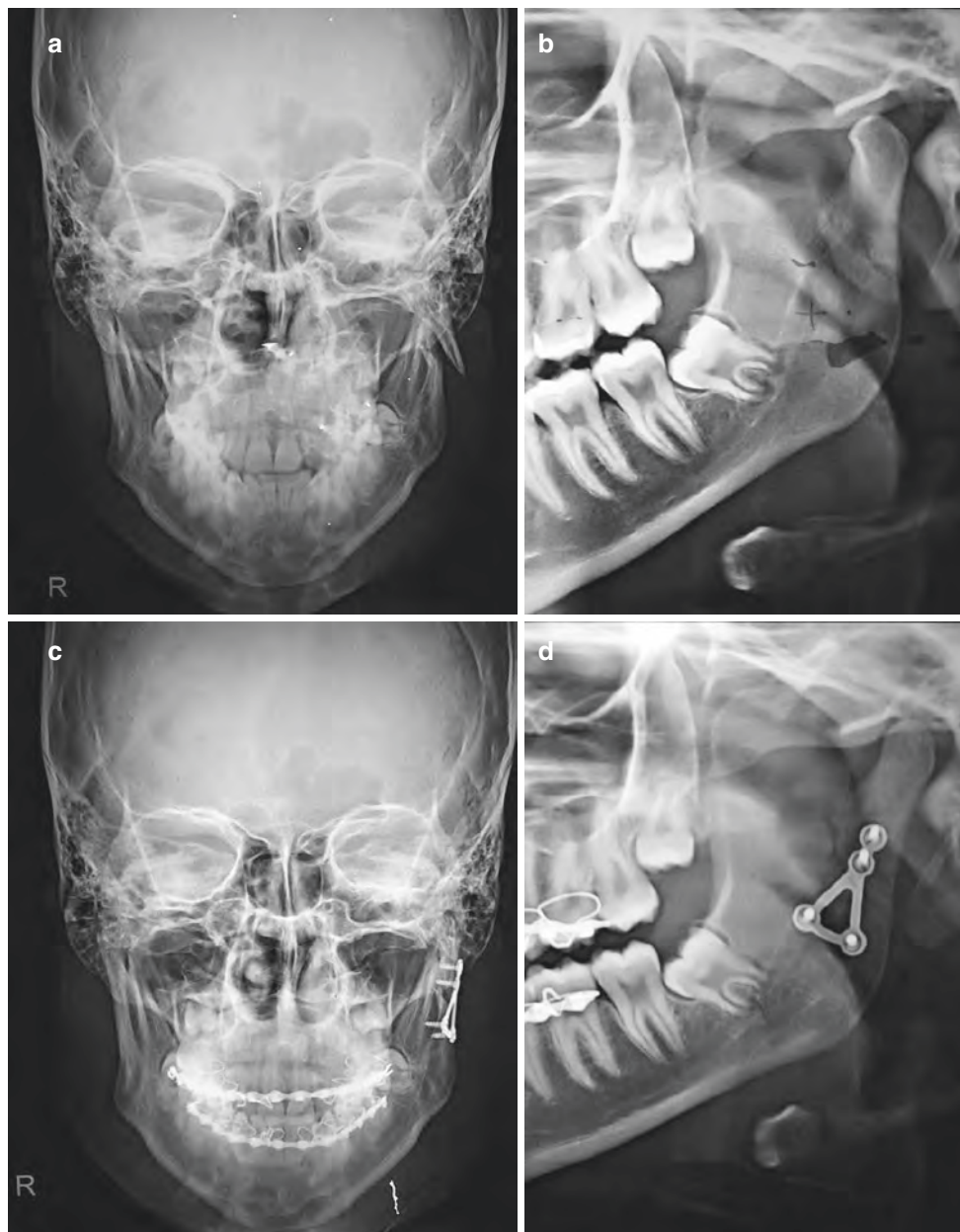Box 53.10. Functional Exercise: Rehabilitation

Targets [52]

1. Maximal mouth opening > 40 mm
2. Lateral excursive movement > 10 mm
3. Protrusive movement > 10 mm
4. Full range of movements which are pain free
5. Close supervision by the surgeon

53.8 Condylar Fractures in Children

The most common fracture seen in the maxillofacial region in children is fracture of the condylar process [53]. Condyle is unique in children as there is a very thin cortical bone surrounding a highly vascular cancellous bone. This can result in a comminuted type of fracture also called mushrooming. Condylar fractures can result in definitive deformities, both in terms of function as well as



Case 4: Fig. 53.24 (a, b) Pre operative PA view and OPG showing fracture left condyle. (c, d) Post operative PA view and OPG showing the fixed Delta plate via Periangular approach

a facial asymmetry in cases of inappropriate treatment. Intracapsular fractures can result in retardation of growth [54, 55] or in excessive growth on the fractured site [56]. Remodelling of the condyle is inversely proportional to age [9, 25, 26]. Children have a better adaptation than the adults. Adaption in children is skeletal, neuromuscular, as well as function. In adults only functional adaptation is seen. For this reason, literature has supported conservative management of fracture of the condylar process. It is paramount to rehabilitate the patient with the restoration

of minimum mouth opening, lateral excursion movement with stable occlusion. However, a long-term follow-up showed 50–53% of patients had complaints even though minor in nature irrespective of the type of treatment carried out [57]. Early mobilization is recommended in children below 15 years. Patients are encouraged to be on soft diet to avoid pain. In cases where an open bite is present, guiding elastics will help in restoring the occlusion. There is no concrete evidence of prolonged period of maxillo-mandibular fixation.

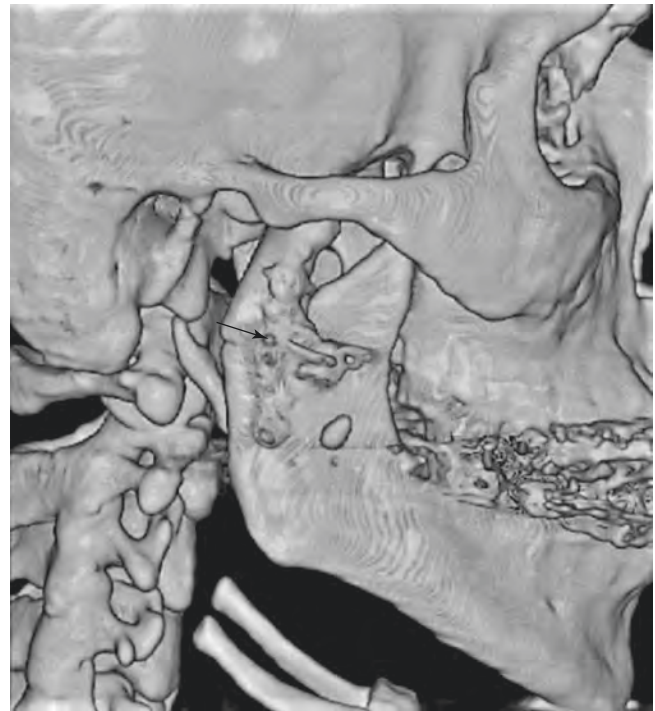


©Association of Oral and Maxillofacial Surgeons of India

Fig. 53.25 Fixation of the condylar head fracture with lag screw

Table 53.1 Comparison of different fixation methods used for fractures of the mandibular condyle

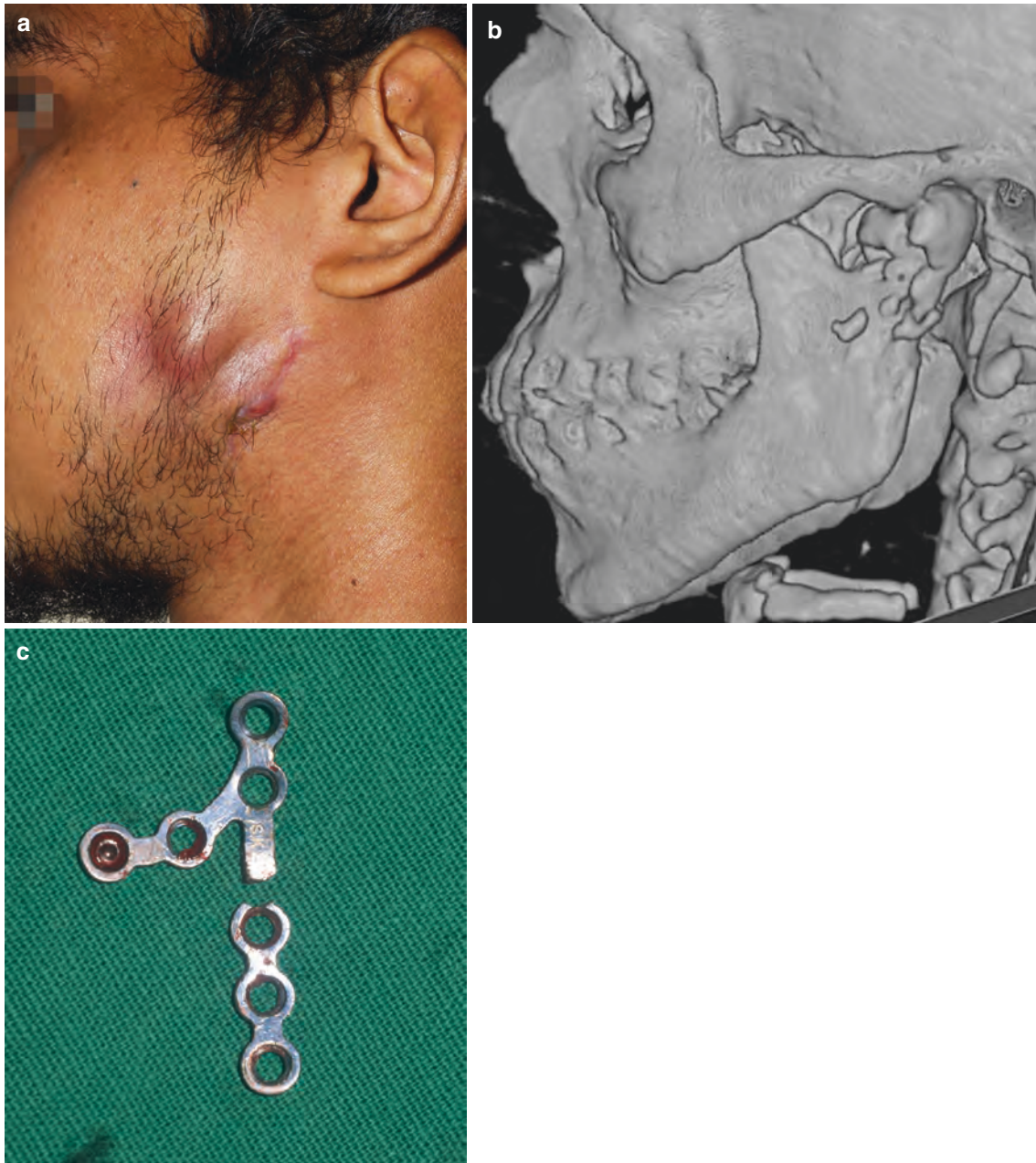Type of plate used for fixation	Advantage	Disadvantage
Single plate	<ul style="list-style-type: none"> • Easy to adapt and fix as placed along the long axis of the condyle. 	<ul style="list-style-type: none"> • Does not neutralize the forces acting on the fracture ends. • Relatively heavier plate needed.
Two plates	<ul style="list-style-type: none"> • Neutralizes the tension and stress along the fracture. • Easy to triangulate. • Aids in reduction of fracture. • Suitable with multiple fractured fragments. 	<ul style="list-style-type: none"> • May be difficult to fix two plates in a narrow neck of the condyle.
Lambda plate	<ul style="list-style-type: none"> • Single plate neutralizes the tension and stress as two lower limb follow the anterior and posterior border of the condyle. • Suitable in narrow neck of the condyle. 	<ul style="list-style-type: none"> • Wider exposure is needed. • Junction of two lower and upper limb area of weakness prone for fracture. • Difficult to adapt as the stock plates may not be suited for all types of fractures.
Delta plate	<ul style="list-style-type: none"> • Single 3D plate neutralizes the tension and stress as two vertical struts follow the anterior and posterior border of the condyle. • Plates don't have an area of weakness. 	<ul style="list-style-type: none"> • Wider exposure is needed. • Difficult to adapt. • At times upper horizontal strut may be wider than the bone available.



Case 5: Fig. 53.26 Shows improperly reduced fracture condyle which has been fixed in a dislocated position of the condyle—arrow points towards the plate fixed in wrong position

53.9 Complications of Condylar Fractures (Case 5: Fig. 53.26) (Case 6: Fig. 53.27a–c)

1. Malocclusion—Quite common with closed reduction if improperly treated. Also seen in patients with prolonged hospitalization [58].
2. Mandibular hypomobility—Prolonged immobilization and delayed physiotherapy, more common in children [59].
3. Ankylosis—seen more commonly in children due to meniscal disruption and lack of physiotherapy. This may be seen in comminuted fractures or disruption of articular disc.
4. Asymmetry—In children due to growth disturbances may result in facial asymmetry, occlusal cants, and reduced ramal height [60]. In adults asymmetry is due to deviation on opening of the mouth.
5. Dysfunctional degeneration—All injured joints can turn arthritic. Factors affecting these are age, long period of immobilization, capsular, or meniscal injury [61].
6. Condylar resorption—Occurs if the condyle becomes devoid of blood supply, but it is extremely rare.
7. Hardware failure—Such as fracture of plates can occur.
8. Infection—Postoperative infection.
9. Chronic pain seen in closed reduction.
10. Neurosensory disturbances—Seen following trauma or inappropriate surgical incisions.



©Association of Oral and Maxillofacial Surgeons of India

Case 6: Fig. 53.27 (a) Chronic infection left side condyle region following reduction and fixation, (b) CT scan showed osteomyelitis like changes at left condyle (c) the fractured infected plate removed

Box 53.11. Recent Advances [49]

- Improvements in imaging (CT scan/MRI) have resulted in better visualization of fracture site and understanding of soft tissue injuries along with the fracture.
- Surgical approaches better understood, and their application is based on the site of condylar fracture.
- Importance of anatomic reduction which leads to early full range of function.
- Improvement in open or assisted internal fixation techniques.
- Ability to approach and manage intracapsular fractures.
- Need to manage soft tissue injury as and when need.
- There is an improvements and wide choice of fixation materials including resorbable materials.
- Early and effective postoperative rehabilitation.

53.10 Conclusion

There have been numerous controversies in management of condylar fractures. They have ranged from which classification to use, surgical approach, type of fixation, and outcome of the treatment. But till date even with all the advances available to us, we still cannot agree on the two schools of thought for management of condylar fracture that is closed or open. Danda et al. [38] concluded in their study that there was no difference in treatment outcome in both the groups. This can be debated as it is not possible to compare the two modalities of treatment in absolute terms. Although it is pointed out that there are better results in function with open reduction and fixation, there are inherent complications that are only seen in cases treated by open reduction [62] such as nerve injuries and scars.

In an alternative interpretation of evidence, Leon A Assael [63] opined that both open and closed reduction have a critical role in management of condylar fractures. Treatment outcome such as full pain free range of movement and good aesthetics is seen in both the groups. Malocclusion, functional deficit, and internal derangement are seen irrespective of line of treatment. Over the years, complications noted in open reduction have reduced with the better understanding and improvement of technique, but it can be burden on the patient. These complications can only be weighed against the functional advantage patient gets in open reduction and fixation. Treatment of a condylar fracture will entirely be dependent on multiple factors.

To conclude it can be safely stated that management of condylar fractures should be patient centric not entirely based on absolute indications mentioned by various authors. Generally, in children and dentulous adult patients, closed reduction is the choice of treatment, whereas open reduction and fixation would be the choice of treatment for the patients with multiple fractures of mandible, panfacial trauma, partially or totally edentulous jaws, and underlying medical conditions preventing maxillo-mandibular fixation. Finally, function should be considered as an important parameter while formulating a treatment plan along with the resources available and skill of the surgeon.

References

1. Desault BX. Memoire sur la fracture des condyles de la machoire inferieure. Paris: Euvres Chirurgicales; 1813.
2. Fletcher MC, Picuch JF, Lieblich SE. Anatomy and pathophysiology of the temporomandibular joint. In: Milora M, Ghali GE, Larsen P, et al., editors. Peterson's principles of oral and maxillofacial surgery. 3rd edn. Shelton, CT: People's Medical Publishing House; 2012. p. 1033–47.
3. Rayne J. Functional anatomy of the temporomandibular joint. *Br J Oral Maxillofac Surg.* 1987;25:92–9.
4. Walker CJ, Stephen PR. MacLeod: anatomy and biomechanics of condylar fractures. *Atlas Oral Maxillofacial Surg Clin N Am.* 2017;25:11–6.
5. Schmidt BL, Pogrel MA. The distribution of the auriculotemporal nerve around the temporomandibular joint. *Oral Surg Oral Med Oral Pathol Oral Radiol Endod.* 1998;86:165–58.
6. Al-Kayat A, Bramley P. A modified pre auricular approach to the temporomandibular joint and malar arch. *Br J Oral Surg.* 1979;17:91–103.
7. Dingmann RO, Grabb WC. Surgical anatomy of the mandibular ramus of the facial nerve based on the dissection of 100 facial halves. *Plast Reconstr Surg Transplant Bull.* 1962;29:266–72.
8. Ellis E, Throckmorton GS. Treatment of mandibular condylar process fractures: biological considerations. *J Oral Maxillofac Surg.* 2005;63:115–34.
9. Lindahl L. Condylar fractures of the mandible. I: classification and relation to age, occlusion and concomitant injuries of the teeth and teeth-supporting structures and fractures of the mandibular body. *Int J Oral Surg.* 1977;6(1):12–21.
10. Chrcanovic BR. Surgical versus non-surgical treatment of mandibular condylar fractures: a meta-analysis. *Int J Oral Maxillofac Surg.* 2015;44(2):158–79.
11. Wassmund M. Frakturen und luxationen des gesichtsschädels unter berücksichtigung der komplikationen des hirnscädels. Ihre klinik, und therapie. Berlin: Meusser; 1927.
12. MacLennan WD. Consideration of 180 cases of typical fractures of the mandibular condylar process. *Br J Plast Surg.* 1952;5(2):122–8.
13. Spiessl B., Schroll K. Spezielle Frakturen- und Luxationslehre. Ein kurzes Handbuch in fünf Bänden. Band I/1 Gesichtsschädel. Stuttgart: Georg Thieme; 1972. p. 317.
14. Rasse M. Diakapituläre frakturen der mandibula. Eine neue operationmethode und erste ergebnisse. *Stomatologie.* 1993;90:413–28.
15. Neff A, Kolk A, Deppe H, et al. Neue aspekte zur indikation der operativen versorgung intraartikulärer und hoher kiefergelenkluxationsfrakturen [New aspects for indications of surgical management of intra-articular and high temporomandibular dislocation fractures]. *Mund Kiefer Gesichtschir.* 1999;3(1):24–9. [in German]

16. Hlawitschka M, Eckelt U. Assessment of patients treated for intracapsular fractures of the mandibular condyle by closed techniques. *J Oral Maxillofac Surg.* 2002;60(7):784–91.
17. Loukota R, Neff A, Rasse M. Nomenclature/classification of fractures of the mandibular condylar head. *Br J Oral Maxillofac Surg.* 2010;48(6):477–8.
18. He D, Yang C, Chen M, Jiang B, Wang B. Intracapsular condylar fracture of the mandible: our classification and open treatment experience. *J Oral Maxillofac Surg.* 2009;67(8):1672–9.
19. Loukota RA, Eckelt U, De Bont L, et al. Subclassification of fractures of the condylar process of the mandible. *Br J Oral Maxillofac Surg.* 2005;43:72–3.
20. Ellis E 3rd, Palmieri C, Throckmorton GS. Further displacement of condylar process fractures after closed treatment. *J Oral Maxillofac Surg.* 1999;59(2):120–9.
21. Neff A, Cornelius CP, Rasse M, et al. The comprehensive AOCMF classification system: condylar process fractures: level 3 tutorial. *Cranio-maxillofac Trauma Reconstr.* 2014;7(Suppl 1):S44–58.
22. Brasileiro BF, Passeri LA. Epidemiological analysis of maxillofacial fractures in Brazil: A five-year prospective study. *Oral Surg Oral Med Oral Pathol Oral Radiol Endod.* 2006;102:28–34.
23. Chrcanovic BR, Freire-Maia B, Souza LN, et al. Facial fractures: A 1 year retrospective study in a hospital in Belo Horizonte. *Braz Oral Res.* 2004;18(1):322–8.
24. Kumar GBA, Dhupar V, Akkara F, Kumar SP. Patterns of maxillofacial fractures in Goa. *J Maxillofac Oral Surg.* 2013;14(2):138–14.
25. Ellis E, Moos KF, el-Attar A. Ten years of mandibular fractures: An analysis of 2,137 cases. *Oral Surg Oral Med Oral Pathol.* 1985;59(2):120–9.
26. Zachariades N, Mezitis M, Mourouzis C, et al. Fractures of the mandibular condyle: A review of 466 cases. Literature review, reflections on treatment and proposals. *J Cranio-maxillofac Surg.* 2006;18:151–3.
27. MacLennan WD. Fractures of the mandibular condylar process. *Br J Oral Surg.* 1969;7:31–9.
28. Sawazaki R, Lima Júnior SM, Asprino L, Moreira RWF, de Moraes M. Incidence and patterns of mandibular condyle fractures. *J Oral Maxillofac Surg.* 2010;68:1252–9.
29. Silvennoinen U, Iizuka T, Lindqvist C, et al. Different patterns of condylar fractures: An analysis of 382 patients in a 3-year period. *J Oral Maxillofac Surg.* 1992;50(10):1032–7.
30. Zachariades N, Koumoura F, Konsolaki-Agouridaki E. Facial trauma in women resulting from violence by men. *J Oral Maxillofac Surg.* 1990;48(12):1250–3.
31. Zachariades N, Papavassiliou D, Koumoura F. Fractures of the facial skeleton in children. *J Cranio-Maxillofacial Surg.* 1990;18(4):151–3.
32. Robert V. Walker: condylar fractures nonsurgical management. *J Oral Maxillofac Surg.* 1994;52:1185–8.
33. Zide MF, Kent JN. Indications for open reduction of mandibular condylar fractures. *J Oral Maxillofac Surg.* 1983;41(2):89–98.
34. AAOMS—special committee on parameter of care indications for open reduction of condylar fractures. https://www.researchgate.net/figure/AAOMS-special-committee-on-parameters-of-care-indications-for-open-reduction-2003_tbl3_230633313. Accessed 1 Feb 2019.
35. Yates DM, Zuniga JR, Zide MF. Traumatic injuries to the mandibular condyle. In: Fonseca RJ, Walker RV, Dexter Barber H, Powers MP, Frost DE, editors. *Oral & maxillofacial trauma*, 4th ed. 2012. p. 331–53.
36. Schneider M, Erasmus F, Gerlach KL, et al. Open reduction and internal fixation versus closed treatment and mandibulomaxillary fixation of fractures of the mandibular condylar process: A randomized prospective, multicenter study with special evaluation of fracture level. *J Oral Maxillofac Surg.* 2008;66:2537–44.
37. Eckelt U, Schneider M, Erasmus F, et al. Open versus closed treatment of fractures of the mandibular condylar process—a prospective randomized multi-centre study. *J Cranio-maxillofac Surg.* 2006;34:306–14.
38. Danda AK, Muthuskar MR, Narayanan V, et al. Open versus closed treatment of unilateral subcondylar and condylar neck fractures: A prospective, randomized clinical study. *J Oral Maxillofac Surg.* 2010;68:1238–41.
39. Ellis E. Method to determine when open treatment of condylar process fractures is not necessary. *J Oral Maxillofac Surg.* 2009;67:1685–90.
40. Haug RH, Assael LA. Outcomes of open versus closed treatment of mandibular subcondylar fractures. *J Oral Maxillofac Surg.* 2001;59:370–5.
41. Silvennoinen U, Iizuka T, Oikarinen K, Lindqvist C. Analysis of possible factors leading to problems after nonsurgical treatment of condylar fractures. *J Oral Maxillofac Surg.* 1994;52:793–9.
42. Kent JN, Neary JP, Silvia C. Open reduction of mandibular condyle fractures. *Oral Maxillofac Clin North Am.* 1990;2:69–72.
43. Raveh J, Vuillennium T, Ladrach K. Open reduction of the dislocated, fractured condylar process: Indications and surgical procedures. *J Oral Maxillofac Surg.* 1989;47:120–6.
44. Pau M, Navisany K, Reinbacher K, et al. Use of a modified high submandibular approach to treat condylar base fractures: Experience with 44 consecutive cases treated in a single institution. *J Cranio-maxillofac Surg.* 2016;44(10):164–45.
45. Trost O, Abu El-Naaj I, Trouilloud P, et al. High cervical transmasseteric anteroparotid approach for open reduction and internal fixation in condylar fracture. *J Oral Maxillofac Surg.* 2008;66:201.
46. Narayanan V, Ramadorai A, Ravi P, Nirvikalpa N. Transmasseteric anteroparotid approach for condylar fractures: experience of 129 cases. *Br J Oral Maxillofac Surg.* 2012;50(5):420–4.
47. Ellis EE, Zide MF. Retromandibular approach. In: Ellis EE, Zide MF, editors. *Surgical approaches to the facial skeleton*. Baltimore, MD: Williams & Wilkins; 1995. p. 139–53.
48. Cienfuegos R, Cornelius C-P, Ellis E III, Kushner G. Mandible-approaches. In: Figari M, Sánchez Aniceto G, editors. *Buchbinder D (general editor) AO surgery reference*. <https://www2.aofoundation.org/wps/portal/surgery?bone=CMF&segment=Mandible&showPage=approach>. Assessed 1 Feb 2019.
49. Kisnisci R. Management of fractures of the condyle condylar neck, and coronoid process. *Oral Maxillofacial Surg Clin N Am.* 2013;25:573–90.
50. Devlin MF, Hislop WS, Carton AT. Open reduction and internal fixation of fractured mandibular condyles by a retro-mandibular approach: surgical morbidity and informed consent. *Br J Oral Maxillofac Surg.* 2002;40:23–5.
51. Vesnaver A. Open reduction and internal fixation of intra-articular fractures of the mandibular condyle: our first experiences. *J Oral Maxillofac Surg.* 2008;66(10):2123–9.
52. Palmieri C, Ellis E, Throckmorton G. Mandibular motion after closed and open treatment of unilateral mandibular condylar process fractures. *J Oral Maxillofac Surg.* 1999;57:764–75.
53. Lee CYS, McCullon C, Blaustein D, Mahammadi H. Sequelae of unrecognized, untreated mandibular condylar fractures in the pediatric patient. *Ann Dent.* 1993;52:5–8.
54. Posnick JC, Wells M, Pron GE. Pediatric facial fractures: Evolving patterns of treatment. *J Oral Maxillofac Surg.* 1993;51:836–4.
55. MacLennan WD, Simpson W. Treatment of fractured mandibular condylar process in children. *Br J Plast Surg.* 1965;18:423–7.
56. Lund K. Mandibular growth and remodelling processes after condylar fracture: A longitudinal roentgen cephalometric study. *Acta Odont Scand.* 1974;32:3–117.

57. Levin SC, Frydendall E, Gao D, Chan KH. Temporomandibular joint dysfunction after mandibular fracture in children: A 10-year review. *Arch Otolaryngol Head Neck Surg.* 2011;137:10–4.
58. Ellis E 3rd. Complications of mandibular condyle fractures. *Int J Oral Maxillofac Surg.* 1998;27:255–7.
59. De Amaratunga NA. Mouth opening after release of maxillo-mandibular fixation in fracture patients. *J Oral Maxillofac Surg.* 1987;45:383–5.
60. Proffit WR, Vig KWL, Turvey TA. Early fracture of the mandibular condyles: Frequently an unsuspected cause of growth disturbances. *Am J Orthod.* 1980;78:1–24.
61. Palmieri C, Ellis E, Throckmorton G. Mandibular motion after closed and open treatment of unilateral mandibular condylar process fractures. *J Oral Maxillofac Surg.* 1999;57:764–75.
62. Brandt MT, Haug RH. Open versus closed reduction of adult mandibular condyle fractures: a review of the literature regarding the evolution of current thoughts on management. *J Oral Maxillofac Surg.* 2003;61:1324–32.
63. Assael LA. Open versus closed reduction of adult mandibular condyle fractures: an alternative interpretation of the evidence. *J Oral Maxillofac Surg.* 2003;61:1333–9.

Open Access This chapter is licensed under the terms of the Creative Commons Attribution 4.0 International License (<http://creativecommons.org/licenses/by/4.0/>), which permits use, sharing, adaptation, distribution and reproduction in any medium or format, as long as you give appropriate credit to the original author(s) and the source, provide a link to the Creative Commons license and indicate if changes were made.

The images or other third party material in this chapter are included in the chapter's Creative Commons license, unless indicated otherwise in a credit line to the material. If material is not included in the chapter's Creative Commons license and your intended use is not permitted by statutory regulation or exceeds the permitted use, you will need to obtain permission directly from the copyright holder.





Intraoral Endoscopic Approach for Treatment of Condylar Fractures of the Mandible

54

Frank Wilde

54.1 Introduction

The literature is replete with techniques regarding the open reduction and fixation of the condylar fractures of the mandible. The extraoral approach is preferred by the majority of surgeons in comparison to the intraoral approach. Nevertheless, open reduction and internal fixation by an extraoral approach has the evident risk to cause transient or even permanent facial nerve injury [1–4], leads inevitably to a facial scar [1, 5], and can course salivary fistulas, sialoceles [1, 6], Frey syndrome, or disturbance of the great auricular nerve [1]. In contrast, an intraoral approach is minimizing these abovementioned risks and facial scars can be avoided in general [7, 8].

Silverman in 1925 was the first person to mention about the intraoral approach to condylar fractures [9]. However, at that time, the surgeons were facing several difficulties treating those fractures due to a lack of adequate instruments. Fritzemeier and Bechthold developed the 90-degree angular screwdriver, and it served as a milestone in the intraoral management of condylar neck fractures. In their study, there were 32 fractures of which 2 cases showed early failures. Other cases during follow-up showed minor deviation from axis, but there were no evident problems in the temporomandibular joint function [10].

Based thereupon, several authors were reporting about the use of an intraoral approach treating condylar fractures surgically. Forty-eight cases of displaced and shortened mandibular condyle fractures were treated by an intraoral approach and studied by Mokros and Erle in 1996. In 2/3 of the treated fractures, the reduction was successful, and no

significant complications were noted in the intraoperative or postoperative period.

TMJ function was good in 90% of the patients, 43% were free of symptoms, and 47% had minor dysfunction. The authors came to the result that proper reduction of the bone fragments is most important for therapeutic success [11].

Schön et al. [8] compared in a study an intraoral endoscopy-assisted approach with an extraoral approach for the treatment of condylar fractures. A reduced risk of facial nerve damage and no visible scars were the major conclusion of the study, and they also opined that intraoral endoscopic approach is a reliable technique for treating condylar fractures [8]. Veras et al. [12] were looking in their study on 25 patients with condylar fractures which were treated surgically by an intraoral approach. The mean mouth opening postoperatively was 4.8 cm. Patients postoperatively did not have clicking of the joint, facial nerve weakness, or pain of the muscles or the joint. They opined that intraoral reduction allowed the anatomic ramus height to be restored and that the functional results were acceptable [12].

Other authors like Jensen et al. [13] or Schneider et al. [14] were not so enthusiastic about the outcome of surgical-treated condylar fractures employing an intraoral approach [13, 14]. Jensen et al. in 2006 stressed on the fact that intraoral approach for the condylar fractures is very technically demanding and there is a chance of getting postoperative complications [13]. Schneider et al. [14] compared in a retrospective study 21 fractures which were treated with an intraoral approach with 24 fractures which were reduced by an extraoral perimandibular approach. In their study, the cases treated by intraoral approach showed sub-optimal radiologic findings, and the patients' subjective feelings pointed to less favorable clinical results. They put forward the suggestion that fractures which do not require extensive manipulation and fractures which can be reduced exactly under a limited view only should be approached intraorally. For all other fractures, they recommend extraoral approaches [14].

F. Wilde (✉)

Department of Oral and Plastic Maxillofacial Surgery,
Armed Forces Hospital, Ulm, Germany

Department of Oral and Maxillofacial Surgery,
University Hospital, Ulm, Germany
e-mail: frank.wilde@uni-ulm.de

54.2 Surgical Technique

From the authors' experience, fractures of the condylar base and the low and medial part of the condylar process can be addressed typically by the following described technique. Treating high condylar neck fractures is demanding and requires experience in using such an approach. Fractures of the condylar head or the transition zone between the neck and head cannot be reached with this approach, and extraoral incisions are still required when this kind of fractures is getting treated surgically.

For the below-described technique, a team of three surgeons (one leading surgeon and two assistant surgeons) are highly recommended.

54.2.1 Special Surgical Instruments and Devices

To facilitate open reduction and internal fixation of condylar fractures via an intraoral approach with predictable results, special equipment is mandatory.

The most important instruments are a 90° angled screwdriver and drill (Fig. 54.1a). The screwdriver should have necessarily a sliding screw-holder which facilitates to hold the screw and plate together (Fig. 54.1b), because positioning a plate with one hand and fixing the screw with the other hand is not appropriate and will lead to unsuccessful procedures. Self-retaining screwdriver-bits or even self-tapping screws should be avoided as well. The authors recommend a straight 90° angled screwdriver with the aforementioned sliding screw-holder and centric-positioned screwdriver-bits. Screwdrivers with eccentric-positioned screwdriver-bits show a lower height indeed.

However, they will lead to tilting of the screwdriver during the activation of the device, which results in an inadequate transfer of the force and a frequent loosening of the screws from the bit.

Besides the 90° angled screwdriver and drill, extra-long instruments in the form of raspatories and reposition hooks have to be recommended insistently (Fig. 54.2). They simplify the manipulation and reduction of the fractured condyle with a good direct view into the operation site. Using standard configured instruments results in less vision due to obstructing the view by the operator's hands.

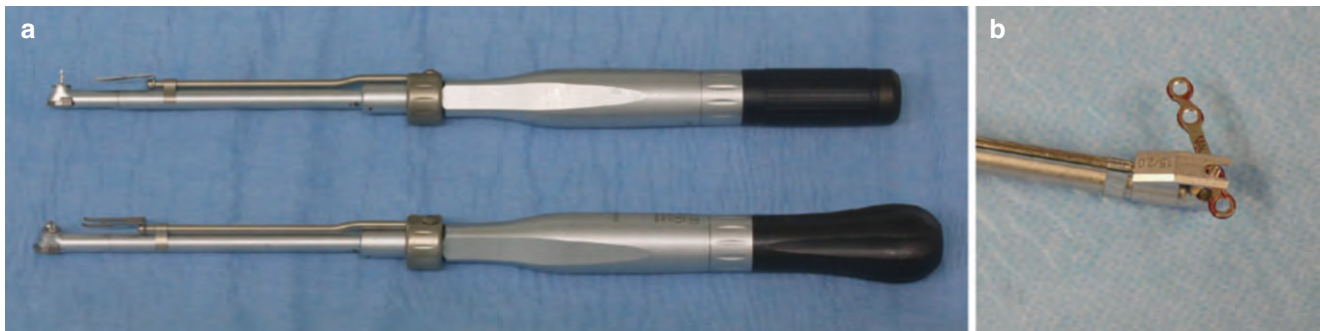An appropriate light-intensive headlight is necessary for proper illumination of the operation site (Fig. 54.3).

A 4 mm caliber 30° angled endoscope has to be recommended as well. In combination with a special retractor in which the endoscope can be inserted, a good visualization, especially of the posterior border of the ramus, can be achieved (Fig. 54.4).

In addition, a special retractor with a fiber-optic light guide which can be positioned buccally to the posterior border of the ramus enables good illumination of the surgical site (Fig. 54.5). Nevertheless, having an appropriate headlight, this instrument seems to be dispensable.

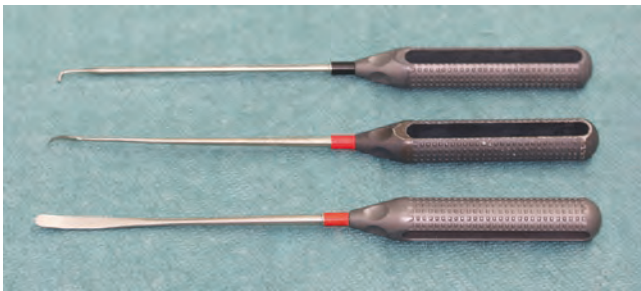
It can be further useful to fix the patient during surgery in a Mayfield head clamp as it is commonly used by the neurosurgeons. This allows traction with the retractors without any movement of the head.

Besides the described instruments, there are several special instruments and devices available on the market to facilitate open reduction and internal fixation using an intraoral approach. However, from the authors' experience, the aforementioned instruments and devices are the most helpful in treating condylar fractures by an intraoral approach.



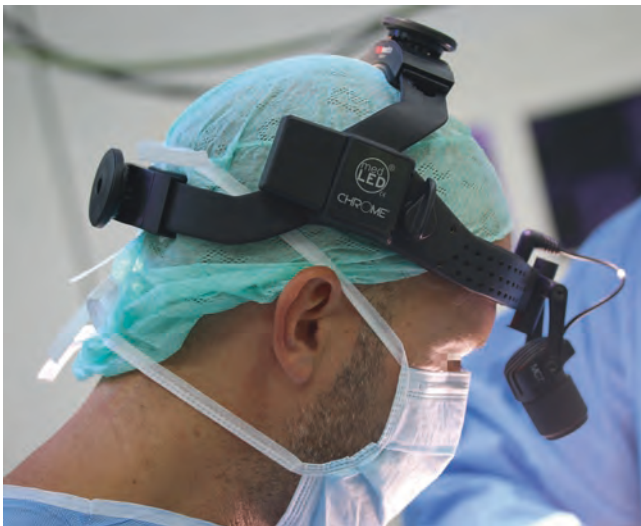©Association of Oral and Maxillofacial Surgeons of India

Fig. 54.1 (a) 90° angled screwdriver and drill. (b) Sliding screw-holder which facilitates to hold the screw and plate together (Medartis, Basel, Switzerland)



©Association of Oral and Maxillofacial Surgeons of India

Fig. 54.2 Extra-long instruments in the form of raspatories and reposition hooks (Karl Storz, Tuttlingen, Germany)

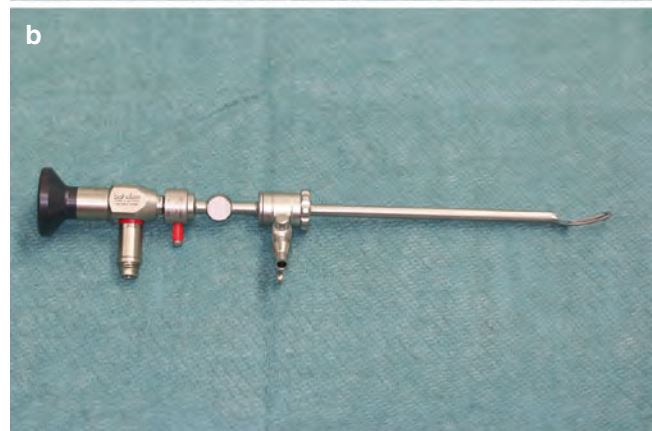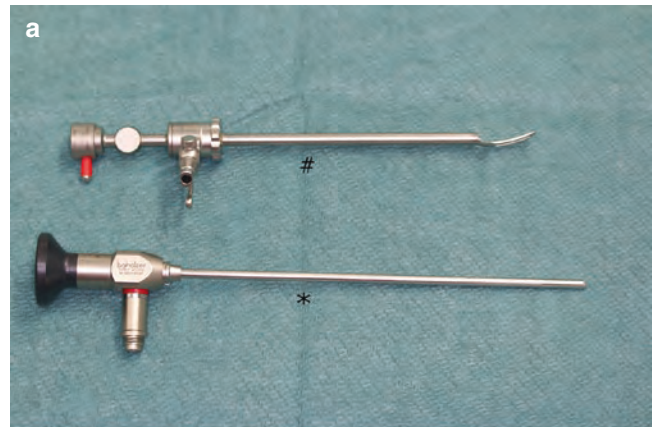


©Association of Oral and Maxillofacial Surgeons of India

Fig. 54.3 LED headlight (KLS Martin, Tuttlingen, Germany)

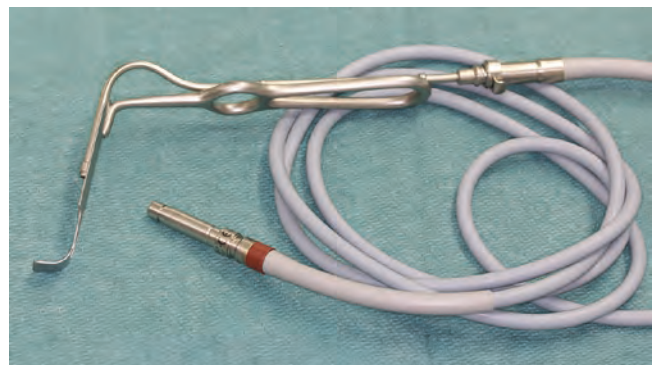
54.2.2 Surgical Access

By extending the standard vestibular incision in a superior direction along the ascending ramus, the ramus and the condyle region can be exposed intraorally (Fig. 54.6). The approach is following Obwegeser's principles of avoiding visible scars by extending his approach to the mandibular ramus for sagittal split osteotomy. During the incision of the oral mucosa, the anatomical course of the buccal nerve has to be taken into account. The dissection of the mucoperiosteal flap starts from the mandibular corpus in the region of the first molar to mandibular angle and far up to the condyle until the fracture line can be explored. To get an appropriate



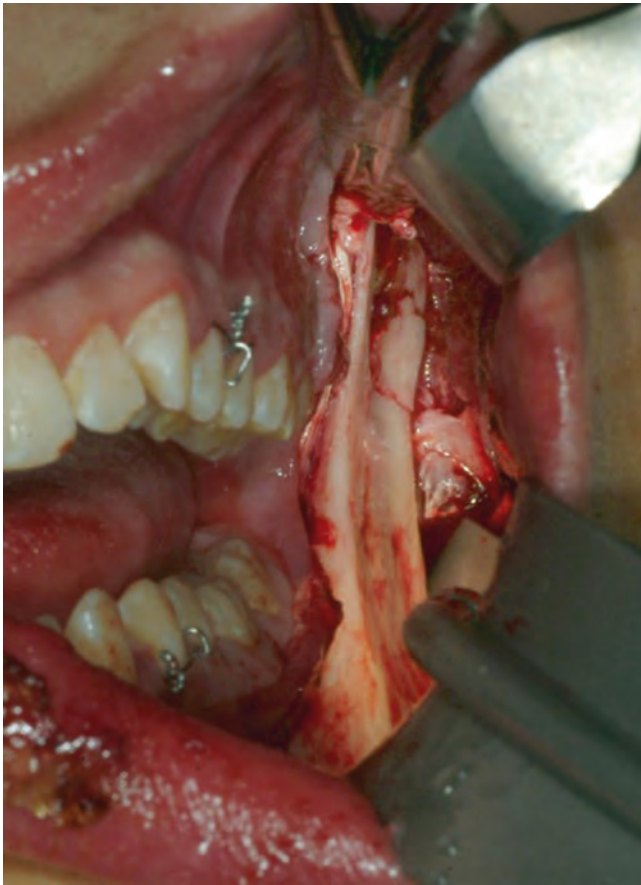©Association of Oral and Maxillofacial Surgeons of India

Fig. 54.4 (a) 4 mm caliber 30° angled endoscope (asterisk) and retractor in which the endoscope can be inserted (hash symbol). (b) Retractor with inserted endoscope (Karl Storz, Tuttlingen, Germany)



©Association of Oral and Maxillofacial Surgeons of India

Fig. 54.5 Retractor with a fiber-optic light guide (Karl Storz, Tuttlingen, Germany)



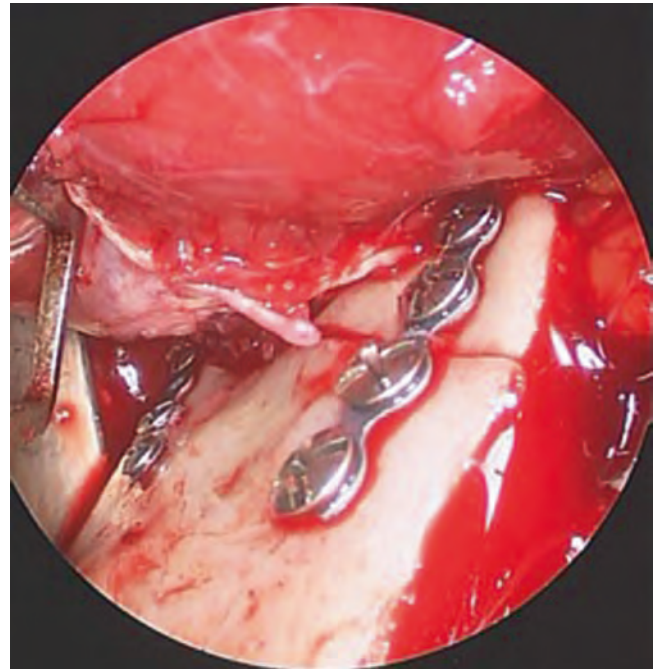
©Association of Oral and Maxillofacial Surgeons of India

Fig. 54.6 Intraoral approach to the condyle region by extending the standard vestibular incision in a superior direction up the ascending ramus

visualization of the condylar neck region, the mucosa including the fibers of the temporal muscle had to be stripped from the coronoid process up to or even higher than the mandibular notch. During dissecting the posterior border of the mandibular ramus, the retromandibular vein has to be taken under consideration. Coagulation in this region has to be done carefully, due to the anatomical proximity to the facial nerve which is running laterally in the parotid gland. This is the region where the facial nerve may be damaged during the procedure. In addition to coagulation, vigorous traction can damage the facial nerve in this location as well.

54.2.3 Surgical Procedure

After dissection to get sufficient access to the condylar neck region, the displaced condyle has to be identified. The best instrument for this is the extra-long raspatorium depicted in Fig. 54.2. During this procedure, the ramus has to be distracted. This can be performed by pulling the mandible caudally by hand. Another option is to fix one mini-screw in the



©Association of Oral and Maxillofacial Surgeons of India

Fig. 54.7 After temporary osteotomy and re-fixation of the coronoid process to get better access for repositioning of medial displaced condyle

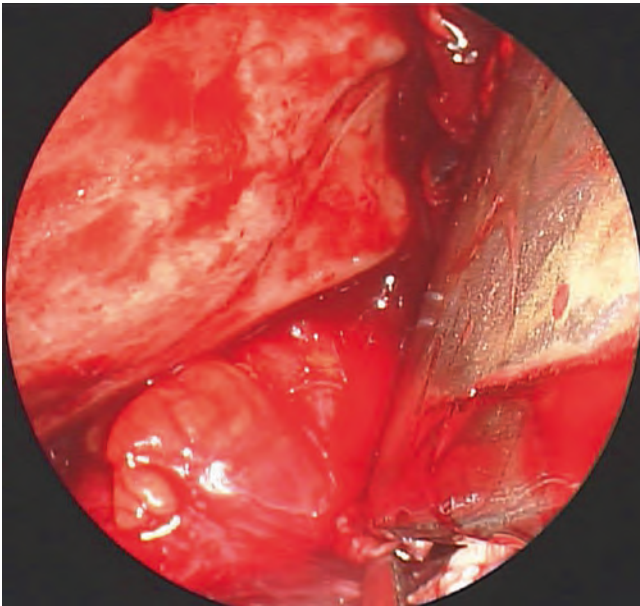
mandibular angle to twist a wire around, which is diverted out of the skin in the mandibular angle region by a stab incision. However, this leads to a small extraoral scar.

For this maneuver, a full relaxation of the patient by the anesthesiologist is recommended. Due to the very low risk for facial nerve damage employing this approach, this can be done without increasing this risk.

For medial displaced condyles in high condylar neck fractures, it is sometimes helpful to perform a temporary osteotomy of the coronoid process to get better access for repositioning. A later re-fixation of the osteomized coronoid process by a miniplate is in theory not needed but recommended by the authors (Fig. 54.7).

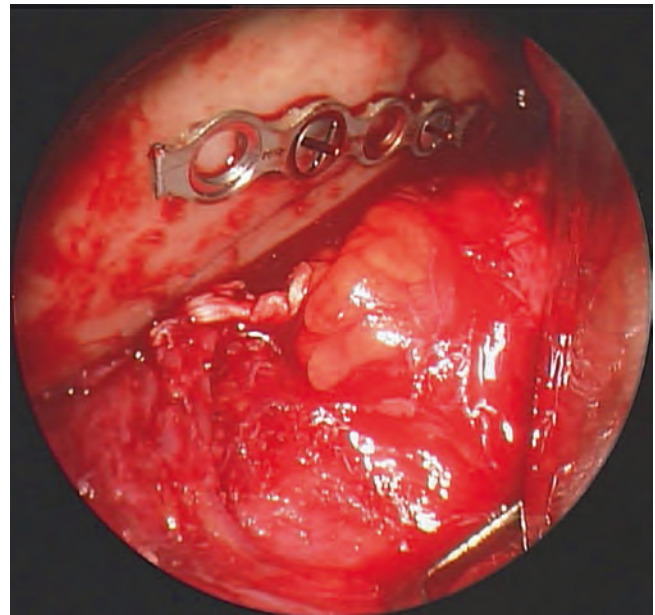
Once the dislocated fragment is identified, it has to be repositioned anatomically. MMF cannot be recommended in all cases. In some cases, it can be helpful to get a stable reduction during osteosynthesis; however, in most cases, MMF is not very helpful. This decision has to be made individually case by case.

In most cases, the reposition of the proximal fragment is not stable from the beginning (Fig. 54.8). Therefore, the authors recommend to drill the first screw hole in the condyle fragment close to the fracture line in the region of the sigmoid notch. A four- or five-hole 1.0 mm up to 1.2-mm-thick miniplate is fixed in this hole with a 5- to 6-mm-long screw with a diameter of 2.0 mm. The screw should not be tightened completely. Then the reduction of condyle fragment



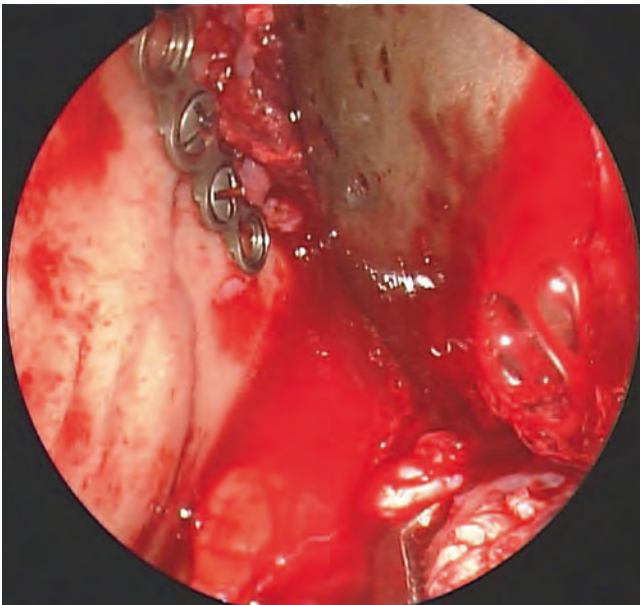
©Association of Oral and Maxillofacial Surgeons of India

Fig. 54.8 Endoscopic view after repositioning of a condylar neck fracture



©Association of Oral and Maxillofacial Surgeons of India

Fig. 54.10 Endoscopic view after fixation of a five-hole miniplate at posterior border with two screws adjacent to the fracture line



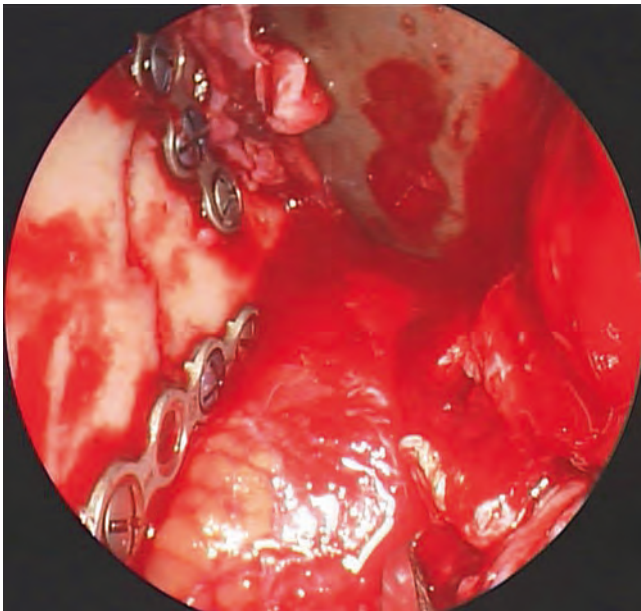
©Association of Oral and Maxillofacial Surgeons of India

Fig. 54.9 Endoscopic view after fixation of a four-hole miniplate close to the sigmoid notch with two screws adjacent to the fracture line

can be achieved by pulling on the miniplate with one of the extra-long reposition hooks. By visual control of the repositioned fragment, the miniplate should now be fixed in the ramus part of the fracture close to the sigmoid notch by eccentric drilling of the screw hole for fracture line compression during screw insertion. After fixing the second screw, the first screw has to be tightened completely (Fig. 54.9).

Once this is facilitated, often a small gap and flaring can be identified at the posterior border of the condylar neck. To close this gap, a second four- to five-hole miniplate has to be fixed at the posterior border of the condylar neck. Here also the hole has to be drilled in the condyle fragment close to the fracture line. First, the plate has to be fixed in this hole and should be aligned along the posterior border of the condylar neck respectively the ramus. Again, the screw should not be tightened completely at this stage. After exact anatomical reposition of the condyle, the next screw is now drilled for compression osteosynthesis in the ramus part of the ramus close the fracture line and immediately fixed with the fourth screw (Fig. 54.10). The third screw is then tightened completely to stabilize the fracture. After attaining control of the anatomical correct reposition with the endoscope or in low condylar neck fractures even with a simple dental mirror, the other screw holes in both plates are drilled and fixed, starting with the plate at the posterior border and ending with plate close to the sigmoid notch. Figure 54.11 shows the final endoscopic view with the two plates fixed. Figure 54.12 is illustrating the recommended sequencing of plate and screw positioning to facilitate open reduction and internal fixation via an intraoral approach using two miniplates.

In addition, the authors recommend intraoperative imaging with a 3D C-arm device at the end of the procedure when available (Fig. 54.13). This allows the intraoperative radiologic control and documentation of the reduced fracture and of the position of the plates in a multiplanar view and enables an immediate intraoperative correction when the result of the



©Association of Oral and Maxillofacial Surgeons of India

Fig. 54.11 Endoscopic view after complete fixation of a condylar neck fracture with two miniplates. One four-hole plate in the region of the sigmoid notch and a second five-hole miniplate at posterior border

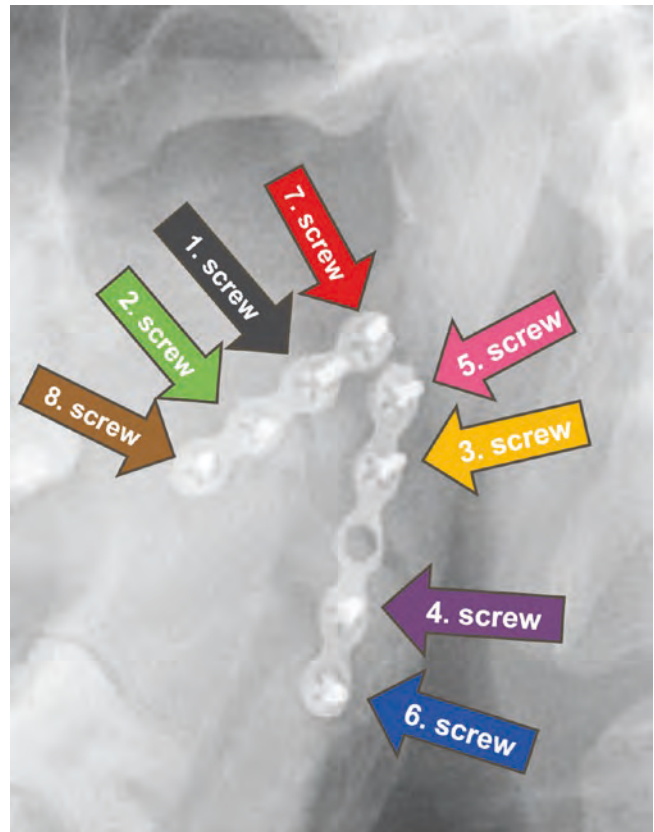procedure is not satisfactory. This reduces the risk for revision surgeries considerably [15, 16].

When the result is satisfactory, the intraoral mucosa has to be closed in the standard way like every intraoral incision. Even when the fracture is reduced and stabilized with success, the authors still recommend a light MMF with elastics strained over two or four MMF screws or arch bars for approximately 1 week for slight immobilization and guidance into the proper occlusion. In case of a postoperative insufficient occlusion, a prolonged functional treatment as in nonsurgical treated condylar fractures with elastics or an orthodontic device like an activator or bionator has to be recommended.

54.2.4 Osteosynthesis Material

As mentioned before, the author is recommending the usage of two miniplates. The plate at the posterior border is responsible for the stability primarily, whereas the plate in the region of the sigmoid notch prevents flaring of the distal fragment during function additionally.

For osteosynthesis, 1.0-mm up to 1.2-mm-thick miniplates can be recommended (Fig. 54.14). It can be favorable to use 1.2-mm-thick miniplates at the posterior border due to stability reasons. The screws should be usually 5–6 mm long with a diameter of 2.0 mm. Locking screws



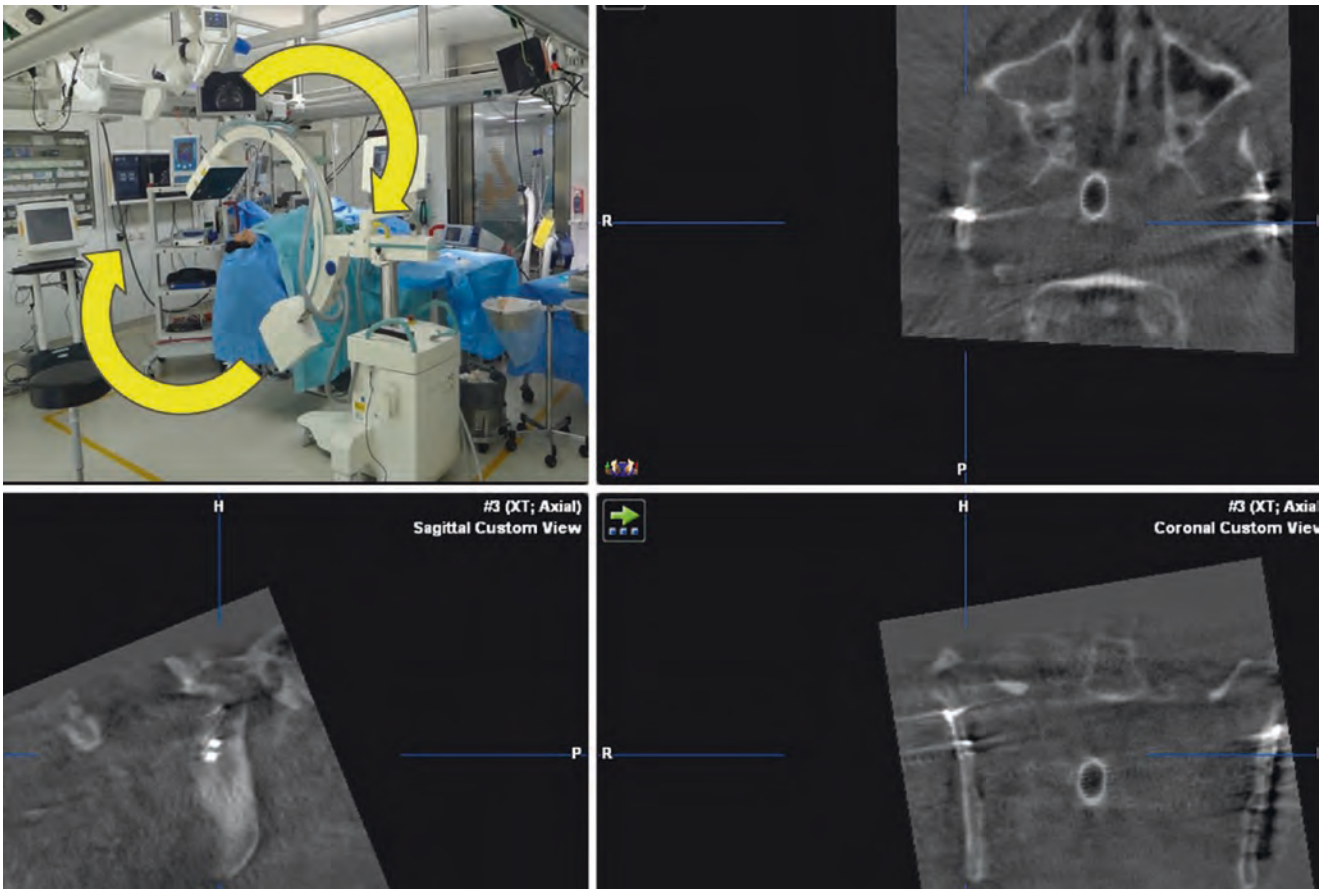
©Association of Oral and Maxillofacial Surgeons of India

Fig. 54.12 Recommended sequencing of plate and screw positioning to facilitate open reduction and internal fixation via an intraoral approach using two miniplates

are not necessary and should never be used for the screw holes which are adjacent to the fracture line. These holes should be drilled eccentric to achieve compression at the fracture line. In modern osteosynthesis systems, locking and non-locking screws can be used with the same plates. Using such a system, it may be advantageous to use locking screws for the fracture-distant screw holes. Nevertheless, as mentioned before, locking screws are not needed in this technique.


Besides standard miniplates, there is the option for the use of so-called 3D plates or special designed condylar neck plates (Fig. 54.15). However, from the authors' experience, plating with two miniplates enables the aforementioned successive repositioning and fixation of the fracture most easily and leads to sufficient stability.

There are new developments of anatomically preformed 3D condylar neck plates with integrated reposition wings for the posterior border and the sigmoid notch (Fig. 54.16). Whether these kinds of plates are beneficial or not has to be investigated in the future.




©Association of Oral and Maxillofacial Surgeons of India

Fig. 54.13 Intraoperative imaging with a 3D C-arm device (Ziehm, Erlangen, Germany) at the end of the procedure and multiplanar view of the surgical result



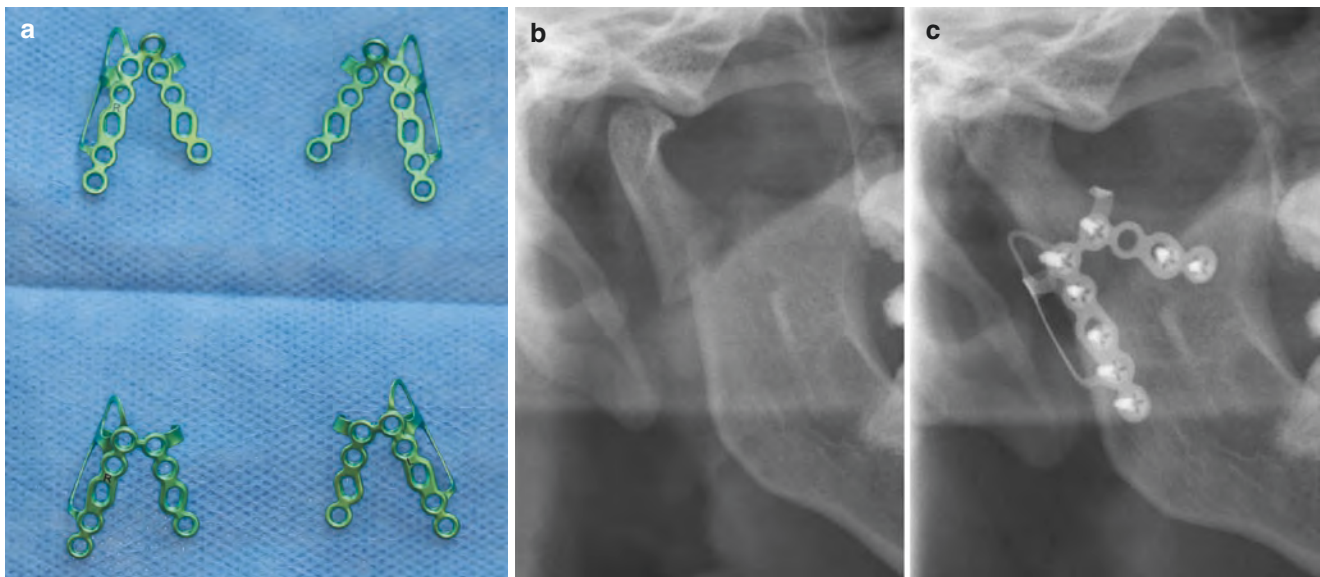
©Association of Oral and Maxillofacial Surgeons of India

Fig. 54.14 1.0-mm and 1.2-mm-thick standard miniplates (DePuySynthes, Zuchwil, Switzerland)



©Association of Oral and Maxillofacial Surgeons of India

Fig. 54.15 3D miniplate (asterisk) and special condylar neck plate (hash symbol) (DePuySynthes, Zuchwil, Switzerland)



©Association of Oral and Maxillofacial Surgeons of India

Fig. 54.16 (a) Anatomically preformed 3D condylar neck plates with integrated reposition wings for the posterior border and the sigmoid notch (KLS Martin, Tuttlingen, Germany). (b) Displaced right condylar

neck fracture. (c) Condylar neck fracture after repositioning and fixation employing an intraoral approach

54.3 Complications

There is no much difference in complications by treating condylar fractures via an intraoral approach in comparison to all other treatment options. Postoperative infection is the most common complication followed by malocclusion. Dysfunctional degeneration of the injured joint can lead to joint clicking, pain, reduced mouth opening, and mandibular deviation during opening and closing. Even severe arthritis or condylar resorption can occur up to the total destruction or loss of the joint. Hardware failure in form of plate fractures or loosening of screws can be seen occasionally as well.

In addition to the avoidance of any visible extraoral scar, the biggest advantage in comparison to all extraoral approaches for surgical treatment of condylar fractures is the very low complication rate concerning facial nerve injuries, salivary fistulas, sialoceles, Frey syndrome, or disturbance of the great auricular nerve.

54.4 Conclusion

The described intraoral approach for the treatment of condylar fractures is favorable for fractures of the condylar base and the condylar process. The biggest benefit and advantage in comparison to all extraoral approaches is the very low complication rate concerning facial nerve injuries and the

Table 54.1 Advantages and disadvantages of an intraoral approach for the treatment of condylar fractures

<i>Advantages</i>
• No visible scars
• Very low risk for facial nerve damaging
• Very low risk for salivary fistulas, sialoceles or Frey syndrome
• No risk for disturbance of the great auricular nerve
<i>Disadvantages</i>
• Need for special equipment
• Technically demanding
• Not suitable for condylar head fractures

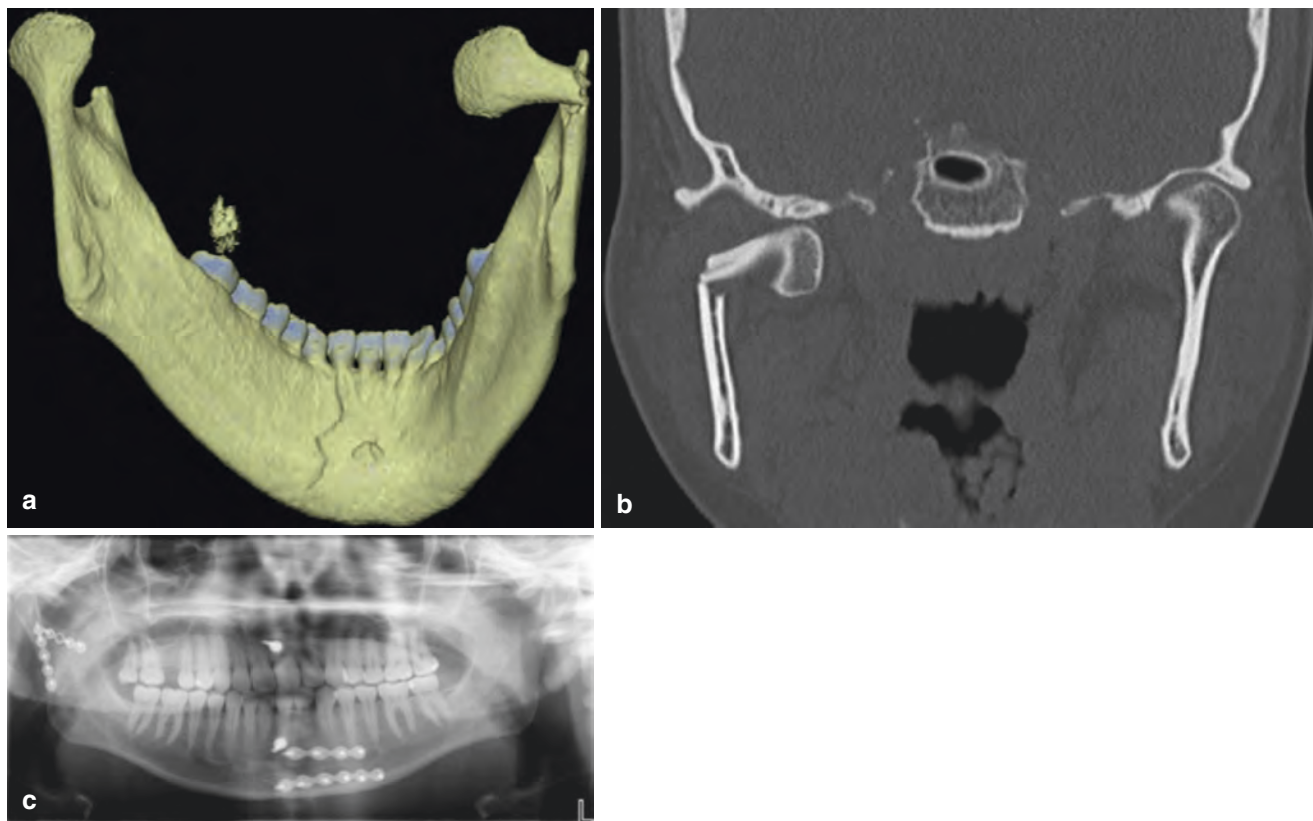
avoidance of extraoral scars. A disadvantage is the need for special equipment to facilitate this technically demanding procedure with regular success (Table 54.1).

54.5 Case Scenario

History: A 24-year-old female with history of a bicycle accident.

Clinical features: Malocclusion with lateral open bite left. Limited and painful mouth opening. Mobile mandible paramedian region left. Chin hematoma.

Diagnosis: Medial displaced condylar process fracture right and slightly displaced paramedian fracture left (Fig. 54.17a–b).



©Association of Oral and Maxillofacial Surgeons of India

Fig. 54.17 (a) 3D reconstruction of the preoperative CT scan showing the medial displaced condylar process fracture right and slightly displaced paramedian fracture left. (b) Coronal view of the preoperative CT scan showing the medial out of the fossa displaced condylar process

fracture right. (c) Postoperative panoramic X-ray showing well-sufficiently reduced and with miniplates stabilized fractures paramedian left and at the condylar process right

Surgical plan: Open reduction and internal fixation of both fractures employing an intraoral approach. The paramedian fracture should be fixed first with two miniplates. A gap of the lingual cortex should be prevented by compression of the mandible in the posterior region and overbending the plates. The condylar neck fracture should be fixed second with two miniplates as well.

Postoperative findings: Sufficiently reduced and stabilized fractures at the condylar process right and paramedian left (Fig. 54.17c). Proper occlusion and regular mouth opening 4 weeks after surgery without any deviation during function.

References

1. Rozeboom AVJ, Dubois L, Bos RRM, Spijker R, de Lange J. Open treatment of condylar fractures via extraoral approaches: A review of complications. *J Craniomaxillofac Surg.* 2018;46(8):1232–40.
2. Vural E. Treatment of adult subcondylar mandibular fractures: closed vs open vs endoscopic approach. *Arch Otolaryngol Head Neck Surg.* 2004;130(10):1228–30.
3. Hall MB. Condylar fractures: surgical management. *J Oral Maxillofac Surg.* 1994;52(11):1189–92.
4. Ellis E 3rd, Dean J. Rigid fixation of mandibular condyle fractures. *Oral Surg Oral Med Oral Pathol.* 1993;76(1):6–15.
5. Haug RH, Assael LA. Outcomes of open versus closed treatment of mandibular subcondylar fractures. *J Oral Maxillofac Surg.* 2001;59(4):370–5. Discussion 375–6
6. Vogt A, Roser M, Weingart D. Transparotidian approach to surgical management of condylar neck fractures. A prospective study. *Mund Kiefer Gesichtschir.* 2005;9(4):246–50 [Article in German].
7. Patil RS, Gudi SS. Management of subcondylar fracture through intraoral approach with rigid internal fixation. *J Maxillofac Oral Surg.* 2011;10(3):209–15.
8. Schön R, Gutwald R, Schramm A, Gellrich NC, Schmelzeisen R. Endoscopy-assisted open treatment of condylar fractures of the mandible: extraoral vs intraoral approach. *Int J Oral Maxillofac Surg.* 2002;31(3):237–43.
9. Silverman SL. A new operation for displaced fractures at the neck of the mandibular condyle. *Dental Cosmos.* 1925;67:876.
10. Fritzemeier C, Bechthold H. Die Osteosynthese von Unterkiefergelenkfortsatzfrakturen mit alleinigen Zugang von intraoral. *Dtsch Z Mund Kiefer Gesichtschir.* 1993;17:66–8.

11. Mokros S, Erle A. Transoral miniplate osteosynthesis of mandibular condyle fractures—optimizing the surgical method. *Fortschr Kiefer Gesichtschir.* 1996;41:136–8.
12. Veras RB, Kriwalsky MS, Eckert AW, Schubert J, Maurer P. Long-term outcomes after treatment of condylar fracture by intraoral access: a functional and radiologic assessment. *J Oral Maxillofac Surg.* 2007;65:1470–6.
13. Jensen T, Jensen J, Nørholt SE, Dahl M, Lenk-Hansen L, Svensson P. Open reduction and rigid internal fixation of mandibular condylar fractures by an intraoral approach: a longterm follow-up study of 15 patients. *J Oral Maxillofac Surg.* 2006;64:1771–9.
14. Schneider M, Lauer G, Eckelt U. Surgical treatment of fractures of the mandibular condyle: a comparison of long-term results following different approaches—functional, axiographical, and radiological findings. *J Craniomaxillofac Surg.* 2007;35:151–60.
15. Schramm A, Wilde F. Computer-assisted reconstruction of the facial skeleton. *HNO.* 2011;59(8):800–6.
16. Wilde F, Schramm A. Intraoperative imaging in orbital and midface reconstruction. *Facial Plast Surg.* 2014;30(5):545–53.

Open Access This chapter is licensed under the terms of the Creative Commons Attribution 4.0 International License (<http://creativecommons.org/licenses/by/4.0/>), which permits use, sharing, adaptation, distribution and reproduction in any medium or format, as long as you give appropriate credit to the original author(s) and the source, provide a link to the Creative Commons license and indicate if changes were made.

The images or other third party material in this chapter are included in the chapter's Creative Commons license, unless indicated otherwise in a credit line to the material. If material is not included in the chapter's Creative Commons license and your intended use is not permitted by statutory regulation or exceeds the permitted use, you will need to obtain permission directly from the copyright holder.



55.1 Introduction

Complex midface trauma has challenged the diagnostic and operative skills of surgeons through the decades. Robert Marciani in his fifty year review article dated 1993, vividly described the challenges faced by early surgeons regarding the clinical and radiological diagnosis of mid face fractures and the compromised surgical results that may ensue [1].

55.1.1 History (Table 55.1)

In an area so anatomically complicated as the midface, the lines of fracture produced in the middle third are classified based upon the experimental studies of René Le Fort in 1901 [2]. The earliest known writings of maxillofacial fractures were recorded in the Edwin Smith papyrus in 1650 BC. Hippocrates who is often portrayed as the “Father of Medicine” described a myriad of facial injuries around 400 BC and his insight provided the basis for bandages and single jaw interdental wiring as methods of fixation and stabilization of facial fractures. Over the subsequent centuries, there appeared many techniques which in essence were vari-

Table 55.1 Milestones of maxillary fractures

Date	Author	Key finding
1822	Charles Fredrick Reiche	First treatise on maxillary fractures
1823	Carl van Graefe	Use of a head frame to treat a maxillary fracture
1901	René Le Fort	Paper on midfacial fracture patterns
1943	Crawford	Used a Halo frame which was secured directly to the skull using pins

ations of what Hippocrates had described. In the nineteenth century, Charles Fredrick Reiche provided the first detailed treatise on maxillary fractures [3]. It was also in the same century that Garretson and Blair advocated mandibular-maxillary fixation with the aid of splints to primarily treat maxillary fractures.

In 1901, a French surgeon René Le Fort published his classic paper on midfacial fracture patterns. He inflicted blunt facial trauma on cadavers, then subsequently removed the soft tissue and examined fracture patterns of the facial skeleton. This study has ever since been the basis for the description of maxillary fractures.

O. A. Jacob (✉)
Department of Oral and Maxillofacial Surgery,
Ananthapuri Hospitals and Research Institute,
Trivandrum, Kerala, India

Kerala Institute of Medical Sciences, Trivandrum, Kerala, India

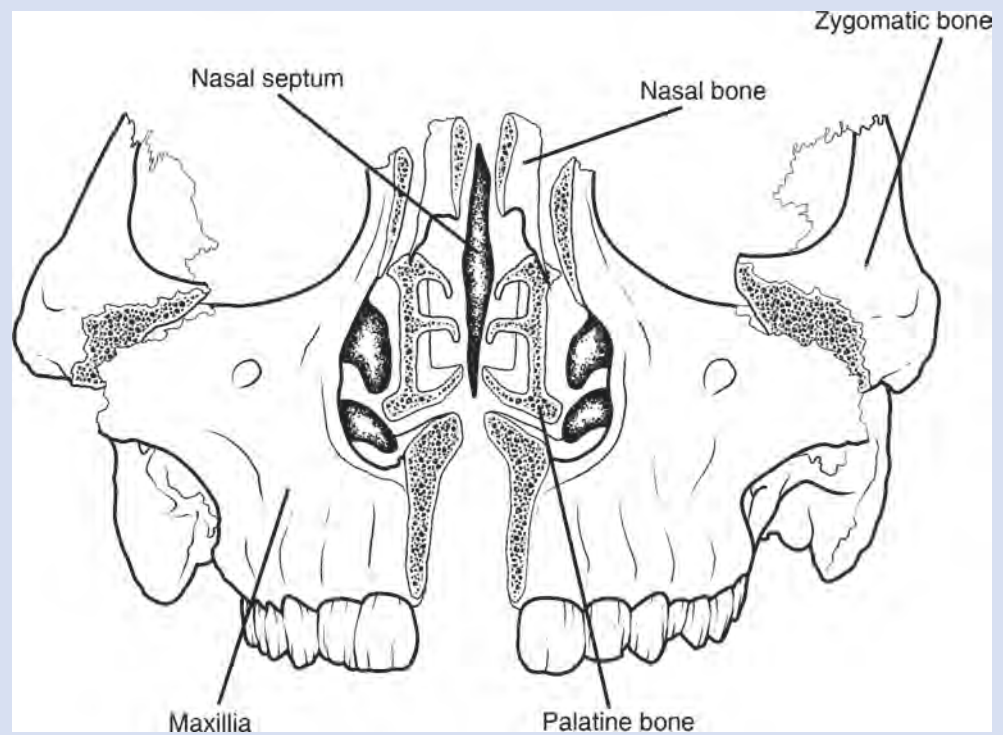
A. Prathap
Pushpagiri College of Dental Sciences, Thiruvalla, Kerala, India

55.1.2 Surgical Anatomy/Osteology

The middle third of the facial skeleton is made up of the following bones (Fig. 55.1)

1. Two maxillae
2. Two zygomatic bones
3. Two zygomatic processes of the temporal bones
4. Two palatine bones
5. Two nasal bones
6. Two lacrimal bones
7. The vomer
8. The ethmoid and its attached conchae
9. Two inferior conchae
10. The pterygoid plates of the sphenoid

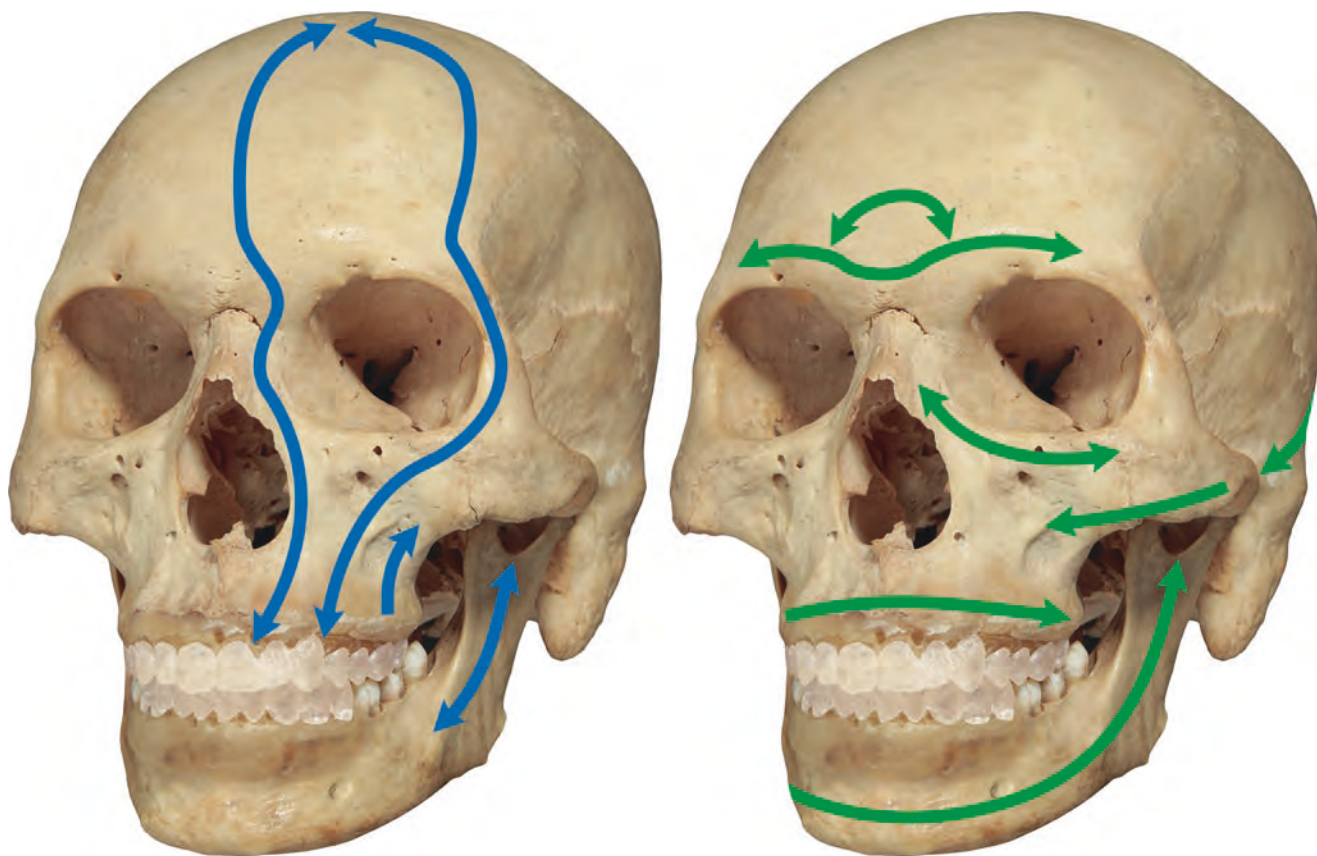
Fig. 55.1 Bones of the midface



©Association of Oral and Maxillofacial Surgeons of India

The middle third of the face is made up of a number of bones which rarely fractures in isolation. The complex nature of the midface is such that it will withstand the forces of mastication from below and provide protection in certain areas for vital structures. The middle third of the facial skeleton consists of a series of bone struts (buttresses) passing upwards from the upper teeth to the bones of the skull [4] (Fig. 55.2).

The relative fragility of the midface skeleton makes it act as a cushion for trauma directed towards the cranium from an anterior or anterolateral direction. The facial skeleton can be designated by this famous figure, where the skull is similar to a helmet, the midface is similar to a matchbox (crumble zone) and the mandible is similar to a hockey stick (Fig. 55.3). The most common causes of facial fractures in the adult population are assaults and motor vehicle accidents [5].



Vertical buttresses

©Association of Oral and Maxillofacial Surgeons of India

Horizontal buttresses

Fig. 55.2 Vertical and horizontal buttresses of the facial skeleton (Also refer Fig. 60.9 and Table 60.2)

55.1.3 Applied Anatomy of the Midfacial Bones

The midface is composed of the nasal, zygoma, maxilla, ethmoid and its conchae, palatine, inferior concha and vomer which are collectively referred to as the middle third of the facial skeleton. The facial bones in isolation are comparatively fragile but gain strength and support as they articulate with each other. It is this strength that has often been described as the facial buttresses which Manson alluded to when describing the vertical and horizontal struts that support the facial skeleton [6]. The horizontal pillars are formed by the frontal bar (composed of the supraorbital rims and nasal process of the frontal bone), the zygomatic arch, the infraorbital rims and the nasal bridge and finally the alveolar process of the maxilla. The vertical pillars are the medial pillar formed by the piriform rims which continues superiorly as the frontal process of the maxilla. The zygomatic buttresses which continue superiorly with the lateral orbital

rims form the lateral pillars, and the most caudal pillars are the pterygoid plates.

55.1.3.1 Maxilla

The maxilla consists of a central body and four processes, namely, the frontal, zygomatic, alveolar and palatine process. The body is hollowed out and contains the maxillary sinus. It is pyramidal shaped with the base being the medial surface facing the nasal cavity and the apex being elongated into the zygomatic process. It has an orbital or superior surface which forms the floor and rim of the orbit, a malar or anterolateral surface which forms part of the cheek and a posterolateral or infratemporal surface which contributes to the infratemporal fossa. The base is rimmed inferiorly by the alveolar process. The alveolar process houses the dental arch with the sockets varying in size according to the teeth. The palatine process is a horizontal process from the body to the alveolar process and medially articulates with the palatine process of the opposite maxilla, while posteriorly it articu-

Fig. 55.3 Helmet, matchbox and hockey stick to illustrate relative bone strength (the matchbox is the crumble zone)



©Association of Oral and Maxillofacial Surgeons of India

lates with the horizontal plate of the palatine bone. The zygomatic process is an extension of the anterolateral surface of the body which contributes to the zygomaticomaxillary suture. The frontal process projects upwards to articulate with the maxillary process of the frontal bone as well as the nasal bone anteriorly and the lacrimal bone posteriorly.

55.1.3.2 Vascular Supply and Innervation

The blood supply to the maxilla and the palatine bones is through the periosteum, the incisive artery and the greater and lesser palatine arteries. The internal maxillary artery lies posterior to the maxillae and the palatine bones and anterior to the pterygoid plates of sphenoid.

The maxillary nerve enters the caudal maxilla ventral to the orbit via the maxillary foramen and runs through the maxilla in the infraorbital canal giving off branches to supply the maxillary cheek and teeth. The nerve then exits the maxilla at the infraorbital foramen.

55.2 Classification

55.2.1 René Le Fort 1901 [2]

Maxillary fractures were classified by René Le Fort based on his experiments on cadavers with low velocity unidirectional frontal trauma. Although the present-day maxillary fractures are caused due to high velocity multi directional trauma, the

Le Fort classification is still widely followed due to its simplicity and the levels of anatomic differentiation it offers. Other authors have attempted classifications based on the anatomical sites and based on the involvement of the occlusion. Marciani modified the basic Le Fort classification by adding frontal bone and zygomatic fractures.

55.2.1.1 Le Fort I

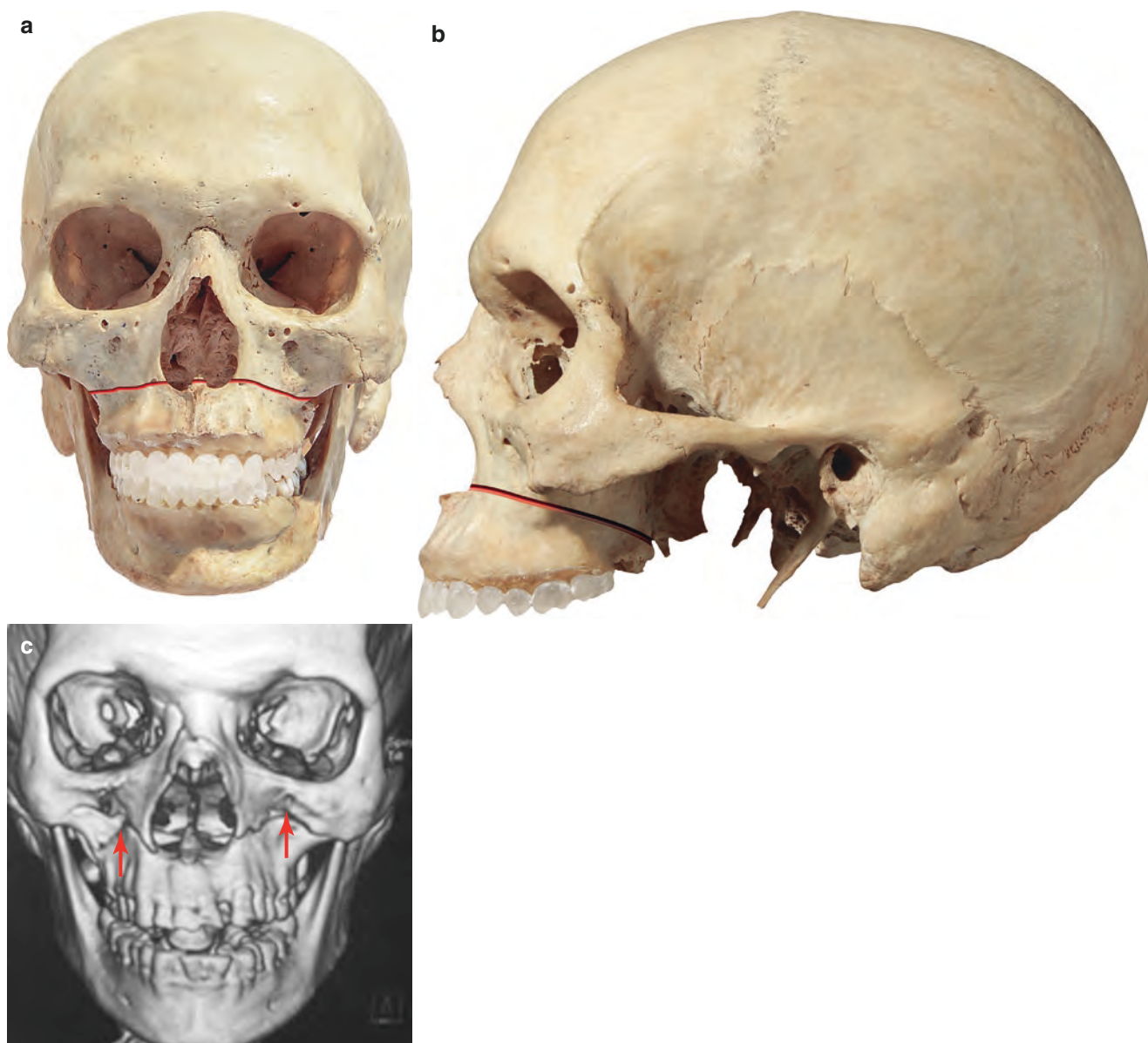Low Level Fracture/Guerin Fracture

The fracture line extends backwards from the lateral margin of the anterior nasal aperture below the zygomatic buttress to cross the lower third of the pterygoid laminae. The fracture also passes along the lateral wall of the nose and the lower third of the septum to join the lateral fracture behind the tuberosity (Fig. 55.4a–c).

55.2.1.2 Le Fort II

Pyramidal or Sub-zygomatic Fracture

This fracture runs from the thin middle area of the nasal bones down either side, crossing the frontal processes of maxillae into the medial wall of each orbit; the fracture line crosses the lacrimal bone behind the lacrimal sac before turning forwards to cross the infraorbital margins slightly medial to or through the infraorbital foramen. The fracture now extends downwards and backwards across the lateral wall of the antrum below the zygomaticomaxillary suture and divides the pterygoid laminae about half way up.



©Association of Oral and Maxillofacial Surgeons of India

Fig. 55.4 (a, b) Le Fort I fracture lines. (c) CT of Le Fort I fracture

Separation of the block from the base of the skull is completed via the nasal septum and may involve the floor of the anterior cranial fossa (Fig. 55.5a–d).

55.2.1.3 Le Fort III

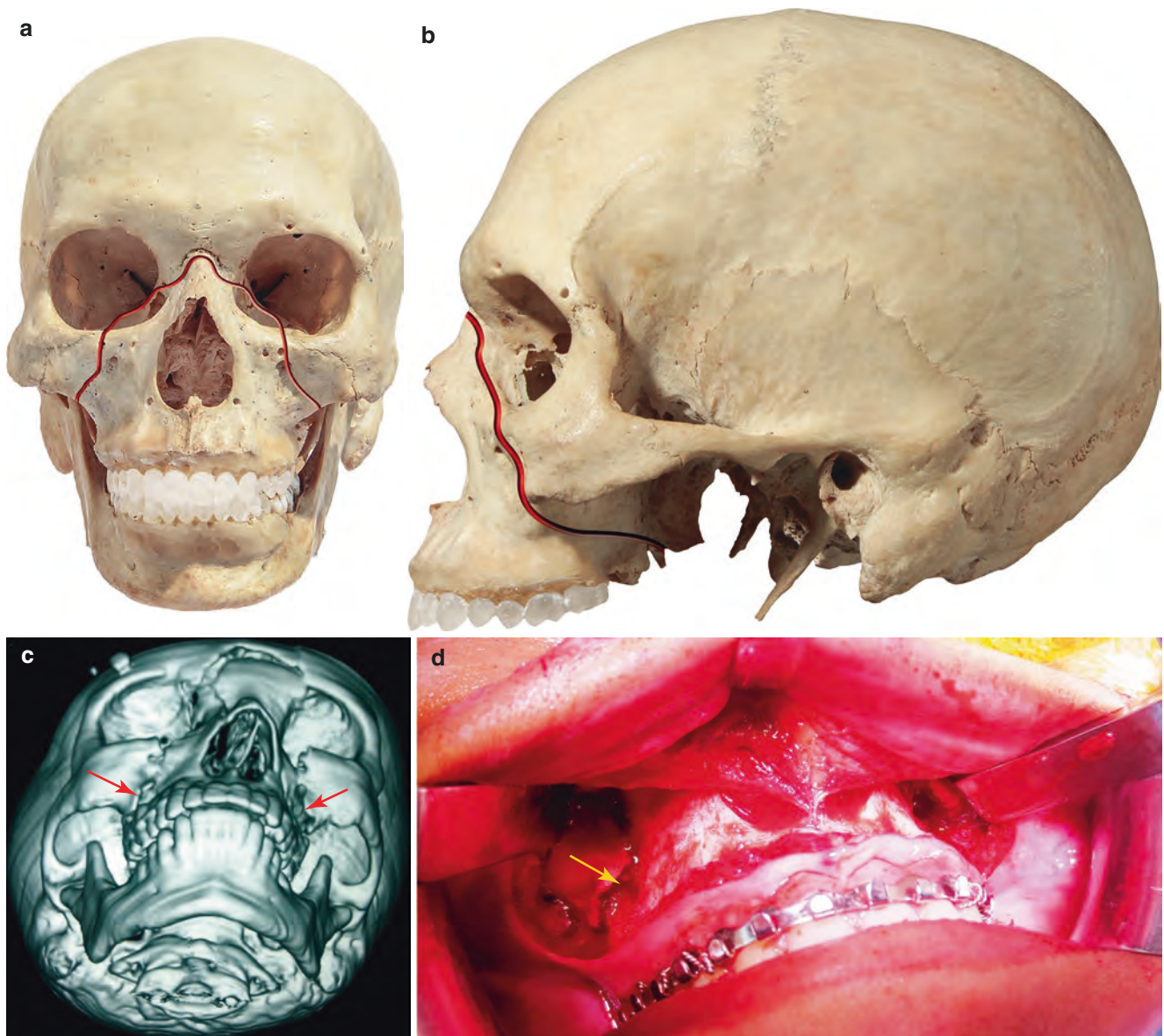
Transverse or Supra-zygomatic Fracture

The fracture runs from near the frontonasal suture transversely backwards and parallel with the base of the skull and involves the full depth of the ethmoid bone including the cribriform plate. Within the orbit the fracture passes below the optic foramen into the posterior limit of the inferior orbital fissure. From the base of the inferior orbital fissure,

the fracture line extends in two directions: backwards across the pterygomaxillary fissure to fracture the roots of the pterygoid laminae and laterally across the lateral wall of the orbit separating the zygomatic bone from the frontal bone. In this way the entire middle third of the facial skeleton gets separated from the cranial base (Fig. 55.6a–c).

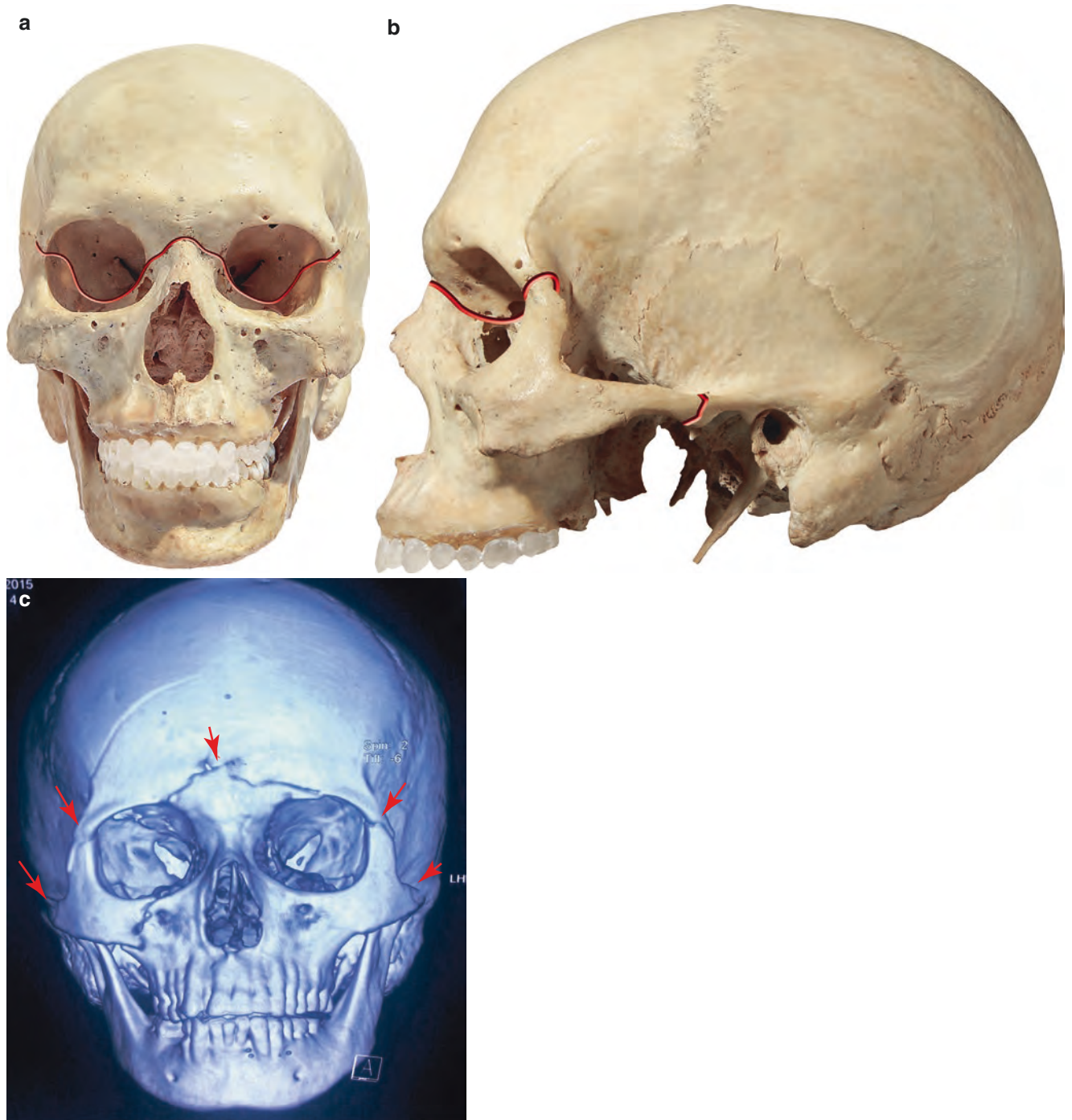
Le Fort classification does not take into consideration:

- Dentoalveolar fractures
- Palatal fractures
- Bone loss



©Association of Oral and Maxillofacial Surgeons of India

Fig. 55.5 (a, b) Le Fort II fracture lines. (c) CT of Le Fort II fracture showing the midface segment impacted (red arrows). (d) Clinical image of case in c, showing the impacted area right side Le Fort II (yellow arrow)



©Association of Oral and Maxillofacial Surgeons of India

Fig. 55.6 (a, b) Le Fort III fracture. (c) CT of Le Fort III fracture (the fracture lines shown with red arrows)

55.2.2 Killey's Classification (1965) [2]
(Table 55.2)

Table 55.2 Killey's classification

1. Dentoalveolar fractures
2. Zygomatic complex fractures
3. Nasal complex fractures
4. Le Fort I
5. Le Fort II
6. Le Fort III
7. Extended Le Fort fractures

55.2.3 Rowe and Williams's Classification (1985) [2] (Table 55.3)

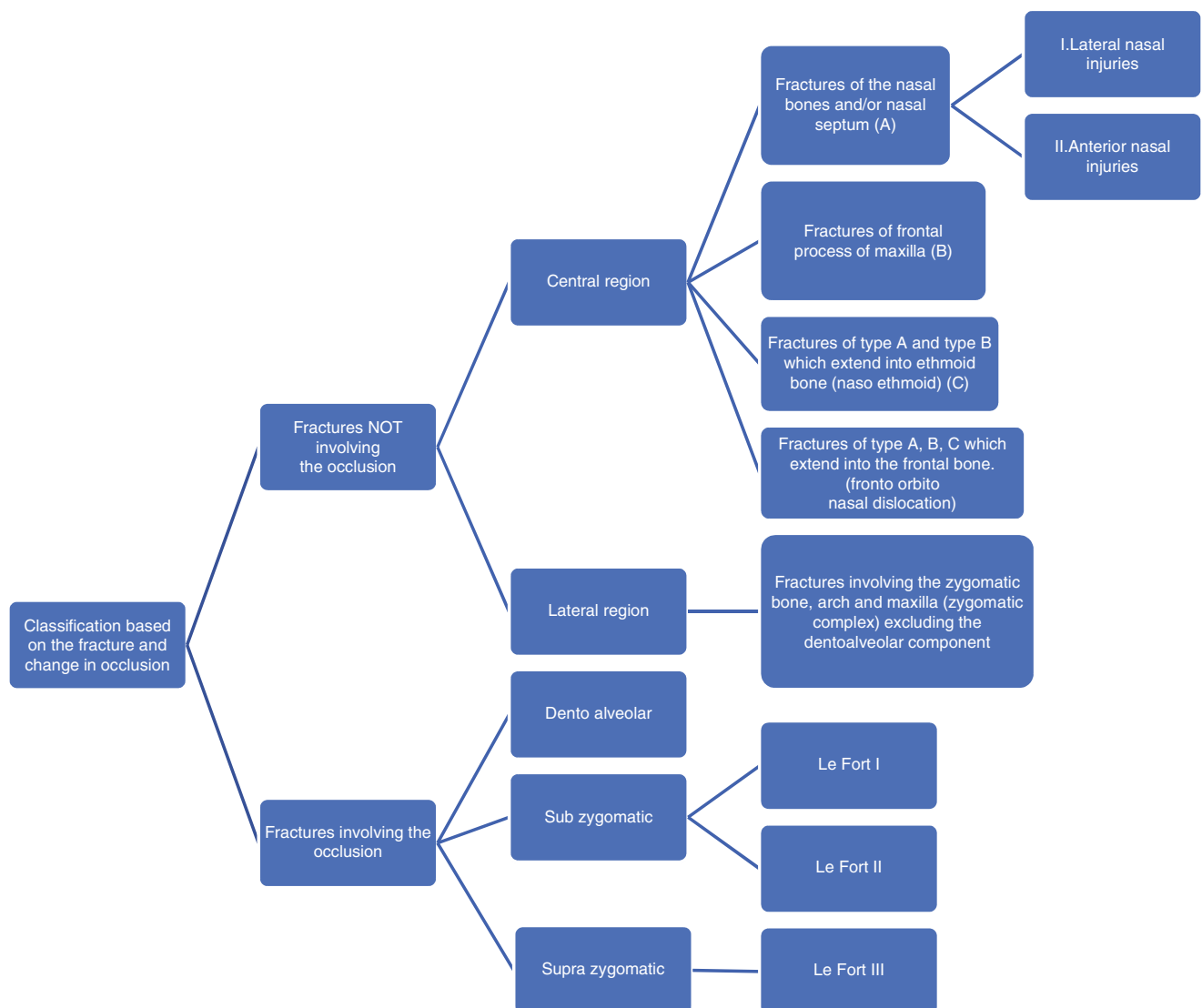


Table 55.3 Rowe and Williams's classification

Addenda

- (i) These fractures may occur unilaterally or be associated independently with a fracture of the zygomatic complex.
- (ii) There may be a midline separation of the maxillae and/or extension of the fracture pattern into the frontal or temporal bones.

55.2.4 Marciani (1993: Modification of Le Fort Fractures) [1]

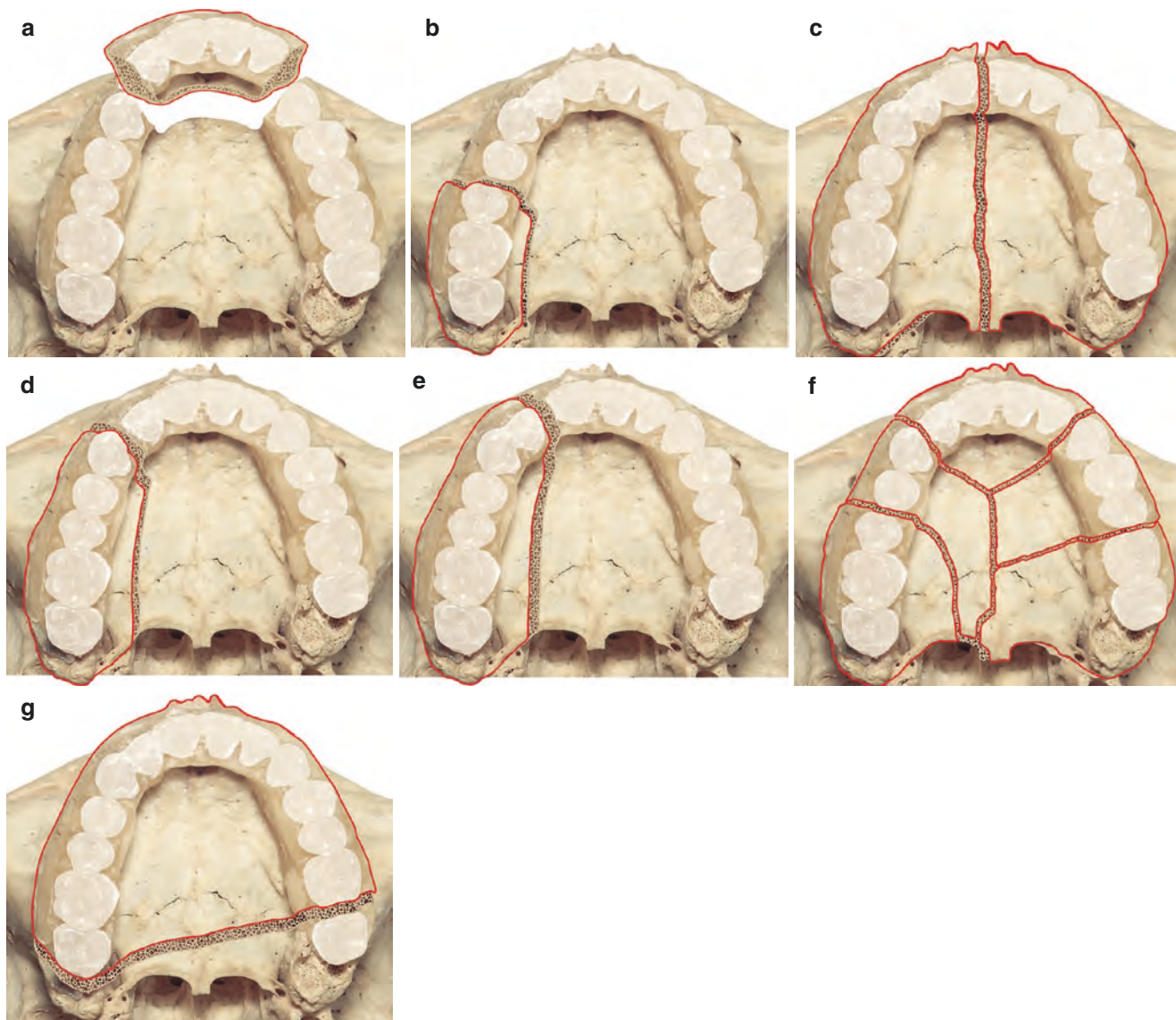
Fractures involving the cranial base and other midface fracture configurations, including severely comminuted segments of the facial skeleton, were not classifiable by the

traditional Le Fort scheme. Hence Marciani proposed a more precise system of describing fracture patterns to define the fracture configuration, establish an accurate diagnosis and to determine potential surgical approaches (Table 55.4).

Table 55.4 Marciani’s modification of Le Fort fracture classification

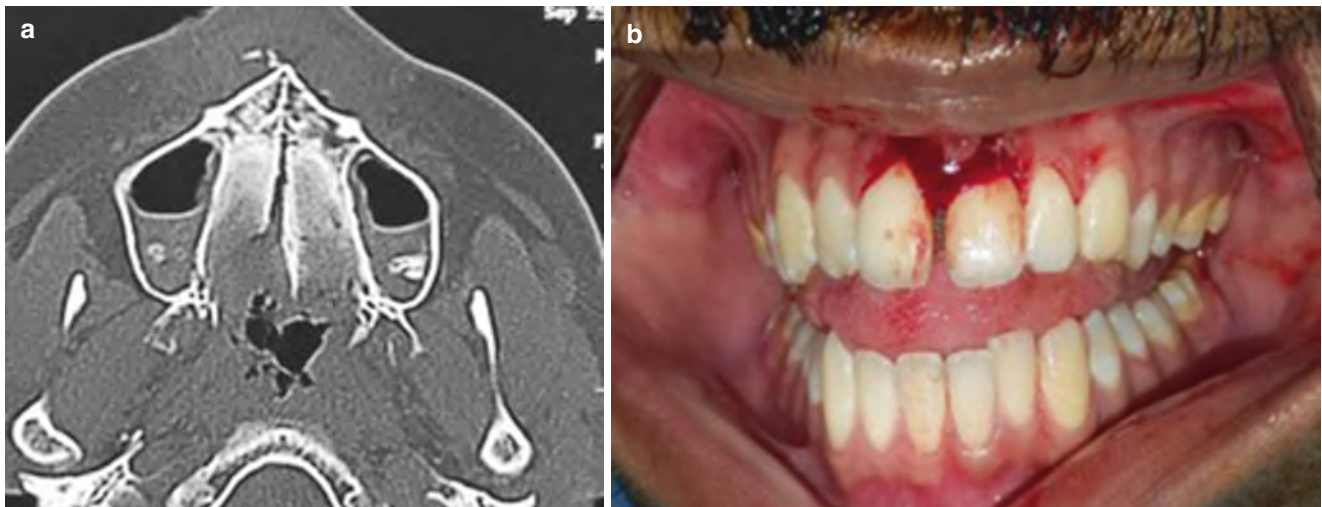
Marciani (1993-modification of Le Fort fractures)	Le Fort I—Low maxillary fracture	Ia—Low maxillary fracture/multiple segments
	Le Fort II—Pyramidal fractures	Ila—Pyramidal and nasal fracture
		I Ib—Pyramidal and NOE fracture
	Le Fort III—Craniofacial dysjunction	III a—craniofacial dysjunction and nasal fracture
III b—craniofacial dysjunction and NOE		
Lefort IV—Le Fort II or III and cranial base fracture	IV a—supraorbital rim fracture	
	IV b—anterior cranial fossa and supraorbital rim fracture	
	IV c—anterior cranial fossa and orbital wall fracture	

55.2.5 Palatal Fractures Classification: Hendrickson’s Classification (1998) [7]
(Figs. 55.7, 55.8, and 55.9; Table 55.5)



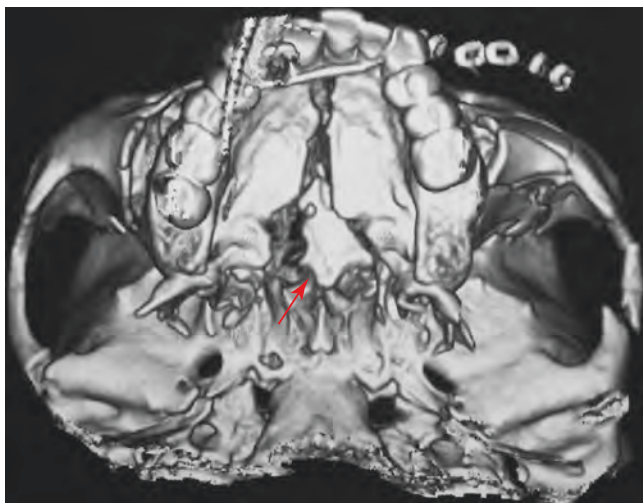
©Association of Oral and Maxillofacial Surgeons of India

Fig. 55.7 Hendrickson’s classification of palatal fractures. (a) Type Ia, (b) Type Ib, (c) Type II, (d) Type III, (e) Type IV, (f) Type V, (g) Type VI



©Association of Oral and Maxillofacial Surgeons of India

Fig. 55.8 (a) CT of Hendrickson's type C fracture. (b) Clinical image of case of a, showing the midline diastema



©Association of Oral and Maxillofacial Surgeons of India

Fig. 55.9 CT of midline palatal fracture with splayed segments, note the posterior displaced fragment, temporary bridle wire has been placed between upper central incisors

55.3 Clinical Features (Box 55.1)

55.3.1 Le Fort I Fractures

Gross facial swelling or facial disfigurement is generally not a feature of Le Fort I fractures, but oedema around the upper lip may occur. Soft tissue injury along the upper lip along with tearing of gingivae may occur due to the causative impact. There can be mobility of the upper dentoalveolus when digital pressure is applied. Mobility of the maxilla at the Le Fort I level must be differentiated from extended maxillary dentoalveolar fracture. Malocclusion

may occur if the fracture is displaced or impacted. Dorsal and caudal pull of the medial pterygoid muscles can contribute to the posterior displacement of the maxilla and the resultant anterior open bite (Fig. 55.10a, b). Bilateral epistaxis is rare although emphysema may occur if the patient blows his nose. Ecchymosis in the upper buccal sulcus is a frequent finding. Percussion of the maxillary teeth produces a dull cracked cup sound. In case of inferiorly displaced Le Fort I fractures, the patient may have to keep the mouth open to accommodate the increased vertical dimension. Due to the extreme downward displacement of the maxilla, the nasal base is lost, leading to stretching of the soft tissues of that area, which makes it possible to see directly into the nares.

The posteriorly impacted Le Fort I fracture may result in an anterior open bite and in these cases the maxilla may be immobile. Usually the impacted maxilla can be mobilized by grasping the maxillary teeth and applying a firm anterior pull. A grate may be felt due to the movement between the fractured segments. In posteriorly impacted fractures, there may be damage to the cusps of maxillary teeth usually in the premolar region, caused by the upward impact of the mandibular teeth at the time of the trauma. The complete Le Fort I fracture may be associated with a split along the median palatal suture. Sometimes more than one fracture line may be present in the palate, so that either one or both fragments may be mobile (Fig. 55.11a–c).

55.3.2 Le Fort II Fractures

Marked facial disfigurement resulting from circumorbital ecchymosis and gross oedema can be a feature of Le Fort II fractures. Frequently the patient will not be able to open

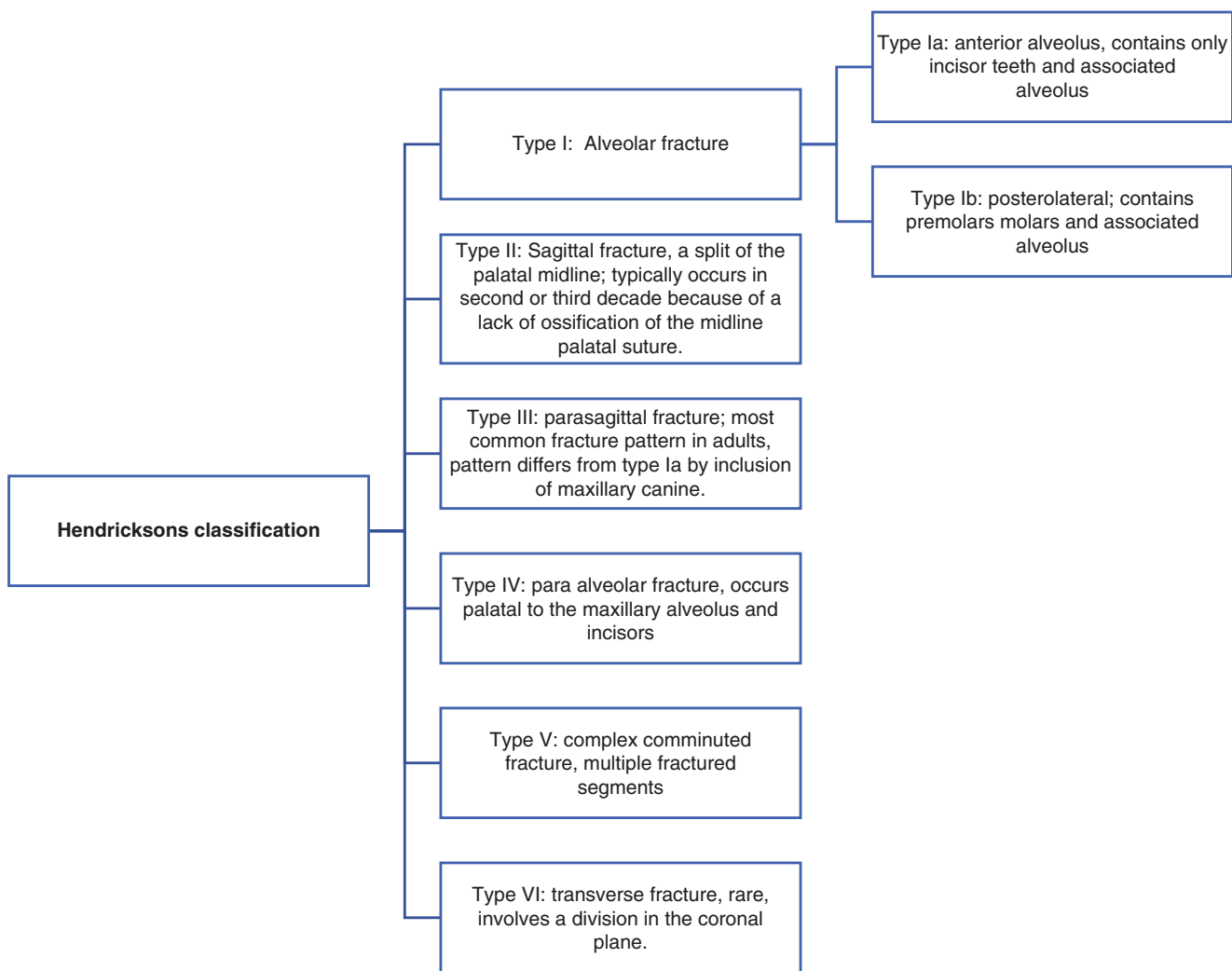
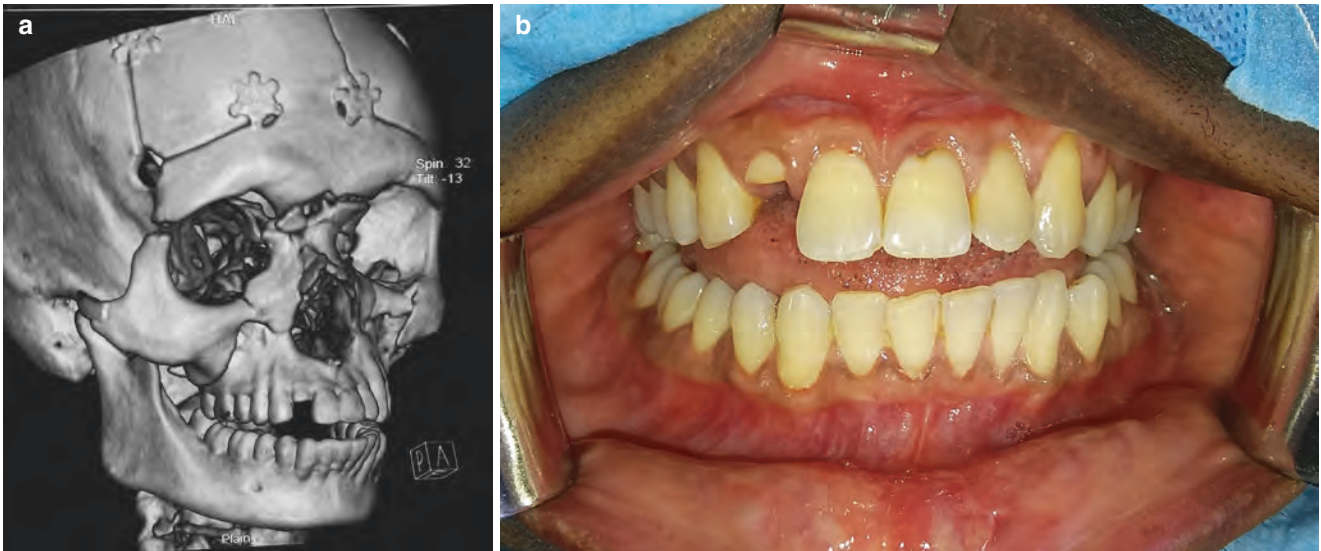


Table 55.5 Hendrickson’s classification: of Palate fractures

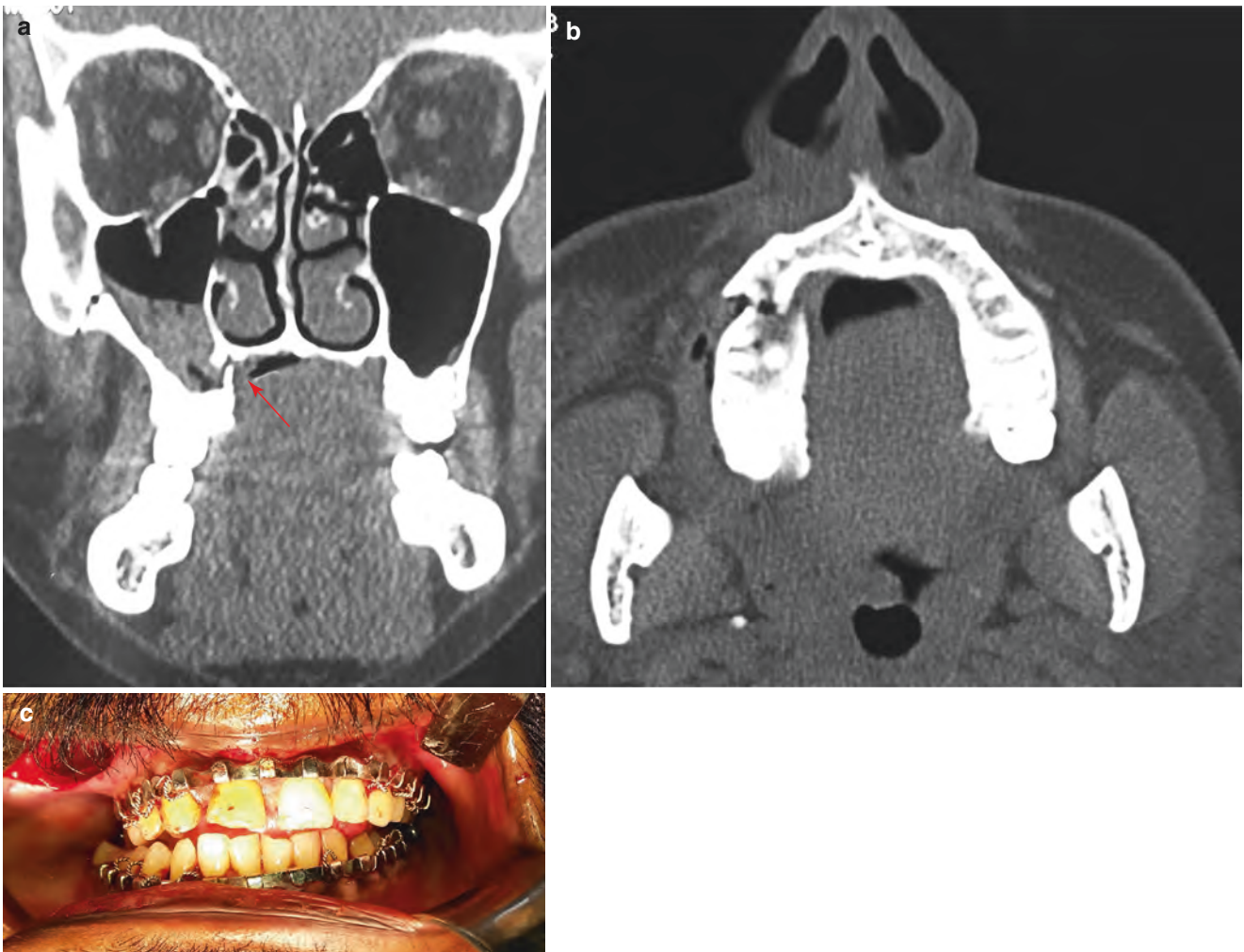
Box 55.1 Clinical features of Le Fort fractures

Clinical features	Le Fort I	Le Fort II	Le Fort III
Intraoral	<ul style="list-style-type: none"> • Floating maxilla • Impacted or telescopic fracture • Anterior open bite • Deranged occlusion • Guerin’s sign • Palatal fracture in some cases 	<ul style="list-style-type: none"> • Deranged occlusion • Posterior gagging of occlusion • Possible airway obstruction 	<ul style="list-style-type: none"> • Deranged occlusion • Posterior gagging of occlusion • Possible airway obstruction
Extraoral	<ul style="list-style-type: none"> • Mild swelling and oedema of midface and upper lip • Epistaxis in some cases • Increased visibility of anterior nares 	<ul style="list-style-type: none"> • Moon face appearance • Peri-orbital oedema • Circumorbital ecchymosis • Subconjunctival haemorrhage • Infraorbital step deformity • Altered sensation of cheek • CSF rhinorrhea • Diplopia 	<ul style="list-style-type: none"> • Separation at FZ suture • CSF rhinorrhea • Hooding of eyes • Anti-mongoloid slant • Dish face deformity



©Association of Oral and Maxillofacial Surgeons of India

Fig. 55.10 (a, b) A posteriorly telescoped Le Fort I fracture maxilla clinically manifesting as anterior open bite



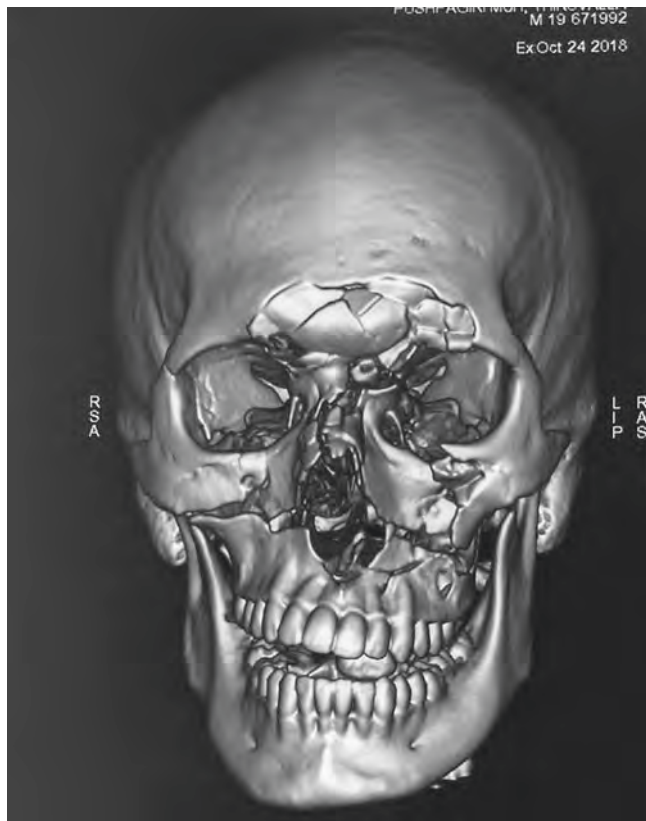
©Association of Oral and Maxillofacial Surgeons of India

Fig. 55.11 CT images (a, b) showing a right zygomatic complex fracture associated with a Hendrickson's type B fracture where the right posterior alveolar and palatal segment was displaced palatally and extruded, causing the occlusal discrepancy (crossbite) as seen in c

his eyelids to allow an ocular examination. Subconjunctival haemorrhage may be present, the posterior limit of which cannot be identified. Bilateral peri-orbital oedema and circumorbital ecchymosis (described as circumorbital as it follows the shape of the orbicularis oculi muscle) are described as racoon eyes or panda facies. There can be severe oedema of the face which is sometimes described as moon facies. Enophthalmos in case of orbital floor fractures may go undetected due to oedema. Considerable lengthening of face with posterior gagging of teeth can also occur. Bilateral epistaxis is common, and CSF leak may be present. The loss of maxillary prominence may result in a dish face appearance. If the fracture line passes through the infraorbital canal there can be associated paresthesia in the infraorbital nerve region. While clinically mobilizing the maxilla in a Le Fort II fracture, transmitted mobility may be felt at the infraorbital rim and the fronto-nasal suture. Figure 55.12 shows a CT image where Le Fort II and III lines are seen

55.3.3 Le Fort III Fractures (Also see Fig. 49.5)

This fracture is clinically similar to the Le Fort II fracture but can demonstrate a more serious condition. Bilateral ecchy-



©Association of Oral and Maxillofacial Surgeons of India

Fig. 55.12 CT image showing Le Fort I and II fractures. Note that maxilla is rotated to the right side with canting on the left side.

mosis with circumorbital oedema may close the eyes completely. As in Le Fort II, the posterior limit of the subconjunctival haemorrhage cannot be seen. The lengthening of the face occurs due to the loss of bony fixation to the base of the skull. The flattening of the face from the disrupted zygomatic bones is usually masked by the gross oedema. The fracture passes above the Whitnall's tubercle and so the support by Lockwoods, suspensory ligament is lost. This results in hooding of upper eyelid which becomes obvious when the oedema subsides. Gagging of occlusion and shift of the maxillary midline may occur. Gross posterior displacement of the maxilla can result in the soft palate touching the posterior part of the tongue causing airway and speech impairment. As with other maxillary fractures, percussion of teeth might produce a cracked cup sound. .

The clinical differentiation between Le Fort II and Le Fort III fractures can be assessed by palpating for step deformity in the infraorbital rim in the former.

55.3.4 Unusual Fracture Patterns

The Le Fort fractures may manifest without the classic fracture patterns as described above. An unilateral fracture at Le Fort I level may occur (identified through imaging) which warrants no intervention unless accompanied by a palatal fracture causing occlusal derangement and/or mobility. Such a unilateral fracture pattern can cause unilateral gagging causing open bite on the contralateral side

The clinician must be aware of the two types of Le Fort I fractures, the mobile and impacted variants; lack of mobility should not be presumed as absence of fracture.

55.4 Radiographic Examination

It is difficult to diagnose fractures of the middle third of the face with plain films and CT scans have now largely replaced radiographs.

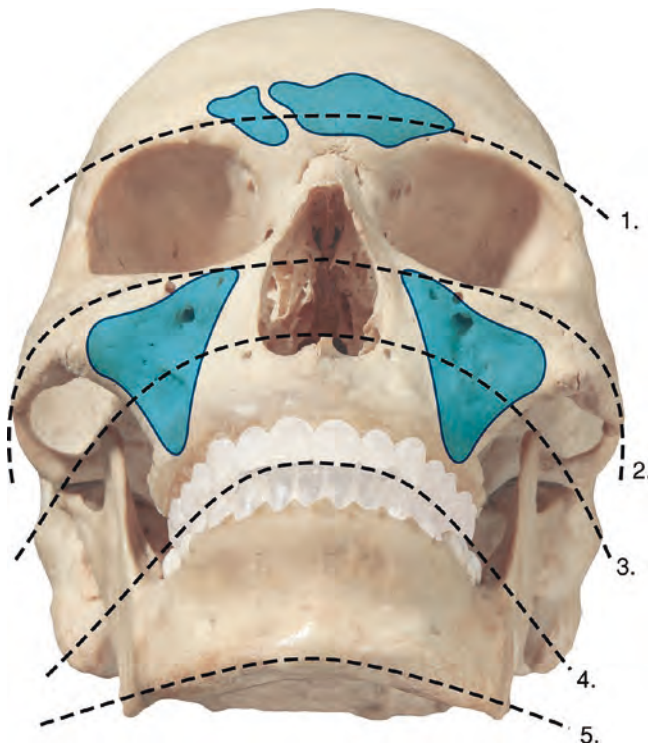
The commonly used radiographs for identifying maxillary fractures are occipitomeatal view (OMV) 10° and 30° and paranasal sinus view 37° (PNS -Waters view).

While assessing maxillary fractures with these radiographs, McGregor-Campbell and Trapnell's lines and Dolan's lines (elephant of Rogers) may be kept in mind [8].

McGregor-Campbell's lines:

These lines were described by McGregor and Campbell for ease of searching on an occipitomeatal view 10-degree frontal projection.

1. First line across the zygomaticofrontal, the superior margin of the orbit and the frontal sinus
2. Second line across the zygomatic arch, zygomatic body, inferior orbital margin and nasal bone



©Association of Oral and Maxillofacial Surgeons of India

Fig. 55.13 McGregor-Campbell and Trapnell's lines

3. Third line across the condyles, coronoid process and the maxillary sinus / Zygomatic buttress region
4. Fourth line across the mandibular ramus, occlusal plane
5. Fifth line (Trapnell's line, added later) across the inferior border of the mandible from angle to angle (Fig. 55.13)

The **four S's** described by Delbalso, Hall and Margarone [8]

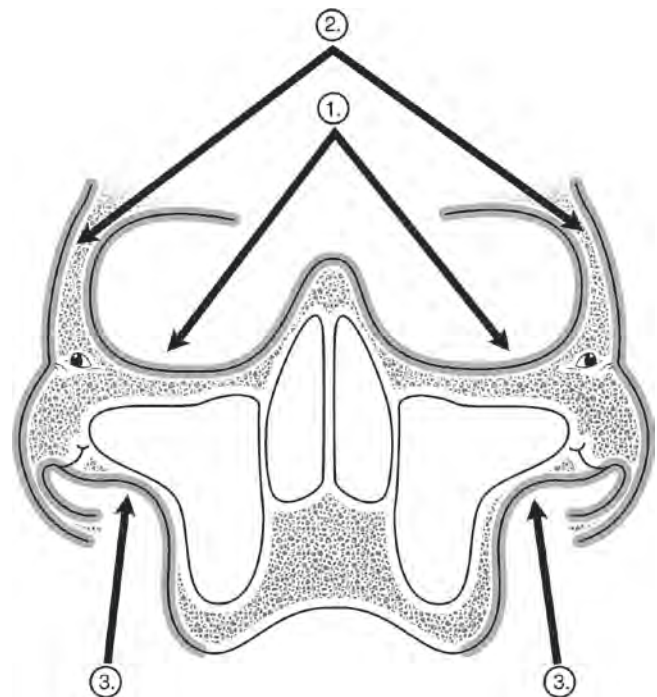
In PNS view, the following four features are to be verified/compared with the unaffected side

1. Symmetry
2. Sharpness
3. Sinus
4. Soft tissues

Dolan's Lines [8] (Fig. 55.14)

Dolan's lines are the collective name given to three lines described by Dolan and Jacoby that aid in evaluating for **maxillofacial fractures** on an **occipitomental skull radiograph**. They are usually used as an adjunct to **McGregor-Campbell lines**.

- **Orbital line (line 1)** traces the inner margins of the lateral, inferior and medial **orbital** walls and the **nasal arch**.



©Association of Oral and Maxillofacial Surgeons of India

Fig. 55.14 Dolan's lines (also see Fig. 56.22)

- **Zygomatic line (line 2)** traces the superior margin of the **zygomatic arch** and **body** extending along the frontal process of the zygoma to the **zygomaticofrontal suture**.
- **Maxillary line (line 3)** traces the inferior margin of the zygomatic arch, body, and buttress and the lateral wall of the **maxillary sinus**.

Elephant of Rogers [8]

Lee Rogers pointed out that the second and third lines of Dolan give the outline of the head of an elephant.

55.4.1 CT Scans

CT scans are now the gold standard for a definitive diagnosis in fractures of the maxilla. A CT scan in all three planes (axial, sagittal and coronal) along with a 3D reconstruction will aid the surgeon in accurate assessment of fracture patterns and also will aid in preoperative planning. The surgeon must never rely on the 3D CT alone but should correlate the images with those obtained in axial sagittal and coronal planes, as there could be reconstruction-related errors which appear as fracture lines or bone defects. CT scan-based fracture patterns may be classified as low, middle or high energy, defined solely by the pattern of segmentation and displacement in the CT scan [9].

55.5 Treatment of Maxillary fractures

The primary aim of treatment of maxillary fractures is to re-establish the dental occlusion and masticatory efficiency. The contribution of the maxilla to the projection and contour of the midface has also to be considered in the management of maxillary fractures and requires a clear understanding of the facial buttress system, subunit anatomy and inter-relationships of the various bones [10]. This aesthetic aspect is often compromised by associated injuries of the zygomatic complex, nose and orbits.

The basic principles of the treatment of maxillary fractures are:

1. Direct exposure and manual reduction of the fractures
2. Reconstitution of the bony buttresses of the midface so as to prevent elongation of the face and/or antero-posterior collapse of the maxilla
3. Re-enforcement of the paranasal and zygomatic buttresses with mini-plates
4. Replacement of missing/grossly comminuted bone at the buttresses with autogenous bone grafts [5]

Factors that influence improved treatment outcome in maxillary fractures are:

1. Early definitive treatment
2. Anatomic and functional repair of naso-orbito-ethmoidal injuries
3. Wide exposure of fracture segments
4. Anatomic repositioning and stable fixation of fracture segments in all planes of space [11]

55.5.1 General Considerations in Treatment of Maxillary Fractures

Proper reduction of maxillary fractures is the key to achieving good dental occlusion and needs proper clinical examination of the fracture pattern after all the accessible fracture sites are exposed. A repeat study of the CT scans (axial, coronal and 3D) and correlation with the exposed maxilla will aid the surgeon in planning adequate reduction and rigid fixation. It should be kept in mind that the fractured maxilla is usually displaced backwards and downwards and hence the reduction should be in the forward and upward direction. To obtain reproducibly good results, even with the most extensive facial dislocations, the surgeon should restore the facial architecture at the Le Fort I Level [12]. In

rare occasions, lateral en bloc displacement of the maxilla is seen, and this requires transverse reduction to achieve the correct dental occlusion. A depressed zygomatic fracture can physically prevent reduction of the maxilla. Hence the fractured zygomatic bone should be reduced prior to manipulating the maxilla.

The most useful instruments for reduction of the maxilla are the Rowe's disimpaction forceps. Even in cases where the fractured maxilla appears to be minimally displaced, it is prudent to mobilize the bone with the disimpaction forceps so as to overcome any bony interferences and thus freeing the maxilla completely. When using this paired forceps, care should be taken to avoid injury to the anterior teeth and also to the palatal mucosa. Mobile, extruded and proclined anterior teeth are at particular risk, and an assistant should closely observe the anterior teeth, while the surgeon is manipulating the fractured maxilla. It would also be advisable to obtain informed consent regarding mobility or loss of these teeth. Trauma to the nasal floor is inevitable when mobilizing the maxilla using the reducing forceps, and some nasal bleeding is usually observed, but this rarely requires a nasal pack.

Adequate reduction of the fractured maxilla is confirmed by:

1. Good dental occlusion
2. Alignment of the paranasal, zygomatic and fronto-zygomatic bony buttresses
3. Adequate reduction of all the observable fracture lines

Problems arise when the patient has few or no teeth and when there is gross comminution of maxilla. In these situations the surgeon has to make do with whatever landmarks are available, and in such cases compromised functional and cosmetic results are not uncommon.

Direct manipulation at the fracture lines is sometimes required especially when the fractured maxilla is telescoped into the superior normal bone. Care must be taken to prevent additional fractures at the bony margins during direct manipulation as this would make fixation more demanding. Using tie wires at the zygomatic buttresses, around the second maxillary premolars/first molars bilaterally and through anterior nasal spine is often useful to physically disimpact and pull the maxilla forwards and upwards thus ensuring good reduction.

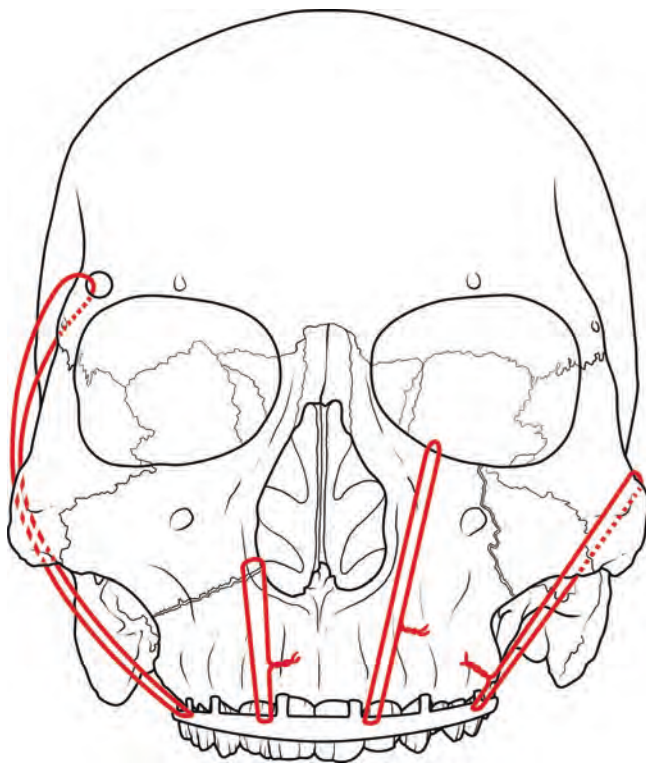
When the maxilla is fractured in multiple levels (e.g. Le Fort I and III levels), reduction using the disimpaction forceps alone may not be adequate. The dental occlusion can be achieved, but the midface projection may be compromised. Here also a combination of reduction with disimpaction forceps, direct manipulation at the fracture site and the use of the above mentioned tie wires is often indicated.

Once adequate reduction of the fractured maxilla is obtained, it is mandatory that rigid maxillomandibular fixation (MMF) is applied. In almost all cases, well-adapted maxillary and mandibular arch bars are required as this ensures multiple points for the MMF. Failure to obtain rigid MMF or manually maintaining the dental occlusion during fixation can result in post-operative occlusal discrepancies. If surgical reduction and fixation of the maxilla has to be delayed, elastic traction will be helpful in obtaining a functional occlusion. The use of MMF screws definitely saves operating time but can be problematic if elastic traction is required later.

If the mandibular condylar fracture exists, this should be reduced and fixed prior to the MMF. Failure to do so may result in an open bite due to loss of posterior mandibular height.

55.5.2 Suspension Wiring

Internal wire suspension involves sandwiching the fractured portion of the maxilla between the mandible and the superior part of the facial skeleton/skull that is not fractured. The use of internal suspension wires is more or less obsolete unless there is severe comminution which precludes rigid internal fixation. Suspension wiring may also be the surgeon's choice



©Association of Oral and Maxillofacial Surgeons of India

Fig. 55.15 Various types of suspension wiring employed for midface fractures

when there is presence of severe infection at the site of surgery (Fig. 55.15).

55.5.3 Rigid Internal Fixation

Although many wiring techniques were practised in the past, rigid internal fixation with titanium bone plates and screws of sufficient rigidity is now the standard of care. For internal fixation of the maxilla, titanium bone plates and screws of sufficient rigidity are used. For providing rigidity, screws with an outer diameter of 1.5 mm is commonly used.

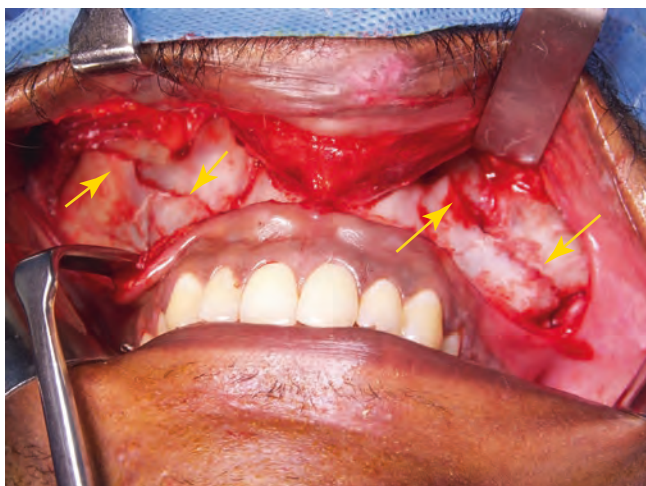55.5.4 Approaches to the Maxilla

When treating a very high Le Fort I fracture and in Le Fort II and III fractures, it may be necessary to use one or more of the following incisions, which are described in chapter 56 and 57 of this book:

1. Skin incisions for exposure of the infraorbital rim. Extension of this incision medially ensures access to the lateral nasal area, while a lateral extension would give access to the upper portion of the zygomatic body.
2. Upper eyelid or lateral eyebrow incision (blepharoplasty) to expose the fronto-zygomatic suture.
3. An existing laceration with or without conservative extension for increased surgical access.

55.5.4.1 Maxillary Vestibular Approach

The maxilla can be approached through a variety of incisions, the most common being the maxillary vestibular approach. In addition to providing access to the lower part of the entire midfacial skeleton, this approach results in a hidden intraoral scar. This approach may result in disruption of the attachments of the facial muscles of the nasolabial region; hence careful repositioning during closure is recommended to avoid unaesthetic changes to the face. The muscles of importance are the nasalis group, the levator labii superioris alaeque nasi, the levator labii superioris, the levator anguli oris and the orbicularis oris. The vestibular incision and subsequent dissection causes stripping of origin/insertion of most muscles originating in the maxilla. These muscles tend to get reattached in a shortened manner due to the action of the zygomaticus muscle. Deepening of the alar groove and splaying of the alar bases, nostrils and nasal tip may occur following lateral displacement of the nasal modiolus. Soft tissue fullness loss in the naso-alveolar region may result in thinning and retraction of upper lip, reduced vermilion exposure and an obtuse nasolabial angle. Detachment of the levators of the upper lip may cause down turning of the corner of the mouth (Fig. 55.16).



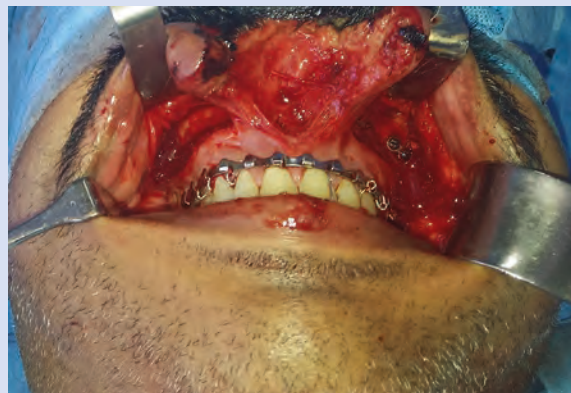©Association of Oral and Maxillofacial Surgeons of India

Fig. 55.16 Maxillary vestibular incision with adequate gingival cuff. Yellow arrows denoted the Le Fort I fracture lines

Clinical Tips for approaching the Le Fort fracture via maxillary vestibular incision

- The use of liquid paraffin will minimize trauma to the lips and corners of the mouth especially in patients with a small oral aperture.
- It is important to place a high vestibular incision to ensure a wide gingival cuff of tissue which will aid in closure of the incision.
- “Counter” elevation of the gingival cuff would aid in closure and also expose the root prominences, and this would be helpful during adaptation of the mini-plates and the subsequent screw fixation.
- It is also recommended that the opening of the Stenson’s duct be identified so that injury to this structure is avoided when the buccal sulcus is stretched while making the incision.
- Some surgeons mark the midline to ensure proper reapproximation of the tissues during closure. This is important in cases where one is forced to use an oral endotracheal tube exiting from one corner of the mouth which may distort the oral tissues.
- Extension of the posterior end of the incision beyond the first molars may cause buccal fat herniation into the surgical site. This is of minimal concern but can be annoying to the surgeon during plate fixation.

- Sharp elevation of the superior flap will ensure a subperiosteal plane of dissection, but this may not always be possible due to adherent tissue at the fracture sites and the presence of bony fragments in comminuted fractures. As far as possible, sizable fragments of loose bone with soft tissue attachments should be retained to avoid large gaps at the fracture site which might delay healing. Even completely denuded bone can be replaced as free autogenous grafts and fixed in place with tissue glue or fine stainless steel wires.
- As the superior dissection proceeds, care should be taken to identify and protect the infraorbital nerve which may be involved in the fracture. It is also prudent to palpate the infraorbital margin to ensure that inadvertent entry into the orbit is avoided especially when comminution of the infraorbital rim and floor is present.
- Once the flap has been adequately raised, long Langenbeck retractors placed superiorly and cheek retractors at the corners of the mouth will ensure good surgical exposure and adequate lighting and thus aid in reduction and fixation of the fracture (Fig. 55.17).
- A variation which can be done is giving two separate vestibular incisions bilaterally without incising the midline frenal attachment. This variation will not disturb the mid line lip anatomy in cases where exposure of the anterior nasal spine region is not required.



©Association of Oral and Maxillofacial Surgeons of India

Fig. 55.17 A clinical situation where the separate vestibular maxillary incisions were given to approach anterior maxilla, due to deep through and through lip laceration upper lip extending down to the frenum region

Early intervention (7–10 days) with open reduction and fixation is the treatment of choice for maxillary Le Fort I fractures. Restoration of normal facial contour and occlusion is considered as optimal outcome of treatment. Bone reconstruction should be completed as early as possible to minimize shrinkage, stiffness and scarring of soft tissues [12].

In complex panfacial fracture management, many authors have stressed the importance of managing the Le-Fort fracture while reconstituting the facial architecture [13, 14].

55.5.5 Fixation of Le Fort I

Adequate fixation of the fractured bone depends on two factors, namely, the rigidity of the plate and the friction between the bone fragments (buttressing of the bony segments). When a gap exists between the bone ends, the latter factor is missing. In these cases, non/fibrous union can result if the masticatory forces are greater than the rigidity of the plate. As a general principle, the paranasal and zygomatic buttresses must be rigidly fixed. The plates should be well adapted especially where the bone stock is poor. At least two screws must be present on either side of the fracture and more the number of screws, better the, load sharing, between the plate and the subjacent bone. Opposed to this is when there is no bone buttressing and the plate has to be 'load bearing'. Also a minimum of two threads of the screw should engage the cortical bone. This may be a problem in thin areas as the anterior wall of the maxillary sinus and the alveolus where roots are present. In the edentulous maxilla, the bone quality is often compromised, and the lower end of the plate may need to be placed on the alveolus. This may necessitate removal of the plate prior to prosthodontic rehabilitation.

Obtaining rigid fixation becomes difficult when the buttresses are comminuted. If only one buttress is amenable for plating the reduction at this fracture interface along with reconstitution of the occlusion must be used as the template for repositioning the maxilla. When all the buttresses are comminuted, the surgeon has to "eye ball" the maxilla into the reduced position. In these situations, a long-span plate extending from the body of the zygomatic bone to the relatively thick bone in the area of the anterior nasal spine with or without a bone graft is often the only option available to maintain the vertical position of the floating maxilla. It has been stated that the lip-tooth relationship is helpful in deciding the position of the reduced maxilla, but in practice this is of limited use.

Loss of bone at the buttresses may require the use of primary bone grafts [10]. Though it has been suggested that a

In essence the decision to graft will depend on:

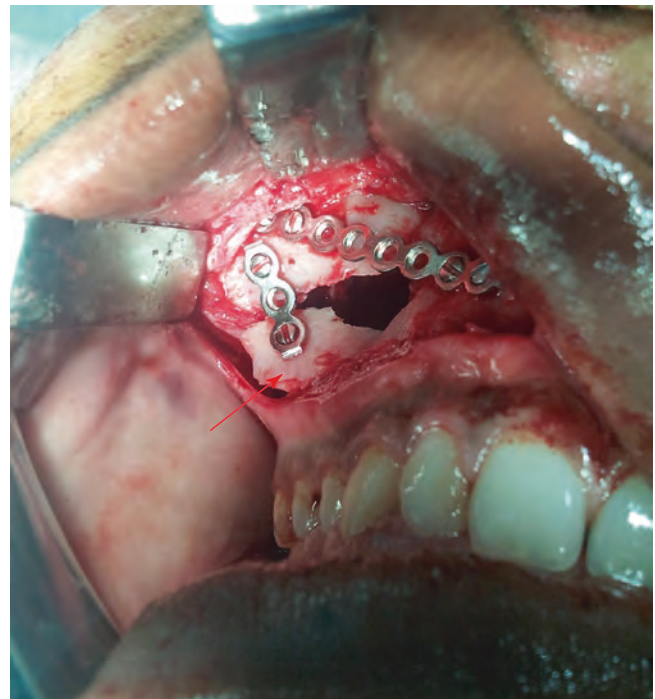
1. The extend of the bony gap
2. The quality of the bone available for plate fixation
3. The rigidity of the fixation
4. Use of post-operative MMF
5. Loss of a large part of the anterior wall of the maxillary sinus (Fig. 55.18) (causing the overlying soft tissue to fall into the sinus causing a contour defect)

gap of more than 5 mm at the buttresses requires a graft, rigid plate fixation followed by MMF is often enough to ensure bony healing.

Primary bone grafting can be done using iliac bone (Fig. 55.26), split calvarium or split ribs. The calvarium is the preferred source because of the following reasons:

1. Large amount of graft available
2. Proximity to the operative field
3. Minimal donor site morbidity

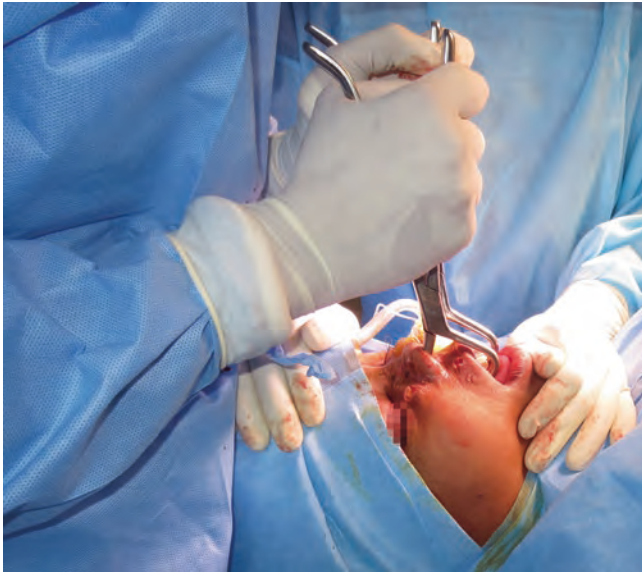The disadvantage is that these grafts are brittle and cannot be contoured. The bone graft has to be mortised to fit the defect and must be fixed rigidly to the plate or lag screwed.



©Association of Oral and Maxillofacial Surgeons of India

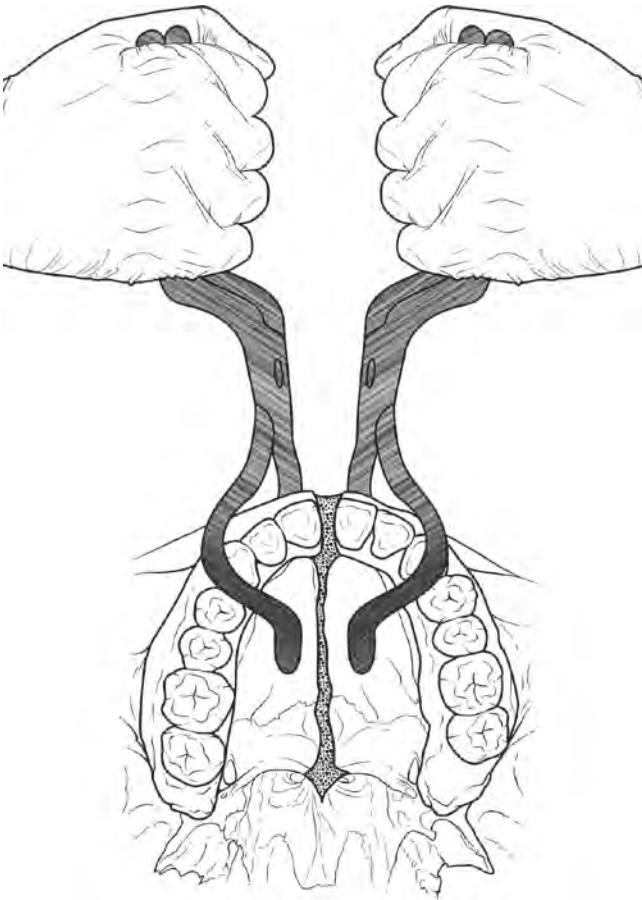
Fig. 55.18 A clinical situation where the defect in the anterior wall maxilla due to comminution of the wall was partly covered by fixing the free segment (red arrow). The long-span plate from the buttress to the anterior maxilla region can also be seen

Incisions for open reduction can be placed from first molar to first molar regions through a vestibular approach for



©Association of Oral and Maxillofacial Surgeons of India

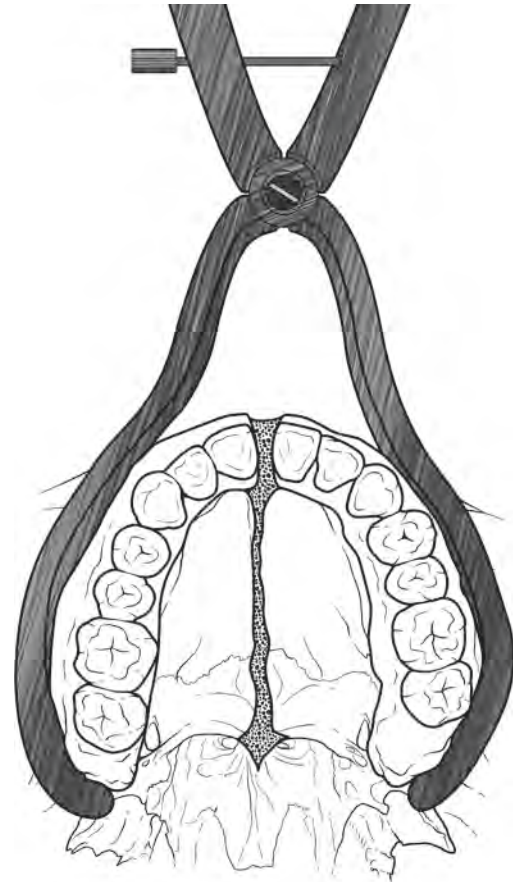
Fig. 55.19 The surgeon stands behind the patient and applies the disimpaction force, while the head is stabilized by the assistant surgeon



©Association of Oral and Maxillofacial Surgeons of India

Fig. 55.20 Use of Rowe's disimpaction forceps

wide exposure of the fracture sites. Rowe's disimpaction forceps and/or Hayton-Williams forceps can be used for mobilizing and reducing the fracture into position. The impacted type of Le Fort I fracture manipulation has to be done by grasping the maxilla with two pairs of Rowe's disimpaction forceps. Osteotomizing the maxilla should be considered if there is significant interval between the time of trauma and surgery. Whenever possible a passive reduction of the maxilla with condyles firmly seated in their correct position should be ensured to avoid post-operative anterior open bite (Figs. 55.19, 55.20, and 55.21).



©Association of Oral and Maxillofacial Surgeons of India

Fig. 55.21 Use of Hayton-Williams forceps

<p>Use of Rowe's disimpaction forceps</p>	<p>Rowe's disimpaction forceps are available as paired (right and left) instruments Each instrument has two blades, one for engaging the palate (to be padded before use to avoid injury to the palatal mucosa) and one to be inserted through the nostril The instrument has an outward bend at the handle which aids in the use of two forceps simultaneously After engaging the forceps, the maxilla has to be moved in all planes to ensure adequate mobilisation</p>
---	--

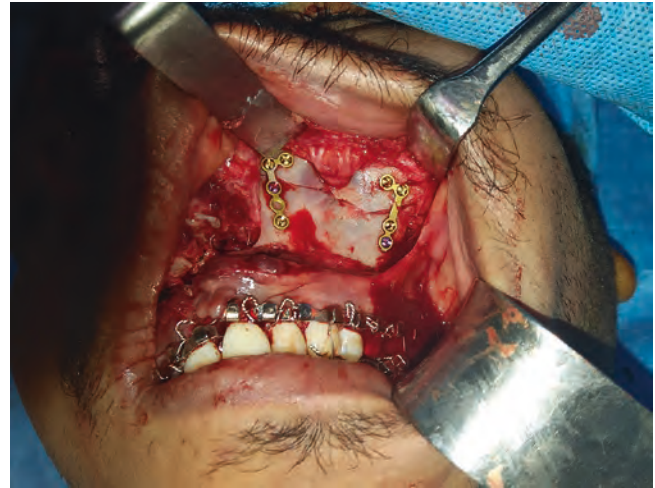Use of Hayton-Williams forceps	The Hayton-Williams forceps is used to hold the fractured maxilla together
	The instrument is inserted after vestibular incision and is engaged at the pterygoid region
	This is the instrument of choice especially in cases with palatal bone fracture

After reduction the maxilla should be placed into maxillo-mandibular fixation. The fixation of the fracture sites (four-point fixation) is done at the vertical pillars of nasomaxillary and zygomaticomaxillary (lateral piriform rim and zygomatic buttress regions) for which the preferred plates and screws used are 1.5-mm thickness with 6-mm long screws. In the zygomatic buttress regions, 2.0-mm profile plates also can be used. The mini-plates are fixed as close as possible to the lateral pyriform rim as the bone is thickest there. Usually stabilization of the fracture is achievable even if any three of the four buttresses are fixed. Apparently, gross comminution at one of the buttress regions will not cause a significant risk of inadequate stabilization. The associated anterior wall of the maxillary sinuses is generally not fixed due to the relative thin nature of bone in this region. The larger free bone fragments can be repositioned and immobilized using wires or be used for reconstruction of orbital floor defects. The circum-vestibular incision is closed with running resorbable sutures after ensuring that the midline of upper lip coincides with the facial midline (Fig. 55.22).

Maxillomandibular fixation of up to 6 weeks also can be considered as alternative for treatment though the results may be less satisfactory with added morbidity to the recovering patient. The readers are advised to refer chapter 50 to read about closed reduction / wiring and intermaxillary fixation techniques.

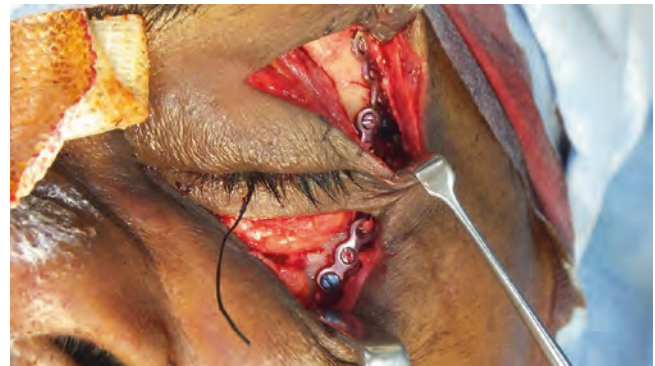
55.5.6 Fixation of Le Fort II Fractures

The pyramidal fracture has the apex of the fracture located at the nasofrontal suture region or at the midnasal bone level. The Le Fort II fractures are ideally fixed at the frontonasal suture region, bilateral infraorbital rims and also both zygomaticomaxillary buttresses. However in majority of the clinical situations fixation at the infra orbital rims and the zygomatic buttress regions gives reasonably good results. Most Nasal bone fractures associated with Le Fort II fractures can be adequately managed by closed reduction techniques. This may require the anaesthetist to change nasal intubation to oral intubation. A submental intubation may also be considered at the beginning of the procedure. If the nasofrontal segment is unstable, fixation of the area can be done through various approaches (existing laceration, Gull wing approach, etc.). A maxillary vestibular incision can frequently provide access to infraorbital fracture alignment and fixation in some cases. The lower eyelid approaches are not always mandatory



©Association of Oral and Maxillofacial Surgeons of India

Fig. 55.22 The zygomatic buttress and paranasal buttress fixed in a classical Le Fort I fracture maxilla



©Association of Oral and Maxillofacial Surgeons of India

Fig. 55.23 Le Fort II fracture lines at the infraorbital rim area may have to be accessed directly, if required, especially with associated zygomatic/orbit fractures. In this case the lateral orbital rim reconstruction is done via combined access from left sub ciliary incision and left supra tarsal incision

for fixation unless simultaneous exploration and reconstruction of orbital floors are also planned.

In Le Fort II fractures that are complicated by an associated palatal fracture, surgical splints may be helpful in obtaining adequate reduction. Placement of maxilla mandibular fixation will ensure accurate alignment of midface structures (Fig. 55.23).

55.5.7 Fixation of Le Fort III Fractures

These are complex fractures which rarely occur in isolation and results in a dysjunction of the facial skeleton from the base of the cranium. The ideal repair time should be within 10–14 days following the injury but may get delayed due to neurosurgical issues and other comorbidities.

Incision design for Le Fort III fractures should facilitate adequate access for reduction as well as fixation of the naso-frontal, frontozygomatic and in some cases the zygomatic arches. Using existing lacerations for access avoids need of a coronal incision, as this allows for complete visualization, reduction and fixation of the frontal area and zygomatic arches. A lateral brow or upper blepharoplasty (supra-tarsal fold) incision may be used to approach the lateral orbital rims. Also in such cases, a thicker plate (2.0) placement at the lateral orbital rim may be beneficial. A coronal approach may have to be considered if bilateral fronto-zygomatic and nasofrontal fracture fixation is planned.

The occlusion is a reliable indicator of adequate reduction in cases where direct visualization of the fractured segment is not possible.

In Le Fort III fractures associated with other fractures (open facial/condyle fractures), various surgical sequences can be followed, which is discussed in chapter 60 on Panfacial fractures.

Rarely, Le Fort fractures may present without mobility, but show occlusal disturbances like crossbite, open bite or loss of intercuspation. These can be managed by using traction elastics but at times warrant mobilization and subsequent rigid fixation [15].

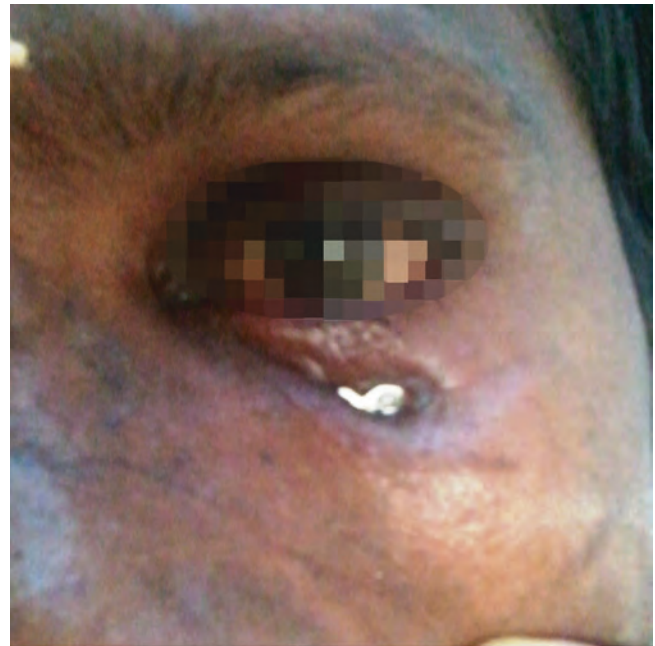

Fig. 55.24 Infraorbital plate exposure

55.6 Complications of Le Fort Fractures

(Table 55.6)

<ul style="list-style-type: none"> • Bleeding • Enophthalmous • Infection • Altered vision • Non-union • Mal-union • malocclusion • Epiphora (due to obstruction of nasolacrimal duct) • Scarring • Sinusitis • Exposed hardware (Fig. 55.24) • Foreign body reactions 	<p>General</p>	<p>Maxillary hypoperfusion</p> <ul style="list-style-type: none"> • Wound dehiscence Necrotic teeth 	<p>Le Fort I</p>	<ul style="list-style-type: none"> • CSF leak (rhinorrhea and /or otorrhea) • Palatal fistula • Nasal Septal deviation • Infra orbital paraesthesia 	<p>Le Fort II</p>	<ul style="list-style-type: none"> • CSF leak (rhinorrhea and /or otorrhea) • Facial Nerve paralysis • Trigeminal nerve injury 	<p>Le Fort III</p>
--	-----------------------	---	------------------	---	-------------------	---	--------------------

Table 55.6 Complications of Le Fort fractures

55.7 Palatal Fractures

Unlike many other areas of the midface, the palatal bone is relatively thick, and hence palatal fractures are not common. A palatal split makes reduction and fixation of maxillary fractures more difficult mainly due to the transverse instability which can cause medial collapse or outward splaying of the maxilla. The use of the Hayton-Williams forceps along with the disimpaction forceps will control outward splaying of the maxilla but at the risk of medially displacement of the dentate segment of the maxilla. Moreover, the use of all the three forceps effectively requires some amount of surgical expertise.

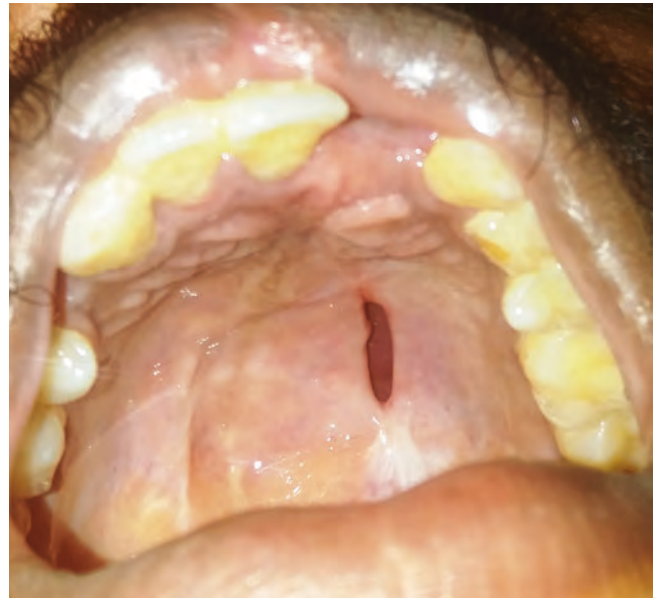Moss et al. [16] have proposed a classification for palatal fractures. There is no consensus regarding the management of palatal fractures, but various options have been suggested.

1. Transpalatal wires in the first molar region.
2. Direct exposure of the fracture through an existing palatal laceration or an incision and rigid plate fixation.
3. External fixation by fixing a screw on either side of the fracture and immobilization with a wire connecting the screws. Alternatively a palatal splint can be fabricated after sectioning a plaster model of the palate.
4. Plating the labial fracture line.
5. Plating the nasal floor.

Transpalatal wires are simple to apply and do not have the problems of soft tissue dehiscence and infection seen in the more invasive methods [17]. However, the reduction of the palatal fracture cannot be ensured, and the wires can be cumbersome to the patient as it affects speech and swallowing. If the palatal wires are passed through an infant feeding tube or a small gauge urinary catheter, injury to the dorsum of the tongue can be minimized. It is also noticed that palatal wires tend to become slack after a few days, and then their value in reduction and fixation of the fracture is questionable. Moreover, these wires are not an option in the edentulous maxilla.

Direct exposure and plate fixation are surgically demanding, but the fracture can be reduced and fixed under direct vision. Ceinfuegos et al. have described the technique of fixing the plate over the palatal mucosa, but this plate would have to be removed at a later date [18]. An alternative would be to use a resorbable plate and screws.

Ma et al. has documented the use of self-drilling screws on either side of the palatal fracture with wires to fix the fracture [19].



©Association of Oral and Maxillofacial Surgeons of India

Fig. 55.25 Oronasal fistula in a patient who had sustained palate fracture

Palatal fractures of the sagittal or parasagittal variety can be stabilized by placing a mini-plate across the fracture line on the labial side. Occasionally the prominence of the anterior nasal spine has to be reduced to facilitate mini-plate placement.

The transpalatal reduction should be supplemented by fixation at the zygomaticomaxillary and nasomaxillary buttresses and the use of an arch bar [20].

Palatal fractures accompanied by soft tissue lacerations often cause a serious challenge to the surgeon regarding its management. The healing of the palatal soft tissue laceration is dependent on the exact reduction of the palatal vault and stabilization. Overzealous attempts at closure of the laceration without accurate reduction may compromise wound healing. A tension-free closure of the palatal mucosa is imperative for wound healing. In some cases, the ensuing oronasal communication will have to be addressed secondarily (Fig. 55.25).

55.7.1 Surgical Splints

Concomitant fractures of the palate present additional challenges to the treatment of Le Fort fractures. They complicate the re-establishment of proper width and height of the maxilla. Depending on the fracture type, patient comorbidities and associated injuries, either closed reduction and wiring or rigid fixation may have to be performed. Dental impressions can be obtained and occlusion assessed prior to surgery.

Fabrication of an acrylic splint may help in re-establishing the transverse width of the palate.

In cases of gross comminution with partial dentition, palatal splints are helpful. Splints are fabricated on casts on which model surgery has been performed. They are designed such that they cover the occlusal surfaces and heights of contour, and care should be taken as to not disturb the soft tissues. Holes placed in the occlusal surfaces in the splint aid in separately ligating it to the arch bar [21]. In case of edentulous patients, Gunning splints are usually used.

55.8 Special Considerations

55.8.1 Maxillary Fractures in Geriatric Patients

Advanced age and compromised medical fitness may increase the morbidity associated with surgical management of maxillary fractures. Loss of teeth leading to reduced alveolar bone, reduced vascularity of maxilla and greater pneumatization of the maxillary sinuses, should be taken into consideration before attempting an open reduction and internal fixation. Modification of existing dentures or Gunning splints are viable options in this population.

55.8.2 Maxillary Fractures in Children

The long-term effects of maxillary fractures on skeletal growth are inconclusive at present. Mobile-displaced maxillary fractures in paediatric patients warrant open reduction and fixation. Removal of hardware in growing patients may be considered to overcome complications of plate translocation (shifting of the position of metal plate due to appositional bone growth), extrusion and possible growth restriction. Resorbable plating systems may offer a solution to overcome such complications.

55.8.3 Haemorrhage Control in Maxillary Fractures

Branches of the internal maxillary artery provide much of the vascular supply to the midface. In patients with epistaxis

or bleeding, ligation of this artery may be necessary. Due to anastomoses from other branches of the internal and external carotid circulation, vascular insufficiency of the maxilla is unlikely even after ligation of maxillary artery. In certain conditions of intractable bleeding not amenable to control by normal packing methods, embolization methods have been used effectively.

55.9 Recent Advances

The use of pre-surgical stereolithographic models helps in plate contouring and precise positioning of fractured segments. Facilitation of the intraoperative three-dimensional bone positioning is possible due to development of sophisticated computed tomography, computer graphics hardware and image processing software capable of reproducing anatomic templates. Automated preoperative “mirroring” of the contralateral uninjured orbito-zygomaticomaxillary complex to the affected side can result in improved results. The use of intraoperative surgical navigation systems along with mobile cone beam CT improves intraoperative quality control. Endoscopic midface fracture management facilitates smaller incisions, reduced recovery time and minimal post-operative complications. These developments are discussed in the Chap. 41.

55.10 Conclusion

Maxillary fractures can sometimes occur with significant cosmetic and functional implications. Accurate diagnosis and early surgical intervention is essential for successful management of these fractures. The surgeon should keep in mind that the surgical management of maxillary fractures primarily aims at restoration of the vertical and horizontal support buttresses.

55.11 Case Scenario - A case of maxillary Lefort I fracture where bone grafting was done (Fig. 55.26a–g)

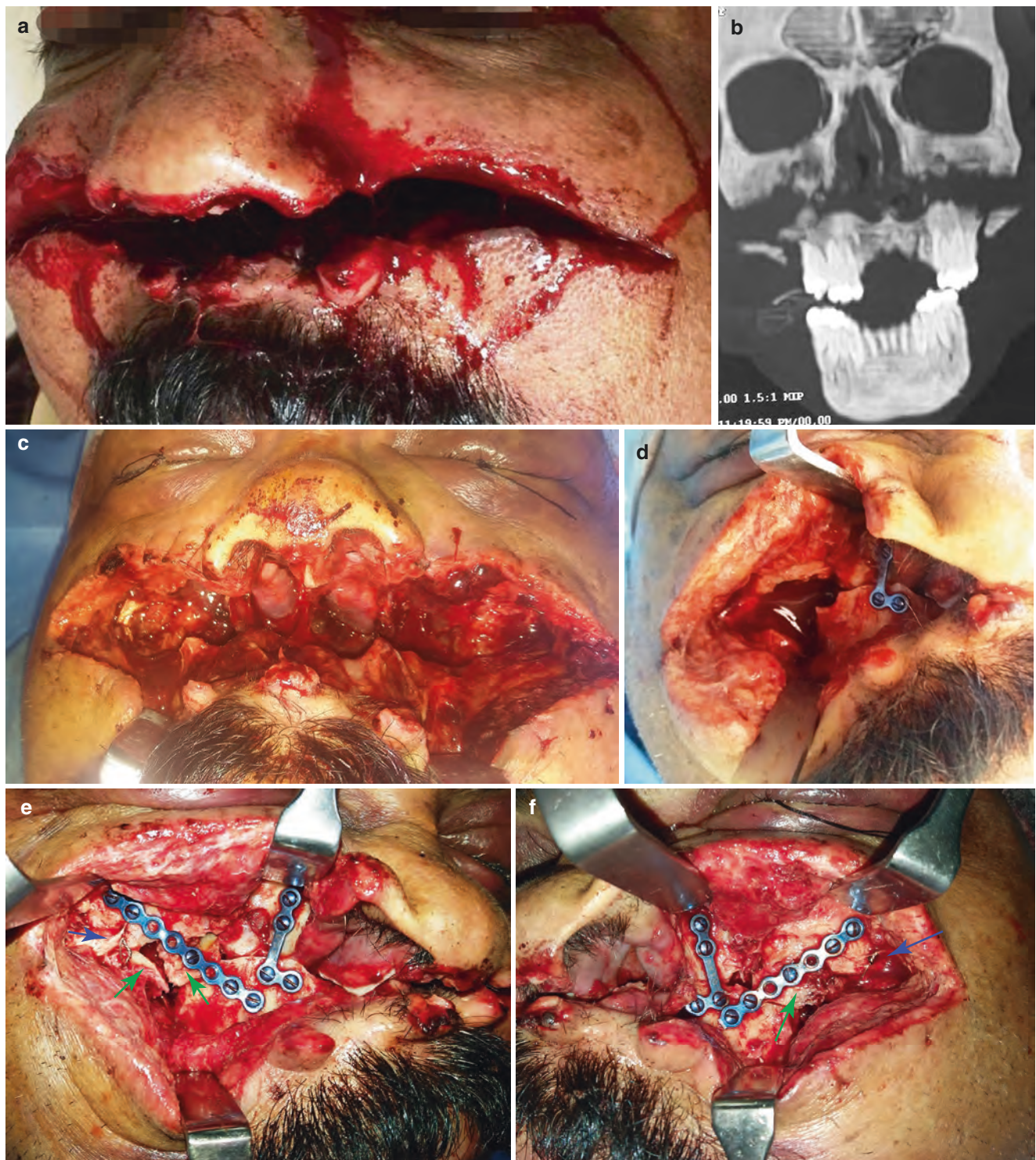
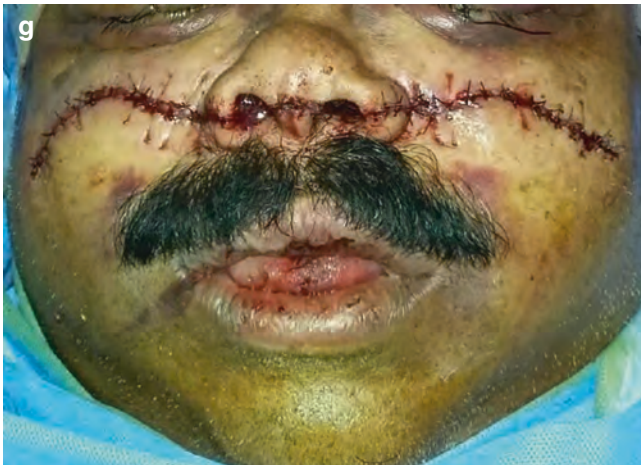

Fig. 55.26 Case scenario (fracture maxilla fixation done with grafting in the anterior maxillary sinus wall). (a) 43-year-old man sustained bone deep laceration on face causing Le Fort I like fracture pattern. In the emergency department, oral intubation was required due to heavy bleeding. Nasal packs were placed, and the wound was primarily tacked as adjunct measures. (b) MIP view of CT scan showing the maxillary segment displaced downwards with loss of anterior maxillary wall height. (c) Intraoperative view showing the severely displaced maxillary segment. Access for the fixation was via the existing laceration. A maxillary vestibular incision was not placed. (d) The paranasal buttress was maintained, but loss of bone structure seen at the anterior wall sinus

region. To attain primary healing and to avoid malunion, iliac crest bone grafts were procured and split into separate pieces. (e) (Right side maxilla) the green arrows point to the graft segments. Initially the graft segment was fixed with wire (blue arrow) and was attached to the titanium plate with screws (the plate was spanned from the zygomatic body to the displaced main fracture segment). (f) Similar technique done on left side. (g) Immediate post-operative view after closure of the laceration. Patient had arch bars fixed and underwent a period of intermaxillary fixation to help in primary union. Post-operative review showed good stability for maxilla and the occlusion was maintained



©Association of Oral and Maxillofacial Surgeons of India

Fig. 55.26 (continued)

References

- Marciani RD. Management of midface fractures: fifty years later. *J Oral Maxillofac Surg.* 1993;51(9):960–8. Review
- Rowe and Williams' maxillofacial injuries (ed 2): Williams JL (ed), with 51 contributors, New York: Churchill Livingstone; 1994, 1067 pages (2 volumes), illustrated. *J Oral Maxillofac Surg.* 1996;54(3):378.
- Cunningham LL, Haug RH. Management of maxillary fractures. In: Miloro M, Ghali GE, Larson P, Waite P, editors. *Peterson's principles of oral and maxillofacial surgery.* BC Decker; 2004. chapter 23.1, p. 434–8.
- Gruss JS, Mackinnon SE. Complex maxillary fractures: role of buttress reconstruction and immediate bone grafts. *Plast Reconstr Surg.* 1986;78(1):9–22.
- Louis M, Agrawal N, Kaufman M, Truong TA. Midface fractures I. *Semin Plast Surg.* 2017;31(2):85–93.
- Manson PN, Hoopes JE, Su CT. Structural pillars of the facial skeleton: an approach to the management of Le Fort fractures. *Plast Reconstr Surg.* 1980;66:54–62.
- Hendrickson M, Clark N, Manson PN, Yaremchuk M, Robertson B, Slezak S, Crawley W, Vander KC. Palatal fractures: classification, patterns, and treatment with rigid internal fixation. *Plast Reconstr Surg.* 1998;101(2):319–32.
- Bowley NB, Brown J. Radiology for maxillofacial trauma. In Booth PW, Schendel SA, Hausamen J-E, editors. *Maxillofacial surgery.* Churchill Livingstone Elsevier; 2007. p. 278–9.
- Manson PN, Markowitz B, Mirvis S, Dunham M, Yaremchuk M. Toward CT-based facial fracture treatment. *Plast Reconstr Surg.* 1990;85(2):202–12. Discussion 213–4
- Gruss JS, Mackinnon SE. Complex maxillary fractures: role of buttress reconstruction and immediate bone grafts. *Plast Reconstr Surg.* 1986;78(1):9–22.
- Nastri AL, Gurney B. Current concepts in midface fracture management. *Curr Opin Otolaryngol Head Neck Surg.* 2016;24(4):368–75.
- Marciani RD, Gonty AA. Principles of management of complex craniofacial trauma. *J Oral Maxillofac Surg.* 1993;51(5):535–42.
- Kelly KJ, Manson PN, Vander Kolk CA, Markowitz BL, Dunham CM, Rumley TO, Crawley WA. Sequencing Le Fort fracture treatment (Organization of treatment for a panfacial fracture). *J Craniofac Surg.* 1990;1(4):168–78.
- Markowitz BL, Manson PN. Panfacial fractures: organization of treatment. *Clin Plast Surg.* 1989;16(1):105–14.
- Romano JJ, Manson PN, Mirvis SE, Dunham M, Crawley W. Le Fort fractures without mobility. *Plast Reconstr Surg.* 1990;85(3):355–62.
- Moss WJ, Kedarisetty S, Jafari A, Schaerer DE, Husseman JW. A review of hard palate fracture repair techniques. *J Oral Maxillofac Surg.* 2016;74(2):328–36. Review
- Chen CH, Wang TY, Tsay PK, Lai JB, Chen CT, Liao HT, Lin CH, Chen YR. A 162-case review of palatal fracture: management strategy from a 10-year experience. *Plast Reconstr Surg.* 2008;121(6):2065–73.
- Cienfuegos R, Sierra E, Ortiz B, Fernández G. Treatment of palatal fractures by osteosynthesis with 2.0-mm locking plates as external fixator. *Craniofacial Trauma Reconstr.* 2010;3(4):223–30.
- Ma D, Guo X, Yao H, Chen J. Transpalatal screw traction: a simple technique for the management of sagittal fractures of the maxilla and palate. *Int J Oral Maxillofac Surg.* 2014;43(12):1465–7.
- Manson PN, Glassman D, Vanderkolk C, Petty P, Crawley WA. Rigid stabilization of sagittal fractures of the maxilla and palate. *Plast Reconstr Surg.* 1990;85(5):711–7.
- Cohen SR, Leonard DK, Markowitz BL, Manson PN. Acrylic splints for dental alignment in complex facial injuries. *Ann Plast Surg.* 1993;31(5):406–12.

Open Access This chapter is licensed under the terms of the Creative Commons Attribution 4.0 International License (<http://creativecommons.org/licenses/by/4.0/>), which permits use, sharing, adaptation, distribution and reproduction in any medium or format, as long as you give appropriate credit to the original author(s) and the source, provide a link to the Creative Commons license and indicate if changes were made.

The images or other third party material in this chapter are included in the chapter's Creative Commons license, unless indicated otherwise in a credit line to the material. If material is not included in the chapter's Creative Commons license and your intended use is not permitted by statutory regulation or exceeds the permitted use, you will need to obtain permission directly from the copyright holder.





Fractures of the Zygomaticomaxillary Complex

56

Elavenil Panneerselvam, Poornima Ravi, and B. Sasikala

56.1 Introduction

The zygomaticomaxillary complex (ZMC) refers to the skeletal unit [1] formed by the zygomatic bone and maxilla (Fig. 56.1). These two bones are referred to as a complex, because of the structural and functional relationship between them; they articulate with each other over a wider area, and any traumatic impact on one bone generally influences the other. This duo complex also constitutes a major part of the orbit, spanning the infra-orbital rim, lateral wall, and floor. Hence the ZMC is also termed *orbitozygomaticomaxillary complex* [2]. Because of its multiple articulations, various names are commonly used to describe ZMC fractures such as “tripod, tetrapod, or pentapod” [3, 4] fractures.

Fractures of the ZMC commonly result in severe cosmetic and functional deficits because of the prominent anatomical position of the zygoma and its proximity to adjacent vital structures such as the globe. Precise reduction and fixation of these fractures is challenging due to their complex anatomic form, multiple articulations, and deformation in multiple planes. The scope of this chapter encompasses the dynamics of ZMC fractures, clinical implications, and guidelines for successful management.

Disclosure: Authors have no financial conflicts to disclose.

Electronic Supplementary Material The online version of this chapter (https://doi.org/10.1007/978-981-15-1346-6_56) contains supplementary material, which is available to authorized users.

E. Panneerselvam (✉)
Department of Oral and Maxillofacial Surgery,
SRM Dental College, Ramapuram, Chennai, Tamil Nadu, India

Department of Orbit and Oculoplasty, Aravind Eye Hospital,
Chennai, Tamil Nadu, India

P. Ravi · B. Sasikala
Department of Oral and Maxillofacial Surgery, SRM Dental
College, Ramapuram, Chennai, Tamil Nadu, India

56.2 Surgical Anatomy

The term zygoma denotes a “yoke or bar,” in Greek. Quite aptly, the zygoma extends as a prominent, sturdy bar across the face, contributing to its transverse width and anteroposterior projection. The clinical significance of this bony complex is attributed to its role in defining facial esthetics and globe function.

56.2.1 Articulations

The zygoma articulates with four bones [5]; superiorly frontal, medially maxilla, laterally temporal bone, and posteriorly sphenoid, through five processes [4] (Fig. 56.1), namely, the zygomaticotemporal (ZT), zygomaticomaxillary (ZM), infra-orbital (IOR), fronto-zygomatic (FZ), and sphenozygomatic (SZ) or zygomaticosphenoid (ZS). These processes are clinically significant in establishing the three-dimensional structural integrity of the upper lateral face.

Fractures of the ZMC have been traditionally called the “tripod or trimalar fractures” because it involved separation at the three processes of the zygoma—the FZ, IOR, and the ZM processes (Fig. 56.2a). The terminology was later modified to “quadripod or quadramalar fracture” to include separation at the fourth point of articulation, the ZT process (Fig. 56.2b). However, the importance of SZ articulation along the lateral wall of the orbit has been recognized lately, and, hence, ZMC fracture is currently called a pentapod fracture (Fig. 56.2c), to emphasize the necessity of restoring the five articulations during fracture management.

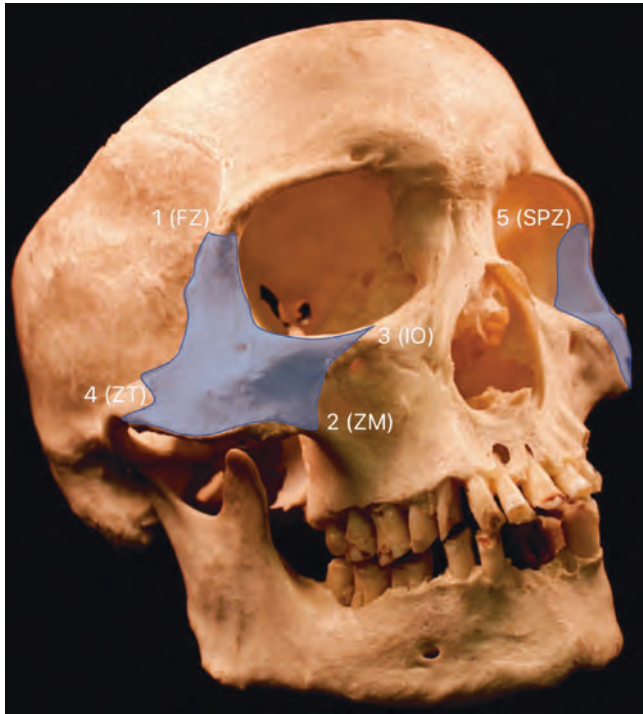56.2.2 Relations

- Zygoma and orbit: ZMC forms the lateral and inferior part of the orbit, protecting as well as supporting the globe and associated soft tissues. The Whitnall’s tubercle present on the zygoma (inferior to the FZ suture) provides

attachment to the suspensory ligament of Lockwood that maintains the horizontal axis of the globe [6] (Fig. 56.3a). A fracture line located above the Whitnall's tubercle leads to inferior displacement of zygoma as well as the lateral attachment of Lockwood ligament resulting in anti-mongoloid slant to the eye (Fig. 56.3b). Thus ZMC fractures greatly influence the structure and function of the orbit. Further, the contents of the orbit including the globe, extraocular muscles, and orbital fat are intimately

related to the zygoma and may be affected in fractures of the ZMC or its surgical manipulation.

- Zygoma and mandible: The zygoma and zygomatic arch are anatomically close to the coronoid process of the mandible. Therefore, a fractured zygoma or arch, when retro/medially positioned, may impede mandibular movements [7]. A displaced and untreated fracture of zygoma/arch which is in close proximity to the coronoid process can result in extra-articular ankylosis [8].
- Zygoma and maxillary sinus: Fractures of the ZMC (except the isolated zygomatic arch fractures) involve the maxillary sinus and show features of hemosinus [4] or sinusitis [3].



©Association of Oral and Maxillofacial Surgeons of India

Fig. 56.1 ZMC skeletal unit. Articulations of zygoma with facial skeleton and articulating processes

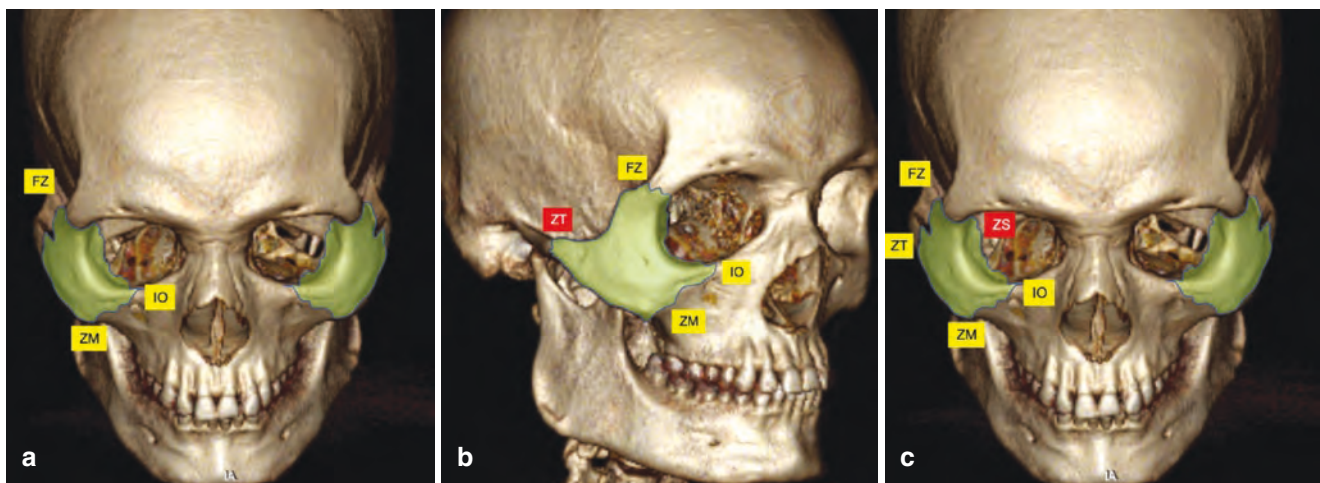
56.2.3 Muscle and Fascia Attachments

The muscles attached to ZMC are the zygomaticus major, zygomaticus minor, orbicularis oculi, and masseter [9]. Masseter is attached to the zygomatic arch on the lateral and inferior aspect as well as the zygomatic tuberosity (Fig. 56.4a). The downward displacing forces of the masseter have been considered by many as the principal cause of post-reduction instability [10].

The temporal fascia attached to the arch superiorly plays a major role in resisting the downward displacement of fractured ZMC or arch due to the inferior pull of the masseter (Fig. 56.4b) [1].

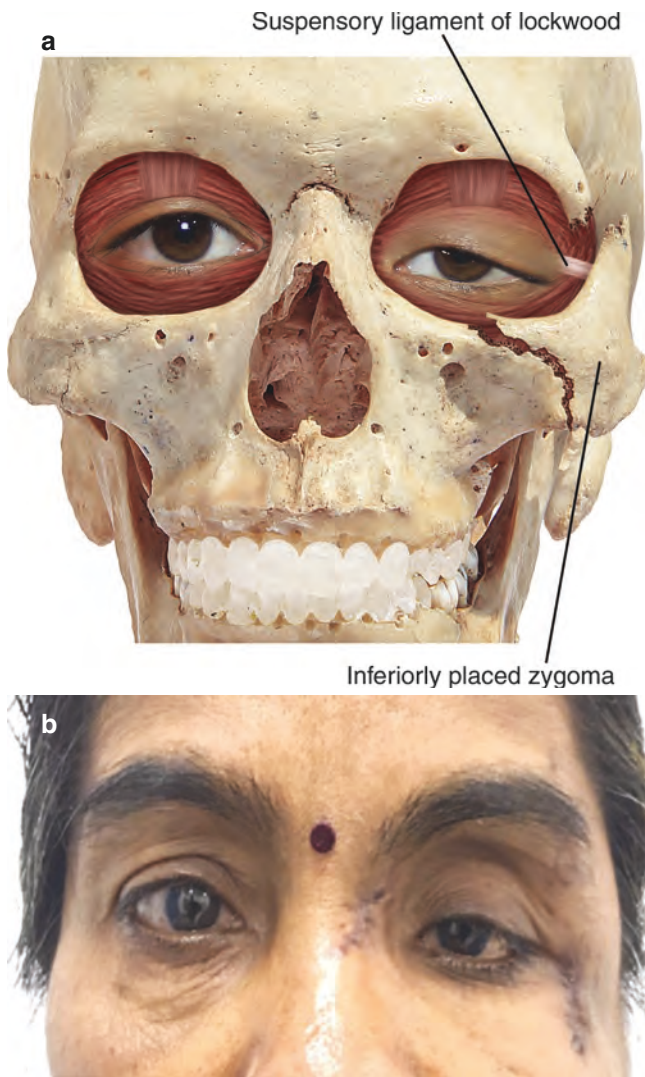
56.2.4 Zygomatic Arch

The arch is the key parameter for re-establishing the sagittal projection as well as transverse width of the face [11]. An arch which is bent outward or inward gets shortened [4]. This leads to retrodisplacement of zygoma resulting in altered facial width (Fig. 56.5b). It is important to remember



©Association of Oral and Maxillofacial Surgeons of India

Fig. 56.2 Types of ZMC fractures. (a) Tripod fracture. (b) Tetrapod fracture. (c) Pentapod fracture



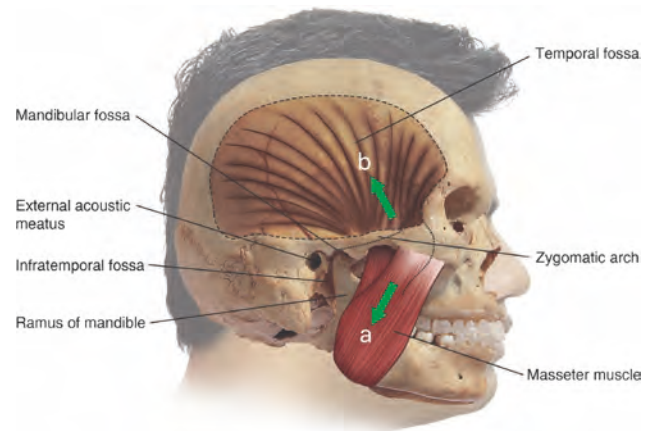
©Association of Oral and Maxillofacial Surgeons of India

Fig. 56.3 Relation of suspensory ligament to zygoma. (a) Displacement of suspensory ligament of Lockwood leading to anti-mongoloid slant. (b) Clinical appearance of anti-mongoloid slant

that in spite of being referred to as an arch, it does not have an exaggerated curvature. Therefore, overzealous contouring during reduction of zygomatic arch fractures can result in compromised esthetics. The arch is encased by a thick periosteal and fascial envelope which counteracts the displacing forces of the masseter [1]. However, when the periosteal envelope is damaged due to high-velocity injuries, the fracture segments show more displacement.

56.2.5 Nerves and Blood Vessels

The nerves in close proximity to the ZMC are (1) infra-orbital nerve and (2) zygomatic nerve [12] (Fig. 56.6a). The infra-orbital nerve runs along the ION groove and enters the



©Association of Oral and Maxillofacial Surgeons of India

Fig. 56.4 Displacing forces acting on the zygoma and arch. (a) Masseter exerting downward force. (b) Temporalis with a superior vector

ION canal giving off the superior dental plexus of nerves before exiting through the ION foramen onto the face. Here it innervates the lower eyelid, lateral aspect of the nose, and upper lip of the ipsilateral side. The zygomatic nerve which enters the orbit through the inferior orbital fissure divides into two branches, the zygomatico-facial and zygomatico-temporal which emerge onto the face through their respective foramina. The zygomaticofacial nerve innervates the skin over the malar area, while the zygomaticotemporal nerve supplies the skin over the anterior temporal region. These nerves may be injured due to trauma or during surgery. The severity of paresthesia which arises is generally proportional to the degree of displacement of a fractured zygoma [13]. The other nerves whose function may be affected in ZMC fractures are the optic nerve [14] and facial nerve [15]. Blood vessels of importance related to the ZMC are infra-orbital artery and vein [16] (Fig. 56.6b) which accompany the infra-orbital nerve. Uncontrolled forces delivered during elevation of zygoma may injure these vessels resulting in severe intra-op bleeding.

56.3 Classification

56.3.1 Classification of ZMC Fractures

Numerous classifications have been proposed for ZMC fractures; this chapter would discuss the most practical ones which help in understanding the biodynamics of fracture as well as facilitate quick decision-making regarding the treatment.

- The classification proposed by Rowe and Williams [1] (Fig. 56.7) is based on the axis of rotation of ZMC and the

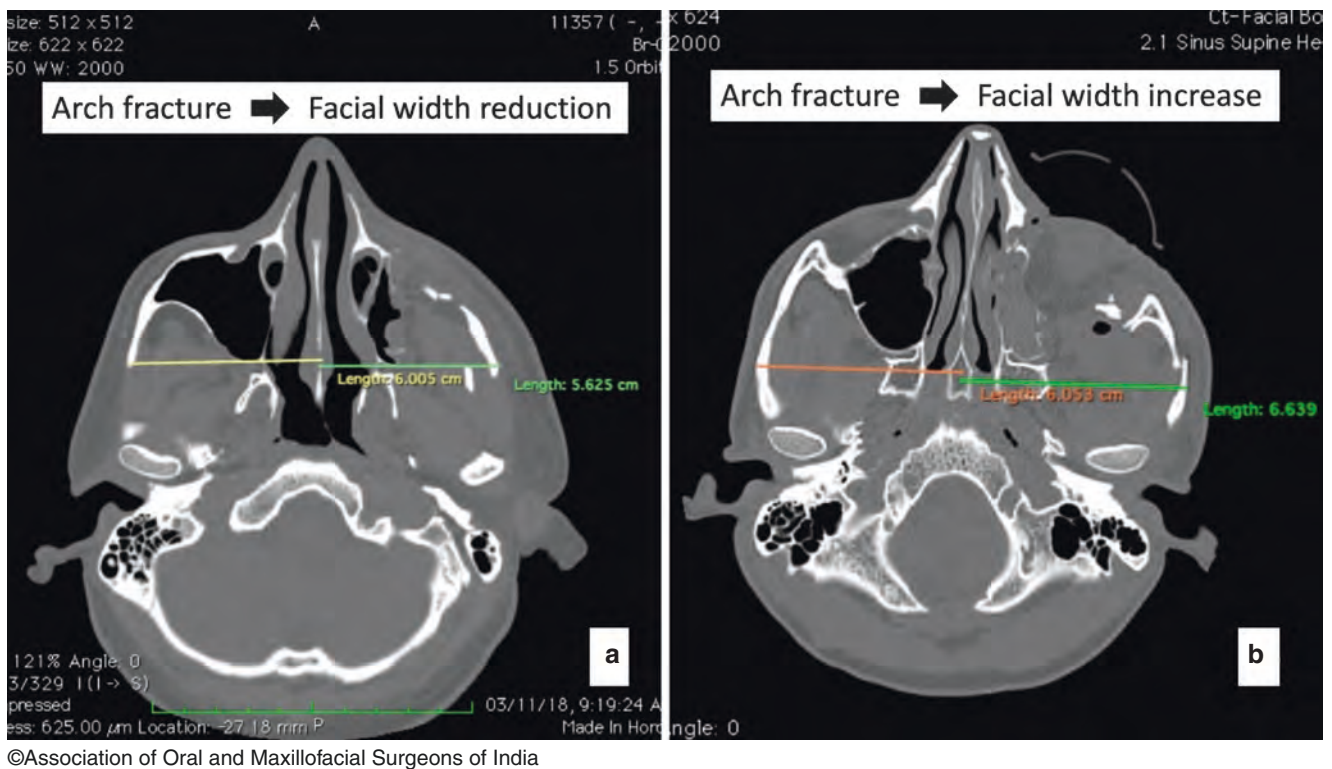


Fig. 56.5 Change in facial dimension in zygomatic arch fractures. (a) Inward bowing of arch. (b) Outward bowing of arch

stability after reduction. Following trauma, the zygoma may undergo rotation along two axes: vertical axis extending through the FZ suture and first molar and horizontal axis running across the infra-orbital foramen and zygomatic arch. According to this classification, fractures were considered as *stable after elevation* when they demonstrated (1) arch only fracture with medial displacement and (2) rotation around vertical axis (medially/laterally), while fractures were categorized as *unstable after reduction* when the following features were observed: (1) arch only fracture with inferior displacement (Fig. 56.8), (2) ZMC fracture rotated around horizontal axis (Fig. 56.7), (3) dislocated en bloc (inferiorly/laterally/medially) (Fig. 56.9a), and (4) comminuted (Fig. 56.9b).

This classification provides clinical guidance regarding the stability of fracture after reduction and the necessity for fixation.

- ZMC fractures have also been classified on the basis of “severity of traumatic impact” [4] into low-, medium-, and high-energy patterns, as demonstrated on CT; low-energy type is associated with non-displaced/minimally displaced “en bloc” fractures, medium-energy type is displaced fractures with or without fragmentation, and high-energy type is associated with fractures with massive displacement, comminution, or fragmentation.
- Zing et al.’s [17] classification (Fig. 56.10a–e) is a simple but practically useful method based on the anatomic site involved; type A1 refers to isolated zygomatic arch frac-

ture, and types A2 and A3 are separation at the FZ suture and IOR, respectively. Type B is a complete monofragment type with separation at all five sites of articulation and type C which is multifragmented.

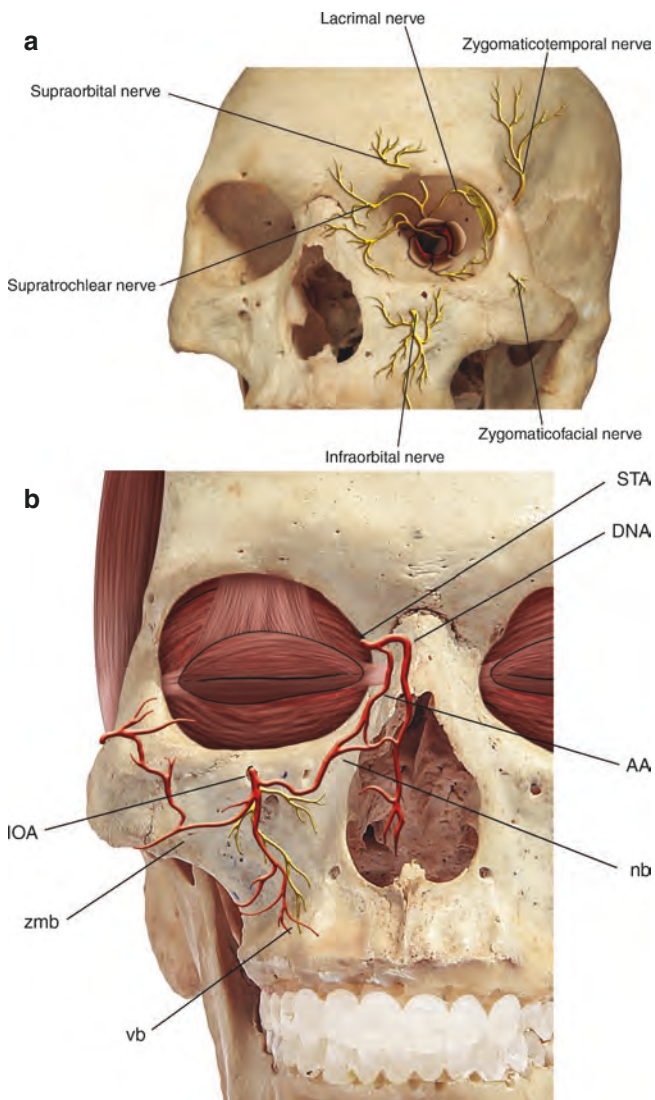
A special and rare variant of zygoma injuries includes *avulsion* of zygoma [18] (Fig. 56.11). These injuries result from tangentially directed forces with high velocity or greater energy. The fractured zygomatic fragment characteristically becomes a non-vascularized-free graft whose management is complex.

56.3.2 Classification of Arch Fractures

The fractures involving the zygomatic arch constitute a separate entity.

The various patterns of zygomatic arch fractures have been described by **Ozyazgan et al.** [19] (Fig. 56.12) based on the number of fracture lines and displacement of fracture fragments:

- Type 1 constitutes the isolated zygomatic arch fractures which are subdivided into (1) dual fracture (type I A) and (2) more than two fractures (type I B). This is further classified into V-shaped (type I B-V) and displaced fracture (type I B-D).
- Combined zygomatic arch fractures are referred to as type II, which can present as two variants: single (type II A)



©Association of Oral and Maxillofacial Surgeons of India

Fig. 56.6 a, b Neurovascular structures related to ZMC fractures. OA, ophthalmic artery; nb, nasal branch; zmb, zygomatico-malar branch; vb, vestibular branch

and plural fracture (type II B). Plural fractures are termed type II B-R when they are approximated or reduced and type II B-D, when displaced.

Yamamoto et al. classification [20] (Fig. 56.13) differentiates fractures based on displacement: type I, no displacement; type II, displacement with bone contact at all fracture lines; type III, displacement without bone contact at one fracture line; type IV, displacement without bone contact at two fracture lines; and type V, comminution or displacement without bone contact at three or more fracture lines. **Honig Merten et al.** [21] (H-M classification) (Fig. 56.14) classified zygomatic arch fractures based on CT findings as class I which indicated isolated tripod fracture, class II as an isolated stick fracture of the arch, and

class III a combined fracture of the malar bone and the zygomatic arch.

56.4 Clinical Assessment

The clinical assessment of ZMC fractures is performed by a thorough examination of the face and the eye. As the zygoma forms an integral part of the orbit (floor and lateral wall), any trauma to the ZMC may have profound impact on the integrity of the globe and vision [2, 22]. This mandates a primary ophthalmic examination prior to facial examination.

56.4.1 Examination of the Eye

The globe is meticulously assessed for its form, position, and function. This is performed by a comprehensive examination protocol called “8-point eye exam” [23] provided by the American Academy of Ophthalmology (refer to Chap. 57).

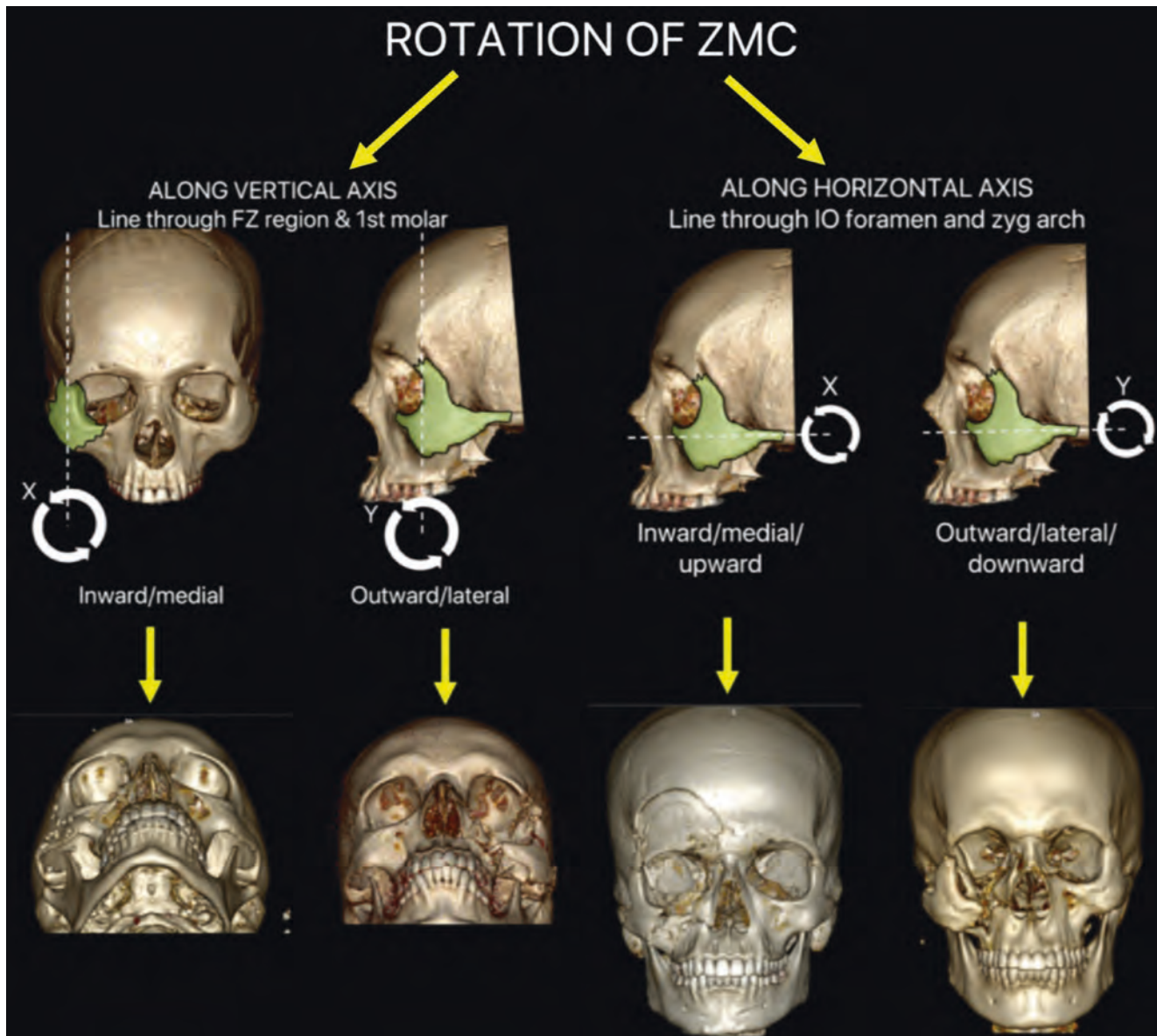
56.4.2 Examination of the Face

The facial examination should focus on assessment of (1) facial symmetry and morphology and (2) functions such as mouth opening, vision, sensory perception, and occlusion.

The clinical characteristics of ZMC fractures [1, 4, 5] may be divided based on their cosmetic and functional implications (Box 56.1).

Box 56.1: Clinical Features of ZMC Fractures

Cosmetic deficits	Functional deficits
<ul style="list-style-type: none"> • <i>Facial asymmetry due to</i> <ul style="list-style-type: none"> – Periorbital edema – Hematoma – Emphysema • <i>Facial asymmetry due to malpositioned zygoma</i> <ul style="list-style-type: none"> – Depression of malar prominence – Transverse facial widening – Changes in AP projection – Orbital dystopia • <i>Discoloration</i> <ul style="list-style-type: none"> – Subconjunctival hemorrhage – Periorbital ecchymosis • <i>Altered morphology/position of eye</i> <ul style="list-style-type: none"> – Anti-mongoloid slant – Increased scleral show – Hypoglobus/hyperglobus – Enophthalmos/exophthalmos 	<ul style="list-style-type: none"> • <i>Vision</i> <ul style="list-style-type: none"> – Diplopia – Loss of vision (partial/total) • <i>Restricted mouth opening</i> • <i>Malocclusion</i> • <i>Neurological deficit</i> <ul style="list-style-type: none"> – Paresthesia <ul style="list-style-type: none"> (i) Infra-orbital nerve (ii) Zygomaticofacial nerve (iii) Zygomaticotemporal nerve – Paresis/palsy <ul style="list-style-type: none"> (i) Facial nerve • <i>Epistaxis/nasal congestion</i> • <i>Compartment syndromes</i> <ul style="list-style-type: none"> – SOF syndrome – Orbital apex syndrome



©Association of Oral and Maxillofacial Surgeons of India

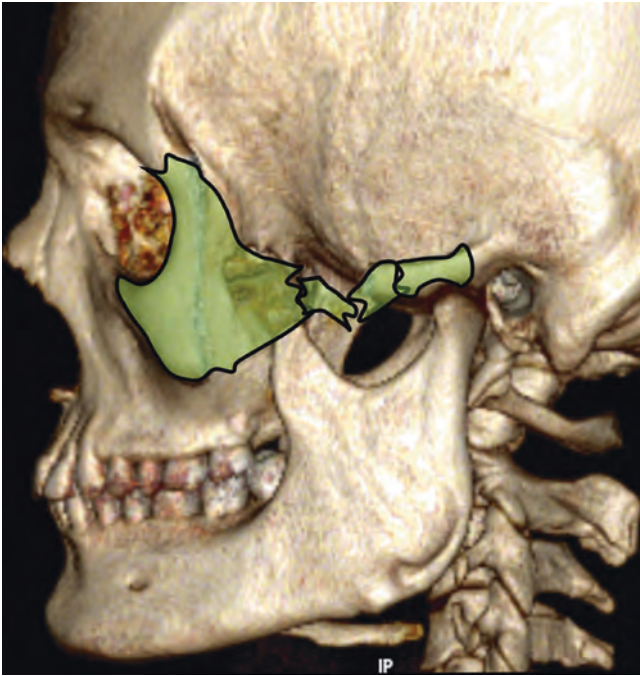
Fig. 56.7 Axes of rotation of ZMC fractures

A description of clinical features with their associated pathophysiology is provided below.

- *Periorbital edema and ecchymosis*: The edema and ecchymosis in ZMC fractures are more dramatic due to the loose connective tissue in the periorbital region. Ecchymosis is commonly seen in the circumorbital region and maxillary buccal sulcus (Fig. 56.15).
- *Subconjunctival hemorrhage (SCH)*: Subconjunctival hemorrhage or hyposphagma (Fig. 56.15) often occurs in ZMC fractures due to collection of the blood into the subconjunctival space, secondary to hemorrhage from the surrounding periosteum. Characteristically, SCH in ZMC fractures does not have a posterior limit in contrast to SCH due to globe injuries [24]. It is important to note that SCH without a posterior limit is also seen in skull base fractures [25]. Chemosis and hyphema are also seen in some cases.
- *Epistaxis*: Occasional epistaxis may be observed due to escape of pooled blood from the maxillary sinus following ZMC fracture. This is typically ipsilateral. Resultant nasal congestion is a common clinical finding.
- *Loss of facial prominence*: Displacement of zygoma due to trauma leads to the characteristic flattening of malar prominence (Fig. 56.16). This is well observed in bird's eye and worm's view. Examination by palpation is done

from behind the patient to detect malar depression. However, the flattening cannot be appreciated in the presence of moderate or severe edema.

- *Eye signs:* The eye signs are a very striking feature of zygomatic injury especially when rotated and inferiorly displaced. Inferior displacement of zygoma results in hypoglobus and an anti-mongoloid slant to the eye (Fig. 56.3b). Inferior or posterior displacement of the infra-orbital rim also causes lowering of the lower eyelid leading to increased scleral show (Fig. 56.17).

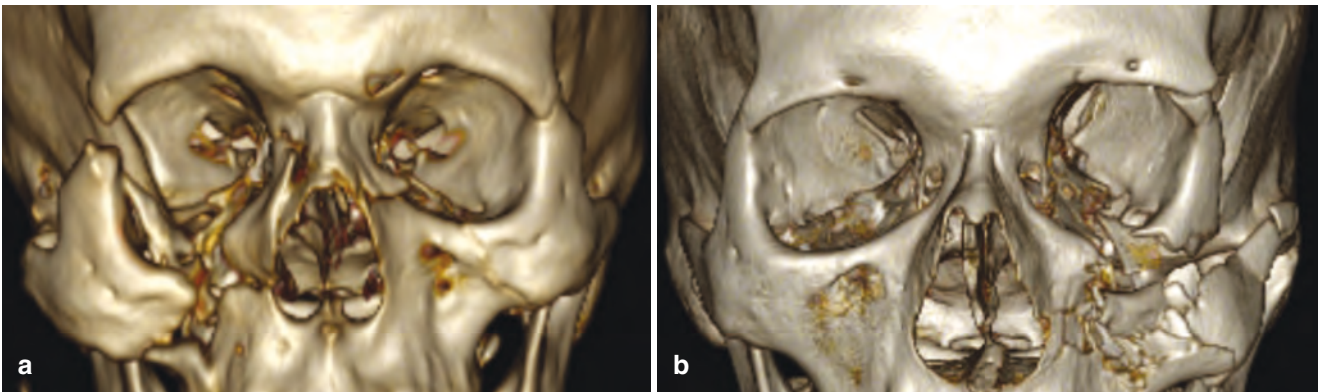


©Association of Oral and Maxillofacial Surgeons of India

Fig. 56.8 Inferior displacement of zygomatic arch

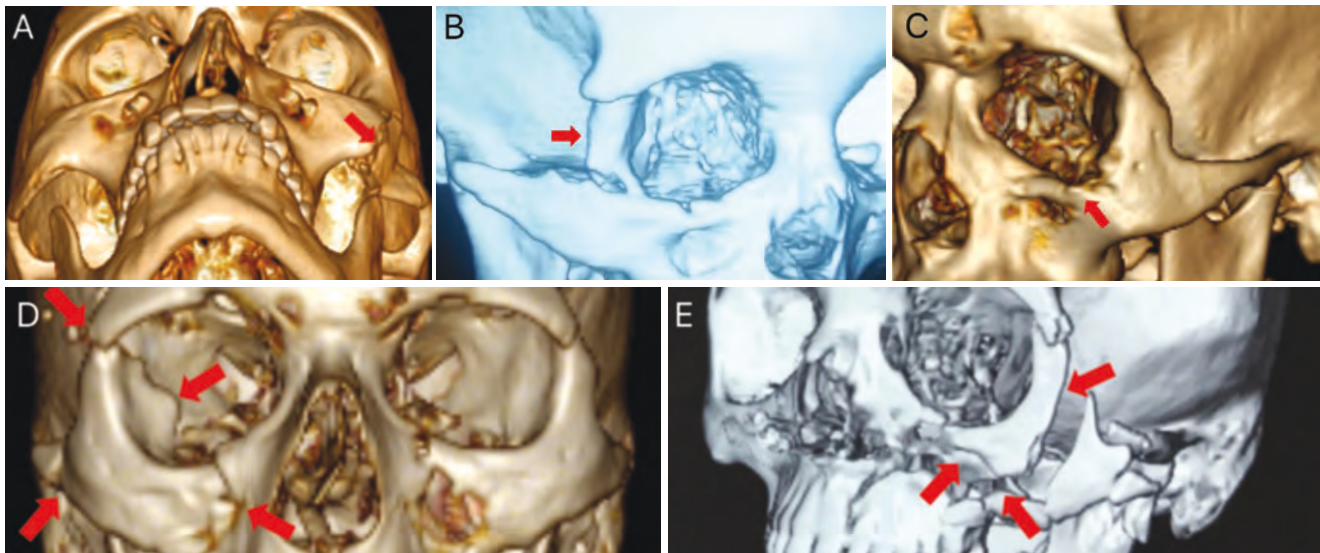
The commonly observed variations in globe position are exophthalmos in posteriorly/medially displaced zygoma (Fig. 56.18a–c) and enophthalmos in laterally and inferiorly displaced zygoma (Fig. 56.19). En/exophthalmos resulting from ZMC fractures must be differentiated from enophthalmos arising from blow-out fractures involving the orbital floor. The clinical implications of the above are explained under “preoperative planning.” Also, it is important to remember that the traditional assessment of en/exophthalmos by Hertel’s exophthalmometer does not reflect the true position of the globe in displaced ZMC fractures because it uses the orbital rim as a point of reference. Naugle’s which utilizes supraorbital rim as a reference is ideal in such cases [26]. However CT evaluation is the most preferred modality [27] (refer Chap. 57 on orbital fractures).

- *Tenderness and step deformity:* When edema is severe and inspectory findings are not conclusive, palpation gives more details. Tenderness on digital palpation, step deformity at the fronto-zygomatic, zygomatic buttress, and IOR are good indicators of fracture.
- *Air emphysema:* Palpation also helps to elicit air emphysema in the form of subcutaneous crackling. This occurs when there is a fracture through a sinus wall which allows air escape into the facial soft tissues. It usually disappears spontaneously, in 2–4 days [28]. However, this can be a potential cause of infection [29].
- *Reduced mouth opening:* Restriction in mouth opening can arise because of two reasons [30]: (1) mechanical obstruction to movement of the mandible by a retrodisplaced zygoma or a fractured zygomatic arch (Fig. 56.20a, b) and (2) a fractured arch impinging on the temporalis muscle causing reflex spasm/trismus. Likewise, injury to the masseter also can lead to trismus.



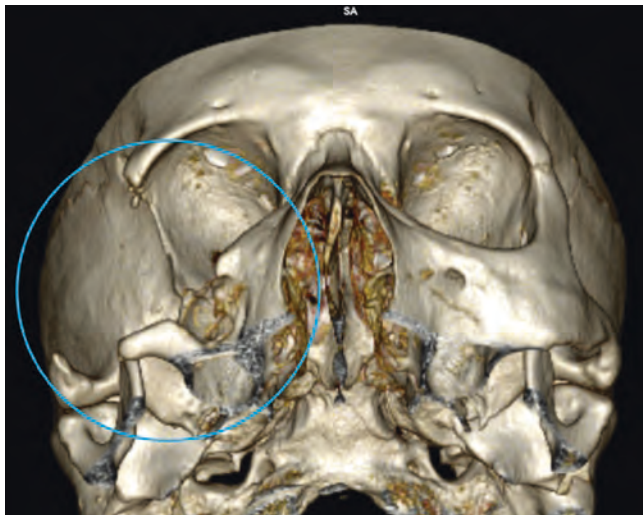
©Association of Oral and Maxillofacial Surgeons of India

Fig. 56.9 En bloc and comminuted ZMC fractures. (a) En bloc displacement of the right ZMC. (b) Comminuted ZMC of left side



©Association of Oral and Maxillofacial Surgeons of India

Fig. 56.10 Zing's classification of ZMC fractures. (a) arch only (Type A1), (b) separation at fronto-zygomatic suture (Type A2), (c) separation at infra-orbital rim (Type A3), (d) complete mono-fragment (Type B) and (e) multi-fragment (Type C)



©Association of Oral and Maxillofacial Surgeons of India

Fig. 56.11 Avulsion of zygoma

- *Paresthesia*: Infra-orbital nerve being closely related to the zygoma gets compressed or pulled in displaced or comminuted ZMC fractures leading to paresthesia along the lower eyelid, upper lip, and lateral aspect of the nose. Occasionally, a patient may also have altered sensation involving the maxillary teeth leading to a perception of altered dental occlusion [5]. The other theory put forward

for altered occlusion is the flexing of the ipsilateral maxillary alveolus leading to premature molar contact [31]. Paresthesia involving the zygomaticofacial and zygomaticotemporal nerves may be present. In rare occurrences, injury to the facial nerve leading to paresis has been observed in severely displaced or high-velocity injuries of the zygoma [15].

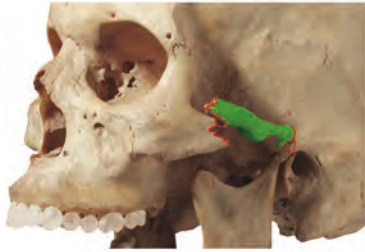- *Altered/loss of vision*: Binocular diplopia is a common finding. The diplopia that develops following trauma can be the result of soft tissue (muscle or periorbital) entrapment, neuromuscular injury, intra-orbital or intramuscular hematoma/edema, or a change in orbital shape, with displacement of the globe [32]. A forced duction test (FDT) (Fig. 56.21) would confirm any physical impediment to ocular motility [4]. Diplopia due to edema/hematoma resolves in a few days, while that due to muscle entrapment does not, necessitating surgical correction.

Another rare but serious sequel to ZMC fractures is traumatic optic neuropathy which may present as total or partial loss of vision [33].

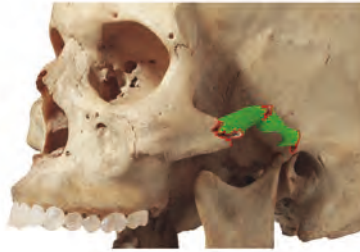
56.5 Imaging for ZMC Fractures

Radiological assessment is essential for accurate diagnosis and assessment of severity of the fracture.

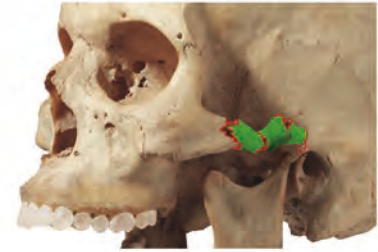
I - Isolated arch



I-A
2 Fractures

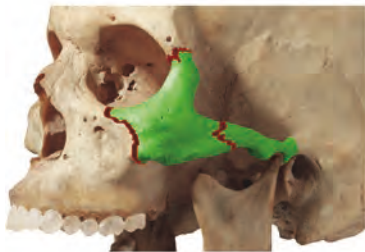


I-B-V
>2 Fractures

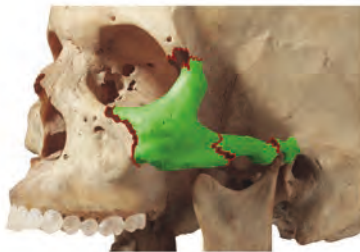

I-A-D
>2 Fractures

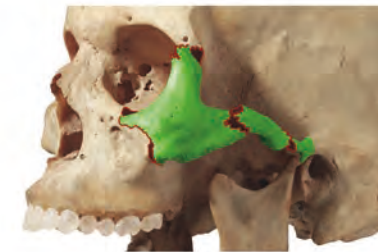II - Combined arch



II-A
Single fracture



II-B
Plural fracture
II-B-R: Reduced



II-B
Plural fracture
II-B-D: Displaced

©Association of Oral and Maxillofacial Surgeons of India

Fig. 56.12 Ozyazgan et al. classification of zygomatic arch fractures

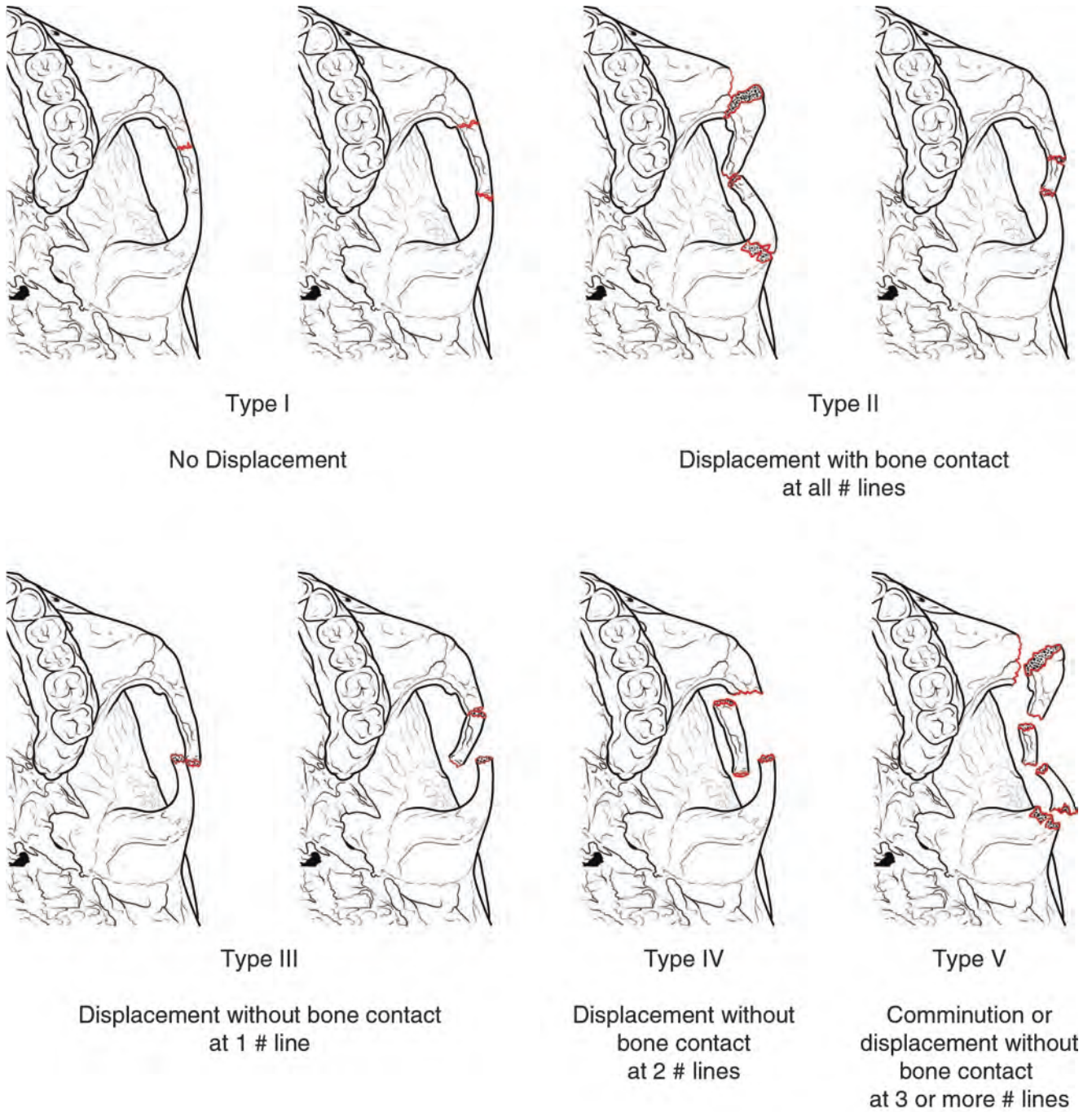
- *Plain radiographs* [31]: Conventional radiographs continue to remain the mainstay of imaging at some centers. Conventional radiographs may also be useful in the post-operative phase, to assess fracture reduction. However conventional radiographs are limited by superimposition of structures.

The commonly used views include the waters view (37° occipitomeatal) (Fig. 56.22) which provides good visualization of the fractured zygoma and helps in comparing with the contralateral side. Tracing the McGrigor-Campbell lines [34] (refer Chap. 55) or the Dolan's lines

[35] are useful in identification of fractures on the Water's view (Box 56.2).

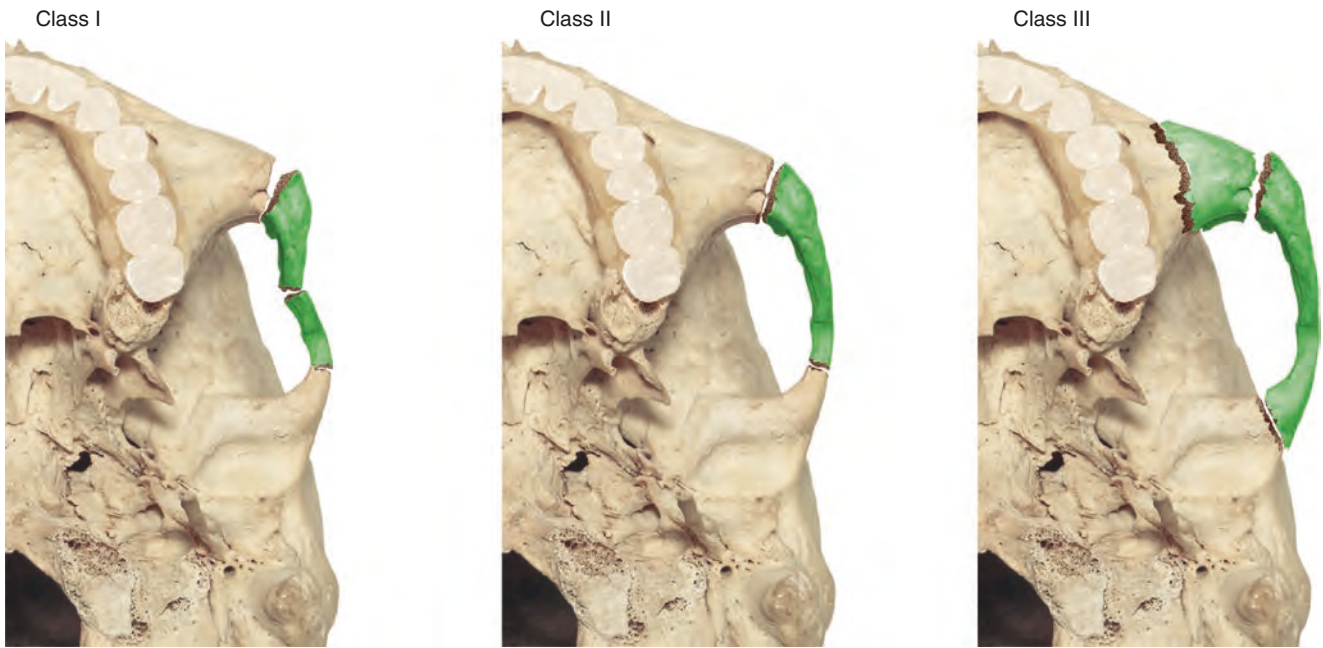
Box 56.2 (Fig. 56.22): Radiographic Appearance in ZMC Fracture

- Disruption of the Dolan's lines
 - Orbital line
 - Zygomatic line
 - Maxillary line
- Loss of elephant trunk appearance



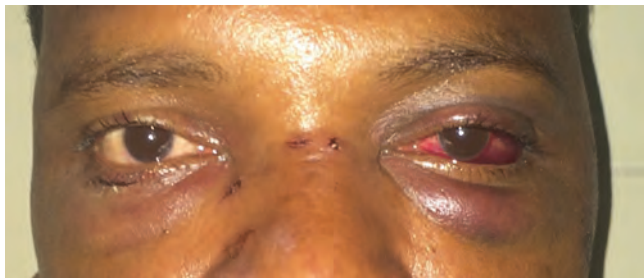
©Association of Oral and Maxillofacial Surgeons of India

Fig. 56.13 Yamamoto et al. classification of zygomatic arch fractures



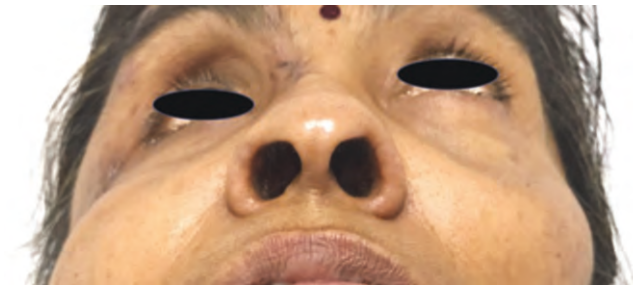©Association of Oral and Maxillofacial Surgeons of India

Fig. 56.14 Hönig Merten (HM) et al. classification of zygomatic arch fractures



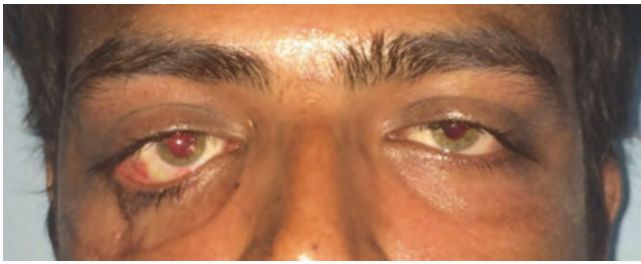©Association of Oral and Maxillofacial Surgeons of India

Fig. 56.15 Periorbital edema, ecchymosis, and subconjunctival hemorrhage



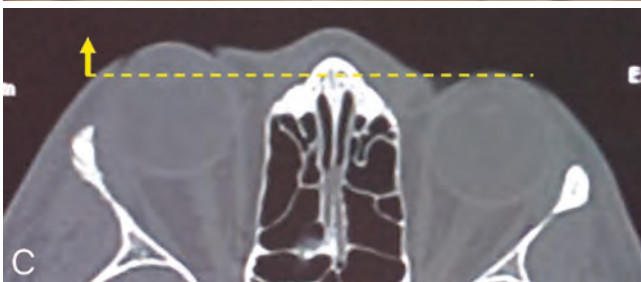
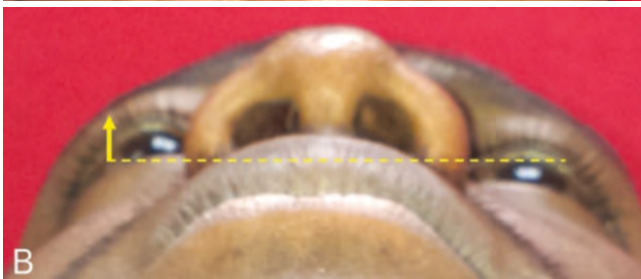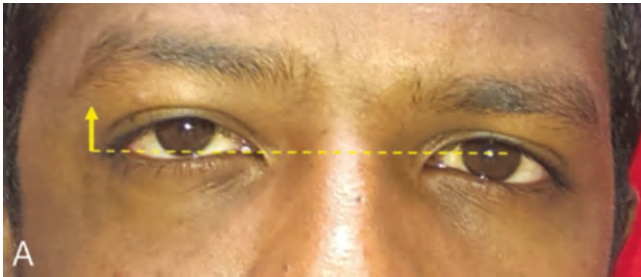
©Association of Oral and Maxillofacial Surgeons of India

Fig. 56.16 Loss of facial prominence in right malar region



©Association of Oral and Maxillofacial Surgeons of India

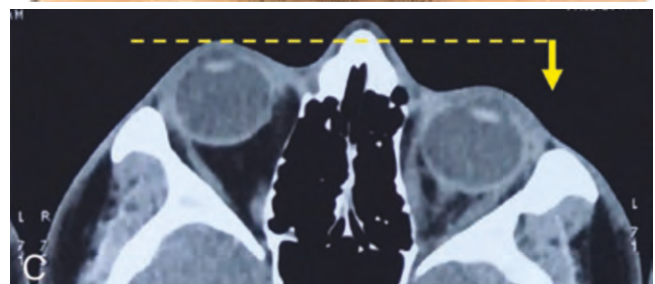
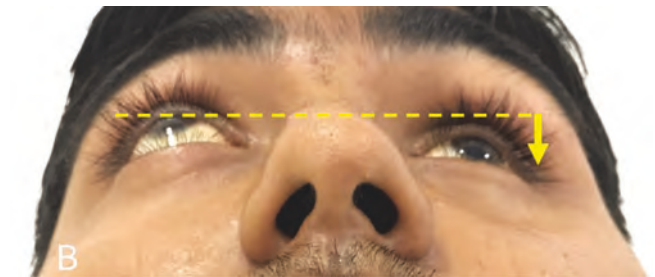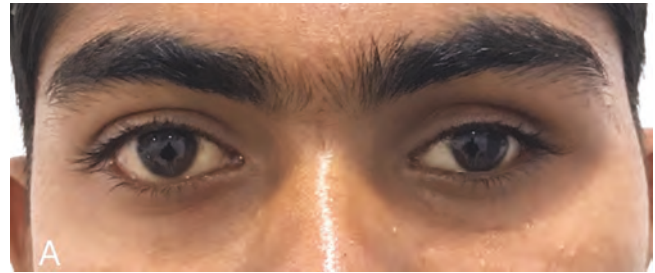Fig. 56.17 Increased scleral show on right side



©Association of Oral and Maxillofacial Surgeons of India

Fig. 56.18 Exophthalmos. (a) Frontal view demonstrating exophthalmos and hyperglobus on right side. (b) Basal view of the same patient showing exophthalmos on right side. (c) Axial CT section demonstrating exophthalmos of the right eye

- The submentovertex/jug handle view [31] (Fig. 56.23) offers the best representation of fractures of the arch. Loss of elephant trunk appearance which is indicative of arch fracture is well appreciated in this view.

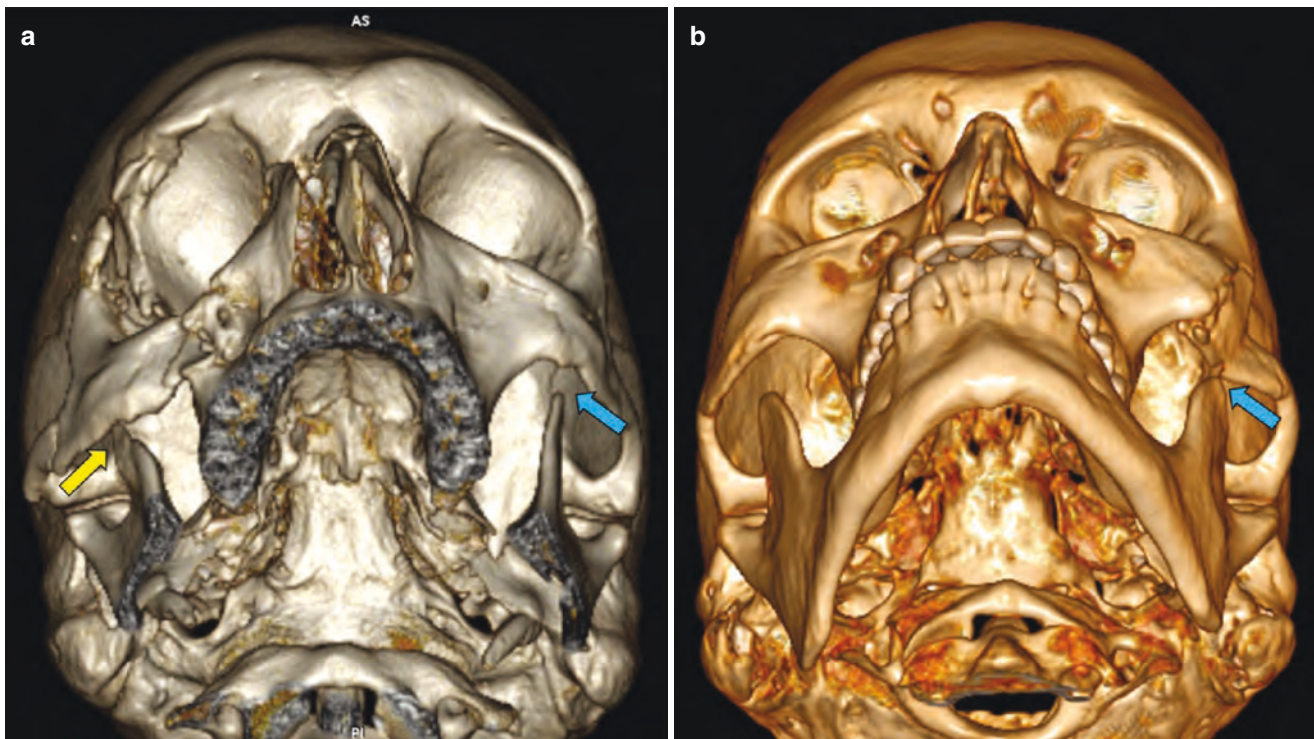


©Association of Oral and Maxillofacial Surgeons of India

Fig. 56.19 Enophthalmos. (a) Frontal view showing enophthalmos on left side. (b) Basal view of the same patient showing enophthalmos on left side. (c) Axial CT section demonstrating enophthalmos of the left eye

- *Computed tomograms:* CT remains the gold standard [31]. It enables a three-dimensional assessment of the fracture along with demonstration of soft tissue entrapment between the fracture fragments. Identification of sphenozygomatic diastasis is best appreciated on CT scans. They also aid in volumetric analysis of the orbital cavity and deficits of the orbital floor. The features demonstrated in different CT sections are highlighted (Fig. 56.24a–d). Figure 56.25 demonstrates CT scan image with volume rendering, which is useful in assessing the spatial orientation of fractured ZMC.
- *USG* is a useful tool for diagnosis of ZMC fractures with high degree of sensitivity for fractures of the arch and infra-orbital rim with the significant advantage of “zero” radiation exposure [36].

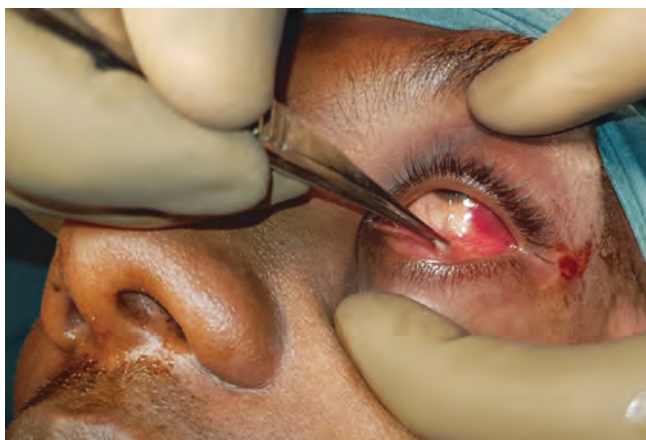The role of intra-operative imaging is discussed in the later segments of the chapter.



©Association of Oral and Maxillofacial Surgeons of India

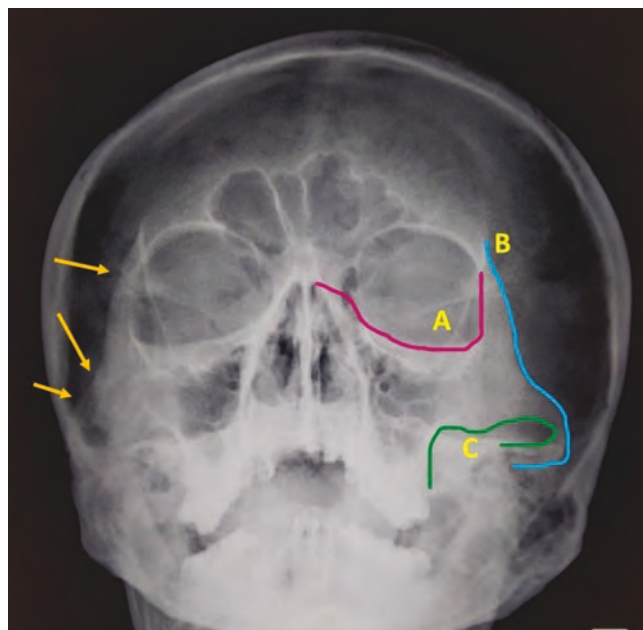
Fig. 56.20 Restricted mouth opening in ZMC fractures. (a) Retrodisplaced zygoma impinging on the coronoid. Yellow arrow demonstrating restriction of space between the body of zygoma and coronoid.

Process, blue arrow demonstrating normal space. (b) Fractured arch impinging on the coronoid (Here, blue arrow demonstrates reduced space)



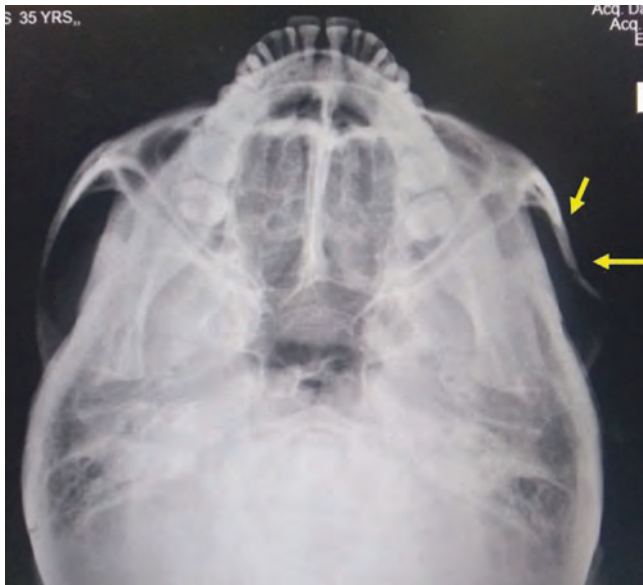©Association of Oral and Maxillofacial Surgeons of India

Fig. 56.21 Forced duction test



©Association of Oral and Maxillofacial Surgeons of India

Fig. 56.22 Waters view with Dolan's lines. (A) Orbital line, (B) Zygomatic line and (C) Maxillary line. The yellow arrows indicate fracture separations noted on the right ZMC



©Association of Oral and Maxillofacial Surgeons of India

Fig. 56.23 Submentovertex view demonstrating fractured arch on left side

56.6 Principles of Management

56.6.1 Indications and Contraindications for Intervention [5, 37]

Surgical outcome of ZMC fractures is greatly influenced by two important factors: (1) choosing the right indications for intervention and (2) ideal time for surgery. Not all fractures of the ZMC require surgical intervention. The decision to intervene should be based on signs and symptoms and presence of functional impairment (Fig. 56.26).

1. It is not necessary to intervene surgically if the fracture is incomplete, undisplaced, or minimally displaced with no compromise in esthetics or function. But such patients must be advised to follow soft, non-chewy diet for 2–6 weeks and monitored to identify displacement [38].
2. Indications for surgery include (1) presence of cosmetic defects in the form of facial deformity, loss of lower eyelid support, or ocular dystopia; (2) functional deficits such as limitation of mouth opening, sensory nerve deficit, and impaired ocular movements; and (3) ZMC fracture associated with OCR reflex in children (please refer to Chap. 57).
3. Postponement of surgical intervention is considered when the general neurologic status of the patient is questionable.
4. Surgical intervention is relatively contraindicated when the involved side has the only seeing eye. In a patient willing for surgery, “potential loss of vision” has to be included in the informed consent.

56.6.2 Timing of Intervention [39]

ZMC fractures are not emergencies, and treatment can be delayed, if necessary.

- When the decision is “no immediate intervention,” surgery may be postponed for up to 2 weeks, following which a reassessment may be made.
- When the indications are questionable, for example, presence of severe edema or fractures with minimal displacement, it is advisable to wait for the edema to subside so that the deformity may be assessed better.
- When the indications are definite, immediate intervention provides better outcomes due to minimal soft tissue scarring and easier reduction of fractures.

56.6.3 Surgical Objectives

Management of ZMC fractures is aimed at achieving the surgical objectives highlighted in Box 56.3 [37].

Box 56.3: Surgical Objectives in ZMC Fracture

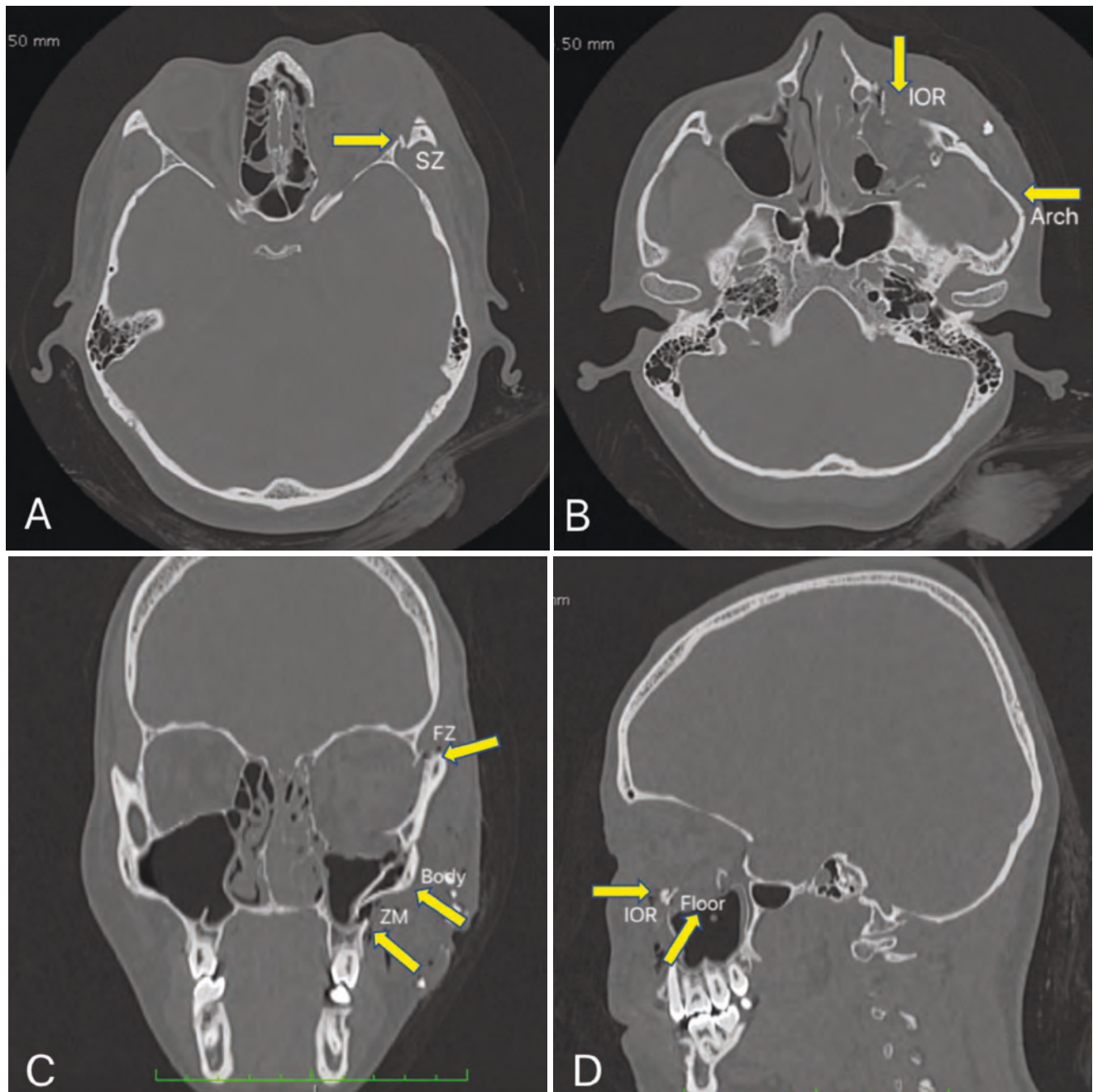
- Restoration of facial esthetics
- Restoration of premorbid ocular function
- Correction or prevention of enophthalmos/exophthalmos
- Restoration of premorbid antral function
- Restoration of mandibular range of motion
Mouth opening of 40 mm, excursion – 4–6 mm

56.6.4 Need for Prophylactic Antibiotics

ZMC fractures may be categorized into three classes based on their propensity to develop postsurgical infection: clean fractures (isolated arch fractures), clean-contaminated (ZMC fractures compound into the antrum), and dirty (fracture which is open to exterior). While type three fractures require regular antibiotic prophylaxis, types 1 and 2 show minimal rates of infection and may either need “no” antibiotic prophylaxis [40] or a modified single-day postsurgical regimen [41].

56.7 Preoperative Planning [42]

ZMC fractures show high propensity for over or under reductions due to lack of objective intra-operative measures to assess reduction. This may be overcome with accurate pre-



©Association of Oral and Maxillofacial Surgeons of India

Fig. 56.24 CT scan of patient with left ZMC fracture. (a) Axial view demonstrating overriding of fracture fragments at SZ suture. (b) Axial section demonstrating fracture at the IOR and buckling of arch. (c) Coronal section showing separation at the FZ and ZM sutures with

medial displacement of the body of zygoma. (d) Sagittal section demonstrating posterior displacement of IOR and large blow-out fracture of orbital floor

operative planning which helps in realizing surgical objectives in a predictable manner.

Preoperative planning includes three vital steps:

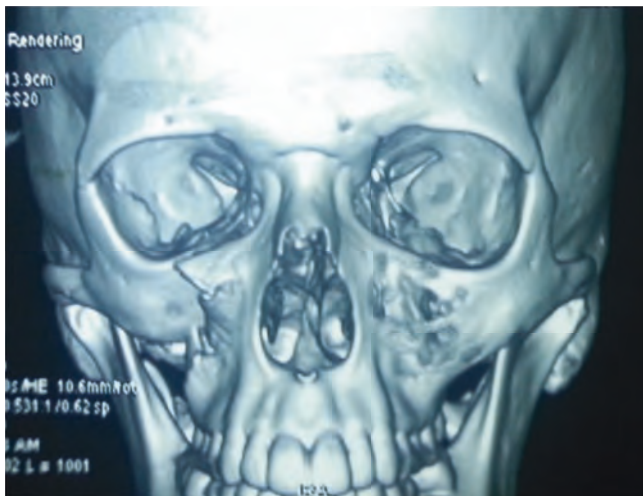
- (i) CT evaluation
- (ii) Model surgery
- (iii) Soft tissue analysis

56.7.1 CT Evaluation

Proper CT evaluation is absolutely essential for choosing the ideal treatment; CT plays a very important role in differentiating en/exophthalmos due to ZMC fractures from those due to orbital fractures. This helps in arriving at a decision regarding internal orbit reconstruction (Box 56.4).

Box 56.4: Relative vs. Absolute En/Exophthalmos

	Enophthalmos in ZMC Relative	Enophthalmos in ZMC +orbit fracture Absolute
Etiology	Change in globe position due to displaced zygoma	Change in globe position due to fracture of orbital floor
Surgical management	Restoration of orbital rims by reduction and fixation of ZMC fracture alone	Restoration of orbital rims by reduction of ZMC fracture as well as reconstruction of orbital floor



©Association of Oral and Maxillofacial Surgeons of India

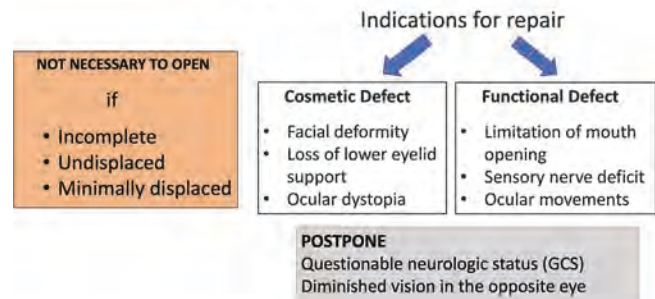
Fig. 56.25 CT with 3D volume rendering demonstrating medially rotated right ZMC fracture**56.7.2 Model Surgery**

The process begins with obtaining CT scans of the patient with minimum slice thickness of 0.6 mm. This is followed by two different sequences of workflow (Fig. 56.27) which are described below.

(A) Planning Using Physical Models

The first step involves generation of a physical stereolithographic model (STL) from the CT scan of the patient. There are two methods by which this can be done.

1. **STL model with the actual deformity:** This model presents the post-traumatic deformity, as observed clinically. A routine model surgery is then performed, by which the displaced fragments are cut and repositioned to obtain optimal anatomical form.

CLINICAL DECISION MAKING

©Association of Oral and Maxillofacial Surgeons of India

Fig. 56.26 Indications and contraindications for intervention

The repositioned fragments are stabilized temporarily with wax. The fixation devices (miniplates) are then pre-contoured over the model. Such pre-contoured implants are used to guide intra-operative fracture reduction as well as fixation. Figure 56.28a–d demonstrates the sequence described.

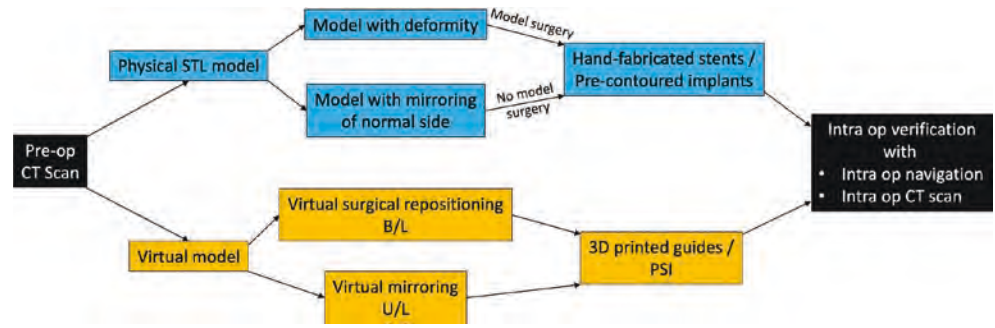
2. **STL model after mirroring:** CT scan is used to generate a virtual model wherein the normal side is mirrored onto the fractured side. The virtual model is used to print a physical model which demonstrates the skull which is bilaterally symmetrical, mimicking ideal reduction status. Similar to the earlier method, implants for fixation are pre-contoured over this model to help achieve optimal results intra-operatively. Figure 56.29a–d demonstrates a similar clinical scenario.

(B) Planning Using Virtual Models

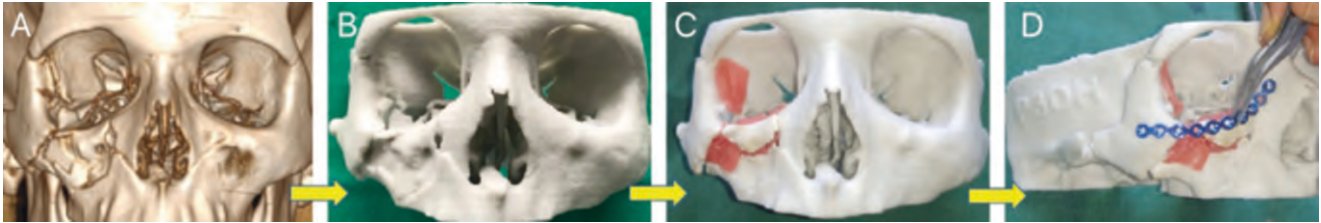
This method utilizes the complete spectrum of computer-assisted surgical planning. A CT scan is obtained to create a virtual model on which the entire surgical sequence of reduction is performed and on which the stents for intra-operative guidance are designed. Intra-operative stents are printed from these virtual designs. There is no physical “handheld” model here (Refer Chap. 41).

- In the case of a unilateral ZMC fracture, the normal side is mirrored to the fractured side to obtain bilateral symmetry. CAS technology is then utilized to design “guidance stents” on the mirrored side. These stents can be utilized intra-operatively to (1) verify ideal reduction position in primary trauma or (2) design the osteotomy and repositioning, in secondary corrections. Another important advancement in recent years is the design and printing of “patient-specific implants” (PSI) using virtual planning. These customized fixation devices double up as guidance stents also (Refer Fig. 57.54).
- In bilateral ZMC fractures [43], mirroring is not an option, and the ideal sequencing for such cases is discussed in Sect. 56.14, of this chapter.

Fig. 56.27 Flow chart for preoperative planning in ZMC fractures

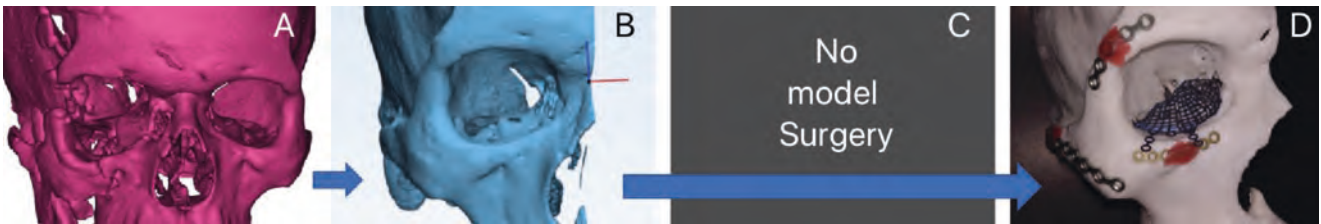


©Association of Oral and Maxillofacial Surgeons of India



©Association of Oral and Maxillofacial Surgeons of India

Fig. 56.28 Model surgery for pre-contouring of implants. (a) CT image demonstrating fractured ZMC of right side. (b) STL model demonstrating deformity. (c) Repositioning of fracture fragments to anatomical position. (d) Pre-contouring of implants



©Association of Oral and Maxillofacial Surgeons of India

Fig. 56.29 Use of mirrored models for pre-contouring of implants. (a) 3D CT image of fracture. (b) Mirroring of zygoma of normal side to fractured side. (d) Generation of mirrored STL model and pre-contouring of implants

56.7.3 Soft Tissue Analysis

Li et al. [44] have described a technique for 3D simulation and prediction of soft tissue—outcome analysis in ZMC fractures. This process enables prediction of postoperative soft tissue changes in patients with ZMC fractures who are indicated for primary/secondary surgical interventions. The planning involves utilization of CT data and 3D stereophotography for the analysis. The technique may also be utilized for evaluation of postsurgical results.

56.8 Reduction of ZMC Fractures

Reduction of zygoma is unique in two aspects:

1. Unlike the other facial bones, “reduction alone” may be the sole treatment in many cases of ZMC fractures.
2. The surgical approach for reduction may be different from that for fixation.

Fracture reduction may be done either by direct or indirect method, and the approaches may be extraoral or intraoral [1].

56.8.1 Direct vs. Indirect Method



The indirect method is a blind technique where fracture is reduced without exposure of the fracture site (e.g., Gillies reduction), while direct method involves reduction of the fracture under direct visualization (e.g., coronal approach to reduce arch fracture). The differences between the two methods are shown in Fig. 56.30. However, indirect method is more commonly practiced. Open method is resorted to when the ZMC fracture is (1) severely displaced, (2) complex or comminuted, (3) when stable reduction is doubtful, and (4) there is a need for internal orbit reconstruction. However, no “single technique” is superior, and sometimes, a combination of techniques is more effective.

56.8.2 Extraoral Techniques

The extraoral reduction techniques may be either percutaneous, temporal, or endoscopic [1, 45].

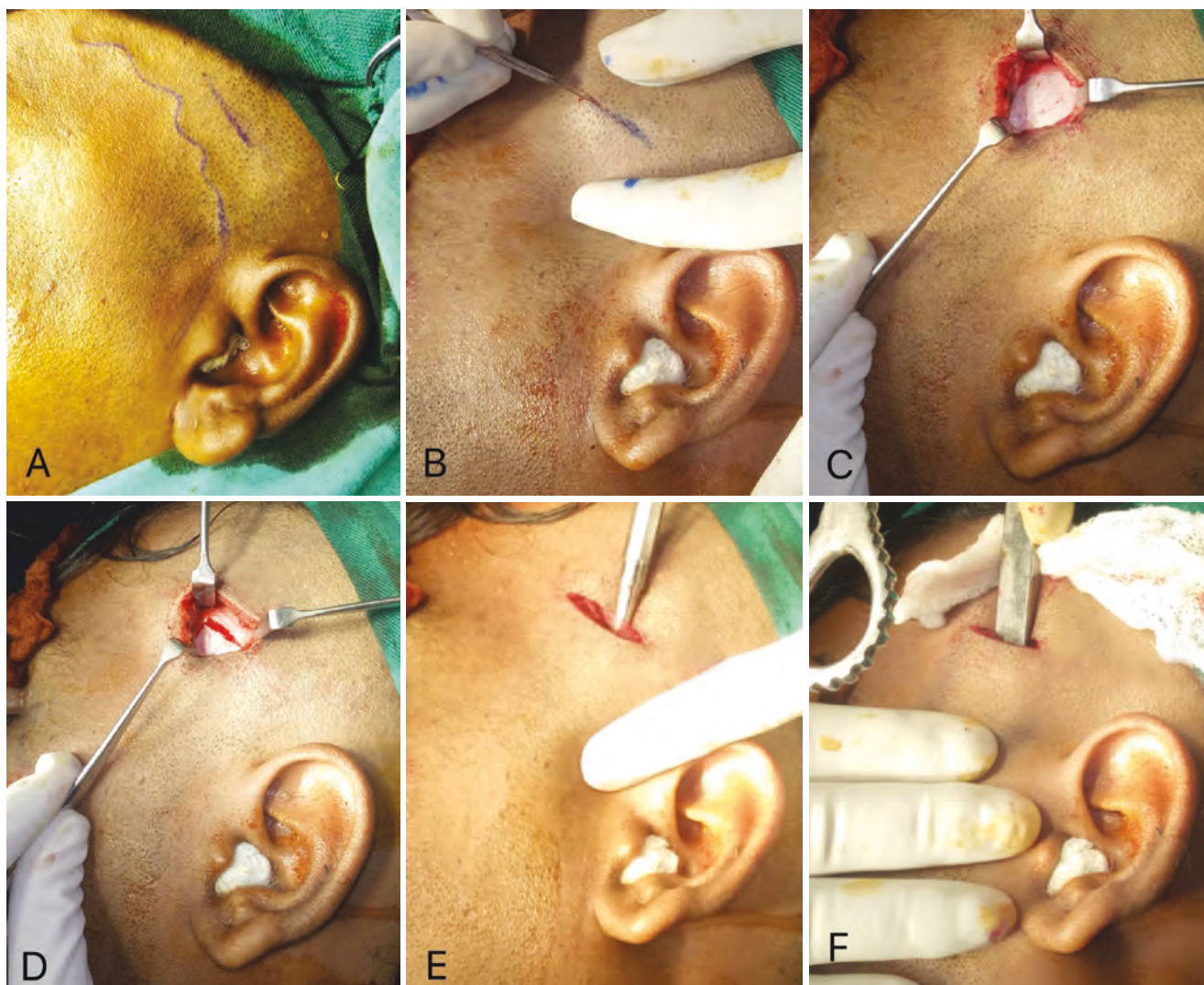
- **Temporal approach** [46], commonly called the Gillie's (Figs. 56.31a–f and 56.32a), is the most popular method of ZMC reduction. This approach is favored because the incision is placed within the hairline which does not leave a visible scar. It also offers a very predictable force during reduction and may be used for reduction of both the arch

as well as the zygoma. The technique is based on the anatomical basis that the plane between the temporalis fascia and the temporalis muscle offers direct access to the zygomatic arch and zygoma. The only contraindication to this approach is the presence of concomitant temporal bone fracture. The incision is placed at a level 2 cm above the helix of the ear, paralleling the anterior branch of the superficial temporal artery, well within the hairline (Fig. 56.33). Dissection is carried down through the skin, subcutaneous tissue, and galea aponeurotica (temporoparietal fascia—TPF) to reach the temporalis fascia.

INDIRECT / CLOSED	DIRECT / OPEN
# site is not visualized Incision & Instrumentation away from # site	# site is visualized Instrumentation at # site
Difficult to assess reduction	Can assess reduction
Precise fixation is not possible	Precise fixation is possible
Surgical outcome- not predictable	Predictable results
	

©Association of Oral and Maxillofacial Surgeons of India

Fig. 56.30 (A) Indirect vs (B) direct reduction



©Association of Oral and Maxillofacial Surgeons of India

Fig. 56.31 Gillies temporal approach. (a) Marking of incision parallel to frontal branch of superficial temporal artery. (b) Placement of incision. (c) Exposure of deep temporal fascia. (d) Incision through deep

temporal fascia exposing temporalis muscle. (e) Developing plane of elevation with periosteal elevator. (f) Placement of Rowe's zygomatic elevator for elevation

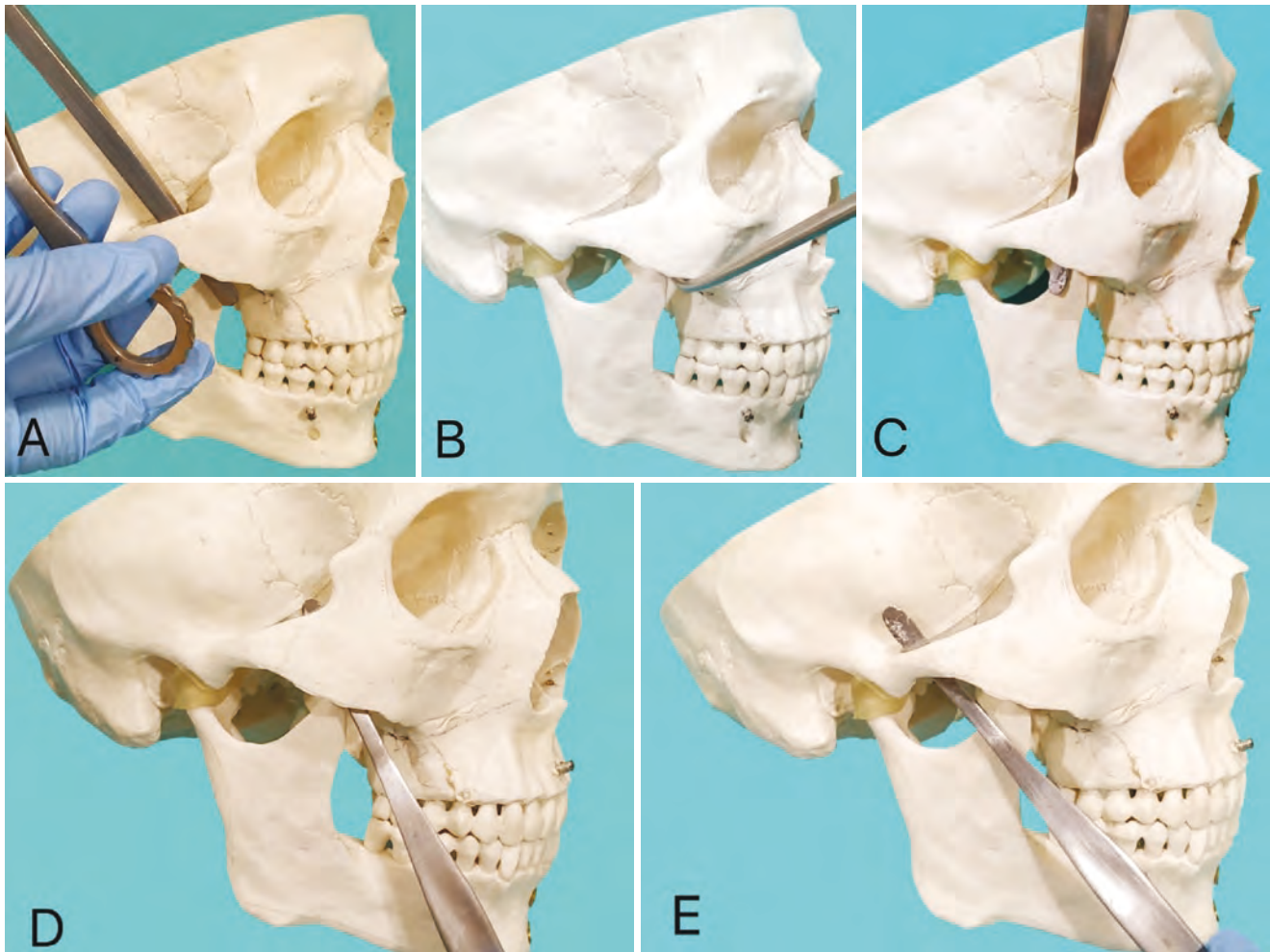
An incision is made through the temporalis fascia to reveal the underlying temporalis muscle. A Howarth's elevator is inserted between the temporalis fascia and the muscle, to create a plane for the zygomatic elevator. Two types of zygomatic elevators, namely, the Bristow's and Rowe's (Fig. 56.34a), are commonly used; the Bristow's has a single flat and elongated working tip attached to a handle and is used like a spatula for elevation, while the Rowe's elevator has an additional arm attached to the working tip which serves two purposes: (1) to provide the necessary countertraction during elevation so that it relieves the fulcrum off the temporal bone and (2) to evaluate the approximate depth of insertion of the working tip when inserted into the tissue. The zygomatic elevator is positioned in the plane created, directed inferiorly to reach the deeper surface of the zygoma and carefully elevated, while an ironing motion is used to smoothen the

collapsed arch form. Care is taken not to lever the elevator against the skull (Video 56.1).

Clinical Tip

1. It is good practice to keep a roll of gauze under the zygomatic elevator to prevent injury to the temporal bone.
2. Instead of extensive shaving of the temporal hair for a Gille's approach, a small patch (1cm by 3cm) of shaving/close trimming of hair can be done for better cosmesis.

- **Percutaneous methods** make use of a minimal facial skin incision, usually right over the zygoma or the lateral brow (Dingman's method) through which instruments may be inserted to manipulate and elevate the displaced zygoma.



©Association of Oral and Maxillofacial Surgeons of India

Fig. 56.32 Different approaches for reduction of fractured ZMC. (a) Gillie's. (b) Poswillo. (c) Dingman. (d) Balasubramaniam. (e) Quinn

- *Poswillo's* approach. This involves a stab incision made at the point of intersection of two imaginary lines—a horizontal from the base of the nose and a vertical from lateral canthus (Fig. 56.35a, b). The incision is oriented along the skin crease, just enough for a Poswillo hook [47] to be engaged underneath the body of the zygoma (Fig. 56.32b and Fig. 56.34b). And the impacted zygoma is pulled upward or outward. Skin incision is closed with a single suture. Reduction through a zygoma approach may also be performed by using a Carroll-Girard screw [48]/universal bone reduction screw (Fig. 56.34c).
- *Dingman's lateral brow approach* [49] (1964) (Fig. 56.32c)

This technique is performed through a standard lateral brow approach where the fracture is visualized by a direct approach to the bone after incising through the skin, subcutaneous tissue, and periosteum. An elevator is then passed laterally and posterior to the orbital rim into the temporal fossa. The temporal aponeurosis (attachment of the deep temporal fascia to the lateral orbital rim) is incised, and the elevator is passed

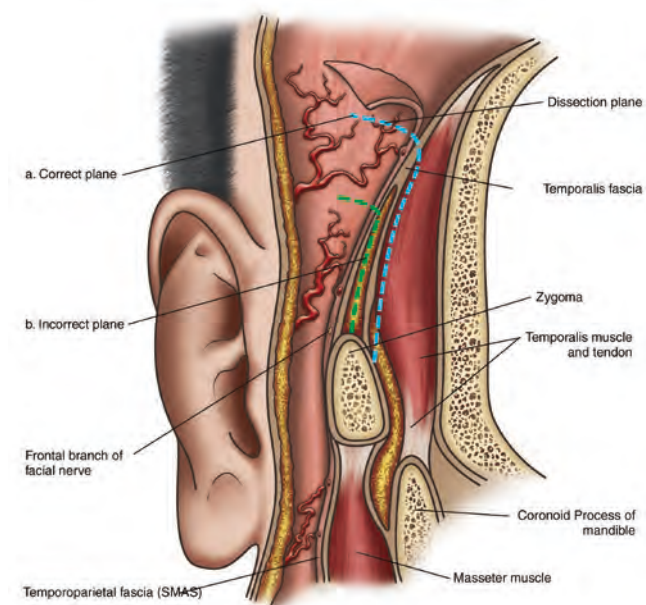
beneath it to lift the arch or the body of the zygoma in an upward, forward, and outward fashion. The original description by Dingman utilized trans-osseous wiring for stabilization of the front-zygomatic suture. However current methods incorporate the use of mini-plate osteosynthesis through this approach.

56.8.3 Intraoral Techniques

The greatest advantage of intraoral techniques is “no skin incision.” Commonly followed methods are:

- *Balasubramaniam's/Keen's approach* (upper buccal sulcus approach) [50] (Fig. 56.32d)

This approach uses a vestibular incision behind the zygomatic buttress. A Howarth's periosteal elevator is inserted in a supraperiosteal plane to engage the infratemporal surface of the zygoma. Reduction is achieved with an upward, forward, and outwardly directed force. When greater force is needed to elevate as in impacted zygomas



©Association of Oral and Maxillofacial Surgeons of India

Fig. 56.33 Gillie's correct plane for elevation. It is important to understand that the deep temporal fascia divides into two, to enclose the zygomatic arch and the fat above, approximately 2 cm above the arch. An incision placed too low may mislead the young surgeon into the fat plane (b, lateral to the arch) rather than the subfascial plane (a, medial to the arch) (Also refer Fig. 85.1a)

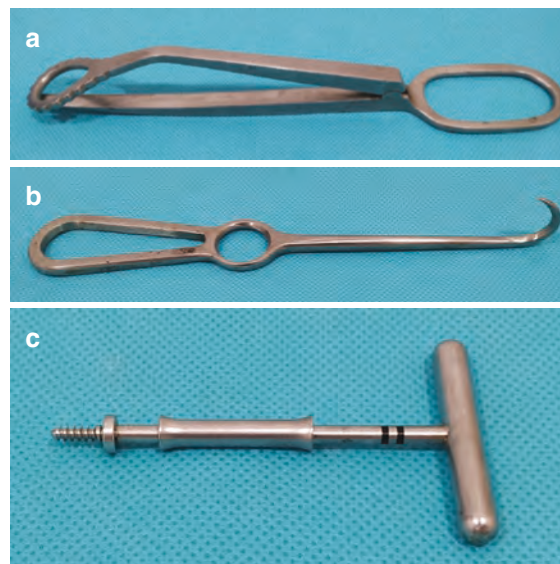
or delayed presentation, a Bristow's/Rowe's zygomatic elevator (Fig. 56.36) or the arm of an upper anterior forceps may be used. The technique offers more mechanical advantage than the extraoral method; less force is needed to elevate, because the force is directed entirely at the center of the zygomatic body, which is considered more effective.

- *Quinn's procedure* (lateral coronoid approach) [51] (Fig. 56.32e) employs an incision over the anterior border of the ramus. An elevator is inserted in a supraperiosteal plane, lateral to the coronoid process and paralleling the temporalis tendon to reach the medial surface of the zygomatic arch. Elevation of the arch may be done in an ironing fashion.

Both the abovementioned intraoral techniques are supra-periosteal methods.

56.8.4 Reduction of Zygomatic Arch

Elevation of the depressed arch is usually performed in an indirect manner, using the Gillie's technique. However numerous techniques have been advocated in literature. These include the "roller-coaster" lateral brow technique [52] and methods using percutaneous towel clip [53], traction suture [54], Foley's catheter [55], K wire [56], and Dingman elevator [57] to reconstitute the arch anatomy.



©Association of Oral and Maxillofacial Surgeons of India

Fig. 56.34 Instruments for reduction. (a) Rowe's . (b) Poswillo hook. (c) Universal bone reduction screw

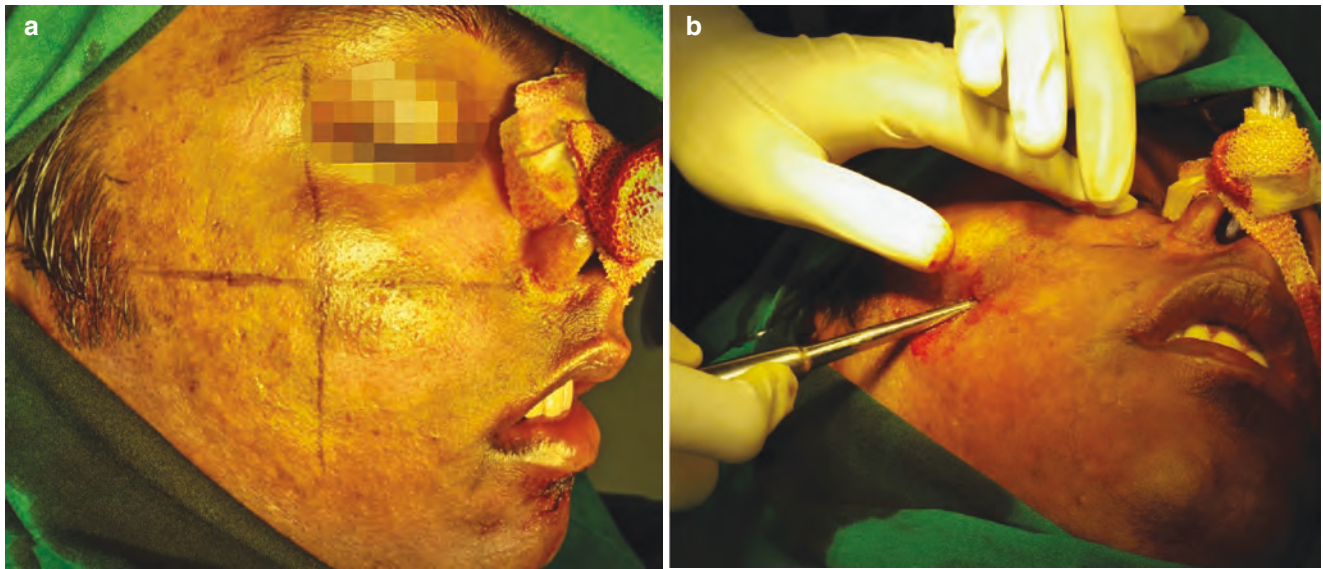
56.8.5 Intra-operative Assessment of Reduction

The intra-operative assessment of reduction is a critical step in zygoma management, especially in closed reduction. The methods commonly used are (1) clinical assessment, (2) imaging, and (3) use of prefabricated guides/stents.

1. **Clinical assessment** is usually done by eyeballing, comparing with the normal side or palpation of the rims for steps. However, the adequacy of reduction may be difficult to assess intra-operatively because of edema as well as patient position. Audible click during manipulation is also indicative of reduction [58]. Surgical exposure of multiple suture sites is the other method to confirm reduction [59] but is less favored because of surgical morbidity. However, exposure at all sites of articulation is not required; two sites are considered perfect indicators of accurate reduction [5] (Box 56.5).
2. **Intra-operative imaging** [58] such as C-arm [60] (Fig. 56.37a, b), CT [59], O arm [61], or endoscopes [45] are valuable guides in confirming reduction of ZMC fractures. However, use of intra-op imaging other than endoscopes mandates use of lead aprons by operating room personnel to prevent radiation exposure.
3. **Prefabricated guides/ stents** [62] are valid tools which ensure accuracy of reduction, intra-operatively.

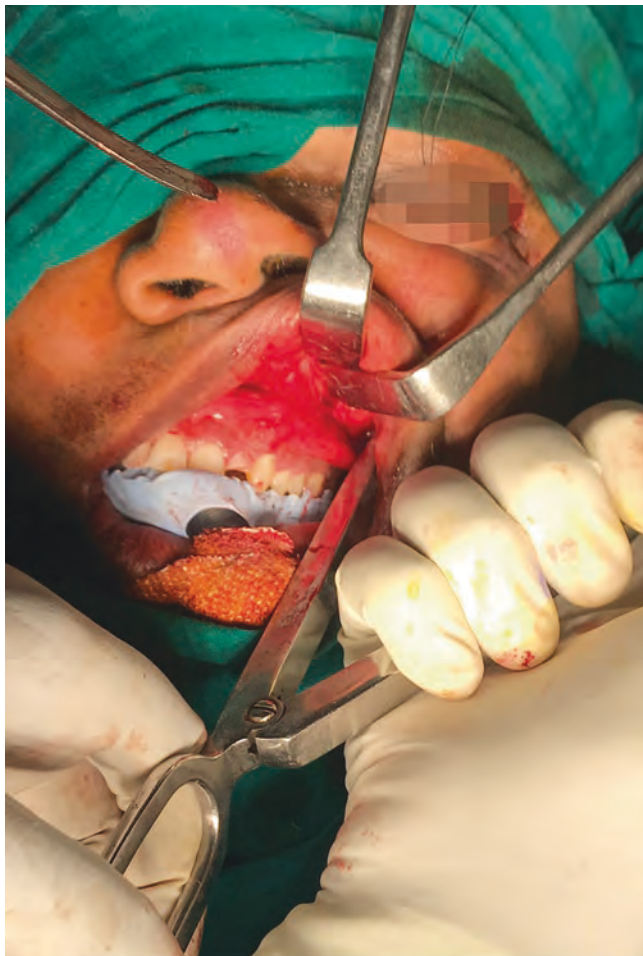Box 56.5: Indicators of Accurate Reduction of ZMC

Reduction along the vertical axis—SZ suture
Reduction along the horizontal axis—ZM suture



©Association of Oral and Maxillofacial Surgeons of India

Fig. 56.35 Percutaneous reduction with Poswillo's technique. (a) Marking on skin. (b) Percutaneous insertion of bone hook



©Association of Oral and Maxillofacial Surgeons of India

Fig. 56.36 Balasubramaniam's technique

56.8.6 Precautions During and After Reduction

Manipulation of zygoma during reduction has been known to cause certain complications such as bleeding from infra-orbital vessels [16]. Use of controlled force during indirect reduction greatly reduces such complications. It is prudent to watch out for stimulation of Oculocardiac reflex (OCR) [63] as described later in the text. OCR may also be prevented by administering regional blocks before elevation [64].

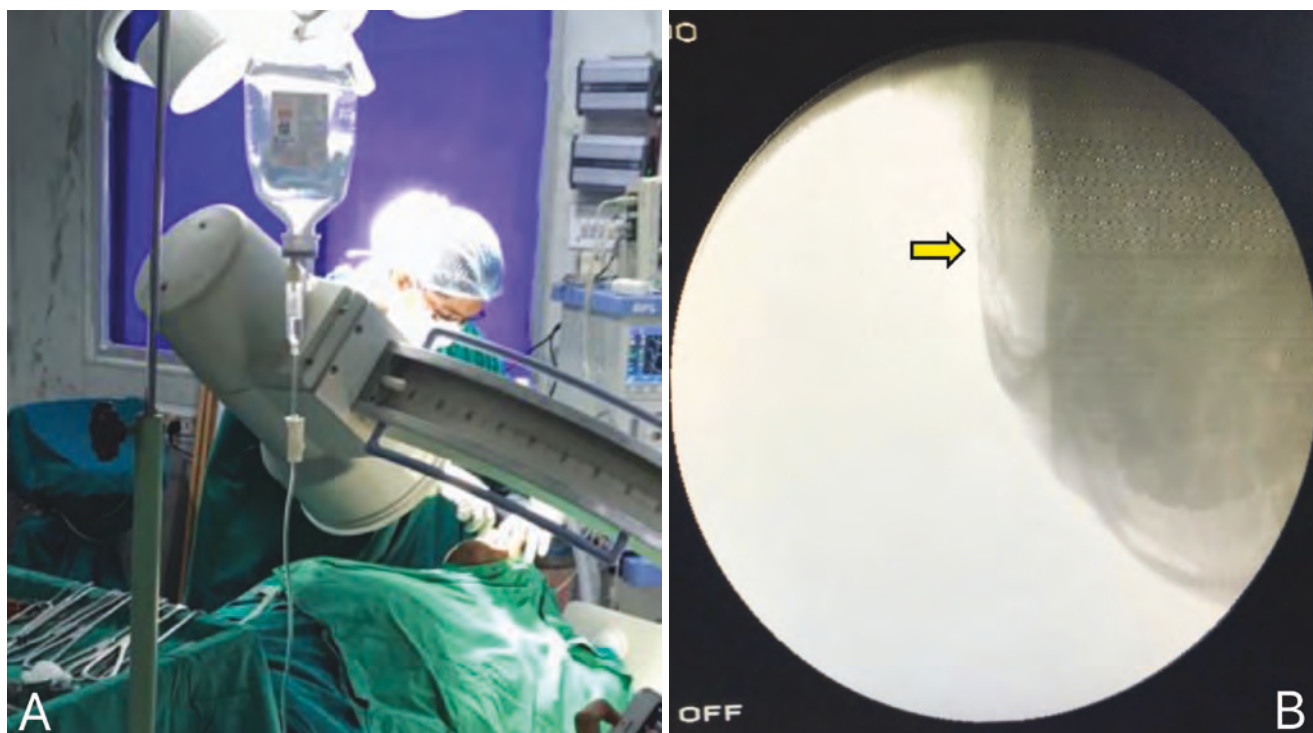
Once the reduction is completed and found satisfactory, the fracture fragments need to be maintained in the reduced state. A Zimmer splint [65] (preformed aluminum splint with foam on the undersurface) may be adapted to the reduced arch and secured with sutures. It is maintained in situ for 2–3 weeks.

Finally, it is mandatory to do a force duction test (FDT) after elevation of zygoma [5] (Box 56.6).

Box 56.6: FDT Is Mandatory After Reduction of ZMC Fractures (Fig. 56.21)

During reduction of ZMC fractures, as the fractured bones get realigned to normal anatomical position, entrapment of surrounding soft tissue or muscles may occur between the fragments

This may lead to post-surgical diplopia, necessitating a surgical revisit.



©Association of Oral and Maxillofacial Surgeons of India

Fig. 56.37 Intra-operative assessment of reduction using C-arm. (a) Intra-operative positioning of C-arm. (b) Image demonstrating zygomatic arch after reduction

56.9 Fixation and Stabilization of ZMC Fractures

56.9.1 Need for Fixation

Fixation needs of ZMC fractures depend on the post-reduction stability. Classification of fracture patterns by Rowe and Williams [1] provides guidance on assessment of fracture stability after reduction. Any fracture classified as stable after reduction does not require fixation, while those considered unstable, mandate fixation. However, a practical method would be to apply moderate digital pressure on the malar eminence after reduction. Displacement secondary to this maneuver, requires fixation [59]. The algorithm proposed by Rodrigo and Belini et al. is also a practical guide to manage ZMC fractures which are not associated with orbital component [3]. For ZMC fractures with orbital involvement, Ellis and Perez advocate guidelines for orbital reconstruction based on CT evaluation. Most of the studies indicate increase of fixation points from 1 to 2, 3, and 4 points based on the status of intra-operative stability after reduction. Involvement of orbit leading to changes in intra-orbital volume requires orbital reconstruction [59].

Box 56.7: Ideal Sequence of Fixation

1. Vertical buttress—to restore facial height
2. Zygomatic arch—to restore anteroposterior projection

56.9.2 Fixation Principles

The current dictum is “any zygoma which when fractured and displaced must be fixed” [37]. The objectives are to achieve a 3D reconstruction (transverse width, vertical height, and anteroposterior projection) and establish the buttresses. Attention needs to be given to the order of restoration [66, 67]. The results of various biomechanical experiments indicate that the vertical buttress needs to be fixed first, to restore the facial height. Then, the anteroposterior projection may be achieved by restoring the arch (Box 56.7).

56.9.3 Surgical Access to Fixation

Surgical approaches for ZMC fixation are chosen based on the fracture pattern and fixation needs. A single or multiple

incision may be used for the surgical exposure of ZMC fractures [30, 68, 69].

The incisions may be broadly classified as:

- Cutaneous (upper eyelid, lateral brow, subciliary, subtarsal, infra-orbital, preauricular, and coronal incisions)
- Conjunctival (transconjunctival with canthotomy/transcaruncular)
- Mucosal (intraoral vestibular)

The list of incisions and the exposure achieved (green shaded areas on Fig. 56.38) by each are highlighted in Box 56.8 (Fig. 56.38)

The following is a description of the various incisions used to access the fixation points in ZMC fractures. It is important to take adequate measures for globe protection while placing any periorbital incisions [70]. The commonly followed methods include either a temporary tarsorrhaphy (Fig. 56.39) or a corneal shield (Fig. 56.40). The tarsorrhaphy also offers the additional advantage of being used as a retraction suture during surgery.

Box 56.8: Approaches to ZMC Fractures

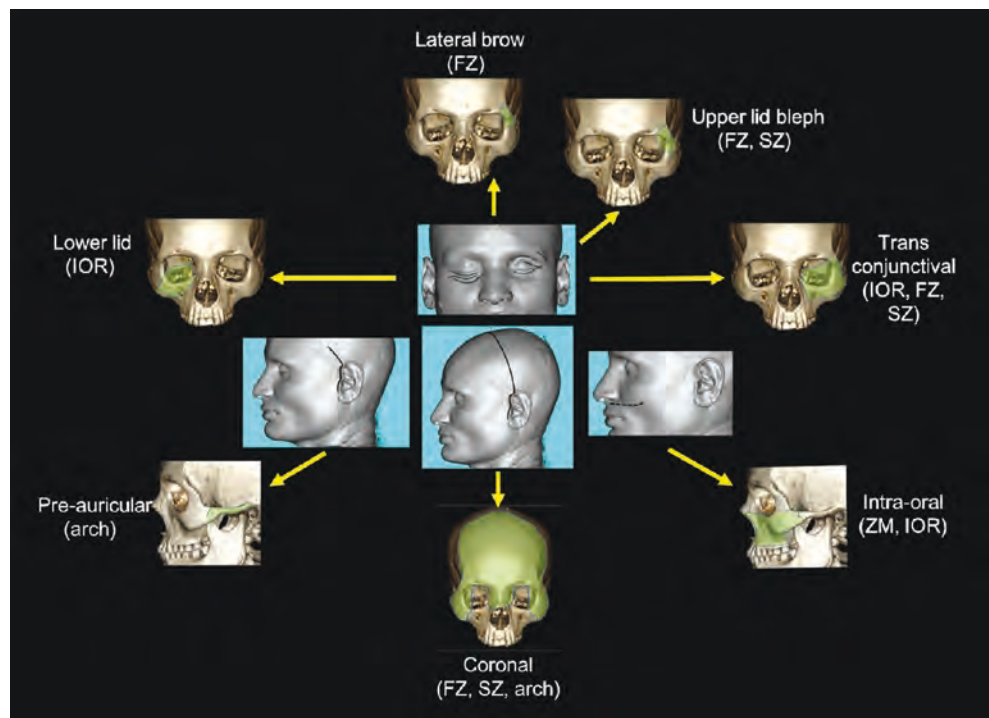
Intraoral vestibular incision	ZM, IOR
Lower eyelid cutaneous incisions (Subtarsal, subciliary, infraorbital)	IOR, orbital floor
Transconjunctival	SZ, FZ, IOR, floor
Lateral brow	FZ, SZ
Upper eyelid	SZ, FZ
Coronal	SZ, FZ, arch
Preauricular	Arch

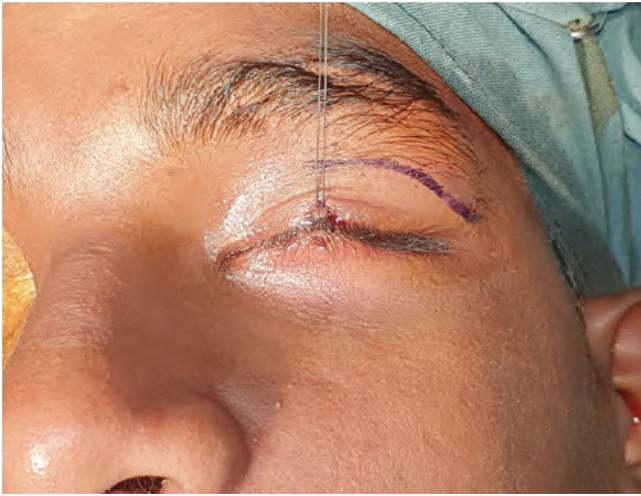56.9.3.1 Supraorbital/Lateral Brow Incision
(Fig. 56.38)

The lateral brow incision is otherwise called as “in the brow” incision and offers a fast and direct access to the fronto-zygomatic suture and lateral part of the supraorbital rim. The extensions for the incision must be well within the eyebrow which provides an ideal camouflage (Fig. 56.41a). However, this incision may not be ideal in people who are cosmetically inclined to maintain a higher eyebrow. Absence of any important neurovascular structures in this area makes this incision easy to perform, even by beginners.

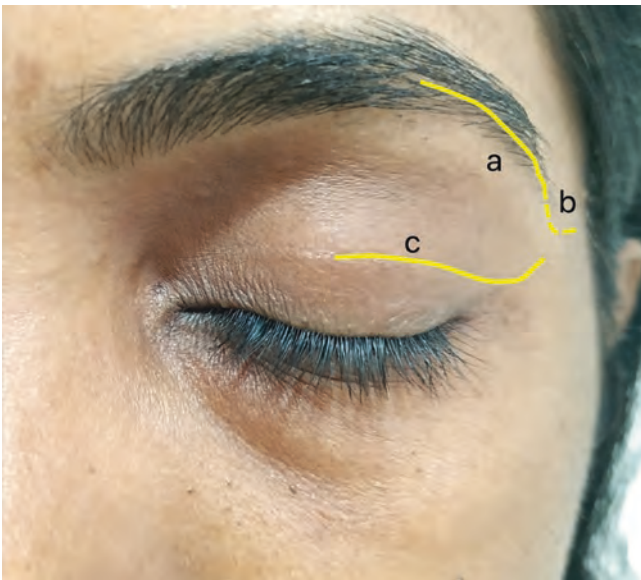
After infiltration of LA solution containing vasoconstrictor, a 2 cm long incision is placed along the curve of the

Fig. 56.38 Incisions to access ZMC fractures





©Association of Oral and Maxillofacial Surgeons of India

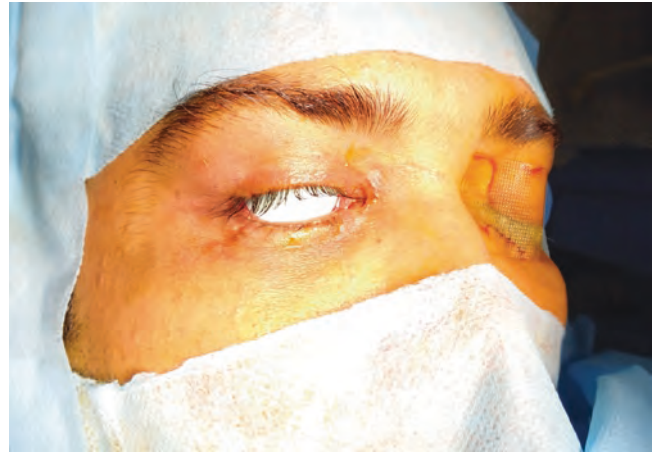Fig. 56.39 Tarsorrhaphy

©Association of Oral and Maxillofacial Surgeons of India

Fig. 56.41 Periorbital incisions for FZ suture. (a) Lateral brow incision. (b) Lateral brow extension (shown in dotted lines). (c) Upper lid blepharoplasty

superolateral part of the orbital rim. Care is taken to incline the blade parallel to the hair so that the shafts are not transected. Failure to do so may cause linear alopecia along the incision line, which may be unaesthetic. Incision is carried through the skin, subcutaneous tissue, and the orbicularis oculi muscle. The flap is undermined in the supraperiosteal plane to permit ease of retraction. A periosteal incision is then placed above the fronto-zygomatic suture for reduction and fixation (Fig. 56.42a, b).

When additional exposure is needed on the medial aspect, the incision is extended up to the supraorbital nerve. For additional inferior extension, a gradual 90° turn into the



©Association of Oral and Maxillofacial Surgeons of India

Fig. 56.40 Corneal shield

crow's feet wrinkle which is restricted to the skin only, is utilized to provide a much wider access [70] (Fig. 56.41b). This extension must remain 6 mm superior to the lateral canthus. Inferior limit of the incision along the lateral orbital rim should not cross the RSTL (resting skin tension lines) to avoid unaesthetic scars.

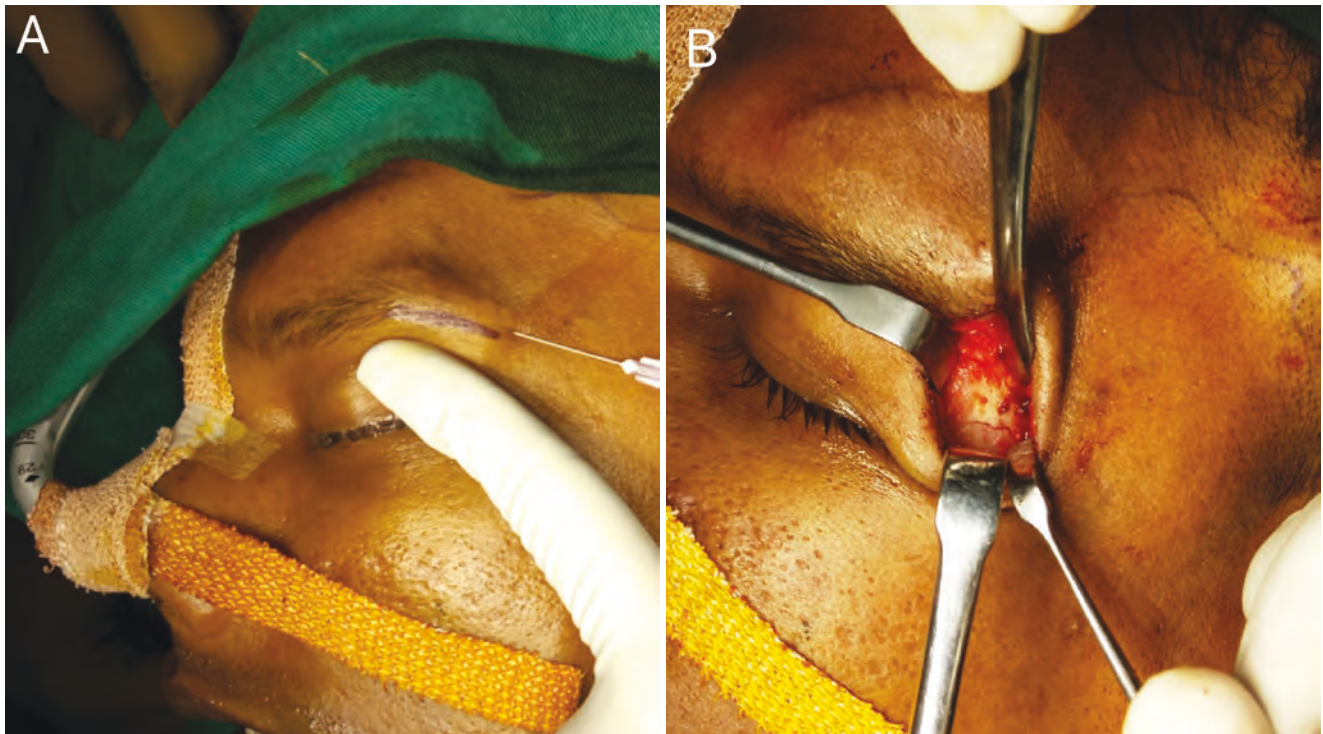
Closure is performed in layers with approximation of the periosteum and subcutaneous tissues (Video 56.2).

56.9.3.2 Upper Eyelid Blepharoplasty Incision (Fig. 56.38)

The upper lid blepharoplasty incision is otherwise called as the *supratarsal fold* or *upper eyelid crease* incision. It offers the most esthetically favorable approach to the fronto-zygomatic suture region. The incision is made along the eyelid crease, 10 mm above the free margin of the eyelid (Fig. 56.41c). As the incision extends laterally, it should be at least 6 mm above the lateral canthus. When eyelid anatomy is distorted with edema or hematoma, the contralateral lid crease measurements are used to mark the incision.

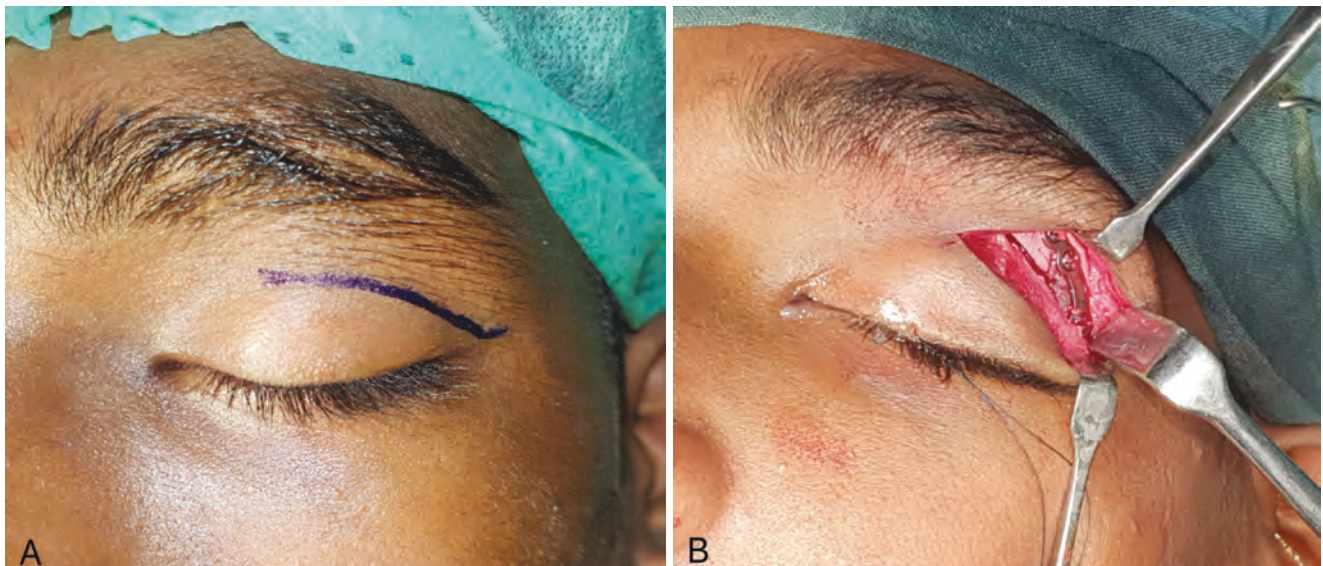The incision is placed through the skin and muscle and is raised as a skin-muscle flap for good viability of the overlying skin. The plane of dissection is below the orbicularis oculi in a superior and lateral fashion to reach the periosteum (Fig. 56.43a, b). The periosteum is sharply incised to expose the bone underneath. Further dissection along the bony margins is strictly subperiosteal; any violation of the periosteum may cause herniation of the lacrimal gland which is present in the superolateral concavity of the orbit. Closure of the incision is done in layers, starting with periosteum, followed by the orbicularis oculi, and the skin.

An important advantage of the upper lid blepharoplasty incision is the extensive access it offers to the entire superolateral aspect of the orbit. It also permits good visualization and access to the spheno-zygomatic suture which is the most important indicator of reduction of ZMC fractures.



©Association of Oral and Maxillofacial Surgeons of India

Fig. 56.42 Lateral brow incision—*intra-operative*. (a) Marking. (b) Exposure



©Association of Oral and Maxillofacial Surgeons of India

Fig. 56.43 Upper lid blepharoplasty *intra-operative*. (a) Marking. (b) Exposure demonstrating ORIF

56.9.3.3 Subciliary Incision [71, 72] (Figs. 56.38, 56.44a and 56.45a, b)

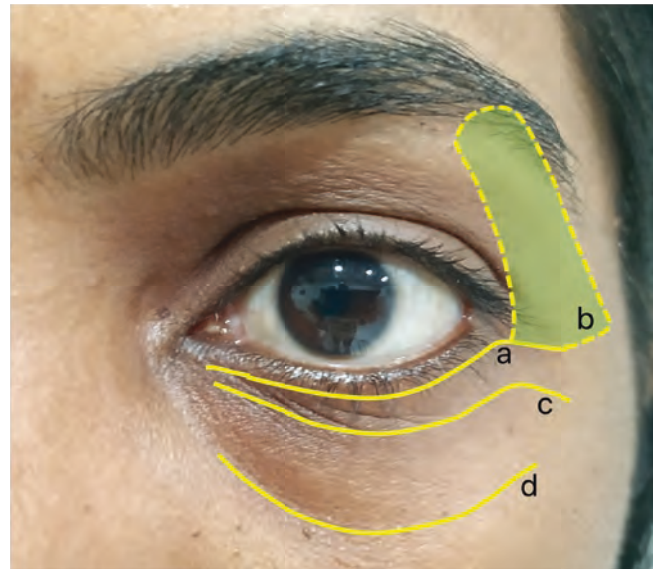
The subciliary incision is a commonly used transcutaneous approach which offers good exposure of the infra-orbital rim along with the entire orbital floor. This may be a very useful approach in the management of ZMC fractures which involve the orbital floor also.

The skin incision is placed along the entire length of the lower eyelid, 2 mm below the level of the eye lashes to conceal the future scar.

The incision must not be extended more than 2 cm lateral to the lateral canthal ligament. This prevents any inadvertent damage to the temporal branch of the facial nerve which is present about 3 cm lateral to the lateral canthal ligament.

Once the skin is incised, the dissection may proceed in three different ways [30, 70] (Fig. 56.45b) (Box 56.9):

- (i) **“Skin-alone” flap technique** where the plane of dissection is along the *subcutaneous plane between the skin of*



©Association of Oral and Maxillofacial Surgeons of India

Fig. 56.44 Lower eyelid incisions. (a) Subciliary. (b) Extended subciliary showing area of exposure shaded. (c) Subtarsal incision. (d) Infra orbital

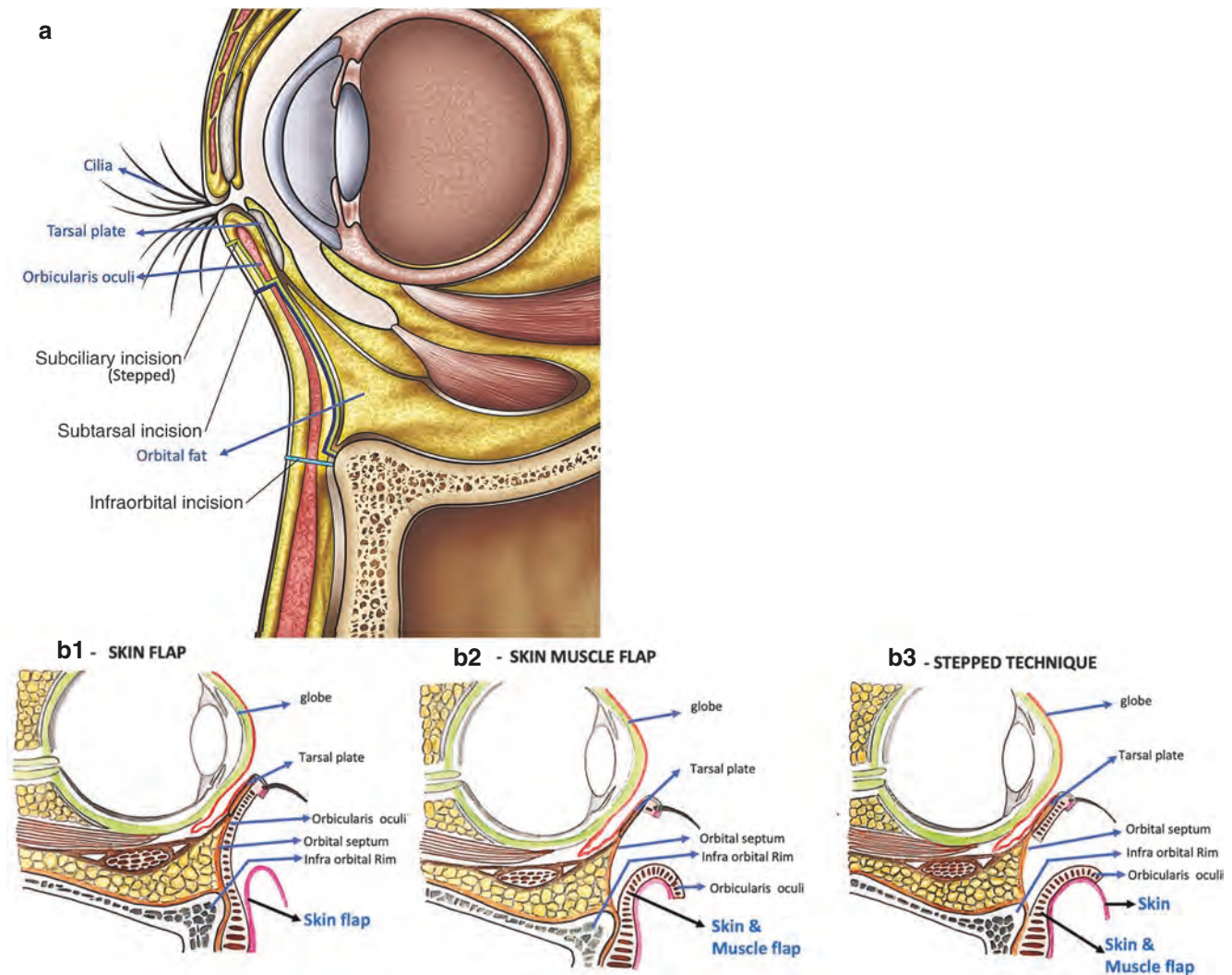
Box 56.9: Comparison of Variants of Subciliary Incisions

	Skin flap	Skin-muscle flap	Stepped skin-muscle flap
Skin incision	2 mm below the cilia	2 mm below the cilia	2 mm below the cilia
Muscle incision	Just below the infra-orbital rim	Same level as skin incision	2–3 mm below the skin incision
Periosteum incision	Just below the infra-orbital rim	Just below the infra-orbital rim	Just below the infra-orbital rim
Plane of dissection	Between skin and orbicularis muscle	Between orbicularis muscle and septum	<ul style="list-style-type: none"> • Stepped • Between skin and orbicularis muscle in pre-tarsal region • Between orbicularis muscle and septum— inferior to the tarsal region
Preservation of pre-tarsal fibers of orbicularis oculi	Preserved	Incised	Preserved
Complications	Skin buttonholing, discoloration	Septal perforation Ectropion Lid shortening Scleral show	Lesser incidence of complications

the eyelid and the orbicularis oculi. On reaching the facial surface of the infra-orbital rim, the orbicularis muscle along with the periosteum is incised to reach the rim. The periosteal incision is generally placed at least 3–4 mm below the level of the infra-orbital rim (Fig. 56.45a and 56.45b1).

- (ii) **“Skin-muscle” technique:** the incision is carried down from the skin into the pre-tarsal fibers of the orbicularis oculi, and the flap is dissected along the *plane deep to the muscle but superficial to the tarsal plate.* The dissection is then carried out superficial to the orbital septum till the rim is reached. Exposure of the rim is performed after sharp dissection of the periosteum just below the level of the rim (Fig. 56.45b2).
- (iii) **“Step” approach** is performed in two different levels and is considered the best approach as it prevents most of the complications which are associated with the two former approaches. The incision is first placed through the skin, and the plane of dissection is carried in the *subcutaneous plane, maintaining the pre-tarsal fibers of the orbicularis oculi.* As the lower end of the tarsal plate is reached, the orbicularis oculi muscle is divided, and the plane is changed to include the muscle along with the skin as a “skin-muscle” flap (Fig. 56.45b3).

The development of a skin-alone flap at the marginal level and a “skin-muscle” flap at the subtarsal level creates a **step** in the plane of dissection. The dissection then proceeds caudally toward the infra-orbital rim in a sub-muscular plane superficial to the orbital septum. On reaching the rim, the periosteum is incised sharply about 3–4 mm below the level of the rim on the facial aspect.



©Association of Oral and Maxillofacial Surgeons of India

Fig. 56.45 Lower eyelid incisions—sagittal view. (a) Subciliary, sub tarsal and infra-orbital (b) Variants of sub-ciliary incision

The incision of the periosteum at this level not only helps preserve the attachment of the orbital septum along the rim margin but also lies above the level of the infra-orbital foramen which is seen about 7–8 mm below the level of the rim. Dissection of the periosteum can be performed along the entire length of the infra-orbital rim, anterior maxilla, and the zygoma to provide excellent exposure.

Advantages of the stepped approach include (1) minimal chances of buttonholing or darkening of the skin due to vascular compromise (2) lesser incidence of ectropion and entropion (3) reduced scarring at the eyelid margins due to preservation of the pre-tarsal orbicularis oculi fibers.

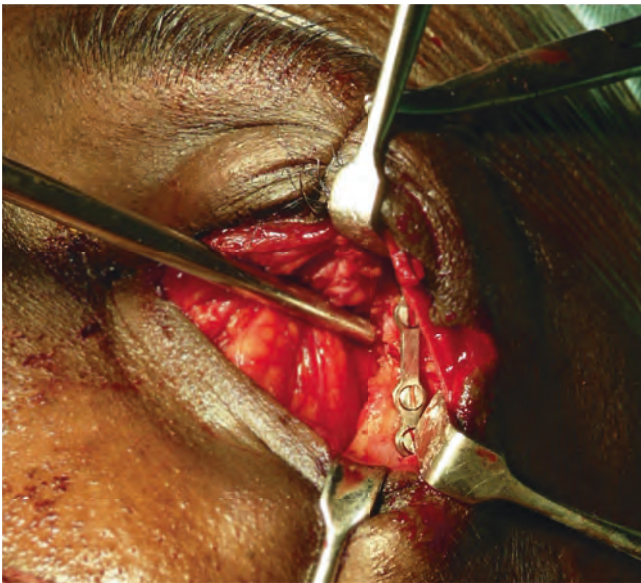
The differences between the three variants of subciliary incision are highlighted in Box 56.9 (Figs. 56.45b).

56.9.3.4 Extended Lateral Exposure with the Subciliary Approach Fig. 56.46 [70]

After placing a standard subciliary incision, supraperiosteal dissection is performed along the lateral orbital rim in the cephalic direction till the FZ suture or a few millimeters beyond (Figs. 56.44b and 56.46). This releases the skin flap and makes it amenable to easy retraction to reach the FZ region. The periosteum is then divided in the center of the lateral orbital rim along its length. In most cases the lateral canthal ligament may be stripped in a subperiosteal fashion to facilitate comfortable access to the FZ suture. This approach may be used to avoid an additional incision for exposure of the FZ suture.

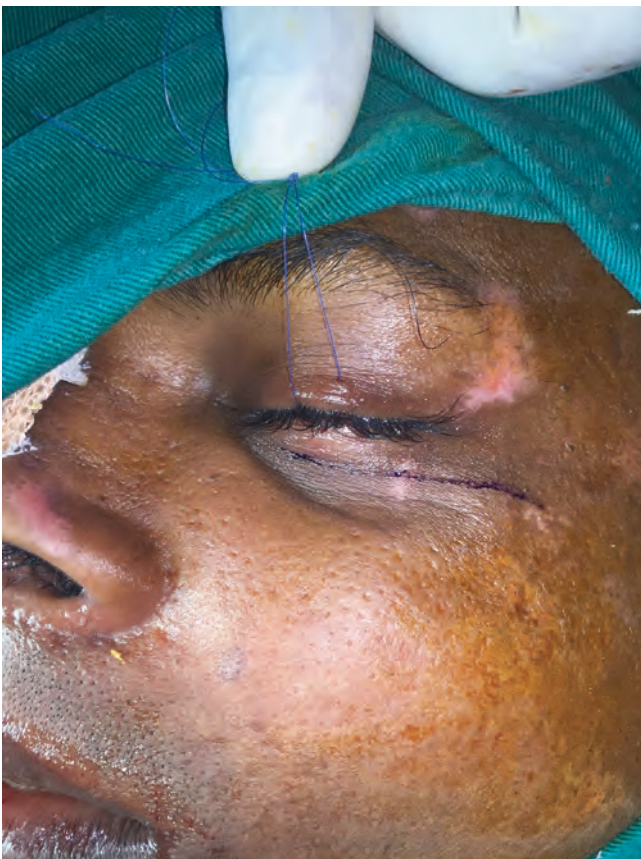56.9.3.5 Subtarsal Approach [73] (Figs. 56.38, 56.44c and 56.47)

Subtarsal or *mid-lid incision* was also described by Converse. The incision is marked 5–7 mm below the inferior lid margin corresponding to the lower border of the tarsal plate, along



©Association of Oral and Maxillofacial Surgeons of India

Fig. 56.46 Subciliary with lateral extension demonstrating exposure of the FZ suture after ORIF



©Association of Oral and Maxillofacial Surgeons of India

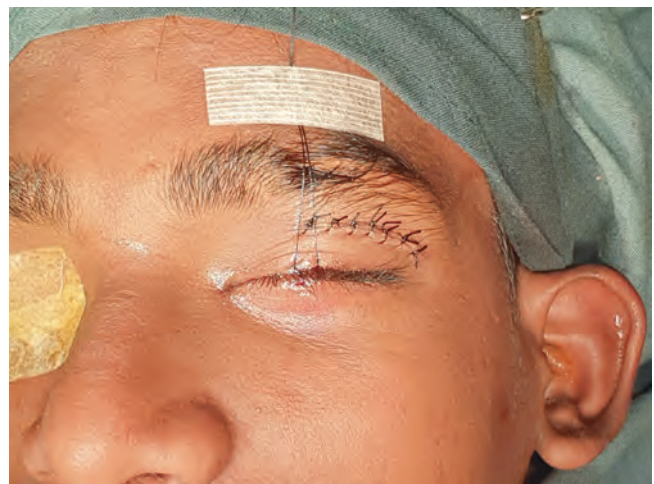Fig. 56.47 Subtarsal marking intra-operative

the subtarsal crease (Fig. 56.47). The lateral extension of the incision may be extended up to 2 cm beyond the lateral canthal ligament similar to the subciliary incision, along one of the resting skin tension lines. The incision is made through the skin and subcutaneous tissue. The *pre-septal fibers of the orbicularis oculi* are also divided at the same level, and the plane of dissection is maintained superficial to the orbital septum. The dissection is carried out caudally to reach the infra-orbital rim, and the periosteum is divided below the level of the rim on the anterior surface of the maxilla and zygoma.

The subtarsal approach is favored more than the subciliary [73] due to its easier technique and lesser incidence of complications (Box 56.10).

Box 56.10: Subtarsal vs. Subciliary Incision

	Subtarsal	Subciliary
Ease of technique	Easy	Technically demanding due to <ul style="list-style-type: none"> • Stepped dissection and closure • Interference of lashes in the surgical field
Time taken for the approach	Quick	Takes almost twice the amount of time
Incidence of scleral show or ectropion	2.7–7.7%	17–42%
Cutaneous scar	More visible	Less visible



©Association of Oral and Maxillofacial Surgeons of India

Fig. 56.48 Figure demonstrates use of frost suture for ZMC fracture approached by transconjunctival and upper lid blepharoplasty incision. *Technique for frost suture.* A 4-0/5-0 nonabsorbable suture on a 3/8th circle needle is passed to engage the inferior tarsal plate, at the middle of the lower eyelid margin. The suture is taken either through the gray line or through the pre-tarsal skin to include the skin, orbicularis, and the tarsus. Appropriate tension is applied in superior direction by the anchoring the suture ends, to the supraorbital skin, 5 mm above the eyebrow using adhesive tapes

An important consideration following lower eyelid approaches is the application of the “frost suture” [74] (temporary lower eyelid suspension suture) (Fig. 56.48), to prevent postoperative ectropion. Frost suture also permits visualization of the globe in the postoperative phase, when required (Refer Fig 11.13).

Nevertheless, lower rim incisions are often associated with postoperative ectropion and scleral show. While scleral show/lid traction refers to abnormal exposure of sclera (1 mm or more) with contact between bulbar conjunctiva and the lid, ectropion refers to eyelid eversion with no contact between bulbar conjunctiva and lid [75]. Ectropion requires correction for cosmetic reasons as well as functional problems arising from keratinization of exposed conjunctiva. Treatment varies from conservative modalities to surgical procedures [76, 77] (Box 56.11).

Box 56.11: Measures to Correct Ectropion and Scleral Show

- *Conservative measures*
Corneal protection measures; artificial tears, ointment, temporary tarsorrhaphy
- *Surgical procedures*
Release of cicatrization, sutures, skin/mucosal grafts, cartilage grafts, rotation flaps

56.9.3.6 Infra-orbital Incision (Figs. 56.38 and 56.44d)

This is performed as an incision which simultaneously divides the skin, orbicularis muscle, and periosteum, along infra-orbital rim. Though the infra-orbital incision offers the

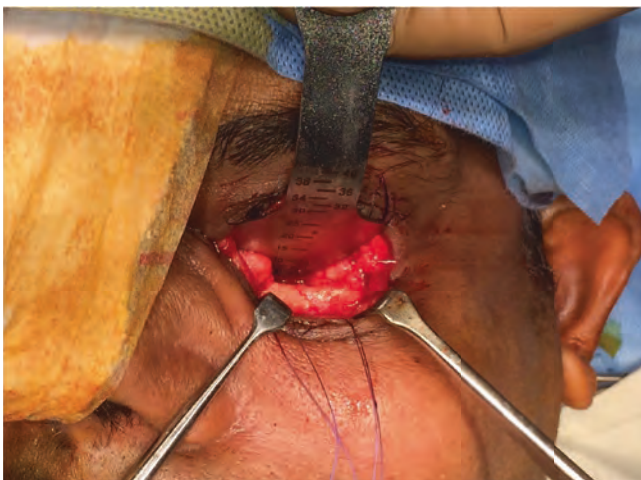
most direct approach to the infra-orbital rim and orbital floor, it is seldom preferred in contemporary surgery due to the unsightly postoperative scar and prolonged edema of the lower lid region due to disruption of lymphatic drainage.

56.9.3.7 Transconjunctival Incision [78, 79] (Figs. 56.38 and 56.49)

Transconjunctival incision has gained popularity because it completely negates the unesthetic scarring associated with skin incisions. This incision offers good access to the infra-orbital rim and SZ regions with either a pre-septal or retro-septal approach. Refer to the Chap. 57 for a detailed description of the approach. The modified transconjunctival incision with a cutaneous Y extension when combined with lateral canthotomy offers excellent exposure to the IOR, SZ, as well as the FZ region [80–82]. The complications of transconjunctival incisions include entropion [82], in-curling of lashes (trichiasis) [83], or growth of the eyelashes in two layers (distichiasis) [84]. Malposed lateral canthus has also been observed following improper repositioning of the lateral canthus after canthotomy [82].

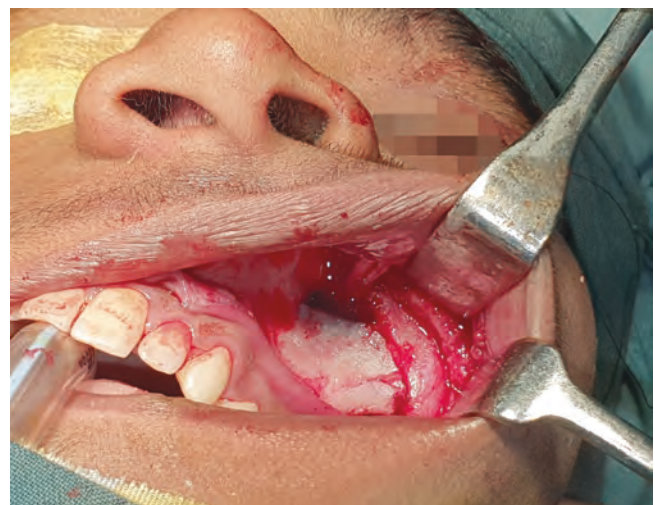56.9.3.8 Vestibular [85] **Incision** (Figs. 56.50 and 55.16)

The vestibular incision is the most frequently used approach to access the ZM buttress. The popularity is due to its application for reduction of ZMC fracture as well as fixation at the ZM buttress. Refer to the Chap. 55 for description of the technique. The author of this chapter (EP) uses the vestibular approach to also fix the zygomatic arch fractures which override at the zygomaticotemporal suture, with transbuccal instrumentation (transoral arch fixation technique) (Refer to recent trends section 56.16).



©Association of Oral and Maxillofacial Surgeons of India

Fig. 56.49 Transconjunctival intra-operative

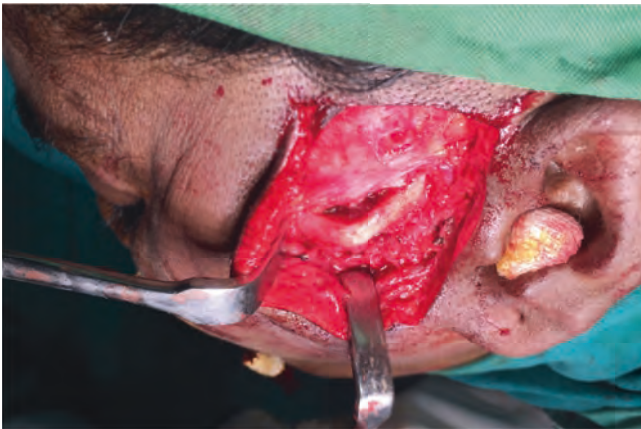

©Association of Oral and Maxillofacial Surgeons of India

Fig. 56.50 Vestibular incision demonstrating fracture at ZM buttress

56.9.3.9 Preauricular [86] (Figs. 56.38, 56.51, 53.17a, b and 65.6) (Refer Video on preauricular approach in Chap. 53)

Preauricular incision is useful for open reduction and fixation of arch fractures. After the routine skin incision, adopting the deep subfascial approach provides better protection to the facial nerve as compared to the other commonly used approaches, namely, the subfascial and suprafascial procedures [87]. Figure 56.51 demonstrates the use of preauricular incision with deep subfascial dissection to expose a malunited zygomatic arch fracture.



©Association of Oral and Maxillofacial Surgeons of India

Fig. 56.51 Preauricular approach demonstrating exposure of malunited zygomatic arch fracture

56.9.3.10 Coronal Incision [88] (Figs. 56.38, 56.52a, b and 85.1)

Tessier introduced the use of coronal incision to access the superior and lateral orbits bilaterally along with naso-orbito-ethmoid complex in congenital facial reconstruction. The approach can be extended with a preauricular incision to include the exposure of the zygomatic body and the arches bilaterally. This incision also facilitates the temporal approach to the SZ suture [82]. Disadvantages of the approach include the extensive length of incision, dissection, temporal hollowing, scar alopecia, risk of injury to the supra-orbital nerve, and temporal branch of the facial nerve.

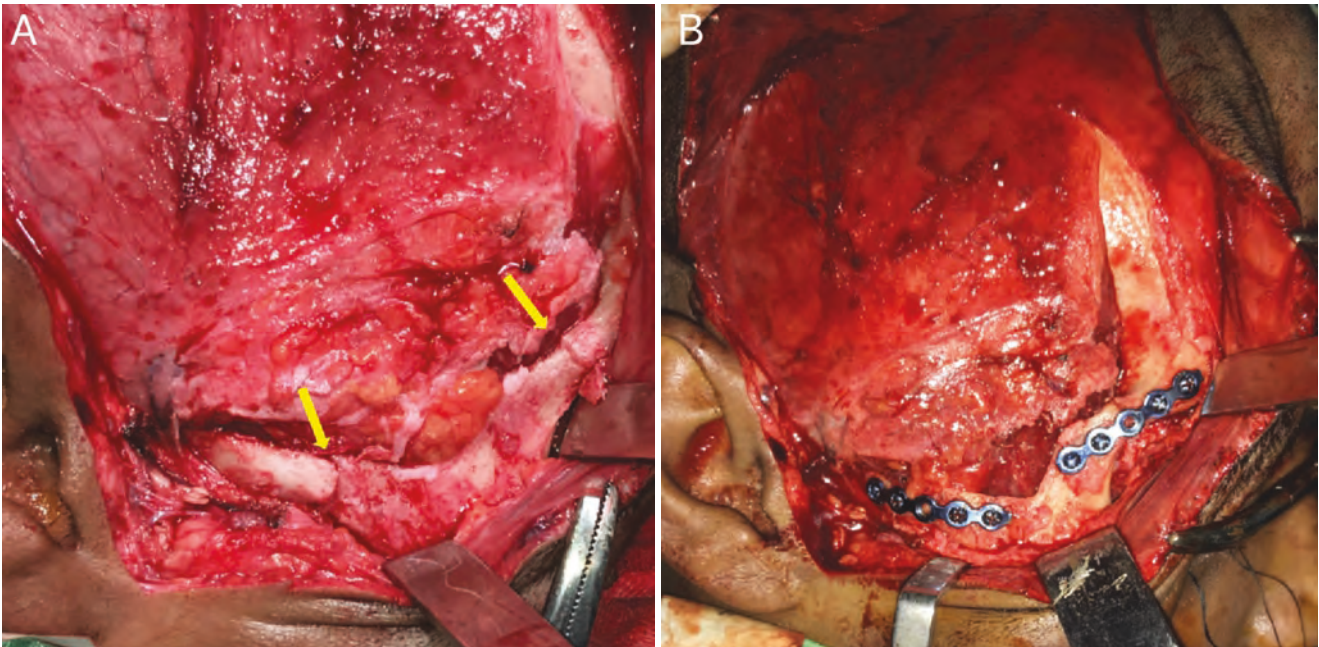
56.9.4 Fixation Methods

Fixation methods for ZMC fractures have evolved through the ages.

Three basic fixation methods are available for ZMC fractures [1] (Table 56.1):

1. Temporary support
2. Indirect fixation and
3. Direct fixation

The trend has gradually shifted from nonrigid fixation methods such as trans-osseous wiring, external pin fixation, and K wires to functionally rigid fixation methods including



©Association of Oral and Maxillofacial Surgeons of India

Fig. 56.52 Coronal approach, intra-operative. (a) Exposure of arch demonstrating fractured zygomatic arch and FZ region (yellow arrows). (b) Arch after reduction and fixation at ZT and FZ region

Table 56.1 Fixation methods for ZMC fractures

	Temporary support	Indirect fixation	Direct fixation
Access to fracture	Fracture is not visualized	Fracture is not visualized	Fracture is visualized by surgical exposure
Fixation technique	Provide support to reduced fragments	Indirectly fixed using anchorage from a distant site	Directly fixed
Modalities	<ul style="list-style-type: none"> • Antral pack • Antral balloon • Silicone wedge • Percutaneous wire with splint (arch) 	<ul style="list-style-type: none"> • Trans-osseous pins (K wire, Steinmann pins) • External fixators • Cranio-zygomatic • Fronto-zygomatic 	<ul style="list-style-type: none"> • Trans-osseous wiring • Miniplates and screws • Microcompressive screws
Advantages	Less surgical morbidity	Less hardware Less invasive	<ul style="list-style-type: none"> • Functionally stable/semi rigid/rigid (lag screw) • Anatomic reduction possible
Limitations	<ul style="list-style-type: none"> • Nonrigid • Not precise • Chances of infection • Poor patient compliance 	<ul style="list-style-type: none"> • Poor patient compliance • Non-precise • Chances of pin track infection • Requires second intervention for removal 	<ul style="list-style-type: none"> • Wiring is nonrigid • Surgical morbidity
Indications	When the surgery must be delayed (eg. compromised systemic status)	<ul style="list-style-type: none"> • Comminuted fractures • Inability to visualise fracture site (Please add bullets for both these points) 	For most fractures, unless contraindicated

miniplates and compressive screws. However, some of the nonrigid fixation modalities are still applicable in certain clinical situations. A brief description of all fixation methods is provided below along with their indications and limitations.


- **Trans-osseous wiring** using stainless steel wires is rarely used in current practice due to its nonrigid mode of fixation that compromises post-reduction stability. However, it still remains a useful technique for fracture reduction by traction, especially at the FZ and IOR. The advantages include minimal periosteal stripping and lesser hardware as compared to use of miniplates and screws.
- **Antral packing** [89] with gauze or balloon/Foley's catheter is used in special scenarios where the ZMC is com-

minuted. But it is an inaccurate technique with high relapse potential and increased possibility of infection.

Antral packing may be done either with a roller gauze pack or balloon. The technique followed for both is similar. The anterolateral wall of the maxilla is exposed by a Caldwell-Luc incision in the vestibule through which the fracture is inspected and manipulated to achieve reduction of the fragments. A trans-nasal antrostomy port is created in the inferior meatus. (refer Sect. 24.10, Fig. 24.24)

- The *medicated ribbon gauze* pack is introduced into the antrum through trans-nasal antrostomy, and one end of the gauze is packed tight in the antrum under direct visualization through the vestibular incision. The oral layer is closed, once the desired level of packing is achieved. The other end which is free is pulled out through the nostril and taped to the cheek. This is later used to retrieve the pack once the healing phase is complete.
- The *inflatable balloon* is positioned within the sinus cavity in a similar manner and verified through the vestibular approach. The balloon is then inflated with about 20cc of saline till adequate support is obtained for the reduced fragments. The vestibular approach is then closed meticulously without damaging the balloon. The balloon is left in situ for the fracture to heal. Removal is accomplished by deflating the balloon and pulling it out through the antrostomy port.
- **Kirchner or K wires and Steinmann pins** [1, 90] (Fig. 56.53a–c) are still popular in some units as they serve as tools of reduction as well as fixation. But these techniques are associated with cutaneous scars and poor patient compliance due to the transcutaneous presence of pins. The noteworthy advantages of external pin fixation are the reduced cost and the possibility of adjusting the fixation in the immediate postoperative period.
- K wires and Steinmann pins constitute an indirect method of fixation whereby the fractured zygomatic bone is fixed in a secure fashion to another stable point in the craniofacial skeleton. Such indirect anchorage may be obtained by using pins (1) to secure the fractured fragment to other stable bones or (2) to provide anchorage for connectors of an external fixator. The different techniques of indirect fixation that have been advocated for management of ZMC fractures include (Fig. 56.54):
 - (A) **Trans-zygomatic**—by this technique, the zygoma is first reduced through an intraoral approach to

Fig. 56.53 Armamentarium for indirect fixation. (a) K wire. (b) Steinmann pin. (c) Manual K-wire driver



©Association of Oral and Maxillofacial Surgeons of India

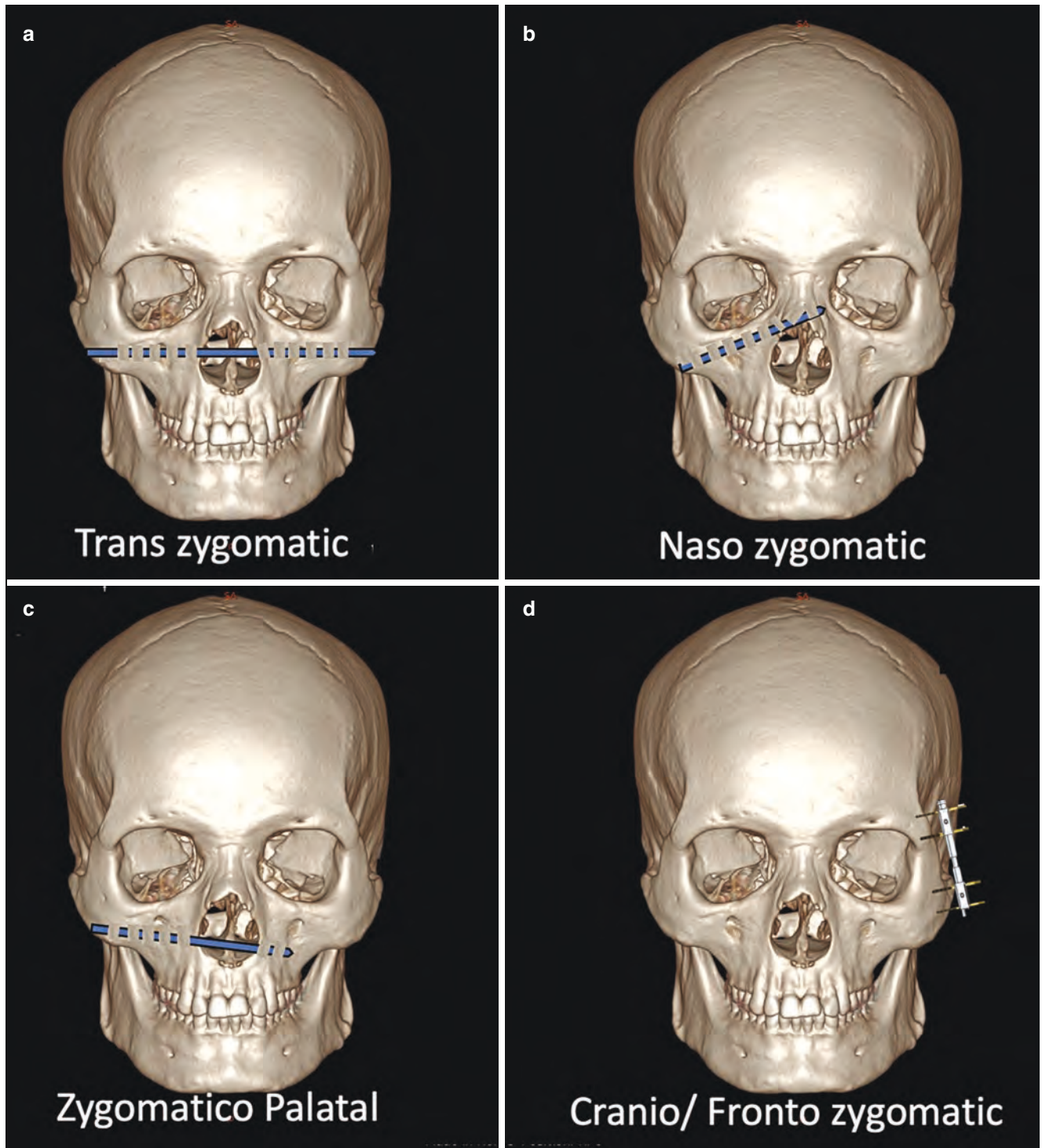
enable adequate visualization of the entry of K wire/pin through the vestibular incision. The reduced ZMC is then stabilized by transfixing it to the contralateral zygoma using a K wire. The K wire is passed from the body of the reduced zygoma in a trans-facial fashion to engage the stable cortex of the contralateral zygoma by the use of a K-wire driver.

- (B) **Naso-zygomatic**—this method involves the use of a K wire to stabilize the reduced ZMC to the frontal process of the maxilla on the contralateral side. The wire is driven from the frontal process of the maxilla in a forward and downward direction to engage the antral surface of the zygomatic body. This must be done with care to prevent any inadvertent damage to the nasolacrimal duct which lies adjacent to the path of pin.
- (C) **Zygomatico-palatal**—this procedure involves fixation of the reduced ZMC to the palatal surface of the contralateral maxilla, by passing a K wire through the reduced ZMC in a downward and oblique direction.

Indirect fixation may also be performed by the use of external fixators or a halo frame that can be

attached to pins for anchorage. This may include the techniques described below.

- (D) **Fronto-zygomatic fixation**: This technique involves the use of a Steinmann pin for anchorage onto the reduced ZMC fragment. The pin is then anchored to another pin which is fixed on the stable orbital process of the frontal bone by the use of an external fixator device.
- (E) **Cranio-zygomatic fixation**: This method is performed in the same fashion as the fronto-zygomatic method, except that the stable component for anchorage is from a halo frame that is cranially anchored, rather than a single pin on the frontal bone.
- **Lag screws** [91] have been found to be an effective alternative at the FZ region because of the additional stability offered by interfragmentary compression. But this technique requires adequate bone stock for fixation.
 - **Micro screws** [92]: Micro screws are 2 mm screws which are used to fix sagittal zygomatic fractures by using the lag screw technique. These screws also reduce hardware (Fig. 56.55a–c).
 - **Miniplates** [3, 4]: The principal method of fixation is miniplate osteosynthesis. Miniplates are chosen based on



©Association of Oral and Maxillofacial Surgeons of India

Fig. 56.54 Techniques for indirect fixation

rigidity requirements, anatomical site involved, presence of bone deficits, and biological considerations pertaining to protection of adjacent vital structures.

Shape of plates: The plates are chosen according to the contour of the bone that needs to be fixed; L plate for the ZM suture and a curved plate for the IOR.

Presence of bone loss: Comminuted fractures or bone loss may result in sagging of overlying soft tissues, especially in the ZM buttress region. This may be negated by using a broad mesh that bridges defects.

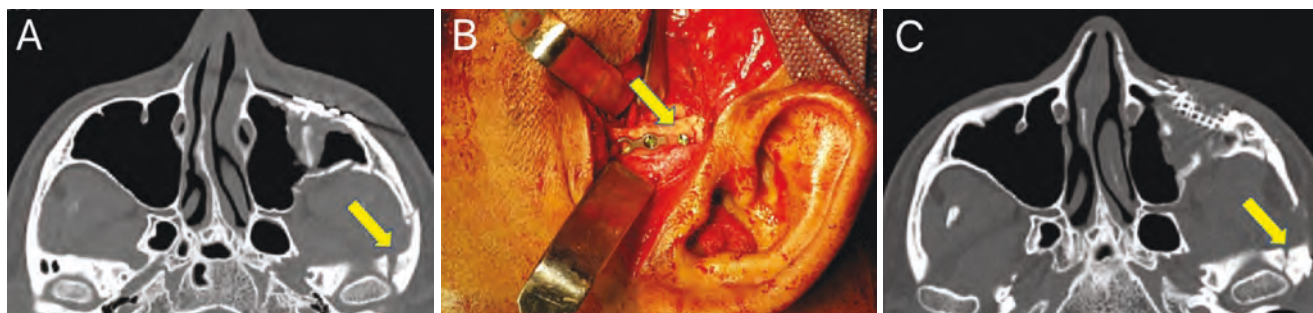
Biological considerations: Care must be taken to protect the roots, infra-orbital nerve and eye during fixation. In regions where the skin is thin, low-profile plates are preferred, 2 mm system for the ZM buttresses and 1.5 mm at the FZ, IOR, arch, and SZ suture [72].

Stability requirements: For ideal stability, screws of 6 mm length with a minimum of two screws on either side of fracture are essential. The only exception being the SZ suture where one screw on either side of the fracture line is adequate.

- *Fixation points:* The number of fixation points is directly proportional to the requirements of stability. Five different possibilities exist (Fig. 56.56a–f):
 - One-point fixation [92] refers to fixation at either the FZ or ZM suture. This has been found to be adequate in resisting post-reduction instability in simple tripod fractures while reducing hardware and surgical exposure.

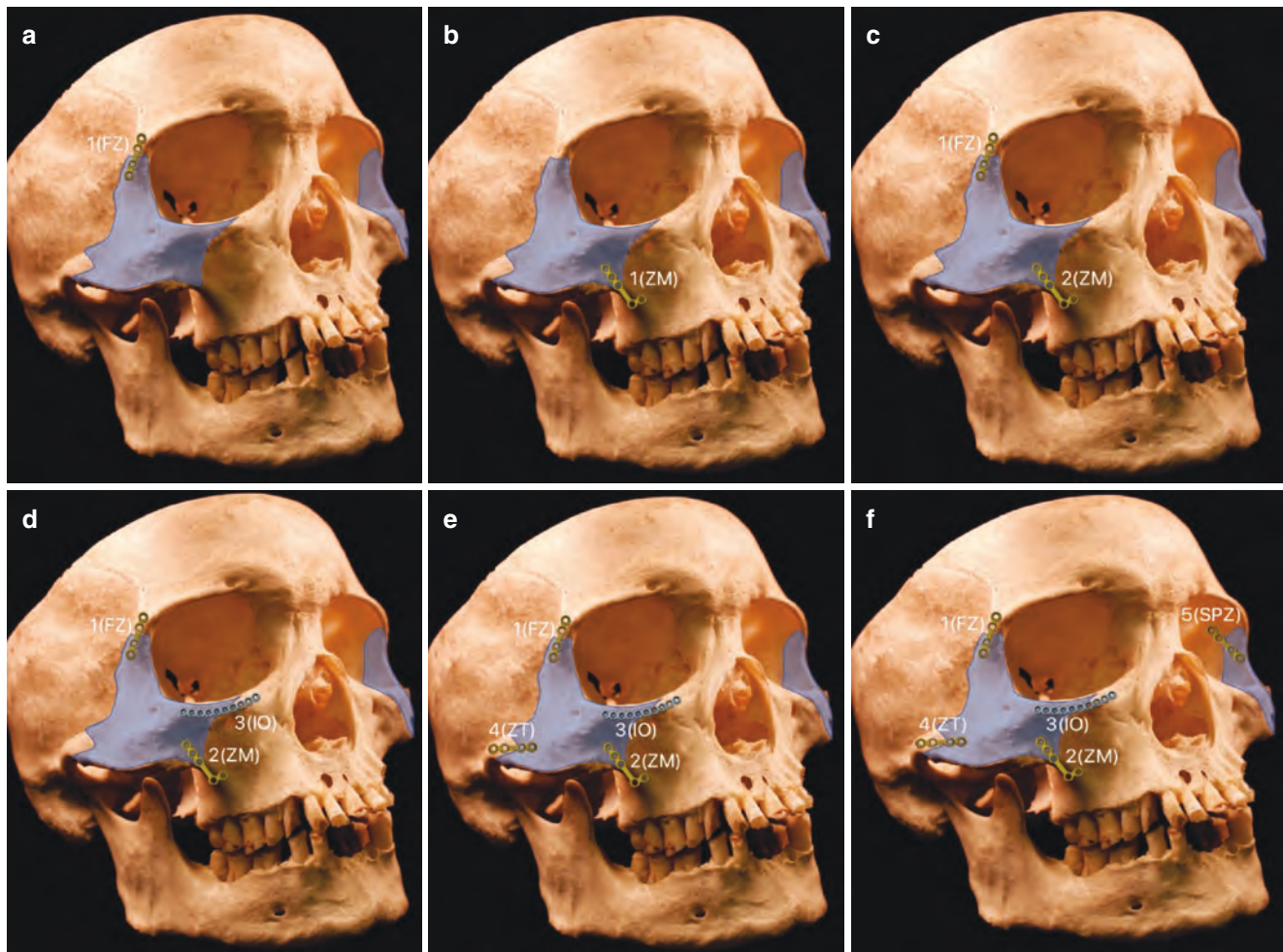
Comparative studies have shown that one-point fixation at the ZM buttress has been found to more advantageous due to many reasons: (1) absence of external scarring; (2) ease of surgical access; (3) unlike the FZ region, adequate soft tissue cover is present; and there are no issues of plate palpability; (4) easier to remove the plate, when needed; and most importantly (5) ZM buttress is a better indicator of zygoma alignment than the FZ region due to the wider area of articulation. However, FZ may be used in fractures with comminuted ZM buttress.

- Two-point fixation indicates fixation at ZM and FZ/ IOR [93, 94].
- Three-point fixation/tripoding includes fixation at the FZ, IOR, and the ZM. A recent meta-analysis indicates that three-point fixation is the most effective in ensuring absolute clinical stability against displacing forces after reduction [94].
- Four-point fixation/tetrapoding [95] involves fixation at the FZ, IOR, arch, and the ZM. This may be indicated in panfacial fractures requiring fixation of the arch to restore the anteroposterior projection of the face (case scenarios 1 and 2).
- Five-point fixation/pentapoding [4] is used to manage severely comminuted or dislocated ZMC fractures wherein the SZ suture is also fixed, in addition to the other four sites of fixation. The SZ fixation may be performed either through a temporal or an intra-orbital approach



©Association of Oral and Maxillofacial Surgeons of India

Fig. 56.55 Fixation of zygomatic arch fracture with microcompressive screws a, b, and c. (a) Preoperative CT showing diastasis at the zygomatic root. (b) Intra-operative picture showing arch fixation with screw. (c) Postoperative CT showing adequate fracture reduction and screw fixation



©Association of Oral and Maxillofacial Surgeons of India

Fig. 56.56 Types of fixation using miniplates. (a) One-point fixation at FZ suture; (b) one-point fixation at ZM buttress; (c) two-point fixation; (d) three-point fixation; (e) four-point fixation; and (f) five-point fixation (the 5th articulation (SPZ) of the right is unseen and hence is depicted on the contralateral side for better understanding)

- ZMC fractures requiring orbital reconstruction [59]: irrespective of the type of fixation, when ZMC fracture is associated with orbit, the orbital rims are fixed first. This is important because it is safer and easier to gauge the depth of orbital dissection from the restored infra-orbital rim and also to facilitate floor reconstruction [66] (case scenario 2). Also, the size of the orbital defect is better assessed when the rims are aligned.

- **Bio-resorbable plates** [96, 97]

Though titanium miniplates are more commonly used to fix ZMC fractures, substantial clinical success has been obtained with use of bio-resorbable plates. They offer comparable post-reduction stability along with the added advantages of preventing thermal sensitivity and avoiding

the need for second surgery to remove plates. Limitations associated with bio-resorbable plates are its technique sensitivity and increased operating time.

56.9.5 Fixation of Zygomatic Arch

The ORIF of arch fracture is indicated when the fragments are unstable after closed reduction and in cases where re-establishment of sagittal projection of face is needed. Fixation may be performed by one of the three methods, based on the fracture pattern (Fig. 56.57a, b, c): (1) a mini-plate for an arch demonstrating a single fracture line (Fig. 56.52b), (2) a spanning adaptation plate (Fig. 56.62b)

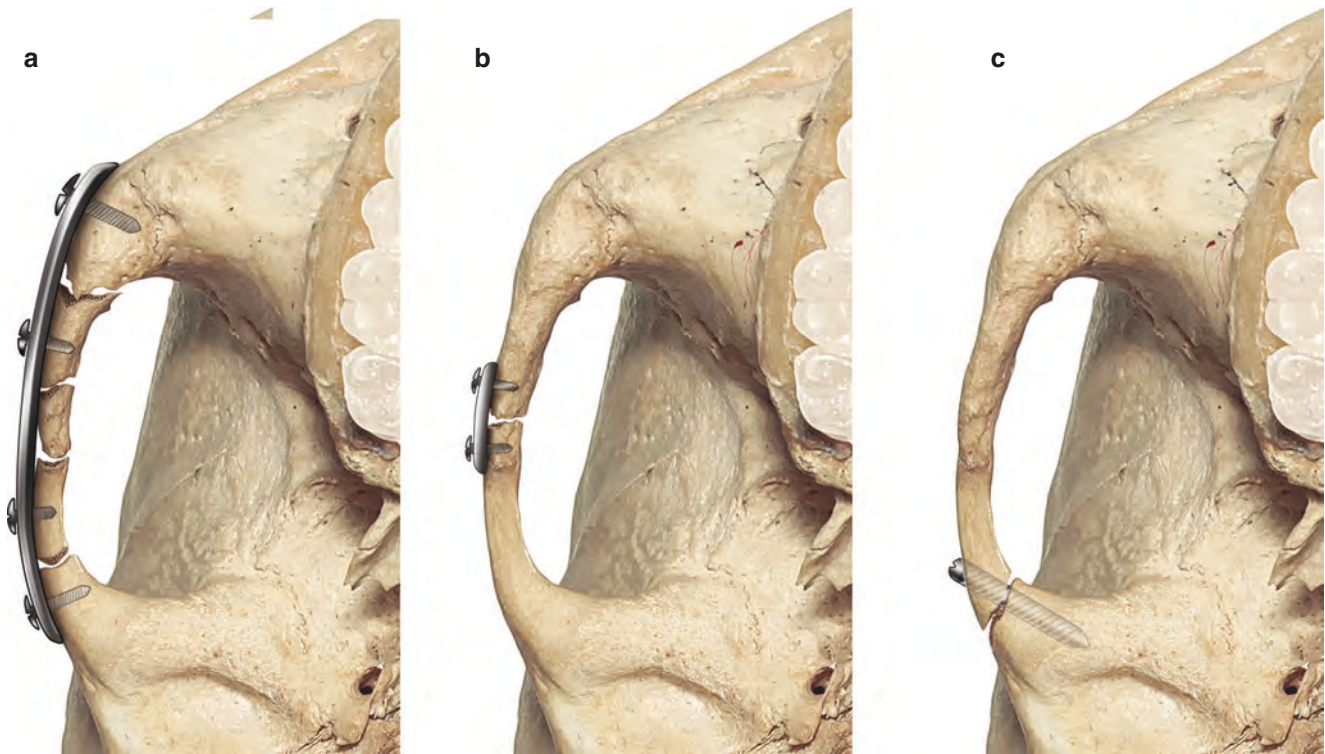
when the arch is multi-fragmented [98], and (3) a micro screw for an outfractured root or sagittal fracture of the arch [99] (Fig. 56.55). Kim et al. proposed plating on the superior surface of the upper border as an alternate line of arch fixation which negated the drawbacks associated with the conventional fixation [100] (Fig. 56.57).

The various changes that may be a sequel to wide subperiosteal dissection of the midface include (1) cheek ptosis, (2) descent of the lower eyelid skin and infra-orbital hollowness, (3) loss of malar prominence due to inferior displacement of the malar fat pad, and (4) exaggeration of the nasolabial fold [101].

56.10 Soft Tissue Resuspension [101, 102]

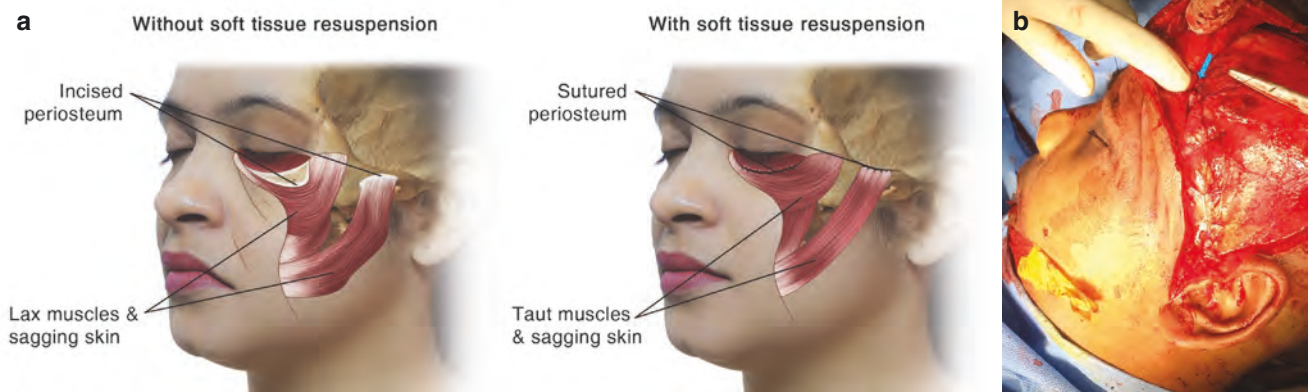
Accurate reduction and fixation of ZMC fractures frequently necessitates the use of multiple incisions on the midface which deglove the entire periosteum-muscle-fat complex of the midface and zygoma. Failure to re-approximate the dissected tissues may lead to undesirable changes in the soft tissue projection and form.

Over the years many authors have documented these undesirable changes and proposed soft tissue resuspension methods to minimize them. This can be achieved by various methods (Fig. 56.58a): (1) re-approximating the incised periosteum using absorbable sutures, (2) by suspending the periosteum using heavy absorbable or nonabsorbable sutures to a drill hole placed in a superiorly positioned bony landmark



©Association of Oral and Maxillofacial Surgeons of India

Fig. 56.57 Different fixation options for zygomatic arch fractures. (a) Adaptation plate. (b) Miniplate. (c) Compressive screw



©Association of Oral and Maxillofacial Surgeons of India

Fig. 56.58 Soft tissue resuspension. (a) Graphical representation. (b) Resuspension of temporal soft tissues to deep temporal fascia (blue arrow)

such as the orbital rim [103], (3) resuspension of lateral facial and temporal soft tissues to the deep temporal fascia in the temporal region [104] (Fig. 56.58b), and (4) prophylactic endoscopic midface lift [101].

56.11 Postoperative Care

Following reduction of ZMC fractures, with or without fixation, the following measures are taken to maintain post-surgical stability and prevent soft tissue complications (Box 56.12):

Box 56.12: Postsurgical Care

- Soft diet
- Protection of surgical site and eye
- Frost suture
- Post-op sinus regimen
- Periodic assessment of vision
- Anti-edema measures
- Anti-emphysema measures
- Physiotherapy (eye and mouth opening)

- Soft diet: Patients managed with conservative methods are advised soft diet for a period of 2 weeks.
- Protection of surgical site: The reduced zygoma or the arch must be protected with a tape labelled “do not touch” to provide cognitive input to the patient and people around.
- Frost suture: This temporary suspension suture is maintained for 3–5 days in any patient undergoing an inferior eyelid approach for the prevention of ectropion.

- Post-op sinus regimen [105]: A sinus regimen including prophylactic antibiotics for sinus coverage and decongestants is advocated by some authors.
- Periodic assessment of vision [66]: Periodic ophthalmic examination for the first 2 postoperative weeks is mandatory, in an awake patient. In an unconscious patient, it is achieved by swinging flashlight test or VEP (visual evoked potential).
- Anti-edema measures: Head end elevation must be maintained to prevent facial edema.
- Anti-emphysema measures, such as avoiding nose blowing [106].
- Protection of eye with ophthalmic ointments.
- Physiotherapy to prevent postoperative trismus: Postoperative trismus is a common phenomenon following ORIF of ZMC fractures due to hematoma, reflex muscle spasms, and fibrosis. Measures such as physiotherapy, forced mouth opening using gag [107], and kinesiology tapes [108] may be used to improve mouth opening.
- Eye movement exercises are encouraged to facilitate resolution of edema and expedite restitution of movements [66].

56.12 Pediatric Considerations

56.12.1 Nonsurgical vs. Surgical Intervention [109]

The incidence of ZMC fractures is high in pediatric population due to its prominence [109]. In children, most authors favor a “nonsurgical” management or “reduction without fixation” of ZMC fractures due to concerns regarding “surgery/implant-induced” growth disturbances of

facial skeleton and injury to teeth. However, literature supports ORIF of zygoma fractures which are grossly displaced or unstable after reduction. This is very important in pediatric population to (1) correct the facial asymmetry which may cause psychological impact, (2) restitute normal mouth opening to permit mastication, and (3) restitute globe position and function to enable normal vision and prevent development of phthisical eye or hypoplasia of zygoma, in the future.

56.12.2 Approaches and Fixation Principles

The preferred approaches include vestibular and lateral brow with minimal soft tissue dissection. Literature suggests one-point fixation at FZ region as adequate for pediatric ZMC fractures because of the short lever arm forces between the FZ and IOR [110]. But current studies have demonstrated that two-point fixations provide adequate stability and are associated with the least complication rates when compared with one and three-point fixations. Similarly, fixation at the zygomaticomaxillary buttress had the least complications when compared against the fronto-zygomatic and infra-orbital fixations [111]. In contrast, Defazio et al. proposed that plating at the FZ and IOR may be done conveniently in children below 6 years without any risk of damage to tooth buds [112].

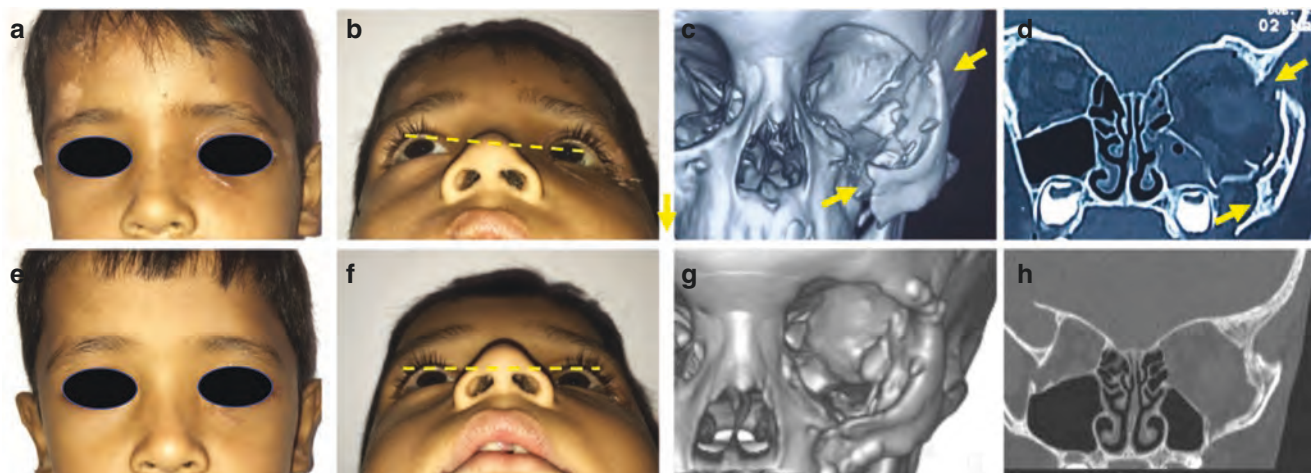
56.12.3 Osteosynthesis Methods

Fixation techniques prior to year 2000 advocated titanium miniplates for pediatric midface. However they must be removed after 2 months to prevent any growth disturbances, plate migration, or burying of plate due to bone apposition. Microplates and self-drilling screws are also reported to give adequate stability and fixation in this age group without compromising vital structures [110]. Alternatively, bio-resorbable plates may be used which became popular after year 2004 to negate the need for re-surgery for plate removal [113]. Figure 56.59a–f shows a case of displaced zygoma fracture in a 5-year-old boy managed by ORIF. The plates were removed after 2 months.

56.13 Malunited ZMC Fractures [114]

Malunion of the zygoma may be a sequel to two clinical scenarios, (1) a neglected ZMC fracture which was never treated and (2) an improperly treated fracture. The protocol for the management of the malunited zygoma is based on the type of deformity which may be either cosmetic or functional. The protocol followed by the author is demonstrated in Fig. 56.60.

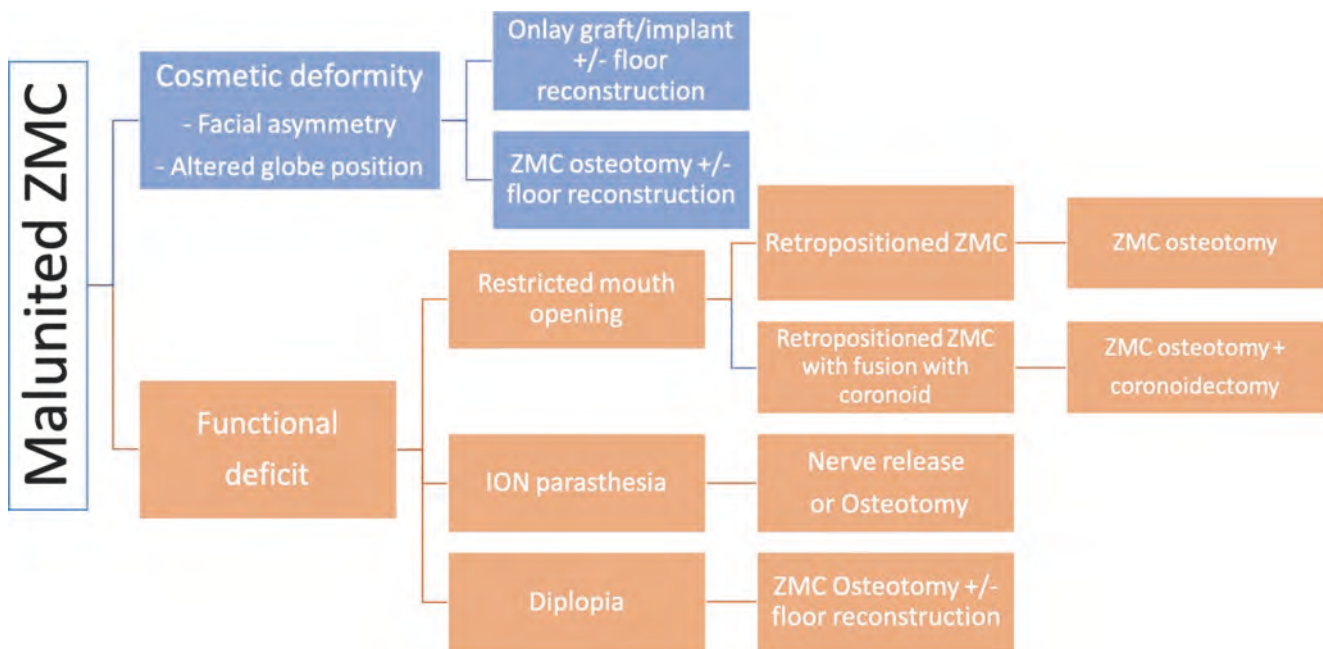
Deformities producing aesthetic concerns may again be subdivided into those demonstrating facial asymmetry or those showing altered globe positions.



©Association of Oral and Maxillofacial Surgeons of India

Fig. 56.59 ZMC fracture management in a pediatric patient. (a) Frontal view of patient with left-sided ZMC fracture. (b) Basal view demonstrating loss of facial projection and enophthalmos of left side. (c) Preoperative 3D CT image demonstrating en bloc displacement of ZMC. (d) Preoperative coronal section demonstrating separation at FZ

suture and lateral displacement of the body of zygoma. (e) Postoperative frontal view. (f) Postoperative basal view demonstrating restoration of facial projection and enophthalmos correction. (g) Postoperative 3D CT. (h) Post-operative coronal section



©Association of Oral and Maxillofacial Surgeons of India

Fig. 56.60 Management of malunited ZMC fracture—algorithm

- The patients with asymmetries involving only the malar or infra-orbital regions with no functional deficits can be treated with onlay grafts which may either be autogenous in nature (rib, iliac crest, calvarium) or alloplastic (Medpore, PEEK (polyether ether ketone), etc.) (Fig. 56.61).
- Patients demonstrating gross facial asymmetry along with orbital dystopia and/or anti-mongoloid slant of the palpebral fissure may not be amenable to treatment with onlay augmentations. In such cases, a conventional osteotomy (re-fracture) and repositioning of the zygomatic complex is advocated (case scenario 2).
- When either of the deformities are associated with large floor defects, they require concomitant orbital floor reconstructions.

Functional deficits secondary to malunited ZMC fractures essentially fall into three categories; Restricted mouth opening, parasthesia and diplopia.

- Restricted mouth opening due to retropositioned zygoma/arch which either (1) forms a mechanical obstacle to mandibular translation or (2) fuses to the coronoid process of the mandible (extra-articular ankylosis) (Fig. 56.62a, b). The choice of treatment in these patients is dictated by the presence or absence of fusion (bony/fibrous); ZMC osteotomy, and repositioning alone are indicated in the absence of fusion, while presence of fusion mandates additional coronoidectomy [8, 115].
- Paresthesia over the infra-orbital nerve (ION) distribution: The entrapment of the ION or constriction of the

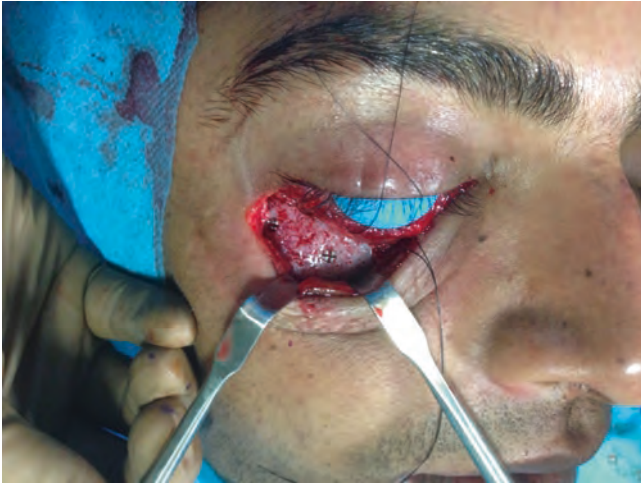infra-orbital foramen is not an uncommon finding. The first line of management in these patients is to perform a nerve release by an osteotomy around the infra-orbital foramen or by repositioning of the ZMC when it is compressing the nerve.

- Diplopia: The major cause for diplopia in ZMC fractures may either be gross displacement of the ZMC or mechanical restriction due to entrapment of orbital soft tissues (muscle, orbital septum, or fat) with resultant fibrosis or adhesions. Correction in these instances is achieved only by an osteotomy along with release of the entrapped tissues. These patients may also require orbital floor reconstructions if they present with floor defects that are large (>2 cm² in area). Non-resolving diplopia may be subjected to management with prism glasses and/or strabismus surgery.

56.14 Bilateral ZMC Fractures

Bilateral fractures of the ZMC are a rare occurrence and present more difficulty in achieving adequate reduction. In contrast to unilateral fractures where the normal side is used as a guide to achieve symmetry on the fractured side, bilateral ZMC fractures are complex in management. Two options exist: (1) reducing the less displaced or comminuted side first and using it as a reference for the more displaced side [116]. This may however result in compromised results, if three- or four-point fixation is not achieved, and (2) meticulous preoperative planning [43] by virtual surgical procedure

to achieve the ideal facial width and projection. This involves a sequence of segmenting and virtually repositioning the fracture fragments to the “best possible fit” position. Once this is completed, the stents for intra-operative guidance can be generated.



©Association of Oral and Maxillofacial Surgeons of India

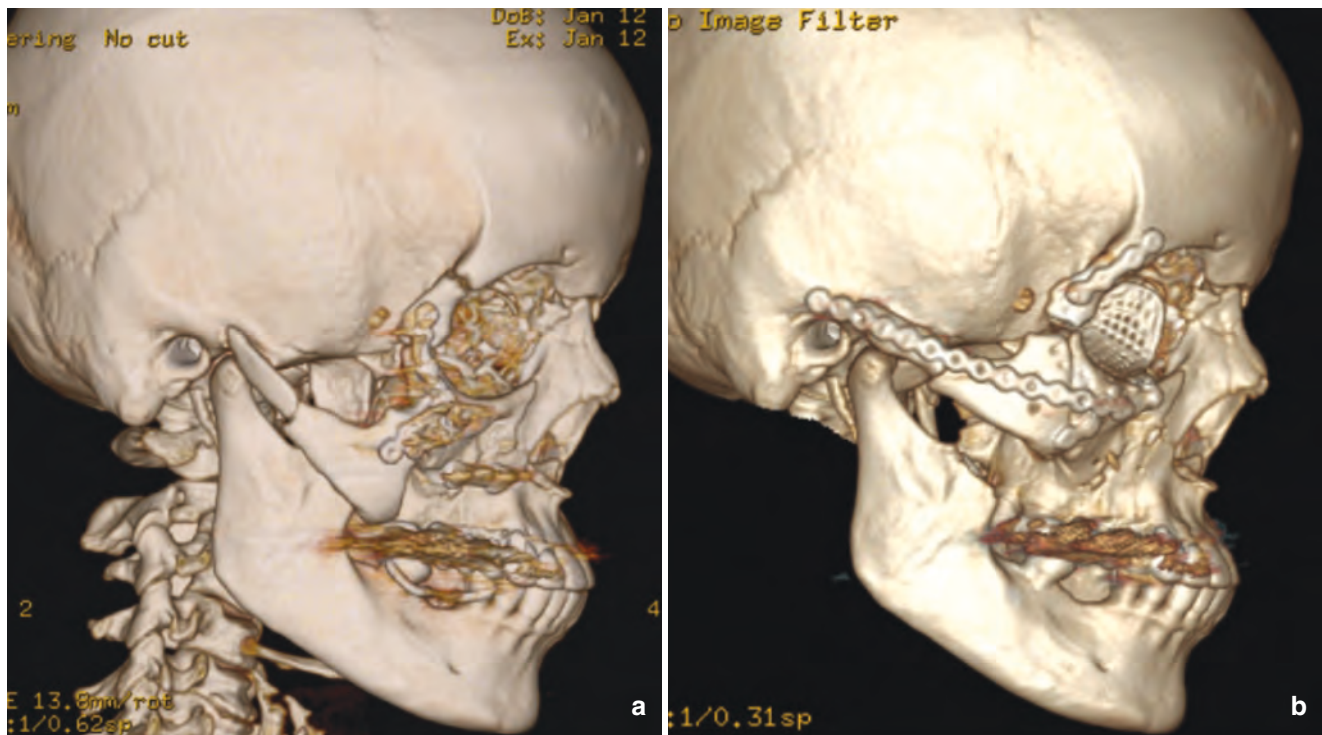
Fig. 56.61 Use of Medpore onlay for malunited fracture

56.15 Complications of ZMC Fractures [3–5]

The incidence of postoperative complications increases with certain risk factors such as severe displacement, presence of sinus infection, and compound/comminuted ZMC fractures [37].

The various complications specific to surgeries of the ZMC may be categorized as intra-operative, immediate post-operative, and delayed postoperative complications.

- **Intra-operative complications:** Commonly encountered intra-operative complications are bradycardia and bleeding. *Bradycardia due to oculocardiac/trigemino-cardiac reflex* occurs typically during elevation of the ZMC [117]. Manipulation of zygoma stimulates the trigeminal nerve which subsequently stimulates the vagus nerve, due to the neuronal interconnections between them. Vagal stimulation is cardioinhibitory and hence results in bradycardia of varying degrees. This complication can be prevented by identifying risk factors and administering prophylactic vagolytic agents or minimizing nerve stimulation by administering regional blocks. However, management of bradycardia after its onset involves temporary cessation of manipulation and or medical management with atropine or epinephrine [64].



©Association of Oral and Maxillofacial Surgeons of India

Fig. 56.62 Coronoidectomy for malunited ZMC fracture. (a) Pre-operative scan showing malunion of the right ZMC with fusion of the body of zygoma and coronoid process, and (b) post-operative scan demonstrating reduction and fixation of the right zmc with ipsilateral coronoidectomy.

Brisk intra-op bleeding can occur due to the sudden rupture of vessels (mainly infra-orbital artery) during reduction.

- **Immediate postoperative complications:** In the immediate postoperative phase, the adverse effects range from maxillary sinusitis, meteorosensitivity [3] (discomfort arising due to change in weather conditions) to infra-orbital nerve paresthesia, diplopia, blindness, and SOF syndrome. The incidence of postoperative infra-orbital nerve paresthesia is higher with ZMC fractures which demonstrate more rotation, displacement, and comminution [118]. Interestingly, recovery from post-trauma ION paresthesia shows better prognosis with reduction and fixation due to de-compression on the nerve. Blindness following surgery may arise either due to direct injury to optic nerve by impingement of fracture fragments or hemorrhage into the optic sheath/retro-bulbar hemorrhage (Refer Fig. 56.16) producing nerve compression [119].
- **Delayed post-op complications** commonly witnessed include enophthalmos and hypophthalmos due to inadequate reduction or inadequate fixation. Oroantral fistula [120], TMJ dysfunction [121], and ankylosis of zygoma to coronoid process, referred to as Jacob's disease [1, 122], are also recorded in literature.

56.16 Recent Trends

Fractures of the ZMC are notorious for their sub-optimal outcomes due to over or under reductions. This may be attributed to difficulty in simultaneous visualization of its multiple articulations without increasing surgical morbidity due to additional exposures.

Technological advancements in the recent years have added ease as well as predictability to the reduction and fixation of these fractures while minimizing surgical morbidity. The most popular methods in contemporary surgical management are discussed below.

1. **Intra-operative reduction and fixation templates** [123]
This has been discussed earlier under the section for preoperative planning.
2. **Computer-assisted patient-specific implants (PSI)** [42]: Another method for improving intra-operative accuracy is the use of virtual surgery to plan for reduction of the fracture and design patient-specific implants (PSI). These PSI designs are then printed using a 3D printer which can double up as intra-operative reduction guides also. Refer to section 57.13.2 in Chap. 57 for additional information
3. **Intra-operative navigation** [124]: Intra-operative navigation is an excellent method for obtaining intra-operative guidance for precise reduction. Refer to Chap. 41. "Computer-assisted navigation surgery in oral and maxil-

lofacial surgery" for additional information. The margin of error with use of intra-operative navigation is less than 1.2 mm with accurate restoration of facial symmetry. A case of deformity secondary to ZMC fracture treated using intra-operative navigation is illustrated in Fig. 56.63.

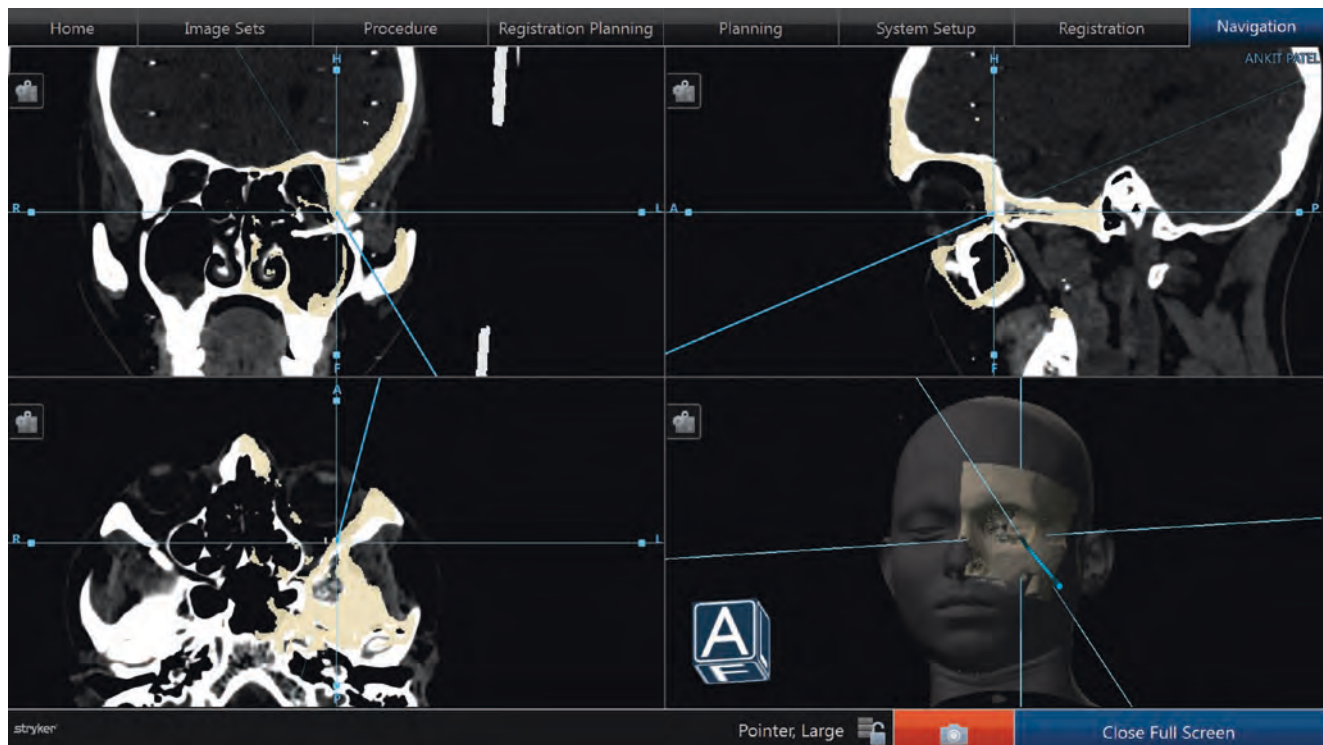4. **Intra-operative imaging:** Intra-operative imaging greatly improves the accuracy of intra-operative fracture reduction. The various imaging modalities that are available include ultrasound, conventional C-arm (videofluoroscopy), and intra-operative CT. The quality of imaging with videofluoroscopy is not accurate in reflecting the complex anatomy of the cranio-facial skeleton. This makes intra-operative CT a more accurate and reliable tool. However, the associated radiation doses may be a concern. This has been surmounted with the advent of the intra-operative CBCT devices [125]. This device has the significant advantages of portability, ease of use, increased accuracy, and reduced radiation exposure.
5. **Transbuccal Arch Fixation:** A technique involving intra oral reduction of zygomatic arch and its fixation by transbuccal instrumentation has been described by Panneerselvam et al for fractures of the zygomatic arch which are displaced at the zygomatico temporal articulation. This technique minimises the potential morbidity associated with the coronal approach which is commonly used for ORIF of zygomatic arch [126].

56.17 Conclusion

The ZMC fracture is one of the most complex fractures to reduce and fix, because of its propensity to undergo displacements in all three planes of orientation, along its five articulations. Accurate reduction is challenging due to the difficulty in intra-operative assessment of reduction, inability to predict the rotation of the zygoma during reduction, and complexity involved in concomitant orbital fractures.

The surgical objectives must include (1) choice of incisions which provide maximal exposure with minimal morbidity, (2) increase in number of fixation points with increase in severity of fracture displacement, (3) achieving three-dimensional stability of ZMC complex and minimizing post-reduction complications, and (4) resuspension of overlying soft tissues to prevent sagging.

Preoperative planning and intra-operative imaging play a great role in improving accuracy of fracture reduction while minimizing surgical exposure and post-reduction complications.



©Association of Oral and Maxillofacial Surgeons of India

Fig. 56.63 Intra-operative navigation for ZMC fracture. Multiplanar sections demonstrating superimposition of patient CT (white) and surgical Plan (pink) with use of intra-operative navigation to verify position during surgery (blue pointer)

Acknowledgment The authors would like to acknowledge the efforts of the postgraduate trainees Dr. Vijitha and Dr. Logitha Sri towards the illustrations.

56.18 Case Scenarios

Case Scenario 1: Fracture of right ZMC (Fig. 56.64)

Patient: 21-Year-Old Male, with History of RTA

Preoperative CT (Fig. 56.64a, c) showing right-sided fracture of the ZMC and arch with undisplaced frontal bone.

The sections demonstrate:

- Medial displacement with reduction of the transverse dimension of the face
- Diastasis at the FZ and ZM sutures
- Overriding of fragments at the IOR and SZ suture
- Medial displacement of the right zygomatic arch

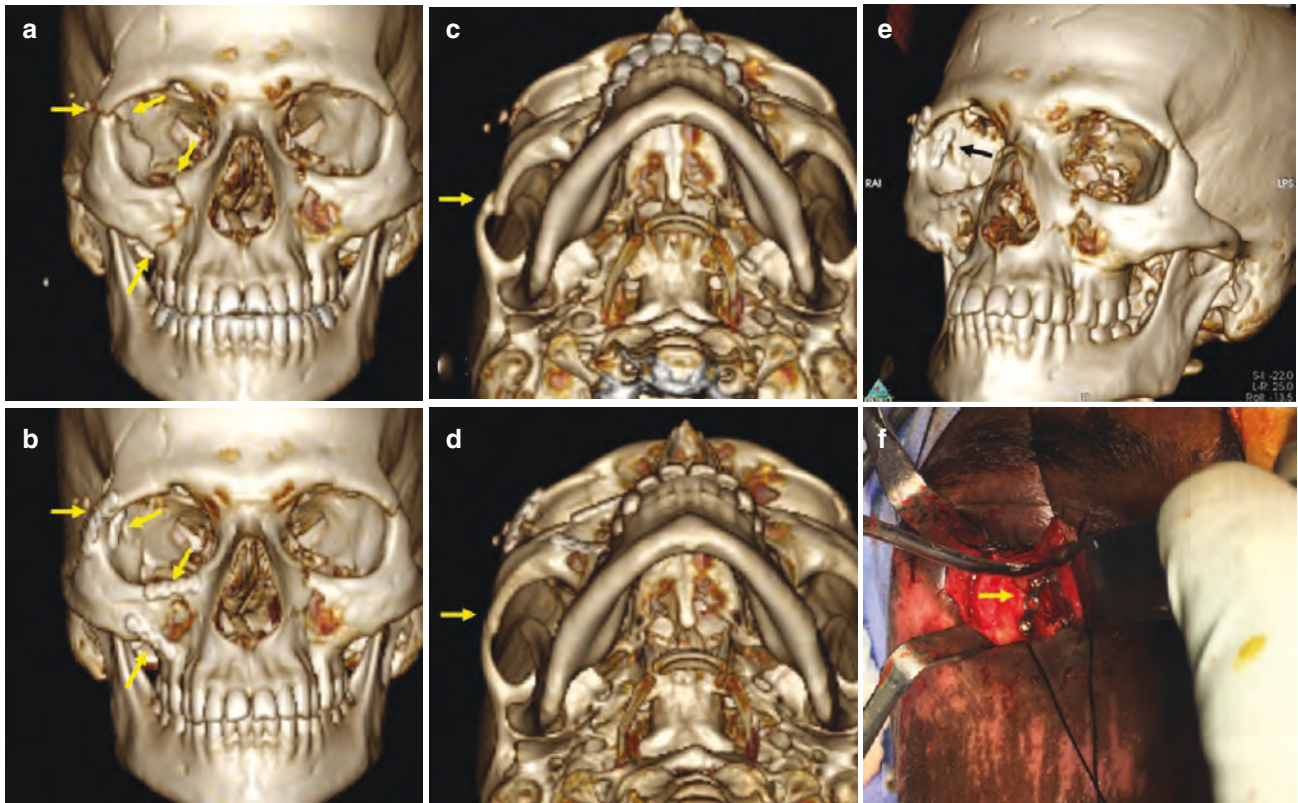
Surgical plan: Reduction of ZMC fracture with four-point fixation

Surgical procedure:

- The exposure of fracture sites was done by:
 1. Trans-conjunctival incision with extended lateral approach
 2. Intraoral buccal sulcus approach
- Reduction of ZMC fracture and arch fracture by Balasubramaniam's approach
- Four-point fixation of fracture was performed at FZ, IOR, ZM, and SZ (Fig. 56.64f) regions with miniplates

Postoperative CT (Fig. 56.64b, d, e):

CT demonstrating optimal reduction of fractured ZMC and arch. The successful surgical outcome may be appreciated by the approximation and fixation at the SZ suture, which is the most reliable indicator of accurate ZMC reduction.



©Association of Oral and Maxillofacial Surgeons of India

Fig. 56.64 Case scenario 1. (a) Preoperative 3D CT-frontal view demonstrating fractures. (b) Postoperative 3D CT-frontal view demonstrating fixation. (c) Preoperative 3D CT-basal view demonstrating arch

fracture. (d) Postoperative 3D CT-basal view demonstrating arch reduction. (e) Postoperative 3D CT demonstrating fixation at SZ suture. (f) Intra-operative fixation at SZ suture

Case Scenario 2: Fracture of left ZMC and orbital floor (Fig. 56.65 a–h)

Patient: 27-Year-Old Male with History of RTA and delayed presentation after 2 months

Preoperative CT findings (Fig. 56.65a, b):

- En bloc fracture of the left ZMC with diastasis at the left infra-orbital rim, zygomatic arch, and FZ and SZ sutures.
- The fracture shows posterior, inferior, and lateral displacement and comminution at the infra-orbital rim, zygomaticomaxillary buttress, and the arch.
- The CT also demonstrates a concomitant left orbital floor fracture with resultant enophthalmos and hypo-ophthalmos (Fig. 56.65g).

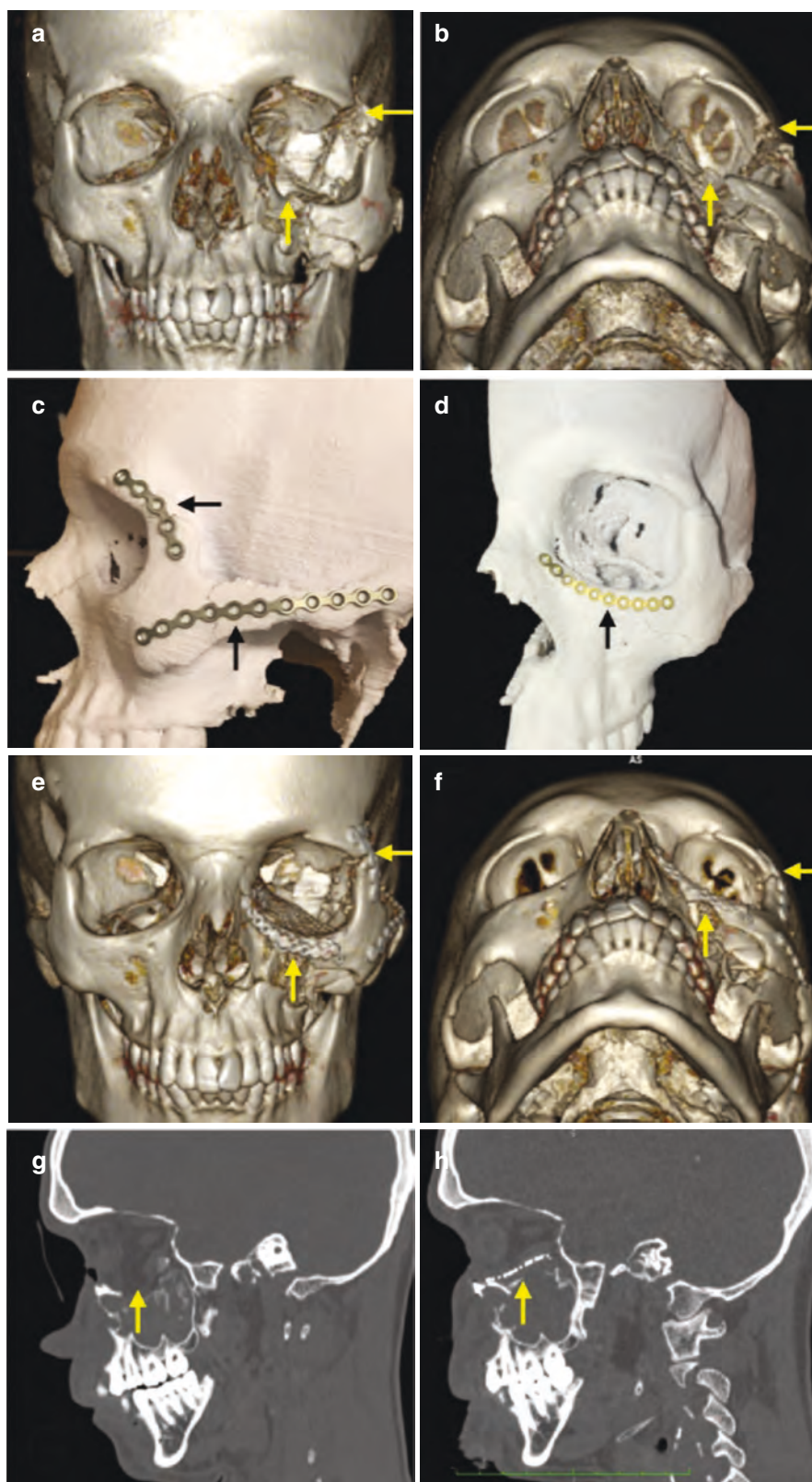
Surgical plan: ZMC osteotomy, repositioning, and internal fixation

Surgical procedure:

- Virtual surgical planning to generate a mirrored STL model for pre-contouring of implants (Fig. 56.65c, d)
- Surgical exposure of the fracture through a transconjunctival (infra-orbital rim and floor), upper lid blepharoplasty (FZ and SZ sutures), vestibular for the ZM buttress, and preauricular approaches for the zygomatic arch.
- Mobilization of the malunited ZMC after osteotomy and ORIF with pre-contoured implants
- Fixation of the fracture performed at the FZ, infra-orbital rim, and the zygomatic arch regions
- Orbital exploration and reconstruction with pre-contoured left-sided anatomical titanium orbital implant

Postoperative features (Fig. 56.65e, f and h):

The postoperative CT demonstrates optimal reduction and fixation of the left ZMC with reconstruction of the left orbital floor defect with titanium implant.



©Association of Oral and Maxillofacial Surgeons of India

Fig. 56.65 Case scenario 2. (a) Preoperative 3D CT-frontal view demonstrating fractures. (b) Preoperative 3D CT-basal view. (c) STL model surgery with pre-contoured plate. (d) STL model demonstrating mirroring of normal side and plate adaptation. (e) Postoperative 3D CT-frontal

view demonstrating fixation. (f) Postoperative 3D CT-basal view demonstrating fixation. (g) Preoperative CT-sagittal view demonstrating floor fracture. (h) Postoperative CT-sagittal view demonstrating reconstruction of floor with orbital mesh

References

- Rowe NL, Williams JL. Maxillofacial injuries, Vol 1. Edinburgh: Churchill Livingstone; 1985. p. 435–537.
- Maturo S, Lopez MA. Zygomatico-orbito-maxillary complex fractures. *Oper Tech Otolaryngol*. 2008;19:86–9.
- Marinho RO, Freire-Maia B. Management of fractures of the zygomaticomaxillary complex. *Oral Maxillofac Surg Clin North Am*. 2013;25:617–36.
- Ehrenfeld M, Manson PN, Prein J. Principles of internal fixation of the craniomaxillofacial skeleton trauma and orthognathic surgery. *AO Foundation*. p. 205–22.
- Fonseca RJ, Walker RV. Oral and maxillofacial trauma, vol. 1. Philadelphia: Saunders; 1991.
- Lockwood CB. The anatomy of the muscles, ligaments, and fasciae of the orbit, including an account of the capsule of Tenon, the check ligaments of the recti, and the suspensory ligaments of the eye. *J Anat Physiol*. 1885;20:i2–i25.
- Brusati R. Mouth opening limitations due to coronoid-zygomatic-malar interference. *Minerva Stomatol*. 1975;24(4):177–98.
- Lee SM, Baek JA, Kim Y. Ankylosis of the coronoid process to the zygomatic bone: a case report and review of the literature. *J Oral Maxillofac Surg*. 2019;77:1230.e1–11.
- Cohen AJ, Narayanan D. Zygomatic complex facial fractures. 2017 (Cited September 17, 2018) Available from <https://emedicine.medscape.com/article/1284142-overview>.
- Karlan MS, Cassisi NJ. Fractures of the zygoma. A geometric, biomechanical, and surgical analysis. *Arch Otolaryngol*. 1979;105:320–7.
- Louis M, Agrawal N, Kaufman M, Truong TA. Midface fractures I. *Semin Plast Surg*. 2017; 31(2): 85–93.
- Buehler JA, Tannyhill RJ 3rd. Complications in the treatment of midfacial fractures. *Oral Maxillofac Surg Clin North Am*. 2003;15:195–212.
- Zachariades N, Papavassiliou D, Papademetriou I. The alterations in sensitivity of the infraorbital nerve following fractures of the zygomaticomaxillary complex. *J Craniomaxillofac Surg*. 1990;18:315–8.
- Jamal BT, Pfahler SM, Lane KA, Bilyk JR, Pribitkin EA, Diecidue RJ, Taub DI. Ophthalmic injuries in patients with zygomaticomaxillary complex fractures requiring surgical repair. *J Oral Maxillofac Surg*. 2009;67:986–9.
- Cavalcante JR, Junior JR, Peixoto TS, de Albuquerque TT, Cavalcanti AL. Reduction and fixation of unstable fractures of the zygomatic arch: report of a series of cases. *J Surg Tech Case Rep*. 2015;7:29–31.
- Susarla SM, Bojovic B. Acute intraorbital hemorrhage following reduction of a displaced orbitozygomaticomaxillary complex fracture. *Craniomaxillofac Trauma Reconstr*. 2015;8:221–7.
- Zingg M, Laedrach K, Chen J, et al. Classification and treatment of zygomatic fractures: a review of 1,025 cases. *J Oral Maxillofac Surg*. 1992;50:778–90.
- Colin-Durand J, Czerwinski M, Parker WL, Crepeau RJ. Repair of an avulsed zygoma: defining optimal management. *J Oral Maxillofac Surg*. 2008;66:2615–6.
- Ozyazgan I, Günay GK, Eskitaşçıoğlu T, Ozköse M, Coruh A. A new proposal of classification of zygomatic arch fractures. *J Oral Maxillofac Surg*. 2007;65:462–9.
- Yamamoto K, Murakami K, Sugiura T, Fujimoto M, Inoue M, Kawakami M, Ohgi K, Kirita T. Clinical analysis of isolated zygomatic arch fractures. *J Oral Maxillofac Surg*. 2007;65:457–61.
- Hönig JF, Merten HA. Classification system and treatment of zygomatic arch fractures in the clinical setting. *J Craniofac Surg*. 2004;15(6):986–9.
- Ellis E, El-Attar A, Moos KF. An analysis of 2,067 cases of zygomatico-orbital fracture. *J Oral Maxillofac Surg*. 1985;43:417–28.
- Rupp J. The 8-Point Eye Exam [Internet]. American Academy of Ophthalmology. 2019 [cited 21 May 2019].
- Qayyum Z, Khan A, Khatib U. Characteristics and etiology of zygomatic complex fractures. *Pak Oral Dent J*. 2007;27(1):93–6.
- King AB, Walsh FB. Trauma to the head with particular reference to the ocular signs: Part I. Injuries involving the cranial nerves. *Am J Ophthalmol*. 1949; 32(2):191–206.
- Jeon HB, Kang DH, Oh SA, Gu JH. Comparative study of Naugle and Hertel exophthalmometry in orbitozygomatic fracture. *J Craniofac Surg*. 2016;27(1):142–4.
- Nkenke E, Benz M, Maier T, Wiltfang J, Holbach LM, Kramer M, Häusler G, Neukam FW. Relative en-and exophthalmometry in zygomatic fractures comparing optical non-contact, non-ionizing 3D imaging to the Hertel instrument and computed tomography. *J Cranio Maxillofac Surg*. 2003; 31(6):362–8.
- Smith SN, Nortjé CJ. Surgical emphysema following an undisplaced fractured zygoma: an unusual radiographic appearance. *Br J Oral Surg*. 1980;18(3):202–4.
- Brasileiro BF, Cortez AL, Asprino L, Passeri LA, de Moraes M, Mazzone R, Moreira RW. Traumatic subcutaneous emphysema of the face associated with paranasal sinus fractures: a prospective study. *J Oral Maxillofac Surg*. 2005;63(8):1080–7.
- Markiewicz MR, Gelesko S, Bell RB. Zygoma reconstruction. *Oral Maxillofac Surg Clin North Am*. 2013;25(2):167–201.
- Perry M, Holmes S. Atlas of operative maxillofacial trauma surgery—primary repair of facial injuries. London: Springer; 2014.
- Roth FS, Koshy JC, Goldberg JS, Soparkar CN. Pearls of orbital trauma management. *Semin Plast Surg*. 2010;24(4):398–410.
- Bossert RP, Giroto JA. Blindness following facial fracture: treatment modalities and outcomes. *Craniomaxillofac Trauma Reconstr*. 2009;2:117–24.
- McGrigor B, Campbell W. The radiology of war injuries. IV. Wounds of the face and jaw. *Br J Radiol*. 1950;23(276):685–96.
- Dolan KD, Jacoby CG. Facial fractures. *Semin Roentgenol*. 1978;13(1):37–51.
- Ogunmuyiwa SA, Fatusi OA, Ugboko VI, Ayoola OO, Maaji SM. The validity of ultrasonography in the diagnosis of zygomaticomaxillary complex fractures. *Int J Oral Maxillofac Surg*. 2012;41(4):500–5.
- Ochs M, Chung W, Powers D. Trauma surgery. *J Oral Maxillofac Surg*. 2017;75(8):e151–94.
- Ellstrom CL, Evans GR. Evidence-based medicine: zygoma fractures. *Plast Reconstr Surg*. 2013;132(6):1649–57.
- Hurrell M, David M, Batstone M. A multi-outcome analysis of the effects of treatment timing in the management of zygomatic fractures. *Int J Oral Maxillofac Surg*. 2015;44:e83.
- Knepil GJ, Loukota RA. Outcomes of prophylactic antibiotics following surgery for zygomatic bone fractures. *J Craniomaxillofac Surg*. 2010;38(2):131–3.
- Soong PL, Schaller B, Zix J, Iizuka T, Mottini M, Lieger O. The role of postoperative prophylactic antibiotics in the treatment of facial fractures: a randomised, double-blind, placebo-controlled pilot clinical study. Part 3: Le Fort and zygomatic fractures in 94 patients. *Br J Oral Maxillofac Surg*. 2014; 52(4):329–33.
- Zhang X, Han CY, Dai MJ, Chen JL, Zheng XH, Long J, Tang W, Tian WD, Liu L. Application of computer-assisted surgery techniques in the management of zygomatic complex fractures. *Chin J Traumatol*. 2018;21(5):281–6.
- Xia JJ, Gateno J, Teichgraber JF. A new paradigm for complex midface reconstruction: a reversed approach. *J Oral Maxillofac Surg*. 2009;67(3):693–703.

44. Li P, Zhou ZW, Ren JY, Zhang Y, Tian WD, Tang W. Accuracy of three-dimensional facial soft tissue simulation in post-traumatic zygoma reconstruction. *Int J Oral Maxillofac Surg.* 2016;45(12):1665–70.
45. Krimmel M, Cornelius CP, Reinert S. Endoscopically assisted zygomatic fracture reduction and osteosynthesis revisited. *Int J Oral Maxillofac Surg.* 2002;31(5):485–8.
46. Gillies HD, Kilner TP, Stone D. Fractures of the Malar-zygomatic compound: With a description of a new X-ray position. *Br J Surg.* 1927;14(56):651–6.
47. Poswillo D. Reduction of the fractured malar by a traction hook. *Br J Oral Surg.* 1976;14(1):76–9.
48. Lee EI, Mohan K, Koshy JC, Hollier LH. Optimizing the surgical management of zygomaticomaxillary complex fractures. *Semin Plast Surg.* 2010;24(4):389–97.
49. Dingman RO, Natvig P. *Surgery of facial fractures.* Philadelphia: WB Saunders; 1964. p. 212–3.
50. Balasubramaniam S. Intra-oral approach for reduction of malar fractures. *Br J Oral Surg.* 1966;4:189–91.
51. Quinn JH. Lateral coronoid approach for intraoral reduction of fractures of the zygomatic arch. *J Oral Surg.* 1977;35(4):321–2.
52. Pilanci O, Basaran K, Datli A, Kuvat SV. “Roller coaster maneuver via lateral orbital approach” for reduction of isolated zygomatic arch fractures. *J Craniofac Surg.* 2013;24(6):2082–4.
53. Carter TG, Bagheri S, Dierks EJ. Towel clip reduction of the depressed zygomatic arch fracture. *J Oral Maxillofac Surg.* 2005;63(8):1244–6.
54. Ahn HC, Youn DH, Choi MSS, Chang JW, Lee JH. Wire or hook traction for reducing zygomatic fracture. *Arch Craniofac Surg.* 2015;16(3):131–5.
55. Bazani PL, Bonardi JP, Magro-Filho O. The use of foley catheter for treatment of unstable fracture zygomatic arch. *J Craniofac Surg.* 2016;27(4):1012.
56. Camilleri AC, Gilhooly M, Cooke ME. Stabilisation of the unstable fractured zygomatic arch with a Kirschner wire. *Br J Oral Maxillofac Surg.* 2005;43(2):183–4. PubMed PMID: 15749224
57. Yoon H, Kim J, Chung S, Chung YK. Effectiveness of dual-manuever using K-wire and dingman elevator for the reduction of unstable zygomatic arch fracture. *Arch Craniofac Surg.* 2014;15(2):59–62.
58. van Hout WM, van Cann EM, Muradin MS, Frank MH, Koole R. Intraoperative imaging for the repair of zygomaticomaxillary complex fractures: a comprehensive review of the literature. *J Craniofac Surg.* 2014;42(8):1918–23.
59. Ellis E 3rd, Perez D. An algorithm for the treatment of isolated zygomatico-orbital fractures. *J Oral Maxillofac Surg.* 2014;72(10):1975–83.
60. Menon A, Karikal A, Shetty V. Does C-arm guidance improve reduction of zygomatic arch fractures? A randomized controlled trial. *J Oral Maxillofac Surg.* 2018;76(11):2376–86.
61. Cannizzaro D, Revay M, Mancarella C, Colletti G, Costa F, Cardia A, Fornari M. Intraoperative imaging O-Arm™ in secondary surgical correction of post-traumatic orbital fractures. *Oral Maxillofac Surg Cases.* 2017;3(3):56–60.
62. Bujtar P, Steele P, Holland I, Halsned M. Buttress guide: direct positioning splint to align a complex fracture of the zygoma. *Br J Oral Maxillofac Surg.* 2017;55(1):97–9.
63. Lubbers HT, Zweifel D, Gratz KW, Kruse A. Classification of potential risk factors for trigeminocardiac reflex in craniomaxillofacial surgery. *J Oral Maxillofac Surg.* 2010;68:1317–21.
64. Shearer ES, Wenstone R. Bradycardia during elevation of zygomatic fractures. A variation of the oculocardiac reflex. *Anaesthesia.* 1987;42:1207–8.
65. Padaki P, Graham R, Markose G. Modified Zimmer finger splint revisited. *Br J Oral Maxillofac Surg.* 2017;55(10):e141.
66. Cornelius C, Gellrich N, Hillerup S, Kusumoto K, Schubert W. Midface - indication - zygoma, zygomatic complex fracture—AO Surgery Reference [Internet]. www2.aofoundation.org. 2019 [cited 18 June 2019]. Available from: <https://www2.aofoundation.org/wps/portal/surgery?bone=CMF&segment=Midface&classification=92-Zygoma,%20Zygomatic%20complex%20fracture&showPage=indication>
67. Gruss JS, Van LW, Phillips JH, Antonyshyn O. The importance of the zygomatic arch in complex midfacial fracture repair and correction of posttraumatic orbitozygomatic deformities. *Plast Reconstr Surg.* 1990;85(6):878–90.
68. Humphrey CD, Kriet JD. Surgical approaches to the orbit. *Oper Tech Otolaryngol Head Neck Surg.* 2008;19(2):132–9.
69. Farber SJ, Nguyen DC, Skolnick GB, Woo AS, Patel KB. Current management of zygomaticomaxillary complex fractures: A multidisciplinary survey and literature review. *Craniofacial Trauma Reconstr.* 2016;9(04):313–22.
70. Ellis E, Zide MF, editors. *Surgical approaches to the facial skeleton.* Lippincott Williams & Wilkins; 2006.
71. Al-Moraissi EA, Thaller SR, Ellis E. Subciliary vs. transconjunctival approach for the management of orbital floor and periorbital fractures: A systematic review and meta-analysis. *J Craniofac Surg.* 2017;45(10):1647–54.
72. Cornelius C, Gellrich N, Hillerup S, Kusumoto K, Schubert W. Midface - indication - zygoma, zygomatic complex fracture—AO Surgery Reference [Internet]. www2.aofoundation.org. 2019 [cited 18 June 2019]. Available from: https://www2.aofoundation.org/wps/portal/surgery?contentUrl=/srg/92/04-Approaches/A30_2-lower-eyelid-transcutan.jsp. Accessed 12 June 2019.
73. Wilson S, Ellis E. Surgical approaches to the infraorbital rim and orbital floor: the case for the subtarsal approach. *J Oral Maxillofac Surg.* 2006;64(1):104–7.
74. Connolly KL, Albertini JG, Miller CJ, Ozog DM. The suspension (Frost) suture: experience and applications. *Dermatol Surg.* 2015;41(3):406–10.
75. Al-Moraissi EA, Elsharkawy AT, Al-Tairi NH, Farhan AH, Abotaleb BM, Al-Sharaee YA, Olufunmilayo OF, Alzubaidi A. What surgical approach has the lowest risk of the lower lid complications in the treatment of orbital floor and periorbital fractures? A frequentist network meta-analysis. *J Craniofacial Surg.* 2018;46:2164–75.
76. Sebastiani AM, Trento GS, Antonini F, Kluppel LE, Scariot R, Costa DJ, Rebellato NL. Cicatricial ectropion correction in the inferior eyelid with cartilaginous tissue graft: Case report. *Int J Med Surg Sci.* 2014;1(3):217–2.
77. Pascali M, Avantaggiato A, Brinci L, Cervelli V, Carinci F. Tarsal sling: an essential stitch to prevent scleral show in lower blepharoplasty. *Aesthet Surg J.* 2015;35(1):11–9.
78. Kushner GM. Surgical approaches to the infraorbital rim and orbital floor: the case for the transconjunctival approach. *J Oral Maxillofac Surg.* 2006;64(1):108–10.
79. Elsheikh E, Hussein AM, Tantawy AA, Abdelbaki YM. Transconjunctival versus subciliary approach to the infraorbital margin for open reduction of zygomaticomaxillary complex fractures: a randomized feasibility study. *Oral Maxillofac Surg.* 2017;21(2):187–92.
80. Ishida K. Evolution of the surgical approach to the orbitozygomatic fracture: From a subciliary to a transconjunctival and to a novel extended transconjunctival approach without skin incisions. *J Plast Reconstr Aesthet Surg.* 2016;69(4):497–505.
81. Martinez AY, Bradrick JP. Y modification of the transconjunctival approach for management of zygomaticomaxillary complex fractures: a technical note. *J Oral Maxillofac Surg.* 2012;70(1):97–101.

82. Sharma R, Singh S, Patrikar S. Retroseptal transconjunctival approach for fractures of the zygomaticomaxillary complex: a retrospective study. *Br J Oral Maxillofac Surg.* 2018;56(1):29–33.
83. Yoon SH, Lee JH. The reliability of the transconjunctival approach for orbital exposure: measurement of positional changes in the lower eyelid. *Arch Craniofac Surg.* 2017;18(4):249.
84. Salhi S, Cordoba C. Distichiasis following transconjunctival approach to the inferior orbital rim and orbital floor. *JPRAS Open.* 2015;5:29–33.
85. Courtney DJ. Upper buccal sulcus approach to management of fractures of the zygomatic complex: a retrospective study of 50 cases. *Br J Oral Maxillofac Surg.* 1999;37(6):464–6.
86. Choi KY, Ryu DW, Yang JD, Chung HY, Cho BC. Feasibility of 4-point fixation using the preauricular approach in a zygomaticomaxillary complex fracture. *J Craniofac Surg.* 2013;24(2):557–62.
87. Massimo P, Corrado T, Roberto C, Fabia C, Massimo R. The deep subfascial approach to the temporomandibular joint. *J Oral Maxillofac Surg.* 2004;62:1097–102.
88. Zhang QB, Dong YJ, Li ZB, Zhao JH. Coronal incision for treating zygomatic complex fractures. *J Craniofac Surg.* 2006;34(3):182–5. Epub 2006 Mar 14.
89. Erich JB. Treatment of fractures of the zygoma and floor of the orbit. *Am J Surg.* 1966;112(3):432–5.
90. Park BY, Song SY, Yun IS, Lee DW, Rah DK, Lee WJ. First percutaneous reduction and next external suspension with Steinmann pin and Kirschner wire of isolated zygomatic fractures. *J Craniofac Surg.* 2010;21(4):1060–5.
91. Chotkowski G, Eggleston TI, Buchbinder D. Lag screw fixation of a nonstable zygomatic complex fracture: case report. *J Oral Maxillofac Surg.* 1997;55(2):183–5.
92. Stevens MR, Menis MA. Microscrew fixation of zygomatic arch fractures. *J Oral Maxillofac Surg.* 1993;51(10):1158–9.
93. Kim ST, Go DH, Jung JH, Cha HE, Woo JH, Kang IG. Comparison of 1-point fixation with 2-point fixation in treating tripod fractures of the zygoma. *J Oral Maxillofac Surg.* 2011;69(11):2848–52.
94. Jazayeri HE, Khavanin N, Jason WY, Lopez J, Shamliyan T, Peacock ZS, Dorafshar AH. Fixation points in the treatment of traumatic zygomaticomaxillary complex fractures: a systematic review and meta-analysis. *J Oral Maxillofac Surg.* 2019.
95. Sharma R, Muralidharan CG, Roy ID, Jain NK, Patrikar S. Radiological evaluation of sphenozygomatic suture fixation for restoration of orbital volume: a retrospective study. *J Craniofac Surg.* 2016;44(12):1903–8.
96. Wu CM, Chen YA, Liao HT, Chen CH, Pan CH, Chen CT. Surgical treatment of isolated zygomatic fracture: outcome comparison between titanium plate and bioabsorbable plate. *Asian J Surg.* 2018;41(4):370–6.
97. Chu SG, Lee JS, Lee JW, Yang JD, Chung HY, Cho BC, Choi KY. Comparisons among four types of absorbable plates used for internal fixation of zygomaticomaxillary complex fractures. *J Craniofac Surg.* 2019;47(3):383–8.
98. Xie L, Shao Y, Hu Y, Li H, Gao L, Hu H. Modification of surgical technique in isolated zygomatic arch fracture repair: seven case studies. *Int J Oral Maxillofac Surg.* 2009;38(10):1096–100.
99. Ribeiro AL, de Souza Rodrigues TM, de Melo A-JS, Pinheiro JD. Interfragmentary screw fixation of the zygomatic arch in complex midface and zygomaticomaxillary fractures. *J Oral Maxillofac Surg.* 2015;73(3):494–8.
100. Kim H, Yoon J, Lee BI. Radiological morphometric analysis of the zygomatic arch: Application of osteosynthesis on the upper arch border for rigid fixation. *J Plast Reconstr Aesthet Surg.* 2019;72(5):831–41.
101. Brown R, Lozada K, Kadakia S, Gordin E, Ducic Y. Prophylactic midface lift in midfacial trauma. *Facial Plast Surg.* 2017;33:347–51.
102. Gruss JS, Whelan MF, Rand RP, Ellenbogen RG. Lessons learnt from the management of 1500 complex facial fractures. *Ann Acad Med Singapore.* 1999;28:677–86.
103. Phillips JH, Gruss JS, Wells MD, Chollet A. Periosteal suspension of the lower eyelid and cheek following subciliary exposure of facial fractures. *Plast Reconstr Surg.* 1991;88:145–8.
104. Frodel JL Jr, Rudderman R. Facial soft tissue resuspension following upper facial skeletal reconstruction. *J Craniofac Surg.* 1996;2:24–30.
105. Susarla SM, Peacock ZS. Zygomaticomaxillary complex fracture. *Eplasty.* 2014;14.
106. Mahmood S, Keith DJ, Lello GE. When can patients blow their nose and fly after treatment for fractures of zygomatic complex: the need for a consensus. *Injury.* 2003;34(12):908–11.
107. Chang CM, Ko EC, Kao CC, Chang PY, Chen MY. Incidence and clinical significance of zygomaticomaxillary complex fracture involving the temporomandibular joint with emphasis on trismus. *Kaohsiung J Med Sci.* 2012;28(6):336–40.
108. Ristow O, Pautke C, Kehl V, Koerdt S, Schwärzler K, Hahnefeld L, Hohlweg-Majert B. Influence of kinesiologic tape on postoperative swelling, pain and trismus after zygomatico-orbital fractures. *J Craniofac Surg.* 2014;42(5):469–76.
109. Ferreira P, Marques M, Pinho C, Rodrigues J, Reis J, Amarante J. Midfacial fractures in children and adolescents: a review of 492 cases. *Br J Oral Maxillofac Surg.* 2004;42:501–5.
110. Zimmermann CE, Troulis MJ, Kaban LB. Pediatric facial fractures: recent advances in prevention, diagnosis and management. *Int J Oral Maxillofac Surg.* 2006;35:2–13.
111. Luck JD, Lopez J, Faateh M, Macmillan A, Yang R, Davidson EH, Nam AJ, Grant MP, Tufaro AP, Redett RJ, Manson PN, Dorafshar AH. Pediatric zygomaticomaxillary complex fracture repair: location and number of fixation sites in growing children. *Plast Reconstr Surg.* 2018;142:51e–60e.
112. DeFazio MV, Fan KL, Avashia YJ, Danton GH, Thaller SR. Fractures of the pediatric zygoma: a review of the clinical trends, management strategies, and outcomes associated with zygomatic fractures in children. *J Craniofac Surg.* 2013;24:1891–7.
113. Iatrou I, Theologie-Lygidakis N, Tzerbos F. Surgical protocols and outcome for the treatment of maxillofacial fractures in children: 9 years' experience. *J Craniofac Surg.* 2010;38:511–6.
114. Perino KE, Zide MF, Kinnebrew MC. Late treatment of malunited malar fractures. *J Oral Maxillofac Surg.* 1984;42(1):20–34.
115. Rikalainen R, Lamberg MA, Tasanen A. Extra-articular fibrous ankylosis of the mandible after zygomatic fracture. *J Maxillofac Surg.* 1981;9:132–6.
116. Ramanathan M, Cherian MP. Isolated bilateral zygomatic complex and arch fracture: a rare case report. *Craniofac Trauma Reconstr.* 2010;3(04):185–8.
117. Loewinger J, Cohen M, Levi E. Bradycardia during elevation of a zygomatic arch fracture. *J Oral Maxillofac Surg.* 1987;45:710–1.
118. Benoliel R, Birenboim R, Regev E, Eliav E. Neurosensory changes in the infraorbital nerve following zygomatic fractures. *Oral Surg Oral Med Oral Pathol Oral Radiol Endod.* 2005;99:657–65.
119. Buckley SB, McAnear JT, Dolwick MF, Aragon SB. Monocular blindness developing 7 days after repair of zygomaticomaxillary complex fracture: A clinical report. *Oral Surg Oral Med Oral Pathol.* 1985;60(1):25–8.
120. Dym H, Wolf JC. Oroantral communication. *Oral Maxillofac Surg Clin North Am.* 2012;24:239–47.
121. Rajantie H, Snäll J, Thorén H. Postoperative temporomandibular dysfunction in patients with fractures of the zygomatic complex: a prospective follow-up study. *Br J Oral Maxillofac Surg.* 2018;56(7):573–7.

122. i de la Torre ÒE, Klok EV, i Roig AM, Mommaerts MY, i Ayats JP. Jacob's disease: report of two cases and review of the literature. *J Craniomaxillofac Surg.* 2001;29(6):372–6.
123. Liu XZ, Shu DL, Ran W, Guo B, Liao X. Digital surgical templates for managing high-energy zygomaticomaxillary complex injuries associated with orbital volume change: a quantitative assessment. *J Oral Maxillofac Surg.* 2013;71:1712–23.
124. Gong X, He Y, An J, Yang Y, Huang X, Liu M, Zhao Y, Zhang Y. Application of a computer-assisted navigation system (CANS) in the delayed treatment of zygomatic fractures: a randomized controlled trial. *J Oral Maxillofac Surg.* 2017;75:1450–63.
125. Pohlenz P, Blake F, Blessmann M, Smeets R, Habermann C, Begemann P, Schmelzle R, Heiland M. Intraoperative cone-beam computed tomography in oral and maxillofacial surgery using a C-arm prototype: first clinical experiences after treatment of zygomaticomaxillary complex fractures. *J Oral Maxillofac Surg.* 2009;67:515–21.
126. Panneerselvam E, Balasubramanian S, Kempuraj J, Babu VR, Raja VBKK. Management of Zygomatic Arch Fractures by Intraoral Open Reduction and Transbuccal Fixation: A Technical Note. *Craniomaxillofacial Trauma & Reconstruction.* 2020 Jun;13(2):130-132. DOI: 10.1177/1943387520911866.

Open Access This chapter is licensed under the terms of the Creative Commons Attribution 4.0 International License (<http://creativecommons.org/licenses/by/4.0/>), which permits use, sharing, adaptation, distribution and reproduction in any medium or format, as long as you give appropriate credit to the original author(s) and the source, provide a link to the Creative Commons license and indicate if changes were made.

The images or other third party material in this chapter are included in the chapter's Creative Commons license, unless indicated otherwise in a credit line to the material. If material is not included in the chapter's Creative Commons license and your intended use is not permitted by statutory regulation or exceeds the permitted use, you will need to obtain permission directly from the copyright holder.





Orbital Fractures

57

Ananthanarayanan Parameswaran,
Madhulaxmi Marimuthu, Shreya Panwar,
and Beat Hammer

57.1 Introduction

Orbital fractures are unique among cranio-maxillofacial (CMF) fractures. They have functional, cosmetic, and psychological implications. Most importantly they are among the few true emergencies in the realm of CMF trauma. Management of orbital fractures poses a challenge to every surgeon because of its complex anatomy, relationship to vital structures such as the globe and the brain, and its direct influence on the most precious of senses, *Vision*.

The orbit is a small bony cone filled with numerous vital and delicate structures, which require absolute precaution while handling and immense precision in its reconstruction. The principles of managing orbital trauma differ significantly from rest of the CMF fractures, which mandate a thorough understanding of its morphology and biodynamics. Choosing the appropriate indication for intervention and management protocol is critical in achieving the desired sur-

gical outcome. This chapter aims to answer the questions of the *When*, *Why*, and *How* of managing orbital trauma.

57.2 Surgical Anatomy of the Orbit

The orbits are bilateral bony cavities which house the globes. Each orbit is made up of seven bones: the maxilla, frontal bone, zygomatic, sphenoid, ethmoid, lacrimal, and the palatine bones (Fig. 57.1). The orbital cavity is a pyramidal structure with a quadrilateral base anteriorly, forming the orbital aperture, and the apex posteriorly which ends at the optic foramen. The apex is superomedially placed, while the base is directed anterior and lateral. The orbit encases two fissures: (1) the inferior orbital fissure also called the sphenozygomatic fissure and (2) the superior orbital fissure otherwise called as the inter-sphenoidal fissure (Fig. 57.2). The major structures within the orbit are provided in Box 57.1.

Electronic Supplementary Material The online version of this chapter (https://doi.org/10.1007/978-981-15-1346-6_57) contains supplementary material, which is available to authorized users.

A. Parameswaran (✉)
Department of Oral and Maxillofacial Surgery, Meenakshiammal
Dental College and Hospital, Chennai, India

Department of Orbit, Oculoplasty, Reconstructive and Aesthetic
Surgery, Shankara Nethralaya, Chennai, India

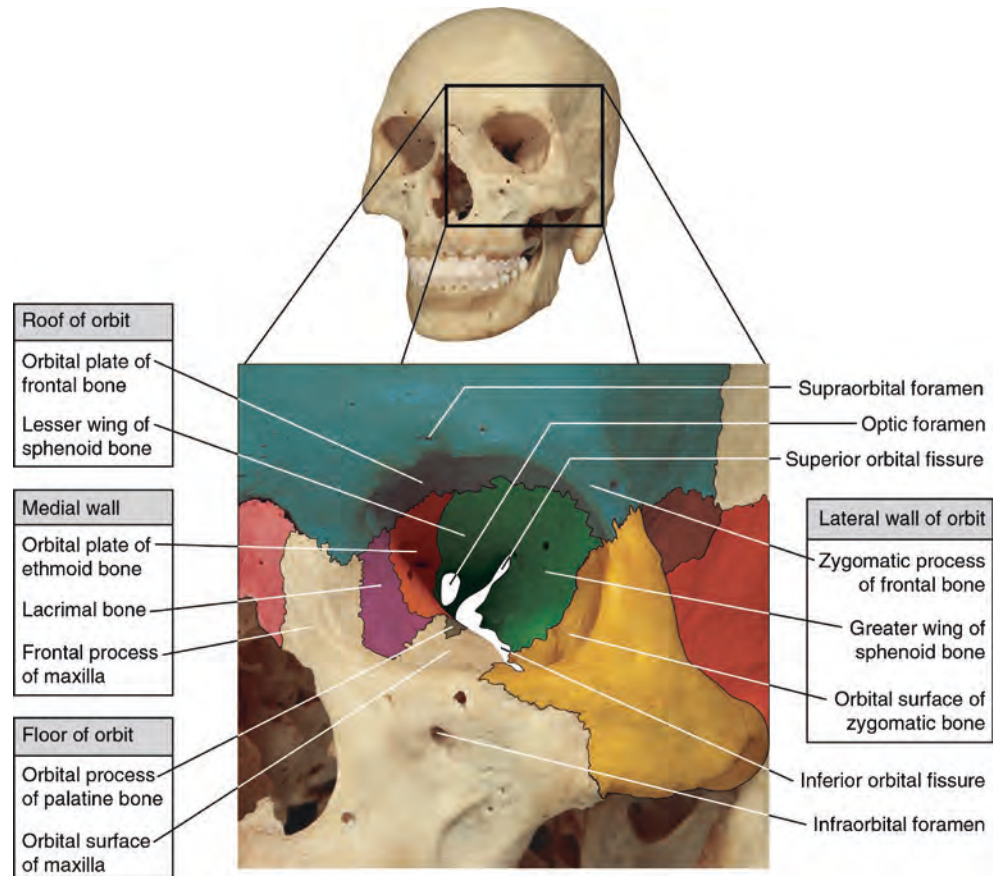
Department of Orbit and Oculoplasty, Aravind Eye Hospitals,
Chennai, India

M. Marimuthu
Department of Oral and Maxillofacial Surgery, Saveetha Dental
College and Hospital, Chennai, India

S. Panwar
Department of Oral and Maxillofacial Surgery, Meenakshiammal
Dental College and Hospital, Chennai, India

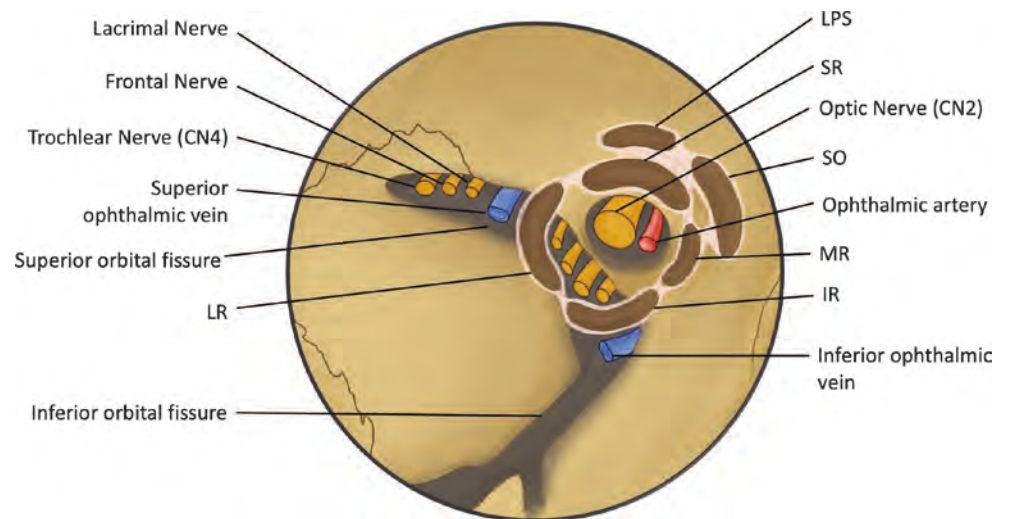
B. Hammer
CFC Hirslanden Kopf Zentrum, Aarau, Switzerland
e-mail: Beat.Hammer@hirslanden.ch

Fig. 57.1 Bones forming the orbit



©Association of Oral and Maxillofacial Surgeons of India

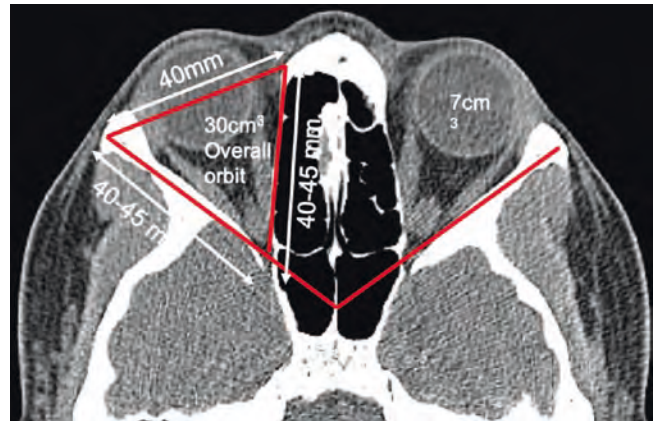
Fig. 57.2 Structures passing through the superior and inferior orbital fissures



©Association of Oral and Maxillofacial Surgeons of India

Box 57.1 The Major Structures that Occupy the Orbit

- Eye/globe
- Orbital fat
- Extraocular muscles
- Ciliary parasympathetic ganglion
- Nasolacrimal apparatus
- Optic nerve
- Oculomotor
- Trochlear
- Abducent nerves
- V1 and V2 of trigeminal nerve
- Ophthalmic vessels



©Association of Oral and Maxillofacial Surgeons of India

Fig. 57.3 Diagrammatic representation of the various measurements of the orbit and the globe

The orbits have an average height of 35 mm and a medio-lateral width of 40 mm [1–3]. The intra-orbital volume of an adult is approximately 30 cc, while the volume of the globe is 7 cc [4]. Generally, the orbital and globe volumes are bilaterally symmetrical at any stage of growth. The medial walls are parallel to each other and around 45–50 mm in length, while the lateral walls are around 90° to each other and 40–45 mm long (Fig. 57.3).

The orbital skeleton may essentially be divided into walls and rims. These include the orbital roof, floor, and medial and lateral walls. The rims include the inferior, superior, medial, and lateral orbital rims. A brief description of the structure of the orbital cavity is provided below.

57.2.1 Orbital Walls

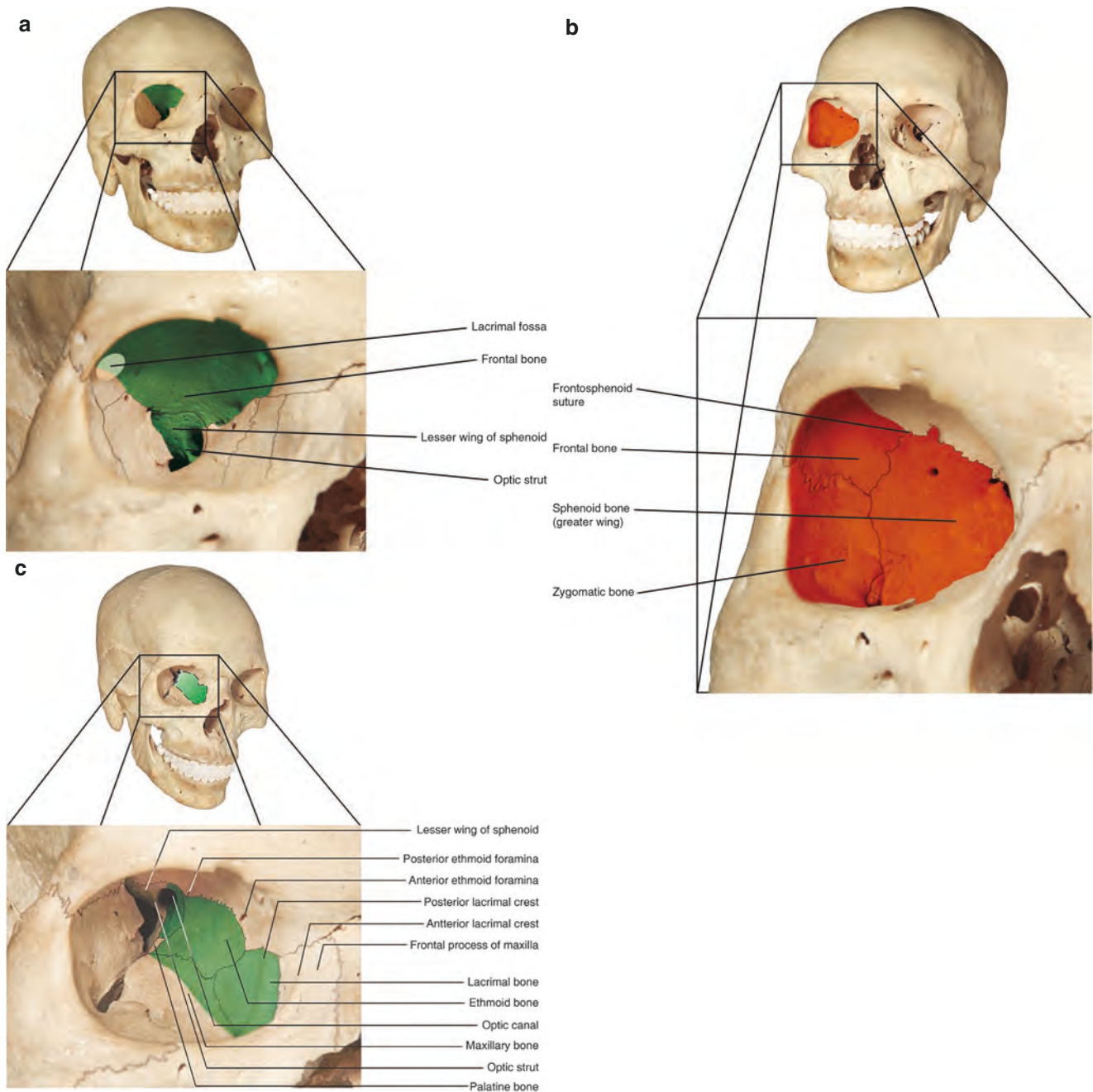
The roof (Fig. 57.4a) is formed by a concave broad plate of the frontal bone which delineates the orbital contents from the cranial cavity. The posterior portion of the roof has a small contribution from the lesser wing of the sphenoid. The anterolateral portion has a shallow depression called the lacrimal fossa, while 5 mm behind the medial aspect of the supraorbital rim is the trochlear fossa which has the cartilaginous pulley of the superior oblique muscle. The roof is triangular in shape and ends in optic foramen, which is the entry of the optic nerve into the orbit.

In older patients there may be spots of resorption in the orbital roof which may cause the dura to adhere to the peri-orbita of the roof. The junction of the medial wall and the roof has a suture line which lies in close proximity to the cribriform of the ethmoid and is prone for fragmentation. This may be a major concern for CSF leak into the orbits or the nose or at times both.

The roof is separated from the lateral orbital wall by the superior orbital fissure which serves as a passage of entry for the cranial nerves III, IV, V1, and VI into the orbit. The other structure coursing through the fissure is the ophthalmic vein. On the anterior aspect of the roof, at the junction between the medial 1/3rd and the lateral 2/3rd of the supraorbital rim is the supraorbital foramen which transmits the supraorbital neurovascular bundle [1–3, 5].

The medial wall (Fig. 57.4c) is quadrangular in shape and is constituted by the ethmoid bone in the center. The antero-superior aspect is formed by the frontal bone, while the antero-inferior part is formed by the lacrimal bone. The sphenoid bone forms the posterior part of the medial wall. The infra-orbital rim continues along the anterior aspect of the medial wall forming the anterior lacrimal crest which is a part of the frontal process of the maxilla, while the superomedial aspect of the supraorbital rim continues inferiorly as the posterior lacrimal crest which is formed by the lacrimal bone. Between these crests lie the fossa which houses the lacrimal sac. This is of importance during access planning for surgery of the medial wall and the anteromedial aspect of the infra-orbital rim.

The anterior and posterior ethmoidal foramen are located along the fronto-ethmoidal suture which signifies the height of the cribriform plate. The anterior ethmoidal foramen which transmits the anterior ethmoidal artery and nerve lies approximately 22–25 mm behind the medial orbital rim while the posterior ethmoidal foramen which transmits the posterior ethmoidal artery and the spheno-ethmoidal nerve is present about 12 mm posterior [6]. The optic foramen is in continuation of the medial wall and is approximately placed 45–50 mm behind the medial rim. The safe distances the sur-



©Association of Oral and Maxillofacial Surgeons of India

Fig. 57.4 (a) Roof, (b) lateral wall, and (c) medial wall of the orbit

geon needs to remember are 24 mm for the anterior ethmoidal artery, with an additional 12 mm for the posterior ethmoidal vessel and a further 6 mm as the limit to stay away from the optic foramen making it 24-12-6, an easy formula to remember. One important structure which may be involved in medial wall trauma is the medial rectus muscle which can get entrapped causing ocular motility disturbances.

The lateral wall (Fig. 57.4b) is the thickest wall and is made primarily by the orbital surface of the zygomatic bone and the greater wing of the sphenoid. A small bony projection seen on the lateral wall is the Whitnall's tubercle which lies 11 mm below the fronto-zygomatic suture and 4 mm behind the rim (Fig. 57.7).

This tubercle forms the attachment of the 4L's:

1. The suspensory ligament of Lockwood
2. The lateral horn of the levator aponeurosis
3. The ligaments of the lateral rectus muscle
4. The lateral palpebral ligament

A small groove may be seen at the anterior end of the inferior orbital fissure which transmits the zygomatico-facial and zygomatico-temporal vessels. These course through the zygoma and exit through independent foramina to supply the face and the temporal regions.

The floor (Fig. 57.5a, b) follows a gentle slope from its medial to lateral side. The highest point lies in the postero-medial aspect of the floor forming a bulge called the "Hammer's key area" [7] (Fig. 57.5a), which influences the position of the globe in the anteroposterior axis. In the sagittal view, the floor follows a "lazy S" shape with the anterior part concave and the posterior convex. The reconstruction of this convexity is important to maintain the anterior position of the globe (Fig. 57.5b). The floor is separated from the lateral wall by the inferior orbital fissure. The fissure communicates with the pterygopalatine fossa extra-orbitally. The maxillary division of the V nerve and its branches, the infra-orbital artery, and branches of the sphenopalatine ganglion are transmitted through the posteromedial aspect of the fissure, while the inferior ophthalmic veins pass through the lateral aspect to communicate with the pterygoid plexus. The floor is formed by the zygomatic bone and the maxilla with a small contribution from the orbital process of the palatine bone in the posteromedial aspect. A rough area at the antero-medial angle of the floor behind the infra orbital rim forms the attachment of the inferior oblique muscle. The infra-orbital groove originates from the inferior orbital fissure and transmits the infra-orbital neurovascular bundle.

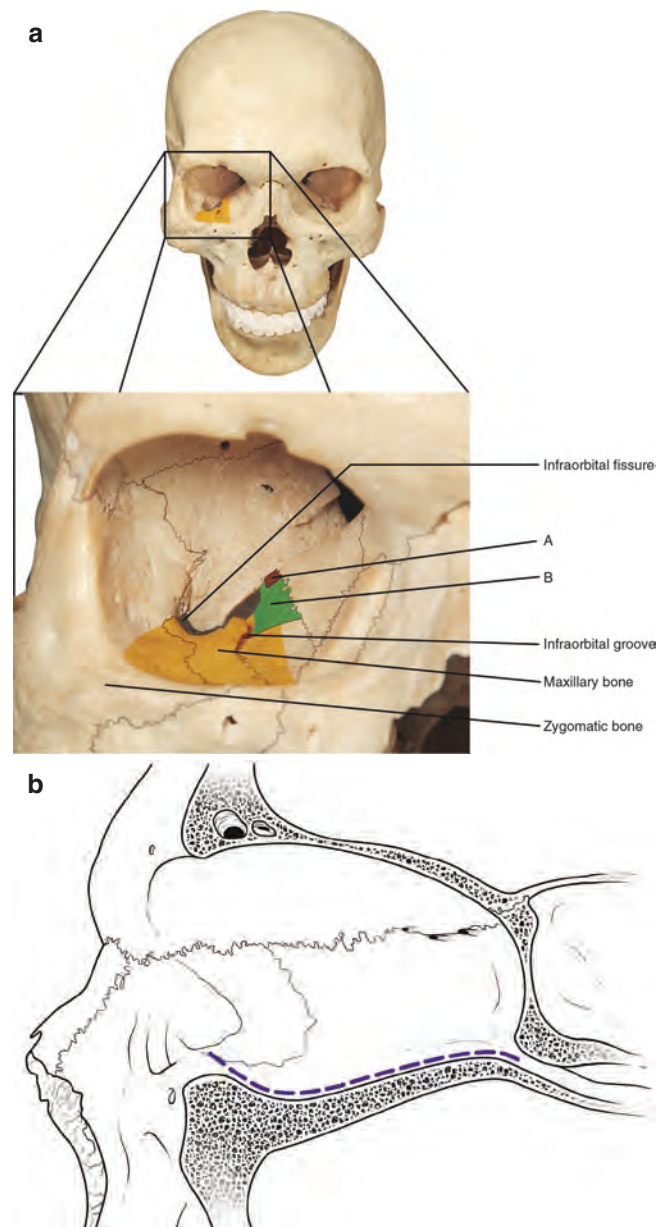
Orbital Rims:

The rims are superior, inferior, medial, and lateral. Three major bones—the maxilla, zygomatic bone, and frontal bone—make up the rims of the orbit. The width of the rims is greater than its height making it into a rectangular form. The presence of the maxillary sinus and the insertion of the inferior oblique muscle make the infra-orbital rim more prone for fracture and comminution.

57.2.2 Muscles of the Orbit (Fig. 57.6a)

Muscles in relation to the orbit can be divided into

- the muscles associated with the lids
- and the muscles associated with the globe.



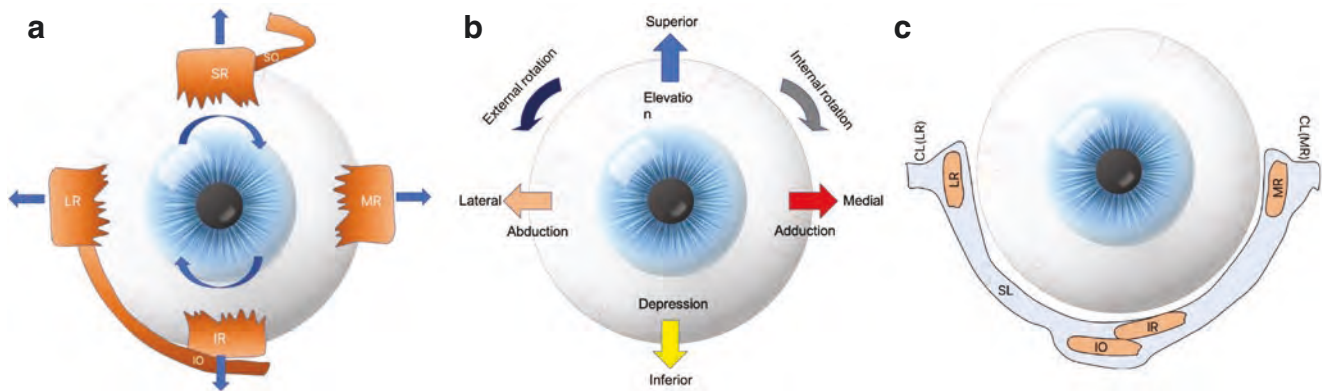
©Association of Oral and Maxillofacial Surgeons of India

Fig. 57.5 The orbital floor in (a) frontal view demonstrating the (A) orbital process of palatine bone and (B) "Hammer's key area." (b) Sagittal view of the floor with the "lazy S" form

The muscles of the lid are:

1. The orbicularis oculi which has a palpebral portion (upper and lower eyelids), the intervening orbital septum, and the inner layer connecting the tarsus
2. The levator palpebrae superioris which is the elevator of the upper eyelid

The levator palpebrae superioris along with the four recti, and the two obliques form the seven extraocular muscles of the human eye.



©Association of Oral and Maxillofacial Surgeons of India

Fig. 57.6 Diagram of right eye demonstrating (a) the extraocular muscles and (b) the movements they cause. (c) The fascial sheath. (SR - Superior Rectus, IR - Inferior Rectus, MR - Medial Rectus, LR - Lateral

Rectus, SO - Superior Oblique, IO - Inferior Oblique, CL(MR) - Check Ligament of Medial Rectus, CL(LR) - Check Ligament of Lateral Rectus, SL - Suspensory Ligament

The origin of the superior rectus is from the common tendinous ring superolateral to the optic canal, and its insertion is into the upper part of the sclera. Its function is to produce elevation of the eye and to move the cornea upward and medially helping in adduction and medial rotation.

The origin of the medial rectus is from the medial aspect of the tendinous ring and inserts into the medial surface of the sclera. The medial rectus helps in moving the eye medially (adduction), and bilateral action of the medial rectus helps in medial convergence of both the corneas. A suspensory attachment to the lacrimal crest is also seen on the medial orbital wall where it blends with the medial canthus and the check ligament (Fig. 57.6c) [2, 3, 6, 8]. The origin of the lateral rectus is from the lateral part of the common tendinous ring, and it inserts into the lateral surface of the sclera. Its primary function is to move the eye laterally (abduction). The inferior rectus arises from the common tendinous ring, below the optic canal, and inserts into sclera below the cornea. It is responsible for depression and lateral rotation of the eye.

The inferior rectus followed by the medial rectus are the most common muscles to be entrapped secondary to orbital trauma and may need to be explored and released surgically as indicated. Delayed release of the recti may cause significant necrosis and fibrosis of the muscles hampering return to normal function.

The superior oblique arises superomedial to the optic canal. It has a pulley action at the trochlea on the anteromedial aspect of the orbital roof and inserts into the sclera behind the equator of the globe. The contraction of the muscle produces depression of the cornea and movement of the eye laterally with medial rotation (intorsion).

The inferior oblique muscle arises from the orbital surface of the maxilla lateral to the nasolacrimal groove and inserts into the lateral part of the sclera behind the equator between the inferior and lateral recti muscle. It produces

elevation of the cornea and helps in moving the eye laterally with lateral rotation (extorsion).

57.2.3 Movements of the Eye and Their Innervation

Box 57.2 The Movements of the Eye

- Elevation
- Depression
- Adduction
- Abduction
- Intorsion
- Extorsion (Fig. 57.6b)

The different movements of the eye are enumerated in Box 57.2. These are facilitated by the extraocular muscles described above and are contained by the check ligaments. The inferior oblique and inferior rectus muscles which course the floor of the orbit serve as the inferior check ligaments. The fascia of the levator palpebrae superioris, which is anchored to the Whitnall's tubercle laterally and the trochlea medially, acts as the superior check ligament [8].

The contraction of the orbicularis oculi innervated by the facial nerve dictates the closure of the upper eyelid. The movements of the globe within the orbit are however dictated by the synchronous movements of the extraocular muscles of the orbit. The oculomotor nerve innervates all the extraocular muscles other than the lateral rectus which is supplied by the abducent nerve and the superior oblique supplied by the trochlear nerve. Reflex closure of the eyelids occurs via the sympathetic pathways traveling to the smooth muscles of the upper and lower eyelids.

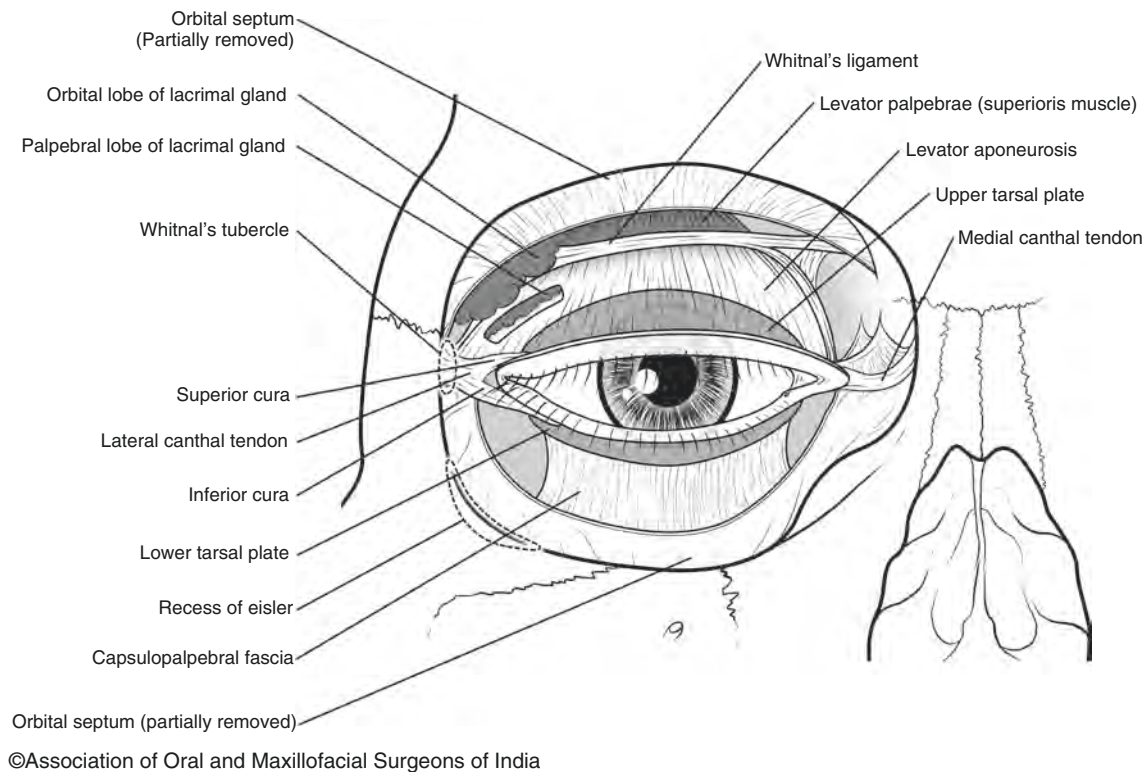


Fig. 57.7 The tarsal apparatus and the orbital septum

57.2.4 Orbital Septum and Tarsal Plates (Fig. 57.7)

The supporting framework for the eyelid is formed by a dense fibrous tissue called the orbital septum which condenses at the lids as the tarsal plates. The orbital septum which separates the orbital and lid contents attaches to the bone and becomes the periorbita inside the orbit and periosteum outside the orbit. The septum of the lower eyelid attaches to the orbital rims, while the septum of the upper eyelid is attached intra-orbitally behind the equator of the globe. The tarsal plates add rigidity to the lids and also serve attachments of multiple muscles and membranes [1, 3].

57.2.5 Conjunctiva

The conjunctiva is the transparent mucous membrane that covers the front surface of the globe and the inner surface of the eyelids.

This has two segments:

1. The bulbar conjunctiva that covers the anterior part of the sclera (the “white” of the eye)

2. The palpebral conjunctiva otherwise known as tarsal conjunctiva which covers the inner aspect of the eyelids

57.2.6 Fascial Sheath of the Eyeball (Fig. 57.6c)

The fascial sheath of the eyeball is called the Tenon’s capsule [8]. It extends from the optic foramen to the sclerocorneal junction enveloping the eyeball on the inferior aspect. It attaches to the sclera on the anterior and posterior surfaces of the eyeball and becomes continuous with the fascia of the muscles posteriorly and around the inferior oblique muscle. The fascial sheath of all muscles blend together and form a continuous fascial band called the suspensory ligament of the eye that provides support for the eyeball [8, 9].

57.2.7 Orbital Fat

The orbital fat is present both intra- and extra-conally. They cushion the globe and muscles of the orbit. The extra-conal fat determines and influences the position of the globe. This may be altered either due to herniation or atrophy secondary to fractures of the orbit resulting in enophthalmos.

57.3 Classification System

Manson [10] and colleagues classified the fractures based on the energy of impact, the degree, and extent of comminution and displacement observed on CT:

- (a) Trap door fractures—low-velocity injuries
- (b) Medial blowout fractures—intermediate-velocity injuries
- (c) Lateral blowout fractures—high-velocity fractures

Converse and Smith [11] termed them “pure” or “impure” based on the involvement of orbital rims (Fig. 57.8):

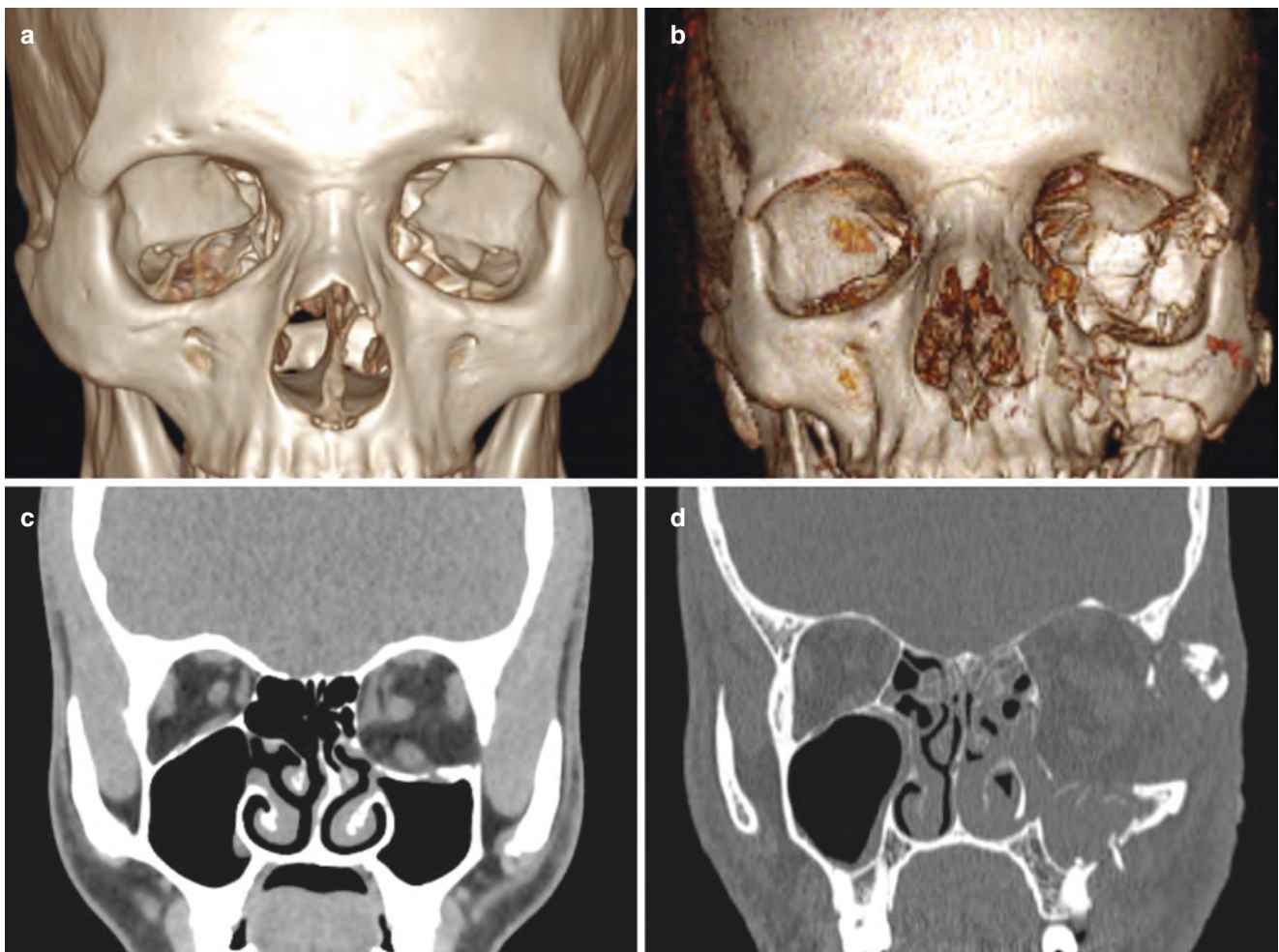
- (a) Pure (blow-in or blowout fractures)—fracture of the internal walls with intact rims
- (b) Impure (complex with involvement of one or more rims)—associated fractures of the rims

Hammer [7] described four classes of orbital fractures based on their occurrence with other fractures of the face (Fig. 57.9):

- (a) *Type I*: Orbito-zygomatic fractures—These involve the fractures of the walls of the orbit along with the zygomatic complex.
- (b) *Type II*: Internal orbital fractures—These involve isolated fractures of any of the walls, roof, and floor.
- (c) *Type III*: Naso-orbito-ethmoid-type fractures—These involve fractures of the naso-orbito-ethmoid complex which involve the orbit.
- (d) *Type IV*: Complex fractures of the face—This type involve fractures of the orbit with concomitant fractures of the face other than the ones mentioned above [7].

57.4 Blowout and Blow-In Fractures

Smith and Converse in 1960 recognized the phenomenon of blowout fractures (Fig. 57.10a). These fractures may involve entrapment or herniation of periorbital tissues resulting in restricted eye movements and/or enophthalmos due to reduction in the volume of intra-orbital contents [3, 11].

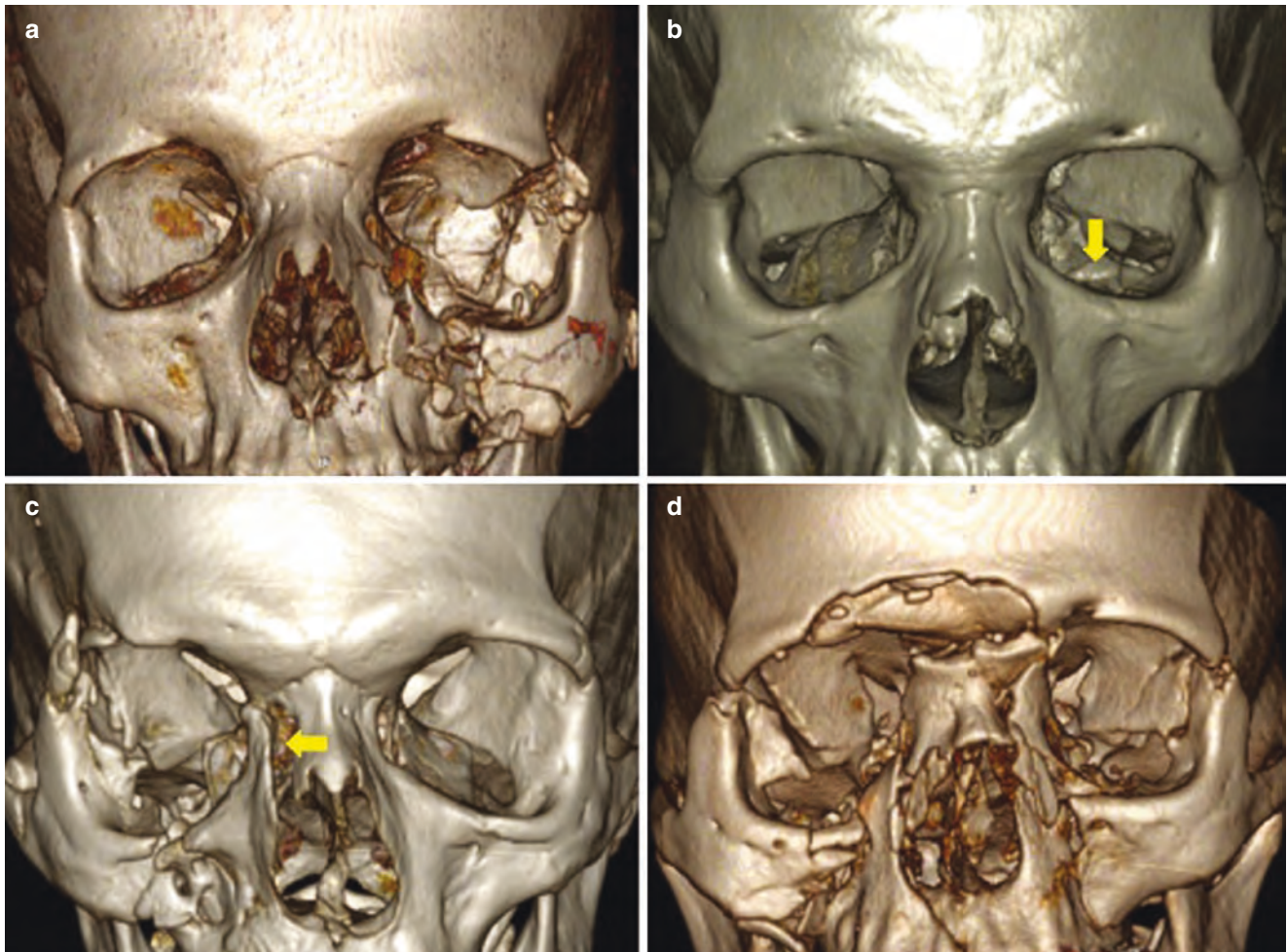


©Association of Oral and Maxillofacial Surgeons of India

Fig. 57.8 CT scans showing Pure (a and c) and impure (b and d) blowout fractures of the orbit

“Blow-in” type of orbital fractures was described by Dingman and Natvig [3, 12] in 1964 wherein the intra-orbital space is reduced by an internally displaced bony fragment

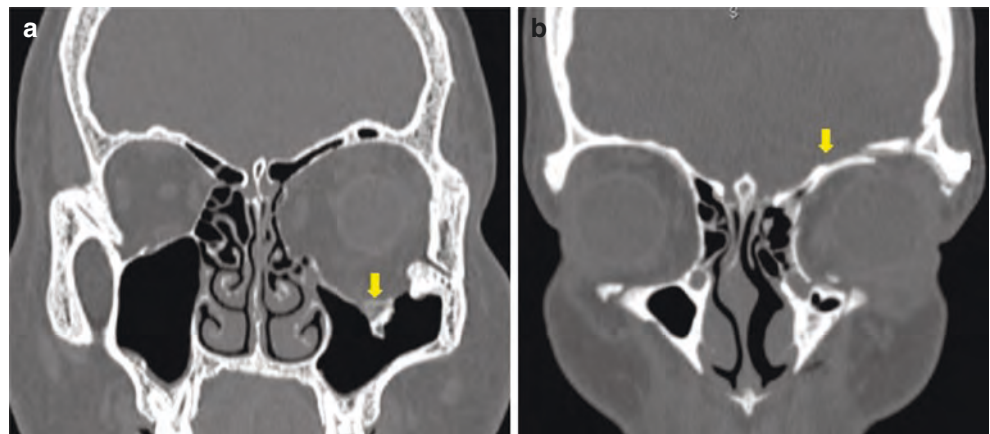
(Fig. 57.10b). Such types of fractures are usually accompanied with proptosis on the affected side [13].



©Association of Oral and Maxillofacial Surgeons of India

Fig. 57.9 CT scan images showing types of orbital fractures: (a) orbito-zygomatic, (b) internal orbital, (c) naso-orbito-ethmoid type, and (d) orbit with complex facial fractures

Fig. 57.10 CT scans demonstrating a blowout of the medial orbital wall and floor (a) and a blow-in fracture of the orbital roof (b)



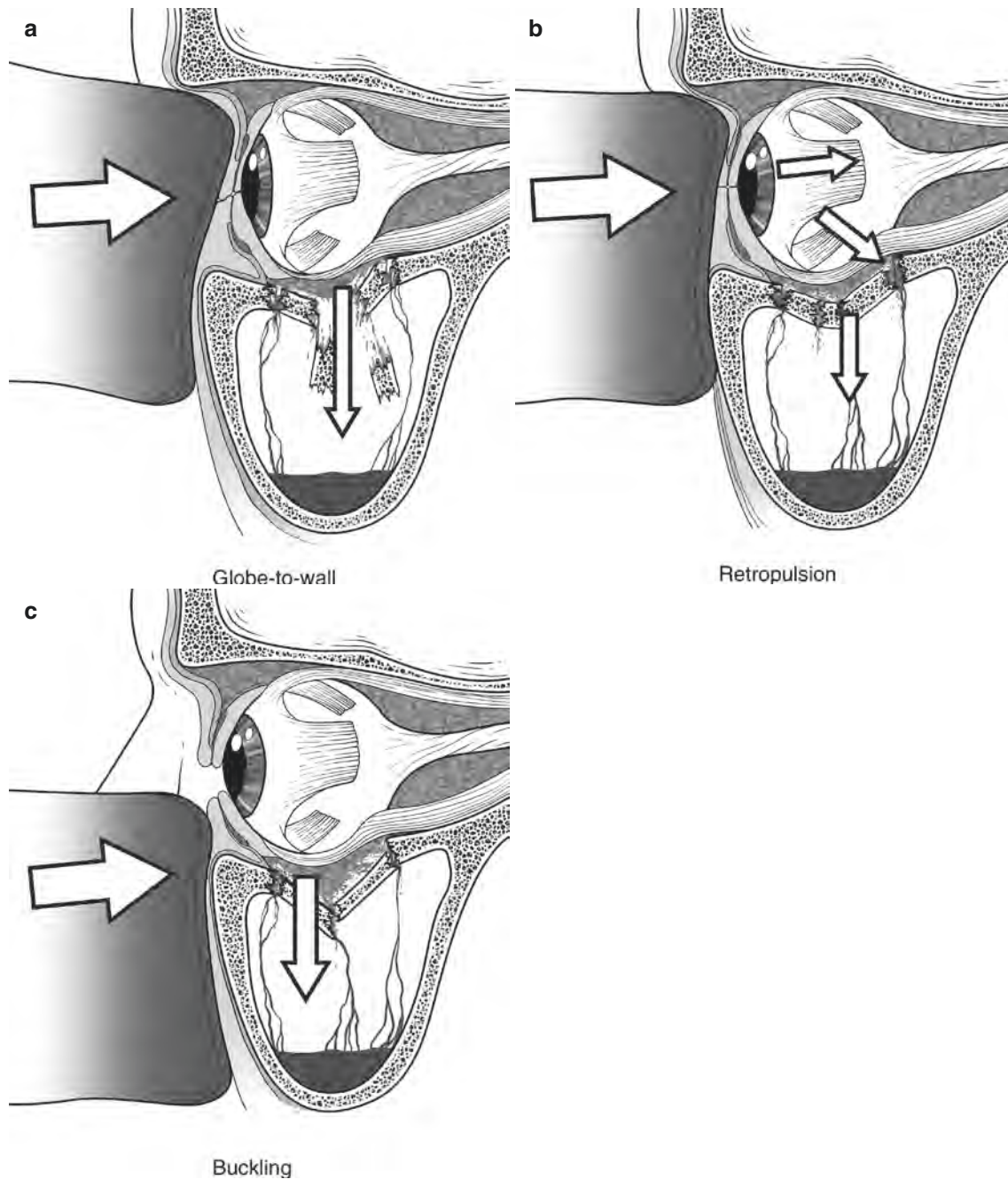
©Association of Oral and Maxillofacial Surgeons of India

57.5 Biomechanics of Injury

One of the first mechanisms of orbital wall fractures was suggested by Pfeiffer [14] in 1943, called *globe-to-wall theory or hydraulic theory* (Fig. 57.11a), wherein posterior displacement of the globe after sustaining a direct hit

was propounded to transmit force along the walls resulting in fracture of the thinner walls. There are two more widely accepted mechanisms of orbital wall fractures, namely, the:

- (i) *Retropulsion theory* (Fig. 57.11b)
- (ii) *Buckling mechanism* [15] (Fig. 57.11c)



©Association of Oral and Maxillofacial Surgeons of India

Fig. 57.11 Diagrammatic representation of (a) hydraulic theory, (b) retropulsion theory, and (c) buckling mechanism

First proposed by King [16] in 1944, retropulsion theory suggests that sudden increase in intra-orbital pressure caused by direct hit from a large object creates stresses along the orbital walls resulting in fractures at the areas of least thickness. The buckling theory or transmission theory explains the injury through a ripple effect created in the floor. The ripple thus created causes compression in an anteroposterior direction and resultant fracture at the posteromedial part of the orbital floor commonly [17, 18].

57.6 Initial Assessment

After initial stabilization of the patient, a thorough facial examination is performed in a way similar to any facial fracture. Special consideration is given to a detailed ophthalmic evaluation followed by eliciting signs and symptoms significant for periorbital trauma which are discussed below. The frontal area and supraorbital rim are examined first, with a logical progression downward, including the lateral and infra-orbital rims, although extensive edema in this area may obscure any steps making the palpatory examination difficult [3, 7, 19–22].

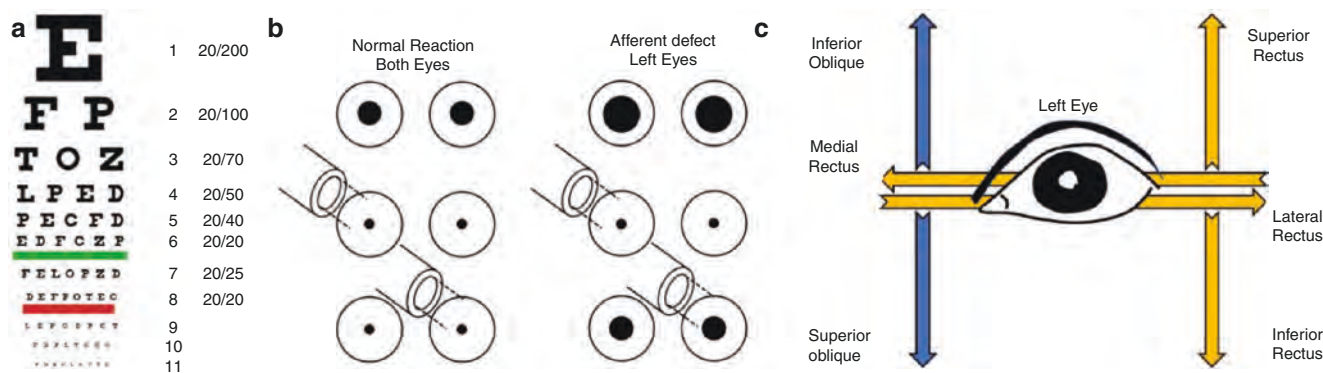
57.6.1 Ophthalmologic Examination

The American Association of Ophthalmology [23] advocates an 8-point ophthalmological examination which includes the following (Box 57.3):

1. *Visual acuity*: Visual acuity test for each eye is recorded using a Snellen chart (Fig. 57.12a) and includes ability to read letters, count fingers, perceive hand movements, and

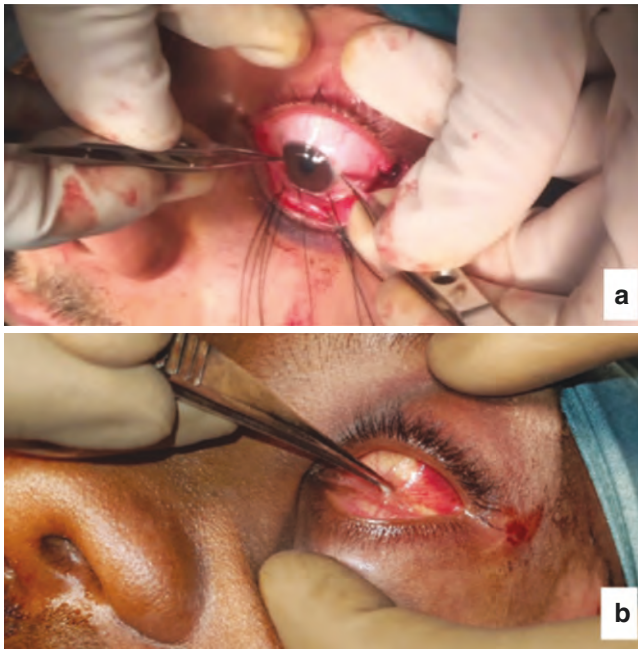
light perception. If visual acuity is extremely poor and recording of a chart test fails, the patient is subjected to a finger counting test or at times even assessed for primary light perception alone.

2. *Pupillary examination*: Pupillary examination is done to note the
 - (a) size,
 - (b) shape,
 - (c) symmetry,
 - (d) and direct/indirect reflex to light.*Glaucoma*, previous history of surgery, and/or injury to ocular system may also account for anisocoria or irregular pupils. Peaked or irregular pupils may also be indicative of perforation of the globe. The swinging flashlight test is performed for relative afferent pupillary defect (RAPD) (Fig. 57.12b).
3. *Extraocular motility and alignment*: The patient is first screened for all the six cardinal gazes (Fig. 57.12c). First checked binocularly for versions of both sides and then checked monocular for ductions. A thorough heterotropia check is also performed. Diplopia and restrictions in gazes are noted. Clinically, a forced duction test under topical anesthesia is done to elicit mechanical impediment to movement of the globe. This may also be performed under general anesthesia intraoperatively (Figs. 56.21, 57.13). A Hess chart examination is a part of the orthoptic assessment protocol for evaluation of ocular motility.
4. *Intraocular pressure*: Tonometry should be performed to evaluate intraocular pressure either in a clinic setting using a Goldmann applanation method or outside using a mobile/portable device. This examination is skipped if there is a suspicion of ruptured globe. The normal IOC



©Association of Oral and Maxillofacial Surgeons of India

Fig. 57.12 Picture showing (a) the Snellen chart, (b) swinging flash light test, and (c) the six cardinal signs of gazes



©Association of Oral and Maxillofacial Surgeons of India

Fig. 57.13 Demonstration of the method of performing intraoperative forced duction test (a) by grasping the limbus (sclero-corneal junction) and (b) by grasping the inferior rectus muscle

is a range between 10 and 21 mmHg with the mean being around 15 mmHg. Low IOP may be suggestive of a ruptured globe or detached retina, while increased IOP may indicate hyphema, glaucoma, or an orbital compartment syndrome like “retrobulbar hemorrhage.” A pressure of more than 30 mmHg is an ophthalmological emergency.

5. *Visual fields:* Visual fields for each eye are checked by asking the patient to determine movements at the periphery of the examiner’s own visual field, while at a distance of about 2 ft from each other. Loss of field may be suggestive of compressive or ischemic injuries to the optic nerve with or without damage to the visual pathway. Goldmann visual field test can also be employed to objectively chart binocular visual field loss wherein patient is asked to look at a center of the chart and is required to track a point source of light.

6. *External examination/periorbital screening:* A thorough clinical evaluation is performed to note down all clinical features detailed below. Orbital trauma is generally associated with possible adnexal injuries which also need to be assessed for intervention and management.
7. *Slit-lamp examination:* A formal slit lamp test is performed if it may be allowed. This provides information about the lids, lashes, lacrimal system, conjunctiva, sclera, anterior chamber, iris, the lens, and the anterior vitreous.
8. *Fundoscopic examination:* A fundoscopic examination is performed to assess the retina, optic nerve head, and the vessels. This is done by the use of an ophthalmoscope. It also provides information about presence of intraocular hemorrhages and foreign bodies.
9. *Globe position:* An important feature in examination of orbital trauma from a cranio-maxillofacial perspective includes the examination of globe positions. This is performed both clinically and by using an exophthalmometer. The Hertel’s exophthalmometer is used in common settings for the evaluation of proptosis or enophthalmos. In case of injuries involving the lateral face, like a fracture of the ZMC, the Naugle’s exophthalmometer is used.

Box 57.3 “8-Point” Ophthalmic Examination Advocated by the American Association of Ophthalmology [23]

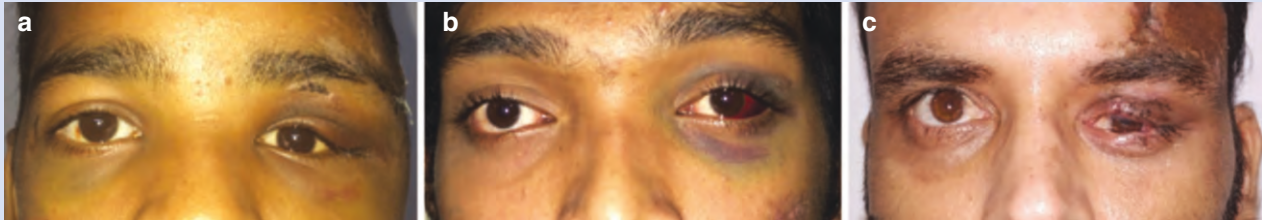1.	Visual acuity and visual fields
2.	Pupillary examination
3.	Extraocular motility and alignment
4.	Intraocular pressure
5.	External examination/periorbital screening
6.	Slit-lamp examination
7.	Fundoscopic examination
8.	Globe position

57.6.2 Clinical Features

A good evaluation of the skeletal and soft tissue components of the orbit as well its associated adnexa (eyelids, lacrimal apparatus, etc.) is mandated. The common clinical features that are presented with in orbital trauma are provided in Box 57.4.

Box 57.4 Common Clinical Features in Orbital Trauma Are Enumerated Below

- Periorbital edema (Fig. 57.14a)
- Periorbital ecchymosis and subconjunctival hemorrhage (Fig. 57.14b)
- Contusions and hematomas
- Subcutaneous emphysema with crepitus
- Lacerations involving the eyelids (Fig. 57.14c)
- Injuries to the canthal apparatus (medial and lateral)
- Neurological deficits of the infra-orbital and facial nerves



©Association of Oral and Maxillofacial Surgeons of India

Fig. 57.14 Clinical pictures demonstrating (a) edema of the left periorbital region, (b) left-sided periorbital ecchymosis and subconjunctival hemorrhage, and (c) soft tissue injury of the left eyelid and supraorbital region

Clinical signs and symptoms that are more exclusive to orbital trauma are discussed further in more detail.

57.6.2.1 Enophthalmos/Hypophthalmos (Fig. 57.15a, b)

Any change in the orbital volume directly impacts the position of the globe and its anteroposterior projection and supero-inferior position [24]. Clinically enophthalmos can be detected by an exaggerated suprapalpebral fold and reduced projection on viewing from an inferior view or worm's view. Hertel's or Naugle's exophthalmometer can also be used to quantify and measure the discrepancy. Other causes of enophthalmos implicated are traumatic atrophy of intra-orbital fat, infections causing cicatricial contraction of retrobulbar tissues, and dislocation of trochlear attachment of superior oblique muscle due to trauma [25, 26]. Hypophthalmos is noted as a change in the horizontal pupillary levels.

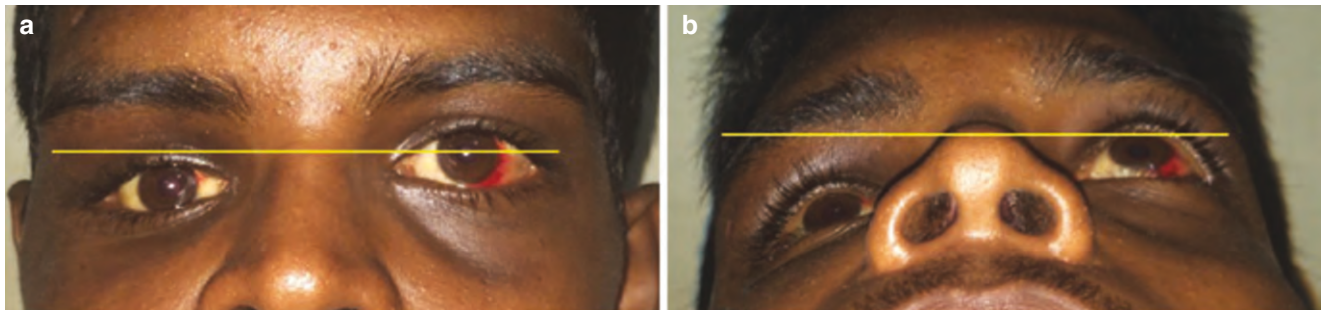
57.6.2.2 Retrobulbar Hemorrhage (Fig. 57.16)

Retrobulbar hemorrhage is a vision threatening emergency which occurs due to accumulation of blood in the retrobulbar

space. This causes increased intra-orbital pressure resulting in compression or stretching of the optic nerve and reduced perfusion to the eye. Orbital trauma especially blunt injury may be associated with retrobulbar hemorrhage which warrants immediate attention. However this may also occur as a complication following surgery to the orbit or pathologies like an aneurysm. Acute post-septal hemorrhage limited anteriorly by the orbital septum and posteriorly by bone may cause permanent loss of vision by creating a compartment syndrome [27]. It presents as reduced ocular motility, elevated intraocular pressure, proptosis, and diminishing vision. In unconscious patients, pupillary assessment, increased pressure, and presence of relative afferent pupillary defect or RAPD are usually diagnostic.

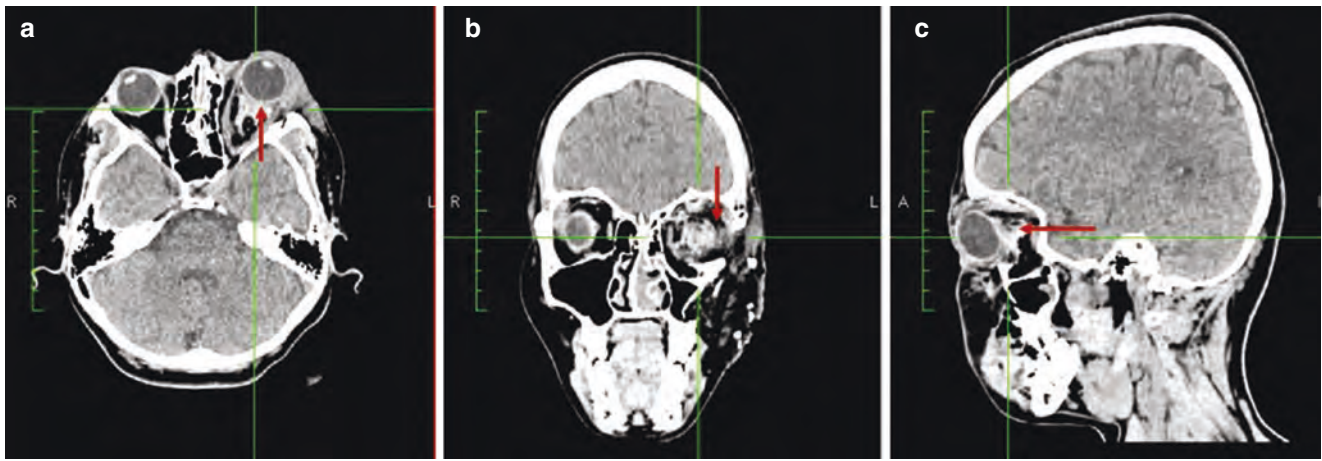
57.6.2.3 Lacrimal System Injuries

Due to its close topographical location to the orbital complex, nasolacrimal system especially the duct may be involved in traumatic injuries to the orbit. Injury to the canaliculi or the nasolacrimal ducts in naso-orbito-ethmoidal injuries may present as epiphora [28]. Patency of



©Association of Oral and Maxillofacial Surgeons of India

Fig. 57.15 Clinical photograph of a patient with both (a) hypophthalmos and (b) enophthalmos of the right globe



©Association of Oral and Maxillofacial Surgeons of India

Fig. 57.16 (a) Axial, (b) coronal, and (c) sagittal section CT scan images demonstrating left-sided retrobulbar hemorrhage

the naso-lacrimal duct and sac can be verified by the Jones tests 1 and 2 or by a simple lacrimal probing test with insertion of a Crawford silicone intubation tubes through the canaliculi and visualization of the same at the distal end of the disruption. ROPLAS test or regurgitation on pressure over lacrimal sac may be performed clinically to elicit post-traumatic blockage of the nasolacrimal duct (Fig. 57.17c). Confirmation however is obtained with a CT dacryocystogram or CT-DCG (Fig. 57.17a, b). Reconstruction of the lacrimal drainage system is achieved by simple intubations or a formal dacryocystorhinostomy as indicated by the clinical scenario.

57.6.2.4 Oculocardiac Reflex (Trigemino-cardiac Reflex)

First described by Dagnini and Aschner in 1908, oculocardiac reflex is bradycardia on manual compression of the eyes. The most common traumatic etiology is the incarceration of inferior rectus muscle in trap-door fractures of the orbital floor [29, 30]. Other causes that may present with oculocardiac reflex are retrobulbar hemorrhage, white-eyed blowout fractures and orbital surgery.

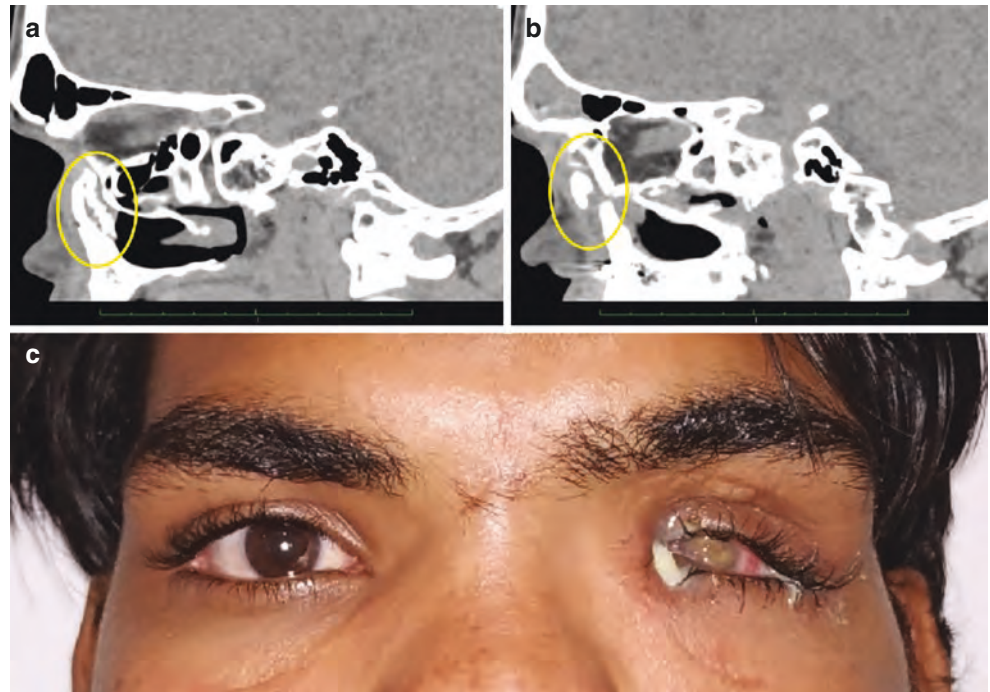
57.6.2.5 Superior Orbital Fissure Syndrome (Box 57.5)

Post-traumatic superior orbital fissure syndrome may be attributed to pressure exerted on the contents of the superior orbital fissure due to hemorrhage or impingement by fractured fragments.

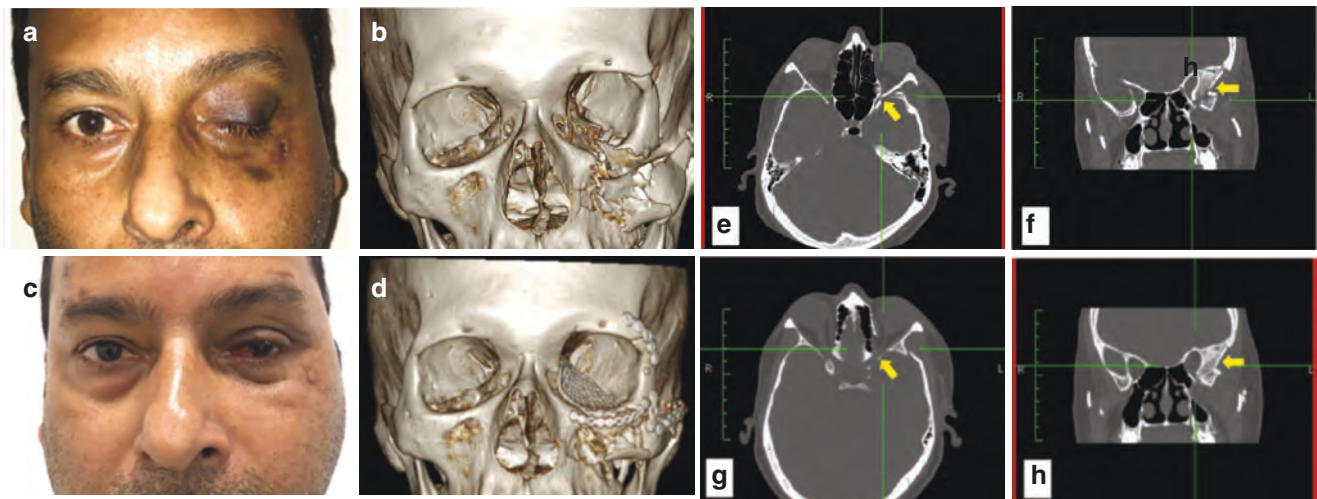
Superior orbital fissure syndrome was first described by Hirschfield in 1858 [31, 32] and symptoms include:

- (i) Ophthalmoplegia due to involvement of III, IV, and VI cranial nerves.
- (ii) Paresthesia over the forehead due to involvement frontal nerve of first division of trigeminal nerve.
- (iii) Ptosis due to impeded action of levator palpebrae superioris and Muller's muscle.
- (iv) Pupillary dilatation due to paresis of circular sphincter muscle and unrestricted action of dilator pupillae.
- (v) Impairment of direct pupillary reflex due to blocked ipsilateral efferent arc, whereas consensual reflex is preserved due to intact ipsilateral efferent and contralateral efferent arcs.

Fig. 57.17 (a) Sagittal section CT DCG demonstrating patent NLD with draining dye and (b) blocked NLD with no drainage of the dye. (c) Clinical photograph of patient with left-sided NOE fracture demonstrating regurgitation of contents due to blocked left naso-lacrimal duct ROPLAS positive



©Association of Oral and Maxillofacial Surgeons of India



©Association of Oral and Maxillofacial Surgeons of India

Fig. 57.18 Clinical pictures and CT scans of patient with orbital apex syndrome. (a) Clinical picture demonstrating left-sided orbito-zygomatic trauma with clinically evident ptosis, (b) 3D CT demonstrating comminuted zygomatico-orbital fracture with medial displacement of the greater wing of sphenoid, (c) clinical picture of patient 2 weeks post-surgery with resolution of ptosis, (d) post-operative 3D CT show-

ing ORIF, (e) pre-operative axial CT demonstrating total compression of the left optic canal (yellow arrow), (f) pre-operative coronal CT demonstrating compression of the left superior orbital fissure (yellow arrow), (g) post-operative CT showing decompressed left optic canal (yellow arrow) and (h) post-operative coronal CT showing decompression of the left superior orbital fissure (yellow arrow)

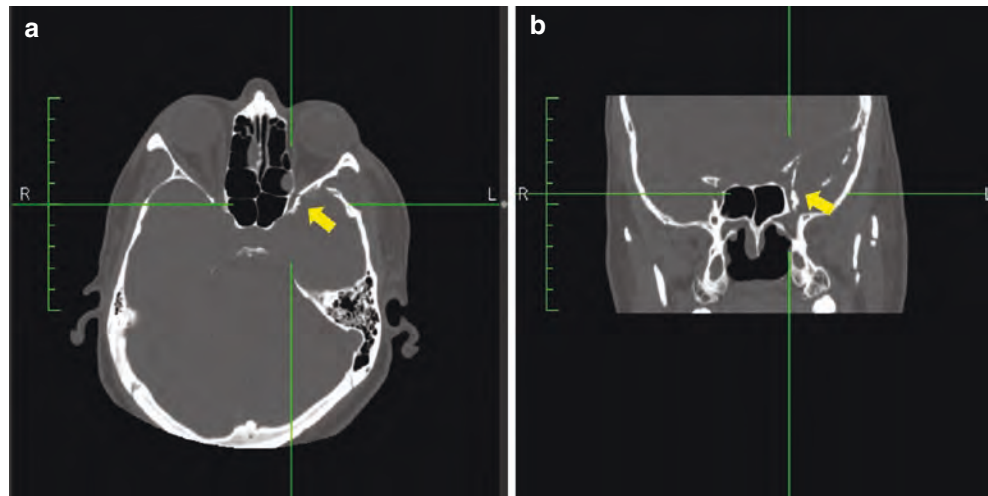
- (vi) Impaired accommodation is because of impaired parasympathetic pathway to the ciliary ganglion.
- (vii) Loss of corneal reflex due to lack of transmission via the nasociliary branch of ophthalmic nerve.
- (viii) Proptosis either due to presence of hemorrhage or paresis and laxity of extraocular muscles which normally aid in globe retraction.

Management may be conservative or exploratory surgery of the orbit including surgical decompression [33].

57.6.2.6 Orbital Apex Syndrome (Fig. 57.18) (Box 57.5)

In severe orbital trauma, optic nerve may also be implicated due its close proximity to the superior orbital fissure [31, 34]. The term orbital apex syndrome was first coined by Kjaer in 1945 [35], and the symptoms include all features

Fig. 57.19 (a, b) Axial CT scan of patient with direct traumatic optic neuropathy demonstrating a skull base fracture and bony spicule at the entry of the optic nerve into the canal



©Association of Oral and Maxillofacial Surgeons of India

of superior orbital fissure syndrome along with partial or loss of vision.

57.6.2.7 Traumatic Optic Neuropathy (TON) (Box 57.5)

TON may be defined as an acute injury to the optic nerve with impairment of visual function. It may occur as a result of:

- (i) Direct trauma to the optic nerve (Fig. 57.19) (physical damage or nerve sheath compression due to compartment syndromes)
- (ii) An indirect insult due to diffuse axonal damage secondary to conduction of forces from blunt head trauma
The occurrence may be unilateral or bilateral.

Clinical features of TON include:

- (i) Afferent pupillary defect
- (ii) Diminished visual acuity
- (iii) Diminished color perception
- (iv) Varying reduction in visual fields

Management of TON is handled under the section of orbital emergencies.

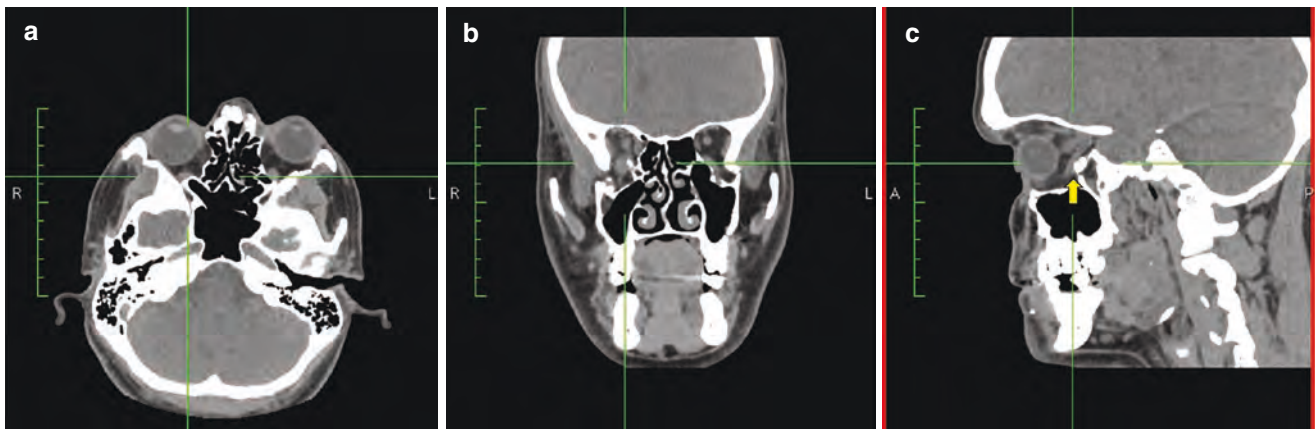
57.6.3 Investigations

Conventional radiographs have a minimal role in the diagnosis and planning of orbital fractures. CT scans (Fig. 57.20a–c) have long been considered the “gold stan-

Box 57.5 Comparison of Clinical Features of Traumatic Optic Neuropathy, Superior Orbital Fissure, and Orbital Apex Syndromes

Traumatic optic neuropathy (TON)	Superior orbital fissure syndrome	Orbital apex syndrome
Unilateral or bilateral	Ophthalmoplegia with involvement of cranial nerves III, IV, & VI	All features of superior orbital fissure syndrome
Relative afferent pupillary defect (RAPD) except in symmetrical bilateral cases	Forehead paresthesia	Partial or total loss of vision
Variable loss of visual acuity (from normal to no vision)	Ptosis	
Impaired color vision	Dilated pupil	
Variable visual field defects	Impaired direct but preserved consensual pupillary reflex. Impaired accommodation Loss of corneal reflex Proptosis	

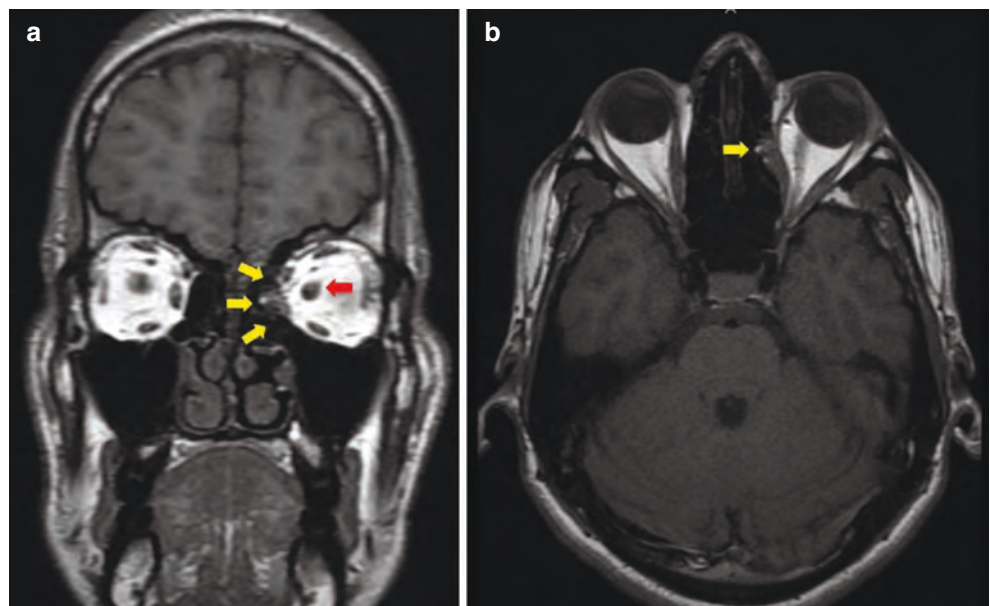
ard” in orbital trauma. The scans are usually ordered in fine cuts of 0.5 mm and taken in all the three planes. The coronal and the sagittal scans are important in the diagnosis



©Association of Oral and Maxillofacial Surgeons of India

Fig. 57.20 CT scans showing (a) axial section with fracture of the medial wall of the right orbit, (b) coronal section showing fractures of the medial wall and floor, and (c) sagittal section showing fracture of the floor with fibrosis of the inferior rectus to the posterior ledge (yellow arrow)

Fig. 57.21 MRI (a) coronal and (b) sagittal sections, demonstrating entrapment of the medial rectus (yellow arrows) and medial displacement of the optic nerve (left orbit)



©Association of Oral and Maxillofacial Surgeons of India

of fractures of the floor and the roof, while the axial scans provide better information regarding the fractures of the medial and lateral walls. Axial sections are also important to study the optic canal integrity.

Indications for an MRI (Fig. 57.21a, b) scan are limited to determining soft tissue injuries and entrapment of muscles and to assessing damage to the optic nerve. It is also used to identify intra-orbital herniation of brain in the case of blow-in fractures.

57.7 Approaches to the Orbit

Box 57.6 Surgical Approaches to the Orbit

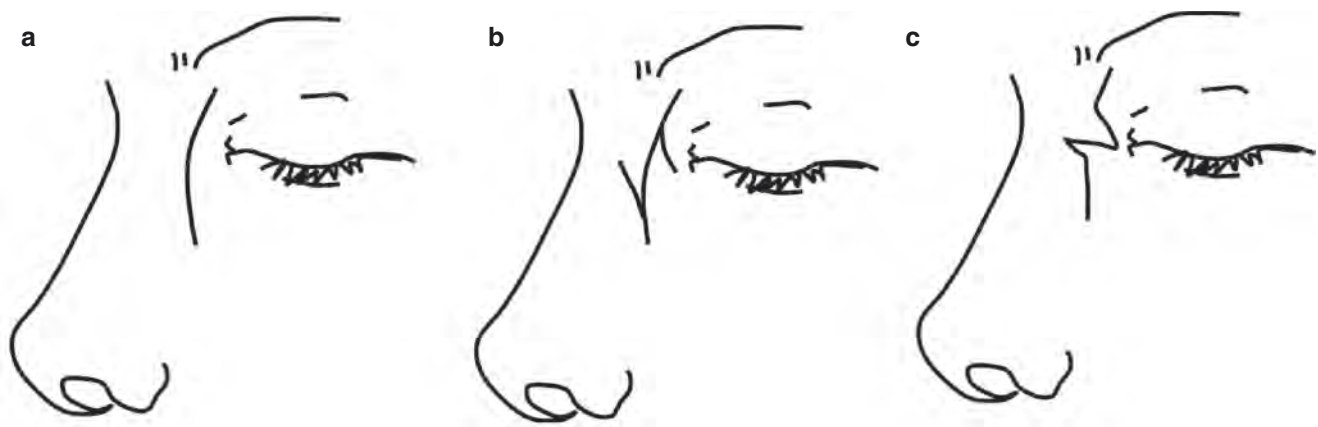
- Transcutaneous-medial and lateral
- Trans-caruncular
- Transconjunctival

57.7.1 Transcutaneous Approaches

1. Lynch
2. Extended glabellar approach
 - (a). Lateral transcutaneous approaches
 - (i) Lateral brow incision
 - (ii) The upper lid blepharoplasty and the sub brow approaches
 - (b). Lower eyelid approaches (Also refer Figs. 56.44, 56.45)
 - (i) Sub-ciliary
 - (ii) Sub-tarsal
 - (iii) Infra-orbital (Video 57.1)

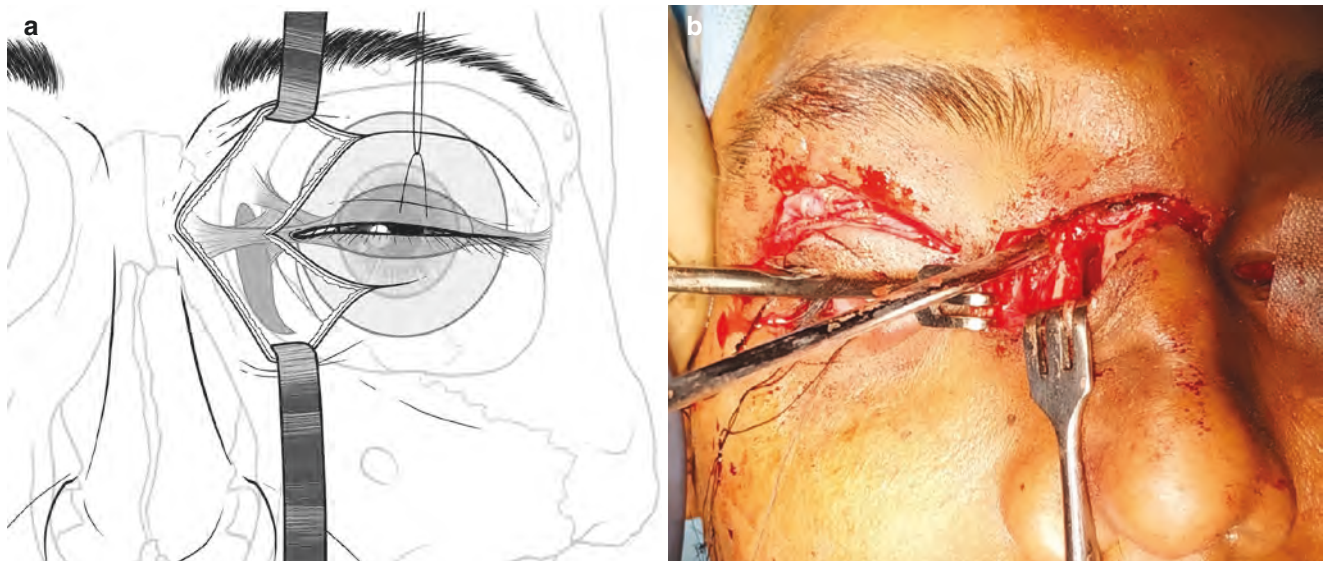
57.7.1.1 Lynch

This incision described by Lynch [36] in 1921 is a semilunar-shaped incision (Fig. 57.22a) placed between the nasal dorsum and the medial canthal ligament that provides direct access to the canthal apparatus and the medial orbital rim and wall. The major drawbacks of this particular incision are chances of developing a web and hence an unsightly scar. There may also be risk of damage to the medial canthal tendon and the lacrimal apparatus that is present infero-laterally. Recent modifications of the Lynch incision have accommodated options to reduce the scarring by the use of “Z” plasties (Fig. 57.22b, c) and other esthetic incision designs.



©Association of Oral and Maxillofacial Surgeons of India

Fig. 57.22 Diagrammatic representation of the (a) classical Lynch incision and (b, c) modification with “Z” plasty



©Association of Oral and Maxillofacial Surgeons of India

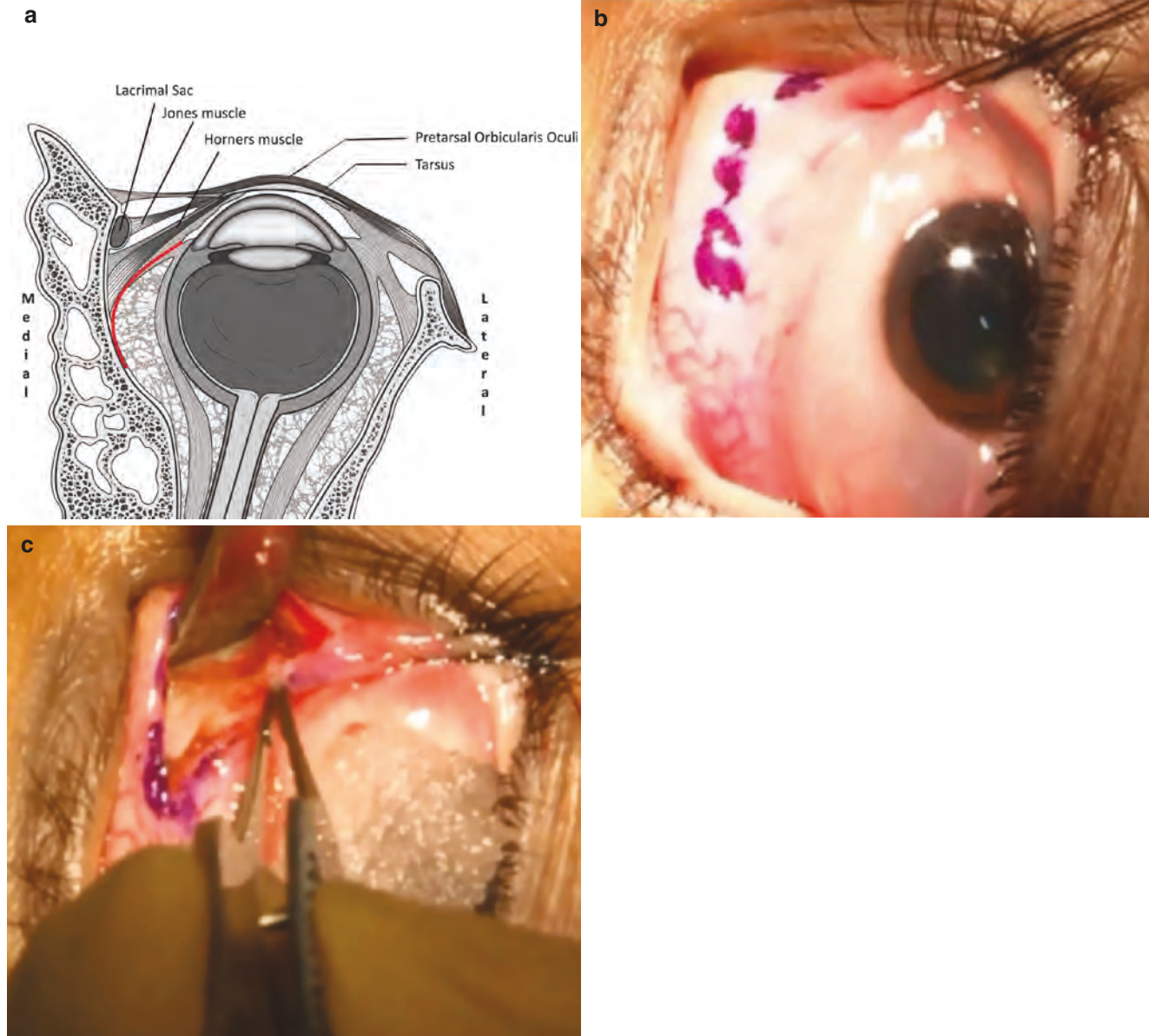
Fig. 57.23 Diagram and intraoperative picture showing extended glabellar approach to the medial orbit

57.7.1.2 Extended Glabellar Approach (Fig. 57.23)

The extended glabellar incision or a horizontal “Y” approach involves a small Y-shaped incision with the fork extending over the upper and lower lid crease with the long arm across the nasal dorsum over the glabellar region. This approach provides excellent access to the medial canthal tendon apparatus and also provides enough room for medial orbital wall exploration cephalad to the tendon.

57.7.2 Trans-caruncular Approach

The trans-caruncular route provides excellent exposure to the medial orbit without causing any esthetic concern. The caruncle is a papular structure seen medial to the plica semilunaris which is a fold of conjunctiva in medial canthal region. An avascular plane is located deep to the caruncle between the medial orbital septum and the Horner’s muscle which on dissection exposes the medial wall of the orbit (Fig. 57.24a) [37].



©Association of Oral and Maxillofacial Surgeons of India

Fig. 57.24 (a) Diagram and (b) intraoperative pictures showing marking for trans-caruncular approach to the medial orbit and (c) exposure of the medial orbital wall. (Courtesy: Dept of Orbit & Oculoplasty, Shankara Nethralaya, Chennai)

After placing retraction sutures on upper and lower eyelids, gentle medial traction is applied over the skin of the nasal dorsum, and incision is placed lateral to the caruncle, while avoiding injury to the lacrimal puncta or canaliculi (Fig. 57.24b). The length of the incision is between 1.5 and 2.5 cm. Dissection through the fibers of the Muller's muscle exposes the medial wall just posterior to the posterior lacrimal crest (Fig. 57.24c). For additional exposure of associated orbital floor fractures, a C-shaped approach can be used including a transconjunctival incision with or without lateral canthotomy and inferior cantholysis in conjunction with the trans-caruncular approach.

As the lateral transcutaneous and lower lid approaches also find use in the management of fractures of the zygomatic complex fractures, they are discussed in detail in chapter on zygomatic complex fractures.

57.7.3 Transconjunctival Approach (Fig. 57.25)

The infra-orbital rim and orbital floor defects can be accessed through a transconjunctival incision (Video 57.2).

Its advantages include:

- (i) Excellent cosmesis
- (ii) Minimal incidence of ectropion
- (iii) Extensive access up to 270° including the floor and medial and lateral walls, with the modifications to the conventional approach

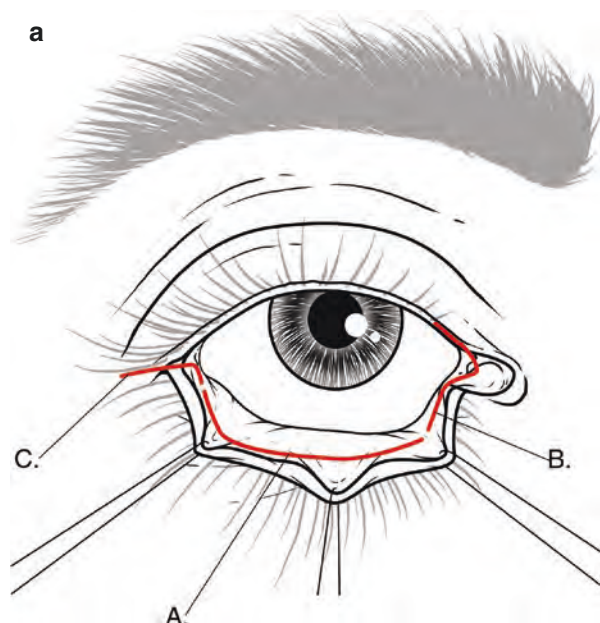
A historical perspective of the description of the transconjunctival approach and its evolution into the most favored approach for access to the floor and medial wall of the orbit along with the infra-orbital rim is provided in Box 57.7.

Box 57.7 Evolution and Modifications of the Transconjunctival Approach

Author	Year	Description
Bourget J	1924	Conjunctival approach for blepharoplasty
Tenzel & Miller	1971	Post-septal approach
Tessier P	1973	Pre-septal approach
McCord & Moses	1979	"Swinging eyelid" with lateral canthotomy
Garcia GH	1998	Trans-caruncular approach

Pre-septal Approach (Fig. 57.26)

The incision is marked 2–3 mm posterior to the tarsal plate along the mediolateral length of the lower palpebral conjunctiva. Dissection is performed along the subconjunctival plane and is carried down toward the inferior orbital rim. This maintains the plane anterior to the orbital septum. Retraction sutures may be placed on the vestibular portion of the conjunctival flap with traction in superior direction, to provide additional protection to the globe. On reaching the facial surface of the infra-orbital rim, the periosteum is incised about

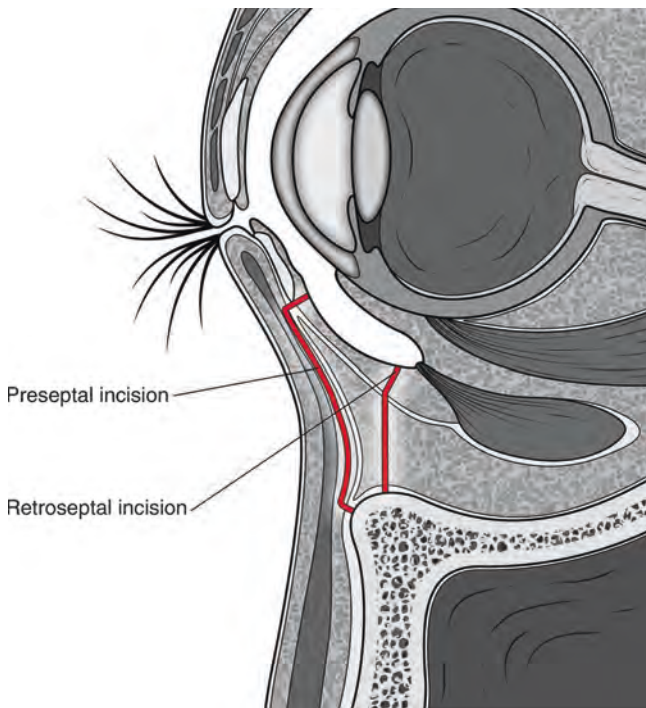


©Association of Oral and Maxillofacial Surgeons of India

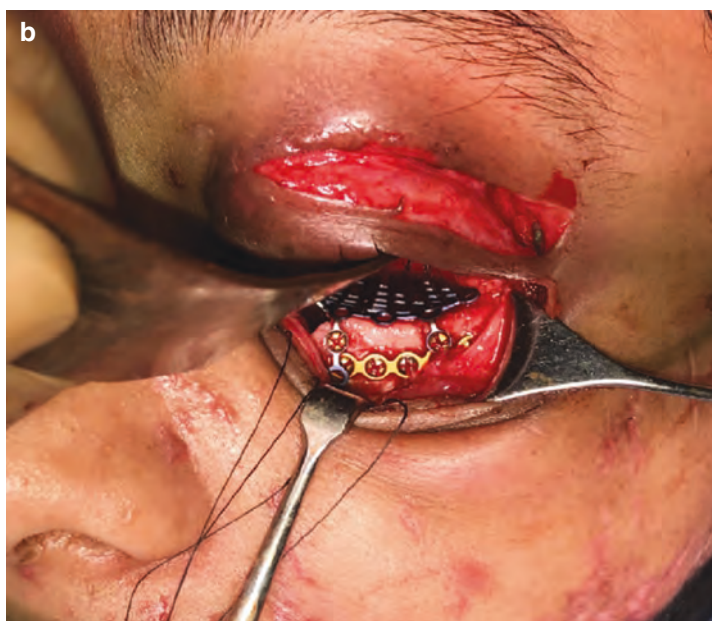

Fig. 57.25 (a) Diagram showing trans-conjunctival approach and its modifications - A. Transconjunctival, B. Trans-caruncular & C. Lateral canthotomy. (b) Intra-operative picture of trans-conjunctival with the lateral canthotomy modification. The picture also shows an upper lid blepharoplasty incision used to access the fronto-zygomatic suture

2 mm inferior to the rim. This is followed by subperiosteal dissection and exploration of the orbital floor by retracting the globe and orbital contents superiorly. Approximately 2–3 mm distance must be maintained from the lower end of the tarsal plates while making the initial conjunctival incision failing which there is vertical shortening of the lower eyelid and entropion post-operatively.



©Association of Oral and Maxillofacial Surgeons of India

Fig. 57.26 Diagrammatic representation of the pre-septal and retro-septal modifications of the transconjunctival approach

Retroseptal Approach (Fig. 57.26)

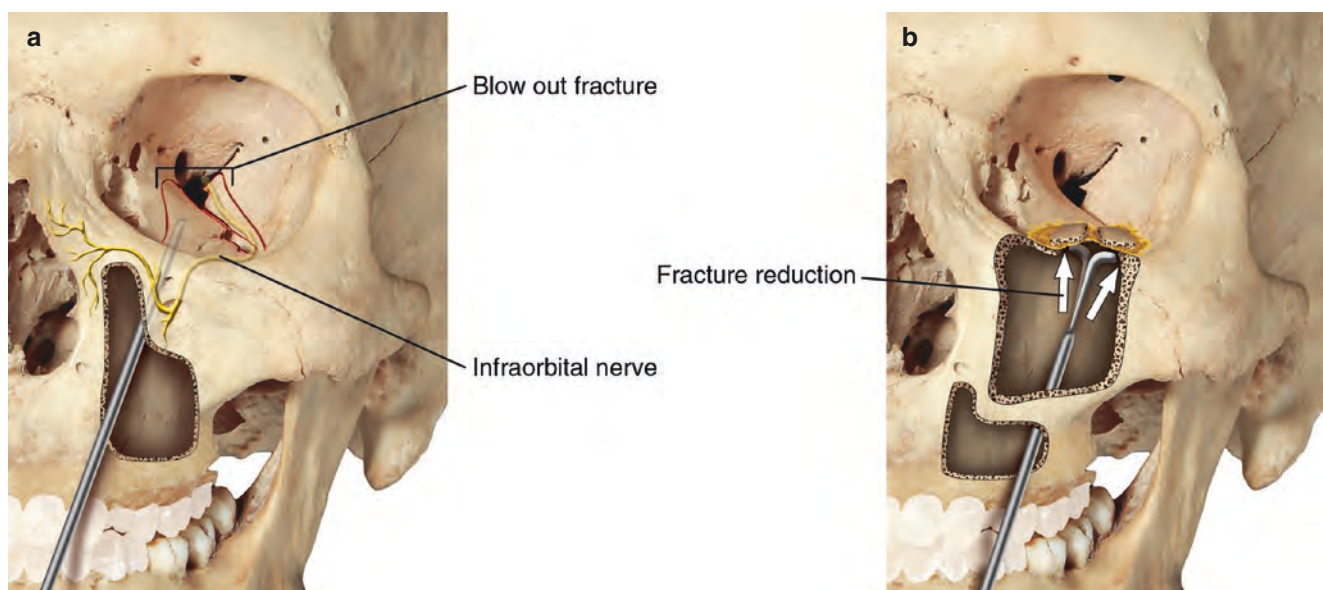
In the retroseptal type, the conjunctival incision is made near the fornix spanning mediolaterally just short of the caruncle. Dissection is posterior to the orbital septum providing a fast and direct access to the floor when compared to the pre-septal type [38]. However, orbital fat is encountered before approaching the orbital floor, which may prove bothersome for dissection and manipulation. The periorbita is incised immediately posterior to the rim after superior retraction of the fat and globe with a malleable retractor. This is followed by subperiosteal dissection and exploration of the floor defect. Excessive manipulation of the orbital fat during orbital reconstruction increases the risk of enophthalmos due to fat disintegration [39, 40]. Placement of the incision too low into the fornix may damage the inferior oblique muscle and retractors of the lower eyelid, compromising esthetics post-operatively due to lower lid entropion.

57.7.4 Trans-antral Endoscopic-Assisted Approach (Fig. 57.27a, b)

The trans-antral approach was attempted by Converse and Smith [41] as early as the 1960s. Entry to the antrum is gained through a transoral Caldwell Luc procedure and a 0° or 30° endoscope may be used to visualize the orbital floor.

57.7.5 Coronal Approach

The coronal approach offers the most extensive exposure of the entire upper and middle third of the face including the orbit. A detailed description of the same is provided in Chap. 85 on access osteotomies.



©Association of Oral and Maxillofacial Surgeons of India

Fig. 57.27 (a, b) Diagram of the trans-antral endoscopy assisted approach to the orbital floor

57.8 A Clinical Sequence for Treatment Planning and Management of Orbital Fractures

A clear understanding of the various patterns of orbital fractures and their clinical implications is absolutely necessary to design and formulate a plan for their reconstruction. The basic management guidelines for the common variations in orbital fractures are detailed below (see Hammer [7] classification, Fig. 57.9).

57.8.1 Type I (Orbito-Zygomatic)

Concomitant fractures of the zygomatic complex and the orbit mandate ORIF of the zygomatic complex first, followed by internal orbital reconstruction. This sequence is

favoured because the orbital rims provide the most accurate guidance for restoration of the internal orbital architecture.

Box 57.8 The Surgical Objectives for Type I Fractures

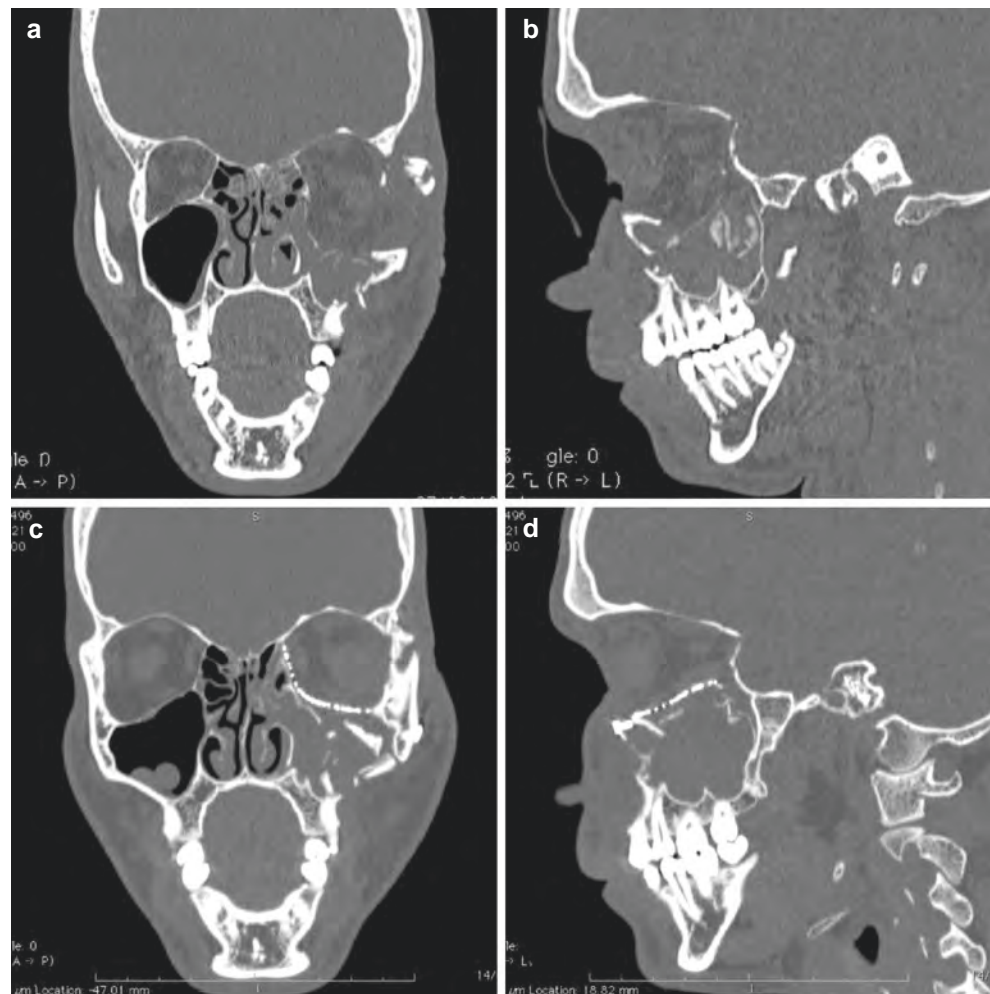
- Restoration of transverse dimension of the face, malar prominence, and the arch anatomy
- Restoration of rim architecture
- Correction of orbital dystopia
- Correction of the axis of the palpebral fissure and
- Reconstruction of the internal orbit

Figures 57.28a–d and 57.29a–d demonstrate a type I fracture managed using the above principles.

Fig. 57.28 3D CT scans of patient with orbito-zygomatic fracture. (a and b) Pre-operative frontal and basal views demonstrating the fracture, (c and d) post-operative frontal and basal views demonstrating fixation of fractures

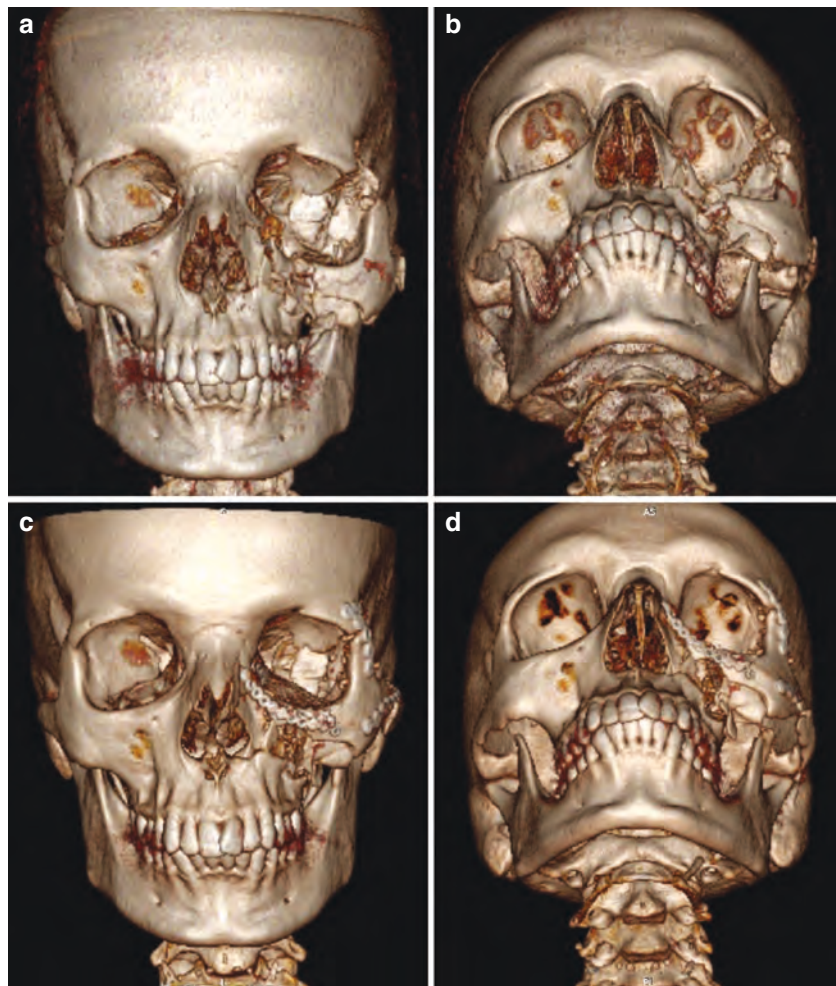

Fig. 57.29 Axial and sagittal scans of the patient in Fig 57.28, with orbito-zygomatic fracture. (a and b) Sections demonstrating fracture of the left zygomatic complex with a large defect of the orbital floor. (c and d) Post-operative sections revealing optimal reduction of the fracture and floor reconstruction with anatomical orbital floor implant



©Association of Oral and Maxillofacial Surgeons of India

57.8.2 Type II (Internal Orbital)

Management of type II orbital fractures, which are essentially the internal fractures (both blow-in and blowout) of the orbit including (1) the roof, (2) the floor, and (3) the medial and (4) lateral walls are detailed below.

Box 57.9 The Management of All Internal Orbital Fractures Can Be Handled Essentially by Answering the Following Basic Questions (Clinical Tip)

- (i) Is there a need for intervention?
- (ii) When is the best time to intervene?
- (iii) Is there a need for reconstruction?
- (iv) What to use for reconstruction?

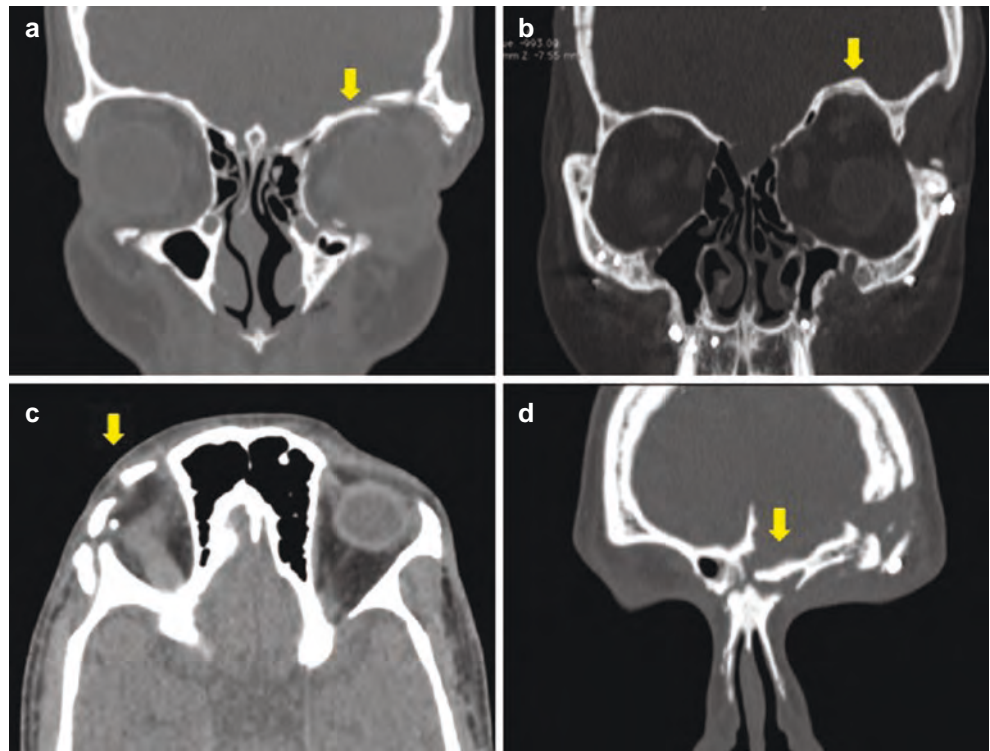
57.8.2.1 Fractures of the Orbital Roof

Isolated fractures of the orbital roof are extremely rare. They usually occur as a part of fronto-basilar fractures, fractures of the frontal sinus, or may occur concomitant with fractures of the supraorbital rim. Orbital roof fractures are present in approximately 5% of all orbital and cranial fractures, while incidence of isolated orbital roof fractures may be as low as 0.7% of all orbital and cranial fractures. The most common etiological factors include motor vehicle accidents, assaults, or falls.

Orbital roof fractures may be associated with more severe neurological symptoms including dural tears, CSF leak, tension pneumocephalus, diffuse cerebral edema, and contusions of the frontal lobe [42]. It is imperative for a neurological and ophthalmological consult prior to management.

In general, orbital roof fractures may be categorized into four types (Fig. 57.30).

Fig. 57.30 CT scan images showing types of roof fractures (a) blow-in fracture, (b) blowout fracture, (c) fracture of the supraorbital rim, and (d) fronto-basilar fracture



©Association of Oral and Maxillofacial Surgeons of India

- I—Blow-in fractures of the orbital roof where there is caudal displacement of the orbital roof with or without herniation of the brain. These may be undisplaced or displaced fractures. Comminuted fractures may leave fragments within the orbital cavity and may produce functional deficits with ophthalmic signs including restriction of extraocular muscle movement, diplopia, ptosis, and even blindness. These are generally caused due to increase in the intra-cranial pressure secondary to injuries.
- II—Blowout fractures of the orbital roof where there is cephalad displacement of the orbital roof into the cranial cavity due to increased intra-orbital pressure pushing the roof above. These injuries may be associated with neurological symptoms.
- III—Fractures involving the supraorbital rim. These may be seen as impure fractures of the orbital roof with an associated fracture of either a blow-in or a blowout nature.
- IV—Fractures involving the frontal sinus and the fronto-basilar complex. These fractures are more severe in nature

and may often be associated with severe neurological implications.

Less than 10% of orbital roof fractures may need any form of surgical intervention [42]. Most are amenable to conservative management with observation and follow-up of neurological and ophthalmic status.

The need for management of fractures of the orbital roof may depend on:

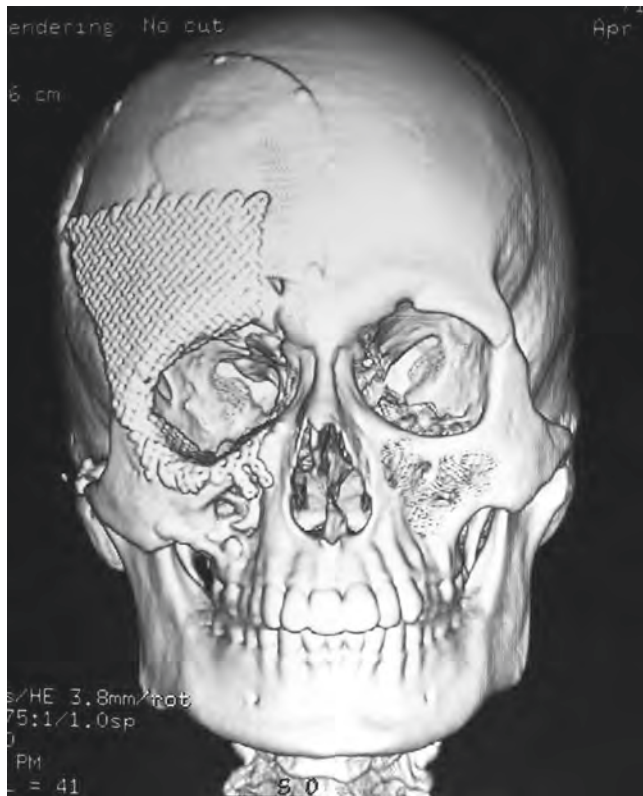
- (i) The presence of CSF leak which may need to be addressed
- (ii) The necessity to retrieve displaced intra cranial fragments
- (iii) Ophthalmic signs with compromise on vision
- (iv) Large displacement of fragments which may act as mechanical impediments or significantly alter intra-orbital volume producing enophthalmos or exophthalmos.

Interventions may be indicated immediately or late primary depending on the indications mentioned above. Reconstruction of the roof of the orbit is not a procedure routinely indicated. However in cases where there is an absolute necessity for reconstruction like prevention of brain herniation or restoration of intra orbital volume which has been significantly altered, the choice may vary between the use of titanium meshes (Fig. 57.31) or porous polyethylene implants fixed with micro-screws to split calvarial grafts.

Figure 57.32a–f demonstrates the management of a mal-united fronto-basilar fracture along with a blow-in fracture of the orbital roof compressing the eyeball producing restriction of movement.

57.8.2.2 Fractures of the Lateral Orbital Wall

Lateral orbital walls are the strongest of all the orbital walls [43]. The lateral wall generally shows diastasis and dis-



©Association of Oral and Maxillofacial Surgeons of India

Fig. 57.31 Reconstruction of complex defect of the frontal bone, orbital roof, and supraorbital rim with a titanium mesh

placement in the case of fractures involving the zygomatico-orbital complex and is restored to its normal anatomy when the reduction of the zygomatic complex is achieved [44]. However this wall gets comminuted in high-velocity injuries [45] necessitating reconstruction in the primary intervention.

The anatomy of the lateral wall plays an important role in the internal orbital volume as demonstrated by development of enophthalmos in unreduced lateral wall fractures [46]. Restoration of the architecture or augmentation of the same ensures correction of enophthalmos.

Reconstruction of the lateral orbital walls is usually accomplished with the use of:

- (i) Alloplasts including titanium meshes, porous polyethylene sheets, and custom-made poly-ether ether ketone (PEEK) implants
- (ii) Bone grafts which may be harvested from either the calvarium or ilium

Figure 57.33a, b demonstrates the management of fracture of the lateral walls of the orbit in a patient with concomitant fracture of the zygomatic complex.

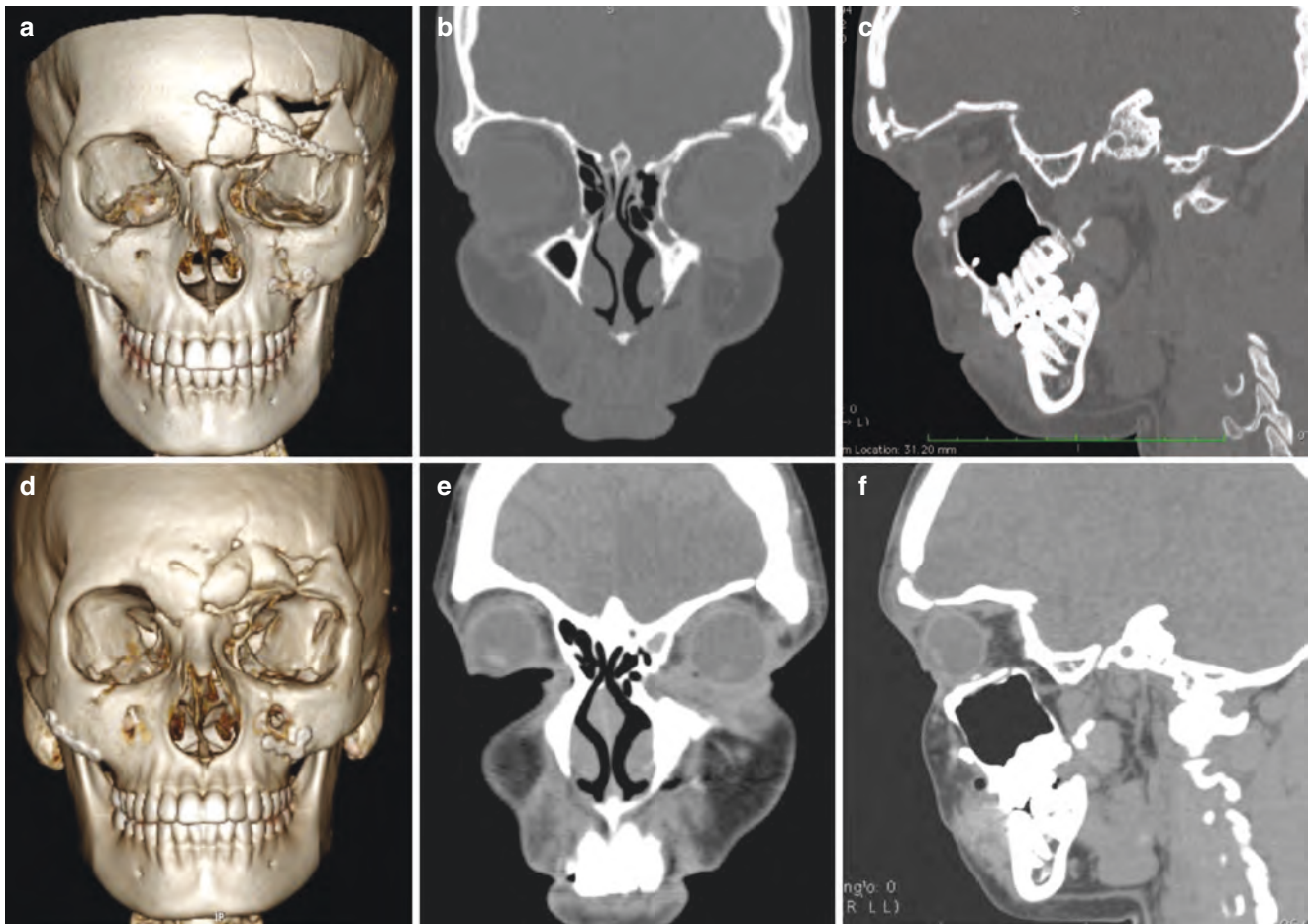
57.8.2.3 Medial Wall Fractures

The medial wall and the floor are the thinnest walls of the orbit and have the propensity to fracture the most [47, 48]. Though the incidence of concomitant fractures of the medial wall with that of the orbital floor have been reported over a wide range of 5–71%, its occurrence in isolation is very rare. Most fractures of the medial wall are incidental findings when CT scans are obtained to study other cranial, facial, or orbital fractures.

The most common type of clinical presentation would either involve a combination of the medial wall and floor (36%) or medial wall, floor, and zygomatic complex (28%) [49–51].

Fractures of the medial wall were managed conservatively in the past, but current literature proposes clear indications [49–51] for the exploration and reconstruction of the medial wall fractures and defects, which include:

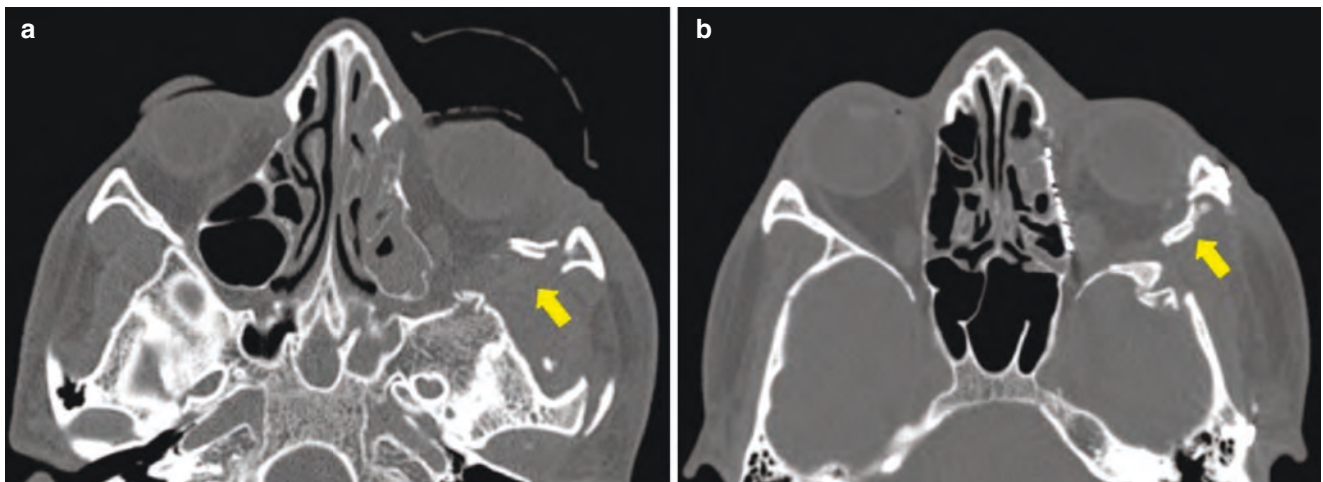
1. Restriction of ocular motility
2. Diplopia
3. Clinically significant enophthalmos



©Association of Oral and Maxillofacial Surgeons of India

Fig. 57.32 CT images of patient with malunited fractures of the orbital roof. (a–c) Pre-operative images demonstrating malunited fracture of the frontal bone and orbital roof of the left side with decrease in intra-orbital volume and compression on the globe. (d–f) Post-operative

images showing recontouring of the supraorbital rim and roof using ultrasonic aspirator system, with resultant expansion of the intra-orbital volume



©Association of Oral and Maxillofacial Surgeons of India

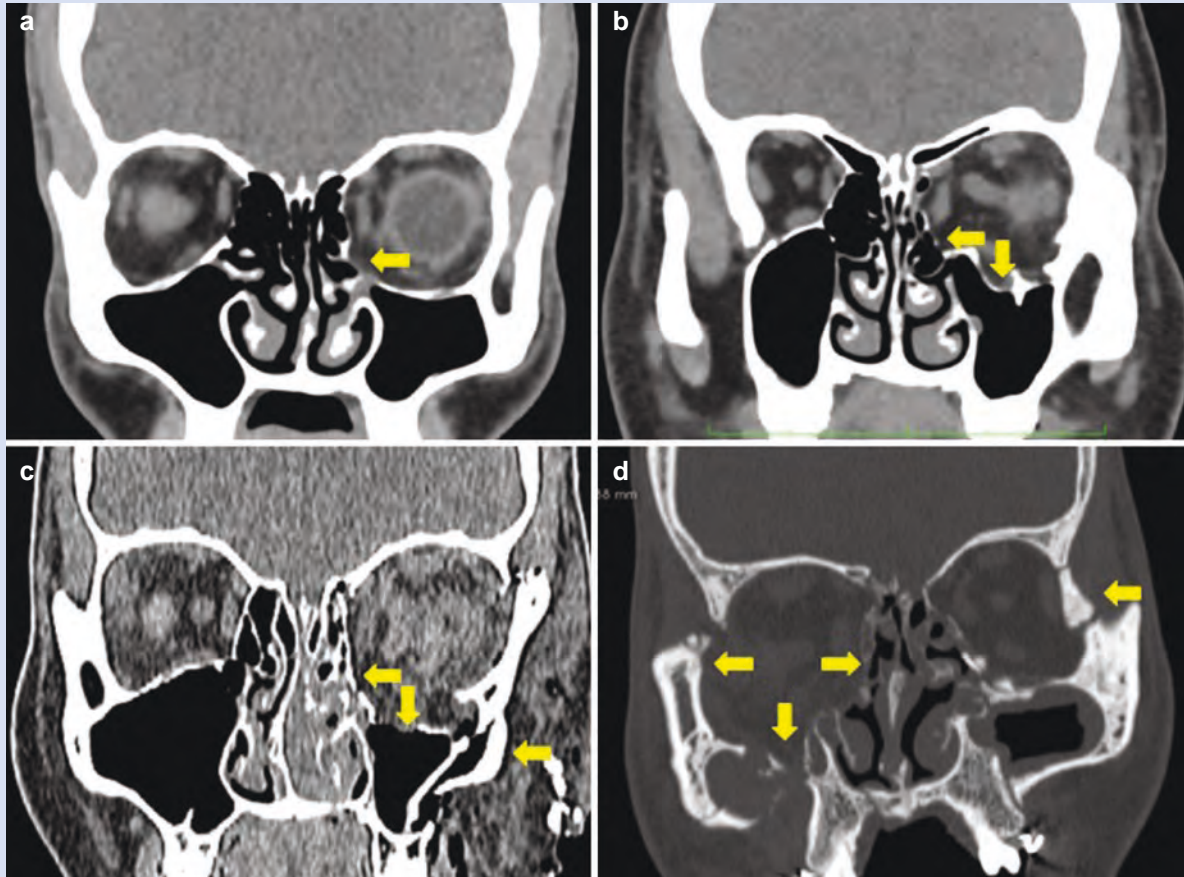
Fig. 57.33 CT scan images of lateral orbital wall with concomitant fracture of the zygomatic complex. (a) Pre-operative image showing fracture and displacement of the lateral wall and (b) post-operative

image showing reduction of the lateral wall and re-establishment of the sphenozygomatic suture continuity

Box 57.10 A Clinically Useful Classification of Medial Wall Fractures Has Been Described by Nolasco et al. [47] in 1995 Based on CT Scan Findings

They describe four patterns of presentations (Fig. 57.34)

- Type I: Isolated medial wall fractures
- Type II: Fracture involving the medial wall and the orbital floor
- Type III: Fractures involving the medial wall, floor, and the zygomatic complex
- Type IV: Medial wall plus complex fractures of the face (maxillary, NOE, etc.)



©Association of Oral and Maxillofacial Surgeons of India

Fig. 57.34 CT scans showing types of medial wall fractures. (a) Isolated medial wall fracture; (b) fracture of medial wall with floor; (c) fracture involving medial wall, floor and zygomatic complex; and (d) concomitant fractures of the medial wall, floor, and midface at LeFort 3 level

Contrary to earlier belief the loss of medial wall integrity also significantly contributes to development of enophthalmos [49]—with any defect involving an area of more than 1.9 cm² or volume expansion of excess of 0.9 ml [50, 51] producing clinically significant enophthalmos (2 mm or more).

Approaches to the medial wall have already been described in detail earlier. The most favored being the trans-caruncular/retro-caruncular approaches which give excellent exposure and access to the medial wall for both exploration and reconstruction [37, 52].

Options for reconstruction include a multitude of materials which may be autogenous or alloplastic as shown in Table 57.1. Bioactive resorbable sheets are also found to produce good outcomes [53].

Figure 57.35a, b demonstrates reconstruction of a medial wall fracture with a Titanium mesh.

57.8.2.4 Orbital Floor Fractures

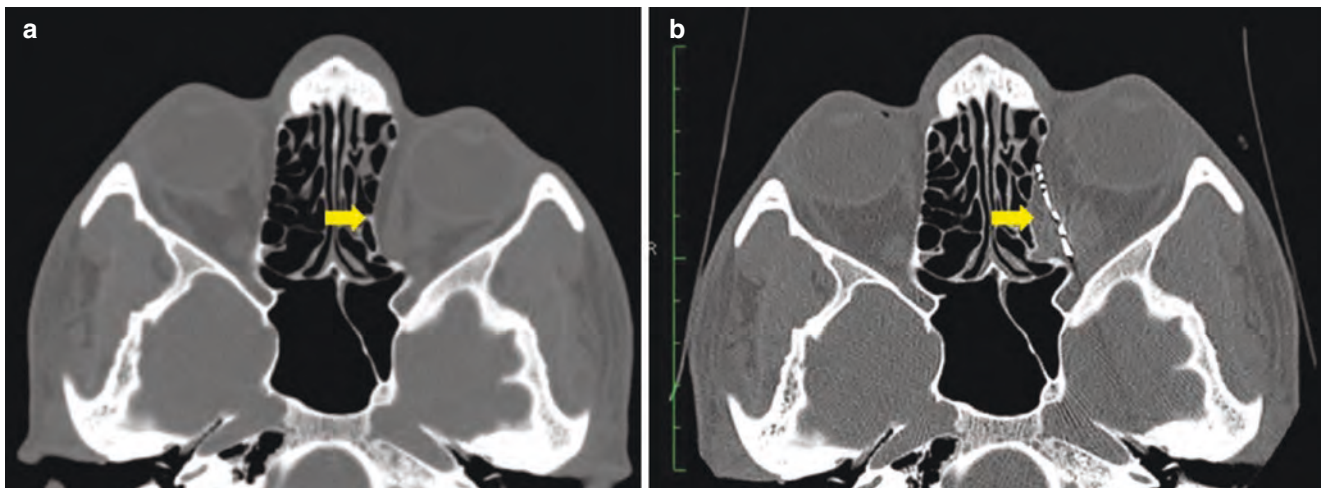
The fractures involving the orbital floor are the most common fractures of the internal orbit either in isolation or concomitant with other facial fractures. A comprehensive classification of floor fractures with clinical guidelines for management is described by Jaquier [54] et al. which lays emphasis on the morphology of the defect and the role of the infero-medial strut of the inferior orbital fissure.

The internal orbit is divided into three zones which helps in evaluating the difficulty of approach and exposure:

- (i) Anterior third
- (ii) Middle third
- (iii) Dorsal third

Table 57.1 Commonly used biomaterials for orbital reconstructions

Material	Stability / fixation (S/F)	Contouring	Biological behavior	Permeability for inflammatory exudate	Donor site morbidity	Radio-opacity	Availability
Titanium	S+++ F++	++	++ (allows tissue in-growth)	+	+	+	+
Bone graft	S++ F+	-	+++	-	-	+	+/-
Porous polyethylene	S+/- F+/- (when thin)	+	++ (allows tissue in-growth)	-	+	-	+
Composite porous polyethylene/Ti	S++ F++	+	++ (allows tissue in-growth)	-	+	+	+
Resorbable (PLLA)	S+/- F+/-	+	+(inflammatory response)	(non-perforated)	+	-	+
Pre-formed anatomical implant	S+++ F++	+++ (minimal contouring needed)	++ (allows tissue in-growth)	+	+	-	+



©Association of Oral and Maxillofacial Surgeons of India

Fig. 57.35 CT images of patient with medial wall fracture. (a) Fracture of the medial orbital wall of the left orbit showing displaced medial rectus. (b) Post-operative image demonstrating medial orbital reconstruction with titanium mesh

Table 57.2 The classification of orbital wall defects (Jaquier et al. modified by Dubois et al.) [53–55]

Category of fracture	Complexity of reconstruction	Defect description	Clinical finding
I	Low	Isolated defect of floor or medial wall, 10–20 mm ² within zone 1 or 2	
II	Moderate	Defect of floor and/or medial wall >20 mm ² within zone 1 and 2	Bony infero-medial strut of the inferior orbital fissure present
III	High	Defect of floor and/or medial wall >20 mm ² within zone 1 and 2	Infero-medial strut of inferior orbital fissure absent
IV	High	Defect of the entire orbital floor with medial wall involving zone 3	Infero-medial strut of inferior orbital fissure absent. The posterior ledge of the floor also may be absent

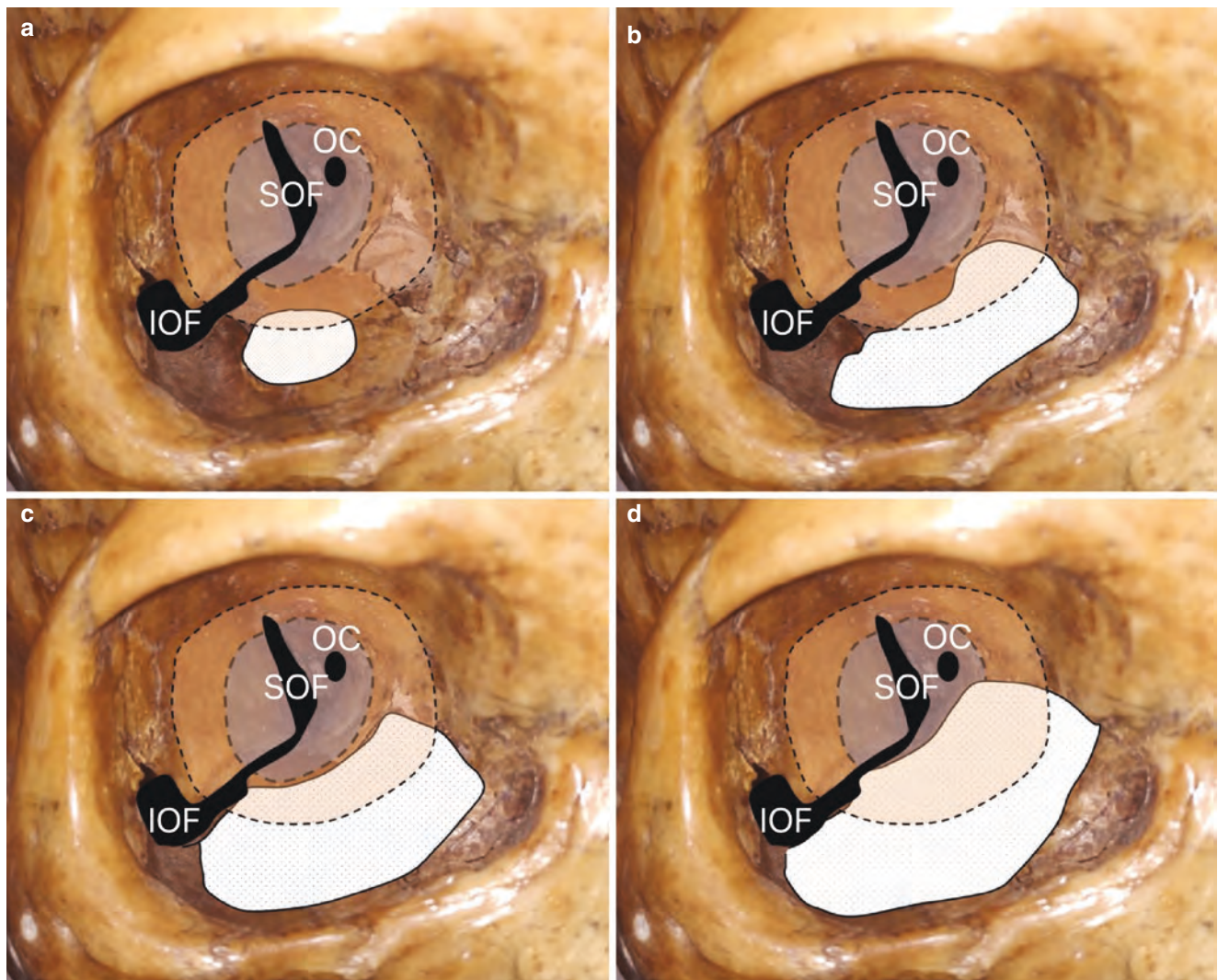
The fractures themselves are then classified into four categories of defects (Table 57.2; Fig. 57.36a–d).

Which Fractures of the Orbital Floor Need Intervention?

Indications and contraindications for floor exploration and repair are well defined.

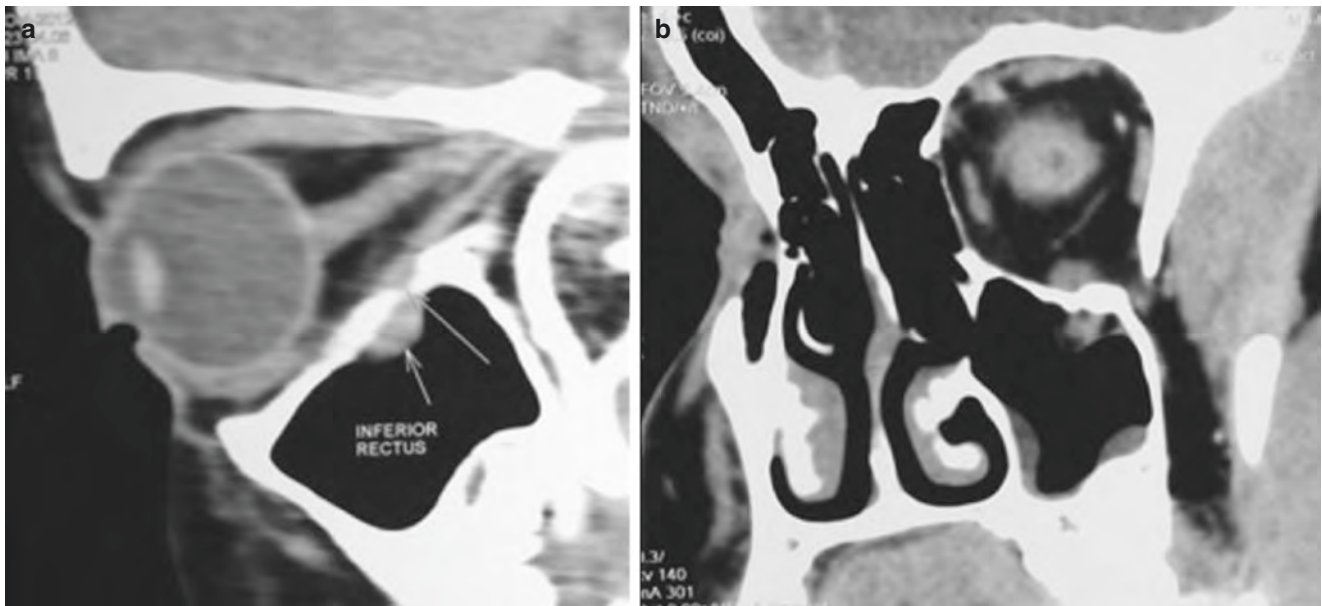
Absolute Indications

1. Acute injury to the orbit showing evidence of immediate clinical enophthalmos and/or hypophthalmos [55] (Fig. 57.15), necessitating a primary surgical intervention. Post-surgical outcome may get compromised with delay due to progressive atrophy of intra-orbital fat.
2. Severe restriction of ocular motility with CT or MRI evidenced muscle entrapment or incarceration of periorbital soft tissue.



©Association of Oral and Maxillofacial Surgeons of India

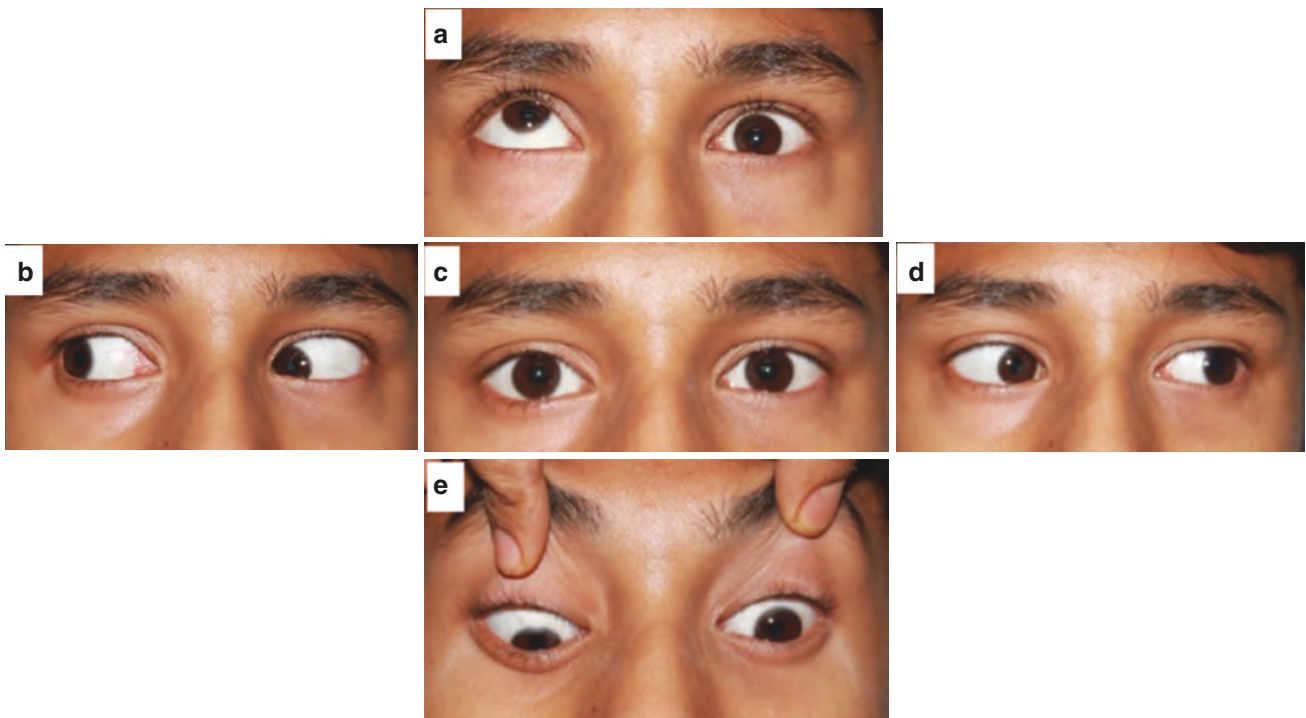
Fig. 57.36 Diagrammatic representation of the different types of defects of the orbital floor which indicate the grades of difficulty to reconstruct. (a) Type I, (b) Type II, (c) Type III and (d) Type IV



©Association of Oral and Maxillofacial Surgeons of India

Fig. 57.37 CT scan images of a young boy with history of orbital trauma. (a) Sagittal and (b) coronal sections demonstrating a “springing trapdoor” fracture of the orbital floor on the left side with entrapped

inferior rectus muscle. (Courtesy: Dept of Orbit & Oculoplasty, Shankara Nethralaya, Chennai)



©Association of Oral and Maxillofacial Surgeons of India

Fig. 57.38 Clinical photographs of a boy with “White eye blowout” fracture, showing restriction of ocular motility in the left eye in the superior (a) and inferior (e) gazes. The other gazes (b, c and d) show no

abnormalities. (Courtesy: Dept of Orbit & Oculoplasty, Shankara Nethralaya, Chennai)

3. “White eye blowout” fracture in a child or young adult with severe restriction of ocular motility (Figs. 57.37a, b and 57.38) and vagal symptoms.

Relative Indications

1. Defects of the orbital floor often larger than 50% of the orbital floor area or greater than 20 × 20 mm of defect size especially in the zone between the floor and the medial wall (Fig. 57.39a).
2. Diplopia which is non-resolving and persistent for more than 2 weeks due to entrapment or fibrosis of orbital soft tissue (Fig. 57.39b) [56, 57].

Relative Contraindications

1. Associated ophthalmic injuries like retinal tears, hyphema, displacement of lens, ruptured globe, avulsion injuries of the globe, etc.
2. Loss of vision in one eye with the only seeing eye involved in a fracture

Figure 57.40a–f demonstrates the delayed management of a patient with an isolated fracture of the floor and medial walls. The CT scan shows fibrosis and adhesion of the inferior rectus muscle to the residual posterior ledge producing diplopia and restriction in superior gaze.

Surgery for Special Indications in Orbital Floor Fractures

Enophthalmos

Enophthalmos is the displacement of the eyeball in a posterior direction and is attributed to increase in the intra-orbital volume. Numerous studies have shown that there is a correlation between increase in intra-orbital volume and the presenting enophthalmos. It is proved that an increase in intra-orbital volume by 0.5–1 cc would produce posterior

displacement of the globe by 1 mm. Enophthalmos of 2 mm or more may be clinically perceivable and warrant surgical intervention [58, 59]. An important aspect of orbital reconstruction lies in the fact that it is the only fracture in CMF region where the onus is not in recreating the anatomical form but rather in the restitution of the intra-orbital volume. Care should be taken to reconstruct the posteromedial aspect of the orbit (Hammer’s key area) to achieve anterior projection of the globe. It is imperative to understand that reconstruction of the floor posterior to the equator of the globe influences anterior projection of the globe, while reconstruction of the equatorial region of the floor influences only the supero-inferior position of the globe (Fig. 57.41).

Figure 57.42a–d shows a case of delayed correction of enophthalmos in a patient with an orbital floor fracture.

Hypophthalmos

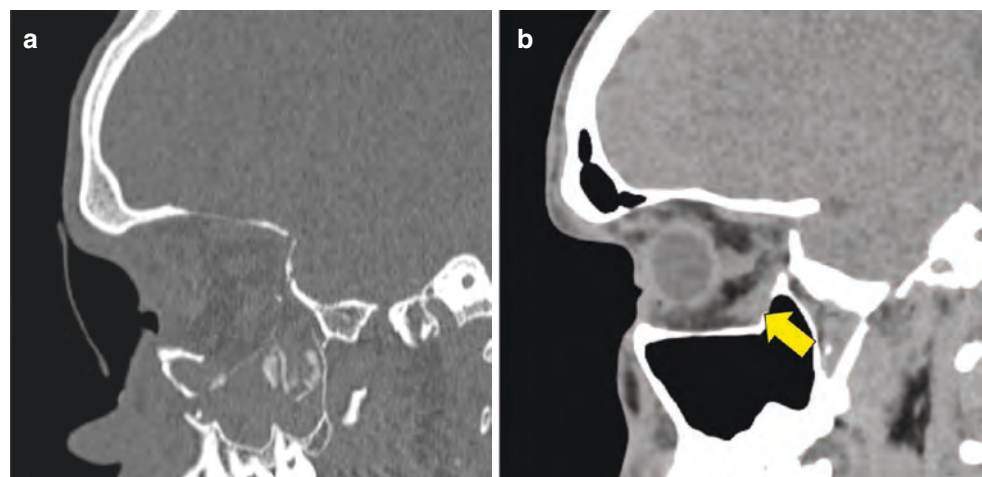
This is otherwise called hypoglobus and signifies the downward displacement of the globe due to the interruption in the anatomical integrity of the orbital floor. The clinical presence of hypoglobus needs to be differentiated from orbital dystopia which essentially means that the entire bony orbit with its contents is displaced caudally, unlike hypophthalmos, where only the globe is displaced caudally.

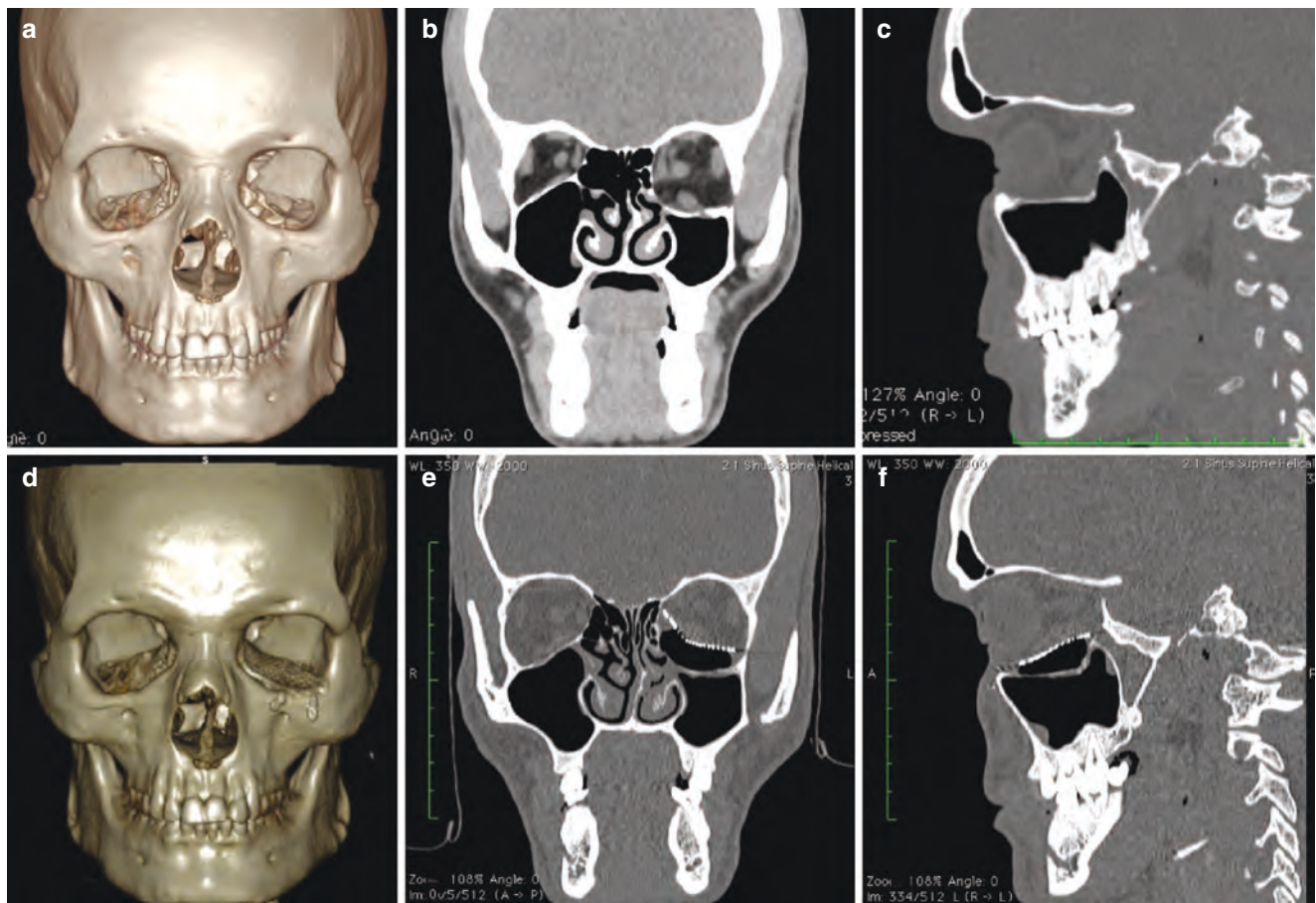
However decision-making for surgical intervention based on both enophthalmos and hypophthalmos is challenging as they may or may not present immediately following trauma. (Refer to clinical scenario 1. Figs. 57.57, 57.58 and 57.59).

Diplopia

Clinically demonstrable double vision is termed diplopia. Generally post-traumatic diplopia due to edema and hemorrhage is self-limiting and shows spontaneous resolution.

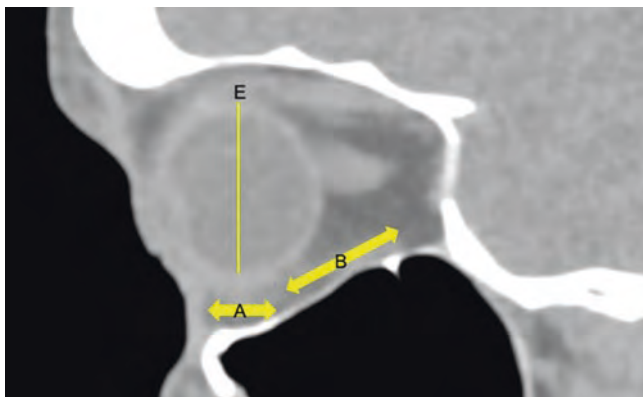
Fig. 57.39 (a) Sagittal section CT demonstrating large defect of the orbital floor. (b) Sagittal section CT demonstrating fibrosis and adhesion of the inferior rectus (yellow arrow) to the posterior ledge of the orbital defect





©Association of Oral and Maxillofacial Surgeons of India

Fig. 57.40 CT scan images of patient with internal orbital fracture. (a–c) 3D, coronal, and sagittal images demonstrating isolated fracture of the left orbital floor and medial wall. (d–f) post-operative images demonstrating reconstruction of the defect with anatomical orbital implant

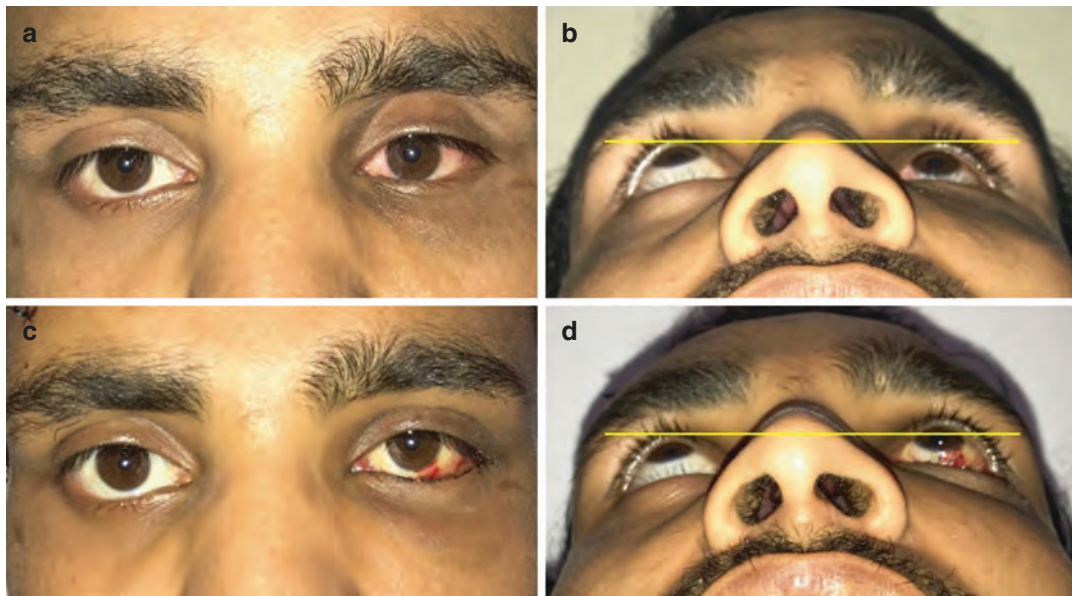


©Association of Oral and Maxillofacial Surgeons of India

Fig. 57.41 Graphical representation of the equator of the globe (E) and the associated equatorial (A) and post-equatorial (B) zones of the floor

Diplopia can manifest in two forms:

- (i) Monocular (diplopia present when seeing through one eye with the other eye closed) which is of more concern where the pathology is generally due to an ophthalmic problem (corneal, retinal, etc.) or neurological where the problem may be due to the optic nerve or the optic disk being injured.
- (ii) Binocular diplopia (diplopia present only when seeing with both eyes, while absent on seeing with one eye) with CT proven muscle entrapment is seen as an indication for immediate intervention. However, it may also be attributed to other reasons including (a) intra-orbital edema or hemorrhage, physical bony spicules or fragments acting as impediments following trauma, (b) entrapment of the periorbita, and in rare cases (c) large changes in intra-orbital volume including massive



©Association of Oral and Maxillofacial Surgeons of India

Fig. 57.42 Clinical photographs of patient with enophthalmos. (a and b) Pre-operative pictures demonstrating significant enophthalmos of the left globe. (c and d) Post-operative pictures demonstrating good surgical outcome

herniations or atrophy of periorbital fat, which do not mandate immediate intervention. Refer to clinical scenario 2.

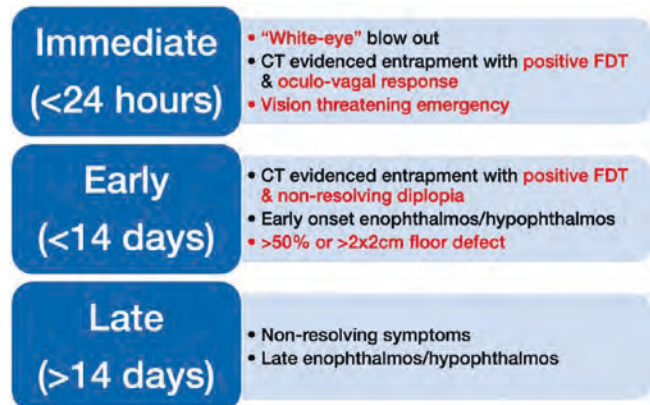
When Is the Right Time to Intervene?

The timing for intervention for fractures of the orbital floor can be divided into three categories—immediate, early, and late. The indication for all three categories are well discussed in literature [57] and are listed in Fig. 57.43.

Indications for immediate repair are of an urgent nature and may require priority as surgical emergencies, generally less than 6 h following trauma.

What to Use for Reconstruction of the Orbital Defect?

A plethora of material both autogenous and alloplastic have been used and documented. A table is provided with the list of the most commonly used materials and their relative merits (Table 57.1). However, contemporary literature favors the use of stock titanium meshes and custom patient specific implants which provide optimal corrections (Fig. 57.44a, b).



©Association of Oral and Maxillofacial Surgeons of India

Fig. 57.43 Chart showing timing for intervention for orbital reconstruction

Guidelines for Deep Orbital Dissection

The dissection of the deep orbit is always a challenge for the surgeon due to the high concentration of vital structures

within a limited space [60]. A few anatomical landmarks that have been suggested for guidance while dissecting in the deep orbit include:

- (a) *Infra-orbital nerve*: the course of the infra-orbital nerve within the orbit is a very important landmark in floor dissection. The point of its entry from the pterygopalatine fossa at the genu/bend where inferior orbital fissure takes a turn and ascends laterally to continue as the superior orbital fissure signifies the safe limit for the posterior extent of floor dissection. Even in the case of badly comminuted fractures or delayed corrections, the nerve may be identifiable and provides a reliable clue to the end of the pre confluence area.
- (b) *Inferior orbital fissure*: the inferior orbital fissure forms a pathway for an extended exposure of the lateral orbit as the contents of the fissure can be safely divided using bipolar cautery dissection. This facilitates easy navigation into the deep orbit behind the fissure and trace the greater wing of sphenoid. It may be of clinical relevance to note that the structures of the lateral orbit are much stronger and less prone to comminution when compared to the medial orbital structures. This makes the lateral approach to the deep orbit more predictable. Furthermore,
- (c) *The greater wing of the sphenoid*: this is a thick and strong bony structure which forms the majority of the lateral orbit and bridges the inferior and superior orbital fissures. Its robust nature makes it less prone for comminution and hence forms a predictable landmark to find even in severe trauma.
- (d) *Orbital process of the palatine bone*: the Orbital process of the palatine bone forms the highest point of the posterior-medial bulge of the orbital floor. This is an integral part of the posterior orbit that needs to be reconstructed to get adequate positioning of the globe in the anteroposterior and vertical directions.
- (e) *Orbital confluence*: the orbital confluence (Fig. 57.45a, b) is formed by the convergence of two bony shelves forming the genu of the internal orbital fissures. This signifies the safe limits of the dissection of the orbital floor. The confluence is formed by the perpendicular plate of the palatine bone on the medial aspect and the bony inferior margin of the greater wing of the sphenoid laterally.

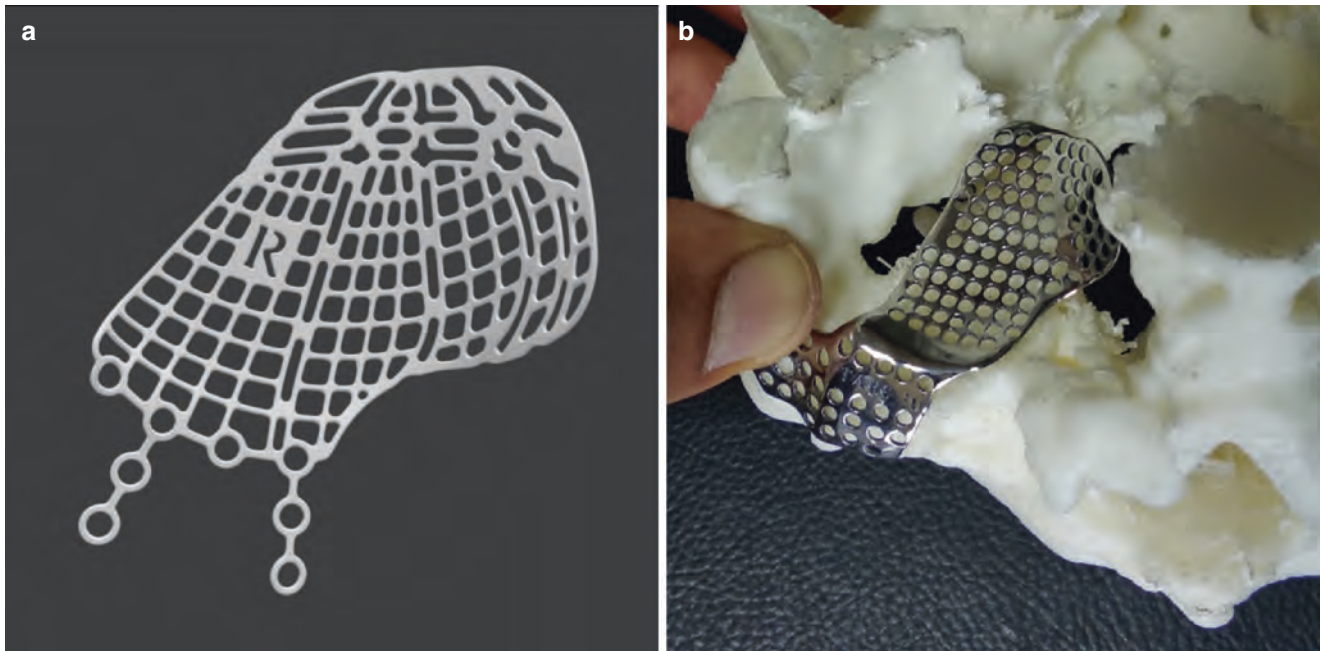
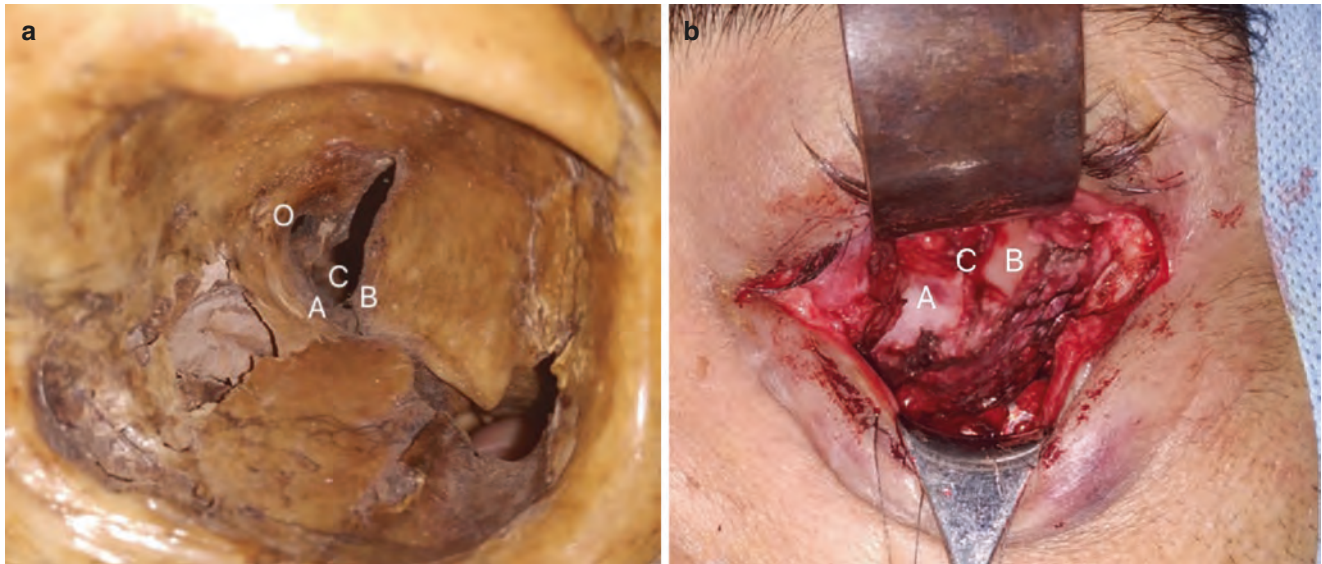


Fig. 57.44 Photographs of (a) Stryker[®] preformed anatomical orbital floor implant and (b) titanium “patient-specific implant” (PSI)

- (f) *Safe distances within the orbit*: an important formula to remember safe distances within the orbit is 24-12-6, where 24 is the distance in mm of the anterior ethmoidal foramen from the medial orbital rim; an additional 12 mm deeper (36 mm) would indicate the posterior ethmoidal foramen followed by another 6 mm deep for the optic nerve (42 mm) [6].
- (g) *Globe protection*: protection of the globe is of vital importance in orbital surgery. Adequate care should also be exercised for the protection of other vital structures like nerves and vessels also. Use of protection devices like specific retractors (Fig. 57.46a, b, c) and corneal shields is mandatory.



©Association of Oral and Maxillofacial Surgeons of India

Fig. 57.45 (a) Demonstration of landmarks on dry skull. (A) Perpendicular plate of the palatine bone. (B) Medial lip of the greater wing of the sphenoid. (C) Orbital confluence and (O) Optic foramen. (b) Intraoperative photograph demonstrating the structures of the deep orbit in a patient undergoing secondary surgery for floor reconstruction with implant replacement

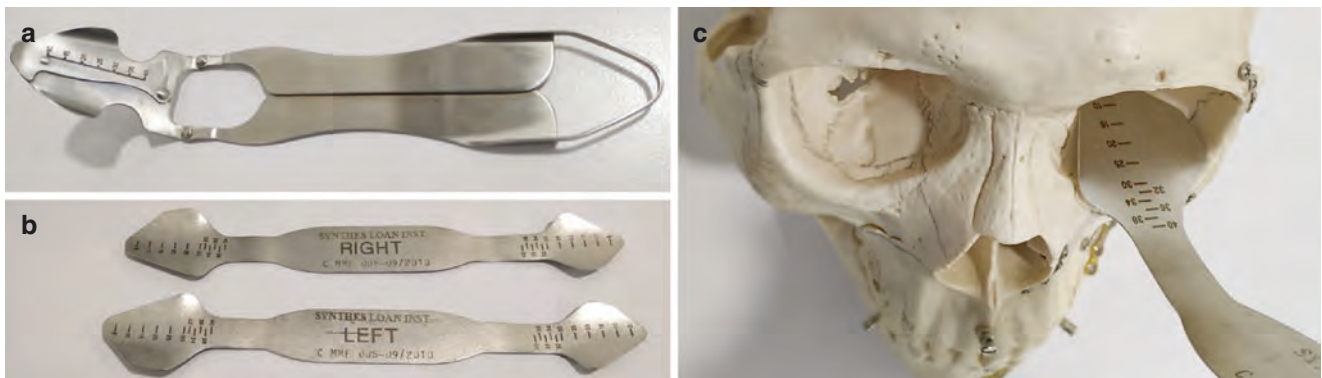
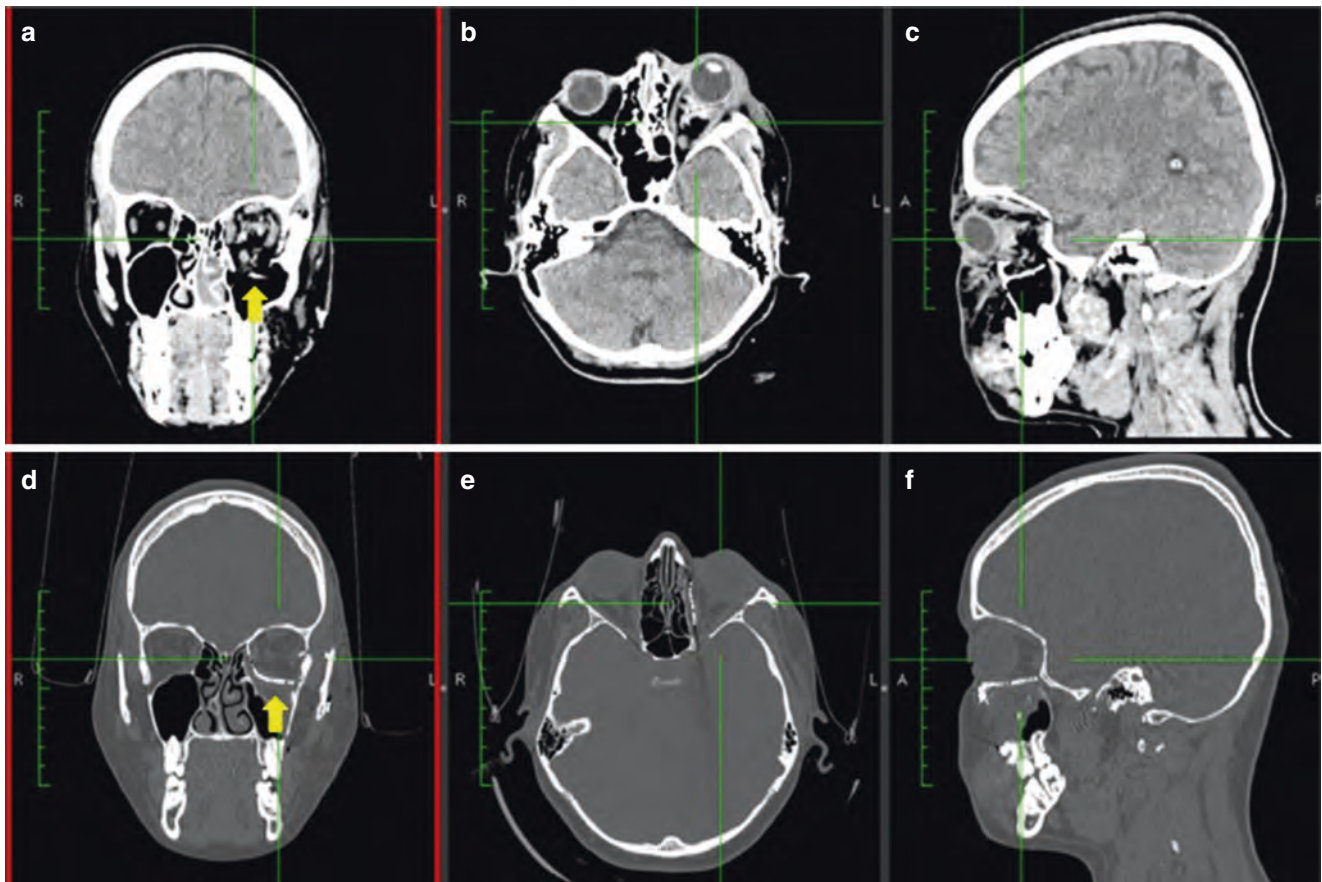


Fig. 57.46 Photographs showing globe protection devices. (a) Stryker[®] globe retractor, (b) Synthes[®] globe retractor and (c) Synthes[®] retractor in anatomical position demonstrating the use of calibration to aid intraoperatively



©Association of Oral and Maxillofacial Surgeons of India

Fig. 57.47 CT scans images demonstrating optimal de-herniation of orbital contents and restoration of intra-orbital volume. (a–c) Pre-operative, (d–f) post-operative

De-herniation of the Orbital Contents and Locating the Posterior Ledge

Two important aspects of floor reconstruction are:

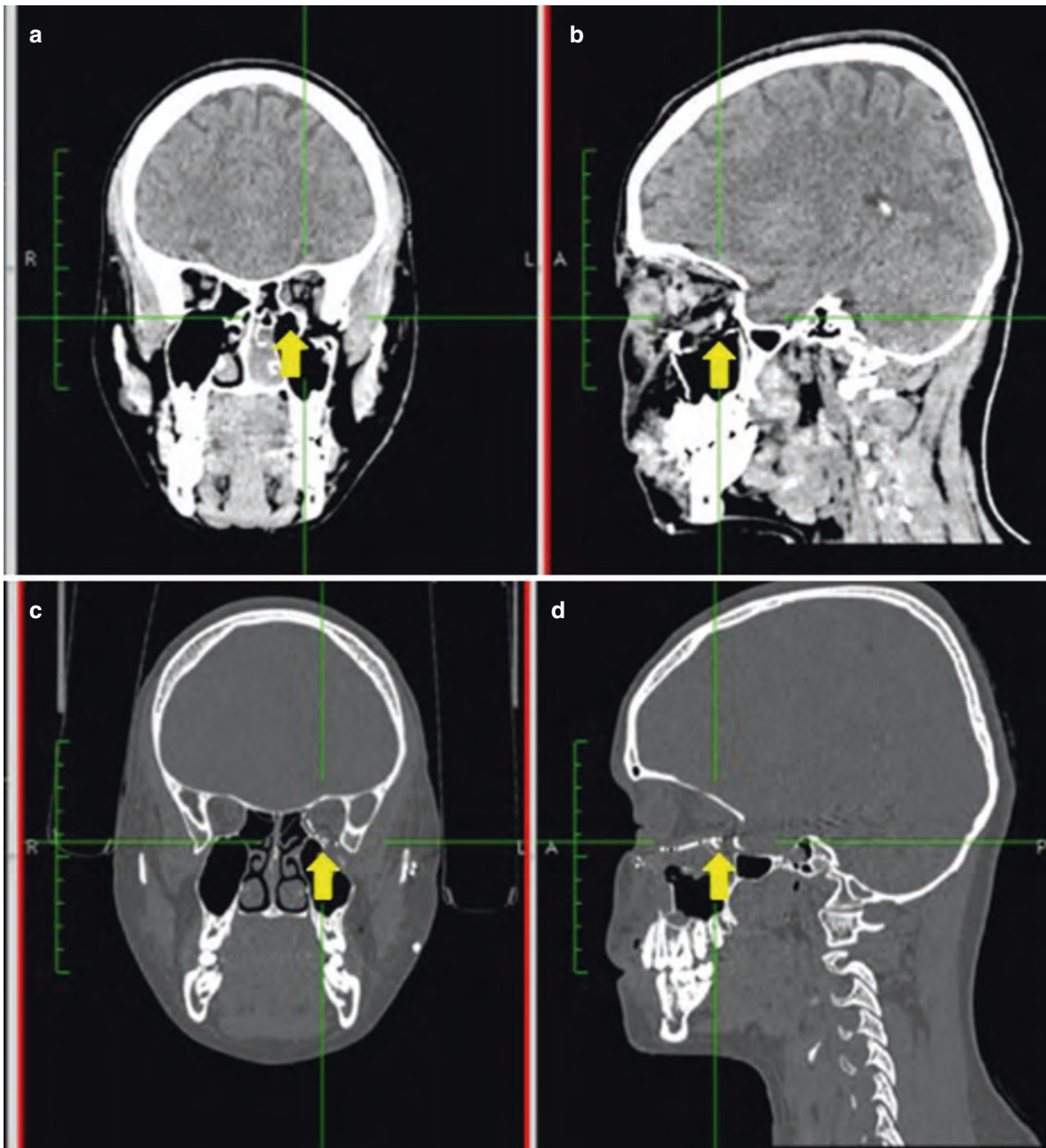
- (i) De-herniation of the orbital (Fig. 57.47a–f) contents to *restore* the internal orbital volume
- (ii) Locating the posterior ledge (Fig. 57.48a–d) for optimal implant positioning

However, locating the posterior ledge in large defects and secondary corrections may be a significant challenge. Absence of posterior ledge in severe orbital trauma is an indication for cantilevered implants which are secured to the infra-orbital rim alone.

57.8.3 Type III (Naso-Orbito-Ethmoid Type) (Refer Chap. 58)

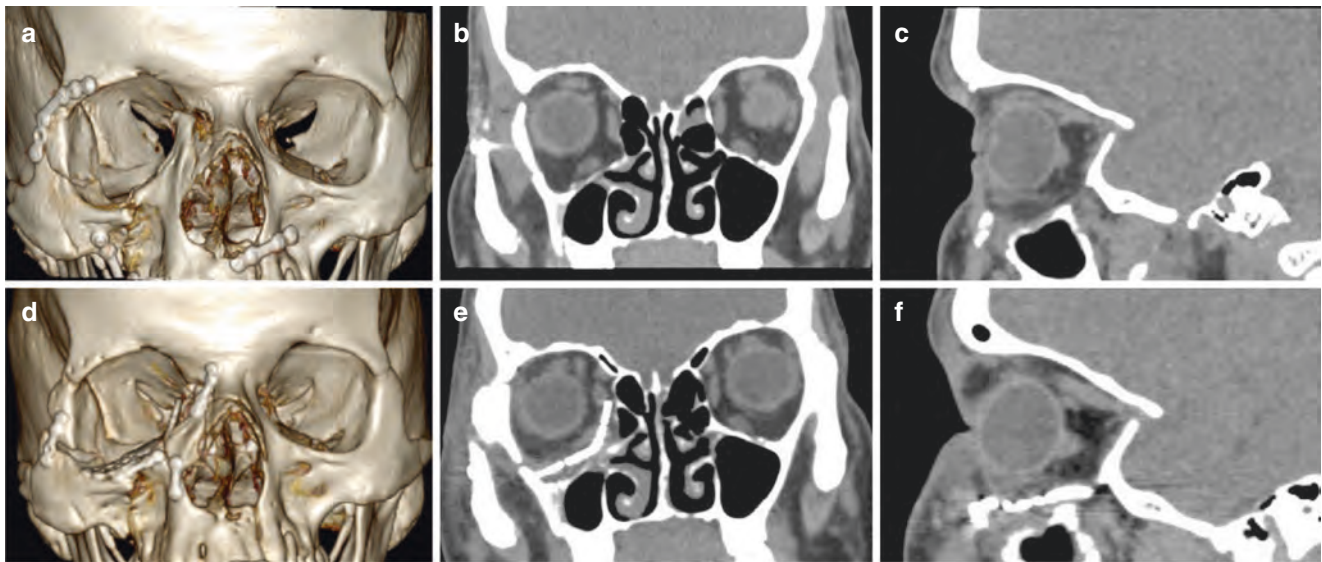
The NOE-type fractures are the most challenging of all the orbital fractures to manage in terms of achieving predictable results. The management of the NOE complex reconstitutes the facial form of the central midface: a key element in facial esthetics. This type is also prone to have concomitant injuries to the lacrimal system which should be identified and treated.

Figure 57.49a–f demonstrates the CT images of a patient with a residual deformity following pan-facial trauma with a right-sided type I NOE and neglected orbital floor fractures.



©Association of Oral and Maxillofacial Surgeons of India

Fig. 57.48 (a and b) Pre-operative coronal and sagittal section CT images demonstrating the location of the posterior ledge of the floor defect. (c and d) Post-operative images showing the placement of the anatomical orbital floor implant in the appropriate position to bridge the defect



©Association of Oral and Maxillofacial Surgeons of India

Fig. 57.49 CT scan images of patient with type I NOE fracture, plus orbito-zygomatic complex on the right side. (a–c) 3D, coronal and sagittal images demonstrating the fractures and the floor defect. (d–f) Post-

operative images demonstrating ORIF of the right NOE fracture, redo of the orbito-zygomatic complex and floor reconstruction with anatomical orbital implant

Box 57.11 The Key Elements for Managing Type III Fractures

- Management of the medial canthal tendon (MCT) as indicated: this can be performed according to the description of Markowitz et al. [61] with the focus being the attachment or avulsion of the medial canthal tendon (MCT) to the fracture fragment
- Management of the soft tissue drape after reposition of the MCT
- Restoration of the nasal dorsum projection, which is of paramount importance
- Evaluation of injuries to the lacrimal system: canaliculi, sac and the nasolacrimal duct (NLD), and its management

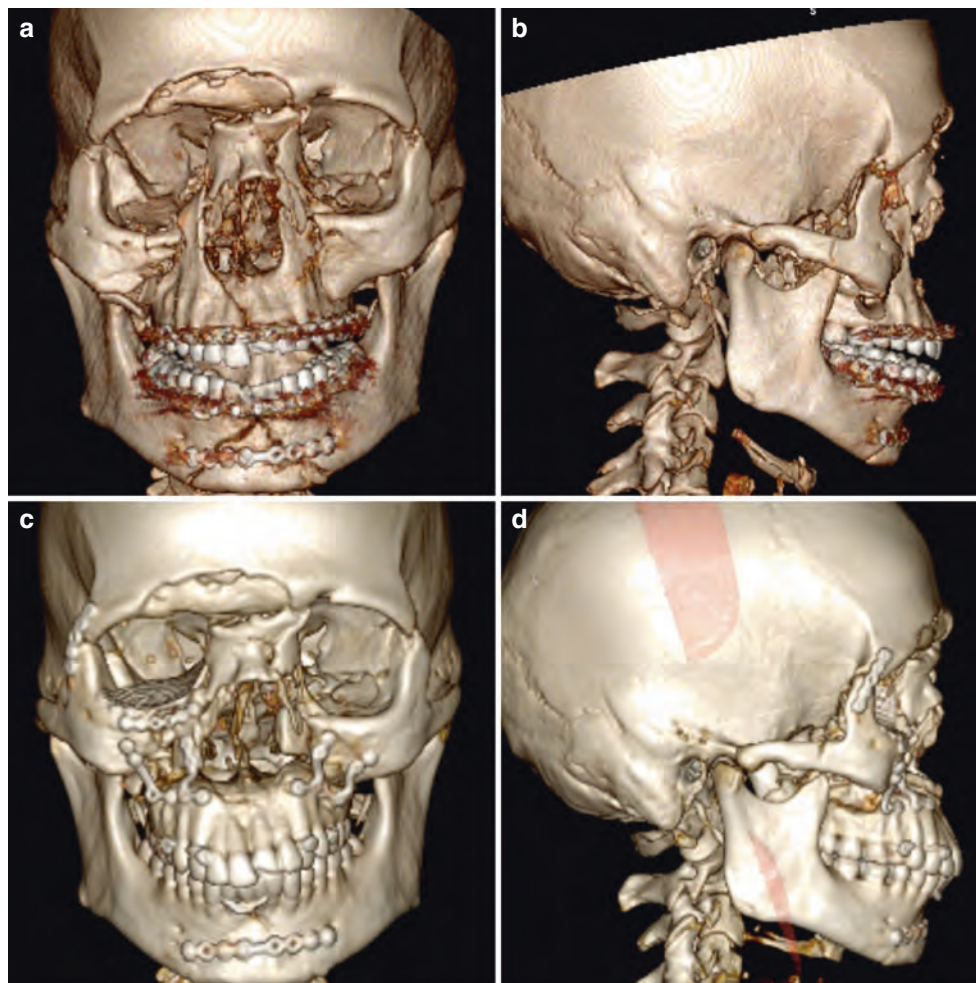
57.8.4 Type IV (Complex Fractures of the Face with Orbital Fractures)

This type includes all the combinations of the fractures of the face which do not fall into the types described above. Sequencing of fractures (refer Chap. 60) such as these including pan-facial fractures requires a thorough understanding of the principles to obtain optimal outcomes. It is to be borne that sequencing and fixation of all facial fractures need to be completed prior to the reconstruction of the internal orbit.

Figures 57.50a–d and 57.51a–d demonstrate a patient with residual facial deformity following RTA. Patient had sub-optimally treated pan-facial and orbital fractures and a malunited mandible fracture. He was operated for a revision surgery addressing his midface and dental occlusion.

57.9 Management of Orbital Emergencies

- Retrolbulbar hemorrhage*: investigations with a CT scan or an MRI as the clinical situation mandates help us with a diagnosis of retrolbulbar hemorrhage. 20% mannitol 2 g/kg body weight or 500 mg acetazolamide is administered to reduce the intraocular pressure in conjunction with 100 mg hydrocortisone for management of edema. Hourly examinations of pupils, visual acuity, and IOP are of great significance as stable ophthalmic status with diminishing signs of vision can be managed medically. Deterioration of vision or changes in visual fields may be considered an emergency [62]. Inferior cantholysis is the most commonly employed procedure for decompression of the retrolbulbar space [63–65].
- Traumatic optic neuropathy*: the management of traumatic optic neuropathy includes observation, use of steroids, and surgical decompression [66]. However, the use of corticosteroids in acute brain trauma is now debatable, and the general consensus is non-use of steroids in patients having concomitant brain trauma [67]. Many clinicians now restrict the use of steroids (bolus



©Association of Oral and Maxillofacial Surgeons of India

Fig. 57.50 3D CT images of patient with neglected pan facial injury and associated orbital fracture. (a and b) Images demonstrating frontal and lateral views showing malunited pan-facial fracture with facial deformity and significant dental malocclusion. (c and d) Post-operative

images demonstrating ORIF of the right orbito-zygomatic complex and a Lefort I osteotomy with restoration of skeletal form, midface projection, and restoration of functional occlusion

dose of 30 mg/Kg body weight of methyl prednisolone followed by 3 mg/Kg/h for 24 h) within the first 8 h of injury, in cases of severe primary vision loss or progressive vision loss.

- (c) *Compartment syndromes*: this includes both superior orbital fissure and orbital apex syndromes. The current protocols indicate early surgical decompression where indicated. The role of steroids is debatable as indicated above.

57.10 Pediatric Considerations

(Figs. 57.52a–d and 57.53a, b)

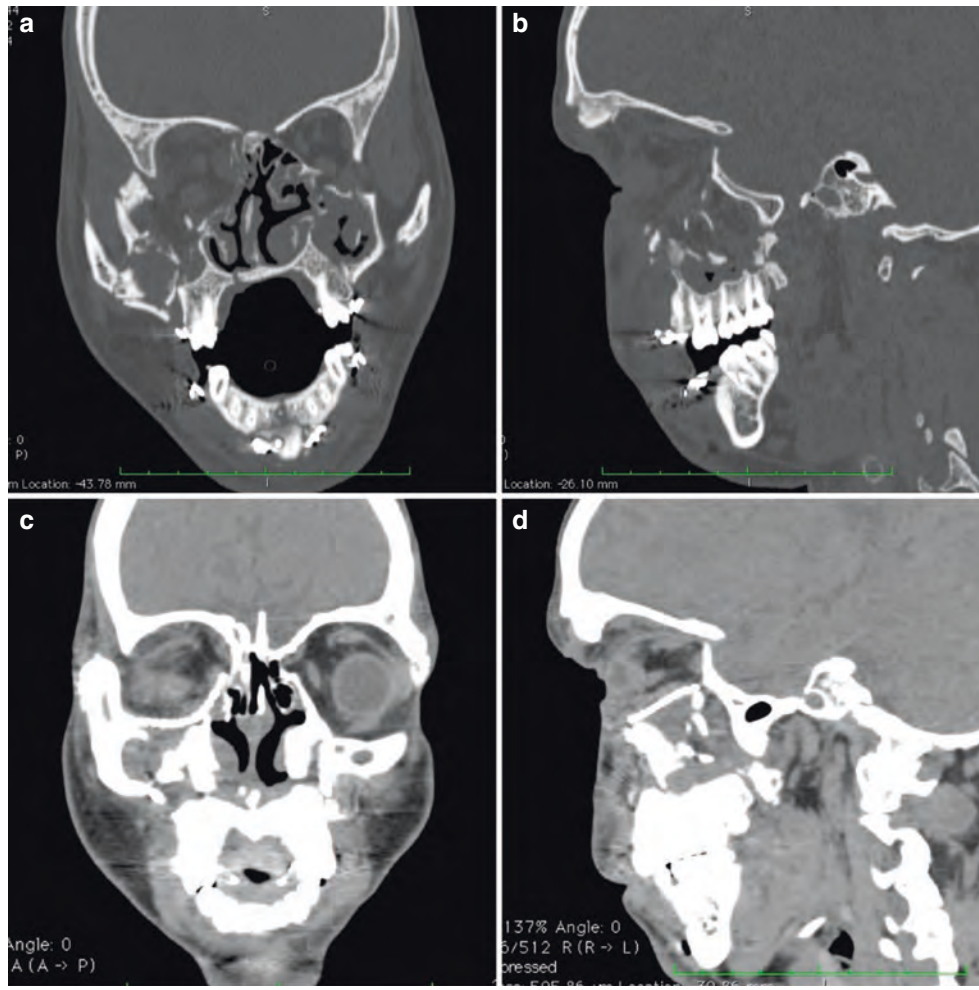
Pediatric consideration in orbital trauma necessitates the discussion of four important aspects which clearly delineate the management principles from adults.

(a) *Ratio of cranium to facial fractures in children*

The face to cranium ratio of an infant is 1:8, while that of a child who is between 4 and 6 is about 1:4. This clearly establishes the fact that the cranium in an infant or a child is much larger than the face and is more exposed to potential trauma. The incidence of orbital roof fractures is much more common in children who are younger than 5 years, while beyond the age of 7, the floor fracture is more commonly seen.

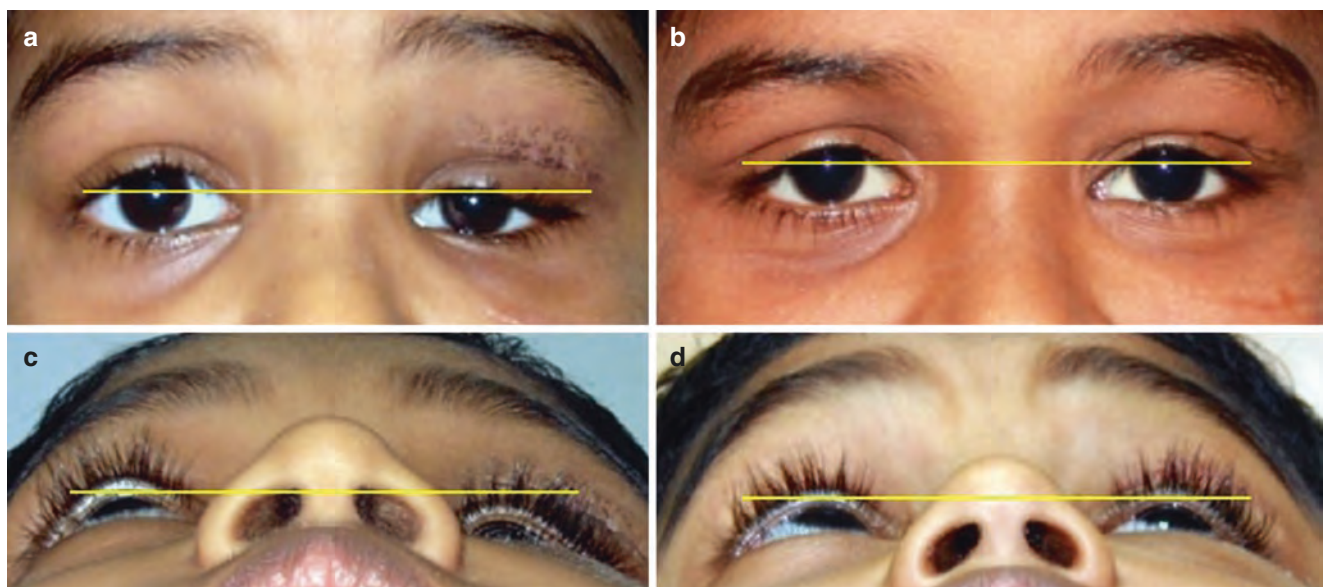
(b) *Pediatric orbital roof fractures*

Roof fractures in children occur in the growing age [68] and cause an entity called the “growing skull fracture,” where the fracture fragments continue to separate due to growth, causing “leptomeningeal” herniation which involves herniation of the meninges and part of the frontal lobe into the orbital cavity. Management of these need to be planned in conjunction with neurosurgical support.



©Association of Oral and Maxillofacial Surgeons of India

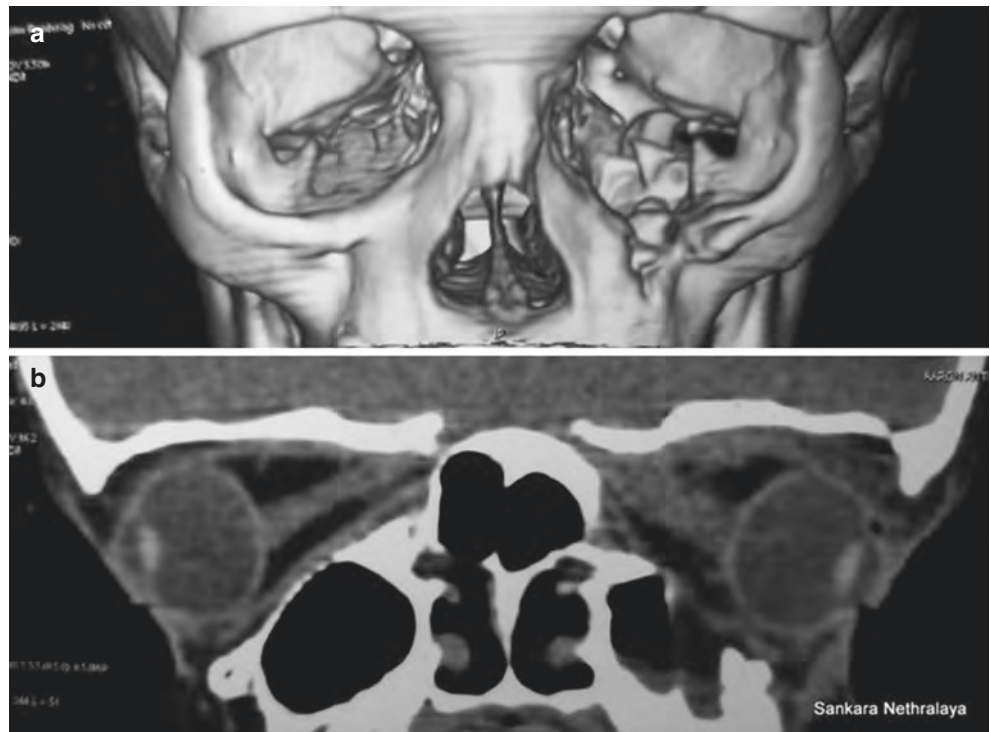Fig. 57.51 Coronal and axial CT images of the patient in Fig 57.50. (a and b) Images demonstrating comminuted fractures of the midface and orbit. (c and d) Post-operative images showing optimal restoration of form of the face and orbit



©Association of Oral and Maxillofacial Surgeons of India

Fig. 57.52 Clinical photographs of a 6-year-old child with left sided orbital trauma (a and c) frontal and basal views demonstrating immediate-onset enophthalmos and hypophthalmos. (b and d) post-operative photographs showing optimal post-surgical outcome. (Courtesy: Dept of Orbit & Oculoplasty, Shankara Nethralaya, Chennai)

Fig. 57.53 CT scan images (a) 3D image demonstrating fracture involving the left infra-orbital rim and orbital floor in a 6 year-old child, (b) sagittal sections of both orbits showing left sided floor fracture. (Courtesy: Dept of Orbit & Oculoplasty, Shankara Nethralaya, Chennai)



©Association of Oral and Maxillofacial Surgeons of India

(c) *White eye blowout*

The presence of floor fractures with restriction in superior gaze, with or without oculo-vagal responses and devoid of any physical signs of hemorrhage or ecchymosis in the eye or periorbital region [69–71]. This is a feature which may be seen in children and young adults as a result of a “self-reducing trapdoor” fracture which entraps the inferior rectus. The white eye blowout is considered a surgical emergency and necessitates immediate intervention.

(d) *Role of resorbable implants*

The cranium and upper face exhibit rapid growth in the early years. The orbit completes almost 80% of its growth within the first 2 years of life and another 10% within the next 2–3 years. Choice of implants in the growing orbit is to be taken into consideration by the surgeon who has to plan for the residual growth of the orbit and possible chances of migration of implants.

57.11 Secondary Correction of Orbital Deformities

Secondary corrections of the internal orbit demand great degrees of skill and are technically demanding even for the trained surgeon due to the nature of fibrosis and contracture

that is already set in and the distortion of bony landmarks within the orbit. This may necessitate more extensive dissection and mobilization of the orbital contents and yet yield sub-optimal outcomes.

57.12 Complications

Complications associated with management of orbital fractures may be categorized into immediate and delayed complications.

Box 57.12 Indications for Secondary Deformity Correction of the Internal Orbit Generally Are

- (a) Restricted ocular movement, which may be either due to muscle entrapments or adhesions of intra orbital and/or periorbita
- (b) Diplopia due to physical impediments like bony interferences and/or soft tissue adhesion/entrapment
- (c) Enophthalmos and/or hypophthalmos

57.12.1 Immediate Complications

The most common immediate complications that are secondary to orbital surgery include:

- edema,
- infection,
- wound dehiscence,
- aberrant implant position,
- extrusion of implants.

Hemorrhage may be an infrequent complication which may happen during the surgery or in the immediate post-operative period.

Complications associated with specific ophthalmic implications like injuries to the cornea, extraocular muscles, lacrimal apparatus, or the optic nerve also may occur.

Blindness is a rare but grievous complication which has to be borne in mind.

The last group includes neurosensory disturbances like paresthesia or dysesthesia associated with the infra-orbital nerve and carrying grades of facial nerve palsy or weakness [72, 73].

57.12.2 Delayed Complications

Delayed complication may present in the form of:

- Persistent enophthalmos/hypophthalmos
- Persistent or worsened diplopia with altered vision
- Restricted ocular movement due to fibrosis and adhesion

Other adverse outcomes include:

- Entropion
- Ectropion
- Hypertrophic scars/keloids
- Change in the axis of the palpebral fissure

57.13 Recent Advances in Management of Orbital Fractures

Orbital reconstruction still remains one of the most challenging and enigmatic areas in the management of cranio-facial trauma and most certainly attracts the latest in terms of technology and developments to refine and improve outcomes. Significant advances in the field of orbital reconstruction include:

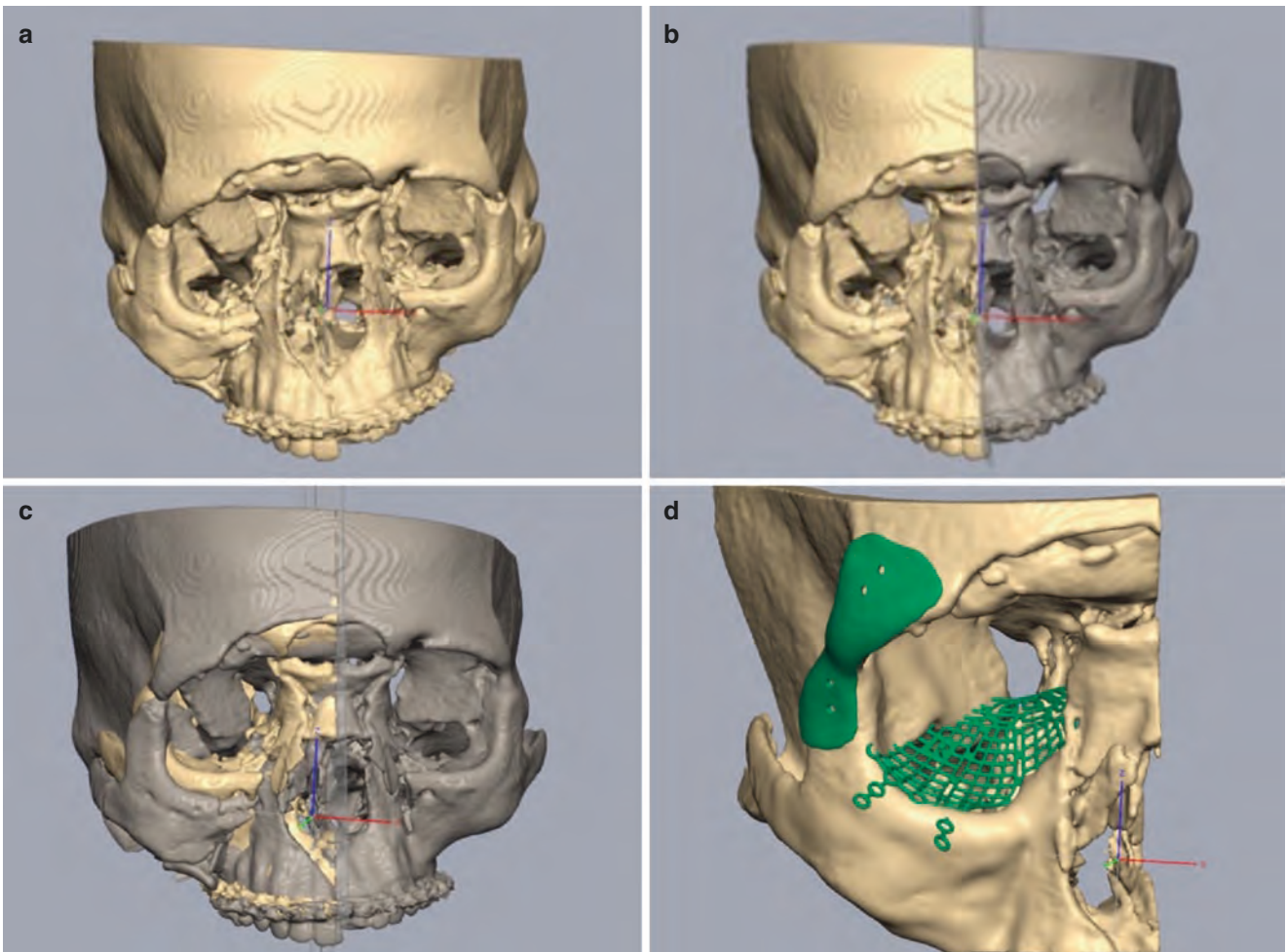
1. Computer-assisted surgery
2. Intraoperative imaging and navigation (refer Chap. 41)
3. Patient-specific implants for reconstruction

57.13.1 Navigation and CAS for Orbital Fractures and Reconstruction

Computer-assisted surgery allows virtual pre-operative planning of the desired reconstruction using pre-operative CT scans (Fig. 57.54a–d) [74]. This virtual plan gives real-time guidance during surgery. Navigation helps visualize the actual surgical outcome during surgery in relation to the pre-operative plan (Fig. 57.55). With this technique, sub-optimal reduction of fractures and positioning of implants can be identified and corrected during surgery, thereby reducing the need for secondary procedures [75–77].

57.13.2 Patient-Specific Implants (Fig. 57.56a–c)

Custom implants for the reconstruction of complex defects and deformities have become vogue now. They offer the advantages of accurate planning and infallible positioning intraoperatively which enormously improve post-surgical



©Association of Oral and Maxillofacial Surgeons of India

Fig. 57.54 Photographs depicting stages in computer-assisted surgery for orbito-facial reconstruction. **(a)** Generation of virtual 3D model; **(b)** segmentation and mirroring of normal side; **(c)** superimposition of the mirrored object on the affected side, enabling a better understanding of

the deformity; and **(d)** creation of patient specific implant design for the fronto-zygomatic region and importing the virtual model of the anatomical orbital implant for floor reconstruction

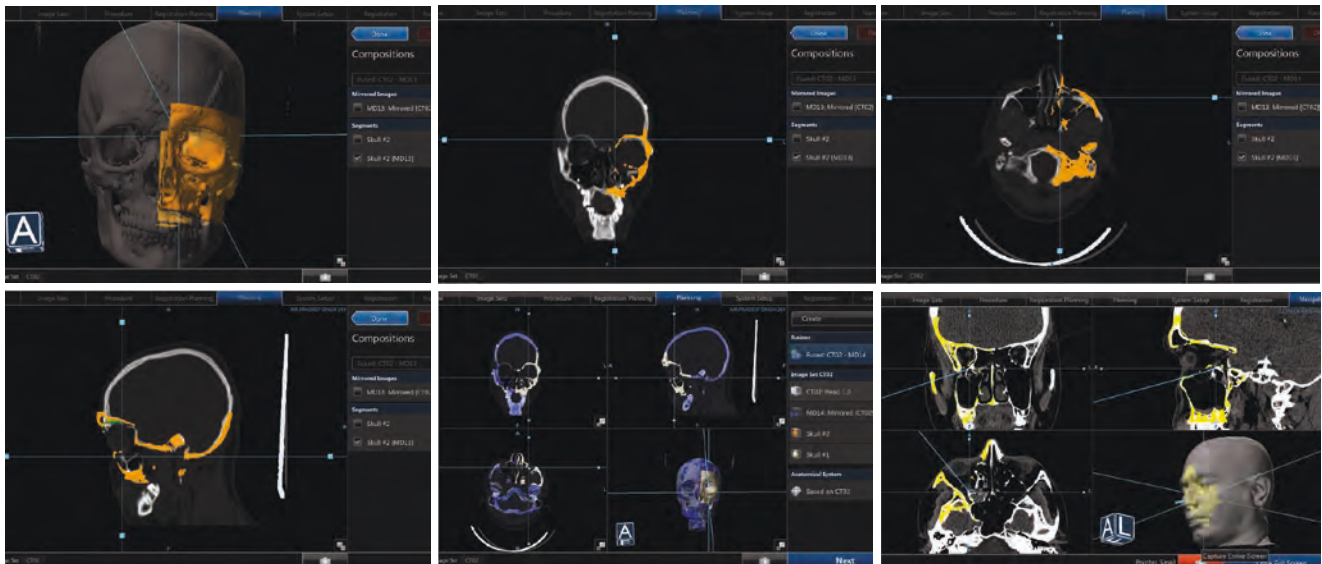
outcomes. The defect can be mapped digitally and a construct can be made after virtual surgical planning to aid in intraoperative guidance. The implants may also function as guidance stents and double up as fixation devices too.

57.14 Conclusion

To conclude, all patients with orbital trauma need to be subjected to ophthalmological examinations both pre- and post-surgery. Globe protection, gentle retraction of tissues, and intraoperative testing for vision are mandatory during orbital surgery.


Box 57.13 Principles to Be Followed During Surgery for Orbital Floor Reconstruction

- (i) Complete exposure of the fracture and defect
- (ii) Meticulous de-herniation of the orbital soft tissues with restitution of intra-orbital volume
- (iii) Identification of the posterior ledge in floor defects which is the posterior limit for reconstruction
- (iv) Restoration of the posteromedial bulge of the orbit (Hammer's key area) [7]
- (v) Choice for the reconstruction material should be based on the complexity of the defect (Dubois et al.) [55]



©Association of Oral and Maxillofacial Surgeons of India

Fig. 57.55 Screenshot images of a left-sided orbital floor with an anatomical orbital floor implant that is virtually planned and executed with the help of intraoperative navigation



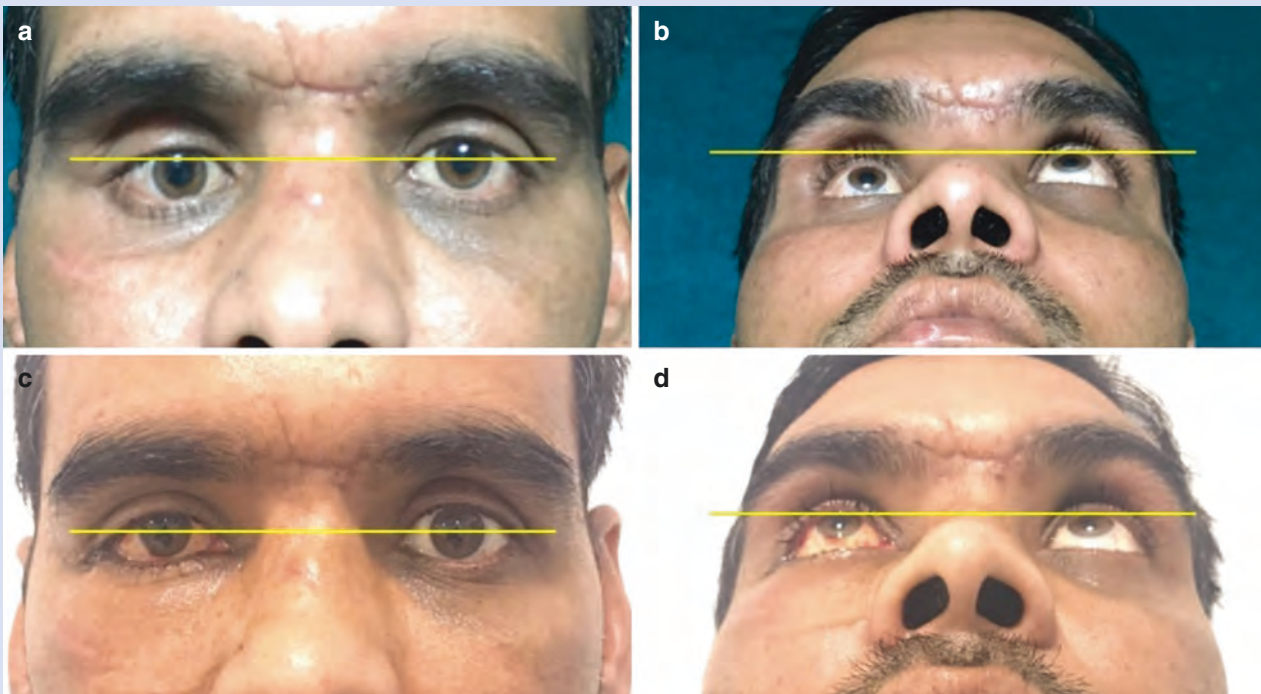
©Association of Oral and Maxillofacial Surgeons of India

Fig. 57.56 PSI designed for reconstruction of a large floor and medial wall defect in the right orbit. (a) Frontal view of PSI on an STL model of the patient, (b) superior view, and (c) intraoperative photograph showing placement of the PSI “in situ”

57.15 Case Scenarios

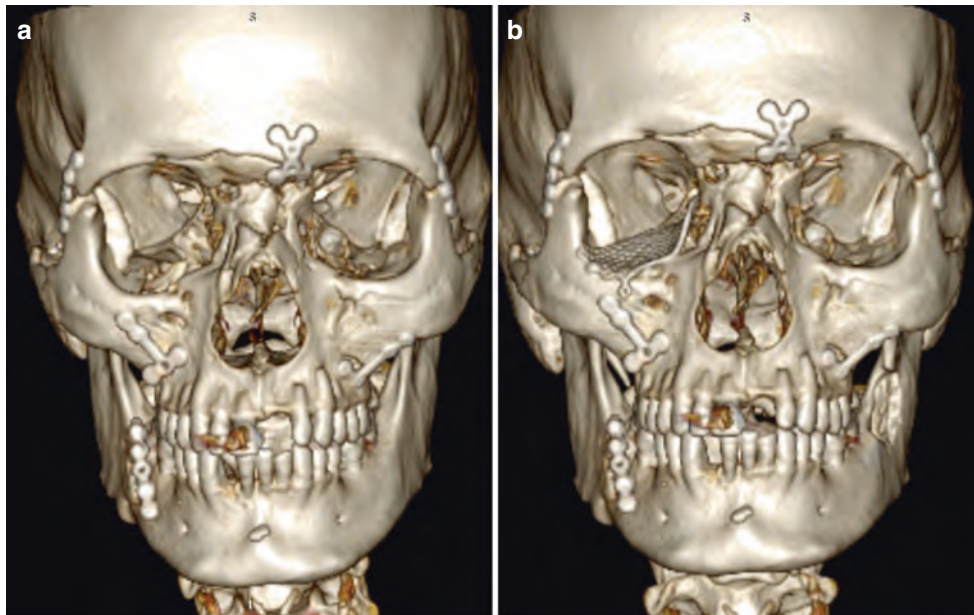
Case 1

Patient with a history of facial trauma 8 months back presented with complaints of change in the position of his eye-balls. He had a history of surgical intervention for management of his pan-facial fractures immediately following the trauma. No intervention was performed for the orbital fractures primarily. Subsequent clinical evaluation performed 8 months later revealed enophthalmos, hypophthalmos and restriction in superior gaze in the right eye. CT scans revealed a large orbital floor defect on the right side with fibrosis and adhesion of the inferior rectus to the posterior ledge of the floor defect. The patient was subjected to secondary surgery for correction of the above mentioned complaints. An orbital exploration was performed on the right side to release the inferior rectus, the infra-orbital rim was augmented with a ramal graft and the floor defect was reconstructed with a “Stryker” anatomical orbital implant. Post-surgical evaluation revealed optimal corrections of the enophthalmos, hypophthalmos and good repositioning of the inferior rectus muscle (Figs. 57.57a–d, 57.58a, b and 57.59a–f).



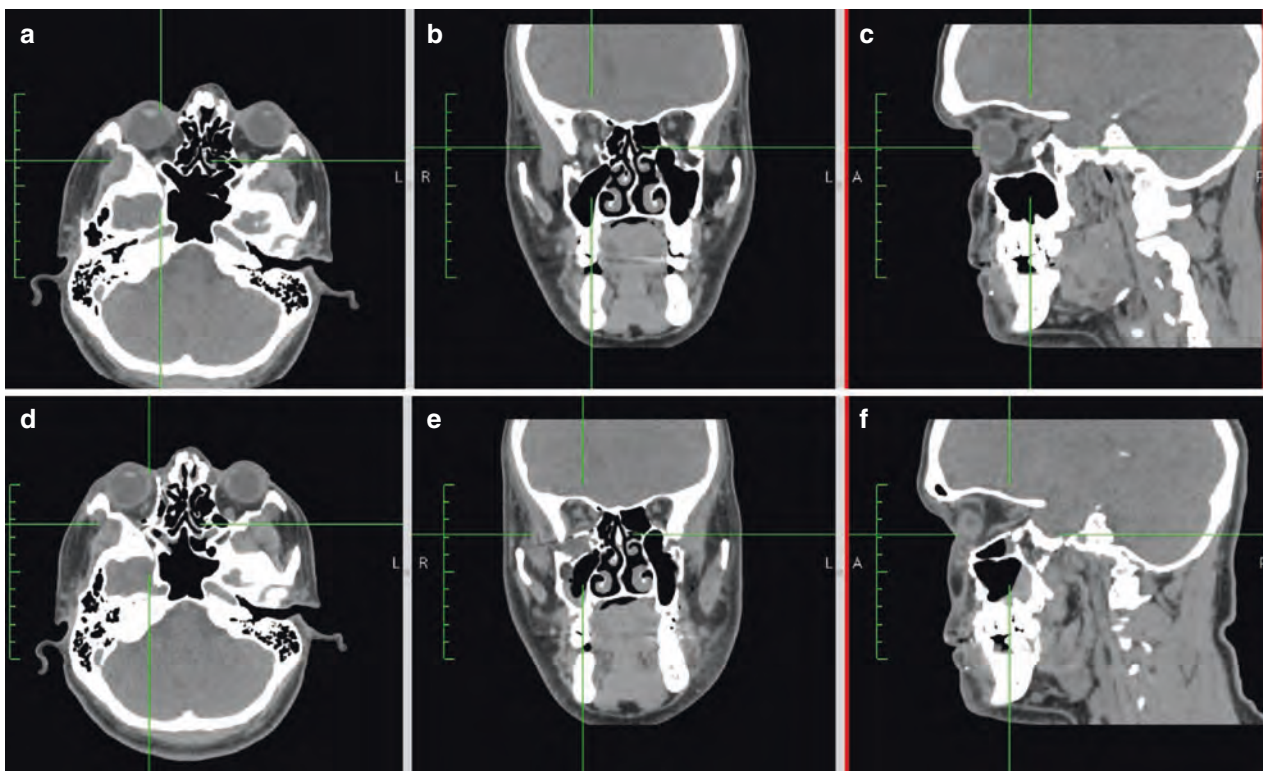
©Association of Oral and Maxillofacial Surgeons of India

Fig. 57.57 (a and b) Pre-operative clinical photographs of patient demonstrating right sided enophthalmos and hypophthalmos. (c and d) Post-operative clinical photographs showing optimal surgical outcomes



©Association of Oral and Maxillofacial Surgeons of India

Fig. 57.58 3D CT reconstructions of patient in Fig 57.57 demonstrating (a) right-sided malunited zygomatic complex fracture with orbital floor defect and (b) post-surgical scan image showing reconstruction of the right orbital floor defect with an anatomical orbital implant after augmentation of the infra-orbital rim with a mandibular ramus bone graft

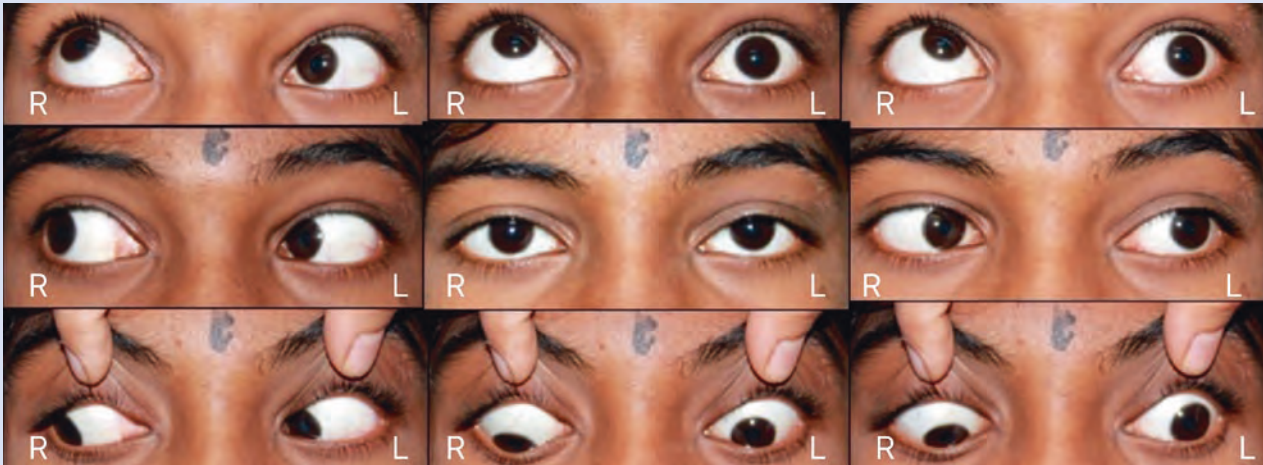


©Association of Oral and Maxillofacial Surgeons of India

Fig. 57.59 (a–c) Pre-operative axial, coronal, and sagittal scans of patient in Fig 57.57 with large defect of the right orbital floor. (d–f) Post-operative sections demonstrating the correction of the floor defect with an anatomical orbital implant

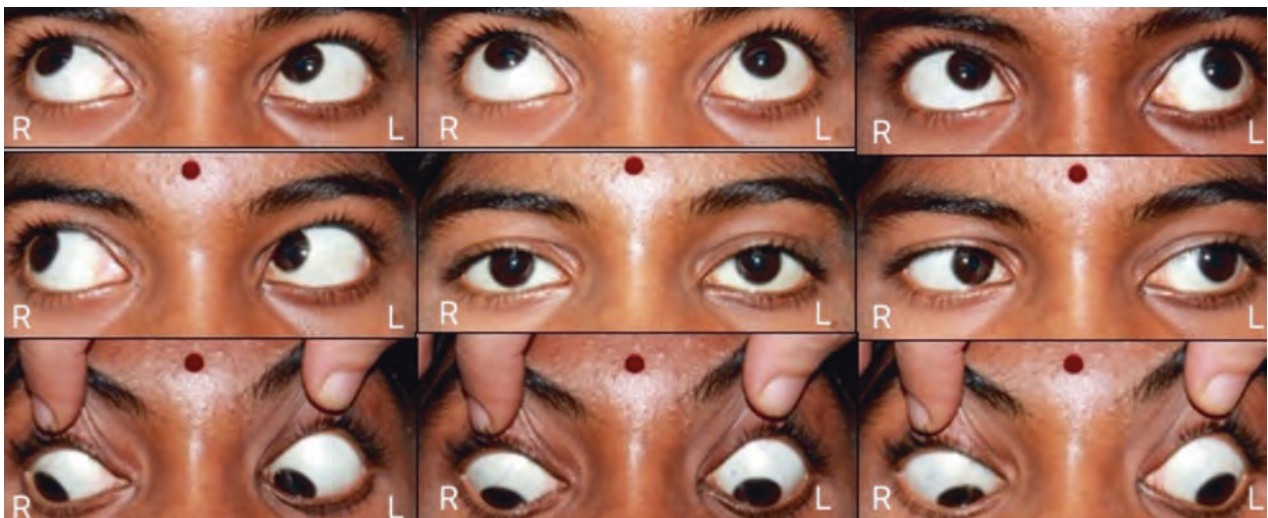
Case 2

A 12 year old girl presented to the surgical OPD with history of blunt injury to the left eye. On examination she had no external signs of injury but revealed restriction in superior gaze in the left eye. CT scan revealed a springing trapdoor fracture of the left orbital floor with entrapment of the inferior rectus muscle. A diplopia charting was performed which revealed moderate to severe restriction of the left eye in the superior gaze. The patient was taken up for immediate surgery for orbital exploration and release of the entrapped muscle with/without floor reconstruction. The exploration was successful and the patient required no reconstruction of the floor. Post operatively the patient demonstrated complete resolution of the symptoms with the full range of ocular movements restored. (Figs. 57.60, 57.61, 57.62a, b) (Courtesy: Dept of Orbit & Oculoplasty, Shankara Nethralaya, Chennai)



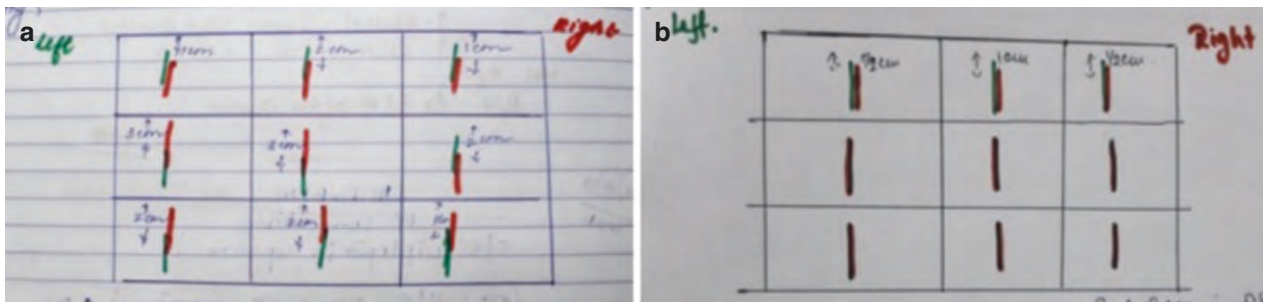
©Association of Oral and Maxillofacial Surgeons of India

Fig. 57.60 Pre-operative photograph demonstrating the nine gazes of a young girl with a “White eye blowout” fracture of the left orbital floor with entrapment of the inferior rectus. (Courtesy: Dept of Orbit & Oculoplasty, Shankara Nethralaya, Chennai)



©Association of Oral and Maxillofacial Surgeons of India

Fig. 57.61 Post-operative photograph demonstrating resolution of symptoms after 3 weeks of surgery (Courtesy: Dept of Orbit & Oculoplasty, Shankara Nethralaya, Chennai)



©Association of Oral and Maxillofacial Surgeons of India

Fig. 57.62 Photograph of documentation of diplopia by charting with two colors (green for left and red for right eyes). The left and right sides are marked in the orientation that the patient sees an object in front of him/her. (a) Pre-operative and (b) post-operative (Courtesy: Dept of Orbit & Oculoplasty, Shankara Nethralaya, Chennai)

References

1. Turvey TA, Golden BA. Orbital anatomy for the surgeon. *Oral Maxillofac Surg Clin North Am.* 2012;24(4):525–36.
2. Ochs MW, Buckley MJ. Anatomy of the orbit. *Oral Maxillofac Surg Clin North Am.* 1993;5:419–29.
3. Rowe NL, Williams JL. *Maxillofacial injuries.* Edinburgh: Churchill Livingstone; 1985.
4. Furuta M. Measurement of orbital volume by computed tomography: especially on the growth of the orbit. *Jpn J Ophthalmol.* 2001;45(6):600–6.
5. Bron AJ, Tripathi RC. *Wolff's anatomy of the eye and orbit.* London: Chapman and Hall Medical; 1997.
6. Zide BM, editor. *Surgical anatomy around the orbit: the system of zones.* Philadelphia: Lippincott Williams & Wilkins; 2006.
7. Hammer B. *Orbital fractures: diagnosis, operative treatment, secondary corrections.* Toronto: Hogrefe & Huber; 1995.
8. Manson PN, Clifford CM, Su CT, Iliff NT, Morgan R. Mechanisms of global support and posttraumatic enophthalmos: I. The anatomy of the ligament sling and its relation to intramuscular cone orbital fat. *Plast Reconstr Surg.* 1986;77(2):193–202.
9. Martins C, Costa e Silva IE, Campero A, Yasuda A, Aguiar LR, Tatabiga M, Rhoton A. Microsurgical anatomy of the orbit: the rule of seven. *Anat Res Int.* 2011;2011:468727.
10. Manson PN, Markowitz B, Mirvis S, Dunham M, Yaremchuk M. Toward CT-based facial fracture treatment. *Plast Reconstr Surg.* 1990 Feb;85(2):202–12.
11. Converse JM, Smith B. Blowout fracture of the floor of the orbit. *Trans Am Acad Ophthalmol Otolaryngol.* 1960;64:676–88.
12. Dingman RO, Natvig P. *Surgery of facial fractures.* London: Saunders; 1964.
13. Fujino T. Experimental “blowout” fracture of the orbit. *Plast Reconstr Surg.* 1974;54(1):81–2.
14. Pfeiffer RL. Traumatic enophthalmos. *Trans Am Ophthalmol Soc.* 1943;41:293–306.
15. Brady SM, Mcmann MA, Mazzoli RA, Bushley DM, Ainbinder DJ, Carroll RB. The diagnosis and management of orbital blowout fractures: update 2001. *Am J Emerg Med.* 2001;19(2):147–54.
16. King EF, Samuel E. Fractures of the orbit. *Trans Ophthalmol Soc U K.* 1944;64:134–53.
17. Ahmad F, Kirkpatrick NA, Lyne J, Urdang M, Waterhouse N. Buckling and hydraulic mechanisms in orbital blowout fractures: fact or fiction? *J Craniofac Surg.* 2006;17(3):438–41.
18. Nagasao T, Miyamoto J, Shimizu Y, Jiang H, Nakajima T. What happens between pure hydraulic and buckling mechanisms of blowout fractures? *J Cranio-Maxillofac Surg.* 2010;38(4):306–13.
19. Al-Qurainy IA, Dutton GN, Titterton DM, Stassen LF, Moos KF, El-Attar A. Midfacial fractures and the eye: the development of a system for detecting patients at risk of eye injury. *Br J Oral Maxillofac Surg.* 1991;29(6):363–7.
20. Soparkar CN, Patrinely JR. The eye examination in facial trauma for the plastic surgeon. *Plast Reconstr Surg.* 2007;120(7):49S–56S.
21. Al-Qurainy IA, Dutton GN, Stassen LF, Moos KF, El-Attar A. The characteristics of midfacial fractures and the association with ocular injury: a prospective study. *Br J Oral Maxillofac Surg.* 1991;29(5):291–301.
22. Ochs MW. Orbital and ocular trauma. In: *Peterson's principles of oral and maxillofacial surgery.* 2nd ed. Hamilton: London; 2004. p. 463–90.
23. American Academy of Ophthalmology. 8-point eye exam. Adopted May 24, 2016 (Cited May 21, 2019). Available from <https://www.aao.org/young-ophthalmologists/yo-info/article/how-to-conduct-eight-point-ophthalmology-exam>
24. Al-Qurainy IA, Dutton GN, Stassen LF, Moos KF, El-Attar A. Diplopia following midfacial fractures. *Br J Oral Maxillofac Surg.* 1991;29(5):302–7.
25. Tahernia A, Erdmann D, Follmar K, Mukundan S, Grimes J, Marcus JR. Clinical implications of orbital volume change in the management of isolated and zygomaticomaxillary complex-associated orbital floor injuries. *Plast Reconstr Surg.* 2009;123(3):968–75.
26. He D, Li Z, Shi W, Sun Y, Zhu H, Lin M, Shen G, Fan X. Orbitozygomatic fractures with enophthalmos: analysis of 64 cases treated late. *J Oral Maxillofac Surg.* 2012;70(3):562–76.
27. Goodall KL, Brahma A, Bates A, Leatherbarrow B. Lateral canthotomy and inferior cantholysis: an effective method of urgent orbital decompression for sight threatening acute retrobulbar haemorrhage. *Injury.* 1999;30(7):485–90.
28. Gruss JS, Hurwitz JJ, Nik NA, Kassel EE. The pattern and incidence of nasolacrimal injury in naso-orbital-ethmoid fractures: the role of delayed assessment and dacryocystorhinostomy. *Br J Plast Surg.* 1985;38(1):116–21.
29. Woernley TC, Wright TL, Lam DN, Jundt JS. Oculocardiac reflex in an orbital fracture without entrapment. *J Oral Maxillofac Surg.* 2017;75(8):1716–21.
30. Schaller B. Trigemino-cardiac reflex. *J Neurol.* 2004;251(6):658–65.
31. Fonseca RJ, Marciani RD, Turvey TA. *Oral and maxillofacial surgery.* Missouri: Saunders Elsevier; 2009.

32. Chen CT, Chen YR. Traumatic superior orbital fissure syndrome: current management. *Craniofacial Trauma Reconstr.* 2010 Mar;3(01):009–16.
33. Zachariades N. The superior orbital fissure syndrome: Review of the literature and report of a case. *Oral Surg Oral Med Oral Pathol.* 1982;53(3):237–40.
34. Warburton RE, Brookes CC, Golden BA, Turvey TA. Orbital apex disorders: a case series. *Int J Oral Maxillofac Surg.* 2016;45(4):497–506.
35. Antonyshyn O, Gruss JS, Kassel EE. Blow-in fractures of the orbit. *Plast Reconstr Surg.* 1989;84(1):10–20.
36. Lynch RC. The technique of a radical frontal sinus operation which has given me the best results. (original communications are received with the understanding) that they are contributed exclusively to the laryngoscope. *Laryngoscope.* 1921;31(1):1–5.
37. Ellis E, Zide MF, editors. *Surgical approaches to the facial skeleton.* Philadelphia: Lippincott Williams & Wilkins; 2006.
38. Perry M, Holmes S. *Manual of operative maxillofacial trauma surgery.* London: Springer; 2014.
39. Cline RA, Rootman J. Enophthalmos: a clinical review. *Ophthalmology.* 1984;91(3):229–37.
40. Athanasiov PA, Prabhakaran VC, Selva D. Non-traumatic enophthalmos: a review. *Acta Ophthalmol.* 2008;86(4):356–64.
41. Converse JM, Smith B, Obear MF, Wood-Smith D. Orbital blowout fractures: a ten-year survey. *Plast Reconstr Surg.* 1967;39(1):20–36.
42. Cossman JP, Morrison CS, Taylor HO, Salter AB, Klinge PM, Sullivan SR. Traumatic orbital roof fractures: interdisciplinary evaluation and management. *Plast Reconstr Surg.* 2014;133(3):335e–43e.
43. Alsuhaibani AH. Orbital fracture: significance of lateral wall. *Saudi J Ophthalmol.* 2010;24(2):49–55.
44. Stanley JR, Sires BS, Funk GF, Nerad JA. Management of displaced lateral orbital wall fractures associated with visual and ocular motility disturbances. *Plast Reconstr Surg.* 1998;102(4):972–9.
45. Manolidis S, Weeks BH, Kirby M, Scarlett M, Hollier L. Classification and surgical management of orbital fractures: experience with 111 orbital reconstructions. *J Craniofac Surg.* 2002;13(6):726–37.
46. McNichols CH, Hatef DA, Thornton JF, Cole PD, de Mitchell CA, Hollier LH Jr. A paradigm shift in correcting medial orbital fracture-related enophthalmos: volumetric augmentation through a lateral approach. *J Craniofac Surg.* 2012;23(3):762–6.
47. Nolasco FP, Mathog RH. Medial orbital wall fractures: classification and clinical profile. *Otolaryngol Head Neck Surg.* 1995 Apr;112(4):549–56.
48. Burm JS, Chung CH, Oh SJ. Pure orbital blowout fracture: new concepts and importance of medial orbital blowout fracture. *Plast Reconstr Surg.* 1999;103(7):1839–49.
49. Lee WT, Kim HK, Chung SM. Relationship between small-size medial orbital wall fracture and late enophthalmos. *J Craniofac Surg.* 2009;20(1):75–80.
50. Jin HR, Shin SO, Choo MJ, Choi YS. Relationship between the extent of fracture and the degree of enophthalmos in isolated blowout fractures of the medial orbital wall. *J Oral Maxillofac Surg.* 2000;58(6):617–20.
51. Saiepour D, Messo E, Hedlund AJ, Nowinski DJ. Radiologic and long-term clinical outcome from treatment of isolated medial orbital wall blowout fractures. *J Craniofac Surg.* 2012;23(5):1252–5.
52. Lee CS, Yoon JS, Lee SY. Combined transconjunctival and transcaruncular approach for repair of large medial orbital wall fractures. *Arch Ophthalmol.* 2009;127(3):291–6.
53. Dubois L, Steenen SA, Gooris PJ, Bos RR, Becking AG. Controversies in orbital reconstruction—III. Biomaterials for orbital reconstruction: a review with clinical recommendations. *Int J Oral Maxillofac Surg.* 2016;45(1):41–50.
54. Jaquiéry C, Aeppli C, Cornelius P, Palmowsky A, Kunz C, Hammer B. Reconstruction of orbital wall defects: critical review of 72 patients. *Int J Oral Maxillofac Surg.* 2007;36(3):193–9.
55. Dubois L, Steenen SA, Gooris PJ, Mourits MP, Becking AG. Controversies in orbital reconstruction—I. Defect-driven orbital reconstruction: a systematic review. *Int J Oral Maxillofac Surg.* 2015;44(3):308–15.
56. Palmieri CF, Ghali GE. Late correction of orbital deformities. *Oral Maxillofac Surg Clin North Am.* 2012;24(4):649–63.
57. Dubois L, Steenen SA, Gooris PJ, Mourits MP, Becking AG. Controversies in orbital reconstruction—II. Timing of post-traumatic orbital reconstruction: a systematic review. *Int J Oral Maxillofac Surg.* 2015;44(4):433–40.
58. Koo L, Hatton MP, Rubin PA. When is enophthalmos “significant”? *Ophthalmic Plast Reconstr Surg.* 2006;22(4):274–7.
59. Sung YS, Chung CM, Hong IP. The correlation between the degree of enophthalmos and the extent of fracture in medial orbital wall fracture left untreated for over six months: a retrospective analysis of 81 cases at a single institution. *Arch Plast Surg.* 2013;40(4):335.
60. Gooris PJ, Muller BS, Dubois L, Bergsma JE, Mensink G, van den Ham MF, Becking AG, Seubring K. Finding the ledge: sagittal analysis of bony landmarks of the orbit. *J Oral Maxillofac Surg.* 2017;75(12):2613–27.
61. Markowitz BL, Manson PN, Sargent L, Vander CAK, Yaremchuk M, Glassman D, et al. Management of the medial canthal tendon in nasoethmoid orbital fractures: the importance of the central fragment in classification and treatment. *Plast Reconstr Surg.* 1991;87(5):843–53.
62. Hayreh SS, Weingeist TA. Experimental occlusion of the central artery of the retina. IV: Retinal tolerance time to acute ischaemia. *Br J Ophthalmol.* 1980;64(11):818–25.
63. Vassallo S, Hartstein M, Howard D, Stetz J. Traumatic retrobulbar hemorrhage: emergent decompression by lateral canthotomy and cantholysis. *J Emerg Med.* 2002;22(3):251–6.
64. Gerbino G, Ramieri GA, Nasi A. Diagnosis and treatment of retrobulbar haematomas following blunt orbital trauma: a description of eight cases. *Int J Oral Maxillofac Surg.* 2005;34(2):127–31.
65. Amrith S, Saw SM, Lim TC, Lee TK. Ophthalmic involvement in cranio-facial trauma. *J Cranio-Maxillofac Surg.* 2000;28(3):140–7.
66. Levin LA, Beck RW, Joseph MP, Seiff S, Kraker R, International Optic Nerve Trauma Study Group. The treatment of traumatic optic neuropathy: the International Optic Nerve Trauma Study. *Ophthalmology.* 1999;106(7):1268–77.
67. Steinsapir KD, Goldberg RA. Traumatic optic neuropathy. *Surv Ophthalmol.* 1994;38(6):487–518.
68. Hoffmeister B. *Pediatric maxillofacial trauma.* In: *Maxillofacial surgery.* London: Churchill Livingstone; 2017. p. 193–9.
69. Sugamata A, Yoshizawa N. A case of blowout fracture of the orbital floor in early childhood. *Int Med Case Rep J.* 2015;8:155–8.
70. Tiwana PS, Vickers A. Pediatric cranio-maxillofacial trauma: mandibular fractures. In: *Current therapy in oral and maxillofacial surgery.* Philadelphia: WB Saunders; 2012. p. 841–50.
71. Yew CC, Shaari R, Rahman SA, Alam MK. White-eyed blowout fracture: diagnostic pitfalls and review of literature. *Injury.* 2015;46(9):1856–9.
72. Benliel R, Birenboim R, Regev E, Eliav E. Neurosensory changes in the infraorbital nerve following zygomatic fractures. *Oral Surg Oral Med Oral Pathol Oral Radiol Endod.* 2005;99(6):657–65.

73. Kumar P, Godhi S, Lall AB, Ram CS. Evaluation of neurosensory changes in the infraorbital nerve following zygomatic fractures. *J Maxillofac Oral Surg.* 2012;11(4):394–9.
74. Bell RB, Markiewicz MR. Computer-assisted planning, stereolithographic modeling, and intraoperative navigation for complex orbital reconstruction: a descriptive study in a preliminary cohort. *J Oral Maxillofac Surg.* 2009;67(12):2559–70.
75. Lauer G, Pradel W, Schneider M, Eckelt U. Efficacy of computer-assisted surgery in secondary orbital reconstruction. *J Cranio-Maxillofac Surg.* 2006;34(5):299–305.
76. Wilde F, Lorenz K, Ebner AK, Krauss O, Mascha F, Schramm A. Intraoperative imaging with a 3D C-arm system after zygomatico-orbital complex fracture reduction. *J Oral Maxillofac Surg.* 2013;71(5):894–910.
77. Wilde F, Schramm A. Intraoperative imaging in orbital and midface reconstruction. *Facial Plast Surg.* 2014;30(05):545–53.

Additional Reading

- Bater MC, Ramchandani PL, Brennan PA. Post-traumatic eye observations. *Br J Oral Maxillofac Surg.* 2005;43(5):410–6.

Open Access This chapter is licensed under the terms of the Creative Commons Attribution 4.0 International License (<http://creativecommons.org/licenses/by/4.0/>), which permits use, sharing, adaptation, distribution and reproduction in any medium or format, as long as you give appropriate credit to the original author(s) and the source, provide a link to the Creative Commons license and indicate if changes were made.

The images or other third party material in this chapter are included in the chapter's Creative Commons license, unless indicated otherwise in a credit line to the material. If material is not included in the chapter's Creative Commons license and your intended use is not permitted by statutory regulation or exceeds the permitted use, you will need to obtain permission directly from the copyright holder.



Frontal and Naso-Orbito-Ethmoid Complex Fractures

58

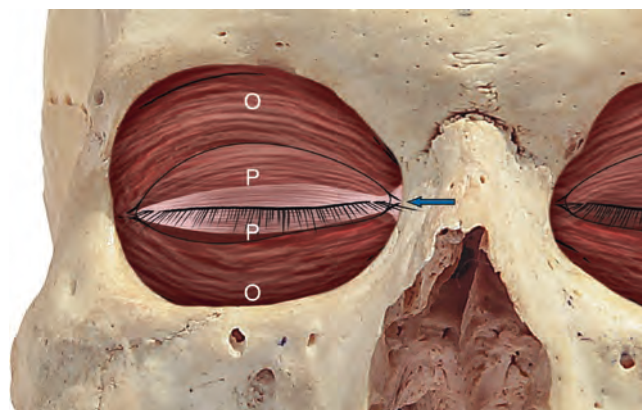
Kannan Balaraman

58.1 Introduction

Naso-orbito-ethmoid (NOE) region is a confluence of critical structures of the face including the nose, orbit and skull base. Hence injuries to the region have a major impact on the function of these regions as well as aesthetics. A deformity of the NOE region tends to catch the eye much more than a deformity elsewhere in the face and hence affecting the individual. The injuries to this area are about 5% of maxillofacial injuries in adults and about 15% in children [1, 2] and mostly occur as a result of road traffic accidents (RTA) [1] especially in the Indian subcontinent. This is especially so due to two-wheeler injuries. Considering the proximity of the region to the brain and globe, these injuries may need multi-disciplinary evaluation before embarking on a definitive treatment plan.

58.2 Applied Surgical Anatomy

The NOE complex is a part of the medial vertical buttress system of the face abutting the cranium. It is made of the nasal bones, the ethmoid bones encompassing the sinuses which also form the medial wall of the orbit articulating above with the frontal bone at the anterior skull base. This ethmoid labyrinth which separates both the orbits acts like a shock absorber during trauma thus minimizing force dissipation into critical structures like the orbital and cranial cavities. Extensive injury or comminution can result in associated anterior cranial base fractures causing cerebrospinal fluid (CSF) leak as well. The frontal process of maxilla and the lacrimal bone also is an integral part of the complex owing to their proximity and involvement in the fracture pattern occurring in the region.



©Association of Oral and Maxillofacial Surgeons of India

Fig. 58.1 MCL anchoring eyelids (O-ocular, P-palpebral)

Apart from the bony parts, the medial canthal ligament (MCL) is an important soft tissue of the complex (Fig. 58.1). The ligament not only anchors the upper and lower eyelids to the nasal complex but also encompasses the lacrimal sac at its anterior, posterior and superior aspect [3]. Certain authors have found that the posterior limb is not always present or clearly defined in certain instances [4]. The ligament being attached to the edges of the lacrimal fossa in the lacrimal bone in these areas helps in emptying of the lacrimal sac during blinking thus effecting drainage of the lacrimal sac. Hence injuries to the region affecting the attachment of the medial canthal ligament can impact the medial eyelid attachment and/or draining off tears from lacrimal sac. The skin and soft tissues drape over the complex like a cloth over a framework, and when the region crumples following an injury, the soft tissue envelope collapses as well causing distinct deformity which if not treated well can result in persistent deformity of the region. The collapsed soft tissue heals/scars over the deformed bony complex and secondary correction at a later date do not help achieve the pre-injury status. Hence optimal primary realignment and repair offer the best chance of achieving optimal results [5].

K. Balaraman (✉)
Department of Oral and Maxillofacial Surgery, Ganga Medical
Centre and Hospitals, Coimbatore, Tamil Nadu, India

58.3 Historical Perspective and Classification [6]

The treatment of NOE complex injuries has evolved from the previous century. Though nasal bone fractures have been recognized for a long time, the fracture of ethmoids was highlighted by Dawson and Fordyce in 1953. Converse and Smith in 1963 identified the involvement of medial orbital wall and termed it as naso-orbital. Stranc was the first to in modern English literature to adopt the terminology naso-ethmoid. Epker recognized the present-day terminology of naso-orbito-ethmoid in 1973, whilst Gruss in 1985 preferred the term naso-ethmoid-orbital [6].

58.3.1 Classification

Rowe and Williams [7] in their classic text highlighted the complexity of the area and stressed the need for primary management. Their classification was quite simple, depending on side involved and association with other fractures.

- Unilateral or bilateral
- Isolated or associated with other facial fractures

Markowitz and Manson (1991) [8] identified the importance of canthal ligament, and their classification reflected the need for getting the position of the canthal ligament either by manipulating the fragment or anchoring the canthus directly. Their classification was as follows (Box 58.1):

Box 58.1 Markowitz and Manson Classification

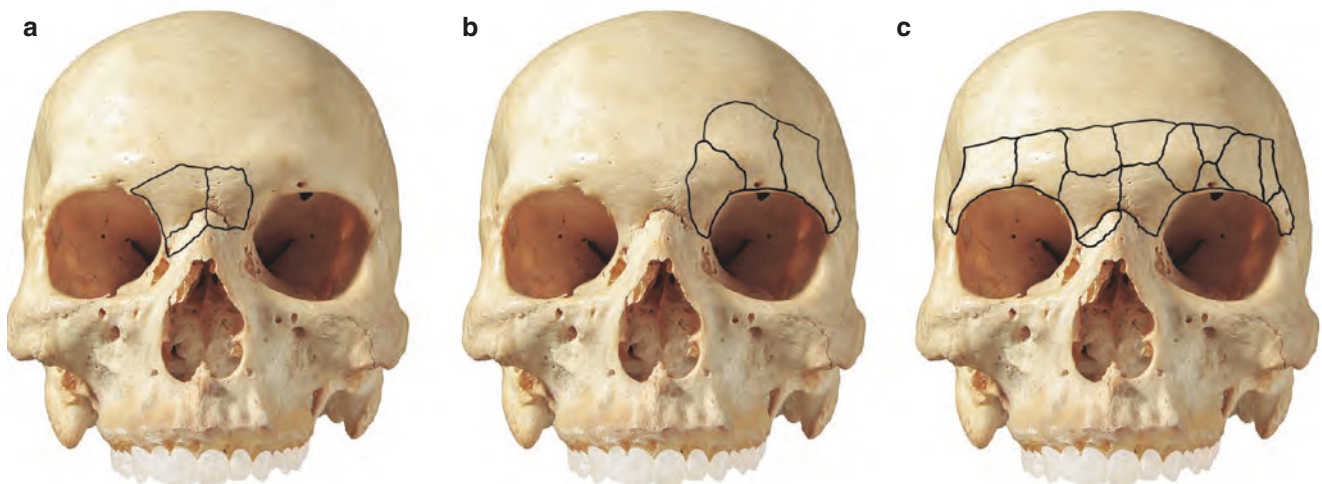
Type I	Simple fracture with canthal ligament attachment intact
Type II	Comminuted fracture with intact canthal attachment in the large fragment (positioning this fragment helps in securing the canthus in the right place)
Type III	Gross comminution with the canthal attachment in a small fragment or detached canthus both necessitating canthopexy

58.3.2 Paediatric NOE Fractures (Fig. 58.2) Classification: Burstein et al.'s [9] (Box 58.2)

Box 58.2 Paediatric NOE Fracture Classification

Paediatric NOE fractures classification types are:

- *Burstein type I fracture*—localized to the upper NOE complex and frontal bone, medial to superior orbital foramen
- *Burstein type II fracture*—involves half of the superior orbital wall, although it does not involve the NOE
- *Burstein type III fracture*—is bilateral and involves the superior orbital walls, upper NOE and bilateral frontal bones



©Association of Oral and Maxillofacial Surgeons of India

Fig. 58.2 Paediatric NOE fractures classification

Markowitz classification of adult NOE fractures does not take into account the differences in paediatric population such as:

- Midface-skull proportions
- Frontal sinus pneumatization

58.4 Aetiology, Clinical Features and Diagnosis

The most common aetiology of the fracture of NOE complex is trauma be it road accidents in unprotected individuals, assaults or fall from height [10].

Initial presentation can be disconcerting for the individual and bystanders due to profuse nasal bleeding and gross oedema around the midfacial skeleton. The signs and symptoms are given in Box 58.3 (symptoms) and Box 58.4 (signs).

Box 58.3 Symptoms of NOE Fracture

Periorbital swelling
Pain and discomfort
Epistaxis
Nasal blockade
– Widening of NOE area

Box 58.4 Signs of NOE Fracture

Nasal deformity with crepitus
Epistaxis—blood or mixed with CSF
Depressed nasal bridge
Upturned nasal tip
Rounded medial canthus
Altered palpebral fissure shape
Blockage of nasolacrimal duct
– Accentuation of the nasojugal skin fold
– Formation of obtuse angle at the base of columella with tension on upper lip
– Lip separation caused due to ruptured tip of nose
Telecanthus
(a) lose of almond shape of palpebral fissure
(b) Transverse shortening of the palpebral aperture
(c) Eyelids become lax
(d) Epicanthal fold become more prominent
(e) Flattening of the bottom of naso-orbital valley
(f) Obliteration of the caruncle
(g) Diminished tension of canthal ligament

From the point of view of the examining clinician, Advanced Trauma Life Support (ATLS) protocols take precedence however gross the presenting scenario is (Refer Chap. 48 of this book). Once primary survey is completed and the patient cleared for secondary survey, definitive clinical examination starts. It is also imperative to rule out underlying injuries to the head/brain, ophthalmologic or associated structures prior to comprehensive maxillofacial assessment.

The main indicators suggesting an underlying NOE fractures include:

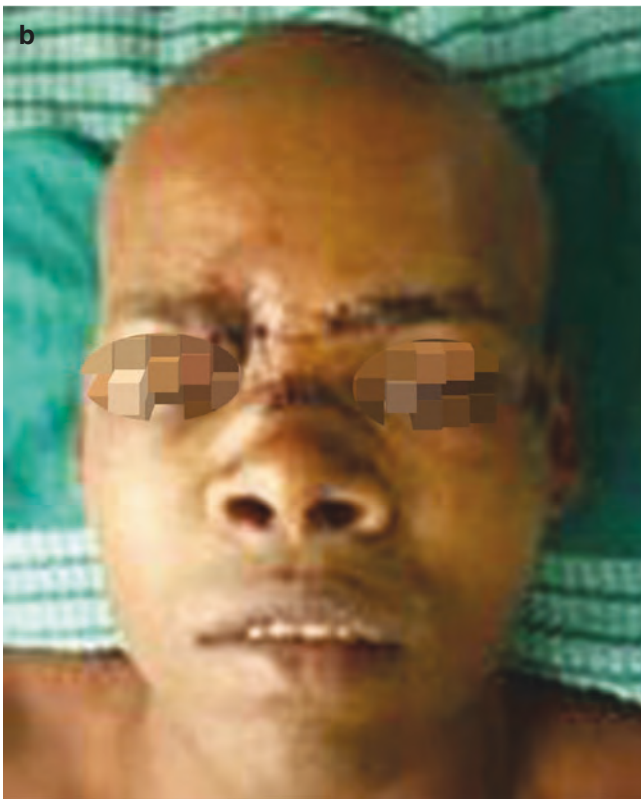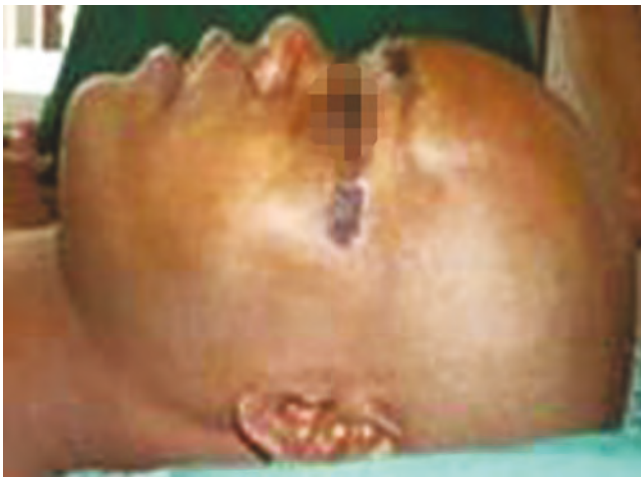- Depressed nasal bridge (with or without upturned nasal tip) is a result of the loss of bony morphology (Fig. 58.3a, b). When the medial canthal ligament attachment is lost, the manifestations include loss of contour of palpebral fissure with rounded medial canthal region. The almond shape of the palpebral fissure is lost and becomes larger, and Bowstring test becomes positive (Fig. 58.4).
- Traumatic telecanthus is a direct indicator of the MCL disruption or widening of the fragments. When there is an intercanthal distance of 35 mm or more, then it may be an indication of the fragment with MCL being displaced. Direct physical examination is useful in identifying the collapsed complex.

Measurement of Intercanthal Distance (ICD):

Normal values are 32–33 mm for females and 33–34 mm for males. The rule of thirds can be applied whilst evaluating NOE fractures. Normally ICD equals the palpebral fissure width. However, in NOE fractures, increased ICD is found, called telecanthus (Fig. 58.5).

Telecanthus deformity is characteristic; the lateral displacement of MCT leads to rounding of the medial palpebral fissure, widening of the NOE region and transverse shortening of the palpebral aperture.

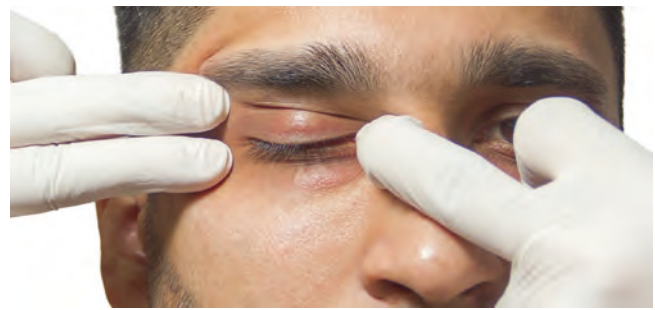- Care should be taken to rule out CSF leak and also damage to the nasolacrimal duct. However the latter is difficult to assess primarily in some of the cases and may become apparent much later. Clear discharge from the nose or watery bloody discharge should arouse a high index of suspicion necessitating further biochemical investigations to differentiate CSF from nasal discharge. Glucose content is more in CSF, but assessment of Tau protein (beta 2 Transferrin) is the confirmatory diagnostic factor. Thorough neurologic and ophthalmologic assessment is also essential. In the acute setting, clinical examination is challenging due to the discomfort and



©Association of Oral and Maxillofacial Surgeons of India

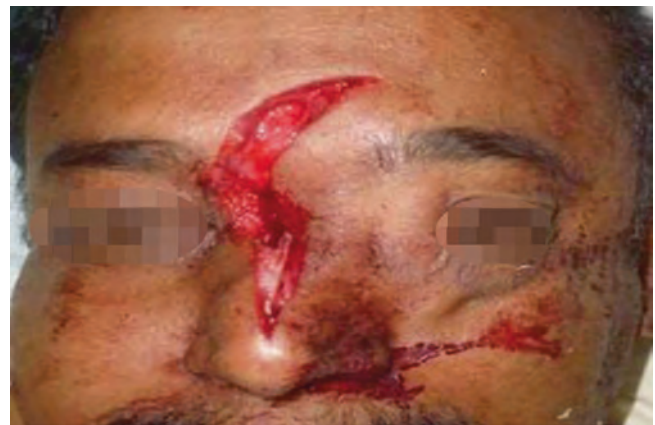Fig. 58.3 (a, b) Depressed, widened nasal complex with upturned tip of the nose

always may be inadequate [11, 12], and hence radiological investigations are mandatory. The diagnosis and understanding of the fractures has evolved over the last century with the advent of CT imaging. CT scan imaging in all planes is the norm in these fractures and helps in ruling injuries to the adjacent structures as well as assess-



©Association of Oral and Maxillofacial Surgeons of India

Fig. 58.4 Bowstring test for assessment of MCL attachment patency

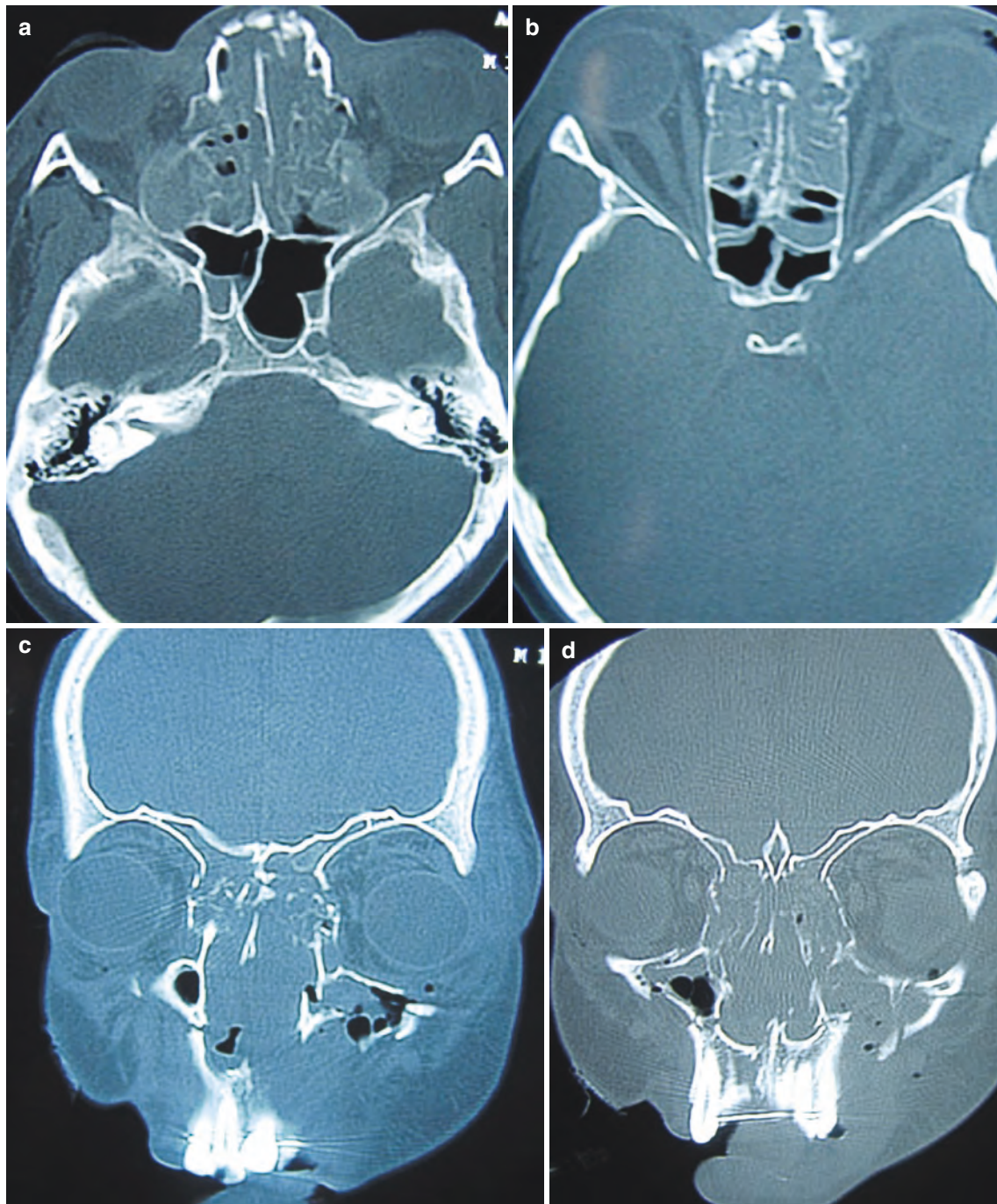


©Association of Oral and Maxillofacial Surgeons of India

Fig. 58.5 Traumatic telecanthus

ing the extent and nature of displacement of NOE complex injuries.

- High-resolution CT scan images in all planes (axial, coronal (Fig. 58.6a–d)) help to identify and assess the fracture pattern accurately. Thin sections (0.6 mm) not only help in better evaluation but also facilitate surgical planning or fabrication of models if required. The CT scans will be mandatory anyway to assess the head injury status in such cases, and these images can be a part of the head injury screening imaging. Communicating with the radiology department of the importance of such images will ensure that the required sections being done at the same instance of head injury assessment scans thus avoiding repeat scans. The axial sections show if there is disruption of the nasal complex or there is splaying of the ethmoid complex. The coronal sections depicts the displacement in the mediolateral aspect (thus the status of the fragment with the MCL), whilst the sagittal sections



©Association of Oral and Maxillofacial Surgeons of India

Fig. 58.6 (a–d) Axial and coronal CT scan images of NOE fracture

depict the displacement in the anteroposterior (AP) aspect (depression).

- 3D reconstructed images show the gross morphologic status and are as accurate as the thinness of the sections.

Such images are good to plan the surgical management, discuss with the assistants the treatment goals and also explain to the patient the nature of the injury and proposed treatment plan as part of informed consent.

Test to Assess Integrity of MCT

NOE fracture is positive if mobility of the medial canthal tendon is appreciated.

It is revealed by a Bowstring or a bimanual test.

- **Bowstring Test:**
When the eyelid is pulled laterally, a lack of resistance or detection of movement of the underlying bone at the tendon area is indicative of a fracture.
- **Bimanual Test:**
An instrument is placed in the nose and pushed laterally. Instability and crepitation felt at the tendon area suggests NOE fracture.

58.5 Management

The initial presentation of such patients occasionally may be dramatic due to profuse epistaxis which may exacerbate in someone lying down. Keeping patients sitting up with packs in the anterior nostril might help reduce the bleed. Persistent profuse bleed may necessitate intubation to secure the airway and packs in both anterior and posterior nasal passages to help prevent aspiration.

The patient once stabilized, and fit to undergo surgery will need a discussion with the anaesthesiologist about options of intubation. Fractures not involving occlusion can be managed by oral intubation, whilst if involving occlusion then options like submental intubation or even tracheostomy of the patient requires prolonged ventilation or due to have further surgical procedures (as in poly trauma patients).

The presence of CSF leak might pose a tricky problem. Instances of CSF leak are higher whenever there is pneumocephalus. Hence in such instances, an approach combined with neurosurgical team may be mandatory, whilst involvement of an ophthalmologist is mandatory when there is involvement of lacrimal drainage system or lid adnexa. The treatment goals of NOE are shown in Box 58.5.

Box 58.5 Treatment Goals of NOE Fracture

Treatment goals

- Restoring the nasal projection
- Restoring nasal dorsal height with adequate nasofrontal angle
- Re-establishing the MCL attachment
- Restoring the latency of nasolacrimal duct

Conventionally the nasal complex was treated with closed reduction till Adam et al. [6] reported on the importance of nasal wiring. The importance of involving the medial canthal region in the treatment plan was initiated by Converse and Smith in 1963 [6]. They emphasized the importance of manipulating the segment with the MCL, forward positioning the fragment and trans nasal wiring over a perforated plate.

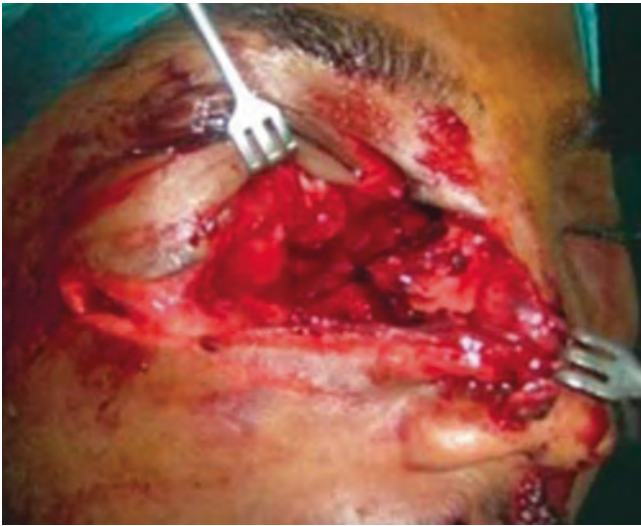The case for open reduction and internal fixation (ORIF) was highlighted by Dingman and Natvig [13]. They reported superior results have been achieved in the more serious injuries (with minimum of effort and with the greatest degree of comfort to the patient) by open reduction with direct fixation. The need and feasibility of identifying MCL and anchoring it across to the other side was described by Mustarde in 1964 [14]. The need for primarily bone grafting when there is severe comminution of the nasal dorsum rendering primary reduction incomplete and also help achieve single-stage reconstruction was highlighted by Cruse [15] and Gruss [16].

Reduction of the nasal complex may be done with Walsham's forceps to realign the deviated/displaced complex. The collapsed complex may be out-fractured, and complex opened out may need to be in-fractured. The depressed complex may be elevated into position by the septal forceps (Ash's). However in displaced or comminuted scenarios, closed reduction isn't optimal. Hence trans nasal wiring may be needed to keep the splayed segments well reduced and minimize telecanthus. In the absence of gross comminution, closed reduction and trans nasal wiring has been proved quite useful and adequate to achieve optimal results as advocated by some authors especially in patients with associated maxillary fractures [17].

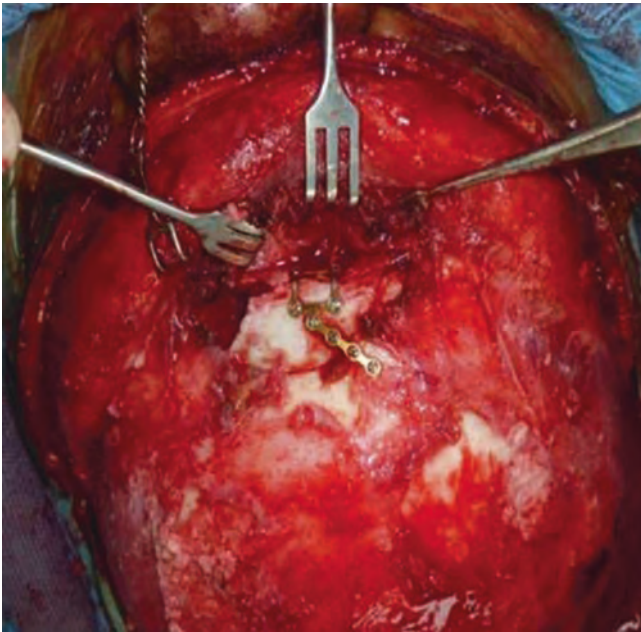
58.5.1 Surgical Access for NOE

1. Existing laceration (Fig. 58.7)
2. Glabella approach—a horizontal skin incision over the glabella region (Fig. 58.8)
3. Bicoronal approach (Fig. 58.9)
4. Butterfly incision (combination of Gullwing and open sky incision) (Fig. 58.10)
5. Vertical incision (Fig. 58.11)
6. H-shaped incision (Fig. 58.12)

Ed Ellis et al. [11] reported on having a sequential plan to proceed with the surgical sequence. They emphasized on adequate exposure for identification of the bone fragment with the MCL tendon, realigning the medial rim and cantho-pxy if required. The nasal dorsum reconstruction is planned at the end.



©Association of Oral and Maxillofacial Surgeons of India

Fig. 58.7 Existing laceration used as an approach

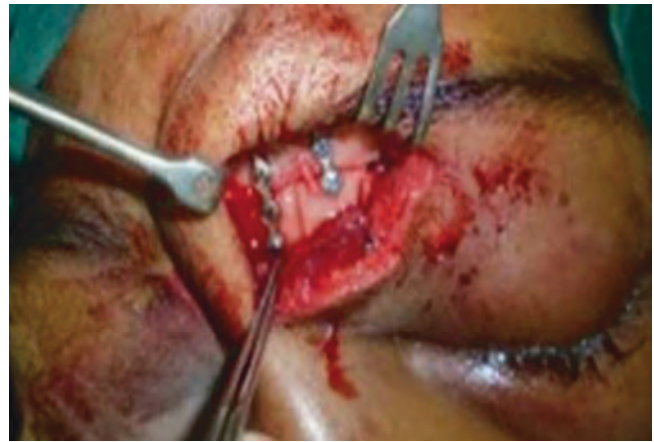©Association of Oral and Maxillofacial Surgeons of India

Fig. 58.9 Bicornal approach

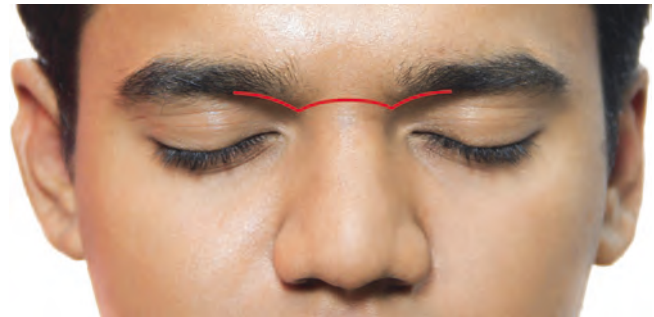According to them pre-treatment photographs are very important in getting good results, and deformity should be overtreated than undertreated because secondary deformity which occurs is difficult to treat.

Trans nasal wiring:

Closed reduction in established fractures with telecanthus rarely helps achieve adequate reduction and MCL reposi-



©Association of Oral and Maxillofacial Surgeons of India

Fig. 58.8 Glabella approach

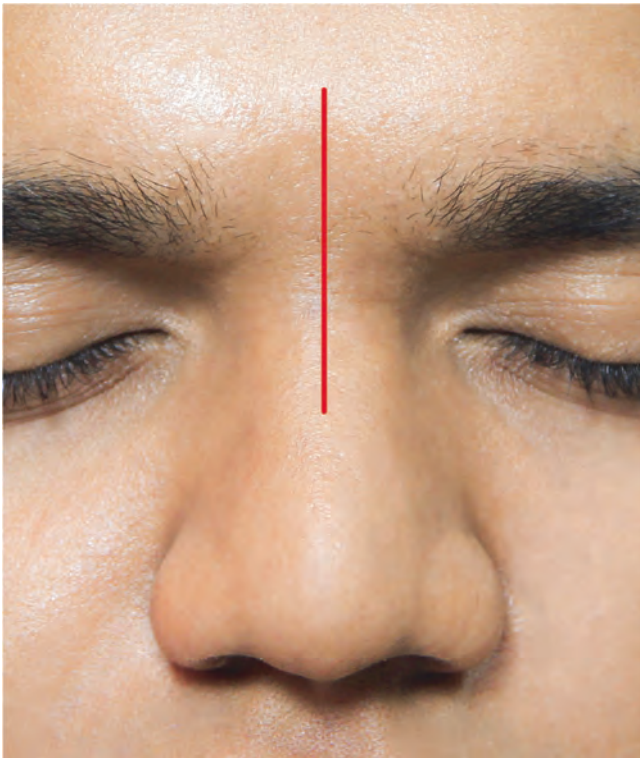©Association of Oral and Maxillofacial Surgeons of India

Fig. 58.10 Butterfly incision (combination of Gullwing and open sky incision)

Steps in Management

- Step 1: Good exposure
- Step 2: Identify the medial canthal tendon/tendon-bearing bone
- Step 3: Reduce and reconstruct medial orbital rim
- Step 4: Reconstruction of medial orbital wall
- Step 5: Trans nasal canthopexy
- Step 6: Reduce septal fracture/displacement
- Step 7: Nasal dorsum reconstruction/augmentation with bone graft
- Step 8: Soft tissue readaptation (nasal splint, trans nasal bolsters, silicone sheeting)

tioning and hence may need trans nasal wiring as well to help with MCL positioning [6, 13]. Using a K wire driver or an awl will help pass a trans nasal wire across the nasal complex and help narrow the area by bringing the sides together. To help achieve adequate narrowing and restore



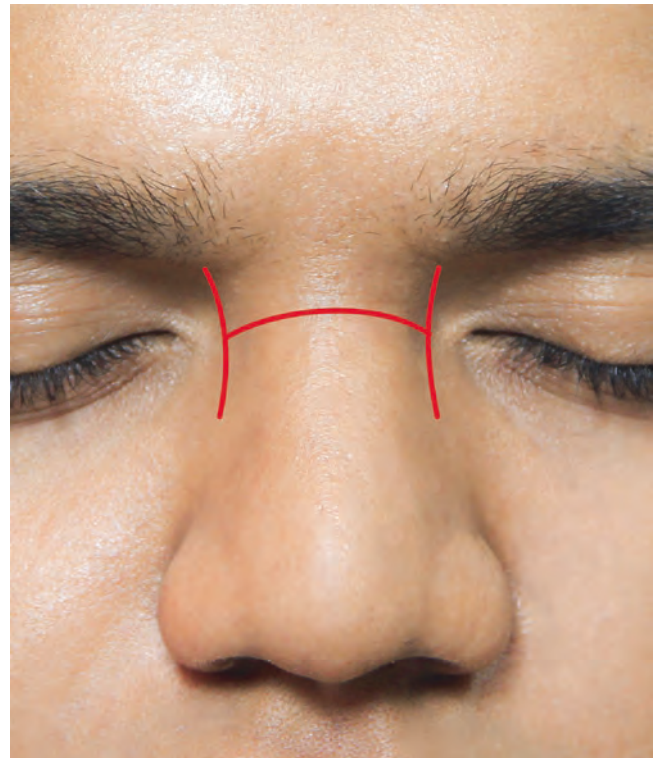
©Association of Oral and Maxillofacial Surgeons of India

Fig 58.11 Vertical incision

the canthal distance, the entry area on the affected site should be just superior and posterior to the posterior lacrimal crest to which the posterior limb of the ligament is attached. The wire entry point anterior to the area can result in widening of the telecanthus as the posterior aspect flares laterally.

As long as a large fragment with MCL attachment is identifiable, open reduction and fixation of the fragment can help in achieving our objectives. Using very low profile titanium plates (1.1–1.3 mm depending on the system used) helps achieve adequate fixation. Rigid fixation needs exposure of a stable area to help achieve the same and may necessitate exposing the glabella or frontal bone superior to it for adequate results. Realignment of the fragments and fixation will help in achieving better results in cases of fracture having multiple fragments and reconstruction with bone graft wherever required (Fig. 58.13 a, b).

MCL disruption or a tiny bony fragment with MCL might necessitate a canthopexy.



©Association of Oral and Maxillofacial Surgeons of India

Fig. 58.12 H shaped incision

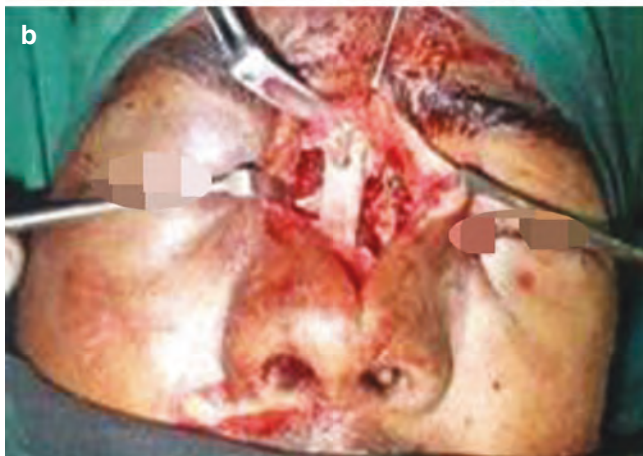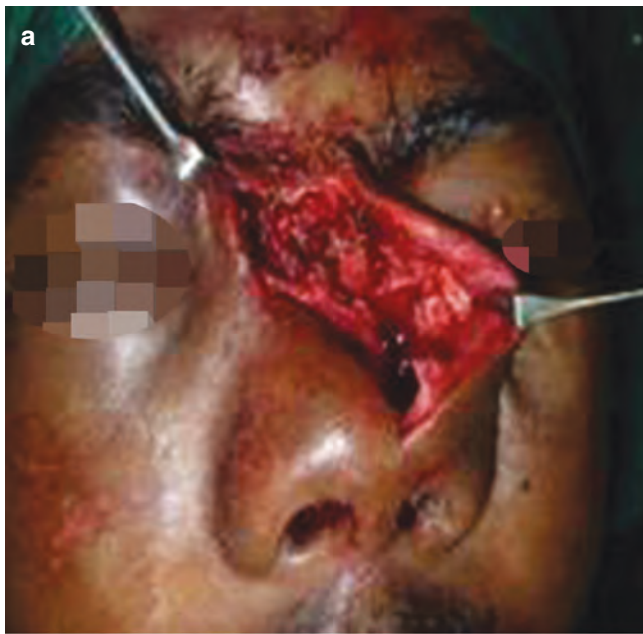58.5.2 Trans Nasal Canthopexy

The objectives of trans nasal canthopexy are:

- To medialize the central fragment
- To position the tendon posterior and superior to posterior lacrimal crest that would give an ideal vector.

The commonly used methods are the trans nasal wiring (Fig. 58.14) or using a canthal barb. The identified ligament edges are either anchored with a suture (size 2–0 prolene) or a wire (26 gauge) and guided to the opposite side. The entry point is posterior and superior to lacrimal crest to ensure adequate positioning. One way to help achieve this is to adapt a plate in medial aspect extending from lateral nose onto the medial wall extending just beyond the lacrimal crest (Fig. 58.15).

The wire or suture anchoring the MCL is passed through a hole of the plate just beyond the lacrimal crest brought to



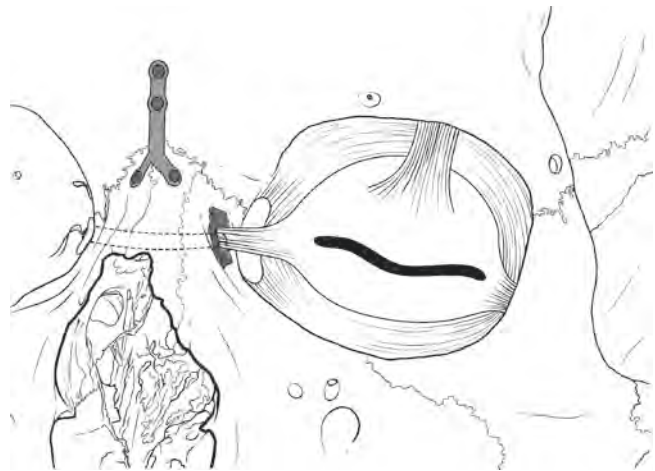
©Association of Oral and Maxillofacial Surgeons of India

Fig. 58.13 (a) Alignment and fixation of stable fragments. (b) Bone grafting of the dorsum of nose

the opposite side and secured around a screw in the forehead adjacent to the midline or a plate to prevent the wire cutting through the bone. Special barbed wires have been advocated by certain authors to engage the MCL and anchor it to help with medial canthopexy with small incisions around the medial canthus. These help especially when there is medial canthal disruption without bony disruption [18, 19].

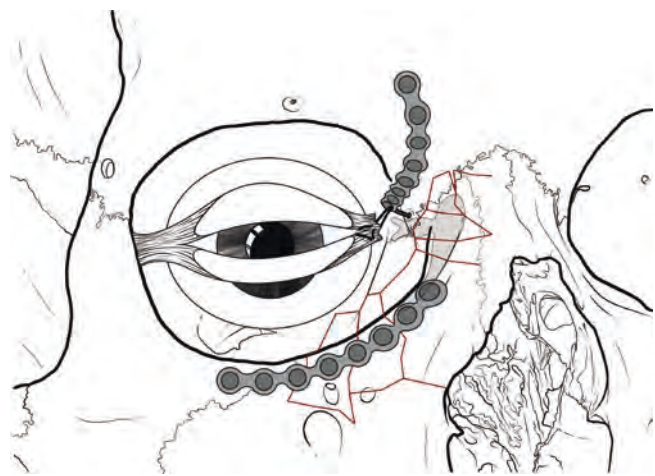
Figure 58.16 shows a clinical case where the MCL has been anchored to the holes of the plate on either sides (arrows) with SS wires.

Paediatric injuries of the naso-maxillary complex are generally under treated, but they need similar management protocols like that of an adult to achieve optimal results [20]. The use of resorbable implants will be of prudence in the paediatric patients [3].



©Association of Oral and Maxillofacial Surgeons of India

Fig. 58.14 Canthopexy with SS wire (note the wire shown as dotted lines)



©Association of Oral and Maxillofacial Surgeons of India

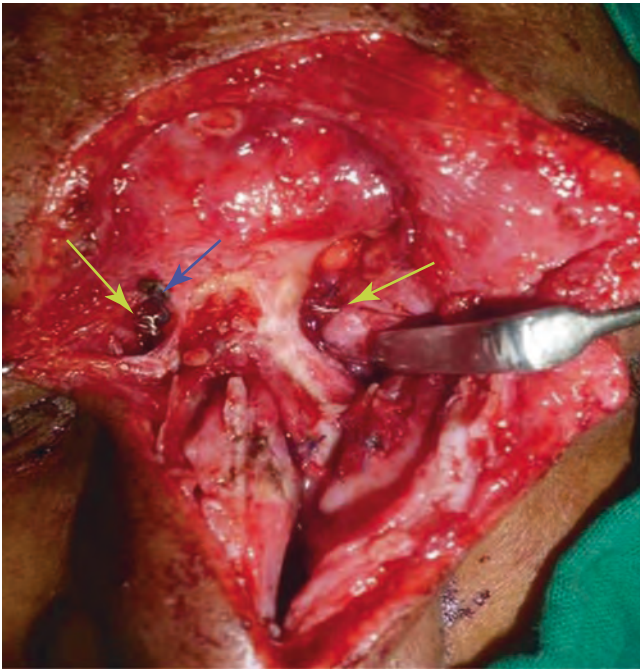Fig. 58.15 Use of plate to guide MCL reattachment (note the MCL fixed to plate with a wire, the red lines denote the fractured bones)

Post-operative aesthetic assessments of outcomes done for the management options comparing the canthal position and nasofrontal angle measurements have indicated that bone grafting may result in obtunded nasofrontal angle as compared to ORIF. Closed reduction of the complex has resulted in under projection of the nasal bridge region [20].

58.5.3 Soft Tissue Readaptation

A post-operative nasal bolster splint is very important after ORIF or NOE fractures. It plays the following functions:

- It reduces post-operative swelling due to oedema and haematoma.



©Association of Oral and Maxillofacial Surgeons of India

Fig. 58.16 shows a clinical case where the MCL has been anchored to the holes of the plate (blue arrow) on either sides with SS wires (yellow arrow)

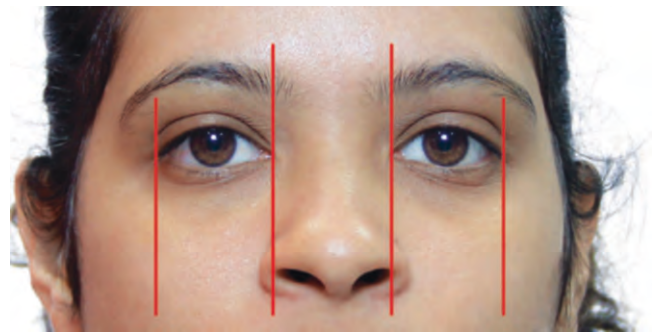
Redrapes soft tissues to underlying skeletal framework and prevents *pseudo telecanthus* (increase in intercanthal distance, in spite of accurate reduction and fixation of fracture fragments. This occurs due to non-adaptation of soft tissues to the underlying NOE complex, with resultant fibrosis of tissues). *Bolster splints may cause skin necrosis if used inappropriately*. After reduction and fixation of NOE, nasal packing has been done with ribbon gauge soaked in paraffin/flavine emulsion or bismuth iodoform paraffin paste (BIPP). Over packing should be avoided. Sometimes it obstructs the airway and a potential source of infection and required removal after 72 h postsurgery.

58.5.4 Post-operative Evaluation [20]

It includes evaluation of:

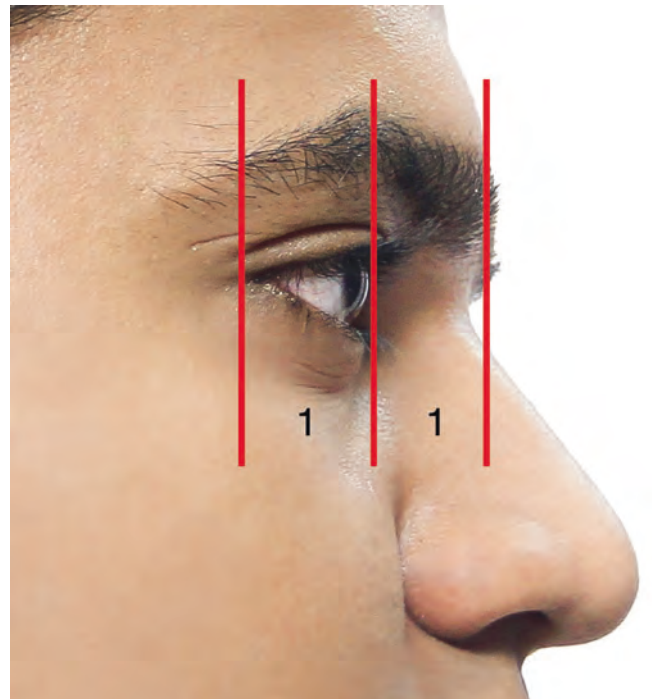
- Nasofrontal angle
- Nasal prominence and
- Intercanthal width

The average distance between the medial canthus should be approximately 1/3rd (33%) of the distance between lateral canthus. The distance from the lateral canthus of the eye to cornea and cornea to nasofrontal junction will be compared, and they should be in 1:1 relationship. The ideal naso-orbital angle is approximately 115–130°. All the three parameters



©Association of Oral and Maxillofacial Surgeons of India

Fig. 58.17 Ideal intercanthal distance



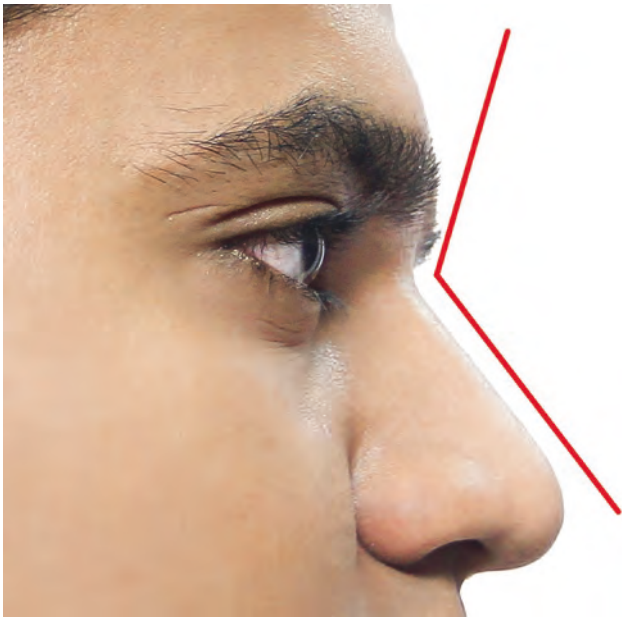
©Association of Oral and Maxillofacial Surgeons of India

Fig. 58.18 Ideal nasal projection (1:1)

should be checked post-operatively to assess the surgical results (Figs. 58.17, 58.18, and 58.19).

58.6 Complications

Inadequate assessment and treatment planning may result in incomplete management of the NOE complex resulting in secondary deformity which can aesthetically inadequate. Deformities of the NOE are quite easily noticeable compared to those in other regions, and hence appropriate management helps achieve good results. The aesthetic issues like persistent telecanthus or depressed nasal bridge are difficult to correct secondarily with suboptimal results. Hence the first time is the best time to address the central nasal component [21,



©Association of Oral and Maxillofacial Surgeons of India

Fig. 58.19 Ideal frontonasal angle

22]. Apart from aesthetic complications, functional issues like epiphora due to nasolacrimal duct injury or obstruction may manifest which may need stenting [23] or dacryocystorhinostomy (creating an osteum in the lateral nasal wall adjacent to the lacrimal sac along with stenting) to establish patency. Involvement of the medial wall may result in diplopia [24] which if not addressed adequately may persist. Another important issue overlooked is anosmia, but if it should occur, recovery is unpredictable, and prior discussion with patients is better. In cases with concomitant brain injuries or CSF leak, risk of associated sequelae is present, and a multidisciplinary approach helps. Though improperly placed trans nasal wires may occlude/impede the lacrimal drainage apparatus, it remains a popular modality to help treat these fractures [25, 26].

58.7 Frontal Sinus Fracture

58.7.1 Introduction

Fractures of the frontal sinus are frequently associated with orbital, NOE, nasal and anterior cranial fossa injury. Frontal sinus is most frequently damaged as a result of high velocity motor vehicle accidents. 70% of frontal sinus fractures were due to automobile accidents and 20% due to assaults. Proximity of sinus to the brain makes untreated disease in this area potentially fatal. Inappropriate treatment of frontal sinus fracture can lead to mucocele formation, recurrent sinusitis, osteomyelitis of frontal bone, brain abscess or thrombosis of cavernous sinus, encephalitis, etc. [27].

58.7.2 Applied Anatomy of Frontal Sinus

Frontal sinuses are two asymmetric sinuses separated by a thin bony septal plate. The average dimensions of frontal sinus are as follows [28]:

- Height: 32 mm
- Width: 26 mm
- Depth: 17 mm
- Surface Area: 720 mm²

The frontal sinus is an air-filled cavity lined by pseudostratified ciliated columnar epithelium encased in bone. It becomes visible radiographically at the age of 6 years. The posterior table is thinner than the anterior table. The posterior table separates the sinus from dura of frontal lobe. Anterior table is covered by a soft tissue layer of frontalis muscle, orbicularis oculi muscle, supra-orbital and supratrochlear nerves, vessels and skin. Posteriorly, the floor of the frontal sinus consists of orbital plate of frontal bone. Anteriorly, the floor of the sinus overlies the anterior ethmoidal sinus and nasal cavity. The frontonasal drainage area of the sinus originates from the posteromedial part of sinus floor. The frontal sinus drains through the frontonasal ducts into the middle meatus of the nasal cavity or directly through the ostia into the nasal cavity.

58.7.3 Functions of Frontal Sinus

Following are the various functions of the frontal sinus:

1. Production and storage of mucus
2. Resonator for voice
3. Humidification and warming of inhaled air
4. Accessory area of olfaction
5. Conservation of heat from the nasal fossae
6. Definition of facial contours
7. “Surge Tank” to dampen the pressure differential that develops during inspiration

The diagnosis of the frontal sinus fracture based on the proper history and physical examination of the patient which includes inspection and palpation of the affected area.

The detailed history includes the following points:

1. Information about events
2. Visual difficulties
3. Numbness
4. Pain
5. Rhinorrhea
6. Sense of smell
7. Previous history of nasal or sinus disease surgery

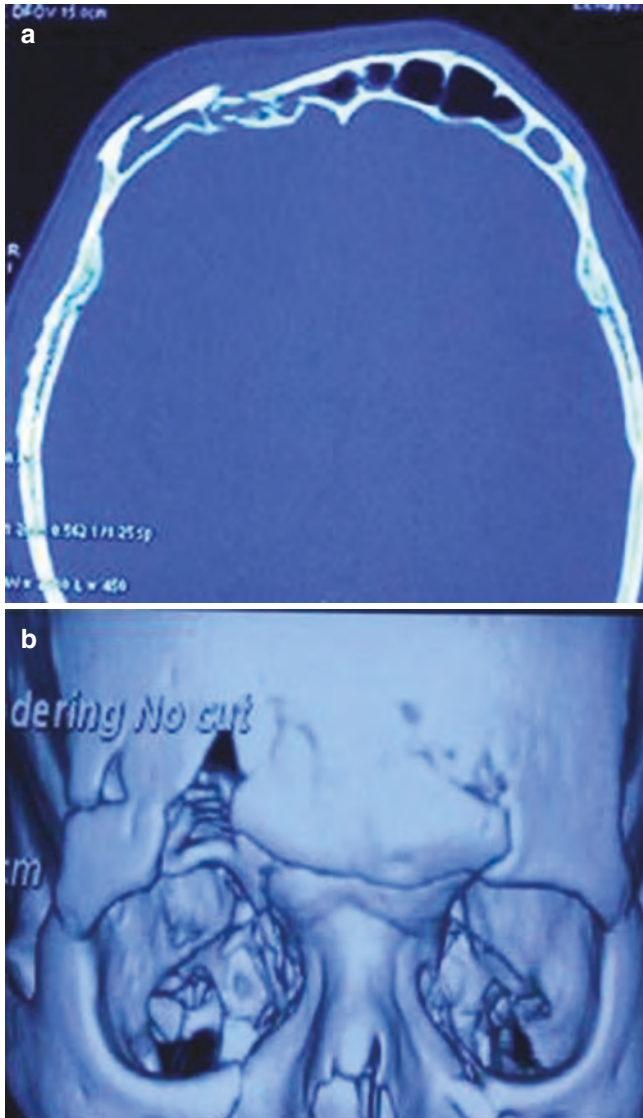
58.7.4 Clinical Features [29]

1. Forehead laceration (58%)
2. Forehead pain (82%)
3. Swelling
4. Frontal bone depression (25%)
5. Periorbital ecchymosis
6. CSF rhinorrhea (1/3rd patients)

58.7.5 Radiographic Features

For an accurate diagnosis of frontal sinus fracture, a CT scan (Fig. 58.20a, b) in different views must be examined [30].

1. Axial view: It reveals location, severity and degree of comminution of anterior and posterior table fractures.



©Association of Oral and Maxillofacial Surgeons of India

Fig. 58.20 (a, b) 3D CT and axial CT image with frontal sinus fracture

2. Coronal view: It reveals frontal sinus floor and orbital roof fractures.
3. Sagittal view: It assesses frontonasal duct.
4. Submentovortex view and lateral view: It visualizes anterior and posterior tables.

58.7.6 Classifications

Frontal sinus fractures are usually classified based on:

- Location
- Extent of injury
- Involvement of frontonasal duct
- Current injury to the dura

58.7.7 Stanley's Classification of Frontal Sinus Fracture [31]

- *Type I: Anterior Table Fracture*
 - Isolated to anterior table
 - Accompanied by supraorbital rim fracture
 - Accompanied by naso-ethmoid complex fracture
- *Type II: Anterior and Posterior Table Fractures*
 - It is a linear fracture either on transverse direction or in vertical direction
- *Type III: Comminuted Fractures*
 - Isolated to both tables
 - Accompanied by naso-ethmoid complex fracture

58.7.8 Gonty Et al. Classification of Frontal Sinus Fracture [32]

- *Type I: Anterior Table Fracture*
 - Isolated to anterior table
 - Accompanied by supraorbital rim fracture
 - Accompanied by naso-ethmoid complex fracture
- *Type II: Anterior and Posterior Table Fractures*
 - A linear fracture either on transverse direction or in vertical direction
 - Comminuted fracture either isolated to both tables or accompanied by naso-ethmoid complex fracture
- *Type III: Posterior Table Fracture*
- *Type IV: Through and Through Frontal Sinus Fracture*

58.7.9 Management (Box 58.6) [33]

Surgical Access:

1. Through existing laceration
2. Butterfly incision (Fig. 58.10)
3. Gullwing or eyeglass incision (Fig. 58.21)

Box 58.6 Guiding Principles for Frontal Sinus Management

- To separate nasal cavity from sinus
- To eliminate dead space
- To separate the frontonasal duct from frontal sinus by obstructing the duct
- To eliminate a functional sinus, sinus mucosa is removed, and sinus is obliterated

4. Bicoronal approach (Fig. 58.9): Khan et al. in 2018 [34] suggests sterile surgical glove tourniquet intraoperatively to get the haemorrhage control and blood less surgical field in elevation of bicoronal flap for the surgical management of frontal sinus fracture.

58.7.10 Indications of Surgery in Frontal Sinus Fractures [35]

1. To avoid immediate complications such as CSF leak, meningitis
2. To avoid long-term complications such as frontal sinusitis, meningitis and brain abscess formation
3. To provide aesthetic contour to the forehead
4. To provide exposure for anatomic reduction of NOE fractures

58.7.11 Management of Anterior Table Fracture [36–38]

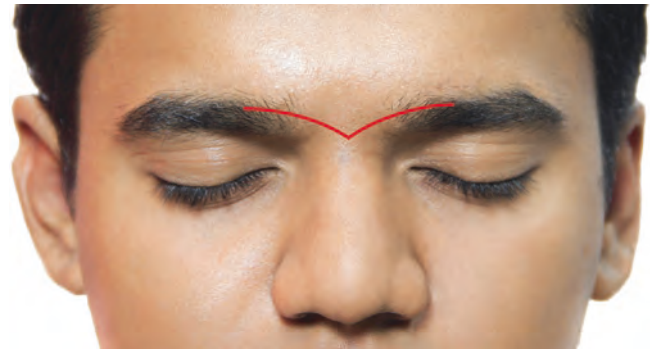
Decision-Making:

- Simple greenstick or undisplaced fracture does not require surgical intervention.
- In depressed anterior wall fracture, frontal sinus explored, careful irrigation carried out, fragments reduced and stabilize by internal fixation. In posterior wall fracture without CSF leak or pneumoencephalus, reconstruction of only anterior wall is done.

Other than surgical intervention, antibiotics, sinus decongestants and analgesics are prescribed to keep the frontonasal duct patent and to prevent infection.

Rai et al. [39] suggested bone mapping/sketching in management of anterior table frontal sinus fracture with great success. To get good post-operative contour, each fracture fragment is to be placed at the original position after debridement of the sinus. For the same purpose, numbers have to be given to the fracture fragments on a plane paper (sterile glove covering paper) or green sheet (Fig. 58.22a–c).

Yoo MH et al. suggested endoscopic trans nasal reduction of anterior table fracture [40]. To support the reduced frag-



©Association of Oral and Maxillofacial Surgeons of India

Fig. 58.21 Gullwing or eyeglass incision

ments, they advocated use of custom made latex glove balloon to be inserted into the frontal sinus then expanded and maintained for 3 weeks. It avoid use of coronal incision is the advantage of endoscopic reduction. It should be avoided in severe comminuted fractures, displaced posterior table fracture with evidence of dura tear, associated orbital roof blow in fracture and extensive skull bone fractures.

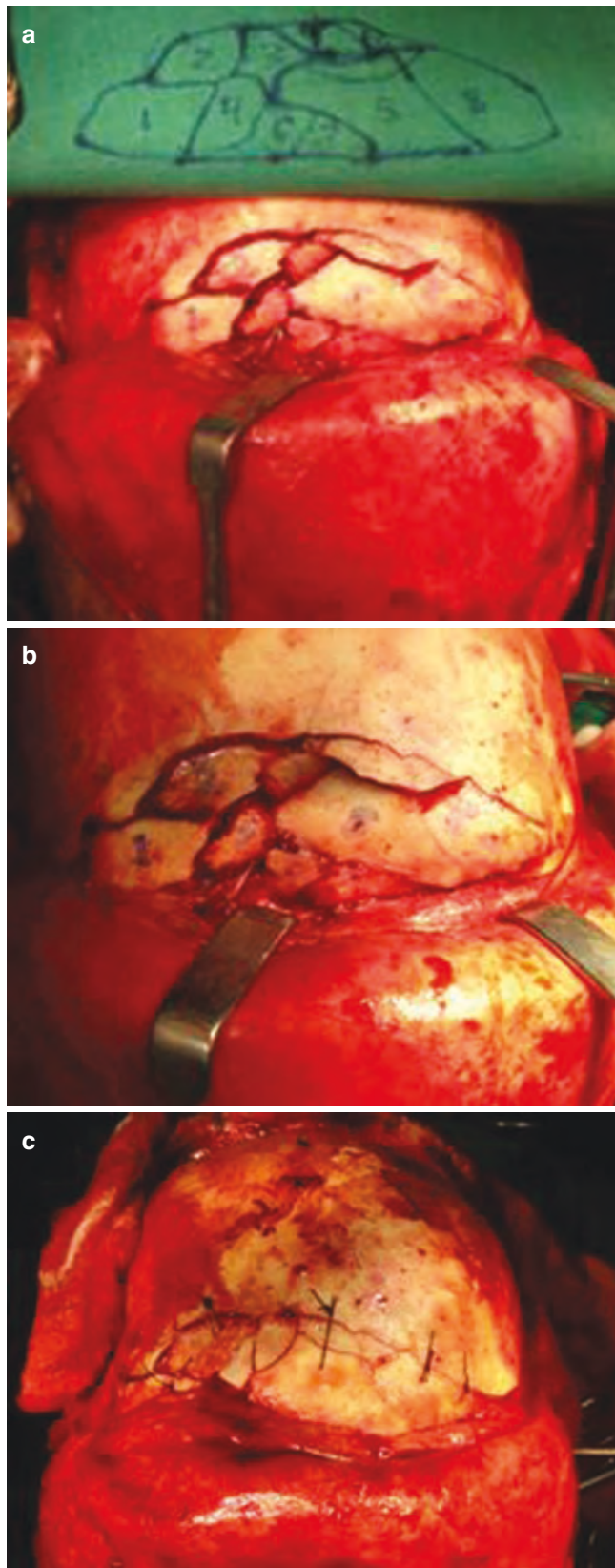
58.7.12 Treatment of Posterior Table Fracture [41]

Patients with displaced and comminuted posterior wall combined with or without anterior wall require the support of a neurosurgeon because of dural and intracranial lesions. To get the good exposure, bifrontal craniotomy is indicated to eliminate the posterior wall.

To widen the neurosurgical access to the anterior floor of the cranium, the supraorbital bandeau will be temporarily removed. The sinus mucosa carefully removed with bur, and sinus is cranialized, and then repair of the dura will be carried out: Calvarial bone graft used to obliterate the nasofrontal duct and bone powder can be used to cover the remaining dead space. Anterior table can be stabilized with bone plates and screws. Bone defect will be treated with calvarial bone graft or titanium mesh. With patent duct and no concurrent dural tears or brain injury exist, any amount of posterior table displacement is inconsequential and managed by observation.

58.7.13 Methods of Treatment of Damaged Frontonasal Duct [42]

The damage to the nasofrontal duct and frontal sinus obstruction increases the risk of mucocele formation and inflammatory complications post-operatively. Obliteration of the duct is indicated in such situation. The muscle, temporalis fascia, bone chips, etc. are the materials used commonly to obstruct the duct.



©Association of Oral and Maxillofacial Surgeons of India

Fig. 58.22 (a–c) Bone mapping/sketching in management of anterior table frontal sinus fracture

Box 58.7 Complications of Frontal Sinus Fractures [46]

Immediate complications	Late complications
1. Wound infection	1. Mucocele
2. CSF leak	2. Mucopyocele
3. Paresthesia of supraorbital nerve	3. Late frontal sinusitis
4. Frontal sinusitis	4. Brain abscess
5. Meningitis	5. Osteomyelitis of frontal bone
6. Neurological injuries secondary to penetrating trauma or displacement of frontal bone into neurocranium	

58.7.13.1 Material Used for Sinus Obliteration [43]

1. Hydroxyapatite
2. Glass wool
3. Bone
4. Cartilage
5. Muscle
6. Absorbable gelatin sponge
7. Temporalis fascia
8. Oxidized segmented cellulose
9. Acrylic or methyl methacrylate
10. Fat (commonly used)

58.7.14 Cranialization [44, 45]

It is another technique to minimize the dead space in sinus. It involves removing posterior table thus permitting brain to expand into frontal sinus resulting in confluence between sinus cavity and anterior cranial fossa. It is done in cases with CSF leak and neurological injury due to displaced posterior table fracture. To isolate the splanchnocranium from the frontal sinus, a pericranial flap is used.

58.7.15 Key Points

- Actual or suspected fractures involving the frontonasal duct are an indication to remove the outer table, so the duct can be inspected.
- If outer table is comminuted and a bony segment over 1.5 cm is missing, a bone graft should be harvested to restore the outer table contour.
- The most common treatment for outer table fracture with injury to duct without inner table fracture is obliteration of frontal sinus to seal the frontonasal duct to prevent nasal infection.
- Adipose tissue from abdomen is used to fill the dead space of frontal sinus because of its resistance to infec-

tion, slow resorption rate, and it is gradually replaced by the fibrous tissue.

Complications of frontal sinus fractures is given in Box 58.7.

58.8 Conclusion

The management of NOE and frontal sinus fracture is always a challenging task. The proper handling of MCL and nasofrontal duct is mandatory to get good post-operative results. Proper treatment planning in the form of incision selection, method of fixation and use of bone graft should be done to avoid unaesthetic results.

References

- Milad Etemadi SH, Shahnasari S, Soltani P, Motamedi MRK. Management of naso-orbito-ethmoid fractures: a 10-year review. *Trauma Mon.* 2017;22:292–30.
- Brasileiro BF, Passeri LA. Epidemiological analysis of maxillofacial fractures in Brazil: a 5-year prospective study. *Oral Surg Oral Med Oral Pathol Oral Radiol Endod.* 2006;102(1):28–34.
- Rosenberger E, Kriet JD, Humphrey C. Management of naso-ethmoid fractures. *Curr Opin Otolaryngol Head Neck Surg.* 2013;21:410–6. (Anatomy of MCL, physical examination of the complex and displacement)
- Poh E, Kakizaki H, Selva D, Leibovitch I. Anatomy of medial canthal tendon in Caucasians. *Clin Exp Ophthalmol.* 2012;40:170–3.
- Merkx MA, Freihofer HP, Borstlap WA, van't Hoff MA. Effectiveness of primary correction of traumatic telecanthus. *Int J Oral Maxillofac Surg.* 1995;24:344–7.
- Heine D, Catone GA, Bavitz B, Grenadier MR. Naso-orbito-ethmoid injury: report of a case and review of the literature. *Oral Surg Oral Med Oral Path.* 2005;69(5):542–9.
- Rowe NL. Rowe and Williams' maxillofacial injuries, vol. 2. 2nd ed. Edinburgh: Churchill Livingstone; 1994.
- Markowitz BL, Manson PN, Sargent L, et al. Management of the medial canthal tendon in nasoethmoid orbital fractures: the importance of the central fragment in classification and treatment. *Plast Reconstr Surg.* 1991;87:843–853.
- Burstein F, Cohen S, Hudgins R, Boydston W. Frontal basilar trauma: classification and treatment. *Plast Reconstr Surg.* 1997;99(5):1314–21.
- Balaraman K, Ramani V, Bharathi R, Venkataramani H, Sabapathy SR. Outcome assessment of Nasoethmoid fractures. *Int J Oral Maxillofac Surg.* 2013;42(10):1220.
- Ellis E III. Sequencing treatment for naso-orbito-ethmoid fractures. *J Oral Maxillofac Surg.* 1993;51:543–558.
- Nguyen M, Koshy JC, Hollier LH Jr. Pearls of nasoorbitoethmoid trauma management. *Semin Plast Surg.* 2010;24:383–8.
- Dingman RO, Grabb WC, Oneal RM. Management of injuries of the naso-orbital complex. *Arch Surg.* 1969;98:566–71.
- Mustarde JC. Epicanthus and telecanthus. *Int Ophthalmol Clin.* 1964;4:359.
- Cruse C, Blevins PK, Luce EA. Naso-ethmoid-orbital fractures. *J Trauma.* 1980;20:551.
- Gruss JS. Naso-ethmoid-orbital fractures: classification and role of primary bone grafting. *Plast Reconstr Surg.* 1985;75:303.
- Baliga S, Urolagin SB. Transnasal fixation of NOE fracture: minimally invasive approach. *J Maxillofac Oral Surg.* 2012;11(1):34–7.
- Timoney PJ, Sokol JA, Hauck MJ, Lee HB, Nunery WR. Transcutaneous medial canthal tendon incision to the medial orbit. *Ophthalm Plast Reconstr Surg.* 2012;28:140–4.
- Goldenberg DC, Bastos EO, Alonso N, Friedhofer H, Ferreira MC. The role of micro-anchor devices in medial canthopexy. *Ann Plast Surg.* 2008;61:47–51.
- Pawar SS, Rhee JS. Frontal sinus and naso-orbital-ethmoid fractures. *JAMA Facial Plast Surg.* 2014;16:284–9.
- Herford AS, Ying T, Brown B. Outcomes of severely comminuted (type III) nasoorbitoethmoid fractures. *J Oral Maxillofac Surg.* 2005;63:1266–77.
- Potter JK, Muzaffar AR, Ellis E, Rohrich RJ, Hackney FL. Aesthetic management of the nasal component of naso-orbital ethmoid fractures. *Plast Reconstr Surg.* 2006;117(1):10e–8e.
- Vora NM, Fedok FG. Management of the central nasal support complex in naso-orbital ethmoid fractures. *Facial Plast Surg.* 2000;16(2):181–91.
- Becelli R, Renzi G, Mannino G, Cerulli G, Iannetti G. Posttraumatic obstruction of lacrimal pathways: a retrospective analysis of 58 consecutive naso-orbitoethmoid fractures. *J Craniofac Surg.* 2004;15:29–33.
- Wei J-J, Tang Z-L, Liu L, Liao X-J, Yu Y-B, Jing W. The management of naso-orbital-ethmoid (NOE) fractures. *Chinese J Traumatol.* 2015;18:296–301.
- Bell RB, Dierks EJ, Homer L, Potter BE. Management of cerebrospinal fluid leak associated with craniomaxillofacial trauma. *J Oral Maxillofac Surg.* 2004;62:676–84.
- Gerbino G, Rocca F, Benec A, Caldarelli C. Analysis of 158 frontal sinus fractures: current surgical management and complications. *J Craniofac Surg.* 2000;28:133–139.
- Haug RH, Cunningham LL. Management of fractures of the frontal bone and frontal sinus, selected Readings. *Oral and Maxillofacial Surgery.* 2002;10(6):1–32.
- Wallis A, Donald PJ. Frontal sinus fractures: a review of 72 cases. *Laryngoscope.* 1988;98:593.
- Finkle DR, Ringler SL, Luttenton CR, Beernink JH, Peterson NT, Dean RE. Comparison of the diagnostic methods used in maxillofacial trauma. *Plast Reconstr Surg.* 1985;75(1):32–41.
- Stanley RB Jr. Fractures of the frontal sinus. *Clin Plast Surg.* 1989;16(1):115–23.
- Gonty AA, Marciani RD, Adornato DC. Management of frontal sinus fractures: a review of 33 cases. *J Oral Maxillofac Surg.* 1999;57:372–9.
- Rohrich RJ, Hollier LH. Management of frontal sinus fractures. Changing concepts. *Clin Plast Surg.* 1992;19:219–32.
- Khan M, Rai A, Jain A. A simple and effective scalp tourniquet for controlling scalp hemorrhage. *J Maxillofac Oral Surg.* 2018;17(2):264–5.
- Manolidis S. Frontal sinus injuries: associated injuries and surgical management of 93 patients. *J Oral Maxillofac Surg.* 2004;62:882–91.
- Fattahi T, Salman S. An aesthetic approach in the repair of anterior frontal sinus fractures. *Int J Oral Maxillofac Surg.* 2016;45(9):1104–7.
- Cole P, Kaufman Y, Momoh A, et al. Techniques in frontal sinus fracture repair. *Plast Reconstr Surg.* 2009;123(5):1578–9.
- Weathers WM, Wolfswinkel EM, Hatef DA, Lee EI, Brown RH, Hollier LH Jr. Frontal sinus fractures: a conservative shift. *Craniofacial Trauma Reconstr.* 2013;6(3):155–60.

39. Rai A, et al. "Bone mapping/sketching" in management of anterior table frontal sinus fracture. *J Maxillofac Oral Surg.* 2017;16(1):127–30.
40. Yoo MH, et al. Endoscopic transnasal reduction of an anterior table frontal sinus fracture: technical note. *Int Journal Oral Maxfac Surg.* 2008;37:573–5.
41. Freeman JL, Winston KR. Breach of posterior wall of frontal sinus: management with preservation of the sinus. *World Neurosurg.* 2015;83(6):1080–9.
42. Rohrich RJ, Hollier L. The role of the nasofrontal duct in frontal sinus fracture management. *J Craniomaxillofac Trauma.* 1996;2:31–40.
43. Mickel TJ, Rohrich RJ, Robinson JB Jr. Frontal sinus obliteration: a comparison of fat, muscle, bone, and spontaneous osteoneogenesis in the cat model. *Plast Reconstr Surg.* 1995;95(3):586–92.
44. Scholsem M, Scholtes F, Collignon F, et al. Surgical management of anterior cranial base fractures with cerebrospinal fluid fistulae: a single institution experience. *Neurosurgery.* 2008;62:463–71.
45. Pollock R, Hill J, Davenport D, et al. Cranialization in a cohort of 154 consecutive patients with frontal sinus fractures (1987–2007): review and update of a compelling procedure in the selected patient. *Ann Plast Surg.* 2013;71(1):54–9.
46. Guy WM, Brissett AE. Contemporary management of traumatic fractures of the frontal sinus. *Otolaryngol Clin North Am.* 2013;46(5):733–48.

Open Access This chapter is licensed under the terms of the Creative Commons Attribution 4.0 International License (<http://creativecommons.org/licenses/by/4.0/>), which permits use, sharing, adaptation, distribution and reproduction in any medium or format, as long as you give appropriate credit to the original author(s) and the source, provide a link to the Creative Commons license and indicate if changes were made.

The images or other third party material in this chapter are included in the chapter's Creative Commons license, unless indicated otherwise in a credit line to the material. If material is not included in the chapter's Creative Commons license and your intended use is not permitted by statutory regulation or exceeds the permitted use, you will need to obtain permission directly from the copyright holder.



Gunshot Injuries of the Maxillofacial Region

59

Lt Col Rohit Sharma and Maj Anson Jose

59.1 Introduction

Gunshot injuries to the maxillofacial region in particular present a challenging situation for the facial reconstructive surgeon. These injuries are relatively rare and hence the true incidence is unknown [1]. Feature common to most maxillofacial gunshot injuries is extensive tissue destruction. The degree of tissue loss, depth of the injury, associated necrosis, and concomitant central nervous system (CNS) injuries may not be apparent at initial presentation [2]. Comprehensive management of such wounds is often challenging because of its heterogeneous nature, composite 3D tissue destruction, and complex structural and functional anatomy of the face.

In contrast to blunt facial trauma, the literature on the management of ballistic facial injury is relatively scarce [1]. The management strategies for patients with facial gunshot wounds are almost as diverse as the case presentation itself. While there has been a gradual shift from conservative delayed operative repair to an early aggressive one-stage management approach, the controversies surrounding the timing and extent of intervention have not yet ceased to exist. Such an ongoing debate is largely due to the fact that the majority of treatment outcomes of gunshot facial injuries continue to be unsatisfactory regardless of treatment methodology adopted. On the other hand, new principles have evolved including the early definitive repair of hard tissues with precise anatomic rigid fixation using bone grafts and definitive soft tissue management with local or vascular flaps allowing for early rehabilitation of patients to their pre-traumatic appearance. This paradigm shift away from delayed to a more immediate definitive reconstruction has been predominantly due to the widespread use of free tissue

transfer, diagnostic computed tomography (CT) scan, and deeper understanding about zone of injury in such cases [3].

Presently the management of gunshot injuries comprises the following steps:

1. Conservative debridement followed by fracture stabilization and primary closure
2. Early reconstruction of missing hard and soft tissues
3. Antibiotics and prevention of infection
4. Postoperative physiotherapy and psychiatric assistance
5. Residual deformity correction and oral rehabilitation [3–6]

This review describes the current management strategies, damage control surgery, and basic protocols employed in the management of high-velocity ballistic injuries to the face.

59.2 Pathologic Anatomy and Classification

Traditionally gunshot injuries have been classified as penetrating, perforated, or avulsive [7]. As the gamut of injuries continues to evolve, the severity and magnitude of facial ballistic wounds demand an expanded classification and can be appropriately classified based on the wounding effects and terminal location of projectile as:

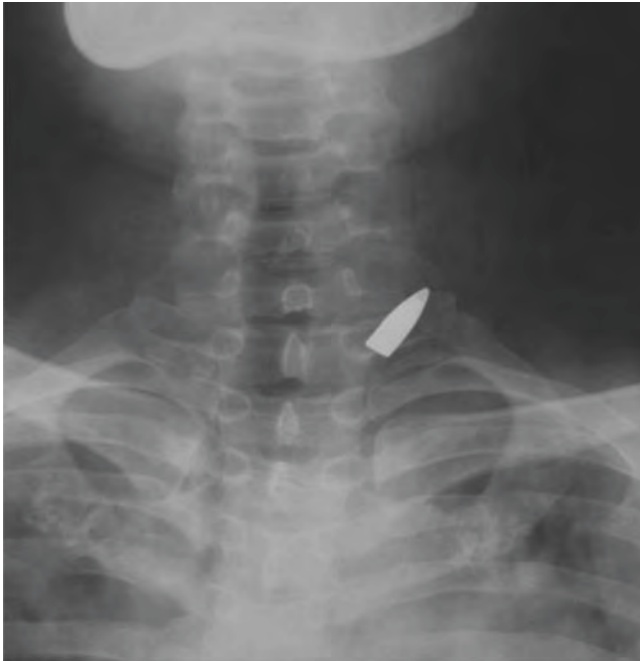- Penetrating
- Perforating
- Avulsive
- Blast
- “Chop off” injuries

Lt Col R. Sharma (✉)
Department of Oral and Maxillofacial Surgery,
11 Corps Dental Unit, Jalandhar Cantt, India

Maj A. Jose
Department of Oral and Maxillofacial Surgery, ADC R&R,
New Delhi, India

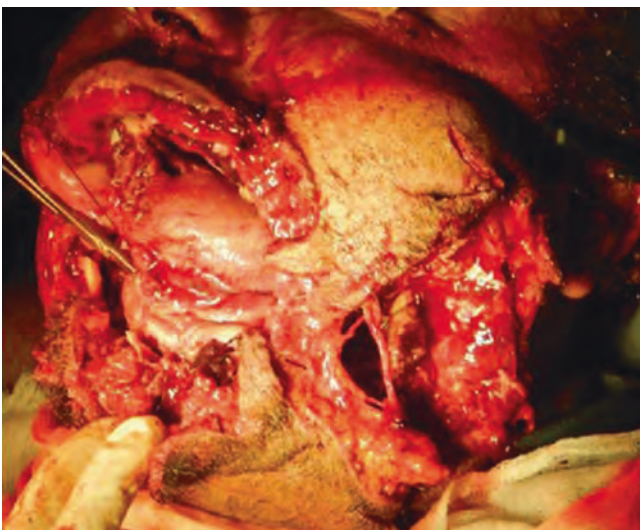
Penetrating injuries are caused when a low-velocity projectile pierces the tissues without making an exit wound (Fig. 59.1).

On the other hand, perforating injuries are distinguished by the presence of a definite exit wound in addition to the entry wound (Figs. 59.2 and 59.3). The exit wounds are often larger with ragged or stellate margins. Avulsive injuries are basically penetrating injuries, characterized by an acute loss and destruction of tissue as a consequence of the passage of the projectile within and out of the body (Fig. 59.4). Blast



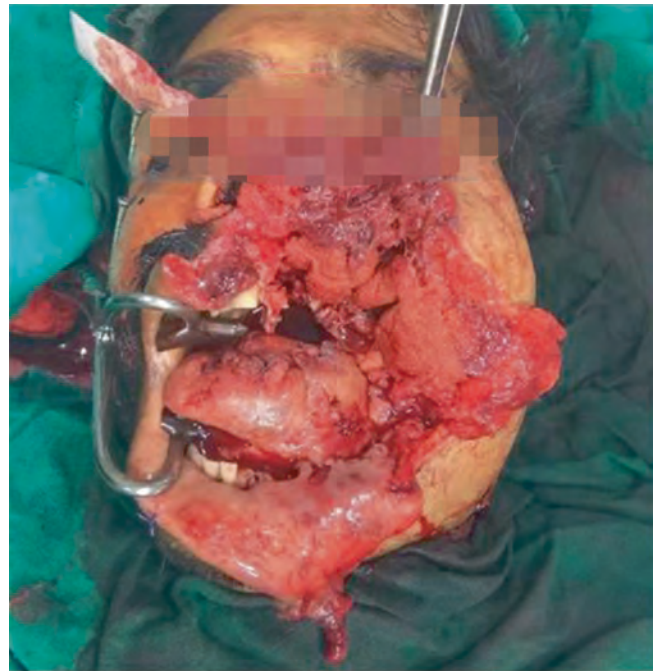©Association of Oral and Maxillofacial Surgeons of India

Fig. 59.1 Penetrating injury with bullet lodged inside the neck



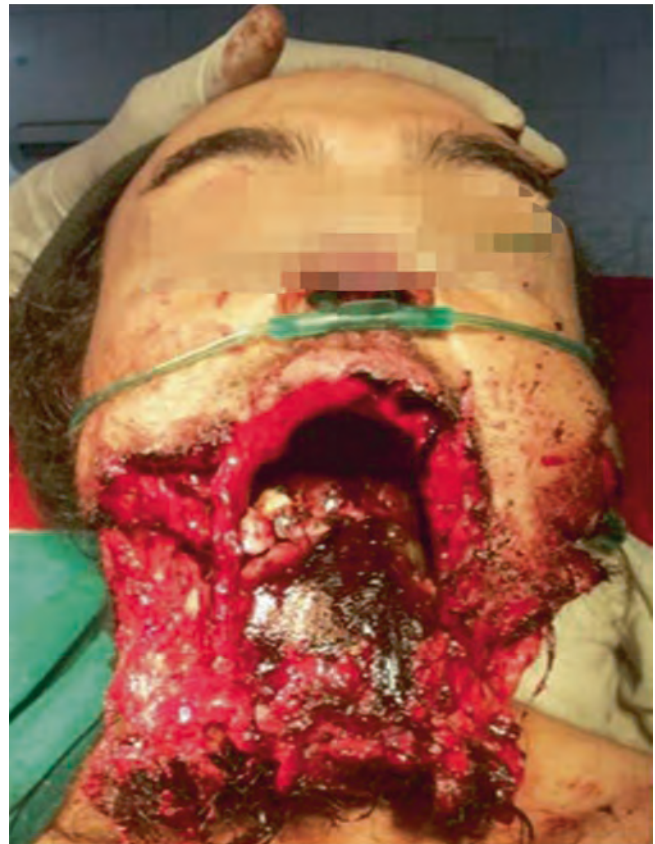©Association of Oral and Maxillofacial Surgeons of India

Fig. 59.2 Perforating injury caused by 7.62 × 39 mm AK-47 rifle. Note the effects of high-energy bullet impact and explosive effects of cavitation on soft tissues resulting in stellate wound margins at the exit



©Association of Oral and Maxillofacial Surgeons of India

Fig. 59.3 Avulsive injury of midface caused by a short-range high-velocity impact. The hallmark of high-velocity injuries are comminuted fractures of the facial skeleton with avulsion of soft tissues



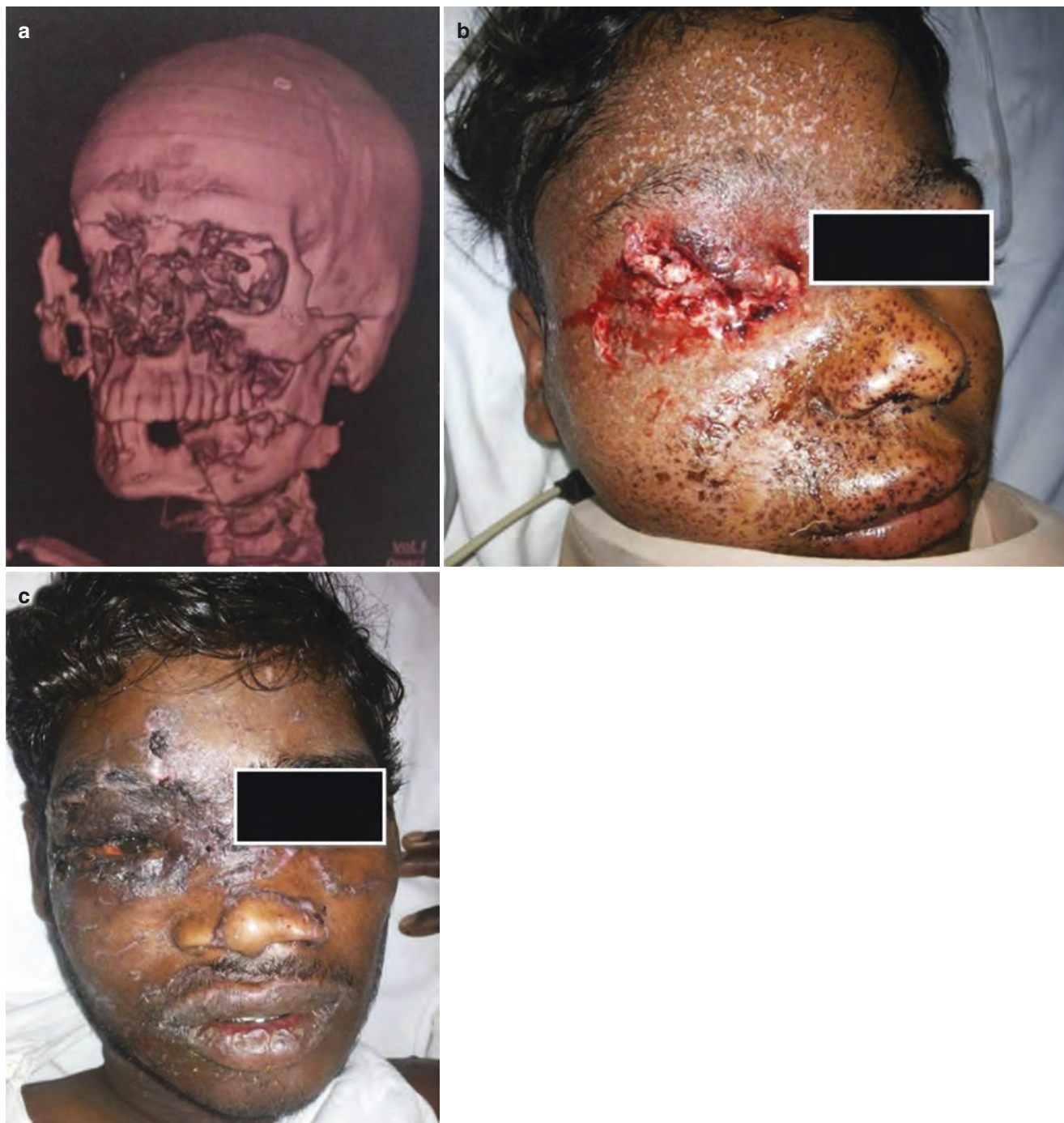©Association of Oral and Maxillofacial Surgeons of India

Fig. 59.4 "Chop off" injury with complete avulsion of the mandible and associated soft tissue caused by velocity projectile from a military assault rifle

injuries are the result of direct or indirect exposure to an explosion caused by military weapons or explosive devices (Fig. 59.5). “Chop off” injuries represent wounds with extensive hard and soft tissue loss as a consequence of high-velocity close-range gunshots [8]. In all these varieties of injuries, the tissue damage is directly proportional to the

kinetic energy transferred by the bullet, time taken for the energy transfer, and area over which the energy is transferred. Hence, the type and variant of injury have significant implications in management.

Apart from this conventional nomenclature, various other classifications have been used for categorizing penetrating



©Association of Oral and Maxillofacial Surgeons of India

Fig. 59.5 (a, b, c) Blast injury caused by propagation of shock waves from the projectile. Soft tissue injury is minimal in such cases with severe comminution of the underlying skeleton

facial injuries; however, its application in clinical scenario is debatable. Similarly, many authors have developed an algorithm for the workup of ballistic wound based on the location of entry wound. Despite having limited application, no significant correlation has been found between site of entrance wound and therapeutic outcome of gunshot wounds [9].

A pragmatic approach to the management of such injuries involves:

1. Establishing an airway
2. Control of hemorrhage
3. Damage control surgery and identifying concomitant injuries
4. Early definitive repair of hard and soft tissues
5. Aesthetic refinements and rehabilitation

59.3 Initial Evaluation, Triage, and Damage Control Surgery

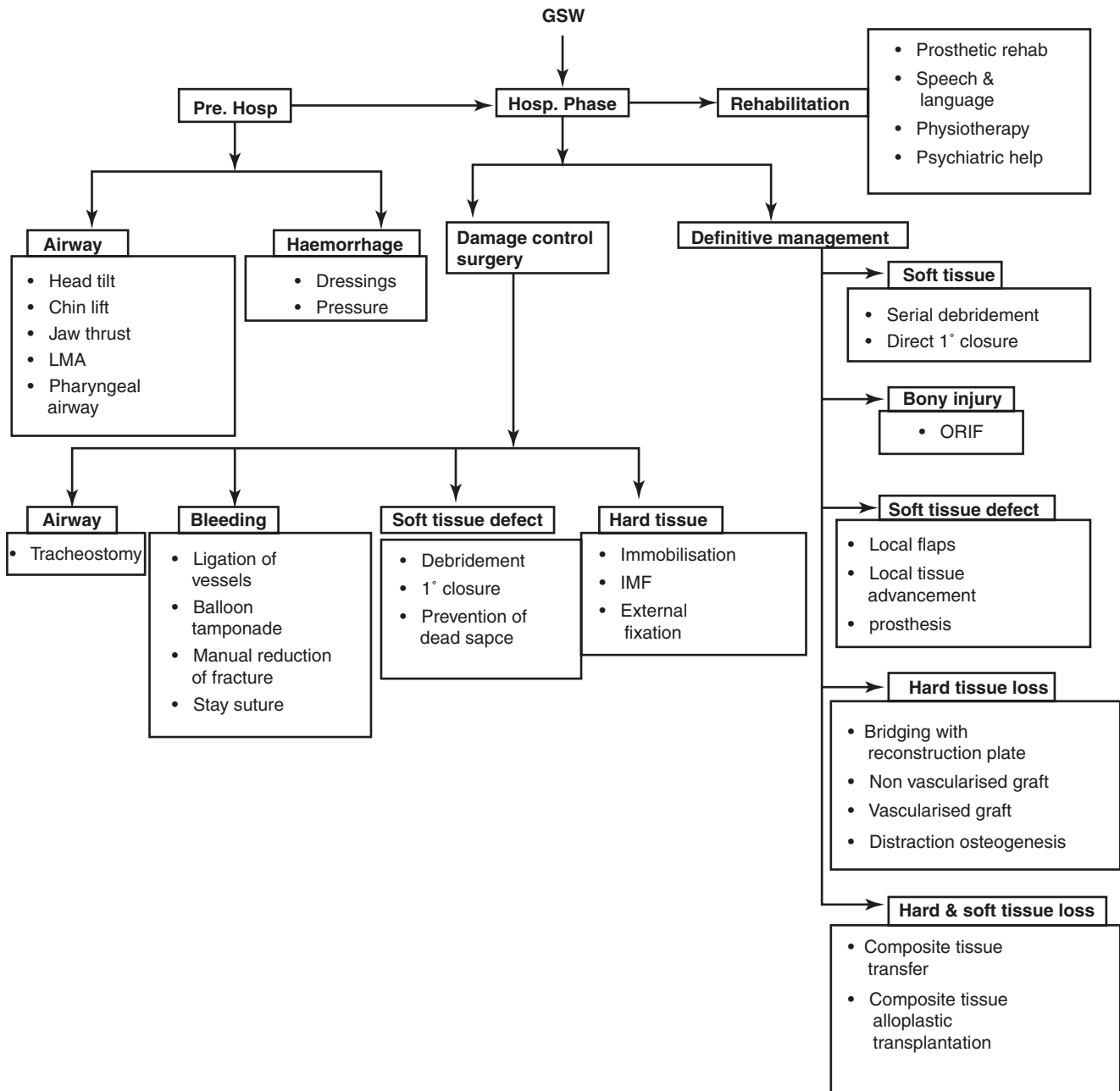
Initial management of gunshot wounds is based on the advanced trauma and life support protocols (also refer Chap. 48 of this book). Gibbons and Breeze [10] have elaborated the modified military protocols pertaining specifically to combat-related ballistic facial injuries. These include emergency management procedures that followed the CABC (catastrophic hemorrhage, airway, breathing, circulation) protocol proposed by Hodgetts et al. [11] which focused the need to control catastrophic bleeding as a priority over airway complications in a polytrauma patient. In a parallel manner, initial evaluation and damage control maxillofacial surgery should commence within the golden hour for effective patient management. Damage control surgery may be perceived as an immediate assessment of life-threatening injuries and addressing them promptly by means of early life-saving resuscitation and surgeries [12]. It is not regarded as a separate entity; it is seen as an essential, initial component in the management of any severely injured patient. In order to clear confusion clouding this highly debated area, a proposed set of damage control procedures that can be applied to ballistic maxillofacial injuries involving the maxillofacial region is given (Table 59.1).

Fortunately, the mortality rate directly attributable to maxillofacial firearms injuries is as low as 2–3% and pre-

dominantly due to a compromised airway [10]. Airway compromise is a serious consequence of all gunshot injuries to the face, and it can be due to a direct or an indirect injury to the airway. Injury to tissues and resultant edema in the vicinity of the air passages invariably handicaps the airway indirectly. Additionally, loss of muscle attachments and fractures of the anterior mandible significantly debilitates the airways. Manual repositioning of the fractured segments of mandible and base of tongue are the fundamental measures to be executed to prevent posterior airway collapse. While nasopharyngeal and oropharyngeal airways afford interim relief, endotracheal intubation is the established approach in emergency condition. This however presents a challenge on account of the edema, bleeding, and avulsed soft tissues that may possibly block the airway [13].

In the author's experience, a vast majority of maxillofacial gunshot wounds require surgical tracheostomy. The probability of concomitant intracranial injuries with low Glasgow Coma Scale (GCS) is also high in such patients [14]. Since most patients in this category require prolonged intubation and most gunshot wounds to the face require multi-phased surgical approach, the authors view surgical tracheostomy as having distinct advantage over other methods. Management of hemorrhage and its allied complications are well known in maxillofacial injuries as emphasized by previous writers on war surgery, yet it needs a descriptive analysis owing to the fatality it can cause. Hemorrhage is an inevitable consequence of all gunshot injuries to the face. Management of bleeding is an important aspect of damage control surgery, and adequate hemodynamic resuscitation is essential for the early physiological recovery of the victim [15].

Bleeding from high-energy ballistic injuries is practically impossible to control by external pressure tamponade due to the presence of bony structures and the inherently vulnerable condition of fragile anatomic structures like the eyes, brain, and airway seen in such injuries. In open injury scenario, hemorrhage can be easily managed by meticulous examination to recognize all the bleeding vessels followed by their ligation. Closed injuries necessitate balloon tamponade with Foley catheter (Fig. 59.5) to control bleeding. If bleeding is not controlled by the usual techniques, external carotid ligation or selective embolization method is used, which is by far the most predictable method to control bleeding from external carotid artery and its tributaries [13, 16].

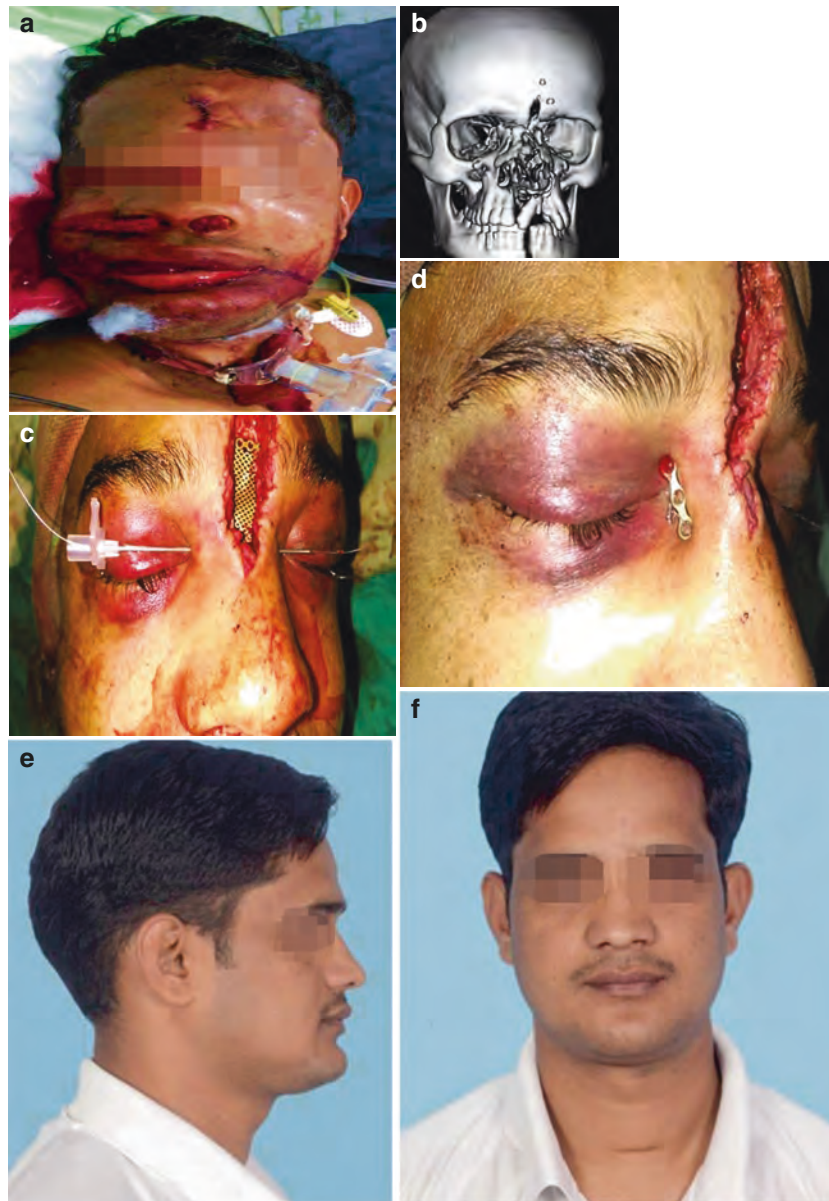Table 59.1 Algorithm in the treatment of Gun Shot Wounds (GSW)

59.4 Diagnostic Imaging

Once airway is secured and bleeding is controlled, attention should be directed toward radiological assessment of the injury. Depending on the severity of injury a plain X-ray, CT scan and CT angiography can be requested [15]. The extent of injury, degree of hard tissue fragmentation, location of metallic splinters, damage to C-spine, and any occult brain injuries can be easily delineated with the help of a CT scan. Similarly, involvement of great vessels, any concealed bleeding, and flow dynamics of vessels suitable for microvascular reconstruction can be studied using CT angiogram. Apart

from the damage characteristics of the wound, another crucial factor which needs to be assessed during radiological examination is the status of C-spine.

Any injury of such magnitude enough to fracture the facial skeleton can invariably cause an occult C-spine injury. The incidence of C-spine injuries varies from 8 to 11% in all maxillofacial traumas [17]. Hence, potential cervical spine injury should be always considered unless proven otherwise clinically or radiologically. It is pertinent to immobilize the cervical spine to prevent further damage especially in unconscious patient (Fig. 59.6). However, substantial evidence is still lacking about the safety and efficacy of cervical collars



©Association of Oral and Maxillofacial Surgeons of India

Fig. 59.6 (a–e) Low-velocity close-range handgun injury—3D CT showing comminution of maxilla and NOE complex. The case was treated by ORIF mandible, maxilla, frontal bone, and cathopexy using

iv cannula and wire. Three years post-surgery—adequate restoration of width and projection of midface

used in such injuries. Moreover, placement of rigid collars interferes during airway management, central line placement, and definitive repair of facial injuries [13].

59.5 Definitive Management of Facial Gunshot Wounds

The prime goal in the management of facial gunshot wounds is to rehabilitate the patient to pre-injury function and aesthetics. However, it is not always easy to get a flawless post-operative outcome with one particular treatment modality or a particular surgical technique. Hence, the treatment should be timed and tailored depending upon the type and severity of the injury, amount of tissue loss, general health status of the patient, surgeon's expertise, and availability of resources. Before initiating any treatment procedures, a thorough assessment of the wound by a multidisciplinary team is imperative as gunshot injury cases are seldom comparable. A comprehensive evaluation and discussion by a diverse panel gives the surgeon valuable perspectives which in turn has a positive impact on the final outcome.

59.6 Debridement

Modern high-velocity firearms transfer heavy cavitation energy inside tissues causing physiological and morphological alterations resulting in hemorrhage, thrombosis, and necrosis [18]. The tissue response toward the high-velocity projectile varies with the type of tissues and elastic deformation it can sustain. The dermis is viscoelastic, and injuries will result in abrasion, traumatic tattooing, and contusion particularly in close-range shots. Muscle tissues can withstand elastic deformation up to four times the size of the projectile, but at a cellular level, it may undergo significant necrosis, devitalization, and denaturation rendering the microenvironment favorable for bacterial multiplication [19]. The injuries to neurovascular bundles behave similar to muscles, thereby causing tearing, shearing, and rupture of blood vessels. At microscopic level, all the three layers of blood vessels get affected resulting in the formation of thrombus, inflammation, and persistent spasm [20]. Cortical bone on the other hand is crystalline in consistency; therefore, penetrating injury causes fragmentation of bone with formation of multiple secondary projectiles. Conventional management of firearm injuries involves initial wound debridement, wound toilet, adequate soft tissue closure, and administration of antibiotics followed by delayed repair of deformities [4]. However, with the advent of vascular flaps and new reconstruction methods, there has been a colossal shift in the management of such injuries to a more definitive early single-stage repair [21].

The management commences with meticulous debridement of wounds to the point of active surgical bleeding. This strategy is particularly important in case of crushed and contaminated wounds wherein the active surgical bleeding encourages the formation of a healthy granulation tissue [18]. Furthermore, it also improves adequate microcirculation at wound margins, thereby promoting rapid healing and tissue resistance to infection. A serial debridement with judicious excision of the necrotic and non-contractile muscle tissues is done to achieve a wound with non-contaminated healthy margins [22].

After generous tissue excision, debridement should be assisted with soft scrubbing brushes and copious irrigation. Removal of deeply embedded splinters or metallic foreign bodies is controversial regarding any particular clinical benefits it offers [10]. The wound debridement should be prompt, and any delay (6–12 h) further complicates the wound management by progressive tissue necrosis. The development of progressive necrosis is a salient feature of gunshot wounds, and contrary to the popular belief, the tissue necrosis is not directly related to energy transfer but rather to the depth of tissues destroyed by the movement of the projectile. Animal studies have shown that beyond that critical time period, identification of necrotic margins will be difficult and hence it complicates the debridement and surgical control of the wound [23].

There are two main areas of conflicts pertaining to debridement in gunshot wounds. Many authors recommend immediate careful conservative soft tissue excision followed by secondary debridement of all tissues with questionable viability at a later stage [24, 25]. These researchers are of the view that it is practically impossible to distinguish between vital and non-vital tissues at initial intervention. On the contrary, a few other professionals believe in single-stage radical debridement on initial intervention [26].

Experimental evidences have shown that the extent of tissue necrosis after gunshot injury is 2 mm and 8 mm from the wound margins in skin and muscle tissues, respectively. In bony skeleton, it may extend up to 5 mm from the fracture line [27]. Thus, there is no convincing evidence to preserve fragmented bone of 1 cm or less during debridement even if it is attached to soft tissues. Similarly, a serial debridement of such wound is often required to deal with the evolving pattern of tissue necrosis over a period of 24–36 h. This allows for early identification of the demarcation zone between vital and non-vital tissues before reconstructive procedures are planned. The consensus of radical wound debridement at initial intervention aims to remove foreign bodies, necrotic tissues, and microbial contamination as early as possible. It also minimizes inflammation, prevents infections, and helps in achieving favorable wound healing. Any late wound management in our opinion eventually increases the chances of infection, operating time, toxemia, and subsequent surgical intervention.

Concomitant injuries to salivary gland ducts and facial nerve are often encountered during initial debridement. The ducts and facial nerve are usually tagged with Prolene sutures for future repair. Most of the ductal injuries can be managed by cannulation and primary repair or by rerouting it into oral cavity. Non-salvageable glands should be removed without hesitation to prevent sialocele, salivary fistula, and complicated wound healing. Damage to facial nerve is mainly by thermal, avulsion, and stretch injury caused by the cavitation. Preferably the nerve should be repaired within 72 h for predictable results. Lacerated nerve is repaired primarily by coaptation or using nerve grafts harvested from greater auricular nerve. The nerve damage caused by cavitation may extend as far as 1.8 cm from the bullet track, and that should be considered during nerve grafting procedure [19]. Any facial nerve injury anterior to a line connecting mental foramen and lateral canthus is generally not repaired as spontaneous recovery is very likely in such cases.

59.7 Infection and Role of Antibiotics

Ballistic facial injuries are often compound and contaminated with high propensity for infection (class IV wounds). Contrary to the popular belief, all ballistic injuries are inherently contaminated, and the infection is primarily by the inoculation of microorganisms carried by the bullet and secondarily as a result of wound contamination in transit or in hospital environment. The actual incidence of infection rates remains elusive and ranges from 7 to 100% of all military facial injuries [28]. However, a general consensus is lacking in the timing, choice, and duration of antimicrobial therapy in combat injuries. Nonetheless the usage of broad-spectrum antibiotics for 10–14 days which provides cover against staphylococci, *Clostridium perfringens*, and *Acinetobacter baumannii* is commonly used [14, 29]. The critical level of bacteria required for initiating an infection reaches peak at 6 h of injury (10^5 bacteria/gm. of tissue), and studies have shown that early administration of antibiotics is paramount and any delay of greater than 6 h renders the treatment ineffective [30]. The accepted guidelines for combat-related injuries recommend administration of short-course, broad-spectrum antibiotics preferably within 3 h of injury [31]. The use of antibiotics is an adjunct to scrupulous debridement for the prevention of infection and should always be considered in the initial management of ballistic injuries.

59.8 Soft Tissue Reconstruction

Gunshot wounds result in composite 3D defects with involvement of the skin, musculature, facial skeleton, and mucosa. The various reconstruction methods for wounds of these natures are prosthetic obturation, non-vascularized grafts with local tissue advancement, loco-regional flaps, and free flaps for large composite defects (Also refer Chaps. 86 and 88 of this book). Before initiating the reconstructive procedure, it should be kept in mind that the management of such wounds is often complicated by the ambiguity in prognosis caused by tissue loss, progressive necrosis, and infection. Therefore most critical facet while handling avulsive wounds lays in achieving and maintaining a favorable intraoral wound closure to minimize the chances of wound infection and wound dehiscence due to oral contamination [32]. It is always crucial to close the wound primarily because of the high propensity toward scarring and functional debility of wounds that heal secondarily. Most gunshot wounds can be closed primarily, and delayed wound closure in maxillofacial region is rarely necessary. However, two exceptions to this are (1) wounds which are not possible to debride completely at initial operation and (2) wounds with questionable vitality of tissues.

Sequencing of primary reconstruction of oro-facial region should follow an inside-out principle [33]. The injuries of the oropharynx are first addressed by repairing the musculature and mucosa. This is followed by repair of oral mucosa, floor of the mouth, and the tongue. The reconstruction of lips, cheeks, and other extra-oral tissues is performed later after oral cavity has been reconstructed. Nonetheless if an acceptable intraoral closure is difficult to achieve, a maxillomandibular fixation is done, and it is prudent to leave the wound to heal secondarily. While selecting a reconstructive option, it is important to consider a treatment plan which reduces the treatment time, patient morbidity, number of surgical intervention, and hospital stay [34]. The best possible function and aesthetics are achieved when debridement and reconstruction of hard and soft tissues are done at an early stage and the residual soft tissue deformities are addressed at a later stage with revision surgeries and local flaps [2]. Extra-oral wounds that cannot be closed primarily due to excessive tissue loss are best managed by employing local, regional pedicled flaps and microvascular flaps.

Use of local flaps and regional flaps at the initial operation appears to be most favorable as far as aesthetics and function

are concerned (Fig. 59.6a). Motamedi [2] advised early use of local flaps in patients with gunshot wounds of the face. He reviewed 30 GSW patients and reported excellent cosmetic and functional outcomes. However, the disadvantages of local flaps are that composite defects cannot be addressed and its availability, limited bulk, and pedicle length. Local tissue rearrangements and local flaps with nonvascular grafts like iliac crest, rib, or cranium can be used for small defects. But large 3D defects and poorly vascularized surrounding tissues caused by cavitation often preclude the use of bone grafts with local tissue rearrangements unlike in tumor reconstruction.

Major avulsive and chop off injuries demand vascularized bone grafts with skin paddle for their reconstruction. Composite free tissue transfer is predictable, provides adequate bulk of well-vascularized tissue to fill the dead space, rehabilitates the buttresses, and reinstates the soft tissue envelope in a limited period of time [15]. The variables affecting the selection of flap depend on the type and amount of tissue loss, location, length of pedicle, donor site injury, and, certainly, surgeon's preference. The most commonly used flaps for facial reconstruction are anterolateral thigh flap, radial forearm, and fibula with skin paddle [5]. It is obligatory to reconstruct both bone and soft tissues in composite defects, and without osseous support, soft tissue-only reconstruction tends to droop over time. After primary healing, the flap is contoured, subsequently unaesthetic skin paddle is excised, and local tissue can be re-advanced for better aesthetic outcomes. Similarly, if adequate vascularized tissue is not used for reconstruction, complications like scar contracture, bone graft resorption, fistula formation, and ultimately collapse of facial envelope will result.

It is clear that reconstruction of avulsive facial defects with free flap should be addressed as early as possible to prevent soft tissue contracture. Nonetheless, how much grace period is required before initiating a free flap reconstruction for optimizing the reconstructive outcomes is still not clear. High-energy cavitation in soft tissue may temporarily damage the local vasculature and hemodynamics at a distance from the margin of permanent wound. While planning a treatment based on microvascular reconstruction, it is imperative to have a conception of the zone of injury in its actual extent. Animal studies have shown that it is safe to place an anastomosis 3 cm away from the margin of wound track [35]. Furthermore, experimental evidences have shown superior results in integrity and patency of facial vessels anasto-

mosed 3 days after injury than those repaired immediately after the injury [20]. If it is so, a composite free tissue transfer as a part of immediate reconstruction in avulsive ballistic injuries should be delayed till 3–4 days. This time period helps in adequate assessment of the extent of devitalized tissues, formulating a treatment plan based on available resources and optimizing the results by executing the treatment before the onset of soft tissue fibrosis and when the blood vessels are devoid of spasm.

Despite several arguments favoring immediate reconstruction for excellent aesthetic outcomes, it is to be noted that scar contracture is inevitable irrespective of the timing of treatment and reconstruction method adopted, although the frequency is more with delayed treatment [36]. Therefore, a review to determine the need for secondary corrective procedures should be conducted in consultation with the interdisciplinary team. Scar contracture is usually managed later by revision surgeries after the maturation of scar. The total number of revision surgeries required for a free flap is less as compared to local or regional flaps. The outcomes of revision surgery depend on the type of flap used, complexity of the defect, and location of the defect with nasal, orbits, and lips requiring the highest number of aesthetic refinements [5]. Similarly other expected soft tissue complications like trismus, microsomia, and other functional disabilities can be addressed by fat grafting, coronoidectomy, commissuroplasty, and Botox injections [37]. Very often the reconstructive surgeries of aesthetically prominent regions of the face like nose and orbits are always suboptimal, and in such cases, prosthetic rehabilitation can be considered even though not physiological and patient compliance is less.

59.9 Fracture Stabilization and Hard Tissue Reconstruction

The methodology for treatment varies and ranges from:

1. Debridement only
2. Debridement and closed reduction with or without fixation
3. Debridement, open reduction, and plate osteosynthesis

In patients without continuity defect, infection and minimal comminution open reduction and internal fixation (ORIF) is simultaneously done along with debridement at the initial stage.

Once initial stabilization is ensured, fixation is generally accomplished by miniplates or reconstruction plates. However, wounds with limited soft issue coverage require a different strategy as the granulation tissues may fail to cover thickness of plate resulting in subsequent plate exposure. Thus, if adequate soft tissue cover cannot be achieved, debridement, external pins, and maxillomandibular fixation (MMF) are the method of choice [33]. Until the introduction of surgical screws and plates, closed treatment was the preferred mode of treatment. The treatment ideology was directed to treat the whole wound as a “bag of bones” using external fixation or MMF in order to avoid periosteal stripping and devitalization of small fragments of bone. Although this therapeutic concept is advocated by several authors, who have reported significantly lesser rates of infection with this technique when compared with ORIF and plates, the value approach continues to be underestimated [38].

The advantages of external fixation are manifold. It helps to prevent bone devascularization, allows for bone regeneration, and also provides adequate support to the comminuted fracture fragments. Additionally, it also enhances the osteogenic potential of the injury site by helping in spontaneous bone regeneration. This phenomenon is more commonly seen in young patients due to hypoxia and acidosis-induced activation of local bone morphogenic proteins (BMPs). The high-velocity trauma causes extensive damage to adjacent muscles and periosteum. This damage along with the effects of local inflammation, hypoxia, and increased carbon dioxide concentration activates BMPs resulting in spontaneous bone formation. The concept and knowledge regarding facial buttress and its implication in trauma management have added a new dimension in the functional and aesthetic reconstruction of the face. As a result, internal fixation using locking plates has greatly replaced external fixators over a period of time. It is currently the most widely used technique in management of GSWs with bone loss and is used if the fracture fragments are large enough to accept screws.

Additionally, bone defects if any should be grafted with harvested iliac crest, ribs, or cranium depending upon the size of the defect (Fig. 59.7). However, the infection rates associated with internal fixation are comparatively higher as quoted by many authors. The increased rates of infection associated with ORIF are due to loosening of hardware and subsequent micromotion at the fracture site and possibly by

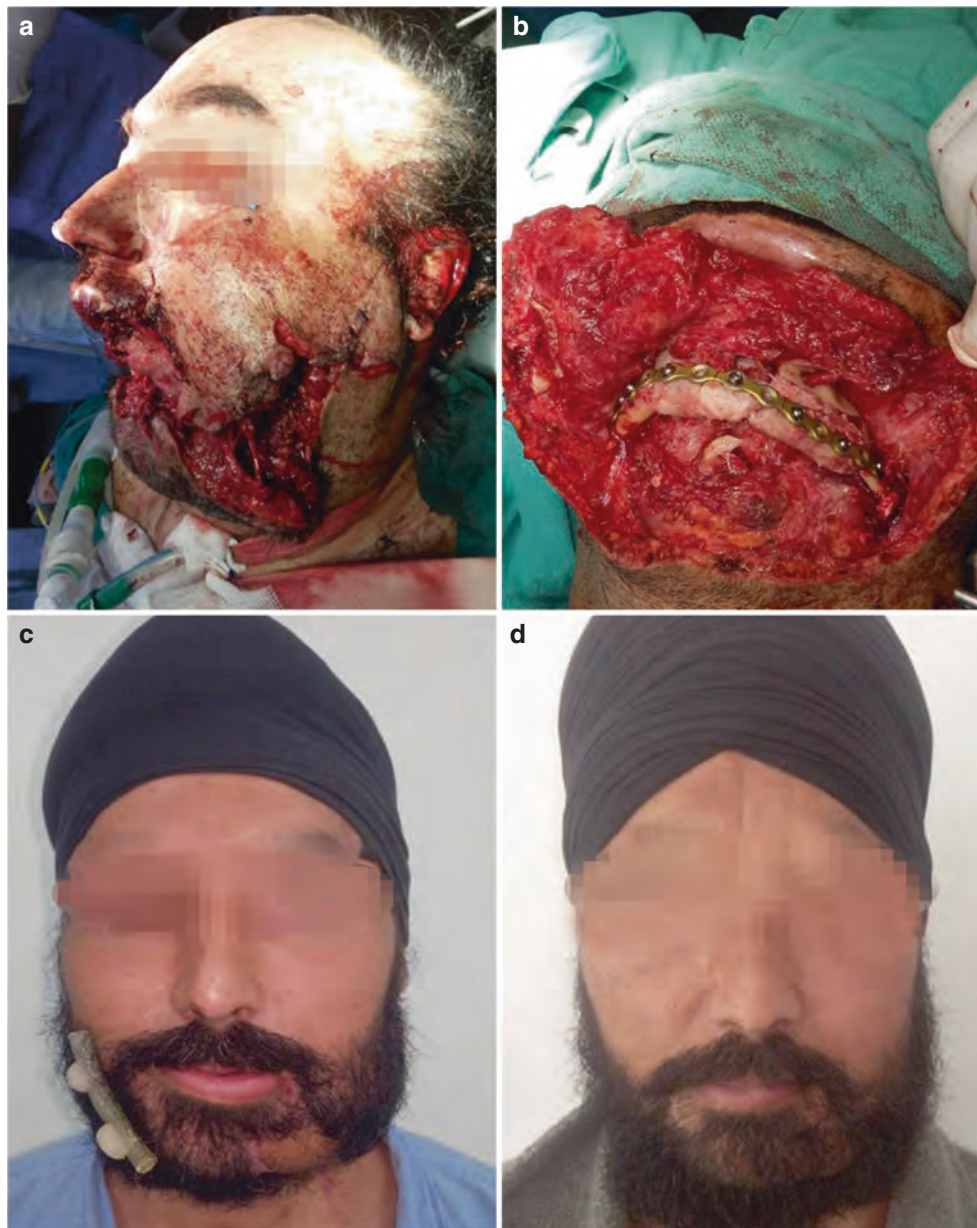contamination by oro-nasal flora. Motammedi [2] reported that it is almost impossible to achieve occlusion without arch bars and MMF in majority of gunshot fractures. Presently ORIF along with arch bars continue to be the mainstay in the management such patients. With the advent of new techniques of reconstruction supplemented by innovative plates and screws, vascular grafts and antibiotics have heralded a paradigm shift in the treatment philosophy. Current principles clearly favor early definitive reconstruction of hard tissues with ORIF using rigid fixation supplemented by MMF and bone grafts whenever required (Fig. 59.8).

59.10 Timing of Definitive Reconstruction

An area of ongoing debate and controversy in the management of gunshot wounds of the face is regarding the timing of definitive reconstruction [6, 39]. Although previous teachings and practices were in favor of delayed reconstruction, the more recent studies demonstrate predictable functional and aesthetic outcomes with immediate definitive reconstruction [40–42]. Scientific studies suggest carrying out definitive reconstruction within a time frame of 48 h would yield the best possible outcome [2].

Advocates of delayed reconstruction believe that the delay in treatment reduces the probability of infection, necrosis, and postoperative wound complications exponentially. Additionally delay in treatment reduces the chances of mortality and morbidity due to infection and progressive tissue necrosis [43, 44]. Any increase in postoperative temperature, raised leukocyte counts, and other local signs of infection may invariably cause a failure in flap due to risk of venous thrombosis. It has also been suggested that the decreased inflammation and edema aid surgeons to have a better assessment of the extent of injury, thereby helping in precise and desired treatment planning which in turn could lead to a better outcome. Therefore in their opinion, it is prudent to wait before applying any principles of primary reconstruction until a healthy tissue bed is achieved. On the other hand, the disadvantages of delayed treatment are increased treatment time, prolonged hospital stay, increased cost of treatment, and patient distress caused by psychosocial impact of disfigurement associated with gunshot injury (Tables 59.2 and 59.3).

Advocates of early primary treatment claim superior functional and aesthetic outcomes, early restoration of facial form, and limited hospital stay with early return to normal



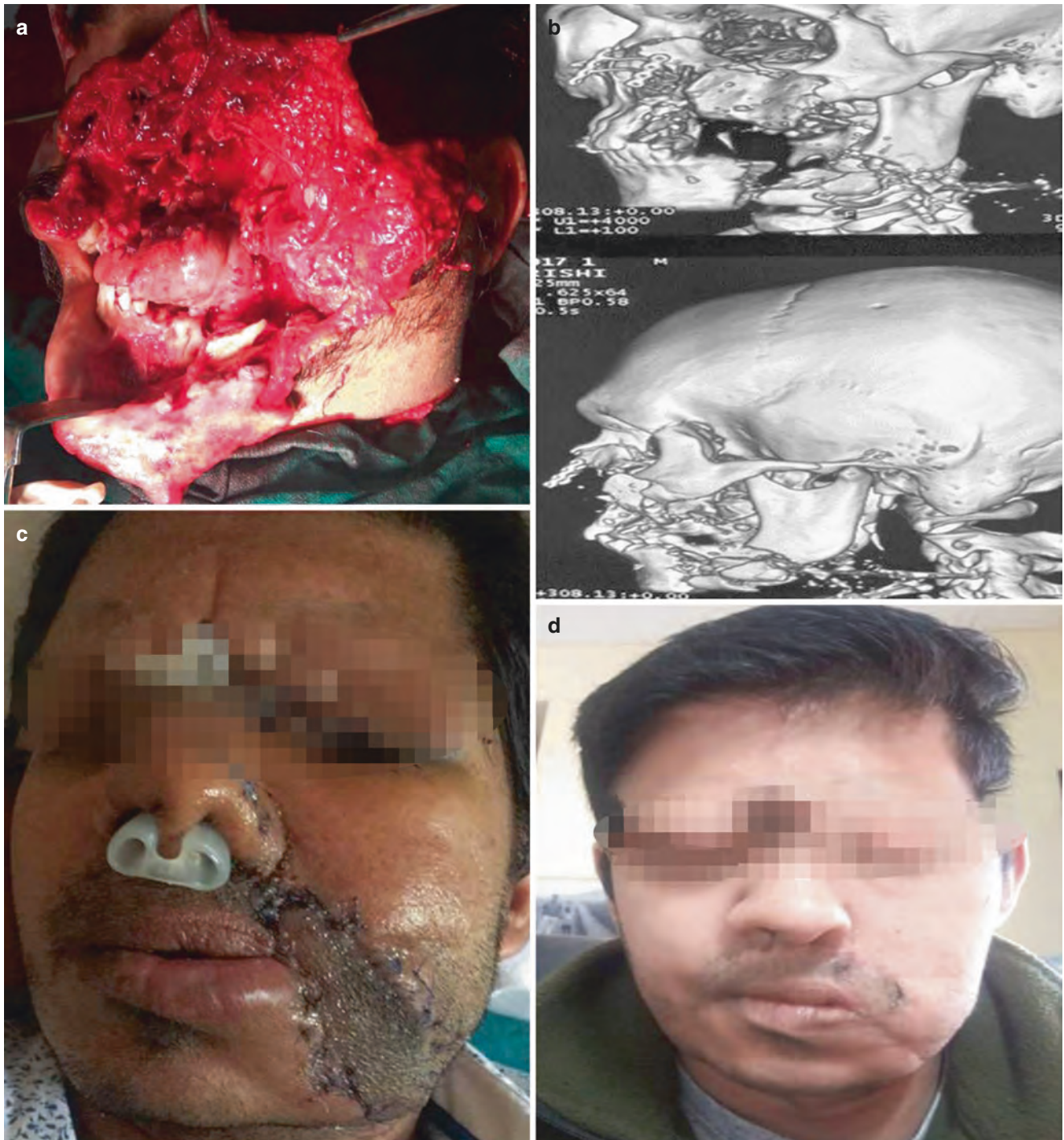©Association of Oral and Maxillofacial Surgeons of India

Fig. 59.7 (a–d) High-velocity close-range assault rifle injury with comminution of mandible and soft tissue loss. Managed initially by non-vascularized graft and later by free fibula osteocutaneous flap

reconstruction. External fixator for stabilizing fibula in place. Follow-up after complete treatment

function [4, 14, 45]. These benefits are predominantly due to the elimination of soft tissue contracture by proper anatomic coverage of soft tissue at an early stage [21]. Vasconez et al. [42] compared the infection rates of gunshot wounds that have been managed by early and late reconstruction in a series of 33 cases. In their observation, they could not find

any significant difference in infection rates between the two groups. However, the delayed group showed an apparent increase in the incidence of scar contracture with significant functional and aesthetic complications. Similarly, several other studies have also reported excellent clinical outcomes when immediate reconstruction is carried out [46].



©Association of Oral and Maxillofacial Surgeons of India

Fig. 59.8 (a–d) High-velocity assault rifle injury to the face with loss of hemimaxilla and mandible along with partial loss of upper lip was done. Reconstruction of the upper lip by hair-bearing submental island flap. Mandible reconstruction is performed by vascularized fibula

Definitive management of most maxillofacial injuries is not a surgical emergency, and treatment is often delayed in polytrauma patients. A standard consensus for delaying treatment and adopting a staged approach in such cases is due to the inability of a critically injured patient to undergo

surgical intervention. However, as soon the patient is deemed to be medically stable, operative intervention targeted toward managing the facial injuries should be initiated. It is imperative to address the bony and soft tissue injuries soon after the resolution of edema and before the initiation of fibrosis of

Table 59.2 Advantages and disadvantages of immediate reconstruction

Advantages of immediate reconstruction	Disadvantages of immediate reconstruction
Less scar contracture, better postoperative function and aesthetics	The margins of devitalized tissues and its extent cannot be appreciated during early repair
Early return to function and less hospital stay	Correction of subtle deformities is difficult and such minor correction always requires second intervention
Less psychological impact on patient because of early recovery	Surgeon's expertise and availability of resources
Proper anatomical coverage of defect so chances of infection are less	Tissue edema immediately following the injury will hamper the judgment of surgeon resulting in suboptimal outcome

Table 59.3 Advantages and disadvantages of delayed reconstruction

Advantages of delayed reconstruction	Disadvantages of delayed reconstruction
Correction of defects after the resolution of edema will give a clear picture of the defect size	Severe scar contracture, less postoperative functional and aesthetic outcome
Correction of minor deformities is possible which may have been missed during immediate reconstruction	Number of hospital stay is increased with more psychological burden to the family and patient due to disfigured face
The necrotic margins can be easily assessed before reconstruction	High chances of infection due to open wound

soft tissues and malunion of fractures. This grace period will allow the surgeon to have an accurate and swift identification of subtle deformities for a major single-stage intervention rather than repeated assault to soft tissues causing fibrosis and decreased vascularity.

The essential difference in the management of routine maxillofacial injury and gunshot wounds of the face is the requirement of a multidisciplinary team for the management of gunshot wounds. Therefore, a short-term delay or temporizing such wounds allows time to procure diagnostic images and study models and lastly for a discussion on inputs from the medical and surgical team. In general, the formulation of treatment plan should be based on the general health status of the patient, availability of resources, surgeon's expertise, and patient's will.

In a vast majority of cases despite the primary management approach, a significant number of gunshot injuries are plagued with residual functional and aesthetic problems. Hence, a good postoperative outcome is multifactorial and is the reflection of all the above factors and not just the early definitive repair. However, a large number of maxillofacial gunshot wounds can be treated definitively at the time of ini-

The general physical status of the patient, timing of surgery, extent of composite tissue damage, good surgical techniques, use of appropriate hardware, antibiotics, and proper rehabilitation are the factors which determine the final outcome and aesthetic result in a penetrating facial injury.

tial intervention if the general condition of the patient and expertise of surgeon permit and the benefits of such an approach are manifold.

59.11 Recent Advances

Several recent advances have significantly improved the morbidity and survival rates in complex maxillofacial gunshot injuries. More importantly they serve as a support system to the surgeons, enabling them to appreciate and attend to the finer aspects of complex composite injuries. This in turn paves the way to achieve far more superior reconstructive outcomes. Contemporary techniques employ virtual surgical planning, patient-specific stereolithographic models, as well as intraoperative navigation and imaging (Refer Chap. 41 of this book). These modern-day techniques help elevate the surgical experience to one that is more precise, faster, and minimally invasive.

Composite tissue alloplastic transplantation or face transplantation is yet another recent innovation in this field. This treatment is rendered for patients with massive loss of hard and soft tissues of the face or in cases where the final outcome is suboptimal even after multiple surgeries. However, it is not in the mainstay treatment of gunshot wound of the face because of the difficulties in finding an appropriate donor, lack of expertise, requirement of long-term immunosuppressants, absence of long-term follow-up, and associated ethical issues.

59.12 Conclusion

In conclusion, the management strategies of patients with facial gunshot wounds are almost as diverse as the case presentation itself. This chapter ascertains that the blueprint for actions in the management of facial gunshot injuries has undergone significant change over the last decade. A new understanding of the inherent osteogenic potential of the human body in the face of contemporary warfare coupled with the availability of state-of-the-art equipments and facilities favors a brisk early approach. Thus, present guidelines

essentially direct surgeons to do as much as possible for the gunshot patient with regard to hard and soft tissue reconstruction of the face and jaws within 48 hours. The treatment in such cases is more comprehensive with intent to simultaneously debride and reconstruct.

References

- McLean JN, Moore CE, Yellin SA. Gunshot wounds to the face—acute management. *Facial Plast Surg.* 2005;21:191–8.
- Motamedi MHK. Primary management of maxillofacial hard and soft tissue gunshot and shrapnel injuries. *J Oral Maxillofac Surg.* 2003;61:1390–8.
- Robertson BC, Manson PN. High-energy ballistic and avulsive injuries. A management protocol for the next millennium. *Surg Clin North Am.* 1999;79:1489–502.
- Motamedi MH, Behnia H. Experience with regional flaps in the comprehensive treatment of maxillofacial soft-tissue injuries in war victims. *J Craniomaxillofac Surg.* 1999;27:256–65.
- Doctor VS, Farwell DG. Gunshot wounds to the head and neck. *Curr Opin Otolaryngol Head Neck Surg.* 2007;15:213–8.
- Kummoona R. Management of missiles injuries of the facial skeleton: primary, intermediate, and secondary phases. *J Craniofac Surg.* 2010;21:976–81.
- Williams CN. Immediate and long-term management of gunshot wounds to the lower face. *Plast Reconstr Surg.* 1988;82:433–9.
- Shuker ST. Emergency treatment strategy and the biodynamic effects of massive, & “chopped off” mandibular tissue and a prolapsed tongue. *J Craniomaxillofac Surg.* 2013;41:e59–63.
- Chen AY, Stewart MG, Raup G. Penetrating injuries of the face. *Otolaryngol Neck Surg.* 1996;115:464–70.
- Breeze J, Tong D, Gibbons A. Contemporary management of maxillofacial ballistic trauma. *Br J Oral Maxillofac Surg.* 2017;55:661–5.
- Hodgetts TJ, Mahoney PF, Kirkman E. Damage control resuscitation. *J R Army Med Corps.* 2007;153:299–300.
- Tong DC, Breeze J. Damage control surgery and combat-related maxillofacial and cervical injuries: a systematic review. *Br J Oral Maxillofac Surg.* 2016;54:8–12.
- Jose A, Nagori SA, Agarwal B, Bhutia O, Roychoudhury A. Management of maxillofacial trauma in emergency: an update of challenges and controversies. *J Emerg Trauma Shock.* 2016;9:73–80.
- Powers DB, Will MJ, Bourgeois SL, Hatt HD. Maxillofacial trauma treatment protocol. *Oral Maxillofac Surg Clin North Am.* 2005;17:341–55.
- Futran ND, Farwell DG, Smith RB, Johnson PE, Funk GF. Definitive management of severe facial trauma utilizing free tissue transfer. *Otolaryngol Head Neck Surg.* 2005;132:75–85.
- Cole RD, Browne JD, Phipps CD. Gunshot wounds to the mandible and midface: evaluation, treatment, and avoidance of complications. *Otolaryngol Head Neck Surg.* 1994;111:739–45.
- DuBose J, Teixeira PGR, Hadjizacharia P, Hannon M, Inaba K, Green DG, et al. The role of routine spinal imaging and immobilisation in asymptomatic patients after gunshot wounds. *Injury.* 2009;40:860–3.
- Shvyrkov MB, Yanushevich OO. Facial gunshot wound debridement: debridement of facial soft tissue gunshot wounds. *J Craniomaxillofac Surg.* 2013;41:e8–16.
- Cunningham LL, Haug RH, Ford J. Firearm injuries to the maxillofacial region: an overview of current thoughts regarding demographics, pathophysiology, and management. *J Oral Maxillofac Surg.* 2003;61:932–42.
- Tan YH, Zhou SX, Liu YQ, Liu BL, Li ZY. Small-vessel pathology and anastomosis following maxillofacial firearm wounds: an experimental study. *J Oral Maxillofac Surg.* 1991;49:348–52.
- Clark N, Birely B, Manson PN, Slezak S, Kolk CV, Robertson B, et al. High-energy ballistic and avulsive facial injuries: classification, patterns, and an algorithm for primary reconstruction. *Plast Reconstr Surg.* 1996;98:583–601.
- Clasper JC, Hill PF, Watkins PE. Contamination of ballistic fractures: an in vitro model. *Injury.* 2002;33:157–60.
- Berlin R, Janzon B, Nordström G, Schantz B. The extent of muscle tissue damage in missile wounds one and six hours after the infliction of trauma studied by the current method of debridement. *Acta Chir Scand.* 1978;144:213–7.
- Rich NM. Vietnam missile wounds evaluated in 750 patients. *Mil Med.* 1968;133:9–22.
- Reis ND, Zinman C, Besser MI, Shifrin LZ, Rosen H. A philosophy of limb salvage in war: use of the fixateur externe. *Mil Med.* 1991;156:505–20.
- Al-Shawi A. Experience in the treatment of missile injuries of the maxillofacial region in Iraq. *Br J Oral Maxillofac Surg.* 1986;24:244–50.
- Zhou S, Lei D, Liu Y, Tan Y, Gu X. Experimental study on firearm wound in maxillofacial region. *Chin Med J.* 1998;111:114–7.
- Suominen E, Tukiainen E. Close-range shotgun and rifle injuries to the face. *Clin Plast Surg.* 2001;28:323–37.
- Petersen K, Hayes DK, Blice JP, Hale RG. Prevention and management of infections associated with combat-related head and neck injuries. *J Trauma.* 2008;64:S265–76.
- Mellor SG, Cooper GJ, Bowyer GW. Efficacy of delayed administration of benzylpenicillin in the control of infection in penetrating soft tissue injuries in war. *J Trauma.* 1996;40:S128–34.
- Hospenthal DR, Murray CK, Andersen RC, Bell RB, Calhoun JH, Cancio LC, et al. Executive summary: guidelines for the prevention of infections associated with combat-related injuries: 2011 update. *J Trauma Inj Infect Crit Care.* 2011;71:S202–9.
- Ray JM. The Treatment of Maxillofacial Trauma in Austere Conditions. *Atlas Oral Maxillofac Surg Clin.* 2013;21:9–14.
- Kummoona R, Muna AM. Evaluation of immediate phase of management of missile injuries affecting maxillofacial region in Iraq. *J Craniofac Surg.* 2006;17:217–23.
- Xavier SP, de Barros Pontes C, Silva ER, de Santana Santos T, Zatiiti SC, de Mello Filho FV. Three-stage mandible reconstruction after firearm injury. *J Craniofac Surg.* 2013;24:e87–8.
- Tan Y, Zhou S, Liu Y, Li Z. A gross and microscopic study of cerebral injuries accompanying maxillofacial high-velocity projectile wounding in dogs. *J Oral Maxillofac Surg.* 1998;56:345–8.
- Behnia H, Motamedi MH. Reconstruction and rehabilitation of short-range, high-velocity gunshot injury to the lower face: a case report. *J Craniomaxillofac Surg.* 1997;25:220–7.
- Gassner HG, Sherris DA, Otley CC. Treatment of facial wounds with botulinum toxin A improves cosmetic outcome in primates. *Plast Reconstr Surg.* 2000;105:1948–53.
- Manson PN, Crawley WA, Yaremchuk MJ, Rochman GM, Hoopes JE, French JH. Midface fractures: advantages of immediate extended open reduction and bone grafting. *Plast Reconstr Surg.* 1985;76:1–12.
- Kaufman Y, Cole P, Hollier L. Facial gunshot wounds: trends in management. *Craniofacial Trauma Reconstr.* 2009;2:85–90.
- Hollier L, Grantcharova EP, Kattash M. Facial gunshot wounds: a 4-year experience. *J Oral Maxillofac Surg.* 2001;59:277–82.

41. Mladick RA, Georgiade NG, Royer J. Immediate flap reconstruction for massive shotgun wound of face. Case report. *Plast Reconstr Surg.* 1970;45:186–8.
42. Vásconez HC, Shockley ME, Luce EA. High-energy gunshot wounds to the face. *Ann Plast Surg.* 1996;36:18–25.
43. Spira M, Hardy SB, Biggs TE, Gerow FJ. Shotgun injuries of the face. *Plast Reconstr Surg.* 1967;39:449–58.
44. Kassan AH, Lalloo R, Kariem G. A retrospective analysis of gunshot injuries to the maxillofacial region. *SADJ.* 2000;55:359–63.
45. Finch DR, Dibbell DG. Immediate reconstruction of gunshot injuries to the face. *J Trauma.* 1979;19:965–8.
46. Gruss JS, Antonyshyn O, Phillips JH. Early definitive bone and soft-tissue reconstruction of major gunshot wounds of the face. *Plast Reconstr Surg.* 1991;87:436–50.

Open Access This chapter is licensed under the terms of the Creative Commons Attribution 4.0 International License (<http://creativecommons.org/licenses/by/4.0/>), which permits use, sharing, adaptation, distribution and reproduction in any medium or format, as long as you give appropriate credit to the original author(s) and the source, provide a link to the Creative Commons license and indicate if changes were made.

The images or other third party material in this chapter are included in the chapter's Creative Commons license, unless indicated otherwise in a credit line to the material. If material is not included in the chapter's Creative Commons license and your intended use is not permitted by statutory regulation or exceeds the permitted use, you will need to obtain permission directly from the copyright holder.





Panfacial Fractures

60

Kiran S. Gadre, Balasubramanya Kumar,
and Divya P. Gadre

60.1 Introduction

Most facial fractures occur in combinations involving various subunits of craniomaxillofacial (CMF) skeleton [1] (Fig. 60.1). Severity of these injuries is determined by multiple factors such as its aetiology, causative factor, force of impact, pre-existing patient factors, etc: High velocity road traffic accidents RTA / assaults are the most common cause of panfacial fractures. With a large number of different patterns these fractures project, it is challenging to have a proper definition of “panfacial fractures”. It is well-known that fractures involving multiple bones of the face is known as panfacial fracture. It could be described as “fractures involving upper third, middle third, and lower third of face with at least one condyle, palate and fronto-naso-orbito-ethmoidal complex (FNOE) fracture” (Fig. 60.2). When there is skull base or co-existing neurosurgical involvement, it is termed as craniofacial fracture. Managing these cases is extremely complicated as each of them present with unique pattern of hard and soft tissue injury. This demands a team approach as these injuries are commonly seen in polytrauma with multisystem involvement. Airway compromise, severe haemorrhage, large open wounds, severe ocular/orbital injuries and coincidental surgical procedure being performed are the only indications for immediate definitive surgical intervention. Restoration of form and function at the earliest opportunity should be the goal of maxillofacial surgeons.

K. S. Gadre (✉)
Gadre Clinic, Pune, Maharashtra, India

Department of Oral and Maxillofacial Surgery, Bharati Vidyapeeth
Dental College and Hospital, Pune, Maharashtra, India

B. Kumar
Department of Maxillofacial Surgery, St. Marthas’s Hospital,
Bangalore, Karnataka, India

Bhagwan Mahaveer Jain Hospital, Vikram Hospital,
Bangalore, Karnataka, India

D. P. Gadre
Gadre Clinic, Pune, Maharashtra, India

60.2 Epidemiology

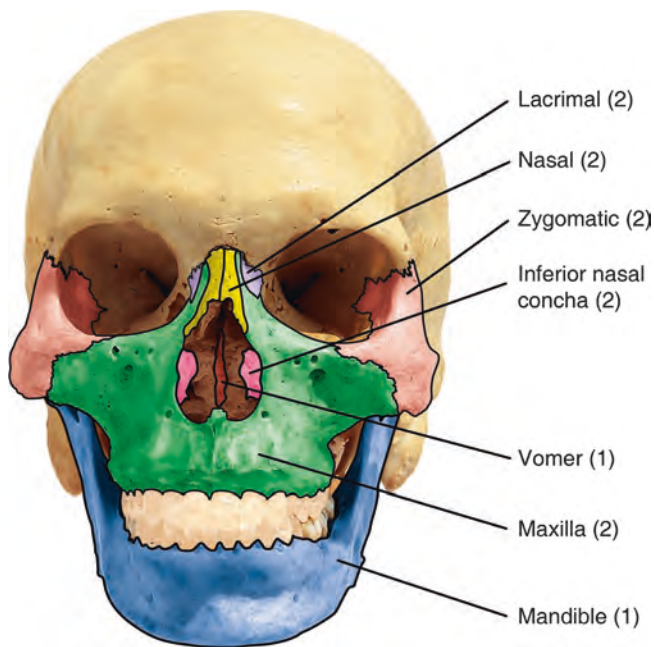
Global status report on road safety (2015) indicates that more than 1.25 million deaths, and 15–20 million injuries occur in road traffic accidents (RTA) costing most countries 3% of their GDP [2]. Countries with low and middle income having 54% of vehicles account for 90% of RTA-related fatalities, mostly of subjects aged between 15 and 44 years. RTA is the main cause of mortality in three quarters of males in 15–29 years age group. The true economic and public health impact is not estimated in most developing countries due to lack of infrastructure and resources [3].

Panfacial fractures are caused by high-energy impact, usually generated as a result of RTA or firearm injury directed at CMF skeleton, and it also has a contrecoup component causing associated cranio-cerebral or cervico-spinal injuries with a low Glasgow coma scale. These injuries can also cause associated injuries like rib fracture/pulmonary contusion, pneumothorax or intra-abdominal injuries, limb and pelvic injuries and require immediate treatment.

60.3 Management Philosophy

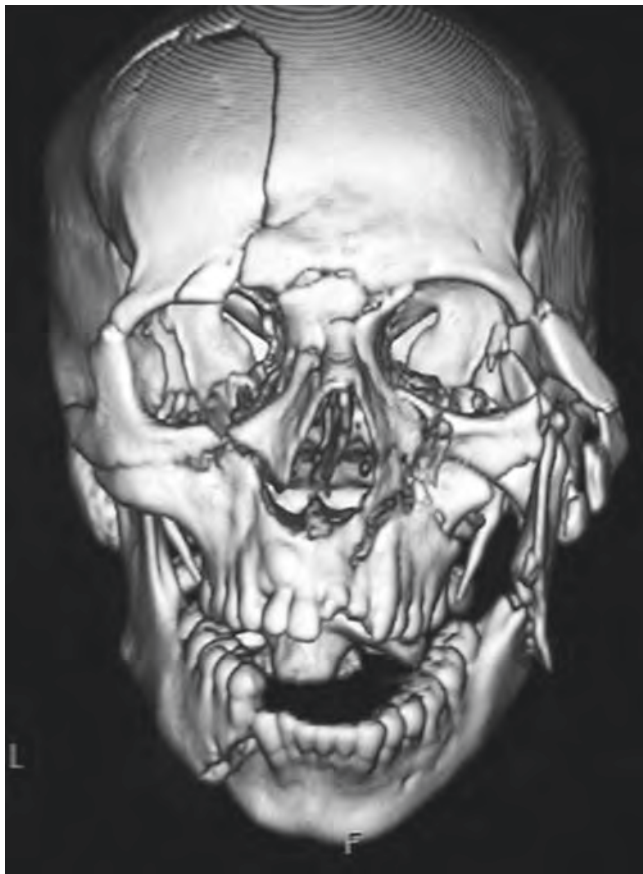Restoration of form and function is the ultimate goal in treating panfacial injuries. Proximity to important structures like the brain, eyes, auditory apparatus and spine necessitates a holistic approach to their management involving neurosurgeons, ophthalmic surgeons, ENT surgeons, maxillofacial surgeons and anaesthetists.

It is challenging to follow an established pattern of repair as each case is unique and requires skill and expertise of the surgeon to restore the pre-traumatic anatomy of facial function with aesthetics. Despite all the aggressive treatment, many patients with panfacial trauma may need further correction of residual deformities.



©Association of Oral and Maxillofacial Surgeons of India

Fig. 60.1 Schematic diagram depicting subunits of facial skeleton



©Association of Oral and Maxillofacial Surgeons of India

Fig. 60.2 3D CT scan image showing panfacial fracture involving the upper, middle and lower third of face

60.3.1 History of Management

The management of panfacial fractures has changed during past few decades, particularly after the 1990s, when indigenous plating systems were more freely available.

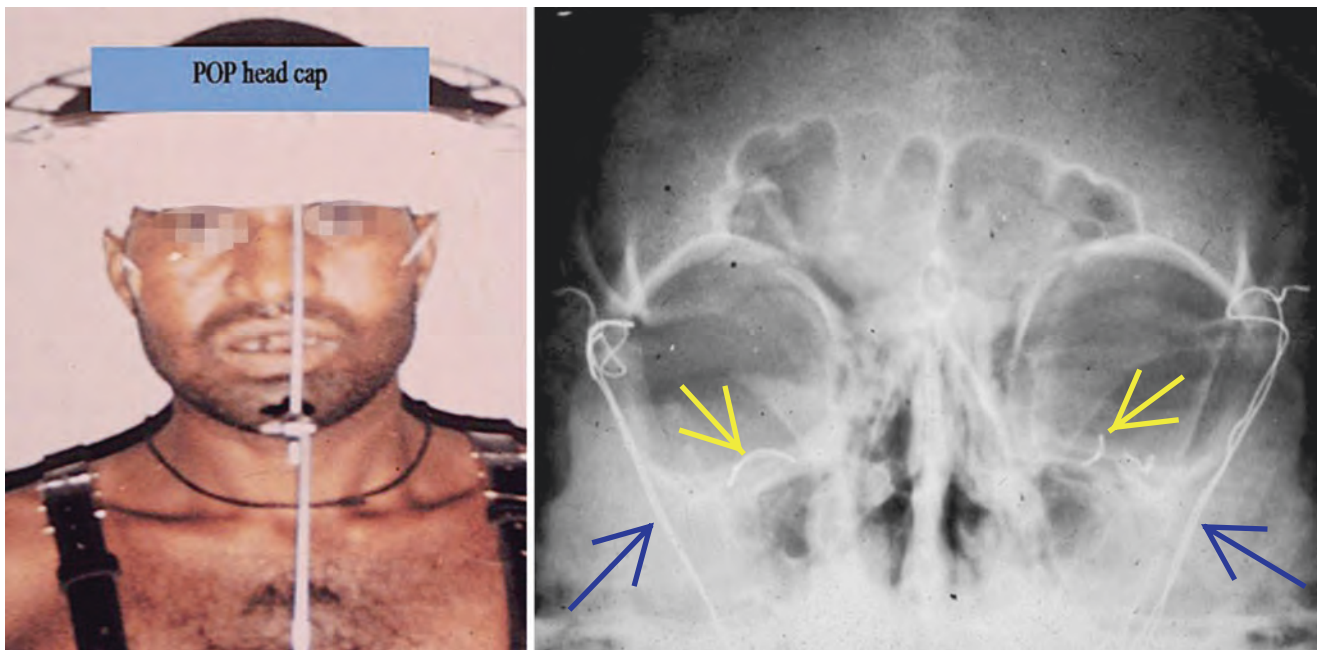
1. Prior to the 1980s, most panfacial fractures were treated with closed reduction using Plaster of Paris (POP) head caps and cranial frames. A variety of trans/interosseous wiring techniques (see Chap. 50 for details on various wiring techniques) and internal suspension methods like cranio-mandibular/maxillary suspension were used (Figs. 60.3a, b and 55.15).
 2. The surgeons of the 1990s generation started using combination of plating at key buttresses and internal suspension techniques [4]—the approach which may be attributed to early learning curve of internal fixation (Fig. 60.4).
 3. Use of internal fixation has revolutionised the management of panfacial fractures [4] (Fig. 60.5a, b), leading to faster recovery and satisfactory outcome of these injuries. (See Chap. 51 for details on Principles of internal fixation)
- A better understanding of anatomy, pathophysiology, anaesthesia, sterilization and asepsis with advances in intubation techniques (transmylohyoid/submental, bronchoscopic) and instrumentation (fiberoptic and endoscopic) and instrumentation has influenced the management of these complex injuries significantly (Chap. 7 deals with Anesthesia and intubation techniques in maxillofacial surgery). Use of engineering technology like three-dimensional planning, stereolithographic models, endoscopic and navigation techniques has simplified the accurate treatment of these fractures, avoiding injury to other vital structures and saving intra-operative time (Fig. 60.6a–d).

60.3.2 Indications

Panfacial fractures can be disfiguring and cause significant functional problems like difficulty in mastication, deglutition, speech, olfaction and abnormalities of vision. Early fixation of displaced fractures causing the above problems is warranted. Undisplaced/minimally displaced fractures can be left for a few days, buying some time to manage other grievous injuries. It is necessary to understand that sense of urgency for treatment should exist in treating any panfacial fracture (within 15 days, provided other parameters are permitting).

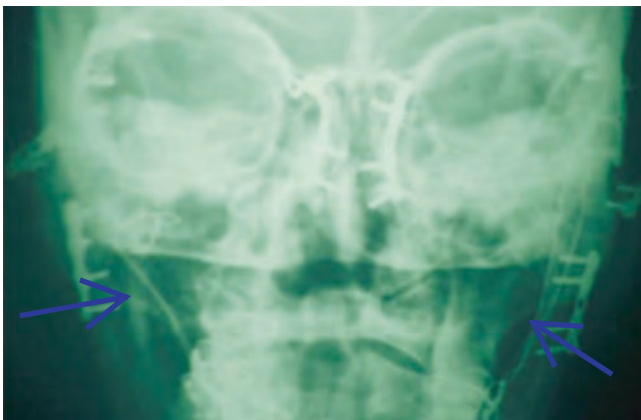60.3.3 Contraindications

There are no absolute contraindications but relative contraindications which cause delay of treatment, are presented below.



©Association of Oral and Maxillofacial Surgeons of India

Fig. 60.3 (a) POP head cap used in traditional days. (b) Interosseous wiring (yellow arrow) with internal suspension (blue arrow)



©Association of Oral and Maxillofacial Surgeons of India

Fig. 60.4 Plating with internal suspension (blue arrows)

1. Definitive treatment of panfacial injuries may be delayed up to 2 weeks in presence of severe, compromising, concomitant systemic or head injury.
2. It is advisable to operate only when patients are neurologically and systemically stable. This period should be used for further surgical assessment and planning. Reduction of facial oedema further unmasks the underlying fractures and facial deformity. This gives an opportunity to review the imaging and prepare necessary splints (see Sect. 55.7.1) (Fig. 60.7a, b). These are very essential to establish width, height and anteroposterior projection of the facial skeleton, particularly where large dento-

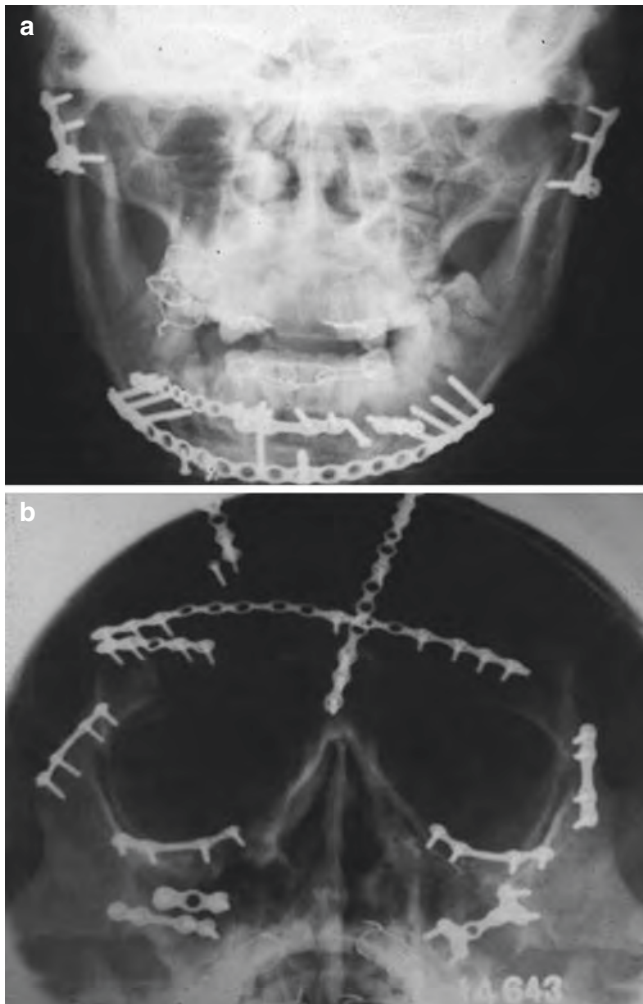
alveolar segments have been lost along with the presence of bilateral condylar fracture.

3. When a combination of avulsive injury (Chap. 49 deals with management of Soft tissue injuries in maxillofacial region) and panfacial fractures is present, golden hour reconstruction should be utilised, if circumstances and conditions permit. This is the best time as patient is in optimal physiologic and physical condition.

60.3.4 Clinical Findings

The clinical findings in panfacial trauma are a combination of signs and symptoms as seen in various subunits of facial fractures with increased severity (readers are advised to refer the respective chapters on maxillofacial trauma for signs and symptoms and management of fractures of mandible in Chap. 52, Fractures of the Condyle in Chaps. 53 and 54, fractures of maxilla in Chap. 55, fractures of the zygomatic complex in Chap. 56, fractures of the orbit in Chap. 57, fractures of the frontal naso orbit ethmoid region in Chap. 58 and Gun shot injuries in Chap. 59).

Facial oedema makes examination and standard radiography difficult. Bilateral raccoon's eyes and elongated dish-shaped face, with presence of orbital dystopia, traumatic telecanthus and deranged occlusion, are commonly seen. There may be elements of severe dento-alveolar trauma and soft tissue injury which may vary from minor contused or lacerated wounds (CLW) to avulsive injuries.



©Association of Oral and Maxillofacial Surgeons of India

Fig. 60.5 (a, b) Plating of panfacial fractures as seen on (a) posterior-anterior Caldwell view of mandible and (b) posterior-anterior Water's view radiographs

Presence of cervical, cranial and other concomitant injuries must be assumed till proved contrary. Similarly absence of teeth, dentures in mouth must be assumed to have been swallowed or aspirated until proven otherwise.

60.4 Workup

The pre operative planning consists of two parts: (a) imaging and (b) diagnostic procedures.

Imaging:

Standard radiographs like posterior-anterior (PA) view, Caldwell view of mandible, Water's view, submento-vertex view, cervical spine radiographs have been used as a baseline in any emergency and are easily available in most settings.

Computed tomography (CT) images with 3D reconstruction is now considered the gold standard in complex facial trauma patients as it provides a 1:1 information of the fracture pattern. 3D planning softwares help the surgeon in meticulously planning cases preoperatively.

CT imaging is commonly done for assessment of brain and spinal cord in a head injury patient to exclude intracranial haemorrhage and other grievous injuries. Facial skeleton should be included in the same scan in suspected facial bone fractures.

Coronal and sagittal sections of the CT scan could be obscured by the endotracheal tube in intubated patients. Axial and three-dimensional images with computer-generated models can be used for assessing most facial fractures in these cases (Fig. 60.8a, b).

Diagnostic Procedures:

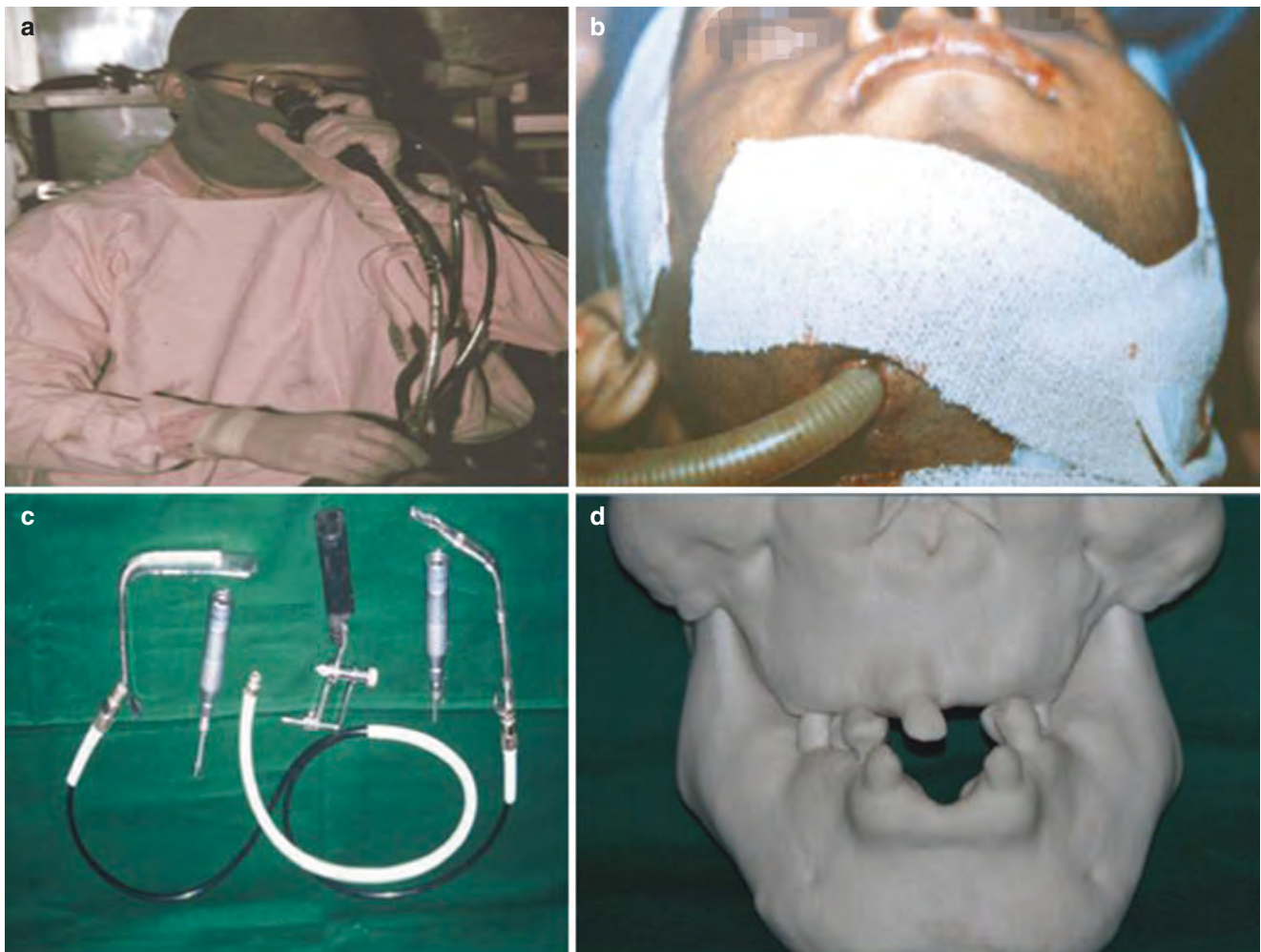
Occlusion of teeth is the key to reduction and fixation of facial bone fractures. Mock surgery using dental models help in repositioning the teeth-bearing segments including dento-alveolar and palatal fractures and aid in fabricating acrylic stents and splints (Fig. 60.7). They are essential in cases where there is gross occlusal disturbance, splaying of basal bone or multiple fractures of dento-alveolar segment.

60.5 Emergency Treatment

Complex maxillofacial trauma are mostly high impact injuries and are usually a part of life-threatening injuries involving other organ systems like central nervous system, chest, abdomen, pelvis or limbs. It is important that these injuries be assessed and managed prior to or simultaneously as facial injuries.

Current standards of care for trauma patients, whether polytrauma or those involving the CMF skeleton, mandate that one must follow the Advanced Trauma Life Support (ATLS) protocol relating to airway, breathing, circulation, disability and exposure in that sequence. Airway and circulation should have the highest priority (Table 60.1). This is followed by an assessment of the patient's neurological, visual and cervical spine status. The details of primary and emergency management of polytrauma patients are dealt in Chap. 48 of this book.

Patients with polytrauma/panfacial fractures can require immediate or late treatment depending on the mechanism and kind of injury. Occasionally, immediate treatment can be the definitive procedure. An immediate intervention may be done merely for initial stabilization of the patient; procedures demanding a more detailed assessment and planning will need to be postponed. Immediate initial treatment in patients with maxillofacial injuries is indicated in following situations.



©Association of Oral and Maxillofacial Surgeons of India

Fig. 60.6 (a–d) Showing few of advances from various specialities of medicine and engineering contributing to advances in management of panfacial fractures. ((a) Bronchoscopic intubation, (b) transmylohyoid intubation, (c) fiberoptic instruments, surgical saw, (d) stereolithographic model)

60.5.1 Airway Compromise

Obstructed airway is an important sequel of panfacial fractures and is managed either by temporarily reducing and stabilizing the fractured facial bones and attached soft tissues or performing a surgical tracheostomy. Patients with C-spine injury can be challenging to intubate due to inability to flex or extend the neck, as is establishment of a surgical airway like tracheostomy.

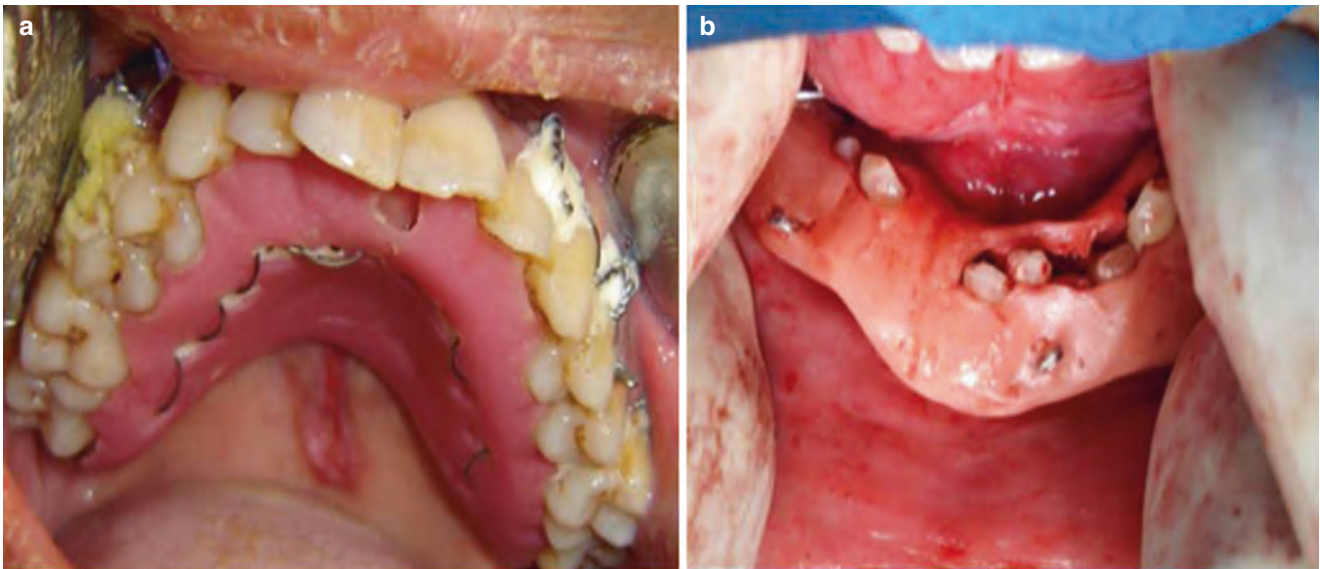
60.5.2 Severe Haemorrhage

Reduction and stabilization of fractured segments not only helps to correct airway but also controls severe bleeding. Haemorrhage not amenable to the above procedure may necessitate packing, identification of causative bleeder and its cauterisation or ligation. Occasional ECA control may

be required, if multiple ipsilateral bleeding areas or unidentified areas of bleeding are seen. In centres where the facility is available, uncontrollable bleeding from facial region (especially after comminuted midface fractures) is controlled with selective embolisation by an interventional radiologist.

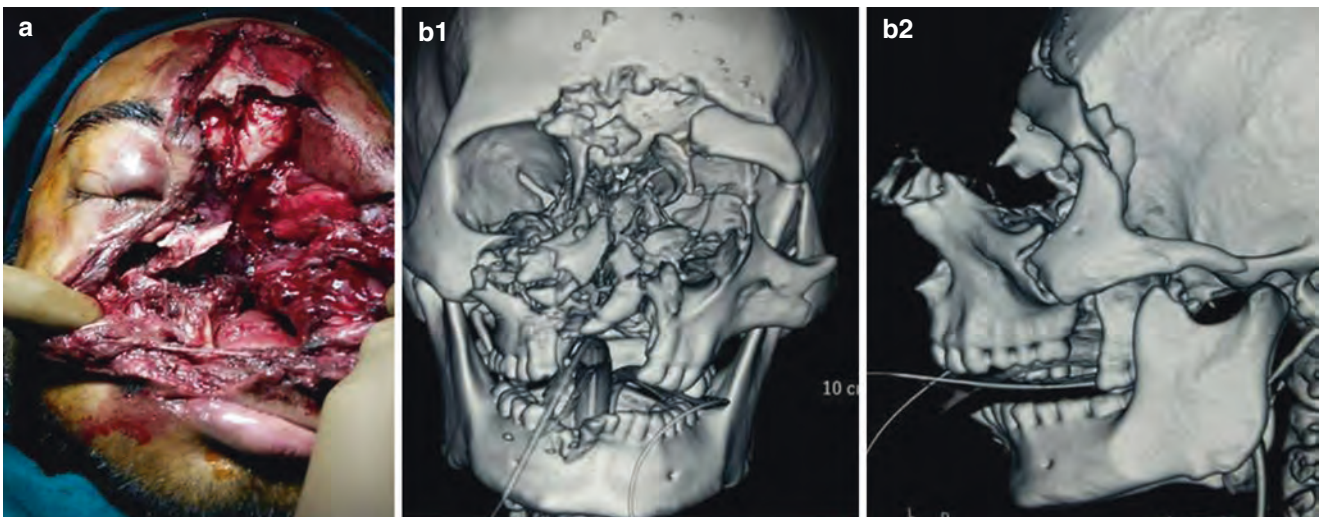
60.5.3 Large Open Wounds

These are commonly used to fix the fractures beneath them. In such situations initial washout and primary approximation should be done when possible for haemostasis and maintaining continuity of vascular supply, especially in cartilaginous areas like the ears and nose. This closure is basically a primary tacking of the wound margins. Layered closure is better done under controlled conditions along with fixation of the fractures under anesthesia [1].



©Association of Oral and Maxillofacial Surgeons of India

Fig. 60.7 (a, b) Showing utility and essentiality of splints in management of panfacial fractures



©Association of Oral and Maxillofacial Surgeons of India

Fig. 60.8 (a, b) Depicting importance of high-resolution CT scan in an avulsive injury to assess nature and extent of injury and achieve predictable outcomes

60.5.4 Surgery for Associated Life-Threatening Injuries

Occasionally, patients with polytrauma undergo immediate surgery to treat other grievous injuries. This provides an opportunity to perform initial debridement, assessment and stabilisation and make dental impressions for fabrication of a customised splint. Considering the planning and surgical time required for comprehensive management of panfacial fractures, it is usually not advisable or possible to perform fixation during emergency management of other more severe injuries (neurological/abdomen/long bones/chest).

It is always wise to initiate assessment of a head injury or polytrauma patient using the ATLS (Advanced Trauma Life Support) protocol. A detailed record of all maxillofacial injuries should be made. Diagrams and representations of fracture patterns and soft tissue injuries make it easy for the understanding and execution of treatment. It is important to document the whereabouts, mechanism and time of injury accurately, to minimise medico-legal problems at a later date. Photographs are a good medium of educating the patients with their attenders and recording the preoperative soft tissue injuries.

Table 60.1 Immediate management of a polytrauma patient

Management	Option 1	Option 2
Airway	Suction, recovery position, Intubation	Tracheostomy. More so with C spine injury
Hemorrhage	Pressure	Ligation
	Grouping cross-matching	Fluids 1–2 liters in adults and 20ml/kg for children
IV	Peripheral with 16 G intra-cath	Central
Catheterization	Nasogastric tube insertion; caution when FNOE fractures	Foley's catheter for input - output chart
Immunisation	Anti gas gangrene	Tetanus
Laboratory	Routine	ABG
Imaging	CT scan: HFN, Chest, Pelvis	Chest X-ray, USG abdomen
Assessment	Circulatory	Neurological

60.5.5 Definitive Treatment

Paul Manson's quote "you never get a second chance" has to be kept in mind, i.e. the time frame [5] regarded appropriate for primary fracture treatment is limited to 2 weeks. After 2 weeks, the treatment is regarded as delayed and may necessitate secondary post-traumatic reconstruction (see Chap. 60 on residual deformities of the maxillofacial region).

60.6 Preoperative Documentation and Planning

Preoperative treatment planning is essential for successful outcomes. One must gather enough information and documentation to help in formulating an accurate treatment plan.

This can include:

1. The topography and extent of fracture involvement
2. Loss of hard and soft tissues with their residual defects
3. Involvement of teeth and teeth-bearing segments
4. Assessment of important structures like parotid and submandibular glands, nasolacrimal duct, trigeminal nerve, facial nerve, muscles of eye and most importantly vision

A proper evaluation by ophthalmologist, ENT surgeon and Neuro Surgeon is mandatory before proceeding with panfacial fracture fixation, and these allied specialities may be part of the surgical team for comprehensive management of the panfacial injuries.

Large bony defects with loss of soft tissue are best treated immediately or secondarily with local, pedicled non-

vascularised or vascularised-free flaps provided the wound is clean and non-infected. Tissue shrinkage should be avoided as much as possible in these special situations by using techniques of maxillomandibular fixation (MMF) and internal or external fixation devices or splints. Immediate reconstruction can be planned in clean wounds. Need for transmylohyoid/submental endotracheal intubation as an alternative to tracheostomy should be explored in discussion with the anaesthesia team [6], especially in panfacial trauma involving nasal bones and skull base fractures needing fixation of maxilla and mandible.

60.7 Intra-operative Details

The essential in treating panfacial fractures is obtaining adequate fixation at key buttresses (Fig. 60.9a, b, Fig 55.2). Its description was first given by Cryer in 1916 [7]. This helps in creating the outer framework for fixation of other fractures.

60.7.1 Buttresses of the Facial Skeleton

These are the regions of thick bones which neutralise the forces applied onto them.

Outcome of maxillofacial reconstruction in terms of restoration of facial height, width and projection in addition to restoring the occlusion depends on proper reduction and fixation of these buttresses [8, 9] (Table 60.2).

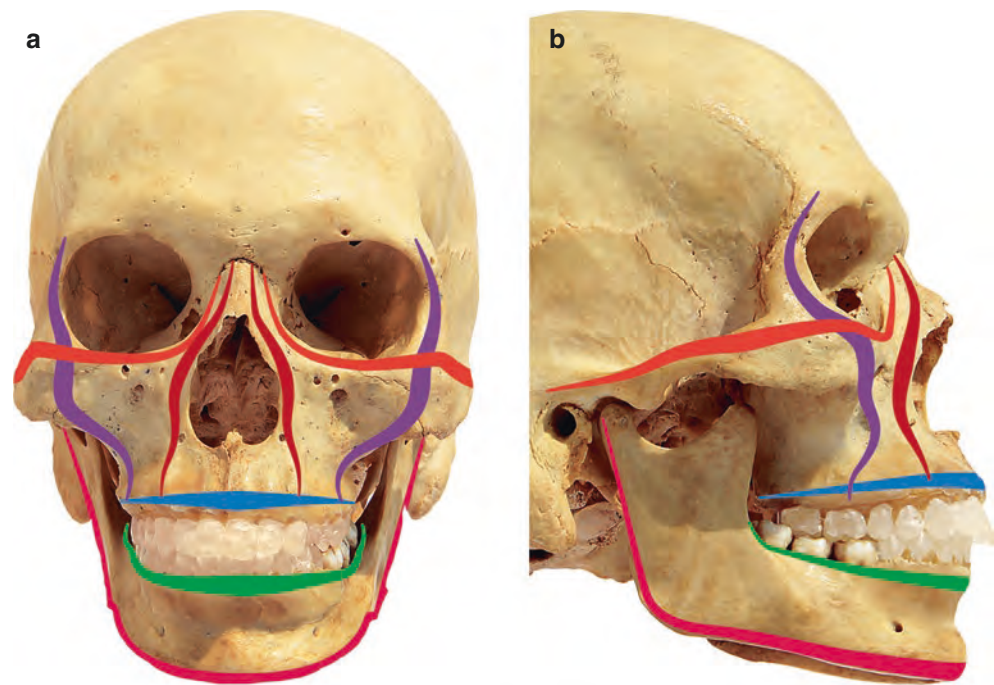
They are important to:

1. Maintain projection and protection of airway
2. Anchor suspension of musculo-aponeurotic system
3. Protection of skull base and structures above like brain and eye with their adjoining structures from masticatory forces

60.7.2 Key Contributors to Facial Architecture

- Central facial width: fronto-naso-orbital-ethmoid (FNOE) complex, palate and the mandibular arch
- Lateral facial width: Frontal bar, zygomatic arches, malar eminences and mandibular angles
- Projection: frontal bone, frontonasomaxillary buttresses, zygomatic arches and mandible from angle to symphysis
- Facial height: frontal bone, midface buttresses, mandibular angles and condyles

Fig. 60.9 (a, b) Schematic markings of facial buttresses (Correlate with Table 60.2) (Also see Fig. 55.2)



Buttresses of face

©Association of Oral and Maxillofacial Surgeons of India

Table 60.2 Buttress of facial skeleton (colour codes of Fig. 60.9 marked)

Vertical buttresses	Horizontal buttresses
Nasomaxillary (red)	Frontal (orange)
Zygomaticomaxillary (purple)	Zygomatic (orange)
Pterygomaxillary	Maxillary (blue)
Condyle and posterior mandible (pink)	Mandibular (green)

60.7.3 Various Approaches to Facial Skeleton

Approaches to individual facial bones are discussed in the respective sections of the book. They are enumerated here for quick reference and revision.

Facial lacerations overlying fractures should be used for access when possible (Fig. 60.10a–d). In situations without any such lacerations, appropriate incisions for respective fractures should be used as described in other sections of this book.

Subciliary or transconjunctival incisions are commonly used to provide access to infraorbital rim and orbital floor; lateral brow or upper blepharoplasty incisions provide access to fronto-zygomatic suture and lateral wall of orbit; intraoral vestibular incision provides access to maxilla and zygomatic buttress; and coronal incision provides access to frontal, fronto-naso-ethmoid complex, zygomatic arches and roof of orbit.

Mandible symphysis, parasymphysis, can be approached through intraoral vestibular or crevicular incisions. Mandibular angle is approached intraorally through an extended 3rd molar incision alone or in combination with

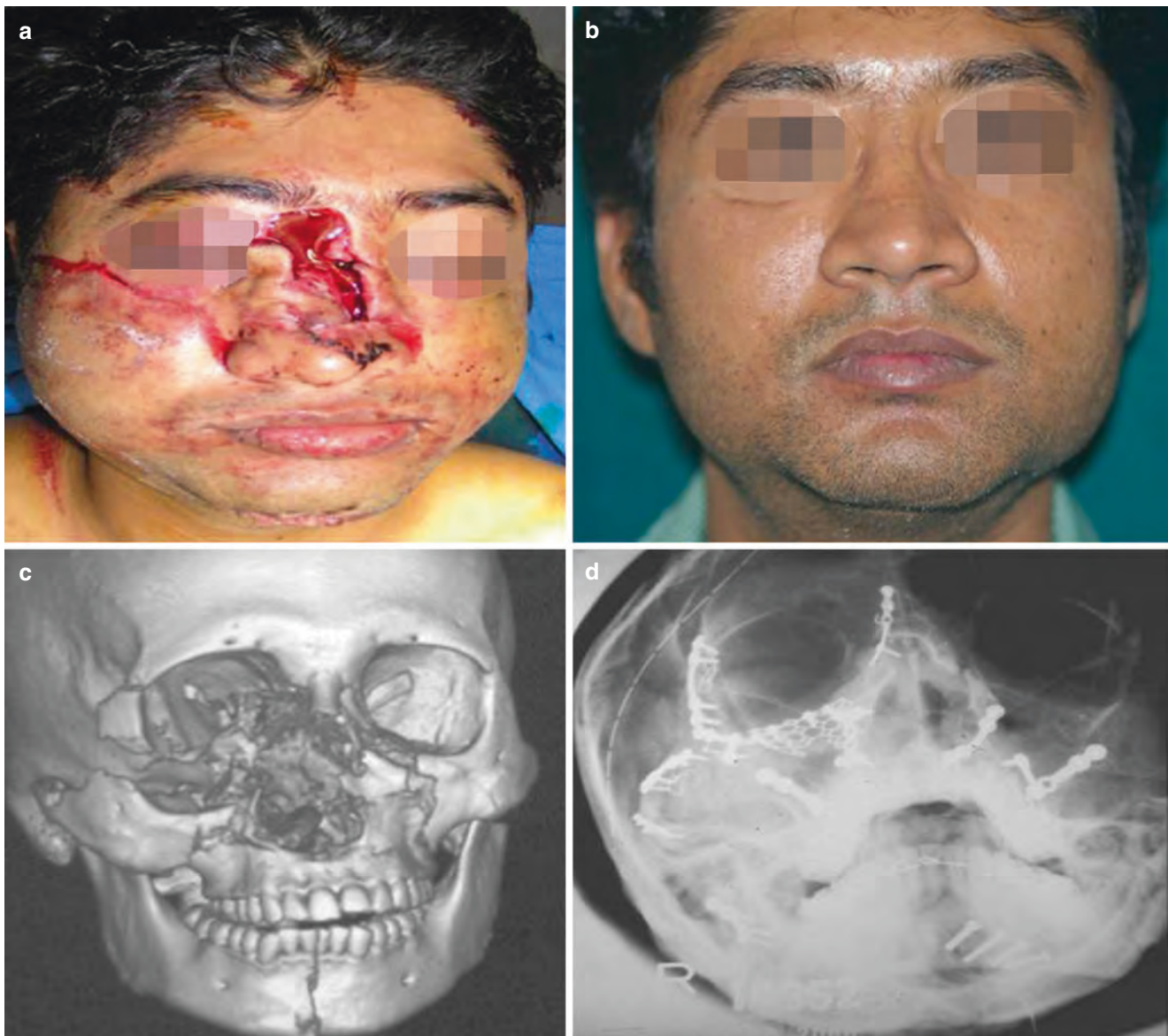
a transbuccal approach using a trochar and cannula. The condylar head will need to be approached through preauricular or bicoronal incision, whereas the mandibular subcondyle and ramus can be approached through retromandibular or peri-angular incision. Endoscopic approach to the mandibular condyle is been popularised in a few units (see Chap. 54 for details on endoscopic approach to condylar fractures).

Sequencing of fixation in panfacial fractures is a challenging task. The sequencing will alter slightly depending on clinical and radiological evaluation.

60.8 Sequencing Options

There are two options for sequencing:

1. *Bottom to top* [10, 11]: This involves restoring the maxillo-mandibular unit using occlusion as guide and fixing maxilla and mandible using semi-rigid or rigid fixation techniques. Thereon reduction and fixation proceeds in caudal direction starting from calvarium. The other fractures are then restored in a build-out fashion with maxilla and mandible being a stable base
2. *Top to bottom*: This involves starting with the reduction and fixation at the level of the calvarium. Then the operator proceeds in a caudal direction with reduction and fixation. In this top to bottom sequencing technique, establishing proper occlusion with MMF is no less



©Association of Oral and Maxillofacial Surgeons of India

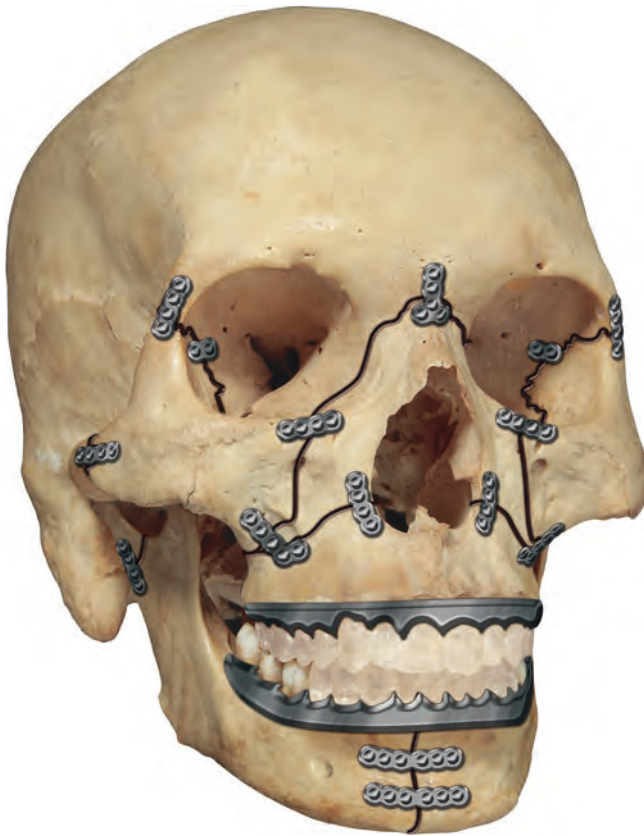Fig. 60.10 (a–d) Use of existing laceration to achieve optimal results

important, and is surely done prior to rigid fixation of Leforte I and mandibular fractures.

Although author's preference is "bottom to top" approach, as establishing functional occlusion is of prime importance, a combination of both the approaches might be necessary in many situations (Fig. 60.11).

60.8.1 Bottom to Top Approach

1. When using this approach one is committed to using the mandible as guide for establishing the height, width and projection of face. Hence after occlusion is established, the mandible is rigidly fixed from one condyle to the other. This makes it necessary to plate minimum one condyle in case bilateral condylar fracture. It is necessary to ensure proper seating of mandibular condyle into the glenoid fossa.
2. Further sequencing will depend on presence or absence of palatal fracture and its nature (comminuted or not). In any case it is very important to establish width of midface correctly so as to achieve optimal functional and aesthetic results.
3. Use of splints made on dental models after model surgery serves an ideal and desirable method to establish correct width of middle and lower face particularly when there is comminution of maxilla and mandible. Use of conventional acrylic splints is the easiest and least time consuming. 3D splint has led to more accurate and predictable results but adds on to the time and cost.



©Association of Oral and Maxillofacial Surgeons of India

Fig. 60.11 Use of combination techniques to achieve stable fixation schematic diagram

4. The next step is to begin the reduction and fixation of the remainder of the midface starting from the calvarium and working in a caudal direction similar to “top to down” sequencing.

60.8.2 Top to Bottom Approach

1. The reconstruction sequence to re-establish midfacial pillars (buttresses) and dimensions starts with the most reliable and stable point on calvarium and on the side with the least comminution.
2. The calvarial, frontal sinus and orbital roof fractures are addressed first using stable point/region on calvarium as reference point for reconstruction of midface.
3. The zygoma is positioned into its proper three-dimensional position, almost as a flat structure and confirming that lateral wall of orbit is in alignment with the greater wing of sphenoid. This helps proper establishment of width and anterior-posterior projection of face. Approximation of the sphenozygomatic suture in the lateral wall of the orbit should be a guide to reduction in cases of comminuted zygomatic fractures [12]

Fixing the zygomatic arch increases the accuracy of multidimensional reconstruction (frontozygomatic suture, infraorbital rim, zygomaticomaxillary buttress, zygomatic arch) of fractured and comminuted zygoma [13, 14].

4. The infraorbital rims and NOE complex are properly aligned to complete the reconstruction of the periorbital area.
5. Where reconstruction of the medial canthal tendon is necessary, it can be addressed towards the end of the procedure.
6. The next step in midface reconstruction is fixation across the Le-Fort I and II level. Maxillomandibular fixation may be done at this stage. If everything has been perfectly aligned, these fractures should also align adequately. Splints play a significant role in determining the facial width at Le-fort I level. Malalignment at this level signifies need for reassessment and realignment of previously fixed fractures.
7. From an aesthetic standpoint, a minimal malalignment at the Le-Fort I level is not as noticeable as a malalignment of the orbits.
8. Fractures of the inferior orbital rim and orbital floor can be now addressed as the true volume of the orbital defect can be seen once other fractures are aligned.
9. The mandibular fractures are then fixed. Condyle fractures may be addressed with separate incisions or managed conservatively depending on the displacement and influence on the vertical height of the mandible, as discussed previously.

Tulio et al advocated fixation of condylar fractures as the first step in fixation of pan facial fractures. In their study there was no evidence of dental or skeletal alterations and measurement of the mandibular ramus and radiographic examination show that posterior facial height as well as projection and width of the inferior lower third of the face, was restored. The correct timing of surgical intervention and the use of rigid fixation allows the restoration of the morphological and functional nature of the face after pan facial fractures [15].

10. The occlusion should be rechecked, and rigid or elastic maxillomandibular fixation may be considered as necessary for 4–6 weeks. The occlusal splints may be fixed using wires for the period of MMF as a guide to maintaining the occlusion.

The sequencing for pan-facial fractures depends more on the clinical situation, than on predefined algorithms as the patterns of clinical presentation may be diverse. However, the general consensus in current literature emphasizes that the dental units are given priority for providing guidance. The dental arches are first stabilised to form a

Table 60.3 Bottom-up inside-out and top-down outside-in, comparison of sequencing

Bottom-up	Top-down
Maxillomandibular fixation (MMF), splints for palate and mandibular lingual in case of gross comminution	Fix calvarium, frontal sinus and orbital roof fractures sequentially
Fix mandibular fractures (symphysis/body/ramus)	Fix zygomaticomaxillary complex (including arch) fractures, with proper alignment of infraorbital rims
Fix condylar fractures, at least one when fracture is bilateral	Fix naso-orbito-ethmoid complex, and nasal fractures
Fix maxilla at LeFort I level	Maxillomandibular fixation (MMF), splints for palate and mandibular lingual in case of gross comminution
Fix calvarium, frontal sinus and orbital roof fractures sequentially	Fix maxilla at Lefort I level
Fix zygomaticomaxillary complex (including arch) fractures, with proper alignment of infraorbital rims	Fix condylar fractures, at least one when fracture is bilateral
Fix naso-orbito-ethmoid complex, and nasal fractures	Repair of Mandibular fractures

cohesive unit, followed by the mandible in its horizontal and vertical dimensions (10, 19) (also see Manson 2012 in additional reading). The mid face is then managed using a top-down or a bottom-up method depending on the presence or absence of bony defects in the calvarium.

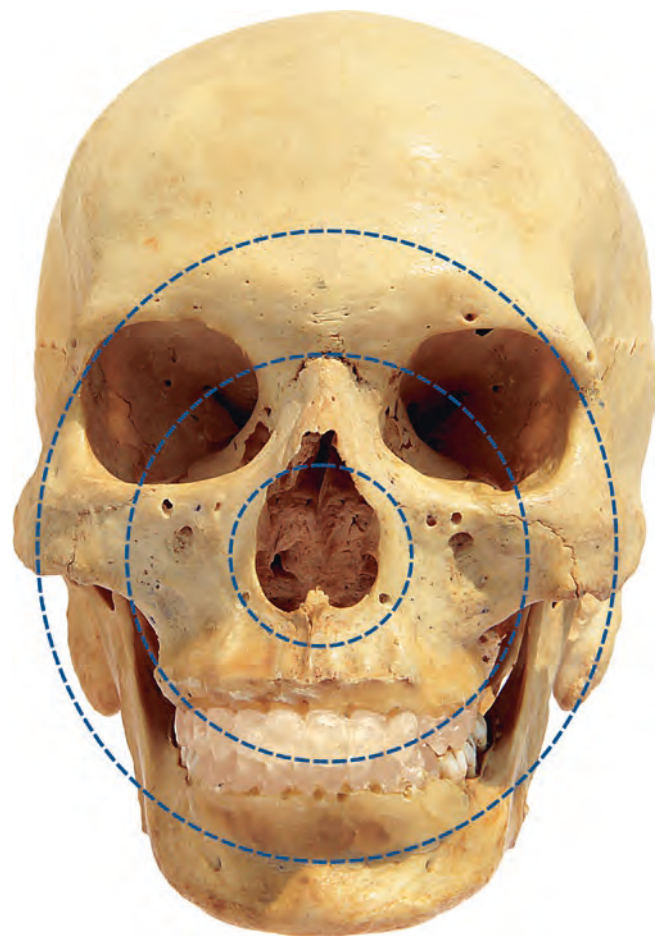
60.8.3 Essentials in Either Approach

1. Soft tissue repair and closure of wounds/incisions of intraoral and pharyngeal areas should be done prior to maxillomandibular fixation. In some cases it might be essential to temporarily release MMF to close lacerations and redo MMF later.
2. Laceration which would be concealed under the splint should be closed prior to fixation of splints.
3. Thoroughly debride perforating wounds before closure.
4. Extraoral incisions and lacerations communicating with the oral cavity should be closed from deep (mucosal) to superficial (skin) in multiple layers.

The sequence of the above approaches are compared in Table 60.3.

Author follows the “Wire before you plate” principle.

It is author’s preference to use initial wire osteosynthesis stainless steel (SS) for better alignment and anatomical reduction at multiple sites before plating. This technique also does away with the requirement of holding fragments together, and with less of instrumentation in the surgical



©Association of Oral and Maxillofacial Surgeons of India

Fig. 60.12 Three concentric circles used as a guide to the reduction of panfacial fractures (Adapted from: H.C Killey. Fractures of Middle-third of facial Skeleton, Issue 3 of Dental Practitioners Handbook, No.3)

field, there is an obvious ease of plating more precisely. Wire osteosynthesis should be removed following fixation of the fractures to avoid or prevent reaction between dissimilar metals, namely, SS (stainless steel) and Ti (titanium).

There are other sequencing methodologies and philosophies as suggested by other authors.

Manson et al. put forward a highly conceptualised treatment protocol where face is divided into groups, units and sections, and each section is assembled in three dimensions. Soft tissue is considered the “fourth dimension” of facial reconstruction. They advised bone reconstruction to be completed as early as possible to minimise soft tissue shrinkage, stiffness and scarring of soft tissues in non-anatomic position [1, 16].

Killey and Kay demonstrated the fixation of panfacial fractures first in the outer ring followed by the middle ring and lastly the nasal complex in the inner ring (Fig. 60.12).

Inside-out sequence was also found to show good results by Kim et al. [17].

The occlusion first approach, with initial reduction of larger segments, enables effective reconstruction of multiple segments. Smaller segments can then be oriented to fixation of these fractures [18].

Role of bone grafts in very comminuted fractures or missing bone demands immediate bone grafting to produce a stable outcome. Commonly used areas of bone and cartilage grafts are rib, calvarium, iliac crest and conchal cartilage [19]. Recipient site requirements determine the ideal donor site for replacing bone. Revascularisation potential and mechanical needs of the donor site are two factors known to influence this [20].

- Increase in facial width secondary to reduction of anterior-posterior facial projection
- Traumatic telecanthus
- Orbital deformities
- Lacrimal apparatus injuries/dacryocystitis
- Malocclusion
- Nasal obstruction and external nasal deformity
- Cerebrospinal fluid leak
- Anosmia
- Blindness
- Temporomandibular joints dysfunction
- Oro nasal fistula from wide palatal fractures (Fig. 55.25)

60.9 Paediatric Panfacial Fractures

They are rare and different as the cranium to face ratio is 8:1, and also differential growth in eyes, brain and face makes a difference in pattern and incidence of fractures. Children should not be treated as small adults as its not only important to restore them to normal form and function, but the growth potential also should be taken into consideration. One must remember that both injury and treatment can lead to growth disturbances, and hence many times conservative management is preferred. Splints are the mainstay in treatment of paediatric fractures (Figs. 52.50 and 52.51). Panfacial fractures are preferably treated with resorbable plates to prevent growth disturbances and damage to tooth buds. This also avoids second surgery for plate removal. Further, it must be kept in mind that minor occlusal discrepancies are self-corrective during transitional dentition phase or can be treated easily with orthodontics at later date. Major emphasis should be on preventing deformities in central midface. Paediatric patients have to be followed up till growth has completed. In developing countries wire/resorbable suture osteosynthesis can be utilised for economic reasons and availability [21].

60.10 Complications

Complications associated with panfacial injuries include those associated with individual fractures of frontal sinus, nasal and fronto-naso-ethmoid, zygomatic, maxillary and mandibular fractures.

- Motor and sensory deficits of motor and sensory nerves like anaesthesia, paresthesia and weakness
- Reduction in posterior facial height
- Anterior open bite

60.11 Tips and Tricks

1. Panfacial fractures do not follow specific patterns but occur in variety of combinations involving all facial subunits.
2. Discuss with patients' relatives about realistic outcomes of surgery. Use of patient photographs prior to injury may act as a guide for the surgeon to establish treatment goals. This may be challenging to assess with the oedema and disfigurement following trauma. Making a record of intra-operative and post-operative photographs is a good practice for comparison and documentation.
3. In patients with displaced midface fractures and bilaterally displaced mandibular condyles, it is important to fix at least one condyle anatomically by open method in order to obtain adequate mandibular positioning and posterior facial height.
4. In either approaches to panfacial fractures seating of condyle into glenoid fossa is absolutely mandatory.
5. If prolonged ventilation is anticipated tracheostomy, percutaneous endoscopic gastrostomy (PEG) should be considered.
6. Vertical and horizontal buttresses should be established and fixed (to attain correct facial width and height) before orbital walls and rim correction.
7. Special attention should be paid to soft tissue repair and need for suspension, more particularly to fractures involving FNOE region.
8. Bicornal exposure allows simultaneous harvesting of calvarial bone graft for bony augmentation and reconstruction like in blow-out orbital fractures.
9. Establish zygomatic arch as linear structure to get perfect facial projection and width.
10. Inadequate and delayed FNOE complex fractures treatment is usually a disaster and at most times is only partially correctable by secondary surgeries.

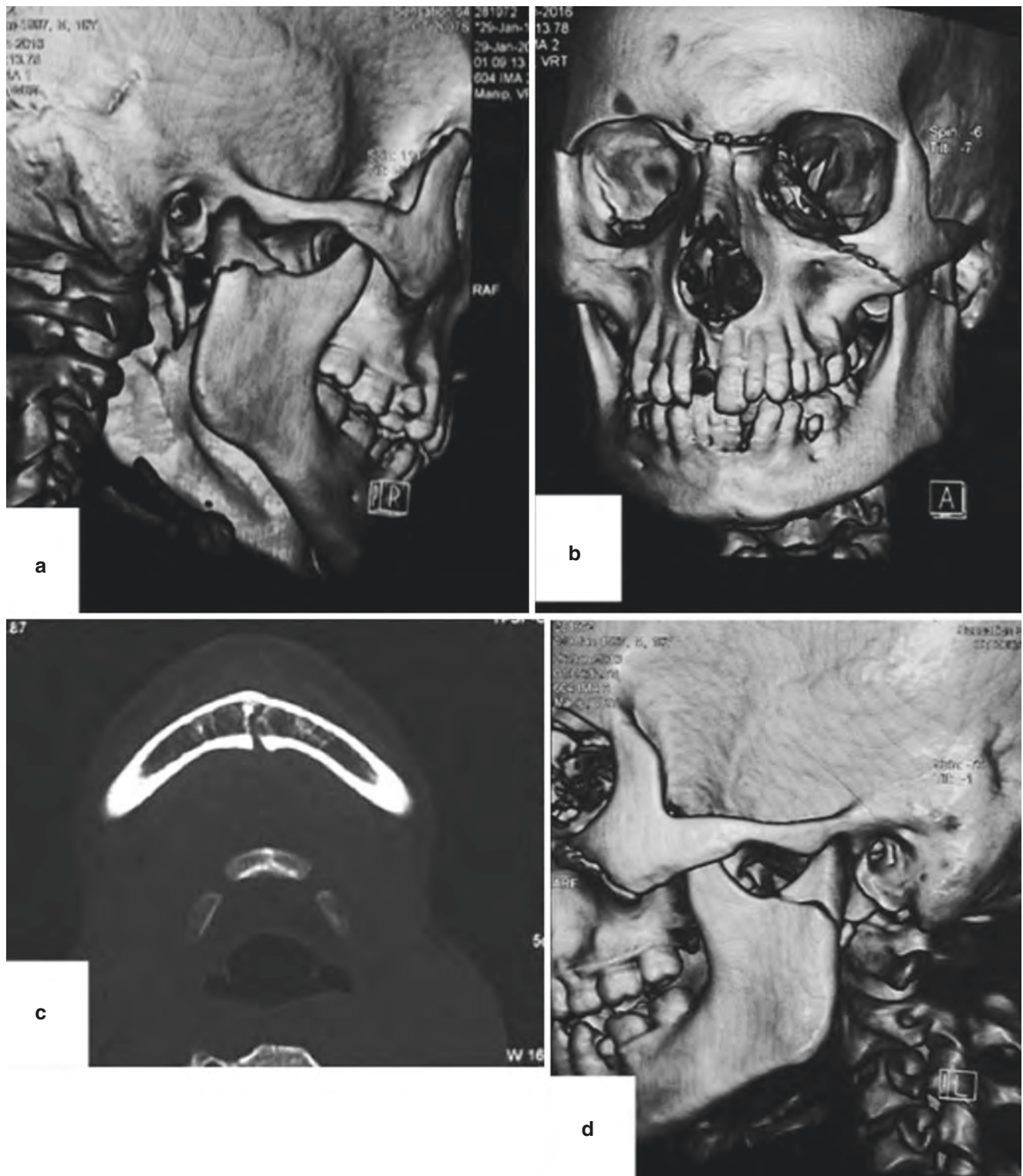11. Preoperative arch impressions and splints fabrication have a major role to play in preventing oro-nasal communication and establishing facial width.
12. MMF is mandatory for proper occlusion intra-operatively. Elastics may be needed during follow-up.
13. Most common residual deformity associated with panfacial fractures is lack of projection, increased facial width, malocclusion, enophthalmos and lacrimal dysfunction.
14. Complete removal of all mucosa and blockage/sealing of fronto-nasal duct should be done before cranialisation or obliteration of frontal sinus.
15. Documentation of details of injury is essential of medico-legal reasons, more so of the mechanism and time of injury; these details if necessary can be noted from other observers. Photographs can serve as legal documentation. These should be taken following a valid patient consent.
16. Close soft tissues from deep to superficial and from intraoral to extraoral. Complete intraoral closure prior to securing the MMF. Debride contaminated wounds thoroughly before closure.
17. Forced duction test is essential before and during surgery in fractures involving orbital walls (Fig. 56.21).
18. Caution: removal of throat pack is a joint responsibility of the anaesthetist and surgeon.

60.12 Case Scenario

Case 1:

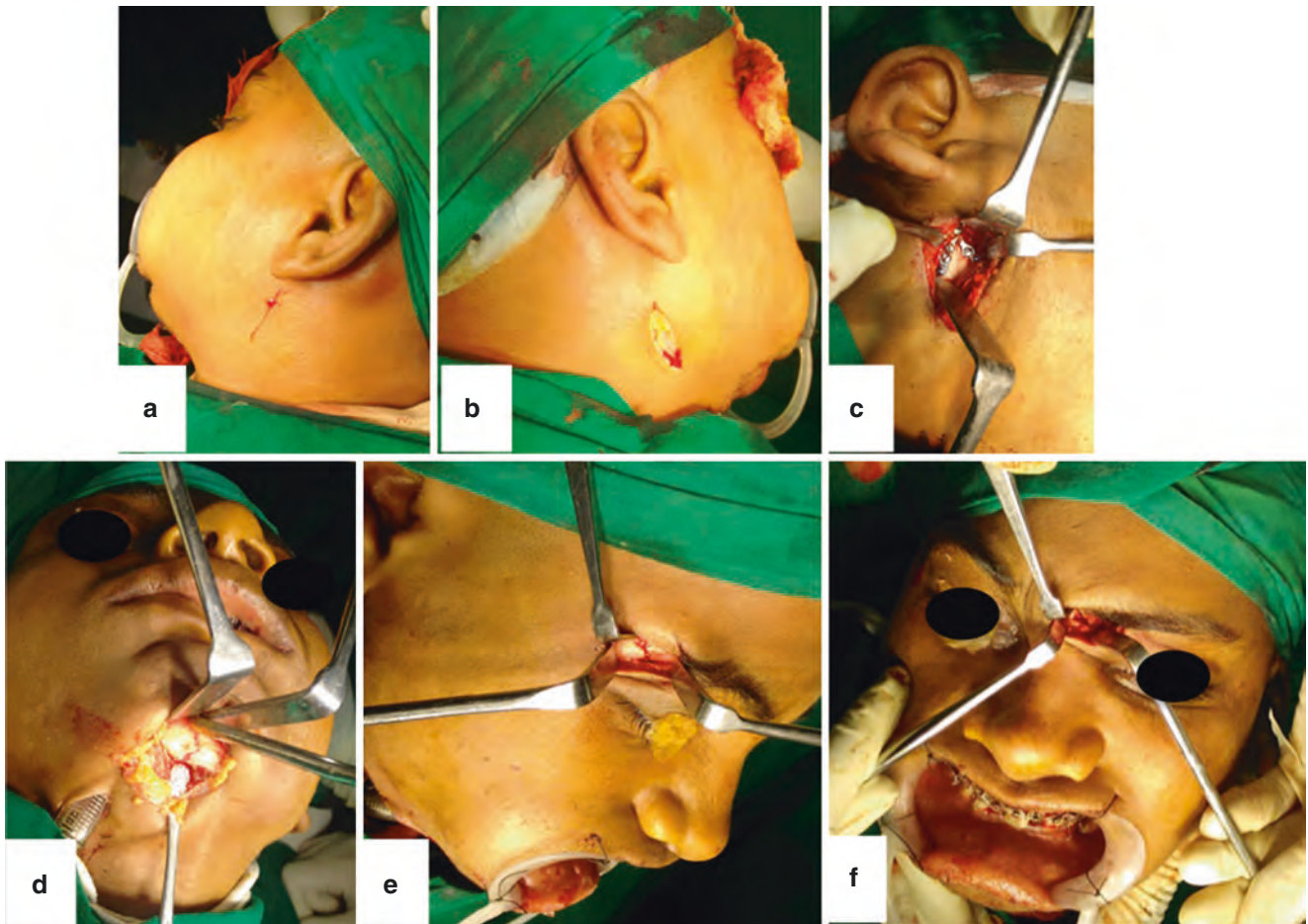
(Figs. 60.13a–d, 60.14a–f, and 60.15a–c) Shows Management of a Case of Pan Facial Fracture

Figure 60.13 shows the pre operative CT scans, Fig. 60.14 show the various surgical approaches used for internal fixation and Fig. 60.14 shows the post operative radiographs showing the fixation.



©Association of Oral and Maxillofacial Surgeons of India

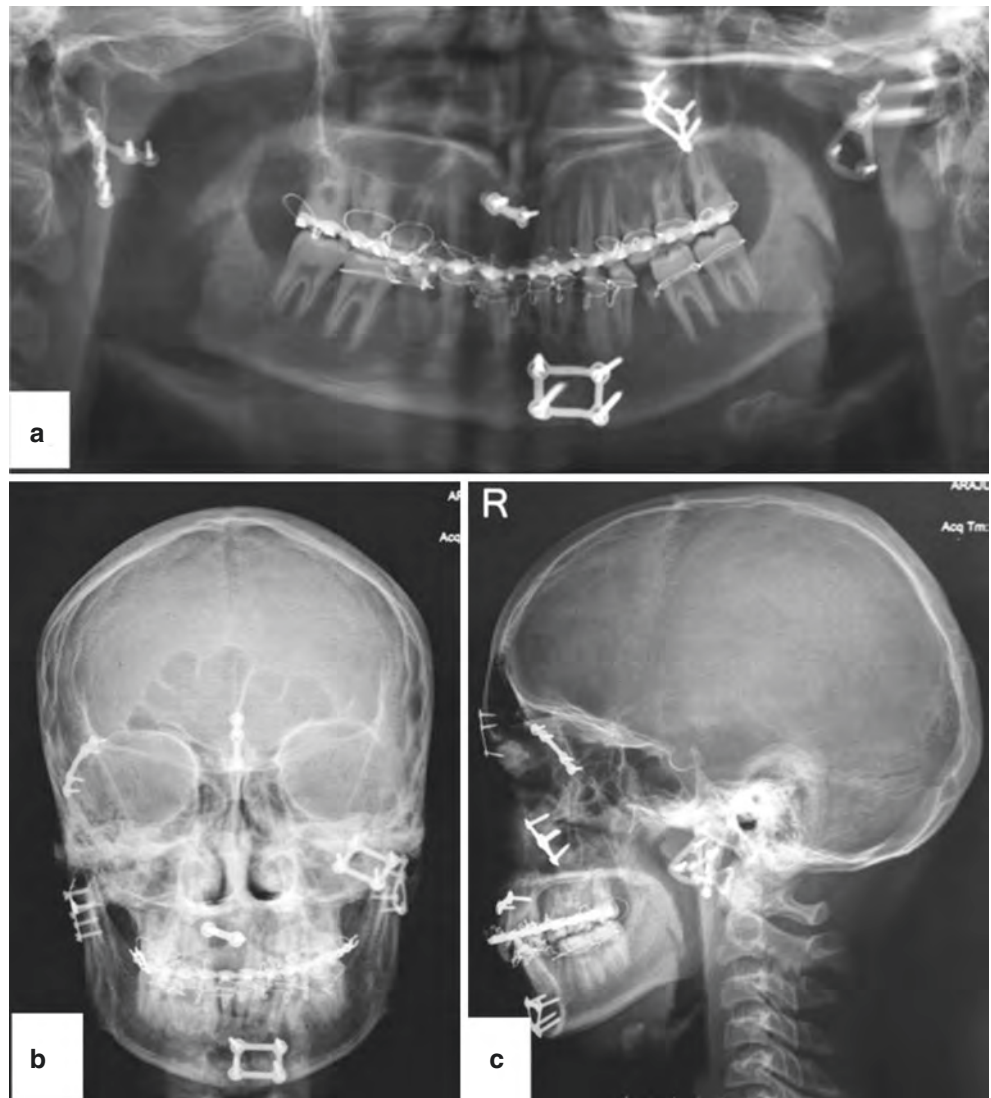
Fig. 60.13 (a–d) Panfacial trauma preoperative CT scan. (a) Right condylar fracture. (b) Naso-ethmoid complex fracture, left zygomatic buttress and infraorbital rim fracture. (c) Mandibular symphysis fracture. (d) Left condylar fracture



©Association of Oral and Maxillofacial Surgeons of India

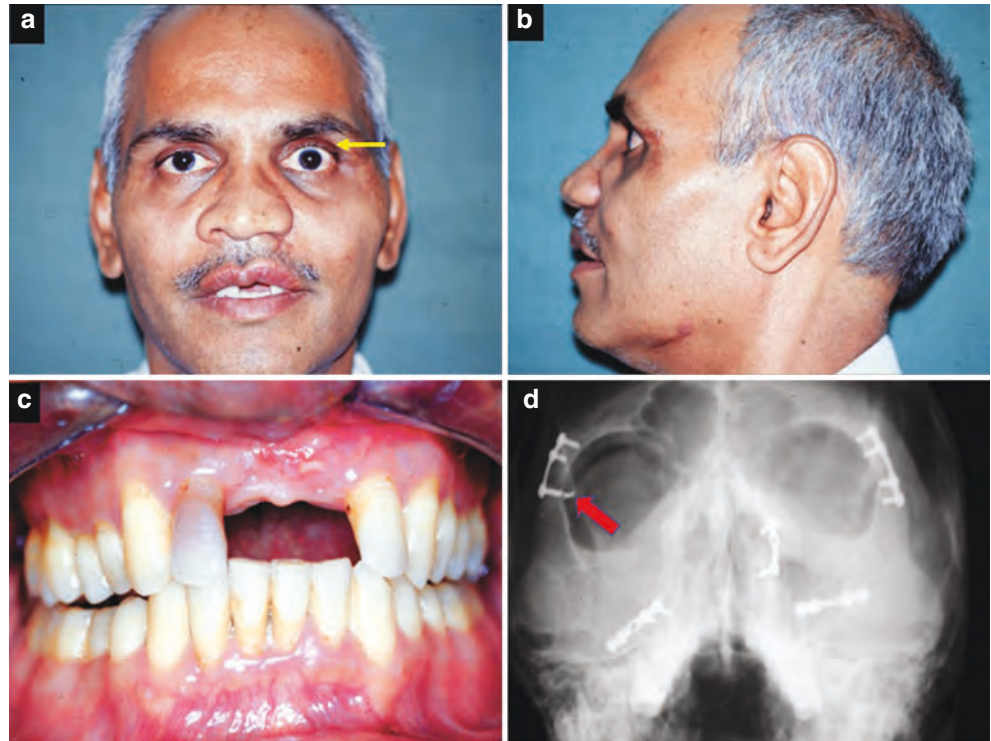
Fig. 60.14 (a–f) Panfacial trauma intra-operative images of case shown in Fig. 60.14. (a) Left retromandibular approach (b) Right retromandibular approach. (c) Right condyle plating. (d) Symphysis exposure. (e) Right frontozygomatic fracture. (f) Naso-ethmoid fracture exposure

Fig. 60.15 (a–c) Panfacial trauma post-operative radiographs of case shown in Fig. 60.14. (a) OPG. (b) PA cephalogram. (c) Lateral cephalogram



©Association of Oral and Maxillofacial Surgeons of India

Fig. 60.16 (a–d) Pre-operative photographs. (a) Frontal view showing asymmetrical face, alar bases, lip and deepened supra tarsal fold (yellow arrow). (b) Lateral view showing upturned lip, increased vertical dimension, scar on left body of mandible. (c) Malocclusion with anterior open bite. (d) Pre-operative P.A. Waters view showing inadequate fixation of midfacial fractures and foreign body within right orbit (Red arrow)



Case 2 (Figs. 60.16a–d, 60.17a–e, and 60.18a–d)

Back ground:

This case was treated in 1997 by the first author, when CT scan was a novelty rather than necessity. Plating system used was stainless steel.

A 43 years male with no comorbidities was referred by dental surgeon for correction of malocclusion and asymmetrical face. Patient had a history of RTA with panfacial fractures, and head injury, cerebral oedema 3 months prior. He was treated conservatively for head injury and had no residual neurological deficit. He was treated by other specialist for panfacial fractures by ORIF and then referred to dentist for prosthetic correction of occlusion. Patient insisted upon simultaneous correction of occlusion and asymmetric face.

Patient reported with complaints of:

Inability to masticate, changed pattern of upper and lower teeth meeting, crooked nose with asymmetric nasal bases, sunken left eyeball, diplopia on superior gaze, and changed facial appearance compared to preinjury status.

Clinical Findings (Fig. 60.16a–d)

1. Significant change in facial appearance as compared to pre-trauma, pre-treatment appearance
2. Elongated face
3. Upturned upper lip and acute nasolabial angle
4. Deviated and depressed nose, with dissimilar alar bases
5. Enophthalmos with increased supratarsal fold left eye. (yellow arrow)
6. Changed pupillary levels, and excessive scleral show of left eye
7. Increased width of face more so on left side
8. Malocclusion, with anterior open bite, increased vertical dimension of face due to posterior and inferior displacement of maxilla with gagging.
9. Scars in Bilateral frontozygomatic, left infraorbital, left mandibular body region.
10. Left mandibular body fracture fixed adequately but patient had left marginal mandibular nerve paresis/ injury.
11. Total mobility of middle third of facial skeleton suggestive of non-union/malunion.

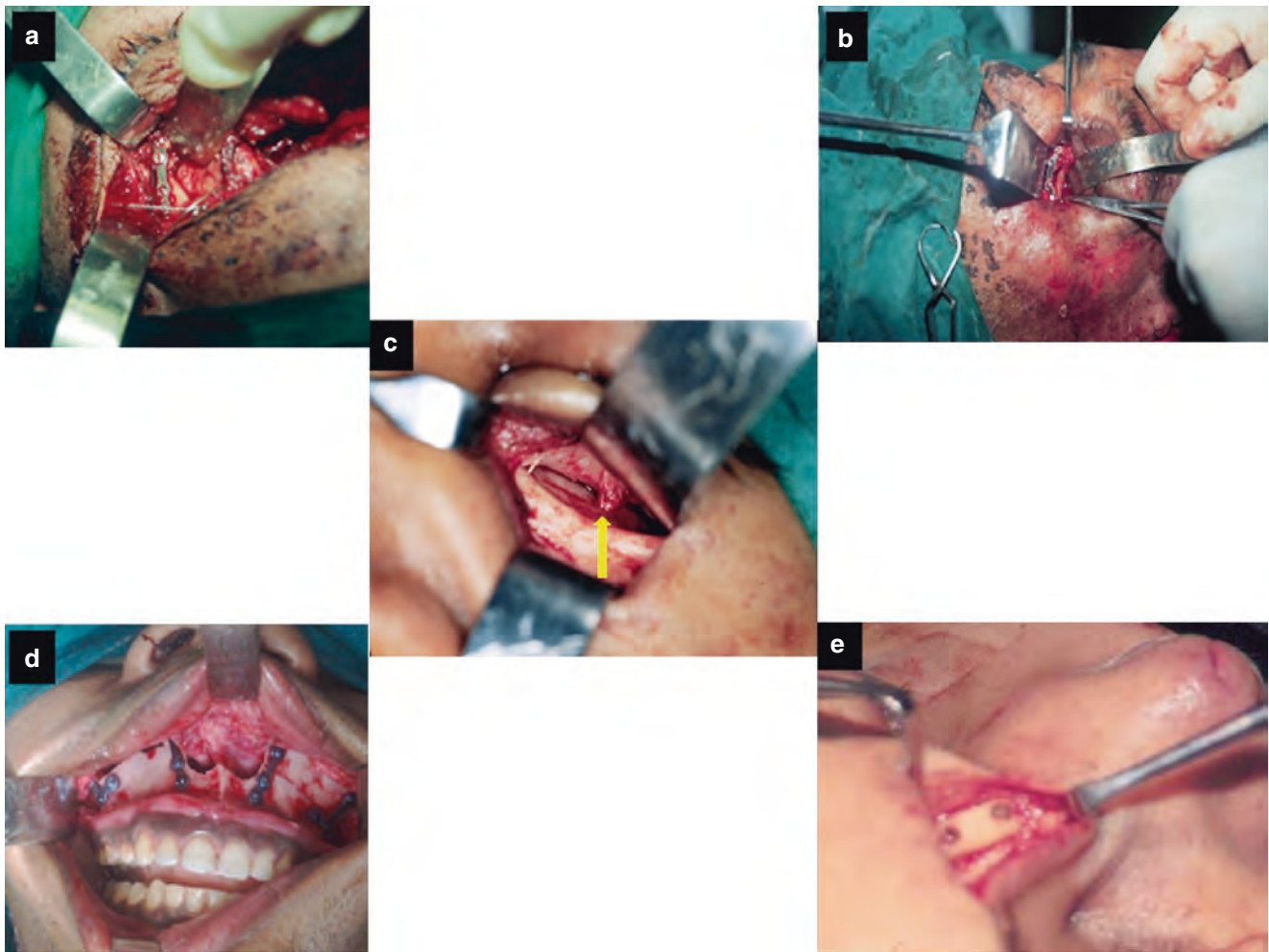


Fig. 60.17 (a–d) Intra-operative representative photos. (a) Fixation at FZ suture. (b) Fixation at inferior orbital rim. (c) Entrapment of inferior rectus, left orbital floor (yellow arrow). (d) Fixation of LeFort I fracture. (e) Fixation of bone graft to augment nasal bridge

Diagnosis:

1. Patient was counselled and asked to undergo X-rays to have 3 dimensional orientation. 1. PA Caldwell.
2. PA Water sinus (full face),
3. Base of skull for zygomatic arches and mandible.
4. Upper and lower occlusal topographic. CT scan of face with 3D reconstruction was not done for financial reasons. Remember CT scans were relatively expensive then.
5. Routine preoperative preparation.

Radiological Findings

Inadequate fixation seen at bilateral Fronto Zygomatic (FZ) suture, LeFort I,II,III level, and FNOE complex. A Foreign body (broken drill) was seen in Right orbit near FZ suture (red arrow). Mandible was fixed adequately both radiologically and clinically.

Plan of action/surgical approach (Fig. 60.17a–e)

1. Transmylohyoid intubation.
2. Mandible fracture being adequately fixed during previous surgery was not addressed
3. Mobilisation/osteotomy of midfacial skeleton to achieve adequate occlusion, projection of midface and reduce mid-facial width.
4. Approach midface fractures through existing scars at FZ suture, and left infraorbital region, subciliary approach to right infraorbital region.
5. Horizontal incision at nasal bridge for alignment of FNOE complex. (Fig 60.17e)
6. Intraoral sub labial approach for LeFort I fracture.
7. Iliac bone grafting at LeFort I level and nasal bridge to achieve prominence and augment the same.
8. Bone graft at left floor of orbit to correct enophthalmos and diplopia.
9. Alar cinch for flared left ala of nose.

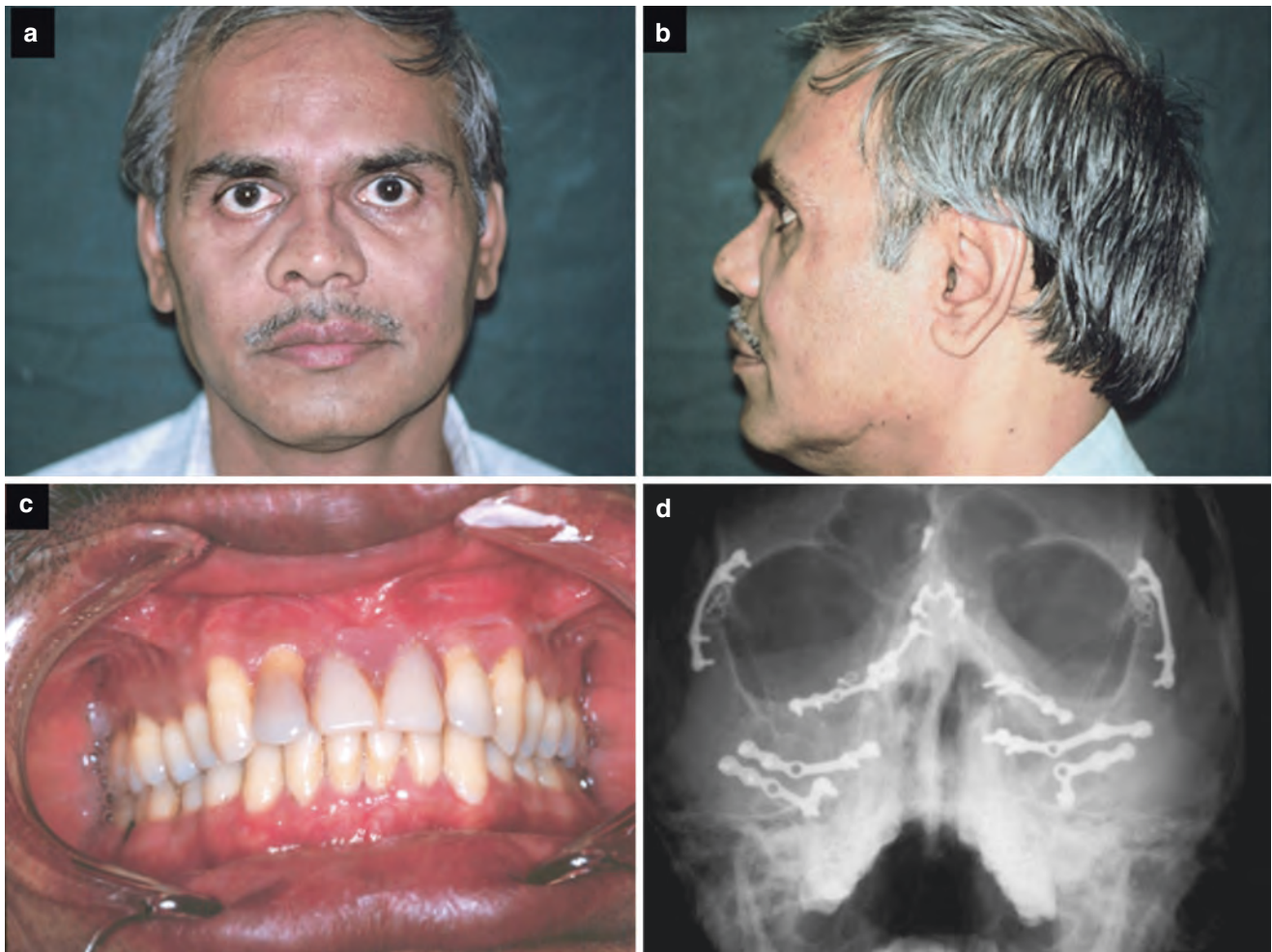

Fig. 60.18 (a–d) Ten years Post-operative photographs. (a) Frontal view showing restored symmetry. (b) Lateral view showing correct lip positioning, corrected vertical dimension, scar on left body of mandible.

(c) Corrected occlusion. (d) Post-operative P.A. Waters view (Full face) showing adequate fixation of midfacial fractures at all the struts

10. Avoid MMF. Post-op X-ray (Fig. 60.18d) shows plating with wires, they were not removed as hardware used then was stainless steel so there was no issue of Eddy's current due to dissimilar metals.

60.13 Conclusion

The increasing number of RTA and related CMF injuries suggests the need for immediate attention from the concerned authorities, to enforce strict laws like mandatory use of seat belts and total head and face guard (that suit climatic conditions) rather than the conventional helmets. Restricting the use of mobile phones and head phones while driving may

lead to decrease in the incidence of RTA. If RTA is considered an epidemic of modern times, then prevention is its vaccine. Increasing public awareness towards voluntary use of safety measures for their own safety rather than merely obeying the rules can reduce most of the cranio-maxillofacial injuries.

Panfacial trauma can appear complex and challenging to treat but is actually the conglomeration of treating individual fractures that are a common place in maxillofacial injuries (it would be wise to “simplify” the fracture in the minds’ eye view and formulating a treatment plan). Adhering to a treatment protocol and treating each fracture as a unit, with adequate fixation, enable the surgeon to obtain good results. Development of a sequential and methodical treatment plan prior to surgery and adherence to the basic principles of maxillofacial trauma is vital in treatment of these patients.

References

- Kelly KJ, Manson PN, Vander Kolk CA, Markowitz BL, Dunham CM, Rumley TO, Crawley WA. Sequencing LeFort fracture treatment (Organization of treatment for a panfacial fracture). *J Craniofac Surg.* 1990;1(4):168–78.
- Gadre KS, et al. Incidence and pattern of cranio-maxillofacial injuries: a 22 year retrospective analysis of cases operated at major trauma hospitals/centres in Pune, India. *J Maxillofac Oral Surg.* 2013;12(4):372–8.
- Hazen A, Ehiri JE. Road traffic injuries: hidden epidemic in less developed countries. *J Natl Med Assoc.* 2006;98:73–82.
- Gruss JS, Phillips JH. Complex facial trauma: the evolving role of rigid fixation and immediate bone graft reconstruction. *Clin Plast Surg.* 1989;16:93–104.
- Manson PN, Crawley WA, Yaremchuk M, et al. Midface fractures: advantages of immediate extended open reduction and bone grafting. *Plast Reconstr Surg.* 1985;76:1–12.
- Gadre KS, Wakis PP. Transmylohyoid/submental intubation: review, analysis, and refinements. *J Craniofac Surg.* 2010;21:516–9.
- Cryer MH. The maxillae. In: *The internal anatomy of the face.* Philadelphia, PA: Lea & Febiger; 1916. p. 76–7.
- Manson PN, Hoopes JE, Su CT. Structural pillars of the facial skeleton: an approach to the management of Le Fort fractures. *Plast Reconstr Surg.* 1980;66:54–62.
- Manson PN, Clark N, Robertson B, Slezak S, Wheatly M, Vander Kolk C, Iliff N. Subunit principles in midface fractures: the importance of sagittal buttresses, soft-tissue reductions, and sequencing treatment of segmental fractures. *Plast Reconstr Surg.* 1999;103(4):1287–306.
- Curtis W, Horswell BB. Panfacial fractures: an approach to management. *Oral Maxillofac Surg Clin North Am.* 2013;25(4):649–60.
- Yang R, Zhang C, Liu Y, Li Z, Li Z. Why should we start from mandibular fractures in the treatment of panfacial fractures? *J Oral Maxillofac Surg.* 2012;70(6):1386–92.
- Rohner D, Tay A, Meny CS, et al. The sphenozygomatic suture as a key site for osteosynthesis of the orbitozygomatic complex in panfacial fractures: a biomechanical study in human cadavers based on clinical practice. *Plast Reconstr Surg.* 2002;110:14630–71.
- Stanley RB Jr. The zygomatic arch as a guide to reconstruction of comminuted malar fractures. *Arch Otolaryngol Head Neck Surg.* 1989;115(10):1459–62.
- Gruss JS, Van Wyck L, Phillips JH, Antonyshyn O. The importance of the zygomatic arch in complex midfacial fracture repair and correction of posttraumatic orbitozygomatic deformities. *Plast Reconstr Surg.* 1990;85(6):878–90.
- Tullio A, Sesenna E. Role of surgical reduction of condylar fractures in the management of panfacial fractures. *Br J Oral Maxillofac Surg.* 2000;38(5):472–6.
- Markowitz BL, Manson PN. Panfacial fractures: organization of treatment. *Clin Plast Surg.* 1989;16:105–14.
- Kim J, Choi JH, Chung YK, Kim SW. Panfacial bone fracture and medial to lateral approach. *Arch Craniofac Surg.* 2016;17(4):181–5.
- Choi JW, Kim MJ. Treatment of panfacial fractures and three-dimensional outcome analysis: the occlusion first approach. *J Craniofac Surg.* 2019;30(4):1255–8.
- Gruss JS, Mackinnon SE, Kassel EE, et al. The role of primary bone grafting in complex craniomaxillofacial trauma. *Plast Reconstr Surg.* 1985;75:17–24.
- Phillips JH, Forrest CR, Gruss JS. Current concepts in the use of bone grafts in facial fractures. Basic science considerations. *Clin Plast Surg.* 1992;19:41–58.
- Iatrou I, et al. Surgical protocols and outcome for the treatment of maxillofacial fractures in children: 9 years' experience. *J Craniomaxillofac Surg.* 2010;38:511–6.

Additional Reading

- Gruss JS, Bubak PJ, Egbert MA. Craniofacial fractures. An algorithm to optimize results. *Clin Plast Surg.* 1992 Jan;19(1):195–206.
- Manson PN. Panfacial Fractures. In: Ehrenfeld M, Manson PN, Prein J, editors. *Principles of Internal Fixation of the Craniomaxillofacial Skeleton, Trauma and Orthognathic Surgery.* Thieme; 2012. p 292–305.

Open Access This chapter is licensed under the terms of the Creative Commons Attribution 4.0 International License (<http://creativecommons.org/licenses/by/4.0/>), which permits use, sharing, adaptation, distribution and reproduction in any medium or format, as long as you give appropriate credit to the original author(s) and the source, provide a link to the Creative Commons license and indicate if changes were made.

The images or other third party material in this chapter are included in the chapter's Creative Commons license, unless indicated otherwise in a credit line to the material. If material is not included in the chapter's Creative Commons license and your intended use is not permitted by statutory regulation or exceeds the permitted use, you will need to obtain permission directly from the copyright holder.





Residual Deformities of the Maxillofacial Region

61

Samson Jimson

61.1 Introduction

A maxillofacial surgeon plays a vital role in not only restoring the structural form of the maxillofacial unit but also aims to restore the pre-traumatic functional status of the patient. Diagnosis, clinical evaluation with enhanced treatment planning and restoration of aesthetics and function is the key for any maxillofacial surgery. However, it is not always possible to achieve the most appropriate results in all cases. It is not uncommon to see failure or mediocre outcomes following maxillofacial trauma surgery. The outcome of the primary treatment may depend on factors such as the extent of the injury/defect, delay in diagnosis/management, improper treatment plan, lack of utilizing modern diagnostic/treatment planning utilities, poor execution of treatment plan and inexperience of the surgeon. These may lead to not expecting the eventual deformities and not coordinating with other specialists to yield the most standard and deserving treatment for the patient with restoration of both form and function [1–3].

Residual deformities are seen following primary treatment of trauma due to one more reason mentioned earlier. Correction of such residual deformities may be challenging to the surgeon but very often a life-changing experience for patients. It is the experience of the surgeon that helps to recognise the challenges ahead in restoring the form and function. Residual deformities are often evaluated by the extent of deformities following primary management. Apart from reasons that may pertain to the experience of the operating surgeon, pathobiology of the healing zone may also contribute to the residual deformities. A variety of such reasons contributes to both soft tissue and hard tissue defects in the maxillofacial unit. This chapter aims to discuss in detail the clinical evaluation, diagnosis, protocols,

management and post-operative care of hard tissue deformities in oral and maxillofacial surgery with emphasis on current trends and future propositions.

61.1.1 Preventive Wound Management [4]

Wound management begins right after the soft tissue injury in the primary or acute stage.

Post-traumatic scarring can be reduced considering the following measures:

- Removal of foreign bodies/debris
- Reduce bacterial carriage by copious irrigation
- Judicious debridement to reduce the persistent scarring
- Management of the adjacent tissue with appropriate closure
- Tension free closure, minimising scar formation
- Wound care management by the use of agents that promote healing
- Prophylactic antibiotics in necessary conditions

Soft tissue injuries/scar revision/soft tissue and hard tissue reconstruction related to management of residual deformities have been dealt in detail in respective chapters of this book (refer Chaps. 36, 49, 86 and 88). Wound care and management begin with preventive measures.

61.1.2 Volume Issues in Deformities [3]

This section briefly discusses management of volume defects using tissue expanders. Volume issues are to be considered with all excision techniques. Loss of tissue volume due to trauma or contraction of the scar may lead to depression and

S. Jimson (✉)
Department of Oral and Maxillofacial Surgery, Tagore Dental
College and hospital, Chennai, India
e-mail: jimsons@tagoredch.in

distortions that are more obvious than the original scar. Such loss of tissue may require volume replacement that can be achieved by other techniques. Surgical flaps may be commonly used to fill the tissues. Likewise, biological fillers can also be taken into consideration in managing depressed or irregular areas. Tissue debulking can be done whenever there is an excess of tissue volume.

Two methods of tissue transfer can be opted whenever there is loss of tissue: a free skin graft and a skin flap. A free skin graft of limited thickness involves the complete removal from the donor site and then placement on the recipient site for survival. This type of graft will not survive in avascular recipient sites. A skin flap with underlying subcutaneous tissue will carry its blood supply necessary for the survival of the flap. These skin flaps are further divided into local flaps or distant flaps (from distant sites). Single-stage transfer of flaps may be done with microvascular surgical techniques (Chart 61.1 shows types of soft tissue deformities with relation to the volume defects).

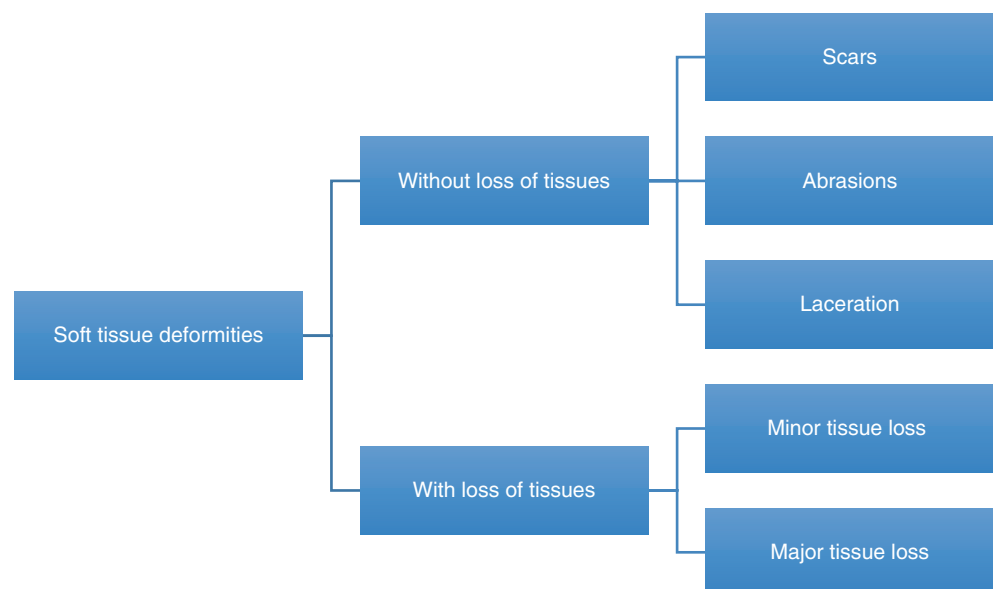
61.1.2.1 Minor Loss of Tissue [3]

- Local flaps should always be considered in case of minor loss of tissue. Facial tissue is naturally the first choice due to the colour and texture for replacement of tissue defects that are not too extensive. In such cases of local flaps, skin bordering the deformity should be raised and rotated into the defect, approximating the scar in a favourable position.
- Small scar defects may not yield a good result with split skin grafts, but full-thickness grafts can potentially give good aesthetic results in the repair of small defects.
- Lower eyelid scarring due to ectropion may be corrected using full-thickness graft (Wolfe's graft) that results in predictable function and aesthetics.

61.1.2.2 Major Loss of Tissue [3]

- Traumatic or gunshot injuries may result in a substantial loss of tissues. Majorly these injuries are associated with loss of soft tissue and skeletal structure.
- The replacement of tissue should involve necessary covering, lining and support to the bone or cartilage.
- Flaps used in all anatomical structures like the antrum, orbit, mouth and nose should have necessary lining epithelium; otherwise it will result in contraction of the tissues and exposure of underlying tissues.
- Complications like nasal airway stenosis, oral stenosis, microsomia and obliterated buccal/labial sulcus may occur.
- A split skin graft may be used in case of nasal or buccal defect.
- Double flap with both inner and outer aspects composed of full-thickness skin or subcutaneous tissue may help to increase the flexibility in case of a cheek flap. In such cases, the extent of fibrosis is decreased and thereby helps in increasing flexibility due to the underlying vascularity.
- *Nasal* lining may be provided by approximating the adjacent in-turned flaps of skin around the surrounding defects. A split skin graft should be preferred whenever such approximation is not possible. Hard tissue nasal deformities are discussed elsewhere.
- *Lip defects* may result in loss of larger tissue. Contraction due to lip re-suture may result in the loss of one-third of the available tissue. Local tissue flaps as full-thickness flaps should be considered ahead of tube pedicle flaps. Whenever permissible, it is better to take a full-thickness flap of the cheek or buccal mucosa, rotate it and form a lip and fill the subsequent secondary defect with tube pedicle.

Chart 61.1 Types of soft tissue residual deformities

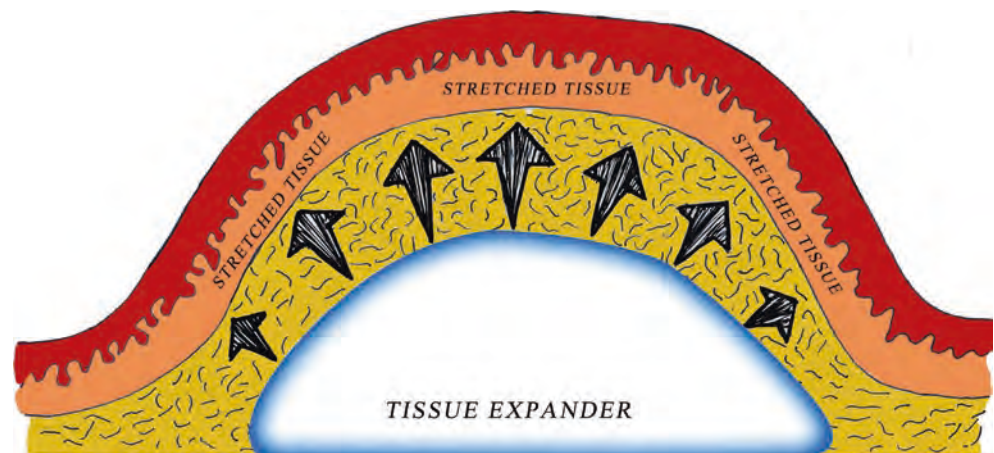


- *Scar adhesions* of the sulcus or obliteration of sulci due to deficient tissues may predispose the difficulty in the construction of a functional and stable prosthesis. The fibrous scar tissue may be excised, or the sulci may be created with dissection followed by insertion of a free split skin graft.
- *Palate*: Substantial loss of tissue may involve the hard palate, soft palate or both areas. Generally, loss of tissue in the hard palate may be closed with an obturator. Scar tissue associated with the hard tissue defect may be managed by dividing the fibrous scar bands and restoring the residual tissues. Rotational flaps may also be used to close the defects. Tissues from additional sources may be used in the closure by using full-thickness flaps. Two-staged full-thickness flaps from the lateral third of the tongue are used, the base of which is divided after 3 weeks. In case of larger defects, myofascial temporalis flaps may be used with downward rotation, and following osteotomy of the zygomatic arch, it may be passed through a mucosal tunnel to reach the oral cavity. Both the flaps provide better results, but the advantage of the latter is being a single-staged technique [3].

61.1.3 Tissue Expanders [4–6]

Tissue expanders are the advised treatment technique when the loss of tissue or the scar surface areas are larger. It is indicated in revision or excision of scar where local or regional flaps may not be feasible to be used in the immediate reconstruction. Although commonly employed for tissue expansion in forehead and scalp, it may be beneficial for any areas with larger defects. Tissue expansion becomes an ideal choice in the scalp due to its inelasticity. It allows replacement of defects with adjacent surrounding tissue which is similar in colour, texture, adnexal structures and innervation (Fig. 61.1)

Fig. 61.1 Schematic representation of a tissue expander



©Association of Oral and Maxillofacial Surgeons of India

61.1.3.1 Properties of Tissue Expanders

[4, 5, 7–9]

Silastic balloons with self-sealing valves which are used as tissue expanders are implanted beneath the skin.

- These tissue expanders are available in different shapes and sizes and can also be custom-made to fit an irregularly bordered defect.
- It is important to choose an expander of sufficient size to provide the necessary expansive force required for the need in tissue gain for reconstruction.
- The expander has to be 2.5 times that of the scar to be corrected while using a rectangular or crescent-shaped expander. On the other hand, the diameter of the base of the circular expander should be 2.5 times that of the scar to be replaced.
- The expanders must be implanted in a position where ideally a simple advancement, rotation or transposition flaps may be developed later.
- The goal is to have the adjacent healthy tissue expanded and not the scar itself. Hence, the proper placement of the tissue expander is vital.
- Scarred, atrophic areas or sites that have undergone prior radiation therapy are contraindicated.
- Sufficient expander volume must be available.

61.1.3.2 Biomechanical Properties

During the period of tissue expansion, a capsule is formed, and the epidermis is thickened and expanded. Increased mitotic activity is seen evidently using the microscope during the expansion. The dermal thickness, which decreases during the expansion phase, returns to normalcy in 2–3 years. Expanders may also result in decreased adjacent muscle thickness, but without any loss of function. The adipose cells may decrease in number, and subcutaneous thinning may also be seen. Viability of expander is maintained with increased angiogenesis. Bone remodelling may also take place beneath

the expander. The morphology and number of hair follicles are usually not affected, and hence this is a key in scalp expansion. Treatment duration can be reduced in areas where more than one expander can be placed. The gradual stretching of the tissue over the expanding subcutaneous tissue is called biological creep. Placement of the balloons and allowing a series of inflations and deflations to result in the stretching of the skin are the principles behind tissue expanders. This inherent nature of the skin to expand beyond its natural extensibility is referred to as mechanical creep [4, 10].

61.1.3.3 Technique

Expanders are implanted by making incisions at the junction of the scar and the healthy tissue. A pocket is made in an avascular fascial plane. Wound closure is done with layers over the expander. 10% volume of expander may be added at the time of surgery to minimise chances of hematoma formation around the expander. Necrosis of the overlying tissues may occur if any wrinkles are present over the surface of the expanders. If the site allows area for placement for more than one expander, it may reduce the overall treatment duration. Two weeks after placement, the expanders are inflated once or twice in a week. Patient discomfort or blanching over the surface of expander should be observed. Overexpansion of tissue is necessary as there will be a degree of contraction after removal of the expander. Likewise, bony contour changes usually regress without any intervention. The capsule of the expander is released along its margins but is left intact (Fig. 61.2). Generally, a waiting period of 2 weeks should be observed before proceeding to the next stage of the surgery/procedure. This allows the skin tension to reduce before the next stage of the surgery [4, 5].

Advantages

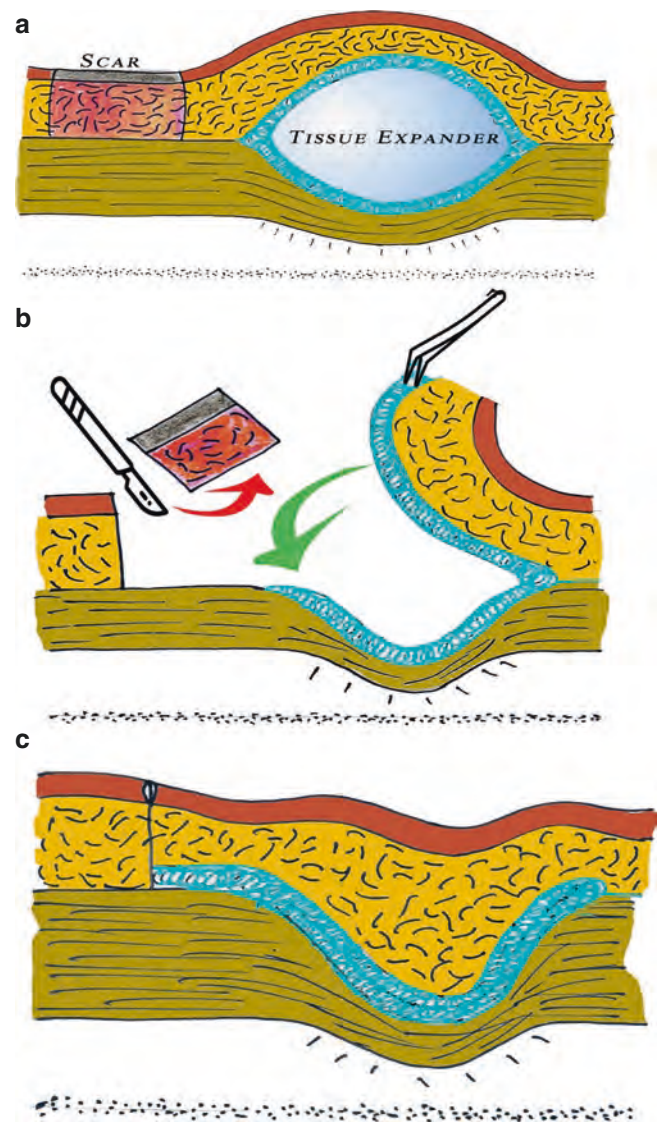
Local usage of tissue by expansion helps in the preservation of the sensation, vascularity and the adnexal structures. This aids well in both aesthetic and functional aspects.

Disadvantages

- Two operative procedures are usually required.
- Frequent inflation of the expanders.
- A temporarily visible deformity when the expander reaches its full inflation may not be socially acceptable by the patient.

Complications

- Pain
- Infection
- Implant failure
- Implant exposure
- Necrosis and tissue breakdown leading to exposure of the expander
- Bony erosion below the implant
- Decreased patient compliance and psychological stress for the patient as the expander increases in size creating a transient compromise in aesthetics



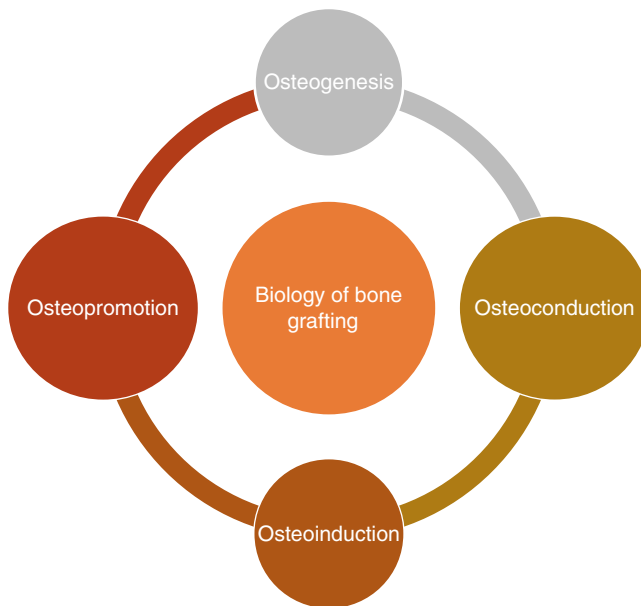
©Association of Oral and Maxillofacial Surgeons of India

Fig. 61.2 Conventional method of tissue expander in management of scar tissue. (a) Expander placed near scar tissue and tissue expansion seen. (b) Adjacent scar tissue removed before closure. (c) Over-expanded tissue closed with adjacent scar tissue removed and the capsule is left intact with release along its margin

This chapter further discusses the use of grafts in residual deformities, management of hard tissue residual deformities and recent advances.

61.2 Grafts in Residual Deformity

Soft tissue and hard tissue defects are best managed by the use of grafts. Secondary or residual use of grafts and flaps is essential in restoring the hard tissue and soft tissue defects. The scope of this chapter briefly describes grafts used in residual deformities. This section also outlines the



©Association of Oral and Maxillofacial Surgeons of India

Chart 61.2 Essentials in biology of bone grafting

biology behind bone grafting and types of bone grafts (Chart 61.2).

61.2.1 Ideal Characteristics of Bone Graft Material [11]

- Biocompatible
- Promotes cell differentiation and proliferation
- Less risk of infection
- Non-toxic
- Non-immunogenic
- Maintains volume over time
- Balance in resorption rate and bone formation
- Ability to replace site with new bone growth

61.2.2 Biology of Bone Grafting

Biology of bone grafting includes the following rationale [12–17] (Table 61.1):

1. Osteoconduction
2. Osteoinduction
3. Osteopromotion
4. Osteogenesis

Table 61.1 Biology of bone grafting

Osteoconduction	Mechanism in which the graft substance serves as a scaffold for new bone growth aided by native bone. Osteoblasts from the source utilize the bone graft as a structural scaffold on which new bone generation takes place. A bone graft should be ideally osteoconductive. Ex: Calcium sulphate, calcium phosphate cements, ceramics, collagen, synthetic polymers
Osteoinduction	Mechanism involves stimulation of osteoprogenitor cells → differentiation into osteoblasts → formation of new bone. Ex: Bone morphogenic proteins. It is ideal to have grafts that are osteoconductive and osteoinductive in nature Ex: DBM (Deminerilised Bone Graft), BMPs, growth factors, genetic therapy
Osteopromotion	Enhancing osteoconduction without osteoinductive properties. It promotes action and can't grow bone independently. Ex: Enamel matrix derivative enhances the osteoinductive property of demineralised freeze-dried bone allograft
Osteogenesis	Formation of new bone with the help of osteoblasts originating from the bone graft material. Ex: Bone marrow aspirate (BMA)

61.2.2.1 Types and Tissue Sources for Grafting (Table 61.2 and Chart 61.3)

Boyne's Ideal Characteristics of Bone Grafts [18]

- It should be easily and readily available and should not require additional surgical intervention in a second donor site.
- It should not stimulate any immunological response.
- It should stimulate rapid osteogenesis.
- It should enhance re-vascularisation and neo-angiogenesis.
- It should be highly osteoinductive.
- It should be osteoconductive in nature.
- It should not affect or impede bone growth.

Grafts play a major role in primary or secondary/residual management, eventually playing a vital role in reconstruction. Bone grafts in residual deformities are ideal to fill volume defects and also aid in reconstruction. Various types and sources of grafts have already been listed (Chart 61.3).

Table 61.2 Types of bone grafts

Type	Highlights
Autografts	<ul style="list-style-type: none"> • Bone grafting from the same individual • Bone harvesting from nonessential sites • Less risk of graft rejection • Osteoconductive, Osteoinductive and osteogenic • Requires an additional surgical site and risk of infection, pain and complications in the donor site • Gold standard and available in many forms
Allografts	<ul style="list-style-type: none"> • Bone grafting from another individual (Human donors). Bone is taken from cadavers. Although it can be from living donors, it is more likely to come from dead individuals • Properties may be limited due to preparation and sterilisation • Preparation removes risk of antigenicity • Limited risk of disease transmission • Osteoinductive • Gold standard and available in many forms
Synthetic variants	Artificial bone substitutes. Constitutes mineral to organic matrix ratio close to that of normal human bone. Grafts not taken from living donors
Xenografts	Grafts from species other than humans
Alloplastic grafts	<ul style="list-style-type: none"> • Strictly a synthetic bone substitute • Osteoconductive in nature • No risk of disease transmission • Unlimited graft options
Growth factors	Produced by recombinant DNA technology. Consists of human growth factors or morphogenic proteins

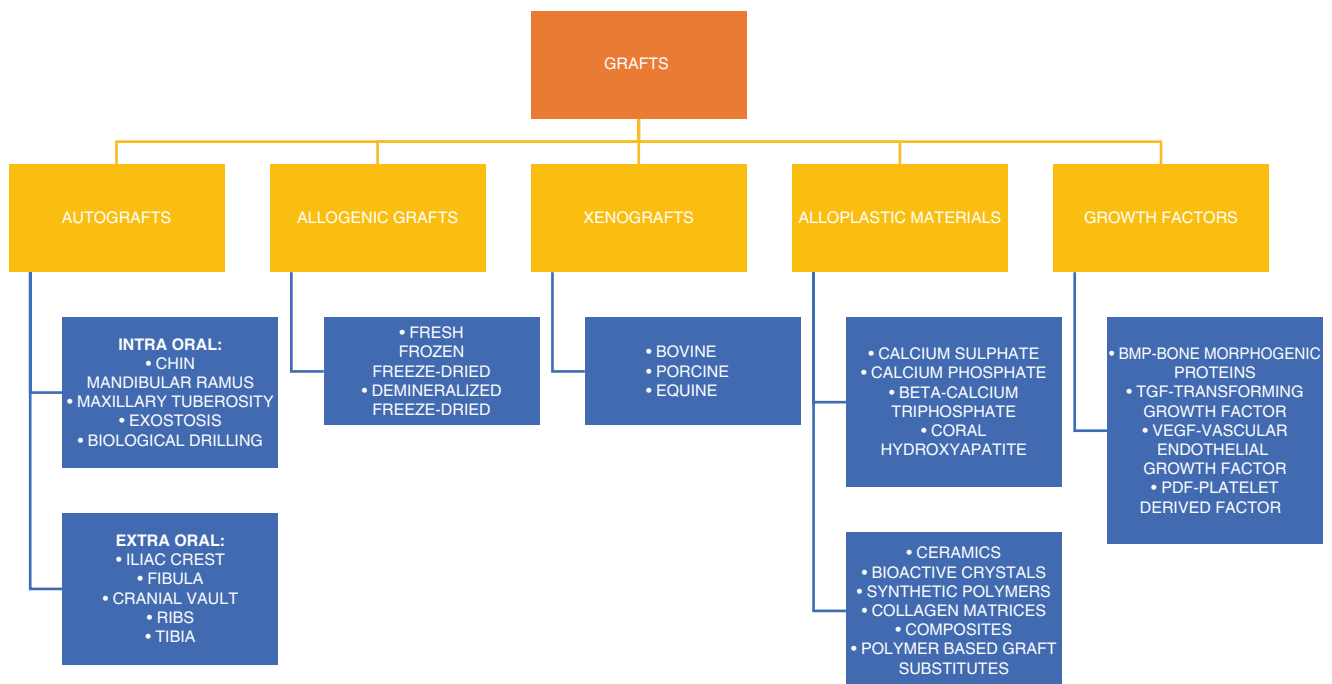
61.2.3 Bone Grafts in Hard Tissue Residual Deformities

61.2.3.1 Nasal Deformities [19]

- Bone grafts for nasal deformities can be readily obtained from cranial bone or iliac bone crest. Costochondral and tibial bone grafts have also been used earlier. Cartilage may be harvested from nasal septum. It may also be harvested from conchal bowl of the ear in case of septal bone loss. *Osteocartilaginous grafts are discussed in nasal reconstruction in detail.*
- Alloplastic materials used in nasal surgeries are silicone, Mersilene mesh, porous polyethylene, proplast, alloderm, etc. The usage depends on the type and size of defects and can be used alone or along with autogenous grafts.

61.2.3.2 Orbital Deformities [19]

- Autogenous bone grafts were earlier considered to be ideal for treatment of orbital floor deformities, but are currently replaced by alloplastic materials. Silastics are currently not considered due to reports of post-operative infection. *Most commonly used alloplastic materials in orbital reconstruction:*
- Titanium mesh.
- High-density porous polyethylene implants (e.g. Medpore).



©Association of Oral and Maxillofacial Surgeons of India

Chart 61.3 Sources of bone grafts

- Orbital floor implants are used by manual adaptation of implants according to the contour of the damaged site. However, custom designed implants with computer-guided surgical planning is best utilised in management of late deformities as there is time to assess, plan, design and custom manufacture the precise implants. Orbital titanium implants can also be manufactured by this method.

61.2.4 Alloplastic Materials [19–24]

Alloplastic materials have been used in surgeries since 1930s, and newer materials are available since then. Prime advantages of alloplastic materials are reduced donor site morbidity, easily usable, good patient compliance and shorter working time compared to autogenous grafts. Sources and types of graft materials are listed in Chart 61.3.

Goal of Alloplastic Materials

- *Biocompatible*
- *Resistant to infection*
- *Easy to use*
- *Cost effective*

Their role in maxillofacial reconstruction is still controversial. These porous alloplastic materials are high-density polyethylene implants that are very stable and flexible in nature and also help in new vascular and tissue growth within. This makes alloplasts an essential commodity in management of maxillofacial defects and also in reconstruction.

Alloplastic materials used in the region of defects for reconstruction are available in various forms like titanium mesh, porous polyethylene (Medpor) and PEEK (poly ether ether ketone) which can be customised as needed. *Medpore (stock)* can be manipulated and adapted in situ according to the defect. It is also possible to make *custom-made Medpore, silicone and PEEK* with the computer-aided designing. Even though they are known to produce good clinical outcomes, it may be predisposed to infection. Careful handling, understanding patient's history and surgical placement are essential to avoid any complications or to manage any failures. Medpore along with fat grafting may serve to restore the contour as well as the volume. These custom-made implants are widely used in management of defects and deformities as part of maxillofacial reconstruction. Applications of MEDPORE are chin augmentation procedures, correcting congenital deformities and improving aesthetic outcome in

nasal, subnasal, paranasal, malar, orbital, and mandibular (angle and body) areas. It is essentially suited for midfacial contouring in patients treated for cleft. The use of these alloplastic materials ideally helps to establish three-dimensional anatomical harmony in correcting defects. Polyether ether ketone (PEEK) is another valuable alloplastic material that precedes with advantages similar to that of Medpore Custom-made patient-specific PEEK implants have proven to offer excellent facial rehabilitation. The durability and malleable property of PEEK make it a biomaterial of choice for maxillofacial surgeons with which complex maxillofacial defects following trauma or neoplastic can be corrected. Often, the use of alloplastic materials may be an adjunct or combined with prosthesis to further complete the facial rehabilitation process.

61.2.5 Use of Grafts in Associated Residual Structural Damages

Traumatic or iatrogenic reasons causing structural or residual damages are areas of concern during maxillofacial surgery. Important structural damages involving nerve tissues, salivary gland apparatus and nasolacrimal system should be identified and best managed during the primary surgery. If left untreated, secondary or delayed management leads to further complications. It is the skill of the surgeon to carefully carry out the surgery with no or minimal trauma to adjoining structures, and it is experience that will help to predict any relative functional damages and manage it accordingly.

Nerve Injuries: Injuries to the peripheral branches of the trigeminal nerve following maxillofacial trauma or surgery often result in sensory and functional problems. Spontaneous recovery of inferior alveolar nerve and infraorbital nerve after facial fractures depends on a number of factors like age, gender, fracture displacement, site, type of management and time interval between injury and management. Localisation and determination of the pattern of injury of trigeminal nerve are done by careful examination of the neurosensory dysfunction (NSD) of sensory dermatome of trigeminal nerve. It may be very difficult in establishing the exact cause in secondary NSD damages. Such residual defects due to injuries can be from nerve compression due to displaced old fracture segments, laceration due to fracture components, dislocated nerve from a displaced fracture, and compression due to soft tissue oedema or secondary ischemia. Injuries may also be related to crushing, avulsion and partial or total nerve transection [25–28].

Determining the exact aetiology of post-operative residual or secondary NSD damage is difficult, and the best way

to manage is assessing the damage during the primary surgery. Accessing and operating the site for correction secondarily may itself cause further damage if not handled properly. Nerve grafts can be used in the management of such damages. It involves microsurgical repair of nerve that requires reconstruction of any continuity defect using an autogenous nerve graft (*donor site—sural or great auricular nerve*). Microsurgical repair helps in improving the clinical outcome in such conditions. Nerve allografts have proven to be successful in improving the neurosensory recovery. Allografts are further beneficial as it alleviates the donor site morbidity. Ichihara et al. suggest the use of alloplastic tubes in short span nerve defects as artificial nerve guides. However, studies need to ascertain their use in long span trigeminal nerve defects. Similar use of autogenous and allogenic grafts is applicable for facial nerve injury as well. The successful outcome of grafts depends on the length/size of the defect and patient factors like age/gender/nutritional status, and it is also important to address factors like previously irradiated sites [29–32].

Salivary Gland/Duct Injuries: Trauma, lacerations, deep injuries and iatrogenic injuries in the parotid region can result in injuries to the important related structures like the buccal branches of facial nerve, Stenson's duct and transverse facial artery and vein. Surgical and non-surgical management of injuries to the salivary gland or its duct is done to improve the clinical outcomes. Non-surgical management includes the use of anti-sialagogues, elastic bandages and reduced oral intake until the defect heals. Microsurgical repair may be done to preserve remaining ductal structures using autologous vein grafts. Reconstruction of the duct is done using autologous vein grafts like saphenous vein, antebrachial vein, facial vein, etc. Alloplastic Gore-Tex has been used, and the outcome was found to be similar to anastomosis in autologous vein grafts in parotid duct reconstruction. Gore-Tex tube carries advantages like decreased graft morbidity and shorter operation time. Timely correction of salivary ducts is important to avoid complications like sialocele, salivary fistula, etc. [33–38].

Nasolacrimal Duct Injury: It is important to reconstruct the nasolacrimal system if damage is seen following orbital or midface trauma. It is similar to other ductal and nerve management. The nasolacrimal duct system can be reconstructed with autogenous and allogenic grafts. Greater saphenous vein can be used as autogenic grafts in such cases. Buccal mucous membrane grafting also shows improved outcomes in removing obstructions in the ducts. Silicone stent intubation is also used in the repair of damaged nasolacrimal duct. Primary management is essential in this condition since delayed management may be difficult to carry out [39–41].

Future of Grafting

Future in grafting promises advances in gene therapy, tissue-engineering, and 3D scaffold. It has created greater perspective with the inclusion of growth factors, stem cells and biological scaffolds that will help in production of laboratory-engineered tissue substitutes in oral and maxillofacial surgery.

Three-dimensional (3D) computed tomography (CT) has brought major changes to visualisation, planning and treatment of maxillofacial defects ever since its introduction. The scanning and surgical planning software have advanced in such a way that a surgeon can meticulously plan a patient-specific protocol to carry out procedures effectively. Preformed and custom printed alloplastic has more accuracy, reduced operative time and a predictable outcome in management. However, conventional implants require intraoperative adaptations and longer duration of operation. All these have been possible with the advances in reconstructive surgeries with CAD-CAM (computer-aided design-computer-aided modelling) software. Such major advances will lead to further improvement in patient-specific implants (PSI) in the three-dimensional management of defects in reconstructive procedures [23, 24, 42, 43].

61.3 Hard Tissue Deformities

Deformities in the maxillofacial bones are due to a variety of causes like pathology, trauma, infection and congenital disabilities. Residual deformities are such defects that are observed even after the primary surgical management and need further cosmetic and functional intervention for an outcome. The size of the defects in the maxillofacial region may vary from small alveolar clefts and nasal deformities to maxilla-mandibulectomy-type defects. Restoration of the deformities to its closest healthy anatomical structure and their essential functioning are the primary goals of any re-intervention procedure.

Any defect (size, shape, position or amount) of the osseous structure can be replaced by reconstructive surgery. The aim is to replace it with the missing structure, i.e. the bone. Various types of bone grafts may be used for this purpose. Correction of soft tissue defects needs a complete understanding of the wound healing biology. Likewise, in hard tissue deformities, it is essential to know the bone physiology, immunology and surgical principles to make the reconstruction a successful procedure.

61.3.1 Patient Assessment

Although general rule implies to replace or reconstruct the lost osseous defect, it is important to evaluate every patient thoroughly before proceeding with any intervention. Analysis should include evaluation of hard tissue and associated soft tissues. When accompanied by soft tissue deformities, it is important to treat with caution considering the soft tissue changes over time as well [44].

61.3.2 Residual Mandibular Deformities [3, 45–50]

General Assessment Points for Mandibular Defects:

- Careful and complete clinical examination.
- Necessary radiographs to assess the amount of osseous defects.
- Site and size of the defect to be taken into detailed evaluation. Such evaluation is of utmost importance in mandibular osseous defects.

Causes for Post-traumatic Mandibular Deformities:

- Poor diagnosis
- Improper surgical methods—inadequate reduction and/or fixation
- Infection
- Healing disorders

Residual Deformities in Mandible:

- Causes like trauma, gunshot wounds and infection may result in loss of a portion of the mandible.
- Loss of tissues results in functional and aesthetic concerns. Small deformities may often go unnoticed.
- Loss of a portion of the alveolar process leading to loss of teeth is a less serious complication.
- Malunion of mandibular fractures can often result in serious consequences in occlusion among adults and children. More serious changes may affect the mandibular growth in children following condylar fractures.
- Loss of anterior attachment of the tongue due to tissue loss causes an airway hazard that needs to be corrected primarily.
- Loss of bone in mental region or large areas:
 - Difficulty in speech
 - Difficulty in swallowing
 - Drooling of saliva
 - Un-aesthetic appearance

61.3.2.1 Deformity in the Ascending Ramus of the Mandible

No treatment is often required if the occlusion is satisfactory. Complete fusion of the bony segments to the temporomandibular joints may occur following the destruction of

the developing mandibular condyle after trauma or secondary infection. In this case, the destruction of the articular disc allows the contact between the bony fragments of ascending ramus and the glenoid fossa, finally resulting in ankylosis. When this occurs in children bilaterally, it shows reduction in lower third dimension resulting in appearance called “Bird Face deformity”. This usually results in aesthetic and airway concerns, and psychological disturbances. Airway disturbances should be viewed with greater importance. Ankylosis in adults will result in occlusal abnormalities and difficulty in enunciation of speech and communication. Sometimes pseudo-ankyloses may also be observed.

61.3.2.2 Surgical Options for Post-traumatic Residual Deformities

Post-traumatic deformities include *non-union, malunion/malocclusion and facial asymmetry*, and they may require secondary correction. These deformities can occur alone or in conjunction, sometimes as a sequel to a deformity.

61.3.2.3 Non-union [45–50]

They are fractures with arrested healing that requires further surgical treatment for correction. It is considered to be non-union when a fractured segment is mobile for 4 weeks without treatment or 8 weeks after surgical treatment.

Causes for Non –union	
<ul style="list-style-type: none"> • Soft tissue infection • Large fracture gaps • Comminuted fractures • Severe atrophic fractures • Osteomyelitis • Movements 	<ul style="list-style-type: none"> • Improper reduction • Delayed treatment • Teeth in the line of fracture • Smoking and alcohol abuse • Poor treatment planning • Inadequate surgical skills • Poor patient compliance

Diagnostic considerations:

Clinical Examination:

- Identify persistent mandibular deformity.
- Tenderness at fracture site.
- Malunion in closed reduction techniques may be identified after release of maxillo-mandibular fixation.

Radiographic Findings:

Irregular radiolucency with mottled fracture ends.

Management:

- Extra-oral approach is the best option as it allows good visualisation. Transoral approaches may be considered in indicated cases.
- It is followed by the debridement for removal of any fibrous tissue, necrotic bone or failed hardware.
- Following this, adequate occlusion and maxillo-mandibular fixation is achieved. The fracture is reduced,

and then reconstruction plates are fixed with the help of screws away from the fracture.

- Considering less mineral (even though appearing normal) content in the site near the fracture, it is recommended to place screws no closer than 7–10mm.
- Autogenous bone grafting may be used to re-establish continuity of mandible in areas where the bone contact is inadequate.
- In younger patients and well-vascularised areas, union of small gaps is successful.

61.3.2.4 Malunion/Malocclusion: [46, 51, 52]

It can occur in any type of mandibular fracture when segments heal in improper alignment. Malunion is often due to inadequately established occlusion, inadequate

anatomic reduction and poor adaptation of fixation plate.

Figs. 61.3, 61.4, 61.5, and 61.6 depicts malocclusion related management of deformities.

Diagnostic Considerations:

It is often diagnosed with malocclusion and more associated with rigid internal fixation. Dental models are used to study and plan the occlusion.

Management Considerations:

- Revisit of the surgical site may be necessary to correct the errors due to rigidity.
- Minor occlusal corrections can be done with orthodontic treatment.

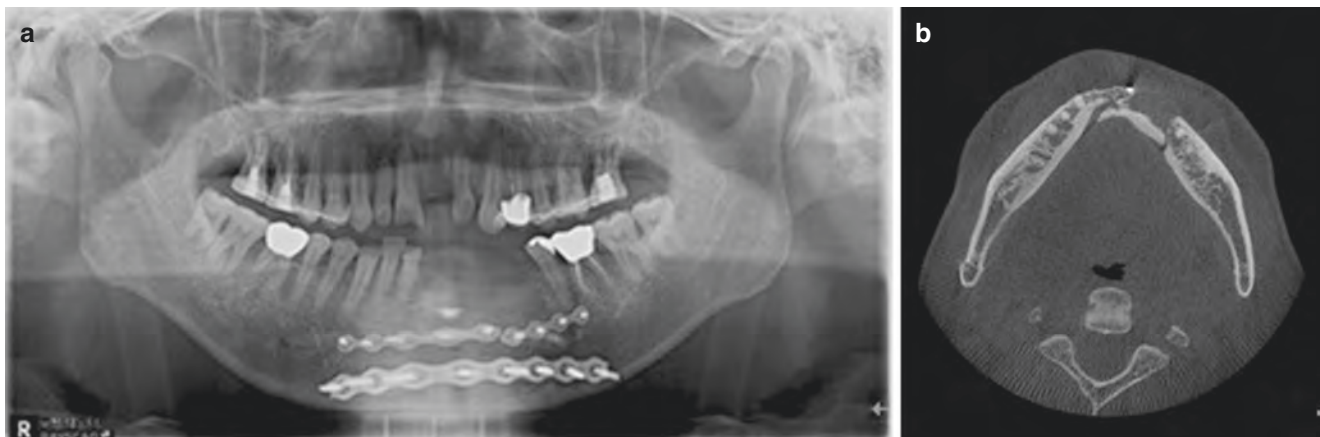

Fig. 61.3 Malocclusion following trauma surgery with multiple loss of teeth in mandible and associated osteonecrosis. Patient managed with iliac grafting of mandibular osteonecrosis site, followed by implant rehabilitation and vestibuloplasty. Preoperative radiograph. (a) Panoramic radiograph (b) Cone beam computed tomography scan.

(Reference for Figs. 61.3, 61.4, 61.5, and 61.6) (<http://creativecommons.org/licenses/by/4.0/>), Kim SY, Choi YH, Kim YK. *Maxillofac Plast Reconstr Surg.* 2018;40(1):27. Published 2018 Oct 15. doi:10.1186/s40902-018-0167-z (springer open)

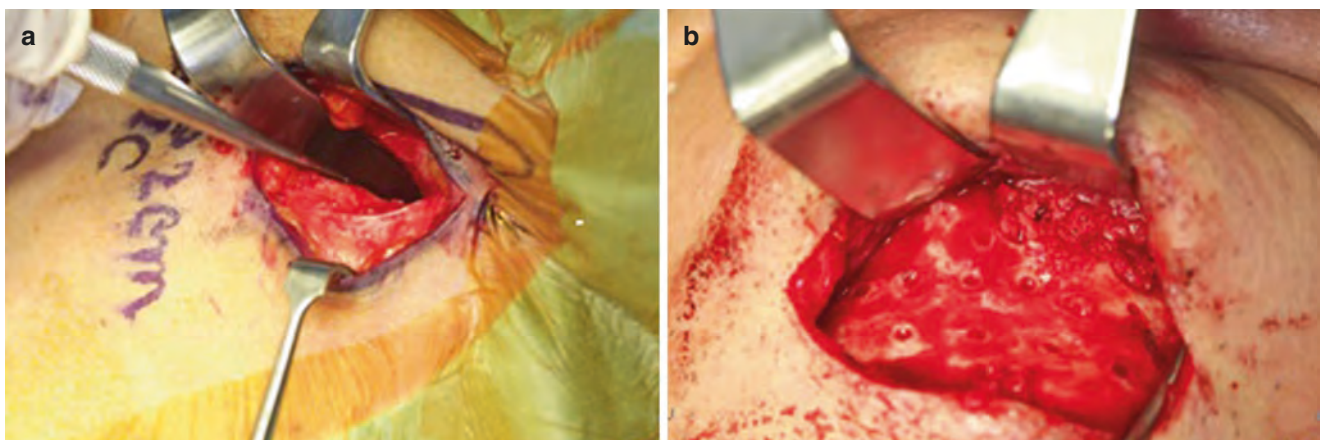


Fig. 61.4 Clinical intra-oral photograph showing. (a) Iliac bone harvesting. (b) Grafting of the harvest iliac bone into the mandible defect

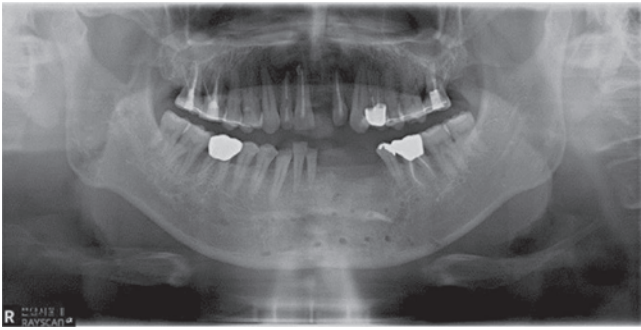


Fig. 61.5 Post-operative OPG

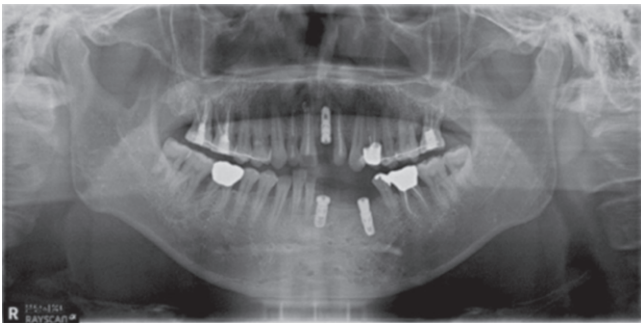


Fig. 61.6 Post-operative OPG after implant placement for dental rehabilitation

61.3.2.5 Early Malunions

- Surgical approach is similar to the primary treatment.
- Old hardware is removed → adequate occlusion achieved → with maxillo-mandibular fixation → fracture reduction if necessary → new fixation is done → new occlusion is verified with release of the fixation.

61.3.2.6 Late Malunions

- Surgical approach is determined based on type of osteotomy.
- Study models are used to study the occlusion and plan a mock surgery.
- Management includes osteotomies for proper establishment of anatomy and occlusion.
- Mandible is re-fractured → occlusion is achieved with the help of a surgical splint → maxillo-mandibular fixation is obtained → new rigid fixation → occlusion is verified after the release of maxillo-mandibular fixation.
- Bone grafts may be used to close gaps whenever necessary.

61.3.2.7 Malunions/Malocclusion and Condylar Fractures [53–56]

- Majority of condylar fractures when treated “closed” may develop malunion. However, condylar malunion may not always cause malocclusion.

- Quality of the functional rehabilitation of the mandible is an more important factor than the type of treatment (closed or open).

Diagnostic Considerations:

- Radiographs and malocclusion are key in examination.
- No treatment or previous unsuccessful treatment is a main reason for malocclusion following condylar fractures.
- Degree of mandibular ramus deformity is essential to determine the necessity for a re-surgery to correct malocclusion following condylar fracture.

Treatment Considerations:

- Unilateral or bilateral fractures.
- Time period between fracture and treatment of malocclusion.
- Availability of remaining stable dentition.

Management Considerations:

- *Minor occlusal discrepancies* may be treated with orthodontics, prosthetic rehabilitation, reconstruction and occlusal adjustments if indicated.
- *TMJ reconstruction* may be indicated—when the remaining ramus is short with multiple fragments and large movements are required to correct occlusion.
- *Orthognathic surgery* may be indicated in long-standing malocclusions.
- *Functional therapy* can be done up to 3 months for management of malocclusion.

61.3.2.8 Facial Asymmetry [46]

- Usually as a sequel to malunion, non-union and inadequate fixation.
- A number of clinical scenarios may present itself to facial asymmetry

Diagnostic Considerations:

- *Early stages*: Difficult to diagnose because of the swelling.
- Antero-posterior cephalometry or CT scans are confirmatory.
- Facial, dental and radiographic analyses are done.

Management Considerations:

- Treatment similar to malunions and malocclusions.
- In cases where the defect is diagnosed early, the mandible can be approached through the initial surgical wound, the hardware may be removed, mal union corrected and new fixation can be placed.
- Orthognathic surgeries in cases of established facial asymmetries. Surgical splints and model surgeries help in

surgical planning. Asymmetry is corrected, and new occlusion is verified with new fixation. The procedure similar to principle treatment. Additional osteotomy may be required depending on the type of original injury.

61.3.2.9 Principles of Mandibular Reconstruction [45, 57]

Reconstruction of larger defects of the mandible is discussed in Chap. 88.

Marx and Saunders listed the goals of mandibular reconstruction in order to consider a grafting procedure successful.

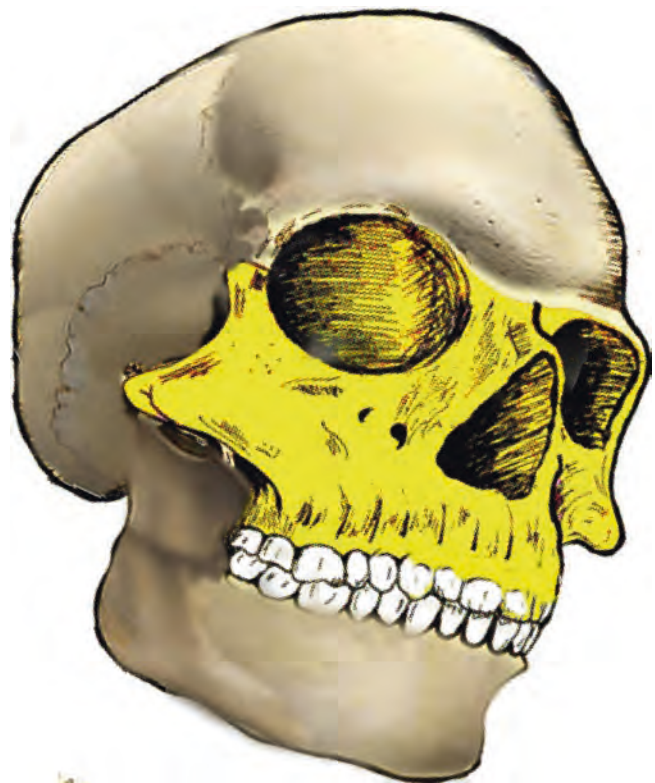- *Restoration of continuity* is the key since the mandible is a bone with two articulating ends supported by muscles with opposing forces. Deviated mandibular segments need to be realigned not only to improve facial aesthetics but also to restore essential function movements.
- *Restoration of alveolar bone* is another essential aspect to aid in the functional rehabilitation of the patient. The process of mastication and the efficiency to masticate are possible only once the necessary alveolar bone height has been obtained. In patients with osseous defects, this helps in the placement of a prosthesis.
- *Restoration of osseous bulk* is vital to provide the required amount of osseous tissue to withstand forces and perform normal function. Fracture of the graft area may occur when the area is too thin, lacking the bulk to withstand functional forces directed towards the bone.

61.3.3 Midface Deformities [3, 58]

The midface is a critical zone of the maxillofacial region concerning both aesthetics and function. Midface includes structures like the maxilla, palate, orbit, cheek, upper lips, eyelid and nose. It is often an area that poses a significant challenge to a maxillofacial surgeon for reconstruction. Orbit is usually challenging to reconstruct in secondary setting mainly due to chances of scarring. Due to the difficulty in obtaining good results in primary surgery, the nose and auricle are best considered for correction in a secondary setting. Figure 61.7 shows areas of the midface.

Objectives in Correcting Midface Deformities [58]

- Restoration of midface projection
- Restoration of occlusion
- Providing support for the orbit
- Filling the volume of the orbit
- Restoration of palate competence
- Restoration of functional harmony



©Association of Oral and Maxillofacial Surgeons of India

Fig. 61.7 Highlighted (yellow) areas represent midface region

Along with the reconstruction of the hard tissue, it is important to correct associated soft tissue defects as well. Failure to correct the primary deformities may result in sequelae of defects of the associated soft tissues and end up in affecting the functional quality of life of the patients.

Indications to Correct Midface Defects [58]

- Untreated/avoided defects during primary reconstruction
- Poor result following primary reconstruction (partial or complete loss of flap, non-union of bone, oro-cutaneous fistula)
- Poor outcome in primary reconstruction due to poor planning
- Post-operative complications that may lead to hematoma and scarring

Diagnostic Workup: [58]

Treatment planning for midface changes requires careful planning and knowledge of previous treatments to achieve the best result.

- Evaluate general status of the patient (age, history of tobacco, alcohol abuse, nutritional status, and presence of co-morbidity)

- Accurate assessment of anatomic defects
- Assessment of quality of tissue involved, surrounding tissues and status of scar
- Availability of healthy surrounding tissue

During the workup, it is necessary to eliminate cases of unresectable conditions like distant metastasis or recurrence in oncology or non-traumatic cases.

Diagnostic Assessment: [58]

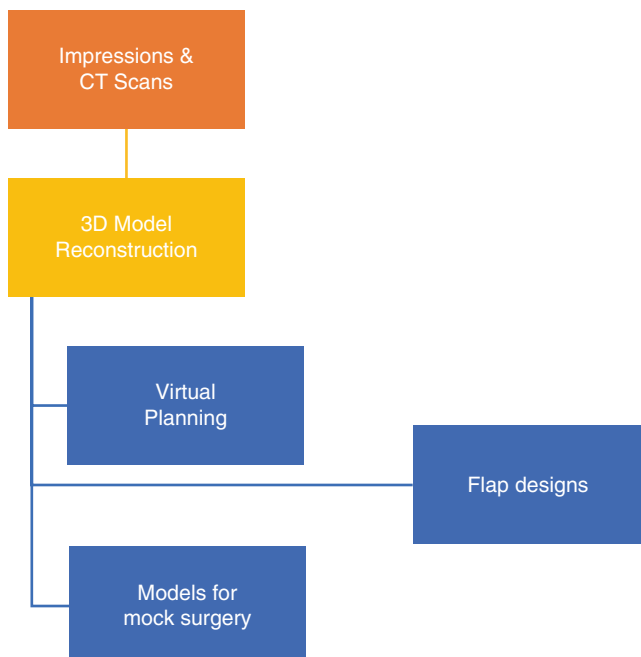
Assessment requires evaluation of surface or volume of missing tissues. Assessment should include evaluating defects in the bone, skin, musculature, innervation and mucosa (Chart 61.4).

Treatment Options: [3, 58]

Surgical correction in this region varies from prosthetic replacement to complex microvascular reconstructive surgeries.

Surgical Options:

- Local or regional flaps for small to moderate defects.
- Secondary free flaps: iliac crest flaps, fibula flaps, subscapular free flaps.
- Microvascular surgeries are primarily done in major defects.
- Microvascular flaps provide adequate and necessary amount of well-vascularised bone and/or soft tissue augmentation, thereby enabling a better 3D fitting flap and closure.



©Association of Oral and Maxillofacial Surgeons of India

Chart 61.4 Diagnostic assessment

- Critical evaluation is to be done in previously irradiated or operated midfacial defects.

Current methods under development include tissue engineering for ideal regeneration of the tissues in head and neck defects. Facial transplantation has also paved newer paths in this field, but indications are restricted.

Other Non-surgical Options: [58]

Maxillofacial prosthesis:

- Palatal obturators in maxillectomy cases.
- Complex defects affecting structures like the nose, orbit and those which cannot be restored with flap reconstruction may be managed by maxillofacial prosthesis. Recent advancements include supporting the prosthesis with dental implants.

Ancillary Procedures: [3, 58–61]

- Additional supportive techniques may help to improve the outcome of a correction in midface re-operative procedures.
- CT images are useful in designing adequate fronto-orbital facial contours.
- Free bone grafts for facial contouring are indicated for upper midface defects. The bone grafts can be obtained from calvaria and synthetic implants—porous polyethylene, methyl methacrylate and titanium mesh. However, it is contraindicated in a previously irradiated area and in cases of oral cavity communication.
- Combination of titanium mesh and soft tissue may be helpful to provide support for the globe.
- *Liposuction* is an excellent alternative technique to fill certain residual defects following midface reconstruction. Microvascular flaps may help fill residual flattened areas.
- *Distraction osteogenesis*: Mainly indicated in mandibular repair, it is also used in the repair of minor maxillary bone defects which cannot be treated with bone flap reconstruction (refer Chap. 87).

Oral Rehabilitation:

- Implant-supported prosthesis with good osseointegration is often considered as the best option in oral rehabilitation. Peri-implant hygiene and osseointegration are important for the success of dental/zygomatic implants in oral rehabilitation procedures.
- Dental implants are most helpful for oral rehabilitation. Implants may be placed during the primary reconstructive procedure or preferably as a secondary procedure.
- Zygomatic implants may also be used when regular alveolar bone reconstruction is not possible.
- Implant placement in previously irradiated areas may not give the best results, and hence it is a contraindication.

61.3.4 Residual Maxillary Deformities [3, 58]

Goals in Correction of Maxillary Deformities

- Restoration of function
- Restoration of occlusion
- Restoration of original relationship between thirds of the face

Common Maxillary Deformities May Be Due to:

- Malpositioned maxillary fractures
- Undiagnosed fractures—untreated dislocated fractures
- Severely comminuted fractures with associated damages
- Untreated old fractures
- Edentulous displaced maxilla
- Post-traumatic hypertelorism

Essentials for Treatment Planning:

- Preoperative *photographs* (full face, profiles pictures, frontal and lateral views of occlusion, palate, floor of the mouth and other required projections).
- Detailed *clinical assessment* and treatment of other existing carious and inflammatory conditions of the oral cavity.
- *Models and radiographs*—OPG, lateral cephalometric X-rays
- Current imaging and planning techniques: CBCT helps in *3D virtual planning* to design flaps and to create 3D models for planning and mock surgery (61.5).

61.3.4.1 Immediate Repositioning of Maxilla and Midface Complex

Open Surgical Immediate Mobilisation Treatment: This is indicated in conditions where total mobilisation is not possible. These are cases that are treated after 6 weeks or more after trauma, or even years later, usually cases where partial or complete consolidation has already taken place. The principle of surgical treatment is often the same as in the treatment of primary maxillary and midface treatments.

Old Fracture Segments: Old fracture segments in the anterior maxilla can be corrected by techniques described by Wassmund (1935) and Wunderer (1962) in cases of protruded maxilla. It is key to observe any scars in the labial vestibule as that may affect the vasculature to the alveolar process. Wassmund's method should be preferred when a scar is present; otherwise, Wunderer's method may be followed in which maintenance of labial blood supply is essential. In contrast, Schuchardt K suggested a single-stage technique which involved an osteotomy of the lateral alveolar process and relocation to its original alveolar location [62–64].

61.3.4.2 Old Le Fort I and II Fractures [3]

Untreated Le Fort I Fractures: An incision may be made at a point horizontally through lateral and anterior maxillary sinus walls. Osteotomy is done to ensure that the plates are placed on both sides of the stable bone region. Line of osteotomy does not precisely follow the line of fracture.

Old Le Fort II Fractures [3]: If there's no cosmetic significance or less damage to the nasal region—similar procedure may be followed. Le Fort II osteotomy is indicated when the nose has sunken, and the midface is shortened.

In the above scenarios, Le Fort I and II osteotomies may be done when either occlusion needs to be restored or there is an aesthetic concern. Bone grafts may be used in the region of the bridge of the nose below the buttress and also between pterygoids and the maxillary tuberosity if possible (Figs. 61.8 and 61.9).

61.3.4.3 Displaced Edentulous Maxilla [3]

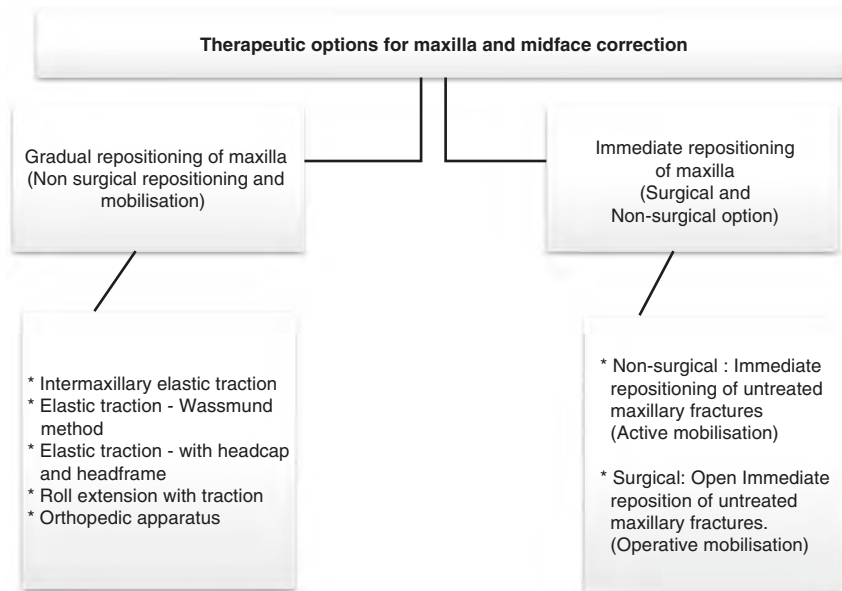
- *Minor displacements* may be corrected with osteotomies, only if the disturbance along the intermaxillary relationship in the sagittal plane is minimal. Otherwise, it is justifiable to treat with a prosthesis.
- *In case of severe displacements* of maxilla which results in the appearance of a skeletal Class III, the maxilla has to be surgically replaced to its original place with the help of bone grafts.

61.3.4.4 Old Le Fort III Fractures (Figs. 61.10 and 61.11)

Le Fort III osteotomy is indicated in old Le Fort III fractures when the deformities may be seen in the entire midface region with dislocations in orbital margins and zygoma. Unilateral osteotomy may be indicated when only one side of the face is affected. Occasionally in cases of comminuted fractures of the midface, a Le Fort I osteotomy may be needed to be done along with Le Fort III osteotomy procedure. This is essential to correct the occlusion in untreated midface fractures. It may be challenging to carry out a re-treatment for comminuted midface fractures. Segments may be stabilised separately considering the complex nature of the fracture. The procedure can be simplified by first mobilising the entire midface complex with Le Fort III osteotomy and then followed by Le Fort I osteotomy (Figs. 61.12, 61.13, 61.14, 61.15, and 61.16 shows surgical management of a mid face deformity by onlay grafting; All images 61.12–61.16 are from the same patient) (Figs. 61.17, 61.18, and 61.19 shows clinical images of management of post operative malocclusion; all images 61.17–61.19 are from the same patient).

Historical perspectives of therapeutic options for maxilla and midface correction³

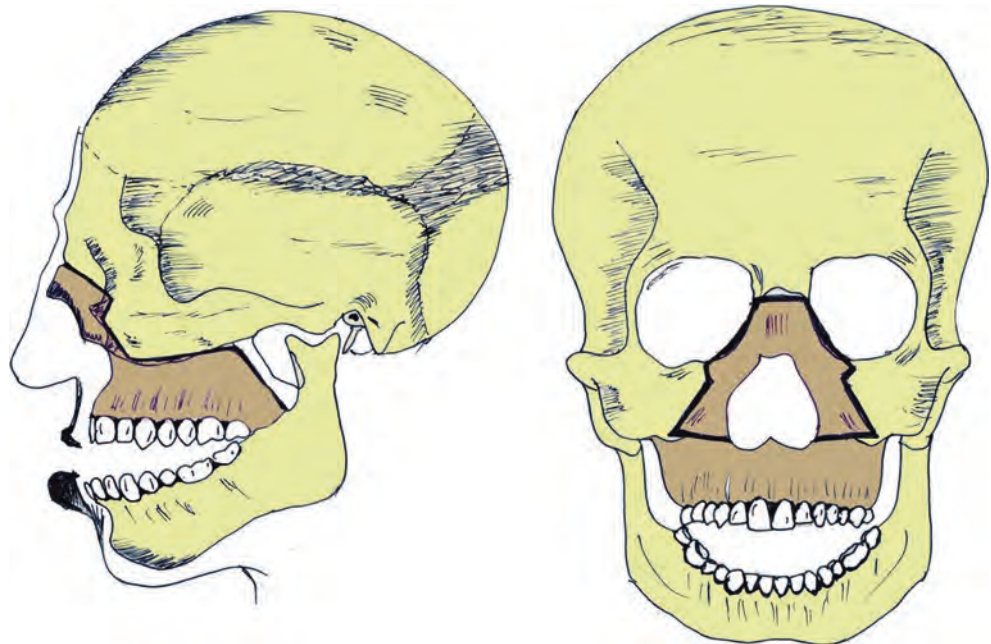
Maxillary mobilisation can be classified into gradual and immediate repositioning. Gradual repositioning of maxilla & midface complex were opted in cases where cicatricial fixation had already taken place. Gradual repositioning of midface/maxilla fractures using elastic traction, headframe, roll extension method, orthopaedic apparatus are mentioned here with respect to the historical perspective of therapeutic options. However, those methods are not current in usage.



©Association of Oral and Maxillofacial Surgeons of India

Chart 61.5 Historical perspectives of therapeutic options for maxilla and midface correction [3]

Fig. 61.8 Schematic diagram showing preoperative old untreated midface fractures



©Association of Oral and Maxillofacial Surgeons of India

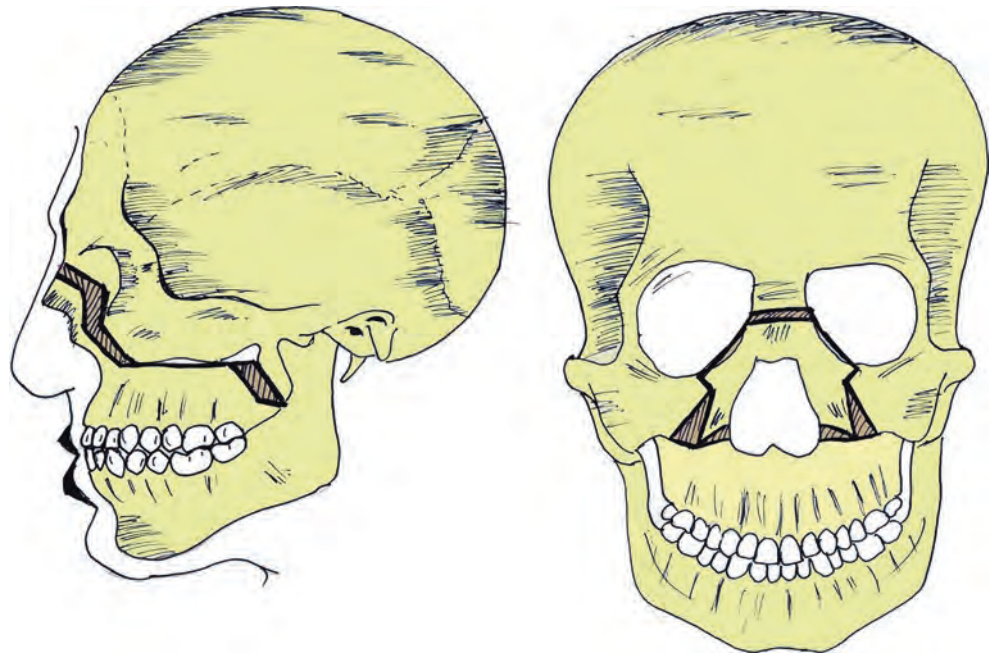
61.3.5 Post-traumatic Hypertelorism

[3, 44, 65–71]

It is a complication that may arise in fractures of midface complex when there is a dislocation of one or both orbits.

Treatment is similar to congenital hypertelorism, and procedure may follow as suggested by Tessier et al. (1967). Stereolithographic models are best used for treatment planning. Although Tessier developed the extra and intracranial approach to correct the deformity, it was further refined later by Tessier, Converse, Van der Meulen et al., Monasterio

Fig. 61.9 Schematic diagram showing post-operative scenario following combined Le Fort I and Le fort II. Defects as a result of repositioning shaded as brown are areas to be filled with bone graft



©Association of Oral and Maxillofacial Surgeons of India

et al. and Marchac et al. They were able to visualise the bony orbit in two parts with the outer square box containing the globe and the inner cone housing the optic nerve. It was established that if these two parts could be separated, the outer box can be moved without affecting the vision.

Goals of surgery for hypertelorism include:

- Correction of orbital dystopia
- Bringing the orbits closer together
- Creation of normal nose with adequate projection
- Narrowing of the nasal dorsum
- Correction of associated soft tissue defects over the nose, nasal clefts or even displaced eyebrows

61.3.6 Residual Zygomatic Deformities [3, 58]

Periorbital area is often a zone of interest in the midface region from a functional and aesthetic point of view. An imbalance in this region could result in aesthetic concern and altered vision. This can be due to malunion of the fracture of the zygomatic complex. Any untreated fracture for longer than *10 weeks* is considered to be an *old fracture* and results

in malunion—a stage at which a procedure needs to be done to correct any deformity.

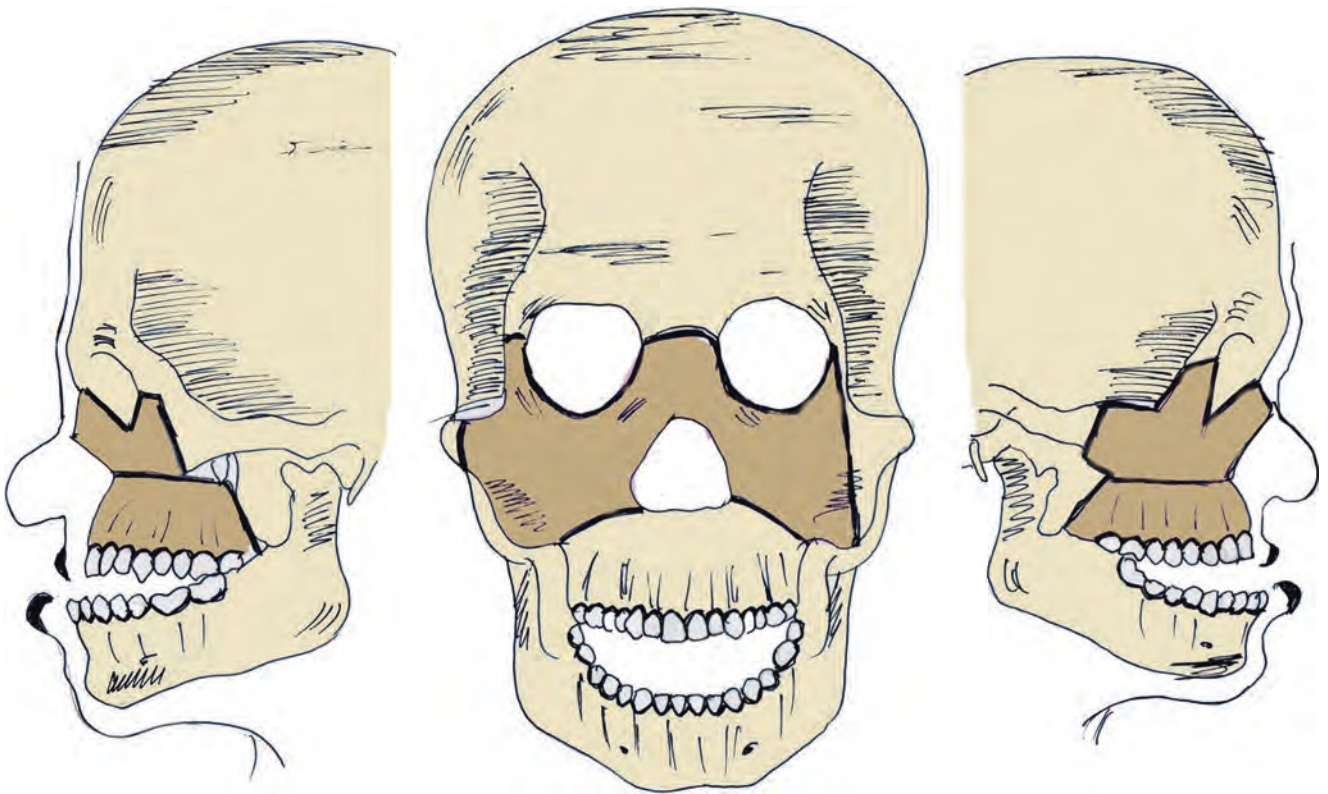
Clinical Signs and Symptoms

1. Facial asymmetry
2. Facial disharmony
3. Dislocated eyeball
4. Diplopia
5. Paraesthesia—infraorbital nerve
6. Limited movements of the mandible

Soft tissue damage like a torn lateral canthal ligament, malpositioned zygomatic bone, zygomatic arch or fragments of the orbital rim may result in an asymmetry of the lateral midface. Corrective surgeries may be required in case of a destroyed orbital bone as well. More often, patients visit the surgeon for aesthetic reasons. It may be often difficult to correct aesthetics when it involves post-traumatic deformities in the malar prominences (Table 61.3).

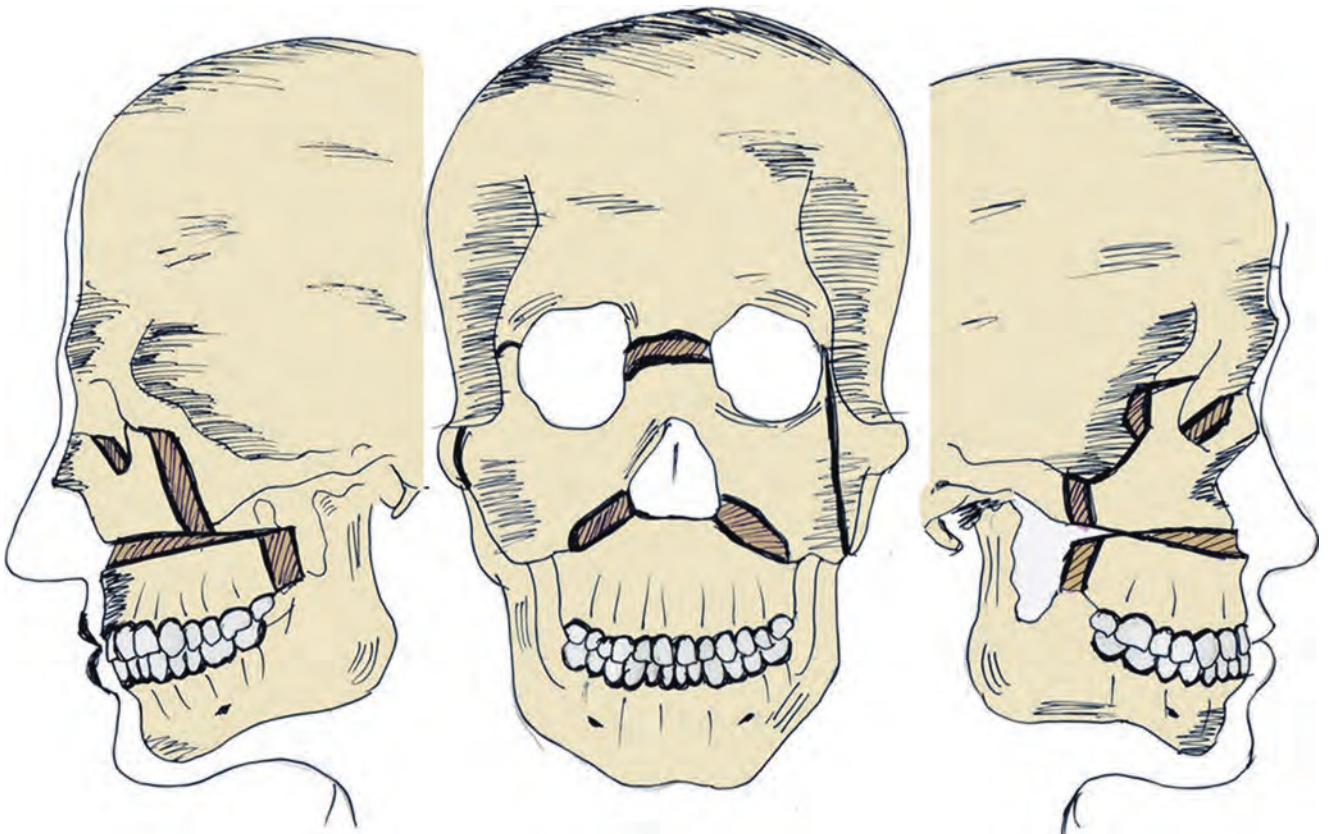
61.3.6.1 Associated Defects of the Orbital Zone [3]

- *Dislocated eyeball:* Usually occurs as a sequel to zygomatic fractures, and slight dislocation may be seen after primary treatment. Displaced orbital floor due to enlargement of the socket or the loss of the orbital content due to



©Association of Oral and Maxillofacial Surgeons of India

Fig. 61.10 Schematic diagram showing old untreated Le fort III fractures



©Association of Oral and Maxillofacial Surgeons of India

Fig. 61.11 Schematic diagram showing post-operative following combined Le Fort I and Le fort III. Defects as a result of repositioning shaded as brown are area to be filled with bone graft

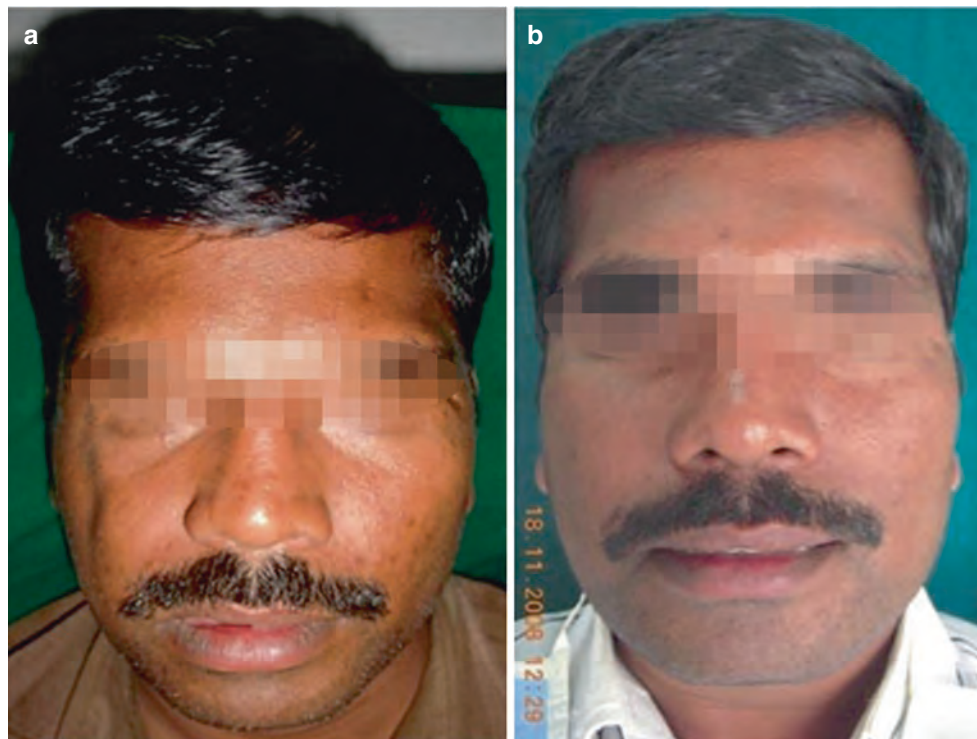
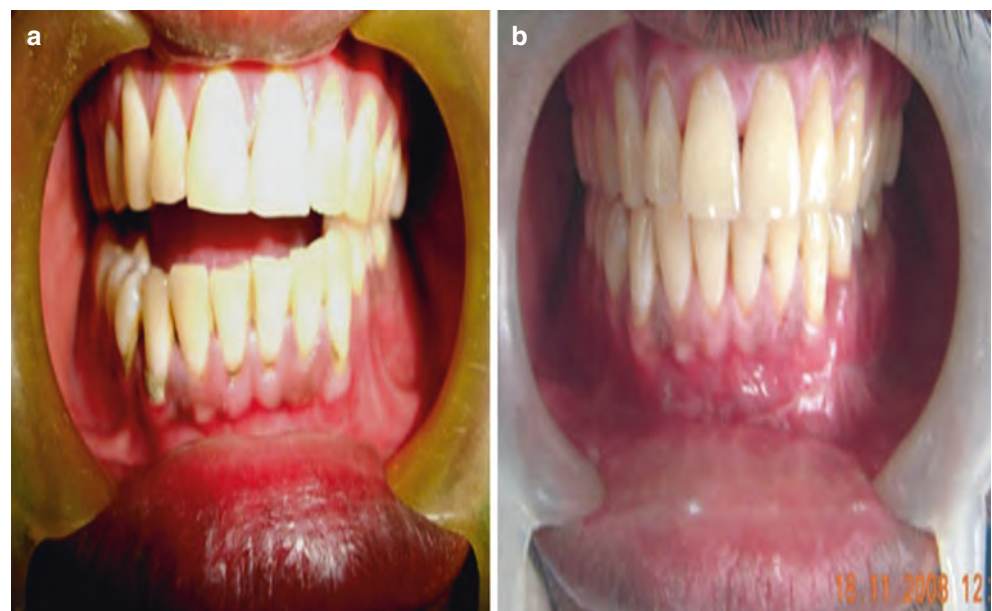
Fig. 61.12 Midface deformities showing residual deformities. (a) pre-operative extra-oral photograph showing facial asymmetry, depressed malar prominence (right side), and incompetent lips. (b) Post-operative extra-oral photograph. (Reference for Figs. 61.12, 61.13, 61.14, 61.15,

and 61.16: Ranganath K, Hemanth Kumar HR. The correction of post-traumatic pan facial residual deformity. *J Maxillofac Oral Surg.* 2011;10(1):20–24. <https://doi.org/10.1007/s12663-010-0088-6> *springer publishers*

Fig. 61.13 (a) Preoperative intra-oral photograph showed deranged occlusion with right anterolateral open bite. (b) Post-operative intra-oral photograph



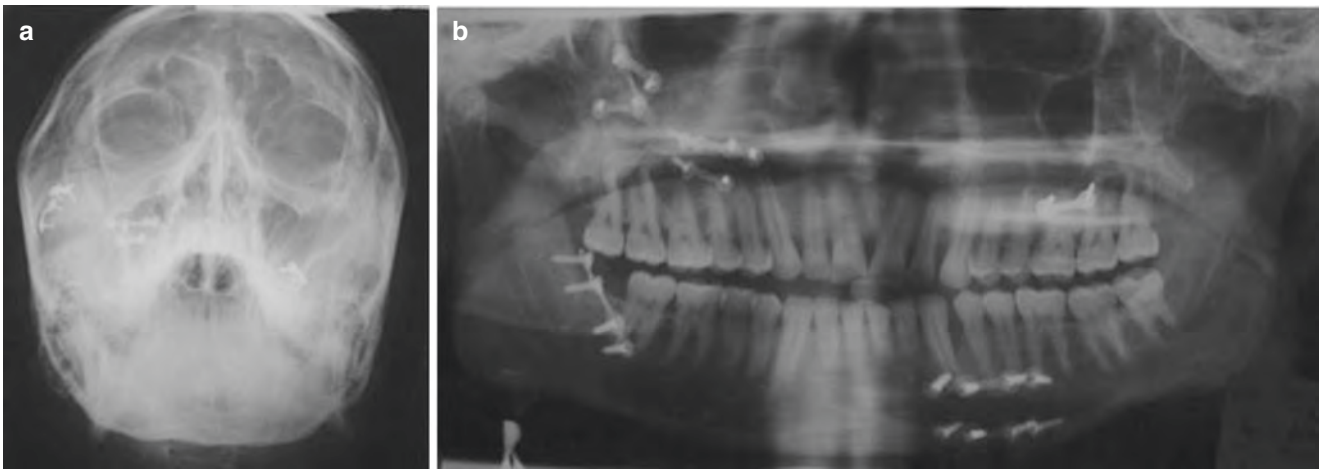


Fig. 61.14 (a) Post-operative PNS radiograph. (b) Post-operative orthopantomograph

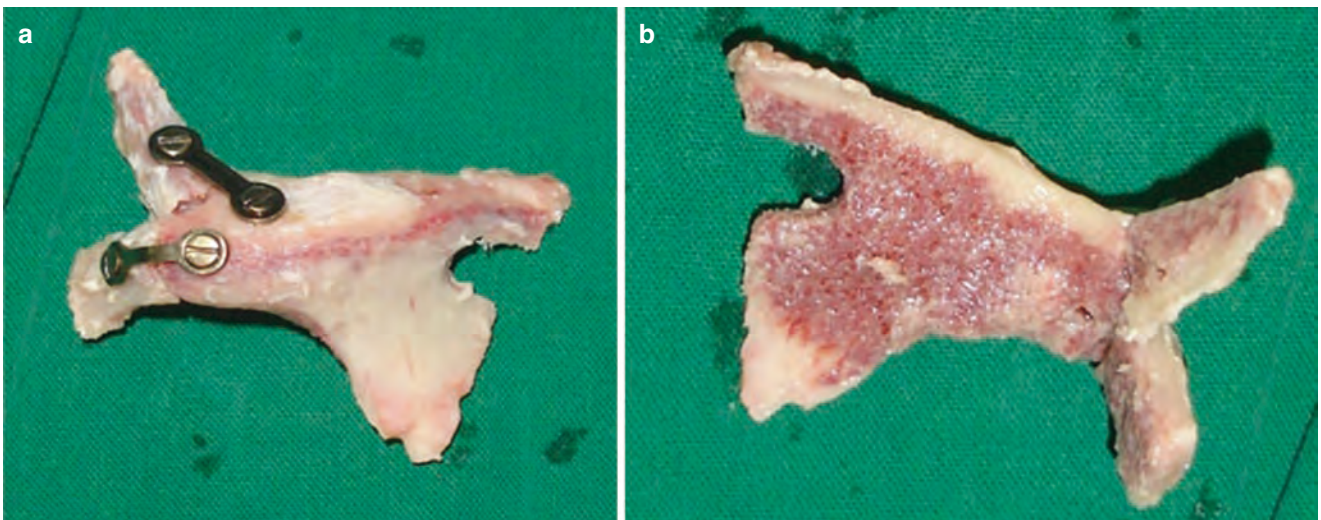


Fig. 61.15 (a, b) Sculptured iliac bone onlay graft

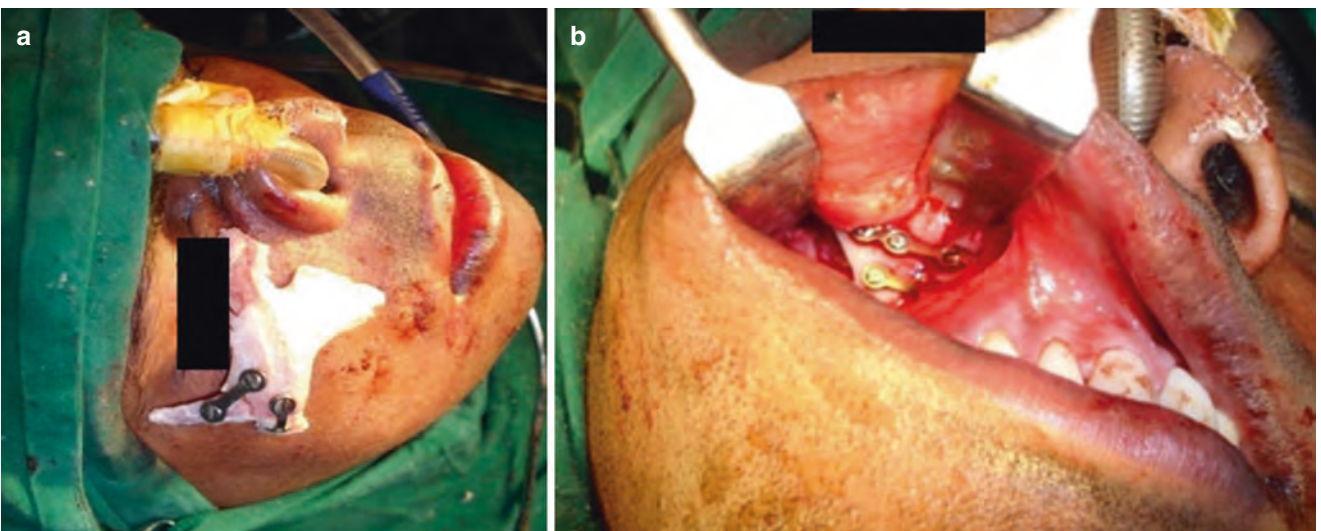


Fig. 61.16 (a) Onlay graft positioned on the patient. (b) Onlay graft plated to the maxilla

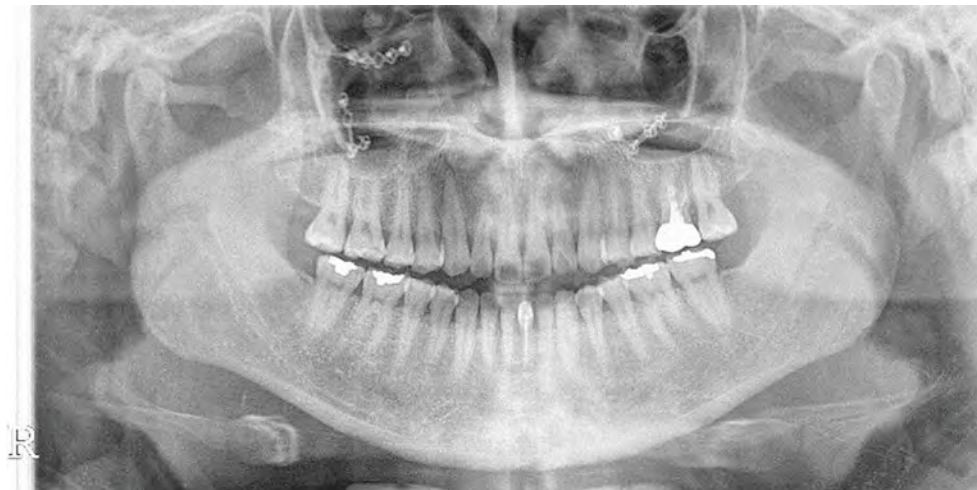


Fig. 61.17 Patient complains of open bite, malocclusion, deviation of maxilla and TMJ tenderness after trauma surgery. Preoperative OPG showing malunion in maxilla and malocclusion. (Reference for Figs. 61.17, 61.18, and 61.19: Kim, Sang-Yun et al. “Post-operative mal-

occlusion after maxillofacial fracture management: a retrospective case study.” *Maxillofacial plastic and reconstructive surgery* vol. 40,1 27. 15 Oct. 2018, <https://doi.org/10.1186/s40902-018-0167-z>. (<http://creativecommons.org/licenses/by/4.0/>), springer open

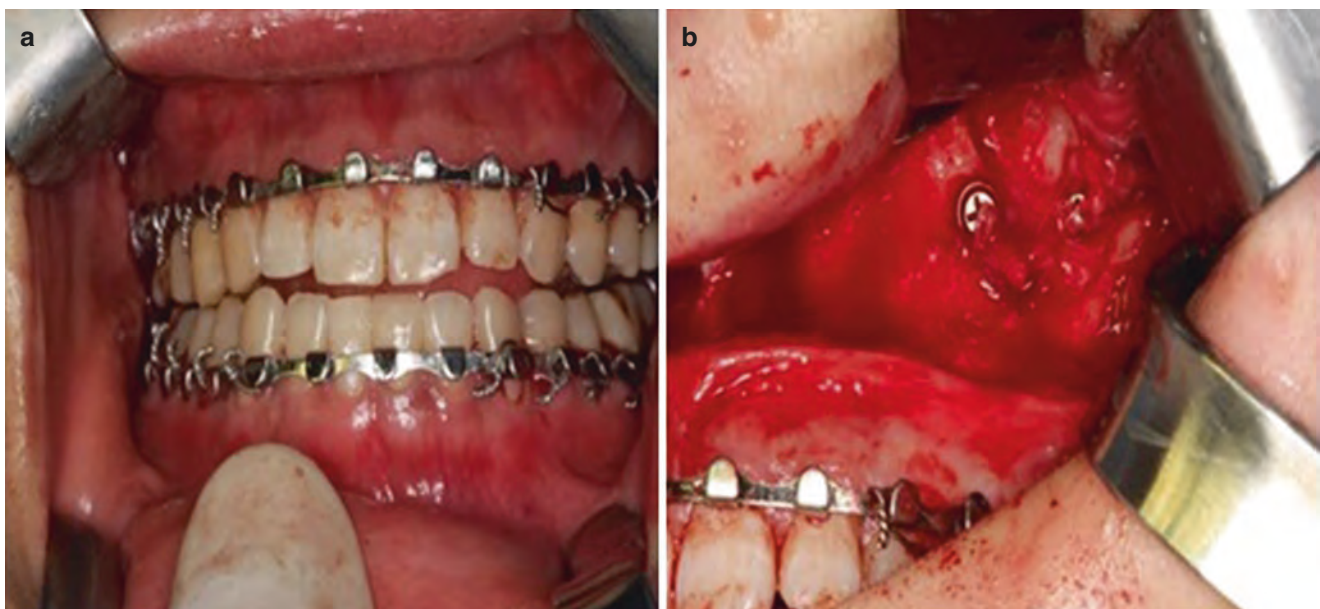


Fig. 61.18 Photograph during the operation. (a) Shows severe malocclusion before second operation. Arch bar placed for intermaxillary fixation. (b) Fracture site exposed, malunion segments detected

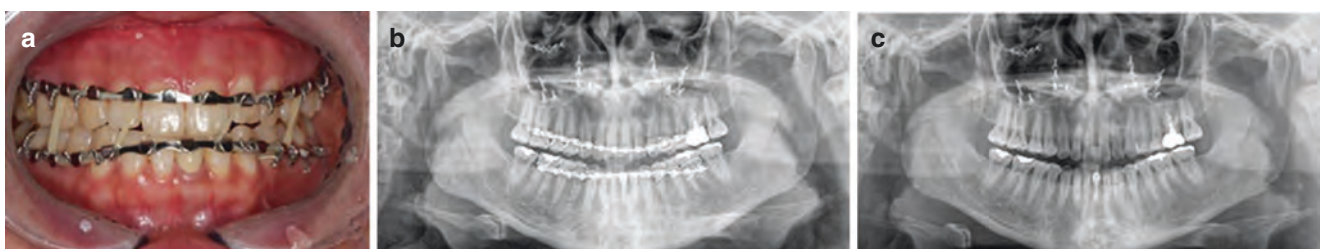

Fig. 61.19 Le fort I osteotomy done under general anaesthesia to resolve malunion and malocclusion. TMJ pain resolved following the treatment. (a) Post-operative (1 month) photograph showing resolution of malocclusion. (b) OPG after 1 month. (c) OPG 1 year after operation

soft tissue displacement or necrosis may result in enophthalmos and/or downward displacement of the globe.

- **Diplopia:** Usually due to severe dislocation of the eyeball, but severe diplopia may more likely occur as a consequence to trauma to the cranial nerves, scarring of the extraocular muscles or prolapse and entrapment of orbital soft tissue. Waiting period before re-treatment of diplopia neural and muscle damage is at least 12 months and 15 months, respectively, to observe if the diplopia subsides. Diplopia is differentiated into heterotropia and heterophoria. While sometimes heterophoria may not even need a correction, in certain cases of severe heterotropia, the patient is advised to maintain a titled head position to avoid any double vision. Sometimes double vision may persist even after the fracture has been corrected.
- **Paraesthesia of the distributing area** due to crushing or tearing of the nerve within the infraorbital canal or foramen. Recovery of the nerve by itself may take at least 1 year.
- **Limited mandibular movements** are caused due to a depressed zygoma impinging on the coronoid process of the mandible, restricting the free excursion of the coronoid process. Patient complains of difficulty to open the mouth, and some cases of difficulty to close the mouth may be due to an open mouth during the blow to the zygomatic complex.
- **Pseudoarthrosis** between the coronoid process and temporal process of the zygomatic bone may occur rarely in old untreated cases [72].

Indications for Surgery: [3]

- Aesthetically *unacceptable asymmetry of the orbital rims*. Pathological difference between the two malar prominences more than 5mm.
- **Diplopia** caused due to downward displacement (*more than 3mm*) of the eyeball due to orbital floor displacement and *not primarily due to neural or muscle damage*.

Table 61.3 Radiographic assessment for detecting malunion at fracture sites

Type of x-ray/view	Use
Occipito-mental (Waters View)	To examine fronto-zygomatic suture, inferior orbital rim and maxillary sinus
Postero-anterior view	To examine orbital floor and rim
Vertico-submental	“Jug-handle” appearance. To view zygomatic arch
Tomograms	To examine orbital floor, space between coronoid process and zygomatic arch
CBCT	To obtain and study oblique images from the three-dimensional data for fracture detection, displacement evaluation, soft tissue herniation

- **Enophthalmos in combination** with displacement of the orbital floor.
- **Paraesthesia of the orbital nerve** after at least 12 months of post-surgical repositioning of bone fragments.
- **Depression of zygomatic arch** impinging the coronoid process that is radiographically evident in causing limited mandibular movement.

Surgical correction of traumatic zygomatic complex fractures is discussed in Chap. 56.

Treatment options: [3] (Chart 61.6) (Table 61.4)

Surgical approach is decided once the operative procedure has been finalised. Common approaches include [3]:

- Periorbital (Chart 61.7)
- Preauricular (Chart 61.7)
- Oral (Chart 61.8)
- Old facial scar

Complications: [3]

- Failed surgery due to insufficient fixation of the re-fractured site or failure due to the implanted materials.
- Untreated pre-existing chronic sinusitis may result in an orbital abscess or phlegmon.
- Serious complications that may lead to blindness.
 - Fracture of bone at the optic canal
 - Misplaced implant that may result in compression of nerve
- Retrobulbar haemorrhage

61.3.7 Secondary Orbital Reconstruction [5, 72, 73]

Post-traumatic secondary deformities include:

- Enophthalmos
- Dystopia

Both deformities are difficult to correct.

Factors Responsible for Globe Malposition:

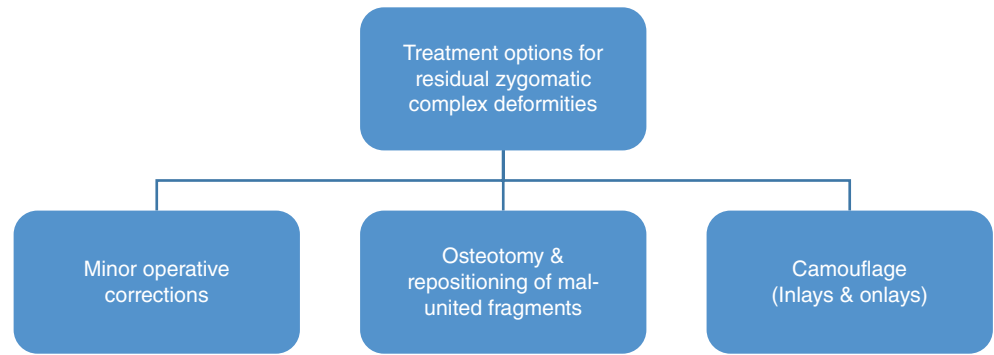
- Displaced or missing periorbital bone
- Orbital fat loss
- Contracture of scar

Factors Responsible for Enophthalmos:

- Pathological increase in bony orbit
- Dislocated zygomatic bone

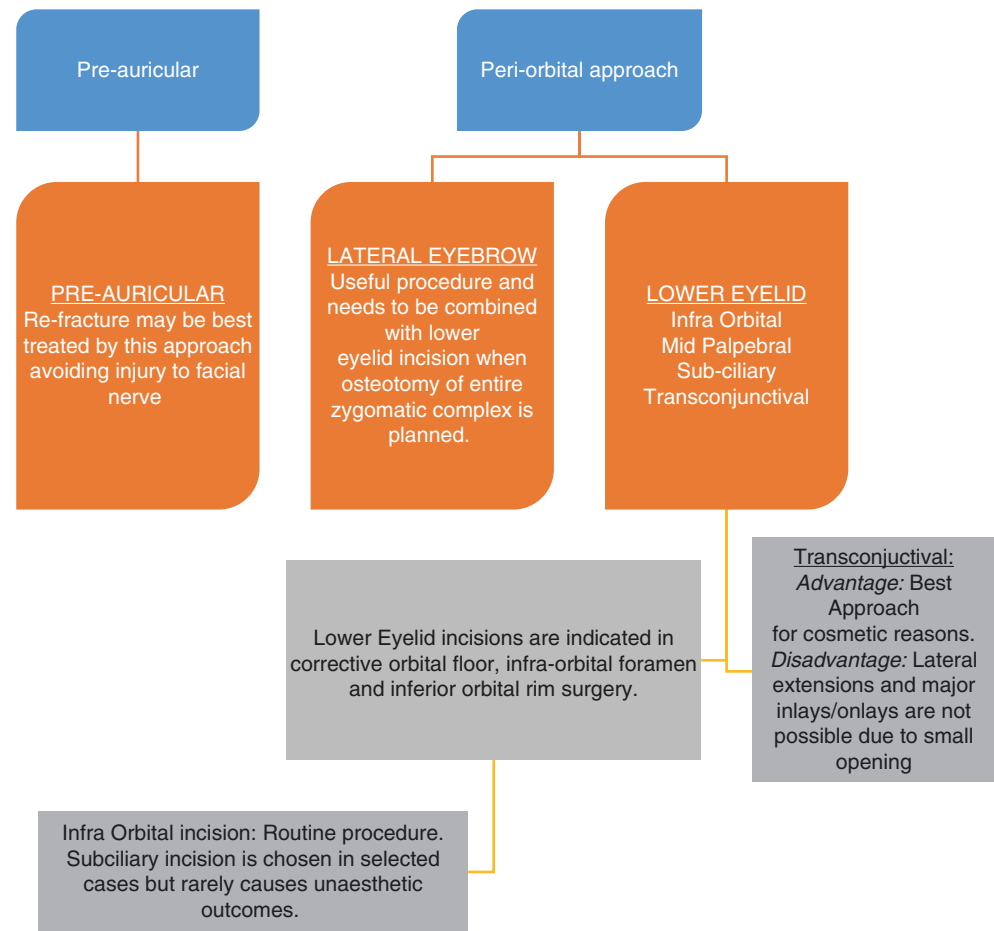
Rotated and displaced zygomatic bone leads to separation of the structures from its normal articulation with the greater wing of the sphenoid and maxilla. A substantial increase in the volume of the orbital cavity is accompanied by fissures along the floor and lateral wall of the orbit. Also, naso-ethmoidal fractures can result in canthal distortion and mal-

Chart 61.6 Treatment options for residual zygomatic complex deformities



©Association of Oral and Maxillofacial Surgeons of India

Chart 61.7 Treatment options for residual zygomatic complex deformities—Preauricular and periorbital approach



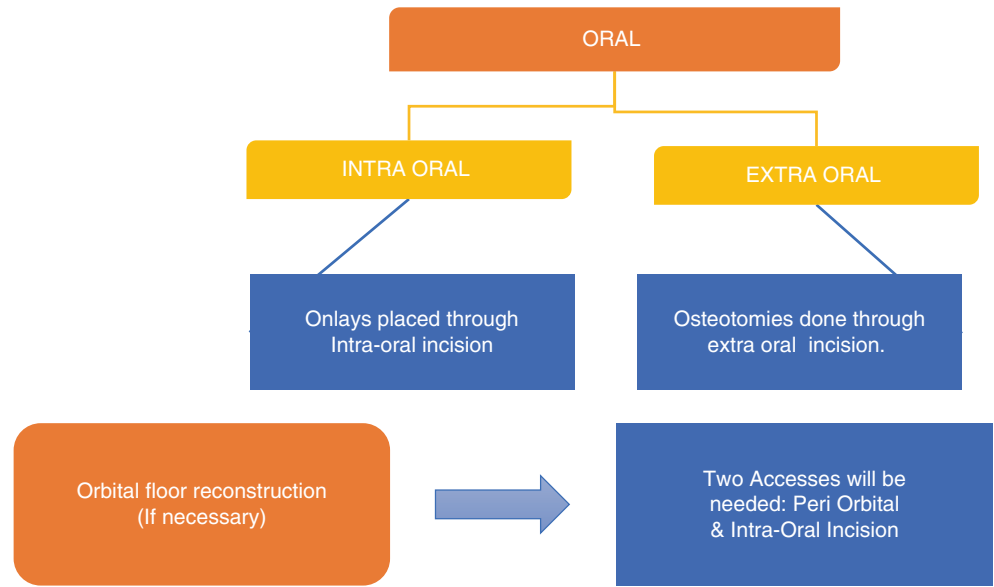
©Association of Oral and Maxillofacial Surgeons of India

position. Telecanthus and canthal height distortion can be difficult to correct if there is a significant loss of soft and hard tissue.

Any excess or deficiency in the horizontal position of the globe is called dystopia and is easier to correct. Inferior displacement (horizontal displacement) is managed by aug-

menting the sub-periosteum of the anterior orbital wall, anterior to the axis of the globe. This technique helps to produce superior movement of the eyeball but does not correct enophthalmos even with the overall decrease in orbital volume [5].

Chart 61.8 Treatment options for residual zygomatic complex deformities—Oral approach



©Association of Oral and Maxillofacial Surgeons of India

Table 61.4 Surgical options for zygomatic residual fractures [3]

Indications	Clinical presentation	Treatment
Removal or reposition of mal-united fragments	• Sequelae of old, mal-united and consolidated fracture of zygomatic complex	Corrective surgery considered
	• No disturbance to intercuspation and occlusion	No major osteotomy is indicated
	• No abnormal ophthalmic findings • Good overall symmetry and harmony of the face • Visible bony step at the orbital rim	<i>Surgically removed</i> through lower eyelid incision. During this, the orbital floor needs to be observed for any adhesions
Paraesthesia	• Persistent paraesthesia is an indication for surgery	<i>Infra orbital foramen</i> is widened to free the nerve When only paraesthesia is present—can be accessed through an intra oral approach When additional exploration of the infra orbital canal is required—lower eyelid incision is indicated
Depressed Zygomatic arch	• Hindering the coronoid process’ free excursion	<i>Refracture, reposition and wire fixation</i> Surgical Approach: Curvilinear, pre-auricular and/or lateral eyebrow incision <i>Older surgical approach:</i> Removal of coronoid process
Complete Zygoma Dislocation	• Depressed malar prominence, caudally displaced eyeball and diplopia	<ul style="list-style-type: none"> • <i>Treated with osteotomy</i> • <i>Camouflage surgery</i> as a second option • Lateral eyebrow incision and infra-orbital incision to explore the zygomatic complex and detach from the frontozygomatic suture at the inferior orbital margin, inferior and lateral walls of the orbit, and the zygomatic arch (if necessary) • Reposition the segments • Fixation of the fragment is further assured by placing bone graft in the gap in lateral or inferior orbital rim • Orbital Floor is finally covered with lyophilised dura. Procedure is done to ensure good support to the malar bone and orbital floor
	• To prevent post-operative relapse after above surgery	<i>Over compensate</i> the pre-operative displacement to a certain extent
	• If downward displacement of globe is not completely resolved after the surgery.	<i>Free transplant of lyophilized dura could be an option</i>

Enophthalmos: [5]

Managing post-traumatic secondary enophthalmos involves reducing the volume of orbital cavity posterior to the globe axis. The three-dimensional anatomy of both external and internal structures of the bony orbit should be restored efficiently by refracturing and rearticulating the skeletal framework (including zygomatic bone).

- The zygomatic bone may be accessed by complete exposure using surgical techniques to free the bone and also to establish the correct alignment.
- The zygomaticofrontal suture and the zygomatic arch are exposed through the coronal flap, and facial and muscular connections including the masseter muscle are released.
- Inferior orbital rim and orbital floor are exposed through a lower eyelid incision. Upper lip gingivobuccal incision is done to uncover the zygomatico-maxillary articulation.
- Bony cuts mimicking zygomatic complex fracture are made with a reciprocating bone saw.
- The zygomatic bone is freed and then replaced into the new position with rigid fixation. Necessary bone grafting needs to be done to close the gaps and also to augment the orbital volume.
- The globe should be left slightly exophthalmic (1–2 mm). If an autologous bone is used in augmenting the orbital volume, this exophthalmos is left behind expecting resorption over the next few months. However, this may be difficult to achieve in cases of excessive scarring.
- Placement of the graft plays a very important role as improper placement of grafts, or displacement into the intramuscular cone can result in dysfunction of the extraocular muscles or damage/injure the optic nerve.
- Management of complication: Creating safe pockets for the graft by carefully dissecting off the periorbita from the underlying bone. The grafts may be placed external to the extraocular muscles if the periorbita had been disrupted from previous trauma.
- Enophthalmos and diplopia may worsen further due to scarring or displacement of the implant. However, post-operatively globe position may moderately improve and is often long-lasting [5, 72–74].

Complications in Correction of Enophthalmos: [12, 74]

- Worsening vision.
- Diplopia—may improve to certain degree.
- Dystopia.
- Persistent enophthalmos.
- Graft displacement/retrobulbar hematoma may result in changes in vision.
- Pressure from grafts posterior to the globe may result in retinal folds and ischemia.

Telecanthus: [74]

- Lateral displacement of the medial canthus is called telecanthus.
- Corrected using medial orbital osteotomy by positioning the tendon and the overlying soft tissue medially.
- Bone cuts that are made along the fracture lines (typical as in nasoethmoid complex fractures) help to free bone segment that inserts into the point of the tendon, followed by medially relocating the bone to its normal anatomical location.
- Rigid fixation of the bone is done to the surrounding bone over the maxilla and inferomedial forehead. Autologous bone grafts may be used to replace missing bone segments.

61.3.8 Nasal Deformities [3, 75]

Residual nasal deformities occur as a consequence of the displacement of bony and cartilaginous components of the nasal skeleton. The basic anatomy of the nasal skeleton includes the nasal bone and the cartilaginous part of the nasal septum. The frontal process forms the lateral walls, and the vomer forms the osseous part of the nasal septum. The nose is the most commonly traumatised area due to its prominent central location and its elevation from the frontal facial plane. However, secondary deformities to nasal trauma are not rare [3].

Reasons for secondary nasal deformities [75]

- | | |
|---|--|
| <ul style="list-style-type: none"> • Inadequate diagnosis • Improper patient selection • Inadequate surgical skills • Improper surgical planning • Inadequate primary treatment • Delayed primary treatment • Inadequate post-operative stabilisation • Post-operative recurrent trauma | <ul style="list-style-type: none"> • Unstable bony and cartilaginous structures due to fracture • Poor nasal septal management—aggressive septal management • Poor nasal narrowing • Poor management of nasal tip/base surgery • Improper intranasal incisions (too many or incorrect) • Incorrect dorsal hump reduction |
|---|--|

61.3.8.1 Potential Complications Associated with Nasal Deformities [3] (Chart 61.9)

Clinical Evaluation: [3, 75]

The patient needs to be aware and educated on the options for a secondary rhinoplasty to correct the residual nasal deformities as the pathology may concern the functional and cosmetic needs of the patient.

- The intensity of the trauma is relative to the type of deformity that may follow.
- Initial low intensity trauma → nasal tip may become malpositioned. There is an evident inward rotation of the lower portion and an upward-outward rotation of the upper portion. This results in a depressed supra tip and a small cephalic hump.
- Increased force → fracture of the bones, cartilage or the nasal dorsum
- Incomplete fracture → late deviation

Preoperative Examination: [3]

- Identify the aesthetic and functional concerns of the patient
- External examination of the nose and the face as a whole
 - Deformity
 - Symmetry
- Internal examination with endoscope and speculum
- Airway examination
- Radiological examination to aid in diagnosis

Morphological Considerations: [3]

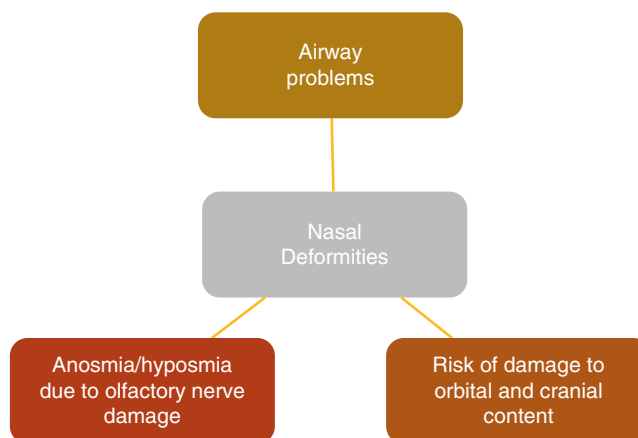
- Profile:
 - Shape/contour
 - Prominence of the nasal bridge
- Symmetrical position: Position and relation with the naso-orbital angles
- Degree of angulation and contour of frontal and the nasal margins at nasofrontal angle
- Evaluation of naso-labial angle

It is important to evaluate the injury as it may be related to [3]

- Exterior framework
 - Posterior ethmoidal maxillary bony base
 - Superior fronto-ethmoidal complex
- Residual deformities may fall in the following groups and are discussed in brief*
- Deformities of the nasal bridge or nasomaxillary region.
 - Deformities of the naso-orbital angle or naso-ethmoidal region.
 - Deformities associated with nasofrontal angle.
 - Complex deformities involving the naso-ethmoido-frontal complex.

61.3.8.2 Deformities of the Nasal Bridge or Nasomaxillary Region [3]

Deformities involving the nasal bridge and lateral walls of the nose not extending into the frontal or orbital regions.



©Association of Oral and Maxillofacial Surgeons of India

Chart 61.9 Potential complications associated with nasal deformities

Pathogenesis:

- Fractures of → nasal bone, frontal process of the maxilla, septal cartilage → untreated and/or inadequately treated fractures, displaced fragment → resorption associated with fibrous union/malunion with excess callus formation.
- Malunion depends on the direction and point of contact of the blow of the original injury.
- Residual callus and subsequent deformity will be evident following fracture of bony or cartilaginous structures or both tissues.
- Force directed from the lateral aspect → deviation of the bridge and lateral wall to the opposite side.
- Force → antero-posterior plane → depression of the nasal bridge and crushing of associated supporting posterior bony elements.
- Blow from the lateral aspect → displacement or bent/twisted nature of the nasal septum → one surface of the septum is therefore outwardly bent → airway obstruction.
- Impact → antero-posterior or sagittal plane → telescoped or folded septum → reduces nasal patency → obstruction of airway

Clinical Features:

- Obvious external deformity—esthetic concern for the patient.
- Nose deviated towards one side or crushed inwards or both deformities together.
- Deviation → curvature of the septum.
- When seen from the front, the bridge and the dorsum of the nose may appear to be in a straight line, but the tip and the base of the septum are deviated, also leading to deformation of the nasal orifice.

Nose:

- Convex on one side (*or*) upper half/lower half—convex, another half—concave.
- Tip of nose may often be straight but is angulated when the cartilaginous dorsum is displaced.
- Profile—straight or depressed along the entire length/ depression confined to nasal prominence (upper or lower half).
- Malunion of septal component—deformity leading to alteration in patency of the nasal airway.
- Narrowing of patency—Unilateral or bilateral → ultimately leads to obstruction.
- Nasal disturbances—Important to evaluate with age, occupation, pre-existing illness or any pulmonary pathology.
- Nasal airway disturbance → may lead to complications of airway tract and paranasal sinuses.
- Depression of nose—depression along the entire nasal crest or depression involving only the lower half.

Surgical Approach for nasal deviation:

- Intranasal approach for aesthetic rhinoplasty—this avoids any external cutaneous scars.
- Dissection is done by Separating or freeing the external investing tissues → elevation of mucous membrane that lines the nasal fossae.
- Dissection includes separation of underlying soft tissues and separation of mucosa.
- Bony and cartilaginous structures freed from the external and internal harvesting tissues.
- This is followed by chondrotomies and osteotomies.
- Chondrotomies are done to mobilise the septal cartilage.
- Osteotomies are done to reduce the displacement of the nasal bridge and dorsum – lateral and median osteotomy.
- Immobilisation aids in maintaining the fragments in position during the union. Careful immobilisation is done internally and externally.

61.3.8.3 Depression of Nose [3] (Saddle-Shaped Deformity)

Treatment differs based on extent of the deformity along the nasal crest (entire length or lower half).

- This deformity is best treated with placement of a bone graft in the region of depression of the bone.
- Intranasal: Best indicated surgical approach but less nasal exposure is a disadvantage.
- Vertical columella incision: Gives good exposure but may leave scars.
- A combined incision with both internal and external incision gives best exposure and leaves a less obvious trans-nasal scar in the anterior one-third of columella. This is almost invisible in the upright position due to its presence in a “dead angle”.

- Surgical steps involve preparation of bony bed at receptor site and preparation of bone graft for placement.
- Stabilisation of bone graft by firm fixation in median, vertical and sagittal planes. Ensure the maintenance of columnar support.
- Sutures placed with adequate immobilisation.

61.3.8.4 Depression of Lower Half of Nasal Crest [3]

Two types of concepts are followed in treatment of such deformities:

- Reduce false or relative prominence by resection of upper half of the nasal crest. Nasal profile is converted to being straight. This might increase the width of the upper half of the nasal crest for which osteotomy of lateral walls may be essential. This concept is to be applied when adequate nasal bone is available to produce a healthy and aesthetic profile.
- The other concept involves the placement of a cartilaginous graft to cover the depression. Fixation may however be difficult in this scenario.

61.3.8.5 Naso-Orbital Deformities [3]

Deformities not only involving the nasal pyramid but also affecting the ethmoid and maxillary components.

Pathogenesis:

- Severe impact → nasal complex → results in extension of fracture lines and displacement of associated components.
- Deformities may extend into the frontal process of the maxilla and the two orbital plates of ethmoid bone (which support the nasal bones).
- Due to the complex anatomy of this region, various combinations in deformities, fracture pattern, injury and pathology may be seen.

Anatomical Characteristics: [3]

Frontal process of the maxilla—

- Determines the morphology of nasal pyramid.
- Determines the orbito-nasal angle
- Forms the lacrimal fossa (anterior part)
- Serves as a point of insertion for the medial palpebral ligament in the anterior crest

Ethmoid bone—

- Determines the formation of lacrimal canal on lateral aspects.
- Continues posteriorly as the orbital plate which forms the medial wall of the orbit.
- Contributes to the formation of the posterior part of the nasal septum.

Clinical Features:

Nasal crest—

- Deviated or often depressed → consequent lateral displacement or antero-posterior crushing of the nasal bones.
Orbito-nasal angle—
- Reduced/obliterated/displaced outwards
Widening of bridge—
- Due to displacement of frontal processes of the maxillae outwards and backwards
- Due to malunion of a comminuted type of fracture.
Displacement of medial canthus—
- External displacement may produce telecanthus.
- Anterior displacement will further increase in obliteration of the orbito-nasal angle.
- Inferior dystopia—vertical displacement deranges the symmetry of two medial canthi.
- Dystopias are due to the bony fragments impinging on the tissues and causing rupture of the medial canthal ligament, avulsion of the ligament and displacement of frontal process of maxilla which houses the medial canthal ligament.
Lacrimal passages—
- The lacrimal canal is blocked due to discontinuity in nasolacrimal apparatus. Bony fragments of comminuted fractures may cause tearing of the lacrimal sac. This may result in epiphora.
- Epiphora → watering of eyes → dacryocystitis.
Nasal airway patency problems due to —
- Deviation of posterior part of nasal septum.
- Blockage caused by nasal septum may further be accentuated by displacement of anterior cartilaginous part of the nasal septum.

Essentials in Correcting the Deformity:

- Repair the base of the nose.
- Repair the naso-orbital angle.
- Restore the lacrimal passages.
- Nasal reconstruction must be carried out while correcting the above mentioned during the same procedure.

61.3.8.6 Surgical Management

Key Points in Treatment:

- Reconstitution of the nasal base is the basic procedure in reconstruction of the nasal pyramid. It has to be supported by a solid base.
- Base has to be aesthetically appealing, smooth, regular and well proportioned.
- Reconstitution of the naso-orbital angle is essential.
- Symmetrical placement of the two medial canthi is necessary. Any asymmetry can affect the appearance of the nose.
- Approach to the lacrimal passages may be obtained by dividing the medial canthal ligament that can be reattached later.

- Quality of repair is subsequently affected in cases of infected lacrimal passages.
- Any deviation of the nasal septum negatively influences nasal reconstruction.

61.3.8.7 Nasofrontal Deformities [3]

Deformities due to secondary post-traumatic lesions involving not only the nasal pyramid but also the nasal base and area of the frontal bone. Concentration of injuries at the nasofrontal angle is proportionate to the degree of violence encountered, thereby resulting in fractures and displacement of tissues.

Nasofrontal angle profile is affected by

- Frontal region (median)
- Paranasal region (inferior)
- Secondary malunited callus

Pathogenesis:

- Trauma → nasal spine of frontal bone → displacement of nasal spine involving middle part of the inferior wall or floor of the sinus
- Trauma → anterior wall of sinus → fracture extending into the anterior wall of sinus or posteriorly communicating with the posterior wall
Lesions on anterior wall—
- When isolated and not involving the other walls → has only aesthetic significance
- Malunited depressed fracture → hollow midline → significant reduction of the nasofrontal angle
Lesions of inferior wall—
- Depression → hollow midline → reduction in nasofrontal angle → has a cosmetic influence and also affects patency of frontonasal duct → blockage of canal → blockage of outflow tract
- Lateral aspect of lesions → involving medial portion of orbital roof → deformed naso-orbital angle → subsequent risk of spread of the infection
Lesions of posterior wall—
- Injury in this zone affects the brain and the meninges.
- Fracture → unhealed fissures → spread of infection to the meninges.
- Deformity in the continuity of bone → herniation of the brain and meninges.
- Sharp bony defect → penetrates the meninges → CSF rhinorrhoea.
Associated lesions—
- When more than one wall is involved → increased deformity of the nasofrontal angle → complications in sinus drainage, brain and meninges
- Resorption of fractured margins → loss of continuity in the anterior or posterior walls → deformed nasofrontal angle

Clinical Features:

- Profile is altered—depression and deviation of nasal bones → unaesthetic profile of the frontonasal angle.
- Greater degree of depression is relative to the retrusion or displacement of middle frontal segment posteriorly, extending above the orbits as far as the bridge of nose.
- Resorption or loss of bony tissue → protrusion of tissue between bony margins → meningocele → increased prominence.

Associated pathological changes—

- Osteitis in fracture zone
- Improper drainage → persistence of infection
- Meningitis
- CSF rhinorrhoea
- Brain abscess

Essentials in Surgical Management:

- Morphological and functional defects should be corrected to avoid any vital injury in the future.
- In case of depression of the nasal crest and deformities involving only the anterior wall of sinus, onlay bone graft is essential to augment the defect.
- Grossly deranged sinus must be treated first and then followed by nasal reconstruction.
- Grafting is not enough when deformities involve the inferior wall/floor and/or posterior wall as it carries the risk of damaging the sinus, brain and meninges.

The principles of the management of nasofrontal deformities in delayed conditions are similar to managing post-traumatic nasofrontal deformities but should be done with caution and must address associated complications seen at the stage of delayed management. In case of nasofrontal deformities, it is important to address post-traumatic dehiscence of frontal sinus wall in delayed management cases. Certain degree of bone loss due to resorption is seen during the post-traumatic phase, and this may increase when the management is delayed. Hence, in such cases it is important to be cautious in resection of minimal tissue of the posterior wall, and it needs to be carefully performed. Reconstruction of the anterior wall with bone grafts may be done, also including the orbital roof and the ethmoidal region if necessary [3].

61.3.8.8 Naso-Fronto-Ethmoidal Deformities [3]

Deformities involving the nasal bony mass are caused due to greater degree of force. The impact may extend as far as the ethmoid bone which forms the upper wall/roof in the posterior part.

Pathogenesis:

- Fractures lines extending from the front, passing behind and across the nasal spine and extending into the cribriform plate
- Displacement due to fracture → affects the passage of olfactory nerve → further lacerates the dura mater → cerebrospinal fluid leakage or CSF rhinorrhoea

Clinical Features:

- Clinically, it may be similar to the deformities involving nasofrontal fractures. A mere extension into the cribriform plate does not increase the severity of the deformity. Features may differ based on the involvement of anterior wall.
- Anosmia—loss of smell sensation.
- If the meningeal tear is not sealed immediately → CSF rhinorrhoea.
- The meningeal tear is always predisposed with long-term risk of leak (even after the leakage has dried) due to lack in quality of scar tissue and increased permeability of the malunited callus.

Essentials in Management of Naso-Fronto-Ethmoidal Deformities:

- Surgery may be carried out by combined neurosurgical and maxillofacial teams.
- Meningeal tear repair can be managed by trans-ethmoidal (low level) approach. However, trans-frontal approach is considered to be safer and effective.
- Sinus-associated lesions should be managed along with nasal reconstruction procedure.
- *The principles of the management of naso-fronto-ethmoidal deformities in delayed conditions are similar to managing post-traumatic naso-fronto-ethmoidal deformities or naso-orbito-ethmoidal complex fractures but should be done with caution, addressing associated complications seen at the stage of delayed management.*

61.3.8.9 Delayed Management of Orbital Hypertelorism and Naso-Orbito-Ethmoidal (NOE) Fractures [73, 75–77]

Acute trauma in the naso-orbito-ethmoidal region could result in chronic orbital and naso-orbital deformities. It is important to be aware of the acute injury to correct the defor-

mity that will be established later. Secondary late corrections in cases of severe orbital hypertelorism may be very difficult to correct. The severity of orbital hypertelorism can be assessed with the help of Tessier score.

Traumatic orbital hypertelorism due to NOE complex fractures

Goals of management:

- Symmetrical restoration of medial canthal anatomy
- Maintenance of physiologic function of the lacrimal system
- Avoid frontal sinus-related complications
- Restoration of globe position and volume

Surgical Management:

- Coronal approach gives the most predictable access and visualisation for the surgeon.
- Frontal sinus should also be evaluated and operated at this stage.
- Reconstruction should be considered in the following order starting first with cranial base, frontal region and outer orbital zone, followed by fixation of the orbital rim and frontonasal buttress. Grafts and plates may be used to restore the nasal dorsum and nasal projection.
- It is then followed by repositioning and fixation of the mini-plate in the medial orbital wall and medial canthal tendon. Mesh and trans-nasal wiring may be used for repositioning the displaced medial canthal tendon.
- It is important to establish a good frontonasal angle and nasal projection to have good aesthetic outcome. Deformity could result in poor aesthetics when there is poor frontonasal angle and poor nasal projection along with orbital hypertelorism.

61.3.8.10 Secondary or Delayed Management of Orbital Hypertelorism Associated with NOE Complex Fractures [75–77]

- Goal is to restore the normal interorbital distance.
- Acute management of chronic long-standing deformities is essential. It is very difficult to correct severe orbital hypertelorism, especially in cases which includes intracranial osteotomies. Such cases are associated with

increased post-operative morbidities. Subcranial osteotomies may be opted in milder cases.

- Aesthetic and functional outcomes in late correction may not be satisfying, and hence the best strategy is to repair the deformities as early as possible following the first injury and hence not delay the treatment.

61.3.8.11 Conclusion

- Repair and reconstruction of nasal deformities are often challenging and technique sensitive for the surgical team (maxillofacial and neurosurgical). It is emotionally and psychologically challenging for the patients as well. Hence, it is essential to identify the pitfalls and carefully carry out the surgical treatment plan. Sometimes, further revision may be necessary even with the best planned surgical procedures. Therefore, it is important for the surgeon and the patient to understand the limitations of the available surgical techniques.

61.4 Post-oncological Deformities

Management of Post-oncological Deformities:

Post-oncological deformities here refer to the soft tissue and hard tissue defects that may be encountered following a primary treatment. Unlike a primary cosmetic therapy, predicting the result of an oncological treatment is often more technique sensitive and should be considerate in establishing the overall physical and mental well-being of the patient. Management of deformities should also aim at a comprehensive functional, aesthetic and social well-being of the patient.

Reconstruction of soft tissue and hard tissue structures following trauma or oncological surgical therapy is primarily essential. Correction of the residual deformities should be carried out along with the principles of reconstructive management.

Reconstruction generally includes the following steps in management [78]:

- Healing by secondary intention
- Primary closure
- Grafting—split or full-thickness graft
- Composite grafts
- Local grafts
- Regional pedicle grating
- Free tissue transfer

We have already discussed in detail the use of above methods in management of traumatic residual deformities in this chapter.

Recurrences, untreated tumours and metastasis which are considered to be residual in nature after primary management are not considered under management of post-oncological deformities. It is important for the surgeons to be more accurate with the surgical margins when surgically operating malignancies. Any re-surgical procedure for recurrence or deformities is often challenging due to factors like previously irradiated areas, previously operated surgical field, under nourished status due to the pre-existing malignant condition and also due minimal surgical options for such patients.

Residual deformities associated with post-oncosurgery results in external facial disfigurement/defects, intra-oral defects and also changes that may affect certain functions. These deformities are often relative to structures which were primarily involved and their corresponding functional deformities. Deformities occurring following surgical treatment of head and neck oncology usually require reconstruction procedures as the complete removal of tumours with margins may involve increased loss of soft or hard tissues.

61.4.1 Lip Deformities [79–83]

Post-oncosurgical defects of the lip are often seen with loss of tissues. Management of such defects is usually considered according to the size of the defects. Secondary deformities of the lower lip after reconstruction are described in (Table 61.5), and they need to be treated accordingly with cosmetic surgeries. *Lip reconstruction is discussed in soft Tissue reconstruction chap. 86.*

Table 61.5 Secondary deformities of lower lip following reconstruction

Type of Flap	Deformities	Complications
Abbe	Relative Microsomia Trap Door deformity due to thickened scar	Vermillion notching Lip asymmetry Scarring beyond submental crease
Estlander	Commissure violation and may require commissuroplasty	
Karpandzic	Microstomia Inversion vermilion Flat mentolabial junction	Dysthesia or Anesthesia of lip
Gillies fan	Oral incompetence may result	
Bernard burrow	Adynamic reconstruction	Post-operative drooling

61.4.2 Management of Intra-oral Defects Involving Floor of the Mouth and Alveolar Ridge Tumours

Defects in these regions are relative to the size of tissues lost and may be corrected with augmentation and reconstruction procedures.

- *Correction of small intra-oral defects is best done with primary closure in the buccal and tongue region, but scar contracture is seen with grafting. Closure by secondary intention can be done in alveolar and hard palate defects where the scar contracture is insignificant [84].*
- *Correction of large intra-oral defects using free flaps is considered ideal in reconstruction procedures [84–86].*
- *Advanced large defects may be seen in cases which require large resection of tissues, as in cases of advanced tumours which may include cortical or segmental mandibulectomy, composite resections, and glossectomy (total/sub-total) procedure. These defects may also involve the lip or skin of the lower third of the face when tumour extends anteriorly [86]. Hemi- or partial loss of mandible may result in severe functional or psychological morbidity for the patients. The loss of anterior mandible results in a defect called as “Andy-Gump” deformity [87]. En bloc resection is best reconstructed with regional free tissue transfer or free flaps. Bony defects are managed with osteocutaneous free flap or with free tissue transfer.*

61.4.3 Management of Defects of Oropharynx

Oropharyngeal defects are managed with primary closure, skin grafts, local pedicle flaps and microvascular-free flaps. Current goals in reconstruction include restoration of the function and closure of defects as well.

61.4.3.1 Management of Soft Palate Defects [88]

- *Soft palate defects cause velopharyngeal incompetency resulting in inability to seal the oropharyngeal and nasopharyngeal cavity during speech and deglutition.*
- *Rhinolalia aperta is caused due to small soft palate defects leading to change in resonance of voice as a result of air escape due to incompetent velum.*
- *Smaller defects are best closed primarily or along with a split-thickness skin graft.*
- *Radial forearm flaps are used in cases following surgical ablation of soft palate and tonsillar defects.*

- *Large or extensive palatomaxillary defects* are managed with obturator prosthesis or with vascularised osteocutaneous free flaps.

61.4.3.2 Management of Tongue Defects [89, 90]

Tongue defects are usually difficult to treat and reconstruct. Management of tongue defects primarily involves improving the functional outcome.

- *Small defects* are managed with primary closure.
- *Large defects* are treated with myocutaneous flaps (rectus or pectoral major flaps and fasciocutaneous flaps)

61.4.3.3 Management of Posterior Pharyngeal Wall [90]

- Primary closure with/without split thickness skin graft is used for closure of small defects. Free flap reconstruction is necessary for large defects.

61.4.4 Deformities Associated with Intra-oral Disfigurement [91–98]

The primary goal in surgical management of oral tumours is to gain surgical access for assessment and visualisation of margins and anatomic relations for resecting the tumours. Surgical margins are vital in establishing a tumour-free zone. Although it is important to have a follow-up on recurrence of tumours and metastasis, it is the complex nature of the oral cavity and head and neck anatomy that requires careful yet skilful management of the adjacent normal tissues by proper closure and post-operative management.

The goal earlier was to achieve access to the tumours, but now it also involves incisions that will facilitate an aesthetic access to the pathology. Increased incidence of dehiscence and unaesthetic scar formation are common in neck incisions (with trifurcation extensions) that do not lie along the natural skin creases. Irradiated areas may cause worsening of scar appearance, or even superficial necrosis may occur. Inadequate, delayed and infected tracheostomy may also result in an unaesthetic tracheostomy scar formation. Prevention of unaesthetic scars can be done by careful tissue handling. It is also essential to protect the skin from additional trauma due to traction, tension or electrocautery. Flaps with adequate vascularity further help to minimise the chances of unaesthetic scars. Following access through the lip to certain tumours in the oral cavity, the site requires to be exactly oriented and aligned with the vermilion lip border, as well as interdigitating orbicularis oris muscle, re-orienting lip skin and oral mucosa to replicate lip competence, aesthetics and function [92–97].

Even though reconstruction of maxillectomy defects is an option, maxillary defects can also be corrected with prosthetic obturators. Maxillary obturator provides adequate structural support to preserve speech, swallowing and essential mastication. Clinically, a good obturator can be fabricated only by the skills of a good prosthodontist [98].

It is important to evaluate any history that may contribute to poor wound healing and also lead to post-operative wound dehiscence and compromised flap vascularity resulting in improper scarring.

61.4.5 Deformities Associated with Healing Tissues [91, 92, 99, 100]

Surgical procedure involving the upper aerodigestive tract through neck incision may lead to fistula formation as a result of salivary leakage.

The formation of fistulas is contributed majorly due to:

- Incision design
- Tumour type
- Tumour stage
- Improper surgical site management
- History of operative site
- Physical and nutritional status of patient

Biological Factors that Contribute to Fistula Formation:

- Effect of radiation on surgical wound closure: Radiation dose and timing play an important role in delayed wound healing, formation of fistula and dehiscence.
- Low oxygen tension: Proportional to flap vascularity and viability.
- Vascularity: Decreased blood supply affects the wound healing property.

Signs and Symptoms of Fistulas:

- Occurs post-surgery as early as 1 week and somewhere between 3 and 4 weeks in late cases of fistula formation. Persistent fistulas are present for more than 1 month.
- Low-grade fever.
- Inflamed and indurated areas of skin that facilitate the drainage.

Management:

- Early assessment of fistula can help to explore the surgical wound and aid in directing saliva from vital structures.
- Site may be explored, irrigated and closed. This is followed by antimicrobial therapy and nutritional support.
- Persistent fistulas are managed with excision of the fistulous tract with closure of oral mucosa and/or skin.

- Hardware failure due to infection can be managed with local debridement, removal/replacement of existing failed hardware and closure with local and regional flaps.
- Management can be combined with anti-cholinergic medications to decrease salivary flow if necessary and only if indicated.

61.4.6 Functional Deformities Associated with Oro-Oncological Surgery

Surgical cancer resection may cause the following functional defects [101]:

- Difficulty in speech, swallowing and chewing
- Difficulty in masticatory function and nutrition
- Neurological complications

61.4.6.1 Spinal Accessory Nerve

Iatrogenic injury may cause “shoulder syndrome”, for which physical therapy may help to improve the functional outcome. Pain, weakness of muscles, restrained shoulder movement, deformity of the upper extremity and inability to abduct upper extremity above 90degrees occur due to denervation of trapezius muscle [91, 92, 102, 103].

61.4.6.2 Phrenic Nerve

Iatrogenic damage causes paralysis of ipsilateral diaphragm. It may even result in long-term pulmonary complications. Such damage can be prevented by limiting surgical dissection to the layer superficial to pre-vertebral fascia and thereby prevent injury to nerve [92, 101, 104].

61.4.6.3 Hypoglossal Nerve and lingual Nerve [92, 101, 104]

- Iatrogenic damage to both the nerves is possible during head and neck dissection. This is aggravated with damage to lingual nerve during excision of tongue and floor of the mouth. Hypoglossal and lingual nerves are often preserved unless there is extensive neural invasion of the tumour.
- Hypoglossal nerve dysfunction/damage causes deviation of tongue to ipsilateral side of injury, tongue biting, dysarthria and difficulty in mastication and deglutition. Bilateral nerve injury may result in upper airway obstruction when the patient is in supine position. Atrophy of tongue muscles may also be observed.
- Damage to lingual nerve may cause ipsilateral loss of sensation, further impacting mastication, speech and swallowing. Injury to tongue during speech and mastication may also be observed.

- Rehabilitation by physical therapy is often useful for improving the speech and swallowing.

61.4.6.4 Vagus Nerve, Recurrent Laryngeal Nerve and Superior Laryngeal Nerve [91]

- Injury to these nerves may occur during dissection around the carotid sheath.
 - Injury to recurrent laryngeal nerve causes unilateral vocal cord paralysis. The damage is usually compensated by the intact contralateral vocal cord. Mild hoarseness is experienced by the patient. Upper airway obstruction is seen with bilateral injury.
 - Injury to branches of superior laryngeal nerve occurs due to dissection around the superior thyroid branch of external carotid artery. The following changes may be associated:
 - Minor swallowing difficulty
 - Decreased sensation in laryngeal inlet
 - Decrease in tensor capability of true vocal cord
 - Fatigue
 - Decreased ability to reach high phonated/pitched sounds
- Management usually begins with accurate diagnosis of the neurological origin. It is best to prevent such injuries with careful dissection.

61.4.6.5 Sympathetic Trunk [92, 101, 104]

Damage or disruption to the sympathetic trunk can result in ipsilateral Horner’s syndrome. Careful evaluation is necessary to diagnose Horner’s syndrome due to damage of nerve fibres, and it involves the following:

- Blepharoptosis (drooping of upper eyelid)
- Miosis or pupillary constriction
- Lack of perspiration of forehead skin
- Enophthalmos
- Vascular dilation (ipsilateral to injury)

61.4.6.6 Marginal Mandibular Branch of Facial Nerve [92, 105]

Injury to This Nerve Causes:

- Altered mobility of corner of the mouth as a result of disruption in innervation to orbicular oris and depressor anguli oris.
- Inability to control lower lip movements during liquid consumption.
- Functional and cosmetic disturbances are seen.

Management:

Careful design and incision considering the anatomic location of the nerve during flap elevation help to prevent

iatrogenic injuries and resultant deformities. It may take several months for neurosensory recovery when the neurologic injury is due to traction and not due to severance.

61.5 Recent Advances

61.5.1 Endoscopy in Residual Deformities [106, 107]

Recent trend in oral surgery includes the use of an endoscope to facilitate oral and maxillofacial procedures. Endoscopy techniques can be used in diagnosis and for treatment with minimal complications in many oral and maxillofacial surgical procedures like TMJ disorders, pathologies of jaw, nasal deformities, trauma and aesthetic procedures. The techniques and applications of endoscopy in oral and maxillofacial surgery are explained in detail elsewhere in this book. The advantages and applications of endoscopy-assisted maxillofacial surgical procedures make its usage a favourite option for maxillofacial surgeons. Minimal complications, good success rates and its efficiency make endoscopy-assisted procedures a viable option.

The following are the best-known applications of endoscopy currently in oral and maxillofacial surgery:

- Trauma
- Orthognathic deformities
- Obstructive salivary gland pathology
- Maxillary sinus surgery
- Trigeminal nerve injury
- Temporomandibular disorders
- Nasal deformities
- Trauma

Endoscopy-assisted minimally invasive technique is used in traumatic deformities like the following:

Orbital Floor Fracture: Requires trans antral approach. Care should be taken to protect the intraorbital contents like musculature, periorbita and optic nerve. Intraoperative conditions may necessitate the need for an additional periorbital approach during the surgery.

Mandibular Angle Fracture: Here, endoscopy can be used to fix the mandible with the superior and inferior plate with the best approximation possible. Endoscopic reduction helps in complete visualisation of the entire fracture line with inclusion of the inferior border. Management with endoscopy-assisted surgery also reduces the risk of facial nerve injury. A single transbuccal trocar technique is used for positioning

and fixation of the plates with easy visualisation of the fracture line. Some surgeons prefer a locking cannula for the precise placement of the fixation hardware. Endoscope is then used to confirm proper fixation and reduction, and it is then closed. Endoscope also aids in appropriate documentation of the procedure.

Sub-condylar Fractures: (Refer Chap. 54 on endoscopic approach for treatment of condylar fractures of mandible) Endoscopy can be applied in management of sub-condylar fractures by open technique, reducing risks of scars, fistula formation and facial nerve injury. Extra-oral and transoral approach may also be used. Although the procedure is technique sensitive, it is proposed with advantages of improved visualisation, magnified field of view, less trauma to tissues, less bleeding, better patient compliance, good reduction and decreased post-operative complications.

Frontal Sinus Fractures: Endoscopy in the management of frontal sinus fractures helps to avoid large incisions and its associated complications like alopecia, paraesthesia, scarring, nerve injury, etc. It helps in better visualisation of sinus wall fractures, nasofrontal duct and the posterior wall of sinus.

- The use of *endoscopy in orthognathic surgery* helps to visualise aspects of the osteotomy so as to improve the efficiency of the surgical outcome.
- Best application of endoscopy in salivary gland pathologies is the usage of sialoendoscopy in the diagnosis and treatment of salivary gland/ductal pathologies in a non-invasive manner.
- TMJ arthroscopy is another area that has gained greater attention.
- Endoscopy is also best utilised in removal of foreign bodies from the cranio-maxillofacial region as it allows visualisation of anatomical structures without extensive incisions.

Endoscopy in nasal deformities: is a developing concept, and there has been an increase in its extensive usage in sinus endoscopic surgeries. The use of endoscope in correction of septal deformities like deviation, aids in better visualisation of the target site and reduced time of the procedure. The primary advantages are improved field of view, reduced morbidity, decreased post-operative swelling and more accuracy in surgical procedure. Endoscopy in nasal corrections is very essential in cases that have gone for prior septal cartilage resection, reducing the need for repeated incisions or extent of dissection. Studies also suggest lesser post-operative symptoms in endoscopic-assisted nasal septal corrective surgeries [107].

61.6 Conclusion

Careful planning, eminent skills and excellent knowledge of the clinical anatomy are of utmost importance in carrying out secondary corrective procedures in treating residual deformities following trauma or oncological procedures. It is the skill of the surgeon to predict the functional and aesthetic outcome of the treatment so as to facilitate a proper treatment planning. It is also the role of the surgeon to educate the patient about the condition and options available for the correction, to provide the best possible outcome. It is recommended that surgeons use available imaging techniques (routine X-rays, CT scans, CBCT, etc.) in their treatment plans and also make best usage of the current trends in 3D models and visual planning software in treatment planning. The use of CAD/CAM-designed patient-specific alloplastic (e.g. Medpore, PEEK) implants should be considered in surgical management. Treatment plan should often accommodate recommendations from other specialities that may be a part of the surgical team.

Both soft tissue and hard tissue deformities should be dealt together in a well-planned manner to provide the patient with an acceptable aesthetic outcome and functional rehabilitation. Likewise, mastication and prosthetic rehabilitation can be aided by dental and zygomatic implants. Most often correction of residual deformities may go together with reconstruction of the lost structures. It becomes essential to carry out the entire treatment phase in a well-planned manner to provide the patient with a final, socially and psychologically acceptable outcome with or without post-operative physical therapy. Surgeons are also recommended to be updated about endoscopy-assisted surgeries and transoral robotic surgeries to further enhance the quality of outcome of the treatment.

References

Introduction

1. Ranganath K, Hemanth Kumar HR. The correction of post-traumatic pan facial residual deformity. *J Maxillofac Oral Surg.* 2011;10(1):20–4.
2. David DJ, Abott JR, Jay M, Nugent MAC. Deformities, textbook of craniomaxillofacial trauma, Chap. 21. New York: Churchill Livingstone; 1995. p. 545–618.
3. Evans AJ, Burwell RG, Merville L, Pfeifer G, Gundlach K, Sailer HF, et al. Residual deformities. In: Rowe NL, Williams JL, editors. *Maxillofacial injuries*, vol. 2. Edinburgh: Churchill Livingstone; 1985. p. 765–868.
4. Ardeshirpour F, et al. Improving posttraumatic facial scars. *Otolaryngol Clin N Am.* 2013;46(5):867–81.
5. Dolan R. Facial plastic, reconstructive and trauma surgery (Textbook). 2016 Apr. p. 716–29.

6. Hoffmann JF. Tissue expansion in the head and neck. *Facial Plast Surg Clin North Am.* 2005;13(2):315–24.
7. Van Rappard JHA, Molenaar J, Van Doorn K, Sonneveld GJ, Borghouts JM. Surface area increase in tissue expansion. *Plast Reconstr Surg.* 1988;82:833–7.
8. Kane WJ, McCaffrey TV, Wang TD, Koval TM. The effects of tissue expansion of previously irradiated skin. *Arch Otolaryngol Head Neck Surg.* 1992;118:419–26.
9. Kabaker SS, Kridel RWH, Krugman ME. Tissue expansions in the treatment of alopecia. *Arch Otolaryngol.* 1986;112:720.
10. Gibson T. The physical properties of skin. In: Converse JM, editor. *Reconstructive plastic surgery*, I. Philadelphia, PA: WB Saunders; 1977. p. 70–7.

Grafts in Residual Deformities

11. Hupp JR, Tucker MR, Ellis E. *Contemporary oral and maxillofacial surgery*, 6th ed. 2014.
12. Labres XR, Camps AR, Salas EJ, Albuquerque R, Ortega EV, et al. Graft materials in oral surgery: revision. *J Biomimetics Biomater Tissue Eng.* 2014;19:124.
13. Kumar P, et al. Bone grafts in dentistry. *J Pharm Bioallied Sci.* 2013;5(Suppl 1):S125–7.
14. Laurencin C, Khan Y, El-Amin SF. Bone graft substitutes. *Expert Rev Med Devices.* 2006;3:49–57.
15. Giannoudis PV, Dinopoulos H, Tsiridis E. Bone substitutes: an update. *Injury.* 2005;36(Suppl 3):S20–7.
16. Conrad EU, Gretch DR, Obermeyer KR, Moogk MS, Sayers M, Wilson JJ, et al. Transimission of the hepatitis-C virus by tissue transplantation. *J Bone Joint Surg Am.* 1995;77:214–24.
17. Centres for disease control and prevention. Septic arthritis following anterior cruciate ligament reconstruction using tendon allografts: Florida and Louisiana, 2000. *MMWR Morb Mortal Wkly Rep.* 2001;50:1081–3.
18. Boyne PJ, Sands NR. Secondary bone grafting of residual alveolar and palatal clefts. *J Oral Surg.* 1972 Feb;30(2):87–92.
19. Meara DJ. Acquired defects of the nose and naso-orbitoethmoid (NOE) region. *Oral Maxillofac Surg Clin North Am.* 2013;25(2):131–49.
20. Rieck KL, Fillmore WJ, Ettinger KS. Late revision or correction of facial trauma-related soft-tissue deformities. *Oral Maxillofac Surg Clin North Am.* 2013;25(4):697–713.
21. Khorasani M, et al. Maxillofacial reconstruction with Medpor porous polyethylene implant: a case series study. *J Korean Assoc Oral Maxillofac Surg.* 2018;44(3):128–35.
22. Schwaiger M, Echlin K, Atherton D, Haers P. The use of Medpor implants for midface contouring in cleft patients. *Int J Oral Maxillofac Surg.* 2019.
23. Scolozzi P. Maxillofacial reconstruction using polyetheretherketone patient-specific implants by “mirroring” computational planning. *Aesthet Plast Surg.* 2012;36(3):660–5.
24. Kim MM, Boahene KDO, Byrne PJ. Use of customized polyetheretherketone (PEEK) Implants in the reconstruction of complex maxillofacial defects. *Arch Facial Plast Surg.* 2009;11(1):53–7.
25. Salomon D, Miloro M, Kolokythas A. Outcomes of immediate allograft reconstruction of long span defects of the inferior alveolar nerve. *J Oral Maxillofac Surg.* 2016.
26. Bagheri SC, Meyer RA, Khan HA, Steed MB. Microsurgical repair of peripheral trigeminal nerve injuries from maxillofacial trauma. *J Oral Maxillofac Surg.* 2009;67(9):1791–9.

27. Renzi G, Carboni A, Perugini M, et al. Posttraumatic trigeminal nerve impairment: A prospective analysis of recovery patterns in a series of 103 consecutive facial fractures. *J Oral Maxillofac Surg.* 2004;62:1341.
28. Thurmuller P, Dodson TB, Kaban LB. Nerve injuries associated with facial trauma: Natural history, management, and outcomes of repair. *Oral Maxillofac Surg Clin North Am.* 2001;13:283.
29. Meyer RA. Nerve harvesting procedures. *Atlas Oral Maxillofac Surg Clin North Am.* 2001;9:77.
30. Joohee J, et al. Per-oral cross-facial sural nerve graft for facial reanimation. *Maxillofac Plast Reconstr Surg.* 2018;40(1):22.
31. Lu X, Cai Z, Peng X, Yu G. Reconstruction of peripheral facial nerve injury. *Int J Oral Maxillofac Surg.* 2009;38(5):511.
32. Ichihara S, Inada Y, Nakamura T. Artificial nerve tubes and their application for repair of peripheral nerve injury: an update of current concepts. *Injury.* 2008;39(Suppl 4):29–39.
33. Gheisari R, et al. Parotid duct repair by facial vein graft versus gore-tex: a sialographic evaluation. *J Dent (Shiraz, Iran).* 2013;14(2):53–6.
34. Raveenthiran V. Reconstruction of traumatically avulsed parotid duct using buccal mucosa flap: report of a new technique. *J Trauma.* 2008;65:732–5.
35. Lewkowicz AA, Hasson O, Nahlieli O. Traumatic injuries to the parotid gland and duct. *J Oral Maxillofac Surg.* 2002;60:676–80.
36. Parekh D, Glezeron G, Stewart M, Esser J, Lawson HH. Post-traumatic parotid fistulae and sialoceles. A prospective study of conservative management in 51 cases. *Ann Surg.* 1989;209:105–11.
37. Ananthakrishnan N. Vein graft repair of a chronic parotid duct fistula. *J Oral Maxillofac Surg.* 1983;41:266–7.
38. Heymans O, Nélisten X, Médot M, Fissette J. Microsurgical repair of Stensen's duct using an interposition vein graft. *J Reconstr Microsurg.* 1999;15:105–7.
39. Tao JP, Luppens D, McCord CD. Buccal mucous membrane graft-assisted lacrimal drainage surgery. *Ophthalmic Plast Reconstr Surg.* 2010;26(1):39–41.
40. Balaji SM. Management of nasolacrimal duct injuries in mid-facial advancement. *Ann Maxillofac Surg.* 2015;5(1):93–5.
41. Tao H, Wu H-Y, Hou S-K. Lacrimal duct reconstruction with grafting of great saphenous vein or labial mucosa via endoscopic transnasal dacryocystorhinostomy: a group comparison in 18 cases. *J Clin Rehabil Tissue Eng Res.* 2009;13(44):8797–800.
42. Terino EO, Edwards MC. Customizing jawlines: the art of alloplastic premandible contouring. *Facial Plast Surg Clin North Am.* 2008;16:99–122.
43. Scolozzi P, Martinez A, Jaques B. Complex orbitofrontotemporal reconstruction using computer-designed PEEK implant. *J Craniofac Surg.* 2007;18:224–8.
44. Mathog RH, Toma V, Clayman L, et al. Nonunion of the mandible: an analysis of contributing factors. *J Oral Maxillofac Surg.* 2000;58(7):746–52.
45. Furr AM, Schweinfurth JM, May WL. Factors associated with long-term complications after repair of mandibular fractures. *Laryngoscope.* 2006;116(3):427–30.
46. De Souza M, Oeltjen JC, Panthaki ZJ, et al. Posttraumatic mandibular deformities. *J Craniofac Surg.* 2007;18(4):912–6.
47. Ellis E. Complications of rigid internal fixation for mandibular fractures. *J Craniomaxillofac Trauma.* 1996;2(2):32–9.
48. Koury M. Complications of mandibular fractures. In: Kaban L, Pogrel A, Perrott D, editors. *Complications in oral and maxillofacial surgery.* 1st ed. Philadelphia: WB Saunders; 1997. p. 121–45.
49. Ellis E, Walker R. Treatment of malocclusion and TMJ dysfunction secondary to condylar fractures. *Craniofacial Trauma Reconstr.* 2009;2(1):1–18.
50. Laskin DM. Management of condylar process fractures. *Oral Maxillofac Surg Clin North Am.* 2009;21(2):193–6.
51. Becking AG, Zijdeveld SA, Tuinzing DB. Management of post-traumatic malocclusion caused by condylar process fractures. *J Oral Maxillofac Surg.* 1998;56(12):1370–4.
52. Ellis E, Throckmorton G. Treatment of mandibular condylar process fractures: biological considerations. *J Oral Maxillofac Surg.* 2005;63(1):115–34.
53. Marx RE, Saunders TR. Reconstruction and rehabilitation of cancer patients. In: Fonseca RJ, Davis WH, editors. *Reconstructive preprosthetic oral and maxillofacial surgery.* Philadelphia, PA: WB Saunders; 1986.
54. Acero J, García E. Reoperative midface reconstruction. *Oral Maxillofac Surg Clin North Am.* 2011;23(1):133–51, vii.
55. Kokemueller H, Tavassol F, Ruecker M, et al. Complex midfacial reconstruction: a combined technique of computer-assisted surgery and microvascular tissue transfer. *J Oral Maxillofac Surg.* 2008;66:2398–406.
56. Zizelmann C, Gellrich NC, Metzger MC, et al. Computer-assisted reconstruction of orbital floor based on cone beam tomography. *Br J Oral Maxillofac Surg.* 2007;45(1):79–80.
57. Coleman SR. Facial recontouring with lipofat. *Clin Plast Surg.* 1997;24:347–67.
58. Wassmund M. *Lehrbuch der praktischen Chirurgie des Mundes und der Kiefer, Bd. I.* Meusser, Leipzig 1935
59. Wunderer S. Die Prognathieoperation mittels frontal gestieltem Maxillafragment. *Ost Z Stomat.* 1962;59:98.
60. Schuchardt K. Formen des offenen Bisses und ihre operativen Behandlungsmöglichkeiten. *Fortschr Kiefer Gesichtschir.* 1955;1:222–30.
61. Tessier P, Guiot G, Rougerie J, Delbet JP, Pastoriza J. Cranio-naso-orbito-facial osteotomies. Hypertelorism. *Ann Chir Plast.* 1967;12:103–18.
62. Tessier P. Total facial osteotomy. Crouzon's syndrome, Apert's syndrome: oxycephaly, scaphocephaly, turriccephaly. *Ann Chir Plast.* 1967;12:273–86.
63. Tessier P. Experiences in the treatment of orbital hypertelorism. *Plast Reconstr Surg.* 1974;53:1–18.
64. Converse JM, Ransohoff J, Mathews ES, Smith B, Molenaar A. Ocular hypertelorism and pseudohypertelorism. Advances in surgical treatment. *Plast Reconstr Surg.* 1970;45:1–13.
65. Van der Meulen JC, Vaandrager JM. Surgery related to the correction of hypertelorism. *Plast Reconstr Surg.* 1983;71:6–19.
66. Ortiz-Monasterio F, del Campo AF, Carrillo A. Advancement of the orbits and the midface in one-piece, combined with frontal

Hard Tissue Deformities

44. Van der Meulen JC. Medial faciotomy. *Br J Plast Surg.* 1979;32:339–42.
45. Hupp JR, Tucker MR, Ellis E. Surgical reconstruction of defects of jaw. *Contemporary oral and maxillofacial surgery, 7th ed.* 2019. p. 628–40.
46. Vega LG. Reoperative mandibular trauma: management of post-traumatic mandibular deformities. *Oral Maxillofac Surg Clin North Am.* 2011;23(1):47–61, v–vi.
47. Haug RH, Schwimmer A. Fibrous union of the mandible: a review of 27 patients. *J Oral Maxillofac Surg.* 1994;52(8):832–9.

- repositioning, for the correction of Crouzon's deformities. *Plast Reconstr Surg.* 1978;61:507–16.
71. Marchac D, Renier D, Arnaud E. Infrafrontal correction of teleorbitism. In: Whitaker L, editor. *Proceedings from the seventh meeting of the ISCFs*. Santa Fe: Menduzzi; 1997. p. 173–5.
 72. Marin PC, Love T, Carpenter R, Iliff NT, Manson PN. Complications of orbital reconstruction: misplacement of bone grafts within the intramuscular cone. *Plast Reconstr Surg.* 1998;101:1323–7.
 73. Wolff J, Sándor GK, Pyysalo M, Miettinen A, Koivumäki AV, Kainulainen VT. Late reconstruction of orbital and naso-orbital deformities. *Oral Maxillofac Surg Clin North Am.* 2013;25(4):683–95.
 74. Cohen SR, Kawamoto HK Jr. Analysis and results of treatment of established posttraumatic facial deformities. *Plast Reconstr Surg.* 1992;90:574–84.
 75. Sandor GK, Clokie CM. Hypertelorism. In: Fonseca RJ, editor. *Oral and maxillofacial surgery*, vol. 6. Philadelphia: W.B. Saunders Company; 2000. p. 221–38.
 76. Tessier P. Anatomical classification of facial, craniofacial, and latero-facial clefts. *J Maxillofac Surg.* 1976;4:69–89.
 77. Lanigan DT, Stoelinga PJ. Fractures of the supraorbital rim. *J Oral Surg.* 1980;38(10):764–70.
- ### Post Oncological Deformities
78. Hurvitz KA, Kobayashi M, Evans GR. Current options in head and neck reconstruction. *Plast Reconstr Surg.* 2006;118(5):122e–33e.
 79. Renner G. Reconstruction of the lip. In: Baker S, editor. *Local flaps in facial reconstruction*. 2nd ed. Philadelphia, PA: Mosby; 2007. p. 475–525.
 80. Abbe R. A new plastic operation for the relief of deformity due to double harelip. *Plast Reconstr Surg.* 1968;42(5):481–3.
 81. Ong WC, Lim J, Lim TC. A modification of the bilobed and Karapandzic flap used for reconstruction of the lower lip. *Plast Reconstr Surg.* 2005;115(7):2154–5.
 82. Anvar BA, Evans BC, Evans GR. Lip reconstruction. *Plast Reconstr Surg.* 2007;120(4):57e–64e.
 83. Ozdemir R, Ortak T, Kocer U, Celebioglu S, Sensoz O, Tiftikcioglu YO. Total lower lip reconstruction using sensate composite radial forearm flap. *J Craniofac Surg.* 2003;14(3):393–405.
 84. McConnel FM, Pauloski BR, Logemann JA, Rademaker AW, Colangelo L, Shedd D, et al. Functional results of primary closure vs flaps in oropharyngeal reconstruction: a prospective study of speech and swallowing. *Arch Otolaryngol Head Neck Surg.* 1998;124(6):625–30.
 85. Yu P. Characteristics of the anterolateral thigh flap in a Western population and its application in head and neck reconstruction. *Head Neck.* 2004;26(9):759–69.
 86. Vos JD, Burkey BB. Functional outcomes after free flap reconstruction of the upper aerodigestive tract. *Curr Opin Otolaryngol Head Neck Surg.* 2004;12(4):305–10.
 87. Aziz SR. Andy Gump and his deformity. *J Oral Maxillofac Surg.* 2010 Mar;68(3):651–3.
 88. Genden EM, Wallace D, Buchbinder D, Okay D, Urken ML. Iliac crest internal oblique osteomusculocutaneous free flap reconstruction of the postablative palatomaxillary defect. *Arch Otolaryngol Head Neck Surg.* 2001;127(7):854–61.
 89. Rieger JM, Zalmanowitz JG, Li SY, Sytsanko A, Harris J, Williams D, et al. Functional outcomes after surgical reconstruction of the base of tongue using the radial forearm free flap in patients with oropharyngeal carcinoma. *Head Neck.* 2007;29(11):1024–32.
 90. Seikaly H, Rieger J, Wolfaardt J, Moysa G, Harris J, Jha N. Functional outcomes after primary oropharyngeal cancer resection and reconstruction with the radial forearm free flap. *Laryngoscope.* 2003;113(5):897–904.
 91. Kolokythas A. Long-term surgical complications in the oral cancer patient: a comprehensive review. Part II. *J Oral Maxillofac Res.* 2010;1(3):e2.
 92. Kim DD, Ord RA. Complications in the treatment of head and neck cancer. *Oral Maxillofac Surg Clin North Am.* 2003;15(2):213–27.
 93. Friess CC, Fontaine DJ, Kornblut AD. Complications of therapy for oral malignant disease. *Otolaryngol Clin N Am.* 1979;12(1):175–81.
 94. Ramon Y, Hendler S, Oberman M. A stepped technique for splitting of the lower lip. *J Oral Maxillofac Surg.* 1984;42(10):689–91.
 95. Lewis VL Jr, Manson PN, Stalneck MC. Some ancillary procedures for correction of depressed adherent tracheostomy scars and associated tracheocutaneous fistulae. *J Trauma.* 1987;27(6):651–5.
 96. Waldron J, Padgham ND, Hurley SE. Complications of emergency and elective tracheostomy: a retrospective study of 150 consecutive cases. *Ann R Coll Surg Engl.* 1990;72(4):218–20.
 97. Hayter JP, Vaughan ED, Brown JS. Aesthetic lip splits. *Br J Oral Maxillofac Surg.* 1996;34(5):432–5.
 98. Haug SP. Maxillofacial prosthetic management of the maxillary resection patient. *Atlas Oral Maxillofac Surg Clin North Am.* 2007;15(1):51–68.
 99. Shah JP, Candela FC, Poddar AK. The patterns of cervical lymph node metastases from squamous carcinoma of the oral cavity. *Cancer.* 1990;66(1):109–13.
 100. Kerawala CJ. Complications of head and neck cancer surgery—prevention and management. *Oral Oncol.* 2010;46(6):433–5.
 101. Kolokythas A. Long-term surgical complications in the oral cancer patient: a comprehensive review. Part I. *J Oral Maxillofac Res.* 2010;1(3):e1.
 102. Capiello J, Piazza C, Nicolai P. The spinal accessory nerve in head and neck surgery. *Curr Opin Otolaryngol Head Neck Surg.* 2007;15(2):107–11.

103. Saunders JR Jr, Hirata RM, Jaques DA. Considering the spinal accessory nerve in head and neck surgery. *Am J Surg*. 1985;150(4):491–4.
 104. Schaubert MD, Fontenelle LJ, Solomon JW, Hanson TL. Cranial/cervical nerve dysfunction after carotid endarterectomy. *J Vasc Surg*. 1997;25(3):481–7.
 105. Dingman RO, Grabb WC. Surgical anatomy of the mandibular ramus of the facial nerve based on the dissection of 100 facial halves. *Plast Reconstr Surg Transplant Bull*. 1962;29:266–72.
- ### Recent Advances: Endoscopy in Management of Residual Deformities
106. Pedroletti F, Johnson BS, McCain JP. Endoscopic techniques in oral and maxillofacial surgery. *Oral Maxillofac Surg Clin North Am*. 2010;22(1):169–82.
 107. Gupta N. Endoscopic septoplasty. *Indian J Otolaryngol Head Neck Surg*. 2005;57(3):240–3.

Open Access This chapter is licensed under the terms of the Creative Commons Attribution 4.0 International License (<http://creativecommons.org/licenses/by/4.0/>), which permits use, sharing, adaptation, distribution and reproduction in any medium or format, as long as you give appropriate credit to the original author(s) and the source, provide a link to the Creative Commons license and indicate if changes were made.

The images or other third party material in this chapter are included in the chapter's Creative Commons license, unless indicated otherwise in a credit line to the material. If material is not included in the chapter's Creative Commons license and your intended use is not permitted by statutory regulation or exceeds the permitted use, you will need to obtain permission directly from the copyright holder.



Part XVII

Temporomandibular Joint Disorders



Myofascial Pain Dysfunction Syndrome

62

Mirza Farhatullah Baig and Yashoda Ashok

62.1 Introduction

There is an accepted concept of triple complex involving both joints and intact dentition forming an integrated system which is carefully monitored by an arthrokinetic reflex muscular activity to ensure a controlled and stable pattern of painless mandibular movement. A disturbance in the coordinated activity of this musculature arising from malocclusion often accentuated by psychological factors inducing neuromuscular tension forms the basis for majority of problems involving temporomandibular joint (TMJ) dysfunction.

There is a large pool of evidence that clearly shows that mind and body are not independently functioning entities but closely interrelated in all aspects of pain direction, detection and perception. TMJ disorders is an umbrella term referring to a classification of musculoskeletal disorders impacting the masticatory muscles and/or the TMJ and is usually subdivided into three main categories. Box 62.1 enumerates the three categories of musculoskeletal disorders, often clubbed as TMJ disorders.

Box 62.1 Subcategories of TMJ Disorders (TMDs)

1. Myofascial pain disorder
2. TMJ disc interference disorders
3. TMJ degenerative diseases

It has always been a challenging job for the clinician to manage temporomandibular disorder (TMD) as it is a conundrum wrapped in enigma.

Management of TMD is controversial because science takes a back seat. We need scientific studies especially randomised clinical trials to overcome this problem. Matching the diagnosis to the treatment is still the most problematic aspect of TMD practice. The solution lies in making an accurate diagnosis to match an appropriate method of treatment.

62.2 Definitions

The definitions for TMJ pain are not universally used. Three currently accepted definitions of TMJ pain are:

1. Temporomandibular pain and dysfunction syndrome (International Association for the Study of Pain: Merskey and Bogduk [1])
 - (a) Aching in the muscles of mastication often associated with restricted jaw movements and popping sounds
2. Oromandibular dysfunction [2] (International Headache Society: Oleson 1988)
 - (a) Temporomandibular joint sounds on movement
 - (b) Limited or jerky jaw movements
 - (c) Pain during jaw function
 - (d) Lock jaw on opening
 - (e) Gnashing of teeth (bruxism)
 - (f) Miscellaneous parafunction (tongue, lips or cheek biting)
3. Facial arthromyalgia [3]
 - (a) Chronic or intermittent pain of TMJ and of its associated musculature

M. F. Baig (✉)
Department of Oral and Maxillofacial Surgery, Saveetha Dental
College, Chennai, India

Y. Ashok
Department of Oral and Maxillofacial Surgery, Meenakshi Ammal
Dental College and Hospitals, Chennai, India

62.2.1 Evolving Terminologies

Over many years, functional disorders of the masticatory system have been referred by many terms contributing to the confusion regarding aetiologic mechanisms and manifestations in this area.

In 1934 James Costen [4], an otolaryngologist, described a set of symptoms focused around the ear and temporomandibular joint (TMJ) leading to the earliest nomenclature of Costen syndrome. Costen believed these symptoms were due to the backward displacement of condyle after overclosure of the bite. Auriculotemporal nerve is found behind the tympanic bone which prevents nerve compression. Hence this theory was rejected.

Schwartz [5] (1959) described myofascial pain dysfunction syndrome (MPDS) characterised by clicking, muscle tenderness, pain in the TMJ region and restricted mouth opening. Following this, much later the term TMJ disturbances became popular, and then, in 1959, Shore [6] introduced the term TMJ dysfunction syndrome. Later Ramfjord and Ash [7] brought forth the term functional TMJ disturbances. To establish a connect with the aetiology, terms such as occluso-mandibular disturbance and myoarthropathy of the TMJ [8] were introduced. When pain and associated muscle involvement became the focus, terminologies such as pain-dysfunction syndrome [9], myofascial pain-dysfunction syndrome [10] and TM pain-dysfunction syndrome [11] arose.

Currently it has been established that these terms attempt to describe conditions with symptoms not always isolated to the TMJ, and for the need of a broader, umbrella term to classify these conditions, some authors believe that the title cra-

niomandibular disorders [12] should be used. Finally, the term which has gained large-scale acceptance was suggested by Bell [13]—"temporomandibular joint disorders".

62.2.2 Current Definition

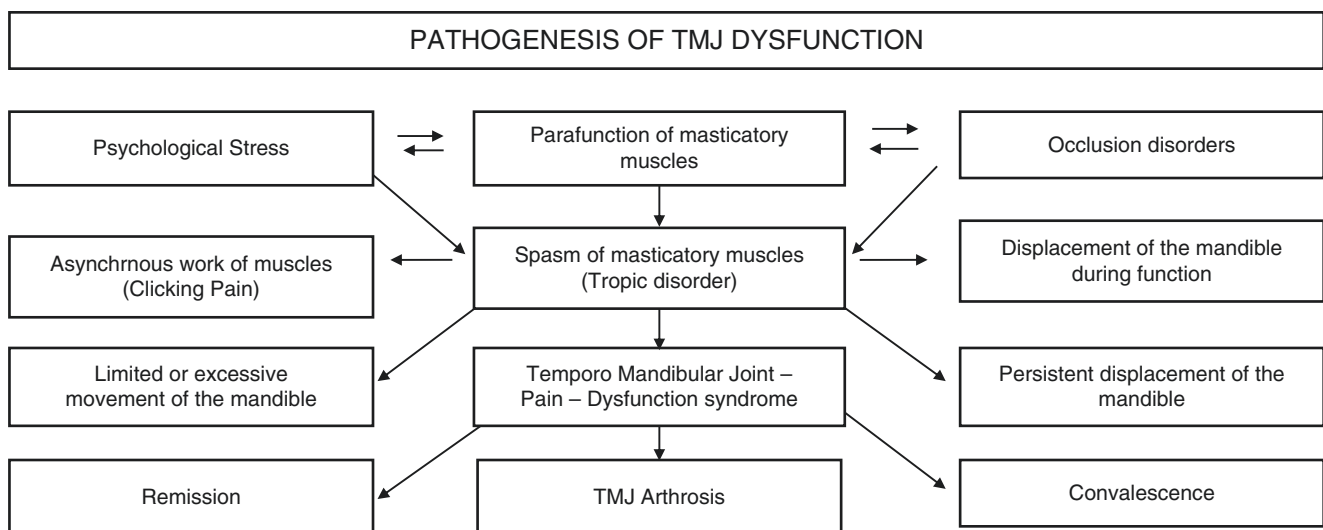
Myofascial pain dysfunction syndrome (MPDS) is a well-known term that is used in many other branches of medical science [14–16]. But in the last few decades, this term has been employed to describe orofacial chronic pain [17–19] often abbreviated in the literature as MPDS.

Presently, myofascial pain can be defined as "a regional myogenous pain condition characterised by local areas of firm, hypersensitive bands of muscle tissue known as trigger points" [20] alternatively called myofascial trigger point pain. The presence of central excitatory effects is a defining characteristic of this myalgic disorder. The presence of referred pain is common, often resembling a tension-type headache.

62.3 Etiopathogenesis and Proposed Mechanisms

A number of mechanisms have been put forth to explain myofascial pain, even though currently a holistic understanding of aetiologies remains elusive (Fig. 62.1):

1. Continuous source of input leading to deep pain [21, 22]
2. Heightened emotional stress [21, 23]
3. Sleep disturbances [21, 24]



©Association of Oral and Maxillofacial Surgeons of India

Fig. 62.1 Pathogenesis of TMJ dysfunction

4. Local factors that govern muscle health, namely, habits, posture and muscle strains
5. Systemic factors like nutritional deficiencies [21], poor physical status, chronic fatigue and viral infections [21]

62.4 Patient History and Clinical Characteristics

The patient's main complaint is often directed towards the site of referred pain and rarely the exact source of pain (the trigger points). The clinician may accidentally direct treatment towards the secondary sites of pain resulting in failure to treat the actual cause of the pain, thereby leading to unsuccessful treatment. History taking must specifically include incidences of repetitive muscle trauma, improper postural habits, presence of occlusal parafunction and mental and emotional stress.

On clinical examination, the patient will display decreased range and speed of mandibular movement which usually correlates to the location and intensity of trigger point pain. The pain is commonly described as a dull ache or pressure which can be throbbing and severe. The masticatory muscles are tender on palpation with identifiable trigger points on palpation [25].

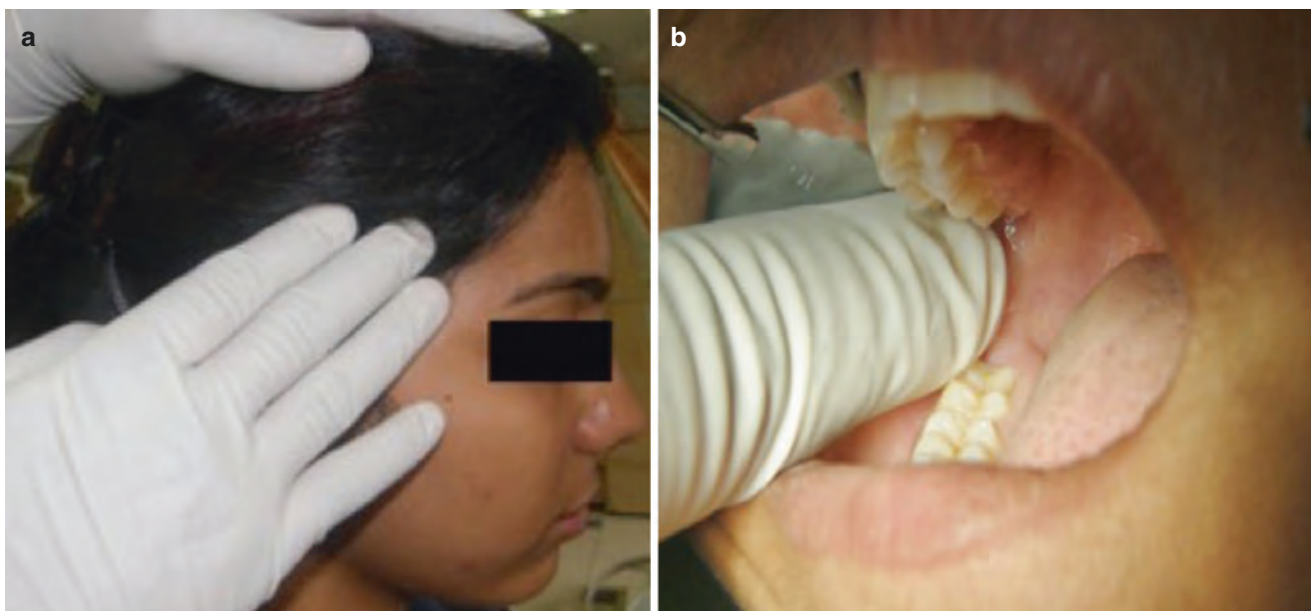
Trigger points are described as firm knots within muscles which are more tender on palpation than the surrounding muscle tissue. The pain that is generated is usually within and beyond the muscle and may occasionally elicit referred pain to a distant site and even an autonomic response.

Temporary inactivation can be tried through a trigger point anaesthetic injection, vapocoolant sprays, transcutaneous electrical nerve stimulation (TENS), etc. [26] which are used by certain practitioners to temporarily inactivate trigger points.

From a clinical standpoint, if the muscle is tender to palpation and none of the other masticatory muscle disorders better describe the patient's condition, the suggested diagnosis is myofascial pain.

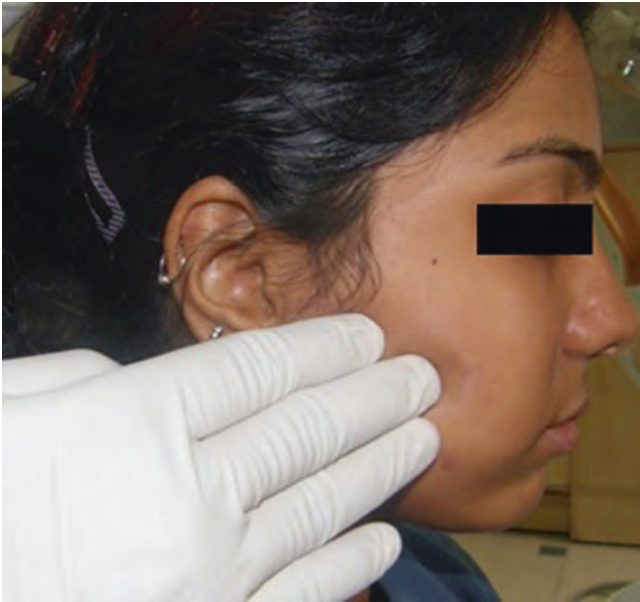62.5 Examination

- Questions concerning pain and restricted mandibular movements and TMJ sounds
 - Visual examination of the head and neck.
 - Palpation of the head and neck—This includes palpation of the individual masticatory muscles for tenderness (Figs. 62.2a, b and 62.3).
 - Listening to TMJ sounds and joint palpation (Fig. 62.4).



©Association of Oral and Maxillofacial Surgeons of India

Fig. 62.2 (a, b) Palpation of temporalis



©Association of Oral and Maxillofacial Surgeons of India

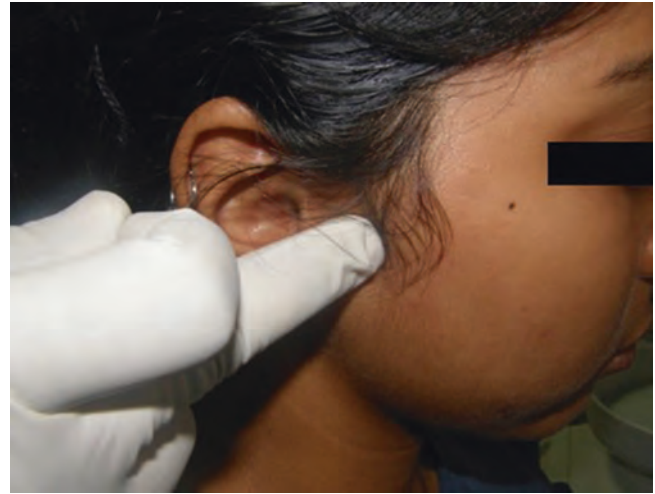Fig. 62.3 Palpation of masseter

- Mandibular movements—For range of motion and deviation.
- Radiographs and other imaging techniques—An OPG (Fig. 62.5) may be easily available in most clinical set-ups. Dental cone beam CTs (Fig. 62.6) offer the advantage of lowered radiation dose with reasonable hard tissue detailing, articular surface erosions and joint space dimensions. MRIs are useful for imaging soft tissues such as the articular disc and joint ligaments (Fig. 62.7a, b).
- General oral examination.
- Occlusion.

62.5.1 Imaging Techniques

Pain in relation to the TM joint and masticatory muscles are among the commonest complaints of patients with TMD. MPDS is unique in that the contributing factors are neurogenic, psychogenic and musculoskeletal in nature. This greatly limits the role of conventional imaging modalities in clinching the diagnosis of MPDS.

OPG and CT are useful in imaging bony articular surfaces for erosions and changes in the joint spaces. MRI is excellent for imaging the disc, capsule and TM joint ligaments. However the usefulness of these imaging techniques appears restricted to ruling out other contributing factors to the patients' pain such as internal derangement and osteo-degenerative disorders. These features may often overlap with myofascial pain, often adding to confusion in diagnosis.



©Association of Oral and Maxillofacial Surgeons of India

Fig. 62.4 Palpation of temporomandibular joint

A thorough clinical examination is the most reliable way to arrive at a diagnosis of MPDS with imaging investigations assisting in ruling out other causative factors. Figures 62.5, 62.6 and 62.7 demonstrate some of the conventional methods of imaging the TM joint and associated structures with relevant findings.

62.6 Psychological Assessment

It is mandatory to do psychological assessment or screening of the patient for history of anxiety, depression and pain-related disability.

62.7 Pathophysiology of TMJ Pain

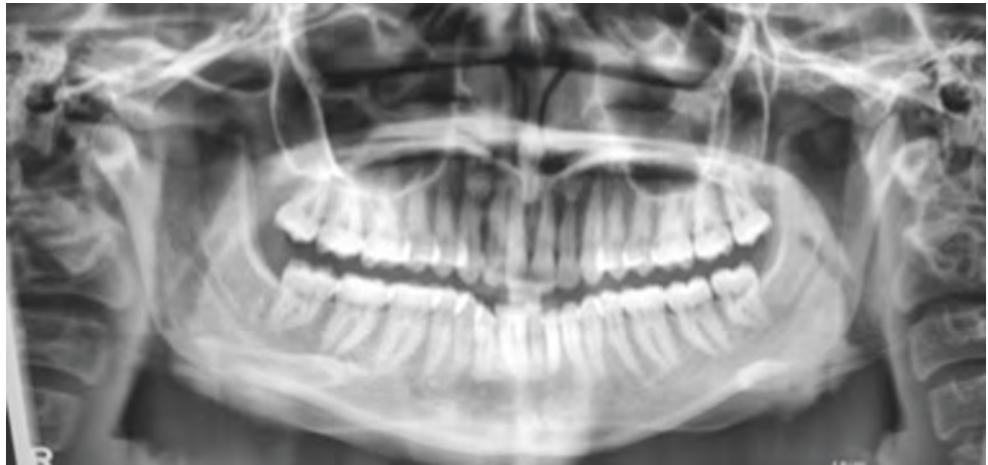Pain An unpleasant sensory and emotional experience associated with actual or potential tissue damage, or described in terms of such damage [27] (*International Association for the Study of Pain 1979*).

Inflammatory Pain Intra-articular tissue damage in association with disc displacement results in local TMJ pain. In addition, it can elicit reflex spasm of masticatory muscles resulting in pain from regions other than TMJ.

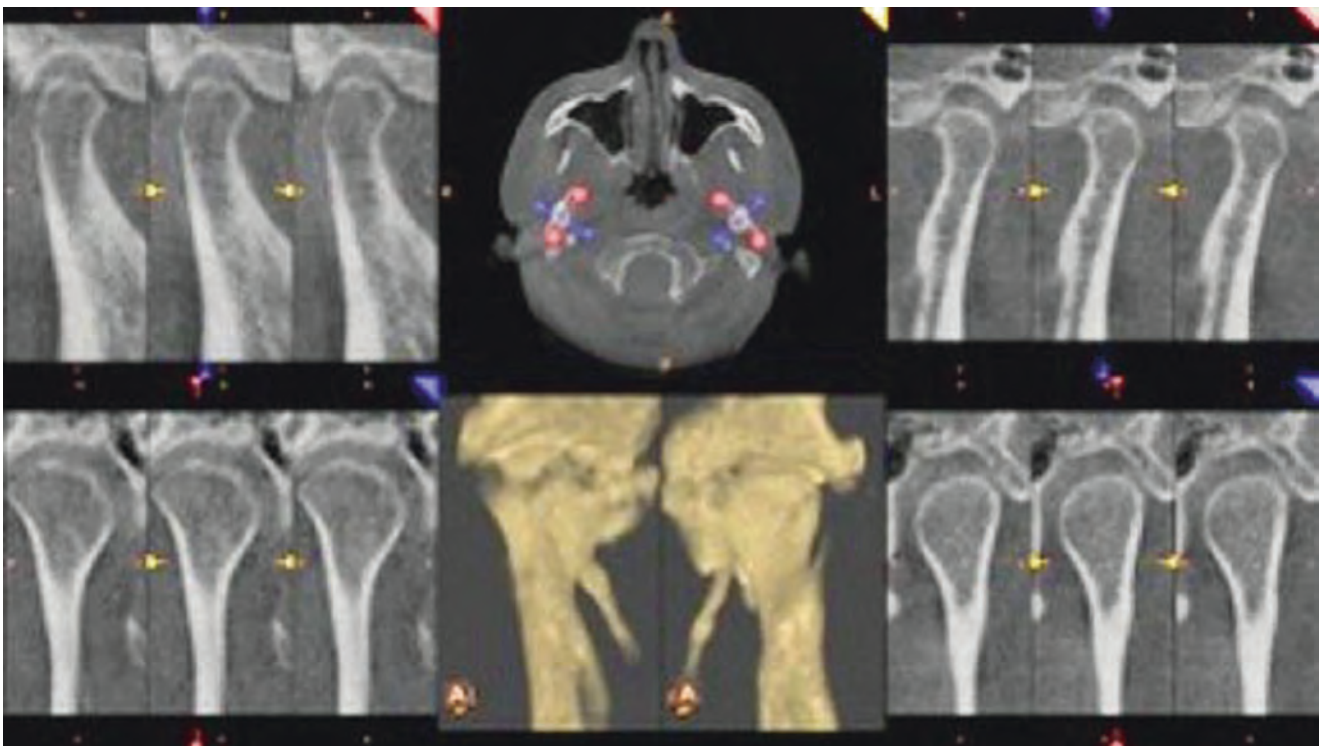
Arthrogenous Pain The patient can point to the worst spot with one finger in the TMJ region. The pain is relieved by giving auriculotemporal nerve (ATN) block.

Myogenous Pain Not relieved by block and diffuse in nature over the muscle.

Fig. 62.5 OPG showing bony articular surfaces of TMJ



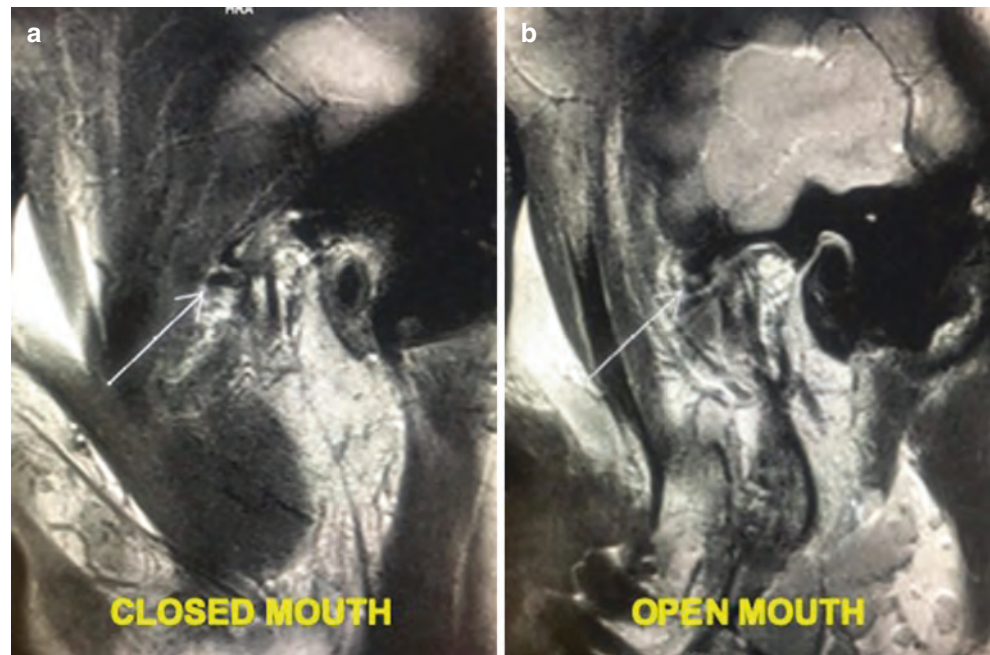©Association of Oral and Maxillofacial Surgeons of India



©Association of Oral and Maxillofacial Surgeons of India

Fig. 62.6 CBCT shows erosions and craters in the head of the condyle and increased joint space

Fig. 62.7 (a, b) MRI showing disc displacement without reduction in open and closed positions



©Association of Oral and Maxillofacial Surgeons of India

62.8 Role of Parafunctional Habits

62.8.1 Bruxism

- Bruxism is defined as an oral habit of involuntary rhythmic non-functional gnashing or clenching of teeth outside of masticatory movements of the mandible [28]—“tooth grinding neurosis”.
- Associated with REM, commonly seen in patients with high trait anxiety or increased depressive symptoms.
- This sustained muscle contraction leads to non-serous inflammatory reaction in masticatory muscles, subsequent fatigue and pain.
- Signs of bruxism: Fig. 62.8a–c
 - Attrition of teeth
 - Scalloping of the tongue
 - Cheek ridging—linea alba

A complete process of risk evaluation and assessment helps to highlight the problematic causative factors. These may include central and peripheral causes as shown in Table 62.1.

62.9 Clinical Signs of MPDS

- Pain in TMJ region
- Clicking/popping noise
- Restriction of mouth opening

- Deviation of mandibular midline to the affected side on mouth opening before clicking
- Restricted laterotrusive jaw movements to the contralateral side (Fig. 62.9a)
- Unrestricted laterotrusive jaw movements to the affected side (Fig. 62.9b, Table 62.2)

62.9.1 Clinical Test

To diagnose clicking caused by disc displacement with reduction:

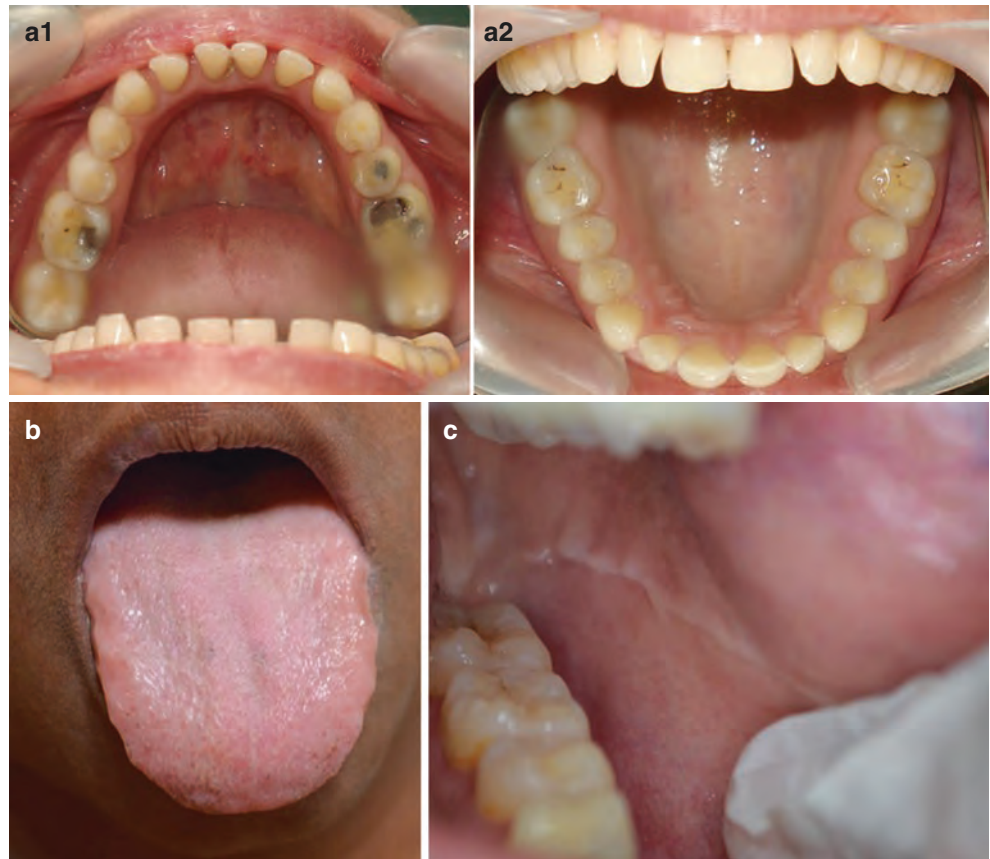- Patient is instructed to occlude the teeth firmly together.
- Patient is instructed to open the mouth until jaw clicking occurs indicating that the disc/condyle relationship is now reduced into normal position.
- No clicking sound is heard after placing the spacer (Fig. 62.10a, b).

62.10 Principles of Management

62.10.1 Role of Evidence-Based Management

The varying manifestation of myofascial pain (MFP) can range from single muscle involvement to complex cases involving multiple sites of pain and numerous contributing

Fig. 62.8 (a) Attrition of teeth from bruxism. (b) Scalloping of tongue margins (c) Linea alba



©Association of Oral and Maxillofacial Surgeons of India

Table 62.1 Central and peripheral causes of MPDS

Central causes	Peripheral causes
Stress	Adverse postural issues
Anxiety	Repetitive localised strain in the form of occlusal parafunction
Depression	

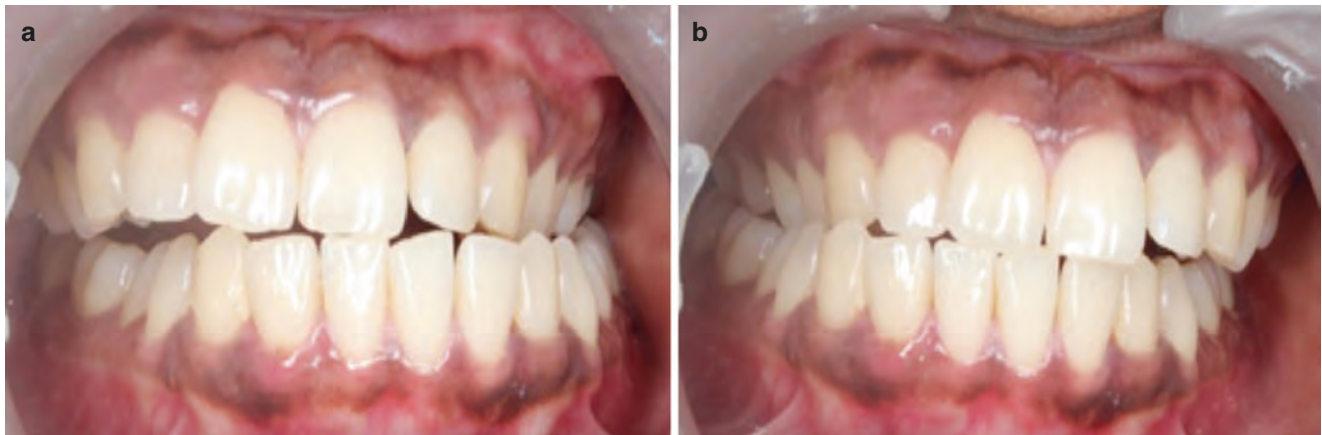
factors. The challenge in management consists of educating patients about the lifestyle factors that contribute to MFP, the persistence of which tends to result in treatment failure. Studies by Fricton and Aronoff [29, 30] et al. indicate that patients with MFP visit multiple practitioners in their quest for relief and are often treated with multiple modalities in a disorganised manner without experiencing improvement other than on a temporary basis.

62.10.2 Formulating a Comprehensive Problem List

Patient must be encouraged to adopt therapeutic lifestyle changes such as diet modification, exercise, proper sleep habits, social support and coping mechanisms which may contribute to more holistic and long-lasting positive outcomes.

62.10.3 Role of Interdisciplinary Management for the Complex Patient

Patients exhibiting multiple and often overlapping risk factors are best approached via an interdisciplinary involvement that uses a team of specialists to address the varied nuances



©Association of Oral and Maxillofacial Surgeons of India

Fig. 62.9 (a) Restricted laterotrusion movements—contralateral side (b) Unrestricted laterotrusion movements—affected side

Table 62.2 Causes of clicking

Causes of clicking
1. Disc displacement with reduction
2. Hypermobility of the condyle
3. Loose intra-articular bodies like arthroliths, intra-articular fracture fragments of the articular surface [29]
4. Thickening of the soft tissue on the slope of articular eminence

of the problem in an organised manner. In both simple and complex cases, the clinician needs to isolate the individual problem area and arrive at a customised solution best suited to the patient.

62.10.4 The Role of Occlusal Splint: Termination of the Cycle of Habitual Pain

Chronic pain is a learnt pattern that arises from repetition and is generated by the CNS. This habitual pattern must be arrested before attempting to treat MPDS. Treatment of MPDS is dependent on breaking the repetitive pattern generated by the central nervous system. Nociceptive responses are carried from peripheries into the central nervous system (CNS) through myelinated (type A-delta) or unmyelinated (type C) nerve fibres [31]. Dental malocclusion as a causative factor for MPDS has been found in literature since most treatment modalities hint at occlusal alteration one way or another. In a study by Laskin et al. [32], the authors remarked

that many aspects of MPDS are yet to be explored; many have agreed that rapid improvement of symptoms is noticed with splint therapy. Splint therapy is an effective method of isolating occlusion as the causative factor as the interposition of a splint can immediately and dramatically break the pain pattern generated by the CNS. It is however necessary that splint therapy be initiated by skilled practitioners.

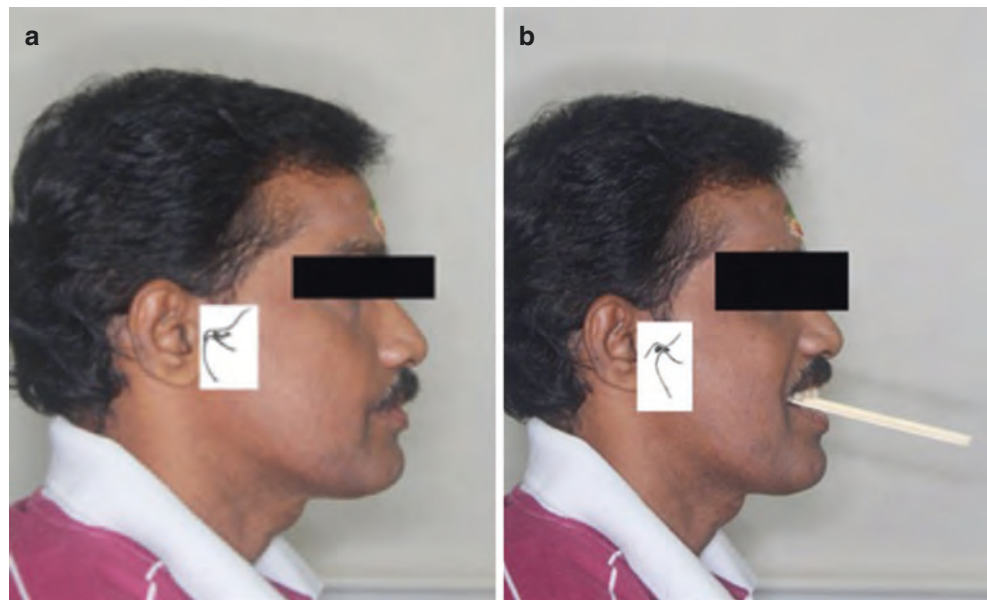
Soft splints are constructed of polyvinyl worn at night. It may act as a habit breaker.

The anterior bite plane or Lucia Jig is recommended for short-term use and is to be worn at night. Stabilisation splints help to disocclude the jaws, thereby restoring normal joint space with prolonged wear. These are also used to correct disc dislocations in internal derangement. The anterior repositioning splint allows the patient to close the mandible in a forward direction; however, this has not yielded successful results in many circumstances.

The gnathological splint was designed based on Roth's philosophy of correction of centric relation-centric occlusion discrepancies. It is a permissive type of hard splint made of heat cure clear acrylic fabricated using a semi-adjustable articulator (SAM 3, AD2, PANADENT articulators). It is usually worn full time in maxillary or mandibular arch. The splint is designed on the concepts of gnathology to correct the centric relation-centric occlusion (CR-CO) discrepancies, which are a sequence of progressive disc derangements.

A few important factors to be considered prior to splint fabrication include diagnosis and institution of therapy by skilled clinicians, and alteration of occlusion results in

Fig. 62.10 Diagnosis of clicking sound in the TMJ. (a) Patient in closed mouth position, with anterior disc displacement (shown by TMJ superimposition) and (b) Condyle translating over the displaced disc (TMJ superimposition), to produce clicking sound



©Association of Oral and Maxillofacial Surgeons of India

changes in masticatory behaviour which in turn alters neuromuscular activity and learnt patterns of pain generation. Regular follow-up is essential after splint usage. This helps to identify any complications as a result of splint therapy which might mandate stoppage of splint therapy altogether [33, 34]. The specific type of splint and duration of treatment must be carefully titrated for individual patients. Overuse of the right splint can also result in worsening of the condition by creating open bites, intrusion of teeth and loss of occlusal contact and worsening of MPDS symptoms [35–37].

62.10.5 Occlusal Adjustments

Wang et al. advocated elimination of premature contacts using occlusal adjustment as one of the most crucial methods for breaking the neuromuscular cycle in MPDS [38]. A thorough occlusal analysis has consistently been an instrumental diagnostic criterion to resolve MPDS symptoms.

62.11 Modalities of Management of MPDS

Because of the prolonged and occasionally varied treatment phases in the management of myofascial pain, the healthcare provider must develop a long-term association with the patient and direct the goals towards fostering a positive attitude towards therapy and commitment to long-term change [39, 40].

62.11.1 Muscle Exercises

Muscle exercises are the most effective for muscle rehabilitation. Active muscle stretching combined with passive exercises diminishes the sensitivity of trigger points. Postural exercises reduce trigger point reactivation, while strengthening exercises serve to enhance circulation and suppleness of the muscles. Determination of the muscular range of motion is the preliminary requirement prior to prescribing physiotherapy.

Postural exercises function to teach the patient to adopt a more neutral and relaxed body position, thereby ameliorating fatigue from undue stress on a set of muscles. Interincisal mouth opening is an effective indicator of muscle range of motion, and limited mouth opening is indicative of tender points in the masticatory muscles. Adverse postures such as jaw thrust and forward head position must also be discouraged.

Correctional exercises include:

1. Placement of the tip of the tongue on the roof of the mouth with the teeth parted.
2. Instruction in proper posture for daily activities like sitting, standing and lifting of objects.
3. Encourage sleeping on the side or back. This is effective for patients who complain of muscle stiffness upon awakening.
4. Incorporate a form of aerobic exercise into the daily routine to improve mood, circulation, strength and muscle endurance [41].

62.11.2 Muscle Treatments

There are various techniques for muscle stimulation.

Non-invasive methods of trigger point (TrPs) inactivation include

- massages,
- acupressure therapy
- and ultrasound application which act as non-invasive mechanisms of disruption.

Relaxation measures include

- moist heat applications,
- ice packs,
- Fluori-Methane sprays
- and diathermy which alter muscle and skin temperature.

Electrical current stimulation through

- transcutaneous electrical nerve stimulation (TENS),
- electro-acupuncture
- and direct current application stimulates the muscles and TrPs.

Methods of chemical and mechanical alteration of TrPs are achieved by:

- acupuncture and
- TrP injections with local anaesthetic,
- saline
- and corticosteroids.

Spray and stretch technique: Local muscle vapocoolant spray application alongside passive stretching renders instant pain relief [21, 42]. Failure of this technique has been attributed to:

- (a) Inadequate achievement of full muscle dimension due to bone or joint abnormalities, muscular contractures or the patient's inability to voluntarily relax
- (b) Incorrect technique of spraying
- (c) Failure to attenuate causative factors

62.11.3 Trigger Point (TrP) Injections

Pain reduction, improvement in range of motion, better exercise tolerance and generalised enhancement of circulation in muscles are some of the positive effects of trigger point injections as documented by Cifala et al. [43] and Jaeger and colleagues [44].

Trigger point injections act by physical disruption of the trigger point from needle entry, and the pain relief may be

seen to last from the anaesthetic duration to several months. Saline injections and “dry needling” have also been reported with varying degrees of success. Dry needling, frequently known as myofascial trigger point dry needling, is an alternative medicine practice comparable to acupuncture. It is carried out by physical therapists where permissible by state laws. The use of a combination of sub-anaesthetic doses of local anaesthetic agents has also been found to be successful. The results of a double-blind controlled trial by Simons et al. [45] suggested 3% chlorprocaine and 5% procaine (without vasoconstrictors) to be effective.

Corticosteroid in combination with a local anaesthetic administered as a local intramuscular injection was first practised in the early 1950s. Though there haven't been randomised trials to prove the efficacy of the same, Gray and colleagues suggested that locally delivered corticosteroids mitigate pain and improve function in patients with MPDS [46].

62.11.4 Trigger Points

These are areas of taut, inflamed muscle bands that elicit pain on palpation. Pain of this origin is usually referred to other sites in the local region. Figure 62.11a–e demonstrates the various muscles of the head and neck and the related trigger points elicited in MPDS.

62.11.5 Bite Adjustment

Despite many MPDS cases being treated from an occlusion-related standpoint, literature has shown dental occlusion or partial and total edentulism to be weakly correlated as causative or maintenance factors of TMPDS [47, 48].

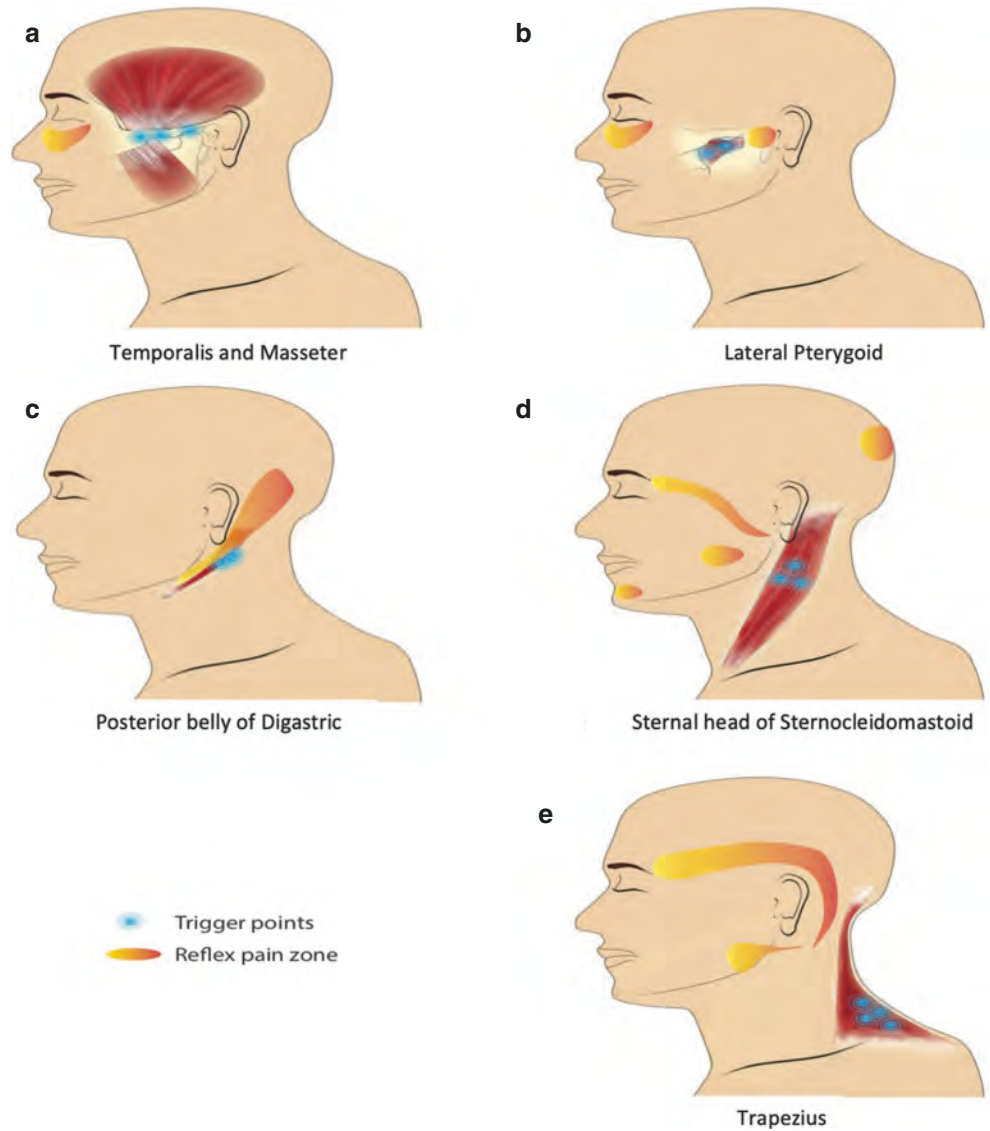
Therapies ranging from occlusal adjustments on natural teeth to extensive prosthetic dental rehabilitation have been reported. Other treatments include oral appliances and orthodontics. Marbach [49] et al. demonstrated that missing teeth, malocclusion and night-time bruxism in control group patients did not correlate with facial pain and vice versa.

62.12 Intraoral Appliance Therapy (Refer to suggested reading at the end of the chapter)

Stabilisation appliances are well accepted, but the clinician must ensure that they are not ill-fitting, bulky, etc., so it is imperative to adjust them for patient comfort and better compliance. Regular reviews and inspection for soft tissue ulceration, dental pain, oral malodours, speech impairment, caries, tooth mobility and occlusal alterations must be carried out.

Splints: Box 62.2 enumerates the broad classification of splints conventionally used in the management of MPDS.

Fig. 62.11 Trigger points (blue) in chewing muscles, neck muscles and reflex pain zone (yellow-orange): (a) Masseter and temporalis. (b) Lateral pterygoid. (c) Posterior belly of digastric. (d) Sternocleidomastoid (e) Trapezius



Soft Bite Guard: Splint is constructed of polyvinyl worn at night. It may act as a habit breaker and also serves to protect the occlusal surfaces of the teeth (Fig. 62.12).

The Anterior Bite Plane or Lucia Jig (Fig. 62.13): For short-term use to be worn at night.

Stabilisation Splint: It is a hard splint made of acrylic for the restoration of occlusion (Fig. 62.14). It minimises abnormal muscle activity and restores neuromuscular balance.

Gnathological Splint: A specialised splint based on Roth's philosophy: To correct centric occlusal-centric relation discrepancies (Fig. 62.15a, b).

62.12.1 Pharmacotherapy

Multiple different pharmacologic therapies have found application in MPDS.

62.12.1.1 Non-steroidal Anti-inflammatory Drugs (NSAIDs)

In the case of TMPDS, few controlled trials exist that indicate daily use of NSAIDs offers little benefit when compared

to the well-known occurrence of side effects as reported by Dionne et al. [50]. Singer and colleagues concluded that a 4-week trial of ibuprofen 1500 mg per day was no more effective than a placebo [51]. Patients report short-term relief with high doses of NSAIDs; however, long-term therapy with NSAIDs is not encouraged.

62.12.1.2 Opioids and Narcotic Analgesics

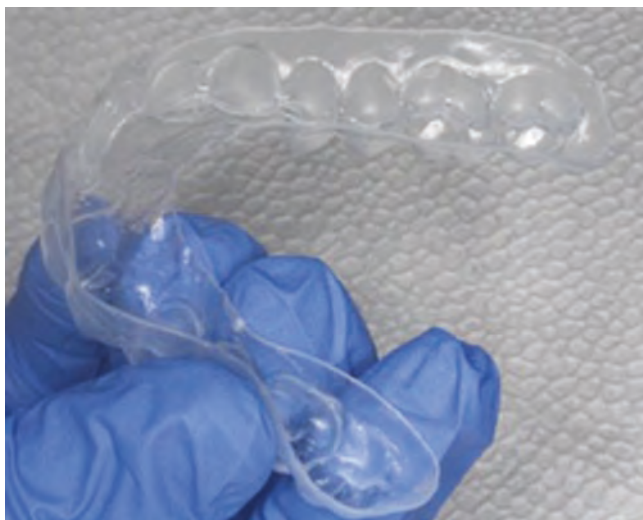With the use of opioid and narcotic analgesics comes the problems of physical dependence, addiction and drug tolerance. There is a lack of controlled studies in literature to guide the clinician regarding the same which restricts the use of these drugs specifically to recalcitrant cases. Patient selection is critical when instituting opioid therapy, and success of therapy is usually measured by reports of reduction in pain intensity, return to quality of life and achievement of a stable dose.

Oral opioids are, namely, sustained release morphine, meperidine and butalbital in combination with aspirin and caffeine. Transdermal fentanyl is effective in some cases.

Box 62.2 Splints Used in the Management of MPDS (Refer to suggested reading at the end of the chapter)

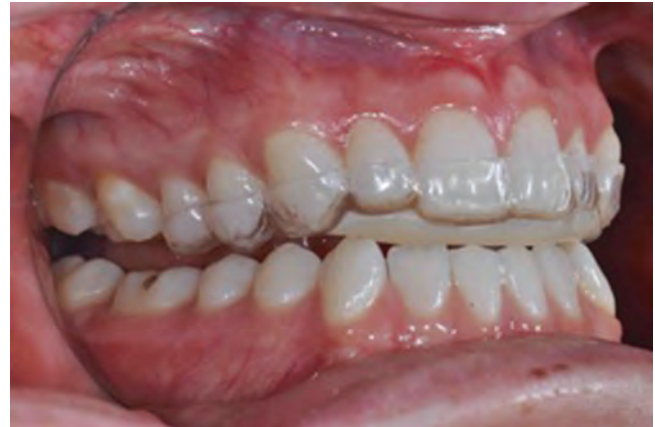Types of splint:

1. Permissive/muscle deprogrammers, e.g. stabilization splints, gnathological splint—Roth philosophy
2. Non-permissive/directive, e.g. anterior repositioning splint



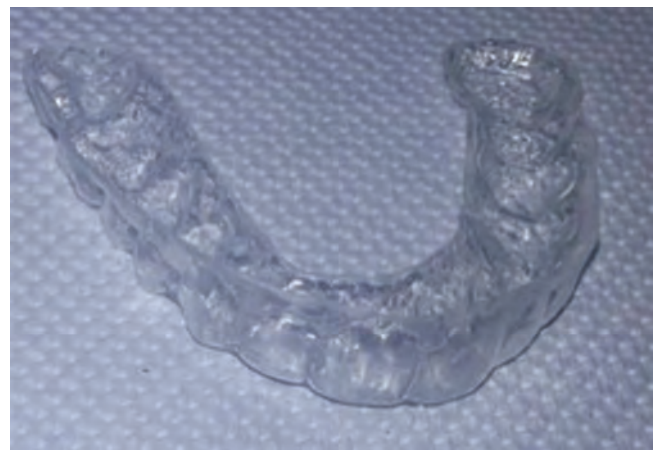
©Association of Oral and Maxillofacial Surgeons of India

Fig. 62.12 Soft splint



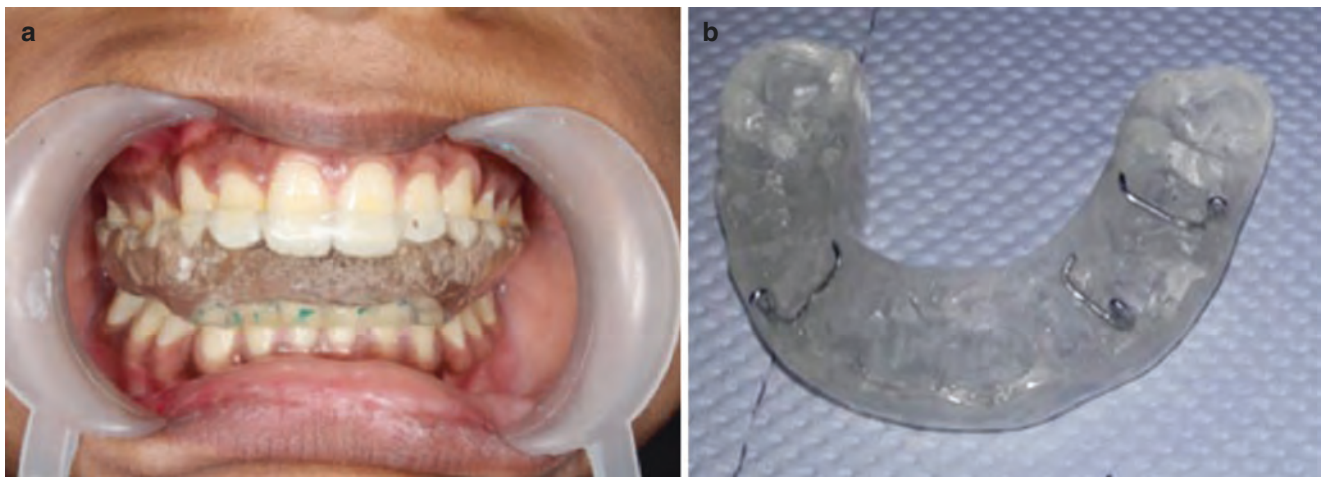©Association of Oral and Maxillofacial Surgeons of India

Fig. 62.13 Anterior bite plane or Lucia Jig



©Association of Oral and Maxillofacial Surgeons of India

Fig. 62.14 Stabilisation splints (hard splint)



©Association of Oral and Maxillofacial Surgeons of India

Fig. 62.15 (a) Gnathological splint (intraoral) (b) Gnathological splint (in vitro)

62.12.1.3 Antidepressants

Antidepressant drugs are frequently used in the management of a number of pain conditions, including MPDS. Studies indicate that these drugs behave independent to their role as antidepressants since they are effective at low doses (on average 23.6 mg for pain relief as opposed to a mean of 129 mg for depression) [52].

Amitriptyline and imipramine have been widely researched for their antidepressant and pain control properties. Dosage is initiated at 10 mg during bedtime and, if needed, is raised in 10 mg increments up to 30–40 mg. Analgesic effects are noted to occur within a few days. Side effects include sedation, constipation and dry mouth. TMPDS case reports have shown anecdotal evidence suggestive of agitation arising from selective serotonin reuptake inhibitors. Citalopram, a Selective Serotonin Reuptake Inhibitor (SSRI), had comparable effects to a placebo in the treatment of fibromyalgia [53]. Earlier sources of literature have also highlighted the efficacy of monoamine oxidase inhibitor drugs (phenelzine, tranylcypromine) in the treatment of orofacial pain conditions [54].

62.12.1.4 Muscle Relaxants

In the short term, diazepam and related muscle relaxants bring about relief from painful muscle spasms but are effective only for a short-term basis.

Benzodiazepines are associated with development of tolerance when used for a long period of time among other side effects. Varying degrees of relief have been reported with relatively low (diazepam, 5 mg bid; clonazepam, 0.5 mg bid or tid) doses, and usually an increase in dosage is not mandated.

62.12.2 Supportive Therapy

62.12.2.1 Ultrasound and Electrogalvanic Stimulation

Painful trigger points have been demonstrated to be managed effectively with therapeutic modalities such as ultrasound application and electrogalvanic stimulation (EG) [55]. Ultrasound causes localised muscle relaxation by producing heat deep within the fibres corresponding to the trigger points [56]. Low-voltage EG stimulation is used to stimulate muscles in a phased and rhythmic manner. This results in muscle relaxation and reduced muscle hyperactivity [57, 58]. These techniques are generally considered conservative and are extremely useful in mild to moderate cases of MPDS.

Box 62.3 outlines the prognosis and some of the important pearls to be borne in mind by the clinician attempting to treat MPDS.

Box 62.3 Clinical Pearls for Successful Outcomes and Prognosis of MPDS

Successful outcomes and prognosis of MPDS are dependent on the following factors:

- Accurate diagnosis—It is essential to isolate MPDS from a host of conditions that may mimic symptoms such as internal derangement, migraines and cluster headaches.
- Appropriate case selection—This necessitates the correct identification of the disease phase and institution of appropriate treatment measures.
- Clinician factors—Experience and patient rapport.
- Patient factors—Compliance, understanding, expectations.
- Multidisciplinary team approach—Effective communication between maxillofacial, orthodontic, orthopaedic and physiotherapy colleagues can ensure holistic management of the patient's condition.

Table 62.3 Summary of MPDS stages and authors' recommendation for management

Phase	Treatment approach
I (Fatigue and spasm causing pain and dysfunction)	<ul style="list-style-type: none"> • Avoidance of clenching and grinding • Soft diet • NSAIDs and muscle relaxants—ibuprofen, Valium
II (Unsuccessful phase I)	<ul style="list-style-type: none"> • Medications are continued • Splints (bite appliances) are introduced to prevent muscle overuse, including bruxism • Encourage to wear night and day • Medications discontinued if relief is obtained
III (Unsuccessful phase II)	<ul style="list-style-type: none"> • Physical therapy of muscles • Ultrasound
IV (Unsuccessful phase III)	<ul style="list-style-type: none"> • Psychological counselling • Referral to multidisciplinary centres • Surgery for recalcitrant cases

solution may be injected into trigger points in different muscles. (refer Chap. 33 for more details)

62.13 Treatment Summary

The management of MPDS can be summarised as follows (Table 62.3). (Refer also to Chap. 63 - Internal Derangements of the Temporomandibular Joint)

62.14 Recent Advances

Newer management methods that have emerged in the recent years for treatment of MPDS include botulinum toxin injections as well as cold and soft laser therapy.

62.14.1 Botulinum Toxin Injections

Botulinum toxin injection enhances vascularity by augmenting the blood flow to the affected muscles and releases the taut muscle fibres caused by abnormally contracting muscles [59]. It has also been reported to increase endogenous endorphin secretion by way of needle insertion into trigger points [60, 61]. However, studies reveal that 3–10% of patients develop neutralising antibodies with long-term adverse effects that include muscular atrophy [62].

The injection solution is prepared by dissolving 100 IU of botulinum toxin into 1.0 mL of sterile saline solution (0.9%) at room temperature to be done immediately before injection. An insulin syringe with a hypodermic needle may be used for administering the injection. Small increments of this

62.14.2 Cold and Soft Lasers

Cold laser therapy or low-level laser therapy (LLLT) has been shown to play a substantial role in the treatment of generalised musculofascial disorders and facial pain relief [63–66]. After a thorough clinical examination of the patient that must reveal clearly the affected muscles, a treatment cycle is formulated which usually consists of low-level laser application like Ga-Al-As (Endolaser) of wavelength 780 nm for 4–6 weeks.

Theories put forth to explain pain reduction via low-level laser therapy include hyperpolarisation of neuronal cell membranes and resultant elevation of pain threshold alongside an increase in the secretion of morphine-like substances such as enkephalin and endorphin which have an analgesic and anti-inflammatory effect [11].

Since trigger points are known to be of inflammatory nature [6], it can be concluded that laser application alleviates oedema, inflammation and pain by inhibiting inflammatory components such as prostaglandin (PGE₂), prostacyclins, histamine and kinin.

62.15 Summary and Conclusion

It would be appropriate to conclude that successful outcomes and prognosis of MPDS are dependent on accurate diagnosis, appropriate case selection and above all an interdisciplinary involvement that uses a team of specialists to address the various nuances of the problems in an organised manner.

The clinician needs to isolate the individual problem area and arrive at a customised solution best suited for the patient.

The following salient points must be borne in mind by the reader on completion of the chapter on MPDS as shown in Box 62.4.

Box 62.4 Summary of Important Points

- Myofascial pain dysfunction syndrome is mainly a pain disorder related to muscles and fasciae, distinct from TMJ disc interference disorders and temporomandibular degenerative diseases.
- Myofascial pain can be defined as “A myogenous pain condition characterised by Local areas of firm, hypersensitive bands of muscle tissue known as trigger points”.
- Bruxism and other parafunctional habits lead to sustained muscle contraction and eventually non-serious inflammatory reaction in masticatory muscles, muscle fatigue and pain.
- Splint therapy as interposition can dramatically break the pain pattern. “Lucia Jig” or anterior bite plane recommended for short-term use helps to disocclude the posterior teeth, thereby relieving muscle fatigue and pain caused by sustained muscle contraction due to clenching.
- Non-invasive method of muscle treatment includes inactivation massage, ice packs and Fluori-Methane sprays.
- Trigger point (TrP) injections with local anaesthetic, saline and steroids mitigate pain and improve function.
- Anti-depressants like amitriptyline in small doses (10 mg) at bedtime along with “Lucia Jig” for short-term use give good pain control results.

62.16 Case Scenarios

Case 1: (Fig. 62.16a–c)

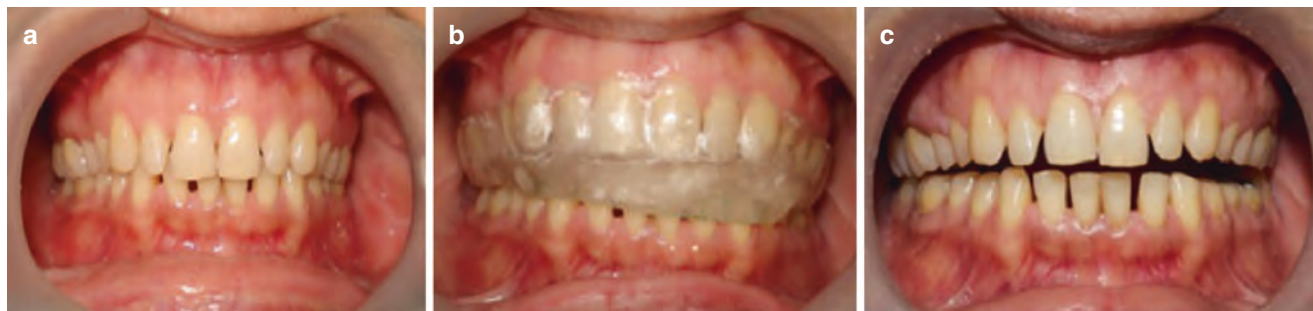A 29-year-old female patient complained of pain in the head and jaw for the past 2 years and underwent medical treatment for the same with little relief. On examination, muscles of mastication were sore and there was difficulty in manipulation of the jaw, and the patient showed a deep bite (Fig. 62.16a). CBCT showed increased joint space and MRI showed normal imaging. Having diagnosed with MPDS, the patient was advised gnathological splint (Fig. 62.16b) for full-time wear. The symptoms improved over 6–8 months. Post splint therapy, the bite was considerably opened (Fig. 62.16c), relieving pressure on the joint structures, and the patient was forwarded for orthodontic settling.

Case 2: (Fig. 62.17a–c)

A 48-year-old female patient complained of pain in the head and neck for the past 1 year. All the symptoms started with dental procedures which lasted long. On examination there was severe muscle spasm with tenderness in muscles of mastication and difficulty in opening mouth due to muscle spasm, and deviation on mouth opening was also seen. Intraorally, she had a deep anterior bite which was almost closed in relation to 11, 21, 31, 41 (Fig. 62.17a). CBCT and MRI showed normal imaging, and hence she was advised a gnathological splint (Fig. 62.17b) for her myofascial pain and to open the bite. The symptoms improved over 3–5 months of full-time wear, the bite was significantly opened and the patient was referred for orthodontic settling of the bite.

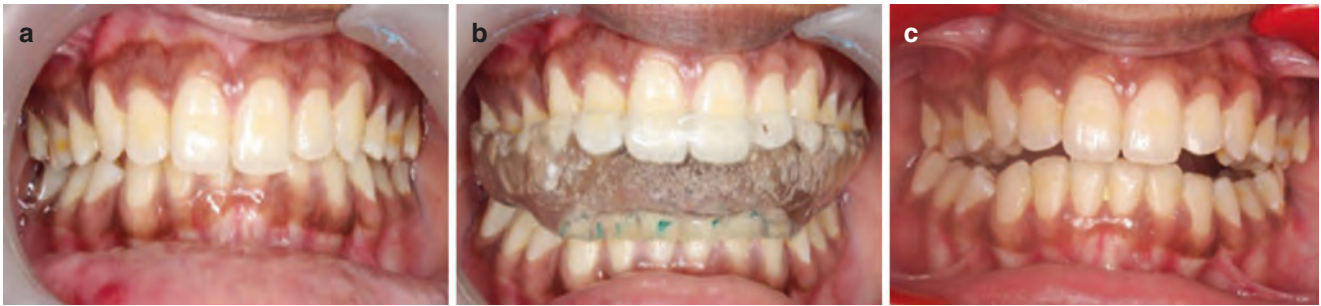Case 3: (Fig. 62.18a–c)

A 21-year-old female patient who was a dental student reported with clicking sounds and pain on both sides of the lower jaw and severe teeth grinding at night for the past 6



©Association of Oral and Maxillofacial Surgeons of India

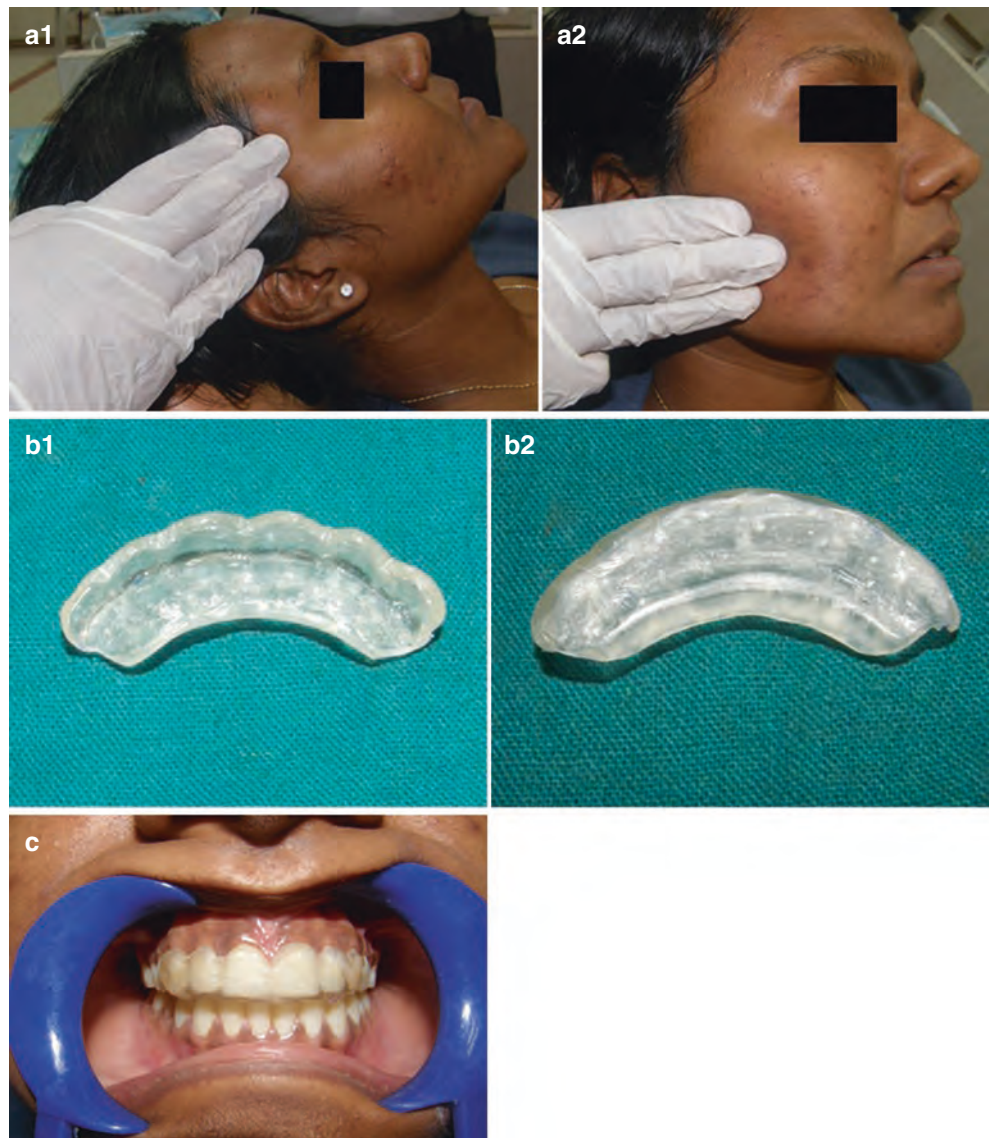Fig. 62.16 (a) Anterior deep bite with spacing in the lower anteriors. (b) Gnathological splint in place. (c) Post splint therapy correction of deep bite prior to orthodontic settling



©Association of Oral and Maxillofacial Surgeons of India

Fig. 62.17 (a) Pretreatment occlusion showing anterior deep bite. (b) Gnathological splint in place. (c) Post splint therapy

Fig. 62.18 (a) Palpation of tender points on the temporalis and masseter muscles. (b) The Lucia Jig. (c) Patient wearing the Lucia Jig



©Association of Oral and Maxillofacial Surgeons of India

months. The patient was clinically examined, severe tenderness was elicited on palpating the masseters and temporalis bilaterally (Fig. 62.18a), and intraoral signs of enamel wear from attrition were apparent. Imaging of the TMJ via MRI showed a normal study. She was advised to wear a Lucia Jig (Fig. 62.18b, c) for 3 months in order to disocclude the posterior teeth. In addition, she was prescribed amitriptyline (10 mg) once a day at night which she took for the same period. On follow-up after 3 months, she had complete relief from the pain and reported complete cessation of the parafunctional habit.

Acknowledgement The authors would like to acknowledge the invaluable contributions of a few who helped make this chapter a rewarding endeavour. We would like to thank Dr Elavenil P for her tireless efforts towards shaping important nuances of this chapter for the textbook. Dr Faisal Tajir and Dr Arvind Muhtukrishnan are sincerely appreciated for their timely contribution of clinical photographs and case scenarios included herein. The authors would like to extend heartfelt thanks to Dr Vidya Devi for the illustrations in this chapter.

Disclosure Authors have no financial conflicts to disclose.

References

- Merskey H, Bogduk N. Classification of chronic pain descriptions of chronic pain syndromes and definitions of pain terms. Task force on taxonomy of the International Association for the Study of Pain. 2nd ed. Seattle, WA: IASP Press; 1994.
- Jensen R, Rasmussen B. Prevalence of oromandibular dysfunction in a general population. *J Orofac Pain*. 1993; Spring;7(2):175–182, 8p.
- Feinmann C, Harris M. Psychogenic facial pain. Part 2: management and prognosis. *Br Dent J*. 1984;156:205–12.
- Costen JB. Syndrome of ear and sinus symptoms dependent upon functions of the temporomandibular joint. *Ann Otol Rhinol Laryngol*. 1934;3:1–4.
- Schwartz RA, Greene CS, Laskin DM. Personality characteristics of patients with myofascial pain-dysfunction (MPD) syndrome unresponsive to conventional therapy. *J Dent Res*. 1979;58:1435–9.
- Shore NA. Occlusal equilibration and temporomandibular joint dysfunction. Philadelphia: Lippincott; 1959.
- Ramfjord SP, Ash MM. Occlusion. Philadelphia: Saunders; 1971.
- Gerber A. Kiefergelenk und Zahnokklusion. *DtschZahnaerztl*. 1971;26:119.
- Graber G. Neurologische und psychosomatische Aspekte der Myoarthropathien des Kauorgans. *Zwr*, 1971;80:997–1005.
- Laskin DM. Etiology of the pain-dysfunction syndrome. *J Am Dent Assoc*. 1969;79(1):147–53.
- Schwartz L. Disorders of the temporomandibular joint. Philadelphia: Saunders; 1959.
- McNeill C, Danzig D, Farrar W, et al. Craniomandibular (TMJ) disorders—state of the art. *J Prosthet Dent*. 1980;44:434–7.
- Bell WE. Clinical management of temporomandibular disorders. Chicago: Year Book; 1982.
- Bennett R. Myofascial pain syndromes and their evaluation. *Best Pract Res Clin Rheumatol*. 2007;21(3):427–45.
- Palla S. Trigger points as a cause of Orofacial pain. *J Musculoskelet Pain*. 2004;12(3–4):29–36.
- Ge HY, Monerde S, Graven-Nielsen T, Arendt-Nielsen L. Latent myofascial trigger points are associated with an increased intramuscular electromyographic activity during synergistic muscle activation. *J Pain*. 2014;15(2):181–7.
- Svensson P. Pain mechanisms in myogenous temporomandibular disorders. *Pain Forum*. 1997;6(3):158–65.
- Kerstein RB. Disclusion time-reduction therapy with immediate complete anterior guidance development to treat chronic myofascial pain-dysfunction syndrome. *Quintessence Int*. 1992;23(11):735–47.
- Kerstein RB. Treatment of myofascial pain dysfunction syndrome with occlusal therapy to reduce lengthy disclusion time—a recall evaluation. *Cranio*. 1995;13(2):105–15.
- Nilner M. Prevalence of functional disturbances and diseases of the stomatognathic system in 15–18 year olds. *Swed Dent J*. 1981;5(5-6):189–97.
- Simons DG, Travell JG, Simons LS. Travell & Simons' myofascial pain and dysfunction: the trigger point manual, chapter 4. 2nd ed. Baltimore: Williams & Wilkins; 1999. p. 220–7.
- Sarlani E, Grace EG, Reynolds MA, Greenspan JD. Evidence for up-regulated central nociceptive processing in patients with masticatory. *Myofascial pain*. *J Orofac Pain*. 2004;18(1):41–55.
- Younger JW, Shen YF, Goddard G, Mackey SC. Chronic myofascial temporomandibular pain is associated with neural abnormalities in the trigeminal and limbic systems. *Pain*. 2010 May;149(2):222–8.
- Moldofsky H, Scarisbrick P. Induction of neuroathenic musculoskeletal pain syndrome by selective sleep stage deprivation. *Psychosom Med*. 1976;38(1):35–44.
- Sciotti VM, Mittak VL, DiMarco L, Ford LM, Plezbert J, Santipadri E, Wigglesworth J, Ball K. Clinical precision of myofascial trigger point location in the trapezius muscle. *Pain*. 2001;93(3):259–66.
- American Academy of Orofacial Pain. In: Okeson JP, editor. Orofacial pain: guidelines for assessment, diagnosis and management. Chicago: Quintessence; 1996. p. 127–41.
- IASP Subcommittee on Taxonomy. The need of a taxonomy. *Pain*. 1979;6:249–52.
- The glossary of prosthodontic terms. *J Prosthet Dent*. 2005;94(1):10–92
- Fricton JR, Velly A, Ouyang W, et al. Does exercise therapy improve headache? A systematic review with meta-analysis. *Curr Pain Headache Rep*. 2009;13(6):413–9.
- Aronoff GM, Evans WO, Enders PL. A review of follow-up studies of multidisciplinary pain units. *Pain*. 1983;16(1):1–11.
- Greene SA. Chronic pain: pathophysiology and treatment implications. *Top Companion Anim Med*. 2010;25(1):5–9.
- Greene CS, Laskin DM. Splint therapy for the myofascial pain-dysfunction (MPD) syndrome: a comparative study. *J Am Dent Assoc*. 1972;84(3):624–8.
- Harden RN, Bruehl SP, Gass S, Niemiec C, Barbick B. Signs and symptoms of the myofascial pain syndrome: a national survey of pain management providers. *Clin J Pain*. 2000;16(1):64–72.
- Donovan TE, Anderson M, Becker W, Cagna DR, Hilton TJ, JR MK. Annual review of selected scientific literature: report of the committee on scientific investigation of the American Academy of Restorative Dentistry. *J Prosthet Dent*. 2012;108(1):15–50.
- Conti PCR, De Alencar EN, Da MotaCorrêa AS, Lauris JRP, Porporatti AL, Costa YM. Behavioural changes and occlusal splints are effective in the management of masticatory myofascial pain: a short-term evaluation. *J Oral Rehabil*. 2012;39(10):754–60.
- Gozler S, Vanlioglu B, Evren B, Gozneli R, Yildiz C, Ozkan YK. The effect of temporary hydrostatic splint on occlusion with computerized occlusal analysis system. *Indian J Dental Res*. 2012;23:617–22.
- Aldemir K, Üstüner E, Erdem E, Demiralp AS, Oztuna D. Ultrasound evaluation of masseter muscle changes in stabilization splint treat-

- ment of myofascial type painful temporomandibular diseases. *Oral Surg Oral Med Oral Pathol Oral Radiol.* 2013;116(3):377–83.
38. Wang C, Yin X. Occlusal risk factors associated with temporomandibular disorders in young adults with normal occlusions. *Oral Surg Oral Med Oral Pathol Oral Radiol.* 2012;114(4):419–23.
 39. Institute of Medicine. *Relieving pain in America: a blueprint for transforming prevention, care, education, and research.* Washington, DC: National Academies Press; 2011.
 40. US Department of Health and Human Services. National Institutes of Health PA-13-118. Available at: <http://grants.nih.gov/grants/guide/pa-files/PA-13-118.html>. Accessed 29 Jun 2016
 41. Friction JR. Management of masticatory myofascial pain. *Semin Orthod.* 1995;1(4):229–43.
 42. Halkovich LR, Personius WJ, Clamann HP, et al. Effect of Fluorimethane spray on passive hip flexion. *Phys Ther.* 1981;61(2):185–9.
 43. Cifala J. Myofascial (trigger point pain) injection: theory and treatment. *Int J Osteopath Med.* 1979:31–6.
 44. Jaeger B, Skoosky SA. Double blind, controlled study of different myofascial trigger point injection techniques. *Pain.* 1987;4(Suppl):S292.
 45. Simons DG. Myofascial pain syndrome: one term but two concepts, a new understanding. *J Musculoskeletal Pain.* 1995;3:7.
 46. Gray RG, Tenenbaum J, Gottlieb NL. Local corticosteroid injection treatment in rheumatic disorders. *Semin Arthritis Rheum.* 1981;10:231.
 47. Pullinger AG, Seligman DA, Gornbein JA. A multiple regression analysis of the risk and relative odds of temporomandibular disorders as a function of common occlusal features. *J Dent Res.* 1993;72:968.
 48. Seligman DA, Pullinger AG. The role of functional occlusal relationships in temporo-mandibular disorders: a review. *J Craniomandib Disord Facial Oral Pain.* 1991;5:265.
 49. Marbach JJ, Raphael KG, Dohrenwend BP, et al. The validity of tooth grinding measures: etiology of pain dysfunction syndrome revisited. *J Am Dent Assoc.* 1990;120:327.
 50. Dionne RA. Pharmacologic treatments for temporomandibular disorders. In: Sessle BJ, Bryant PS, Dionne RA, editors. *Temporomandibular disorders and related pain conditions.* Seattle: IASP Press; 1995. p. 363.
 51. Singer EJ, Sharav Y, Dubner R, et al. The efficacy of diazepam and ibuprofen in the treatment of chronic myofascial orofacial pain. *Pain.* 1987;30:S83.
 52. Sharav Y, Singer E, Schmidt E, et al. The analgesic effect of amitriptyline on chronic facial pain. *Pain.* 1987;31:199.
 53. Norregaard J, Volkmann H, Danneskiold-Samsøe S. A randomized controlled trial of citalopram in the treatment of fibromyalgia. *Pain.* 1995;61:445.
 54. Lascelles RG. Atypical facial pain and depression. *Br J Psychiatry.* 1966;112:651.
 55. Ay S, Dogan SK, Evcik D, Baser OC. Comparison the efficacy of phonophoresis and ultrasound therapy in myofascial pain syndrome. *Rheumatol Int.* 2011;31(9):1203–8.
 56. Zohn DA, Mennell JM. *Musculoskeletal pain: diagnosis and physical treatment.* Boston: Little Brown; 1976. p. 126–37.
 57. Bonica JJ. Management of myofascial pain syndromes in general practice. *J Am Med Assoc.* 1957;164(7):732.
 58. Kamyszek G, Ketcham R, Garcia R, Radke J. Electromyographic evidence of reduced muscle activity when ULF-TENS is applied to the Vth and VIIth cranial nerves. *Cranio.* 2001;19(3):162–8.
 59. Von Lindern JJ, Niederhagen B, Bergé S, Appel T. Type A botulinum toxin in the treatment of chronic facial pain associated with masticatory hyperactivity. *J Oral Maxillofac Surg.* 2003;61:774–8.
 60. Aoki KR. Evidence for antinociceptive activity of botulinum toxin type A in pain management. *Headache.* 2003;43(Suppl 1):S9–15.
 61. Jabbari B. Botulinum neurotoxins in the treatment of refractory pain. *Nat Clin Pract Neurol.* 2008;4:676–85.
 62. Anderson TJ, Rivest J, Stell R, Steiger MJ, Cohen H, Thompson PD. Botulinum toxin in the treatment of spasmodic torticollis. *J R Soc Med.* 1992;85:524–9.
 63. Gur A, Sarac AJ, Cevik R, Altindag O, Sarac S. Efficacy of 904 nm gallium arsenide low level laser therapy in the management of chronic myofascial pain in the neck: a double-blind and randomized-controlled trial. *Lasers Surg Med.* 2004;35:229–35.
 64. Venanciorde A, Camparis C, Lizarellirde F. Low intensity laser therapy in the treatment of temporomandibular disorders. *J Oral Rehabil.* 2005;32:800–7.
 65. Nunez SC, Garcez AS, Suzuki SS, Ribeiro MS. Management of mouth opening in patients with temporomandibular disorders. *Photomed Laser Surg.* 2006;24:45–9.
 66. Dundar U, Eucik D, Samli F. The effect of gallium arsenide aluminum laser therapy in the treatment of temporomandibular joint disorders. *J Clin Rheumatol.* 2006;33:229–35.

Suggested reading

- Basics of Occlusal Splint Therapy (Internet). *Dentistry Today* 2002 (Cited October 21, 2020). Available at <https://www.dentistrytoday.com/prosthodontics/prosthetics/1716>.

Open Access This chapter is licensed under the terms of the Creative Commons Attribution 4.0 International License (<http://creativecommons.org/licenses/by/4.0/>), which permits use, sharing, adaptation, distribution and reproduction in any medium or format, as long as you give appropriate credit to the original author(s) and the source, provide a link to the Creative Commons license and indicate if changes were made.

The images or other third party material in this chapter are included in the chapter's Creative Commons license, unless indicated otherwise in a credit line to the material. If material is not included in the chapter's Creative Commons license and your intended use is not permitted by statutory regulation or exceeds the permitted use, you will need to obtain permission directly from the copyright holder.





Internal Derangements of the Temporomandibular Joint

63

Gary Warburton

63.1 Introduction

The term “internal derangement” has been used for more than a century in surgical and orthopedic literature to describe conditions that interfere with normal joint function [1, 2]. In the knee, the term internal derangement is broadly used to describe a torn, ruptured, or deranged meniscus of the knee, a partial or complete cruciate rupture, with or without injury to the capsular ligament of the knee, resulting in ongoing or intermittent signs and symptoms such as pain, instability, or abnormal mobility. Alterations in the disc, condyle-fossa relationships in the temporomandibular joint (TMJ) were suspected as early as 1887 by Sir Astley Cooper and published by Annandale in the *Lancet* “on displacement of the inter-articular cartilage of the lower jaw, and its treatment by operation” [3]. The term internal derangement was adopted and used to describe disturbances between the articulating components of the TMJ, alluding to the damage to the internal structures and dysfunction of the joint associated with changes in the position of the disc [4, 5].

In the TMJ literature, the term has evolved to be synonymous with disc displacement. In the 1970s and 1980s, TMJ internal derangement was perceived as a mechanical problem and resulted in attempts to reposition or replace the disc. In 1979, McCarty and Farrar stressed on the relevance of disc displacement as a major disorder of the TMJ [5]. It was believed that a displaced or abnormal disc was a progressive problem that led to degenerative joint disease and as a result importance was given to repositioning the displaced disc. Conservative therapy was done by mandibular manipulations and oral appliances, and surgical repositioning was per-

formed for patients who had persistent symptoms. A commonly performed surgical procedure was repositioning of the disc, and if the disc was perforated or beyond repair, even discectomy was performed. Various materials and tissues were used for disc replacement (cartilage, dermis, muscle fascia, fat, silastic, and Proplast-Teflon). However, the use of Proplast-Teflon resulted in severe destruction of the articular surfaces due to foreign body giant cell reactions [6–8].

Over the past few decades, there has been a conceptual shift from internal derangement and disc displacement being a primary diagnosis toward our current understanding that disc displacement/internal derangement is an endpoint and a manifestation of a process in which there is damage to articular tissues and biomechanical failure from a specific cause that must be identified if treatment is to be successful.

Clinical and basic science research has led us to the conclusion that internal derangement represents a variety of stages of biomechanical failure of the joint tissues, resulting from different causes. Wilkes staging system (Table 63.1) categorizes the extent of joint damage in internal derangement without being specific for the underlying cause that is responsible for the failure of the joint tissues. With this limitation in mind, Wilkes classification [9] is still useful today in communicating severity and guiding treatment.

The realization in the 1990s that arthroplasty with disc repositioning or discectomy often leads to degenerative joint disease and fibrosis, coupled with the fact that the disc repositioning was not reliably maintained, caused a major change in surgical management. Arthroscopic surgery of the TMJ was shown to be an effective alternative to arthroplasty. Arthroscopy was a reliable procedure to reduce the pain and to improve the maximal incisal opening without causing a change in position of the disc [10–15]. The role of disc displacement and disc position in symptomatic patients has been further questioned due to the fact that MRI studies have documented disc displacement in 32–38% of asymptomatic patients and volunteers [16, 17]. We now know that the abnormally positioned disc is not the primary cause on pain and dysfunction for many

Electronic Supplementary Material The online version of this chapter (https://doi.org/10.1007/978-981-15-1346-6_63) contains supplementary material, which is available to authorized users.

G. Warburton (✉)
Department of Oral and Maxillofacial Surgery, University of
Maryland School of Dentistry, Baltimore, MD, USA
e-mail: gwarburton@umaryland.edu

Table 63.1 Wilkes classification

Stage I Early	Painless clicking Anterior disc displacement with reduction
Stage II Early intermediate	Clicking with intermittent pain and locking Anterior disc displacement with reduction
Stage III Intermediate	Pain, joint tenderness, frequent and prolonged locking, restricted motion, No degenerative changes Anterior disc displacement with or without reduction
Stage IV Intermediate-late	Chronic pain, restricted motion, no clicking, degenerative bony changes Adhesions Anterior disc displacement without reduction
Stage V Late	Variable pain, painful function, reduced function, crepitus, advanced degenerative bony changes, gross disc deformity and/or perforation Advanced adhesions Anterior disc displacement without reduction

patients as the majority of patients with displaced discs are asymptomatic through the process of adaptation.

Arthrocentesis was subsequently introduced as another effective yet minimally invasive means of treating patients with symptomatic internal derangement [18–22]. Arthroscopy and arthrocentesis allowed sampling synovial fluid and has been of tremendous value in our understanding of the biochemical mediators and cytokines responsible for inflammation, cartilage degeneration, and destruction of joint tissue leading to internal derangement [23–26].

Diagnostic criteria for temporomandibular disorders (TMD) for research and clinical purposes were recently updated in 2014 [27] and include internal derangement or disc displacement which is presented as:

- Disc displacement with reduction
- Disc displacement with reduction with intermittent locking
- Disc displacement without reduction with limited opening
- Disc displacement without reduction without limited opening

Normal disc position, displacement with reduction, and displacement without reduction are depicted in Fig. 63.1.

63.2 Epidemiology

Internal derangement of the TMJ is a relatively common problem. Farrar estimated that up to 25% of the population has TMJ internal derangement [28]. Epidemiologic studies have shown that TMJ clicking is detectable in up to 31% of

the population, and crepitus is detectable in up to 40% of the population on auscultation, with a higher prevalence among women.

MRI studies have documented disc displacement in 32–38% of *asymptomatic* patients and volunteers [15, 16]. The mean age for TMJ disorders is 34 with 90% of patients falling within 15–45 years of age range. Agerberg et al. studied 637 people aged 18–65 and found an incidence of 21% clicking in men and 28% in women, while crepitus was noted in 26% of men and 40% of women [29]. Disc displacement occurs most commonly in the anterior or anteromedial direction, which is the most common direction of displacement followed by lateral and rarely posterior displacement accounting for only 0.7% of displacements [30].

63.3 Etiology

Internal derangement is an endpoint and a manifestation of a process in which there is damage to articular tissues and biomechanical failure from a specific cause that must be identified if treatment is to be successful. The broad etiologic categories resulting in internal derangement are:

- Macrotrauma—major impact to jaw, e.g., sports injury, assault
- Microtrauma—parafunctional habits (clenching and bruxism)
- Systemic arthropathy—rheumatoid, SLE, psoriatic arthritis, HLA B27, infective, etc.

An alternative framework regarding etiology is:

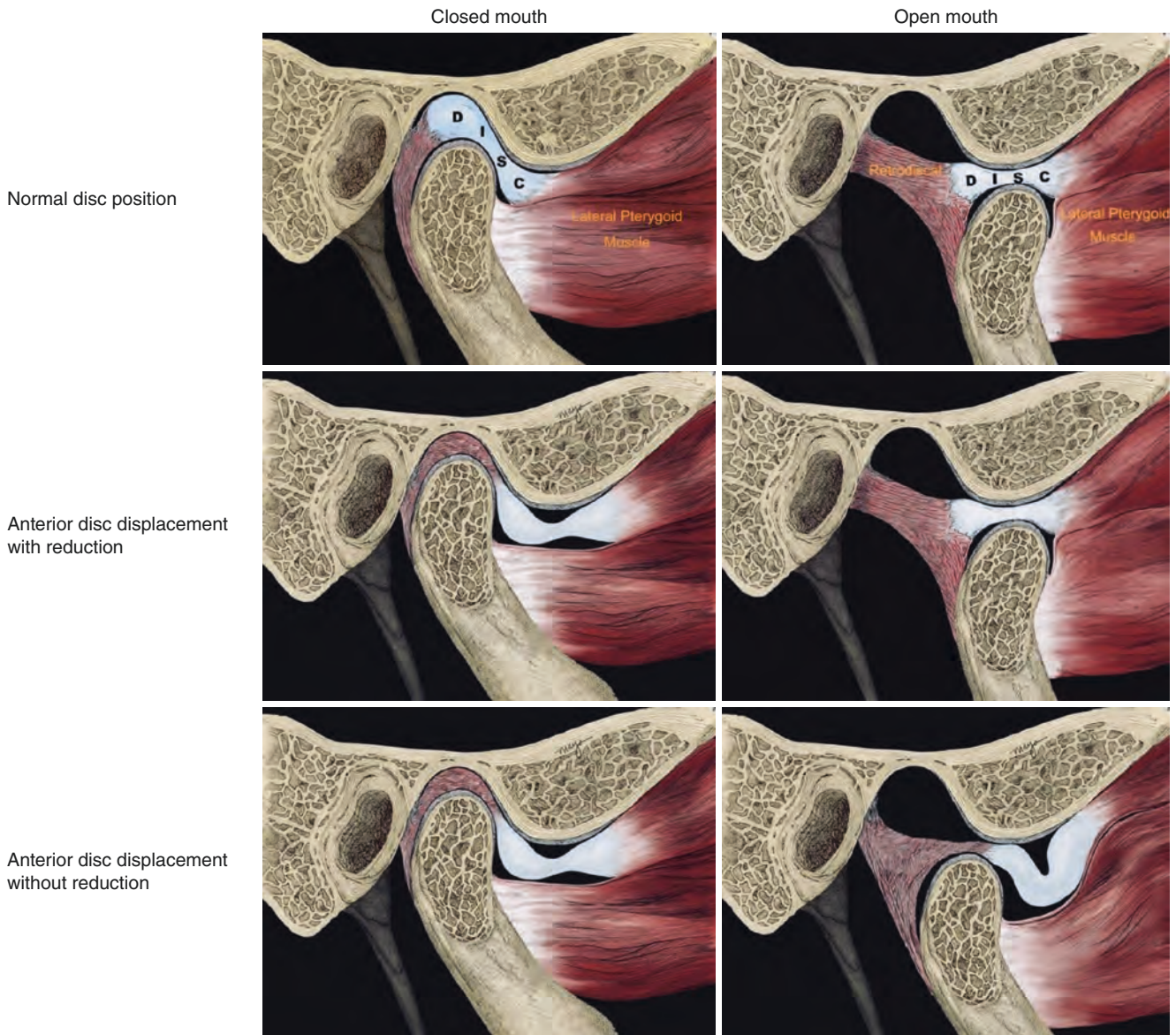
- A normal joint subjected to overload (trauma or parafunction)
- An abnormal joint subjected to normal load (rheumatoid, SLE or psoriatic arthritis, osteochondroma, chondromatosis)

The majority of patients fall into the normal joint subjected to overload etiologic category and in particular due to parafunctional habits of clenching or bruxism during the day or at night.

Historically occlusion has been considered a primary etiologic factor, but this has now been refuted in current evidence-based literature [31, 32].

63.4 Anatomy and Function Relevant to Internal Derangement

The TMJ is a hinging and sliding synovial joint (ginglymoarthrodial joint) and forms the articulation between the mandibular condyle and the temporal bone. The articular surfaces



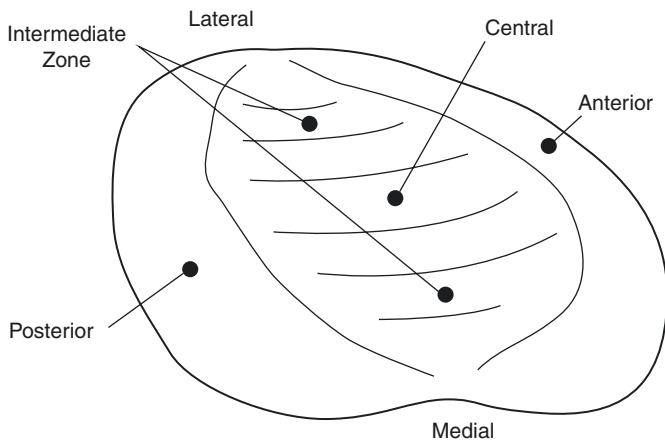
©Association of Oral and Maxillofacial Surgeons of India

Fig. 63.1 Normal and displaced disc positions, with and without reduction (modified with the permission of Dr. Robert Talley)

are covered with fibrocartilage, while most other synovial joints are composed of hyaline cartilage. Fibrocartilage is composed of fibrochondrocytes, fibroblast-like cells, type I collagen, and proteoglycans. Fibrocartilage is less susceptible to degeneration and also has a greater repair capacity compared to hyaline cartilage [33]. The articular disc or meniscus that is interposed between the mandibular condyle and articular eminence of the temporal bone is also a fibrocartilaginous structure in the shape of a biconcave elliptical disc. It has a thicker posterior and anterior band with a thinner intermediate zone in between (Fig. 63.2). From a lateral viewpoint in the closed mouth position when the condyle is seated in the glenoid fossa, the posterior band is normally positioned at the 12 o'clock position from a point in the cen-

ter of the condyle. As the condyle rotates and translates forward beneath the disc during mouth opening, the disc comes to lie above the condyle (this has been termed "roofing"). The disc itself is an avascular structure and that has no innervation. The metabolic and nutritional requirements of the avascular disc are provided by the surrounding synovial fluid through a process known as weeping lubrication (whereby a small amount of synovial fluid is forced into and out of the disc during the compressive forces generated by joint function and loading of the disc). The disc is anchored to the medial and lateral poles of the condyle by the collateral (discal) ligaments (Fig. 63.3).

Figure 63.4 shows the attachments of the disc in a sagittal view. The posterior attachment of the disc is the retrodiscal



©Association of Oral and Maxillofacial Surgeons of India

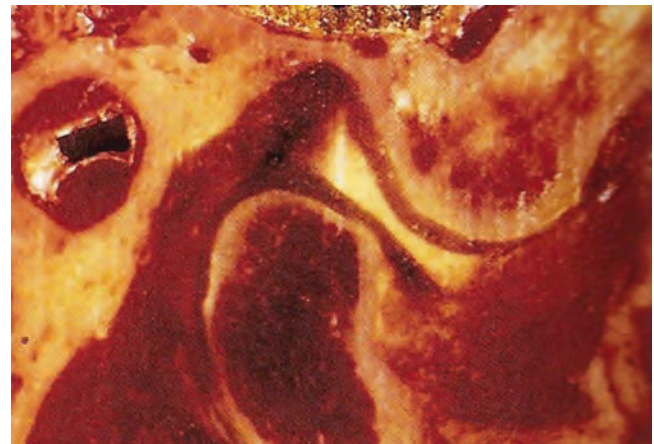
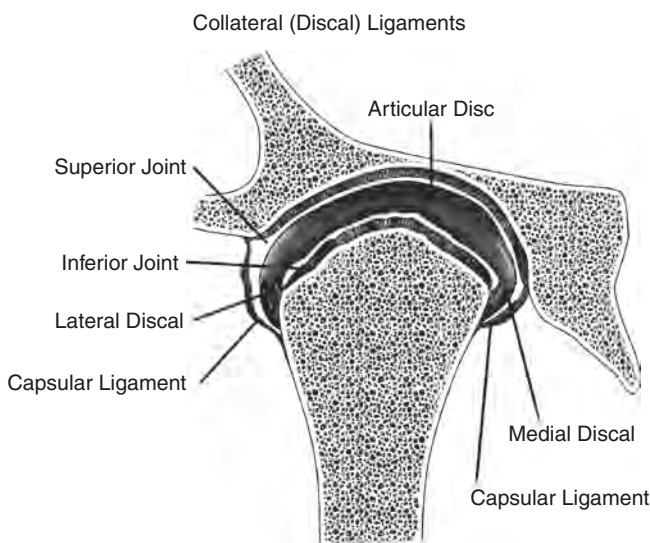
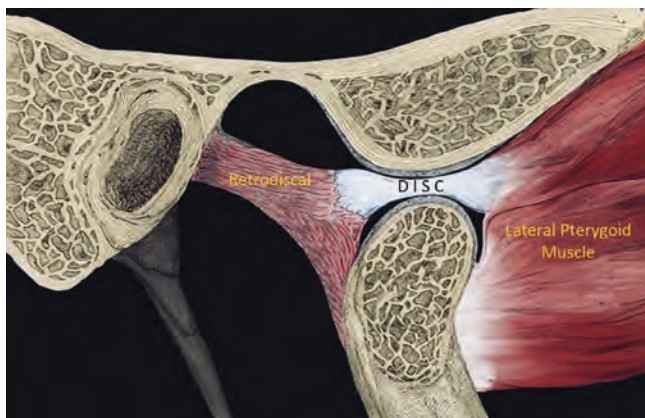

Fig. 63.2 Articular disc or meniscus (normal position) (Also see normal disc position in open mouth and closed position in Fig. 63.1)



©Association of Oral and Maxillofacial Surgeons of India

Fig. 63.3 Coronal view of the medial and lateral collateral (discal) ligaments



©Association of Oral and Maxillofacial Surgeons of India

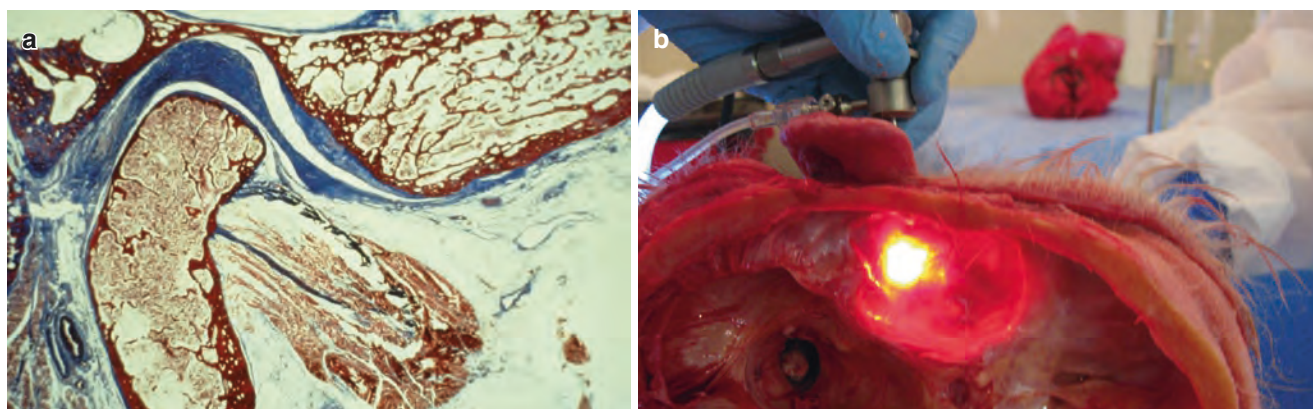
Fig. 63.4 Attachments of the disc in a sagittal view (modified with the permission of Dr. Robert Talley)

tissue. The retrodiscal tissue is a bilaminar structure with a superior lamina, inferior lamina, and intervening loose connective tissue that is very vascular and well-innervated. The retrodiscal attachment connects the disc to the tympanic plate of the temporal bone by the superior lamina, which is composed of connective tissue and elastic fibers. These elastic fibers condense to form a prominence recognized arthroscopically as the posterior oblique protuberance/band. The inferior lamina is composed of collagen fibers and inserts into the condylar neck. The disc and retrodiscal tissue together divide the TMJ into upper and lower joint spaces which are filled with synovial fluid. The anterior attachment of the disc is to the temporal bone, the anterior condylar neck, and the upper head of the lateral pterygoid muscle, while the medial and lateral attachments are to the capsular ligaments as well as the collateral ligaments. All the joint surfaces are covered with synovial lining except the disc itself, glenoid fossa, articular eminence, and condylar head.

It is the collateral (discal) ligaments along with the superior and inferior lamina of the retrodiscal tissue that are disrupted and elongated when the disc is displaced anteriorly in internal derangement.

The glenoid fossa of the temporal bone lies immediately beneath the middle cranial fossa (Fig. 63.5a, b). From both arthroscopic and open surgical standpoints, one must recognize that the bony roof of the fossa is extremely thin. An autopsy study revealed that the glenoid fossa was only 0.2–1.5 mm thick in normal joints and 0.5–2.0 mm thick in joints with disc displacement [34]. Care must be taken not to perforate the thin roof of the fossa during arthroscopic and open TMJ surgical procedures.

The TMJ is innervated by the trigeminal nerve, predominantly through the auriculotemporal branch of the mandibular division which passes behind the condylar neck and penetrates the capsule to enter the joint. However, some innervation also comes from the deep temporal and masseteric branches.



©Association of Oral and Maxillofacial Surgeons of India

Fig. 63.5 (a) Sagittal section through TMJ and glenoid fossa. (b) Cadaveric specimen viewed from the middle cranial fossa (brain removed) with an arthroscope in the left TMJ. Both demonstrate the thin roof of the glenoid fossa

63.5 Clinical Features and Diagnosis

The most common presenting complaints in patients with TMJ internal derangement include:

- Pain
- Joint noises (click or crepitation)
- Loss of function
- Occasionally a change in occlusion

The loss of function may be due to limited mouth opening (closed lock in anterior disc displacement without reduction), a mechanically obstructive click, or dietary compromise secondary to pain.

63.5.1 Patient History

A good clinical history is essential for accurate diagnosis of any TMJ disorder including internal derangement. Questions including onset and evolution of the problem may reveal a classical story of a clicking or “popping” joint, indicating a disc displacement with reduction, or a story in which a patient with a history of a clicking joint notices that the click suddenly disappears and at the same time develops limited mouth opening and pain indicative of progression to disc displacement without reduction. Questions regarding initiating factors are helpful in identifying the underlying etiology (trauma or parafunction). Patient reports of pain increasing with stress or pain present on waking from sleep are strongly suggestive of parafunctional habits.

The answers to these pain questions may suggest pain originating from the joint when the pain is localized over the preauricular area, compared to muscular pain when it is more

Other questions should include details of prior treatment attempts and specific questions regarding pain:

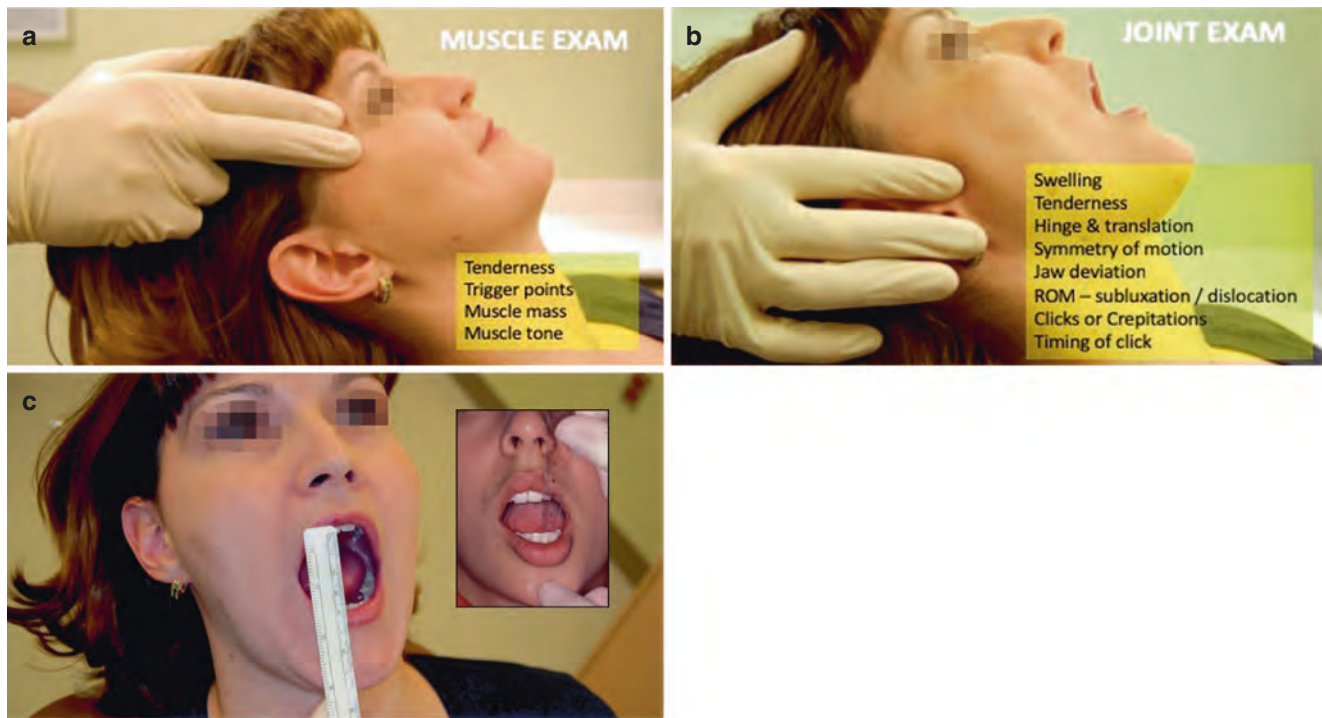
- Location
- Radiation
- Severity
- Timing (intermittent or constant)
- Duration and frequency of episodes
- Exacerbating factors
- Relieving factors
- Associated symptoms (headache, tinnitus, etc.)

widespread, a critical differentiation in determining appropriate management. Problems with other joints such as pain or laxity may suggest systemic arthritis or even conditions such as Ehlers-Danlos syndrome.

63.5.2 Patient Examination (Fig. 63.6a–c)

Should include examination of the muscles of mastication, TMJ, range of mandibular motion, and intraoral examination to evaluate occlusion and signs of parafunction (buccal mucosal ridging at the level of the occlusal plane, scalloping of the lateral border of the tongue, tooth wear, and fractured teeth or restorations).

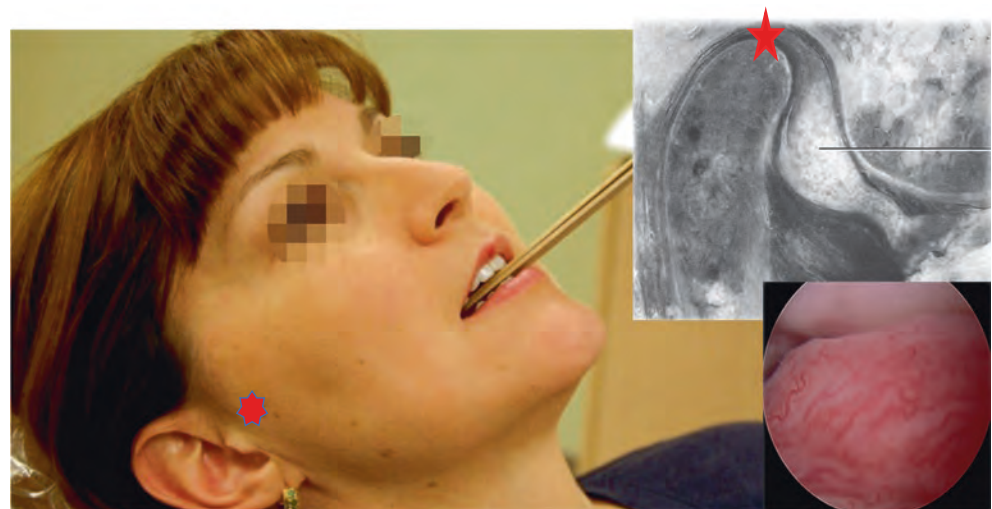
When examining each pair of muscles, one should evaluate for tenderness, trigger points, muscle mass, and tone. If the patient reports pain on palpation (indicating myalgia), it is helpful to determine if the pain is localized to the point of palpation (local myalgia), spreading beyond the point of palpation but within the muscle boundary (myofascial pain), or radiates outside the muscle boundary (myofascial pain with referral).



©Association of Oral and Maxillofacial Surgeons of India

Fig. 63.6 (a–c) Examination of muscles, joint, and range of motion

Fig. 63.7 Anterior disc displacement and retrodiscitis (as seen in the inset arthroscopic image) with a positive direct pressure loading test of the right TMJ = biting on tongue blades between left canines loads the right TMJ, and pain is reported in the right TMJ



©Association of Oral and Maxillofacial Surgeons of India

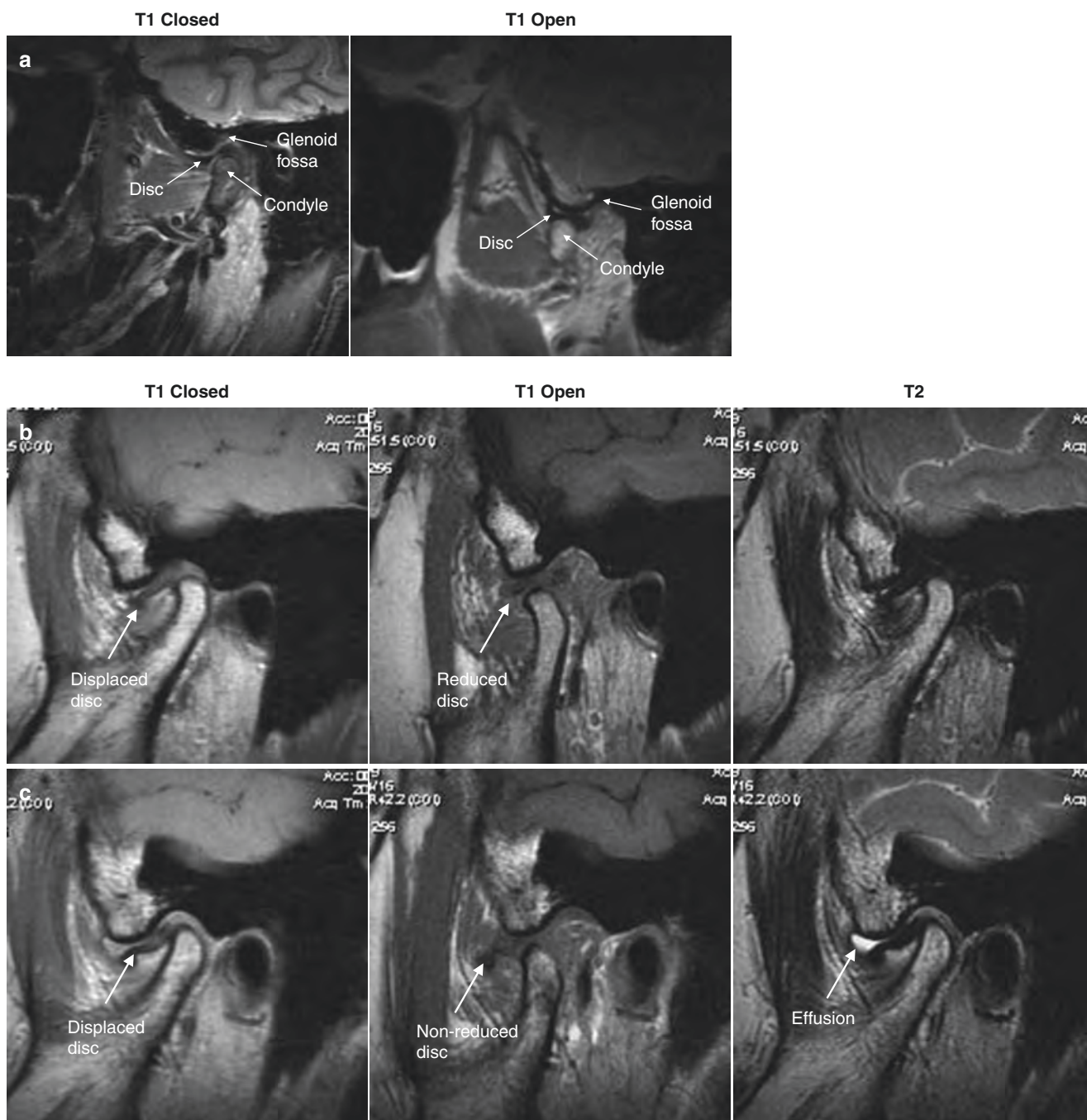
When examining the joint, one should evaluate for tenderness, swelling, range of motion (hinge and translation), symmetry of motion or deviations, subluxation/dislocation, clicks, and crepitation. Joint noises may be audible or palpable, but some may only be detected by auscultation. Timing of any opening click provides clinical information on the extent of disc displacement before reduction. A very early click on condylar translation suggests minimal anterior disc displacement before reduction, while a late click suggests greater anterior displacement of the disc. If the disc is

anteriorly displaced, there may be significant retrodiscitis due to the condyle functioning on the retrodiscal tissue rather than the disc itself (Fig. 63.7). If the patient is asked to bite on two wooden tongue blades between the canine teeth and they report pain localized to the contralateral TMJ that is now being loaded, this is pathognomonic for retrodiscitis and is known as a positive direct pressure loading test. Crepitations often indicate perforation, usually in the retrodiscal tissues, and may occur due to long-term function on the retrodiscal tissue or trauma.

63.5.3 Radiographic Evaluation

While plain radiographs and CT scans are useful for evaluating bony changes, MRI scans are best suited for evaluating disc position and displacement and have a diagnostic accuracy of at least 90% [35]. MRI should be ordered with both T1 and T2 images in the open and closed mouth positions

(Fig. 63.8a–c); often additional imaging sequences are helpful such as fat suppressed or STIR sequences which help to show edema in tissues that contain fat. This can be helpful in evaluating edema in the cancellous bone of the condylar head. Using MRI, one can assess the bone of the condyle, fossa, and eminence (looking for sclerosis, erosions, flattening, osteophytes, and breaks in cortical continuity), the disc



©Association of Oral and Maxillofacial Surgeons of India

Fig. 63.8 (a–c) MRI scan—T1 and T2 images in closed and open mouth positions. (a) Normal disc position. (b) Anterior disc displacement with reduction. (c) Anterior disc displacement without reduction and superior joint space effusion

(looking at its position, density, shape, size, and continuity in cases of perforation), effusions which are easily seen on T2 sequences, and finally for collapse of the joint space. The sagittal closed and open mouth images determine if the disc is displaced and whether or not it reduces on opening.

63.5.4 Serology

Is helpful in the diagnosis of primary inflammatory arthritis (Table 63.2). Rheumatoid factors (RFs) occur in 60–80% of patients with rheumatoid arthritis (RA) [36]. While they are sensitive, their diagnostic utility is limited by their relatively poor specificity, since they are also found in 5–10% of healthy individuals, 20–30% of people with SLE, virtually all patients with mixed cryoglobulinemia (usually caused by hepatitis C virus infections), and those with many other inflammatory conditions. Higher titers of RFs (at least three times the upper limit of normal) have somewhat greater specificity for RA. The prevalence of RF positivity in healthy individuals rises with age. More recently, other antibody markers have been utilized. Anti-cyclic citrullinated peptide (anti-CCP) antibodies have a similar sensitivity to RF for RA but have a much higher specificity (95–98%). Anti-CCP antibodies are also present early in the disease, and their presence often correlates with more severe forms of RA, making them better prognostic indicators [37]. HLA-B27 is associated with seronegative spondyloarthropathies, psoriatic and reactive arthritis [38].

Table 63.2 Serology in primary inflammatory arthritis

Serology	<ul style="list-style-type: none"> • Rheumatoid factor → Rheumatoid arthritis • HLA B-27 → Reactive arthritis, ankylosing spondylitis, juvenile reactive arthritis • ANA → Autoimmune D/O (e.g. rheumatoid arthritis, systemic lupus erythematosus) • Anti-citrullinated protein antibody ACCP → Aid in dx of RA and its prognosis
----------	--

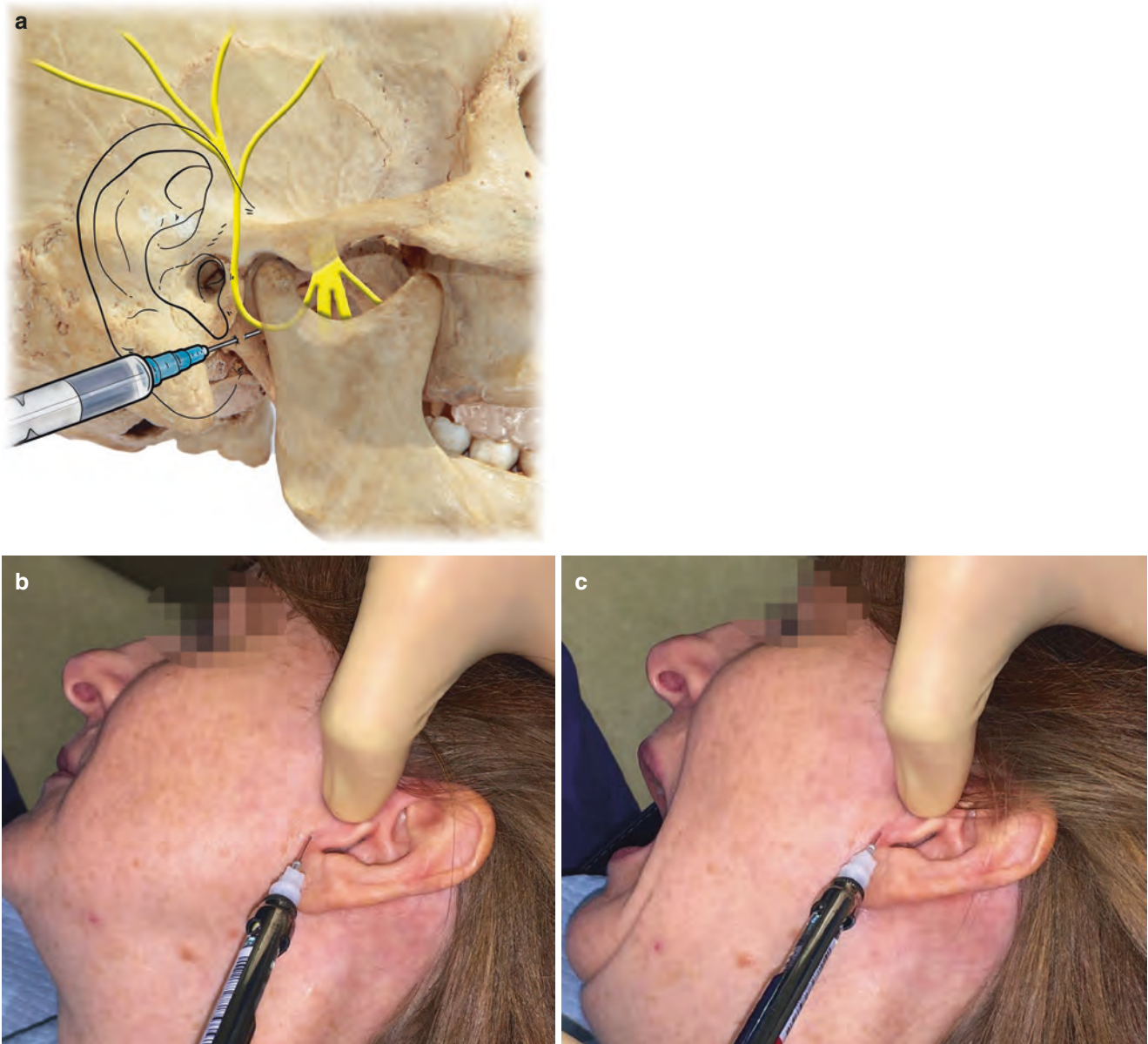
63.5.5 Diagnostic Local Anesthetic Block

In complex cases where history and examination fail to clearly confirm pain originating from the joint itself, or in cases that have undergone previous surgeries on the TMJ, or in chronic pain patients, an auriculotemporal nerve block and injection of local anesthetic into the superior joint space is very helpful and can demonstrate the amount of pain originating from the joint. The author uses 3% mepivacaine injected using a dental syringe (Fig. 63.9a–c). With the patient in occlusion, the needle is inserted and advanced to contact the posterior condylar neck where half the carpule is injected as an auriculotemporal nerve block. The patient then opens their mouth, and the needle is advanced superiorly to contact the posterior slope of the articular eminence, and the remaining anesthetic is deposited into the superior joint space. The patients pain score before is compared to the pain score 10–15 min after injection. Any portion of pain that has resolved is most likely originating from the joint. This is helpful in determining if surgery is indicated and also in providing realistic postoperative pain expectations for the surgical patient.

63.6 Treatment of Internal Derangement

Treatment for internal derangement can be divided into nonsurgical and surgical options, but the general treatment goals are the same:

- Decrease joint overload
- Decrease pain
- Reduce inflammation
- Improvement in the range of motion
- Restore function
- Causative factors to be identified and controlled



©Association of Oral and Maxillofacial Surgeons of India

Fig. 63.9 (a–c) Diagnostic auriculotemporal nerve block and TMJ injection

Clinical research [39–41] into the natural progression of TMJ internal derangement has shown:

- Without any treatment, improvement is seen in many patients.
- On an average, about 1 year is required for the resolution of symptoms, but this time is variable.
- About 25–33% of patients do not improve.
- Older patients and those with MRI evidence of more advanced disease (osteoarthritis and advanced internal derangement) are at higher risk for not improving spontaneously.

63.6.1 Nonsurgical Treatment

Nonsurgical options include:

Patient education
 Soft diet
 Occlusal appliance/orthotic devices
 Parafunctional habit awareness
 Biofeedback
 Nonsteroidal anti-inflammatory medication
 Muscle relaxants
 Botulinum toxin
 Physical therapy

Occasionally, psychology referral and counselling are indicated in certain patients.

Patient education is of great value. A simple explanation of the mechanics causing a clicking joint with internal derangement with the information that around 30% of the population have internal derangement can be very reassuring and put a patient's mind at ease. Furthermore, educating the patient in habit awareness to avoid daytime clenching is a key element in the long-term success of any nonsurgical or surgical treatment (Table 63.3).

Orthotic devices or occlusal appliances may help to reduce nighttime parafunctional habits. However, our understanding of orthotic devices has changed significantly over time. In the late 1930s and 1940s, temporomandibular joint disorders (TMD) used to be seen as problems related to occlusal or skeletal disharmony. Costen was an otolaryngol-

ogist who in 1934 first suggested the link between occlusion, TMJ disorders, and ear symptoms based on his observations in 11 patients [42]. This evolved into orthotics and occlusal therapies being used for the treatment of TMJ disorders in the 1940s and 1950s. However, a significant paradigm shift has occurred as the classic dental and skeletal etiologic theories have been challenged and refuted by studies conducted around the world, and a biopsychosocial medical model of orthopedics, pain phenomenology, and behavioral factors has gradually replaced them. As a result, the conceptual basis for occlusal appliances/orthotic use has significantly changed over the years. Occlusal appliances/orthotics were initially conceived and used based on these old dental and skeletal etiologies and were thought to produce occlusal disengagement, relax jaw musculature, restore vertical dimension of occlusion, unload the joint(s), or reposition the condyle and or disc. Even today, these are often described as deprogrammers or jaw-repositioning devices that can establish ideal craniomandibular relationships while relieving pain and restoring function. Until the 1960s, there were no well-controlled, well-designed, systematic studies evaluating the treatment of TMD. Instead, there were a number of anecdotal reports claiming success with various mechano-dental treatments, including various designs of oral appliance or orthotic [43, 44]. As the evidence-based literature has evolved, these reports have been refuted. Lundh [45] divided patients with symptomatic TMJ disc displacement into two treatment groups: one group with no treatment and one group with an occlusal appliance/orthotic and compared outcomes. After 12 months, pain had resolved in around 33% of patients in both groups. 40% of patients reported increased pain in the occlusal appliance/orthotic group compared to 16% in the no treatment group. Truelove [46] evaluated 200 patients with anterior disc displacement with reduction, arthralgia, and myalgia who were randomly assigned into three treatment groups: group 1 had basic nonsurgical treatment (education, self-care, hot/cold packs, and passive stretching), group 2 had hard flat plane occlusal appliance/orthotic, and group 3 had soft splint. Outcomes were evaluated after 3 and 12 months, and there were no significant differences in success among the three groups. Greene [47] and Laskin [48] studied the placebo effect using mock/sham occlusal appliances and sham occlusal adjustments. They found that non-occluding appliances/orthotics helped over 40% of patients and mock/sham occlusal adjustments helped almost two-thirds of patients. Furthermore, the use of occlusal appliances/orthotics may increase the parafunctional habit in some resulting in a patient complaining of increased pain and/or stiffness after use. In addition, partial coverage devices may result in occlusal changes if used for more than a few months due to eruption of teeth. Therefore, our perception of occlusal appliances/orthotics must take into consideration the current evidence-based literature.

Table 63.3 Nonsurgical management

Patient education (explain the condition)
Patient home care instructions
<ul style="list-style-type: none"> • Soft diet • Awareness and avoid clenching habits • Night time bruxism—night guard/orthotic • Range of motion • Heat and massage to muscles
Pharmacotherapy
<ul style="list-style-type: none"> • NSAIDs, muscle relaxants, tricyclics, sedatives, Botox
Occlusal appliance/orthotic
<ul style="list-style-type: none"> • For nighttime parafunctional habits
Physical therapy
<ul style="list-style-type: none"> • Posture training • Mobilization/manipulation/joint distraction • Massage/muscle conditioning • Physical agents or modalities • TENS, ultrasound, iontophoresis, phonophoresis, electrogalvanic stimulation, thermal
Stress reduction
<ul style="list-style-type: none"> • Psychologist • Counselor • Psychiatrist

In review of evidence-based literature on occlusal appliance/orthotics [45–47, 49, 50], we can conclude:

- Symptoms of myalgia and arthralgia may be decreased by occlusal appliances.
- Wear on the dentition caused by parafunctional habits may be reduced.
- Risk is low if they are not worn 24 h a day.
- The disc position is not changed by the appliance.
- Over time, many patients show improvement in signs and symptoms.
- There is no appreciable significant difference between the nontreatment and treatment group.
- Palliative care (NSAIDs, education, diet modification, exercises) seem to be as effective as more expensive appliance therapy.
- All treatments have a powerful placebo effect.

In Klasser’s review [50] of occlusal appliances/orthotics, he concludes that rather than trying to establish new horizontal or vertical jaw relationships, occlusal appliance/orthotics today should be viewed as “oromandibular crutches,” which are analogous to back braces or ankle support orthotics because they support the joint and provide symptomatic relief while the joints are recovering. Table 63.4 outlines Klasser’s conclusions on occlusal appliance use and limitations.

Most often, painful internal derangement causes a reactive muscle response. This muscle response and myalgia can be treated by soft diet, heat, and massage to the affected muscles, limiting the range of motion to within the pain-free range, NSAIDs, muscle relaxants, physical therapy, and even botulinum toxin injections (e.g., Botox).

Table 63.4 Occlusal appliance/orthotic device limitations [50]

Can do	Can’t do
<ul style="list-style-type: none"> • Protect teeth/restorations from fracture due to bruxism/clenching • Reduce/change the loading of the TMJ by reducing intensity, frequency, and duration of bruxism/clenching • Adding a foreign body into the occlusion briefly reduces muscle activity • Reduce headaches related to bruxism/clenching • Reduce internal derangement symptoms related to bruxism/clenching upon awakening • Change the neuromuscular engrams deprogramming 	<ul style="list-style-type: none"> • Unload the disc by pivoting the mandible on the molars and distracting the condyle • Retrain muscle to be less active upon cessation of the appliance • Recapture and reposition discs • Permanently reduce bruxism/clenching • Relieve headaches that are neurovascular or vascular in origin

63.6.2 Surgical Treatment (Fig. 63.10)

The vast majority (approximately 90%) of TMD patients will experience symptom resolution either spontaneously or with nonsurgical treatment [51]. This resolution of symptoms occurs due to the underlying adaptive capacity of the TMJ. Given that internal derangement is a common MRI finding in 32–38% of asymptomatic patients and volunteers [16, 17] and that arthrocentesis or arthroscopy without disc repositioning is so successful, it is evident that the TMJ has the ability to adapt to the disc displacement in the vast majority of patients. Those patients with internal derangement and disc displacement that do not adapt are potential surgical candidates. It is the authors’ preference to follow a surgical pyramid algorithm with most patients beginning with arthroscopy unless there are specific indications otherwise (e.g., ankylosis). Since no single surgical procedure carries a 100% success rate, patients who fail one level (phase 1) on the algorithm progress further up the pyramid to a second (phase 2) surgical procedure with phase 2 procedure being determined by the arthroscopic findings of phase 1.

63.6.3 Arthrocentesis

This minimally invasive procedure was introduced after the success of simple arthroscopy was recognized. Arthrocentesis in the TMJ was first described in 1987 by Murakami using a single needle pumping technique to create a hydraulic distention of the upper joint space [52]. Nitzan and Dolwick [18] subsequently modified the technique and used two needles. It provides lysis and lavage of the upper joint space

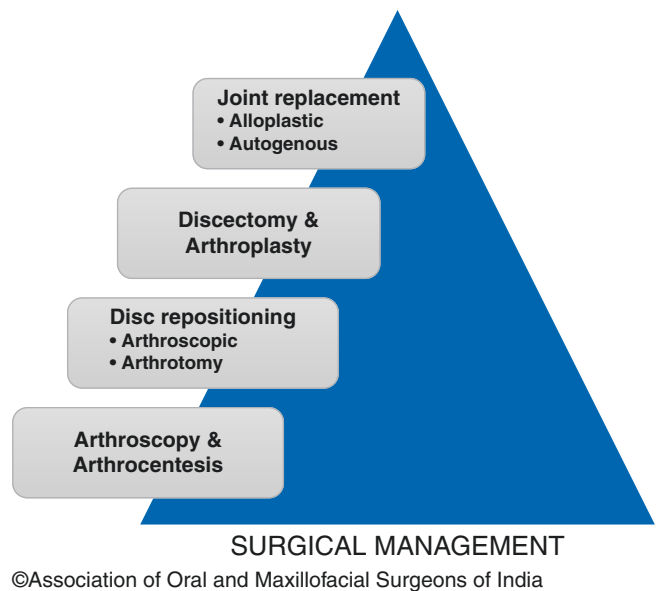
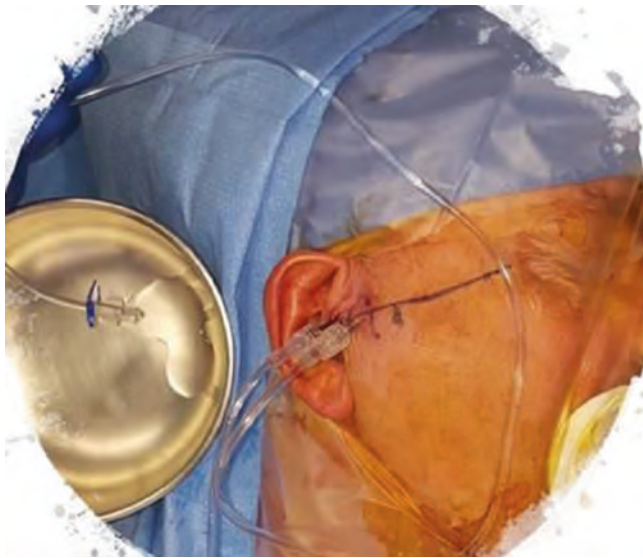


Fig. 63.10 Surgical treatment options



©Association of Oral and Maxillofacial Surgeons of India

Fig. 63.11 Arthrocentesis—using the Holmlund-Hellsing markings measured along the trago-canthal line (10 mm forward from mid-tragus and 2 mm down correspond to the glenoid fossa entry site)

using an inflow needle, an outflow needle, and at least 300 ml Lactated Ringer's irrigation solution (Fig. 63.11). The lysis is accomplished by the hydraulic distention of the superior joint space, while the lavage removes inflammatory mediators, cytokines, and debris (Fig. 63.12). It is through the lysis and lavage that the adhesions are separated and the inflammatory mediators and debris are removed. Several authors have since reported success rates of arthrocentesis in the management of internal derangement ranging from 70 to 95% [18–22].

63.6.4 Arthroscopy

Minimally invasive arthroscopic surgery for the TMJ was first performed by Ohnishi in 1974 and subsequently developed in the 1980s by several surgeons (Murakami, Holmlund, McCain, Saunders, and others). TMJ arthroscopy has proven to be an effective and reliable alternative to open joint surgery for many patients, resulting in reduced pain and improved maximum incisal opening [10–15] with success rates as high as 91% [12]. TMJ arthroscopy can be as simple as a visually assisted lysis and lavage or as complex as performing disc repositioning and fixation. The author uses McCain's terminology to categorize different levels of arthroscopy according to complexity and number of portals of entry (Table 63.5).

The authors preferred surgical sequence for performing a level 1 arthroscopy as outlined in Table 63.6 (Video 63.1). All arthroscopy should begin with an examination under anesthe-

Arthrocentesis	
LYSIS	LAVAGE
Hydraulic distention of the joint space lyses adhesions.	REMOVES:
Restores lubrication and Synovial fluid flow	Debris
Improves ROM	Inflammatory mediators
	Cytokines
	Matrix metalloproteinases
	Proteolytic enzymes

©Association of Oral and Maxillofacial Surgeons of India

Fig. 63.12 Arthrocentesis—lysis and lavage

Table 63.5 Levels of TMJ arthroscopy (McCain's terminology)

Level I Arthroscopy
• Single puncture & outflow needle
• Lysis & lavage
• Diagnostic sweep
• Needle/scope adhesiolysis
Level II Arthroscopy
• Double puncture & outflow needle
• Level I
• Instrumentation port (laser, coblation, grasper, probe etc.)
Level III Arthroscopy
• Triple puncture & outflow needle
• Level II
• Discopexy (suture/screw)

Table 63.6 Level 1 arthroscopy sequence

• Examination under anesthesia
• Marking landmarks
• Superior joint space insufflation
• Trocar and cannula puncture
• Backwash
• Insert scope (confirm entry)
• Establish outflow
• Diagnostic sweep
• Medications (Steroid, hyaluronic acid or PRP etc.)
• Manipulation

sia of the TMJ. The EUA allows the surgeon to anticipate what might be encountered upon entering the joint arthroscopically. The range of condylar translation is noted, and whether translation is onto the peak of the articular eminence stops short of the peak or beyond the peak of the eminence as in subluxation and even dislocation. In addition, if there is very limited translation or just hinging, the surgeon might expect a tight joint space filled with adhesions and a fibrous arthrosis potentially making the arthroscopic puncture, joint access, and visualization difficult. Joint noises (clicking and crepitation) should be noted, and bone-on-bone crepitations are indicative of a perforation in the retrodiscal tissue.

In addition to the lysis and lavage as in arthrocentesis (Table 63.6), a level 1 arthroscopy provides a diagnosis and identifies intra-articular pathology (Fig. 63.13a–f). A systematic diagnostic sweep through the entire superior joint space is performed to obtain the diagnostic information. Level 1 arthroscopy can be accomplished using a standard operative arthroscope (usually 1.9–2.7 mm) or the more recently available disposable scopes (1.2 mm). While the image quality from a disposable scope is currently not as good as the traditional operative arthroscopes, it does allow for adequate visualization and a diagnosis.

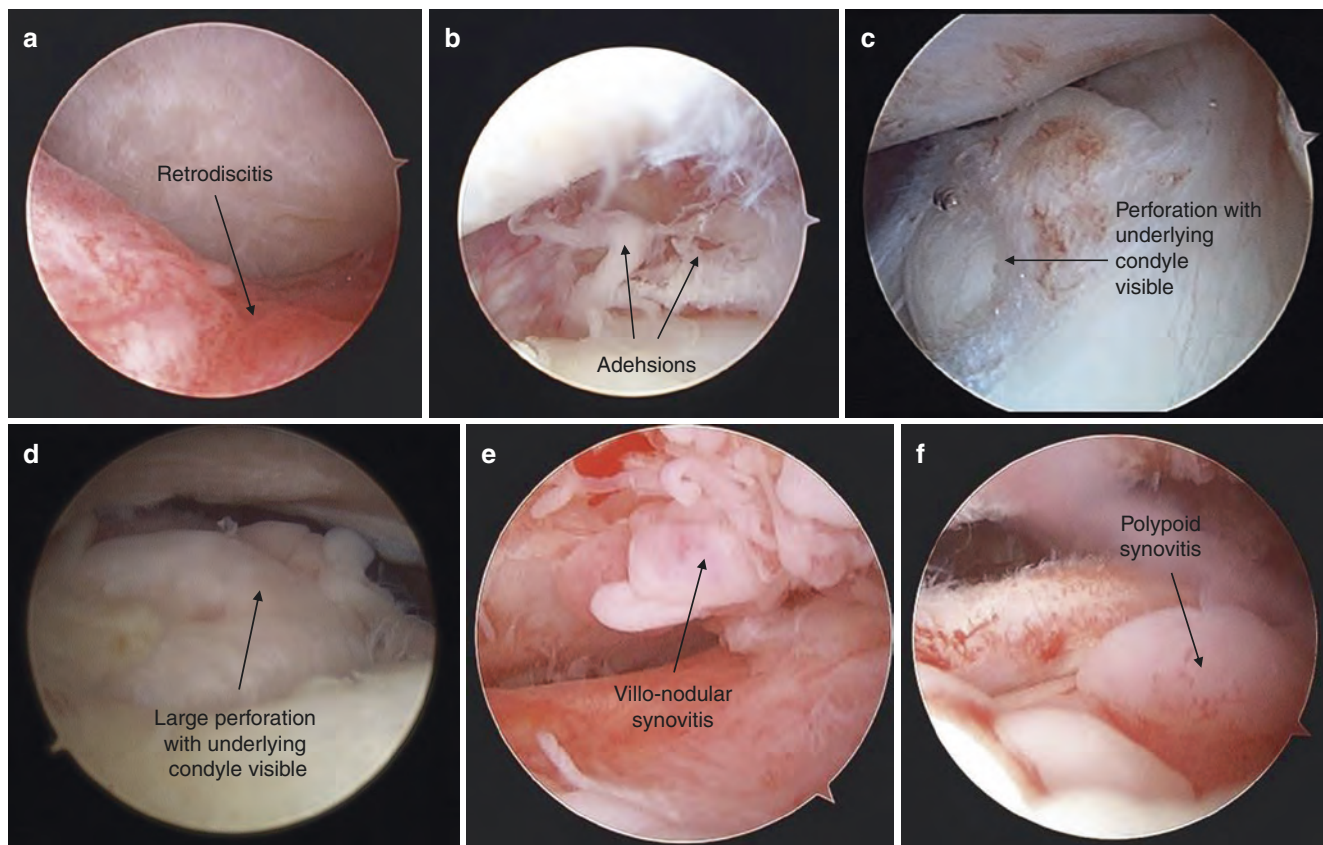
Level 2 arthroscopy includes a second puncture with an operative cannula and allows for additional procedures such as disc mobilization, biopsy, laser ablation, or coblation to be performed. Video 63.2 shows the second cannula being inserted, disc mobilization with a probe, and laser ablation of hyperplastic polypoid synovitis.

Level 3 arthroscopy with multiple cannulas allows for more advanced techniques and disc repositioning with fixation, using sutures, wires, pins, or screws. The author uses a suture technique

to anchor the repositioned disc as shown in the Video 63.3. Figure 63.14a, b shows the suture placed through the posterior band of the disc anchoring it into the reduced position. The arthroscopic suture video clearly shows how tightening the suture reduces the anteriorly displaced disc.

Several surgeons have described and published techniques to reposition and fixate the displaced disc [53–59]. Success in the early reports of arthroscopic disc repositioning was not high. Yang reported better success rates with partial and later complete anterior release of the disc from its anterior attachment and suggested that relapse rates without complete anterior release are high [55]. While more recent success rates of disc repositioning as high as 95.3% [60] have been reported, many of these studies have relatively short-term follow-up and/or no MRI confirmation of long-term stability of the disc repositioning.

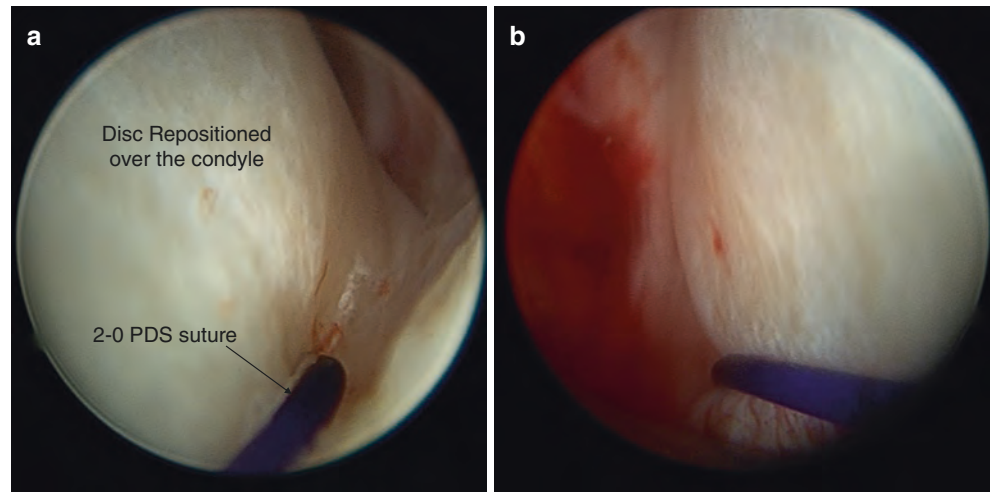
It is the authors' opinion that level 3 arthroscopy should be performed primarily for functional reasons, e.g., a mechanically obstructive click, closed lock, or subluxation. In McCain's publication on arthroscopic discopexy [59], the



©Association of Oral and Maxillofacial Surgeons of India

Fig. 63.13 (a–f) Arthroscopic pathology. (a) Retrodiscitis (b) Adhesions (c) Small disc tear/perforation (d) Large perforation with condyle visible (e) Villonodular synovitis (f) Polypoid synovitis

Fig. 63.14 (a, b)
Arthroscopic suture discopexy—suture placed through the posterior band of the disc anchoring it into the correct reduced position



©Association of Oral and Maxillofacial Surgeons of India

success rate in 42 joints was 86.7% in Wilkes II and III but only 25% in Wilkes IV and V which emphasizes that case selection is a key element to success. For disc repositioning to be indicated and have good outcomes, the disc must be salvageable, and there must be sufficient posterior joint space height in which to reposition the disc. In other words, the disc must be intact, and MRI evaluation must confirm normal disc morphology with adequate posterior joint space height in which to reposition the disc. If the joint space has collapsed as is often the case in longer-standing/chronic disc displacement, the load placed during function on the repositioned disc will be excessive, and the fixation will likely fail, leading to displacement again. Postoperatively, all patients will notice a malocclusion with slight mandibular deviation to the contralateral side. However, the majority of these malocclusions will resolve within 3 weeks. Additional factors to success are the postoperative physical therapy and dietary instructions. The author instructs his patients to perform “limited range of motion” exercises for the first 3 weeks to minimize the risk of the fixation failing or tearing through the disc. This is achieved by instructing the patient to keep the tongue on the roof of the mouth while performing opening exercises. The diet should be soft with minimal chewing and as for all surgical cases and any parafunctional habits should be well controlled. After 3 weeks, the patients gradually increase their mouth opening with daily stretching exercises. Associated myalgias may improve once the joint pain and function improve following arthroscopy, but often concomitant nonsurgical treatment of the muscle disorder is also required.

At the end of the arthroscopic procedure, the surgeon has the option of injecting medications including steroid, hyaluronic acid (HA), and platelet-rich plasma (PRP).

63.6.4.1 Viscosupplementation with Hyaluronic Acid

Hyaluronic acid is a glycosaminoglycan polysaccharide naturally found in synovial fluid. It is produced by the chondrocytes and synoviocytes and plays an important role in joint function and nutrition. HA is the main contributor to the viscosity of synovial fluid and provides protection under joint loading. Inflammatory disorders of the TMJ including internal derangement are associated with reduced quantity and quality of HA through a process of destruction and also the production of HA that is lower in molecular weight [61, 62]. The short half-life of injected HA makes it unlikely that its effectiveness is due to restoration of the viscosity of the synovial fluid [63]. It is suggested that supplementation with injectable HA could have anti-inflammatory and analgesic effects [64]. Altman suggested that injection of HA could lead to repair of the articular cartilage/fibrocartilage and normalize the synthesis of endogenous HA [65].

Viscosupplementation has been described in orthopedic literature for many years, but there are discrepancies in the evidence to support the widespread use of intra-articular hyaluronic acid to treat knee osteoarthritis. However, several recent studies have shown hyaluronic acid to be a viable treatment option showing longer-term improvement in both knee pain and function. Unfortunately, similar uncertainty exists regarding the effectiveness of viscosupplementation using hyaluronic acid in the TMJ [66–68]. Beyond viscosupplementation, there are some additional benefits to using HA in TMJ arthroscopy. If the surgeon is having difficulty maneuvering the scope because of a tight joint space, the lubricant properties of HA may be helpful in minimizing iatrogenic damage to the joint surfaces and disc. It is also help-

ful at the end of the procedure in reducing the bleeding from a hyperemic joint.

63.6.4.2 Platelet-Rich Plasma

Is a concentration of platelets and growth factors taken from autologous blood. It has reported beneficial effects in joint degeneration and tendinopathy [69–72], and there is both literature supporting its effectiveness in TMJ arthroscopy [73–75] and conflicting literature reporting no benefit [76, 77]. Therefore, the use of PRP after TMJ arthroscopy remains controversial, and further studies are needed [78].

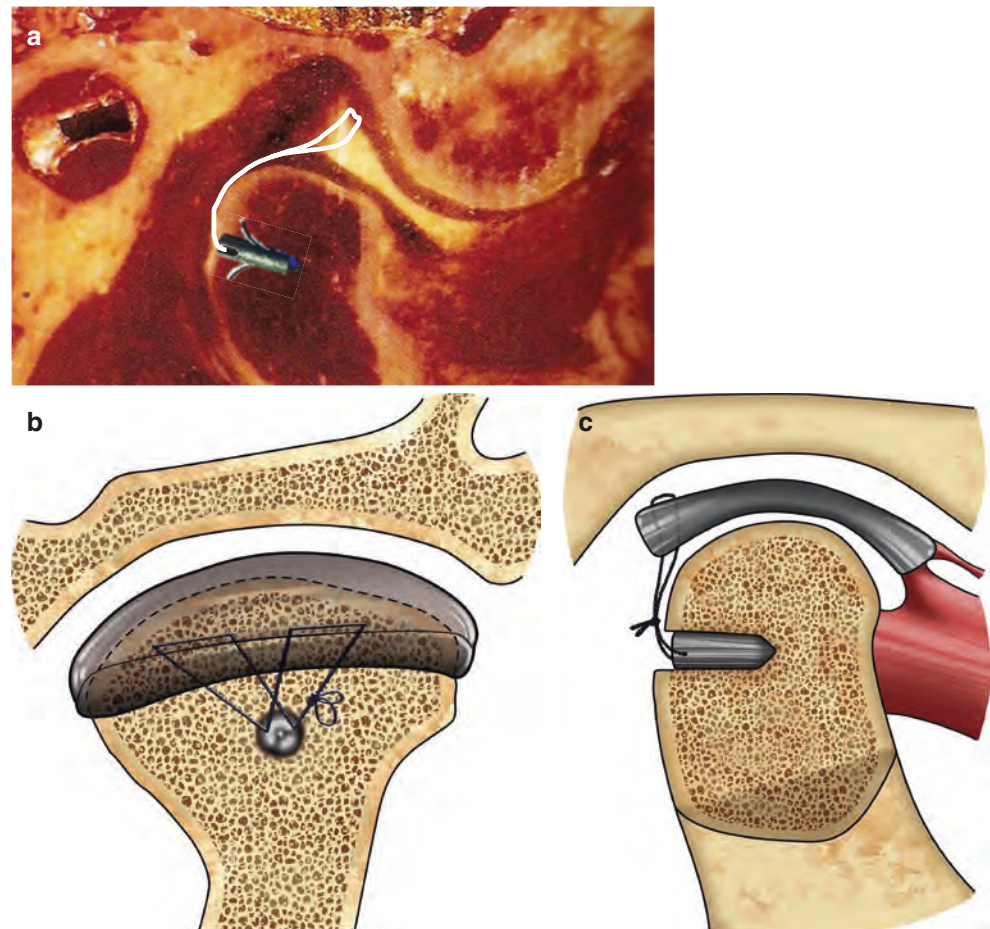
63.6.4.3 Open Joint Surgery and Arthroplasty

The effectiveness of minimally invasive procedures such as arthrocentesis and arthroscopy has significantly reduced the frequency and volume of open joint surgery (disc repositioning or discectomy). However, currently there are very few surgeons trained in the advanced technique of arthroscopic discopexy, and so for patients who fail level 1 or 2 arthroscopy and require disc repositioning surgery, open joint surgery with disc repositioning may be the next surgical step in moving up the surgical pyramid. Annandale first published “On displacement of the inter-articular cartilage of the lower jaw and its treatment by operation” in 1887 [3], but it wasn’t until later that surgery for internal derangement became popular. Surgical interest in disc displacement began with reports from McCarty and Farrar [5] claiming disc repositioning success rates of 94% using a wedge resection and suture plication technique. However, other surgeons were not as successful, and the long-term stability of suture plication techniques was low, leading to multiple variations of open surgical disc repositioning and methods of fixation [79–82]. In 2001, Wolford reported a more rigid fixation technique using a Mitek mini-bone anchor to fixate the repositioned disc [83]. In this technique, the anterior and lateral disc attachments are released allowing passive disc repositioning. The disc is separated at its junction with the retrodiscal tissue, and Mitek anchor is inserted into a 2-mm hole drilled into the posterior condyle 8–10mm below articulating surface. Two 0-Ethibond braided sutures are inserted through the posterior band of the disc in a mattress suture fashion fixing the disc to the Mitek anchor (Fig. 63.15a–c). Although radiographs at the longest follow-up showed no condylar resorption and stable position of the metal anchor, the stability of the disc repositioning was not evaluated by MRI. Despite this, Wolford reported that there was a statistically significant reduction in TMJ pain, facial pain, headaches, TMJ noises, and disability and improvement in jaw function and diet.

Alternative fixation and anchoring devices are available on the market today. He et al. use a self-drilling mini-screw and have modified the technique to include a complete anterior release and overcorrection of the disc position for better stability of the repositioning. They report stable short-term (mean 10 months) disc position on MRI in 98.6% of patients [84]. Zhou et al. evaluated the same technique in 149 joints and the long-term stability of the repositioned disc on MRI at a mean longest follow-up of 23.4 months (range 12–84 months) and reported that 95.3% of discs were still in position, whereas 4.7% had relapsed anteriorly [85]. They also reported new condylar bone formation in 74.5% of joints and even greater in young patients (under the age of 20), 90% of whom had new bone formation, suggesting that adolescents may have growth ability after disc repositioning which might reduce facial asymmetry. Mandibular asymmetry in unilateral disc displacement has been reported in the literature. Xie et al. [86] reported mandibular asymmetry in 72% of 165 patients with anterior disc displacement and the severity of the asymmetry correlated with the degree of disc displacement, disc deformity, and condylar shortening. Therefore, disc repositioning may allow for condylar bone formation and reduce mandibular asymmetry that may develop as a result of the displaced disc. The overall clinical outcomes of disc repositioning surgery are good with reduced pain, improved diet, and improved range of motion with 94% of patients reporting improved quality of life [87].

For those patients with discs that are not salvageable, discectomy is the next step in the surgical pyramid. This involves removal of the disc and the area surrounding any perforation in the retrodiscal tissue, and possible replacement of the disc is an option. There are several long-term studies demonstrating greater than 80% success rates following discectomy [88–91] with a few following patients for more than 20 years [92–94] with almost complete resolution of pain and restoration of normal diet. A 5-year follow-up study of discectomy without any disc replacement reported 87% of patients fulfilling the criteria for success with reduced pain on function and increased mouth opening, although pain at rest was unchanged [95]. Following discectomy, radiographs will show altered condylar morphology in the operated joint, and this is thought to be an adaptive process of remodeling because the reduced symptoms do not correlate with the radiographic changes [96, 97]. While the literature demonstrates the long-term success of discectomy without replacement [89, 90], disc replacement options have been explored in attempts to reduce the crepitation these patients experience and also with the intent to reduce the

Fig. 63.15 (a–c) Use of a Mitek anchor according to Wolford's technique



©Association of Oral and Maxillofacial Surgeons of India

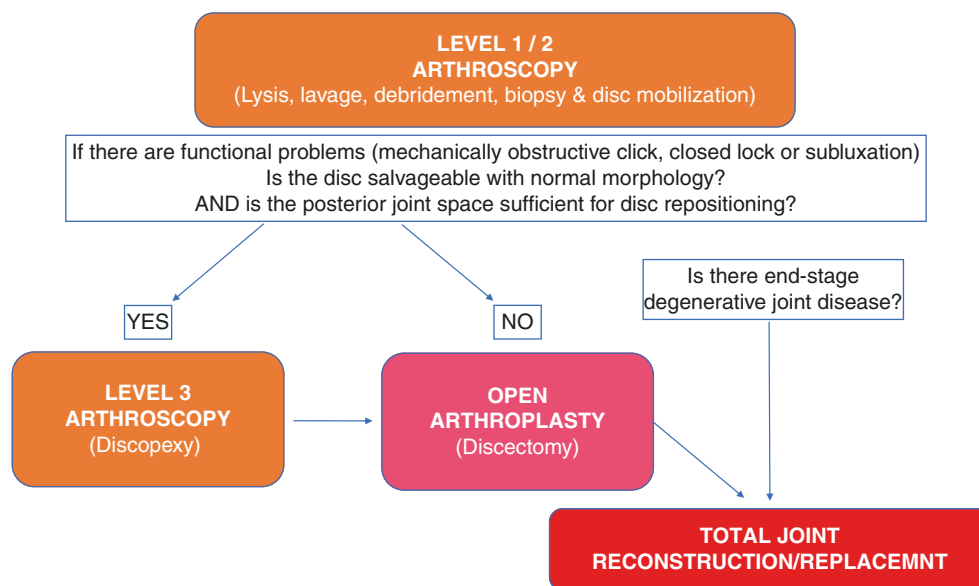
remodeling. Many autogenous, allogenic, and alloplastic disc replacements have been tried with varying degrees of success (Table 63.7), and some such as Proplast have caused joint destruction necessitating joint reconstruction and replacement [99]. At the current time, there is a lack of evidence to support the routine use of any disc replacement after discectomy.

The use of tissue engineering is emerging as a promising option to repair or potentially replace the diseased tissues of the TMJ and may provide additional treatment options in the future. Progress has already been made toward the development of appropriate tools for TMJ tissue engineering. The goal is to develop an approach to produce new tissues *de novo* (neotissues) with qualities similar to the native TMJ. This may be accomplished by (1) *in situ* tissue engineering, which involves an acellular scaffold matrix attracting local cells (cell homing) guiding the process of regeneration, and (2) *ex vivo* cell seeding on

Table 63.7 Disc replacement options [98]

Alloplastic	Methyl methacrylate Silastic Proplast-Teflon Fossa prosthesis
Allogenic	Dura (cryopreserved) Cartilage (lyophilized, freeze-dried)
Autogenous	Temporalis muscle/fascia Ear/rib cartilage Dermis skin grafts Abdominal fat
Xenograft	Bovine collagen/cartilage

the scaffold, which provides enough competent cells to orchestrate the regenerative process. The second strategy appears better suited for TMJ regeneration because of its limited capacities of self-repair and the rapid regeneration expected [100].

Table 63.9 Algorithm and decision framework**Table 63.8** Failed level 1 or 2 arthroscopy—now what?

• Wilkes II/III/early IV → Discopexy
• Wilkes IV/V → Advanced debridement
• Primary arthritis → Establish diagnosis
• Rheumatology referral
• Joint replacement

63.7 Conclusion

Internal derangement of the TMJ is a common problem resulting in pain and limited function for some patients. While the vast majority of patients adapt to the internal derangement over time or with nonsurgical treatment, surgery may be indicated for those with ongoing problems. There are no surgical procedures for the TMJ that have a 100% success rate; it therefore makes sense to undertake the least invasive procedures first. The surgical pyramid presented in this chapter provides a stepwise progression for TMJ surgical patients. In the authors' clinical practice, most surgical patients begin with a level 1 or 2 arthroscopic surgery and only step up the pyramid if this fails. If the diagnosis after arthroscopy is Wilkes II, III, or early IV, phase 2 procedure would be disc repositioning and discopexy if the disc is intact and has normal morphology and there is sufficient posterior joint space in which to reposition it. In Wilkes IV and V, phase 2 procedure would be joint debridement and discectomy (Table 63.8).

Finally, Table 63.9 presents an algorithm and decision framework that guides the progression through the various surgical procedures discussed in this chapter.

References

1. Steele AB. Internal derangement of the knee joint. *BMJ*. 1855;3(114):224–5.
2. Annandale T. An address on internal derangements of the knee-joint and their treatment by operation. *Br Med J*. 1887;1(1363):319–21.
3. Annandale T. On displacement of the inter-articular cartilage of the lower jaw, and its treatment by operation. *Lancet*. 1887;129(3313):411.
4. Porter RS. In: Porter RS, editor. *The Merck manual of diagnosis and therapy*, 20th ed. 2018.
5. McCarty WL, Farrar WB. Surgery for internal derangements of the temporomandibular joint. *J Prosthet Dent*. 1979;42(2):191–6.
6. Kaplan PA, Ruskin JD, Tu HK, Knibbe MA. Erosive arthritis of the temporomandibular joint caused by Teflon-Proplast implants: plain film features. *AJR Am J Roentgenol*. 1988;151(2):337–9.
7. Smith RM, Goldwasser MS, Sabol SR. Erosion of a Teflon-Proplast implant into the middle cranial fossa. *J Oral Maxillofac Surg*. 1993;51(11):1268–71.
8. Lypka M, Yamashita D-DR. Exuberant foreign body giant cell reaction to a teflon/proplast temporomandibular joint implant: report of a case. *J Oral Maxillofac Surg*. 2007;65(9):1680–4.
9. Wilkes CH. Internal derangements of the temporomandibular joint. Pathologic variations. *Arch Otolaryngol Head Neck Surg*. 1989;115:469–477.
10. Sanders B, Buoncristiani R. Diagnostic and surgical arthroscopy of the temporomandibular joint: clinical experience with 137 procedures over a 2-year period. *J Craniomandib Disord*. 1987;1(3):202–13.

11. Moses JJ, Poker ID. TMJ arthroscopic surgery: an analysis of 237 patients. *J Oral Maxillofac Surg.* 1989;47(8):790–4.
12. McCain JP, Sanders B, Koslin MG, Quinn JH, Peters PB, Indresano AT, et al. Temporomandibular joint arthroscopy: a 6-year multi-center retrospective study of 4,831 joints. *J Oral Maxillofac Surg.* 1992;50(9):926–30.
13. Hoffman DC, Cubillos L. The effect of arthroscopic surgery on mandibular range of motion. *Cranio.* 1994;12(1):11–8.
14. Dimitroulis G. A review of 56 cases of chronic closed lock treated with temporomandibular joint arthroscopy. *J Oral Maxillofac Surg.* 2002;60(5):519–24.
15. Dimitroulis G. Outcomes of temporomandibular joint arthroscopy in patients with painful but otherwise normal joints. *J Craniomaxillofac Surg.* 2015;43(6):940–3.
16. Kircos LT, Ortendahl DA, Mark AS, Arakawa M. Magnetic resonance imaging of the TMJ disc in asymptomatic volunteers. *J Oral Maxillofac Surg.* 1987;45(10):852–4.
17. Katzberg RW, Westesson PL, Tallents RH, Drake CM. Anatomic disorders of the temporomandibular joint disc in asymptomatic subjects. *J Oral Maxillofac Surg.* 1996;54(2):147–53.
18. Nitzan DW, Dolwick MF, Martinez GA. Temporomandibular joint arthrocentesis: a simplified treatment for severe, limited mouth opening. *J Oral Maxillofac Surg.* 1991;49(11):1163–7.
19. Nitzan DW, Samson B, Better H. Long-term outcome of arthrocentesis for sudden-onset, persistent, severe closed lock of the temporomandibular joint. *J Oral Maxillofac Surg.* 1997;55(2):151–7.
20. Dimitroulis G, Dolwick MF, Martinez A. Temporomandibular joint arthrocentesis and lavage for the treatment of closed lock: a follow-up study. *Br J Oral Maxillofac Surg.* 1995;33(1):23–6.
21. Hosaka H, Murakami K, Goto K, Iizuka T. Outcome of arthrocentesis for temporomandibular joint with closed lock at 3 years follow-up. *Oral Surg Oral Med Oral Pathol Oral Radiol Endod.* 1996;82(5):501–4.
22. Sembronio S, Albiero AM, Toro C, Robiony M, Politi M. Is there a role for arthrocentesis in recapturing the displaced disc in patients with closed lock of the temporomandibular joint? *Oral Surg Oral Med Oral Pathol Oral Radiol Endod.* 2008;105(3):274–80.
23. Quinn JH, Bazan NG. Identification of prostaglandin E2 and leukotriene B4 in the synovial fluid of painful, dysfunctional temporomandibular joints. *J Oral Maxillofac Surg.* 1990;48(9):968–71.
24. Shafer DM, Assael L, White LB, Rossomando EF. Tumor necrosis factor-alpha as a biochemical marker of pain and outcome in temporomandibular joints with internal derangements. *J Oral Maxillofac Surg.* 1994;52(8):786–91.
25. Kopp S. Neuroendocrine, immune, and local responses related to temporomandibular disorders. *J Orofac Pain.* 2001;15(1):9–28.
26. Kubota E, Kubota T, Matsumoto J, Shibata T, Murakami KI. Synovial fluid cytokines and proteinases as markers of temporomandibular joint disease. *J Oral Maxillofac Surg.* 1998;56(2):192–8.
27. Schiffman E, Ohrbach R, Truelove E, Look J, Anderson G, Goulet J-P, et al. Diagnostic Criteria for Temporomandibular Disorders (DC/TMD) for Clinical and Research Applications: recommendations of the International RDC/TMD Consortium Network and Orofacial Pain Special Interest Group†. *J Oral Facial Pain Headache.* 2014;28(1):6–27.
28. Farrar WB. Letter: myofascial pain dysfunction syndrome. *J Am Dent Assoc.* 1975;91(2):205–6.
29. Agerberg G, Inkapööl I. Craniomandibular disorders in an urban Swedish population. *J Craniomandib Disord.* 1990;4(3):154–64.
30. Santos KCP, Dutra MEP, Warmling LV, Oliveira JX. Correlation among the changes observed in temporomandibular joint internal derangements assessed by magnetic resonance in symptomatic patients. *J Oral Maxillofac Surg.* 2013;71(9):1504–12.
31. Rinchuse DJ, McMinn JT. Summary of evidence-based systematic reviews of temporomandibular disorders. *Am J Orthod Dentofacial Orthop.* 2006;130(6):715–20.
32. Türp JC, Schindler H. The dental occlusion as a suspected cause for TMDs: epidemiological and etiological considerations. *J Oral Rehabil.* 2012;39(7):502–12.
33. Okeson JP. Management of temporomandibular disorders and occlusion. St. Louis: Elsevier Health Sciences; 2007. 1 p.
34. Honda K, Larheim TA, Sano T, Hashimoto K, Shinoda K, Westesson PL. Thickening of the glenoid fossa in osteoarthritis of the temporomandibular joint. An autopsy study. *Dentomaxillofac Radiol.* 2001 Jan;30(1):10–3.
35. Larheim TA. Current trends in temporomandibular joint imaging. *Oral Surg Oral Med Oral Pathol Oral Radiol Endod.* 1995;80(5):555–76.
36. Song YW, Kang EH. Autoantibodies in rheumatoid arthritis: rheumatoid factors and anticitrullinated protein antibodies. *QJM.* 2010;103(3):139–46.
37. Niewold TB, Harrison MJ, Paget SA. Anti-CCP antibody testing as a diagnostic and prognostic tool in rheumatoid arthritis. *QJM.* 2007;100(4):193–201.
38. García-Kutzbach A, Chacón-Súchite J, García-Ferrer H, Iraheta I. Reactive arthritis: update 2018. *Clin Rheumatol.* 2018;37(4):869–74.
39. Sato S, Goto S, Nasu F, Motegi K. Natural course of disc displacement with reduction of the temporomandibular joint: changes in clinical signs and symptoms. *J Oral Maxillofac Surg.* 2003;61(1):32–4.
40. Sato S, Kawamura H, Nagasaka H, Motegi K. The natural course of anterior disc displacement without reduction in the temporomandibular joint: follow-up at 6, 12, and 18 months. *J Oral Maxillofac Surg.* 1997;55(3):234–8.
41. Kurita K, Westesson PL, Yuasa H, Toyama M, Machida J, Ogi N. Natural course of untreated symptomatic temporomandibular joint disc displacement without reduction. *J Dent Res.* 1998;77(2):361–5.
42. Costen JB. A syndrome of ear and sinus symptoms dependent upon disturbed function of the temporomandibular joint. 1934. *Annal Otol Rhinol Laryngol.* 1997;106(10 Pt 1):805–19.
43. Block LS. Diagnosis and treatment of disturbances of the temporomandibular joint especially in relation to vertical dimension. *J Am Dent Assoc.* 1947;34(4):253–60.
44. Posselt U. The temporomandibular joint syndrome and occlusion. *J Prosthet Dent.* 1971;25(4):432–8.
45. Lundh H, Westesson PL, Eriksson L, Brooks SL. Temporomandibular joint disk displacement without reduction. Treatment with flat occlusal splint versus no treatment. *Oral Surg Oral Med Oral Pathol.* 1992;73(6):655–8.
46. Truelove E, Huggins KH, Mancl L, Dworkin SF. The efficacy of traditional, low-cost and nonsplint therapies for temporomandibular disorder: a randomized controlled trial. *J Am Dent Assoc.* 2006;137(8):1099–107.
47. Greene CS, Goddard G, Macaluso GM, Mauro G. Topical review: placebo responses and therapeutic responses. How are they related? *J Orofac Pain.* 2009;23(2):93–107.
48. Greene CS, Laskin DM. Splint therapy for the myofascial pain—dysfunction (MPD) syndrome: a comparative study. *J Am Dent Assoc.* 1972;84(3):624–8.
49. Minakuchi H, Kuboki T, Matsuka Y, Maekawa K, Yatani H, Yamashita A. Randomized controlled evaluation of non-surgical treatments for temporomandibular joint anterior disk displacement without reduction. *J Dent Res.* 2001;80(3):924–8.
50. Klasser GD, Greene CS. Oral appliances in the management of temporomandibular disorders. *Oral Surg Oral Med Oral Pathol Oral Radiol Endod.* 2009;107(2):212–3.

51. Randolph CS, Greene CS, Moretti R, Forbes D, Perry HT. Conservative management of temporomandibular disorders: a posttreatment comparison between patients from a university clinic and from private practice. *Am J Orthod Dentofacial Orthop.* 1990;98(1):77–82.
52. Murakami KI, Iizuka T, Matsuki M, Ono T. Recapturing the persistent anteriorly displaced disk by mandibular manipulation after pumping and hydraulic pressure to the upper joint cavity of the temporomandibular joint. *Cranio.* 1987;5(1):17–24.
53. McCain JP, Podrasky AE, Zabiegalski NA. Arthroscopic disc repositioning and suturing: a preliminary report. *J Oral Maxillofac Surg.* 1992;50(6):568–79.
54. Zhang S-Y, Liu X-M, Yang C, Cai X-Y, Chen M-J, Haddad MS, et al. New arthroscopic disc repositioning and suturing technique for treating internal derangement of the temporomandibular joint: part II—magnetic resonance imaging evaluation. *J Oral Maxillofac Surg.* 2010;68(8):1813–7.
55. Yang C, Cai X-Y, Chen M-J, Zhang S-Y. New arthroscopic disc repositioning and suturing technique for treating an anteriorly displaced disc of the temporomandibular joint: part I—technique introduction. *Int J Oral Maxillofac Surg.* 2012;41(9):1058–63.
56. Zhu Y, Zheng C, Deng Y, Wang Y. Arthroscopic surgery for treatment of anterior displacement of the disc without reduction of the temporomandibular joint. *Br J Oral Maxillofac Surg.* 2012;50(2):144–8.
57. Goizueta-Adame CC, Pastor-Zuazaga D, Orts Bañón JE. Arthroscopic disc fixation to the condylar head. Use of resorbable pins for internal derangement of the temporomandibular joint (stage II-IV). Preliminary report of 34 joints. *J Craniomaxillofac Surg.* 2014;42(4):340–6.
58. Goizueta-Adame CC, Muñoz-Guerra MF. The posterior double pass suture in repositioning of the temporomandibular disc during arthroscopic surgery: a report of 16 cases. *J Craniomaxillofac Surg.* 2012;40(1):86–91.
59. McCain JP, Hossameldin RH, Srouji S, Maher A. Arthroscopic discopexy is effective in managing temporomandibular joint internal derangement in patients with Wilkes stage II and III. *J Oral Maxillofac Surg.* 2015;73(3):391–401.
60. Liu X, Zheng J, Cai X, Abdelrehem A, Yang C. Techniques of Yang's arthroscopic discopexy for temporomandibular joint rotational anterior disc displacement. *Int J Oral Maxillofac Surg.* 2018;48(6):769–78.
61. Nitzan DW. The process of lubrication impairment and its involvement in temporomandibular joint disc displacement: a theoretical concept. *J Oral Maxillofac Surg.* 2001;59(1):36–45.
62. Sharma A, Rana AS, Jain G, Kalra P, Gupta D, Sharma S. Evaluation of efficacy of arthrocentesis (with normal saline) with or without sodium hyaluronate in treatment of internal derangement of TMJ—a prospective randomized study in 20 patients. *J Oral Biol Craniofac Res.* 2013;3(3):112–9.
63. Machado RC, Capela S, Rocha FAC. Polysaccharides as viscosupplementation agents: structural molecular characteristics but not rheology appear crucial to the therapeutic response. *Front Med (Lausanne).* 2017;4:82.
64. Gencer ZK, Özkiriş M, Okur A, Korkmaz M, Saydam L. A comparative study on the impact of intra-articular injections of hyaluronic acid, tenoxicam and betametazon on the relief of temporomandibular joint disorder complaints. *J Craniomaxillofac Surg.* 2014;42(7):1117–21.
65. Altman RD, Manjoo A, Fierlinger A, Niazi F, Nicholls M. The mechanism of action for hyaluronic acid treatment in the osteoarthritic knee: a systematic review. *BMC Musculoskelet Disord.* 2015;16(1):321.
66. Ferreira N, Masterson D, Lopes de Lima R, de Souza Moura B, Oliveira AT, Kelly da Silva Fidalgo T, et al. Efficacy of viscosupplementation with hyaluronic acid in temporomandibular disorders: a systematic review. *J Craniomaxillofac Surg.* 2018;46(11):1943–52.
67. Bouloux GF, Chou J, Krishnan D, Aghaloo T, Kahenasa N, Smith JA, et al. Is hyaluronic acid or corticosteroid superior to lactated ringer solution in the short-term reduction of temporomandibular joint pain after arthrocentesis? Part 1. *J Oral Maxillofac Surg.* 2017;75(1):52–62.
68. Bouloux GF, Chou J, Krishnan D, Aghaloo T, Kahenasa N, Smith JA, et al. Is hyaluronic acid or corticosteroid superior to lactated ringer solution in the short term for improving function and quality of life after arthrocentesis? Part 2. *J Oral Maxillofac Surg.* 2017;75(1):63–72.
69. Foster TE, Puskas BL, Mandelbaum BR, Gerhardt MB, Rodeo SA. Platelet-rich plasma: from basic science to clinical applications. *Am J Sports Med.* 2009;37(11):2259–72.
70. Dai W-L, Zhou A-G, Zhang H, Zhang J. Efficacy of platelet-rich plasma in the treatment of knee osteoarthritis: a meta-analysis of randomized controlled trials. *Arthroscopy.* 2017;33(3):659–670. e1.
71. Fitzpatrick J, Bulsara MK, O'Donnell J, McCrory PR, Zheng MH. The effectiveness of platelet-rich plasma injections in gluteal tendinopathy: a randomized, double-blind controlled trial comparing a single platelet-rich plasma injection with a single corticosteroid injection. *Am J Sports Med.* 2018;46(4):933–9.
72. Fitzpatrick J, Bulsara M, Zheng MH. The effectiveness of platelet-rich plasma in the treatment of tendinopathy: a meta-analysis of randomized controlled clinical trials. *Am J Sports Med.* 2017;45(1):226–33.
73. Bousnaki M, Bakopoulou A, Koidis P. Platelet-rich plasma for the therapeutic management of temporomandibular joint disorders: a systematic review. *Int J Oral Maxillofac Surg.* 2018;47(2):188–98.
74. Hegab AF, Ali HE, Elmasry M, Khallaf MG. Platelet-rich plasma injection as an effective treatment for temporomandibular joint osteoarthritis. *J Oral Maxillofac Surg.* 2015;73(9):1706–13.
75. Chung P-Y, Lin M-T, Chang H-P. Effectiveness of platelet-rich plasma injection in patients with temporomandibular joint osteoarthritis: a systematic review and meta-analysis of randomized controlled trials. *Oral Surg Oral Med Oral Pathol Oral Radiol.* 2019;127(2):106–16.
76. Cömert Kiliç S, Güngörmüş M. Is arthrocentesis plus platelet-rich plasma superior to arthrocentesis plus hyaluronic acid for the treatment of temporomandibular joint osteoarthritis: a randomized clinical trial. *Int J Oral Maxillofac Surg.* 2016;45(12):1538–44.
77. Fernández Sanromán J, Fernández Ferro M, Costas López A, Arenaz Bua J, López A. Does injection of plasma rich in growth factors after temporomandibular joint arthroscopy improve outcomes in patients with Wilkes stage IV internal derangement? A randomized prospective clinical study. *Int J Oral Maxillofac Surg.* 2016;45(7):828–35.
78. Haigler MC, Abdulrehman E, Siddappa S, Kishore R, Padilla M, Enciso R. Use of platelet-rich plasma, platelet-rich growth factor with arthrocentesis or arthroscopy to treat temporomandibular joint osteoarthritis: Systematic review with meta-analyses. *J Am Dent Assoc.* 2018;149(11):940–2.
79. Leopard PJ. Anterior dislocation of the temporomandibular disc. *Br J Oral Maxillofac Surg.* 1984;22(1):9–17.
80. Walker RV, Kalamchi S. A surgical technique for management of internal derangement of the temporomandibular joint. *J Oral Maxillofac Surg.* 1987;45(4):299–305.
81. Weinberg S, Cousens G. Meniscocondylar plication: a modified operation for surgical repositioning of the ectopic temporomandibular joint meniscus. Rationale and operative technique. *Oral Surg Oral Med Oral Pathol.* 1987;63(4):393–402.
82. Zetz MR, Ash DC. Double-layer closure for temporomandibular joint discoplasty. *J Oral Maxillofac Surg.* 1990;48(4):427–9.

83. Mehra P, Wolford LM. The Mitek mini anchor for TMJ disc repositioning: surgical technique and results. *Int J Oral Maxillofac Surg.* 2001;30(6):497–503.
84. He D, Yang C, Zhang S, Wilson JJ. Modified temporomandibular joint disc repositioning with miniscrew anchor: part I—surgical technique. *J Oral Maxillofac Surg.* 2015;73(1):47.e1–9.
85. Zhou Q, Zhu H, He D, Yang C, Song X, Ellis E. Modified temporomandibular joint disc repositioning with mini-screw anchor: part ii-stability evaluation by magnetic resonance imaging. *J Oral Maxillofac Surg.* 2019;77(2):273–9.
86. Xie Q, Yang C, He D, Cai X, Ma Z. Is mandibular asymmetry more frequent and severe with unilateral disc displacement? *J Craniomaxillofac Surg.* 2015;43(1):81–6.
87. Abramowicz S, Dolwick MF. 20-year follow-up study of disc repositioning surgery for temporomandibular joint internal derangement. *J Oral Maxillofac Surg.* 2010;68(2):239–42.
88. Merrill RG. Historical perspectives and comparisons of TMJ surgery for internal disk derangements and arthropathy. *Cranio.* 1986;4(1):74–85.
89. McKenna SJ. Discectomy for the treatment of internal derangements of the temporomandibular joint. *J Oral Maxillofac Surg.* 2001;59(9):1051–6.
90. Holmlund AB, Gynther G, Axelsson S. Discectomy in treatment of internal derangement of the temporomandibular joint. Follow-up at 1, 3, and 5 years. *Oral Surg Oral Med Oral Pathol.* 1993;76(3):266–71.
91. Miloro M, McKnight M, Han MD, Markiewicz MR. Discectomy without replacement improves function in patients with internal derangement of the temporomandibular joint. *J Craniomaxillofac Surg.* 2017;45(9):1425–31.
92. Silver CM. Long-term results of meniscectomy of the temporomandibular joint. *Cranio.* 1984;3(1):46–57.
93. Takaku S, Toyoda T. Long-term evaluation of discectomy of the temporomandibular joint. *J Oral Maxillofac Surg.* 1994;52(7):722–6.
94. Tolvanen M, Oikarinen VJ, Wolf J. A 30-year follow-up study of temporomandibular joint meniscectomies: a report on five patients. *Br J Oral Maxillofac Surg.* 1988;26(4):311–6.
95. Nyberg J, Adell R, Svensson B. Temporomandibular joint discectomy for treatment of unilateral internal derangements—a 5-year follow-up evaluation. *Int J Oral Maxillofac Surg.* 2004;33(1):8–12.
96. Agerberg G, Lundberg M. Changes in the temporomandibular joint after surgical treatment. A radiologic follow-up study. *Oral Surg Oral Med Oral Pathol.* 1971;32(6):865–75.
97. Hansson LG, Hansson T, Petersson A. A comparison between clinical and radiologic findings in 259 temporomandibular joint patients. *J Prosthet Dent.* 1983;50(1):89–94.
98. Dimitroulis G. A critical review of interpositional grafts following temporomandibular joint discectomy with an overview of the dermis-fat graft. *Int J Oral Maxillofac Surg.* 2011;40(6):561–8.
99. Henry CH, Wolford LM. Treatment outcomes for temporomandibular joint reconstruction after Proplast-Teflon implant failure. *J Oral Maxillofac Surg.* 1993;51(4):352–8.
100. Van Bellinghen X, Idoux-Gillet Y, Pugliano M, Strub M, Bornert F, Clauss F, et al. Temporomandibular joint regenerative medicine. *Int J Mol Sci.* 2018;19(2):446.

Open Access This chapter is licensed under the terms of the Creative Commons Attribution 4.0 International License (<http://creativecommons.org/licenses/by/4.0/>), which permits use, sharing, adaptation, distribution and reproduction in any medium or format, as long as you give appropriate credit to the original author(s) and the source, provide a link to the Creative Commons license and indicate if changes were made.

The images or other third party material in this chapter are included in the chapter's Creative Commons license, unless indicated otherwise in a credit line to the material. If material is not included in the chapter's Creative Commons license and your intended use is not permitted by statutory regulation or exceeds the permitted use, you will need to obtain permission directly from the copyright holder.





Temporomandibular Joint Dislocation

64

V. B. Krishnakumar Raja

64.1 Introduction

Hypermobility disorders of the temporomandibular joint (TMJ) present in two major forms:

1. Dislocation
2. Subluxation [1]

The differences between dislocation and subluxation have been highlighted in Box 64.1.

The condyle may be displaced either anteriorly, posteriorly, medially, or laterally of which anterior dislocation is the most common [1]. The incidence of TMJ dislocation constitutes about 3% of the dislocations occurring in other joints of the body with female predilection. The reported incidence of TMJ dislocation is 7% with a preponderance in people in the second and third decades [2].

Box 64.1 Definition of Dislocation and Subluxation

Dislocation refers the phenomenon in which condyle is displaced out of the glenoid fossa and traverses in front of the articular eminence. In contrast, subluxation is the condition in which the dislocated condyle can be reduced back into the normal position by patient themselves, without any professional assistance.

64.2 Classification (Box 64.2)

Dislocation has been classified by numerous methods. Rowe and Killey [3] based it on the duration of the dislocation episode as:

Box 64.2 Classification of Dislocation

Based on duration of displacement

- Acute dislocation
- Habitual dislocation/subluxation
- Chronic recurrent dislocation
- Long-standing/chronic protracted dislocation

Based on direction of displacement

- Anterior
 - Posterior
 - Medial
 - Lateral
 - Superior
- Based on side of displacement*
- Unilateral
 - Bilateral

1. Acute
2. Chronic

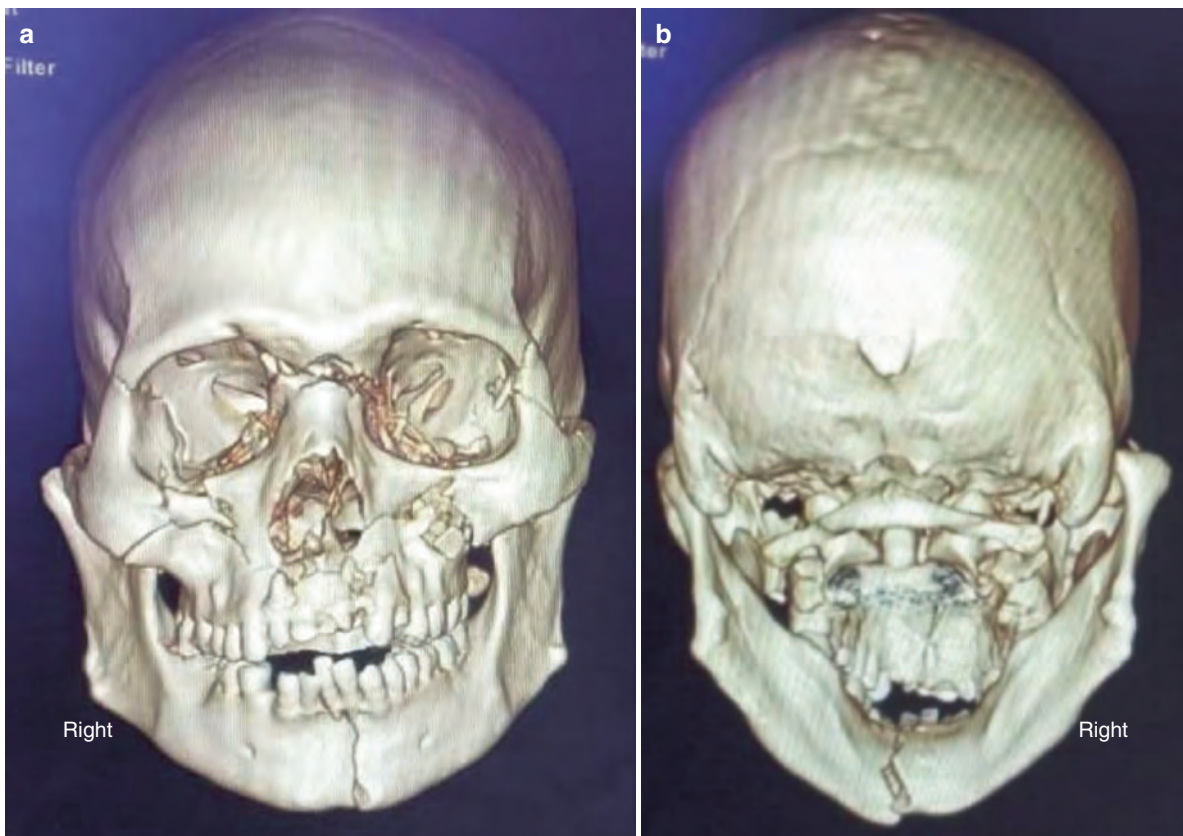
Dislocation recurring more than once is termed as chronic recurrent dislocation. The term *chronic protracted dislocation* is used to describe dislocation persisting for more than 1 month, while dislocation present for more than 6 months is called *extra-long-standing dislocation* [4].

Based on the direction of displacement [2], dislocation may be categorized as:

- Anterior
- Posterior
- Lateral
- Superior

Anterior dislocation is the most common type of dislocation due the weakness of the capsule in the anterior region.

V. B. Krishnakumar Raja (✉)
Department of Oral and Maxillofacial Surgery, SRM Dental
College and Hospital, Ramapuram, Chennai, Tamil Nadu, India



©Association of Oral and Maxillofacial Surgeons of India

Fig. 64.1 Lateral dislocation of condyle, Post trauma, on the right side. (a) Frontal view showing lateral dislocation on right side (b) Posterior view showing lateral dislocation on right side

Posterior dislocation occurs following fracture of the external auditory canal and skull base. Allen and Young classified lateral dislocation into Type I and Type II. This type of dislocation occurs in mandibular trauma (Fig. 64.1a, b):

- Type I refers to lateral subluxation.
- Type II indicated lateral and superior dislocation into the temporal fossa [2].

Superior dislocation results when condyle is pushed into the middle cranial fossa accompanied by glenoid fossa fracture. Small and round-shaped condyle is predisposed to this type of dislocation [2].

64.3 Etiopathogenesis (Table 64.1)

A multitude of causes have been described in the etiopathogenesis of TMJ dislocation including congenital, iatrogenic, anatomical aberrations, spontaneous, pharmacological, neurological, neuromuscular, etc. Proper diagnosis of the etiology is important to institute problem-specific treatment.

Table 64.1 Etiology of dislocation

Trauma	
Medical and surgical procedures	Dental procedures which require wide mouth opening for prolonged time Intubation procedures, gastrointestinal endoscopy, laryngoscopy/bronchoscopy ENT procedures
Spontaneous	Laughing Yawning Biting Vomiting Singing Epileptic seizures
Anatomical aberrations	Small condyle Poorly grooved glenoid fossa, shallow/steep articular eminence, laxity of ligaments and capsule for more prone for dislocation
Systemic disorders	Ehlers-Danlos disease Marfan's syndrome Huntington disease Parkinson disease Multiple sclerosis Muscle dystrophies or dystonias
Medications	Antipsychiatric Antiemetic
Occlusal conditions	Edentulous posterior region

Daily activities which involve wide mouth opening such as laughing, yawning, and biting may induce TMJ dislocation. It may also occur spontaneously during epileptic seizures, vomiting, yawning, and singing. Trauma is another cause which might cause posterior, superior, and lateral dislocation in addition to anterior dislocation [5]. Iatrogenic causes include dental procedures which require wide mouth opening for prolonged time, intubation procedures, gastrointestinal endoscopy, and laryngoscopy/bronchoscopy. Anatomical aberrations such as small condyle, underdeveloped glenoid fossa, shallow/steep articular eminence and laxity of ligaments and capsule are more prone for dislocation.

Predisposing risk factors include connective tissue disorders such as Ehlers-Danlos disease and Marfan's syndrome which predispose to laxity of the joint and hypermobility. Muscle spasms occur in neurodegenerative or neurodysfunctional diseases, namely, Huntington disease, Parkinson disease, multiple sclerosis, muscle dystrophies, or dystonias.

Medications which induce dislocation are antipsychiatric (phenothiazines) and antiemetic (metoclopramide) drugs which produce unwanted extrapyramidal reactions which eventually lead to muscular imbalance attributed to dislocation.

Reduced vertical dimension due to loss of posterior teeth in advanced age may also predispose an individual to dislocation [5].

Though various theories of pathogenesis have been described in literature, the most accepted was muscular inco-

ordination during mandibular movements. In the initial stages of mouth closure, elevators are activated prior to the relaxation of depressors mainly lateral pterygoid which pulls the condyle forward. This initial dislocation facilitates the further dislocation [5].

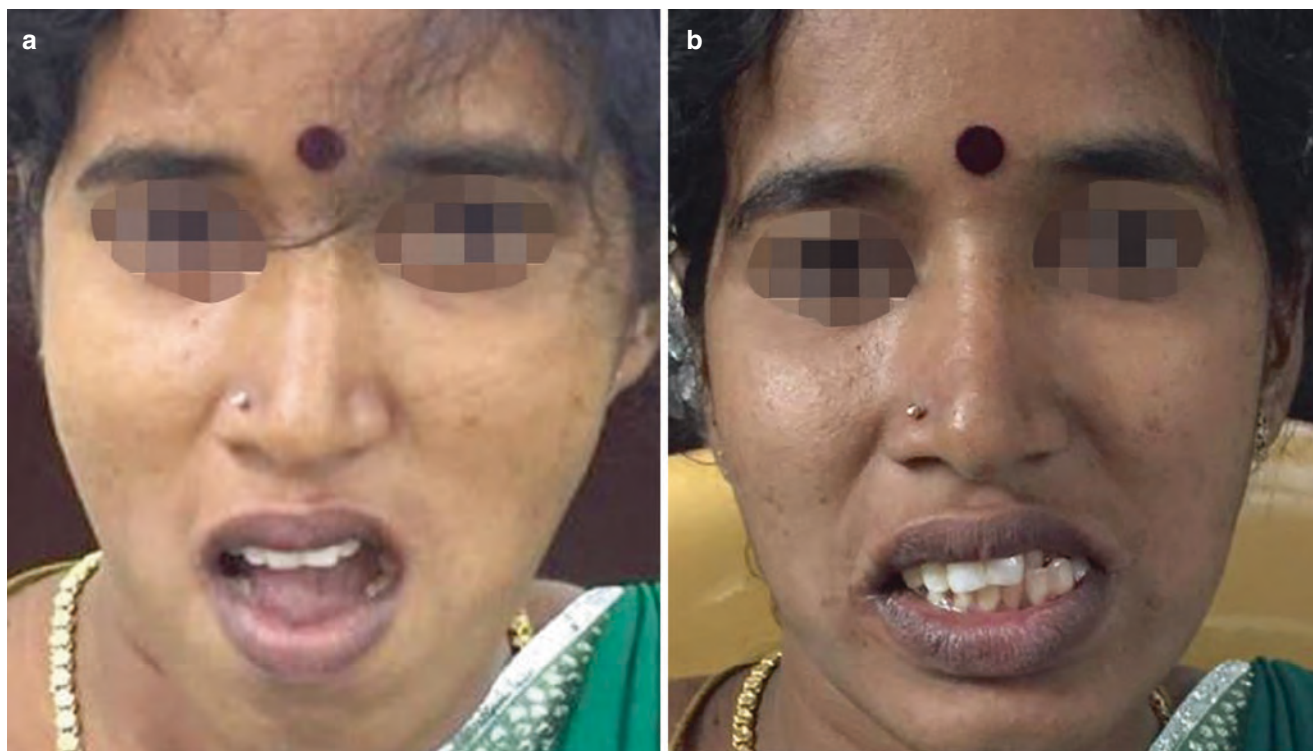64.4 Clinical Features (Mentioned in Box 64.3; Figs. 64.2a, b, 64.3, 64.4a, b, and 64.5a, b)

Box 64.3 Clinical Features of Dislocation

The classical clinical features of dislocation are:

1. Pain in the preauricular and surrounding region.
2. Preauricular depression/hollowing.
3. Protruding chin.
4. Inability to close mouth.
5. Drooling of saliva.
6. Inability to speak, swallow, or masticate.
7. Tense masticatory muscles are also a characteristic feature [6]

Unilateral dislocation is associated with deviation of chin towards contralateral side.

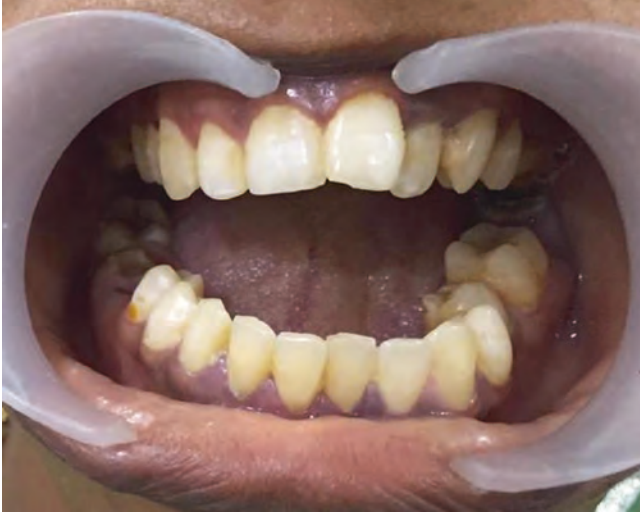

©Association of Oral and Maxillofacial Surgeons of India

Fig. 64.2 (a, b) Bilateral TMJ dislocation. (a) Before reduction (b) After reduction

64.5 Investigations

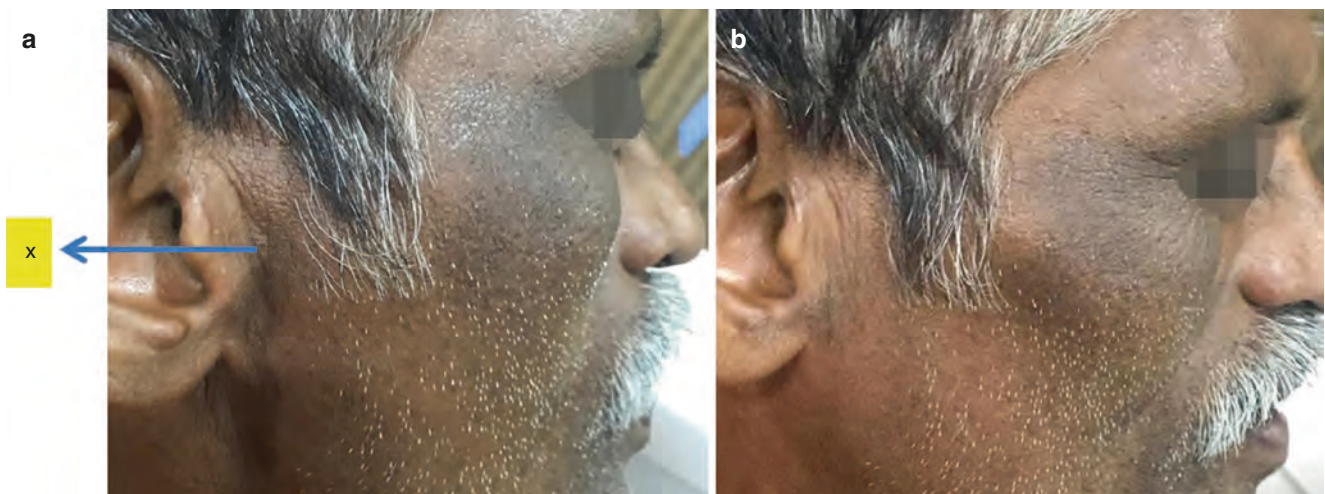- *Orthopantomogram (OPG)* (open and closed) (Fig. 64.6)
This is the commonly used screening modality for the examination of TMJ. Morphology of condyle, articular eminence, and joint space can be evaluated. Open mouth OPG shows the position of the condyle in relation to the articular eminence.



©Association of Oral and Maxillofacial Surgeons of India

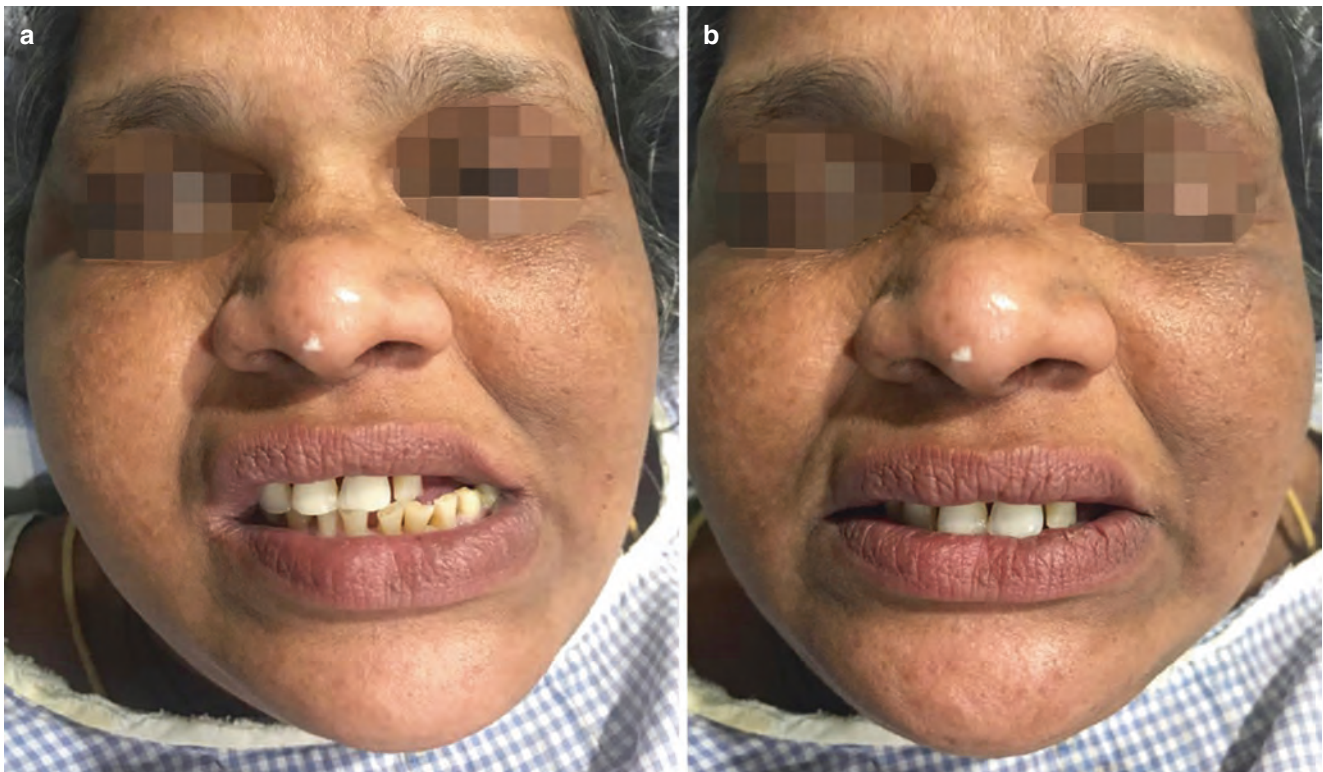Fig. 64.3 Bilateral TMJ dislocation showing openbite

- *TMJ tomogram*
Open and closed mouth TMJ images can be obtained in different slices.
- *Computed tomography(CT)*
Evaluation of the morphology of osseous TMJ components—condyle, articular eminence and the glenoid fossa—are better assessed with CT.
- *Cone beam computed tomography CBCT*
CBCT facilitates accurate measurement of condylar height, width, and length as well as inclination of articular eminence.
- *Magnetic resonance imaging (MRI)*
MRI demonstrates the soft tissue morphology, particularly disc shape, displacement, and effusion of the joint frequently associated with dislocation.
- *Electromyography (EMG)*
EMG evaluates the activity of the muscles which may be hypoactive, normoactive, or hyperactive.
- *Ultrasonography (USG)*
Thickness and length of the muscles can be evaluated both at rest and clenching by USG.



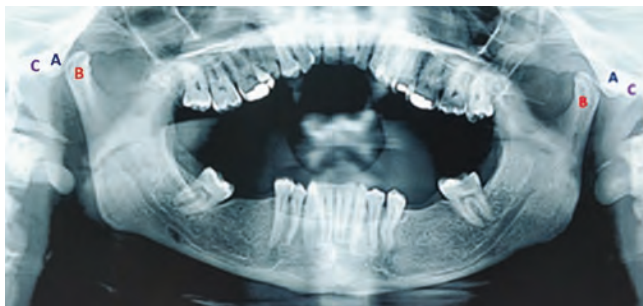
©Association of Oral and Maxillofacial Surgeons of India

Fig. 64.4 (a, b) Preauricular depression. (a) Before reduction. x—Preauricular depression. (b) After reduction



©Association of Oral and Maxillofacial Surgeons of India

Fig. 64.5 (a, b) Unilateral TMJ dislocation on the right side. (a) Before reduction (b) After reduction



©Association of Oral and Maxillofacial Surgeons of India

Fig. 64.6 OPG demonstrating dislocation. A: Articular eminence. B: Condyle in front of articular eminence. C: Glenoid fossa

64.6 Management of Dislocation (Box 64.4)

64.6.1 Acute Dislocation

Reducing the dislocated condyle poses a great challenge. Reduction is more complicated with the accompanied mus-

cle spasm persisting for longer duration. In difficult situations, reduction can be facilitated with the help of local anesthesia, conscious sedation, and general anesthesia. Following reduction, a Barton's bandage, chin strap, or intermaxillary fixation is advised for 3–6 weeks to prevent further dislocation. Several reduction techniques have been employed with varying rates of success.

Box 64.4 Management of Acute Dislocation

- Conventional technique—Hippocratic/Nelaton's method
- Wrist pivot technique
- Extraoral technique
- Gag reflex

64.6.1.1 Hippocratic/Nelaton's Technique (Fig. 64.7)

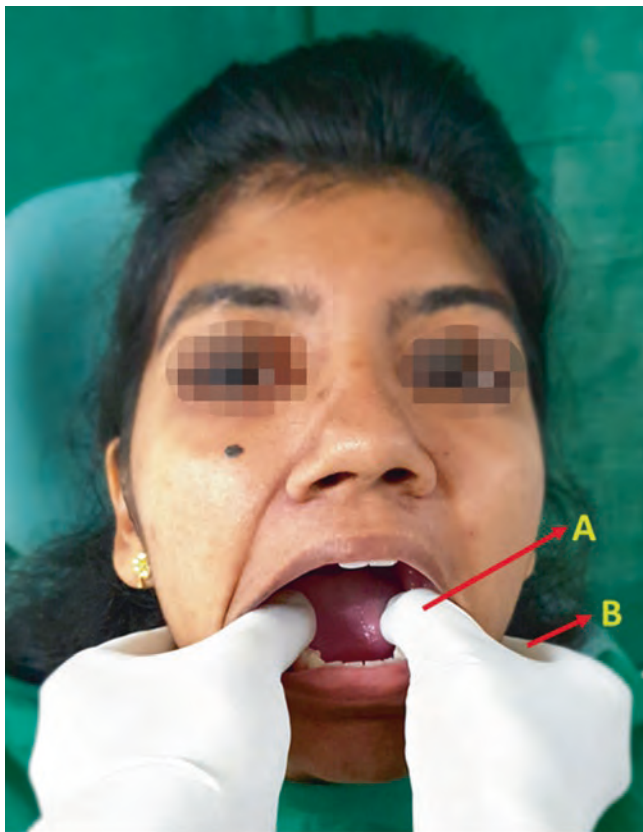
This is the conventional method of reduction of acute dislocation in which physician stands in front of the patient, with the thumb placed either on the external oblique ridge or on the lower molars and other fingers positioned along the lower border of the mandible. A steady downward, backward, and superior force should be given to reduce the dislocated condyle. The thumb should be protected either with a plastic splint or gauze wrapped around it to prevent injury to the thumb while reducing dislocation.

64.6.1.2 Gag Reflex [3]

Gag reflex is induced by probing the soft palate using mouth mirror. In alert individuals, this reflex relaxes the lateral pterygoid muscle through coordinated neuromuscular activities which reduces dislocation in natural way.

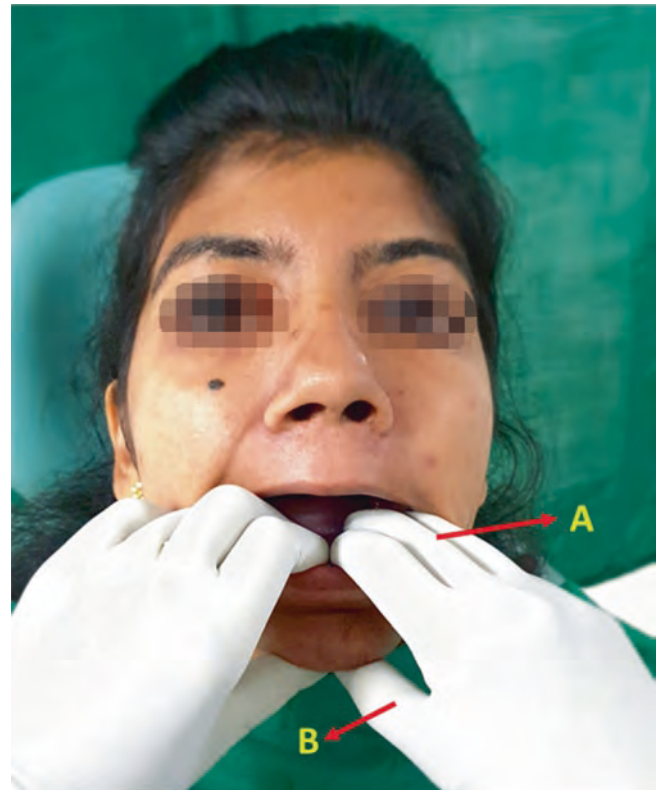64.6.1.3 Wrist Pivot Method [7] (Fig. 64.8)

This method utilizes existing myospasm of the elevators for reduction. The thumb is placed under the chin, while other fingers are placed over the occlusal surfaces of lower teeth.



©Association of Oral and Maxillofacial Surgeons of India

Fig. 64.7 Nelaton's method. A: Thumb intraorally on the occlusal surface lower teeth. B: Other fingers at the inferior border of body and angle of the mandible



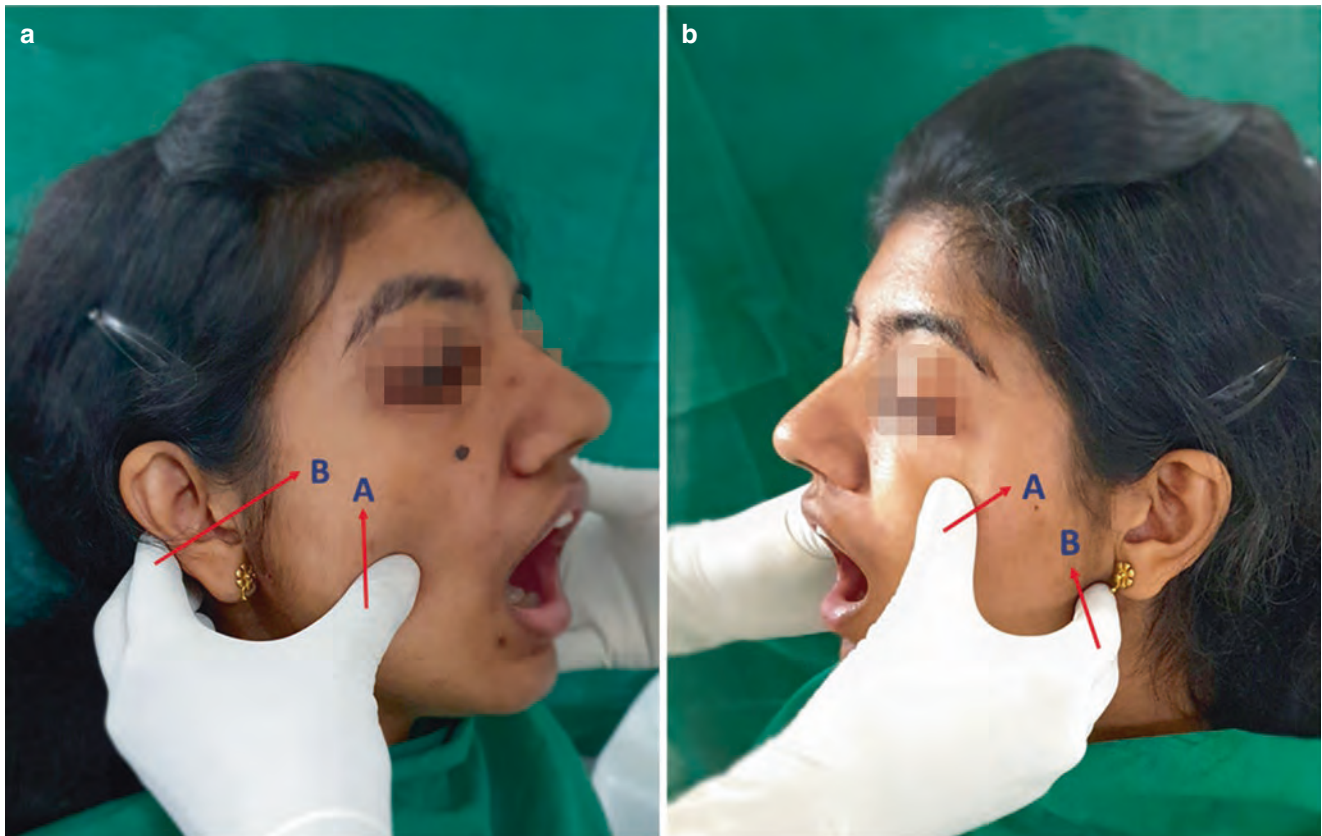
©Association of Oral and Maxillofacial Surgeons of India

Fig. 64.8 Wrist-pivot method. A: Other fingers intraorally on the occlusal surface lower teeth. B: Thumb on the chin

Then upward movement is applied by the thumb, and concomitant inferior force is given by other fingers with pivoting the wrist. The advantage of this technique is that it utilizes the force created by the muscles of mastication rather than overcoming this force as in Nelaton's technique.

64.6.1.4 Extraoral Method [8] (Fig. 64.9a, b)

Intraoral methods described previously have the risk of human bite in which there are chances of infection transmission. To overcome this, extraoral method has been described. In the dislocated mandible, coronoid process comes forward which is easy to palpate. On one side, the thumb is positioned over the coronoid process which pushes the mandible backward, while the other fingers are located over the mastoid process to deliver counteracting force (Fig. 64.9a). On the other side, the mandible is pulled further forward with the thumb on the malar eminence and rest of the fingers on the mandibular angle (Fig. 64.9b). Pulling the mandible on one side with simultaneous pushing of the mandible on the other side reduces the dislocation on one side first and then subsequently on the other side. This technique is applicable in unilateral dislocation as one side is reduced first and then the other is reduced thereafter.



©Association of Oral and Maxillofacial Surgeons of India

Fig. 64.9 (a, b) Extraoral method for reduction of dislocation. (a) A: Thumb on coronoid process. B: Other fingers on mastoid process. (b) A: Thumb on malar eminence. B: Other fingers on angle of the mandible

64.6.2 Management of Chronic Recurrent Dislocation/Subluxation (Box 64.5 and 64.6)

Box 64.5 Management of Chronic Recurrent Dislocation/Subluxation

Conservative

1. Physiotherapy
2. Intermaxillary fixation
3. Chin straps
4. Barton's bandage
5. Kinesio taping

Minimally invasive

1. Injection of sclerosing agents
2. Autologous blood injection
3. Prolotherapy
4. Botulinum toxin injection

Box 64.6 Management of Chronic Recurrent Dislocation/Subluxation

Surgical procedures

1. Capsular tightening procedure
 - (a) Capsulorrhaphy
2. Creation of mechanical obstacle
 - (a) Dautrey's procedure
 - (b) Glenotemporal osteotomy
3. Removal of mechanical obstacle
 - (a) Eminectomy
 - (b) Condylectomy
4. Creation of new muscular balance
 - (a) Temporalis scarification
 - (b) Lateral pterygoid myotomy
 - (c) Pterygoid dysjunction

Numerous treatment modalities have been described for TMJ dislocation, as it has multifactorial etiology. Miller and Murphy [9] proposed a comprehensive list of treatment options which targeted specific anatomical sites of the joint that exhibited abnormality: the capsule, eminence, and condylar head.

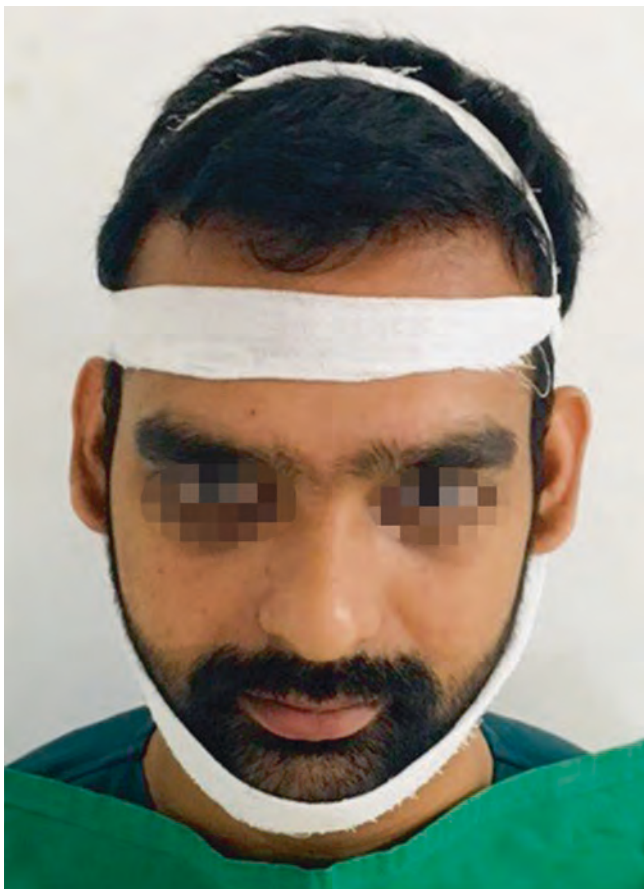For practical purposes, the types of management may be broadly classified based on the degree of invasiveness as:

1. Conservative
2. Minimally invasive
3. Surgical

64.6.2.1 Conservative Methods

Conservative methods may be used following reduction of dislocation to prevent further dislocation, such as:

1. Physiotherapy
2. Intermaxillary fixation
3. Chin straps
4. Barton's bandage (Fig. 64.10)
5. Kinesio taping



©Association of Oral and Maxillofacial Surgeons of India

Fig. 64.10 Barton's bandage

Intermaxillary fixation, chin strap, and Barton's bandage are done for 4 weeks to induce fibrosis of soft tissues around the joint so that further dislocation is prevented. Physiotherapy including ultrasound and infrared therapy are advised to reduce pain. Isotonic and isometric exercise are advised to strengthen the muscle involved in TMJ function [9].

Kinesio Taping (Fig. 64.11)

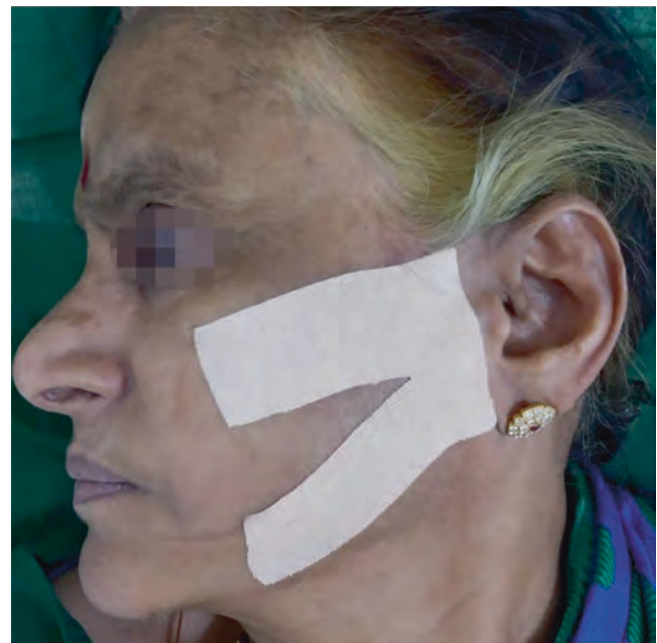In the year 1970, Dr. Kenzo Kase, a Japanese chiropractor, first described the techniques of Kinesio taping. The thin elastic tape acts by lifting the skin which increases the blood and lymphatic flow, thereby reducing inflammation and accumulation of pain mediators. It also helps in better muscle function and joint realignment which is utilized in reduction of TMJ dislocation.

64.6.2.2 Minimally Invasive Treatment

Injection of Sclerosing Solutions [9]

This procedure involves repeated injection of sclerosing solution into the capsule aimed at fibrosis of the capsule which would eventually limit the mouth opening. The solutions commonly used to perform the procedure are:

- Sodium psylliate
- Sodium tetradecylsulfate
- Sodium morrhuate
- Ethanolamine oleate 5%
- Tincture of iodine
- OK-432 (Picibanil)



©Association of Oral and Maxillofacial Surgeons of India

Fig. 64.11 Kinesio taping

These injections are usually given intra-articularly and in pericapsular region and can be repeated every 2–3 weeks till the fibrosis occurs. However, the outcome of this technique is not satisfactory and is also associated with complications such as TMJ ankylosis and facial nerve injury [9].

OK-432 which is a streptococcal derivative inactivated by penicillin G is used as sclerosing agent for the treatment of TMJ dislocation. A 21-gauge needle is used to inject 1.25 KE/ml concentration of OK-432 into the superior joint space and pericapsular region. 2 ml of the solution is injected in each region. This produces fibrosis in and around the joint by inducing local inflammation and formation of granulation tissue. Mouth opening is restricted for 4 days following injection by elastic bandage.

Autologous Blood Injection [1]

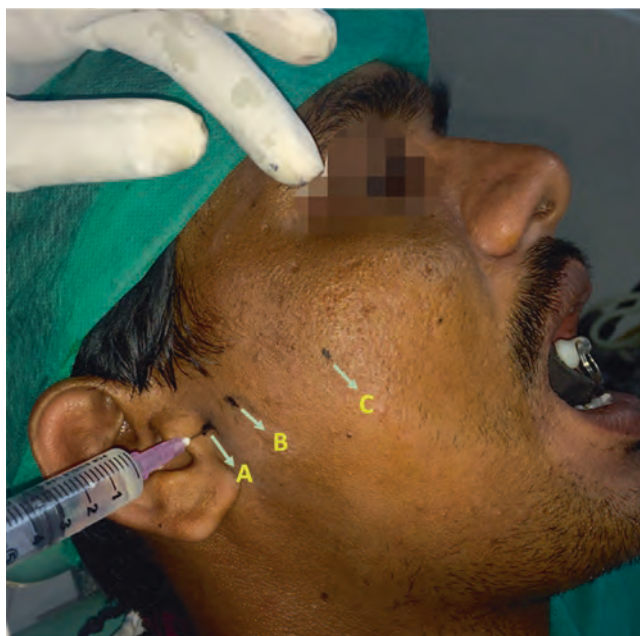This procedure works by producing fibrosis which restricts the opening of the mouth wide. It involves injection of patient's own blood into the superior joint space and pericapsular region following two puncture arthrocentesis. Prior to the injection of blood into the joint, lavage should be done using two needles in the superior joint space, and then one needle is removed. Blood is injected through the other needle into the joint and around the joint. It may be injected either unilaterally or bilaterally. It can be given as a single or multiple injections with intervals.

Injection of Platelet Rich Plasma (PRP) (Refer suggested reading at the end of the chapter)

Platelet rich plasma is a yet another minimally invasive technique used to treat various Temporomandibular joint disorders. It is prepared from 10 ml of patient's own blood which was centrifuged at 3200 rpm for 12 minutes. The 2ml solution was then injected it to the superior joint space which was located 10 mm forward and 2 mm downward on the cantho-tragal line. Another 1ml of the solution was injected into the pericapsular tissues. Patients were advised for various mandibular movements for a minute following injection for the equal distribution of PRP in the joint. Elastic bandage is given for a week followed by mandibular exercise advised. PRP has 3-8 folds concentration of platelets and various growth factors such as platelet derived growth factor, transforming growth factor beta and vascular endothelial growth factor which helps in healing of the tissues. In a comparative study between autologous blood injection and PRP for TMJ dislocation demonstrated both groups were equally effective in decreasing mouth opening in TMJ dislocation.

Prolotherapy [1]

It is also called as regenerative injection therapy. This involves injection of solutions into the joint to stimulate regeneration potential. Various prolotherapy solutions are available such as psyllium oil, glycerin, phenol, etc. of which



©Association of Oral and Maxillofacial Surgeons of India

Fig. 64.12 Injection sites for prolotherapy. A: Posterior joint space. B: Anterior attachment of disc to lateral pterygoid muscle. C: Most tender point of masseter muscle

dextrose is the most commonly used solution. 2 ml of 10–50% dextrose can be injected in and around the joint space. Either single or multiple injections are needed based on severity of dislocation. This technique is indicated in laxity of the ligaments and capsule. It induces low-grade inflammation which releases growth factors. These growth factors stimulate fibroblasts which deposit new collagen fibers that strengthen ligaments and tendons.

Landmarks—prolotherapy solutions are given in the following three points (Fig. 64.12):

- Posterior joint space—palpate the depression posterior to condyle when mouth is opened.
- Attachment of disc to lateral pterygoid muscle—depression felt anterior to the condyle when mouth is closed.
- Tender spot in the masseter tendon.

Injection of Botulinum Toxin [1]

The first reported use of botulinum toxin for TMJ dislocation was described by Daelen et al. in the year 1995. Botulinum toxin type A weakens the skeletal muscle when injected by preventing the release of acetylcholine at the neuromuscular junction. It can be injected into any of the masticatory muscle, but injection into lateral pterygoid muscle is effective because forward movement of condyle is prevented. The dosage used is 25–50 units of botulinum toxin. It can be injected either by extraoral or intraoral route with or without EMG guidance (Refer Chap. 33 on Botox injections).

Extraoral Technique

A 30-gauge needle is inserted into the skin 1 cm below the central zygomatic arch to the depth of 3–4 cm based on the measurements obtained from computed tomogram of the patient. The 25–50 units of toxin is deposited into the lateral pterygoid muscle following aspiration.

Intraoral Technique

Hypodermic needle electrode is inserted in the mucobuccal fold of distal root of upper second molar directed superiorly and posteriorly to the depth of 25–30 mm; the position of the needle in the lateral pterygoid muscle is confirmed by EMG reading. After aspiration, 25–50 units of toxin is deposited into the muscle.

The injection should be repeated every 3–6 months as the action of this toxin lasts within 6 months. Complications of this technique included dysphagia, dysarthria, and hemorrhage.

Arthroscopy [1] (Refer Chap. 63 on Internal Derangements of TMJ)

Arthroscopic capsulorrhaphy is done by using either laser or cautery which produces contractions. Sclerosing solutions may be injected into the joint and capsule under direct visualization using arthroscopy.

Arthroscopic Capsulorrhaphy

A 1.7 mm TMJ arthroscope is introduced into the fossa portal following the double puncture technique described by McCain. Once the arthroscope reached the anterior recess, the second puncture is done using triangulation technique. Deep lesional burns are created in the oblique protuberance, laterally and the posterior wall using either bipolar cautery or holmium laser which causes shortening of the capsule.

Arthroscopic Eminectomy

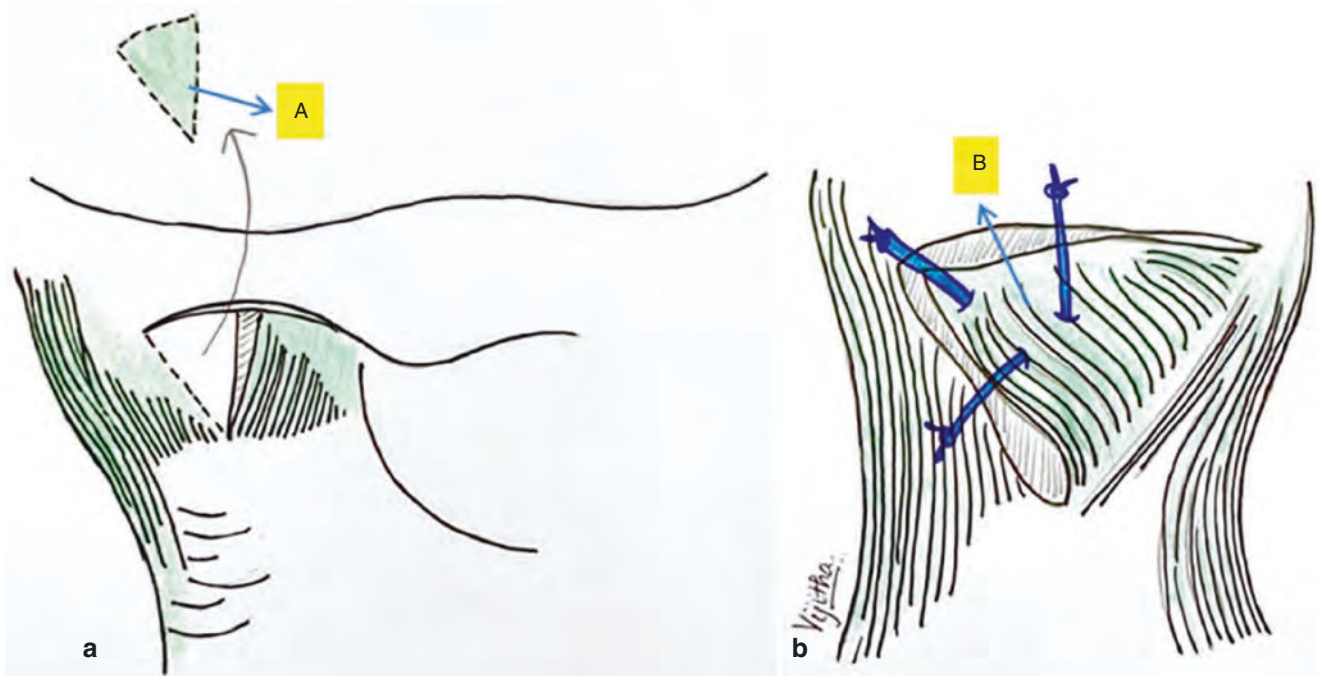
The arthroscope is introduced into the joint through inferolateral approach, and then the articular eminence is reduced by electronic shaver which is introduced by triangulation technique.

64.6.2.3 Surgical Treatment

The following is a brief description of surgical procedures which are commonly employed for treating TMJ dislocation.

Capsular Tightening Procedure

Temporomandibular joint is completely covered by capsule which is attached superiorly from all around the rim of the glenoid fossa and inferiorly till the neck of the condyle. This capsule holds the joint components in position, which is later-



©Association of Oral and Maxillofacial Surgeons of India

Fig. 64.13 (a–b) Capsulorrhaphy. Excised margin of the capsule. (A) Capsule is tightened by suturing it to the adjacent soft tissues (B)

ally strengthened by lateral ligament. Lax capsule is considered as one of the reasons for TMJ dislocation. So, capsular tightening procedures are done to address this problem.

Capsulorrhaphy (Fig. 64.13a, b)

This procedure was first implemented in the year 1907 by Perthes who excised a portion of the lateral capsule and sutured it together to increase the tautness of the capsule and thus restrain condyle. Later on, many modifications had been proposed including suturing of the capsule to zygomatic arch and overlapping of the capsule after making vertical incision on the capsule [9].

Creation of Mechanical Obstacle

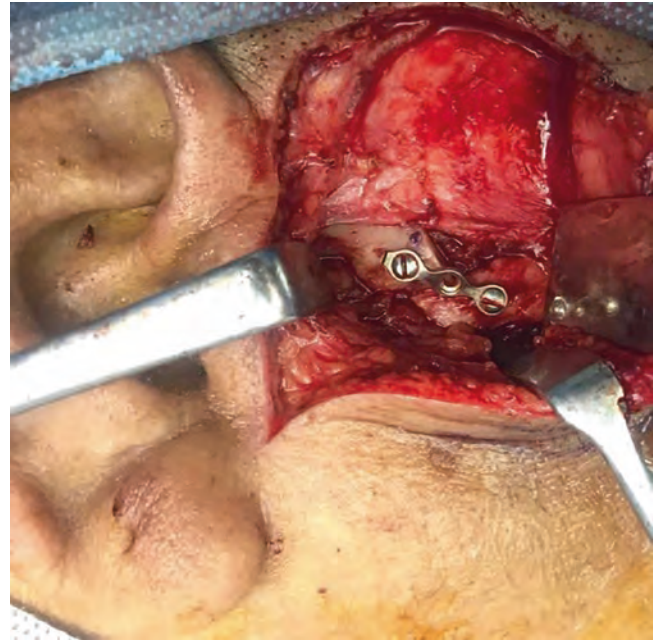Excessive translation of the condyle which is observed in dislocation is prohibited by creating impediment in the path of the condyle. Konjetzny (1921) had used articular disc as a mechanical impediment by bringing it forward and suturing it anteriorly. Lindemann and Mayer used articular tubercle to prevent condylar dislocation by either bending it down or placing a graft obtained from zygoma [9].

Dautrey's Procedure [10] (Fig. 64.14a, b)

Mayer (1933) created a mechanical obstacle by dislocating a part of the zygomatic arch down, in front of the articular eminence. Vertical osteotomy of the zygomatic arch and repositioning the osteotomized arch downward as a mechanical impediment has been described by LeClerc and Girard in the year 1943.

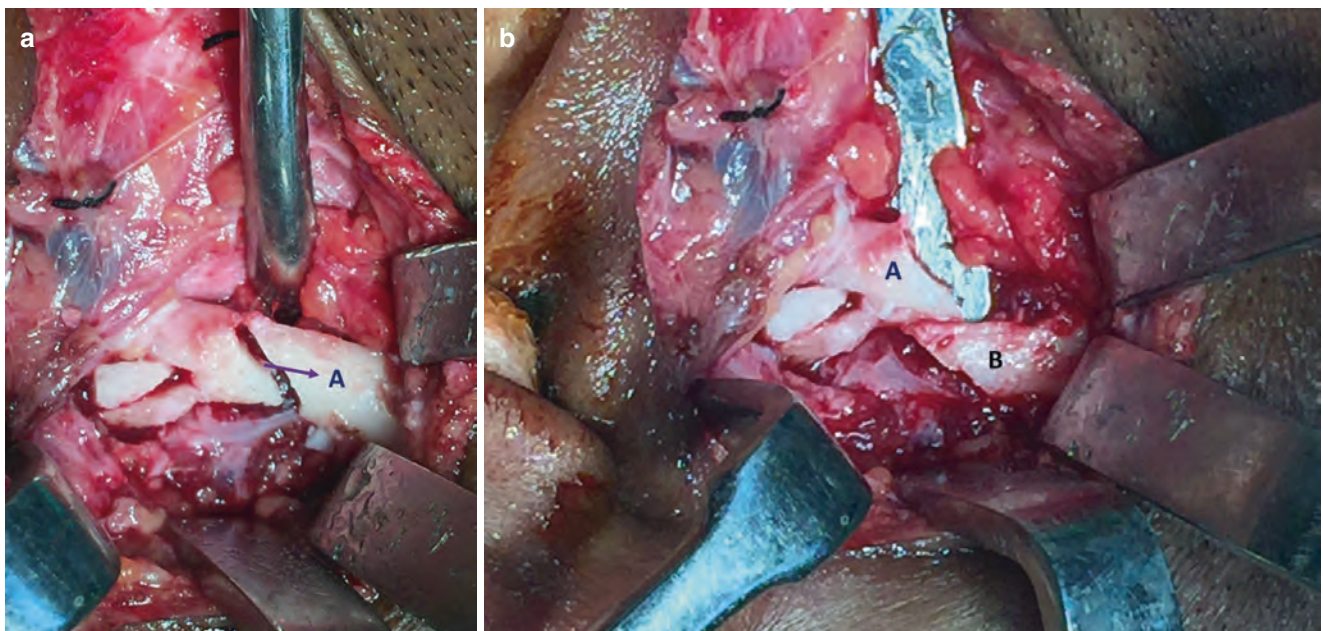
In 1967 Gosserez and Dautrey made an oblique osteotomy of the arch in front of the articular eminence extending

from posterior-superior to the anterior-inferior direction. With gentle pressure towards inferior direction, a greenstick fracture was created at the zygomatico-temporal suture. The segment was then pushed downwards to create obstruction for the condylar movement. If this downfractured segment is unstable, plating can be done to prevent displacement (Fig. 64.15).



©Association of Oral and Maxillofacial Surgeons of India

Fig. 64.15 Fixation of downfractured zygomatic arch segment using miniplates



©Association of Oral and Maxillofacial Surgeons of India

Fig. 64.14 (a, b) Dautrey's procedure. (a) A: Osteotomy of zygomatic arch (b) A: Proximal segment of zygomatic arch. B: Downfractured distal segment of zygomatic arch

The limitations of the technique include the following:

1. Not suitable for elderly individual as it may cause fracturing of the arch instead of greenstick fracture at the zygomatico-temporal suture.
2. Relocation of the fragments after repositioning [10].
3. Medial escape of the condyle as the width of the zygomatic arch is narrow.
4. Presence of a small condyle.

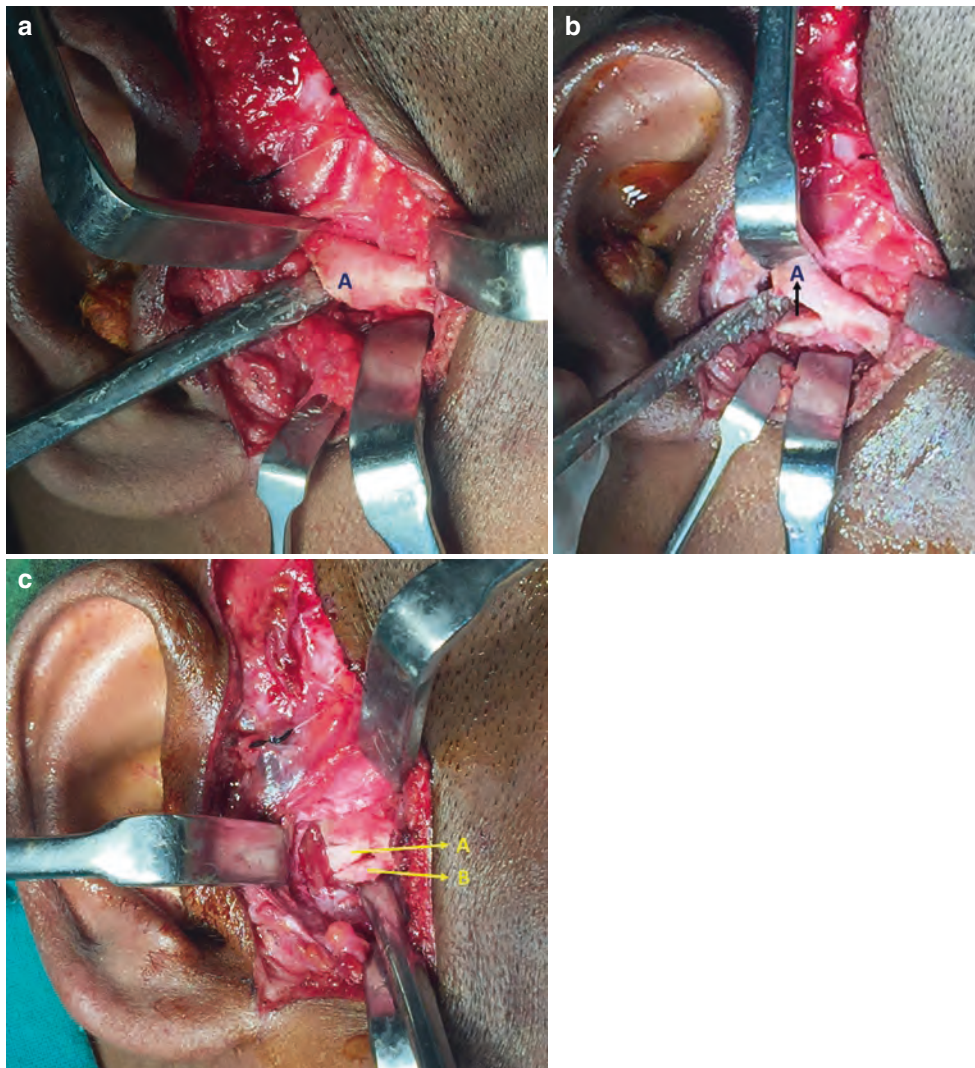
Glenotemporal Osteotomy (Fig. 64.16a, b and c)

Norman [10] described glenotemporal osteotomy as a definitive technique for dislocation. TMJ is exposed through any of the open surgical approaches described for TMJ, without violating the capsule. An oblique osteotomy

on the articular eminence is made, following which the fragment is gently moved downwards to create a wedge-shaped defect which is grafted using bone taken from ilium, calvarium, symphysis, etc. Usually it is not necessary to fix these grafts as they stay in that wedge-shaped space created by osteotomy. Miniplates or screws can be placed on the eminence so that excessive condylar translation is prevented. Long-term results of this technique showed screw loosening and fracture of the plate.

Modifications of Norman's Procedure

Sharma et al. [11] added two modifications to the conventional glenotemporal osteotomy. Temporalis fascial flap was used to strengthen the capsule, and pterygoid dysfunction was performed to address the TMJ pain due to internal derangement which coexists with dislocation.



©Association of Oral and Maxillofacial Surgeons of India

Fig. 64.16 (a, b, c) Glenotemporal osteotomy. (a) A: Articular eminence. (b) A: Osteotomy of articular eminence. (c) A: Chin graft in position. B: Downfractured articular eminence

Removal of Mechanical Obstacle

Eminectomy (Fig. 64.17a, b)

The first reported evidence of eminectomy for the treatment of TMJ dislocation was performed by Hilmar Myrhaug in the year 1951. This procedure is generally accomplished under general anesthesia or local anesthesia, or conscious sedation has also been used for patients with systemic conditions that prohibit general anesthesia. Though there are many techniques available to address this condition, this particular technique may be considered for those patients with neurological disorder, epilepsy, and advanced age [12].

Hall et al. [13] had studied the eminence configuration using 38 cadavers. The observations included the following:

1. Anteroposterior width of eminence—9–18 mm
2. Latero-medial width of eminence—16–25 mm
3. Articular tubercle to temporal bone measurement—5–14 mm
4. Deepest portion of the glenoid fossa thickness—0.1–8 mm

Articular eminence thicknesses in anterior and posterior regions were also mentioned [6]. These measurements provide guidelines while performing eminectomy procedure to avoid complications.

According to this technique, the joint may be approached through any of the incisions indicated for TMJ surgeries. Following exposure of the eminence, rotary instruments, osteotome, chisel, or piezo surgery device can be used to reduce the height of the eminence. Either total eminectomy or partial eminectomy may be done. Irregular bony surfaces and edges should be smoothed well. Segami et al. [14] described arthroscopic eminectomy where double puncture

technique has been used. Motorized shaver was used to reduce the eminence.

Navigation system has also been used for accurate reduction of eminence especially on the medial side and superior surface to avoid intracranial exposure [6].

Eminectomy works by allowing free movement of the condyle over the eminence so that locking of the condyle is prevented. There are observations of reduced mouth opening following eminectomy that might be due to adhesions formed in and around the joint. This can be performed unilaterally or bilaterally [6].

The major problem associated with this technique is the excessive forward movement of the condyle than what is actually needed which leads to stretching of muscles and ligaments which is potentially injurious to the articular structures [11].

Condylotomy and Condylectomy (Fig. 64.18a, b)

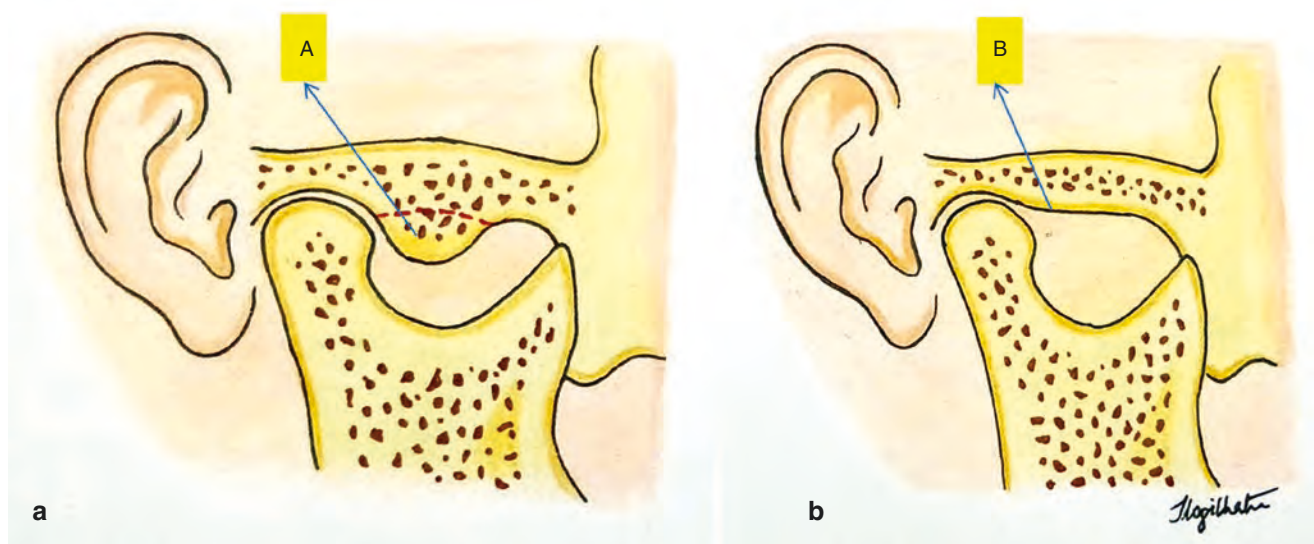
Closed condylotomy is a blind procedure in which Gigli saw is used to cut the condyle as described by Kosteka [2].

Part of the condyle is removed to prevent the obstruction; at the same time, it allows the free translation of the condyle along the articular eminence.

Preauricular incision is used to approach the condyle, and then the condyle is sectioned at the inferior level of the articular eminence.

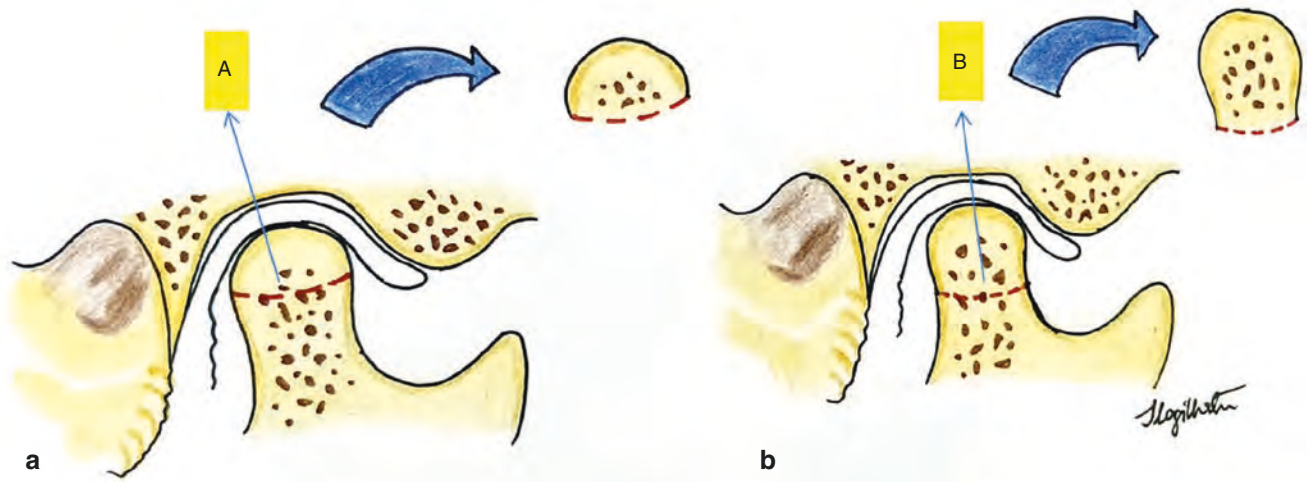
Creating New Muscular Balance

- *Temporalis Scarification* [1]
A portion of the temporalis muscle is removed by this technique so that the scarring and fibrosis induced by surgery restrict the mouth opening.
- *Lateral Pterygoid Myotomy* [1] (Fig. 64.19a, b)



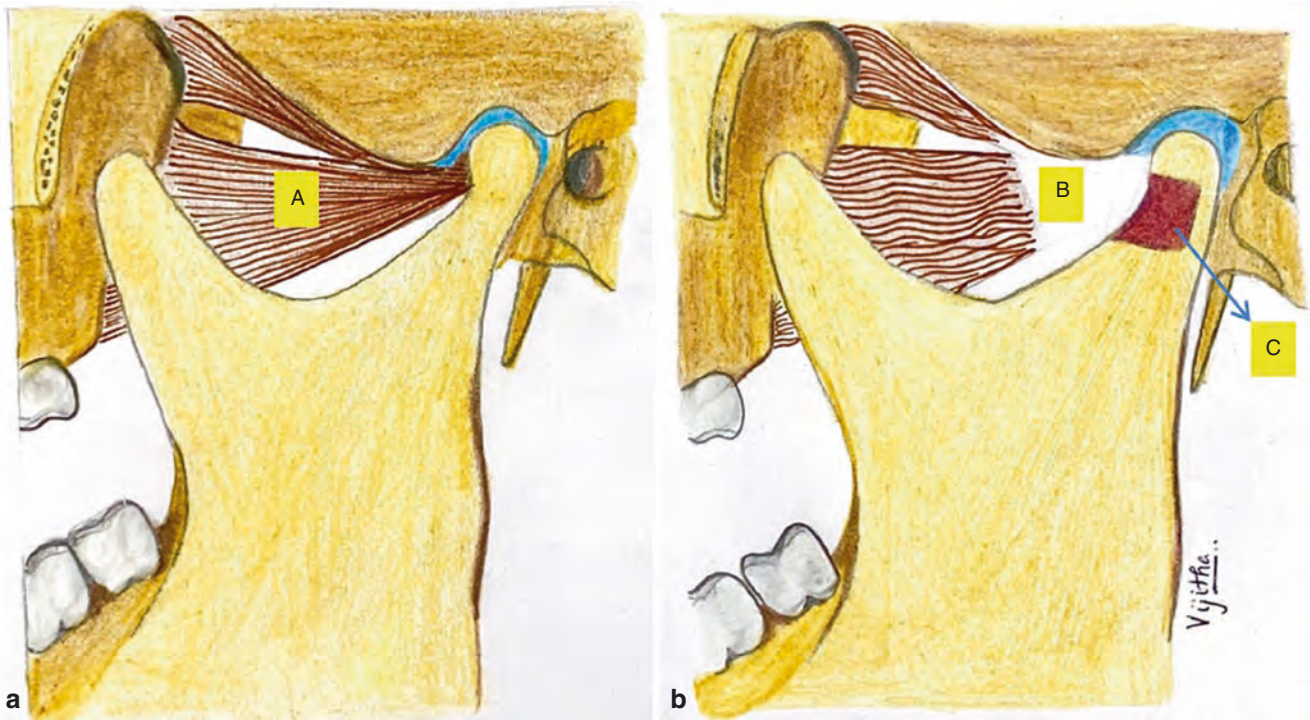
©Association of Oral and Maxillofacial Surgeons of India

Fig. 64.17 (a–b) Eminectomy. (A) Articular eminence (B) Eminence removed



©Association of Oral and Maxillofacial Surgeons of India

Fig. 64.18 (a–b) Condylectomy. (A) High condylectomy (B) Low condylectomy



©Association of Oral and Maxillofacial Surgeons of India

Fig. 64.19 (a–b) Lateral pterygoid myotomy. (A) Lateral pterygoid muscle (B) Part of the lateral pterygoid muscle excised (C) Barrier is placed

This technique was described by Bowman in 1949. This procedure may be performed through either intraoral by making incision along the anterior border of the ramus from coronoid to the third molar region or extraoral route through preauricular approach. Dissection is carried out to visualize the attachment of lateral pterygoid to condyle and capsule, and the attachment is then severed and then silastic sheet

fixed to the anterior surface of the condyle. This results in restriction of mouth opening for short period of time.

Pterygoid Dysjunction

It is an intraoral procedure done to reduce the activity of the lateral pterygoid on the condyle so that forward movement of the condyle is reduced [11].

Intraoral vestibular incision is made in relation to the upper molars, and dissection is done to expose the posterolateral wall of the maxilla and pterygomaxillary suture. Pterygoid chisel is used to separate the pterygoid plates from maxilla, so that lateral pterygoid muscle along with pterygoid plate is detached.

64.6.3 Chronic Protracted Dislocation (Box 64.7)

Box 64.7 Management of Long Standing Dislocation

Conservative

1. Manual reduction
2. Continuous elastic traction using bite block
3. Indirect reduction
 - (a) Using a wire passing in the mandibular angle region
 - (b) Using a hook in the sigmoid notch

Surgical procedures

1. Joint procedures
 - (a) Condylotomy, condylectomy
 - (b) Myotomy
 - (c) Joint prostheses
2. Procedures not involving the joint
 - (a) Sagittal split osteotomy
 - (b) Vertical ramus osteotomy
 - (c) Inverted L osteotomy
 - (d) Midline mandibulotomy

Initially conservative method is employed to reduce dislocation. Manual reduction is attempted either using local anesthesia, sedation, or general anesthesia. Continuous elastic traction may also be applied with the bite block in the posterior region which might reduce the dislocation [15].

Indirect reduction can be performed by inserting wire into the mandibular angle region, or bone hook is passed into the sigmoid notch through a small incision made on the angle region (Rowe and Killey 1968) [4]. Lewis in 1981 used Bristow's elevator for the reduction by giving downward and posterior force.

In long-standing persistent dislocation, patient might have functional movement due to pseudo joint formation in front of the articular eminence. In this scenario, the goal is to establish the occlusion by osteotomy procedures such as sagittal split osteotomy or vertical ramus osteotomy.

Adekeye (1976) [4] suggested inverted L osteotomy instead of vertical and horizontal osteotomies due to the coronoid hindrance. Lateral and medial surface of the ramus is

exposed either through submandibular incision or intraoral incision extending from the coronoid process along the anterior border of the ramus to the vestibule of second molar region. Medial osteotomy (horizontal cut) is performed 4–5 mm above and posterior to the lingula and parallel to the occlusal plane. Vertical cut is performed from the distal aspect of the horizontal cut to the mandibular angle. Then the dentate segment is manipulated to get the desired occlusion. Proximal and distal segments are fixed with miniplates.

Other methods such as condylectomy, condylotomy, and myotomy (as described in previous sections) and TMJ prostheses are proposed to treat this condition [4].

Ratten et al. described midline mandibulotomy to reduce the dislocation [16].

Through the intraoral approach, the mandible is sectioned in the midline, and then each hemimandible is manipulated to reduce the dislocation on each side separately. Following reduction, mandibular midline is fixed with miniplates.

64.7 Recent Advances

64.7.1 Raja's Coronoid Repositioning Technique [17]

This is a new technique performed for the management of TMJ dislocation. Intraoral vertical incision extending from the coronoid process to the molar region is made, and the coronoid and anterior border of ramus is exposed, and then coronoid is osteotomized and inferiorly pulled along with temporalis muscle and fixed with miniplates on the lateral surface of the ramus. The advantage of this technique is that the temporalis is stretched to give new muscle balance and restricts the excessive opening of the mouth.

64.7.2 Wolford's Anchoring Technique [18] (Fig. 63.15)

This technique prevents the dislocation by using two Mitek screw with attached suture material. One screw is attached to the zygomatic arch and another to the posterolateral surface of the condyle, and the sutures are tied together to get the desired mouth opening. These suture materials act as artificial ligaments that control condylar movement.

Acknowledgment I would like to acknowledge Dr. Vijitha and Dr. Logitha for illustrations.

Disclosure Authors have no financial conflicts to disclose.

64.8 Case Scenarios

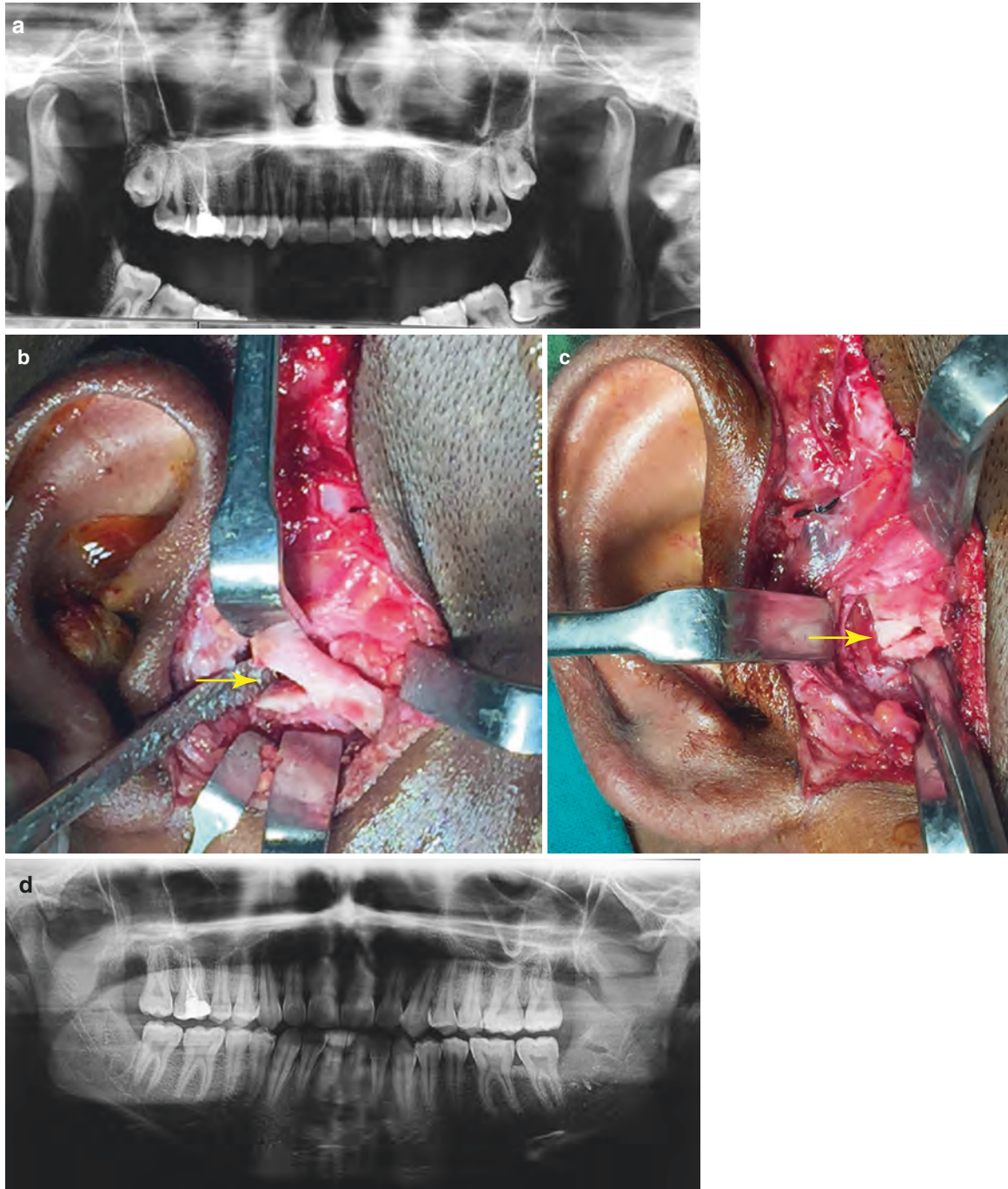
Case 1 (Fig. 64.20a–d)

Patient A 24-year-old male, with complaints of locking of the jaw after wide mouth opening

Preoperative open mouth OPG revealed bilateral TMJ dislocation (Fig. 64.20a)

OPG demonstrates:

- Displacement of condyle out of the glenoid fossa bilaterally
- Condylar head is antero-superior to articular eminence on both sides



©Association of Oral and Maxillofacial Surgeons of India

Fig. 64.20 Case scenario 1 (a) Pre op “open mouth “OPG showing bilateral dislocation of TMJ. (b) Osteotomy of articular eminence (yellow arrow). (c) Chin graft sandwiched between segments (yellow arrow). (d) Post op OPG showing increase in the height of articular eminence on right side

Surgical plan Augmentation of articular eminence by glenotemporal osteotomy on the right side. The right side was chosen for intervention as the symptoms were pronounced on that side

Surgical procedure

- Right TMJ was approached through preauricular incision with temporal extension
- Osteotomy of articular eminence (Fig. 64.20b)
- Wedging the chin graft between the osteotomy cut of articular eminence (Fig. 64.20c)

Postoperative OPG

OPG demonstrating increase in the height of articular eminence on the right side of TMJ (Fig. 64.20d)

Case 2 (Fig. 64.21a–d)

Patient A 54-year-old female, with pain in front of the ear and difficulty in closing the mouth following yawning

Preoperative open mouth OPG demonstrated bilateral TMJ dislocation (Fig. 64.21a)

OPG demonstrates:

- Displacement of condyle out of the glenoid fossa on both sides
- Condylar head is antero-superior to articular eminence

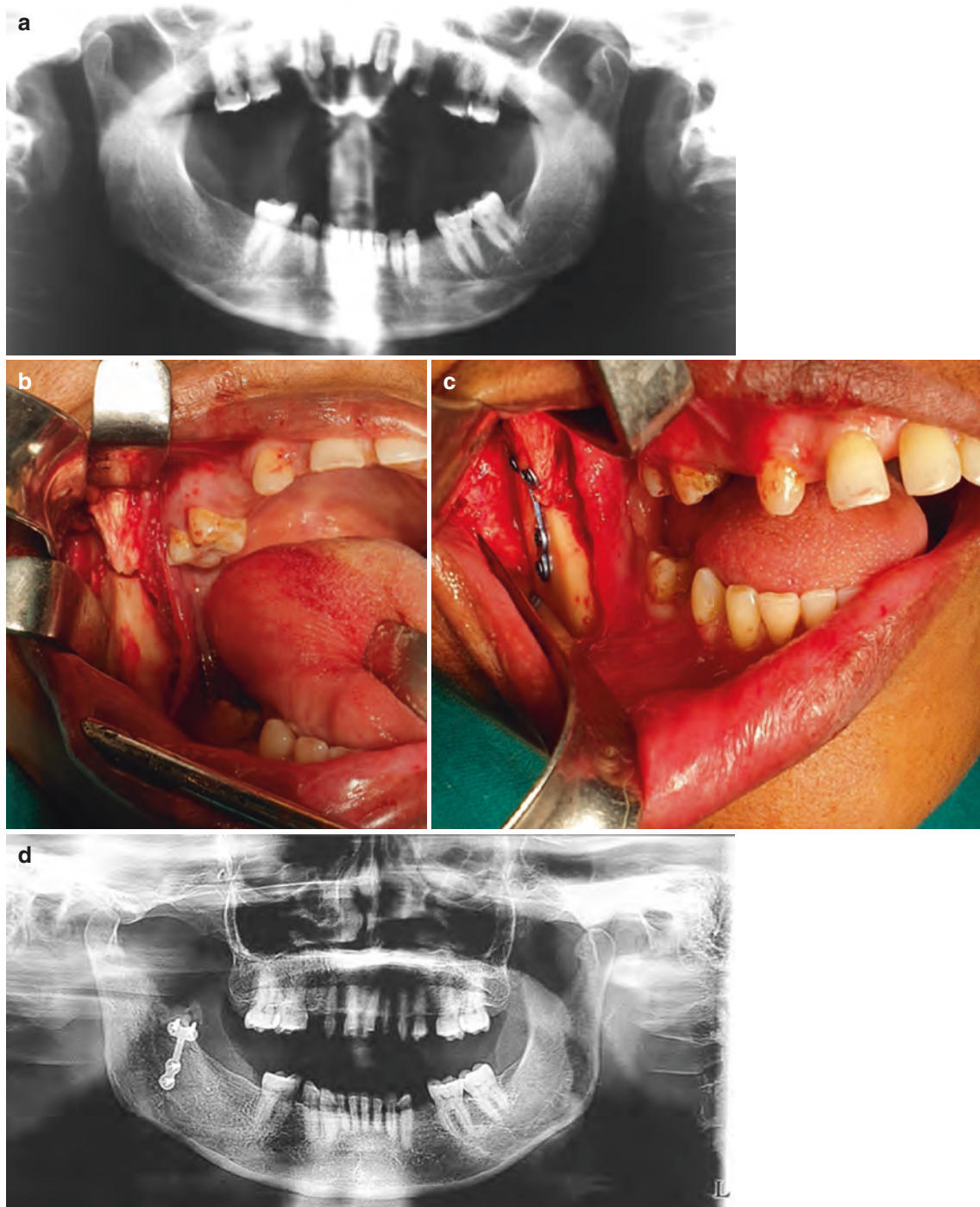
Surgical plan Inferior repositioning of the coronoid on the right side. The right side was chosen for surgery as the patient complained of more pain on that side

Surgical procedure

- Right coronoid was exposed through vestibular incision extending from lower second molar to anterior border of the ramus.
- Osteotomy cut was made from sigmoid notch to anterior border of the ramus (Fig. 64.21b).
- Trough was created on the lateral surface of the ramus just below the osteotomy cut.
- Coronoid was pulled down over the trough and fixed with miniplate (Fig. 64.21c).

Postoperative OPG (Fig. 64.21d)

Open mouth OPG demonstrating the condyle within the glenoid fossa on both the sides and coronoid fixed inferiorly on the right side



©Association of Oral and Maxillofacial Surgeons of India

Fig. 64.21 Case scenario 2 (a) Pre- op “open mouth” OPG showing bilateral dislocation of TMJ. (b) Osteotomy of coronoid. (c) Inferiorly positioned coronoid fixed with 2 mm miniplate. (d) Post -op “open

mouth” OPG showing normal positioning of condyle in relation to articular eminence

References

- Liddell A, Perez DE. Temporomandibular joint dislocation. *Oral Maxillofac Surg Clin North Am.* 2015;27(1):125–36.
- Shakya S, Ongole R, Sumanth KN, Denny CE. Chronic bilateral dislocation of Temporomandibular joint. *Kathmandu Univ Med J (KUMJ).* 2010;8(30):251–6.
- Awang MN. A new approach to the reduction of acute dislocation of the Temporomandibular Joint: a report of three cases. *Br J Oral Maxillofac Surg.* 1987;25:244–9.
- Marqués-Mateo M, Puche-Torres M, Iglesias-Gimilio ME. Temporomandibular chronic dislocation: the long-standing condition. *Med Oral Patol Oral Cir Bucal.* 2016;21:e776–83.
- Prechel U, Ottl P, Ahlers OM, Neff A. Clinical practice guideline: The treatment of temporomandibular joint dislocation—a systematic review. *Dtsch Arztebl Int.* 2018;115:59–64.
- Undt G. Temporomandibular joint eminectomy for recurrent dislocation. *Atlas Oral Maxillofac Surg Clin North Am.* 2011;19(2):189–206.
- Lowery LE, Beeson MS, Lum KK. The wrist pivot method, a novel technique for temporo-mandibular joint reduction. *J Emerg Med.* 2004;27:167–70.
- Chen YC, Chen CT, Lin CH, Chen YR. A safe and effective way for reduction of temporo-mandibular joint dislocation. *Ann Plast Surg.* 2007;58:105–8.
- Miller GA, Murphy EJ. External pterygoid myotomy for recurrent mandibular dislocation: review of the literature and report of a case. *Oral Surg.* 1976;42:705.
- Norman J, Ede B, Bramley P. A textbook and colour atlas of the temporomandibular joint. London: Wolfe Medical; 1990. p. 136–50.
- Sharma R. Modifications to Norman's procedure for hypermobility of the TMJ. *Med J Armed Forces India.* 2012;68(3):231–5.
- Iwanaga J, Nakamura Y, Kusakawa J, Tubbs RS. Eminectomy for habitual luxation of the temporomandibular joint with sedation and local anesthesia: a case series. *Case Rep Dent.* 2016;2016:2505864.
- Hall MB, Randall WB, Sclar AG. Anatomy of the TMJ articular eminence before and after surgical reduction. *J Craniomandibular Pract.* 1984;2:135–40.
- Segami N, Kaneyama K, Tsurusako S, et al. Arthroscopic eminoplasty for habitual dislocation of the temporomandibular joint: preliminary study. *J Craniomaxillofac Surg.* 1999;27(6):390–7.
- Pradhan L, Jaisani MR, Sagtani A, Win A. Conservative management of chronic TMJ dislocation: an old technique revived. *J Maxillofac Oral Surg.* 2015;14(Suppl 1):S267–70.
- Lee SH, Son SI, Park JH, Park IS, Nam JH. Reduction of prolonged bilateral temporomandibular joint dislocation by midline mandibulotomy. *Int J Oral Maxillofac Surg.* 2006;35:1054–6.
- Krishnakumar Raja VB, Balasubramanian S, Sridharan G, Tarun S, Panneerselvam E. Inferior Repositioning of Coronoid Process for the Treatment of Temporomandibular Joint Subluxation/Dislocation. *Ann Maxillofac Surg.* 2019;9(2):397–399. doi:10.4103/ams.ams_137_19
- Wolford LM, Pitta MC, Mehra P. Mitek anchors for treatment of chronic mandibular dislocation. *Oral Surg Oral Med Oral Pathol Oral Radiol Endod.* 2001;92(5):495–8.

Suggested Reading

- Yasso MM, Fahmy MH, Mohamad NS. Comparative study between Autologous Blood and Platelet Rich Plasma in Treatment of Recurrent Temporomandibular Joint Dislocation. *Alex Dent J.* 2018;43:101–107.

Open Access This chapter is licensed under the terms of the Creative Commons Attribution 4.0 International License (<http://creativecommons.org/licenses/by/4.0/>), which permits use, sharing, adaptation, distribution and reproduction in any medium or format, as long as you give appropriate credit to the original author(s) and the source, provide a link to the Creative Commons license and indicate if changes were made.

The images or other third party material in this chapter are included in the chapter's Creative Commons license, unless indicated otherwise in a credit line to the material. If material is not included in the chapter's Creative Commons license and your intended use is not permitted by statutory regulation or exceeds the permitted use, you will need to obtain permission directly from the copyright holder.



Sonal Anchlia

65.1 Introduction and Etiopathogenesis

Temporomandibular joint (TMJ) ankylosis is defined as bony or fibrous adhesion of the anatomic joint components accompanied by limitation of mouth opening, causing difficulty in mastication, speech, and oral hygiene. This may also influence symmetry of the facial skeleton, especially in cases which occur when patient is still in the growth phase [1].

According to Kaban [2], trauma is the most common cause (31–98%), followed by local or systemic infection (10–49%), and lastly any systemic disease (10%). Infection occurring in the joint commonly occurs due to spread from otitis media or mastoiditis or from the hematogenous route—tuberculosis, gonorrhoea, scarlet fever, etc. Systemic etiology may include ankylosing spondylitis, rheumatoid arthritis, or psoriasis.

Classically, hemarthrosis following trauma is the pathogenic factor for bone formation in TMJ ankylosis [3]. Condylar trauma may lead to hemarthrosis due to injury to the periosteum and capsular ligament. When this intracapsular hematoma organizes, hypertrophic bone is formed from the disrupted periosteum or metaplasia of non-osteogenic connective tissue. This may lead to hypomobility, and bony ankylosis may eventually develop.

Yan et al. in 2014 [4] put forth the hypotheses of hypertrophic nonunion. He described the sagittal fracture of condyle along with displacement of the disc. Herein, trauma also occurs in the glenoid fossa, thereby establishing the microenvironment in the articular surfaces for bone healing.

Electronic Supplementary Material The online version of this chapter (https://doi.org/10.1007/978-981-15-1346-6_65) contains supplementary material, which is available to authorized users.

S. Anchlia (✉)

Department of Oral and Maxillofacial Surgery, Government Dental College and Hospital, Ahmedabad, Gujarat, India

When the condylar trauma is recent, mouth opening will exert a dual effect on new bone formation. This is explained in Fig. 65.1. Restricted jaw movement is not a determinant but rather a promoting agent for ankylosis. Injuries to both the articular disc and the articular surfaces are prerequisites to TMJ ankylosis.

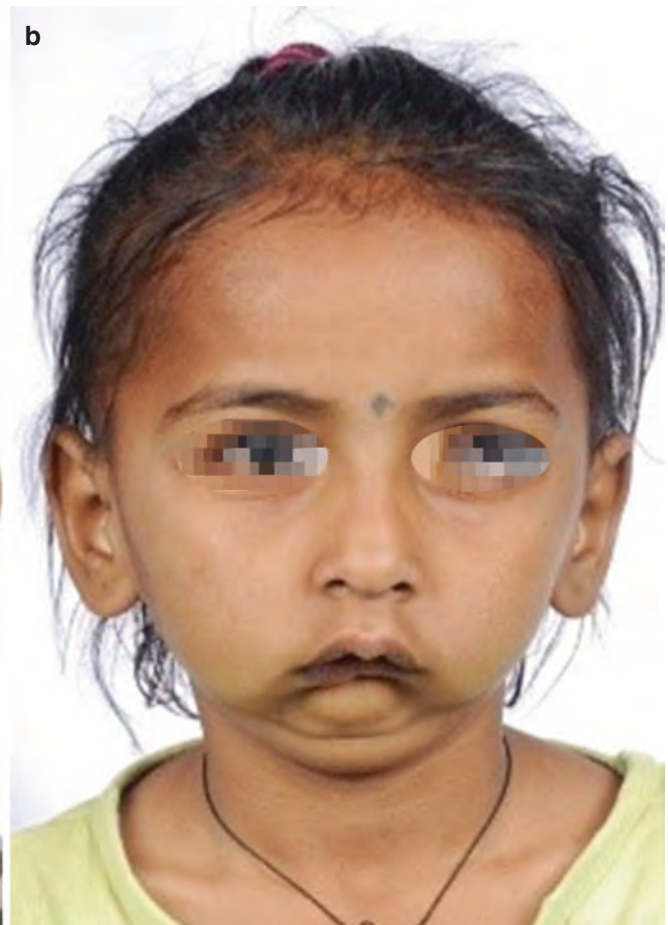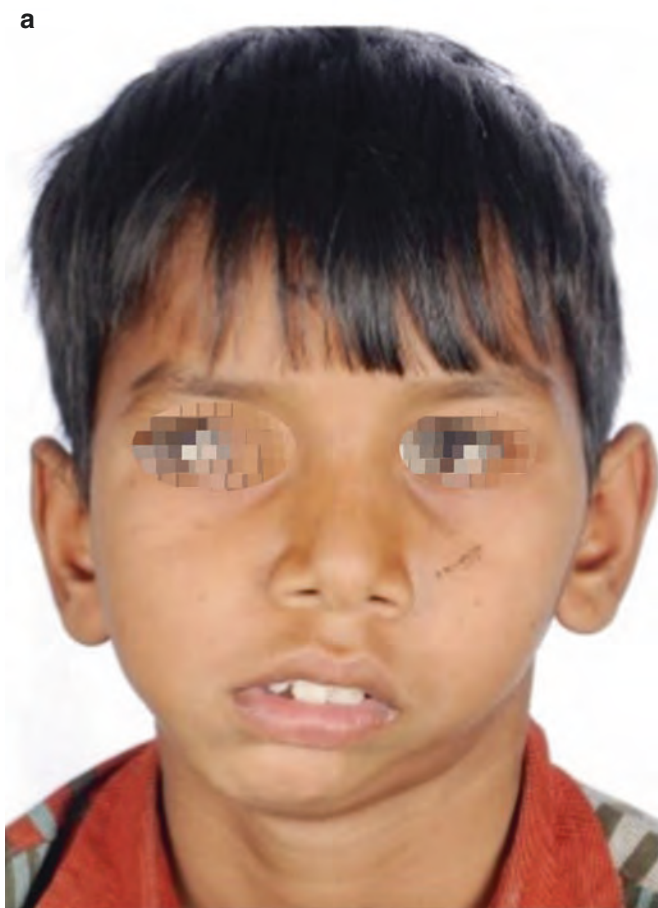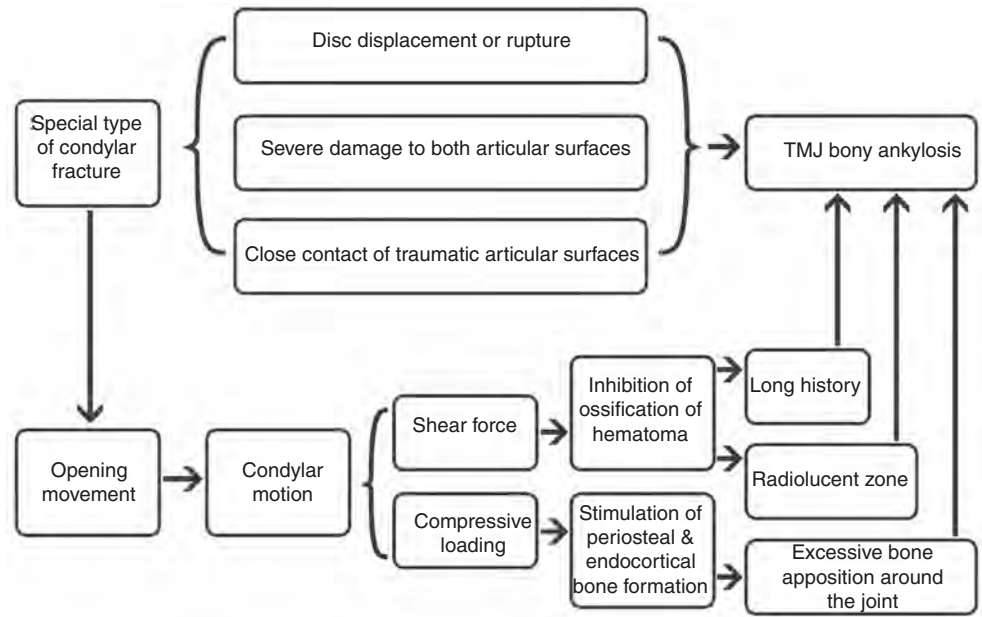
65.2 Clinical Features (Fig. 65.2)

In ankylosis, TMJ movements may be partially or completely restricted in opening, protrusion, and lateral excursions. Palpation of joint movements is better in fibrous than bony ankylosis. In children even in bony ankylosis, joint movements can be palpated because of stretching in the cranial sutures.

Ankylosis results in issues with mastication, digestion, speech, and oral hygiene. This may lead to caries, periodontitis, encumbered eruption of mandibular molars, crowding of teeth, and anterior open bite. Mandibular incisors often show supra-eruption and labial tipping as nature's compensation since the mandible is placed much posterior to the maxilla, thereby reducing lip competence. In severe cases, the lower lip may be trapped under the maxillary incisors.

As the vertical growth of the ramus is restricted, the lower face is significantly shortened. The digastric and mylohyoid muscles produce marked antegonial notching at the inferior part of the mandible just anterior to the insertion of the masseter and medial pterygoid. Failure of condylar growth impedes the forward and downward movement of mandible resulting in localized thickening of the bone at the angle due to subperiosteal apposition which accentuates the antegonion. The mandibular warping is caused due to this, as well as the obtuse angle between the inferior border of the mandible and the base of the skull [5]. The long-standing contractions of the masticatory muscles also give rise to elongation and thickening of the coronoid process, ramal shortening, and chin recession.

Fig. 65.1 Dual effect of mouth opening on new bone formation in recent condylar trauma



©Association of Oral and Maxillofacial Surgeons of India

Fig. 65.2 (a) Unilateral ankylosis of the right side, (b) bilateral ankylosis

In unilateral cases, the chin deviates to the affected side due to restricted mandibular growth on the affected side and normal growth on the unaffected side. In growing patients, this may also restrict ipsilateral growth of the maxilla, although there is normal growth on the unaffected side. In some cases, the growth of the maxilla on the affected side may be normal but that on the unaffected side may be excess, due to uninhibited growth of the normal side. Both these phenomena result in a maxillary cant, though on opposite sides.

In bilateral cases, the mandible is visibly retruded, lacks a chin and the patient presents with an obtuse cervicomental angle. The posterior maxillary height is shortened, giving rise to steep occlusal planes. This convex facial profile or the bird face deformity is also described as the “Andy Gump deformity.” Andy Gump was a cartoon character with a very insignificant chin, who first appeared in the Chicago Tribune in 1917, created by cartoonist Sidney Smith [6].

Worsened aesthetics of their appearance often becomes a reason for depressive disorders, psychological problems such as stubbornness, low self-esteem, and an inferiority complex.

The longer the duration of hypomobility, the more severe is the muscle atrophy and facial asymmetry. The prognosis for a favorable outcome with treatment is inversely related to the number of years of ankylosis.

65.2.1 Importance of Obstructive Sleep Apnea-Hypopnea Syndrome (OSAHS)

The presence of retruded mandible and micrognathia in patients with TMJ ankylosis creates narrowing of the pharyngeal airway space (PAS) with mechanical obstruction to respiration, more so in the supine position and during sleep. This process forms a complex syndrome of apneic episodes with significant reduction in the mean oxygen saturation levels and secondary cardiac and respiratory problems, known as OSAHS [7]. Therefore, for patients in whom the release of TMJ ankylosis is carried out without the advancement of the mandible for the correction of OSA, there is worsening of an already compromised airway. In such cases wide mouth opening during post-operative jaw exercises can lead to upper airway collapse—a sense of choking, bradycardia, and restlessness or apnea-like episodes, hence increasing chances of ankylosis [8].

65.2.2 Radiographic Features of Bony Ankylosis (Fig. 65.3)

According to Yan et al. [4], the deformed TMJ is characterized by an enlarged condyle, thickened temporal bone, excessive bone formation, and a radiolucent zone in the bony

fusion area. No scattered calcified dots are found in the radiolucent zone, showing that ossification occurs only in the existing bones.

Bony fusion is located in the lateral part of the joint with decreased/absent bone marrow cavity and osteosclerosis. The medial non-bony fusion area shows the atrophic condylar head and rudimentary joint space. Here, the morphology of the bone marrow cavity and bone mineral density is similar to that of normal bone.

Wu et al. [9] demonstrated that in fibrous ankylosis, there is fibrous tissue intruding into the bone marrow of the condyle as well as degeneration of the condylar cartilage. In bony ankylosis, there occurs new bone formation on the rough ankylotic surface of the condyle and slight bone degeneration.

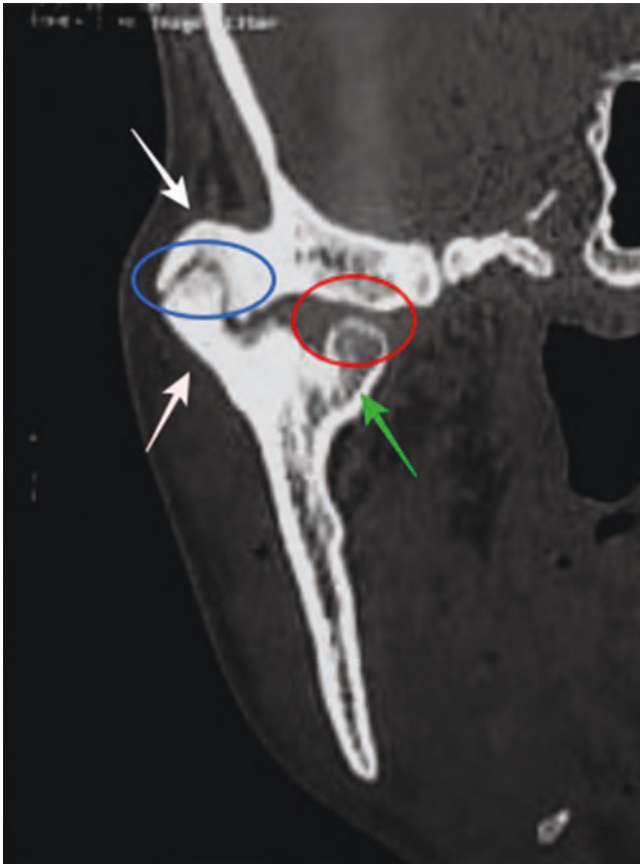
65.3 Classifications

Ankylosis has been classified by various authors according to its extent, site, development, heterotrophic bone formation, symptoms, and most recently, the extent of ankylosis guiding the treatment plan (Table 65.1).

65.4 Preoperative Assessment

65.4.1 Investigations

1. Detailed history, complete clinical examination, professional photographs, for documenting the:
 - (a) Age of onset of ankylosis
 - (b) Type, duration, and extent of ankylosis
 - (c) Type of joint injury or infection
 - (d) Maximal interincisal opening
 - (e) Dental characteristics and occlusion
 - (f) Type of facial deformity
 - (g) Previous surgery
2. Routine hemogram and pre-op major investigations
3. Radiological examinations for evaluation of extent of ankylotic mass, discrepancy of jaws, and treatment planning (Fig. 65.4)
 - (a) Orthopantomogram:
 - (i) Decreased joint space
 - (ii) Absence/presence of normal condylar and coronoid anatomy
 - (iii) Prominent antegonial notch
 - (iv) Markings for osteotomy cuts (for distraction)
 - (b) PA cephalogram:
 - (i) Chin deviation—Cg-ANS-Me (Crista Galli - Anterior Nasal Spine - Menton)
 - (ii) Occlusal cant
 - (iii) Grummon’s analysis



©Association of Oral and Maxillofacial Surgeons of India

Fig. 65.3 The computerized tomographic features of TMJ bony ankylosis. The blue circle refers to the bony fusion area located in the lateral part of the joint; in this area, a radiolucent zone can be observed. The red circle refers to the atrophic condylar head and rudimentary joint space located in the medial part of the joint. The green arrow indicates that bone mineral density and morphology of the bone marrow cavity in the non-bony fusion area were normal. The white arrows indicate excessive bone formation around the joint

- (c) Lateral cephalogram:
 - (i) Ramal length: Ar-Go (Articulare-Gonion)
 - (ii) Corpus length: Go-Pog (Gonion-Pogonion)
 - (iii) Pharyngeal airway space (PAS)
 - (iv) N perpendicular to Pog (Nasion perpendicular to Pogonion)
 - (d) Facial CT scan:
 - (i) Three-dimensional anatomy of bony morphology
 - (ii) Any anatomical measurements as and when required, e.g., size of ankylotic mass, location of ligula, airway space volume, etc.
 - (e) CT Angiography may be required to assess the relationship of internal maxillary artery to the ankylotic mass. There are chances of the vessel being inside the bone, especially in re-ankylosis cases.
4. Assessment of OSA may be done using Epworth sleepiness scale, Pittsburgh sleep quality index, and polysomnography (PSG) for:

- (a) Apneic-hypopneic index (AHI)
 - (b) Nocturnal desaturation episodes
 - (c) Average respiratory disturbance index
 - (d) Average lowest arterial oxygen saturation
5. 3D stereolithographic models printed, with the help of CT scan, may be used in treatment planning. Patient-specific surgical guides aid planning, precise control during operation, and thus more foreseeable treatment results.

65.4.2 Airway Implications of TMJ Ankylosis

65.4.2.1 Assessment

McNamara's airway analysis on lateral cephalogram helps to assess the PAS, CT provides volumetric assessment of the same, whereas PSG helps to assess the AHI. Moderate to severe AHI may require delayed extubation/tracheostomy.

65.4.2.2 Types of Intubation According to Clinical Situations

Blind nasal intubation was done historically, but it was traumatic, unpredictable, and unsafe. Tracheostomy is a traumatic experience, but nowadays, awake intubation is performed using midazolam and fentanyl [10]. Fiberoptic-assisted nasotracheal intubation has become the gold standard for such patients.

However, emergency tracheostomy during/after extubation may be required if:

- (a) Bilateral ankylosis release is performed, but RCU reconstruction for ramal height rehabilitation has not been done.
- (b) OSA is severe and release precedes mandibular advancement.

In these two situations, the mandible may fall back as there is no posterosuperior stop for the ramus and may impinge on the airway, causing further increase in OSA.

65.5 Surgical Anatomy [11]


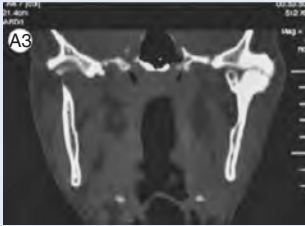
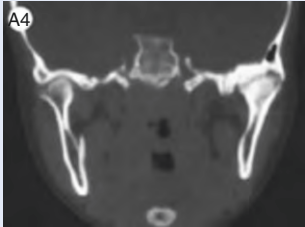
65.5.1 Nerve Anatomy (Figs. 46.6 and 65.5)

65.5.1.1 Facial Nerve

The main trunk of the facial nerve exits from the skull at the stylomastoid foramen. Approximately 1.3 cm of the facial nerve is visible until it divides into temporofacial and cervicofacial branches.

According to Al-Kayat and Bramley (1979) [12], the distance from the lowest point of the bony external auditory canal (EAC) to this bifurcation measures 1.5–2.8 cm (mean 2.3 cm). The postglenoid tubercle to the bifurcation measures 2.4–3.5 cm (mean 3.0 cm). However, the point at which the upper trunk crosses the zygomatic arch is the most vari-

Table 65.1 Classifications

I. Topazian (1964)	
<ul style="list-style-type: none"> • Stage 1: Ankylotic bone limited to the condylar process • Stage 2: Ankylotic bone extending to the sigmoid notch • Stage 3: Ankylotic bone extending to the coronoid process 	
II. Sawhney's classification (1986)	
<ul style="list-style-type: none"> • Type 1: Minimal bony fusion but extensive fibrous adhesions around the joint • Type 2: Bony fusion at the outer edge of the articular surface but no fusion on medial area of the joint • Type 3: Bridge of bone between the mandible and temporal bone • Type 4: Joint is replaced by a mass of bone 	
III. Turlington and Durr (1993)	
According to heterotopic bone formation within the ankylotic mass	
<ul style="list-style-type: none"> • Grade 0: No bone islands visible • Grade 1: Islands of bone visible within the soft tissue around the joint • Grade 2: Periarticular bone formation • Grade 3: Apparent bony ankylosis 	
Grades 1, 2, and 3 are further classified as symptomatic (S) and asymptomatic (A)	
IV. Recent advances: Dongmei He and Colleagues (2011)	
Type of Ankylosis	Suggested Treatment Plan
<ul style="list-style-type: none"> • Type A1: Fibrous ankylosis without bony fusion of joint • Type A2: Bony fusion on lateral side of joint, residual condyle bigger than half of condylar head on medial side 	<ul style="list-style-type: none"> • Ankylosis release temporalis muscle flap, costochondral graft • Lateral arthroplasty
	
<ul style="list-style-type: none"> • Type A3: Similar to A2 but residual condylar fragment is smaller than half 	<ul style="list-style-type: none"> • Resection of ankylotic mass, costochondral graft
	
<ul style="list-style-type: none"> • Type A4: Ankylosis with complete bony fusion of joint 	<ul style="list-style-type: none"> • Resection of ankylotic mass, costochondral graft
	
V. Recent advances: Yan and colleagues (2014)	
Based on its development, ankylosis can be classified into three phases:	
<ul style="list-style-type: none"> • Fibrous-chondral phase demonstrating fibrous tissue and chondrocytes occupied the joint gap • Chondral-calcified cartilage phase manifesting abundant chondrocytes, cartilage matrix, and neo-formative endochondral ossification in the joint space • Bone-cartilage phase showing compacted bone bridge in the lateral joint gap and cartilage in the medial joint gap 	

able in terms of distance. It may be anywhere from 8 to 35 mm anterior to the most anterior portion of the bony EAC (mean 2.0 cm). If the superficial layer of the temporalis fascia and the periosteum over the arch is incised within 8 mm, one can prevent injury to the upper trunk branches.

However, Miloro et al. [13] showed that the average distance anterior to bony EAC was 2.12 cm. (1.68–2.49 cm). His was an MRI-based study as compared to cadaveric dissection-based work of Al-Kayat and Bramley.

The temporal branch of the facial nerve emerges from the parotid gland and crosses the zygoma under the temporoparietal fascia to innervate the frontalis muscle in the forehead.

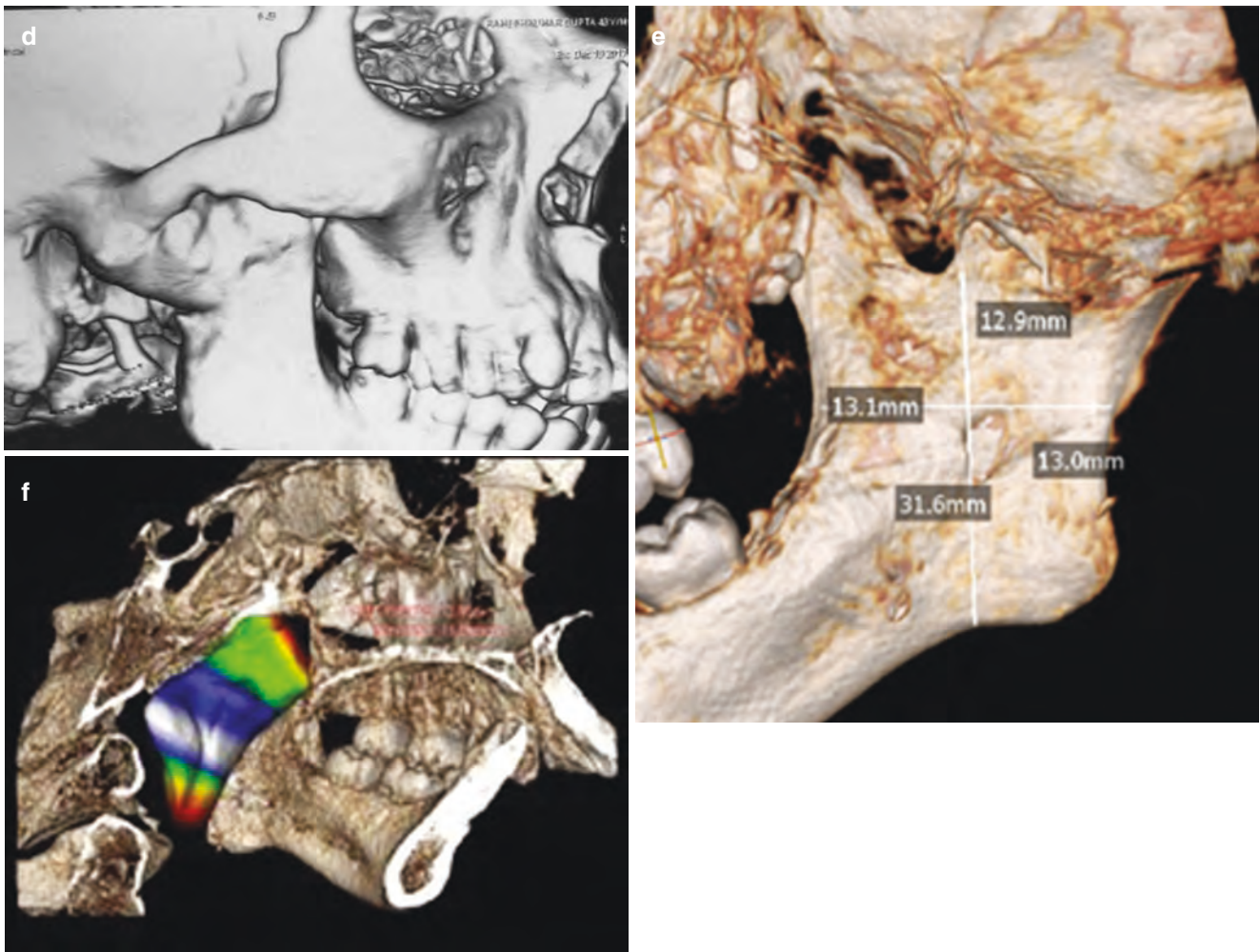
Postsurgical palsy manifests as an inability to raise the eyebrow and ptosis of the brow. Damage to the zygomatic branch results in paralysis to the orbicularis oculi. Nerve damage may necessitate either tarsorrhaphy or gold weight implants into the upper eyelid for gravity-assisted closure. Transcutaneous nerve stimulation may be helpful in cases of neuropraxia.

65.5.1.2 Trigeminal Nerve

The auriculotemporal nerve courses from the medial side of the posterior neck of the condyle and turns superiorly, running over the zygomatic root of the temporal bone.

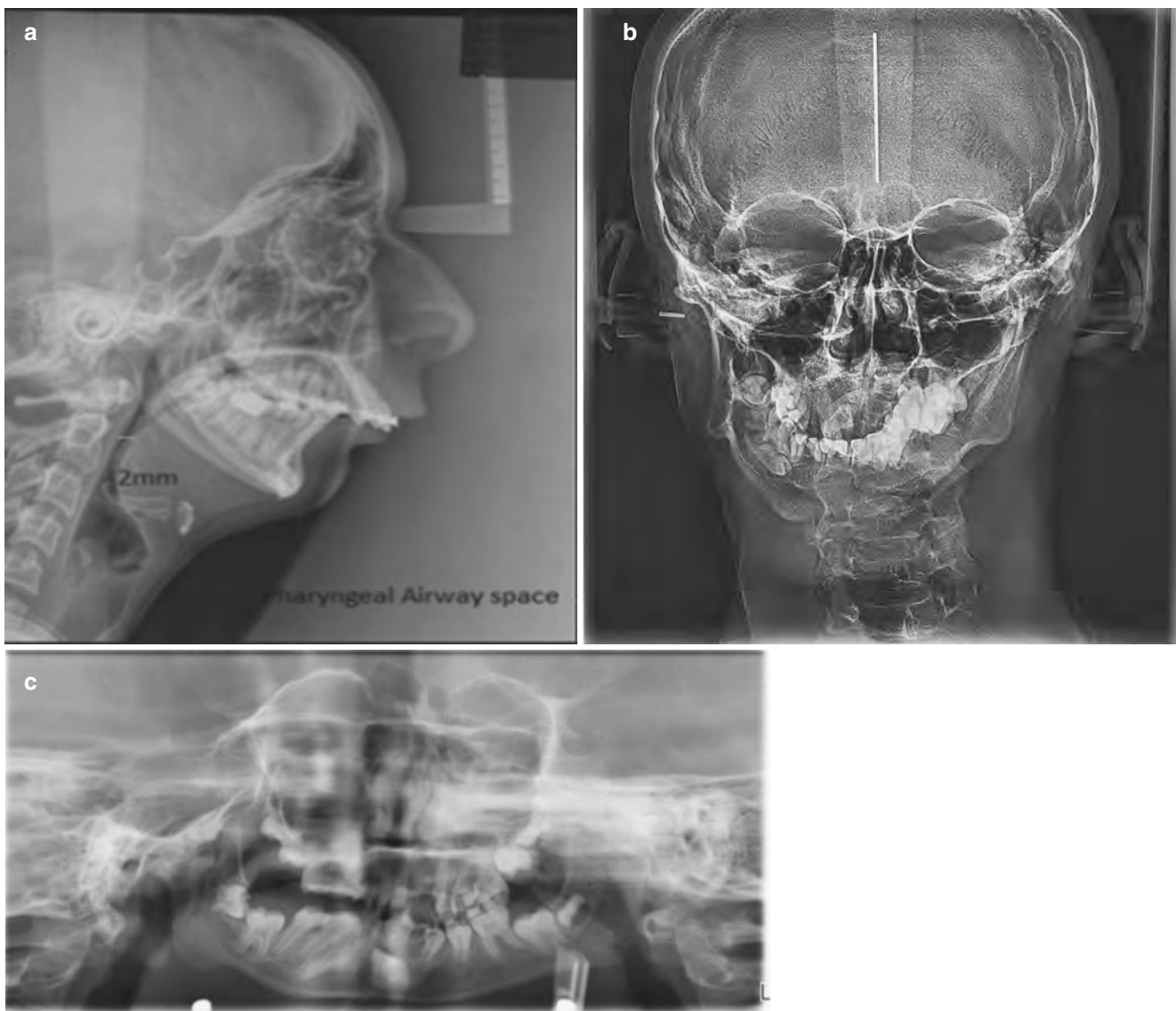

Fig. 65.4 (a) Lateral cephalogram, (b) PA cephalogram, (c) orthopantomogram, (d) facial CT scan, (e) facial cone beam CT, (f) volumetric assessment of pharyngeal airway space on CBCT



©Association of Oral and Maxillofacial Surgeons of India

Fig. 65.4 (continued)

Preauricular exposure of the TMJ area invariably injures the nerve. Damage is minimized by incision and dissection in close apposition to the cartilaginous portion of the external auditory meatus.

65.5.2 Vascular Anatomy (Fig. 65.5)

The superficial temporal artery and internal maxillary artery are the terminal branches of the external carotid artery. In the preauricular approach, the internal maxillary artery runs about 3 mm medial to the mid-sigmoid notch.

The most commonly injured artery during temporomandibular procedures is the middle meningeal branch of the internal maxillary artery. Pogrel [14] in a cadaver study of structures medial to the temporomandibular joint found the middle meningeal artery to be a mean of 31 mm (21–43 mm) medial to the zygomatic arch and a mean of 2.4 mm (2–8 mm) anterior from the height of the glenoid fossa.

65.5.3 Incisions (Fig. 65.6) [5]

65.5.3.1 Dingman's Preauricular Approach (Refer video on Pre auricular approach in Chap. 53 and Fig. 53.17)

It is the most commonly used incision with many variations. Classically, the incision begins along the course of the helix, just in front of the tragus till the attachment of the ear lobule. Going through the skin and superficial fascia, about 2 cm above the zygomatic arch, an oblique incision is made through the superficial layer of temporal fascia. Just above the arch, the periosteum of the zygomatic arch is incised and turned forward as one flap with the outer layer of the temporal fascia, superficial fascia containing nerves, and skin. The ankylotic mass now stands exposed.

65.5.3.2 Blair (1914)

It is like the Dingman's incision in preauricular fold, but unlike the former it bends in the region of the zygomatic arch

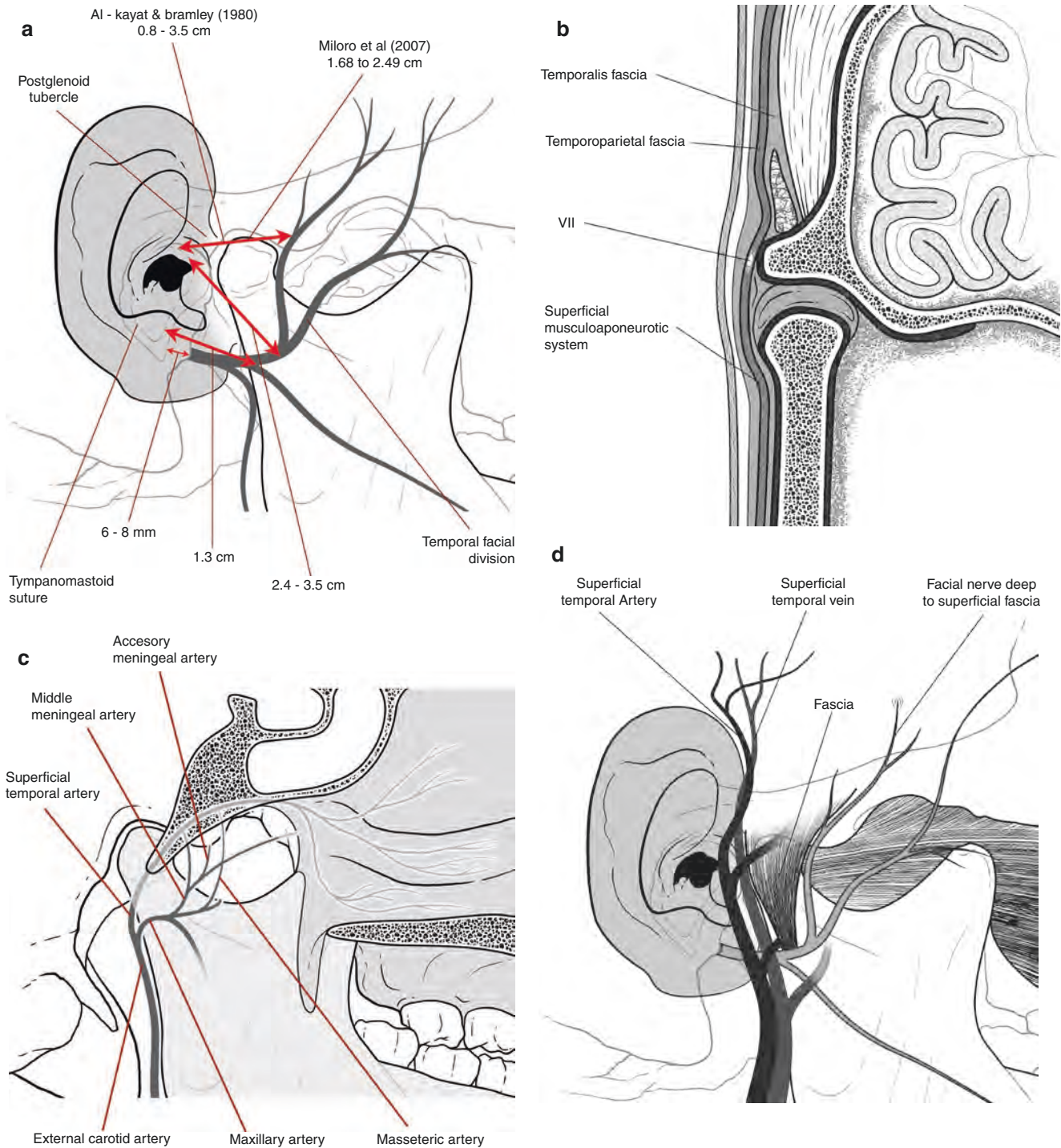
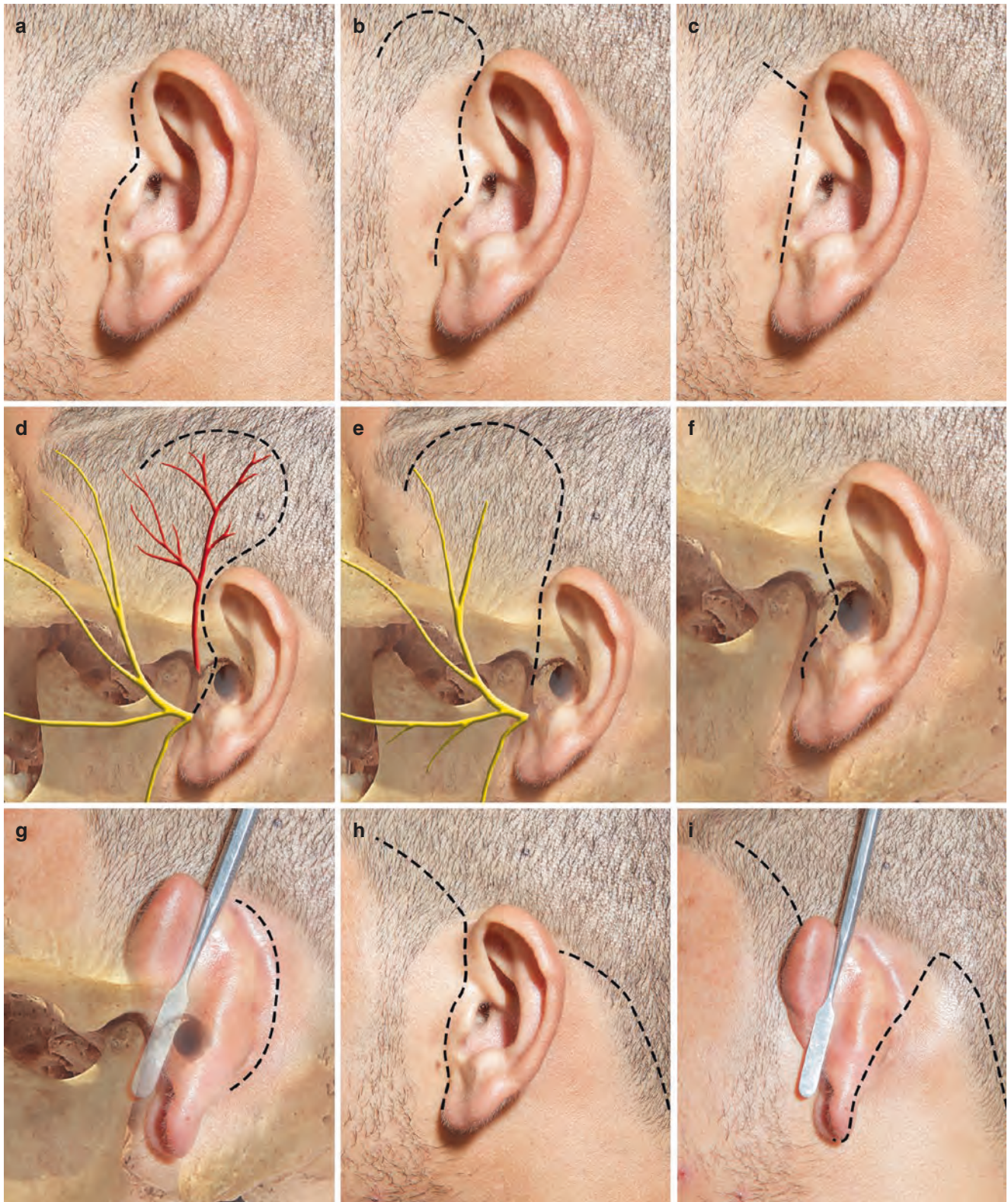


Fig. 65.5 (a) Surgical landmarks for identifying the location of main trunk of the facial nerve and the temporal-facial division during temporomandibular arthroplastic dissection. (b) Coronal diagram of the fascial layers and facial nerve at the level of the temporoparietal fascia. (c) View from medial aspect of the mandible. Note proximity of middle

meningeal, external maxillary, and masseteric arteries. Care should be taken to protect these structures at the level of the condylar neck and sigmoid notch during osteotomies. (d) Relative position of the superficial temporal artery and vein and the temporal branch of the facial nerve



©Association of Oral and Maxillofacial Surgeons of India

Fig. 65.6 (a) Dingman, (b) Blair's inverted hockey stick, (c) Thoma's, (d) Al-Kayat and Bramley, (e) Popowich's modification, (f) endaural, (g) postauricular, (h) rhytidectomy, (i) retro-auricular limb of rhytidectomy incision

like a hockey stick. The disadvantages include an unsightly scar and possible damage to the frontal branch of the facial nerve.

65.5.3.3 Thoma (1945)

The vertical limb is in the preauricular fold but angulated at 45° in the hairline near the bifurcation of the superficial temporal vessels.

65.5.3.4 Al-Kayat and Bramley (1979) (refer video on Al Kayat Bramley approach in Chap. 53)

This reverse question mark cosmetically acceptable incision gives excellent access to the TMJ without causing any damage to important anatomical structures. It starts superiorly through the scalp in the temporal region and extends to the inferior tragus. The superficial layer of the temporalis fascia is identified and incised at the root of the arch at 45° anterosuperiorly to avoid branches of the facial nerve. A vertical incision may be used if the temporalis fascia or muscle is to be used.

65.5.3.5 Popowich's Modification of Al-Kayat and Bramley [5]

This approach to the zygomatic arch and joint gives excellent visibility with safety. It is longer and wider than the conventional and question mark shaped and begins about a pinna's length away from the ear, anteroposterior just within the hair line, curves backward and downward well posterior to the main branches of the temporal vessels, till it meets the upper attachment of the ear.

65.5.3.6 Endaural [10]

This was first described by Rongetti in 1954, with the incision carried in the external ear. The advantages are good aesthetics and excellent access to the TMJ. However, the disadvantages include perichondritis, infection, paresthesia of the pinna, and deformity of the ear.

65.5.3.7 Coronal Extension of Preauricular Incision

The anterosuperior extension over the scalp of the preauricular incision gives a more aesthetic scar.

65.5.3.8 Rhytidectomy [10]

The endaural incision is extended in a curvilinear fashion around the mastoid tip, with an S-shaped extension ending in a submandibular incision. This allows access to the entire posterior border of the mandible and allows for identification of the main trunk of the facial nerve.

65.5.3.9 Postauricular

First described by Alexander [15] in 1975, its biggest advantage is that it avoids facial nerve injury and salivary fistula. However, possible complications include stenosis

of external auditory canal, infection, and paresthesia of the pinna.

65.6 Treatment Protocol

Kaban [2] and colleagues described an approach for the treatment of TMJ ankylosis to minimize the incidence of re-ankylosis and produce satisfactory movement of the joint. Their study in 1990 became a landmark management protocol for the management of TMJ ankylosis (Table 65.2).

Yet again in 2009, Kaban [16] considered the potential effect of time and growth (i.e., the fourth dimension) on the outcome of TMJ ankylosis in children and presented another protocol (Table 65.2).

65.6.1 Surgical Options for Ankylosis Release (Fig. 65.7a–c)

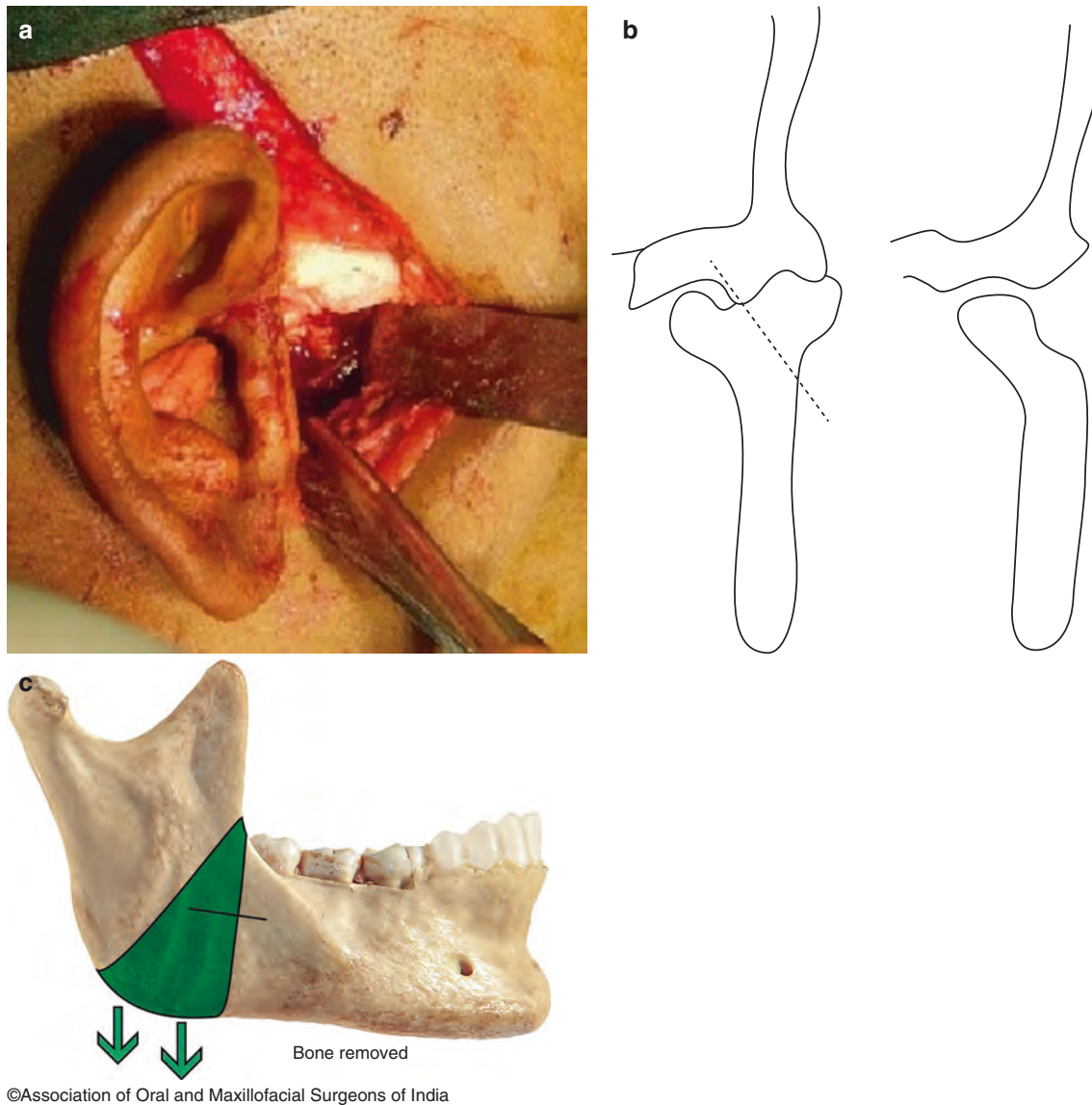
History Ankylosis release surgeries, i.e., various ways of separation of the ramus from the skull have undergone great evolution during the nineteenth century. Esmarch [17] osteotomized the angle to release TMJ ankylosis in 1851. The first interpositional material was the pterygomasseteric sling, also developed by Esmarch. Condylectomy was first advocated by Humphrey in 1854. Abbe performed the first gap arthroplasty in 1880. But it was Topazian in the 1960s [18, 19] who signified the importance of interpositional grafts for reducing re-ankylosis.

65.6.1.1 Gap Arthroplasty

The conventional surgical treatment of TMJ ankylosis by gap arthroplasty includes complete resection of the ankylotic

Table 65.2 Kaban's protocols for TMJ ankylosis

1. Kaban's protocol for management of temporomandibular joint ankylosis (1990) [2]
(a) Aggressive resection of the ankylotic segment
(b) Ipsilateral coronoidectomy
(c) Contralateral coronoidectomy when necessary
(d) Lining the joint with temporalis fascia or cartilage
(e) Reconstruction of the ramus with a costochondral graft
(f) Rigid fixation of the graft
(g) Early mobilization and aggressive physiotherapy
2. Kaban's modified protocol for management of TMJ ankylosis in children (2009) [16]
(a) Aggressive excision of fibrous and/or bony mass
(b) Coronoidectomy on affected side
(c) Coronoidectomy on opposite side if steps 1 and 2 do not result in MIO of 35 mm or to point of dislocation of opposite side
(d) Lining of joint with temporalis fascia or the native disk, if it can be salvaged
(e) Reconstruction of RCU with either DO or CCG and rigid fixation
(f) Early mobilization of jaw; if DO used to reconstruct RCU, mobilize day of surgery; if CCG used, early mobilization with minimal intermaxillary fixation (not > 10 days)
(g) Aggressive physiotherapy



©Association of Oral and Maxillofacial Surgeons of India

Fig. 65.7 (a) Gap arthroplasty, (b) Lateral arthroplasty (LAP), (c) Esmarch's procedure

mass with no soft tissue as an interposition between two cut ends. When a soft tissue is placed between the cut ends, it is known as interpositional arthroplasty. Gap arthroplasty is a relatively simple procedure requiring less operative time; however, it may cause ramal shortening, malocclusion, OSA, and, most distressingly, re-ankylosis. But it may still be used in certain adult patients, where the removal of a small ankylotic mass would not decrease the ramal height significantly.

Patients are operated under general anesthesia using a preauricular approach. After the ankylotic mass is exposed, the upper cut is marked, and the lower cut is placed 1.5 cm below it. In cases where normal architecture of the joint is maintained, the lower osteotomy cut is placed from the anterior to the posterior border of ramus just below the sigmoid notch. In cases where normal architecture is not clear, a cut

is placed 1.5 cm below the lower border of zygomatic arch. Then the upper cut is completed, and the ankylotic mass is removed. The osteotomy is directed at 45° to prevent fracture of middle cranial fossa. The venous plexus if encountered medially needs only be packed to control bleeding.

A condylar retractor is kept below the ankylotic mass to prevent injury to the internal maxillary artery. Bone is cut initially using a bur/saw/piezoelectric unit through two thirds of its thickness. The remaining one thirds may be removed with an osteotome. A Piezoelectric unit if used, may cut bone till its very end. In case of a larger mass, it may also be removed in pieces. The ipsilateral coronoid process is always resected. Care is always taken to stop the application of Heister's mouth gag intraoperatively just before the opposite condyle dislocates.

In some patients with longstanding ankylosis, the coronoid process of the opposite site becomes hyperplastic. There may also occur fibrosis of the masseter, which would restrict jaw movements further. Thus, not only would the contralateral coronoidectomy be required, but the masseter attachment would also need to be completely dissected off the zygomatic arch. A coronoidotomy may not be adequate, as it may reform and attach again to the temporalis and subsequently cause decrease in mouth opening. An intact disc may not require another soft tissue interpositional graft but may itself be mobilized and repositioned into the new glenoid fossa.

R. F. Elgazzar [20] reviewed 101 patients (109 joints) and, on follow-up, reported that in comparison with other techniques of ankylosis release, gap arthroplasty had the least amount of mouth opening. Interpositional arthroplasty with temporalis gives better results in comparison.

Surgical navigation systems are useful in TMJ ankylosis surgery as they improve both the safety and accuracy of the surgery. The distance from the top of the glenoid fossa to the middle cranial fossa and that from the posterior margin of the fossa to the anterior border of the bony external auditory canal can be monitored via the navigation system. A safety distance of at least 3 mm from the middle cranial fossa and bony external auditory canal should be maintained to avoid injury. It reduces the risks of bleeding and CSF leak [21].

65.6.1.2 Esmarch's Procedure

This is of historical significance only. Esmarch [22] made a small incision posterior to the angle of the mandible and dissected the masseter and medial pterygoid muscles off the bone. A 2.5 cm wide wedge of bone, at the angle of the mandible with apex at upper border and base at the posteroinferior border, was removed. The muscles were then sutured back.

The disadvantage is that since the osteotomy is in the ramus, no ramal osteotomy or distraction can be done for correction of facial deformity. Hence, it is no longer used for ankylosis release.

65.6.1.3 Lateral Arthroplasty (LAP)

Nitzan hypothesized that in Sawhney's [3] Type II TMJ ankylosis or He's Type A2 [23], if the integrity and location of the displaced condyle and disc can be determined (despite morphological and positional alterations), both could be preserved to fulfill their roles in mandibular growth and function. Only the lateral part of the ankylosed mass was resected. Eight young patients were kept under observation for a period ranging from 6 to 60 months after surgery. She found significant improvement in facial symmetry and thereby concluded that the residual condyle retained its own growth potential and helped maintain normal mandibular movement function and occlusion [24].

Yang and Dongmei He evaluated long-term results after LAP in nine growing children and concluded that the residual condyle continues to grow after LAP. This then decreases the amount of further facial asymmetry [25].

65.6.2 Arthroplasty with Ramus-Condyle Unit (RCU) Reconstruction (*Details Covered Under "Hard Tissue Interposition"*)

Interpositional arthroplasty with RCU reconstruction is the procedure of choice in recent times. The procedure consists of:

- (i) Removal of the ankylotic mass.
- (ii) Reconstruction of the RCU may be considered from amongst any of the following in costochondral graft, coronoid process graft, distraction osteogenesis (DO), total alloplastic joint replacement.

Early postoperative exercises and appropriate physiotherapy are essential to prevent re-ankylosis, adhesions, and soft tissue contracture and to regain normal function of the muscles. Dynamic mouth opening exercise initiated in the immediate postop period by achieving pain control using local infiltration of bupivacaine. Dynamic mouth exercises would have to be continued for at least 6 months after surgery.

65.7 Soft Tissue Interpositional Materials (Video 65.1)

65.7.1 Temporalis Myofascial Flap (Fig. 65.8d, e)

Historically, it has been the most commonly used material for interpositional arthroplasty as it is simple in technique and in the vicinity of the original area of surgery. An inferiorly based pedicled composite (fascia and muscle), temporalis myofascial flap is raised supraperiosteally which is finger shaped and about 5 × 2 cm. The flap is taken either over/under the zygomatic arch and sutured medially and posteriorly. However, its potential disadvantages include an extended incision, temporal hollowing, increased chances of facial nerve injury, inability to be used again in cases of re-ankylosis, and myofascial pain secondary to muscle flap compression.

Albert and Merrill described the use of a posterior temporalis myofascial flap to prevent a visible anterior flap hollowing [26]. Pogrel and Kaban used an axial patterned temporalis myofascial flap, based on a branch of the middle temporal artery [27].

65.7.2 Dermal Fat Graft (Fig. 65.8a, b, c)

The abdominal dermal fat graft is harvested from the suprapubic area using an elliptical incision of around 7 × 3 cm. The fat is then de-epithelized to procure a volume of 6–20 ml. About 20–30% excess is taken than the actual requirement. The graft is folded onto itself with the dermis surfaces apposed.

It can be procured quickly and easily with a hidden scar. It is easy to sculpt into the gap after ankylosis release.

Minimal heterotopic calcification is the advantage of dermal fat graft. However, since this is a non-vascularized graft, it may be prone to resorption.

Dimitroulis presented his study on dermal fat grafts. After a mean follow-up of 41.5 months, only 1 out of the 13 joints reported recurrence of ankylosis [28]. Thangavelu presented a review of eight ankylosed joints treated using full-thickness skin subcutaneous fat grafts and concluded that they were safe and effective [29].

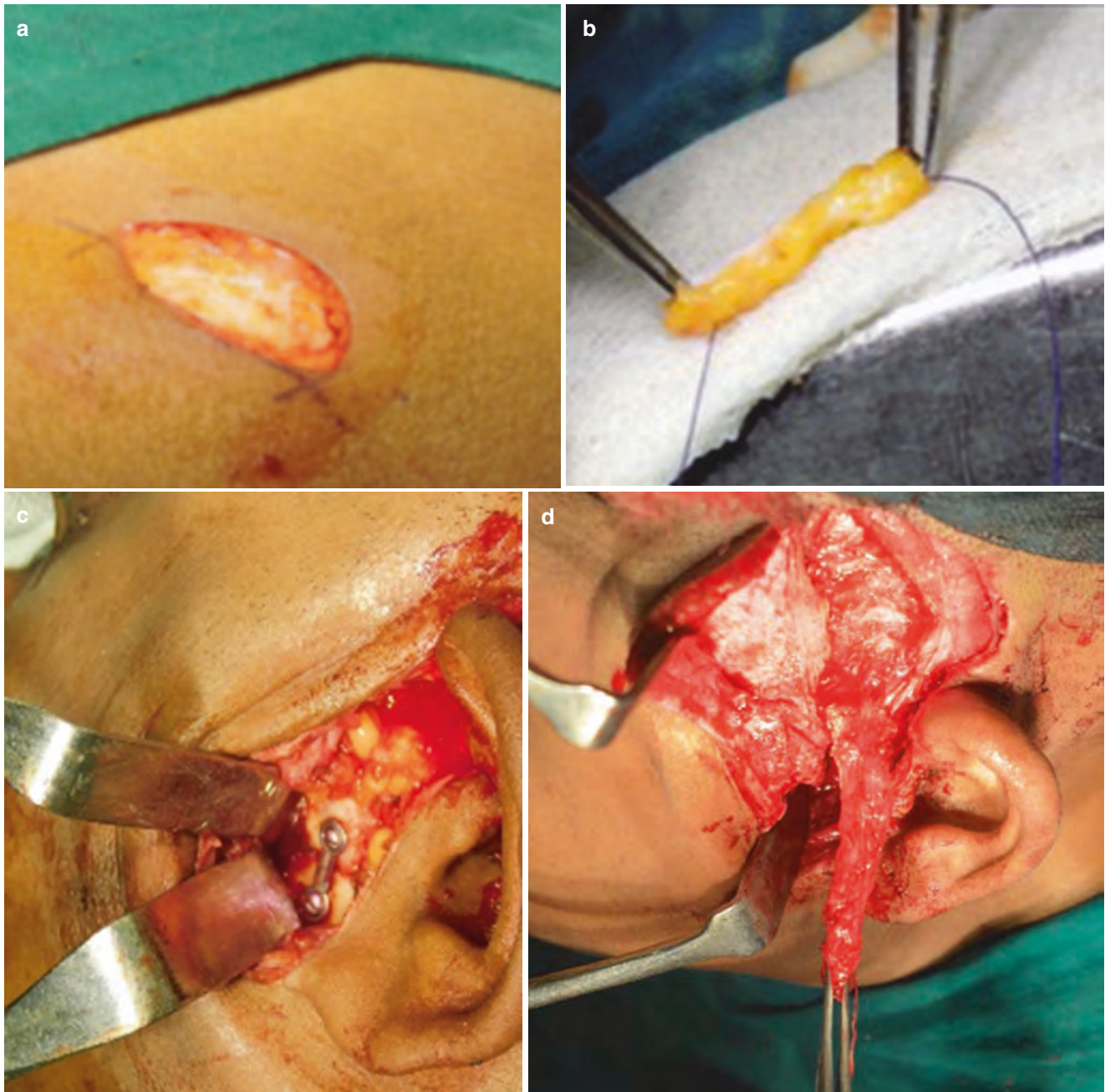
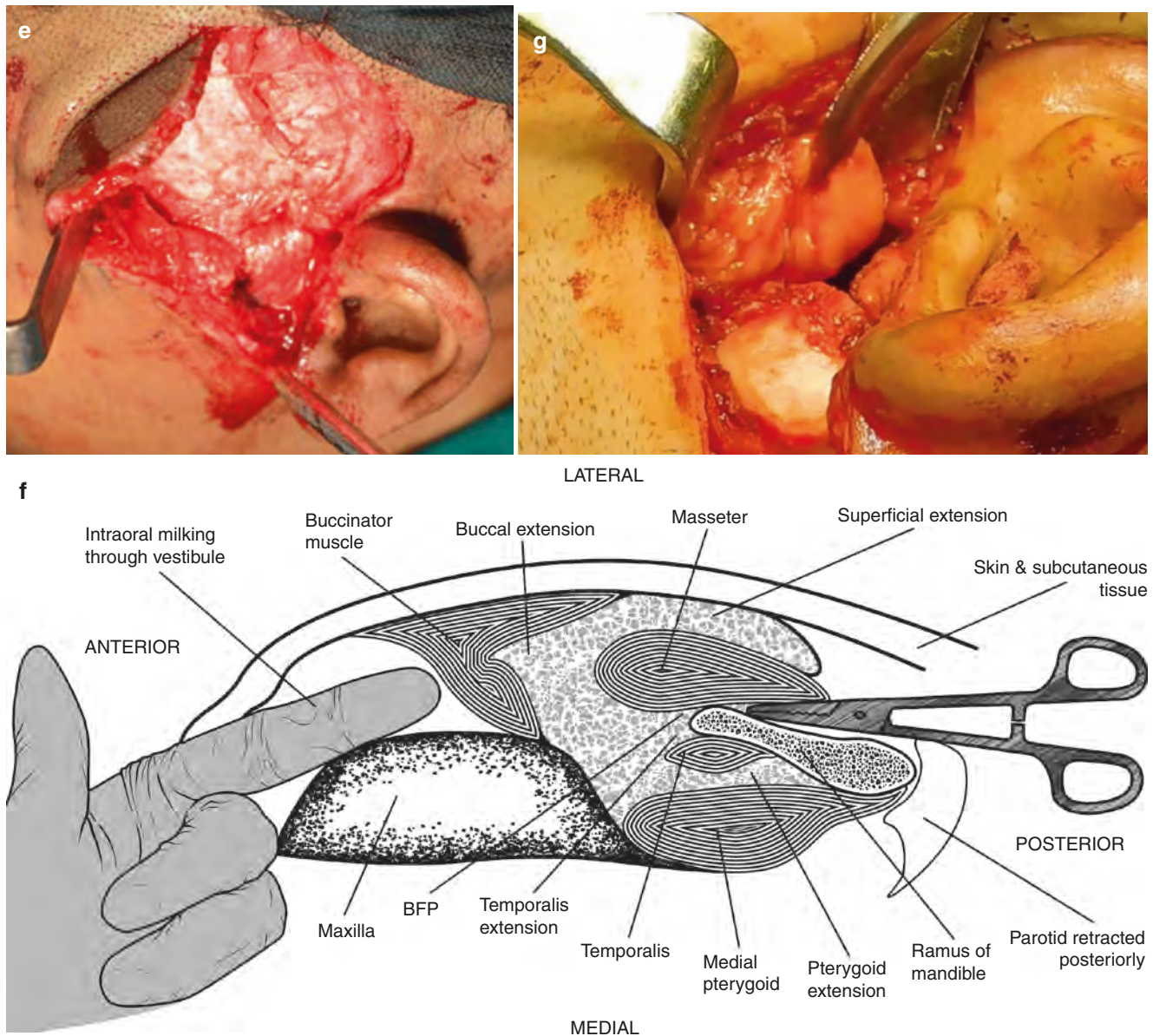


Fig. 65.8 (a) Abdominal fat graft donor site and (b) harvested graft, (c) abdominal fat graft in place, (d) harvested temporalis flap, (e) temporalis flap in place, (f) maneuver for harvesting buccal fat pad, (g) harvested buccal fat pad



©Association of Oral and Maxillofacial Surgeons of India

Fig. 65.8 (continued)

65.7.3 Buccal Fat Pad Graft (BFP) (Fig. 65.8f, g)

After the coronoid process is removed, dissection may be performed along the anterior border of ramus. The main part and temporal extension of buccal fat pad are in close approximation to the coronoid process and tendon of the temporalis. Thus, incising through the periosteum and fascial envelope of BFP at the anterior most edge of the coronoid stump/superior most stump of anterior border of ramus exposes the yellowish buccal pad of fat.

Further blunt dissection is performed to herniate the BFP into the defect with a little teasing and simultaneous milking of maxillary buccal sulcus intraorally near second and third molar region. The main advantage is that its vascularity would maintain the volume of fat for a longer duration with minimal resorption.

Gaba et al. prospectively assessed the fate of BFP following interpositional arthroplasty in 23 joints. In 18 cases, BFP was viable even after 1 year [30]. Refer Chap. 24 for detailed anatomy of the Buccal fat pad.

65.7.4 Amniotic Membrane

The amniotic membrane, being a natural biologic entity, prevents inflammation, reduces scarring, and promotes healing and re-epithelialization. It also has pluripotent, non-antigenic properties. Akhter M. et al. used gamma radiation sterilized and freeze-dried amniotic membranes in 13 patients of TMJ ankylosis and showed that it prevented recurrence of ankylosis [31].

65.7.5 Auricular Cartilage

Parko in 1973 first published the use of aural cartilage to replace the meniscus. The biggest advantage of auricular cartilage graft is that it can be harvested from the same surgical field, remains viable and inert and takes the shape of the glenoid fossa.

However, there are studies that have reported adhesions between the auricular cartilage graft and the condyle, leading to re-ankylosis.

65.8 Hard Tissue Interpositional Materials (RCU Reconstruction)

65.8.1 Rationale for RCU Reconstruction

The goal of RCU reconstruction in TMJ ankylosis includes restoration of ramal height. This not only avoids occlusal discrepancies and deviation on mouth opening in unilateral cases but also anterior open bite in bilateral ankylosis. It also provides enough bone stock for future jaw corrective surgeries. The RCU may not contribute as much to facial aesthetics but impacts function greatly. In cases where RCU has not been reconstructed, the jaw deviates laterally when opening the mouth. When closing the mouth, tangential rather than vertical striking occurs on the occlusal surfaces, making mastication difficult.

Most importantly, in bilateral TMJ ankylosis after gap arthroplasty without RCU reconstruction, there are increased chances of OSA because the ramus falls back due to lack of posterosuperior stop. Also, it may be possible that restoring normal jaw movement and a symmetric mandible will allow future soft and hard tissue development. This would probably lead to decrease in facial asymmetry by giving as near normal anatomy as possible by restoration of growth spurts (Moss's functional matrix theory).

65.8.2 Options, Techniques, Advantages, and Disadvantages

65.8.2.1 Ankylotic Mass (Fig. 65.9a)

The ankylotic mass is recontoured and utilized to reconstruct the RCU and thereby restore the mandibular ramal height. All neocondyles after RCU reconstruction are fixed into position with miniplates/screws in the new glenoid fossa just 2 mm short of the soft tissue interpositional material after placing the patient into intermaxillary fixation (IMF).

R. Gunaseelan excised the ankylotic mass, recontoured and reimplanted it, and used it successfully for three cases of condylar reconstruction [32]. However, only if the ankylotic mass is resected as a whole (which poses greater risk to mid-

dle meningeal artery) can it be recontoured in an adequate size to reconstruct the RCU, hence the difficulty in routine use.

65.8.2.2 Coronoid Process Graft (Fig. 65.9b)

Khadka and Hu first reconstructed RCU using the coronoid process [33]. Reshaped, the coronoid process provides good bone of adequate quality and quantity to reconstruct the RCU. Its membranous origin leads to lesser resorption. Also, a secondary donor site is not utilized. However, as the coronoid is a nonvascular graft, there does exist a very real possibility of its resorption.

Gagan Mehta and Shadab Mohammad conducted a study on 20 cases and reported that there did occur resorption of the coronoid in most of the cases. However, that did not change mandibular function and occlusion [34].

Another method of using the coronoid process is to use it as RCU with its attachment to the temporalis kept intact. Most of the attachment may be stripped of, and only the anterior part of temporalis may be kept attached to the tip of the coronoid. It may cause less resorption as it would be a pedicled graft. Yiming Liu studied 48 patients and compared free vs. pedicled coronoid process grafts and proved that pedicled grafts showed less resorption on prolonged follow-up [35].

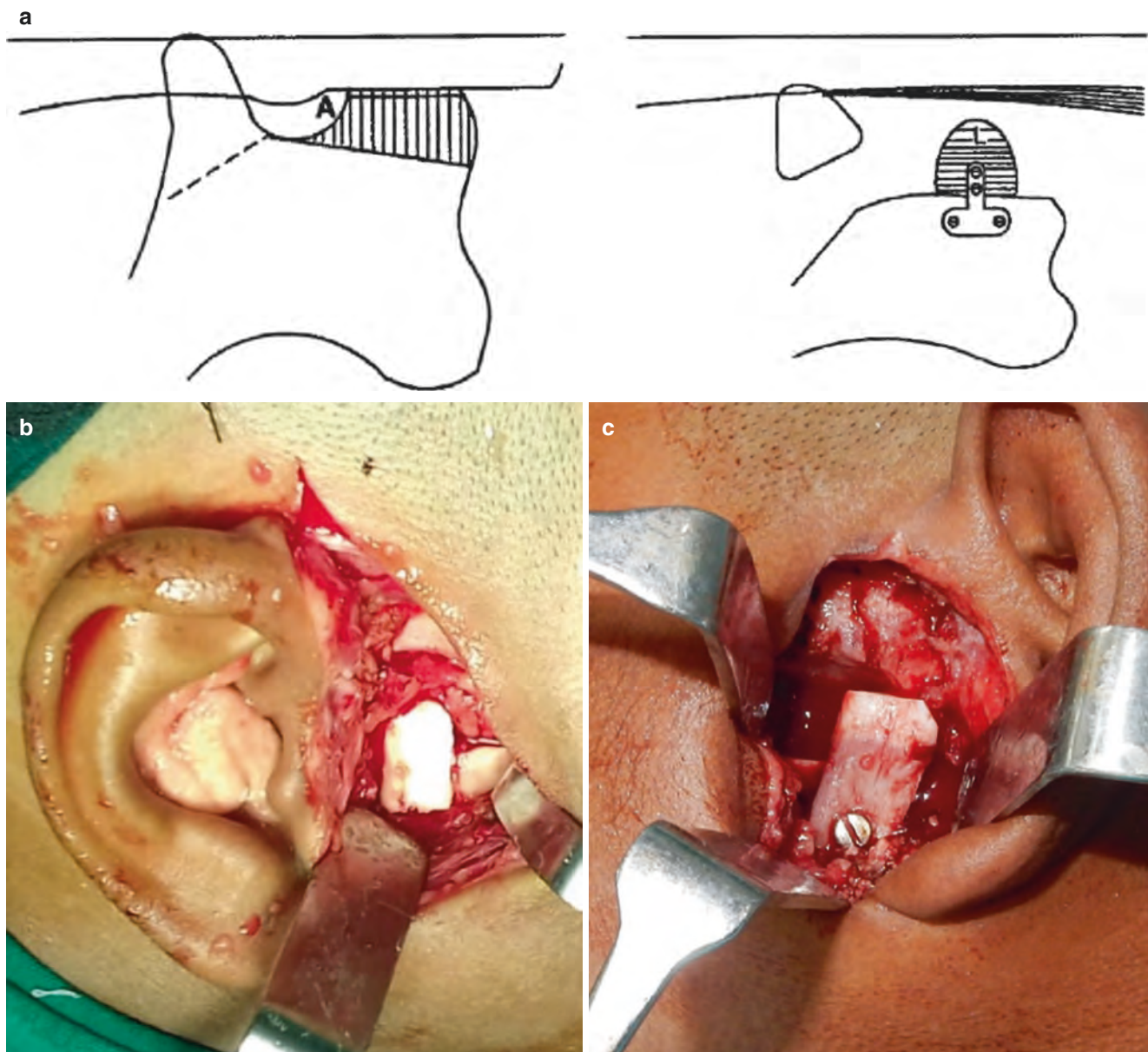
65.8.2.3 Costochondral Graft (CCG) (Fig. 65.9c)

Poswillo popularized the procedure for using CCG for TMJ ankylosis in 1987. In unilateral cases, CCG may be taken from the fifth rib using a submammary incision. If required on both the sides, alternate ribs, i.e., fifth and seventh, are used [36].

CCG has various benefits including its growth potential, its biological compatibility and the fact that it can remodel to form a new condyle. However, donor site morbidity, resorption or excessive growth on the treated side, and inability to catch up with the speed of growth on the normal side are its potential demerits. Perrott and Kaban [16] described two types of overgrowth—(a) linear overgrowth causing an

Box 65.1 Technical Tip

To maximize the chances of survival rate of CCG, the following techniques may be followed: meticulous dissection of periosteum and perichondrium, harvesting alternate ribs to prevent pain and pleural tear, retaining intact periosteum and perichondrium at costochondral junction, sectioning the chondral before the osseous part to reduce fracture at the costochondral junction, and only 2–3 mm chondral portion to prevent overgrowth.



©Association of Oral and Maxillofacial Surgeons of India

Fig. 65.9 (a) Ankylosis mass, (b) coronoid graft, (c) costochondral graft

asymmetric or bilateral prognathism and (b) tumor-like overgrowth causing re-ankylosis.

There are various controversies regarding which ribs and how much cartilaginous cap should be taken, how to fix, whether post-op IMF is required or not, and resorption vs. hypertrophy of the graft. Jean Salash reported that out of 72 cases, excessive growth occurred in 54% and equal growth occurred in 38% [37].

Hence, CCG may be used for RCU reconstruction in children less than 8 years of age with facial asymme-

try. The justification is that it may help in growth. However, if it overgrows, the overgrowth may be treated like condylar hypertrophy, and the superior 2–3 mm may be cut off.

Children less than 8 years but without facial asymmetry would probably not need a growth impetus, in which cases, a coronoid graft would be sufficient. In children more than 8 years of age, vertical ramus osteotomies may be used to recreate the RCU.

65.8.2.4 Ramus Osteotomy Pedicled Grafts

(Fig. 65.10a, b)

Y. Liu [38] used the method of total (Vertical ramus osteotomy—VRO) and partial (L-ramus osteotomy—LRO) sliding osteotomy on the posterior border of the ramus for reconstructing the mandibular condyle in TMJ ankylosis.

The chances of bony resorption and graft failure of the newly reconstructed RCU are greatly reduced as this segment is a pedicled graft with attachment to the medial pterygoid muscle and periosteum and is not a free graft. Hence the height of the ramus is maintained. This also leads to adequate bone stock for further corrective surgeries if and when so required.

For the VRO, the cut is made in a vertical direction starting from the sigmoid notch to the inferior border of the mandible just lateral to the lingula and parallel to the posterior border of the ramus. While retaining an adequate

amount of medial pterygoid, the proximal segment is pushed upward to recreate the RCU and plated in the new position. A small triangular chunk of bone just anterior to the osteotomy cut is resected to reshape the lower border and mandibular angle.

For the LRO, an L-shaped cut is made from sigmoid notch parallel to the posterior border of the mandibular ramus, just lateral to the lingula, till 10 mm above the angle of the mandible. The osteotomized segment is shifted upward and fixed with a mini plate creating a gap between the osteotomized segment and remaining mandibular angle. The coronoid process on the affected side is resected, recontoured, and fixed in that gap with another mini plate. The upper part of the ramus is then reshaped like a condyle.

LRO and VRO differ in the residual height of the ramus left after ramal osteotomy. In LRO it is retained, and in VRO it decreases due to the removal of the step at the inferior bor-

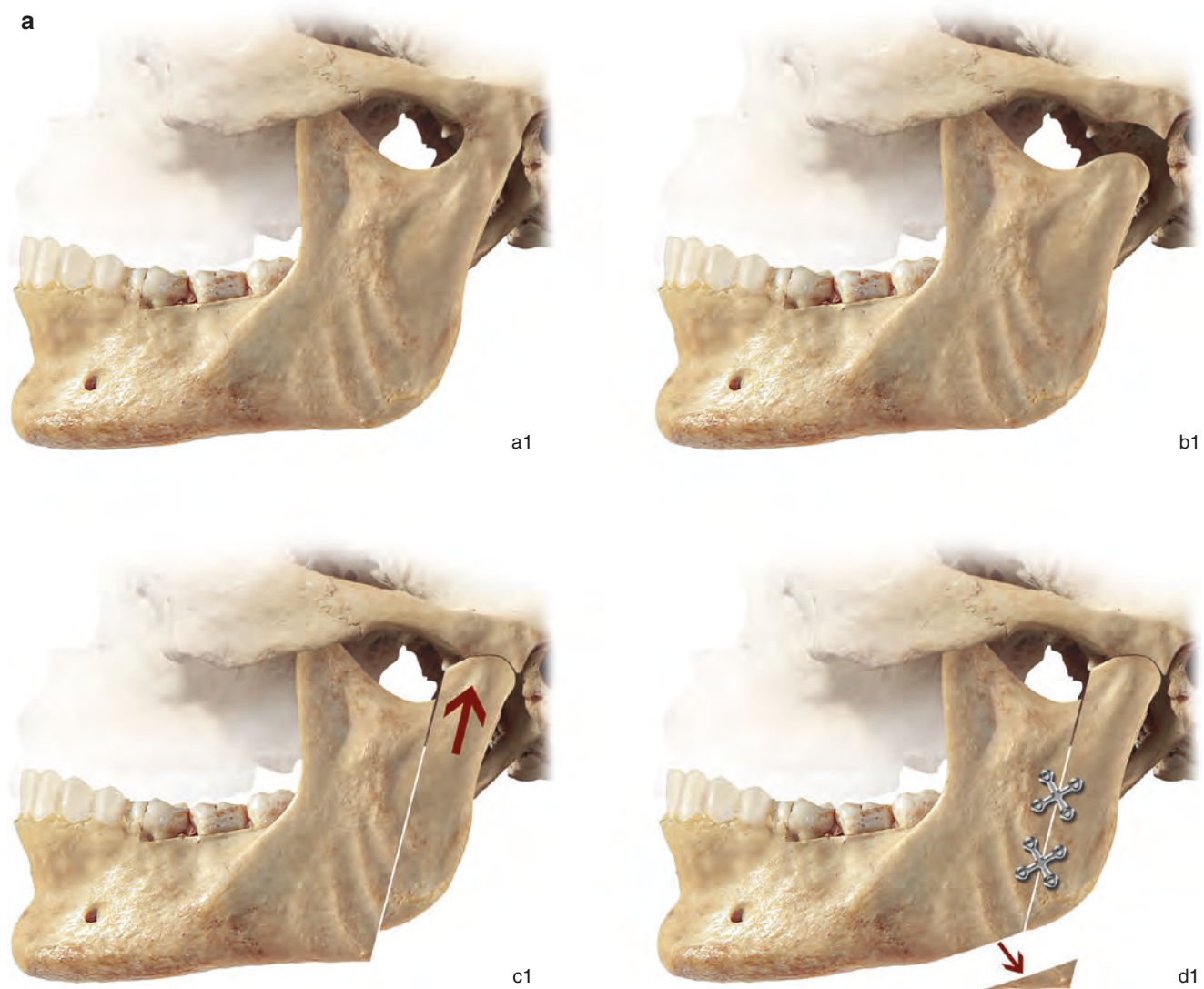
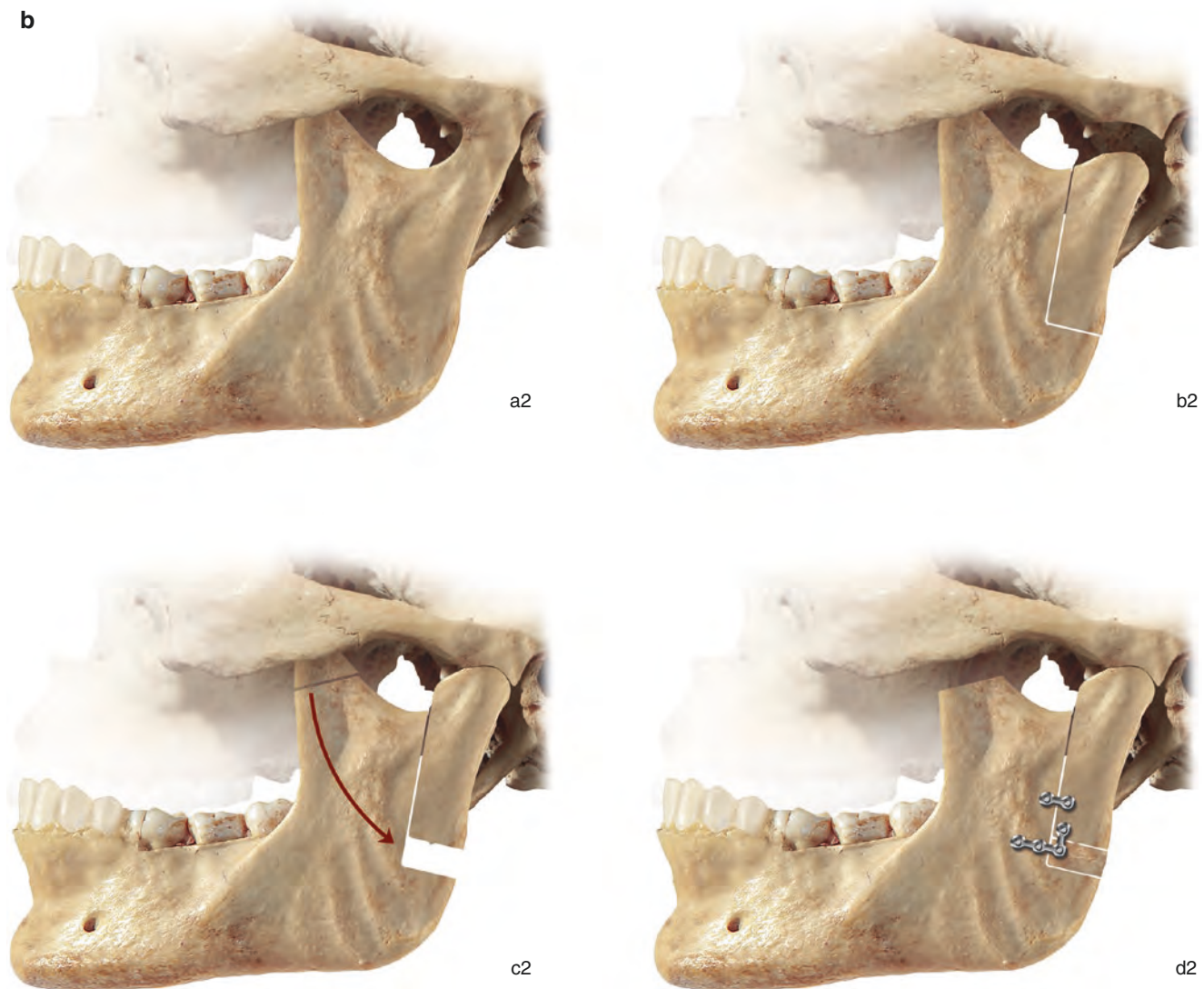


Fig. 65.10 (a) V Ramus osteotomy, (b) L Ramus osteotomy [38]



©Association of Oral and Maxillofacial Surgeons of India

Fig. 65.10 (continued)

der. Thus, VRO may be performed in cases where a pronounced antegonial notch is present.

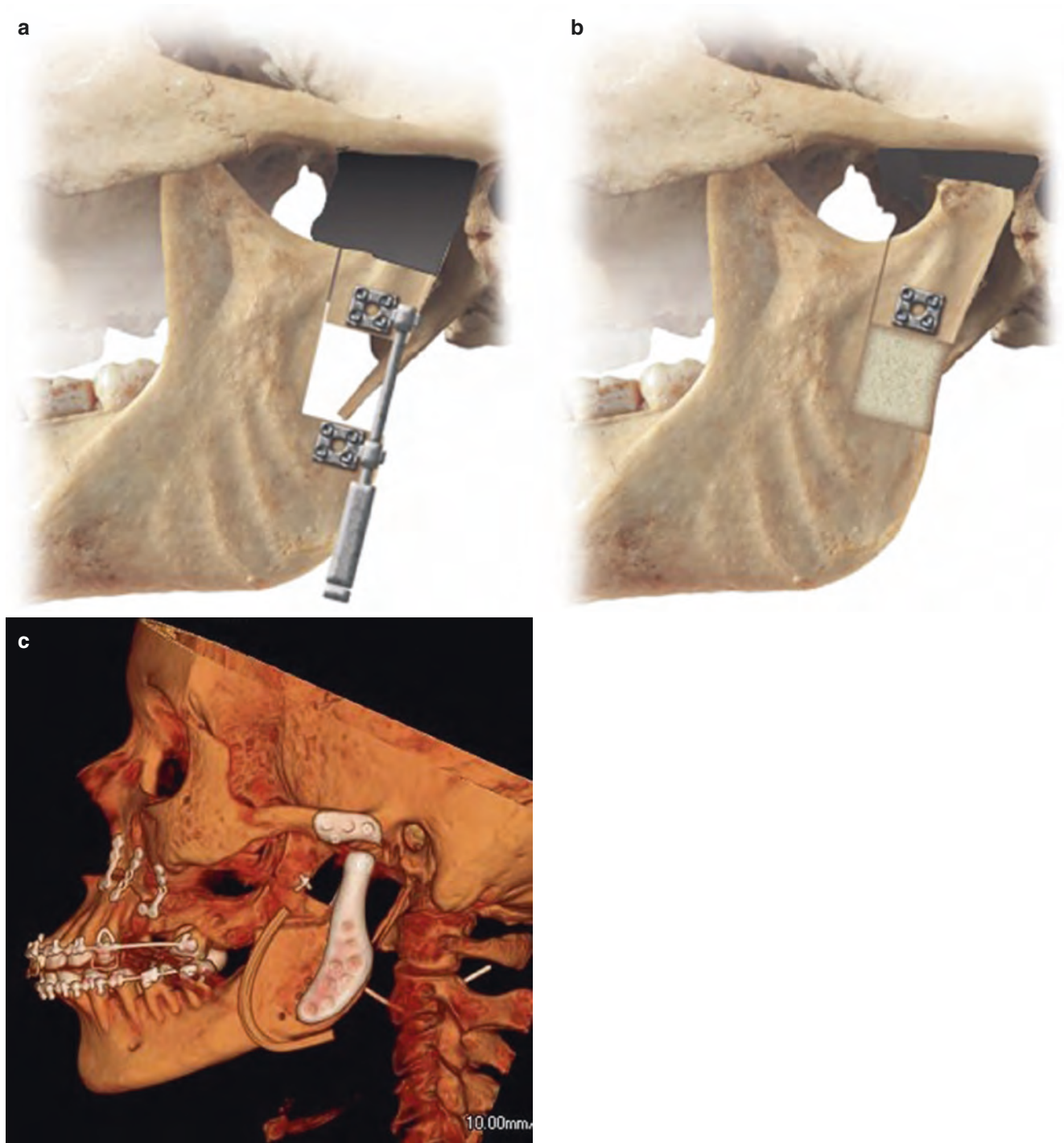
However, these osteotomies cannot be performed in patients less than 8 years because as observed on CBCT, the amount of bone behind the lingula is generally not enough to osteotomize the posterior border of the ramus.

65.8.2.5 Transport Distraction Osteogenesis (Fig. 65.11a, b) (Refer Chap. 87)

In multiple operated patients, scar tissue forms with each surgery, which may affect angiogenesis due to limited diffusion. Thus, free autogenous tissue grafts, such as costochondral and coronoid grafts often fail in such cases. Hence, transport distraction osteogenesis is considered as an option

for RCU reconstruction, especially in re-ankylosis cases in children. The same L osteotomy cut may be used to fix the distractor.

When RCU reconstruction is performed by transport distraction, it forms a fibrous/pseudo-disc by compressing the connective tissue between the transport segment and the glenoid fossa. This disk decreases the chances of re-ankylosis [39]. Sharma et al. in 2019 carried out neocondyle distraction in five patients and reported adequate mouth opening and functional movements in all patients. None of them reported re-ankylosis [40]. But a long-term follow-up study found that the height of these condyles was unstable. Also, these mandibles exhibited some degree of asymmetry [41].



©Association of Oral and Maxillofacial Surgeons of India

Fig. 65.11 (a) Transport distraction osteogenesis, (b) shows woven bone formation in place of callus in distracted gap, (c) alloplastic TMJ replacement with simultaneous release and OGS

65.8.2.6 Alloplastic Total TMJ Replacement (TJR) (Fig. 65.11c)

The alloplastic joint consists of a fossa component and a ramal component, as a stock or a custom-made prosthesis. Re-ankylotic scar tissue in an adult is best treated by total alloplastic TM joint replacement. Dongmei He and Yi Hui

Hu reported that alloplastic TMJ prosthesis is a reliable method to treat recurrent TMJ ankylosis. It may be accompanied by bimaxillary osteotomies for simultaneous correction of secondary ankylotic deformity as well. Its distinct disadvantage is the fact that if used in children, it would need to be replaced [42].

Mercuri et al. [43] specified the indications of TJR (Box 65.2).

Based on all the above RCU reconstruction options, guidelines are proposed for technique of RCU reconstruction in various clinical situations (Table 65.3).

Box 65.2

1. Recurrent fibrous or bony ankylosis not responsive to the modalities of treatment which have been hitherto applied
2. Failed (bone and soft) tissue grafts
3. Loss of vertical mandibular height and occlusal relationship due to bone resorption, trauma, developmental abnormalities, or pathological lesions
4. Severe inflammation of TMJ involving damage to its structures and lack of response to other treatment methods.

Table 65.3 Guidelines for technique of RCU reconstruction in various clinical situations

Situations	Technique	Justification
1. <8 years	(a) With facial asymmetry Costochondral Graft ± eventual high condylectomy	<ul style="list-style-type: none"> • Potential for growth • Treat overgrowth like condylar hypertrophy
	(b) Without facial asymmetry Coronoid graft	<ul style="list-style-type: none"> • Potential for growth not required • Cannot do ramus osteotomy because of inadequate ramal width
2. >8 years	(a) With prominent antegonial notch Vertical ramus osteotomy	<ul style="list-style-type: none"> • Reduces antegonial notch
	(b) Without prominent antegonial notch L-shaped ramus osteotomy	<ul style="list-style-type: none"> • Maintains height of ramus • Adequate ramal size
3. Re-ankylosis	(a) Child Ramal distraction	<ul style="list-style-type: none"> • Free graft will not take in scar tissue • Alloplastic joint will not grow
	(b) Adult Total alloplastic TMJ replacement	<ul style="list-style-type: none"> • Best option for scarred tissue

Table 65.4 Treatment guidelines for different types of ankylotic deformities

Type I (presence of occlusal cant): treatment planning for both maxilla and mandible
1. Involved side is normal and other side is excess (<6 mm deficiency)
(a) Differential maxillary impaction
(b) Mandibular ramus osteotomy
(i) Sagittal split osteotomy
(ii) Inverted L ramus osteotomy
(c) ± Genioplasty
2. Involved side is deficient and other side is normal (<6 mm deficiency)
(a) Differential down fracture and bone grafting of maxilla
(b) Mandibular ramus osteotomy
(i) Sagittal split osteotomy
(ii) Inverted L ramus osteotomy
(c) ± Genioplasty
3. 6–8 mm discrepancy in maxilla (6–8 mm in mandible)
(a) Simultaneous maxillomandibular distraction
4. 6–8 mm discrepancy in maxilla (>8 mm discrepancy in mandible)
(a) Cant correction in maxilla
(b) Mandibular distraction as per type II-4, 5, 6
(c) Simultaneous OGS with TJR
Type II: (with minimal occlusal cant) treatment planning for mandible alone
1. Mandibular ramus osteotomy
2. Genioplasty
3. Orthomorphic osteotomy
4. Orthomorphic distraction
5. Unidirectional distraction
6. Bidirectional distraction
7. Simultaneous OGS with TJR

65.9 Facial Deformity Secondary to TMJ Ankylosis

TMJ ankylosis leads to mandibular deformity of varying magnitude and morphology in the form of decreased ramus and/or body length, deviation of chin, retrognathic/micrognathia, bird face deformity, and narrow PAS leading to OSA (refer Fig. 68.18). Hence, establishing a single set treatment protocol for all clinical situations is not possible. Table 65.4 is an attempt to classify and thereby establish treatment guidelines for different types of ankylotic deformities.

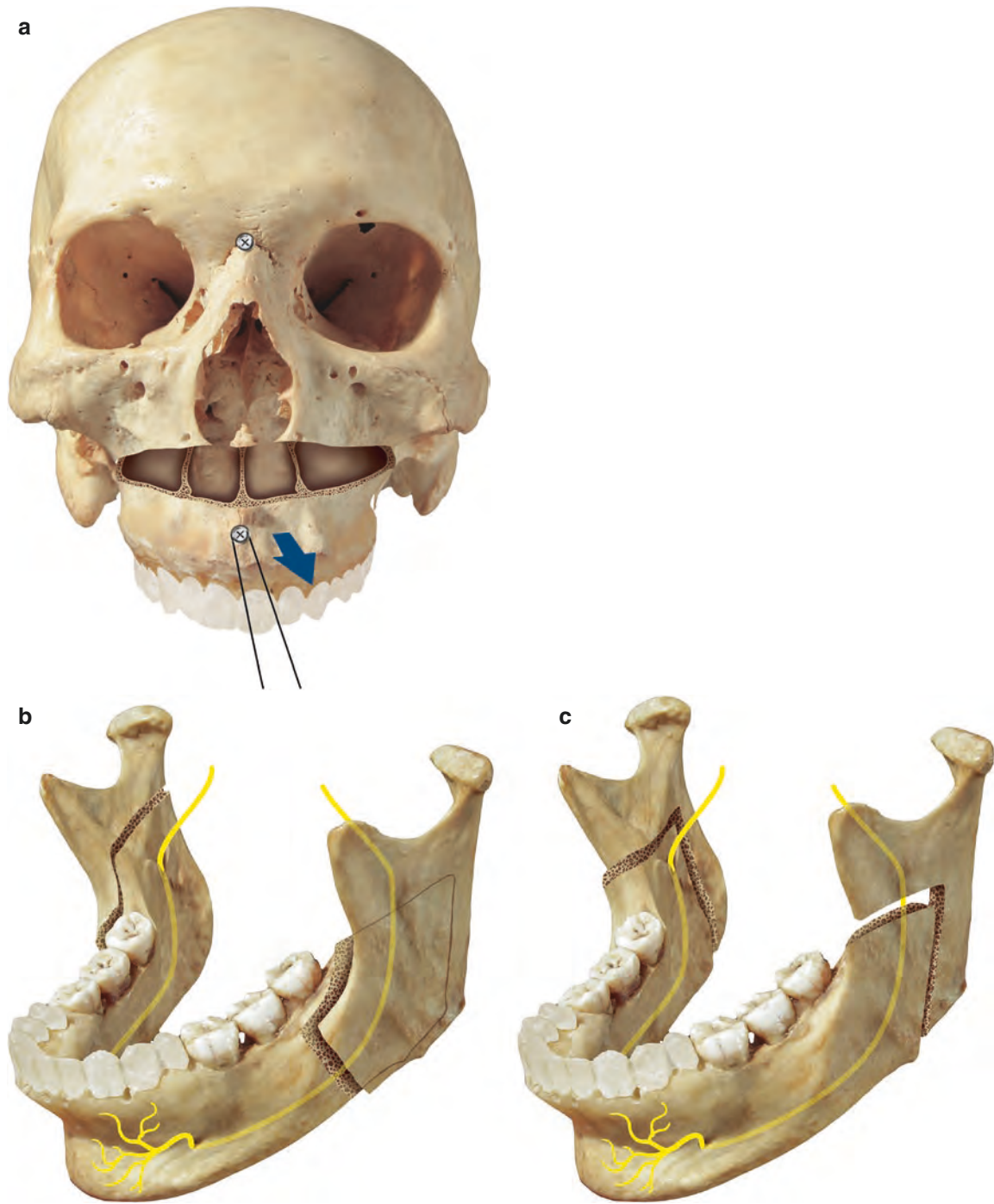
Surgical Techniques and Indications:

65.9.1 Osteotomies (Fig. 65.12a–c)

They are indicated for movements of about 6–8 mm. For maxilla, Le Fort osteotomies and, for mandible, sagittal split osteotomy or inverted L ramus osteotomy may be performed.

65.9.1.1 Le Fort I Osteotomy (Refer Chap. 69)

It allows correction in three dimensions including roll, pitch, and yaw. For vertical maxillary excess, differential maxillary



©Association of Oral and Maxillofacial Surgeons of India

Fig. 65.12 (a) Le Fort I osteotomy, (b) sagittal split osteotomy (SSO), (c) inverted L ramus osteotomy (ILRO)

impaction may be performed, while for vertical maxillary deficiency, maxillary down fracture may be done along with bone grafting. Posterior maxillary height adjustments may also be required.

65.9.1.2 Sagittal Split Osteotomy (SSO) (Refer Chap. 68)

SSO is useful to differentially settle the occlusion according to the movement of the maxilla, as well as bring the retrognathic mandible forward. The procedure involves three corticotomies—the lingual horizontal, the buccal vertical, and the intermediate cuts. This osteotomy is generally done on the normal side in case of unilateral ankylosis. On the affected side, ramal contour and condylar anatomy distortions, reduced height of the ramus and steep mandibular plane angle make SSO difficult to perform.

65.9.1.3 Inverted L Ramus Osteotomy (ILRO) (Fig. 68.6)

ILRO can be better utilized for increasing the ramal height. This technique is advocated in cases which require significant counterclockwise movement to increase projection of the lower third of the face when the ramal anatomy is altered.

The cuts are placed using a submandibular and/or an intraoral approach, posterior and superior to the inferior alveolar canal. A horizontal cut is made above and behind the lingula and then joined to the vertical cut from the inferior border of the mandible.

65.9.1.4 Genioplasty (Figs. 68.29, 68.32 and 68.34)

Patients indicated for genioplasty have normal ramal height, functional occlusion, deficient or normal pharyngeal airway space, and chin deviation or retrusion up to a maximum of 10 mm, hence minimally deformed cases.

An extended genioplasty is performed with the osteotomy cuts extending up to the first molar on both sides. Advancement and translational movements in coronal and sagittal planes are carried out. Interpositional or onlay bone grafting may be done so as to achieve further symmetry wherever required.

Alloplastic chin implants made of PTFE, silicon, PEEK, or customized titanium are alternatives to the traditional genioplasty.

65.9.1.5 Orthomorphic Osteotomy

As opposed to conventional orthognathic surgery, an osteotomy used to restore morphology is termed “orthomorphic correction.”

Patients who may undergo orthomorphic osteotomies are the ones having normal ramal height, functional occlusion, deficient or normal posterior airway space, and chin deviation or retrusion up to a maximum of 10 mm, but this can be

done only in cases of unilateral ankylosis. Most importantly, the primary indication for this surgery is the presence of soft tissue depression over the mandibular ramus on the unaffected side resulting in a contour defect. The osteotomy cuts are placed on the unaffected side.

Paul Salins [44] designed the osteotomy as an eccentric genioplasty extending from the body to the buccal cortex of the mandible. The cut changes from full thickness from the body to the sagittal buccal cortical cut in the ramus. The segment is then repositioned in such a way that it corrects the midline, the anteroposterior deficit, as well as the lateral morphological contour defects Fig. 65.13a.

65.9.2 Distraction Osteogenesis (DO)

Traditional bone grafting and orthognathic surgery have disadvantages—bony resorption, necrosis, donor site morbidity, limited advancement, relapse, etc.

Advancement of the mandible using SSO generally is restricted to a maximum of 10–12 mm. In ankylotic patients, the mandible requires much greater movements. Kohn et al. have reported high relapse after SSO [45], especially when used for advancement of mandible. Patients with ankylosis may report higher relapse rate than others. All the above issues may be dealt with DO.

Mandible lengthening with distraction leads to increase in bone stock of the mandible as well as proportionate and harmonious growth of the surrounding soft tissues. This bony regeneration is principally dependent on intramembranous ossification. Also healing and mineralization need adequate vascularity. Therefore, the incision to perform the surgery may be kept as limited as possible.

Early distraction may have beneficial effects, on the facial harmony as well as on the TMJ. If the anatomy and thereby function of the soft and hard tissues of craniofacial skeleton is established early in life, it may be possible to regain as near normal growth of the face.

Distraction in TMJ ankylosis patients with obstructive sleep apnea has led to decrease in snoring, daytime somnolence, Apnoea Hypopnoea Index (AHI), and oxygen desaturation episodes. The disadvantage however is that the device may be costly and needs to remain in situ for several months.

65.9.2.1 Simultaneous Maxillomandibular DO

This technique was first described by Molina and Monasterio in 1997 [46]. The first stage of surgery comprises of a Le Fort I osteotomy and a unilateral mandibular osteotomy. The distraction device is fixed to the mandible on the affected site. Under IMF, as the mandible moves forward, the maxilla comes downward, thereby correcting the cant and, simultaneously, the anteroposterior deficiency of the mandible. As this whole procedure is done under IMF, occlusion is main-

tained. The second stage comprises of removal distraction device and an additional genioplasty if required.

This is indicated when the occlusal cant is such that there is vertical maxillary deficiency but with presence of functional occlusion. If the mandible alone is distracted, it may lead to occlusal disasters, hence the need to keep the patient under IMF while the distraction is being performed.

65.9.2.2 Orthomorphic DO (Figs. 65.13a–d, 78.23, 78.24 and 78.25)

As laid down by Manikandan et al. [47], the concept of orthomorphic distraction of the mandible is a modification of Paul Salin's morphometric osteotomy. It involves the distraction of mandibular basal bone to correct the asymmetry in all dimensions, despite a deficient soft tissue capsule. It also provides more movement than that attainable via osteotomy.

The osteotomy design is similar to the one used in conventional orthomorphic surgery. Once the osteotomized segment is mobilized, an internal/external distractor may be placed. Maintenance of the periosteal attachment at the pterygomassetric sling region brings about a pivotal movement at the gonion facilitating the lateralization and advancement of the osteotomized segment. The mechanics of the mandibular asymmetry correction is based on the law of parallelogram of vectors.

65.9.2.3 Genial Distraction

Distraction of the chin may be performed either in isolation or simultaneously with ankylosis release. A case report on the latter has been published by Gunaseelan et al. [48] in 2007 wherein an extended genioplasty osteotomy was performed and external distractors placed and activated. They suggested that simultaneous genial distraction and arthroplasty may be performed in adults, as the mandible is no longer growing.

This is advocated in adults because they have functional stable occlusion. Therefore, distraction of the basal bone of the mandible without distracting the occlusion bearing segment will only correct the mandibular deformity and the OSAS, but not interfere with the occlusion. However, in children, dental relationships due to mandibular hypoplasia may be very severe and therefore this may not be the treatment of choice. Also, the eruption of the permanent teeth may interfere in osteotomy used in this technique.

Genial distraction is an option to gain larger advancements, although may be limited by an unsightly labiomental fold as advancement increases.

65.9.2.4 Unidirectional DO (Fig. 65.14a–i)

This procedure is indicated in patients with near normal ramal height but deficient corpus length, chin retrusion and

deviation greater than 10 mm, and presence of mild to moderate OSA.

For deficient corpus length, osteotomy cut is placed in the body region, generally between second premolar and first molar or between first and second molars. If the patient has not undergone presurgical orthodontics or if distraction is being performed pre-ankylosis release, the cut depends on the distance between the roots of the teeth and presence of impacted teeth. Maria B. Papageorge [49] advised that the cut should be placed in such a manner that the integrity of mandibular angle is maintained as it forms a very important aesthetic component of the face.

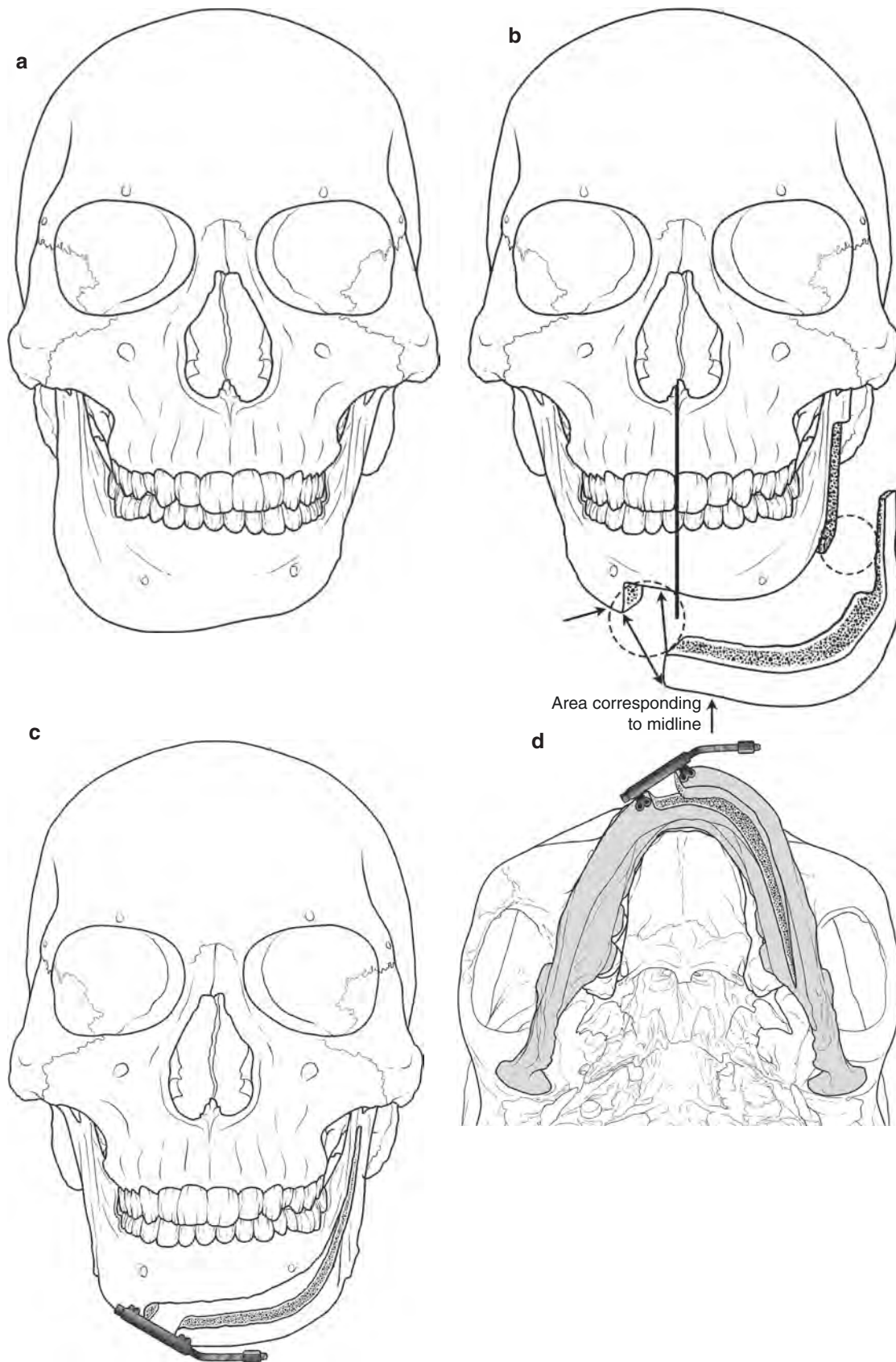
According to Samchukov, the vector of distraction should always be parallel to the occlusal plane, regardless of the direction of the osteotomy, to prevent anterior open bite deformity. Kunz et al. [50] has stated it to be a well-known complication of mandibular distraction. Unidirectional distraction is contraindicated in patients exhibiting vertical growth pattern. This is because unidirectional distraction in patients with a steep mandibular plane angle and substantially deficient ramal height may again lead to anterior open bite.

Internal distraction has a definite edge over external distraction in terms of aesthetics and patient compliance. However, chances of postoperative infection are greater with internal distractors. Also, they have limitations in terms of the amount of distraction possible.

Unidirectional distractors may be placed through either intraoral or extraoral approach. Surgical splints may be prepared on 3D-printed models preoperatively. Upon exposure of the bone, these premarked splints are positioned. Using them as guides, corticotomy sites and sites for distractor pins/screws are marked. Buccal corticotomy and lower border full-thickness cuts are placed. Distractor is fixed and the osteotomy cuts are completed. In case impacted teeth are in the way of the osteotomy cuts, they may be removed intraoperatively itself.

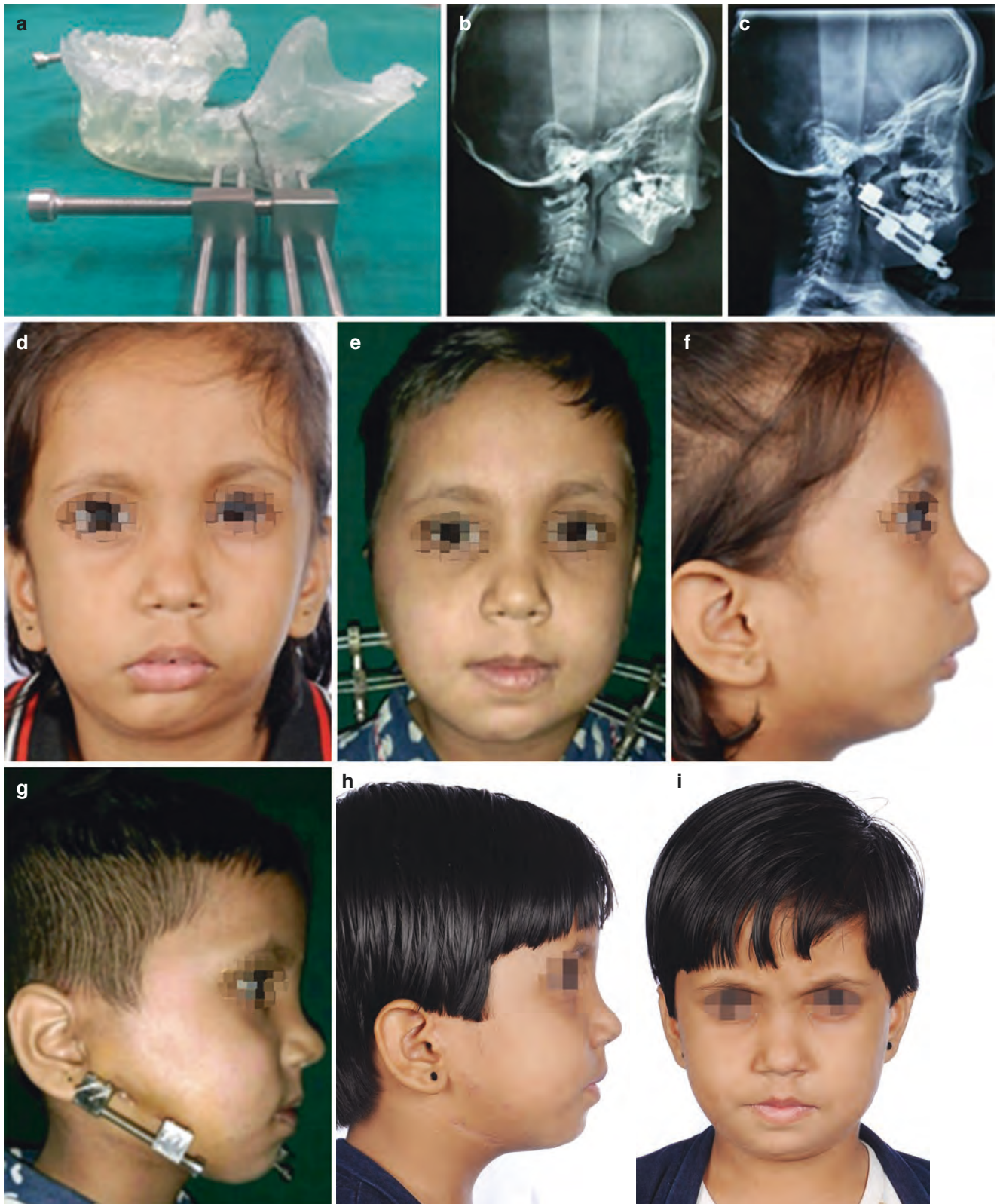The distractors are activated to check completeness of the cuts and then brought back. Latency period is of 5–7 days, depending on the patient's age. Larger movements require larger periods of consolidation to prevent relapse.

After distracting for around 8–10 days, shape of the regenerate may be changed (callus molding) during the distraction process. Complications may include infection, tooth fracture, change of vector, loosening of pin, anterior open bite, and parotid fistula, but all can be managed conservatively. Callous molding can take care of occlusal discrepancies to a large extent, except that if there is absolutely no overjet. However, with some amount of overjet present, differential distraction may be done on the superior and inferior borders of the mandible. Herein, with the help of callous molding using IMF screws/eyelets and elastics, the inferior border may be distracted more than the superior border.



©Association of Oral and Maxillofacial Surgeons of India

Fig. 65.13 (a, b) Orthomorphics osteotomy, (c, d) orthomorphics distraction



©Association of Oral and Maxillofacial Surgeons of India

Fig. 65.14 (a) Uniplanar distractor fixed on the 3D stereolithographic model with osteotomy cut marked, (b) preoperative lateral cephalogram, (c) post-distraction lateral cephalogram, (d) preoperative frontal

view, (e) post-distraction, frontal view (f) preoperative lateral view, (g) post-distraction lateral view, (h) six-month follow-up lateral, (i) six month follow-up frontal

Sometimes there may be occlusal locking thereby preventing the distracted regenerate from moving in the direction that is required. A composite block may be prepared on the tooth to first disocclude it and thereby get distraction in the favorable direction. Later occlusion may be regained by callous molding. The molding of the regenerate substantially reduces the time required for post operative orthodontics.

65.9.2.5 Bidirectional DO (Fig. 65.15a–g)

Bidirectional distractors are indicated for patients with severely shortened ramal height as well as corpal (body) length, requiring vertical as well as horizontal components of distraction. They are also indicated in cases with increased mandibular plane angle as well as for patients with moderate to severe OSA.

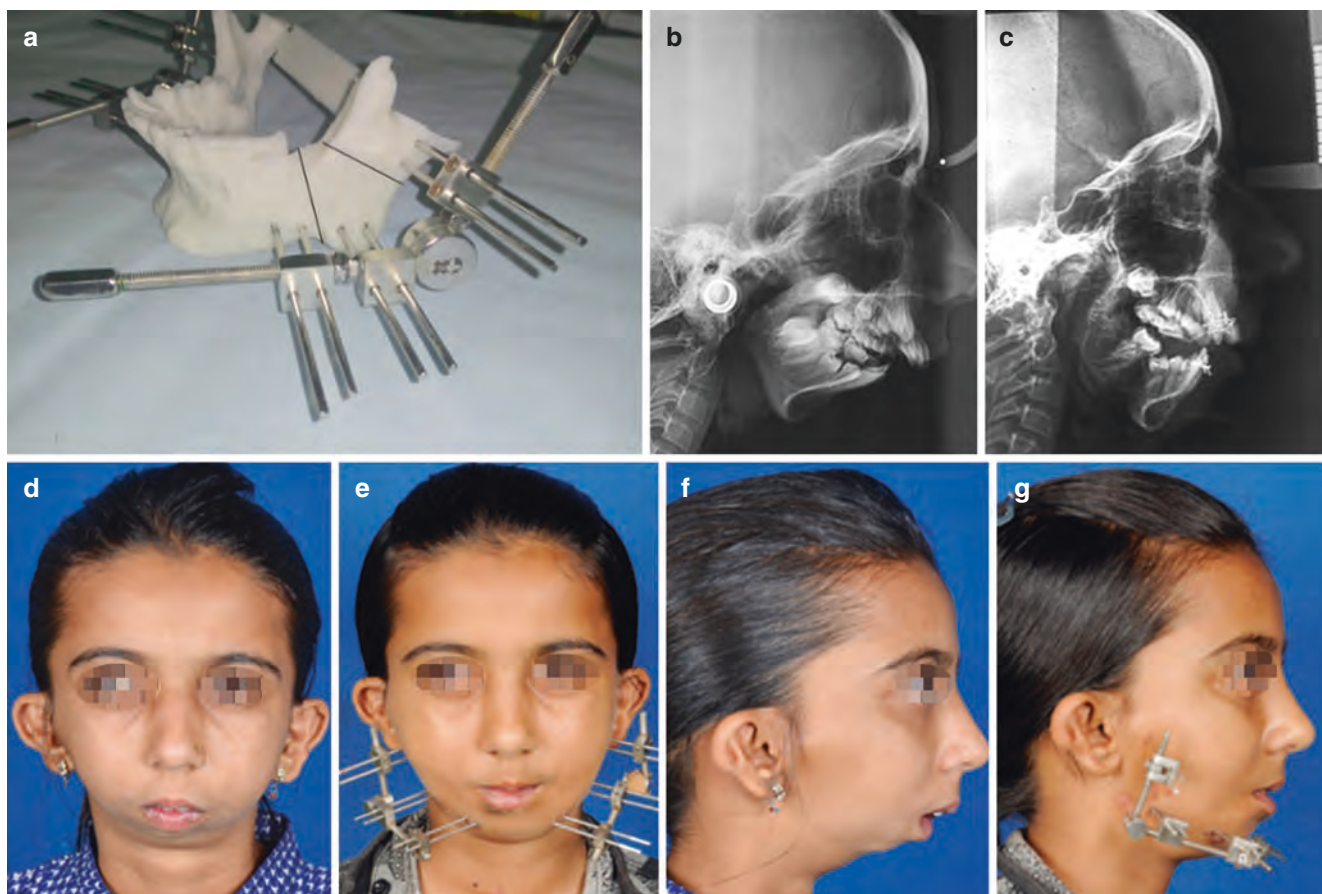
Surgical splints are prepared on 3D-printed models. Upon exposure of bone through a submandibular incision, two osteotomy cuts are placed on either side. One osteotomy cut is placed on the ramus and the other in the body region on either side of the angle, keeping the intermediate segment between 2.5 and 3 cm to avoid avascular necrosis. The device

is secured to the mandible with six percutaneous pins (Schantz' pins)—one pair each at the ramus, angle, and corpus. The same procedure may be used for internal distractors as well.

The osteotomy site depends on position of teeth, lingula, mental foramen, and size of the intermediate segment. Vector of horizontal distraction should be parallel to occlusal plane, and vector of vertical distraction should be parallel to posterior border of ramus. In bilateral cases, horizontal and vertical components of either side should be parallel to each other. A 2–3 mm overcorrection is generally advisable. Callous molding may be used for occlusal adjustments. A single osteotomy cut may however be used for 3D or multi-vector distractors, thereby considerably reducing the surgical difficulty as well as the intraoperative time. Their main drawback is their prohibitive cost.

65.9.2.6 Impact of Mandibular DO on OSA

The ankylotic retruded mandible has an inefficient genial muscular apparatus as well, thereby causing retroglottal airway obstruction, therefore, OSAS. Mandibular advancement



©Association of Oral and Maxillofacial Surgeons of India

Fig. 65.15 (a) Biplanar distractor fixed on the 3D stereolithographic model with osteotomy cuts marked, (b) preoperative lateral cephalogram, (c) post-distraction lateral cephalogram (marked increase in PAS

can be appreciated) (d) preoperative frontal view, (e) post-distraction frontal view, (f) preoperative lateral view, (g) post-distraction lateral view

in such cases has shown 97% success in pediatric and 100% success in adult patients. Decrease in OSAS may be evaluated by an AHI less than 50% decrease in the AHI with a near normal peripheral oxygen saturation.

65.10 Sequence of Release and Deformity Correction

OSA, in terms of AHI and PAS, is the principal factor that determines the sequence of release and deformity correction, i.e., whether to release first or distract first (refer Chap. 71 on OSAS and Figs. 71.8, 71.9, 71.10, 71.11, 71.12, 71.13 and 71.14).

Single-Stage vs. Multistage Procedure:

Treatment protocols can generally be categorized into single-stage or multistage treatments. Single-stage treatments institute ankylosis release and correction of secondary deformities (in the form of maxillary and mandibular osteotomies or distraction) all together. In the multistage protocol, ankylosis is released, and deformities are corrected in different stages.

65.10.1 Multistage Surgical Treatment

Severe secondary deformities are candidates for multistage procedures as a single-stage surgery may cause severe malocclusion. Correction of the same would require unrealistic amount of tooth movement.

Advantages: The multistage protocol is generally better for patients with significant medical comorbidity. This is so because a single-stage procedure obviously demands greater surgical time, thereby increasing the intraoperative risks. Multistage procedures facilitate early postoperative physiotherapy and, thus, a more stable postsurgical outcome. Also, the relapse monitoring is easier.

Disadvantages: Multiple surgeries, increased cost, and patient compliance issues

65.10.1.1 Multistage with Ankylosis Release First

According to López et al. [51], mandibular distraction should be performed after ankylosis release, as only then would be complete growth potential of the mandible be known. Releasing the ankylosis first would ensure adequate food intake, preparing the patients for subsequent, more complex surgeries. Also, surgeons could then formulate customized treatment plans based on individual clinical requirements and thereby provide more accurate correction of the deformity.

65.10.1.2 Multistage with Distraction First

Some surgeons recommend that distraction may be first used to restore the length and projection of the mandible. Later arthroplasty may be followed by orthognathic surgery to obtain mouth opening and settle the occlusion.

Advantages: The mandibular bone deficiency and the airway volume are both increased simultaneously. The subsequent intubation is much safer. Secondly, for patients with OSA, this treatment sequence reduces the incidence of post-operative airway issues—if ankylosis is released first, as the mandible falls back specially in bilateral cases, the already reduced airway space then gets further reduced, requiring reintubation or emergency tracheostomy. This incident can be avoided if distraction proceeds release.

65.10.2 Single-Stage Surgical Treatment

Patients with mild to moderate dental and skeletal deformities are ideal candidates for single-stage procedures. The minimal malocclusion may be treated by orthodontics alone. In these such cases, ankylosis release along with facial aesthetic surgeries which do not involve the occlusion may be performed, e.g., genioplasty, mandibular recontouring, and alloplastic implants.

Advantages: This corrects the restricted mouth opening as well as the secondary deformity simultaneously and avoids further surgeries. It provides low cost, immediate satisfaction, particularly in patients with psychological issues, and mild OSA.

Disadvantages: Maxillomandibular fixation often required after orthognathic surgery interferes with postoperative mouth opening exercises and therefore increases the chances of re-ankylosis. In case of internal distraction devices, there still arises the need for a second surgery to remove it. Also, the effect of distraction may be unsatisfactory because of the unstable condyle—if the osteotomy is placed in the ramus, the proximal segment may go up into the gap created after ankylotic mass removal, cause loss of vector and thereby re-ankylosis. Thus, to prevent this complication, while performing concomitant release and distraction, osteotomy cut may be placed only anterior to the angle, in the body region.

Another potential complication is the interference between physical exercises and distraction. A pseudo-joint may be formed in the callus area when the patient exercises, with the mouth opening force being directed toward the callus instead of the newly released joint. To prevent this complication, intensive active mouth opening exercise with wooden sticks/heisters may be started from postoperative day 1 itself. Mouth

opening exercise from day 7 onward, i.e., once distraction is started, should exclude the use of the above.

65.10.2.1 Single-Stage Release with Orthognathic Surgery (OGS)

As mentioned earlier, in patients that exhibit mild dental and skeletal deformities, aesthetic surgeries not involving the tooth-bearing segments may be performed.

For the patients with moderate skeletal deformities, SSO along with ILRO and bone grafts may be used to lengthen the affected ramus. If necessary, Le Fort I osteotomy may be used to correct the occlusal cant in unilateral cases or bring the posterior maxilla down in bilateral cases.

Songsong Zhu [52] performed a study on 27 adult patients who underwent simultaneous ankylosis release and correction of secondary deformity as a single surgery. No relapse occurred.

Yi Hui Hu [42] studied 11 patients where CAD/CAM technique was utilized as a guide to determine level of removal of ankylotic mass and placement of TMJ prosthesis. Simultaneous Le Fort I osteotomy was performed in two patients guided by digital templates. Results showed that alloplastic TMJ prosthesis is a reliable treatment for recurrent ankylosis. The CAD/CAM technique produces accurate therefore stable results.

Many cases would require a custom-made prosthesis, typically fabricated with a stereolithographic model. Ryu et al. in 2016 reported a case where bilateral TM joints were replaced with a custom-made TMJ prosthesis. Virtual surgical planning (VSP) and STL model simulation helped in placing the mandible in a new improved occlusal and aesthetic profile [53]. This has become a routine procedure now in adult patients, i.e., custom-made joints based on VSP along with simultaneous OGS.

65.10.2.2 Single-Stage Release with DO

Simultaneous interpositional arthroplasty with DO for TMJ ankylosis, apart from increasing the length of the mandible, leads to the correction of gross facial asymmetry and midline shift and provides space for eruption of hitherto unerupted teeth. It helps reduce treatment time and need for an additional surgery and also alleviates the need for second tracheostomy, if the fiberoptic intubation is not possible.

Only unidirectional distraction in the mandibular body (in patients with AHI 15–30) may be performed along with release. If bidirectional distraction is performed, after placing the arthroplasty cuts, if two more cuts are placed in the body and the ramus, there are increased chances of avascular necrosis of the segments. Thus, bidirectional distraction may

not be performed along with release; it may be performed either pre- or post-release, unless a 3D distractor is being used.

Krishna Rao et al. [54] performed a study on six patients and concluded that simultaneous release with DO should be used to correct ankylosis with facial asymmetry and reported satisfactory cosmetic correction of deformities. Girish B Giraddi et al. [55] performed a similar study with nine cases and concluded that it not only corrects the facial deformity but also saves the trauma of a second difficult intubation.

Lopez and Dogliotti [51] in 2004 asked a pertinent question—“Is it reasonable to perform ankylosis release and mandibular distraction simultaneously without knowing which patients will be able to experience growth with time? In that case it would be necessary to predict growth to apply the exact amount of mandibular distraction for obtaining stable results.” This question can now be answered—in children, the only indications for simultaneous release with distraction would be moderate to severe OSA, with AHI 15–30 (however with normal ramal height) and extreme facial deformity causing issues with the child’s psyche.

65.10.2.3 Single-Stage Release with Genioplasty

Most literature till date has either been looking at ankylosis in isolation from facial asymmetry and has been dealing with only ankylosis release or facial deformity as staged events or has been looking at correcting one of the biggest facial deformities, all at one go. There is no middle path mentioned in literature wherein ankylosis and a substantial part of its related deformities can be corrected without the following problems—a supra-major surgery under general anesthesia, extremely expensive 3D-printed splints and alloplastic joint replacements, expensive and protracted orthodontics requiring multiple hospital visits from the underprivileged, undernourished patients living in far-flung areas, and long-term patient noncompliance for distraction. Also, if osteotomies are performed before the TMJ attains stability, surgical outcome may be less than satisfactory as related to aesthetics and occlusion.

A suggested solution for the above problem in adults with mild to moderate OSA is a single-stage surgery—ankylosis release by interpositional arthroplasty simultaneously with genioplasty. It would provide a one-step solution to restoration of function and reasonable aesthetics within a reasonable amount of general anesthesia time, no occlusal discrepancies, no compliance for distraction, and no need for orthodontics. Most importantly, it would not interfere with any other secondary corrective procedure later, if the patient so desires.

The author has conducted a study on 43 ankylosed joints & set forth single-staged treatment guidelines—ankylosis release, RCU reconstruction, and extended advancement centering genioplasty for increase in mouth opening, restoration of ramal height, and improvement in facial asymmetry as well as OSA. Average mouth opening at maximum follow-up of 20 months was 34.36 mm with no reported recurrence. Average increase in N perpendicular to Pog was 7.16 mm, average decrease in neck-chin angle and labiomental angle was 31.6° and 35.4°; respectively, average increase in PAS was 2.92 mm. Average 50% improvement of AHI was seen in all 18 patients who had OSA [56].

65.11 Guidelines for sequencing of release and deformity correction

65.11.1 In Ankylosed Patients: To Decide Regarding Distraction Pre-/Post-/ Simultaneously with Release (Table 65.5)

- AHI >30: Children and adults—distract first
- AHI <15
 - Children
 - Release first
 - Simultaneous release and unidirectional distraction
 - Adult
 - Release first
 - Simultaneous release with/without joint replacement and osteotomies
 - Simultaneous release and unidirectional distraction
- AHI 15–30
 - Short ramus (requiring bidirectional distraction)
 - Children and adults: distract first
 - Normal ramus (requiring unidirectional distraction)
 - Children: simultaneous release and distraction
 - Adults
 - Joint replacement with osteotomies
 - Simultaneous release with distraction

Table 65.5 Relation of Apnea-hypopnea index with PAS

PAS (mm)	AHI	Rating
>8	<5	Normal
8	5–10	Mild sleep apnea
5–7	15–30	Moderate sleep apnea
<4	>30	Severe sleep apnea

65.11.2 In Released Patients: To Decide Regarding Type of DO

- Only body deficiency with normal Mandibular Plane Angle (MPA)—unidirectional distraction
- Body and ramus deficiency with steep MPA—bidirectional distraction
- AHI >30—bidirectional distraction
- Asymmetry of mandibular angles—one side unidirectional, one side bidirectional distraction
- Dysmorphic asymmetry: orthomorphic distraction
- Functional occlusion in adults with normal ramus: genial distraction

65.12 Unfavorable Results in TMJ Ankylosis Surgery (Table 65.6)

Table 65.6

1. Issues in primary surgery
(a) <i>Incomplete appreciation of the extent of the deformity</i>
(i) Unilateral or bilateral
(ii) Length of the coronoid process
(b) <i>Anaesthesia-related issues</i>
(i) Excessive bleeding during fiberoptic intubation
(ii) Emergency tracheostomy
(c) <i>Intra- and immediate postoperative issues</i>
(i) Surgical mishaps
1. Nerve traction
2. Inadequate exposure of the bony block
3. Bleeding from pterygoid venous plexus
4. Injury to the internal maxillary artery
(ii) Failure to achieve adequate mouth opening
1. Ipsilateral joint release → ipsilateral coronoidectomy → contralateral intraoral coronoidotomy
(iii) Severe bradycardia on mouth opening
(iv) Postoperatively open bite after bilateral arthroplasty/coronoidectomy
(d) <i>Intermediate and long-term issues following primary surgery</i>
(i) Re-ankylosis—reasons
1. Incomplete or inadequate primary release
2. Inadequate mouth opening exercises
(ii) Growth alterations of costochondral graft
2. Issues related to secondary surgery of deformities
(a) No control of movement of proximal segment
(b) Careful calculation of the vector

65.13 Conclusion

- Traditionally, TMJ ankylosis and its associated micrognathia have been treated in multiple stages. Rehabilitation of mandibular function, prevention of re-ankylosis, and promotion of mandibular growth have been the main aims of treatment. The treatment has now advanced from only

ankylosis release to total joint replacement as well as facial deformity correction, all simultaneously as far as possible.

- The patient at the time of presentation itself is looked at holistically. A more nuanced decision tree for treatment planning is formulated, be it for release, new joint reconstruction, distraction, osteotomies, or the sequencing of release vs. facial deformity correction. The most critical deciding factor in the treatment planning is obstructive sleep apnea, and the key for successful treatment is appropriate planning at each stage.
- Therefore, just because in the past, we were releasing all ankylosis first and doing corrective surgeries later, we cannot continue doing the same; albeit neither can we distract all patients first because that is the latest fad. An extensive review of literature as well as the vast experience of the author has helped lay down guidelines for most clinical scenarios of varying magnitude of deformities in TMJ ankylosis.
- In a few patients, some degree of facial imbalance may continue to persist even after surgical interventions. Additional aesthetic surgery, such as malarplasty reshaping of the chin, angle and lower border of the mandible, may be required to achieve the best results [57].
- Since TMJ ankylosis is generally a disease of the underprivileged and socioeconomically backward strata of society, it should be noted that the deformity cannot be the only criteria to select the surgical procedure. Patient's preference, the treatment cost, and compliance also need to be taken into consideration. Some patients are more concerned about their mouth opening and aesthetics rather than their occlusal disharmony.

Acknowledgment I wish to convey my deepest thanks and sincerest gratitude to my resident Dr. Hrushikesh Gosai, without whose observations, comments, and technical expertise this manuscript would have not been possible. A mere word of thanks is not sufficient to express the unflinching support and inestimable aid of my staff Dr. Jigar, Dr. Utsav, and Dr. Bipin and my residents Dr. Hiral, Dr. Philip and Dr. Nisha during the preparation of this chapter. I would be failing in my duty if I did not recognize the contribution of my biggest teacher in TMJ ankylosis, my Ex-Hod Dr. Babu Parmar.

Disclosure Authors have no financial conflicts to disclose

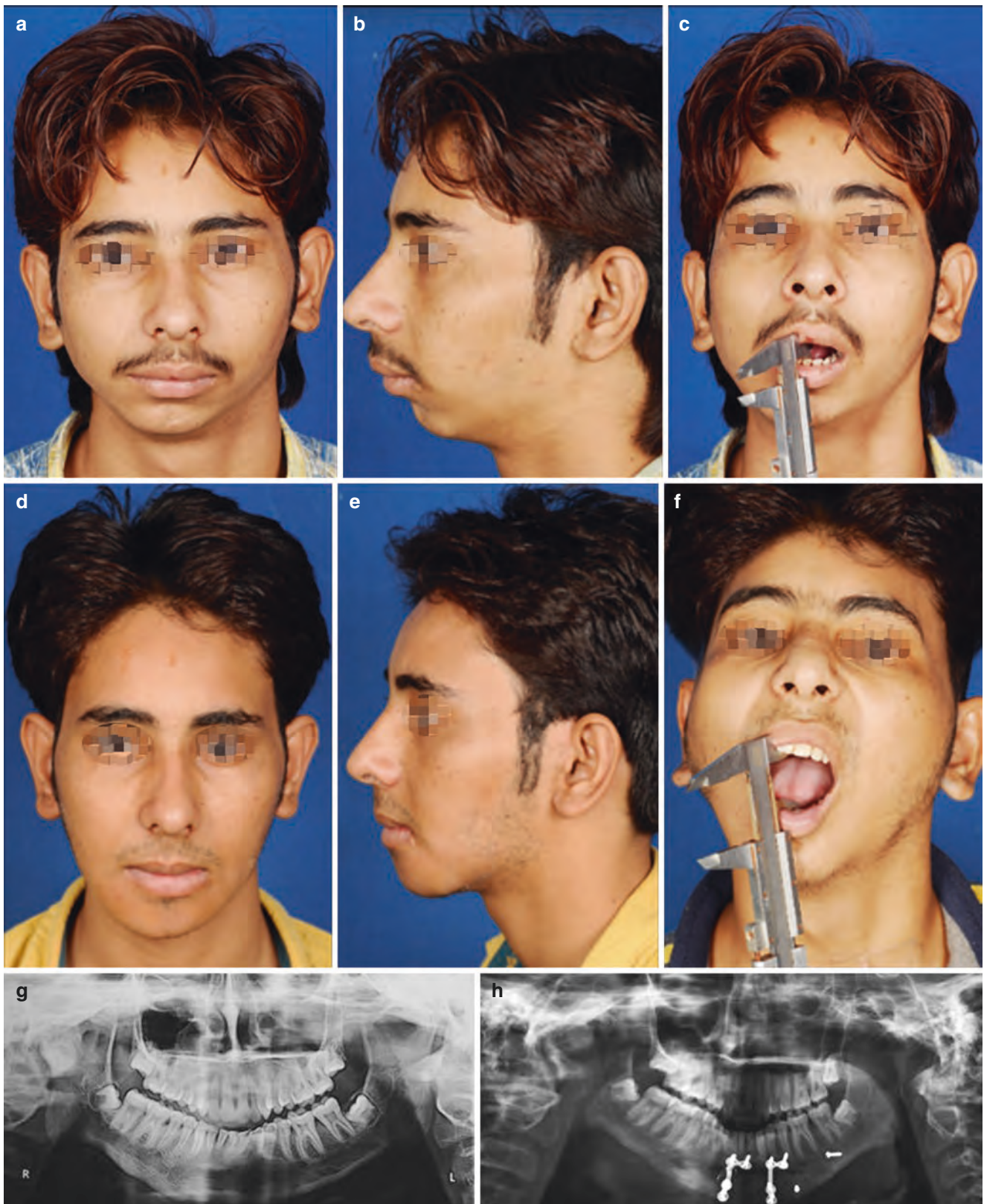
65.14 Case Scenarios

Case 1 (Fig. 65.16a–h)

A 23-year-old male patient presented with unilateral right-sided bony ankylosis with retruded and deviated chin with body and ramal length near normal. So, the patient was planned for advancement centering genioplasty and onlay bone graft along with TMJ ankylosis release.

Case 2 (Fig. 65.17a–f)

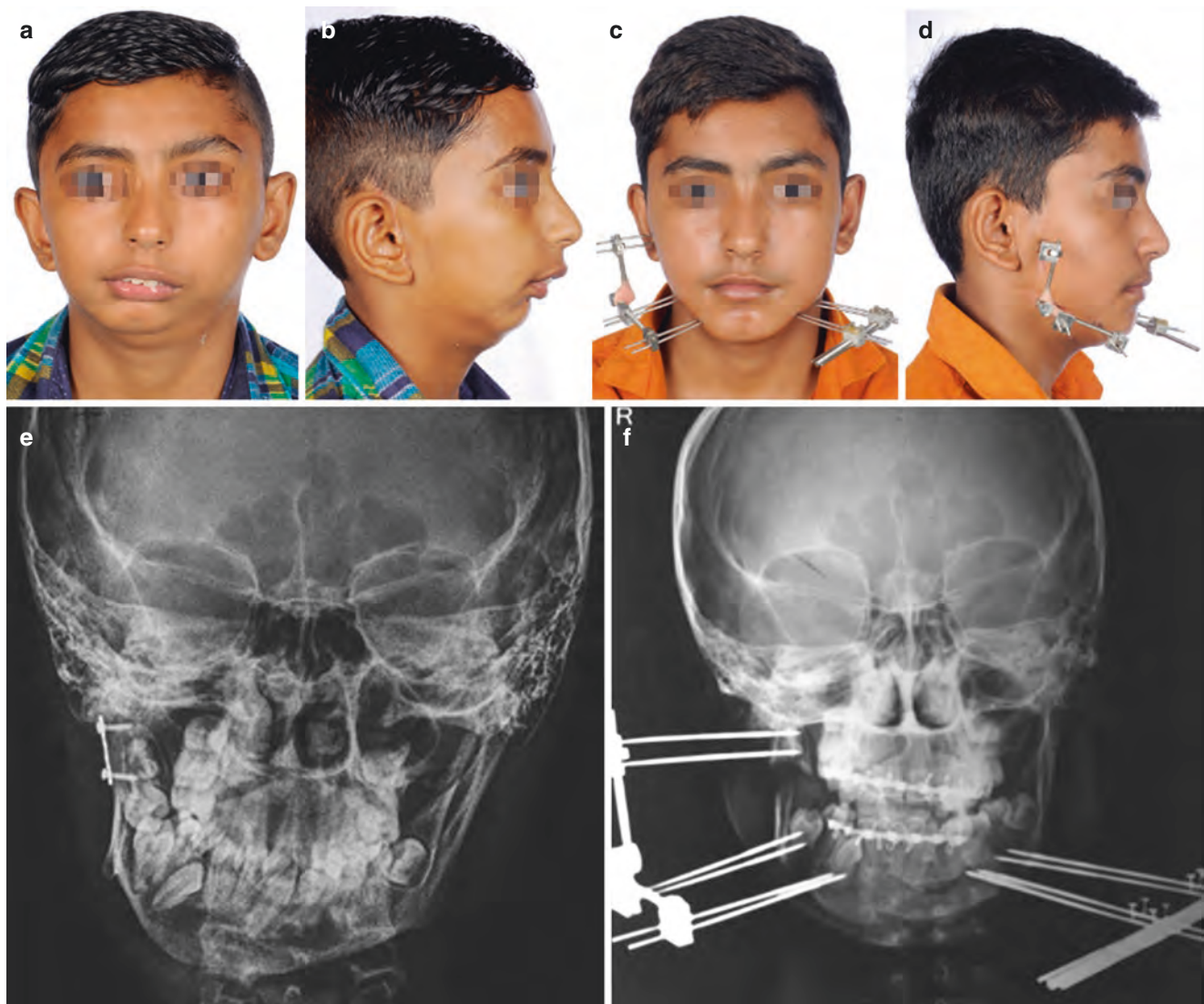
A 14-year-old male patient presented with facial asymmetry secondary to TMJ ankylosis with moderate OSA. Cephalometric analysis revealed deficiencies in the length of the mandibular ramus and corpus of the right side and the corpus alone on the left side. So, he was planned for biplanar distraction on right side and uniplanar distraction on left side.



©Association of Oral and Maxillofacial Surgeons of India

Fig. 65.16 (a–h) Case 1 Right side TMJ ankylosis (a) Preoperative frontal view, (b) preoperative lateral view, (c) preoperative mouth opening, (d) postoperative frontal view, (e) postoperative lateral view, (f)

postoperative mouth opening, (g) preoperative orthopantomogram, (h) postoperative orthopantomogram (note the genioplasty and onlay bone graft fixations)



©Association of Oral and Maxillofacial Surgeons of India

Fig. 65.17 Case 2 (a) Preoperative frontal view, (b) preoperative lateral view, (c) postoperative frontal view, (d) postoperative lateral view, (e) Pre-distraction PA cephalogram, showing implant on the right side

from the earlier surgery for interposition arthroplasty, (f) postoperative PA cephalogram

References

- Sporniak-Tutak K, Janiszewska-Olszowska J, Kowalczyk R. Management of temporomandibular ankylosis—compromise or individualization—a literature review. *Med Sci Monit.* 2011;17(5):RA111–6.
- Kaban LB, Perrott DH, Fisher K. A protocol for management of temporomandibular joint ankylosis. *J Oral Maxillofac Surg.* 1990;48:1145–51.
- Sawhney C. Bony ankylosis of the temporomandibular joint: follow-up of 70 patients treated with arthroplasty and acrylic space interposition. *Plast Reconstr Surg.* 1986;77:29–38.
- Yan Y-B, Liang S-X, Shen J, Zhang J-C, Zhang Y. Current concepts in the pathogenesis of traumatic temporomandibular joint ankylosis. *Head Face Med.* 2014;10:35.
- Mehrotra D, Sidebottom AJ. Management of ankylosis of the temporomandibular joint. In: Brennan P, Schliephake H, Ghali GE, Cascarini L, editors. *Maxillofacial surgery.* 3rd ed. Edinburgh: Churchill Livingstone; 2017.
- Aziz SR. Andy Gump and his deformity. *J Oral Maxillofac Surg.* 2010;68(3):651–3.
- Anantanarayanan P, Narayanan V, Manikandhan R, Kumar D, et al. *Int J Pediatr Otorhinolaryngol.* 2008;72:385–9.
- Andrade NN, Raikwar KR. Management of patients with obstructive sleep apnoea induced by temporomandibular joint ankylosis: a novel 2-stage surgical protocol and report of 5 cases. *Asian J Oral Maxillofac Surg.* 2009;21:27–32.
- Wu XG, Hong M, Sun KH. Severe osteoarthritis after fracture of the mandibular condyle: a clinical and histologic study of seven patients. *J Oral Maxillofac Surg.* 1994;52(2):138–42.
- Dhasmana S, Singh V, Pal US. Awake blind nasotracheal intubation in temporomandibular joint ankylosis patients under conscious sedation using fentanyl and midazolam. *J Maxillofac Oral Surg.* 2010;9(4):377–81.

11. Quinn PD, Granquist EJ ; Surgical approaches to temporomandibular joint; In: Quinn PD, Granquist EJ (eds) Atlas of temporomandibular joint surgery 2 Wiley Chichester 2015, 31–55.
12. Al-Kayat A, Bramley P. A modified pre-auricular approach to the temporomandibular joint and malar arch. *Br J Oral Surg.* 1979;17:91–103.
13. Miloro M, Redlinger S, Pennington DM, Kolodge T. In situ location of the temporal branch of the facial nerve. *J Oral Maxillofac Surg.* 2007;65:2466–9.
14. Talebzadeh N, Rosenstein TP, Pogrel MA. Anatomy of the structures medial to the temporomandibular joint. *Oral Surg Oral Med Oral Pathol Oral Radiol Endod.* 1999;88:674–8.
15. Alexander RW, James RB. Postauricular approach for surgery of the temporomandibular articulation. *J Oral Surg.* 1975;33:346–50.
16. Kaban LB, Bouchard C, Troulis MJ. A protocol for management of temporomandibular joint ankylosis in children. *J Oral Maxillofac Surg.* 2009;67(9):1966–78.
17. Clarkson P, Kenshole HH. Esmarch's operation for the relief of ankylosis and of pain in the temporomandibular joint; a modified operative technique. *Br Dental J.* 1949;87:257–64.
18. Topazian RG. Etiology of ankylosis of temporomandibular joint: analysis of 44 cases. *J Oral Surg Anesth Hosp Dent Serv.* 1964;22:227–33.
19. Topazian RG. Comparison of gap and interposition arthroplasty in the treatment of temporomandibular joint ankylosis. *J Oral Surg Am Dent Assoc.* 1966;24:405–9.
20. Elgazzar RF, Abdelhady AI, Saad KA, Elshaal MA, Hussain MM, Abdelal SE, Sadakah AA. Treatment modalities of TMJ ankylosis: experience in Delta Nile, Egypt. *Int J Oral Maxillofac Surg.* 2010;39:333–42.
21. He Y, Huang T, Zhang Y, An J, He L. Application of a computer-assisted surgical navigation system in temporomandibular joint ankylosis surgery: a retrospective study. *Int J Oral Maxillofac Surg.* 2017;46:189–97.
22. Ray PDA, Sundar Biswas DP, Chatterjee DA. Trismus—an old concept for successful treatment in the present era—case reports. *IOSR J Dent Med Sci.* 2016;15(9):12–6.
23. He D, Yang C, Chen M, Zhang X, Qiu Y, Yang X, Li L, Fang B. Traumatic temporomandibular joint ankylosis: our classification and treatment experience. *J Oral Maxillofac Surg.* 2011;69:1600–7.
24. Nitzan DW, Tair JA, Lehman H. Is entire removal of a post-traumatic temporomandibular joint ankylosis site necessary for an optimal outcome? *J Oral Maxillofac Surg.* 2012;70(12):e683–99.
25. Yang X, Lu C, Dong M, He D, Yang C, Hu Y. Evaluation of the condyle remodeling after lateral arthroplasty in growing children with temporomandibular joint ankylosis. *Sci Rep.* 2017;7:1–827.
26. Albert TW, Merrill RG. Temporalis myofascial for reconstruction of temporomandibular joint. *Oral Maxillofac Surg Clin North Am.* 1989;1:346.
27. Pogrel MA, Kaban LB. The role of a temporalis fascia and muscle flap in temporomandibular joint surgery. *J Oral Maxillofac Surg.* 1990;48:14–9.
28. Dimitroulis G. The interpositional dermis-fat graft in the management of temporomandibular joint ankylosis. *Int J Oral Maxillofac Surg.* 2004;33:755–60.
29. Thangavelu A, Thiruneelakandan S, Prasath CH, Chatterjee D. Fate of free fat dermis graft in TMJ interpositional gap arthroplasty: a long term MRI study. *J Maxillofac Oral Surg.* 2015;14(2):321–6.
30. Gaba S, Sharma RK, Rattan V, Khandelwal N. The long-term fate of pedicled buccal pad fat used for interpositional arthroplasty in TMJ ankylosis. *J Plast Reconstr Aesthet Surg.* 2012;65:1468–73.
31. Akhter M, Ahmed N, Arefin MRU, Sobhan MU, Molla MR, Kamal M. Outcome of amniotic membrane as an interpositional arthroplasty of TMJ ankylosis. *Oral Maxillofac Surg.* 2016;20(1):63–71.
32. Gunaseelan R. Condylar reconstruction in extensive ankylosis of temporomandibular joint in adults using resected segment as autograft. A new technique. *Int J Oral Maxillofac Surg.* 1997;26:405–7.
33. Khadka A, Hu J. Autogenous grafts for condylar reconstruction in treatment of TMJ ankylosis: current concepts and considerations for the future. *Int J Oral Maxillofac Surg.* 2012;41:94–102.
34. Mehta G, Mohammad S, Ram H, Singh V, Chak RK, Garg S, Vishwakarma K. Re-assessment of coronoid as a graft for condylar reconstruction in TMJ ankylosis patients: a prospective study and literature review. *J Maxillofac Oral Surg.* 2017;16(2):175–80.
35. Liu Y, Li J, Hu J, Zhu S, Luo E, Hsu Y. Autogenous coronoid process pedicled on temporal muscle grafts for reconstruction of the mandible condylar in patients with temporomandibular joint ankylosis. *Oral Surg Oral Med Oral Pathol Oral Radiol Endod.* 2010;109(2):203–10.
36. Poswillo DE. Biological reconstruction of the mandibular condyle. *Br J Oral Maxillofac Surg.* 1987;25(2):100–4.
37. Salash JR, Hossameldin RH, Almarza AJ, Chou JC, McCain JP, Mercuri LG, Wolford LM, Detamore MS. Potential indications for tissue engineering in temporomandibular joint surgery. *J Oral Maxillofac Surg.* 2016;74:705–11.
38. Liu Y, Khadka A, Li J, Hu J, Zhu S, Hsu Y, Wang Q, Wang D. Sliding reconstruction of the condyle using posterior border of mandibular ramus in patients with temporomandibular joint ankylosis. *Int J Oral Maxillofac Surg.* 2011;40:1238–45.
39. Cheung LK, Zheng LW, Ma L, Shi XJ. Transport distraction versus costochondral graft for reconstruction of temporomandibular joint ankylosis: which is better? *Oral Surg Oral Med Oral Pathol Oral Radiol Endod.* 2009;108(1):32–40.
40. Sharma R, Manikandhan R, Sneha P, Parameswaran A, Kumar JN, Sailer H. Neocondyle distraction osteogenesis in the management of temporomandibular joint ankylosis: report of five cases with review of literature. *Indian J Dent Res.* 2017;28(3):269–74.
41. Xiao E, Zhang Y, An J, Li J, Long-term YY. Long-term evaluation of the stability of reconstructed condyles by transport distraction osteogenesis. *Int J Oral Maxillofac Surg.* 2012;41:1490–4.
42. Hu YH, Zhang L, He DM, Yang C, Chen MJ, Zhang SY, Li H, Ellis E. Simultaneous treatment of temporomandibular joint ankylosis with severe mandibular deficiency by standard TMJ prosthesis. *Sci Rep.* 2017;7:45271.
43. Movahed R, Mercuri LG. Management of temporomandibular joint ankylosis. *Oral Maxillofac Surg Clin NA.* 2015;27(1):27–35.
44. Salins PC, Venkatraman B, Kavaroody M. Morphometric basis for orthomorphic correction of mandibular asymmetry. *J Oral Maxillofac Surg.* 2008;66:1523–31.
45. Kohn MW. Analysis of relapse after mandibular advancement surgery. *J Oral Surg.* 1978;36:676–84.
46. Ortiz Monasterio F, Molina F, Andrade L, Rodriguez C, Sainz Arregui J. Simultaneous mandibular and maxillary distraction in hemifacial microsomia in adults: avoiding occlusal disasters. *Plast Reconstr Surg.* 1997;100:852–61.
47. Parameswaran A, Ramanathan M, Pendem S, Jeyakumar N. Orthomorphic distraction—a new concept and its mechanics. *J Cleft Lip Palate and Craniofac Anomal.* 2013;4:1.
48. Gunaseelan R, Anantanarayanan P, Veerabahu M, Vikraman B. Simultaneous genial distraction and interposition arthroplasty for management of sleep apnoea associated with temporomandibular joint ankylosis. *Int J Oral Maxillofac Surg.* 2007;36:845–8.
49. Kunz C, Hammer B, Prein J. Manipulation of callus after linear distraction: a “lifeboat” or an alternative to multivectorial distraction osteogenesis of the mandible? *Plast Reconstr Surg.* 2000;105:674–9.
50. Papageorge MB, Apostolidis C. Simultaneous mandibular distraction and arthroplasty in a patient with temporomandibular joint ankylosis and mandibular hypoplasia. *Case Rep.* 1999;57(3):328–33.

51. Lopez EN, Dogliotti PL. Treatment of temporomandibular joint ankylosis in children: is it necessary to perform mandibular distraction simultaneously? *J Craniofac Surg.* 2004;15:875–9.
52. Zhu S, Jiang Y, Pokhrel N, Hu J. Simultaneous correction of temporomandibular joint ankylosis and secondary dentofacial deformities in adult patients: surgical technique, treatment outcomes, and a consideration of the factors involved. *J Craniofac Surg.* 2015;26:2351–6.
53. Ryu J, Cho J, Kim HM. Bilateral temporomandibular joint replacement using computer-assisted surgical simulation and three-dimensional printing. *J Craniofac Surg.* 2016;27:e450–2.
54. Rao K, Kumar S, Kumar V, Singh AK, Bhatnagar SK. The role of simultaneous gap arthroplasty and distraction osteogenesis in the management of temporo-mandibular joint ankylosis with mandibular deformity in children. *J Craniomaxillofac Surg.* 2004;5182:38–42.
55. Giraddi G, Arora K, Sai Anusha A. Distraction osteogenesis in the treatment of temporomandibular joint ankylosis with mandibular micrognathia. *Ann Maxillofac Surg.* 2016;6:68.
56. Anchlia S, Vyas SM, Dayatar RG, Domadia HL, Nagavadiya V. Guidelines for single-stage correction of TMJ ankylosis, facial asymmetry and OSA in adults. *J Maxillofac Oral Surg.* 2018;18(3):419–27.
57. Zhu S, Wang D, Yin Q, Hu J. Treatment guidelines for temporomandibular joint ankylosis with secondary dentofacial deformities in adults. *J Cranio-Maxillofac Surg.* 2013;41:e117–27.

Open Access This chapter is licensed under the terms of the Creative Commons Attribution 4.0 International License (<http://creativecommons.org/licenses/by/4.0/>), which permits use, sharing, adaptation, distribution and reproduction in any medium or format, as long as you give appropriate credit to the original author(s) and the source, provide a link to the Creative Commons license and indicate if changes were made.

The images or other third party material in this chapter are included in the chapter's Creative Commons license, unless indicated otherwise in a credit line to the material. If material is not included in the chapter's Creative Commons license and your intended use is not permitted by statutory regulation or exceeds the permitted use, you will need to obtain permission directly from the copyright holder.



Part XVIII

Orthognathic Surgery



Diagnosis and Planning in Orthognathic Surgery

66

Johan P. Reyneke and Carlo Ferretti

66.1 Introduction

Over the last four decades, the scientific foundations for the art of changing facial appearance and improving orofacial function through orthognathic surgery were laid, and the value of treatment to improve lives is undisputed. The main treatment objective is currently not limited to achieving short-term improved occlusal function but also enhanced facial aesthetics and an open airway. Orthognathic surgery requires the combined skills of the specialities of orthodontics and oral and maxillofacial surgery; however, there remain major limitations relating to the uneven geographical distribution of experienced dedicated clinicians and financial barriers to the correction of dentofacial deformities. The treatment of some malocclusions combined with mild skeletal disharmony is possible by orthodontic compensation of the dentition with compromised facial aesthetics. Borderline cases therefore require meticulous assessment before finally deciding on orthodontic treatment alone or a combination of orthodontics and surgery as treatment approach.

Most compromised treatments lead to suboptimal results such as:

- Dental instability
- Skeletal instability

J. P. Reyneke (✉)

Director of The Center for Orthognathic Surgery, Mediclinic, Cape Town, South Africa

Department of Oral and Maxillofacial Surgery, Faculty of Health Sciences, University of the Western Cape, Cape Town, South Africa

Department of Oral and Maxillofacial Surgery, University of Oklahoma, Oklahoma City, OK, USA
e-mail: johanrey@worldonline.co.za

C. Ferretti

Department of Maxillofacial and Oral Surgery, University of Pretoria, Pretoria, South Africa

Private practice, Johannesburg, South Africa

- Poor facial aesthetics
- Airway problems
- Periodontal problems

Which treatment plan to adopt should be discussed with the patient (and perhaps the parents or spouse) and all the advantages and disadvantages of each approach explained. The decision may also be influenced by factors such as the orthodontist's experience, financial insurance cover, available surgical expertise, and the patient's attitude and preferences [1].

Patients with dentofacial deformities are treated with four prime goals in mind:

1. *Function.* Apart from establishing normal masticatory function, the clinicians should also consider other problems caused by an abnormal jaw relationship such as speech defects, sleep apnea, attrition of the teeth, periodontal problems, and temporomandibular joint problems.
2. *Stability of results.* Definitive orthognathic treatment is a change for life, and it is important to achieve dental and skeletal stability following treatment.
3. *Aesthetics.* Facial appearance is often the patient's main concern, but patients are often reticent to voice these concerns. However, the surgeon should resist the temptation to determine unilaterally what a patient's aesthetic concerns are but should encourage the patient to express these.
4. *Airway.* The impact of jaw malalignment (and its correction) on the patency of the upper airways is a relatively recent addition to the treatment considerations in patients with dentoskeletal malocclusion. The support of the retropharyngeal soft tissues is determined to a large degree by the position of the anterior osseous attachments. Inadequate support for

these soft tissues will contribute greatly to the development of sleep apnea especially as soft tissue laxity develops with aging. This consideration may influence treatment decisions particularly in Class III malocclusion. For example, we may be loath to unduly setback a mandible in a young adult due the future potential for sleep apnea development. Thus, in double jaw surgery, a treatment plan that favors greater maxillary advancement or in a single jaw surgery case a maxillary advancement may be preferable to a mandibular setback. These considerations add a further layer of complexity to the treatment algorithm as airway considerations may mean a compromise of aesthetics and vice versa [2, 3].

66.2 Systematic Aesthetic Facial Evaluation

The clinical assessment of the face is the most valuable of all diagnostic procedures and should be performed in a systematic fashion. The facial examination should start at the first instant a clinician meets the patient and continues during the initial informal discussion. During this period the patient is not self-aware, and facial function and features will be at their most natural. The focused facial examination follows and should be done while the patient is seated comfortably in natural head posture, the teeth in centric occlusion and the lips relaxed. The goal of the facial examination is to determine what components of the face are detracting from facial harmony and what functional problems may accompany the malocclusion and to make a tentative diagnosis.

It is helpful to structure the facial examination into frontal and profile views [4].

66.2.1 Frontal View

Facial appearance when viewed from the front is, not surprisingly, what a patient will value most.

A helpful first step is to assess the facial form.

- Facial form (Fig. 66.1a–h)—The relationship between the facial width and height has a strong influence on facial harmony. The ratio of facial width to facial height is more important than absolute values in establishing the overall facial type. Attractive faces tend to have proportions that

fall within normative values. When evaluating facial form, the overall body build of the individual (corporo-facial relationship) should be considered (i.e., short and stocky versus long and thin). The height-to-width proportion (trichion to menton: bizygomatic width) is 1.3:1 for females and 1.35:1 for males. The bigonial width should be approximately 30% less than the bizygomatic dimension, and the width and shape of the chin should form a harmonious part of the overall facial contour. Leptoprosopic faces (long and narrow) are often associated with vertical maxillary excess, a narrow nose, mandibular anteroposterior deficiency, narrow gonial angles, microgenia, a high palatal vault, and an anterior open bite (Fig. 66.1a–c), while dolichoprosopic faces (short and square) are often associated with vertical maxillary deficiency, masseter hyperplasia, wide gonial angles, macrogenia, and Class III deep bite malocclusions (Fig. 66.1d, e). Individuals from Asia often have round oval faces (Fig. 66.1f). Patients with mandibular deficiency often have a tapered facial lower facial third and microgenia (Fig. 66.1g, h).

- Transverse facial dimensions (Fig. 66.2)—In general terms the *rule of fifths* is a convenient method used to evaluate the transverse proportions of the face. The face is sagittally divided into five equal parts, each the approximate width of the eye, from helix of the outer ears.
 - *Outer fifths*: Is measured from the lateral helix of the ear to the lateral canthus and is an indication of the width of the ears. Bat ears can be camouflaged by an appropriate hairstyle; however, otoplastic surgical procedures are relatively atraumatic and can improve the facial appearance dramatically. Otoplasty can be performed at the same time as orthognathic procedures.
 - *Medial fifths*: Are measured from the outer to the inner canthus of the eyes. The outer border should coincide with the gonial angles of the mandible. In patients with long and narrow faces, the gonial angles will fall medial to this line, while in patients with broad and square faces, the gonial angles will fall lateral to these lines. Within these fifths it should be noted that the distance between the inner margins of the irides of the eyes should be equal to the width of the mouth. Abnormal interpupillary and intercanthal distance are often observed in syndromic patients and can only be altered by means of craniofacial surgery.
 - *Middle fifth*: Is demarcated by the lines through the inner canthus of the eyes. In patients with hypertelorism, this fifth would be relatively larger than the others. The ala of the nose (alar base width) should coincide with these lines, while the nasal dorsum



©Association of Oral and Maxillofacial Surgeons of India

Fig. 66.1 The relationship between the facial height and width influences facial harmony. The variations of facial form: (a) narrow, (b) long, (c) tapered, (d) square, (e) round, (f) oval, (g) sharp, and (h) pointed, are demonstrated

should be approximately half of the intercanthal distance. For patients in whom maxillary advancement and/or superior repositioning is planned, this measurement should be considered and surgical control of the alar base may be indicated.

- Vertical evaluation (Fig. 66.3)—By convention the face is divided into three parts by horizontal lines adjacent to the hairline (trichion) to the soft tissue glabella, the nasal base (subnasale), and the lower border of the chin (menton). An aesthetically pleasing face should have approximate equivalence of the three parts.
 - *Upper third:* Deformities in this third can fortunately often be masked by an appropriate hairstyle; however,

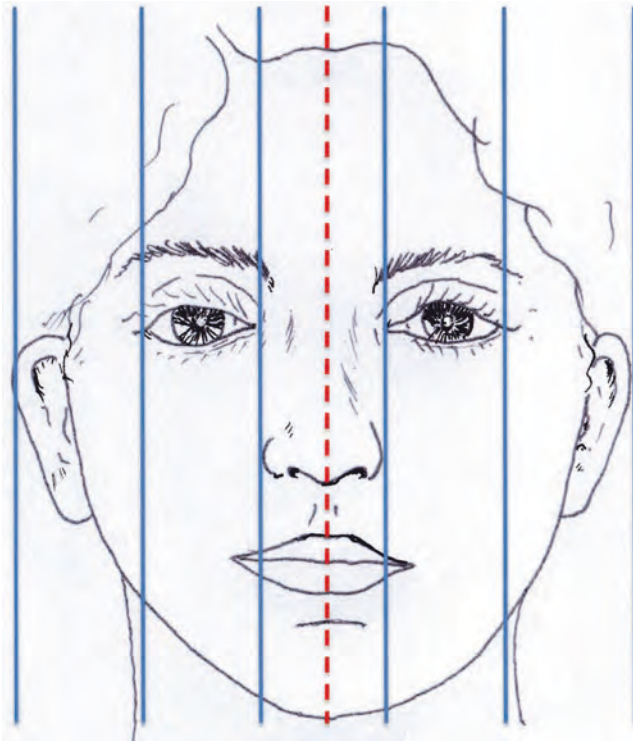
it is important to record deformities in this area as they may indicate craniofacial syndromes.

- *Middle third:* Generally, no sclera is seen above and below the iris in a relaxed eyelid position. Individuals with midface deficiency tend to show sclera under the iris of the eye and will tend to have a long narrow nose. The cheekbone-nasal base-upper lip-lower lip contour line is a convenient indicator of the harmony of the structures of the midface (zygoma, maxilla, and nasal base) with the paranasal area and upper lip. This imaginary line starts just anterior to the ear, extends anteriorly across the cheekbone, and then curves antero-inferior over the maxilla adjacent to the alar

base of the nose, ending lateral and slightly below the commissure of the mouth. The line should form a smooth, continuous curve (Fig. 66.4a, c). A skeletal deformity will cause an interruption of the curve, and

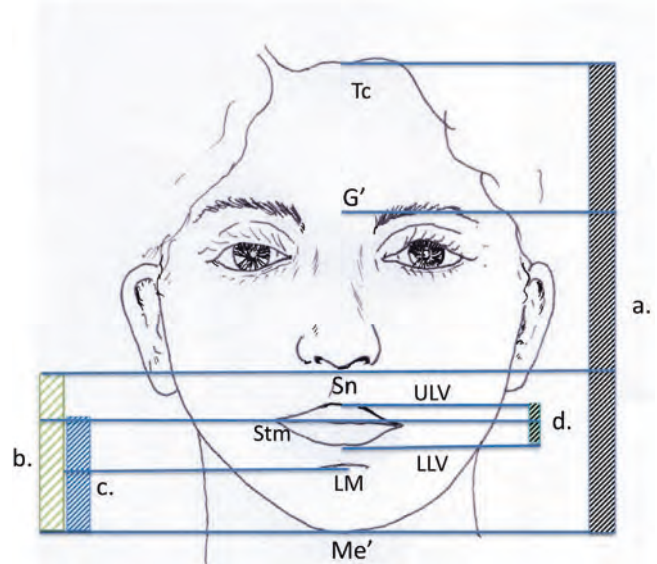
the area of interruption in the line is often an indication of a specific underlying deformity (Fig. 66.4b).

– *Lower third:* (Fig. 66.3) The middle to lower third vertical height of the face should have a 5:6 ratio. In the well-balanced lower third of the face, the upper lip makes up one third, while the lower lip and chin composes the lower two thirds. Normal upper lip length is 20 ± 2 mm for females and 22 ± 2 mm for males and measured from subnasale to upper lip sto-



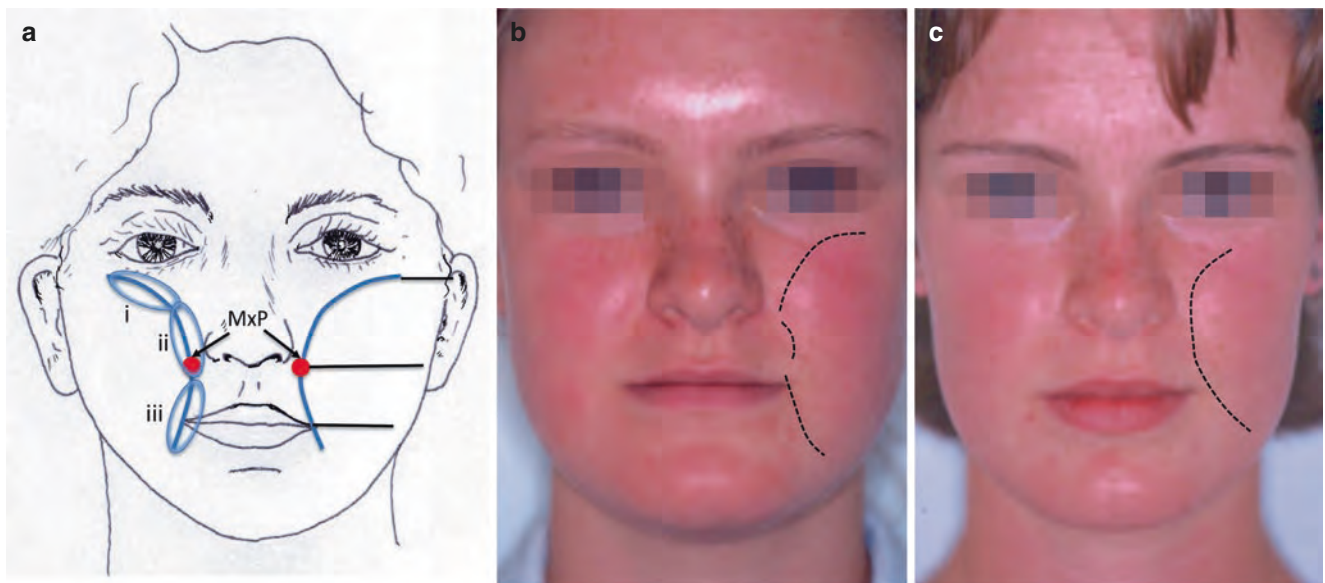
©Association of Oral and Maxillofacial Surgeons of India

Fig. 66.2 Transverse facial proportions



©Association of Oral and Maxillofacial Surgeons of India

Fig. 66.3 Vertical facial proportions



©Association of Oral and Maxillofacial Surgeons of India

Fig. 66.4 (a) Cheekbone-nasal base-lip contour. (b) The interruption of the curve at MxP (maxillary plane) indicates maxillary anteroposterior deficiency. (c) Correction of the malocclusion establishes a smooth contour line

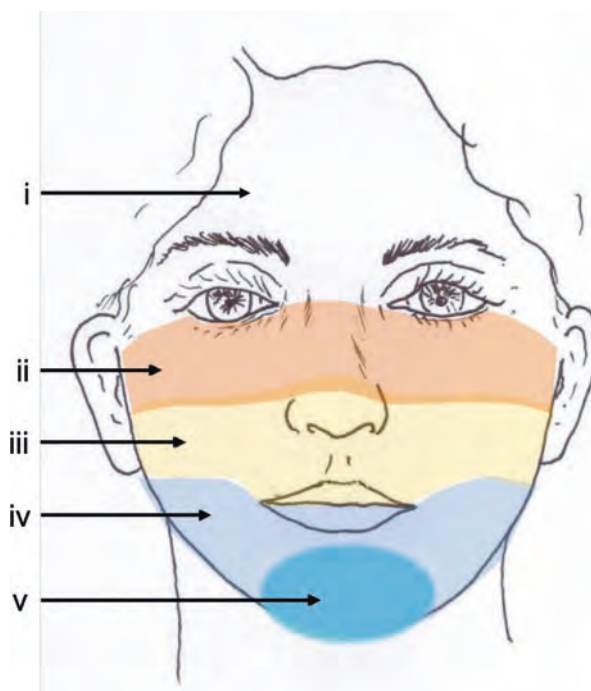
mion (stomion superius). When the upper lip is relatively short, there will be a tendency to an increased interlabial gap and excessive upper incisor exposure with normal facial height. This should not be confused with the same observations in patients with vertical maxillary excess (Fig. 66.8). Normal lower lip length is 40 ± 2 mm for females and 44 ± 2 mm for males. The lower lip may give the false impression of being short due to a deep bite. It is mandatory that the interlabial gap and tooth exposure be evaluated with the teeth in occlusion and the lips in repose (Fig. 66.8b). A gummy smile is not a definite indication of vertical maxillary excess as some patients may have a normal maxillary height but hyperactive upper lip when smiling. An increased interlabial gap (more than 3 mm), excessive upper incisor exposure (more than 4mm), and a gummy smile are typical characteristics of vertical maxillary excess (Fig. 66.9). For patients in whom the upper incisors are not visible under the upper lip, the tooth lip relationship should be evaluated with the mandible rotated open until the lips just separate (Fig. 66.8a). Lack of upper incisor exposure is indicative of vertical maxillary deficiency and usually occurs in combination with decreased lower facial height. The height of the lower face can also be influenced by the height of the mandible, and the height of the chin should be noted in any discrepancy in vertical facial height.

The arbitrary subdivision of the face into vertical thirds has a critical flaw. The effects of a deformity of one jaw and the correction thereof may stretch across two conventional facial thirds.

It is for this reason that the authors believe a more pragmatic approach to facial aesthetic assessment is to divide the face into zones of influence, i.e., zones which can be modified by orthodontics and orthognathic surgery.

The *Ferretti-Reyneke analysis* (Fig. 66.5) divides the face into five zones of influence, i.e., zones of soft tissue facial integument that are under the influence of the corresponding underlying skeleton:

- *The fore-head zone* (i). Extending from trichion (hairline) to a line connecting the eyebrows across glabella.
- *The oculonasal zone* (ii). Extending inferiorly from the eyebrow line to a line extending from the lower border of the zygomatic arch curving upward to the infraorbital foramen onto the nose above the supra tip break and continuing to the opposite side.



©Association of Oral and Maxillofacial Surgeons of India

Fig. 66.5 The *Ferretti-Reyneke analysis*

- *The gnathic complex*. This subunit is subdivided into an upper *maxillary component* (iii) which extends from the lower aspect of the oculonasal complex to a curved line extending along the lower margin of the upper lip (or the incisal edge of exposed maxillary teeth) to the angle of the mouth and proceeding in a curvilinear fashion to the lower attachment of the auricle and a lower *mandibular component* (iv) which extends to the lower border of the mandible and contains in its anterior aspect the oval *mental subunit* (v) which delimits the soft tissue chin.

It is critical to remember that facial evaluation is not the search for deviation from the norm of a single subunit but the search for proportion. For example, a facial form diagnosed as vertically excessive means it is excessive in relation to its transverse dimension, *not* that it is longer than the norm. By increasing only the transverse or only the vertical dimension, facial harmony will be lost; however, harmony is re-established by increasing both the transverse and vertical dimensions.

Facial Symmetry

The facial midline is the reference line to evaluate the forehead (glabella), nasal dorsum, nasal tip, maxillary dental midline, columella of the nose, philtrum of the upper lip, mandibular dental midline, lower lip, and the chin (Figs. 66.2 and 66.6). In the initial overall assessment of facial asymmetry, we should establish whether the asymmetry involves

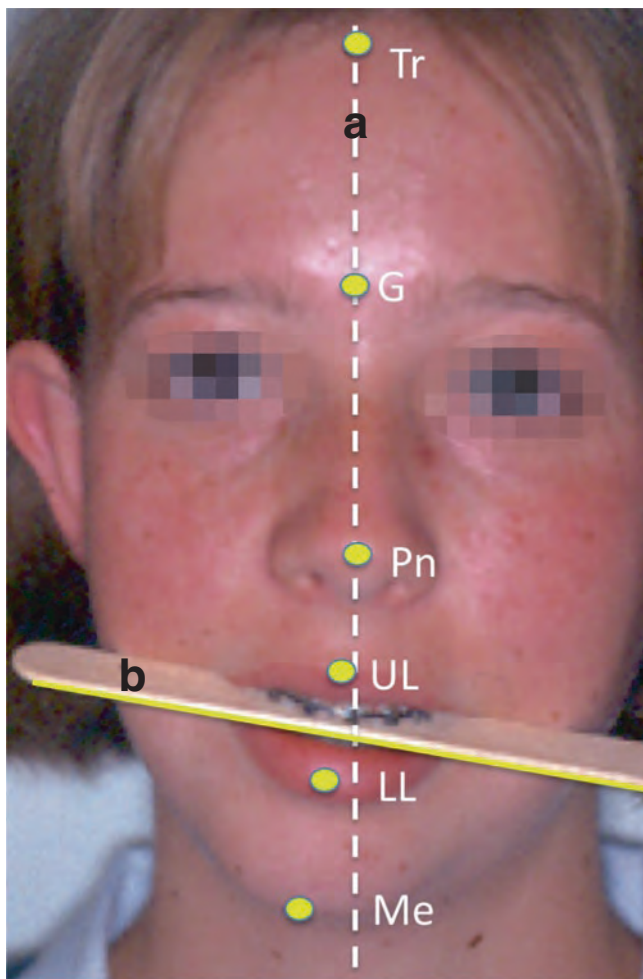
the chin, the mandible or the maxilla, or a combination of the structures. Careful assessment of an occlusal cant of the maxilla is mandatory as it will play an important role in the correction of the asymmetry. Soft tissue asymmetry, either primary or secondary to skeletal asymmetry, should be noted. Finally, symmetry of the nose, orbits, and forehead should be evaluated (Figs. 66.2 and 66.6).

The face is a three-dimensional structure, and the symmetry of the face will be influenced by deformities in the vertical, anteroposterior, and transverse planes. Clinical frontal assessment of the face is however the most critical, and discrepancies should be correlated with posterior facial asymmetry by noting any transverse, anteroposterior, and/or sagittal cants in the occlusal plane. The occlusal plane should be parallel to the interpupillary line, provided there is no orbital dystopia. Surgical correction of an occlusal plane cant often corrects facial asymmetry, and the severity of the cant should correlate with the dental and facial asymmetry. During treatment planning the clinicians should assess if orthodontic

or surgical correction of dental midlines is required. With skeletal asymmetry the dental midline should not be orthodontically coordinated but rather aligned in the center of each jaw to allow surgical correction of the skeletal asymmetry. Keep in mind that no face is perfectly symmetric.

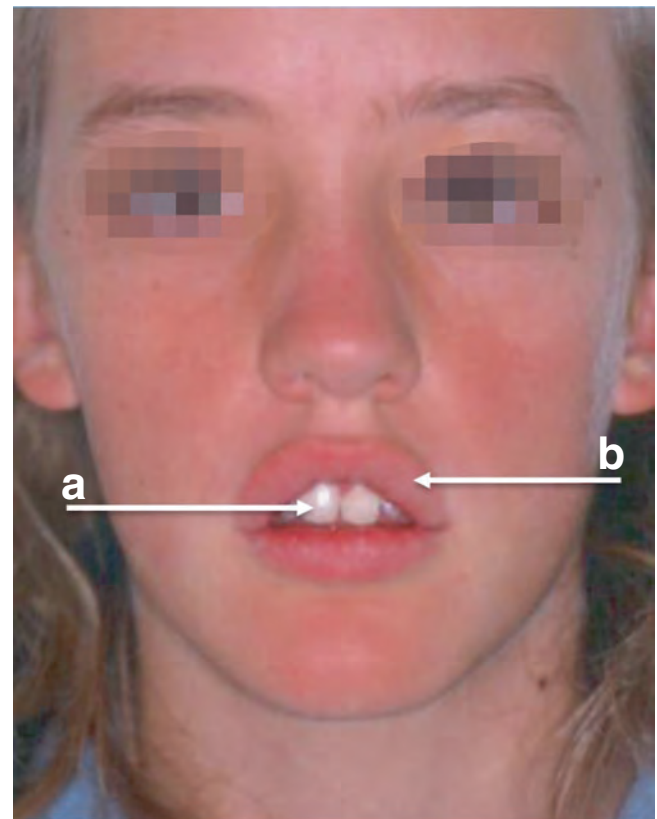Lips

The lips play an extremely important role in the overall facial aesthetics, and careful assessment is required. Lip symmetry should be evaluated in the rest position as well as when the patient is smiling. Lip symmetry may be influenced by facial nerve dysfunction, underlying dentoskeletal deformities, scarring due to previous trauma, congenital clefting, microstomia, macrostomia, or hyperplasia. The lower lip generally exhibits 25% more vermilion than the upper lip. With the presence of an accentuated Cupid's bow, only the upper incisor may be visible under the upper lip and very little or even no lateral incisor (Fig. 66.7). An interlabial gap of 0 to 4mm and 1 to 4mm of upper incisor tooth exposure under the upper lip with the lips in repose are considered pleasing while the full crown of the incisor exposed when smiling.



©Association of Oral and Maxillofacial Surgeons of India

Fig. 66.6 The facial midline (a), and occlusal cant (b)



©Association of Oral and Maxillofacial Surgeons of India

Fig. 66.7 An increased interlabial gap with excessive amount of upper incisor exposure under the upper lip (a). A poorly shaped upper lip (distorted Cupid's bow) and excessive amount of vermilion excessive exposure (b)

Note any asymmetry of the lips when smiling (Fig. 66.10). When vertical skeletal or dental corrections are contemplated, the vertical relationship of all four incisors to the upper lip should be clinically considered. Only the upper central incisors are visible on a lateral cephalometric radiograph and should not be used to plan vertical maxillary changes (c in Fig. 66.13).

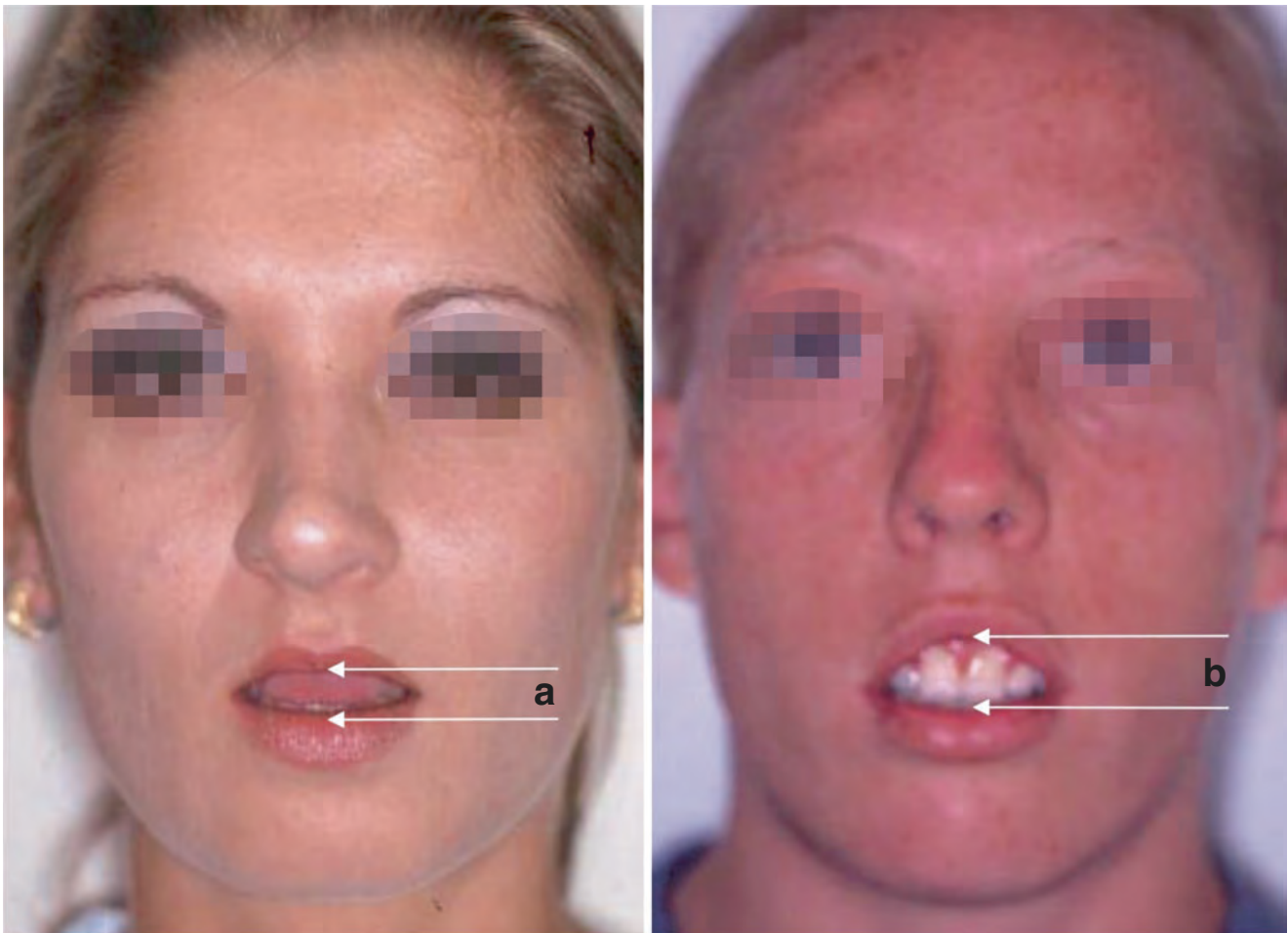66.2.2 Profile View

Although it is emphasized that the clinical assessment of the face is mandatory, the cephalometric analysis of the lateral cephalometric radiograph has been the predominant method of profile evaluation. Many orthodontists are accustomed to using the quantitative data obtained from the lateral cephalometric analysis as the main diagnostic tool. The contempo-

rary orthodontist and facial surgeon rely on facial proportionality and more subjective aesthetic evaluation criteria than linear and angular measurements. Treatment decisions should rather be made by what is most aesthetically appealing rather than by what the cephalometric norms indicate. The plethora of cephalometric values available can lead to confusion and unnecessary complexity. The undermentioned cephalometric measurements are the most useful indicators to confirm a clinical diagnosis.

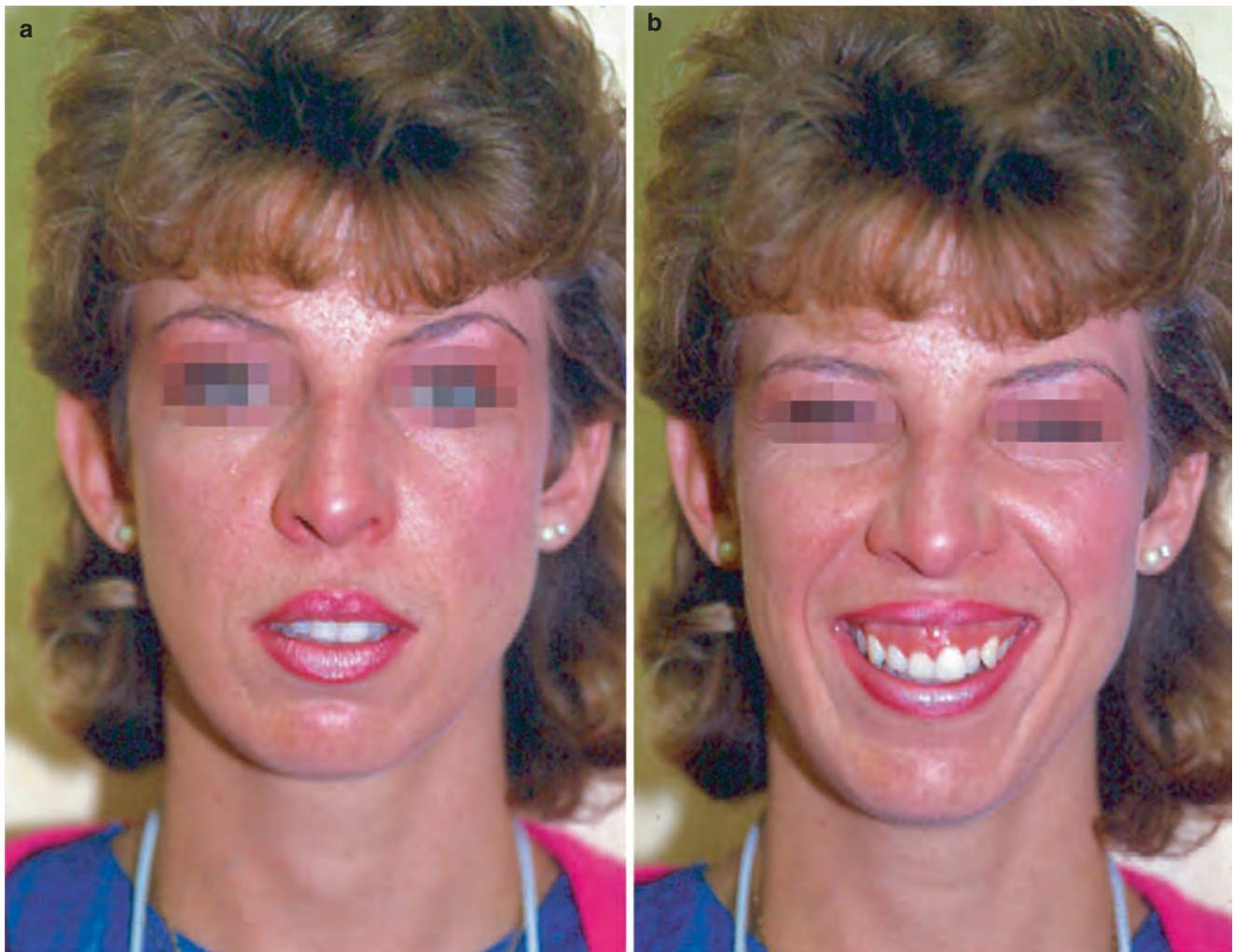Nasolabial Angle (a in Fig. 66.11)

The angle is measured between the columella of the nose and the upper lip and should be between 85° and 105°. It is influenced by the position and angle of the upper incisor teeth and the anatomy of the nasal columella. Excessive orthodontic retraction of the upper incisor teeth (i.e., com-



©Association of Oral and Maxillofacial Surgeons of India

Fig. 66.8 No upper incisor exposure under the upper lip leads to a “toothless” look (a). An increased interlabial gap with excessive upper incisor exposure suggests vertical maxillary excess (b). The assessment should always be done with the lips in repose



©Association of Oral and Maxillofacial Surgeons of India

Fig. 66.9 A patient with vertical maxillary excess. Note the increased interlabial gap with the lips in repose (a) and gummy smile (b)

promised treatment for a Class II occlusion) will lead to poor upper lip support and an increased nasolabial angle. This will often lead to early wrinkling and an aging appearance of the lip. An over-closed bite will cause an acute angle, while a hanging columella of the nose will increase the angle.

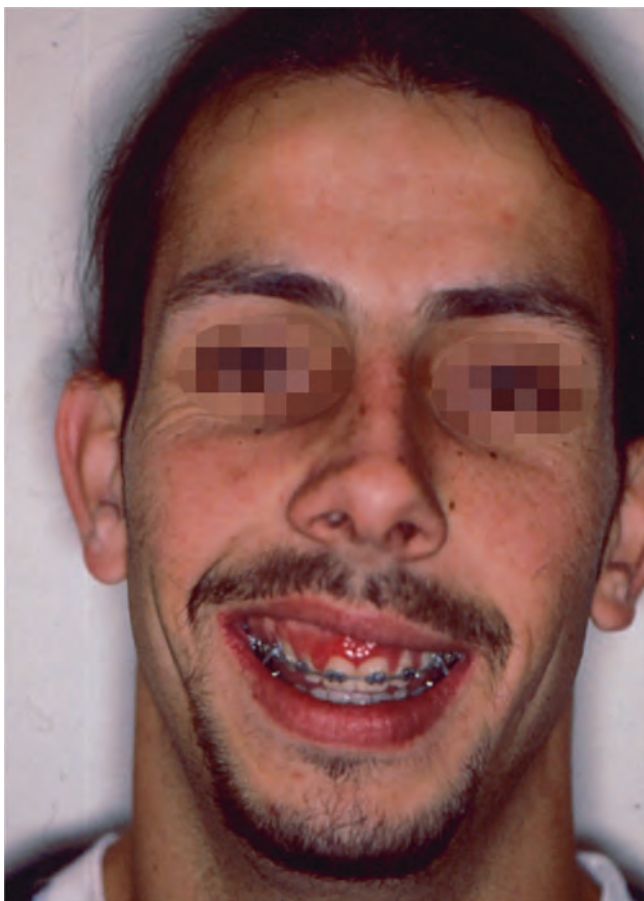Labiomental Angle (b in Fig. 66.11)

This angle is formed by the intersection of the lower lip and chin measured at the soft tissue of the chin. The angle is a gentle curve and should be $120^\circ \pm 10^\circ$. The lower lip, the depth of the labiomental fold, and chin button should form a smooth and harmonious S-shaped curve with the labiomen-

tal fold dividing the chin into an upper third and lower two thirds. The angle is acute in patients with Class II dentoskeletal deformities due to the everted lower lip or patients with macrogenia. Individuals with Class III dentoskeletal deformities and the lower incisors retroclined (compensated) or patients with microgenia will exhibit an obtuse labiomental angle.

Lip-Chin-Throat Angle ((i) in Fig. 66.12)

The angle is formed between the lower border of the chin and a line connecting the lower lip and soft tissue pogonion. The chin and submental area are considered attractive with an angle between 100° and 120° .

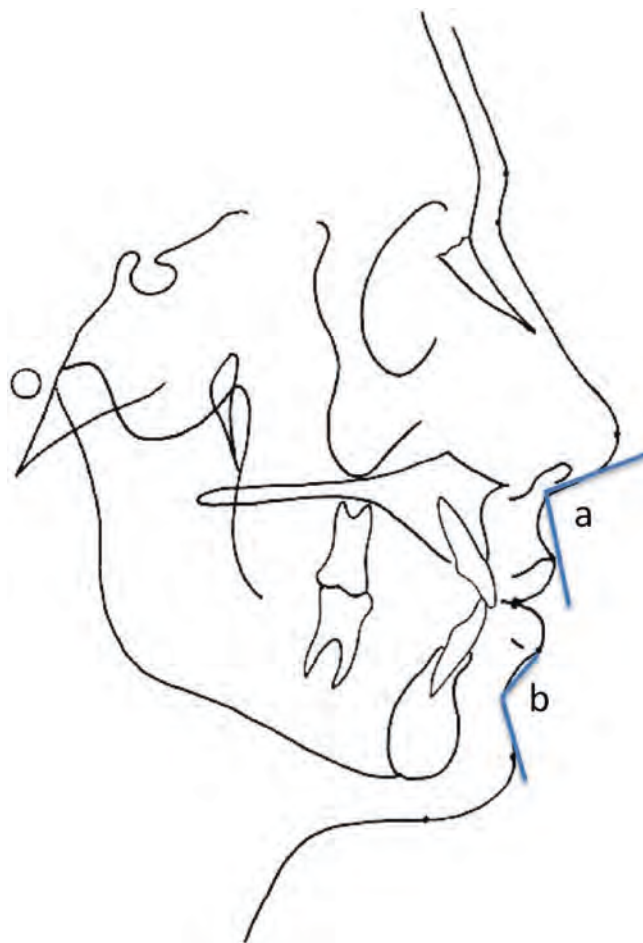


©Association of Oral and Maxillofacial Surgeons of India

Fig. 66.10 An asymmetric smile

Chin-Throat Length ((ii) in Fig. 66.12)

It is measured from the angle of the throat to the soft tissue menton. It is only meaningful when this angle is measured with the patient's head in natural posture. A length of between 38 and 48mm is considered to be normal and is significant when assessing mandibular length. This measurement is helpful for differentiating between mandibular anteroposterior excess and maxillary anteroposterior deficiency. For a patient with a Class III malocclusion and normal chin-throat length, maxillary deficiency should be suspected.



©Association of Oral and Maxillofacial Surgeons of India

Fig. 66.11 (a) The nasolabial angle, measured between the inclination of the columella of the nose and the upper lip, should be 85° – 105° . (b) Labiomental fold. The lower lip-chin angle should be 130° . However the general shape of the chin should be considered

Upper Lip Length (b in Fig. 66.13)

The length of the upper lip is measured from subnasale to the lower border of the upper lip (stomion superius) and should be 18–22 mm in females and 20–24 mm in males. This measurement should be performed with the lips in repose. During the planning of tooth-lip relationship, it should be kept in mind that the upper lip will increase in length with age.

Interlabial gap (d in Fig. 66.13)

The interlabial gap should be assessed with the lips in repose and the teeth in occlusion. It is measured between stomion superius and stomion inferius (0–4 mm). If the lips touch when the teeth are in occlusion, the upper incisor-lip relationship should be evaluated with the lower jaw rotated open until the lips are slightly apart.

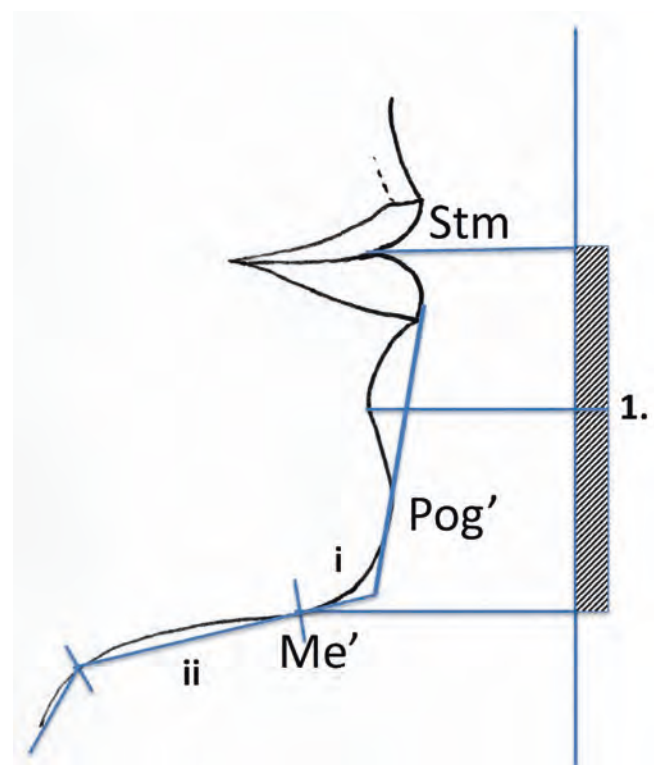
Facial Contour Angle (e in Fig. 66.13)

This measurement will give the clinician an indication of facial convexity or concavity and is influenced by the antero-posterior relationship between glabella, subnasale, and menton. The angle is formed between the upper facial plane (glabella-subnasale) and lower facial plane (subnasale-pogonion). The angle is recorded above subnasale and expressed as negative when the angle is ahead of the upper facial plane (in convex profiles) and as positive when the angle is behind the upper facial plane (usually in concave profiles). A pleasing facial profile for females will have a facial contour angle of $-13^{\circ} \pm 4^{\circ}$ and for males $-11^{\circ} \pm 4^{\circ}$. This measurement will also be influenced by the height of the maxilla. The mandible will rotate counterclockwise (upward and forward) with vertical maxillary deficiency leading to a more concave profile, while it will rotate clockwise (downward and backward) with vertical maxillary excess leading to a more convex profile.

Nose (Fig. 66.14)

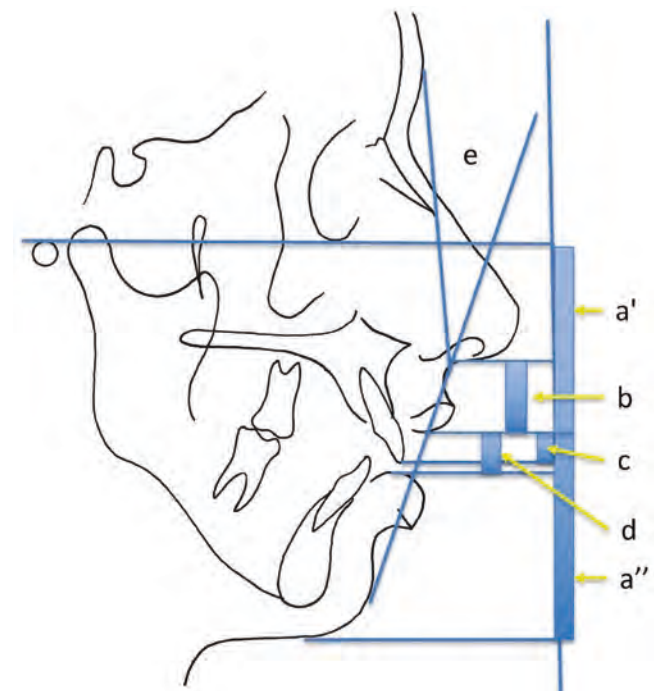
This important anatomic structure is situated in the middle of the face, and its important influence on facial aesthetics has often been neglected by orthodontists and maxillofacial surgeons in the past. More focus is placed on the aesthetic evaluation of the nose by the fact that the relative nasal aesthetics can be influenced by orthodontic treatment and certainly by orthognathic surgery. The fact that rhinoplasty is now considered to be part of the field of treatment for many orthognathic surgeons has certainly made the careful aesthetic evaluation of the nose an important consideration. In many cases nasal reconstruction will form part of the orthognathic treatment plan, and in some cases, reconstruction can be performed concurrently with orthognathic surgery. The authors prefer to defer most nasal reconstructions to 6 months after orthognathic surgery due to the substantial relative effects orthognathic surgery has on nasal aesthetic.

The amount of nostril show in profile view may be affected by either a hanging columella or retracted alae (Fig. 66.14a). The shape of the dorsum should be noted as normal, convex, or concave. It is important to distinguish between a large dorsum and a turned-down nasal tip as the treatment would be entirely different. The relationship between the lengths of the nasal dorsum and the projection



©Association of Oral and Maxillofacial Surgeons of India

Fig. 66.12 The lip-chin-throat angle (i). Chin-throat length (ii)



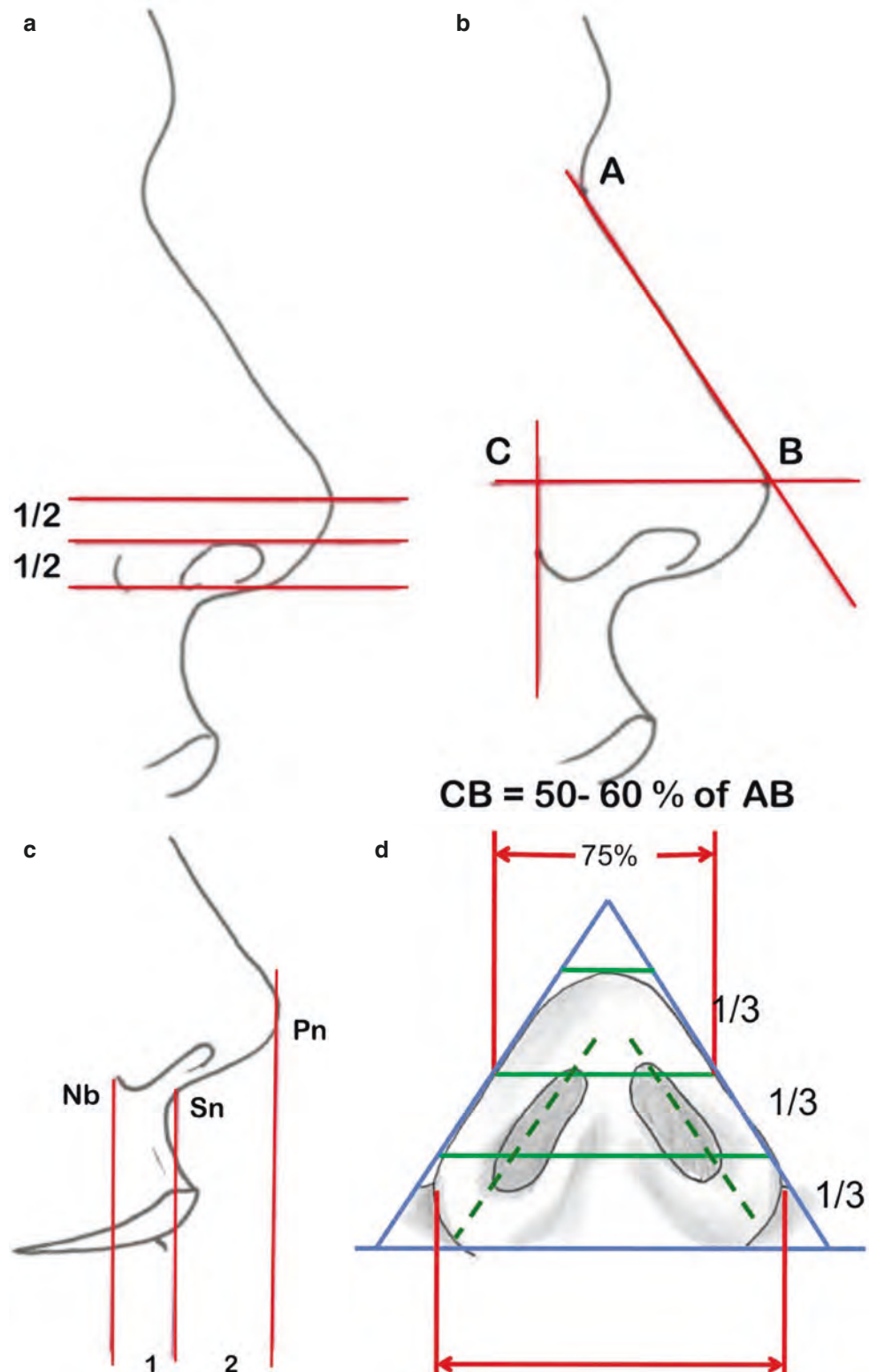
©Association of Oral and Maxillofacial Surgeons of India

Fig. 66.13 Midface height (a'), lower facial height (a''), upper lip length (b), upper lip vermilion (c), interlabial gap (d), and facial contour angle (e)

of the nose can be evaluated by the method of Goode. According to Goode the length of the nose should be about 55–60% greater than the projection of the nose (Fig. 66.14b). From nasal base to the tip, the ratio of projection should be 1–2 (Fig. 66.14c). The nostrils and columella should be

assessed from a “worm’s eye” view (Fig. 66.14d). The nasal bridge should project about 5–8 mm in front of the globes of the eyes. The nasal tip should be noted as narrow, bulbous, asymmetric, or normal. The width of the nasal base, the acuteness of the supra tip break, the visibility of the nostrils,

Fig. 66.14 Assessment of nostril show (a). Nasal projection (CB) to nasal length (AB), according to Goode’s ratio: $CB:AB = 0.55:0.6$ is normal (b). Horizontal assessment of nasal projection: from nasal base (Nb), the Pn-Sn to Sn-Nb should be 2:1 (c). Nasal base (“worm’s eye”) view assessment of the nose. The general shape of the alar base should resemble an isosceles triangle (d)



and symmetry of the columella are important factors to consider when maxillary surgery (especially superior repositioning or advancement) is contemplated. Fortunately, adverse aesthetic effects as a result of maxillary surgery can be controlled during surgery [4].

Cheeks (Fig. 66.15)

As in the frontal evaluation, the *cheekbone-nasal base-upper lip-lower lip curve* contour line is also very helpful in the profile analysis. The line starts just in front of the ear, extending forward over the cheekbone, downward over the maxilla adjacent the ala of the nose, and ending lateral to the commissure of the mouth. The line should form a smooth continuous curve, and any interruption may indicate an underlying skeletal deformity (Fig. 66.15). The variations in interruptions in the curve and the possible underlying skeletal deformities responsible for the soft tissue deformities are demonstrated in Fig. 66.15b, c [5].

Orbit

The globes of the eye generally project 0–2 mm ahead of the infraorbital rims, while the lateral orbital rims lie 8–12 mm behind the most anterior projection of the globes. The bridge

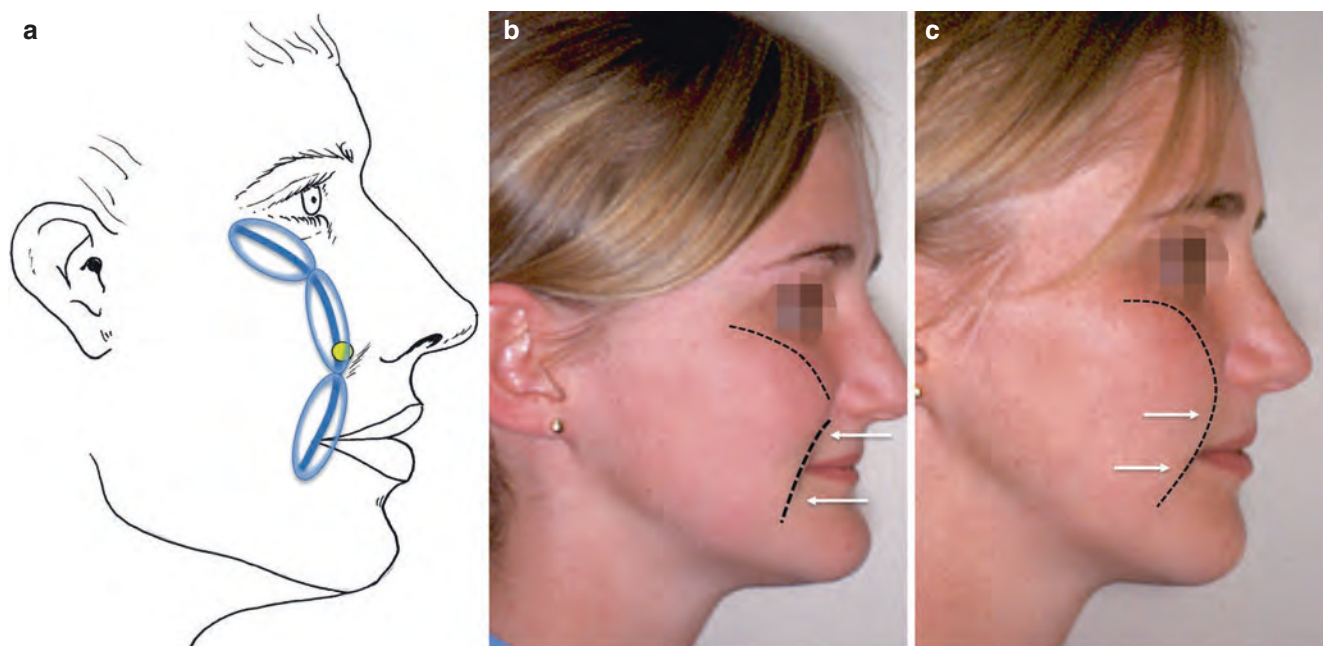
of the nose should be about 7 mm ahead of the globes although there is a significant ethnic difference in this measurement (Fig. 66.14) [6].

Paranasal Area

The flatness or fullness of the paranasal areas is an important indicator to distinguish between middle third deficiency and mandibular anteroposterior excess. Another useful indicator of midface deficiency is the ratio of the linear distance from the nasal tip to subnasale and from subnasale to the alar base crease. The ratio should be 2:1 (Fig. 66.14). A ratio closer to 1:1 will indicate maxillary anteroposterior deficiency, while an increased ratio will indicate decreased nasal projection.

Lips

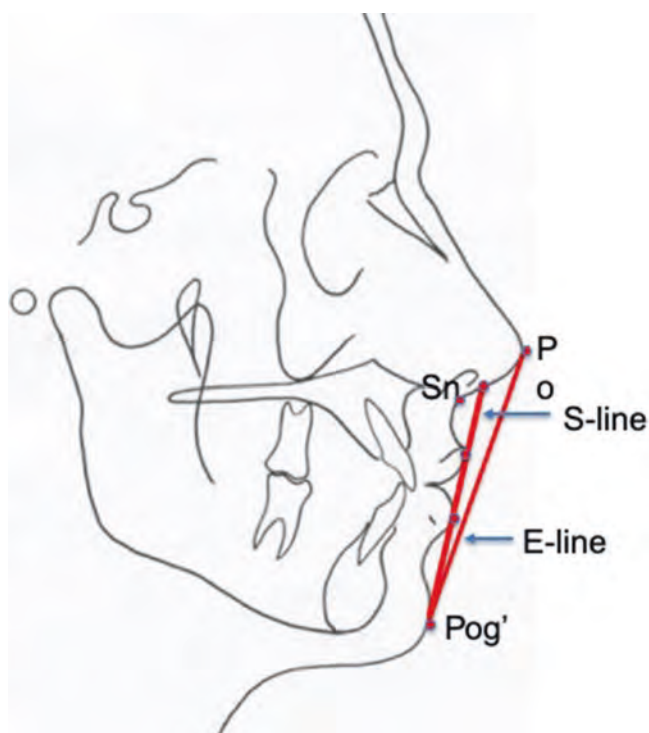
The lips play an important part in the overall aesthetics of the face and should be carefully assessed before treatment. The effects of treatment as well as the aesthetic changes that may take place during the aging process should be considered. The upper lip usually projects slightly anterior to the lower lip, and the E-line and S-line are helpful guides to assess the projection of the lips (Fig. 66.16) [7].



©Association of Oral and Maxillofacial Surgeons of India

Fig. 66.15 (a) The cheekbone-nasal base-lip curve contour. The curve should be uninterrupted and smooth in an individual with good facial proportions. (b) The cheekbone-nasal base-lip curve contour. The interruption of the curve (arrows) indicates maxillary as well as mandibular

anteroposterior deficiency. (c) The cheekbone-nasal base-lip curve contour. Following maxillary and mandibular advancement, the curve is uninterrupted and smooth (arrows)



©Association of Oral and Maxillofacial Surgeons of India

Fig 66.16 Lip prominence. Li should be 2 ± 2 mm behind the E-line (Pn-Pog'). Li – Labrae inferioris and Ls – Labrae superioris should just touch the S-line (S-line follows Pog' to the point between Sn and Pn)

Chin

The chin is one of the most noticeable structures in the face and demands special evaluation. The shape of the chin is more important than the position of pogonion. Chin surgery should not be considered for patients requiring mandibular surgery. Performing an advancement genioplasty for a patient as compromise treatment for mandibular advancement may achieve correct chin projection; however, the balance and harmony of the chin will be poor. The authors use seven criteria for the aesthetic profile evaluation of the chin which also serve as a guide to surgical treatment planning (Figs. 66.11, 66.12, and 66.13) [8].

1. Height of the chin. The chin height is measured from lower lip stomion to soft tissue menton and should be equivalent to two thirds of the lower facial height. The linear height should be 40 ± 2 mm for females and 44 ± 2 mm for males. For individuals with deep bites, the measurement should be performed with the teeth apart and the lip separated (i in Fig. 66.12).
2. Vermillion exposure. The lower lip vermilion exposure should be 25% more than the upper lip. The lower lip will be everted with increased vermilion exposure when the

lower incisors are proclined or in individuals with an increased overjet (Fig. 66.13).

3. The labiomenal fold. The depth of the fold should divide the chin into an upper third and lower two thirds (Fig. 66.11).
4. Chin throat length. Patients with mandibular anteroposterior deficiency will have short chin-throat lengths and vice versa for individuals with mandibular anteroposterior excess. Normal length is considered to be 42 ± 6 mm. This measurement is important when considering setback or advancement of the chin (ii in Fig. 66.12).
5. Lower lip-chin-throat angle. The angle is considered pleasing at $110^\circ \pm 8^\circ$ and tends to be acute in mandibular prognathism and obtuse in mandibular deficiency (Fig. 66.12).
6. S-shaped curvature. The profile of the chin should form a well-proportioned, harmonious and smooth curve (Fig. 66.12).
7. The lower lip position. A helpful guide to the lower lip position is the E-line (aesthetic line). The E-line is drawn from the nasal tip (pronasale) to pogonion. The lower lip should be 2 ± 2 mm behind the line. The measurement will be influenced by the projection of the nose and the anteroposterior position of the chin which should be kept in mind during this evaluation (Fig. 66.13).

Most of the aforementioned aesthetics parameters can also be assessed on a lateral cephalometric radiograph; however, there is no substitute for clinical evaluation of facial harmony. It is hoped that the short overview of the clinical assessment of facial aesthetics will increase the reader's acuity in the treatment of his/her patients. In most instances the orthodontist is the first professional to see patients with malocclusions. Some of these patients may require skeletal and/or soft tissue modification incorporated into the treatment plan, and the responsibility lies with the orthodontist to recognize the dental, skeletal, and soft tissue problems and then to appropriately inform the patient. The aesthetic outcome following orthodontic (and surgical) treatment should be a priority for the contemporary orthodontist.

66.3 Clinical Evaluation

The clinical assessment of the face is probably the most valuable of all diagnostic procedures. While an astute clinical diagnosis can be made at the chair side, photographs are essential for accurate assessment and record purposes. The face is systematically assessed from a frontal view, profile view, and three-quarter view. Figures 66.1, 66.2, 66.3, 66.4, 66.5, 66.6, 66.7, 66.8, 66.9, 66.10, 66.11, 66.12, and 66.13 illustrate some angular and linear parameters used during the clinical assessment of the face.

66.4 Special Investigations

Cephalometric and panoramic radiographs and dental casts are essential; however, temporomandibular joint investigations, Technetium bone scans, hand wrist radiographs, CT scans, etc. may be required. The lateral cephalometric radiograph taken in centric occlusion and the lips in repose allows the clinician to analyze and evaluate the soft tissue, skeletal, and dental relations of a dentofacial deformity.

66.5 Diagnosis and Problem List

A diagnosis is made following the clinical evaluation of the patient, a radiographic evaluation and cephalometric analysis, model analysis, and other indicated evaluations. The data base is used to compile a problem list.

66.6 Treatment Objectives

Clear orthodontic and surgical treatment objectives regarding soft tissue, skeletal, and dental structures should be identified and noted.

Development of a Visual Orthodontic and Surgical Cephalometric Treatment Objective The lateral cephalometric radiograph tracing is used to develop an orthodontic visual treatment objective to predict orthodontic tooth movements. This is followed by the development of a surgical visual treatment objective predicting the required jaw repositioning and expected soft tissue changes [10].

66.7 Treatment Plan

All the factors identified in the diagnosis and problem list as well as patient concerns and reasons for considering orthognathic surgery are considered to formulate a final treatment

plan (Flowchart 1). The sequence of treatment and the treatment to be performed by all healthcare professionals concerned are outlined. When defining the treatment plan, a thorough knowledge of the many types of dentofacial deformities and the treatment modalities available to correct them is essential.

The flowchart (Fig. 66.17) summarizes the systematic gathering of data leading to diagnosis and, finally, the development of a treatment plan [9–11].

The basic treatment plan will consist of:

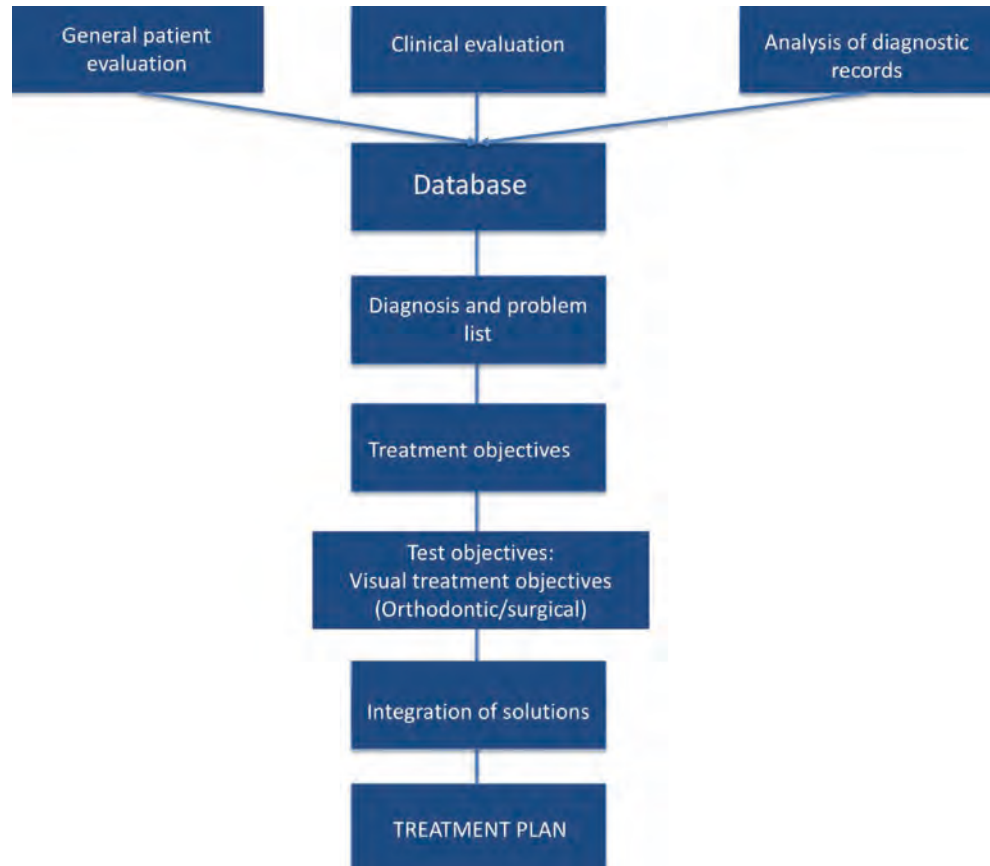
Presurgical Orthodontic Treatment

1. Alignment of both dental arches (with or without tooth extractions)
2. Levelling of both dental arches (in segments or one piece)
3. Deviation of tooth roots at planned interdental osteotomies areas
4. Decompensation of any dental compensations
5. Coordination of dental arches (or segments)

Surgery

The treatment of patients with dentofacial deformities can broadly be divided into four groups. The specific surgical procedure(s) will be indicated by the problem list as discussed:

1. Single jaw surgery—mandibular repositioning (advancement or setback)
2. Single jaw surgery—maxillary repositioning (advancement or setback or superior repositioning or downgraft and/or segmental surgery or a combination)
3. Double jaw surgery
4. Rotation of the maxillomandibular complex

Fig. 66.17 Flowchart 1

©Association of Oral and Maxillofacial Surgeons of India

For each of the above surgical treatment categories, the orthodontist and the surgeon will have specific responsibilities to make the treatment efforts occur smoothly and successfully. In most surgeries, conventional treatment planning using lateral cephalometric and PA cephalometric radiographs and cast model surgery with surgical splint fabrication is indicated. However the authors use 3D virtual treatment planning for more challenging surgeries such as facial asymmetries, rotation of the maxillomandibular complex, etc. [12, 13].

66.8 Treatment

Although the orthodontist and the oral and maxillofacial surgeon are the main role players, comprehensive correction of dentofacial deformities may involve several members of the healthcare team. The surgeon should understand the orthodontic decision-making process, while the orthodontist must understand the pre- and postsurgical orthodontic requirements. It is mandatory that the therapeutic management is carried out as planned and any problem or change in

treatment plan should be communicated to the treatment team. Successful and knowledgeable practitioners always maintain good interprofessional communication and mutual respect to achieve the best treatment results.

66.9 Conclusion

Successful orthognathic surgery relies on understanding and interpreting a patient's desires, correlating these with the diagnosis, and finally developing a treatment plan and executing it accurately. While virtual 3D planning has provided

another tool to aid in diagnosis and surgical planning, it behooves surgeons to continue to develop proficiency in traditional cephalometry-based treatment planning.

66.10 Case Scenarios

Case 1: A female patient suffering from hemifacial microsomia on the left (Figs. 66.18, 66.19, 66.20, 66.21, 66.22, 66.23 and 66.24).

Case 2: A male patient suffering from skeletal Class 3 malocclusion (Figs. 66.25, 66.26 and 66.27)

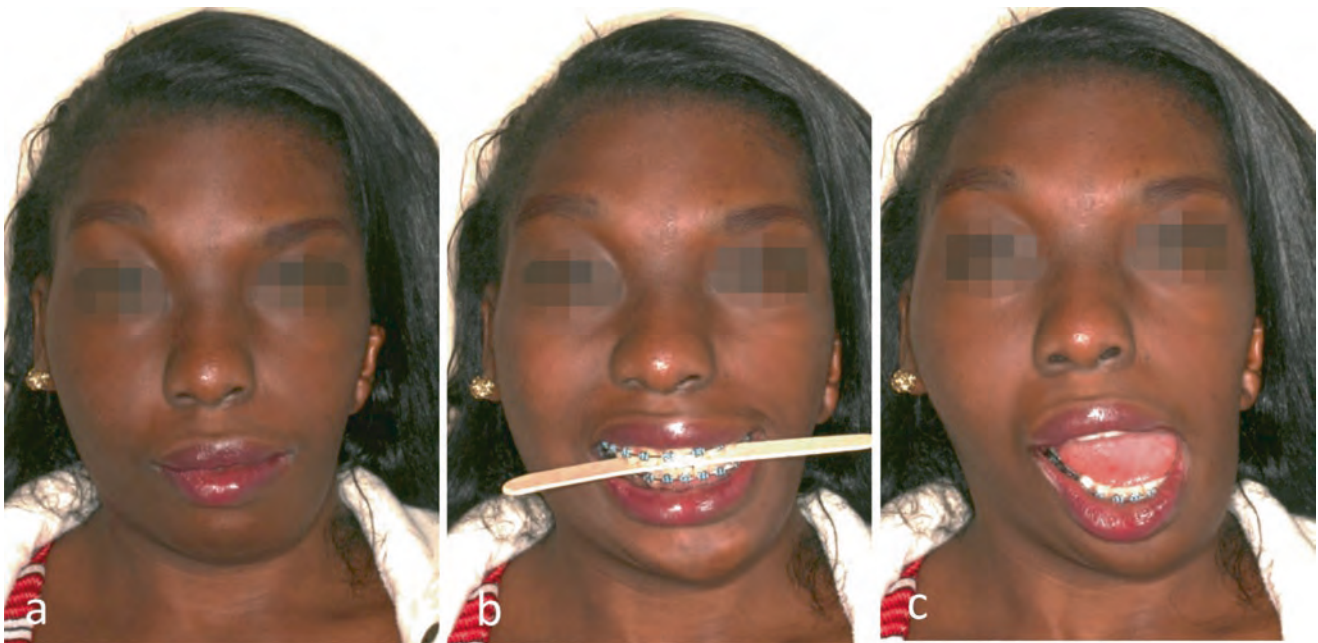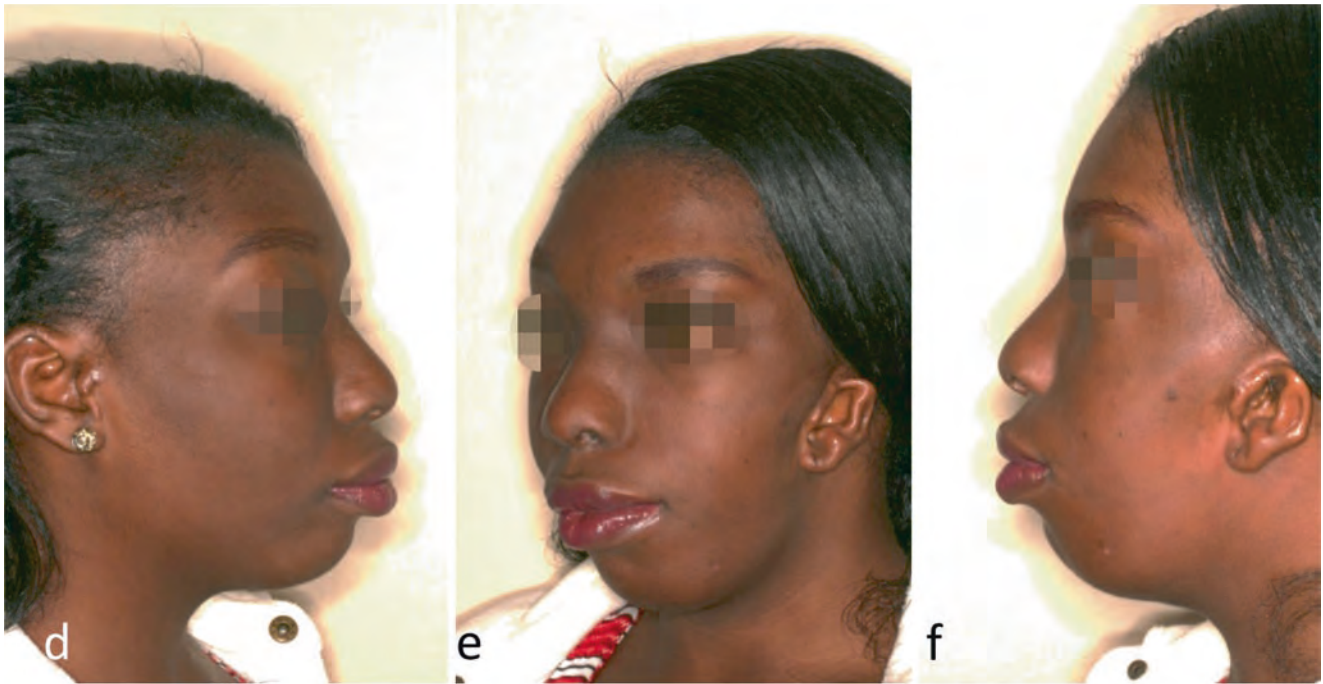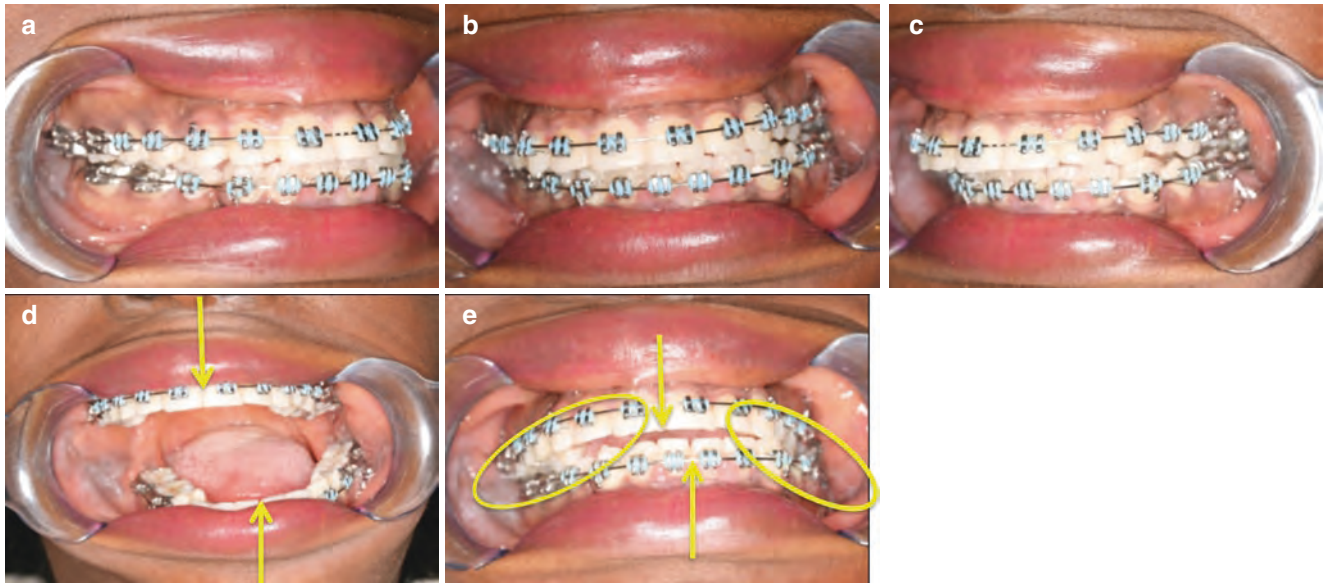


Fig. 66.18 (a) Frontal view; (b) note the occlusal cant; (c) the mandible swing to the affected side; (d) right side profile view; (e) left side three-quarter view, note the microtia; and (f) the left side profile view, note the microtia



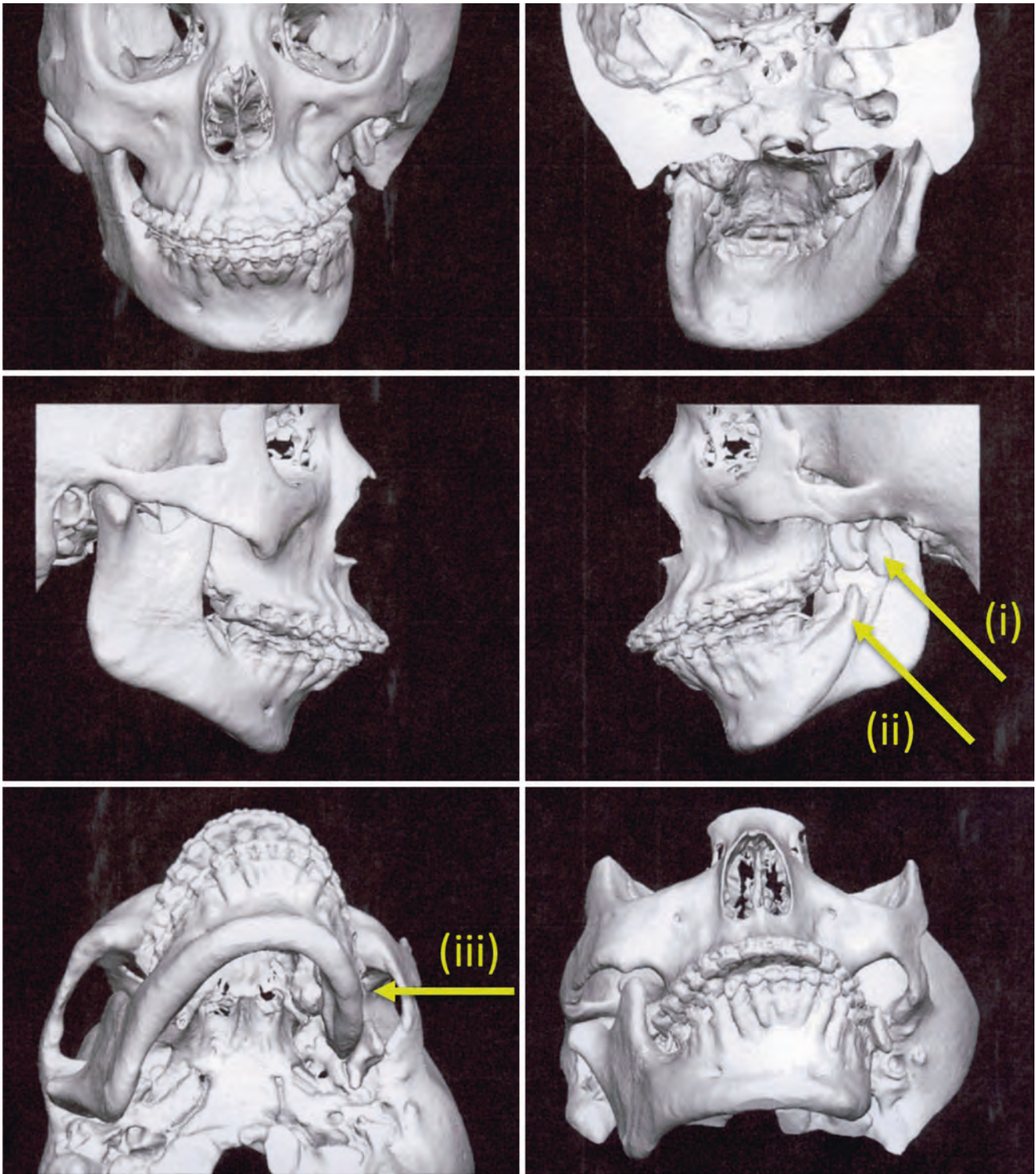
©Association of Oral and Maxillofacial Surgeons of India

Fig. 66.18 (continued)



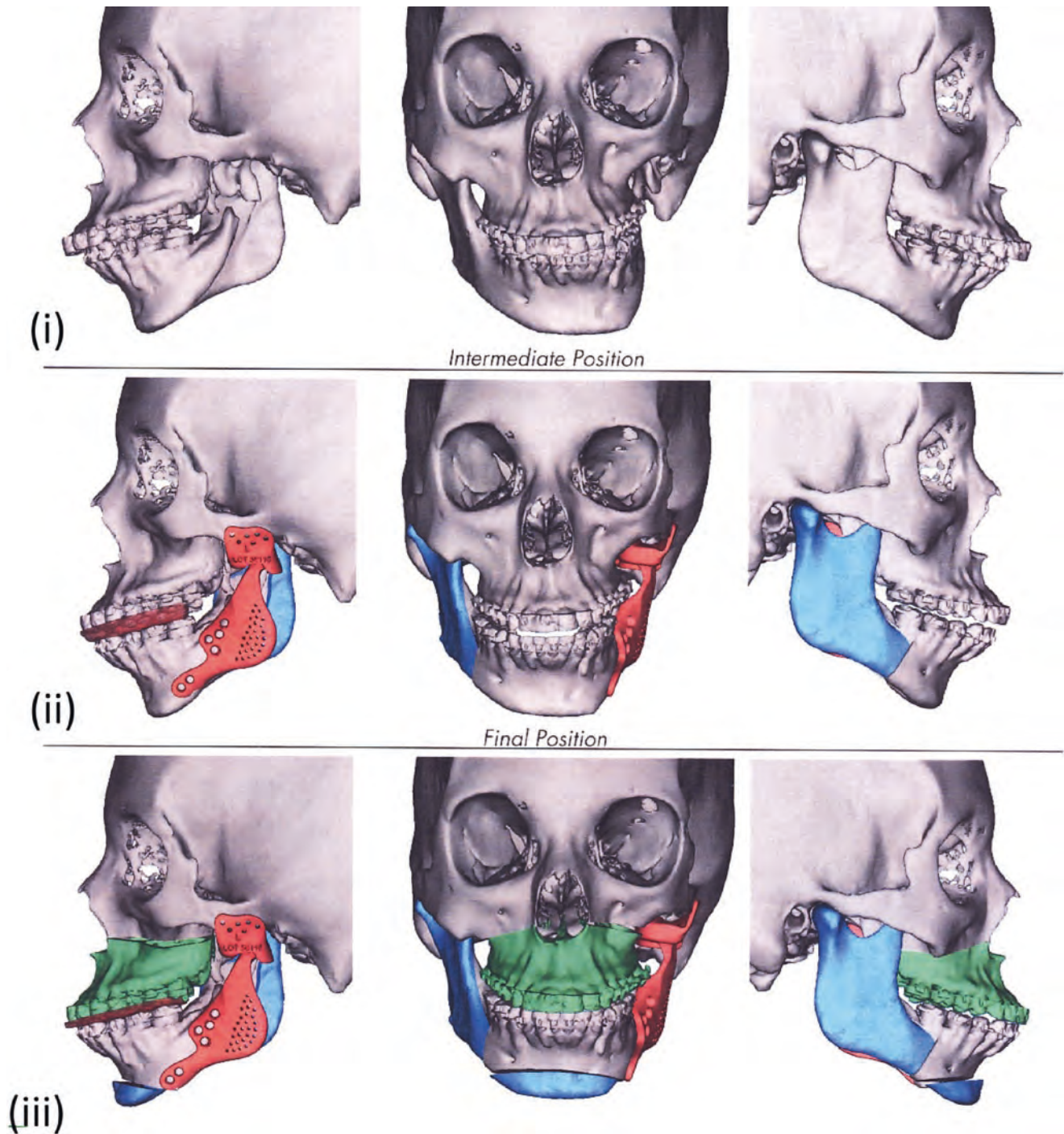
©Association of Oral and Maxillofacial Surgeons of India

Fig. 66.19 (a–c) Presurgical occlusion, (d) the occlusion swings to the left on mouth opening, and (e) the lower dental midline is displaced to the left (arrows) and bilateral cross bites (circles)



©Association of Oral and Maxillofacial Surgeons of India

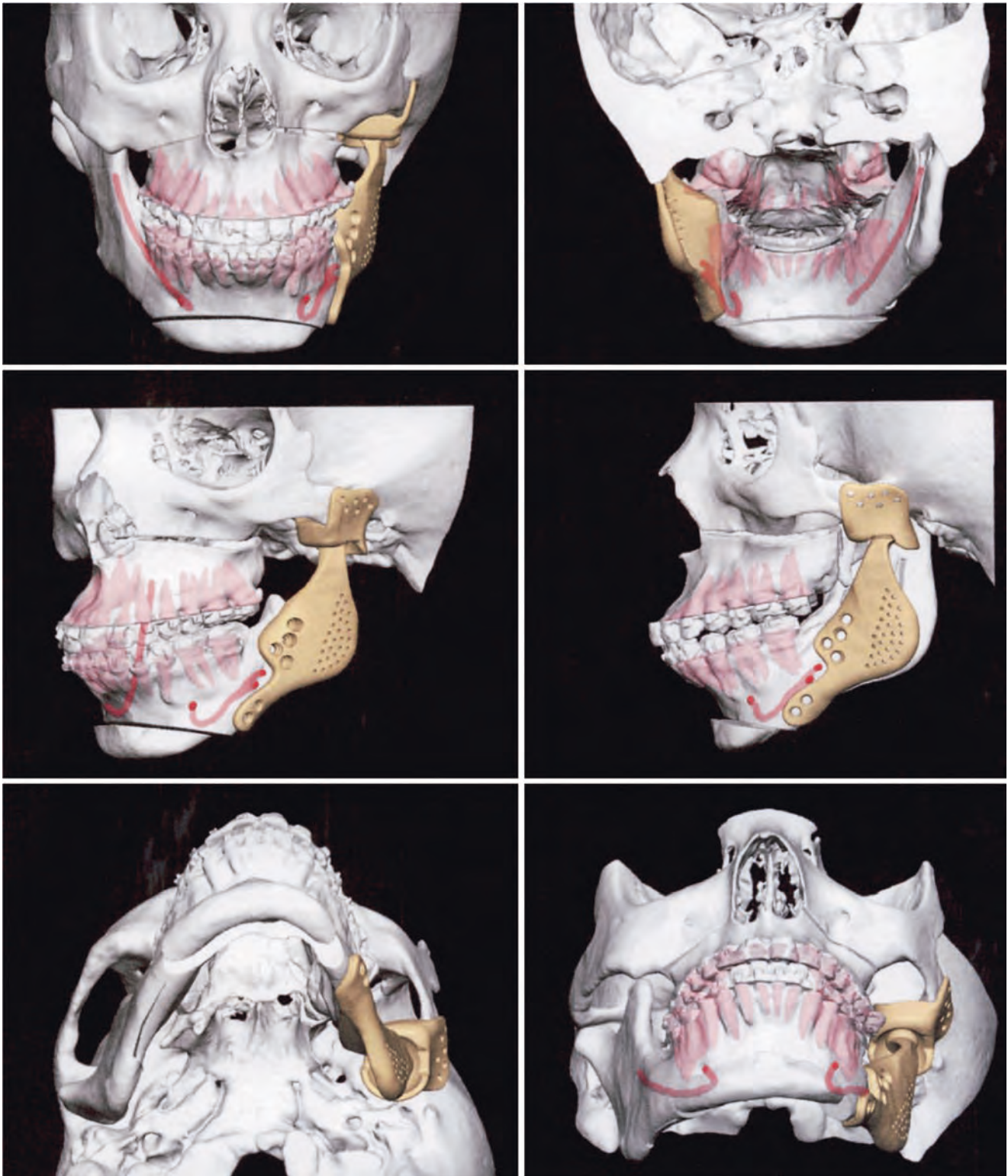
Fig. 66.20 3D images of the skeletal deformities. Note the absence of the left condyle and mandibular ramus (Kaban type III) (i) absence of glenoid fossa, (ii) absence of mandibular condyle, (iii) deficient mandibular ramus on the left side, basal view)



©Association of Oral and Maxillofacial Surgeons of India

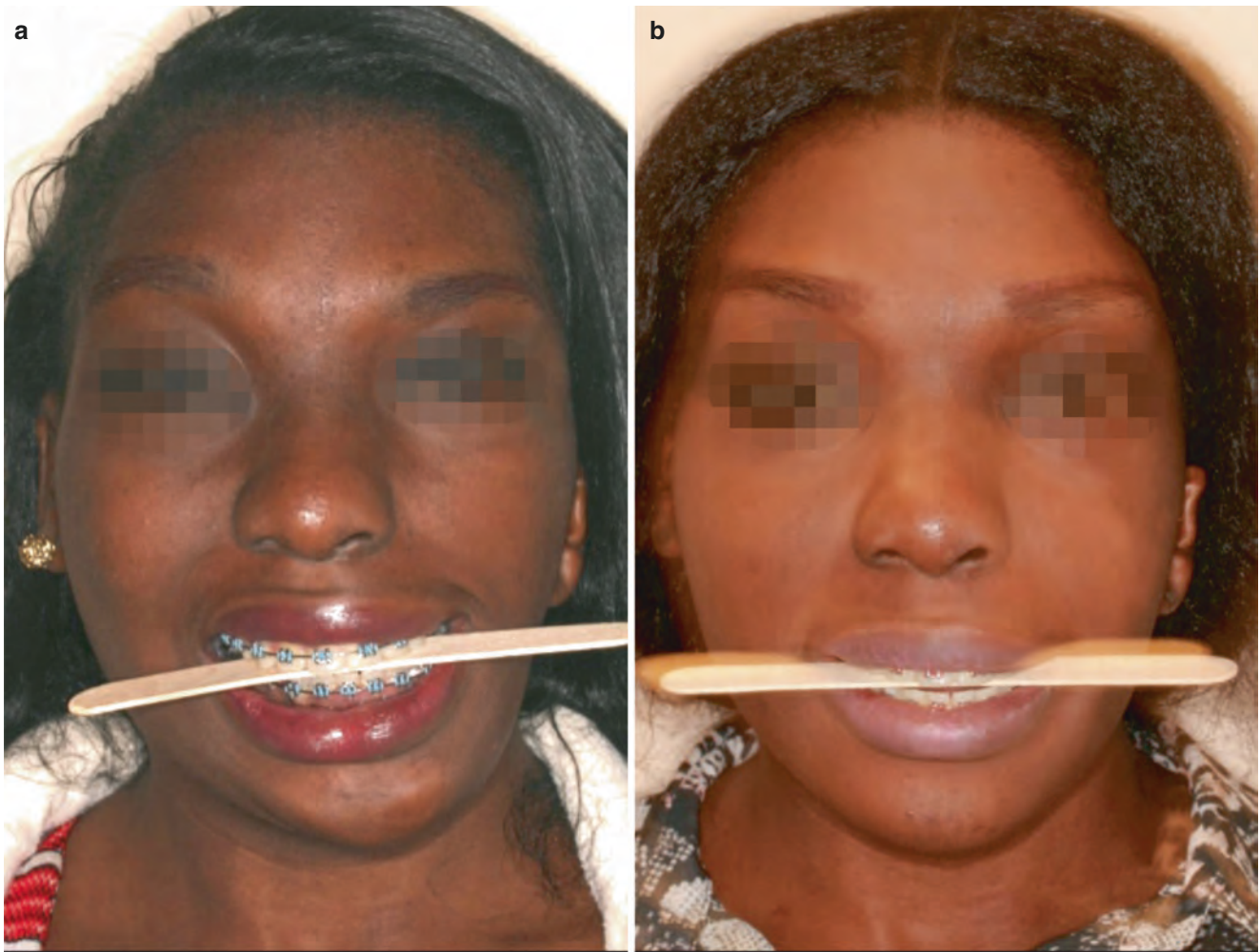Fig. 66.21 The 3D orthognathic virtual surgical plan: Total joint reconstruction on the left, Le Fort I osteotomy correcting of the maxillary cant, unilateral sagittal split ramus osteotomy on the right, and an

advancement genioplasty. (i) Pre-surgical, (ii) intermediate position after mandibular surgery, (iii) Final position after maxillary surgery and genioplasty



©Association of Oral and Maxillofacial Surgeons of India

Fig. 66.22 The 3D surgical plan for patient-matched left alloplastic condyle, mandibular ramus and angle



©Association of Oral and Maxillofacial Surgeons of India

Fig. 66.23 (a) Presurgical frontal view, (b) postsurgical frontal view. Note the correction of the occlusal cant

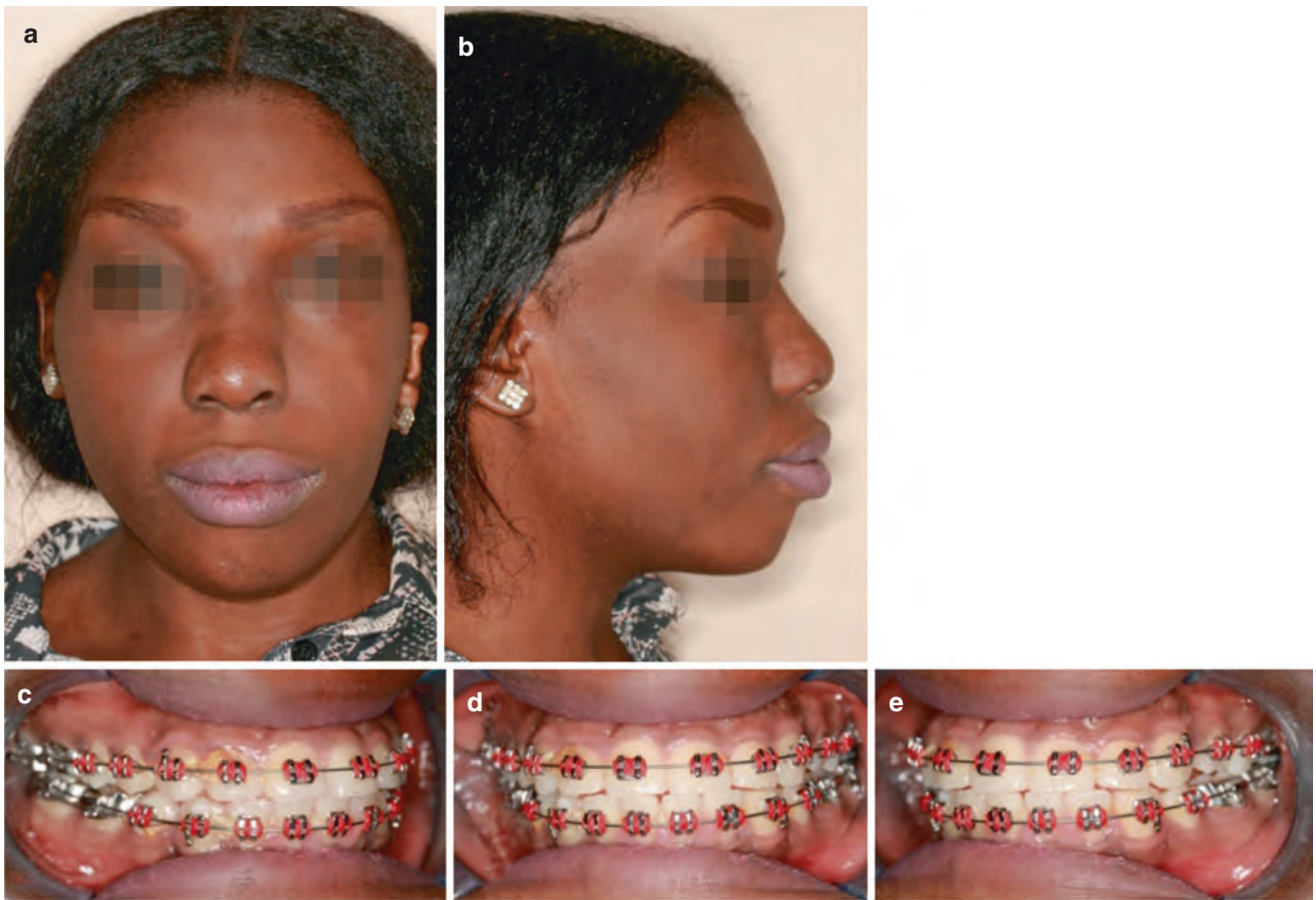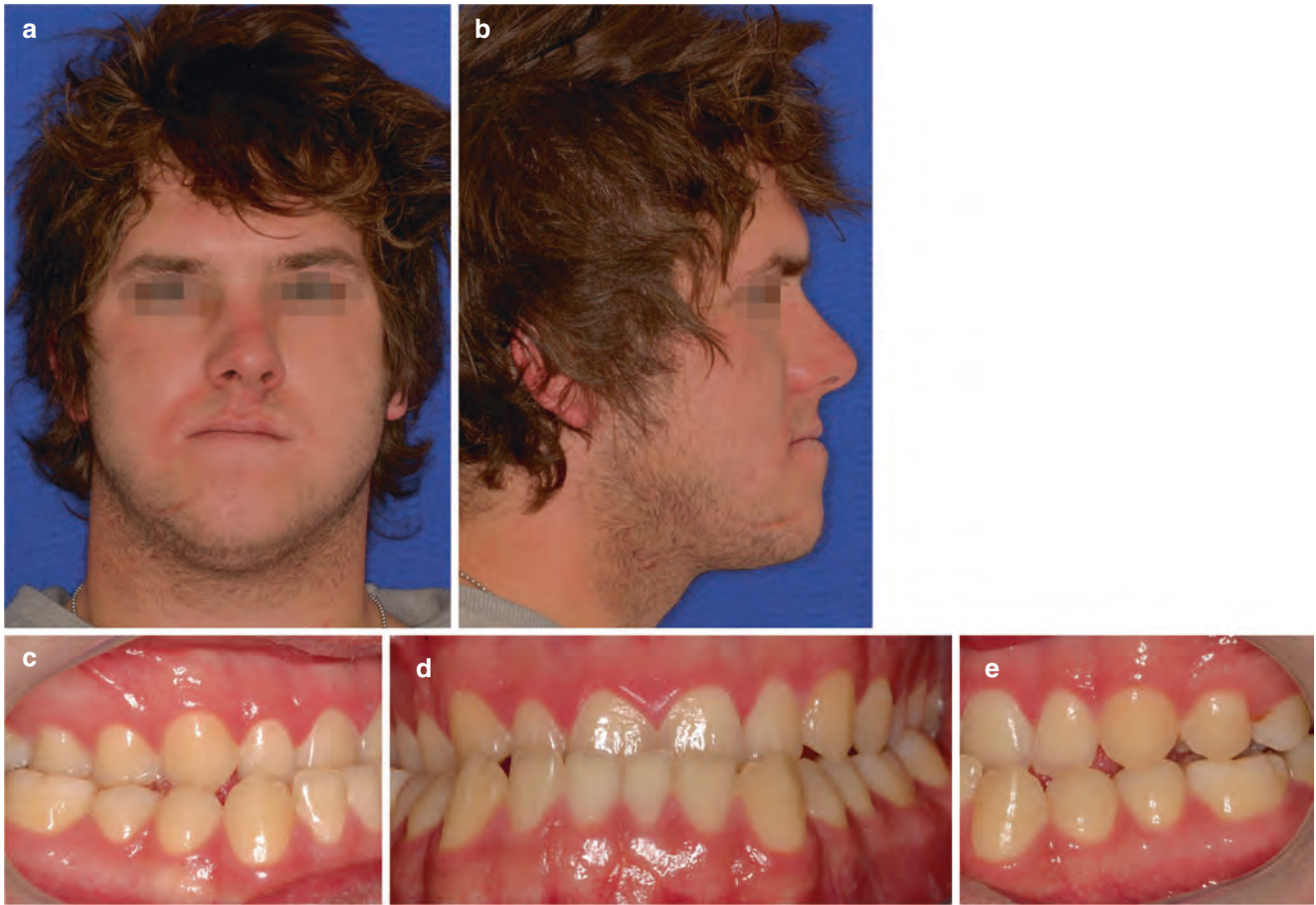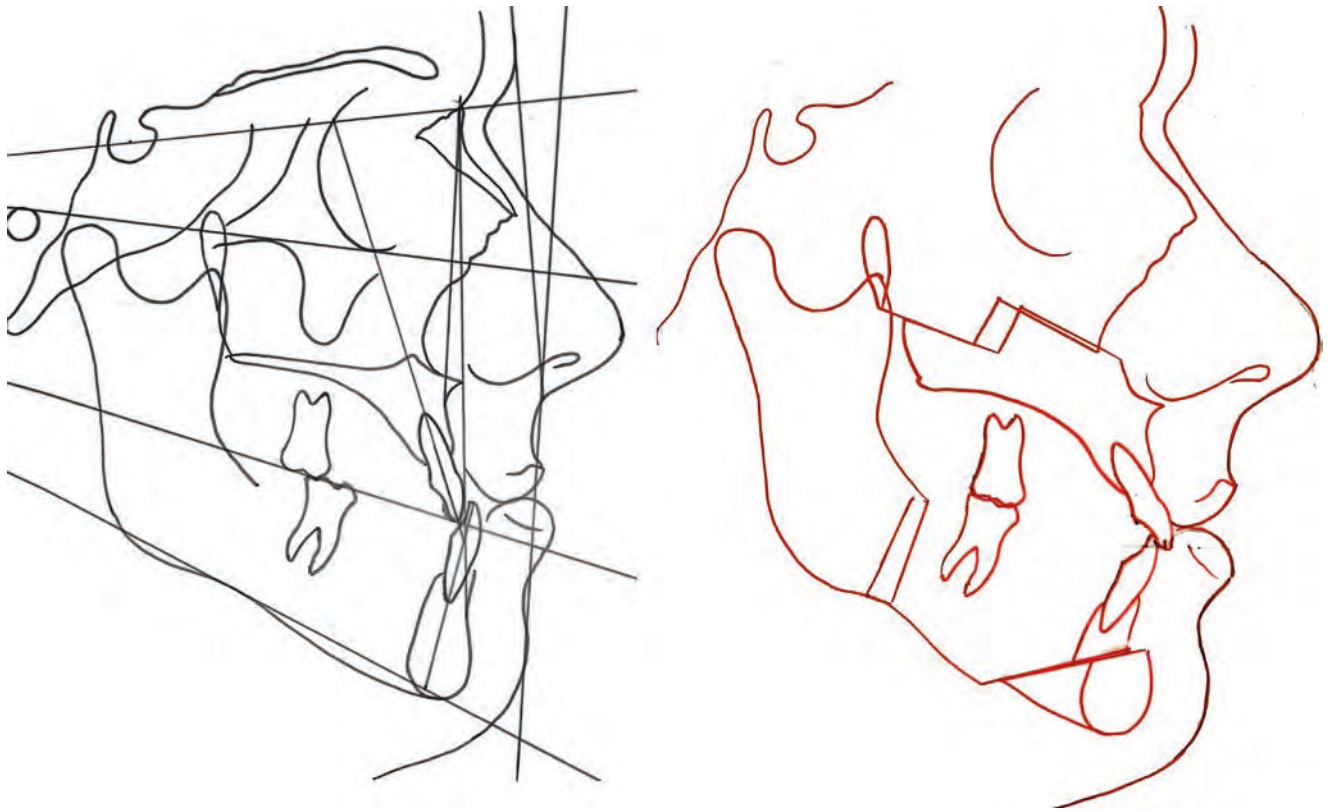


Fig. 66.24 (a–e) Postsurgical frontal and profile views and occlusion



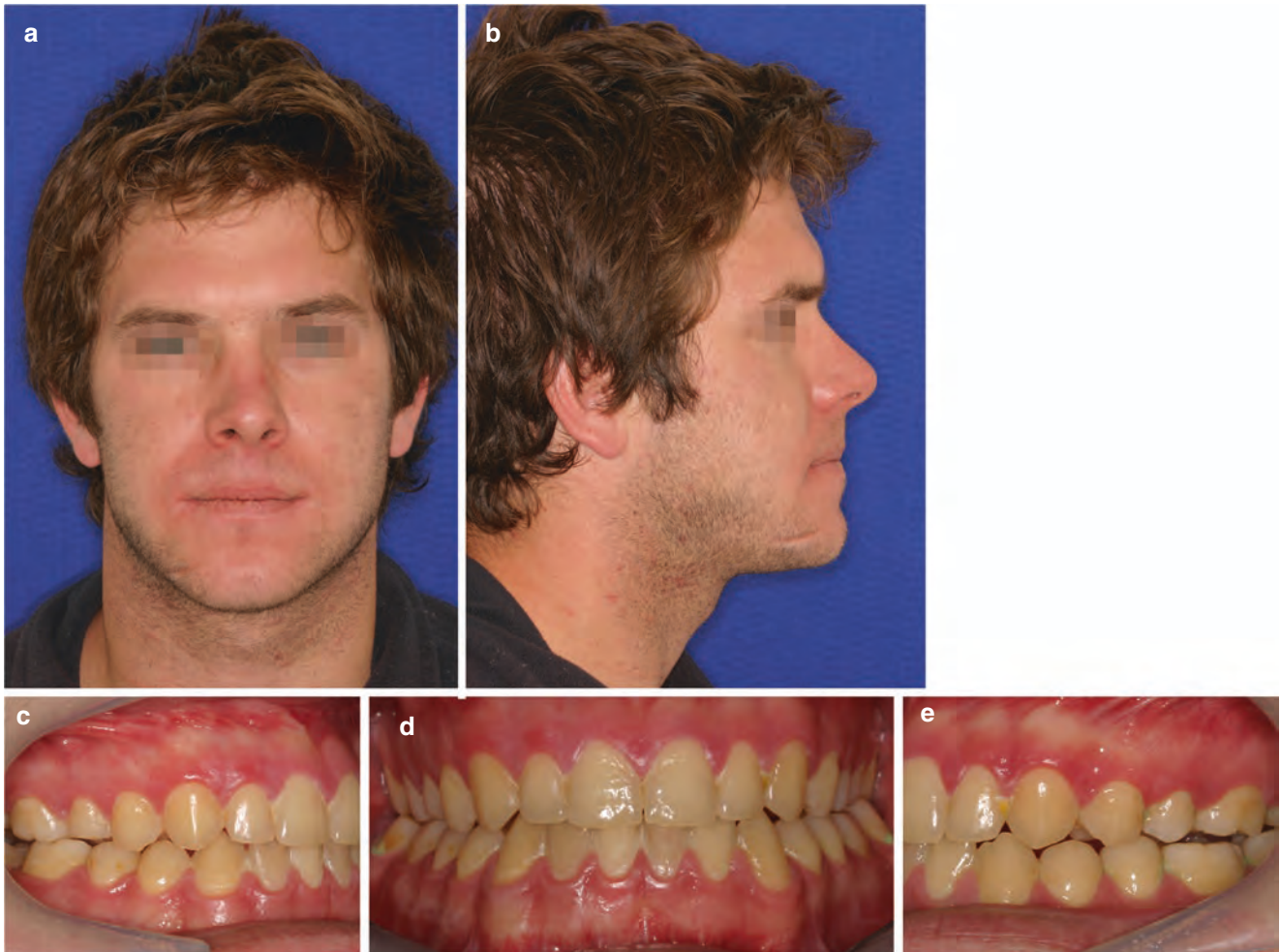©Association of Oral and Maxillofacial Surgeons of India

Fig. 66.25 (a–e) Frontal, profile, and intraoral views of patient with Class III malocclusion. Patient has paranasal flattening, mandible deviated to right, and flat facial profile. Negative overjet, Class III dental occlusion, and mandibular midline to the right



©Association of Oral and Maxillofacial Surgeons of India

Fig. 66.26 2D cephalometric analysis and 2D surgical treatment planning. Surgical plan is Le Fort I downslide, mandibular setback, and advancement genioplasty



©Association of Oral and Maxillofacial Surgeons of India

Fig. 66.27 (a–e) Postsurgical views show that the treatment planning goals have been achieved

References

- Bell WH. Modern practice in orthognathic and reconstructive surgery, vol. 1. Philadelphia: Saunders; 1992.
- Hart PS, McIntyre BP, Kadioglu O, Currier GF, Sullivan SM, Li J, et al. Postsurgical volumetric airway changes in 2-jaw orthognathic surgery patients. *Am J Orthod Dentofacial Orthop.* 2015;147:536–46.
- Hernandez-Alfaro F, Guijarro-Martinez R, Marque-Bueno J. Effect of mono- and bimaxillary advancement on pharyngeal airway volume: cone-beam computed tomography evaluation. *J Oral Maxillofac Surg.* 2011;69:E395–400.
- Naini FB. Facial aesthetics, concepts & clinical diagnosis, Ch. 14. In: *The nose.* London: Wiley-Blackwell. 2007. p. 214–36.
- Naini FB, Gill DS. Patient evaluation and clinical diagnosis, Ch. 12. In: Naini FB, Gill DS, editors. *Orthognathic surgery, principles, planning and practice.* London: Wiley-Blackwell; 2017. p. 199–206.
- Reyneke JP, Ferretti C. Diagnosis and treatment planning for orthognathic surgery. In: Anderson L, Khanberg K-E, Pogrel MA, editors. *Oral and maxillofacial surgery.* London: Wiley-Blackwell; 2010. p. 973–1012.
- Reyneke JP, Ferretti C. Correction of dentofacial deformities. In: Anderson L, Khanberg K-E, Pogrel MA, editors. *Essentials of oral and maxillofacial surgery.* London: Wiley-Blackwell; 2014. p. 315–30.
- Reyneke JP. Systematic evaluation of the chin. In: *The art and science of the sliding genioplasty.* Gainesville: REAeducation. 2018.
- Sarver DM. *Esthetic orthodontic and orthognathic surgery.* St Louis: Mosby; 1998.
- Posnick JC. *Orthognathic surgery, principles & practice.* St Louis: Elsevier; 2014.
- Arnett GW, McLaughlin RP. *Facial and dental planning for orthodontists and oral surgeons.* St Louis: Mosby; 2004.
- Reyneke JP. *Esthetic facial evaluation in: essentials of orthognathic surgery.* 2nd ed. Chicago: Quintessence; 2011.
- Swennen GR, Mollemans W, Schutyser F. Three-dimensional treatment planning of orthognathic surgery in the era of virtual imaging. *J Oral Maxillofac Surg.* 2009;67:2080–92.

Open Access This chapter is licensed under the terms of the Creative Commons Attribution 4.0 International License (<http://creativecommons.org/licenses/by/4.0/>), which permits use, sharing, adaptation, distribution and reproduction in any medium or format, as long as you give appropriate credit to the original author(s) and the source, provide a link to the Creative Commons license and indicate if changes were made.

The images or other third party material in this chapter are included in the chapter's Creative Commons license, unless indicated otherwise in a credit line to the material. If material is not included in the chapter's Creative Commons license and your intended use is not permitted by statutory regulation or exceeds the permitted use, you will need to obtain permission directly from the copyright holder.





67.1 Introduction

Treatment philosophies for the management of dentofacial deformities are varied. Milder forms of dentofacial deformity not manifesting as a significant skeletal discrepancy can be corrected by orthodontic treatment alone called “orthodontic camouflage”, but those presenting with significant skeletal discrepancy need the skills of both the orthodontist and the maxillofacial surgeon. Hence, correction of dentofacial deformities has come to be a confederate work between both specialties. The dentition and maxillomandibular skeletal complex (MMSC) are intertwined, and changes to one will invariably affect the other, especially more so when the MMSC positional and spatial relationships change. Over the years many new concepts have evolved in orthognathic surgery, and the odyssey between the surgical and orthodontic teams is only getting more inseparable and interesting.

67.2 Background

Looking back to 1960s when techniques of mandibular and maxillary orthognathic surgeries were still evolving from the works of Obwegeser and Trauner, surgeons often performed the procedures either before orthodontic treatment or well after the completion of orthodontic treatment, and rarely any surgeon depended on an orthodontist to move the teeth into certain relationship before undertaking surgery [1]. With time it was realized that the natural dental compensations became a hindrance to the optimal movement of MMSC, thus compromising the results and final outcome.

Poulton et al. [1] in 1963 reported few cases of excessive mandibular growth (mandibular prognathism) which were treated surgically without any pre-surgical orthodontics. In

the process, the authors observed that the overjet relationship between the upper and lower anterior teeth limited the amount of mandibular setback, thereby compromising the overall treatment outcome. They concluded that proper alignment of teeth in upper and lower arches is a prerequisite to get adequate mandibular setback. This proposal had almost paved the way for the “orthodontics-first” concept for correcting dentofacial deformities. Worms et al. [2] in the 1970s popularized the concept of “orthodontics first” for all orthognathic surgeries which led to the split of orthodontic treatment into two phases: the pre-surgical orthodontics phase and post-surgical orthodontics phase with an intervening surgical phase.

The pre-surgical orthodontics phase, which essentially antecedes the orthognathic surgical phase, brings out the accurate skeletal discordance by decompensating the natural compensations which have occurred, thereby helping the surgeon to perform a more precise spatial relocation of the MMSC during surgery [3]. However, the pre-surgical phase of orthodontic treatment, also called reverse orthodontics, is a long-drawn process lasting anywhere between 1 and 2 years depending on the complexity of the discrepancy [4]. To add to the woes, during this phase there is gradual deterioration of facial form and dental function [5–7]. Worsening of the facial profile has become a great deterrent for the patients seeking orthognathic surgery because the very reason for seeking the orthognathic surgery for improving facial aesthetics stands defeated and therefore fails to address the patients’ chief complaint. Also, the long preoperative preparatory phase can aggravate or initiate other dental problems like dental caries or periodontal problems. For all these reasons, the “orthodontics-first” concept can produce a negative influence on the patient’s compliance [8] (Table 67.1).

N. V. V. Reddy (✉) · A. Potturi
SVS Institute of Dental Sciences, Mahabubnagar, Telangana, India

Table 67.1 Challenges associated with conventional “orthodontics-first” approach

1. Time-consuming
2. Deterioration of facial form
3. Difficulty to chew or masticate during pre-surgical phase
4. Psychosocial problems
5. Other complications like dental decay, gum recession and root resorption or root damage

67.3 Surgery-First Orthognathic Approach (SFOA)

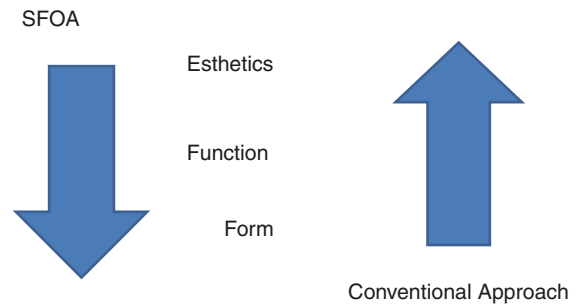
In order to overcome the shortcoming of conventional orthognathic surgery, a new approach has been conceptualized called “surgery-first orthognathic approach (SFOA)”.

Even though some surgeons expressed the necessity to reposition the MMSC before performing any orthodontics in the past, it did not gain much popularity. With the advent of skeletal anchorage system in orthodontics and rigid fixation system in orthognathic surgery, the problem of skeletal relapse due to unstable bony segments during post-surgical orthodontics has been significantly reduced, paving the way for popularization of SFOA [8, 9].

Correction of various skeletal deformities like Class III [10] and Class II [11] and facial asymmetry [12] using SFOA technique has been reported in the past, and all of them claimed shortening of the total treatment time as a significant and greatest advantage over the conventional technique. William Bell, the “godfather” of orthognathic surgery, during one of his clinical rounds with his residents, highlighted the changing trends in orthognathic surgery by contending that the present orthognathic surgical procedures remain too complicated, too invasive, too time-consuming, too expensive, and too unpredictable, and he literally set the tone for discussing “paradigm shifts in orthognathic surgery” [13]. After the clinical applications of advanced three-dimensional imaging and office-based surgery, the 2011 symposium on SFOA created a broader interest in complete elimination of time-consuming pre-surgical reverse orthodontics and paved the way for worldwide acceptance of this paradigm shift in orthognathic surgery [14, 15].

SFOA technique is fundamentally a “face-first” approach wherein the patient’s chief complaint is taken care immediately by improving the facial soft tissue profile and thereby increasing the patient’s compliance to overall treatment (Fig. 67.1). In SFOA, greater part of the dentition remains at the same position with respect to their respective arches as there is no pre-surgical orthodontic phase involved. Following the orthognathic surgery, MMSC will be in a Class I relationship, yet the upper and lower dentition may not fit perfectly into occlusion. A *treatable malocclusion*, called *transitional occlusion*, is set at the end of surgery which can be corrected by the orthodontists. Hence, the

First – Face Approach:



©Association of Oral and Maxillofacial Surgeons of India

Fig. 67.1 The flow diagram demonstrating fundamental differences and the order of priority between the SFOA and conventional approach

Comparison between Conventional technique and SFOA

Conventional	SFOA
Three phases	Two phases
Decompensation required	Not required/minimal
Worsening of facial profile	Immediate improvement of facial profile
Stable post – surgical occlusion	Semi stable post-surgical occlusion
Prolonged treatment duration	Shorter treatment duration

Fig. 67.2 The comparison chart demonstrating various steps for conventional technique and SFOA

orthodontist must actively participate in the treatment planning in SFOA so as to achieve a treatable transitional occlusion at the end of surgery. The orthodontist must be able to foresee the resulting occlusion even before the surgery, and this ability to plan and foresee the resultant transitional occlusion accurately is the linchpin of the entire SFOA technique. Therefore, in SFOA technique the orthodontic principles and guidelines must be established in advance so as to ensure that treatable malocclusions are attained.

Kim JH et al. [8] in their treatise called “Guidelines for “surgery first” orthodontic treatment” have emphasized caution when embarking on SFOA technique. The entire planning process (Fig. 67.2) is laborious since the skeletal changes should be preconceived and the casts should be mounted accordingly to determine the anticipated post-operative orthodontic teeth movements, and, even for the highly accomplished orthodontic and surgical team, it is

challenging to pinpoint accurately the occlusal relationship that will balance ideal aesthetic and functional results. It should be remembered during planning that surgical movement should be adequate enough such that dental decompensation is possible after the surgery. Customarily, the dentition is bonded/banded and a passive arch wire is placed before surgery. Active orthodontic tooth movement begins within a relatively short period of time after the jaw(s) are repositioned to take advantage on the inherent phenomena called accelerated tooth movement [8].

67.4 Regional Accelerated Phenomena (RAP)

It is observed that the orthodontic tooth movement following orthognathic surgery is rapid and it is significantly rapid during initial 4–5 post-operative months. This rapid tooth movement post-surgery is attributed to RAP, and it is observed with all the three planes, sagittal, vertical and transverse.

It is an established fact that orthodontic tooth movement is a metabolic event of alveolar bone resorption in the areas of pressure and bone formation in the areas of tension [16, 17]. In order to analyse post-surgical changes in bone metabolism after orthognathic surgery and the corresponding response in the dento-alveolus, Liou et al. conducted a prospective clinical pilot study in 2011. All 22 adult patients who participated in their study underwent both maxillary LeFort I osteotomy and mandibular bilateral sagittal split osteotomy for repositioning of their jaws. Each of these patients was evaluated for serum alkaline phosphatase (ALP) and C-terminal telopeptide of type I collagen (ICTP) before and after surgery at sequential intervals for up to 4 months post-operatively [14].

ALP and ICTP are two bone markers which are indicative of bone turnover rate. ICTP is a bone resorption metabolite of type I collagen in bone and has been associated with the activities of osteoclasts [18]. ALP is an enzyme for bone formation and has been found to associate with osteoblasts function [19]. The results of Liou et al.'s study [14] showed transient increase in the levels of both ICTP and ALP in the immediate post-surgical period indicating burst in the activity of bone remodelling and turnover activity. It was observed from Liou et al.'s [14] study that the ICTP levels peaked from 1 week to 3 months and the ALP levels from 1 to 4 months post orthognathic surgery. This increase in bone turnover markers in the initial post-operative period is a clear indicator of high metabolic activity in the bone and therefore can be used to advantage in shortening the total treatment time in SFOA.

The RAP is not isolated to SFOA. Even in conventional, orthodontics-first approach, this phenomenon plays its role in post-surgical orthodontics. The only difference is that in

conventional technique the surgery is done after the decompensation is achieved. The SFOA technique utilizes the golden opportunity of RAP by speeding up the decompensation process which occurs after the orthognathic surgery contrary to that in conventional technique. Therefore, in SFOA, the surgical procedure increases the bone metabolic rate of dento-alveolus in the first 4 post-operative months, which in turn accelerates the orthodontic tooth movement. Hence to make complete use of RAP in SFOA, the post-surgical orthodontic tooth movements have to be begun as early as 1st week and completed by the 4th month.

67.5 Indications

Though SFOA technique can be employed in any kind of maxillomandibular skeletal discrepancy, Liou et al. proposed the following indications in 2011 (Box 67.1) which could help in easy case selection and will act as a guide for the beginners.

67.6 Treatment Planning Considerations

67.6.1 General Guidelines

- The upper and lower dentition are bonded and banded before the surgery without placing any arch wire in order to keep the dentition undisturbed and solid during and after the surgery.
- When planning for SFOA, multiple treatment options must be taken into account. It is very important for the orthodontist to plan the resulting occlusion on the preoperative model set-up in order to achieve relatively stable occlusion on the table during surgery.
- The decompensation of the teeth to normal positions and angulations will be done after surgery, and hence transitional occlusion should allow any orthodontic teeth movement after the surgery. Since the incisors cannot be used as a guide to foresee the final form of occlusion in SFOA, the molar relationship can be utilized as a starting point to come up with a temporary occlusion.

Box 67.1 Proposed indications for SFOA technique

- Well-aligned to mildly crowded anterior teeth
- Flat to mild curve of Spee
- Normal to mildly proclined/retroclined incisors
- Minimal transverse discrepancies
- Cases in which decompensation is not required or minimal decompensation is required

- For the model surgery, the maxillary and mandibular casts are positioned in a proper molar relationship and with a positive overbite. The molar relation could be set up in Class I in cases of non-extraction or bimaxillary first premolar extraction, Class III in cases of lower first premolar extraction and Class II in cases of maxillary first premolar extraction. Once the molar relationship has been established, the overjet should also have been determined.
- The inclination and angulations of upper incisors determine the pattern of extractions. If upper incisors are excessively inclined, then premolar extraction needs to be planned in order to allow post-operative retraction of upper incisors. As a rule of thumb, if the upper incisor to occlusal plane angulation is less than 53–55°, extraction must be considered [20].
- The transverse dimension often creates a special challenge when performing model surgery in surgery-first cases. The upper and lower midlines must be coincident or close to it post-surgery, and proper buccal overjet must be established bilaterally.
- Once surgery is completed, the post-operative orthodontic treatment can begin anytime between 1 week and 1 month post-operatively in order to take the advantage of RAP.

Envisioning the final dental occlusion based on the present occlusion is the key factor in success of SFOA. The interim transitional occlusion achieved on preoperative model set-up must be stable enough to allow predictable splint preparation and skeletal movement. *It is highly recommended that at least three point contacts are achieved between upper and lower teeth when planning for interim transitional occlusion.* In situations where such transient occlusion cannot be established, it is advisable to commence some orthodontic movement in order to assuage some of the interferences and allow for a more stable transitional malocclusion to be established.

67.6.2 Specific Guidelines [15]

Anteroposterior and Vertical Decompensation in Class III Cases

- The sagittal decompensation for proclined upper incisors in a Class III case could be achieved by an anterior segmental osteotomy with removal of the maxillary first bicuspids or by clockwise rotation of the maxilla by LeFort I osteotomy to upright the maxillary incisor inclination.
- The anteroposterior decompensation for moderately retroclined and crowded lower incisors in a Class III case could be achieved by setting up the molars in a Class I relationship with an excessive incisor overjet, and then the mandibular incisors could be aligned after the surgery to obtain the desired overjet.

- The sagittal decompensation for severely retroclined and crowded lower incisors in a Class III situation could be achieved by extraction of the lower first bicuspid and anterior segmental osteotomy, setting up the molars in a Class III relationship with an excessive incisor overjet, and then the lower incisors could be aligned after the surgery to obtain a desired overjet.
- A moderate to deep mandibular curve of Spee in a Class III case is better levelled preoperatively or surgically by anterior segmental osteotomy to avoid the upward and forward rotation of the mandible post-operatively. Alternatively, the lower incisors could be intruded, and the upper incisors at the same time could be extruded post-operatively.

Anteroposterior and Vertical Decompensation in Class II Cases

- For a moderate to deep mandibular curve of Spee and proclined mandibular incisors in Class II mandibular retrognathism, the anterior segment of the lower jaw could be levelled and intruded surgically through anterior segmental osteotomy so that the mandible could be advanced accurately.
- Alternatively, the mandible could be surgically advanced to an edge-to-edge incisor relationship and without occlusal contact in the posterior teeth, and then post-surgically, the lower anterior teeth could be orthodontically intruded so that the mandible rotates upwards and forwards for posterior occlusal contact and a better chin projection.

67.7 Treatment Protocol (Table 67.2)

The protocol variations between the conventional orthognathic surgery and SFOA can be clearly appreciated in the Table 67.2 highlighted in Bold fonts. A simulation of pre-

Table 67.2 Treatment protocol comparing SFOA technique to conventional technique

Conventional technique	SFOA technique
1. Initial diagnosis	1. Initial diagnosis
2. Surgical planning—STO	2. Surgical planning—STO
3. Pre surgical orthodontic treatment	3. Simulation of pre-surgical orthodontic treatment
	Model mounting and model setup
	4. Simulation of orthognathic surgery
4. Surgical arch wire	5. Surgical arch wire
5. Fabrication of splints	6. Fabrication of splints
6. Orthognathic surgery and post-op care	7. Orthognathic surgery and post-op care
7. Orthodontic rediagnosis	8. Orthodontic rediagnosis
8. Orthodontic treatment	9. Orthodontic treatment
9. Finishing	10. Finishing

surgical orthodontic treatment using model mounting and set-up will compensate the pre-surgical orthodontic treatment.

67.8 Protocol Variations

Although the sequence of treatment is similar, different protocols are being used to prepare the patient for surgery, perform the operative procedure, and commence the orthodontic treatment.

67.8.1 Timing of Bonding

- Chung C Yu and Villegas [12]—1 week before orthognathic surgery
- Sugawara and Nagasaka [10, 11]; E Liou et al. [15]—Just before surgery
- Federico Hernandez [21]—brackets 10–14 days after surgery

67.8.2 Initial Arch Wires

- Liou et al. [15]—did not place any orthodontic arch wires before surgery
- Sugawara and Nagasaka [10, 11]—preferred 0.019" × 0.025" SS wires in 0.022" slot

Placement of passive stainless steel arch wires bent and adapted to each tooth before surgery will preclude any untoward tooth movement during or immediately after the surgery. The authors wishing to capitalize on the RAP concept immediately after surgery prefer to place active nickel-titanium arch wires prior to surgery. Nonetheless, in doing so, the orthodontist loses an opportunity to observe the stability of the surgical correction prior to beginning of the tooth movement. The rapid acceleratory phenomenon not just influences the tooth movement but also can disturb the alveolar bone [8].

There are also protocol variations regarding the usage of surgical splints after the surgery among the various authors. While some authors suggested the use of the surgical splints only intraoperatively, others have advocated its use anywhere between 1 and 4 post-operative weeks. Nagasaka et al. have used removable Gelb-type splints post-surgery [10]. Kim's

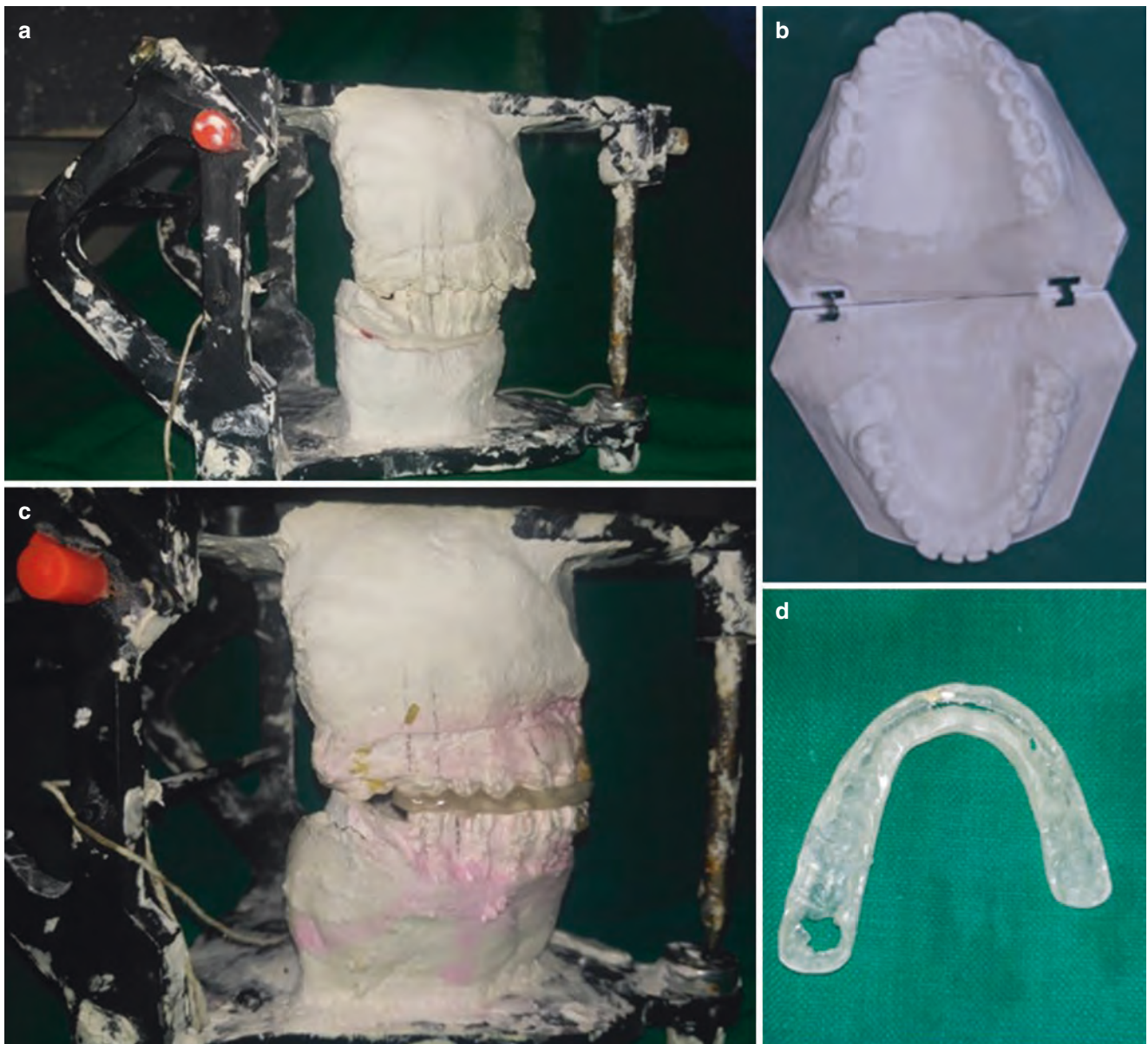
preference is to leave the splint in for about 1 month to 1 and a half months post-operatively and if an open bite is observed to use elastics between the splint and the mini-screws placed into the bone or to leave the splint for an even longer time period [8].

67.9 Procedural Guidelines for Model Mounting and Model Set-Up in SFOA (Fig. 67.3)

- Once the treatment planning and diagnosis is completed, impressions are made and customary model mounting is performed with bite registration to scrutinize the present state of the occlusion.
- In the model set-up, teeth that have adapted by natural compensation to the existing skeletal discrepancy are simulated and reorganized into anticipated occlusion similar to the preoperative orthodontic treatment plan. All the teeth on the set-up model are rearranged as if orthodontic treatment is done in the real patient in conventional orthognathic surgery technique into the desired preoperative occlusal relationship.
- Once the desired dental occlusion is set on the models, the amount of the skeletal movement required in the maxilla, mandible or both will become evident. Subsequently, a simulation of the actual orthognathic surgery is performed on the mounted models as in conventional technique. This will indicate the possible occlusal outcome of the standard approach.
- Intermediate and final splint can then be made on these mounted models as they are set up into the planned skeletal movements.
- With the advent of virtual planning and three-dimensional simulation softwares, the same set-up model surgery can be performed by scanning the physical models and bite registration details into the software, and the three-dimensional intermediate and final splints can be printed.

67.10 Surgical Procedures (Fig. 67.4)

The surgical procedures in the maxilla, mandible or chin are themselves performed using described standard techniques, whether it is the conventional technique or the SFOA technique.

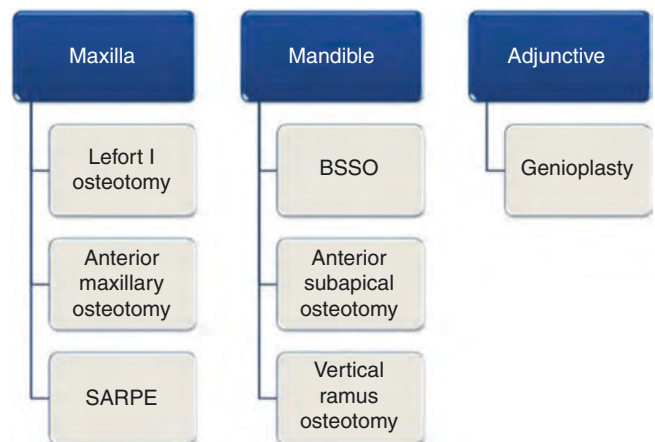


©Association of Oral and Maxillofacial Surgeons of India

Fig. 67.3 (a) Standard model mounting. (b) Before the procedure, the teeth that have adapted to the skeletal discrepancy are simulated and reorganized into their predicted location, similar to real pre-surgical

orthodontic treatment. (c) Simulation of actual orthognathic surgery is then performed. (d) Surgical splints fabricated to aid in real-time surgery

Fig. 67.4 Flow diagram showing various surgical procedures in each of the jaws



©Association of Oral and Maxillofacial Surgeons of India

67.11 Advantages and Disadvantages of SFOA (Table 67.3)

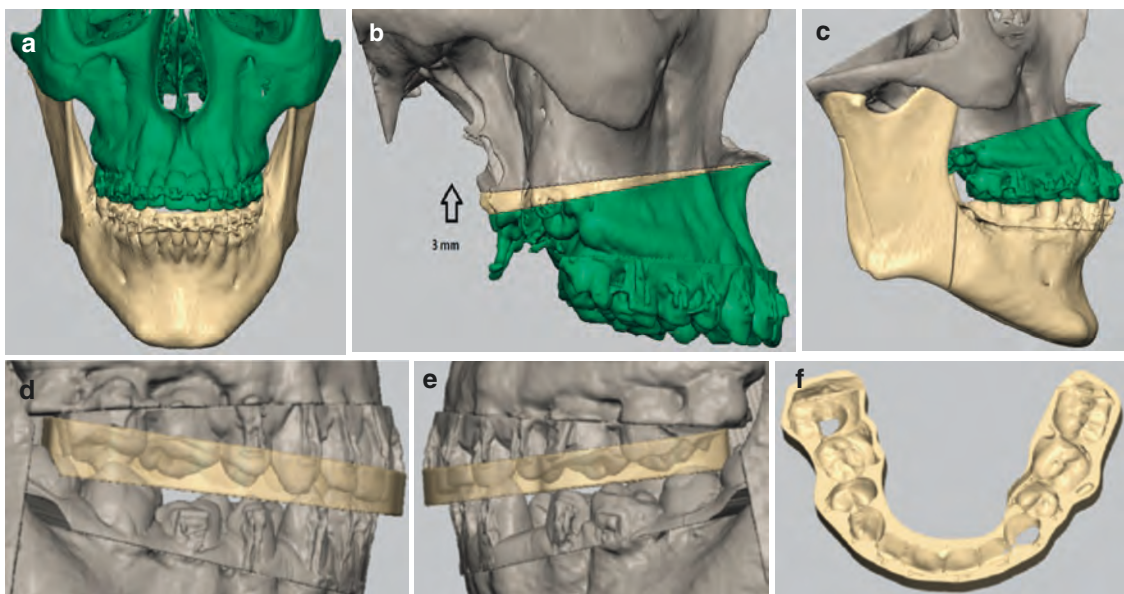
Systematic review published by Peiró-Guijarro et al. [21] in 2006 reviewed 179 publications and finally selected 11 articles for final reporting. They found that the SFOA technique was most commonly reported in Class III skeletal malocclusion than in skeletal Class II malocclusion with prevalence of about 84.7%. The single largest advantage described was shortened treatment duration time owing to the RAP concept, and the disadvantage was potential error in predicting the post-operative occlusal outcome resulting in greater or lesser surgical movements of the jaws.

67.12 The Future of “Surgery-First” Approach

The future of SFOA technique lies in using augmented skull models, virtual orthodontic set-up to replace the mounted study model set-up and the computer-aided design and computer-aided manufacturing fabrication of intraoperative splints (Fig. 67.5). The 3D virtual orthodontic set-up will help the orthodontist to predict the eventual (at the end of orthodontic treatment) position and the axial inclination of each tooth scrupulously. This is a compelling step before the surgeon’s skeletal base correction simulation, since the patient’s prevailing occlusion

Table 67.3 Advantages and disadvantages of the surgery-first approach

Advantages
1. Total duration of treatment is shorter
2. The facial profile is improved from the commencement of treatment as a result of skeletal base correction
3. Patient and orthodontist satisfaction rates are high. High patient satisfaction is associated with improved cooperation during post-operative orthodontics
4. Orthodontic decompensation is efficient and effectual in response to the establishment of a proper maxillomandibular relationship and the regional acceleratory phenomenon
5. Surgical movements may not be curbed due to orthodontic constraints. There is more freedom to choose the surgical movement in accordance with the clinical requirement for individual patients
6. Patient recovery takes place expeditiously
7. When sleep-disordered breathing is the main indication for treatment, early maxillomandibular advancement increases the dimensions of the upper airway immediately
Disadvantages
1. Case selection is critical because the baseline occlusion cannot guide treatment objectives. Therefore, high clinical expertise, meticulous prediction of post-operative tooth movement and precise assessment of skeletal discrepancy are imperative
2. The bending procedure for a passive surgical wire is tedious and complex
3. Bonding and removal of the surgical wire are taxing; there is a relatively high bonding failure rate before and during surgery
4. The extent of surgical movements is necessarily greater, because surgical correction needs to make up for dental compensation
5. Impacted lower third molars could add difficulty to surgery
6. Post-surgical fluidity during bone healing could cause skeletal instability, and its impact on relapse has not yet been fully investigated
7. Orthodontic appointments should be scheduled more often than in a traditional approach. This could be stressful for the orthodontist
8. Constant correspondence between the surgeon and the orthodontist is indispensable



©Association of Oral and Maxillofacial Surgeons of India

Fig. 67.5 The workflow demonstrating the pre-surgical orthodontic movement set-up (a), the surgical procedure on the maxilla (b), the procedure on the mandible (c), the post-operative ensuing dental occlusion with splint in situ (d, e) and the design of the final splint (f)

cannot serve as a guide for skeletal repositioning as it lies in a compensated state.

Usability of temporary anchorage devices (TAD) and interdental corticotomies is a factor which can add to the future of SFOA. The TAD permits a wider range of orthodontic vectors and avoids premature bracket loading with secondary troublesome dental extrusion. Interdental corticotomies can augment the RAP and further enhance the orthodontic treatment duration.

67.13 Conclusion

Performing orthognathic surgery even before any orthodontic tooth movement (SFOA) offers a unique advantage of addressing the patient's chief complaint at the very beginning, thereby improving the acceptance and compliance of the patient to overall treatment. It also offers the big advantage of significant decrease in total duration time by making use of the RAP. The final outcomes, in the way of facial aesthetics, dental occlusion and stability, are similar when using orthodontics-first and surgery-first approaches. However, it must be remem-

bered that both the surgeon and the orthodontist must trend with care as there is a premium on patient selection and both should be involved as a team during every stage of the treatment, starting from diagnosis to debonding. Surgeon-orthodontist team should know the orthodontic principles and understand the limits of orthodontic teeth movement and must accommodate dental decompensation in their initial treatment planning. The surgeon should be capable of carrying out designated osteotomy and intermaxillary fixation with occlusion bite plate on misaligned dental arches and providing the stability after skeletal reposition. The future of orthognathic surgery is geared towards reducing the overall treatment duration without compromising the final outcome. Disclosure Authors have no financial conflicts to disclose.

67.14 Case Scenarios

Case Scenario 1 (Fig. 67.6)

Case Scenario 2 (Fig. 67.7)

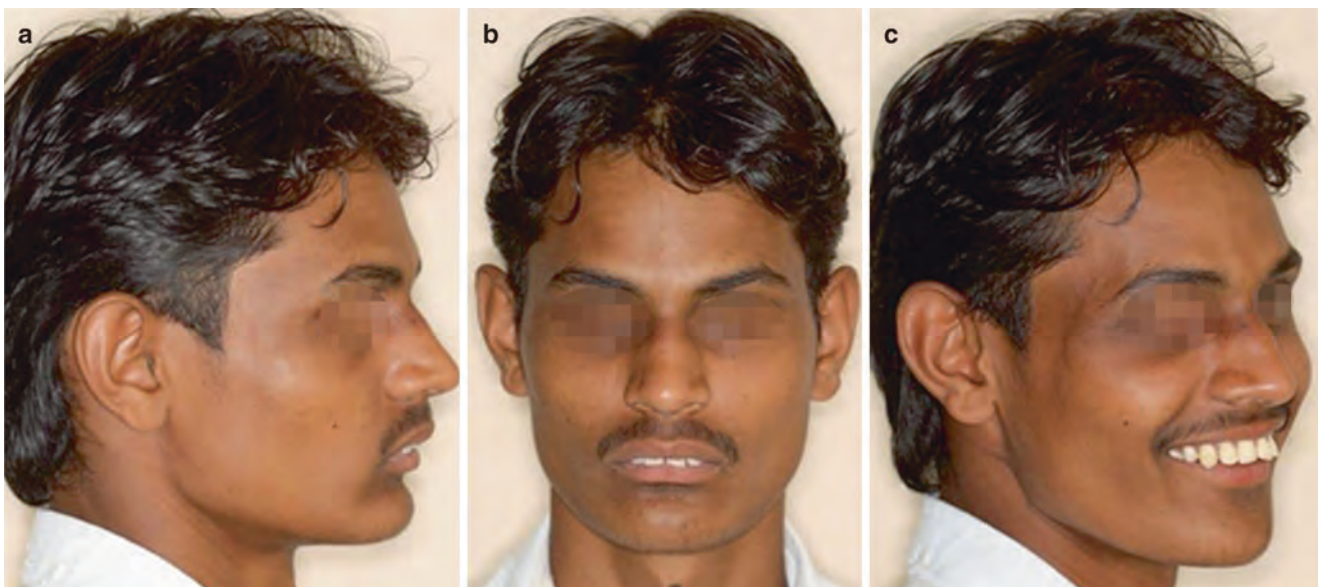

Fig. 67.6 Case Scenario 1. A 19-year-old male presenting with forwardly placed upper front teeth. (a–c) Preoperative pics showing frontal, profile and right lateral views. (d, e) Preoperative occlusion showing end on molar relation and compensated dental occlusion with anterior deep bite and excessive overjet. (f, g) Post-surgical orthodontic treat-

ment in progress. Excessive nature of curve of Spee can be noted, and the change in overjet and overbite post-surgery can be appreciated. (h–j) Post-treatment facial pics: frontal, smiling and lateral views. (k, l) Post-treatment intraoral pics. (m, n) Comparison of pre-operative and post-operative lateral cephalograms

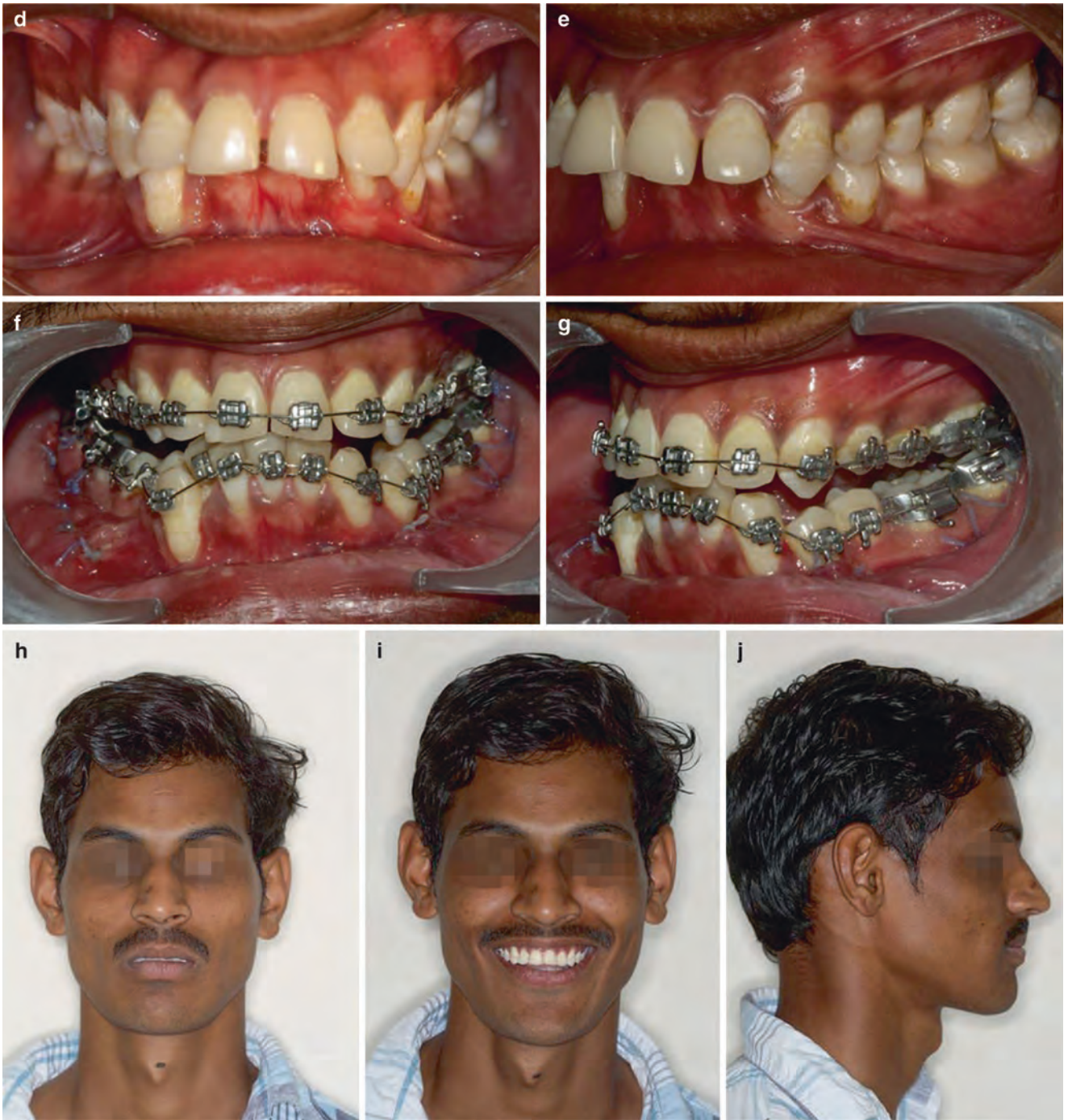
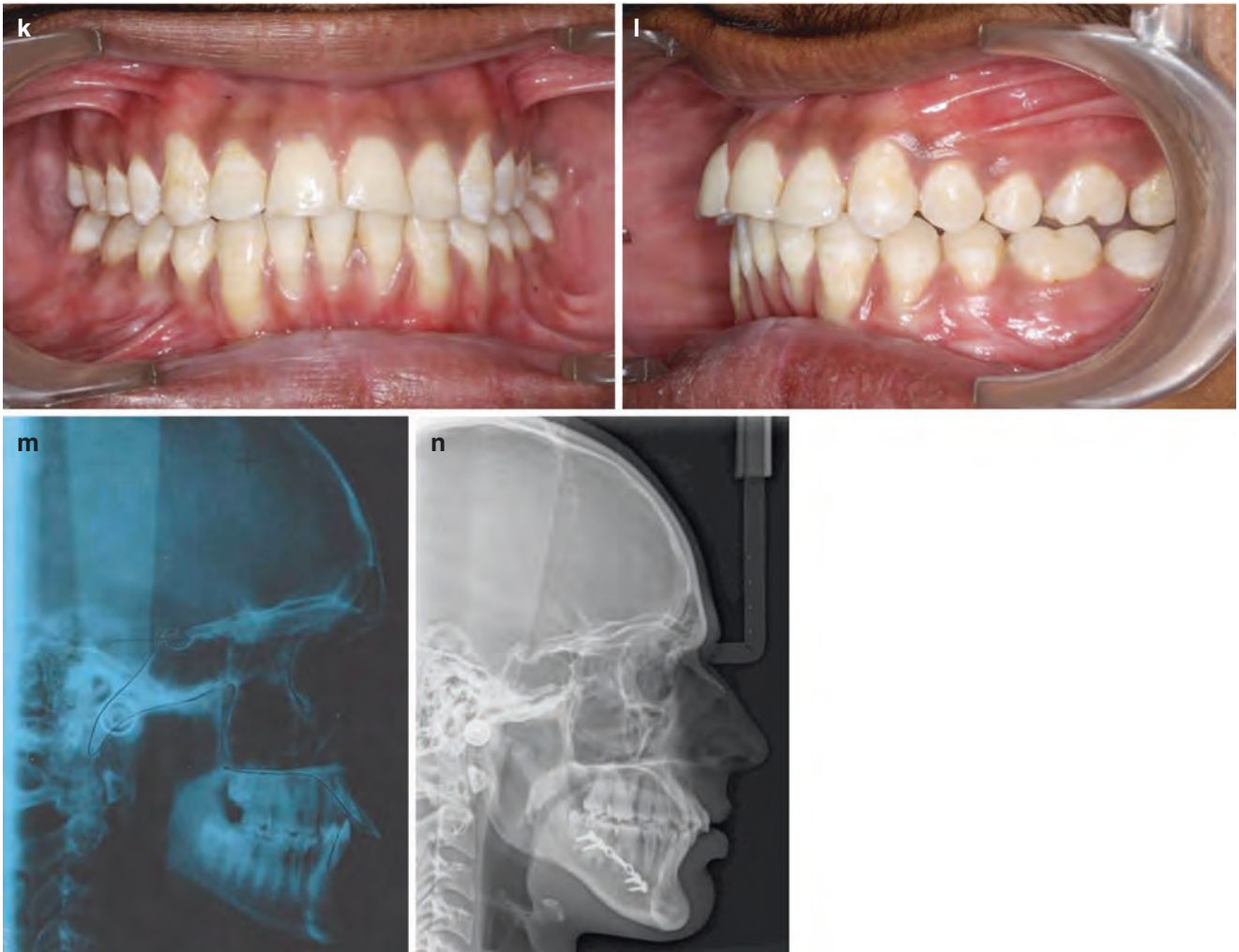
Fig. 67.6 (continued)



©Association of Oral and Maxillofacial Surgeons of India

Fig. 67.6 (continued)

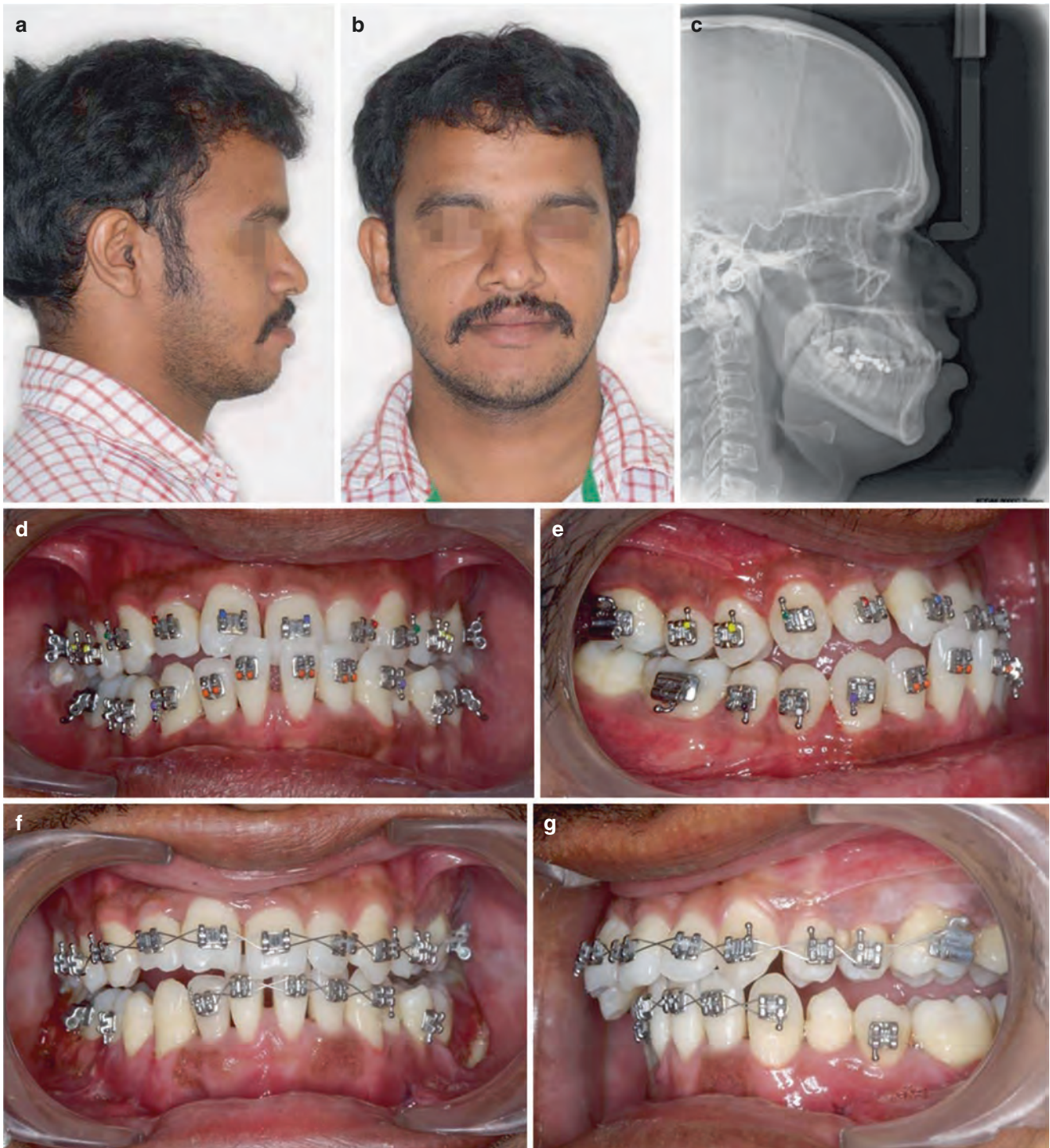
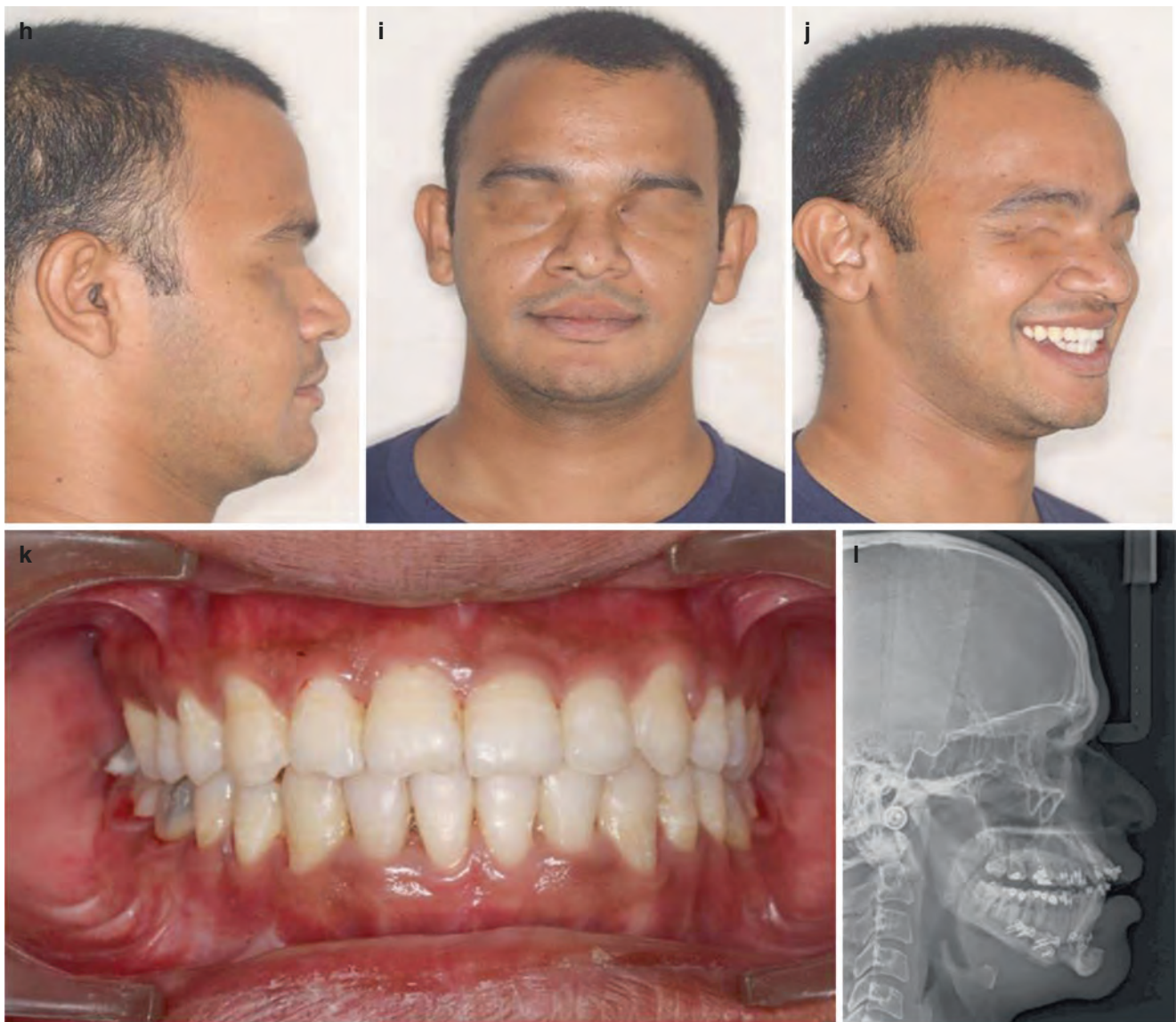

Fig. 67.7 Case Scenario 2. A 26-year-old male presenting with prominent lower facial appearance and mobile lower front teeth. (a, b) Clinical pics showing lateral and frontal views: Concave facial profile can be appreciated with acute nasolabial angle. (c) Lateral cephalogram showing skeletal Class III jaw bases with normodivergence. (d, e) Intraoral picture showing reverse overjet, Class III molar relationship

and spacing in lower anteriors. (f, g) Post-surgical orthodontics in progress. Reversal of overjet can be noticed. (h–j) Post-treatment facial pics in profile and frontal. (k) Intraoral post-treatment pic showing occlusal relationship with normal overjet and Class I molar relationship. (l) Post-operative cephalogram



©Association of Oral and Maxillofacial Surgeons of India

Fig. 67.7 (continued)

References

1. Poulton DR, Taylor RC, Ware WH. Cephalometric x-ray evaluation of the vertical osteotomy correction of mandibular prognathism. *Oral Surg Oral Med Oral Pathol.* 1963;16:807–20.
2. Worms FW, Isaacson RJ, Speidel TM. Surgical orthodontic treatment planning: profile analysis and mandibular surgery. *Angle Orthod.* 1976;46(1):1–25.
3. Sabri R. Orthodontic objectives in orthognathic surgery: state of the art today. *World J Orthod.* 2006;7(2):177–91.
4. Grubb J, Evans C. Orthodontic management of dentofacial skeletal deformities. *Clin Plast Surg.* 2007;34(3):403–15.
5. Bailey LTJ, Proffit WR. Combined surgical and orthodontic treatment. In: Sarver DM, Fields HW, Proffit WR, editors. *Contemporary orthodontics.* 3rd ed. Philadelphia, PA: Mosby; 1999. p. 674–709.
6. Jacobs JD, Sinclair PM. Principles of orthodontic mechanics in orthognathic surgery cases. *Am J Orthod.* 1983;84(5):399–407.
7. Proffit WR, White RP, Sarver DM. Combining surgery and orthognathics: who does what, when? In: Proffit WR, White RP, Sarver DM, editors. *Contemporary treatment of dentofacial deformity.* 1st ed. St Louis, MO: Mosby; 2003. p. 245–67.
8. Kim JH, Mahdavi NN, Evans CA. Guidelines for “surgery first” orthodontic treatment. In: Bourzgui F, editor. *Orthodontics—basic aspects and clinical considerations.* 1st ed. Casablanca: University Hassan II of Casablanca: IntechOpen; 2012. p. 265–300.
9. Huang CS, Chen YR. Orthodontic principles and guidelines for the surgery-first approach to orthognathic surgery. *Int J Oral Maxillofac Surg.* 2015;44(12):1457–62.
10. Nagasaka H, Sugawara J, Kawamura H, Nanda R. “Surgery first” skeletal class III correction using the skeletal anchorage system. *J Clin Orthod.* 2009;43(2):97–105.
11. Sugawara J, Aymach Z, Nagasaka DH, Kawamura H, Nanda R. “Surgery first” orthognathics to correct a skeletal class II malocclusion with an impinging bite. *J Clin Orthod.* 2010;44(7):429–38.

12. Villegas C, Uribe F, Sugawara J, Nanda R. Expedited correction of significant dentofacial asymmetry using a “surgery first” approach. *J Clin Orthod*. 2010;44(2):97–103.
13. Assael LA. The biggest movement: orthognathic surgery undergoes another paradigm shift. *J Oral Maxillofac Surg*. 2008;66(3):419–20.
14. Liou EJ, Chen PH, Wang YC, Yu CC, Huang CS, Chen YR. Surgery-first accelerated orthognathic surgery: postoperative rapid orthodontic tooth movement. *J Oral Maxillofac Surg*. 2011;69(3):781–5.
15. Liou EJ, Chen PH, Wang YC, Yu CC, Huang CS, Chen YR. Surgery-first accelerated orthognathic surgery: orthodontic guidelines and setup for model surgery. *J Oral Maxillofac Surg*. 2011;69(3):771–80.
16. Storey E. The nature of tooth movement. *Am J Orthod*. 1973;63(3):292–314.
17. Reitan K. Some factors determining the evaluation of forces in orthodontics. *Am J Orthod*. 1957;43(1):32–45.
18. Pellegrini GG, Gonzales CM, Somoza JC, Friedman SM, Zeni SN. Correlation between salivary and serum markers of bone turnover in osteopenic rats. *J Periodontol*. 2008;79(1):158–65.
19. Binder T, Goodson J, Socransky S. Gingival fluid levels of acid and alkaline phosphatase. *J Periodontol Res*. 1987;22(1):14–9.
20. Liao YF, Chiu YT, Huang CS, Ko EW, Chen YR. Presurgical orthodontics versus no presurgical orthodontics: treatment outcome of surgical-orthodontic correction for skeletal class III open bite. *Plast Reconstr Surg*. 2010;126(6):2074–83.
21. Peiró-Guijarro MA, Guijarro-Martínez R, Hernández-Alfaro F. Surgery first in orthognathic surgery: a systematic review of the literature. *Am J Orthod Dentofac Orthop*. 2016;149(4):448–62.

Open Access This chapter is licensed under the terms of the Creative Commons Attribution 4.0 International License (<http://creativecommons.org/licenses/by/4.0/>), which permits use, sharing, adaptation, distribution and reproduction in any medium or format, as long as you give appropriate credit to the original author(s) and the source, provide a link to the Creative Commons license and indicate if changes were made.

The images or other third party material in this chapter are included in the chapter's Creative Commons license, unless indicated otherwise in a credit line to the material. If material is not included in the chapter's Creative Commons license and your intended use is not permitted by statutory regulation or exceeds the permitted use, you will need to obtain permission directly from the copyright holder.



Varghese Mani

68.1 Introduction

Proper balance and harmony between the different parts of the face—forehead, eyebrows, eyes, nose, ears, cheeks, lips, mouth, jaws, chin, etc.—are the main factors deciding aesthetics. Aesthetic evaluation is mandatory to understand the problems systematically. During the primate evolution, jaws lost many functions, and the size suffered a gradual reduction, which resulted in an orthomorphic face. The facial muscles gained fine expression and smile, the exceptional features of *Homo sapiens*.

Mandible forms the movable lower part of the head. Mandible is attached to the upper part of the head by ligaments and musculature. It articulates with the glenoid fossa of temporal bone through temporomandibular joint, a synovial joint having translator and rotator movements (ginglymoarthrodial). These movements facilitate chewing and grinding functions. In our prehuman ancestors, the body of the mandible was parallel. In humans, since the brain case has expanded, the temporal bones were pushed apart, TMJ followed suit giving the lower jaw a parabolic contour. The Simian shelf reduced to genial tubercles to facilitate speech and to compensate and strengthen the jaw and the chin developed in humans. Metaphorically it is often stated that “the brain case has expanded at the expense of the jaws”.

In some people, surgical repositioning of the mandible may be required to achieve an ideal facial form and restore functions such as mastication and breathing.

68.2 Surgical Anatomy of the Mandible (Fig. 68.1a, b)

Mandible is the sturdiest bone of the face with strong basal bone and the alveolar part housing the dentition. The near round protuberances seen bilaterally at the cephalic end of the mandible are called condyles, and they form its articulation with the TMJ. The mandibular condyles articulate with the temporal bone and help in the rotatory and translatory movements of the mandible as well as to transmit forces from the mandible to the skull base. A good understanding of the gross anatomy of the mandible is essential to understand its surgical implications. This needs to include the TMJ, the dentition, the supporting ligaments, and the muscles of mastication (Fig. 68.2a, b) and facial expression.

On the medial aspect of the vertical ramus is the mandibular foramen just posterior to halfway between the antero-posterior width of the vertical ramus almost in line with the most concave part of the anterior border of the ramus. Just above is the lingula, a triangular prominence to which the sphenomandibular ligament is attached. Mandibular neurovascular bundle enters the mandibular foramen on the lingual side of the mandible and runs below the tooth roots in the body of the jaw, in the inferior alveolar canal. It curves upward and backward by about 2 mm and gives out the main branch, mental nerve, below the second premolar area, and gives sensory supply to the lower lip and chin [1].

Electronic Supplementary Material The online version of this chapter (https://doi.org/10.1007/978-981-15-1346-6_68) contains supplementary material, which is available to authorized users.

V. Mani (✉)
Department of Oral and Maxillofacial Surgery, Mar Baselios
Dental College, Kothamangalam, Kerala, India

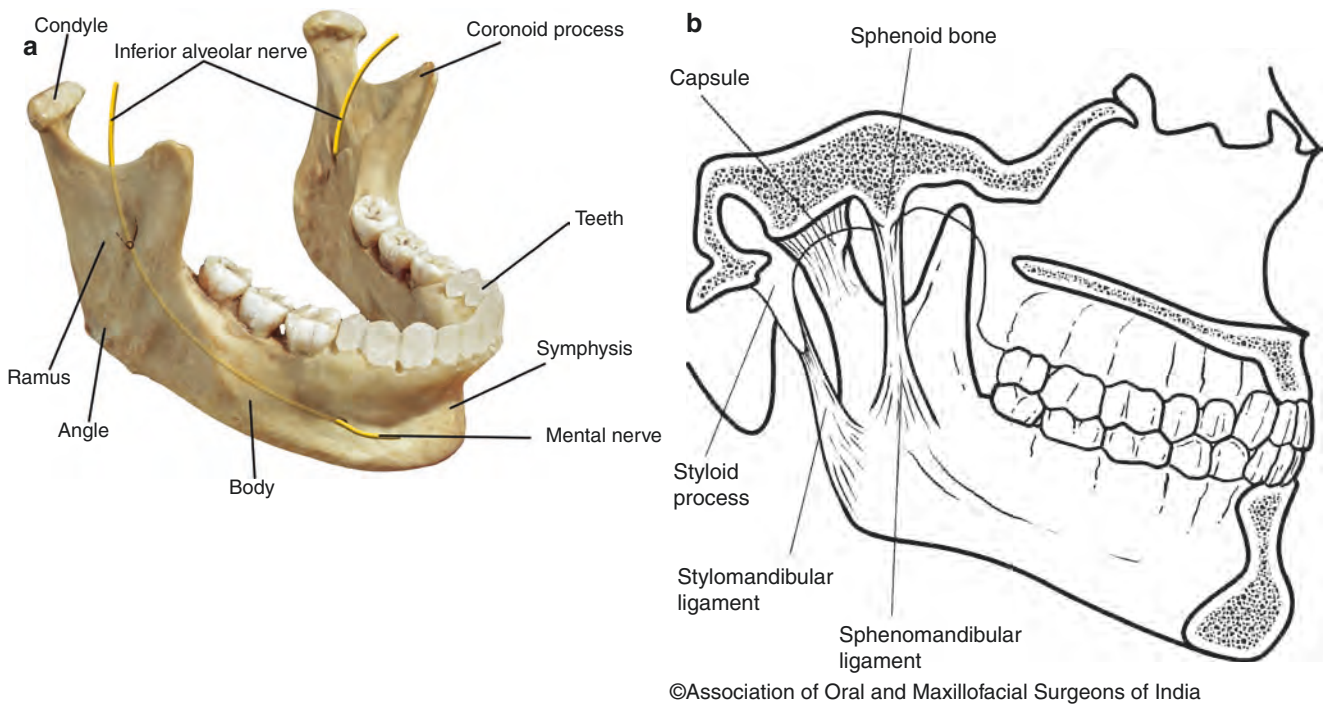


Fig. 68.1 (a) Gross anatomy of mandible, (b) ligaments attached to mandible

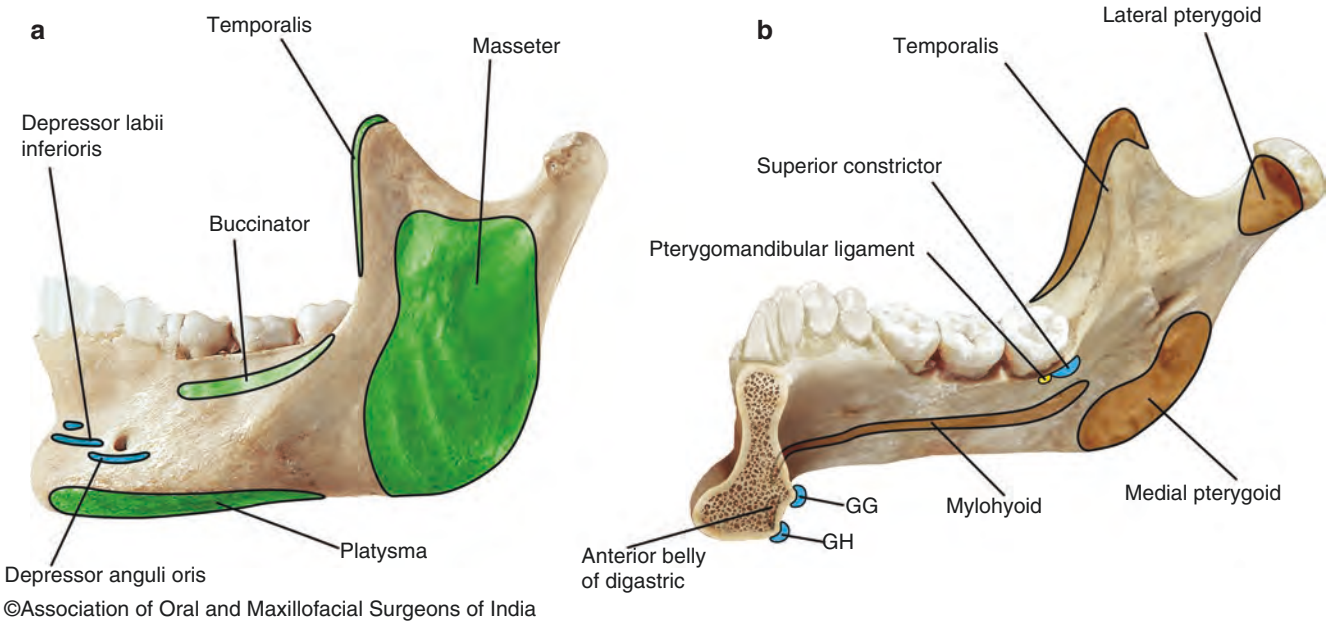
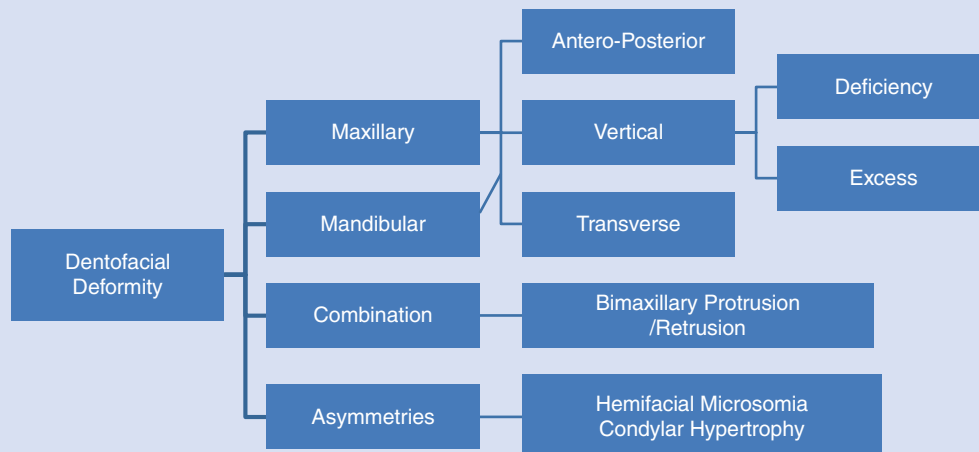


Fig. 68.2 Muscles attached to mandible. (a) Buccal aspect and (b) lingual aspect. (GG) Genioglossus and (GH) Geniohyoid

68.3 Classification of Deformities of the Mandible (Table 68.1)

Table 68.1 Classification of dentofacial deformities



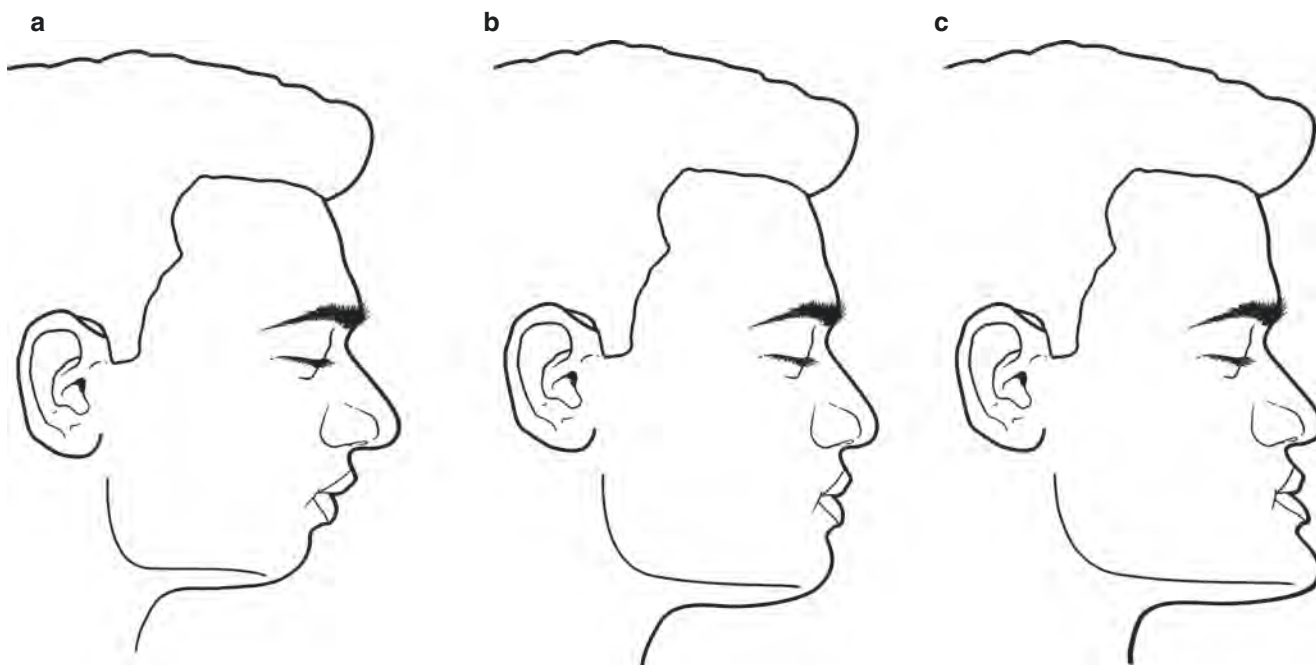
Deformities of the jaws can be associated with the dento-alveolar complex, the skeletal base or both.

They may be either an excess or a deficiency.

These problems can occur in three different vectors: Antero-posterior, Transverse and Vertical

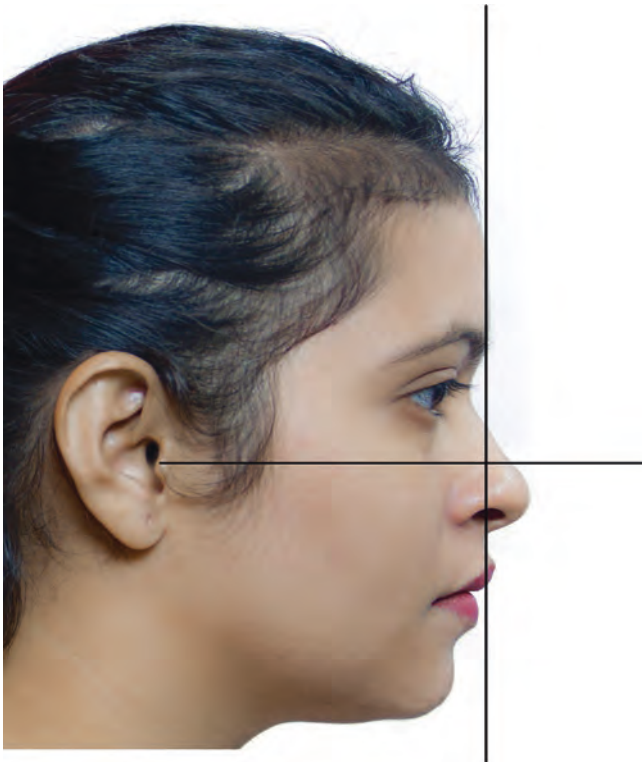Before venturing into the classification of the jaw deformities it will be appropriate to assess the relationship of the lower jaw to the rest of the face. Certain parameters are used to assess the deformity objectively. Clinical evaluation is the most important of them all. Face has to be assessed frontally and laterally.

Profile analysis of the face is the most important of them all—it could be convex, straight, or concave. Convexity can be due to protruded maxilla or retruded mandible/chin. Concave face can be due to retruded maxilla or prognathic mandible/chin (Fig. 68.3a, b, c).



©Association of Oral and Maxillofacial Surgeons of India

Fig. 68.3 On profile analysis face can be convex (a), straight (b), or concave (c)

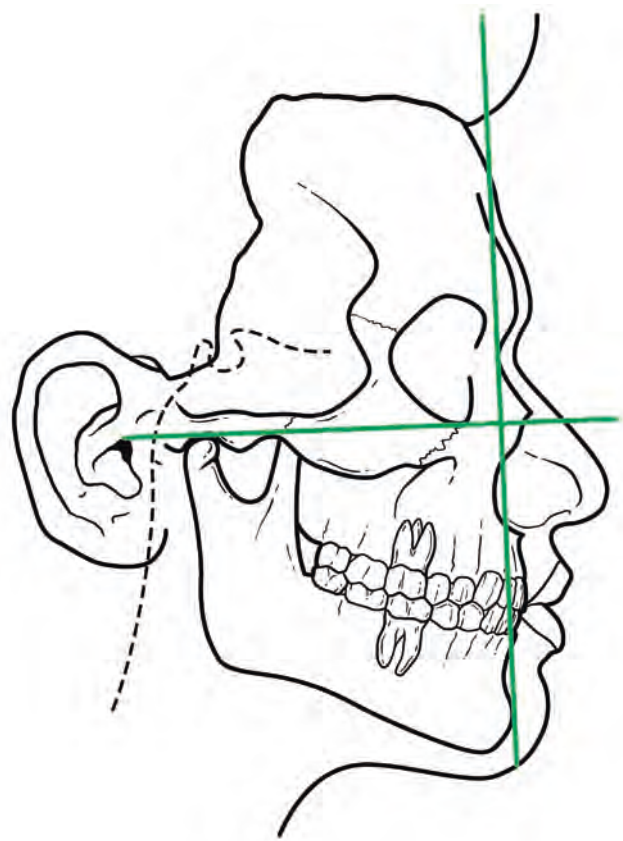


©Association of Oral and Maxillofacial Surgeons of India

Fig. 68.4 Subnasale perpendicular to FH plane

Subnasale perpendicular is another important tool for assessing the profile. A line is drawn perpendicular to the Frankfort horizontal plane through the point Subnasale. This line is expected to go through the upper vermilion border, 2 mm anterior to the lower vermilion border and 4 mm anterior to the soft tissue (Fig. 68.4) Pogonion. ± 2 mm is considered to be within normal limits. This is an important assessment tool for understanding the sagittal relationship of both the maxilla, mandible and dentition.

Likewise another perpendicular line is drawn from Nasion. (N. Perpendicular). This line is ahead by 5.3 ± 6.7 mm in males and 6.9 ± 4.3 mm in females. This indicates the position of mandible. Regarding the bony pogonion this line is ahead by 4.3 ± 8.5 mm in males and 6.5 ± 5.1 mm in females. This indicates the position of the chin. Angle SNB is 80 ± 2 normally. Less indicates retruded mandible and more indicates protrusion of mandible. All these measurements are in relation to the cranial base, the portion that is not changed in routine orthognathic surgery. (Fig. 68.5) (Refer Chap. 66 for further details).



©Association of Oral and Maxillofacial Surgeons of India

Fig. 68.5 Nasion perpendicular to FH plane

- Mandibular prognathism
 - (a) Skeletal
 - (b) Dento- alveolar
- Mandibular retrusion
 - (a) Skeletal
 - (b) Dento- alveolar
- Mandibular Transverse Deformity
 - (a) Broad
 - (b) Narrow
- Chin Deformity-Excess
 - (a) Vertical
 - (b) Transverse
 - (c) Antero posterior
- Chin deformity deficient
 - (a) Vertical
 - (b) Transverse
 - (c) Antero posterior
- Deep bite deformity
- Open bite deformity(Apertognathia)
- Asymmetry

Specific conditions like presence of deep bites and open bites can occur with these clinical situations and may help us understand the dentoalveolar compensations that occur with them. Assessment of patients is done with facial analysis and cephalometrics.

68.3.1 Mandibular Excess

Common cause for mandibular excess is either developmental or genetic. Very large mandible may be associated with acromegaly.

The clinical features associated with mandibular excess are the following:

1. Prognathic mandible.
2. Anterior cross bite.
3. Elongated face.
4. Relatively long lower third of the face
5. Stomion-menton length—proportionately long.
6. Concave facial profile.
7. Lower lip and chin are more anteriorly placed than normal (SN perpendicular)
8. Class III relationship of occlusion.
9. Angle SNB—more than 82° .

68.3.2 Mandibular Deficiency

It is often due to genetical or developmental reasons. Ankylosis of temporomandibular joint, trauma to mandibular condyle and aplasia of condyle can also cause deficiency in mandibular growth.

Clinical features associated with mandibular deficiency are the following:

1. Bird face appearance.
2. Severe over jet.
3. Class II relationship of dentition.
4. Crowding of lower anterior teeth.
5. Flaring compensation of lower anterior teeth.
6. Face appears small.
7. Lower third of the face is short.
8. Stomion-menton is proportionately short.
9. Labiomental fold is usually absent.
10. Chin neck angle is obtuse.
11. Angle SNB—less than 78° .
12. Angle FHP N P—less than 82° .

68.3.3 Deformities of Chin

Deformities of chin could be three dimensional—vertical, antero-posterior, or horizontal.

Vertical and antero-posterior excess of chin are usually associated with mandibular prognathism. Though in prognathic mandible, chin appears prominent, it need not be so in objective analysis. Hence it is essential that the chin be assessed independently in relation to the other structures. To assess the vertical discrepancy, the best technique is to measure the length from stomion of the lower lip to the menton and compare this to the length obtained from measuring the subnasale to stomion of the upper lip, in rest position. The former should be double the latter normally.

68.3.4 Facial Asymmetry

The reasons for facial asymmetry are many.

A few of the etiological factors are the following:

1. Hemifacial microsomia/dysplasia
2. Unilateral cleft lip and palate, and other unilateral clefting syndromes
3. Childhood trauma especially to the condyle
4. Discrepancy in blood supply to the maxillofacial region
5. Habits
6. Early unilateral loss of teeth
7. Faulty use of functional appliances
8. Pathologies and childhood surgeries of the face

Asymmetry could be pan facial or limited to certain areas. Frontal analysis is the ideal method to assess asymmetries. Drawing vertical and horizontal parallel lines on the face will help to locate the area of asymmetry. This can also be done using a grid. PA cephalogram and frontal photographs are helpful in analyzing facial symmetry.

Orthognathic surgery to the mandible involves numerous procedures that facilitate the correction of deformities of the mandible and its dentoalveolar complex in all planes of space. This encompasses a wide array of techniques which may be classified based on the anatomical location they are applicable to.

Osteotomies of the Mandible

1. Dentoalveolar complex
 - (a) Anterior subapical
 - (b) Total subapical
2. Midline symphyseal osteotomy
3. Body osteotomy
4. Ramus Osteotomy
 - (a) Vertical sub-sigmoid osteotomy—intra- and extraoral
 - (b) Sagittal split ramus osteotomy (BSSO)
5. Subcondylar osteotomy

The discussion of all the techniques is beyond the scope of this chapter, and hence, detailed description of the vertical ramus osteotomy, the sagittal split ramus osteotomy, and the anterior subapical osteotomy are provided here.

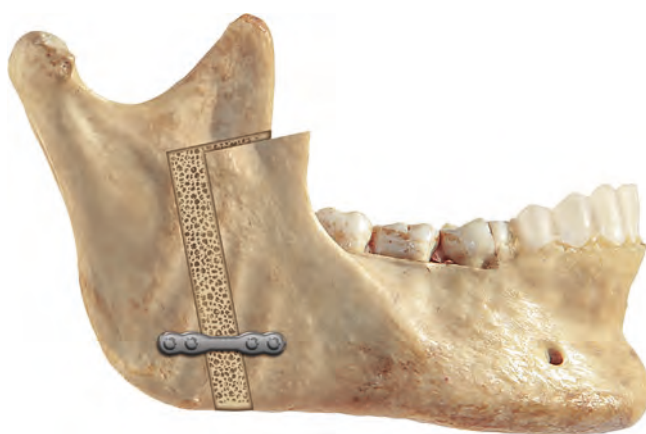
68.4 Ramus Osteotomies

Movement of the mandible in the antero-posterior direction is usually achieved by ramus osteotomy. Limberg in 1925 reported subcondylar oblique osteotomy [2]. Thomas, Robinson, Shira, and others described buccal osteotomy which involved the ramus. Later, Caldwell and Letterman (1954) described vertical subcondylar osteotomy by extraoral approach, which became very popular [3]. This technique minimized trauma of the inferior alveolar neurovascular bundle.

In 1927 Wassmund described the inverted “L” osteotomy. Though the primary indication was mandibular prognathism, many surgeons advocated vertical osteotomy and certain modifications like inverted “L” osteotomy [4] and “C” osteotomy for advancement of the mandible [5]. Bone grafting has to be done to fill the gap created (Fig. 68.6).

In 1937 Lane described a sagittal osteotomy. Obwegeser modified the Lane’s technique in 1955, and the technique of sagittal split osteotomy is credited to him. Sagittal split is a versatile technique and has the following superiority over others [6]. It gives great flexibility in repositioning the distal tooth-bearing segment. There is better cancellous bone contact, which enhances healing. The alterations in the position of the condyles and muscles of mastication are minimal. There is no extraoral scar. Injury to the marginal mandibular nerve is avoided. However, chance of injury to the inferior alveolar neurovascular bundle is high [7].

Dal Pont made the modification to sagittal split by a vertical cut through the lateral cortex [8]. Hunsuck extended the medial cut only to a point above the lingula. This minimized trauma to overlying tissue [9].



©Association of Oral and Maxillofacial Surgeons of India

Fig. 68.6 Inverted “L” osteotomy of the ramus used for advancing the mandible

68.4.1 Extraoral Vertical Ramus Osteotomy

This was one of the most popular procedures for correcting mandibular prognathism. Rigid internal fixation techniques and certain modifications like “C” osteotomy and inverted “L” osteotomy have been used for advancement of the mandible. After “C” or “L” osteotomy, the gap created while advancing or rotating the distal segment is filled with bone graft [10].

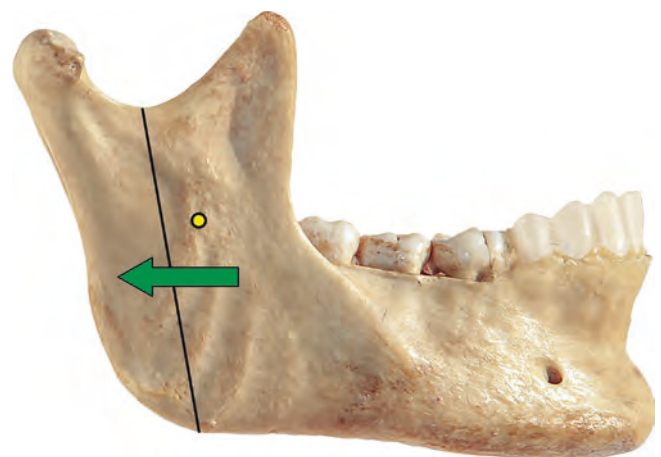
The major disadvantages are the external scar and the possible inadvertent damage to the marginal mandibular nerve. With judicious care, these problems can be minimized. Better visibility is the major advantage (Fig. 68.7).

Surgical Technique:

Submandibular skin incision is placed, about 1.5 cm below the angle of the mandible. The incision is taken down to the platysma, which is then divided. Marginal mandibular nerve lies below the platysma running parallel to and often below the lower border of the mandible, crossing the facial vessels superficially as it passes upward. Attempt should be made to identify this structure and preserve it.

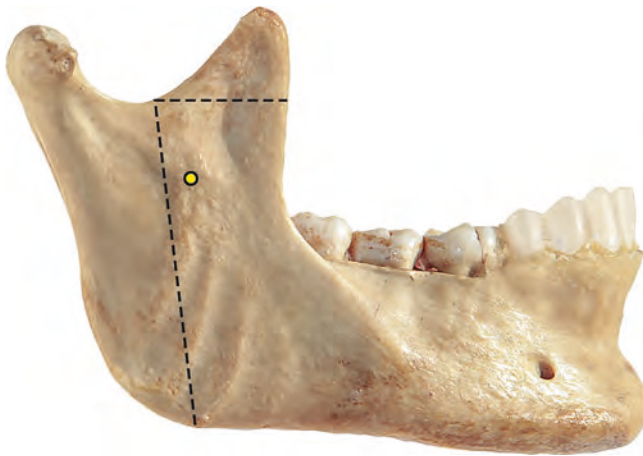
After identification and protection of the marginal mandibular nerve, dissection is carried down to the bone. The periosteum is incised over the angle. The periosteum is reflected superiorly to the level of the sigmoid notch on the lateral aspect of the ramus. Coronoid process may be cut in cases when more than 1 cm of posterior movement is required (Fig. 68.8).

Lateral aspect of the ramus is inspected for a small bulge corresponding to the lingula. This helps to identify the mandibular foramen. Osteotomy is performed posterior to the anti-mandibular foramen bulge so that the mandibular nerve is not injured. (The position of the bulge is arbitrary and not definite.) A vertical bony cut is made starting at the sigmoid notch and progressing to the lower border near the angle of the mandible. Condylar segment is separated from the distal part of the mandible and is detached from the medial pterygoid muscle. The condylar part is



©Association of Oral and Maxillofacial Surgeons of India

Fig. 68.7 Subsigmoid vertical osteotomy was the most popular technique before the introduction of sagittal split osteotomy. This technique is used for correcting mandibular prognathism



©Association of Oral and Maxillofacial Surgeons of India

Fig. 68.8 When the push back required in subsigmoid vertical osteotomy is more than 1 cm, sectioning of the coronoid process helps in better stability

laterally placed on the distal segment. After packing the wound, the same steps are followed on the contralateral side.

The mandible is repositioned into the desired position with the help of the splint, and intermaxillary fixation is done. The site of surgery is again approached. Some surgeons prefer to leave the condyle as such on the lateral aspect without any transosseous wiring. There is no consensus regarding the decortication of the opposing surfaces.

Removal of bone or decortication may be done if it helps the condyle to achieve a proper position within the glenoid fossa with minimal displacement. Decortication helps better contact of the cancellous bone enhancing healing. Stabilization of the fragments by transosseous wires or screws and plates can be done. Rigid internal fixation eliminates intermaxillary fixation. Except in rigid internal fixation, intermaxillary fixation for a period of 4–6 weeks is mandatory. After the fixation is removed, elastics may be used to guide the movements.

Wound closure is done in layers. Skin may be closed by monofilament 6-0 or smaller sutures. A pressure dressing is applied for the first 24–48 h. Drain is usually not necessary and, if done, has to be done through a separate stab incision below the main incision. Sutures are removed after 5–7 days, and the wound is supported by dressing for a period of another 1 week, if required.

Complications are usually rare. Bleeding may occur due to injury to the retromandibular vein or masseteric artery where it crosses laterally through the sigmoid notch. Bleeding can be controlled by routine methods like pressure packs, ligation, etc. Injury to the marginal mandibular nerve is another possibility. A transitory deficiency in the function of the lower lip may be anticipated due to traction on the nerve. This often recovers completely. In case of sectioning of the nerve, micro-surgical repositioning is advised.

If care is taken in closure, and infection is avoided, scar formation is minimal. If scar is formed, revision may be done subsequently (Fig 68.9a–d).

68.4.2 Sagittal Split Osteotomy

Sagittal split osteotomy (SSO) can be employed for correcting both retrognathism and prognathism. Modifications by Dal Pont, Hunsuck, and Epker have made the procedure simpler and more acceptable biologically. Schuchardt and Lane described sagittal split osteotomy of the vertical ramus [11]. It was Obwegeser who popularized it. His medial cut was above the mandibular foramen, and his lateral cut was below that of Schuchardt's and extended to a part just above the angle, at least 25 mm below the lingual cortical cut. Obwegeser and Trauner in 1955 described the bilateral sagittal split osteotomy [6].

Dal Pont in 1961 made a major modification by extending the cut anteriorly and making the vertical cut just below the second molar [8]. Hunsuck in 1968 modified the cut in the medial cortex of the vertical ramus, limiting the cut to just behind the mandibular foramen. Postoperative complications got reduced [9] (Fig. 68.10a, b).

Bell and Schendel and Epker extended the vertical cut on the buccal side to the lower border of the mandible reducing the incidence of wrong splits [12, 13]. A reciprocating osteotomy saw, which is specifically meant for the inferior border (right and left) may be used to perform inferior border osteotomy [14].

Performing an inferior border osteotomy results in much lower incidence of persisting inferior border defects. Hence, during advancement of the mandible, it is advisable to exclude the lingual cortex in the split. Piezosurgery has been compared with conventional surgical drills/saws by several authors for BSSO. They have reported substantially longer surgery time for piezosurgery. Image-guided surgery has also become popular in the recent years, and this allows the surgeon to track the position of the instruments and segments during the operation in real time. Modern intraoperative navigation systems are being used in orthognathic surgery also [15].

A. Incision and Dissection:

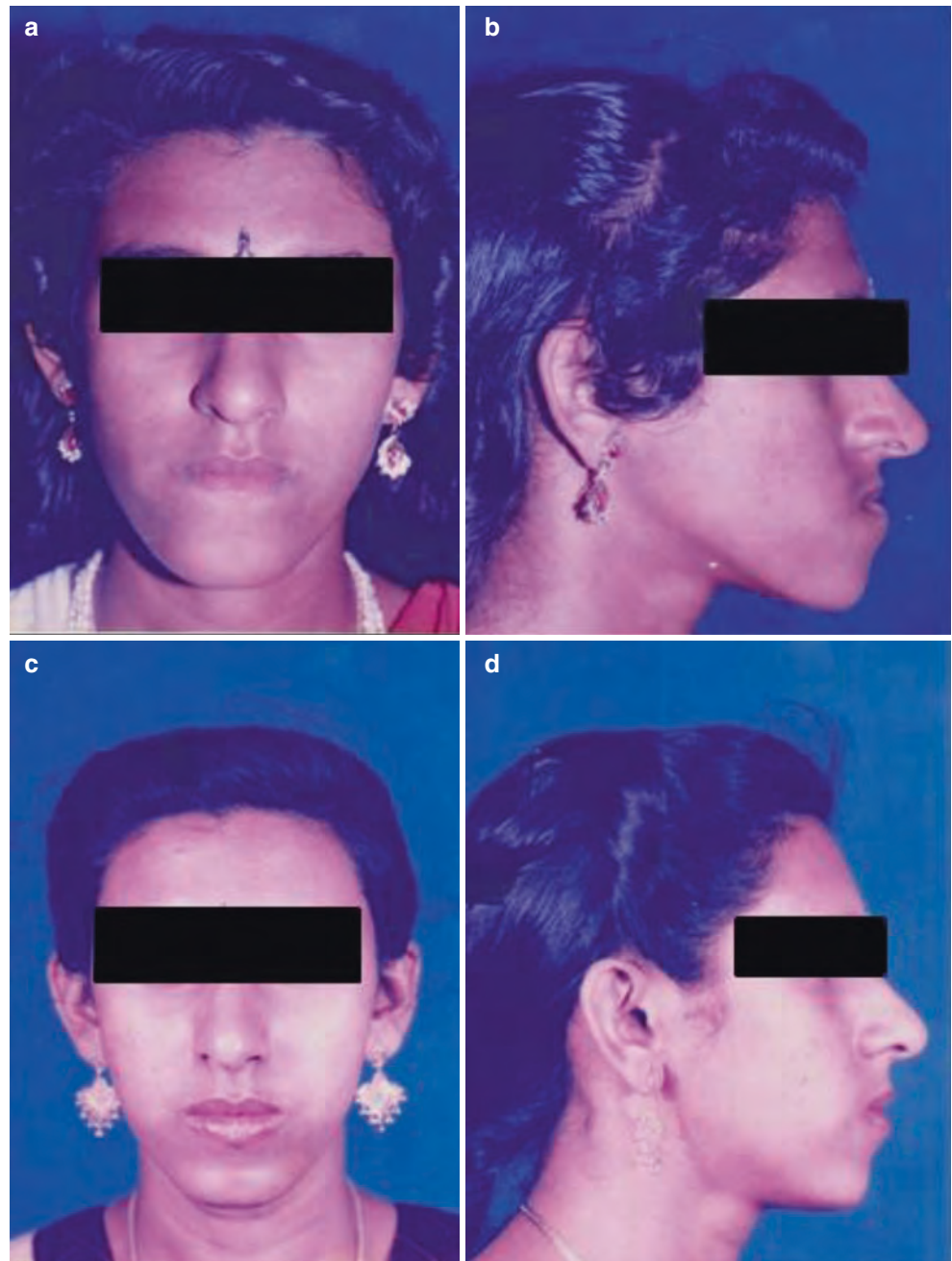Incision is placed over the region of the ramus to the mid ramus. It is carried over the external oblique ridge, extends up to the first molar region, and curves down to the buccal vestibule.

Initially only the mucosa is incised over the ramus region. Retracting the tissue buccally, before incision, prevents the exposure of the buccal pad of fat, a troublesome interference, during surgery. Sharp dissection at the ramus is continued to the periosteum, using scissors, knife, and periosteal elevators.

Periosteal elevation of the lateral aspect of the mandible at the molar region is performed down to the inferior border. On the ramus, lateral dissection may be kept minimal but enough to achieve proper visibility and access.

Medial dissection is done very carefully on the medial side of the ramus. The level of the lingula and the entry of the inferior alveolar nerve into mandibular foramen are visualized. This is usually in level with the deepest concavity along

Fig. 68.9 Mandibular prognathism corrected by subsigmoid vertical osteotomy of the ramus on both sides to set back the mandible. (a, b) Preop pictures, (c, d) postop pictures



©Association of Oral and Maxillofacial Surgeons of India

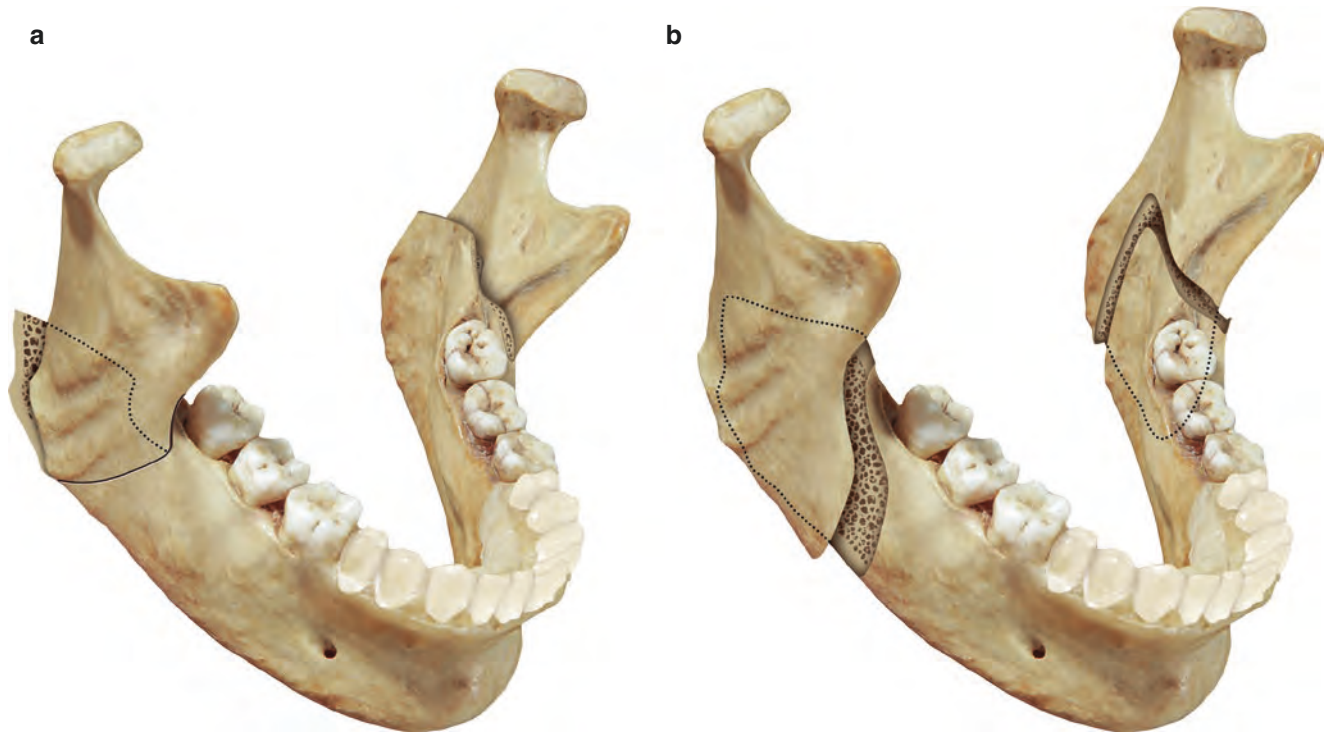
the anterior border of the coronoid and ramus. With a small flexible Freer Elevator, the tissue is dissected taking care not to perforate the periosteum on the medial aspect. Dissection should be above the level of the mandibular foramen. Using a bigger elevator, the medial aspect of the mandible above the lingula is exposed subperiosteally. (Perforation of the periosteum not only induces bleeding but may injure the mandibular nerve.) Sigmoid notch is identified for better orientation. Subperiosteal dissection should be minimal, but enough to retract the tissues medially without much traction on the mandibular neurovascular bundle [16].

B. Osteotomy (Videos 68.1 and 68.2):

Osteotomy is initiated by cutting the cortical bone above the lingula on the medial side. This cut should extend behind

the mandibular foramen but need not be up to the posterior border of the ramus (about half to two-thirds of the antero-posterior dimension of the ramus). The cut is taken downward along the external oblique ridge to the second or first molar region. The depth of the cut should be minimal, just enough to reach the cancellous bone (Figs. 68.11 and 68.12).

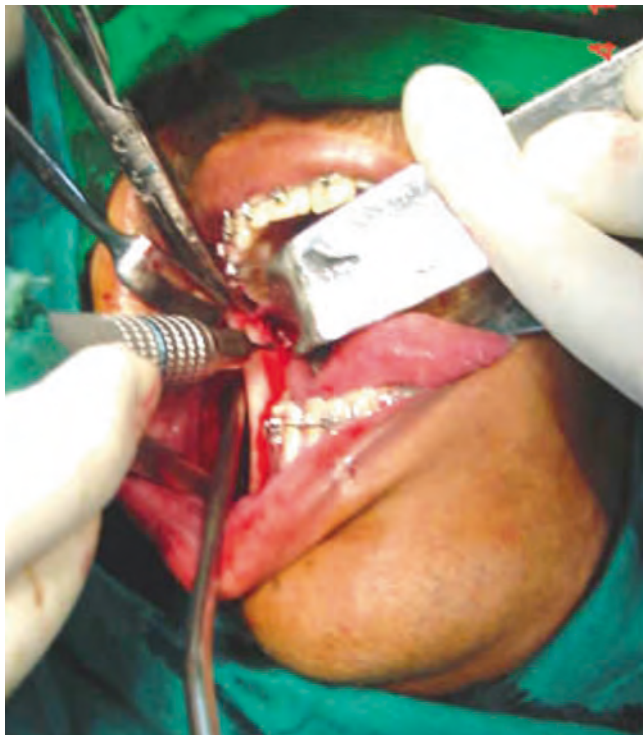Conventionally the vertical cut is made at the second molar region as the bone is thicker there. The CT analysis conducted by Y Tsuji et al. on prognathic mandible demonstrated that the mandibular thickness of the mandible increased along the mandibular foramen toward the mandibular body. The mandibular canal was located relatively lingually at all sites. They also observed that marrow space, located on the buccal side, was thicker at the region of mandibular body [17].



©Association of Oral and Maxillofacial Surgeons of India

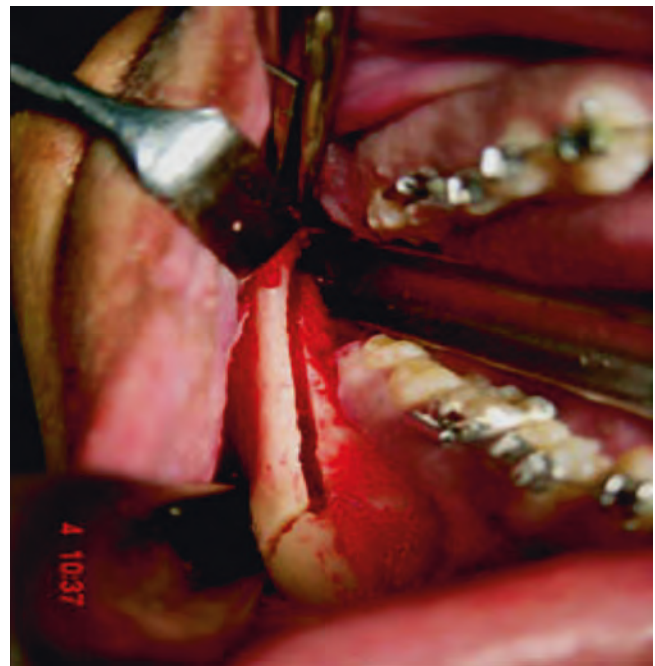Fig. 68.10 Bilateral Sagittal Split Ramus Osteotomy (BSSO/BSSRO). (a) Obwegeser split: Initially the medial cut in sagittal split osteotomy extended up to the posterior border, and when the distal segment was pushed back, the margin used to jut out, which had disadvantages like

relapse tendency and injury to the retromandibular tissues. (b) Hunsuck split: At present the medial cut is taken above the mandibular foramen much short of the posterior border but behind the foramen. The complications are much less (also see Fig. 65.12b)



©Association of Oral and Maxillofacial Surgeons of India

Fig. 68.11 The medial cut is taken above and behind the mandibular foramen and deepened to the cancellous bone



©Association of Oral and Maxillofacial Surgeons of India

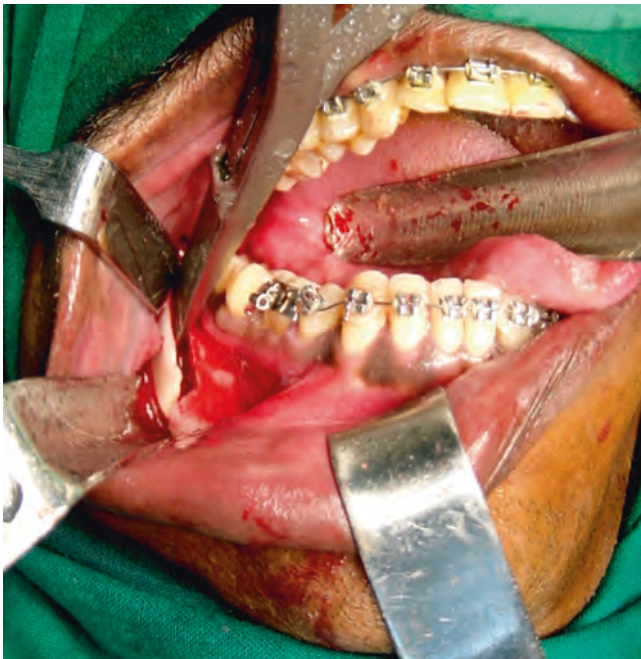Fig. 68.12 The cut is extended obliquely through the anterior border of the mandible to the buccal plate and taken downward at the level of the first or second molar region, up to the inferior border. Only the cortex need be cut. Deeper cuts could injure the inferior alveolar nerve and may cause wrong splits (also see Figs. 69.31 a-c and 70.24 c, d)

A study on cadaveric mandible by Promma et al. reported that the thickness of buccal cortex to the mandibular canal is about 6.5 and 5 mm at the second molar and first molar regions, respectively [18].

Some surgeons prefer to take the cut more forward to the first molar region. This gives better accessibility for intraoral plating. When the vertical cut is made, it is mandatory to protect the soft tissue over the inferior border by using a channel retractor. If the vertical cut includes the inferior border, the direction of the split is controlled. A rotary instrument or a reciprocating saw is used for cutting. Once the cortical cut is completed, a small spatula osteotome is malleted to the site beginning from the medial cut to the vertical cut. Osteotome should be directed laterally just beneath the cortical plate so that the neurovascular bundle is not injured. Larger osteotomes are used, and slowly the fragments are pried apart using a smith spreader (Fig. 68.13).

As the splitting takes place, the neurovascular bundle is visualized, and care is taken to maintain it to the medial fragment. If it is attached to the proximal segment, the NV bundle is freed with a periosteal elevator. Next the fragments are pried apart using the spreader. The procedure is repeated on the opposite side.

Sagittal split osteotomy can be used for either mandibular advancement or setting back. If mandibular advancement is to be done, the medial pterygoid muscle is separated from the inferior border of the distal segment with a periosteal elevator. When the mandible is set back, medial pterygoid and masseter may have to be stripped, if needed, to prevent the displacement of the condylar segment posteriorly. Posterior stripping of the pterygomasseteric sling in SSO should be minimized to the antegonial notch. In excessive stripping, possibility for avascular necrosis increases [19].



©Association of Oral and Maxillofacial Surgeons of India

Fig. 68.13 A spreader is used to split the mandible at the ramus region

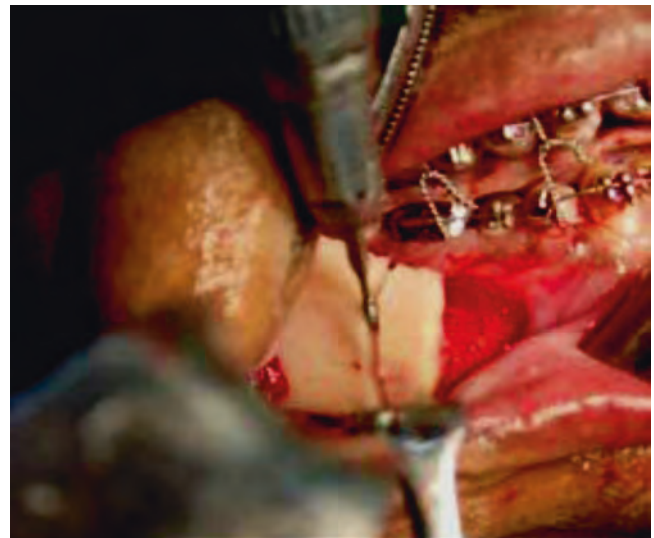When the tooth bearing segment (distal segment) is pushed back, the buccal plate of the condylar segment (proximal segment) overlaps the distal. This overlapping part is excised, and the proximal segment is allowed to rest on the cancellous part without any tension (Fig. 68.14).

Pushing the mandible backward reduces the space in the oral cavity. The tongue may not have enough space, and sometimes this induces tongue thrusting, snoring, etc. Some authors advocate reduction glossectomy to improve function related to airway speech and mastication. They also opine that reduction glossectomy improves aesthetics and controls unfavorable mandibular growth [20].

Mommaerts reported that mandibular lengthening done through endoscopic surgery, with transoral osteosynthesis, reduced stripping of the periosteum and therefore consequent edema [21]. In certain clinical situations Unilateral sagittal osteotomy is performed. Refer case scenario in Fig. 69.31 (Maxillary orthognathic surgery Chap. 69) where an unilateral sagittal osteotomy was combined with maxillary osteotomy to correct canting of the maxilla.

C. Stabilization and Fixation:

Rigid internal fixation (RIF) using plates and screws or lag screws is the preferred way of fixation. Prior to RIF, the position of the jaw is adjusted, and intermaxillary fixation is done with splint in position. Both fragments are allowed to be in passive position before RIF is performed. Intermaxillary fixation (IMF) is removed after rigid fixation. However, some surgeons prefer to keep the IMF for 1 week. For rigid fixation 2.5 mm four-hole mini plate with gap is used for push back (Fig. 68.15). Longer plates are used for advancement. Multiple lag screws can also be used. Skeletal rigid fixation has been shown to reduce relapse following mandibular advancement [22–24] (Figs. 68.16a, b, c, and 68.17a, b, c).

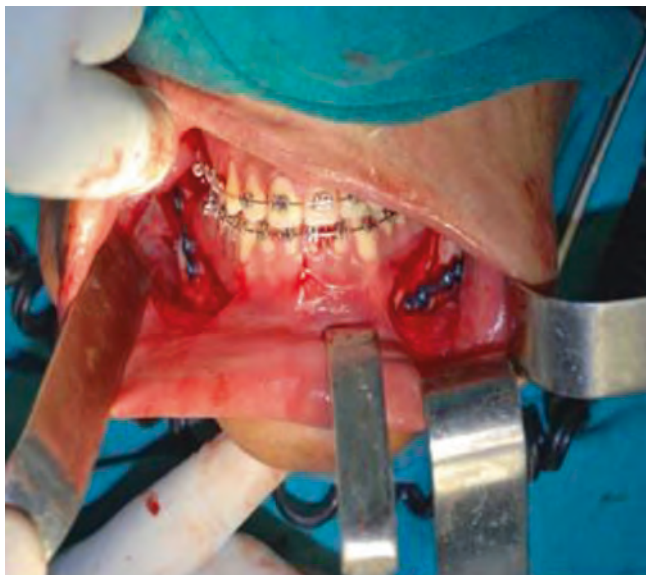

©Association of Oral and Maxillofacial Surgeons of India

Fig. 68.14 Excess of the buccal plate is cut off when the intention is to push the mandible backward

Rachmiel et al. in their study found improved stability with four-hole plate and monocortical screws, with a relapse rate of about 18% only [25].

Based on a 10-year experience of using bioresorbable plates in orthognathic surgery, Laine P et al. opine that these devices are safe to be used. Relapse rate with bioresorbable screws is the same as with metal in SSO [26]. Another method of fixation is wiring. If resorting to wiring, intermaxillary fixation has to be kept for 5–6 weeks. Maturation of soft and bony



©Association of Oral and Maxillofacial Surgeons of India

Fig. 68.15 Rigid fixation after sagittal split osteotomy of the mandible using mini plate

tissues continues at the surgical site and approximates that of non-surgical sites at 12 weeks postoperatively [27–29].

The inferior alveolar nerve is less likely to get damaged when monocortical screws are used. These screws also allow for readjustment if there is any inadvertent malposition during surgery can be readjusted more easily [30]. An in vitro study on sheep mandibles found that both mini plates and bicortical screws resulted in a similar level of stability [31]. (Figs. 68.18a, b, c, d, 68.19a, b, c, and 68.20a, b, c).

D. Wound Closure:

Wounds are irrigated well and bleeding is controlled by routine methods. If there is continued bleeding drain is indicated. Wounds are closed by 3-0 Vicryl sutures.

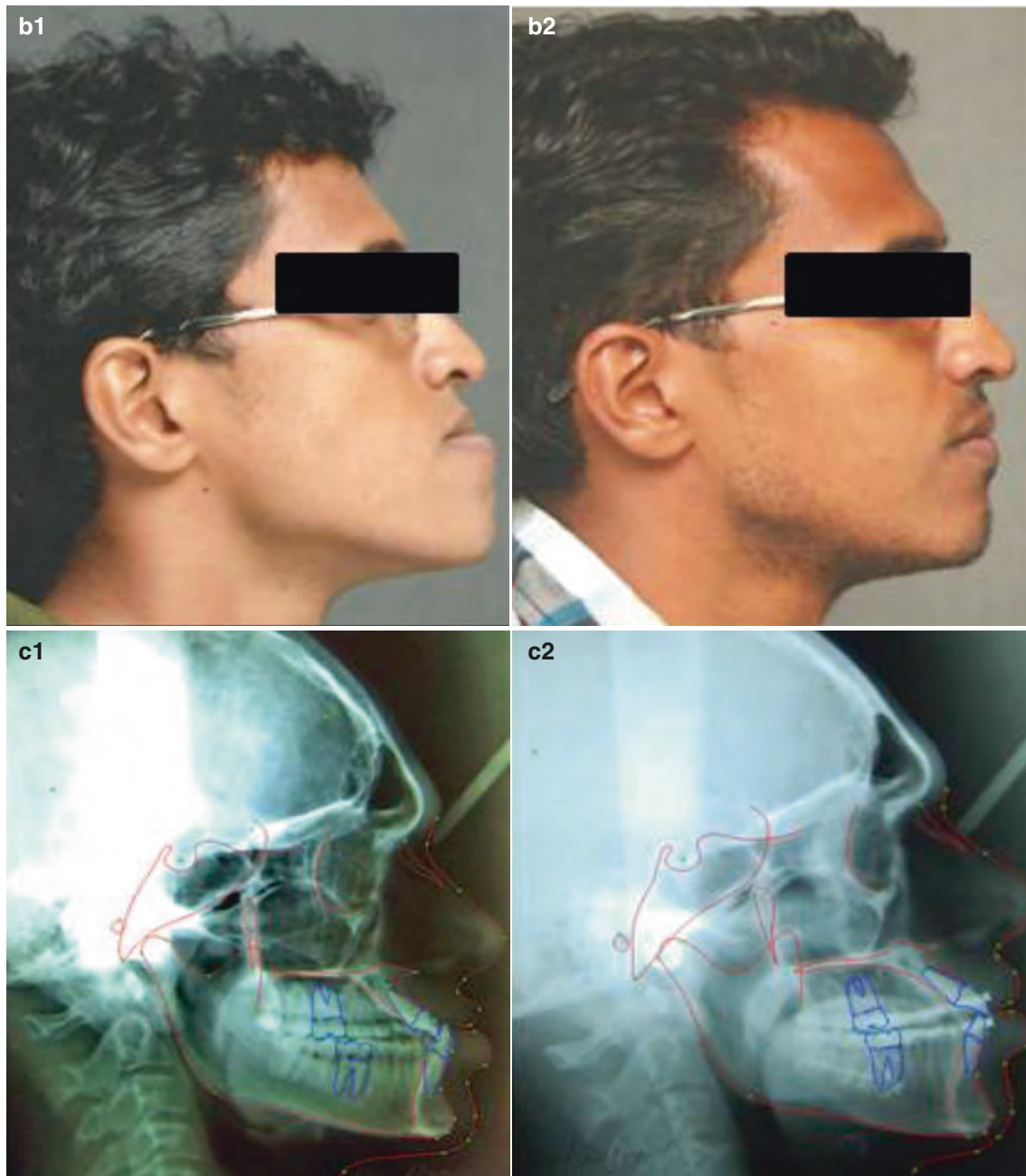E. Postoperative Sequelae:

Edema is expected after sagittal split osteotomy. It resolves within 2 weeks. Edema at the angle is the last to resolve. Suction drainage minimizes tissue edema following mandibular surgeries. Betamethasone administration significantly reduces postoperative edema. Widar H. et al. has also observed less bleeding intraoperatively, but no difference in neurosurgery disturbances [32].

Diminished sensation over the lip is experienced by most of the patients and is mainly due to traction on the neurovascular bundle. If there is no injury to the neurovascular bundle, sensation returns within a few weeks. More than two-thirds of the patients experience some sensory deficit even after 1 year. However, most of the patients get adjusted to this altered sensation and are satisfied with the overall result. Limitation of movements of jaw in all direction after osteotomy is often experienced. Sagittal split advancements often cause significant limitation of range of motion [33].



Fig. 68.16 Bilateral sagittal split osteotomy to set back the mandible, with rigid fixation. (a1, b1) Preoperative photographs. (a2, b2) Postoperative photographs. (c1, c2) Pre and post operative lateral cephalograms with superimposed tracings



©Association of Oral and Maxillofacial Surgeons of India

Fig. 68.16 (continued)

Physiotherapy following rigid fixation showed minimal limitation [34].

F. Complications:

Important complications associated with sagittal split osteotomy are:

1. Bad split
2. Injury to the neurovascular bundle
3. TMJ problems
4. Excessive bleeding
5. Relapse

1. Bad Split:

A systematic review of fracture patterns in sagittal split was analyzed by Steenen and Becking and reported 2.3% bad splits in sagittal splits. The most common was buccal plate fracture of the proximal segment and lingual plate fracture of the distal segment. Coronoid and condylar neck fractures were seldom [35].

Wrong split usually occurs in cases where the last molar is removed at the time of surgery. Hence it is advised to have the third molar removed (if needed) about 6 months

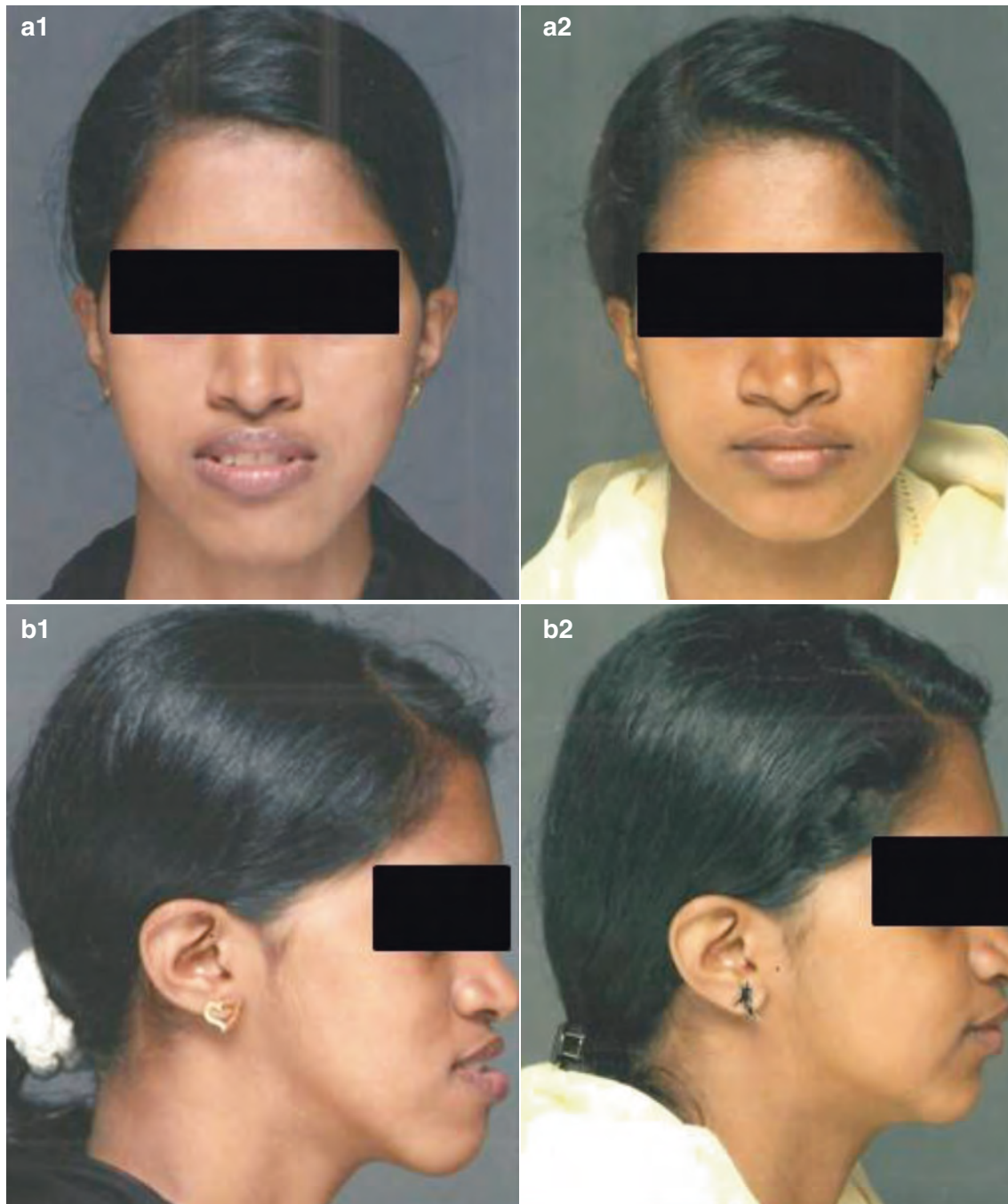
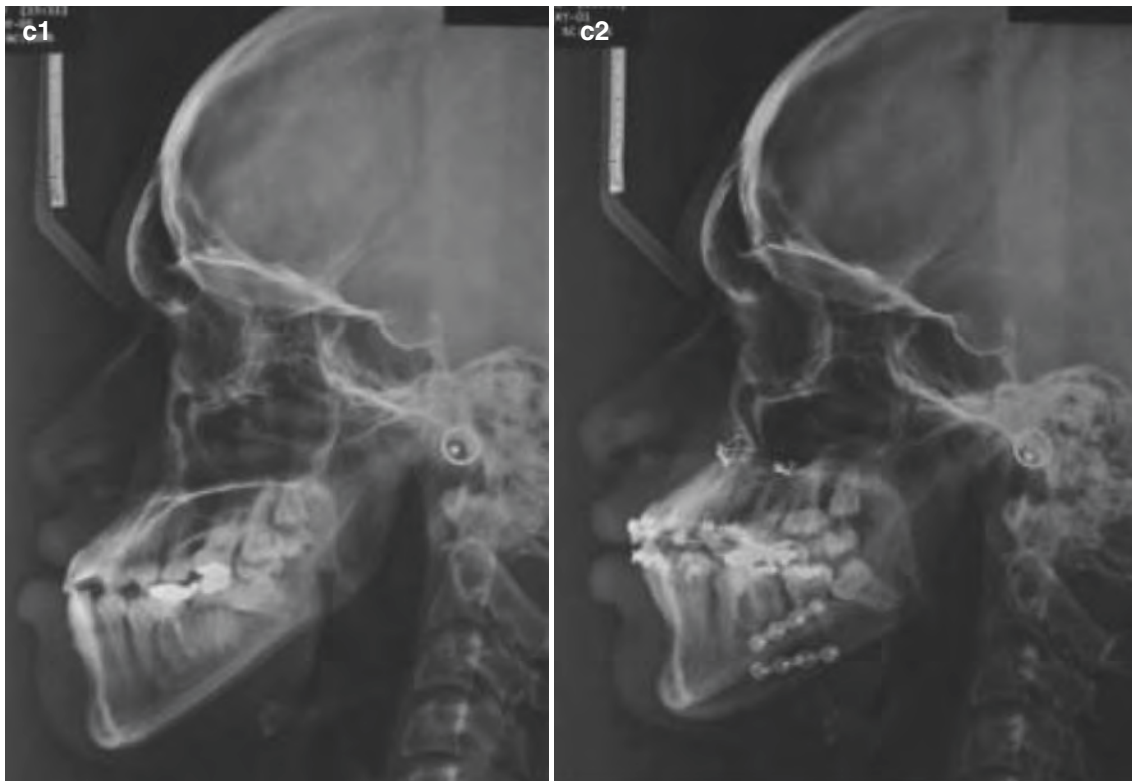
Fig. 68.17 Case of mandibular prognathism with maxillary deficiency, managed by maxillary advancement and mandibular set back by BSSO. (a1, b1) Preop pictures. (a2, b2) Postop pictures. (c1) Preop cephalogram. (c2) Postop cephalogram

prior to the osteotomy. If the lingual cortical plate is broken, soft tissue separation from the lingual plate should be kept to the minimum, so that the blood supply is not jeopardized. Patients with a shorter ramus and buccolingually thin mandible are more susceptible to wrong split during SSO [36]. Advanced age can increase the risk of a bad split. Use of a spreader helps to reduce the incidence of wrong splits.

2. Injury to the Neurovascular Bundle:

Care should be taken to maintain the continuity of the neurovascular bundle. If it is transected, ideally the cut ends are micro-anastomosed. However, in common practice, where a micro-surgeon may be unavailable, it is advisable to perform direct suturing to attain epineural approximation. With a repositioned and repaired neurovascular bundle, the sensation is recovered though the period it takes is longer.



©Association of Oral and Maxillofacial Surgeons of India

Fig. 68.17 (continued)

Long-lasting neurosensory deficiency (NSD) was underestimated by the surgeons as compared to the patient's subjective symptoms. Long-lasting NSD was reported as 7.5% (Questionnaire) and 3.8% (Record), after intraoral vertical ramus osteotomy, and as 11.6% (Questionnaire) and 8.1% (Record) after sagittal split osteotomy [37]. Vertical subsigmoid osteotomy with rigid fixation may be considered as a viable alternative if it is important to avoid alterations in sensation, whereas BSSO maybe preferred if retromandibular scar is of concern. Neurosensory disturbance, after SSO with additional genioplasty, is more than after SSO alone [38].

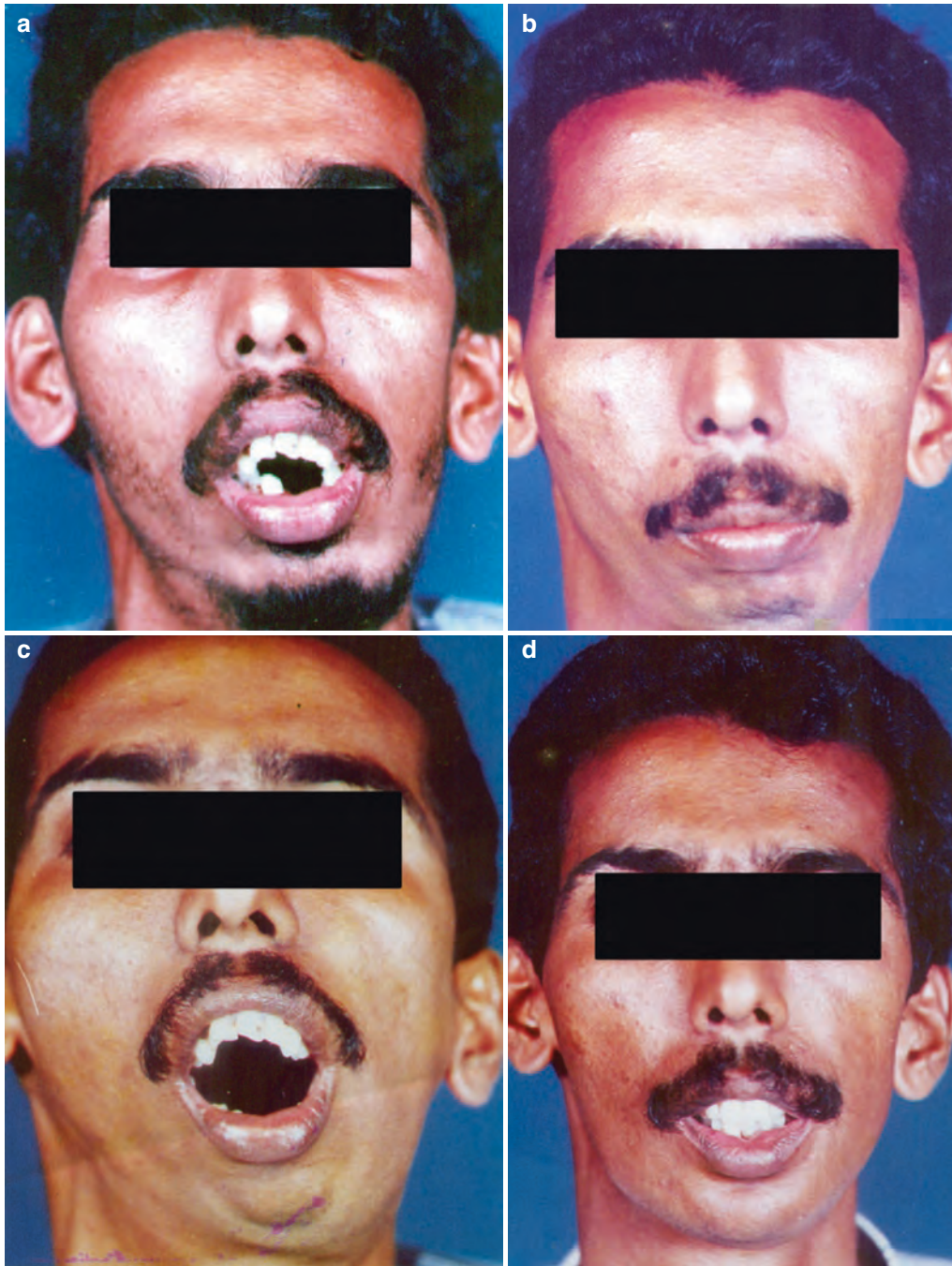3. TMJ Problems:

Care should be taken while plating the segments. Improper plating can pull or push the condyle to an untoward position. Postoperative X-rays are taken to assess the situation. If needed, the displacement has to be corrected by returning the patient to surgery. Displacement of the condyle from the fossa is one of the main reasons for relapse [24, 39] (Fig. 68.21).

Beukes J. et al. in 2016 studied condylar rotational tolerance in BSSO treatments and reported a range of 10° – 15° after orthognathic surgery.

Unilateral SSO is a safe procedure in lateral prognathism of mandible due to unilateral condylar hyperplasia or traumatic malocclusions [40]. The condyle that was not operated on, only rotated 3 – 4° within the glenoid cavity, and it was established that this is within the range of functional articular adaptation [41]. Mendez-Manjon R. et al. observed that mandibular advancement by BSSO can positively displace the condyle especially on the posterior aspect [42].

In their study Borstlap et al. observed that in sagittal split advancement postoperatively, 8% of patients showed postoperative condylar resorption. Patients of relatively low age are at risk of condylar alterations or resorption. Occurrence of pain and TMJ sounds in the first few months postoperatively are highly indicative of condylar changes to occur in the preceding months [43]. Predisposition in females for condylar resorption after sagittal split osteotomy may be attributed to



©Association of Oral and Maxillofacial Surgeons of India

Fig. 68.18 A case of left unilateral ankylosis of the TMJ resulting in trismus and facial deformity. Treated by release of ankylosis by gap arthroplasty, temporal myofascial flap interposing, and extended lateral

sliding genioplasty. (a) Pre operative picture before ankylosis correction (b) frontal view with facial asymmetry (c) after release of ankylosis, (d) after correcting facial asymmetry

the modulation of biologic response, by estrogen and prolactin [44]. Mobarak compared the skeletal stability of postoperative changes in low angle and high angle CI II patients following mandibular advancement. High angle had more horizontal skeletal relapse due to condylar movement in a superior direction. Changes in intercondylar angle and width after BSSO advancement or set back may influence TMJ function [45–48].

4. Excessive Bleeding:

Bleeding can be from inferior alveolar neurovascular bundle, medullary bed, and facial vessels or rarely from retro-mandibular vein. Bleeding from the former two can be

controlled by local measures; but the facial vessels will have to be clamped and tied, for which an extraoral incision may be required. Using the channel retractor with a cup to hold the inferior border and cutting with a Steiger-type carbide bur (this has side cutting and rounded cutting end and cuts bone with minimal injury to the soft tissue) prevents injury to the facial vessels.

Injury to the retromandibular vein is very rare and is due to inadvertent injury to the soft tissues behind the mandible. Bleeding can be controlled by absorbable gelatin sponge. Excessive oozing can cause significant edema, and if oozing is present, a drain may be placed.

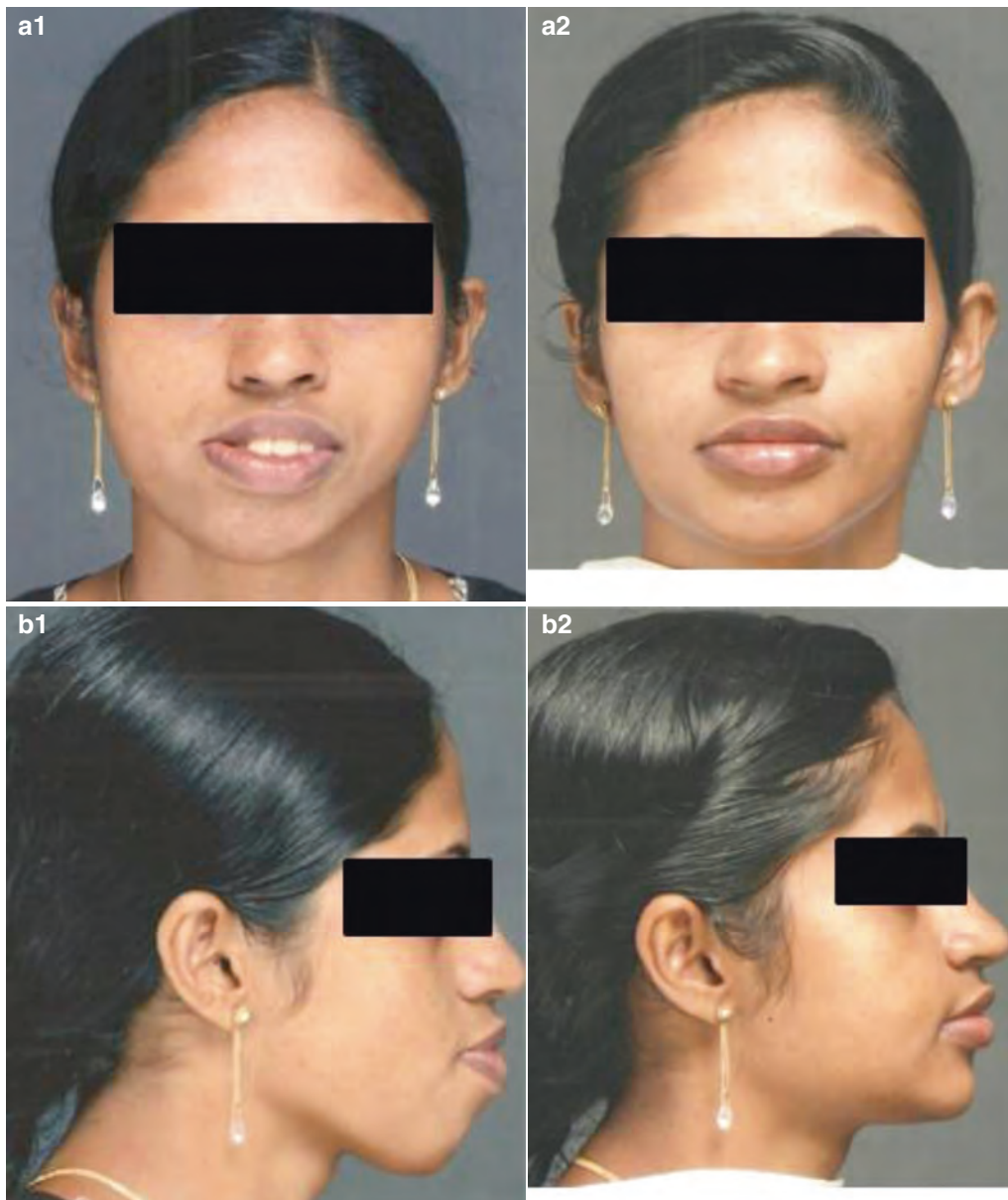
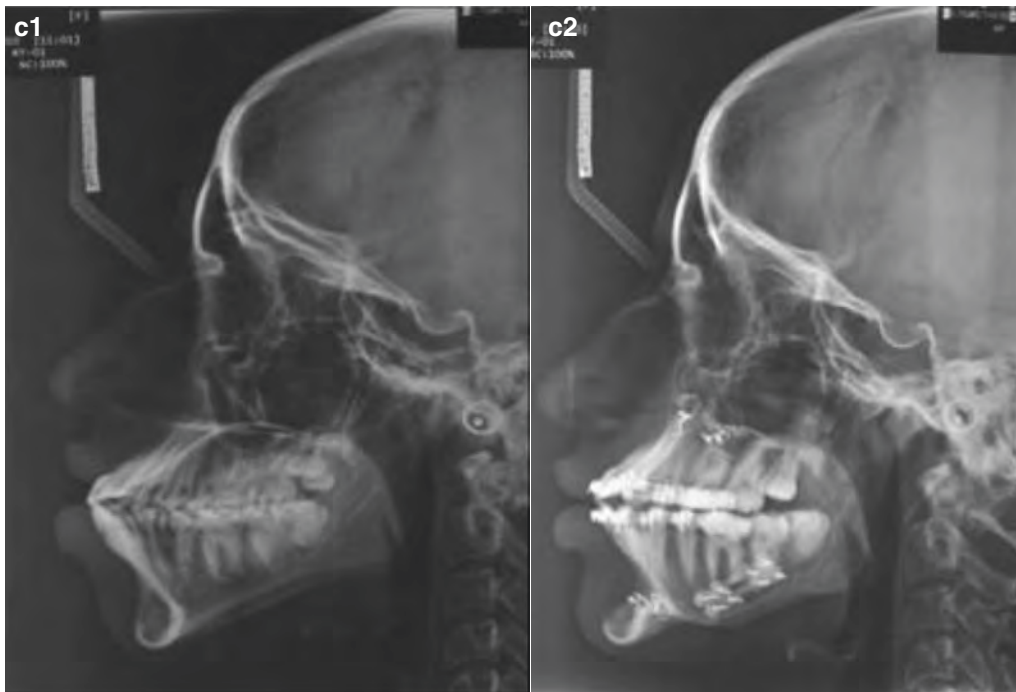
Fig. 68.19 Facial asymmetry and vertical and sagittal excess of maxilla corrected by LeFort I, anterior maxillary osteotomy, bilateral sagittal split osteotomy and advancement genioplasty. (a1, b1) Preoperative pictures. (a2, b2) Postoperative pictures. (c1) Preoperative lateral cephalogram. (c2) Postoperative lateral cephalogram



©Association of Oral and Maxillofacial Surgeons of India

Fig. 68.19 (continued)

68.4.3 Vertical Ramus Osteotomy: Intraoral Approach

It was Caldwell and Letterman who developed the intraoral vertical ramus osteotomy in 1954 [3]. Later in 1964, this was described by Moose [49] and Winstanley in 1968 [50], and modifications have been suggested by many others. Intraoral approaches medially and laterally to ramus were described [49, 50]. Herbert and associates in 1970 described the use of special oscillating saw and popularized the intraoral technique to reach the ramus (Fig. 68.22).

The procedure overcomes the disadvantages of extraoral vertical ramus osteotomy. The advantages are the following: (1) external scar is avoided and (2) there is no injury to the marginal mandibular nerve. The advantages over sagittal split osteotomy are that injury to the mandibular neurovascular bundle is avoided. The main disadvantage is the difficulty in access and visualization of the area. However, there is a delay in healing and possibility of projection of antegonial notch [51]. Mandibular nerve hypoesthesia can be expected to improve faster in young patients than the older ones. So IVRO may be a better option for elder patients [52].

Surgical Technique

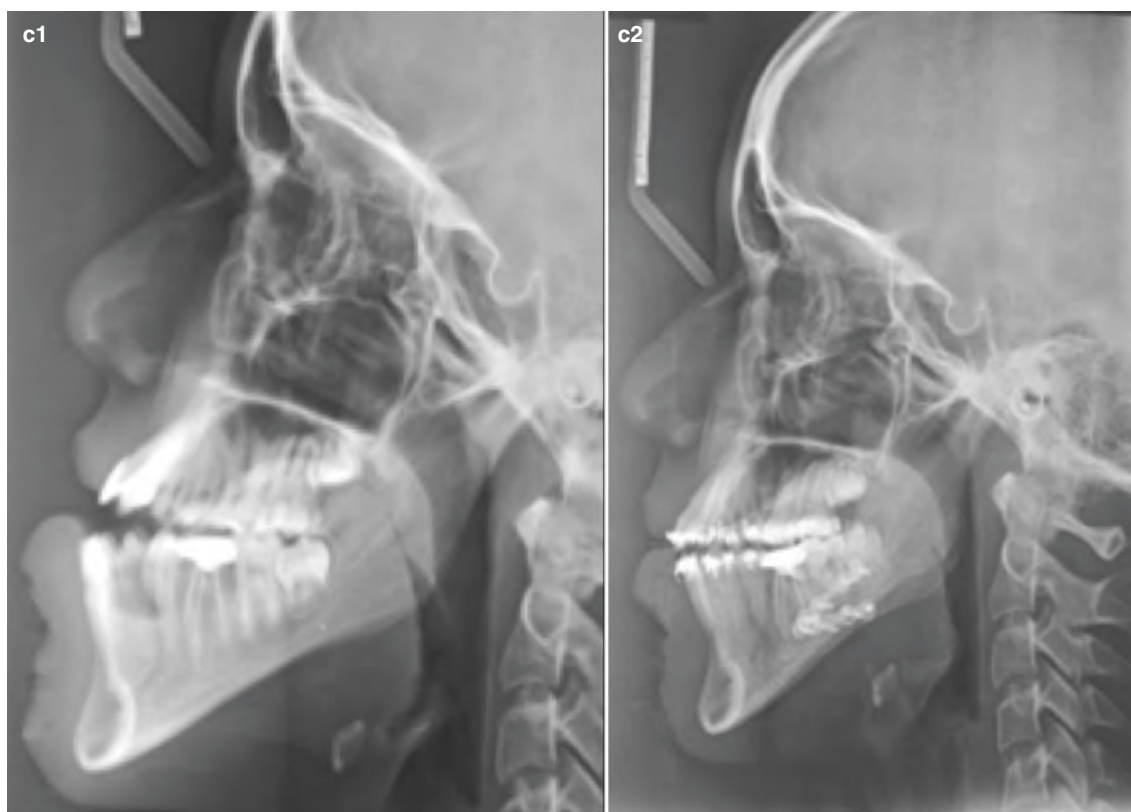
A mucosal incision is made along the anterior border of the mandibular ramus. This is extended to the coronoid process and extended laterally up to the first molar area and subperiosteally dissected to expose the sigmoid notch, inferior border, and the posterior border of the ramus. Two fibro-optic lit Bauer retractors (left and right) are used—one on the sigmoid notch and the other at the angle area to get excellent exposure of the ramus. An oscillating saw angled at 105° is used to do the osteotomy. The cut is made posterior to the ante lingula prominence and directed superiorly to the sigmoid notch and inferiorly to the mandibular angle.

If circummandibular wiring fixation is planned, the medial aspect of the ramus above the lingula is dissected subperiosteally to the posterior border. The width need only be enough to pass the wires.

Osteotomy, as in the extraoral approach, extends from the sigmoid notch to the inferior border behind the entry of the mandibular nerve. The intraoral vertical cut should be made no more than 5–7 mm anterior into the posterior border. This will be behind the mandibular foramen [53]. According to some, ante lingual prominence as a landmark is unpredictable [54].

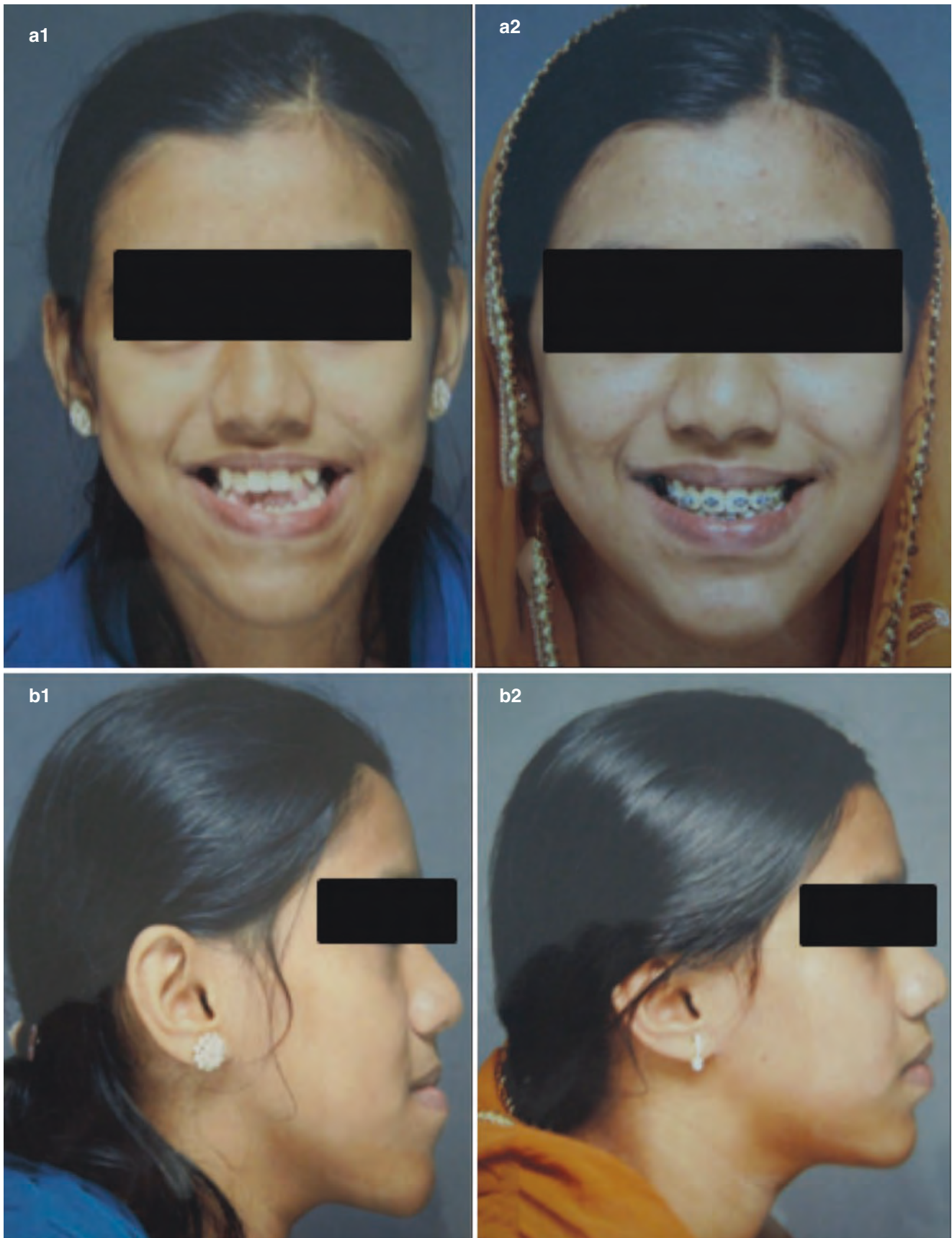

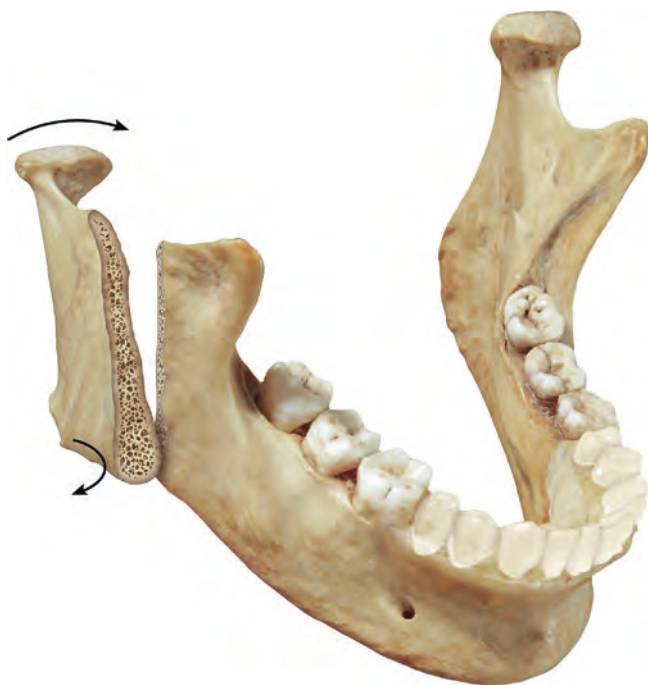Fig. 68.20 Case of open bite managed by BSSO. (a1, b1) Preoperative pictures. (a2, b2) Postoperative pictures. (c1) Preoperative lateral cephalogram. (c2) Postoperative lateral cephalogram



©Association of Oral and Maxillofacial Surgeons of India

Fig. 68.20 (continued)



©Association of Oral and Maxillofacial Surgeons of India

Fig. 68.21 Displacement of the condyle due to torquing as demonstrated here in a vertical ramus osteotomy, is the most common reason for TMJ problems

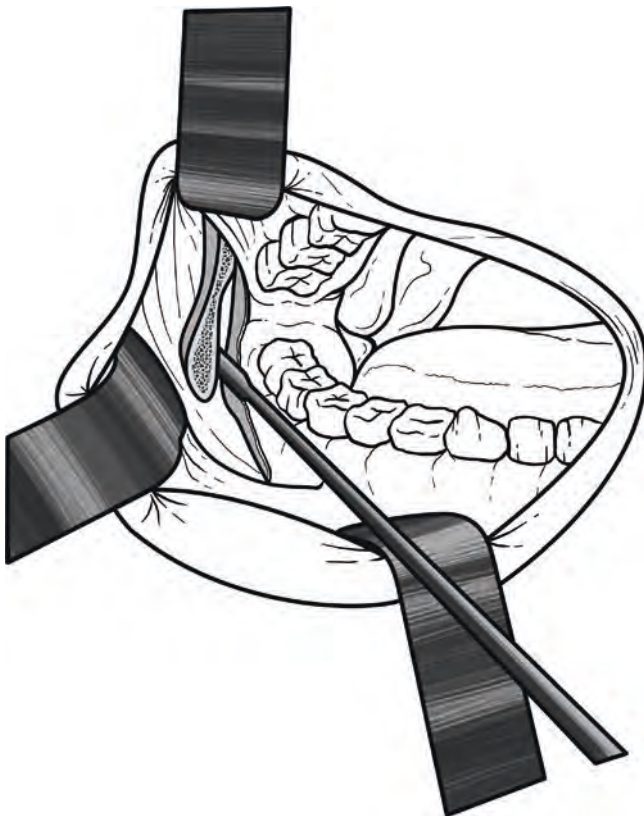
For better access, as well as visibility and mobility of the fragments, the coronoid process can be separated using a reciprocating saw. The coronoid process is allowed to retract with the temporal muscle.

An appropriate retractor with a cup at the end can be held hooked to the posterior border, and the soft tissue is held retracted laterally. Care should be taken to orient the cut and also to prevent injury to the soft tissues.

After the osteotomy, the condylar segment is overlapped laterally over the mandible. Medial pterygoid attached to the medial aspect may be stripped in the anterior region of the segment to facilitate tension-free positioning of the condylar segment. The same osteotomy is performed on the opposite side, and intermaxillary fixation is maintained for 6 weeks. Extraoral approach for vertical subsigmoid osteotomy is advocated for large mandibular set back of greater than 10 mm [55, 56].

Over correcting the mandibular set back by 2 mm to provide compensation for relapse is also recommended [57]. The use of skeletal wire fixation seems to stabilize the initial movement, but does not influence long-term relapse [58].

Ghali and Sikes have reported that IVRO improves TMJ functions and relieves TMJ symptoms more effectively when compared with SSRO, due to the final position of the condyle more anteriorly and inferiorly which



©Association of Oral and Maxillofacial Surgeons of India

Fig. 68.22 Diagram for intraoral subsigmoid vertical osteotomy

results in an increased joint space and better disk-condyle relationship [59].

Raúl González-García described endoscopically assisted intraoral vertical ramus (IVRO) and subcondylar (ISCO) osteotomies for the treatment of symmetric mandibular prognathism. He claimed the use of saw and bone chisel under the continuous control of the endoscope provides a safer approach since the osteotomy is controlled during the whole process and provides complete visualization of the osteotomy site [60].

Stabilization, Fixation, and Wound Closure

Most surgeons use circummandibular or transosseous wires. Rigid internal fixation using plates is rather difficult to place and carries greater risk of injury to the mandibular nerve. Lag screws or mini plates are sometimes used.

Intermaxillary fixation for a period of 6 weeks is advised, if rigid fixation is not used. Wound closure is done as in sagittal split, adhering to the basic principles.

TMJ Considerations

Radiographically there is an anterior downward and forward movement of the condyle after ramus osteotomy. However,

there is a tendency to return to its preoperative position [61–63]. Double contouring of the condyle after 6 months was reported which is attributed to condylar remodeling [64]. Remodeling of the glenoid fossa also has been documented [65]. Complications and their management are very much similar to those of sagittal split.

68.5 Body Osteotomy of Mandible

This was one of the earlier procedures used for mandibular prognathism. Blair reported a body osteotomy at the premolar level for mandibular prognathism in 1906 [19]. Since the advent of the ramus procedures, body osteotomy has lost its popularity. However, in certain conditions, body osteotomy may have to be resorted to.

Surgical Procedure

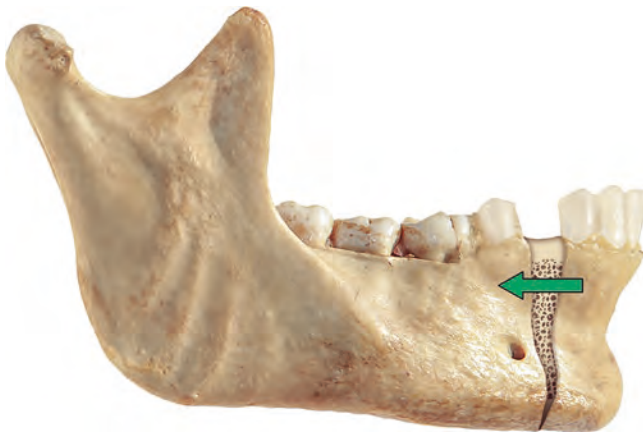Depending on the site of osteotomy, soft tissue dissection varies. The basic principle is to reflect the buccal mucoperiosteum down to the inferior border taking care not to injure the mental nerve, but at the same time, exposing it.

The next step is to remove the buccal cortical plate from the mental foramen region backward to behind the osteotomy/osteotomy site for release of the neurovascular bundle. The tooth at the osteotomy site is extracted.

Using a fissure bur, the outer cortical plate is marked and a window is cut. Using curettes and chisels, the cancellous bone around the neurovascular bundle is removed. The nerve is released using a nerve hook. Anterior continuation of the inferior alveolar nerve (the incisal branch) is severed. This helps in better retraction of the nerve. Continuation of the mental nerve is preserved. Mucoperiosteum on the lingual aspect is elevated and protected by a periosteal elevator. Osteotomy is completed adhering to the basic principles. The same procedure is repeated on the contralateral side. Body osteotomy at the molar level is almost outdated since the advent of sagittal split osteotomy.

Body osteotomy anterior to the mental foramen can be resorted to in certain specific cases. The main indication of this procedure is lower dentoalveolar protrusion with anterior open bite. “V” osteotomy is done at the first premolar region. This will not reduce the total mandibular length but rotates the anterior segment upward and backward. Maintenance of the arch and occlusion is important. Rigid fixation is mandatory as tendency for relapse is very high due to the pull exerted by the genioglossus and geniohyoid muscles (Fig. 68.23).

Stabilization is achieved by arch bars or by orthodontic means. Fixation using two plates (each plate having a minimum of 4 holes) on each side is advised.



©Association of Oral and Maxillofacial Surgeons of India

Fig. 68.23 Body osteotomy at the level of the premolar region. Diagrammatic representation

68.6 Symphyseal Osteotomy

Midline osteotomy is used either to narrow or to expand the mandible. Expansion is more difficult than narrowing, due to tissue resistance. Before narrowing the mandible, a space must be created at the symphysis by extracting an anterior tooth (Fig. 68.24). Parasymphyseal step osteotomy approach with a hybrid mode of force application might be the most viable option for true mandibular arch expansion.

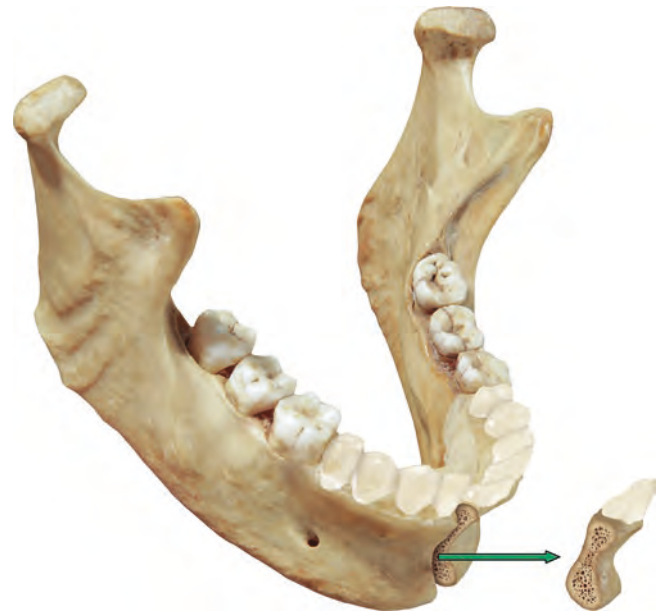
68.7 Lower Anterior Subapical Osteotomy

Hullihen performed the first ever anterior subapical osteotomy and published it in 1849 [66]. This procedure was done for a girl who had sustained burns and had the anterior segment of the mandible got distracted anteriorly by the traction of the scar resulting in everted lip, protrusion of teeth, and open bite.

Hofer used anterior subapical osteotomy to advance anterior teeth for correction of mandibular dentoalveolar retrusion [67]. Kole used this technique to correct an anterior open bite.

Lower anterior subapical osteotomy is widely used in the following conditions:

1. To retrude the lower anterior dentoalveolar segment; often used in conjunction with subapical osteotomy in bimaxillary protrusion
2. To close minimal anterior open bite
3. To intrude the anterior segment in deep bite deformity



©Association of Oral and Maxillofacial Surgeons of India

Fig. 68.24 Midline osteotomy (Diagrammatic representation)

Surgery

Sulcus incision is made and the mucoperiosteal flap is reflected. Subperiosteal tunneling is done at the lingual aspect of the planned osteotomy site. Extraction of tooth (usually the first premolar) is done, if the intention is to retrude the dentoalveolar segment (Figs. 68.25a, b, c and 68.26a, b, c).

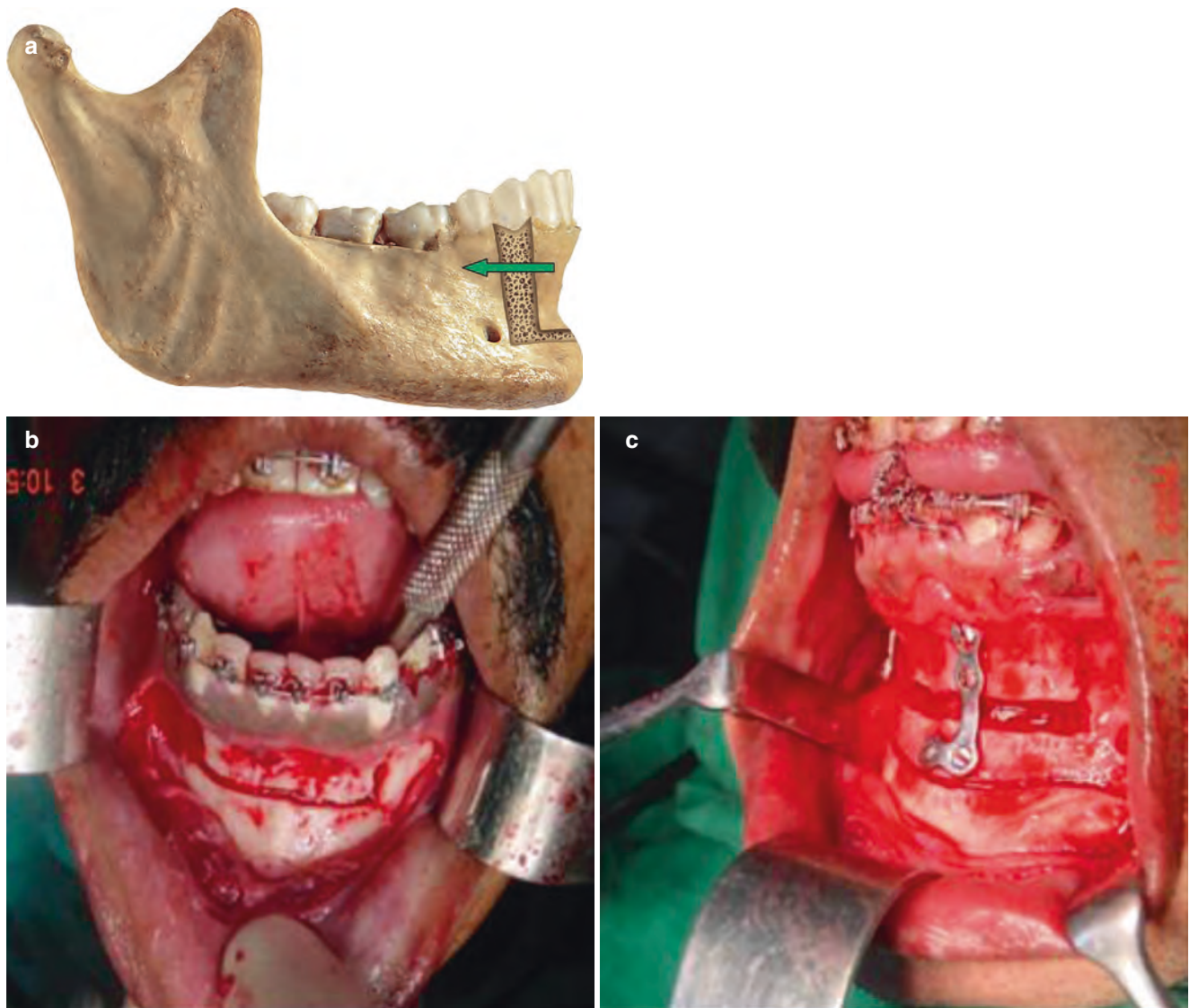
Osteotomy or ostectomy is done as planned. Stabilization and fixation are done in the preplanned position using prefabricated occlusal wafer splint or arch wires. Stabilization is done by using lag screws, position screws, or wires. Semi rigid bone plates are considered superior.

In cases where the anterior segment of the mandible is repositioned superiorly, a gap is created at the osteotomy site (subapically). Autogenous bone grafting is advised to fill this gap.

When the osteotomy is planned behind the mental foramen, the neurovascular bundle may be released from the mandibular canal and protected.

68.8 Total Subapical Osteotomy Mandible

Mcintosh in 1974 described total mandibular alveolar osteotomy. In 1942 Hofer [67] described horizontal osteotomy of mandible for horizontal deficiency or excess and asymmetry.



©Association of Oral and Maxillofacial Surgeons of India

Fig. 68.25 Lower anterior subapical osteotomy. (a) Diagrammatic representation. (b) Photograph demonstrating the vertical interstitial and the horizontal connecting osteotomies. (c) Lower subapical osteotomy can also be combined with genioplasty

Total subapical osteotomy of the mandible is used mainly for the following indications:

1. For repositioning the entire dentoalveolar segment.
2. When the mandibular length and chin position are compatible with the maxilla and its position, but the deformity is mainly in the dentoalveolar part.

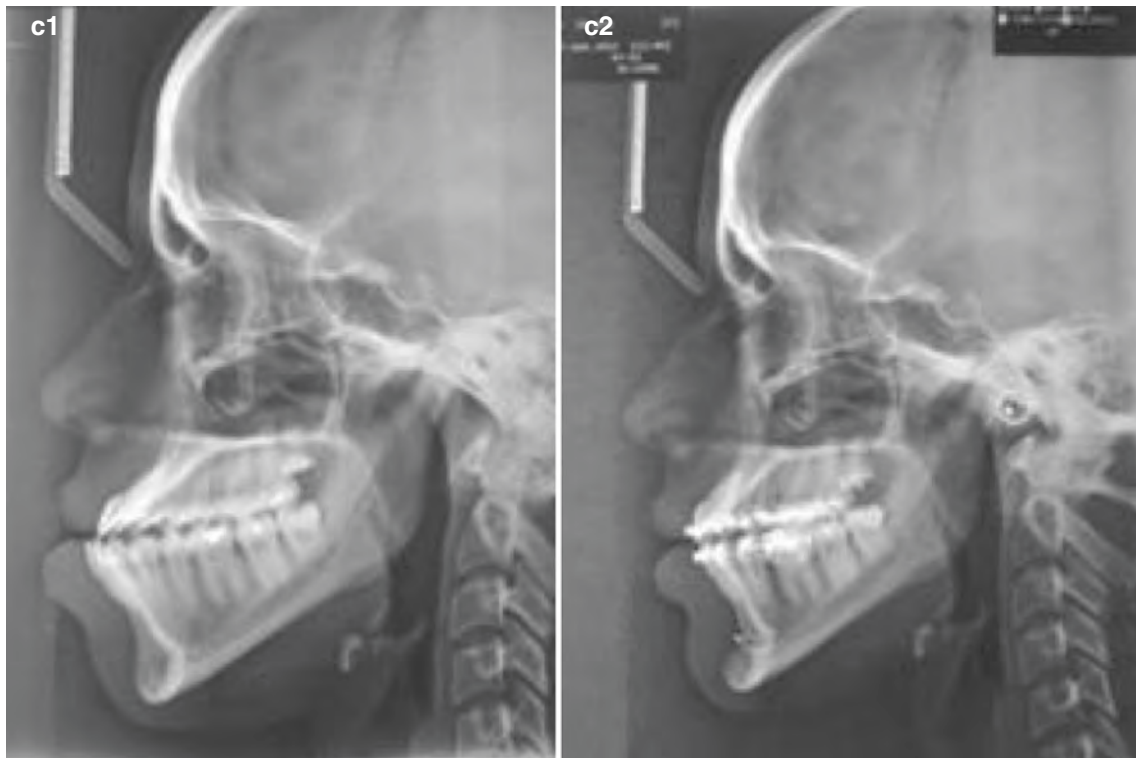
Adequate bone should be present below the apices of the roots.

Surgery (Fig. 68.27a, b, c)

Mucoperiosteal flap is reflected. The neurovascular bundle is released as described earlier (under “Body Osteotomy of Mandible”). Osteotomy is started behind the most posterior teeth. The cut is made using reciprocating saw or bur. Care should be taken not to damage the lingual tissues. Osteotomy is continued anteriorly, without injuring the released neurovascular bundle. About 4 mm of bone should be left below the apices of the teeth to ensure proper blood supply. The dentoalveolar segment is freed and mobilized. Preplanned

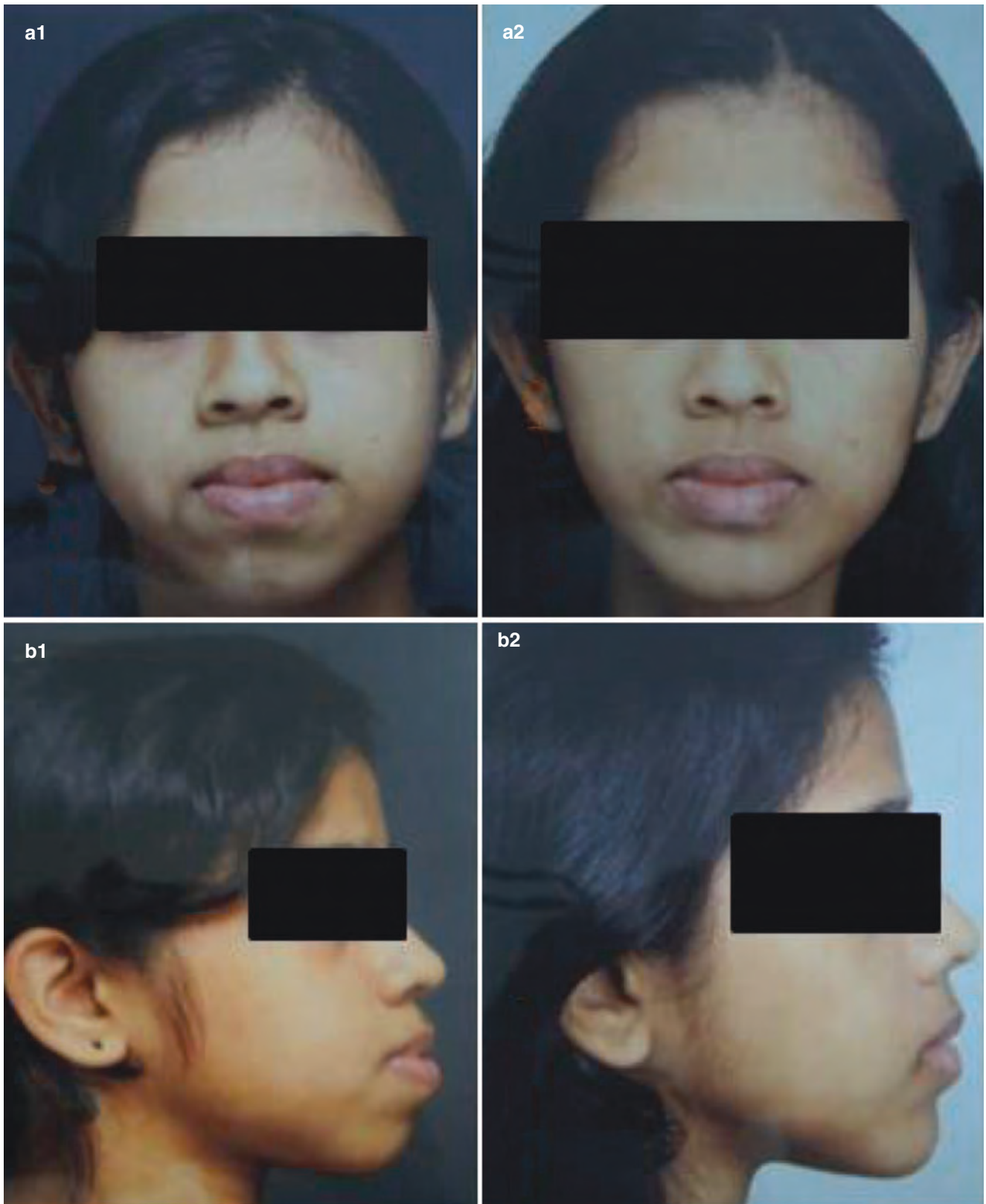

Fig. 68.26 Protrusion anterior dentoalveolar segment of mandible treated by lower anterior subapical osteotomy. (a1, b1) Preoperative pictures. (a2, b2) Postoperative pictures. (c1) Preoperative lateral cephalogram. (c2) Postoperative lateral cephalogram



©Association of Oral and Maxillofacial Surgeons of India

Fig. 68.26 (continued)

occlusion is established. Maxillomandibular fixation is aided by wafer splint. The neurovascular bundle is repositioned and secured in position using struts of bone [68].

Stabilization is done using rigid internal fixation. Postoperative sequelae are usually marked by edema which gets resolved in about 2 weeks. Sensory disturbances, though present, usually recover with time. Injury to the neurovascular bundle may cause permanent anesthesia.

Complications are usually rare. The importance of proper blood supply through the lingual pedicle is of utmost importance. This is mainly through the mylohyoid, genio-glossus, and geniohyoid muscle attachments.

68.9 Posterior Subapical Osteotomy Mandible (Fig. 68.28)

The basic plan of the surgery is not very different from that of total subapical osteotomy. The incision is limited to the posterior area. The decompression of the neurovascular bundle is done, and the osteotomy is performed as described earlier.

The main indications are to shift the dentoalveolar segment in question to the required direction in all three dimensions of space, i.e., antero-posterior, vertical, or horizontal.

68.10 Genioplasty

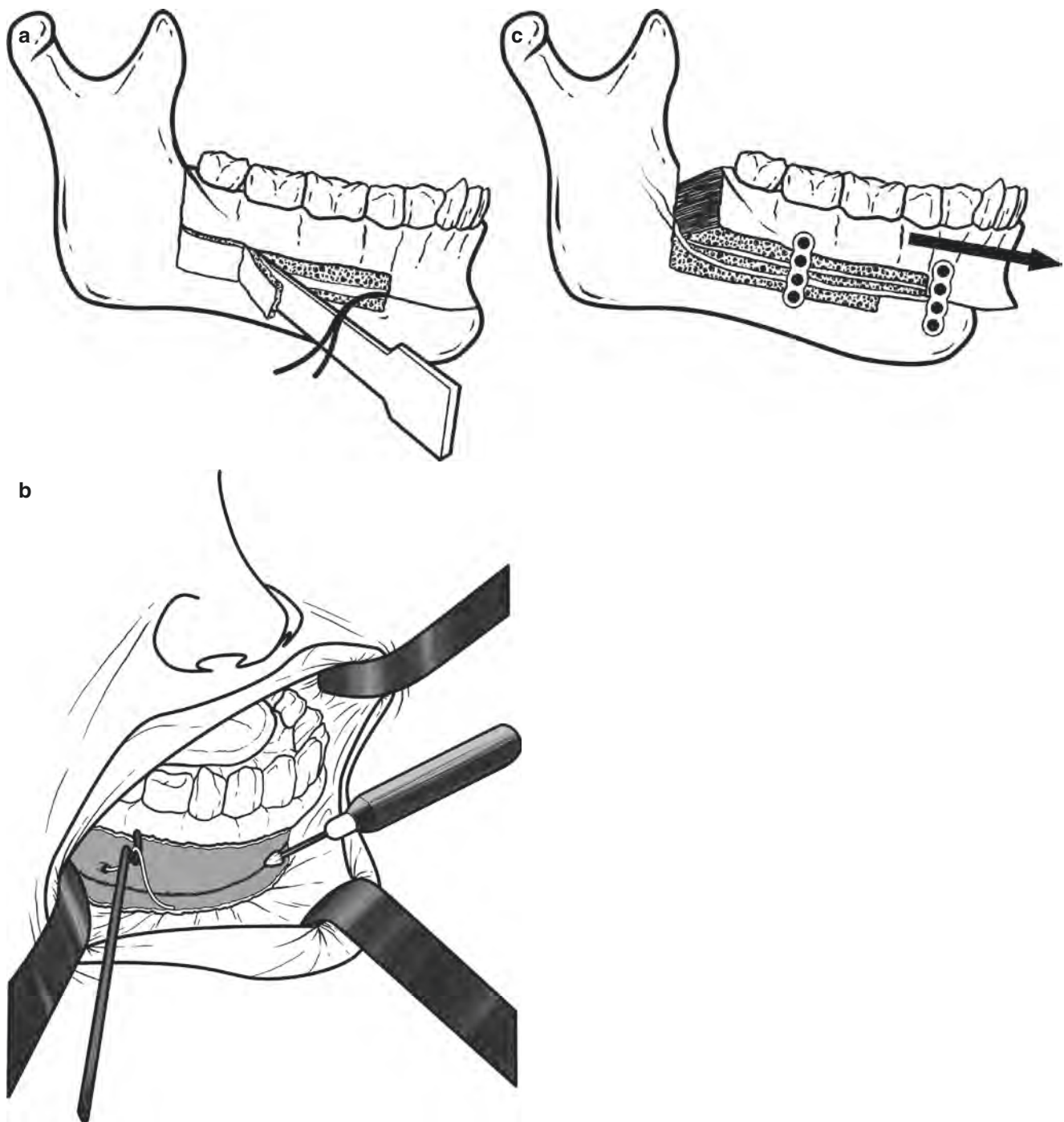
Genioplasty is used for the correction of deformities of the chin. It is possible to reposition the chin in all the three dimensions of space. Hofer in 1942 introduced horizontal osteotomy of the symphysis [67]. By repositioning the inferior mandibular symphysis, a more stable and natural appearance can be attained [69].

Surgical Procedure (Fig. 68.29a, b) (Video 68.3)

Incision is made on the labial mucosa on the lower lip. It is extended from the premolar region to the opposite symmetrical site. The incision is taken to the periosteum, which is reflected to expose the bone. Subperiosteal dissection is done to expose the inferior border of the mandible. Mental nerve is identified and protected.

Osteotomy/Ostectomy

Bony cut is made on the chin about 4.5 mm below the apices of the teeth. The posterior end of the cut should taper to the inferior border, behind and below the mental foramen. (This prevents step defects at the site which may be manifested in the soft tissue also.) The segmented portion is freed from the rest of the mandible but remains pedicled to the digastric and geniohyoid. If the inferior segment is stripped off the periosteum, making it a free graft, intense inflammatory reaction



©Association of Oral and Maxillofacial Surgeons of India

Fig. 68.27 Total subapical osteotomy. (a) Neurovascular bundle is released. (b) Osteotomy is done using bur or saw. (c) The dentoalveolar segment is positioned and fixed rigidly.

and necrosis may occur [70, 71]. The degree of bone resorption and necrosis is indirectly proportional to the amount of pedicle attached to the segment [72].

For vertical reduction, another horizontal cut is made below the original cut, and the measured segment of bone between the two cuts is removed. It is not advisable to cut off

the bone from the inferior border as this can imperil the normal contour of the chin. Unilateral vertical reduction/augmentation can be done for correction of asymmetry, since the chin can be moved in all three dimensions (Fig. 68.31a, b).

Increase in the height of the chin can be achieved by bone grafting (preferably autogenous) and rigid internal fixation

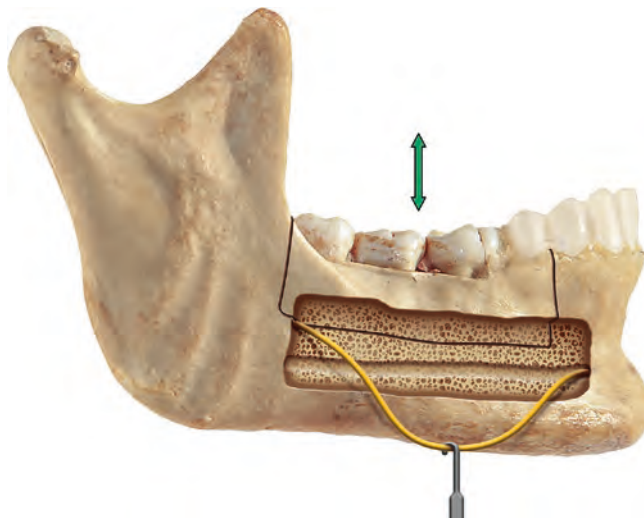
using plates. Unilateral height increase can be done in asymmetry. However, high morbidity is associated with bone graft and alloplastic materials, such as recurrence, infection, and resorption [73]. Chin can be augmented (augmentation genioplasty) (Fig. 68.30a–c) by bringing the cut inferior segment anteriorly and fixing it by rigid fixation. For major advancement, stepwise augmentation, slicing the inferior border into more than one horizontal segment is advocated (Figs. 68.32 and 68.33a, b, c) (Also refer Fig. 78.42).

Retropositioning of the chin can also be done, but the soft tissue adaptation following posterior positioning of the chin is

not 100%. While positioning the inferior border posteriorly, the labiomental fold may get compromised (Fig. 68.34a, b).

Genioplasty can be used for widening and narrowing the chin in the horizontal direction. In mild mandibular asymmetry, the midpoint of the chin may be off the facial midline. By horizontal repositioning of the inferior border, the midpoint of the chin can be brought to the midline of the face, and the mandibular asymmetry can be camouflaged (Fig. 68.35).

Following surgery, the wound is closed adhering to the basic principles. Like in other osteotomies, 3–6 months are necessary for the lip to adapt to the new position and resume normal function. Complications are rare with this procedure. Wound dehiscence occurs in some cases. Meticulous irrigation and aseptic measures can reduce the chances of infection. Sensory loss for a period may be noticed due to traction on the mental nerve. Often sensation is regained within 3–6 months. Rigid fixation technique has reduced the chances shifting of position of the moved segment. Though the reported relapse rates vary in genioplasty, most authors agree that relapse occurs within the first year [38, 70].

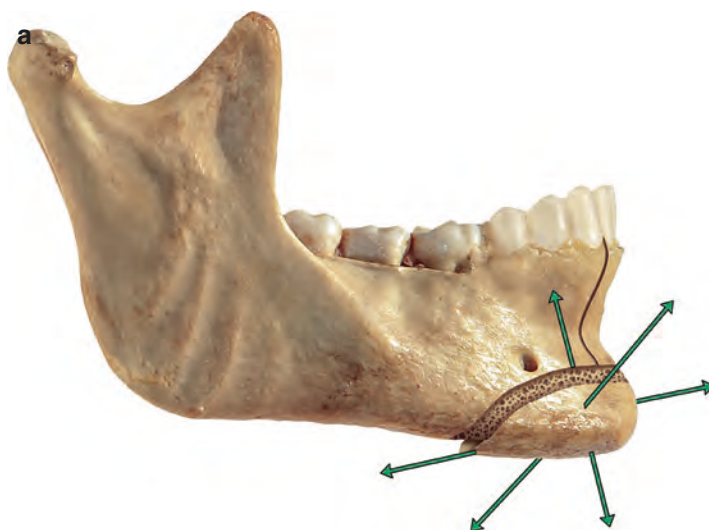

©Association of Oral and Maxillofacial Surgeons of India

Fig. 68.28 Posterior subapical osteotomy

68.11 Extended Genioplasty/Mandibular Basal Osteotomy

Mandibular basal osteotomy is an innovative predictable technique for correction of deficiency, excess, and/or asymmetry of the inferior mandibular border, decreasing morbidity, and many other complications of traditional bone grafts and alloplastic techniques [74].



©Association of Oral and Maxillofacial Surgeons of India

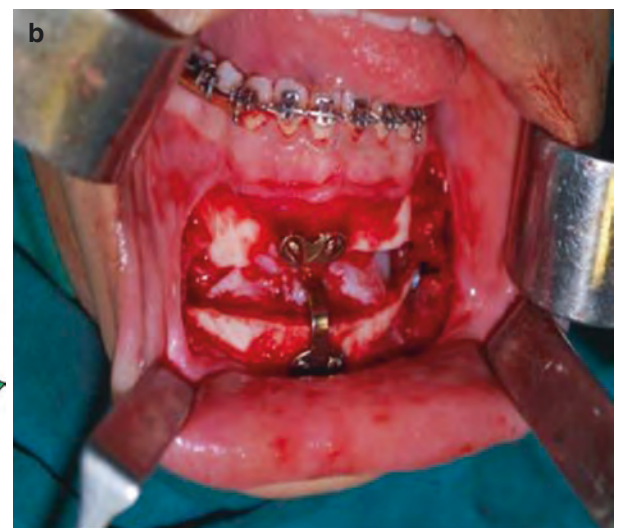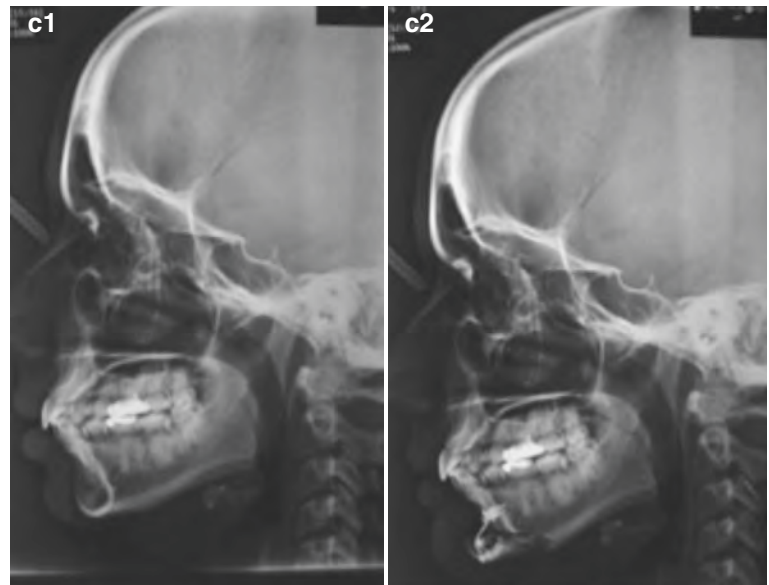


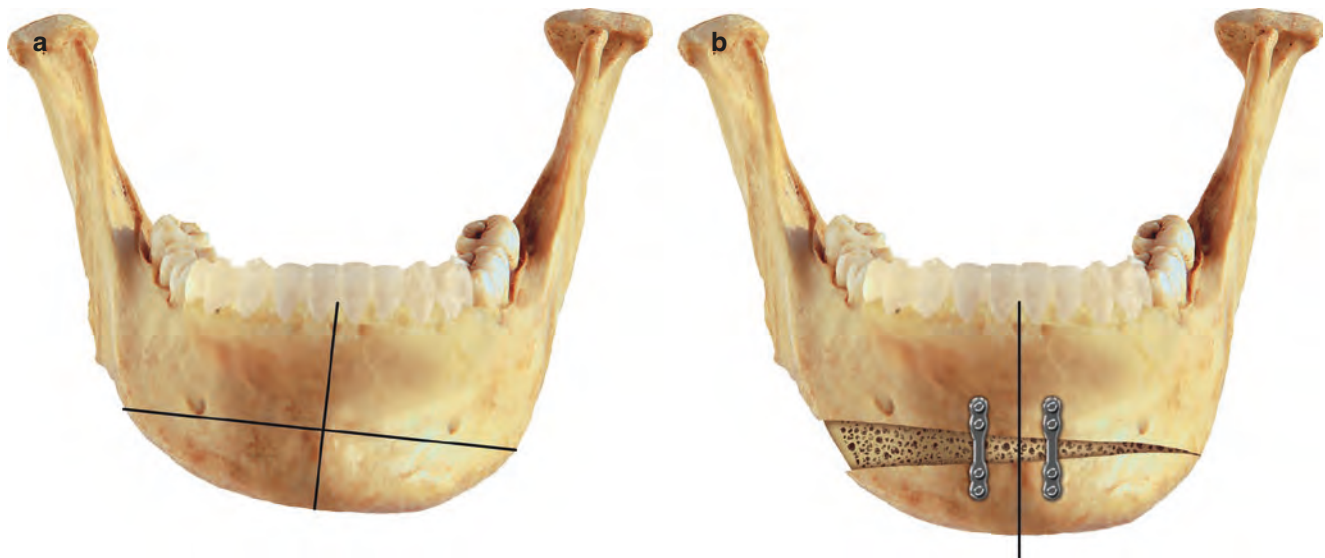
Fig. 68.29 (a) Osteotomized chin can be moved in all the three dimensions. (b) Advancement genioplasty

Fig. 68.30 Case of augmentation genioplasty. (a1, b1) Preoperative pictures. (a2, b2) Postoperative pictures. (c1) Preop lateral cephalogram. (c2) Post op lateral cephalogram

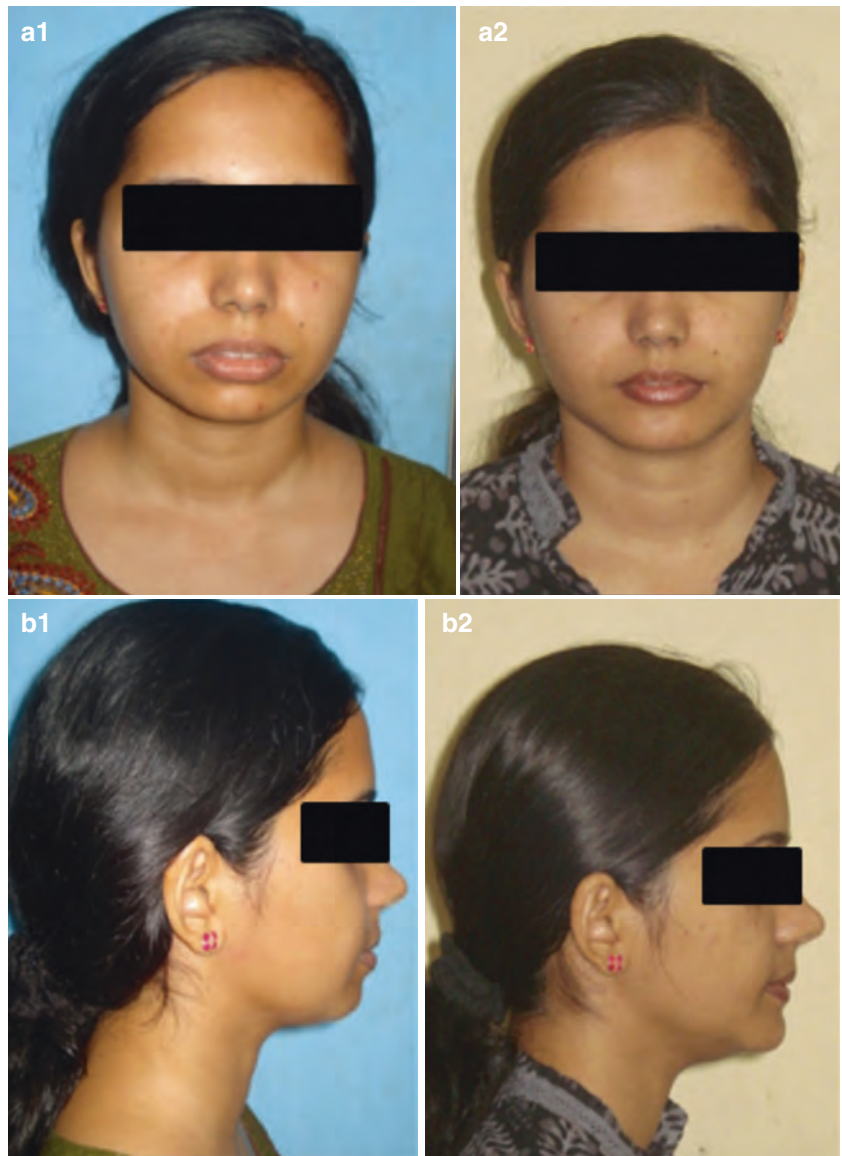

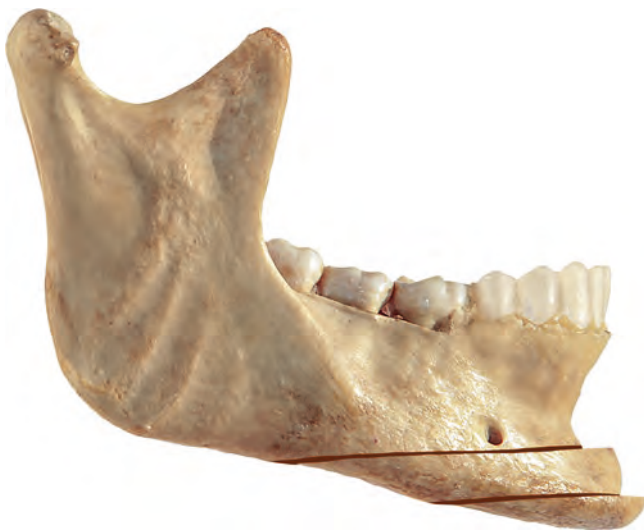Fig. 68.30 (continued)





©Association of Oral and Maxillofacial Surgeons of India

Fig. 68.31 Mild facial asymmetry can be corrected by bone grafting on one side, after osteotomy. (a) Pre-operative assessment and (b) treatment (osteotomy design)



©Association of Oral and Maxillofacial Surgeons of India

Fig. 68.32 Major advancement of the chin can be effected by a double sliding genioplasty, which is a step osteotomy of the lower border

In extended genioplasty dissection and exposure of the chin, mental nerve and body of the mandible is recommended by a degloving incision. With complete dissection and mobilization of nerves, an extended osteotomy to the antegonial angle may be carried out (Fig. 68.36a, b). The basal osteotomy below the inferior alveolar canal ensures proper proportionality between the advanced segment and the posterior mandible [75]. By laterally sliding the lower border (extended lateral sliding genioplasty), facial asymmetry can be corrected. This procedure can be used for minimal to moderate hemifacial microsomia and facial deformity

resulting from unilateral ankylosis of the temporomandibular joint [76] (Fig. 68.37a, b).

68.12 Distraction Osteogenesis

Distraction osteogenesis is a recent introduction into the field of orthognathic surgery. This technique has revolutionized the possibilities of orthognathic surgery. It was Ilizarov, a Russian orthopedic surgeon, who popularized this technique. The first team to report gradual distraction of human mandible was McCarthy et al. in 1992 [77]. As bone has got regenerative capabilities, it is possible to create new bone and lengthen the bone in a cut segment by slowly distracting it. The technique is very useful in the management of deficiency of bone in the maxillofacial region as this is an excellent method to increase bone quantity. The spectrum of indications for distraction is widening and innovations are coming up in the field rapidly. During distraction certain important principles are to be followed.

It is advisable to complete the osteotomy and mobilize the segment as far as possible and then put back the segment to its original position and distract it gradually. During distraction directional stability should be ensured, in order to counteract the pull of the soft tissue and the muscles [78]. A new terminology “distraction histogenesis” has come into vogue as not only the bone but the surrounding tissues also get lengthened. Geniohyoid muscle can be lengthened to a maximum of 20% of its resting length [79]. It is possible to distract the inferior alveolar nerve as well [80]. It is important that the distracted tissue is attached to vital tissue to maintain

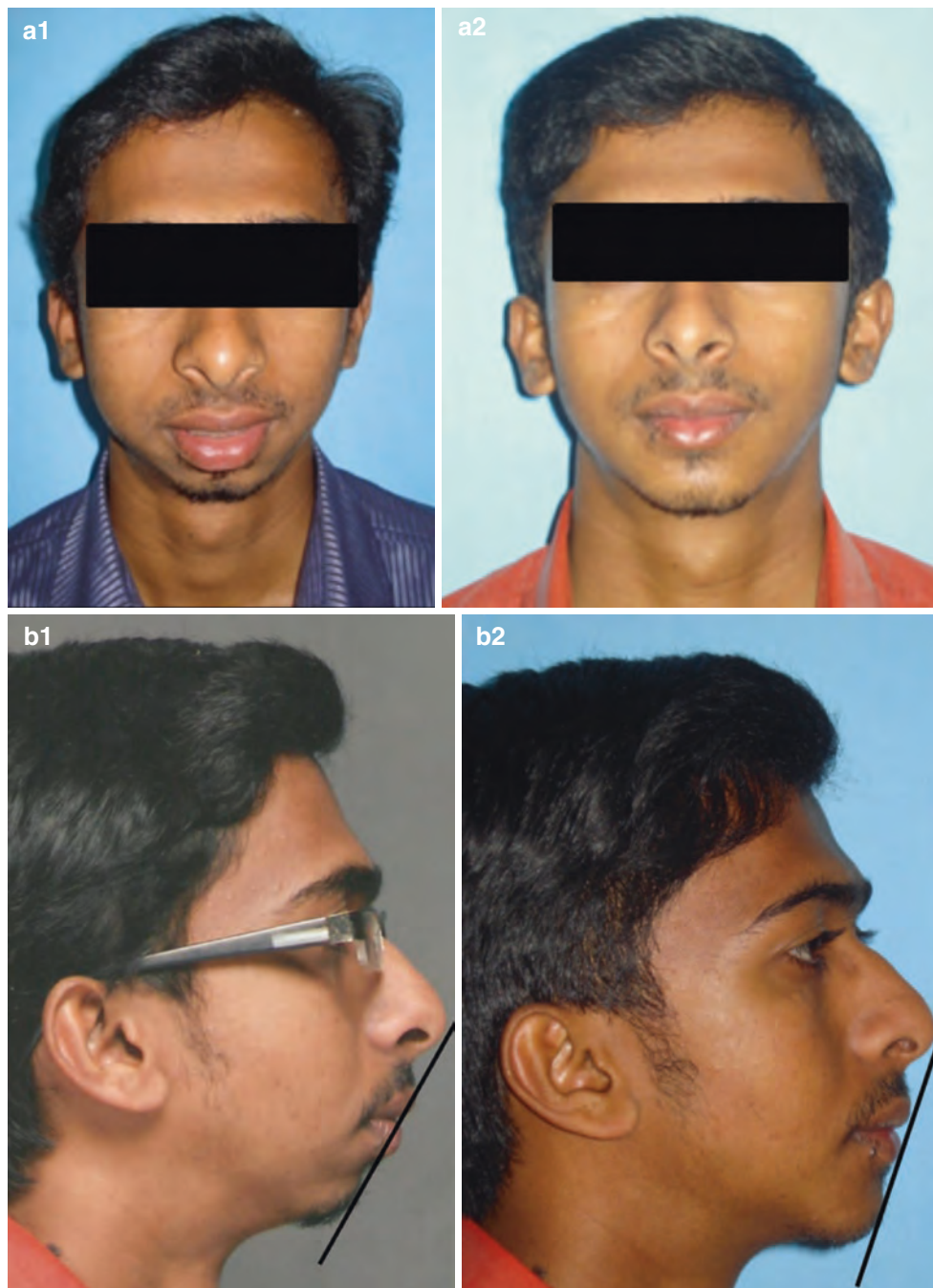

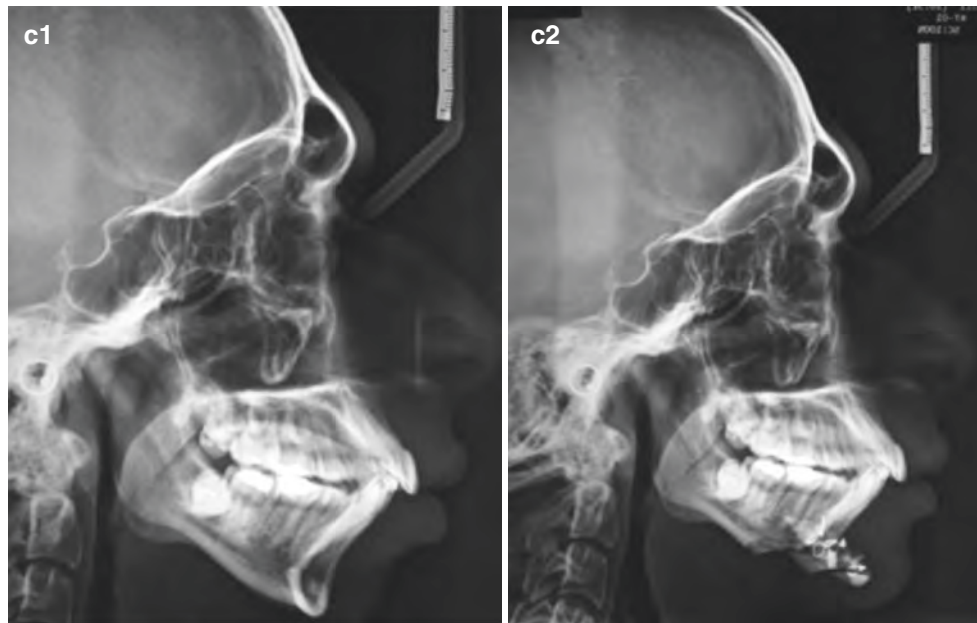
Fig. 68.33 Case of retruded chin corrected by double sliding advancement genioplasty. (a1, b1) Preoperative pictures. (a2, b2) Postoperative pictures. (c1) Preoperative lateral cephalogram. (c2) Postoperative lateral cephalogram

perfusion. Periosteum is rich in osteogenic cells, and for callus distraction and bone lengthening, the periosteum should be intact, and hence it should be preserved [48].

After osteotomy a latency period of 4–7 days is advised to provide time for the soft tissue to heal. However other factors like age, stability of fixation, type of operative procedure that affects the formation process during the initial stages of distraction, etc. are to be considered before deciding on the latency

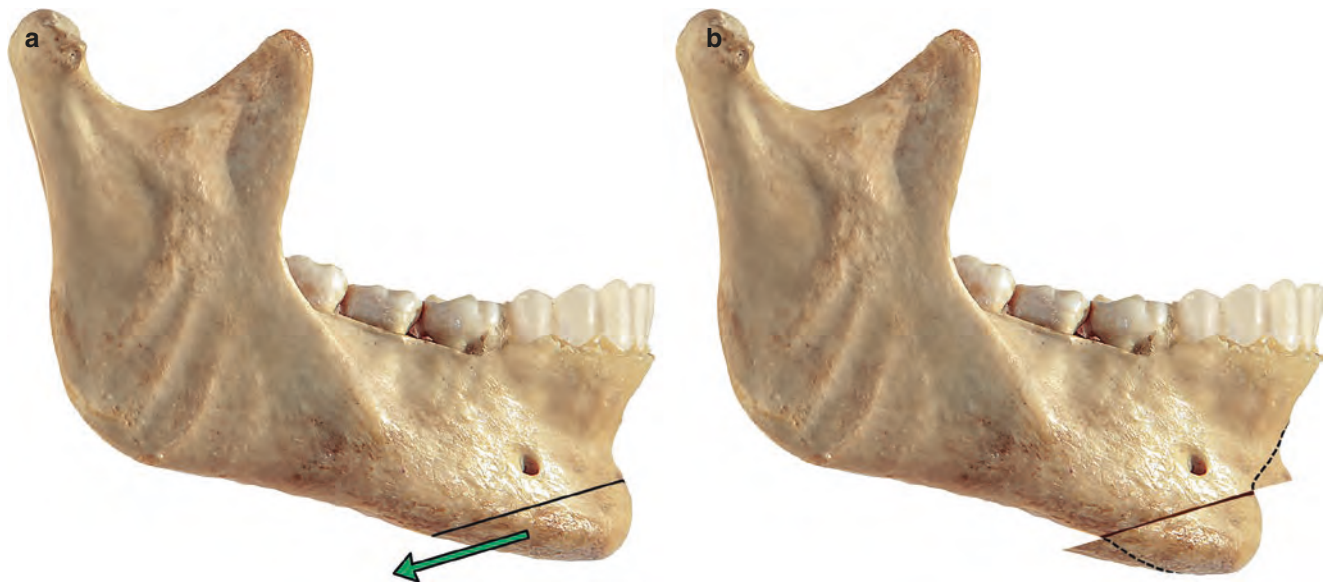period [81]. Certain other studies did not show any difference between no latency period and a latency period [82, 83].

Four stages are recognized in distraction osteogenesis—(a) fibrovascular hematoma formation, (b) formation of collagen fibers parallel to distraction vector, (c) bone formation and remodeling of new bone, and (d) formation of solid compact bone. In fast distraction collagen fibers may lose contact, and bone formation may not take place. In slow



©Association of Oral and Maxillofacial Surgeons of India

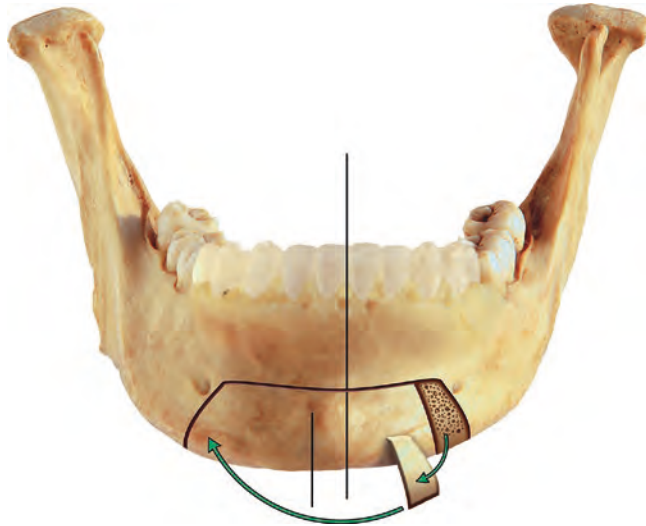
Fig. 68.33 (continued)



©Association of Oral and Maxillofacial Surgeons of India

Fig. 68.34 Reduction of the chin can also be achieved. However, sharp margins are to be trimmed off. (a) Pre-operative planning and (b) treatment (osteotomy design)

distraction, consolidation of bone may occur earlier [84]. Karp et al. demonstrated that intramembranous ossification is what occurs predominantly [85]. Distraction of 1 mm per day is the widely accepted rate [86]. Direct current electrical stimulation may be useful in activation and consolidation



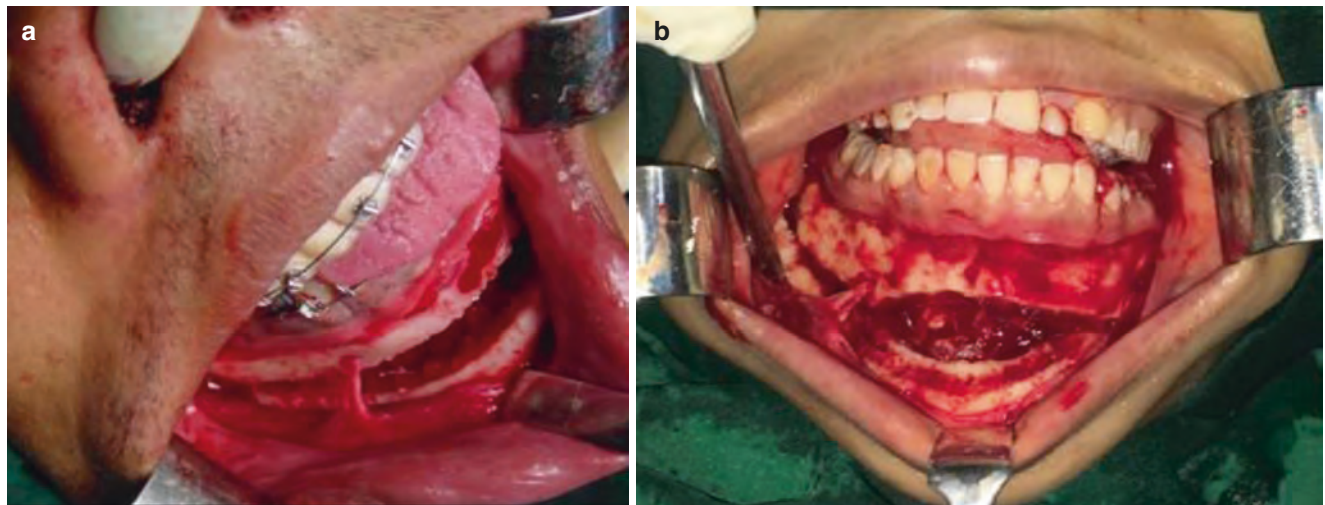
©Association of Oral and Maxillofacial Surgeons of India

Fig. 68.35 Osteotomy plan for mild facial asymmetry pertaining to the chin

period [87–89]. Insufficient distraction and defective vectors can compromise the final result. These complications can be, to some extent, managed by manipulating the regenerate bone by the application of orthodontic traction [79, 90–92]. OW and Cheung reported a lower incidence of persistent IAN disturbance (3%) after MDO compared with BSSO, of which the incidence was 28% [93]. In terms of skeletal stability in small to moderate advancements, there is no significant difference between BSSO and DO. DO requires a second surgery for removal of the distractor, which goes in favor of BSSO [94].

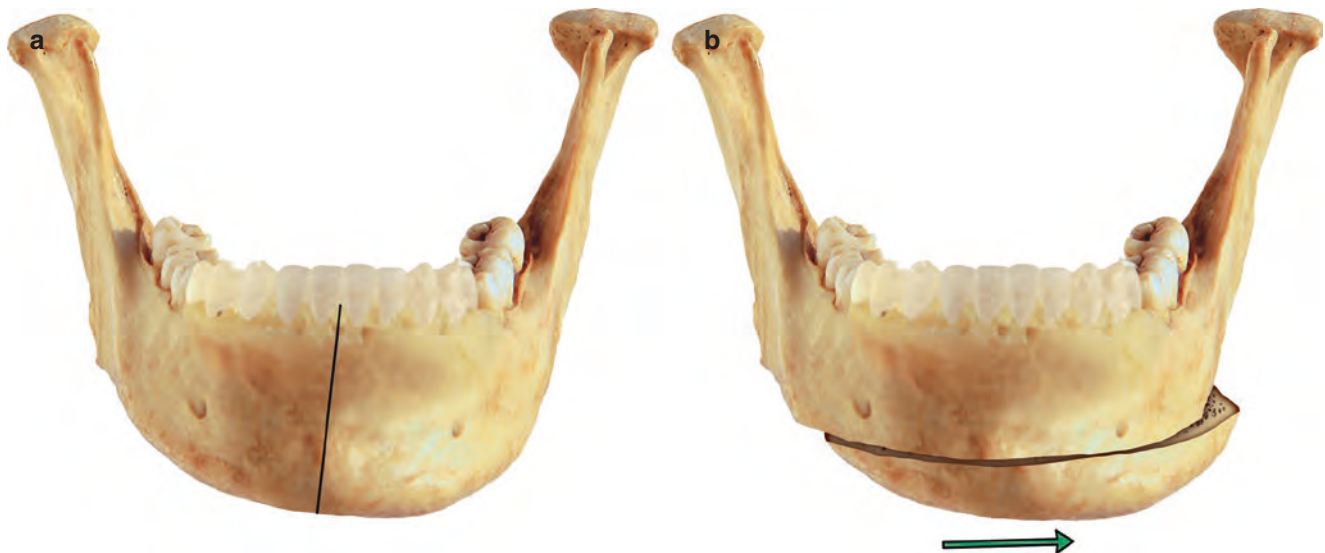Distraction osteogenesis has got an important role in managing sleep apnea, in cases like micrognathia, Pierre Robin syndrome, hemifacial microsomia, Treacher Collins syndrome, etc. [4, 95]. Due to its complex nature, it is rather difficult to treat unilateral craniofacial microsomia, in growing children. Maxilla, zygoma, mandible, external and middle ear, facial and trigeminal nerves, muscles of mastication, and overlying soft tissues are the structures of the first and second arch which are involved [96] (Refer Chap. 78 on Hemifacial microsomia and Treacher Collins syndrome).

In severe cases, in neonatals, tracheostomy may become necessary. Mandibular distraction is an effective method in resolving upper airway obstruction and decannulation of tracheostomy [97–99]. Rachmiel A. et al. have reported an increase of mandibular volume by 28.4%, increase of upper airway volume



©Association of Oral and Maxillofacial Surgeons of India

Fig. 68.36 After making a degloving incision an extended genioplasty may be done. it is possible to preserve the mental nerve. (a) Oblique view and (b) frontal view



©Association of Oral and Maxillofacial Surgeons of India

Fig. 68.37 Major asymmetry of the mandible can be corrected to a great extent by extended lateral sliding genioplasty. (a) Pre-operative plan and (b) treatment (osteotomy design)

by 71.92%, and increase in oxygen saturation. This study was conducted in children between 13 months and 7 years of age [25] (refer Chap. 87 on distraction osteogenesis).

In severely hypoplastic mandible multi-stage correction starting from young age may be considered for functional and psychological reasons. Less severe cases may be taken up for single stage correction after the permanent dentition is erupted [100].

68.13 Conclusion

Mandible is a horse shoe-shaped bone hinged to the skull and performs the major function, chewing, and forms the lower part of the mouth which houses the tongue and other musculature. All the muscles of mastication and many other muscles of facial expression are attached to the mandible. Hence mandible is an important structure in both function and aesthetics. Different osteotomies of mandible can move the jaw in almost all the three directions and change the size and shape of the jaw and face to achieve better function and aesthetics. This chapter is intended to elucidate various osteotomy techniques on the mandible.

Disclosure Authors have no financial conflicts to disclose.

68.14 Case Scenarios

Case 1 (Fig. 68.38a, b, c)

Patient aged 22 years, female, reported with complaint of facial deformity with a history of fall when she was about 8

years old. No deformity was noticed, and no treatment was taken at that time, and as she grew up, she started developing deviation of the face.

On examination she had facial asymmetry with deviation of the jaw to left side. She had class II occlusion and deficient chin. Radiographs revealed under developed and deformed condyle on the left side. The mandible was shifted to the left side due to underdevelopment of the mandible on left side (Fig. 68.38a1, b1, c1).

Treatment: Pre-surgical orthodontic treatment with sagittal split osteotomy and extended lateral sliding genioplasty with rib bone grafting on right side.

Postoperative pictures after 1 year (Fig. 68.38a2, b2, c2).

Case 2 (Fig. 68.19a, b, c)

Patient aged 19 years reported with complaint of protruded teeth and facial deviation with no relevant history.

On examination, she had vertical maxillary excess with mandibular prognathism. Other clinical findings included incompetent lips, convex facial profile, acute nasolabial angle, and facial asymmetry with deviation of chin toward right side. Radiographs revealed vertical and antero-posterior maxillary excess with mandibular prognathism and deficient chin.

Preoperative pictures (Fig. 68.19a1, b1, c1)

Treatment plan: Pre-surgical orthodontic treatment followed by surgery.

Surgery: LeFort 1, anterior maxillary osteotomy, bilateral sagittal split osteotomy, and genioplasty were done for the patient under general anesthesia.

Postoperative pictures after 1 year (Fig. 68.19a2, b2, c2)

References

- Batra APS, Mahajan A, Gupta K. Marginal mandibular branch of the facial nerve: an anatomical study. *Indian J Plast Surg.* 2010;43(1):60–4.
- Limberg A. Treatment of open bite by means of plastic oblique osteotomy of the ascending rami of the mandible. *Dent Cosmos.* 1925;67:1191–7.
- Caldwell JB, Letterman GS. Vertical osteotomy in the mandibular rami for correction of prognathism. *J Oral Surg.* 1954;12:185–202.
- Cosman B, Criilair G. Mandibular hyperplasia and the late development of glossopharyngeal airway obstruction. *Plast Reconstr Surg.* 1972;50:573–9.
- Caldwell JB, Hayward JR, Lister RL. Correction of mandibular retrognathia by vertical L osteotomy: a new technique. *J Oral Surg.* 1968;26:259–64.
- Obwegeser H, Trauner R. Zur Operationstechnik bei der progenie und anderen unterkieferanomalien. *Dtsch Z Mund Kieferheilkd.* 1955;23:H1–2.
- Trauner R, Obwegeser H. Zur Operationstechnik bei der progenie und anderen unterkieferanomalien [The surgical correction of mandibular prognathism and retrognathia with consideration of genioplasty]. *Dtsch Zahn Mund Kieferheilkd.* 1955;23(1):1–26.
- DalPont G. Retromolar osteotomy for the correction of prognathism. *J Oral Surg Anesth Hosp Dent Serv.* 1961;19:42–7.
- Hunsuck EE. Modified intraoral sagittal split technique for correction of mandibular prognathism. *J Oral Surg.* 1968;26:250–3.
- Reitzik M, Barer PG, Wainwright WM, Lim B. The surgical treatment of skeletal anterior open-bite deformities with rigid internal fixation in the mandible. *Am J Orthod Dentofac Orthop.* 1990;97(1):52–7.
- Hensel GC. The surgical correction of mandibular protrusion, retraction, and fractures of the ascending rami. *Int J Orthodont Oral Surg.* 1937;23:184.
- Bell WH, Schendel SA. Biological basis for the modification of the sagittal ramus split operation. *J Oral Surg.* 1977;35:362–9.
- Epker BN, Wolford LM, Fish LC. Mandibular deficiency syndrome: surgical considerations for mandibular advancement. *Oral Surg.* 1978;45:349–63.
- Wolford LM. Influence of osteotomy design mandibular ramus sagittal split osteotomy. *J Oral Maxillofac Surg.* 2015;73(10):1994–2004.
- Pietruski P, Majak M, Swiatek-Najwer E, Popek M, Szram D, Zuk M, Jaworowski J. Accuracy of experimental mandibular osteotomy using the image-guided sagittal saw. *Int J Oral Maxillofac Surg.* 2016;45:793–800.
- Panula K, Finne K, Oikarinen K. Neurosensory deficits after bilateral sagittal split ramus osteotomy of the mandible—influences of soft tissue handling medial to the ascending ramus. *Int J Oral Maxillofac Surg.* 2004;33:543–8.
- Tsuji Y, Muto T, Kawakami T, Takeda S. Computed tomographic analysis of the position and course of the mandibular canal: relevance to the sagittal split ramus osteotomy. *Int J Oral Maxillofac Surg.* 2005;34:243–6.
- Promma L, Sakulsak N, Putiwat P, Amarttayakong P, Iamsaard S, Trakulsuk H, Hirunyakorn K, Suarbuva S, Wattanaraengchai Y. Cortical bone thickness of the mandibular canal and implications for bilateral sagittal split osteotomy: a cadaveric study. *Int J Oral Maxillofac Surg.* 2017;46:572–7.
- Blair VP. Report of a case of double resection for the correction of protrusion of the mandible. *Dent Cosmos.* 1906;48:817–20.
- Wolford LM, Cottrell DA. Diagnosis of macroglossia and indications for reduction glossectomy. *Am J Orthod Dentofac Orthop.* 1996;110:170–7.
- Mommaerts MY. Endoscopically assisted sagittal split osteotomy for mandibular lengthening: technical note and initial experience. *J Craniomaxillofac Surg.* 2010;38:108–12.
- Ellis E III, Gallo WJ. Relapse following mandibular advancement with dental plus skeletal maxillomandibular fixation. *J Oral Maxillofac Surg.* 1986;44:509–15.
- Ellis E III, Reynolds S, Carlson DS. Stability of the mandible following advancement: a comparison of three post surgical fixation techniques. *Am J Orthod Dentofac Orthop.* 1988;94:38–49.
- Schendel SA, Epker BN. Result after mandibular advancement surgery: an analysis of 87 cases. *J Oral Surg.* 1980;38:265–81.
- Rachmiel A, Aizenbud D, Pillar G, Srouji S, Peled M. Bilateral mandibular distraction for patients with compromised airway analyzed by three dimensional CT. *Int J Oral Maxillofac Surg.* 2005;34(1):9–18.
- Laine P, Kontio R, Lindqvist C, Suuronen R. Are there any complications with bioabsorbable fixation devices? A 10 year review in orthognathic surgery. *Int J Oral Maxillofac Surg.* 2004;33:240–4.
- Bell WH, Fonseca RJ, Kennedy JW III, Levy BM. Bone healing and revascularization after total maxillary osteotomy. *J Oral Surg.* 1975;33:253–60.
- Bell WH, Levy BM. Revascularisation and bone healing after posterior maxillary osteotomy. *J Oral Surg.* 1971;29:313–20.
- Bell WH. Revascularisation and bone healing after anterior maxillary osteotomy: a study using adult rhesus monkeys. *J Oral Surg.* 1969;27:249–55.
- Stoelinga PJ, Borslap WA. The fixation of sagittal split osteotomies with mini plates the versatility of a technique. *J Oral Maxillofac Surg.* 2003;61:1471–6.
- Foley WL, Beckman TW. In vitro comparison of screw versus plate fixation in the sagittal split ramus osteotomy. *Int J Adult Orthodon Orthognath Surg.* 1992;7:147–51.
- Behrman SJ. Complications associated with orthognathic surgery. In: Irby WB, editor. *Current advances in oral surgery.* St Louis: CV Mosby; 1974. p. 109.
- Storum KA, Bell WH. Hypo mobility after maxillary and mandibular osteotomies. *J Oral Surg.* 1984;57:7–12.
- Aragon SB, VanSickels JE. Mandibular range of motion with rigid/no rigid fixation. *Oral Surg.* 1987;63:408–11.
- Steenen SA, Becking AG. Bad splits in bilateral sagittal split osteotomy: systematic review of fracture patterns. *Int J Oral Maxillofac Surg.* 2016;45:887–97.
- Aarabi M, Tabrizi R, Hekmat M, Shahidi S, Puzesh A. Relationship between mandibular anatomy and the occurrence of a bad split upon sagittal split osteotomy. *J Oral Maxillofac Surg.* 2014;72:2508–13.
- Al Bishri A, Barghash Z, Rosenquist J, Sunzel B. Neurosensory disturbance after sagittal split and intra oral vertical ramus osteotomy: as reported in questionnaires and patients records. *Int J Oral Maxillofac Surg.* 2005;34:247–51.
- Posnick JL, Qattan MM, Stepner NM. Alteration in focal sensibility in adolescents following sagittal split and chin osteotomies of the mandible. *Plast Reconstr Surg.* 1996;97:920–7.
- Lake SL, McNeill RW, Little RM, West RA. Surgical mandibular advancement: a cephalometric analysis of treatment response. *Am J Orthod.* 1981;80:376–94.
- Fariña R, Pintor F, Pérez J, Pantoja R, Berner D. Low condylectomy as the sole treatment for active condylar hyperplasia: facial, occlusal and skeletal changes. An observational study. *Int J Oral Maxillofac Surg.* 2015;44:217–25.
- Lee SG, Kang YH, Byun JH, Kim UK, Kim JR, Park BW. Stability of unilateral sagittal split ramus osteotomy for correction of facial asymmetry: long-term case series and literature review. *J Korean Assoc Oral Maxillofac Surg.* 2015;41:156–64.
- Mendez-Manjon I, Guijarro-Martinez R, Valls-Ontanon A, Hernandez-Alfaro F. Early changes in condylar position after

- mandibular advancement: a three-dimensional analysis. *Int J Oral Maxillofac Surg.* 2016;45:787–92.
43. Borstlap WA, Steolinga PJW, Hoppenreijns TJM, Van't Hof MA. Stabilization of sagittal split advancement osteotomies with mini plates: a prospective multi centre study with two year follow up part III—condylar remodeling and resorption. *Int J Oral Maxillofac Surg.* 2004;33:649–55.
 44. Arnett GW, Milam SB, Gottesman L. Progressive mandibular retrusion—idiopathic condylar resorption part I. *Am J Orthod Dentofac Orthop.* 1996;110:8–15.
 45. Alder ME, Deahl ST, Matteson SR, Van Sickle JE, Tiner BD, Rugh JD. Short term change of condylar position after sagittal split osteotomy for mandibular advancement. *Oral Surg Oral Med Oral Pathol Oral Radiol Endod.* 1999;87:159–65.
 46. Ueki K, Nakagawa K, Marukawa K, Takazakara D, Shimada M, Takatsuka S, Yamamoto E. Changes in condylar long axis and skeletal stability after bilateral sagittal split ramus osteotomy with poly-L-lactic acid or titanium plate fixation. *Int J Oral Maxillofac Surg.* 2005;34:627–34.
 47. Mobarak KA, Espeland L, Krogstad O, Lyberg T. Mandibular advancement surgery in high-angle and low-angle class II patients: different long-term skeletal responses. *Am J Orthod Dentofac Orthop.* 2001;119:368–81.
 48. Kojimoto H, Yasin N, Goto T, Matsudo S, Shimomura Y. Bone lengthening in rabbits by callus distraction. The role of periosteum and endosteum. *J Bone Joint Surg Br.* 1988;70:543–9.
 49. Moose SM. Surgical correction of mandibular prognathism by intra oral subcondylar osteotomy. *J Oral Surg.* 1964;22:197–201.
 50. Winstanley RP. Subcondylar osteotomy of the mandible and the intra oral approach. *Br J Oral Surg.* 1968;6:134–6.
 51. Rokutanda S, Yamada S, Yanamoto S, Omori K, Fujimura Y, Morita Y, Rokutanda H, Kohara H, Fujishita A, Nakamura T, Yoshimi T, Yoshida N, Umeda M. Comparison of osseous healing after sagittal split ramus osteotomy and intraoral vertical ramus osteotomy. *Int J Oral Maxillofac Surg.* 2018;47(10):1316–21.
 52. Al-Moraissi EA, Ellis E 3rd. Is there a difference in stability or neurosensory function between bilateral sagittal split ramus osteotomy and intraoral vertical ramus osteotomy for mandibular setback? *J Oral Maxillofac Surg.* 2015;73:1360–71.
 53. Hall HD, Chase DC, Payor LG. Evaluation and refinement of the intraoral vertical subcondylar osteotomy. *J Oral Surg.* 1975;33:333–41.
 54. Tornes K, Wisth PJ. Stability after vertical subcondylar ramus osteotomy for correction of mandibular prognathism. *Int J Oral Maxillofac Surg.* 1988;17:242–8.
 55. Nystrom E, Rosenquist J, Astrand P, Nordin T. Intraoral or extra oral approaches in oblique sliding osteotomy of the mandibular ramus. *J Maxillofac Surg.* 1984;12:277–82.
 56. Reitzk M, Griffiths RR, Mirels H. Surgical anatomy of the ascending ramus of the mandible. *Br J Oral Surg.* 1976;14(2):150–5.
 57. Goldstein A. Appraisal of results of surgical correction of class III malocclusions. *Angle Orthod.* 1974;17(3-4):59.
 58. Komiri E, Aigase K, Sugisaki M, Tanabe H. Skeletal fixation versus skeletal relapse. *Am J Orthod Dentofac Orthop.* 1987;92(5):412–21.
 59. Ghali GE, Sikes JW Jr. Intraoral vertical ramus osteotomy as the preferred treatment for mandibular prognathism. *J Oral Maxillofac Surg.* 2000;58:313e315.
 60. González-García R. Endoscopically-assisted subcondylar and vertical ramus osteotomies for the treatment of symmetrical mandibular prognathism. *J Craniomaxillofac Surg.* 2012;40:393–5.
 61. Poulton DR, Taylor RC, Ware WH. Cephalometric x-rays evaluation of the vertical osteotomy correction of mandibular prognathism. *Oral Surg Oral Med Oral Pathol.* 1963;16:807–20.
 62. Ritzau M, Wenzel A, Williams S. Changing in condyle position after bilateral vertical ramus osteotomy with and without osteosynthesis. *Am J Orthod Dentofac Orthop.* 1989;96:507–13.
 63. Sund G, Eckerdal O, Astrand P. Changes in the temporomandibular joint after oblique sliding osteotomy of the mandibular rami: a longitudinal radiological study. *J Maxillofac Surg.* 1983;11(2):87–91.
 64. Hollender L, Ridell A. Radiography of the temporomandibular joint after oblique sliding osteotomy of the mandibular ramis. *Scand J Dent Res.* 1974;82:466–9.
 65. Sund G, Eckerdal O, Astrand P. Skeletal remodeling in the temporomandibular joint after oblique sliding osteotomy of the mandibular rami. *Int J Oral Maxillofac Surg.* 1986;15(3):233–9.
 66. Hullihen SP. Case of elongation of the under jaw and distortion of the face and neck, caused by a burn, successfully treated. *Am J Dent Sci.* 1849;9:157.
 67. Hofer O. Operation der prognathie und Mikrogenie. *Dtsch Zahn Mund Kieferheilk.* 1942;9:121–32.
 68. Boye T, Doyle P, McKeown F, Sandler J. Total subapical mandibular osteotomy to correct class 2 division 1, dento-facial deformity. *J Craniomaxillofac Surg.* 2011;40(3):238–42.
 69. Bell WH, Gallagher DM. Versatility of genioplasty with broad pedicle. *J Oral Maxillofac Surg.* 1983;41:763–9.
 70. Mercuri LG, Laskin DM. Avascular necrosis after anterior horizontal augmentation genioplasty. *J Oral Surg.* 1977;35:296–8.
 71. Storum KA, Bell WH, Nagura H. Micro angiographic and histologic evaluation of revascularization and healing after genioplasty by osteotomy of the inferior border of the mandible. *J Oral Maxillofac Surg.* 1988;48:210–6.
 72. Fitzpatrick BN. Reconstruction of the chin in cosmetic surgery (genioplasty). *Oral Surg.* 1975;39:522–35.
 73. Cohen SR, Mardach OL, Kawawata HK. Chin disfigurement following removal of alloplastic chin implants. *Plast Reconstr Surg.* 1991;88:62.
 74. Lopez PE, Guerrero CA, Mujica EV. Mandibular basal osteotomy: new designs and fixation techniques. *J Oral Maxillofac Surg.* 2011;69:786–97.
 75. Troulis MJ, Kearns GJ, Perrott DH, Kaban LB. Extended genioplasty, long term cephalometric, morphometric and sensory results. *Int J Oral Maxillofac Surg.* 2000;29:167–75.
 76. Mani V, et al. Extended lateral sliding genioplasty for the correction of facial asymmetry. *Asian J Oral Maxillofac Surg.* 2004;16(2):84–90.
 77. McCarthy JG, Schreiber JS, Karp NCH, Thorne CH, Grayson BH. Lengthening of the human mandible by gradual distraction. *Plast Reconstr Surg.* 1992;89:1–10.
 78. Raghoebar GM, Heydenrijk K, Vissink A. Vertical distraction of the severely resorbed mandible. The Groningen distraction device. *Int J Oral Maxillofac Surg.* 2001;59:728–33.
 79. Suhr MAA, Kreatsch T. Technical considerations in distraction osteogenesis. *Int J Oral Maxillofac Surg.* 2004;33:89–94.
 80. Hu J, Tang Z, Wang D, Buckley MJ. Changes in the inferior alveolar nerve after mandibular lengthening with different rates of distraction. *J Oral Maxillofac Surg.* 2001;108(5):1103–14.
 81. Aida T, Yoshioka I, Tominaga K, Fukuda J. Effects of latency period in a rabbit mandibular distraction osteogenesis. *Int J Oral Maxillofac Surg.* 2003;32:54–62.
 82. Tavakoli K, Walsh WR, Bonar F, Smart R, Wulf S, Poole M. The role of latency in mandibular osteo-distraction. *J Craniomaxillofac Surg.* 1998;26(4):209–19.
 83. Troulis MJ, Glowacki J, Perrott DH, Kaban LB. The effects of latency and rate on distraction osteogenesis of the porcine mandible. *J Oral Maxillofac Surg.* 2000;58(5):507–14.
 84. Koudstaal MJ, Poort Poort LT, Vandel Wal KGH, Wolvers EB, Prahl Anderson B, Schulten AJM. Surgically assisted rapid max-

- illary expansion (SDRME) a review of the literature. *Int J Oral Maxillofac Surg.* 2005;34:709–14.
85. Karp NS, McCarthy JG, Schreiber JS, Sissions HA, Thorne CHM. Membranous bones lengthening: a serial histological study. *Ann Plast Surg.* 1992;29:2–7.
 86. Al Ruhaimi KA. Comparison of different distraction rates in the mandible: an experimental investigation. *Int J Oral Maxillofac Surg.* 2001;30:220–7.
 87. El-Hakin E, Azins AMA, El Hanson MFA, Maree SM. Preliminary investigation into the effects of electrical stimulation on mandibular distraction osteogenesis in goats. *Int J Oral Maxillofac Surg.* 2004;33:42–7.
 88. Friedenber ZB, Kohanin M. Effect of direct current on bone. *Surg Gynecol Obstet.* 1968;127:97–102.
 89. Hagiwara T, Bell WH. Effect of electrical stimulation on mandibular distraction osteogenesis. *J Craniomaxillofac Surg.* 2000;28:12–9.
 90. Hoffmeister B, Marks CH, Wolff KD. The floating bone concept in intraoral mandibular distraction. *J Craniomaxillofac Surg.* 1998;26:76–7.
 91. McCarthy J, Hopper R, Hollier L, Peltomaki T, Katzen T, Grayson B. Molding of the degenerate in mandibular distraction—clinical experience. *Plast Reconstr Surg.* 2003;12:1239–46.
 92. Peltonaki T, Greyson B, Venditelli B, Katzen T, McCarthy J. Moulding the generate to control open bite during mandibular distraction osteogenesis. *Eur J Orthod.* 2002;24:639–45.
 93. Ow ATC, Cheung LK. Skeletal stability and complications of Bilateral Sagittal Split Osteotomies (BSSO) and Mandibular Distraction Osteogenesis (MDO): an evidence-based review. *J Oral Maxillofac Surg.* 2009;67:2344–53.
 94. Baas EM, Bierenbroodspot F, de Lange J. Skeletal stability after bilateral sagittal split osteotomy or distraction osteogenesis of the mandible: a randomized clinical trial. *Int J Oral Maxillofac Surg.* 2015;44:615–20.
 95. Sjolui S. Hypoplasia of the mandible as a cause of respiratory difficulties in the infant. *Acta Paediatr Scand.* 1950;39:255–6.
 96. Keogh IJ, Troulis MJ, Monroy AA, Eavey RD, Kaban LB. Isolated microtia as a marker for unsuspected hemifacial microsomia. *Arch Otolaryngol Head Neck Surg.* 2007;13:997–1001.
 97. Moore MH, Guzman-Stein G, Proudman TW, Abott AH, Netherway DJ, David DJ. Mandibular lengthening by distraction for airway obstruction in Treacher collins syndrome. *J Craniofac Surg.* 1994;5:22–5.
 98. Morovic CG, Monasterio L. Distraction osteogenesis for obstructive apneas in patients with congenital craniofacial malformations. *Plast Reconstr Surg.* 2000;105:2324–30.
 99. Perkins JA, Sie KCY, Miczuk K, Richardson MA. Airway management in children with cranio facial anomalies. *Cleft Palate Craniofac J.* 1997;34:135–40.
 100. Pluijmers C, Caron JJM, Dunaway DJ, Wolvius EB, Koudstaal MJ, Posnick JC, Al-Quattan MM, Stepner NM. Alteration in facial sensibility in adolescents following sagittal split and chin osteotomies of the mandible. *Plast Reconstr Surg.* 1996;97:920–7.

Open Access This chapter is licensed under the terms of the Creative Commons Attribution 4.0 International License (<http://creativecommons.org/licenses/by/4.0/>), which permits use, sharing, adaptation, distribution and reproduction in any medium or format, as long as you give appropriate credit to the original author(s) and the source, provide a link to the Creative Commons license and indicate if changes were made.

The images or other third party material in this chapter are included in the chapter's Creative Commons license, unless indicated otherwise in a credit line to the material. If material is not included in the chapter's Creative Commons license and your intended use is not permitted by statutory regulation or exceeds the permitted use, you will need to obtain permission directly from the copyright holder.





Orthognathic Surgery for the Maxilla-LeFort I and Anterior Maxillary Osteotomy

69

Ashok Dabir and Jayesh Vahanwala

69.1 History of Maxillary Osteotomies

Maxillary Osteotomies

One does not know a science completely without knowing its history.

Auguste Comte (1798–1857) [1]

The Le Fort I-Type Maxillary Osteotomy

The development of modern maxillary orthognathic surgical procedures had diverse historical origins and contributions. The removal of nasal and nasopharyngeal polyps via hemimaxillary osteotomy was being undertaken in Europe in the mid-nineteenth century, notably by the German surgeon Bernhard Rudolf Konrad von Langenbeck (1810–1887) in Berlin [2]. The first maxillary procedure that would today be described as a total Le Fort I-type osteotomy appears to have been undertaken in 1868 by the American surgeon, David Williams Cheever (1831–1915) in Boston City Hospital to provide surgical access for removal of a large nasopharyngeal polyp [3]. One year prior to this, in 1867, Cheever had undertaken a down-fracture of the right hemimaxilla for similar surgical access in another patient, who had made a complete recovery [4]. The total down-fracture of the maxilla at the Le Fort I level performed in 1868, described as Cheever's "double operation," though technically successful, had an unfortunate postoperative outcome in that the patient

subsequently died 5 days later, though probably not as a direct result of the maxillary procedure [5, 6].

In 1901, a French surgeon from Lille named René Le Fort (1869–1951) conducted experiments using blunt trauma to intact cadaveric faces, from different directions and varying magnitudes, and thereby described the natural planes of maxillary and facial fractures [7, 8] now known as the Le Fort classification of facial fractures. The names of the Le Fort I-, II-, and III-type osteotomies are due to their similarity to the Le Fort fractures.

In 1927, Wassmund carried out a maxillary osteotomy at the Le Fort I level, without pterygoid plate disjunction or mobilization at the time of surgery [9]. He used elastics to close an anterior open bite, without placing a bone graft, which subsequently relapsed. In 1934, Axhausen in Berlin described advancement of the maxilla at the Le Fort I level, which was incompletely mobilized, again with postoperative elastic traction [10].

Wassmund was the first to apply osteotomies at the Le Fort I level for correction of midfacial deformities [11]. The technique was subsequently modified by several surgeons including Axhausen [12], Schuchardt [13], and Willmar [14]. In 1965, Obwegeser improved the precision of the Le Fort I osteotomy by suggesting complete mobilization of the maxilla so that repositioning was achieved without tension [15, 16]. The operation was slow to gain popularity until 1973, till Bell's description of the remarkably resilient maxillary blood supply [17]. With advancement in technique and the introduction of safe hypotensive anesthesia, the Le Fort I osteotomy has been increasingly utilized over the last four decades. Over the years, various modifications of the osteotomies, ORIF methods and bone grafting to the mobilized maxilla, have continued to evolve and progress.

Electronic Supplementary Material The online version of this chapter (https://doi.org/10.1007/978-981-15-1346-6_69) contains supplementary material, which is available to authorized users.

A. Dabir (✉)
D. Y. Patil University School of Dentistry, Nerul, Navi Mumbai,
India

Breach Candy Hospital, Mumbai, India

J. Vahanwala (✉)
Department of Oral Surgery, Vaidik Dental College and Research
Centre, Nani Daman, Daman, India

Breach Candy Hospital, Mumbai, India

69.2 Surgical Anatomy

The paired maxillae are made up of a body and four projections: frontal, zygomatic, palatine, and the alveolar process. The maxilla forms the inferior and medial borders of the

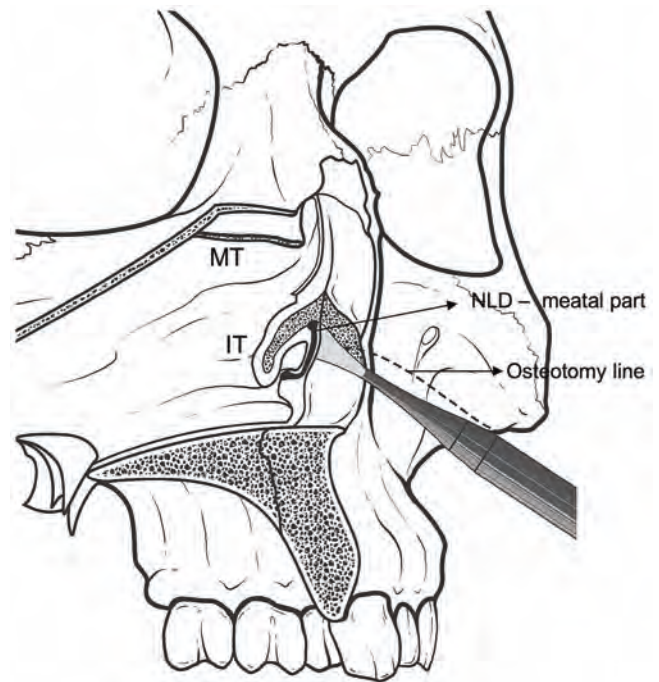
orbits. The infraorbital foramen is located at an average distance of 7.8 mm, positioned inferiorly to the infraorbital rim in women and 8.5 mm in men [18]. The vascular and sensory supplies to the cheek, lateral aspect of the nose, and upper lip exit the bone from this foramen.

The anterior alveolar processes surround the piriform apertures and join to form the anterior nasal spine in the midline. The anterior nasal spine is the most anterior inferior attachment for the cartilaginous nasal septum, which extends posteriorly along the nasal crest and articulates with the vomer.

The maxillary sinuses are housed in body of maxilla. Anteriorly, palatine process of each maxilla and posteriorly, horizontal lamina of palatine bone form the hard palate. The greater palatine foramen is located on each side approximately 10 mm posteromedial to the second molar.

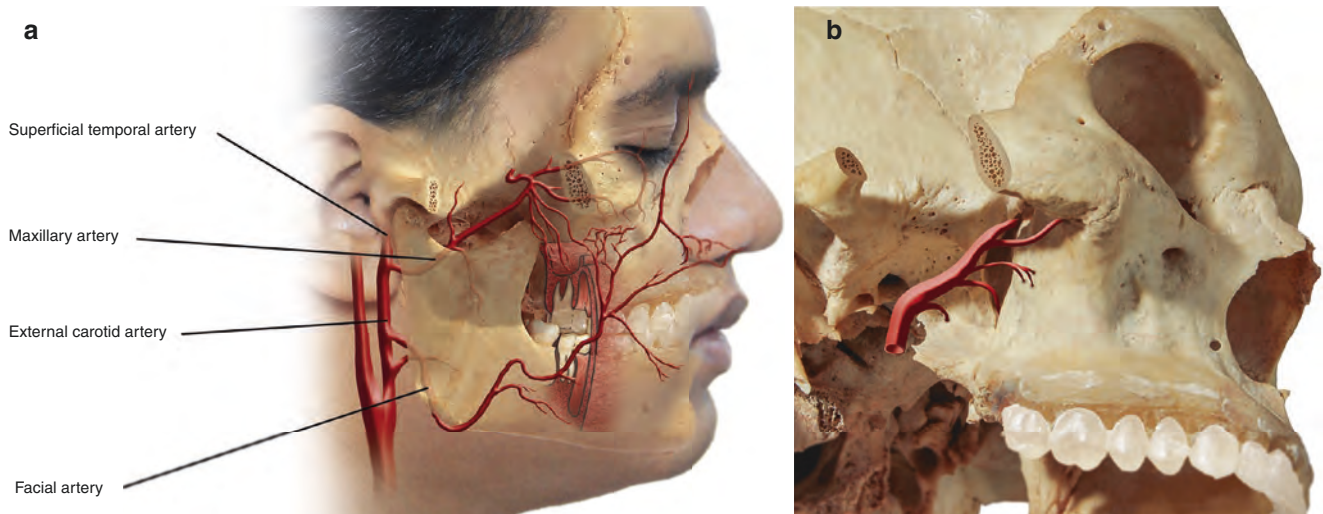
The nasolacrimal duct travels within the bony wall between the nasal cavity and the maxillary sinus before terminating below the inferior turbinate. It can be injured during the Le Fort I osteotomy or during an inferior turbinectomy performed to allow superior repositioning of the maxilla (Fig. 69.1) [19, 20].

Posterolaterally, the maxilla articulates with the pyramidal processes of the palatine bones and the pterygoid plates of the sphenoid bone. This pterygomaxillary junction extends superiorly as a fissure, which ends at the pterygopalatine fossa. The terminal portion of the internal maxillary artery traverses the pterygopalatine fossa and gives off several branches that can be encountered during a Le Fort I osteotomy (Fig. 69.2a, b). The average distance between the infe-



©Association of Oral and Maxillofacial Surgeons of India

Fig. 69.1 Relationship of the nasolacrimal duct to the Le Fort I osteotomy cut. The meatus of the nasolacrimal duct is unlikely to be injured if the osteotomy is made just beneath the infraorbital foramen and into the piriform rim at the level of the inferior turbinate (IT). *MT* middle turbinate



©Association of Oral and Maxillofacial Surgeons of India

Fig. 69.2 (a) Branches of external carotid artery, (b) terminal branches of internal maxillary artery

rior extent of the pterygomaxillary junction and the posterior superior alveolar artery is 15 mm, the infraorbital artery is 32 mm, and the descending palatine artery is 25 mm. The descending palatine arteries travel through the perpendicular plate of the palatine bones and are located approximately 34 mm posterior to the piriform rims and within 10 mm medial to the pterygomaxillary fissures [21].

Osteotomies of the lateral nasal walls and at the pterygomaxillary fissures must be completed carefully to avoid injuring these vessels. The internal maxillary artery is 23–25 mm above the base of the junction of the maxilla with the pterygoid plates, with an average diameter of 2.5 mm. In addition to the direct vascular supply of the maxilla by the descending palatine arteries, there is a rich collateral vascular network from the soft palate supplied by the ascending pharyngeal arteries and the ascending palatine branches of the facial arteries (Fig. 69.3). The risk of damaging the artery can be minimized by ensuring the pterygoid osteotome is directed downward toward the palate and is less than 1.5 cm above the inferior part of the fissure [22, 23].

Bell's work revealed that ligation of the bilateral descending palatine arteries does not compromise the vascularity of the maxilla as long as the soft palate pedicle is preserved [24, 25].

The pterygoid plexus of veins is located between the temporalis and lateral pterygoid muscles and between the medial and lateral pterygoid muscles. It receives tributaries corresponding to the branches of the maxillary artery and drains

into the maxillary vein. Venous bleeding from this plexus may be encountered during the posterolateral maxillary dissection and pterygomaxillary disjunction.

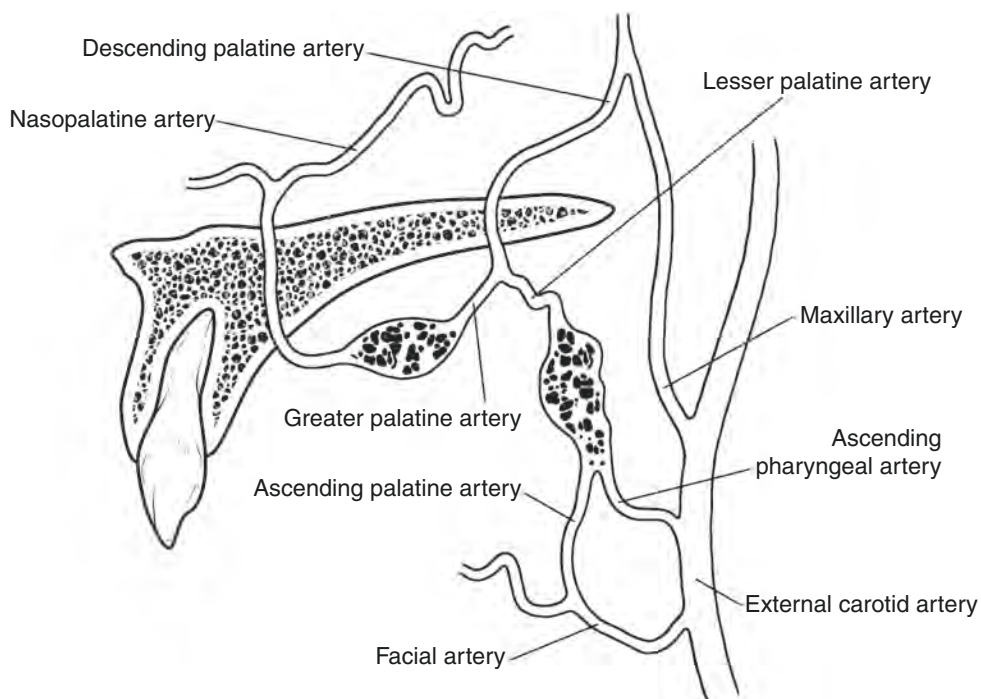
The risk of damaging the artery can be minimized by ensuring the pterygoid osteotome is directed downwards towards the palate and is less than 1.5 cm above the inferior part of the fissure [22, 23].

Bell's work revealed that ligation of the bilateral descending palatine arteries does not compromise the vascularity of the maxilla as long as the soft palate pedicle is preserved [24, 25].

S. Bruneder et al. studied a special type of arterial variation of the Le Fort I segment's blood supply. Individuals with this special arterial anatomy may clinically be at high risk for hypoperfusion and avascular segment necrosis after surgery. Individualized operation planning that takes the patient's arterial anatomy into consideration may help to prevent ischemic vascular complications of the Le Fort I segment and improve operative outcomes in at-risk patients [26].

S. Salmanet et al. studied Dynamic analysis of maxillary perfusion during Le Fort I osteotomy using indocyanine green and concluded that there was a statistically significant decrease in perfusion, as assessed by intraoperative dynamic angiography, to the anterior maxilla following maxillary down-fracture. Patient age, conventional versus segmental Le Fort I osteotomy, changes in mean arterial pressure and/or heart rate, and preservation of the descending palatine vessels had no statistically significant effect on perfusion [27].

Fig. 69.3 The vascular supply of the osteotomised LeFort I segment. The ascending pharyngeal arteries and the ascending palatine branches of the facial artery



The patient's sex and aspects of the skeletal and craniofacial pattern have an influence on the pterygomaxillary area and descending palatine canal anatomy. A preoperative computed tomography analysis involving this evaluation could reduce the risk of surgical complications. A preoperative CT analysis should be performed on an individual basis and should identify the differences between the two sides in the same patient to allow a safer surgical procedure during Le Fort I osteotomy [28].

69.3 The Anterior Segmental Maxillary Osteotomy

The first anterior segmental maxillary osteotomy (ASMO) was reported at the beginning of the twentieth century by Günther Cohn-Stock [29], wherein he tried to surgically "correct a marked overjet and overbite of the central maxillary teeth." In his pioneering article in 1921, he described the evolution of his idea to perform an osteotomy of the anterior segment of the maxilla while preserving the vestibular pedicle and, in a later design, also the palatal artery [29].

After Cohn-Stock's original report, three variations of the procedure were developed by Wassmund [9], Wunderer [30], and Cupar [31]. These variations were designed to maintain sufficient blood supply to the maxilla while giving adequate access for instrumentation [32, 33].

In 1927 Wassmund [9] improved Cohn-Stock's design by creating a direct approach to the labial premaxillary cortex using three vertical incisions and subperiosteal tunnelling for completion of the labial osteotomy without reflection of labial or palatal flaps. Both the labial and palatal blood supply are maintained; however, the osteotomy is made in a relatively blind fashion. This method may be indicated for closure of multiple interdental spaces [33] and for anteroposterior repositioning of the premaxilla [34]. It was found to maintain the best vascularity of the repositioned segment in comparison to all other ASMO methods [35].

In 1954 Cupar [31] described a different approach for down-fracture of the anterior maxilla: exposure of the labial aspect of the maxillary bone by a vestibular circumferential cut and labial flap to facilitate the labial osteotomy under direct vision. A palatal osteotomy was performed through a tunnel, maintaining the palatal blood supply. This technique is indicated for superior repositioning of the anterior maxilla in cases of vertical maxillary excess.

In 1963 Wunderer [30] advocated reflection of a palatal flap without fracturing of the anterior maxilla and maintenance of the labial blood supply. Direct access for the palatal osteotomy is the main advantage of this technique, especially if posterior segments of the premaxilla must be removed.

Therefore, this technique may be indicated for setback of the anterior part of the maxilla. Blood flow studies have demonstrated that the transpalatal approach causes the greatest decrease in blood supply to the anterior maxilla [36]. However, transpalatal soft tissue incision and labial osteotomies impair vascular supply to the anterior maxilla from the greater palatine vessels and the superior alveolar vessels, respectively, leaving the labial collaterals as the sole blood supply to the anterior maxilla [37].

In 1977 Epker modified the Cupar technique for down-fracture of the anterior maxilla. He used only labial flaps and vertical tunnels labial to the teeth to be extracted, which were usually premolars on both sides [38]. Epker's modification enables repositioning of the anterior maxilla superiorly, posteriorly, and inferiorly. The main advantages of the Epker modification include preservation of the palatal pedicle, ease of placement of internal fixation, provide access to the nasal septal structures to prevent buckling of the nasal septum with superior repositioning of the maxilla, and a direct approach for removal of palatal bone. When required, bone grafting for stabilization of an inferiorly positioned anterior maxilla may also be done using this method.

The segmental Le Fort I osteotomy should not be excluded from the technical armamentarium in orthognathic surgery. On the contrary, the literature consulted suggests it to be a useful tool for the three-dimensional surgical correction of maxillary malposition [39].

69.3.1 Technique (Video 69.1)

Anaesthetic and Positioning Considerations: Controlled hypotensive anesthesia has been shown to reduce bleeding from mucosal and bone edges that contain a rich network of small vessels, which cannot easily be identified and controlled with surgical techniques. In healthy patients, a reduction in mean arterial pressure (MAP) of 30% below the patient's baseline with a minimum MAP of 50 mmHg is safe [40]. In bimaxillary surgery, postoperative blood transfusions are necessary in 13–48% of patients who do not have controlled hypotension during the operation [41, 42]. The need for transfusion has been nearly eliminated by using this technique. Placement of an indwelling bladder catheter for intraoperative monitoring of urine output as a marker of renal perfusion should be considered when using controlled hypotension. After induction of general anesthesia, the patient is nasally intubated. Because intraoperative maxillo-mandibular fixation is essential to establish the postoperative position of the anterior maxilla, oral intubation is less desirable and should be avoided. The endotracheal tube must be sufficiently below the level of the vocal cords to prevent

unintended dislodgement during premaxillary manipulation. A shoulder roll is inserted to extend the neck without creating hyperextension. A sterile preparation and draping is performed, leaving the orbits and nasion exposed. After the planned mucosal incision is marked, local anaesthetic with vasoconstrictor (lidocaine with 1:100,000 epinephrine) is infiltrated in the labial sulcus. Palatal injection should be avoided so as not to induce vasoconstriction in the palatal pedicle.

69.3.2 Exposure

A horizontal buccal sulcus incision is made by diathermy or a #15 scalpel blade in one strike to the bone in the deepest section of the buccal vestibule, circumferentially from right to left second premolar. Next, the periosteum is reflected superiorly to expose the entire canine fossa and piriform aperture bilaterally. Inferiorly, minimum mucoperiosteal stripping should be done, to maximize blood supply to the osteotomized maxilla. The alveolar mucoperiosteum should be undermined to the crestal bone only at preplanned osteotomy or ostectomy sites. The nasal mucoperiosteum should be carefully separated from the nasal cavity floor to prevent intraoperative bleeding, postoperative oronasal communication, and fistula formation. The cartilaginous nasal septum is separated from the nasal groove of the maxilla to facilitate its manipulation later.

69.3.3 Extractions and Horizontal Osteotomies

As per surgical plan, maxillary premolars are extracted on each side. Then, a reciprocating saw or piezo-surgical saw is used to perform horizontal osteotomies. These bone cuts should run posteriorly from each side of the piriform rim, including the lateral maxillary walls and the lateral nasal cavity walls. The nasal mucosa is protected with a curved periosteal elevator. Due care should be taken to avoid injury to the infraorbital nerve during retraction of the upper mucoperiosteal flap. The posterior limit for these osteotomies is the planned vertical osteotomy/ostectomy, usually the first or second premolar (Fig. 69.4a–d).

Figure 69.4b and Fig. 69.5 indicates the horizontal and vertical osteotomies/ostectomies that are performed using a #701 bur, mini-saw, or piezo. Precise bone removal should be done to ensure an accurate postoperative position and sufficient intersegmental bony contacts.

Meticulous tissue handling is of paramount importance at this stage. Failure to preserve buccal mucosa may lead to an impaired blood supply to the down-fractured maxilla or

establishment of an oroantral fistula, in addition to periodontal compromise of the adjacent teeth.

69.3.4 Final Osteotomy and Down-Fracture of the Premaxilla

After completion of the planned osteotomies and ostectomies under direct visualization, the final osteotomy is done using an osteotome. Neither a palatal incision nor a mucosal undermining is done at this stage. A palpating finger is positioned on the palatal mucosa, and the transpalatal osteotomy is completed with an osteotome. Down-fracture of the premaxilla is accomplished with a bone hook. Additional transpalatal and nasal ostectomies may be necessary at this stage and should be finalized under direct access gained to the nasal aspect of the down-fractured premaxilla. Careful separation of the mucoperiosteum from the posterior segment of the palate facilitates setback of the anterior segment and prevents it from becoming detached from the anterior segment, compromising the blood supply (Fig. 69.6a, b).

69.3.5 Midpalatal Osteotomy

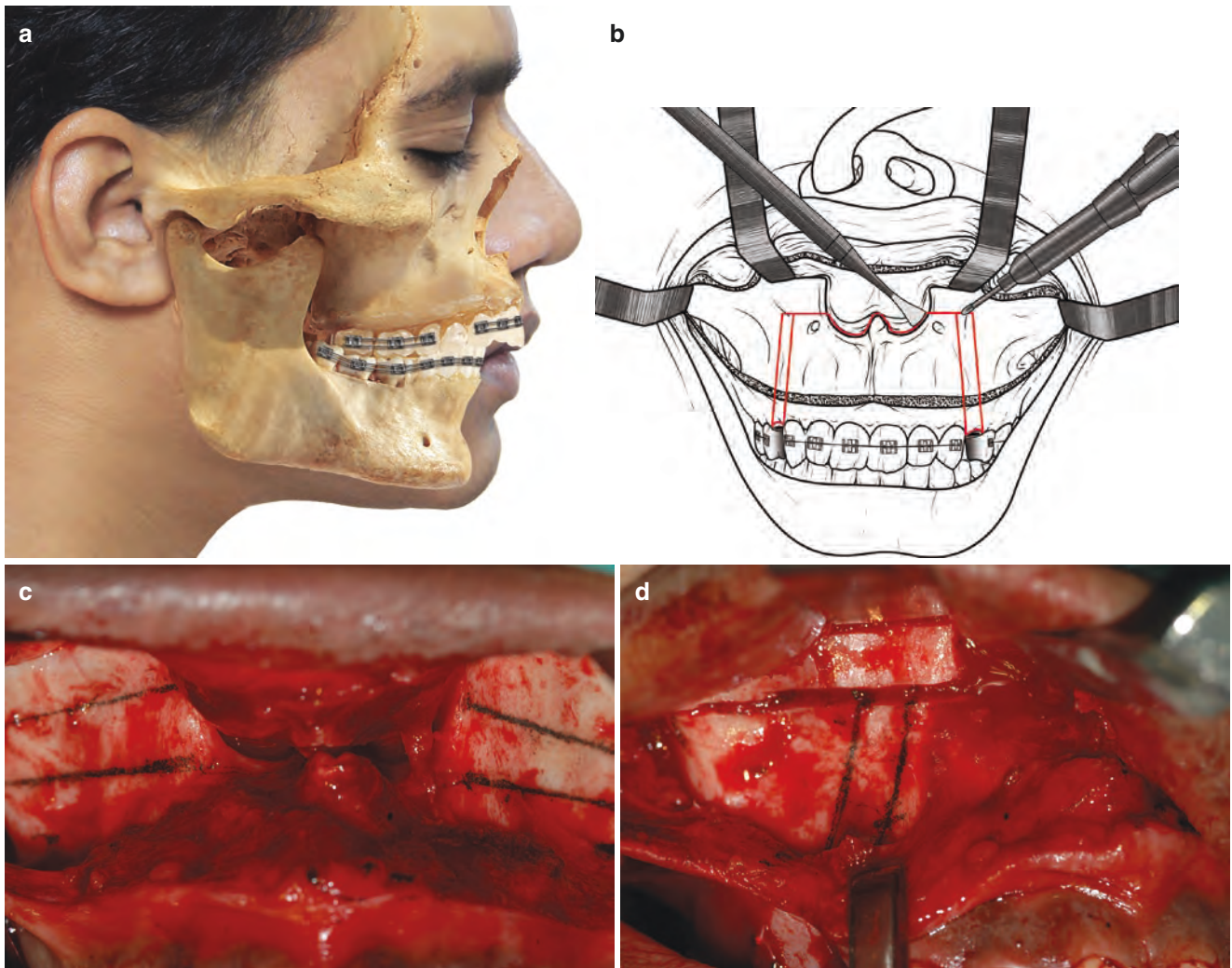
If indicated for transverse widening or narrowing of the premaxilla or closure of a diastema, a midpalatal osteotomy is performed with an osteotome or piezo-surgical saw (Fig. 69.7a, b).

69.3.6 Fixation

After completion of the ostectomies, maxillary teeth are placed into a preformed acrylic occlusal wafer, which is wired to the maxillary dentition. Temporary maxillomandibular fixation then is done, and a standard 1.5 or 2.0 maxillary plating system is used at the maxillary buttresses to fixate the bone segments in their planned postoperative position (Fig. 69.8a–c).

69.3.7 Closure

After thorough irrigation of the surgical site with saline, the mucosal incisions are closed with 3-0/4-0 vicryl suture. If indicated, alar cinch and V-Y closure of the buccal incision are performed at this stage. Maxillomandibular fixation is removed at the end of the procedure. The maxillary surgical wafer may be kept in place for 6 weeks for additional stability of the maxillary segments and occlusal guidance (Fig. 69.9a, b).



©Association of Oral and Maxillofacial Surgeons of India

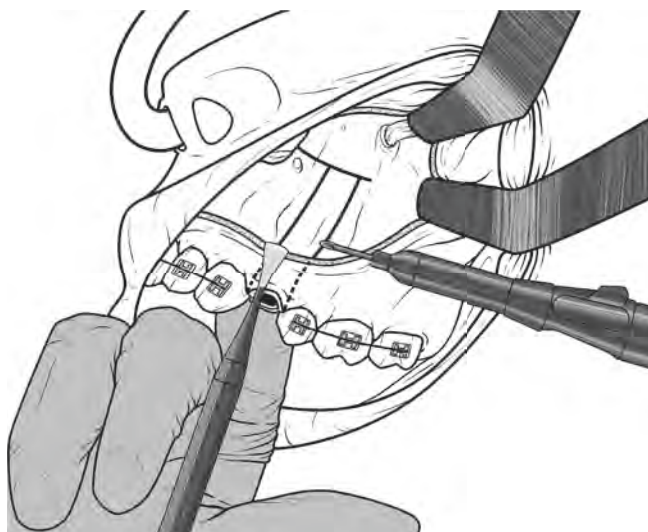
Fig. 69.4 (a–d) Epker's modification of Cupar's down-fracture anterior maxillary osteotomy. (a) Anterior maxillary excess with first premolar to be extracted, not bonded orthodontically, (b) vestibular incision (5 mm superior to mucogingival junction). Osteotomy marked, which includes a horizontal cut beginning at the pyriform rim, going lateral

above the apices of the anterior teeth and vertical cuts to complete the bone removal at the site of the extracted premolar, (c, d) Osteotomy marking with autoclaved pencil and cuts for anterior maxillary segmental osteotomy. (see Fig. 69.10a2 for clinical profile view)

69.4 Le Fort I Osteotomy

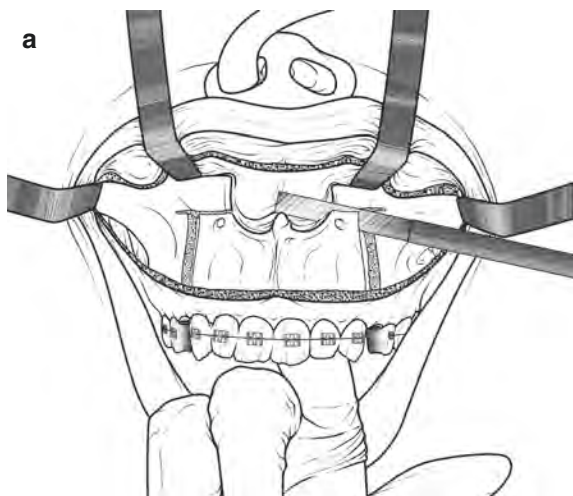
69.4.1 Operative Technique (Video 69.2)

There are many acceptable modifications to the Le Fort I osteotomy, and the sequence of steps may vary from surgeon to surgeon. Figures 69.10a, b and 69.11a, b demonstrate a patient who has undergone a Lefort 1 with anterior maxillary osteotomy and mandibular subapical osteotomy for addressing her Vertical Maxillary Excess and dento-alveolar protrusion. The following is a description of the authors' preferred approach.



©Association of Oral and Maxillofacial Surgeons of India

Fig. 69.5 Horizontal and Vertical Osteotomy Cuts (5 mm superior to mucogingival junction) Osteotomy marked, Horizontal cut 5 mm above the canine root tip, Vertical osteotomy marked approximate mesiodistal width of premolar



©Association of Oral and Maxillofacial Surgeons of India

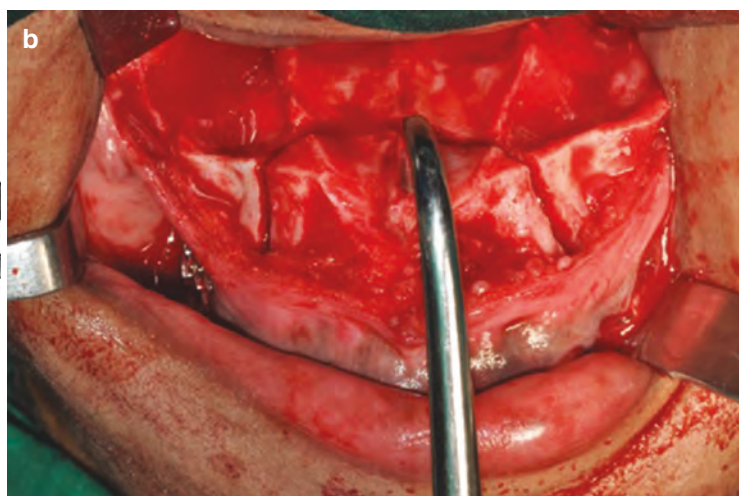


Fig. 69.6 (a, b) Final palatal bone cut with osteotome, palatal mucosa protected with non-dominant hand for tactile sensation

Anaesthetic and Positioning Considerations:

Anaesthetic and positioning considerations must be followed as previously discussed in the anterior segmental maxillary osteotomy technique.

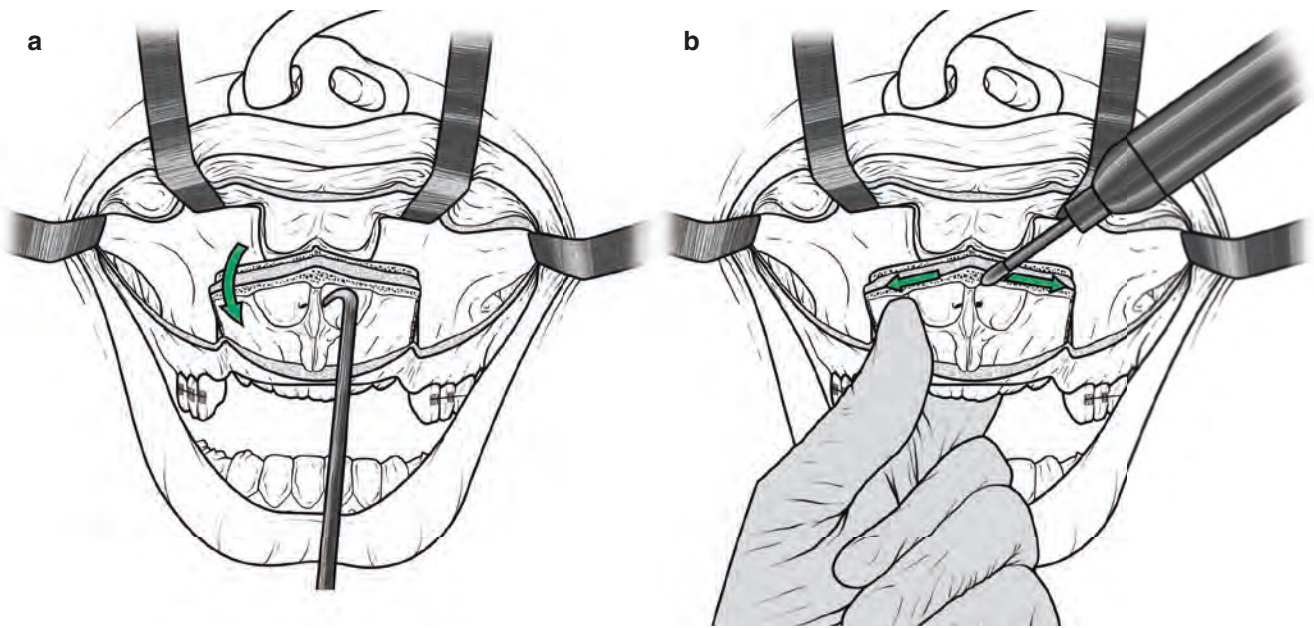
69.4.2 External Reference Marker

An external reference marker is placed at the nasion to facilitate proper positioning of the maxilla in the vertical plane (Fig. 69.12a). Common techniques include insertion of a Kirschner wire or a bone fixation screw. Less invasive methods include marking with a skin scribe, a suture or tape, but these may be less reproducible due to skin mobility at the site. Occasionally a soft tissue landmark such as the medial canthus can also be used as a guide to measure from the incisal edge of the anterior teeth (Fig. 69.12b)

External reference points have been shown to be superior to internal references (lines or burr holes placed on the maxilla above and below the osteotomy), which are prone to inaccuracy due to the complex three-dimensional movement of the maxilla [43, 44]. Preoperative measurements are then obtained from the reference site to reproducible midline and lateral maxillary landmarks, typically the maxillary dental midline and the bilateral canine cusp tips or orthodontic brackets.

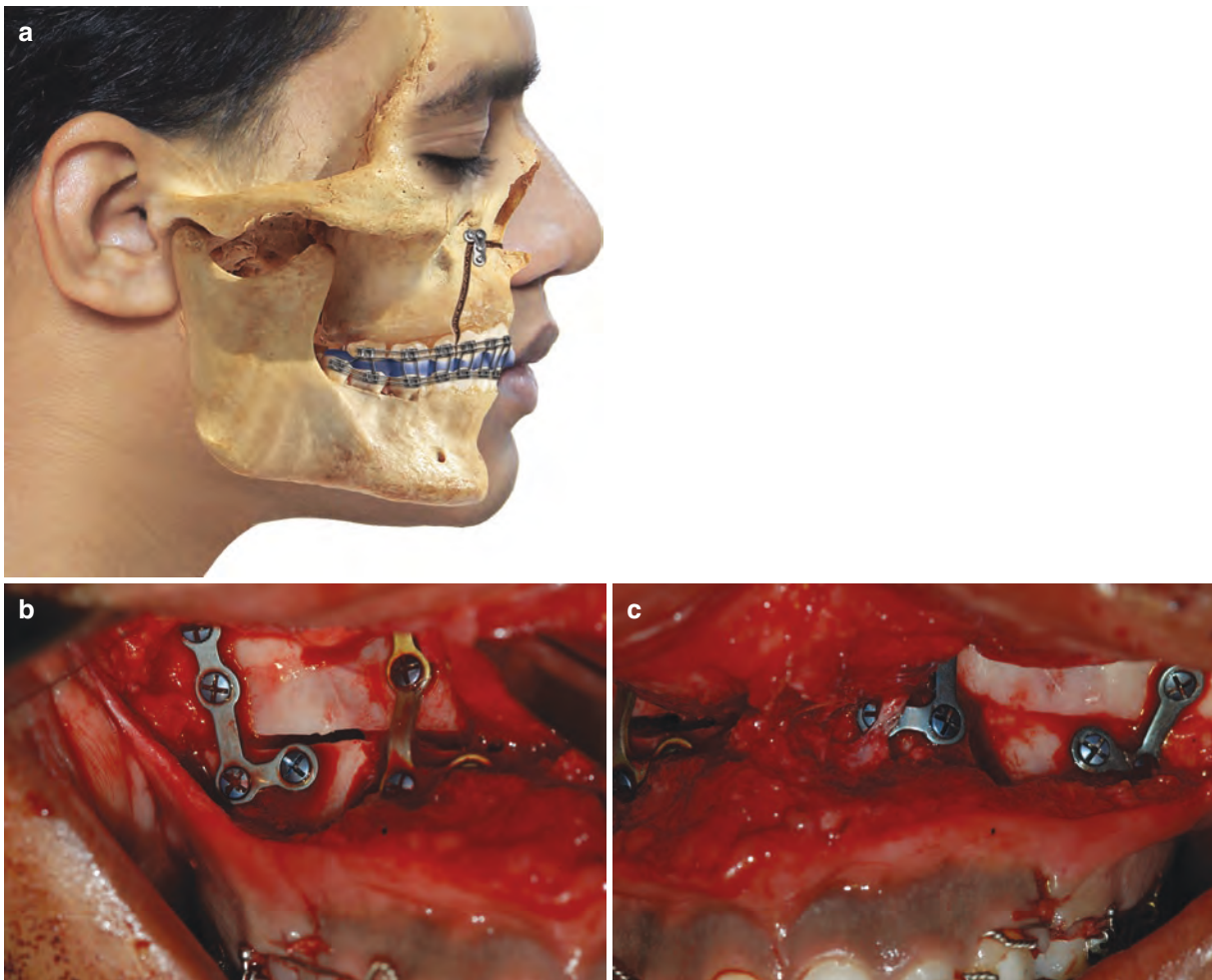
69.4.3 Surgical Exposure

Local anesthesia with vasoconstrictor is infiltrated labially and buccally from the pterygoid plate region, forward to the midline bilaterally. A full-thickness mucosal and periosteal



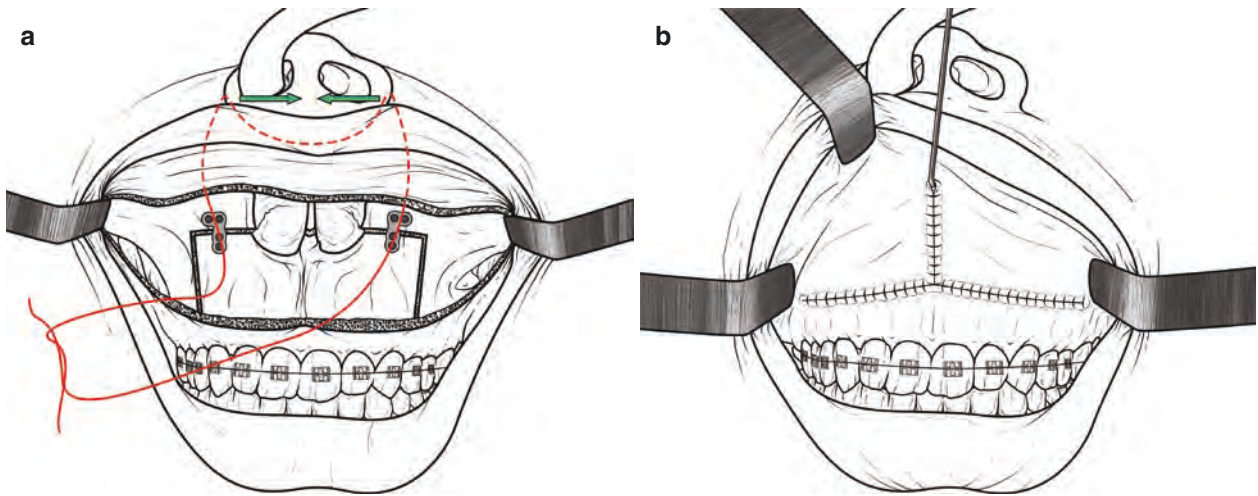
©Association of Oral and Maxillofacial Surgeons of India

Fig. 69.7 (a) Down-fracture anterior segment of maxilla and maintaining palatal mucosa. (b) Midline or paramidline osteotomy for horizontal movement



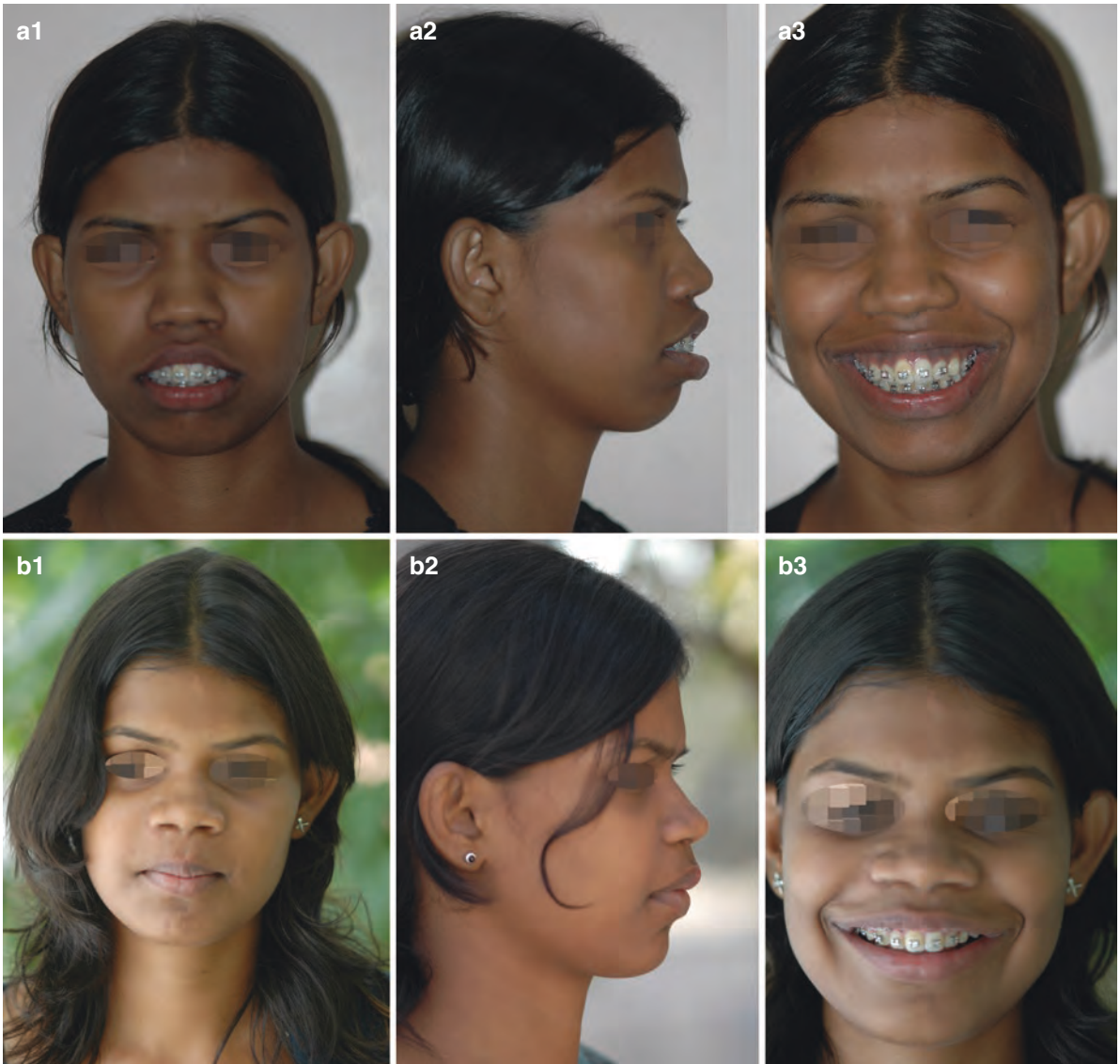©Association of Oral and Maxillofacial Surgeons of India

Fig. 69.8 (a–c) Maxillary plating system used at the maxillary buttresses and pyriform region to fixate the bone segments in their planned post-operative position in case of Le Fort I with AMO, (b) right side (c) left side



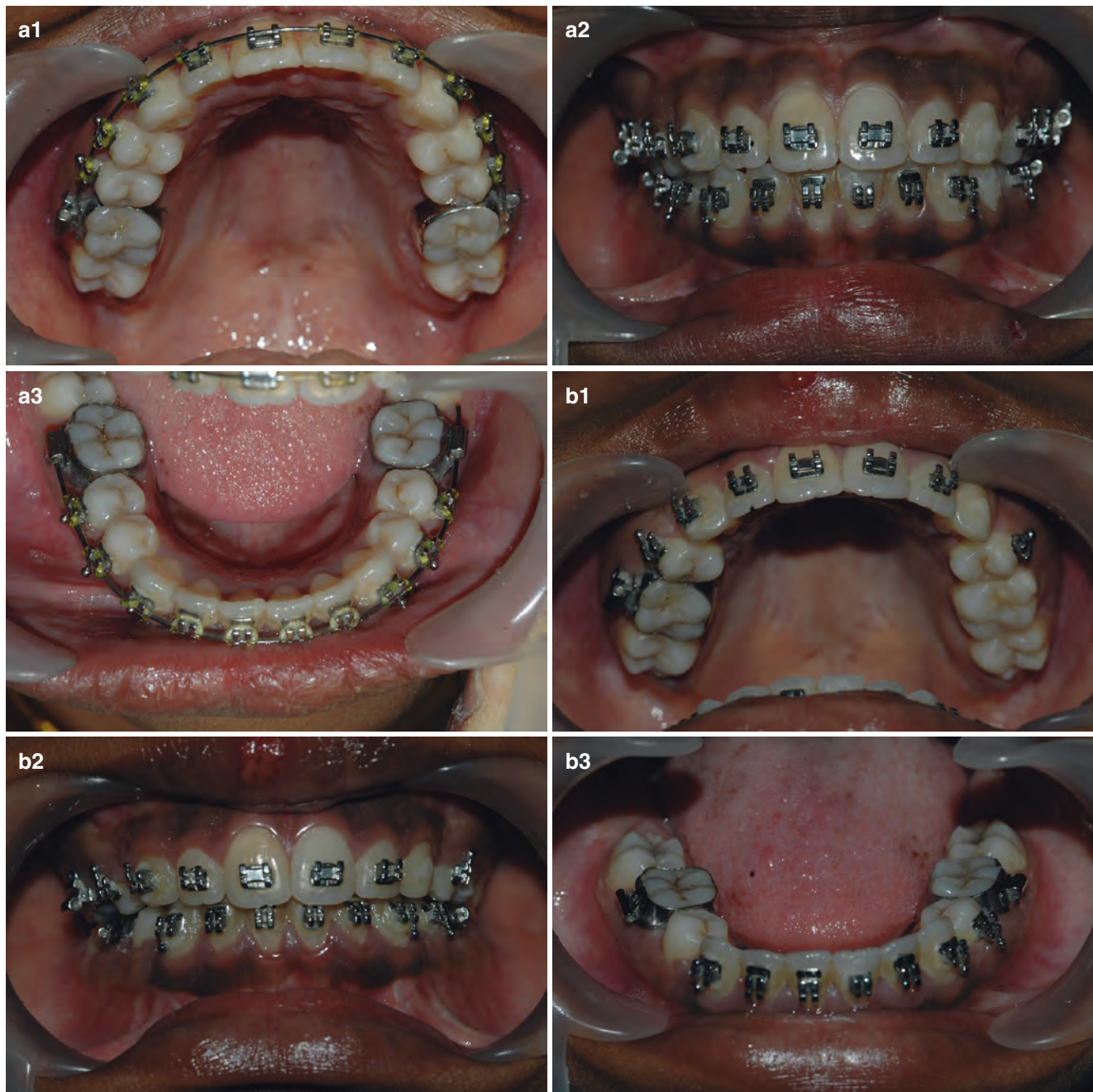
©Association of Oral and Maxillofacial Surgeons of India

Fig. 69.9 (a, b) (a) Alar cinch placement to control alar base, (b) V-Y closure of mucosa to maintain upper lip length



©Association of Oral and Maxillofacial Surgeons of India

Fig. 69.10 (a, b) (a1, a2, a3) Pre-surgical images of the patient. (b1, b2, b3) Post Le Fort I and anterior maxillary osteotomy images of the patient

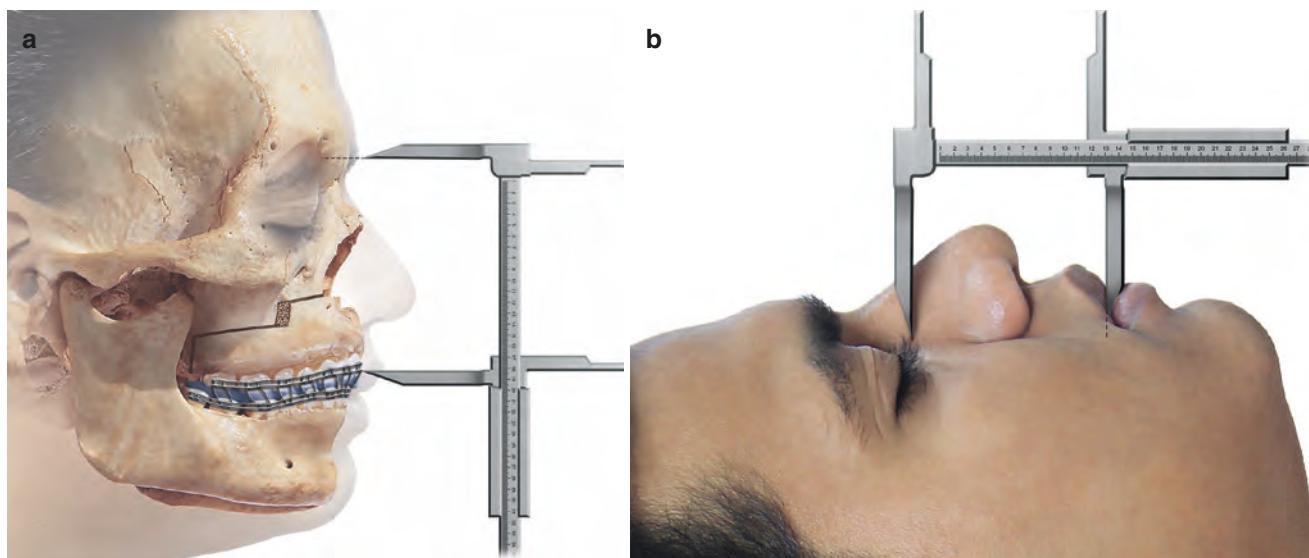


©Association of Oral and Maxillofacial Surgeons of India

Fig. 69.11 (a, b) Intra oral photos of the same patient as in Fig. 69.10. (a1, a2, a3) Pre-surgical images of the occlusion. (b1, b2, b3) Post anterior maxillary osteotomy images of the occlusion. A mandibular sub-apical osteotomy was also done for this patient (b2, b3)

incision is made in the soft tissue extending from the buttress of the zygoma on the either side, 3–4 cm above the mucogingival junction with attention in the midline to a V-shaped incision to allow for aesthetic closure [45, 46] (Fig. 69.13). The incision can be made with a scalpel or electrocautery Colorado needle. While layered incisions serve no advantage for the dissection, electrocautery seems to control some hemorrhage at the time of the incision.

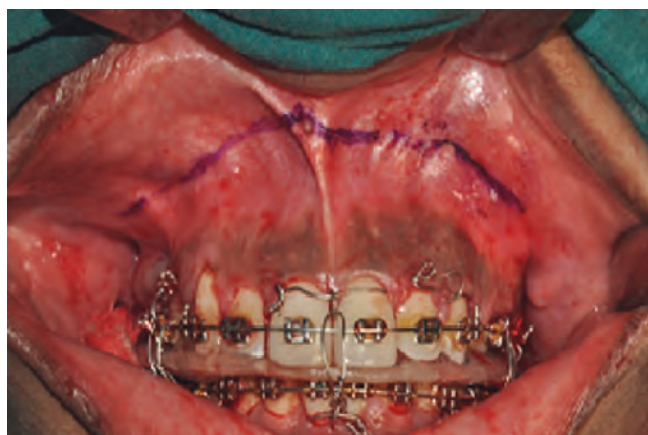Retraction is maintained with down-turned Obwegeser retractors, and the superior mucoperiosteal flap is elevated with a #9 Molt periosteal elevator. The anterior nasal spine, piriform rim, infraorbital foramen, lateral maxillary wall, and zygomaticomaxillary junction are exposed. Exposure of the posterior maxillary wall and pterygomaxillary junction is next performed with a Molt periosteal elevator, placed parallel to the maxillary teeth and advanced posteriorly below



©Association of Oral and Maxillofacial Surgeons of India

Fig. 69.12 (a, b) (a) External reference marker (skeletal landmark). A stable extraoral reference point is established with a 0.035-inch K-wire placed in the nasion. A caliper is used to measure the vertical distance from the K-wire to the brackets of the central incisor teeth, and these

measurements are recorded. (b) A extraoral reference point at medial canthal (soft tissue landmark). A caliper is used to measure the vertical distance from medial canthal to the brackets of the central incisor teeth

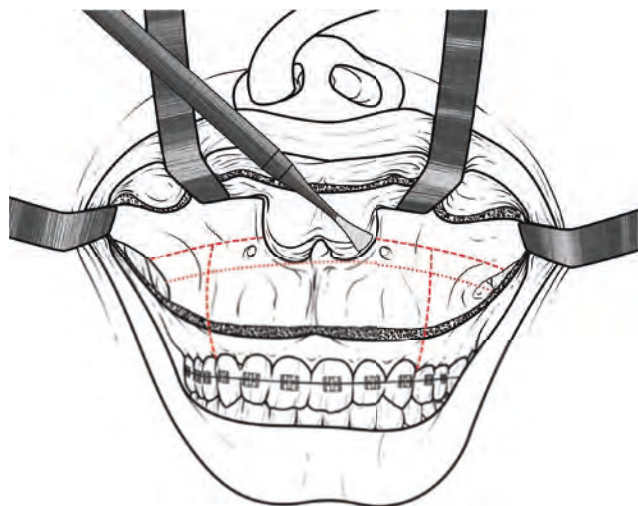

©Association of Oral and Maxillofacial Surgeons of India

Fig. 69.13 Maintain a small inverted “V” shape over the midline frenum, with the lateral extension of the incision being 5mm above the mucogingival junction, from first molar one side to the other

periosteum until the pterygomaxillary junction is encountered. The periosteal elevator on the bone and in a subperiosteal plane is maintained with angulation as it proceeds posteriorly to incline inferiorly or toward the hamular process of the sphenoid bone. This alleviates the potential problem of entering the pterygomaxillary fissure and concomitant increased hemorrhage [23, 47].

The nasal/septal mucosal dissection is performed after the bilateral maxillary osteotomies have been completed and involves elevation of the nasal mucosa with a curved freer elevator to the posterior palatine bone (Fig. 69.14).



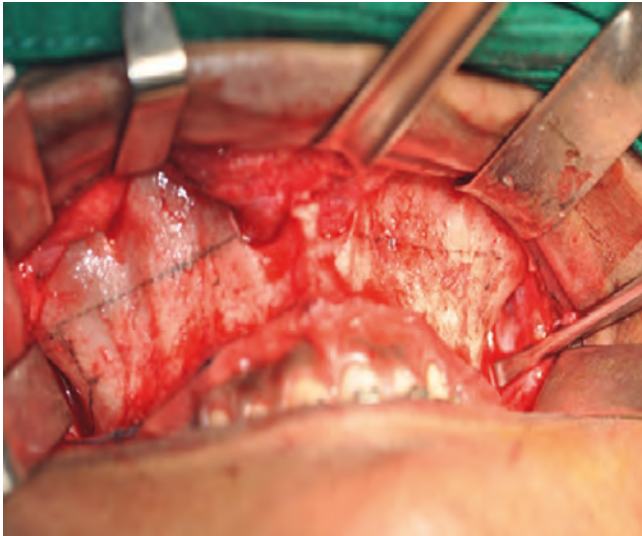
©Association of Oral and Maxillofacial Surgeons of India

Fig. 69.14 Exposure of the maxilla is achieved with a full horizontal vestibular incision superior to the mucogingival junction. With appropriate retraction, the infraorbital nerves, piriform rims, posterior maxilla, and anterior nasal spine will be identified

As may be preferred by some surgeons, reference marks are placed vertically in the lateral wall of the maxilla, or bone reference holes are placed a standardized distance apart (15 mm seems to be a reasonable distance) vertically in the buttress and in the pyriform rim region (Fig. 69.15) [48–50].

Alternatively, a non-threaded Kirschner wire or Steinmann pin is placed in the nasal dorsum, and a reference measurement is taken from that Kirschner wire to the anterior dentition to allow for determination of the amount of superior repositioning of the anterior maxilla [51, 52].

With the use of a Tessier caliper, the vertical distance (height) between the medial canthus and the mid-maxillary incisor crown is measured on the left and right sides and recorded; this generally measures between 55 and 70 mm



©Association of Oral and Maxillofacial Surgeons of India

Fig. 69.15 Marking of osteotomy cuts, horizontal cut minimum of 5 mm above the apices of the teeth, step or sloping downward and backward toward to maxillary pterygoid plates or Le Fort I level with step-ladder cut

(Fig. 69.12). This is a reproducible relative measure of the anterior vertical maxillary height [53].

69.4.4 Bony Osteotomies

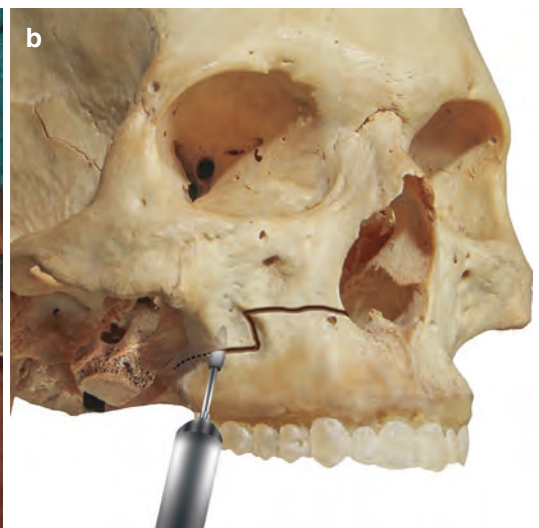
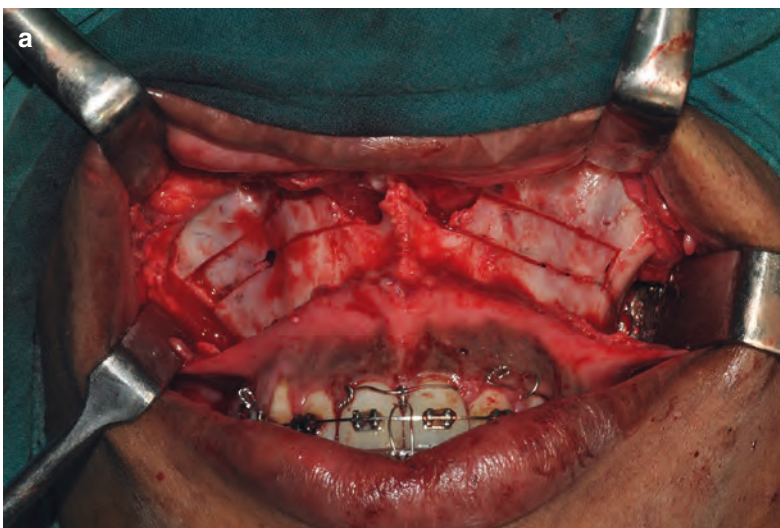
69.4.4.1 Lateral Osteotomies

A 701 straight fissure bur or reciprocating saw creates the lateral maxillary osteotomy from the lateral nasal rim to the zygomaticomaxillary junction. The osteotomy starts 3–4 mm above the nasal floor and is carried to the depth of the maxillary sinus, back to the pterygomaxillary junction, approximately 30–35 mm above the bracket on the first molar tooth. Cuts are made at least 5 mm above the roots of the teeth and can be made higher as needed. A vertical step at the first molar is carried inferiorly for 5–10 mm (step osteotomy permits grafting in the zygomaticomaxillary buttress area subsequently, if required) [54], and then it is continued in a horizontal plane to the posterior maxilla ending in front of the pterygomaxillary junction (Fig. 69.16a, b).

69.4.4.2 Pterygoid Plate Separation

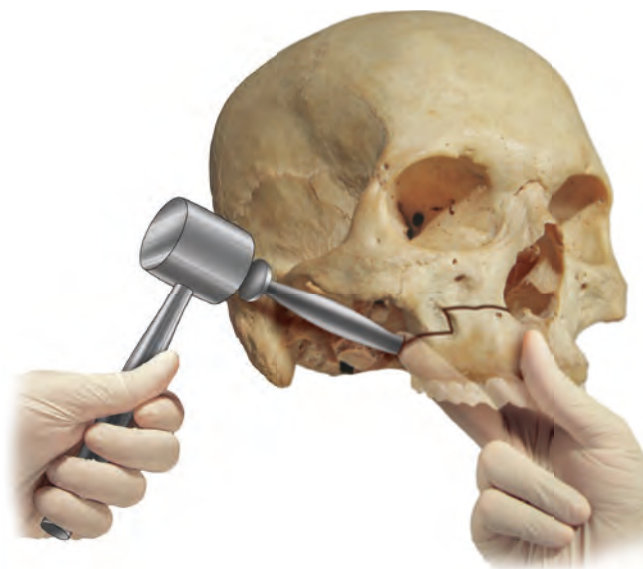A 6- to 8-mm-wide, curved osteotome is placed in the pterygomaxillary junction, with the leading edge angled inferior, medial, and anterior. It is positioned in the junction with the horizontal osteotomy centered over the middle of the osteotome.

A finger can be placed palatally at the junction of the hamulus with the tuberosity, and the mallet is used to drive the chisel through the junction. The end of the osteotome should be palpated on the palatal side as it comes through the junction, but it should not penetrate through



©Association of Oral and Maxillofacial Surgeons of India

Fig. 69.16 (a, b) (a) The lateral maxillary wall osteotomy is carried posteriorly from the piriform rim to the pterygomaxillary junction, (b) with a vertical step ladder cut in the first molar region. The osteotomy is placed at least 5 mm superior to the root apices



©Association of Oral and Maxillofacial Surgeons of India

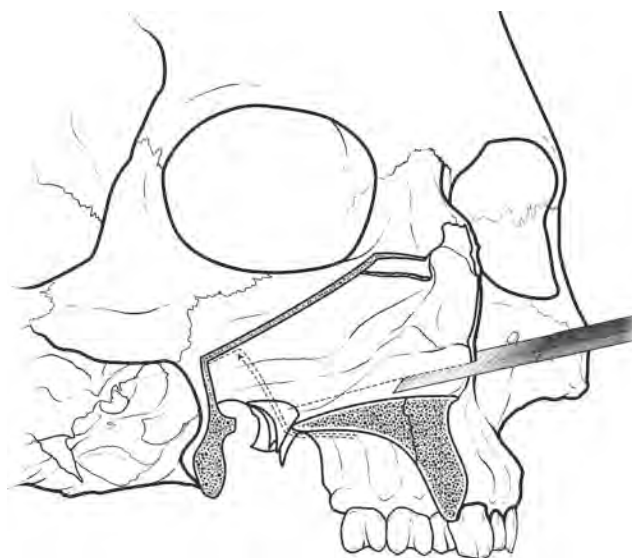
Fig. 69.17 A curved osteotome is placed in the pterygomaxillary junction, with the superior edge of the osteotome just above the horizontal osteotomy. A finger is placed on the palatal side of the junction, and the osteotome is gently tapped through the junction until palpated on the palatal side, without perforating the soft tissue

the palatal tissue. There should be minimal resistance to separation, and if significant resistance is encountered, the osteotome position should be evaluated and repositioned (Fig. 69.17).

The scientific literature cites examples of damage to the cranial nerves during the Le Fort I osteotomy [55–58].

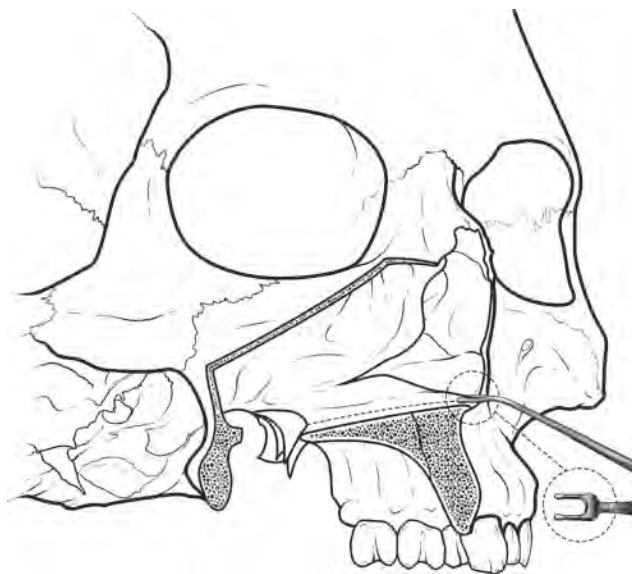
69.4.4.3 Lateral Nasal Wall and Septal Osteotomies

A small safe-sided osteotome initiates the lateral nasal osteotomy at the piriform rim in the anterior extension of the lateral maxillary osteotomy. A mallet drives the osteotome posterior, parallel to the nasal floor, below the inferior turbinate. One must take care not to go beyond 25 and 30 mm in depth during osteotomy. The lateral nasal wall diverges (widens) posteriorly, and the osteotome must follow that divergence. Minimal resistance will be encountered until the pyramidal process of the palatine bone is encountered. At this resistance point, the osteotome can be driven another few millimeters to influence the fracture plane through this structure during down-fracture (Fig. 69.18). The nasal septum osteotomy is next performed with a guarded U-shaped osteotome. The osteotome is introduced at the top of the nasal spine and is driven inferiorly and posteriorly along the nasal floor to separate the maxilla and palatine bone from the septum (Fig. 69.19).



©Association of Oral and Maxillofacial Surgeons of India

Fig. 69.18 The lateral nasal wall osteotomy is completed from the inferior piriform rim to the anterior portion of the pyramidal process of the palatine bone. Care is taken to avoid a complete osteotomy through the pyramidal process in order to prevent injury to the greater palatine artery and nerve. The right maxilla has been removed to show the desired cross-section clearly

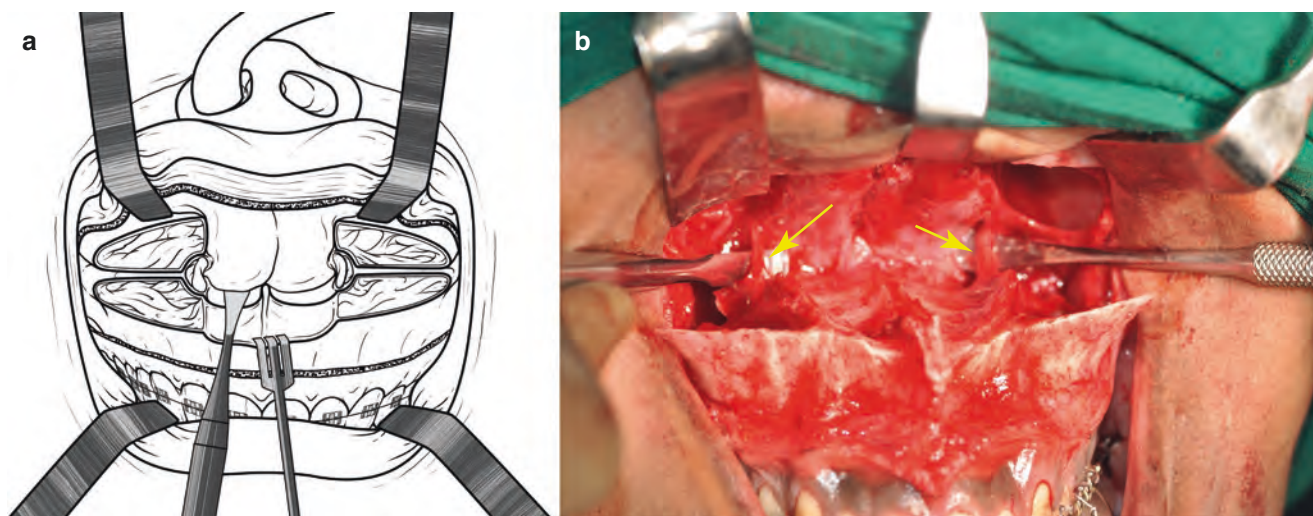


©Association of Oral and Maxillofacial Surgeons of India

Fig. 69.19 The septal osteotomy is completed from the anterior nasal spine through the vomer bone posteriorly, with the guarded prongs on the septal osteotome angled inferiorly. Care is taken to retract the nasal mucosa to minimize injury and bleeding to the soft tissue. The right maxilla has been removed to show the desired cross-section clearly

69.4.5 Down-Fracture and Mobilization

Once the osteotomy cuts have been completed, some mobility should be readily evident, and down-fracturing be easily



©Association of Oral and Maxillofacial Surgeons of India

Fig. 69.20 (a, b) (a) Once the maxilla is mobilized, the nasal mucosa can be completely freed from the maxilla in the piriform rim region, (b) The greater palatine nerve and artery can be visualized and protected

during posterior bone removal from the lateral nasal wall area (yellow arrows) (also see Fig. 65.12a)

done with either bilateral manual digital pressure in the canine fossa or with instrumentation support at the piriform rim. Slowly separate the maxilla by pulling the anterior portion inferiorly while observing the nasal mucosa to avoid tears. If significant resistance is encountered, revise the osteotomy cuts thoroughly to ensure complete separation. To avoid complications related to pterygomaxillary disjunction, we prefer to extract maxillary third molar and make a vertical osteotomy cut through the socket connecting the horizontal cut on the posterolateral surface of maxilla.

Precious et al. (1991) did a study of 138 consecutive Le Fort I osteotomies with successful down-fracture of the maxilla by digital pressure alone (with no serious complications except transient epistaxis that responded to local packing) [59, 60].

Once the down-fracture is completed, place a Seldin elevator or tongue depressor behind the tuberosity, and pull the posterior maxilla forward. This will fully mobilize the maxilla from its attachments. For large advancements, freeing the tissue from the nasal side of the posterior maxilla in the soft palate area will provide significantly more forward mobility. In addition, in repeat maxillary surgery, mobilizing the maxilla will most likely be more difficult, and time must be spent freeing hard and soft tissue attachments to ensure passive movements and surgical stability.

69.4.6 Removal of Posterior Interferences

Removal of posterior interferences should be done immediately after down-fracture which will make it easier to set the maxillary position later. The maxillary bony septum is reduced most easily with a bur. The lateral nasal wall can be

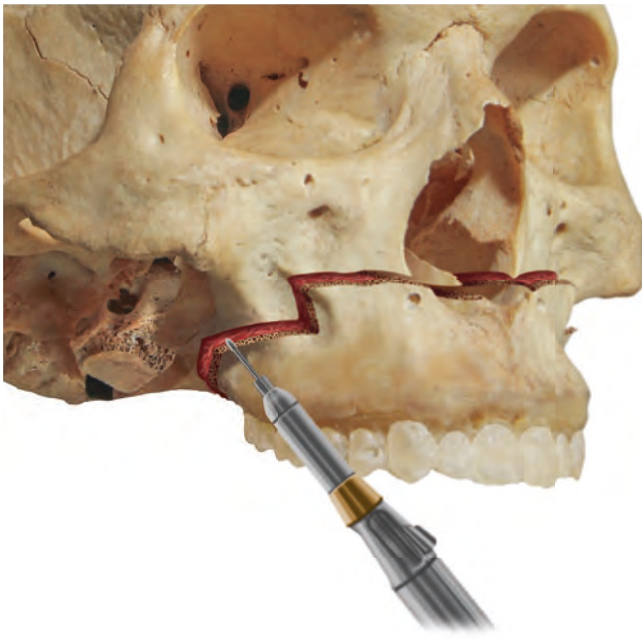reduced with a rongeur, bur, or reciprocating saw. While protecting the descending palatine nerve and artery with a curved freer (Fig. 69.20a, b), the pyramidal process of palatine bone is most safely reduced with the reciprocating saw or bone file. Sometimes a thin spatula osteotome can be used. Finally, the posterior tuberosity, anterior pterygoid plate, and posterior lateral maxillary wall can be reduced with a bur or reciprocating saw (Fig. 69.21). If the superior movement of the maxillary is more than 6 or 7 mm, a partial inferior turbinectomy may be indicated to allow a passive impaction. The nasal mucosa is incised with a scalpel blade along its inferior surface in an anterior-posterior direction. The inferior half of the turbinate is grasped with a large curved hemostat, and a dean scissor is used to excise this portion. Complete removal of the inferior turbinate is rarely necessary and can result in unpleasant clinical side effects. Electrocautery is used to coagulate the incised edge of the turbinate to minimize bleeding. The nasal mucosa is then sutured with a running 4-0 vicryl suture.

69.4.7 Placement of Surgical Guide

A prepared surgical guide is necessary to ensure accurate positioning of the maxilla. The guide is generally ligated to the upper teeth with 26–28 gauge wire. The upper and lower teeth are then wired together with 26–28 gauge wire, elastics, or power chain (Fig. 69.22).

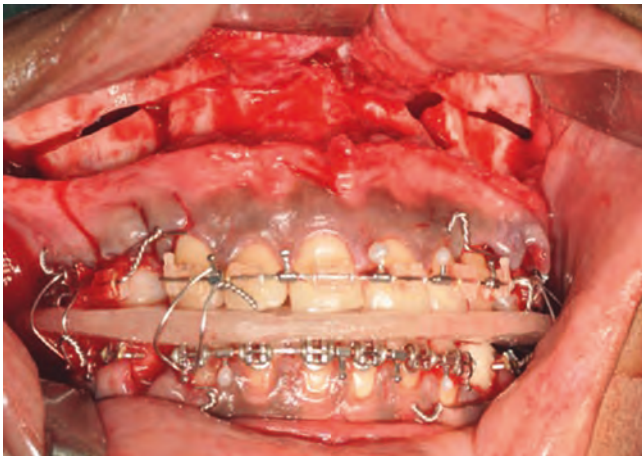
69.4.8 Removal of Anterior Interferences

With the maxilla now fixed to the mandible, it is rotated into position by applying posterior and superior pressure on the



©Association of Oral and Maxillofacial Surgeons of India

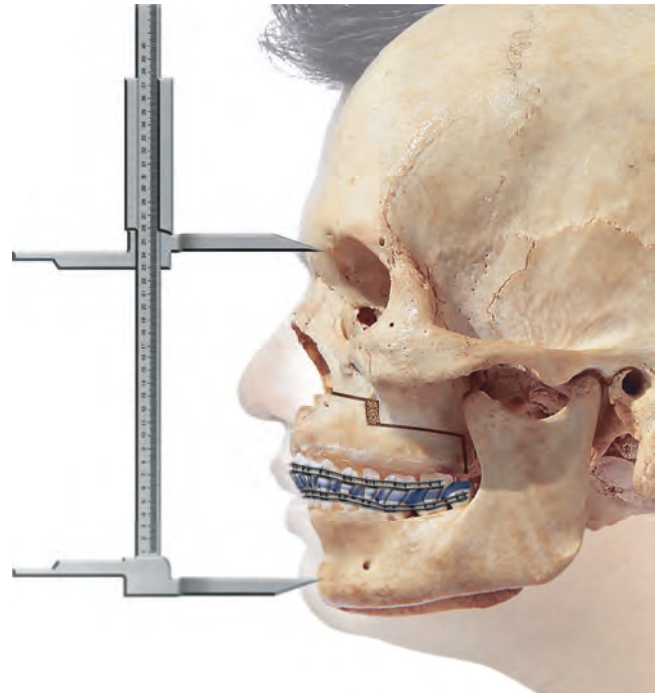
Fig. 69.21 Posterior interferences are initially removed from the posterior septum, lateral nasal walls, pyramidal processes of the palatine bones, and lateral maxillary walls. This allows for passive seating of the maxilla without posterior pivoting



©Association of Oral and Maxillofacial Surgeons of India

Fig. 69.22 Placement of surgical guide and achieve desire stable occlusion. The lefort I osteotomy and AMO cuts are visible

mandible. To properly rotate the mandible, the surgeon places two fingers at the gonial notch regions of the mandible and the thumb of the same hand at the chin. Upward pressure is exerted with the two fingers at the gonial notches, and the thumb exerts a posterior and downward pressure. This “triangular” finger formation ensures full seating of the condyles during mandible rotation and maxillary positioning. The surgeon then rotates the mandible and maxilla upward, keeping pressure on the two fingers and thumb (Fig. 69.38a–c). Upward rotation is



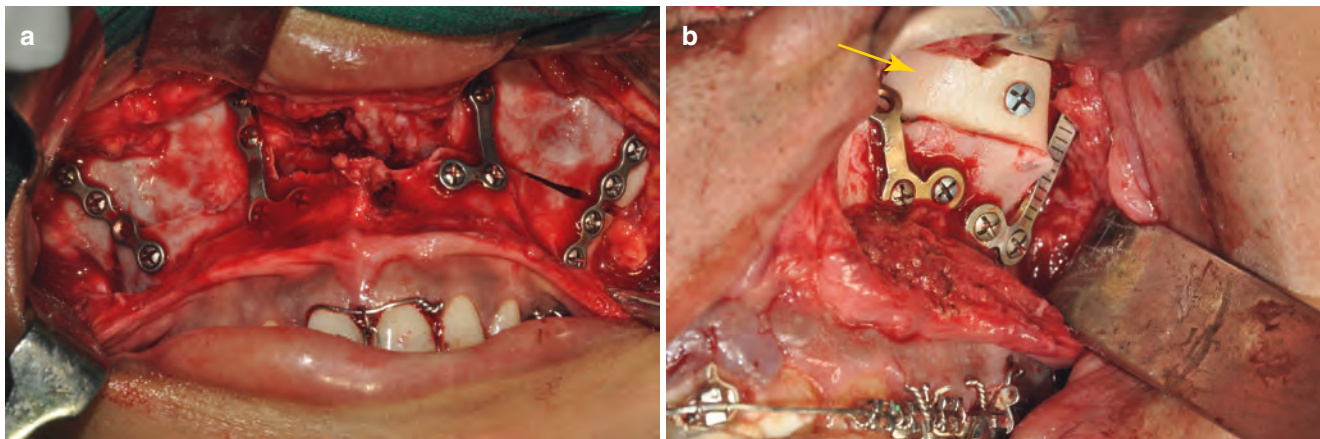
©Association of Oral and Maxillofacial Surgeons of India

Fig. 69.23 The maxilla is rotated into place and anterior interferences are removed to ensure full seating of the condyles at the desired vertical position. Seating of the condyles of the mandible is achieved with superior pressure at the gonial notches and posterior pressure at the chin. Once the correct vertical maxillary positioning is achieved, the mandibular-maxillary complex can be reproducibly rotated with the condyles in the fossa without any bone or soft tissue pre maturities (Also see Fig. 69.12a, b)

stopped as soon as the first contact is detected, and this interference is reduced accordingly. Anterior interferences can be easily reduced with a bur. The caliper is used to check the vertical distance from the anterior brackets to the K-wire and interferences are reduced accordingly. Closely observe the nasal septum for early inferences and deviation. When all the bony interferences have been completely removed, utilizing the “triangular” finger formation, the mandible and maxilla can be easily rotated up into a stable reproducible position, with the condyles fully seated (Fig. 69.23).

69.4.9 Fixation, Grafts, and Final Measurements

With the maxilla positioned, four miniplates are accurately bent to passively fit across the osteotomy in the piriform and anterior buttress areas of the maxilla. Typically, there are two fixation holes above and below the osteotomy in each bone plate, for placement of four screws. Thin bone or large bone gaps may require more fixation screws in each plate or even require additional plates. Bone grafts can be adapted into the



©Association of Oral and Maxillofacial Surgeons of India

Fig. 69.24 (a, b) (a) Rigid fixation with four plates provides vertical and horizontal stability to the maxilla. The nasal septum should be free of deviation, and the occlusion should be reproducible once interdental fixation is released. Bone plates are used to stabilize the osteotomy bilaterally at the nasomaxillary and zygomaticomaxillary buttress

areas. (b) Autogenous bone grafts have been adapted and fixated in the osseous gaps to optimize bone healing and minimize postsurgical relapse. Grafting may be indicated in complex movements, especially large advancements and down grafting cases (yellow arrow)

osteotomy gaps, and press-fit into position, or rigidly fixed if necessary [61]. Once the fixation has been completed, final measurements with calipers are made to confirm proper vertical placement (Fig. 69.24a, b).

is also manipulated out of the way if it is interfering with closure. There should be a smooth closure into the splint without any shifting or deviation of the occlusion. Contact should occur simultaneously in the anterior and posterior areas.

69.4.10 Checks to Be Made Before Plate Fixation of the Maxilla

1. Ensure there are no bony interferences.
2. Check that the teeth are occluding into the splint correctly (particularly posteriorly, ensure the tongue is out of the way) and the condyles are seated correctly.
3. Check there are no soft tissue/septal interferences.
4. Check the nasal septum is in center (suture or cut groove into anterior nasal spine). Ensure that tears in the nasal mucosa if any are sutured.
5. Check any septal adjustment and piriform aperture bony adjustments have been made.
6. Make sure the maxillary dental midline and transverse maxillary occlusal plane cant are correct.
7. Ensure facial appearance, incisor exposure and aesthetics are optimal.
8. Check occlusion.

Once the maxillary fixation is completed, the intermaxillary fixation is released. The mandible is hinged with the condyles fully seated using the “triangular” finger formation. Retractors should be used to hold the cheeks away from the posterior teeth, and the mandible is rotated upward such that the teeth fit into the maxillary splint. The tongue

69.4.11 Closure

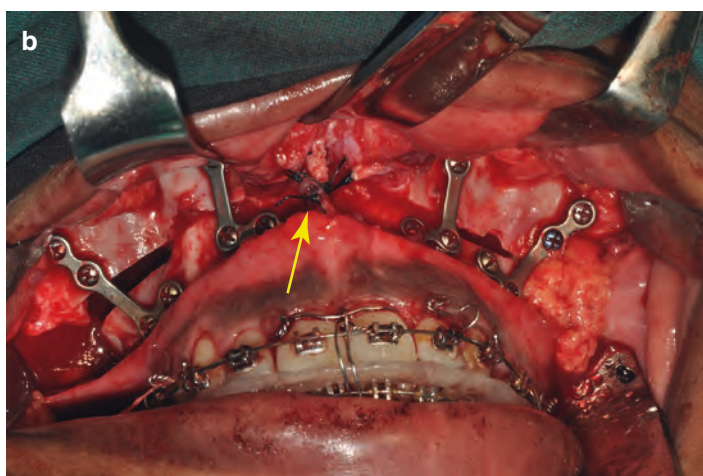
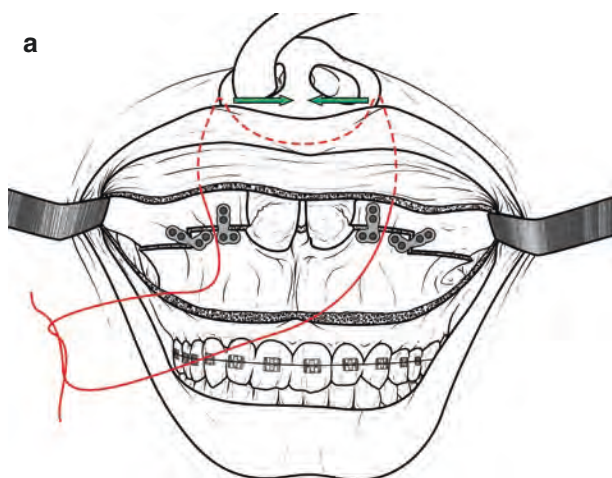
Proper closure occurs in three steps.

69.4.11.1 Nasal Cinch Suture (Alar-Base Suture) [62]

With the dissection and exposure of the paranasal musculature during Le Fort I osteotomy, the nasal cinch suture provides appropriate repositioning of the soft tissue to minimize postoperative nasal base widening. A slowly resorbing suture (e.g., 2-0 polyglycolic acid) is placed from an intraoral approach into the alar base bilaterally, pulling the alar bases toward each other when tightened (Fig. 69.25a, b). If properly done, tightening should result in an equal or shorter alar base width when compared to the preoperative width. This will frequently result in an immediate upturned appearance of the nose, a protruded positioning of the upper lip, and edema. These immediate changes are transient and will disappear within a few weeks. Following healing, the procedure results in minimal widening of alar base from the preoperative measurement (Fig. 69.26a, b).

69.4.11.2 V-Y Closure [63]

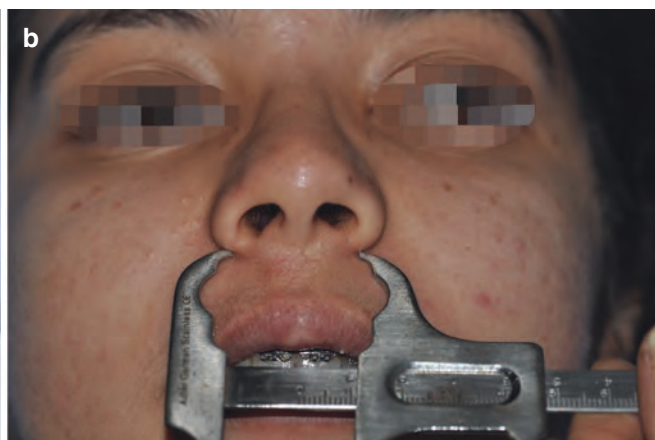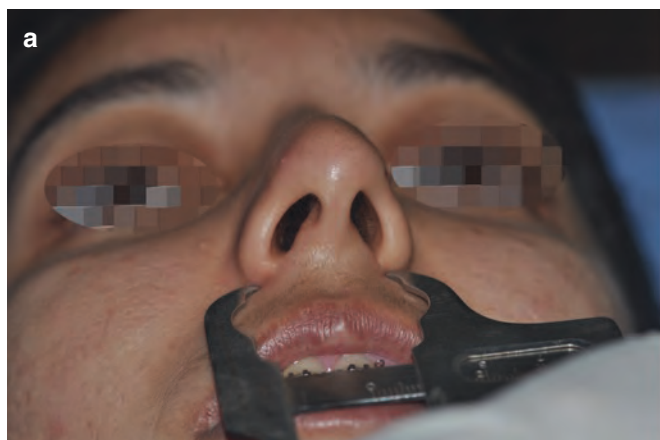
Typical movements of the maxilla and normal healing of the circumvestibular incision can result in lip shortening,



©Association of Oral and Maxillofacial Surgeons of India

Fig. 69.25 (a, b) An alar base cinch suture controls the alar base width and counteracts postsurgical widening of the alar base. Care is taken to correctly place the suture in the fibro adipose tissue and transverse nasalis muscle at the lateral nasal base, allowing medial positioning of the alar base during suture tying (yellow arrow)

lis muscle at the lateral nasal base, allowing medial positioning of the alar base during suture tying (yellow arrow)



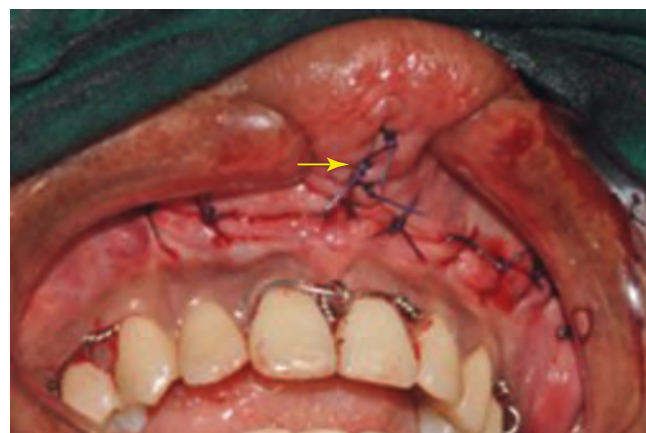©Association of Oral and Maxillofacial Surgeons of India

Fig. 69.26 (a, b) Measuring the alar base pre-surgically (a) and post-surgically (after edema subsides and soft-tissue settles) (b) and confirming that the size remains same

lip thinning, and decreased vermilion show. The Le fort I incision transects various components of the midface musculature, including the transverse part of the nasalis muscle, the myrtiformis muscle), and the levator anguli oris muscle.

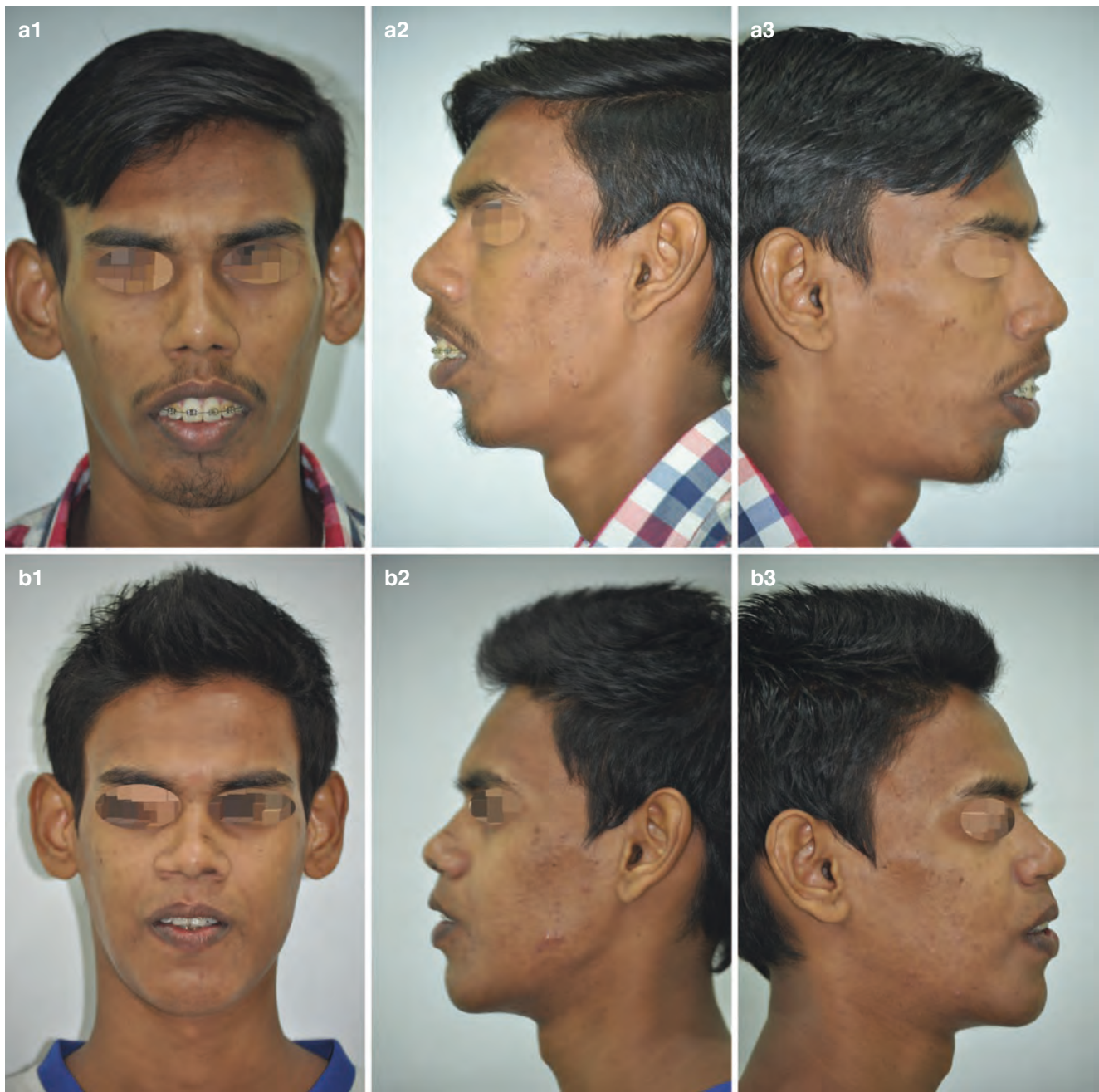It is important to correctly suture the deep muscular layers in proper anatomic orientation, so that the facial contour may be maintained [64].

The V-Y closure is performed to combat these undesirable changes. With the use of a skin hook, the tissue of the midline vestibular incision is grasped and pulled superiorly. Using a resorbable suture (e.g., 4-0 vicryl), the incision is closed vertically by grasping the tissue 1 cm away from the midline on either side of the skin hook and advancing these edges together by tightening the suture. This provides for a 1 cm V-Y closure. The remaining closure is completed with either a continuous suture or interrupted sutures. The closure generally requires four or five throws of the suture (Fig. 69.27, Fig. 69.9b).



©Association of Oral and Maxillofacial Surgeons of India

Fig. 69.27 Vestibular soft tissue closure is performed with a running resorbable suture. A midline V-Y closure provides support to the upper lip and rolls the vermilion upward and outward, gives fullness to the lip, and makes a prominent white-roll. Closure is started posteriorly and moved anterior to bring the labial side mucosa forward, which is then, closed in the midline in the form of an inverted “Y” (yellow arrow)



©Association of Oral and Maxillofacial Surgeons of India

Fig. 69.28 (a, b) A case of vertical maxillary excess treated with superior positioning of the maxilla showing frontal, right lateral and left lateral views. (a1, a2, a3) Pre-surgical photos of the patient; (b1, b2,

b3) post-surgical photos of patient (Also see Figs. 69.29 and 69.39 for the full case series images)

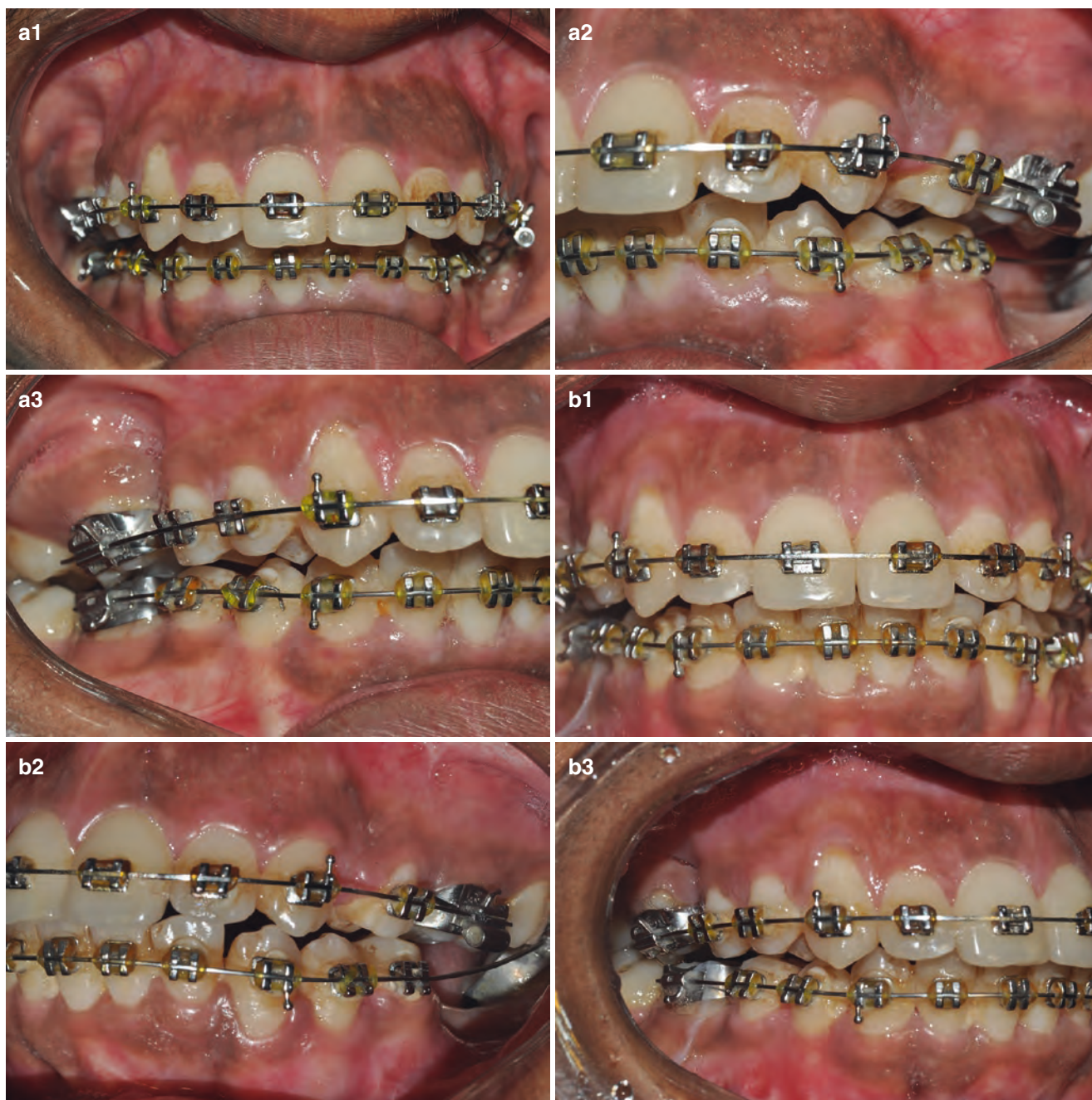
69.4.11.3 Vestibular Closure

The remaining vestibular closure continues from the posterior portion of the incision. A running resorbable suture (e.g., 4-0 vicryl) is passed in a simple running fashion. Figures 69.10, 69.11, 69.28a, b, 69.29a, b, 69.30a, b and 69.32a, b depict the results achieved by the technique described above for different clinical indications. Figure 69.31 demonstrates steps involved in performing a Lefort I osteotomy in a bi-maxillary setting.

69.5 Quadrilateral (Quadrangular) Osteotomy

This high-level osteotomy is a variant of the Le fort I osteotomy and extends up to the lower part of the zygoma, to a point just below the infraorbital nerve bilaterally.

The indications for this osteotomy are midface retrusion, including excessive scleral exposure.



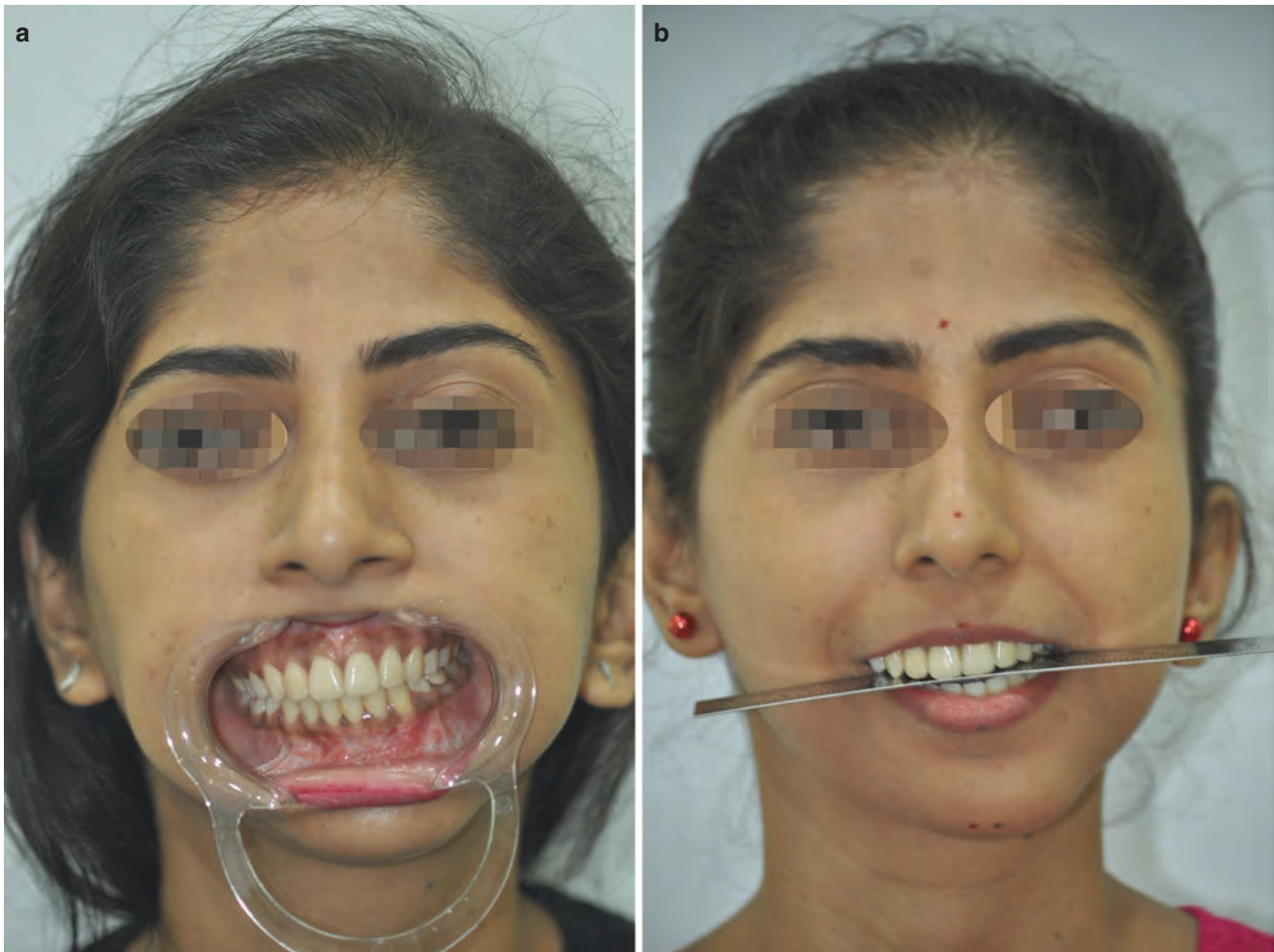©Association of Oral and Maxillofacial Surgeons of India

Fig. 69.29 (a, b) (a1, a2, a3) Pre-surgical occlusion of the same patient as in Fig. 69.28, treated with LeFort I superior repositioning. (b1, b2, b3) Post-surgical occlusion of the same patient

The benefits of the quadrangular osteotomy are that it improves the appearance of midfacial retrusion and flattening and improves zygomatic prominence and support for the lower eyelid. This osteotomy has minimal surgical morbidity and has acceptable outcomes. This may therefore be considered, especially in Asian patients, as a viable treatment alternative for midfacial advancement without augmentation of the malar region [65].

If the cuts are made from high to low a significant inferior movement of the maxilla can be achieved thus reducing the necessity for an interpositional bone graft (which would be

required following a maxillary set down) and alloplastic onlay grafts for the zygomatic regions. It is more stable than conventional inferior positioning of the maxilla as there is good bone contact with native bone and no bone graft. This osteotomy also produces less rotation of the nasal tip than the conventional Le Fort I osteotomy. However, it is important to recognize that if there is a mild facial asymmetry in the maxillary region, this asymmetry can be emphasized with this high-level cut as the maxilla is advanced. The surgical technique is the same as for the conventional Le Fort I osteotomy, but significant sharp dissection of the masseter muscle from



©Association of Oral and Maxillofacial Surgeons of India

Fig. 69.30 (a, b) Patient with maxillary occlusion cant and asymmetry (also see Figs. 69.31, 69.32 and 69.40)

the zygoma is required to expose the prominence of the zygomatic bone. The bony cuts are demonstrated in Fig. 69.33. The cuts are made just below the infraorbital nerves.

The bone over the zygomatic prominence is thick, and control over the shape of the cuts is easier using a burr and a saw. This ensures that the bony cut does not propagate upward to the cranial base but instead is directed downward to the normal pterygomaxillary disjunction level. The other steps to complete the bony cuts and down-fracture the Le Fort I cut are made as above. Fixation is with miniplates. However, care must be taken to ensure the plates are not palpable in the infraorbital regions.

69.6 Surgically Assisted Rapid Palatal Expansion (SARPE)

SARPE is a combination of orthodontic and surgical techniques to expand the maxillary arch. This is ideal in patients with of transverse maxillary deficiency, where the palatal

suture has completely fused. This concept initially was met with skepticism but later was repopularized through the works of several clinicians, including Issacson and Ingram [66] and Haas [67], as a viable method of treating maxillary transverse deficiency. SARPE is indicated in cases where skeletal maturity has been achieved, transverse maxillary deficiency is present, excessive display of buccal corridors when smiling, and presence of anterior dental crowding. It has been shown that the midpalatal suture undergoes ossification at a wide range of ages [68]. In general, SARPE is recommended for patients who are over 16 years of age [69]. Nonsurgical expansions can be a reasonable consideration for patients younger than 12 years of age.

Before starting the surgery, it is important to confirm the secure placement of the appliance and also the presence of the device key to activate the appliance.

This procedure follows Le Fort I single piece osteotomy.

The maxilla is *not* down-fractured. Relieving of the osteotomies present at the zygomaticomaxillary buttresses is done, as this allows clearance during separation. The midline

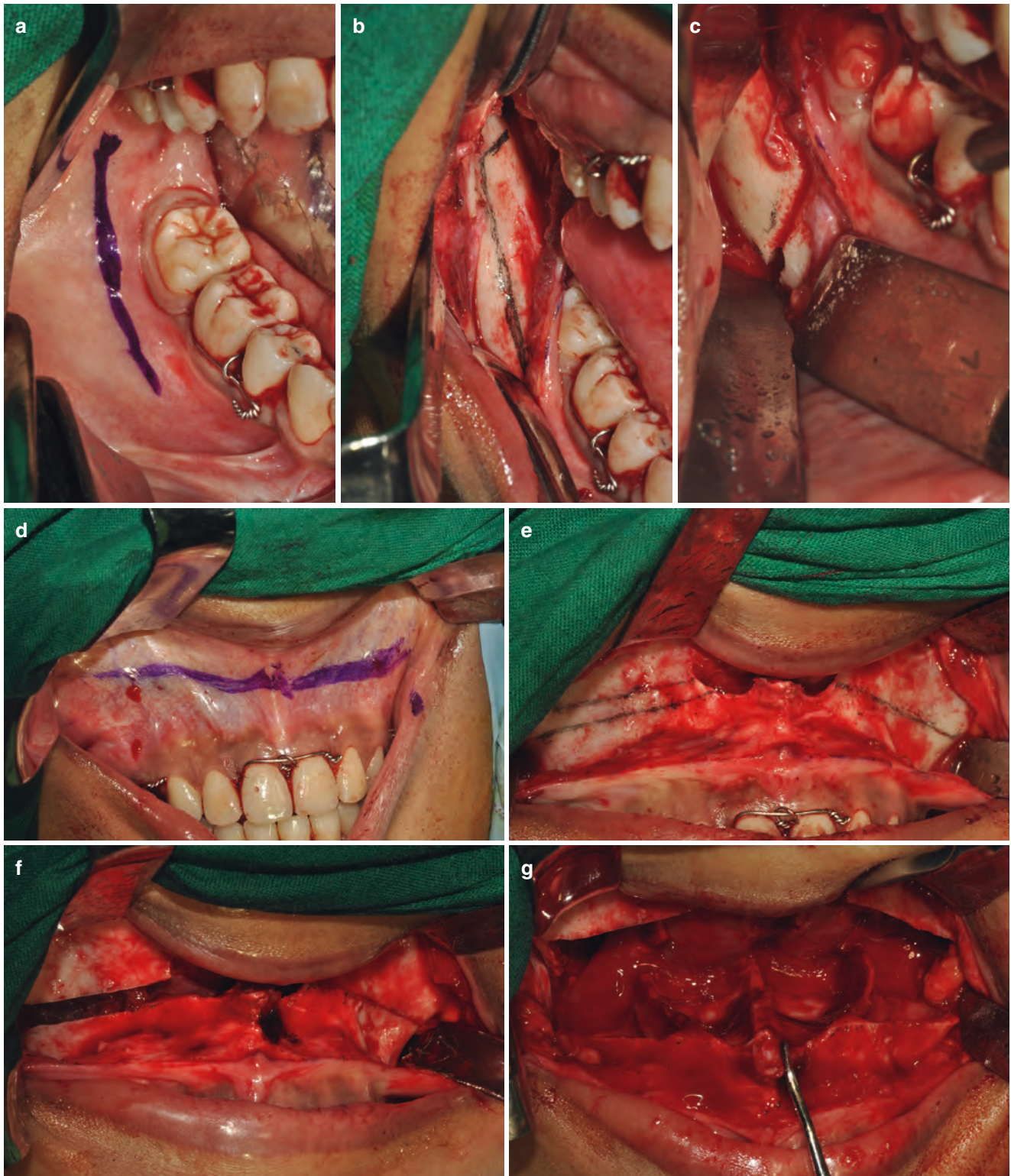
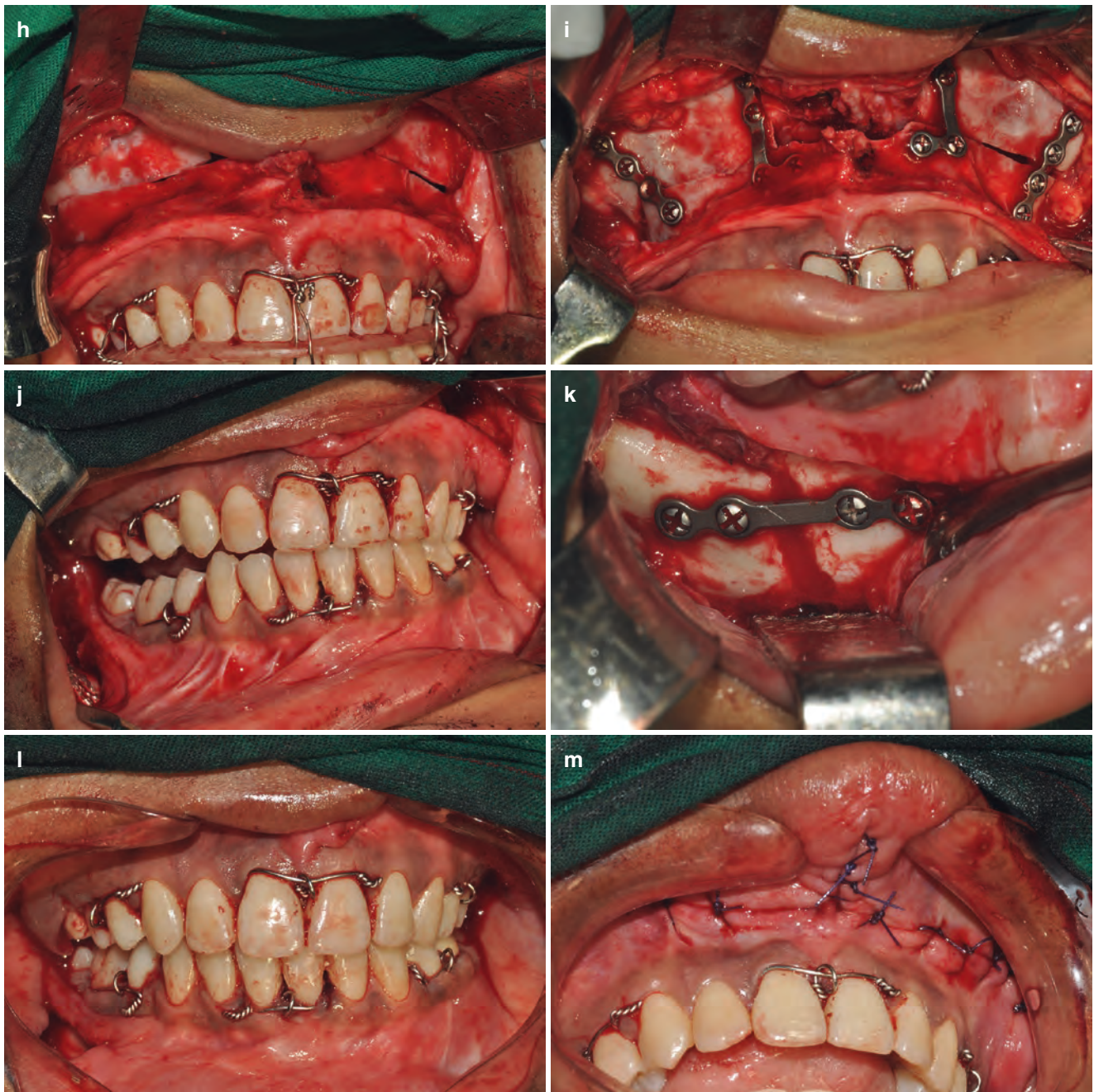

Fig. 69.31 (a–m) Surgical procedure for correcting the maxillary occlusion cant (also see Figs. 69.30, 69.32 and 69.40). (a–c) Sagittal split osteotomy cuts. (d) Incision marking for le fort Osteotomy. (e, f) Osteotomy cuts marked and made for asymmetric superior repositioning of maxilla. (g) Down-fracture of maxilla. (h) Superior repositioning

of maxilla. (i) Fixation of maxilla with mini plates and screws. (j) Open bite on right side of occlusion because of asymmetric superior repositioning. (k) Unilateral sagittal split osteotomy of mandible split and fixed with mini plates and screws. (l) New Occlusion achieved. (m) Closure of wound done



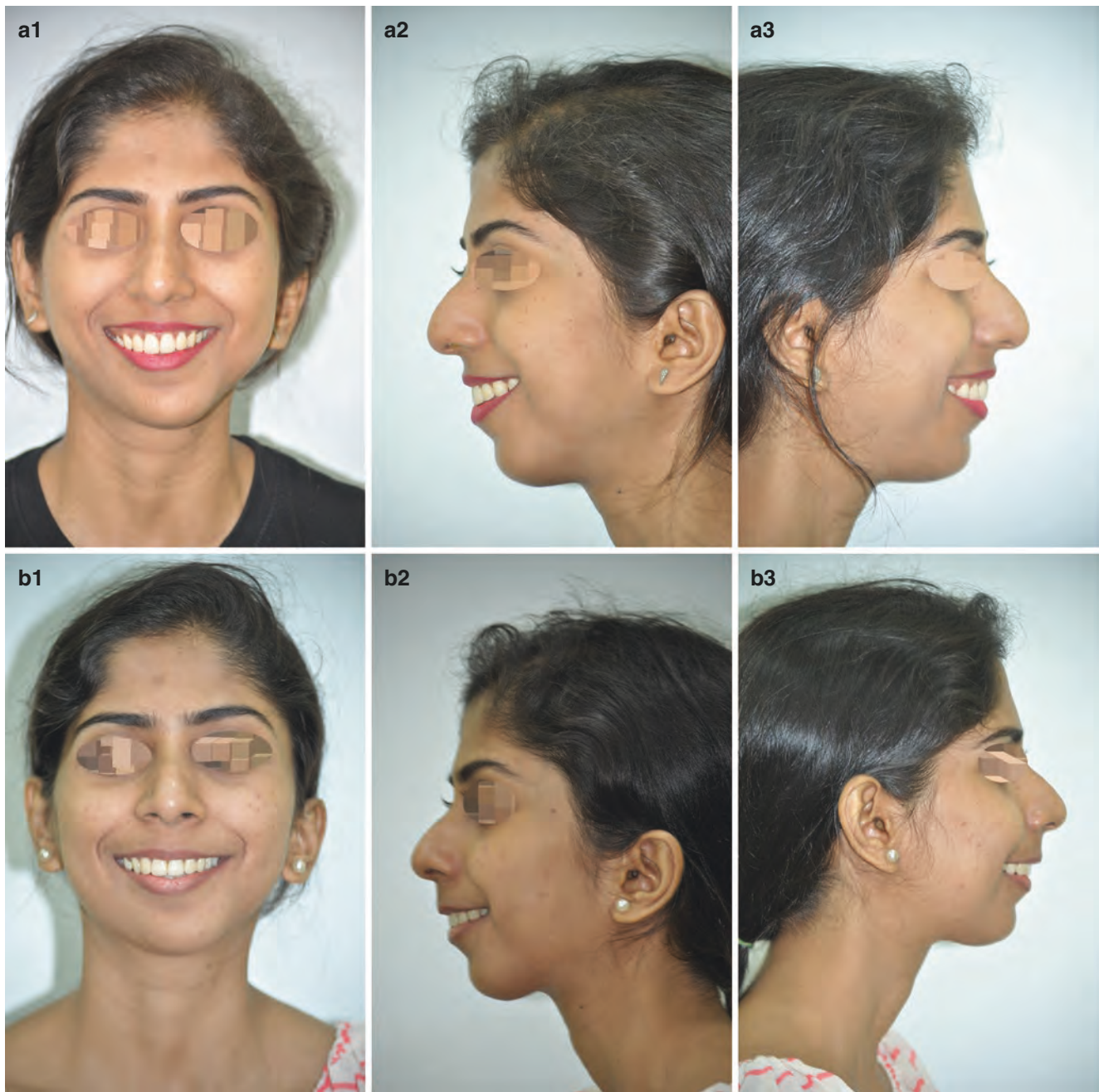©Association of Oral and Maxillofacial Surgeons of India

Fig. 69.31 (continued)

gingiva is elevated to expose the alveolus. The midline osteotomy is carried out using a sagittal or piezo saw from the piriform rim of the nose, to the alveolus. The mid-palatal suture osteotomy is completed with chisels. The zygomaticomaxillary buttresses clearance is confirmed intraoperatively by activating the palatal appliance (Fig. 69.34a–c). The remainder of the procedure is according to Le Fort 1 single piece osteotomy [70].

Salient Features of SARPE

1. SARPE is usually performed on arches that are V shaped.
2. The scope of orthodontics is limited in masking a skeletal transverse discrepancy that is greater than 5 mm. A segmental Le Fort expansion cannot be carried out for movements greater than 7 mm. If a significant amount of maxillary expansion is required, presumably greater than

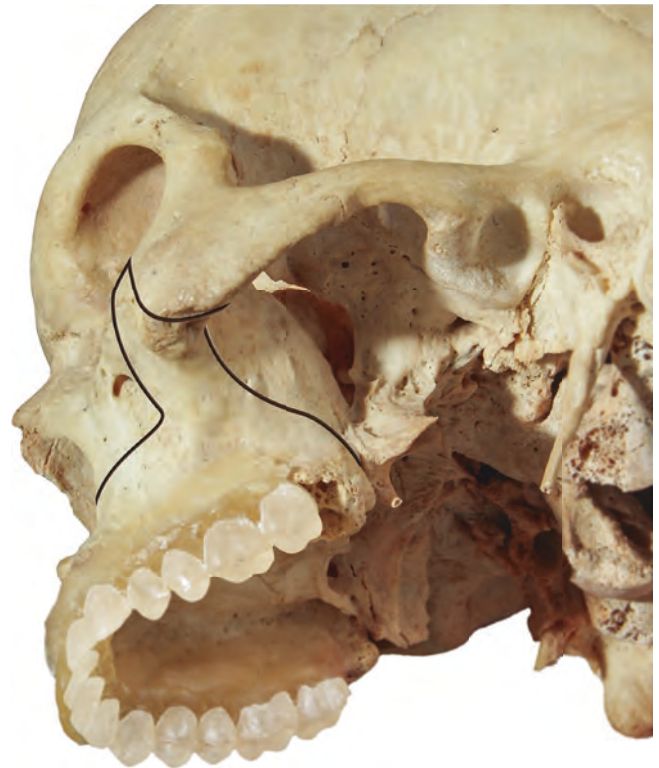


©Association of Oral and Maxillofacial Surgeons of India

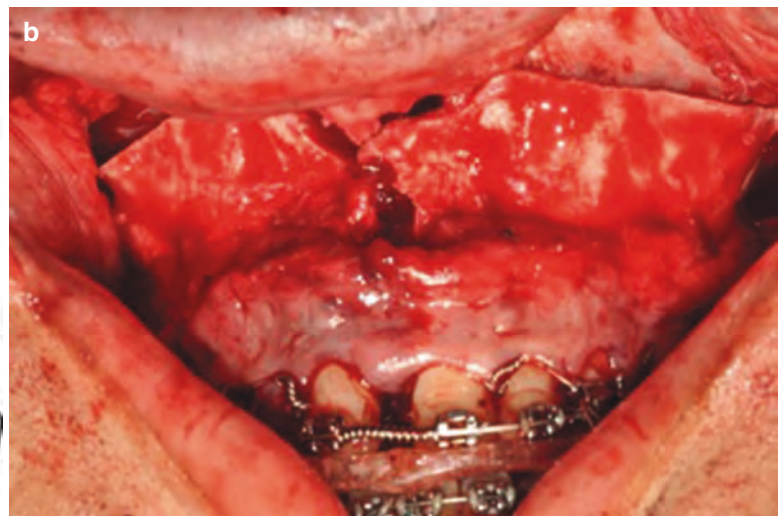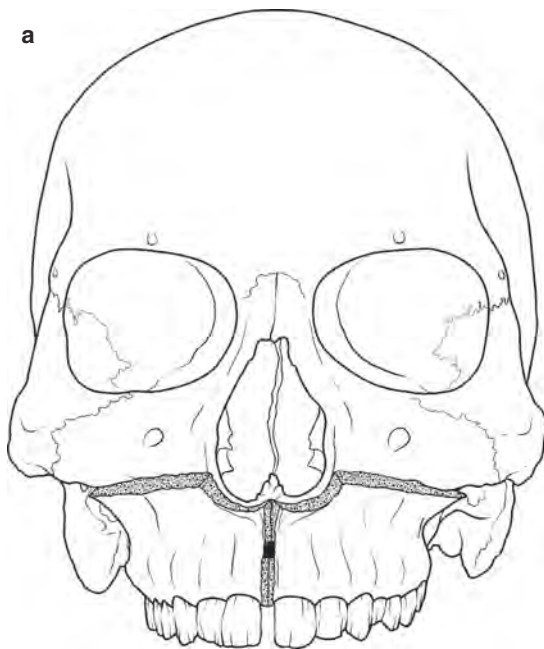
Fig. 69.32 (a, b) (a1, a2, a3) Pre-surgical pictures of patient with cant; (b1, b2, b3) postoperative asymmetric superior repositioning of maxilla and unilateral sagittal split osteotomy of the mandible to close the open bite created (Also see Figs. 69.30, 69.31 and 69.40)

- 7 mm, a SARPE procedure is preferred as it would offer more stability.
3. An IOPA X-ray is taken to ensure that sufficient space exists for an interdental osteotomy.
4. Osteotomies performed during a Le Fort I are replicated for the SARPE procedure, without down-fracturing the maxilla.
5. Pterygoid plates are separated for the posterior expansion of maxilla.
6. The zygomaticomaxillary buttresses offer greatest resistance to maxillary expansion. Activation of the palatal appliance must be done within the operating room. This will ensure that the maxilla is able to expand bilaterally, in a symmetric fashion, with no interferences.

Fig. 69.33 It is important to continue the saw or cut with a fissure bur through the inferior part of the zygomatic arch and extend it inferiorly and posteriorly to enable the important back cut to the pterygoid plates. This reduces the possibility of unwanted propagation of fractures to the cranial base



©Association of Oral and Maxillofacial Surgeons of India



©Association of Oral and Maxillofacial Surgeons of India

Fig. 69.34 (a) Maxilla down-fracture, paramedial osteotomy, palatal expansion device in situ, and checking for the horizontal segmental movement. (b) Midline palatal osteotomy, device for palatal expansion, (c) Tooth-borne Haas & Hyrax Appliance

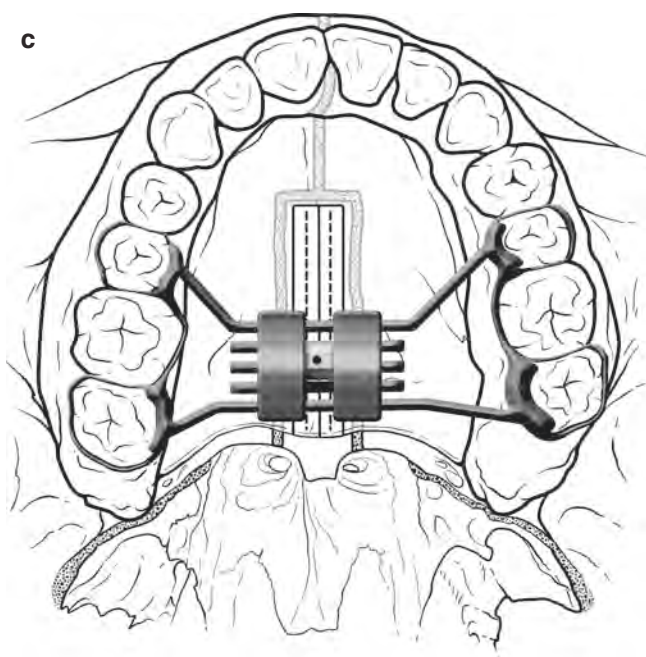


Fig. 69.34 (continued)

7. Overcorrection is recommended to allow for relapse. This is because maximum instability is associated with transverse maxillary expansion.
8. Either a tooth-borne appliance (Haas and Hyrax appliance) or a bone-borne palatal appliance may be used. The tooth-borne appliances may be more acceptable for patients, as they are less invasive and more hygienic. The disadvantage of these appliances is that they can create an occlusal tipping effect at the level of the alveolar bone and teeth. This may be minimized by engaging at least three posterior teeth. On the other hand, a bone-borne appliance offers better control over orthopedic movements at the level of the palate, but it requires a steep palatal vault for anchorage and is more invasive [71, 72].

69.7 Sequence of Bimaxillary Surgery

(Fig. 69.31a–m)

A single surgical procedure can be employed to correct skeletal deformities of the mandible and the maxilla as well. The surgeon generally determines the preferred sequence. The authors personal preference is provided below.

1. The mandibular bony cuts are usually performed first, without splitting the mandible. This is followed by completion of the maxillary osteotomy, repositioning and fixation. In the past, fixation was only by trans-osseous

wiring. Hence, when the mandible was performed first, its position was arbitrary as it incorporated the mobile proximal fragment (due to the TMJ) based on which the final maxillary position was determined. To avoid this the maxilla was completed first.

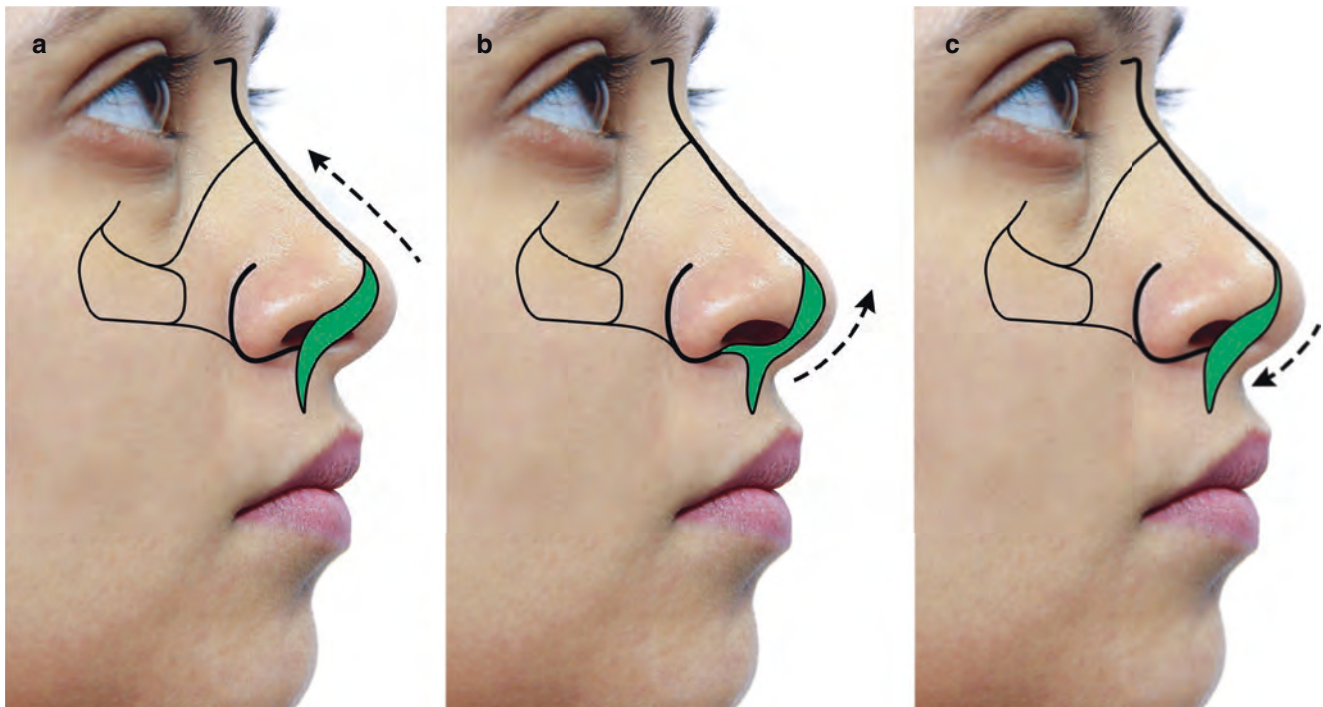
2. The mandible is exposed, and the bony osteotomy cuts are completed. However the formal split is not completed.
3. The maxilla is exposed, osteotomy completed and fixed in its final position.
4. The split for the mandible is completed, followed by the reposition of the mandible to the desired position. The mandible is then stabilised and fixed in its final position. This eliminates the possibility of any undesired maxillary movement as the movement of the maxilla is completed based on a stable intact mandible.
5. Finally, the genioplasty cuts are stabilized.
6. The same order must be considered during model surgery and when fabricating the intermediate and final splints for guidance.

The authors personal preference has been detailed above. Alternatively, mandibular splitting may be performed first, and an intermediate splint may be used to fix the mandible to the unoperated maxilla. The maxilla may then be stabilized to the operated and repositioned mandible. However, it must be noted that stabilization and fixation of the mandible are more challenging than for the maxilla. Rigid fixation may be more challenging if an improper or misdirected split occurs. The procedure may even need to be aborted altogether. However, by stabilizing the maxilla first, the mandible can use appropriately positioned maxilla for stabilization. Therefore, we have always preferred to complete the maxillary surgery before mandibular surgery.

Having listed a general guide above, we reiterate that no dogma should be given regarding the sequence of maxillary or mandibular surgery. Proper planning and preparation will in turn logically dictate the sequence, which must be kept flexible [73].

69.8 Soft Tissue Changes with Le Fort I Osteotomy

Changes in the jaw position in turn lead to changes in the position of soft tissues such as the lips, cheeks, and nose [74]. The lips may show thinning, reduced vermilion show, and may lack adequate lip support [46]. The nasal tip may be upturned, the alar base width may increase, and the nasolabial angle may widen [75] (Fig. 69.35a–c). Soft tissue swelling



©Association of Oral and Maxillofacial Surgeons of India

Fig. 69.35 (a–c) (a) reduction of a strip along the caudal septum will shorten the nose; (b) reduction involving the nasal tip as shown will increase the nasolabial angle; (c) wedge reduction predominantly at the septal base will reduce the nasolabial angle

may take up to a year to resolve, so these changes may not be apparent immediately [76]. In some regions, such as the subnasale, and the lips, greater than 10% change has been documented over 5 years [4]. Nasal changes are quite complex and are therefore unpredictable. Both the structure of the nose (including nasal cartilage connective tissue, anterior nasal spine, and the other nasal cartilages) and the degree of movement of the maxilla play a role in nasal changes. Other patient-related factors, including thickness and morphology of the soft tissue, postoperative healing, age, and ethnicity, can also affect nasal changes, which may either be favorable or unfavorable or beneficial. The nasal width alone increases predictably in Le Fort I osteotomies, and the increase in width depends on the extent of maxillary movement. Adjunctive procedures to limit widening of the nasal width may be performed intraoperatively. These include alar cinch suture and piriform aperture sculpting. Alternatively, the changes may be accepted and later procedures can be performed if necessary. The disadvantage of this is the need for an additional surgical procedure, e.g., alar wedge resection rhinoplasty. The alar cinch suture and V-Y closure (ACVY) is efficient and less invasive in controlling nasolabial changes. Its long-term results need to be evaluated. One study showed that the alar base cinch suture reduced the inter-alar width to its preoperative width following a Le Fort I osteotomy. The suture was stable when evaluated at 12 months and 3 years postoperatively [77]. There have been

studies comparing nasal and maxillary vermilion morphology after Lefort osteotomies by simple primary closure, Single VY closure and Double VY closure. The results indicated that better aesthetics are seen in double VY closure cases (See Hackney et al. 1989, Ledezma et al. 2014, in Additional reading provided). However a systematic review in 2014 couldn't reach a conclusion regarding the efficacy of various methods of closure in Lefort Osteotomies.

69.9 Specific Considerations

1. Attempts to study the nasal changes resulting from maxillary movements have demonstrated very variable results. The general consensus is that nasal changes are unpredictable after Le Fort I osteotomy [78].
2. The ascending pharyngeal artery and ascending palatine artery maintain blood perfusion to the down-fractured maxilla.
3. Impacted, unerupted, or erupted wisdom teeth may be removed during the Le Fort I surgery. The curved pterygoid osteotome must be placed posterior to the impacted teeth or through the socket. The technique of pterygoid separation through the socket of the third molar was described by Trimble et al in 1983 (Refer additional reading).
4. If posterior bony interferences are present, they may cause condylar displacement, condylar distraction, asym-

metrical jaw movements (deviations), malocclusion, and aberrant maxillary position.

5. If the maxilla is not mobilized sufficiently prior to fixation, this may hinder optimal advancements.
6. The zygomaticomaxillary and nasomaxillary buttresses consist of thick struts of bone and are ideal for securing fixation [79].
7. Blood loss is variable but rarely warrants transfusion. A review of over 500 osteotomies concluded an average loss of just under 300 mL, greater for bimaxillary osteotomies and less for single jaw surgery [80].

69.9.1 Adjustment to the Anterior Nasal Spine and Piriform Aperture

Mommaerts et al. reported that the anterior nasal spine is a significant component of nasal tip projection and may be reduced to limit the degree of nasal tip rotation [81]. Betts et al. also stated that changes in the lateral part of the piriform aperture significantly affected the soft tissue of the nasal base and nasal tip projection [82].

It is important not to remove too much of the septum as this can produce a retracted columella, which is a potentially unattractive feature.

Osseous recontouring of the nasal crest of the maxilla and/or resection of a portion of the caudal extent of the cartilaginous septum is recommended to keep interference at bay. Placement of a suture through the anterior nasal spine and

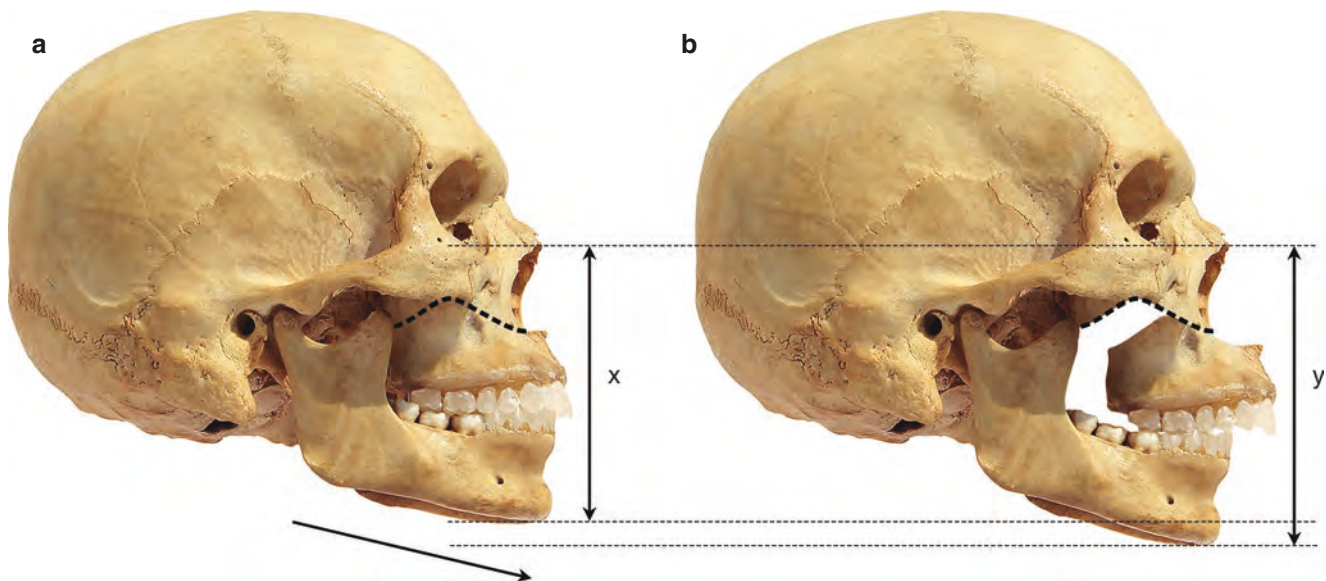
cartilaginous septum to prevent its displacement upon removal of the nasoendotracheal tube is beneficial.

69.9.2 Effect of Changing the Inclination (Slope) of the Osteotomy Cut

If the osteotomy cut is made in a parallel direction to the occlusal plane and the maxilla is advanced, the maxillary incisor exposure will increase but the face height will not change. However, if the osteotomy cut starts high posteriorly and slopes downwards toward the piriform aperture, the maxilla will move down the slope as it is advanced, thus increasing the maxillary incisor exposure. The mandible will subsequently rotate in a clockwise direction and the lower anterior face height will increase (Fig. 69.36a, b). The opposite is true for the osteotomy cuts that start low posteriorly and slopes upward toward the piriform aperture (Fig. 69.37a, b).

69.9.3 Impacted Wisdom Teeth

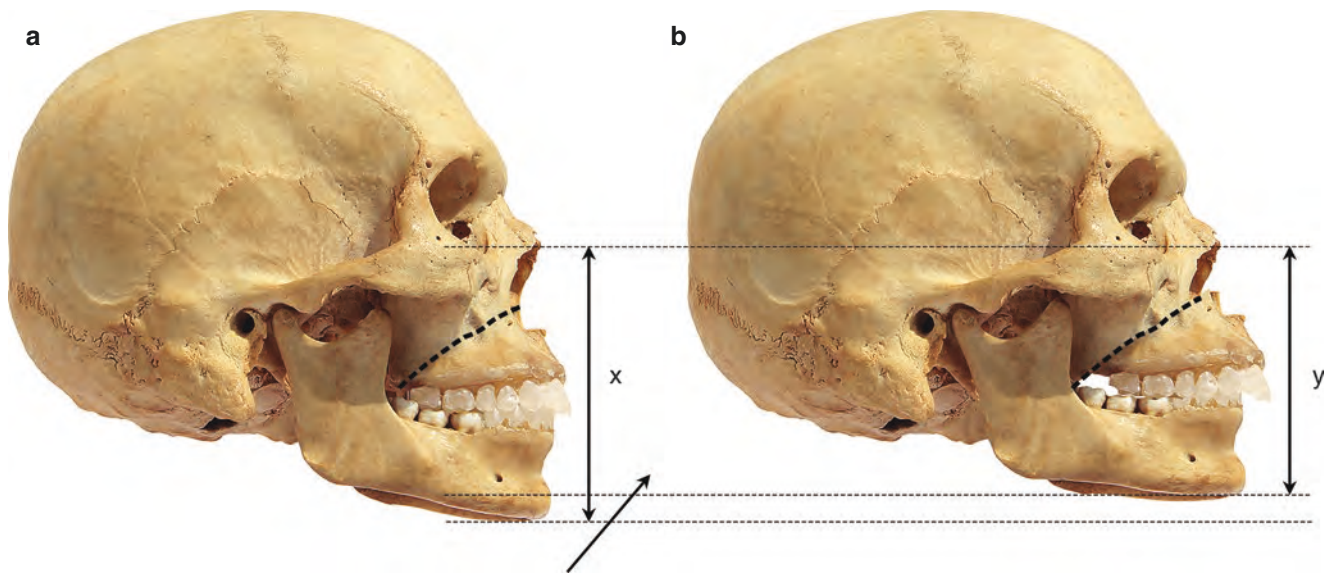
If an impacted maxillary wisdom tooth is indicated for removal, this is done through the sinus floor. Using a rotary drill with a rosette bur, the bone from the sinus floor, which lies above the impacted tooth, is removed. Next, a tapered fissure bur is used, and the bone just adjacent to the impacted tooth is removed. The impacted wisdom teeth may also be sectioned if necessary



©Association of Oral and Maxillofacial Surgeons of India

Fig. 69.36 (a, b) Diagram showing effects of the inclination (high to low postero-anteriorly) of the osteotomy cut when advancing the maxilla—(a) osteotomy inclination to increase incisor exposure and poten-

tially increase lower face height, (b) advancement of maxilla producing increase of lower facial height due to downward ramp effect



©Association of Oral and Maxillofacial Surgeons of India

Fig. 69.37 (a, b) Diagram showing effects of the inclination (low to high postero-anteriorly) of the osteotomy cut when advancing the maxilla—(a) osteotomy inclination to reduce incisor exposure and poten-

tially reduce lower face height, (b) advancement of maxilla producing reduction of lower facial height due to upward ramp effect

to aid in removal; this usually depends on the developmental stage. The tooth is delivered using a dental elevator. Rarely, perforation through the palatal mucosa may occur.

69.9.4 Erupted Wisdom Teeth

If the maxillary wisdom tooth is completely erupted, this may be extracted prior to down-fracture. This will allow the operator to have a stable “workbench” during extraction. In order to maintain the blood supply to the down-fractured maxilla, the adjacent palatal and labial mucosa must be preserved carefully at the time of extraction.

69.9.5 Considerations of Pre-operative Difficulties

The pre-surgical workup and planning of patients who require corrective jaw surgery required detailed analysis of clinical features, study models, and plane radiographs. Radiographic analysis includes comprehensive assessment of lateral cephalograms, postero-anterior cephalograms, and orthopantomograms. The need for multiple individual planar views has been replaced by the advent of cone beam technology.

69.9.6 Considerations of Operative Difficulties

Horizontal osteotomy of the maxilla should result in a clean pterygomaxillary separation to subsequently allow for

down-fracture and mobilization. At this step, the pterygoid plates should ideally remain intact and attached to the skull base. However, in some exceptional cases, such as patients with cleft maxilla, the pterygoid plates are unusually thick and well buttressed. On the other hand, some patients have thin and almost translucent pterygoid plates [83]. Pterygomaxillary synostosis (fusion) may be seen in up to 12% of all patients [21].

If the pterygoid plates fracture at a lower level, this may cause difficulties in down-fracture and mobilization, because of the attachment of the pterygoid musculature. On the other hand, if the plates fracture at a higher level, the fracture may propagate into and along the skull base, which can potentially cause neuro-ophthalmic complications.

On postoperative CT scans, the incidence of pterygoid plate fracture after a Le Fort I osteotomy was found to range from 58 to 75% [84, 85]. However, despite this high incidence, the incidence of fractures propagating to the skull base/orbit is low [83].

Lanigan et al. carried out a study on unfixed fresh cadavers and found that 26% of cases were “difficult down-fracture.” They stated that this was probably due to the presence of “thick bony maxillary walls” [83].

These authors stated that if a difficult down-fracture was encountered after a routine Le Fort I osteotomy, then the posterior walls of the maxilla must be sectioned completely using an osteotome. Alternatively, sectioning through the tuberosity could be performed, using a micro-oscillating saw or straight osteotome, as this would avoid the thick posterior walls and aid in pterygomaxillary separation. However, these authors have stated that it would not be possible to totally prevent

untoward fractures that could occur during pterygomaxillary disjunction and down-fracture. We emphasize that thorough CBCT imaging should be undertaken preoperatively, as this would familiarize the surgeon with the maxillary morphology.

The following maneuvers may help if the surgeon finds difficulty in down-fracture following osteotomy and disjunction:

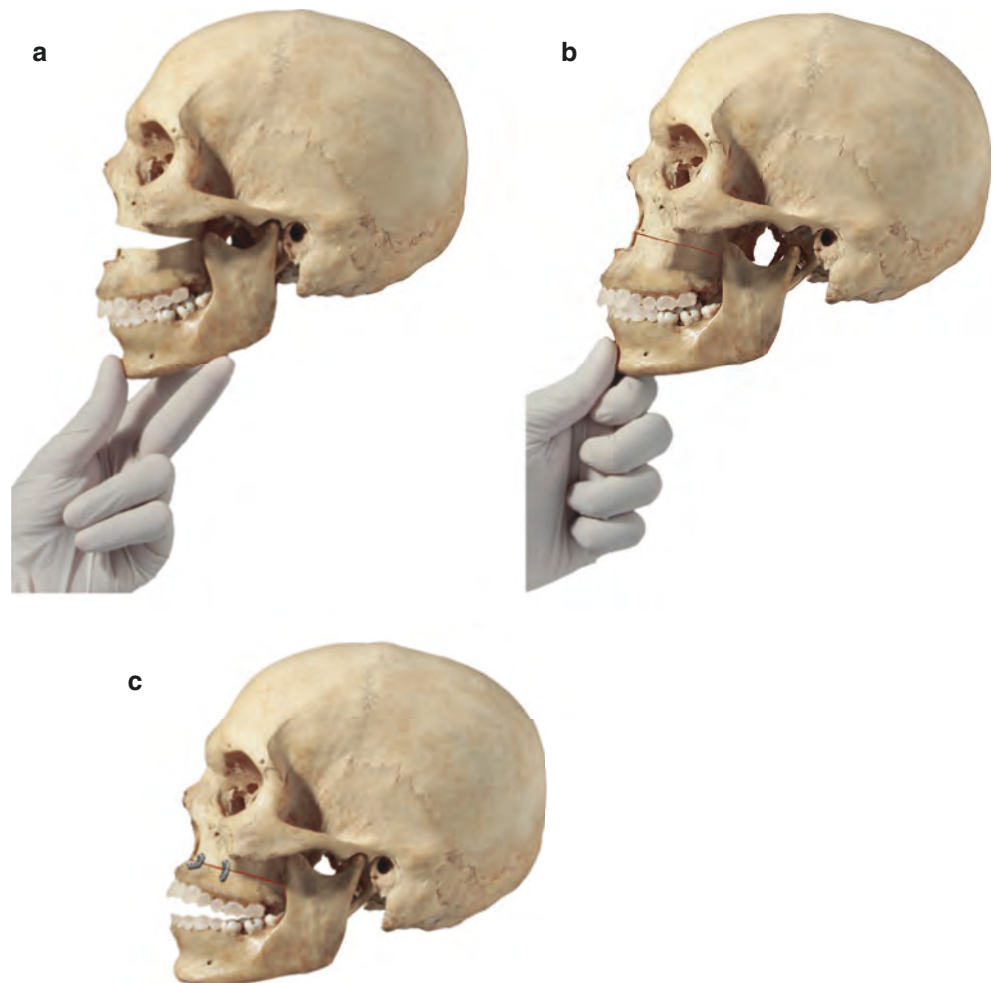
1. Revise the osteotomy cuts at all accessible sites, including anteromedial antral, lateral antral, and superior-nasal crest.
2. The maxilla may be “hinged down” to directly visualize the posterior maxilla, after which the cuts in this region may be completed, using a straight 4 mm osteotome.
3. Down-fracture can then be undertaken under direct vision.

O’Regan and Bharadwaj stated that an osteotome or saw must never be used blindly in these situations [86].

69.9.7 Proper Positioning

- Proper positioning can be difficult in isolated maxillary surgery, usually due to unrecognized posterior bony interferences.
- With an unrecognized posterior interference and inadequate effort or improper seating of the condyles, the maxilla can rotate around this interference, resulting in an anterior open bite after release of intermaxillary fixation. The maxillo-mandibular complex should be rotated with pressure seating the condyles in the glenoid fossa (Fig. 69.38a, b, c).
- Looking for the posterior interferences and eliminating them will result in the intended postoperative occlusion. Prior to any attempt to position the maxilla, effort is devoted to removing bone in the most likely areas of potential posterior interference, that being the area posterior to the second molar and along the perpendicular process of the palatine bone.
- Whether or not there is a potential for interference in the region of the pterygoid plates, per se, depends upon the

Fig. 69.38 (a–c) (a) The proper method for condylar seating at the time of maxillary positioning prior to fixation. Posterior prematurities are best appreciated with this method. (b) Pressure on the chin to push the anterior aspect of the maxillary osteotomy together may rotate the condyles inferiorly and posteriorly while maxillary fixation is applied. (c) Upon release of intermaxillary fixation, the condyles may return to the fosse, and an open bite may appear. Unfortunately, this open bite may not appear immediately, especially if postoperative elastics are used to “guide” the occlusion



surgical move. This is much less likely with advancement than it is with other moves such as impaction.

- It is often easiest to adapt the plates for fixation with Le Fort osteotomy and initially secure them only to the inferior fragment. Once all the plates are properly bent and secured to the inferior fragment, the maxillomandibular complex and condyles can be positioned with great care, and the shape and bending of the plates critically evaluated and secured to the superior fragment in succession, while the maxillomandibular complex is held in position.

69.9.8 Nutritional Support

Orthognathic surgery throws up many physiological challenges. These include postoperative facial swelling and catabolism which increase the nitrogen requirements. If these are not met, wound healing may be compromised. A diet fortified with macro- and micronutrients and adequate hydration is therefore essential [87].

Mandibular movements may be restricted in the postoperative period, owing to facial swelling and pain. Meeting the daily nutritional needs and hydration requirements (Table 69.1) may therefore be difficult. Studies have shown that in 6 weeks following surgery, patients can lose between 3.1 and 6.8 kg of weight [88].

It is important to adapt the diet to suit these needs, to promote wound healing, and to minimize postoperative complications. Another important factor in patient recovery is the patient's mood. Adequate nutrition and hydration will serve to improve the patient's mood, thereby diminishing postoperative irritability or depression [89]. Dietician assessment of nutritional status is essential to ensure that the above goals are achieved.

The modification of the diet is a sequential process. This aims at reducing the masticatory forces on the underlying healing bone, which in turn optimizes the conditions for healing.

1. The first 7 days following surgery should consist of a diet rich in energy and protein. This must be in a liquid form, and foods may be completely blended in a food processor to a smooth liquid consistency.
2. After the first week, patients can start consuming food with a small spoon or fork. It is still advised to minimize

chewing, and foods may be mashed. The high-energy-high-protein diet must be continued.

3. After the second week, light chewing may be done, and a soft diet is recommended. The jaw muscles may fatigue easily at first, but gradually the muscles adapt to the new position. The soft diet is continued for two months, after which regular diet may be resumed [87, 90–98].

69.9.9 Complications

1. *Hardware failure*: Unstable orthoappliance, splints/wafer, must be tried separately on each arch pre-operatively. Hardware exposure or fracture, palpable hardware, and loosening of screws are certain complications in hardware failure. Management involves removal of hardware with or without replacement, depending on the amount of bone union and time duration after surgery.
2. *Unanticipated fracture of maxilla*: A occlusal splint with a palatal vault extension is essential to counter this complication.
3. *Hemorrhage*: Bleeding commonly occurs from the descending palatine artery and pterygoid plexus. Injury to pterygoid plexus may happen while performing pterygomaxillary disjunction. This may lead to arteriovenous malformations which may cause life-threatening bleeding 2–4 weeks post-surgery. It needs to be managed with selective embolization. Hemorrhage may occur in patients with undiagnosed bleeding disorders.
4. *Deviated nasal septum*: This can occur when inferior septoplasty is inadequate during superior repositioning of the maxilla. It is managed postoperatively with adjunctive septoplasty.
5. *Damage to apices of teeth*: The horizontal osteotomy should be placed at least 5 mm above the apices of the maxillary teeth to avoid damage to the apices.
6. *Malunion and nonunion*: This can occur if fixation is inadequate fixation or has failed.

Rigid fixation with plates provides the initial stability until bone has united. Bone first unites in the pterygoid region [99]. The most stable maxillary movement is superior repositioning, followed by advancement, and the least stable is inferior repositioning. However, the studies looking at the inferior positioning of the maxilla have been based on the need for bone grafting. Studies have reported relapse rates for maxillary superior repositioning of the maxilla ranges from a mean of 0–18% for the anterior maxilla and 6–7% for the posterior maxilla. Relapse rates for maxillary advancement range from 5 to 15%. As with most orthognathic surgery, relapse is greater with increase in the maxillary advancement. With inferior maxillary reposition-

Table 69.1 Recommended postoperative nutrition requirements for patients above 16 years, undergoing orthognathic surgery [87]

	Energy (kcls)	Protein (g)	Fluid (ml)
Male	2500	1 g/kg/day	35 mL/kg/day
Female	2000	1 g/kg/day	35 mL/kg/day

ing (using bone grafts), there may be 28% anterior relapse and up to 70% posterior relapse [100]. Nonunion is rare and probably associated with failure of the initial plate fixation and poor bony contact. If this persists for greater than 6 months, further surgery with rigid fixation and autogenous bone grafting is recommended [101]. Maxillary advancement and posterior and superior movements are shown to be stable, whereas inferior and transverse movements are unstable [99–110]. The use of autogenous bone grafts and/or hydroxyapatite has been proposed to improve the stability of inferior repositioning of the maxilla [101, 111–117].

7. *Unfavorable aesthetic result:* This results from poor treatment planning or unrealistic patient expectations.
8. *Infection:* Infection may occur in rare cases and is managed with systemic antibiotics with or without placement of a drain and the causative hardware removal. Septic complications have been recorded in 1.1% of osteotomy operations [55].
9. *Dental problems:* As a result of the osteotomy cut, the maxillary teeth lose their nerve supply. Generally, the nerve supply is re-established after 18 months to 2 years [118]. The teeth maintain their viability from the collateral blood supply. Patients should be warned that their teeth and gingivae may be numb for up to 2 years [119]. Osteotomy cuts should be a minimum of 5 mm above the root apices to avoid complications.
10. *Trigemino-cardiac reflex (TCR):* The stimulation of trigeminal nerve branches during Le Fort I osteotomy can be a possible cause of the TCR, and transient cessation of the procedure is adequate to allow the heart rate and blood pressure to normalize and dysrhythmia to stop [120].

69.10 Recent Advances (Refer Figs. 66.21 and 78.51)

- (a) *Virtual planning in Orthognathic Surgery:* the last decade has seen a tremendous evolution in the field of surgical planning. Computer Assisted Virtual Surgical Planning and the use of CAD-CAM designed splints have significantly improved intra-operative accuracy of maxillary repositioning in orthognathic surgery [121].
- (b) *Waferless Orthognathic Surgery:* Another technique which has created a paradigm change is the design of custom-fabricated cutting stents and patient specific implant for fixation, which help not only perform the osteotomy but also fix the segment in the desired position without the use of occlusal wafers [122].

69.11 Conclusion

The development of modern maxillary orthognathic surgical procedures had diverse historical origins and contributions. With advancement in technique and the introduction of safe hypotensive anesthesia, the Le Fort I osteotomy has been increasingly utilized over the last four decades. Over the years, various modifications of the osteotomies, ORIF methods and bone grafting to the mobilized maxilla, have continued to evolve and progress. The Le Fort I osteotomy of the maxilla is one of the core procedures in orthognathic surgery for the management of facial skeletal deformities. The surgery, often used in conjunction with the bilateral sagittal split osteotomy, is used to correct functional and cosmetic irregularities in all three planes of space and can be utilized in the treatment of a wide range of malocclusions. Traditionally, the surgery has been known for its low technical difficulty and dependable results. Changes in the soft tissue of the nose, lips, and cheeks due to this surgical procedure need due consideration.

The risk of complications is higher in patients with segmental Le Fort I osteotomies or anterior movements greater than 9 mm. Efforts to minimize maxillary movement (e.g., with two-jaw surgery) are recommended to reduce complications. An emphasis should be placed on proper pre-surgical orthodontics and solid pre-surgical planning to ensure predictable and stable results. It is also imperative to plan and provide for optimal nutrition as Orthognathic surgery throws up many physiological challenges that may compromise the nutritional status including catabolism, postoperative facial swelling, and increased nitrogen requirements to promote wound healing. The premise of maxillary orthognathic surgery is therefore a multidimensional approach through planning, execution, and postoperative management.

Disclosure Authors have no financial conflicts to disclose. Authors have written consent and reconfirmation from the patients for the use of clinical pictures.

69.12 Case Scenarios

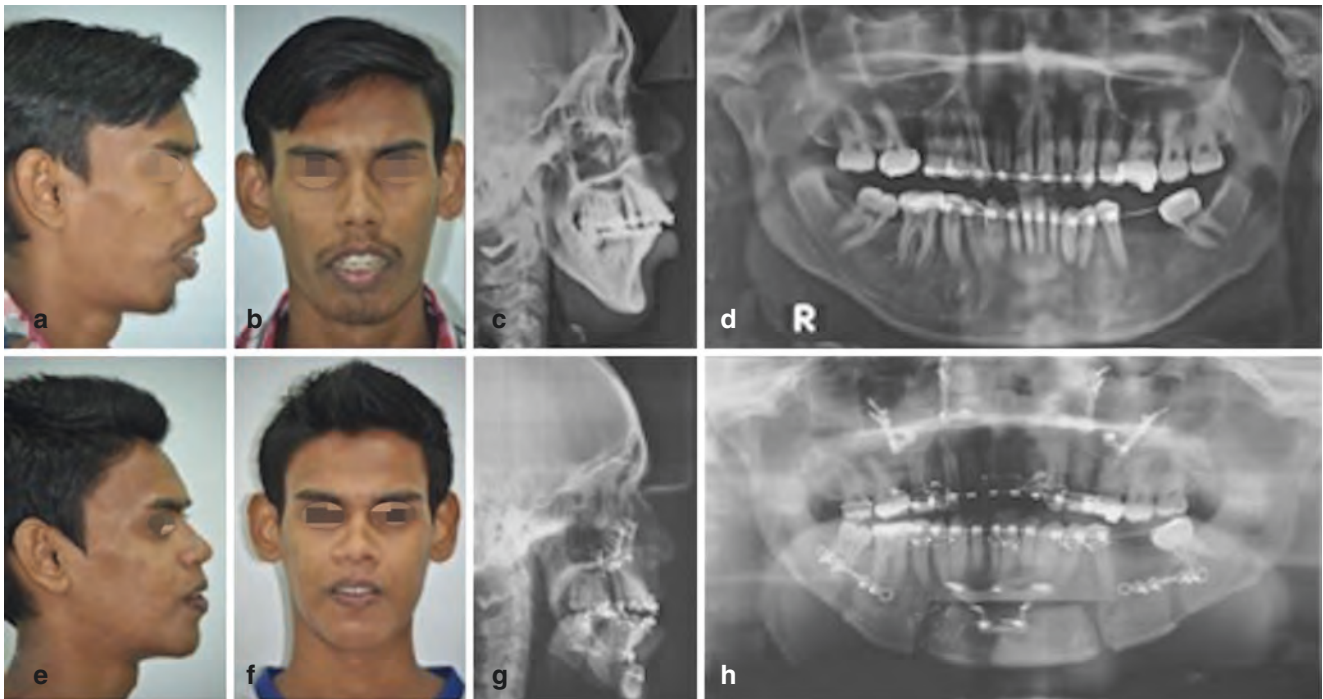Case Scenario 1 (Figs. 69.28, 69.29 and 69.39a–h)

(A) Chief Complaints

- Gummy smile
- Long face
- Deficient chin
- Protruding upper front teeth

(B) Postoperative Result

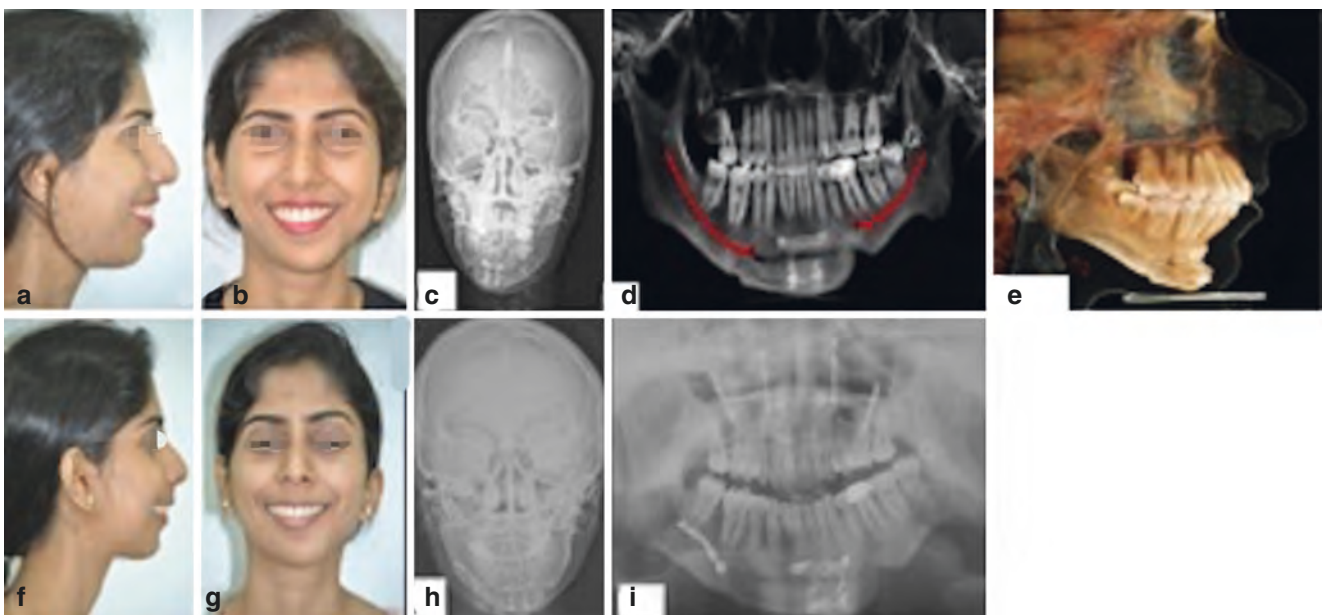
- Competent lips
- Normal chin projection
- Balanced face



©Association of Oral and Maxillofacial Surgeons of India

Fig. 69.39 (a–h) Vertical maxillary excess with mandibular deficiency. Treatment: Le fort I with superior repositioning of maxilla; bilateral sagittal split ramus osteotomy advancement; advancement genioplasty. (a) Pre-operative profile picture; (b) pre-operative frontal

view; (c) pre-operative lateral cephalogram. (d) Pre-operative OPG; (e) postoperative lateral profile; (f) postoperative frontal view; (g) postoperative lateral cephalogram; (h) postoperative OPG showing the implants and the osteotomy cuts in mandible. (Also see Fig. 69.28)



©Association of Oral and Maxillofacial Surgeons of India

Fig. 69.40 (a–i) Facial asymmetry with maxillary occlusal cant, deviation of chin (surgery for left TMJ ankylosis and genioplasty done previously elsewhere). Treatment: Le fort I osteotomy for correction of maxillary occlusal cant; right unilateral sagittal split ramus osteotomy to close the open bite. (a) Pre-operative profile picture; (b) pre-operative

frontal view; (c) pre-operative PA skull; (d) pre-operative OPG; (e) pre-operative lateral cephalogram; (f) postoperative profile picture; (g) postoperative frontal view; (h) postoperative PA skull; (i) Post-operative OPG (Also see Figs. 69.30, 69.31 and 69.32)

Surgical Procedure

Le fort I osteotomy for superior repositioning of maxilla

Bilateral Sagittal Split Ramus osteotomy for advancement of mandible

Advancement genioplasty

Later rhinoplasty was done.

Case Scenario 2 (Figs. 69.30, 69.31, 69.32, and 69.40a–i)

Chief Complaints

Facial asymmetry

Deviation of chin to left

Incisal/occlusion cant (Fig. 69.30)

Facial asymmetry was secondary to ankylosis of left TMJ. Left side treated with costochondral graft when patient was younger.

Pre-operative Findings

Occlusal cant

Asymmetry of face

The patient presented with occlusal canting visible at the anterior region. This needed to be addressed as it is clinically evident and may affect visual cosmesis.

Judge the incisal cant by drawing an imaginary interpuillary line and its inclination with incisal cant represented by the metal scale held in incisors

Surgical Plan (Figs. 69.31 and 69.32)

Le Fort I osteotomy for superior repositioning of maxilla on right side by 5 mm

Sagittal split osteotomy on right side of mandible to match mandible to maxilla

References

- Comte A. The positive philosophy of Auguste Comte. Freely translated and condensed by Harriet Martineau (1855). London: George Bell & Sons; 1896.
- Von Langenbeck B. Beitrage zur osteoplastik. In: Goschen A, editor. Die osteoplastische resektion des oberkierers. Deutsche Klinik. Berlin: Reimer; 1859.
- Cheever D. Displacement of the upper jaw. *Med Surg Rep Boston City Hosp.* 1870;1:156.
- Cheever D. Nasopharyngeal polypus, attached to the basilar process of occipital and body of the sphenoid bone successfully removed by a section, displacement, and subsequent replacement and reunion of the superior maxillary bone. *Boston Med Surg.* 1867;8:162.
- Moloney F, Worthington P. The origin of the Le Fort I maxillary osteotomy: Cheever's operation. *J Oral Surg.* 1981;39:731–4.
- Halvorson EG, Mulliken JB. Cheever's double operation: the first Le Fort I osteotomy. *Plast Reconstr Surg.* 2008;121:1375–81.
- Le Fort R. Etude experimentale sur les fractures de la machoire superieure. *Rev Chir.* 1901;1:208, 260, 479.
- Le Fort R. Experimental study of fractures of the upper jaw (paper of 1901 translated by Paul Tessier). *Plast Reconstr Surg.* 1972;50:497–506.
- Wassmund M. Frakturen und luxationen des gesichtsschadels. Leipzig: Meusser; 1927.
- Axhausen G. Zur behandlung veralteter disloziert geheilter oberkieferbruche. *Dtsch Zahn Mund Kieferheilk.* 1934;1:334–9.
- Wassmund M. *Frakturen und Lurationen des Gesichtsschadels.* Berlin: Meusser; 1927.
- Axhausen G. Zur Behandlung veralteter desloziert verheilte Oberkieferbrunche. *Dtsch Zahn Mund Kieferheilk.* 1934;1:334.
- Schuchardt D. Ein Beitrag zur chirurgischen Kieferorthopadie unter Berucksichtigung ihrer Bedertung fur die Behandlung angeborener und erworbener Kieferdeformatiten bei Soldaten. *Dtsch Zahn Mund Kieferheilk.* 1942;9:73.
- Willmar K. On Le Fort I osteotomy: a follow-up study of 106 operated patients with maxillo-facial deformity. *Scand J Plast Reconstr Surg.* 1974;12(Suppl 12):11–68.
- Obwegeser H. Surgery of the maxilla for the correction of prognathism. *SSO Schweiz Monatsschr Zahnheilkd.* 1965;75:365–74.
- Obwegeser HL. Surgical correction of small or retrodisplaced maxillae. The “dish-face” deformity. *Plast Reconstr Surg.* 1969;43:351–65.
- Bell WH. Biologic basis for maxillary osteotomies. *Am J Phys Anthropol.* 1973;38:279–89.
- Aziz SR, Marchena JM, Puran A. Anatomic characteristics of the infraorbital foramen: a cadaver study. *J Oral Maxillofac Surg.* 2000;58:992–6.
- Demas PN, Sotereanos GC. Incidence of nasolacrimal injury and turbinectomy—associated atrophic rhinitis with Le Fort I osteotomies. *J Craniomaxillofac Surg.* 1989;17:116–8.
- You ZH, Bell WH, Finn RA. Location of the nasolacrimal canal in relation to the high Le Fort I osteotomy. *J Oral Maxillofac Surg.* 1992;50:1075–80.
- Cheung LK, Fung SC, Li T, et al. Posterior maxillary anatomy: implications for Le Fort I osteotomy. *Int J Oral Maxillofac Surg.* 1998;27:346–51.
- Choi J, Park H. The anatomy of the maxillary artery in the pterygopalatine fossa. *Int J Oral Maxillofac Surg.* 1999;28(Suppl 1):133.
- Turvey TA, Fonseca RJ. The anatomy of the internal maxillary artery in the pterygopalatine fossa: its relationship to maxillary surgery. *J Oral Surg.* 1980;38:92–5.
- Bell WH. Revascularization and bone healing after anterior maxillary osteotomy: a study using adult rhesus monkeys. *J Oral Surg.* 1969;27:249–55.
- Bell WH, Fonseca RJ, Kenneky JW, et al. Bone healing and revascularization after total maxillary osteotomy. *J Oral Surg.* 1975;33:253–60.
- Bruneder S, et al. Anatomy of the Le Fort I segment: are arterial variations a potential risk factor for avascular bone necrosis in Le Fort I osteotomies? *J Craniomaxillofac Surg.* 2018;46:1285–95.
- Salman S, Fattahi T, Fernandes R, Steinberg B. Dynamic analysis of maxillary perfusion during Le Fort I osteotomy using indocyanine green. *Int J Oral Maxillofac Surg.* 2018;47:1311–5.
- Oliveira GQV, Rossi MA, Vasconcelos TV, Neves FS, Crusoe-Rebello I. Cone beam computed tomography assessment of the pterygomaxillary region and palatine canal for Le Fort I osteotomy. *Int J Oral Maxillofac Surg.* 2017;46:1017–23.
- Cohn-Stock G. Die Chirurgische Immediatregulierung der Kiefer, Speziell die Chirurgische Behandlung der Prognathie. *Vjschr Zahnheilk.* 1921;37:320.

30. Wunderer S. Erfahrungen mit der Operativen Behandlung Hochgradiger Prognathien. *Dtsch Zahn Mund Kieferheilk.* 1963;39:451.
31. Cupar I. Die chirurgische Behandlung der Form- und Stellungsveränderungen des Oberkiefers. *Ost Z Stomatol.* 1954;51:565.
32. Bell WH. Revascularization and bone healing after anterior maxillary osteotomy. *J Oral Surg.* 1969;27:249.
33. Bell WH. Correction of maxillary excess by anterior maxillary osteotomy. *Oral Surg Oral Med Oral Pathol.* 1977;43:323.
34. Gunaseelan R, Anantanarayanan P, Veerabahu M, et al. Intraoperative and perioperative complications in anterior maxillary osteotomy: a retrospective evaluation of 103 patients. *J Oral Maxillofac Surg.* 2009;67:1269.
35. Rosenquist B. Anterior segmental maxillary osteotomy: a 24-month follow-up. *Int J Oral Maxillofac Surg.* 1993;22:210.
36. Meyer MW, Cavanaugh CD. Blood flow changes after orthognathic surgery: maxillary and mandibular subapical osteotomy. *J Oral Surg.* 1976;34:495.
37. Epker NB. Vascular considerations in orthognathic surgery: maxillary osteotomies. *J Oral Surg.* 1984;57:473.
38. Epker NB. A modified anterior maxillary osteotomy. *J Maxillofac Surg.* 1977;5:35.
39. Haas Junior OL, Guijarro-Martínez R, de Sousa Gil AP, da Silva Meirelles L, de Oliveira RB, Hernández-Alfaro F. Stability and surgical complications in segmental Le Fort I osteotomy: a systematic review. *Int J Oral Maxillofac Surg.* 2017;46:1071–87.
40. Rodrigo C. Induced hypotension during anesthesia with special reference to orthognathic surgery. *Anesth Prog.* 1995;42:41–58.
41. Zellin G, Rasmusson L, Palsson J, et al. Evaluation of haemorrhage depressors on blood loss during orthognathic surgery: a retrospective study. *J Oral Maxillofac Surg.* 2004;62:662–6.
42. Carlos E, Monnazzi MS, Castiglia YM, et al. Orthognathic surgery with or without induced hypotension. *Int J Oral Maxillofac Surg.* 2014;43:577–80.
43. Van Sickels JE, Larsen AJ, Triplett RG. Predictability of maxillary surgery: a comparison of internal and external reference marks. *Oral Surg Oral Med Oral Pathol.* 1986;61:542–5.
44. Ferguson JW, Luyk NH. Control of vertical dimension during maxillary orthognathic surgery. A clinical trial comparing internal and external fixed reference points. *J Craniomaxillofac Surg.* 1992;20:333–6.
45. Hackney FL, Nishioka GJ, VanSickels JE. Frontal soft-tissue morphology with double V-Y closure following LeFort I osteotomy. *J Oral Maxillofac Surg.* 1988;46:850–5.
46. Schendel SA, Williamson LW. Muscle reorientation following superior repositioning of the maxilla. *J Oral Maxillofac Surg.* 1983;41(4):235–40.
47. Newhouse RF, Schow SR, Kraut RA, et al. Life-threatening haemorrhage from a Le Fort I osteotomy. *J Oral Maxillofac Surg.* 1982;40(2):117–9.
48. Epker BN, Fish LC. *Dentofacial deformities, integrated orthodontic and surgical correction*, vol. 1. St Louis: Mosby; 1986.
49. Epker BN. Superior surgical repositioning of the maxilla: long-term results. *J Maxillofac Surg.* 1981;9(4):237–46.
50. Maloney F, West RA, McNeill W. Surgical correction of vertical maxillary excess: a re-evaluation. *J Maxillofac Surg.* 1982;10(2):84–91.
51. Johnson DG. Intraoperative measurement of maxillary repositioning: an ancillary technique. *Oral Surg Oral Med Oral Pathol.* 1985;60(3):266–8.
52. Nishioka GJ, Van Sickels JE. Modified external reference measurement technique for vertical repositioning of the maxilla. *Oral Surg Oral Med Oral Pathol.* 1987;64(1):22–3.
53. Posnick JC. 15: Sequencing of orthognathic procedures: step-by-step approach. In: Posnick JC, editor. *Orthognathic surgery: principles & practice*. St Louis: Saunders; 2014.
54. Bennett MA, Wolford LM. The maxillary step osteotomy and Steinmann pin stabilization. *J Oral Maxillofac Surg.* 1985;43:307.
55. Kramer FJ, Baethge C, Swennen G, Teltzrow T, Schulze A, Berten J, Brachvogel P. Intra- and perioperative complications of the Le Fort I osteotomy: a prospective evaluation of 1000 patients. *J Craniofac Surg.* 2004;15:971–9.
56. Aldridge T, Gulati A, Baker N. Theories of acquired blindness following Le Fort I osteotomy. *Br J Oral Maxillofac Surg.* 2013;51:e86.
57. Bays RA, Bouloux GF. Complications of orthognathic surgery. *Oral Maxillofac Surg Clin North Am.* 2003;15:229–42.
58. Richardson D. Avoiding surgical complications in orthognathic surgery. In: Ward-Booth P, Schendel S, Hausamen J, editors. *Maxillofacial surgery*. 2nd ed. London: Churchill Livingstone; 2006. p. 1259–74.
59. Breeze J, et al. comReview Is an osteotome necessary for pterygomaxillary dysjunction or dysjunction through the tuberosity during Le Fort I osteotomy? A systematic review. *Br J Oral Maxillofac Surg.* 2016;54:248–52.
60. Precious DS, Morrison A, Ricard D. Pterygomaxillary separation without the use of an osteotome. *J Oral Maxillofac Surg.* 1991;49:98–9.
61. Mehra P, Hopkin JK, Castro V, Freitas RZ. Stability of maxillary advancement using rigid fixation and bone grafting: cleft lip versus non-cleft patients. *Int J Adult Orthodon Orthognath Surg.* 2001;16:193.
62. Muradin MS, Seubring K, Stoelinga PJ, et al. A prospective study on the effect of modified alar base cinch sutures and V-Y closure versus simple closing sutures on nasolabial changes after Le Fort I intrusion and advancement osteotomies. *J Oral Maxillofac Surg.* 2011;69:870.
63. Peled M, Ardekian L, Krausz AA, Aizenbud D. Comparing the effects of V-Y advancement versus simple closure on upper lip esthetics after Le Fort I advancement. *J Oral Maxillofac Surg.* 2004;62:315.
64. Vercruyse H Jr, et al. The effect of a Le Fort I incision on nose and upper lip dynamics: unraveling the mystery of the “Le Fort I lip”. *J Craniomaxillofac Surg.* 2016;44:1917–21.
65. Lee H-J, Park H-S, Kyung H-M, Kwon T-G. Soft tissue changes and skeletal stability after modified quadrangular Le Fort I osteotomy. *Int J Oral Maxillofac Surg.* 2015;44:356–61.
66. Issacson R, Ingram A. Forces produced by rapid maxillary expansion: forces present during treatment. *Angle Orthod.* 1964;34:256.
67. Haas AJ. The treatment of maxillary deficiency by opening the midpalatal suture. *Angle Orthod.* 1965;35:200.
68. Persson M, Thilander B. Palatal suture closure in man from age 15 to 35 years of age. *Am J Orthod.* 1977;72:42.
69. Epker BN, Wolford LM. *Transverse maxillary deficiency dentofacial deformities: integrated orthodontic and surgical correction*. St Louis: Mosby; 1980.
70. Spalding PM. Craniofacial growth and development: current understanding and clinical considerations. In: Miloro M, editor. *Peterson's principles of oral and maxillofacial surgery*. 2nd ed. London: BC Decker; 2004. p. 1051–86.
71. Suri L, Taneja P. Surgically assisted rapid palatal expansion: a literature review. *Am J Orthod Dentofac Orthop.* 2008;133:290–302.
72. Verquin M, Daems L, Politis C. Short-term complications after surgically assisted rapid palatal expansion: a retrospective cohort study. *Int J Oral Maxillofac Surg.* 2017;46:303–8.

73. Turvey T. Sequencing of two-jaw surgery: the case for operating on the maxilla first. *J Oral Maxillofac Surg.* 2011;69:2225.
74. Guymon M, Crosby DR, Wolford LM. The alar base cinch suture to control nasal width in maxillary osteotomies. *Int J Adult Orthodon Orthognath Surg.* 1988;3:89–95.
75. Betts NJ, Vig KW, Vig P, Spalding P, Fonseca RJ. Changes in the nasal and labial soft tissues after surgical repositioning of the maxilla. *Int J Adult Orthodon Orthognath Surg.* 1993;8:7–23.
76. Hack GA, de Mol van Otterloo JJ, Nanda R. Long-term stability and prediction of soft tissue changes after LeFort I surgery. *Am J Orthod Dentofac Orthop.* 1993;104:544–55.
77. Raithatha R, Naini FB, Patel S, Sherriff M, Witherow H. Long-term stability of limiting nasal alar base width changes with a cinch suture following Le Fort I osteotomy with submental intubation. *Int J Oral Maxillofac Surg.* 2017;46:1372–9.
78. Schendel SA, Carlotti AE. Nasal considerations in orthognathic surgery. *Am J Orthod Dentofac Orthop.* 1991;100:197–208.
79. Perciaccante VJ, Bays RA. Maxillary orthognathic surgery. In: Miloro M, editor. *Peterson's principles of oral and maxillofacial surgery.* 2nd ed. London: BC Decker; 2004. p. 1179–204.
80. Moenning JE, Bussard DA, Lapp TH, Garrison BT. Average blood loss and the risk of requiring perioperative blood transfusion in 506 orthognathic surgical procedures. *J Oral Maxillofac Surg.* 1995;53:880–3.
81. Mommaerts MY, Abeloos JV, De Clercq CA, Neyt LF. The effect of the subspinal Le Fort I-type osteotomy on interalar rim width. *Int J Adult Orthodon Orthognath Surg.* 1997;12:95–100.
82. Betts NJ, Vig KW, Vig P, Spalding P, Fonseca RJ. Changes in the nasal and labial soft tissues after surgical repositioning of the maxilla. *Int J Adult Orthod Orthognath Surg.* 1993;8:7–23.
83. Lanigan DT, Guest P. Alternative approaches to pterygomaxillary separation. *Int J Oral Maxillofac Surg.* 1993;22:131–8.
84. Renick BM, Symington JM. Postoperative computed tomography study of pterygomaxillary separation during the Le Fort I osteotomy. *J Oral Maxillofac Surg.* 1991;49:1061–5.
85. Robinson PP, Hendy CW. Pterygoid plate fractures caused by the Le Fort I osteotomy. *Br J Oral Maxillofac Surg.* 1986;24:198–202.
86. O'Regan B, Bharadwaj G. Prospective study of the incidence of serious posterior maxillary haemorrhage during a tuberosity osteotomy in low level Le Fort I operations. *Br J Oral Maxillofac Surg.* 2007;45:538–42.
87. Gustafsson UO, Scott MJ, Schwenk W, Demartines N, Roulin D, Francis N, McNaught CE, MacFie J, Liberman S, Soop M, Hill A, Kennedy RH, Lobo DN, Fearon K, Ljungqvist O. Guidelines for perioperative care in elective colonic surgery: enhanced recovery after surgery (ERAS) society recommendations. *Clin Nutr.* 2012;31:783–800.
88. Robinson RC, Holm RL. Orthognathic surgery for patients with maxillofacial deformities. *Assoc Periop Regist Nurs.* 2010;92:28–52.
89. Hoffman GR, Islam S. The difficult Le Fort I osteotomy and downfracture: a review with consideration given to an atypical maxillary morphology. *J Plast Reconstr Aesthet Surg.* 2008;61:1029–33.
90. Kendall BD, Fonseca RJ, Lee M. Postoperative nutritional supplementation for the orthognathic surgery patient. *J Oral Maxillofac Surg.* 1982;40:205–13.
91. Olejko TD, Fonseca RJ. Preoperative nutritional supplementation for the orthognathic surgery patient. *J Oral Maxillofac Surg.* 1984;42:573–7.
92. Chidylo SA, Chidylo R. Nutritional evaluation prior to oral and maxillofacial surgery. *NY State Dent J.* 1989;55:38–40.
93. Kehlet H. Multimodal approach to control postoperative pathophysiology and rehabilitation. *Br J Anaesth.* 1997;78:606–17.
94. Fearon KC, Luff R. The nutritional management of surgical patients: enhanced recovery after surgery. *Proc Nutr Soc.* 2003;62:807–11.
95. Younis J, Salerno G, Fanto D, Hadjipavlou M, Chellar D, Trickett JP. Focused preoperative patient stoma education, prior to ileostomy formation after anterior resection, contributes to a reduction in delayed discharge within the enhanced recovery programme. *Int J Colorect Dis.* 2011;27:43–7.
96. Aarts MA, Okrainec A, Glicksman A, Pearsall E, Victor JC, McLeod RS. Adoption of enhanced recovery after surgery (ERAS) strategies for colorectal surgery at academic teaching hospitals and impact on total length of hospital stay. *Surg Endosc.* 2012;26:442–50.
97. Larsson J, Akerlind I, Permerth J, Hornqvist JO. The relation between nutritional state and quality of life in surgical patients. *Eur J Surg.* 1994;160:329–34.
98. Nygren J, Thacker J, Carli F, Fearon KCH, Norderval S, Lobo DN, Ljungqvist O, Soop M, Ramirez J. Guidelines for perioperative care in elective rectal/pelvic surgery: enhanced recovery after surgery (ERAS) society recommendations. *Clin Nutr.* 2012;31:801–16.
99. Piecuch J, Tideman H, DeKooomen H. Short face syndrome: treatment of myofascial pain dysfunction by maxillary disimpaction. *Oral Surg.* 1980;49:112.
100. Baker DL, Stoelting PJ, Blijdorp PA, Brouns JJ. Long-term stability after inferior maxillary repositioning by miniplate fixation. *Int J Oral Maxillofac Surg.* 1992;21:320.
101. Wardrop RW, Wolford LM. Maxillary stability following down-graft and/or advancement procedures with stabilization using rigid fixation and porous block hydroxyapatite implants. *J Oral Maxillofac Surg.* 1989;47:336.
102. Proffit WR, Phillips C, Turvey TA. Stability following superior repositioning of the maxilla by LeFort I osteotomy. *Am J Orthod Dentofac Orthop.* 1987;92(2):151–61.
103. Proffit WR, Turvey TA, Phillips C. Orthognathic surgery: a hierarchy of stability. *Int J Adult Orthodon Orthognath Surg.* 1996;11:191.
104. Dowling PA, Espeland L, Sandvik L, Mobarak KA, Hogevoid HE. Le Fort I maxillary advancement: 3-year stability and risk factors for relapse. *Am J Orthod Dentofac Orthop.* 2005;128:560.
105. Louis PJ, Waite PD, Austin RB. Long-term skeletal stability after rigid fixation of LeFort I osteotomies with advancements. *Int J Oral Maxillofac Surg.* 1993;22:82.
106. Nimkarn Y, Miles PG, Waite PD. Maxillomandibular advancement surgery in obstructive sleep apnea syndrome patients: long-term surgical stability. *J Oral Maxillofac Surg.* 1995;53:1414.
107. Bishara SE, Chu GW. Comparisons of postsurgical stability of the LeFort I maxillary impaction and maxillary advancement. *Am J Orthod Dentofac Orthop.* 1992;102:335.
108. Bailey LJ, Phillips C, Proffit WR, Turvey TA. Stability following superior repositioning of the maxilla by LeFort I osteotomy: five-year follow-up. *Int J Adult Orthodon Orthognath Surg.* 1994;9:163.
109. Emshoff R, Scheiderbauer A, Gerhard S, Norer B. Stability after rigid fixation of simultaneous maxillary impaction and mandibular advancement osteotomies. *Int J Oral Maxillofac Surg.* 2003;32:137.
110. Mogavero FJ, Buschang PH, Wolford LM. Orthognathic surgery effects on maxillary growth in patients with vertical maxillary excess. *Am J Orthod Dentofac Orthop.* 1997;111:288.

111. Hedemark A, Freihofer HP. The behavior of the maxilla in vertical movements after LeFort I osteotomy. *J Maxillofac Surg.* 1978;6:244.
112. Ellis E III, Carlson DS, Frydenlund S. Stability of midface augmentation: an experimental study of musculoskeletal interaction and fixation methods. *J Oral Maxillofac Surg.* 1989;47:1062.
113. Rosen HM. Definitive surgical correction of vertical maxillary deficiency. *Plast Reconstr Surg.* 1990;85:215.
114. Major PW, Philippon GE, Glover KE, Grace MG. Stability of maxilla downgrafting after rigid or wire fixation. *J Oral Maxillofac Surg.* 1996;54:1287.
115. de Mol van Otterloo JJ, Tuinzing DB, Kostense P. Inferior positioning of the maxilla by a LeFort I osteotomy: a review of 25 patients with vertical maxillary deficiency. *J Craniomaxillofac Surg.* 1996;24:69.
116. Chow J, Hagg U, Tideman H. The stability of segmentalized LeFort I osteotomies with miniplate fixation in patients with maxillary hypoplasia. *J Oral Maxillofac Surg.* 1995;53:1407.
117. Junger TH, Krenkel C, Howaldt HP. LeFort I sliding osteotomy: a procedure for stable inferior repositioning of the maxilla. *J Craniomaxillofac Surg.* 2003;31:92.
118. Gulabivala K, Naini FB. The orthodontic-endodontic interface. In: Gulabivala K, Ng YL, editors. *Endodontics.* 4th ed. St Louis: Mosby; 2014.
119. El Deeb M, Wolford L, Bevis R. Complications of orthognathic surgery. *J Clin Plast Surg.* 1989;16(4):825–40.
120. Kiani MT, Tajik G, Ajami M, Fazli H, Kharazifard MJ, Mesgarzadeh A. Trigemino-cardiac reflex and haemodynamic changes during Le Fort I osteotomy. *Int J Oral Maxillofac Surg.* 2016;45:567–70.
121. Chen Z, Mo S, Fan X, et al. A Meta-analysis and Systematic Review Comparing the Effectiveness of Traditional and Virtual Surgical Planning for Orthognathic Surgery: Based on Randomized Clinical Trials. *Journal of Oral and Maxillofacial Surgery: Official Journal of the American Association of Oral and Maxillofacial Surgeons.* 2020 Sep. <https://doi.org/10.1016/j.joms.2020.09.005>.
122. Heufelder M, Wilde F, Pietzka S, et al. Clinical accuracy of waferless maxillary positioning using customized surgical guides and patient specific osteosynthesis in bimaxillary orthognathic surgery. *Journal of Cranio-maxillo-facial Surgery: Official Publication of the European Association for Cranio-maxillo-facial Surgery.* 2017;45(9):1578–85.

Additional Readings

- Laster Z, Ardekian L, Rachmiel A, Peled M. Use of the ‘shark-fin’ osteotome in separation of the pterygomaxillary junction in Le Fort I osteotomy: a clinical and computerized tomography study. *Int J Oral Maxillofac Surg.* 2002;31(1):100–3.
- Cheng LH, Robinson PP. Evaluation of a swan’s neck osteotome for pterygomaxillary dysjunction in the Le Fort I osteotomy. *Br J Oral Maxillofac Surg.* 1993;31(1):52–3.
- Stajčić Z. Altering the angulation of a curved osteotome—does it have effects on the type of pterygomaxillary disjunction in Le Fort I osteotomy? An experimental study. *Int J Oral Maxillofac Surg.* 1991;20(5):301–3.
- Trimble LD, Tideman H, Stoelinga PJ. A modification of the pterygoid plate separation in low-level maxillary osteotomies. *J Oral Maxillofac Surg.* 1983;41(8):544–6.
- Perez D, Ellis E 3rd. Sequencing bimaxillary surgery: mandible first. *J Oral Maxillofac Surg.* 2011;69(8):2217–24.
- Hackney FL, Timmis DP, Van Sickels JE. Esthetic evaluation of frontal labial morphology after double V-Y closure following Le Fort I osteotomy. *J Oral Maxillofac Surg.* 1989;47(12):1277–80; discussion 1281.
- Khamashta-Ledezma L, Naini FB. Systematic review of changes in maxillary incisor exposure and upper lip position with Le Fort I type osteotomies with or without cinch sutures and/or VY closures. *Int J Oral Maxillofac Surg.* 2014;43(1):46–61.

Open Access This chapter is licensed under the terms of the Creative Commons Attribution 4.0 International License (<http://creativecommons.org/licenses/by/4.0/>), which permits use, sharing, adaptation, distribution and reproduction in any medium or format, as long as you give appropriate credit to the original author(s) and the source, provide a link to the Creative Commons license and indicate if changes were made.

The images or other third party material in this chapter are included in the chapter's Creative Commons license, unless indicated otherwise in a credit line to the material. If material is not included in the chapter's Creative Commons license and your intended use is not permitted by statutory regulation or exceeds the permitted use, you will need to obtain permission directly from the copyright holder.





70.1 Introduction

Physical appearance is of much significance to the humans, as the human mind perceives the slightest form of deviation from normal form, function, and symmetry of the body and especially of the face as it is easily discernible [1]. Facial asymmetry could be defined as a clinically perceptible and significant difference between the two halves of the face. Every individual has some degree of asymmetry which may provide a uniqueness to the face. However, the magnitude and acceptability of the same depend on the location of the asymmetry and the patient's perception of disproportion. Facial asymmetry may also adversely affect the patient's nutritional and psychosocial development [2].

Any abnormality of the soft or hard tissues can lead to asymmetry. This could be a consequence of a congenital anomaly, a developmental, or an acquired defect. Asymmetry can be progressive in nature, while those acquired due to trauma or ablative surgeries are non-progressive [2, 3]. It is prudent for the clinician to consider the aetiology of the asymmetry, the extent, and its severity in all three dimensions in order to provide an optimal treatment plan. Besides, it is important to take into consideration factors such as growth, timing of treatment, and psychological aspirations of the patients when deciding the treatment plan [3, 4].

The present chapter will discuss the etiopathogenesis and classifications, clinical considerations, and diagnosis, evaluation, and treatment planning of facial asymmetries. Few interesting case scenarios will also be discussed for a better understanding of clinical presentations and their management.

70.2 Classification

Understanding the etiopathogenesis and classification of facial asymmetry allows for accurate diagnosis, optimal treatment planning, and improved surgical outcomes. Facial asymmetries are most commonly classified according to aetiology or morphology. Other classifications are based on time of onset, structures involved, and surgical planning outcomes and may even be restricted to the mandible alone. Table 70.1 is a summary of the various classification systems available to us today [5–19].

We have identified three classifications that are essential for the evaluation and treatment planning of facial asymmetries [Table 70.2 by Cheong et al. (2011) [13], Table 70.3 by Wolford et al. in (2009) [11], Table 70.4 by Wolford et al. (2014) [2, 19–21]].

70.3 Diagnostic Evaluation

Facial asymmetry is usually the least at the cranial base level and increases toward the lower levels of the face, with the mandible and chin commonly exhibiting the greatest asymmetry. Hence, the cranial base is used as a reference plane for assessing the type and severity of the asymmetry in the middle and lower thirds of the face. Conditions where the cranial base is also involved like syndromic or non-syndromic craniosynostosis, tumors of the cranium, and midface and Tessier's craniofacial clefts cannot be assessed in a routine manner. The presence of orbital dystopia, unequal pupillary heights, and/or unequal ear heights will make the assessment more challenging [2, 20, 22, 23].

Every clinical examination begins with identifying the chief complaint of the patient followed by a detailed physical and medical evaluation of the patient. In order to better understand the facial asymmetry, it is studied in the sagittal, coronal, and vertical dimensions with the cranial base as the reference plane. Common facial planes that represent the

N. N. Andrade (✉) · P. Mathai · N. Aggarwal
Department of OMFS, Nair Hospital Dental College, Mumbai
Central, Mumbai, India

Table 70.1 Summary of the various classification systems

Author	Based on	Classification subsets
Pirttiniemi, 1994 [5]	Time of onset	Pre-natal [further divided into embryonal and fetal] and post-natal
Bishara, 1994 [6]	Structures	Dental, skeletal, muscular, functional, and combination
Lundstrom, 1961 [7]	Etiology	Genetic, non-genetic, and combination
Plint, 1974 [8]	Etiology	Laterocclusion [apparent asymmetry due to occlusal disharmony] and laterognathism [true facial asymmetry]
Chia, 2008 [9]	Etiology	Pathological, functional, traumatic, and developmental
Haraguchi, 2008 [10]	Etiology	Hereditary factors of pre-natal origin and acquired factors of post-natal origin
Wolford, 2009 [11]	Etiology	Pseudo-asymmetry, normal facial asymmetry [non-pathologic], unilateral overdevelopment, and unilateral underdevelopment
Reyeneke, 2010 [12]	Etiology	Congenital, developmental, post-traumatic, and pathology-related
Cheong, 2011 [13]	Etiology	Congenital [pre-natal origin], acquired [injury or disease], and developmental [unknown origin]
Waite, 2012 [4]	Etiology	Congenital [malformation, deformities, and disruptions], developmental [primary and secondary growth deformities], acquired [trauma and pathology], and idiopathic
Obwegeser, 1986 [mandible only] [15]	Morphology	Hemi-mandibular elongation, Hemi-mandibular hyperplasia, combined/hybrid forms
Cohen, 1995 [16]	Morphology	Hemi-hyperplasia [hemifacial hypertrophy], Hemi-hypoplasia [hemifacial microsomia], Hemi-atrophy [Parry Romberg syndrome], and miscellaneous entities [hemi-maxillofacial dysplasia]
Kim, 2014 [mandible only] [17]	Morphology centric surgical outcome	TML system for optimal surgical planning in mandibular prognathism cases only: menton deviation with transverse asymmetry [T], maxillary cant [M], and lip cant [L]
Hwang, 2007 [mandible only] [8]	Morphology	Based on deviation of the chin and bilateral difference between mandibular rami length
Wolford, 2014 [mandible only] [19]	Morphology, imaging, etiology, histology	Restricted to condylar hyperplasia [CH] only: Type 1 CH [prolonged accelerated growth], Type 2 CH [osteochondroma], Type 3 CH [benign tumors other than osteochondroma], and Type 4 CH [malignant tumors]

Table 70.2 Major etiological factors of facial asymmetry, according to Cheong et al. (2011) [13]

Congenital factors	Acquired factors	Developmental factors
Cleft land cleft palate	TMJ ankylosis	Unknown cause
Tessier's clefts	Facial trauma	
Hemifacial Microsomia	Children's radiotherapy	
Neurofibromatosis	Fibrous dysplasia	
Congenital muscular torticollis	Facial tumors	
Craniosynostoses	Unilateral condylar hyperplasia	
Vascular disorders	Parry Romberg syndrome	
Others	Others	

cranial base are the pupillary plane, the ear plane, and the clinical Frankfort horizontal plane. It is also important to note that patients may hold the head in an abnormal position or use hairstyles and mannerisms to mask the extent of the asymmetry [e.g., a patient with a deficient mandible may tip his head upward in order to improve chin projection]. It is important to identify these compensatory mechanisms during the treatment planning process. Similarly, it can be beneficial to study the lower or middle third individually in comparison with the unaffected upper third [cranial base] by blocking out the part not being studied with an opaque sheet [e.g., card board] [20, 23].

70.3.1 Clinical Evaluation: Frontal, Axial, and Profile

Frontal View

The patient's head is positioned such that the interpupillary plane or ear plane [passing through the bottom of the ear lobes or tragi of the ears] is parallel to the floor. The pupillary plane can also be used for assessing bilateral vertical discrepancies by measuring height differences from the plane to the mandibular angles, chin, nose, and commissures (Fig. 70.1). The facial midline is represented by a vertical plane passing through the nasion or glabella, perpendicular to the pupillary plane and ear plane (Fig. 70.2). It allows to compare the degree of left-to-right asymmetry and transverse facial width discrepancies of various facial structures [e.g., orbits, pupils, malar eminences, nose, commissures, and mandibular angles]. In case of some imbalance in the frontonasal region [e.g., past naso-orbito-ethmoidal trauma], other landmarks can also be used as a reference to identify the facial midline, e.g., half the interpupillary or inter-canthal distance, the subnasal point, or the philtrum [20, 22].

Table 70.3 Wolford's classification of facial asymmetry 2009 [11]

Pseudo-asymmetry	Normal facial asymmetry	Unilateral	
		Overdevelopment	Underdevelopment
Occlusal interferences	Genetics	Condylar hyperplasia / Mandibular hyperplasia/Deviant prognathism	Acquired: trauma, infection, TMJ ankylosis, and iatrogenicities [due to tumor resection, radiation, unstable orthognathic procedures and adverse surgical events], failed TMJ alloplastic implants, and failed autogenous tissue grafts
Neuromuscular dysfunction	Intrauterine moulding	Osteochondroma/osteoma	
Habitual posturing	Natural growth variance	Unilateral muscle hyperplasia [masseteric muscle hypertrophy]	
Condylar dislocation		Other benign/malignant tumors	
Temporary unilateral facial swelling due to trauma/infection		Neuromuscular disorders [facial nerve trauma, Bell's palsy, Ramsey-Hunt syndrome, Mobius syndrome, mastoid infections, and cerebral vascular accidents affecting the facial nerve]	Congenital deformities [unilateral cleft lip and palate, hemifacial microsomia, and Treacher Collins syndrome]
			Adolescent idiopathic condylar resorption
			TMJ reactive [inflammatory] arthritis
			Connective tissue and autoimmune diseases

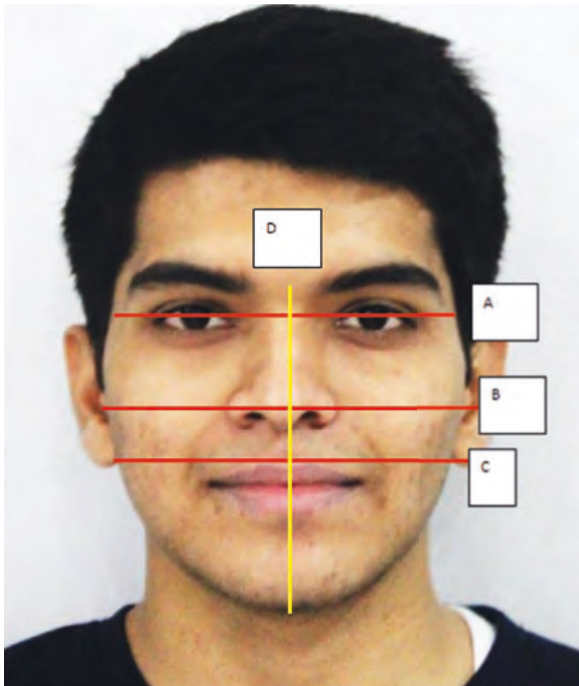
Table 70.4 Wolford's classification of condylar hyperplasia [CH] 2014 [2, 19–21]

CH type	Age at onset	Clinical findings	Imaging	Histology
CH Type 1 [similar to hemi-mandibular elongation]: Type 1A and Type 1B	Puberty	Type 1A Bilateral [BL] or Type 1B Unilateral [UL] accelerated growth; self-limiting; Class 3 occlusion; prognathic mandible	UL/BL elongated condylar head, neck and body; normal condylar head shape	Normally growing condyle; may show chondrocyte proliferation during initial and active phases, with normal bone after growth ceases
CH Type 2 [similar to hemi-mandibular hyperplasia]: Type 2A and Type 2B	Two-thirds of cases begin in 2nd decade	UL vertical elongation of face and jaws; non-self-limiting; ipsilateral posterior open bite; occlusal cant occasionally	Unilateral vertical enlarged condylar head, neck, ramus and body; Type 2A: Enlargement without horizontal exophytic growth of the condyle; Type 2B: enlargement with exophytic growth of the condyle	Osteochondroma; cartilaginous cap similar to that seen in a normal growth cartilage; endochondral ossification; cartilaginous islands in the sub-cortical bone; thickened irregular bony trabeculae
CH Type 3	No specific age	UL facial enlargement	Varies from normal anatomy of condyle; usually presenting as condylar enlargement	Benign tumors, e.g., osteoma, neurofibroma, giant cell tumor, fibrous dysplasia, chondroma, chondroblastoma, and arterio-venous malformation
CH Type 4	No specific age	UL facial enlargement	Varies from normal anatomy of condyle; usually presenting as condylar enlargement with lytic lesions	Malignant tumors, e.g., chondrosarcoma, multiple myeloma, osteosarcoma, metastatic lesion, and Ewing's sarcoma

The patient should be reminded to relax the peri-oral musculature for assessing the tooth to upper lip relation at rest [e.g., patients with vertical maxillary excess will constantly purse their lips to reduce excessive gum and teeth show]. The smile needs to be assessed for the amount of gingival show on either side, tooth to upper lip relation, comparison of dental midline with facial midline and symmetry by comparing parallelism of commissural and pupillary lines. Finally, a tongue blade or thin ruler can be placed between the maxillary and mandibular canines and premo-

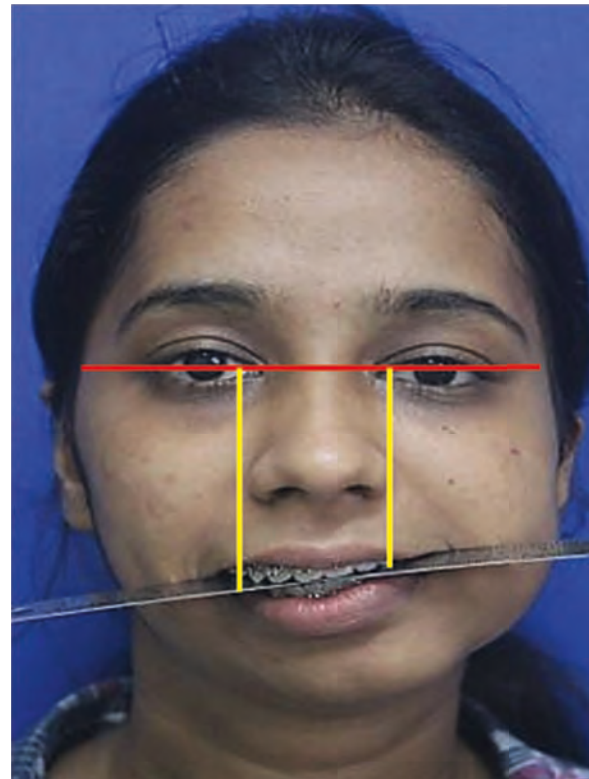
lars to assess the presence of a cant in relation to the pupillary plane (Fig. 70.2). Comparing the vertical heights from the pupillary plane to the canine tips on either side can help quantify the cant. An occlusal plane inclination of greater than 4° is said to cause significant perceptible asymmetry.

Assessment of midline structures such as nasal bridge, nasal tip, philtrum, and the chin point should also be carried out. Submental [worm's-eye] (Fig. 70.3) and superior [bird's-eye] views (Fig. 70.4) are very useful in assessing deviation of the abovementioned structures. We can also assess symmetry



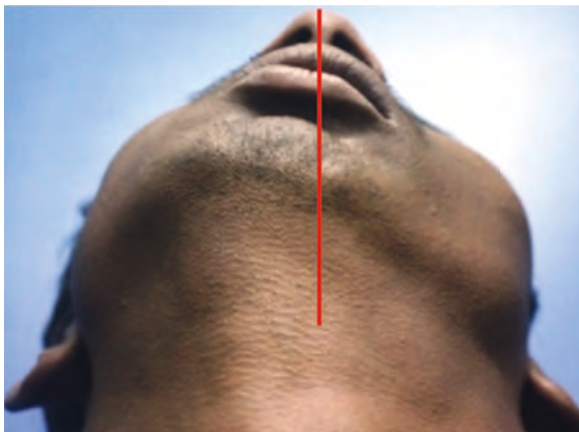©Association of Oral and Maxillofacial Surgeons of India

Fig. 70.1 Various facial planes **A** horizontal plane (interpupillary plane) **B** horizontal plane (intertragal plane) **C** horizontal plane (plane marked through ear lobes) **D** vertical plane (mid-sagittal plane)



©Association of Oral and Maxillofacial Surgeons of India

Fig. 70.2 Occlusal cant in relation to the pupillary plane and asymmetry marked from medial canthi to the oral commissure



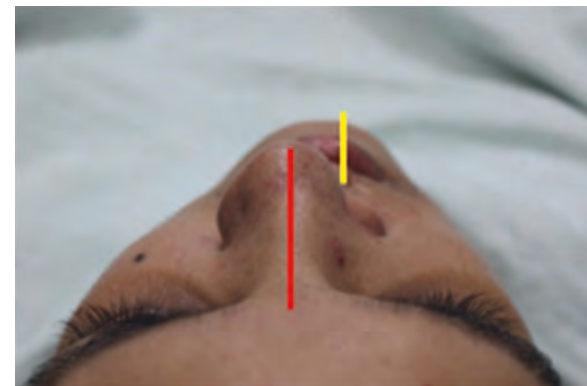©Association of Oral and Maxillofacial Surgeons of India

Fig. 70.3 Submental (worm's-eye) view exhibiting asymmetry in the lower facial third and skeletal midline

and projection of the anterior cranial vault, orbital areas, nose, cheeks, malar eminences, and mandibular body contours.

Profile View

In order to avoid underestimating the severity of the facial asymmetry due to compensatory head postures, it is



©Association of Oral and Maxillofacial Surgeons of India

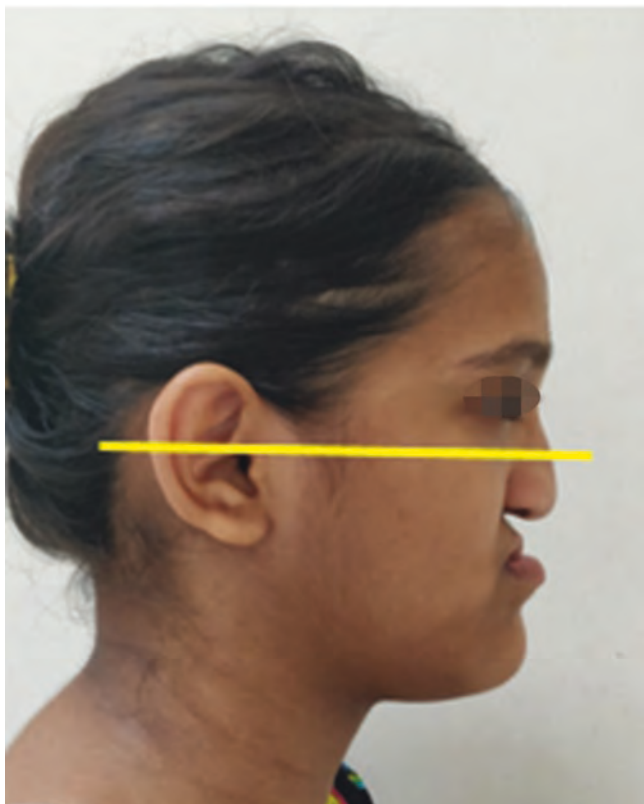Fig. 70.4 Superior (bird's-eye) view exhibiting midline discrepancy and rotation of the face

essential to position the head so that the clinical Frankfort horizontal plane (a line from the tragus of the ear through the palpable bony infraorbital rim) is parallel to the floor (Fig. 70.5). The patient should also be reminded to relax the peri-oral musculature to better assess the tooth to upper lip relation at rest. Evaluating the left and right

sides from the profile view will allow assessment of discrepancies in the antero-posterior and vertical dimensions [e.g., maxilla, mandible, and chin] rather than asymmetry evaluation.

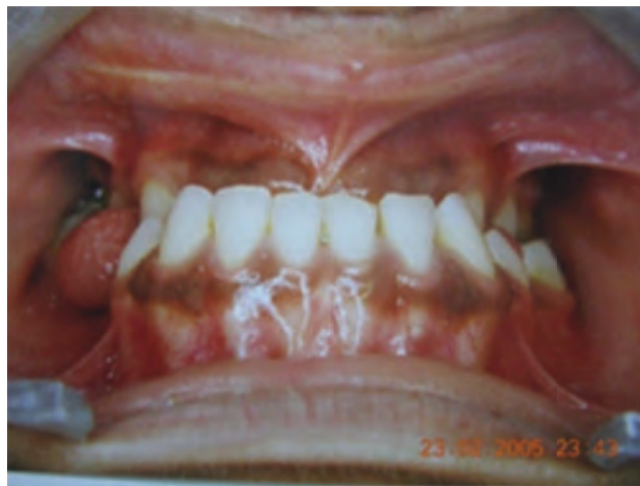70.3.2 Oral Examination

Orthodontic study models mounted in centric relation by face-bow transfer onto a semi-adjustable anatomic articulator help in dento-alveolar and occlusal assessment with a further advantage of studying the occlusion from the lingual aspect. The dental arches are evaluated for overdevelopment, underdevelopment, presence of yaw, and asymmetry in the antero-posterior, transverse, and vertical planes. The dental examination should include the presence or absence of missing, deformed, carious, impacted, or ankylosed teeth; dental midline shift; dental crowding or spacing; congenital deformity [e.g., cleft alveolus in a case of cleft lip and palate]; habitual pattern [e.g., tongue thrusting or thumb sucking]; pathology; and size of tongue and trauma (Figs. 70.6, 70.7, and 70.8). These findings can be incorporated into the treatment planning.



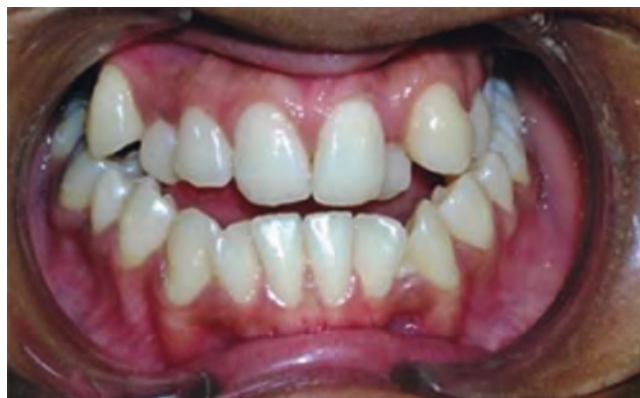©Association of Oral and Maxillofacial Surgeons of India

Fig. 70.5 Orientation of FH plane parallel to the floor



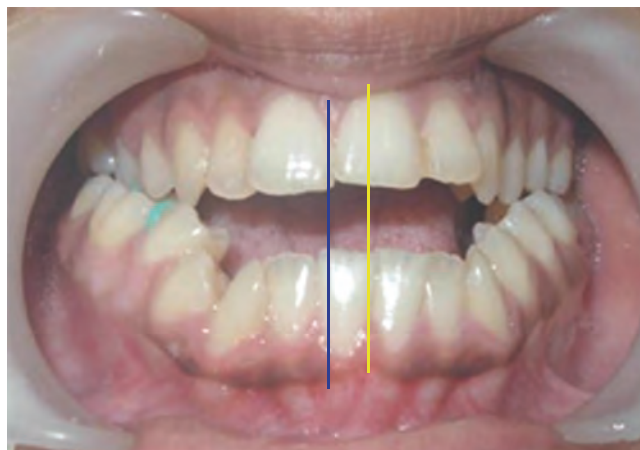©Association of Oral and Maxillofacial Surgeons of India

Fig. 70.6 Complete telescoping of the maxilla



©Association of Oral and Maxillofacial Surgeons of India

Fig. 70.7 Crowding in both arches along with a reverse overjet



©Association of Oral and Maxillofacial Surgeons of India

Fig. 70.8 Non co-incident dental midlines (blue-upper dental mid line, yellow-lower dental midline)

70.3.3 Photographic Examination

A dedicated photography room where extra-oral and intra-oral photographs are taken under standardized settings [e.g., lighting, background, focal length, and distance-to-subject] is ideal. Extra-oral photographs of the frontal [with and without smile, occlusal and mandibular inferior border cant], three-quarter, submental, and superior views are essential for the assessment of facial asymmetry. Intra-oral frontal, lateral, superior [45° to the occlusal plane from above], and inferior [45° to the occlusal plane from below] views with the teeth in occlusion are essential for dento-alveolar assessment [11, 23–26].

70.3.4 Radiographic Examination

The three primary radiographic examinations performed in the assessment of facial asymmetry are lateral cephalometry, postero-anterior cephalometry, and orthopantomography. They have been described briefly below. As a rule, serial cephalometric assessment every 6 months for a minimum duration of 1 year may be helpful in determining if the asymmetry is static and stable or if it is progressive [24, 25].

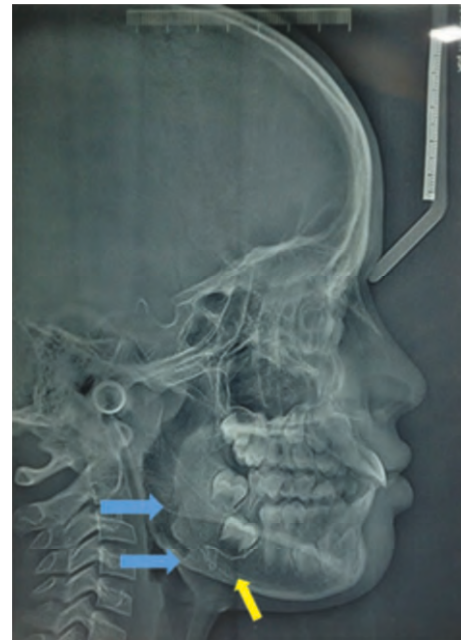1. Lateral Cephalometry:

It is used to assess hard tissue and soft tissue relationships in 2D, i.e., antero-posterior and vertical dimensions. This tool is less commonly used to assess facial asymmetry. The head is placed into a reproducible position within the cephalostat with the help of the nasal bridge indicator and ear roads which closely approximates the clinical Frankfort horizontal plane. The patient keep should also be instructed to keep the jaws in centric relation with the teeth lightly touching and the lips slightly parted or relaxed. The ability of the cephalostat to reproduce the near about the same position every time allows for comparative cephalometric analysis and super-imposition of tracings. Bilateral vertical discrepancies [e.g., increased vertical dimension of the body and ramus-condyle unit of the mandible in unilateral condylar hyperplasia type 2] can usually be assessed in a lateral cephalogram. The right and left sides are presented as two separate non-super-imposing lines, and this can be measured as a discrepancy between the two images of the occlusal plane and inferior borders of the mandible (Fig. 70.9).

2. Orthopantomograph [OPG]:

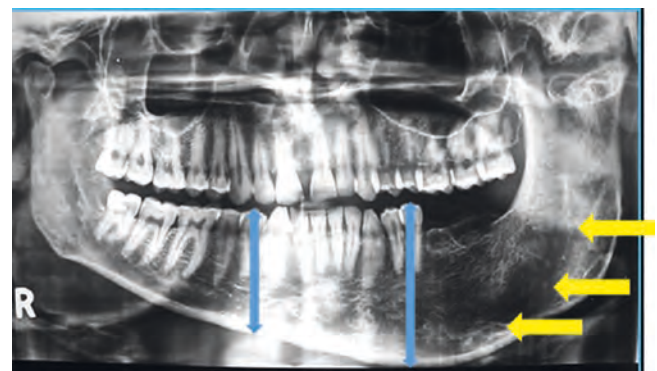
The OPG is an excellent tool to evaluate mandibular asymmetry and dental status. The anatomy of the condyle—ramus unit, body, and inferior border of the mandible is readily discernible. Increase or decrease in dimensions or changes in mandibular morphology can be studied. In cases of unilateral asymmetry, the affected side

can be compared to the normal side. The course of the inferior alveolar nerve can also be assessed and is of vital importance if an inferior border osteotomy is being performed [e.g., inferior border osteotomy in cases of unilateral condylar hyperplasia type 2 where the inferior alveolar nerve might be coursing near the lower border of the mandible] (Fig. 70.10). The OPG is also an excellent tool for the screening of maxillofacial pathology that may cause facial asymmetry, e.g., tumors and fibro-osseous lesions.



©Association of Oral and Maxillofacial Surgeons of India

Fig. 70.9 Lateral cephalogram showing double images of the inferior border of the mandible (blue arrows) along with displaced IAN canal (yellow arrow) in a case of type 2 condylar hyperplasia



©Association of Oral and Maxillofacial Surgeons of India

Fig. 70.10 OPG demonstrating the difference in height of the mandibular body (blue arrows), displacement of the IAN canal toward the inferior border (yellow arrows)

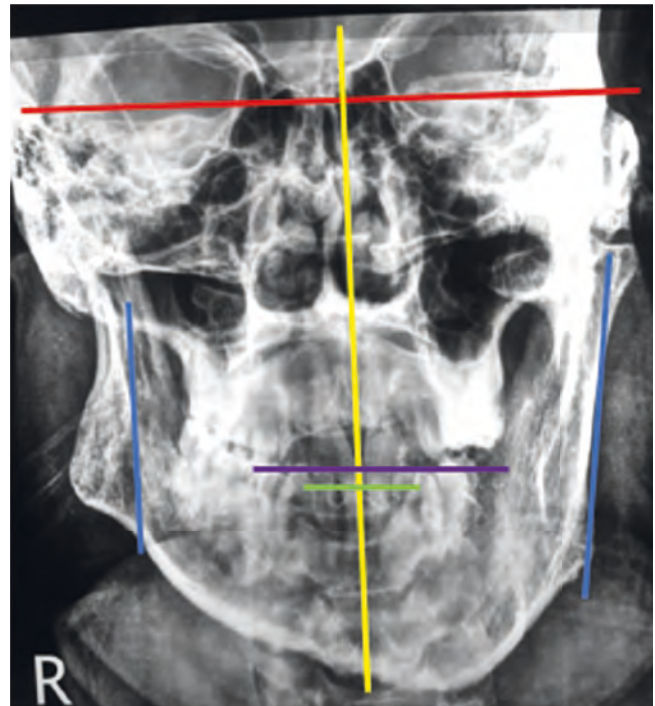
3. Postero-antero Cephalometry:

The PA cephalogram allows a comparative study of the symmetry between the structures of the right and left sides. Projections can be obtained in both open mouth position and centric occlusion with head oriented in natural head position to identify the full extent of static and dynamic [functional] asymmetry. The horizontal reference plane is represented by a line passing through the bilateral zygomatico-frontal sutures. The vertical reference plane is a line perpendicular to the horizontal plane passing through crista galli. Transverse and vertical distances of various facial structures are measured by drawing perpendicular lines drawn from the structures in question to the vertical and horizontal reference planes. By comparing the distances measured bilaterally, the type and extent of the underlying asymmetry can be assessed. Additionally, a shift in the dental midlines can be assessed by comparing them to the skeletal midline. The Grummons and Ricketts analyses are commonly used PA cephalometric analyses for the evaluation of facial asymmetry (Fig. 70.11).

4. Computed Tomography/Cone Beam CT with 3D Reconstruction:

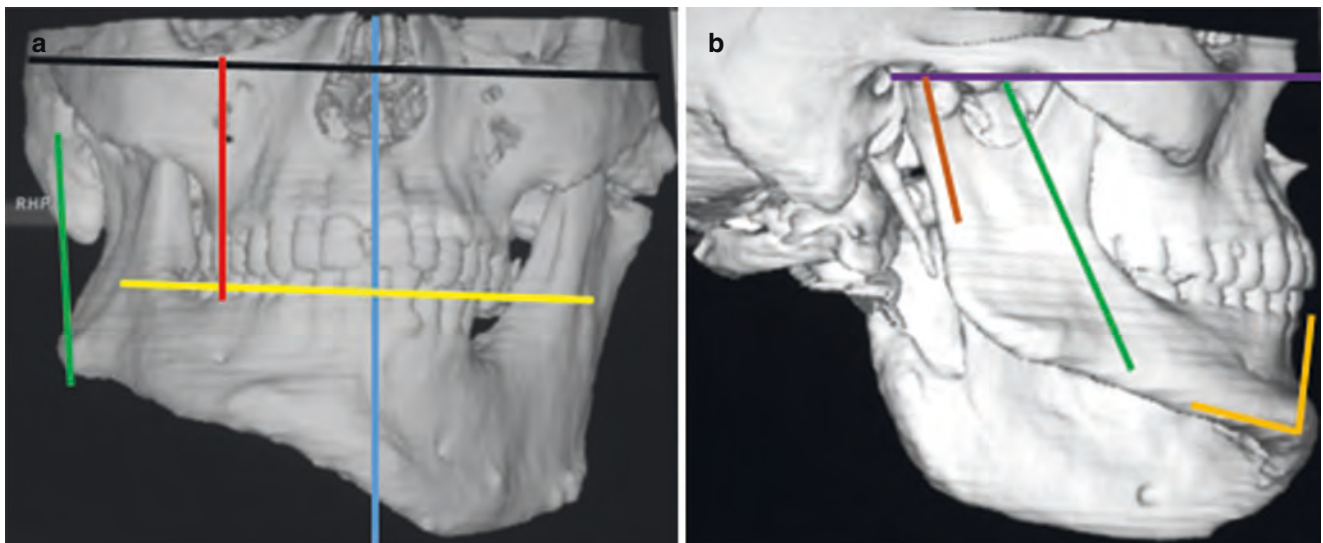
The main advantage of the 3D CT scan is that it helps in visualization and treatment planning of complex facial asymmetry in cases like craniosynostosis, Treacher Collins syndrome, hemifacial microsomia (Figs. 78.4, 78.5 and 78.6), TMJ ankylosis, and unilateral condylar hyperplasia (Fig. 70.12a, b). Unlike cephalometric and panoramic radiographs, there is no superimposition of structures, the absolute position of anatomical landmarks

can be defined, and viewing is possible from any angle. It is also an excellent tool for patient education. The CT scan data can be used for fabrication of stereolithographic



©Association of Oral and Maxillofacial Surgeons of India

Fig. 70.11 Grummons and Ricketts analysis using PA Cephalogram for evaluating the facial asymmetry. Horizontal reference plane (red); vertical reference plane (yellow); ramal height (blue); intercuspid width (green); intermolar width (purple). Refer to additional reading



©Association of Oral and Maxillofacial Surgeons of India

Fig. 70.12 (a, b) 3DCT face analysis for assessing the facial asymmetry. Various parameters include, Arbitrary horizontal reference plane assuming orbits are normal (black); FH plane (purple); mandibular height [canine to mandibular plane (orange)]; maxillary height (first

molar to FH) (red); ramal length (Co superior to Go inferior) (green); occlusal plane (yellow); lateral ramal inclination (Co superior to Go posterior to FH) (brown); midsagittal plane (light blue)

medical models which help make surgical planning even easier. The disadvantage of the CT scan is the exposure to a high radiation dose; with the introduction of the CBCT, the amount of radiation exposure has been greatly reduced. 3D reconstruction, stereolithographic model printing and integration with 3D stereo photogrammetry data allows for treatment planning, treatment simulation, and assessment customized according to the patient [e.g., Dolphin 3D, IPS by KLS Martin]. Lastly, both CT and CBCT provide valuable information regarding the hard tissue status of the TMJ and aid in the diagnosis of reactive [inflammatory] arthritis of the TMJ, osteoarthritis of the TMJ, idiopathic condylar resorption, avascular necrosis, and degenerative remodeling of hard tissues of the TMJ in dentofacial asymmetries [24, 25].

5. Magnetic Resonance Imaging:

MRI is primarily used to study the soft tissues of the TMJ [e.g., disc, capsule, ligaments] and combined with the CT/CBCT scan data is able to accurately diagnose reactive [inflammatory arthritis] of the TMJ, internal derangements, condylar resorption, and degenerative remodeling of soft tissue of the TMJ in dentofacial asymmetries (Fig. 70.13a, b) [e.g., thinning and displacement of the disc of the contralateral unaffected TMJ in cases of unilateral condylar hyperplasia] [24, 25].

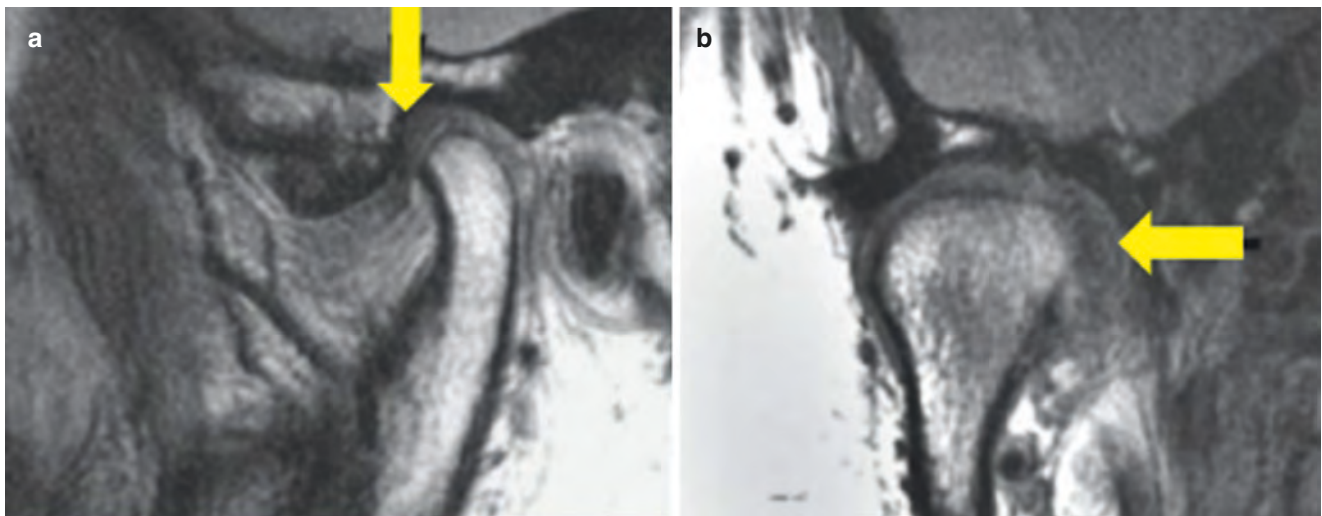
70.3.5 Stereophotogrammetry

It is the construction of a three-dimensional model based on the positions of recognizable points or landmarks in several different photographs. It utilizes two or more cam-

eras configured to capture a pair of stereo images of the surface of patient's face which are then used to generate a 3D image of the face by triangulation performed through sophisticated stereo algorithms. The technique is minimally invasive and has an expanded coverage of close to 360° of the structure being studied with quick capture speeds (often under 1 second). These advantages make it particularly useful when working with young children [with craniofacial deformities] for whom quantification of facial features can be challenging [25, 26]. The ability to store images for subsequent use, accurate reproduction of the surface geometry of the face, and ability to map realistic color and texture data onto the recorded geometric shape make this technique the preferred facial surface imaging modality over older conventional imaging modalities like laser scanning [26].

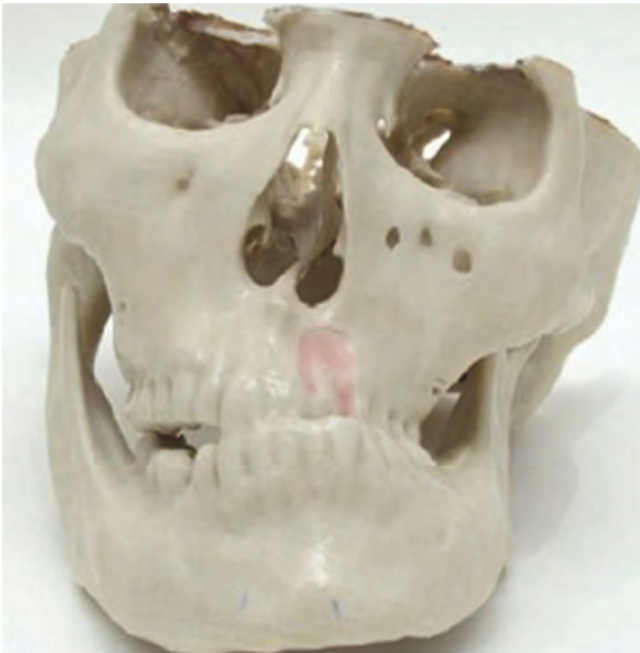70.3.6 Stereolithographic [SLA] Models

Medical modelling involves first acquiring a CT, CBCT, or MRI. This data consists of a series of cross-sectional images of the region being studied. The selected part is now created in a layer-by-layer fashion using photopolymerization ultimately forming a three-dimensional solid. The use of such models in maxillofacial surgery has significantly improved predictability of clinical outcomes in facial asymmetry cases when compared to similar treatments without its use. The models facilitate direct visualization of complex 3D facial asymmetry, decrease operating time due to better treatment planning, and can also be used as an educational tool for patients (Fig. 70.14) [27].



©Association of Oral and Maxillofacial Surgeons of India

Fig. 70.13 (a, b) MRI of TMJ showing anteromedial disc displacement (yellow arrows)



©Association of Oral and Maxillofacial Surgeons of India

Fig. 70.14 Facial asymmetry demonstrated on STL model involving both the midface and mandible with hyperplasia involving the right side

70.3.7 Virtual Surgical Planning [VSP]/ Computer-Aided Surgical Simulation [CASS]

VSP/CASS involves four key stages demonstrated in Box 70.1.

Figure 70.15 shows the sequence involved in VSP/CASS. The advantages are an increased dental relationship accuracy, reduced OR time, increased patient satisfaction, and decreased costs. Simulating surgery preoperatively allows measurements to the 1/100th of a millimeter, and when combined with 3D-printed splints and customized pre-bent plates, the reconstructive and aesthetic outcome is supe-

Box 70.1 Four key stages in virtual surgical planning

- Data collection and pre-surgical workup
- Virtual treatment planning
- Splint fabrication
- Surgery and accuracy

Data collection and presurgical work-up

Clinical examination

Occlusal record (casts)

Centric relation record

CBCT or CT scan

Final occlusion established by surgeon

Data transfer to planning center

Planning specifics – order from (osteotomy design, order of osteotomy, and anticipated movements)

Virtual treatment planning – web meeting/video conferencing (for sequence of treatment planning)

Natural head position based on clinical examination

Frontal planning – midline/yaw or cant/roll correction

Profile planning – repositioning of central incisor/pitch changes (anteroposterior and vertical)

 Occlusal plane changes (clockwise or counterclockwise)

 Based on 2-D imaging programs

Yaw/ orientation of proximal and distal segments

Segment orientation/ interferences

Splint design

Surgery

Transfer of virtual planning to operating room

Occlusal splints

Cutting guides to aid in orientation of bony osteotomy

Occlusal borne guides to aid in repositioning of bony segment

Templates to aid in contouring of bone grafts

Predictive hole placement for custom plating of osteotomies

Accuracy

Merger of postoperative scans to virtual plan

CASS more accurate than traditional model surgery

Improved clinical outcomes with CASS

Fig. 70.15 Flow chart outlining the steps involved in virtual surgical planning has been reproduced after permission from the article “Farrell BB, Franco PB, Tucker MR. Virtual surgical planning in orthognathic surgery. Oral Maxillofac Surg Clin North Am. 2014; 26(4):459–73” [28]

rior to traditional 2-dimensional (2D) modelling and cephalometric tracing [28].

70.3.8 TMJ Examination

TMJs must be healthy for predictable orthognathic surgery outcomes. The TMJ must be assessed before and after orthognathic surgery for joint noises (clicking and popping), localized tenderness, radiating facial [e.g., headaches] and neck pain, and limitation of mouth opening and jaw locking. The literature reports a higher incidence of TMD in patients with retrognathic mandibles and in those with steep occlusal planes [29, 30].

There is no conclusive evidence regarding the effect of orthognathic surgery on TMD with opinions split between improvement, no change, or worsening of signs and symptoms. However, high-angle, class II patients with pre-existing TMD undergoing counterclockwise rotation or large mandibular advancement procedures are known to experience worsening of symptoms. Figure 70.16 is the Boston University Protocol for the management of facial asymmetry requiring orthognathic surgery with pre-existing TMD [29].

70.3.9 Nuclear Medicine Imaging Modalities (Scintigraphy)

A bone scan is a nuclear imaging test that involves injecting a small amount radiotracer that into the bloodstream. The radiotracer travels through the area being examined and gives off radiation in the form of gamma rays which are detected by a special gamma camera and a computer to create images of your bones. Thus, skeletal scintigraphy offers the potential to identify disease in its earliest stages as it is able to identify any abnormal increases in metabolic activity [31].

Cisneros first used bone scintigraphy to study mandibular asymmetry in patients [31]. There are two types of bone scan techniques commonly used: skeletal scintigraphy [subtypes: planar bone scanning and single-photon emission-computed tomography] using technetium-99m methylene diphosphate and positron emission tomography [subtypes: with and without CT, full ring and half ring] using radiolabeled 18F-2-fluoro-2-deoxyglucose [glucose analog].

Planar [regular] scintigraphy is not very accurate as it is only a two-dimensional assessment of three-dimensional anatomy. On the other hand, SPECT [single-photon emission computed tomography] allows three-dimensional assessment as the isotope is dispersed in the subject's body thus allowing spatial localization of the pathology in the mapped body organ.

Dedicated/full-ring PET [as compared to half-ring PET] provides better spatial resolution than a planar bone scanning and SPECT (Refer Fig. 78.13) because of its narrower electronic collimation [full width half maximum (FWHM) central resolution for PET being 6 mm compared with 11 mm for SPECT] [21, 32, 33]. As the condylar growth plate is thin, PET gives an advantage to identify pathologies like condylar hyperplasia.

Important factors to be taken into account when assessing a bone scan:

- The efficacy of bone scan is reduced during the growing phase as condyles are growth centers and both will show increased metabolic activity.
- The efficacy of bone scan is increased after the growth phase is completed as only the affected condyles will show increased metabolic activity.
- The efficacy of bone scan is increased in unilateral cases and reduced in bilateral cases.
- *Condylar Hyperplasia Type 1*
 - The growth in type 1 condylar hyperplasia is only slightly faster than the normal condylar growth rate. Therefore, the difference in intensity of radiotracer uptake between a normal and affected condyle is negligible.
 - The cellular growth activity is confined to a narrow band at the normal growth center resulting in low uptake of the radiotracer.
 - Condylar hyperplasia type 1A cases: It is difficult to differentiate CH type 1A from normal growth as it a bilateral condition with both joints involved.
 - Condylar hyperplasia type 1B cases: As this is a unilateral condition, it is easy to identify clinically. There has to be a difference in activity of at least 10% between the affected side and the normal side for a diagnosis of asymmetric growth activity/unilateral condylar involvement to be made.
- *Condylar Hyperplasia Type 2*
 - It is easy to diagnose on the bone scan as it is usually a unilateral condition with a tumorous rate.
 - There is diffuse cellular activity throughout the tumor in the condylar head which makes it easier to diagnose on the bone scan.

70.4 Clinical Considerations

70.4.1 Occlusal and Orthodontic Considerations

Asymmetries with congenital and developmental etiology are commonly associated with dental compensations in all three dimensions as growth ensues. Rotations and crowding are

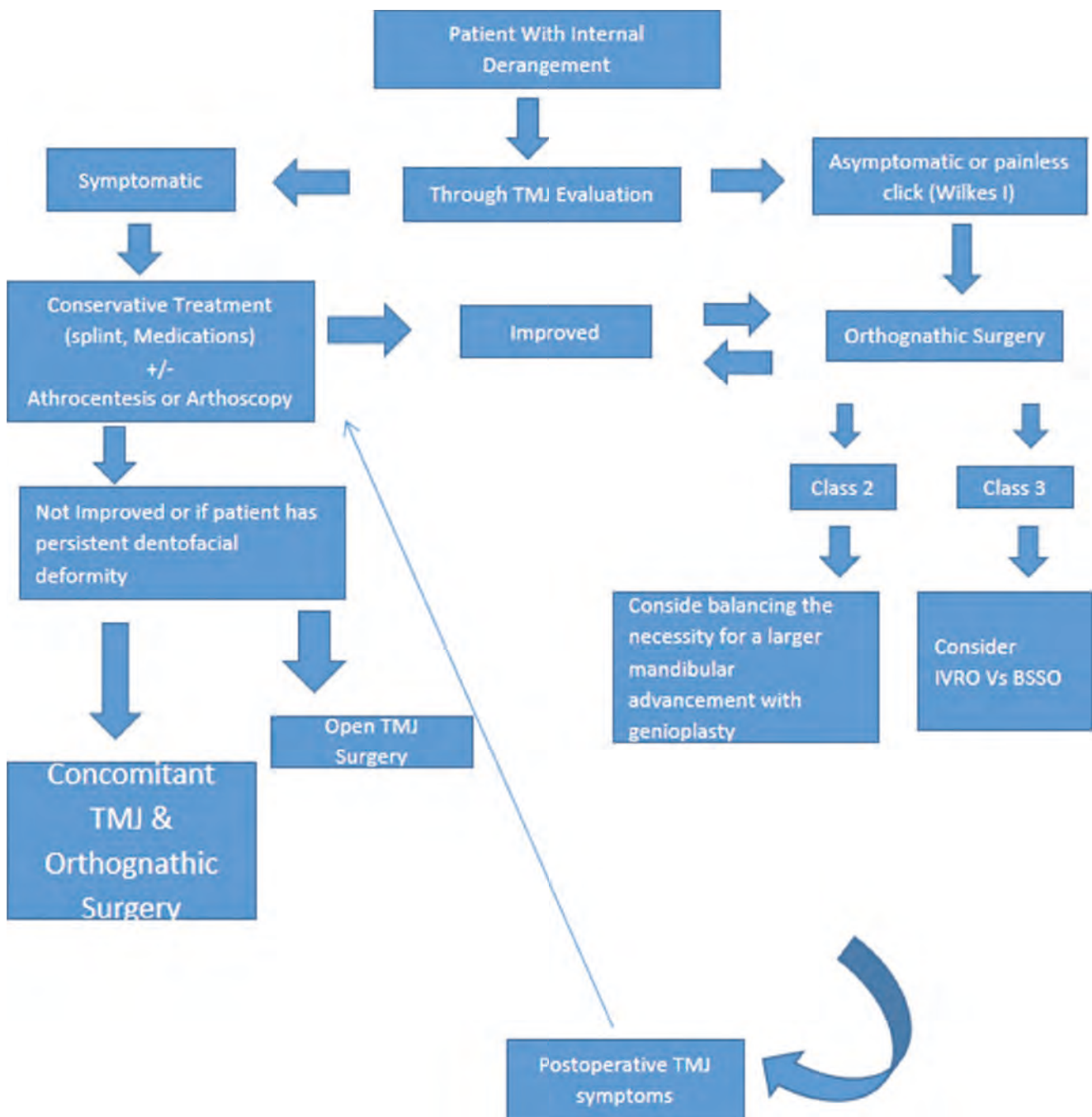


Fig. 70.16 The flow chart outlines the Boston University Protocol for the management of temporomandibular disorders in patients who present for orthognathic surgery and has been reproduced from the article

“Nadershah M, Mehra P. Orthognathic Surgery in the Presence of Temporomandibular Dysfunction. What Happens Next? Oral Maxillofac Surg Clin North Am. 2015; 27(1):11–26” [29]

seen in hypoplasia cases such as hemifacial microsomia, and spacing and cross bites can be encountered in case of overdevelopment such as condylar hyperplasia. Transverse growth discrepancies also result in different arch shapes and Bolton discrepancy. Also, the extent of maxillary asymmetry should be accounted for, as maxilla tends to be ignored in obvious mandibular asymmetry. Thus, pitch, yaw, and roll need to be

adjusted or decompensated keeping the surgical movement in mind [34]. Pre-surgical orthodontic treatment in patients with facial asymmetry must include the following:

- (a) The presence of a dental and facial midline mismatch indicates a discrepancy in the yaw of the affected jaw[s]. Midline correction at the time of orthognathic surgery provides the best results.

- (b) Any occlusal cant correction should not be attempted orthodontically. Cant is evidently skeletal in nature and should be corrected surgically.
- (c) Levelling and alignment of the dental arches should be done.
- (d) Post-operative position of the upper incisor and the upper lip-maxillary incisor relationship is the most important factor determining surgical result. This should be checked intra-operatively before fixation of the maxilla.
- (e) Position of the symphysis similarly is another important determinant of a satisfactory postsurgical correction in cases of asymmetry; thus the anatomical position and surgical limits of symphysis correction should be determined pre-surgically.
- (f) The facial midline reference should be taken from the unaffected jaw.
- (g) In cases of hemifacial microsomia and temporomandibular joint ankylosis, a unilateral open bite is created after increasing the ramus height. This is done to correct the skeletal cant by allowing the vertical alveolar growth of maxilla.
- (h) Cephalometric analyses are essential but seldom definitive in determining the amount of advancement in antero-posterior and vertical movements. Prediction tracings are helpful but not mandatory in planning post-surgical outcome. Specific norms available are not always applicable especially in asymmetry cases as the etiology is variable. The etiology and duration of asymmetry influence the extent and severity of the case.
- (i) Based on the severity of crowding, the amount of retraction and uprighting needed; upper second bicuspid extraction [minimal decompensation] or upper first bicuspid extraction [greater decompensation] is indicated.

70.4.2 Growth and Development of the Craniofacial Skeleton

Importance of understanding growth of the maxillofacial skeleton in an individual presenting with asymmetry cannot be emphasized enough. Almost half of the asymmetries are either due to an underdevelopment or an overdevelopment of the TMJ resulting in a deviated mandible in the vertical or antero-posterior direction or both of the involved side or the contralateral side. If this development takes place in the growing period, the maxilla follows the deviation of the mandible. Interceptive orthodontics can be applied in growing areas to arrest or limit the extent of asymmetry of the maxilla and mandible [35]. However, surgical intervention is

generally needed after completion of growth period for the final skeletal and dental correction. Surgical treatment performed before growth completion is unpredictable on account of the continual growth that the patient experiences till skeletal maturity and as such is reserved only for those cases suffering from extreme functional, aesthetic, and psychological problems. Additional surgery may be needed to correct the recurrent asymmetry. Thus, timing of surgery relies very much on the growth completion.

Serial cephalometric radiographs, scintigraphy, and SPECT scans are useful to assess growth potential. The absence of activity in the TMJ and other areas helps the surgeon to proceed for corrective orthognathic surgery. The second factor for determining the timing of treatment is the progression of the asymmetry. If the asymmetry is progressive like condylar hyperplasia, it is better to wait or perform high condylectomy to check any further asymmetric growth. On the contrary, non-progressive asymmetries such as hemifacial microsomia, treatment can be initiated in early years [36]. Comparably, early surgery has usually been performed for individuals with marked malformations such as plagiocephaly, cleft lip and palate, and/or severe functional burden (e.g., increased intracranial pressure, severe obstructive sleep apnea, etc.). Lastly, in few cases of acquired asymmetry such as tumor resection, “wait-and-watch” policy needs to be adopted to eliminate chances of recurrence before a definitive reconstruction can be planned.

70.4.3 Role of Functional Orthopedics and Interceptive Orthodontics

Functional orthopedics play a substantial role in congenital asymmetries, the greatest example being nasoalveolar molding in cleft lip and palate cases to bring the maxillary segments into a more desirable position prior to surgery. Growth modification with the use of functional appliances is directed toward eruption of the dentition in a more favorable position and prevents worsening of the skeletal asymmetry exacerbated during growth period. Functional therapy is also aimed at maintaining the condyle in a more anatomical position to allow further growth in a symmetrical pattern. Studies have shown that an asymmetric lateral force during the growth period results in growth modification by influencing the morphology of the mandibular bone and the overlying masseter muscle. Occlusal splints can be fabricated to allow for mandibular shifts toward midline, and open bite can be created to eliminate canting. This is especially helpful in hemifacial microsomia and TMJ ankylosis cases. Patient compliance is a prerequisite in functional therapy cases. Also, keeping in view the growth potential, long-term follow-up is always warranted.

70.4.4 Role of TMJ and Considerations for Treatment

TMJ is the driving force in the development of an asymmetry. Although the role of condylar cartilage has been proved to be secondary in mandibular growth and development, any pathological change leading to under- or overdevelopment can cause severe progressive asymmetry. As mentioned, TMJ-related asymmetries can be categorized as underdevelopment or overdevelopment of the condyle and in some cases both. Pseudo-asymmetry occurs due to lateral shifts on account of dental pre-maturities. Kaban and Pruzansky have also graded hemifacial microsomia (Refer Chap. 78) based on the anatomy of the ramus condyle unit [RCU] and the glenoid fossa which make up the TMJ [36, 37]. Management of the TMJ pathology should be performed initially following which any skeletal correction should be attempted. Failure to do so has led to relapse due to the unpredictability of TMJ behavior and growth. Clinical and diagnostic imaging should be performed prior to any asymmetry correction to assess the status of TMJ. CT scans are a must for assessment in all three axes, as TMJ tumors like osteochondroma may not be discernible on 2D imaging. High or low condylectomy, ankylosis release, and RCU reconstruction should be done prior or simultaneously with orthognathic surgery. Distraction osteogenesis has also been used for neo-condyle formation. Alloplastic reconstruction of the TMJ is the most recent advancement with stable long-term results. The rationale for TMJ reconstruction is to provide a functional stable and reproducible movement which is harmonious with the stomatognathic system. Asymmetrical patients have also been found to have a higher incidence of condylar morphological changes and temporomandibular disorders on the affected side. Over time, due to the imbalance of masticatory loads and poor jaw function, the TMJ of the unaffected side also displays similar pathological changes [38].

70.5 Treatment Planning

Following issues need to be considered before planning orthognathic surgery (Box 70.2):

Box 70.2 Issues that need to be considered before planning orthognathic surgery

1. Single jaw versus bi-jaw surgery
2. Mandible first versus maxilla first approach
3. Surgery first approach
4. Traditional planning versus virtual planning
5. Modifications in surgical technique for asymmetry cases

70.5.1 Single Jaw Versus Bi-Jaw Surgery

Facial asymmetries are rarely corrected by single jaw surgery. When the amount of discrepancy is excessive, it is best treated by dividing the overjet as well as the cant between the two jaws to achieve optimal results. During growth in congenital and developmental cases, maxilla follows and is equally involved as the mandible. Thus, it is prudent to do a bi-jaw surgery. Also, in cleft maxillary hypoplasia cases, differential maxillary advancement with simultaneous setback is the treatment of choice. We have presented a case where simultaneous maxillary distraction was done with mandibular setback. Owing to the presence of a cleft, maxilla has severely deviated midline with an extreme reverse overjet. In such cases, maxillary distraction allows slowly advancing the maxilla and simultaneously correcting the midline by distracting more on the deficient side [39] (Fig. 70.17a–c). Segmental osteotomies or differential surgically assisted rapid palatal expansion (SARPE) might also be needed in some cases to correct transverse asymmetry (Fig. 70.18a–c). Additionally, bone contouring of the mandible and zygoma may be needed to reduce the hyperostotic bone to achieve a harmonious facial contour. This is true in case of hemifacial hypertrophy and hemi mandibular hyperplasia. Similarly, additional augmentation of paranasal areas, malar prominence, and angle of mandible augmentation are frequently indicated in hypoplasia cases.

70.5.2 Mandible First Versus Maxilla First Approach

Either of the surgical sequences can produce similar outcomes when properly planned and executed in the vast majority of bimaxillary cases. Mandible first approach is specially mentioned here as it is important in Class 3 asymmetries. Firstly, in cases where maxilla may be hypoplastic, especially in the syndromic cases of mandibular hyperplasia, rigid fixation of maxilla and down-grafting may not give stable results. Thus mandible should be fixed first, then maxilla. Secondly, because of differential load on the TMJ, CO-CR discrepancy exists, and it is difficult to achieve a stable centric. In such cases fixing the mandible first is beneficial [40]. Lastly, Class 3 asymmetries are associated with concomitant TMJ pathologies, hence TMJ surgeries such as high condylectomy may be needed to be performed simultaneously, in such cases, and mandible first approach is generally the preferred choice.

70.5.3 Surgery First Approach (Refer Chap. 67)

The surgery first approach [SFA] came about as there was a need for immediate aesthetic improvement with shortening

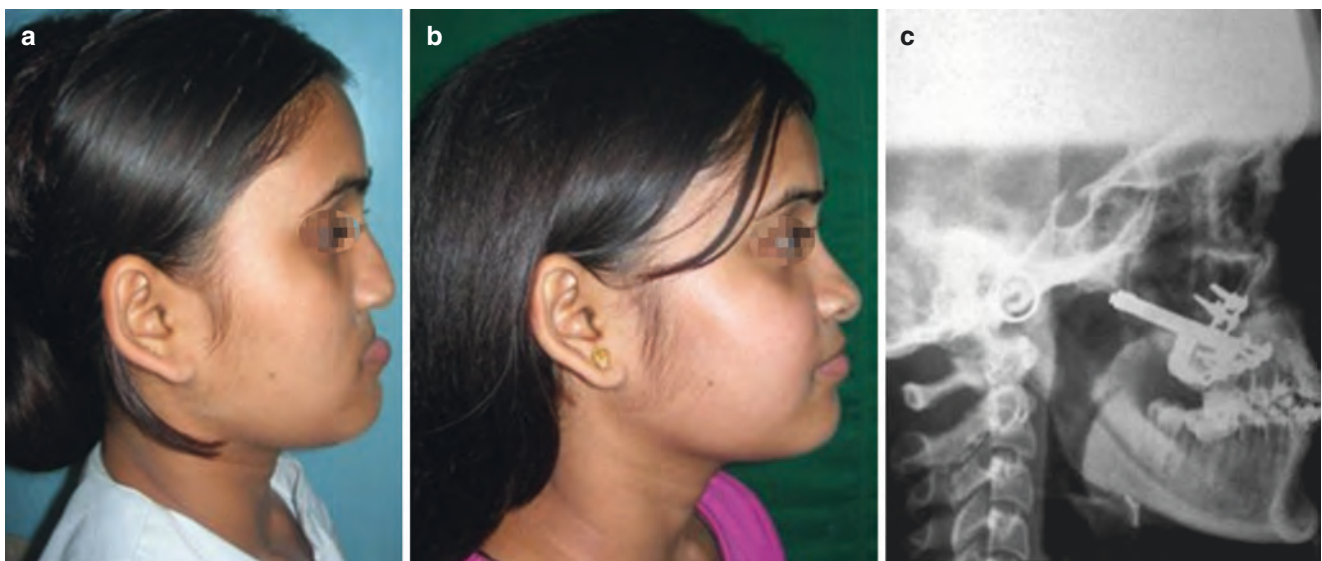
of the overall duration of treatment. However, it should be known that not all cases fulfil the criteria for SFA [e.g., flat curve of Spee and minimal crowding and rotations]. The total treatment duration can be shorter than the conventional three-staged surgical orthodontic treatment owing to the lack of need of pre-operative orthodontics and the subsequent post-surgical “regional acceleratory phenomenon.” However, reliability of SFA is still questionable, especially in more complex dentofacial deformities, like facial asymmetry.

Park et al. reported no significant differences in postoperative stability between SFA and OFA after bimaxillary surgery in skeletal class III malocclusion patients [41]. In SFA, vertical dimension in surgical occlusion can increase due to occlusal interference and lead to postoperative counter

clockwise rotation of the mandible as occlusal settling progresses during the postoperative orthodontic period. This may contribute toward greater postoperative mandibular forward movement.

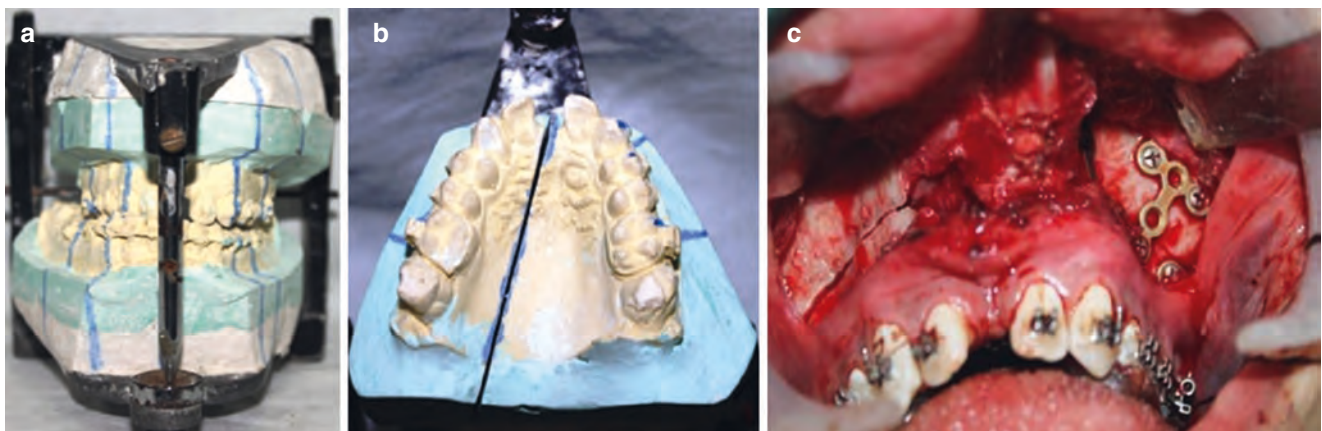
70.5.4 Modifications in Surgical Technique for Asymmetry Cases

The bilateral sagittal split osteotomy is the commonly used technique in asymmetry cases. It is highly flexible and adaptable in all movements. The three-dimensional anatomy of the mandible must be retained when planning a BSSO. According to Schwartz, three types of surgical move-



©Association of Oral and Maxillofacial Surgeons of India

Fig. 70.17 Case of cleft maxillary hypoplasia who underwent maxillary distraction using internal device. (a) Pre-operative profile photo showing retruded midface, (b) post-operative profile photo showing good midface fullness, (c) post-distraction lateral cephalogram showing distractor in-situ



©Association of Oral and Maxillofacial Surgeons of India

Fig. 70.18 (a) View of the maxillary study model. (b) Osteotomy cut marked for SARPE. (c) Fixation done using miniplate only on left side. This is done to ensure expansion of the only the right side on activation of appliance

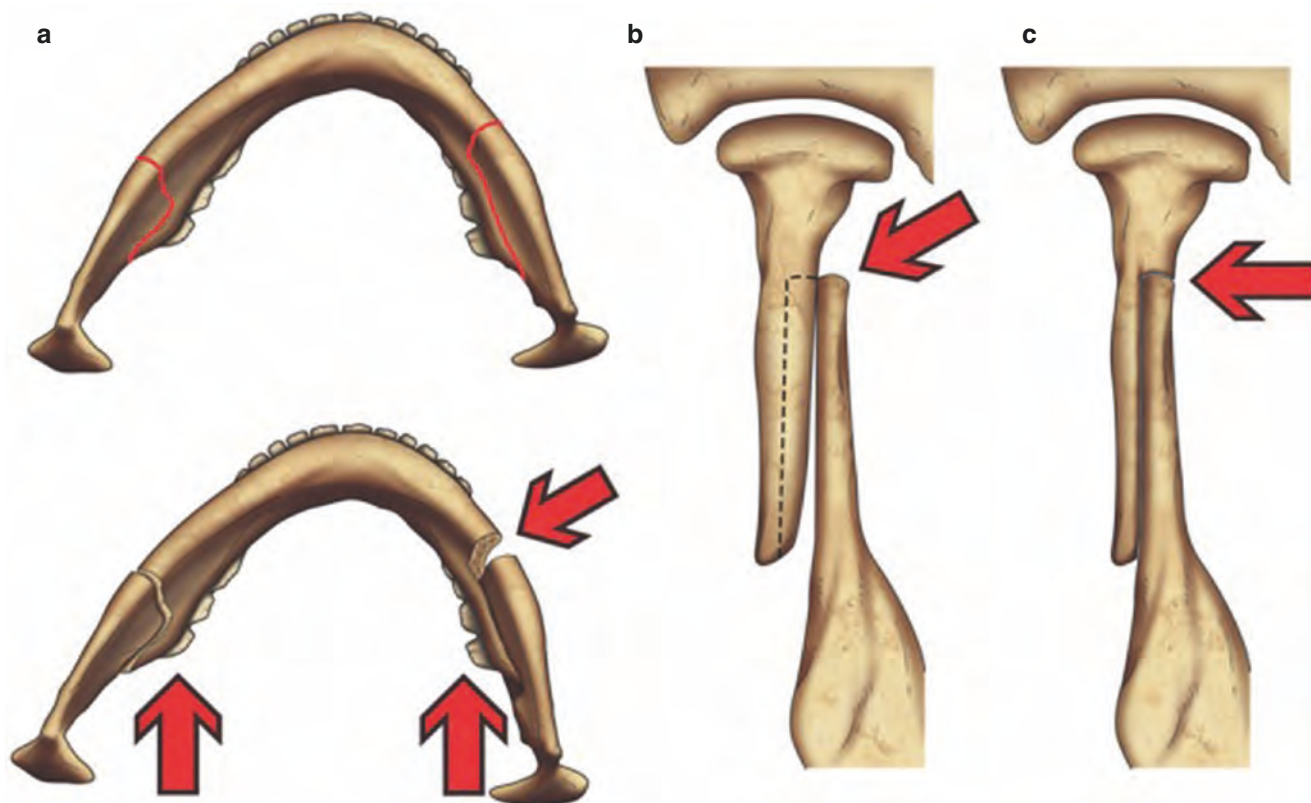


Fig. 70.19 (a) When an asymmetric case is viewed along the vertical axis, areas that require immediate bone removal become obvious. Heavy interferences will take place anteriorly on the long side and posteriorly on the short side; (b) After the condyle is seated, premature bone contact is noted posteriorly. The area proposed for additional bone

removal is indicated by the dotted line; (c) Good bone contact has been achieved. Image Source: Schwartz HC. Efficient surgical management of mandibular asymmetry. *J Oral Maxillofac Surg.* 2011 Mar;69(3):645–54. doi: 10.1016/j.joms.2009.03.009. Epub 2010 Oct 8. PubMed PMID: 20934795 [42]

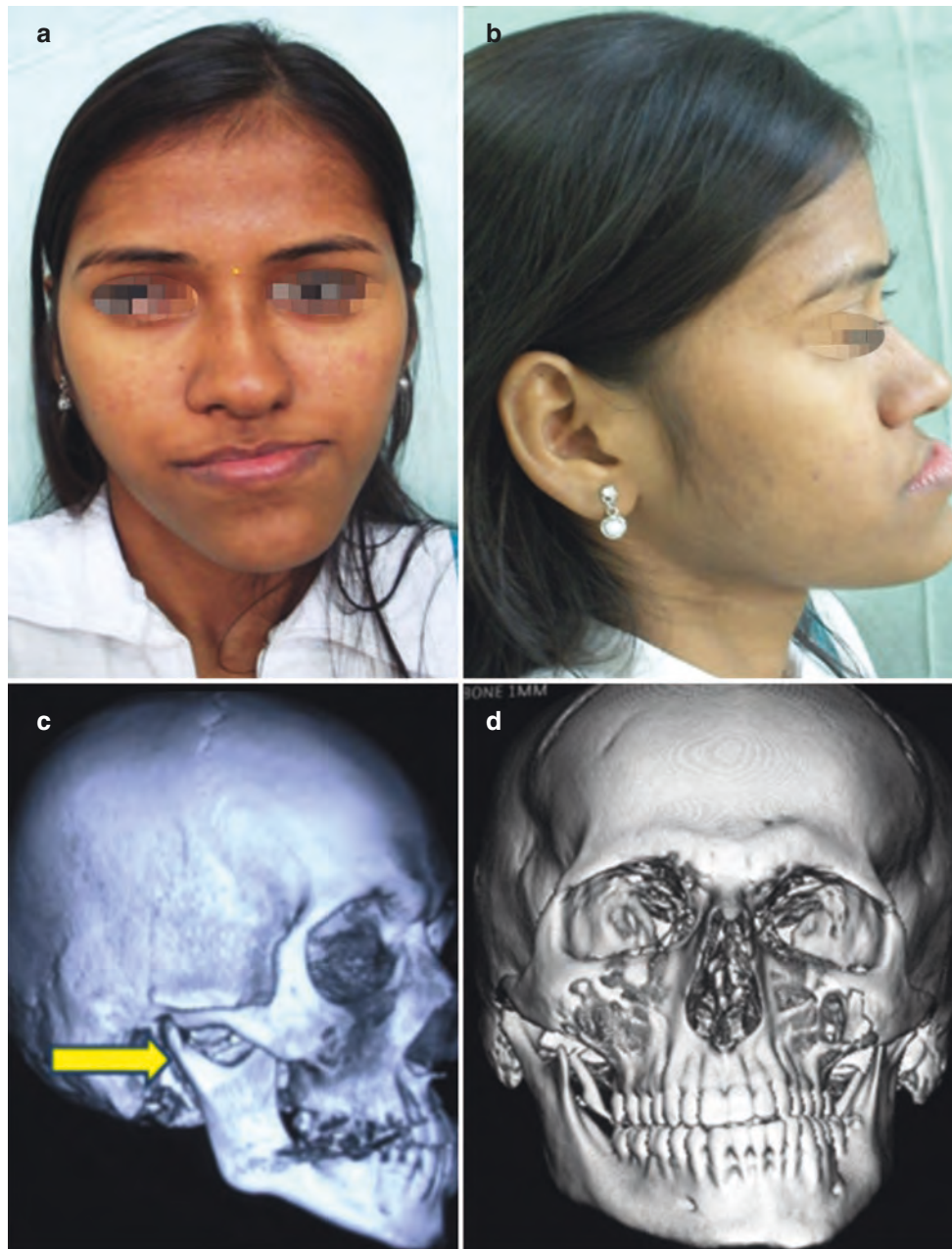
ments can be planned with BSSO in asymmetry cases: in case of a normal overjet and overbite, differential movements will be made that is setback on the long side and advancement on the short side. In Class II asymmetry, in order to achieve symmetrical advancement, there will be a longer advancement on the short side than on the long side and lastly in Class III cases, there will be a larger setback on the long side than on the short side. During surgery, the distal segment rotates from the short side to the long side as the midline is corrected (Fig. 70.19a). Selective bone removal from the area of interferences should be done before the distal segment has been passively repositioned. Bone is removed from the anterior and medial aspects of the proximal segment until there is broad contact along segments. On the short side, first contact will occur posteriorly [42]. Bone is removed from the medial aspect of the proximal segment posteriorly (Fig. 70.19b, c). This is done to reduce condylar torque during rigid internal fixation to ensure stability of the movement. Figures 70.20a–d and 70.21a, b show a case of unilateral condylar elongation treated with differential BSSO.

70.5.5 Soft Tissue Interventions

The asymmetrical growth of soft tissues may lead to residual soft tissue asymmetry even after correction of the underlying bony deformity. Furthermore, some asymmetrical craniofacial regions cannot be corrected by means of conventional surgical techniques. Adjunctive soft tissue procedures [e.g., dermis fat transplant, autologous fat transfer, microvascular adipose free flaps] might be indicated to achieve bulk in deficient soft tissue deformities such as Parry Romberg syndrome, TMJ ankylosis, etc. Alloplasts such as Medpore, silicone, nanogels, tissue expander, etc. have also been used with varying degrees of success (Sect. 70.7 “Case Scenarios”).

70.5.6 Distraction Osteogenesis (Also refer Chap. 87)

Distraction osteogenesis is the process of native bone formation via traction of osteotomized segments. On account of distraction histogenesis, simultaneous soft tissue and



©Association of Oral and Maxillofacial Surgeons of India

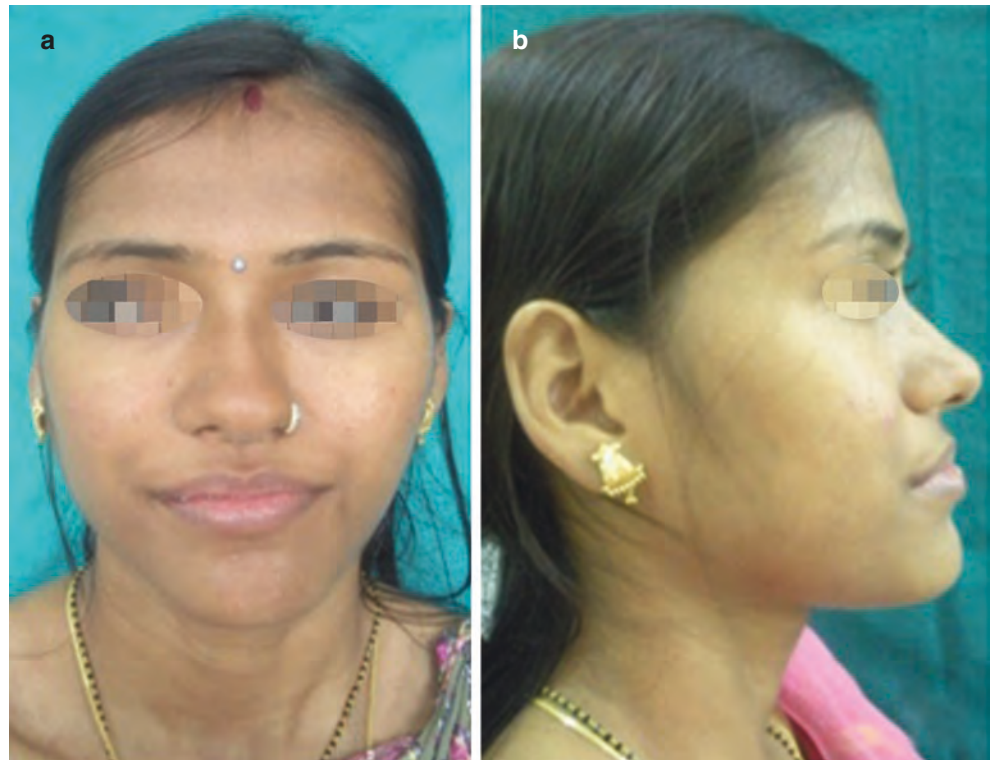Fig. 70.20 (a–d) Clinical and radiographic images showing a case of image showing severe facial asymmetry with unilateral condylar elongation on the right side. (a) frontal photo, (b) profile photo, (c, d) lateral and frontal views on volume rendered 3D CT scan

hard tissue augmentation can be achieved. Adequate amounts of advancements can be achieved without any soft tissue limitations. Various cases have been treated successfully with DO that are presented in this chapter. DO has various advantages over conventional osteotomies in complex facial asymmetries. Pre-arthroplastic distraction in ankylosis-related asymmetries has been reported to have excellent results [43]. This is because simultaneous distraction of skin, muscle, and tissue takes place with bone regeneration. Thus, better esthetics are achieved without any need for additional soft tissue procedures. Distraction

is often the only procedure of choice in large advancements, rate of relapse is significantly lower, and results are much stable. Figures 70.22a–e, 70.23a, b, 70.24a–d and 70.25a–g show a case of facial asymmetry secondary costochondral graft resorption in a case of TMJ ankylosis, treated with stage one distraction osteogenesis followed by definitive correction with BSSO.

(Also refer Figs. 78.43, 78.44, 78.45, 78.46, 78.47, 78.48, 78.49, 78.50, 78.51, 78.52, and 78.53 for management of facial asymmetry cases due to Hemifacial microsomia and Traeher Collins syndrome).

Fig. 70.21 Same patient as in Fig. 70.20 demonstrating corrected facial midline and mandibular prognathism postoperatively (a) frontal view, (b) profile view



©Association of Oral and Maxillofacial Surgeons of India

70.6 Conclusion

Facial asymmetry is a three-dimensional facial deformity having multiple etiologies. Complete and thorough knowledge of the etiological factors, the progressive nature of the asymmetry plays a crucial role in formulating a treatment plan. Growth and development of the individual and timing of intervention is the single most important factor affecting the stability of results in any form of asymmetry. Severe relapses could occur if the exact cause of asymmetry is overlooked and treatment is attempted before completion of growth [44, 45].

Acknowledgment Gratitude and acknowledgments to Dr. Harsh Desai and Dr. Shibani Nerurkar for their sincere efforts in collection of data and editing of the contents.

Disclosure Authors have no financial conflicts to disclose.

70.7 Case Scenarios

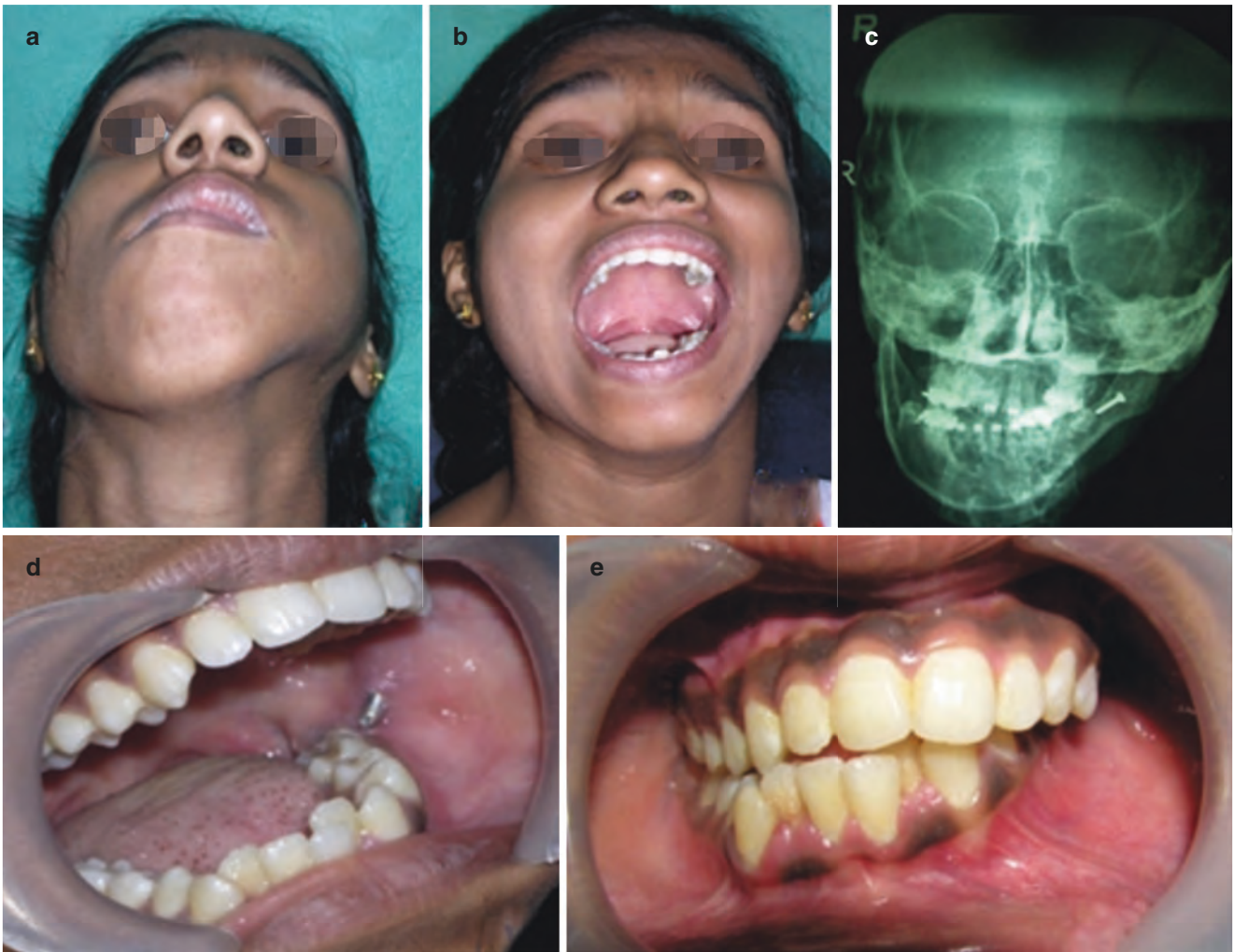Case 1: Condylar Hyperplasia with Concomitant Masseteric Hypertrophy (Figs. 70.26a, b, c, 70.27a, b, 70.28a, b and 70.29a, b)

A 27-year-old female patient reported with a complaint of a progressive facial asymmetry and an appearance of fullness over the left angle of the mandible.

On examination, the patient had a tapered, triangular shape of the face with an obvious facial asymmetry which was evident along with elongation of the right side of the face and fullness over the left angle region (Fig. 70.26a). The mandible revealed bowing on the right side with a mild symphysis kink. TMJ on palpation revealed mild clicking on the right side and otherwise equal movements along with unrestricted mouth opening was noted. On assessing the left angle region, an outward projection was noted due to the underlying hyper functioning of the masseter muscle. On clenching, significant enlargement of the involved muscle was seen as compared to the contralateral side (Fig. 70.26b).

Intraoral examination did not reveal any occlusal cant (Fig. 70.26c). There was an absence of cross bite/open bite, on either side, along with a stable occlusal relationship. The dental midlines were coincident with the skeletal midline and with each other too. No other dental abnormalities were evident on examination.

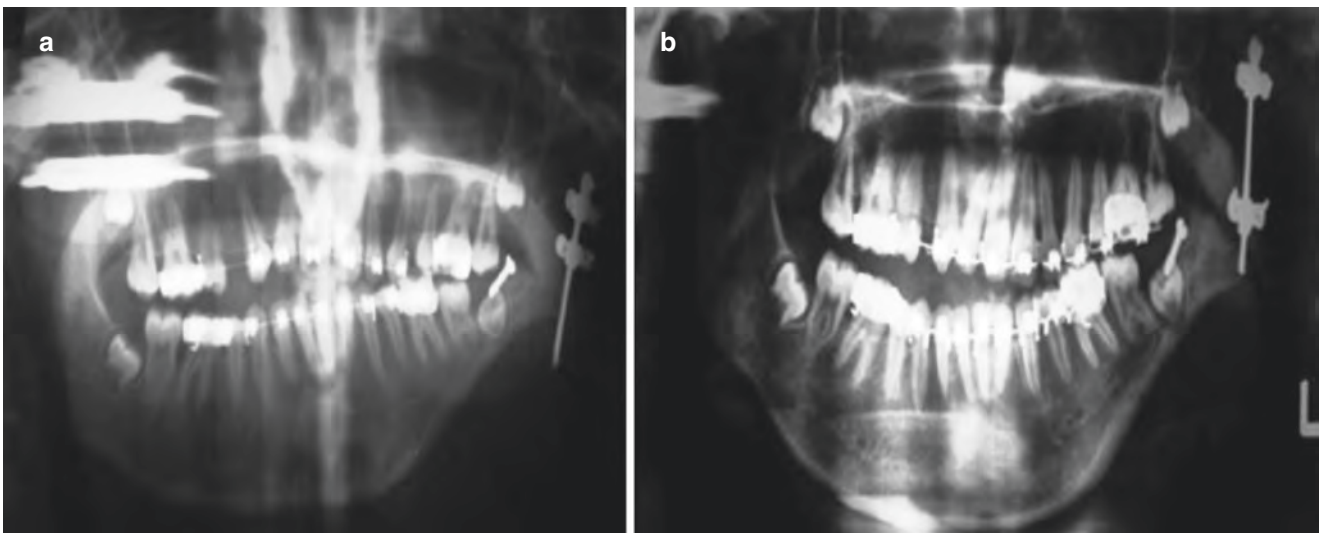
Imaging studies revealed mild degree of deflection of the chin and mandible toward the left side (Fig. 70.27a, b). Transverse mandibular asymmetry was reported. The condylar head appeared to be irregularly deformed, while the neck on the right side appeared broader as compared to the left side. The ascending ramus appeared elongated with a rounded gonial angle. The mandibular lower border was bowed downward and positioned lower on the right side as compared to the left side. The distance between the tooth



©Association of Oral and Maxillofacial Surgeons of India

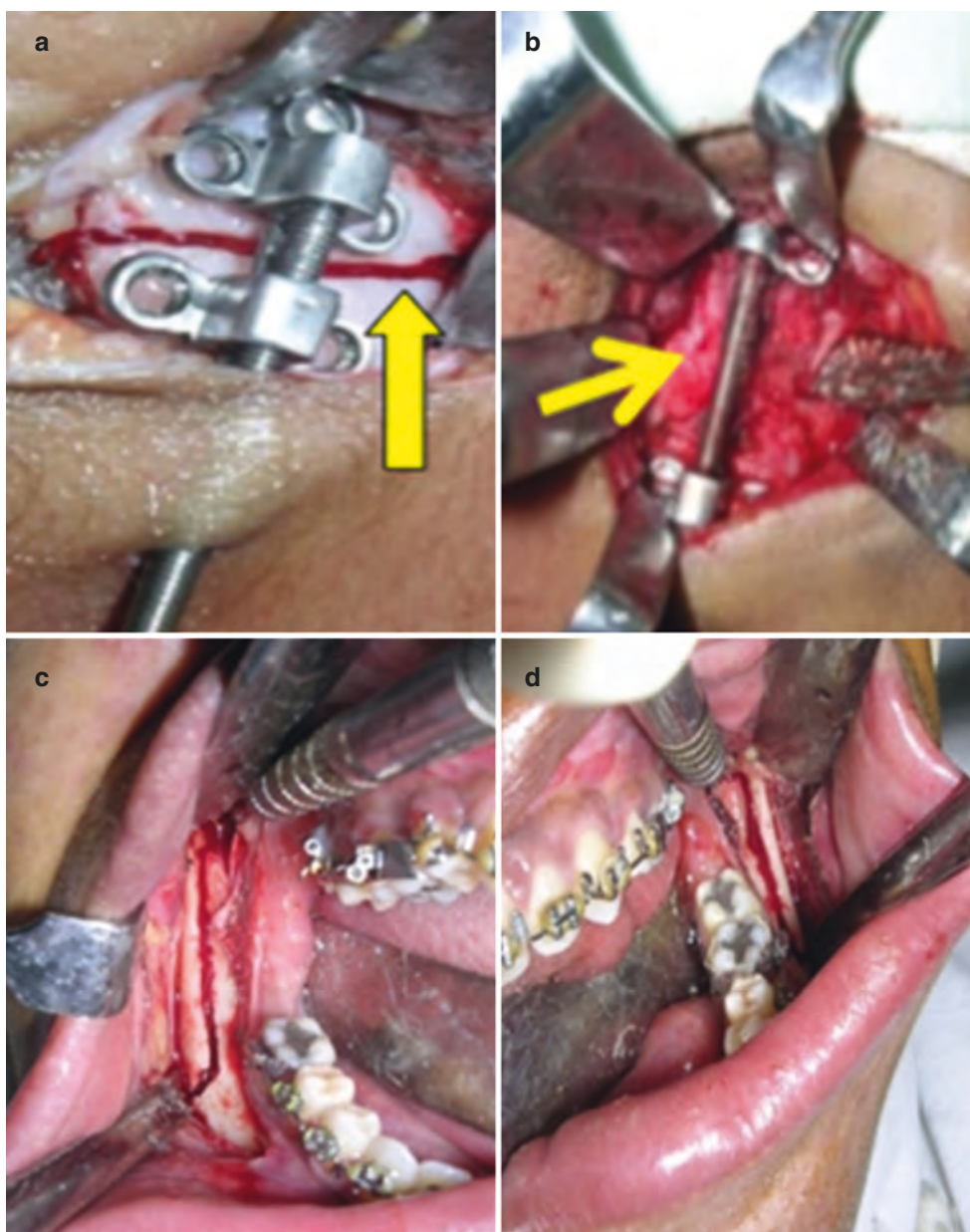
Fig.70.22 (a–e) Case of facial asymmetry post-TMJ ankylosis treatment, due to resorption of costochondral graft. Note the exposed screw intraorally. Left side of mandibular arch fully telescoped inside the maxilla. (a) basal view showing gross asymmetry, (b) patient retaining good mouth opening after surgery for ankylosis, (c) Antero-posterior

skull view showing asymmetry on the left side with screw from earlier costo-chondral graft fixation, (d) photograph showing trans-oral exposure of screw and (e) malocclusion with midline shift to the right, dental crowding and left sided lingual cross-bite



©Association of Oral and Maxillofacial Surgeons of India

Fig. 70.23 (a, b) Stage 1 treatment in the same patient as in Fig. 70.22, left side vertical ramus distraction to establish equal ramal height. (a) Initial height of ramus prior to beginning distraction, (b) vertical lengthening of ramus after completion of distraction



©Association of Oral and Maxillofacial Surgeons of India

Fig. 70.24 (a–d) Second stage treatment in same patient as in Fig. 70.22: distractor removal with differential BSSO. (a) intra-operative photo from stage 1 surgery, showing osteotomy line for distraction (yel-

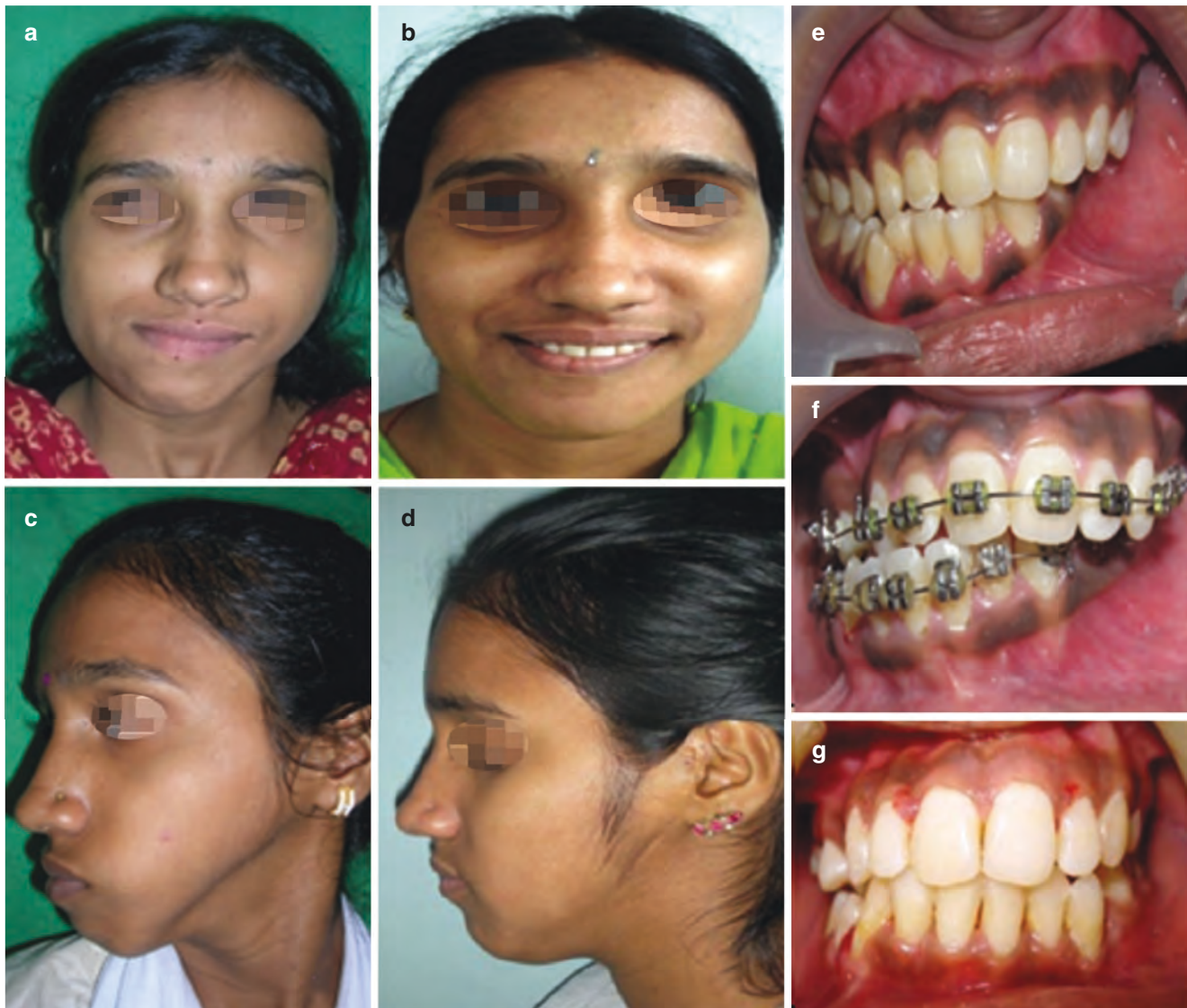low arrow), (b) intra-operative photo during distractor removal demonstrating new bone formation (yellow arrow), (c, d) intra-operative photos showing osteotomy cuts for BSSO

roots and mandibular canal was increased with displacement of the latter towards the lower border of the mandible on the right side. The right side vertical ramus appeared relatively increased height as compared to the left. Thickened trabecular pattern was also evident on the right side.

Management

Following preparation for the administration of GA and a scintigraphy report which did not reveal an active mandibular hyperplastic condyle on the right side, the patient was

prepared to be taken up for the procedure of an intraoral inferior border osteotomy. An intraoral vestibular incision was taken from 33 regions up to the external oblique ridge on the right side. Complete degloving was done to expose the inferior border in the anterior, body, and angle region of the mandible on the right side. Care was taken to identify the mental foramen and salvage the nerve. Methylene blue ink was used to mark the osteotomy line extending from the right central incisor posteriorly up to the angle region (Fig. 70.28a). It was correlated with the position of the neu-



©Association of Oral and Maxillofacial Surgeons of India

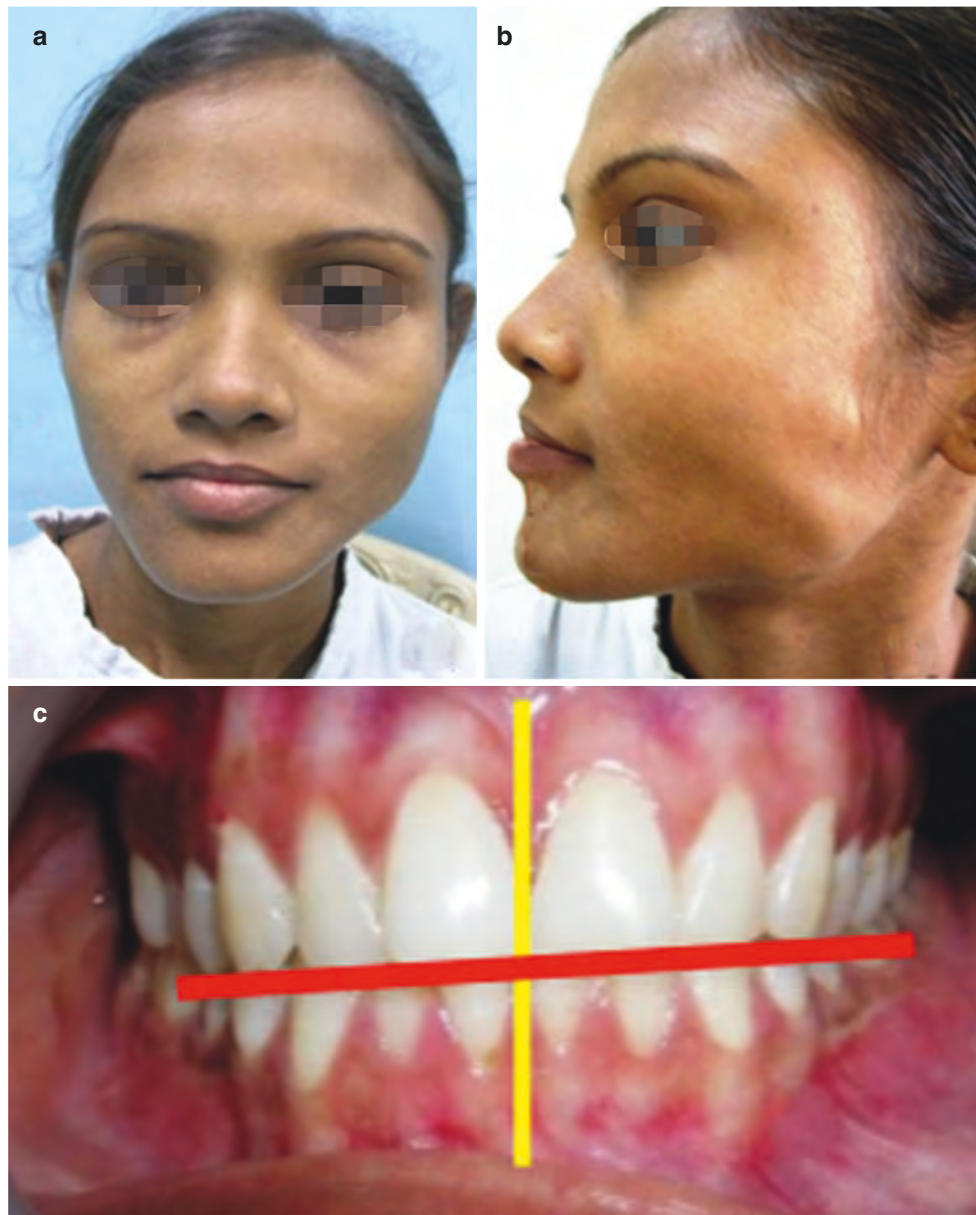Fig. 70.25 (a–g) Pre- and postoperative photographs of the same patient as in Fig. 70.22, showing restoration of symmetry and midline (a, b) pre and post-operative frontal photographs showing correction of asymmetry, (c, d) pre and post-operative profile photographs demonstrating increased vertical height of ramus, (e) pre-treatment intra oral

occlusion demonstrating severe shift in the dental midline with lingual crossbite on the left side, (f) orthodontic strap-up for dental and arch alignment, (g) post-treatment occlusion showing good dental rehabilitation

rovascular bundle, so as to prevent any damage to the same. The cut was initiated with a fine fissure bur under copious saline irrigation extending from buccal cortical plate to lingual cortical plate. With the help of an osteotome, the anterior cut was completed, and the lower inferior hyperplastic border was removed in one piece (Fig. 70.28b). The raw surface was smoothed with a vulcanite bur, and contouring was done to match the normal left side. The wound was closed in two layers with interrupted sutures using 3-0 vicryl. The surgical site was flushed with 2% povidone iodine solution.

For the masseteric hypertrophy on the left side, Botox [botulinum toxin Type A, Allergan™] powder was reconstituted with normal saline solution, pushed within the vial, and 30 units of it were administered using an insulin syringe and 30 gauge needle within the substance of the muscle, divided equally at three sites in a triangular fashion (Refer Chap. 33 and Fig. 33.10 for details on Botox injection to treat masseteric hypertrophy).

Complete correction of facial asymmetry with left side masseteric hypertrophy and right side condylar hyperplasia features was achieved with this surgical method (Fig. 70.29a, b).



©Association of Oral and Maxillofacial Surgeons of India

Fig. 70.26 (a, b) Frontal and profile views showing facial asymmetry due to condylar hyperplasia of the right side. (c) Occlusal view showing dental cant on account of condylar hyperplasia

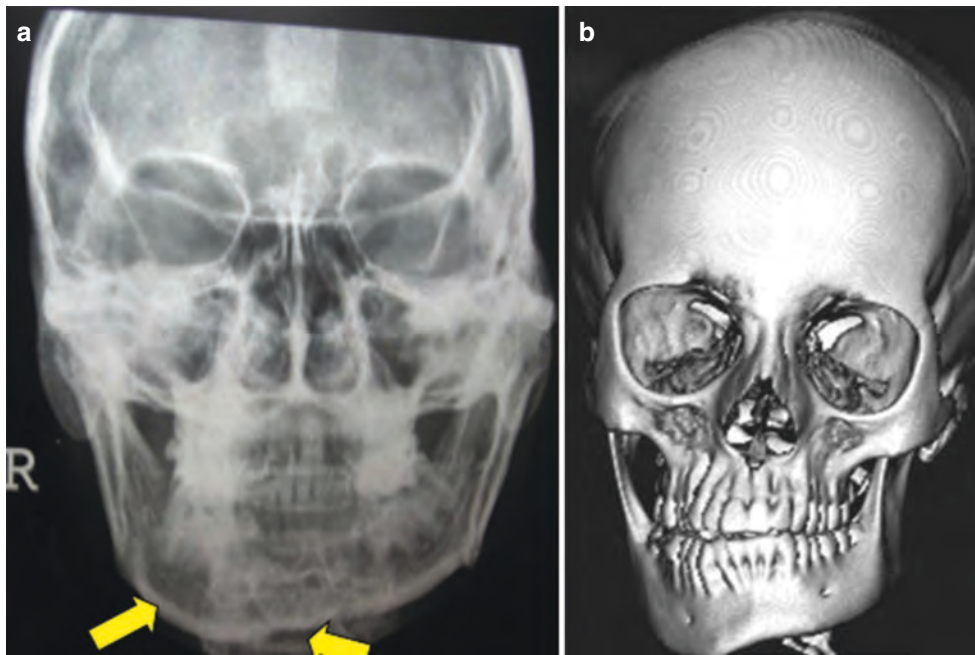
Case 2: Parry Romberg Syndrome (Figs. 70.30a, b, 70.31a, b, 70.32a, b, c, 70.33a–h and 70.34a–f)

An 18-year-old female patient reported with gradual disfigurement and shrinkage of the right side her face since last 8–9 years.

Clinical examination revealed an asymmetry of the face on the right side with a marked atrophy of facial soft tissue (Fig. 70.30a). Significant orbital dystopia along with a hypoplastic soft tissues in the right, evident on worm's view (Fig. 70.30b). Clinically, a deformed and

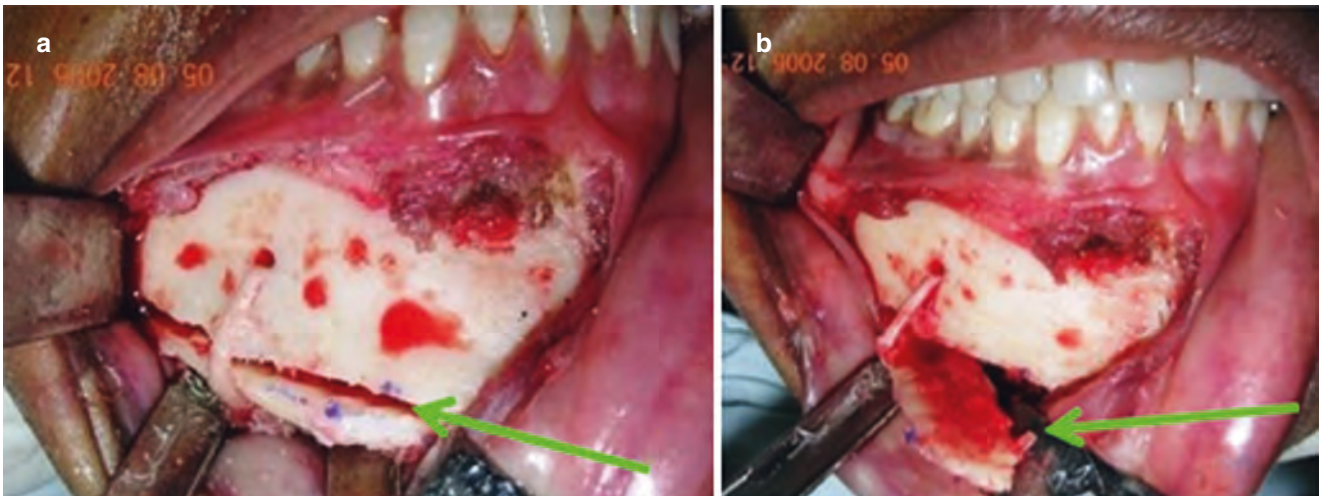
hypoplastic upper lip was seen with an increased vermilion show of the lower lip, resulting in a slanting rima oris. The right commissure, right ala of the nose, and the right supraorbital ridge region revealed obvious depression.

Intraoral examination revealed a missing upper right permanent canine along with crowding in the premolar region. Alveolar height in the maxillary right premolar region was reduced which was a pathognomonic sign of Parry Romberg (Fig. 70.31a, b). The occlusion was deranged, with a shift of the dental midline to the right.



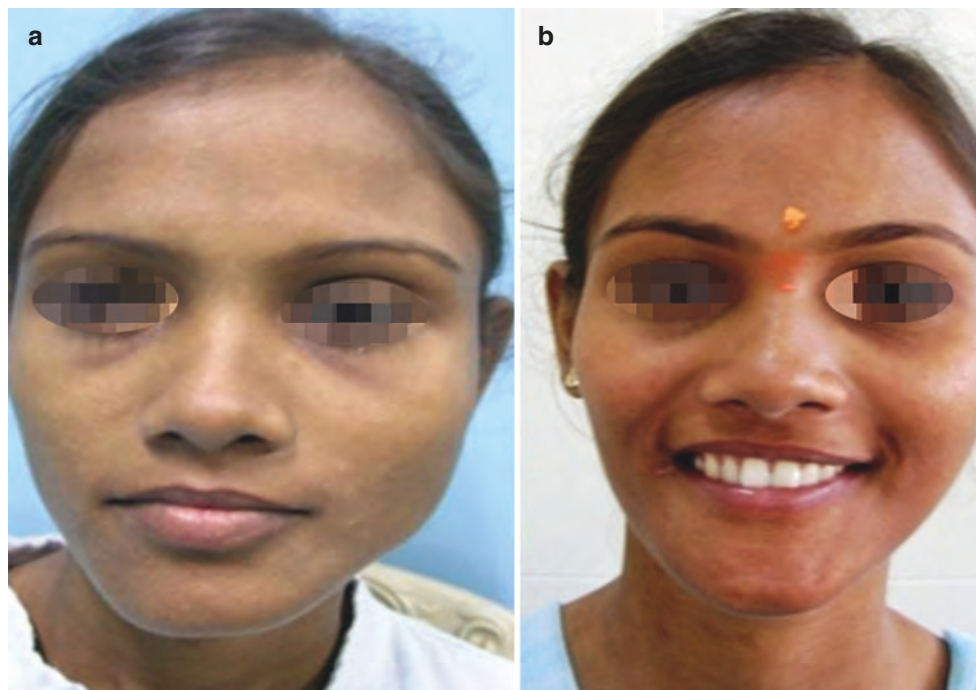©Association of Oral and Maxillofacial Surgeons of India

Fig. 70.27 (a) PA mandible showing inferior border bowing on the right side and kink in chin region (yellow arrows) which stops at the midline. (b) 3D CT shows mild degree of tilting of chin and mandible toward the left side



©Association of Oral and Maxillofacial Surgeons of India

Fig. 70.28 (a, b) Inferior border osteotomy to remove the excessive contour below the mental nerve



©Association of Oral and Maxillofacial Surgeons of India

Fig. 70.29 (a) Pre- and (b) post-op correction in facial asymmetry. Reduction of fullness on left side and centralization of chin

Imaging studies revealed some degree of hypoplasia of mandible, zygoma, and maxilla on the right side. Presence of impacted permanent right maxillary canine was evident. The body-angle ramus, coronoid, and condylar process however appeared normal. Alveolar height was reduced in the right maxillary premolar region (Fig. 70.32a, b, c).

Management

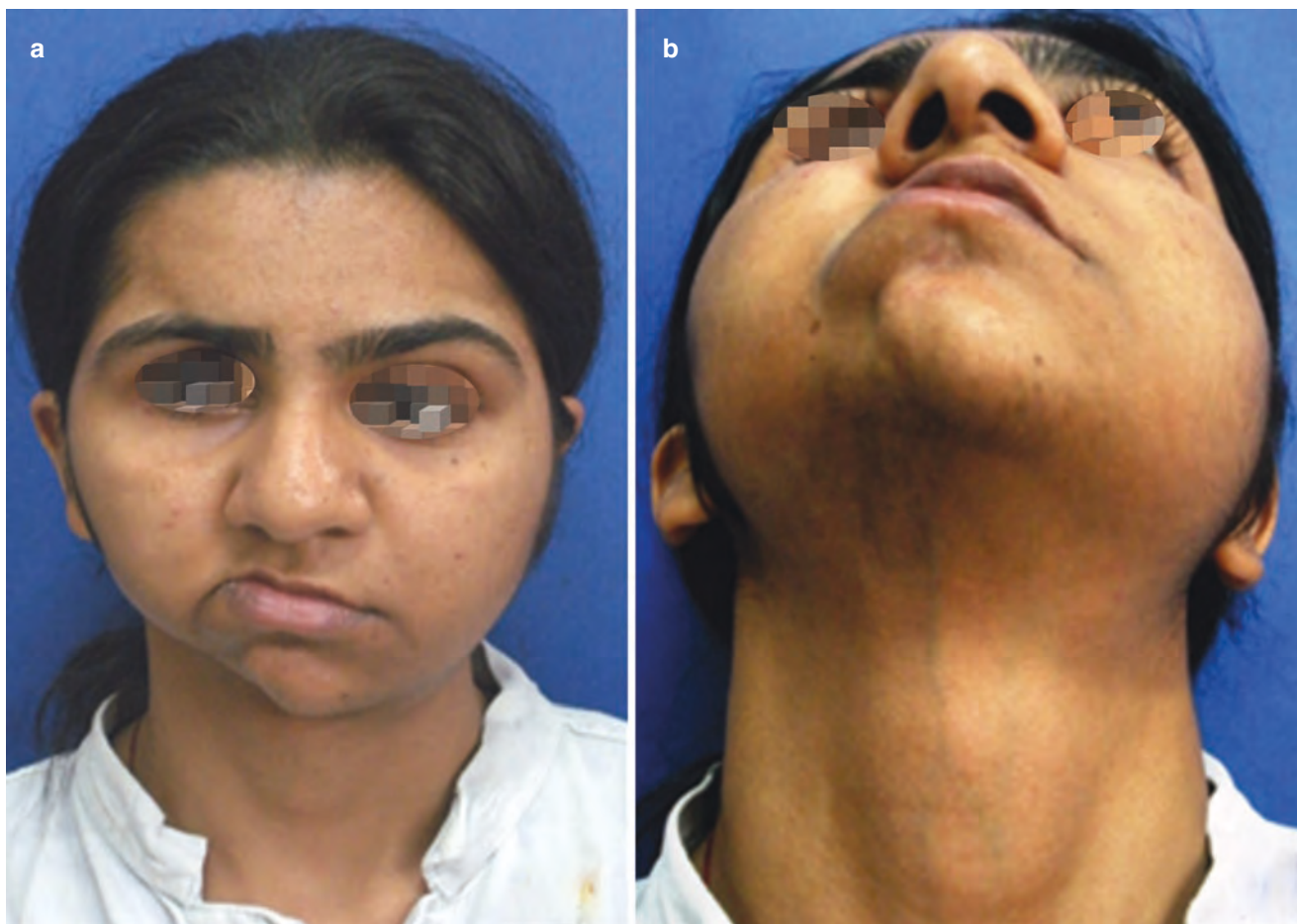The patient was prepared for GA administration for correction of facial asymmetry. A camouflage technique was planned wherein multiple Medpore© implants were used to fill up the deficient areas on the right side of her face in the right supra-orbital, right maxillary alveolar region in the canine, and premolar areas right parasymphysis region of the body of mandible and right side chin along with autologous lipo transfer to increase the volume of the upper lip. Two separate small incisions were taken in the submandibular region anteriorly and posteriorly keeping the intervening skin and tissues intact. Layerwise dissection was done to reach the angle, body, and the anterior regions of the mandible. Tunnelling was done between the two incisions so as to receive the pre-shaped Medpore© implant, which was inserted from the anterior site and was pushed posteriorly to sit on the body, angle, and a portion of the ramus. The implant was notched in the superior aspect, in the region of the mental nerve to prevent impingement of the same. Four long titanium screws were used to fix

the Medpore© implant on the body of the mandible on the right side (Fig. 70.33a). An additional half chin implant was placed to augment the deficient chin on the right side for achieving symmetry and was fixed with 2 long titanium screws (Fig. 70.33b). The incision sites were closed in two layers.

Another lateral eyebrow incision was taken on the right side (Fig. 70.33e). Dissection was done to expose the supra-orbital rim. Supraorbital foramen and nerve were identified. An infra-orbital rim Medpore© implant for the right side was inverted and placed on the right supraorbital region to augment this deficient area. Two long titanium screws were used to stabilize the Medpore© implants.

Intra-orally a vestibular incision was taken in the right premolar and canine region. A full-thickness mucoperiosteal flap was raised. The infra-orbital nerve was identified and protected. A paranasal Medpore© implant was fixed with 1 long titanium screw to give fullness in this region. The wound was sutured in two layers with 3-0 vicryl.

Periumbilical and medial thigh regions were prepared to harvest fat cells. Manual aspiration of the fat cells was done. Following the simple method of sedimentation, the fat cells were separated from the blood components (Fig. 70.33f). 2 mm incisions were taken on either side of the oral commissure. A large 16 gauge epidural needle attached to 10cc syringe was used to push the fat within the substance of the upper lip from either side (more on right side than on the left) increasing the



©Association of Oral and Maxillofacial Surgeons of India

Fig. 70.30 (a) Frontal view—right side reveals marked atrophy in the distribution of all three branches of trigeminal nerve. (b) Asymmetry of the inferior border evident on worm's-view involving soft and hard tissue

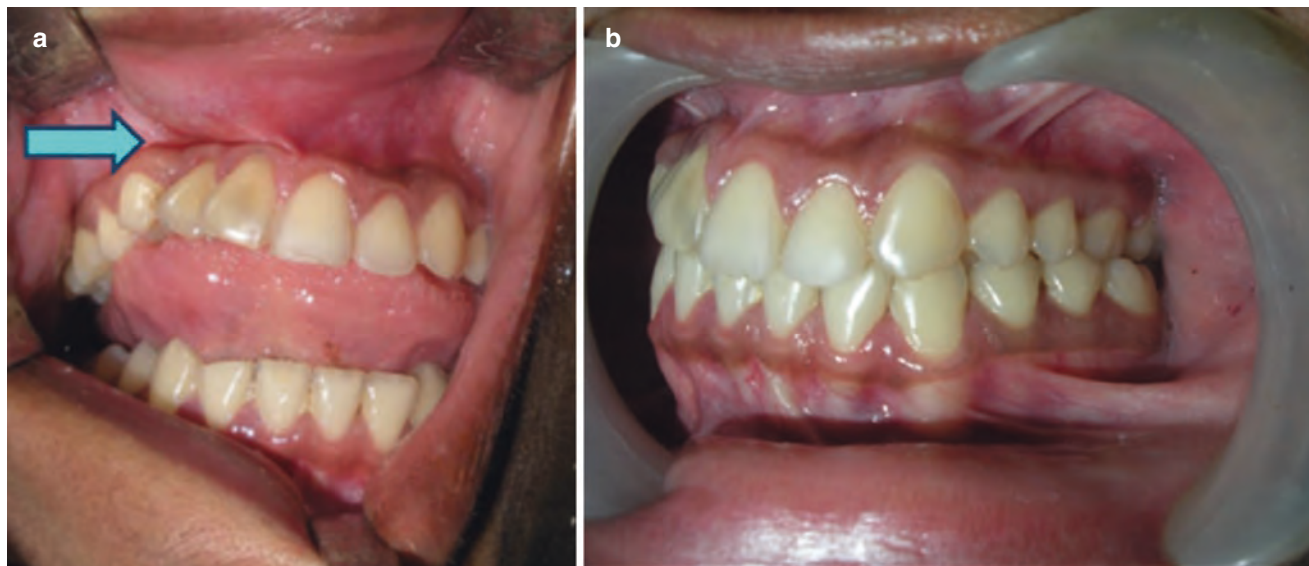

Fig. 70.31 (a, b) Intraoral examination of the same patient as in Fig. 70.30, reveals reduced alveolar height (blue arrow) in the right premolar region (a), as compared to the left side (b). Alveolar height reduction is an important clinical finding in Romberg's disease

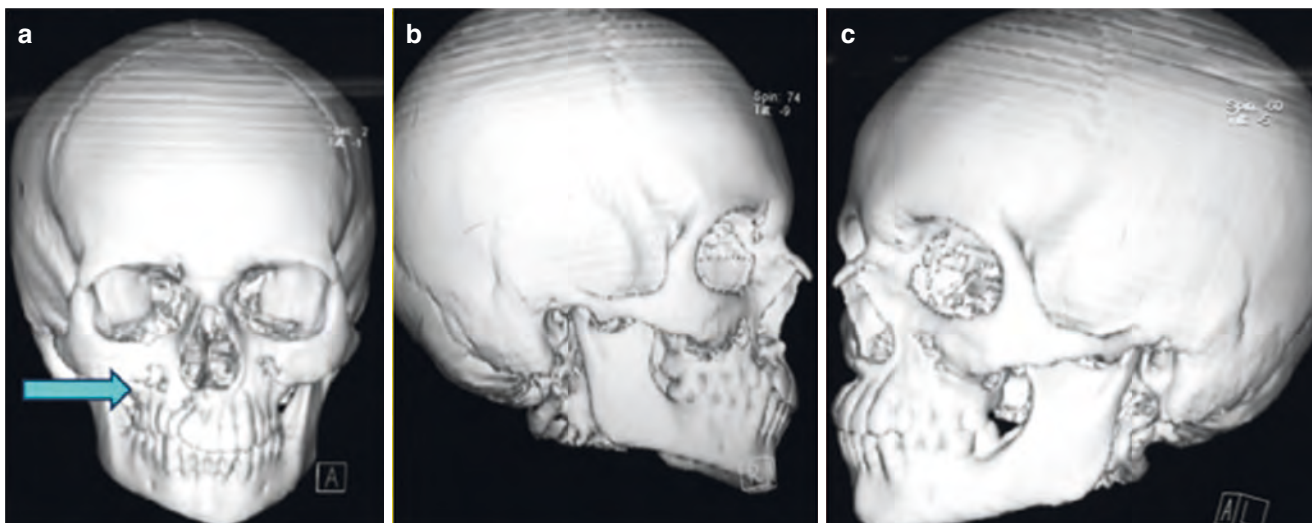
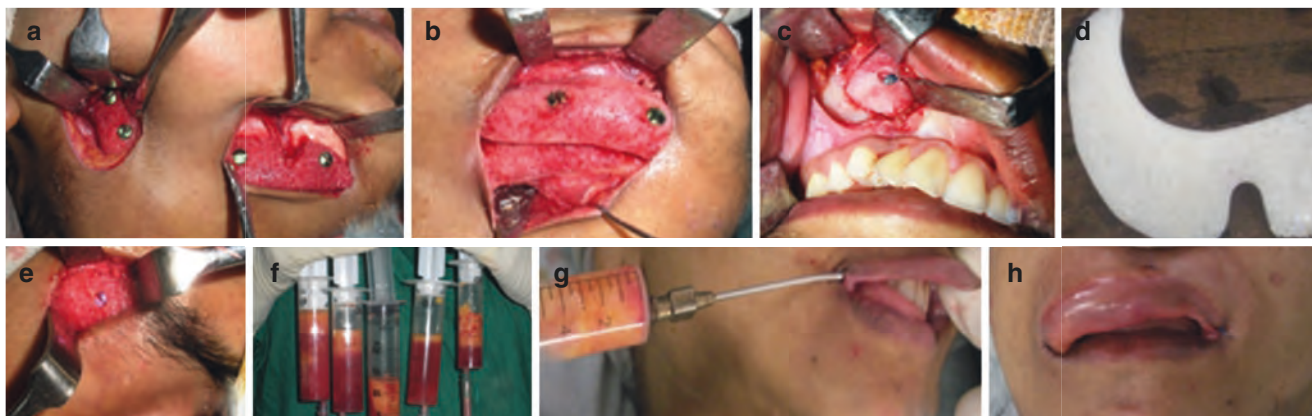


Fig. 70.32 (a, b) 3D CT of the patient in Fig. 70.30 reveals skeletal deficiency of alveolar height on right side (blue arrow), and reduction in vertical height of the ramus and body of the mandible on right side, (c) left side shows normal anatomy



©Association of Oral and Maxillofacial Surgeons of India

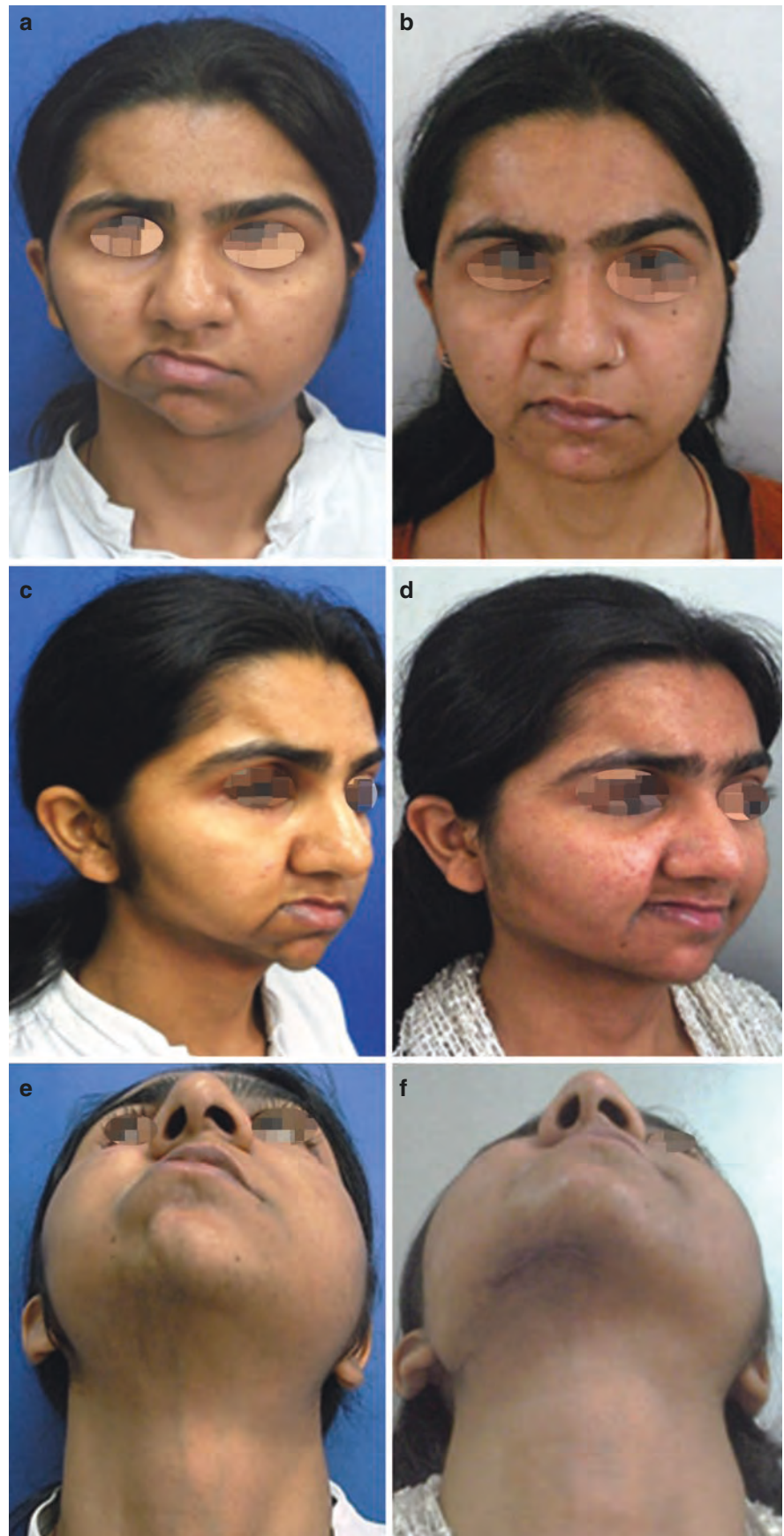Fig. 70.33 (a) Extra-oral incisions—submandibular incisions made anteriorly and posteriorly. Medpore implant in ramus and body fixed with four titanium screws. (b) Additional half chin implant fixed with two titanium screws on right side of chin region. (c) Paranasal and alveolar Medpore implant fixed through intra-oral approach with titanium screws. Infraorbital nerve protected. (d, e) Use of Medpore implant for

right side supra orbital rim. Notch placed superiorly to protect the supraorbital nerve. (f) Sedimentation to separate fat cells from blood components. Harvesting autologous fat grafts. (g) Introduction of fat cells into the upper lip through needle prick in right commissure. (h) Overcorrection achieved on table

volume of upper lip (Fig. 70.33g). A stitch on either side of the commissure was taken to prevent escape of fat cells (Fig. 70.33h). Overcorrection was done on table. Postoperatively, good facial symmetry was achieved with fullness at the deficient site using fat and implant (Fig. 70.34a–f).

For further case scenarios on management of facial asymmetry refer Figs. 68.19 and 68.38, in Chap. 68 on mandibular orthognathic procedures and Figs. 69.30, 69.31, 69.32 and 69.40 in Chap. 69 on maxillary orthognathic procedures.

Fig. 70.34 (a–f) Comparison of pre and post op results after 4 years. Satisfactory correction in facial asymmetry achieved. Pre (Fig. 70.30a) and post treatment frontal photographs (a, b) oblique facial views (c, d) and basal views (e, f) demonstrating better soft tissue balance and symmetry



References

- Little AC, Jones BC, De Bruine LM. Facial attractiveness: evolutionary based research. *Philos Trans R Soc Lond Ser B Biol Sci.* 2011;366(1571):1638–59.
- Thiesen G, Gribel BF, Freitas MPM. Facial asymmetry: a current review. *Dental Press J Orthod.* 2015;20(6):110–25.
- Chouinard AF, Kaban LB, Peacock ZS. Acquired abnormalities of the temporomandibular joint. *Oral Maxillofac Surg Clin North Am.* 2018;30(1):83–96.
- Wolford LM, Gonçalves JR. Condylar resorption of the temporomandibular joint: how do we treat it? *Oral Maxillofac Surg Clin North Am.* 2015;27(1):47–67.
- Pirttiniemi PM. Associations of mandibular and facial asymmetries. *Am J Orthod Dentofac Orthop.* 1994;106:191–200.
- Bishara SE, Burkey PS, Kharouf JG. Dental and facial asymmetries: a review. *Angle Orthod.* 1994;64:89–98.
- Lundström A. Some asymmetries of the dental arches, jaws, and skull, and their etiological significance. *Am J Orthod.* 1961;47(2):81–106.
- Plint DA, Ellisdon PS. Facial asymmetries and mandibular displacements. *Br J Orthod.* 1974;5:227–35.
- Chia MS, Naini FB, Gill DS. The aetiology, diagnosis and management of mandibular asymmetry. *Ortho Update.* 2008;1(1):44–52.
- Haraguchi S, Iguchi Y, Takada K. Asymmetry of the face in orthodontic patients. *Angle Orthod.* 2008;78(3):421–6.
- Wolford LM. Facial asymmetry: diagnosis and treatment considerations. In: Fonseca's oral and maxillofacial surgery, vol. III. 3rd ed. St. Louis, MO: Saunders; 2017.
- Reyeneke JP. Basic guidelines for the diagnosis and treatment of specific dentofacial deformities. 2nd ed. New Malden: Quintessence Publishing; 2010.
- Cheong YW, Lo LJ. Facial asymmetry: etiology, evaluation, and management. *Chang Gung Med J.* 2011;34(4):341–51.
- Waite P, Urban S. Facial asymmetry. In: Peterson's principles of oral and maxillofacial surgery. 3rd ed. New York: McGraw-Hill Medical; 2012.
- Obwegeser HL, Makek MS. Hemimandibular hyperplasia: hemimandibular elongation. *J Maxillofac Surg.* 1986;14(4):183–208.
- Cohen MM Jr. Perspectives of craniofacial asymmetry. Part IV. Hemi-asymmetries. *Int J Oral Maxillofac Surg.* 1995;24:134–41.
- Kim JY, Jung HD, Jung YS, Hwang CJ, Park HS. A simple classification of facial asymmetry by TML system. *J Craniomaxillofac Surg.* 2014;42(4):313–20.
- Hwang HS. A new classification of facial asymmetry. In: McNamara JA, editor. Early orthodontic treatment: is the benefit worth the burden? Craniofacial growth series, vol. 44. Ann Arbor: University of Michigan; 2007. p. 269–94.
- Wolford LM, Movahed R, Perez DE. A classification system for conditions causing condylar hyperplasia. *J Oral Maxillofac Surg.* 2014;72(3):567–95.
- Srivastava D, Singh H, Mishra S, Sharma P, Kapoor P, Chandra L. Facial asymmetry revisited: part I-diagnosis and treatment planning. *J Oral Biol Craniofac Res.* 2018;8(1):40–3.
- Rodrigues DB, Castro V. Condylar hyperplasia of the temporomandibular joint. Types, treatment, and surgical implications. *Oral Maxillofac Surg Clin North Am.* 2015;27(1):155–67.
- Srivastava D, Singh H, Mishra S, Sharma P, Kapoor P, Chandra L. Facial asymmetry revisited: part I-diagnosis and treatment planning. *J Oral Biol Craniofac Res.* 2018;8(1):7–14.
- Cheong Y-W, Lo L-J. Facial asymmetry: etiology, evaluation, and management. *Chang Gung Med J.* 2011;34(1):341–51.
- Choi KY. Analysis of facial asymmetry. *Arch Craniofac Surg.* 2015;16(1):1.
- Photogrammetry [Internet]. Available from: <https://en.wikipedia.org/wiki/Photogrammetry>
- Heike CL, Upson K, Stuhau E, Weinberg SM. 3D digital stereophotogrammetry: a practical guide to facial image acquisition. *Head Face Med.* 2010;6(1):1–11.
- Stereolithography [Internet]. Available from: <https://en.wikipedia.org/wiki/Stereolithography>
- Farrell BB, Franco PB, Tucker MR. Virtual surgical planning in orthognathic surgery. *Oral Maxillofac Surg Clin North Am.* 2014;26(4):459–73.
- Nadershah M, Mehra P. Orthognathic surgery in the presence of temporomandibular dysfunction. What happens next? *Oral Maxillofac Surg Clin North Am.* 2015;27(1):11–26.
- Saridin CP, Raijmakers PGHM, Tuinzing DB, Becking AG. Bone scintigraphy as a diagnostic method in unilateral hyperactivity of the mandibular condyles: a review and meta-analysis of the literature. *Int J Oral Maxillofac Surg.* 2011;40(1):11–7.
- Cisneros GJ, Kaban LB. Computerized skeletal scintigraphy for assessment of mandibular asymmetry. *J Oral Maxillofac Surg.* 1984;42(8):513–20.
- Oron A, Arieli I, Pritsch T, Even-Sapir E, Halperin N, Agar G. SPECT versus planar scintigraphy as a clinical aid in evaluation of the elderly with knee pain. *ISRN Orthop.* 2013;2013:1–11.
- Laverick S, Bounds G, Wong WL. [18F]-fluoride positron emission tomography for imaging condylar hyperplasia. *Br J Oral Maxillofac Surg.* 2009;47(3):196–9.
- Srivastava D, Singh H, Mishra S, Sharma P, Kapoor P, Chandra L. Facial asymmetry revisited: part II-conceptualizing the management. *J Oral Biol Craniofac Res.* 2018;8(1):15–9.
- Costello BJ, Rivera RD, Shand J, Mooney M. Growth and development considerations for craniomaxillofacial surgery. *Oral Maxillofac Surg Clin North Am.* 2012;24(3):377–96.
- Pruzansky S. Not all dwarfed mandibles are alike. *Birth Defects.* 1969;5:120.
- Kaban LB, Padwa BL, Mulliken JB. Surgical correction of mandibular hypoplasia in hemifacial microsomia: the case for treatment in early childhood. *J Oral Maxillofac Surg.* 1998;56:628–38.
- Al-Moraissi EA, Wolford LM, Perez D, Laskin DM, Ellis E III. Does orthognathic surgery cause or cure temporomandibular disorders? A systematic review and meta-analysis Q2 Q24. *J Oral Maxillofac Surg.* 2017;75(9):1835–47.
- Bawane SS, Andrade NN. Hard and soft tissue changes following maxillary distraction osteogenesis and mandibular setback with bilateral sagittal split osteotomy. *J Maxillofac Oral Surg.* 2016;15(4):491–500.
- Posnick JC, Ricalde P, Ng P. A modified approach to “model planning” in orthognathic surgery for patients without a reliable centric relation. *J Oral Maxillofac Surg.* 2006;64(2):347–56.
- Guo J, Wang T, Han JJ, Jung S, Kook MS, Park HJ, Oh HK. Corrective outcome and transverse stability after orthognathic surgery using a surgery-first approach in mandibular prognathism with and without facial asymmetry. *Oral Surg Oral Med Oral Pathol Oral Radiol.* 2018;126(1):22–30.
- Schwartz HC. Efficient surgical management of mandibular asymmetry. *J Oral Maxillofac Surg.* 2011;69(3):645–54.
- Andrade NN, Aggarwal N, Mathai P, Nerurkar S. Versatility of uniplanar prearthroplastic distraction osteogenesis in the correction of post-ankylosis facial deformities—a report of five different cases. *Oral Maxillofac Surg.* 2018;22(4):463–74.

44. Wolford LM, Karras SC, Mehra P. Considerations for orthognathic surgery during growth, part 1: mandibular deformities. *Am J Orthod Dentofac Orthop.* 2001;119(2):95–101.
45. Wolford LM, Karras SC, Mehra P. Considerations for orthognathic surgery during growth, part 2: maxillary deformities. *Am J Orthod Dentofac Orthop.* 2001;119(2):102–5.

Additional Reading

- Grummons DC, Kappeyne van de Coppello MA. A frontal asymmetry analysis. *Journal of Clinical Orthodontics: JCO.* 1987;21(7):448–465.

Open Access This chapter is licensed under the terms of the Creative Commons Attribution 4.0 International License (<http://creativecommons.org/licenses/by/4.0/>), which permits use, sharing, adaptation, distribution and reproduction in any medium or format, as long as you give appropriate credit to the original author(s) and the source, provide a link to the Creative Commons license and indicate if changes were made.

The images or other third party material in this chapter are included in the chapter's Creative Commons license, unless indicated otherwise in a credit line to the material. If material is not included in the chapter's Creative Commons license and your intended use is not permitted by statutory regulation or exceeds the permitted use, you will need to obtain permission directly from the copyright holder.





Suresh Menon

71.1 Introduction

Obstructive sleep apnea (OSA) is a condition that affects 2–4% of the adult population. This disease has reached a proportion of increasing importance due to its neurological and cardiological consequences. Abnormal pharyngeal anatomy and altered activity of the upper airway musculature dilator physiology are primarily responsible for the collapse of the pharyngeal walls during sleep.

71.2 Definition

OSA is defined by the occurrence of daytime sleepiness, loud snoring, witnessed breathing interruptions, or awakenings due to gasping or choking in the presence of at least five obstructive respiratory events (apneas, hypopneas, or respiratory effort-related arousals) per hour of sleep [1].

When OSA is accompanied by excessive daytime sleepiness, it is termed Obstructive Sleep Apnea Syndrome.

The common terms that are used in OSA are apnea, hypopnea, apnea hypopnea index (AHI), and respiratory distress index (RDI) [2].

1. *Apnea* is the cessation of airflow, exceeding 10 seconds.
2. A *hypopnea* is reduced airflow exceeding 10 seconds accompanied by a desaturation of 3% or more of oxygen and/or electroencephalographic evidence of arousal.
3. The *apnea hypopnea index* (AHI) is the number of apneas and hypopneas per hour of sleep. A value of 5–15 represents mild sleep apnea, 15–30 moderate, and greater than 30, severe.
4. *Respiratory distress index* (RDI) includes other parameters in addition to apnea and hypopnea like respiratory effort-related arousals (RERAs). This is characterized by

increasing respiratory effort for 10 or more seconds leading to an arousal from sleep but not meeting the criteria of an apnea or hypopnea [3].

71.3 Etiopathogenesis

The upper airway is a flexible structure consisting of muscle and fat tissue and is usually only passively supported by bones. Therefore, it can be easily influenced by soft tissue factors like fat deposition in the parapharyngeal structures, edema/inflammation of the parapharyngeal region, hypertrophy of adenotonsillar tissues, or enlarged tongue.

The primary actor in the pathophysiology of OSA is the narrow, floppy upper airway. There is increased resistance of the upper airway due to anatomic factors that creates a negative airway pressure. This results in impaired function of airway-dilating muscles, thus increasing collapsibility. During sleep, the loss of skeletal muscle tone narrows the upper airway, making it floppier, especially during rapid eye movement (REM) sleep when muscle relaxation is intense. This results in two significant actions:

- The turbulent flow patterns that occur lead to vibration of structures causing snoring.
- The pharynx collapses due to the Bernoulli effect. This causes an obstruction which could be partial or complete. This tends to persist until sleep is interrupted and muscle tone is restored. These interruptions usually last less than 15 seconds, and the individual is unaware of them. Sometimes, the obstruction results in an awakening, and the individual complains of suddenly waking with a snort or a snore. Breathing is reestablished on arousal, and after a few breaths deeper sleep resumes with repetition of the cycle during muscle relaxation.

S. Menon (✉)

Department of Oral and Maxillofacial Surgery, Vydehi Institute of Dental Sciences and Research Centre, Bangalore, India

Additional factors that can increase the severity of upper airway resistance during sleep are mouth opening or a supine posture which allows the gravitational forces to push the tongue and soft palate back. Upper airway resistance can occur anywhere from the nasopharynx to the hypopharynx but primarily involves the oropharynx (Fig. 71.1).

71.4 Risk Factors for OSA

71.4.1 Age

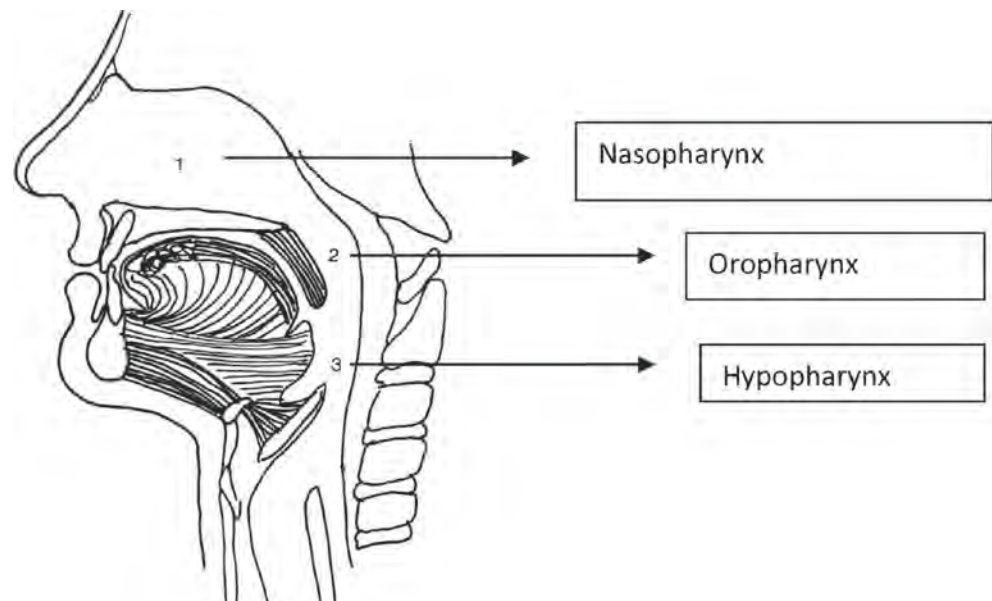
The disease prevalence increases steadily with age and reaches a stable level after the age of 60 years. The probable explanations for the age-related increase in prevalence include increased fat deposition in the parapharyngeal area, soft palate lengthening, etc.

71.4.2 Excess Body Weight

Body weight is an important risk factor for OSA, and studies have endorsed the positive effects of dieting and surgical weight loss on reducing OSA. Body weight increase can affect normal upper airway mechanics during sleep through:

1. Reduction of upper airway by increased parapharyngeal fat deposition.
2. Changing neural compensatory mechanisms that maintain patency of airway.
3. Instability of respiratory control system.
4. Reduction in functional residual capacity.

Fig. 71.1 Areas causing OSA



©Association of Oral and Maxillofacial Surgeons of India

71.4.3 Gender

It is an established fact that men are more vulnerable than women toward developing OSA. The differences exist not only in prevalence but also in polysomnographic characteristics of sleep and breathing patterns. Women were seen to have a lower AHI in non-rapid eye movement (non-REM) sleep. Disordered breathing events in women have a shorter duration and are associated with less oxyhemoglobin desaturation than in men.

71.4.4 Craniofacial Anatomy

The mechanical properties of the upper airway and the tendency to collapse during sleep can be influenced by both hard and soft tissues in the region. Findings in the craniofacial region like large tongue or soft palate, reduced mandibular size, or tonsillar hypertrophy in addition to inferiorly placed hyoid, maxillary, and mandibular retropositioning can narrow upper airway dimensions and leading to episodes of apneas and hypopneas during sleep.

71.4.5 Familial and Genetic Predisposition

Inheritance and familial factors also play a major role in OSA. First-degree relatives of OSA patients seem to be at risk more likely than others. The familial susceptibility tends to increase directly with the number of affected relatives.

Heredity and genetic factors also have been found to have a role in determining the volume of the lateral parapharyngeal

walls, tongue, and total soft tissue structures. A detailed family history can help in identifying those that have the disorder but remain undiagnosed.

71.4.6 Smoking and Alcohol Consumption

Cigarette smoking and alcohol are also possible risk factors for obstructive sleep apnea. Airway inflammation can occur due to cigarette smoke that could modify the properties of upper airway and increase its collapsibility during sleep. Alcohol consumption before sleep increases upper airway collapsibility and the precipitate apneic and hypopneic episodes during sleep. Another effect of alcohol is to inhibit respiratory motor output to the upper airway, causing hypotonia of the oropharyngeal muscles.

71.4.7 Medical Comorbidity

There is enough evidence to suggest that OSA can be a factor in the development of hypertension, coronary artery disease, congestive heart failure, and stroke [4].

OSA is also associated with diabetes mellitus. Therefore, diagnosing the condition and intervening early could directly or indirectly enhance glycemic control [5]. The role of positive airway pressure (PAP) therapy could result in reduced day time fatigue, better physical activity, resulting in improved metabolic control.

71.5 Clinical Sequelae [6]

71.5.1 Endocrine and Metabolic Effects

The central effects of sleep fragmentation and hypoxemia have been seen to induce a reversible neuroendocrine defect in growth hormone and testosterone secretion. This may explain impaired growth seen in children with upper airway obstruction which seems to get better after adenotonsillectomy.

71.5.2 Neuropsychological and Social Consequences

The classic feature of OSA prevalent as excessive daytime sleepiness may lead to both impaired work performance and driving. OSA patients seem to perform poorly on psychometric tests, and improvement has been seen after nasal CPAP therapy.

71.5.3 Cardiovascular Sequelae

There are two serious consequences of OSA involving the cardiovascular system. Initially acute cardiovascular changes occur during an apnea. This is followed by more chronic cardiovascular conditions like hypertension, myocardial infarction, stroke, and death.

71.6 Epidemiology [7, 8]

OSA has no specific age predilections, but a study by Young et al. estimated the prevalence in middle age to be 4% for men and 2% for women. Their study estimated that 1 of every 5 adults has at least mild OSA and 1 of every 15 has at least moderate OSA.

71.7 Diagnosis [1]

A detailed study of clinical signs and symptoms established during a comprehensive sleep evaluation and findings identified by sleep testing lead to the diagnosis of OSA.

71.7.1 History and Physical Examination

The diagnosis of OSA begins with a sleep history in one of three settings:

1. Part of routine health maintenance evaluation.
2. Part of an evaluation of symptoms of OSA.
3. Part of the comprehensive evaluation of patients at high risk for OSA.

Of the available, the Epworth sleepiness scale (ESS) (Table 71.1) is a popular subjective-based self-assessment of sleepiness that determines the degrees of sleepiness [9]. When scores are greater than 10, further investigations are recommended. However as about 10% of the population have a score of 11 or more, this score should be complemented by a narrative confirmation of intrusive somnolence.

71.7.2 Polysomnography (PSG)

This is an overnight sleep study monitored by a sleep technologist and is considered the “gold standard” in sleep medicine (Fig. 71.2). The physiologic parameters measured during PSG include simultaneous monitoring of

Table 71.1 Epworth sleepiness scale

Name:	Date:
Age:	Sex:
How likely are you to doze off or fall asleep in the following situations, in contrast to feeling just tired?	
Use the following scale to choose the most appropriate number for each situation:	
0—Would never doze	
1—Slight chance of dozing	
2—Moderate chance of dozing	
3—High chance of dozing	
<i>Situation</i>	<i>Chance of dozing (0–3)</i>
1. Sitting and reading.	-----
2. Watching TV.	-----
3. Sitting inactive in a public place like theatre/meeting.	-----
4. As a passenger in a car for an hour without break.	-----
5. Lying down to rest in the afternoon when circumstances permit.	-----
6. Sitting and talking to someone.	-----
7. Sitting quietly after lunch without alcohol.	-----
8. In a car, while stopped for a few minutes in traffic.	-----

brain wave activity continuously, eye movements, muscle activity of the legs and mandible, body position, heart rate and rhythm, blood pressure, snoring, and respiratory activity including breathing patterns and oxygen saturation. A detailed analysis of these can reveal apneic, hypopneic activities, etc.

Presence of obesity or signs of upper airway narrowing should also be documented.

Patients at High Risk for OSA and Who all should be evaluated for OSA Symptoms [1]

1. Obesity (BMI > 35).
2. Congestive heart failure.
3. Atrial fibrillation.
4. Treatment refractory hypertension.
5. Type 2 diabetes.
6. Nocturnal dysrhythmias.
7. Stroke.
8. Pulmonary hypertension.
9. High-risk driving populations.
10. Alcohol consumption.
11. Preoperative for bariatric surgery.

OSA Symptoms That Should Be Evaluated During a Comprehensive Sleep Evaluation

1. Witnessed apneas.
2. Snoring.
3. Gasping/choking at night.
4. Excessive sleepiness not explained by other factors.
5. Non refreshing sleep.
6. Total sleep amount.
7. Sleep fragmentation/maintenance insomnia.
8. Nocturia.
9. Morning headaches.
10. Decreased concentration.
11. Memory loss.
12. Decreased libido.
13. Irritability.

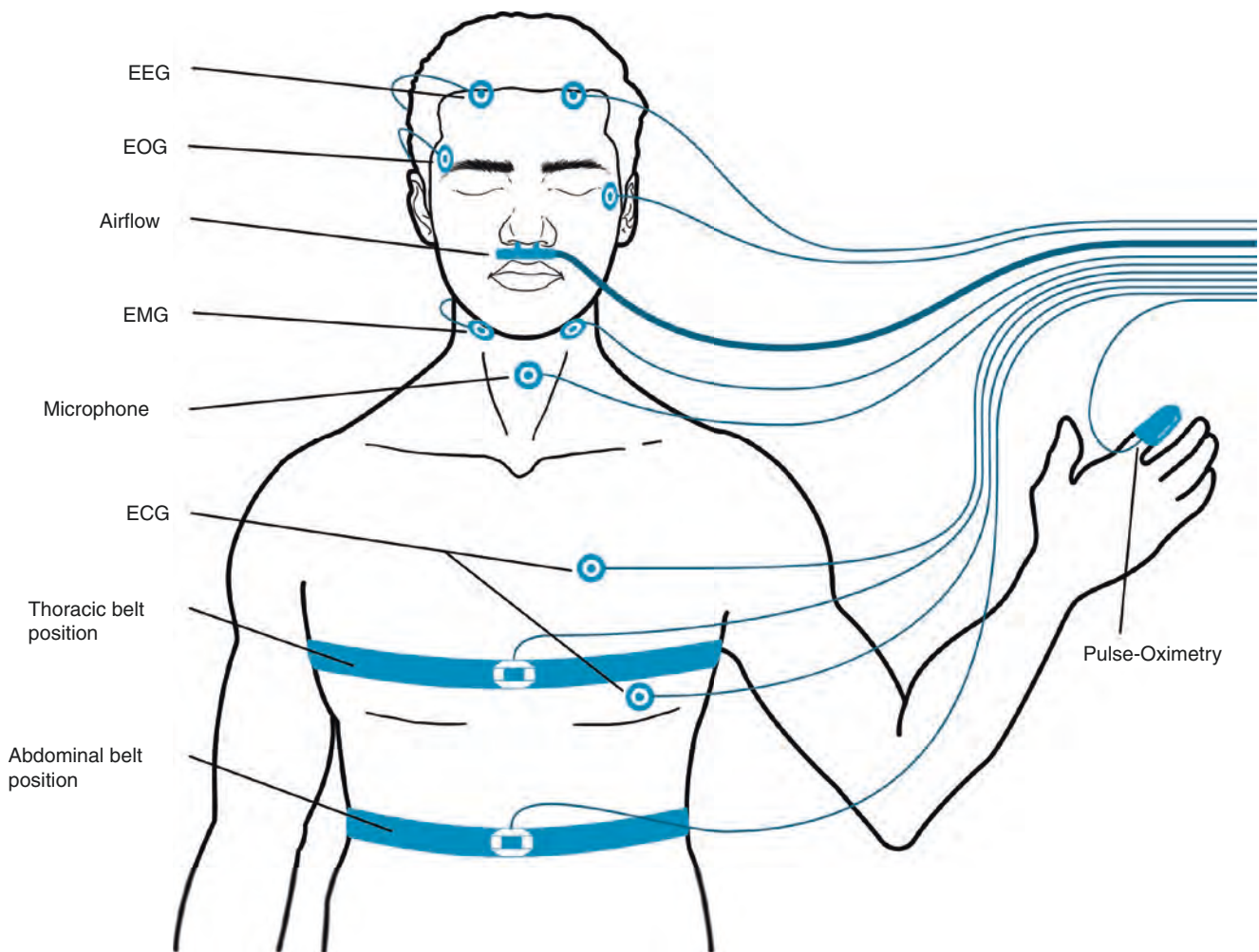
71.7.3 Imaging Aids

71.7.3.1 Cephalometrics

There is a plethora of imaging aids to help diagnose and plan the management of OSA. Cephalometrics has been the oldest imaging modality in the diagnosis of OSA. However, its role in quantification of the pharyngeal volume is controversial as the image that is two-dimensional is used to evaluate a three-dimensional structure [3].

It is a known fact that the lateral pharyngeal wall collapse has a bigger influence on severe sleep apnea than retropalatal and retrolingual collapse as studied with dynamic MRI, and this would not appear evident on a lateral cephalogram [10]. Another shortcoming of lateral cephalograms is that they are taken with the patient upright and awake and therefore do not characterize the asleep or supine airway.

Cephalometric images however have other advantages that can be used to predict OSA. It can be used to measure the upper airway length (UAL) (Fig. 71.3). UAL is significantly longer in OSA patients due to the relation between UAL and airflow resistance. Since the part of the airway is primarily composed of the soft tissues compared to the more rigid, cartilaginous, subglottic airway, this region may predispose to collapse. Studies have proved that male patients with UAL ≥ 72 mm have an eightfold increase in the probability of OSA while females with UAL ≥ 62 mm have a fivefold increase in OSA probability [11].



©Association of Oral and Maxillofacial Surgeons of India

Fig. 71.2 Polysomnography leads and parameters. *EEG* Electroencephalogram, *EOG* Electrooculography, *EMG* Electromyography, *ECG* Electrocardiography

Cephalometrics can also be used to predict the success in multilevel phase I therapy for patients. Skeletal class II patients with a more retrognathic mandible are poor responders. Other patients who could be poor responders include those with hyperdivergent vertical pattern with a larger mandibular plane angle, longer lower facial height, and steeper occlusal plane [9].

71.7.3.2 Dynamic Upper Airway Imaging [12]

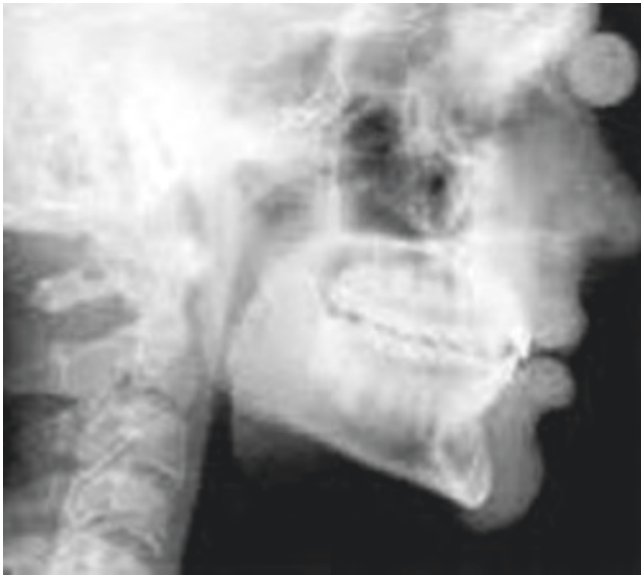Dynamically assessment of the level of upper airway obstruction in OSA patients will allow targeted intervention and allow planning a specific surgical procedure by allowing a delineation of the site and specifying degree and pattern of obstruction. It can also be used to exclude pathology like

tumors. Dynamic sleep MRI and drug-induced sleep CT scan characterize the airway in OSA with the advantage of ability to evaluate the airway in a multiplane fashion in the sleeping state or a simulated sleep state.

Drug-induced sleep endoscopy (DISE) is an alternative to conventional endoscopy with the goal of more accurately representing patterns of collapse during the sleeping state.

71.7.3.3 Acoustic Reflex Ion Test

In this test, sound waves are projected into the airway and are reflected into the tube to a computer which creates an image that determines the location of obstruction. This can also predict the effect of mandibular advancement and protrusion on upper airway.



©Association of Oral and Maxillofacial Surgeons of India

Fig. 71.3 Narrowing of oropharynx and long upper airway length in OSA

71.8 Clinical Features (Tables 71.2 and 71.3)

71.9 Treatment Modalities

OSA is a chronic condition that would require multidisciplinary management over a long period of time. There is a myriad of options to treat the condition ranging from behavioral to medical to surgical options. The success of treatment would have to ensure the voluntary active participation of the patient.

71.9.1 Positive Airway Pressure [13]

Continuous positive airway pressure (CPAP) is usually the first line of treatment for OSA. It works on the principle of binding the upper airway in an open position to improve patency during sleep (Fig. 71.4).

This was first described by Sullivan [14] in 1981. The pneumatic splinting action is effective in reducing the AHI. PAP may be delivered in either continuous (CPAP), bilevel (BPAP), or auto titrating (APAP) modes. CPAP is the first line of treatment for moderate to severe OSA and may be used occasionally in mild OSA. CPAP has also found to be effective as an adjunctive therapy to alter blood pressure in OSA patients having hypertension.

Some of these patients may elicit intolerance for CPAP therapy. In these cases, BPAP, pressure relief, or APAP can be considered as an alternative. In addition to its splinting

Table 71.2 Symptoms of OSAS

Adult	Children
Heavy snoring	Snoring
Excessive daytime sleepiness	Restless sleeping
Apneas	Somnolence
Sudden awakenings with 'choking'	Aggression/behavioral problems
Accidents related to sleepiness	Hyperactivity
Poor memory/concentration	Odd sleeping postures
Delirium	Frequent coughs/colds
Gastroesophageal reflux	
Mood/personality changes	
Nocturnal sweating	
Restlessness during sleep	
Nocturia	
Enuresis	
Dry mouth on awakening	
Nocturnal or morning headache	
Impotence	
Nocturnal epilepsy	

Table 71.3 Signs of OSAS

Edematous soft palate or uvula
Long soft palate and uvula
Decreased oropharyngeal dimensions
Nasal obstruction
Maxillary hypoplasia
Retrognathia
Central adiposity/increased neck circumference
Hypertension and other cardiovascular consequences

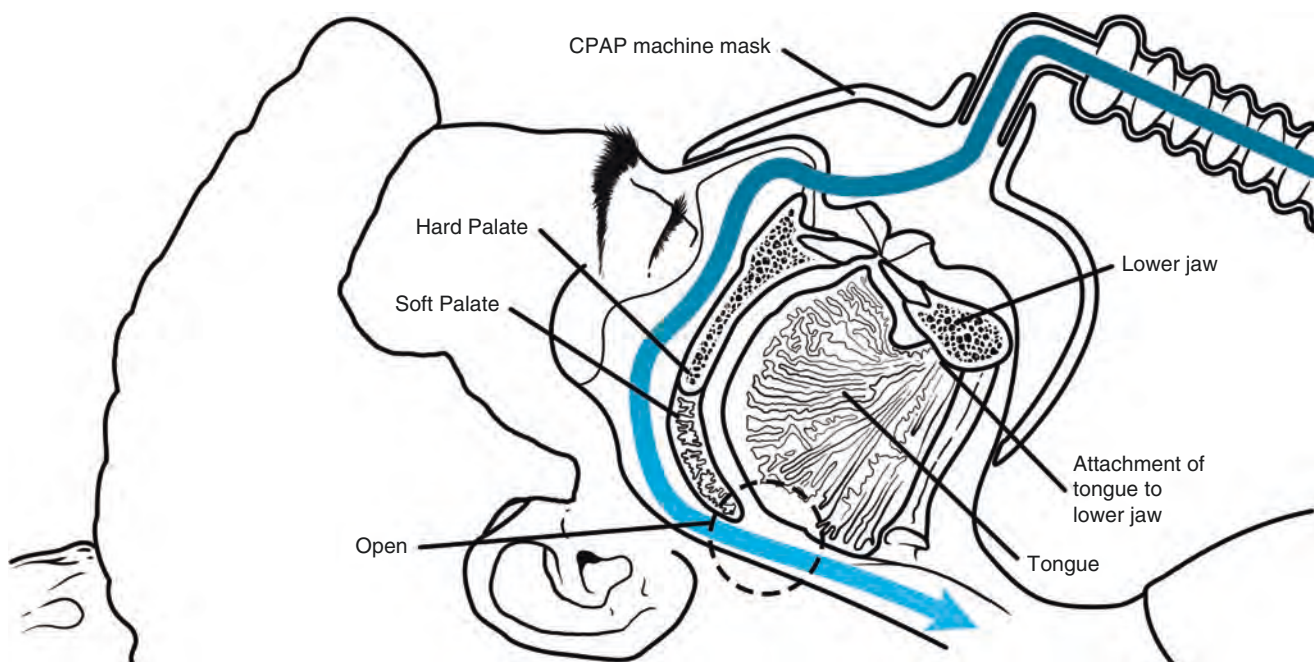
action, CPAP increases vagal tone, cardiac output, and stroke volume and decreases systemic vascular resistance, and there is reduced risk of cardiovascular mortality.

Compliance with nasal CPAP (nCPAP) ranges from 50 to 89% [15]. Reasons for noncompliance are usually due to tolerance problems like dry mouth, conjunctivitis, rhinorrhea, skin irritation, pressure sores, nasal congestion, and epistaxis. Other less common causes of noncompliance include aerophagia, chest discomfort, and bed partner intolerance or psychological problems arising from lack of motivation, claustrophobia, and anxiety.

Though there is no established known lower limit of nightly use below which nCPAP therapy is ineffective, it is suggested that 3.4 h per night of nCPAP use may be adequate to improve cognitive function and quality of life.

71.9.2 Behavioral Strategies [16]

Behavioral strategies have also been used as treatment methods in OSA. These include weight loss, regular exercise, positional therapy, and sleep hygiene which involves alcohol abstinence and consumption of sedatives before sleep. Sleep position while supine can decrease the lateral upper airway dimensions, particularly while in the supine position.



©Association of Oral and Maxillofacial Surgeons of India

Fig. 71.4 CPAP usage

Therefore, in positional therapy, the patient is kept in a non-supine position.

71.9.3 Oral Appliances [17]

The primary role of oral appliances (OAs) is to enlarge the posterior oropharyngeal airway space, leading to reduction of chances of the upper airway collapsing during sleep. They are ideally indicated in mild and moderate cases of OSA who are noncompliant/poorly compliant to nasal CPAP. Oral appliances are of two types: tongue retaining or mandibular repositioning.

- *Tongue retaining devices* [18]: These appliances position the tongue anteriorly by means of negative pressure and are indicated for patients who have few teeth or are edentulous, have macroglossia, or who are unable to adequately advance their mandible. The result is increase of the volume of the upper airway.
- *Mandibular repositioning devices (MRD)* [19]: As the name suggests, they reposition the mandible and structures attached to it like the tongue and hyoid bone anteriorly, thus increasing the upper airway dimensions in both sagittal and transverse planes, especially at the level of the velopharynx (Fig. 71.5). The appliances completely cover the maxillary and mandibular dentition and hold the mandible forward with respect to the resting position. The amount of advancement is titrated depending on the symptoms not exceeding 80% of the patient's maximum

protrusive capacity. This is followed by polysomnography to check the efficacy.

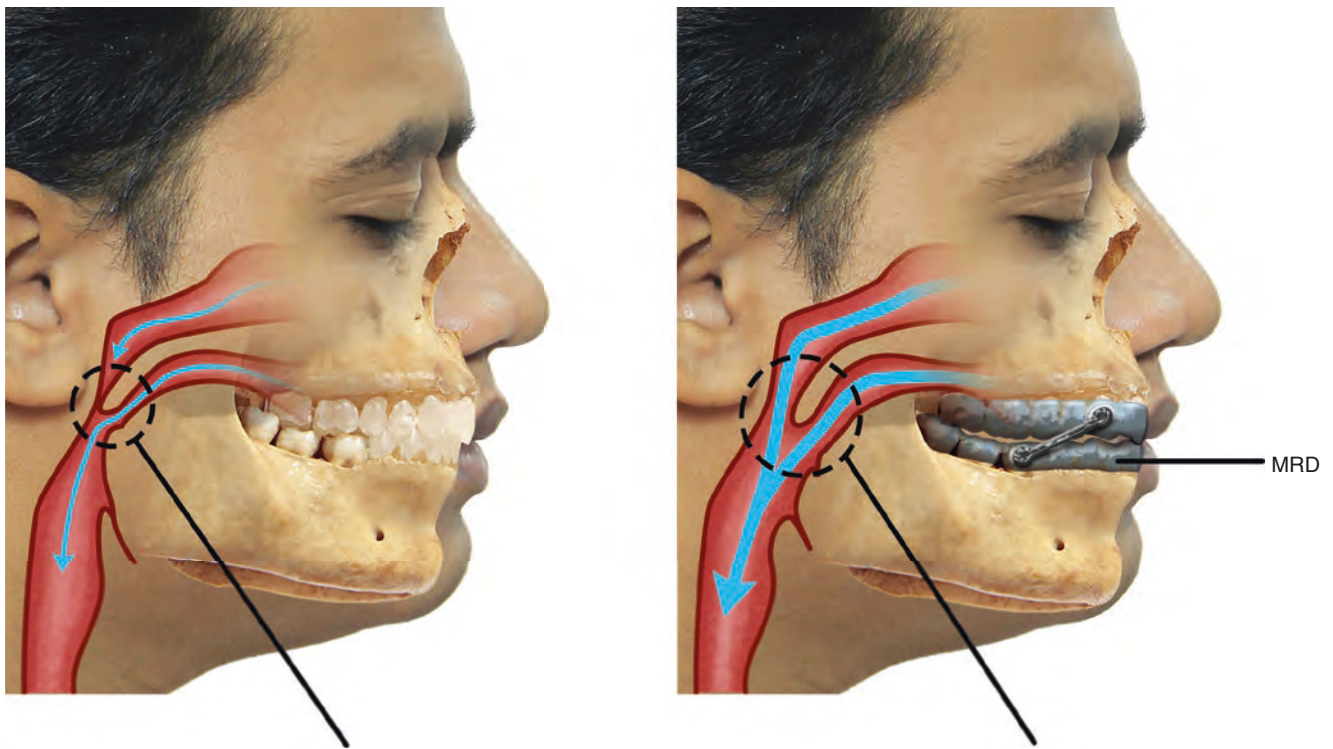
It is mandatory for patients using MRD to have adequate number of teeth to seat the appliance. There should not be any deleterious TMJ disorder, and the patients should have an adequate range of jaw motion and adequate manual dexterity and should be motivated to use the appliance.

The MRD device is customized and the material used is flexible polyamide.

In general, OAs are either titratable or non-titratable. Titratable OAs permit varying amounts of mandibular protrusion. Non-titratable OAs hold the mandible in a single protrusive position without any possibility to change the position during treatment. Some of the non-titratable devices are a simple splint, bionator, Karwatsky activator, or Herbst appliance [20].

71.9.4 Surgical Treatment of Obstructive Sleep Apnea [21] (Table 71.4)

Surgical procedures to correct or treat OSA essentially provide site-specific treatment to increase airway size and decrease airway resistance, thus reducing the effort required in breathing. The site of obstruction is specific to each patient and is as unique as fingerprints. Therefore, one needs to know which the most appropriate procedure is to guarantee success. Since no single factor is predictive of OSA, the significance of a thorough physical examination and imaging to



During sleep there is restricted airway space

©Association of Oral and Maxillofacial Surgeons of India

Mandibular Repositioning Device (MRD) increases airway space

Fig. 71.5 Mandibular repositioning device

Table 71.4 Common surgical procedures for OSA by site

Procedures that bypass the upper airway	Tracheostomy
Nasal procedures	Septoplasty
	Functional rhinoplasty
	Nasal valve surgery
	Turbinate reduction
	Nasal polypectomy
	Endoscopic procedures
Oral, oropharyngeal, and nasopharyngeal procedures	uvulopalatopharyngoplasty
	Palatal advancement pharyngoplasty
	Tonsillectomy/adenoidectomy
	Tori mandibularis excision
Hypopharyngeal procedures	Tongue reduction
	Lingual tonsillectomy
	Genioglossus advancement
	Hyoid suspension
	Mandibular advancement
Laryngeal procedures	Epiglottoplasty
	Hyoid suspension
Global airway procedures	Maxillomandibular advancement
	Bariatric surgery

identify the target site of airway resistance cannot be over emphasized.

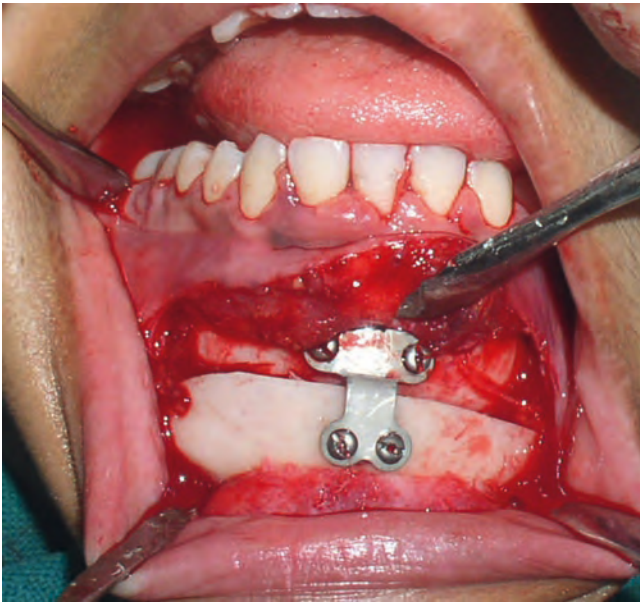
Tracheostomy has been used to bypasses the upper airway and is thus a successful modality in treatment, but the morbidity associated with it limits its application.

Factors in the nasal cavity may also play a role in influencing the pharyngeal stability through abnormalities like septal deviation and inferior turbinate. *Nasal surgery* to remove these abnormalities can improve nasal airflow, thus having a positive effect on OSA.

Multiple surgical procedures of the palate like uvulopalatopharyngoplasty (UPPP), which involves removal of the tonsils, uvula, and posterior velum in patients with large tonsils and relatively normal palatal position, are also good adjunctive procedures.

UPPP can also be done assisted by lasers allowing more precise incision and excision than conventional surgery. It also has the advantages of avoiding the need for general anesthesia and with minimal bleeding.

Tonsillectomy with adenoidectomy is the usually first line of surgery for children with OSA without significant cranio-facial anomalies.



©Association of Oral and Maxillofacial Surgeons of India

Fig. 71.6 Genioglossal advancement

Tongue reduction is also a part of the surgical option in enlarges tongue cases where partial glossectomy can reduce the tongue volume.

Surgical procedures of the genial segment of the mandible like *Genioglossal advancement* moves the genial tubercles forward along with the genioglossus muscle, resulting in a more forwardly positioned base of tongue. In addition, it also causes the forward movement of the hyoid bone. This shift increases the posterior airway space and avoids the collapse of its walls during the REM phase of sleep. There are a lot of modifications of the genial advancement procedures.

The standard procedure moves the whole genial segment including the chin. A modified technique allows the surgeon to advance the genial tubercle without altering the normal anatomic position or shape of a patient's chin by only moving the rectangular bony component involving the tubercle (Fig. 71.6).

Hyoid myotomy involves the detachment of infrahyoid muscles and moving the hyoid forward and upward and fixing it with sutures. Another procedure moves the hyoid forward and downward with excision of the lesser cornu and fixing the hyoid anterior to the thyroid cartilage by sutures.

Surgical procedures can also be performed at different levels either concomitantly or in a staged manner. This is done when patients have more than one site of obstruction.

Hypoglossal nerve stimulators (HGNS) are a new addition to the armamentarium for treatment of OSA. It was approved by the FDA for treatment of moderate to severe OSA in 2014 [22].

The device which acts like a pacemaker monitors the breathing patterns and gets activated during sleep to stimulate the hypoglossal nerve, thus controlling upper airway muscles.

Maxillomandibular advancement (MMA) is undoubtedly the most successful surgical technique in OSA. This advantage of this procedure is the effect in correcting airway obstruction at multiple levels. The surgical advancement of the maxillomandibular skeletal framework corrects the airway collapsibility at the nasopharyngeal and oropharyngeal levels and is ideal in patients with moderate and severe OSA who exhibit multilevel obstruction.

The Le Fort I osteotomy of the maxilla along with mandibular sagittal split osteotomy is performed for advancing maxilla and mandible, thus increasing the airway space as it draws the base of the tongue and soft palate forwards (Fig. 71.7).

Achieving *MMA by distraction* is another alternative technique, especially in cases of TMJ ankylosis (Figs. 71.8 and 71.9) where a deficient mandible in the sagittal plane is primarily responsible for the obstructed airway.

The dimensions of maxilla and mandible can also be increased in the transverse plane by distraction resulting in increase in the dimensions of nasopharynx, oropharynx, and the nasal cavity along with movement of tonsillar pillars and the musculature of the velum. Maxillomandibular transverse distraction osteogenesis can be concomitantly be performed with their sagittal advancement for a more effective form of treatment MMA alone.

71.10 Adjunctive Therapies

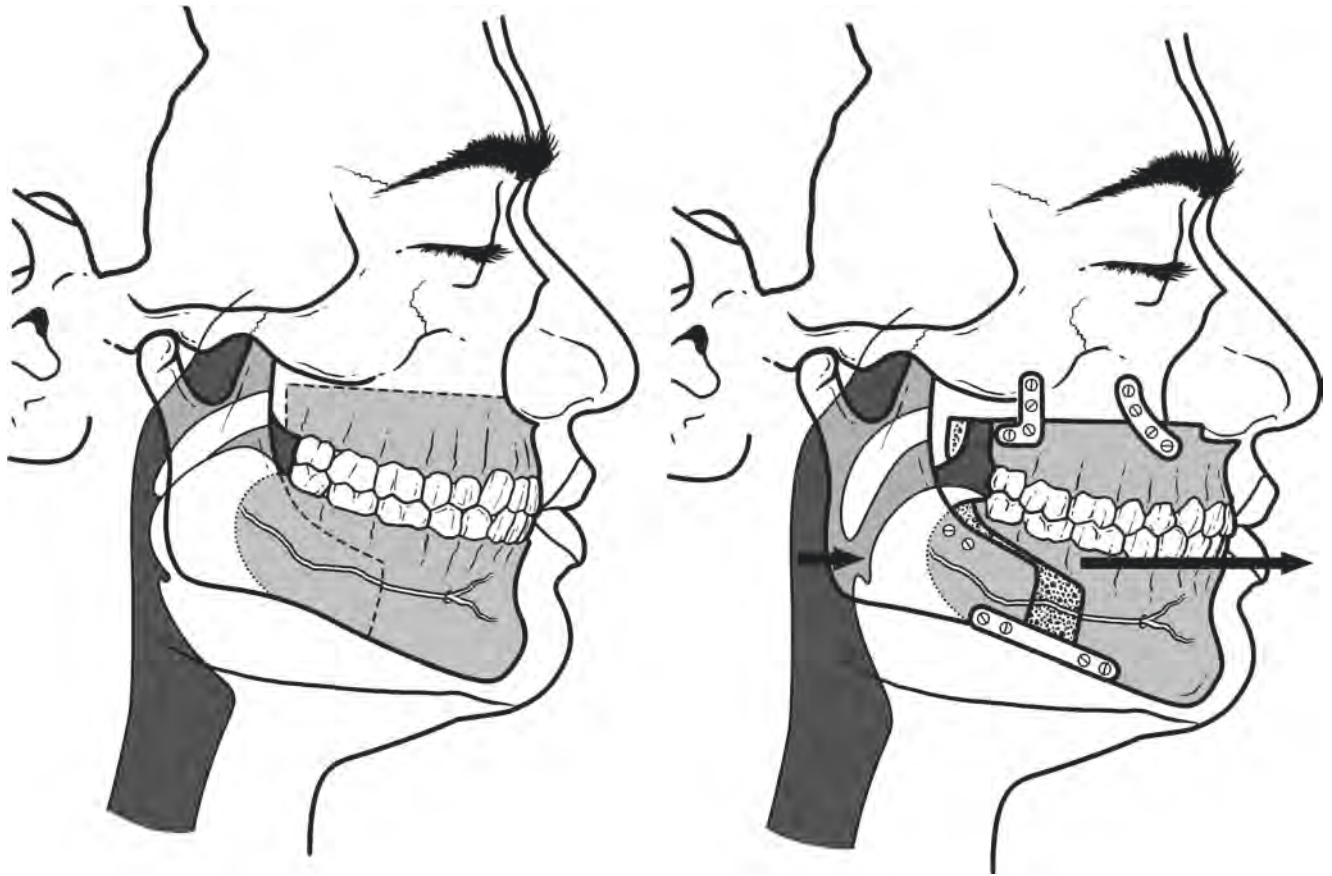
71.10.1 Bariatric Surgery [23]

Weight loss procedures through bariatric surgery is indicated in patients with a body mass index (BMI) ≥ 40 kg/m² or those with a BMI ≥ 35 kg/m² with important comorbidities especially when dietary attempts are ineffective.

71.10.2 Medications [23]

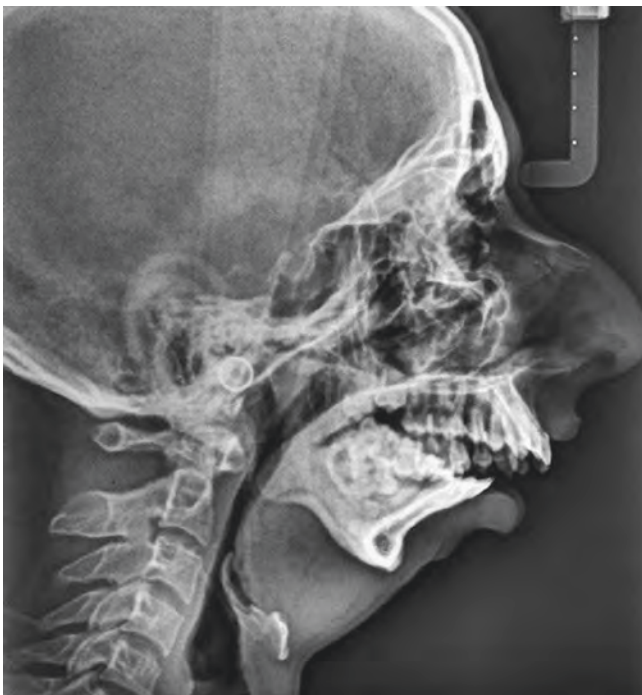Pharmacologic agents can on occasion be used with some degree of success in treating OSA by increasing glossopharyngeal neurologic activity or decreasing REM sleep.

Protriptyline, a tricyclic antidepressant reduces the frequency of apnea and desaturation in non-REM sleep and suppressing REM activity. It also increases the tone of the upper airway muscles. The anticholinergic activity of the drug however limits its use.



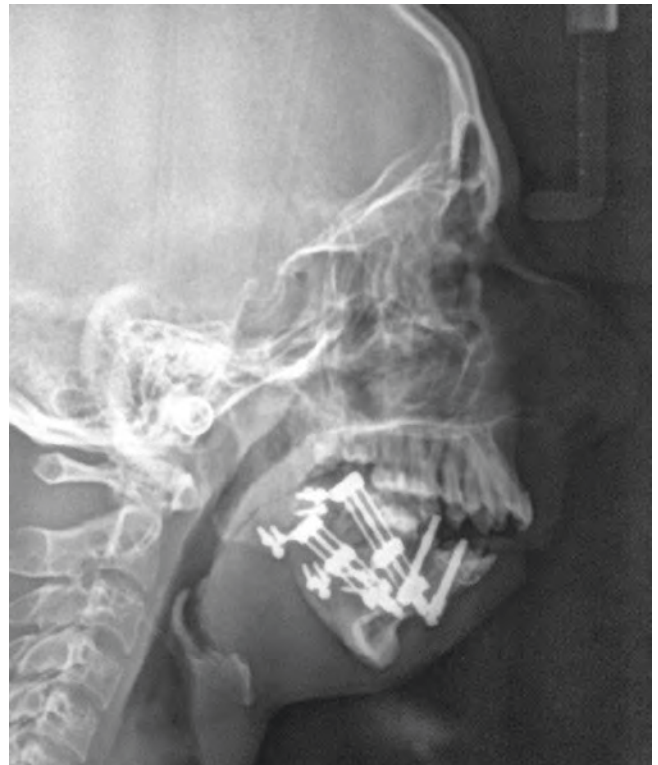
©Association of Oral and Maxillofacial Surgeons of India

Fig. 71.7 Maxillomandibular advancement and its effect on the airway



©Association of Oral and Maxillofacial Surgeons of India

Fig. 71.8 Compromised airway in ankylosis



©Association of Oral and Maxillofacial Surgeons of India

Fig. 71.9 Improved airway after mandibular distraction in a TMJ ankylosis case

Theophylline reduces the episodes of apneas and hypopneas, but the quality of sleep deteriorates.

Modafinil is a wake-promoting medication that can improve residual daytime sleepiness in OSA patients despite regular use of CPAP. It is however avoided in patients who are noncompliant with CPAP. The adverse effects of these drugs are headache and nervousness.

Topical nasal corticosteroids have also been recommended in patients suffering from concurrent rhinitis.

71.11 Conclusion

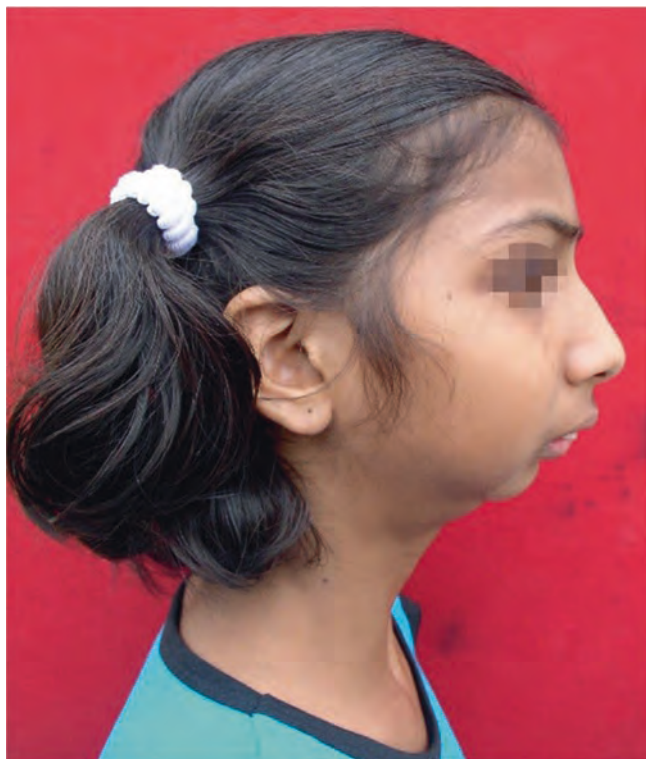Obstructive sleep apnea is a multi-factorial and multi-level condition whose management needs to be customized for every patient after a correct diagnosis. Treatment is regulated starting with the non-surgical options and moving to specific site surgical procedures depending on the area of involvement.

71.12 Case Scenario

A 12-year-old female patient with history of sleeping difficulty due to airway obstruction.

Clinical features: Retruded chin, incompetent lips, dry mouth, short chin throat distance (Fig. 71.10).

Preoperative radiographic findings: Deficient mandible, posteriorly placed menton, narrowed oropharynx (Fig. 71.11).



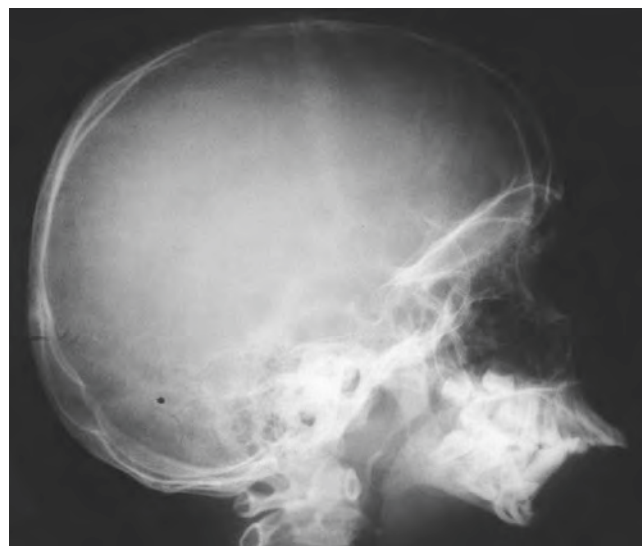
©Association of Oral and Maxillofacial Surgeons of India

Fig. 71.10 Patients profile

PSG report: Episodes of 33 apneas and 76 hypopneas confirming OSA (Box 71.1).

Treatment plan: Mandibular advancement of 10 mm by distraction (Fig. 71.12).

Post op findings: Improved profile, no episodes of apneas hypopneas (Figs. 71.13, 71.14 and Box 71.2).

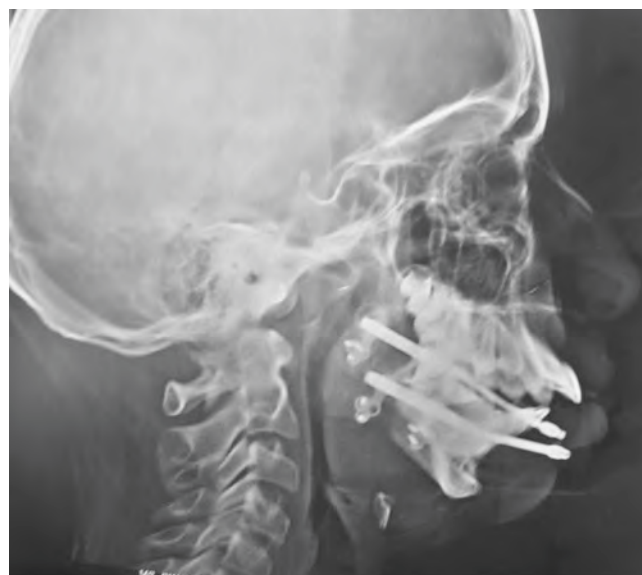

©Association of Oral and Maxillofacial Surgeons of India

Fig. 71.11 Preoperative cephalogram

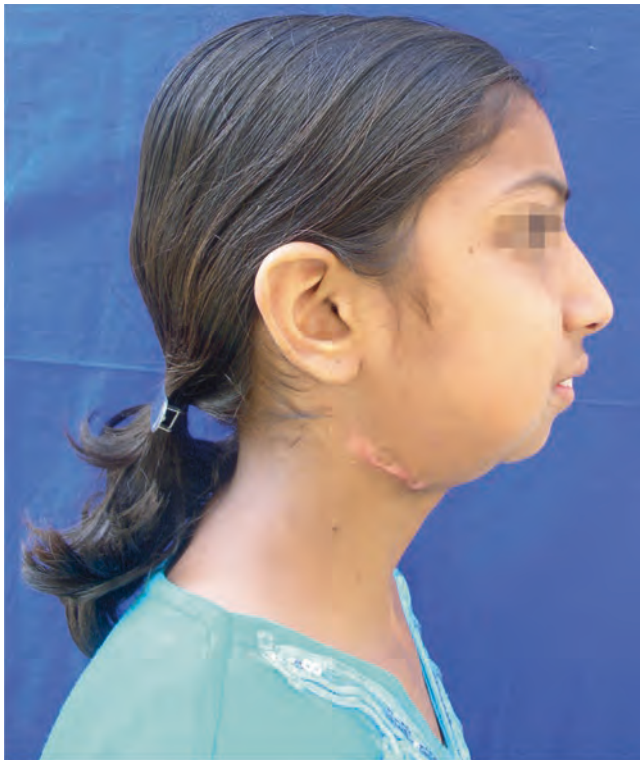Box 71.1 Preoperative PSG report

Events	Number
Apnoeas	33
Hypopnoeas	76



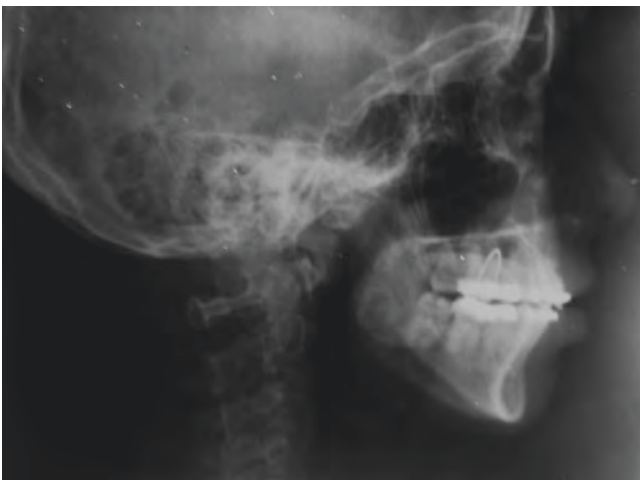©Association of Oral and Maxillofacial Surgeons of India

Fig. 71.12 Mandibular distraction



©Association of Oral and Maxillofacial Surgeons of India

Fig. 71.13 Postoperative profile of the patient



©Association of Oral and Maxillofacial Surgeons of India

Fig. 71.14 Postoperative cephalogram showing improved airway

Box 71.2 Post distraction PSG report

Events	Number
Apnoeas	0
Hypopnoeas	0

References

1. Epstein LJ, Kristo D, Strollo PJ, Friedman N, Malhotra A, Patil SP, et al. Clinical guideline for the evaluation, management and long-term care of obstructive sleep apnea in adults. *J Clin Sleep Med*. 2009 Jun 15;5(3):263–76.
2. Susarla SM, Thomas RJ, Abramson ZR, Kaban LB. Biomechanics of the upper airway: changing concepts in the pathogenesis of obstructive sleep apnea. *Int J Oral Maxillofac Surg*. 2010;39:1149–59.
3. Carolyn C, Brookes D, Boyd SB. Controversies in obstructive sleep apnea. *Surg Oral Maxillofac Surg Clin N Am*. 2017;29:503–13.
4. Javaheri S, Barbe F, Campos-Rodriguez F, Dempsey JA, Khayat R, Javaheri S, et al. Sleep apnea types, mechanisms, and clinical cardiovascular consequences. *J Am Coll Cardiol*. 2017;69(7):841–58.
5. Kaur A, Mokhlesi B. The effect of OSA therapy on glucose metabolism: it's all about CPAP adherence! *J Clin Sleep Med*. 2017 Mar 15;13(3):365–7.
6. Yee B, Liu P, Phillips C, Grunstein R. Neuroendocrine changes in sleep apnea. *Curr Opin Pulm Med*. 2004 November;10(6):475–81.
7. Young T, Palta M, Dempsey J, Skatrud J, Weber S, Badr S. The occurrence of sleep disordered breathing among middle aged adults. *N Engl J Med*. 1993;328:1230.
8. Young T, Peppard PE, Gottlieb DJ. Epidemiology of obstructive sleep apnea. *Am J Respir Crit Care Med*. 2002;165:1217.
9. Kim S-J, Kim Y-S, Park J-H, Kim S-W. Cephalometric predictors of therapeutic response to multilevel surgery in patients with obstructive sleep apnea. *J Oral Maxillofac Surg*. 2012;70:1404–12.
10. Tangugsorn V, Krogstad O, Espeland L, Lyberg T. Obstructive sleep apnoea: multiple comparisons of cephalometric variables of obese and non-obese patients. *J Cranio Maxillofac Surg*. 2000;28:204–12.
11. Gotsopoulos H, Kelly JJ, Cistulli PA. Treatment of OSA oral appliance therapy reduces blood pressure in obstructive sleep apnea: a randomized, controlled trial. *Sleep*. 2004;27(5):934–41.
12. Herford AS, Finn R. Single-stage CO2 laser assisted uvuloplasty for treatment of snoring and mild obstructive sleep apnoea. *J Cranio-Maxillofac Surg*. 2000;28:213–6.
13. Barbick MB, Dolwick MF. Genial tubercle advancement and sleep apnea. *J Oral Maxillofac Surg*. 2009;67:1767–70.
14. Sullivan C, Berthson-Jones M, Issa F. Nocturnal nasal-airway pressure for sleep apnea. *N Engl J Med*. 1983;309:112.
15. Li KK, Riley RW, Powell NB, Troell RJ. Obstructive sleep apnea surgery: Genioglossus advancement revisited. *J Oral Maxillofac Surg*. 2004;59:1181–4.
16. Foltan R, Hoffmannova J, Pretl M, Donev F, Marek VLK. Genioglossus advancement and hyoid myotomy in treating obstructive sleep apnoea syndrome – a follow-up study. *J Cranio-Maxillofac Surg*. 2007;35:246–51.
17. de Ruiter MHT, Apperloo RC, Milstein DMJ, de Lange J. Assessment of obstructive sleep apnoea treatment success or failure after maxillomandibular advancement. *Int J Oral Maxillofac Surg*. 2017;46:1357–62.
18. Scott Conleya R, Leganb HL. Correction of severe obstructive sleep apnea with bimaxillary transverse distraction osteogenesis and maxillomandibular advancement. *Am J Orthod Dentofac Orthop*. 2006;129:283–92.
19. Louro RS, Calasans-Maia JA, Mattos CT, Masterson D, Calasans-Maia MD, Maia LC. Three-dimensional changes to the upper airway after maxillomandibular advancement with counterclockwise rotation: a systematic review and meta-analysis. *Int J Oral Maxillofac Surg*. 2018;47:622–9.

20. Jayan B, Prasad BNBM, Bhattacharya D, Rajput AK, Dhiman RK. Management of a case of severe obstructive sleep apnoea with acrylic Herbst splint appliance: a case report Indian. *J Sleep Med.* 2006;1(3):157–60.
21. Fleisher KE, Krieger AC. Current trends in the treatment of obstructive sleep apnea. *J Oral Maxillofac Surg.* 2007;65:2056–68.
22. Hochban W, Podszus T, Eisele DW, Schwarz AR, Smith PL, Erickson D, Testerman R. Hypoglossal nerve stimulation for obstructive sleep apnoea. *Int J Oral Maxillofac Surg.* 1997;26:156.
23. W Keith Thornton and D Heath Roberts. Non-surgical management of the Obstructive sleep apnea patient. *J Oral Maxillofac Surg.* 1996;54:1103–8.

Suggested Reading

- Carolyn C. Dicus Brookes, Scott B. Boyd: Controversies in Obstructive Sleep Apnea Surgery. *Oral Maxillofacial Surg Clin N Am* 29 (2017) 503–513.
- Kasey K Li: Maxillomandibular advancement for Obstructive Sleep Apnea. *J Oral Maxillofac Surg* 69:687–694, 2011.
- Lawrence J. Epstein, David Kristo, Patrick J. Strollo, Norman Friedman, Atul Malhotra, Susheel P. Patil et al. Clinical Guideline for the Evaluation, Management and Long-term Care of Obstructive Sleep Apnea in Adults. *J Clin Sleep Med.* 2009 Jun 15; 5(3): 263–276.

Open Access This chapter is licensed under the terms of the Creative Commons Attribution 4.0 International License (<http://creativecommons.org/licenses/by/4.0/>), which permits use, sharing, adaptation, distribution and reproduction in any medium or format, as long as you give appropriate credit to the original author(s) and the source, provide a link to the Creative Commons license and indicate if changes were made.

The images or other third party material in this chapter are included in the chapter's Creative Commons license, unless indicated otherwise in a credit line to the material. If material is not included in the chapter's Creative Commons license and your intended use is not permitted by statutory regulation or exceeds the permitted use, you will need to obtain permission directly from the copyright holder.



Part XIX

**Developmental Deformities of the Oral
and Maxillofacial Region**



Pritham N. Shetty, Jaideep Singh Chauhan,
Mamatha Patil, Neha Aggarwal, and Dipesh Rao

72.1 Introduction

A cleft lip [CL] is defined as a congenital defect in lip continuity due to an embryological malformation. Cleft lip and palate [CLP] have an overall incidence of 1 in 1000 live births [1]. For different ethnicities, the incidence varies. Like other facial deformities, cleft lip and palate produce a considerable degree of disfigurement and functional impairment. A comprehensive treatment involving a cleft surgeon, otolaryngologist, geneticist, speech pathologist, orthodontist and others are required at multiple stages right from infancy to adulthood. A successful lip repair requires careful consideration of presentation of the cleft, the availability of tissues or the lack thereof and effect of intervention on growth and function. We have tried to simplify this concept, keeping certain key points in mind necessary for comprehension of the subject. In this chapter, we have discussed embryology, anatomy and clinical presentation of cleft as an integrated phenomenon for better understanding of cleft lip. The author's technique of cleft lip is discussed in a stepwise manner.

Electronic Supplementary Material The online version of this chapter (https://doi.org/10.1007/978-981-15-1346-6_72) contains supplementary material, which is available to authorized users.

P. N. Shetty (✉)
OMFS, Bangalore Institute of Dental Science, Bangalore, India

J. S. Chauhan
Department of Maxillofacial Surgery and the Smile Train, CHL Hospital, Indore, India

M. Patil
Sparsh Hospital Bommasandra Industrial Area, Bangalore, India

N. Aggarwal
Cleft and Craniofacial Surgery, Meenakshi Cleft and Craniofacial Centre, Chennai, India

D. Rao
Bhagwan Mahaveer Jain Hospital, Bangalore, Karnataka, India

72.1.1 History of Cleft Lip Repair

The enigma of cleft lip and the historic journey to repair the defect has been well described in the narrative book by Millard [2]. The excerpts from it illustrates the documentation of the first cleft lip repair in the year 390 AD where an unidentified Chinese physician cut the edges of the cleft and stitched it together with a postoperative order of limited lip movements for the next 100 days. The need to identify an ideal technique was derived on the basis of the anatomical outcome of the repair and also the postoperative scarring. The concepts of cleft lip repair have evolved from straight line repairs to a variety of techniques using various cutbacks, triangles, z-plasties and other flaps.

The techniques for cleft lip can be broadly classified into:

- Straight line repairs.
- Geometric designed techniques.
- Rotational advancement techniques.

We will discuss certain techniques to explain the evolution from a historical point of view. The rotation-advancement technique with its modifications will be discussed later in this chapter.

72.2 Embryology

72.2.1 Development of the External Face

The face is derived from two sources: the frontonasal process that covers the forebrain (neural crest origin) and the tissues of first pharyngeal arch (mixed mesoderm and neural crest origin). These tissues surround the oropharyngeal membrane. From the frontonasal process, two medial nasal processes and lateral nasal processes arise [3]. The first pharyngeal arch gives

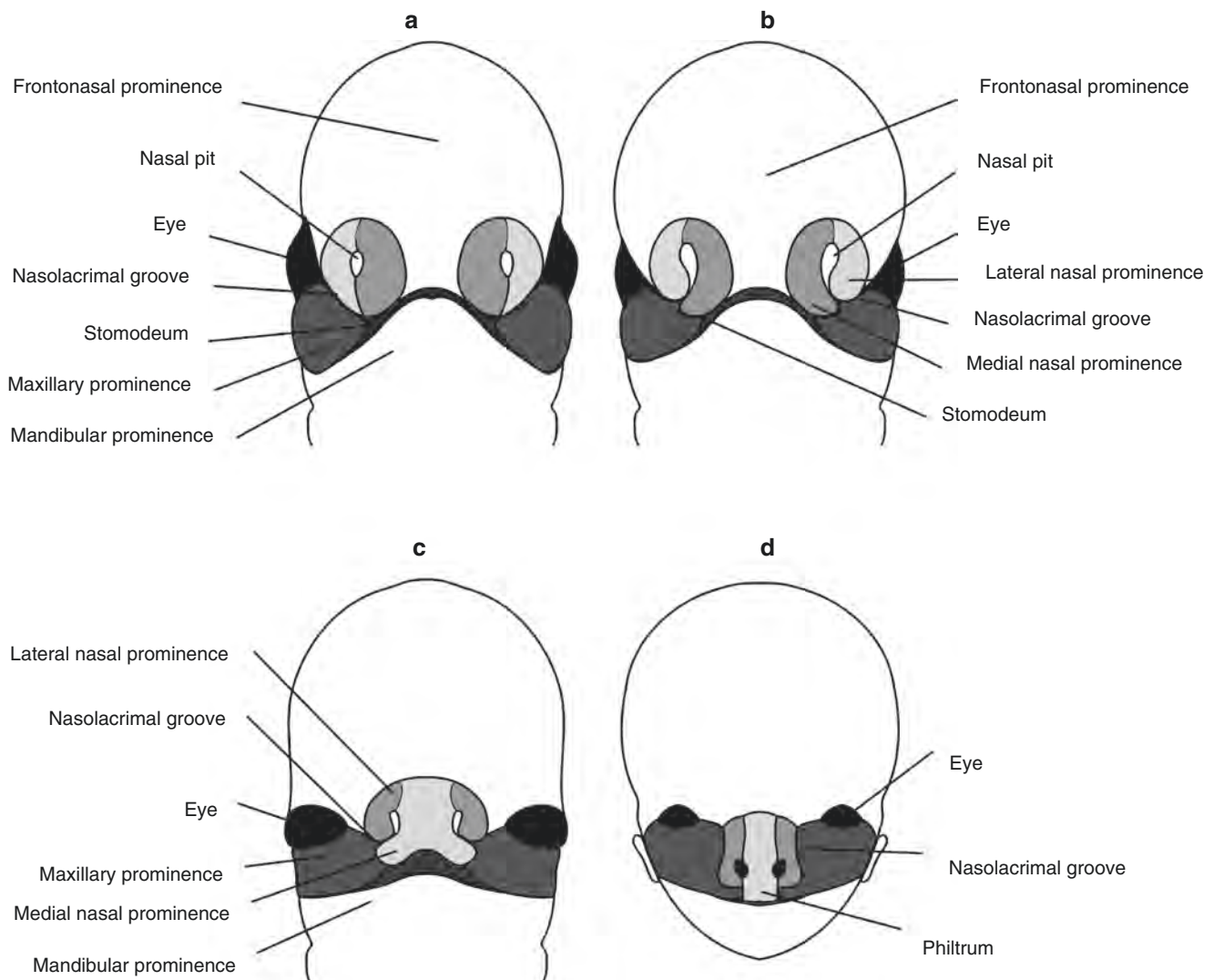
rise to a pair of mandibular processes and a pair of maxillary processes from which palatal processes arise [3]. The maxillary prominences continue to grow medially, compressing the medial nasal prominences towards the midline, subsequently meeting the lateral nasal processes and then the lower part of the medial nasal processes (Figs. 72.1, 77.1). This lower part is known as the globular or premaxillary process. The components derived from various parts are given in Table 72.1.

Abnormalities throughout this complicated developmental process occur in the most severe congenital forms if they develop early in facial embryogenesis (4–8 weeks) to the relatively minor problems developing later (8–12 weeks). Cleft lip varies from a notch in lips red border to extending into the floor of nostril and the alveolar ridge. It may be unilateral or bilateral (Fig. 72.2). Some other forms of facial clefts have also been described in a pictorial form as a result of failure of fusion of the same processes but in a different trajectory and various permutations and combinations (Fig. 72.3).

1. Unilateral cleft lip—due to the failure of the maxillary prominence to join with the merged median nasal prominences which results in a cleft.
2. Bilateral cleft lip—due to failure of fusion of the maxillary prominences with merged nasal prominences bilaterally. The extent of clefting may or may not be similar on both sides.

Table 72.1 Components of face derived from various prominences

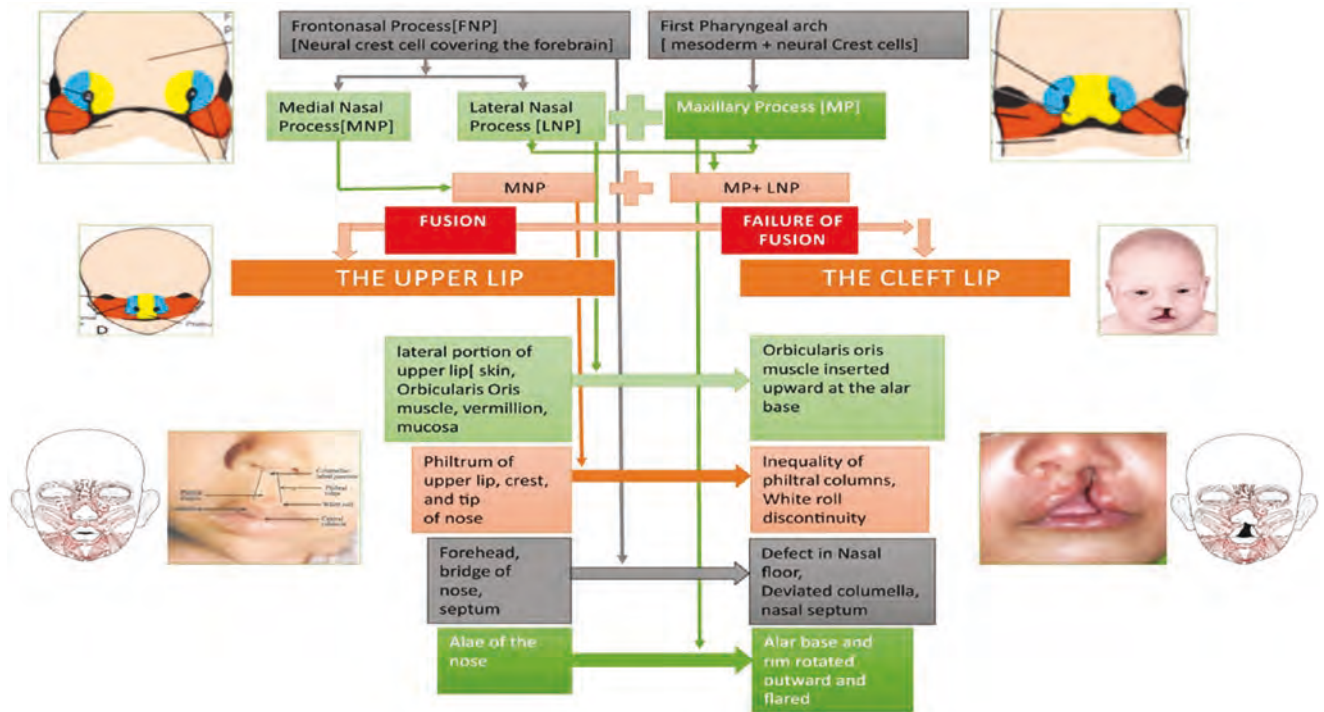
Prominence	External face derivatives
Frontonasal	The forehead, the bridge of nose, median and lateral nasal processes
Medial nasal	The philtrum of the upper lip, crest and tip of the nose
Lateral nasal	Alae of the nose
Maxillary process (first pharyngeal arch)	Lateral portion of the upper lip
Mandibular process (first pharyngeal arch)	The lower lip



©Association of Oral and Maxillofacial Surgeons of India

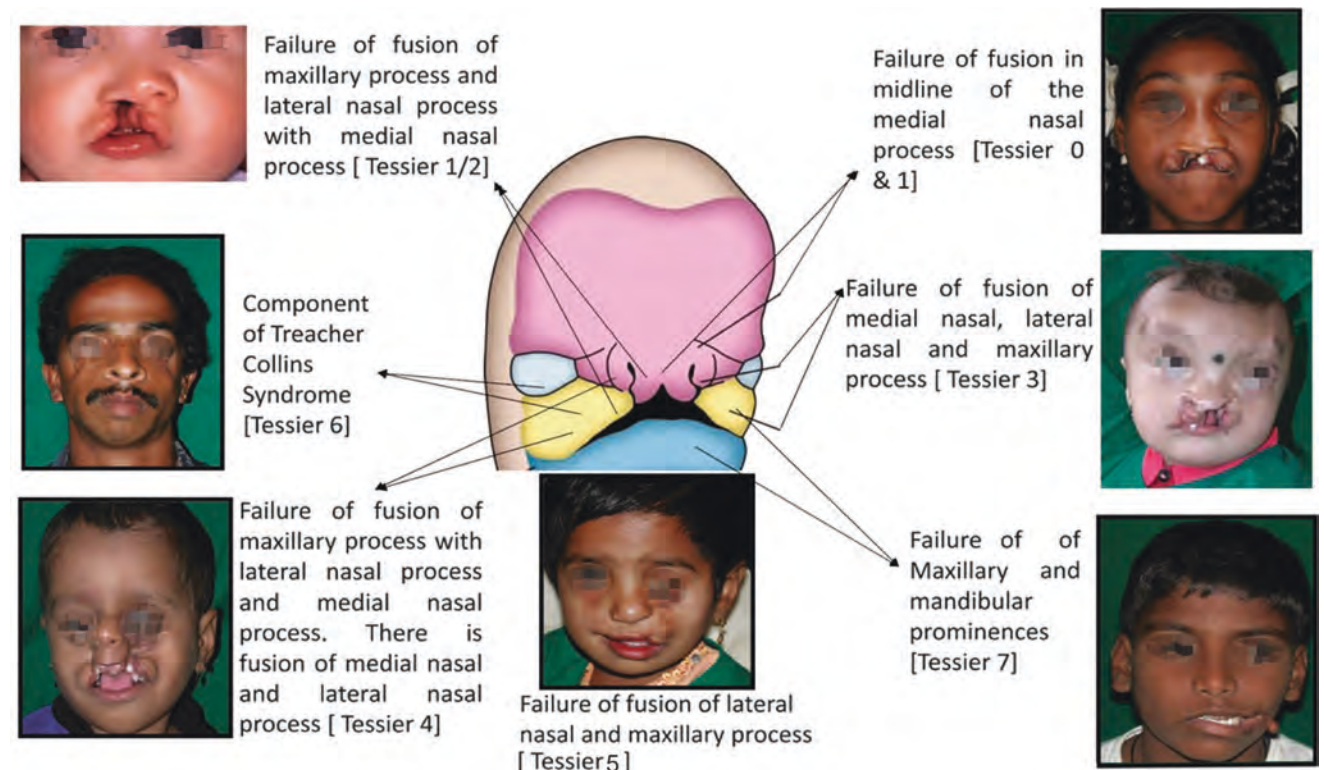
Fig. 72.1 (a–d) Development of the face. (a) Lateral nasal and medial nasal swellings that surround the nasal placodes appear on the frontonasal process (b) Paired maxillary processes grow medially, compressing

the medial nasal prominences towards the midline. (c) Medial nasal processes fuse with each other, lateral nasal processes and the maxillary processes. (d) Complete development of the nose and upper lip



©Association of Oral and Maxillofacial Surgeons of India

Fig. 72.2 Relation of embryological derivative to the anatomical and clinical description of cleft lip



©Association of Oral and Maxillofacial Surgeons of India

Fig. 72.3 Embryology of various facial clefts

3. Median cleft lip—a very rare condition. Occurs due to the partial or complete failure of fusion of the two medial nasal prominences to form the intermaxillary segment. It is the characteristic feature of Mohr's syndrome.

72.2.2 Embryology of Cleft and its Surgical Implications

1. Mesodermal Migration: There are various theories to describe how a cleft occurs. These theories explain that cleft rises as a result of failure of fusion of the five processes. These processes are formed as a result of mesodermal migration resulting in heaping under the ectodermal layer. Insufficient or late migration of mesoderm leads to partial or total cleft as a result of epithelial breakdown.

Mesoderm gives rise to the fibromuscular layer of the lip. The importance of mesodermal migration carries in itself an important principle of cleft repair, i.e. muscle approximation. The author's technique presented later in this chapter describes this step as an important step in functional cleft repair. Also the mesoderm has chondrogenic potential which explains the accompanying deficit in the development of nasal capsule [4].

2. Vascular Supply: The philtrum and premaxilla derive their blood supply from the posterior septal artery and ter-

minial branches of the ethmoidal artery (Fig. 72.4). Knowledge of this embryological vascular supply is important while designing the incision on the prolabium in a bilateral cleft lip repair. As the prolabium derives its blood supply solely from the frontonasal process, no back cuts are given during dissection of prolabial flap (Fig. 72.4). This is discussed again in surgical technique.

3. Premaxilla: In complete bilateral cleft lips, the labial artery fails to unite with its counterpart on the other side. In addition the arcade made by anastomosis of the posterior septal branch with the greater palatine artery through the incisive foramen is absent. Thus the blood supply of the premaxilla is derived from three sources: periosteal supply from the vomer, branches of the sphenopalatine and ethmoidal artery. This principle is used in anterior palate repair with concomitant lip repair in bilateral clefts. It is postulated that anterior palate repair using the vomerine flap can lead to premaxillary necrosis due to cutoff of blood supply from the posterior septal arteries. However, in author's opinion and experience, the premaxilla has a robust blood supply even after using vomerine flaps for anterior palate repair [5].
4. The maxillary process carries within itself the superior labial artery which supplies the orbicularis oris muscle. During muscle dissection, the artery is encountered within the muscle going upward. This vessel should be identified throughout the length of incision and muscle dissection and should be carefully cauterised.

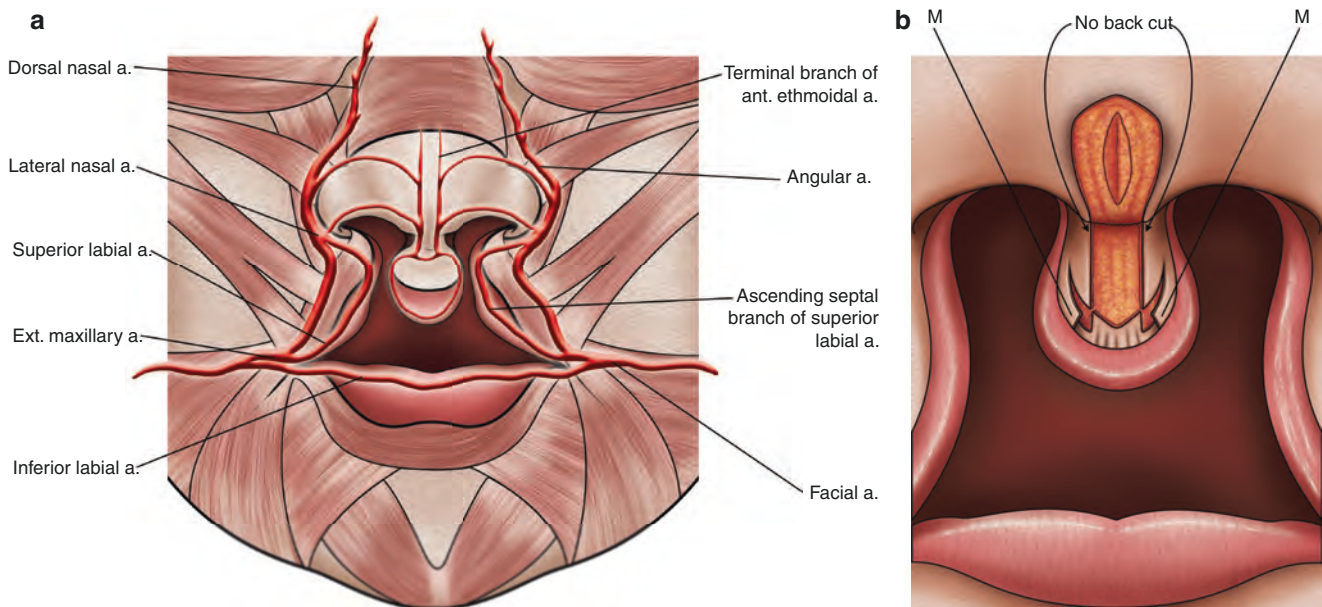


Fig. 72.4 (a, b) As the philtrum and premaxilla are derived from the frontonasal process, their blood supply is from the posterior septal artery and terminal branches of the ethmoidal artery (a). As the pro-

labium derives its blood supply solely from the frontonasal process, no back cuts are given during dissection of prolabial flap (b)

72.2.3 Prenatal Diagnosis in Cleft Lip

Cleft lip can be diagnosed in the intrauterine stage with the help of routine ultrasound scanning at different intervals of gestation. The prenatal diagnosis is usually established during the second and third trimester [6]. Recent data suggests that during the 11–13 gestational weeks, a midsagittal view of the fetal head, face and brain, in addition to certain measurable abnormalities, such as a smaller palatino-maxillary diameter, can make grounds for an underlying CLP. 3D sonography can construct a computerized volumetric rendering of the foetus, similar to 3D CT volumetric reconstructions. Detection rates of up to 75% have been described by specialist maternal-fetal medicine [MFM] physicians and radiologists. Thus, prenatal counselling continues to be important with evolving diagnostic procedures. Although there is currently no intrauterine treatment of cleft lip and palate, research has indicated that both mother and child benefit from early diagnosis and counselling. Prenatal counselling has positive psychological implications on the parents of a child with cleft as they are better prepared and motivated for treatment.

72.3 Surgical Anatomy

Anatomy of the cleft lip patient includes two major components: the lip and the nose. Both the structures vary greatly in a unilateral and bilateral cleft lip deformity and are discussed individually here.

The upper lip is attached above to the nose and blends laterally into the cheek, curving into the lower lip at the commissures. It is formed of muscles and glands covered superficially with skin and lined internally with mucous membrane. These layers are tightly adherent to the muscles and are sealed along the free margin (Box 72.1).

Box 72.1 Components of an Upper Lip

Normal upper lip anatomy

1. Skin, mucous membranes and vermillion with labial mucosal glands.
2. Muscles: orbicularis oris insertion is displaced in unilateral and bilateral cleft patients.
3. Vascular supply: superior labial artery, inferior labial artery and septal arteries are the major blood supplies of the lips and the nose.

72.3.1 Surface Anatomy

The following anatomical surface components of the upper lip are to be kept in mind when assessing a patient with cleft lip (Fig. 72.5). Anatomical equal repositioning of these features is essential for an aesthetic and functional outcome (Box 72.2).

Box 72.2 Anatomic Landmarks

Philtral columns: They are paired bilateral vertical lip bulges created by the dermal insertion of orbicularis oris fibres into the skin of the upper lip.

Philtral dimple: It's a concavity between the philtral columns created by relative deficiency of muscle fibres.

White roll: The white roll is a prominent ridge just above cutaneous-vermillion border. It appears very distinct and white/light in colour due to reflection of light off the skin. This is due to insertion of pars marginalis of orbicularis muscle and absence of hair in this region.

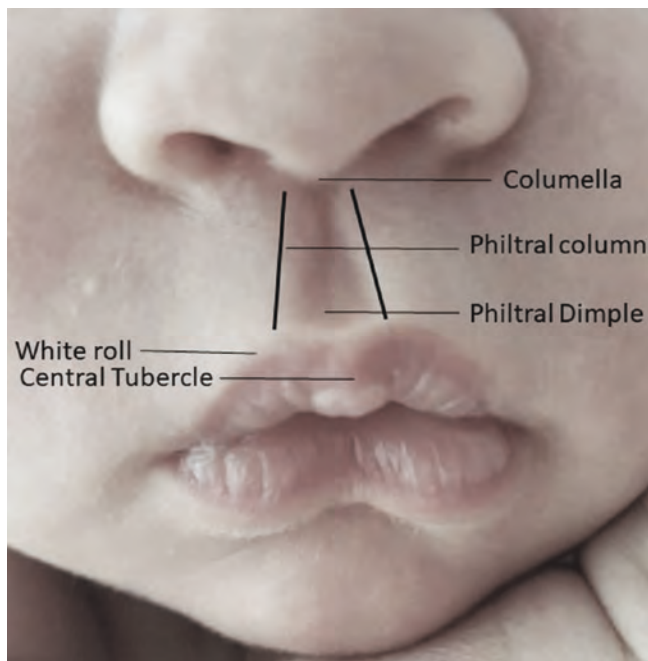
Vermillion: It's the red mucosal portion of lip divided into dry (keratinized) and wet (nonkeratinized) mucosa.

Red line: It's the junction between wet and dry vermillion mucosa.

Cupid's bow: A curvature of central white roll, formed by the two lateral peaks as the philtral columns extend inferiorly.

Tubercle: Vermillion fullness at central inferior apex of Cupid's bow.

In the normal lip, the columella is a central straight column reaching up to the nasal tip. At its base the columella blends into the nostril sill in front of the nasal floors laterally towards the alar bases. The arches of the alae are symmetrical with equal bulges of the alar cartilages. The eversion of the upper lip places it slightly out in front of the lower lip at the mucocutaneous junction of the upper lip. There is a continuous 1–2 mm rounded roll from commissure to commissure which tops the vermillion and picks up white light it coincides in its curves with the peaks of the Cupid's bow of the vermillion which has central tubercle flanked by, each arch of the bow. The abundance of eleidin in the epithelial cell layers increases the translucency, and the numerous rich capillaries of the papillae create the red colour of this area [5].



©Association of Oral and Maxillofacial Surgeons of India

Fig. 72.5 Surface landmarks of a normal lip and nose

72.3.2 Muscles

The *orbicularis oris* consists of numerous layers of muscle fibres surrounding the rima oris traversing in different directions. It is partly derived from muscle fibres of the other facial muscles which are inserted into the lips and partly fibres of its own inserted into the skin near the midline. The main fibres of the lips are oblique and pass from the skin to the mucous membrane, throughout the lip thickness. In the upper lip, these fibres group into two bands bilaterally, lateral and medial [total of four bands]: the *lateral band* originating from the alveolus of the lateral incisor tooth and the *medial band* connecting the upper lip to the septum of the nose. The area between the two medial bands forms the *philtrum*, below the septum of the nose. The additional fibres for the lower lip arise on either side of the midline lateral to the mentalis and merge with the other muscles at the commissure [7].

Orbicularis oris derives from eight muscle components with their origins in the modiolus at each angle of the mouth. Orbicularis fibres of one side end by decussating in the median line with fibres from the opposite side. The orbicularis is composed of four pars peripheralis extending from the rima oris on the right and left side. Intimately associated with the pars peripheralis is the pars marginalis with its two right and left components lying in a plane superficial to the pars peripheralis and confined to the area beneath the vermil-

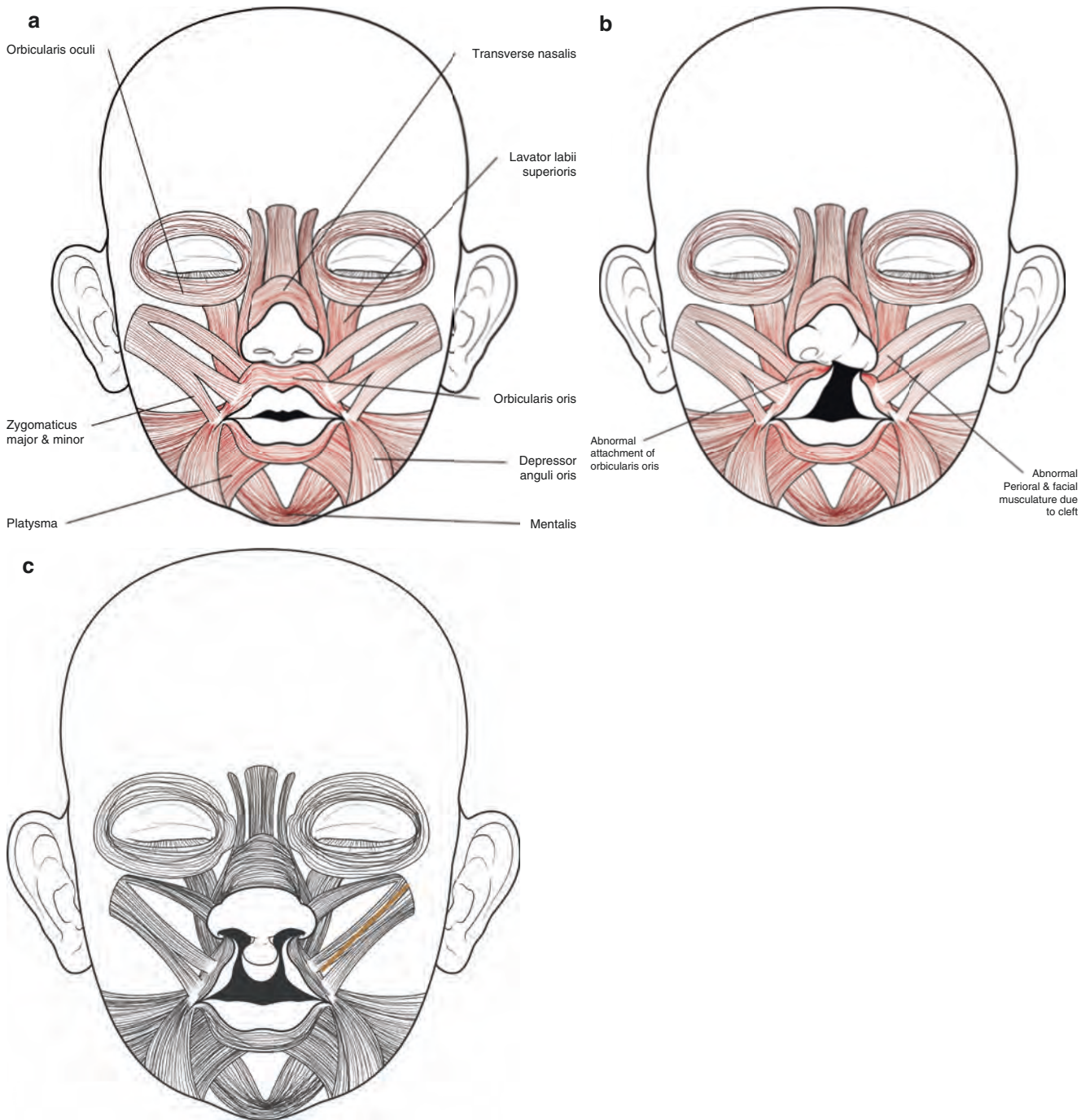
lion. Pars marginalis is responsible for fine movement (speech) and pars peripheralis for gross movement of the lips (Fig. 72.6a–c). In the presence of cleft, the orbicularis oris muscle fibres do not decussate transversely across the midline but tend to go parallel to the cleft edges towards the base of the nose with their integrity divided. In addition, the transverse nasalis muscle, levator labii superioris and depressor septi do not insert and are prolapsed laterally. They often contract abnormally which has a ripple effect of the lip and the nose. Muscles make the most of their advantage exerting unnatural lateral lifting and distortion of the lip elements in both incomplete and complete clefts. They play a role in displacement of alar base to the side of cleft and the nasal septum on non-cleft healthy side.

72.3.3 Vascular Supply

The major vascular supply to the lip and nose area is derived from the facial artery, branch of the external carotid artery. Other additional sources are from the ophthalmic and the infraorbital arteries. The facial artery gives off inferior and superior labial branches which arise near the corner of the mouth and course as the coronary vessels beneath the free border of the lips deep to the muscle and close to the mucous membrane. The right and left labial arteries freely anastomose to form a circle surrounding the oral aperture. The facial artery then proceeds upwards along the nasolabial fold and gives off the lateral nasal branch and then becomes the angular artery proceeding up to anastomose with the dorsal nasal branch of the ophthalmic artery. The posterior septal artery arising from the sphenopalatine artery in the roof of the nasal cavity courses down the vomerine groove to the incisive foramen anastomosing with the major palatine and ascending septal branches of the superior labial arteries (Fig. 72.7a, b).

Near the inferior lateral attachment of the ala, the lateral nasal artery divides to run one branch along the lower border and another along the superior margin of the lower lateral cartilage. These branches anastomose in the midline with the terminal branches of the anterior ethmoidal artery. It enters the nose and passes along the undersurface of the nasal bone continuing distally over the upper lateral cartilages to the tip of the nose. It joins the lateral nasal branches to continue into the columella anastomosing with the ascending septal branches of the superior labial artery [5].

Vascular anatomy in a cleft lip has been described pictographically in Fig. 72.8. There is an interruption in the usual arcade in the upper lip in unilateral clefts. However, there is sufficient blood supply to both lip elements and the nose to ensure adequate healing.

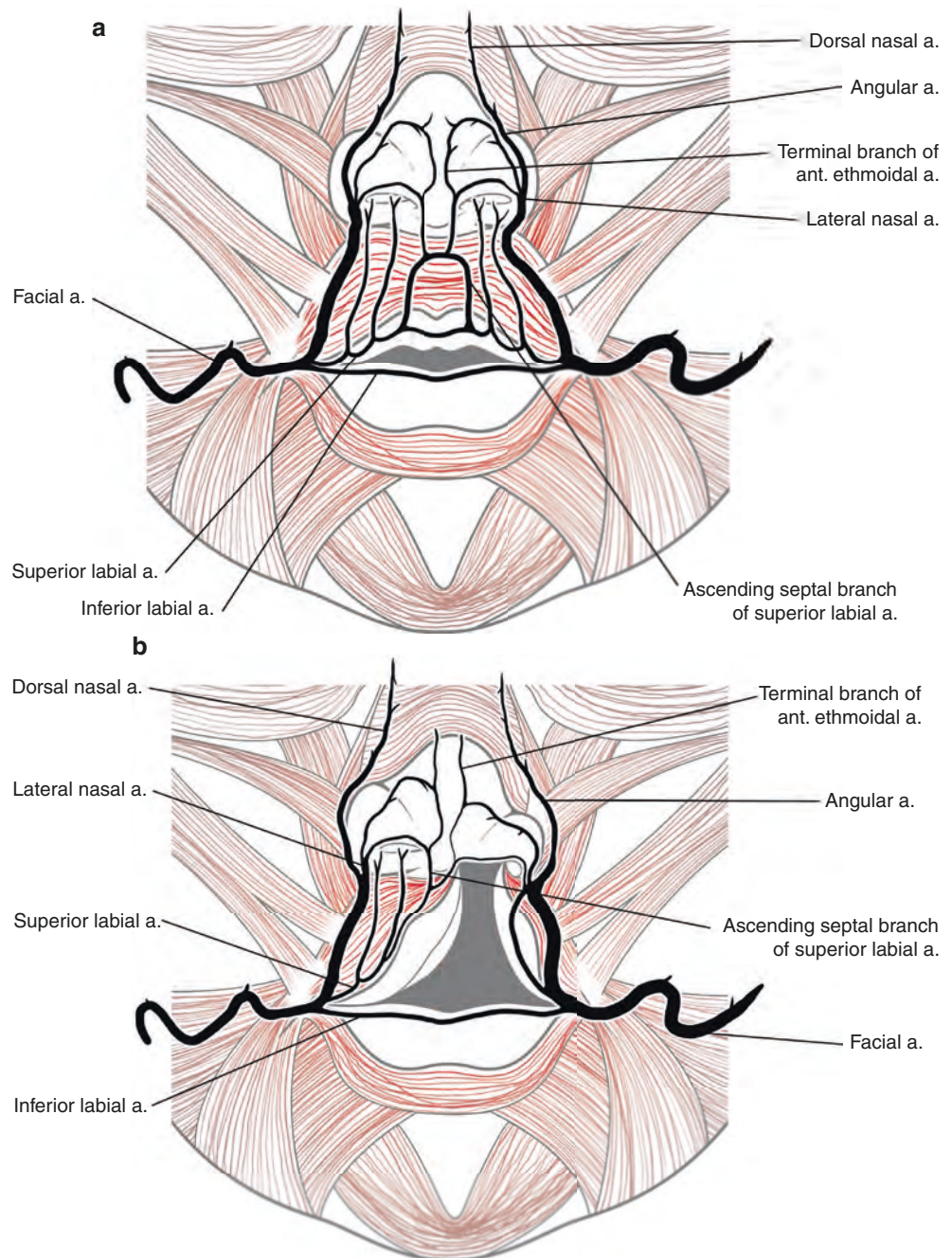


©Association of Oral and Maxillofacial Surgeons of India

Fig. 72.6 (a–c) Concentric band of orbicularis oris forming oral sphincter. Upper and lower fibres arise from each modiolus and decussate in the midline. Superficial fibres upper lip criss-cross at midline to

attach to the dermis of the overlying skin at the philtrum. Deeper fibres attach to the anterior nasal spine [left]. Note the abnormal attachments in unilateral and bilateral clefts [middle and right]

Fig. 72.7 (a, b) Vascular anatomy of a complete lip (a) and a unilateral cleft lip (b)



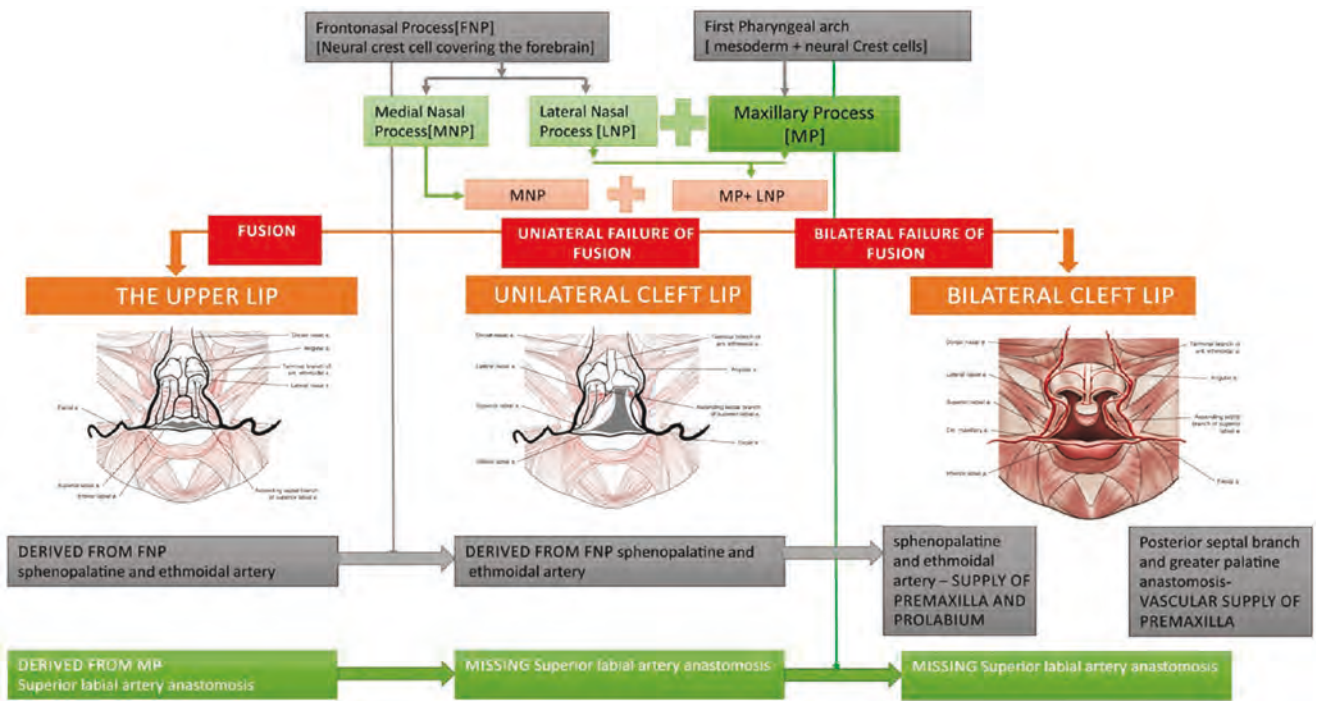
©Association of Oral and Maxillofacial Surgeons of India

72.3.4 Nerve Supply

The sensory nerve supply to the involved areas of the lips and nose comes from branches of the fifth cranial nerve, trigeminal nerve surfacing through the infraorbital foramen as the infraorbital nerve and through the mental foramen as the mental nerve. The motor nerve supply to the muscles of the lips and nose comes from the seventh or facial nerve through its zygomatic, buccal and mandibular branches.

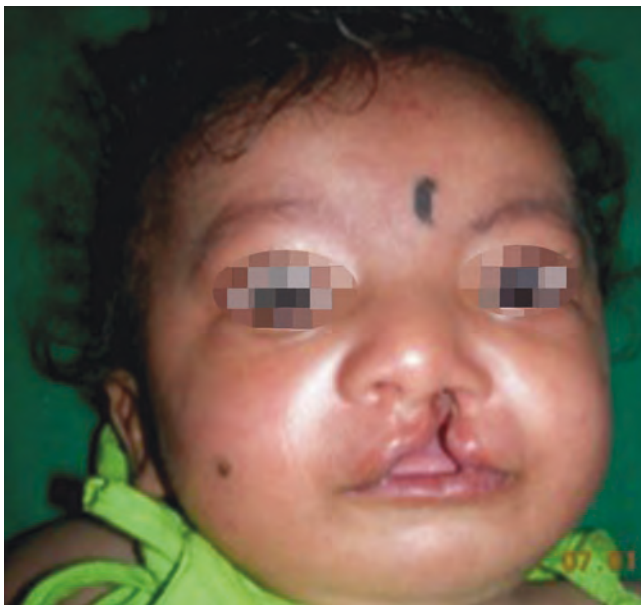72.3.5 Anatomy of the Unilateral Cleft Lip

A thorough knowledge of the normal lip anatomy can help us understand the abnormal anatomy in cleft. Displacement of muscle insertions and deformation and functional hypotrophy leading to paucity of tissues result in a distorted anatomy of labial clefts (Fig. 72.9). The following are the characteristics of the cleft lip and nose deformity (Table 72.2):



©Association of Oral and Maxillofacial Surgeons of India

Fig. 72.8 Embryological basis of vascular anatomy in unilateral and bilateral cleft lip



©Association of Oral and Maxillofacial Surgeons of India

Fig. 72.9 Presentation of a unilateral cleft lip. Note the abnormal anatomy of the lip and nose compared to the non-cleft side

Table 72.2 Comparison of normal and cleft anatomy

Normal anatomy	Unilateral cleft anatomy	Bilateral cleft anatomy
Labial skin	Non-fusion of the lip, the skin on both sides of the lip is less projected or drawn out	One prolabium and bilateral lip elements. The prolabium is the central lip element that has severe paucity of tissues
Philtral columns	Philtral columns are on the non-cleft side, obliquity and discrepancy in their length	No philtral columns present on any element
White roll	Lateral side, the white roll gradually diminishes to about 2–3 mm before it disappears. On the medial side, the demarcation of the white roll is less clear	The white roll on the prolabium is rounded and indistinct
Mucosa	Absence of a labial glandular bed, paucity of compressor muscles, thinner and finer mucosa	Absence of a labial glandular bed, paucity of compressor muscles, thinner and finer mucosa
Orbicularis oris	No muscle decussating in the midline. Abnormal attachment at alar base	Muscle runs bilaterally up into the alar bases, no muscle on the median lip element

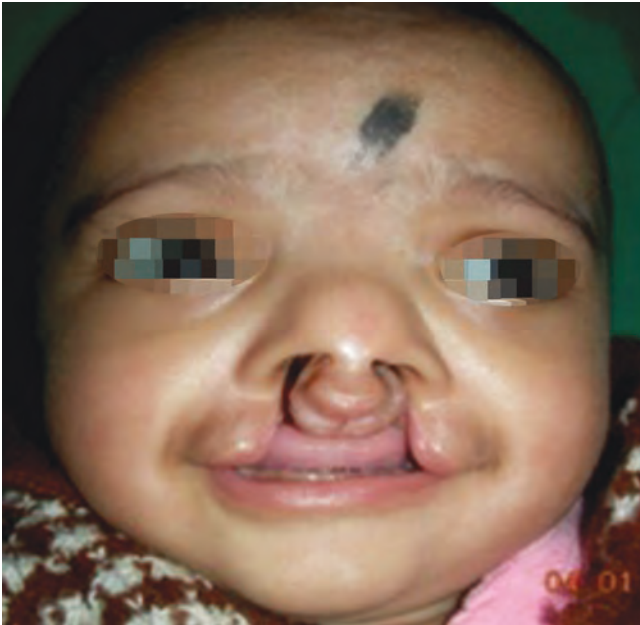1. Labial skin: Apart from the non-fusion of the lip, the skin on both sides of the lip is less projected or drawn out. This leads to a hypoplastic or decreased cutaneous length of the skin. However, the skin is thicker than in normal individuals. The lip consists of the skin, orbicularis oris muscle, minor salivary glands and the labial mucosa. These anatomical planes are important to identify while dissecting the muscle layer. Only 1–2 mm of subdermal dissection should be done, whereas on the mucosal side, the plane of dissection is between the muscle on one side and minor salivary glands and mucosa as a single layer.
2. Unequal philtral columns: The philtral columns are on the non-cleft side, with an obliquity due to discrepancy in their length leaning towards the contralateral sides.
Matching of the philtral columns of both sides is central to a successful lip repair. The philtral columns are the paired elevated soft tissue structures of the face which make an important aesthetic subunit. Various surgical manoeuvres have been used to achieve symmetry of the philtral columns. The surgical design of rotation-advancement technique is also based on making the philtral columns of the same height.
3. White roll abnormality: From the lateral side, the white roll gradually diminishes to about 2–3 mm before it disappears. On the medial side, the demarcation of the white roll is less clear. Identifying the white roll is pivotal in making incision markings during surgery. A practical tip is to identify maximum width of the dark/dry mucosa; it is generally the most pertinent area to mark the point where the white roll starts diminishing. This is discussed again in the surgical technique.
4. Mucosa: In cleft lip, due to absence of a labial glandular bed and the paucity of compressor muscles, the mucosa of the cleft side is thinner and finer. Also, the mucosa merges with the skin closer to the nose and rolls inward. This mucosa of the cleft region is considered redundant and excised frequently. However, in author's clinical judgement, this tissue can be converted into a flap to close the nasal floor, thus precluding the need for any vestibular releasing incision.
5. Nostril skin on the lip: The skin of the lateral alar part, the columella and part of nasal vestibule intrudes onto the lip in the upper part. Distinction can be made between nostril skin and labial skin as the former is finely stippled while the latter is finely striated and has hair.
2. Septum: Lower border of the septum is dislocated out from the vomerine groove, thus twisting the nasal tip and columella.
3. Columella: Unilateral shortness in vertical dimension is seen with deflection towards the non-cleft side.
4. Nasal floor: Has a defect in the skin, muscle and bone.
5. Lower lateral cartilage: The cleft alar cartilage is flattened and more horizontal in its long axis and stretched at an obtuse angle.
6. Alar crease: Due to the absence of alar cartilage bulge, alar crease continues across the tip to produce a disjointed effect.
7. Alar base: Rotated outwardly in a flare.
8. Alar rim: There is a skin curtain of ala that is without cartilage further reducing the apparent length of the columella on the cleft side (Fig. 72.9).

72.3.6 Anatomy of the Bilateral Cleft

The following are the salient anatomical features of a bilateral cleft:

- Prolabium and premaxilla: The prolabium and premaxilla isolated from lateral segments (lip and maxilla). The premaxilla is not found in the alveolar arch and either protruded or deviated or rotated. This is probably because of the excessive forward growth of the premaxillary-vomerine suture and uninhibited forward growth of the cartilaginous nasal septum (Fig. 72.10).
 - The prolabium is the central lip element that has paucity of tissues. The prolabium has no muscle, is non-mobile and has a limited blood supply. The white roll on the prolabium is rounded and indistinct.
 - Nasal deformity depends on the premaxilla and size and position of the prolabium. The columella is very short or absent. The base of the ala is positioned laterally and posteroinferiorly. There is a wide nasal base. The deformity in LLC is presented by the elongated lateral crus and shorter medial crus. The nasal tip is flat with increased distance between alar domes. Only in cases of asymmetric bilateral clefts, the septum is deviated.
 - The orbicularis oris muscle runs bilaterally up into the alar bases. There is no muscle on the median lip element (Fig. 72.4).
 - In complete bilateral cleft lips, the labial artery fails to unite with its counterpart on the other side. In addition the arcade made by anastomosis of the posterior septal branch with the greater palatine artery through the incisive foramen is absent. The philtrum and premaxilla therefore derive their blood supply from the posterior septal artery and terminal branches of the ethmoidal artery.
1. Platform: The base, i.e. the premaxilla, is projected and rotated outwards, whereas the lateral maxillary segment is repositioned. Consequently, there is nasal asymmetry at the base.

72.3.5.1 Nose



©Association of Oral and Maxillofacial Surgeons of India

Fig. 72.10 Presentation of a bilateral cleft lip

72.4 Classification and Presentations of Cleft

As we discussed in embryology, insufficient or late migration of mesoderm leads to epithelial breakdown resulting in a cleft. Thus, a cleft lip presents in various forms, and the management differs slightly for all forms of cleft. The basic classification is based on the side of presentation, i.e. left and right and complete and incomplete (Figs. 72.11 and 72.12). The incomplete cleft lip can be further classified into various types (Box 72.3).

Box 72.3 Presentation of Incomplete Clefts

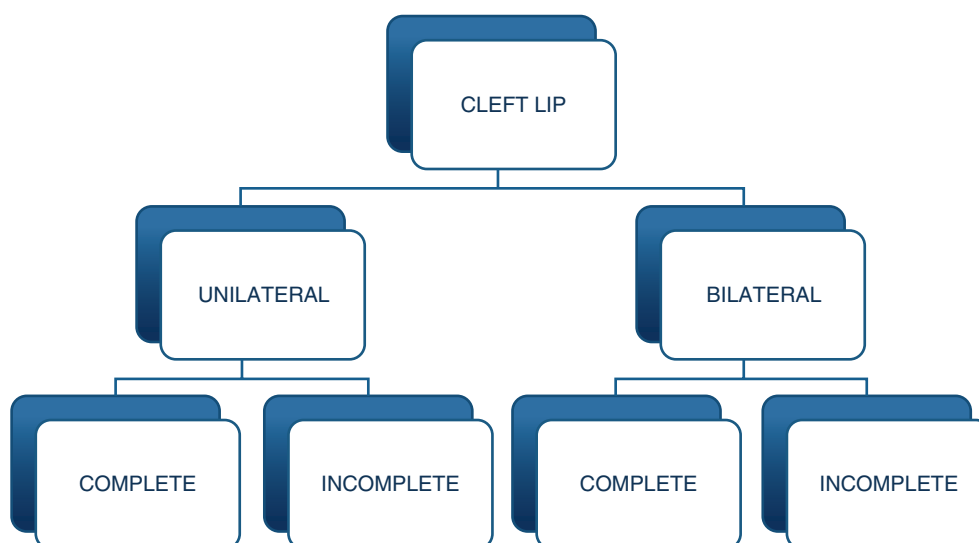
Incomplete clefts can be further divided on the basis of extent of involvement of the mucosa, skin and nasal floor.

1. Incomplete cleft lip with mucosal notch not extending into the skin.
2. Incomplete cleft lip with mucosal and skin notching.
3. Incomplete cleft lip involving the mucosa and skin extending upwards but not up to the nasal floor.
4. Incomplete cleft lip with Simonart's band. Simonart's band is a bridge of tissue between the premaxilla and the lateral lip element. Its prevalence is approximately 20%.

Similarly, bilateral cleft lip can be divided into complete and incomplete clefts. Complete clefts can be further divided on the basis of status of the premaxilla. The premaxilla can be severely, moderately or mildly protruded. However, this is a clinical classification and helps in deciding treatment of a bilateral cleft lip.

72.4.1 Classification

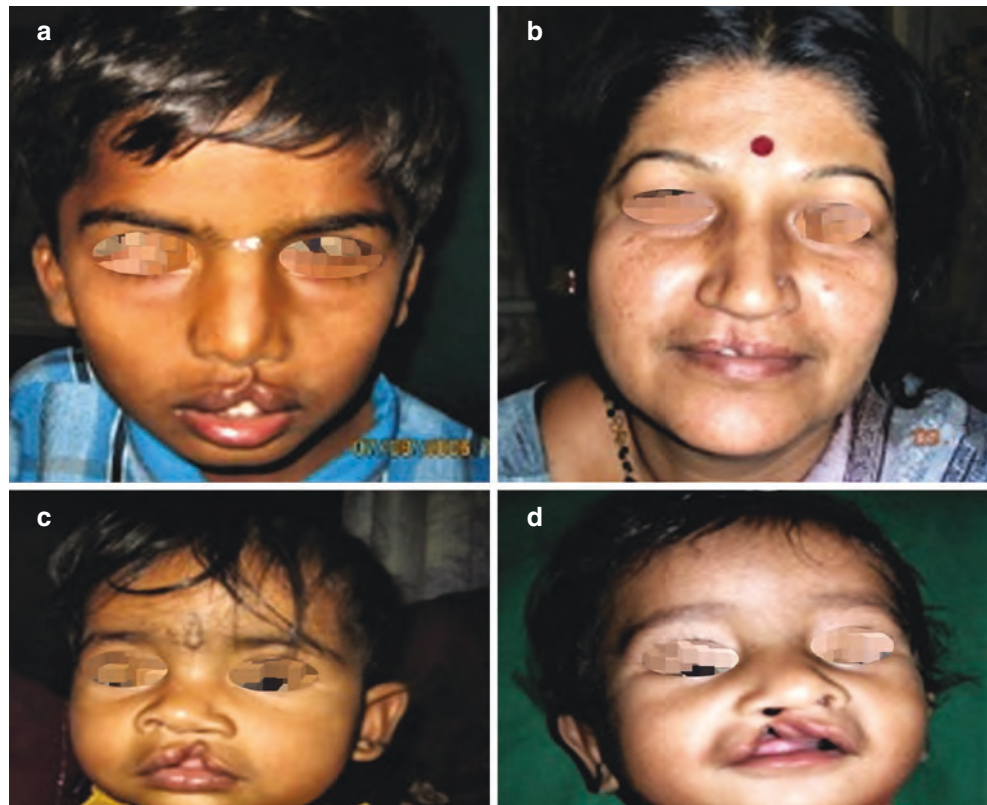Throughout history, many surgeons have attempted to classify cleft lip and palate in their own ways. Classifications made have been on three bases: laterality, severity and morphology of the cleft. At the least any classification system should be able to specify the laterality, extent and severity of



©Association of Oral and Maxillofacial Surgeons of India

Fig. 72.11 Basic classification of cleft lip

Fig. 72.12 Incomplete cleft lip with mucosal notch not extending into the skin. (a) Incomplete cleft lip with mucosal and skin notching. (b) Incomplete cleft lip involving the mucosa and skin extending upwards but not up to the nasal floor. (c) Incomplete cleft lip with Simonart's band



©Association of Oral and Maxillofacial Surgeons of India

the labial cleft and the palatal cleft necessary for treatment planning or outcome assessment (Tables 72.3 and 72.4).

Apart from the above-mentioned classifications, there are various reports of individual classifications by many international and Indian surgeons based on their experience and perspective. An ideal classification should be simple, clear and universally acceptable for purpose of communication and documentation.

72.5 Treatment of Cleft Lip

72.5.1 Timing of Intervention

Cleft lip repair constitutes the first surgical step in cleft lip and palate. Each cleft protocol team advocates different timings for lip reconstruction, with slight variations from the neonatal period to 6 months and later. Timing of intervention can be broadly categorised based on chronological age of the cleft patient or based on certain dental age milestones and status of dentition (Tables 72.5 and 72.6). There are a number of protocols adopted by various centres around the world. Proponents of traditional repair at the chronological age of 10–12 weeks argue that it poses a decreased risk of anaesthesia-related complications and provides improved aesthetic outcomes and positive psychological assurance to the parents. Surgery was traditionally delayed for several weeks based on the “rule of tens”, i.e. infant weighing a min-

imum of 10 pounds, having a haemoglobin level of 10 g/mL and reaching an age of 10 weeks. This rule was based on the fact that the musculature of the lip is more evolved by this age and thus allows for proper reconstruction [23]. Another important milestone is the neck holding capacity of the baby. It is generally present at 3–4 months of age. It is prudent to wait till this milestone is achieved. This is crucial in cautious transfer of the infant as he/she is transferred to the operating room, recovery or intensive care unit and is handled by various healthcare personnel.

72.5.2 Basic Treatment Algorithm

We have devised a basic treatment algorithm for unilateral and bilateral cleft lip repair that we follow at our centre. Due to lack of awareness, prenatal and postnatal counselling and the social taboo, many patients in India do not report at the correct age for surgery. As a result, the treatment methods have been modified based on the age of presentation of the cleft patient to provide the optimal outcome (Figs. 72.13 and 72.14).

72.5.3 Presurgical Nasoalveolar Moulding

Wider, extensive clefts and bilateral clefts are associated with significant deformities of nasolabial complex, presenting a greater surgical challenge in approximating anatomic struc-

Table 72.3 Summary of all classifications given so far

Year	Author	Foundation point
1922–1923	Davis and Ritchie [8]	Alveolus
		<p>Group I: Prealveolar process cleft (clefts affecting the Lip)</p> <ol style="list-style-type: none"> 1. Unilateral (right/left: Complete/incomplete) 2. Bilateral (right, complete/incomplete; left, complete/incomplete) 3. Median (complete/incomplete) <p>Group II: Postalveolar process cleft (clefts affecting the palate)</p> <ol style="list-style-type: none"> 1. Soft palate 2. Hard palate <p>Group III: Alveolar process cleft (any cleft involving the alveolar process)</p> <ol style="list-style-type: none"> 1. Unilateral (right/left: Complete/incomplete) 2. Bilateral (right, complete/incomplete; left, complete/incomplete) 3. Median (complete/incomplete) <p>16 categories of distinct morphological forms of cleft palate with/without cleft lip</p>
1921–1923	Brophy [9]	Based on morphology
1931	Veau [10]	Extent, laterality and morphology
		<ol style="list-style-type: none"> I. Clefts of the soft palate II. Clefts of the soft and hard palate, up to the incisive foramen III. Clefts of the soft and hard palate extending unilaterally through the alveolus IV. Clefts of the soft and hard palate extending bilaterally through the alveolus
1958	Kernahan and Stark [11]	Incisive foramen
		<ol style="list-style-type: none"> 1. Clefts of structures anterior to the incisive foramen 2. Clefts of structures posterior to the incisive foramen 3. Clefts affecting structures anterior and posterior to the incisive foramen
1962	American Cleft Palate-Craniofacial Association Classification [12]	Two principal anatomical landmarks: The “prepalate”, anterior to the incisive foramen and the “palate”, posterior to the incisive foramen
		<ol style="list-style-type: none"> 1. Clefts of the prepalate (cleft of lip and embryologic primary palate) <ol style="list-style-type: none"> (a) Cleft lip (cheiloschisis) (b) Cleft alveolus (alveoloschisis) (c) Cleft lip, alveolus and primary palate (cheiloalveoloschisis) 2. Clefts of the palate (cleft of the embryologic secondary palate) <ol style="list-style-type: none"> (a) Cleft of the hard palate (uranoschisis) (b) Cleft of the soft palate (staphyloschisis or veloschisis) (c) Cleft of the hard and soft palate (uranostaphyloschisis) 3. Clefts of the prepalate and palate (alveolocheilopalatoschisis) 4. Facial clefts other than prepalatal and palatal <ol style="list-style-type: none"> (a) Cleft of the mandibular process (b) Naso-ocular clefts (c) Oro-ocular clefts
1969	International Classification (Broadbent et al., 1969)	Categorization of clefts of the lip, alveolus and palate based on embryologic origin and rare facial clefts based on topographic findings
		<ol style="list-style-type: none"> 1. Clefts of the anterior (primary) palate 2. Clefts of the anterior (primary) and posterior (secondary) palates 3. Clefts of the posterior (secondary) palate

(continued)

Table 72.3 (continued)

Year	Author	Foundation point
1971	Kernahan pictographic form [13]	Striped Y Most accepted
1973	Spina [14]	Modified international classification: Renamed group 1 as preforaminal clefts, group 2 as transforaminal clefts
1973 and 1976	Kernahan's striped Y modified by Elsahy (1973), Millard (1976), Friedman and Smith [15–19]	Most accepted classification

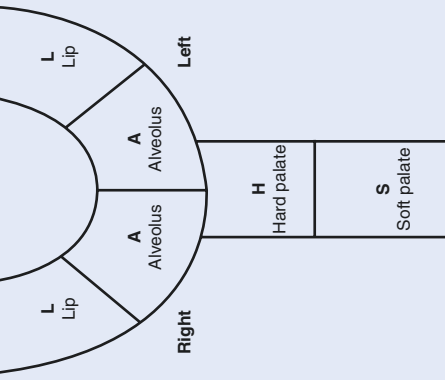
	Cleft type	Original abbreviation
1975	Balakrishnan [20]	
	Cleft lip	Gp1
	Cleft palate	Gp2
	Cleft lip, alveolus and palate	Gp3
	Right	R
	Left	L
	Midline	M
	Alveolus	A
	Additional abbreviations	
	Partial	P
	Submucosal	S
	Simonart's band	sb
	Microform	micro
1987	Kreins O (cited by Hodgkinson et al) [21]	
	<p data-bbox="885 829 909 1480">LAHSAL system is a diagrammatic classification of cleft lip and palate</p> 	

Table 72.4 Incomplete cleft lip can be further divided into minor-form, microform and mini-microform [22]

Minor-form	Microform	Mini-microform
<ol style="list-style-type: none"> 1. Notched vermilion-cutaneous junction extending 3 mm or more above the normal Cupid's bow peak 2. Deficient vermilion on the medial cleft side 3. Cutaneous groove and muscular depression that is evident on puckering 4. Hypoplastic median tubercle 5. Nasal deformity 	<ol style="list-style-type: none"> 1. Medial vermilion-cutaneous point less than 3 mm above the normal Cupid's bow peak 2. Deficient vermilion on the medial cleft side 3. Lower cutaneous lip shows a variable glabrous strip 4. Philtral line shows muscular depression, with a prominent medial component of the philtral ridge 5. Nearly normal length of the hemicolumella, the sill shows a small depression, slight slump of the alar genu and 1 to 2 mm lateral displacement and outward flare of the alar base 	<ol style="list-style-type: none"> 1. Discontinuous vermilion-cutaneous junction 2. Level Cupid's bow peaks 3. Notched free mucosal margin 4. Variable muscular depression 5. Variable nasal deformity; mostly a depressed sill

Table 72.5 Timing of intervention based on chronological age

Timing	Procedure
After 16 weeks of pregnancy	Cleft lip diagnosis by USG images
Prenatal	Discussion with surgeon Consultation with a geneticist
Neonatal	Presurgical orthopaedics Feeding instructions
12 weeks of age	Cleft lip surgery
6–12 months of age	Cleft palate repair with intravelar veloplasty
14 years or later	Orthognathic surgery
Adulthood	Secondary rhinoplasty

Table 72.6 Timing of intervention based on status of dentition

Timing	Procedure
Prior to cleft lip repair	Presurgical orthopaedics [NAM]
Primary dentition	Orthodontic maxillary expansion
Mixed dentition	Orthodontic maxillary expansion and protraction
Before eruption of permanent dentition	Secondary alveolar bone graft using iliac crest particulate cancellous bone marrow
Permanent dentition	Orthodontic treatment for dental arch alignment
After full eruption of permanent dentition	Dental arch alignment and levelling
Orthognathic surgery for maxillary advancement	After orthognathic alignment
Postsurgical orthodontics	For space closure and final settling of occlusion Prosthetic rehabilitation

tures, thus obtaining an optimum functional and aesthetic result. The basic goal of any surgical technique is to restore normal anatomy and function. Thus in such cases, where it is difficult to achieve goals of primary repair due to wide discrepancies, presurgical maxillofacial orthopaedic appliances mould the nasolabial structures through specifically directed forces, thus reducing the deformity before surgery for an easy repair.

Currently, presurgical nasal alveolar moulding (PNAM) is a widely used orthopaedic technique for presurgical cleft deformity correction [23, 24]. PNAM theory is based on the theory that increased hyaluronic acid content is present in the infant cartilage, which makes the cartilaginous structure

more pliable and plastic. By the age of 3 months, the cartilage becomes more rigid with less plasticity. PNAM can significantly improve the nasal symmetry, by elongating the columella, bolstering the alae, narrowing the cleft and restoring the alveolar arch form, thus demonstrating favourable immediate and long-term outcomes.

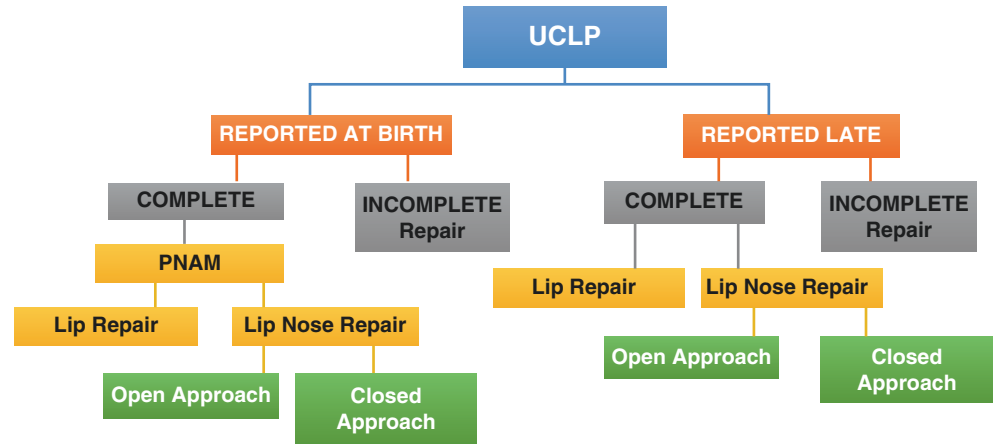
PNAM is based on the principles of negative sculpting and passive moulding of the alveolus, lip and nasal tissues. An initial impression is obtained, and custom-made plates are fabricated. A series of modifications are made to the surface of the appliances with the addition and deletion of materials in certain areas. This process is called negative sculpting [25]. The purpose of this is achieving approximation and symmetry of the two maxillary alveolar segments and addressing the nasal deformity by moulding the cartilage in anatomical position [26, 27] (Fig. 72.15). The process should be explained to the parents; insertion of the appliance should be carefully taught and made to practice. Parents should be explained the importance of this exercise through videos and photos of previous patients.

Impression Making A heavy-bodied polyvinyl siloxane impression material should be used for the first impression. The infant is held in prone position to keep the tongue forward and to allow any material or saliva to drain out of the oral cavity and prevent aspiration. This should be done in a hospital setting to manage any airway emergency in the presence of an anaesthetist available if needed. Once impression is made, the mouth should be examined for any residual material.

Device Fabrication The moulding plate is made with clear methyl methacrylate lined with a soft denture material on the dental stone model. The borders should be trimmed and smoothed to prevent any ulceration. The oral surface should be smooth and polished with good retention and no extensions into the cleft area.

Insertion and Moulding The moulding plate is to be worn full-time by the patient. It should be removed for cleaning and routine hygiene practices to prevent infection and check for any ulceration. Suckling should be checked with the plate in position and to check gagging. The plate is secured to the

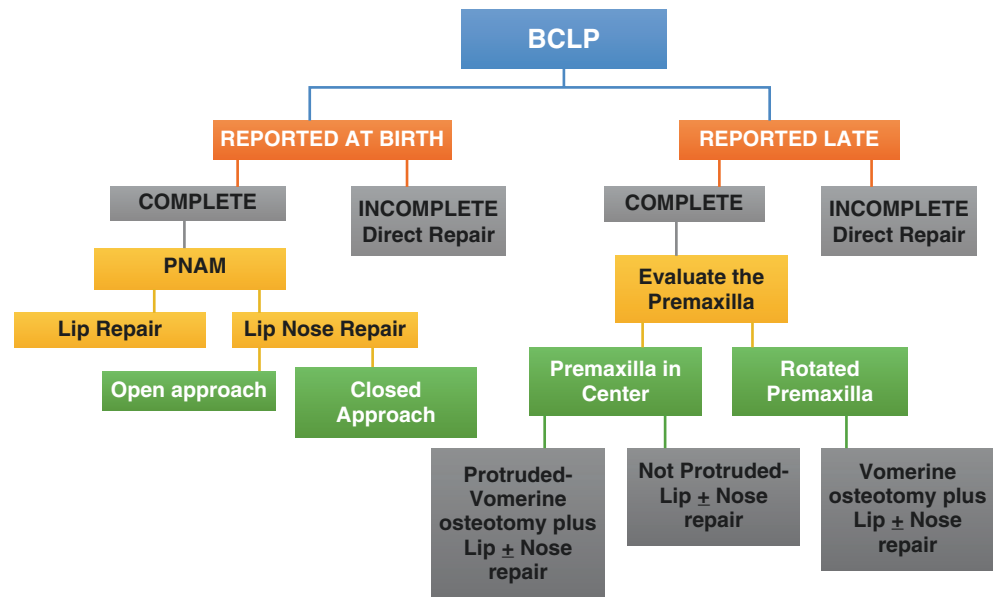
Fig. 72.13 Basic treatment algorithm for unilateral cleft lip



Note: Authors suggest use of nasal conformers

©Association of Oral and Maxillofacial Surgeons of India

Fig. 72.14 Basic treatment algorithm for bilateral cleft lip



©Association of Oral and Maxillofacial Surgeons of India

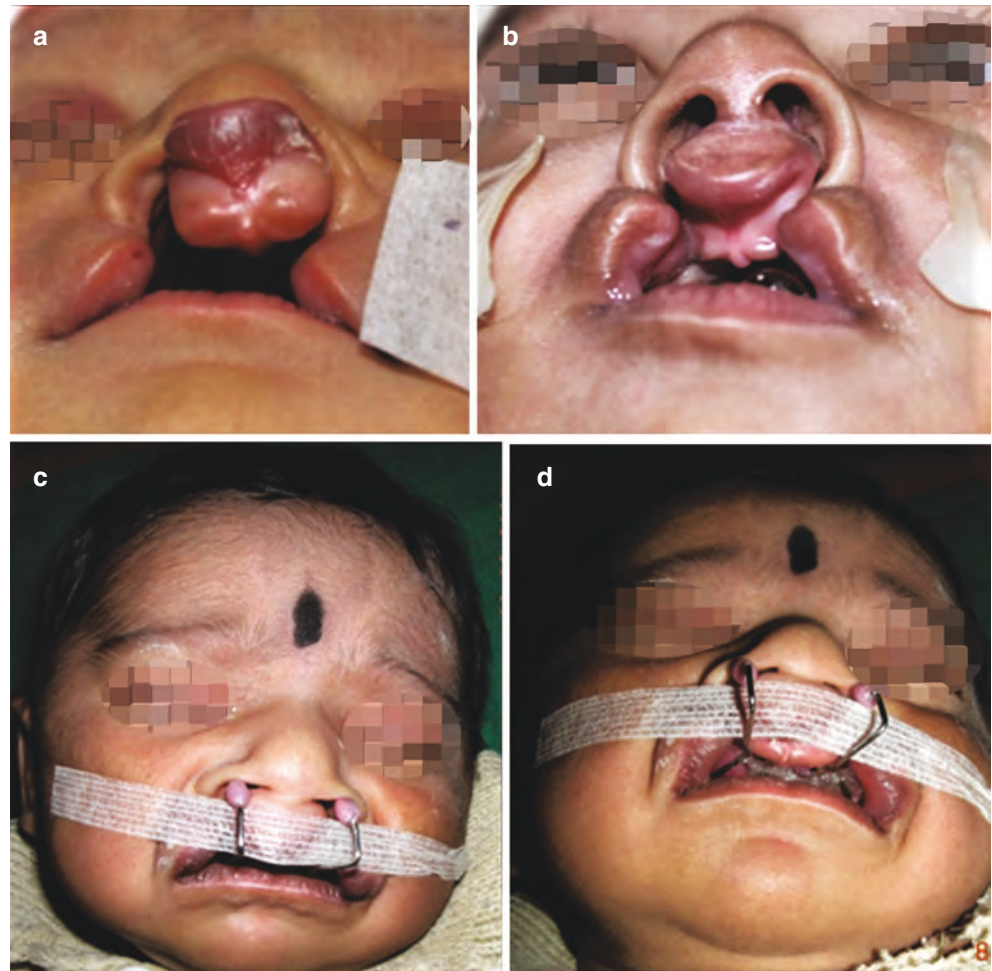cheek bilaterally using orthodontic elastics going to the opposite side and secured with surgical tapes. The elastic loop extends from the retention arm approximately in a 40–45 degree angle, thus pulling the anterior flange of the plate posterosuperior vector for activation. 2 ounces of traction force is given by stretching the elastic to twice its original. The surgical tape is applied to a layer of wound dressing material like micropore tape and not the skin directly. The tape is to be changed once a day. The tape should be applied to the non-cleft side first and then pulled over to the cleft side. Weekly follow-ups should be made to evaluate the moulding plate for retention and changes in the alveolar segments.

Moulding Plate Modification Selective grinding of acrylic material is done from the region into which the alveolar segments are to move. At the same time, soft denture lining

material is selectively added to the plate to direct the alveolar segments to the midline, as desired. In a patient with bilateral cleft, the premaxilla is retracted and derotated, to bring to a normal maxillary arch alignment. An ideal surgical result may be obtained when 1–2 mm gap remains between alveolar segments.

Nasal Stent When the maxillary alveolar segment approximation has been achieved, the nasal moulding should begin. The nasal stent is added to the existing moulding plate in the form of a stainless steel wire projecting out of the plate outwards going into the nose like a “swan neck”. A small wire loop can be made on which a bilobed intranasal acrylic component is made with a layer of soft denture liner. Nasal stent is placed 3–4 mm inside the ala and gently lifted towards dome until slight blanching is noted.

Fig. 72.15 PNAM treatment in a case of bilateral lip. (a and b) Pre- and postoperative PNAM. Note the changes in the nasal tip, alar cartilages and position of the premaxilla. (c and d) PNAM device with the nasal stent and lip taping



©Association of Oral and Maxillofacial Surgeons of India

Blanching of the nasal tip as the baby suckles activates the appliance. Lip taping is continued after the nasal stent appliance is added.

In a follow-up study over 6–9 years, Bennum et al. observed that patients treated with PNAM within 15 days after birth maintained satisfactory nasal symmetry [28]. Ezzat et al. compared 12 unilateral cleft lip and palate patients with PNAM treatment and found narrowing of the alveolar cleft, increased posterior width of the dental arch, uprighting of the columella and improved nasal symmetry [29]. Yang et al. reported similar results from 45 unilateral complete cleft lip and palate patients [30]. In a large multi-centre study sample, Ross argued that orthopaedic correction of the premaxilla failed to stimulate maxillary growth and thus was not necessary [31].

The authors conducted a study to evaluate the nasolabial aesthetics on two-dimensional photographs at 6 months post cheiloplasty. Cupid's bow, vermilion symmetry, vermilion notching, premaxillary show at rest, scar aesthetics, columella height and bialar width were all significantly better in the PNAM group [32].

72.5.4 Protocols

There is no universal protocol for management of cleft lip, and there is a striking diversity of clinical practice. There is a paucity of higher-level evidence (i.e. systematic reviews and randomized controlled trials) on cleft lip and palate. There have been few RCTs comparing individual treatment steps. The Eurocleft study showed that among the 201 European centres, 194 different treatment protocols existed for unilateral clefts [33]. Listed below are some standard protocols followed worldwide.

- Rule of tens.
- IOWA Protocol [34].
- Dallas Protocol [35].
- Warsaw Protocol [36].
- Oslo Protocol [37].
- Malek Protocol [38].
- American Cleft Protocol [39].
- Australian Cleft Craniofacial Society Protocol [40].
- European Studies and results [41, 42].

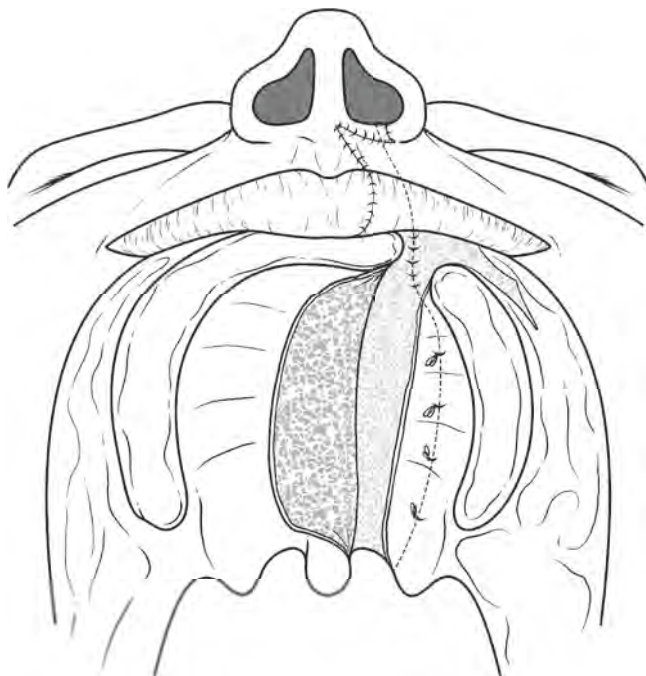
Discussion of each protocol is beyond the scope of this chapter. However, we have tried to compare and discuss in detail few protocols for a comprehensive understanding of cleft lip and palate repair

The basic protocols of cleft lip repair can also be classified as follows:

1. Primary cleft lip repair.
2. Primary cleft lip and anterior palate repair.
3. Primary cleft lip and soft palate repair.
4. Primary cleft lip and palate repair.

Primary Cleft Lip Repair Only: This protocol of early lip repair at 3–4 months of age following the rule of tens is followed popularly at various centres. The author's centre also follows the same protocol. The timing of intervention has been discussed previously in the chapter.

Primary lip and anterior palate repair: was proposed by Abyholm in Oslo protocol [37]. In the first operation, cleft



©Association of Oral and Maxillofacial Surgeons of India

Fig. 72.16 Cleft lip and anterior palate repair: Veau's vomer flap (Veau, 1931). An incision was made on the medial side of the cleft along the border line between oral and nasal mucosae or in bilateral clefts, along the free edge of the vomer. A mucoperiosteal flap is raised from the vomer and turned across the cleft. The lateral edge of the cleft is incised, and the palatal mucoperiosteum is elevated, allowing the vomer flap to be put under the mucoperiosteum and fixed with mattress sutures. In the alveolar area, and in continuity with the vomer flap plasty, the nasal mucoperiosteum is mobilised on both sides and joined across the cleft to complete the nasal floor anterior to the vomer flap. Towards the oral cavity, the raw surfaces of the vomer and of the flap are left uncovered

lip repair using Millard technique with simultaneous anterior hard palate closure using a single layer vomer flap. The mean age for first surgery was 3.3 months. The soft palate was closed at a mean age of 17.2 months (Fig. 72.16).

Primary lip and soft palate repair: It is a well-established early palatal closure which causes maxillary hypoplasia. Because of this reason, many surgeons used to perform palate repair in two stages, i.e. soft palate first followed by hard palate. At the time of introduction of this protocol, the soft palate was repaired along with the lip at around 4–6 months of age, and the hard palate was repaired at the age of 10–12 years. This was later reduced to 4–5 years.

Complete Lip and Palate Repair: one-stage simultaneous repair of the entire cleft is a simple and economic treatment of complete unilateral cleft lip and palate [43]. The concept of one-stage repair was first introduced in 1958, when Farina (1958) described the surgical technique. A decreased risk associated with general anaesthesia, better healing, lower incidence of fistulae and reduced hospitalization costs has been the rationale for performing such repair. This repair performed in children above 10 months of age has been claimed by surgeons with extremely good results without any complications. Overall, the cleft teams from Brussels, Belgium; Konya and Zonguldak, Turkey; and Warsaw, Poland, found that their protocols employing one-stage closure of UCLP produced favourable morphological results [36, 37, 44, 45].

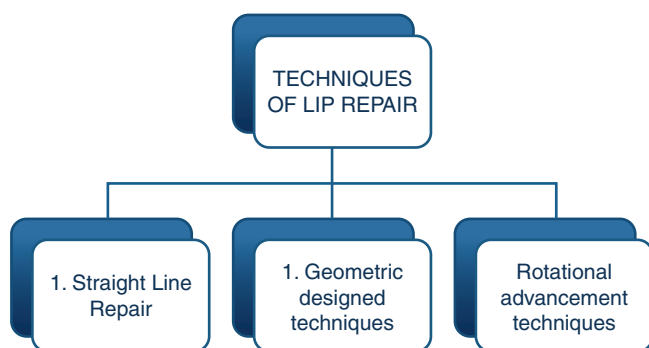
72.6 Unilateral Cleft Lip Repair

72.6.1 Techniques of Cleft Lip Repair

The evolution of cleft repair was bound to happen mainly due to the nature of the aesthetics that had to consider the anatomical parameters, namely:

- (a) Cupid's bow.
- (b) White roll continuity.
- (c) Vermillion continuity.
- (d) Muscle continuity.
- (e) Philtral columns and equality of length on both cleft and non-cleft sides.
- (f) Minimizing scarring on the anatomical unit of the lip, i.e. philtral column, philtral dimple and nasal base.

Broadly over the period of cleft history, lip repair can be divided into three basic types depending on the design of flap used (Fig. 72.17). These are straight line repairs (Box 72.4), geometric flap repairs (Box 72.5) and rotation-advancement flap.



©Association of Oral and Maxillofacial Surgeons of India

Fig. 72.17 Basic techniques of lip repair

Box 72.4 Straight Line Repairs

- Rose [1981] [46].
- Thompson [1912] [47].
- Veau [1925] [48].
- Pfeifer [1970].
- Delaire [1975] [49].
- Chaid [2007] [50].
- Nakajima [2008] [51].

Box 72.5 Geometric Flap Repairs

- Joseph Malgaigne [1843] [52].
- G Mirault [1844] [52–54].
- Triangular flap.
- Le Mesurier [1849] [55, 56].
- Tennison [1952] and Randall [1959] [57, 58].
- Skoog [1969] [59].

Millard's Rotation-Advancement Flap.

Ralph Millard (1957) [2] revolutionized the cleft repair technique with most of its principles applicable and widely used in current day practice. His innovation was in designing the incisions without disrupting the aesthetic subunits. The cut as you go technique was simplified further by understanding the anatomy of the lip. He realized that two thirds of the Cupid's bow, complete with tubercle, white roll of the mucocutaneous junction, one column and the dimple of the philtrum, were all present in the non-cleft side but askew and thus had to be rotated down to normal position [60].

72.6.1.1 Basic Components of Millard's Repair (Video 72.1)

Labelling of the Flaps

A—Non-cleft side (with Cupid's bow and dimple—rotation). In Millard's original description, the incision for the

rotation flap begins at the peak of the Cupid's bow [cleft side], marked along the cleft edge up to the junction with the columella, and curves under the base, crossing the midline, but doesn't cross the contralateral philtral column. Millard later added a back cut at the end of the incision, to allow for adequate rotation of the medial lip element and less tension on the repair [61, 62].

B—Cleft side (advancement).

The incision on the lateral lip element of cleft forms the advancement flap. It is made along the cleft edge, extending up to the nasal floor. This incision should match the length of the incision on the medial side of the cleft.

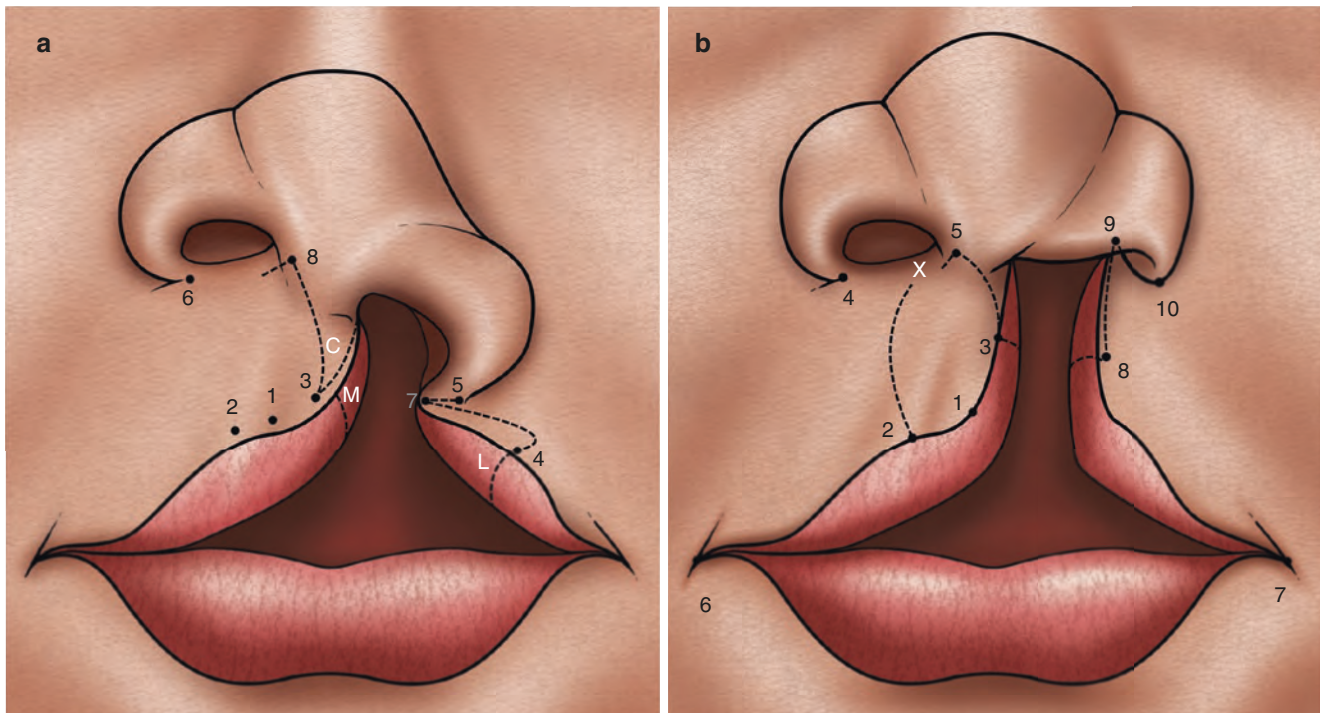
C—A small triangular flap attached to the columella from the non-cleft side left after the incision.

72.6.1.2 Points Marked: The Following Points are Marked in a Classic Millard's Technique (Fig. 72.18a, b)

1. Deepest point on the Cupid's bow.
2. Bow peak on the non-cleft side (distance usually 4 mm).
3. Bow peak on the cleft side (equal to distance between point 1 and 2 from point 1).
4. The alar base on normal side.
5. Final extent of the incision following a rotational curve, skirting the columella-lip junction and extending past the midline of columella base almost as far as the philtrum column on the normal side but no farther.
6. Commissure of the lip on the non-cleft side.
7. Commissure of the lip on the cleft side.
8. Equidistant point from 6 to 2 marked on the mucocutaneous junction (usually 20 mm), and distance between 10 and 8 is equal to 4 and 2.
9. Most medial point or leading point of the advancement flap.
10. The alar base on the cleft side.

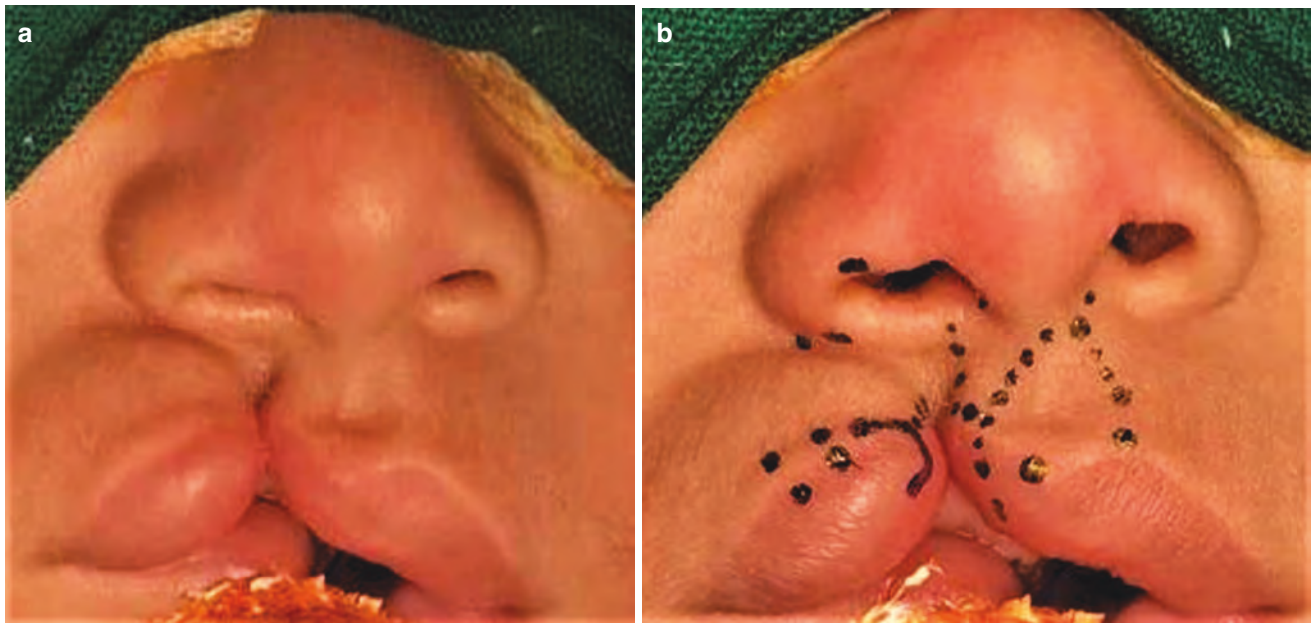
Despite being seemingly complicated, a simple exercise of carrying out the points over an illustration of complete cleft lip shall allow the reader to completely understand the simplicity of the description (Fig. 72.19). Complete surgical technique of Millard's cleft lip repair with the author's modification is discussed later in this chapter.

Once the markings are made, the rotation and advancement flaps are designed. The basic aim is to achieve symmetry of the philtral columns. This can be achieved by the following methods in a Millard's repair:



©Association of Oral and Maxillofacial Surgeons of India

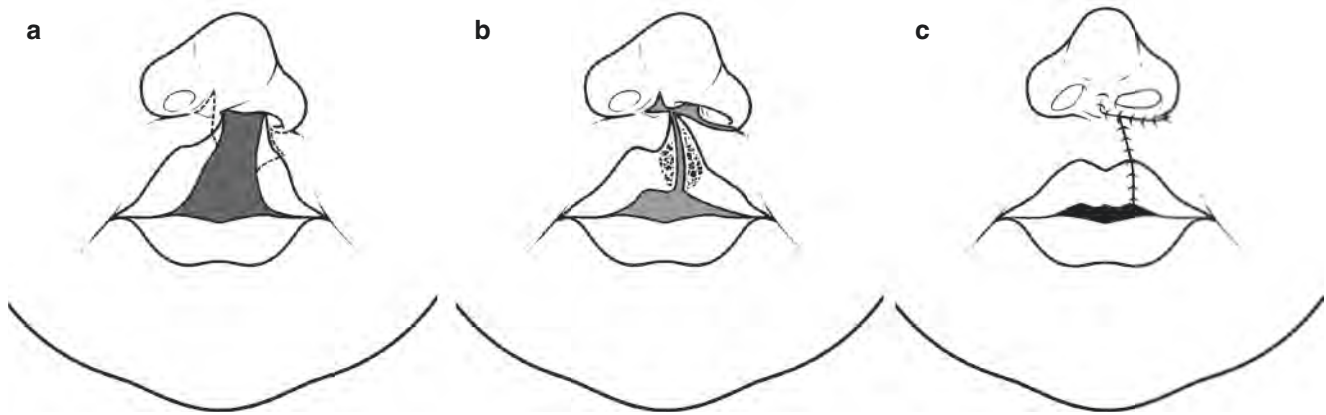
Fig. 72.18 (a, b) Basic design of Millard's technique



©Association of Oral and Maxillofacial Surgeons of India

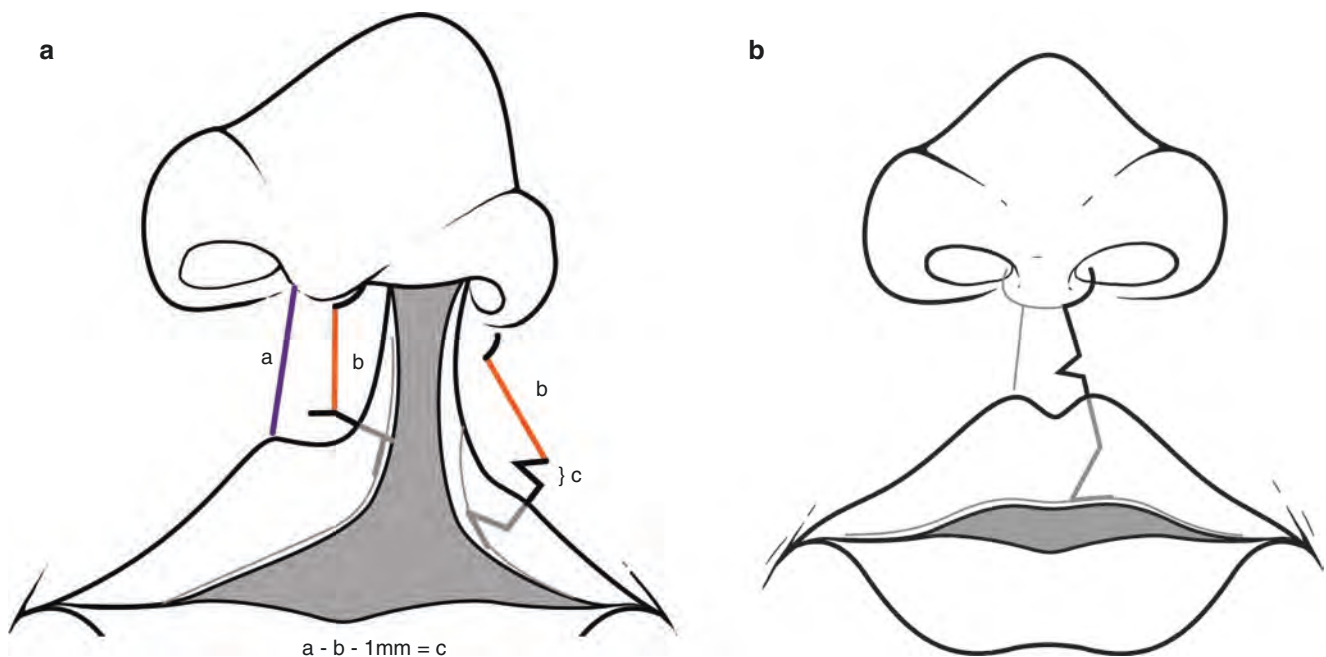
Fig. 72.19 (a, b) Marking of incisions

1. Curve the incision on the rotation side; this helps in gaining length on the cleft side philtral column.
2. Back cut: The role of the back cut comes into force when the rotation is not adequate to provide enough length to match the normal philtral column. It can be made to cross the midline or made parallel to the normal side philtral column as in Mohler's modification.
3. Role of "C" flap: The "C" flap can be designed to accomplish either of the following goals: closure of nasal sill, columellar lengthening or back into the defect created by rotation of the flap [63].



©Association of Oral and Maxillofacial Surgeons of India

Fig. 72.20 (a–c) Mohler's modification of Millard's technique



©Association of Oral and Maxillofacial Surgeons of India

Fig. 72.21 (a, b) Fischer's modification

72.6.1.3 Modifications to Millard's Technique

In the original Millard's technique, the advancement flap often disrupts the upper third of the cleft side philtral column. Also, in wider clefts the advancement flap results in an unaesthetic scar around the alar base. This led to a series of modifications to the conventional Millard's rotational advancement technique:

External Scar Placement

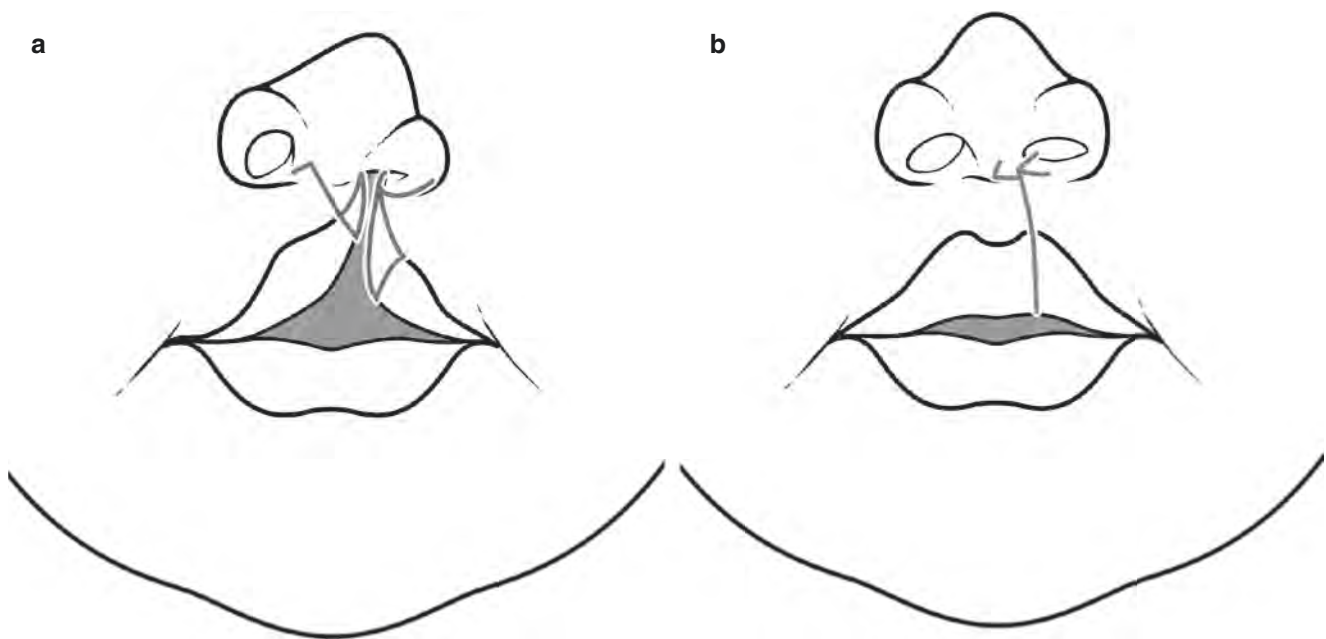
1. *Mohler (1987) [64]*: The medial lip rotation incision was modified to extend onto the columella. The back cut was added which was confined to the columella. The C flap is used to fill the defect created by rotating

the medial lip element at the base of the columella. Thus it is used for lengthening the shortened columella (Fig. 72.20).

2. *Fisher (2005) [65]* merged techniques of the Tennison triangle repair and rotation-advancement from Millard. It uses a small triangle above the white roll at the out-set and avoids the use of rotation incision allowing most scar to be placed along the ideal philtral column (Fig. 72.21a, b).
3. *Vermilion Repair/Noordhoff's [66]* technique:

In Noordhoff's words the essential features of this technique are as follows:

- (a) No dissection over the maxillary base.
- (b) No "back cuts" in rotation flap.



©Association of Oral and Maxillofacial Surgeons of India

Fig. 72.22 (a, b) Cutting's modification

- (c) In cases where the rotation is inadequate, the use of a small triangular flap of the skin above the "white roll" will be used to achieve adequate rotation without distorting the philtral column. These flaps heal well and are aesthetic.
 - (d) A lateral vermilion flap used for reconstruction of deficient vermilion on the cleft side Cupid's bow.
 - (e) Muscle reconstruction.
 - (f) Complete closure of mucosa of all areas using inferior turbinate mucosal flap that allows for repositioning of the lower lateral cartilage and adds mucosa wherever there is a deficiency.
 - (g) Fixation of the lower lateral cartilage to the upper lateral cartilage at its base and to the skin with alar transfixion sutures.
 - (h) Delayed upper limb rotation-advancement incisions limiting scars around the ala and nostril floor.
 - (i) The alar groove should be defined well.
 - (j) Postoperative splinting with a nasal silicone conformer to limit wound contracture.
4. **Columella Flap/Cutting Repair:** Cutting uses a technique that does not curve the incision towards the cleft and extends up onto the columella 1.5 to 2.0 mm slightly to the non-cleft side [67]. This yields a wider C flap thus filling the entire medial defect, allowing for a straight line closure (Fig. 72.22a, b).
5. **Muscle Repair:**
The following modifications have been made in muscle repair:
- (a) *Cutting* [67]: Interposition orbicularis muscle repair.
 - (b) *Mulliken* [68]: Vertical mattress sutures for end-to-end muscle repair to evert the orbicularis.
 - (c) *Fischer* [65]: On both medial and lateral cleft elements, dissection of the overlying skin from the orbicularis. Dissection on the medial lip is limited to 1 mm from cut edge whereas of the lateral lip extends to the alar base to eliminate orbicularis bulge.

72.6.2 Step-by-Step Technique of Unilateral Cleft Lip Repair: Author's Technique (Figs. 72.23, 72.24, 72.25, 72.26, 72.27, 72.28, 72.29, 72.30, 72.31, 72.32, 72.33 and 72.34)

Lip Repair:

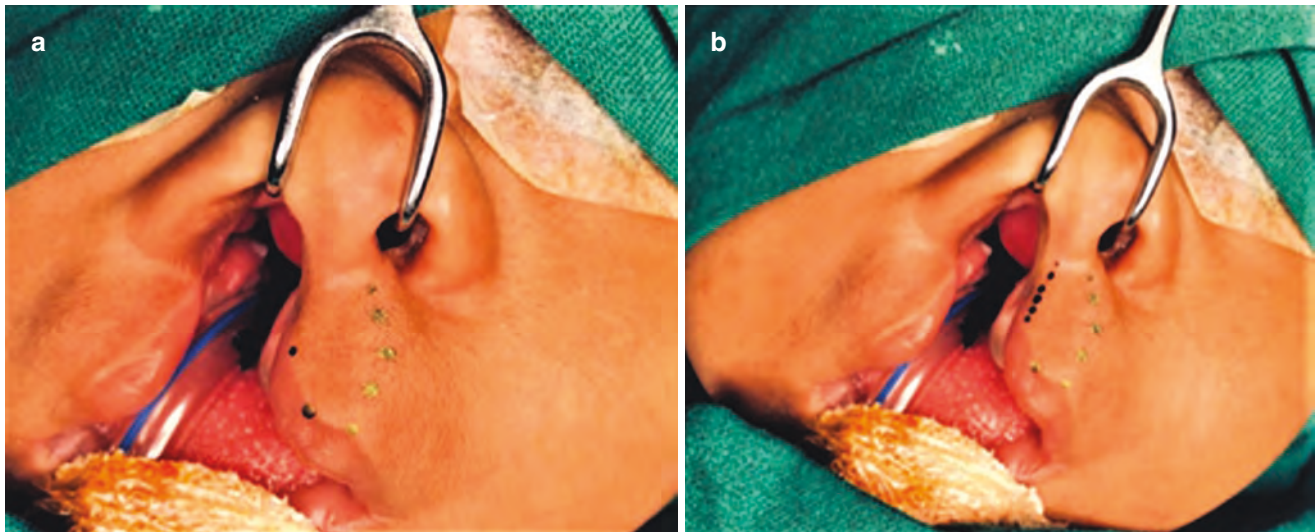
The authors have presented their technique of lip repair in a stepwise manner.

The following steps have been described:

- **Markings:** The most important principle of cleft lip repair is to identify the normal and abnormal structures. This includes the length of the philtral columns and the width of wet and dry mucosa. All the soft tissues should be kept in mind while designing the flap. No soft tissue should be discarded or considered redundant.

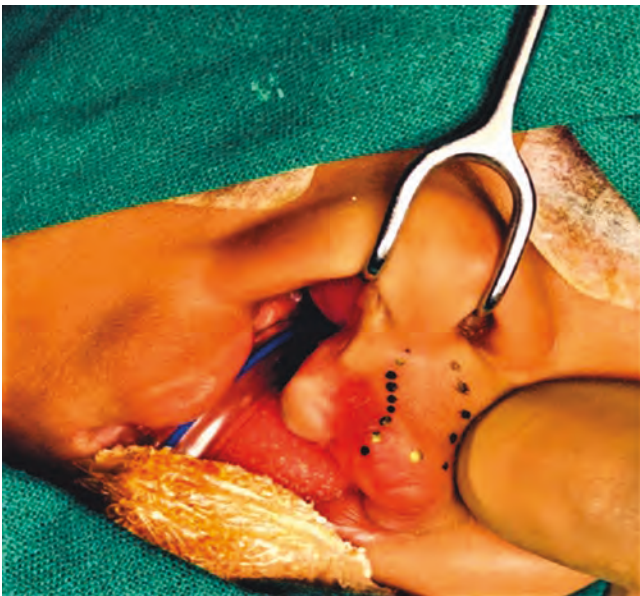Non-Cleft Side.

Deepest point on cupid's bow, peak on non-cleft side and normal philtral column. (To make the philtral column prominent, one may use a two-pronged nasal hook to pull and retract the columella.)



©Association of Oral and Maxillofacial Surgeons of India

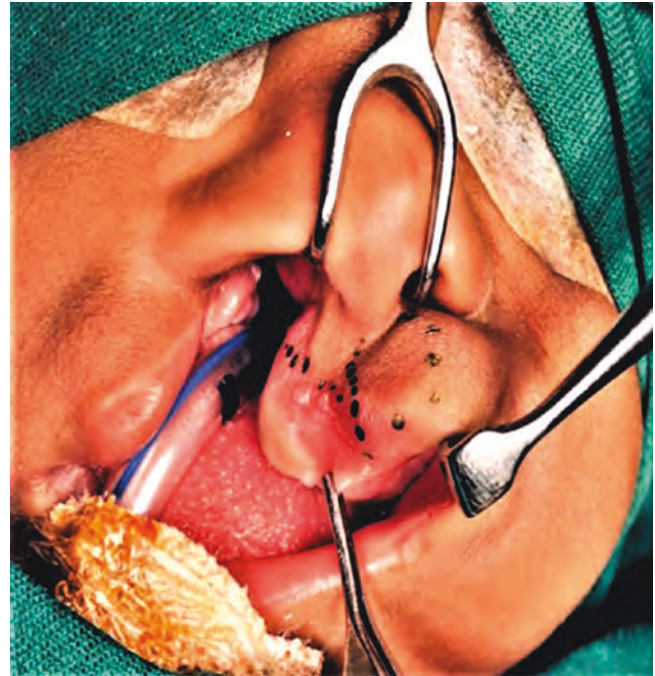Fig. 72.23 (a) Mark the highest point on the cupid's bow (cleft side), and also notice the philtral dimple. (b) Mark the future philtral column, and continue it up to the columella without cutting across the columella



©Association of Oral and Maxillofacial Surgeons of India

Fig. 72.24 From the peak of cupid's bow on the cleft side, mark the incision on the dry mucosa till the junction of wet and dry mucosa

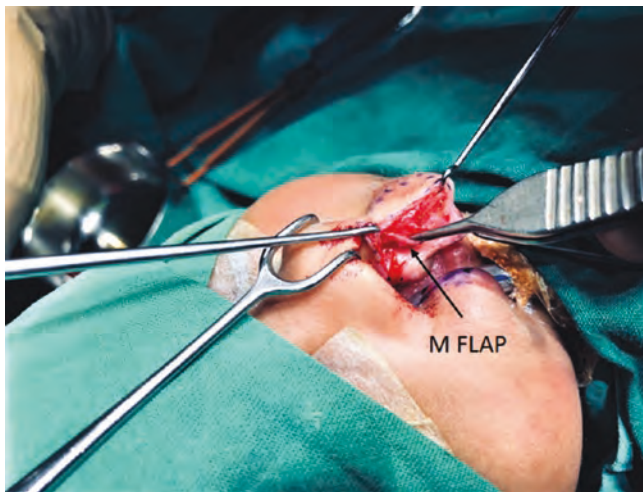
- Mark the highest point on the cupid's bow (cleft side), and also notice the philtral dimple (Fig. 72.23a).
- Mark the future philtral column, and continue it up to the columella without cutting across the columella (Fig. 72.23b).
- At this point the surgeon should compare the mark with the philtral column on the normal side. It might appear shorter; however, it will increase in length once the muscle is dissected from the abnormal attachment. The back cut discussed previously is used for adequate rotation of



©Association of Oral and Maxillofacial Surgeons of India

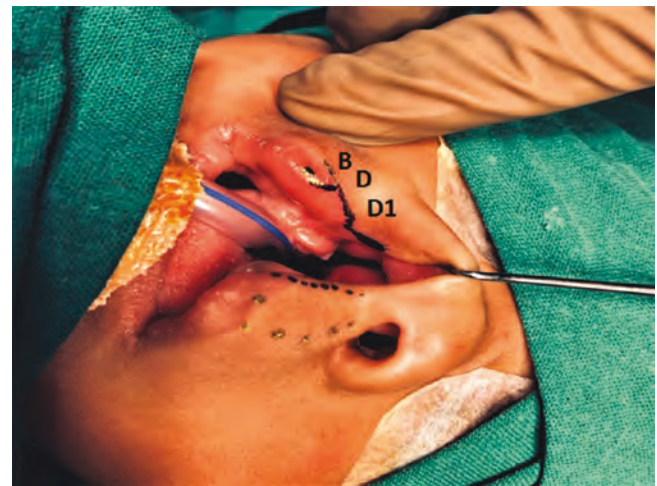
Fig. 72.25 Marking of C flap: A triangular flap between the mucosa and the future philtral column

- the cleft side philtral column. The back cut should be made after the muscle closure.
- From the peak of cupid's bow on the cleft side, mark the incision on the dry mucosa till the junction of wet and dry mucosa (Fig. 72.24).
- Marking of C Flap: A triangular flap between the mucosa and the future philtral column. Continue between the skin



©Association of Oral and Maxillofacial Surgeons of India

Fig. 72.26 M flap: The mucosal element on the non-cleft segment after raising the C flap becomes the M flap and is raised to expose the underlying muscle

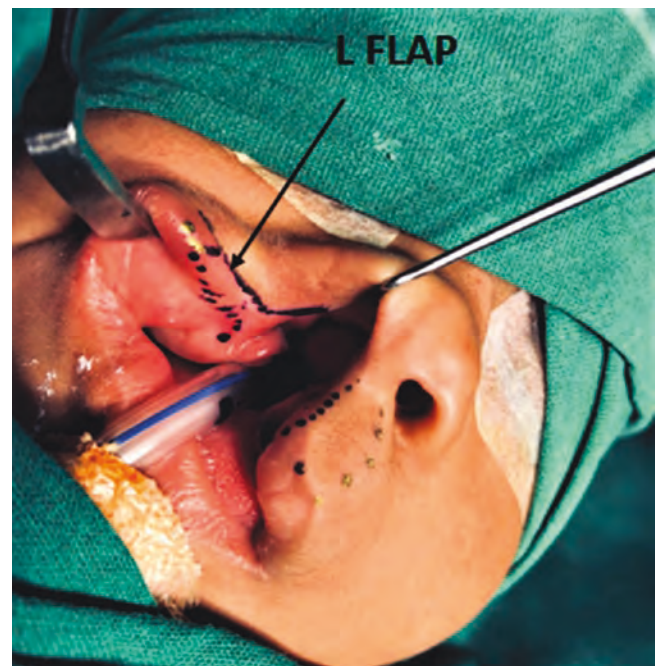


©Association of Oral and Maxillofacial Surgeons of India

Fig. 72.27 On the side of the cleft, mark the point B. From the B point, extend the incision along the mucocutaneous junction till point D. From point D, marking goes into the nose to separate the nasal mucosa and the skin [D1]

and mucosa junction down to the mucosa to keep enough mucosa for nasal layer closure (Fig. 72.25).

- C flap originally described by Millard was used to augment the lateral lip at the insertion of alar base. We use the C flap either to create the nasal sill or if a back cut is given; it can be used to reconstruct the columella-lip junction.
- M Flap: The mucosal element on the non-cleft segment after raising the C flap becomes the M flap and is raised to expose the underlying muscle (Fig. 72.26).
- Rotational Flap: The muscle is now exposed, and the preparation of the lateral element can be divided into three easy steps:
 - Oral mucosal layer: Separation of this layer from the muscle bulk can be identified with the plane where the minor salivary glands exist. Bleeding is generally encountered in this plane and should be managed early to reduce blood loss and keep a good plane of dissection.
 - Skin-muscle dissection: The incision between this plane is to ensure just adequate separation to provide room for suturing the muscle bulk. Overexposing the muscle not only leads to excessive swelling postoperatively but also distorts the natural anatomical curves of the non-cleft element. On the cleft side, only 1–2 mm of subdermal dissection should be done. Closure of the skin later reinforced by the underlying muscle gives better elevation of the future philtral column as compared to overzealous separation of the muscle from the overlying skin.
 - Release of abnormal muscle attachment: The abnormal attachments are usually near the alveolus and the base of the columella. At this point blunt dissection can be done to straighten out the septum.

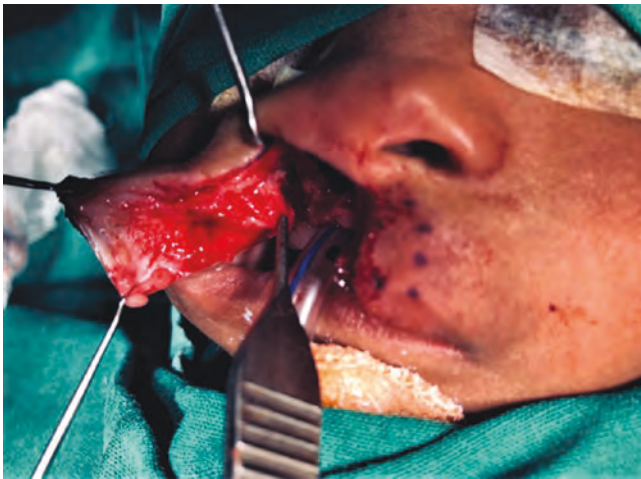

©Association of Oral and Maxillofacial Surgeons of India

Fig. 72.28 Marking of L flap

Cleft Side:

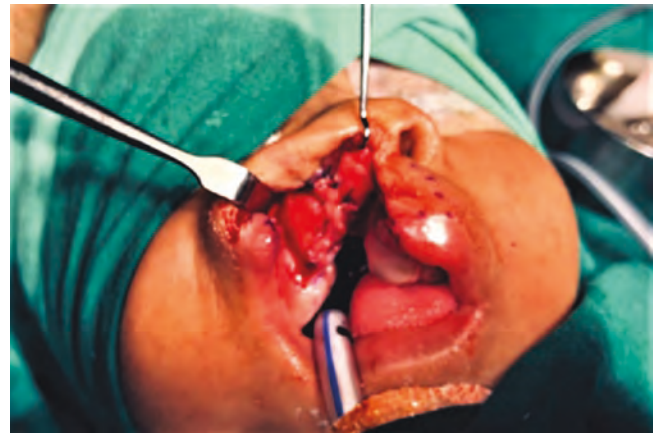- On the side of the cleft, mark the point B. First identify the white roll, and look for the point where the white roll starts to diminish; that is the exact point to join the Cupid's bow. Drop an imaginary line from this point to the junction of dry and wet mucosa. The maximum mucosal width is present at this point.



©Association of Oral and Maxillofacial Surgeons of India

Fig. 72.29 Incision starts from the deepest point of the Cupid's bow till the columella base. The plane of dissection is just above the muscle

- From the B point, extend the incision along the mucocutaneous junction till point D. Point D is a point at the edge of the lip at the junction of the skin and mucosa. From point D, marking goes into the nose to separate the nasal mucosa and the skin (Fig. 72.27).
- After marking the L flap, the incision is continued down to the alveolus, to free the abnormal muscle attachment at the base of the alveolus. In a classic Millard's technique, additional incision is given into the vestibule on the cleft side to get adequate mobilization of the advancement flap and medicalization of the cleft side alar base for nasal sill closure. Few surgeons also advocate subperiosteal or supraperiosteal dissection, through the intraoral incision at the pyriform region. However, in the author's experience, the need for this vestibular incision is not always necessary. An "L" flap can be designed from the mucosa of the cleft side as shown in the figure. This flap is continued upwards into the nasal mucosa and not towards the alveolar mucosa. The importance of this lies in the fact that, once harvested, the flap is retracted upwards into the nasal base and is thus used for closure of nasal sill. Moreover, due to this upward pull, the abnormal alar base attachment that leads to flattening of the alar rim is corrected. Thus, it helps in reducing the nasal symmetry (Fig. 72.28).
- Incision starts from the deepest point of the Cupid's bow till the columella base. The plane of dissection is just above the muscle. On the mucosa the incision continues till the junction of the dry and wet mucosa to expose the muscle. Insert a skin hook which will stretch the lip and aid in further dissection. *Note:* The superior labial artery can be encountered at this point and may need cauterization (Fig. 72.29).

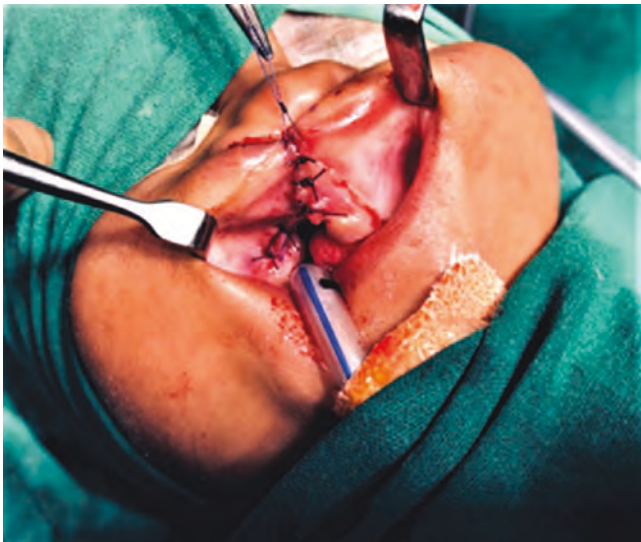

©Association of Oral and Maxillofacial Surgeons of India

Fig. 72.30 Nasal layers are now sutured from both the cleft and non-cleft sides and sutured using a 4.0 Vicryl

- Begin the incision from the point where the white roll diminishes, and carry it along the marking between the skin and mucosa to reach the junction between the nasal skin and mucosa.
- A small mucosal triangle containing the dark mucosa is maintained, and incision is then carried out to raise the L flap.
- Once the L flap is raised, the muscle of the cleft side element is exposed.
- Incision is made between the mucosa and muscle similar to the non-cleft side in the plane of existing minor salivary glands.
- The incision between the skin and muscle is similar to the lateral element.
- The abnormal muscle attachments on this side are at the base of the alar and the pyriform region that would require subperiosteal dissection to release the attachment.
- *Insertion of Flaps and Suturing.*
- The final step of closing the flaps into desired position begins with inseting the L and M flaps.
- *Step 1*
- Using the M flap is optional. The author generally discards the M flap but occasional uses it to reduce tension while doing the nasal floor repair in very wide clefts.
- The L flap is used to create the nasal layer on the cleft side by lining it between the nasal skin and the nasal floor.
- *Step 2*
- *Creating the Nasal Floor:* Nasal layers are now sutured from both the cleft and non-cleft sides and sutured using a 4.0 Vicryl (Fig. 72.30).
- At this point of time, the septum is exposed. When the nasal layer is being raised, if required the septum can be straightened.
- *Step 3*

- *Suturing the Oral Mucosa:* Begin at the point where the wet and dry mucosae meet. The alignment of these two points from both elements is crucial for good mucosal repair. The rest is completed till the alveolar base. The suture material used here is 4.0 Vicryl. The dry mucosa will be closed last (Fig. 72.31).
- *Muscle Suturing:* The preference is to suture the muscle at the junction of white roll and Cupid's bow. The suture allows reassessment of adequate rotation of the flap to create equal length of the philtral columns. A back cut can now be placed to accommodate for discrepancies. The back cut is made parallel to the existing philtral column at the base of the columella.
- Muscle layer suturing is then completed carefully reorienting the fibres at equal height and bites from both elements. At this stage the lip anatomy should

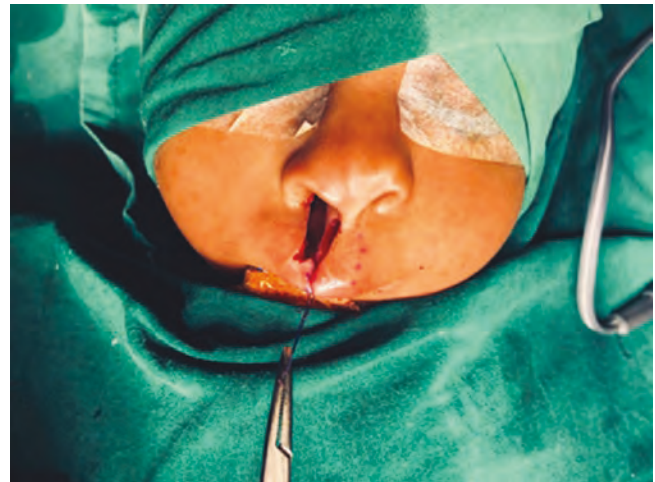

©Association of Oral and Maxillofacial Surgeons of India

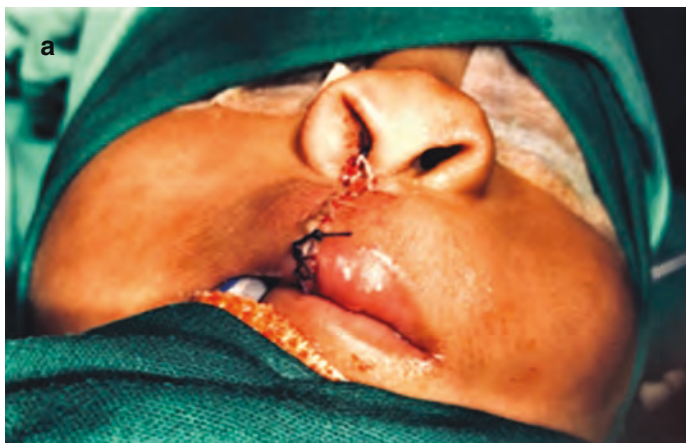Fig. 72.31 Suturing of the oral mucosa

correspond to final anatomy, and the skin should be passively seated over the muscle layer. The suturing is completed using 4.0 Vicryl, and the knots are cut flush to prevent any extrusion of sutures on the skin surface (Fig. 72.32).

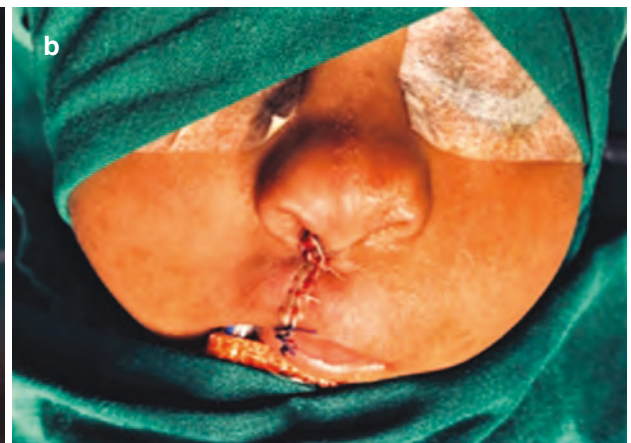- *Skin Suturing:* The first step in suturing the skin is to evaluate the area where the C flap is going to be utilized and also the dimension of the flap needed. The excess flap can be trimmed or in some instances completely discarded (Fig. 72.33a).
- The preference of the C flap is to use it as a hemi-columella or nasal sill. Using the C flap into the back cut defect creates an unnatural scar across the cutaneous lip and columella junction.
- Once the C flap is tucked beneath the skin, excess skin tissue if any is trimmed, and suturing begins from the base of the columella down to the vermilion. The suture

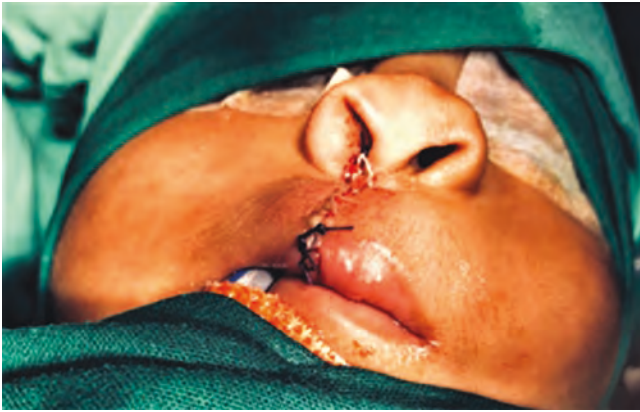

©Association of Oral and Maxillofacial Surgeons of India

Fig. 72.32 Muscle suturing

©Association of Oral and Maxillofacial Surgeons of India

**Fig. 72.33** (a) Skin suturing. (b) Note the matching of the white roll



©Association of Oral and Maxillofacial Surgeons of India

Fig. 72.34 Dry mucosa suturing

used here is 5.0 Vicryl Rapide or 6.0 Vicryl Rapide (Fig. 72.33b).

- *Dry Mucosa Suturing:* At the end of skin suturing, the vermilion continuity is established by using the V-shaped mucosal flap established from the cleft segment tucked into the non-cleft mucosa. At this stage care should be taken to secure a suture beneath the vermilion for muscle repair, and the mucosal stitch should be passive to reduce necrosis of the mucosal tip (Fig. 72.34).
- A good repair depends upon minimal handling of the tissues and a tension-free closure of all layers especially the skin as the muscle bears the stress of tension forces.

72.7 Bilateral Lip Repair

James Barrett Brown said “Bilateral clefts are twice as hard as unilateral clefts, and the results are less than half as good” [69]. Bilateral cleft lip repair can be one-stage or two-stage. Proponents of one-stage repair stress on creating a symmetric, balanced lip. This is indicated in cases of complete or incomplete symmetric bilateral clefts or where the premaxilla is within the arch. Two-stage repair is indicated in the presence of a small prolabium, an asymmetric cleft or a protruded premaxilla. Proponents of two-stage repair advocate this technique for conversion of a bilateral into unilateral cleft, to encourage the growth of prolabium and to avoid excessive lip tension. In earlier techniques of bilateral lip repair, excision of the prolabium was made mistakenly assuming it to be a displaced columella. This was because surgeons failed to recognize the potential of the prolabium to grow in width and height when attached to the dynamic lateral lip elements.

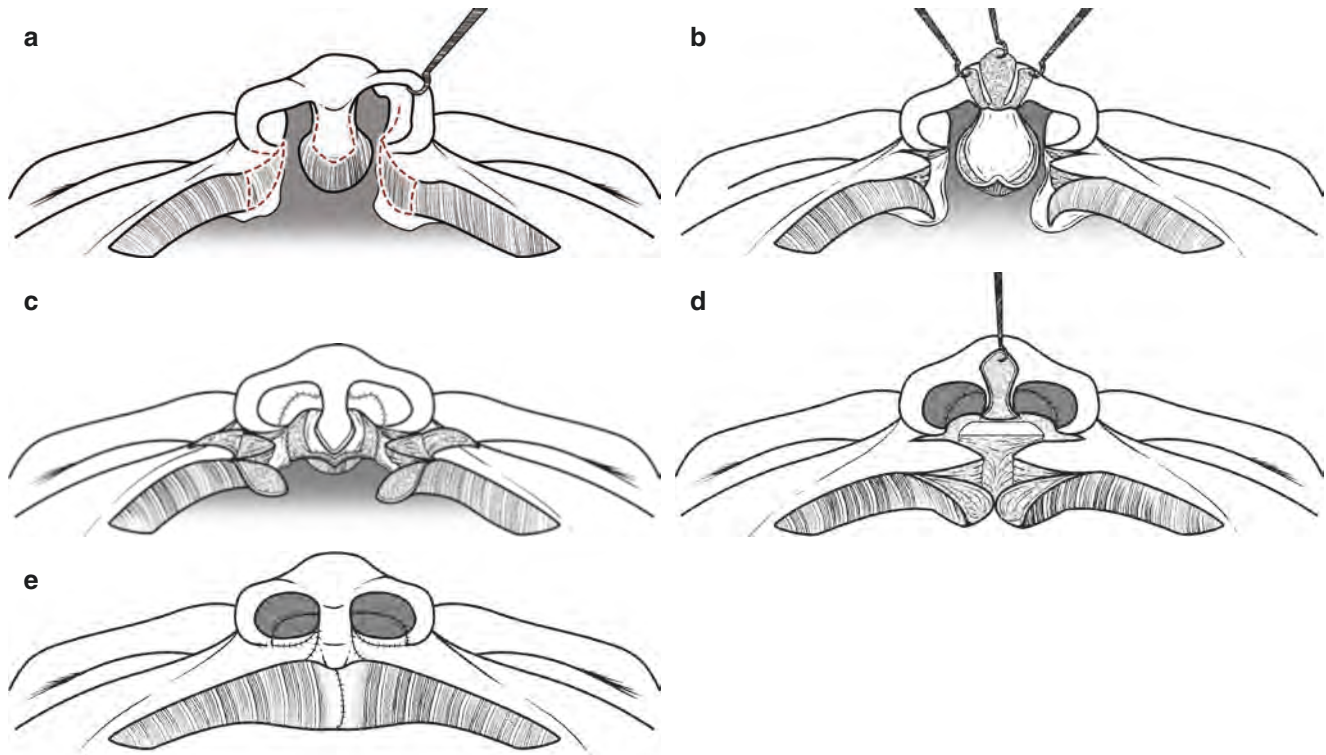
Principles of Bilateral Cleft Lip Repair: Certain key points and landmarks need to be kept in mind while considering a bilateral cleft lip repair. The following principles of bilateral cleft lip repair should be adhered to:

1. Symmetry must be established. In case of staged repairs, this is hindered which lead to asymmetrical results.
2. The surgeon should anticipate a fourth dimensional changes that occur with growth. Failure to account for this may result in a widened philtrum. This is attributable to slower-growing areas such as the lengthening columella and projection of the nasal tip, compared with faster-growing areas such as the philtral width [70] Thus, there is a need to undercorrect fast-growing areas and overcorrect the slow-growing structures.
3. Prolabium: No matter how small it is, the prolabium is always sufficient for reconstruction. It should always be used for reconstruction of the midportion and not used for partial reconstruction of the philtrum and columella. When white line is present in the prolabium, it must be used, however, a short prolabium pulls down nasal tip creating a secondary nasal deformity.
4. Premaxilla: Presurgical orthopaedic treatment should be done only to expand the maxillary segments. Closure and joining the muscle at the midline create enough pressure to reposition the protruding premaxilla. Sometimes, resection of the vomer behind the vomerine-premaxillary suture can be done, and the premaxilla can be repositioned using plating or K-wire with or without bone graft.
5. Vermillion: There is a very narrow strip of vermilion present in a bilateral cleft lip. A vermilion flap from lateral lip elements should be taken for fullness and protrusion of the lip.
6. Muscle repair: As the prolabium is without muscle fibres, muscle continuity under the prolabium is necessary for a functional lip. There is a need to release the abnormal attachment at the base of the ala from the vertical to horizontal and functional attachment.
7. The nasal deformity can be addressed either primarily or secondarily.

72.7.1 Techniques of Bilateral Cleft Lip Repair (Video 72.2)

72.7.1.1 Straight Line Repair

Bardach used a straight line repair. The prolabium was used for the entire central portion of the lip. This caused a problem in case of a short prolabium or a protruded premaxilla [71]. Salyer also used a straight line repair. In his repair, no tissue is discarded, the entire prolabium is lengthened and philtral and skin flaps are used for vestibular lining [72].



©Association of Oral and Maxillofacial Surgeons of India

Fig. 72.35 (a–e) Millard's technique of bilateral lip repair

72.7.1.2 Millard's Repair

Millard's repair allowed rotation of the Cupid's bow with the gap filled from skin advanced from the lateral element [73]. It allowed complete elevation of the prolabium and suturing of the orbicularis across the premaxilla. In addition, Millard created lateral segments of the prolabium as "forked flaps". These flaps were banked to add columellar height at a later stage, thus addressing the vertical height deficiency, and it also corrected the wide alar bases (Fig. 72.35a–e). The key elements of bilateral lip repair are given in Box 72.6.

72.7.1.3 Mulliken's Repair

Mulliken designed a narrow prolabial flap with slightly concave sides; 2; 2.5 mm at base and 3.5–4 mm between Cupid's bow peak. The surgical stratagem is symmetrical labial

Box 72.6 Key Elements of Bilateral Lip Repair

- Bringing in a new white roll from the lateral lip elements.
- The prolabium parings are banked for future columella lengthening.
- Bringing lateral vermilion flaps beneath the prolabium.
- Reconstructing the orbicularis muscle beneath the elevated prolabium.

repair and synchronous anatomic positioning of the alar cartilages with sculpturing/draping of the nasal soft tissues. It consists of following elements:

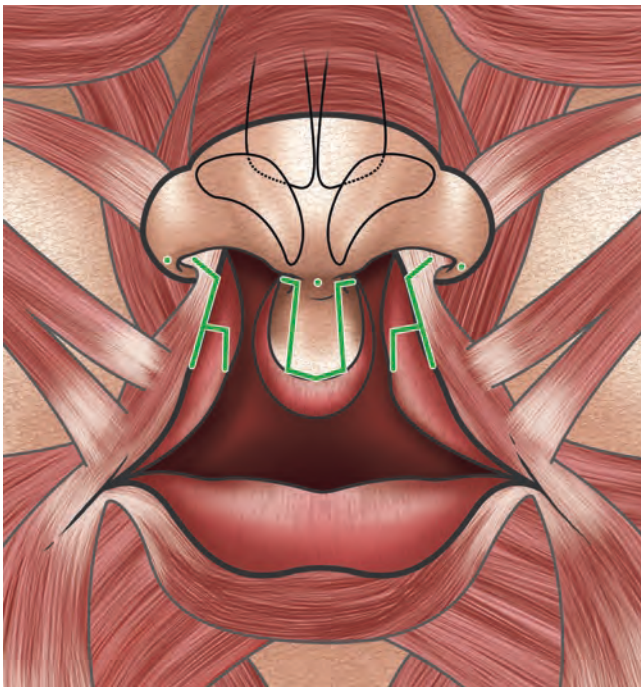
- Suture of the orbicularis oris in the midline.
- Fixation to anterior nasal spine.
- Positioning dislocated lower lateral cartilages: interdomal suture.
- Suspension over ipsilateral upper lateral cartilage with intercartilaginous suture.
- Suture of the orbicularis oris in the midline.
- Fixation to the anterior nasal spine.
- Positioning dislocated lower lateral cartilages: interdomal suture.
- Suspension over the ipsilateral upper lateral cartilage with intercartilaginous suture.

72.7.2 Bilateral Lip Repair: Author's Technique

Markings: Fig. 72.36 shows the marking of the prolabial flap and the lateral flaps.

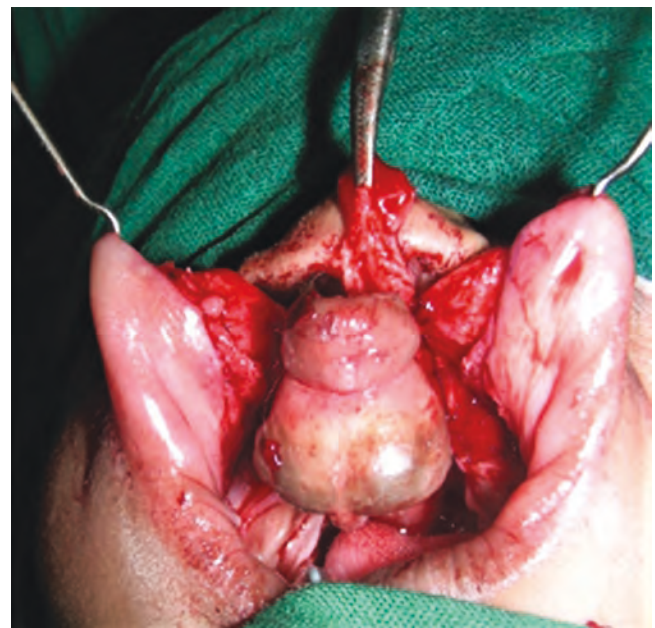- Once all incisions are designed, the lip is infiltrated with 1:100,000 epinephrine. We can start with either the prolabium or lateral flaps. Grab the lip between fingers for better control during incision and bloodless field.

- Incision starts on the prolabium following the previous markings, the medial flap is for philtral reconstruction, and two lateral segments of the skin are discarded (Fig. 72.37a).
- The philtral flap is dissected, leaving a generous amount of deeper soft tissues attached. The flap is raised in a preperiosteal plane off the premaxilla and up to the base of the columella (Fig. 72.37b).
- Next step is creation of mucosal flap from the prolabium for sulcus reconstruction and exposure of anterior nasal spine.
- Incision in lateral lip following the marks in the skin and mucosa of the vermilion is made (Fig. 72.38).
- Incision is carried on the vermilion-cutaneous junction, dissecting the vermilion to the point where the peak of the Cupid's bow is marked.
- Full thickness cuts are made through the orbicularis oris and the oral mucosa of the upper lip.
- Incision in the sulcus to aid in the detachment of the abnormal lateral lip element, especially the muscle.
- Those incisions facilitate mobilization of the lateral lip elements so they can be brought up and over the premaxilla which aids in decreasing tension.



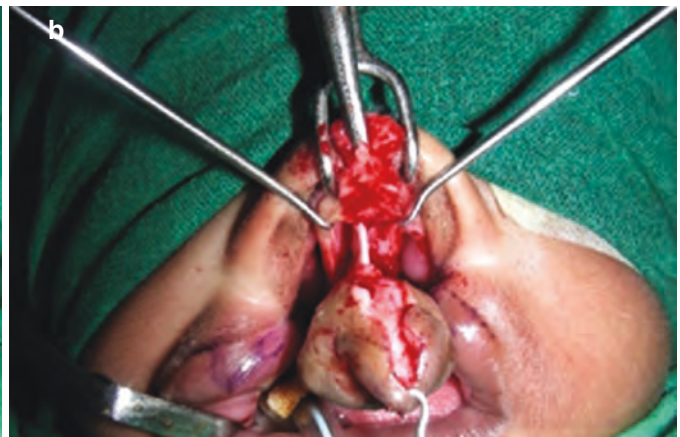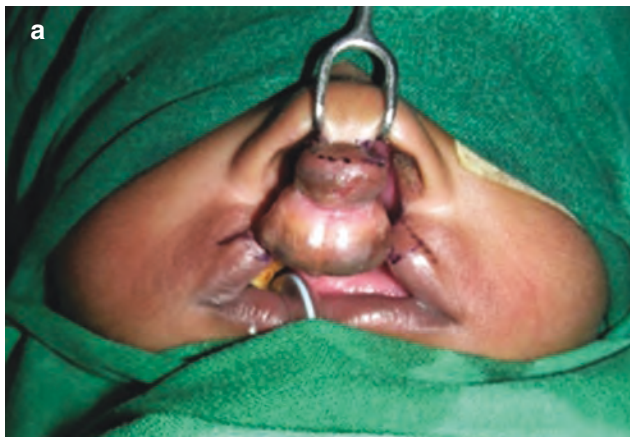©Association of Oral and Maxillofacial Surgeons of India

Fig. 72.36 Markings for bilateral lip repair



©Association of Oral and Maxillofacial Surgeons of India

Fig. 72.38 Dissection of the lateral flaps



©Association of Oral and Maxillofacial Surgeons of India

Fig. 72.37 (a) Marking of the prolabium flap and lateral flap. (b) The prolabium flap dissected

- The muscle is dissected as a separate layer from the mucosa not from the skin. Undermining of the soft tissue, dissection and release are carried up to the inferior orbital nerve.
- Subperiosteal dissection of the pyriform aperture towards the frontomaxillary pillar, to release the ala from its abnormal insertions.

Release and repositioning of the following structures from their abnormal attachment:

- Alar base.
- Muscular, ligamentous and lining attachments.
- Fibrous attachments with the accessory chain of the lateral crus.
- Full-thickness cut is made along the nasal lining at the pyriform aperture. This release creates a lining defect that will be filled with the septal flap.
- Dissection of mucoperiosteal flap from lateral nasal wall.
- Liberation of the orbicularis oris, freeing it from its abnormal attachment around the base of the nose.
- Reposition of the orbicularis from vertical to horizontal position with retrograde dissection without dissection of the muscle and the skin in the free border.

Suturing

(a) Nasal Floor

- Mucoperiosteal flap from lateral nasal wall and mucoperichondrial flap from the nasal septum are sutured to form the nasal floor. This helps to bring the base of the ala medially, thus narrowing the width of the nostril.

(b) Recreating the Sulcus

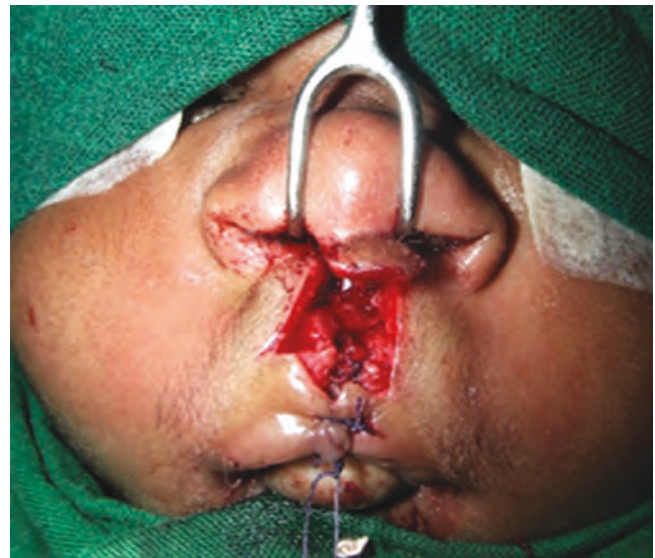- Advance prolabial mucosal flap superiorly to establish the lining of the labial sulcus, trimmed as needed, and fixing it to the periosteum inferiorly to the nasal spine.
- Medial advancing of mucosal flaps and fixation to the mucosal flap of the prolabium, previously fixed. Then they are sutured together in the middle line from inferior to superior, starting in the red line (key stitch).

(c) Muscle Repair

- Medial advanced musculocutaneous flaps from the lateral lips.
- Muscle is brought across the midline below the prolabium.
- Apposition of the muscle is done from distal (key stitch) to proximal area (Fig. 72.39).
- Proximal segment fixed to the periosteum of the anterior nasal spine in the middle line.

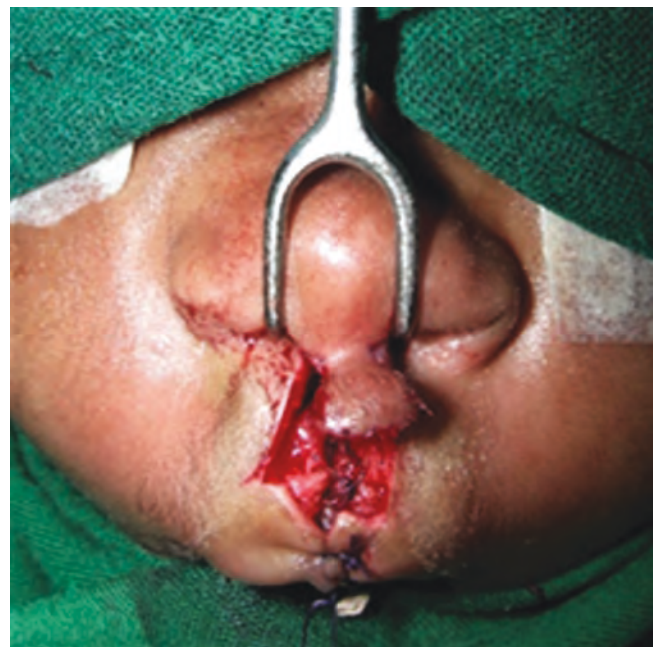(d) Vermillion Repair

- The midportion of the vermilion is reconstructed by bringing lateral vermilion flaps below the philtrum flap (Fig. 72.40).



©Association of Oral and Maxillofacial Surgeons of India

Fig. 72.39 Lateral flaps sutured beneath the prolabium. Muscle sutured to create the continuity

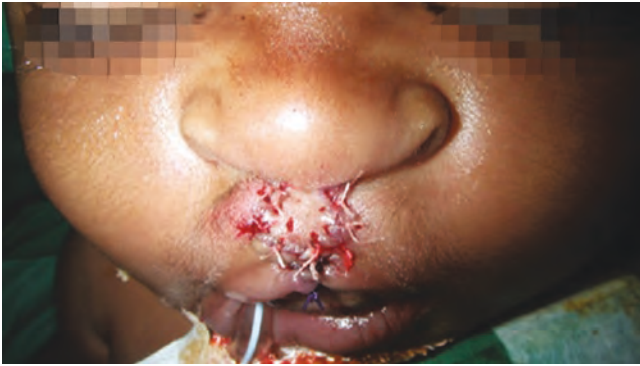

©Association of Oral and Maxillofacial Surgeons of India

Fig. 72.40 Position of the prolabium to create the future philtral column

(e) Skin

- Preventing or minimizing lip tension is the key to successful bilateral cleft repair (Fig. 72.41).
- Excessive tension: tethering of the columella, increased scarring and facial growth problems.
- Attention is given to construction of the Cupid's bow.



©Association of Oral and Maxillofacial Surgeons of India

Fig. 72.41 Skin suturing done

72.8 Primary Chielorhinoplasty

A variety of options exists to address the nasal deformity with cleft lip. These include preoperative nasolabial moulding, overcorrection of the nostril width and alar cartilage at the time of lip repair and postoperative use of nasal conformers. Primary treatment of the nose at the time of lip repair has become popular, in order to gain early restoration of the symmetry by repositioning the alar cartilage and lengthening the columella. However, relapse is frequent due to the elastic deformed alar cartilage. Various theories and opinions have been popularized regarding correction of the septum, to either straighten the septum or leave for later correction. A study done by Mancini et al. involves three-dimensional analysis of unilateral cleft lip and palate patients treated with PNAM and primary rhinoplasty, which demonstrated significant improvements in nasal projection, columellar length, nasal symmetry and nasal width [74].

72.9 Postoperative Wound Care and Outcome Assessment

Postoperative wound care is extremely important in determining the results of lip repair and is often a factor resulting in the need of a lip revision.

1. Suture area should be cleaned daily with saline and baby soap twice; topical application of antibiotics is recommended for 10 days.
2. 3 weeks post-op, we recommend to massage the scar towards the mucosa to prevent scar contracture.
3. Massage can be done with vitamin E cream/silicone gel/oil. It is recommended to massage for at least 6 months.

72.9.1 Outcomes

Improper surgical technique and tissue dissection can lead to certain undesirable outcomes. Other factors such as wide deformities, severely displaced premaxilla, inadequate postoperative care, poor healing and infection can also lead to aesthetic results. Understanding the process and severity of the outcome helps in addressing the problem in secondary lip repair or lip scar revisions. The outcomes can be divided into the following types:

- **Mucosal notching**—As pointed above, the mucosal dissection should always be in the plane between the muscles and the mucosa plus minor salivary glands. Failure to maintain that results in a thin mucosa that inverts after suturing. This leads to mucosal notching. As a trainee, one can also give mattress sutures to achieve mucosal eversion. In case of very mild mucosal notching presenting at 3 weeks, it is advised to continue the massage. If notching persists after 6 months of lip repair, it can be treated by surgically improving placement of muscle; thus we recommend a lip revision.
- **Scarring**—A scar can present in various forms. A scar can be linear but hypertrophic in appearance. Such scars can be avoided if proper massaging is done in the postoperative phase. If the scar has keloid tendency, triamcinolone injections are to be given at an interval of 15 days followed by vigorous massage.
- **Contracture**—A scar can also present as a gross or mild vertical contracture. This usually results due to inadequate rotation, thus pulling the lip towards the nose resulting in vertical shortening of cleft side philtral column. Improper muscle closure or overzealous separation of the skin from the muscle can lead to scarring of the skin.
- **Inadequate philtral column matching**—This again results due to lack of a proper design and improper mobilization of the rotation flap.
- **Complete breakdown of the surgical wound** may be the most severe adverse outcome in the immediate post-operative phase.

72.10 Indications for Lip Revision

Scarred fibrous tissues with poor vascularity always make secondary surgery more challenging. Dissection and reapproximation of surgical landmarks are difficult in such cases. The basic surgical principles that should be followed are identification and preservation of all the vital anatomic structures.

The basic indications for a lip revision surgery are:

1. Unilateral.
 - The scar is not in line with the natural philtral column.
 - The lip length is short.
 - There is a mucosal notching.
 - There is a white roll to Cupid's bow mismatch.
 - There is a nasolabial fistula.
2. Bilateral.
 - There is a wide philtral column.
 - Mucosal notching.
 - Whistling defect.
 - No sulcus depth.

72.11 Conclusion

In our course of learning of cleft, we often understand embryology, anatomy and the surgical technique as separate

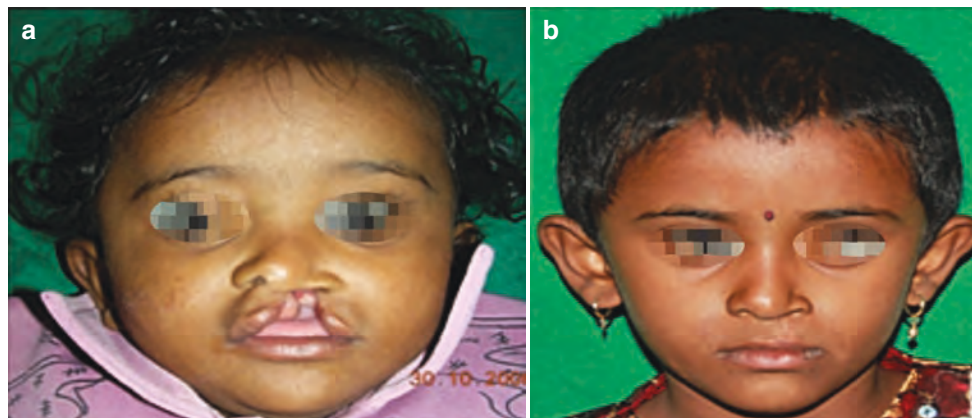
concepts. In this chapter, we have tried to integrate them and tried to explain the rationale behind the surgical steps. Embryological basis of normal anatomy and then of cleft is pivotal to understand the arrangements of muscles, the vascular supply and thus the basis of incisions. We have described our surgical technique of cleft lip repair with long-term follow-ups. In the congenital deformity of cleft where there is paucity and deformation of tissues, preserving the tissues during surgery is one of the important principles of lip repair.

72.12 Case Scenarios

Figures 72.42, 72.43, 72.44, 72.45 and 72.46 represent cases of operated unilateral and bilateral cleft lip with long-term follow-ups.

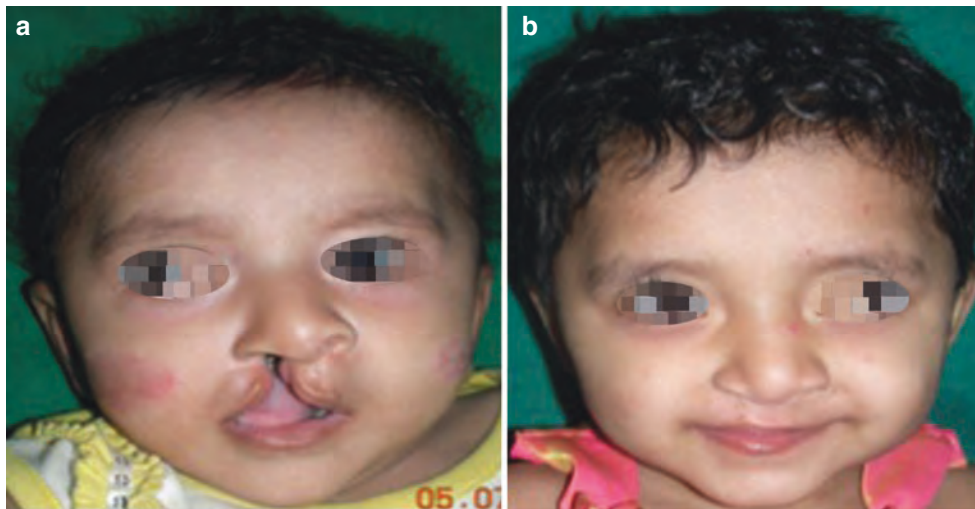Figures 72.47, 72.48, 72.49 and 72.50 represents cases of lip revisions with follow-ups.

Disclosure: Authors have no financial conflicts to disclose.



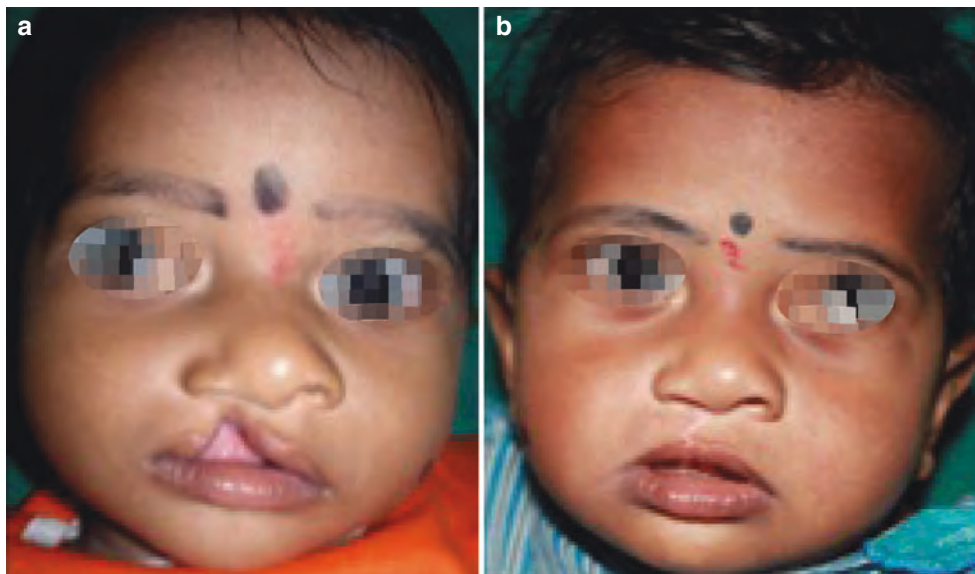
©Association of Oral and Maxillofacial Surgeons of India

Fig. 72.42 (a, b) Pre operative (a) and postoperative (b) Photograph of repair of unilateral cleft lip using author's technique of lip repair [7-year follow-up]



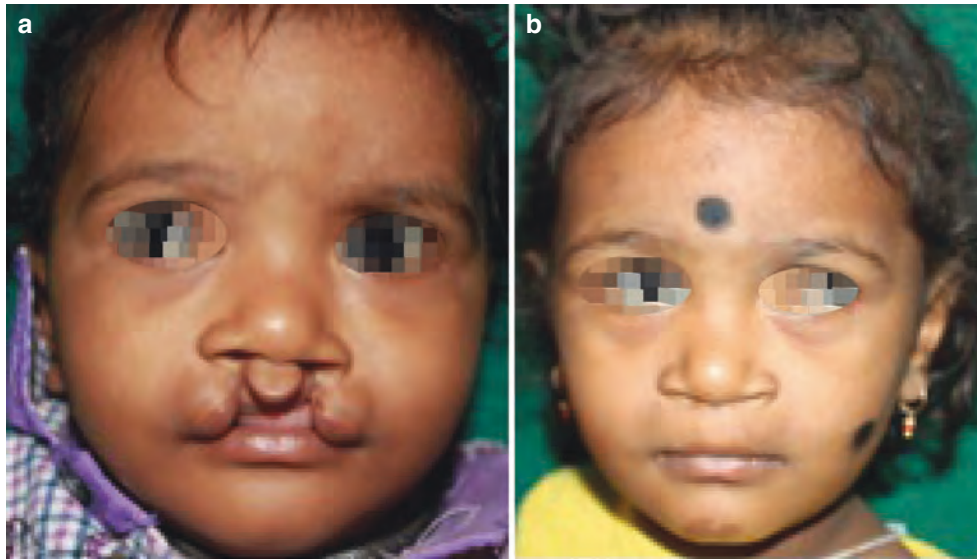©Association of Oral and Maxillofacial Surgeons of India

Fig. 72.43 (a, b) Another case of a 3-month-old female of complete unilateral cleft lip repaired. Left, preoperative; right, postoperative after a 4-years follow-up



©Association of Oral and Maxillofacial Surgeons of India

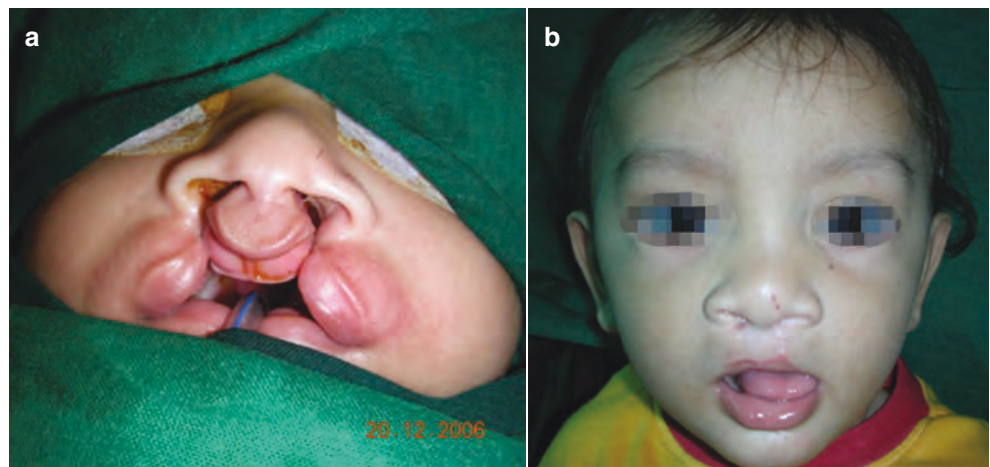
Fig. 72.44 (a, b) Operated case of an incomplete cleft lip, 2-year follow-up



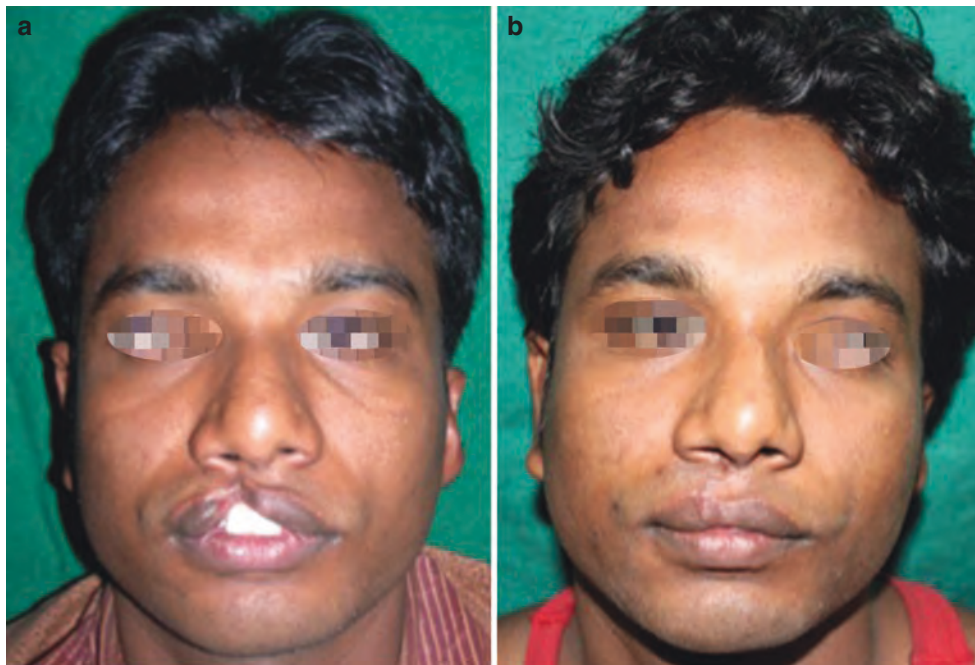©Association of Oral and Maxillofacial Surgeons of India

Fig. 72.45 (a, b) Pre-op and post-op photograph of a case of bilateral cleft lip repair, 5-year follow-up

Fig. 72.46 (a, b) Another case of operated bilateral cleft lip

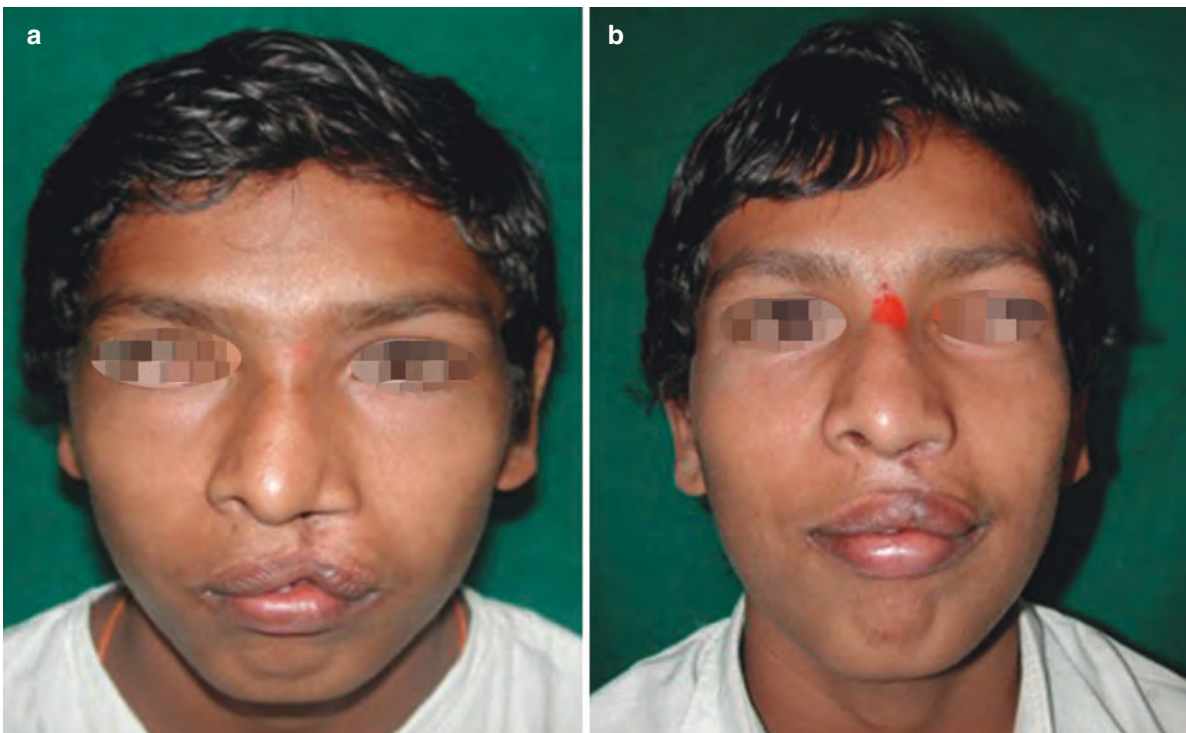


©Association of Oral and Maxillofacial Surgeons of India



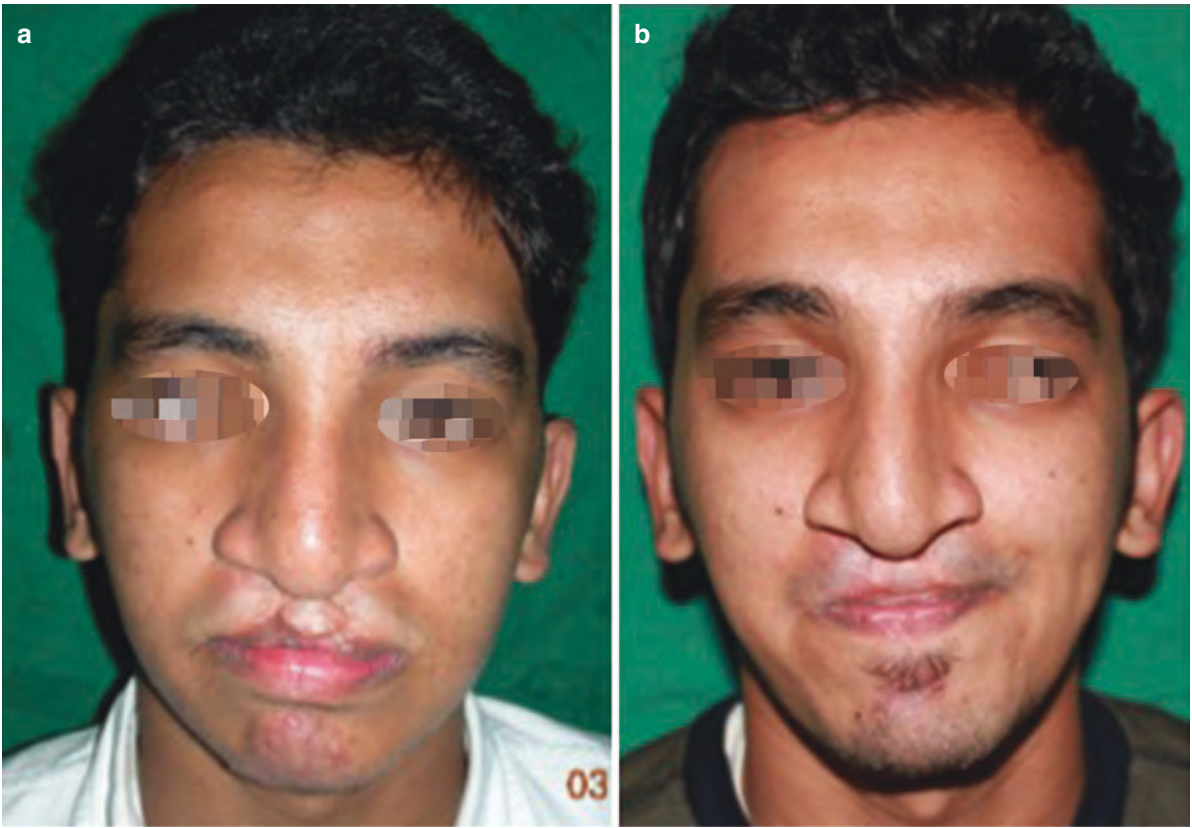©Association of Oral and Maxillofacial Surgeons of India

Fig. 72.47 (a, b) A case of mucosal notching in an adult lip (a) Postoperative image after a 2-year follow-up (b)



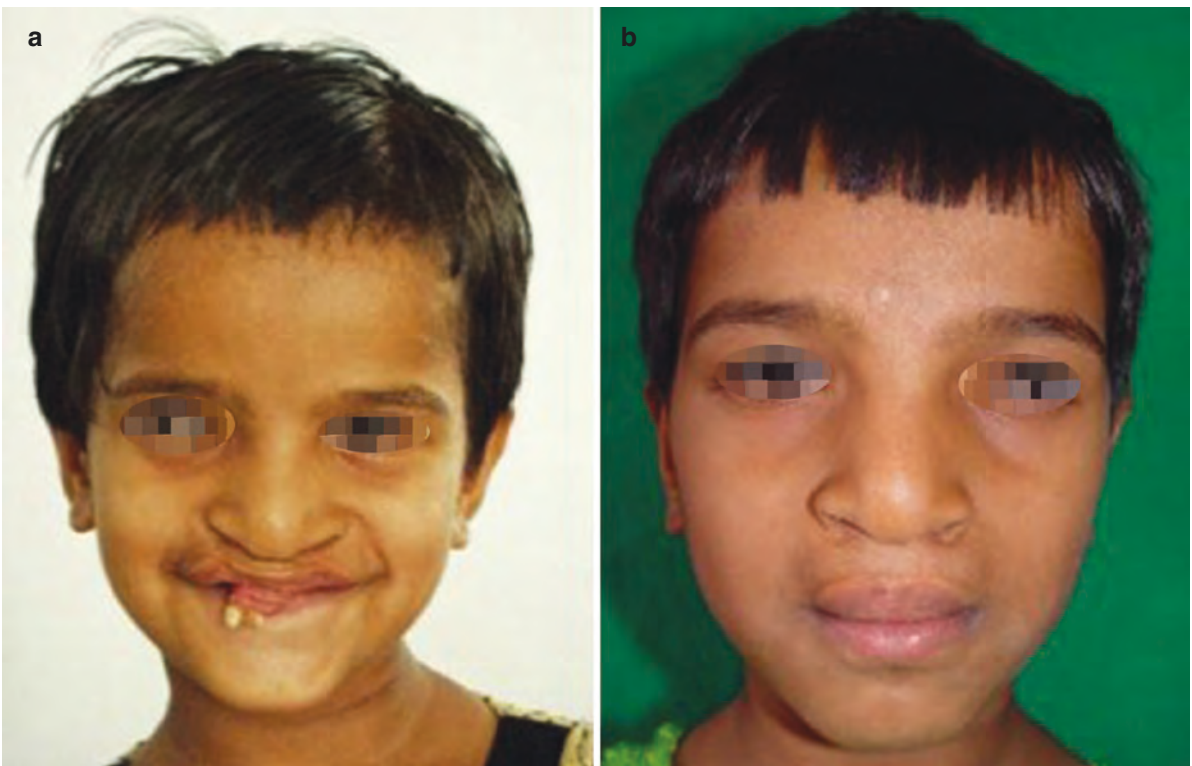©Association of Oral and Maxillofacial Surgeons of India

Fig. 72.48 (a, b) A case of operated unilateral cleft lip with mucosal notching and vertical scar contracture (a) Postoperative image after lip revision (b)



©Association of Oral and Maxillofacial Surgeons of India

Fig. 72.49 (a, b) An operated case of bilateral cleft lip before (a) and after (b) lip revision



©Association of Oral and Maxillofacial Surgeons of India

Fig. 72.50 (a, b) A case of an operated bilateral cleft lip with protruding premaxilla and a wide lip (a) Postoperative image (b) after lip revision and premaxillary repositioning

References

- Kadir A, Mossey PA, Blencowe H, Moorthie S, Lawn JE, Mastroiacovo P, et al. Systematic review and meta-analysis of the birth prevalence of orofacial clefts in low- and middle-income countries. *Cleft Palate Craniofac J*. 2017;54:571–81.
- Millard DR Jr. *Cleft craft: evolution of its surgery*. In: *The unilateral deformity*, vol. 1. Boston: Little, Brown; 1976.
- Sadler TW, Langman J. *Langman's medical embryology*. 12th ed. Philadelphia: Wolters Kluwer Health/Lippincott Williams & Wilkins; 2012.
- Millard DR Jr. *Cleft craft: evolution of its surgery*. In: *Embryological theories*, vol. 1. Boston: Little, Brown; 1976.
- Millard DR Jr. *Cleft craft: evolution of its surgery*. In: *Anatomy in multiple dimensions*, vol. 1. Boston: Little, Brown; 1976.
- Ghi T, Perolo A, Banzi C, et al. Two-dimensional ultrasound is accurate in the diagnosis of fetal craniofacial malformation. *Ultrasound Obstet Gynecol*. 2002;19:543–51.
- Drake RL, Vogl W, Mitchell AWM, Gray H. *Gray's anatomy for students*. Philadelphia: Elsevier/Churchill Livingstone; 2005.
- Davis JS, Ritchie HP. Classification of congenital clefts of the lip and palate. *JAMA*. 1922;79:1323–7.
- Brophy TW. Cleft palate and harelip procedures. *Int J Orthod Oral Surg*. 1921;7:319–30.
- Veau V. *Division Palantine*. Paris: Masson et Cie; 1931.
- Kernahan DA, Stark RB. A new classification for cleft lip and cleft palate. *Plast Reconstr Surg Transplant Bull*. 1958;22:435–41.
- Harkins CS, Berlin A, Harding RL, Longacre JJ, Snodgrass RM. A classification of cleft lip and cleft palate. *Plast Reconstr Surg Transplant Bull*. 1962;29:31–9.
- Kernahan DA. The striped Y – a symbolic classification for cleft lip and palate. *Plast Reconstr Surg*. 1971;47:469–70.
- Spina V. A proposed modification for the classification of cleft lip and cleft palate. *Cleft Palate J*. 1973;10:251–2.
- Elsahy NI. The modified striped Y – a systematic classification for cleft lip and palate. *Cleft Palate J*. 1973;10:247–50.
- Millard DR Jr. *Cleft craft*, vol. I. Boston: Little, Brown and Company; 1977. p. 41–55.
- Friedman HI, Sayetta RB, Coston GN, Hussey JR. Symbolic representation of cleft lip and palate. *Cleft Palate Craniofac J*. 1991;28:252–9.
- Kernahan DA. On cleft lip and palate classification. *Plast Reconstr Surg*. 1973;51:578.
- Smith AW, Khoo AK, Jackson IT. A modification of the Kernahan “Y” classification in cleft lip and palate deformities. *Plast Reconstr Surg*. 1998;102:1842–7.
- Balakrishnan C. Indian classification of cleft lip and palate. *Indian J Plast Surg*. 1975;8:23.
- Kriens O. Lahshal: a concise documentation system for cleft lip, alveolus and palate diagnoses. In: Kriens O, editor. *What is cleft lip and palate? A multidisciplinary update workshop*, Bremen 1987. Stuttgart: Thieme; 1989.
- Yuzuriha S, Mulliken JB. Minor-form, microform, and mini-microform cleft lip: anatomical features, operative techniques, and revisions. *Plast Reconstr Surg*. 2008;122(5):1485–93.
- Bhuskute AA, Tollefson TT. Cleft lip repair, Nasoalveolar molding, and primary cleft rhinoplasty. *Facial Plast Surg Clin North Am*. 2016;24(4):453–466.
- Cutting C, Grayson B, Brecht L, Santiago P, Wood R, Kwon S. Presurgical columellar elongation and primary retrograde nasal reconstruction in one-stage bilateral cleft lip and nose repair. *Plast Reconstr Surg*. 1998;101:630–9.
- Smith KS, Henry BT, Scott MA. Presurgical Dentofacial orthopedic management of the cleft patient. *Oral Maxillofac Surg Clin North Am*. 2016;28(2):169–176.
- Santiago PE, Grayson BH, Cutting CB, et al. Reduced need for alveolar bone grafting by presurgical orthopedics and primary gingivoperiosteoplasty. *Cleft Palate Craniofac J*. 1998;35(1):77–80.
- Wood RJ, Grayson BH, Cutting CB. Gingivoperiosteoplasty and midfacial growth. *Cleft Palate Craniofac J*. 1997;34(1):17–20.
- Bennun RD, Perandones C, Sepiarsky VA, et al. Nonsurgical correction of nasal deformity in unilateral complete cleft lip: a 6-year follow-up. *Plast Reconstr Surg*. 1999;104(3):616–30.
- Ezzat CF, Chavarria C, Teichgraber JF, et al. Presurgical nasoalveolar molding therapy for the treatment of unilateral cleft lip and palate: a preliminary study. *Cleft Palate Craniofac J*. 2007;44(1):8–12.
- Yang C, Huang N, Shi B. [Clinical research of presurgical orthodontic treatment of complete cleft lip and palate infant.] *Hua Xi Kou Qiang Yi Xue Za Zhi*. 2011;29(4):396–399. Chinese.
- Ross RB. Growth of the facial skeleton following the Malek repair for unilateral cleft lip and palate. *Cleft Palate Craniofac J*. 1995;32(3):194–8.
- Bonanthaya K, Nayak T, Bitra S, Rachwalski M, Shetty PN. An assessment and comparison of nasolabial aesthetics in bilateral clefts using the anatomical subunit-based scale: a nasoalveolar moulding versus non-nasoalveolar moulding study. *Int J Oral Maxillofac Surg*. 2019;48(3):298–301.
- de Ladeira PR, Alonso N. Protocols in cleft lip and palate treatment: systematic review. *Plast Surg Int*. 2012;2012:562892.
- <https://medicine.uiowa.edu/iowaprotocols/cleft-lip-and-palate-protocols>
- Salyer KE, Xu H, Genecov ER. Unilateral cleft lip and nose repair; closed approach Dallas protocol completed patients. *J Craniofac Surg*. 2009;20 Suppl 2:1939–1955.
- Dudkiewicz Z. Ocena jednoetapowego chirurgicznego leczenia jednostronnych rozszczepów podniebienia pierwotnego i wtórno. *Probl Chir Dziec*. 1991;18:8e19. [in Polish]
- Åbyholm F. Primary closure of cleft lip and palate. In: Turvey TA, KWL V, Fonseca RJ, editors. *Facial clefts and craniosynostosis*. Philadelphia: WB Saunders; 1996. p. 370–83.
- Ross RB. Growth of the facial skeleton following the Malek repair for unilateral cleft lip and palate. *Cleft Palate Craniofac J*. 1995 May;32(3):194–8.
- Russell K, Long RE Jr, Hathaway R, Daskalogiannakis J, Mercado A, Cohen M, et al. The Americleft study: an inter-center study of treatment outcomes for patients with unilateral cleft lip and palate part 5. General discussion and conclusions. *Cleft Palate Craniofac J*. 2011;48:265–70.
- http://www.wch.sa.gov.au/services/az/divisions/psurg/craniofacial/documents/management_cleft_lip_palate.pdf.
- Shaw WC, Brattström V, Mølsted K, Prah-Andersen B, Roberts CT, Semb G. The Eurocleft study: intercenter study of treatment outcome in patients with complete cleft lip and palate. Part 5: discussion and conclusions. *Cleft Palate Craniofac J*. 2005;42:93–8.
- Shaw WC, Semb G, Nelson P, Brattström V, Mølsted K, Prah-Andersen B. *The Eurocleft project 1996–2000. Standards of care for cleft lip and palate in Europe*. Amsterdam: IOS Press; 2000.
- Lehman JA Jr, Douglas BK, Ho WC, Husami TW. One-stage closure of the entire primary palate. *Plast Reconstr Surg*. 1990;86:675–81.
- Farina R. Total unilateral harelip: correction of severe deformity of the palate and lips in a single operation; Le Mesurier's cheiloplasty & Veau-Ernst's gnathourano-staphyloplasty. *Ann Chir Plast*. 3:199–205. 1958 In French.
- Fudalej P, Surowiec Z, Offert B, Dudkiewicz Z, Katsaros C. Craniofacial morphology in complete unilateral cleft lip and palate patients consecutively treated with 1-stage repair of the cleft. *J Craniofac Surg*. 2010;21:1468–73.
- Rose W. *On harelip and cleft palate*. London: H.K. Lewis; 1891.
- Thompson JE. An artistic and mathematically accurate method of repairing the defect in cases of hairlip. *Surg Gynecol Obstet*. 1912;14:498–504.

48. Veau V. Le role tubercle median dans la constitution de la face. *Ann Anat Pathol (Paris)*. 1926;3:305–48.
49. Pfeifer G. Lip corrections following earlier cleft surgery by way of wave-line incisions. *Dtsch Zahnarztl Z*. 1970;25:569–76.
50. Delaire J. Primary cheilorhinoplasty for congenital unilateral labio-maxillary fissure. Trial schematization of a technic. *Rev Stomatol Chir Maxillofac*. 1975;76:193–215.
51. Chait L, Kadwa A, Potgieter A, et al. The ultimate straight line repair for unilateral cleft lips. *J Plast Reconstr Aesthet Surg*. 2009 Jan; 62:50–55. [Epub 2007 Nov 26].
52. Mirault G. Deux lettres sur l'operation du bec-de-lievre. *J Chir Paris*. 1844:1–12.
53. Blair VP, Brown JB. Mirault operation for single harelip. *Surg Gynecol Obstet*. 1930;51:81.
54. Brown JB, McDowell F. Simplified design for repair of single cleft lip. *Surg Gynecol Obstet*. 1945;80:12.
55. LeMesurier AB. The quadrilateral mirault flap operation for harelip. *Plast Reconstr Surg* (1946). 1955;16:422–33.
56. Hagedorn W. Uber eine Modifikation der Hasenschartenoperation. *Zentralbl Chir*. 1884;11:756.
57. Tennison CW. The repair of unilateral cleft lip by the stencil method. *Plast Reconstr Surg*. 1952;9:115.
58. Randall P. A triangular flap operation for the primary repair of unilateral clefts of the lip. *Plast Reconstr Surg Transplant Bull*. 1959;23:331–47.
59. Millard DR Jr. A primary camouflage of the unilateral Harelook. In: Skoog T, editor. *Transactions of the first international congress of plastic surgery, stockholm, 1955*. Baltimore: Williams & Wilkins; 1957. p. 160–6.
60. Millard DR. Complete unilateral clefts of the lip. *Plast Reconstr Surg*. 1960;25:595–605.
61. Millard DR. A radical rotation in single harelip. *Am J Surg*. 1958;95:318–22.
62. Millard DR. Refinements in rotation-advancement cleft lip technique. *Plast Reconstr Surg*. 1964;33:26–38.
63. Stal S, Brown RH, Higuera S, Hollier LH Jr, Byrd HS, Cutting CB, Mulliken JB. Fifty years of the Millard rotation-advancement: looking back and moving forward. *Plast Reconstr Surg*. 2009;123(4):1364–77.
64. Mohler LR. Unilateral cleft lip repair. *Plast Reconstr Surg*. 1987;80:511–7.
65. Fisher DM. Unilateral cleft lip repair: an anatomical subunit approximation technique. *Plast Reconstr Surg*. 2005;116:61–71.
66. Noordhoff MS. Reconstruction of vermilion in unilateral and bilateral cleft lips. *Plast Reconstr Surg*. 1984;73:52.
67. Cutting CB, Dayan JH. Lip height and lip width after extended Mohler unilateral cleft lip repair. *Plast Reconstr Surg*. 2003;111:17–23.
68. Mulliken JB, Martinez-Perez D. The principle of rotation advancement for repair of unilateral complete cleft lip and nasal deformity: technical variations and analysis of results. *Plast Reconstr Surg*. 1999;104:1247–60.
69. Wolfe SA. Repair of bilateral incomplete cleft lip: techniques and outcomes. *Plast Reconstr Surg*. 2014;134(1):166e–168e.
70. Zhang JX, Arneja JS. Evidence-based medicine: the bilateral cleft lip repair. *Plast Reconstr Surg*. 2017;140(1):152e–165e. Review.
71. Bardach J, Cutting C. Anatomy of the unilateral and bilateral cleft lip and nose. In: Bardach J, Morris HL, editors. *Multidisciplinary Management of Cleft lip and Palate*. Philadelphia: Saunders; 1990. p. 150–9.
72. Salyer KE, Bardach J. Salyer & Bardach's atlas of craniofacial & cleft surgery: craniofacial surgery. Philadelphia: Lippincott-Raven Publishers; 1999.
73. Trier WC. Repair of bilateral cleft lip: Millard's technique. *Clin Plast Surg*. 1985 Oct;12(4):605–25.
74. Mancini L, Gibson TL, Grayson BH, Flores RL, Staffenberg D, Shetye PR. Three-dimensional soft tissue nasal changes after Nasoalveolar molding and primary Cheilorhinoplasty in infants with unilateral cleft lip and palate. *Cleft Palate Craniofac J*. 2019;56(1):31–38.

Open Access This chapter is licensed under the terms of the Creative Commons Attribution 4.0 International License (<http://creativecommons.org/licenses/by/4.0/>), which permits use, sharing, adaptation, distribution and reproduction in any medium or format, as long as you give appropriate credit to the original author(s) and the source, provide a link to the Creative Commons license and indicate if changes were made.

The images or other third party material in this chapter are included in the chapter's Creative Commons license, unless indicated otherwise in a credit line to the material. If material is not included in the chapter's Creative Commons license and your intended use is not permitted by statutory regulation or exceeds the permitted use, you will need to obtain permission directly from the copyright holder.



73.1 Introduction

It was Kilner who said, “Ask not for a spatula and torch to check your cleft palate repair, but listen to your patient speak.” By this obvious but profound statement, he drew the cleft surgeons’ attention to the fact that gone are the days of breakdowns and fistulae and that if your child does not speak well, your operation is a failure, for such a child would be out of the mainstream of life forever. In spite of the advances in technique and execution, experienced cleft surgeons all over the world still struggle to obtain perfect speech in a large percentage of cases.

In view of the obvious difficulties of intraoral surgery, it is not surprising that cleft lips were repaired way before anyone tried to repair a cleft palate. Credit for the first successful repair of a cleft palate goes to Le Monnier, a French dentist from Roven. Le Monnier in 1766 cauterized to freshen the cleft edges and sutured them successfully [1].

Cleft surgery then passed through a stormy period of uncertainty in the hands of giants like Ferdinand von Graefe [2], Roux, Dupuytren [3], Dieffenbach [4], and Warren [5]. Mucosal flaps were used, and even lateral osteotomies were tried to move the hard palate medially. In 1859, almost a hundred years after the first hard palate was repaired, von Langenbeck [6] emphasized the need to raise mucoperiosteal bipedicled flaps to repair a palate. Langenbeck procedure was a fundamental breakthrough, and with this major advance, breakdowns of the palate were reduced. In its wake

refinements followed. In 1931, Victor Veau [7] parted from the bipedicled flap to single pedicled flaps based on the greater palatine vessels. Veau stressed the importance of repairing the nasal lining of the palate and the need to lengthen it.

In 1937, Kilner [8] working in Oxford and Wardill [9] working in Newcastle on Tyne independently used a four flap procedure for the complete cleft palate.

The weakness of this procedure was a high fistula rate at the junction of the four flaps. In the 1940s, Dorrance [10], Cronin [11], and others used various flaps to lengthen the palate. In 1966 Millard [12] introduced his island flaps based on the greater palatine arteries to lengthen the nasal lining. Ravin Thatte [13] went a step further and took two island flaps one for lining and one for cover and used a tongue flap on the denuded hard palate. All these procedures had their day but were short lived in popularity. However, special mention must be made of the buccal myomucosal flap originally called the cheek flap by Padgett [14]. This flap was revived 30 years later by Murari Mukherjee [15] of Calcutta. He changed the direction of the flap. Recently Ian Jackson has introduced muscle into this mucosal flap to make it more robust, and he calls it a myomucosal flap. He uses it in all his palates to lengthen the nasal lining by 1.5 cm and believes that as a result he achieves better speech. Robert Mann [16] does a Furlow’s and covers the residual raw areas with two buccal flaps. His rationale is that there is deficiency of tissue in the palate and therefore, on first plastic surgical principles, bring in tissue from outside. This may become the philosophy of the future.

Electronic Supplementary Material The online version of this chapter (https://doi.org/10.1007/978-981-15-1346-6_73) contains supplementary material, which is available to authorized users.

P. V. Narayanan (✉)
Consultant Plastic Surgeon, Jubilee Mission Medical College and Research Institute, Thrissur, Kerala, India

H. S. Adenwalla
Department of Plastic Surgery, Burns and the Charles Pinto Centre for Cleft Lip, Palate and Craniofacial Anomalies, Jubilee Mission Medical College and Research Institute, Thrissur, Kerala, India

73.2 Embryology and Anatomy (Figs. 72.1 and 77.1)

73.2.1 Embryology

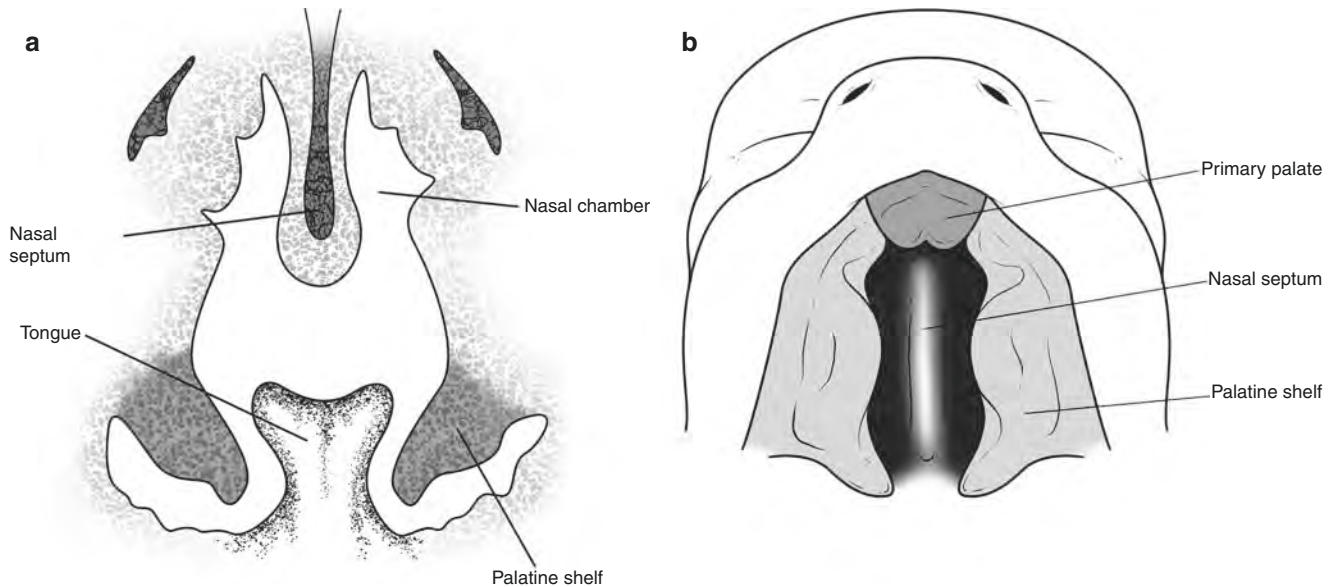
The primary palate is derived from the intermaxillary segment derived from the frontonasal and medial nasal

prominences. The main part of the definitive palate is formed by two shelf-like outgrowths from the maxillary prominences. These outgrowths, the *palatine shelves*, appear in the sixth week of development and are directed obliquely downward on each side of the tongue (Fig. 73.1a and b).

In the seventh week, however, the palatine shelves ascend to attain a horizontal position above the tongue and fuse, forming the *secondary palate* (Fig. 73.2a and b). Anteriorly, the shelves fuse with the triangular primary palate, and the *incisive foramen* is the midline landmark between the pri-

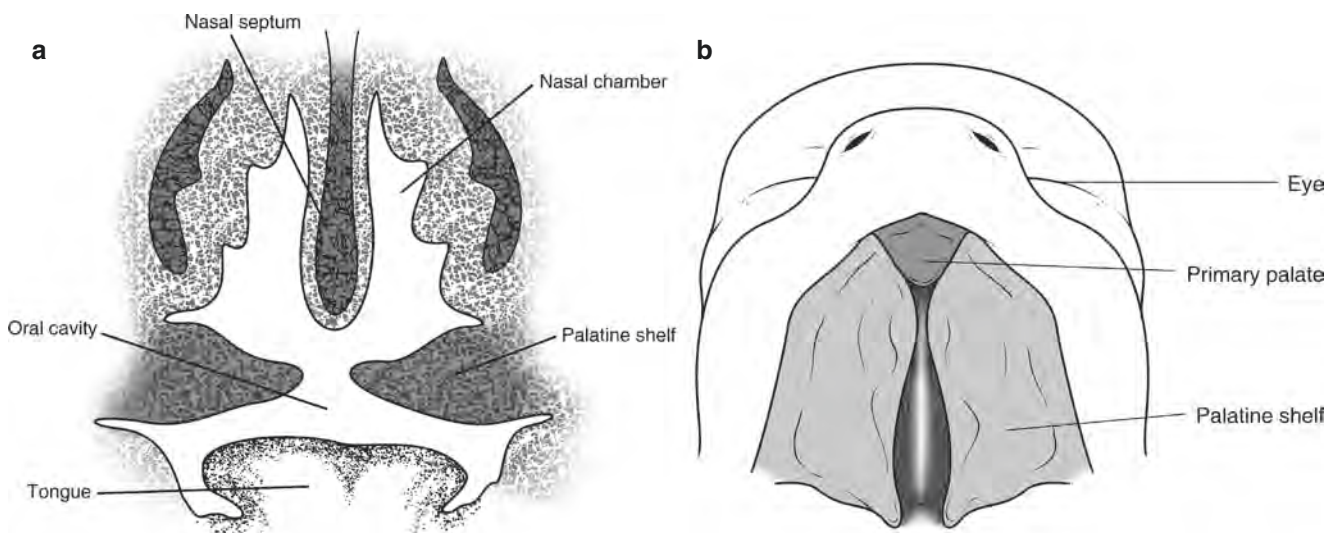
mary and secondary palates. At the same time as the palatine shelves fuse, the nasal septum grows down and joins with the cephalic aspect of the newly formed palate (Fig. 73.3a and b).

The secondary palate lies posterior to the incisive foramen and consists of the bony hard palate anteriorly and the soft palate posteriorly, terminating at the uvula. The hard palate consists of the palatine bony shelves on either side, attached to the vomer in the midline. The soft palate consists of a sandwich of muscles enveloped by oral and nasal mucosa.



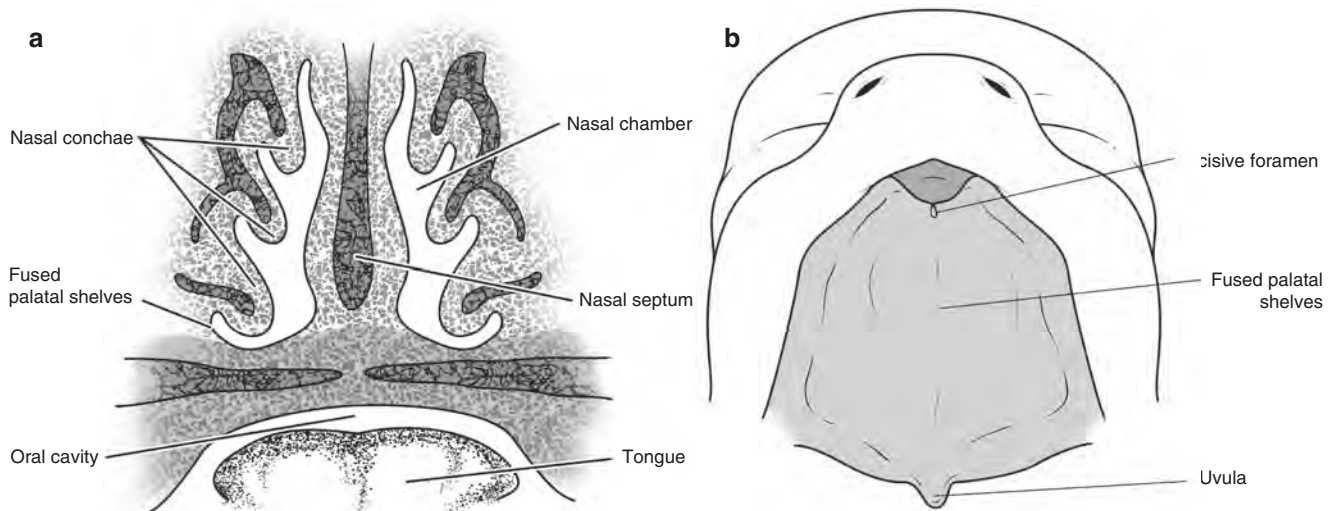
©Association of Oral and Maxillofacial Surgeons of India

Fig. 73.1 (a, b) Embryology of palate—primary palate



©Association of Oral and Maxillofacial Surgeons of India

Fig. 73.2 (a, b) Embryology of palate—secondary palate



©Association of Oral and Maxillofacial Surgeons of India

Fig. 73.3 (a, b) Embryology of palate—completion of palate

73.2.2 Muscles

The muscles of the soft palate include intrinsic muscle, i.e., musculus uvulae, and the insertions of several extrinsic muscles. Apart from this, large amount of glandular material is present in the anterior inferior portion of the velum and an anterior aponeurosis. Extrinsic muscles of the velum include the tensor veli palatine, levator veli palatini, palatopharyngeus, palatoglossus, and fibers of the superior constrictor. Pharyngeal muscles usually described as having functional role in velopharyngeal movement include the superior constrictor and the salpingopharyngeus (Fig. 73.4).

Following is a tabular summary for the muscles of palate and their abnormal anatomy in a cleft palate (Table 73.1).

From functional standpoint, it is apparent that the levator veli palatini muscle is the principal and quite possibly the only muscle to function for elevation of the velum in speech. The differences between the normal and the cleft arrangement of the muscles of velopharyngeal closure occur because the muscles extending toward the central line of the soft palate cannot attach themselves in the midline of the velum so they insert at some substitute points. These points prevent the muscles from becoming fully functional, and therefore their development is retarded. With the preservation of normal origins, the atypical insertions and hypoplasia of the muscles are the main pathological features in the cleft palate. The abnormal insertions of levators in clefts illustrate that the function of these muscles in cleft palate is almost opposite to that in normal one. While the muscles of both sides normally join in the raphe to form a sling lifting the palate upward, in cleft palate each muscle pulls its own half of the soft palate in an entirely different direction, i.e., superolaterally, causing further widening of the cleft.

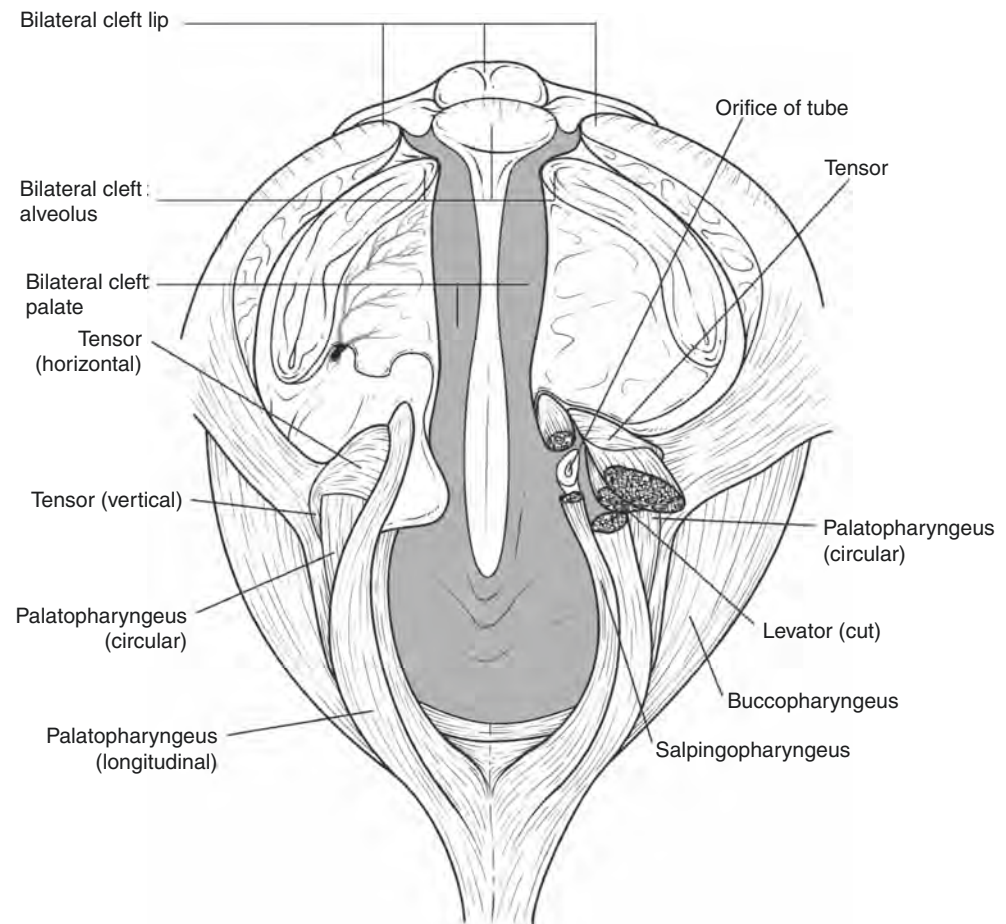
73.2.3 Vascular Supply (Fig. 73.5a and b)

The internal maxillary artery gives off the descending palatine artery, which in turn gives off several branches to the tonsils and soft palate. It then passes through the posterior palatine foramen, just above the periosteum, and proceeds forward close to the alveolar margin on each side as the greater major palatine artery to the incisive fossa. At that point it sends terminal branch through the incisive foramen to anastomose with the terminal branch of the sphenopalatine artery. The vascular supply of importance is discussed under two headings, anterior and posterior palate.

73.2.3.1 Vascular Supply of the Anterior Palate/Premaxilla

The blood supply to the anterior alveolar process of the maxilla comes from the arterial complex composed of the major palatine, anterior and superior alveolar, and branches of the sphenopalatine artery. The posterior septal artery arises from the sphenopalatine artery in the roof of the nasal cavity and courses down the groove of the vomer to the incisive foramen. In the complete bilateral cleft lip and palate, the union of the superior labial arteries is lacking; thus they do not contribute to the blood supply of the philtrum. Also the anastomosis of the posterior septal artery with the major palatine artery is absent. Therefore premaxilla and philtrum must derive their blood supply from the posterior septal artery and to some degree from the lateral and terminal branches of the anterior ethmoid vessels which pass through the columella. There is usually one well-developed vessel on either side of the premaxilla in the region where the incisive foramen should have been. Each of these vessels moves anteriorly and inferiorly into

Fig. 73.4 Muscles of the palate demonstrated in a complete cleft of the lip, palate and alveolus (bilateral)



©Association of Oral and Maxillofacial Surgeons of India

Table 73.1 Muscles of soft palate

Muscle	Origin	Insertion	Function	Pathological anatomy in cleft palate
Tensor veli palatini	Originates from the scaphoid fossa at the base of the medial pterygoid plate, spina angularis of the sphenoid and from the cartilaginous part of the auditory tube	The muscle descends anteroinferiorly and winds around the pterygoid hamulus, to which some fibers are attached, and passes into a tendon that fans out to form the palatine aponeurosis few fibers are attached to the maxillary tuberosity	The main role of the tensor is to dilate the Eustachian tube and its role in speech is insignificant	In a cleft palate child, the palatine aponeurosis is deficient, especially medially
Levator veli palatini	Arises from the petrous part of the temporal bone and from the cartilaginous part of the Eustachian tubes	The muscle descends on either side, enters the intermediate 40% of the soft palate, and forms a muscular sling with its counterpart on the other side	When the paired muscle contracts, it elevates the soft palate superiorly and posteriorly to enable closure of the velopharyngeal sphincter. The latter is formed by the soft palate anteriorly, the posterior pillars of the fauces on either side, and the posterior pharyngeal wall posteriorly	In a cleft child, as there is obviously no continuity across the midline due to the cleft, there are abnormal attachments of the levator muscle to the palatopharyngeus muscle posteriorly, to the edge of the cleft medially, to the tensor veli palatini, and to the posterior edge of the hard palate anteriorly

Table 73.1 (continued)

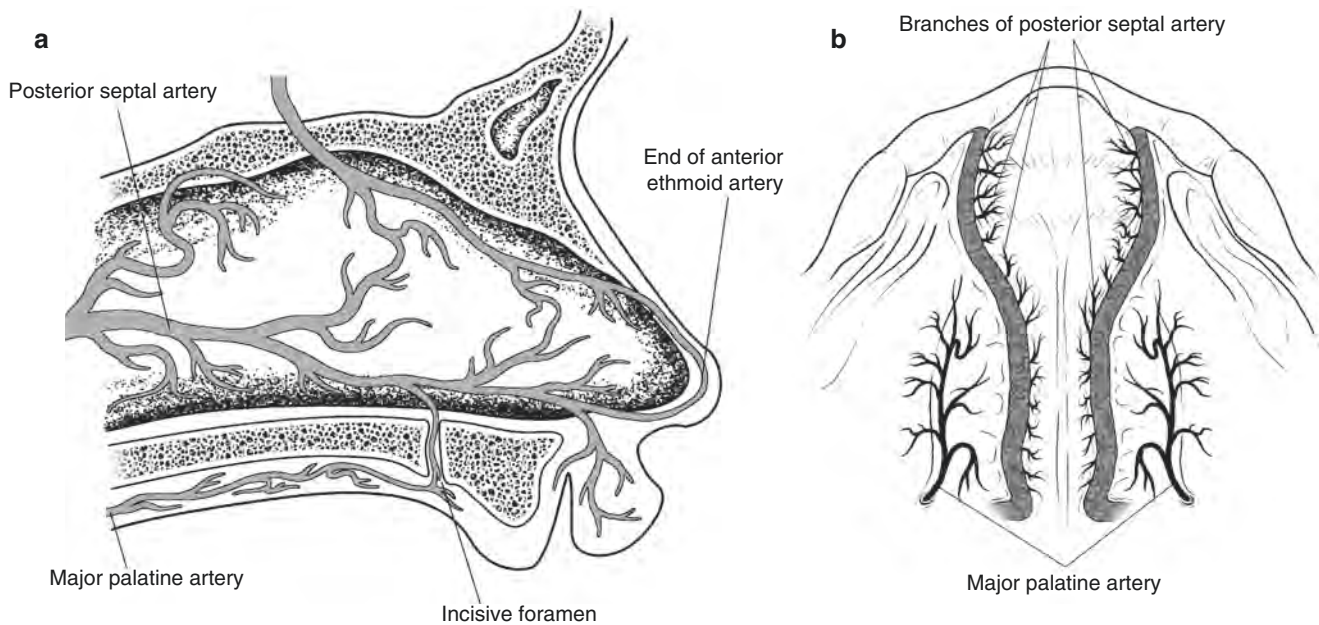
Muscle	Origin	Insertion	Function	Pathological anatomy in cleft palate
Palatopharyngeus	Has a palatine portion, a pterygopalatine portion and the salpingopharyngeal part. It arises from the lateral and posterior part of pharynx and attaches into the velum. Its superior fibers arise from complex intermingling with the superior constrictor muscle. Lower fibers of the palatopharyngeus arise from the inferior part of the lateral wall of the pharynx, medial to the middle and inferior constrictor muscles. Some fibers may arise from the thyroid cartilage. These lower fibers pass through the palatopharyngeal arch to insert into the velum	It is found in the posterior pillar of the fauces. The fibers pass horizontally into the posterior three fourths of the soft palate inferior to the fibers of the levator palatini muscle	The muscle helps to narrow the velopharyngeal opening by bringing the palatopharyngeal arches together	The muscle is relatively well developed in the cleft palate child and ends partly along the cleft edge and partly along the posterior edge of the hard palate. Some fibers pass along the edge of the cleft along with the levator to form the muscle of veau
Palatoglossus	Arises from the tongue	Inserts into the soft palate	The paired muscle forms the anterior part of the sphincter and narrows the isthmus. It is antagonistic to the levator in its action, drawing the palate inferiorly	This muscle doesn't play a major role in cleft palate anatomy
Musculus uvulae	Arises from the posterior nasal spine and the palatine aponeurosis	Passes posteriorly along either side of the midline and inserts into the junction of the proximal and middle thirds of the uvula. The rest of the uvula contains only mucous glands	Contraction of the muscle aids the levator in forming the levator eminence, which is a hump like projection formed proximal to the uvula and aids in closure of the velopharynx during speech	The presence and extent of the muscle in a cleft palate child is disputed. It is also supposed to be absent in occult submucous cleft patients
Superior pharyngeal constrictor	Quadrangular muscle in the upper third of the posterior pharyngeal wall. Origin at the hamulus and the adjacent pterygomandibular raphe	Merges with the palatopharyngeus.. Fibers pass around and through the lateral pharyngeal wall, and merge with the corresponding fibers of the opposite side forming a tendinous strip- the pharyngeal raphe, which runs in the midline from the pharyngeal tubercle of the occipital bone through the entire length of the pharynx	The upper most fibers are responsible for the formation of the passavant's ridge, which is a projection on the posterior pharyngeal wall during speech. However, the edge is usually below the level of closure of the velopharyngeal sphincter, and in only about one third of the patients, it is believed to contribute to closure of the sphincter (the mistake of passavant)	

the philtrum and forms an arcuate anastomosis across the midline in the inferior part of the philtrum.

73.2.3.2 Vascular Supply of Posterior Palate

The greater palatine artery supplies the oral surface of the hard palate and gives off a few fine branches which perforate the horizontal plate of the maxilla to supply the nasal mucosa. It also sends twigs to the gingiva and the palatoglossal arch. The lesser palatine artery supplies the anterior half of the oral

surface of the soft palate. A branch of the facial artery, the ascending palatine artery, is the largest vessel entering the soft palate. It ascends on the lateral side of the superior constrictor muscle to turn downward and forward into the soft palate, between the tensor and levator palati giving small branches to these muscles. Twigs from the tonsillar and ascending pharyngeal arteries also reach the soft palate. In the secondary palate, the existence or absence of cleft makes little difference to the vascular pattern. The palatal mucoperios-



©Association of Oral and Maxillofacial Surgeons of India

Fig. 73.5 (a, b) Vascular supply of the palate

teum is detached from its bony base in the palatal pedicle flap, and as a result the recurrent bony branches are severed. These branches result in bleeding from their cut stumps at the bony surface. This may be judged insignificant at the time of surgery; however, after the flap is repositioned, should bleeding continue, blood may pool beneath the repositioned flap [17].

73.3 Classification and Presentations of Cleft Palate

Many of the historical and contemporary classifications have been discussed in brief in the Chap. 72 on cleft lip. However, Veau's classification for palate is the most practical and therefore is mentioned again here.

Submucous cleft palate exhibits at least one of Calnan's three criteria [17]:

- A palpable notch on the posterior border of the hard palate.
- Zona pellucida or a bluish tinge in the midline of the soft palate due to the paucity of muscle bulk at this level.
- Bifid uvula- this may extend from a mere groove on the uvula to complete bifidity.

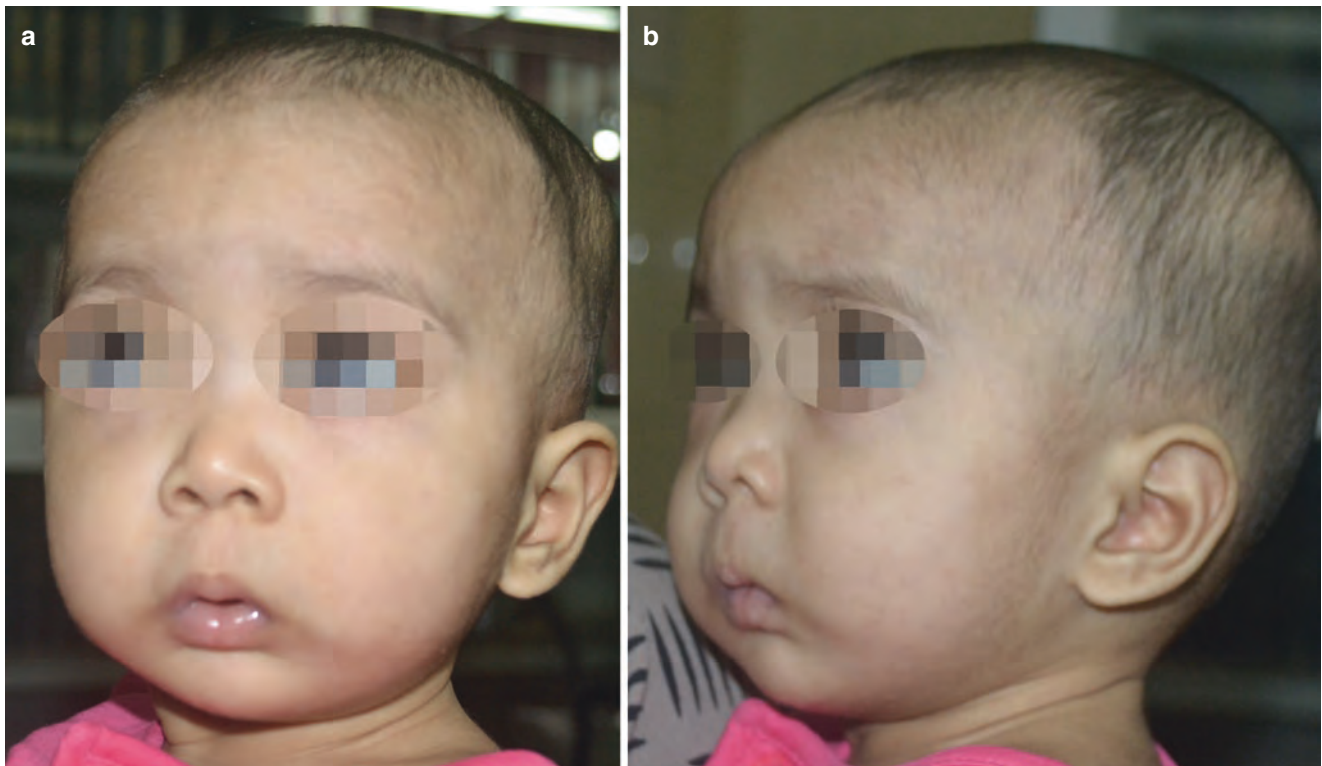
Table 73.2 Veau's classification of cleft palate

I.	Cleft of the soft palate alone
II.	Complete cleft of the palate up to the incisive foramen
III.	Unilateral complete cleft of the palate and pre-palate. In these the vomer is attached to the maxilla on the non-cleft side
IV.	Complete bilateral cleft of the palate and pre-palate. These patients have a protruding premaxilla, and the vomer is in the midline

Victor Veau (1931) has classified cleft palates into four groups [7] (Table 73.2)

Clefts of the palate that are less extensive in magnitude include the submucous cleft palate and the occult submucous in cleft palate.

Sommerlad has devised a grading system for the submucous cleft palate with three points for each of the above criteria [18]. A lesser score in this system naturally denotes more trivial clefting. However, paradoxically a lower score reflects a poorer prognosis for speech according to this study. An occult submucous cleft does not exhibit any of Calnan's criteria but shows a trough-like depression on the superior surface of the soft palate as seen in nasoendoscopy. Croft believed that in these patients, the musculus uvulae is absent. It is suspected when a child with a normal palate speaks with nasal emission.



©Association of Oral and Maxillofacial Surgeons of India

Fig. 73.6 (a, b) Picture of child with Pierre Robin Sequence

73.4 Clinical Evaluation of the Cleft Palate Patient

73.4.1 General Examination

A routine per-oral examination of the neonate reveals the cleft of the palate with or without cleft lip. The extent of clefting is noted. General examination is mandatory as it is important to identify syndromic patients. These are more common in isolated cleft palate patients [19]. Pierre Robin sequence is a fairly common presentation with micrognathia or retrognathia (Fig. 73.6 and b). As the bony abnormalities are believed to be the cause of the non-descent of the tongue in utero leading to the clefting of the palate, this is now believed to be a sequence and not a syndrome. Syndromic patients include Treacher Collins syndrome, Goldenhar syndrome, etc.

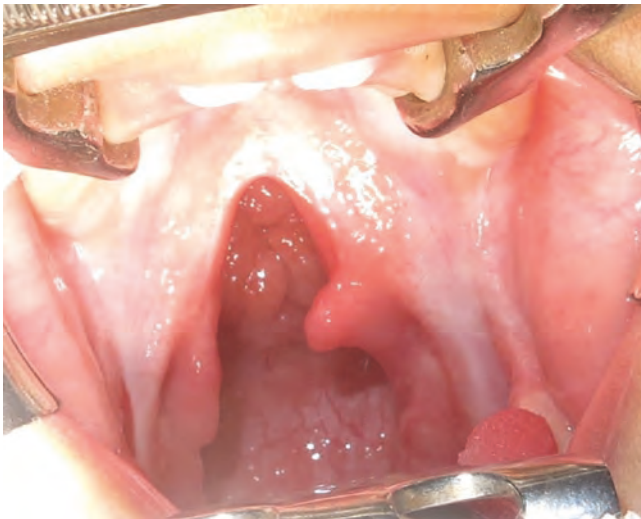
73.4.2 Clinical Assessment of the Cleft

The first clinical visit usually happens soon after birth. The extent cleft is assessed, i.e., the length of the palate and the

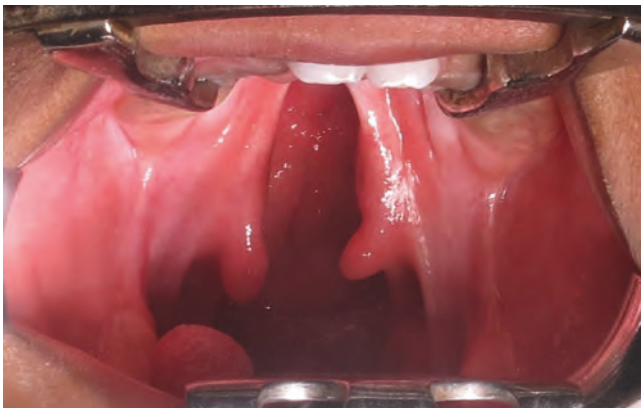width of the cleft. Randall has classified cleft palate on the basis of length into four types [20]. Clefts may be partial or complete. A partial cleft of the secondary palate is confined to the soft palate (Fig. 73.7).

A complete cleft includes both the soft and the hard palate up to the incisive foramen (Fig. 73.8). In patients with bilateral cleft lips, the associated cleft palate usually presents with a central vomer and clefting on either side of the vomer (Fig. 73.9).

A pediatric assessment is made for other anomalies, weight of the baby is noted, and feeding instructions are given during this visit. A squeezable feeding bottle is usually advisable to overcome child's difficulties in sucking. The child is fed with the head held slightly higher. Parents are counselled about the need for immunization. They are also explained about the need for surgery and are shown results of the procedure on similar patients. It is very important to allay their anxiety as they are very often crestfallen on seeing the deformity in their baby. Subsequent visits, possibly at monthly intervals, aim to assess the growth and development of the baby. Associated cardiac or other anomalies if present need investigation.



©Association of Oral and Maxillofacial Surgeons of India

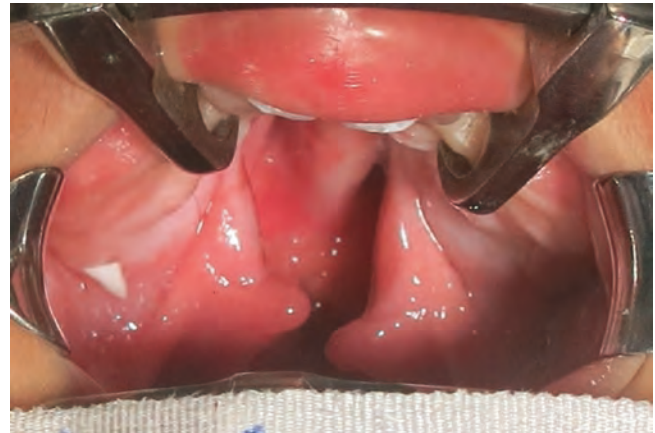
Fig. 73.7 A child with partial cleft palate

©Association of Oral and Maxillofacial Surgeons of India

Fig. 73.8 A child with complete cleft palate

73.4.3 Imaging and Other Investigations

Routine imaging is not generally practiced in the evaluation of cleft palate patients. Syndromic patients require other investigations as part of the various manifestations of their syndromes. For instance, children with velocardiofacial syndrome may require echocardiogram in view of the associated cardiac anomalies. Children with delayed development, microcephaly, etc. will require neurological assessment and will usually need an MRI of the brain. Rarely a child may have a meningoencephalocele presenting behind the palate. MRI has been used to evaluate submucous clefts with a view to help in the planning of the management. If it can be shown that there is not adequate muscle continuity across the midline, an early decision can be taken to operate on the child at the usual time of cleft palate repair. On the other hand, if there is good muscle across the midline, these repairs can be



©Association of Oral and Maxillofacial Surgeons of India

Fig. 73.9 A child with bilateral cleft palate

justifiably delayed until the development of speech. MRI has also been used to assess the Eustachian tube function. Hearing assessment should be mandatory in all cleft palate patients.

73.5 Preoperative Factors (Box 73.1)

Box 73.1 Preoperative Considerations

- Timing of repair.
- One stage or two stage repair.
- Anatomy of the cleft.
- Airway.
- Feeding.
- Pediatric consultation.
- Cardiac consultation.
- Neuro consultation.
- Ent consultation.
- Anesthesia.

1. Timing and Age of the Patient.

The dilemma regarding the timing of repair is between earlier repair with better prognosis for speech, but worse prognosis for maxillary growth, and late repair which is exactly the opposite. Most surgeons today agree that the cleft palate is to be operated close to 1 year. Some prefer 9 months, where others wait for up to a year and 4 months. At our center we have been operating on these children at about 11 months of age. The Oslo school of surgeons [21, 22] devised a protocol of operating on the lip with the soft palate in the first stage and operating on the hard palate much later. In some centers, the palate has been repaired

first at initial presentation, and the cleft lip is repaired, subsequently, in view of the fact the children may not be brought back for treatment of the palate once the lip is repaired [23].

2. Airway.

Airway management is important at the time of birth in cleft palate patients, as most of isolated cleft palates may be associated with a smaller airway at birth. This may be due to associated sequence or syndromes, such as Pierre Robin sequence or Treacher Collins syndrome. Such patients might require emergency tracheostomy or tongue lip adhesion to secure airway. Definitive management for mandibular advancement and cleft palate repair can be undertaken at a later stage.

3. Feeding.

As mentioned already, the parents are counselled about feeding practices during the first visit itself. Expressed breast milk is to be preferred. Special feeding bottles like the Haberman feeding bottle are used when the common methods like the use of simple squeezable bottles are not effective. As a cleft child swallows air along with the milk, frequent burping is essential to avoid regurgitation of feeds.

4. Anesthesia.

The operation is performed under general anesthesia with an endotracheal tube. RAE tubes are preferred for cleft palate patients. Previously, Oxford red rubber tubes were used. These were well adapted to the needs of the cleft children but often caused laryngeal edema presumably due to the latex in the tubes. At our center we have given up the use of these otherwise very useful tubes.

Preoperatively, the child must be assessed by a good pediatrician and also by a senior anesthetist. Respiratory infections are common in these children and must be treated if significant. X-ray of the chest is usually done to rule out heart or lung anomalies. Cardiology clearance is required when there are suspected cardiac anomalies. We have come across one case with a congenital absence of the lung.

The anesthetist should be experienced in pediatric anesthesia. In patients with Pierre Robin sequence or other anomalies like shoulder or spinal anomalies, difficult intubation is to be anticipated, and appropriate equipment such as intubating endoscopes, etc. should be at hand, and the anesthetist must be familiar with its use.

73.6 Principles and Methods of Repair

There are various surgical techniques described in literature. The techniques have been mentioned (Box 73.2), with the author's surgical technique described in detail (Figs. 73.23, 73.24, 73.25, 73.26, 73.27, 73.28, 73.29, 73.30, and 73.31).

The major objectives of a cleft palate operation are:

- To produce anatomical closure of the defect.
- To create an apparatus for development and production of normal speech.
- To minimize the maxillary growth disturbances.

The basic principles of cleft palate repair are:

- Closure of the defect.
- Repositioning of the abnormal position of the muscles of the soft palate.
- Reconstruction of the muscle sling.
- Favorable retro positioning of the soft palate and uvula so as to achieve velopharyngeal closure during speech.
- Last and most important is tension-free suturing [24, 25].

Box 73.2 Methods of Cleft Palate Repair

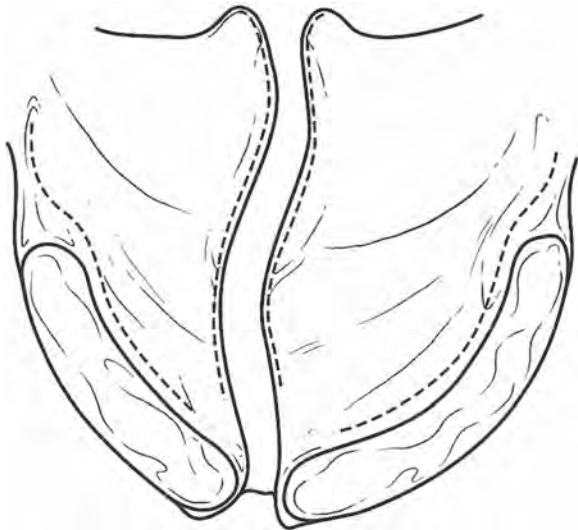
Methods of repair

- *Von Langenbeck's bipedicle flap technique* (Fig. 73.10).
- *Veau-Wardill-Kilner Pushback technique* (Fig. 73.11).
- *Bardach's-Pinto-Wardill two-flap technique*.
- *Furlow double opposing Z-Plasty*.
- *Two-stage palatal repair*.
- *Whole in one repair*.
- *Palatoplasty*.
- *Alveolar extension palatoplasty (AEP)*.
- *Primary pharyngeal flap*.
- *Intravelar veloplasty*.
- *Vomer flap*.
- *Buccal myomucosal flap*.

73.7 Surgical Technique (Figs. 73.12, 73.13, 73.14, 73.15, 73.16, 73.17, 73.18, 73.19, 73.20, 73.21, 73.22, 73.23, 73.24, 73.25, 73.26, 73.27, and 73.28)

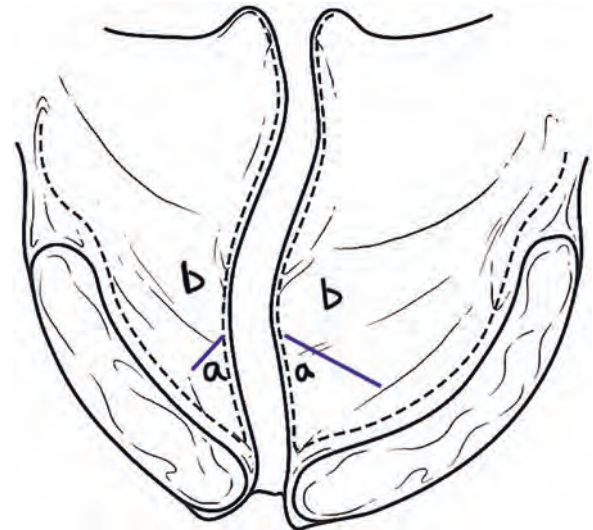
Once intubated, the child is placed with the neck extended for adequate visualization of the palate. A pillow under the shoulder helps in this positioning. A suitable mouth gag is used. We use the Dott's gag (Fig. 73.12) with the Kilner suture carrier. A popular gag used widely is the Dingman's gag.

Infiltration: A solution of lignocaine with 1 in 200,000 adrenaline is infiltrated under the mucoperiosteum of the hard



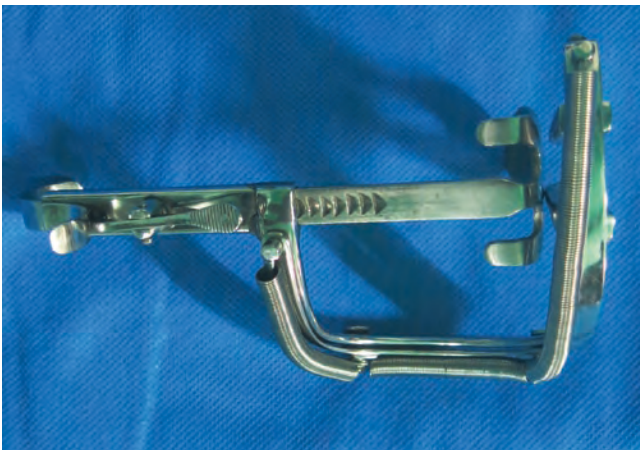
©Association of Oral and Maxillofacial Surgeons of India

Fig. 73.10 Langenbeck procedure. Incisions are placed to raise flaps which remain attached in the anterior palatal region



©Association of Oral and Maxillofacial Surgeons of India

Fig. 73.11 Wardill's four flap palate repair. (a) are the anterior flaps while (b) form the posterior flaps that are closed in a "V to Y" fashion to gain length for the "push-back"



©Association of Oral and Maxillofacial Surgeons of India

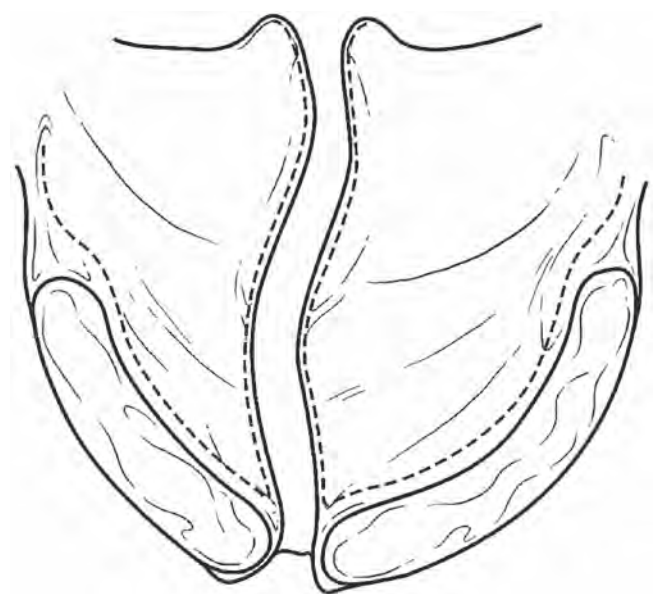
Fig. 73.12 Dott's gag

palate and above the nasal mucosa in the soft palate. A dental syringe with a short-beveled needle is very useful for this purpose.

Surgical procedure: At our center, we use the two long-flap technique popularized in India by Charles Pinto and the world over by Bardach (Fig. 73.13). The technique was originally used by Veau. The cleft edges are pared (Fig. 73.14).

The lateral incision is made from the maxillary tuberosity area toward the retromolar area posteriorly. The pterygoid hamulus is dissected, fractured, and detached (Fig. 73.15a and b).

This aids in mobilization of the nasal layer subsequently. However, there are many surgeons nowadays



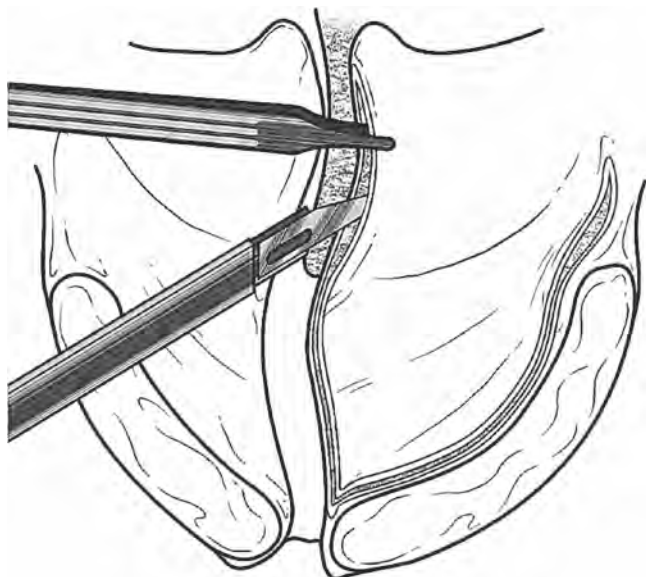
©Association of Oral and Maxillofacial Surgeons of India

Fig. 73.13 Pinto Wardill (Bardach) two long-flap procedure. Classical method of raising two flaps detached at the anterior pedicled on the greater palatine artery

who do not believe in fracturing the hamulus. It has, however, been shown in different studies that fracture of the hamulus does not cause any deleterious effects on hearing [26].

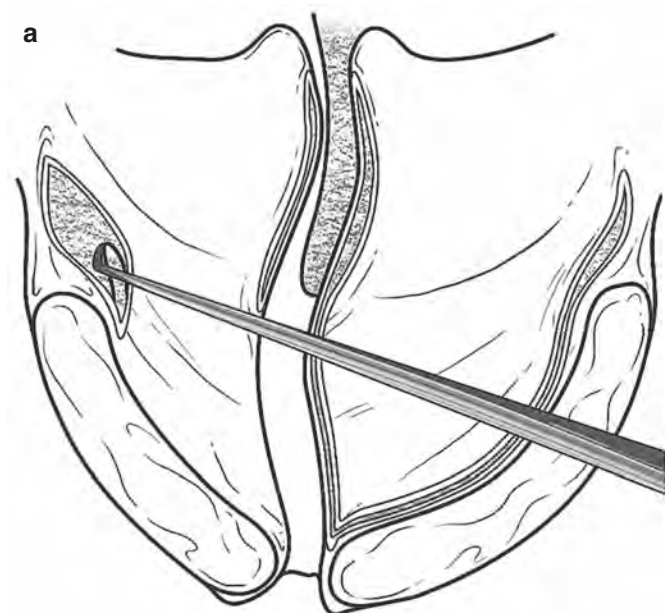
The lateral incision is then carried anteriorly and the oral mucoperiosteal flap is lifted off till the medial edge of the hard palate using Kilner's palate elevators (Fig. 73.16a and b).

An incision is then made on the medial border of the hard palate, and the flap is also divided anteriorly taking care to secure the end of the greater palatine vessels. The oral flap is then raised till the posterior border of the hard palate. Laterally, the greater palatine vessel is identified and skeletonized, after incising the cone of periosteum which binds the vessel behind it (Fig. 73.17a, b, c and d).



©Association of Oral and Maxillofacial Surgeons of India

Fig. 73.14 Pared cleft edges



©Association of Oral and Maxillofacial Surgeons of India

Fig.73.15 (a, b) Fracture of the pterygoid hamulus

After the hamulus is fractured, the medial pterygoid plate is denuded of any soft tissue attachments (Fig. 73.18).

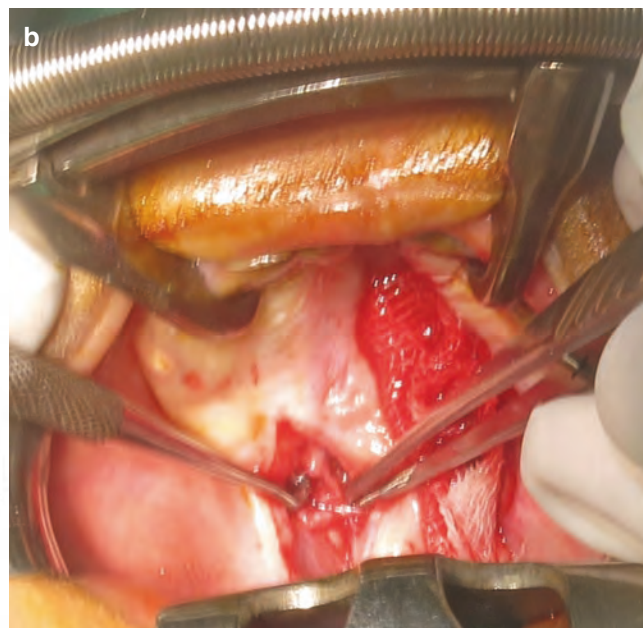
Similarly, the posterior border of the hard palate is also cleared of muscular attachments (Fig. 73.19a and b).

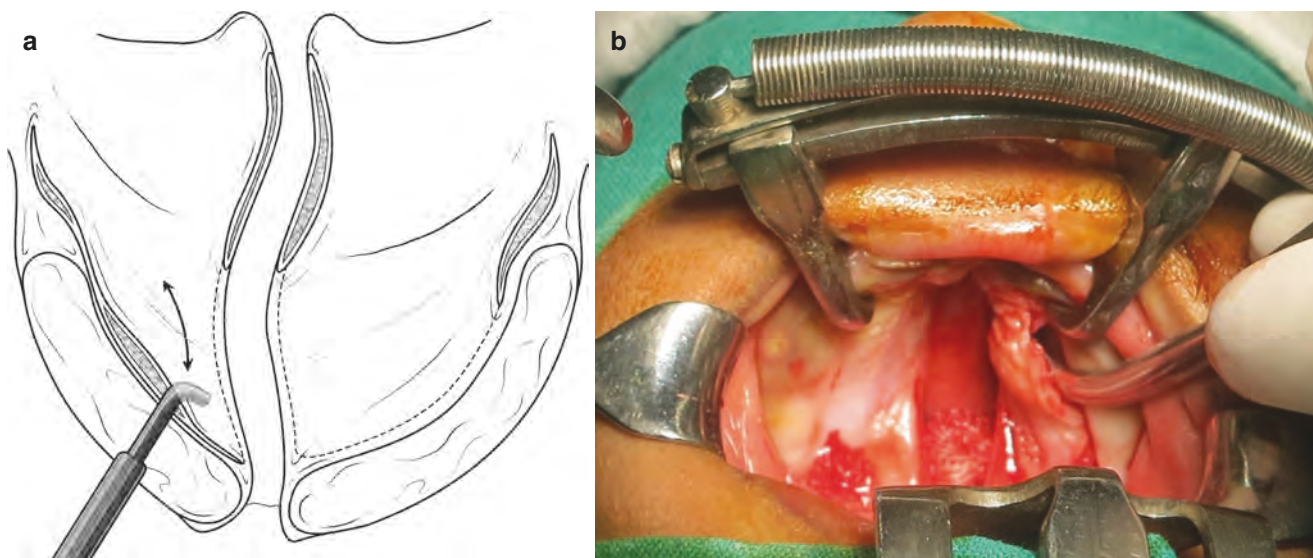
A Cumine Scaler is introduced over the bare medial pterygoid plate and then turned anteriorly to separate the nasal layer from the hard palate in one clean sweep. This dissection is then completed on a deeper plane with a Wallace's finisher (Fig. 73.20a and b).

This practice of separating the nasal layer from behind forward was originally introduced by Kilner [8] but has somehow not been followed widely. It is much easier than the alternative method of separating the nasal layer from the hard palate starting anteriorly. Very often this results in tearing of the nasal layer.

Similar dissection is performed on the other side also, raising a long oral mucoperiosteal flap. The vomer flap is raised (Fig. 73.21) and used when accessible and necessary.

Rarely, the vomer is receding and cannot be used. In a bilateral cleft lip patient, the vomer is in the midline, and a central incision on the vomer is made to raise two mucoperiosteal flaps, one on each side, to be sutured to the corresponding side in nasal layer of the hard palate.





©Association of Oral and Maxillofacial Surgeons of India

Fig. 73.16 (a, b) Elevation of the oral flap with Kilner's elevator

73.7.1 Dissection of the Soft Palate

The early techniques of cleft palate repair only detached all false attachments of muscles from the posterior border of the hard palate (Fig. 73.22).

Surgeons like Braithwaite [27] and Kriens [28] emphasized the importance of the dissection and retroposition of the levator veli palati muscle. This was popularized by Sommerlad [29] and Tambewekar in India.

Infiltration of lignocaine with 1:200,000 adrenaline is made between the nasal mucosa and the muscle (Fig. 73.23).

A transverse incision is made on the aponeurotic layer just beyond the hard palate (Fig. 73.24).

Then the muscle is dissected off the underlying mucosa leaving behind enough tissue on the nasal layer, to avoid its tearing during suturing. Also, a narrow layer of muscle is retained along the cleft edges to hold the sutures. The muscle is dissected till just short of the uvula. The muscle contains the levator veli palati mostly. However, it also contains other muscles like the palatopharyngeus ("muscle of Veau") (Fig. 73.25).

The extent of dissection of the muscle on the soft palate varies. The authors [30] only separate it from the nasal layer. Others like Sommerlad [29] also separate it off the oral layer. However, if there is any suspicion of injury to the greater palatine vessels during dissection, then the levator muscle should not be dissected free of the oral mucosa.

73.7.2 Suturing

Suturing commences on the nasal layer from anteriorly, proceeding backward. The sutures are not tied but held on the Kilner suture carrier.

73.7.2.1 Uvula

The last suture on the nasal layer is a mattress suture (Fig. 73.26) [30].

Next, an apical mattress suture is placed on the tip of the uvula, and this suture is left long and held on an artery forceps, thus turning the uvula over, providing access to the nasopharyngeal aspect of the uvula. Two or three simple sutures are placed between the mattress suture and the apical stitch (Fig. 73.27a).

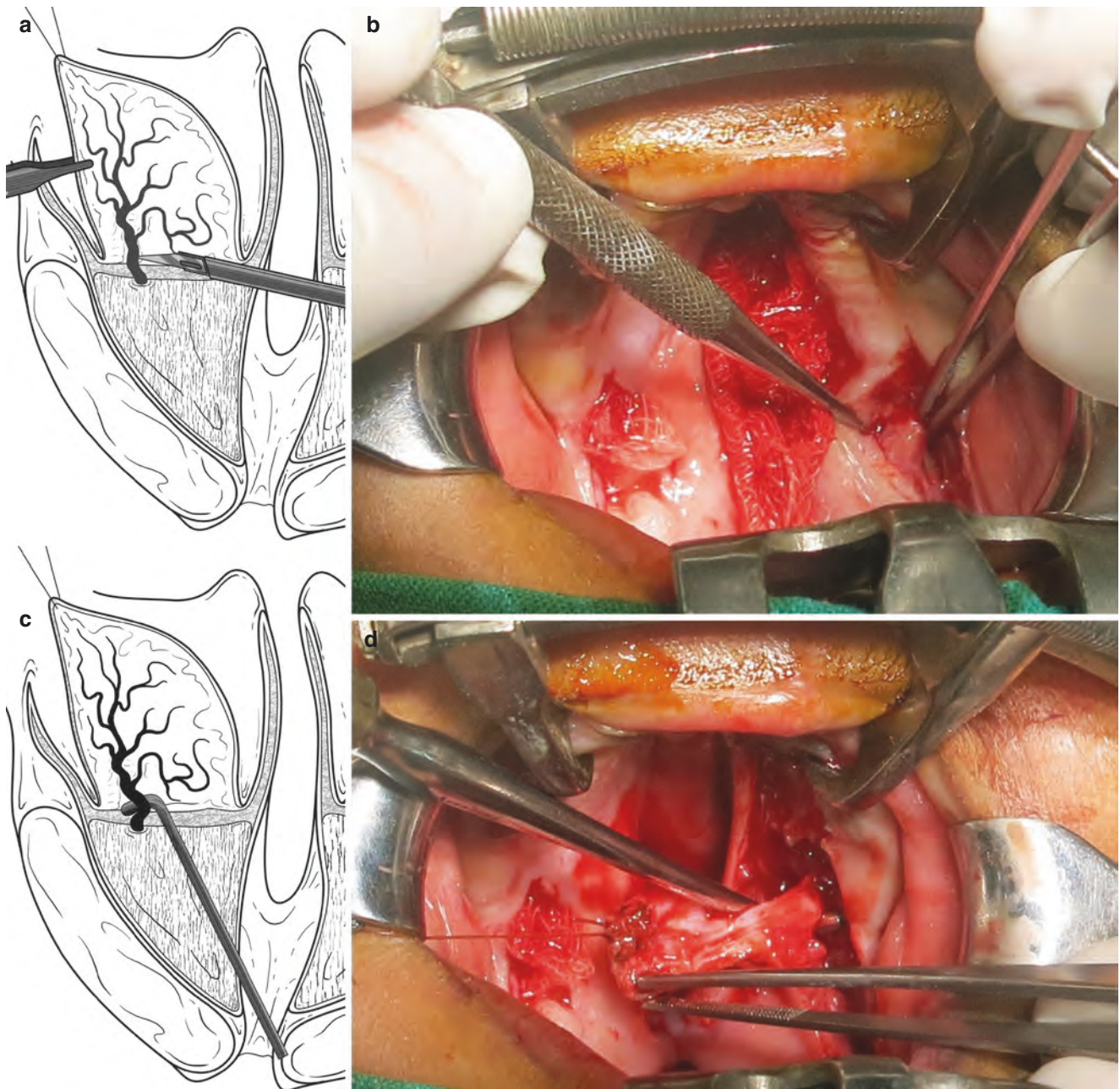
Then two or three mattress sutures are placed on the oral aspect of the uvula (Fig. 73.27b).

The nasal layer sutures are then tied from behind forward.

"A" suture: this is the suture placed at the junction of the hard and soft palate. It goes through the nasal mucosa and later crisscrosses into the oral mucosa, resembling the letter A, but is like the figure of "8" when tied.

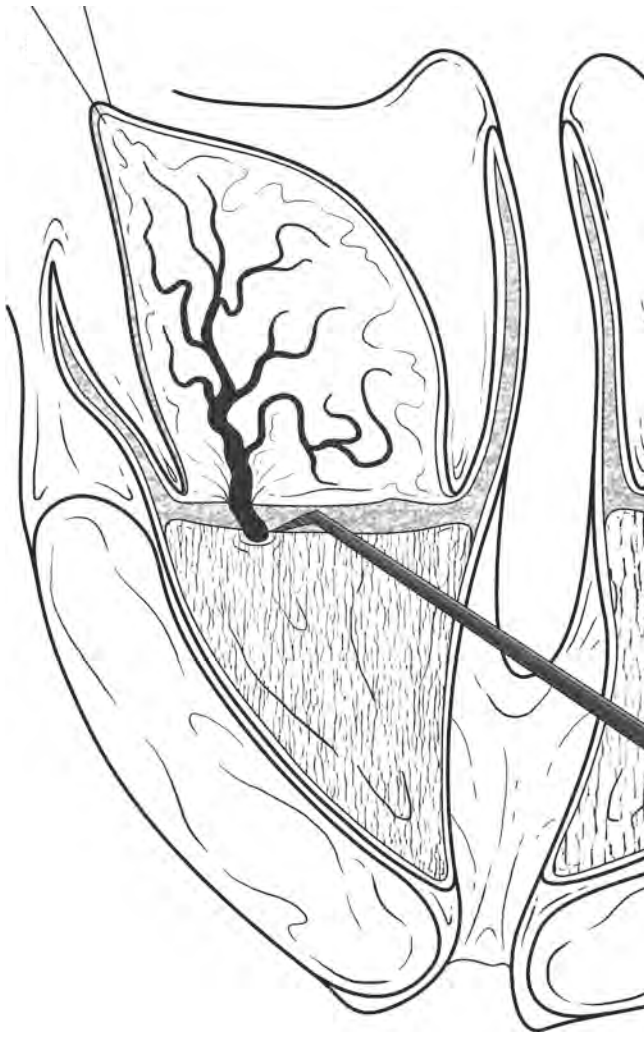
Anterior sutures are also tied but retained long.

Suturing of the oral layers then proceeds from behind forward, with every suture picking up a bite on the nasal layer to obliterate dead space. The dissected levator mus-



©Association of Oral and Maxillofacial Surgeons of India

Fig. 73.17 (a, b) Incising the Periosteal cone to free the greater palatine artery. (c, d) Hooking out the greater palatine vessels (the vessel is pulled out like a bird pulls a worm out of the ground). This reduces the tension on the flaps on suturing



©Association of Oral and Maxillofacial Surgeons of India

Fig. 73.18 Medial pterygoid plate dissection

cle is also included in these oral sutures. Some surgeons close the levator muscle as a separate layer. The anterior sutures are then brought through the oral layer also, helping in anchoring the oral layer. In the absence of the anchoring, the oral layer may sag postoperatively causing a “fallen palate.”

Laterally the raw areas are sutured with interrupted sutures without tension. This helps in hemostasis (Fig. 73.28).

Previously, this area used to be packed with different materials, but there was often bleeding from the areas on removal of the pack postoperatively.

Buccal pad of fat harvested through a stab incision on the buccal aspect bilaterally has also been used to fill large lateral raw areas.

73.8 Complications: (Box 73.3)

Box 73.3 Complications

Immediate complications.

- Haemorrhage.
- Respiratory obstruction.
- Hanging palate.
- Dehiscence of the repair.
- Oronasal fistula formation.

Late complications.

- Bifid uvula.
- Velopharyngeal incompetence.
- Abnormal speech.
- Maxillary hypoplasia.
- Dental malpositioning and malalignment.
- Otitis media.

73.8.1 Early Complications

Hemorrhage

This is often from the apices of the long flaps, from the cut ends of the greater palatine vessels. Arterial bleeding points need to be ligated or cauterized using diathermy. Small venous bleeding areas can be controlled by the use of pressure with fingers or by the use of crushed ice or topical hemostatic agents like tranexamic acid.

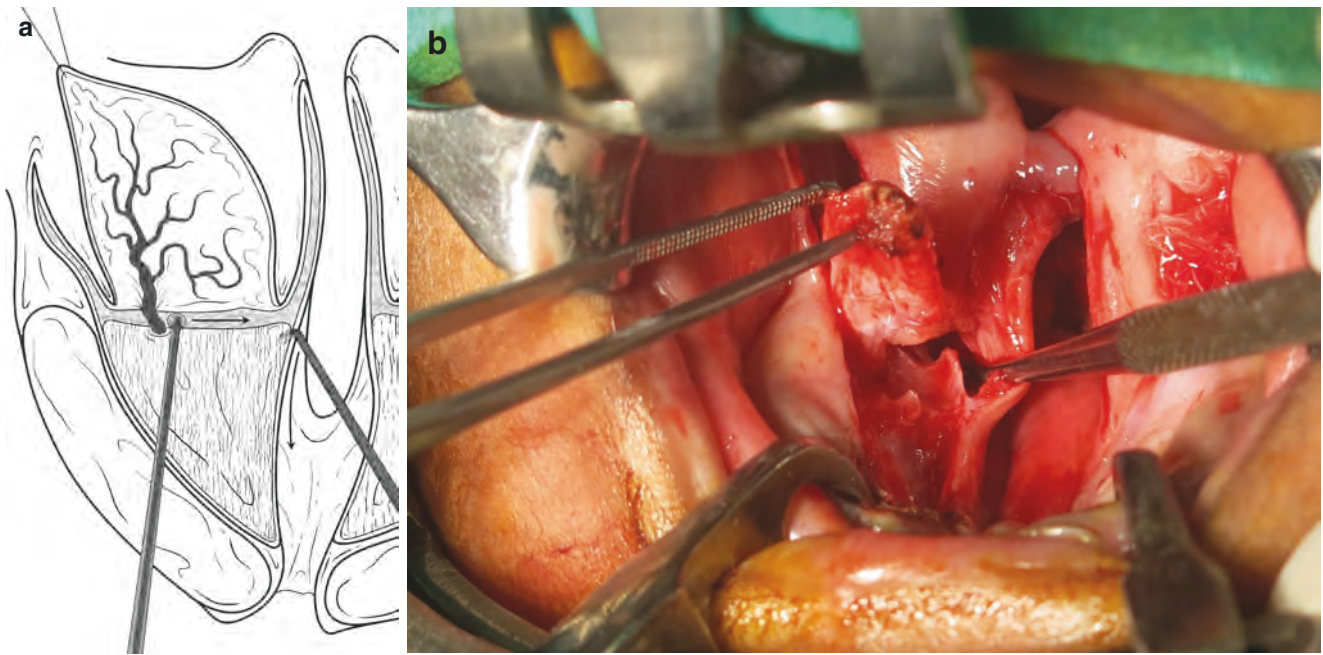
Respiratory Obstruction

This may be from tongue fall and can be avoided by use of a tongue stitch at the time of palate repair. The tongue stitch has to be placed well posteriorly and must include a good bulk of the tongue tissue to avoid the sutures from tearing through.

When a wide cleft palate is closed, the child may have difficulty in learning to breathe adequately through the nose. Laryngeal edema due to endotracheal tube-related trauma may present with a hoarse cry and, in severe cases, chest retraction. Early detection is important, and this can be reversed by intravenous steroids and nebulization.

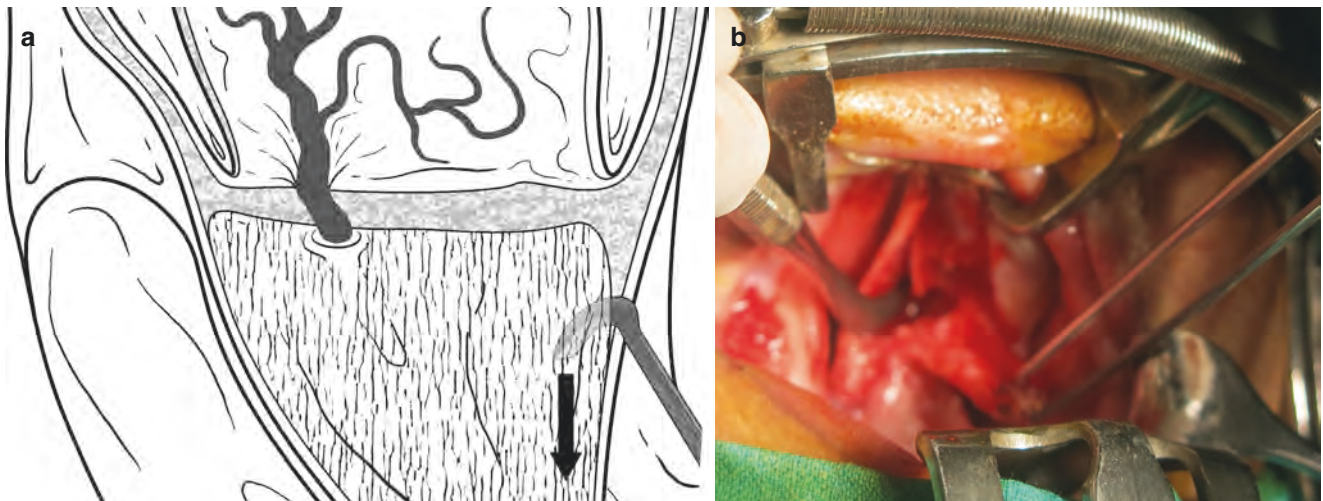
Breakdown of the Repair

It may result in fistulas or complete breakdown of the repair. The most common cause of these, especially at the junctional area, is suturing of the cleft edges under tension due to inadequate mobilization.



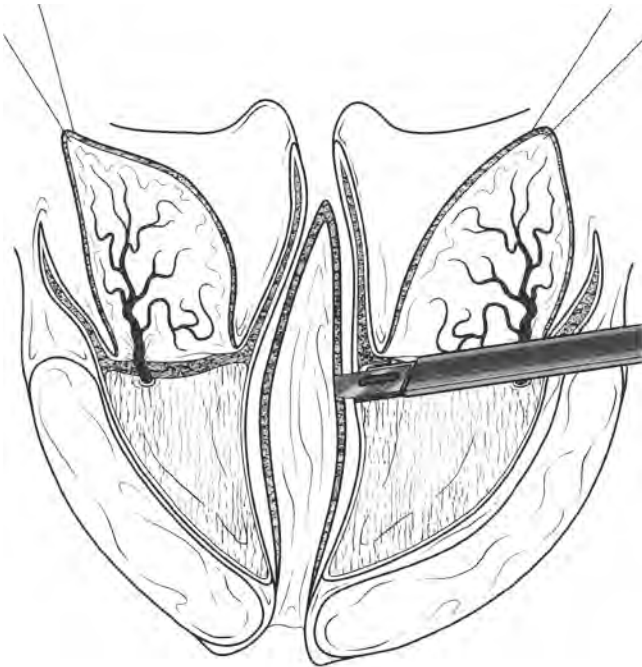
©Association of Oral and Maxillofacial Surgeons of India

Fig. 73.19 (a, b) Dissection of the posterior end of the hard palate



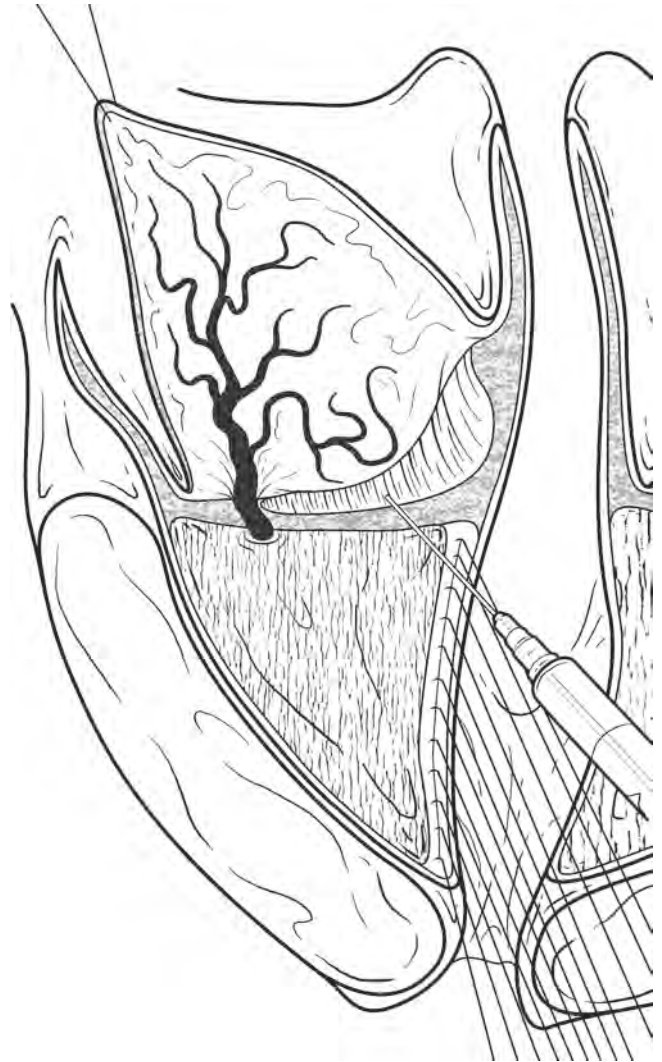
©Association of Oral and Maxillofacial Surgeons of India

Fig. 73.20 (a, b) Completion of nasal layer dissection with Wallace's Finisher



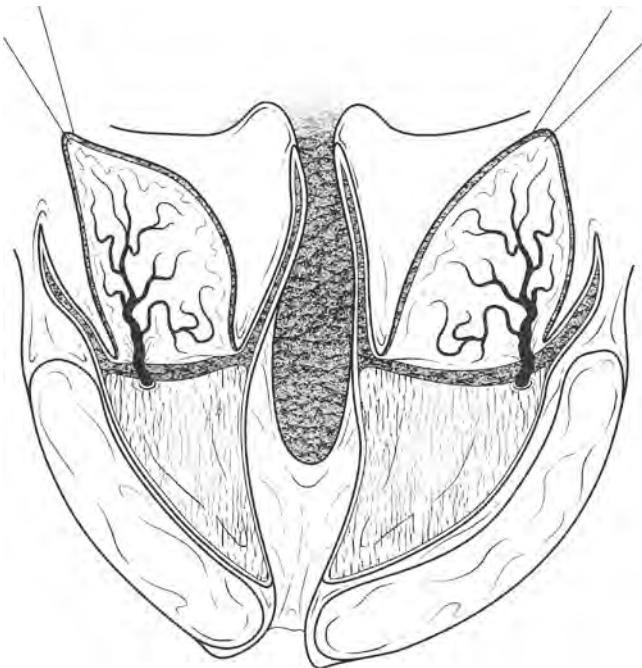
©Association of Oral and Maxillofacial Surgeons of India

Fig. 73.21 Posterior incision on the vomer



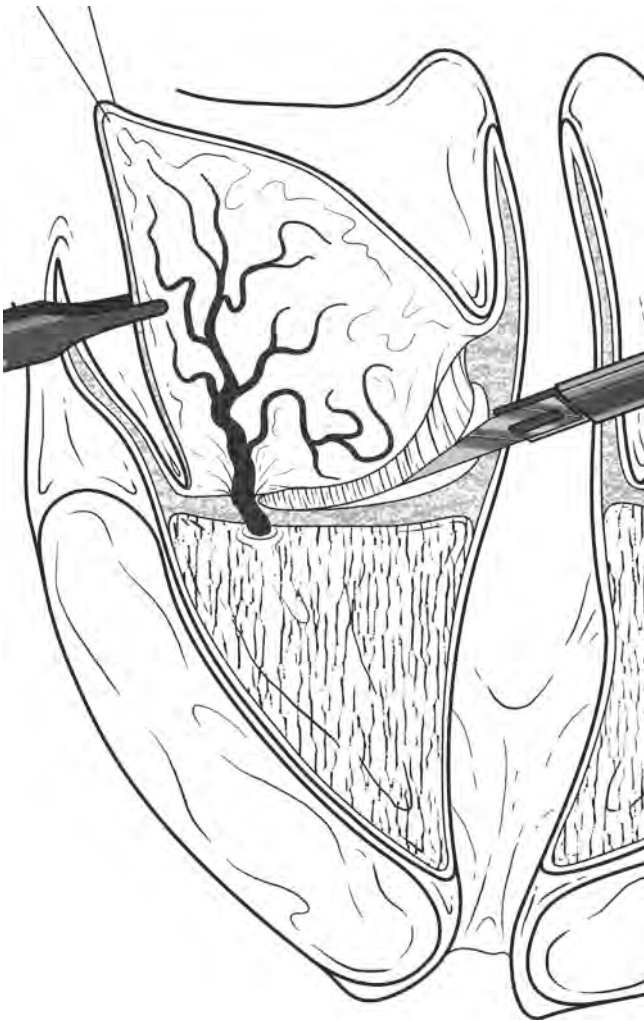
©Association of Oral and Maxillofacial Surgeons of India

Fig. 73.23 Infiltration of adrenaline beneath the palatine aponeurosis



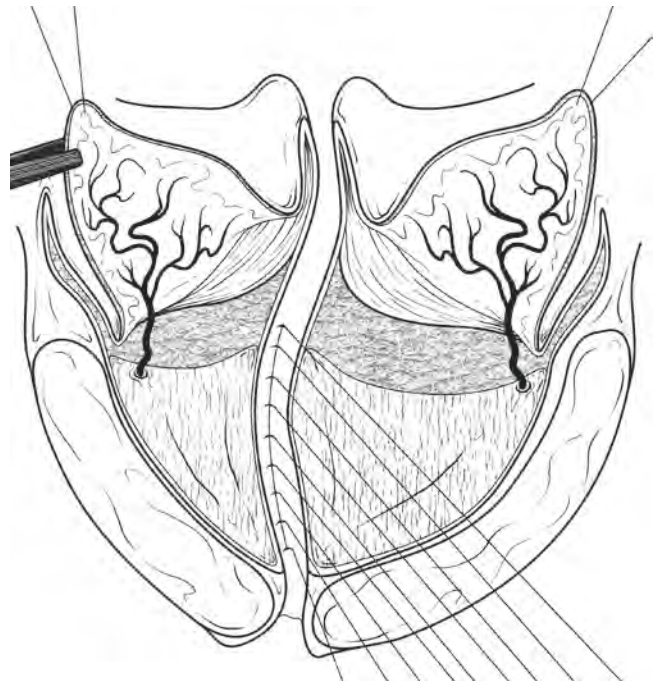
©Association of Oral and Maxillofacial Surgeons of India

Fig. 73.22 Complete dissection of the oral and nasal layers



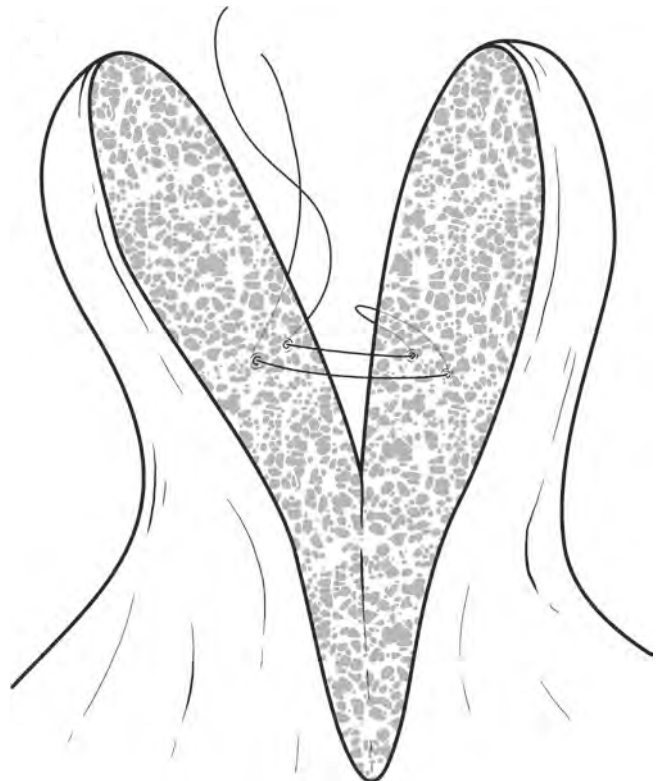
©Association of Oral and Maxillofacial Surgeons of India

Fig. 73.24 Incision of the palatine aponeurosis



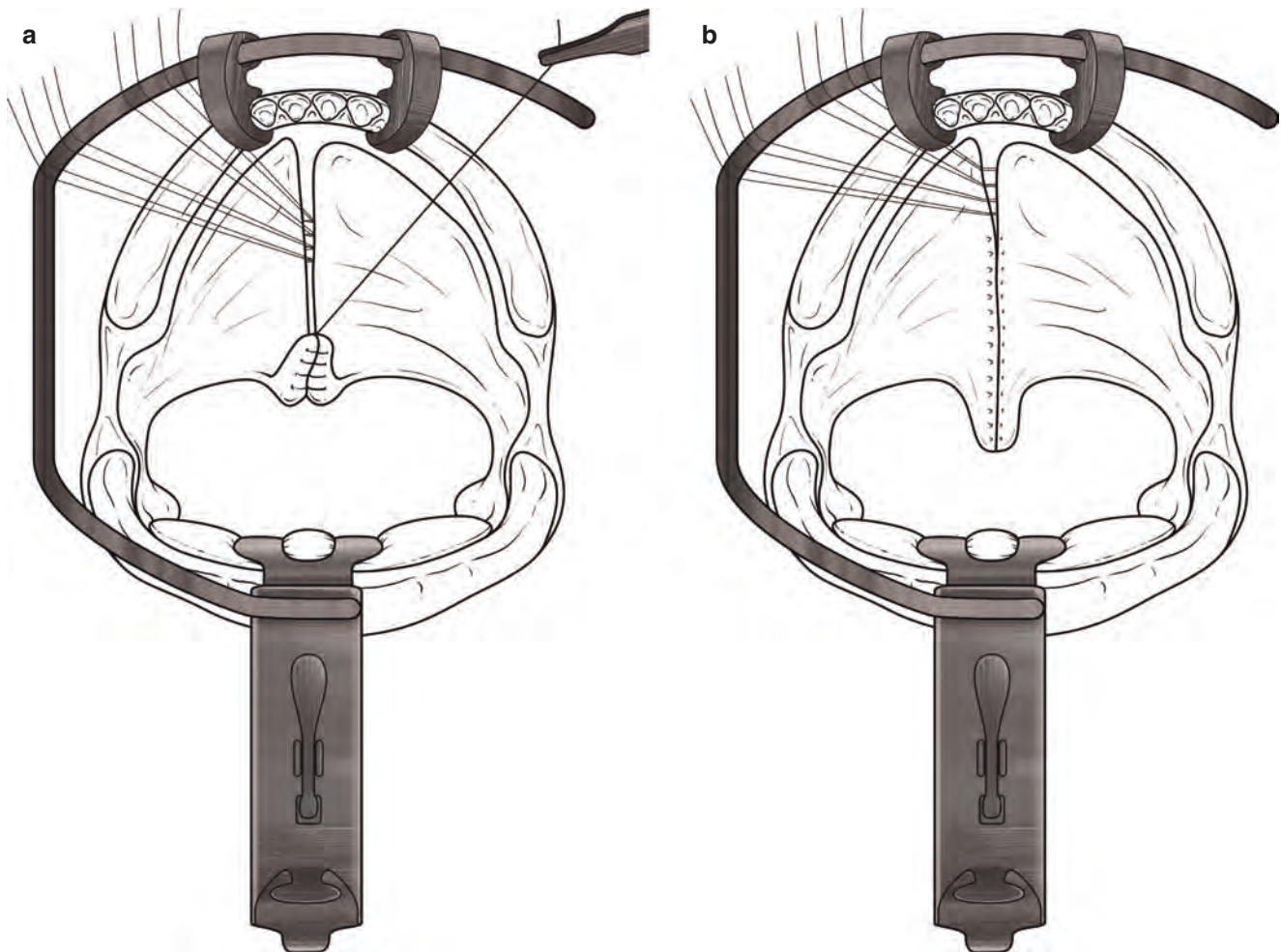
©Association of Oral and Maxillofacial Surgeons of India

Fig. 73.25 Complete dissection and retroposition of the levator palati muscle



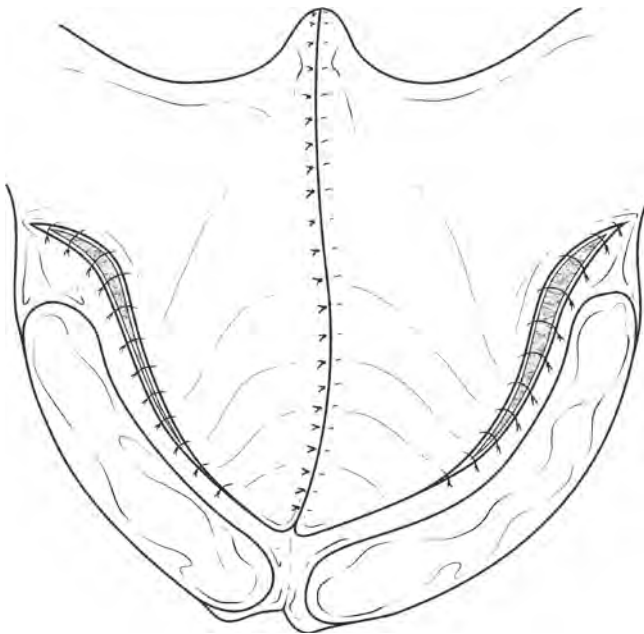
©Association of Oral and Maxillofacial Surgeons of India

Fig. 73.26 Mattress suture at the base of uvula



©Association of Oral and Maxillofacial Surgeons of India

Fig. 73.27 (a) Apical suture on uvula turned over and posterior sutures placed. (b) Completion of uvular reconstruction



©Association of Oral and Maxillofacial Surgeons of India

Fig. 73.28 Completed suturing of the palate and the lateral raw areas

73.8.2 Long-Term Complications

Long-term complications include poor speech. Adequate muscle repair has helped in better speech results. Nonetheless, speech is an enigma that has not been adequately understood and mastered. The variables like width of the cleft, the gap between the uvula and the pharynx, and the adequacy of the muscle repair all have a bearing on the speech results. Despite all the advancements in the repair of the cleft palate, no surgeon can truly claim to achieve perfect speech results in all patients consistently.

73.9 Long-Term Results

The long-term evaluation of cleft palate patients should include the presence or absence of a fistula, the quality of speech, and the growth parameters of the maxilla, i.e., whether there is maxillary hypoplasia.

At present, many centers are able to produce fistula-free palates in a majority of patients. Tension-free closure of the palate and meticulous suturing are the key factors in the prevention of fistulas. A review of literature reveals a huge range in the incidence of fistula after cleft palate repair. The range is from 2.6 to 58%. In between these extremes, many have reported around 10%, some 15 and 23% [31, 32].

The emphasis on good levator veli palatini dissection and repair has led to improved speech results overall. However, one can never perfectly predict the speech outcome, as speech itself is an enigma. Probably as a result of the variation in the presentation, mode of repairs and age at the time of repair, etc., the published literature notes a VPI rate of 5.9–70% [32].

Maxillary growth continues to be a problem. Operations like these of Robert Mann show promise in this direction. Again, owing to variability involved in the type and extent of cleft, the time of repair and the nature of the surgery, the need for maxillary advancement may range from 10 to 40% in non-syndromic cleft patients [32].

73.9.1 Secondary Repair and Revision

The age old saying that primary surgery is the best chance for the surgeon to obtain optimal results is very apt in the repair of the cleft palate. A badly repaired cleft palate sometimes leaves behind a grossly scarred palate with paucity of tissue. Small soft palate fistula can be repaired by freshening of the edge and two-layered closure. Small hard palate fistulas can be repaired by local turn over flaps for lining and oral mucoperiosteal flaps for the oral layer. Larger ones and those with poor speech will require revision palate repair. When there is gross deficiency of tissue, flaps like the tongue flaps, or temporalis musculocutaneous flap, facial artery muscle mucosal (Famm) flap may be necessary [33, 34].

Secondary palate repair is also required for velopharyngeal incompetence (VPI). A detailed discussion about the management of such incompetence is beyond the scope of this chapter. Diagnosis of VPI is by speech assessment, nasoendoscopy, or videofluoroscopy. Once a diagnosis is made, treatment modalities will include redo palate repair, sphincter pharyngoplasty, or flap pharyngoplasties, depending on whether it is the palate, lateral wall (palatopharyngeus) or the posterior wall, or a capacious pharynx as seen on investigations.

Subsequent interventions will be required for maxillary hypoplasia when significant. This is again out of the scope of this chapter. In brief, anterior maxillary distraction is done if the maxillary advancement required is significant and the facial bones are still growing. Some of these do require a LeFort 1 osteotomy later on if there is relapse.

When the growth is completed, then a LeFort 1 osteotomy is required when there is significant maxillary hypoplasia. When the advancement required is more than in 1 cm, bi-jaw surgery is needed, with a LeFort 1 advancement in the maxilla and a bilateral sagittal split osteotomy of the mandible.

73.10 Recent Techniques

The use of the buccal mucosal flap in primary repair was pioneered by Padgett [14] and then used extensively by Murari Mukherjee [15]. Later Ian Jackson incorporated buccinator muscle into the flap and used it on the nasal layer transverse to provide for lengthening of the soft palate.

Furlow's Double Opposing Z plasty described by Furlow [35] is increasingly used both for primary and secondary repair of cleft palates. This illustrated in the figure (Fig. 73.29a, b, c and d). Robert Mann has described the extensive use of the double opposing "Z" plasty with the buccal flaps over the nasal and/or oral layers to avoid lateral incisions and to promote for better bony growth. This is probably the method of the future as it shows promise of good speech and good maxillary growth. However, extensive suturing of the buccal flaps is involved and this is not the optimal surgery for the novice to try. The Mann procedure is for the experienced cleft surgeons [36].

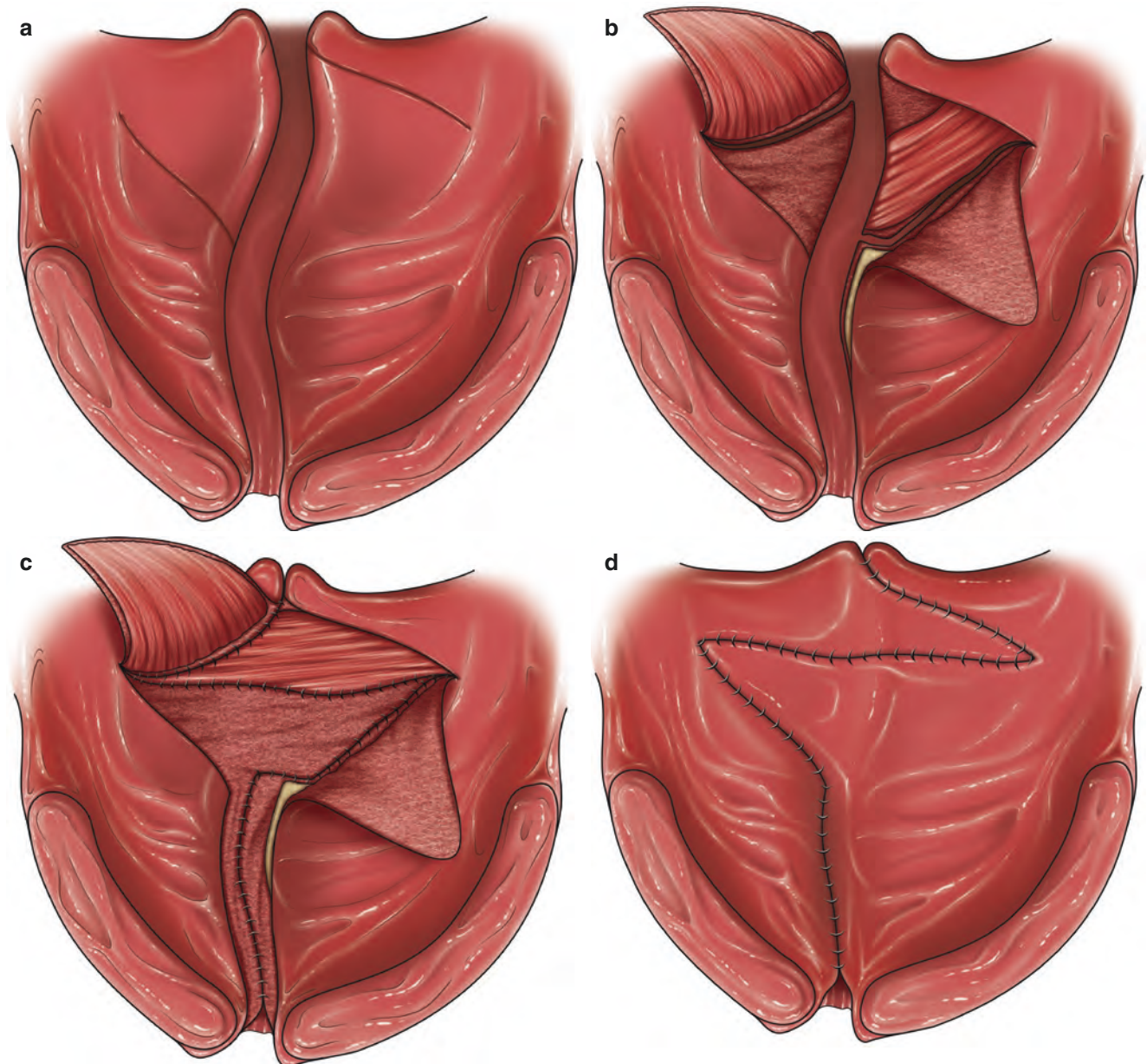
73.11 Case Scenario

Case 1

This is a patient with a partial cleft of the secondary palate (Fig. 73.30). The hard palate is intact. The cleft palate was repaired at the age of 11 months using the Veau-Wardill V-to-Y repair and radical muscle dissection in the soft palate. Subsequently the child is undergoing regular follow-up and speech assessment.

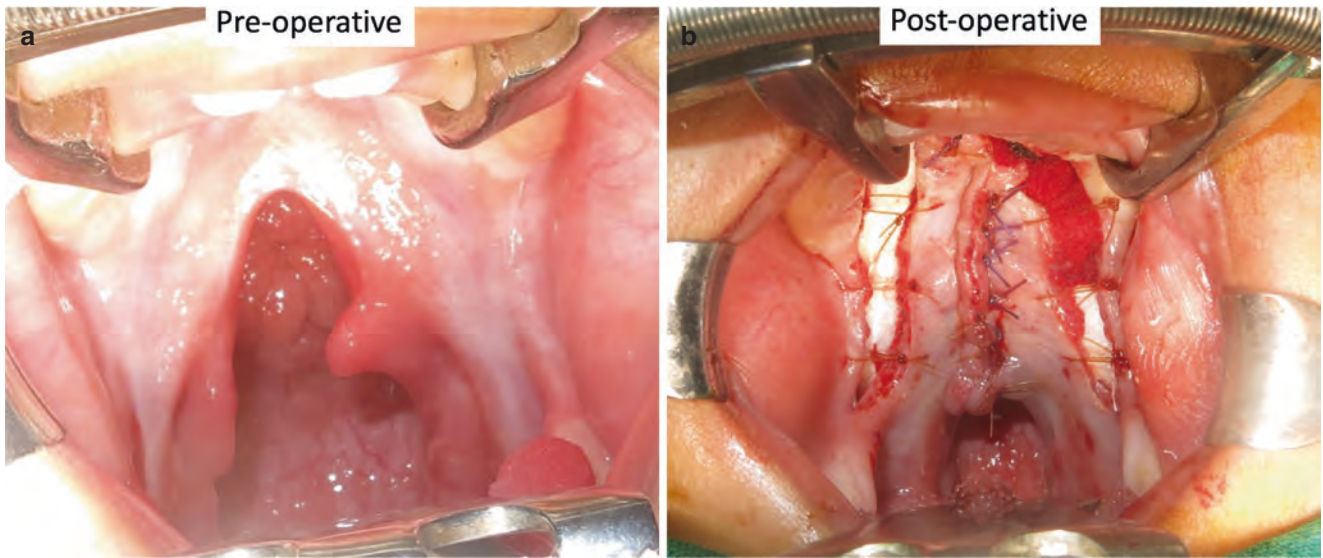
Case 2

This is a child with a complete cleft of the primary and secondary palate on the (Fig. 73.31). The cleft lip was repaired at 6 months of age using the Millard's rotation advancement technique. At 11 months, the cleft palate was repaired using the two long-flap procedure popularized in India by Charles Pinto, the mentor of the senior author, and, worldwide, by Bardach. The child is now being subjected to constant follow-up and speech therapy.



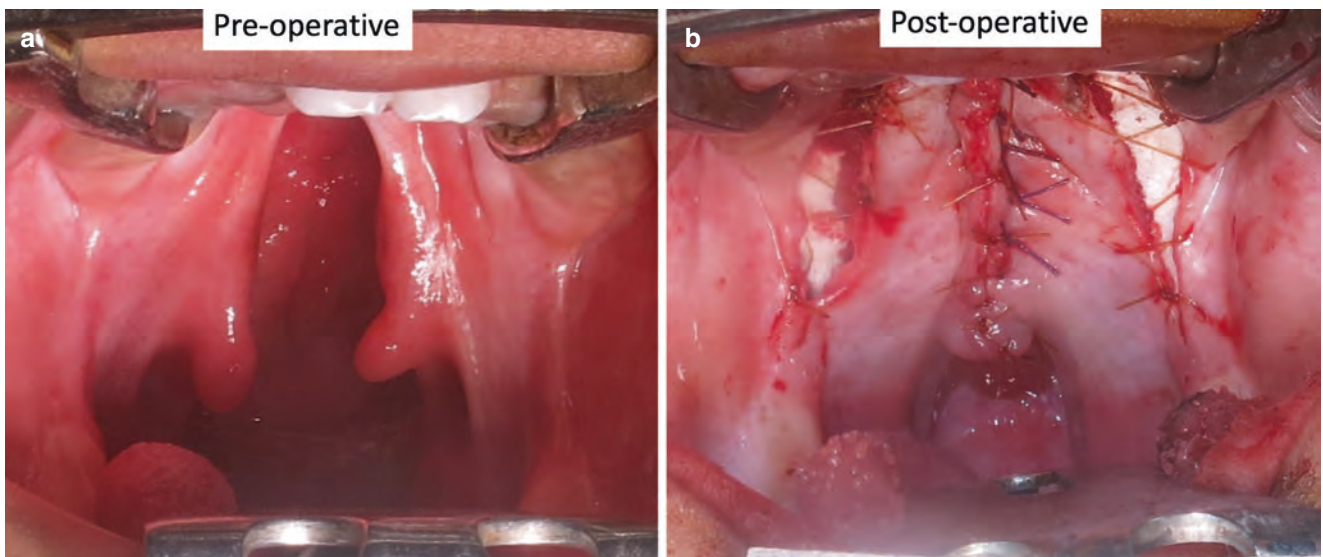
©Association of Oral and Maxillofacial Surgeons of India

Fig. 73.29 (a, b) Furlow's double opposing "Z" plasty (a) incision, (b) flaps raised and mucosal incisions placed, (c) double opposing Z plasty completed and (d) oral flaps inset



©Association of Oral and Maxillofacial Surgeons of India

Fig. 73.30 Repair of incomplete cleft palate



©Association of Oral and Maxillofacial Surgeons of India

Fig. 73.31 Repair of complete Cleft palate

73.12 Disclosure

Authors have no financial conflicts to disclose.

References

1. Holdsworth WG. Cleft lip and plate, vol. 82. London: William Heinemann; 1957.
2. Von Graefe CF. Kurze nachrichten and auszuge. *J Pract Azneck Wundartzk.* 1817;44:116.
3. Randall P, Rossa D. Cleft palate in plastic surgery. In: JC MC, editor. *Cleft lip, palate and craniofacial anomalies*, vol. 4. Philadelphia: Saunders; 1990. p. 2723–4.
4. Dieffenbach JF. *Die operative chirurgie*, vol. 1. Leipzig: F.S. Brockhaus; 1845.
5. Warren JM. Operations for fissures of the soft and hard palate. *Am J Med Sci.* 1843;6:257.
6. Von Langenbeck B. Beitrage zur osteoplastik. *Deutsche Klin.* 1859;2:471.
7. Veau V. *Division palatine, anatomie, chirurgie, phonetique.* Paris: Masson et cie; 1931.
8. Kilner TP. Cleft lip and palate repair technique. *St Thomas Hosp Rep.* 1937;2:127.
9. Wardill WEM. Techniques of operation for cleft palate. *Br J Surg.* 1937;15:117.
10. Dorrance GM, Bransfield JW. The pushback operation for repair of cleft palate. *Plast Reconstr Surg.* 1946;1:145.
11. Cronin TD. Pushback palatorrhaphy with nasal mucosal flaps. In: Grabb WC, Rosenstein SW, Bzoch KR, editors. *Cleft lip and palate: surgical, dental, and speech aspects.* Boston: Little, Brown And Company; 1971.
12. Millard DR. *Cleft craft*, vols. i, ii, iii. Boston: Little, Brown and Company; 1976, 1977, 1980.
13. Thatte R, Govilkar P, Patel J. The tongue flap in the primary treatment of cleft palate: a report of 19 cases. *Br J Plast Surg.* 1992;45(2):150–4.
14. Padgett EC. The repair of cleft palates after unsuccessful operations. *Arch Surg.* 1930;20:453–72.
15. Mukherji MM. Cheek flap for short palates. *Cleft Palate J.* 1969;6:415–20.
16. Mann RJ, Fisher DM. Bilateral buccal flaps with double opposing z-plasty for wider palatal clefts, *Plast Reconstr Surg.* 1997 Oct;100(5):1139–1143; discussion 1144–5.
17. Calnan J. Submucous cleft palate. *Br J Plast Surg.* 1954;6(4):264–82.
18. Sommerlad BC, Fenn C, Harland K, Sell D, Birch MJ, Dave R, Lees M, Barnett A. Submucous cleft palate: a grading system and review of 40 consecutive submucous cleft palate repairs. *Cleft Palate Craniofac J.* 2004 Mar;41(2):114–23.
19. Cohen MM. Syndromes with cleft lip and cleft palate. *Cleft Palate J.* 1978;15:306–28.
20. Randall P, La Rossa D, McWilliams BJ, Cohen M, Solot C, Jawad AF. Palatal length in cleft palate as a predictor of speech outcome. *Plast Reconstr Surg.* 2000;106:1254–9.
21. Åbyholm F. Primary closure of cleft lip and palate. In: Turvey TA, KWL V, Fonseca RJ, editors. *Facial clefts and craniosynostosis.* Philadelphia: WB Saunders; 1996. p. 370e383.
22. Friede H, Lilja J, Lohmander A. Long term, longitudinal follow up of individuals with UCLP after the Gothenburg primary early veloplasty and delayed hard palate closure protocol: maxillofacial growth outcome. *Cleft Palate Craniofac J.* 2012 Nov;49(6):649–56.
23. Agrawal K, Panda K. A modified surgical schedule for primary management of cleft lip and palate in developing countries. *Agrawal K, Panda K. Cleft Palate Craniofac. J.* 2011;48(1):1–8.
24. Peet E. The Oxford technique of cleft palate repair. *Plast Reconstr Surg Bull.* 1961;28:282–94.
25. Lehman JA Jr, Douglas BK, Ho WC, Husami TW. One-stage closure of the entire primary palate. *Plast Reconstr Surg.* 1990;86:675–81.
26. Kane AA, Lo LJ, Yen BD, Chen YR, Noordhoff MS. The effect of hamulus fracture on the outcome of palatoplasty: a preliminary report of a prospective, alternating study. *Cleft Palate Craniofac J.* 2000 Sep;5:506–11.
27. Braithwaite F, Maurice DG. The importance of the levator palatini muscle in cleft palate closure. *Br J Plast Surg.* 1968;21:60–2.
28. Kriens OB. Anatomy of velopharyngeal area in cleft palate. *Clin Plast Surg.* 1975;2:261.
29. Sommerlad BC. A technique for cleft palate repair. *Plast Reconstr Surg.* 2003 Nov;112(6):1542–8.
30. Adenwalla HS, Narayanan PV. *Primary cleft palate repair, surgical correction, facial deformity varghese mani.* Kochi: Jaypee; 2010.
31. Lindsay WK, Witzel MA. Cleft palate repair: Von Langenbeck technique. In: Bardach J, Morris HL, editors. *Multidisciplinary management of cleft lip and palate.* Philadelphia: W.B. Saunders Company; 1990. p. 303.
32. Pomerantz JH, Hoffmann WM. In: Nelegan P, editor. *Chapter 23 cleft palates in plastic surgery.* 4th ed. Philadelphia: Elsevier; 2010. p. 579.
33. Gue-Santos J, Altamirano JT. The use of lingual flaps in repair of fistulas of the hard palate. *Plast Reconstr Surg.* 1966;38(2):123–8.
34. Pribaz J, Stephens W, Crespol, Gifford G. a new intraoral facial artery musculomucosal (Famm) flap. *Plast Reconstr Surg.* 1992;90(3):421–9.
35. Furlow LT Jr. Cleft palate repair by double opposing Z-plasty. *Plast Reconstr Surg.* 1986;78:724–38.
36. Mann RJ, Martin MD, Eichhorn MG, Neaman KC, Sierzant CG, Polley JW, Giroto JA. The double opposing z-plasty plus or minus buccal flap approach for repair of cleft palate: a review of 505 consecutive cases. *Plast Reconstr Surg.* 2017 Mar;139(3):735e–44e.

Open Access This chapter is licensed under the terms of the Creative Commons Attribution 4.0 International License (<http://creativecommons.org/licenses/by/4.0/>), which permits use, sharing, adaptation, distribution and reproduction in any medium or format, as long as you give appropriate credit to the original author(s) and the source, provide a link to the Creative Commons license and indicate if changes were made.

The images or other third party material in this chapter are included in the chapter's Creative Commons license, unless indicated otherwise in a credit line to the material. If material is not included in the chapter's Creative Commons license and your intended use is not permitted by statutory regulation or exceeds the permitted use, you will need to obtain permission directly from the copyright holder.



Veerabahu Muthusubramanian
and Kalarikkal Mukundan Harish

74.1 Introduction

Attempts to graft the alveolus started in the early 1900. The rationale for the procedure however has changed over the period. From its use as a procedure for establishing continuity over a defect, it has evolved and made itself indispensable in both cleft-related orthodontics and orthognathic surgery. Over the years, the technique has evolved, and the materials used have also been constantly studied and improved upon. This chapter aims to elaborate on the morphology of the alveolar cleft, its implications on dentition as well as facial skeleton, and the various management strategies and evolving trends.

74.2 Normal Anatomy of Alveolus

The alveolar process is that part of the jaw that contains the tooth sockets and forms a bridge between the teeth and the basal bones. The alveolar process is present in both the maxilla and the mandible. The status of the alveolar process and its development depends on the status of the teeth; if the teeth are absent or lost in later life, it reduces in size, eventually disappearing completely.

74.2.1 Development of Alveolar Process (Figs. 72.1, 73.1, and 77.1)

The alveolar process begins to form in the end of the second month of fetal life. The maxilla and mandible develop a groove-like structure that opens toward the surface of the oral cavity. This groove contains the tooth germs, the dental nerves, and vessels. Gradually, bony septa begin to develop between adjacent tooth germs. Later the primitive mandibu-

lar canal is separated from the dental crypts through a horizontal plate of bone. The alveolar process remains fused to the body of the maxilla and mandible, and its formation is completed during tooth eruption.

74.2.2 Structure of Alveolar Process

There is no distinct boundary between the body of the maxilla or mandible and their corresponding alveolar processes. In conditions where the alveolus is not functionally related to teeth, it may be fused with and partly masked by bone.

Based on function, the alveolar process consists of two parts:

1. *Alveolar bone proper*: It consists of a thin lamella of bone which surrounds the root of the tooth and gives attachment to the periodontal membrane.
2. *Supporting bone*: It is the structure which surrounds the alveolar bone and gives support to the socket. The latter, in turn, consists of two parts.
 - (i) The compact bone/cortical plate forming the vestibular and oral plates of the alveolar processes.
 - (ii) The spongy bone between these plates and the alveolar bone proper.

The cortical plates are usually much thinner in the maxilla than in the mandible. They are thickest in the bicuspid and molar region of the mandible especially on the buccal side. In the maxilla, the outer cortical plate is perforated by many small openings through which blood and lymph vessels pass. In the mandible, the cortical bone of the alveolar process is dense and, occasionally, shows small foramina. In the region of the anterior teeth of both jaws, the supporting bone is, usually, very thin. No spongy bone is found here and the cortical plate is fused with the alveolar bone proper.

The interdental and interradicular septa contain the perforating canals of *Zuckerkanal* and *Hirschfeld*, which house

V. Muthusubramanian (✉) · K. M. Harish
Department of Oral and Maxillofacial Surgery, Ragas Dental
College, Uthandi, Chennai, India

the interdental and interradicular arteries, veins, lymph vessels, and nerves. The alveolar bone proper which forms the inner wall of the socket contains many openings which transmit branches of the interalveolar nerves and blood vessels into the periodontal membrane. It is named cribriform plate or lamina dura.

74.2.3 Functions of Alveolar Bone

The primary functions of the alveolar bone are highlighted in (Box 74.1).

74.3 Alveolar Anatomy in Cleft Patients

The alveolar cleft is usually represented either by a notch in the alveolus on the labial aspect or as a complete gap between the alveolar segments. In unilateral alveolar clefts, the cleft side of the maxilla (referred to as the lesser segment) is underdeveloped, causing abnormalities of the alveolus, as well as the lip, nose, and palate.

74.3.1 Abnormalities of the Alveolus and Dentition

The abnormalities of the alveolus and the dentition are projected in (Box 74.2).

74.3.2 Abnormalities of the Lip-nasal Complex

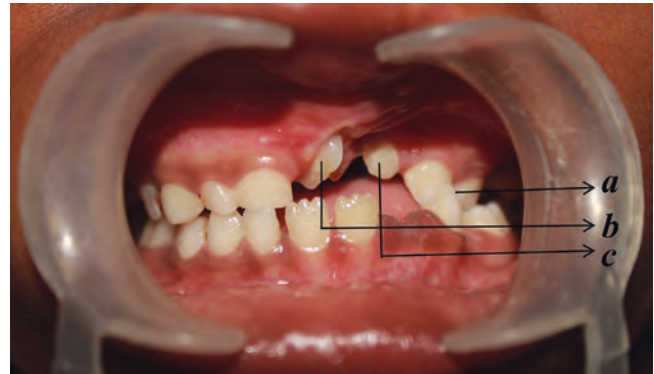- The pyriform rim on the cleft side, when viewed sagittally, appears retrusive.
- The nasal floor is displaced inferiorly, and there is transverse constriction of the anterior bony nasal aperture.
- The nasal tip is asymmetrical.

Box 74.1 Primary Functions of the Alveolar Bone

1. Protection: Alveolar bone forms and protects the dental roots.
2. Attachment: It gives the attachment for periodontal ligament fibers, which are the principle fibers. These fibers which enter into the bone are called as Sharpey's fibers.
3. Support: It supports tooth roots on the facial and the palatal/lingual sides.
4. Shock absorber: It helps to absorb forces placed upon the tooth by disseminating the force to underlying basal bones.

Box 74.2 Abnormalities of the Alveolus and the Dentition

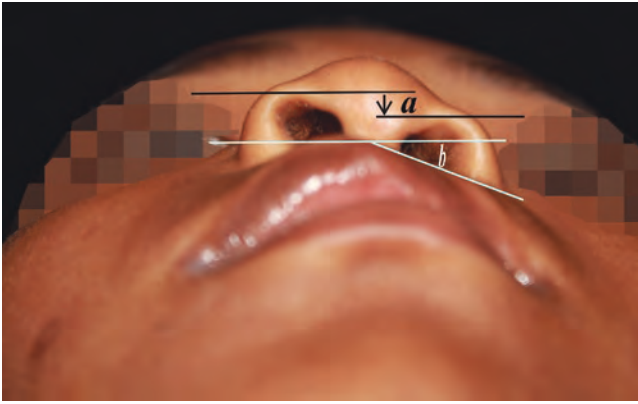
- There is medial collapse of the arch, producing dental crossbites (Fig. 74.1a).
- The position of the premaxilla may be altered with the arch being normal or rotated toward the non-cleft side. There is change in the position of the premaxilla.
- The central incisor is usually rotated toward the cleft side (Fig. 74.1b).
- The lateral incisor may be congenitally absent or hypoplastic or at times resemble a supernumerary tooth. It may also protrude through the nasal floor and lie within the cleft (Fig. 74.1c).
- The periodontal attachments of the central incisor and canine on the cleft side are poor and have high risk of future bone loss.



©Association of Oral and Maxillofacial Surgeons of India

Fig. 74.1 Intraoral frontal picture demonstrating clinical features of cleft alveolus (left side). (Refer to Box 74.2 for description of a, b and c)

- The medial crus of the nasal cartilage is short, and the upper and lower lateral cartilages do not overlap. There is a mismatch in the level of lower lateral cartilages (Fig. 74.2a).
- The columella, caudal septum, and anterior nasal spine tend to deviate to the non-cleft side.
- The above factors result in lack of support for the external nose, especially around the alar base, which is displaced laterally, inferiorly, and posteriorly, widening the nasal aperture (Fig. 74.2b).
- The fibers of the orbicularis oris muscle do not run transversely and instead turn upward along the margins of the cleft, to terminate beneath the base of the columella medially and below the alar base and periosteum of the pyriform rim laterally. Due to the abnormal muscle attachment, there will be a bulge on the unrepaired cleft lip, distortion of the ala of the nose, and deflection of the nasal septum and anterior nasal spine.



©Association of Oral and Maxillofacial Surgeons of India

Fig. 74.2 Basal view picture demonstrating abnormalities of the lip-nasal complex (a) mismatch of the lower lateral cartilages and (b) widening of the nostril due to lack of support for the cleft side alar base

Box 74.3 Goals of Orthodontics in Alveolar Bone Grafting (ABG)

1. Alignment of arches in preparation for ABG.
2. Stabilize the arches.
3. Arch expansion to correct the transverse discrepancy.
4. Align the teeth.
5. Increase the cleft width in preparation to receive the graft.

74.4 Role of the Orthodontist in Patients with Alveolar Cleft (Box 74.3)

The objective of alveolar bone grafting (ABG) primarily involves restoring the structural and functional integrity of maxillary alveolar arch. This would further facilitate the eruption of the canine or lateral incisor into their respective position in the maxillary alveolar arch. The further employment of orthodontic treatment would help in stabilizing the arches and achieving proper alignment of misaligned teeth. The aim of orthodontics in ABG are highlighted in Box 74.3.

The orthodontist must be involved at all stages of dental development, namely, infancy, primary, mixed dentitions, and the permanent dentition stages.

74.4.1 Infancy

1. Pre-surgical orthopedics can be done with the use of appliances such as Latham's appliance, etc. It consists of a pin-retained device that is inserted into the palate with

acrylic extensions onto the alveolar ridges. Further a screw mechanism is then used to manipulate the segments as desired.

2. Primary bone grafting is also an option, which is done in some cases, as it was believed that defect, which when corrected earlier, would allow normal development and function. However, it remains controversial, as there are no important benefits compared to secondary bone grafting done. In addition, scarring can cause deleterious effects and retard growth.
3. Gingivoperioplasty can also be done to improve the closure. It involves creation of a mucoperiosteal bridge across alveolar cleft region, thus creating a subperiosteal tunnel. This in turn facilitates bone generation.

In case of untreated clefts, the maxillary development was found to be normal. Which indicates that early lip repair may affect maxillary growth.
4. In case of a bilateral cleft repair, posterior alveolar segments behind the premaxilla are collapsed leading to a protruded and superiorly positioned premaxilla.
5. Orthodontist's role would be to reposition the maxilla and expand the collapsed alveolar segments.

Jackscrew and spring-loaded appliance are some of the orthopedic appliances used. However, the effect of these appliances are still controversial.

74.4.2 Primary Dentition

1. In a primary dentition, the orthodontist has no role to play unless the children have crossbites.
2. Routine dental screening is advised to detect any caries.

74.4.3 Mixed Dentition

1. Standard records for orthodontic diagnosis are procured for the patient. Some of them being OPG, IOPA, and occlusal radiographs.
2. Missing teeth, supernumerary teeth, and bone requirement are assessed with these radiographs.
3. Presence of posterior crossbite, malaligned upper incisors, and bone defects at the cleft area are documented.
4. Bone grafting should be done prior to any orthodontic treatment, which is to prevent root exposure or periodontal defects.
5. Arch expansion done should be limited if the patient is supposed to undergo orthognathic surgery later.
6. The expansion is usually limited by the zygomatic buttress and scar tissue present.
7. The direction of the expansion, its extent, the presence or absence of teeth, the resistance of tissue (which can

be high in scarring), surgical access to cleft area, and compliance of the patient are factors that determine the selection of appliance.

8. Spring appliances offer lighter forces with quad helix providing better control in the expansion.
9. Any fistulae that are present in the patient should be corrected during bone grafting.
10. In case of bilateral cleft, the mobile premaxilla is stabilized by grafting, and orthodontic treatment is started only after the bony union is complete, which may be a range between 2 and 6 months.
11. Orthopedic appliances like headgears can be given to patients with mild maxillary deficiencies.
12. Distraction osteogenesis or orthognathic surgery should be chosen depending on the patient's growth status (refer Chap. 69 on maxillary orthognathic surgeries, Chap. 75 on cleft maxillary hypoplasia and Chap. 87 on distraction osteogenesis).

74.4.4 Permanent Dentition

1. Fresh set of diagnostic records are obtained.
2. Most common problems which are seen are missing or malformed teeth.
3. Sometimes teeth may be present but compromised. Most often it is the lateral incisor. One must decide whether this has to be treated with canine substitution or prosthetic replacement.
4. In cases where there is (i) deviation of the dental midline toward the non-cleft side, with the canine erupted mesially with favorable root position, or (ii) the canine is small and wide with both premolars present on the cleft side, and the molar and canine relationships on same side are *class II*, the right choice of treatment would be canine substitution. It involves extraction of the malformed lateral incisor with poor periodontal support, followed by facilitating the eruption of canine in the place of lateral incisor.
5. In cases in which both the maxillary canine and the first molar have a *class I* relationship, or the canine is positioned with the crown mesially and root distally, with a shift of the maxillary midline to the cleft side, prosthetic replacement is ideal. Adequate space should be planned to accommodate the prosthesis.
6. Comprehensive orthodontic treatment starts almost a year or 2 prior to surgery.
7. Dental decompensation for cleft maxillary osteotomy surgery must be planned and executed. Surgical preparation should include wire placements, retentive hooks for IMF, and plans for post-surgical retention.
8. If relapse is noticed post-surgically, it is immediately addressed with *class III* elastics or a reverse pull headgear.

74.5 Alveolar Bone Grafting Procedure

74.5.1 History [1]

Attempts to graft the alveolus started in the early 1900s. In the beginning, the goal was to prevent collapse of the alveolar ridge. Therefore, it was done during infancy. In 1970, reconstructive surgeons like Boyne [2, 3] stated that the ideal age for grafting the cleft was between 9 and 11 years. This was done to allow eruption of the canine.

74.5.2 Classification

Alveolar bone grafting procedures are classified into four types based on the age and timing of the procedure:

- *Primary*—This is performed in infancy, with the patient being below 2 years of age. This is done following lip repair but before the palate is repaired.
- *Early secondary*—This is done between 2 and 5 years of age, prior to the eruption of incisors.
- *Secondary*—Performed between 8 and 11 years of age, prior to eruption of the maxillary permanent canine.
- *Late secondary*—Performed above 12 years of age, after the canine has erupted.

The advantages and disadvantages of the various methods are highlighted in Table 74.1.

74.5.3 Materials Used in Alveolar Bone Grafting

A variety of materials have been used in grafting in secondary cleft deformities.

These include autogenous, allogenic, or alloplastic materials.

The success rate differs for each type, but fresh autologous cancellous bone is considered to be superior because it allows cells that are immune-compatible and integrate fully into the maxilla and trigger osteogenesis. In addition, it is the only bone source which possesses all the properties that promote bone formation—osteogenesis, osteo-conduction, and osteo-induction.

74.5.3.1 Bone Grafts

- *Cortical*:
Cortical bone refers to the compact outer part of the bone. This is generally less vascular, and so establishment of nutritional supply to cortical cells is a slow pro-

Table 74.1 Comparison of advantages and disadvantages of different ABG techniques

Procedure	Advantage	Disadvantage
Primary grafting	Limited dissection. Reduced maxillary growth discrepancy	Alveolar segments have to be aligned orthopedically. Requires additional surgeries. Reduced success rates [4]
Early secondary grafting	Possibly could facilitate eruption of lateral incisor as well	Not accepted widely in literature [4]
Secondary grafting	Minimal influence in maxillary growth as most of the maxillary growth is completed by 6–7 years [4]. Sufficient quantity of bone at donor site is available. Better patient cooperation. Orthodontic treatment acceptance is good. Allows eruption of permanent teeth through the graft, thus maintaining good periodontal health	Earlier intervention could result in eruption of lateral incisors as well
Late secondary grafting	No significant advantage. Mandibular symphysis could be considered as good donor site as the chances of damaging unerupted teeth are less	Less success rate. Loss of osseous support to teeth adjacent to cleft. Less chances of salvaging lateral incisor. Delay in orthodontic correction of underlying deformity

cess. Therefore, this graft generally resorbs and is replaced by invasion of bone cells originating from the recipient site. The rate of metabolic turnover and cortical bone remodeling is much slower than in cancellous bone. Therefore, keeping the tooth-bearing function in mind, cortical grafts may not be feasible for the alveolar process.

- **Cancellous:**
Cancellous bone refers to the softer trabecular bone that is more vascular. This allows better ingrowth from the recipient site. The formation of new bone starts at the surface of the existing cancellous bone. Cancellous bone theoretically heals by osteogenesis, followed by bone resorption and deposition. This graft is harvested as a particulate form, so it may be difficult to stabilize it in the recipient site.
- **Cortico-cancellous:**
A combination of the two produces good results and enables good vascularization to help incorporate bone with surrounding structures. It also adds good mechanical strength.

74.5.3.2 Autogenous Materials

The following sites are commonly used as sources for autogenous material used in alveolar bone grafting:

1. **Cranium [5]**
 - The cranium, or calvarial bone, is a source of both cortical and cancellous bone.
 - This site is associated with low morbidity and minimum postoperative pain.
 - Scar will be unseen within the hair with early discharge and good prognosis.
 - It has poor outcomes as compared to iliac crest bone.
2. **Iliac Crest [6]**
 - It has huge quantity of cancellous bone which aid osteogenesis. The process of condensing bone chips into the defect increases the reliability of this bone.
 - Bone from this region may be harvested using a trephine or through an open approach.
 - Approach needs to be planned well as it may leave an unacceptable scar.
 - The main disadvantage of using iliac crest is postoperative pain, which may require extended hospitalization, which can be surmounted by regional anesthetic techniques for post-surgical pain control.
 - This is the most preferred donor site and is used by 87% of European surgeons and 83% of North American surgeons performing ABGs [6].
3. **Mandibular Symphysis [7]**
 - Bone provided is more cortical and is limited compared to the ilium.
 - Damage to the adjacent teeth and mental nerve has been reported.
 - It is used by 4% of surgeons in Europe [7].
4. **Tibia [8]**
 - It has sufficient bone which is quick to harvest.
 - There is minimal scarring, and patient may be mobilized early but is restricted from sports for 3 weeks.
 - In children where the tibia is usually small, there is a possibility of damage to the epiphyseal cartilage.
 - Used by 3% of European and 2% of North American surgeons [8].
5. **Rib [9]**
 - This is rarely used, as it provides limited amount of bone.
 - Postoperative risk of chest infections and prolonged discomfort may be present.
 - Esthetically identical scar to other sources.
 - 0.5% of European and 3% of North American surgeons use this method [9].
6. **Femur**
 - Bone may also be harvested from the intermedullary canal of the femur, but it carries the risk of high morbidity.

74.5.3.3 Alloplastic Materials

Alloplastic materials that have been used for ABG include rhBMP-2 (recombinant human bone morphogenetic protein), undecalcified freeze-dried bone, TEOM (tissue-engineered osteogenic material), and bioglass.

1. rhBMP-2
 - This is recombinant bone morphogenic protein, with superior bone quality reported in BMP-2 group [10].
 - Studies have shown that this material, when used for ABG, had high chances of successful grafting as is considered very effective in situations involving a larger bony defect, and does not demonstrate any detrimental effect on neighboring anatomical structures and no evidences of ectopic bone formation [11].
2. TEOM
 - This material contains MSC (mesenchymal stem cells), PRP (platelet-rich plasma), human thrombin, and mixed air.
 - Available in a gel form.
 - Claimed rate of success is about 70%.
3. Bioactive Glasses
 - This commercially available material is made up of silicone dioxide, sodium dioxide, calcium oxide, and phosphorus pentoxide.
 - It binds both to the soft tissue and bone.
 - Designed to engender surface reaction, which leads to osseointegration.

74.5.3.4 Allogenic Materials

These materials are comparable to autogenous materials and allow for eruption of teeth while avoiding donor site morbidity. However, they do not have osteogenic potential, which causes delayed graft incorporation.

These materials include:

- Undecalcified freeze-dried bone.
- Allograft CTBA [Cells and Tissuebank Austria].
- Osteograft.
- Maxgraft.

Most of the abovementioned products involve bone obtained from genetically dissimilar individuals. These allogenic bone particles are subjected to various processes to ensure the allogenic graft material is devoid of any microbial contamination however retaining the organic matrix and the inorganic components. They are available in various particle sizes or as block grafts or can even be milled for specific patients using CAD CAM technology.

Box 74.4 Goals of ABG

- To allow closure of the oronasal fistula.
- To provide tension-free, watertight closure to retain the graft and establish soft tissue continuity.
- To pack adequate volume of graft in the defect and restore bony continuity.
- Aid in the eruption and alignment of teeth.
- Add stability to the maxilla as a single unit while planning for orthognathic surgery.

74.5.4 Technique for Alveolar Bone Grafting

The technique of alveolar bone grafting must be performed with the following goals in mind (Box 74.4).

Alveolar bone grafting procedure is performed under general anesthesia. It can be performed comfortably using both naso-tracheal and oro-tracheal intubation. When iliac crest is the chosen donor site, a two-team approach can be followed simultaneously. The surgical sequence for unilateral ABG (Figs. 74.3a–f and 74.4a–f) and bilateral ABG (Fig. 74.5) are detailed below.

Surgery in the oral cavity is begun with infiltration of local anesthesia containing adrenaline to assist hemostasis. It has to be borne in mind that the reconstruction of cleft alveolus involves neat and precise development of labial/palatal/nasal layers and creating of a pocket for placement of graft, as this will ensure creation of structural and functional integrity of the alveolar arch. A fine needle gauge is used to probe the bony edges of the cleft in order to identify the site of the first incisions (Fig. 74.5b). The initial incision must be made through the mucosa lying over the cleft and must pass down to the bony margins (Fig. 74.3a, b). Try to preserve the soft tissue on the labial and palatal sides. Adequate (and sometimes excess) tissue is usually present within the oronasal fistula, which may be sacrificed after planning for the oral layer closure. In the region of the pyriform aperture, there is no bony margin. Hence, at this site the soft tissue is divided to provide a layer for the superior most extent of the nasal closure. A similar kind of division of the mucosa is necessary on the palatal side too (Fig. 74.3c).

Next, incisions are made around the cervical region of the teeth on the labial aspect of the alveolus. The incisions should extend several teeth posteriorly from the cleft with the exact distance determined by the width of the cleft. A full-thickness mucoperiosteal dissection should be begun to raise a large advancement flap. A similar procedure is carried out on the palate, where incisions are made around the neck of the teeth followed by full-thickness mucoperiosteal dissection. As an alternative oblique sliding flaps can also be raised (Fig. 74.3a, b). As these dissections are proceeding,

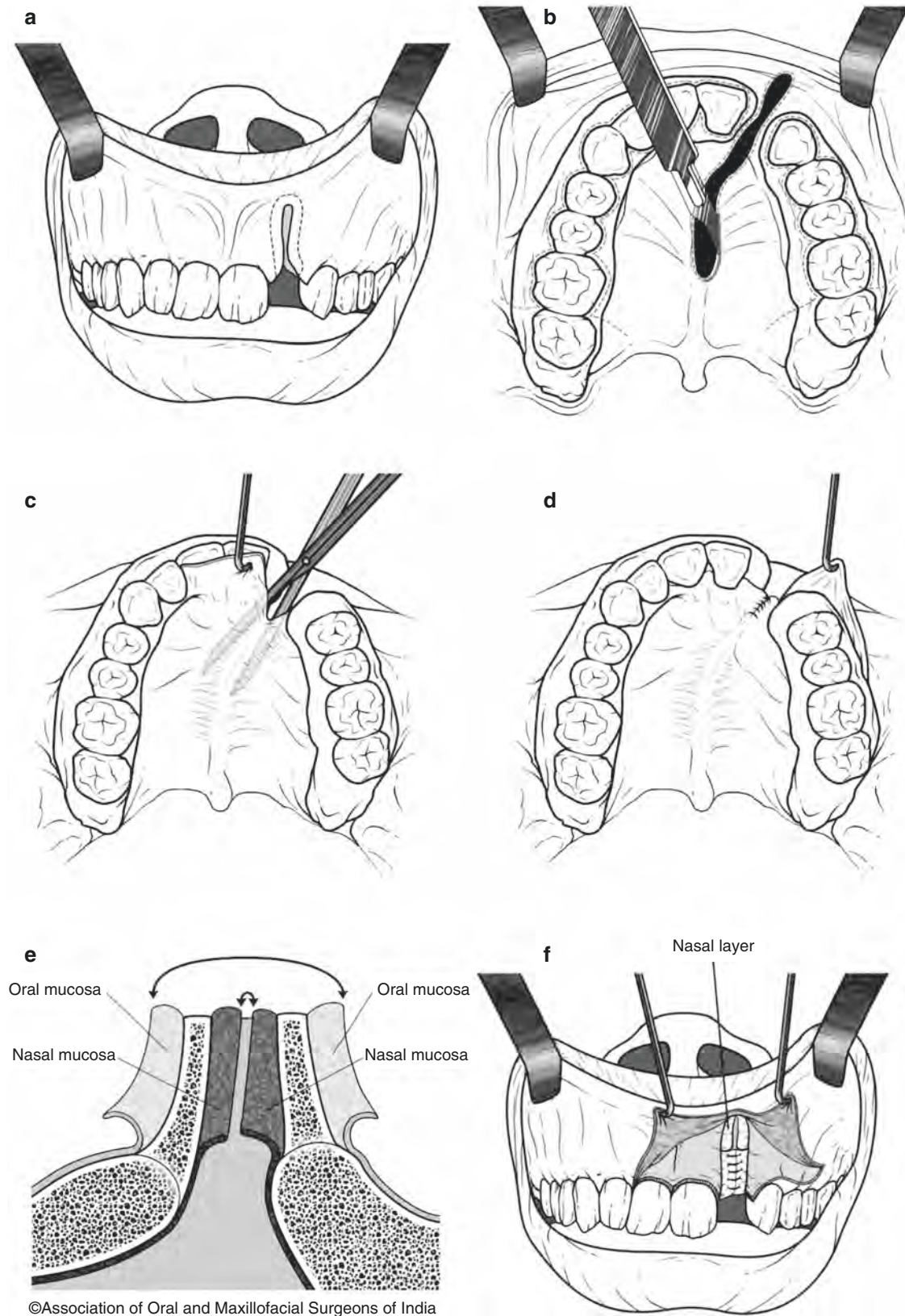


Fig. 74.3 (a–f) (a and b) Incisions around the cleft margin and for developing oblique sliding flaps (dashed lines), (c) Palatal flaps are developed sharply with scissors. This also separates the nasal mucosa from the palatal tissue. (d) Palatal closure. This can be done before or

after the nasal mucosa is closed. (e) Depiction of the nasal mucosal flap along with the closure of the oral mucosa. (f) Nasal mucosal flaps are reflected from the bony walls of the cleft. The palatal flap facilitates packing and protects the palatal closure [4]

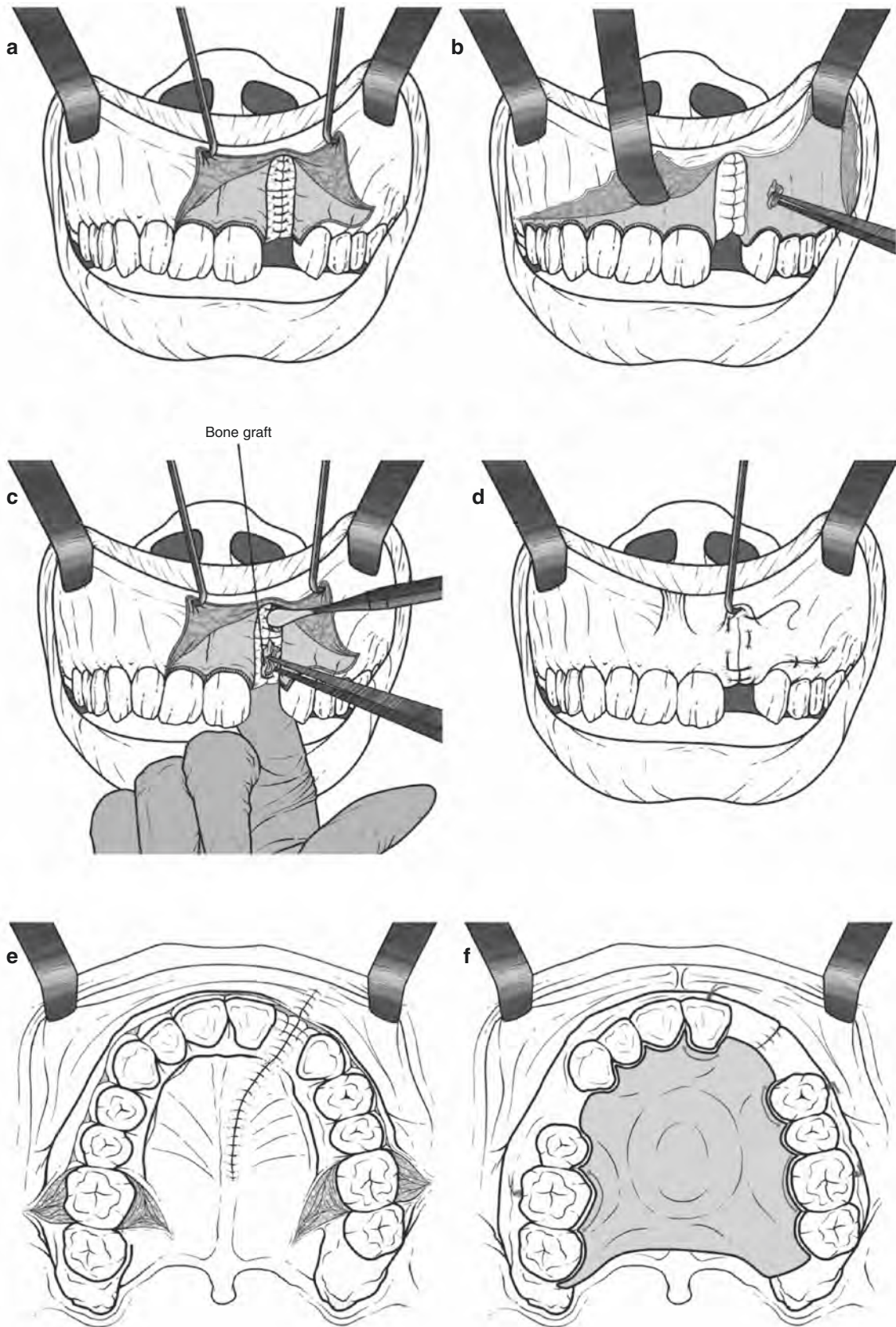


Fig. 74.4 (a–f). (a) Nasal flaps are approximated with sutures burying the knots when possible. (b) The closure of the nasal mucosa and the introduction of the bone graft to the alveolar defect. (c) Bone is packed into the defect with a periosteal elevator or orthodontic band pusher. Digital pressure against the palatal flap facilitates packing and protects

the palatal closure [4]. (d) Closure of the labial oblique sliding flap. (e) Final mucosal closure of the labial and palatal oblique sliding flaps. (f) A palatal splint placed over the closure area to prevent formation of a hematoma and stabilize the bone graft

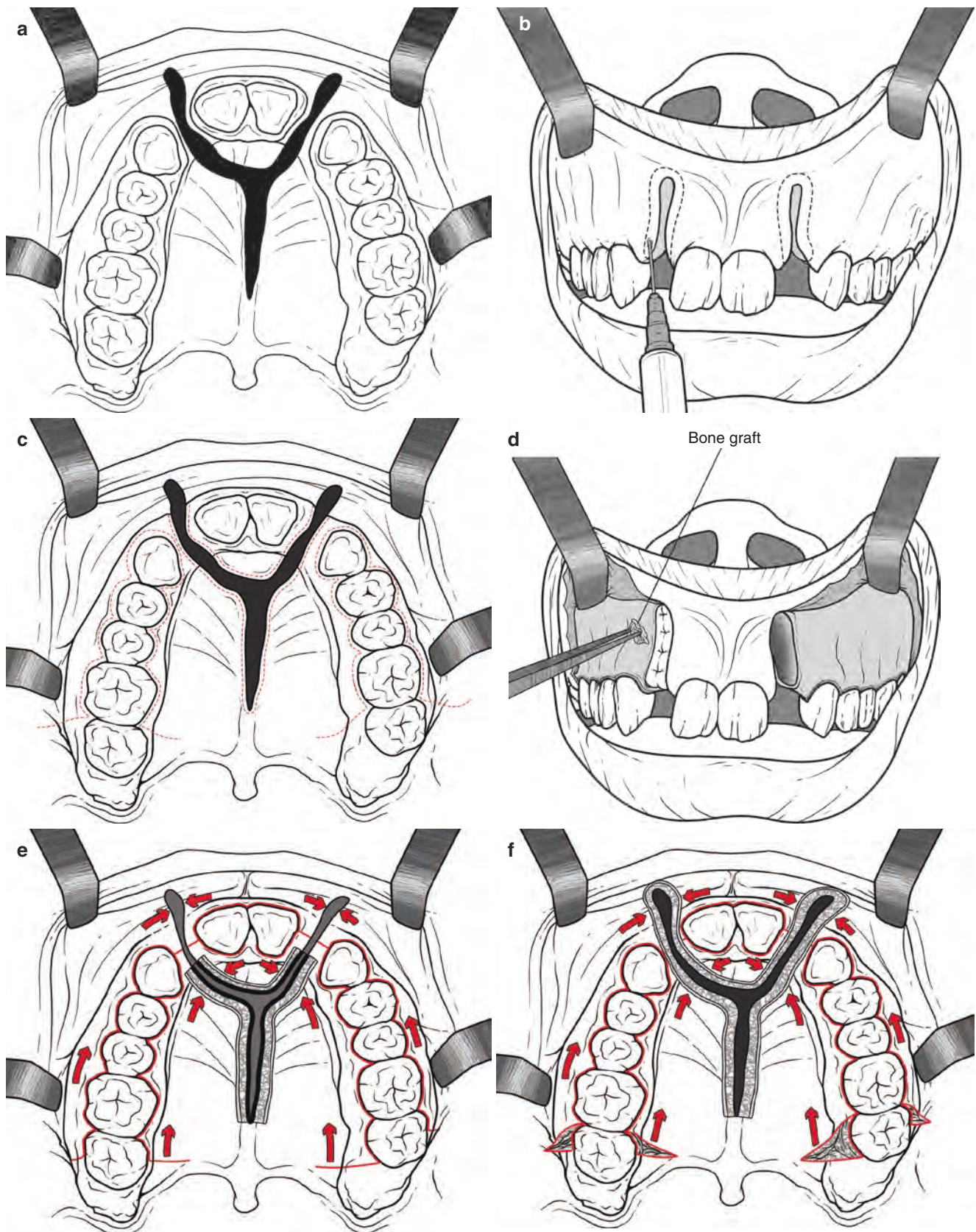
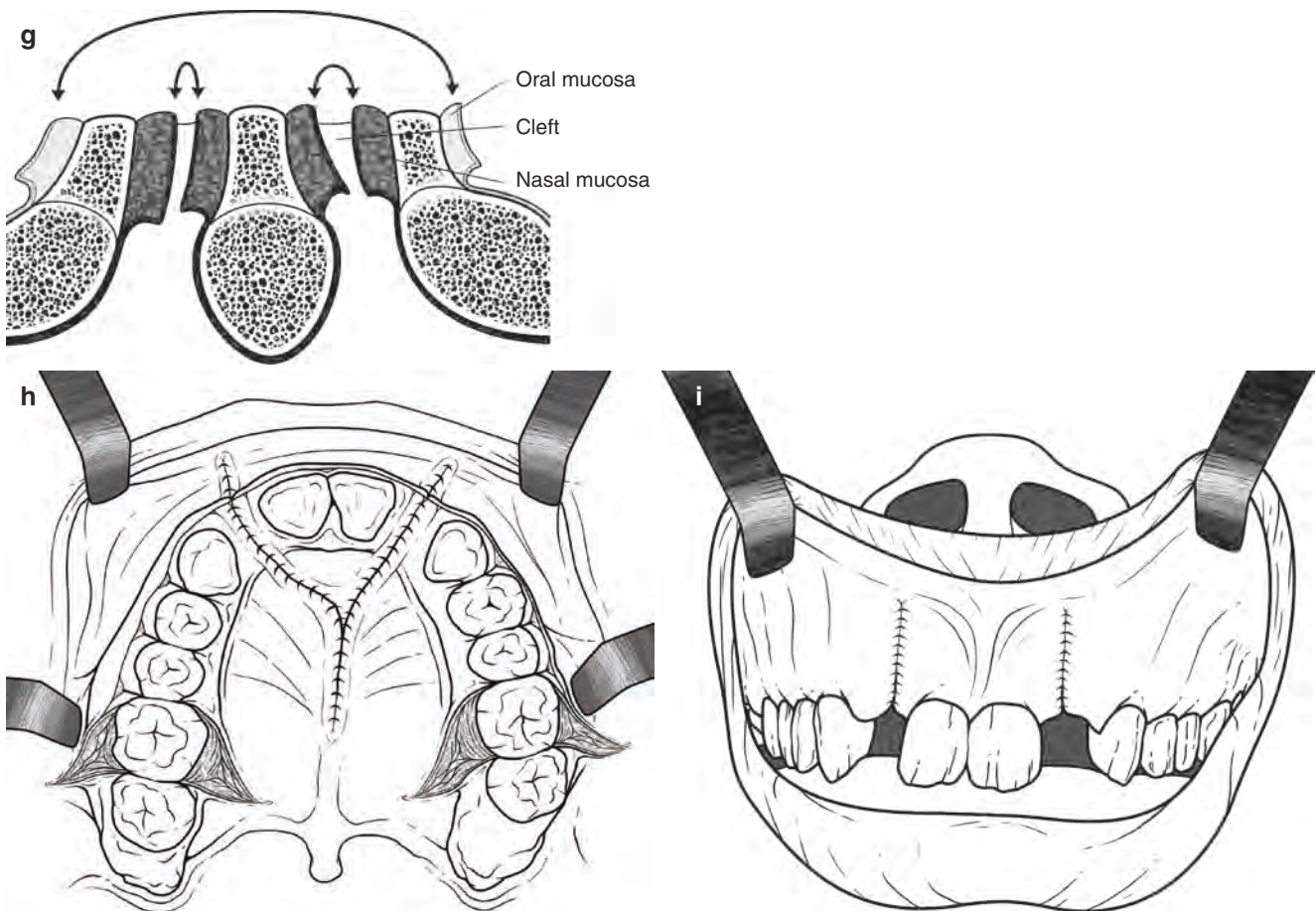


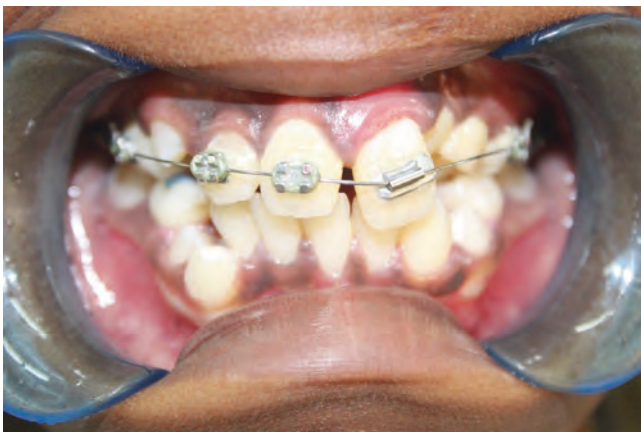Fig. 74.5 (a–i) (a) A bilateral alveolar cleft palate. (b) Needle palpation of the bony edges of the alveolar cleft while injecting local anesthesia. (c) The incision line (dashed line). (d) Elevation of the nasal mucosa on the left and closure of the nasal mucosa on the right. Placement of

the bone graft. (e, f) Palatal depiction of the movement of the adjacent mucosa in the oblique sliding flap technique. (g) Mucosal closure in a bilateral alveolar cleft. (h and i) Final closure of the bilateral alveolar cleft repair using an oblique sliding flap technique



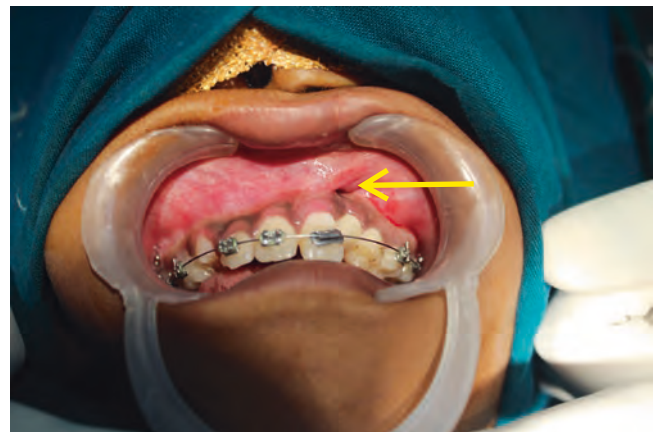©Association of Oral and Maxillofacial Surgeons of India

Fig. 74.5 (continued)



©Association of Oral and Maxillofacial Surgeons of India

Fig. 74.6 Pre-operative intra oral picture demonstrating collapsed maxillary arches with hidden oro-nasal fistula

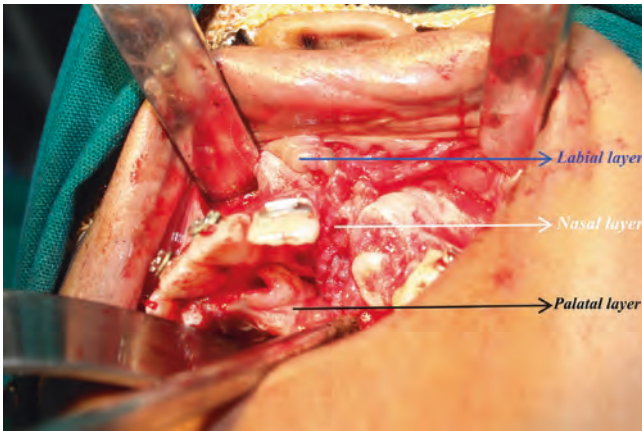


©Association of Oral and Maxillofacial Surgeons of India

Fig. 74.7 Pre-operative intra-oral maxillary arch view of the same patient in Fig. 74.6, providing good visualisation of the oro-nasal fistula

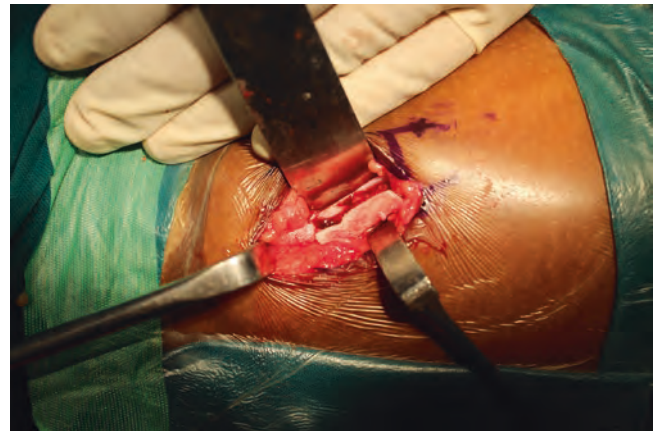
the periosteal elevator may be carried around the cleft to allow the mucoperiosteum within the fistula to be rotated superiorly. This allows the full extent of the bony cleft to be visualized. Excess tissue within the nasal portion of the cleft

can be trimmed, and then the nasal flaps are sutured to provide closure of the nasal floor. This helps in the closure of a persistent oro-nasal fistula (Figs. 74.6, 74.7, and 74.8). It is ideal to evert these flaps into the nose and to use inverted



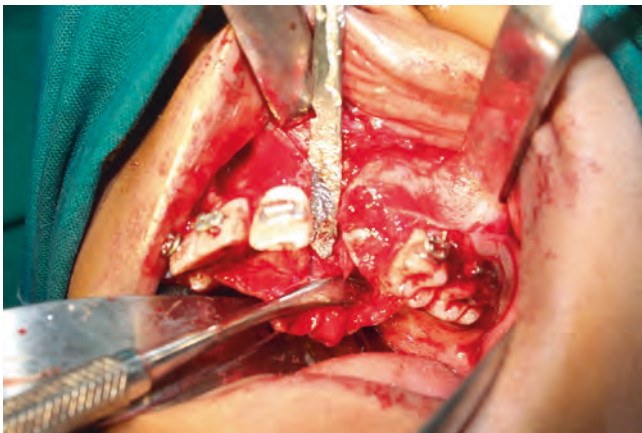
©Association of Oral and Maxillofacial Surgeons of India

Fig. 74.8 Clinical picture demonstrating labial and palatal flap reflection and closure of nasal layer



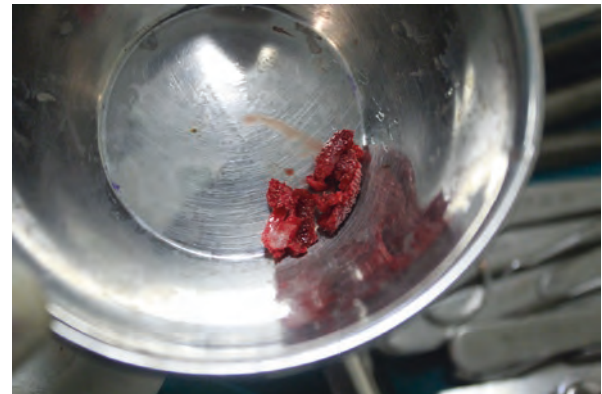©Association of Oral and Maxillofacial Surgeons of India

Fig. 74.11 Exposure of the iliac crest to harvest bone graft



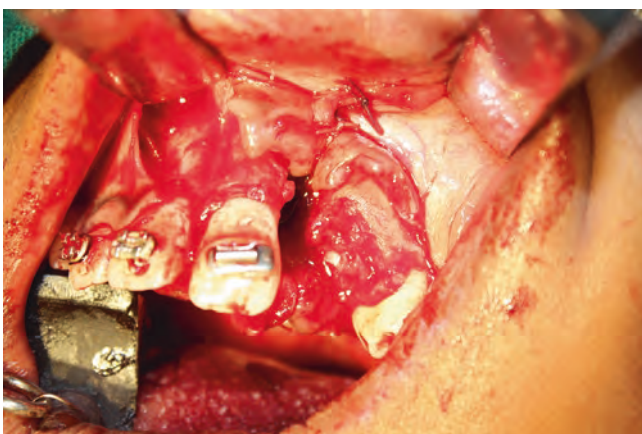
©Association of Oral and Maxillofacial Surgeons of India

Fig. 74.9 Clinical step in which a periosteal elevator is used to define the alveolar cleft after closure of the nasal layer



©Association of Oral and Maxillofacial Surgeons of India

Fig. 74.12 Cancellous bone graft harvested from iliac crest



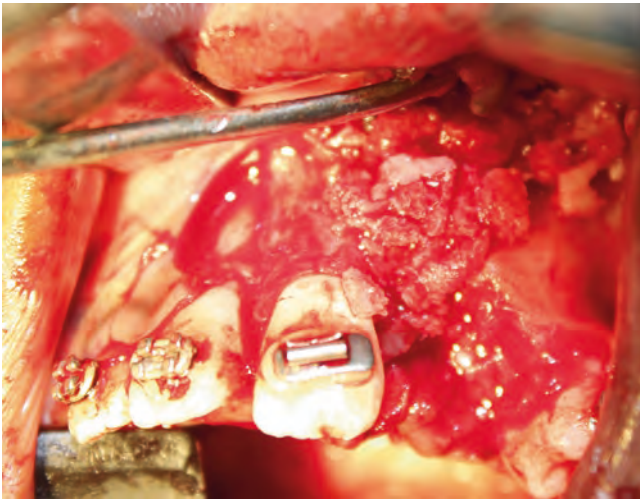
©Association of Oral and Maxillofacial Surgeons of India

Fig. 74.10 Creation of a pouch with closure of the labial flaps in the alveolar cleft region to facilitate bone grafting

sutures so that the knots are on the nasal side. One should mobilize the palatal flaps toward the cleft (Fig. 74.8), utilizing releasing incisions if necessary. The palatal flaps may be sutured using interrupted sutures (Figs. 74.9 and 74.10).

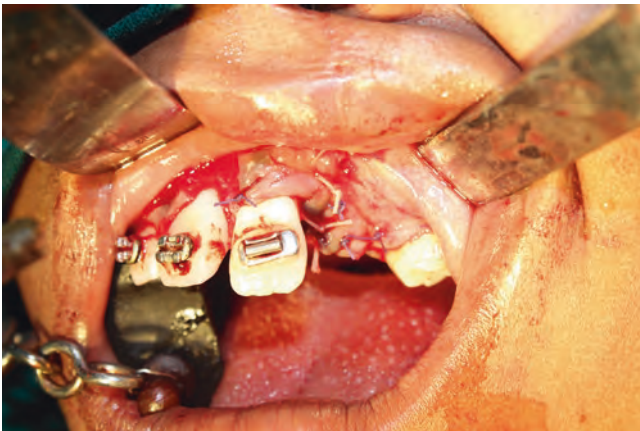The harvested bone is then (Figs. 74.11 and 74.12) condensed into a syringe prior to placement and packed tightly into the exposed bony cleft. While placing the bone graft, it is important to establish a normal contour to the pyriform aperture region. The labial flaps can be then advanced over the graft. This usually requires the utilization of the periosteal-releasing incisions made perpendicular to the direction of the advancement. A tension-free closure is mandatory for this technique (Fig. 74.13).

The two palatal and two labial flaps are then closed, utilizing a suture that simultaneously approximates all four corners. The final closure is completed with interrupted sutures closing the labial flaps and the interdental releases (Fig. 74.14). Closure is performed in a way that retains the attached gingiva overlying the reconstructed alveolus. Rarely, it may not be possible to obtain adequate advancement of flaps which necessitate the use of a cheek flap or a free gingival graft.



©Association of Oral and Maxillofacial Surgeons of India

Fig. 74.13 Grafting of the alveolar cleft using harvested cancellous bone from the iliac crest



©Association of Oral and Maxillofacial Surgeons of India

Fig. 74.14 Watertight closure of the alveolar cleft after grafting

74.5.5 Postoperative Assessment of Alveolar Bone Grafting

The success of alveolar bone grafting depends on certain outcomes, which include Box 74.5.

Box 74.5 Factors Determining Success of ABG

1. Closure of the oronasal fistula.
2. Adequate bone support that allows eruption of the canine and support for adjacent teeth.
3. Architecture of the grafted bone.

Several scales are used to assess the success based on the above criteria. These scales use periapical, panoramic, or occlusal radiographs. A few of these scales are given below:

- *Bergland scale* [12] (Fig 74.15a–d).

This scale is the gold standard of assessment, and success is judged based on the height of the post-graft interdental bone septum. It is assessed after the eruption of permanent canine. Four categories of success are defined, with

Types I and II being satisfactory outcomes and Types III and IV being unsatisfactory:

Type I: Interdental septum height is almost normal (<25% of bone resorption).

Type II: Interdental septum height is equal to or greater than $\frac{3}{4}$ of the normal height (bone resorption 25%–50%).

Type III: Interdental septum height is less than $\frac{3}{4}$ of the normal height (bone resorption 50%–75%).

Type IV: Bone graft failure; no continuous bony bridge is visible across the cleft (bone resorption $\geq 75\%$) (Fig. 74.15).

- *Chelsea scale* [14] (Fig 74.16a–f).

This scale evaluates the presence of bone in relation to the teeth adjacent to the cleft. Based on this, six categories have been identified. Only Types A and C represent satisfactory outcomes.

Type A: Bone tissue is present at the cementoamel junction of the teeth adjacent to the cleft. At least 75% of roots on either side are covered by bone.

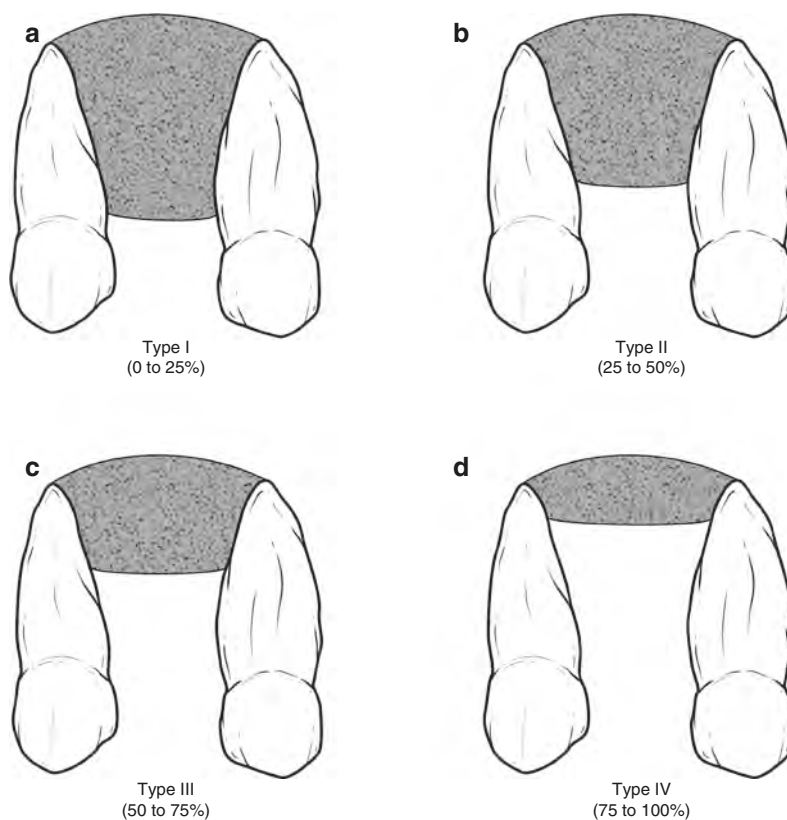
Type B: Bone tissue is present at the cementoamel junction of the teeth adjacent to the cleft. At least 25% of roots on either side are covered by bone.

Type C: Bone tissue is present and surrounds at least 75% of the roots on either side of the cleft, in an apical direction.

Type D: Bone tissue surrounds at least 50% of roots on either side of the cleft, with an apical to coronal direction.

Type E: Bone tissue bridge is present in the cleft, except in the apical and coronal directions.

Type F: Less than 25% of bone tissue is present around both roots in the apical direction (Fig. 74.16).

Fig. 74.15 (a–d) Bergland scale [13]

©Association of Oral and Maxillofacial Surgeons of India

- *Trindade-Suedam scale* [15].

These authors modified the Bergland scale described above and used alphabets to describe success or failure:

E (Excellent): Interdental septum height is normal.

G (Good): The bony septum is visible, with minimal disability.

R (Regular): Bone graft is enough to allow for canine eruption. However, tooth movement is deficient, or a defect that is more than 25% of root length is seen.

B (Bad): Deficient bone in the nasal region, which does not permit tooth movement.

F (Failure): Bone graft is completely resorbed.

- *Kindelan scale* [16].

This scale compares pre-operative and postoperative occlusal radiographs, to assess the percentage of bone fill. This also considers the eruption of the canine.

Grade 1—Bone fill >75% (Fig. 74.17).

Grade 2—Bone Fill 50–75%.

Grade 3—Bone fill <50%.

Grade 4—Complete absence of bone.

74.6 Complications of Alveolar Bone Grafting

The complications of alveolar bone grafting may be witnessed at the donor as well as the recipient site.

Fig. 74.16 (a–f) Chelsea scale [13]. (a) bone present at the Amelo-cemental Junction (ACJ) and covering 75% of both the roots, (b) bone present at the ACJ covering atleast 25% of both the roots, (c) bone covering atleast 75% of both the roots from the apical direction, (d) bone covering atleast 50% of the roots from the apical direction, (e) bony bridge present across cleft but no bone apically or coronally and (f) less than 25% bone cover from the apical direction

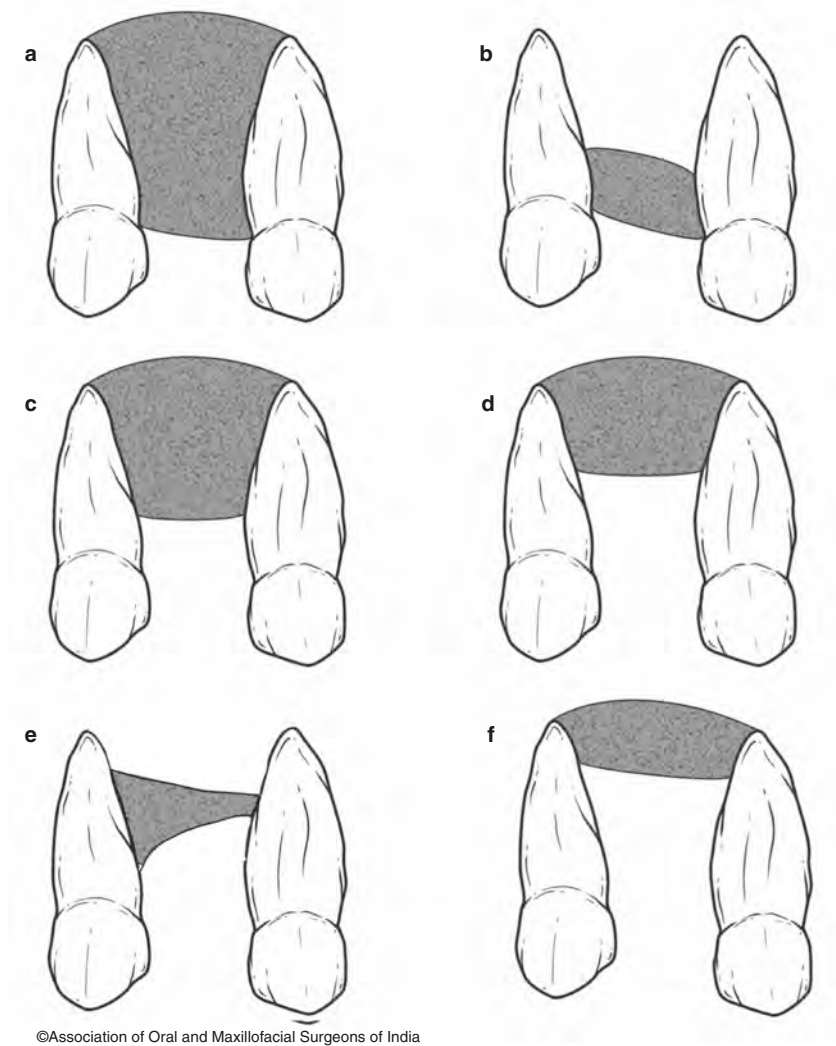
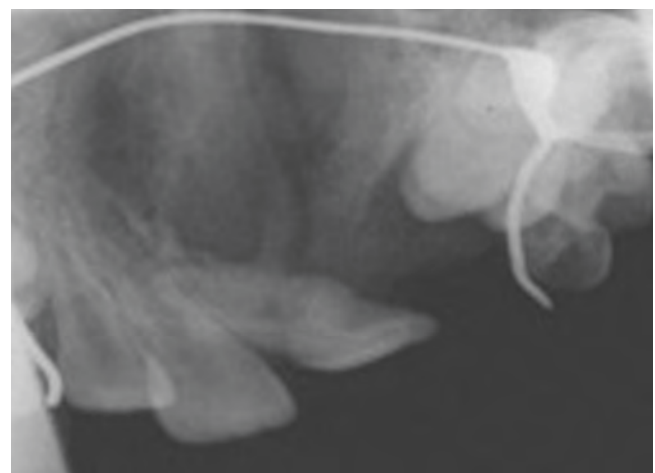


Fig. 74.17 Occlusal radiograph after bone graft with a Kindlean score of 1



74.6.1 Donor Site Complications

The site-specific donor site complications are highlighted in Box 74.6.

74.6.2 Recipient Site Complications

1. Damage to canine or central incisor roots.
2. Graft resorption: Graft resorption signifies complete failure of ABG, which can occur due to the following reasons:
 - (a) Osteoresorptive cells and an environment suitable for bone resorption—this occurs with deciduous tooth extraction.
 - (b) Excessive tension or trauma after surgery, resulting in exposure and loss of the graft.
 - (c) Overpacking of the graft, causing alveolar notching and graft resorption.
 - (d) Poor oral hygiene.

74.7 Conclusion

Alveolar bone grafting aims at restoring the functional integrity of the alveolar arch. In addition, they facilitate the eruption of teeth through the grafted bone into their respective positions. The timing of alveolar bone grafting is very crucial and can be effectively assessed by evaluating the thickness of bone covering the crown (of the lateral incisor or of the canine), rather than the degree of root formation of these teeth. The usage of autologous cancellous bone from the iliac crest is the most widely accepted graft in the mixed dentition period. In recent years, bone substitutes have also been used

Box 74.6 Donor Site Complications

- (a) Iliac crest:
 - Excessive blood loss.
 - Hematoma.
 - Delayed wound healing.
 - Long and adherent and scars under belts or clothing which may be painful.
 - Hypoesthesia or anesthesia over the lateral femoral cutaneous nerve and in its distribution areas.
- (b) Cranium:
 - Risk of inner table penetration.
- (c) Rib grafts:
 - Postoperative chest infection.
 - Pneumothorax.
- (d) Mandible grafts:
 - Injury to mental nerve.

because of a tendency toward limited bone harvesting. These allograft or alloplastic sources of bone graft are especially useful in case of deficient donor autogenous bone material or to minimize donor site morbidity or in complicated cases. However, autologous bone is still the ideal choice for alveolar bone grafting, and none of the currently available methods can replace autologous bone completely. The future trend in alveolar bone grafting could be related to the usage of stem cells for bone regeneration; however many long-term clinical trials have to be conducted using stem cells to ensure its wide usage and cost-effectiveness.

Disclosure Authors have no financial conflicts to disclose.

74.8 Case Scenarios

Case 1 (Fig. 74.18a–f)

An 11-year-old female patient who was treated for unilateral cleft lip and palate on the left side presented with the complaint of leakage of fluid from the nose and escape of air from the oral cavity. She had undergone primary unilateral lip repair when she was 6 months old, and a palatal repair was done when she was 2 years old.

Procedures, which were performed at this stage—fistula closure and alveolar bone grafting.

A sulcular incision along with incision around the fistula was performed both on the labial and palatal side so to enable direct access to the fistula and bony defect. Oral and nasal layers were separated. The nasal layer was initially closed in a watertight manner. Cancellous bone graft was obtained from the iliac crest, and the bone graft was placed into the defect, and watertight closure was obtained.

Future treatment required—pre-surgical orthodontics, orthognathic surgery, post-surgical orthodontics, and rhinoplasty (if required).

Case 2 (Fig. 74.19a–j)

Case Presentation

A 10-year-old female patient who was diagnosed with unilateral cleft lip and alveolus on the left side (Fig. 74.19a, b) reported to us with a chief complaint of leakage of fluid from the nose. She had previously undergone primary lip repair at 8 months of age. An OPG and IOPA revealed the extent of alveolar cleft (Fig. 74.19c, d). Pre-surgical orthodontic treatment was started to align the teeth and facilitate the eruption of 23 (Fig. 74.19e).

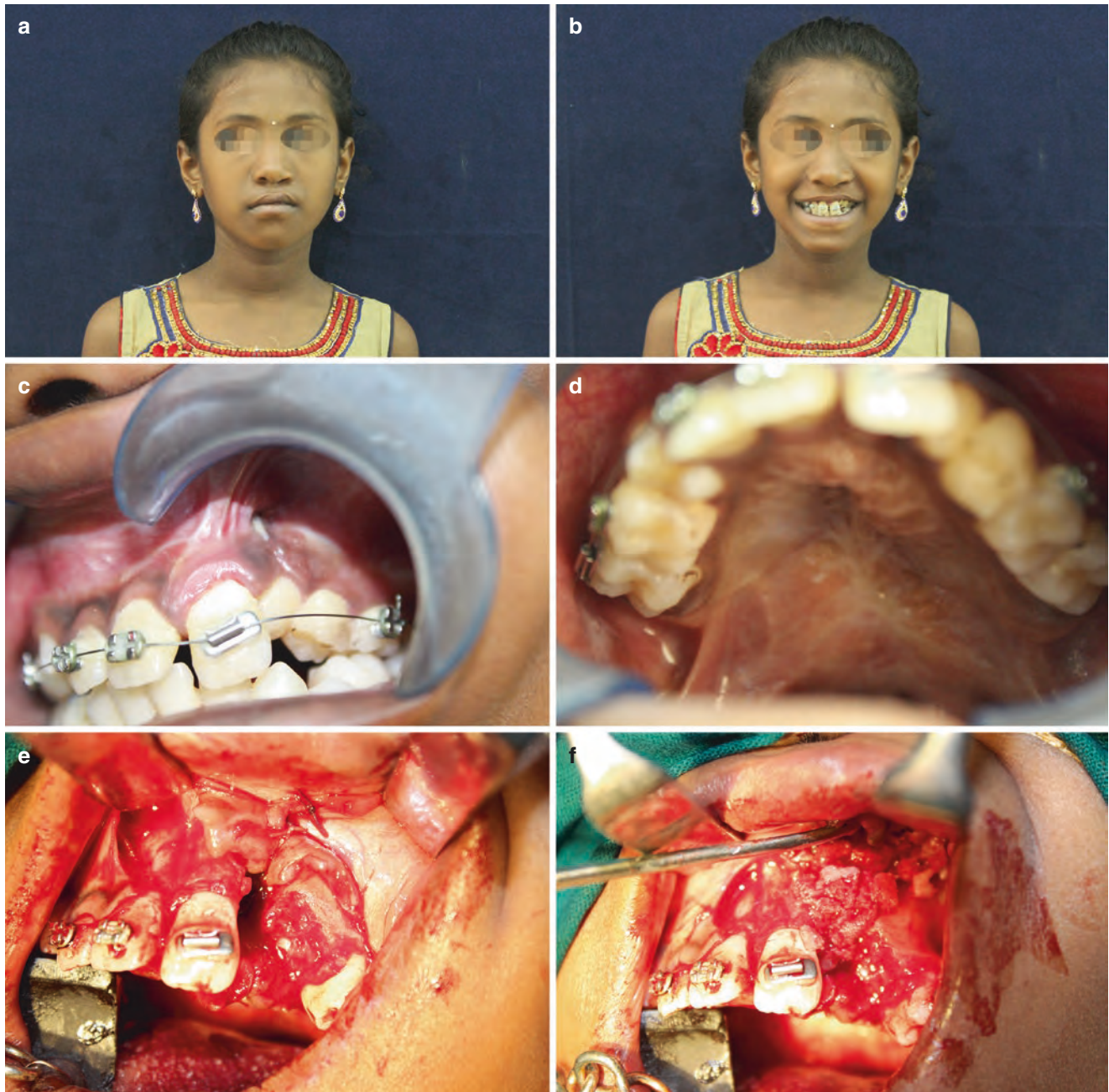Procedures, which were performed at this stage—fistula closure and alveolar bone grafting.

A sulcular incision was placed around the involved teeth both on labial and palatal sides which exposed the fistula and

the alveolar defect. A careful dissection was performed so as to separate the nasal layer and oral layer. The nasal layer was initially closed in a watertight manner. An adequate quantity of cancellous bone graft was harvested from the iliac crest. Thus obtained bone graft was placed into the alveolar defect, and a watertight closure was performed (Fig. 74.19f). The alveolar bone graft was assessed 6 months post-surgery using IOPA (Fig. 74.19g). The orthodontic treatment was completed after facilitating the eruption of canine and achieving leveling and alignment of teeth (Fig. 74.19h, i, j).

Future treatment required—Patient has to be assessed after growth completion, and if required the following treatment will have to be carried out:

- Pre-surgical orthodontics.
- Orthognathic surgery.
- Post-surgical orthodontics.
- Rhinoplasty.



©Association of Oral and Maxillofacial Surgeons of India

Fig. 74.18 (a–f) (a) Extraoral frontal picture at rest. (b) Extraoral frontal picture at smile. (c) Intraoral picture demonstrating fistula. (d) Palate post-repair. (e) Creation of a pouch in the alveolar cleft region to

facilitate bone grafting. (f) Grafting of the alveolar cleft using harvested cancellous bone from the iliac crest. (Fig. 74.14 shows Watertight closure of the alveolar cleft case shown in Fig. 74.18, after grafting)

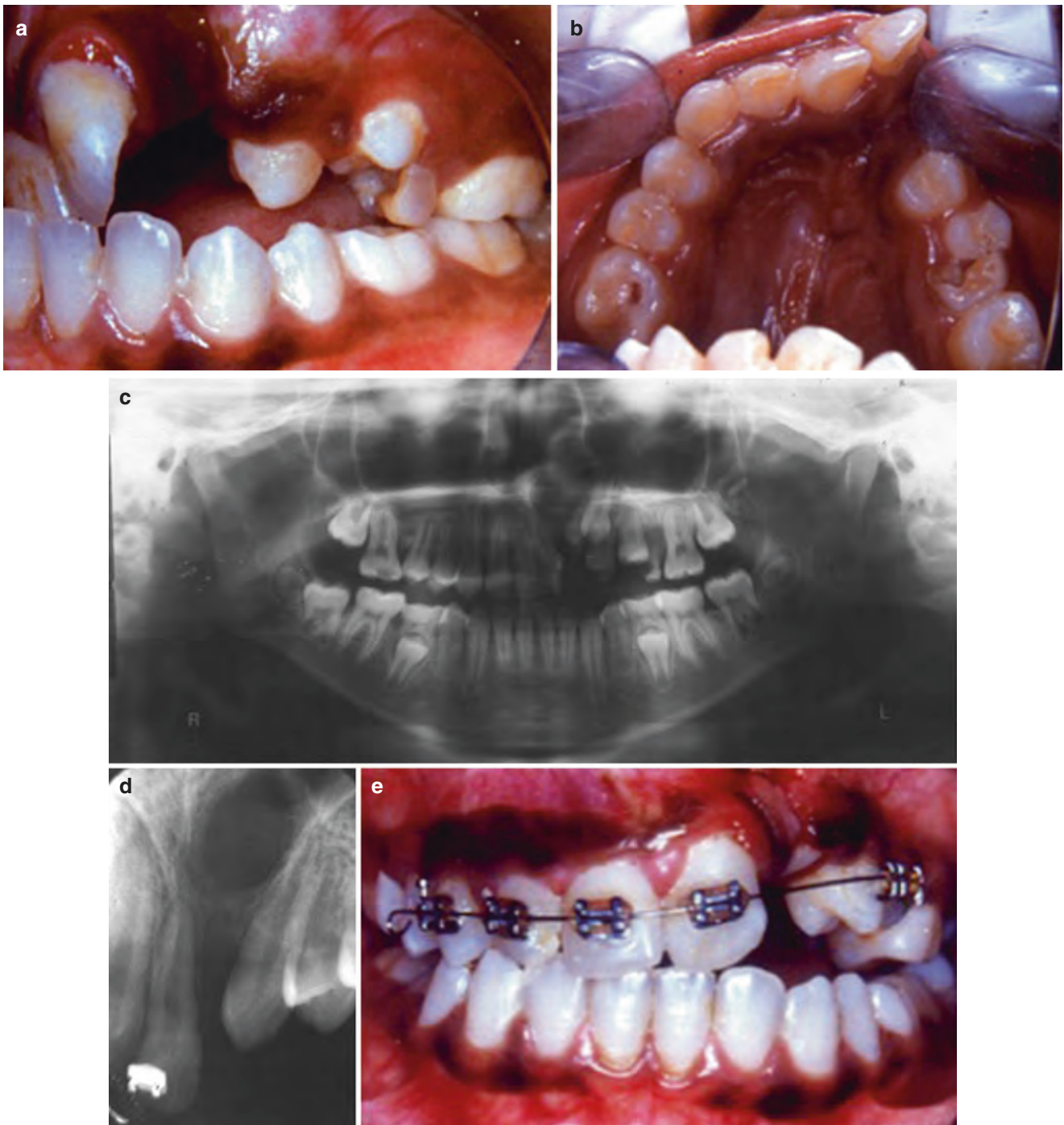
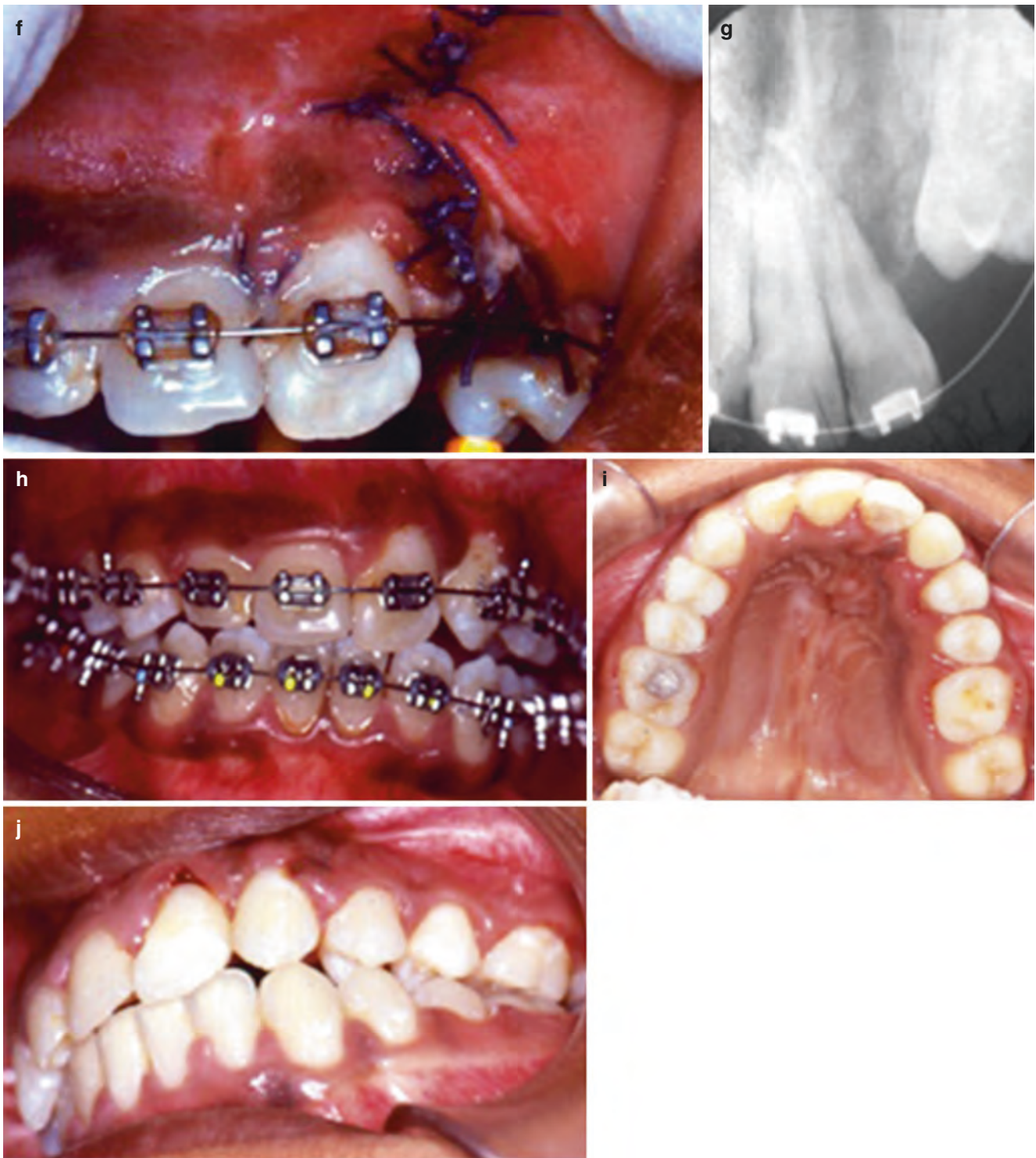


Fig. 74.19 (a–j) (a) Intraoral frontal picture demonstrating alveolar cleft on the left side of maxilla and associated fistula. (b) Intraoral maxillary occlusal picture demonstrating alveolar cleft and fistula. (c) OPG demonstrating the alveolar cleft on the left side and the eruptive status of the upper left permanent canine. (d) IOPA demonstrating the presence of alveolar cleft between upper left central incisor and upper left canine. (e) Intraoral frontal picture. Orthodontic treatment to facilitate tooth alignment and eruption of permanent upper left canine. (f) Intraoral picture demonstrating the completion of alveolar bone graft-

ing. (g) IOPA demonstrating the uptake of alveolar bone graft in the region of alveolar cleft between upper left central incisor and upper left canine. (h) Intraoral frontal picture demonstrating orthodontic treatment. The permanent canine on the left side has been clinically moved to the occlusal plane. (i) Intraoral maxillary occlusal photograph post-orthodontic treatment demonstrating the eruption and alignment of upper left canine in the alveolar arch. (j) Intraoral photograph post-orthodontic treatment demonstrating the eruption and alignment of upper left canine in the alveolar arch



©Association of Oral and Maxillofacial Surgeons of India

Fig. 74.19 (continued)

References

1. McCarthy JG, editor. Plastic surgery. vol 1, General principles. Philadelphia: Saunders. p. 77.
2. Boyne PJ, Sands NR. Combined orthodontic-surgical management of residual palato-alveolar cleft defects. *Am J Orthod* 1976 Jul;70(1):20–37. PubMed PMID:782258.
3. Boyne PJ, Sands NR. Secondary bone grafting of residual alveolar and palatal clefts. *J Oral Surg* 1972 Feb;30(2):87–92. PubMed PMID: 4550446.
4. Peterson's principles of Oral and Maxillofacial surgery, chapter 43, 2:867.
5. Deatherage J. Bone materials available for alveolar grafting. *Oral Maxillofac Surg Clin North Am*. 2010 Aug;22(3):347–52.
6. Swan MC, Goodacre TEE. Morbidity at the iliac crest donor site following bone grafting of the cleft alve. *Br J Oral Maxillofac Surg*. 2006;44:129–33.
7. Enemark H, Jensen J, Bosch C. Mandibular bone graft material for reconstruction of alveolar cleft defects: long-term results. *Cleft Palate Craniofac J*. 2001, March;38(2):155–63.
8. Hughes CW, Revington PJ. The proximity tibia donor site in cleft alveolar bone grafting: experience of 75 consecutive cases. *J Cranio Maxillofac Surg*. 2002;30:12–6.
9. Borstlap WA, Heidbuchel KLWM, Freihofe HPM, Kuijpers-Jagtman AM. Early secondary bone grafting of alveolar cleft defects – a comparison between Chin and Rib grafts. *J Cranio Max Fac Surg*. 1990;18:205.
10. Hibi H, Yamada Y, Ueda M, Endo Y. Alveolar cleft osteoplasty using tissue-engineered osteogenic material. *Int J Oral Maxillofac Surg*. 2006;35:551–5.
11. Chin M, Ng T, Tom WK, Carstens M. Repair of alveolar clefts with recombinant human bone morphogenetic protein (rhBMP-2) in patients with clefts. *J Craniofac Surg*. 2005;16(5):778–89.
12. Bergland O, Semb G, Abyholm F. Elimination of residual alveolar clefts by secondary bone grafting and subsequent orthodontic treatment. *Cleft Palate J*. 1986;23:175–205.
13. Khalil W, De Musis C, Volpato L, Veiga KA, EMM V, Aranha A. Clinical and radiographic assessment of secondary bone graft outcomes in cleft lip and palate patients. *Int Sch Res Notices*. 2014;2014:1–8.
14. Witherow H, Cox S, Jones E, Carr R, Waterhouse N. A new scale to assess radiographic success of secondary alveolar bone grafts. *Cleft Palate Craniofac J*. 2002;39(3):255–60.
15. Trindade-Suedam IK, da Silva Filho OG, Carvalho RM, et al. Timing of alveolar bone grafting determines different outcomes in patients with unilateral cleft palate. *J Craniofac Surg*. 2012;23(5):1283–6.
16. Kindelan JD, Nashed RR, Bromige MR. Radiographic assessment of secondary alveolar bone grafting in cleft lip and palate patients. *Cleft Palate Craniofacial J*. 1997;34:195–8.

Open Access This chapter is licensed under the terms of the Creative Commons Attribution 4.0 International License (<http://creativecommons.org/licenses/by/4.0/>), which permits use, sharing, adaptation, distribution and reproduction in any medium or format, as long as you give appropriate credit to the original author(s) and the source, provide a link to the Creative Commons license and indicate if changes were made.

The images or other third party material in this chapter are included in the chapter's Creative Commons license, unless indicated otherwise in a credit line to the material. If material is not included in the chapter's Creative Commons license and your intended use is not permitted by statutory regulation or exceeds the permitted use, you will need to obtain permission directly from the copyright holder.





75.1 Introduction

Studies of adult patients with unoperated cleft lip and palate (CLP) indicate that the maxilla in the unoperated patient is normally positioned or protruded. There are two major factors contributing to the protruded maxilla. The first is the absence of normal functional forces that are provided by the perioral muscle and tissue continuity. The tongue pressure pushes the teeth and the alveolus forward while the pressure from the cleft lip and affected perioral tissues is insufficient to balance this force out. The second factor contributing to the prognathic maxilla is the missing surgical scar [1–3].

Studies comparing unoperated cleft lip cases versus those with cleft lip repair show minimal difference in the growth of the maxilla. Thus, it has been proven that cheiloplasty has little effect on the growth of the maxilla and its dentition. On the other hand, palatal surgery has been identified as the main cause of inhibition of midface growth. Scar tissue forms across sutural areas as a result of palatoplasty surgery. This scar tissue interferes in the downward and forward translation of the maxilla that plays a major role in normal development. Furthermore, the scar tissue across the palate

causes the constriction of the maxilla leading to a collapsed bite or crossbite [1–3].

Maxillary hypoplasia is a secondary deformity that occurs as a result of cleft lip and palate surgery with a reported incidence of about 9–45% with isolated cleft lip cases having the lowest incidence. The need for surgical correction of the same can be identified as early as age 10. Factors frequently associated with maxillary hypoplasia are congenitally missing maxillary teeth, revision palatoplasty procedures, pharyngeal flaps, and delayed orthodontic care [4–7]. However, recent evidence has suggested that presence of a pharyngeal flap does not affect maxillary growth [8].

75.2 Features of Cleft Maxillary Hypoplasia

Cleft maxillary hypoplasia presents as a three-dimensional deficiency. The degree of deficiency increases with the severity of orofacial clefting and affects different anatomical subunits, e.g., dentoalveolar, para-nasal, infra-orbital, and zygomatic regions. The clinical features associated with cleft maxillary hypoplasia are described in Boxes 75.1–75.3 [1–3, 7].

The presence of the cleft alveolus causes the dentoalveolar segment to collapse palatally on the affected side(s) leading to the creation of anterior and posterior crossbites. The failure to perform an alveolar bone grafting and orthodontics during the growing phase increases the severity of the malocclusion [9, 10]. The extent of this abnormal growth of the midface varies from mild to severe and is also affected by genetic endowment, the severity of clefting (extent of orofacial and labio-palatal involvement), timing of surgery, surgeon skills, and the number of primary and revision surgeries performed in the process of re-habilitating the patient. It has not been conclusively proven if any particular palate closure technique or if a staged technique has reduced effects on maxillary growth. It is the author's opinion that techniques that leave a raw area on the palate like push-back palatoplasty are generally associated with greater maxillary regression [1–3, 11–15].

Disclosures: The authors have no financial conflicts to disclose

Electronic Supplementary Material The online version of this chapter (https://doi.org/10.1007/978-981-15-1346-6_75) contains supplementary material, which is available to authorized users.

P. Mathew (✉)

Head of Department of Oral and Maxillofacial Surgery, Jubilee Mission Medical College and Hospital, Thrissur, Kerala, India

Mustafa. K

Department of Craniofacial Surgery, Kanachur Institute of Medical Sciences, Mangalore, Karnataka, India

P. Mathai

Senior Resident cum Fellow of Orthognathic Surgery, Department of Oral and Maxillofacial Surgery, Jubilee Mission Medical College and Hospital, Thrissur, Kerala, India

Box 75.1: Primary Features of Cleft Maxillary Hypoplasia

- Concave facial profile
- Class 3 skeletal relationship,
- Increased scleral show,
- Lack of normal cheek contour,
- Inadequate support of nasal tip and upper lip,
- Short upper lip and Acute nasolabial angle [subject to variability],
- Steep mandibular plane angle,
- Retruded chin,
- Decreased posterior facial height,
- Increased anterior facial height,
- Anterior and posterior cross bites,
- Increased mandibular plane – cranial base angle,
- Anterior open bite [less common],
- Chin and mandibular skeletal asymmetry [less common].

Box 75.2: Secondary Residual Deformities in Cleft Lip and Palate Patients

- Speech and hearing impairments (chronic otitis and velopharyngeal insufficiency)
- Residual oronasal fistula
- Residual bony defects
- Obstructive nasal breathing (septum deformity/enlarged inferior turbinates/intranasal strictures/enlarged tonsils and adenoids/pharyngeal flaps)

Box 75.3: Dental Anomalies in Cleft Lip and Palate Patients

- Delayed eruption of teeth, severe crowding of arches (with impacted, malformed and supernumerary teeth)
- Palatally collapsed dentoalveolar segments (cleft side)
- Anterior and posterior crossbites
- Anomalous or missing lateral incisor, infra-erupted, rotated, and tipped cleft-adjacent teeth

In most cases, photographic and cephalometric analysis reveals that the mandibular plane-cranial base angle is increased leading to a more backwardly placed mandible. Thus, the mandible tends to have a mild retrognathic appear-

ance in spite of having normal dimensions. An anterior open bite is observed if the patient has an underlying tongue thrust habit as well. In certain rare cases, the chin and mandible may also exhibit a degree of skeletal asymmetry [1–3] (Box 75.2).

The need for orthognathic surgery should be based not only on occlusion and jaw relationship but also on facial proportions, midface projection, and complaints of the patient [1–3].

75.3 Objectives of Treatment (Box 75.4)**Box 75.4: Objectives of Treatment in Cleft Maxillary Hypoplasia**

1. To improve facial aesthetics
2. To improve psychological health
3. Achieve adequate occlusion for efficient mastication
4. Improve phonation and airway dimensions
5. Avoid deterioration of velopharyngeal insufficiency

75.4 Sequencing Treatment in CMH (Box 75.5)**Box 75.5: Sequencing Treatment in CMH**

1. Growth modulation—7–16 years.
2. Phase 1 orthodontics—7–11 years
3. Alveolar bone grafting—8–11 years
4. Phase 2 orthodontics—12–17 years
5. Anterior maxillary distraction—after 12 years
6. Orthognathic surgery at 17 years and up
7. Phase 3 orthodontics after orthognathic surgery

75.5 Orthodontics in Cleft Lip and Palate Patients

Owing to the severity of the condition, period of orthodontics can be prolonged and is carried out in three phases. Sometimes patients with CLP have a limited ability to open their mouth further increasing the difficulty of orthodontic treatment.

Phase 1 Treatment It is carried out between 7 and 12 years of age. Maxillary transverse expansion is carried out in cases

that present with maxillary constriction. Maxillary protraction may be carried out in cases with significant midface regression. This phase also involves monitoring facial growth, space management, monitoring eruption of permanent teeth, and preventing ectopic eruption of permanent teeth [1–3].

In preparation for secondary alveolar bone grafting, extractions of supernumerary teeth and deciduous teeth on either side of the cleft and closure of oronasal fistulae are performed [16]. Box 75.6 outlines the controversy regarding whether maxillary expansion should be performed before or after alveolar bone grafting [17–19].

Box 75.6: Arch expansion, before or after Alveolar Bone Grafting (ABG)

Expansion before ABG	Expansion after ABG
Greater expansion can be achieved with the lower bony resistance between the maxillary segments	Though expansion is possible, the degree of expansion obtained is less predictable
Nasal floor mucosa layer can be easily visualized and reconstructed as the cleft has been widened	Difficult to visualize and reconstruct the nasal floor mucosa layer as the cleft is narrow
Widening of the cleft alveolus leads to increased tension on the overlying suture site after grafting, which increases the risk of wound dehiscence and graft failure	As the cleft is narrow at the time of grafting, there is lesser tension on the overlying suture site after grafting, which reduces the risk of wound dehiscence and graft failure
Increased risk for cleft-adjacent teeth moving into the cleft alveolus while widening, thus compromising their periodontal support	Decreased risk of loss of periodontal support as the teeth will move into an already grafted cleft alveolus
Clinical studies have shown that there is minimal risk for graft loss when expansion was performed before grafting	Clinical studies have shown that bone graft was not lost when expansion was performed after grafting; instead, some degree of stimulation of graft took place

Phase 2 (Presurgical phase) Treatment It is carried out between 12 and 17 years of age. It involves maintaining the previously attained expansion and further expanding the arch in cases of relapse or if no prior expansion was done. In case the skeletal discrepancy is minimal, we can also consider camouflage orthodontics to correct the occlusal discrepancy. Camouflage orthodontics involves correction of crowding and rotations, extraction of teeth that have erupted ectopically

and cannot be accommodated, proclination of maxillary incisors, and retraction of mandibular incisors.

In case the skeletal discrepancy is moderate to severe, then we will have to consider surgical correction (distraction osteogenesis or orthognathic surgery) of the deformity. Presurgical fixed orthodontics is started to facilitate the planned skeletal movements and is described in Box 75.7.

Box 75.7: Objectives of Pre-surgical Orthodontics

- Removal of dental compensations
- Alignment of teeth, de-crowding and de-rotation of teeth
- Flattening of the curve of Spee
- Incorporating divergence in roots for segmental osteotomies
- Co-ordination of dental arches

In case the lateral incisor is missing, the decision to maintain space for prosthetic rehabilitation or substitute it with the adjacent canine needs to be made during this phase [1–3]. There is also a need to extract the mandibular third molars in case a bilateral sagittal split osteotomy is planned. There is an increased risk for bad splits associated with un-erupted and impacted mandibular third molars in the age group of less than 20 years on account of thinner and immature cortical bone [20].

Phase 3 (Postsurgical Phase) Treatment It is performed after surgical correction of the facial deformity (orthognathic surgery or distraction osteogenesis). It involves fine-tuning of the occlusion and maintaining achieved results in the long term through retentive appliances. One may have to consider re-creating dental compensations to accommodate for increased rates of relapse after cleft-orthognathic surgery.

75.6 Considerations Before Surgery

75.6.1 Timing of Surgery

Facial growth is normally completed by 16 years of age in females and by 17 years of age in males. It is advisable to perform orthognathic surgery only after skeletal maturity is achieved, in order to increase stability of the surgical results in the long term. In selective cases, orthognathic surgery is performed during growth for psychosocial or functional rea-

sons. However, this has shown unpredictable results because of continued growth of the mandible with relapse rates in the range of 50–70% when operated before 18 years of age [2, 21, 22].

As an alternative, one may consider distraction osteogenesis prior to 17 years of age. A study by Meazzini et al. [23] reported a relapse rate of 26% in the long term when distraction osteogenesis of the maxilla was carried out during the growing phase. A systematic review by Liu et al. [24] reported a relapse rate 12–46% at “point A” and 26–77% for the SNA angle in the long term. Thus, the patient will require additional surgery after skeletal maturity for correction of the residual facial deformity, irrespective of whether distraction osteogenesis or orthognathic surgery was performed.

75.6.2 Status of Alveolar Bone Grafting and Oronasal Fistulae

Patients with cleft lip and palate usually present with a cleft alveolus. This cleft communicates with the nasal cavity, thus, creating an oronasal fistula. The cleft is also a source of weakness in the maxillary arch and increases the risk of arch collapse, thus, creating dentoalveolar deformities (e.g., crossbites) which make later surgical procedures like orthognathic surgery unstable. Lastly, the permanent teeth that erupt into the cleft will have a poor prognosis due to lack of bony support and inadequate periodontium. Thus, it is of utmost importance to graft the cleft alveolar region, and the benefits associated with it are described in Box 75.8 [9, 25].

Box 75.8: Benefits of Alveolar Bone Grafting

Reduction of oronasal fistula, creation of continuity of the maxillary alveolar arch, eruption of permanent teeth into the cleft site, elevation of the alar nasal base, and stability for future surgical procedures like orthognathic surgery and rhinoplasty

A prerequisite to a successful alveolar bone grafting is the closure of oronasal fistulae. Small fistulae can be closed at the time of grafting. However, the presence of a large fistula requires a staged reconstruction with the fistula closure initially and alveolar bone grafting later.

It is not rare to see a patient with a complaint of maxillary regression who presents at a later age (17 years and above) with a history of no alveolar bone grafting or failed alveolar bone grafting. If we proceed with a LeFort I osteotomy in this clinical scenario, the difficulty of the surgical procedure increases significantly as the maxilla is not a single unit.

There are three possible treatment protocols that we can follow:

1. The patient is willing to undergo a staged approach with alveolar bone grafting followed by orthognathic surgery at later stage. Though this is the ideal approach, it adds to the cost and time of overall treatment. It is important to note that tertiary alveolar bone grafting has an overall lower success rate [26, 27].
2. The patient is willing to undergo alveolar bone grafting as long as it is done simultaneously with orthognathic surgery. This approach saves time and cost of overall treatment. Keeping in mind that tertiary alveolar bone grafting already has a lower success rate; it is the author’s opinion that risk for graft failure might increase when this step is combined with orthognathic surgery. This is on account of the compromise in vascularity that occurs as extensive mucoperiosteal flap refelction is performed to accommodate orthognathic surgery.
3. In case the patient wants to avoid bone grafting, one can use the modified LeFort I osteotomy approach by Posnick et al. [3, 28, 29]. It allows for simultaneous correction of maxillary hypoplasia, cleft dental gaps, alveolar defects, and small residual oronasal fistulas through the use of modified skeletal osteotomies. The cleft alveolar defect is closed by differential repositioning of the cleft maxilla segments. This technique requires a transverse plate to be placed across the cleft site just below the pyriform aperture so as to convert the cleft-maxilla into a single unit. In a study by Posnick et al. [30], the modified LeFort I osteotomy technique had stable results in more than 90% of the subjects at 1 year with a low complication rate. It is the author’s opinion that along with the midline transverse plate, one can also use a dental prosthesis (fixed partial denture) spanning the cleft alveolus site to add stability to the cleft maxilla. However, there is a risk for failure of the prosthesis and loss of abutment teeth in the long term due to increased movement across the cleft alveolus site.

75.6.3 Velopharyngeal Insufficiency (VPI)

If air or sound is allowed to leak through or resonate in the nasal cavity during the production of the non-nasal sounds (all phonemes except /m/, /n/, and /ng/), speech will be marked by hyper-nasality (nasal twang) and nasal air emission. VPI describes a structural or anatomic defect that prevents closure of the velopharyngeal mechanism during function. It is most commonly observed in patients with an overt cleft palate (unoperated > operated cases) and submucous cleft palate. In operated cleft palate patients, the incidence of VPI can range between 20 and 50% [31]. Chua et al. [32] and Pereira et al. [33] proposed the usage of perceptual speech assessment, acoustic measurement with

nasometer, video nasoendoscopy (or video fluoroscopy), and cephalometric analysis for the assessment of preoperative speech and VPI.

When the maxilla is advanced in operated cases of the cleft palate, speech articulation is improved on account of improved lip competency and correction of previous dental malocclusion [34, 35]. There is also an associated increase in the velopharyngeal cavity depth [36]. As compared to the normal palate, the scarred cleft palate has decreased ability to adapt to such changes as it is unable to stretch adequately [37]. This leads to an increase in the risk for worsening of preoperative VPI. The effect of maxillary advancement on VPI, especially in cleft palate patients, is still a controversial topic [34, 38].

There are two methods that are commonly used to advance the maxilla as given in Box 75.9.

Box 75.9: Methods Used for Maxillary Advancement

1. Distraction osteogenesis: total maxillary distraction and anterior maxillary distraction
 - (a) Total maxillary distraction: internal maxillary distraction and rigid external distraction
2. Conventional orthognathic surgery

The theoretical advantage of distraction is that the maxilla is advanced slowly which allows the patient to adapt to the changes in the velopharyngeal dimensions through increased velar muscle activity. Furthermore, distraction can be halted at any point of time that speech begins to deteriorate. Orthognathic surgery, unlike distraction, creates an immediate surgical advancement of the maxilla and does not allow speech to be assessed incrementally or allow for gradual adaptation of the palate to the increase in the velopharyngeal cavity depth.

A randomized controlled trial by Chua et al. [32] for moderate maxillary advancement (4–10 mm) in cleft patients demonstrated that distraction osteogenesis had no advantage over orthognathic surgery for the purpose of preventing velopharyngeal incompetence and speech disturbance. Furthermore, no correlation was found between the amount of advancement and speech parameters. However, it should be noted that extreme advancements of the maxilla (greater than 10 mm) were excluded from the study.

A study by McComb et al. [37] helped identify predictors for worsening of VPI in cases of cleft maxillary advancement using conventional orthognathic surgery. Short preoperative soft palate, large postoperative velopharyngeal cavity depth, preoperative perceptual speech assessment, nasometry, and video nasoendoscopy were identified as clinically significant predictors. Preoperative velopharyngeal cavity depth was not considered a satisfactory predictor as changes in the velopharyngeal space did not correspond proportionally to maxillary advancement [39]. Lastly, the span of

maxillary advancement (2–16 mm) did not show a significant association with the worsening of VPI [37].

Janulewicz et al. [35], Philips et al. [40], Alaluusua [41], Smedberg [42], Seok-Kwun Kim et al. [43], Kelly Schultz et al. [44], and Pereira et al. [33] studied the relation between postoperative worsening of VPI and maxillary advancement using conventional LeFort I osteotomy in cleft patients. They established that preoperative borderline and higher grades of VPI were highly prone to worsening in the postoperative phase. Absent to negligible VPI pre-operatively, carries minimal risk of worsening during the post-operative period. Furthermore, the amount of maxillary advancement and the cleft type did not influence the degree of worsening of VPI. In the author's opinion, the only confounding factor in the above studies was that some of the patients already had a preoperative pharyngeal flap.

A study by Trindade et al. [45] suggested that deterioration in the VPI after orthognathic surgery was transient and improved over time. Compensatory changes are known to occur in the velopharyngeal region during that time as documented by the study of Yu Wu et al. [36]. The velar length and angle and the velopharyngeal depth all increased. However, velar thickness, posterior pharyngeal wall thickness, and velar motility remained unchanged. During certain phonations, the motion of the posterior pharyngeal wall and the thickness of the Passavant's ridge increased significantly. Thus, it is advisable to wait for at least 1 year prior to considering surgical correction for VPI [35].

Poole et al. [46] and James et al. [47] suggested alternative surgical approaches to the routine LeFort I maxillary advancement which involved transecting the palatal mucosa followed by mobilizing the soft palate lying distal to the incision. This was combined with strategically placed vertical incisions in the maxillary buccal mucosa to avoid circulation injury. The advantage of the procedure was that the maxilla could be advanced by large amounts without worsening of speech and VPI as the soft palate did not move anteriorly with the maxilla. The disadvantage of the procedure was that a significant portion of the palate was left denuded and was expected to heal secondarily. Though the results were promising, the techniques did not become mainstream.

Anterior maxillary distraction (AMD) is a versatile, stable, and simple technique that can be used to correct the maxillary dentoalveolar regression in the cleft maxilla after the mixed dentition phase (Video 75.1). As the osteotomy is anterior to the junction of the hard and soft palate, the velopharyngeal dimensions and soft palate activity are not affected. Thus, it is considered optimal for the correction of cleft maxillary regression in cases with preoperative moderate to severe VPI. When used in the age group of 10–16 years, there is also an associated posterior movement of the distal maxilla owing to the elasticity of the bone which may also reduce preoperative VPI to a certain extent. An added advantage is that the increased arch length can be used to accommodate un-erupted teeth and correct crowding [48–53].

In case postoperative VPI develops, it is advisable to wait and watch for at least 1 year prior to resorting to surgical correction. During this period, one can try conservative methods like speech therapy and bulb palatal lift prosthesis and minimally invasive methods like autologous fat injections into the soft palate and the posterior pharyngeal wall [31, 54, 55]. If the VPI does not improve to a clinically acceptable level even after a year, then surgical options need to be considered.

In terms of risk of development of postoperative obstructive sleep apnea, Furlow palatoplasty and buccal myomucosal flaps have the least adverse effect followed by sphincter pharyngoplasty and finally pharyngeal flap which has the most adverse effect [56, 57]. Nonetheless, the pharyngeal flap is the most commonly used method, and a recent paper by Dentino et al. [58] demonstrated that the superiorly based pharyngeal flap was highly successful in correcting VPI after cleft maxillary advancement.

75.6.4 Degree of Maxillary Hypoplasia

The classification of cleft maxillary hypoplasia is given in Box 75.10.

Box 75.10: Classification of Maxillary Hypoplasia

- Mild cases—reverse overjet below 6 mm
- Moderate cases—reverse overjet between 6 and 10 mm
- Severe cases—reverse jet between 11 and 16 mm
- Extreme cases—reverse overjet equal to or greater than 17 mm

The above classification of maxillary hypoplasia needs to be combined with the age at which the patient presents for optimal treatment planning. It should be noted that the regression is calculated only on the basis of reverse dental overjet. The presence or severity of para-nasal hollowing is not accounted for in the above classification.

75.7 Treatment Plans

75.7.1 Pearls for Treatment Planning

- If surgical treatment (distraction osteogenesis or orthognathic surgery) is performed prior to the skeletal maturity, there is a high chance of relapse due to continued skeletal growth. Thus, additional surgery will be required to correct the residual skeletal deformity. Nonetheless, distraction osteogenesis is preferred over orthognathic surgery in the growing patient.
- Time constraints and patient's needs might require you to modify the ideal treatment plan. Though the overall facial profile is important, it is equally essential to establish a functional occlusion with positive overjet and good intercuspation as they go a long way in preventing relapse.
- Procedures like camouflage orthodontics, face mask protraction, and anterior maxillary distraction produce a greater change at the dentoalveolar level and fail to significantly improve para-nasal hollowing. In case of AMD, the anterior maxillary osteotomy does not extend sufficiently enough in to the posterior and superior aspect of the zygomaticomaxillary buttress region.
- Orthognathic surgery and total maxillary distraction (TMD; subtypes, internal maxillary distraction and rigid external distraction) can both correct para-nasal hollowing when combined with a modified high-level LeFort I osteotomy.
- While operating, the facial profile and occlusion can be immediately appreciated during orthognathic surgery. Results can similarly be approximated in total maxillary distraction (TMD) by activating the distractor to the desired extent on the operating table. This is possible as the posterior extent of a conventional LeFort I osteotomy lies in the region of the more mobile soft palate.
- While performing anterior maxillary distraction, the final facial profile and occlusion cannot be immediately appreciated on the OT table as the posterior extent of the maxillary osteotomy lies anterior to the permanent first molar. The palatal mucosa in this region is firmly attached to the underlying bone, and excessive activation of the distractor can lead to stripping of the mucosa from the underlying bone.
- Masticatory efficiency is not significantly compromised during AMD, as the device is fairly rigid and the posterior limit of the osteotomy is anterior to the permanent first molars. A complete LeFort I osteotomy, like that used in total maxillary distraction (TMD), reduces masticatory efficiency on account of increased mobility of the whole maxilla on the application of masticatory loads.
- One needs to take into account that a reverse overjet of "x mm" requires a net advancement of "x + 2 mm" to obtain adequate overjet and overbite. Hence, a reverse overjet of 8 mm requires a net advancement of 10 mm for adequate correction. If one wants to accommodate for expected relapse, then one needs to overcorrect by at least 20%. Hence, the actual amount of advancement required would be 10 + 2, i.e., 12 mm.
- Limits of movements with orthognathic surgery: Conventional orthognathic surgical advancement of the maxilla beyond 10 mm increases the risk of relapse on account of the scar tissue in the soft palate and upper lip

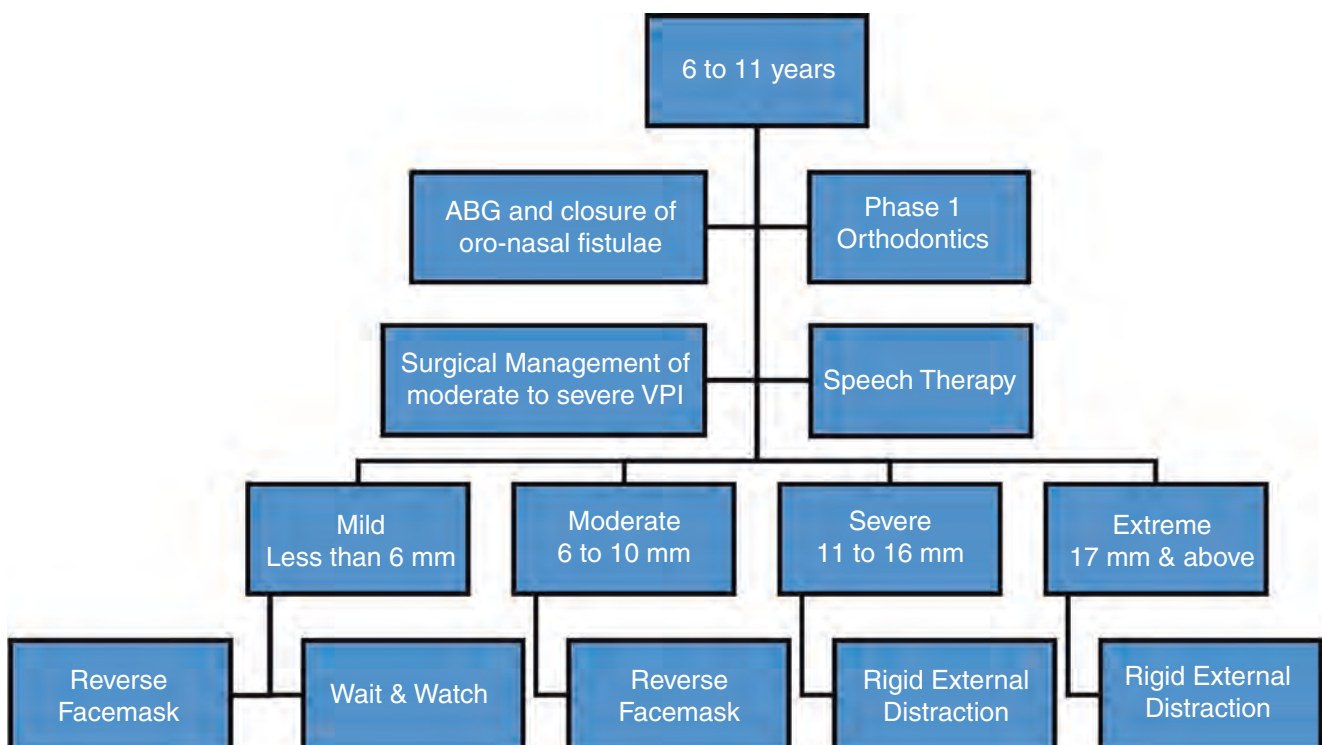
regions. As the mandible is usually unaffected in cleft maxillary hypoplasia, a setback beyond 8 mm leads to a poor aesthetic result and is also associated with higher relapse rates.

- A reverse overjet of 16 mm in cleft maxillary hypoplasia requires a net advancement of 18 mm. The maxilla can be advanced by 10 mm, and the mandible can be setback by 8 mm to achieve the desired correction. Thus, a reverse overjet of 16 mm can be treated by orthognathic surgery with acceptable stability in the long term. Although it is possible to treat a reverse overjet greater than 16 mm with orthognathic surgery, it is associated with a higher relapse rate.
- When the cleft maxilla is advanced > 10 mm, there is an increased risk of damage to the palatal vascular pedicle on account of the inability of the scarred soft palate to stretch and accommodate the change [59]. Furthermore, there is also risk of suture site dehiscence in the maxillary labial vestibule as this region would be closed under tension on account of the presence of scarred tissue with minimal elasticity [37, 60].
- Distraction osteogenesis (AMD/TMD) can be used for all spans of maxillary advancement and is preferred for advancements > 10 mm on account of the stability of results in the long term [61, 62]. There is also minimal risk of damage to the palatal vascular pedicle as the advancement is gradual and a certain degree of histogenesis accompanies the distraction osteogenesis.

- The span of movement (small or large) or mode of advancement (total maxillary distraction or orthognathic surgery) is not to be associated with an increased risk for deterioration of preoperative VPI.
 - Determining preoperative speech and VPI status is a must: perceptual speech assessment, acoustic measurement with nasometer, video nasoendoscopy (or video fluoroscopy), and lateral cephalometric analysis.
 - If there is no preoperative VPI, then there is minimal risk for worsening of speech and occurrence of VPI postoperatively.
 - If there is borderline (or greater) VPI preoperatively, then there is a high risk for worsening of VPI postoperatively.
 - Wait for at least 1 year before considering surgical correction of postoperative VPI.

75.7.2 Age Group of 6–11 Years (Fig. 75.1)

The patient has a mixed dentition during this phase. There are multiple un-erupted dental follicles present that can pose a problem to certain surgical procedures. Alveolar bone grafting is preferably performed during this phase as it is associated with higher success rates [26]. Large oronasal fistulae, if present, need to be closed prior to secondary alveolar bone grafting.



©Association of Oral and Maxillofacial Surgeons of India

Fig. 75.1 Treatment plan for age group 6–11 years

If the child presents with a mild regression, one can choose to wait and watch or proceed with dentofacial orthopedics using a reverse pull headgear to achieve protraction of the maxilla. If the child presents with moderate regression, then one must proceed with reverse pull headgear therapy to achieve some degree of correction.

The usage of reverse facemask therapy requires considerable patient co-operation and works by stimulating growth at the various maxillary suture sites (Fig. 75.2a–c). It is usually combined with a maxillary expansion appliance that helps disrupt the circum-maxillary sutural system and increase the effects of the orthopedic face mask. The general effect produced is that of a downward and forward movement of the maxilla, backward rotation of the mandible, and a net increase in the lower facial height. However, the response varies widely from individual to individual, and long-term stability is also questionable [7, 63–66].

The stability and extent of correction with reverse facemask therapy reduces with increasing severity of labio-palatal clefting and absence (or failure) of prior alveolar bone grafting [63–66]. The degree of ossification of the zygomaticomaxillary buttress also plays an important role in the results of facial protraction therapy. Earlier stages (younger age group) of ossification are associated with a greater span of movement and skeletal and dental changes. Later stages of ossification (older age group) are associated with a smaller span of movement and mainly dento-alveolar changes [67, 68]. Today, skeletal anchorage is slowly replacing traditional tooth borne anchorage on account of better control of degree of rotation of the mandible and greater potential for skeletal movements [69, 70]. In patients who are less co-operative, one can consider using a modified technique with inter-maxillary elastics between a miniplate secured to the zygomaticomaxillary buttress region posteriorly and another miniplate secured to the mandible anteriorly (Bone-anchored maxillary protraction - BAMP). This technique has provided promising results which are comparable to traditional reverse facemask therapy. However, this modification can be performed only after the eruption of the mandibular canine to allow for plating in the anterior mandible [69, 71, 72].

Very rarely will a child present with severe or extreme regression in this age group. Rigid external distraction (RED) is the only option available for the correction of such a severe discrepancy and is mainly used in syndromic patients presenting with moderate to severe obstructive sleep apnea and in patients with a poor psychological status. RED allows for high osteotomies as it does not rely on rigid fixation techniques to secure the distractor. This helps avoid injury to tooth follicles in the growing patient while simultaneously correcting para-nasal hollowing. On the contrary, internal total maxillary distraction (ITMD) and anterior maxillary

distraction (AMD) cannot be used as the lower-level osteotomies used in these procedures will damage the un-erupted dental follicles. The plates of the internal distractor also need to be secured to the bone with screws, which will also cause damage to the tooth follicles.

In spite of the above treatments, it is difficult to maintain results in the long term on account of continued mandibular growth. Thus, surgery will mostly be required once the patient reaches skeletal maturity to correct any residual skeletal deformity. However, the final amount of maxillary advancement will be much lesser resulting in increased post-operative stability of the cleft maxilla.

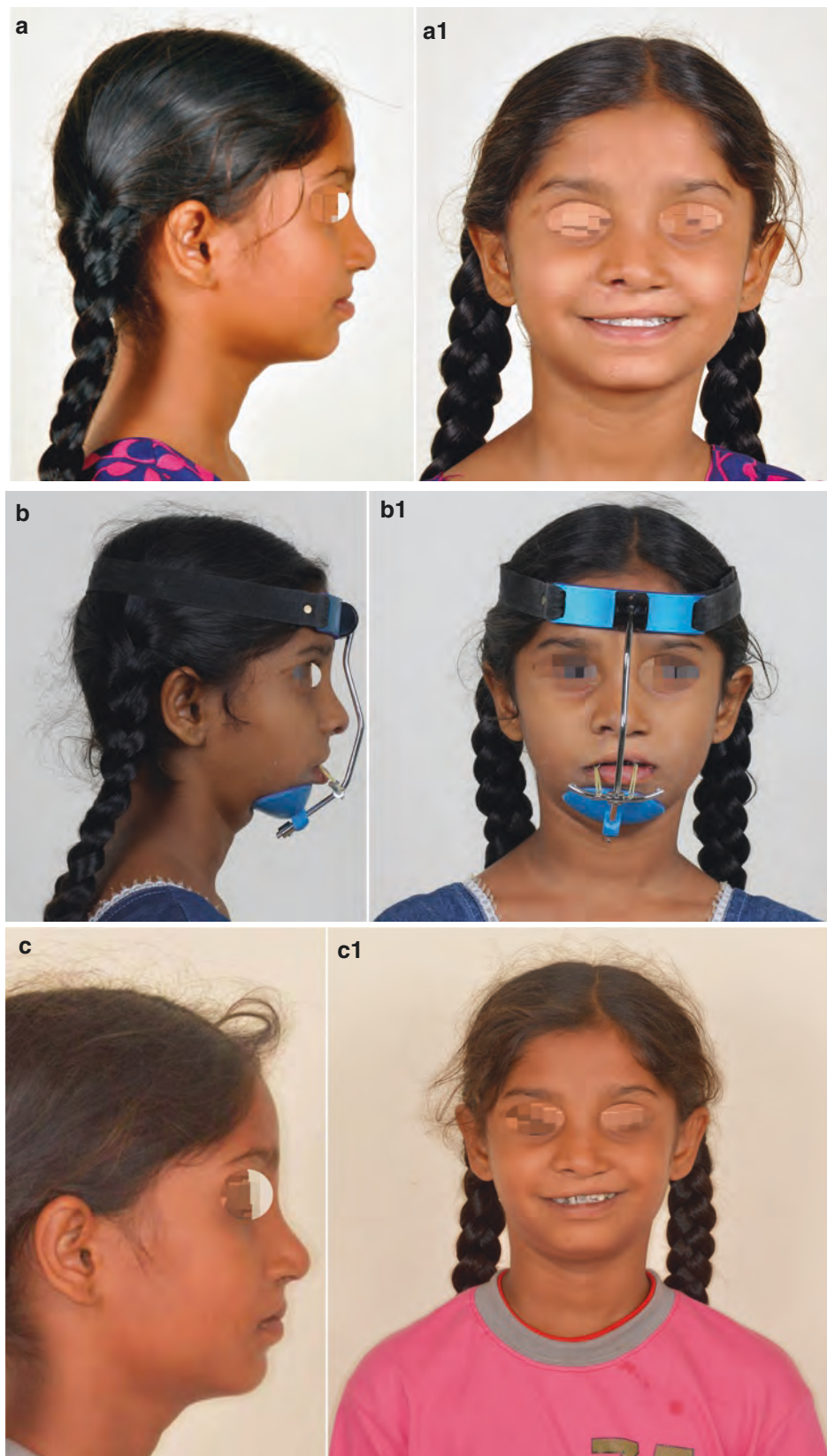
75.7.3 Age 12–16 Years (Fig. 75.3)

All permanent teeth (except the third molars) have erupted. The absence of un-erupted dental follicles makes procedures like AMD and ITMD (internal total maxillary distraction) feasible in this age group. Due to deficient arch length, there may be moderate to severe crowding. Some permanent teeth may have remained un-erupted, impacted, or erupted ectopically adding to the complexity of the treatment. If alveolar bone grafting has not been done prior or has failed, it needs to be performed during this phase. Large oronasal fistulae, if present, also need to be closed in preparation for orthognathic surgery.

If the regression is mild to moderate, one can consider camouflage orthodontics, maxillary protraction therapy, or AMD in order to create an acceptable occlusion. Alternatively, we can choose to wait and watch and directly correct the maxillary hypoplasia once growth is complete (Fig. 75.4a, b).

Severe to extreme maxillary regression is preferably treated with AMD. The available span of most commercially available hyrax screws does not exceed 13 mm. Thus, there are two options available to the clinician: repeat the AMD twice in a single stage or in a two-staged manner (at least 1 year apart) [50]. The author prefers to repeat the AMD activation twice, in a single stage. This requires the fabrication and immediate application of a fresh appliance, once the first appliance has attained complete activation of the incorporated Hyrax screw. Great care should be taken to avoid excessive pressure on the anterior maxilla while fitting the new appliance as the callus is not fully mature and large forces may easily destroy it. Alternatively, we can consider total maxillary distraction (ITMD or RED) (Figs. 75.5a–d and 75.6a–f) as long as the patient does not have moderate to severe preoperative VPI (Also see Fig. 70.17).

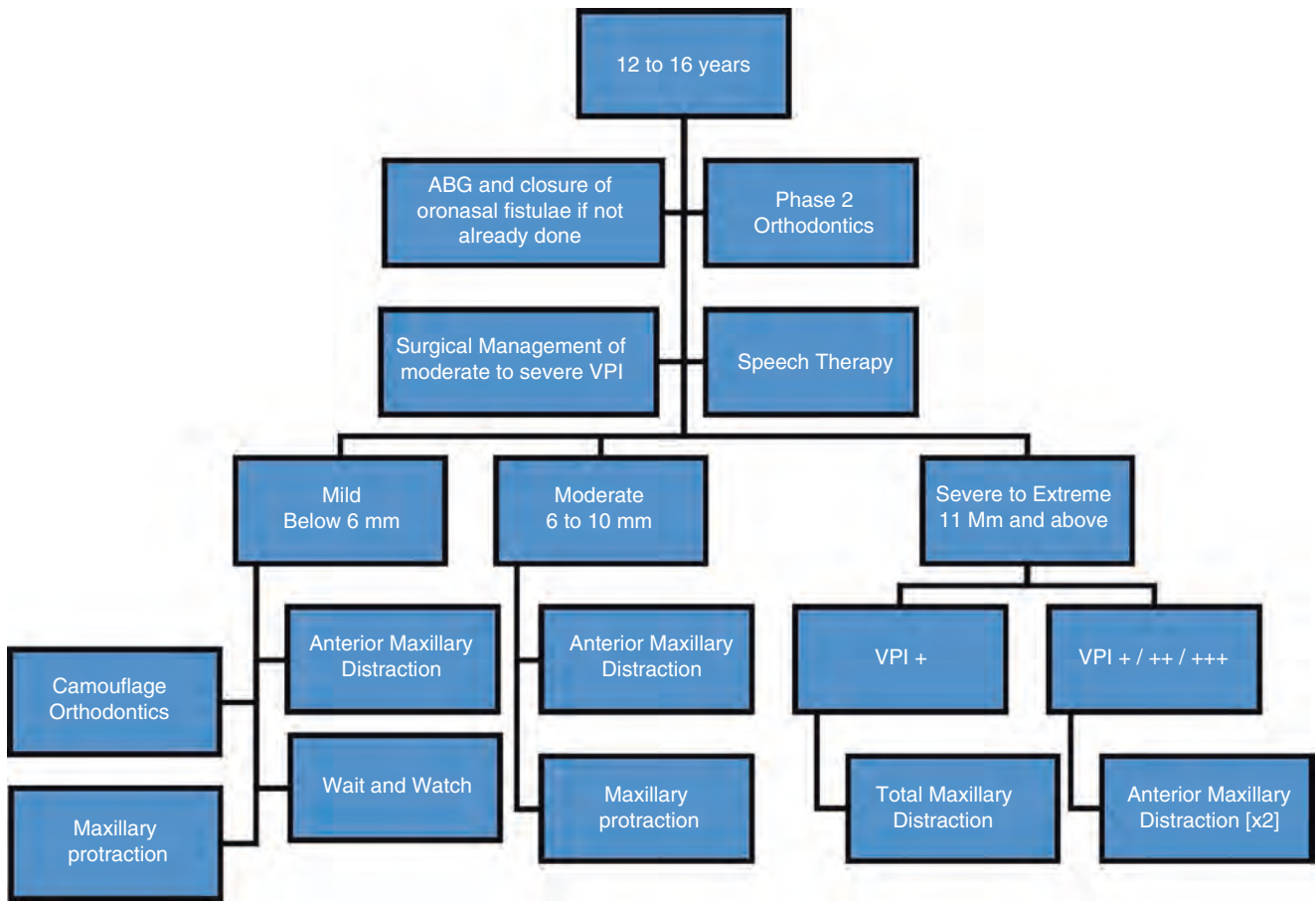
In spite of the above treatments, it is difficult to maintain results in the long term on account of continued mandibular growth. Thus, surgery will mostly be required once the patient reaches skeletal maturity to correct any residual skeletal



©Association of Oral and Maxillofacial Surgeons of India

Fig. 75.2 (a–c) Reverse pull headgear therapy in a growing child with cleft maxillary hypoplasia. (a, a1) Pre-treatment profile and frontal photographs, (b, b1) Profile and frontal photographs of patient after

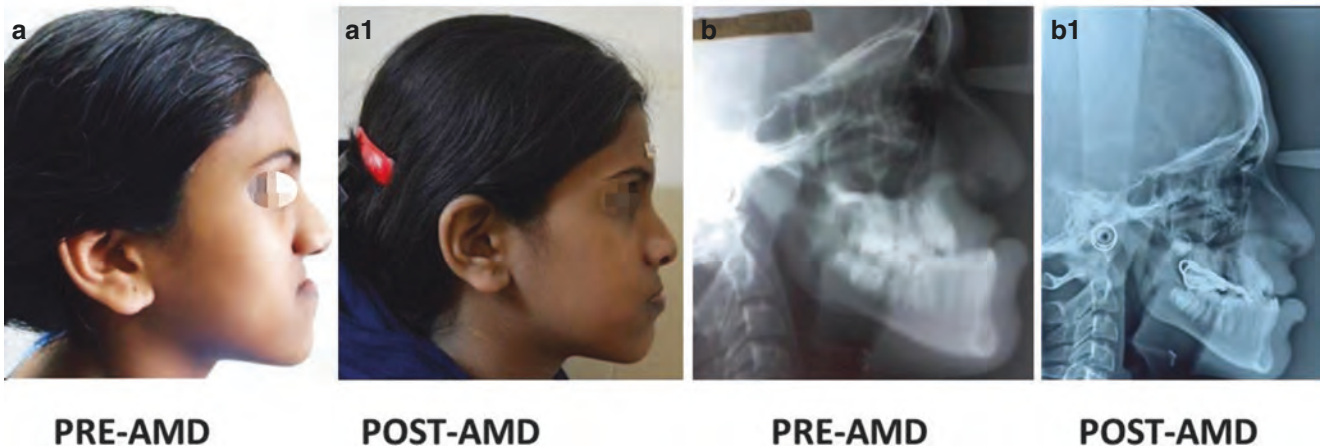
application of “reverse-pull headgear”, (c, c1) Post-treatment profile and frontal photographs demonstrating an improvement in the patient’s profile



©Association of Oral and Maxillofacial Surgeons of India

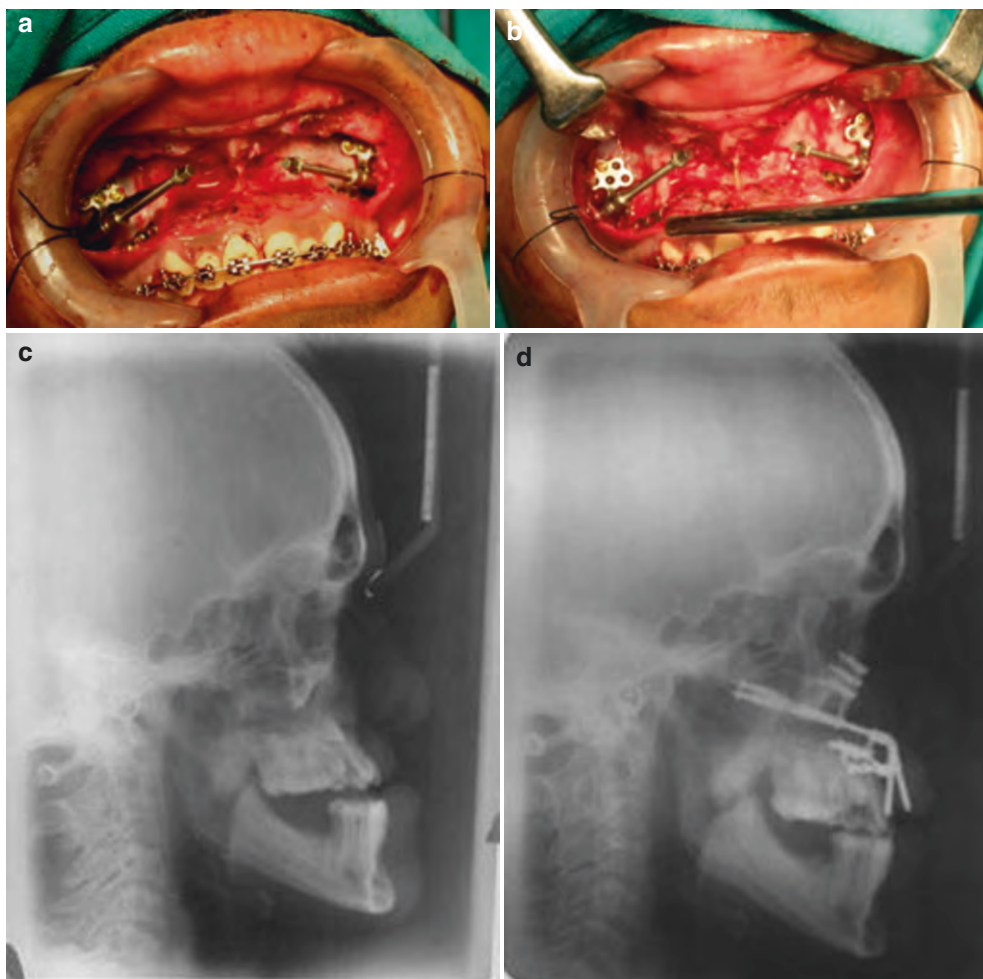
Fig. 75.3 Treatment plan for age group 12–16 years

SEVERE – 11 TO 16 mm



©Association of Oral and Maxillofacial Surgeons of India

Fig. 75.4 (a, b) Severe reverse overjet at 14 years of age and mild VPI. Anterior maxillary distraction was performed (AMD). Final correction with orthognathic surgery to be done after 16 years of age



©Association of Oral and Maxillofacial Surgeons of India

Fig. 75.5 (a–d) Use of internal maxillary distraction in the management of CMH. (a) Intra-operative positioning of internal maxillary distractors, (b) post-distraction picture prior to the removal of distractor

devices, (c) Pre-operative lateral cephalogram and (d) Post-operative lateral cephalogram demonstrating distractor in-situ

etal deformity. However, the final amount of maxillary advancement will be much lesser resulting in increased post-operative stability of the cleft maxilla.

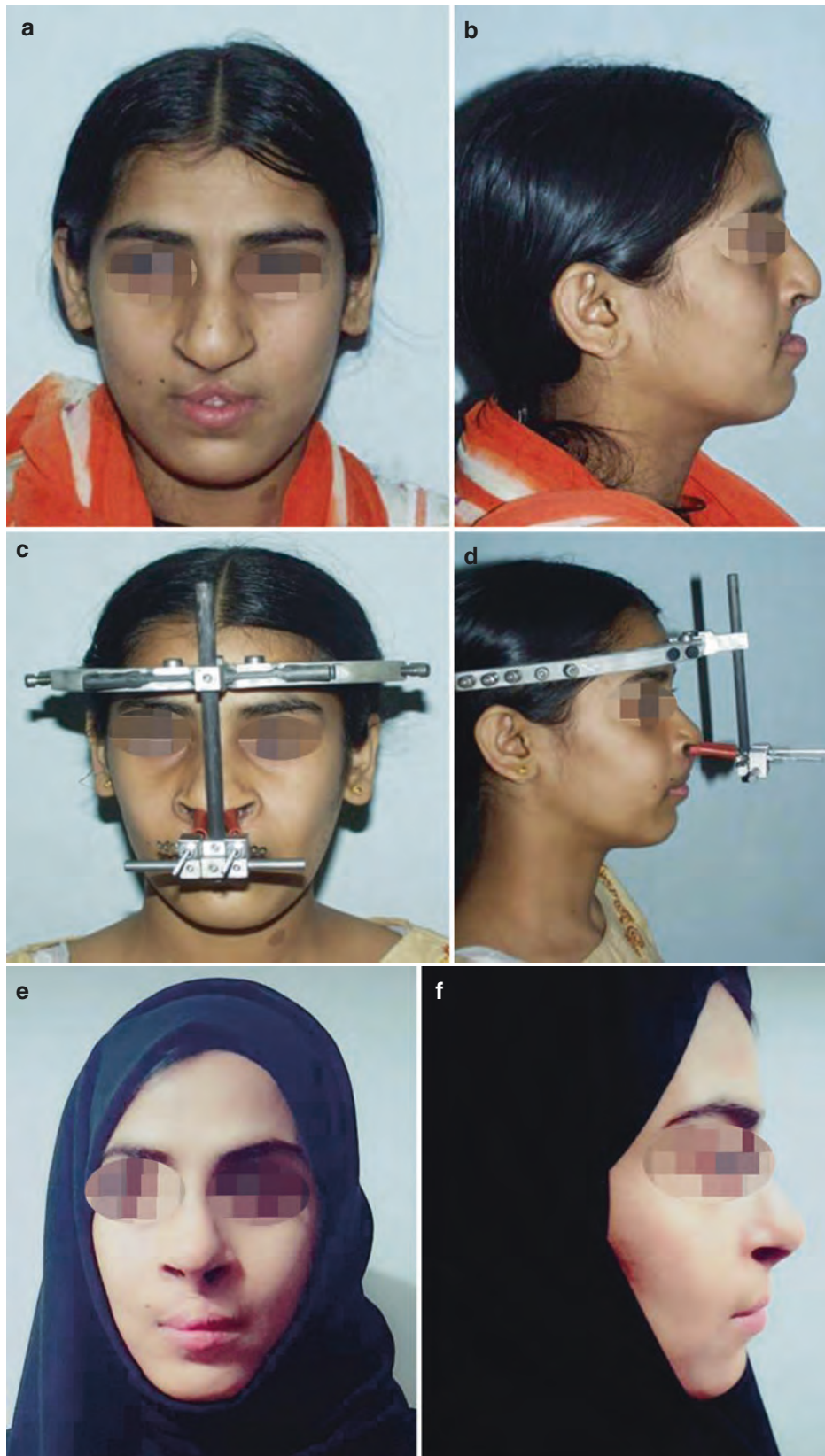
75.7.4 Age 17 Years and Above (Fig. 75.7)

If prior alveolar bone grafting has failed or has not been performed, a decision should be made as to whether it needs to be performed or not. Large oronasal fistulae, if present, need to be closed in preparation for orthognathic surgery.

If the regression is mild to moderate and VPI is absent or negligible, then either total maxillary distraction, AMD, or orthognathic surgery can be performed. Orthognathic surgery

is preferred in this scenario as we can achieve immediate improvement in facial profile and occlusion (Figs. 75.8a–h, 75.9a–h). If there is moderate to severe VPI preoperatively, then it is advisable to perform AMD to avoid further deterioration of the same.

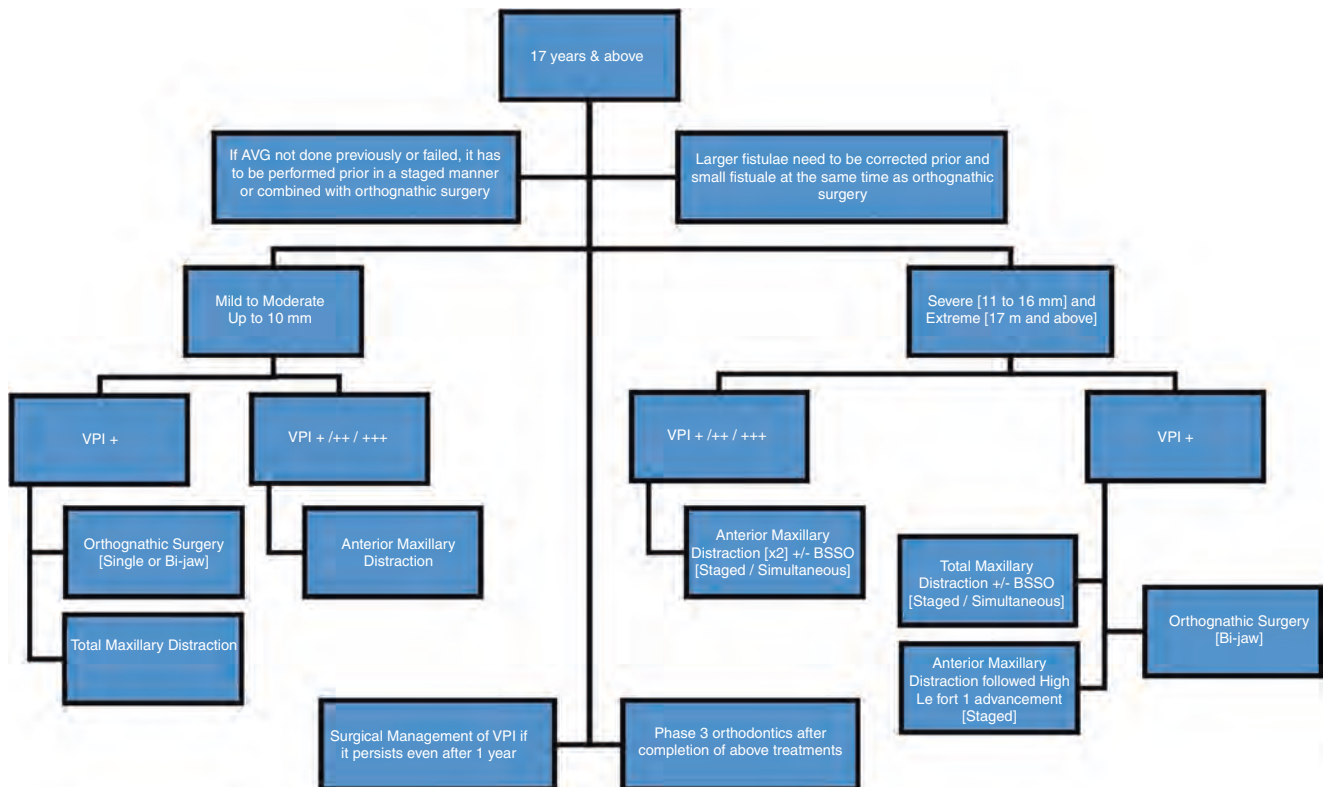
If the regression is severe to extreme and the VPI is absent or negligible, then either orthognathic surgery (Fig. 75.10a–f), AMD, or TMD can be performed. AMD may have to be repeated twice in the same sitting or in a stage manner as described previously. If optimal esthetics is the goal, then AMD followed by conventional LeFort I maxillary advancement is the ideal treatment plan (Fig. 75.11a–g). The only drawback of this procedure is the prolonged treatment duration as a minimum waiting period



©Association of Oral and Maxillofacial Surgeons of India

Fig. 75.6 (a–f) Patient treated with rigid external distractor (RED). (a, b) Pre-operative frontal and profile photographs, demonstrating hypoplastic midface and concave profile. (c, d) Frontal and profile pho-

tographs showing RED in situ. (e, f) Post-operative frontal and profile photographs demonstrating good midface fullness and a convex facial profile



©Association of Oral and Maxillofacial Surgeons of India

Fig. 75.7 Treatment plan for age group 17 years and above

of 1 year is needed between both surgeries. If there is moderate to severe VPI preoperatively, then it is advisable to perform AMD to avoid further deterioration of the same. As a means of saving time or if the mandible is truly prognathic, AMD and TMD can be combined with a mandibular setback (using bilateral sagittal split osteotomy) in a simultaneous or staged manner to reduce the span needed to be distracted [73].

75.8 LeFort I Procedure for Cleft Maxillary Hypoplasia

The protocol preferred by the authors is described below.

75.8.1 Preoperative Investigations

The preoperative investigations are described in Box 75.11.

Chronic Maxillary Sinusitis Most CLP patients suffer from chronic maxillary sinusitis on account of the presence of

nasal obstructions and residual oronasal fistulae. It is the author's opinion that such patients need to be referred to an ENT specialist at least 3 months prior as active sinusitis affects the quality of the bone in the maxilla.

Box 75.11: Preoperative Investigations

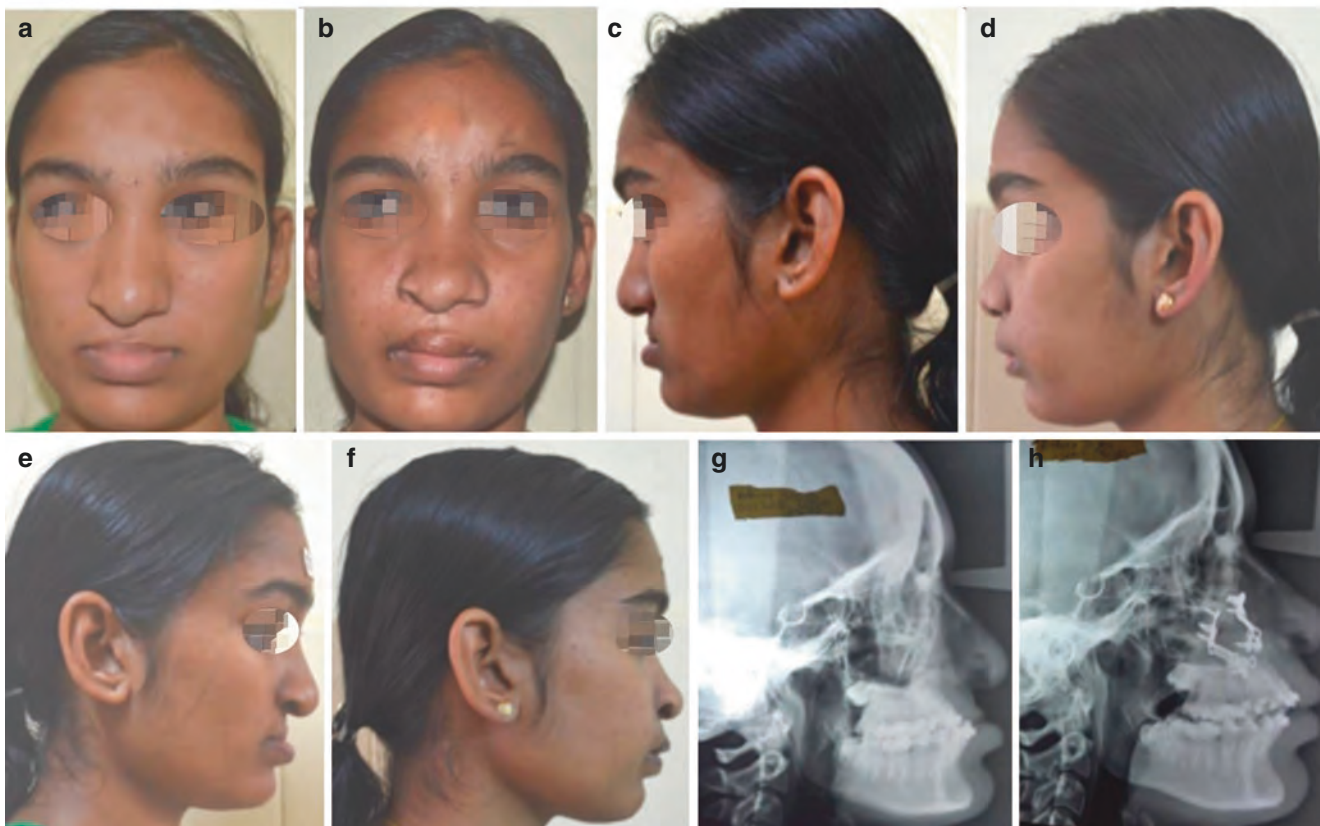
Primary Investigations

Clinical diagnosis, pre-anesthetic assessment (blood investigations, chest x-ray, ECG, additional investigations for any significant medical history), facial photographs, cephalometric analysis (lateral cephalogram and postero-anterior cephalogram), articulated study models with bite registration and facebow transfer, dental model analysis, orthopantomogram, perceptual speech assessment, video nasoendoscopy (or video fluoroscopy) for velopharyngeal insufficiency, psychological screening, and patient education regarding realistic expectations

Adjunctive Investigations

3D computed tomography scans, stereolithographic model, sleep studies, and 3D virtual surgical planning

Mild – Below 6 mm



©Association of Oral and Maxillofacial Surgeons of India

Fig. 75.8 (a–h) Mild reverse overjet and no preoperative VPI. The patient was treated with single jaw orthognathic surgery (maxillary advancement). (a, b) Pre and post-operative frontal photographs. (c, d)

Pre and post operative profile photographs (left side). (e, f) Pre and post-operative profile photographs (right side). (g, h) Pre and post-operative lateral cephalograms

75.8.2 Preoperative Preparation

A single dose of 8 mg dexamethasone (half-life of 36–54 h) is given preoperatively to help reduce postsurgical airway and maxillofacial edema. It also has a synergistic analgesic effect when combined with postoperative analgesics. As a only a single dose is given, it is associated with minimum side effects [74, 75]. A single dose of 1 gm tranexamic acid is given 1 h preoperatively as it helps reduce intraoperative blood loss [76].

75.8.3 Intubation

Nasal intubation is preferred followed by submental intubation. In case a pharyngeal flap or nasal obstruction (enlarged inferior turbinates or deviated nasal septum) is present, it is advisable to perform fiber-optic assisted awake intubation.

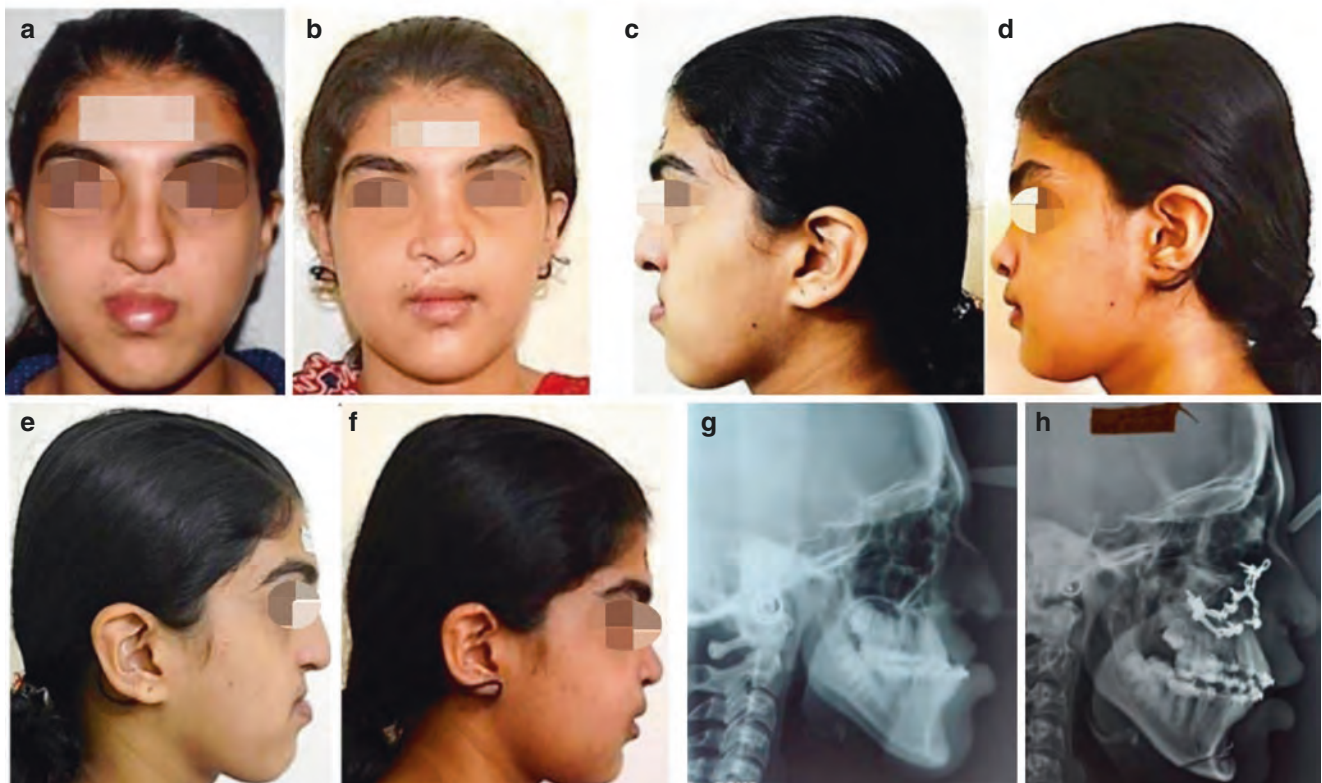
Alternatively, it may be necessary to pass a more rigid tube or catheter initially after which the endotracheal tube is passed over it.

The author always prefers to use a flexometallic nasoro-endotracheal tube as the tube is able to maintain its integrity even if damaged during the LeFort I osteotomy on account of the additional strength imparted by the metal coils.

75.8.4 General Anesthesia

The author commonly uses hypotensive anesthesia during orthognathic surgery as it provides a clean hemostatic field, reduces blood loss, and shortens hospital stay. There is an association between hypotensive anesthesia, forces generated during pterygomaxillary dysjunction, and optic nerve damage. Risk for optic nerve damage increases when hypotensive anesthesia is used in head and neck surgery which is

MODERATE – 6 to 10 mm



©Association of Oral and Maxillofacial Surgeons of India

Fig. 75.9 (a–h) - Moderate reverse overjet and mild preoperative VPI. The patient was treated with orthognathic surgery alone (maxillary advancement and advancement genioplasty). (a, b) Pre and post-operative

frontal photographs. (c, d) Pre and post operative profile photographs (left side) (e, f) Pre and post-operative profile photographs (right side). (g, h) Pre and post-operative lateral cephalograms

prolonged (>6 h) and large amount of blood loss (> 1 l) has taken place [77–82].

A larger amount of force is needed for pterygomaxillary dysjunction in CLP patients on account of the thicker pterygomaxillary junction. The stray forces, generated as a result of the dysjunction, can dissipate toward the orbital cavity and optic foramen with a magnitude potent enough to cause damage to the optic nerve. This is possible due to the orbital extensions of the palatine and sphenoid bones [7, 83, 84]. Thus, the author prefers to maintain hypotensive anesthesia during the entire orthognathic surgery except during pterygomaxillary dysjunction.

75.8.5 Cleft LeFort I Osteotomy (Video 75.2)

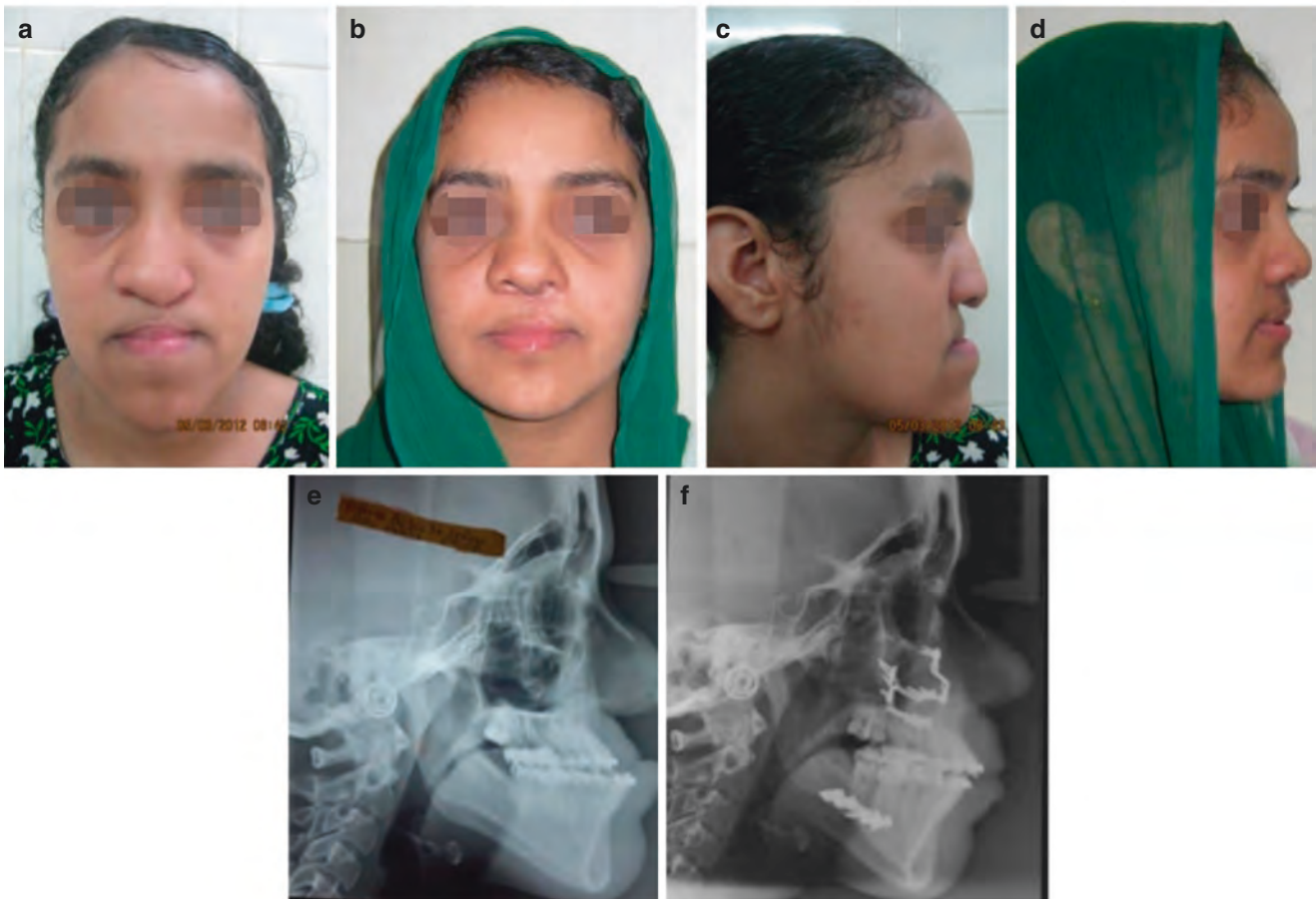In cases of unilateral CLP, a routine incision in the height of the maxillary vestibule is used, and care should be taken that it extends only to the mesial surface of the first maxillary

molars on both sides [7, 30, 85] (Refer Chap. 69 on Maxillary orthognathic procedures).

In cases of bilateral CLP, the incision is modified such that it extends from the lateral incisor to mesial surface of the first molar on both sides. A vertical stab incision is made in the midline to allow for placement of the nasal septal osteotome. This is to preserve blood supply to the pre-maxillary segment as most of its blood supply comes from the upper lip [2, 7, 28, 30].

Frequent surgery in the cleft maxilla leads to creation of scar tissue in the buccal, palatal, and upper lip regions. This scar tissue has compromised vascularity and healing ability. Therefore, it is essential to maintain an adequate soft tissue pedicle. There have also been suggestions to use modified vertical incisions instead of circumvestibular incisions, but it increases the difficulty of the procedure manifold due to poor access and visualization [2, 3, 86]. Careful and gentle retraction of tissues (especially the pedicles) is essential throughout the procedure and especially during the down-fracture process.

SEVERE – 11 to 16 mm



©Association of Oral and Maxillofacial Surgeons of India

Fig. 75.10 (a–f) Severe reverse overjet and mild preoperative VPI. The patient was treated with bi-jaw orthognathic surgery. (a, b) Pre and post operative frontal photographs. (c, d) Pre and post operative profile photographs. (e, f) Pre and post operative lateral cephalograms

The nasal mucosa is routinely elevated from the walls and floor of the nasal cavity prior to starting the LeFort I osteotomy. In the cleft maxilla, there is no intervening bone between the oral and nasal cavity in the region of the cleft; instead, the nasal mucosa is fused to the palatal mucosa due to the previously performed palatoplasty. This tissue should be sharply dissected close to the nasal floor, and care should be taken to avoid perforating the palatal mucosa. This step also aids in the down-fracture and mobilization of the maxilla.

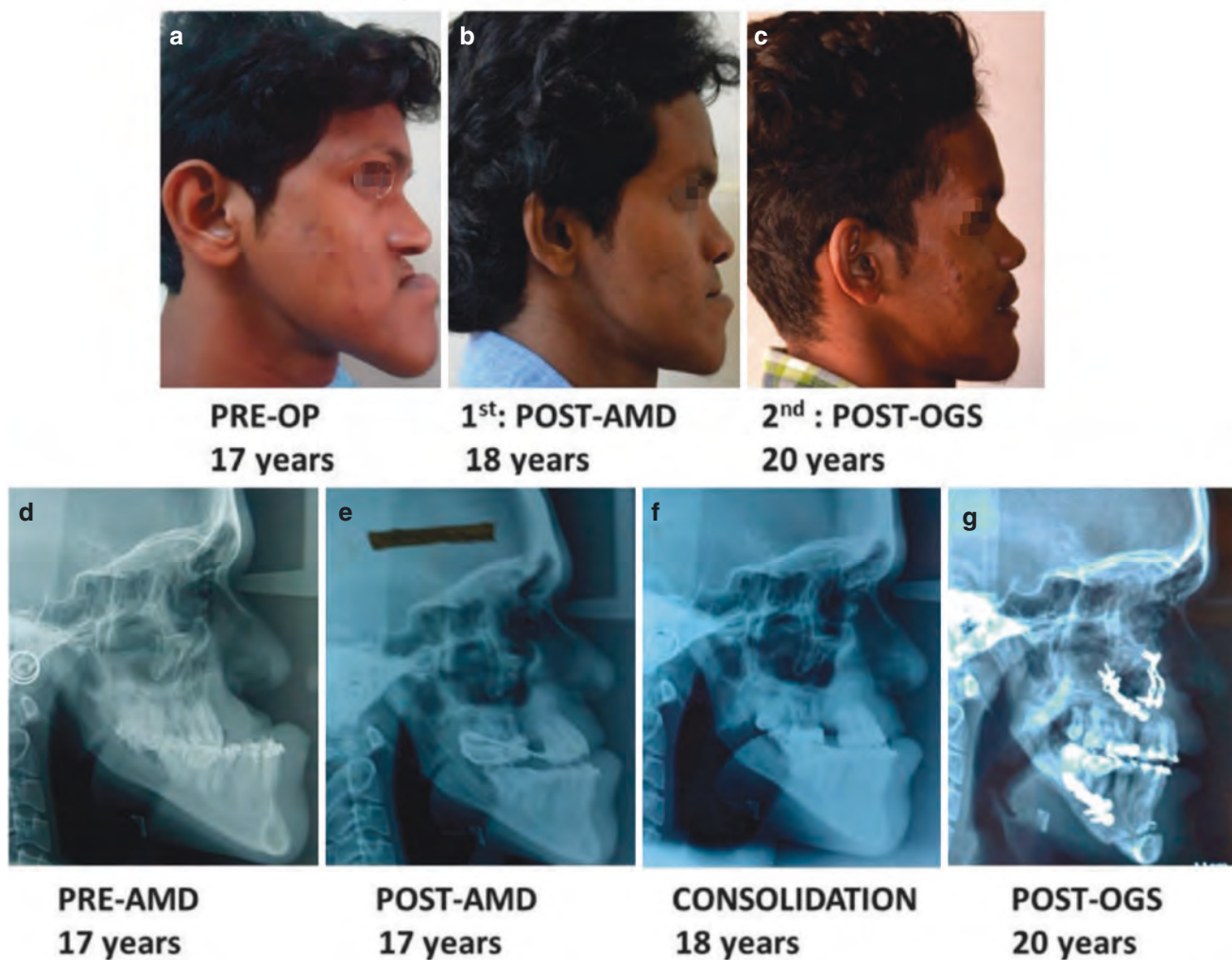
The cleft maxilla usually exhibits para-nasal hollowing. Hence, the routine LeFort I osteotomy may not suffice for complete correction of cleft maxillary hypoplasia. Instead a high LeFort I osteotomy is used which has the added advantage of correcting the para-nasal hollowing as well [7, 30, 86]. Care should be taken to avoid damage to the tooth roots

and the infra-orbital nerve as it exits from the infra-orbital foramen (Fig. 75.12). One should keep in mind that the descending palatine artery is closer to the lateral pyriform rim while performing the lateral nasal wall osteotomy.

To completely mobilize the maxilla during a LeFort I osteotomy, it is necessary to perform a pterygomaxillary dysjunction which separates the maxilla from the pterygoid plates. The maneuver is essentially blind and involves orienting a pterygoid chisel (curved osteotome) in a downward, medial, and anterior direction such that it engages the lower part of the pterygomaxillary fissure while maintaining a safe distance from the internal maxillary artery [87–89].

Studies have revealed that the medial pterygoid plate is shorter and the pterygomaxillary junction is thicker in cleft patients as the region around the hamular notch is fre-

EXTREME – Equal to or Greater than 17 mm



©Association of Oral and Maxillofacial Surgeons of India

Fig. 75.11 (a–g) Extreme reverse overjet and mild preoperative VPI. 1st stage corrected by anterior maxillary distraction (AMD). Note the persistent para-nasal hollowing that is only partially corrected by AMD. 2nd stage completed by bi-jaw orthognathic surgery (OGS) with improvement in para-nasal hollowing. (a) Pre-operative profile photo-

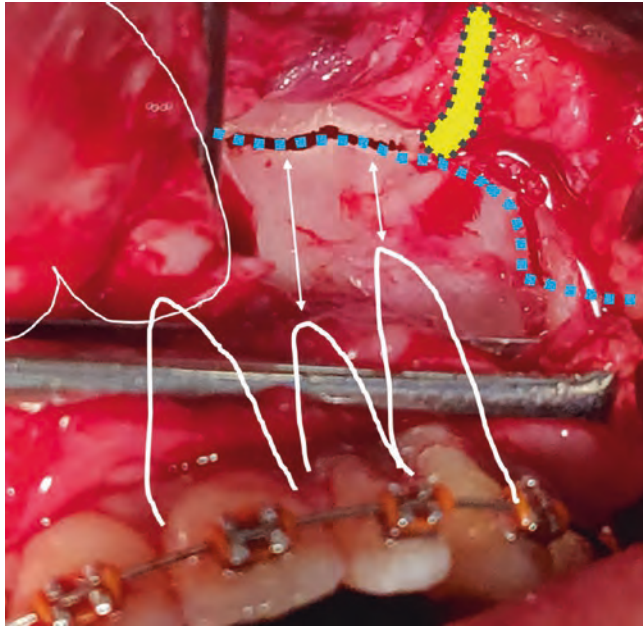
graph. (b) Profile after stage 1 correction with the AMD. (c) Profile after stage 2 correction with orthognathic surgery. (d) Pre-operative lateral cephalogram. (e) Lateral cephalogram after stage 1 - AMD. (f) Post-consolidation lateral cephalogram. (g) Lateral cephalogram after stage 2 -orthognathic surgery

quently manipulated during palatoplasty. The shorter medial pterygoid plate, by virtue of its smaller dimensions, may be more prone to fracture which increases the risk for vascular complications [87, 88]. Furthermore, the thicker pterygomaxillary junction requires a larger magnitude of force to achieve adequate separation. The usage of greater force leads to less control over this blind manoeuvre, thus increasing the risk for vascular complications (internal maxillary artery damage, carotid cavernous sinus) and neurologic (optic nerve damage) and skull base fractures (sphenoid fractures) [84].

There have been many modifications suggested to the original technique with an intention to reduce complications [87, 88, 90–95]. However, their use has never been documented widely in CLP cases. One may also attempt to use a piezo-surgical instrument or sequentially increase the size of the osteotomes to help reduce the force required for final pterygomaxillary separation [96, 97]. Another important consideration would be the preference of a third molar vertical osteotomy cut instead of a pterygomaxillary disjunction. This manoeuvre is anatomically less hazardous, allows greater mobility of the segments, allows a larger vascular

pedicle to be maintained and permits the use of interpositional bone graft in the osteotomised area, after the advancement in order to prevent relapse.

Once pterygomaxillary dysjunction has been performed, the maxilla is down-fractured using leverage or specialized instruments like the Smith's spreader. If the



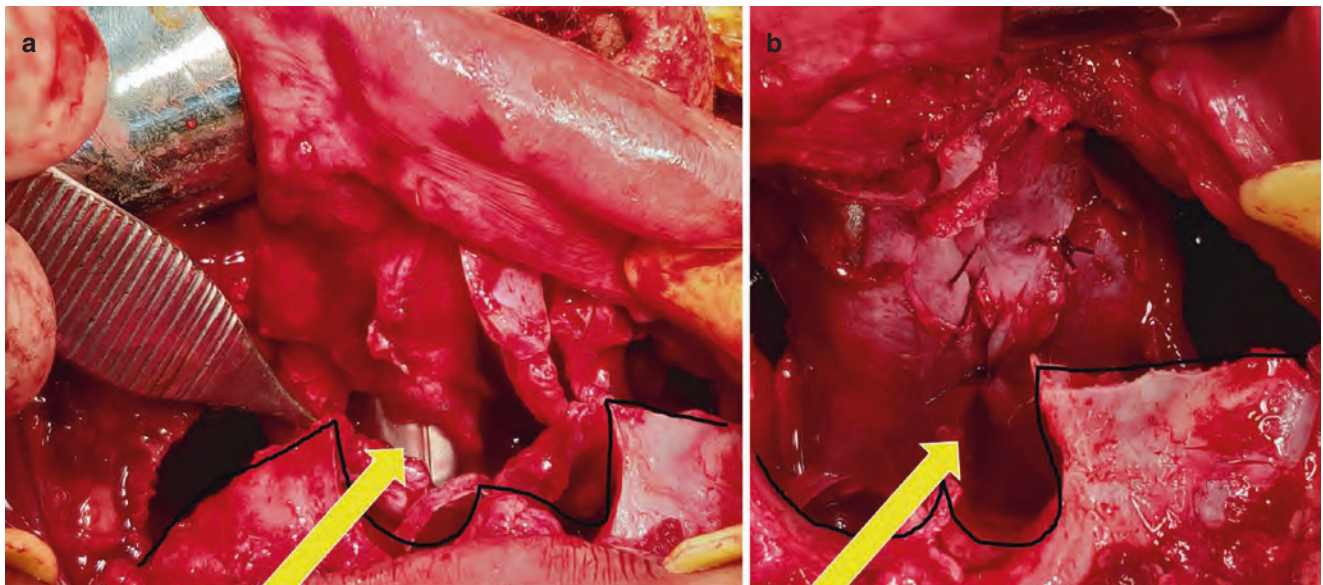
©Association of Oral and Maxillofacial Surgeons of India

Fig. 75.12 Modified high LeFort I osteotomy (blue) cut to help correct para-nasal hollowing. Avoid damage to the infra-orbital nerve (yellow) and roots of teeth (white) while making the osteotomy. The pyriform rim is marked in orange

nasal mucosa has not been dissected from the palatal mucosa previously, then it has to be done at this point [2, 7, 30]. After the down-fracture, it is important to suture the divided edges of the nasal mucosa to regain continuity of nasal lining. In the author's opinion, the edges of the divided nasal mucosa are a common source of bleeding postoperatively if left un-sutured (Fig. 75.13a, b). The presence of nasal obstructions like enlarged inferior turbinates can be corrected at this time.

After the down-fracture, the process of mobilizing the maxilla is done in a gradual progressive manner as the scarred tissues are less compliant. Specialized instruments like the Tessier's mobilizer can be used. If a pharyngeal flap is present and is impeding maxillary advancement, it may need to be incised. The maxilla is finally advanced to its desired position and should be seated in a passive manner. Signs of resistance at this point may indicate that the maxilla has not been adequately mobilized, and the previous steps need to be revisited. If resistance to the desired maxillary position persists, then one must consider to switch to maxillary distraction or setback the mandible to avoid postoperative relapse. In situations where an alveolar bone grafting procedure has not been performed, or where the take of the grafting is sub-optimal, the cleft maxilla may present as a two-piece (unilateral cleft) or a three-piece (bilateral) maxilla. This may necessitate the use of transverse maxillary plating (Fig. 75.14a, b), for stabilization of the segmented bone.

There may also be need for segmental osteotomies as it is difficult to completely co-ordinate both arches with presurgical orthodontics on account of the variable anatomy of the cleft maxilla. The cleft alveolar gap can be opened or closed



©Association of Oral and Maxillofacial Surgeons of India

Fig. 75.13 (a) Torn nasal floor mucosa after down-fracture of maxilla. The endotracheal tube is visible. (b) The torn edges should be sutured back to prevent postoperative bleeding

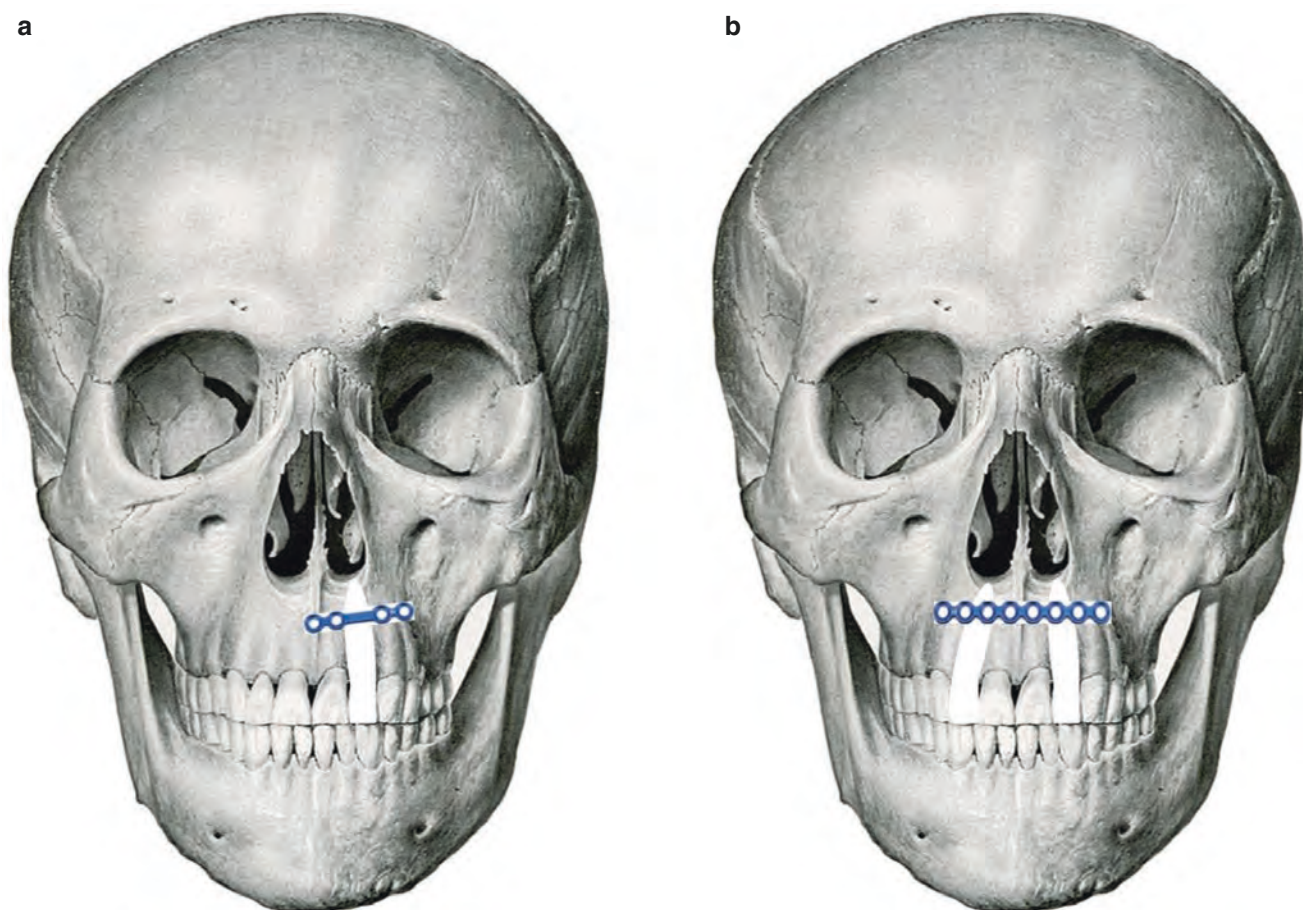


Fig. 75.14 Transverse plate across maxilla for stability during LeFort I osteotomy in a cleft. (a) Unilateral cleft of maxilla (b) Bilateral cleft of maxilla

to facilitate alveolar bone grafting or close alveolar fistulas. It can widen the maxillary arch within acceptable limits, allow differential movement of greater and lesser segments, align the occlusal plane, and maximize intercuspation to improve postoperative stability [98].

The presence of a persistent oronasal fistula and alveolar cleft defect requires careful soft tissue closure and bone grafting. One can also augment the deficient area along the lateral piriform rim on the cleft side to improve the contour of the alar base. The maxilla can fracture at the cleft alveolus site into two segments during the down-fracture and mobilization, even when the alveolar cleft site has been previously grafted. A preoperatively fabricated surgical palatal stent helps stabilize the maxilla in this situation.

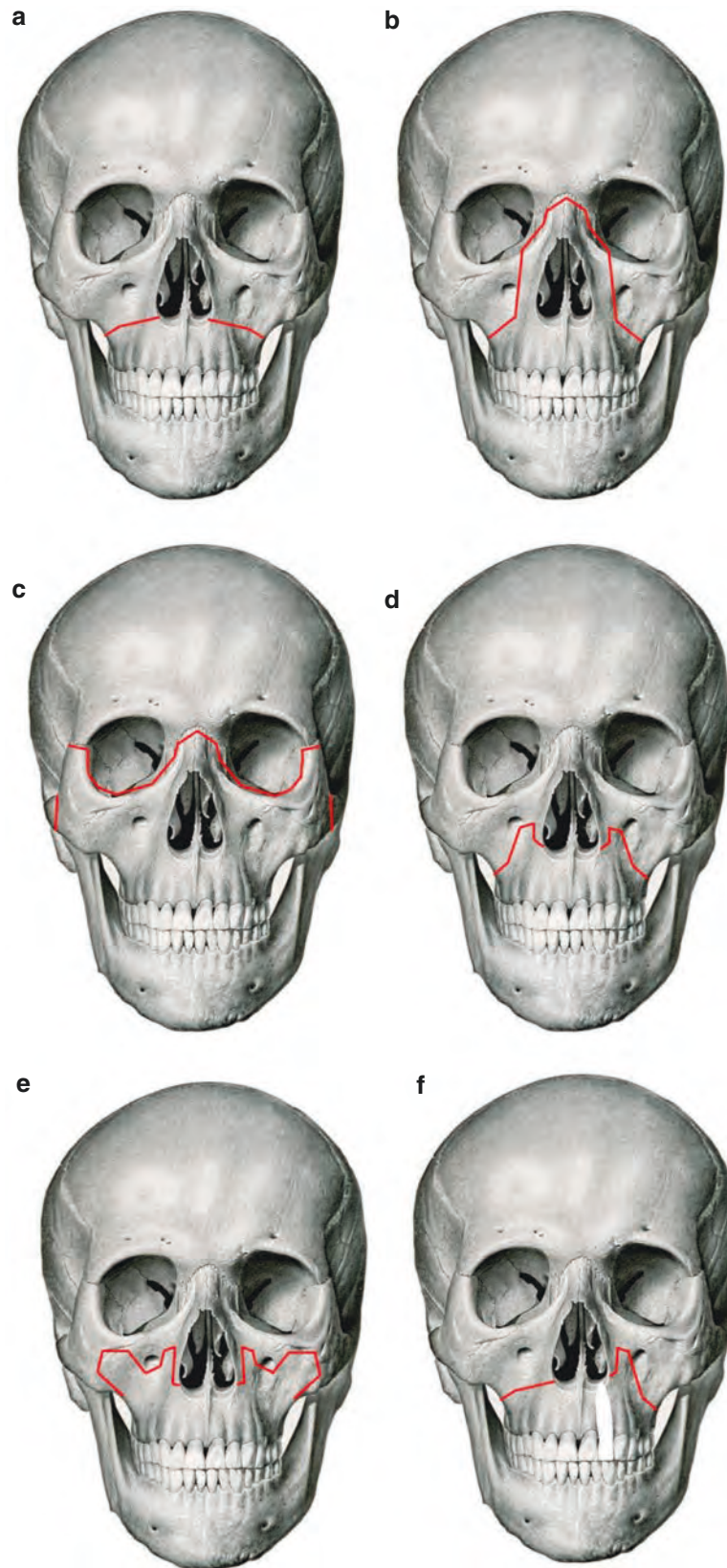
Rigid fixation with mini plates and screws is preferred to stabilize the maxilla in its final position with a preference for the lateral piriform rim and zygomaticomaxillary buttress regions as the bone here is thicker [83, 99]. One should pay attention while suturing and prevent entrapment of soft tissues into the osteotomy sites. The soft tissue of the upper lip may be

tight with a shallow vestibular depth and deficient vermilion show that may become worse following maxillary advancement. “V-Y” closure can be used to reduce lip shortening.

75.8.6 Additional Steps Performed on a Case-to-Case Basis

75.8.6.1 Deciding the Level of Midface Advancement (Fig. 75.15a–f)

In most of the cases, a traditional LeFort I (Fig. 75.15a) osteotomy is advocated. However, in some rare instances, it may need a LeFort II (Fig. 75.15b) or LeFort III (Fig. 75.15c) osteotomy depending on the severity and the extent of the involvement. As the CMH involves the piriform, the paranasal, and the zygomatic areas, though not symmetrical, the LeFort I osteotomy design in such situations may need modification to involve the para-nasal (Fig. 75.15d) and/or zygomatic (Fig. 75.15e) areas unilaterally (Fig. 75.15f) or bilaterally as the case may be.



©Association of Oral and Maxillofacial Surgeons of India

Fig. 75.15 Levels of midface advancement (a) LeFort I, (b) LeFort II, (c) LeFort III osteotomies. Modifications of LeFort I osteotomy (d), para-nasal extension, (e) para-nasal and zygomatic extensions, and (f) conventional LeFort I on the unaffected side and para-nasal extension on the affected side

75.8.6.2 Preserving the Descending Palatine Artery

Studies by Bell et al. established that the descending palatine artery did not contribute significantly to the re-vascularization of the maxilla after a total maxillary osteotomy in routine cases [100, 101]. However, the greater palatine arterial network in CLP patients may become narrow and develop vascular anomalies because of the presence of scar tissue created by the palatoplasty procedure [7, 60, 83]. Considering the unique scenario of the cleft maxilla, it is advisable that efforts should be made to preserve the descending palatine artery and secure it as an additional source blood supply for the osteotomized maxilla [7, 102]. Techniques to identify and preserve the descending palatine artery have been documented in the literature [103–108]. However, the above technique needs to be tailored to the cleft maxillary anatomy as it is highly variable. Studies have established that the distance between the lateral pyriform aperture and the descending palatine artery is on an average 3–4 mm lesser in CLP patients. Similarly, the posterior and lateral distances to the descending palatine artery were greater on in CLP patients on account of the thickened pterygomaxillary junction [7, 83, 84]. The perpendicular process of the palatine bone surrounding the descending palatine artery is also of the dense cortical type adding to the difficulty of isolating the vessel [99]. The author reserves this step only when the patient has undergone a large number of revision surgeries in the palate.

75.8.6.3 Grafting of the Osteotomy Site

The cleft maxilla is deficient in all three dimensions, and hence its correction requires complex large movements. Cortico-cancellous bone grafts can be placed across the gap created in the region of the lateral osteotomy [2, 3, 7, 86, 109]. The ideal source of autogenous bone grafting is the anterior iliac crest [110]. As an alternative, one can also use autogenous genial grafts, allogenic grafts, or synthetic hydroxyapatite bone blocks [111–114]. The author prefers to graft the osteotomy site only when down-grafting the maxilla or advancing the maxilla more than 10 mm.

75.9 Clinical Morbidity and Psychological Response

According to Stork et al. and Chua et al., there was no major difference between clinical morbidity between distraction osteogenesis and orthognathic surgery and between grafted and non-grafted patients, the source of graft being the anterior iliac crest [115–117].

Patients undergoing distraction osteogenesis experienced greater levels of stress in the short term. Over time,

the distraction group had a higher satisfaction with life [118–120]. This may be because of the better stability of the distraction osteogenesis in the long term as well as the self-perceived contribution of the patients to the success of their treatment. There is also an aspect of superior soft tissue response to distraction as compared to orthognathic surgery which may improve the final aesthetic result (refer Chap. 87 to read more about Distraction Osteogenesis) [121].

Nonetheless, psychological support from family and friends is recommended for patients undergoing either distraction or orthognathic surgery so as to achieve a better life satisfaction in the long term.

75.10 Stability of Results

The postoperative stability after orthognathic surgery in cleft patients is lower than non-cleft patients [2, 3, 7, 86]. Maximum relapse in cleft orthognathic surgery occurs in the first 6 months, and the situation stabilizes 2 years postoperatively [122].

75.10.1 Soft Tissue Envelope

The presence of scarred tissue in the palate and the lip prevents the maxilla from being adequately mobilized. Though the maxilla might be secured into its desired position with the help of rigid fixation and bone grafting, the excess stress placed on the maxilla due to the scarred soft tissue envelope leads to relapse in both the sagittal and vertical dimensions [2, 3, 7, 86, 123]. The severity of labio-palatal clefting and history of multiple revision surgeries increase the risk for relapse.

75.10.2 Magnitude of Planned Surgical Movement

The amount of surgical movement is the most important factor that determines the degree of relapse in cleft and non-cleft cases. Thus, most surgeons tend to overcorrect by an additional 20% to account for the possible relapse [2, 3, 7, 86, 124].

However, a recent study by Watts et al. [125] suggested that amount of linear advancement was not a major cause for skeletal and dental relapse rate in cleft orthognathic. Studies by Bhatia et al. [59] and Hoffman et al. [126] suggested the same. Nonetheless, the general trend is to perform bi-jaw orthognathic surgery or distract the maxilla if more than 10 mm advancement is needed.

75.10.3 Status of Alveolar Bone Grafting

Lack of alveolar bone grafting increases the difficulty of performing cleft orthognathic surgery. However, though alveolar bone grafting contributes to transverse stability of the maxillary arch and improve outcomes in orthodontia, it does not improve stability of sagittal, vertical, or rotational movements [122, 124].

75.10.4 Intraoperative Factors

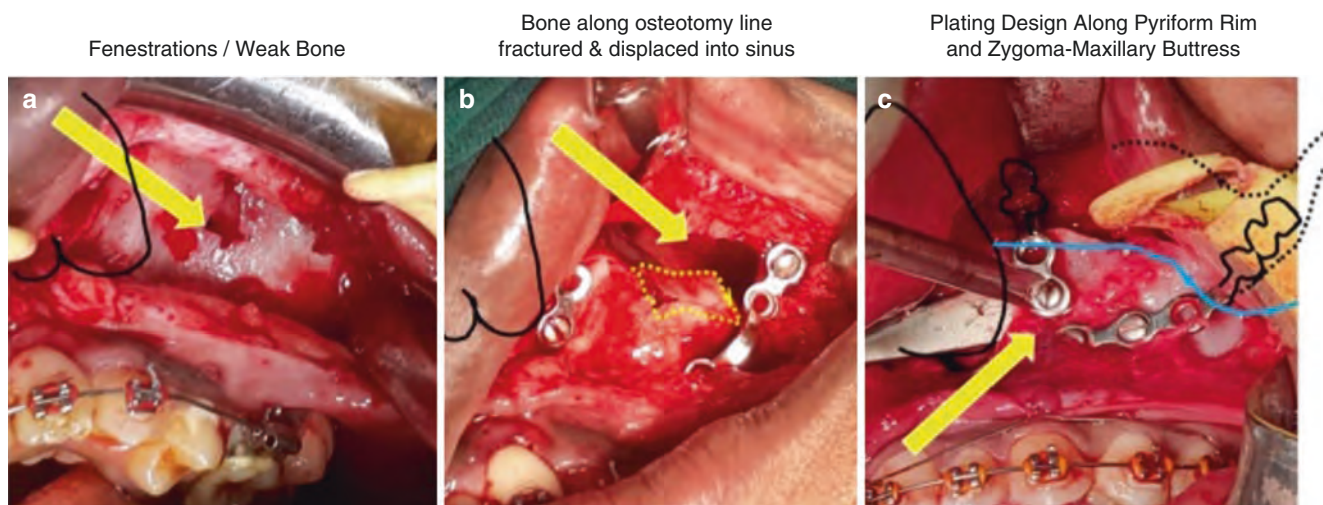
Inadequate separation at the pterygomaxillary junction due to its thicker form in CLP patients, the presence of a pharyngeal flap, a shallow overbite, and the absence of multiple teeth leading to poor intercuspation may contribute to relapse as well [2, 3, 7, 86, 124]. Segmentation of the maxilla as compared to one-piece maxilla was not associated with greater relapse rates in CLP patients and instead could correct orthodontic and occlusal problems that were distinctive to the cleft maxilla. Nonetheless, no attempt should be made to significantly widen the cleft maxilla as using a segmental osteotomy is a highly unstable procedure [98, 127, 128].

In the author's opinion, poor-quality bone in the cleft maxilla makes rigid fixation difficult and increases the risk for relapse [2, 3, 7]. Thus, it is advisable to always secure plates in the region of thick cortical bone, i.e., the zygomaticomaxillary buttress region posteriorly and the lateral pyriform aperture anteriorly (Fig. 75.16a–c). Bony fenestrations can be encountered in cases with prior AMD during maxillary orthognathic surgery; extra care must be taken during plating the same (Fig. 75.17).

Owing to the large advancements commonly performed in cleft orthognathic surgery, the gap between the osteotomized segments is large. When the contact area between the bony shelves is small, there may be instability or fibrous union between segments which increases the risk for relapse. By grating these gaps, there is increased bony contact which helps in optimal healing. Rarely, the space posterior to the maxillary tuberosity after advancement of the maxilla is also grafted to help prevent relapse [46]. Owing to the hostile environment of the cleft maxilla, it is general consensus that autogenous bone grafts provide the best results in terms of take up of the graft and significantly lower complication rates. It is interesting to note that a recent study by Stork et al. [115] suggested that grafting was not a major factor in preventing postoperative skeletal relapse in cleft and non-cleft patients contrary to the currently accepted methodology. A study by Hoffman et al. [129] in non-cleft patients suggested the same. The author's opinion is in line with both the above authors and grafts the osteotomy site only when advancing the maxilla more than 10 mm or down-grafting the maxilla.

75.10.5 Timing of Surgery

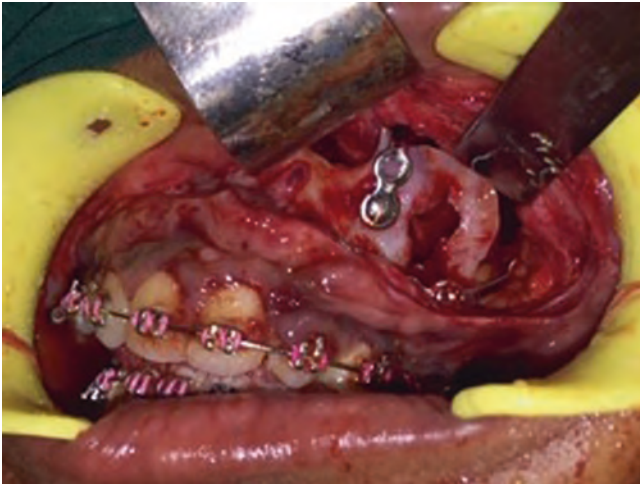
As previously mentioned, surgery performed before skeletal maturity is associated with a higher relapse rate in both horizontal and vertical dimensions due to continued growth. This is applicable irrespective of the type of surgery being performed: orthognathic surgery or distraction osteogenesis [21, 23, 24]. Secondary surgery for the correction of residual growth deformities is required after growth is complete. It is



©Association of Oral and Maxillofacial Surgeons of India

Fig. 75.16 (a–c) Poor-quality bone seen in the anterolateral and posterolateral walls of the maxilla. Always plate along the lateral pyriform rim and zygomaticomaxillary buttress (dotted) region which are known to

have good-quality bone. Part of the miniplate obscured by the retractor and tissues has been traced for better understanding of the plate position. Blue line denotes line of osteotomy on the dental side



©Association of Oral and Maxillofacial Surgeons of India

Fig. 75.17 Large bony fenestration in anterolateral wall of the maxilla at the time of orthognathic surgery. It is commonly found where prior anterior maxillary distraction was done. The presence of such a large fenestration can make plating difficult

important to note that distraction osteogenesis was more commonly preferred in the growing patient [2, 3, 7, 22, 130, 131].

75.10.6 Degree of Relapse

A review by Kloukos et al. [120] established that results obtained with distraction osteogenesis were more stable as compared to conventional orthognathic surgery 5 years post-operatively. A review by Saltaji et al. [132, 133] reported average horizontal relapse rates of 10 % in distraction cases and 25–30 % in orthognathic cases for cleft patients. Vertical relapse rates in cleft orthognathic patients were high with an average rate of 40–50 %. Similar results have been documented in other studies and reviews with up to 5-year follow-ups [134–140]. The rate for re-operation in cleft orthognathic surgery was approximately 12.2% [140]. Internal distractors were also found to be more stable than external distractors. This can be attributed to the rigidity provided by the internal distractor during the consolidation phase. The use of rigid fixation with miniplates was attributed with the least amount of relapse in cleft orthognathic surgery [2, 3, 7, 132].

Based on the above evidence, distraction osteogenesis has become the mainstay for the management of severe to extreme cleft maxillary hypoplasia (reverse overjet greater than 11 mm) as the slow distraction of bone and the accompanying histogenic abilities help reduce skeletal relapse. Orthognathic surgery is preferred for mild to moderate cleft maxillary hypoplasia (reverse overjet lesser than 11 mm).

75.10.7 Clinical Suggestions to Avoid Relapse

Commonly used methods to prevent or control relapse are as follows: overcorrection of the final surgical result by 20%, prolonged intermaxillary fixation during the postoperative phase, using face masks with reverse traction of the maxilla, interpositioning bone grafts between the gaps created by maxillary advancement, and performing bi-jaw surgery or distraction when advancements greater than 10 mm are required [114]. A study by Tabrizi et al. [141] established that the use of rigid fixation after the consolidation phase of cleft maxillary distraction did not increase stability of results. In anterior maxillary distraction, it is essential to lock the appliance with wire or acrylic plug during the consolidation phase to prevent backward rotation of the hyrax screw.

75.11 Complications

A study by Metalwala et al. [142] established that there is increased risk for infection and prolonged hospital stay in patients with craniofacial anomalies undergoing orthognathic surgery. The incidence of complications in non-cleft patients has been reported at 6.4% as compared to 25.2% in cleft patients [83].

Studies by Yamaguchi et al. [140] and Moran et al. [143] revealed that an average of 15–30 % of patients present with perioperative complications. The most common complications were closure failure of pre-existing palatal fistula, velopharyngeal impairment, temporary paresthesia of the infra-orbital nerve, and surgical site infection. A review by Santos et al. [144] established that cleft maxilla patients present with the highest incidence of cranial nerve damage on account of the anatomically higher modified LeFort I osteotomy cut and excessive forces needed at the time of pterygomaxillary dysjunction. Rare and severe complications like arteriovenous fistula, maxillary aneurysm, cavernous sinus thrombosis, skull base fractures, and maxillary necrosis blindness are more common among patients with craniofacial anomalies but have an incidence of lesser than 0.5% [140, 143, 145]. It has been suggested by Eduardo et al. [146] that the use of piezo-electric surgical instruments in orthognathic surgery is associated with a lower complication rate.

With the author's experience (PM) of approximately 900 cleft orthognathic cases while using the traditional dysjunction technique, there has been no major vascular complication or skull base fractures. However, two patients experienced transient blindness with partial recovery of vision in the long term [79].

75.12 Conclusion

Skeletal surgery is a critical component of surgical management of CLP. On account of the unique anatomy of the cleft maxilla that has been subjected to previous lip & palate interventions, the conventional LeFort I osteotomy technique and orthognathic surgical principles need to be adapted accordingly. The ultimate goal of treatment should be to achieve intelligible speech and an acceptable appearance with good balance of facial skeleton, soft tissues, and occlusion. Distraction osteogenesis is a useful technique in the management of severe maxillary deficiency, but does not replace conventional orthognathic surgery. Maxillofacial surgeons who treat these deformities should be part of a craniofacial team to provide interdisciplinary care for the patient. The aim of the team should be to help the child to develop into a confident young adult.

Acknowledgment Dr. Rahul Tiwari (M.D.S Oral and Maxillofacial Surgery) for manuscript preparation

Designation: Fellow of Orthognathic Surgery

Institutional Address with pin code: Jubilee Mission Medical College and Hospital, Thrissur 680005

References

- Shetye PR. Facial growth of adults with unoperated clefts. *Clin Plast Surg*. 2004;31(2):361–71.
- Chigurupati R. Orthognathic surgery for secondary cleft and craniofacial deformities. *Oral Maxillofac Surg Clin North Am*. 2005;17(4):503–17.
- Posnick JC, Ricalde P. Cleft-orthognathic surgery. *Clin Plast Surg*. 2004;31(2):315–30.
- Oberoi S, Chigurupati R, Vargervik K. Morphologic and management characteristics of individuals with unilateral cleft lip and palate who required maxillary advancement. *Cleft Palate Craniofac J*. 2008;45(1):42–9.
- Oberoi S, Hoffman WY, Chigurupati R, Vargervik K. Frequency of surgical correction for maxillary hypoplasia in cleft lip and palate. *J Craniofac Surg*. 2012;23(6):1665–7.
- Good PM, Mulliken JB, Padwa BL. Frequency of Le Fort I osteotomy after repaired cleft lip and palate or cleft palate. *Cleft Palate Craniofac J*. 2007;44(4):396–401.
- Chigurupati R. Cleft lip and palate: Timing and approaches to reconstruction. In: Saunderson, editor. *Current therapy in oral and maxillofacial surgery*. 1st ed. Elsevier; 2012. p. 726–50.
- Jones CM, Mackay AFJ, Mackay DR, Long RE. Do pharyngeal flaps restrict early midface growth in patients with clefts? *Cleft Palate Craniofacial J*. 2016;53(6):629–33.
- Abyholm FE, Otaki S. *Cleft lip and palate*. 3rd ed. Berkowitz S, editor. Berlin: Springer; 2013. p. 601–12.
- Gopinath VK, Samsudin AR, Noor SNFM, Sharab HYM. Facial profile and maxillary arch dimensions in unilateral cleft lip and palate children in the mixed dentition stage. *Eur J Dent*. 2018;11(1):76–82.
- Lee Y, Liao Y. Hard palate-repair technique and facial growth in patients with cleft lip and palate: a systematic review. *Br J Oral Maxillofac Surg*. 2013;51(8):851–7.
- Campbell A, Costello BJ, Ruiz RL. Cleft lip and palate surgery: an update of clinical outcomes for primary repair. *Oral Maxillofac Surg Clin North Am*. 2010;22(1):43–58.
- Yang I, Liao Y. Cleft lip and palate the effect of 1-stage versus 2-stage palate repair on facial growth in patients with cleft lip and palate: a review. *Int J Oral Maxillofac Surg*. 2010;39(10):945–50.
- Stein S, Dunsche A, Gellrich NC, Härle F, Jonas I. One- or two-stage palate closure in patients with unilateral cleft lip and palate: Comparing cephalometric and occlusal outcomes. *Cleft Palate Craniofac J*. 2007;44(1):13–22.
- Xu X, Kwon HJ, Shi B, Zheng Q, Yin H, Li C. Influence of different palate repair protocols on facial growth in unilateral complete cleft lip and palate. *J Cranio Maxillofac Surg*. 2015;43(1):43–7.
- Santiago PE, Schuster LA, Levy-Bercowski D. Management of the alveolar cleft. *Clin Plast Surg*. 2014;41(2):219–32.
- Da Silva Filho OG, Boiani E, Cavassan ADO, Santamaria M. Rapid maxillary expansion after secondary alveolar bone grafting in patients with alveolar cleft. *Cleft Palate Craniofac J*. 2009;46(3):331–8.
- Emodi O, Noy D, Hazan-Molina H, Aizenbud D, Rachmiel A. Secondary bone grafting of the cleft maxilla following reverse quad-helix expansion in 103 patients. *Ann Maxillofac Surg*. 2015;5(1):32.
- Uzel A, Benlidayı ME, Kürkçü M, Kesiktaş E. The effects of maxillary expansion on late alveolar bone grafting in patients with unilateral cleft lip and palate. *J Oral Maxillofac Surg*. 2019;77(3):607–14.
- Reyneke JP, Tsakiris P, Becker P. Age as a factor in the complication rate after removal of unerupted/impacted third molars at the time of mandibular sagittal split osteotomy. *J Oral Maxillofac Surg*. 2002;60(6):654–9.
- Wolford LM, Cassano DS, Cottrell DA, El Deeb M, Karras SC, Goncalves JR. Orthognathic surgery in the young cleft patient: preliminary study on subsequent facial growth. *J Oral Maxillofac Surg*. 2008;66(12):2524–36.
- Wolford LM, Karras SC, Mehra P. Considerations for orthognathic surgery during growth, Part 2: Maxillary deformities. *Am J Orthod Dentofac Orthop*. 2001;119(2):95–101.
- Meazzini MC, Basile V, Mazzoleni F, Bozzetti A, Brusati R. Long-term follow-up of large maxillary advancements with distraction osteogenesis in growing and non-growing cleft lip and palate patients. *J Plast Reconstr Aesthetic Surg*. 2015;68(1):79–86.
- Liu K, Zhou N. Long-term skeletal changes after maxillary distraction osteogenesis in growing children with cleft lip/palate. *J Craniofac Surg*. 2018;29(4):e349–52.
- Turvey TA, Golden BA, Brookes CD. Techniques in bone grafting of cleft maxilla. In: Saunders, editor. *Atlas of oral and maxillofacial surgery*. 1st ed. 2015. p. 569–78.
- Dempf R, Teltzrow T, Kramer F-J, Hausamen J-E. Alveolar bone grafting in patients with complete clefts: a comparative study between secondary and tertiary bone grafting. *Cleft Palate Craniofac J*. 2002;39(1):18–25.
- Kaura AS, Srinivasa DR, Kasten SJ. Optimal timing of alveolar cleft bone grafting for maxillary clefts in the cleft palate population. *J Craniofac Surg*. 2018;29(6):1551–7.
- Posnick JC, Tompson B. Modification of the maxillary Le Fort I osteotomy in cleft-orthognathic surgery: The bilateral cleft lip and palate deformity. *J Oral Maxillofac Surg*. 1993;51(1):2–11.
- Posnick JC, Tompson B. Modification of the maxillary Le Fort I osteotomy in cleft-orthognathic surgery: the unilateral cleft lip and palate deformity. *J Oral Maxillofac Surg*. 1992;50(7):666–75. Discussion 675–6
- Posnick JC, Tompson B. Cleft-orthognathic surgery: complications and long-term results. *Plast Reconstr Surg*. 1995;96(2):255–66.
- Glade RS, Deal R. Diagnosis and management of velopharyngeal dysfunction. *Oral Maxillofac Surg Clin North Am*. 2016;28(2):181–8.

32. Chua HDP, Whitehill TL, Samman N, Cheung LK. Maxillary distraction versus orthognathic surgery in cleft lip and palate patients: effects on speech and velopharyngeal function. *Int J Oral Maxillofac Surg.* 2010;39(7):633–40.
33. Pereira VJ, Sell D, Tuomainen J. Effect of maxillary osteotomy on speech in cleft lip and palate: Perceptual outcomes of velopharyngeal function. *Int J Lang Commun Disord.* 2013;48(6):640–50.
34. O'Gara M, Wilson K. The effects of maxillofacial surgery on speech and velopharyngeal function. *Clin Plast Surg.* 2007;34(3):395–402.
35. Janulewicz J, Costello BJ, Buckley MJ, Ford MD, Close J, Gassner R. The effects of Le Fort I osteotomies on velopharyngeal and speech functions in cleft patients. *J Oral Maxillofac Surg.* 2004;62(3):308–14.
36. Wu Y, Wang X, Ma L, Li Z. Velopharyngeal configuration changes following Le Fort I osteotomy with maxillary advancement in patients with cleft lip and palate: A cephalometric study. *Cleft Palate Craniofac J.* 2015;52(6):711–6.
37. McComb RW, Marrinan EM, Nuss RC, Labrie RA, Mulliken JB, Padwa BL. Predictors of velopharyngeal insufficiency after Le Fort I maxillary advancement in patients with cleft palate. *J Oral Maxillofac Surg.* 2011;69(8):2226–32.
38. Chanchareonsook N, Samman N, Whitehill TL. The effect of cranio-maxillofacial osteotomies and distraction osteogenesis on speech and velopharyngeal status: A critical review. *Cleft Palate Craniofac J.* 2006;43(4):477–87.
39. Satoh K, Nagata J, Shomura K, Wada T, Tachimura T, Fukuda J, et al. Morphological evaluation of changes in velopharyngeal function following maxillary distraction in patients with repaired cleft palate during mixed dentition. *Cleft Palate Craniofac J.* 2004;41(4):355–63.
40. Phillips JH, Klaiman P, Delorey R, MacDonald DB. Predictors of velopharyngeal insufficiency in cleft palate orthognathic surgery. *Plast Reconstr Surg.* 2005;115(3):681–6.
41. Alaluusua S, Turunen L, Saarikko A, Geneid A, Leikola J, Heliövaara A. The effects of Le Fort I osteotomy on velopharyngeal function in cleft patients. *J Cranio Maxillofac Surg.* 2019;47(2):239–44.
42. Smedberg E, Neovius E, Lohmander A. Impact of maxillary advancement on speech and velopharyngeal function in patients with cleft lip and palate. *Cleft Palate Craniofac J.* 2014;51(3):334–43.
43. Kim SK, Kim JC, Moon JB, Lee KC. Perceptual speech assessment after maxillary advancement osteotomy in patients with a repaired cleft lip and palate. *Arch Plast Surg.* 2012;39(3):198–202.
44. Schultz KP, Braun TL, Hernandez C, Wilson KD, Moore EE, Wirthlin JO, et al. Speech outcomes after LeFort I advancement among cleft lip and palate patients. *Ann Plast Surg.* 2019;82(2):174–9.
45. Trindade IEK, Yamashita RP, Suguimoto RM, Mazzottini R, Trindade AS. Effects of orthognathic surgery on speech and breathing of subjects with cleft lip and palate: Acoustic and aerodynamic assessment. *Cleft Palate Craniofac J.* 2003;40(1):54–64.
46. Poole MD, Robinson PP, Nunn ME. Maxillary advancement in cleft palate patients. *Plast Reconstr Surg.* 1987;80(1):154.
47. James DR, Brook K. Maxillary hypoplasia in patients with cleft lip and palate deformity—the alternative surgical approach. *Eur J Orthod.* 1985;7(4):231–47.
48. Richardson S, Seelan NS, Selvaraj D, Khandeparker R V, Gnanamony S. Perceptual speech assessment after anterior maxillary distraction in patients with cleft maxillary hypoplasia. *J Oral Maxillofac Surg.* 2016;74(6):1239.e1–9.
49. Richardson S, Agni NA, Selvaraj D. Anterior maxillary distraction using a tooth-borne device for hypoplastic cleft maxillas—a pilot study. *J Oral Maxillofac Surg.* 2011;69(12):e542–8.
50. Richardson S, Krishna S, Bansal A. Use of repeat anterior maxillary distraction to correct residual midface hypoplasia in cleft patients. *J Korean Assoc Oral Maxillofac Surg.* 2018;43(6):407.
51. Richardson S, Selvaraj D, Khandeparker R V, Seelan NS, Richardson S. Tooth-borne anterior maxillary distraction for cleft maxillary hypoplasia: our experience with 147 patients. *J Oral Maxillofac Surg.* 2016;74(12):2504.e1–14.
52. Richardson S, Krishna S, Khandeparker RV. A comprehensive management protocol to treat cleft maxillary hypoplasia. *J Cranio Maxillofacial Surg.* 2018;46(2):356–61.
53. Tahmasbi S, Jamilian A, Showkatbakhsh R, Pourdanesh F, Behnaz M. Cephalometric changes in nasopharyngeal area after anterior maxillary segmental distraction versus Le Fort I osteotomy in patients with cleft lip and palate. *Eur J Dent.* 2018;12(3):393–7.
54. Takahashi K, Dahy KG, Saito K, Masuoka H, Suzuki S, Bessho K. Patient with cleft maxillary hypoplasia who underwent distraction osteogenesis and conservative therapies to postoperative velopharyngeal insufficiency. *J Craniofac Surg.* 2017;28(5):1302–4.
55. Gart MS, Gosain AK. Surgical management of velopharyngeal insufficiency. *Clin Plast Surg.* 2014;41(2):253–70.
56. Denadai R, Sabbag A, Raposo-Amaral CE, Filho JCP, Nagae MH, Raposo-Amaral CA. Bilateral buccinator myomucosal flap outcomes in nonsyndromic patients with repaired cleft palate and velopharyngeal insufficiency. *J Plast Reconstr Aesthetic Surg.* 2017;70(11):1598–607.
57. Abdel-Aziz M, Hussien A, Kamel A, Azooz K, Fawaz M. The impact of velopharyngeal surgery on the polysomnographic parameters after cleft palate repair. *J Craniofac Surg.* 2018;29(3):717–9.
58. Dentino KM, Marrinan EM, Brustowicz K, Mulliken JB, Padwa BL. Pharyngeal flap is effective treatment for post maxillary advancement velopharyngeal insufficiency in patients with repaired cleft lip and palate. *J Oral Maxillofac Surg.* 2016;74(6):1207–14.
59. Bhatia S, Bocca A, Jones J, Sugar AW. Le Fort I advancement osteotomies of 1 cm or more. How safe or stable? *Br J Oral Maxillofac Surg.* 2016;54(3):346–50.
60. Drommer R. Selective angiographic studies prior to Le Fort I osteotomy in patients with cleft lip and palate. *J Maxillofac Surg.* 1979;7(C):264–70.
61. Rachmiel A. Treatment of maxillary cleft palate: distraction osteogenesis versus orthognathic surgery—part one: maxillary distraction. *J Oral Maxillofac Surg.* 2007;65(4):753–7.
62. Rachmiel A, Even-Almos M, Aizenbud D. Treatment of maxillary cleft palate: Distraction osteogenesis vs. orthognathic surgery. *Ann Maxillofac Surg.* 2012;2(2):127–30.
63. Zhang Y, Jia H, Fu Z, Huang Y, Wang Z, Guo R, et al. Dentoskeletal effects of facemask therapy in skeletal Class III cleft patients with or without bone graft. *Am J Orthod Dentofac Orthop.* 2018;153(4):542–9.
64. Ahn HW, Kim KW, Yang IH, Choi JY, Baek SH. Comparison of the effects of maxillary protraction using facemask and miniplate anchorage between unilateral and bilateral cleft lip and palate patients. *Angle Orthod.* 2012;82(5):935–41.
65. Zhang Y, Fu Z, Jia H, Huang Y, Li X, Liu H, et al. Long-term stability of maxillary protraction therapy in Class III patients with complete unilateral cleft lip and palate. *Angle Orthod.* 2019;89(2):214–20.
66. Tindlund RS. Skeletal response to maxillary protraction in patients with cleft lip and palate before age 10 years. *Cleft Palate Craniofac J.* 1994;31(4):295–308.
67. Angelieri F, Franchi L, Cevidanes LHS, Hino CT, Nguyen T, McNamara JA. Zygomaticomaxillary suture maturation: A predictor of maxillary protraction? Part I—A classification method. *Orthod Craniofac Res.* 2017;20(2):85–94.
68. Angelieri F, Ruellas AC, Yatabe MS, Cevidanes LHS, Franchi L, Toyama-Hino C, et al. Zygomaticomaxillary suture maturation: Part II—The influence of sutural maturation on the response to maxillary protraction. *Orthod Craniofac Res.* 2017;20(3):152–63.
69. Hino CT, Cevidanes LHS, Nguyen TT, De Clerck HJ, Franchi L, McNamara JA. Three-dimensional analysis of maxillary changes

- associated with facemask and rapid maxillary expansion compared with bone anchored maxillary protraction. *Am J Orthod Dentofac Orthop.* 2013;144(5):705–14.
70. On SW, Baek SH, Choi JY. Effect of long-term use of facemask with miniplate on maxillary protraction in patients with cleft lip and palate. *J Craniofac Surg.* 2018;29(2):309–14.
 71. Jahanbin A, Kazemian M, Eslami N, Pouya IS. Maxillary protraction with intermaxillary elastics to miniplates versus bone-anchored face-mask therapy in cleft lip and palate patients. *J Craniofac Surg.* 2016;27(5):1247–52.
 72. Faco R, Yatabe M, Cevidanes LHS, Timmerman H, De Clerck HJ, Garib D. Bone-anchored maxillary protraction in unilateral cleft lip and palate: a cephalometric appraisal. *Eur J Orthod.* 2019:1–7.
 73. Susami T, Mori Y, Ohkubo K, Takahashi M, Hirano Y, Saijo H, et al. Changes in maxillofacial morphology and velopharyngeal function with two-stage maxillary distraction–mandibular setback surgery in patients with cleft lip and palate. *Int J Oral Maxillofac Surg.* 2018;47(3):357–65.
 74. Dan AEB, Thygesen TH, Pinholt EM. Corticosteroid administration in oral and orthognathic surgery: A systematic review of the literature and meta-analysis. *J Oral Maxillofac Surg.* 2010;68(9):2207–20.
 75. Jean S, Dionne PL, Bouchard C, Giasson L, Turgeon AF. Perioperative systemic corticosteroids in orthognathic surgery: a systematic review and meta-analysis. *J Oral Maxillofac Surg.* 2017;75(12):2638–49.
 76. Olsen JJ, Skov J, Ingerslev J, Thorn JJ, Pinholt EM. Prevention of bleeding in orthognathic surgery—A systematic review and meta-analysis of randomized controlled trials. *J Oral Maxillofac Surg.* 2016; 74:139–150.
 77. Choi WS, Samman N. Risks and benefits of deliberate hypotension in anaesthesia: a systematic review. *Int J Oral Maxillofac Surg.* 2008;37(8):687–703.
 78. Rodríguez-Navarro A, Gonzalez-Valverde FM. Unilateral blindness after orthognathic surgery: hypotensive anaesthesia is not the primary cause. *Int J Oral Maxillofac Surg.* 2018;47(1):79–82.
 79. Mathew P, Adenwalla HS, Narayanan PV, Nyamu E. A report of 2 patients with transient blindness following Le Fort I osteotomy and a review of past reported cases. *Indian J Plast Surg.* 2015;48(3):297–300.
 80. Lo L-J, Hung K-F, Chen Y-R. Blindness as a complication of Le Fort I osteotomy for maxillary distraction. *Plast Reconstr Surg.* 2002;109(2):688–98. Discussion 699–700
 81. Ettinger KS, Yildirim Y, Weingarten TN, Van Ess JM, Viozzi CF, Arce K. Hypotensive anesthesia is associated with shortened length of hospital stay following orthognathic surgery. *J Oral Maxillofac Surg.* 2016;74(1):130–8.
 82. Lin S, McKenna SJ, Yao CF, Chen YR, Chen C. Effects of hypotensive anesthesia on reducing intraoperative blood loss, duration of operation, and quality of surgical field during orthognathic surgery: a systematic review and meta-analysis of randomized controlled trials. *J Oral Maxillofac Surg.* 2017;75:73–86.
 83. Watanabe M, Watanabe A, Takano N, Saito C, Shibahara T. Morphologic evaluation for safe le fort I osteotomy in cleft lip and palate. *Cleft Palate Craniofac J.* 2018;55(5):728–35.
 84. Lee SH, Lee SH, Mori Y, Minami K, Park HS, Kwon TG. Evaluation of pterygomaxillary anatomy using computed tomography: Are there any structural variations in cleft patients? *J Oral Maxillofac Surg.* 2011;69(10):2644–9.
 85. Hoffman GR, Islam S. The difficult Le Fort I osteotomy and downfracture: a review with consideration given to an atypical maxillary morphology. *J Plast Reconstr Aesthetic Surg.* 2008;61(9):1029–33.
 86. Phillips JH, Nish I, Daskalogiannakis J. Orthognathic surgery in cleft patients. *Plast Reconstr Surg.* 2012;129(3):535e–48e.
 87. Precious DS, Goodday RH, Bourget L, Skulsky FG. Pterygoid plate fracture in Le Fort I osteotomy with and without pterygoid chisel: a computed tomography scan evaluation of 58 patients. *J Oral Maxillofac Surg.* 1993;51(2):151–3.
 88. Precious DS, Morrison A, Ricard D. Pterygomaxillary separation without the use of an osteotome. *J Oral Maxillofac Surg.* 1991;49(1):98–9.
 89. Turvey TA, Fonseca RJ. The anatomy of the internal maxillary artery in the pterygopalatine fossa: its relationship to maxillary surgery. *J Oral Surg.* 1980;38(2):92–5.
 90. Laster Z, Ardekian L, Rachmiel A, Peled M. Use of the “shark-fin” osteotome in separation of the pterygomaxillary junction in Le Fort I osteotomy: A clinical and computerized tomography study. *Int J Oral Maxillofac Surg.* 2002;31(1):100–3.
 91. Trimble LD, Tideman H, Stoelting PJW. A modification of the pterygoid plate separation in low-level maxillary osteotomies. *J Oral Maxillofac Surg.* 1983;41(8):544–6.
 92. Kanazawa T, Kuroyanagi N, Miyachi H, Ochiai S, Kamiya N, Nagao T, et al. Factors predictive of pterygoid process fractures after pterygomaxillary separation without using an osteotome in le Fort i osteotomy. *Oral Surg Oral Med Oral Pathol Oral Radiol.* 2013;115(3):310–8.
 93. Breeze J, Linares CV, Stockton P. Is an osteotome necessary for pterygomaxillary dysjunction or dysjunction through the tuberosity during le Fort i osteotomy? A systematic review. *Br J Oral Maxillofac Surg.* 2016;54:248–52.
 94. Dadwal H, Shanmugasundaram S, Krishnakumar Raja VB. Preoperative and postoperative CT scan assessment of pterygomaxillary junction in patients undergoing Le Fort I osteotomy: comparison of pterygomaxillary dysjunction technique and Trimble technique—a pilot study. *J Maxillofac Oral Surg.* 2015;14(3):713–9.
 95. Hernández-Alfaro F, Guijarro-Martínez R. “Twist technique” for pterygomaxillary dysjunction in minimally invasive Le Fort I osteotomy. *J Oral Maxillofac Surg.* 2013;71(2):389–92.
 96. Ueki K, Nakagawa K, Marukawa K, Yamamoto E. Le Fort I osteotomy using an ultrasonic bone curette to fracture the pterygoid plates. *J Cranio Maxillofac Surg.* 2004;32(6):381–6.
 97. Ueki K, Hashiba Y, Marukawa K, Okabe K, Alam S, Nakagawa K, et al. Assessment of pterygomaxillary separation in Le Fort I osteotomy in class III patients. *J Oral Maxillofac Surg.* 2009;67(4):833–9.
 98. Watts GD, Antonarakis GS, Forrest CR, Tompson BD, Phillips JH. Single versus segmental maxillary osteotomies and long-term stability in unilateral cleft lip and palate related malocclusion. *J Oral Maxillofac Surg.* 2014;72(12):2514–21.
 99. James JN, Costello BJ, Ruiz RL. Management of cleft lip and palate and cleft orthognathic considerations. *Oral Maxillofac Surg Clin North Am.* 2014;26(4):565–72.
 100. Bell WH, Fonseca RJ, Kenney JW, Levy BM. Bone healing and revascularization after total maxillary osteotomy. *J Oral Surg.* 1975;33(4):253–60.
 101. Bell WH, Levy BM. Revascularization and bone healing after maxillary corticotomies. *J Oral Surg.* 1972;30(9):640–8.
 102. Lanigan DT. Ligation of the descending palatine artery: pro and con. *J Oral Maxillofac Surg.* 1997;55(12):1502–4.
 103. Regan BO, Bharadwaj G. The identification and protection of the descending palatine artery in Le Fort I osteotomy: a forgotten technique? *Br J Oral Maxillofac Surg.* 2007;45(5):412–4.
 104. Omura S, Iwai T, Honda K, Shibutani N, Fujita K, Yamashita Y, et al. U-shaped osteotomy around the descending palatine artery to prevent posterior osseous interference for superior/posterior repositioning of the maxilla in le Fort i osteotomy. *J Craniofac Surg.* 2015;26(5):1613–5.
 105. Omura S, Iwai T, Murata S, Tohna I. Use of a simple handmade retractor to protect the descending palatine artery during removal

- of posterior osseous interferences for maxillary impaction in le fort i osteotomy. *J Craniofac Surg.* 2013;24(3):978–9.
106. Johnson LM, Arnett GW. Pyramidal osseous release around the descending palatine artery: a surgical technique. *J Oral Maxillofac Surg.* 1991;49(12):1356–7.
 107. Betts NJ, Fonseca RJ. Location of the descending palatine artery in relation to the Le Fort I osteotomy. *J Oral Maxillofac Surg.* 1996;54(7):826–7.
 108. Li KK, Meara JG, Alexander A. Location of the descending palatine artery in relation to the Le Fort I osteotomy. *J Oral Maxillofac Surg.* 1996;54(7):822–5.
 109. Waite PD, Tejera TJ, Anucul B. The stability of maxillary advancement using Le Fort I osteotomy with and without genial bone grafting. *Int J Oral Maxillofac Surg.* 1996;25(4):264–7.
 110. Posnick JC, Gray JA. Is it safe to re-harvest the anterior iliac crest to manage Le Fort I interpositional defects in young adults with a repaired cleft? *J Oral Maxillofac Surg.* 2015;73(12):S32–9.
 111. Wardrop RW, Wolford LM. Maxillary stability following down-graft and/or advancement procedures with stabilization using rigid fixation and porous block hydroxyapatite implants. *J Oral Maxillofac Surg.* 1989;47(4):336–42.
 112. Mehra P, Castro V, Freitas RZ, Wolford LM. Stability of the Le Fort I osteotomy for maxillary advancement using rigid fixation and porous block hydroxyapatite grafting. *Oral Surg Oral Med Oral Pathol Oral Radiol Endod.* 2002;94(1):18–23.
 113. Mehra P, Wolford LM, Hopkin JK, Castro V, Frietas R. Stability of maxillary advancement using rigid fixation and porous-block hydroxyapatite grafting: cleft palate versus non-cleft patients. *Int J Adult Orthodon Orthognath Surg.* 2001;16(3):193–9.
 114. Gomes KU, Martins WDB, Ribas M de O. Horizontal and vertical maxillary osteotomy stability, in cleft lip and palate patients, using allogeneic bone graft. *Dental Press J Orthod.* 2013;18(5):84–90.
 115. Stork JT, Kim RH, Regennitter FJ, Keller EE. Maxillary quadrangular le Fort i osteotomy: Long-term skeletal stability and clinical outcome. *Int J Oral Maxillofac Surg.* 2013;42(12):1533–46.
 116. Cheung LK, Chua HDP, Hägg MB. Cleft maxillary distraction versus orthognathic surgery: clinical morbidities and surgical relapse. *Plast Reconstr Surg.* 2006;118(4):996–1008. Discussion 1009
 117. Cheung LK, Chua HDP. A meta-analysis of cleft maxillary osteotomy and distraction osteogenesis. *Int J Oral Maxillofac Surg.* 2006;35(1):14–24.
 118. Kwong Cheung L, Ser Pheng Loh J, Ho SMY. The early psychological adjustment of cleft patients after maxillary distraction osteogenesis and conventional orthognathic surgery: a preliminary study. *J Oral Maxillofac Surg.* 2006;64(12):1743–1750.
 119. Chua HDP, Ho SMY, Cheung LK. The comparison of psychological adjustment of patients with cleft lip and palate after maxillary distraction osteogenesis and conventional orthognathic surgery. *Oral Surg Oral Med Oral Pathol Oral Radiol.* 2012;114(5 Suppl):S5–10.
 120. Kloukos D, Fudalej P, Sequeira-Byron P, Katsaros C. Maxillary distraction osteogenesis versus orthognathic surgery for cleft lip and palate patients. *Cochrane Database Syst Rev.* 2018;8(8):CD010403.
 121. Chua HDP, Cheung LK. Soft tissue changes from maxillary distraction osteogenesis versus orthognathic surgery in patients with cleft lip and palate—A randomized controlled clinical trial. *J Oral Maxillofac Surg.* 2012;70(7):1648–58.
 122. Thongdee P, Samman N. Stability of maxillary surgical movement in unilateral cleft lip and palate with preceding alveolar bone grafting. *Cleft Palate Craniofac J.* 2005;42(6):664–674.
 123. Precious DS. Treatment of retruded maxilla in cleft lip and palate—orthognathic surgery versus distraction osteogenesis: the case for orthognathic surgery. *J Oral Maxillofac Surg.* 2007;65(4):758–61.
 124. Hirano A, Suzuki H. Factors related to relapse after Le Fort I maxillary advancement osteotomy in patients with cleft lip and palate. *Cleft Palate Craniofac J.* 2001;38(1):1–10.
 125. Watts GD, Antonarakis GS, Forrest CR, Tompson BD, Phillips JH. Is linear advancement related to relapse in unilateral cleft lip and palate orthognathic surgery? *Cleft Palate Craniofac J.* 2015;52(6):717–23.
 126. Hoffman GR, Brennan PA. The skeletal stability of one-piece Le Fort I osteotomy to advance the maxilla Part 2. The influence of uncontrollable clinical variables. *Br J Oral Maxillofac Surg.* 2004;42(3):226–30.
 127. Haas Junior OL, Guizarro-Martínez R, de Sousa Gil AP, da Silva Meirelles L, Scolari N, Muñoz-Pereira ME, et al. Hierarchy of surgical stability in orthognathic surgery: overview of systematic reviews. *Int J Oral Maxillofac Surg.* 2019;48:1415.
 128. Proffit WR, Turvey TA, Phillips C. The hierarchy of stability and predictability in orthognathic surgery with rigid fixation: An update and extension. *Head Face Med.* 2007;3(1):1–11.
 129. Hoffman GR, Brennan PA. The skeletal stability of one-piece Le Fort I osteotomy to advance the maxilla Part 1. Stability resulting from non-bone grafted rigid fixation. *Br J Oral Maxillofac Surg.* 2004;42(3):221–5.
 130. Kanno T, Mitsugi M, Hosoe M, Sukegawa S, Yamauchi K, Furuki Y. Long-term skeletal stability after maxillary advancement with distraction osteogenesis in nongrowing patients. *J Oral Maxillofac Surg.* 2008;66(9):1833–46.
 131. Wolford LM, Karras SC, Mehra P. Considerations for orthognathic surgery during growth, Part 1: Mandibular deformities. *Am J Orthod Dentofac Orthop.* 2001;119(2):95–101.
 132. Saltaji H, Major MP, Altalibi M, Youssef M, Flores-Mir C. Long-term skeletal stability after maxillary advancement with distraction osteogenesis in cleft lip and palate patients: A systematic review. *Angle Orthod.* 2012;82(6):1115–22.
 133. Saltaji H, Major MP, Alfakir H, Al-Saleh MAQ, Flores-Mir C. Maxillary advancement with conventional orthognathic surgery in patients with cleft lip and palate: Is it a stable technique? *J Oral Maxillofac Surg.* 2012;70(12):2859–66.
 134. Andersen K, Svenstrup M, Pedersen TK, Küsel A, Jensen J, Nørholt SE. Stability after cleft maxillary distraction osteogenesis or conventional orthognathic surgery. *J Oral Maxillofac Res.* 2015;6(2):e2.
 135. Serafin B, Perciaccante VJ, Cunningham LL. Stability of orthognathic surgery and distraction osteogenesis: options and alternatives. *Oral Maxillofac Surg Clin North Am.* 2007;19(3): 311–20, v.
 136. Hirjak D, Reyneke JP, Janec J, Beno M, Kupcova I. Long-term results of maxillary distraction osteogenesis in nongrowing cleft: 5-years experience using internal device. *Bratisl Lek Listy.* 2016;117(12):685–90.
 137. Gürsoy S, Hukki J, Hurmerinta K. Five-year follow-up of maxillary distraction osteogenesis on the dentofacial structures of children with cleft lip and palate. *J Oral Maxillofac Surg.* 2010;68(4):744–50.
 138. Chua HDP, Hgg MB, Cheung LK. Cleft maxillary distraction versus orthognathic surgery—which one is more stable in 5 years? *Oral Surg. Oral Med Oral Pathol Oral Radiol Endodontol.* 2010;109(6):803–14.
 139. Figueroa AA, Polley JW, Friede H, Ko EW. Long-term skeletal stability after maxillary advancement with distraction osteogenesis using a rigid external distraction device in cleft maxillary deformities. *Plast Reconstr Surg.* 2004;114(6):1382–92.
 140. Yamaguchi K, Lonic D, Lo LJ. Complications following orthognathic surgery for patients with cleft lip/palate: A systematic review. *J Formos Med Assoc.* 2016;115(4):269–77.
 141. Tabrizi R, Tumer K, Shafiei S, Rashad A. Can use of rigid fixation after consolidation increase stability in cleft patients fol-

- lowing distraction osteogenesis? *J Oral Maxillofac Surg.* 2018;76(6):1309–15.
142. Metalwala Z, Okunseri C, Fletcher S, Allareddy V. Orthognathic surgical outcomes in patients with and without craniofacial anomalies. *J Oral Maxillofac Surg.* 2018;76(2):436.e1–8.
143. Moran I, Virdee S, Sharp I, Sulh J. Postoperative complications following LeFort 1 maxillary advancement surgery in cleft palate patients: A 5-year retrospective study. *Cleft Palate Craniofac J.* 2018;55(2):231–7.
144. dos Santos Alves JM, de Freitas Alves BW, de Figueiredo Costa AC, Carneiro BGDS, de Sousa LM, Gondim DV. Cranial nerve injuries in Le Fort I osteotomy: a systematic review. *Int J Oral Maxillofac Surg.* 2018;10–2.
145. Ohrmann D, Hoyte-Williams PE, Chen PK-T. Update on complications in cleft orthognathic surgery. *Curr Opin Otolaryngol Head Neck Surg.* 2018;1
146. Eduardo Charles Pagotto L, de Santana Santos T, Juliana de Abreu de Vasconcellos S, Silva Santos J, Saquete Martins-Filho PR. Piezoelectric versus conventional techniques for orthognathic surgery: Systematic review and meta-analysis. *J Cranio Maxillofacial Surg.* 2017;45(10):1607–13.

Open Access This chapter is licensed under the terms of the Creative Commons Attribution 4.0 International License (<http://creativecommons.org/licenses/by/4.0/>), which permits use, sharing, adaptation, distribution and reproduction in any medium or format, as long as you give appropriate credit to the original author(s) and the source, provide a link to the Creative Commons license and indicate if changes were made.

The images or other third party material in this chapter are included in the chapter's Creative Commons license, unless indicated otherwise in a credit line to the material. If material is not included in the chapter's Creative Commons license and your intended use is not permitted by statutory regulation or exceeds the permitted use, you will need to obtain permission directly from the copyright holder.



76.1 Introduction

Rhinoplasties in cleft lip and palate (CLP) patients are considered one of the most difficult and challenging surgeries to carry out. The reasons understood for this are twofold: the principal reason being the simultaneous involvement of all the layers of the nose, including the skin, cartilage, skeleton and vestibular lining, and the other the significant scarring that accompanies multiple previous surgical interventions. The deformity has a major impact on nasal aesthetics as well as function and can range from being absolutely inconspicuous to catastrophic.

The literature is flooded with numerous techniques for ultimate correction of unilateral and bilateral cleft lip-nasal deformities. More recently, most cleft surgeons have started opting for primary rhinoplasties at the time of lip repair with or without presurgical orthopaedics. These early interventions have definitely improved the nasal deformity and the overall nasal symmetry; however, definitive rhinoplasty may still be required at a later date as the child grows. Despite all the recent developments in cleft surgery, an optimal surgical modality that addresses the issues of desired nasal form coupled with long-term stability for correction of cleft lip-nasal deformity still fails to exist.

Disclosure: Authors have no financial conflicts to disclose

Electronic Supplementary Material The online version of this chapter (https://doi.org/10.1007/978-981-15-1346-6_76) contains supplementary material, which is available to authorized users.

S. Richardson (✉)
Richardson's Dental and Craniofacial Hospital,
Chunkan Kadai, Nagercoil, Tamil Nadu, India

R. V. S. Khandeparker
Department of Oral and Maxillofacial Surgery, Goa Dental College
and Hospital, Bambolim, Goa, India

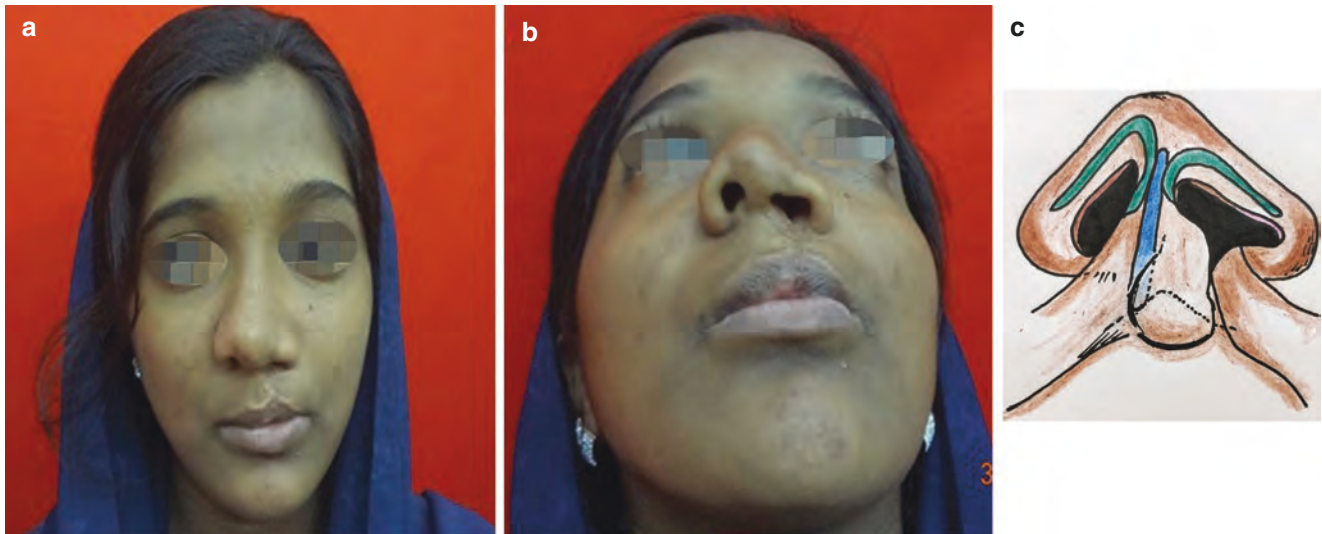
76.2 Pathologic Anatomy

A clear understanding of the associated complex anatomical and pathological abnormalities is paramount to obtaining desired nasal form and function [1].

76.2.1 Unilateral Cleft Nasal Deformity

The hallmark of unilateral cleft nasal deformity is a three-dimensional asymmetry of the nasal tip and the alar base (Fig. 76.1a–c). The characteristic features include:

1. **Asymmetric nasal tip:** This is principally due to a shorter medial crus and longer lateral crus of the lower lateral cartilage (LLC) on the cleft side as compared to the non-cleft side. This contributes to a poorly defined nasal tip with less projection [2]. Furthermore, the angle between the medial and lateral crura on the cleft side is increased.
2. **Alar dome is flat and wider on the cleft side** due to posterolateral displacement of the alar dome [2].
3. **Deviation of the columellar base to the non-cleft side:** The unilateral cleft results in a discontinuous insertion of the orbicularis oris muscle into the columellar base on the non-cleft side rather than a horizontal insertion and continuous decussation as seen in the normal lip. The contraction of the orbicularis oris muscle results in an unopposed pull of the columella, caudal septum and premaxilla to the non-cleft side [3].
4. **Alar base on the cleft side is directed laterally, posteriorly and inferiorly:** Two factors contribute to this: one being the insertion of the orbicularis oris into the alar base and the other the deficient maxillary skeletal framework at the alar base [3].
5. **Hypoplastic maxilla on the cleft side.**
6. **Wide and horizontally directed nostril on the cleft side:** This is brought about by a combination of vector of



©Association of Oral and Maxillofacial Surgeons of India

Fig. 76.1 (a–c) Photographs depicting the pathologic anatomy as observed in unilateral cleft nasal deformity. (a) Frontal view showing the deviation of the nasal root towards the non-cleft side with asymmetrical appearing nasal tip. (b) Basal view depicting the deviation of the base of the columella to the non-cleft side. Also, observe the wide

and horizontally directed nostril on the cleft side. Furthermore, the alar base on the cleft side is directed laterally, posteriorly and inferiorly. (c) Pictorial depiction of deviation of the caudal nasal septum (blue) towards the non-cleft side

orbicularis oris muscle pull and asymmetric LLC on the cleft side [4, 5].

7. **Deviation of the caudal septum to the non-cleft side:** The unopposed pull of the orbicularis oris muscle due to its improper insertion into the columellar base results in deviation of the caudal septum to the non-cleft side [3]. This force affects only the caudal septum and results in deflection of the cartilaginous and bony septum into the cleft side posteriorly. This alone or in association with hypertrophied nasal turbinates significantly narrows the opening of the nasal airway and contributes to nasal airway obstruction [6].
8. **Compromised external nasal valve:** This is the consequence of two related factors: introversion of the nasal ala and webbing of the nasal vestibule. Due to the position of the columella and alar base on the cleft side, the LLC is subjected to distortional forces that causes it to rotate posteroinferiorly and brings about introversion of the cleft side nasal ala [7]. This leads to hooding and thickening of the ala and together with surgical scarring forms an oblique fold and contributes to webbing of the nasal vestibule. This tissue bulk has an influence on the nasal airflow and significantly alters the relationship of upper lateral cartilages (ULCs) and LLCs.
9. **Weakened upper lateral cartilages (ULC) and abnormal relationship to LLCs:** On the cleft side, the ULC displays side-to-side relationship rather than the typical

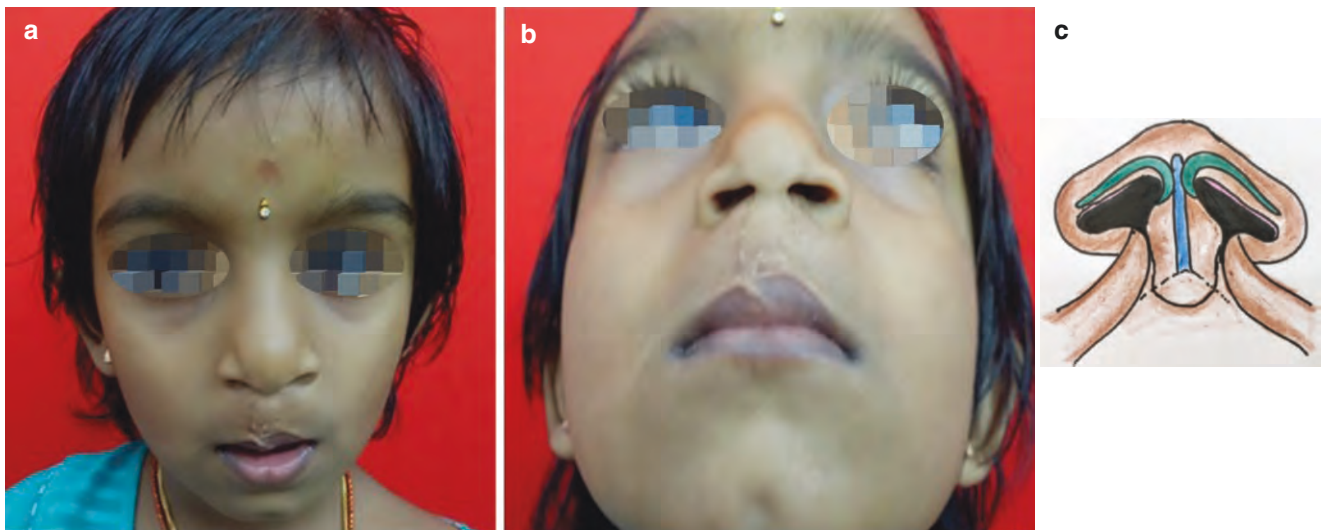overlap type of relationship seen on the non-cleft side. The ULC on the cleft side is also weakened by inadequate skeletal support [8]. The consequence of both these factors is reduced support and collapse of the ULC with deep inspiration.

10. **Compromised internal nasal valve on the cleft side:** This is primarily because of septal bowing into the cleft side at the internal nasal valve together with weakened support of the ULC at the cleft side which causes the cartilage to collapse with respiration.

76.2.2 Bilateral Cleft Nasal Deformity

The bilateral cleft lip nasal deformity is grossly symmetrical and shares similar clinical characteristics as observed in unilateral cleft deformity [9, 10] (Fig. 76.2a–c). The clinical characteristics include:

1. **Under-projected and bifid nasal tip:** The lateral crus of the LLC is long, and the medial crus is short which leads to under-projection of the nasal tip. The medial crura are typically splayed, producing a poorly defined, bifid tip [11]. The nose is wide and depressed.
2. **Blunting of the alar dome with a more obtuse angle** due to posterolateral displacement of the alar domes [11].



©Association of Oral and Maxillofacial Surgeons of India

Fig. 76.2 (a–c) Photographs depicting the pathologic anatomy as observed in bilateral cleft nasal deformity. (a) Frontal view demonstrating a more or less symmetrical deformity with bifid nasal tip and blunting of the alar dome. (b) Basal view depicting symmetrical position of

the caudal nasal septum, short columella and bilateral displacement of the alar bases laterally, posteriorly and inferiorly with wide and horizontally directed nostrils bilaterally. (c) Pictorial depiction of the classical midline position of the caudal nasal septum

3. **Short columella with a wider base:** The columella is short or nearly absent as a consequence of decreased soft tissue and skin between the nasal tip and the upper lip [12].
4. **Alar bases are displaced laterally, posteriorly and inferiorly.** This brings about flaring of the alar bases and widening of the nostrils.
5. **Hypoplastic maxillae bilaterally.**
6. **Nostrils are wide and horizontally directed with margins buckling inwards.**
7. **Classical midline positioning of the septum.** The nasal septum is classically midline; however, in case of a slight discrepancy, the septum deviates to the less affected side [13, 14].
8. **The external nasal valve is compromised by** introversion of the LLCs and webbing of the nasal vestibules bilaterally.
9. **The ULCs are weakened and display abnormal relationship to LLCs** similar to that seen in the unilateral cleft nasal deformity.
10. **The internal nasal valve is compromised by weakened support of the ULC:** It is important to note that midline positioning of the nasal septum in bilateral cleft nasal deformity results in compromise of the internal nasal valve to a lesser significant degree as compared to the unilateral cleft nasal deformity.

76.3 Surgical Timing

The timing of cleft lip nasal repairs can be divided into primary, intermediate and secondary or definitive repairs.

76.3.1 Primary Rhinoplasty

Initially, most surgeons were sceptical with early nasal interventions at the time of cleft lip repair following demonstrations of impairment of nasal and midfacial growth in experimental studies that resulted after large submucosal resections of the nasal septum. However, studies by McComb and Coghlan [7] have dispelled this philosophy and demonstrated that early interventions seldom interfere with growth provided the lower lateral cartilage is only repositioned and not resected. Primary rhinoplasties are now increasingly accepted, and their positive effects on secondary rhinoplasties are well documented.

Primary cleft rhinoplasty is typically carried out at 3 months of age at the time of primary cheiloplasty [15]. An early intervention improves the existing cleft nasal deformity by achieving better symmetry, allowing the nose to grow in a symmetric fashion and potentially improving long-term appearance and the final outcome.

The definite goals of the procedure are highlighted in Box 76.1.

Box 76.1: Definite Goals of Primary Cleft Rhinoplasty

- To bring about approximation of the nasal floor to establish a muscle and soft tissue sill across the nasal base
- Symmetrical positioning of the abnormally positioned LLC
- Providing nasal tip support
- Repositioning of the alar base and correction of the webbed lateral alar mucosa by plicating skin and mucosa [16]

The addition of presurgical naso-alveolar moulding device is advocated by some authors in conjunction with primary surgery. The technique delivers continuous low-level pressure on the alveolar segments and is highly successful in shaping the nasal cartilage within the initial 6 weeks due to high levels of circulating maternal oestrogen that makes the cartilage increasingly elastic [17].

The technique helps in bringing the alveolar segments closer thereby narrowing the cleft gap, improving the alar base symmetry, expanding the soft tissue envelope and elongating the columella [18, 19].

76.3.2 Intermediate Rhinoplasty

Intermediate rhinoplasty is reserved for procedures that are carried out prior to completion of nasal growth, in the time interval spanning between definitive lip repair and secondary rhinoplasty. The procedures are planned on the lines of conservation with the singular aim to achieve symmetry during continued nasal growth, ultimately creating a definitive platform for a more successful definitive repair.

The primary goal of surgery is to correct the abnormal position of the LLC on the cleft side so that there is no exacerbation of the deformity following nasal growth in future. It is imperative to perform a septorhinoplasty or cartilage grafting procedures in the post-adolescence age so that the nasal growth proceeds unimpeded [11].

Intermediate rhinoplasty can be carried out at two distinct time intervals [20]. One corresponds to 4–6 years of age, and this age group coincides with the timing of lip revision if required and also helps in achieving a better nasal symmetry. Also, this is the time when the peer pressure starts to mount

necessitating the need for intermediate rhinoplasty in this age group. Furthermore, any lateral vestibular webbing can be dealt with preventing the obstruction of the external nasal valve.

The other instance when an intermediate rhinoplasty can be carried out is after completion of orthodontic alignment and secondary alveolar bone grafting (8–12 years). This helps in creating a solid skeletal platform to affect a long-lasting correction of severe nasal deformities.

76.3.3 Secondary or Definitive Rhinoplasty

Secondary or definitive rhinoplasty is performed once the maxillary and nasal growth ceases, which corresponds to 14–16 years of age in females and 16–18 years of age in males [21]. The procedure has to be definitive and provides an opportunity to introduce aggressive surgical interventions like septorhinoplasty, nasal osteotomies and cartilage grafting manoeuvres without fear of jeopardising the maxillary or nasal growth.

The goals of definitive rhinoplasty are mentioned in Box 76.2.

Box 76.2: Goals of Definitive Rhinoplasty

- Create a lasting symmetry and definition of the nasal base and tip.
- Relieve nasal obstruction.
- Manage nasal scarring and webbing.
- Correct short columellar skin if present, and augment the nasal dorsum in cases of bilateral cleft nasal deformities [1].

Most CLP patients present with maxillary hypoplasia and therefore require maxillary advancement surgery in the form of either LeFort I osteotomy, total maxillary distraction or anterior maxillary distraction. The maxillary projection can be improved with these procedures without affecting the nasal dorsum adversely [22]. These procedures also allow for forward movement of LLC and improvement of the tip projection. In scenarios such as this, definitive rhinoplasty is often carried out after addressing the skeletal discrepancies.

76.4 Preoperative Evaluation

Prior to carrying out a rhinoplasty surgery, it is prudent to carry out a thorough evaluation of the nose in a meticulous manner. This when backed up with sound knowledge of nasal anatomy can bring about aesthetically pleasing results in cleft rhinoplasty.

76.4.1 History

It is imperative to address any patient concerns as related to symmetry of the lip and nose, nasal airway, etc. prior to carrying out a rhinoplasty surgery. Any previous nasal surgeries have to be documented accurately. The effects of such surgeries on the postoperative outcomes have to be explained to the patient beforehand.

76.4.2 Physical Examination

A thorough physical examination involves examining both the external appearance and the internal nasal structures.

External examination of the nose must be carried out in accordance with its position on the facial skeleton. Measurements as traced on preoperative photographs can provide a guide in the surgical planning (Fig. 76.3a–d).

Internal nasal examination proceeds in a systematic and repeatable manner and is performed using a nasal speculum to evaluate for the nasal function.

When performing the physical examination of the nose, the clinical characteristics of unilateral and bilateral cleft nasal deformities as previously described are looked up for in a systematic manner. Gunter diagrams can be a valuable aid for the purpose of preoperative planning [21].

76.4.3 Photographic Documentation

76.4.3.1 Two-Dimensional Photographs

Appropriate documentation of the deformity is made possible by taking preoperative photographs in all views, viz. frontal, basal, lateral and oblique views (Fig. 76.4a–f). These photographs serve diagnostic purpose as well as help in protecting the surgeon in cases of medico-legal implications. The photographs also help in explaining the goals of surgery

adequately to the patient. Furthermore, the photographs can serve as a visual guide to the surgeon intraoperatively, helping in implementing the planned surgical goals precisely.

76.4.3.2 Three-Dimensional Imaging

This method requires a set of devices, viz. an optical system, digital communication network and a computer with a calculation program which helps in determining the shape of the three-dimensional object by transforming the image from analogue to digital form (Fig. 76.5a). The technique is reliable, can be safely employed in child patients due to its non-ionising nature and offers both qualitative and quantitative assessments, and the digital model can be employed in the clinical setting immediately. The disadvantages include the cost, long time that is required for patient preparation and data acquisition and inability to measure bony or interactive landmarks.

76.4.4 Radiographic Assessment

76.4.4.1 Cephalometric Analysis

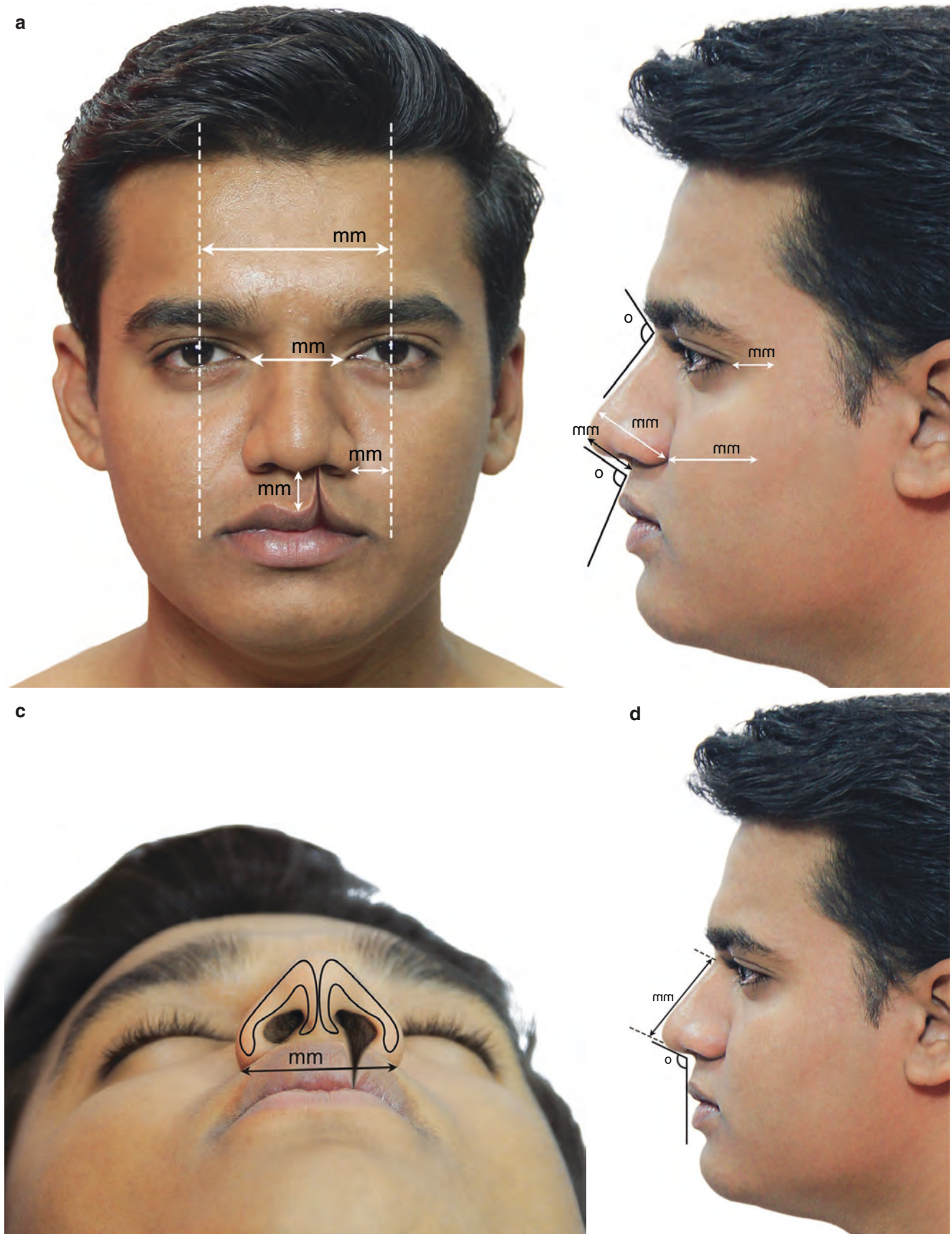
Cephalometric analysis aids in evaluating the maxillary position and its possible implications on the patient's nose [21] (Fig. 76.5b). The need for any maxillary advancement surgery and the importance of performing it before any rhinoplasty surgery should be conveyed to the patient. Cephalometric analysis also allows for evaluation of chin position [21].

76.4.4.2 Computed Tomography (CT)/Cone Beam Computed Tomography (CBCT)

CT scans of the paranasal sinuses in axial and coronal views help in defining the deformation of the septum as well as other intra-nasal structures. CBCT is an attraction alternative to CT with regard to decreased ionising radiation to the patient and image quality for hard tissues on par with CT. No modalities other than CT/CBCT allow for evaluation of nasal septum objectively [23] (Fig. 76.5c).

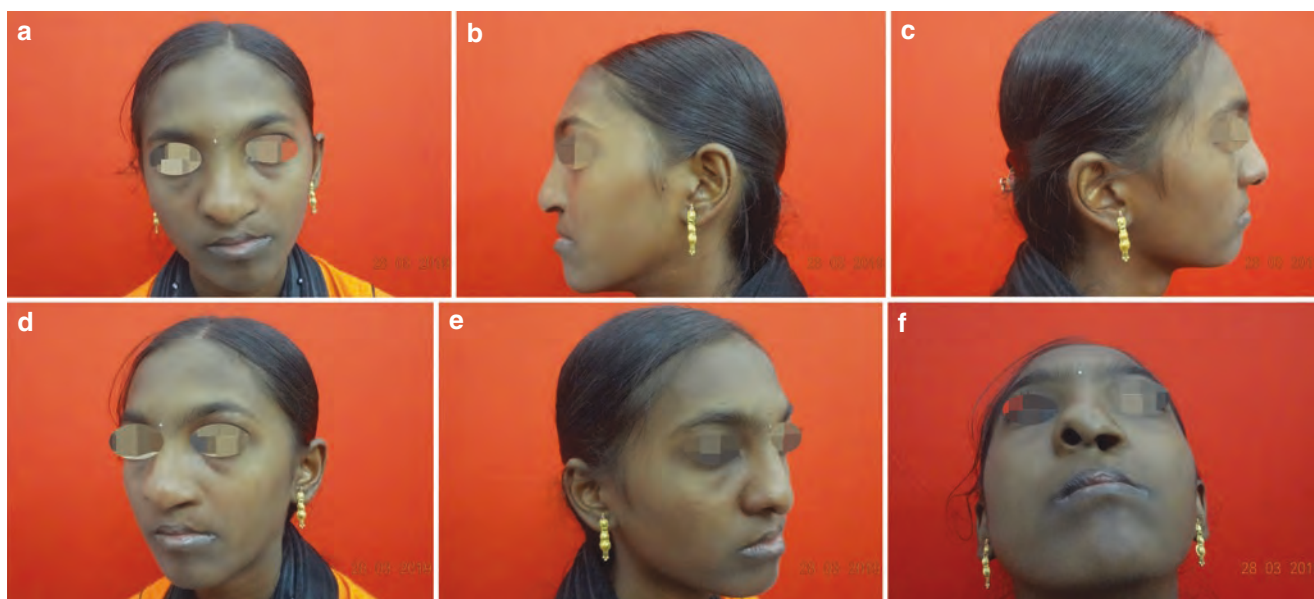76.4.5 Facial Casts

Facial casts have been employed by authors to study the nasal morphology by direct anthropometry [24] (Fig. 76.5d). The technique is found to be objective and cost-effective and



©Association of Oral and Maxillofacial Surgeons of India

Fig. 76.3 (a–d) Important angular and linear measurements as traced from preoperative photographs can serve as a guide for preoperative surgical planning



©Association of Oral and Maxillofacial Surgeons of India

Fig. 76.4 (a–f) Standard photographic views for cleft rhinoplasty. (a) Frontal view. (b) Left lateral view. (c) Right lateral view. (d) Left lateral oblique view. (e) Right lateral oblique view. (f) Basal view

allows precise recording of selected parameters as the soft tissues are not deformed.

76.4.6 Video Recording

Some authors [25, 26] have also resorted to video recordings that make assessment of movements possible and eliminates the need for clinical photographs as these can be generated from the video records. The disadvantages include increased time and need for trained personnel with considerable cooperation from the patients.

76.4.7 Functional Assessment

Function is as important as nasal aesthetics. Functional assessment can be established using rhinomanometry; however the usefulness of such an evaluation is limited.

76.5 Surgical Correction

76.5.1 Surgical Approaches

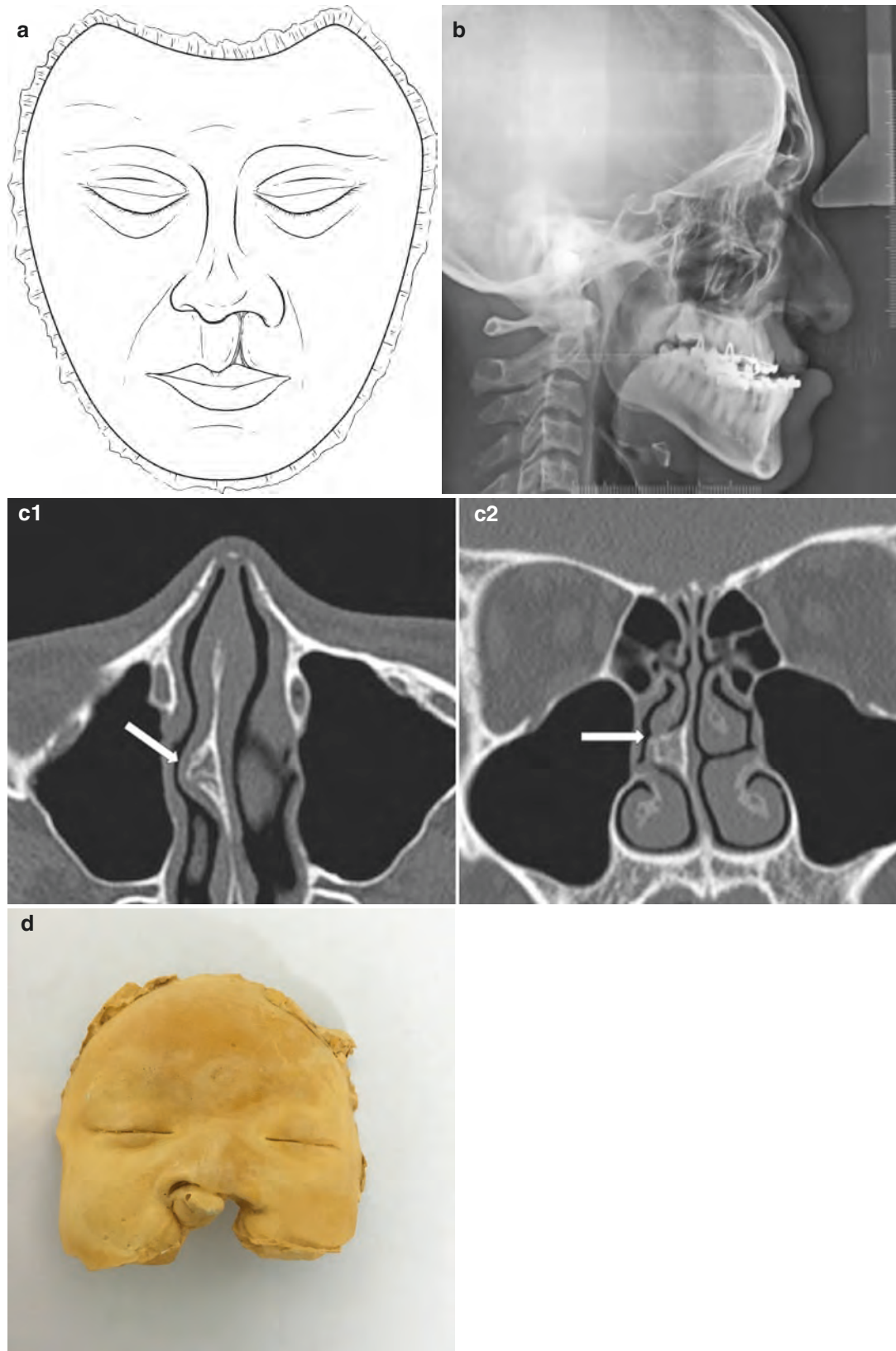
Cleft rhinoplasty can be accomplished using either an open or closed approach.

While primary rhinoplasty can be carried out using either of the two approaches, definitive rhinoplasty is almost always accomplished using an open approach.

The open approach allows for both superior visual control and enhanced surgical exposure of all the abnormal components facilitating their anatomical reconstruction under direct vision. Furthermore, the approach facilitates nasal sculpting either by suturing or by introduction and fixation of different types of grafts. The approach also helps in saving time when compared to the closed approach. When employing the open approach, a combination of bilateral marginal incisions with an inverted V mid-columellar incision is preferred among most surgeons [27] (Fig. 76.6a, b).

Sometimes, additional skin needs to be recruited in the columella. In such cases, the typical external columellar incision can be modified. When addressing the unilateral cleft nasal deformity, columellar lengthening can be achieved with the help of an asymmetric V to Y incision on the side of the cleft. The V to Y incision is made in the midline, recruiting the skin from the upper lip into the columella in cases of bilateral cleft nasal deformity. A viable alternative incision in cases of bilateral cleft noses is an upper lip forked flaps which achieve columellar lengthening together with narrowing of the central segment [28].

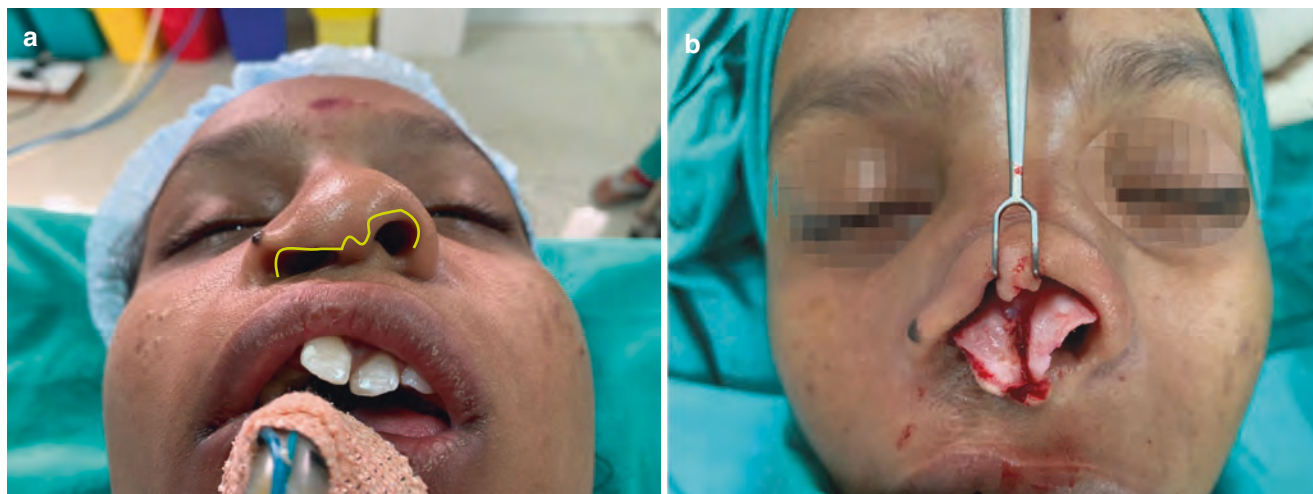Other viable options include the use of prolabium advancement flap together with an Abbe flap, composite graft of skin and auricular cartilage and skin rim rotation flap [29].



©Association of Oral and Maxillofacial Surgeons of India

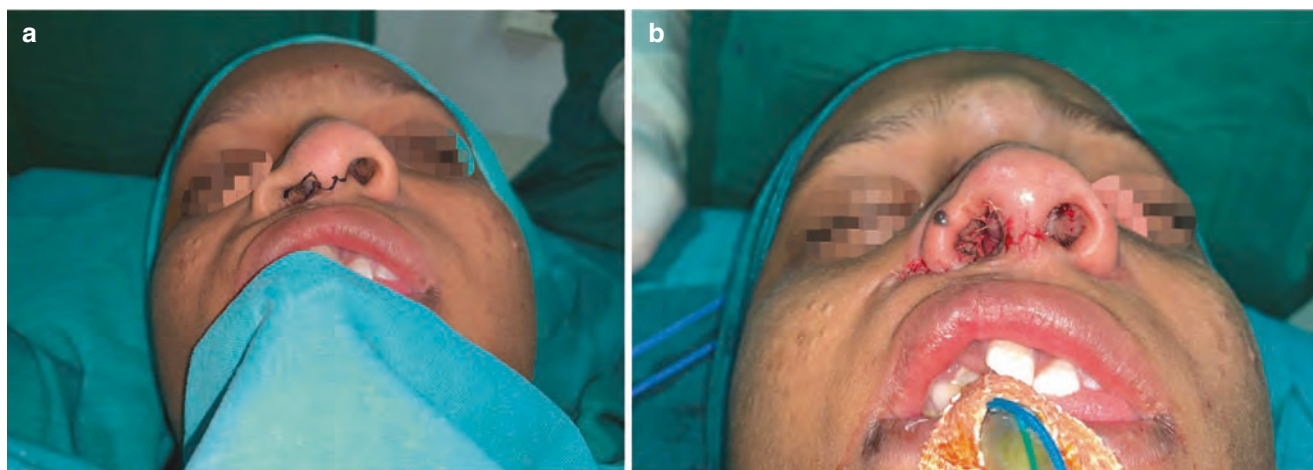
Fig. 76.5 (a–d) Tools for preoperative patient evaluation for cleft rhinoplasty. (a) Three-dimensional model of the face. (b) Lateral cephalogram for cephalometric analysis for evaluating the maxillary and chin

position prior to cleft rhinoplasty. (c) (1 and 2): Axial and coronal CT scan views allow for evaluation of the nasal septal deviation objectively (white arrows). (d) Facial cast for evaluating the nasal morphology



©Association of Oral and Maxillofacial Surgeons of India

Fig. 76.6 Open approach for cleft rhinoplasty. A combination of inverted V (a, b) transcolumnellar and bilateral marginal incisions is typically employed. (a) Marking of the incision. (b) Skeletonisation of the nose using the above incision



©Association of Oral and Maxillofacial Surgeons of India

Fig. 76.7 (a, b) Tajima and Maruyama reverse U incision for correction of nostril asymmetry. (a) Marking of the reverse U incision on to the external nasal skin on the right side of the nostril. (b) Correction of nostril asymmetry following closure (also see Fig. 76.17)

Most patients with unilateral cleft nasal deformity are often disturbed with the nostril asymmetry that accompanies such a deformity. This has been addressed using a reverse U incision as described by Tajima and Maruyama in 1977 [30]. The technique involves extending the marginal incision into a rim incision at the point of the alar web. The skin of the web is incorporated with the LLC flap and vestibular skin, and the flap is suspended both medially and cephalically from the LLC to the ipsilateral ULC and the septum using sutures (Fig. 76.7a, b). This helps in recruiting the external skin of the alar web to the vestibular lining which also helps in addressing the issue of deficient vestibular skin associated with unilateral cleft noses. This incision is well accepted among surgeons for correction of nostril asymmetry.

76.6 Primary Rhinoplasty

The aim of the surgery is to attain symmetry of the nasal tip and alar base.

76.6.1 Unilateral Cleft Nasal Deformity

The literature has reported a number of techniques for achieving symmetry in unilateral cleft nasal deformities primarily [15, 31]. The salient points that are common to most of these techniques include:

- Completely freeing the soft tissue attachments of the alar base from the pyriform aperture and maxilla for symmet-

rical repositioning of the retro-positioned alar base on the cleft side.

- Nasal tip plasty is carried out to increase the nasal tip projection. This is made possible by utilising the incisions for lip repair. Dissecting through these incisions, the skin overlying the LLC's is dissected with the help of medial and lateral tunnels, and the cutaneous attachments of the lateral crura are separated [1] (Fig. 76.8a).
- Repairing the caudal septum by attaching it to the anterior nasal spine.
- Finally, following complete closure of the lip and repositioning of the alar base, the LLC is secured in the new position using either transnasal sutures or nasal bolsters [32]. These sutures help in recreating the cleft side dome thereby increasing the nasal tip projection and improving the tip symmetry (Fig. 76.8b).

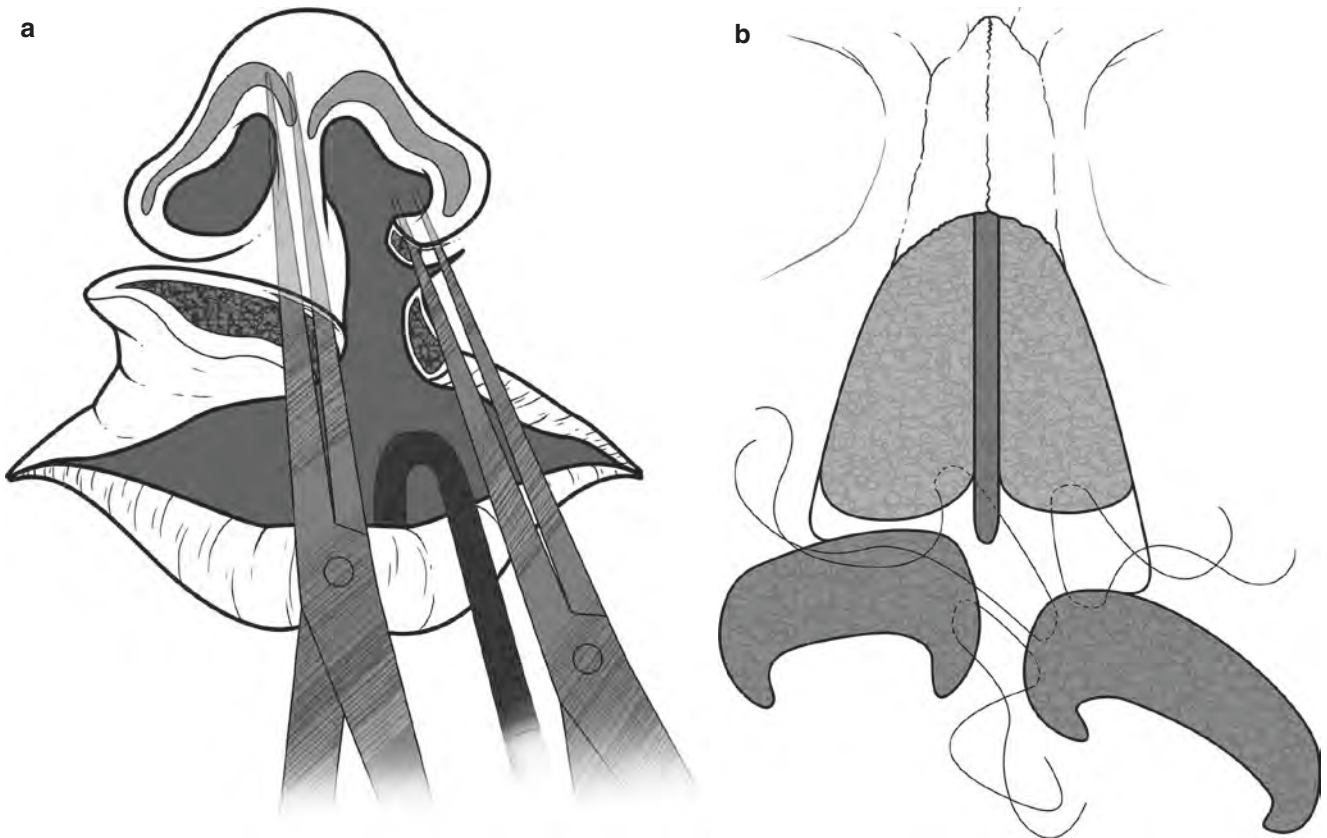
76.6.2 Bilateral Cleft Nasal Deformity

In bilateral cleft nasal deformities, the retro-positioned alar bases are released from the nasal lining laterally and positioned symmetrically by securing the nasalis muscle to the nasal septum on both sides. The nasal muscular ring is reconstructed as performed in the unilateral cleft noses. Nasal tip surgery is not performed at this stage but is carried out at the time of intermediate rhinoplasty [21].

76.7 Intermediate Rhinoplasty

76.7.1 Unilateral Cleft Nasal Deformity

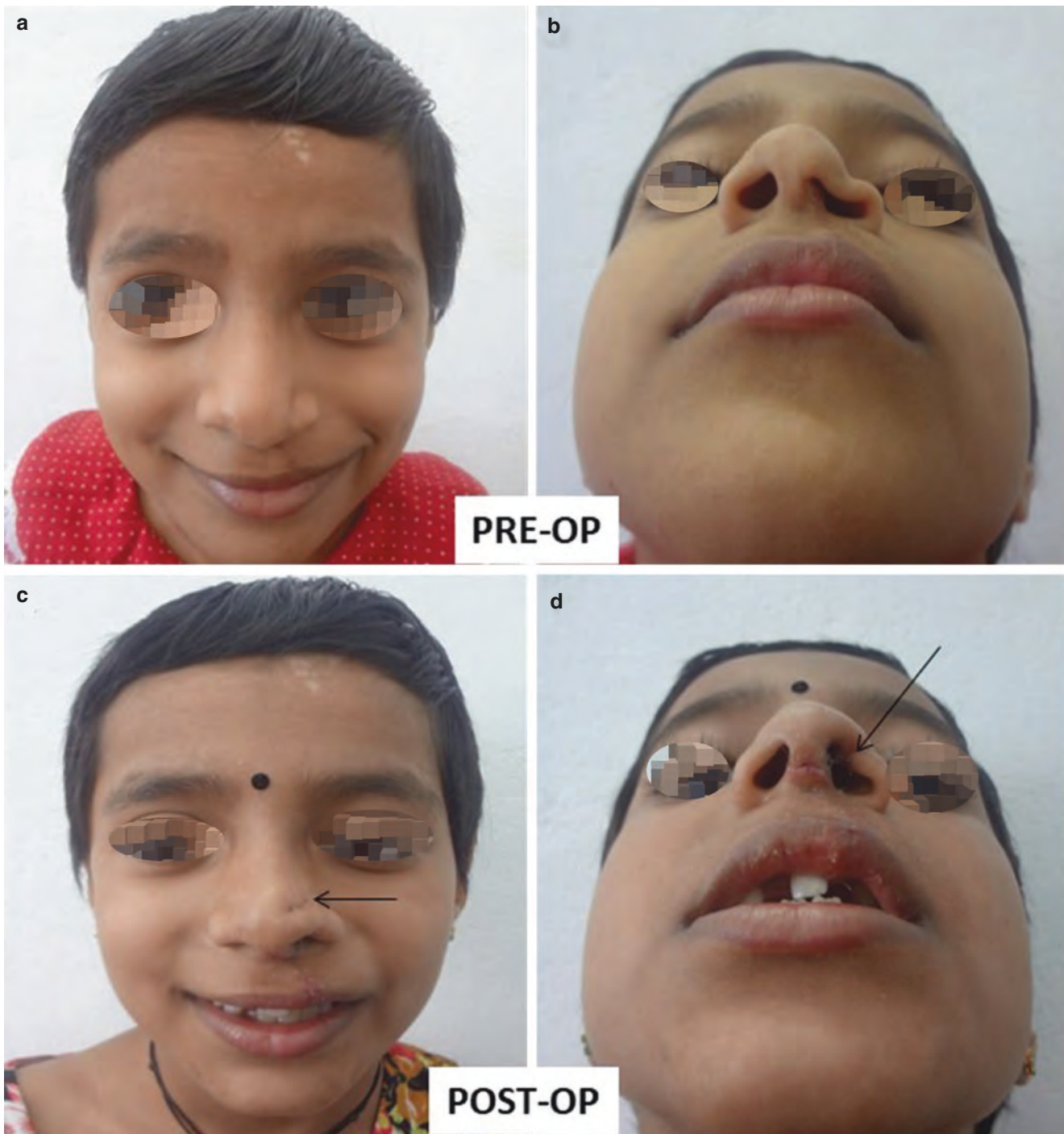The intermediate rhinoplasty addresses two issues in unilateral cleft nose: the asymmetric position of LLC on the side of the cleft and vestibular webbing laterally (Fig. 76.9a–d).



©Association of Oral and Maxillofacial Surgeons of India

Fig. 76.8 (a, b) Schematic representation of primary rhinoplasty in a unilateral cleft lip nasal deformity case. (a) Dissection for access to crura utilising the incisions for lip repair. (b) Recreating the cleft side nasal dome using transnasal sutures for better symmetry and projection. The sutures are made to pass through the nose, vestibular lining and

LLCs and through the nasal skin before being reintroduced through the nasal skin and ULC and sutured down within the nasal vestibule. It is important to reintroduce them through the same hole they exited to prevent necrosis of the nasal skin



©Association of Oral and Maxillofacial Surgeons of India

Fig. 76.9 (a–d) A case of unilateral cleft nasal deformity in a 6-year-old child managed using intermediate rhinoplasty. (a) Preoperative frontal view. (b) Preoperative basal view showing the abnormal position of LLC on the cleft side (Left). (c) Postoperative frontal view. The

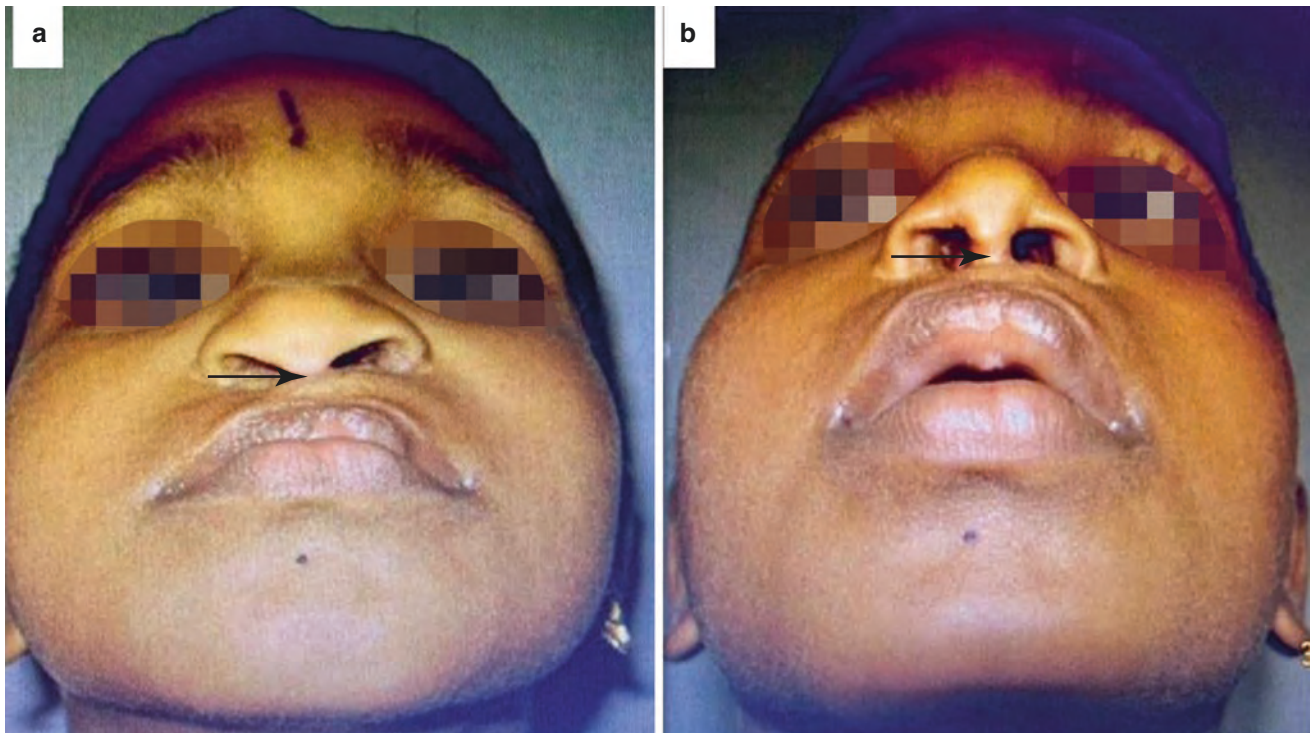
abnormal position of the LLC on the cleft side is corrected using an open approach (inverted V transcolumellar incision) and transnasal sutures (black arrow). (d) Postoperative basal view showing symmetrical positioning of the LLC on the cleft side (black arrow)

In cases of asymmetric position of the LLC on the cleft side, an open approach is usually preferred that exposes the LLCs bilaterally so that the geometric differences between the two sides can be appreciated and subsequently corrected using suture techniques followed by closure along the columellar incision [33].

In cases of lateral vestibular webbing, a V/Y-type incision or a back cut can be carried out to affect the lateral nasal sidewall lengthening which will subsequently bring the LLC forward [1].

76.7.2 Bilateral Cleft Nasal Deformity

In such cases, intermediate rhinoplasty corrects the depressed LLCs as well as affects lengthening of the short columella [1, 34] (Fig. 76.10a, b). An open approach is employed for correction of the above-mentioned scenarios. Following exposure of the LLCs, the angle of divergence between the domes is decreased using transdomal suture, helping in increasing the projection of the nasal tip [34].



©Association of Oral and Maxillofacial Surgeons of India

Fig. 76.10 (a, b) A case of bilateral cleft nasal deformity in a 5-year-old managed using intermediate rhinoplasty. (a) Preoperative basal view showing the abnormal position of the LLCs as well as short columella (black arrow). (b) Postoperative basal view. One can appreciate

76.8 Secondary or Definitive Rhinoplasty (Video 76.1)

Despite an excellent primary rhinoplasty, secondary deformities coupled with scarring are bound to occur. These issues are tackled upon by definitive rhinoplasty. The surgeon's skill and his expertise will ultimately decide the success of primary cleft lip nose repair and the severity of secondary deformities. The success of definitive rhinoplasty depends on addressing every component of the deformity in a systematic manner beginning with the nasal base and ending with the alar base reduction.

76.8.1 Nasal Base

Creating a strong base for the nose represents the preliminary step in correction of either unilateral or bilateral cleft nasal deformity, the foundation for which is laid down at the time of primary cheilorhinoplasty with the approximation of the nasal floor with the lip. This is followed by addressing

lengthening of the columella that is achieved (black arrow). The correction of LLCs is also affected bilaterally. An open approach was utilised with bilateral reverse U incision to correct the horizontal orientation of the nostrils

the skeletal deficiency in the maxilla and premaxilla and correction of the retro-positioned alar base. In some cases, the nasal sill and the nasal base might still have to be augmented at the time of secondary rhinoplasty using local tissue flaps [35].

76.8.2 Septum

The caudal septum is seen to deviate to the non-cleft side, bowing away from the anterior nasal spine with resultant nasal airway obstruction. This requires resection of this portion of the septum, maintaining at least 1 cm dorsal, and caudal septal segments in the form of a L strut to help in preserving the nasal tip and the dorsal support [21] (Fig. 76.11a–i). When doing so, more than 40% contact point must be allowed between the crest of the maxilla and L strut which helps by subjecting the septum to decreased load forces thereby preventing nasal deformities like saddle nose deformity or ptosis of the nasal tip from developing in the future. It is observed in most cases that despite resecting the deviated portion of the septum, the L strut continues to remain deviated due to residual memory that is present in the L strut. In such cases, sutures can be placed through the ULC and the septum applying force in the direction opposite of the deviation to aid in correcting the asymmetry [36]. In cases of severe septal deviation, one needs to resort to using caudal septal extension graft as struts along the dorsal margins followed by surgical repositioning of the caudal septum [37, 38] (Fig. 76.11). The resected portion of the septal cartilage can itself be used as a spreader graft. In cases where the resected septal cartilage is inadequate, one can use rib cartilage as a spreader graft. The caudal portion of the L strut is secured to the anterior nasal spine with the help of sutures. Some surgeons also prefer to make a notch in the anterior nasal spine to which the L strut can be secured. If there exists any residual memory in the septal cartilage after securing it to the nasal spine, it can be relieved by cartilage scoring with the help of a no. 15 blade.

Access to the caudal nasal septum is achieved using an open approach and by dissecting between the medial crura of the LLCs [21]. From this point onwards, a sub-perichondrial flap can be developed. Make sure that the dissection is in the proper plane. The blue appearance of the septal cartilage serves as a guide to correct plane of dissection. The mucoperichondrial flap should be cautiously raised without perforating the surrounding mucosa to provide superior coverage for a large septal extension graft especially from the rib.

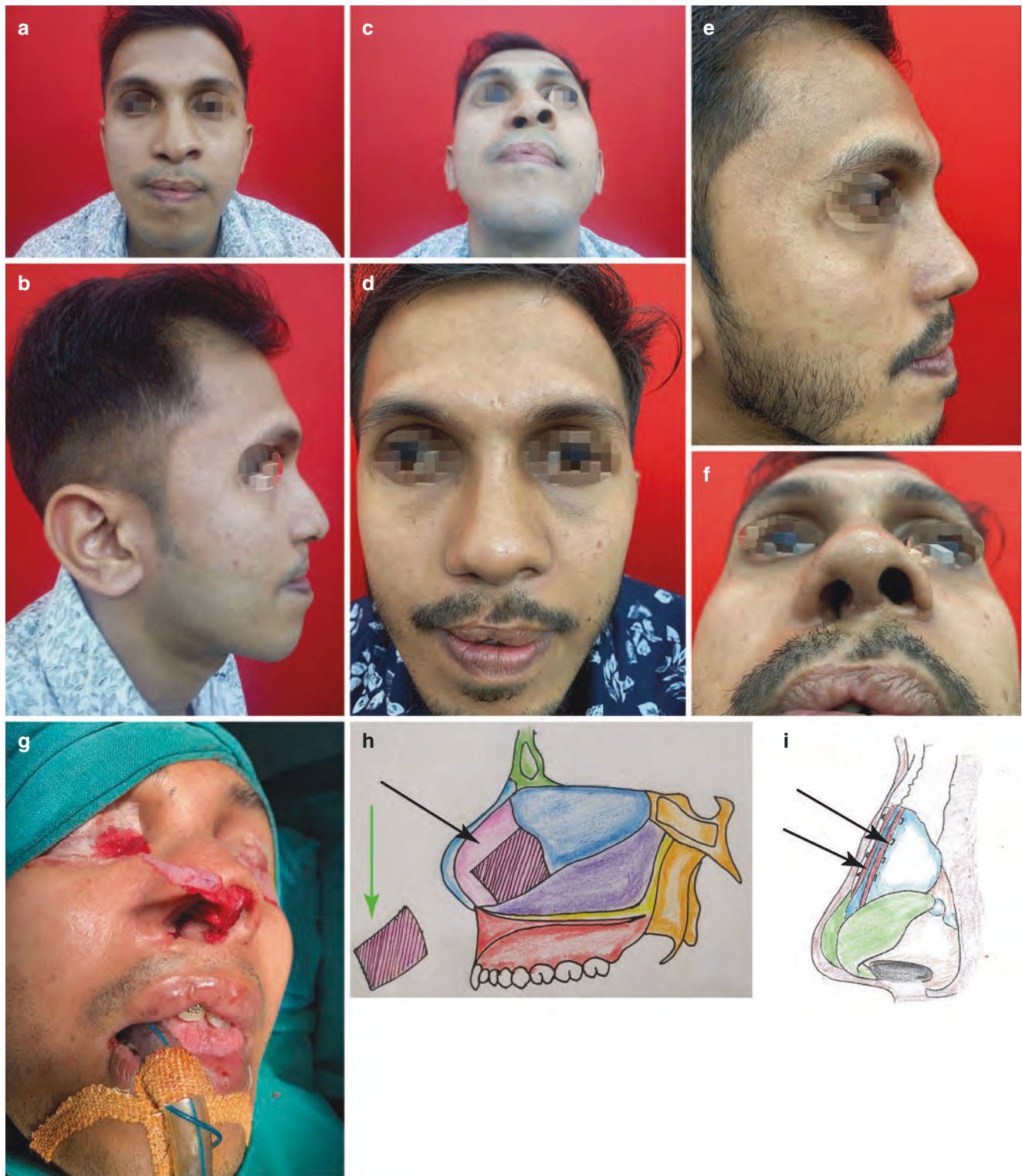76.8.3 Middle Third of the Nose

The middle third of the nose has poor support on the side of the cleft and therefore the ULCs tend to collapse resulting in internal valve dysfunction which affects the patient's ability to breathe normally. In such instances, spreader grafts placed between the septum and ULCs on either side and stabilised using sutures can help open the internal nasal valve and improve breathing [39, 40] (Fig. 76.11i).

76.8.4 Nasal Tip or LLCs

Once the caudal septum is stabilised, attention is shifted to the correction of asymmetric LLC and the nasal tip complex. Various techniques are advocated for the same.

- **Cephalic trimming:** Wide LLCs can make the nose appear asymmetric. In such cases, following surgical exposure of the LLCs via an open approach, small cephalic strips of LLCs can be excised advocating more excision on the larger side and leaving at least 5 mm for support. This manoeuvre narrows a bulbous nasal tip and improves symmetry. Cephalic trimming is followed by correction of the septal deviation by resection and replacement (Fig. 76.12a).
- **Septal extension graft:** A strong septal extension graft helps in providing support to the nasal tip and improves the tip projection by rotating an acute nasolabial angle which is the consequence of tip ptosis back to normal [22, 41]. The graft is ideally sutured in between the medial crura of LLCs and the caudal septum (Fig. 76.12b). Prior to suture stabilisation of the septal extension graft, the medial crus of LLC on the cleft side is advanced superiorly to match the vestibular dome height of the non-cleft side. This is then secured to the extension graft using mattress sutures (Fig. 76.12c). In cases where spreader grafts are used to relieve the internal nasal valve collapse, the extension graft can be secured to the spreader grafts. In such cases, the base of the nose is fortified with bolster sutures from medial crus to the septal extension graft. The strut (extension graft) is ideally placed slightly behind the medial crura to prevent the columella from either looking too wide or feeling too firm for the patient [39]. A good tip support entails extension of the septal extension graft for at least 4–5 mm beyond the septum maintaining a thickness of at least 1 mm. This also helps to resist deprojection from the resulting scar tissue that will form in this region.



©Association of Oral and Maxillofacial Surgeons of India

Fig. 76.11 (a-i) 22-year-old patient with unilateral cleft lip and palate before (a-c) and 2 months after (d-f) open rhinoplasty performed to correct the severely deviated caudal septum. (g) Intraop picture showing batten grafting. (h) Resection of septal cartilage in cases of severely

deviated nasal septum, maintaining an L shaped contact (black arrow) for preserving tip and dorsal support. The resected portion can be utilised as a septal extension graft (green arrow). (i) Spreader grafts placed between ULCs and nasal septum (black arrows)

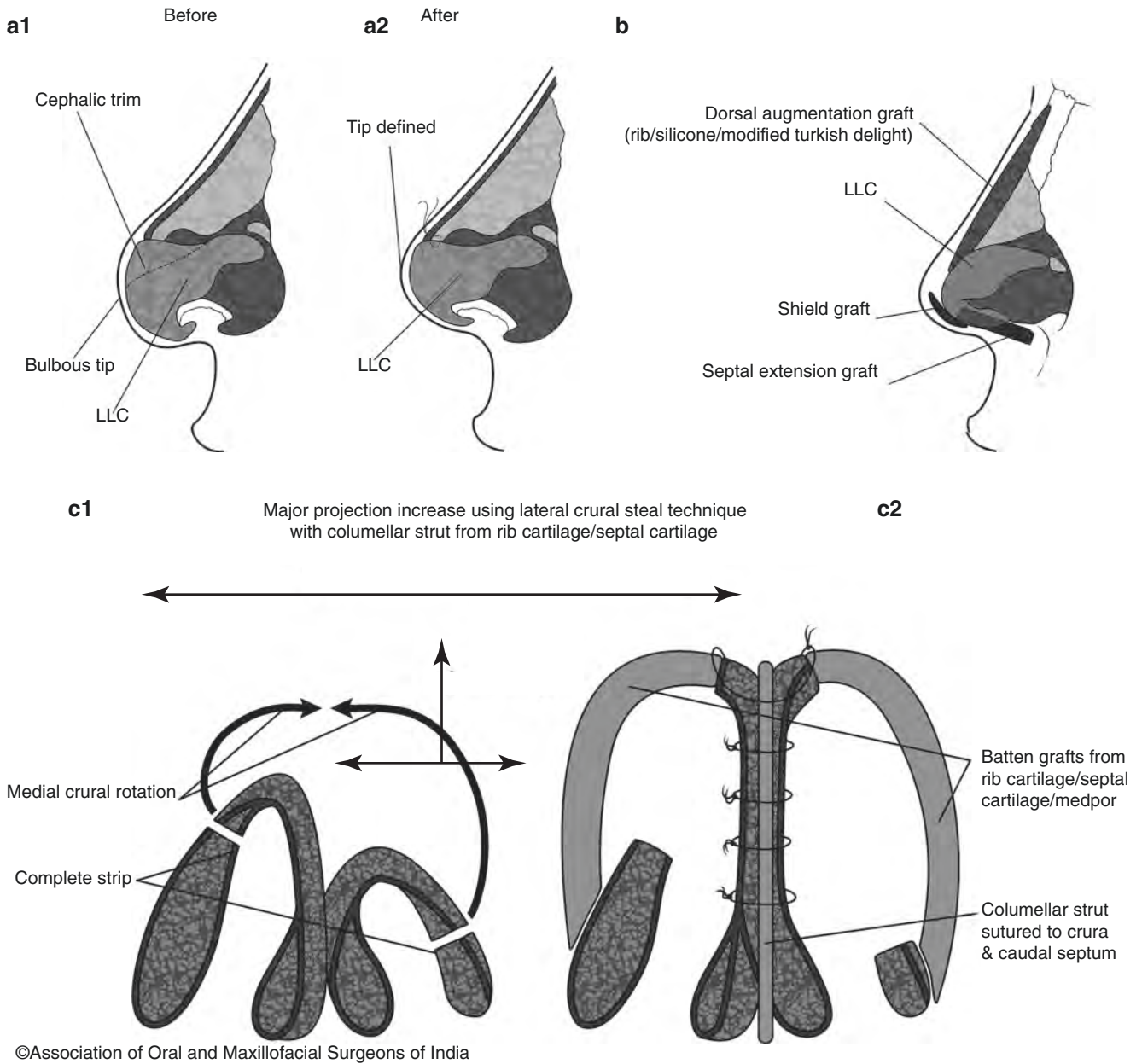


Fig. 76.12 (a–c) Schematic representation of techniques for correction of asymmetric LLCs and nasal tip complex. (a1, a2) Cephalic trimming (before and after). (b) Shield grafts, caudal septal extension grafts

for improving the symmetry and projection of the nasal tip. Dorsal nasal augmentation is also been shown. (c1, c2) Lateral crural steal technique

- **Lateral crural steal or advancement flaps:** The medial crus of the LLC on the cleft side is shorter in vertical length, whereas the lateral crus is longer with a horizontal orientation as compared to the non-cleft side. In such cases, lengthening of LLC on the cleft side is achieved using the lateral crural steal technique which requires cutting of the longer part of the lateral crus of the LLC on the cleft side and shorter part of the lateral crus of LLC on the non-cleft side [39] (Fig. 76.12b). This facilitates utilisation of the longer crural flap on the side of the cleft for increasing the nasal tip projection on the cleft side thereby contributing to improved nasal tip symmetry. The lateral crura are then reconstructed using either robust cartilage struts or batten grafts in onlay or inlay fashion.
- **Shield graft:** These grafts are utilised to accentuate the tip projection further as well as improve the symmetry and tip shape (Fig. 76.12b).

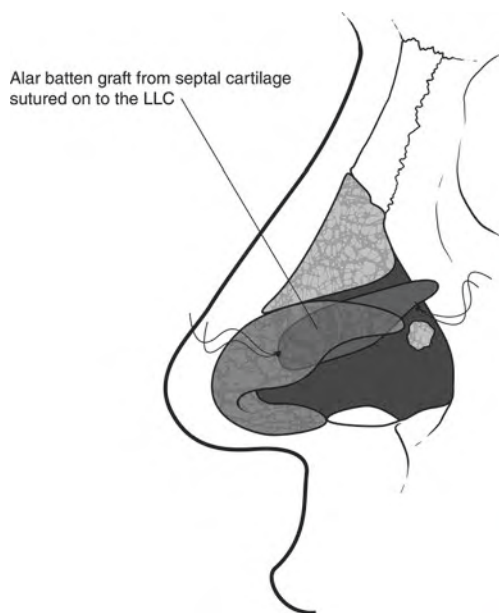
In bilateral cleft nasal deformities, LLCs of either side need repositioning with tip suture techniques. In cases of weak cartilages, septal extension grafts as columellar struts as well as in onlay position need be used for ideal projection [42]. Large nasal tip can benefit from cephalic trimming of both LLCs. The goal is to decrease the angle of divergence between the domal points of the lower lateral cartilages, cre-

ate a more defined nasal tip and provide a strong nasal framework for better tip projection.

76.8.5 Alar Rim (Lateral Crus of LLC)

The LLC on the cleft side has poor skeletal support on the medial and lateral sides which makes the LLC concave with an introverted contour to the ala [43]. This concavity can be managed with different techniques, viz. suture techniques using horizontal mattress sutures, underlay alar batten grafts, onlay grafts and autcartilage flaps [44]. The lateral crus of LLC can also be dissected from the underlying vestibular skin, removed, flipped and resutured in a convex fashion.

Alar batten grafts either are placed below the residual lateral crus as underlay graft or can be placed above it as an onlay graft. This graft strengthens the lateral crus of the LLC and removes the concavity of LLC [39] (Fig. 76.13). Suture techniques such as horizontal mattress sutures also strengthen and flatten the lateral crus of the LLC. Lastly, the cephalic margin of the LLC can be made into an advancement flap which can be advanced to provide support to the remaining LLC. Each of these techniques provides support to the lateral crus of the LLC and fortifies the external nasal valve.



©Association of Oral and Maxillofacial Surgeons of India

Fig. 76.13 Alar batten grafting demonstrated in a case of unilateral cleft nasal deformity. The graft fortifies the LLC and removes the concavity of the same (Refer Fig. 76.17i)

76.8.6 Nasal Dorsum and Nasal Osteotomies

The following issues are observed when addressing this area in definitive rhinoplasty.

- **Flat and under-projected dorsum deviating away from the cleft:** The authors' preferred technique for addressing this issue is by using a dorsal onlay graft from rib or modified Turkish delight. In modified Turkish delight technique, the authors use morselised Medpor mixed with autogenous blood and wrapped in Surgicel to affect dorsal nasal augmentation [45] (Figs. 76.12b and 76.14a–d). This cancels out the need to carry out harvesting of the rib cartilage and there eliminates the donor site complications associated with the same. Although silicone implant can also be used for this purpose, there is increased possibility of infection, graft migration or displacement or possible extrusion. It should be noted that the dorsal nasal pocket dissected should just accommodate the implant so that the implant fits snugly without much displacement or migration.
- **Dorsal humps:** The dorsal hump usually peaks at the region of the rhinion where the nasal bones and ULC join.

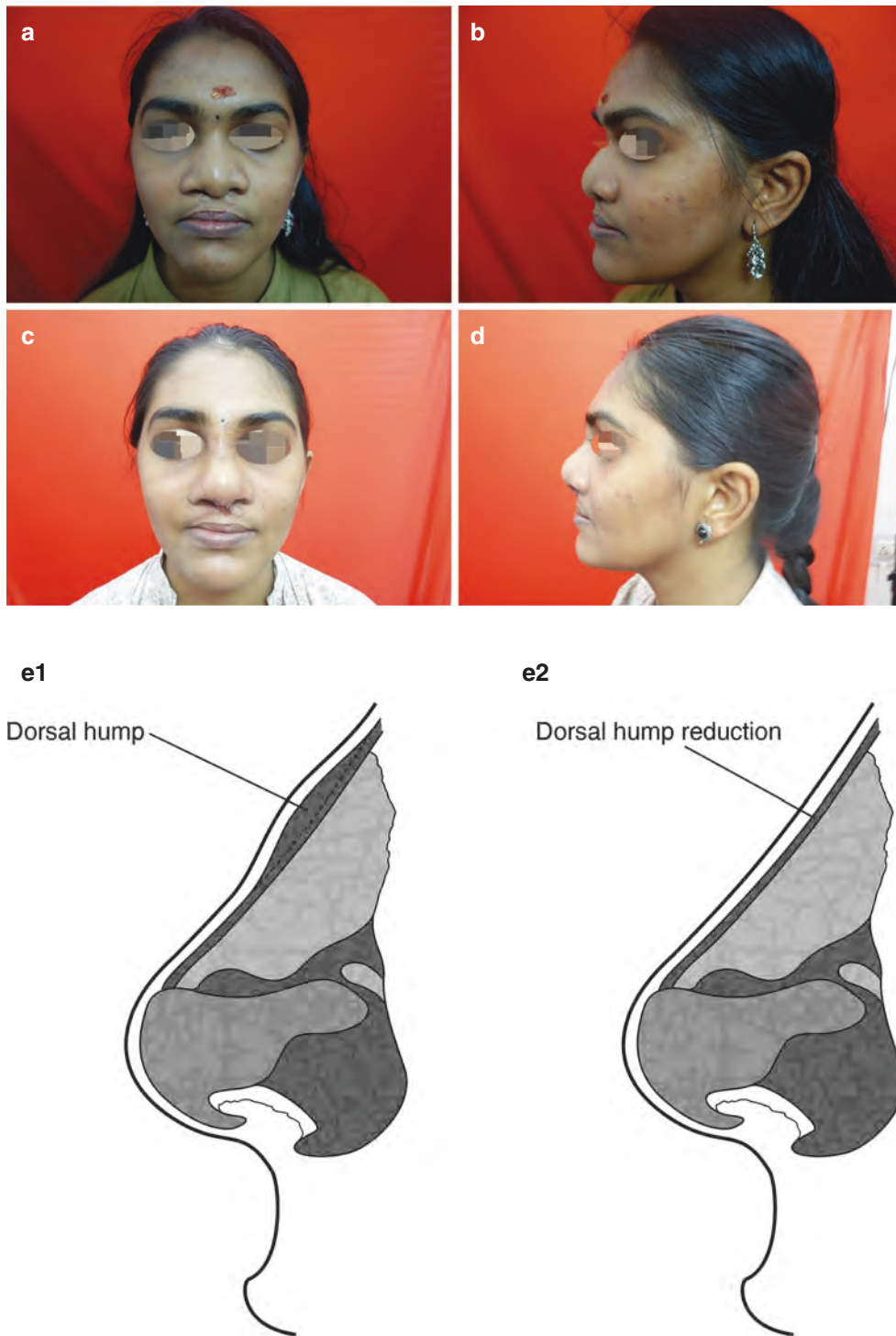
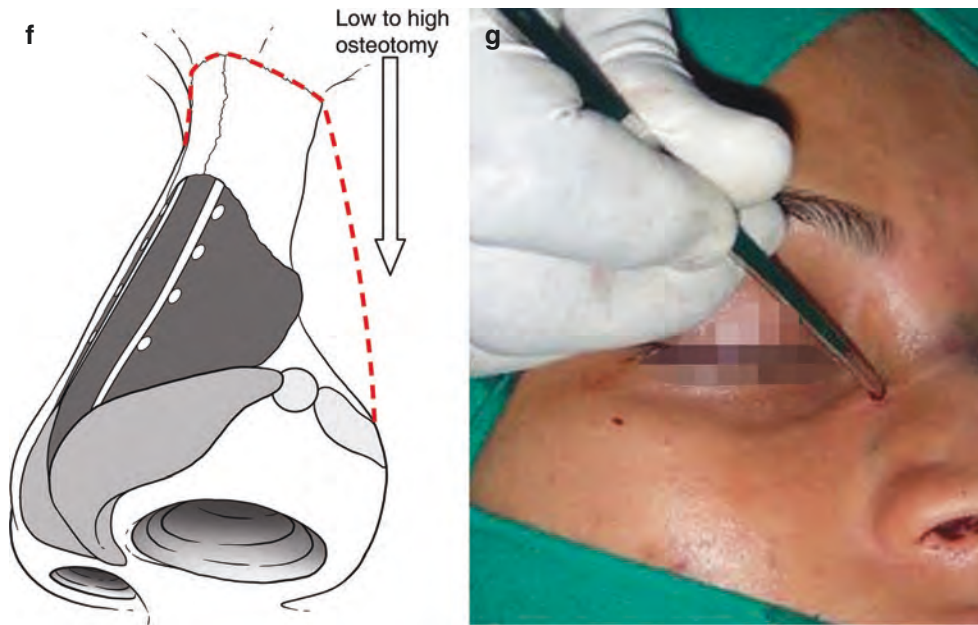


Fig. 76.14 Addressing the nasal dorsum and nasal osteotomies. A case of flat and under-projected dorsum managed using modified Turkish delight technique. (a, b) Pre op frontal and lateral. (c, d) Post op frontal

and lateral. (e1, e2) Schematic representation of dorsal hump reduction. (f, g) Schematic and clinical lateral nasal osteotomies



©Association of Oral and Maxillofacial Surgeons of India

Fig. 76.14 (continued)

Dorsal hump should be addressed in conjunction with other aspects of the nose, or else an open roof deformity will be the consequence. The correction is carried out by reduction of the bone by rasping and the ULC using either scissors or number 15 blades (Fig. 76.14e).

- **Thick and wide nasal bones with deviation towards the non-cleft side with wide dorsum:** Such cases require either lateral or paramedian osteotomies to narrow the dorsal width and bring about symmetry. The authors' preferred technique for lateral osteotomies is by introducing a 2–3 mm osteotome transcutaneously to create micro punctures along the planned osteotomy going from low to high [42] (Fig. 76.14f, g). The same can also be carried out by introducing the osteotome transnasally. If this does not affect narrowing of the dorsum adequately, then the authors resort to paramedian osteotomies to create an open roof deformity followed by in-fracturing the nasal bones. This manoeuvre almost always requires placement of spreader grafts to prevent collapse of the internal nasal valve.

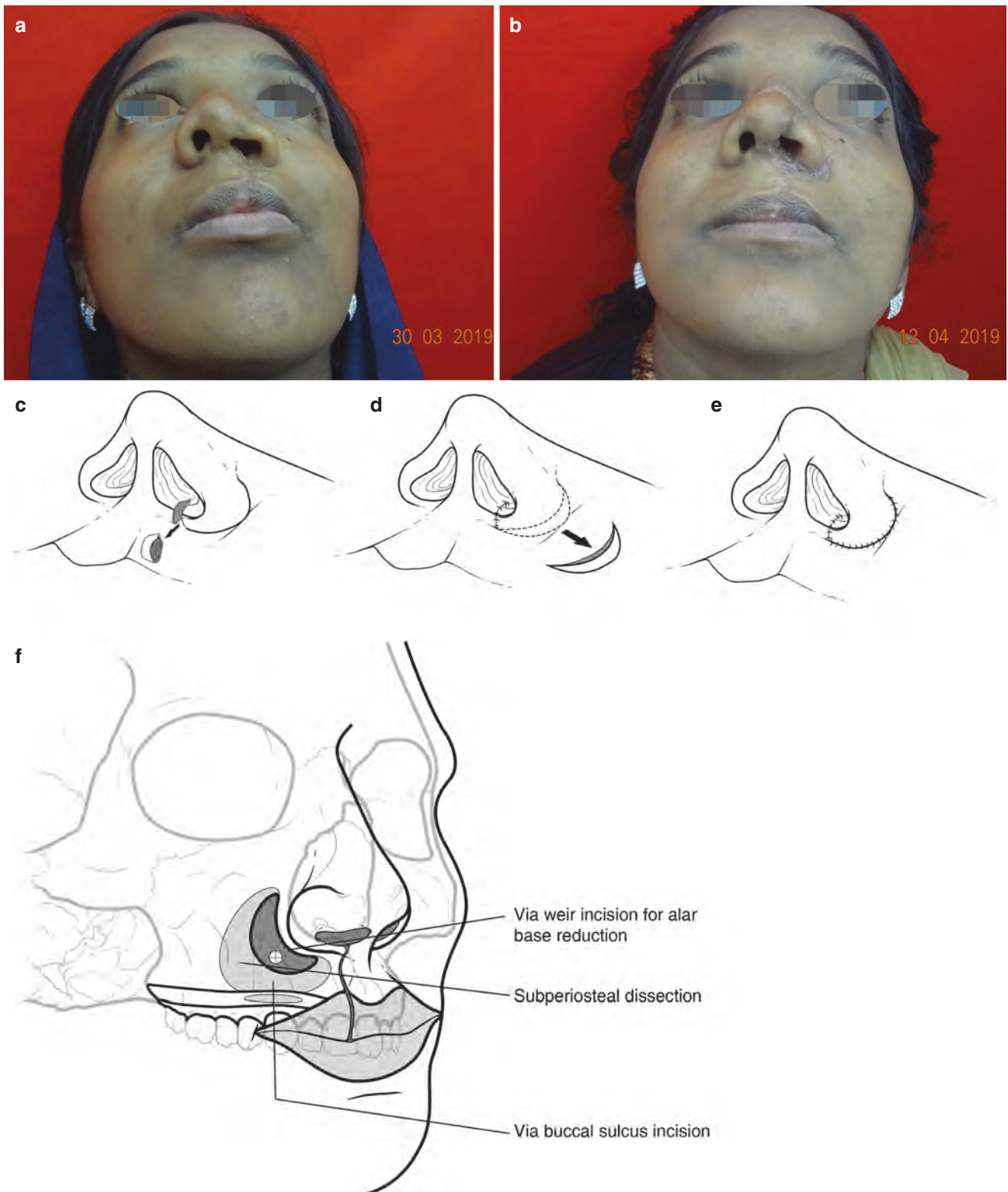
76.8.7 Piriform Rim and Pre-maxilla Augmentation

Cleft noses whether unilateral or bilateral present with skeletal deficiency in the region of the premaxilla and piriform rim which brings about posteroinferior displacement of the nose. If this area is left unattended, the final result is bound to be asymmetric despite addressing all the other aspects of

rhinoplasty well [39]. This area can be augmented using a portion of the rib graft and securing it with a screw (Fig. 76.15). This allows for improving the anterior projection. Other options include the use of silicone implant, cortical one or fat grafting [21].

76.8.8 Nasal Alae

The nasal alae in cleft noses as discussed previously are usually displaced in a lateral and inferior direction. Correcting the abnormal orientation of the nasal alae represents the concluding steps in definitive rhinoplasty. This is usually achieved using two techniques, viz. V to Y advancement and Weir procedure (alar resection) along the alar facial groove [46–48]. These two procedures need to be supplemented with augmentation of the piriform rim as well as vertical enlargement of the nostril on the cleft side in order to achieve true symmetry. Vertical enlargement of the nostril can be achieved using skin grafts or composite grafts just inside the ala. Superior results are possible despite not addressing the nostril except from the basal view which will make the vertical height discrepancy of the nostril evident. Weir procedure is used in cases of excess skin laterally and allows for symmetrical correction of the alar base on the cleft side nostril which is usually longer and elongated (Fig. 76.15a–g). It also provides access for carrying out augmentation of the piriform rim using grafts. Nostril retainers are often sutured in place for the purpose of helping in moulding and maintaining the nasal sill.



©Association of Oral and Maxillofacial Surgeons of India

Fig. 76.15 (a–f) Piriform rim augmentation and alar base reduction using Weir procedure. (a, b) Pre op and post op basal views. (c) Alar base resection. (d) Peri alar resection. (e) Closure. (f) Piriform rim augmentation

76.9 Use of Grafts in Definitive Rhinoplasty

Grafts are pivotal to the long-standing success of definitive rhinoplasty in terms of nasal aesthetics and function. Autologous tissue is the norm and always preferred over synthetic substitutes like Medpor and silicone which presents with higher incidences of infection, displacement as well as possible extrusion. Among the autologous options available, cartilage (harvested from septum, auricle or rib) and bone (harvested from cranium, rib or iliac crest) are widely used.

Cartilage grafts harvested from the septum have the advantage of being located in the same surgical field, requiring no additional incisions and therefore preventing any additional donor site morbidity. Furthermore, simultaneous correction of septal deviations is possible with the use of this graft. The disadvantages include minimal amounts of cartilage available for grafting and presence of residual memory subjecting it to deformation. When the amount of available septal cartilage is inadequate, auricular cartilage can be the source of grafting. It may offer a large area for graft harvesting, and usually does not induce local sequelae. When larger amount of cartilage is needed especially for the purpose of dorsal augmentation, rib cartilage is an excellent source especially from the right seventh, eighth or ninth rib. This cartilage is present in abundance, is quite sturdy and robust, resists deformation by scar contracture, is easy to shape and also provides superior support for optimising the nasal projection [39]. The disadvantages include graft warpage, increased operating time, visible external scar, post-operative pain and risk of pneumothorax. Another disadvantage is ossification of cartilage in older patients [39].

Cartilage grafts are classically divided into contouring grafts and structural grafts.

76.9.1 Contouring Grafts

These grafts are added to the native osteocartilaginous nose in the coronal plane to improve upon the existing nasal aesthetics. Two most common sites for placement of these grafts are the dorsum and the infratip regions of the nose which help in optimising the tip projection. These grafts are stabilised using either resorbable or non-resorbable sutures or glue. Examples of contouring cartilage graft include dorsal onlay graft or shield-type tip graft.

- **Dorsal onlay graft:** It is used for dorsal nasal augmentation. The rib cartilage is the obvious choice. We have also utilised the modified Turkish delight (diced Medpor

mixed with autologous blood and wrapped in Surgicel) for the same purpose with reasonable success.

- **Shield-type tip graft:** Onlay shield grafts help in defining the nasal tip better, optimise the tip projection as well as provide support and hide any minor tip asymmetries.

76.9.2 Reconstructive Grafts

These grafts strengthen the cartilaginous framework of the nose which improves upon the existing nasal function. These grafts are placed in the sagittal plane and display long-term stability especially when an open approach is used to secure the same. They allow structural and functional reconstruction of the nasal tip in cases of definitive rhinoplasty. Examples include spreader grafts, alar batten grafts, columellar strut grafts, etc.

- **Spreader graft:** Spreader grafts serve to open the internal nasal valve and improve nasal breathing. Options for harvest include the septal or rib cartilages. The graft can also be made to extend more caudally making it to function like a strut for improved nasal tip support as well as to straighten and stabilise the septum. Severe septal deviation can be also corrected by placing the grafts along the dorsal septum while reattaching the caudal strut to the nasal spine between the medial crura by suture fixation.
- **Alar batten graft:** Batten grafts serve to strengthen the lateral crura of the LLC. The curved portion of the rib cartilage can be used to the advantage for harvesting these grafts. They are stabilised to the LLC and the strut to mimic the natural convex form of the external nasal valve and provide structural support. These grafts are critical for the correcting alar retraction whenever present.
- **Columellar strut graft or septal extension graft:** Such a graft provides support to the nasal base and can be a platform upon which the nasal tip can be suture stabilised. It can be harvested from the septal cartilage or from the interior of the rib cartilage.

76.10 Treatment Strategy for Unilateral and Bilateral Cleft Nasal Deformities

Nakamura N has devised a treatment strategy for both unilateral and bilateral cleft noses that addresses each anatomical and pathological abnormality that is seen in either scenarios [49].

76.10.1 Unilateral Cleft Nasal Deformity

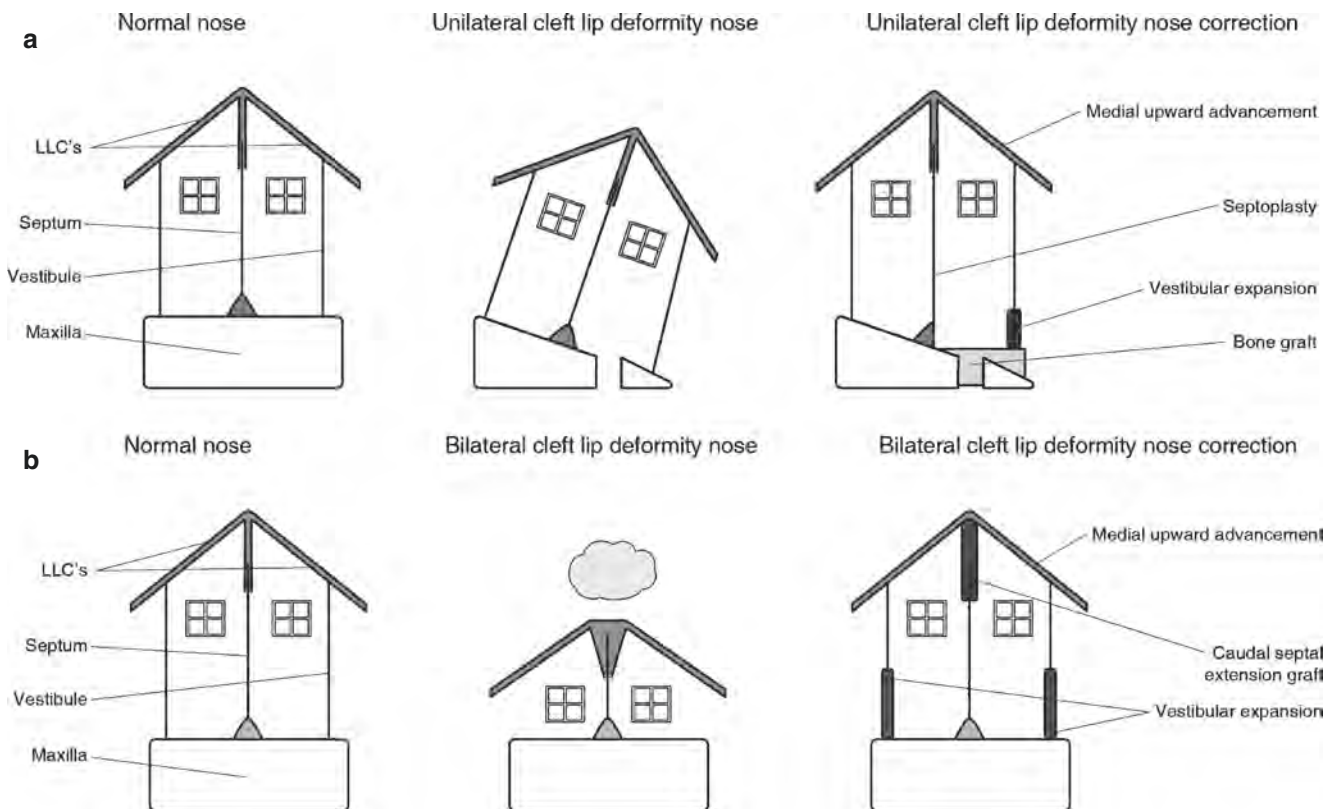The pathologic abnormalities that have been previously mentioned are best explained by Nakamura N by comparing the unilateral cleft nose to a house that is built on a slope. The mid-pole of the house can be thought to be nasal septum, whereas the roof is the LLC and skin, the lateral pole is the vestibule and the base of the house is the maxillary bone. As the house is present on the slope, the mid-pole and the roof incline towards the downward side. In such cases, a straight house can be built on the slope by up righting the centre pole in the centre of the pillar with expansion of the lateral pole and by lifting the roof upward [49] (Fig 76.16a).

Nakamura N's treatment strategy addresses each anatomical and pathological abnormality that causes the main deformities in unilateral cleft nasal deformity listed in Table 76.1. The author's steps in definitive rhinoplasty consist of an open approach; septoplasty; repositioning of the lower lateral cartilage; medial and upward advancement of the lip and nose components, the nasal vestibular tissues, the nasal ala, nasalis muscle and the upper part of the lip including orbicular oris muscle; and nasal vestibular expansion with or without bone graft [50].

76.10.2 Bilateral Cleft Nasal Deformity

The pathologic abnormalities that have been previously mentioned are best explained by Nakamura N by likening the bilateral cleft nose to a house that is compressed by stress. In such cases, normal form of the nose can be created by extending the centre pole at the centre, advancing the roof upwards and extension of the lateral poles on each side (Fig. 76.16b). It is very critical to relieve the stress which in other words means relieving the pull on the nasal tip due to columellar skin shortage [49].

The treatment strategy devised by Nakamura N is based on the principle that the ideal technique of definitive rhinoplasty should minimise damage to either or both the upper and lower lip tissue. This strategy also addresses each anatomical and pathological abnormality that causes the main deformities of the bilateral cleft lip-nose as shown in Table 76.2. Therefore, the author's secondary correction involves open rhinoplasty, repositioning of the lower lateral cartilages, a caudal septal extension graft, medial and upward advancement of the lip and nose components, nasal vestibular expansion and columella lengthening using a nostril rim rotation flap, if necessary [51].



©Association of Oral and Maxillofacial Surgeons of India

Fig. 76.16 (a, b) Simplifying cleft nasal anatomy by Nakamura N. (a) Unilateral cleft nasal anatomy. (b) Bilateral cleft nasal anatomy

Table 76.1 Treatment strategy for unilateral cleft nasal deformity

Nasal deformities	Anatomical pathological abnormalities	Secondary correction
Deviated columella	<ul style="list-style-type: none"> • Deviation of maxillary midline • Deviated septal cartilage 	<ul style="list-style-type: none"> • Dissection around anterior nasal spine • Reposition of the inferior base of septal cartilage if necessary
Depressed and deviated nasal tip	<ul style="list-style-type: none"> • Distally and downwardly dislocated LLC on the cleft side • Growth disturbances of septal cartilage 	<ul style="list-style-type: none"> • Freeing and repositioning of LLC by overlapping on ULC • Caudal septal extension graft
Wide and snub nasal ala on the cleft side	<ul style="list-style-type: none"> • Retro-positioned anterior maxillary wall • Dislocation of the attachment of nasalis muscle 	<ul style="list-style-type: none"> • Secondary bone graft if necessary • Supra-periosteal dissection around piriform margin • Reposition of the nasalis muscle by medial upward advancement of nasolabial components
Flat and V shaped nostril	<ul style="list-style-type: none"> • Webbing of the rim skin • Shortage of nasalis vestibular lining • Disconnection of orbicularis oris muscle 	<ul style="list-style-type: none"> • Bilaterally symmetric reverse U incision • Expansion of the nasal vestibule • Overlapped suturing of orbicularis oris muscle

Nakamura N et al., J Oral Maxillofac Surg 2010; 68: 2248 [50]

Table 76.2 Treatment strategy for bilateral cleft nasal deformity

Nasal deformities	Anatomical pathological abnormalities	Secondary correction
Short columella	<ul style="list-style-type: none"> • Shortage of columellar skin • Tightness of subcutaneous tissue in the columella 	<ul style="list-style-type: none"> • Bilateral reverse U incision • Nostril rim rotation flap if necessary • V-Y elongation of fibrous tissue
Flat and flared nasal tip	<ul style="list-style-type: none"> • Growth disturbance of septal cartilage • Lateral and downward dislocation of LLC • Thin skin envelope of nasal tip 	<ul style="list-style-type: none"> • Caudal septal extension graft. • Freeing and reposition of LLC by overlapping on ULC • Molding of fibrous tissue on nasal tip
Wide and snub nasal ala	<ul style="list-style-type: none"> • Dislocation of the attachment of nasalis muscle 	<ul style="list-style-type: none"> • Supra-periosteal dissection around piriform margin • Reposition of the nasalis muscle by medial upward advancement of nasal alar component
Flat and V shaped nostril	<ul style="list-style-type: none"> • Webbing of the rim skin • Shortage of nasalis vestibular lining • Disconnection of orbicularis oris muscle 	<ul style="list-style-type: none"> • Bilateral reverse U incision • Free mucosal graft in the nasal vestibule • Reposition of orbicularis oris muscle

Nakamura N et al, J Cranio Maxillofac Surg 2011; 39: 305 [51]

76.11 Outcomes in Cleft Rhinoplasty

Over the past few years, there has been an increased emphasis on the functional rather than aesthetic outcomes in cleft rhinoplasty [52]. Techniques like primary cleft rhinoplasty and naso-alveolar moulding have also been laden with complications. Although several studies have compared the different techniques of rhinoplasty to determine which technique offers the best surgical outcome, these studies lack standardised objective measurements to draw any meaningful conclusions.

The data regarding functional outcomes in cleft rhinoplasty is also sparse. In one of the prospective studies with 68 cleft patients, the authors evaluated aesthetic and respiratory outcomes at two intervals, viz. pre- and 6 months postoperatively using an active anterior rhinomanometry, rhinore-sistometry and acoustic rhinometry [53]. The study showed significant improvement in many parameters. The authors

concluded that while aesthetic improvement of the cleft nose is a goal, which can be achieved with regularity, nasal respiration still seems to be a challenge in cleft patients. This study highlights the need of recording functional data to study about the effects of surgery.

The outcome that is clearly documented in literature is the high satisfaction rates in patients undergoing surgery for cleft nose deformity. A study incorporating 35 patients with cleft nasal deformity was carried out by Sandor and Ylikontiola [54]. An open approach of rhinoplasty followed by alar base relocation and asymmetric nasal tip augmentation with auricular cartilage grafts was carried out in all patients. The patients' level of satisfaction was recorded in the form of a survey and interview 2 years post-surgery. A visual analogue scale (VAS) numbered 0–10 was also used by the patients to grade outcome compared to preoperative appearance at four anatomic sites. The study demonstrated highest improvements in VAS

score for the tip, followed by alar position and dorsum and symmetry of nostrils. They noted that all patients were willing to undergo such procedure for a second time, if necessary. Two more studies have also reported high patient satisfaction rates for patients undergoing surgery for cleft nasal deformities [55, 56].

76.12 Further Revisions in Cleft Rhinoplasty

Although secondary cleft rhinoplasty is considered the ultimate revision rhinoplasty, in certain cases like those involving asymmetries or scarring, the patient's overall functional and aesthetic outcome may be compromised necessitating further revisions. It is important to remember that the principles that are followed in revision rhinoplasties are similar to those followed in primary and secondary rhinoplasties. The emphasis should be on early recognition after the definitive rhinoplasty so that revision is possible before scarring sets in.

76.13 Complications

The complications noted in cleft rhinoplasty are similar to those noted in the traditional open rhinoplasty in non-cleft patients. As cartilage grafts are employed, there exists a possibility of infection. Over the long term, the grafts, whether autologous, allogeneous or alloplastic, can demonstrate failure. There is no difference in the risk of bleeding between cleft rhinoplasty and traditional rhinoplasty. All patients should be made aware of possible need for secondary rhinoplasty, need for revision either major or minor, existence of nostril asymmetry, visible scars, necrosis of the skin, nasal system dysfunction and morbidity associated with the donor site. One can fail to create the nasal contour as desired as well as fail in creating a normal looking appearance, and these are very common findings in cleft rhinoplasty.

76.14 Conclusion

Cleft rhinoplasty as a surgical procedure is often complex and complicated due to multiple surgical procedures that the patient needs over the years. Despite all the challenges that the procedure offers, the final surgical outcome could serve as a life changer for the patient in terms of aesthetics,

function as well as symmetry. One should stick to the concepts of restoring symmetry and definition to the nasal tip and alar base, realigning and re-establishing the patency of nasal airway and preventing scarring and webbing from jeopardising the outcome. All cases have to be thoroughly planned preoperatively using the right assessment tools, and the surgery should be executed to near perfection. An increased emphasis should be placed on carrying out a primary rhinoplasty procedure keeping in mind that a definitive rhinoplasty will almost always be required to fine-tune the results.

76.15 Case Scenarios

Case 1 Figure 76.17 represents a case of right unilateral cleft nasal rhinoplasty in a 20-year-old female managed with definitive rhinoplasty. The patient presented with the chief complaint of crooked nose and difficulty in breathing from the right nostril. The patient was subjected to thorough clinical examination of both the external and internal nasal anatomy. The following features of the cleft nose were noted: deviated nasal dorsum away from the cleft in frontal view and horizontally oriented right nostril in basal view with deviated base of columella to the left. Deviated caudal septum was also noted with difficulty in breathing in the right nostril. Concavity of the right LLC was also observed in the basal view. In the lateral view, tip ptosis was observed. The patient was subjected to open rhinoplasty approach using inverted V transcolumellar incision with incorporation of the reverse U incision on the right side to correct the right nostril asymmetry. Following skeletonisation of the nose, dissection was carried between the medial crura of LLCs to expose the caudal septum which was resected to correct the septal deviation. *The authors would like to stress on the importance of addressing the nasal septum almost always in all cases when performing a definitive rhinoplasty in a unilateral cleft nasal deformity.* Substantial amount of septal cartilage was harvested to be used as a caudal extension graft to correct septal deviation as well as to improve tip projection. The cartilage was also utilised as an alar batten graft sutured to the lateral crura of LLC of the right side to correct the concavity of the right LLC. Bilateral spreader grafts were sutured between the ULC and the septum to improve the nasal breathing by improving the internal nasal valve function. Lateral crural steal was performed on the right side to maximise the projection of the nose, and further tip projection was achieved using

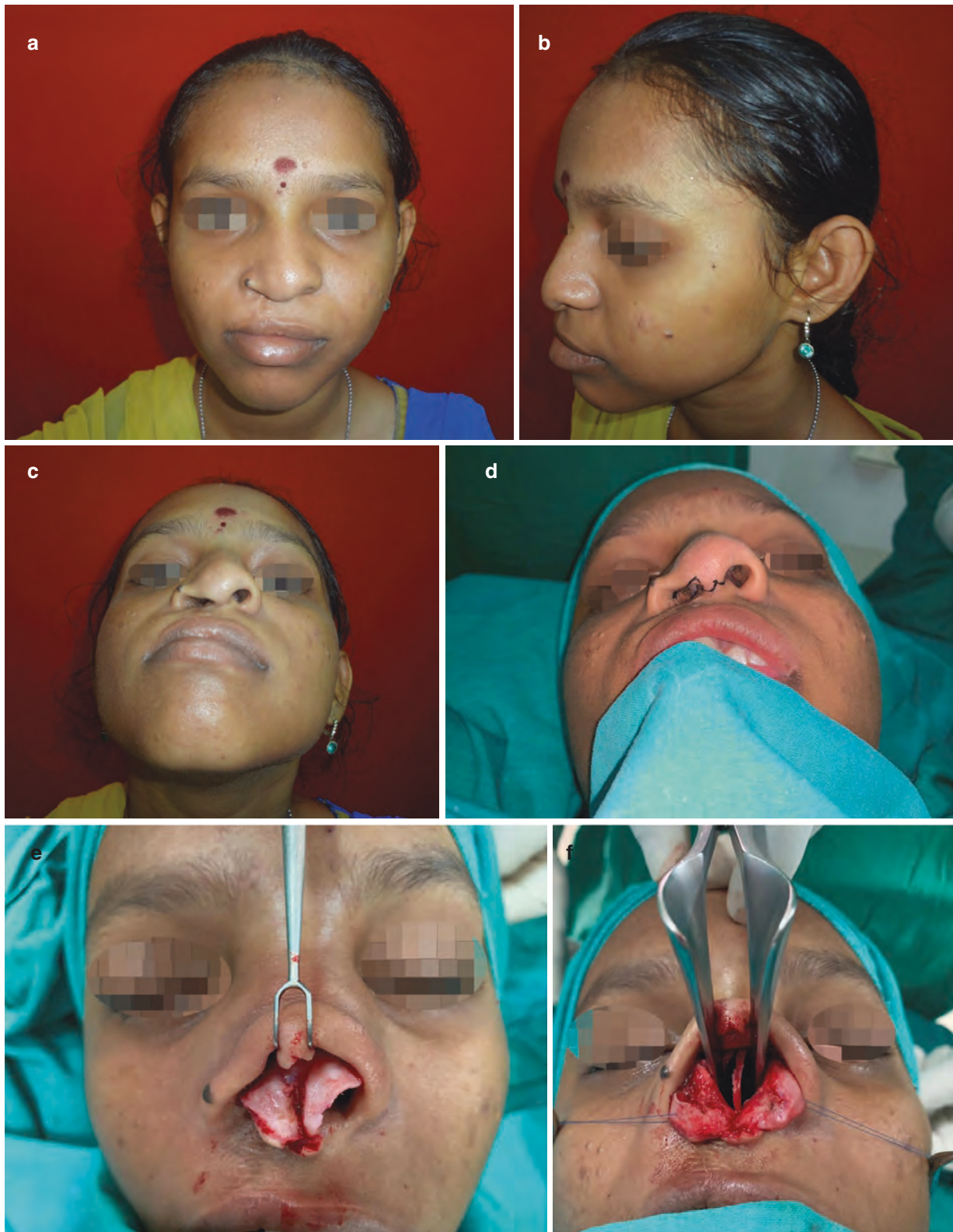

Fig. 76.17 (a–n) Clinical Scenario 1: A case of unilateral cleft nasal deformity in a 20-year-old female managed with definitive rhinoplasty. (a) Pre op frontal. (b) Pre op lateral. (c) Pre op basal. (d) Incision marking (inverted V with Tajima modification). (e) Exposure of lower lateral

cartilages. (f) Exposure of nasal septum. (g) Spreader grafts placement bilaterally. (h) Columellar strut. (i) Columellar reconstruction and alar batten graft. (j) Intra op frontal. (k) Intra op basal. (l) Post op frontal. (m) Post op lateral. (n) post op basal

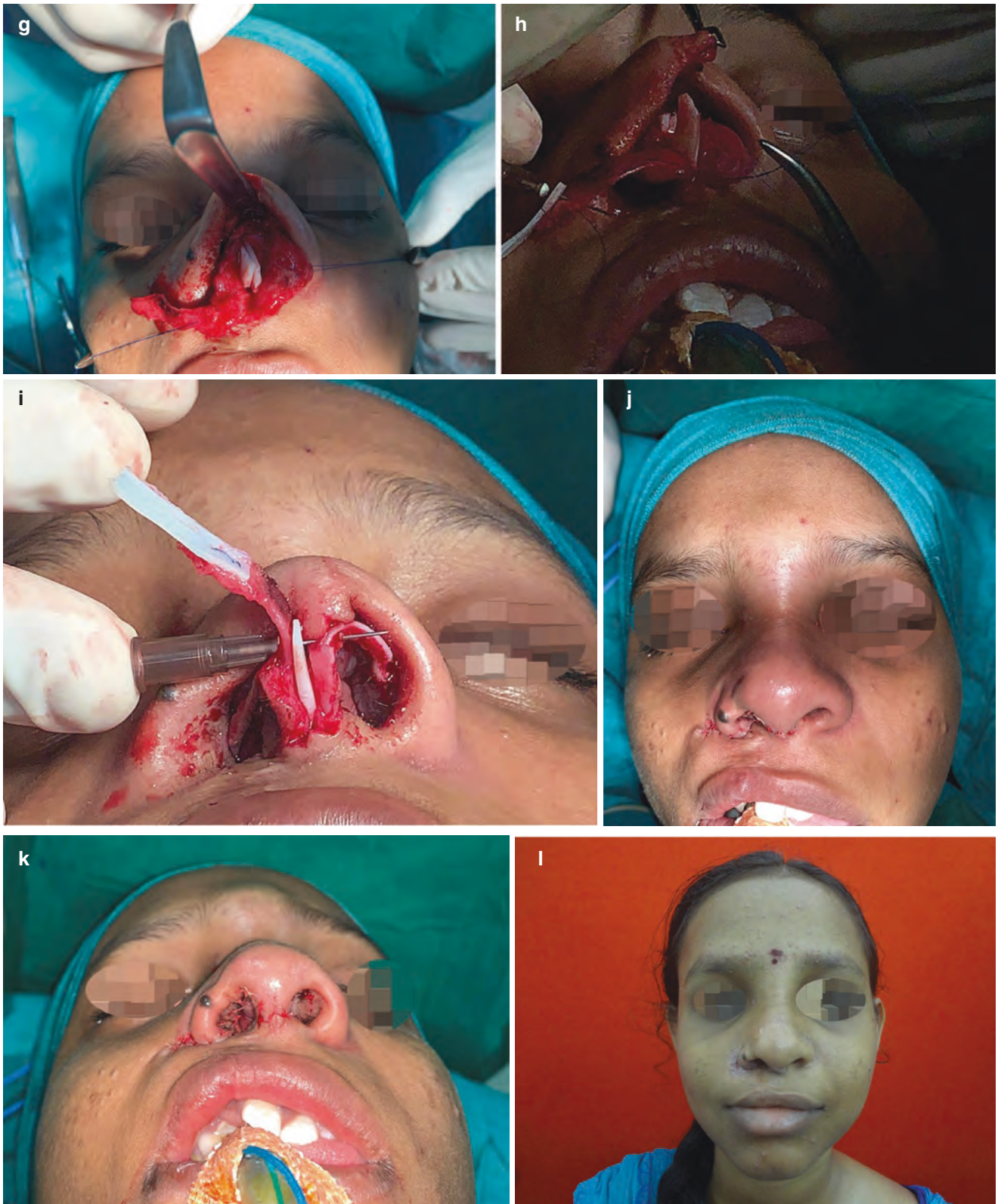
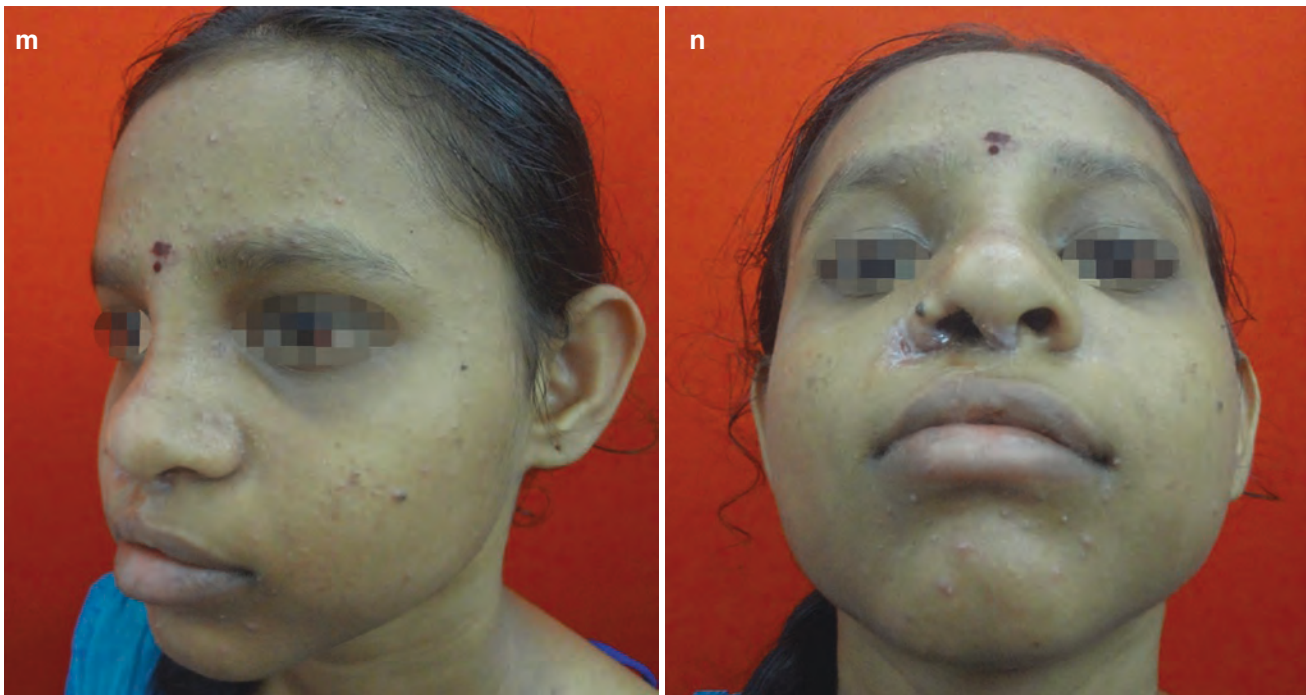
Fig. 76.17 (continued)



©Association of Oral and Maxillofacial Surgeons of India

Fig. 76.17 (continued)

interdomal sutures. The deviated nasal dorsum away from the cleft was corrected using transcutaneous lateral osteotomies bilaterally in a low to high fashion. Lastly, right alar base reduction using a Weir procedure was carried out to achieve symmetry between the two alar bases. Closure of the incision was carried out using 4-0 Vicryl Rapide sutures. Comparison of the pre- and 4 weeks postoperative photographs demonstrate significant improvement in the nasal aesthetics. The patient is very satisfied with the overall result and has no complains of difficulty in breathing.

Case 2 Figure 76.18a–k represents a case of bilateral cleft nasal deformity in a 6-year-old male managed with intermediate rhinoplasty. On clinical examination, all the features characteristic of bilateral cleft nasal deformity was evident some of which included wide dorsum with bifid nasal tip, horizontally oriented nostrils, tip ptosis and short columella with a wide base. The septum was classically midline.

Intermediate rhinoplasty was planned via an open approach in this case. An inverted V transcolumellar incision with bilateral reverse U incisions was planned to correct the horizontal orientation of the nostrils. The goal of the surgery was to primarily affect symmetric positioning of LLCs as well as to increase the length of the columella. Following exposure, dissection of the LLCs was carried out. A columellar strut from medpor was utilised which served to increase the tip projection. Symmetric positioning of LLC's was affected and sutured in place using horizontal mattress sutures. Transdomal sutures were also added to correct the bifid tip and decrease the angle of divergence between the alar domes. A modified Turkish delight graft was utilised for the purpose of dorsal nasal augmentation, and closure was affected with vicryl rapide sutures. It is important to note that any septal procedures were avoided to prevent growth disturbances. The pre- and 2 months postoperative photographs reveal a dramatic improvement and achievement of the preoperative goals.

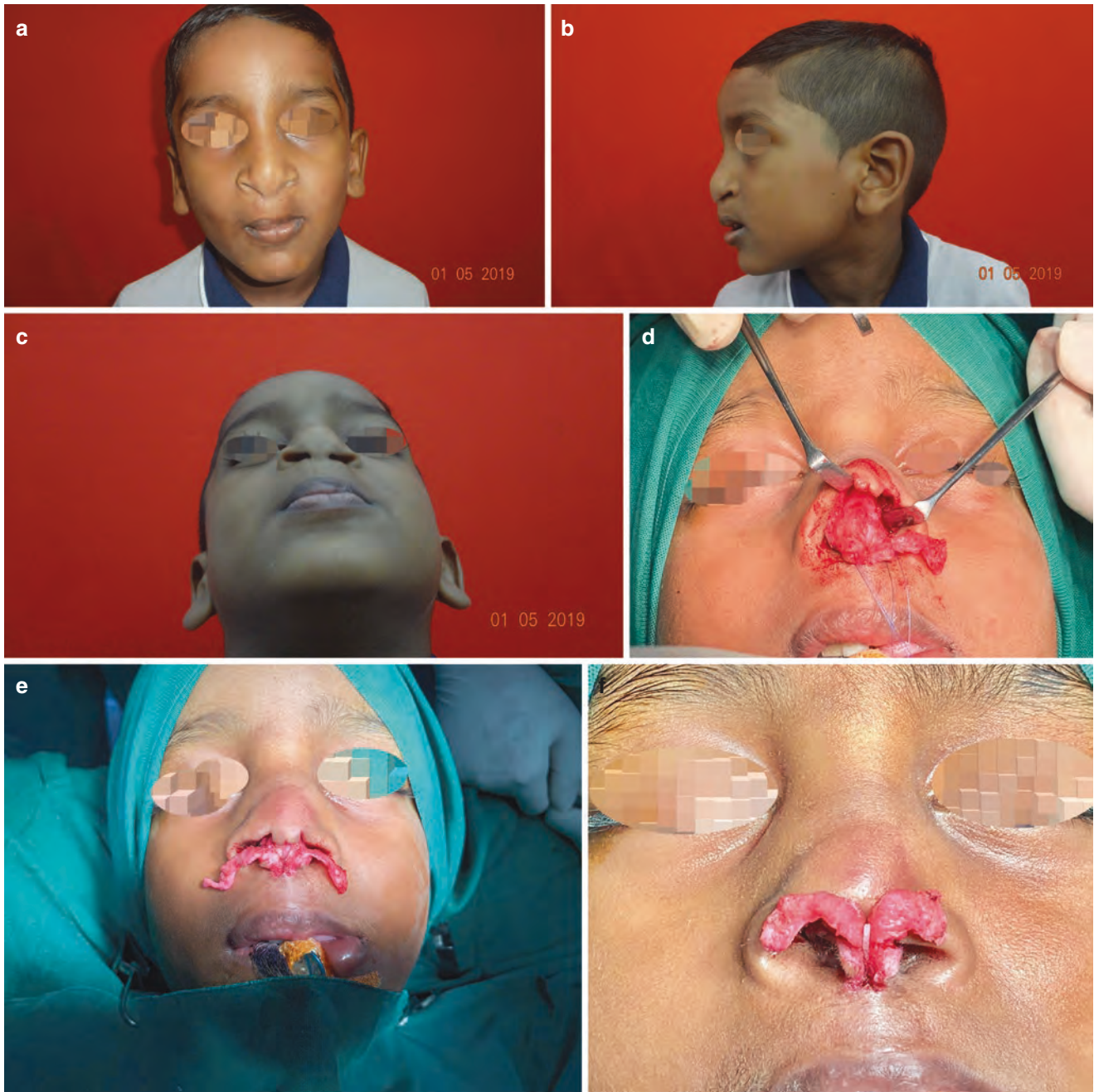
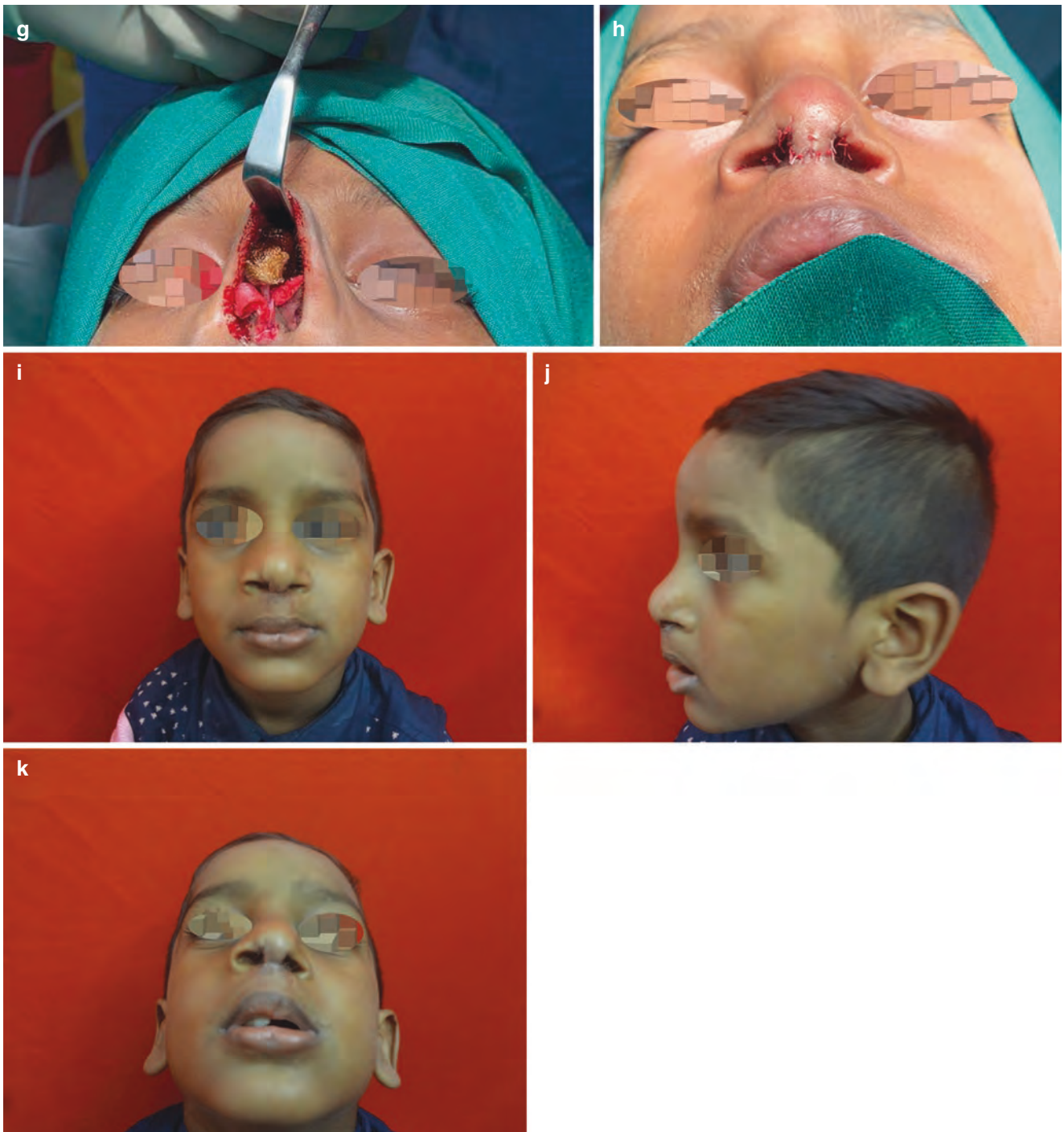
Fig. 76.18 (a–k) Clinical Scenario 2: A case of bilateral cleft nasal deformity in a 6-year-old male managed with intermediate rhinoplasty. (a) Pre op frontal. (b) Pre op lateral. (c) Pre op basal. (d) Exposure of lower lateral cartilages. (e) Cartilage delivery after lower lateral steal.

(f) Columellar strut for columellar reconstruction. (g) Modified Turkish delight for dorsal augmentation. (h) Closure. (i) Post op frontal. (j) Post op lateral. (k) Post op basal



©Association of Oral and Maxillofacial Surgeons of India

Fig. 76.18 (continued)

References

- Shih CW, Sykes JM. Correction of cleft lip nasal deformity. *Facial Plast Surg.* 2002;18:253.
- Bryd HS, El-Musa KA, Yazdani A. Definitive repair of the unilateral cleft lip nasal deformity. *Plast Reconstr Surg.* 2007;120:1348–56.
- Fisher DM, Sommerlad BC. Cleft lip, cleft palate and velopharyngeal insufficiency. *Plast Reconstr Surg.* 2011;128:342e–60e.
- Huffman WC, Lierle DM. Studies on the pathologic anatomy of the unilateral hare-lip nose. *Plast Reconstr Surg.* 1949;4:225–34.
- Avery JK. The nasal capsule in cleft palate. *Anat Anz.* 1962;109(Suppl):722.
- Latham RA. The pathogenesis of skeletal deformity associated with unilateral cleft lip and palate. *Cleft Palate J.* 1969;6:404–14.
- McComb HK, Coghlan BA. Primary repair of the unilateral cleft lip nose. Completion of a longitudinal study. *Cleft palate Craniofac J.* 1996;33:23–31.
- Bernstein L. Early submucous resection of nasal septal cartilage. A pilot study in canine pups. *Arch Otolaryngol.* 1973;97:272–85.
- Sykes JM, Senders CW. Surgery of the cleft lip and nasal deformity. *Oper Tech Otolaryngol Head Neck Surg.* 1990;1:219–24.
- Sykes JM, Senders CW. Surgical treatment of the unilateral cleft nasal deformity at the time of lip repair. *Facial Plast Surg Clin North Am.* 1995;3:69–77.
- Fisher DM, Mann RJ. A model for the cleft lip nasal deformity. *Plast Reconstr Surg.* 1998;101:1448–56.
- Penfold C, Dominguez-Gonzalez S. Bilateral cleft lip and nose repair. *Br J Oral Maxillofac Surg.* 2011;49:165–71.
- Mulliken JB. Correction of the bilateral cleft lip nasal deformity. Evolution of a surgical concept. *Cleft Palate Craniofac J.* 1992;29:540–5.
- Noordhoff MS. Bilateral cleft lip reconstruction. *Plast Reconstr Surg.* 1986;78:45–54.
- Morovic CG, Cutting C. Combining the Cutting and Mulliken methods for primary repair of the bilateral cleft lip nose. *Plast Reconstr Surg.* 2005;116:1613–9. Discussion 1620–2
- Cronin TD. The bilateral cleft lip with bilateral cleft of the primary palate. In: Converse JM, editor. *Reconstructive plastic surgery.* Philadelphia: WB Saunders; 1964.
- Subramanian CS, et al. A modified presurgical orthopaedic (nasal-alveolar molding) device in the treatment of unilateral cleft lip and palate. *Eur J Dent.* 2016;10:435–8.
- Mulliken JB, Martinez-Perez D. The principle of rotation advancement for the repair of unilateral complete cleft lip and nasal deformity: Technical variations and analysis of results. *Plast Reconstr Surg.* 1999;104:1247–9.
- Cronin TD. Lengthening columella by use of skin from nasal floor and alae. *Plast Reconstr Surg Transplant Bull.* 1958;21:417–26.
- Wang TD. Secondary rhinoplasty in unilateral cleft nasal deformity. *Facial Plast Surg.* 2007;23:123–7.
- Kaufman Y, Buchanan EP, Wolfswinkel EM, Wethers WM, Stal S. Cleft nasal deformity and rhinoplasty. *Semin Plast Surg.* 2012;26:184–90.
- Garri JI, O'Leary K, Gabbay JS, et al. Improved nasal tip projection in the treatment of bilateral cleft nasal deformity. *J Craniofac Surg.* 2005;16:834–9.
- Li J, Shi B, Liu K, Zheung Q. A preliminary study of hard-soft tissue relationships among unoperated secondary unilateral cleft nose deformities. *Oral Surg Oral Med Oral Pathol Oral Radiol.* 2012;113:300–7.
- Duskova M, Kristen M, Smahel Z. The anthropometric verification of corrective surgery outcome in cleft secondary deformities. *J Craniofac Surg.* 2006;17:447–53.
- Trottman CA, Faraway JJ, Losken HW, van Aalst JA. Functional outcomes of cleft lip surgery: Part II: Quantification of nasolabial movement. *Cleft Palate Craniofac Surg.* 2007;44:607–16.
- Morrant DG, Shaw WC. Use of standardised video recording to assess cleft surgery outcome. *Cleft Palate Craniofac J.* 1996;33:134–42.
- Sykes JM, Senders JW, Wang TD, Cook TA. Use of the open approach for repair of secondary cleft lip-nasal deformities. *Facial Plast Surg.* 1993;1:111–26.
- Millard DR Jr. Columella lengthening by a forked flap. *Plast Reconstr Surg.* 1958;22:545.
- Nakamura N, Sasaguri M, Okawachi T, Nishihara K, Nozoe E. Secondary correction of bilateral cleft lip nose deformity. Clinical and three-dimensional observations on pre- and postoperative outcome. *J Craniofac Surg.* 2011;39:305–12.
- Tajima S, Maruyama M. Reverse U incision for secondary repair of cleft lip nose. *Plast Reconstr Surg.* 1977;60:256–61.
- Haddock NT, McRae MH, Cutting CB. Long term effect of primary cleft rhinoplasty on secondary cleft rhinoplasty in patients with unilateral cleft lip cleft palate. *Plast Reconstr Surg.* 2012;129:740–8.
- Tajima S. Follow up results of unilateral primary cleft lip operation with special reference to primary nasal correction by the author's method. *Facial Plast Surg.* 1990;7:97–104.
- Bryd HS, Salomon J. Primary correction of the unilateral cleft nasal deformity. *Plast Reconstr Surg.* 2000;106:1276–86.
- Mulliken JB. Primary repair of bilateral cleft lip and nasal deformity. *Plast Reconstr Surg.* 2001;108:181–6.
- Park SS. Treatment of the internal nasal valve. *Facial Plast Surg.* 1999;7:333–45.
- Teymoortash A, Fasunla JA, Sazgar AA. The value of spreader grafts in rhinoplasty: A critical review. *Eur Arch Otorhinolaryngol.* 2012;269:1411–6.
- Jablón H, Sykes JM. Nasal airway problems in the cleft lip population. *Facial Plast Surg Clin North Am.* 1999;7:391–403.
- Crockett D, Burnstead R. Nasal airway, otologic and audiological problems associated with cleft lip and palate. In: Bradach J, Morris HL, editors. *Multidisciplinary management of cleft lip and palate.* Philadelphia: WB Saunders; 1990.
- Cuzalina A, Jung C. Rhinoplasty for the cleft lip and palate patient. *Oral Maxillofac Surg Clin North Am.* 2016;28:189–202.
- Ingels KJ, Orhan KS, Van Heerbeek N. The effect of spreader grafts on nasal dorsal width in patients with nasal valve insufficiency. *Arch Facial Plast Surg.* 2008;10:354–6.
- Cho BC, Choi KY, Lee JH et al. The correction of a secondary bilateral cleft lip nasal deformity using refined open rhinoplasty with reverse U incision, V plasty and selective combination with composite grafting: Long term results. *Arch Plast Surg* 2012; 39:190–7.
- Guyuron B. MOC-PS(SM) CME article. Late cleft lip nasal deformity. *Plast Reconstr Surg.* 2008;121(4, Suppl):1–11.
- Park BY, Lew DH, Lee YH. A comparative study of the lateral crus of alar cartilage in unilateral cleft lip nasal deformity. *Plast Reconstr Surg.* 1998;101:905–19.
- Chand MS, Toriumi DM. Treatment of the external nasal valve. *Facial Plast Surg.* 1999;7:347–55.
- Richardson S, Agni NA, Pasha Z. Modified Turkish delight: morselized polyethylene dorsal graft for rhinoplasty. *Int J Oral Maxillofac Surg.* 2011;40:979–82.
- Yan W, Zhao ZM, Yin NB, et al. A new modified forked flap and a reverse V shaped flap for secondary correction of bilateral cleft lip nasal deformities. *Chin Med J (Engl).* 2011;124:3993–6.
- Rikimaru H, Kiyokawa K, Koga N, et al. A new modified forked flap with subcutaneous pedicles for adult cases of bilateral cleft lip nasal deformity: from normalisation to aesthetic improvement. *J Craniofac Surg.* 2008;19:1374–80.

48. Cheon YW, Park BY. Long term evaluation of elongating columella using conchal composite graft in bilateral secondary cleft lip and nose deformity. *Plast Reconstr Surg.* 2010;126:543–53.
49. Nakamura N. Surgical strategy for surgical correction of unilateral and bilateral cleft lip nose deformities. In: Brenner MJ, editor. *Rhinoplasty*. Croatia: In Tech; 2011.
50. Nakamura N, Okawachi T, Nishihara K, Hirahara N, Nozoe E. Surgical technique for secondary correction of unilateral cleft lip nose deformity—Clinical and three-dimensional observations of pre- and post-operative nasal forms. *J Oral Maxillofac Surg.* 2010;68:2248.
51. Nakamura N, Okawachi T, Nishihara K, Hirahara N, Nozoe E. Surgical technique for secondary correction of unilateral cleft lip nose deformity—Clinical and three-dimensional observations on pre- and post-operative nasal forms. *J Cranio Maxillofac Surg.* 2011;39:305.
52. Lee TS, Schwartz GM, Tatum SA. Rhinoplasty for cleft and heman-gioma related nasal deformities. *Curr Opin Otolaryngol Head Neck Surg.* 2010;18:526–35.
53. Huempfer-Hierl H, Hemprich A, Hierl T. Results of prospective anthropometric and functional study about aesthetics and nasal respiration after secondary rhinoplasty in cleft lip and palate patients. *J Craniofac Surg.* 2009;20(Suppl 2):1863–75.
54. Sandor GK, Ylikontiola LP. Patient evaluation of outcomes of external rhinoplasty for unilateral cleft lip and palate. *Int J Oral Maxillofac Surg.* 2006;35:407–11.
55. Chaithanyaa N, Rai KK, Shivakumar HR, Upasi A. Evaluation of the outcome of secondary rhinoplasty in cleft lip and palate patients. *J Plast Reconstr Aesthet Surg.* 2011;64:27–33.
56. Pitak-Arnop P, Hemprich A, Dhanuthai K, Pausch NC. Outcome research on secondary cleft rhinoplasty: The Leipzig experience. *J Plast Reconstr Aesthet Surg.* 2011;64:277–8.

Open Access This chapter is licensed under the terms of the Creative Commons Attribution 4.0 International License (<http://creativecommons.org/licenses/by/4.0/>), which permits use, sharing, adaptation, distribution and reproduction in any medium or format, as long as you give appropriate credit to the original author(s) and the source, provide a link to the Creative Commons license and indicate if changes were made.

The images or other third party material in this chapter are included in the chapter's Creative Commons license, unless indicated otherwise in a credit line to the material. If material is not included in the chapter's Creative Commons license and your intended use is not permitted by statutory regulation or exceeds the permitted use, you will need to obtain permission directly from the copyright holder.



Part XX

Craniofacial Anomalies



77.1 Introduction

Since ages, congenital deformities were considered evil and wizard, and infants were abandoned to die in isolation. Jean Yperman (1295–1351) valued the congenital origin of the clefts. He additionally characterized the different types of the condition and set out the standards for their treatment. Fabricius ab Aquapendente (1537–1619) and William His of college of Leipzig independently researched and published embryological premise of clefts [1].

Laroche was the first to separate between common cleft lip or harelip and clefts of the cheek. Further qualification was made in 1864 by Pelvet, who isolated oblique clefts including the nose from the other cheek clefts, and drawing on Ahlfeld's work, in 1887 Morian gathered 29 cases from the writing, contributing 7 instances of his own. Morian perceived three unique groups of oblique facial clefts. From that point forward, astounding audits have been composed by Grinberg in 1913, Boo-Chai in 1970, Paul Tessier in 1976 [2] and Millard in 1977 [3].

Craniofacial cleft by definition is “a fissure of the soft tissues that corresponds as a general rule with a cleft of the bony structures.” [1] The greatest research on craniofacial clefts was finished by Tessier and is credited for the formation of the craniofacial surgery for establishing the framework of the advanced craniofacial surgery by fundamentally breaking down facial clefts and portraying facial osteotomies [4].

Craniofacial clefts are significant clefts affecting the face, cranium, or both. These clefts cause distortion of the face and cranium with lacks or abundances of tissue that cleave anatomic planes in a straight fashion [2]. Craniofacial clefts exist in changing degrees of seriousness, and practically every one of them happens along the anticipated embryologic

lines. These clefts can be either complete or incomplete and can seem alone or in relationship with other facial clefts. Seriousness of craniofacial clefts fluctuates extensively, running from a scarcely distinguishable indent on the lip or on the nose or a scar-like structure on the cheek to an extensive partition of all layers of facial structures. Notwithstanding one parted sort can show on one side of the face, while an alternate kind is available on the other side [2, 3].

Craniofacial clefts need comprehensive rehabilitation. Past the physical consequences for the patient, they have monstrous mental and financial impacts on both patient and family, prompting disturbance of psychosocial working and diminished nature of life [4, 5].

Cleft repair is a necessary part of the modern craniomaxillo-facial surgical spectrum and remains a challenge on account of inadequate and contorted tissue (minor to major) at the site of the deformity [6]. The outcomes are additionally impacted by the short and long haul aesthetic (soft tissue and facial skeletal appearance) [7] and useful (occlusal and discourse) outcomes [8]. What's more, the kind of careful fix, the specialist's abilities and the compliance of the patient likewise, affects the stylish [9] and utilitarian [10] outcomes. The real test isn't just understanding the hereditary qualities [11], in addition to plan the standard conventions for the surgery in these phenomenal kinds of clefts [12].

77.2 Incidence

Craniofacial clefts are a lot rarer than the simple cleft lip/palate deformity [13]. The precise occurrence of craniofacial clefts has not been exactly documented in view of their rarity. However, the reported frequency of craniofacial clefts is 1.5–6.0 per 100,000 live births [14]. The occurrence of uncommon craniofacial clefts contrasted with ordinary cleft lip and palate may vary from 9.5 to 34 for every 1000 [15].

Disclosure: Authors have no financial conflicts to disclose.

S. Gosla Reddy (✉) · A. P. Acharya
GSR Institute of Cranio-maxillofacial & Facial Plastic Surgery,
Hyderabad, Telangana, India

Lateral or transverse clefts of the lip are very uncommon and have commonly archived to have a rate of 0.3% of 1.0% of all of the facial cleft deformity spectrum (Boo-Chai 1969; Hawkins et al. 1973; Bauer et al. 1982; Verheyden 1988; Gleizal et al. 2007), or of 0.02% of live births (Kuriyama et al. 2008) [16]. Median clefts of the lower lip are very rare and only 68 cases have been accounted for till date [17].

77.3 Embryology

Successful treatment of innate craniofacial defects depends on an intensive comprehension of the embryologic procedures prompting their development [18]. There are various interesting highlights that plainly recognize craniofacial improvement from the advancement of different tissues in the body.

One of these novel highlights is the double starting point of craniofacial tissues: the skeletal framework and the vast majority of the connective tissues, including veins, begin from a gathering of cells called the cranial neural crest, while the musculature and some parts of the skull begin from mesoderm.

A second one of a kind component is the unit of intricate, complementary tissue interactions between the neuroectoderm, the mesenchyme, and facial ectoderm that drive ordinary advancement.

A third novel element is the extravagantly arranged morphogenetic developments—brought about by both uninvolvement cell removal and dynamic cell movement—that characterize head advancement. Any procedure that upsets the rate, the planning, or the degree of these complex cell conduct can result in a craniofacial birth imperfection.

77.3.1 The Initiation of Craniofacial Development

77.3.1.1 Establishment and Fusion of the Facial Prominences (Figs. 77.1 and 72.3)

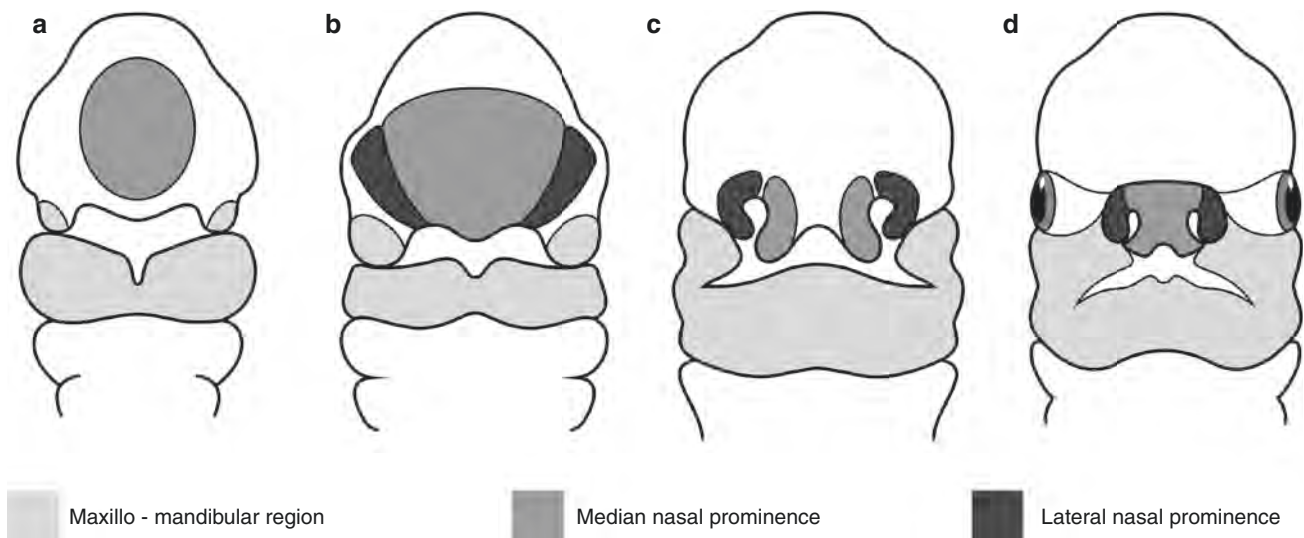
The basic morphology of the face is established between the 4th and 10th week of human development. The face is formed as a result of fusion of the midline frontonasal prominence and three paired prominences, the maxillary, lateral nasal, and mandibular prominences. Each of these prominences is filled with cranial neural crest cells that originated at different positions along the neural tube.

77.3.1.2 The Frontonasal Prominence

The frontonasal prominence gives rise to the forehead, midline of the nose, the philtrum, the middle portion of the upper lip, and the primary palate. Interruptions in frontonasal growth often result in a bilateral cleft lip, where the primary palate frequently “everts.” In the mildest cases, clefts involving frontonasal prominence-derived structures may be limited to a notch in the vermilion border of the lip. In more severe cases, frontonasal clefts involve all of the tissues of the lip, and these cases may most likely occur because of a failure of fusion between the frontonasal and maxillary prominences.

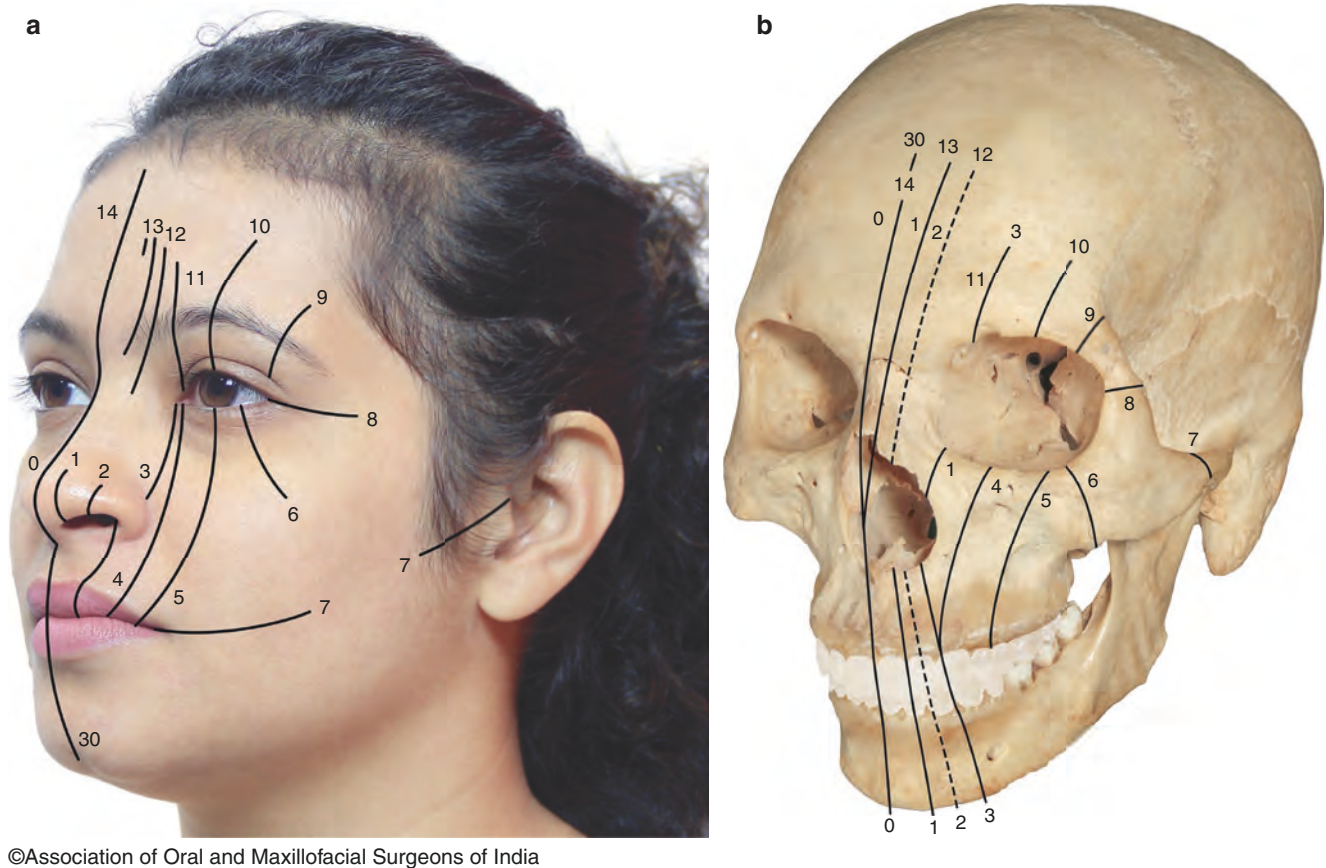
77.3.1.3 The Lateral Nasal Prominences

The lateral nasal prominences give rise to the alae of the nose. Clefts that involve the side of the nose often result from a failure in the fusion between the lateral nasal prominences and either the frontonasal or the maxillary processes.



©Association of Oral and Maxillofacial Surgeons of India

Fig. 77.1 (a–d) Embryological representation of fusion of nasal prominences



©Association of Oral and Maxillofacial Surgeons of India

Fig. 77.2 (a) Tessier classification for soft tissue clefting. (b) Tessier classification for bony clefting

77.3.1.4 The Maxillary Prominences

The maxillary prominences develop into the upper jaw, the facial halves, the upper lips, and the secondary palate. The nasal passage is divided from the pharynx by the secondary palate, which is formed from the neural crest cells. The palatal shelves first drop vertically and then rotate into a horizontal plane on the dorsal side of the tongue before fusing. The epithelium of the palatal shelves sloughs off, with only the basal layer of epithelium remaining to cover the later palate.

77.3.1.5 The Mandibular Prominences

This develops into the lower jaw and lower lip. Clefts of the lower jaw are very rare, presenting with a wide variety of phenotypes, ranging from a vermillion notch on the lip to a complete cleft involving the anterior mandible, chin, tongue, and lower lip and occasionally involving midline structures of the neck up to the manubrium sterni [19].

77.4 Etiology and Pathogenesis

Development of the head and face contains a standout among the most mind-boggling events among embryonic advancement. Disturbance of this firmly controlled course can result in a facial cleft where the facial primordia fail to meet and

form the suitable structures [20]. The definite instrument of the cause of facial clefts is obscure, yet they are accepted to have a multifactorial etiology including a mix of natural and hereditary causes during embryonic development [21, 22]. In India affiliation and healthful inadequacies in pregnant mothers are the main cause of clefts [23].

The discussion is as yet in contention between the supporters of Meckel who trusted that clefts were brought about by a developmental arrest and Geoffroy St. Hilaire (1832) who felt that amniotic groups were responsible [15].

Fogh-Andersen previously characterized hereditary factors in clefting, which have been affirmed by segregation analysis [23]. Research in molecular genetics have identified genes responsible for rare facial clefts which may be syndromic and also for complex non-syndromic variants [24].

The non-syndromic types of orofacial clefts are likely due to secondary gene-environment interactions [25]. Non-syndromic cleft is a heterogeneous disease entity with candidate clefting loci on chromosomes [1, 2, 4, 6, 11, 14, 17, 19].

Four general classes of natural “cleftogens” have been distinguished to date, as follows [26]:

Radiation. Huge dosages of radiation have been associated with microcephaly.

Infections. The offspring of mothers with toxoplasmosis, rubella, or cytomegalovirus diseases display expanded frequencies of facial clefts.

Maternal idiosyncrasies. Mothers of children with CLP display an increased rate of phenylketonuria. The oculo-auriculovertbral range has been seen with strange recurrence among neonates with mothers who are diabetic. Numerous examinations have proposed maternal factors, for example, age, weight, and general well-being, as potential reasons for distortions.

Chemicals. Nutrient deficiencies are related with expanded rates of CLP, which might be decreased with vitamin supplementation for expectant mothers. Vitamin A, its subsidiaries, and related compounds, for example, isotretinoin, have been involved in the developments of facial clefts and hemifacial microsomia [26].

Any maternal liquor consumption during pregnancy increases the frequency of orofacial clefting [27]. The impact of maternal smoking also may be responsible [28]. Multiple studies have demonstrated that folate deficiency is related with clefts. Pre-birth folic acid supplementation has shown to diminish this hazard. At present, folic acid supplementation is the main empirical safeguard to diminish the frequency of facial clefting [2].

77.5 Classification

An all-round grouping plan that completely envelops, precisely depicts, and coordinates all the different types of orofacial and craniofacial clefts does not exist [2]. Soemmering (1791), Morian in 1886, Degenhardt (1961), the American Association of Cleft Palate Rehabilitation (AACPR) (1962), and Boo-Chai have made huge contributions in building up a classification [29–32].

77.5.1 Tessier Classification

In 1976, Paul Tessier depicted an anatomical order framework in which a number is doled out to every abnormality based on its position with respect to the sagittal midline [33].

This framework has moved towards global acknowledgment and allows reliable correspondence among clinicians [34].

This classification involves the orbit as the principle reference point. Fifteen areas of clefting have been demonstrated with discussion of their soft tissue and hard tissue involvement [33] (Fig. 77.2a, b).

The numbered clefts relate the soft tissue features to underlying bony involvement.

These have been verified by operative findings and more recently preoperative 3D CT assessments [35]. The clefts are radially distributed around the orbit with the midline 0 cleft named as median facial dysrhapia [33].

77.5.1.1 Number Zero

The no. 0 cleft is the most widely recognized of the craniofacial clefts [36]. No. 0 and 14 is also called as midline craniofacial dysrhapia. Clinically, this cleft shows up as an absence of conclusion of the front neuropore [33].

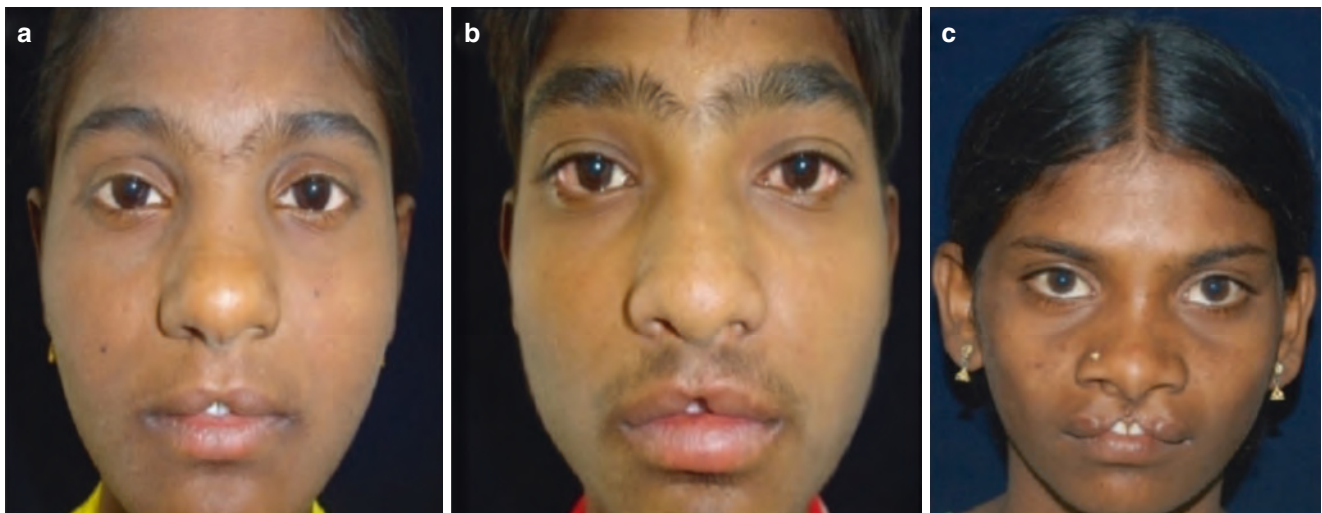
It shows two variants: a true and false middle congenital cleft, with or without related hypo- or hypertelorism [36]. Developmental cause of Tessier no. 0 isn't evident; however, it is realized that midline facial deformities can be followed to a period relating to the third week of gestation [36]. The cleft expresses as a duplication of the crista galli in frontal bone ("skull bifidum" and middle encephalocele), and as nasal septal duplication, and cleft through the columella, maxilla, and lip [33]. This form of cleft may have either a deficiency or abundance of tissue: with tissue agenesis and holoprosencephaly toward one side and frontonasal hyperplasia and inordinate tissue (the hyperplasias) at the opposing end. Midway inconsistencies with normal tissue volume possess the center segment of the spectrum [37].

Features of true midline congenital fissure:

1. Split upper lip with renal duplication
2. Bifid nose with wide columella and a wide furrow in the nasal dorsum
3. Duplication of the nasal septum
4. Overprojected nose due to fibromuscular connection of the alar ligaments and the frontal bone
5. Hypertelorism
6. Low placed cribriform plate of the ethmoid bone
7. Occasional midline encephalocele [38]

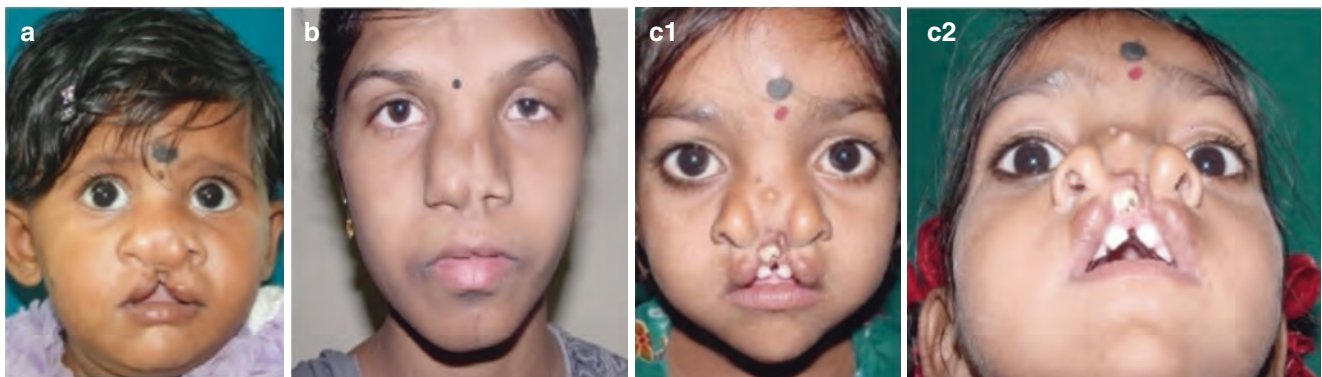Features of the pseudo midline congenital fissure include:

1. Hypotelorism
2. Absence of the philtrum of the lip, premaxilla, nasal septum, columella, and the crista galli [33]
3. Clefting along the entire length of the upper lip
4. Hypoplastic nasal septum
5. Holoprosencephaly
6. Hypoplastic ethmoid bones [37]
7. Widened body of the sphenoid bone with separation of the pterygoid plate [35]



©Association of Oral and Maxillofacial Surgeons of India

Fig. 77.3 (a–c) Clinical subclassification of Tessier number 0. (a) Type I—Involving only vermilion not involving the white roll. (b) Type II—Involving vermilion and white roll. (c) Type III—Involving vermilion, white roll, and philtrum



©Association of Oral and Maxillofacial Surgeons of India

Fig. 77.4 (a–c) Clinical subclassification of Tessier no. 0. (a) Type IV—Involving vermilion, white roll, philtrum, columella. (b) Type V—Involving columella and tip, supratip, and dorsum of the nose.

(c1, c2) Type VI—Involving columella, tips, supratip, dorsum of the nose and frontonasal area

Millard [39] classified a middle split of the lip as any vertical cleft through the focal point of the upper lip, paying little heed to the degree (Fig. 77.3a–c). Middle clefts have been isolated into two gatherings by Millard and Williams [39]. The principal bunching includes agenesis of the frontonasal procedure, and the second gathering is portrayed as separated to the middle component. The last is related with different degrees of nasal bifurcation and cranial malformations including hypertelorism [40–42] (Fig. 77.4a–c).

77.5.1.2 Number 1 Cleft

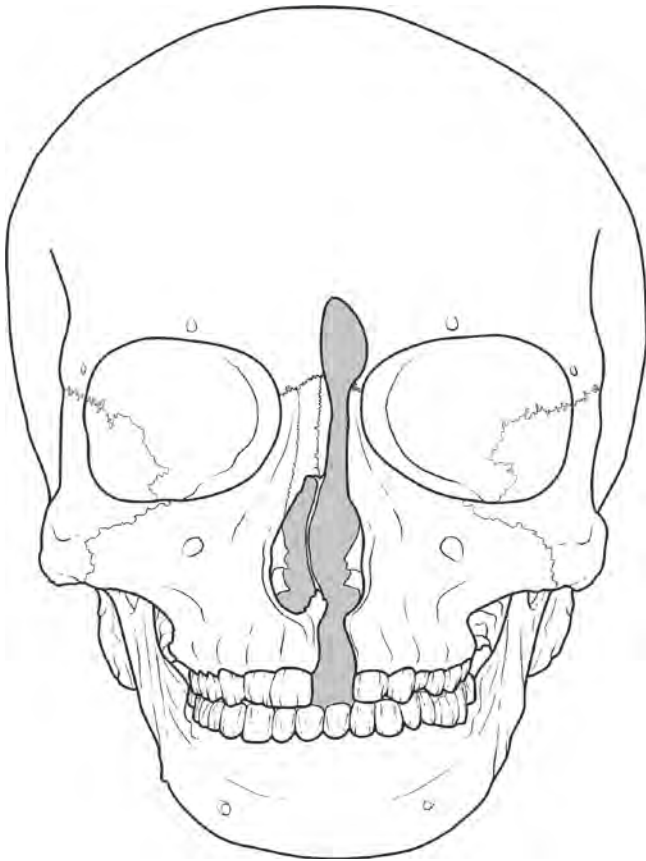
The number 1 cleft is also called as a paramedian cleft. Skeletally it passes through the frontal bone affecting the olfactory groove along the ethmoid producing hypertelorism

(Fig. 77.5). It also widens the area between the nasal bone and the frontal process of maxilla. The soft tissue component involves the dome of the nose and may involve the alveolus and the lip. It may have a cranial counterpart in No 13 cleft. [33]

Soft Tissue Characteristics:

Soft tissue characteristics of No 1 cleft include:

1. Alar clefting that produces deviation of the nose to the opposite
2. Vertical ridges and furrows on the nasal dorsum
3. Vertical orbital dystopia and telecanthus
4. Tongue-shaped frontal hairline which is indicative of no. 13 cleft [35]



©Association of Oral and Maxillofacial Surgeons of India

Fig. 77.5 Tessier 1

Skeletal Involvement:

Skeletal features are as follows:

1. Clefting of the maxilla extending posteriorly as a total cleft of the hard palate.
2. Hypoplastic maxilla.
3. Nasal dorsum is deviated.
4. Asymmetry of the pterygoid plates and increased prominence of the lesser wing of the sphenoid bone.
5. Mild plagiocephaly may also be an associated feature [35].

77.5.1.3 Number 2 Cleft

Tessier no. 2 clefts are found parallel to the midline Tessier No. 0 clefts [33]. The deformation of the middle third of the nostril rim is a characteristic feature of the Tessier 2 cleft. This produces widening of the nasal bridge and flattening of the lateral side of the nose (Fig. 77.6a–e).

Skeletal features of Tessier 2 clefts are as follows:

1. Alveolar dysplasia from the lateral incisor to the pyriform aperture.

2. Palatal cleft may or may not be seen.
3. Deviated nasal septum.
4. A bony indentation is seen near the naso-maxillary suture [35].
5. Dysplasia of the lateral ethmoid region with orbital hypertelorism [43].
6. Cranial base asymmetry.
7. Dislodged medial canthus with intact lacrimal duct [44].

77.5.1.4 Number 3 Cleft

No. 3 is the oculo-nasal cleft (Morian I). This is also called “medial” orbito-maxillary cleft which passes through the lacrimal segment of the lower eyelid. This paranasal cleft occurs obliquely involving the lacrimal groove [33]. The patient may have microphthalmia [35] but anophthalmia is rare [45] (Figs. 77.7a–c and 77.8a–c).

Soft Tissue Characteristics [35, 46]

The important soft tissue features of the Tessier 3 cleft are:

1. Soft tissue hypoplasia of the face in the vertical direction [35]
2. Clefting of the alar base involving the nasolabial groove
3. Alveolar cleft with cleft of the lip
4. Displacement of the medial canthal apparatus and the lacrimal punctum of the lower eyelid
5. No patency of the lacrimal duct into the nose
6. Normal globe with orbital dystopia

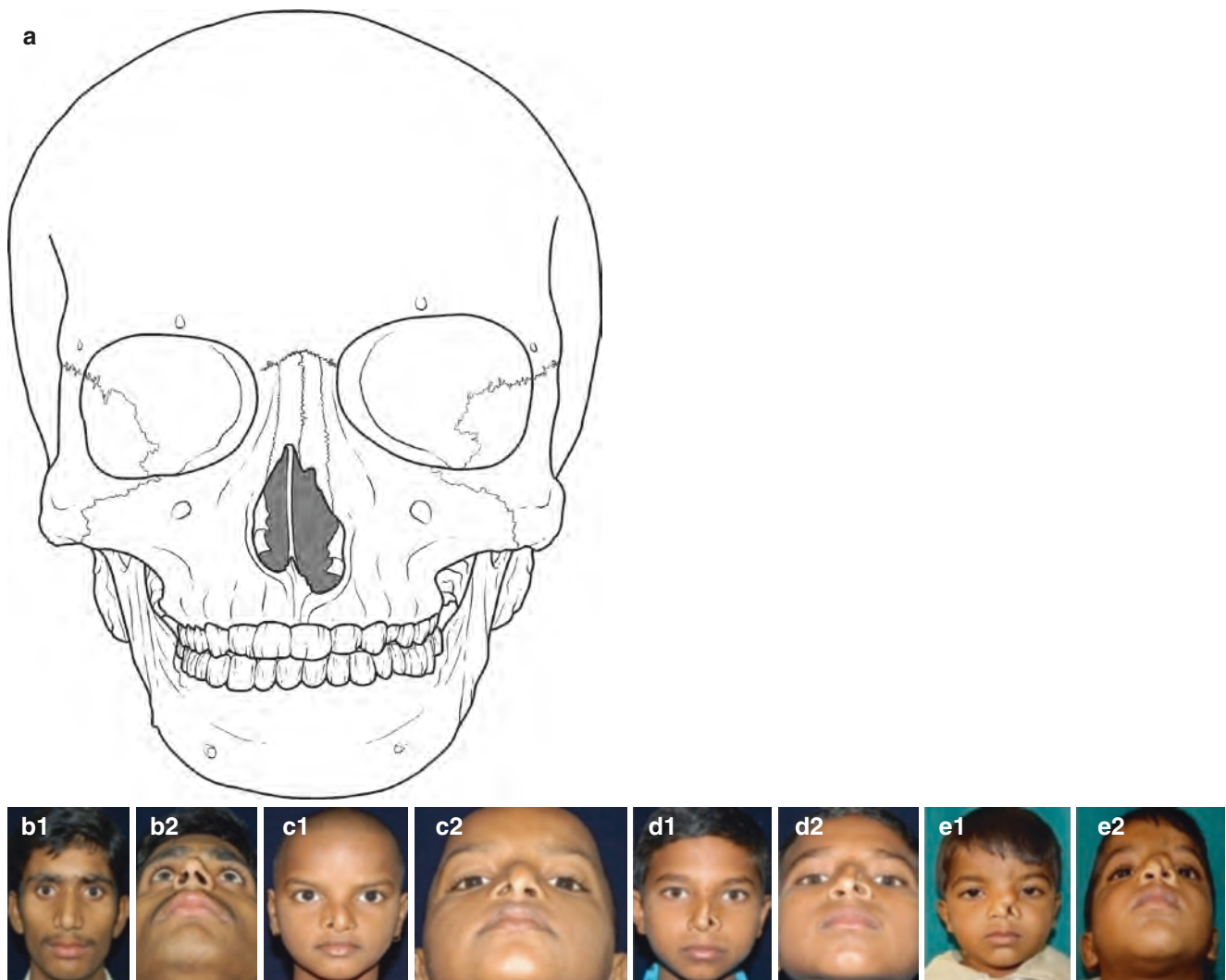
Skeletal involvement include the following features:

1. Absence of the frontal process of the maxilla and medial wall of the maxillary sinus [33]
2. Deviated nasal septum
3. Cleft lip and palate
4. Continuity of the nasal cavity into the maxilla with no bony lateral nasal wall [35]
5. Hypoplastic maxilla
6. Narrowing of the ethmoid body and sinus on the affected side [35]
7. May be associated with a cranial cleft No 10 or 11 [33]

77.5.1.5 Number 4 Cleft

The No 4 Tessier cleft is a rare, complex, and gruesome craniofacial malformation [47]. No. 4 is the oculo-facial separated I (Morian II). This is a “focal” orbito-maxillary cleft [33].

It may range from a unilateral notch paramedially to large bilateral tissue defects extending from the mouth to the eyes with huge bony fissures [47] (Fig. 77.9a–f).



©Association of Oral and Maxillofacial Surgeons of India

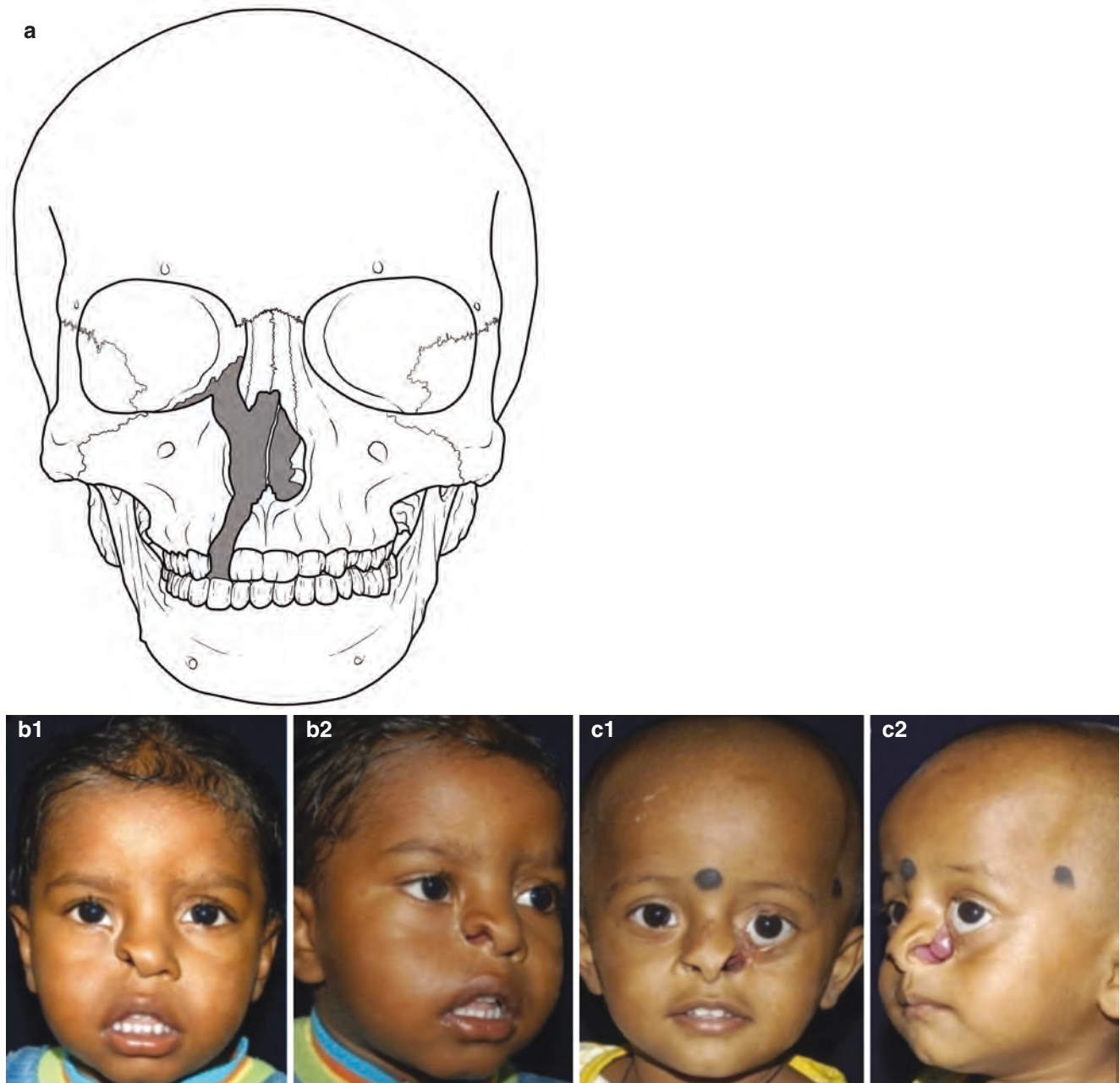
Fig. 77.6 (a–e) Tessier 2 clefts ranging from microform defect to more severe

Soft tissue characteristics include:

1. Clefting extending halfway between the philtral crest and the labial commissure
2. Extreme degree of vertical tissue deficiency extending from the labial cleft to the ocular separation in the lower eyelid [35]
3. Decreased oro-ocular distance
4. Microphthalmia with exposure keratitis secondary to eyelid deficiency [47]
5. Dystopia and inferior placement of the involved globe

Skeletal characteristics are enumerated below:

1. Bony cleft starting caudally between the lateral incisor and the canine proceeding cephalically medial to the infra-orbital foramen onto the orbital floor.
2. Prolapse of the orbital contents into the maxillary sinus due to the orbital defect.
3. Naso-lacrimal duct is intact, but the inferior lacrimal canaliculi may be hypoplastic or absent [47].
4. This may be associated with a cranial cleft no 12.



©Association of Oral and Maxillofacial Surgeons of India

Fig. 77.7 (a–c) Tessier 3 cleft with ocular involvement

77.5.1.6 Number 5 Cleft

The Tessier No 5 cleft is a very uncommon malformation and is also referred as the oculofacial cleft II (Morian III). This lateral orbito-maxillary cleft gets through the medial third of the lower eyelid [33] (Fig. 77.10a, b).

Soft tissue involvement demonstrates:

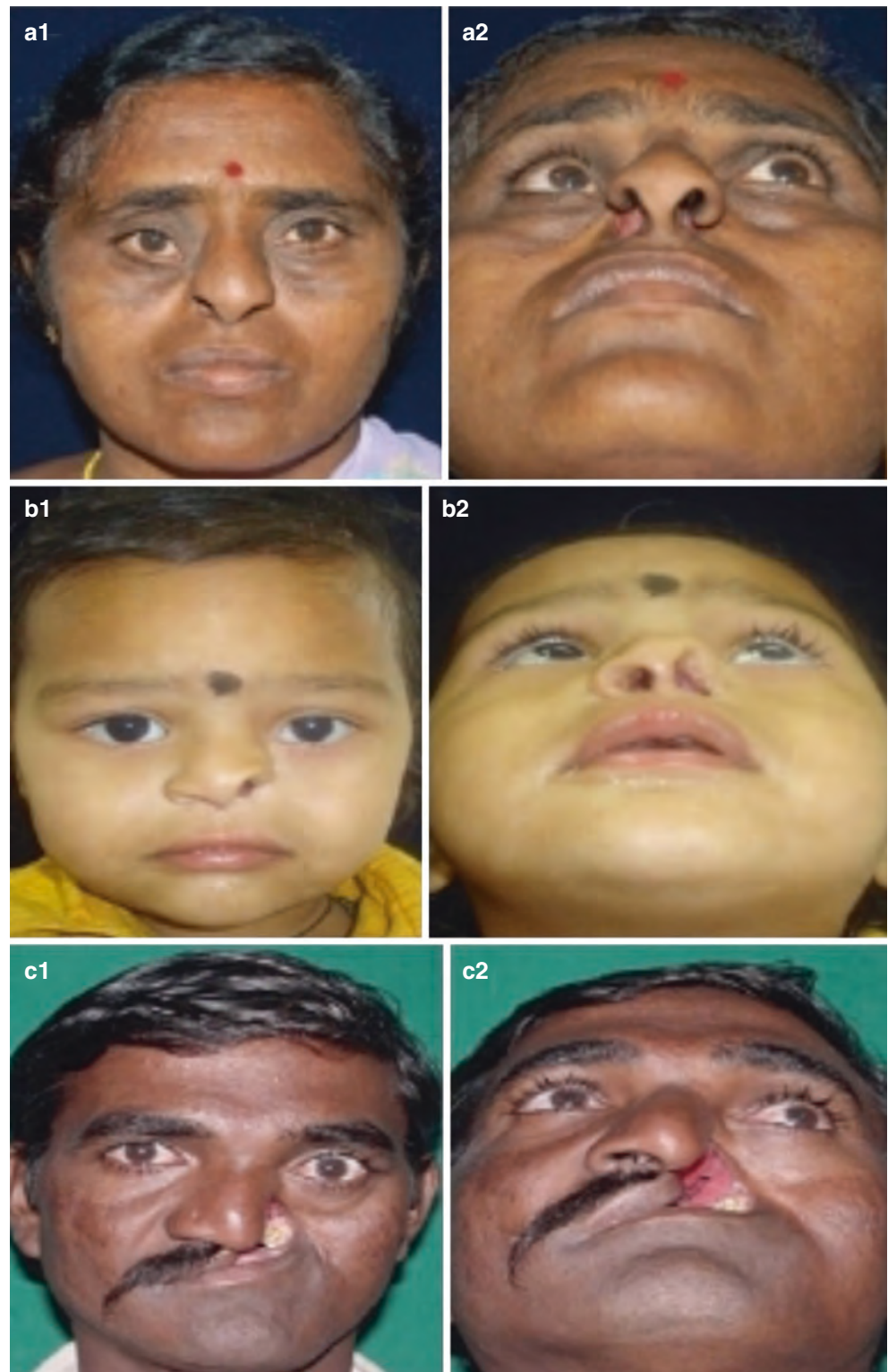1. Clefting immediately medial to the commissure which courses along the cheek lateral to the ala of the nose, ending in the lateral half of the lower eyelid.

2. The globes are usually normal but may occasionally show microphthalmia [35].

Skeletal involvement:

1. The alveolar cleft starts lateral to and travels lateral to the infra-orbital foramen and ends in the lateral part of the orbital floor. There may be associated hypoplasia of the maxillary sinus [48].

Fig. 77.8 (a–c) Tessier 3. (a) With bilateral involvement (b) without ocular involvement (c) with oral involvement

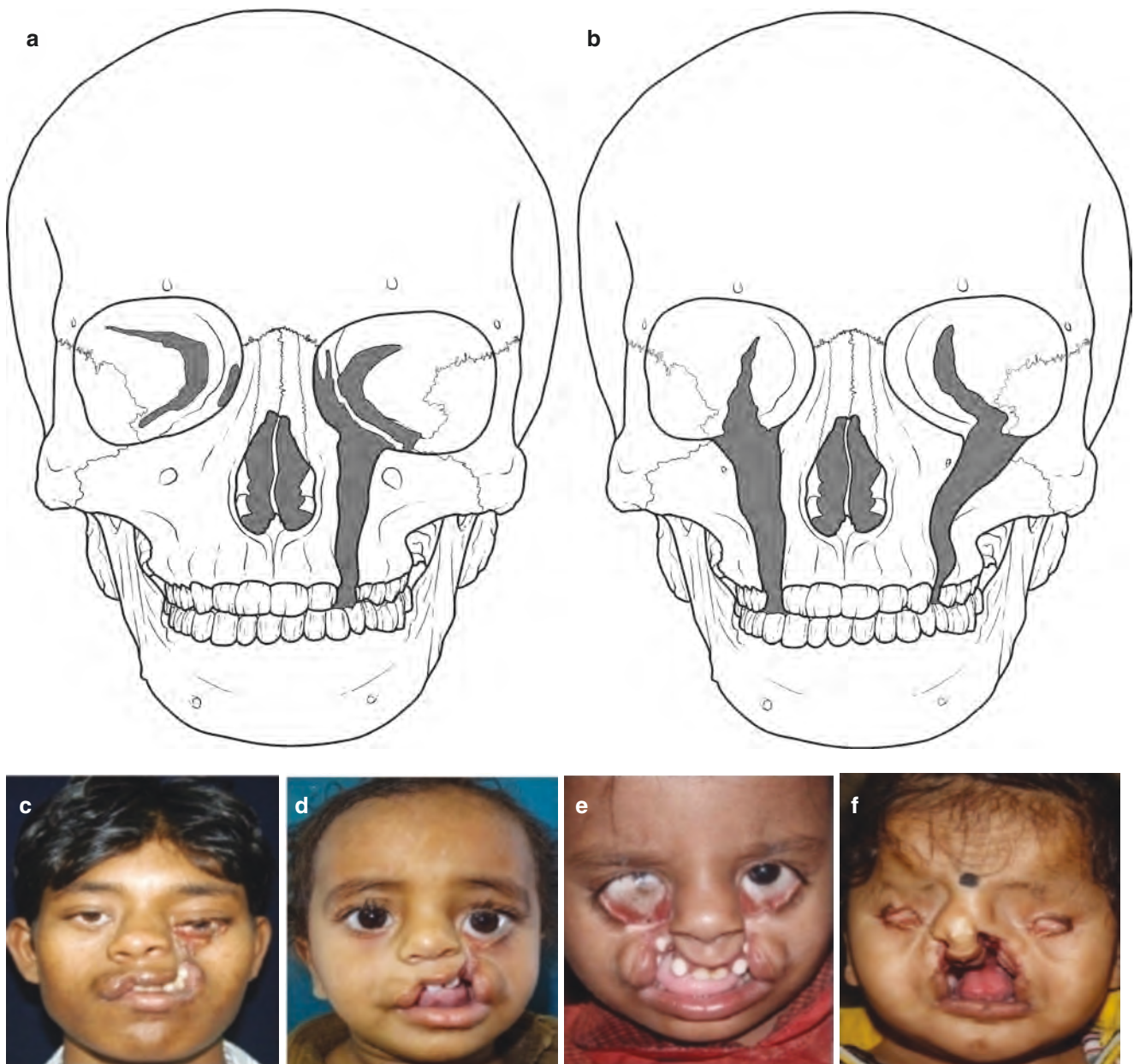


©Association of Oral and Maxillofacial Surgeons of India

2. Vertical orbital dystopia due to prolapse of the orbital contents.
3. Thickened lateral orbital wall and abnormal greater wing of the sphenoid bone.
4. Cranial base may be generally normal [35].

77.5.1.7 Number 6 Cleft

This is otherwise called as zygomaticomaxillary cleft which may form an incomplete variant of the Treacher Collins syndrome (Fig. 77.11a, b). It was named as maxillozygomatic dysplasia by Van der Meulen [33, 49].



©Association of Oral and Maxillofacial Surgeons of India

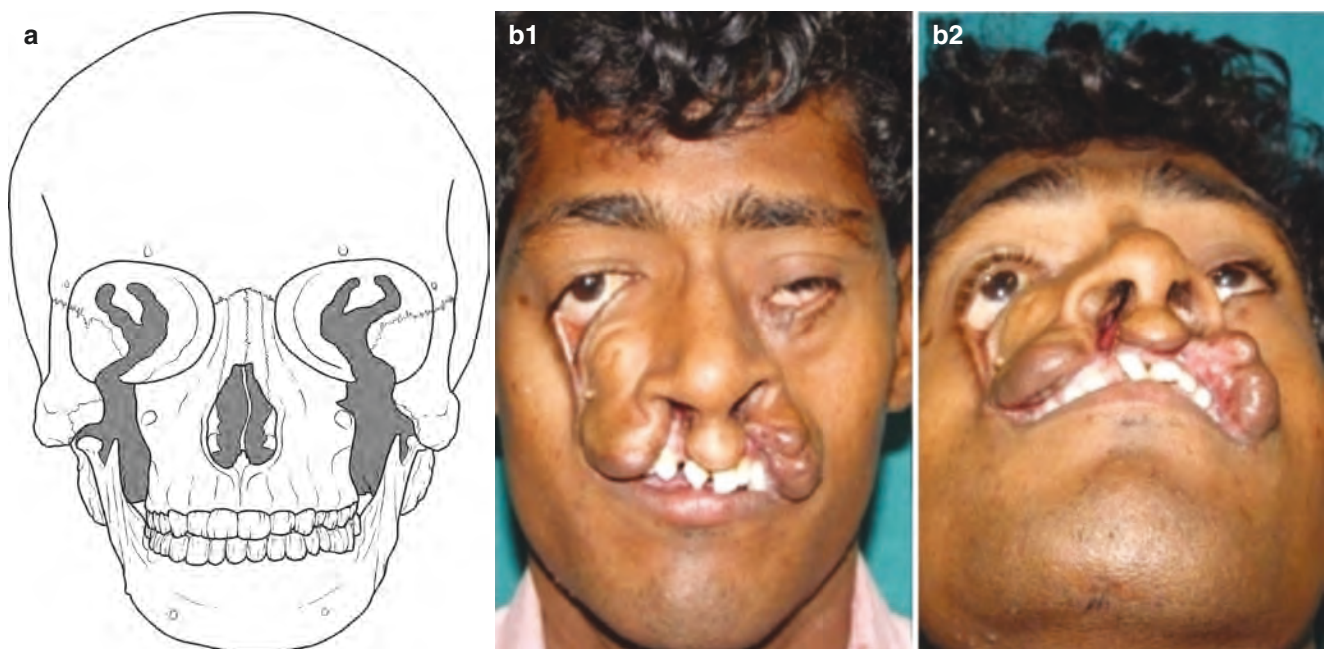
Fig. 77.9 (a–f) Tessier 4. (a, b) Skeletal Tessier 4. (c, d) Unilateral Tessier 4. (e, f) Bilateral Tessier 4

Soft tissue involvement of the No 6 cleft is detailed below:

1. Vertical cleft furrow extending from the oral commissure to the lateral aspect of the lower eyelid.
2. This also involves the zygomatic eminence pulling the lateral aspect of the palpebral fissure down with inferior displacement of the lateral canthus [33].
3. This gives the appearance of an anti-mongoloid slant and lower lid ectropion.
4. Colobomas may be seen in the lateral lower eyelid region [33].

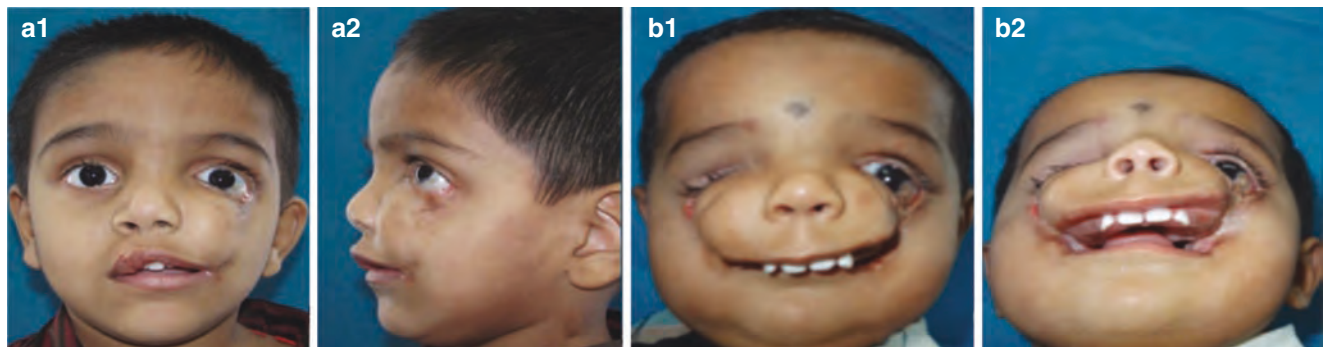Skeletal involvement is as follows:

1. A bony split is seen along the zygomaticomaxillary suture separating the maxilla and the zygoma [33].
2. Usually there is no alveolar cleft.
3. The maxilla may be shorter antero-posteriorly.
4. The cleft enters the orbit at the lateral orbital floor.
5. The zygoma is hypoplastic with change in the cheek contour.
6. The anterior cranial fossa is narrow but sphenoid is normal [35].



©Association of Oral and Maxillofacial Surgeons of India

Fig. 77.10 (a, b) Tessier 5



©Association of Oral and Maxillofacial Surgeons of India

Fig. 77.11 (a, b) Tessier 6. Skeletal Tessier 6. (a) Unilateral Tessier 6. (b) Bilateral Tessier 6

77.5.1.8 Number 7 Cleft

This is a temporo-zygomatic cleft and is the most well-known of all the craniofacial clefts [35] (Figs. 77.12 and 77.13a–d). It may occur along with hemifacial microsomia.

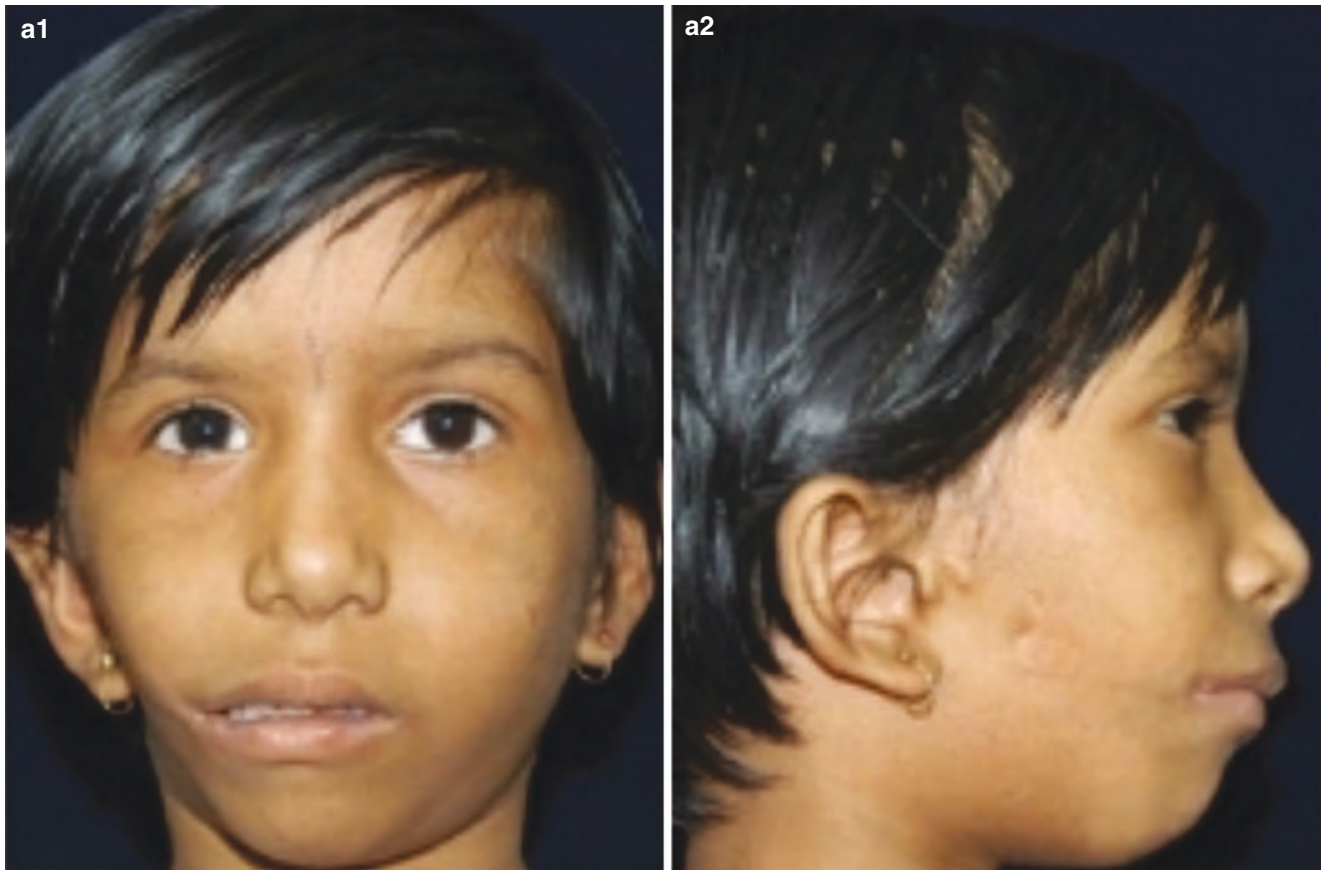
Soft tissue features include:

1. Soft tissue clefting from the oral commissure to the pre-auricular hairline.
2. It may range from a mild broadening of the oral commissure with pre-auricular skin tags to a complete fissure ending in a microtic ear [35].
3. There may be deficiency of the ipsilateral tongue, soft palate, and muscles of mastication.

4. There may be absence of the parotid gland and duct.
5. There may be external and middle ear abnormalities [50–52].
6. Abnormal pre-auricular hair form in hemifacial microsomia and Treacher Collins disorder [35].

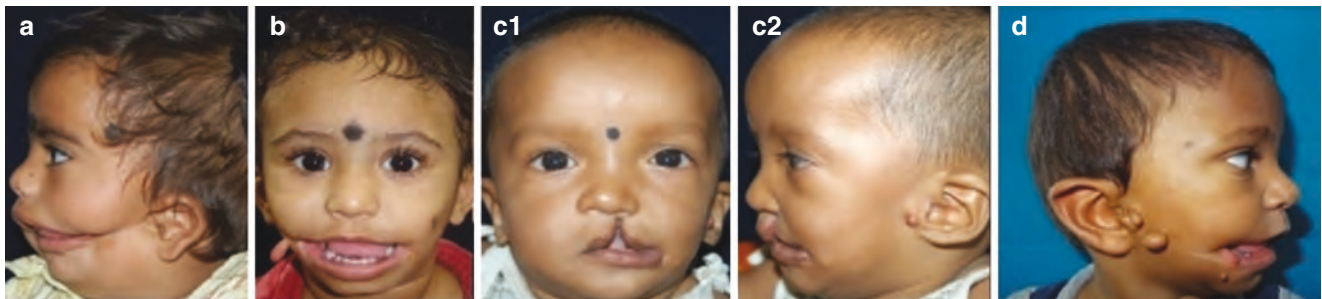Skeletal qualities include [35, 53, 54]:

1. Skeletal cleft involves the pterygo-maxillary junction.
2. Hypoplasia of the posterior maxilla, mandibular ramus, coronoid, and condylar process with occlusal canting [33].



©Association of Oral and Maxillofacial Surgeons of India

Fig. 77.12 Tessier 7



©Association of Oral and Maxillofacial Surgeons of India

Fig. 77.13 (a–d) Subclassification of Tessier 7. (a) Oro-aural Tessier 7. (b) Bilateral Tessier 7. (c) Tessier 7 with cleft lip. (d) Tessier with ear tag

3. Hypoplasia of the zygoma with displacement and deformation. In extreme cases the arch may manifest as a little stump alone.
4. There may be true orbital dystopia in severe cases.
5. There may be a tilt of the cranial base [35].

77.5.1.9 Number 8 Cleft (Fig. 77.2)

This fronto-zygomatic cleft situated at the lateral canthus forms the equator of the Tessier craniofacial cleft sphere. It is a part of the zygomatico-frontal dysplasias [49]. The number 8 cleft seldom occurs in isolation and usually occurs as a part

of other craniofacial clefts. It corresponds to the cranial occurrence of the No 6 cleft. In bilateral occurrences it is associated with numbers 6 and 7. This shows features similar to the Treacher-Collins and the Goldenhar's disorder with the former showing more skeletal deformities and the latter soft tissue ones [55].

Soft tissue features include [56, 57]:

1. Cleft extends from the lateral canthus to the temporal region.
2. They may present with dermatoceles and colobomas with absence of the lateral canthal apparatus.
3. Abnormal hair patterns may be present between the temporal area and the lateral canthus.
4. Globe may show eye bulbar dermoids.

Skeletal involvement includes [58, 59]:

1. Bony clefting at the fronto-zygomatic suture [58].
2. Features of the Goldenhar's or Treacher-Collins syndromes may be seen with the zygoma being hypoplastic or missing along with the lateral orbital wall [59].
3. The palpebral fissure shows a lateral descent due to the absence of the zygoma.

77.5.1.10 Number 9 Cleft

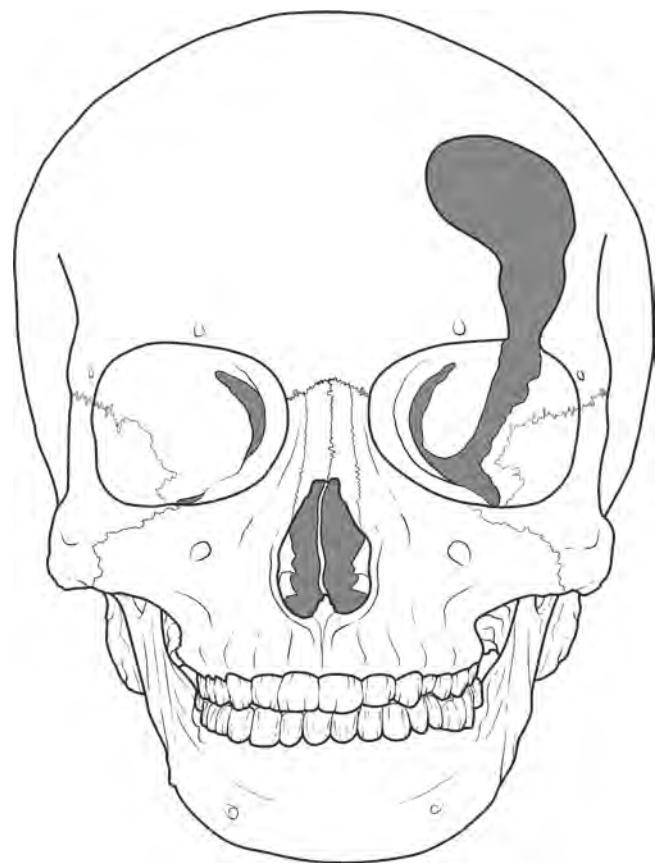No. 9 is a form of the upper "lateral" orbital cleft. The clefting is seen in the lateral third of the upper eyelid and the lateral supra-orbital angle (Fig. 77.14). It is the cranial extension of the number 5 facial cleft [52]. There may be a deficient greater sphenoid wing in this type [60].

Soft tissue involvement shows:

1. Anomalies of the lateral third of the upper eyelid and the eyebrow.
2. Distortion of the lateral canthus.
3. Severe cases show microphthalmia.
4. The superolateral bony deficiency in the orbit may be the cause of lateral displacement of the globes.
5. Anterior displacement of the temporal hairline with temporal projection.
6. Palsy of the 7th cranial nerve with temporal and eyelid signs may be common.

Skeletal involvement:

1. Cleft extending through the superolateral aspect of the orbit.
2. The greater wing of the sphenoid may be distorted affecting morphology of the orbital wall.



©Association of Oral and Maxillofacial Surgeons of India

Fig. 77.14 Tessier number 9

3. Hypoplasia of the pterygoid plates.
4. Decrease in the antero-posterior dimensions of the anterior cranial fossa [35].

77.5.1.11 Number 10 Cleft

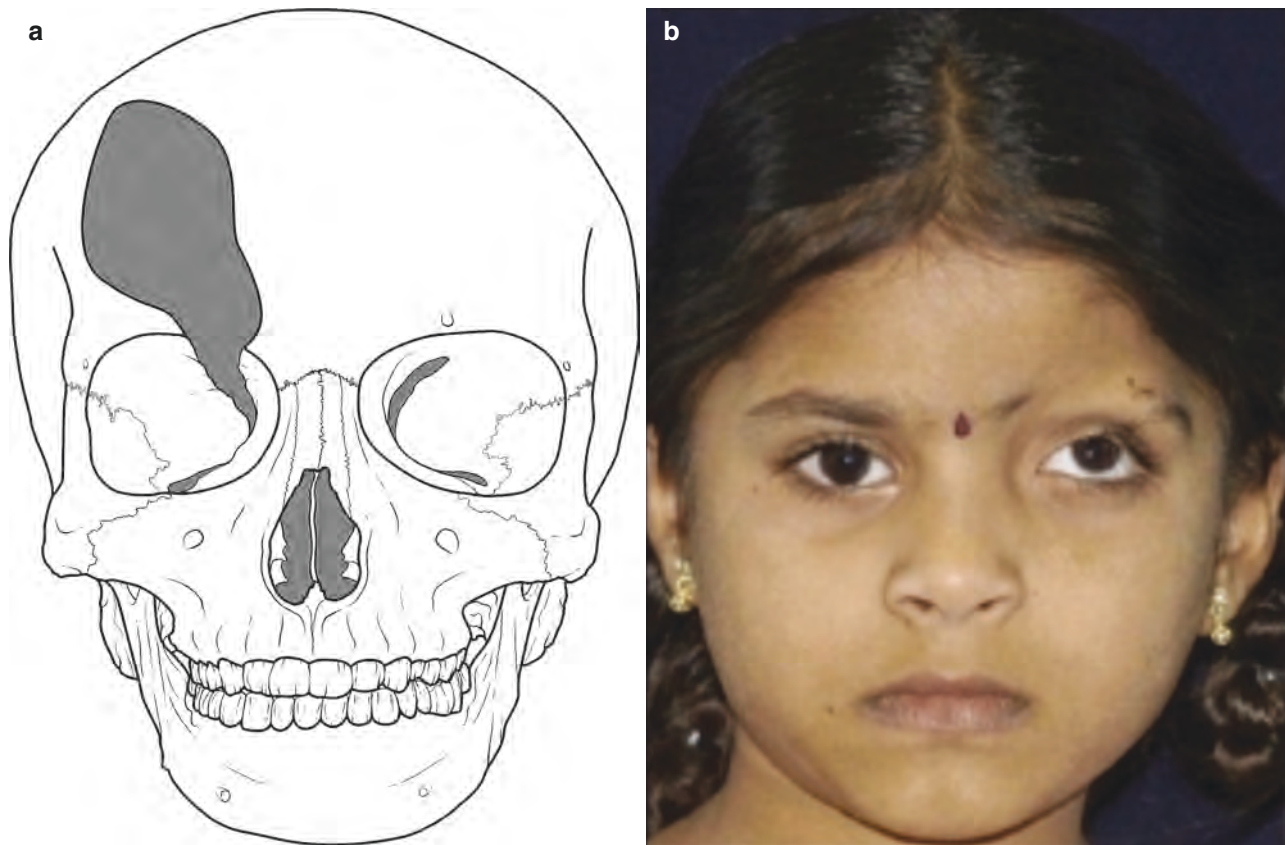
No. 10 is an upper "central" orbital cleft with the cleft happening in the middle third of

the supra-orbital edge, lateral to the supra-orbital nerve (Fig. 77.15a, b) [33]. This is the cranial counterpart of the No 4 cleft. Both present with similar ocular deformities and may show colobomata of the iris [33].

This cleft causes a large defect in the frontal bone [46].

Soft tissue features include:

1. Elongated palpebral fissure
2. Amblyopia with inferior and laterally displaced eye [35]
3. Eyebrow which is deficient medially and is more dispersed laterally [46]
4. Occurrence of frontal encephalocele involving the middle third of the frontal bone and the orbital roof [35]



©Association of Oral and Maxillofacial Surgeons of India

Fig. 77.15 (a, b) Tessier number 10

Skeletal involvement:

1. Cleft defect on the lateral aspect of the supra-orbital rim which may involve an encephalocele.
2. Orbital deformity with a latero-inferior rotation.
3. Orbital hypertelorism may be a feature in severe cases with distortion of the anterior cranial base [35].

77.5.1.12 Number 11 Cleft (Fig. 77.2)

No. 11 is the upper “medial” orbital cleft. This shows coloboma of the medial third of the upper eyelid, with stretching of the eyebrow [33]. This cleft is often associated with the facial cleft No 3 [35]. Van der Meulen incorporated this deformity in his frontal dysplasia group [49].

Soft tissue involvement includes:

1. Coloboma of the upper eyelid in the medial third
2. Disturbance in the upper eyebrow with a tilt toward the frontal hairline
3. Tongue-like projection of the frontal hairline [35]

Skeletal involvement:

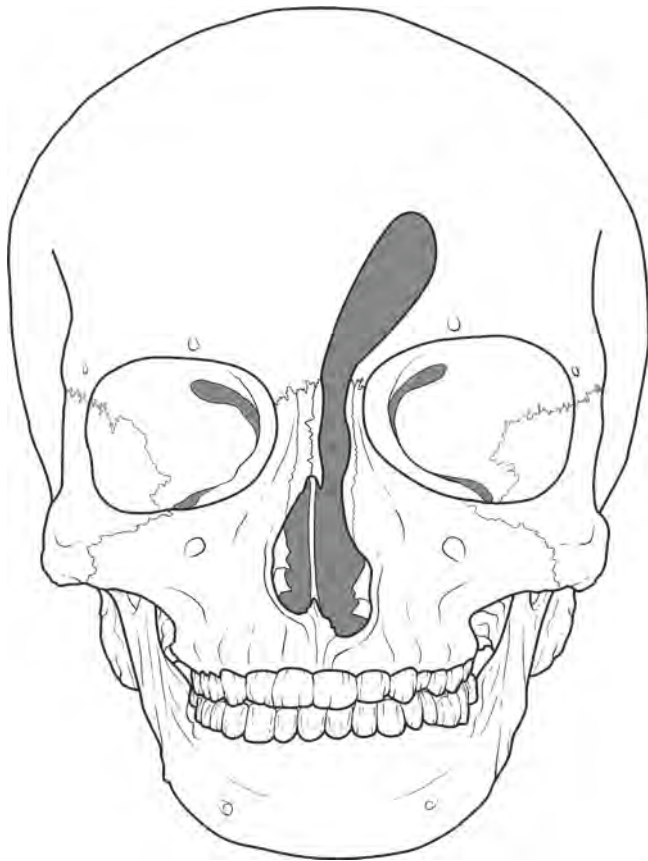
1. Frontal bone defect medial to the supra-orbital nerve and lateral to the ethmoid and lacrimal bones
2. Bony defect of the medial orbit
3. Fronto-ethmoid encephalocele with resultant orbital dystopia
4. Deficiency of the lacrimal bone with associated lacrimal stenosis [46]

77.5.1.13 Number 12 Cleft

The No 12 cleft shows deficiencies in the ethmoid labyrinth and the glabella [46]. This cleft is usually found medial to the medial canthus [35] (Fig. 77.16).

Soft tissue characteristics include:

1. Soft tissue dehiscence medial to the medial canthal apparatus [33]
2. Lateral displacement of the medial canthus with aplasia of the medial eyebrow



©Association of Oral and Maxillofacial Surgeons of India

Fig. 77.16 Tessier number 12

3. Presence of a V-shaped frontal hairline in the paramedial region of the forehead [35]

Skeletal involvement:

1. There is a flattened widening of the affected bone.
2. May present with grades of hypertelorism or telecanthus.
3. Normal sphenoids with mild hyper-pneumatization of the frontal sinus.
4. Obtuse fronto-nasal angle.
5. Low incidence of associated encephaloceles.

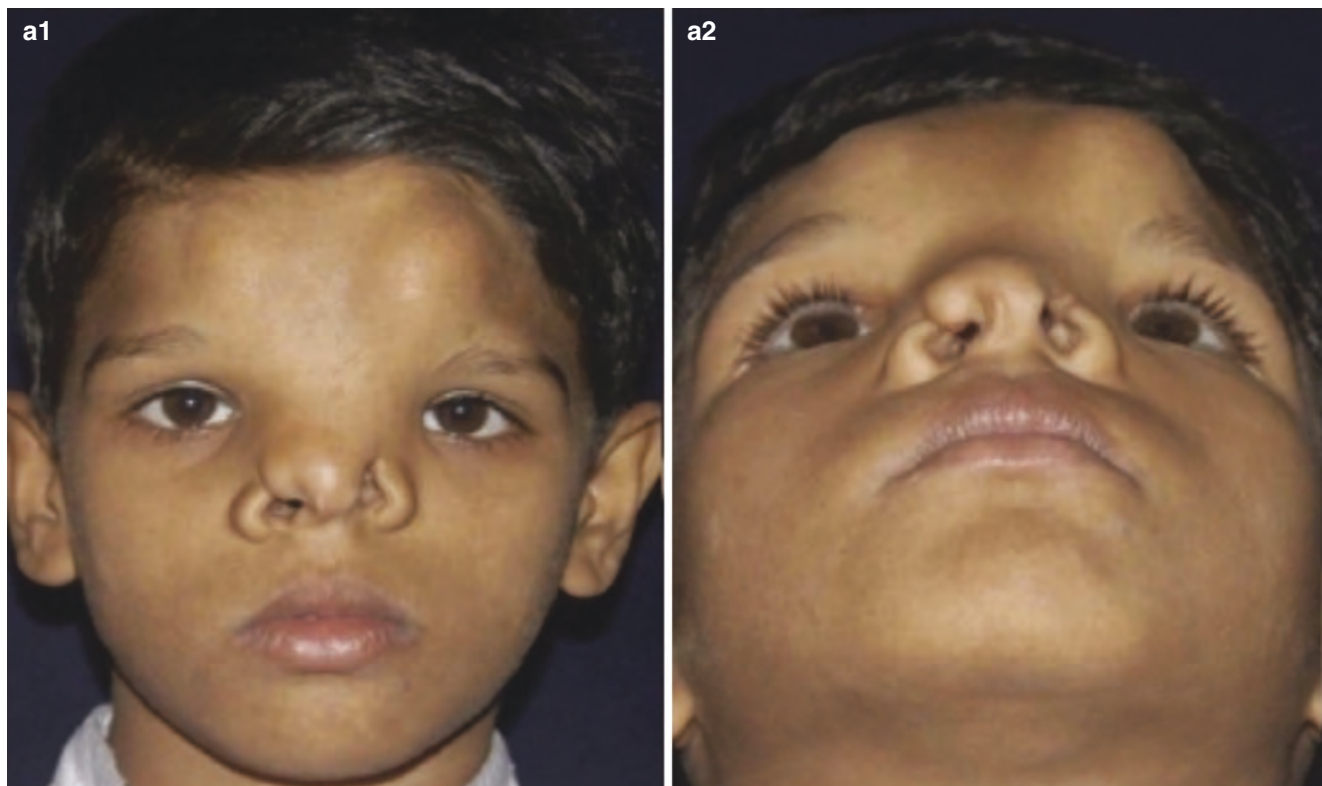77.5.1.14 Number 13 Cleft

The number 13 cleft is the cranial counterpart of the paramedian facial cleft 1.

It is situated between the nasal bone and the frontal process of the maxilla passing through the frontal bones and along the olfactory groove [36] (Fig. 77.17).

Soft tissue characteristics include the following:

1. This occurs medial to the eyebrow which remains undivided [36].
2. The cleft produces a paramedian widows peak [35].
3. The cleft may descend and pass through the intersection of the nasal skin and alar skin and results in an alar cartilage cleft [46].



©Association of Oral and Maxillofacial Surgeons of India

Fig. 77.17 Tessier number 13

Skeletal involvement:

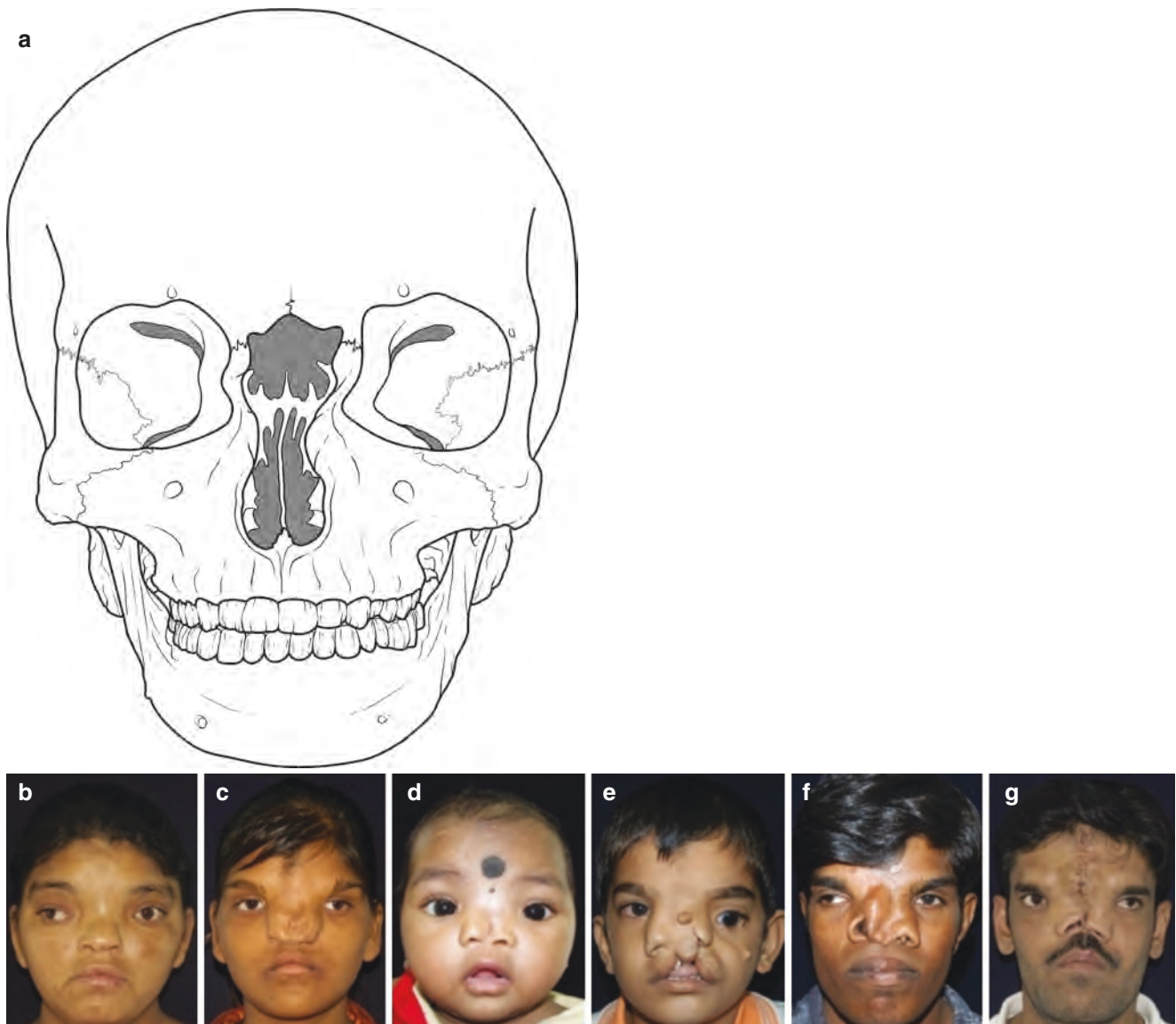
1. Deformities of the medial aspect of the cribriform plate [46].
2. There may be olfactory groove widening with associated widening of the cribriform plate and the ethmoid sinus with resultant hypertelorism.
3. Paramedian frontal encephalocele may cause inferior displacement of the cribriform plate with orbital dystopia.
4. Unilateral and bilateral types of the number 13 cleft exist with bilateral demonstrating the most extreme forms of hypertelorism [4].

77.5.1.15 Number 14 Cleft

No. 14 is the cranial congener of the cleft no. 0, which is the median craniofacial dysrhapia. The terms frontonasal and frontonasothmoid dysplasia were utilized by Van der Meulen for this group of deformities [49] (Fig. 77.18a–g).

Soft tissue characteristics:

1. Severe lateral displacement of the medial canthal apparatus bilaterally.
2. Glabellar flattening.
3. The periorbita including the eyelids and eyebrows is generally normal.



©Association of Oral and Maxillofacial Surgeons of India

Fig. 77.18 (a–g) Tessier number 14 with variable degree of nasal duplication and hypertelorism

4. Midline projection of the frontal hairline [35].
5. There is distortion of the nasal capsule and the developing forebrain stays in a lower position.

Skeletal characteristics:

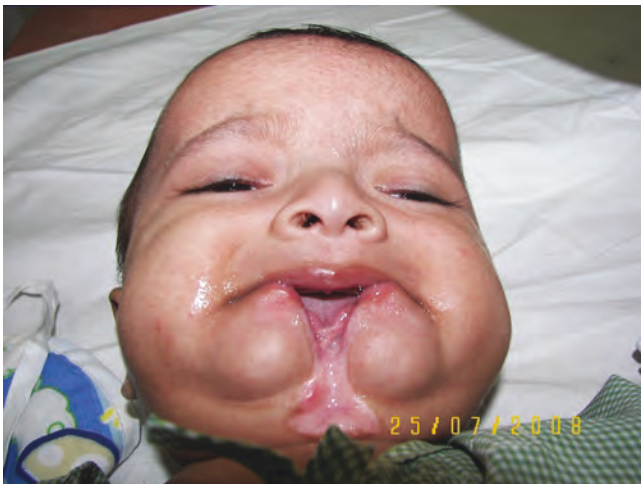1. Severe hypertelorism.
2. Frontal encephalocele may be seen herniating through the midline frontal bone defect.
3. Caudal flattening of the frontal bone is flattened with flattened glabellar region
4. Absence of frontal sinus pneumatization.
5. The crista galli and the perpendicular plate of the ethmoid are bifid, and there is an expanded separation between the olfactory grooves [35].
6. The crista galli and ethmoids are widened with caudal dislodgement.
7. There may be a shortening of the middle cranial fossa.
8. The anterior cranial fossa is tilted upward, producing a harlequin eye disfigurement on plain radiographs [35].

77.5.1.16 Number 30 Cleft

Tessier 30 cleft otherwise known as lower midline facial cleft or median mandibular cleft is a rarity (Fig. 77.19). Median cleft of the lower jaw was first described in 1819 by Couronne [30].

It is generally constrained to a deformity in the soft tissue of the lower lip.

In its severe form, it may groove or split the mandibular symphysis and at times involve the midline structures of the



©Association of Oral and Maxillofacial Surgeons of India

Fig. 77.19 Tessier no 30

neck including the hyoid bone, the thyroid, and even the strap muscles. The anterior part of the tongue may be bifid, showing ankyloglossia [54], with one case of absence of tongue being reported [55].

77.6 Treatment of Craniofacial Clefts

Surgery for facial deformities involves the best balance of art and science. The restoration of the malformed anatomy requires artistic creativity, while the science lies in the reestablishment of impaired function [57].

From a careful perspective, even microform clefts might deform. Contingent upon the level of distortion, an arranged strategy has been viewed as the treatment of choice [58]. Due to their multifaceted nature; the individual level of cleft involves successful reconstruction and the rehabilitation in practically every one of the cases request multistep and multi-proficient procedure [59]. Besides cautious examination, imaging methods are important to evaluate the individual level of skeletal inclusion. For correct determination current imaging frameworks seen in systems, for example, CT, MRI, and 3D CT, permit better preoperative comprehension of the issue and planning of the surgeries. Analysis ought to be founded on a classification relying upon the site and types of defects (morphology) which helps in foundation of a legitimate treatment plan [60] (Figs. 77.20, 77.21, and 77.22a–e).

Institutionalized treatment plans are not constantly conceivable in light of the assortment of craniofacial clefts and dimensions of seriousness. Be that as it may, core values are useful in deciding the best possible planning and stages for restorative surgery [30]. The Australian Craniofacial Unit Treatment Protocol, which is a pioneering center with international acclaim, has recommended the following:

- Early repair of the soft tissue defects and preventing exposure keratitis
- Orthodontic intervention interceptive orthodontics and speech therapy for the school-going years (4–10 years)
- Reconstruction of the orbital floor, orthognathic surgery, and rhinoplasty to be done after growth completion [30]

77.6.1 Tessier No. 0–14 Cleft

Literature reveals that the midline Tessier 0 and 14 clefts are among the most common encountered [5], while the combination of 0 and 14 is the most common combination of non-isolated clefts [61].

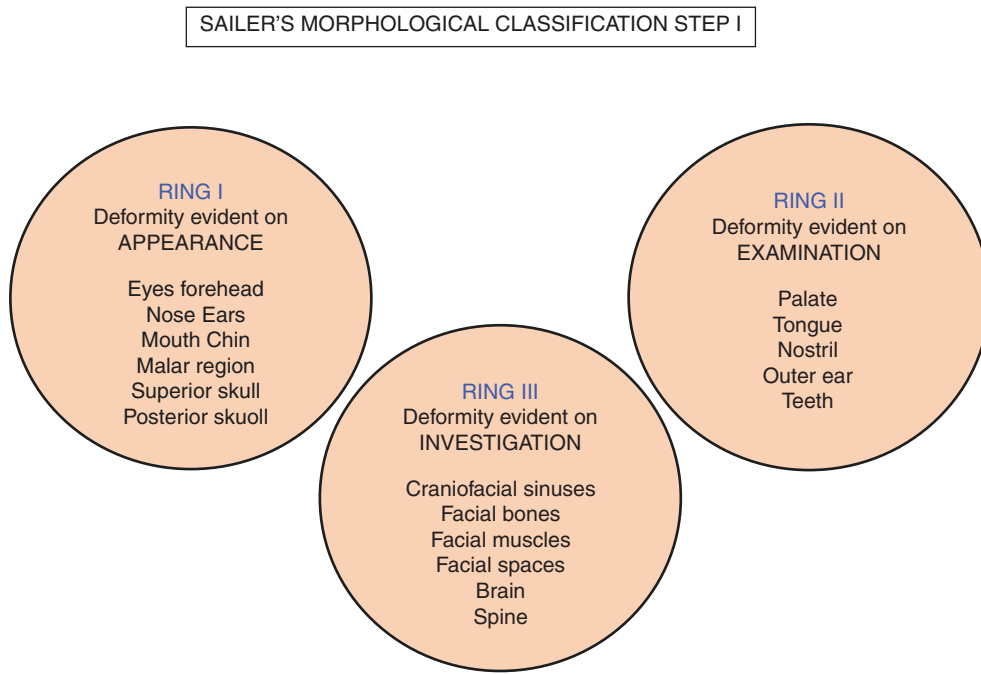
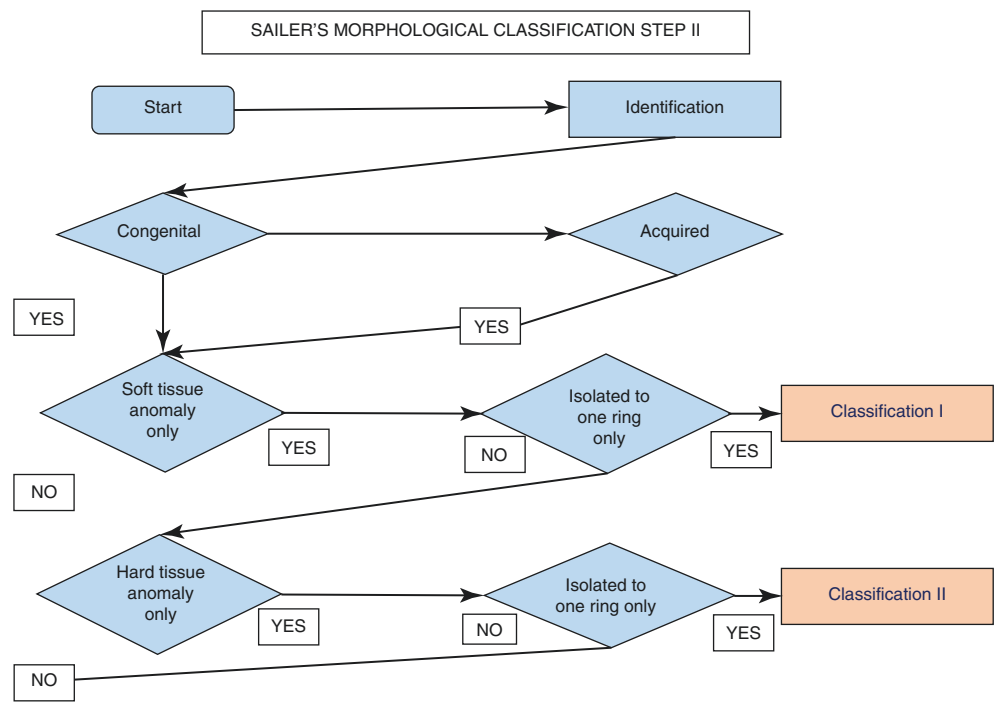
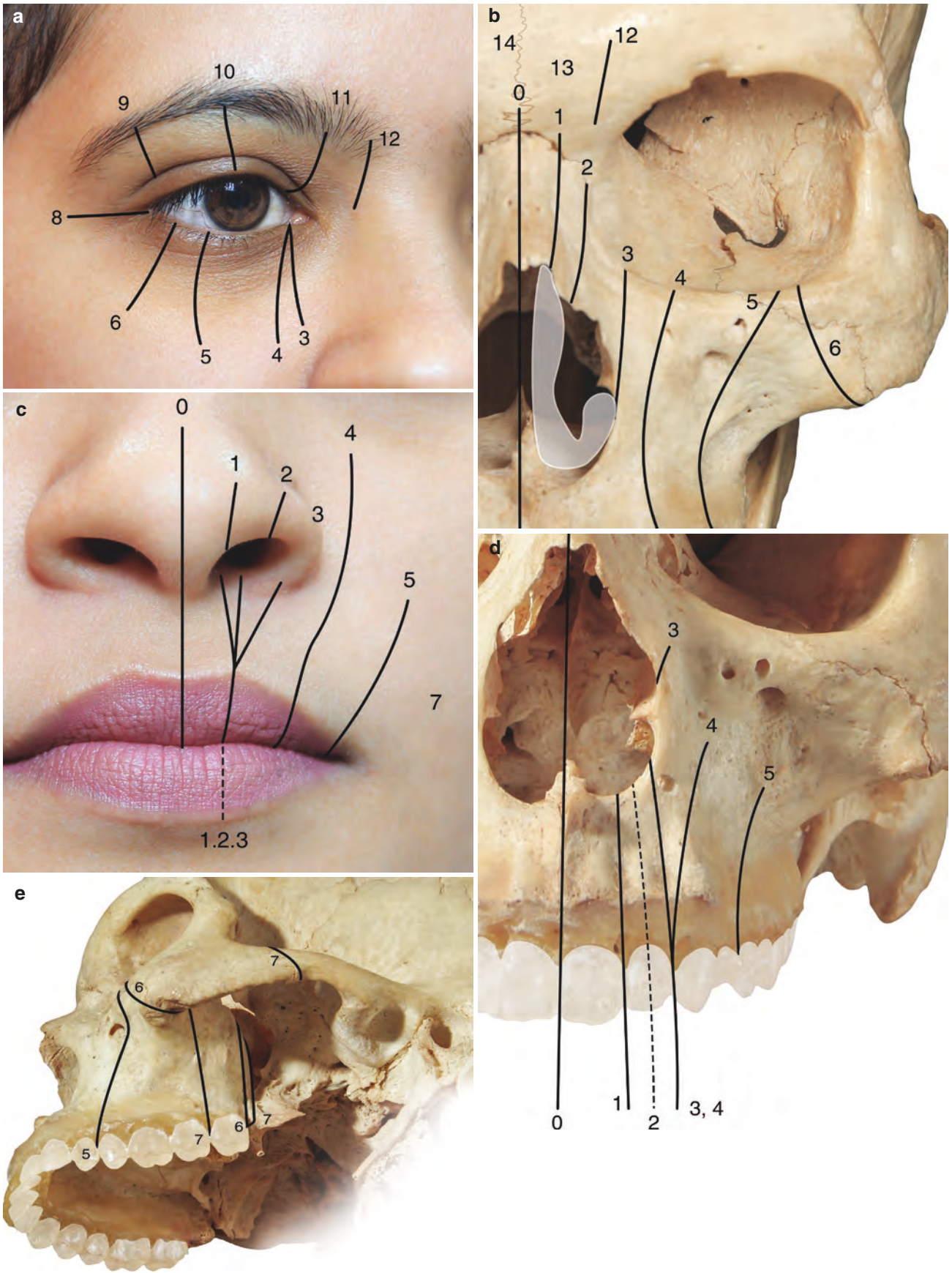


Fig. 77.20 Sailer's morphological classification step I

Fig. 77.21 Sailer's morphological classification step II





©Association of Oral and Maxillofacial Surgeons of India

Fig. 77.22 (a-e) Anatomical classification of facial, craniocalvarial clefting

The most commonly adapted protocol for Tessier no. 0–14 is modified from surgical protocol for midline Tessier 0–14 craniofacial clefts (David 2006) (Fig. 77.23).

As per Sailer's morphological classification, Tessier 0–14 clefts involve:

- (i) The medial orbital zone
- (ii) The zone of the maxilla, oral cavity, and lips
- (iii) The zone of the nose

Treatment is generally formulated based on the degree of involvement of these zones (Figs. 77.20 and 77.21).

77.6.2 The Orbital Zone and Skull Bone Defect

77.6.2.1 Resection of Encephalocele

An encephalocele is a herniation of a part of the cerebral matter through a deformity in the skull. This may contain meninges (meningocele), or meninges, cerebrum, and ventricle (meningoencephalocystocele) [61].

Tessier no. 0–14 is most generally connected with frontoethmoidal gathering of encephaloceles group which can be subdivided into nasofrontal, nasoethmoidal, and nasoorbital types.

The objectives of repair involve:

1. Meticulous repair of skin deformities. This helps prevent contamination and desiccation of brain tissue.

2. Water-tight dural repair with removal or invagination of the non-functional brain tissue which is present extra-cranially.
3. Complete craniofacial reconstruction of skeletal components. Care taken to prevent appearance of a long nose [62].

77.6.3 Orbital Hypertelorism

Hypertelorism is the most common indication for major craniofacial correction in a Tessier 0–14. Treatment strategies are varied and range from medialization of the medial wall of the orbits to total repositioning of the orbital and facial bipartition [63]. Hypertelorism is a physical finding in many craniofacial malformations, which is characterized by an increase in interorbital distance. It may be a part of a syndrome but it is not a syndrome by itself.

In 1924, Greig called orbital hypertelorism as “ox-eyed” and also coined the term “ocular hypertelorism” [64]. The more accurate term of “orbital hypertelorism” to denote true lateralization of the orbital complex was coined by Tessier in 1972 [65]. Tessier classified hypertelorism into three degrees based on the interorbital distance [65, 66] (Fig. 77.24).

77.6.3.1 En Bloc Osteotomies (Fig. 77.25a–d)

Radical mobilization of the orbits to correct increased interorbital distance is one of the most challenging procedures in craniofacial surgery [67].

Paul Tessier was the first to perform orbital mobilization using a trans-cranial approach [53]. This surgical intervention was planned to eliminate undue risk to the

Fig. 77.23 Surgical protocol for midline Tessier 0–14 craniofacial clefts

Adapted Surgical Protocol for Midline 0–14 Tessier Craniofacial Clefts (David, 2006) [16, 17]

Birth to 1 year

- Preserve the essential functions of the airway, feeding, sight, and; hearing
- Repair any encephaloceles
- Craniosynostosis correction by fronto-orbital advancement at 3–6 months

5 years

- Orbital box osteotomy once the tooth buds can be reliably preserved
- As an alternative, a medial faciotomy (facial bipartition) can be performed slightly later
- Possible use of tissue expanders beneath the zygomatic periosteum in extreme hypertelorism
- Temporary nasad reconstruction, as this will not be repeated later

5 to 10 years

- Orthodontic management is commenced when enough permanent teeth are present
- Alveolar bone grafting is carried out to correct the more extensive defects in the maxilla that may to present

10 years until the completion of growth

- Maintenance of the orthodontic therapy with retainers
- Further preservation of the eyes and hearing if required

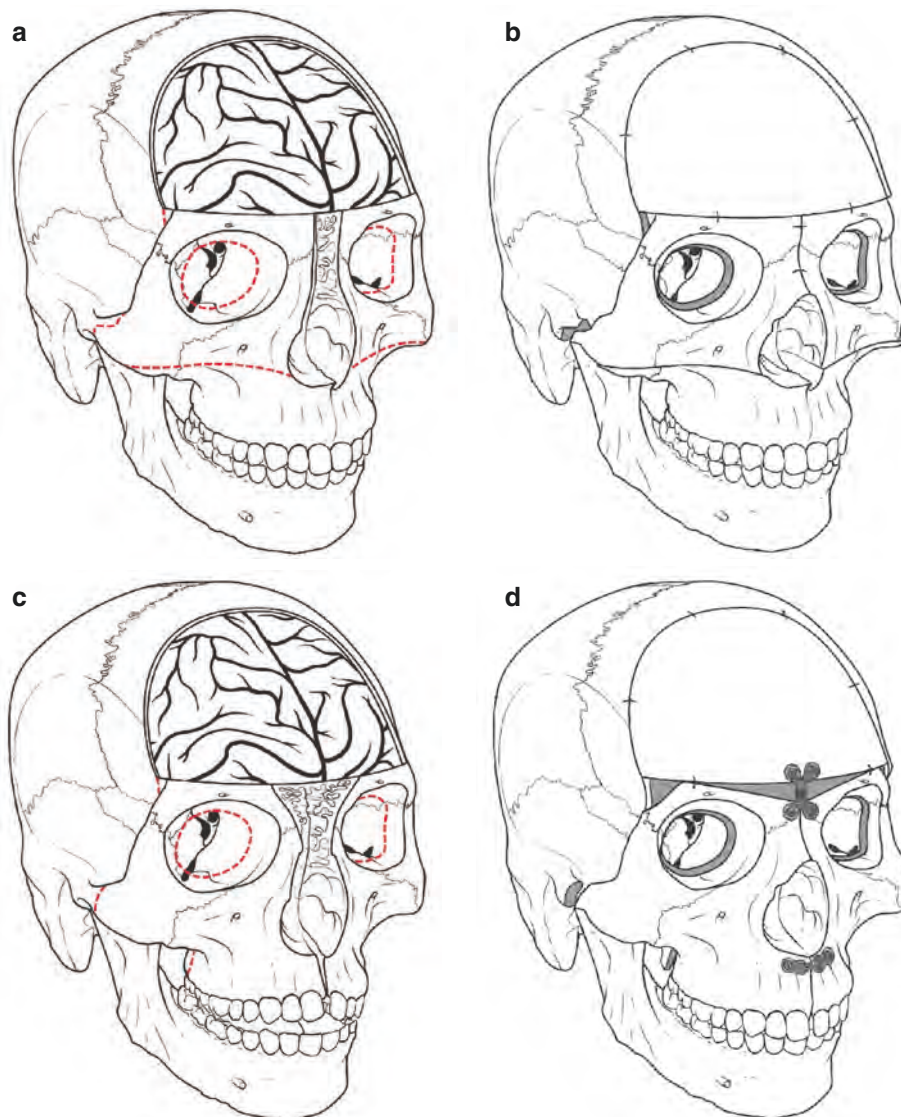
Completion of growth

- Orthodontic preparation for midface surgery
- Midface surgery performed at any level, with or without bone grafting/mandibuloar surgery depending on need
- After establishment of the facial platform, platform, definitive nasal reconstruction is performed
- Further secondary surgery is performed if necessary

HYPERTELORISM		
Degree		Interorbital distance (mm)
I.	Slight	30 to 34
II.	Moderate	35 to 39
III.	Severe	40 +

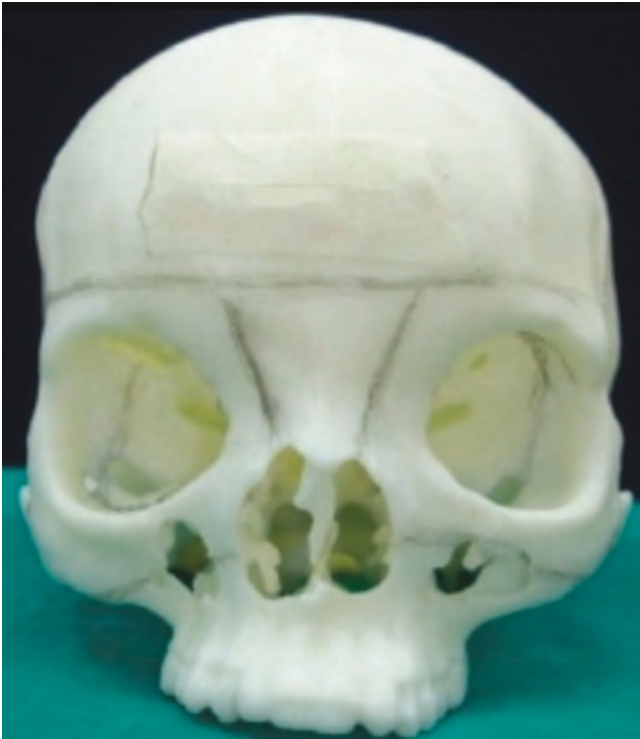Fig. 77.24 Hypertelorism

optic nerve [65]. Converse described in 1968 preservation of the olfactory nerves by performing subcranial U-shaped osteotomy [68]. Schmid described the extra-cranial circumferential orbital osteotomies for medializing the orbits [68], while Jacques van der Meulen described the facial bipartition in 1983 [69]. Medialization of the medial orbital walls and hemifacial rotation do not interrupt mid-facial growth and thus were performed before age 5 in the majority of patients. Orbital translocation causes growth disturbances and thus is to be performed after attaining skeletal maturity [63].



©Association of Oral and Maxillofacial Surgeons of India

Fig. 77.25 En bloc osteotomies (a–d)



©Association of Oral and Maxillofacial Surgeons of India

Fig. 77.26 Stereolithographic models—simulation

Pre-op Evaluation

Pre-op evaluation for orbital hypertelorism includes the following:

External facial measurements

Dental casts

Posteroanterior x-ray cephalometry [70]

Modern aids like computed tomographic scan

Three-dimensional imaging and stereolithographic models [71] (Fig. 77.26)

Facial Bipartition

The facial bipartition procedure involves the mobilization and rotation of the entire midface in a monobloc fashion (Fig. 77.27a, b). The osteotomy involves the supra-orbital rims first. It is then continued along the lateral orbital walls in a similar fashion to the LeFort 3 osteotomy and is dropped caudally to involve the dentate segment also in the mobilized segment. The intra-orbital circumferential osteotomies are performed using a combined trans-cranial and trans-facial approach once the hemifacial segments are mobilized, the intervening ethmoids are resected creating space for the upper face to be rotated medially. This causes the maxillary dentate segment and the palate to have a lateral rotation increasing the transverse dimension of the face and correct-

ing the palatal crossbite of the upper posterior teeth. This procedure can also be combined with an advancement of the midface complex by combining it with a LeFort 3 type modification [72].

77.6.3.2 Box Osteotomy (Fig. 77.28a–d)

Correction of orbital hypertelorism done using a box osteotomy may include corrections of associated nasal deformities. Bone and cartilage grafts may be necessary to provide nasal framework. Skin grafts may be required for nasal coverage and may be accomplished by local flaps. The box osteotomy is generally preferred when the dental occlusion is normal.

Van den Elzen et al. (2011) advocated waiting until after age 10 (after eruption of permanent dentition) to perform orbital box osteotomy. Monasterio and Taylor [61] supported the use of orbital translocation after skeletal maturity and have stated that early intervention retards midfacial growth. Tessier (1973) noted that neuro-ophthalmological benefit was increased by correcting hypertelorism at 3 years and psychosocial benefit was heightened by operating at 6 years, before schooling begins, or after 12 years to preserve the dentition. Marchac et al. (1999) also described the use of box osteotomies after 12 years of age.

77.6.3.3 Spectacle Osteotomy (Fig. 77.29a–e)

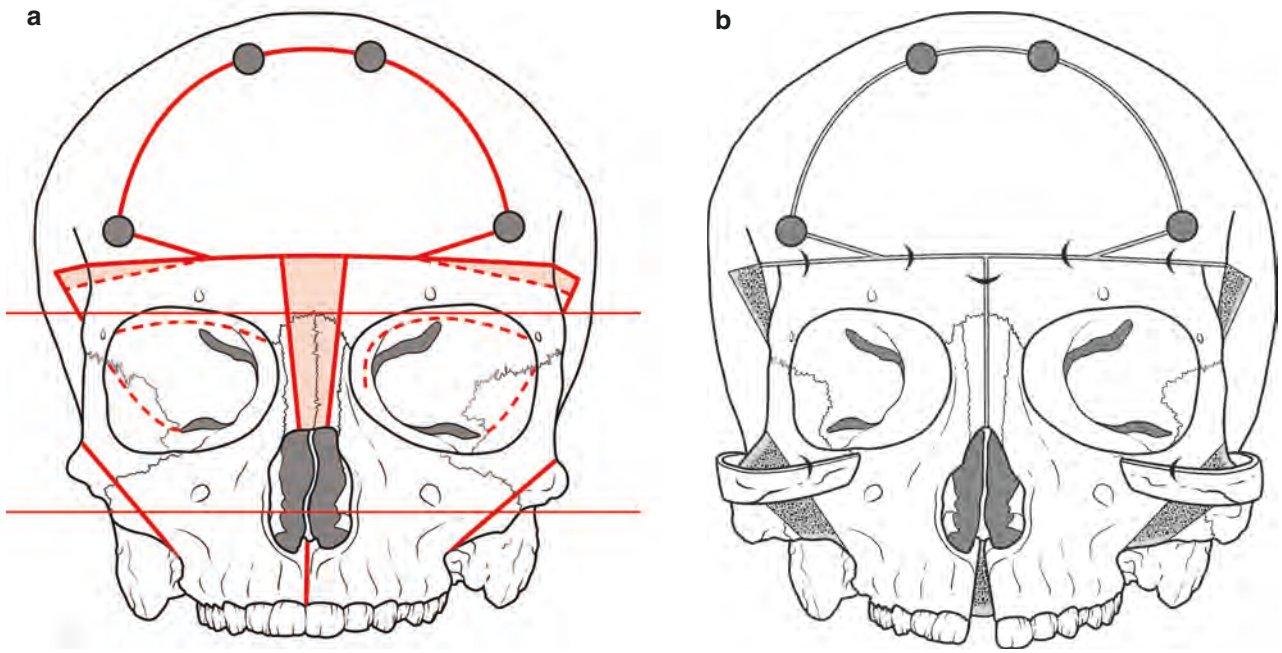
The spectacle osteotomy is done by performing the trans-frontal craniotomy and preservation of frontal bandeau along with trimming of the bone in the periorbital region and around the pyriform aperture with *medialization* of the orbits.

A lateral canthopexy is an integral part of this procedure [48]. The medial canthi should be recognized and anchored using trans-nasal wires. At times this is performed with a mini-plate anchor for orienting the wires in the right direction [72]. The plate is secured to the thick nasal bone, and the lower hole is kept at the level of the lacrimal crest. The canthi are independently fixed to these holes bilaterally utilizing steel wires (Also refer Chap. 79 on craniofacial syndromes) [73].

77.6.3.4 Soft Tissue Management

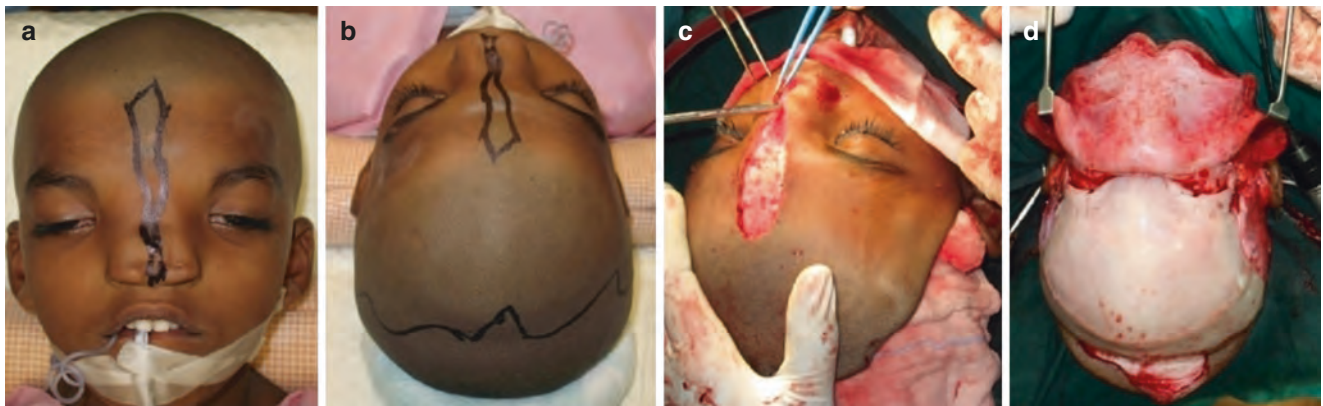
The midline cleft lip notch can be successfully treated by holding fast to three noteworthy standards (Fig. 77.30a, b):

1. Excision of the constrictive band on the lip
2. Approximation of the split orbicularis oris muscle at the midline
3. Mucosal lengthening using “Z”-plasties [36, 42, 74–76]



©Association of Oral and Maxillofacial Surgeons of India

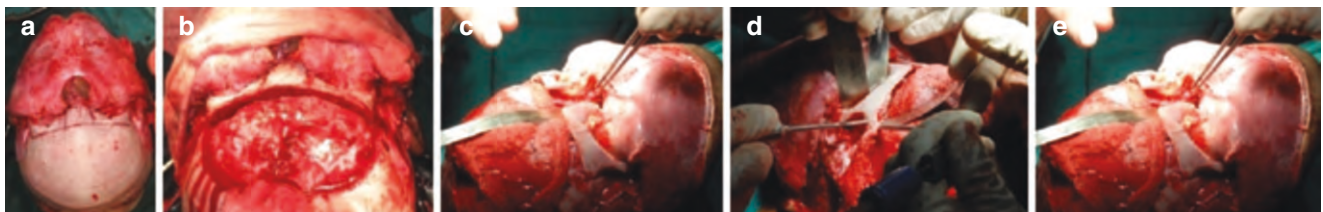
Fig. 77.27 (a, b) Facial bipartition



©Association of Oral and Maxillofacial Surgeons of India

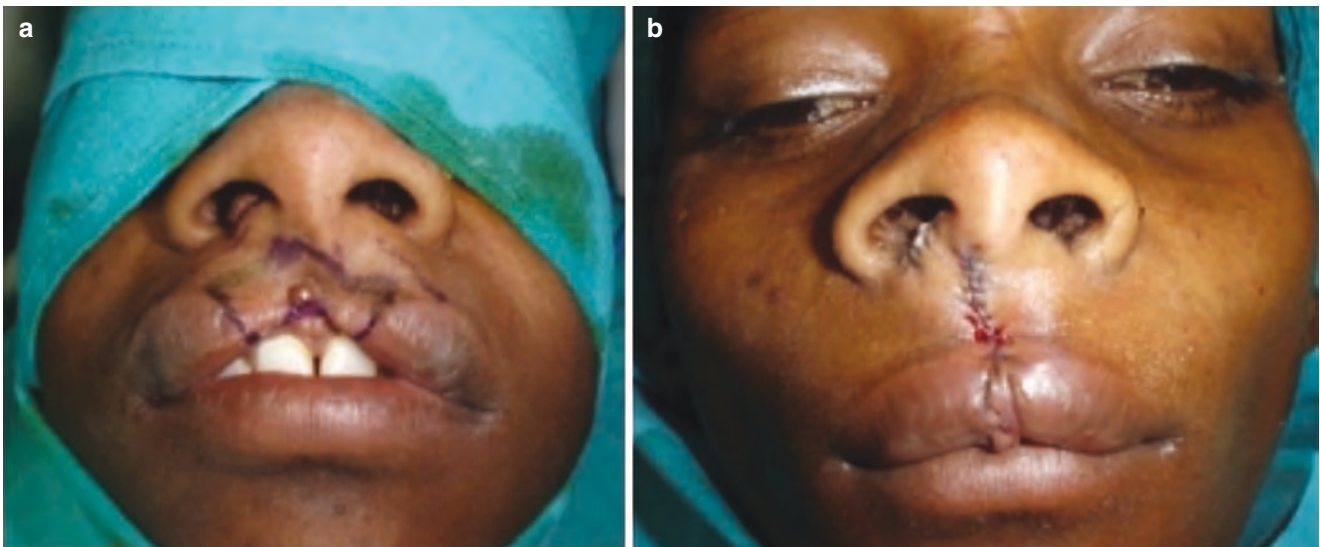
Fig. 77.28 (a–d) Box osteotomy—skin incision for the intracranial correction of the orbital hypertelorism consists of bicoronal incision, transfrontal craniotomy sparing the frontal bar, periorbital osteotomy,

block bone removed near pyriform area, calvarial bone graft, miniplate fixation and closure



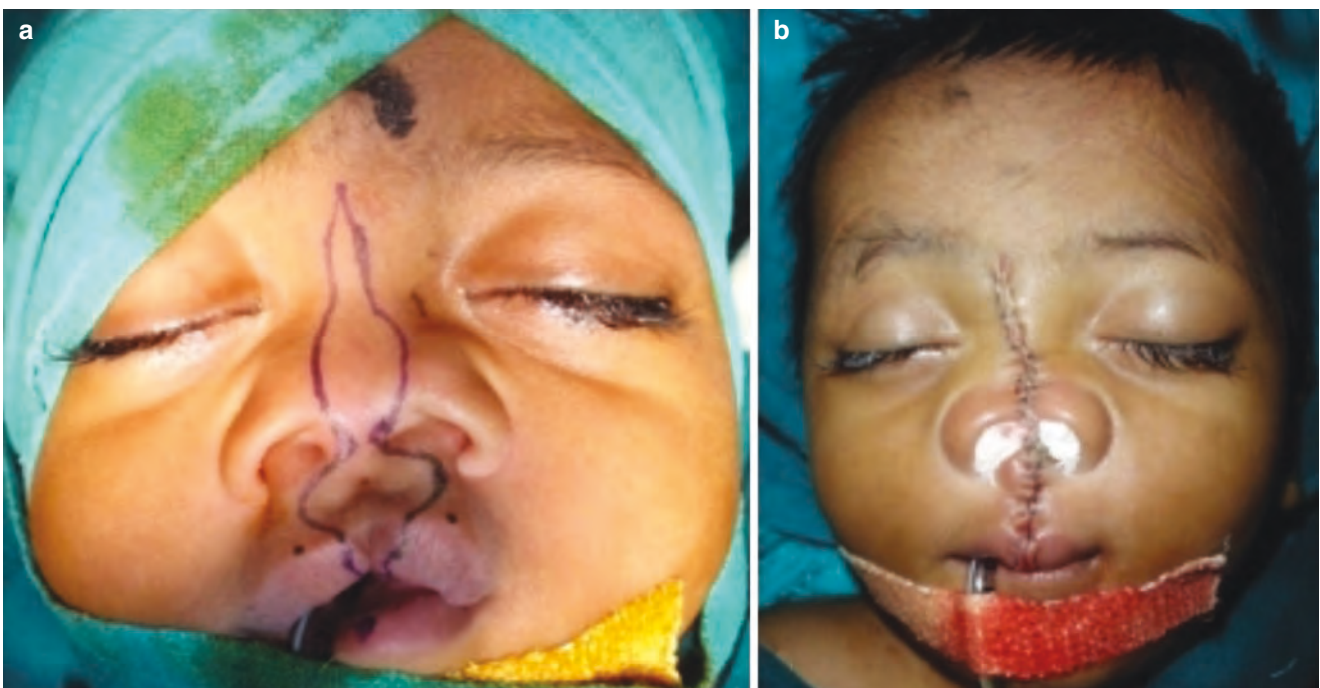©Association of Oral and Maxillofacial Surgeons of India

Fig. 77.29 (a–e) Spectacle osteotomy



©Association of Oral and Maxillofacial Surgeons of India

Fig. 77.30 (a, b) Reconstruction of Cupid's bow and philtrum



©Association of Oral and Maxillofacial Surgeons of India

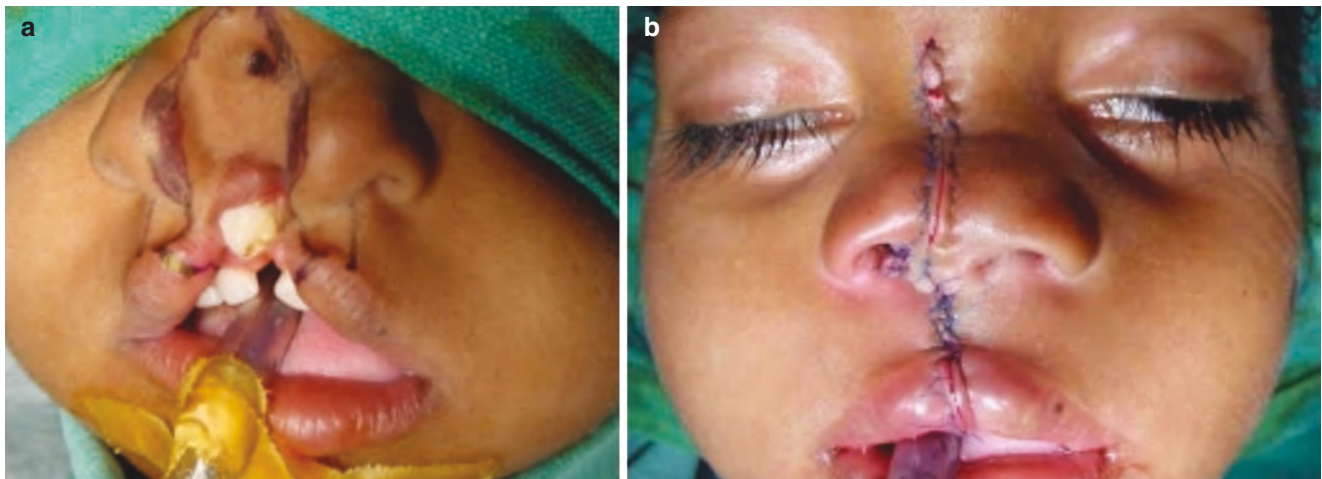Fig. 77.31 (a, b) Resection of the excess skin of the nasal dorsum and closing in the midline

In managing the 0–14 cleft, the clinician should be able to diagnose if it is a true or a pseudo occurrence. In cases of a true midline cleft, care should be taken to reconstitute the important components of the lip, external nose, and nasal septum. Resection of excess skin also needs to be planned and performed [36] (Figs. 77.31a, b and 77.32a, b).

Nasal Clefts

Nasal clefts include Tessier no. 2 and Tessier no. 3 clefts.

Principles of surgical management (Fig. 77.33). Because of their rarity and extreme variability, it is not surprising that *standardized* methods of correction have not been established for patients with nasal clefts. Therefore, each case



©Association of Oral and Maxillofacial Surgeons of India

Fig. 77.32 (a, b) Reconstruction of the lip and resection of the excess skin of the nasal dorsum and closing in the midline

Principles of Management of Complex Nasal Clefts

- Precise Clinical and Radiographic Diagnosis
- Physical examination
- CT/MRI

Inventory of Nasal Components

- Skin
- support
 - Cartilage
 - Bone
- Lining
- Staged Reconstruction
- First things first
- Do not burn bridges
- Replace Like with Like
- Re-establish Nasal/Facial Esthetics

Fig. 77.33 Principles of management of complex nasal clefts

must be approached on an individual basis using the basic principles of nasal reconstruction as a foundation.

The fundamental principles and techniques of nasal reconstruction are to assess what is present, what is missing, utilization of available tissue, and importing required tissue as indicated by the deformity.

Inventory of Nasal Components

Each component of the nose, skin, lining, and support (bony and cartilaginous), must be evaluated in a quantitative and qualitative manner. The quality and quantity of external skin and nasal lining are evaluated for deficiency or excess. The integrity of the cartilaginous framework, nasal septum, has to be assessed.

Staged Reconstruction

Patients with complex craniofacial clefts frequently require multiple staged reconstructive procedures. Planning of these procedures must be tailor-made to each patient. Surgical stages must be planned and executed with all subsequent surgical sessions clearly in mind.

Replace Like with Like

Whenever possible absent or deformed tissue should be replaced with identical or similar autogenous material.

Bony defects may be present along the cleft from the alveolus to the orbit. It is essential to reestablish a stable anatomic bony base to ensure adequate support for the soft tissue reconstruction of the nose and orbit. Autogenous split calvarial, rib, and iliac graft are the general preferences.

Cartilage

Free cartilage grafts alone may often suffice to correct small deficiencies of the alar rim, nasal rim, nasal dorsum, or tip. Larger defects of the upper and lower lateral cartilages can be replaced using conchal or septal cartilage grafts. Thin bone from the perpendicular plate of the ethmoid can be used to replace upper lateral cartilage.

Small composite chondro-cutaneous grafts from the concha can be used to replace small defects if additional lining is needed. For larger cartilage defects in the area of the upper laterals, septal hinge flaps can be used. Reconstruction of lower lateral cartilage can be accomplished using conchal cartilages or chondromucosal grafts from nasal septum.

Nasal Lining

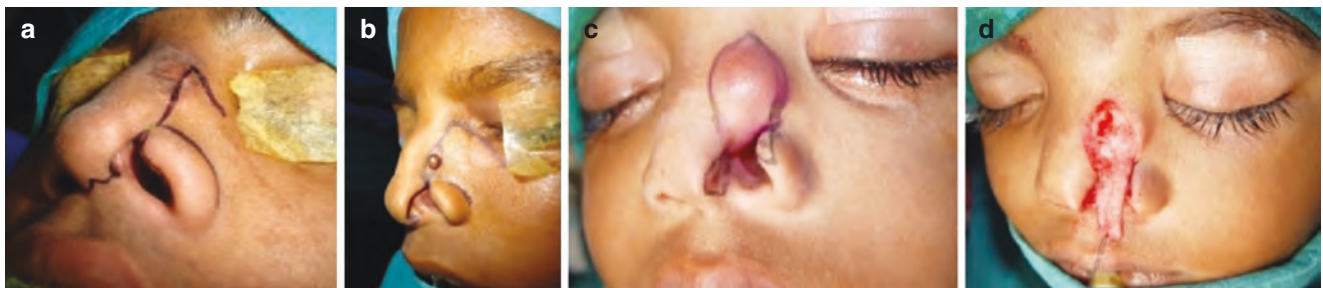Adequate lining to the nose is critical to achieve a functional and predictable aesthetic result. This is also essential to reestablish vascularity to the underlying tissue and to minimize contracture of the soft tissues. Local turnover flaps are useful for small defects, while larger defects may require vascularized tissue transfer.

Skin

Small nasal clefts are amenable with local tissue transfer in the form of rotation flaps from the lateral nasal area. Onus in simple nasal clefts is given to the reestablishment of the alar rim contour [68]. The use of z-plasty techniques and composite grafts helps in achieving additional symmetry [77].

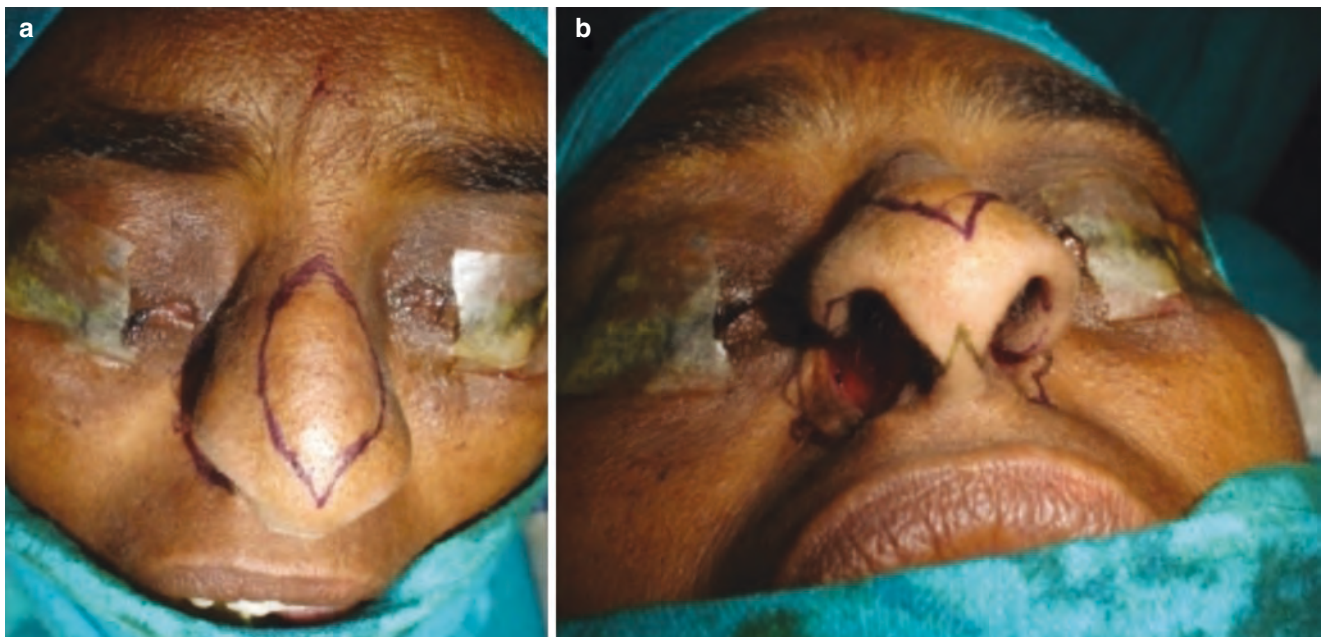Downward rotation of the cephalically displaced alar rim is the first step in this process. This may require the use of a back cut to rotate the alar margin caudally. The triangular defect produced by the alar rotation is then filled by a transposition flap from adjacent areas having excess skin [78, 79].

Descriptions of a nasal dorsal rotation flap (Figs. 77.34a–d and 77.35a, b) for a Tessier 2 cleft and a brow-eyelid-nasal transposition flap for a Tessier 3 are predictable techniques [80].



©Association of Oral and Maxillofacial Surgeons of India

Fig. 77.34 (a–d) Design for bilateral Tessier no. 3 cleft—nasal dorsum rotational flap



©Association of Oral and Maxillofacial Surgeons of India

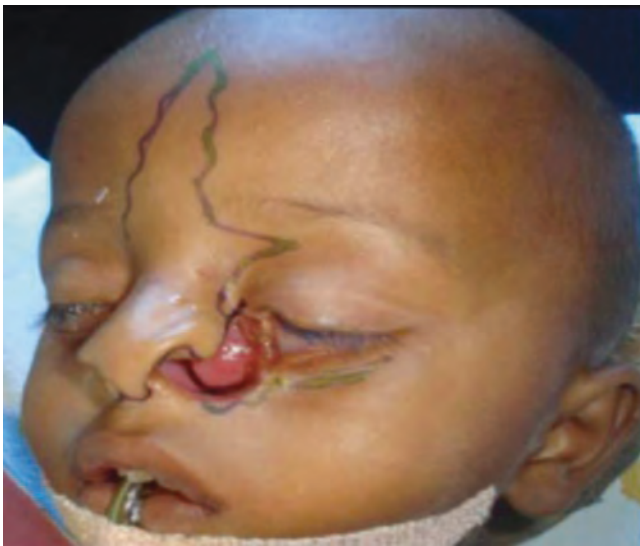Fig. 77.35 (a, b) Nasal dorsum rotational flap

The nasal dorsum rotational flap design to correct Tessier no. 2 clefts improves alar symmetry at the cost of reduced nostril size. A notch on the affected ala is a major problem to handle in this technique [80, 81].

The forehead-eyelid-nasal transposition flap (Fig. 77.36) technique involves the use of an inter-eyebrow-forehead flap which is pedicled on the tissue of the nasal bridge. The rotation achieved by the flap gives both the alar and nostril symmetry while reducing the need for revision [80].

Reestablish Nasal/Facial Aesthetics

Optimal reconstruction of the nose should be based on the principle of aesthetic subunits as described by Gonzalez-Ulloa and Castillo (1954) and refined by Burget and Menick



©Association of Oral and Maxillofacial Surgeons of India

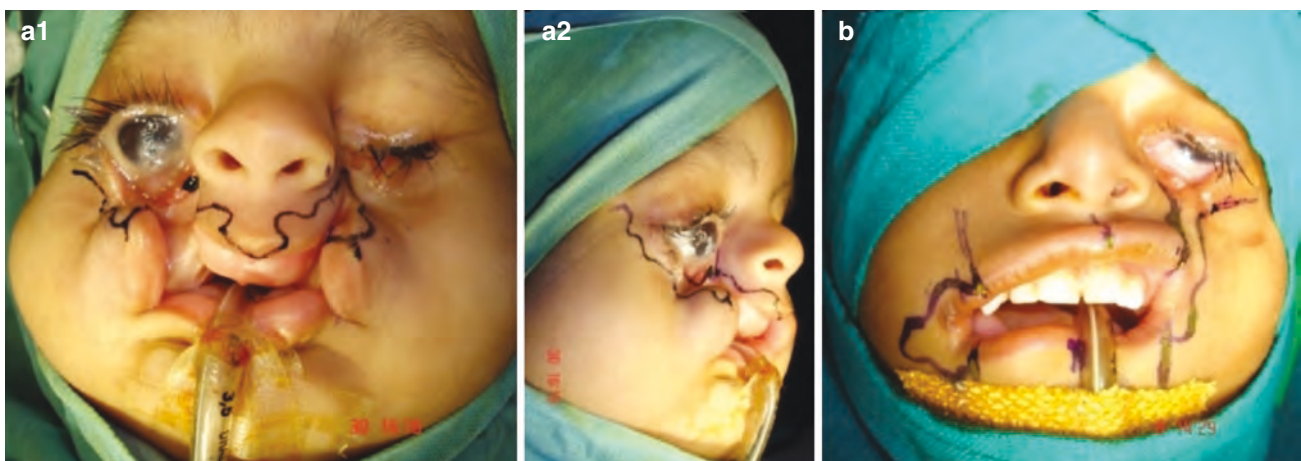
Fig. 77.36 Forehead-eyelid-nasal transposition flap

(1985). Superior results are better achieved by replacing the entire subunit of the nose rather than simply patching the defect. The achievement of the nasal proportions should be in conjunction with facial proportions though there are many aesthetic and surgical limitations because of associated severe craniofacial deformities. Definitive nasal reconstruction may need to be delayed or staged as explained, until optimal canthal, orbital, and maxillary relationships are obtained.

77.6.4 Tessier No. 4 (Fig. 77.37a, b)

Tessier no. 4 cleft is a rare, complex malformation which has severe implications on both the soft tissue and skeletal structures of the face. As a general rule, priority needs to be given for reconstructing the soft tissue envelop, and the skeletal repair should in the form of osteotomies or bone grafting procedures need to be deferred until the school-going years. This is due to the fact that early intervention to the bony skeleton may hinder the development of the midface and associated (Resnick and Kawamoto 1990; Kawamoto and Patel 1998) [76].

An important clinical indication that necessitates emergency intervention is exposure keratitis of the cornea and resultant blindness. This depends on the gravity of the cleft deformity. In narrow cases of Tessier 4 cleft, the clefting is more toward the medial side of the orbit which retains a large bony component of the lateral orbit. This lends support to the globe and enables reasonable competence of the upper eyelid to cover the cornea. In such instances the early surgical intervention may be avoided [82]. On the other hand in severe cases, there is total absence of the orbital floor causing the globe to sink downward with the cornea facing upward due to a lax supporting structure. This prevents the upper



©Association of Oral and Maxillofacial Surgeons of India

Fig. 77.37 (a) Incision for bilateral Tessier no. 4 (b) unilateral tessier 4 on left side with tessier 7 on right side

eyelid from being able to protect the cornea, with the resultant problem of exposure keratitis and permanent corneal damage. Such instances produce an emergency, and a repair of the orbital support system is mandated. In cases where an early intervention is not possible due to medical and anesthetic implications, emergency intervention at least in the form of a tarsorrhaphy is performed within 2–4 days of birth.

While treating severe deformities like the Tessier no. 3 and Tessier no. 4 clefts, a “split method” of management can be utilized to handle the anatomical regions individually as given below [83].

The affected regions were divided into three segments:

1. Lid segment
2. Lip segment
3. Nasomalar segment

77.6.4.1 Managing the Lid Segment

An ectropion like deformity is commonly present. This can be managed using conventional techniques. They include (a) a back-cut release of the lower eyelid to cheek junction and medial advancement of the lower eyelid with medial canthopexy, (b) lower lid resection with inferior layered tarsal strip, or augmentation of the tarsal plate with spacer grafts. However in cases where there is inadequate tissue locally, tissue must be imported into the lower eyelid for optimal results [83]. Some of the commonly used flaps for this include the median forehead flap and the nasolabial flap. However, free vascularized tissue transfer techniques also may be adopted [84].

Numerous techniques have been described for the management of the Tessier 4 cleft. But most of them result due to the interdigitating scars produce a sub-optimal outcome [33] (Tessier 1976; Kawamoto 1990). Longaker et al. (1997) proposed the superiorly based nasolabial flap that was transposed to the lower eyelid. Though this technique had an advantage cosmetically, it had that limitation that it was useful only for mild forms of the cleft. The cheek advancement technique described by Van der Meulen [4] had the advantages of being useful even for wider clefts and favorable scars along aesthetic facial subunits. Van der Meulen likewise depicted that it was significant for improving the scarring caused by anchoring the cheek flap firmly to the pyriform aperture [85]. However, despite the options available, it is better to understand that a single flap may be insufficient at times to reconstruct the eyelid [86]. To overcome these challenges, the use of tissue expanders and free vascularized transfers have also been advocated [87, 88].

The Veau III method of bilateral lip repair can be used for correcting the lip component. The last area to be addressed is the naso-malar junction [89].

77.6.5 Tessier No. 5–9 Cleft (Fig. 77.38a, b)

The primary outcomes that are needed for the correction of these clefts include:

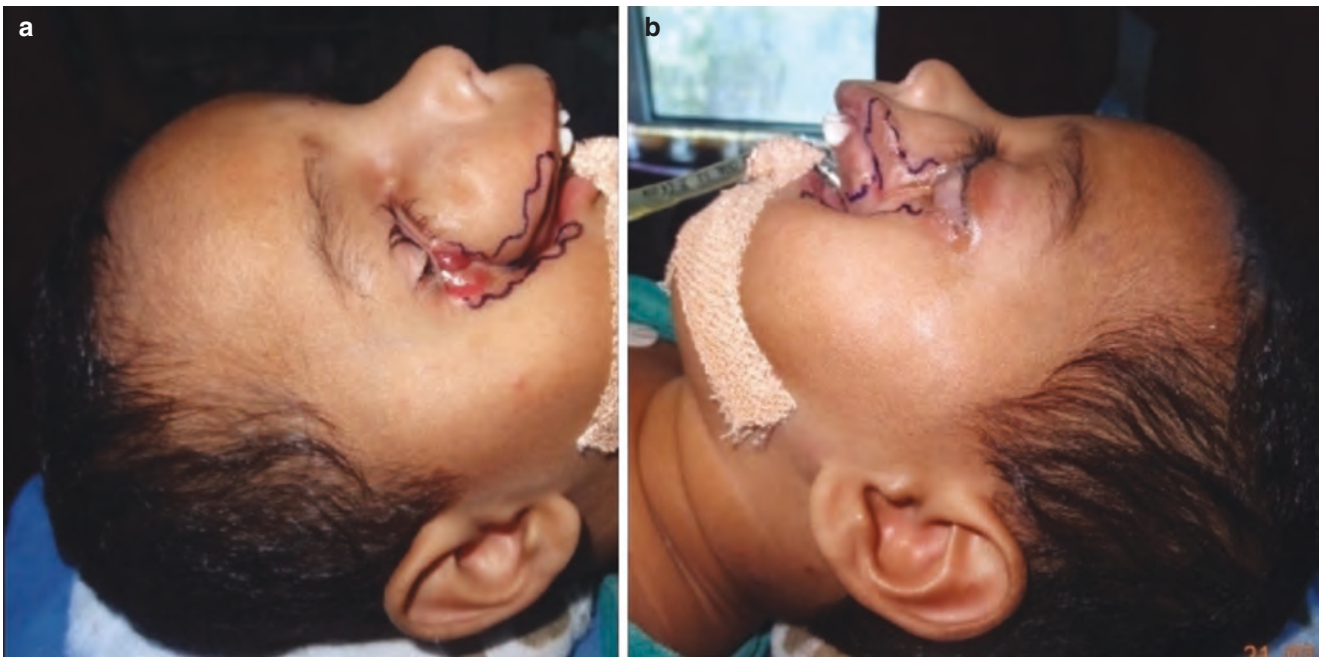
- Lower eyelid reconstruction
- Lateral canthal repositioning
- Repair of the labio-maxillary cleft
- Skeletal continuity restoration (this includes the orbital floor) using bone grafts

The principles to be borne in mind in the management of the Tessier 5–9 spectrum have been modified by different surgeons: Tessier (1971) advocated early correction of orbital dystopia – prior to 1 year of age. In all forms of facial clefts that affect the ocular region, priority is given to the preservation of vision by early interventions to prevent exposure keratitis of the cornea. Pre-surgical care includes use of ophthalmic ointments or temporary tarsorrhaphy procedures [48, 89]. Kara and Öçsel (2001) have reported the use of multiple z-plasties for the soft tissue reconstruction as early as 8th day after birth.

77.6.6 Tessier No. 7

Lateral facial cleft or Tessier no. 7 cleft is generally unilateral in presentation, though may also occur bilaterally. The bilateral form produces more gross clinical appearance with the face being amphibious in nature with an expanded mouth and infero-laterally placed commissures.

The condition is often related to syndromes of the first and second branchial arches. The cleft involves the skin, mucosa, and muscles of the oral sphincter (i.e., the orbicularis oris and the buccinator) [89]. In rare instances the cleft may involve the masseter [90]. This is a condition which may be concurrent with a lot of other deformities mandating a very thorough investigation in any patient exhibiting the classical feature of macrostomia [89].



©Association of Oral and Maxillofacial Surgeons of India

Fig. 77.38 (a, b) Tessier no 5–9 management

The surgical objectives for the management of the lateral facial cleft have been detailed as follows [90] (Fig. 77.39a–d):

1. Reconstituting the oral sphincter by reconstructing the orbicularis oris and the buccinator
2. Identification and reattachment of the other muscles of facial expression and the masseter in cases
3. Reconstruction of a natural and symmetrical commissure bilaterally
4. Attaining lip symmetry
5. Closure of the defect in layers with the mucosa, muscle, subcutaneous layer and skin [91]

Numerous procedures for the repair of macrostomia have been described in literature; [16, 17, 92, 93, 96, 97] Onizuka 1965; Boo-Chai 1969; Mansfield and Herbert 1972; Skoog 1974; Talukder 1980; Kaplan 1981; Bauer et al. 1982; Fukuda and Takeda 1985; Verheyden 1988; Yoshimura et al. 1992; Torkut and Coskunfirat 1997; Ono and Tateshita 1999.

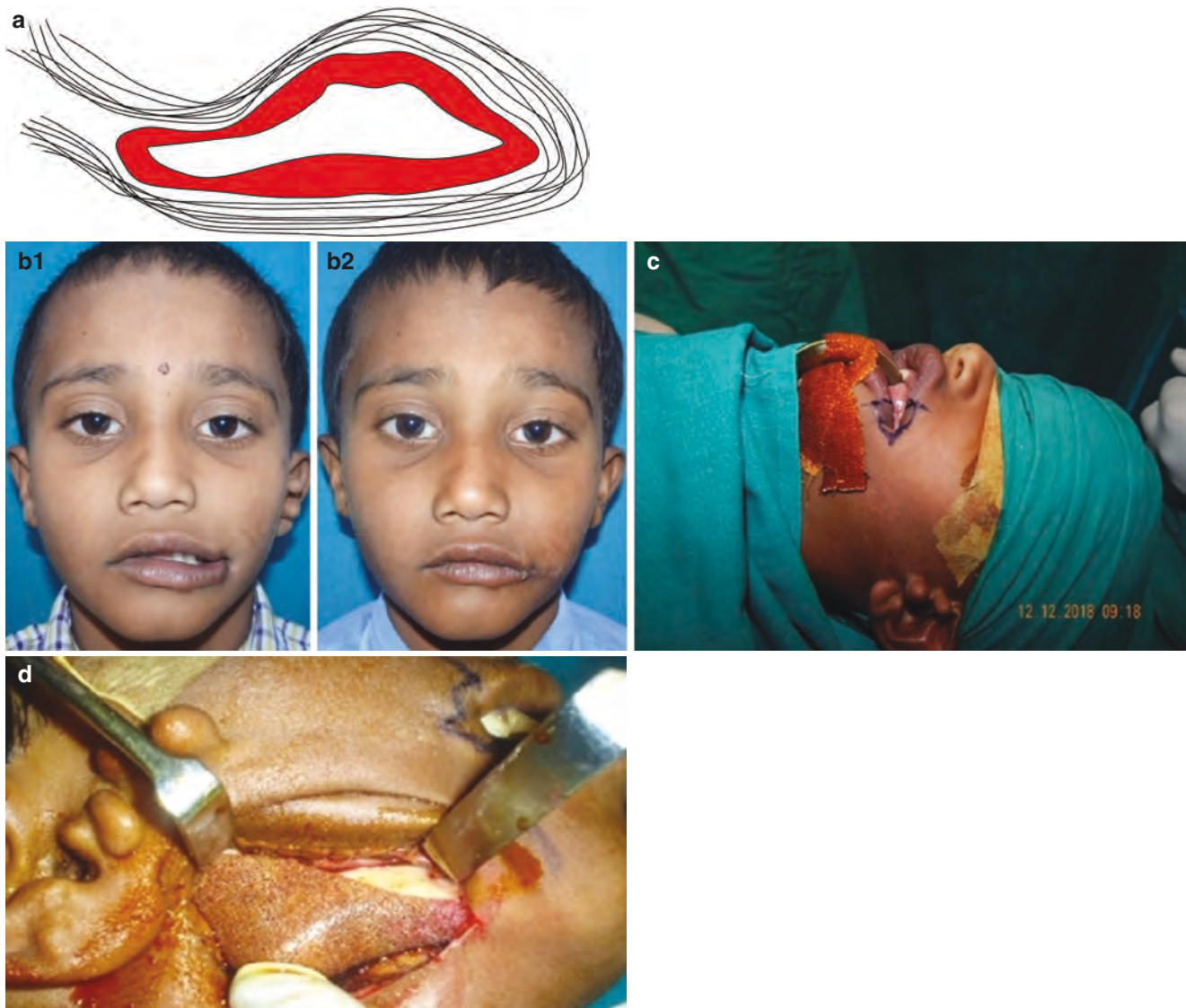Maximal care is exercised on the repair of the involved muscles with an overlapping technique [94, 95]. In severe

cases other muscles of facial expression like the buccinator and the risorius also need to be repaired (Ono and Tateshita) [93]. This ensures normalization of both form and function of the perioral region [94].

The skin repair consists of two parts: repair of the cheek wall and commissuroplasty. Commissuroplasty denotes the reconstruction of the skin mucosa junction at the corner of the lips. Care is taken to design the repair in such a way that there is no associated contracture in the post-surgical period. There are various descriptions for the commissural repair. The triangular flap repair of Ono and Tateshita [93]. This procedure produced better aesthetics due to the triangular design of the flaps. Kawai et al. in 1998 described an inferiorly based triangular flap taken close to the lower lip to minimize the re-expansion of the commissure in the long term.

Eguchi et al. used the vermilion square flap method for commissuroplasty [96].

Other popular techniques described for the skin repair of the lateral lip element include to direct linear suturing, Z-plasty [94], and W-plasty [96]. The purpose of a Z-plasty is to break the long linear scar. But it is seen that the use of multiple Z-plasty or W-plasty procedures violates the relaxed skin tension lines. Therefore, a single Z-plasty with vertical limb lying in the nasolabial crease is preferred [90].



©Association of Oral and Maxillofacial Surgeons of India

Fig. 77.39 (a–d) Tessier no. 7. (a) Diagram demonstrating abnormal oral aperture with distorted anatomy of orbicularis oris. (b1, b2) Clinical presentation of patient with macrostomia. (c) Incision marking. (d) Angle grafting

77.6.6.1 Bone Grafts

The establishment of normal contour of the soft tissues is never complete without the much needed skeletal support system. The skeletal reconstruction of craniofacial clefts essentially needs the use of bone grafts to fill and bridge both minor and major defects. The consolidation and take of the bone graft in the recipient site happens in two important steps: (i) the bony union of the joints between the grafted bone and the native bone and (ii) graft remodeling and creeping substitution [97]. Bone grafting can be performed at any age and is generally combined with soft tissue reconstruction [97].

Repairs performed in the early years of life can be accomplished with bone stock from the rib or iliac crest. However,

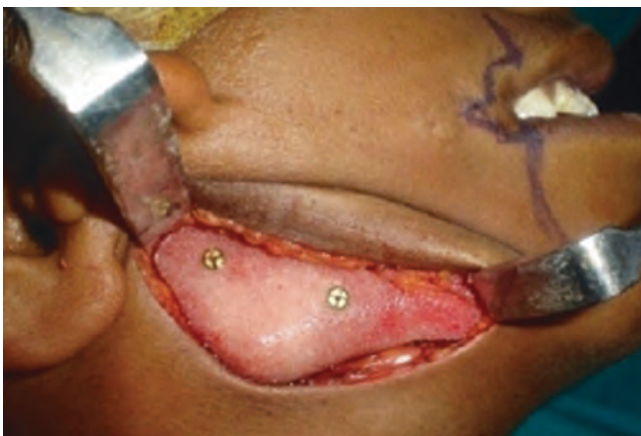the quality of the bone supplied by the ilium is better suited for this work. The cortico-cancellous graft material can be placed as such or carried over titanium cribs. It is important to note that the general consensus for the use of non-vascularized grafts is for defects less than 6 cm [98].

- Iliac crest grafts are the most favored with a good stock of available cortico-cancellous bone. Generally the anterior iliac crest is preferred as the posterior iliac crest requires a change of position to prone and may not accommodate simultaneous work from two teams. Donor site morbidity rate for anterior iliac crest grafts is around 23% and much less for posterior iliac crest. Complications include post-operative pain, iliac or acetabular fractures or instability,

persistent hematoma, herniation of abdominal contents, vascular injury, lateral femoral cutaneous nerve injury, and contour defects along the iliac crest [17].

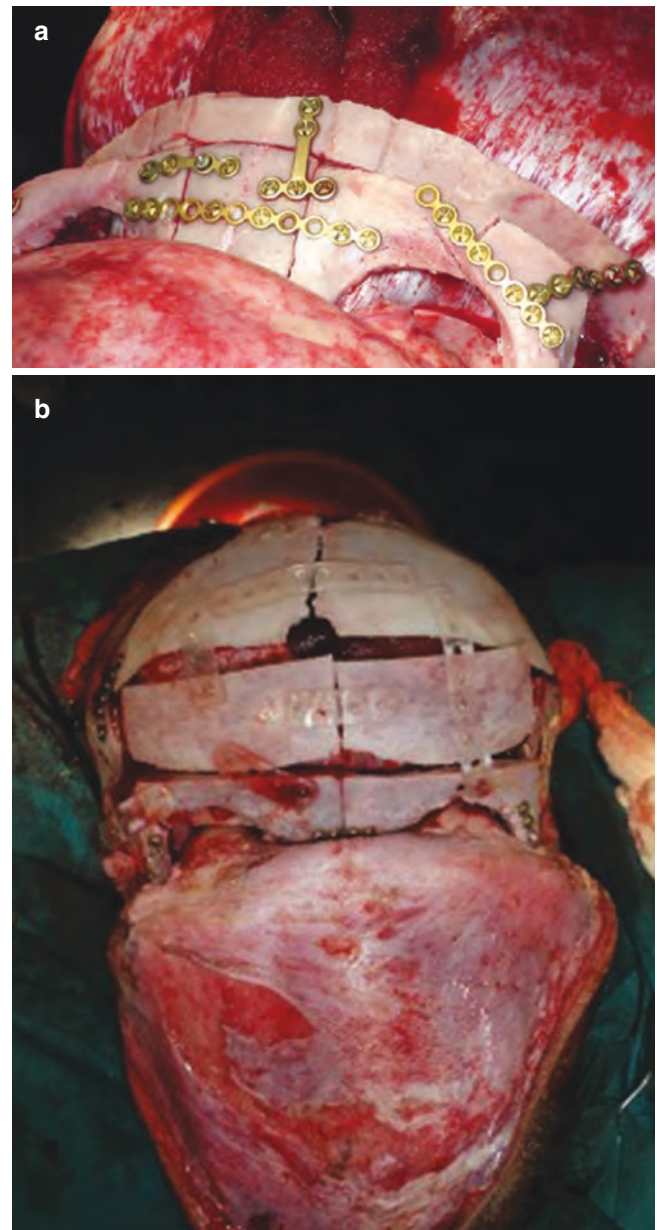
- Occasionally the use of alloplastic materials like Medpor may also be used (Fig. 77.40).
- Calvarial bone is another preferred site and can be freely available when the surgery involves cranial procedures and trans-cranial approaches. It has the lowest rate of resorption among all the bone grafts making it a preferred choice for facial and orbital reconstruction (Fig. 77.41a, b). The parietal calvarium can safely provide up to 8×10 cm of the bone for harvesting [99]. The temporo-parietal region provides more curved bone suitable for orbital or malar reconstruction. Generally the grafting is performed in strips so that there are no gross fractures and later the strips are joined together to reconstruct larger defects. Calvarium is harvested in three main forms: partial-thickness outer cortex, full-thickness outer cortex, and bicortical grafts. Partial-thickness outer cortex grafts are ideally harvested from children between 4 and 8 years of age, using an osteotome to produce a curling sheet of the bone.
- Calvarial grafts are safe in adults and are the standard indication when simultaneous craniotomy is performed. A bicortical graft is harvested and the graft is split. The inner cortex is used for reconstruction, while the outer cortex is replaced to fill the donor site defect and contour.
- Complications of calvarial grafting include contour defects of the donor site, graft fractures, and rarely dural tears while harvesting bicortical grafts. Dural tears mandate a thorough and formal dural repair to prevent further complications. Intra-cranial hemorrhage is a very rare complication during this procedure but has been documented [100].

- Grafts of ample volume can also be harvested from the anterior tibia both in the form of cancellous bone or in the form of cortical strip from the anterior tibial plateau.
- Rib bone or costochondral grafts can be harvested from ribs 5 to 7 which may be used as full-thickness or split rib grafts. Costochondral grafts are extensively used in the reconstruction of ascending mandibular ramus and condylar defects. Site-specific complications include postoperative pain, injury to the pleura with associated pneumothorax, hemothorax, or pneumohemothorax. Occasionally it may cause exaggerated facial asymmetry due to overgrowth.



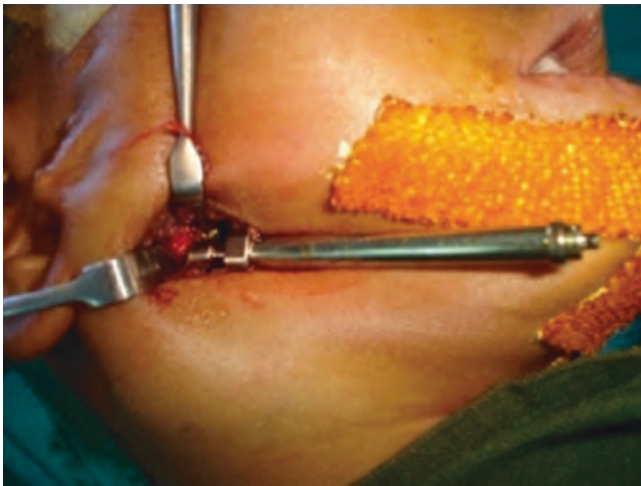©Association of Oral and Maxillofacial Surgeons of India

Fig. 77.40 Angle Medpor implant



©Association of Oral and Maxillofacial Surgeons of India

Fig. 77.41 (a, b) Calvarial bone graft



©Association of Oral and Maxillofacial Surgeons of India

Fig. 77.42 Distraction osteogenesis in the correction of asymmetry

Defects which are larger and demand more complex reconstruction may not be amenable to bone grafting alone and may require well-designed osteotomy techniques [82, 101] or at times, even distraction osteogenesis (introduced by McCarthy and co-workers) [102] to form better contour of the involved skeletal framework and improve function (Refer Chap. 87 on Distraction osteogenesis) (Fig. 77.42).

77.7 Conclusion

The uncommonness of craniofacial clefts has made the accumulation and complete anatomic documentation of this extensive arrangement troublesome. Preoperative and postoperative CT examinations with 3D reproductions will improve the understanding of these complex deformities. The test of managing these monstrous deformities still challenges the skill and experience of many a craniofacial surgeon [35].

This is an effort to bring a comprehensive account on the varied presentation and management techniques employed in the management of craniofacial clefts of the head and face. We also emphasize the utilization of the brilliant and time-tested diagnostic and surgical principles detailed here to establish new protocols for the comprehensive management of these deformities. Moreover we also advocate that more standardization along with structured investigation and planning methods should be utilized to come to sensible yet efficient treatment models that can be utilized by all for the treatment of this unfortunate set of people.

References

1. His WE. Beobachtungen zur Gesichte und Gammennbildung beim menschlichen Embryo. Kgl Akad Wiss. 1901;
2. Tessier P. Anatomical classification of facial, cranio-facial and laterofacial clefts. *J Maxillofac Surg.* 1969;4:69e92.
3. Bhattacharya S, Khanna V, Kohli R. Cleft lip: The historical perspective. *Indian J Plast Surg.* 2009;42(Suppl):S4–s8.
4. van der Meulen JCH. Oblique facial clefts. *Plastic Reconstr Surg.* 1984;76(2 j); revised January 28, 1985
5. Moore MH. Rare craniofacial clefts. *J Craniofac Surg.* 1996;7:408–11.
6. Eppley BL, van Aalst JA, Robey A, Havlik JR. The spectrum of orofacial clefting. *Plast Reconst Surg.* 2005;115:101–14.
7. Wehby GL, Cassell CH. The impact of orofacial clefts on quality of life and healthcare use and costs. *Oral Dis.* 2010;16(1):3–10.
8. Marcusson A, Akerlind I, Paulin G. Quality of life in adults with repaired complete cleft lip and palate. *Cleft Palate Craniofac J.* 2001;38(4):379–385.
9. Nagy K, Mommaerts MY. Analysis of the cleft-lip nose in submental-vertical view, Part I—Reliability of a new measurement instrument. *J Cranio-Maxillofac Surg* 2007; 35:265-277
10. Nollet PJPM, Kuijpers-Jagtman AM, Chatzigianni A, Semb G, Shaw WC, Bronkhorst EM, Katsaros C. Nasolabial appearance in unilateral cleft lip, alveolus and palate: a comparison with Eurocleft. *J Craniomaxillofac Surg.* 2007;35:278–86.
11. Joos U, Wernker K, Kruse-Löesler B, Kleinheinz J. Influence of treatment concept, velopharyngoplasty, gender and age on hypernasality in patients with cleft lip, alveolus and palate. *J Craniomaxillofac Surg.* 2006;34:472–7.
12. Carlino F. Modified forked flap for controlling columella length in cleft lip open rhinoplasty. *J Craniomaxillofac Surg.* 2008;36:131–7.
13. Li Y, Shi B, Song Q-G, Zuo H, Zheng Q. Effects of lip repair on maxillary growth and soft tissue development in patients with a complete unilateral cleft lip, alveolus and palate. *J Craniomaxillofac Surg.* 2006;34:355–61.
14. Dostal A, Nemeckova J, Gaillyova R. The 18q deletion syndrome and analysis of the critical region for orofacial cleft at 18q22.3. *J Craniomaxillofac Surg.* 2009;37:272–5.
15. Bütow K-W. Construction of the congenitally missing columella in midline clefts. *J Craniomaxillofac Surg.* 2007;35:287–92.
16. Berkowitz S. State of art of cleft palate orofacial growth and dentistry: A historical perspective. *Am J Orthodontics.* 1978;74(4):564–76.
17. Ghareeb FM, Hanafy AM. Surgical planning and correction of median craniofacial cleft. *Egypt J Plast Reconstr Surg.* 2003;27(1):143–52.
18. Bhatt YC. Proboscis lateralis: review of literature and a case report. *Internet J Plast Surg.* 2008;5:1–11.
19. Carstens MH. Neural tube programming and the pathogenesis of craniofacial clefts, part I: the neuromeric organization of the head and neck. In: Sarnat HB, Curatolo P, editors. *Handbook of clinical neurology*, vol. 87. London: Elsevier; 2008. Chapter 16.
20. Ishii M, Ishii Y, Moriyama T, et al. Seventeen-year follow-up of a patient with median cleft of the lower lip, mandible, and tongue with flexion contracture: a case report. *Cleft Palate Craniofac J.* 2002;39(5):555–9.
21. Wyszynski DF, Beaty TH, Maestri NE. Genetics of nonsyndromic oral clefts revisited. *Cleft Palate Craniofac J.* 1996;33:406–17.
22. Niemeier MF, van der Meulen J. The genetics of craniofacial malformations. In: Stricker M, Van der Meulen J, editors. *Craniofacial malformations*. London: Churchill Livingstone; 1990.

23. Reddy SG. Incidence of cleft lip and palate in the state of Andhra Pradesh, South India. *Indian J Plastic Surg.* 2010;43(2):184–9.
24. Murray JC. Gene/environment causes of cleft lip and/or palate. *Clin Genet.* 2002;61:248–56.
25. Schuttler BC et al. The many faces and factors of orofacial clefts. *Hum Mol Genet.* 1999;8(10):1853–9.
26. Prescott NJ, Winter RM, Malcolm S. Nonsyndromic cleft lip and palate: Complex genetics and environmental effects. *Ann Hum Genet.* 2001;65:505–515
27. Hunt JA, Hobar PC. Common craniofacial anomalies: facial clefts and encephaloceles. *Plast Reconstr Surg.* 112(2):606–15.
28. Werler MM, Lammer EJ, Rosenberg L, et al. Maternal alcohol use in relation to selected birth defects. *Am J Epidemiol.* 1991;134:691.
29. Erickson A, Kallen B, Westerholm P. Cigarette smoking as an etiologic factor in cleft lip and palate. *Am J Obstet Gynecol.* 1979;135:348.
30. Van der Meulen JC, Mazzola R, Stricker M, Raphael B, Kawamoto HK, David JD. Classification of craniofacial malformations . Rare craniofacial clefts. In: McCarthy JG, editor. *Plastic surgery.* Philadelphia: W.B. Saunders; 1990. p. 2922–2973.
31. Kawamoto HK Jr. The kaleidoscopic world of rare craniofacial clefts: order out of chaos (Tessier classification). *Clin Plast Surg.* 1976;3:529.
32. Dufresne C, Jelks G. Classification of craniofacial anomalies. In: Smith B, editor. *Ophthalmic plastic and reconstructive surgery.* Philadelphia: C.V. Mosby; 1987. p. 1185–207.
33. Boo-chai K. The bifid nose. *Plast Reconstr Surg.* 1965;36:626.
34. Tessier P. Anatomical classification of facial, cranio-facial and latero-facial clefts. *J Maxillofac Surg.* 1976;4:69–92.
35. Hunt JA, Hober PC. Common craniofacial anomalies: The facial dysostoses. *J Craniofac Surg.* 2008;110(7):1714–1725.
36. David DJ, Moore MH, Cootes RD. Tessier clefts revisited with a third dimension. *Cleft Palate J.* 1989;26:163.
37. Da Silva Freitas RI, Alonso N, Shin JH et al. Surgical correction of Tessier number 0 cleft. *J Craniofac Surg.* 2008;19(5):1348–52.
38. Mullin WR. Management of congenital bilateral cleft nose. *Plast Reconstr Surg.* 1985;75:253.
39. Edwards WA. Median cleft face syndrome. *Am J Ophthalmol.* 1971;72:202.
40. Mazzola RF. Congenital malformations in the frontonasal area: their pathogenesis and classification. *Clin Plast Surg.* 1976;3:573–609.
41. Veau V. Hasencharten menschlicher Keimlinge auf der Stufe 21–23mm SSL. *Z Anat Entwicklungsgesch.* 1937;108:459.
42. DeMyer W. The median cleft face syndrome: differential diagnosis of cranium bifidum occultum, hypertelorism, and median cleft nose, lip, and palate. *Neurology.* 1967;17:961–71.
43. Millard DR Jr, Williams S. Median lip clefts of the upper lip. *Plast Reconstr Surg.* 1968;42:4–14.
44. Ozek C, Gundogan H, Bilkay U, Cankayali R, Guner U, Gurler T, et al. Rare craniofacial anomaly: Tessier no 2 cleft. *J Craniofac Surg.* 2001;12:355–61.
45. Bradley JP, Kawamoto Jr HK. Craniofacial Clefts. In: Neligan PC. *Plastic Surgery.* 4ed. St Louis: Elsevier, 2018. p 711–38.
46. Wenbin Z, Hanjiang W, Xiaoli C, Zhonglin L. Tessier 3 cleft with clinical anophthalmia: two case reports and a review of the literature. *Cleft Palate Craniofac J.* 2007;44(1):1597–05
47. Ewings EL, Carstens MH. Neuroembryology and functional anatomy of craniofacial clefts. *Indian J Plastic Surg.* 2009;42(2):182–7.
48. Alonso N, da Silva Freitas R, de Oliveira e Cruz GA, Goldenberg D, Dall'Oglio Tolazzi AR. Tessier no. 4 facial cleft: evolution of surgical treatment in a large series of patients. *Plast Reconstr Surg.* 2008;122:1505–13.
49. da Silva Freitas R, Alonso N, Shin JH, Busato L, Dall'Oglio Tolazzi AR, de Oliveria e Cruz GA. Tessier number 5 facial cleft: surgical strategies and outcomes in six patients. *Cleft Palate Craniofac J.* 46(2).
50. Van der Meulen JC, Mazzola R, Vermey-Keers C, et al. A morphogenetic classification of craniofacial malformations. *Plast Reconstr Surg.* 1983;71:560.
51. Longacre JJ, Stevens GA, Holmstrand KE. The surgical management of first and second branchial arch syndrome. *Plast Reconstr Surg.* 1963;31:507.
52. Grabb WC. The first and second branchial arch syndrome. *Plast Reconstr Surg.* 1965;36:485.
53. Converse JM, Coccaro PJ, Becker M, et al. On hemifacial microsomia. *Plast Reconstr Surg.* 1973;51:268.
54. Tessier P, Guiot J, Rougerie JP, et al. Ostéotomies cranio-naso-orbito-faciales. *Hypertelorisme Ann Chir Plast.* 1967;12:103.
55. Millard Jr, Lehman JA Jr, Deane M, Garst WP. Median cleft of the lower lip and mandible: a case report. *Br J Plast Surg.* 1971;24(4):391–5.
56. Rosenthal R. Aglossia congenital: Report of a case of the condition combined with other congenital malformations. *J Dis Child.* 1932;44:383–5.
57. Fearon JA. Rare craniofacial clefts: a surgical classification. *J Craniofac Surg.* 2008;19(1):110–2.
58. da Silva Freitas R, Alonso N, Busato L, et al. Series of facial cleft number 2-12: strategies for treatment. *Rev Bras Craniomaxillofac.* 2010;13(4):225–30.
59. da Silva Freitas R, Alonso N, Shin JH. Surgical correction of Tessier number 0 cleft. *J Craniofac Surg.* 2008;19(5):1348–52.
60. Johnston MC. Embryology of the head and neck. In: McCarthy JG, editor. *Plastic surgery.* Philadelphia: WB Saunders; 1990.
61. Monasterio FO, Taylor JA. Major craniofacial clefts: case series and treatment philosophy. *Plast Reconstr Surg.* 2008;122(2):534–43.
62. Jackson IT, Tanner NSB, Hide TAH. Frontonasal encephalocele: "Long nose hypertelorism." *Ann Plast Surg.* 1983;11:490,
63. Holmes AD, Meara JG, Kolker AR, Rosenfeld JV, Klug GL. Frontoethmoidal encephaloceles: reconstruction and refinements. *J Craniofac Surg.* 2001; 12(1).
64. Ortiz-Monasterio F, Medina O, Musolas A. Geometrical planning for the correction of hypertelorism. *Plast Reconstr Surg.* 1990;86:650.
65. Greig DM. Hypertelorism: A hitherto undifferentiated congenital craniofacial deformity. *Edinb Med J.* 1924;31:560–93.
66. Tessier P. Orbital hypertelorism: I. Successive surgical attempts, material and methods: Causes and mechanism. *Scand J Plast Reconstr Surg.* 1972;6:135–55.
67. Munro I. Orbito-cranio-facial surgery. The team approach. *Plast Reconstr Surg.* 1975;55:170.
68. Marchac D, Sati S, Renier D, Deschamps-Braly J, Marchac A. Hypertelorism correction: what happens with growth? evaluation of a series of 95 surgical cases. *Plast Reconstr Surg.* 2012;129:713–27.
69. Schmid et al. New method for the correction of hypertelorism with preservation of the olfactory nerve. *Plast Reconstr Surg.* 1996;97:719–25A.
70. Frodel JL. Calvarial bone graft harvesting techniques: considerations for their use with rigid fixation techniques in the craniomaxillofacial region. In: Greenberg A, Prein J, editors. *Craniomaxillofacial reconstructive and corrective bone surgery.* New York: Springer; 2002. p. 700–712.

71. Van der Meulen JC. Medial fasciotomy. *Br J Plast Surg.* 1979;32(4):339–42.
72. Sailer HF, Haers PE, Zollikofer CPE, Warnke T, Carls FR, Stucki P. The value of stereolithographic models for preoperative diagnosis of craniofacial deformities and planning of surgical corrections. *Int J Oral Maxillofac Surg.* 1998;27(5):327–33.
73. Balaji SM. Modified facial bipartition. *Ann Maxillofac Surg.* 2012; 2(2):170–3.
74. Sharma RK, Makkar SS, Nanda V. Simple innovation for medial canthal tendon fixation. *Plast Reconstr Surg.* 2005;116:2046.
75. Ramesh K, Sharma hypertelorism. *Indian J Plast Surg.* 2014;47(3):284–92.
76. Urata MM, Kawamoto H. Median clefts of the upper lip: a review and surgical management of a minor manifestation. *Cleft Palat Craniofac J.* 2010;47(5):104–6.
77. Wiemer DR, Hardy SB, Spira M. Anatomical findings in median cleft of upper lip. *Plast Reconstr Surg.* 1978;62(6):866–9.
78. Francesconi G, Fortunato G. Median dysraphia of the face. *Plast Reconstr Surg.* 1969;43(5):481–91.
79. Bilen BT, Kiliç H. A congenital isolated alar cleft. *J Craniofac Surg.* 2006;17(3):602–4.
80. Rashid M, Islam MZ, Tamimy MS, Haq EU, Aman S, Aslam A. Rotation-transposition correction of nasal deformity in Tessier number 1 and 2 clefts. *Cleft Palate Craniofac J.* 2009;46(6):674–80.
81. Jinka JR, Chekuri H, Annavarapu G. Isolated cleft of the ala nasi: A report of seven cases. *Indian J Plast Surg.* 2012;45(3):512–5.
82. Ortiz Monasterio F, Fuente del Campo A, Dimopolulos A. Nasal clefts. *Ann Plast Surg.* 1987;18(5):377–97.
83. Mishra RK, Purwar R. Formatting the surgical management of Tessier cleft types 3 and 4. *Indian J Plast Surg.* 2009;42(Suppl):S174–83.
84. Stretch JR, Poole MD, et al Nasolacrimal abnormalities in oblique facial clefts. *Br J Plast Surg.* 1990; 43(4):463–467.
85. Longaker MT, Siebert JW. Microsurgical correction of facial contour in congenital craniofacial malformations: the marriage of hard and soft tissue. *Plast Reconstr Surg.* 1996;98(6):942–50.
86. Van der Meulen J, Vaandrager JM. Surgery related to the correction of hypertelorism. *Plast Reconstr Surg.* 1983;71:6.
87. Tokioka K, et al. Two cases of Tessier no. 4 cleft with anophthalmia. *Cleft Palate Craniofac J.* 2005;42(4):448–52.
88. Menard RM, Moore MH, David DJ. Tissue expansion in the reconstruction of Tessier craniofacial clefts: a series of 17 patients. *Plast Reconstr Surg.* 2012;129(6):1337–44.
89. Chen PK, Chang FC, Chan FC, Chen YR, Noordhoff MS. Repair of Tessier no. 3 and no. 4 craniofacial clefts with facial unit and muscle repositioning by midface rotation advancement without Z-plasties. *Plast Reconstr Surg.* 2012;129(6):1337–44.
90. Pereira FJ, Milbratz GH, Cruz AAV, Vasconcelos JJA. Ophthalmic considerations in the management of Tessier cleft 5/9. *Ophthal Plast Reconstr Surg.* 2010 ;26(6).
91. Shima Y, Ogawa K, Kuwabara Y, Takechi N, Shin S. Newborn with transverse facial cleft associated with polyhydramnios. *J Perinatol.* 2002;22:91–2.
92. Yencha M. Congenital macrostomia. *Otolaryngol Head Neck Surg.* 2001;124:353–4.
93. Tomoaki E, Hirotsuka A, Akihiko T, Tsuyoshi T, Kiyonori H. Surgical repair for congenital macrostomia: vermilion square flap method. *Ann Plast Surg.* 2001;47:629–35.
94. Ono I, Tateshita T. New surgical technique for macrostomia repair with two triangular flaps. *Plast Reconstr Surg.* 1999;105:688–94.
95. Bauer BS, Margulis A. Invited discussion of surgical repair for congenital macrostomia vermilion square flap method. *Ann Plast Surg.* 2001;47:328–9.
96. Franco D, Franco T, da Silva FR, Alonso N. Commissuroplasty for macrostomia. *J Craniofac Surg.* 2007;18:691–4.
97. Eguchi T, Asato H, Takushima A, Takato T, Harii K. Surgical repair for congenital macrostomia: vermilion square flap method. *Ann Plast Surg.* 2001;47:629–35.
98. Stevenson S, Li XQ, Davy DT, Klein L, Goldberg VM. Critical biological determinants of incorporation of non-vascularized cortical bone grafts. Quantification of a complex process and structure. *J Bone Joint Surg Am.* 1997;79(1):1–16.
99. Podlesh S, Anthony JP, Alexander A comparison of vascularized and nonvascularized bone grafts for reconstruction of mandibular continuity defects. *J Oral Maxillofac Surg.* 1997;55(11):1200–6.
100. Nocini PF, Bedogni A, Valsecchi S, Trevisiol L, Ferrari F, Fior A, Saia G. Fractures of the iliac crest following anterior and posterior bone graft harvesting. Review of the literature and case presentation. *Minerva Stomatol.* 2003; 52(10):441–8.
101. Ortiz-Monasterio F, Medina O, Musolas A. Geometrical planning for the correction of hypertelorism. *Plast Reconstr Surg.* 1990;86:650.
102. McCarthy JG, Staffenberg DA, Wood RJ, Cutting CB, Grayson BH, Thorne CH. Introduction of an intraoral bone-lengthening device. *Plast Reconstr Surg.* 1994;96:978–81.

Open Access This chapter is licensed under the terms of the Creative Commons Attribution 4.0 International License (<http://creativecommons.org/licenses/by/4.0/>), which permits use, sharing, adaptation, distribution and reproduction in any medium or format, as long as you give appropriate credit to the original author(s) and the source, provide a link to the Creative Commons license and indicate if changes were made.

The images or other third party material in this chapter are included in the chapter's Creative Commons license, unless indicated otherwise in a credit line to the material. If material is not included in the chapter's Creative Commons license and your intended use is not permitted by statutory regulation or exceeds the permitted use, you will need to obtain permission directly from the copyright holder.



Hemifacial Microsomia (HFM) and Treacher Collins Syndrome

Manikandhan Ramanathan

78.1 Introduction

Hemifacial microsomia (HFM) is a three-dimensional congenital deformity of the craniofacial region characterized by abnormal and underdevelopment of the first and second pharyngeal arches. Due to involvement of multiple structures, this disorder has a broad spectrum of involvement with diverse clinical features [1].

The highly variable phenotypes have probably led to variation in its nomenclature as well, alternatives used being craniofacial microsomia (CFM), otomandibular dysostosis, facio-auriculo-vertebral spectrum, oculo-auriculo-vertebral spectrum, first and second branchial arch syndrome, otomandibular-facial dysmorphogenesis, and lateral facial dysplasia [2].

This disorder is characteristically unilateral; however, incidence of bilateral cases is 10–15%. Although this disorder was described first by Carl Ferdinand von Arlt, a German physician in 1881, “hemifacial microsomia” got its name from Gorlin and Pindborg in the early 1960s. Converse et al. proposed the name, craniofacial microsomia, in cases of coexisting cranial deformities where HFM is also associated with vertebral, cardiac, and renal defects, in a condition called as Goldenhar syndrome. It was termed “oculoauriculo-vertebral dysplasia” (OAVD) by Gorlin. It is also associated with epibulbar dermoids and ear deformities [2, 3].

78.1.1 Epidemiology and Etiopathogenesis

HFM is the second most common congenital anomaly of the face, with a male predilection and which is more common in

the right than the left side. The incidence of HFM ranges between 1 in 3500 and 1 in 26,000 live births [4–7].

The cause of HFM remains largely unknown. Poswillo in 1973 reported that hematomas resulting from disruption of embryonic arteries (stapedial artery) in utero produce abnormalities in the development of the structures derived from the first and second pharyngeal arches. The extent of the hematoma and consequent tissue damage during the first 6 weeks of gestation determines the severities of deformities. He was able to produce the CFM phenotype in mice, thus proving his theory. He administered teratogens to produce a hematoma of the stapedial artery and the artery of the second arch which resulted in regional necrosis [4] (Fig. 78.1a, b).

The second widely accepted hypothesis is a change in the migration of neural crest cells (Fig. 78.2). Retinoic acid is believed to influence and alter the migration and distribution of neural crest cells, which may predispose to abnormalities in the pharyngeal arch derivatives. The intake of retinoic acid in humans during the early stages of pregnancy may cause multiple disorders collectively known as “retinoic acid embryopathies” (RAEs); these include variable defects of the jaws and the middle and external ear [3–5]. Apart from retinoic acid, thalidomide, primidone, ethanol and isotretinoin have also been studied as causative agents in HFM through their teratogenic effects [6, 7].

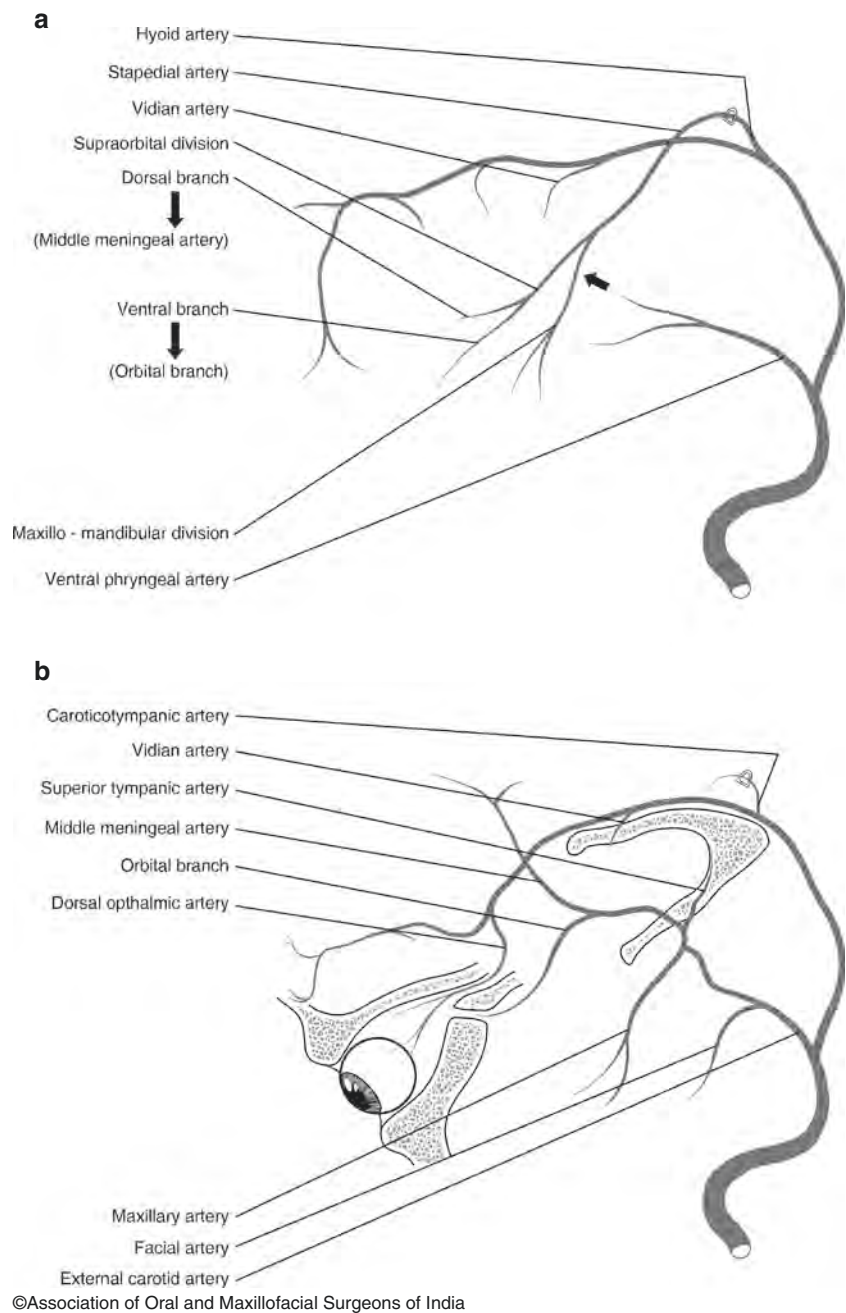
More recent studies have demonstrated an association between HFM and multiple gestations, along with other maternal risk factors such as assisted reproduction, smoking, maternal diabetes mellitus and vasoactive drugs. Moreover, HFM may demonstrate autosomal dominant and recessive Mendelian patterns in families. Positive family history accounts for 50% occurrence of features [8].

Genetic events like duplication of the OTX2 gene (chromosome 14q22.3) have also been researched upon. OTX2 encodes a transcription factor, essential for craniofacial development and anterior brain morphogenesis. Heterogeneity in aetiology along with variable penetrance

M. Ramanathan (✉)
Department of OMFS, Meenakshi Ammal Dental College and Hospital, MAHER University, Chennai, India

Meenakshi Cleft and Craniofacial Centre, Meenakshi Ammal Dental College and Hospital, Chennai, India

Fig. 78.1 (a, b) Anatomy of the stapedia artery during embryonic development



and expression is postulated to account for the widely variable phenotypic spectrum of HFM [9, 10].

78.1.2 Classification Systems

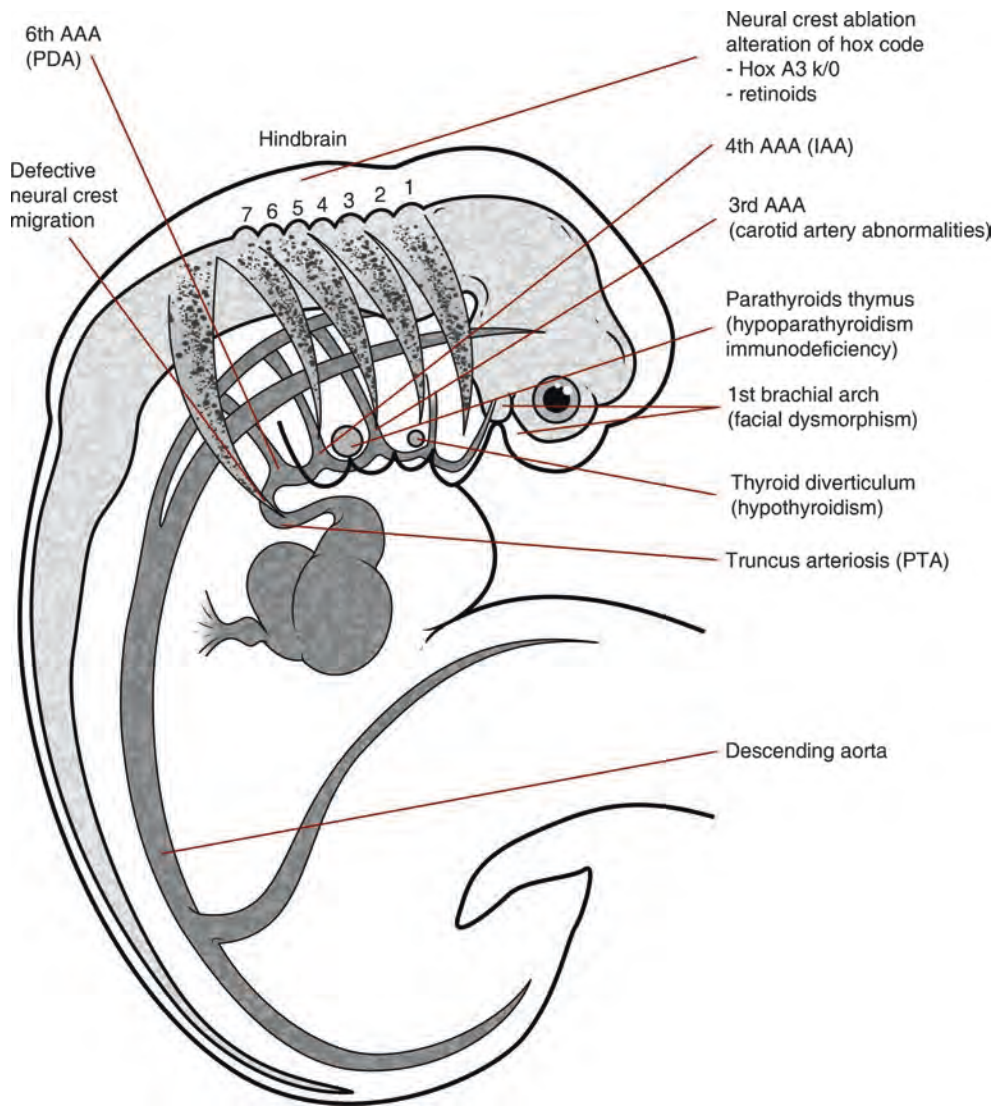
Various classifications have attempted to categorize various features of HFM as enumerated below [11–13]:

1. SAT classification.
2. OMENS classification.
3. Kaban-Pruzansky classification.

78.1.2.1 SAT Classification

The skeletal, auricle, and soft tissue (SAT) classification.

The SAT and the OMENS (Tables 78.1 and 78.2) classifications provide an elaborate system covering simple to complex skeletal, soft tissue and neurological involvement. On the other hand, the Kaban-Pruzansky classification explains malformations involving the mandible, masticatory muscles, and TMJ. Therefore, it is more useful for orthodontists and maxillofacial surgeons in reconstruction of the mandible and TMJ. Thus, this classification has become the gold standard. It involves four classes—



©Association of Oral and Maxillofacial Surgeons of India

Fig. 78.2 Migration of neural crest cells during embryonic development

Table 78.1 SAT classification of HFM

Skeletal categories (S)	Auricle categories (A)	Soft tissue categories (T)
S1 = small mandible—Normal shape	A0 = Normal	T1 = contour defect minimal—No cranial nerve involvement
S2 = condyle, ramus, sigmoid notch discernible, distorted; mandible remarkably different in size and shape	A1 = small, malformed auricle—With characteristic features	T2 = moderate defect
S3 = severe mandibular deformity, poorly discernible, to agenesis of ramus	A2 = rudimentary auricle with hook at cranial end corresponding to the helix	
S4 = an S3 mandible with orbital involvement, lateral and inferior orbital rims displaced posteriorly	A3 = malformed lobule, pinna absent	
S5 = the S4 defects plus orbital dystopia, hypoplastic, asymmetric, neurocranium and a flat temporal fossa		

Table 78.2 OMENS classification

Orbit	Mandible	Ear	Nerve (cranial nerve VII)	Soft tissue
0 = Normal	Type I	Type I = small ear, the normal structure	0 = Normal	0 = Normal
1 = small size	Type IIA	Type II = severe external ear deformity with a rudimentary auricle	1 = upper branches impaired	1 = mild hypoplasia
2 = poor position	Type IIB	Type III = small rudiment of external ear with no pinna	2 = lower branches impaired	2 = moderate hypoplasia
3 = small size and poor position	Type III	Type IV = Anotia	3 = upper and lower branches impaired	3 = severe hypoplasia

the Type 1, Type 2A, Type 2B, and Type 3 (Fig. 78.3a–d).

Type 1

In this category, the TMJ morphology is normal with adequate bulk and function of masticatory muscles. The mandible is slightly hypoplastic and retruded which may project as a mild asymmetry with deviation of the chin to the affected side (Fig. 78.4a, b).

Type 2A

In this type, the affected side TMJ is shifted anteriorly and medially than its counterpart, but the overall morphology of the condyle and glenoid fossa remains unchanged. The joint is functional associated with moderate muscular hypoplasia. The patient demonstrates moderate hypoplasia of the mandible with occlusal canting or open bite, and the chin is deviated to the affected side.

Type 2B

There is moderate-to-severe involvement of the joint with condyle and the glenoid fossa grossly hypoplastic. The joint exhibits only rotation movement of the condyle and near-normal function. Involvement of other facial bones and deficiency of masticatory muscles are clinically evident. The patient demonstrates severe asymmetry and occlusal canting with or without an open bite (Fig. 78.5a, b).

Type 3

There is gross facial asymmetry with severely hypoplastic or absent muscles of mastication. There is associated severe deformity of the skull and orbito-zygomatic complex as well. The mandible is severely affected with a “floating mandible” appearance due to absence of the condyle and ramus (Fig. 78.6a, b). These patients from birth may often present with signs of a compromised airway due to severe degrees of mandibular retrusion.

78.1.3 Clinical Features

The diagnosis of HFM is challenging owing to its wide phenotypic spectrum. There are no definite diagnostic crite-

ria and classifications. The condition is diagnosed based on its clinical features of phenotype ranging from involving the orbit or ear alone to full-blown hemifacial microsomia under development with jaw malformations. For this reason, certain classification systems have been established to standardize the assessment in an organized manner and formulate treatment plan accordingly. The areas of examination include various components of the face, i.e. external ear, mandible, temporal bone, zygoma, orbit middle ear, facial musculature, facial nerve supply, and other adjacent bony and soft tissues [2, 5, 7, 14] (Fig. 78.7a–d and Table 78.3).

78.1.3.1 Skeletal Defects

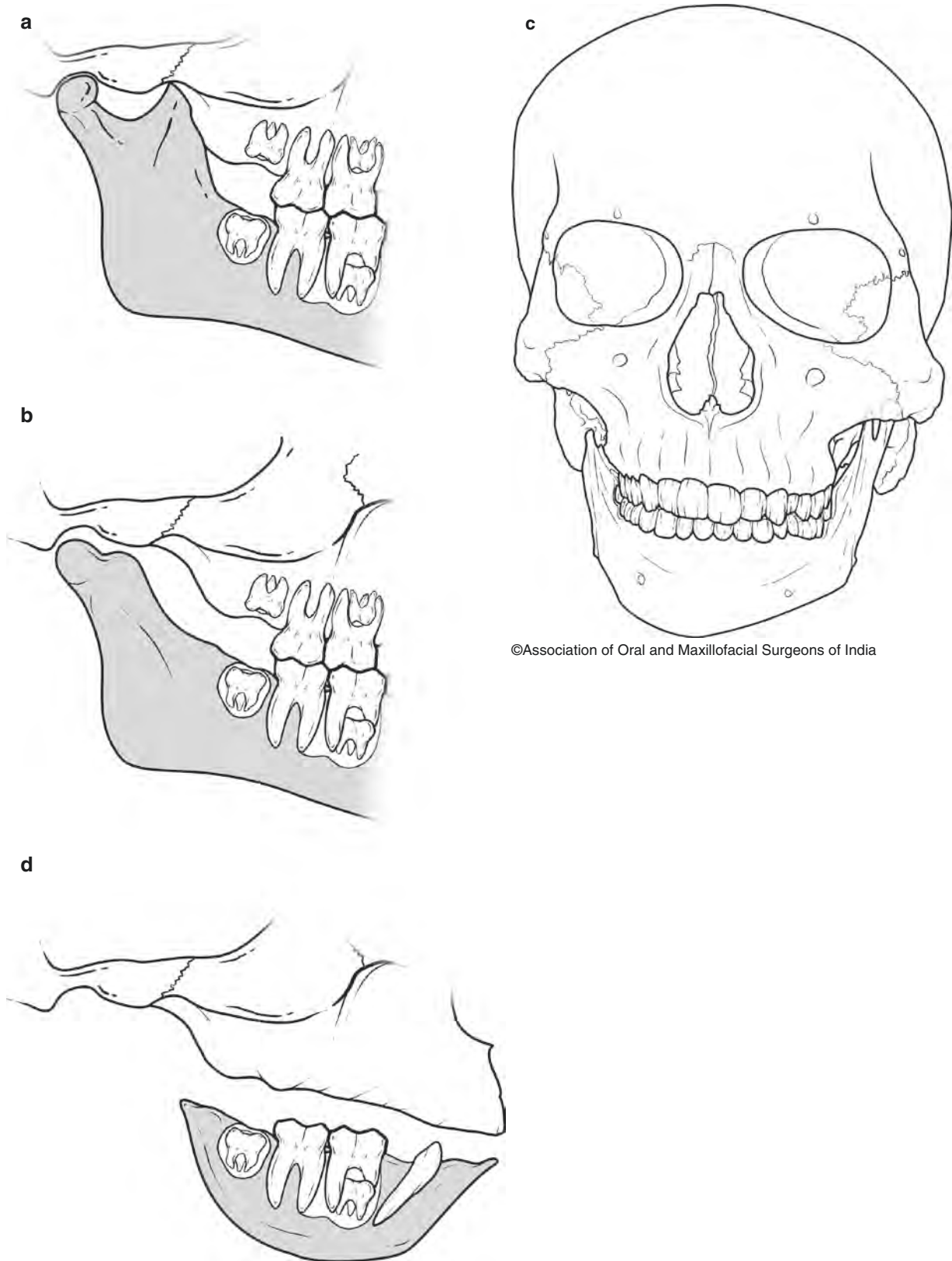
Cranio-orbital

The cranial involvement is mainly limited to the squamous part of the temporal bone. Most individuals affected with HFM demonstrate hypoplasia of the zygomatico-maxillary complex. These patients clinically show malar depression with orbital dystopia. The zygomatic bone hypoplasia can lead to alterations in the glenoid fossa.

Maxillomandibular

The maxillomandibular region is primarily affected due to abnormal development of the first and second branchial arches. It presents as unilateral facial deformities with reduced dimensions of facial bones in all three dimensions (3D). This produces varying degrees of gross morphological asymmetry of the face and compensatory changes of the contralateral side. The affected side in HFM may vary in severity and also alters the morphology of the so-called normal contralateral side, resulting in gross deviation in 3D, making it a difficult term as unaffected normal side (Figs. 78.5, 78.7, 78.8a–c and 78.9a–c).

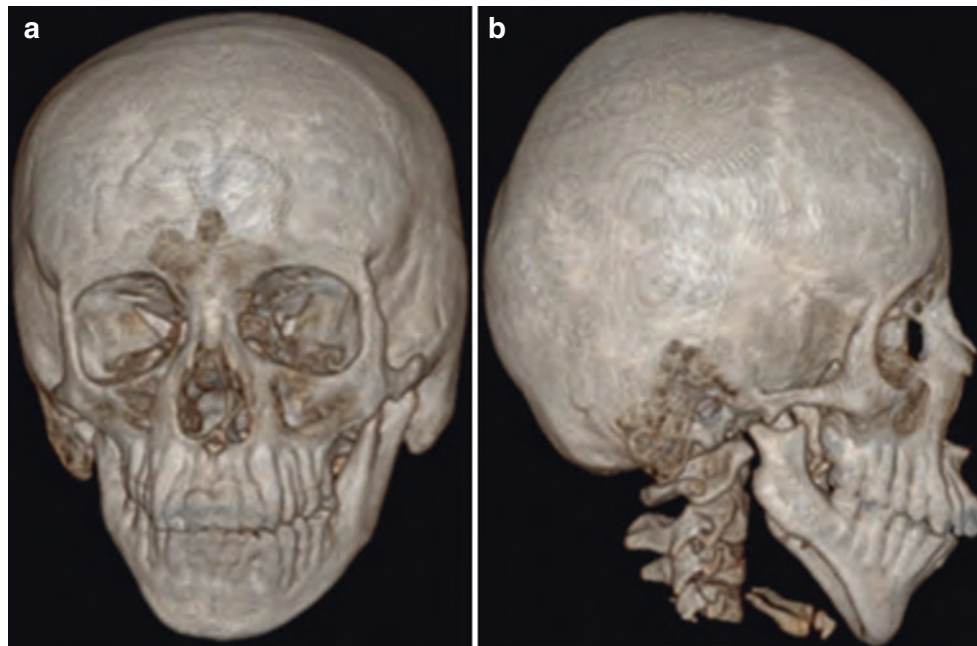
Mandibular growth changes are the earliest manifestations of HFM and are accountable for its classical presentation of facial asymmetry. The ramus of the mandible is either absent or short, with a medial displacement. The contour of the entire mandibular corpus is altered with a shift of the Genium to the affected side. Dental compensations occur for the skeletal discrepancy, which may mask the actual severity of the clinical condition.



©Association of Oral and Maxillofacial Surgeons of India

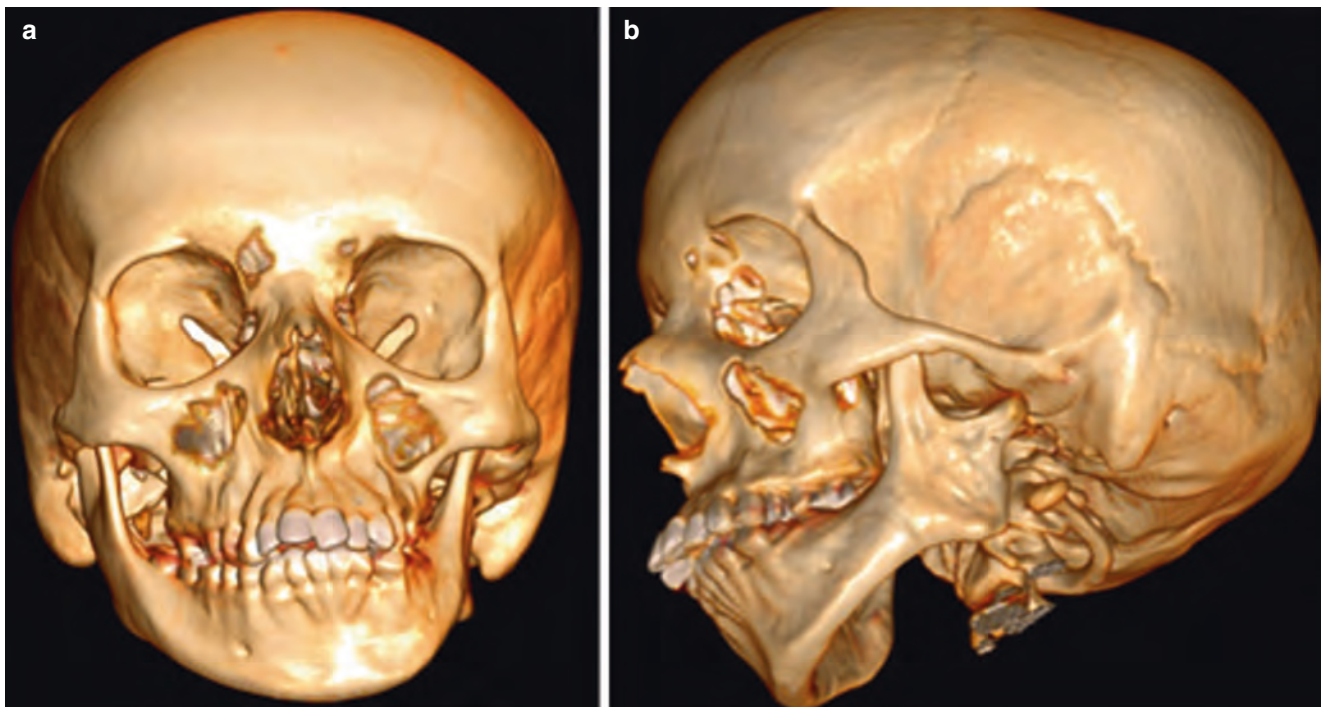
Fig. 78.3 (a–d) Kaban's modification of Pruzansky's classification for hemifacial microsomia (HFM). (a) Type 1, (b) Type 2A, (c) Type 2B (d) Type 3 Note that the temporomandibular joint (TMJ) in Type IIB is

medially, inferiorly and anteriorly displaced so as to be operationally equivalent to Type III



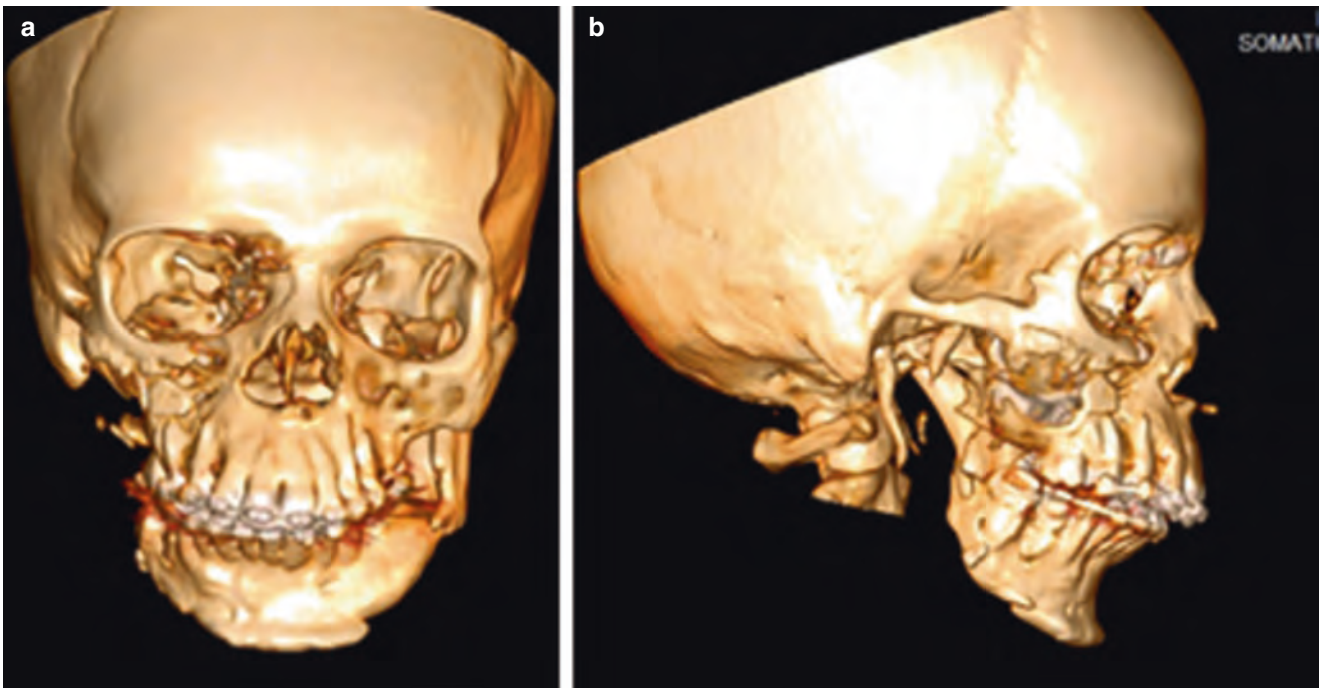
©Association of Oral and Maxillofacial Surgeons of India

Fig. 78.4 (a, b) CT scan of patient with left-sided Type 1 Kaban-Pruzansky deformity



©Association of Oral and Maxillofacial Surgeons of India

Fig. 78.5 (a, b) CT scan of patient with right-sided Type 2B Kaban-Pruzansky deformity



©Association of Oral and Maxillofacial Surgeons of India

Fig. 78.6 (a, b) CT scan of patient with right-sided Type 3 Kaban-Pruzansky deformity

78.1.3.2 Soft Tissue Defect

Soft tissue deformities may involve the ear, the seventh nerve and the muscles of facial expression and mastication. Subcutaneous tissues of the face may also be affected to varying degrees. Macrostomia is a common feature along with the presence of skin tags between the tragus and the commissure of the mouth. Lateral facial clefts (Tessiers 6, 7 and 8) may be present involving the soft tissue or hard tissue or both. Function of the cranial nerves, essentially the seventh and rarely the fifth, may be compromised [15, 16]. General soft tissue bulk of the subcutaneous fat and muscles may exhibit deficiency (Fig. 78.7). There may also be compromise in the function of the soft palate.

Skin Tags

Vestigial skin rests also called as auxiliary hillocks or skin tags are usually present along an imaginary line connecting the tragus of the ear to the commissure of the mouth. This is the embryonic line of fusion between the first and second pharyngeal arches. The tags are frequently present in varying

numbers and are associated with cartilaginous remnants, blind sinus tracts that may form inclusion cysts if obstructed [4–6] (Fig. 78.7).

Macrostomia

Macrostomia occurs as a result of failure of fusion of the maxillary and mandibular processes, leading to a cleft at the oral commissure including the skin and the underlying orbicularis oris (Fig. 78.10a, b). Sixty-one per cent of patients with HFM exhibit macrostomia as reported by Vento and colleagues [12].

External Ear Deformities

Meurman described a classification for deformities of the external ear which was modified by Marx [17, 18] (Fig. 78.11a–c):

- Grade I: Mild hypoplasia, with all structures present and obvious malformation.
- Grade II: Atresia of the external auditory canal, with a vertically orientated cartilaginous remnant.

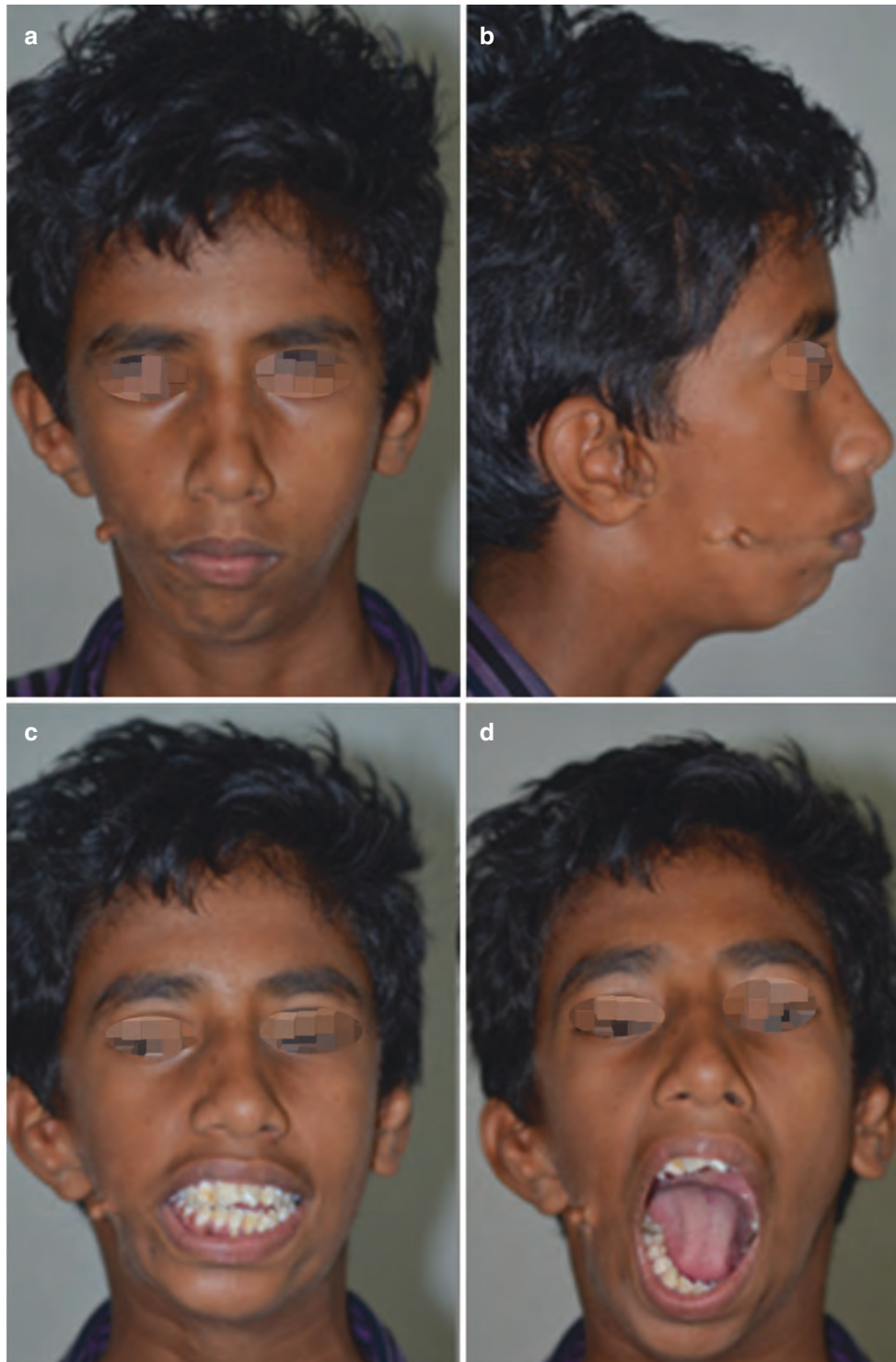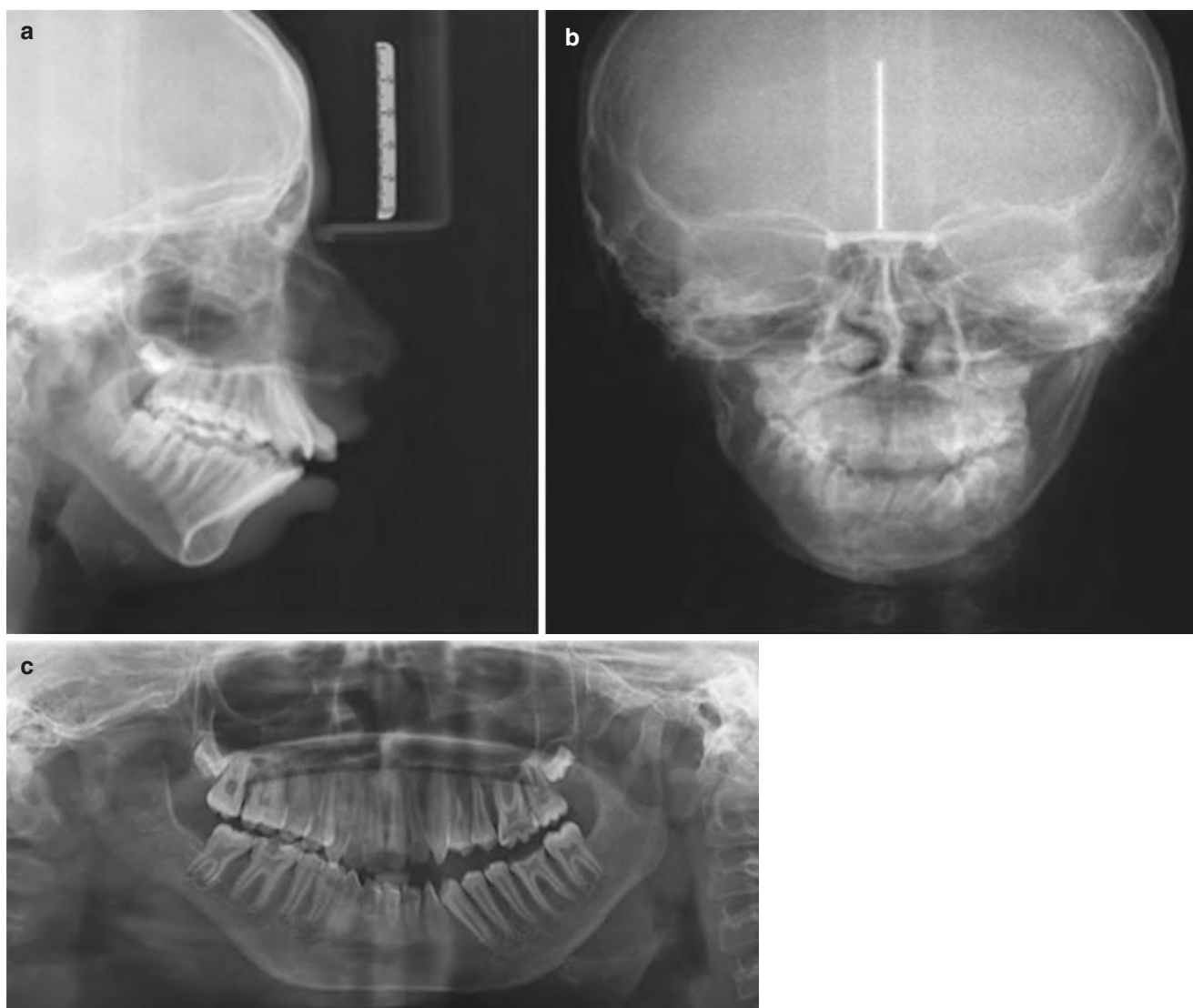


Fig. 78.7 (a–d) 15-year-old male, frontal and profile view (a, b) showing features of hemifacial microsomia such as lateral cleft and preauricular skin tags. (c) demonstrates macrostomia and malocclusion while

(d) shows exaggerated oral aperture with deviation of mandible to the right side on mouth opening (Also see Fig. 78.30b)

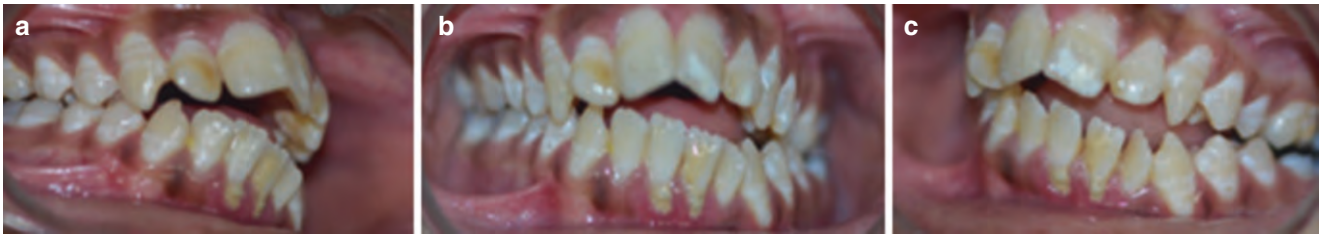Table 78.3 Clinical features of hemifacial microsomia and the spectrum of associated anomalies

Head and neck	Associated congenital anomalies
Maxillary and mandibular asymmetry with hypoplasia on the affected side	Cardiac defects (tetralogy of Fallot, ventricular septal defect, aortic coarctation, patent ductus arteriosus)
Microphthalmia	Lung hypoplasia
Hypoplastic adnexal structures	Renal agenesis, ectopic kidney, multicystic
Coloboma	Dysplastic kidney, vesicoureteral reflux, or ureteropelvic junction obstruction
Zygomatic hypoplasia	Vertebral anomalies
External ear abnormalities or atresia	Mental retardation, Arnold-Chiari malformation, encephalocele
Internal ear abnormalities	
Temporomandibular joint hypoplasia or absence	
Hypoplastic dentition or oligodontia	
Parotid hypoplasia or agenesis	
Plagiocephaly	
Torticollis	



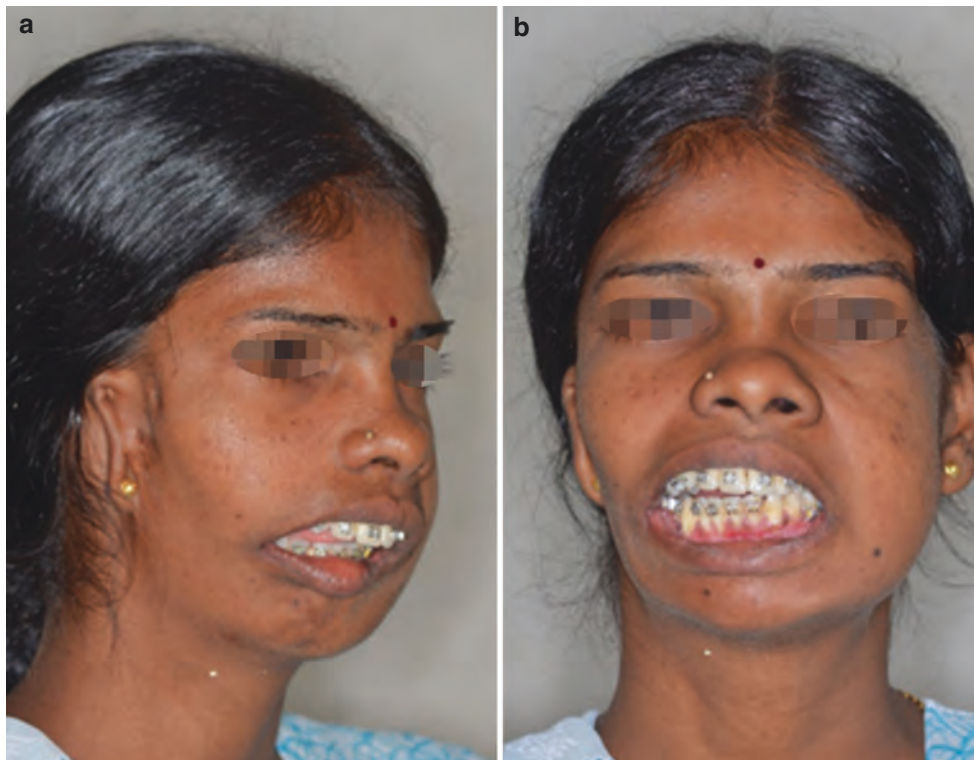©Association of Oral and Maxillofacial Surgeons of India

Fig. 78.8 (a–c) Radiographs lateral cephalogram (a), posteroanterior cephalogram (b) and OPG (c) showing features of asymmetry. OPG showing deficient body and ramus region



©Association of Oral and Maxillofacial Surgeons of India

Fig. 78.9 (a–c) Intraoral views showing malocclusion, asymmetric anterior open bite, canting and crowding



©Association of Oral and Maxillofacial Surgeons of India

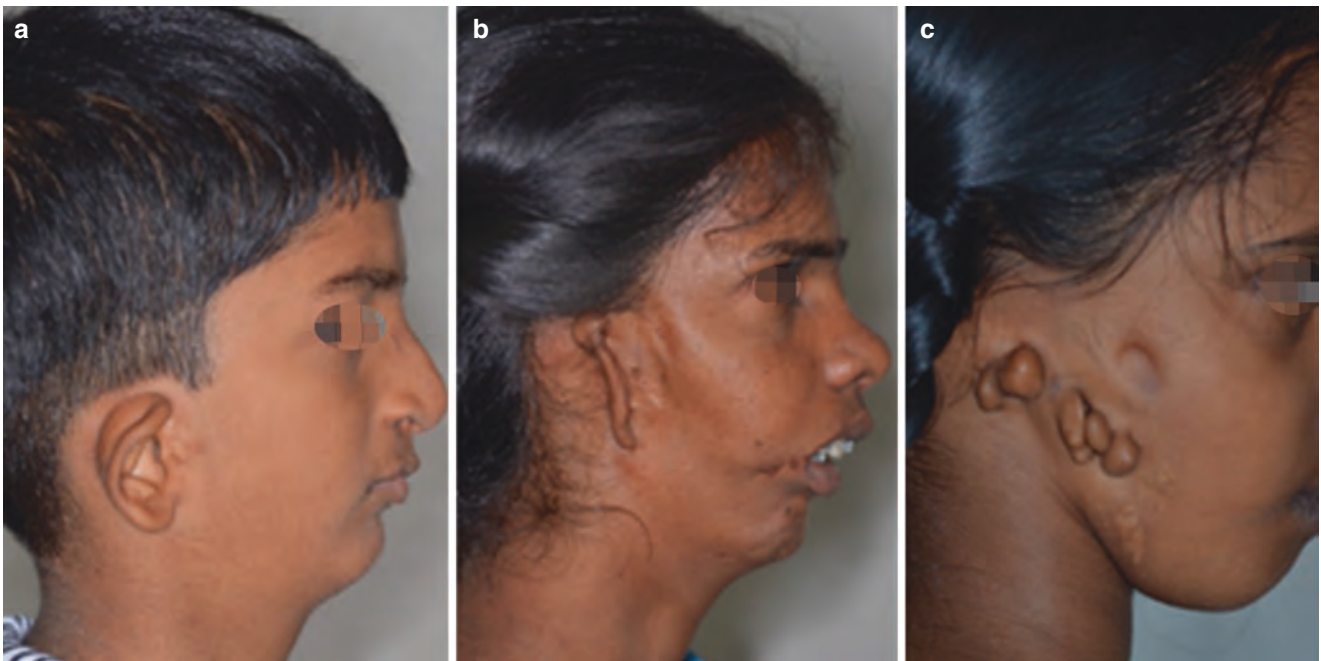Fig. 78.10 (a, b) (Left, profile view; right, frontal view): Adult with right-sided hemifacial macrostomia. Note the deviation on mouth opening to the deficient right side. Also note the preauricular skin tags and epibulbar lesions

- Grade III: Absent auricle, anteriorly and inferiorly displaced lobular remnant.
- Radiological assessment using temporal bone CT scans should be used to assess the middle ear structures.

Muscle Deficit

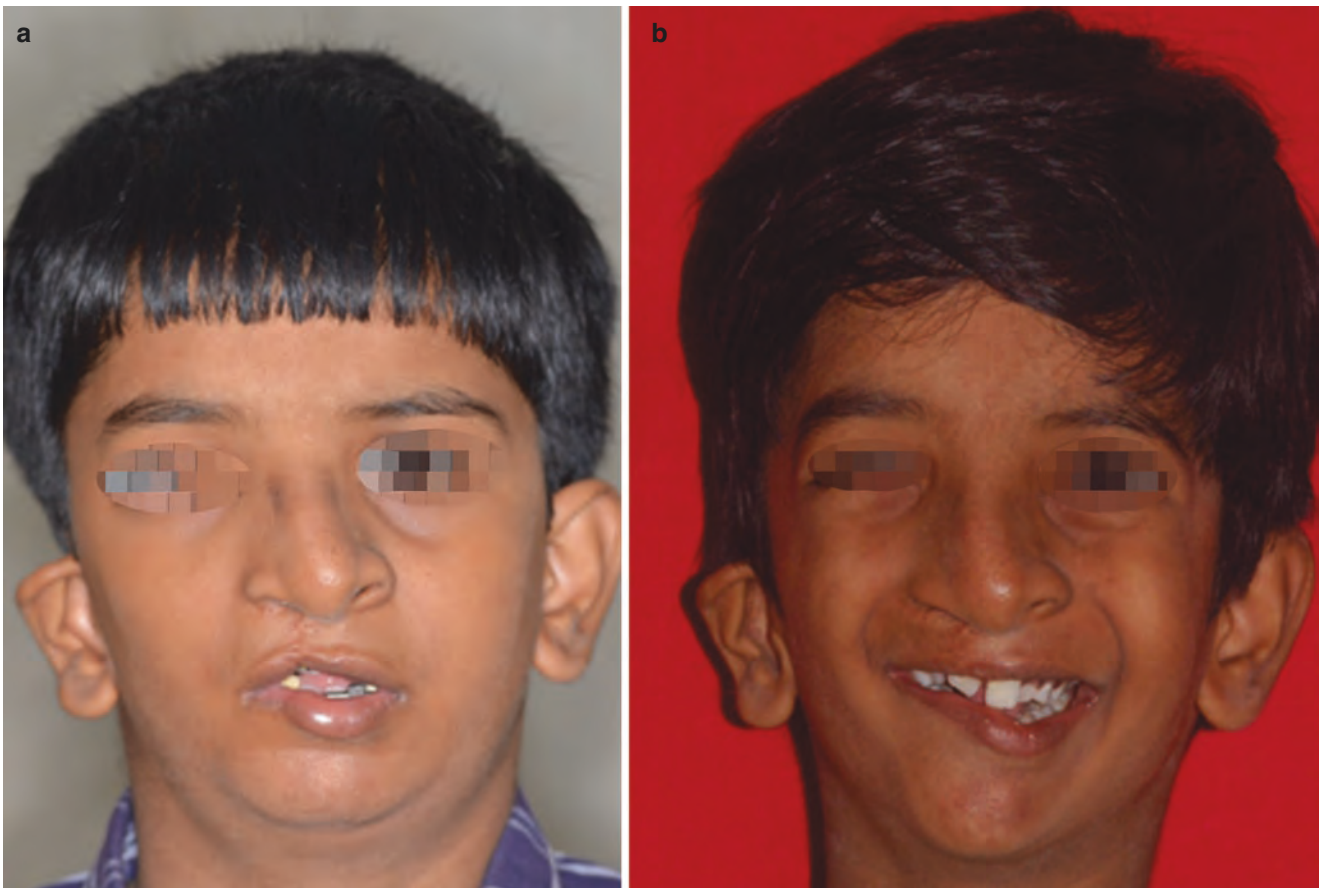Deficits in the temporalis and the pterygo-masseteric group of muscles may be seen in HFM. This also contributes to the skeletal deficit seen. A hypoplastic temporalis may be associated with a hypoplastic or at times absent ramus-condyle unit (RCU) which includes the coronoid process also; a similar

association is also evident with the presentation of the pterygo-masseteric muscles and the ramus of the mandible. With cases of increasing severity, the proximal aspect of the zygomatic arch may also be absent with the aponeurosis of the hypoplastic masticatory muscles filling that space. Lateral pterygoid muscle hypoplasia ranges from mild to complete absence and correlates with the extent of the skeletal defect. Hypoplasia of the muscles and deficiency of the RCU lead to abnormalities of the TMJ and also with absence or altered joint structures. This often leads to deviation of the mandible to the affected side at rest and on mouth opening (Fig. 78.12a).



©Association of Oral and Maxillofacial Surgeons of India

Fig. 78.11 (a) Grade 1 mild ear deformity, (b) Grade 2 moderate ear deformity, (c) Grade 3 severe ear deformity



©Association of Oral and Maxillofacial Surgeons of India

Fig. 78.12 (a) Unilateral cleft lip and palate patient with right-sided hemifacial microsomia, Grade 1 ear deformity, right-sided muscle weakness of orbicularis oris, buccinator and orbicularis oculi. (b) Deviated smile due to facial nerve deformity

Cranial Nerve Abnormalities

Approximately 25% of the patients with HFM are affected with cranial nerve deficits, resulting in features ranging from nerve weakness to complete paralysis. The marginal mandibular branch is the most commonly affected followed by the frontalis muscle dysfunction. Rarely, there may be a sensory deficit due to trigeminal nerve involvement along with total involvement of the facial nerve [19] (Fig. 78.12b).

Soft Palate Function

The cause for the soft palate deviation (to the normal side) in HFM has long been debated. It is proposed that the deviation may be due to a combination of skeletal asymmetry, neurological deficits, and hypoplastic musculature. Literature shows that patients with HFM are predisposed to velopharyngeal dysfunction, even in the absence of a palatal cleft [20].

78.1.4 Radiological Assessment

Considering the three-dimensional skeletal nature of the deformity, radiological assessment is of paramount importance. Conventional methods of 2D imaging are very helpful and still relevant in assessing the condyle anatomy and extent of asymmetry. Orthopantomogram, posteroanterior cephalogram, and lateral cephalogram should be taken for initial assessment (Fig. 78.9). With the advent of reconstructed 3D imaging, the surgeons can now evaluate the full extent of asymmetry including the cranial base and glenoid fossa (Figs. 78.5, 78.6 and 78.7). Scintigraphy or technetium scan can be done in these cases to rule out apparent hypoplasia due to hyperplasia of one side condyle (Fig. 78.13a, b).

78.1.5 Differential Diagnosis of Hemifacial Microsomia

Patient with HFM must be distinguished from those with Goldenhar syndrome, Treacher Collins syndrome, hemimandibular elongation, Parry-Romberg syndrome, juvenile rheumatoid arthritis, Nager syndrome, traumatic postnatal deformity, postaxial acrofacial dysostosis, muscle dysfunction, branchio-oto-renal syndrome (BOR), and maxillofacial dysostosis. The following is a table of distinguishing features of hemifacial microsomia and other entities (Table 78.4).

Hemifacial Microsomia with Cleft Lip and Palate

The incidence of HFM with concomitant orofacial clefting is a range between 18 and 61%, including presentations of atypical clefts and macrostomia. Fan et al. reported cleft lip with/without cleft palate in 10% of HFM patients. Thus, cleft lip and palate may actually be considered as a part of the HFM spectrum [20, 21]. The laterality and severity of presentation of cleft lip/palate correlate with the severity and side of presentation of HFM. This shows common embryological aetiopathogenesis of HFM and orofacial clefting. However, patients with HFM often present with velar deficiencies, leading to hypernasality and velopharyngeal insufficiency. Patients with HFM have a higher incidence of cleft maxillary hypoplasia than non-syndromic cleft patients. The already present abnormality in maxillary growth in HFM may further influence the midface deficiency seen in HFM patients with CL only.

78.1.6 Principles of Management of Craniofacial/Hemifacial Microsomia

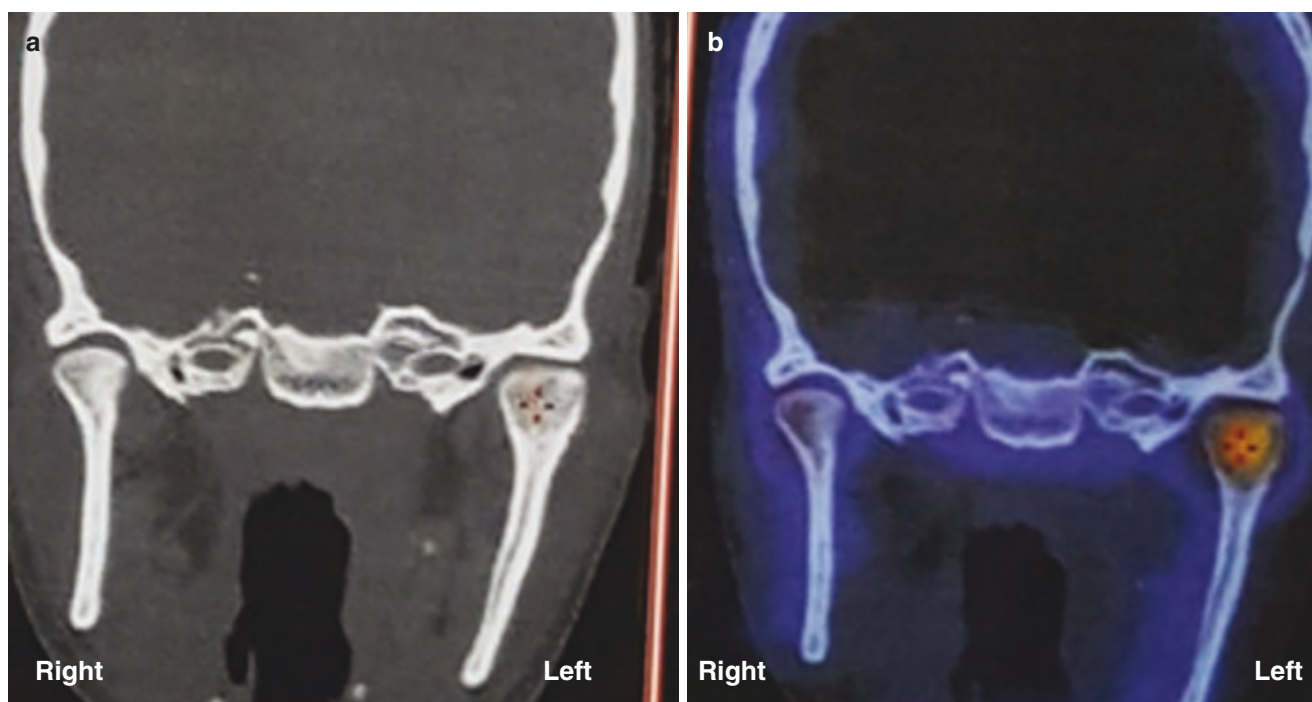
The principles involved in the management of HFM are described below. We have categorized them as per age and the required intervention. Growth considerations are important in formulating treatment plan. Various challenges and treatment methods have been described in literature with focus on the mandible and TMJ reconstruction (Fig. 78.14 and Table 78.5).

78.1.6.1 Neonates and Infants

Due to the morphological severity of the skeletal deformities, severe functional compromise of the infant's airway can happen after birth. Later on, the presence of a compromised airway can also affect the child's ability to swallow. Hence, the primary management in a neonate should be focused on stabilization of the airway and assisted feeding [22].

78.1.6.2 Airway

A grossly compromised airway may necessitate procedures to maintain the patency of the child's airway and facilitate the child to thrive. These procedures are neonatal distraction (early distraction osteogenesis), tongue lip adhesion, or tracheostomy [22, 23]. The neonatal distraction has fallen into disfavour due to future unpredictable



©Association of Oral and Maxillofacial Surgeons of India

Fig. 78.13 (a) SPECT scan in the case of facial asymmetry. (b) Note the active uptake on the left side. Technetium scan can be done to rule out asymmetry due to contralateral condylar hyperplasia

Table 78.4 Differential diagnosis of Hemifacial Microsomia

Other entities	Distinguishing features
Treacher Collins	Always bilateral
Old undiagnosed condylar trauma	Condyle and ramus are short, absence of any other soft tissue features and normal ears. History of trauma at birth
Goldenhar syndrome	Vertebral anomalies and epibulbar dermoids and/or eyelid colobomas
Hemimandibular elongation	Mandible deviates to unaffected side. Normal form and size of condyle, slender neck and long ramus Not present since birth, unlike HFM
Juvenile rheumatoid arthritis	Pain and morning stiffness in the affected joint. Multi-articular nature of disease
Parry-Romberg syndrome	Facial atrophy of subcutaneous fat, associated skin, cartilage, and bone which is often unilateral and slow progressing Multisystem involvement in some cases. Presence of coup de sabre Acquired unlike HFM
Nager acrofacial dysostosis	Disorder of facial, limb, and skeletal morphogenesis

growth and possibility of tooth bud damages. Most children presenting with HFM may require assisted feeding using nasogastric tubes or gastrostomy for a few weeks to months.

78.1.6.3 Management of Associated Orofacial Clefting

The incidence of orofacial clefting occurring with HFM is approximately 10%. The most common form of clefting apart from cleft lip is Tessier 7 facial cleft or macrostomia (Fig. 78.15a, b). The cleft is repaired at 3–6 months of age as per the standard protocol [20]. Cleft lip and palate is more severe in HFM and is associated with worse outcomes. There is tissue hypoplasia and neuromuscular deficiency of pharyngeal muscles in patients with HFM. This may be responsible for the development of palatal fistulas and exacerbation of VPI, making management of cleft palate more challenging in such cases.

78.1.6.4 Intermediate Surgical and Orthodontic Management

Management during the growth phase in HFM differs from that of an adult. Intermediate surgical management includes reconstruction of the external ear which may be planned at 6–7 years as the contralateral ear achieves its full growth during this time. Reconstruction of the cranio-orbital region is usually accomplished between 7 and 9 years as calvarial growth is almost complete during this time. A split calvarial graft to reconstruct the lateral orbital rim and zygoma is the

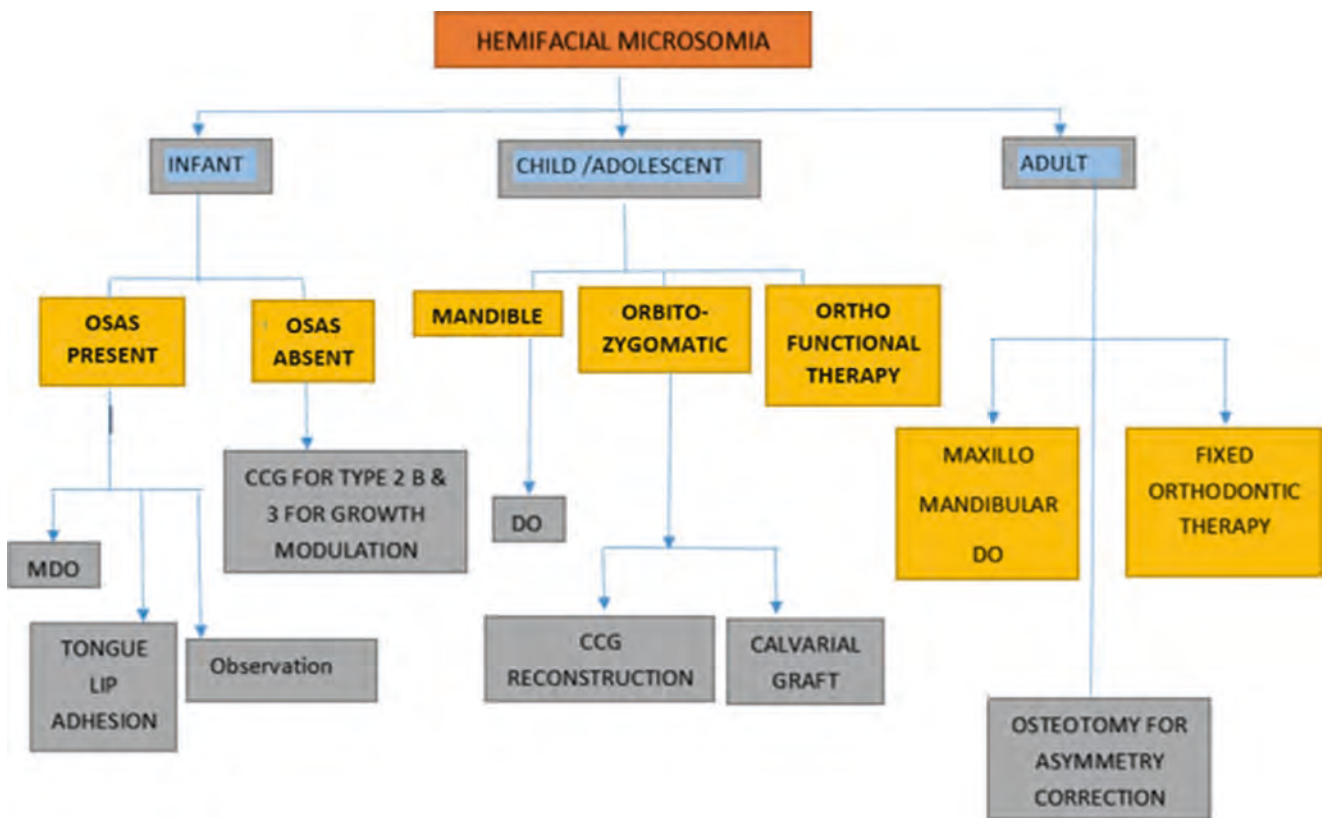


Fig. 78.14 Flowchart depicting algorithm of treatment at various levels according to growth

Table 78.5 Challenges and corrections needed necessary at different ages

Early	Intermediate (during growth)	Delayed (after completion of growth)
<ul style="list-style-type: none"> • Airway • Swallowing • Vision • Hearing • Cleft lip and palate 	<ul style="list-style-type: none"> • Skeletal correction (DO) • Soft tissue correction (free fat transfer) • Nerve deficit 	<ul style="list-style-type: none"> • Definitive skeletal correction (DO + OGS) • Soft tissue correction (fat/microvascular free flaps)

graft of choice for reconstruction of deficient zygomatico-orbital region. Surgeons have also used temporo-parietal myo-osseous flaps for better bulk, contour and retention of graft in place.

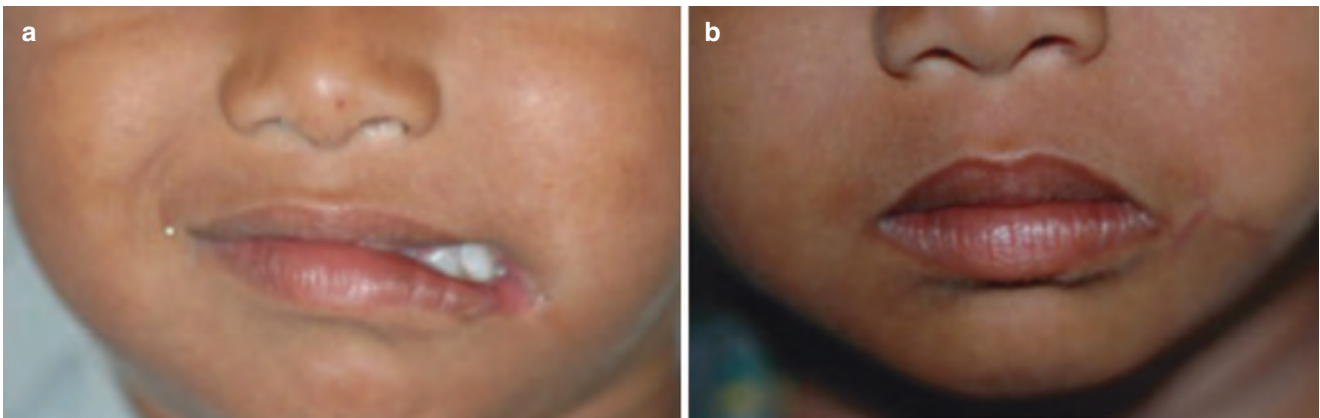
Orthopaedic growth modification can help these patients to correct occlusion in early stage [23–25]. If the patient has growth potential, with the stimulus provided by a hybrid functional appliance and stretching the soft tissue, growth can be increased on the affected side. The child must have at least 20 mm mouth opening to ensure that proper translation of condyles allows mandible growth. An asymmetric func-

tional appliance (hybrid) that guides the mandible to a new postural position, controls the eruption of teeth and inhibits the soft tissue pressure is used [26]. It directs the developmental growth of mandible three dimensionally.

An orthodontist should constantly monitor the eruption of primary and permanent teeth to improve mandibular deficiency and maxillary canting. After the adolescent growth spurt, occlusion can be achieved by means of fixed orthodontic appliances.

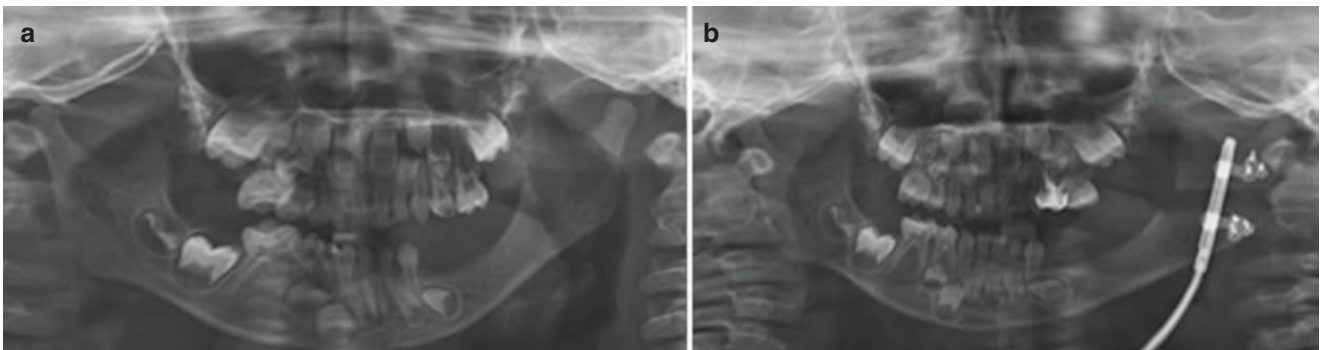
78.1.6.5 Correction of Maxillomandibular Complex

Variations in the maxillomandibular complex management range from early intervention (Figs. 78.16a, b, 78.17a, b and 78.18a, b) to late reconstruction after growth completion. Wait-and-watch policy with only dental and orthodontic interventions may be adopted to reduce the impact of the deformity on the dental occlusion and masticatory function. Definitive surgical reconstruction of the maxilla, mandible and TMJ can be taken up after cessation of growth [27–31].



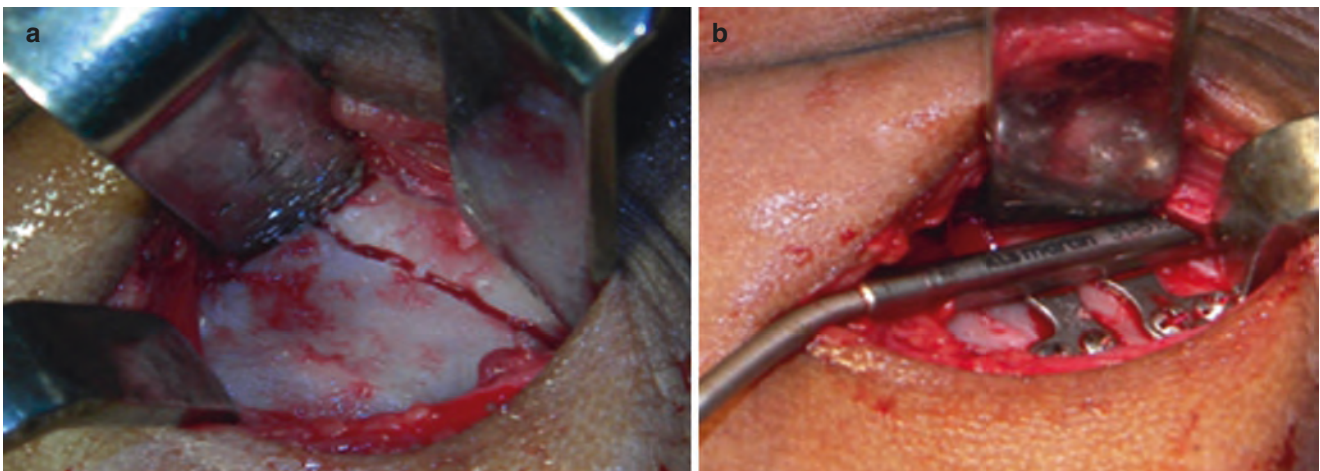
©Association of Oral and Maxillofacial Surgeons of India

Fig. 78.15 (a, b) Surgical correction of lateral facial cleft through commissuroplasty. (a) pre-operative photo showing macrostomia. (b) post-operative photo demonstrating correction with commissure reconstruction



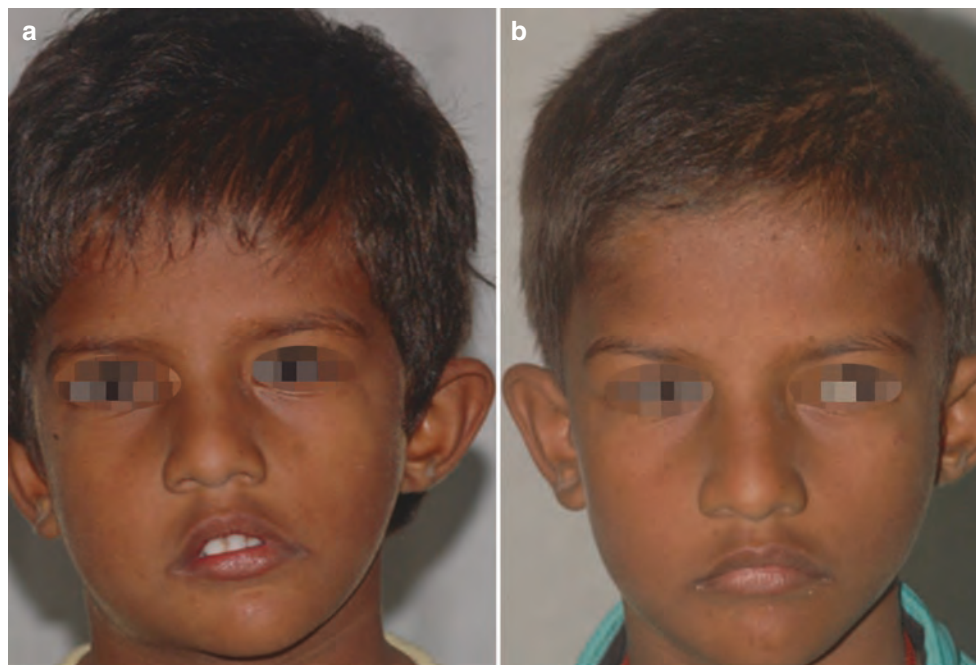©Association of Oral and Maxillofacial Surgeons of India

Fig. 78.16 (a) Preoperative radiograph-deficient left ramus and body. Note the absence of teeth and tooth buds on the left side. (b) Vertical ramus distraction done to achieve symmetry of the mandible and chin



©Association of Oral and Maxillofacial Surgeons of India

Fig. 78.17 (a) Intraoperative photograph of the same patient as in Fig. 78.16, showing the horizontal cut. (b) Distractor removal after 3 months showing consolidated anatomic bone formation



©Association of Oral and Maxillofacial Surgeons of India

Fig. 78.18 (a) Preoperative frontal photo of the same patient in Fig. 78.16 showing left-sided HFM with ipsilateral chin deviation and facial asymmetry. (b) Postoperative view showing considerable symmetry of the face

Functional Appliance Therapy

In cases where the ramus-condyle unit (RCU) shows reasonable function to translate into skeletal growth, growth modification with the use of functional appliances does play a role by achieving the following outcomes:

1. To facilitate eruption of the dentition in a favourable pattern.
2. To prevent dentoalveolar compensatory mechanisms from worsening the deformity.
3. To passively guide the growth of the ramus-condyle unit.

The focus of functional therapy is repositioning the affected condyle to a more inferior and anterior position to enable the mandible to grow and catch up for the intrinsic skeletal deficit [29–31].

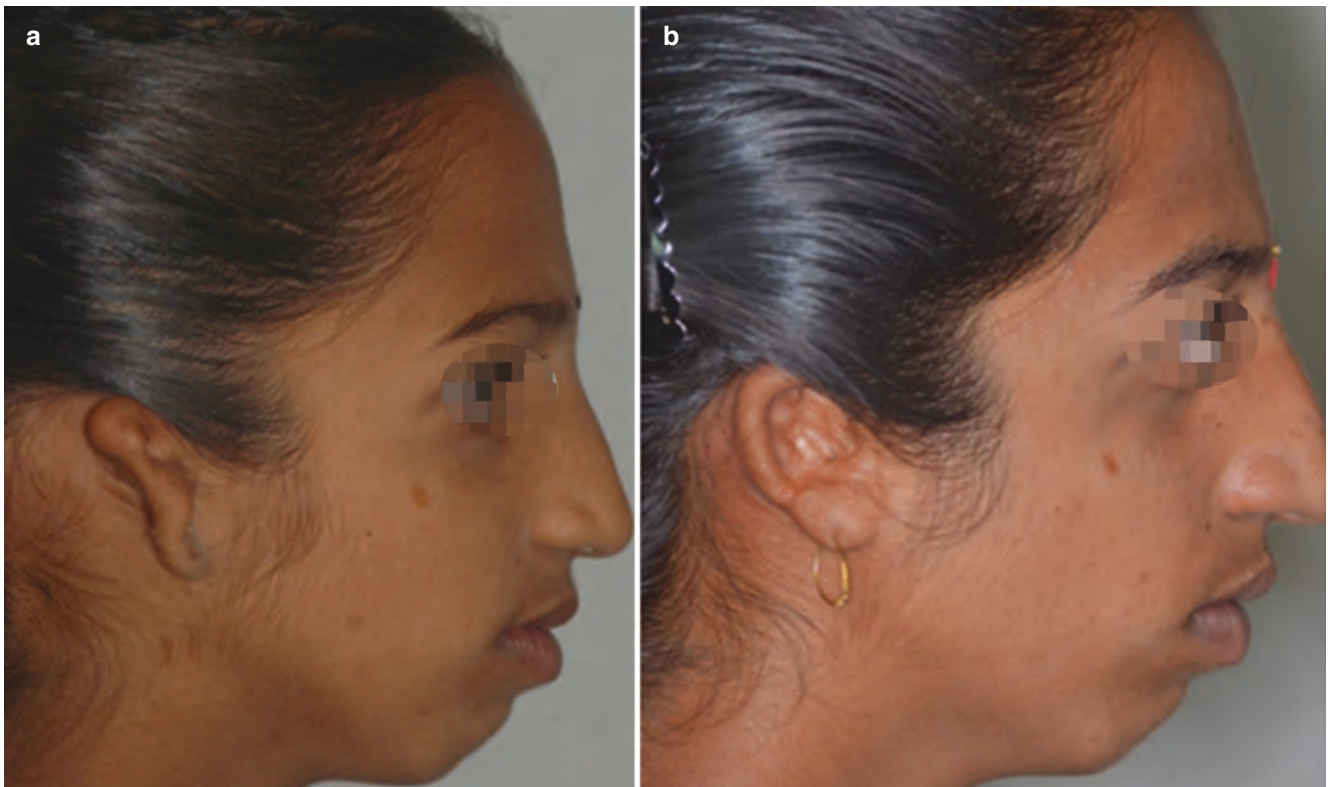Ear Reconstruction

Construction of the external ear is a priority in the aesthetic management of HFM patients. Two important factors that affect the ability to construct the ear are the decreased anteroposterior dimension of the upper face and the absence

of an adequate platform (i.e. temporal bone cavity). The position and quality of the soft tissue remnants should also be kept in mind while planning surgery. An ear reconstructive surgeon and the maxillofacial surgeon should work collaboratively to determine the most ideal location of the ear relative to the future constructed ramus-condyle unit. Reconstruction options include (1) autogenous rib cartilage, (2) alloplastic options such as Medpore, and (3) tissue-engineered auricular framework. The technique of ear reconstruction is dealt with in detail in Chap. 35 on “Ear Reconstruction”.

Though autologous chondral cartilage for reconstruction still remains the best option, it requires a multistage approach to (1) harvest the costal cartilage grafts and create a framework by carving (time-consuming and fixation and retaining of shape challenges), (2) place the graft (positioning as per existing altered morphology), (3) transpose the lobule (soft tissue deficiency—tissue expander may have to be used) and (4) create a post-auricular sulcus (with skin graft and split temporalis graft) (Fig. 78.19a, b).

Various materials have been used for alloplastic ear reconstruction with varied results. Porous polyethylene’s inert nature and pore size provide and allow for some tissue ingrowth and are safe to use. The alloplastic materials always carry a risk of rejection and infection and may not have accurate sizes and shapes as they are stock implants with limited sizes.



©Association of Oral and Maxillofacial Surgeons of India

Fig. 78.19 (a) Pre- and (b) post operative photograph of ear reconstruction using rib graft (Also refer Chap. 35 on Ear reconstruction)

Tissue-engineered 3D cartilage reconstruction and its use in regular clinical practice are under trial in many parts of the world though long-term clinical studies still lack regarding its application and optimal results.

Delayed Management in Adults

Management in adults includes definitive reconstruction for skeletal and residual soft tissue deficits. With the advent of 3D imaging and computer-assisted surgical planning and printing, precise spatial relationship of the cranial structures with maxillomandibular complex can be studied. This printed models give the surgeon extra weapon outside theatre to simulate surgery and make appropriate decisions before going to theatre. Appropriate treatment plan can be virtually executed, and a CAD-CAM splint can be fabricated to facilitate the accurate surgical outcome [32, 33] (Table 78.6).

Orthodontics for Definitive Skeletal Surgery

Orthodontic preparation before definitive surgical correction of the face is similar to the conventional pre-surgical orthodontic protocols. These include arch levelling and alignments, de-crowding and transverse widening if neces-

Table 78.6 Principles of management of the deformed temporomandibular joint

Type of TMJ involvement	Management
Type I	Correction of vertical dimension Adjusting maxillomandibular relationship and facial asymmetry
Type IIa	Augmentation of RCU, preservation of condyle/glenoid fossa
Type IIb	Neocondyle reconstruction/preservation of glenoid fossa, augmentation of RCU + type I management
Type III	Neocondyle and glenoid reconstruction, augmentation of RCU + type I management Autogenous or alloplastic reconstruction (refer Chap. 89)

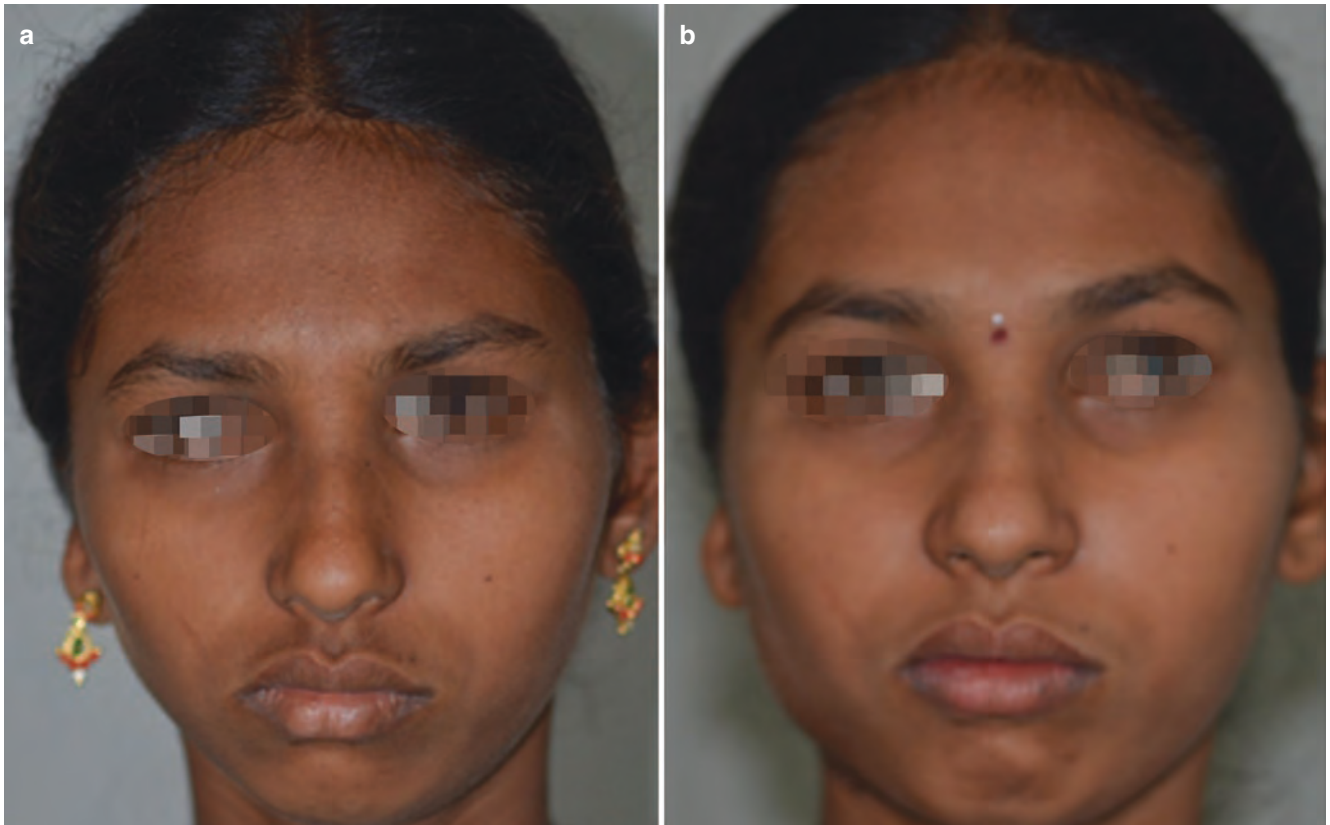sary. Compromise may be necessary in many cases due to the extreme lingual tilt on the affected premolar-molar areas, leaving few options for the orthodontist due to limited bone availability for straightening the teeth [29, 30].

Conventional orthodontic treatment may take longer period and may necessitate the use of anchorage screws for aligning some teeth.

Type 1 and 2A

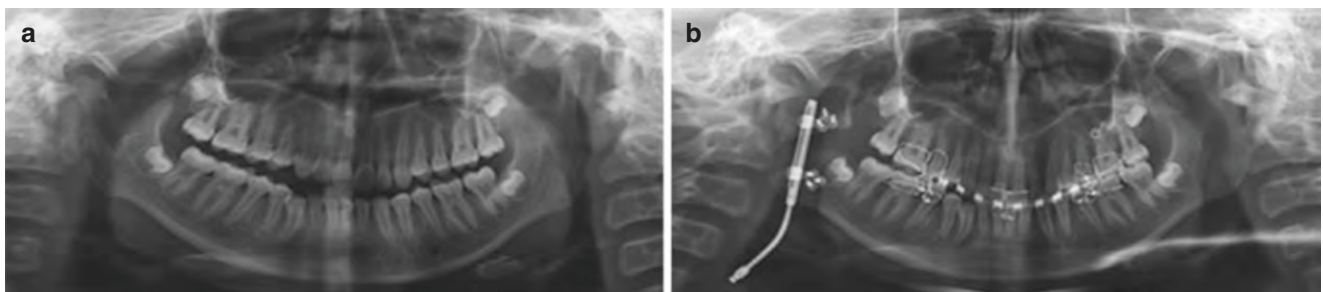
In types 1 and 2A, the glenoid and condylar components of TMJ are morphologically intact with minimal hypoplasia. There is no specific indication for the reconstruction of the TMJ since the joint exhibits normal movement characteristics, and the patient is able to demonstrate adequate mouth opening and masticatory function. Deviation while mouth opening can be seen towards the affected side.

Teeth eruption and angle of its placement will be hampered even in these two types of situations which will require further definitive treatment. Simultaneous maxillo-mandibular distraction introduced by Monasterio and Molina is an alternate method for achieving maxillary and mandibular corrections without disturbing the dental intercuspation and occlusal cant [34] (Figs. 78.20a, b and 78.21a, b).



©Association of Oral and Maxillofacial Surgeons of India

Fig. 78.20 (a) Preoperative view showing right-sided maxillomandibular deficiency. (b) Postoperative view showing correction of asymmetry following simultaneous maxillomandibular distraction



©Association of Oral and Maxillofacial Surgeons of India

Fig. 78.21 (a, b) Radiographs of the same patient as in Fig. 78.20 treated with maxillomandibular distraction (Molina's technique). (a) Pre-distraction orthopantomogram demonstrating vertically deficient

ramus-condyle unit on the right side. (b) Post-distraction xray showing lengthening of the right ramus-condyle unit with the distractor in-situ

Type 2B

Type 2B patients exhibit severe hypoplasia of both the condylar and the glenoid elements of the joint, thus causing altered functioning of the joint. This greatly reduces or there is a complete absence of the translatory movement of the joint sparing the rotatory movement. The mandible may completely deviate towards the affected side. The arc of rotation completely shifted, leading to malocclusion and scissor bites sometimes.

Distraction osteogenesis can be used to correct the deficiency of the mandibular body along with reshaping the glenoid and condylar process. The use of osteotomies to correct the dentofacial deformity is also performed either in the same setting or in a staged manner.

Options for reconstruction of the ramal-condylar unit are another concern which can be approached with costochondral grafting and alloplastic joint reconstruction [35]. The costochondral graft for stimulated growth should be used by the age of 7 years, which can be used as an onlay graft on top of the existing ramal segment in the correct position of glenoid fossa. However, large series of cases with success in this technique lacks the scientific evidence of growth similar to the unaffected joint, and reports of under- and overcorrection are plenty in literature.

Type 3

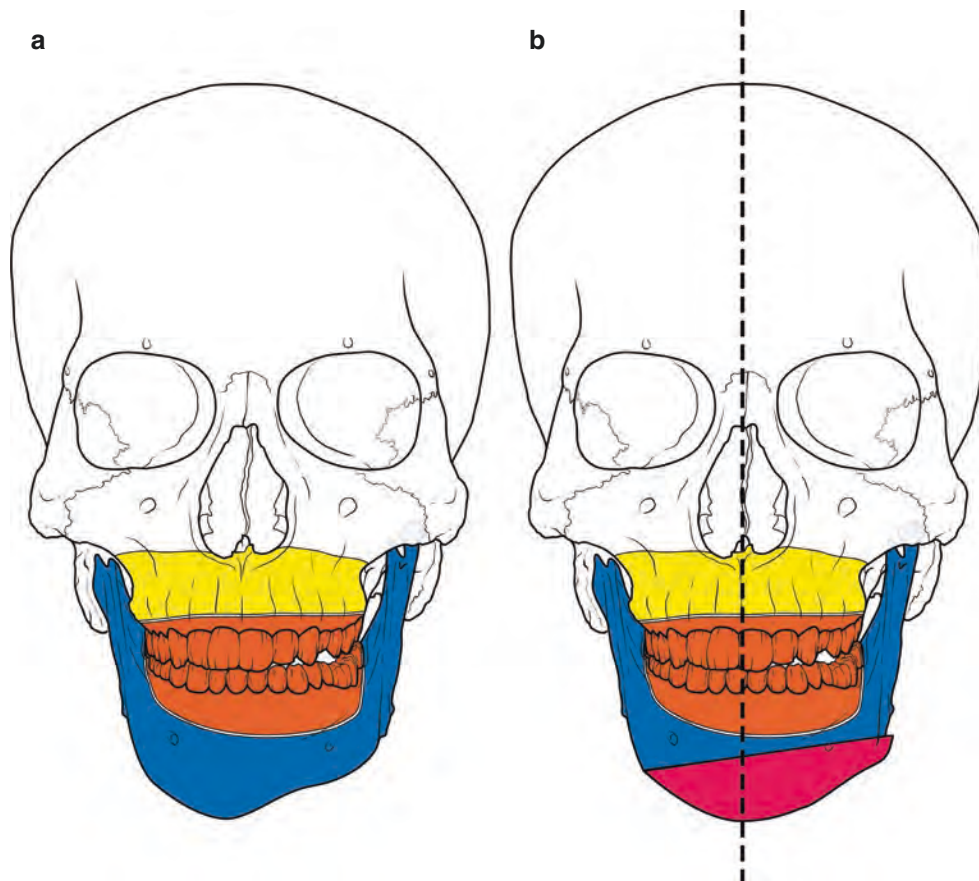
Patients with Type 3 deformities require total reconstruction of the TMJ, i.e. the glenoid-zygomatic complex region and the ramal-condylar unit. For the growing adolescent due to growth completion, glenoid reshaping and costochondral graft reconstruction of the RCU may be undertaken. Total alloplastic joint reconstruction with concomitant orthognathic surgery should be done in adults.

Posterior distraction of existing mandibular segment to create ramal-condylar unit has ended up with limited success due to lack of posterior support of distraction advancing segment and unpredicted movement in 3D dimensions. It was found in authors' experience that the correct direction control of upwardly directing condylar segment is difficult to achieve towards a missing or defective glenoid fossa, and many times the position can alter more medial and anterior than expected rather than posterior towards external auditory meatus.

Management of the Maxillomandibular Complex

Type 1

The minimal asymmetry and deformity associated with a Type 1 HFM may be amenable to minor surgical corrections such as genioplasty (Fig. 78.22a, b). Since the occlusion may



©Association of Oral and Maxillofacial Surgeons of India

Fig. 78.22 (a, b) Diagrammatic representation of surgical management of Type 1 Kaban-Pruzansky (a) deformity with isolated genioplasty for asymmetry correction (b)

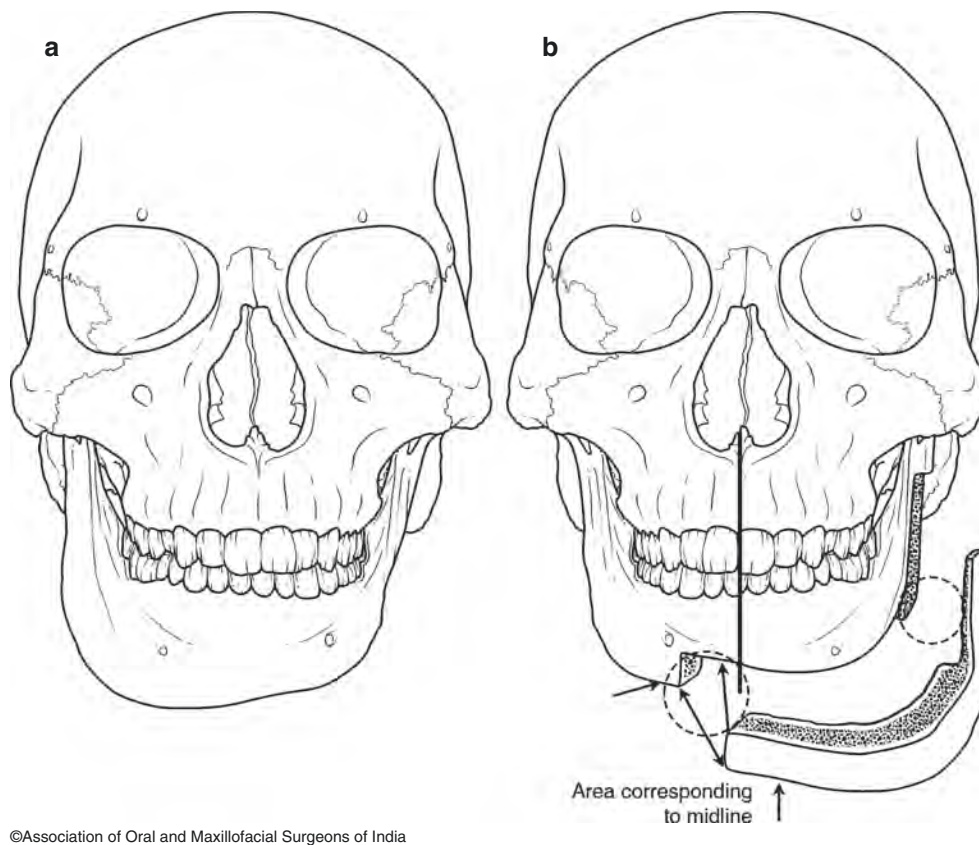
be normal or demonstrate minimal occlusal canting, orthognathic surgical correction may not be warranted.

In cases with minimal asymmetry where the patient is not willing to undergo a surgery of the entire maxilla-mandibular complex, it is possible to achieve facial midline symmetry by means of altering the midline chin and mandibular body orientation through an extended operation involving the basal bone of the chin and body of the mandible. It was published by Paul C Salins in 2008 [36]. The author of this chapter was happy to have learned this technique from Salins himself and greatly understood the concept of this 3D movement of genial bone along with body and ramus of the mandible to the unaffected side without altering the occlusal relationship of the maxilla or mandible.

But this technique had obvious disadvantage in the form of significant relapse due to large movements and requirement for multiple points of fixation.

At this juncture, the author of this chapter has designed a distractor which can be placed below the lower border of the mandible to move the genial-body-ramus unit in desired direction by incremental distraction similar to other distraction protocols. This completely eliminated the need for any plate usage, better stability without relapse and more or less excellent unlimited movement in all three directions. This is completely a basal bone distraction which can be either performed in isolation or in combination with other distractions and osteotomies of the maxilla-mandibular skeleton (Figs. 78.23a, b, 78.24a, b, and 78.25a, b).

One of the key advantages of MDO is that the bone movement produces good contour of the chin area along with flat unaffected part of the mandible, and it obviously stretches and accommodates the redundant excess submental-submandibular skin available to a more symmetrical position as shown in Fig. 78.26a, b.



©Association of Oral and Maxillofacial Surgeons of India

Fig. 78.23 (a, b) Orthomorphosis of deficient mandible. (a) Diagrammatic representation of a left sided HFM, (b) osteotomy design for correction of the left sided deficiency

Type 2A

Patients with Type 2A deformities require planned pre-surgical orthodontic interventions for definitive orthognathic correction (Fig. 78.27a–d).

Bimaxillary surgery is planned to achieve the following goals:

Maxilla and midface

1. Segmental maxillary procedures for correction of cross-bites.
2. Derotation of the maxilla to achieve midline corrections.
3. Augmentation of the zygomatic complex where necessary.
4. Cant correction.

Mandible

1. Bilateral sagittal split osteotomy procedure to correct the occlusal canting and yaw correction.
2. An inverted “L” or a subsigmoid osteotomy is indicated to achieve elongation of the RCU.

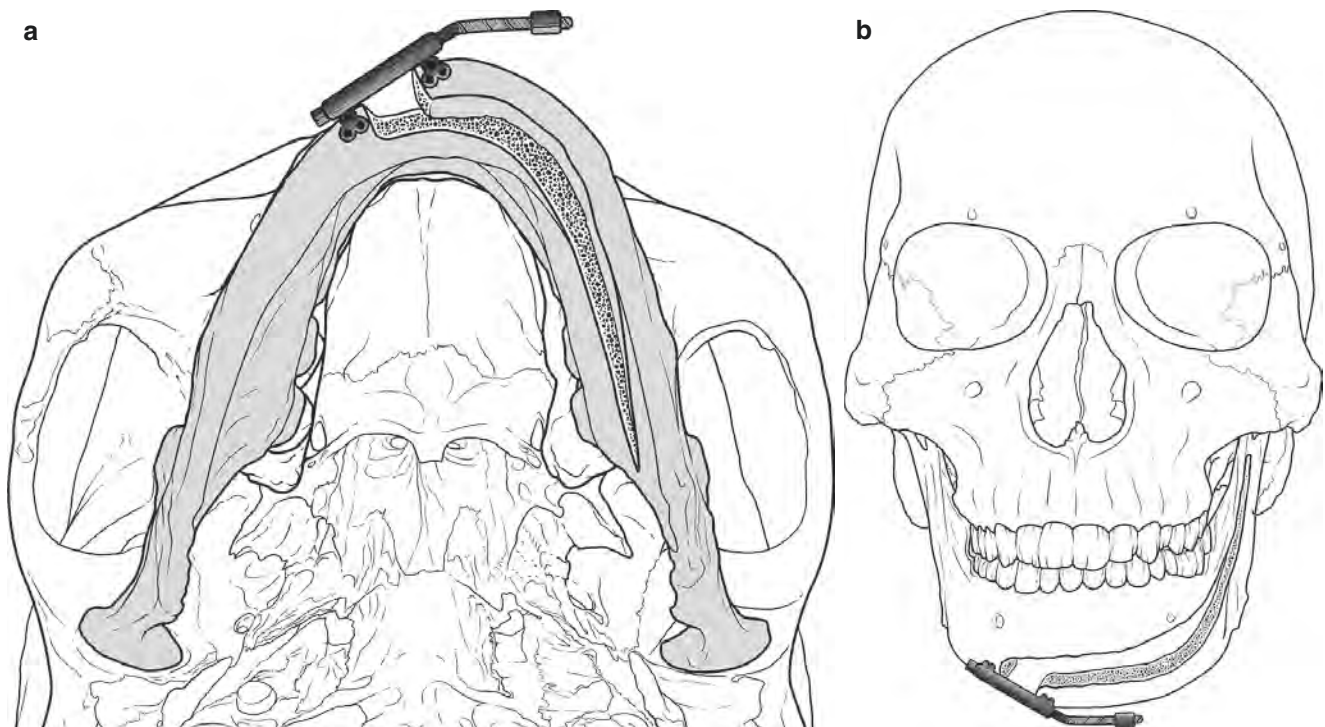
Types 2B and 3

As explained earlier, types 2B and 3 patients require reconstruction of the TMJ as the primary goal. This may be executed either as a Stage 1 correction with only maxillomandibular correction or as Stage 2 with joint reconstruction (Fig. 78.27).

Thus, although skeletal correction improves the dental occlusion and skeletal symmetry, it may accentuate the existing soft tissue discrepancy. Soft tissue augmentation should be taken up after hard tissue correction. Various methods are available such as fat transfer, microvascular free flap for adipose tissue transfer and alloplasts such as Medpore and nanogels to give shape to deficient soft tissue (Fig. 78.28a, b).

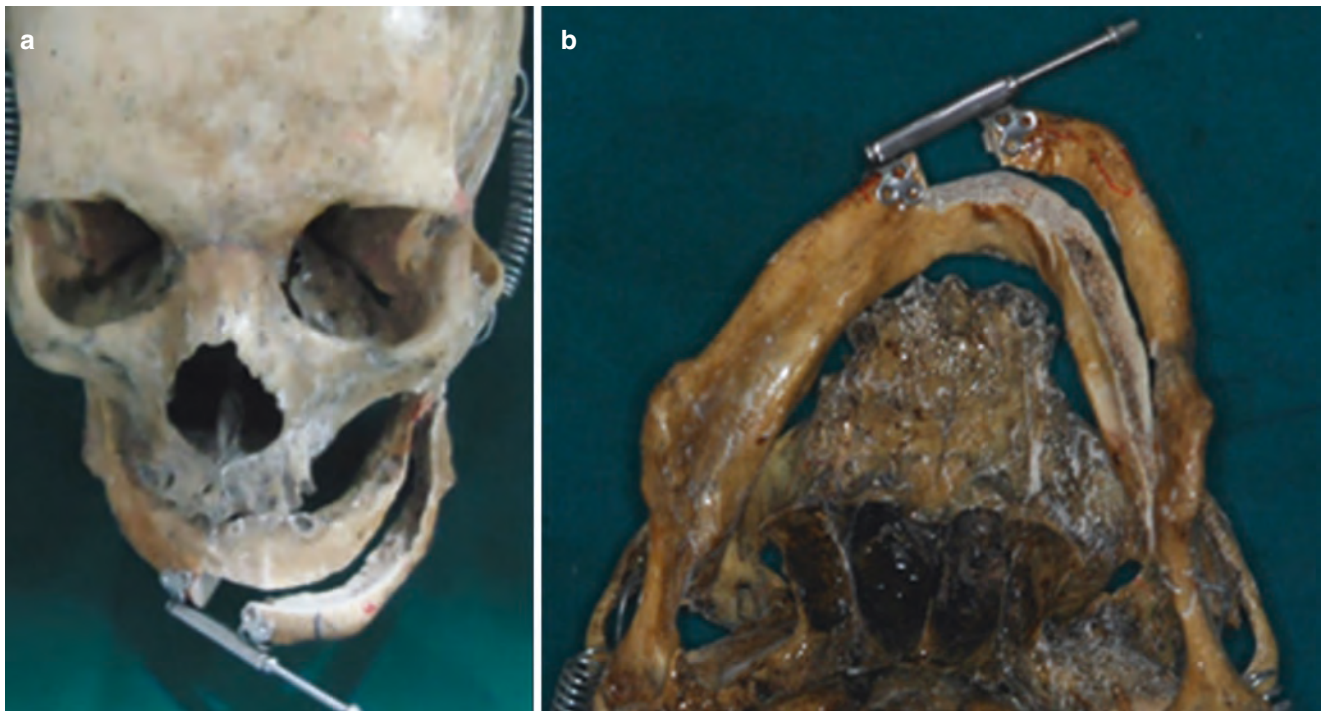
78.1.7 Controversies in Surgical Management of HFM*Growth Considerations and Role of Early Mandibular Reconstruction in HFM.*

HFM has been reported as a nonprogressive disorder, i.e. proportional deficiency of the face is maintained throughout the growth of the child. Indications for early reconstruction of the RCU during early childhood, especially in types 2B and 3



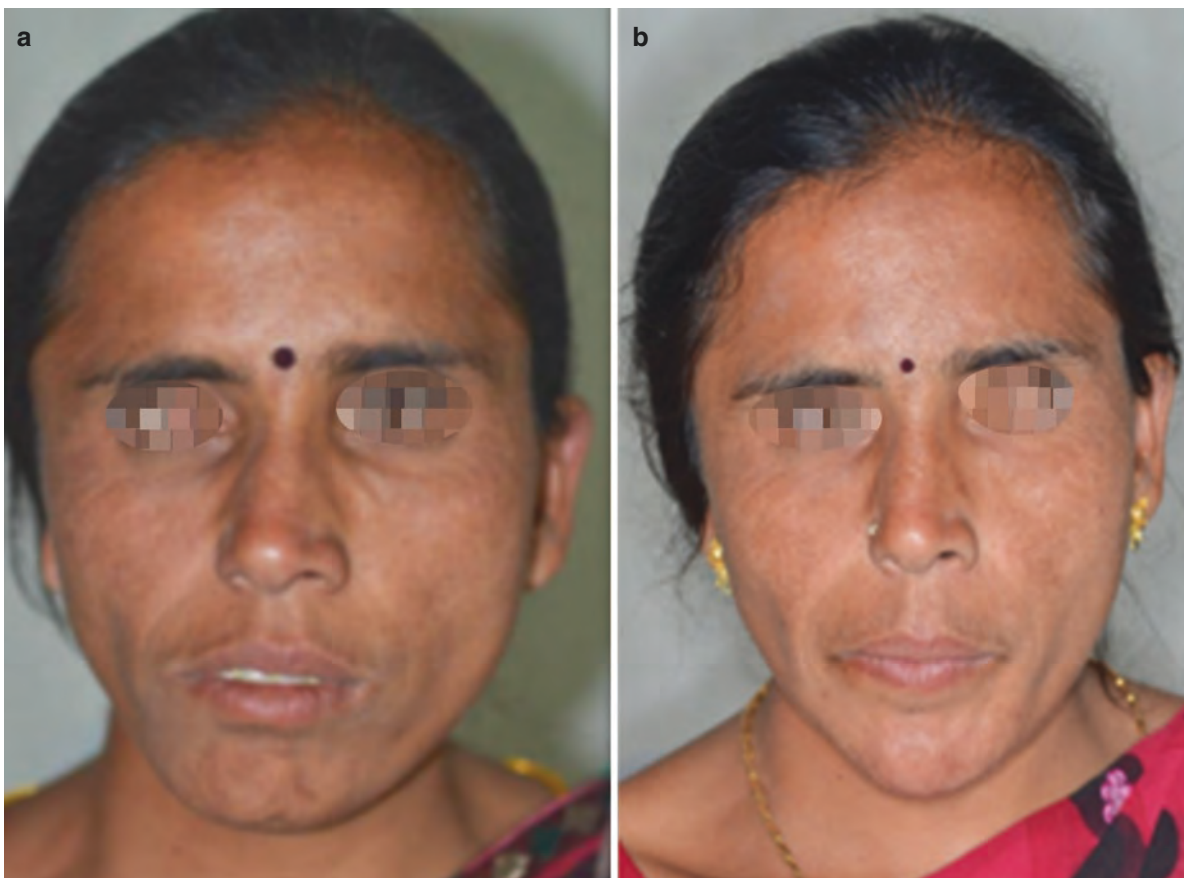©Association of Oral and Maxillofacial Surgeons of India

Fig. 78.24 (a, b) Pictorial view of basal bone osteotomy and orthomorph distractor placement. (a) Basal view showing distractor position for orthomorph distraction method, (b) frontal view of the distractor position



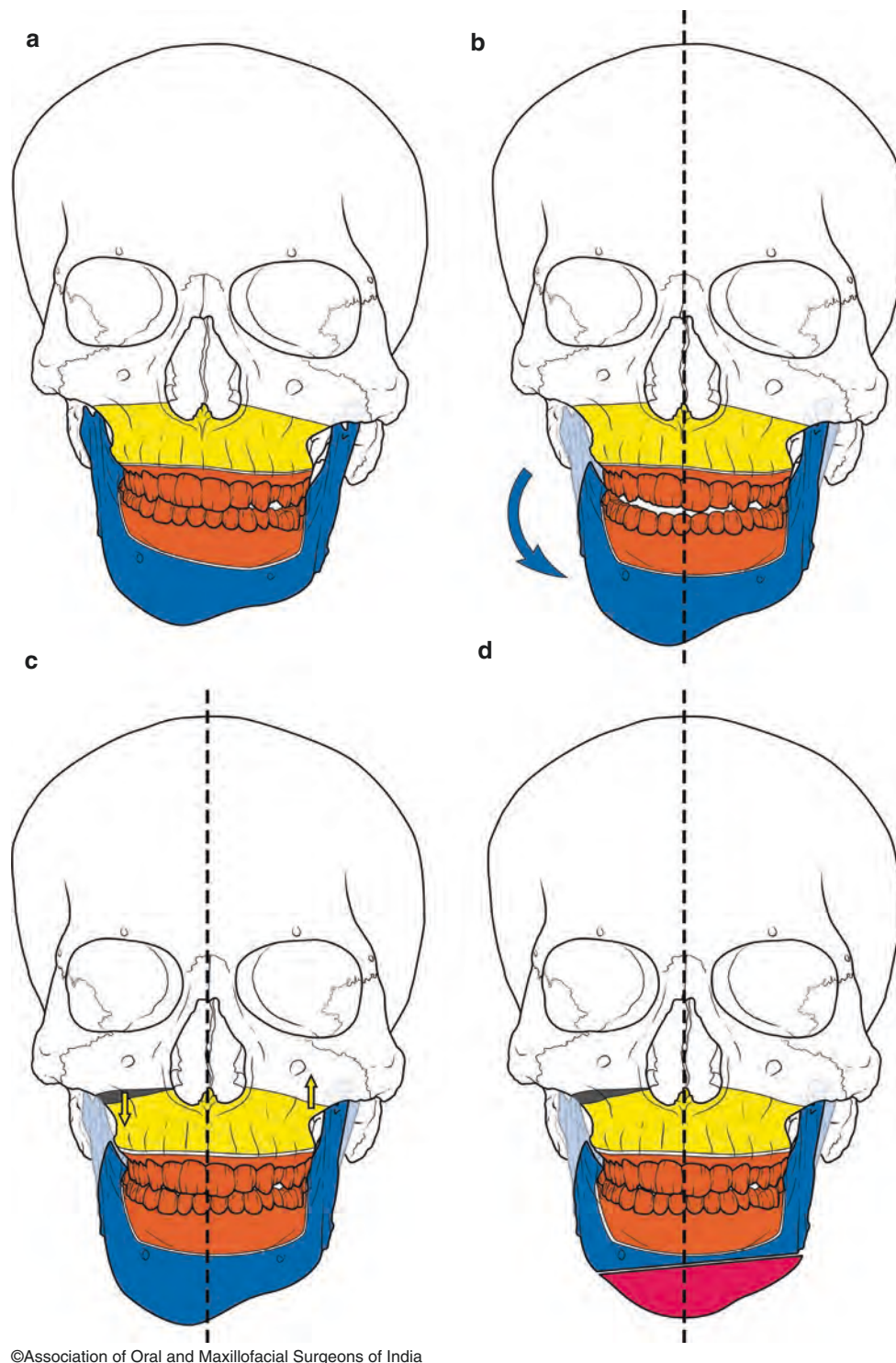
©Association of Oral and Maxillofacial Surgeons of India

Fig. 78.25 (a, b) Indigenous distractor made and modified, placement showed in a dry skull mandible. Note the placement of distractor on the basal bone. (a) frontal view of distractor placement, (b) basal view



©Association of Oral and Maxillofacial Surgeons of India

Fig. 78.26 (a, b) Orthomorphing distraction done in a patient having hemifacial microsomia. (a) Pre- and (b) postoperative photograph showing achievement of anatomic chin and contour and mandibular asymmetry



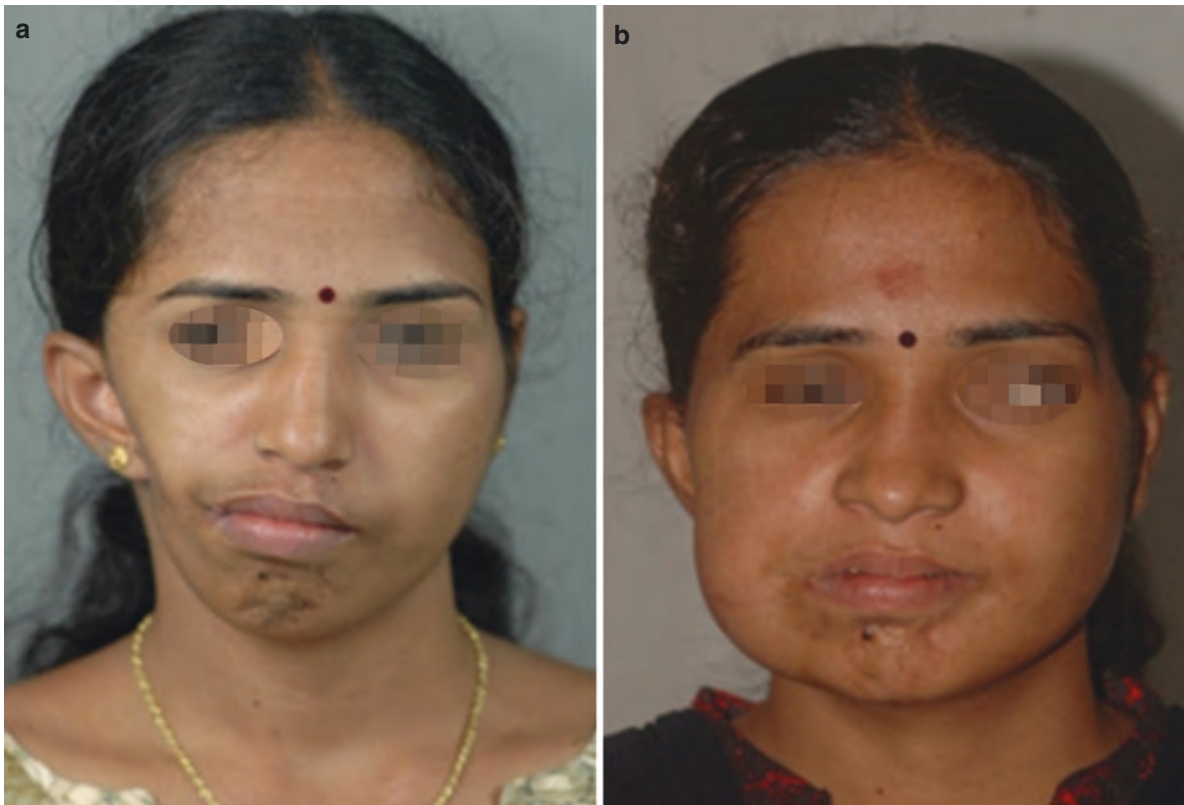©Association of Oral and Maxillofacial Surgeons of India

Fig. 78.27 (a–d) Diagrammatic representation of surgical management of Type 2 Kaban-Pruzansky deformity (a). Derotation of the maxilla-mandibular complex by orthognathic surgery (b and c). Midline skeletal correction with a centring genioplasty (d)

classes, has mixed reports of success. Longitudinal studies provide evidence for stable results with early osteodistraction in mild-to-moderate skeletal deformities [20, 33, 34] (Type 1 and Type 2A). However, the role of mandibular distraction may be more relevant in severe deformities. It is also suggested that early intervention makes definitive final correction easier to achieve, since the extent of deformity is reduced.

78.1.8 Long-Term Results

Long-term evaluation of growing HFM patients treated by surgical correction and distraction osteogenesis depends on two main factors: the time of intervention and the severity of the skeletal deformity. According to Hollier et al., by achieving normal mandibular dimensions at a young age, it is



©Association of Oral and Maxillofacial Surgeons of India

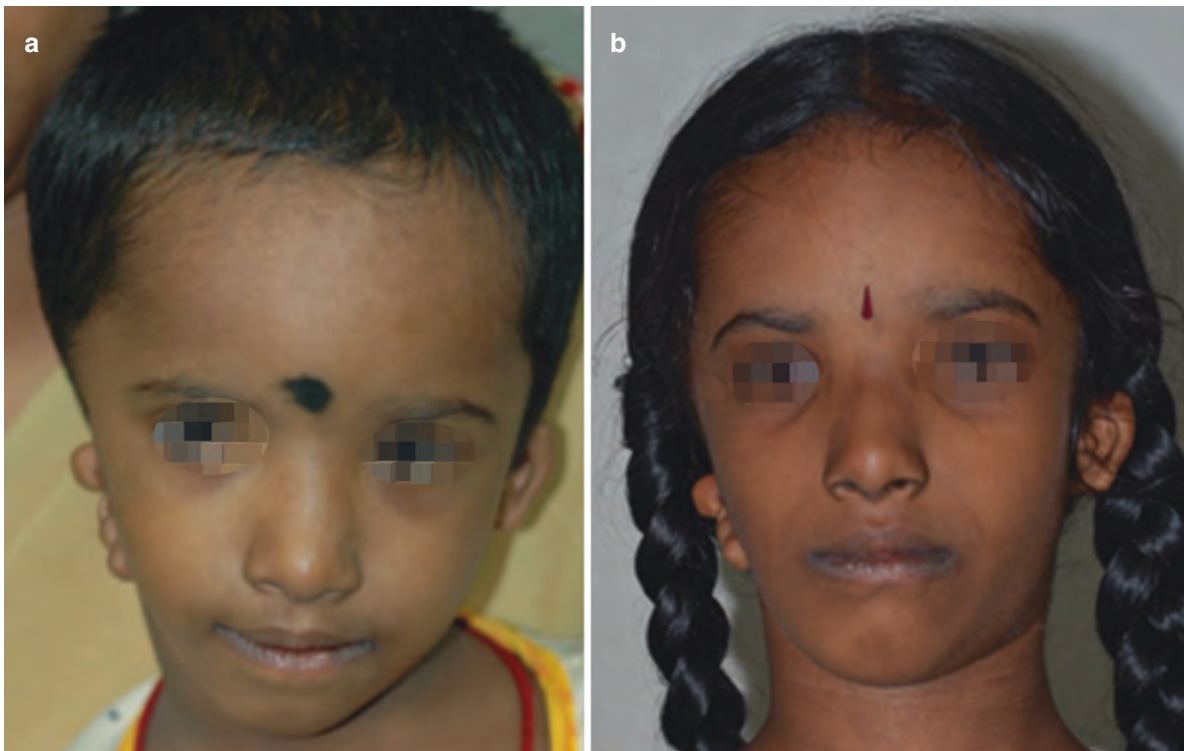Fig. 78.28 (a, b) Soft tissue augmentation using abdominal autologous fat transplant. (a) pre-surgical frontal view demonstrating severe right sided deficiency in a patient with HFM, (b) frontal view showing soft tissue augmentation

hypothesized that the maxilla, overlying muscle and soft tissue envelope may develop along with a balanced functional matrix [19]. Proponents of mandibular distraction believe that an early intervention would prevent the secondary compensations from taking place or would unravel the compensations at the onset. This means the contralateral and ipsilateral distortions can be reduced in comparison with patients not undergoing distraction in the younger age (Figs. 78.29a, b and 78.30). Clinicians have found that early distraction can also prevent the long orthodontic decompensation phase followed by orthognathic surgery. Considering severity of deformity, the more severe deformities demonstrate less stable and favourable results when attempted early.

The indications for early skeletal correction maybe (1) compromise of airway necessitating immediate mandibular lengthening irrespective of age and (2) negative psychological impact on the child in school-going age.

In authors' experience irrespective of area and direction of distraction in the mandible or in maxilla in younger age, the following findings were concluded in 20 years of clinical follow-up:

1. It is difficult to predict the future growth of already distracted area of bone though claims of growth potential on distracted bone have been debated by many.
2. In majority of the cases, the intensity of the severity of the disease has reduced due to distraction than simply curing the disease as the age advances.
3. The 3D volume achievement in the ipsilateral side is difficult to achieve irrespective of technique of distraction and conventional osteotomies in later ages.
4. Orthodontic compensations, alignment and other associated corrections of teeth on a weak hypoplastic bone are difficult at least in some cases.
5. Many cases after pubertal age needed conventional orthognathic surgeries to achieve symmetry.
6. Soft tissue augmentation was necessary in many patients to balance the soft tissue profile equal on both sides.
7. Compromised occlusions and dental rehabilitation were necessary in some cases especially Type 2B and Type 3 cases and accepted as standard norms to finish orthodontic alignments.
8. The airway disease is not cured to 100% in all cases due to extreme variability treatment outcomes and procedures followed by different surgeons.
9. Expectations of the patient may not be achieved completely, so caution should be given to patient the compromised results outcomes in extreme cases of asymmetry.



©Association of Oral and Maxillofacial Surgeons of India

Fig. 78.29 (a, b) Long-term results of patient treated with mandibular distraction in childhood. (a) frontal photo of patient with right sided HFM at, (b) frontal photo of patient after 8 years follow up

- Alloplastic prosthetic condyles should be reserved as a last resort if all other techniques fail to achieve a functionally stable total agenesis of condyles [21].

78.1.9 Recent Advances

The assessment of facial topography using non-invasive methods, such as laser surface scanners, stereophotogrammetry or ultrasonographic measurements, has been recently reported in several studies. Particularly, 3D stereophotogrammetry for the evaluation of soft tissue surface facial asymmetry has been extensively studied [36]. In distraction osteogenesis, recent advancements like automated distraction using battery-operated and hydraulic distractors have been tried. Since hemifacial microsomia involves bone augmentation in a multiplanar fashion, the advent of curvilinear and multiplanar distractors has greatly helped overcome this challenge [37, 38].

Tissue-engineered osteogenic material comprising of culture-expanded mesenchymal stem cells (MSCs) and platelet-rich plasma (PRP) can now be injected at the distraction site to ensure more predictable bone formation. Not only animal studies but also clinical trials have demonstrated that this material can effectively regenerate osseous tissue [39, 40].

78.2 Treacher Collins Syndrome

78.2.1 Introduction

Treacher Collins syndrome (TCS), also called mandibulofacial dysostosis (MFD), is an autosomal dominant disorder of craniofacial development with variable penetrance. It has a worldwide incidence of 1 in 50,000 live births (Gorlin et al. 1990) [41]. Early descriptions were given by Berry (1889), Treacher Collins (1900) and Franceschetti and Klein in 1949. Therefore, this entity is also named as Berry's syndrome and Franceschetti-Zwahlen-Klein syndrome [42, 43]. While 40% of TCS cases have a previous family history, 60% of cases could possibly arise as a result of de novo mutations (Jones et al. 1975) [44].

The TCOF1 gene plays an important role during early embryonic development for tissues derived from the first and second branchial arches, ectodermal clefts and endodermal pouches. TCOF1 gene encodes a nuclear phosphoprotein "Treacle" that may serve as a link between rRNA gene transcription and pre-rRNA processing. TCOF1 mutation leads to abnormal neural crest cell migration or anomalies in the extracellular matrix [45]. Sulik et al. also documented excessive cell death in the maxillary and mandibular processes of the first branchial arch and the apical ectodermal ridge of the limb bud [46]. These deductions have been made on the basis of experimental studies wherein animals were exposed to



©Association of Oral and Maxillofacial Surgeons of India

Fig. 78.30 (a, b) Definitive skeletal management of patient with HFM. (a) Preoperative Frontal photo of patient with right sided HFM at 15 years of age. He underwent mandibular distraction for correction of

asymmetry followed by second stage Bi maxillary orthognathic surgery at 18 years of age (Fig. 78.7a). (b) Stable skeletal results after a 7 year followup when patient is 25 years of age

teratogenic cis- or trans-retinoic acid during embryonic development. Recently, Dauwerse et al. [47] detected mutations in genes encoding subunits of RNA polymerases I and III in Treacher Collins patients.

Normally, prenatal diagnosis is recommended for families with a history of TCS using fetoscopy or ultrasound imaging [USG]. Prenatal diagnosis using either of these methods can only be performed in the second trimester of pregnancy (approximately 18 weeks). Due to the late nature of the diagnosis, termination of pregnancy can be a particularly traumatic procedure. Imaging with USG has improved immensely in recent years [e.g. 3D sonography], allowing non-invasive prenatal diagnosis to be made. However, mild cases of TCS are still difficult to diagnose. Genetic counseling is highly recommended for affected individuals and their families for prevention of further affected child birth.

78.2.2 Clinical Features and Presentation

The complete spectrum of features which can be present are explained in the table below [48] (Table 78.7).

A case of Treacher Collins syndrome in a 13-year-old female with the following features (Fig. 78.31a, b):

- **Eyes:** Antimongoloid palpebral fissures are short and slope laterally downwards with either a notch or coloboma of the outer third of the lower eyelid. Lashes are absent medial to coloboma.
- **Face:** Bilateral and usually symmetric hypoplasia of facial bones is present, e.g. malar and mandibular bones. Depressed cheekbones, receding chin, tongue-shaped process of the hair that extends towards the cheek and large down-turned mouth can be identified.

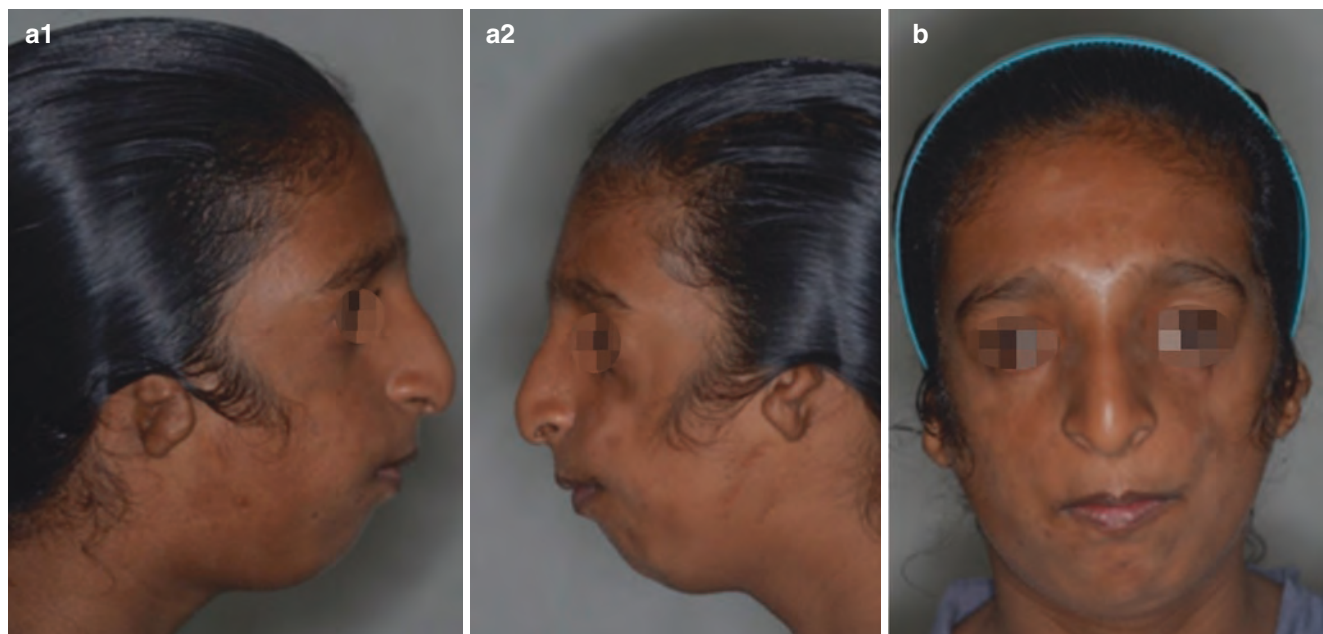- Ears: Malformation of the external, middle and inner ear, with low implantation of the auricle which is common. The pinnae are often crumpled and misplaced towards the angle of the mandible. Bat-fan ears, deafness, microtia, extra ear tags and blind fistulas [which may occur anywhere between the tragus and the angle of the mouth] are the other common findings.
- Oral findings: Cleft palate, congenital palatopharyngeal incompetence, high-arched palate and a narrow maxillary and mandibular arch with dental crowding are common (Fig. 78.32a–e).
- Nose: The nose appears larger due to the hypoplastic mid-face skeletal structures. Hypoplastic alar cartilages, narrow nares and obliteration of the nasofrontal angle are also common.

Table 78.7 Clinical features of TCS

Region	Characteristic feature
Eyes	Antimongoloid slant of palpebral fissures
	Colobomata and hypoplasia of the lower lids and lateral canthi
	Hypertelorism
	Partial absence of eyelid cilia
Ears	Microtia
	Conductive hearing loss
	Hypoplasia of middle ear ossicles
Nose/mouth	Nasal deformity
	Cleft palate with or without cleft lip
	High-arched palate
	Class II or III malocclusion open bite
Facial bone formation	Hypoplasia of the malar bones
	Hypoplastic lateral aspects of orbits
	Hypoplastic maxilla and mandible
	Variable effects on the temporomandibular joints
	Anterior open bite
	A steep occlusal plane

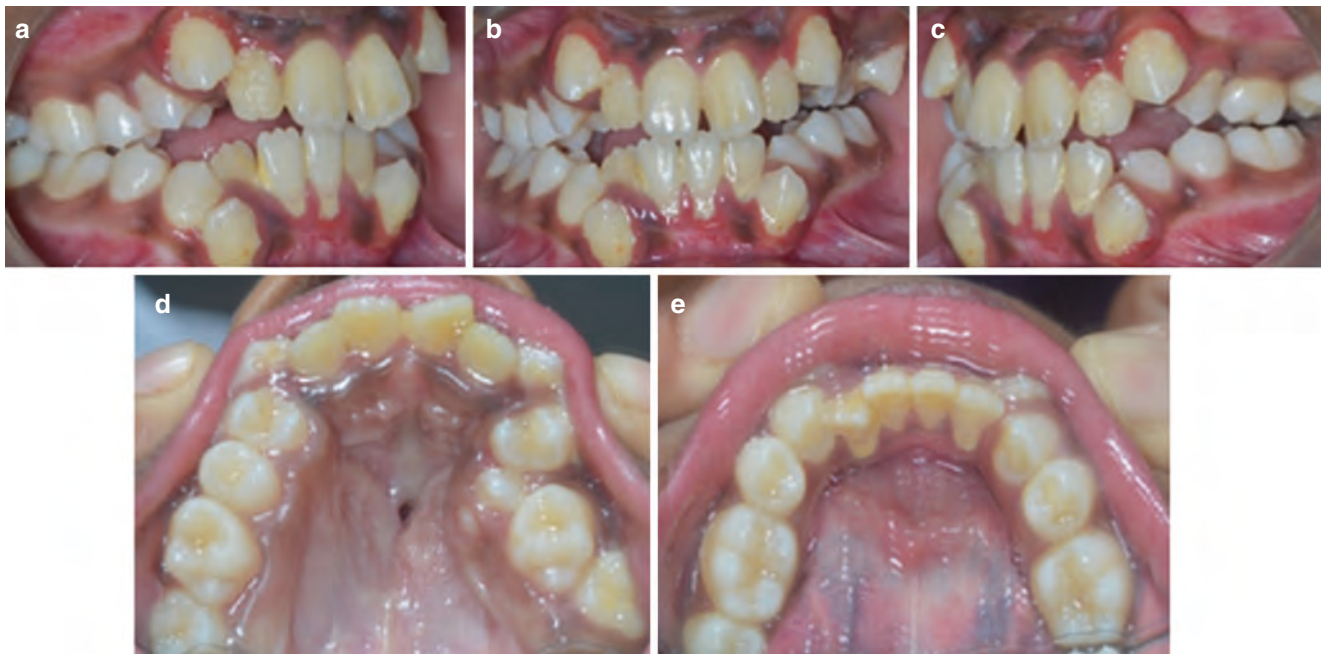
78.2.3 Imaging for TCS

The conventional OPG and the lateral and frontal cephalometric image are pivotal in diagnosing TCS along with clinical correlation. The OPG helps identify the following: hypoplastic condyle with a short condylar neck, absent articular eminence, shortened ramus-condyle unit and severely hypoplastic coronoid process (Figs. 78.33 and 78.34). The lateral cephalogram shows a severely retrognathic mandible with microgenia, clockwise-rotated maxillomandibular complex and a reduced posterior airway space. However, three-dimensional computed tomography [3DCT] is the gold standard in diagnosis as well as treatment planning (Fig. 78.35a–c). The features that are remarkably seen on the 3DCT are hypoplasia of the orbito-zygomatic complex, poorly developed lateral orbital and supraorbital ridges, mandibular hypoplasia and reduced overall facial width. The orbits are hyper-teloric and the infraorbital foramen is usu-



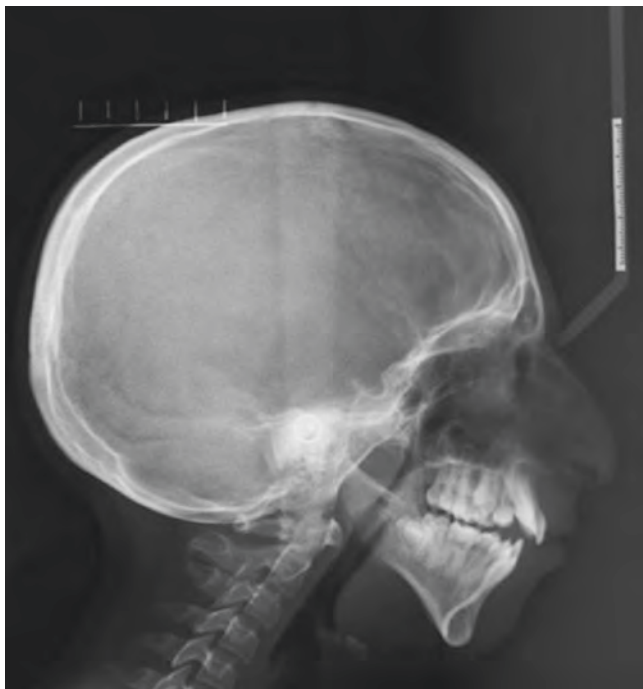©Association of Oral and Maxillofacial Surgeons of India

Fig. 78.31 (a, b) Case of a 13-year-old female with Treacher Collins syndrome, (a) profile and (b) frontal photos (Also see Fig. 78.41b)



©Association of Oral and Maxillofacial Surgeons of India

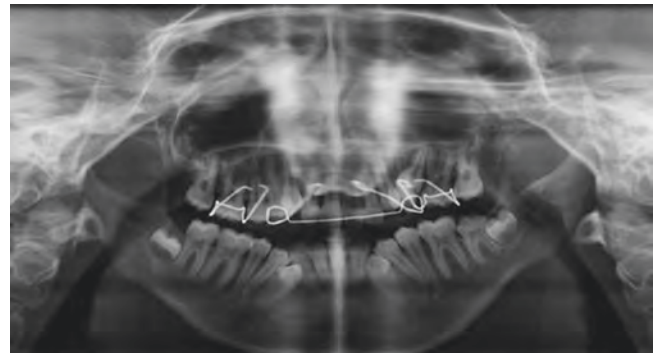
Fig. 78.32 (a–e) Intraoral pictures of the same patient in Fig. 78.30 showing operated cleft palate, mixed dentition stage with severe crowding. (a–c) frontal and lateral intra-oral dental views, (d) maxillary occlusal and (e) mandibular occlusal views



©Association of Oral and Maxillofacial Surgeons of India

Fig. 78.33 Lateral cephalogram of the same patient in Fig. 78.31 showing reduced posterior airway space, micrognathia and microgenia

ally absent. The paranasal sinuses are often small and may be completely absent. Furthermore, the mastoids are not pneumatized and are frequently sclerotic. The cranial base is also progressively kyphotic [48]. Lastly, these patients require



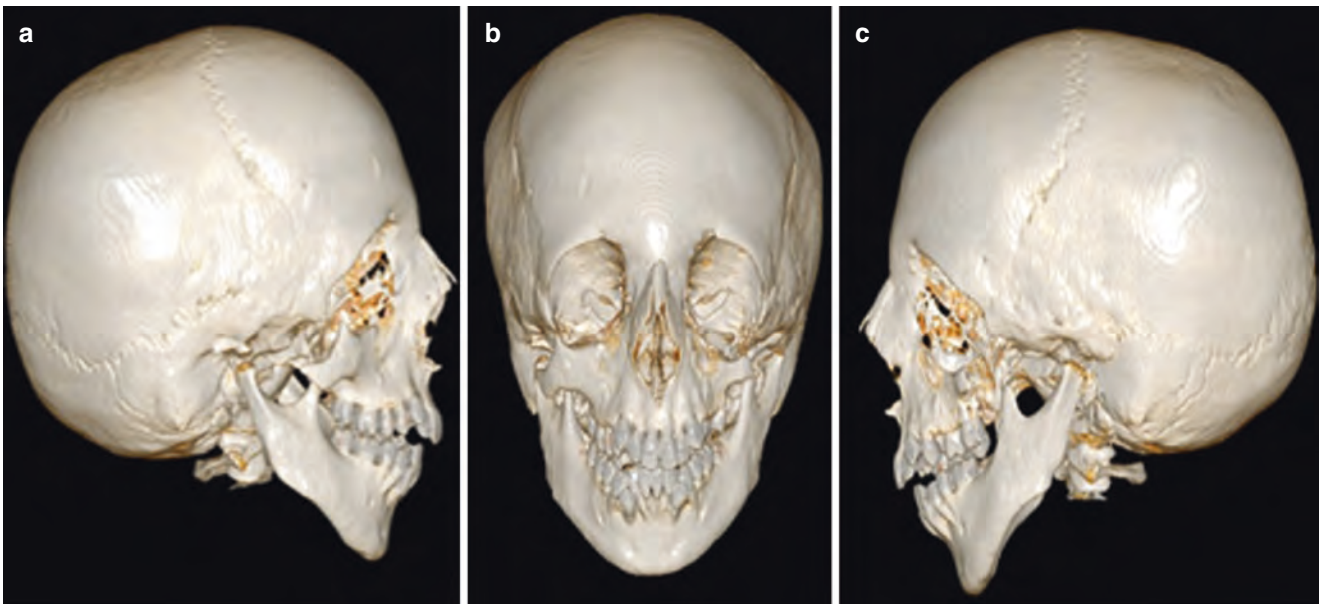
©Association of Oral and Maxillofacial Surgeons of India

Fig. 78.34 Orthopantomogram of the same patient in Fig. 78.31 showing hypoplastic ramus-condyle unit

long-term follow-up in order to evaluate the effects of mandibular growth, airway dimensions, degree of surgical relapse and the need for additional surgical intervention.

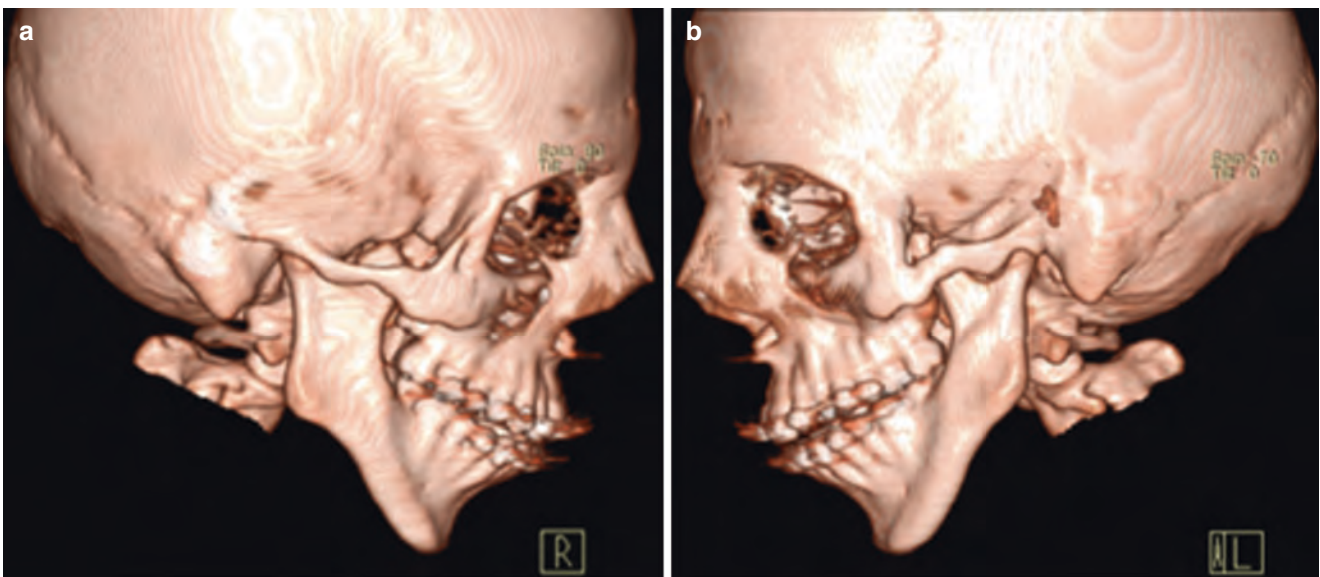
78.2.4 Proposed Classification

A classification system of the orbito-zygomatic skeletal deformities seen in TCS has been proposed by Nikkah D et al. The classification is designed to characterize the degree of deformity and as a guide to the reconstructive planning [49]. Treatment planning becomes complex as TCS can have a variable presentation with respect to the severity of the hypoplasia/dysplasia of the skeletal and soft



©Association of Oral and Maxillofacial Surgeons of India

Fig. 78.35 (a–c) 3DCT view of TCS patient showing hypoplasia of orbito-zygomatic complex. (a) Right lateral view demonstrating type 2b deformity, (b) frontal view showing type 2b deformity on the right and type 3 deformity on the left, (c) left lateral view showing type 3 deformity



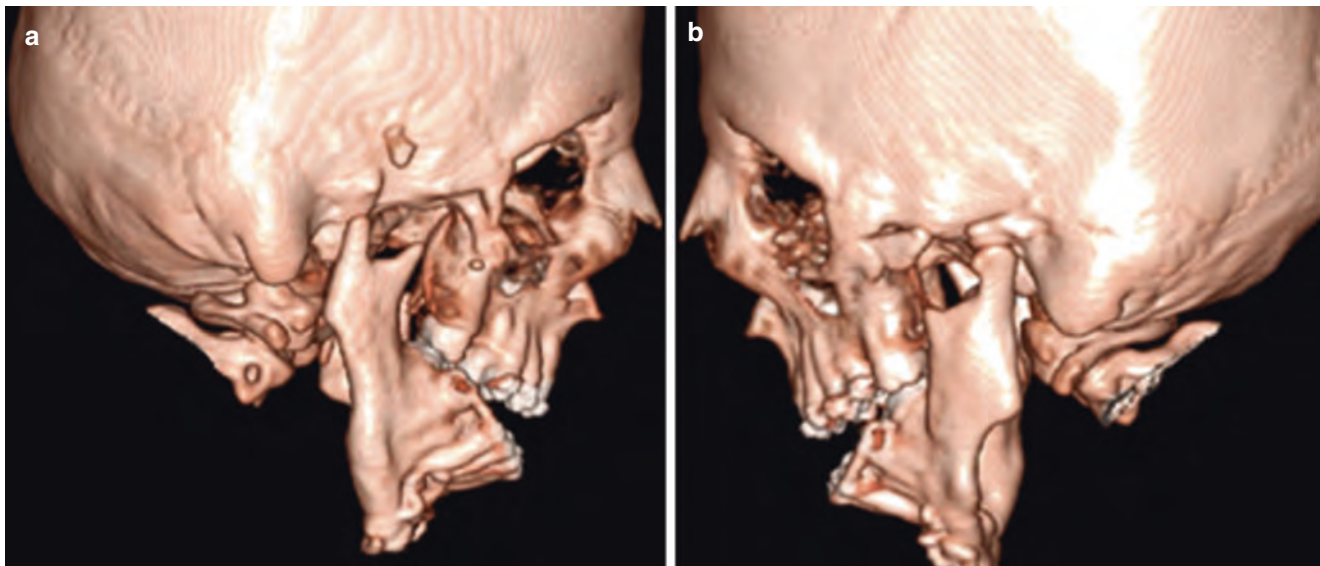
©Association of Oral and Maxillofacial Surgeons of India

Fig. 78.36 (a, b) Type 1: Patients have the entire orbito-zygomatic complex present but the region is dysplastic and hypoplastic

tissue elements, shape and position of the affected structures and resulting functional deformity. Thus, the challenges faced in treating TCS are similar to those faced in treating HFM.

78.2.4.1 Methods

- *Type 1*: orbito-zygomatic complex present but, dysplastic and hypoplastic (Fig. 78.36a, b).
- *Type 2*: a hypoplastic zygomatic body with a vestigial zygomatic temporal process and a lateral orbital wall that is either dysplastic (2a) or absent (2b) (Fig. 78.35a, b).
- *Type 3*: a hypoplastic zygomatic body and dysplastic orbital wall but with complete absence of the zygomatic temporal process (Fig. 78.35b, c).
- *Type 4*: complete absence of the entire orbito-zygomatic complex (Fig. 78.37a, b).



©Association of Oral and Maxillofacial Surgeons of India

Fig. 78.37 (a, b) Type 4: Is the most severe with complete absence of the entire orbito-zygomatic complex

There is not always a symmetrical classification as 25% of the TCS demonstrated asymmetry.

78.2.4.2 Classification of Temporomandibular Joint and Mandibular Malformation

The Kaban and Pruzansky classification system for the degree of TMJ-mandibular malformation in HFM is applicable to TCS patients as well [13, 26]. This classification is useful in defining the anomalies and directing reconstruction similar to HFM patients.

78.2.5 Differential Diagnosis

Differential diagnosis of TCS includes acrofacial dysostosis (Nager and Miller syndromes) and oculo-auriculo-vertebral spectrum (hemifacial microsomia and Goldenhar syndrome).

Nager syndrome has facial features similar to that of TCS. In addition, the thumb[s] may be hypoplastic, aplastic or duplicated, and there may be fusion of the radius and ulna. Miller syndrome also has features similar to TCS. Ectropion or out-turning of the lower lids is an additional diagnostic feature. Clefting of the lip and palate is more common in this syndrome than in TCS [50]. HFM primarily affects development of the ear, mouth and mandible. Goldenhar syndrome has a spectrum of deformities that include those of HFM in addition to vertebral abnormalities and epibulbar dermoids [51].

78.2.6 Treatment

Though there have been immense medical advances in terms of in utero surgery, stem cell therapy and genetic manipulation, there is currently no treatment for TCS in utero. Treatment is performed postnatally according to the nature of the deformity and severity of functional disturbance [52].

The following issues are present in case of TCS:

1. Airway, i.e. obstructive sleep apnoea.
2. Feeding problems.
3. Brain development.
4. Orbito-zygomatic growth.
5. Mandibular retrognathism with open bite.
6. Dentoalveolar issues including orthodontic alignment.
7. Cleft palate.
8. Hearing issues.
9. Psychosocial development.
10. Deficient soft tissue.

These issues can challenge clinicians from birth to adulthood as concerns vary from aesthetic to functional in nature. Thus, a multidisciplinary approach is indispensable for achieving optimal outcomes.

78.2.6.1 Multidisciplinary Management: Team Members Necessary from Birth to Adult Stage

1. Geneticist.
2. Paediatrician.
3. Anaesthetists.
4. Oral and maxillofacial surgeon.
5. Orthodontist.
6. Paedodontist.
7. General dentist.
8. Paediatric neurosurgeon.
9. Psychiatrist.
10. ENT surgeon.
11. Audiologist.
12. Pulmonologist.
13. Paediatric neuro-physician.
14. Speech therapist.
15. Oculoplastic surgeon.

78.2.6.2 Airway Management

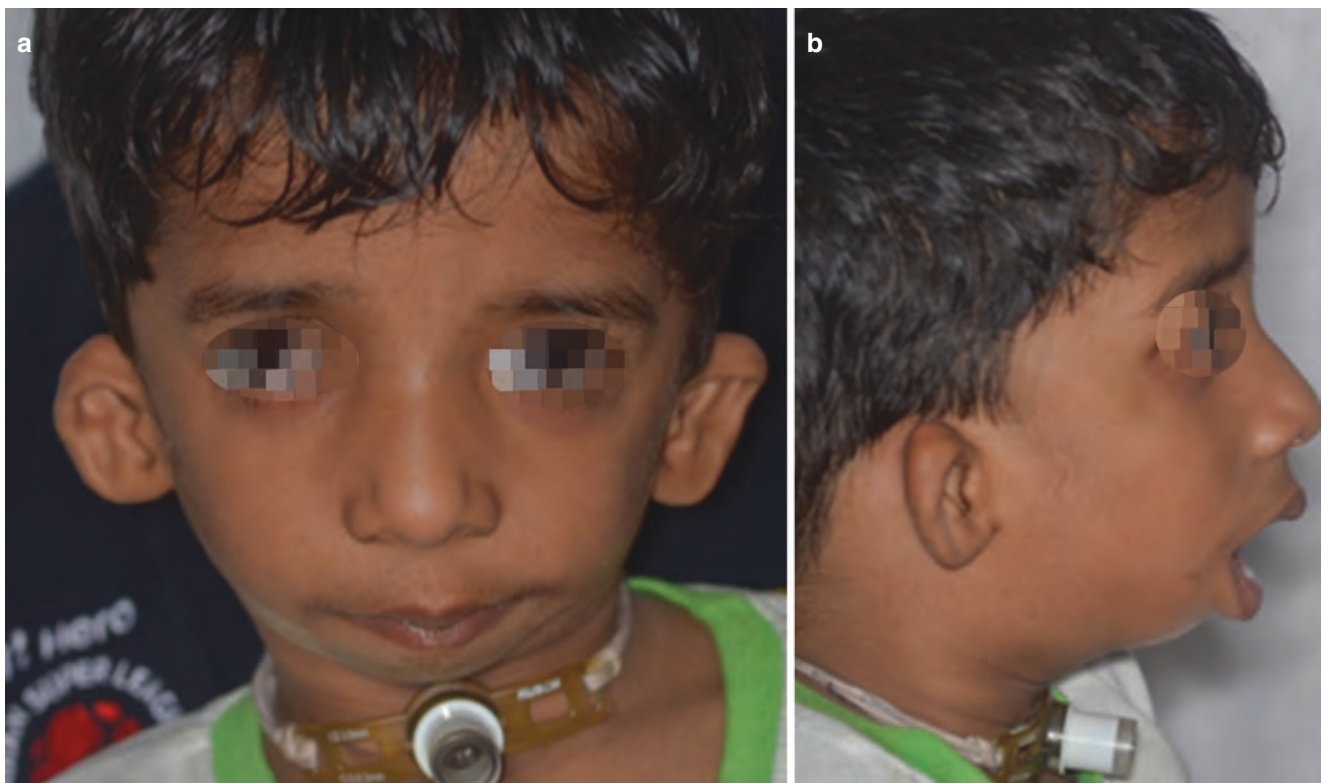
Syndromic patients [e.g. TCS] with micrognathia suffer from OSA frequently due to narrowing of the upper airway

[53]. Despite respiratory effort, partial or complete obstruction of the upper takes place, leading to frequent episodes of oxygen desaturation and sleep disruption. In the long term, OSA can harm an individual's physical and mental health, as has been documented recently in the literature [54].

Respiratory compromise is due to two reasons:

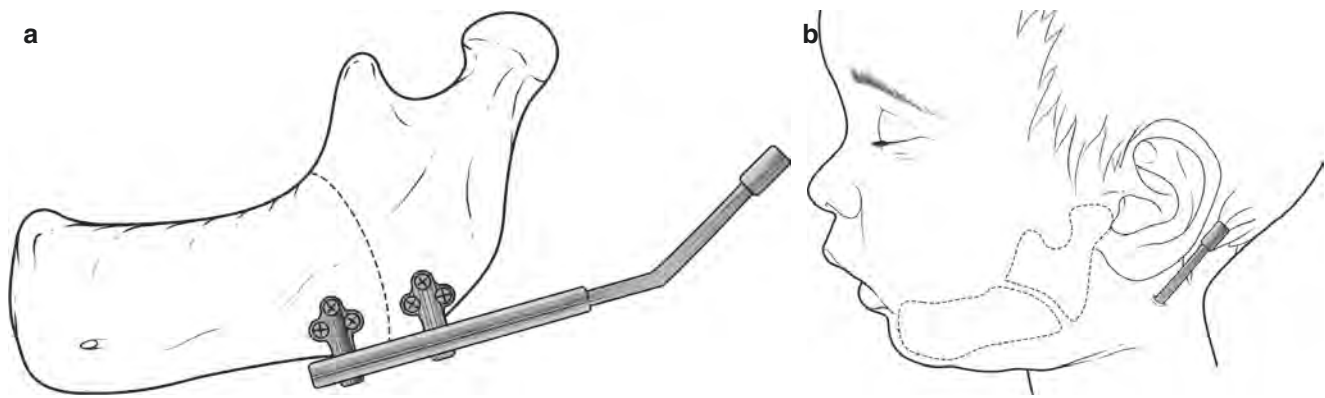
- (i) Maxillary hypoplasia, constricting the nasal passages and resulting in a degree of choanal stenosis or atresia.
- (ii) Mandibular micrognathia and a retro-positioned tongue obstructing the oropharyngeal and hypopharyngeal airway.

Earlier, long-term tracheostomy was the only solution available for severe cases of infantile OSA. However, long-term tracheostomies are commonly associated with morbidities like tracheomalacia, chronic bronchitis, throat tightness and dislocation of the tracheostomy tube [55] (Fig. 78.38a, b). Today, distraction osteogenesis [DO] has become the favoured treatment method for TCS patients with OSA. Mandibular advancement by means of DO helps in increasing the posterior airway space, thus relieving the symptoms of OSA and preventing severe respiratory distress [56]. Due to the unique mandibular and oropharyngeal anat-



©Association of Oral and Maxillofacial Surgeons of India

Fig. 78.38 (a, b) Photograph of a 4-year-old male with TCS. Patient had history of hospitalization due to respiratory distress. Tracheostomy tube in situ since 7 months of age



©Association of Oral and Maxillofacial Surgeons of India

Fig. 78.39 (a, b) Mandibular advancement using distraction in neonates to increase posterior airway space as a treatment of obstructive sleep apnoea. (a) Position of the distractor on the mandible, (b) Emergence of activation port in the retromandibular region

omy of TCS patients, a fibre-optic-assisted intubation method similar to that described by Ellis et al. can be successfully used [57].

Paediatric mandibular advancement was initially performed using bilateral external distractors which are advantageous because of their ease of use, manipulation and versatility [58]. However, external devices also create aesthetic [e.g. scarring] and social problems. Another important point to be noted is that retention period of such devices is reduced and an increased relapse rate is seen compared to internal distractor devices [59]. If the child is extremely uncooperative and parents are unable to maintain and monitor the external distractors, an internal distractor should be used (Fig. 78.39a, b).

Recently, paediatric mandibular distraction for OSA has been discouraged in many centres around the world due to concern of permanently damaging the teeth buds. Instead, tongue lip adhesion (TLA) has been popularized by many centres instead of DO as it has significantly lower morbidity. After the airway improves, better feeding and weight gain are expected and cleft palate closure is done. Subsequently, TLA release can be attempted [60]. In comparison to DO, the TLA needs stricter postoperative care in intensive setup as feeding and breathing need to be assessed regularly for a week at the minimum.

78.2.6.3 Feeding Problem

The abnormal or hypoplastic craniofacial issues in TCS can sometimes produce severe feeding problem for infants, leading to weight loss and failure to thrive. Most feeding problems relate to cleft lip and palate, retrognathic jaws and airway problems. Ideally, a craniofacial feeding management team should guide the parents regarding position of feeding, type of nutrition and dietary plan for such children.

Position (holding the baby upright or supporting the cheek and jaw while feeding) is important to avoid aspiration.

It is also preferable to do a video-fluoroscopic swallow study (VFSS) to understand the swallowing pattern of the patient and its coordination with breathing [61].

Primary palatoplasty for closure of the cleft palate should be done once the patient gains weight, to assist in normalizing the swallowing pattern without nasal regurgitation.

78.2.6.4 Brain and Psychological Development in TCS

Individuals with TCS have a tendency towards a shorter stature, at least early in life. Intelligence is usually unaffected, but brain and behavioural anomalies such as microcephaly and psychomotor delay have been occasionally reported as part of the condition. Additionally, the facial deformity of this syndrome may affect psychosocial development, school adjustment and other milestones. A psychologist or social worker should be made available for evaluation and counselling if needed.

In the Indian scenario, poor parental awareness, lack of medical advice, social taboos and feeding difficulties lead to failure to thrive among TCS infants and children belonging to lower socio-economic classes. Psychological stress during schooling [e.g. marked out as different by peers] is one of the more challenging issues to be addressed throughout the life of the patient.

78.2.6.5 Management of Cleft Palate

Isolated cleft of the soft palate is the most common form of cleft in TCS. Complete cleft palate up to the alveolus may also be seen. Closure of the soft palate is routinely done at the end of 1 year. Meticulous dissection and suturing of soft palate muscles can produce excellent results, nearing to that of a normal palate. Postoperative maintenance of oral hygiene is necessary and can become challenging in these children for fear of aspiration. Velopharyngeal insufficiency [VPI] is a common issue in these children. VPI can be cor-

rected secondarily with intra-velar palatoplasties or buccal advancement flaps for velar lengthening.

78.2.6.6 Ophthalmological, Auricular and Hearing Issues

Ophthalmological Issues

Eye anomalies include aberrations in the extraocular muscle function, corneal exposure difficulties and visual acuity. Ophthalmologic issues may include vision loss (37%), amblyopia (33%), refractive errors (58%), anisometropia (17%) and strabismus (37%). A thorough paediatric ophthalmological assessment should be done to establish proper management.

Hearing Issues

A 3D CT of the petrous temporal bones should be done to accurately assess the external auditory canal and middle and inner ear anatomy. TCS patients with microtia can have congenital aural atresia and extremely narrow canals, leading to significant conductive hearing loss as the bone blocks passage of sounds to tympanic area and middle ear. Furthermore, exfoliated skin cells and ear wax cannot drain out, leading to otitis media and occasionally form cholesteatoma. Despite hearing loss, these children tend to grow normally. However, the chances of developmental cognitive deficits are not uncommon.

Microtia Correction

Microtia ear correction can be done when the patient is around 6 to 7 years old, an age at which external ear development is complete. The most preferred way of auricle reconstruction is the use of autogenous rib cartilage, in a staged manner. The rib cartilage is harvested from the sixth to the ninth rib. The sixth and seventh rib cartilage are utilized to form the base of the framework. The triangular fossa and scapha are carved in the superior portion of the previously created cartilaginous base. The eighth rib cartilage is then carved to replicate the helical rim. The carved cartilage is then inserted under the skin in the region of the missing ear, with or without skin expansion (Fig. 78.19).

Bone-conduction hearing aids such as the bone-anchored hearing appliance (BAHA) or a middle ear implantable prosthetic device can significantly improve hearing in these patients.

78.2.6.7 Nasal Issues

Nasal deformities can be classified as external or internal in nature. Commonly seen external nasal deformities are the dorsal hump (73%), external deviation ($\leq 55\%$), bifid or bulbous nasal tip (55%) and columellar septal luxation (55%). Commonly seen internal nasal deformities are nasal obstructions due to septal deviation and presence of spurs. Due to presence of the above structural deformities, functional

problems, e.g. snoring and impaired phonation, are commonly present in these patients.

A detailed physical examination along with nasal endoscopy and 3D CT of the nasal and paranasal regions can help identify all the deformities present. The commonly performed procedures that should be paid attention to are dorsal hump reduction, correction of the deviated external osseous deformity, septoplasty and tip plasty.

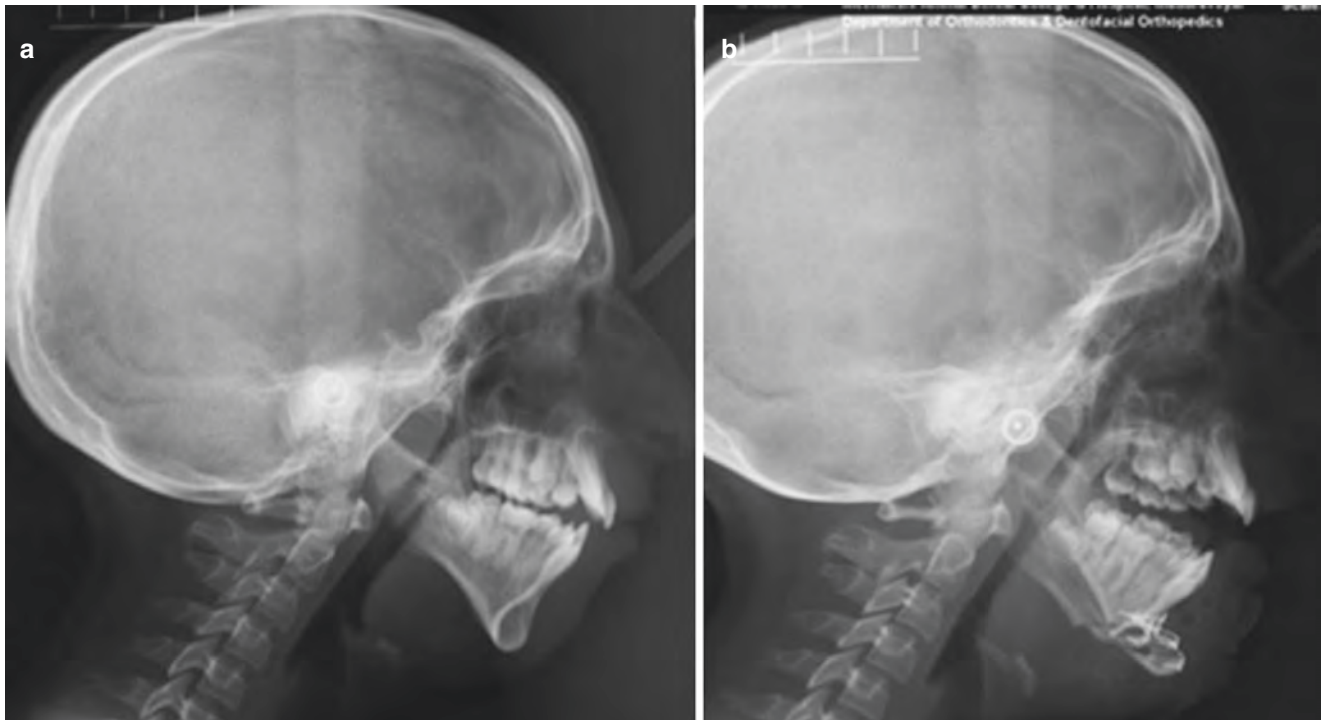78.2.6.8 Dentoalveolar Issues and Orthodontic Alignment

- Due to the presence of an anterior open bite and compulsive mouth breathing, there is an increased risk for poor oral hygiene. This is evidenced by the fact that up to 60% of TCS patients need dental care [e.g. restorative treatment]. However, the difficulty of performing even simple dental procedures is far higher due to reduced mouth opening, presence of concurrent medical co-morbidities [e.g. congenital heart defects], decreased posterior airway space and hearing loss [61, 62].
- During the late mixed dentition phase, orthodontic treatment aims to increase the transverse dimensions of the constricted maxilla [e.g. quad helix]. In the permanent dentition phase, the fixed therapy is used in order to achieve intercuspation and arch levelling.
- For moderately severe cases, the final goal is to prepare the patient for orthognathic surgical correction of the anterior open bite and skeletal class 2 relationship [63]. Studies have established that bimaxillary orthognathic surgery gives stable long-term results in TCS patients [64]. Sometimes, additional procedures to improve the shape of the chin are required. Figures 78.40a, b, 78.41 and 78.42a, b show double sliding genioplasty done in a patient in early age due to psychological impact owing to the facial appearance.
- For severe cases, DO with external distractors is the ideal surgical intervention wherein gonial angle control is necessary for increase in height of the ramus and lengthening the body of the mandible. In this aspect, multi-vector devices have an advantage with respect to the ability to control the transverse width during distraction (Fig. 78.43a–f).

78.2.6.9 Management of the Adult TCS Patient

Clinical and Cephalometric Features

The adult patient with TCS has a convex facial profile due to severe mandibular retrognathia. However, the horizontal projection of the maxilla to the cranial base remains normal. Over the growth period, the facial convexity angle remains relatively constant, thus confirming that the facial profile morphology of the infant with TCS remains similar to that of the adult.



©Association of Oral and Maxillofacial Surgeons of India

Fig. 78.40 (a) Preoperative and (b) postoperative lateral cephalogram radiographic view of a patient with Treacher Collins syndrome who underwent double sliding genioplasty

The total facial height is often excessive, with a normal upper facial height. This is due to combination of anterior open-bite malocclusion, mandibular retrognathism and chin dysplasia. Hypoplasia of the orbito-zygomatic complex is a characteristic feature. These hypoplastic facial skeletal features have variable effects on the TMJ, masticatory function and facial soft tissues and expressions.

Both the maxilla and mandible are rotated in a counter-clockwise rotation. Thus, the maxillary and mandibular plane angles are excessively steep. Clinically, this translates to a shorter posterior facial height in TCS patients.

The mandible size is evidently decreased in both the ramus height and the body length. The gonial angle is obtuse with anti-gonial notching. The steepness due to clockwise rotation of the maxillomandibular complex along with the anterior and posterior vertical height disproportions and severe horizontal deficiency is reflected in the A-point-to-B-point discrepancy. All of these cephalometric findings explain the clinical facial dysmorphology.

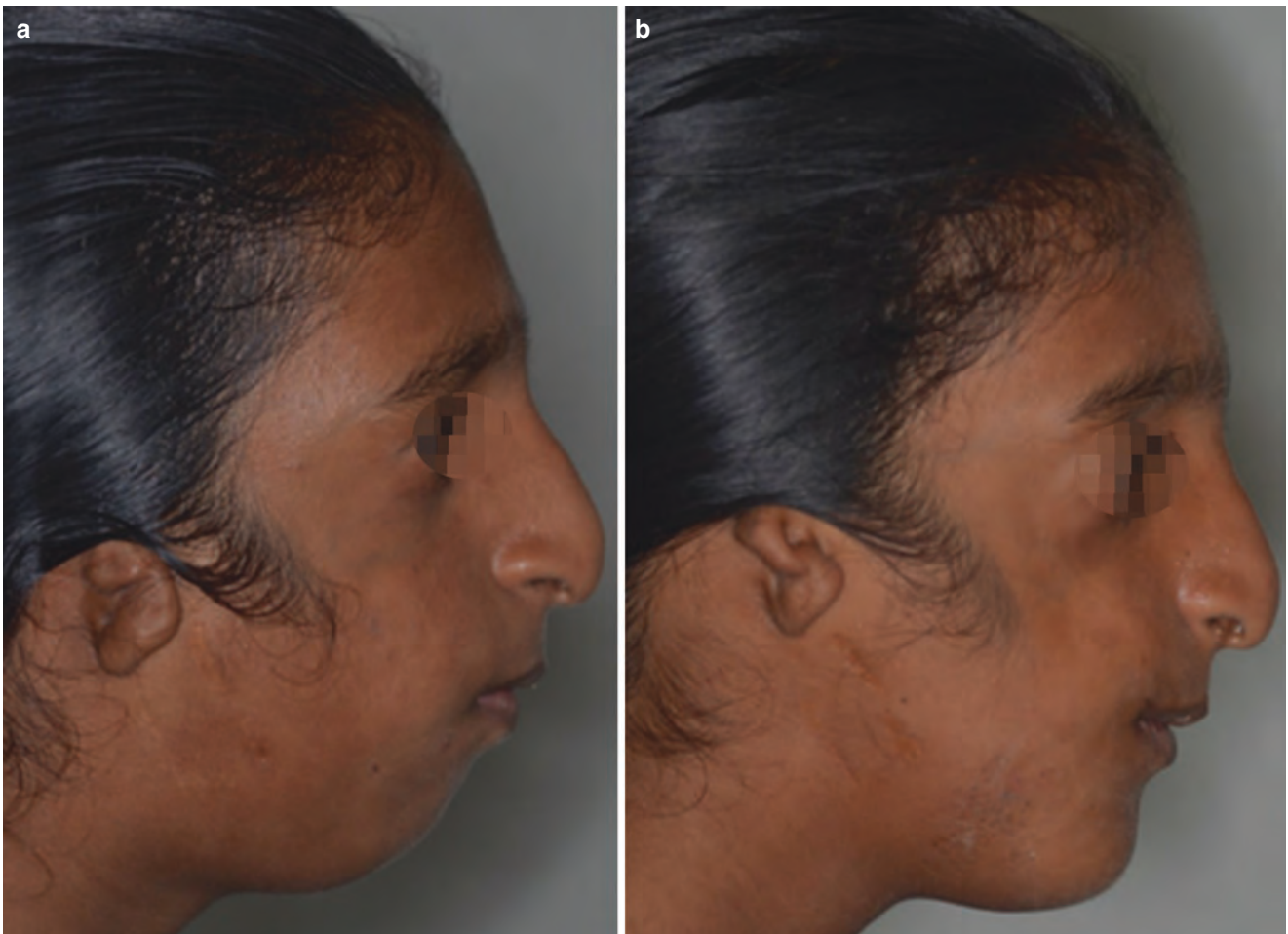Incidence of cleft palate with or without cleft lip (and choanal atresia of the nasal cavity) is variable. Dental anomalies are present in 60% of individuals such as tooth agenesis enamel opacities and ectopic eruption of the maxillary first molars.

78.2.6.10 Surgical Management of the Orbito-zygomatic Region

Treatment of the skeletal defect in the orbito-zygomatic region varies according to the severity of the defect. The following classification categorizes the deformities according to severity and their treatment. Since this region attains growth by age of 9, most surgeons postpone definitive reconstruction up to this age.

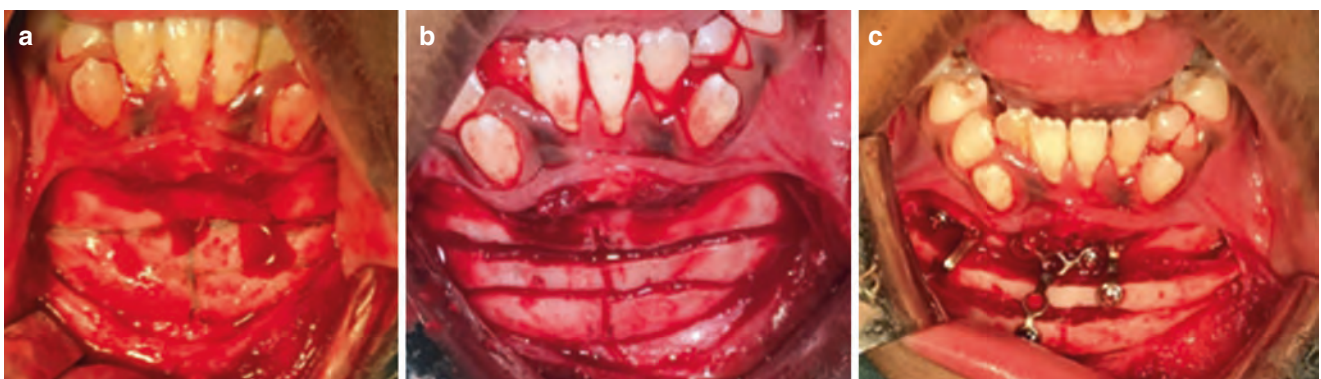Type 1 defects: The orbito-zygomatic complex is dysplastic and hypoplastic. Type 1 represents the mildest form of the defect and can be easily treated by autologous fat, either by liposuction and injection or dermis fat graft [65]. The merit of autologous fat grafting is that it is repeatable with minimal donor site morbidity and can be done before growth completion. It is ideal for growing children who are psychologically affected due to a poor facial appearance. The disadvantage of this technique is that it may have to be performed repeatedly to maintain the volume of correction.

Fat transfer can be used alone for correction of minor defects. It has more of an adjunctive role in severe defects after wherein hard tissue augmentation is the preferred intervention.



©Association of Oral and Maxillofacial Surgeons of India

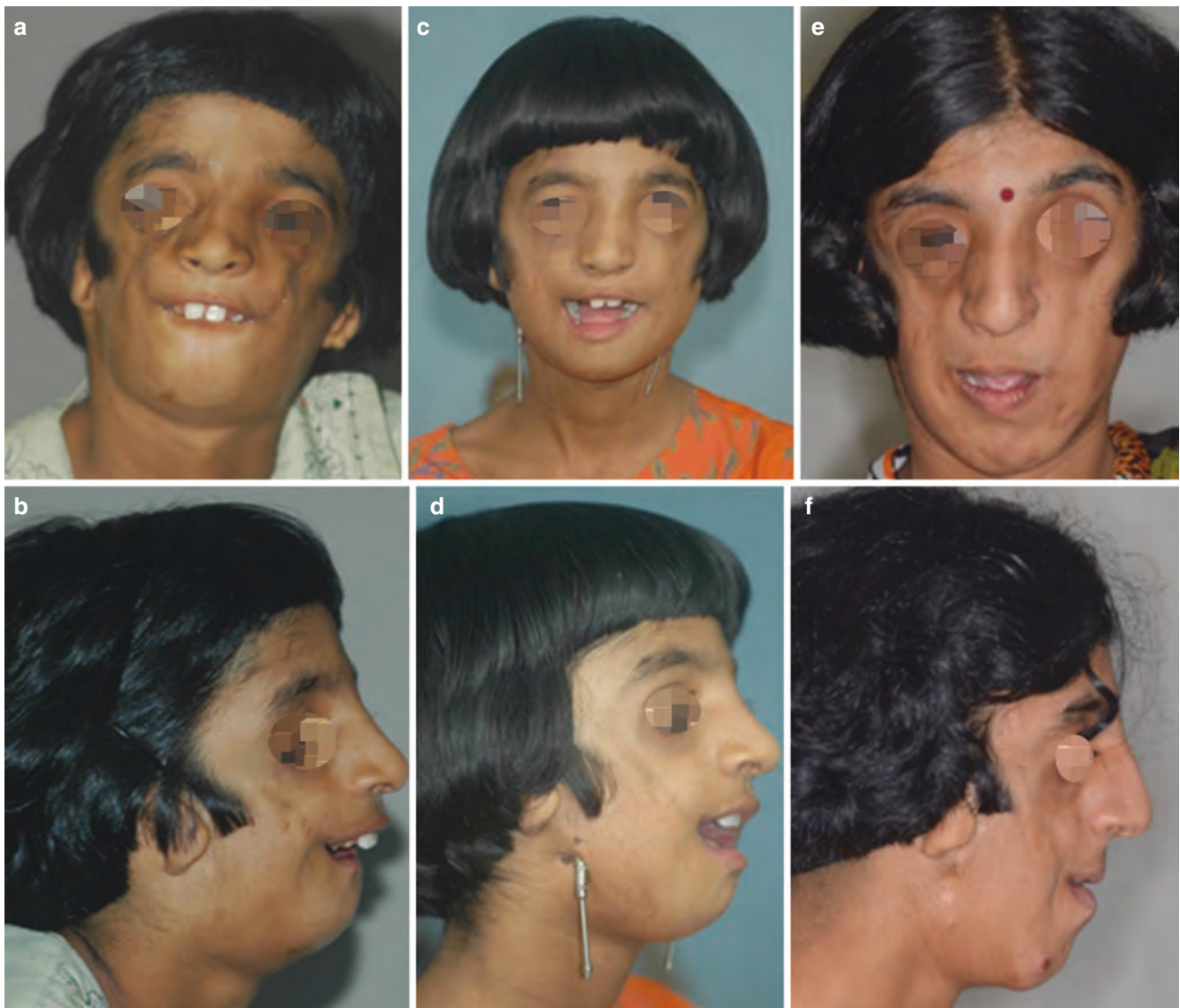Fig. 78.41 (a, b) Extraoral profile view showing marked improvement in the lower third of the face. (a) Pre-surgical profile photo showing retrogenia (Fig. 78.31a1), (b) post-surgical profile photo after a double sliding genioplasty, showing good chin prominence



©Association of Oral and Maxillofacial Surgeons of India

Fig. 78.42 (a–c) Intraoperative view of double sliding genioplasty done for the same patient as in Fig. 78.41. (a) Surgical exposure of the genium, (b) osteotomy design marked on the chin and (c) completion of

genioplasty with fixation (also see Figs. 68.32 and 68.33 for use of double sliding genioplasty in other clinical situations)



©Association of Oral and Maxillofacial Surgeons of India

Fig. 78.43 (a–f) Case of TCS who underwent early osteodistraction. (a, b) Pre-operative frontal and profile photos, (c, d) Frontal and profile photos post distraction with bilateral uni-directional distractors, (e, f) Frontal and profile views after five years follow-up

Type 2 defects: Defect consists of hypoplastic zygomatic body with a reduced zygomatic temporal process and a dysplastic or absent lateral orbital wall. This class of defect usually requires surgery to address the bony deficiency. Studies have established that a malar osteotomy offers better contour as compared to onlay bone autografting [66]. Though the malar osteotomy is aimed at correcting the width of the midface, it is difficult to augment anteroposterior projection by osteotomy only. It should be noted that this defect is characterized by a deficient vertical dimension as well. Thus, a zygomatic osteotomy is preferably combined with an onlay graft. The Mommaerts zygomatic osteotomy is favoured in some units because it does not alter orbital dimensions. Alloplastic materials [e.g. Medpore] can be very effective alternatives to the traditional onlays [67].

Types 3 and 4

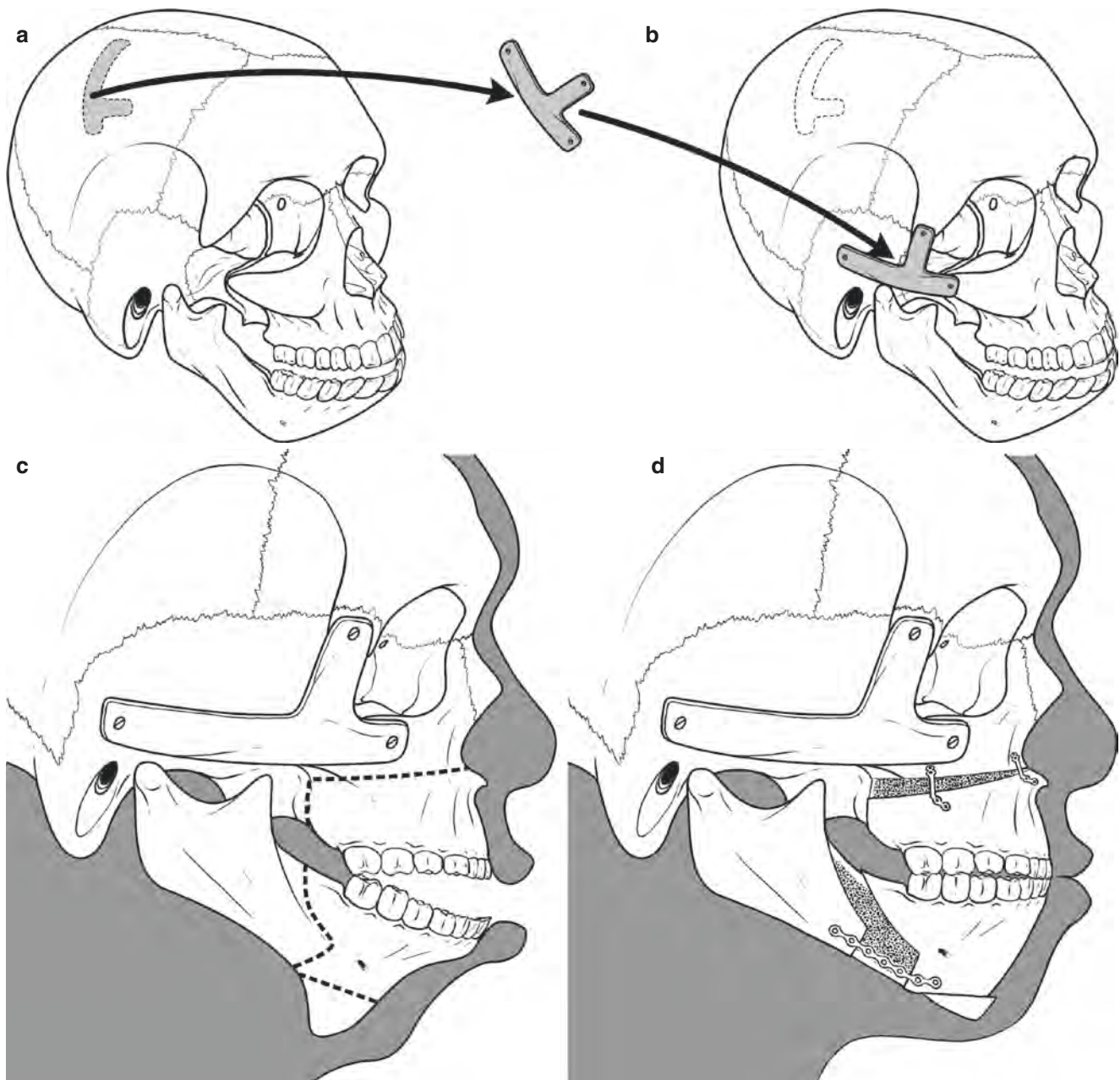
The defects range from severe hypoplasia/dysplasia to complete absence of orbito-zygomatic bony complex. Patients belonging to these groups require bony augmentation. In adults, alloplastic augmentation with patient-specific implants can be considered as they provide optimal results.

In general, the zygomatico-maxillary-orbital bone complex can be reconstructed using an autologous free bone or regional pedicle graft. Non-vascularized autologous bone grafting for larger defects is increasingly prone to loss of graft due to infection and resorption if not fully covered by surrounding soft tissue. Studies have established that resorption occurs due to reduced vascularity and increased functional loads on the graft. Therefore, it is prudent to line the bone grafts by soft tissue on its inner side in the proximity of maxillary sinus and nasal cavity [68].

Calvarial bone grafts have been used for reconstruction of midface in various craniofacial deformities. Full-thickness calvarial grafting outcomes are more stable in the long term due to the dense cortical nature of the graft (Fig. 78.44a, b). Studies [69] have also established that dense membranous bone grafts [e.g. calvarial] are more effective than endochondral grafts [e.g. iliac crest] in the craniofacial skeleton. Calvarial bone grafts have become popular because of their low resorption rates and minimal donor site morbidity for orbito-zygomatic complex reconstruction [70].

78.3 Conclusion

Hemifacial microsomia and Treacher Collins syndrome are both congenital craniofacial anomalies that negatively impact the physiological and psychological wellbeing of an individual [71]. Due to multidimensional nature of the deformity, a multidisciplinary holistic approach is required with proper guidance and counselling of the patients at every level of treatment. However, with the advances in regenerative sciences and genetic engineering, diagnosis and management of such congenital deformities is becoming less challenging. Disclosure Authors have no financial conflicts to disclose.



©Association of Oral and Maxillofacial Surgeons of India

Fig. 78.44 Skeletal correction for TCS. (a) Calvarial graft harvest for reconstruction of zygoma, (b) graft in place, (c) osteotomy design for orthognathic correction with bimaxillary surgery and genioplasty, (d) diagram showing post orthognathic final correction

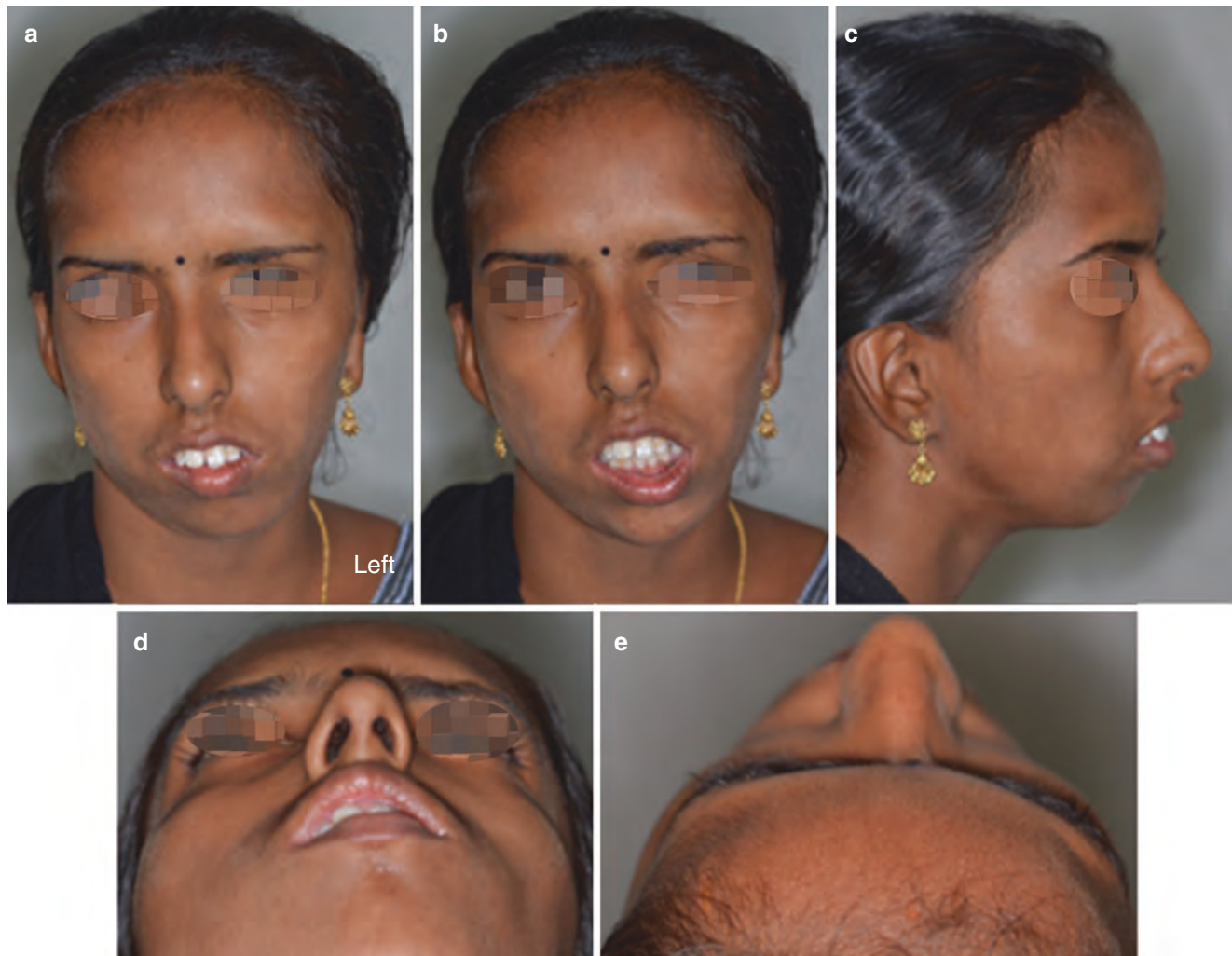78.4 Case Scenarios

Case 1: Treacher Collins Syndrome (Fig. 78.43a–f)

Case of TCS who underwent early osteodistraction. Note the mandibular advancement using bilateral unidirectional distractors. Follow-up after 5 years. Patient is currently undergoing orthodontic treatment.

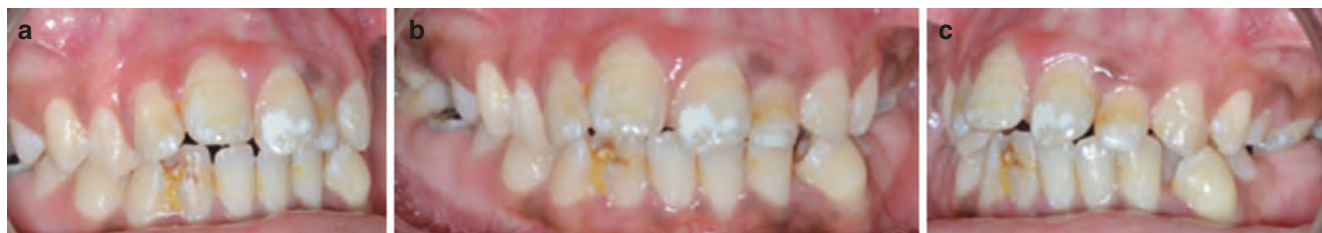Case 2: Hemifacial Microsomia (Figs. 78.45a–e, 78.46a–c, 78.47a, b, 78.48a–c, 78.49a–c, 78.50a, b, 78.51, 78.52a–d, 78.53a, b)

Case of a 20-year-old girl having HFM, undergoing osteotomy for asymmetry correction. Preoperative photographs, radiographs and CT scans showing the extent of asymmetry. Pre-surgical orthodontics for levelling and alignment. Virtual planning to fabricate CAD-CAM splint. Final postoperative



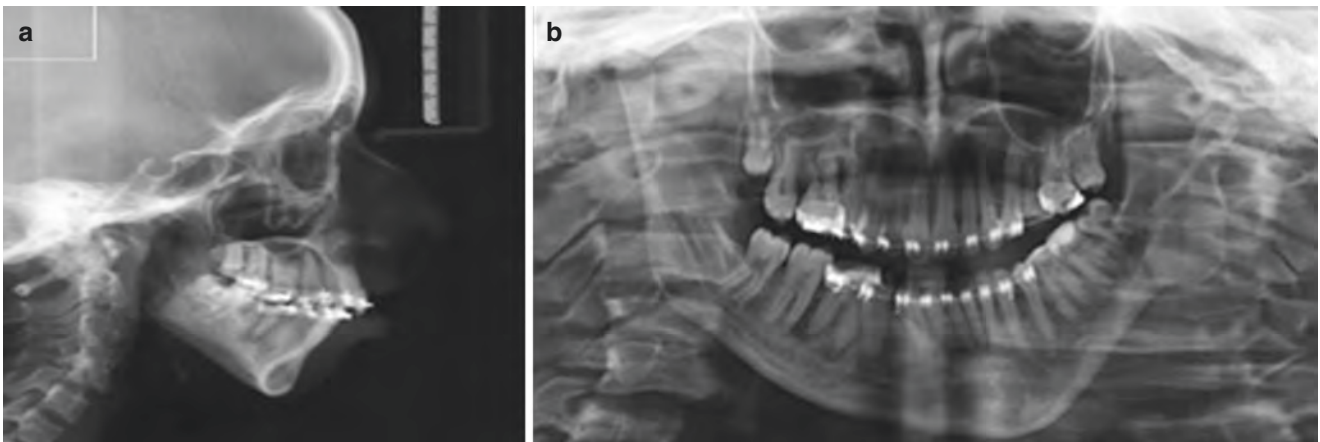
©Association of Oral and Maxillofacial Surgeons of India

Fig. 78.45 (a–e) Preoperative views of a female patient with facial asymmetry and deviation towards the left side



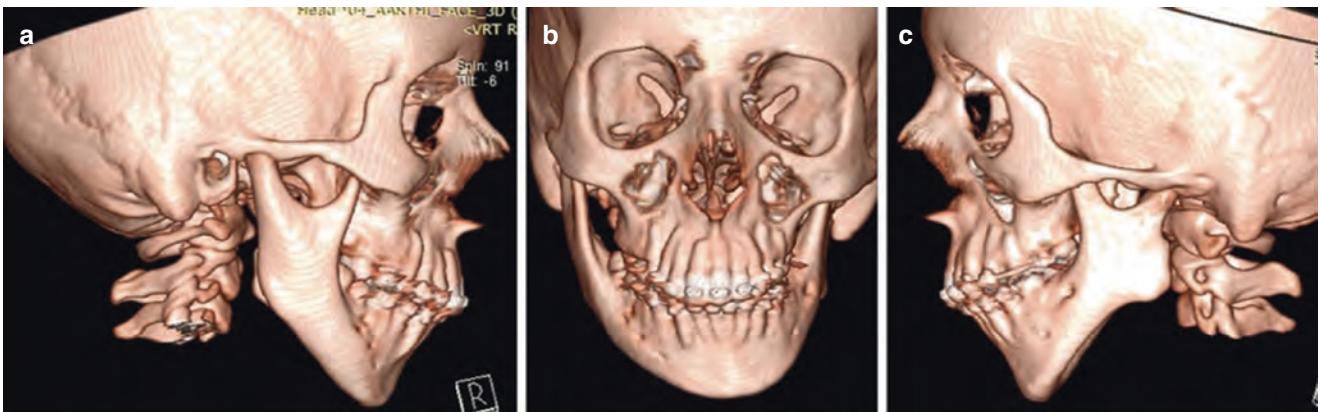
©Association of Oral and Maxillofacial Surgeons of India

Fig. 78.46 (a–c) Intraoral view showing malocclusion, crowding and midline deviation



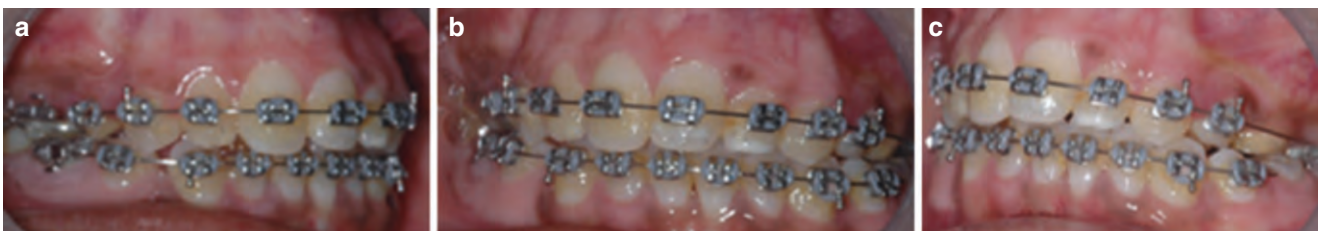©Association of Oral and Maxillofacial Surgeons of India

Fig. 78.47 (a, b) Preoperative (a) lateral cephalogram and (b) OPG showing Class II skeletal profile with left-sided TMJ deformity



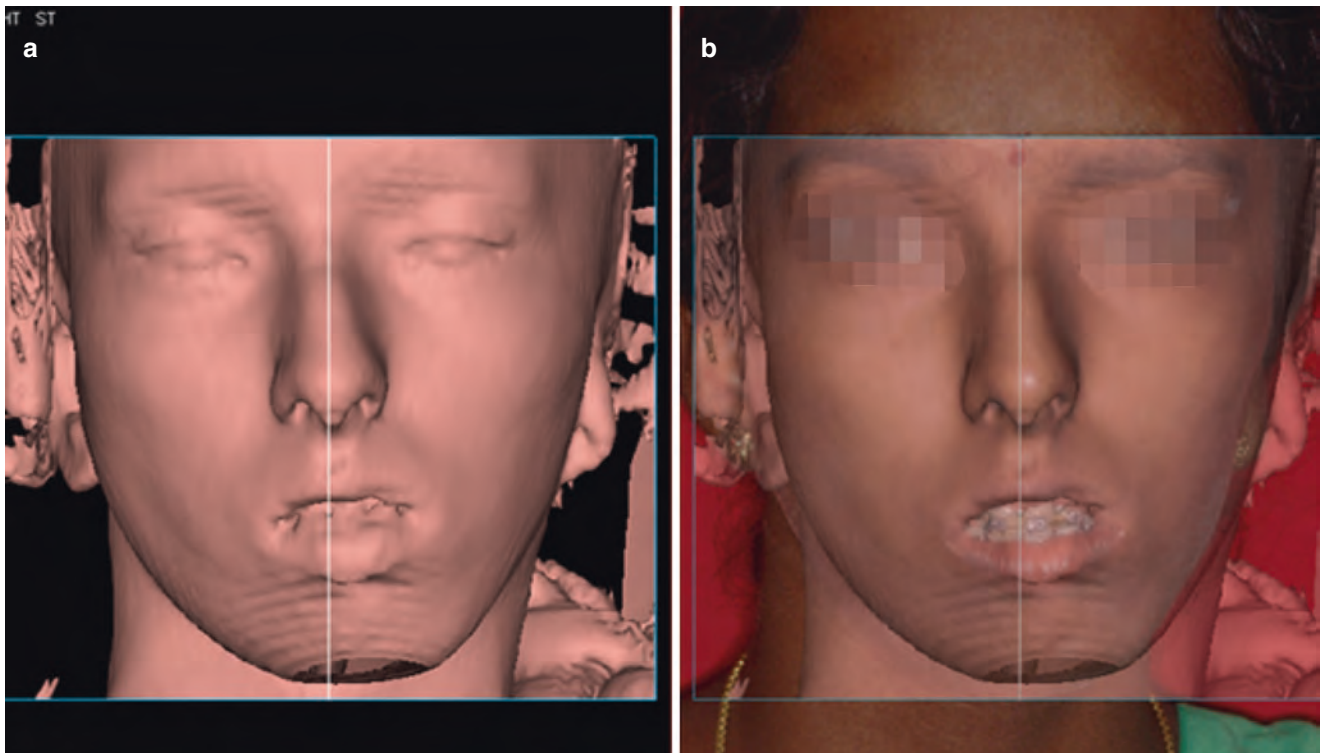
©Association of Oral and Maxillofacial Surgeons of India

Fig. 78.48 (a–c) Preoperative CT scans showing TMJ deformity on the left side



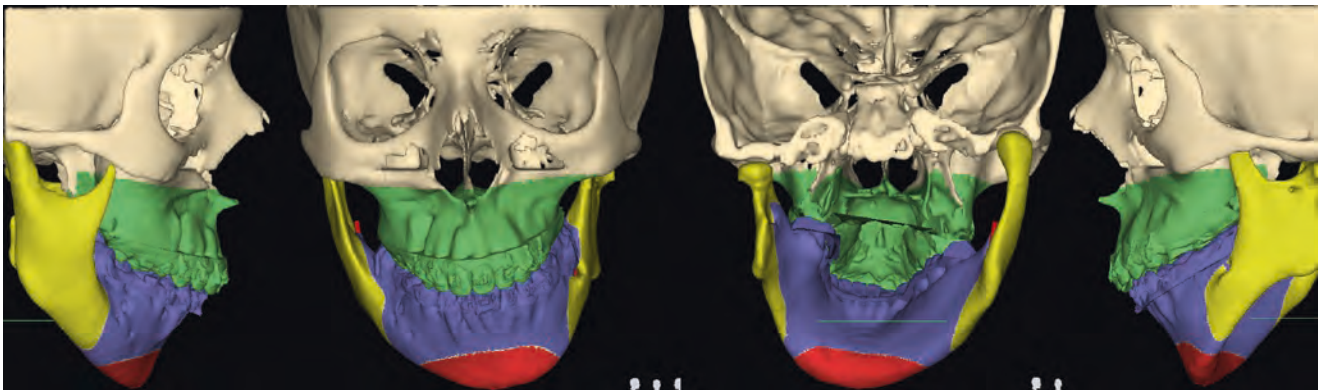
©Association of Oral and Maxillofacial Surgeons of India

Fig. 78.49 (a–c) Pre-surgical intermediate orthodontics treatment for alignment and levelling



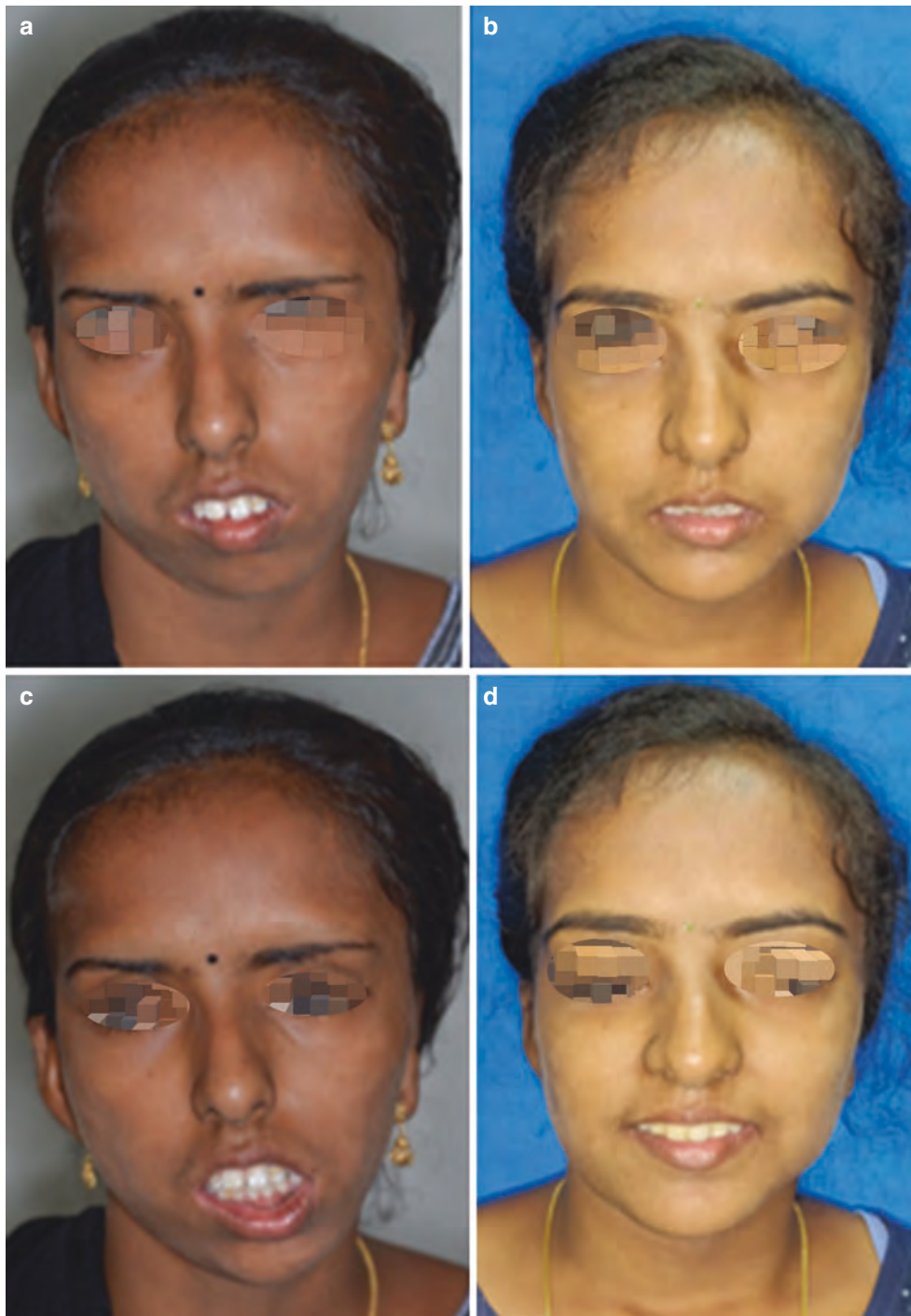©Association of Oral and Maxillofacial Surgeons of India

Fig. 78.50 (a, b) Virtual planning using 3D photogrammetry. (a) soft tissue reconstruction from the CT data. (b) superimposition of the patients photograph on the CT model



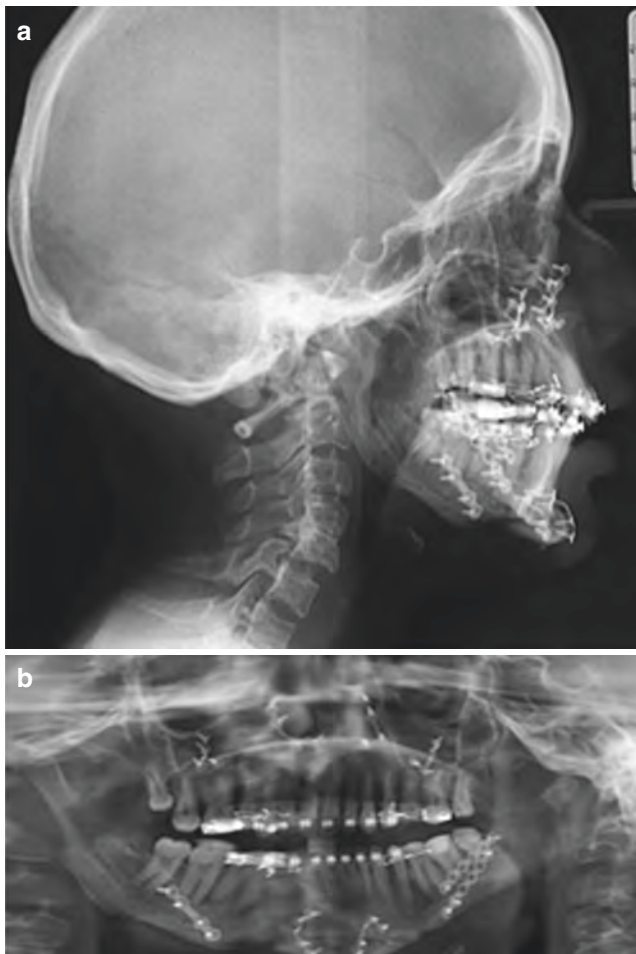
©Association of Oral and Maxillofacial Surgeons of India

Fig. 78.51 Virtual planning of orthognathic surgery to correct pitching, roll and yaw defect of the maxilla and mandible with genioplasty



©Association of Oral and Maxillofacial Surgeons of India

Fig. 78.52 (a–d): Pre (a, c) and post operative (b, d) photograph showing correction of asymmetry in patient with HFM



©Association of Oral and Maxillofacial Surgeons of India

Fig. 78.53 (a, b) Postoperative (a) lateral cephalogram and (b) OPG showing correction of maxillomandibular relation. Refer to Fig. 78.47 for pre-operative xrays

photographs and radiographs showing correction of asymmetry.

References

1. Posnick JC. Hemifacial macrosomia: evaluation and treatment. Principles and practice of orthognathic surgery. St. Louis, Missouri: Elsevier; 2014.
2. Brandstetter KA, Patel KG. Craniofacial Microsomia. *Facial Plast Surg Clin North Am* 2016 Nov;24(4):495–515. Review.
3. Poswillo D. The aetiology and pathogenesis of craniofacial deformity. *Development*. 1988;103(Suppl):207–12.
4. Scambler PJ. The 22q11 deletion syndromes. *Hum Mol Genet*. 2000, Oct 1;9(16):2421–6.
5. Poswillo D. The pathogenesis of the first and second branchial arch syndrome. *Oral Surg Oral Med Oral Pathol*. 1973;35(3):302–28.
6. Werler MM, Sheehan JE, Hayes C, Mitchell AA, Mulliken JB. Vasoactive exposures, vascular events, and hemifacial microsomia. *Birth Defects Res A Clin Mol Teratol*. 2004;70(6):389–95.
7. Werler MM, Sheehan JE, Hayes C, Padwa BL, Mitchell AA, Mulliken JB. Demographic and reproductive factors associated with hemifacial microsomia. *Cleft Palate Craniofac J*. 2004;41(5):494–50.
8. Taysi K, Marsh JL, Wise DM. Familial hemifacial microsomia. *Cleft Palate J*. 1983;20(1):47–53.
9. Juriloff DM, Harris MJ, Froster-Iskenius U. Hemifacial deficiency induced by a shift in dominance of the mouse mutation *far*: a possible genetic model for hemifacial microsomia. *J Craniofac Genet Dev Biol*. 1987;7(1):27–44.
10. Poonawalla HH, Kaye CI, Rosenthal IM, Pruzansky S. Hemifacial microsomia in a patient with Klinefelter syndrome. *Cleft Palate J*. 1980;17(3):194–6.
11. David DJ, Mahatumarat C, Cooter RD. Hemifacial microsomia: a multisystem classification. *Plast Reconstr Surg*. 1987;80:525–35.
12. Vento AR, LaBrie RA, Mulliken JB. The O.M.E.N.S. classification of hemifacial microsomia. *Cleft Palate Craniofac J* 1991;28:68–76. discussion 77.
13. Kaban LB, Mulliken JB, Murray JE. Three-dimensional approach to analysis and treatment of hemifacial microsomia. *Cleft Palate J*. 1981;18:90–9.
14. Grabb WC. The first and second branchial arch syndrome. *Plast Reconstr Surg*. 1965;36(5):485–508.
15. Rollnick BR, Kaye CI. Hemifacial microsomia and variants: pedigree data. *Am J Med Genet*. 1983;15(2):233–53.
16. Stark RB, Saunders DE. The first branchial syndrome. The oral-mandibular-auricular syndrome. *Plast Reconstr Surg Transplant Bull*. 1962;29:229–39.
17. Die MH. Missbildungen des ohres. In: Denker AK, editor. *Handbuch der Spez Path Anatomie Histologie*. Berlin: Springer; 1926. p. 131.
18. Meurman Y. Congenital microtia and meatal atresia; observations and aspects of treatment. *AMA Arch Otolaryngol*. 1957;66:443–63.
19. Hollier LH, Rowe NM, Mackool RJ, Williams JK, Kim JH, Longaker MT, Grayson BH, JG MC. Controlled multiplanar distraction of the mandible. Part III: Laboratory studies of sagittal (anteroposterior) and horizontal (mediolateral) movements. *J Craniofac Surg*. 2000 Mar;11(2):83–95.
20. Fan WS, Mulliken JB, Padwa BL. An association between hemifacial microsomia and facial clefting. *J Oral Maxillofac Surg*. 2005;63:330–4.
21. Parameswaran A, Ramanathan M. Hemifacial microsomia. *J Indian Orthodontic Soc*. 2018 Jul 1;52(3):155.
22. Tahiri Y, Viezel-Mathieu A, Aldekhayel S, Lee J, Gilardino M. The effectiveness of mandibular distraction in improving airway obstruction in the pediatric population. *Plast Reconstr Surg*. 2014;133:352e–9e.
23. Nagy K, Kuijpers-Jagtman AM, Mommaerts MY. No evidence for long-term effectiveness of early osteodistraction in hemifacial microsomia. *Plast Reconstr Surg*. 2009;124:2061–71.
24. Mishra L, Misra SR, Kumar M, Tripathy R. Hemifacial microsomia: a series of three case reports. *J Clin Diagn Res*. 2013 Oct;7(10):2383–6.
25. Munro I. Hemifacial micorosmia: the skeletal correction. *Oper Tech Plast Reconstr Surg*. 1994;1:77–92.
26. Kaban LB, Moses MH, Mulliken JB. Correction of hemifacial microsomia in thegrowing child: a follow-up study. *Cleft Palate J*. 1986;23(Suppl 1):50.

27. Kaban LB, Padwa BL, Mulliken JB. Surgical correction of mandibular hypoplasia in hemifacial microsomia: the case for treatment in early childhood. *J Oral Maxillofac Surg.* 1998;56:628–38.
28. Ohtani J, Hoffman WY, Vargervik K, Oberoi S. Team management and treatment outcomes for patients with hemifacial microsomia. *Am J Orthod Dentofac Orthop.* 2012;141(4 Suppl):S74–81.
29. Silvestri A, Natali G, Iannetti G. Functional therapy in hemifacial microsomia: therapeutic protocol for growing children. *J Oral Maxillofac Surg.* 1996;54:271–8. discussion 278–80
30. Zanardi G, Parente EV, Esteves LS, Louro RS, Capelli J Jr. Orthodontic and surgical treatment of a patient with hemifacial microsomia. *Am J Orthod Dentofac Orthop.* 2012;141(4 Suppl):S130–9.
31. Tahiri Y, Chang CS, Tuin J, Paliga JT, Lowe KM, Taylor JA, et al. Costochondral grafting in craniofacial microsomia. *Plast Reconstr Surg.* 2015;135:530–41.
32. Murra JE, Mulliken JB, Kaban IB. Twenty-year experience in maxillofacial surgery: an evaluation of early surgery on growth function and body image. *Ann Surg.* 1979;190:320.
33. Ongkosuwito EM, van Vooren J, van Neck JW, Wattel E, Wolvius EB, van Adrichem LN, et al. Changes of mandibular ramal height, during growth in unilateral hemifacial microsomia patients and unaffected controls. *J Craniomaxillofac Surg.* 2013;41:92–7.
34. Ortiz Monasterio F, Molina F, Andrade L, Rodriguez C, Sainz AJ. Simultaneous mandibular and maxillary distraction in hemifacial microsomia in adults: avoiding occlusal disasters. *Plast Reconstr Surg.* 1997;100:852–6.
35. Suh J, Choi TH, Baek SH, Kim JC, Kim S. Mandibular distraction in unilateral craniofacial microsomia: longitudinal results until the completion of growth. *Plast Reconstr Surg.* 2013;132:1244–52.
36. Salins PC, Venkatraman B, Kavavody M. Morphometric basis for orthomorphic correction of mandibular asymmetry. *J Oral Maxillofac Surg.* 2008 Jul;66(7):1523–31.
37. Weichman KE, Jacobs J, Patel P, Szpalski C, Shetye P, Grayson B, et al. Early distraction for mild to moderate unilateral craniofacial microsomia: long-term follow-up, outcomes, and recommendations. *Plast Reconstr Surg.* 2017;139:941e–53e.
38. Cassi D, Battistoni G, Magnifico M, et al. Three-dimensional evaluation of facial asymmetry in patients with hemifacial microsomia using stereophotogrammetry. *J Craniomaxillofac Surg.* 2019;47(1):179–84.
39. Peacock ZS, Tricomi BJ, Faquin WC, et al. Bilateral continuous automated distraction osteogenesis: proof of principle. *J Craniofac Surg.* 2015;26(8):2320–4.
40. Yamada Y, Ueda M, Hibi H, Nagasaka T. Translational research for injectable tissue-engineered bone regeneration using mesenchymal stem cells and platelet-rich plasma: from basic research to clinical application. *Cell Transplant.* 2004;13:343–55.
41. Gorlin RJ, Cohen MM Jr, Levin LS. Syndromes of the head and neck. 3rd ed. New York: Oxford University Press; 1990. p. 649–52.
42. Franceschetti A, Klein D. The mandibulofacial dysostosis; a new hereditary syndrome. *Acta Ophthalmol.* 1949;27(2):143–224.
43. Rogers BO. Berry-treacher collins syndrome: a review of 200 cases (mandibulo-facial dysostosis; franceschetti-zwahlen-klein syndromes). *Br J Plast Surg.* 1964 Apr;17:109–37. Pubmed pmid: 14150863.
44. Jones KL, Smith DW, Harvey MAS, Hall BD, Quan L. Older paternal age and fresh gene mutation: data on additional disorders. *J Pediatr.* 1975;86:84–8.
45. Posnick JC, Ruiz RL. Treacher Collins syndrome: current evaluation, treatment, and future directions. *Cleft Palate Craniofac J.* 2000;37:434.
46. Sulik KK, Johnston MC, Smiley SJ, Speight HS, Jarvis BE. Mandibulofacial dysostosis (Treacher Collins syndrome): a new proposal for its pathogenesis. *Am J Med Genet.* 1987;27:359–72.
47. Dauwerse JG, Dixon J, Seland S, Ruivenkamp CA, van Haeringen A, Hoefsloot LH, et al. Mutations in genes encoding subunits of RNA polymerases I and III cause Treacher Collins syndrome. *Nat Genet.* 2011;43:20–2.
48. Andrade EC, Júnior VS, Didoni AL, Freitas PZ, Carneiro AF, Yoshimoto FR. Treacher Collins syndrome with choanal atresia: a case report and review of disease features. *Braz J Otorhinolaryngol.* 2005;71:107–10.
49. Nikkhhah D, Ponniah A, Ruff C, Dunaway D. Planning surgical reconstruction in Treacher-Collins syndrome using virtual simulation. *Plastic Reconstr Surg.* 2013;132:790e–805e.
50. Marszałek B, Wójcicki P, Kobus K, Trzeciak WH. Clinical features, treatment and genetic background of Treacher Collins syndrome. *J Appl Genet.* 2002;43:223–33.
51. Shete P, Tupkari J, Benjamin T, Singh A. Treacher Collins syndrome. *J Oral Maxillofac Pathol.* 2011;15:348–51.
52. Waitzman AA, Posnick JC, Armstrong DC, Pron GE. Craniofacial skeletal measurements based on computed tomography: part II. Normal values and growth trends. *Cleft Palate Craniofac J.* 1992, Mar 01;29(2):118–28.
53. Trainor PA, Dixon J, Dixon MJ. Treacher Collins syndrome: etiology, pathogenesis and prevention. *Eur J Hum Genet.* 2009;17:275–83.
54. Sher AE. Obstructive sleep apnea syndrome: a complex disorder of the upper airway. *Otolaryngol Clin N Am.* 1990;23(4):593–608.
55. Hoeve LJ, Pijpers M, Joosten KF. OSAS in craniofacial syndromes: an unsolved problem. *Int J Pediatr Otorhinolaryngol.* 2003;67.
56. Rachmiel A, Emodi O, Aizenbud D. Management of obstructive sleep apnea in pediatric craniofacial anomalies. *Ann Maxillofac Surg.* 2012;2:111–5.
57. Ellis DS, Potluri PK, O’Flaherty JE, et al. Difficult airway management in the neonate: a simple method of intubating through a laryngeal mask airway. *Paediatr Anaesth.* 1999;9:460–2.
58. Morovic CG, Monasterio L. Distraction osteogenesis for obstructive apneas in patients with congenital craniofacial malformations. *Plast Reconstr Surg.* 2000;105:2324–30.
59. Rachmiel A, Emodi O, Rachmiel D, Aizenbud D. Internal mandibular distraction to relieve airway obstruction in children with severe micrognathia. *Int J Oral Maxillofac Surg.* 2014;43:1176–81.
60. Diner PA, Kollar E, Martinez H, Vazquez MP. Submerged intraoral device for mandibular lengthening. *J Craniomaxillofac Surg.* 1997;25:116–23.
61. Hwang DW, Jung KJ, Kim SY, Kim JH. Usefulness of videofluoroscopic swallow study in treacher Collins syndrome with cleft palate: a case report. *Ann Rehabil Med* 2014 Oct;38(5):707–11.
62. da Silva Dalben G, Teixeira das Neves L, Ribeiro Gomide M. Oral health status of children with treacher Collins syndrome. *Spec Care Dentist* 2006 Mar–Apr; 26 (2):71–75. quiz 85-7.
63. Okada R, Kuroda T. Orthodontic treatment for a patient with Treacher-Collins syndrome: a case report. *World J Orthod* 2008 Winter; 9 (4):e37–e47. PubMed PMID:19641756.
64. Hylton JB, Leon-Salazar V, Anderson GC, De Felipe NL. Multidisciplinary treatment approach in Treacher Collins syndrome. *J Dent Child (Chic)* 2012 Jan–Apr; 79 (1):15–21. Review. PubMed PMID: 22449504.
65. Lim AA, Fan K, Allam KA, et al. Autologous fat transplantation in the craniofacial patient: the UCLA experience. *J Craniofac Surg* 2012;23(4):1061e6 [Epub 2012/07/11].

66. Posnick JC, Goldstein JA, Waitzman AA. Surgical correction of the Treacher Collins malar deficiency: quantitative CT scan analysis of long-term results. *Plast Reconstr Surg*. 1993;92(1):12–22.
67. Mommaerts MY, Nadjmi N, Abeloos JV, Neyt LF. Six year's experience with the zygomatic "sandwich" osteotomy for correction of malar deficiency. *J Oral Maxillofac Surg Off J Am Assoc Oral Maxillofac Surg* 1999;57(1):8e13. discussion 4e5. Epub 1999/01/23.
68. Smolka W, Eggenesperger N, Kollar A, Iizuka T. Midfacial reconstruction using Calvarial Split bone grafts. *Arch Otolaryngol Head Neck Surg*. 2005;131(2):131–6.
69. Freihofer HP. Variations in the correction of Treacher Collins syndrome. *Plast Reconstr Surg* 1997;99(3):647e57.
70. Marsh JL, Celin SE, Vannier MW, Gado M. The skeletal anatomy of mandibulofacial dysostosis (Treacher Collins syndrome). *Plast Reconstr Surg* 1986;78(4):460e70. [Epub 1986/10/01].
71. Murray JE, Kaban LB, Mulliken JB. Analysis and treatment of hemifacial microsomia. *J Craniofac Surg*. 1985;33:377.

Open Access This chapter is licensed under the terms of the Creative Commons Attribution 4.0 International License (<http://creativecommons.org/licenses/by/4.0/>), which permits use, sharing, adaptation, distribution and reproduction in any medium or format, as long as you give appropriate credit to the original author(s) and the source, provide a link to the Creative Commons license and indicate if changes were made.

The images or other third party material in this chapter are included in the chapter's Creative Commons license, unless indicated otherwise in a credit line to the material. If material is not included in the chapter's Creative Commons license and your intended use is not permitted by statutory regulation or exceeds the permitted use, you will need to obtain permission directly from the copyright holder.





David Koppel and Jaime Grant

79.1 Introduction

The different presentations of craniosynostosis form the majority of the workload of craniofacial services, and it is important to note that the surgical interventions only form a small part of the overall management of this vulnerable group of patients and their families.

79.1.1 Definition

Craniosynostosis is defined as the premature fusion of one or more of the cranial sutures. This premature fusion can either be an isolated disorder (e.g. sagittal synostosis) or form part of a syndrome (e.g. Apert syndrome). In many cases the resultant head shape is typical of the involved suture such that the Greek/Latin descriptive terms are used synonymously with the description of the affected suture. For example scaphocephaly (boat-shaped head) is used to describe sagittal synostosis; however this approach can lead to confusion as can be seen in the use of the term plagiocephaly (flat head) which may refer to a unicoronal synostosis but also can be used in unilateral lambdoid synostosis, skull base torsion, the deformity resulting from torticollis and positional skull deformities. For this reason it is probably best to avoid the Latin/Greek descriptive terms and identify the affected suture(s) by name.

The majority of craniosynostoses are primary in nature and congenital; however a small proportion are termed

secondary—caused by another pathology, usually resulting in reduced brain growth as seen in microcephaly or post-shunting.

79.1.2 Aetiology

79.1.2.1 Primary Craniosynostosis

In the majority of cases, no cause for the synostosis is identified, but in an increasing proportion (currently about 25%), a mutation is identified. A significant proportion of these mutations are related to six genes FGFR2, FGFR3, TWIST1, EFNB1, TCF12 and ERF, however there is an increasing frequency of additional mutations being identified by more complex genetic analysis.

The incidence of identifying a mutation is much higher in syndromic craniosynostosis cases (69%), but the rate of mutation identification in the non-syndromic cases is increasing (currently 5%) particularly in the bicoronal, multisuture and unicoronal (in decreasing frequency) [1].

These genetic advances have assisted in the diagnosis of these conditions and influence the genetic counselling but have yet to impact on the management of the resultant problems related to the premature suture closure. As the mechanisms of sutural control and homeostasis are elucidated, novel therapies may be introduced.

79.1.2.2 Secondary Craniosynostosis

Microcephaly and babies who have been shunted as well as other systemic conditions such as sickle cell disease, thalassaemia and rickets can lead to synostosis usually affecting all the sutures. In cases of microcephaly, it is important to differentiate between a primary pansynostosis resulting in a small head often with raised intracranial pressure from a secondary synostosis with normal intracranial pressure [2].

D. Koppel (✉)

Consultant Craniofacial/Oral & Maxillofacial Surgeon, Clinical Director Surgery & Gastroenterology, Clinical Lead Scottish National Craniofacial Service for Children and Young People, Royal Hospital for Children, Glasgow, UK
e-mail: davidkoppel@nhs.net

J. Grant

Craniofacial Fellow, Birmingham Children's Hospital, Glasgow, UK
e-mail: jaimegrant@nhs.net

79.1.3 Epidemiology

The incidence of craniosynostosis ranges from 1 in 1400 to 1 in 2100 live births worldwide with a slight male preponderance.

The different types of craniosynostosis occur in the following proportions:

- Sagittal 45%.
- Metopic 20%.
- Bicoronal and unicoronal 15%.
- Multiple suture 5%.
- Lambdoid <2% [3].

79.1.4 Classification

The classification of craniosynostosis has, in recent years, changed; the previously utilised terminology of simple and complex, referring to single-suture and multiple suture abnormalities, respectively, has been abandoned. It has little

utility and is in fact misleading—the deformity as a result of a unicoronal synostosis is extremely complex and as more is understood about the genetic basis the more complex the condition becomes.

In terms of utility, the craniosynostosis is best classified by the suture(s) involved and whether this is associated with a syndrome (i.e. other abnormalities). See Table 79.1 and Illustrations 79.1, 79.2, 79.3, 79.4, 79.5, 79.6 and 79.7. The condition can be further defined by the genetic abnormalities. In general the syndromic craniosynostosis cases tend to be more severe and have a greater incidence of complicating features.

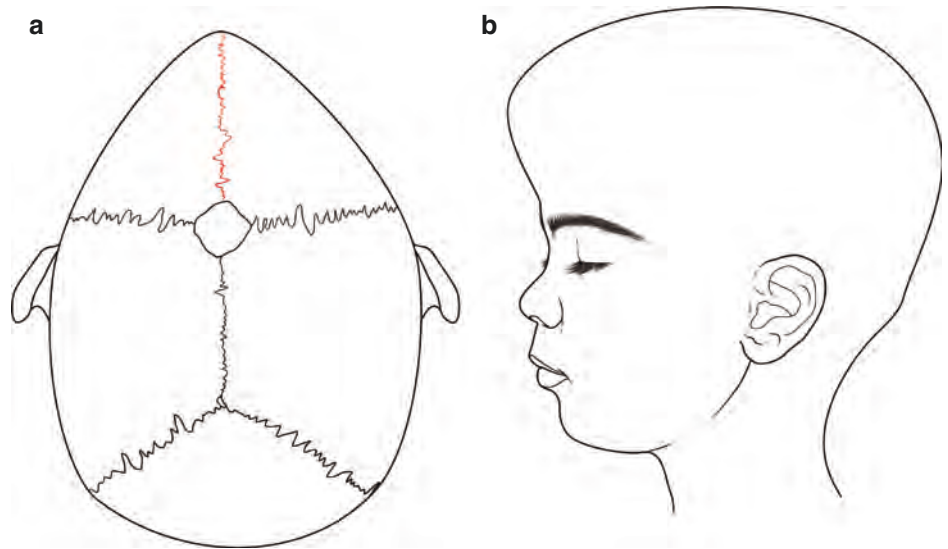
79.2 Management

The care of babies and children with craniosynostosis is best delivered in a centre with access to a full multidisciplinary team. This team involves the core specialities of paediatric neurosurgery and craniofacial surgery (either OMFS or plastics based) as well as support from paediatricians, neonatologists, geneticists, respiratory specialists, ophthalmologists and ENT surgeons. The input from specialist nurses and psychologists is vital [4].

Table 79.1 Overview of craniosynostoses

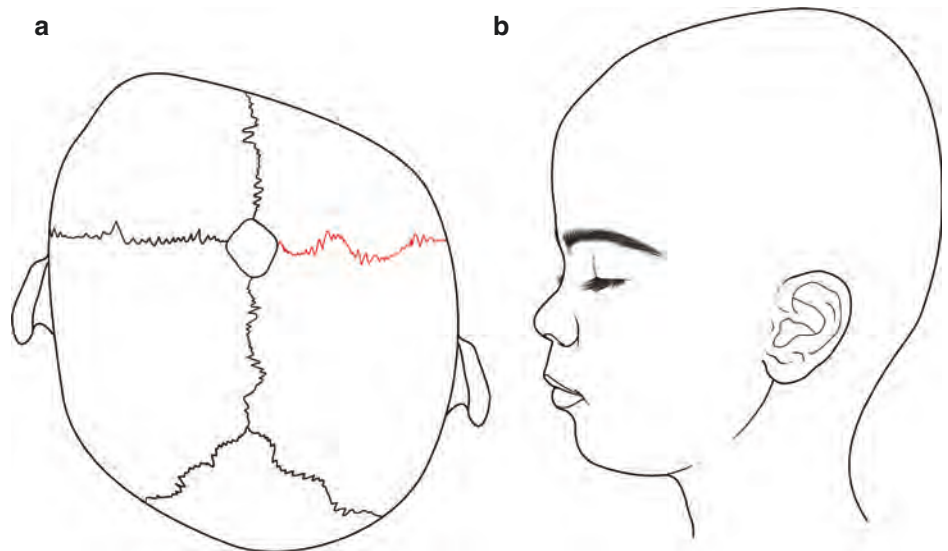
Suture affected	Description of shape	Diagram of shape	Description
Metopic	Trigonocephaly	Illustration 79.1a, b	Pointed, protuberant, prow-shaped forehead Reduced intercanthal distance Bitemporal narrowing
Unicoronal	Anterior plagiocephaly	Illustration 79.2a, b	Flattened forehead on affected side with raised eyebrow and shallower orbit Failure of forward growth of the hemiforehead with the ipsilateral ear also posterior
Bicoronal	Brachycephaly	Illustration 79.3a, b	Shortened AP—Coronal dimension Flattening of whole forehead Flattened supraorbital rims
Sagittal	Scaphocephaly	Illustration 79.4a, b	Forehead bossing Occipital bulleting Bitemporal narrowing Increased AP—Coronal dimension
Lambdoid	Posterior plagiocephaly	Illustration 79.5a, b	Bossing of mastoid on affected side Contralateral parietal bossing Ipsilateral ear posteriorised
Pansynostosis	Turricephaly or Oxycephaly	Illustration 79.6a, b	Restricted growth at all or multiple sutures—Upward growth in the region of the Fontanelle Small circumference 'Cone'- or 'turret'-shaped head
Positional	Plagiocephaly	Illustration 79.7a, b	Parallelogramming of the whole head Ears move with the segments No ridging of any sutures

Illustration 79.1 (a, b)
Metopic suture affected in
trigonocephaly



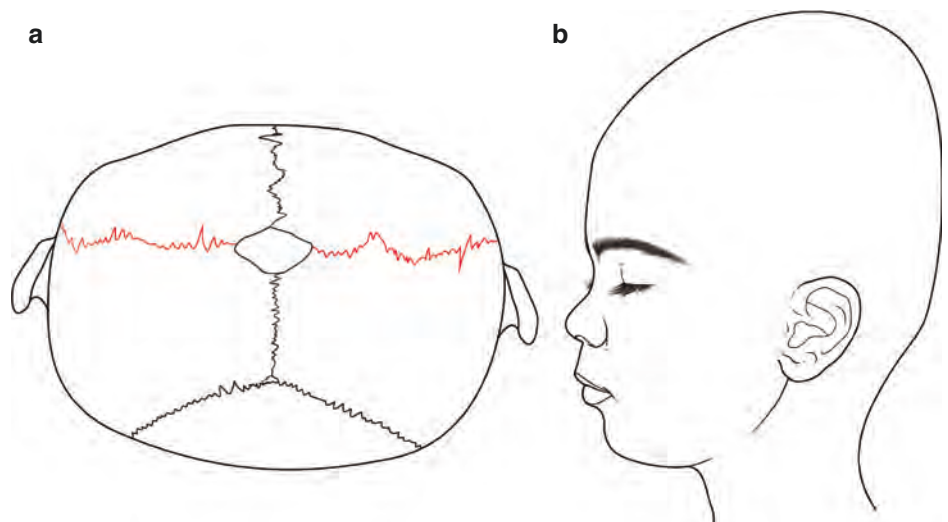
©Association of Oral and Maxillofacial Surgeons of India

Illustration 79.2 (a, b)
Unicoronal suture affected in
anterior plagiocephaly



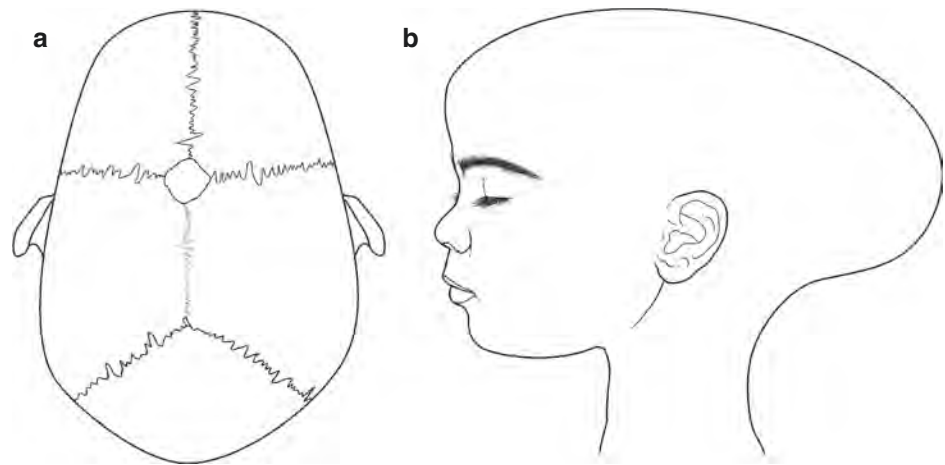
©Association of Oral and Maxillofacial Surgeons of India

Illustration 79.3 (a, b)
Bicoronal suture affected in
brachycephaly



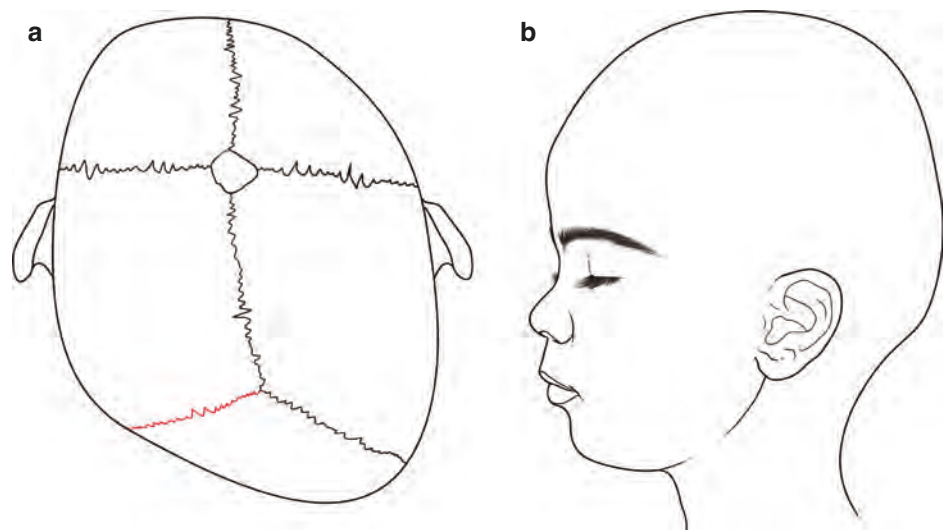
©Association of Oral and Maxillofacial Surgeons of India

Illustration 79.4 (a, b)
Sagittal suture affected in
scaphocephaly



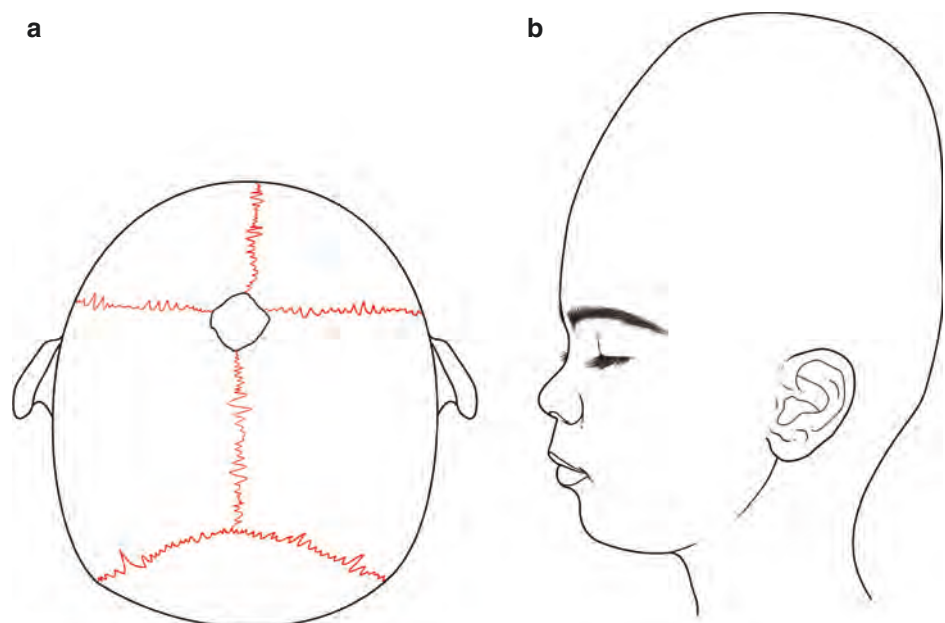
©Association of Oral and Maxillofacial Surgeons of India

Illustration 79.5 (a, b)
Lambdoid suture affected in
posterior plagiocephaly

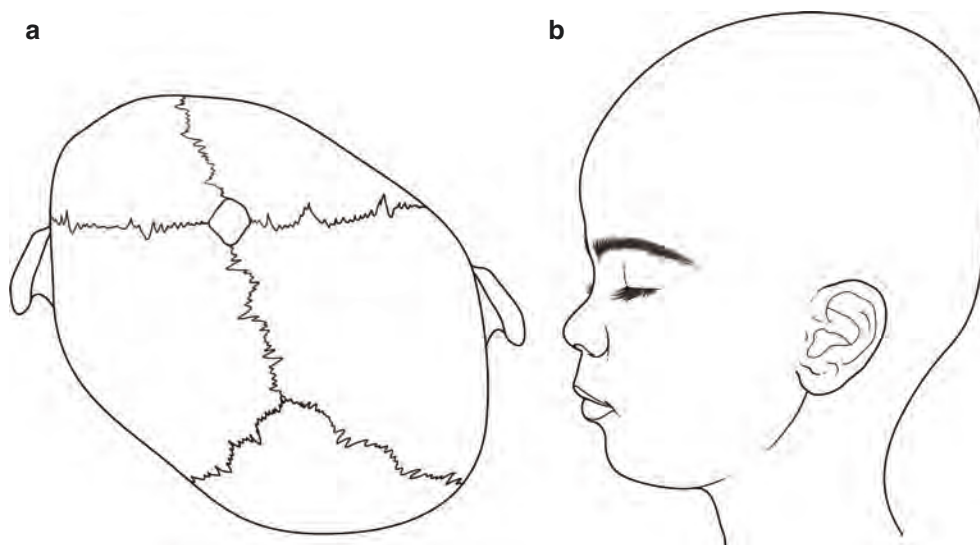


©Association of Oral and Maxillofacial Surgeons of India

Illustration 79.6 (a, b)
Pansynostosis causing
turricephaly or oxycephaly



©Association of Oral and Maxillofacial Surgeons of India

Illustration 79.7 (a, b)
Positional plagiocephaly

©Association of Oral and Maxillofacial Surgeons of India

Table 79.2 Treatment options in infancy for complex synostosis problems

Clinical problem	Emergency/urgent treatment options	Definitive treatment options
Upper airway obstruction 2° to midface retrusion	Nasopharyngeal airway Intubation, O ₂ support, CPAP, tracheostomy	Transcranial monobloc advancement (± distraction), CPAP, tracheostomy, Subcranial Le fort III advancement
Corneal exposure	Intensive eye care, tarsorrhaphy	Fronto-orbital advancement, Monobloc advancement
Hydrocephalus	External ventricular drain, ventriculo-peritoneal shunt, third ventriculostomy (in selected cases)	Ventriculo-peritoneal shunt
Elevated ICP	Medical treatment with acetazolamide, steroids	Skull vault expansion, fronto-orbital advancement and remodelling (FOAR), monobloc advancement ± implanted telemetric device

79.2.1 Prenatal Diagnosis

The use of high-definition prenatal ultrasound has increased the early diagnosis of both hydrocephalus and craniosynostosis [5]. This facilitates the preparation of parents for the birth of a child who is likely to have additional medical, surgical and emotional needs. In these circumstances parents getting to know the craniofacial team and being better informed of the potential problems often makes supporting them much easier.

79.2.2 Perinatal Care (Table 7.2)

In the perinatal period, care is directed at optimising the airway, ensuring the child is well oxygenated, preventing corneal damage (ocular protection) and confirming the diagnosis. In the majority of single-suture abnormalities, there are often no issues that prompt early intervention; however in the complex syndromic cases, this is not the case. Airway problems due to severe midface retrusion; breathing disturbance due to central problems, often due to posterior fossa crowding and Chiari malformation; corneal

exposure secondary to midface and brow retrusion; and associated non-craniofacial anomalies prompt more urgent interventions. The necessity for such interventions is greatest in the syndromic conditions such as Apert, Pfeiffer, Crouzon and Carpenter syndromes. In cases where there is significant midface retrusion, there may also be feeding difficulties [6].

In the severe cases, initial care is supportive. The airway should be assessed and intervention initiated if necessary. It is important to assess the oxygen saturation and the work of breathing and correlate these findings with formal blood gas measurements. This assessment can be augmented with a formal sleep study, and on occasion simultaneous measurement of intracranial pressure may be helpful. Airway support can range from positional nursing, the use of a nasopharyngeal airway, intubation and in some cases tracheostomy. As part of this assessment, when the airway is an issue of concern, consideration should be given to performing a CT scan, and this will be useful to look at cranial anatomy but also the nasal anatomy, particularly to exclude choanal atresia. In assessing the airway, babies often manage satisfactorily but may suddenly decompensate with a minor upper respiratory tract infection or whilst feeding [6].

Surgical intervention in this period is only undertaken when the airway is such that no simple measures are able to overcome the symptoms; often a period of intubation is helpful to allow for a more thorough assessment rather than rushing to either tracheostomy or a monobloc fronto-facial advance. During this period parents and family members have to come to terms with the often unexpected consequences of having a child with additional needs and medical interventions. Early and ongoing support needs to be delivered; this can and should be through multiple avenues. Many such children are born in institutions with little or no experience of the condition(s), and this professional unfamiliarity often adds to parental anxiety. For these reasons early contact with a dedicated craniofacial team is invaluable. Specialist nurses, psychologists and support groups can often ease the stress of this difficult time [7].

79.2.3 Care in Infancy

The management of craniosynostosis in infancy is primarily aimed at addressing the primary consequences of the premature suture closure as well as dealing with the associated problems.

The management of the synostosis has, over the years, evolved considerably and in some respect completed a complete circle. The treatment is aimed at ensuring cranial volume is satisfactory to ensure that there is no elevation of ICP (in the absence of hydrocephalus) as well as attempting to normalise the head shape. The normalisation of head shape is done to maximise the chances of a normal head shape at the completion of growth. Initial treatment introduced in the second half of the last century involved a procedure known as suturectomy [8]. The principle of this was to excise the pathological, prematurely fused suture with the idea that removal of the pathology would allow the skull to continue to grow into a normal shape possibly aided by the continued growth of the brain. This was found to be partially effective especially when done before the age of 18 months [9]. It was however noted that in many cases re-fusion of the suture occurred and a number of surgeons began wrapping the bone edges on either side of the resected suture with silicone edging in an attempt to minimise the chances of re-fusion. Unfortunately this approach did not prevent re-fusion, and this often occurred on the dural side of the silicone edging. In pansynostosis cases the sutures were excised and the remain-

der of the skull was morsellised [9]. These simple techniques have been superseded with more complex reconstructive procedures involving suturectomy and remodelling. (See case series examples (Figs. 79.2, 79.3, 79.4 and 79.5). When the coronal sutures are involved, either unilaterally or bilaterally, and/or the metopic sutures, the mainstay of treatment is a fronto-orbital advancement, with remodelling of the affected bones. When the sagittal suture is involved, the affected suture is excised and the remaining skull remodelled. The extent of remodelling varies from case to case but can involve addressing the frontal bossing, bitemporal narrowing and the occipital bullet [4]. These procedures involve extensive exposure and blood loss with their attendant risks, and for these reasons there has been a move to attempt to correct these abnormalities with less invasive procedures. These less invasive approaches utilise endoscopic suturectomy coupled with active postoperative helmet therapy to mould and harness the ongoing brain and hence skull growth [10]; another approach has used a minimal access suturectomy and specially designed springs to actively separate the affected suture edges [11]. A further technique, particularly in bicoronal or pansynostosis cases, is to utilise distraction osteogenesis; a craniotomy of the occipital bone is performed, and two or three distraction devices are applied; these are then activated over a period of 2–3 weeks, expanding the skull volume and in many cases improving the posterior fossa crowding seen in such cases. For reasons not fully understood, this technique often leads to a significant improvement in the contour of the frontal bones [12].

In terms of timing of surgery, there is considerable variation between different centres. In general elective (not motivated by functional concerns), suturectomy and skull remodelling procedures are performed between the ages of 5 months and 2½ years. The younger the patient, the greater the contribution of normal brain growth in normalising head shape; however the drawback of earlier surgery is the fragility of the skull bones and most importantly the risks of complications—particularly excessive blood loss [13].

During this period patients are generally followed up to monitor for signs of raised intracranial pressure, obstructive sleep apnoea (OSA) and evidence of a significant change in the rate of head growth as indicated by head circumference. Discrepancies between the plots on the growth charts (Fig. 79.1a, b) for length, weight and head circumference as well as plots crossing the centile lines should prompt further investigation.

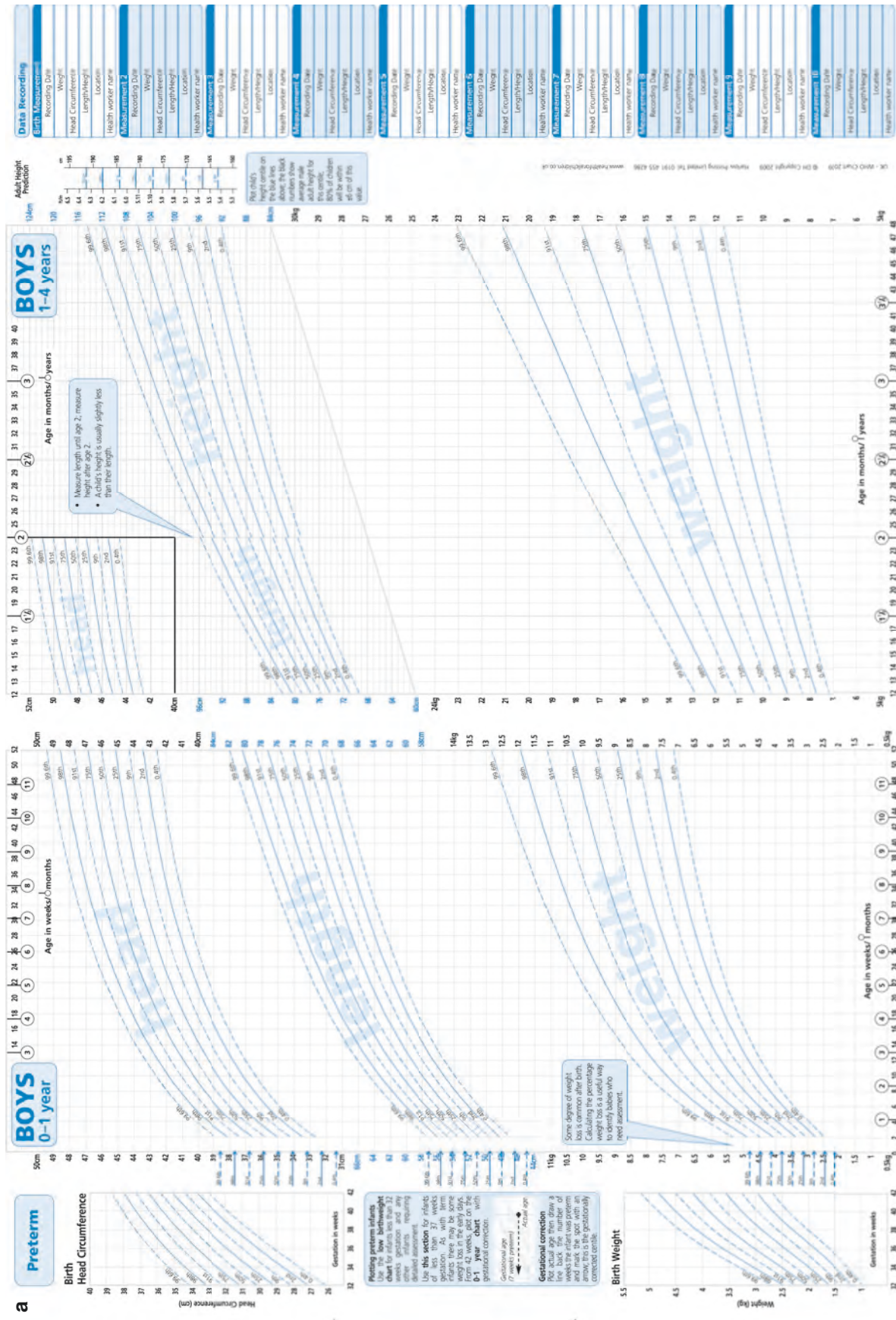


Fig. 79.1 (a) (boys), (b) (girls) WHO UK growth the chart (a) and (b) is available Online at <https://www.rcpch.ac.uk/resources/uk-who-growth-charts-0-4-years>

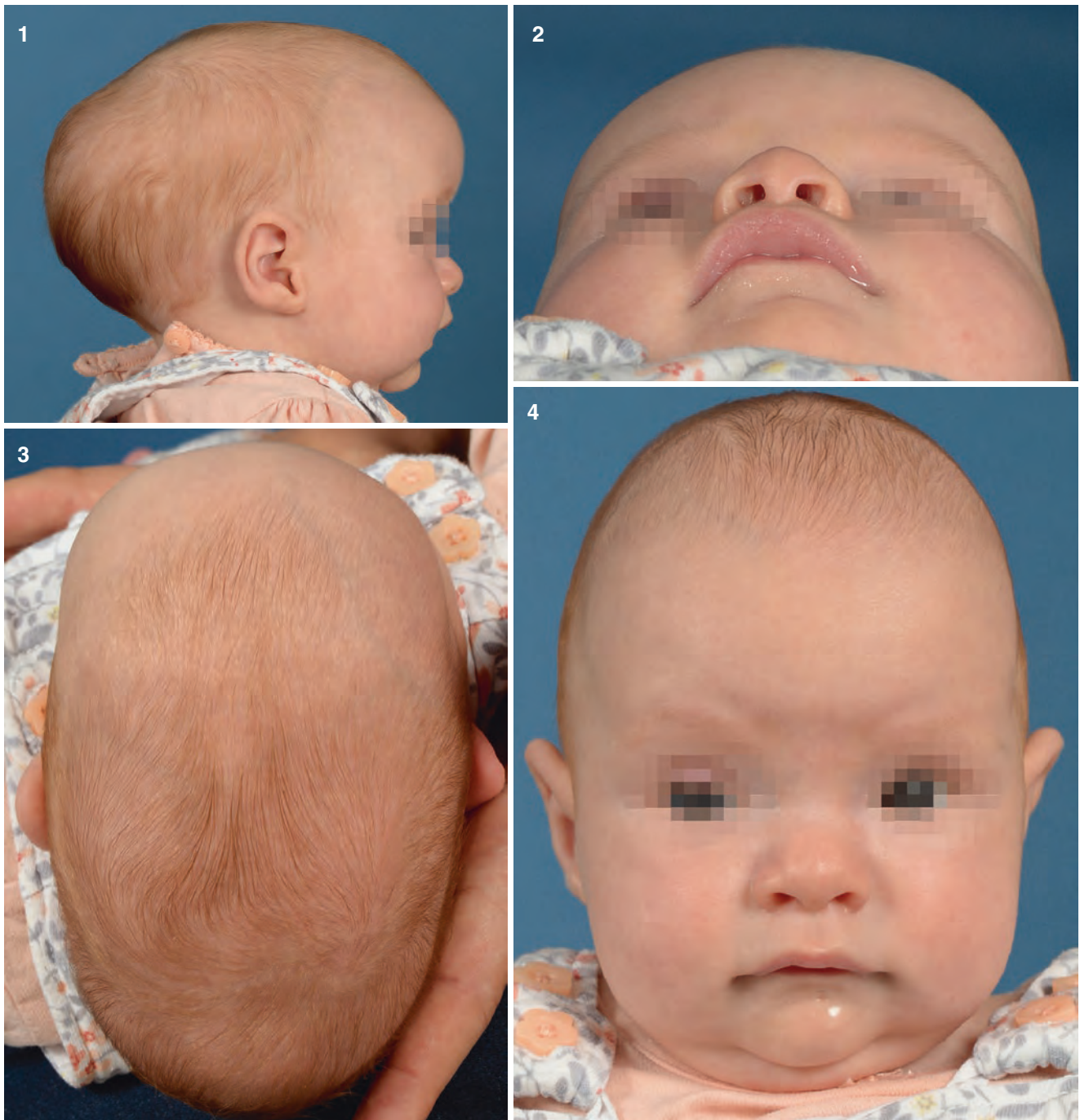

Fig. 79.2 (2.1–2.9) Case series of sagittal synostosis. (2.1–2.4) Preoperative facial views of patient with sagittal synostosis aged 13 weeks. Note elongated A-P dimension and bitemporal narrowing with

prominent forehead and occiput. (2.5–2.7) Postoperative facial views of patient with sagittal synostosis after full calvarial remodelling. (2.8 and 2.9) Preoperative CT scan of the same patient with sagittal synostosis

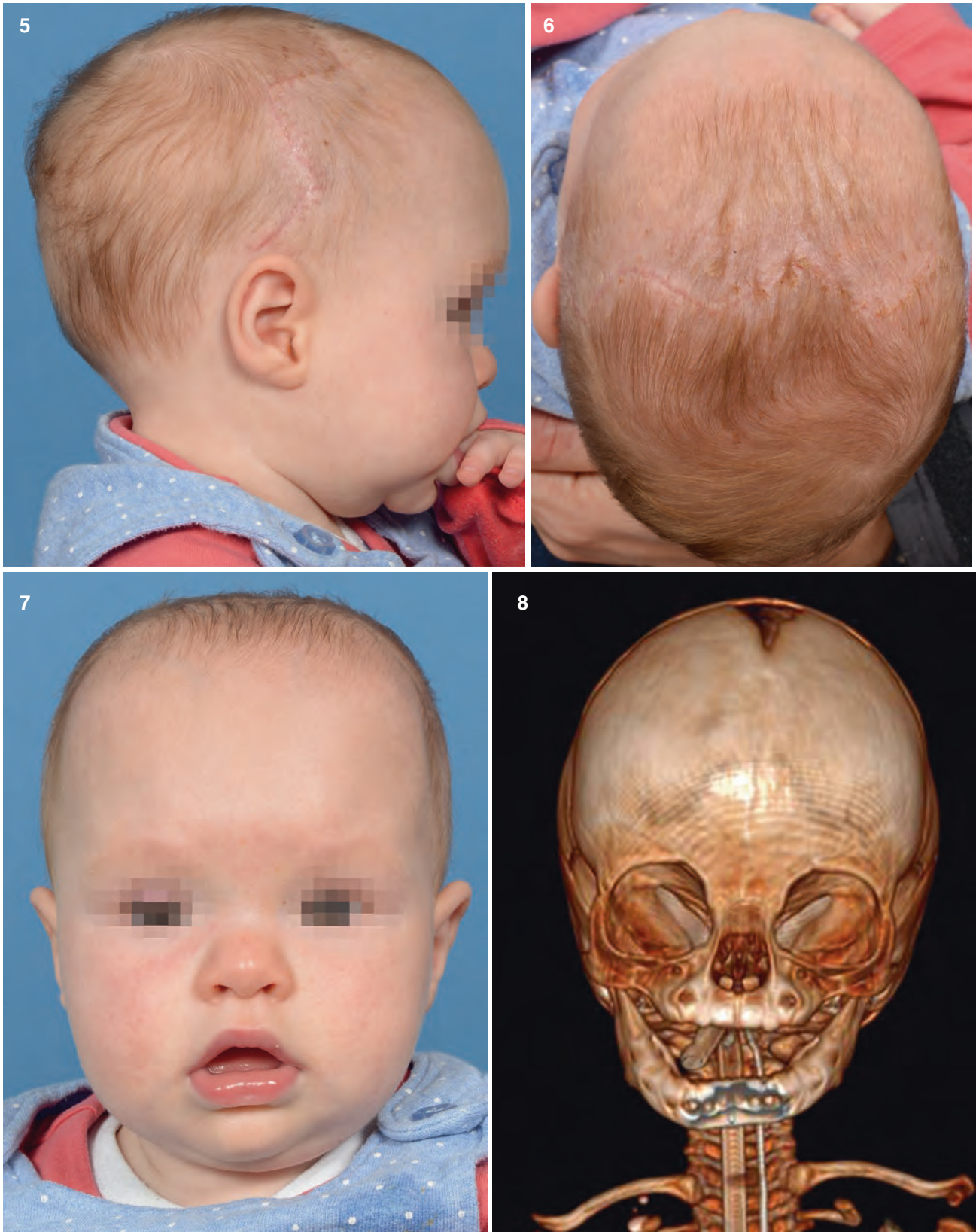
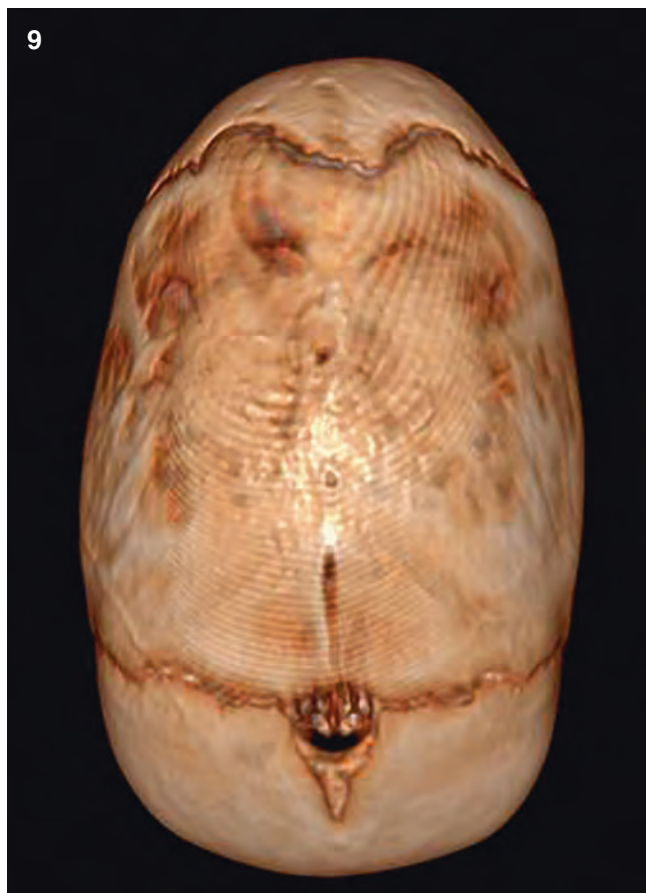
Fig. 79.2 (continued)



©Association of Oral and Maxillofacial Surgeons of India

Fig. 79.2 (continued)

Elevated ICP manifests as distressed behaviour, inconsolable crying and headbanging with symptoms being worse at night. When symptoms are combined with papilloedema, urgent intervention is indicated. The absence of papilloedema does not exclude raised ICP, but its presence is of significance. In cases of doubt, formal ICP monitoring can be undertaken. In established cases the use of an indwelling telemetric ICP measurement device may be helpful [14].

Formal ophthalmological assessment should be undertaken and appropriate intervention initiated. Regular assessments are necessary to identify deterioration, particularly to identify corneal exposure and avoid the development of amblyopia.

Routine computerised tomography (CT) cross-sectional imaging is not indicated, and the diagnosis can, in the vast majority of cases, be made on clinical findings alone. In cases where the diagnosis is in doubt or there is the suspicion that there may be posterior fossa crowding, Chiari malformation or craniocervical abnormalities, a CT is indicated. Magnetic resonance imaging (MRI) is indicated to investigate the brain for structural abnormalities. The objective with this very conservative approach to imaging is to minimise the ionising radiation exposure, which has been demonstrated to adversely affect brain development and damage the developing eye [15].

Obstructive sleep apnoea can manifest as noisy snoring, characteristically crescendoing to a maximum followed by a period of silence, representing the apnoeic period with a cyclical restart, or a failure to thrive coupled with daytime tiredness. If OSA is suspected, an initial overnight pulse oximetry study can be undertaken, and if this proves to be suggestive of OSA, a full polysomnogram sleep study should be performed. This can be combined with formal ICP monitoring should there be any concerns about raised ICP. The active management of established OSA requires intervention from the multidisciplinary team, and the respiratory/ENT specialist input is paramount. It is important to establish the causes of sleep disorder and the level(s) of airway obstruction so that the most appropriate intervention(s) can be employed. Further investigations might involve micro-laryngoscopy to exclude tracheal abnormalities. Imaging with CT is useful, and interventions should be stepwise with consideration being given to tonsillectomy and adenoidectomy [16].

In the majority of cases of non-syndromic single-suture abnormalities, a single intervention for the surgical correction of the head shape is the norm [4]. Whilst there is considerable variation between different units regarding

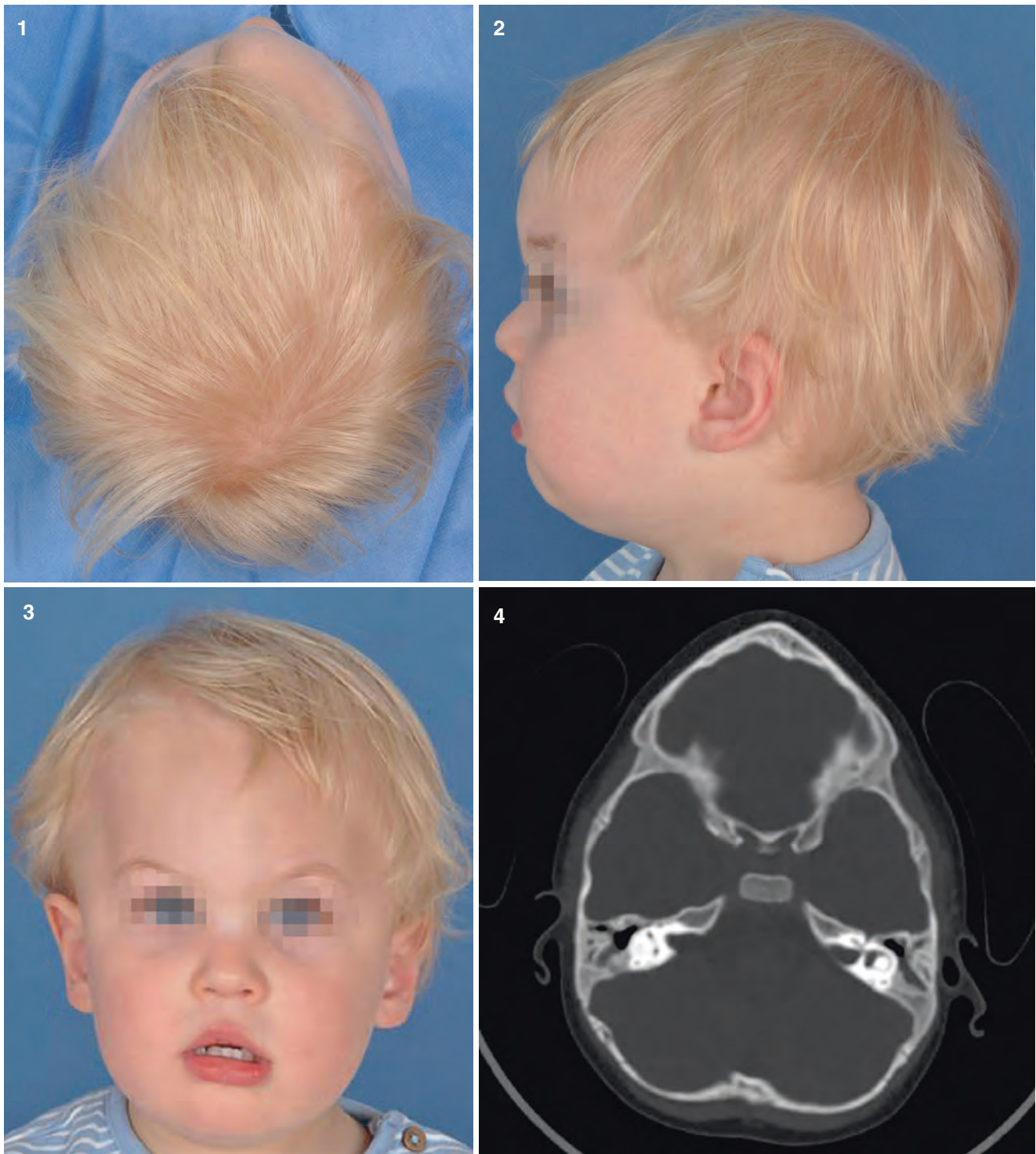


Fig. 79.3 (3.1–3.17) Case series of metopic synostosis. (3.1–3.3) Preoperative facial views of patient with metopic synostosis, age 23 months (late presentation), note pointed brow, triangular-shaped skull and hypertelorism. (3.4–3.6) Preoperative CT scan of the same patient with metopic synostosis—note it is not our usual practice to obtain preoperative CT in metopic synostosis; however this was taken due to the subtle (and late) presentation. (3.7–3.14) Intraoperative views of fronto-orbital remodelling. (3.7) Frontal bar after removal prior to remodelling. (3.8) Frontal bar and frontal bones after removal

prior to remodelling. (3.9, 3.10) Frontal bar after remodelling with mid-line graft to correct hypotelorism. (3.11) Frontal bone osteotomised ready for remodelling. (3.12–3.14) Final views after fixation—fronto-orbital remodelling or anterior two-thirds remodelling. Note use of absorbable plates in load-/tension-bearing areas and absorbable sutures or stainless steel wires in less critical regions. Bone dust and bone dust putty (fibrin sealant mixed with bone dust) are used in resultant bone defects to encourage ossification. (3.15–3.17) Postoperative facial views of patient with metopic synostosis

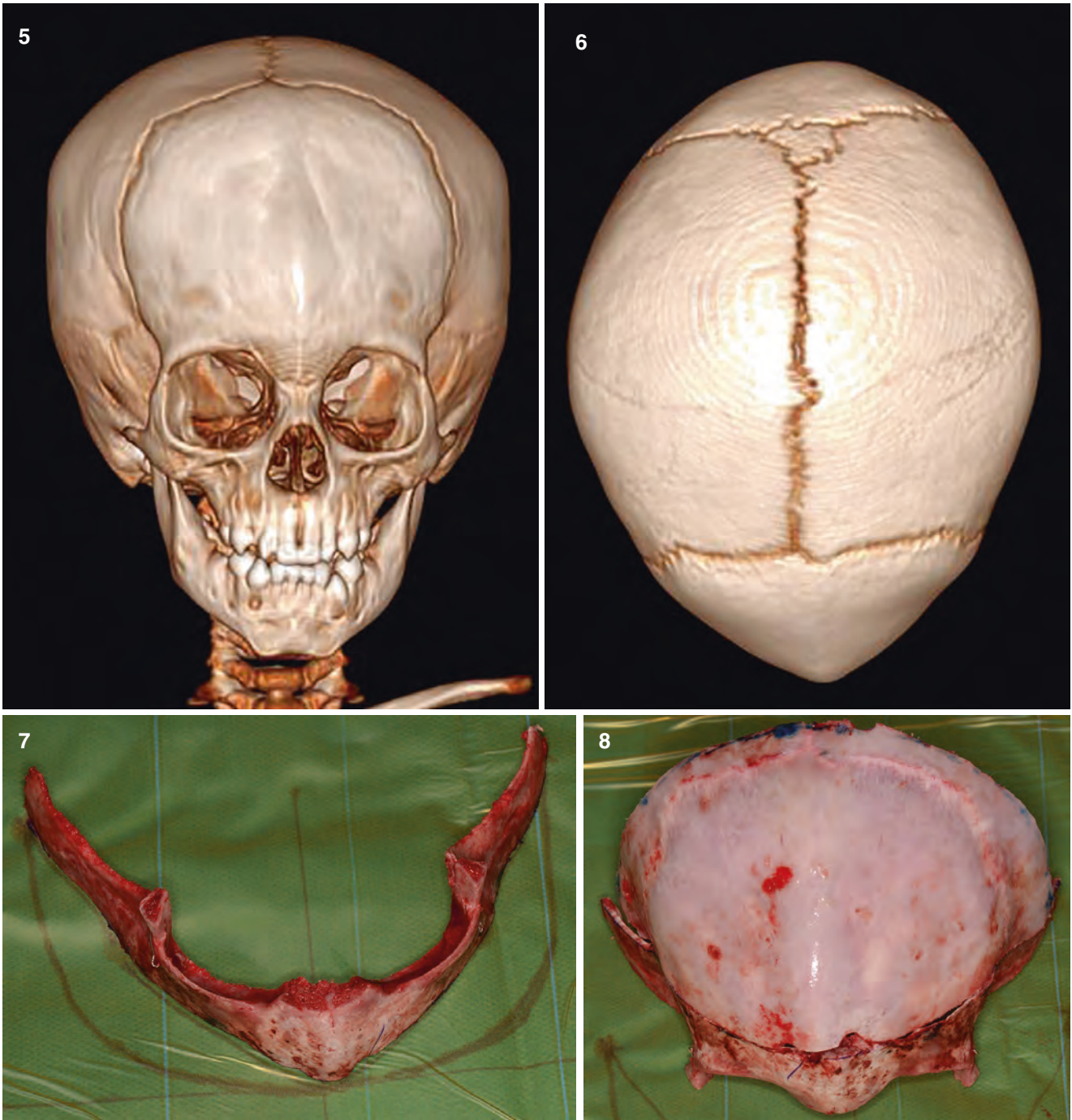


Fig. 79.3 (continued)

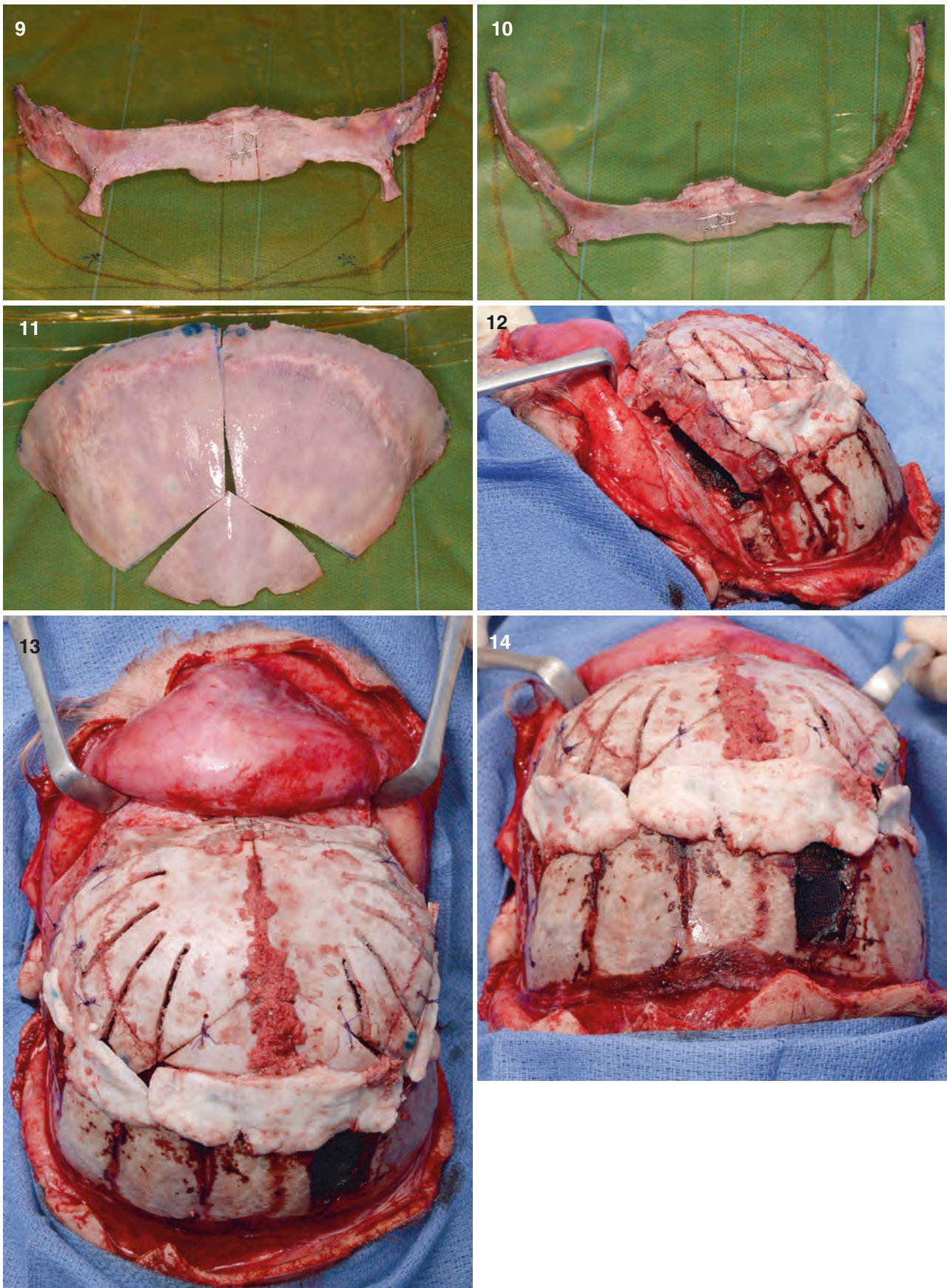
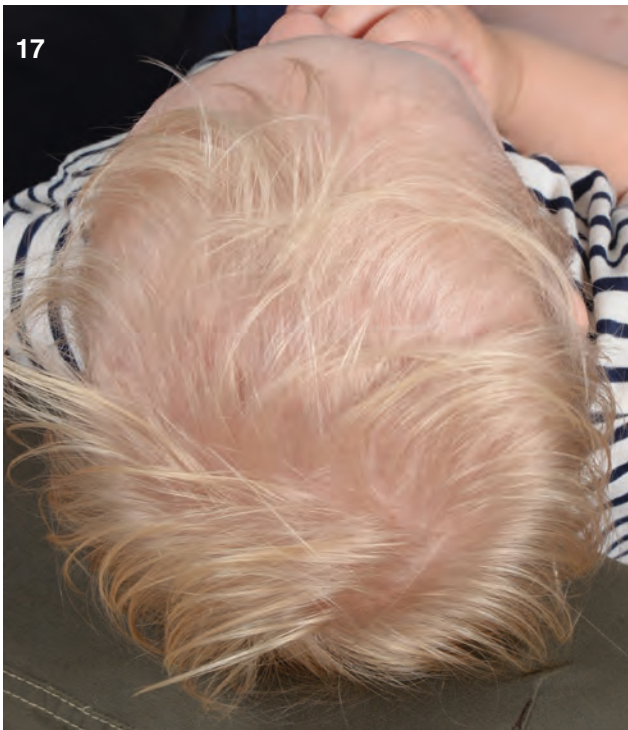
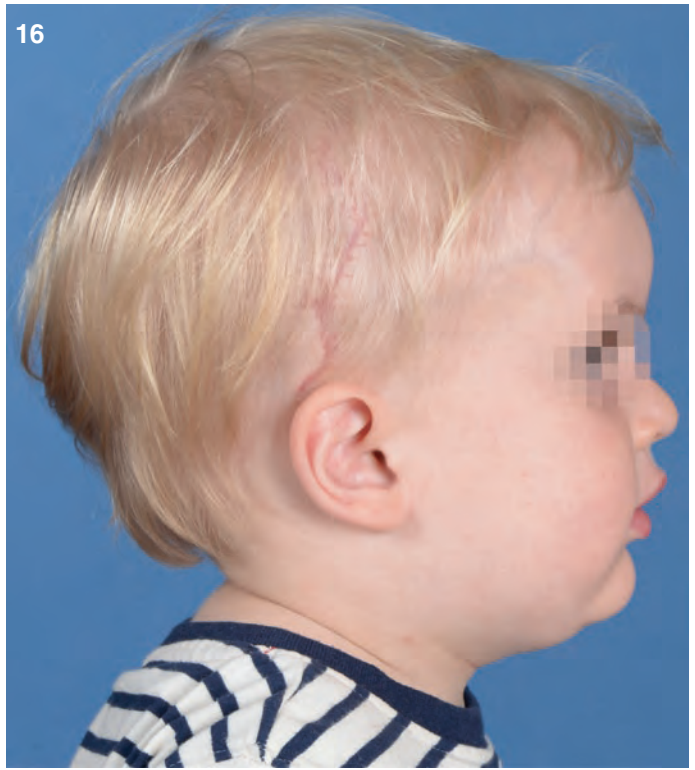
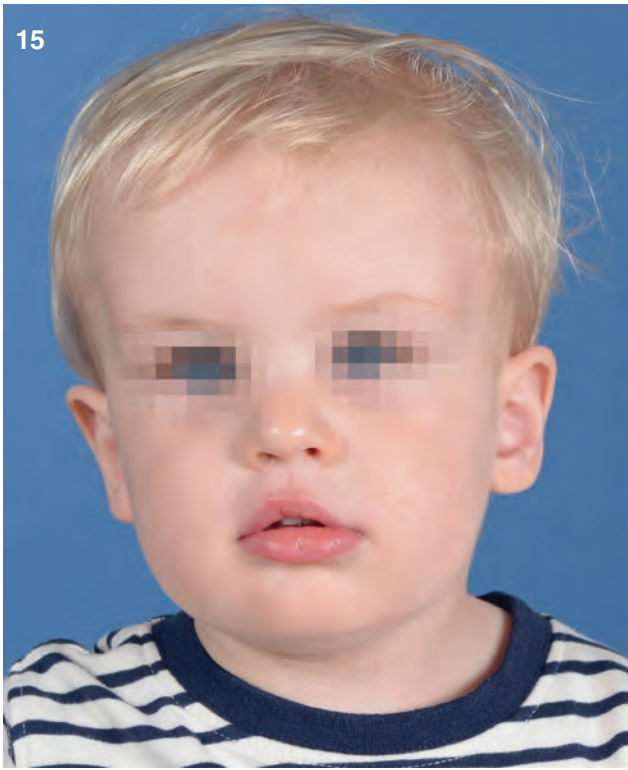Fig. 79.3 (continued)



©Association of Oral and Maxillofacial Surgeons of India

Fig. 79.3 (continued)

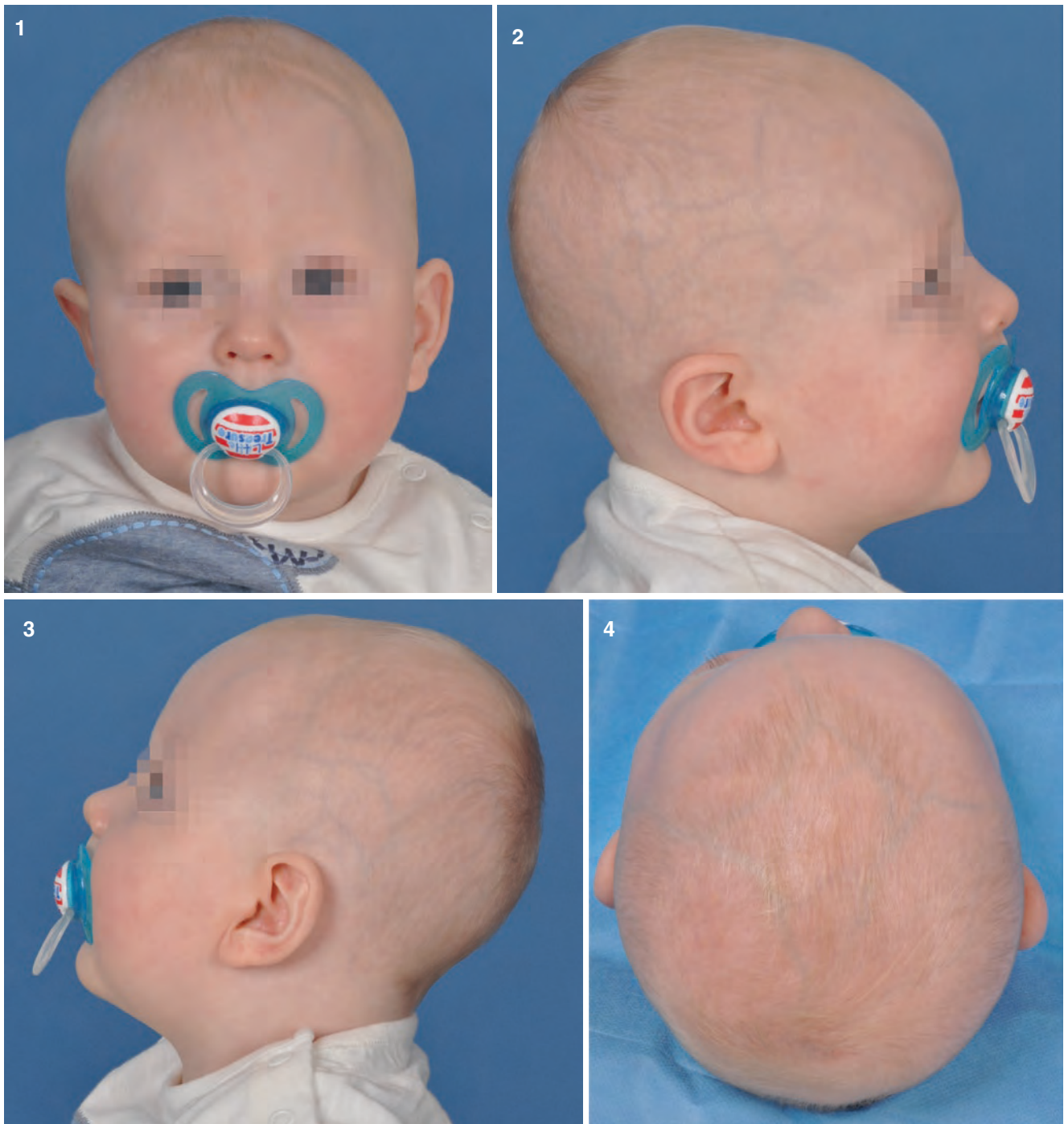

Fig. 79.4 (4.1–4.12) Case series of unicoronal synostosis. (4.1–4.4) Preoperative facial views of patient with unicoronal synostosis, patient aged 31 weeks—left unicoronal synostosis—flattened left brow anterior plagiocephaly when viewed from above and ridging of the involved left coronal suture. (4.5–4.9) Intraoperative views of asymmetric fronto-orbital advance. (4.5) Precraniotomy planning—note the fused

left coronal suture. (4.6–4.9) After fixation of the osteotomised segments—asymmetric fronto-orbital advancement; note onlay bone graft to left supraorbital region, fixation with absorbable plates and pins as well as absorbable sutures. (4.10–4.12) Postoperative facial views of patient with unicoronal synostosis

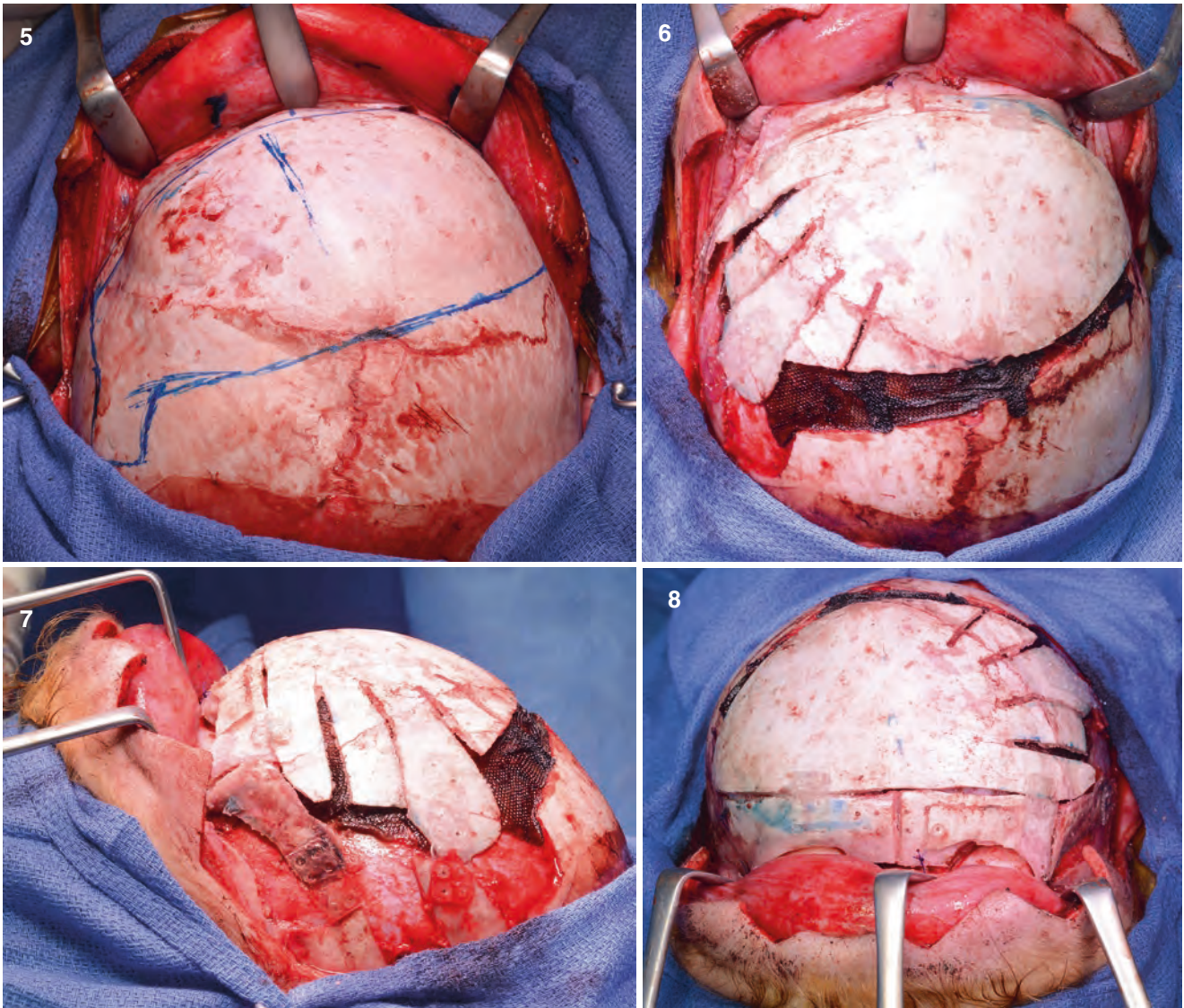
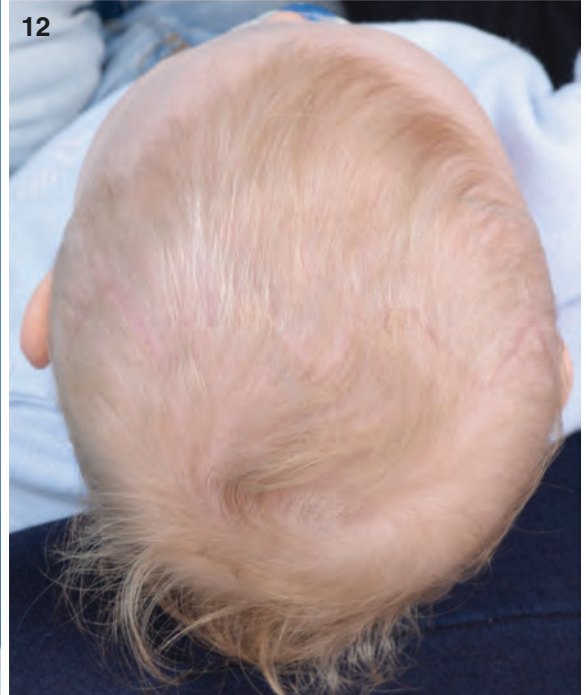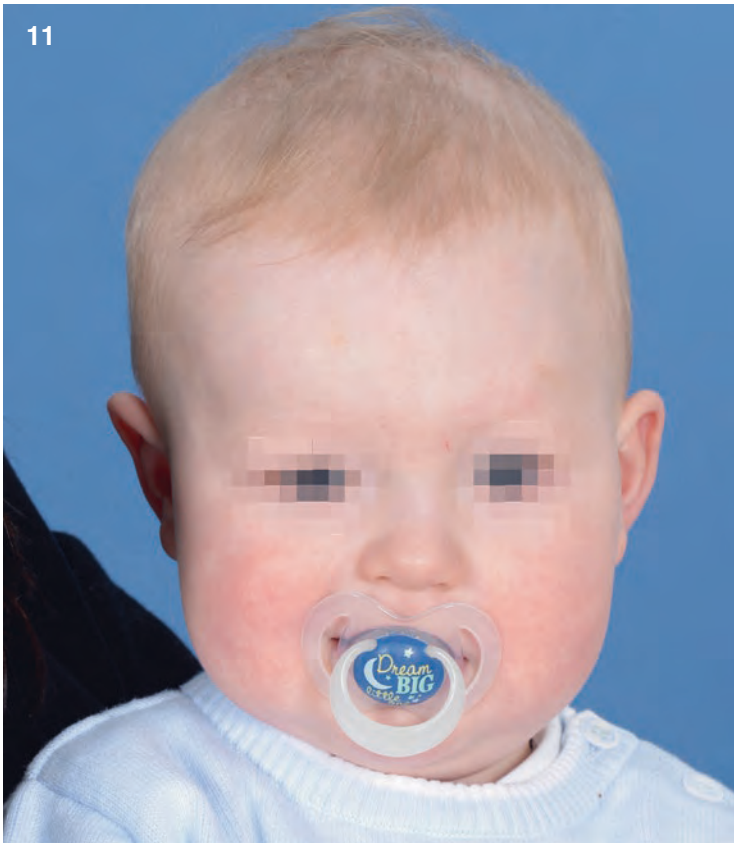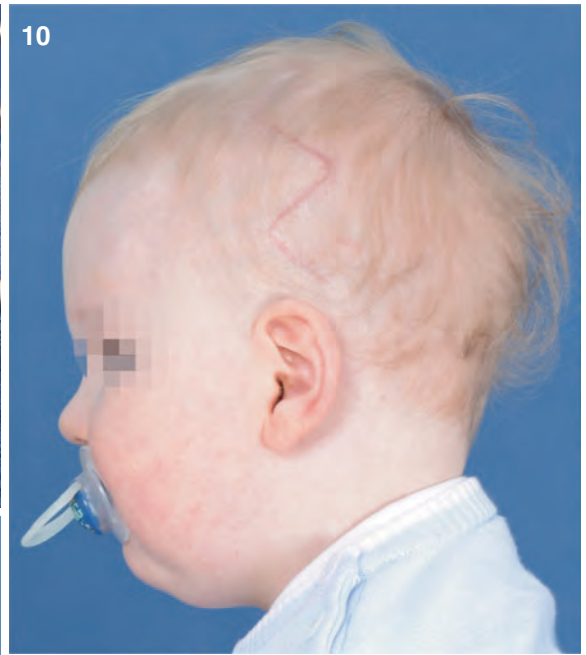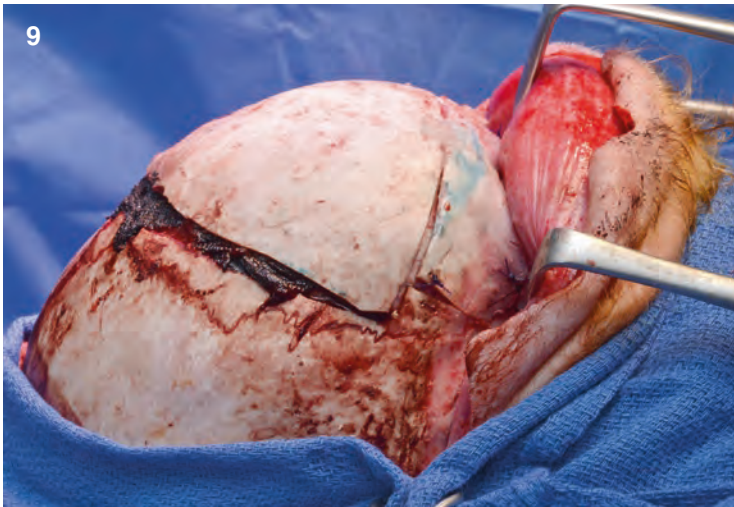


Fig. 79.4 (continued)



©Association of Oral and Maxillofacial Surgeons of India

Fig. 79.4 (continued)

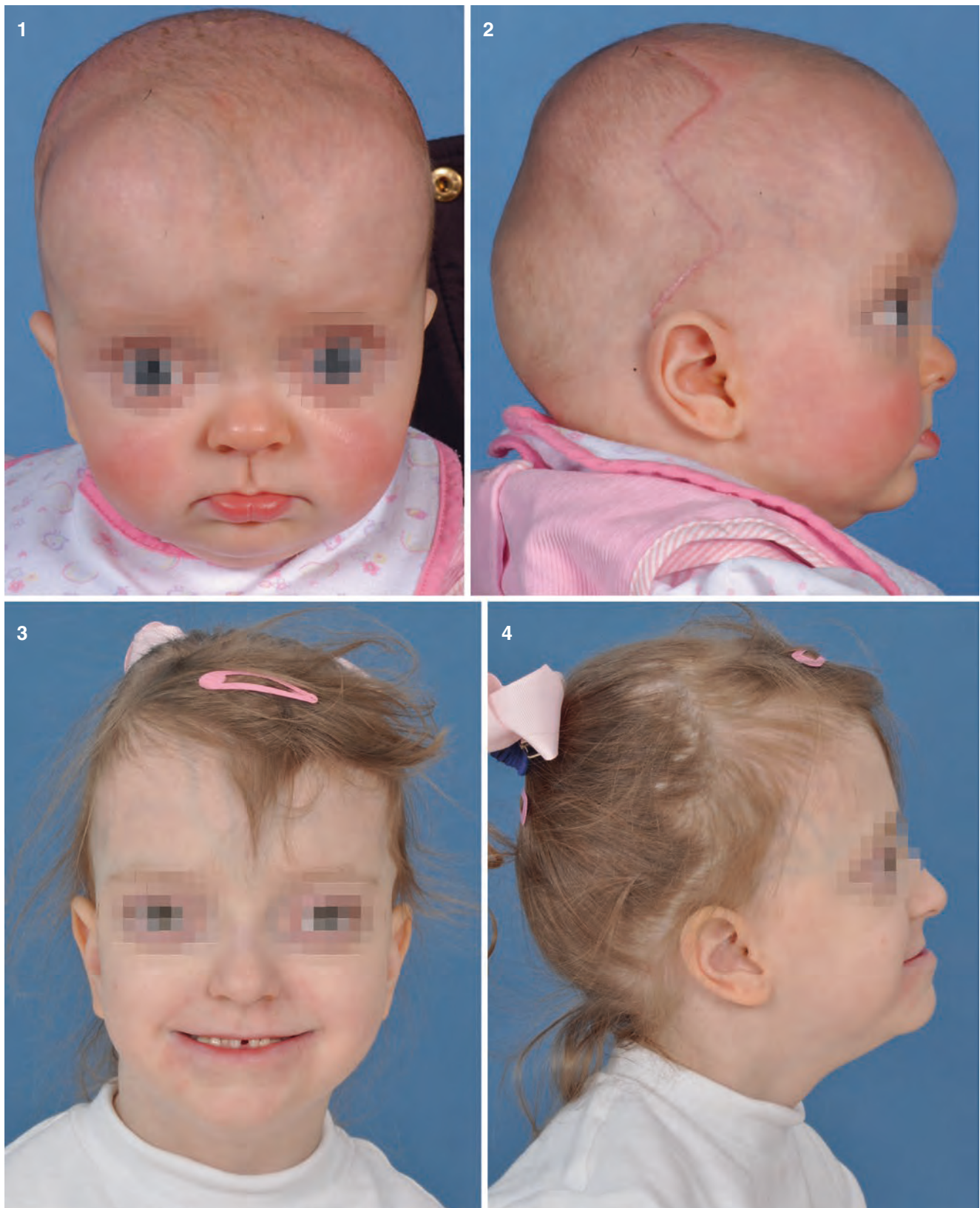


Fig. 79.5 (5.1–5.13) Case series of Crouzon syndrome. (5.1 and 5.2) Patient with Crouzon syndrome after initial calvarial remodelling aged 34 weeks. (5.3 and 5.4) Preoperative facial views of same patient aged 5 with Crouzon's type facies. (5.5–5.7) Postoperative facial views after Le Fort III distraction osteotomies and static fronto-orbital advance with the rigid external distractor (RED frame) and internal distractors in place (day 1 post-op). The use of the internal distractors allows for the early removal of the external device after the active distraction period, acting as fixation devices for the retention period. (5.8–5.9) Final post-

operative result immediately after RED frame distractor removal. (5.10–5.11) Late postoperative result following internal distractor removal. (5.12 and 5.13) Pre- and mid-distraction CT images of Le Fort III distraction and static fronto-orbital advance. Note internal distractors engaging zygoma (pushing Le fort III and external RED frame pulling midface). It is not our usual practice to obtain a CT mid treatment, but this was carried out due to concerns around a possible CSF leak. The static fronto-orbital advance is secured with absorbable, radiolucent, plates, but the multiple pin holes are visible

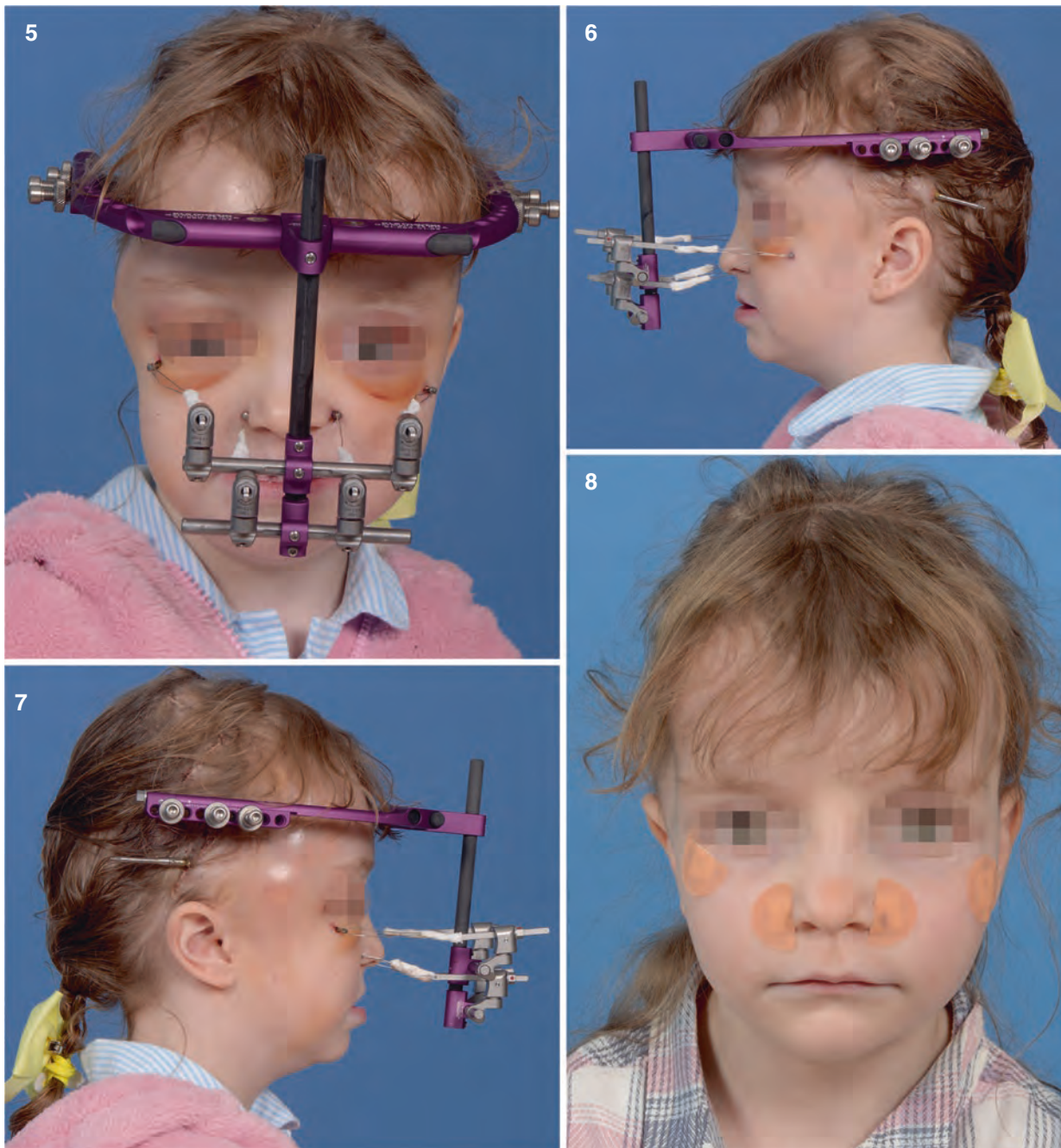


Fig. 79.5 (continued)

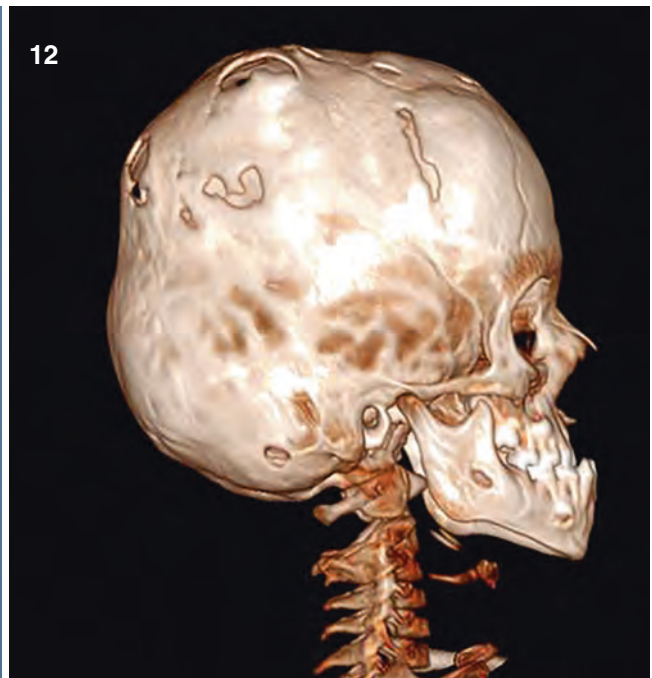
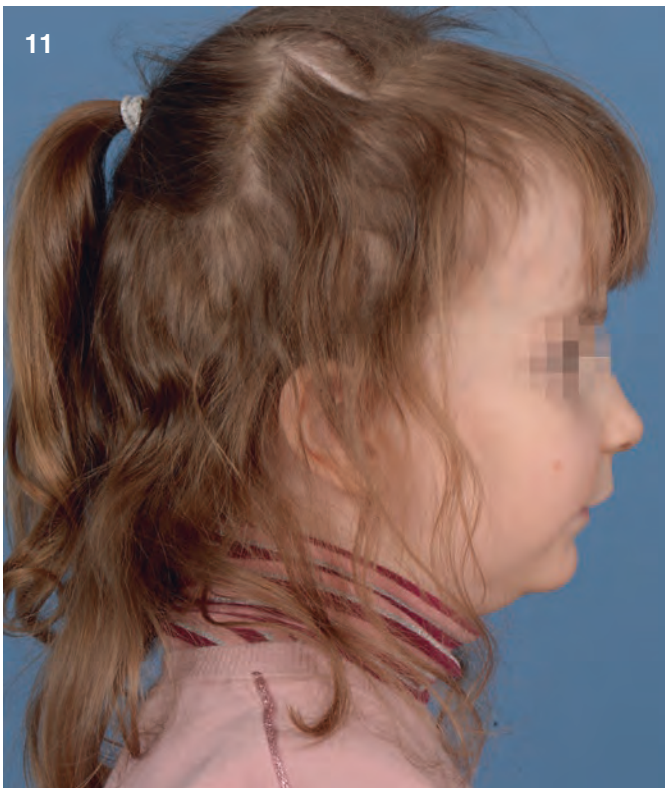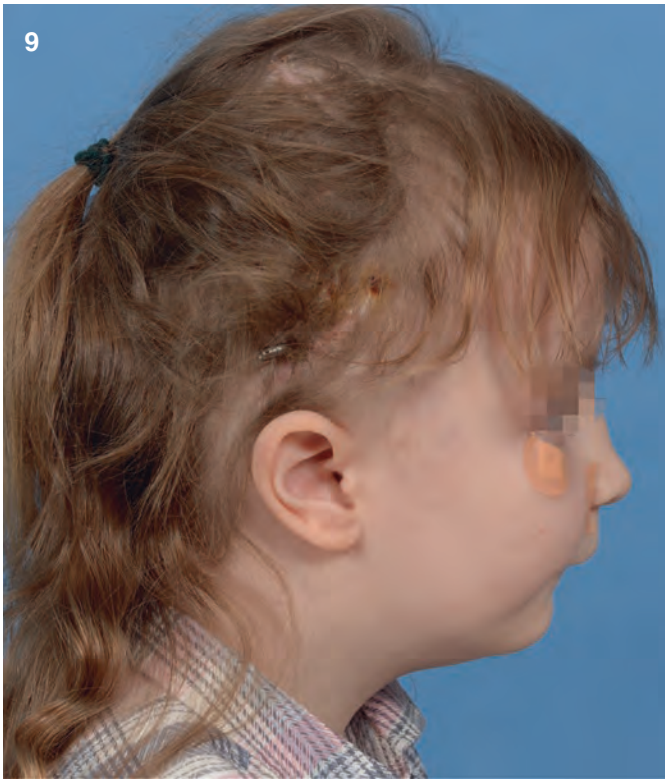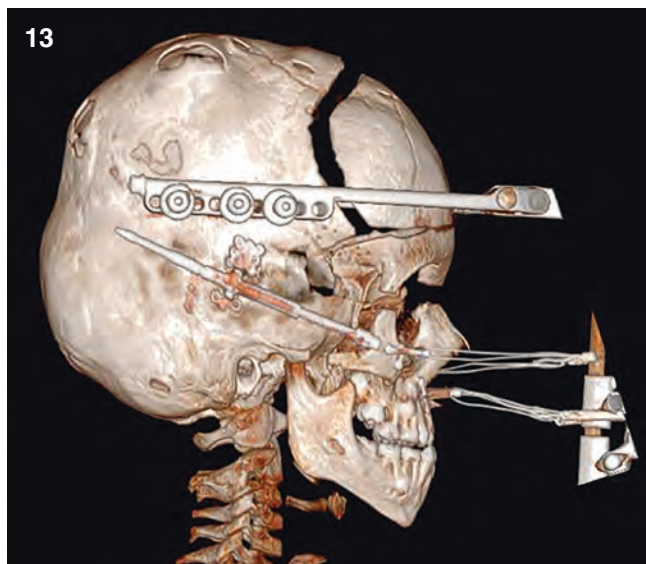


Fig. 79.5 (continued)



©Association of Oral and Maxillofacial Surgeons of India

Fig. 79.5 (continued)

timing and actual intervention, the Glasgow craniofacial service protocol is outlined in Table 79.3. See also Table 79.4 for an outline of the surgical procedures commonly carried out and the case series (Figs. 79.2, 79.3, 79.4 and 79.5) for an overview of treatment outcomes.

In the management of the syndromic cases, the treatment has to be more flexible and problem driven. There is considerable variation in the severity and comorbidities in this group of patients. Overall the aim is to minimise the number of surgical interventions; however re-synostosis, systemic problems, corneal exposure, airway obstruction and raised ICP are much more common in the group [14]. In the absence of additional pressing clinical issues, the syndromic synostosis cases can be managed as the non-syndromic cases in terms of the timing and extent of skull surgery.

79.2.4 Management in Early Childhood (3–8 Years)

In this period the management is primarily of observation. The non-syndromic cases are followed up 6 weeks, 6 months and 1 year post-skull vault surgery with growth, particularly head circumference, development and vision being moni-

Table 79.3 Glasgow protocol for the management of non-syndromic synostosis

Condition	Ideal age for intervention	Usual procedure
Sagittal synostosis	5–7 months	Total vault remodelling
Metopic synostosis	10–14 months	Fronto-orbital advancement, anterior remodelling ± hypotelorism correction
Unicoronal synostosis	10–14 months	Fronto-orbital advancement, anterior remodelling—Bilateral
Bicoronal synostosis	5–18 months 10–14 months	Posterior vault distraction Bilateral fronto-orbital advancement, anterior remodelling
Lambdoid synostosis ^a	10–14 months	Posterior vault expansion static or with distraction

^aIn the presence of elevated ICP

tored. A final review is usually undertaken immediately prior to the child starting school. Some units have a much longer follow-up period; however we reserve longer follow-up for the small proportion of patients who encounter ongoing development problems or symptoms. This protocol should be modified if there is a less well-developed community-based health surveillance programme.

The syndromic cases are followed up more closely with a minimum of annual reviews. In addition to the parameters noted above, the development of OSA may be insidious, and therefore at every review this should be asked about specifically. Towards the end of this period, consideration can be given to performing either a midface advancement or hypertelorism correction. This decision should be primarily driven by clinical problems rather than purely aesthetics, though teasing, bullying and psychological issues can, and should, play a role in decision-making. The input of child psychologists is often very helpful in developing a treatment plan and choosing the optimal timing [17].

During this period it is also important to monitor dental development and try to optimise routine dental care. In addition, at some time the patient should be referred for a full genetic consultation, though the timing of this can be determined by the needs and desires of the family. Throughout the care of the patient development, psychological, educational, physical and speech and language development should be monitored and intervention initiated when necessary.

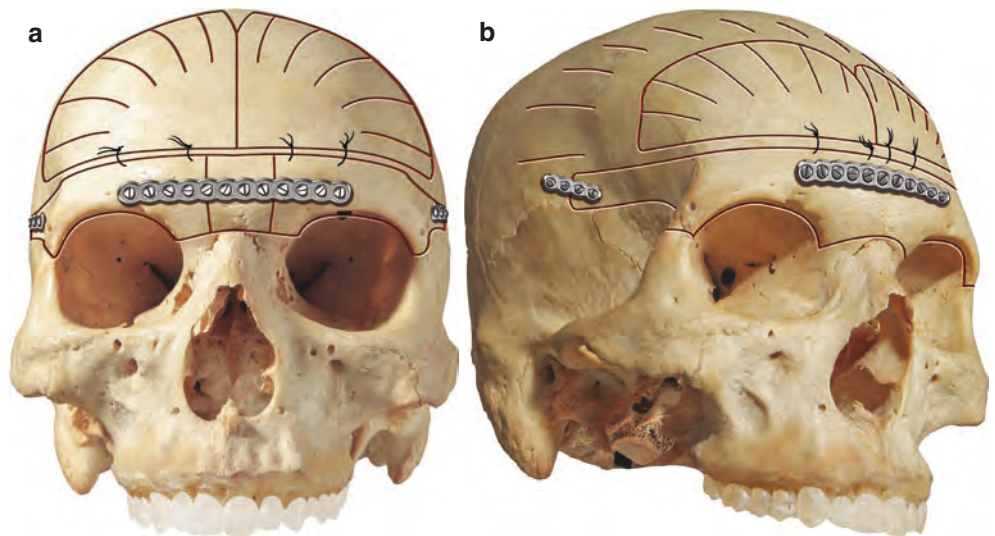
Table 79.4 Surgical procedures in craniofacial surgery

Procedure	Access	Technical notes	Illustrations
Fronto-orbital advance and remodelling	<ul style="list-style-type: none"> – Bicoronal stealth incision in the Alice band region – Anterior dissection to superior orbit for access to frontal bandeau inferiorly (may require osteotomies to free supraorbital nerves/vessels) 	<ol style="list-style-type: none"> 1. Design mapped out and bur holes made for access with matchstick craniotome. 2. Frontal bone removed (pre-/post-suture). 3. Frontal bandeau removed—Cuts from anterior cranial fossa with direct vision inferiorly via the superior orbit. 4. Frontal bandeau and frontal bone remodelled as necessary and secured in advanced position. 	Illustration 79.8a, b
Sagittal remodelling Total vault remodelling	<ul style="list-style-type: none"> – Mid-cranial stealth incision for access to anterior and posterior calvarium – Start in prone position with careful eye positioning and intermittent relief and then turn supine – Dissection posteriorly to base of occipit and anteriorly to brow 	<ol style="list-style-type: none"> 1. Map out dural sinuses. 2. Draw plan for osteotomies and create bur holes for access with matchstick craniotome. 3. Remove occipital bullet and barrel stave (sun) (bone harvesting as required from inner table). 4. Sagittal suturectomy and lateral barrel staving of mid calvarium/moulding laterally as far anteriorly as permitted whilst prone. 5. Secure occipital portion with PDS. 6. Turn the patient. 7. Frontal craniotomy/remodelling and inner table bone harvesting as required. 8. Complete suturectomy and barrel staving anteriorly. 9. Secure frontal bone (resorbable plates). 10. Fill in areas of bony discontinuity with bone putty (bone dust and tisseal). 	Illustration 79.9
Metopic remodelling	<ul style="list-style-type: none"> – Bicoronal stealth incision in the Alice band region – Anterior dissection to superior orbit for access to frontal bandeau inferiorly (may require osteotomies to free supraorbital nerves/vessels) 	<ol style="list-style-type: none"> 1. Design mapped out and bur holes made for access with matchstick craniotome. 2. Frontal bone removed (pre-/post-suture). 3. Frontal bandeau removed—Cuts from anterior cranial fossa with direct vision inferiorly via the superior orbit. 4. Frontal bandeau remodelled with interposing bone graft to increase width and flatten midline prominence. <ul style="list-style-type: none"> • Internal resorbable strut plate for strength. • Resorbable plates bitemporally ± bone graft in gap from advancement. • Brow resecured in midline (resorbable plate/PDS). 5. Frontal bone remodelling (sectioning and repositioning ± barrel staving). 6. ± barrel staving and moulding of mid calvarium 7. Frontal bone placed and secured (resorbable plates/PDS). 	Same as Illustration 79.8b
Unicoronal	<ul style="list-style-type: none"> – Bicoronal stealth incision in the Alice band region – Anterior dissection to superior orbit for access to frontal bandeau inferiorly (may require osteotomies to free supraorbital nerves/vessels) 	<ol style="list-style-type: none"> 1. Design mapped out and bur holes made for access with matchstick craniotome. 2. Frontal bone removed (post-coronal suture). 3. Frontal bandeau removed—Cuts from anterior cranial fossa with direct vision inferiorly via the superior orbit. 4. Frontal bandeau remodelled and secured: <ul style="list-style-type: none"> • Internal resorbable strut plate for strength. • Resorbable plates bitemporally ± bone graft in gap from advancement. • Brow resecured in midline (resorbable plate/PDS). 5. Frontal bone remodelling (sectioning and repositioning ± barrel staving). 6. Frontal bone placed and secured (resorbable plates). 	Asymmetric fronto-orbital advancement for unicoronal synostosis Illustration 79.10

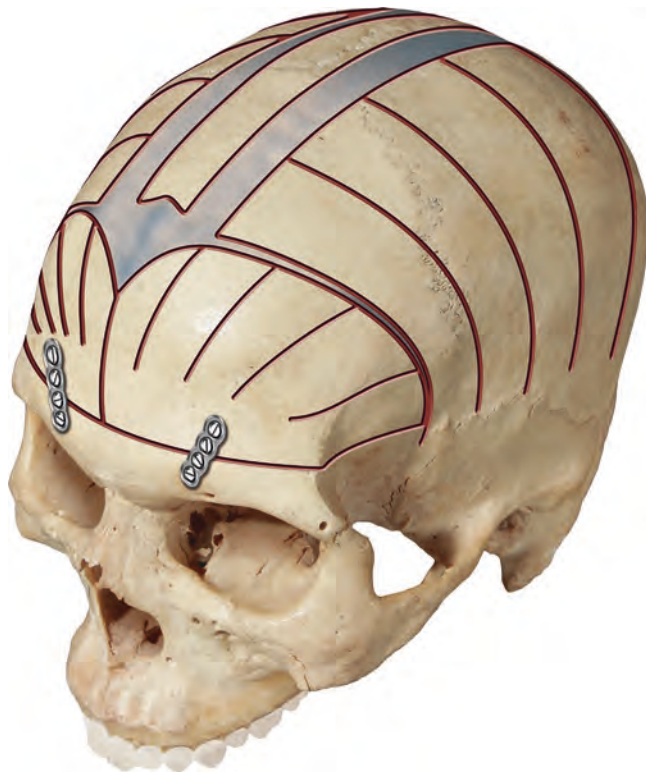Table 79.4 (continued)

Procedure	Access	Technical notes	Illustrations
Monobloc	<ul style="list-style-type: none"> – Bicoronal stealth incision in the Alice band region – Anterior dissection (separate pericranial flap) to superior orbit for access to frontal bandeau inferiorly (may require osteotomies to free supraorbital nerves/vessels) – Dissection to zygomatic arch bilaterally – Intraoral access posterior to hamulus for pterygomaxillary disjunction – Transconjunctival access to orbital floor 	<ol style="list-style-type: none"> 1. Design mapped out and bur holes made for access with matchstick craniotome. 2. Frontal bone removed (pre-/post-suture). 3. Access to anterior cranial fossa and superior orbit. 4. Cuts as per frontal bandeau cuts in anterior cranial fossa with direct vision from superior orbit. 5. Cuts at zygomatic arches bilaterally. 6. Inferior orbital cuts from inferior orbital fissure laterally and then superiorly to join superior orbit cuts and medially from inferior orbital fissure running superiorly to join superior cuts. 7. Osteotomes used to achieve pterygomandibular disjunction. 8. Smiths/osteotomes to propagate splits. 9. Fixation may be for: <ul style="list-style-type: none"> • Static advancement with plates at frontal bandeau butt joint posterior frontal bone bilateral zygomatic arches. • Distraction—Internal distractor at posterior part of frontal process of zygomatic bone and pins for the RED frame in the body of the zygoma and paranasally. • A combination—Static fronto-orbital advancement/remodelling (as for FOAR) with distraction of the Le fort III segment. 	Illustration 79.11a, b
Subcranial Le fort III	<ul style="list-style-type: none"> – Bicoronal stealth incision in the Alice band region – Anterior dissection to superior orbit for access to frontonasal junction (may require osteotomies to free supraorbital nerves/vessels) – Dissection to zygomatic arch bilaterally – Intraoral access posterior to hamulus for pterygomaxillary disjunction ± anteriorly for placement of distractors – Transconjunctival access to orbital floor 	<ol style="list-style-type: none"> 1. Cuts in orbital floors avoiding lacrimal apparatus leaving medial canthal tendon attached to bone. 2. Zygomatic cuts may be made from above or below depending on access. 3. Osteotome used to achieve frontonasal disjunction and pterygomaxillary disjunction. 4. Smiths to propagate splits. 5. Fixation may be for distraction as shown (and as per monobloc) or static advancement with fixation at the zygomatic arch, frontozygomatic suture, frontonasal junction and intermaxillary fixation. 	Illustration 79.12—subcranial le fort III
Posterior vault distraction	<ul style="list-style-type: none"> – Mid-cranial stealth incision for access to the posterior calvarium – Posterior dissection to base of occiput – Stealth mapping of dural venous sinuses 	<ol style="list-style-type: none"> 1. Posterior bullet osteotomy with matchstick bur and craniotome. 2. Dural mobilisation. 3. Positioning of 2/3 distractors and tunnelling anteriorly to exit either through the wound or anterior to it. 4. May incorporate foramen magnum decompression or insertion of telemetry can ICP monitor if required. 	Illustration 79.13—Posterior vault distraction
Facial bipartition/orbital osteotomies	<ul style="list-style-type: none"> – Bicoronal stealth incision in the Alice band region – Anterior dissection (separate pericranial flap) to superior orbit for access to frontal bandeau inferiorly (may require osteotomies to free supraorbital nerves/vessels) – Dissection to zygomatic arch bilaterally – Intraoral access posterior to hamulus for pterygomaxillary disjunction and anteriorly to separate nasal septum and split palate – Transconjunctival access to orbital floor 	<p>As per monobloc with additional:</p> <ol style="list-style-type: none"> 1. Separation of the nasal septum from the palate via an intraoral incision. 2. Midline osteotomy of the palate. 3. Midline removal of bone as required from glabella/nasal region. 4. Secure as per monobloc with additional midline fixation and a palatal splint. <p>Box osteotomies of the orbits to achieve orbital movement separate from the maxillary movement involve the same cuts without disjunction at the Le fort I level</p>	Illustration 79.14a, b

Illustration 79.8 (a, b)
Fronto-orbital advance and
remodelling

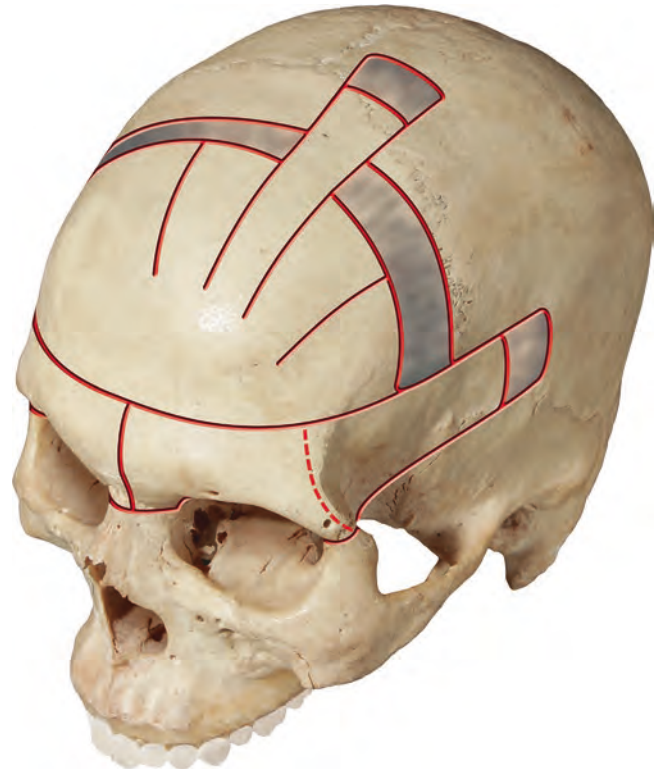


©Association of Oral and Maxillofacial Surgeons of India



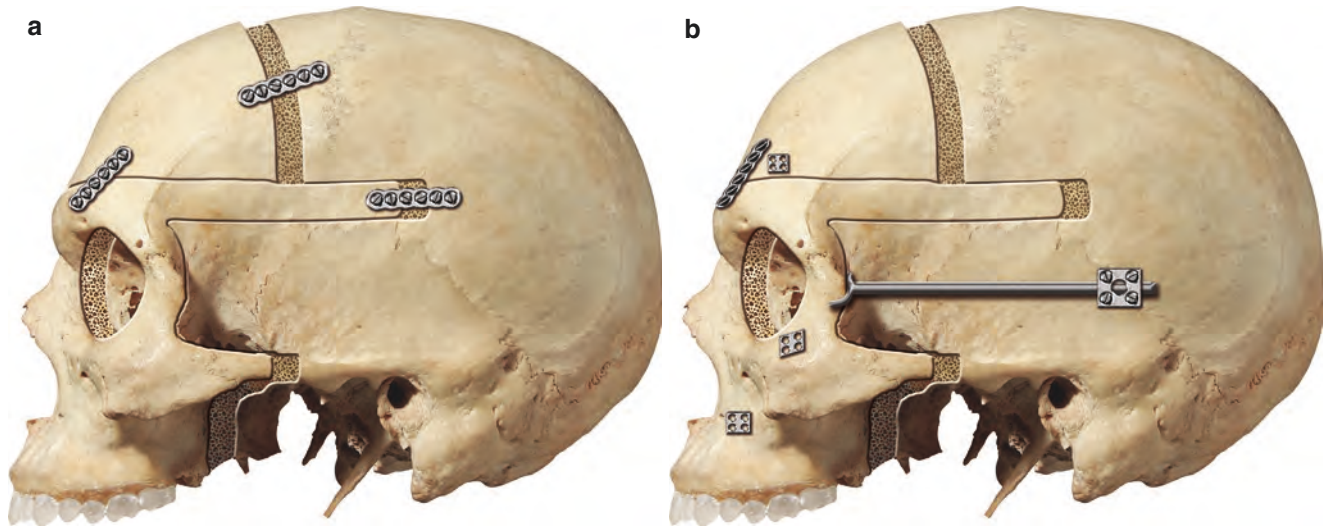
©Association of Oral and Maxillofacial Surgeons of India

Illustration 79.9 Sagittal remodelling/total vault remodelling



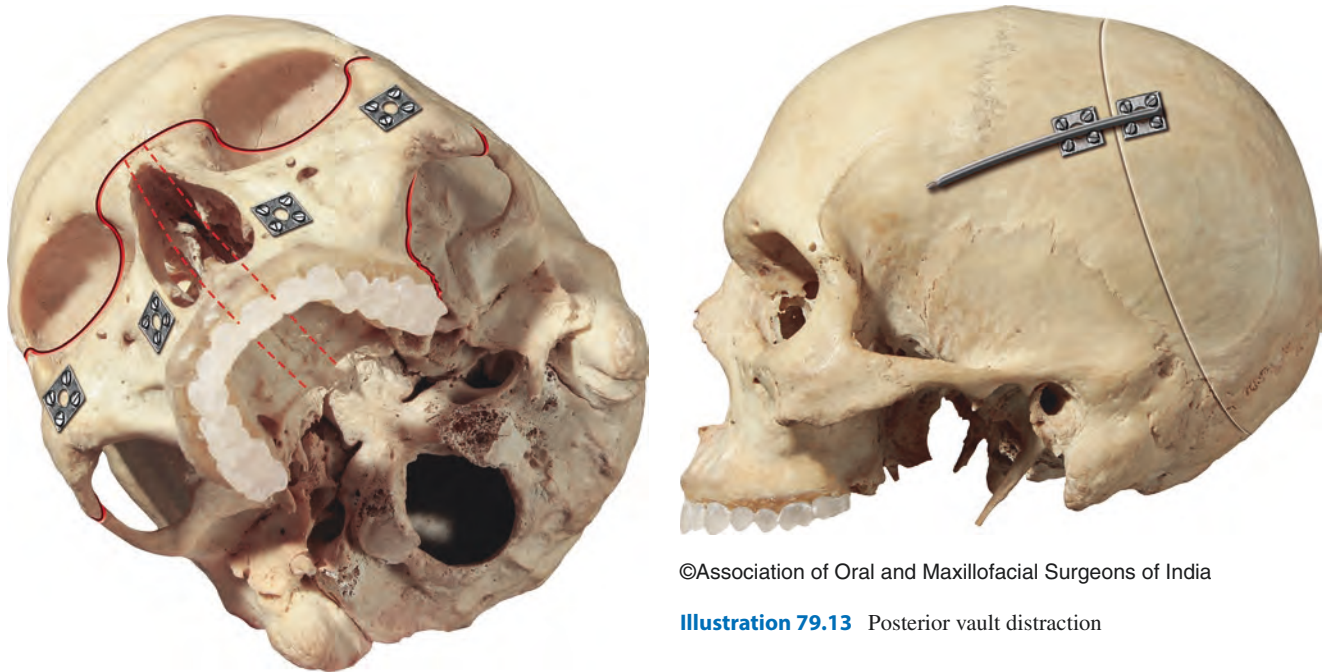
©Association of Oral and Maxillofacial Surgeons of India

Illustration 79.10 Asymmetric fronto-orbital advancement for
unicoronal synostosis



©Association of Oral and Maxillofacial Surgeons of India

Illustration 79.11 (a, b) Monobloc advancement

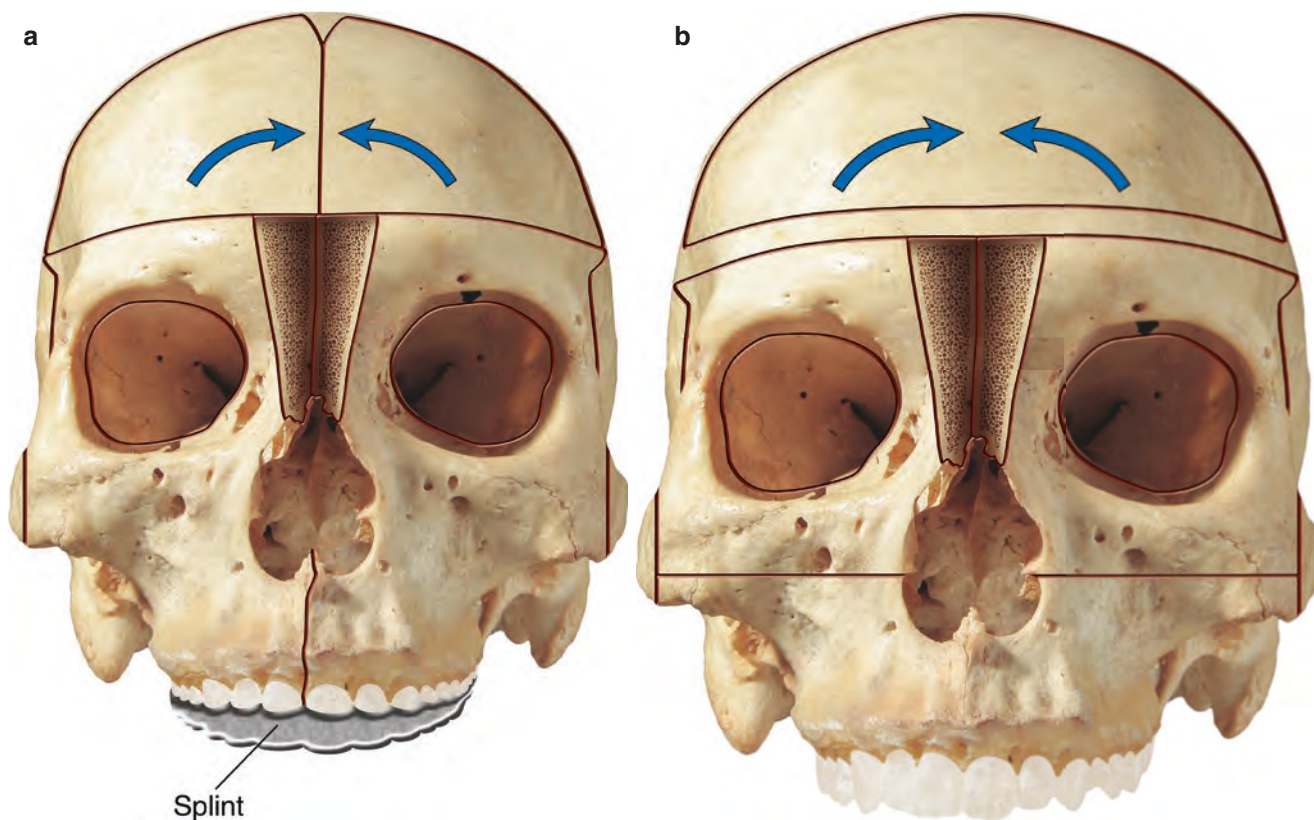


©Association of Oral and Maxillofacial Surgeons of India

Illustration 79.13 Posterior vault distraction

©Association of Oral and Maxillofacial Surgeons of India

Illustration 79.12 Subcranial Le Fort III



©Association of Oral and Maxillofacial Surgeons of India

Illustration 79.14 (a) Facial bipartition. (b) Box osteotomy to correct hypertelorism

79.2.5 Management in Middle Childhood (8–12 Years)

During this period routine monitoring is necessary, and as the face and dentition develop, attention can be turned to managing the midface and occlusion. During the transition from the deciduous to permanent dentition, it is important to have an orthodontic assessment—so that a definitive orthodontic/orthognathic plan can be developed. One of the major factors that may prompt early midface surgery would be the development of OSA; thus regular questioning and targeted investigations at review appointments are necessary. In considering orthodontics it is important to be mindful of the fact that repeated courses of orthodontics will lead to root shortening and also potentially exhaust the tolerance and cooperation of the patient and his/her family [18].

In general, the routine correction of hypertelorism can be safely performed from about the age of 8 years; however this is determined by the chosen technique (facial bipartition vs box osteotomy) (illustration 79.14a, b) and whether an early midface advancement is necessary for the management of OSA [19]. As with all surgery aimed primarily at improving

facial appearance, the indications, objectives and expectations of surgery must be discussed at length with the patient and his/her family and a consensus reached. The input from specialist child psychologists is often very helpful. The transition from primary to middle or secondary school is often traumatic, and interventions before this time can be very helpful from a psychological perspective, but it needs to be acknowledged and accepted that further surgery at the completion of growth may well be necessary [18].

79.2.6 Management in Adolescence and after the Completion of Growth

At this stage in development, definitive corrective surgery (when necessary) should be planned and an integrated orthodontic/surgical plan developed. In the syndromic cases, ongoing monitoring for functional and developmental issues is required, and as the child matures, the drive and the responsibility for decision-making will move towards the patient and away from their parents. Many adolescents at this stage are tired of multiple hospital appointments and are not keen on further interventions; in these circumstances it is

important to work with the patient and their family to provide care but also respect the patient's wishes and desires. It is better to postpone treatment rather than have a half completed course of orthodontics with poor cooperation and the consequent complications and finally lose the confidence of the patient.

The planning of comprehensive surgery will need assessment in the following areas:

1. Skull shape—irregularities, defects.
2. Orbital position and symmetry.
3. Upper midface morphology.
4. Lower midface morphology.
5. Mandibular morphology.
6. Nasal form.
7. Soft tissue issues.

It is always best to offer and plan for a total correction in the first instance. The discussion around further transcranial surgery is often key to the decision-making. Many patients and families do not want to undertake any further transcranial surgery, in spite of the significant benefits, particularly for hypertelorism or dystopia corrections. None the less these procedures can offer significant improvements in the final result [19].

For residual skull defects of approximately 2 cm diameter or larger, it is usual to offer some form of reconstruction; this could be autologous (usually cranial bone), or alloplastic. Alloplastic reconstructions may be of a variety of materials and can be CAD/CAM designed or shaped intraoperatively. One of the most common residual defects following a fronto-orbital advancement is a degree of temporal hollowing; this can be effectively addressed with the use of mouldable hydroxyapatite synthetic bone material. This technique can be used to satisfactorily address minor skull irregularities and defects, and it is also possible to combine this technique with the use of alloplastic custom-made cranioplasties (e.g. titanium or PEEK) [20].

The assessment of orbital position is critical to deciding on what operative procedure to offer. The combination of hypertelorism and marked maxillary narrowing (particularly if the upper incisors are crossed), as is often seen in Apert syndrome, lends itself to correction with a facial bipartition; this technique can also be used early as the bone cuts do not result in damage to the dentition. The major drawback of this technique is that orbital asymmetries cannot be addressed. The more conventional box osteotomy is used to effect asymmetric movements, hypertelorism and dystopia corrections. The overall aesthetic outcome is often enhanced with nasal augmentation and soft tissue surgery, but the final improvement (particularly in severe hypertelorism cases)

unfortunately often does not match the skeletal changes achieved.

The upper midface can be advanced, either as part of the bipartition procedure, transcranial Le Fort III (monobloc), subcranial Le Fort III or Le Fort II. These procedures can be performed conventionally with bone grafting and fixation with either absorbable or titanium plates and screws or with the use of distraction techniques. If distraction is being utilised, the devices can be a halo-based external device or buried devices. It is sometimes helpful to combine external distraction devices with buried devices which facilitate the early removal of the somewhat cumbersome halo device for the retention period [21]. In addition to advancement movements, it is possible to incorporate height changes, but rotatory movements (e.g. to correct the upper dental midline) are very difficult unless the symmetry is equal at all facial levels. Furthermore if the maxillary advancement required has a significant differential between the upper component and dental component, it is possible to combine a Le Fort III (transcranial or subcranial) or a monobloc advance with a simultaneous Le Fort I osteotomy. This additional level of movement allows for differential advancements and/or height changes as well as rotations at the lower level. See case series in Fig. 79.5 of Crouzon syndrome.

The mandible including the chin should be considered as one would for conventional orthognathic surgery, but caution should be exercised in setback procedures as correction of the occlusion to a retrusive maxilla may worsen or precipitate OSA.

Nasal deformity is best dealt with as close to the end of treatment as possible; the range of deformity is considerable; each patient should be treated on their own merits. In cases with severe deficiency, dorsal augmentation with alloplastic or autologous material may be necessary, and this can be refined with nasal tip surgery.

The final phase of surgery is the management of the soft tissues, and again a variety of techniques can be employed to improve the overall aesthetic result. As well as rhinoplasty techniques, facelifting, brow suspension, eyelid surgery, soft tissue augmentation with fillers or fat transfer and soft tissue reduction with direct excision or liposuction all have their place.

See Table 79.2 for an outline of the management of common clinical problems and Table 79.4 for an outline of surgical procedures.

References

1. Wilkie AO, Byren JC, Hurst JA, Jayamohan J, Johnson D, Knight SJ, et al. Prevalence and complications of single-gene and chromosomal disorders in craniosynostosis. *Pediatrics*. 2010;126(2):e391–400.
2. Bhadkamkar MA, Albright SB, Wolfswinkel EM, Bollo R, Buchanan EP. Posterior cranial vault distraction in the treatment

- of shunt-induced craniosynostosis. *J Craniofac Surg.* 2015 Jan 1;26(1):e70–2.
3. Di Rocco F, Arnaud E, Renier D. Evolution in the frequency of non-syndromic craniosynostosis. *J Neurosurg Pediatr.* 2009;4(1):21–5.
 4. Mathijssen IM. Guideline for Care of Patients with the diagnoses of Craniosynostosis: working group on Craniosynostosis. *J Craniofac Surg.* 2015;26(6):1735–807.
 5. Cornelissen MJ, Apon I, van der Meulen JJ, Groenenberg IA, Kraan-van der Est MN, Mathijssen IM, Bonsel GJ, Cohen-Overbeek TE. Prenatal ultrasound parameters in single-suture craniosynostosis. *J Matern Fetal Neonatal Med.* 2018 Aug 3;31(15):2050–7.
 6. Edmond JC, Nischal K, Forbes B, Katowitz W, Costakos D. Update on the management of patients with craniostenosis. *J AAPOS.* 2011;15(1):e35.
 7. Burokas L. Craniosynostosis: caring for infants and their families. *Crit Care Nurse.* 2013;33(4):39–50.
 8. Mehta VA, Bettegowda C, Jallo GI, Ahn ES. The evolution of surgical management for craniosynostosis. *Neurosurg Focus.* 2010;29(6):E5.
 9. Ingraham FD, Alexander E, Matson DD. Clinical studies in craniosynostosis: analysis of fifty cases and description of a method of surgical treatment. *Surgery.* 1948 Sep 1;24(3):518–41.
 10. Jimenez DF, Barone CM, Cartwright CC, Baker L. Early management of craniosynostosis using endoscopic-assisted strip craniectomies and cranial orthotic molding therapy. *Pediatrics.* 2002;110(1 Pt 1):97–104.
 11. Lauritzen CG, Davis C, Ivarsson A, Sanger C, Hewitt TD. The evolving role of springs in craniofacial surgery: the first 100 clinical cases. *Plast Reconstr Surg.* 2008;121(2):545–54.
 12. Khechoyan D, Schook C, Birgfeld CB, Khosla RK, Saltzman B, Teng CC, Ettinger R, Gruss JS, Ellenbogen R, Hopper RA. Changes in frontal morphology after single-stage open posterior–middle vault expansion for sagittal craniosynostosis. *Plast Reconstr Surg.* 2012 Feb 1;129(2):504–16.
 13. Garza RM, Khosla RK. Nonsyndromic craniosynostosis. *Semin Plast Surg.* 2012;26(2):53–63.
 14. Beez T, O’kane R, Piper I, Koppel D, Sangra M. Telemetric intracranial pressure monitoring in syndromic craniosynostosis. *J Craniofac Surg.* 2016 Jun 1;27(4):1032–4.
 15. Benson ML, Oliverio PJ, Yue NC, Zinreich SJ. Primary craniosynostosis: imaging features. *AJR Am J Roentgenol.* 1996;166(3):697–703.
 16. Gonzalez S, Hayward R, Jones B, Lane R. Upper airway obstruction and raised intracranial pressure in children with craniosynostosis. *Eur Respir J.* 1997 Feb 1;10(2):367–75.
 17. Broder HL. Using psychological assessment and therapeutic strategies to enhance Well-being. *Cleft Palate Craniofac J.* 2001;38(3):248–54.
 18. Evans RD, Bradford R. The dental and orthodontic management of craniosynostosis. In: Bux M, editor. *The clinical Management of Craniosynostosis* ch 11. London: Mac Keith Press; 2004. p. 211–7.
 19. Gonzalez AM, Elahi M, Barakat K, Yavuzer R, Brinkmann B, Jackson IT. Hypertelorism: the importance of three-dimensional imaging and trends in the surgical correction by facial bipartition. *Plast Reconstr Surg.* 2005 May 1;115(6):1537–46.
 20. Feroze AH, Walmsley GG, Choudhri O, Lorenz HP, Grant GA, Edwards MS. Evolution of cranioplasty techniques in neurosurgery: historical review, pediatric considerations, and current trends. *J Neurosurg.* 2015 Oct;123(4):1098–107.
 21. Schulten A, Lim AA, Bruun RA, Hayes C, Mulliken JB, Padwa BL. Combined push-pull distraction for correction of syndromic midfacial hypoplasia. *J Oral Maxillofac Surg.* 2006 Jan 1;64(1):23–30.

Open Access This chapter is licensed under the terms of the Creative Commons Attribution 4.0 International License (<http://creativecommons.org/licenses/by/4.0/>), which permits use, sharing, adaptation, distribution and reproduction in any medium or format, as long as you give appropriate credit to the original author(s) and the source, provide a link to the Creative Commons license and indicate if changes were made.

The images or other third party material in this chapter are included in the chapter's Creative Commons license, unless indicated otherwise in a credit line to the material. If material is not included in the chapter's Creative Commons license and your intended use is not permitted by statutory regulation or exceeds the permitted use, you will need to obtain permission directly from the copyright holder.



Part XXI

**Malignant Pathologies of the Oral
and Maxillofacial Region**



Premalignant Lesions and Conditions of the Oral Cavity

80

El Mustafa, Sat Parmar, and Prav Praveen

80.1 Premalignant Lesions

It is well established that oral cavity cancer develops in a two-step process and, consequently, that most malignant ulcers are preceded by a precursor lesions [1]. These lesions are typically red or white patches referred to altogether in the 2007 WHO consensus statement as the group of potentially malignant disorders (PMDs) [2] (Table 80.1). Clinical identification of PMDs offers a window for intervention: eliminating diseased mucosa and exclusion of occult invasive cancers. This is important from a clinician's perspective on several fronts. Firstly, it is important to be able to recognise high-risk lesions among a multitude of innocent oral conditions that present with similar features. Some conditions such as oral lichen plans may have a potential for malignant change, but the condition is so prevalent that it becomes impractical to monitor every single patient with the disease. To avoid additional burdens on clinical services, the oral physician or surgeon needs to make a decision as to which patients must be kept under review at a specialist centre and which may be safely referred back for ongoing follow-up in the community. Among those who are reviewed at a specialist practice, ongoing decisions are made at each visit, when to intervene and to what extent one should be aggressive with the treatment plan offered. On a second front are the difficulties of recognition of tumour recurrences following treatment. Surgical treatment and radiotherapy change the tissue appearance and texture irreversibly. Among these patients, it is known that a proportion would develop either a second tumour at the site of surgery or a new tumour in a neighbouring area. It is challenging enough to identify precancerous lesions in nascent tissue, and thus the clinician must be much more vigilant in recognising potentially cancerous new

Table 80.1 Potentially malignant lesions

Potentially malignant lesions
Leukoplakia (idiopathic)
Proliferative verrucous leukoplakia
Erythroplakia
Oral submucous fibrosis
Oral lichen planus
Chronic hyperplastic candidosis

lesions in patients under follow-up posttreatment of head and neck cancer.

Further to these concerns, we know that premalignant conditions tend to develop in what is known as field change. This means that for any subsite within the oral cavity at which cellular nuclear damage resulted in a PMD (or even cancer), the adjacent mucosa is almost equally at risk of producing additional PMD lesions even if they appear normal to the naked eye.

Knowledge of the patterns and behaviour of PMDs (pre-malignant disorder) is thus an essential part of oral medicine and oral surgery practice.

The commonest PMDs are leukoplakia with an overall prevalence of 2.9% in the general population [3] and submucous fibrosis with a prevalence of nearly 11% in high-risk populations [4]. The risk for submucous fibrosis is specific to populations where paan use is prevalent unlike the risk for leukoplakia which is universally applicable. Lesions are considered potentially malignant rather than premalignant. Clinical behaviour is unpredictable; some lesions remain stable; others regress, but in up to 30% of cases, oral malignancy is diagnosed within 5 years of follow-up. Cancer may arise from the lesion itself or at a different subsite within the oral cavity reflecting the concept of 'field cancerisation' explained previously.

It is important to note that a role for primary prevention in patients with leukoplakia is not confirmed. For example, smoking is a risk factor for the development of leukoplakia,

E. Mustafa · S. Parmar · P. Praveen (✉)
Department of Oral and Maxillofacial Surgery, Queen Elizabeth Hospital, Birmingham, UK
e-mail: Prav.Praveen@uhb.nhs.uk

but smoking cessation does not necessarily reduce the risk of developing OCC. There is, however, benefit in screening for potentially malignant lesions, and this was demonstrated in a recent review of the US SEER-Medicare database of head and neck cancer. Yanik et al. [5] reported better treatment and survival outcomes in patients who developed oral cell carcinoma whilst under follow-up for a premalignant lesion [5]. This correlated with the fact that oral cancers were identified at an earlier stage in this patient cohort. Patients without the benefit of such close observation tended to present with more developed or advanced tumour forms. A role for screening patients following treatment for head and neck cancer recurrence is not known, and thus secondary prevention is not currently known to be effective. It is likely, however, that the principle of recognising early tumours and potentially malignant lesions would still result in timely provision of therapy. Table 80.1 enlists premalignant lesions discussed in this chapter.

80.2 Aetiogenesis

Development of a malignancy is a complex multistep process resulting from failures in several regulatory cellular pathways. Dysplasia in oral cancer is usually the first step in the malignant down spiral. Dysplasia is a descriptive term used on microscopic assessment. It indicates that the tissue has accrued a significant population of abnormal cells that display a pattern of nuclear damage that is known to herald cancerous behaviour. These changes are summarised in Table 80.2. Usually but not always, these changes are followed by unregulated hyperplasia (cellular multiplication). The tumour cells have gained autonomy meaning they escaped nuclear and immune mechanisms that limit excess growth and prevent accumulation of damaged cells. The final step is loss of integrity of the basement membrane at the boundary between mucosa and submucosa; the dysplastic cells begin to invade into the surrounding tissues or directly gain access to vascular channels. Each of these steps is controlled by molecular pathways directed by gatekeeper genes and gene products.

Two cellular or microscopic changes broadly define oral premalignancy: *hyperplasia* which results from over activation of the retinoblastoma pathway and the development of various degrees of *dysplasia* due to mutations in the p53

Table 80.2 Histological features of cellular dysplasia

Dysplastic changes
Irregular cell shape and orientation
Increased and abnormal mitoses
Nuclear pleomorphism
Coarse and clumped chromatin
Increased nuclear-to-cytoplasmic ratio
Prominent nucleoli
Dyskeratosis

gene. In health and normal physiology, genes along the retinoblastoma pathway activate transcription factors required for taking the cells from the indolent G1 to the active S phase. Overactivation of these genes leads to loss of control of orderly cell division resulting in epithelial hyperplasia. A product of the CDKN2A gene, the p16 protein, usually keeps this stage of cell cycle in check. This protein may become inactivated either because of a mutation/deletion/epigenetic silencing of the parent gene CDKN2A or through direct degradation by a viral product, the E7 protein, of the HPV virus (relevant to the development of oropharyngeal cancer). The retinoblastoma pathway may also be directly upregulated by amplification of the Cyclin D1 gene, a proto-oncogene of the locus 11q13 [6].

With each cell division, there is a probability of errors arising in the nuclear DNA resulting in a defective daughter cell. Most errors are corrected during cell division, or the cells are removed by immune mechanisms. Defective cells that have escaped these reparative measures may still be suppressed by transcription factors that induce apoptosis. Apoptosis is triggered through p53, a tumour suppressor protein. The protein p14 is an alternative reading frame of the CDKN2A gene responsible for initiating the p53 pathway. Direct degradation of p53 by the E6 viral protein (HPV-related cancer) or genetic mutations in the parent gene (in 60% of non HPV cancer) restricts protective physiological apoptosis leading to a shift in cell population and accumulation of dysplastic cells. The premise behind looking out for premalignant disorders is that oral mucosa will change appearance with the onset of dysplastic changes and that the extent of dysplasia does correlate with malignant potential. High-grade dysplastic lesions indicate treatment is required imminently, whereas mild dysplastic lesions may be observed and are even considered a feature of benign chronic inflammation. Dysplasia is classified according to several grading systems summarised in Table 80.3, the most common system in use being the one proposed by the WHO in 2005. Further

Table 80.3 Grading systems for dysplasia

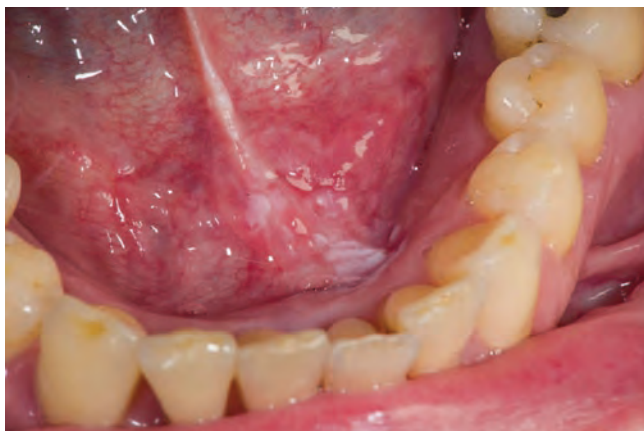Definition	WHO 2005	Ljubljana system	Equivalent SIN (squamous intra-epithelial neoplasia)
Increase in the number of normal cells	Squamous cell hyperplasia	Squamous cell (simple) hyperplasia	
Atypical changes confined to the lower 1/3 of the epithelium	Mild dysplasia	Basal/parabasal cell hyperplasia	SIN1
Atypical changes to the middle 1/3 of the epithelium	Moderate dysplasia	Atypical hyperplasia	SIN2
Changes involve at least 2/3 of the epithelium	Severe dysplasia	Atypical hyperplasia	SIN3

genetic changes are involved in progression towards invasiveness, but these are not as well defined as these are outside the scope of the chapter.

80.3 Leukoplakia

Idiopathic leukoplakia is the most common premalignant disorder. Nearly one in every 10 cases of oral cavity cancer (OCC) is known to arise in leukoplakia (Fig. 80.1), usually within 3 months of diagnosis of the lesion [5]. These lesions are defined as ‘white plaques of questionable risk having excluded disorders that carry no increased risk for cancer’ [2]. Table 80.4 enlists white lesions without a known malignant potential. These are rare, and thus most persistent white patches are best treated with suspicion until further evaluation.

Clinical variants of leukoplakia include homogenous plaques, nodules, speckled erythroleukoplakia and a distinct subtype discussed separately: proliferative verrucous subtype. Leukoplakia is present in less than 1% of the general population [5] but with greater prevalence reported among those older than 75 years of age and tobacco users of all age groups [7]. Men are twice as much likely to develop leukoplakia compared with women. In the Indian subcontinent, in regions where betel is consumed, prevalence rates approach 5% [8]. The annual risk of malignant transformation is estimated between 1 and 2% [9]. Larger non-homogeneous



©Association of Oral and Maxillofacial Surgeons of India

Fig. 80.1 Leukoplakia

Table 80.4 Innocent white patches

White lesions not known to association with oral cancer	
Developmental	Cannon white sponge nevus
Metabolic	Uremic stomatitis
Immune mediated	Benign migratory glossitis
Viral immune suppression	Oral hairy leukoplakia associated with HIV

Table 80.5 Risk predictors for malignant transformation

Risk factors for malignant transformation
Duration
Non-homogeneous type
Size >200 mm squared
Site: Tongue, floor of the mouth
Leukoplakia in a non-smoker
Epithelial dysplasia

lesions, particularly those on the tongue and floor of the mouth, are associated with the highest conversion rates to oral squamous cell carcinoma. Table 80.5 lists clinical risk predictors for malignant transformation.

Tissue biopsy is required to assess the degree of epithelial dysplasia, an independent and consistently reliable risk factor for malignant transformation. Liu et al., using a binary grading of dysplasia, found that patients with high-risk lesions (moderate/severe dysplasia) eight times as likely to be diagnosed with oral cancer as those with low-risk (no/mild dysplasia) lesions [10]. Histological evaluation may also identify other conditions that are clinically indistinguishable from idiopathic leukoplakia such as hyperplastic candidosis, oral lichen planus variants, lichenoid reactions and discoid lupus.

Categorisation into high- and low-risk lesions is helpful in identifying target areas for surgical removal and those that may be safely observed but closely followed up.

However, in populations with high incidence of oral cancer, studies have shown oral leukoplakia as foci of invasive cancer and have advocated surgical excision of these lesions.

Toluidine blue dye improves visual detection of high-risk mucosa [11] and helps determine the extent of peripheral margins required for complete excision. It is not established whether surgical intervention reduces the risk of subsequent cancer, but a resection specimen may upgrade the histological evaluation or identify areas of occult focal invasion. Recurrence following surgery is observed in 10% of cases [12]. Laser surgery is effective in controlling low-grade leukoplakia, but significantly higher failure rates of up to 9% were reported in high-grade lesions and erythroleukoplakia [13]. Recent reviews have examined photodynamic therapy as a treatment option particularly helpful in controlling widespread and multifocal leukoplakia [14]. Partial and complete response rates as high as 70–100% were reported, but the range of photosensitisers used and photo-irradiation protocols applied varied greatly between individual authors.

Medical treatments for oral premalignancy include systemic vitamin A, systemic beta carotene and topical bleomycin. These were shown to control premalignant lesions, but a 2016 Cochrane review concluded that relapse rates were high and that transformation into oral cancer was not effectively reduced [15].

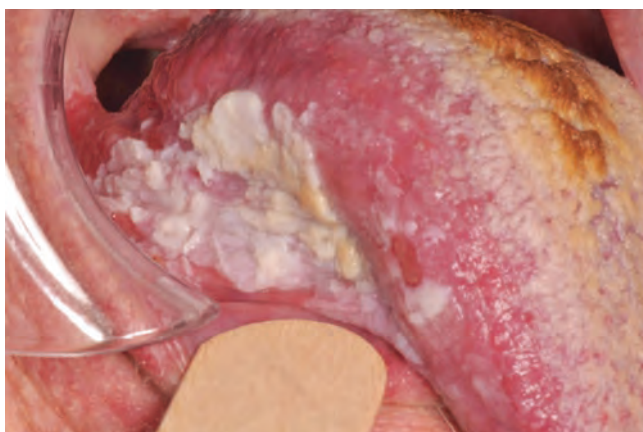80.4 Proliferative Verrucous Leukoplakia

Proliferative verrucous leukoplakia (PVL) is a distinct and aggressive form of leukoplakia with one of the highest known malignant transformation rates. It is typically diagnosed in elderly women (4:1 female ration) without a history of tobacco use [16]. Aetiology is thus largely unknown. Lesions often start as isolated flat white plaques but gradually spread to become diffuse and multifocal with a characteristic warty appearance (Fig. 80.2). There typically is no erosive component. The lesions tend to present on the tongue or buccal mucosa or well as the alveolar ridge. They can be mistaken for hyperplastic candidosis or frictional keratosis particularly in denture wearers. Histological appearance is dependent on the stage of the disease ranging from benign hyperkeratosis to dysplastic keratosis merging into verrucous carcinoma. Malignant transformation may also happen simultaneously at multiple foci, and this is one of the clearest manifestations of the field cancerisation concept introduced earlier. Verrucous carcinoma is a squamous cancer with well-differentiated histopathological architecture that displays very little cellular atypia.

PVL is a lesion that benefits from excision biopsy rather than an incisional sample (see biopsy discussion below) for it is estimated that 20% of verrucous lesions, if adequately sampled, would reveal foci of conventional pattern squamous cell carcinoma. Local control is, however, difficult with high recurrence rates following surgical excision and greater malignant transformation rates in excess of 70% [17]. It is also one of the most difficult lesions to follow up, requiring multiple biopsies to monitor behaviour over time.

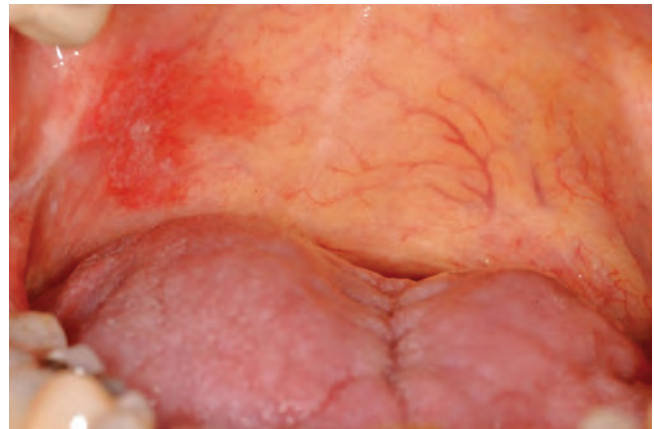
80.5 Erythroplakia

Erythroplastic lesions (Fig. 80.3) are similarly defined to oral leukoplakia but as red velvety lesions following exclusion of other named entities. It is a rare disorder with prevalence



©Association of Oral and Maxillofacial Surgeons of India

Fig. 80.2 Proliferative verrucous leukoplakia



©Association of Oral and Maxillofacial Surgeons of India

Fig. 80.3 Erythroplakia

between 0.01 and 0.2% but a much higher transformation rate compared to leukoplakia, reportedly between 51 and 90% [16]. Clinical appearance tends to follow one of three patterns: the homogenous, granular and speckled types [12]. Most common subsides are the palate, the buccal mucosa and the floor of the mouth. Lesions are rarely multicentric and may present a similar clinical appearance to erosive and atrophic oral lichen planus, erythema migrans, stomatitis, candidosis, lymphatic malformations and desquamative gingivitis (e.g. vesiculobullous lesions and gingival lichen planus). Speckled erythroplakia and leukoplakia most likely refer to the same disorder with red appearance correlating to high-risk epithelial dysplasia. Treatment options are surgical excision, laser excision or evaporation as per leukoplakia with a lower threshold for application for wide local excision due to the higher risk of cancer development.

80.6 Submucous Fibrosis

Oral submucous fibrosis is progressive scarring disorder linked to the use of betel products (paan). Additional risk for oral squamous cell carcinoma is conferred by the addition of slaked lime to the betel quid or concurrent use of tobacco. The active ingredients in paan include arecoline, copper and polyphenol fragments (flavonols, tannins) which stimulate an intense acute inflammatory response characterised by a polymorphic infiltrate and vascular dilatation. This gives way to a chronic immune response and constrictive vascular changes that end with obliteration of blood vessels in the affected region. Over time, this leads to an epithelial to mesenchymal transition mediated by TGF- β [18]. Fibroblasts are activated, and collagen is deposited steadily replacing the submucous tissues with hyalinised cartilage almost devoid of cellular components. Several genes are known to associate with the risk of developing submucous fibrosis including MMP3 gene promoter region and CYP1A1/CYP2E1 genes,

Table 80.6 Histopathological changes in submucous fibrosis

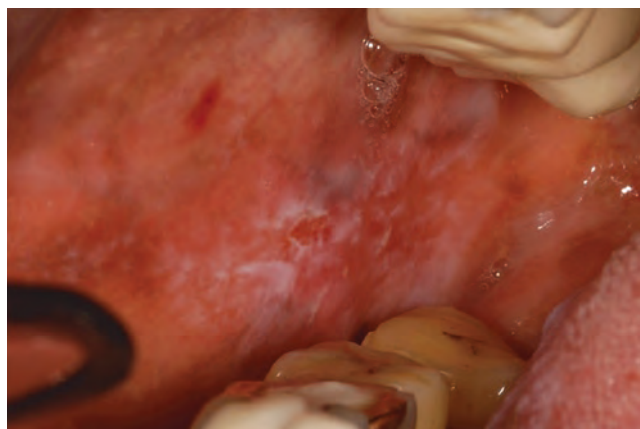Very early Stage I	Early Stage II	Moderate advanced Stage III	Advanced Stage IV
• Fine fibrillar collagen and marked oedema.	• Early junctional epithelial hyalinisation	• Moderately hyalinised collagen.	• Completely hyalinised collagen.
• Strong fibroblastic response.	• Moderate fibroblastic response.	• Predominantly fibrocytes, reduced fibroblasts.	• Hyalinised collagen devoid of fibroblasts.
• Acute polymorphic inflammatory cell infiltrate.	• Mononuclear and lymphocytic inflammatory cell infiltrate.	• Lymphocytic and plasma cell inflammatory cell infiltrate.	• Lymphocytic and plasma cell inflammatory cell infiltrate.
• Normal or dilated-congested blood vessels.	• Dilated-congested blood vessels.	• Normal to constricted vessels.	• Markedly constricted or completely obliterated blood vessels.

but the genetic basis for transformation into squamous cell carcinoma is not currently defined. Table 80.6 summarised the histopathological evolution and progression of submucous fibrosis.

Consumption of paan is common in Southeast Asia and the Western Pacific but is now also seen in Europe and North America. It is estimated that more than half a billion persons consume betel worldwide [19]. Early presentation reflects the early histological picture with non-specific inflammatory mucosal changes. The diagnosis becomes clearer when early changes are replaced by the characteristic hypo-vascular blanched appearance with a fibrous texture although these changes may be patchy or reticular causing potential confusion with unrelated mucosal changes (e.g. lichen planus). In general, submucous fibrosis tends to present in young adults (predominantly males) with worsening trismus (37.2% of patients), painful dysesthesia (25.9%), excess salivation (22.5% of patients) and recurrent ulceration. Clinical findings on examination are white patches particularly in the buccal mucosa (20.8%) and the palate (17.7%) followed by the floor of mouth and the retromolar trigone [20]. Clinical signs develop within 3–5 years following commencement of chewing betel preparations. Patients are 19 times as likely to develop oral cancer particularly with betel quid containing tobacco [4]. Malignant transformation rates are reportedly 4–13% [21].

Conservative and medical measures are considered for the early clinical stages. This includes physiotherapy, immune modulators steroids and promoters of blood flow such as pentoxifylline. Many other medical treatments are reported but none with definitive clinical benefit.

Surgical options are limited and complete excision unlikely, but surgery is usually indicated for local release of



©Association of Oral and Maxillofacial Surgeons of India

Fig. 80.4 Oral lichen planus

retromolar or buccal scarring to help relieve trismus. Release of trismus is usually necessary at the mouth opening of 25 mm and less and is achieved with incisions, local V–Y flaps and masticator muscle myotomy, resurfacing the defect with the buccal fat pad or other grafts.

80.7 Oral Lichen Planus

Lichen planus (LP) (Fig. 80.4) is a prevalent inflammatory much cutaneous disease affecting 5% of the population worldwide. The pathogenesis is not well understood but is essentially an autoimmune response to the epidermal basal cell layer mediated by cytotoxic T cells. Characteristically, T cells are seen to infiltrate into the lamina propria on microscopy and the damaged basal keratinocytes degrade into apoptotic residues known as civatte bodies (not pathognomonic for LP) [22]. Aetiology is unknown, but it is well recognised that appearances of lichen plans can result from a hypersensitivity reaction to nonsteroidal anti-inflammatories, angiotensin-converting enzyme inhibitors and dental amalgam. These reactions are more commonly referred to as lichenoid mucositis. In rare instances, the disease associates with viral hepatitis (B and C), but in most patients LP, there is no triggering factor. Stress is thought to be a contributing factor.

Commonly, oral lichen planus (OLP) presents as reticular white patterns on the buccal mucosa or the tongue known as Wickham's striae. Many varieties and presentations are recognised such as desquamative gingivitis, plaque form and an unusual form that presents with vesicular bullae. An erosive form is also recognised giving the appearance of the high-risk erythroplakia and mixed red and white lesions [23]. Some authors use the term erosive OLP to refer to the ulcerated type of lesion and erythematous OLP as the commoner type which affects atrophied buccal mucosa (usually seen

with reticular lesions). Distribution is usually symmetrical, a feature it shares with discoid lupus.

It is not clear whether oral lichen planus (OLP), a relatively common benign condition, is an independent risk factor for malignancy. A meta-analysis of 7806 patients concluded that just over 1% of patients OLP develop oral cavity cancer [24]. The highest risk subsites were predominantly the tongue (51%) and the buccal mucosa (32%). Malignant transformation was three times as likely in females as it was in men. It is proposed that changes at lower-power magnification of oral leukoplakia resemble lichen planus or that lichenoid changes in epithelial dysplasia are common. Clinically, there is overlap between the clinical appearance of the various types of OLP and between erythroleukoplakia and verrucous leukoplakia. A diagnosis of OLP is more likely in symmetric lesions, but only a biopsy demonstrating epithelial dysplasia would confirm truly high-risk lesions. Correlation between malignant change and certain subtypes of OLP, namely, the erosive and plaque-like forms, has not been consistent. Interestingly a co-existence with proliferative verrucous leukoplakia has been noted by several authors [25, 26].

80.8 Chronic Hyperplastic Candidosis

Candida is present in the oral cavity in between 40 and 60% of healthy individuals. Association between *Candida* infection and cancer is through smoking, an independent risk factor equally for the development of chronic hyperplastic candidosis (CHC) and premalignant mucosal lesions. Once hyperplastic candidosis is established, these lesions manifest and behave similar to homogeneous or speckled leukoplakia with 15% risk of progression to epithelial dysplasia [27]. CHC is usually resistant to antifungal therapy, and thus surgery is indicated particularly for well-defined lesions.

80.9 Premalignant Conditions

Premalignant conditions are a disparate group of rare congenital and acquired disorders of immune regulation, inheritable genetic instability and infectious diseases. Table 80.7 enlists conditions that associate with mucosal SCC followed by Table 80.8 which also provides a summary of clinical features, site distribution and risk probabilities for conditions that associate with the cutaneous type of squamous carcinoma. Reports of malignant transformations are generally few and data concerning the natural history of OCC limited. Conditions that rarely associate with oral SCC such as Plummer-Vinson syndrome are not discussed here.

Table 80.7 Potentially malignant conditions: mucosal SCC

Potentially malignant conditions: mucosal SCC	Aetiology	Clinical characteristics
Dyskeratosis congenita (mucocutaneous variant) [28]	Multigene defects, telomere dysfunction and bone marrow failure. Sporadic de novo, autosomal dominant and X-linked recessive types	Triad: Nail dystrophy, reticular skin pigmentation, oral leukoplakia. Oral leukoplakia in 80% of patients. 40–5% malignant transformation into SCC
Syphilis	Spirochete infection	Verrucous type and speckled leukoplakia in tertiary syphilis. Usually in the lips, tongue or palate. 3–33% risk of transformation
Graft versus host disease	Complication of allogenic stem cell transplantation	Oral lichenoid, erosions and painful ulcers. Few case reports of cancer transformation
Acquired immune deficiency syndrome [29]	HIV virus	HPV positive oropharyngeal SCC. Kaposi sarcoma

Table 80.8 Potentially malignant conditions: cutaneous SCC

Potentially malignant conditions: cutaneous SCC	Aetiology	Clinical characteristics
Actinic cheilitis	Solar radiation	Diffuse, atrophic, ulcerative or keratotic patches in the lower lip. 6% risk of malignant transformation
Xeroderma pigmentosum	Autosomal recessive inheritance	Cutaneous-type SCC on the lower lip observed in young adults, age < 20 years
Discoid Lupus [30]		1.3–6.5% risk of developing SCC and BCC with lighter skin. Risk increased to 22% in discoid lesions. Locally aggressive lesions with high recurrence rates

80.10 Tissue Biopsy

A sample of tissue is required whenever a premalignant disorder is suspected. Dysplasia cannot be visualised on clinical inspection. It is true that some lesions such as the speckled red and white lesions are most likely to harbour dysplastic cells, but it is hard to characterise white patches as dysplastic or not on clinical examination alone. Most sites within the oral cavity are accessible for a biopsy under

local anaesthetic. General anaesthetic may well be indicated in some cases depending on tumour site particularly in the oropharynx or in patients not compliant with awake procedures. A biopsy may be obtained either by using a scalpel blade or through a punch biopsy applicator with pre-set width.

A small amount of local anaesthetic is administered locally within the site of the lesion for it provides pain relief and vasoconstriction through the action of an additive. Concentrations of 1:50,000 to 1:200,000 epinephrine are used as vasoconstrictor additives typically to lidocaine. Other vasoconstrictor agents include felypressin typically combined with prilocaine as a local anaesthetic. Care should be taken in patients who take anti-platelets agents or anticoagulant medications. The oral mucosa has a rich blood supply, and bleeding from small biopsy sites may prove to be difficult to control.

Excision of the abnormal patch as a whole may be achievable in smaller lesions, but in large and extensive lesions, an incisional sample is indicated. The site for taking a biopsy in this case is important. A white lesion may contain within multiple foci, and a biopsy from a uniform looking area may miss an area of dysplasia or early invasive cancers. Within a white lesion, it is advisable to take a biopsy from a speckled area, an area where there is induration/thickening and an erosive patch or where there is frank ulceration. When there is ulceration, then removal of tissue from the centre of the ulcer may return tissue that is necrotic and hard for the pathologist to interpret. Thus, it is also advised to take a biopsy from the margin of the ulcer particularly if the margin is elevated or everted. A small extension to incorporate normal looking tissue is helpful to enable the pathologist to visualise pathological transition into normal background architecture and pick up subtle changes that may otherwise be difficult to interpret.

The full thickness of mucosa is required for complete assessment. Invasiveness is impossible to interpret without inclusion of the basement membrane in the tissue biopsy. Traditionally that may not have been crucial for at the highest end of the dysplastic spectrum severe dysplasia is also considered to be at least as intra-epithelial neoplasia and in most cases surgical excision would be indicated. However, recent modifications of the TNM classification system and the work of D'Cruz et al. have highlighted depth of invasion as an independent risk predictor for regional metastasis [31].

Thus a biopsy may not only identify the nature of the lesion and reveal unexpected invasiveness; it may also determine the next step in treatment whether surgical excision of the lesion is enough or whether the threshold for regional surgery (i.e. a neck dissection) is required as well.

Once the sample is removed, haemostasis is required with either bipolar diathermy or, in small sites, chemical cautery

with silver nitrate that is useful too. Most biopsy sites lend themselves to primary closure with a resorbable suture, whereas particular sites such as the mucosa overlying the hard palate may be safely left to heal by secondary intent.

80.11 Conclusion

Clinical examination of the oral cavity must include active screening for mucosal changes that are potentially cancerous. This may take place in the primary care setting, in dental practice, for these lesions are mostly asymptomatic and the patients may not be aware of their presence. A high index of suspicion is required for it is well known that although some lesions associate with known risk factors (e.g. oral submucous fibrosis), many lesions do not (e.g. verrucous leukoplakia). Clinical features may be ambiguous with some lesions that are red, erosive or speckled lending themselves to easier recognition compared with faint leukoplakia and subtle early changes in long-standing lichen planus. A low threshold for biopsy is recommended unless the lesion is demonstrably consistent with candidosis (i.e. may be clinically wiped off) or in the case of striated lichen planus that has remained consistent and well defined. Clinical photography is helpful in establishing objective documentation lesions for it is likely that the patient would be reviewed by different clinicians during follow-up. Once identified and histology is characterised, then lesions require stratification into high-risk and low-risk categories in order to determine the long-term plan for the patients, namely, surgical removal versus clinical observation, and the appropriate recall intervals for future follow-up. As discussed above, the treatment options are diverse and are tailored to the size of the lesion and degree of epithelial dysplasia. Although surgical removal does not eliminate the risk of malignant change entirely, early identification and close follow-up of premalignant lesions offer the best chance for achievement of good local control if and when oral cancer develops.

References

1. Reibel J. Prognosis of Oral pre-malignant lesions: significance of clinical, histopathological, and molecular biological characteristics. *Crit Rev Oral Biol Med.* 2003;14:47–62.
2. Warnakulasuriya S, Johnson NW, van der Waal I. Nomenclature and classification of potentially malignant disorders of the oral mucosa. *J Oral Pathol Med.* 2007;36(10):575–80.
3. Bánóczy J, Gintner Z, Dombi C. Tobacco use and oral leukoplakia. *J Dent Educ.* 2001;65(4):322–7.
4. Wollina U, Verma SB, Ali FM, Patil K. Oral submucous fibrosis: an update. *Clin Cosmet Investig Dermatol.* 2015;8:193–204.
5. Yanik EL, Katki HA, Silverberg MJ, Manos MM, Engels EA, Chaturvedi AK. Leukoplakia, oral cavity cancer risk, and cancer survival in the U.S. elderly. *Cancer Prev Res (Phila).* 2015;8(9):857–63.

6. Pitiyage G, Tilakaratne WM, Tavassoli M, Warnakulasuriya S. Molecular markers in oral epithelial dysplasia: review. *J Oral Pathol Med.* 2009;38(10):737–52.
7. Amagasa T. Oral premalignant lesions. *Int Clin Oncol.* 2011;16:1–4.
8. Gupta PC, Mehta FS, Daftary DK, Pindborg JJ, Bhonsle RB, Jainawalla PN, et al. Incidence of oral cancer and natural history of oral precancerous lesions in a 10-year follow-up study of Indian villagers. *Community Dent Oral Epidemiol.* 1980;8:283–333.
9. Brouns ER, Baart JA, Bloemena E, Karagozlu H, van der Waal I. The relevance of uniform reporting in oral leukoplakia: definition, certainty factor and staging based on experience with 275 patients. *Med Oral Patol Oral Cir Bucal.* 2012;18(1):e19–26.
10. Liu W, Wang YF, Zhou HW, Shi P, Zhou ZT, Tang GY. Malignant transformation of oral leukoplakia: a retrospective cohort study of 218 Chinese patients. *BMC Cancer.* 2010;10:685.
11. Chainani-Wu N, Madden E, Cox D, Sroussi H, Epstein J, Silverman S Jr. Toluidine blue aids in detection of dysplasia and carcinoma in suspicious oral lesions. *Oral Dis.* 2015;21(7):879–85.
12. Lodi G, Porter S. Management of potentially malignant disorders: evidence and critique. *J Oral Pathol Med.* 2008;37:63–9.
13. Thomson PJ, Goodson ML, Cocks K, Turner JE. Interventional laser surgery for oral potentially malignant disorders: a longitudinal patient cohort study. *Int J Oral Maxillofac Surg.* 2017;46(3):337–42.
14. Gondivkar SM, Gadbaile AR, Choudhary MG, Vedpathak PR, Likhitkar MS. Photodynamic treatment outcomes of potentially malignant lesions and malignancies of the head and neck region: A systematic review. *J Investig Clin Dent.* 2018;9(1)
15. Lodi G, Franchini R, Warnakulasuriya S, Varoni E, Sardella A, Kerr AR, Carrassi A, MacDonald LCI, Worthington HV. Interventions for treating oral leukoplakia to prevent oral cancer. *Cochrane Database Syst Rev.* 2016;7(7):CD001829.
16. Mortazavi H, Baharvand M, Mehdipour M. Oral potentially malignant disorders: an overview of more than 20 entities. *J Dent Res Dent Clin Dent Prospects.* 2014;8(1):6–14.
17. Munde A, Karle R. Proliferative verrucous leukoplakia: an update. *J Cancer Res Ther.* 2016;12(2):469–73.
18. Hu Y, Jian X, Peng J, Jiang X, Li N, Zhou S. Gene expression profiling of oral submucous fibrosis using oligonucleotide microarray. *Oncol Rep.* 2008;20(2):287–94.
19. Nelson BS, Heischouer B. Betel nut: a common drug used by naturalized citizens from India, Far East Asia, and the South Pacific Islands. *Ann Emerg Med.* 1999;34(2):238–43.
20. Pandya S, Chaudhary AK, Singh M, Singh M, Mehrotra R. Correlation of histopathological diagnosis with habits and clinical findings in oral submucous fibrosis. *Head Neck Oncol.* 2009;1:10.
21. Yaming P, Urs AB, Saxena A, Zuberi M. Roles of CYP1A1 and CYP2E1 gene polymorphisms in Oral submucous fibrosis. *Asian Pac J Cancer Prev.* 2016;17(7):3335–40.
22. Pranay T, Kumar AS, Chhabra S. Civatte bodies: a diagnostic clue. *Indian J Dermatol.* 2013;58(4):327.
23. Olson MA, Rogers RS 3rd, Bruce AJ. Oral lichen planus. *Clin Dermatol.* 2016;34(4):495–504.
24. Fitzpatrick SG, Hirsch SA, Gordon SC. The malignant transformation of oral lichen planus and oral lichenoid lesions: a systematic review. *J Am Dent Assoc.* 2014;145:45–56.
25. Lopes MA, Feio P, Santos-Silva AR, Vargas PA. Proliferative verrucous leukoplakia may initially mimic lichenoid reactions. *World J Clin Cases.* 2015;3(10):861–3.
26. Garcia-Pola MJ, Llorente-Pendás S, González-García M, García-Martín JM. The development of proliferative verrucous leukoplakia in oral lichen planus. A preliminary study. *Med Oral Patol Oral Cir Bucal.* 2016;21(3):e328–34.
27. Shah N, Ray JG, Kundu S, Sardana D. Surgical management of chronic hyperplastic candidiasis refractory to systemic antifungal treatment. *J Lab Physicians.* 2017;9(2):136–9.
28. Alter BP, Giri N, Savage SA, Rosenberg PS. Cancer in dyskeratosis congenita. *Blood.* 2009;113(26):6549–57.
29. McLemore MS, Haigentz M, Smith RV, et al. Head and neck squamous cell carcinomas in HIV-positive patients: a preliminary investigation of viral associations. *Head Neck Pathol.* 2010;4(2):97–105.
30. Bhat MR, Hulmani M, Dandakeri S, Kambil SM, Gatti R. Disseminated discoid lupus erythematosus leading to squamous cell carcinoma. *Indian J Dermatol.* 2012;57(2):158–61.
31. D'Cruz AK, Vaish R, Kapre N, Dandekar M, Gupta S, Hawaldar R, et al. Head and neck disease management group. Elective versus therapeutic neck dissection in node-negative oral cancer. *N Engl J Med.* 2015 Aug 6;373(6):521–9.

Open Access This chapter is licensed under the terms of the Creative Commons Attribution 4.0 International License (<http://creativecommons.org/licenses/by/4.0/>), which permits use, sharing, adaptation, distribution and reproduction in any medium or format, as long as you give appropriate credit to the original author(s) and the source, provide a link to the Creative Commons license and indicate if changes were made.

The images or other third party material in this chapter are included in the chapter's Creative Commons license, unless indicated otherwise in a credit line to the material. If material is not included in the chapter's Creative Commons license and your intended use is not permitted by statutory regulation or exceeds the permitted use, you will need to obtain permission directly from the copyright holder.





Oral Squamous Cell Carcinoma: Diagnosis and Treatment Planning

81

Vijay Deshmukh and Kishore Shekar

81.1 Background and Incidence

The incidence of oral and oropharyngeal SCC is on the rise. Each year approximately 263,000 new cases of oral cancer are detected worldwide, and 127,000 people die of the disease [1]. In India it is the third most common cancer and accounts for almost 40% of deaths. Among men it is the second most common site, and in women it is the fourth in India [2]. In 2012, the incidence rate for male was 10.1/1,00,000 and for female 4.3/1,00,000 [3].

81.2 Introduction

Oral carcinoma commonly called as the oral squamous cell carcinoma (OSCC) occurs as an ulceroproliferative lesion of the oral mucosa affecting any site starting from the lips to the oropharynx. The commonest sites are gingivobuccal sulcus of mandible followed by the tongue and floor of the mouth. It should be understood that Indian cancer is much different to other parts of the world. The habit of the tobacco chewing (smokeless tobacco) and pan masala, i.e., a mixture of the tobacco, betel nut, and unknown chemicals used for the color and flavors, is the commonest cause. Classical Indian cancer is the gingivobuccal sulcus (GBS) of the mandible due to the

placement and holding of the tobacco-lime mixture, in the area. Over the last three decades, pan masala has become popular, due to the easy availability in pre-mixed packed. This maybe chewed or kept in the oral cavity, i.e., GBS, which leads to continuous action of the contents on the oral mucosa. The constant irritation leads to fibrosis and with time results in submucous fibrosis.

81.3 Etiology of Oral Carcinoma

Etiology of oral SCC is multifactorial. Local irritants contribute significantly to the conversion of a premalignant process to invasive carcinoma. Damage to the epithelial layer followed by the basement membrane and submucosa secondary to chemical and mechanical injury leads to fibrosis of the mucous membrane.

The prominent etiological factors are:

1. Tobacco consumption—All forms of tobacco smoke as well as smokeless have carcinogenic potential. Evidence for smokeless tobacco causing oral and pharyngeal cancer was evaluated and confirmed [4]. India is the third largest producer and consumer of smoked and smokeless forms of tobacco. Tobacco-related cancers account for nearly 50% of all cancers among men and 25% of all cancers among women with the burden of tobacco-related cancers in 2001 estimated to be nearly 0.33 million cases annually. It has been predicted that an incidence of seven-fold increase in tobacco-related cancer is expected between 1995 and 2025 resulting in an increase by 220% of cancer deaths simply related to tobacco use [5]. In India chewable tobacco is consumed in various forms. The traditional form is called the pan (Figs. 81.1, 81.2 and 81.3). Local form of smoking tobacco is called as bidi, which is a crude form of cigarette. This is considered to be more carcinogenic. It commonly causes carcinoma of the palate, oropharynx, and larynx.

Electronic Supplementary Material The online version of this chapter (https://doi.org/10.1007/978-981-15-1346-6_81) contains supplementary material, which is available to authorized users.

V. Deshmukh (✉)

Maxillofacial and Microvascular Surgeon, Deshmukh Institute of Maxillofacial Surgery and Research Centre, Aurangabad, India

Department of Dentistry and Maxillofacial Surgery, JIU'S Indian Institute of Medical Sciences, Maharashtra, Jalna, India

K. Shekar

Head and Neck Surgeon (OMFS), Ninewells Hospital and Dundee University Medical School, Dundee, UK

e-mail: Kishore.Shekar2@nhs.scot



©Association of Oral and Maxillofacial Surgeons of India

Fig. 81.1 Betel nut (areca nut). Various forms. Raw red in color and roasted white in color. It is broken in pieces with a special cutting device. Pieces are chewed with tobacco-lime mixture or with betel quid (pan)



©Association of Oral and Maxillofacial Surgeons of India

Fig. 81.2 Pan masala (gutkha) pouches. Ready to eat mixture of tobacco, betel nut, lime, catechu, and unknown chemical coloring and flavoring agents

2. Alcohol—Alcohol is considered to be causally associated with oral cancer. As heavy alcohol drinkers are frequently heavy smokers as well, a synergistic effect with cigarette smoking is implicated in oral cancer [6–8]. Excess alcohol consumption is associated with nutritional deficiencies. This acts as an aggravating factor.
3. Betel nut chewing (areca nut)—Chronic chewing of the betel nut leads to abnormal fibrosis of the oral-pharyngeal areas. Betel nut is the endosperm of the fruit of *Areca catechu*. It is consumed in various forms. It is used fresh



©Association of Oral and Maxillofacial Surgeons of India

Fig. 81.3 Pan-betel quid. Betel leaf coated with lime-catechu-flavored tobacco-betel nut. It is rolled, wrapped, and pinned with clove. Most commonly chewed in Indian subcontinent

- or dried or may be cured before use by boiling, baking, or roasting. The abrasive mechanical property causes attrition of teeth and physical damage to the mucosa. This sandpaper action makes the mucosa more susceptible to the chemical properties of beetle nut. In India alone 38 different combinations of areca nut with tobacco have been documented (Fig. 81.1). The number of patients with a pan masala chewing habit (68.0%) was higher than the number of patients with betel nut (17.4%) or betel quid chewing habits (14.6%). The chewing of pan masala is associated with earlier presentation of oral submucous fibrosis (OSMF) as compared to betel nut chewing [9]. Pan masala (Fig. 81.2) is the artificial mixture available in small pouches having contents of tobacco, betel nut, spices, coloring and flavoring agents, preservatives, as well as unspecified agents. This has proven to be highly carcinogenic. Consumption of this mixtures leads to OSMF which is a precancerous condition. Development of precancerous lesions like leukoplakia in preexisting fibrosis potentiates carcinoma conversion. Betel nut is also consumed with a pan (Fig. 81.3) a freshly prepared mixture on the betel leaf with tobacco, slaked lime, catechu, and clove. This is chewed over a longer time and remains in contact with oral mucosa causing mechanical and chemical irritation. The important flavonoid components in areca nut are tannins and catechins. These alkaloids undergo nitrosation and give rise to N-nitrosamine which might have cytotoxic effect on cells [10].
4. Nutritional deficiencies—Dietary deficiencies of vitamin A, folate, riboflavin, iodine, and iron add to the risk of cancer. High dietary fiber; vitamins C, E, and A; and selenium offer protection against cancer [11, 12].

5. Poor oral hygiene and traumatic injury of dental origin—Poor oral hygiene is often associated with gingivoperiodontal infections raising bacterial colony count leading to a constant inflammatory response. This together with traumatic tooth injury can lead to a carcinogenic effect.
6. Viral infections—The role of human papillomavirus (HPV) in pharyngeal cancer is well established. However its effect on the oral cavity is still being researched. Globally, HPV infection is relatively more common in OSCC patients [12].

81.4 Precancerous Situations of Oral Cavity

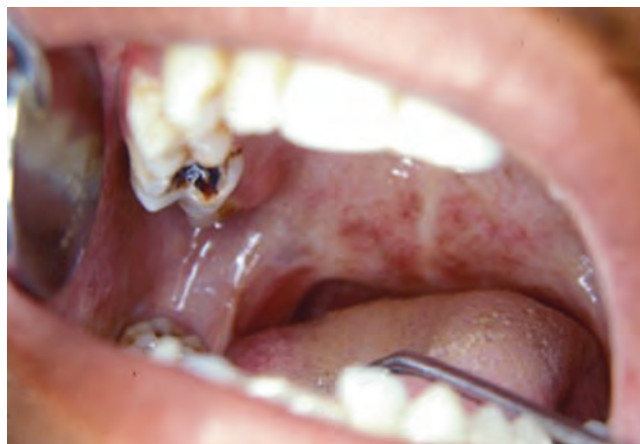Precancerous situations can be broadly divided into precancerous conditions and precancerous lesions. Precancerous conditions most commonly seen in India are oral submucous fibrosis (OSMF) and oral lichen planus. Precancerous conditions can be associated with the precancerous lesions (please also see Chap. 80 on premalignant lesions and conditions).

81.4.1 Precancerous Conditions

Precancerous conditions make every part of the oral cavity susceptible to cancer conversion as is seen in oral submucous fibrosis (OSMF). The phenomenon simulates field cancerization. Development of a second primary despite adequate treatment of the first is common. Sometimes two primaries at distant anatomical sites are noted in extensive long-standing OSMF.

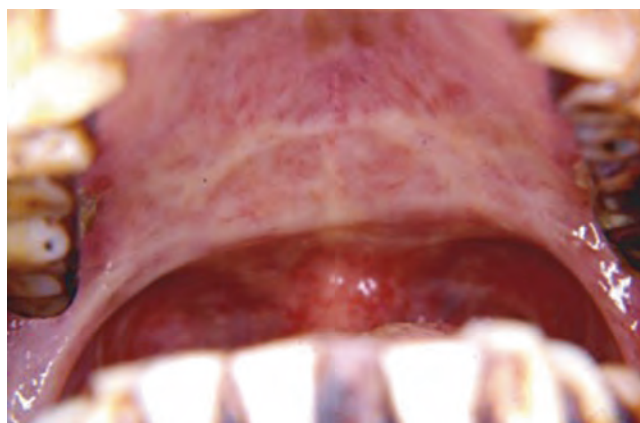
81.4.2 Oral Submucous Fibrosis (OSMF)

Oral submucous fibrosis is a chronic insidious disease of the oral mucosa characterized by loss of mucosal elasticity and excessive fibrosis (Figs. 81.4, 81.5, 81.6 and 81.7). It is always associated with juxta-epithelial inflammation and progressive hyalinization of lamina propria [13]. Oral submucous fibrosis (OSMF) is predominantly seen among betel quid chewers and pan masala chewers in India. OSMF generally starts at the RMT (retromolar trigone), anterior faucial pillars, and the adjoining area of the soft palate. It extends to involve the buccal mucosa, commissure, lips, and rima oris. Resulting trismus is due to mucosal and muscle fibrosis in the masseter and pterygoids. Figures 81.8 and 81.9 shows the traumatic ulcers caused in buccal mucosa and RMT area in OSMF cases mainly due to the limited mouth opening and fibrosis. In such cases early dental intervention or extractions



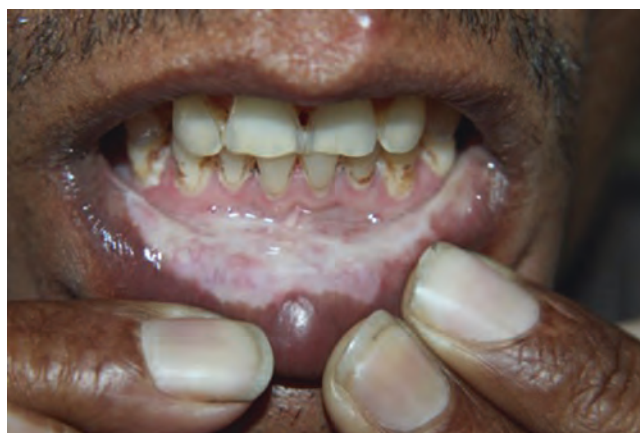©Association of Oral and Maxillofacial Surgeons of India

Fig. 81.4 OSMF (oral submucous fibrosis). Note fibrosis affecting RMT, faucial pillars, buccal mucosa, as well as rima oris



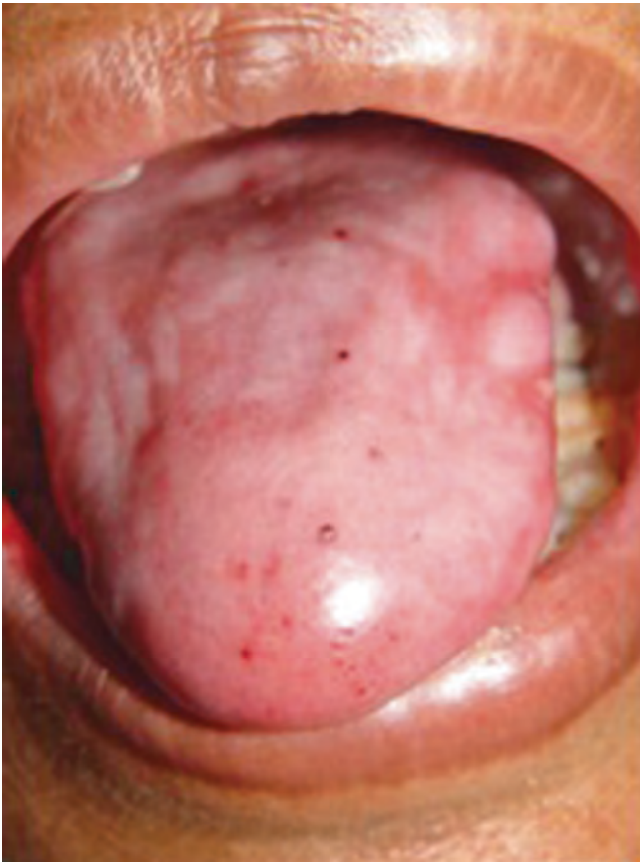
©Association of Oral and Maxillofacial Surgeons of India

Fig. 81.5 OSMF (oral submucous fibrosis). Note fibrosis affecting RMT, faucial pillars



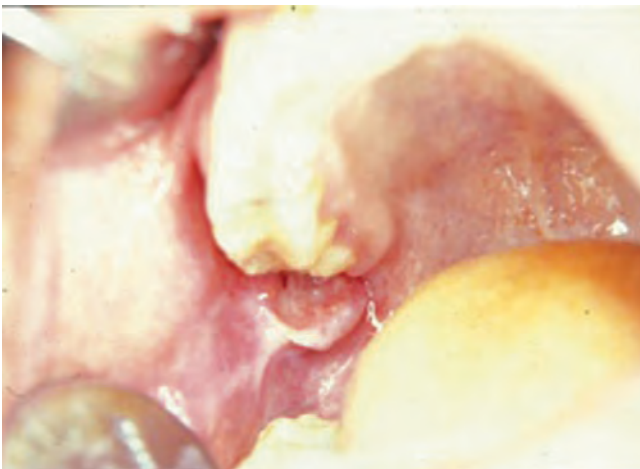
©Association of Oral and Maxillofacial Surgeons of India

Fig. 81.6 OSMF (oral submucous fibrosis). Note fibrosis affecting lower lip and blanching of mucosa. Note pale nails due to anemia



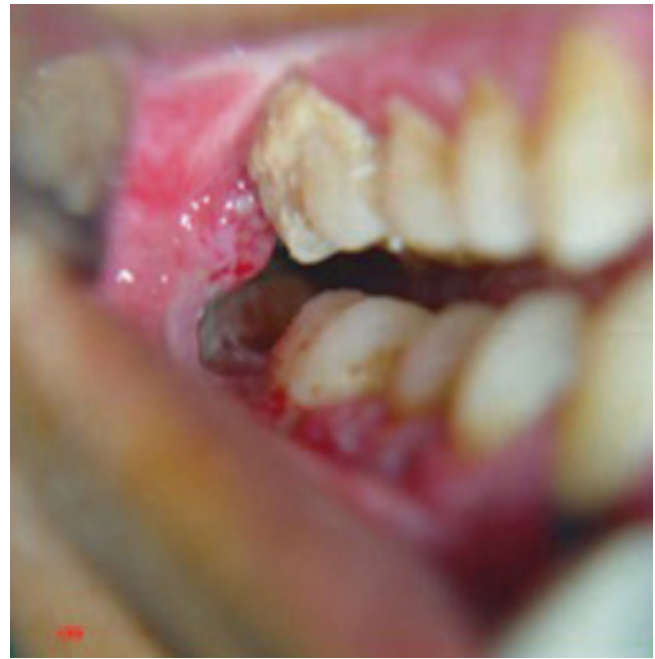©Association of Oral and Maxillofacial Surgeons of India

Fig. 81.7 Bald tongue in OSMF. Has high malignant potential



©Association of Oral and Maxillofacial Surgeons of India

Fig. 81.8 OSMF with traumatic ulceration from last molars



©Association of Oral and Maxillofacial Surgeons of India

Fig. 81.9 OSMF with traumatic ulceration from last molars

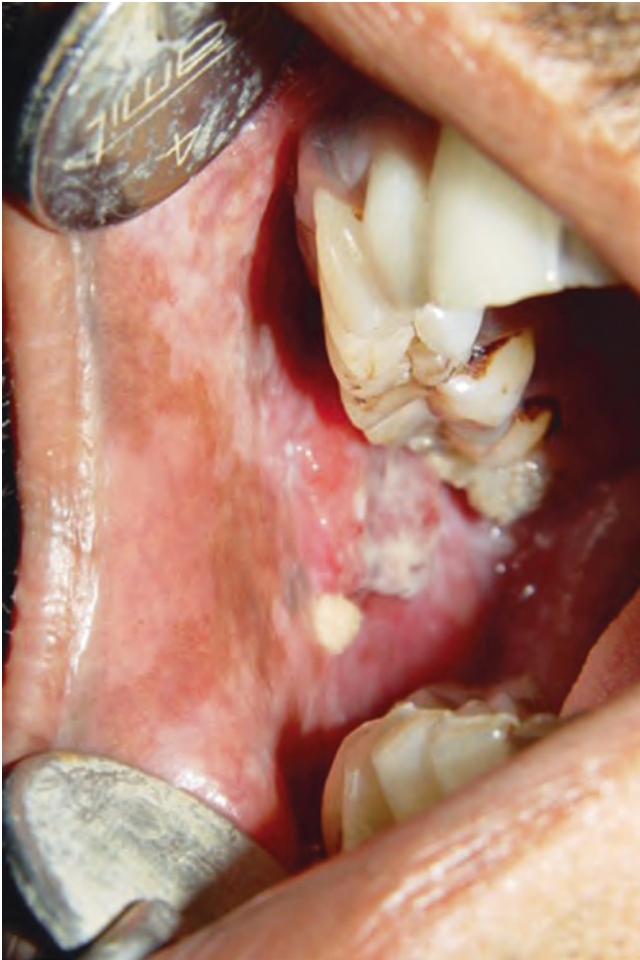may be delayed due to the difficulty in access to the posterior teeth due to trismus. Such chronic traumatic ulceration may undergo malignant change as seen in Fig. 81.10.

81.4.2.1 Molecular Pathogenesis of OSMF

Time and constant irritation lead to inflammation with mucosal atrophy. It can thus be considered that induction of oral mucosal inflammation by betel quid is a critical event in the pathogenesis of OSMF. Cytokines like interleukin-6 (IL-6), tumor necrosis factor (TNF), interferon- α (INF- α), and growth factors like TGF- β are synthesized at the site of inflammation.

TGF- β 1 is a key regulator of extracellular matrix (ECM) assembly and remodeling. TGF- β 1 increases collagen production and decreases its degradation [14]. OSMF has characteristic clinical presentation depending on the stage of the disease. The majority of patients have intolerance to spicy food, roughness of oral mucosa, and varying degrees of difficulty in opening the mouth.

OSMF is a well-recognized potentially premalignant condition of the oral cavity. The transformation rate is as high as 7.6% over a period of 10 years [15]. In this group, primary malignancy develops in the buccal mucosa extending to involve the retromolar trigone. This is unique in the context



©Association of Oral and Maxillofacial Surgeons of India

Fig. 81.10 Malignant transformation in posterior buccal mucosa in a case of OSMF, accompanied by chronic trauma from tooth

of the Indian subcontinent, as pure tobacco chewing habit has decreased and is replaced by the gutkha chewing habit. Tobacco-lime preparation used to be kept in the GBS or the floor of the mouth for longer period. This led to leukoplakia and/or erythroplakia, followed by malignant transformation. The current preparation is not constantly placed in the GBS but chewed for long time and swallowed. The chemical effect leads to OSMF and field concretization.

81.4.3 Oral Lichen Planus

Oral lichen planus (OLP) tends to often present bilaterally as white striae on the buccal mucosa. Any mucosal site in the mouth may be involved. Other sites, in decreasing order of

frequency, may include the tongue, lips, gingivae, floor of the mouth, and very rarely palate [16].

Six clinical forms of oral lichen planus are recognized [17]: reticular, erosive/ulcerative, papular, plaque-like, atrophic, and bullous. Atrophic/erosive lichen planus is associated with a risk of cancerous transformation [18]. Patients with OLP tend to be monitored closely to detect any potential change early.

The rate of malignant transformation in individual studies ranged from 0 to 3.5%. The overall rate of transformation was 1.09% for OLP.

81.4.4 Precancerous Lesions

Precancerous lesion is a pathology of the oral mucosa which has a tendency to transform into the squamous cell carcinoma. The commonly prevalent lesions are leukoplakia erythroplakia, carcinoma in situ, and smoker's palate.

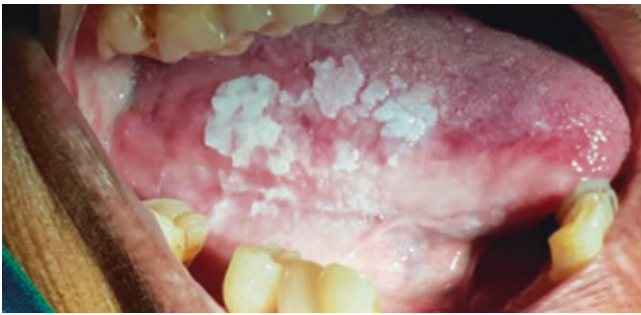
81.5 Diagnosis of Oral Squamous Cell Carcinoma (OSCC)

Diagnosis of oral squamous cell carcinoma is not a challenging task except in the cases of an unknown primary. History of risk factors, classic clinical appearance of an indurated ulcer, involvement of lymph nodes, and destruction of bone are common features in advanced disease.

81.5.1 Clinical Features of Oral Carcinoma

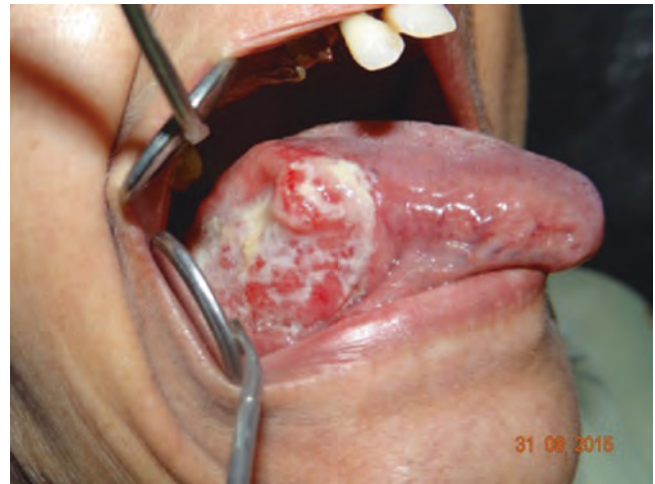Oral squamous cell carcinoma often presents as an indurated ulcer, exophytic growth, indurated non-ulcerative patch (endophytic), or a combination of the above appearances. Figures 81.11, 81.12, 81.13, 81.14, 81.15, 81.16, 81.17, and 81.18 shows the various clinical presentation of SCC in tongue. Fig. 81.19 shows multiple primary tumors arising in case of OSMF.

Important parameters to be recorded at the primary site in clinical examination are site of the tumor; size; extension to involve adjacent structures like the skin, muscles, bone of maxilla and/or mandible, and skull base; and extensions into compartments such as the paranasal sinuses, nasal cavity, orbit, pterygoid space, masticatory compartment, and infra-temporal fossa. Regional spread to the lymph node basin in the neck needs clinical and radiologic correlation. Evaluation of distant metastasis to lungs and bones forms a part of the staging process.



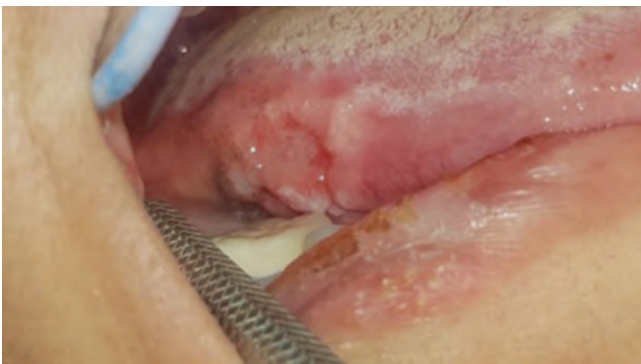
©Association of Oral and Maxillofacial Surgeons of India

Fig. 81.11 Precancerous lesion of the tongue—diffuse leukoplakia. Lesion has a potential to undergo SCC



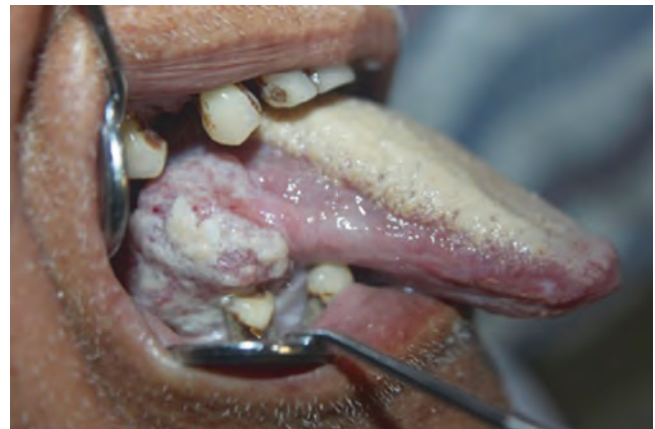©Association of Oral and Maxillofacial Surgeons of India

Fig. 81.14 OSCC of the tongue—exophytic growth. Lesions have nonaggressive behavior with better prognosis



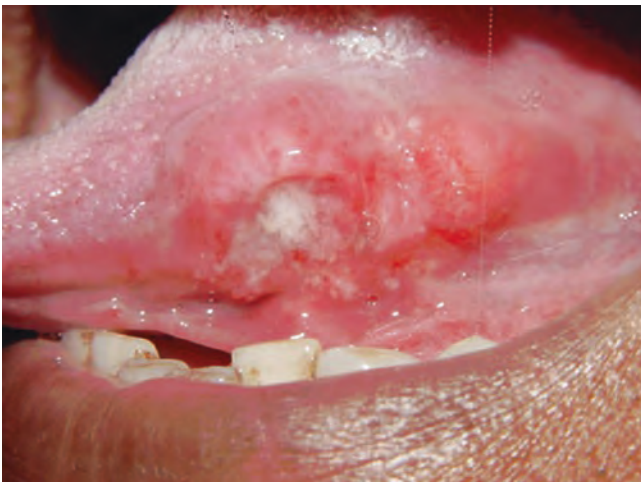©Association of Oral and Maxillofacial Surgeons of India

Fig. 81.12 OSCC of the tongue—inverted margins. Lesion not associated with any habit. These lesions often can have genetic predilection and behave aggressively



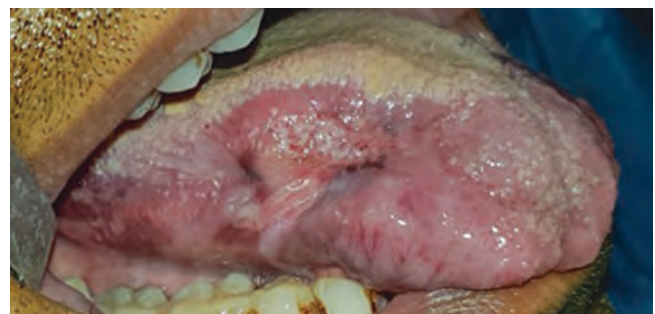©Association of Oral and Maxillofacial Surgeons of India

Fig. 81.15 Another case of OSCC of the tongue—exophytic growth. Lesions have nonaggressive behavior with better prognosis



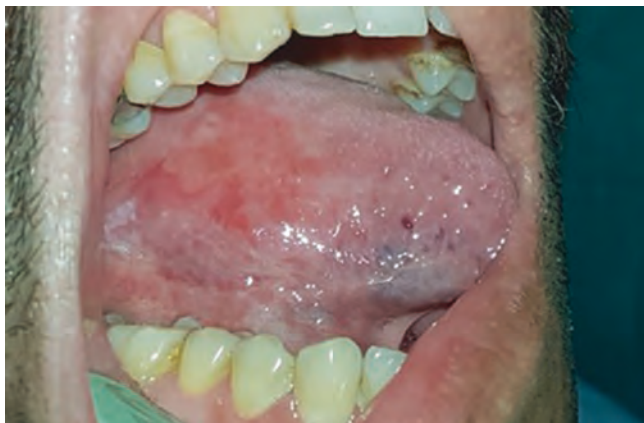©Association of Oral and Maxillofacial Surgeons of India

Fig. 81.13 OSCC of the tongue—everted margins. Lesion can behave aggressively often associated with tobacco-related habit



©Association of Oral and Maxillofacial Surgeons of India

Fig. 81.16 OSCC of the tongue—ulcerative patch. Lesion is not associated with any habit. Genetic predilection



©Association of Oral and Maxillofacial Surgeons of India

Fig. 81.17 OSCC of the tongue—non-ulcerative patch. Lesion is frequently associated with smoking

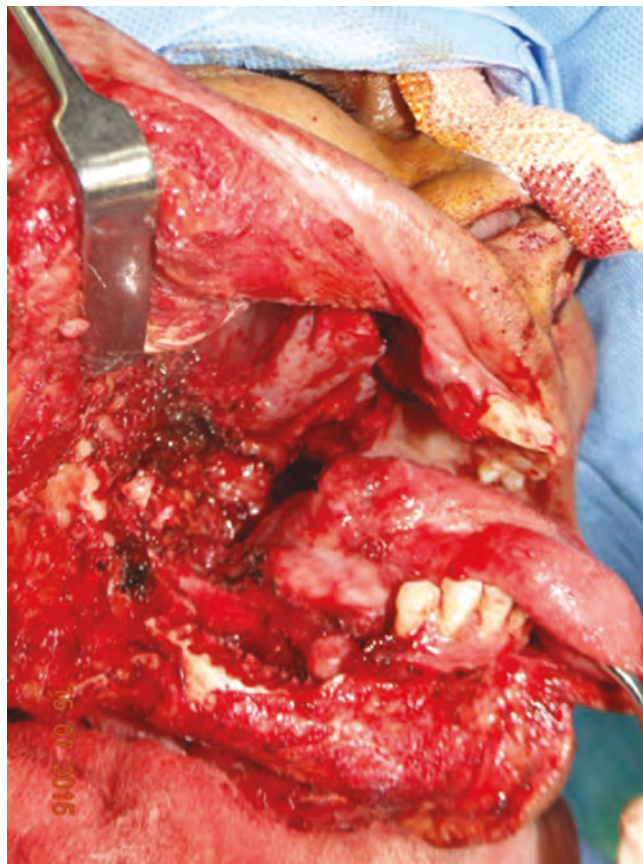
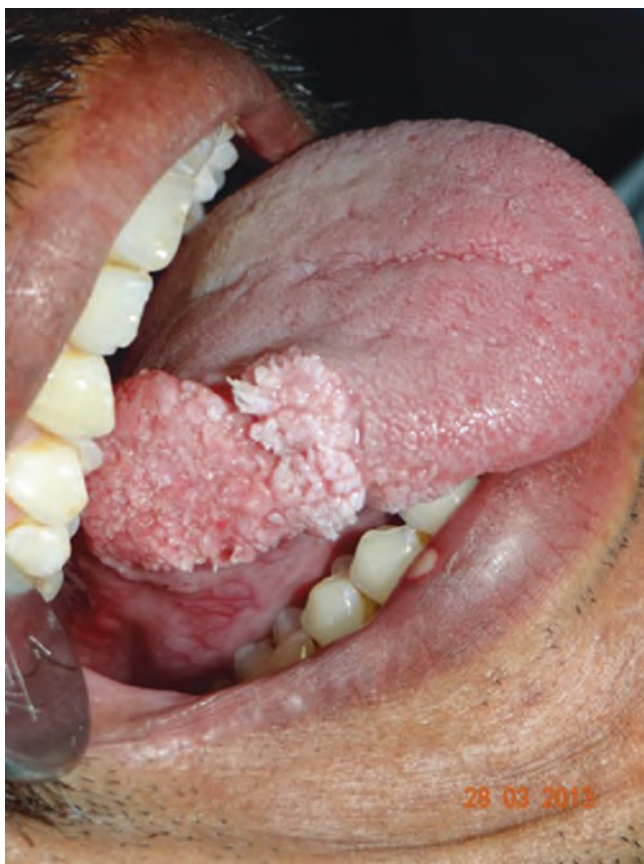

Fig. 81.19 Intraoperative picture. Multiple primary tumors—SCC in OSMF. Rt.GBS/BM—resected, with Tongue-Rt. side. Either of these can be considered as Second Primary Tumour (SPT)



©Association of Oral and Maxillofacial Surgeons of India

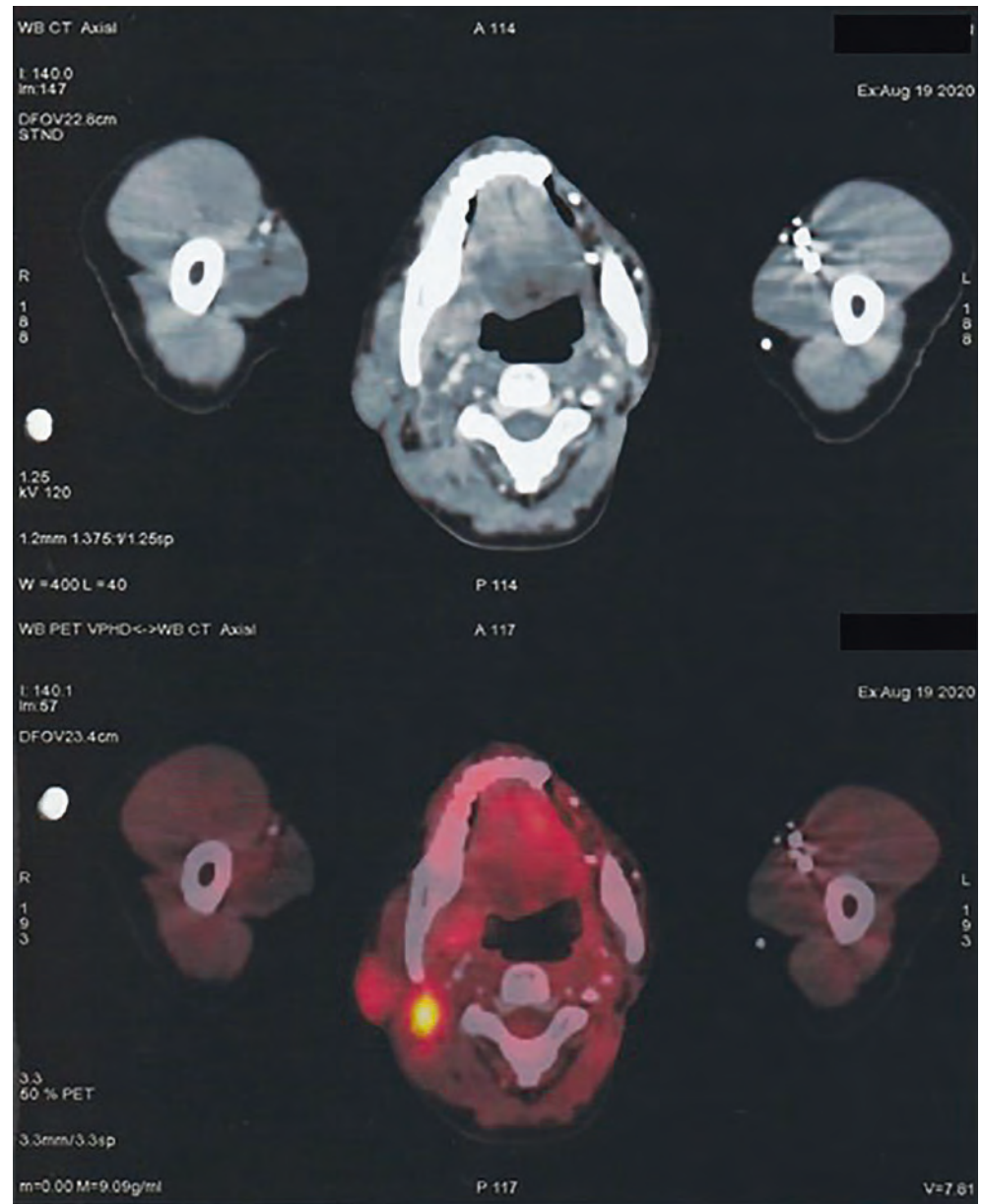
Fig. 81.18 OSCC of the tongue—verrucous growth. Lesion generally has dormant behavior with better prognosis

81.6 Imaging in OSCC Diagnosis

The minimum radiologic investigation for the primary site and neck should include imaging from the skull base to the clavicle. Staging of the chest is to detect both metastatic disease and synchronous tumors. MRI and/or CT with contrast is considered to be the gold standard. In poorer socioeconomic background, one could consider ultrasound scan of the neck as a staging modality. This will however not adhere to the current international guidelines. In our units the minimum standard is a MRI of the neck (including the primary) and CT chest. A double-contrast CT of the neck is as valuable as a MRI. Radiologic examination provides a greater accuracy in the staging process. Prognosticators such as depth of invasion and extracapsular spread in lymph nodes can be studied with good accuracy.

Where there is involvement of bone, a MRI and CT will provide better definition for resection. Marrow signal changes can only be evaluated on a MRI. The CT provides

Fig. 81.20 PET-CT-SCC—
Contralateral neck metastasis,
at IIA, of second primary in
Lt. Maxilla



©Association of Oral and Maxillofacial Surgeons of India

better information on cortical erosion. In addition a thin slice CT helps in 3D planning prior to free flap reconstruction.

The role of a PET-CT is limited. Its primary indication is to detect an unknown primary prior to targeted biopsy. A further role for the PET-CT is in post-radiotherapy evaluation of the neck (Fig. 81.20).

MRI scans offer better accuracy of soft tissue extension of tumor. Studying fat planes between muscle groups allows for compartment resections in T4 tumors.

81.7 Tissue Sampling

Incisional biopsy is the gold standard in the diagnosis of squamous cell carcinoma. FNAC is used for the detection of lymph node metastasis. However with the increased accuracy in MRI

and USS reporting, this modality is used less. Biopsy tissue should be taken from the most indurated portion of the tumor. Taking a biopsy from the summit or the center of an ulcer may yield a false-negative result. Scalpel, punch, and low-voltage electrocautery are all good options. Minimum size of the sampled tissue should be ideally 6 mm in all three dimensions. Mapping biopsy from multiple sites may be required at times to evaluate the extent of involvement and to prevent a false-negative result. This is especially the case when a tumor develops in the background of a premalignant lesion.

Deep biopsy is required to get estimation on the depth of invasion (DOI). In cases of exophytic lesions, tumor thickness may cause difficulty in getting deeper tissue; in such cases tumor margin area can be chosen. In order to obtain a good-quality oral biopsy, the clinician should avoid crushing the sample with the tissue-holding forceps, infiltrating anes-

thetic solution within the lesion, using an insufficient volume of fixing solution and taking insufficient amount of tissue in extension and depth. The specimen should be handled gently, avoiding any crushing, and introduced in the fixing solution such as 10% formalin.

In inaccessible areas, due to the site of tumor or reduced mouth opening, it is good practice to carry out an examination under anesthesia to evaluate the extent of the tumor. This also provides an opportunity for the lesion to be accurately biopsied in a more controlled environment of theaters.

81.7.1 Histopathology

Pathologist is expected to report on the tumor grade—well-differentiated squamous cell carcinoma, Grade 1; moderately differentiated squamous cell carcinoma, Grade 2; or poorly differentiated squamous cell carcinoma, Grade 3. Well-differentiated tumors resemble normal squamous epithelium to a large degree (Fig. 81.21), poorly differentiated tumors exhibiting little or no histologic traits of the squamous phenotype, and moderately differentiated tumors having an intermediate morphology between the two ends of the spectrum. Higher grades have strong potential for recurrence and lymph node metastasis [19].

Several prognostic indicators have consistently demonstrated a correlation with disease-specific survival, local and regional recurrence, and lymph node metastasis in numerous single or multicenter studies. The prognosticators are depth of invasion (DOI), pattern of invasion (POI), perineural invasion (PNI), lymphovascular invasion (LVI), and extranodal extension (ENE).

81.7.2 Depth of Invasion/Tumor Thickness

It is important to differentiate between depth of invasion and tumor thickness. The DOI is a more predictable prognostica-

tor compared to the latter. It is known that exophytic tumors (verrucous carcinomas being the prototype) or predominantly exophytic tumors have a good prognosis, whereas endophytic or deeply infiltrating tumors are aggressive [20]. Depth of invasion (DOI) is an important independent factor in prognosis with strong effect on disease-free survival and overall survival, correlating with propensity for nodal spread better than tumor size in oral cancer [21–25]. In the floor of the mouth, 1-cm-wide tumor infiltrating at 0.7 cm depth will likely have a worse outcome and carries a higher risk of neck metastasis than a 2-cm-wide tumor with microinvasion or superficial invasion (e.g., less than 2 mm in thickness) [26–28].

81.7.3 Pattern of Invasion

Pattern of tumor invasion is an important prognostic factor. Tumor interface abutting deeper tissues has better prognostic value as compared to multiple tumor satellites into the deeper tissues [20].

81.7.4 Perineural Invasion (PNI)

PNI presence is a soft indicator for local recurrence and decreased survival. Multiple studies have shown conflicting results [29]. However it is one of the most important predictors of neck metastasis [30] alongside DOI. PNI increases the rate of occult metastasis [31].

81.7.5 Lymphovascular Invasion (LVI)

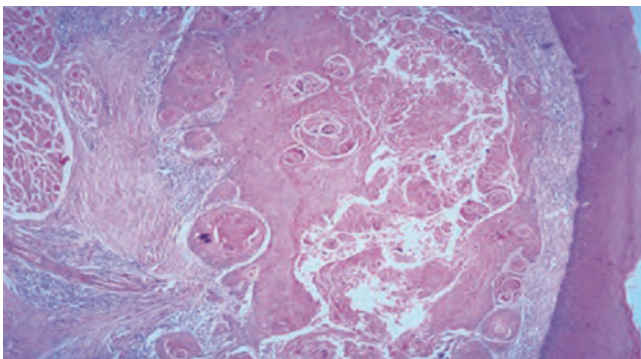
Histopathological presence of lymphovascular invasion has poorer prognostic outcome. The presence of LVI is associated with nodal spread or occult metastases [23, 32–34]. Literature review has conflicting evidence regarding the importance of LVI.

81.7.6 Bone Invasion

It is common to see OSCC of GBS and retromolar trigone (RMT) invade the adjoining mandible, maxilla, and pterygoid column. This upstages the tumor to a T4.

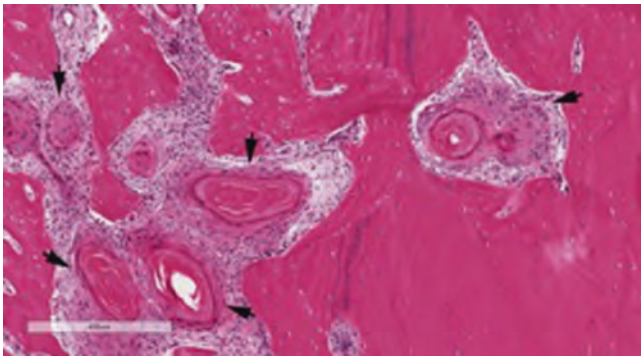
The increased risk of local recurrence can be attributed to two factors—tumor character and margin status following resection. Invasion into the pterygoid spaces makes surgical resection difficult. Close margin is expected in these advanced tumors.

Mandible infiltration can be of periosteal fixation, cortical erosion, or medullary invasion. Deeper invasion has poor prognosis [35] (Fig. 81.22).



©Association of Oral and Maxillofacial Surgeons of India

Fig. 81.21 Well-differentiated OSCC. H&E 10x



©Association of Oral and Maxillofacial Surgeons of India

Fig. 81.22 OSCC with bone invasion. H&E 10X

81.8 Neck Assessment in OSCC

A positive neck node is the single most important prognosticator for disease-free survival at 5 years. Size, number of levels involved, fixation to adjacent structures, and extranodal extensions (ENE) are of significance in lymph node assessment of the neck.

In a N0 neck, the pickup rate of a sub-centimeter positive node is less than 50% on clinical examination alone. Use of radiologic examination increases the pickup rate to 90%. A staging neck dissection is the only modality that has a pickup rate greater than 98% [36–38].

A well-lateralized tumor often spreads to the ipsilateral neck. In 5% of patients, the first echelon can be the contralateral neck. Tongue cancers have the propensity for skip metastasis and contralateral spread. For all other regions of the oral cavity, the first echelon spread is at level I/II.

Depending on the literature one reads, the specificity and sensitivity between MRI and CT are confusing. The authors recommend that the radiologist choose the modality he has the greatest confidence in reporting. Ultrasound scan as a screening tool is useful in the outpatient setting.

Radiologic signs of nodal involvement are increases in size of the lymph node, obliteration of the fatty hilum, increased vascularity, an ill-defined outline, and intranodal necrosis. Ten millimeters or more in an axial section are considered positive for nodal involvement in the neck. However, false-positive or false-negative results of 15–20% are noted in the literature [39, 40].

81.9 Distant Metastasis

Distant metastasis needs to be suspected in lungs and vertebrae. Evaluation is done by CT alone or a PET-CT scan.

81.10 TNM Staging System

Cancer staging can be divided into a clinical stage and a pathologic stage. In the **TNM** (Tumor, Node, and Metastasis) system, clinical stage and pathologic stage are denoted by a small “c” or “p” before the stage (e.g., cT3N1M0 or pT2N0). This staging system is used for most forms of cancer. Accurate staging is critical as treatment is often based on clinical and radiologic stage.

Currently AJCC eighth Edition is used; this includes both the depth of primary tumor invasion and extracapsular extension of lymph node metastases. The AJCC eighth Edition OSCC staging system showed improved disease-free survival discrimination between overall stages and between T categories, while AJCC seventh Edition did not [19].

81.10.1 AJCC Eighth Edition Clinical Staging System

T—Primary tumor.

Tx—Primary tumor cannot be assessed.

Tis—Carcinoma in situ.

T1—Tumor ≤ 2 cm in greatest dimension, ≤ 5 mm depth of invasion (DOI not tumor thickness).

T2—Tumor ≤ 2 cm with DOI > 5 mm or tumor > 2 cm and ≤ 4 cm with DOI ≤ 10 mm.

T3—Tumor > 2 cm and ≤ 4 cm with DOI > 10 mm or tumor > 4 cm with DOI ≤ 10 mm.

T4—Moderately advanced or very advanced local disease.

T4a—Moderately advanced local disease.

Lip: tumor invades through cortical bone or involves the inferior alveolar nerve, floor of the mouth, or skin of the face (i.e., chin or nose).

Oral cavity: tumor invades adjacent structures only (e.g., through cortical bone of the mandible or maxilla, or involves the maxillary sinus or skin of the face). Note: Superficial erosion of bone/tooth socket (alone) by a gingival primary is not sufficient to classify a tumor as T4.

T4b—Very advanced local disease. Tumor invades masticator space, pterygoid plates, or skull base and/or encases internal carotid artery.

Regional lymph nodes (N) ENE—extranodal extension.

Nx—Regional lymph nodes cannot be assessed.

N0—No regional lymph node metastasis.

N1—Metastasis in a single ipsilateral lymph node, ≤ 3 cm in greatest dimension and ENE (–).

N2—Metastasis in a single ipsilateral lymph node, > 3 cm but ≤ 6 cm in greatest dimension and ENE (–); or mets in multiple ipsilateral lymph nodes, ≤ 6 cm in greatest dimen-

Table 81.1 AJCC prognostic staging groups according to the eighth AJCC edition

Clinical group	T	N	M
0	Tis	N0	M0
I	T1	N0	M0
II	T2	N0	M0
III	T3	N0	M0
	T1 T2 T3	N1	M0
IVA	T4a	N0	M0
	T1T2T3T4a	N1, N2	M0
IVB	T4b	Any N	M0
	Any T	N3	M0
IVC	Any T	Any N	M1

sion and ENE (-); *or* mets in bilateral or contralateral lymph nodes, ≤ 6 cm in greatest dimension and ENE (-).

N2a—Metastasis in single ipsilateral lymph node >3 cm but ≤ 6 cm in greatest dimension and ENE (-).

N2b—Metastasis in multiple ipsilateral lymph nodes ≤ 6 cm in greatest dimension and ENE (-).

N2c—Metastasis in bilateral or contralateral lymph nodes ≤ 6 cm in greatest dimension and ENE (-).

N3—Metastasis in a lymph node >6 cm in greatest dimension and ENE (-) *or* metastasis in any lymph node(s) with clinically overt ENE (+).

N3a—Metastasis in a lymph node >6 cm in greatest dimension and ENE (-).

N3b—Metastasis in any lymph node(s) with clinically overt ENE (+).

Distant metastasis (M).

M0—No distant metastasis (no pathologic M0; use clinical M to complete stage group).

M1—Distant metastasis.

AJCC prognostic stage groups are provided in Table 81.1.

81.11 Treatment Planning for the Management of Head and Neck Malignancy

81.11.1 Introduction

The management of head and neck cancer has undergone a sea change since the 1980s. The most important change that has been to the benefit of both patients and clinicians is the emphasis on evidence-based practice, and this has led to the development of the multidisciplinary team (MDT) or the tumor board as it is also known as.

In the more recent past, a new thought process is the practice of realistic medicine. The emphasis is on a more personalized approach to patient care and changing our style to

shared decision-making. This is an approach that has been rolled out across Scotland.

81.11.2 MAGIC: Making Good Decisions in Collaboration

The key questions to be asked are:

1. Is this test, treatment, or procedure really needed?
2. What are the potential risks and benefits?
3. What are the potential side effects?
4. Are there alternative simpler, safer treatment options?
5. What would happen if one did nothing?

81.11.3 The Start of Treatment Planning

The beginning of planning treatment starts on the receipt of a referral or patients' attendance. Patients with a history of a neck or salivary gland lump, non-healing ulcer of the oral cavity, bleeding, pain refractory to analgesia, hoarseness, and dysphagia are seen in the clinic within 2 weeks. Clinical examination should include the examination of the tongue base, tonsils, larynx, and nasopharynx with flexible nasoendoscope.

Developing a one-stop clinic helps in avoiding delays, and this has a significant impact on patients' psychological well-being. The one-stop clinic includes a biopsy on the same day for visible lesions and an ultrasound-guided core biopsy of neck lumps. The results of these preliminary investigations should be available in a week, setting up for a second meeting.

81.11.4 The Second Meeting

The second meeting or breaking bad news is perhaps the most important consultation in treatment planning. Patients are invited to attend the clinic with members of their family. Consultation is held in a quiet atmosphere in the presence of a clinical nurse specialist. It is important to be factual and honest. Unrealistic expectations should not be given. One must also bear in mind the impact the diagnosis will have on patients and their families. Empathy is very important. A good rapport with the patient and their family is invaluable.

81.11.5 Staging Scans

The minimum staging scans for head and neck cancer include a MRI and/or CT neck and CT chest. The rationale for staging is localization of the tumor and detection of regional and

distant lymph node metastases. This has an importance in both the extent of therapeutic intervention and the disease-specific survival.

81.11.6 Localization of Primary Tumor

The localization of the primary tumor helps in the decision-making regarding the resectability of the lesion with clear margins. Tumor resection with a R1 margin is considered a futile procedure, and at the best it is palliative and at its worst just a “big biopsy.” Anatomical areas of interest in localization are the skull base with particular interest to the carotid canal, involvement of the infratemporal fossa, the extent into the orbit, and in the case of tongue tumors proximity to the tongue base and larynx. Involvement of any of the above structure carries a very high risk of a positive or close margins resulting in increased risk of recurrence. Adjuvant treatment would then be inevitable. Functional outcomes are poorer.

MRI of the soft tissues is our preference for localization of the tumor as it helps in planning anatomic resection by determining the depth of infiltration. This can be in the form of compartment resection—medial masticatory compartment resection for retromolar, soft palate, and posterior tongue tumors. Anatomical resections in tongue tumors uses muscle planes to identify margins and vascularity of the remainder tongue. The muscle groups most important to this are the mylohyoid, styloglossus, and stylohyoid. With tumors extending to the infratemporal fossa and skull base, a key landmark is the styloid. Prestyloid resections are considered straightforward, and a R0 margin is to be expected. Tumors in the poststyloid space carry the risk of a close margin.

Tumors involving the mandible and maxilla, in our practice, have a CT and MRI. The MRI helps in determination of marrow signal change and gives an aid to planning resection margins. The CT has a two fold advantage. CT helps localize cortical breach and complements the MRI in planning resection. It has also the added advantage of obtaining 3D models which helps in planning bone reconstruction with a free flap.

For malignancies of the salivary glands, our first line of investigation remains an USS-guided core biopsy followed by a full staging of the neck and chest with MRI and CT, respectively. Tumors of the skull base and infratemporal fossa have both MRI and CT for localization of the primary.

For patients with suspected recurrence, especially under a free tissue flap transfer, the preferred modality is a PET-CT. PET-CT allows for a functional evaluation of the suspect area. In areas of previous surgery, the MRI has higher false-positive rates due to loss of fat planes and the inability to differentiate from scarification. A double-contrast CT scan may give better definition of a recurrence; however both specificity and sensitivity are low. The CT may give better

spatial resolution. However false-negative results are high in glottic tumors and in mucosal disease with superficial spread with CT.

The role of PET-CT in our practice is limited to neck lumps with unknown primary, small malignancies and in recurrent SCC. The major drawback for a PET-CT is poor anatomical depiction. Anatomical resection is not possible with a PET-CT alone. PET-CT adds little value in patients who have had recent surgery, i.e., biopsy. This invariably gives rise to a hot spot in inflamed tissue. However, it is more sensitive than CT and MRI in detecting small malignancy. In more than 30% of cases, the PET-CT picks up malignancy not identified by other modalities, and the majority of these are at the tongue base and supraglottic space.

Direct evaluation by examination under anesthesia and pan endoscopy provides probably the most accurate assessment for localization and planning surgery.

81.11.7 Evaluation of the Neck

There are numerous papers regarding the sensitivity and specificity of different evaluation techniques—clinical examination, duplex ultrasound scan, CT scan, MRI, and PET. It is agreed by all that clinical examination of the neck provides the least reliable results of all and an adjunct investigation is necessary. It is the opinion of the authors that both CT and MRI give equally reliable results. The decision to which modality suits an individual team the best is reliant on the expertise of the head and neck radiologist in reporting the scans. In our own clinical practice, we feel that the MRI scan provides a good diagnostic value for staging the neck. In T1 tumors where there is a N0 neck clinically and radiologically, the evidence for staging neck dissection is limited. In cases where the MRI is equivocal, an USS with a FNAC (fine needle aspiration cytology) may be indicated. The USS would evaluate the lymph node for size criteria, presence of necrosis, and the absence of normal hilum. Lymph nodes that are rounded and greater than 1 cm in the neck are regarded to be pathologic until proven otherwise.

The role of USS should not be easily dismissed with the advent of cross-sectional imaging. The USS has many advantages. The spatial resolution of a good USS is better than that of a CT or MRI. Taking account of shape, contour, echogenicity, grouping, internal architecture, necrosis, and pattern of Doppler vascularity enhances the accuracy of US for nodal metastases to greater than 90%.

The USS is a cheap and quick modality that can be used. There is no radiation exposure. Its use as a surveillance scans cannot be surpassed in today's economic constraints. The one major drawback we have noted in our practice is that its sensitivity and specificity are highly operator dependent. It cannot detect retropharyngeal, retrotracheal, and mediastinal

lymphadenopathy. In these instances a CT or MRI gives better information.

PET-CT has a limited role in the staging of the neck. PET-CT is a useful tool to look at post-chemoradiation treatment response and to evaluate the neck following radiotherapy with residual neck mass. In the head and neck, misregistration of PET to CT can cause difficulty in reporting and increase false-positive results.

81.11.8 The Role of Sentinel Node Biopsy

The presence of metastatic disease to the neck is an important prognostic factor for disease-free survival in head and neck cancer. Recent papers by Anil D Cruz et al. have shown that patients who had an elective neck dissection fared much better than those on the watchful waiting strategy in both T1 and T2 tumors [29].

Sentinel node biopsy relies on the fact that metastases to the regional lymph nodes follow a predictive pattern in most cases. Migration of cancer cells is often to the first echelon node. It is therefore predicted that if the first echelon node is negative, the more distal node is unlikely to have cancer cell migration. Validation studies involving elective neck dissection have shown that there is 95% detection rate in sentinel nodes. The first echelon node in most oral cancers is at level I or level II. In a well-lateralized tumor, the first echelon node more often than not is on the ipsilateral side.

The indications for a sentinel node biopsy are:

1. T1/T2 tumors which are node negative on staging scans.
2. To assess the need for bilateral neck dissection in tumors close to or just crossing the midline.
3. To clarify the need for contralateral neck dissection in large tumors.

Proponents of SLN biopsy claim the following advantages: reduces the morbidity of elective neck dissection, more accurate staging of the neck, and better prediction in those who have an unpredictable pattern of metastatic disease, therefore guides decision-making, helps identify skip metastases and micrometastases, and saves time and expense.

It is the opinion of the authors that sentinel node biopsy is a very good adjunct. Recent meta-analysis and systematic reviews suggest that high sensitivity, negative predictive value, and accuracy of SNB make this a valid diagnostic tool. NICE (National Institute of Clinical Excellence) guidelines recommend that a SLNB should be offered to all patients with T1 and T2 tumors with a node-negative neck. A word of caution, however, for T1 and T2 tumors with a tumor thickness greater than 5 mm, an elective neck dissection may still be indicated.

81.11.9 The Multidisciplinary Team

Following completion of all diagnostic requisites, the findings are discussed at the weekly MDT or the tumor board meeting. The MDT has a core group of clinicians and healthcare professionals. The MDT comprises of maxillofacial surgeons, ENT surgeons, oncologist, speech and language therapist (SALT), dietician, clinical nurse specialist (CNS), head and neck radiologist, head and neck pathologist, restorative dentist, and cancer audit officer to collect data. We have two clinicians from each of the subspecialties at our MDT. The MDT should not be regarded as a forum to advance individual pride or agenda. This is a group that helps balance evidence base in the management of patients and makes a realistic recommendation of treatment strategy.

The responsibility of the MDT is to protect and facilitate the patients' pathway through cancer treatment. The first and foremost recommendation made by the MDT is the treatment intent—curative or palliative. This is followed by the treatment strategy—surgery or radiotherapy ± chemotherapy (Refer Chap. 84 to read about Adjunctive therapy in oral cancer).

At our MDT, the nature of surgery or the form of reconstruction is rarely discussed. The certainty of achieving tumor clearance and potential morbidity associated with the treatment form the majority of the discussions. Speech and language team assess the need for potential future PEG (gastrostomy) or nasogastric feed. Where there is a high index of suspicion that a PEG feed will be necessary, this is done pre-treatment. Dieticians help in planning feeding regimes both pre- and postoperatively. The restorative dentist offers an opinion on unrestorable teeth that need to be extracted at the time of surgery or prior to chemoradiation to reduce the incidence of future osteoradionecrosis.

81.11.10 Planning Reconstruction

The choice of reconstruction is numerous (Refer Chap. 82 to read about principles of surgical management of oral cancer. Chapter 85 deals with the access osteotomies to maxillofacial region while Chaps. 86 and 88 deals with soft and hard tissue reconstruction respectively). The preferred choice is dependent on the following factors:

- Patient's overall health to withstand long surgery.
- Associated postoperative functional deficit if no reconstruction is carried out.
- Skill of the surgeons.
- Socioeconomic factors.

The best form of reconstruction is to try and substitute like for like. A simple but effective way of looking at reconstruction would be:

- Flaps for lining the defect in T2 defects—radial forearm free flap, anterolateral thigh perforator flap (ALT), medial sural artery free flap, submental flap, nasolabial flaps.
- Flaps that are required for increasing bulk or low volume—anterolateral thigh flap, pectoralis major flap.
- Flaps for major resection which require high volume—rectus flap, latissimus dorsi flap.
- Flaps for lining the pharynx—radial forearm free flap, ALT, pectoralis major flap.
- Skull base defects that require a long pedicle—rectus abdominis flap, ALT, or latissimus dorsi free flap.
- Bone reconstruction—fibula free flap, DCIA (deep circumflex iliac artery) flap, scapula flap.
- Composite defect—combination of the above or scapula flap.

81.11.11 Conclusion

A good functional MDT that practices evidence-based medicine with a realistic approach that is patient centered will be an effective oncology team that will deliver high-quality care for patients.

References

1. Niranjana VR, et al. Oral cancer epidemiology of Aurangabad district (Maharashtra) of India from 2005 to 2014: understanding the burden of disease. *Int J Community Med Public Health*. 2017 Jul;4(7):2275–81.
2. Gupta B, Ariyawardana A, Johnson NW. Oral cancer in India continues in epidemic proportions: evidence base and policy initiatives. *Int Dent J*. 2013;63(1):12–25.
3. Park K. Park's textbook of preventive and social medicine. 23rd ed. Jabalpur: M/S Banarsidas Bhanot; 2015.
4. International Agency on Research for Cancer. Smokeless tobacco and some tobacco-specific N-nitrosamines. Monographs, vol. 89. Lyon: IARC; 2007.
5. Murthy NS, Mathew A. Cancer epidemiology, prevention and control. *Curr Sci*. 2004;86(4):518–27.
6. Gupta PC, Mehta HC. Cohort study of all-cause mortality among tobacco users in Mumbai. *India Bull WHO*. 2000;78:877–83.
7. Sankaranarayanan R, Duffy SW, Padmakumary G. Tobacco and alcohol as risk factors in the larynx in Kerala. *India Int J Cancer*. 1990;45:879–82.
8. IARC. Monographs on the evaluation of carcinogenic risk to humans: alcohol drinking, vol. 44. Lyon: IARC; 1988.
9. Kiran Kumar K, Saraswathi TR, Ranganathan K, Devi MU, Elizabeth J. Oral submucous fibrosis: a clinicohistopathological study in Chennai. *IJDR*. 2007;18:106–11.
10. Anonymous IARC. Tobacco habits other than smoking: betel quid and areca nut chewing and some related nitrosamines. *IARC Monogr Eval Carcinog Risk Chem Hum*. 1985;37:141–200.
11. Sharma JD, Barman D, Sarma MK, Sharma A, Kalita M, Kataki AC, et al. Burden of head and neck cancers in Kamrup urban district cancer registry of Assam, India: a retrospective study. *Int J Res Med Sci*. 2014;2:1382–7.
12. Gupta B, Ariyawardana A, Johnson NW. Oral cancer in India continues in epidemic proportions: evidence base and policy initiatives. *Int Dent J*. 2013;63(1):12–25.
13. Pillai R, Balaram P. Pathogenesis of oral sub mucous fibrosis – relationship to risk factors associated with oral cancer. *Cancer*. 1992;69:2011–20.
14. Roberts AB, Flanders KC, Kondaiah P, Thompson NL, Van Obberghen-Schilling E, et al. Transforming growth factor beta: biochemistry and roles in embryogenesis, tissue repair and remodeling, and carcinogenesis. *Recent Prog Horm Res*. 1988;44:157–97.
15. Neville BW, Damm DD, Allen CM – Oral and maxillofacial pathology. 2nd ed. Philadelphia: WB Saunders; 2002. p. 349–50.
16. Thongprasom K, Carrozzo M, Furness S, Lodi G. Interventions for treating oral lichen planus. *Cochrane Database Syst Rev*. Jul 6, 2011;7:CD001168.
17. Farhi D, Dupin N. Pathophysiology, etiologic factors, and clinical management of oral lichen planus, part I: facts and controversies. *Clin Dermatol*. 2010;28(1):100–8.
18. Fitzpatrick SG, Hirsch SA, Gordon SC. The malignant transformation of oral lichen planus and oral lichenoid lesions: A systematic review. *J Am Dent Assoc*. 2014 Jan;145(1):45–56.
19. Pollaers K, Hinton-Bayre A, Friedland PL, Farah CS. AJCC 8th Edition oral cavity squamous cell carcinoma staging – Is it an improvement on the AJCC 7th Edition. *Oral Oncol*. 2018 Jul;82:23–8.
20. Moore C, Kuhns JG, Greenberg RA. Thickness as prognostic aid in upper aerodigestive tract cancer. *Arch Surg*. 1986;121(12):1410–4.
21. Mohit-Tabatabai MA, Sobel HJ, Rush BF, Mashberg A. Relation of thickness of floor of mouth stage I and II cancers to regional metastasis. *Am J Surg*. 1986;152(4):351–3.
22. Brown B, Barnes L, Mazariegos J, Taylor F, Johnson J, Wagner RL. Prognostic factors in mobile tongue and floor of mouth carcinoma. *Cancer*. 1989;64(6):1195–202.
23. Woolgar JA, Scott J. Prediction of cervical lymph node metastasis in squamous cell carcinoma of the tongue/floor of mouth. *Head Neck*. 1995;17(6):463–72.
24. O-charoenrat P, Pillai G, Patel S, Fisher C, Archer D, Eccles S, et al. Tumor thickness predicts cervical nodal metastases and survival in early tongue cancer. *Oral Oncol*. 2003;39:386–90.
25. Ling W, Mijiti A, Moming A. Survival pattern and prognostic factors of patients with squamous cell carcinoma of the tongue: a retrospective analysis of 210 cases. *J Oral Maxillofac Surg*. 2013;71(4):775–85.
26. Gonzalez-Moles MA, Esteban F, Rodriguez-Archilla A, Ruiz-Avila I, Gonzales-Moles S. Importance of tumour thickness measurement in prognosis of tongue cancer. *Oral Oncol*. 2002;38:394–7.
27. Umeda M, Yokoo S, Take Y, Omori A, Nakanishi K, Shimada K. Lymph node metastasis in squamous cell carcinoma of the oral cavity: correlation between histologic features and the prevalence of metastasis. *Head Neck*. 1992;14(4):263–72.
28. Kane SV, Gupta M, Kakade AC, D'Cruz A. Depth of invasion is the most significant histological predictor of subclinical cervical lymph node metastasis in early squamous carcinomas of the oral cavity. *Eur J Surg Oncol*. 2006;32:795–803.
29. Thiagarajan S, Nair S, Nair D, Chaturvedi P, Kane SV, Agarwal JP, D'Cruz AK. Predictors of prognosis for squamous cell carcinoma of oral tongue. *J Surg Oncol*. 2014;109(7):639–44.
30. Morton RP, Ferguson CM, Lambie NK, Whitlock RM. Tumor thickness in early tongue cancer. *Arch Otolaryngol Head Neck Surg*. 1994;120(7):717–20.

31. Tai SK, Li WY, Yang MH, Chu PY, Wang YF, Chang PM. Perineural invasion as a major determinant for the aggressiveness associated with increased tumor thickness in t1–2 oral tongue and buccal squamous cell carcinoma. *Ann Surg Oncol*. 2013;20(11):3568–74.
32. Matsushita Y, Yanamoto S, Takahashi H, Yamada S, Naruse T, Sakamoto Y, Ikeda H, Shiraishi T, Fujita S, Ikeda T, Asahina I, Umeda M. A clinicopathological study of perineural invasion and vascular invasion in oral tongue squamous cell carcinoma. *Int J Oral Maxillofac Surg*. 2015;44(5):543–8.
33. Sparano A, Weinstein G, Chalian A, Yodul M, Weber R. Multivariate predictors of occult neck metastasis in early oral tongue cancer. *Otolaryngol Head Neck Surg*. 2004;131:472–6.
34. Close LG, Brown PM, Vuitch MF, Reisch J, Schaefer SD. Microvascular invasion and survival in cancer of the oral cavity and oropharynx. *Arch Otolaryngol Head Neck Surg*. 1989;115(11):1304–9.
35. Vincent N, Dassonville O, Chamorey E, Poissonnet G, Pierre CS, Nao EE, Peyrade F, Benezery K, Viel D, Sudaka A, Marcy PY, Vallicioni J, Demard F, Santini J, Bozec A. Clinical and histological prognostic factors in locally advanced oral cavity cancers treated with primary surgery. *Eur Ann Otorhinolaryngol Head Neck Dis*. 2012;129(6):291–6.
36. de Bondt RB, Nelemans PJ, Hofman PA, et al. Detection of lymph node metastases in head and neck cancer: a meta-analysis comparing US, USg FNAC, CT and MR imaging. *Eur J Radiol*. 2007;64:266–72.
37. Wu LM, Xu JR, Liu MJ, et al. Value of magnetic resonance imaging for nodal staging in patients with head and neck squamous cell carcinoma: a meta-analysis. *Acad Radiol*. 2012;19:331–40.
38. Kyzas PA, Evangelou E, Denaxa-Kyza D, et al. 18F-fluorodeoxyglucose positron emission tomography to evaluate cervical node metastases in patients with head and neck squamous cell carcinoma: a meta-analysis. *J Natl Cancer Inst*. 2008;100:712–20.
39. Som PM, Brandwein-Gensler MS. Lymph nodes of the neck. In: Som PM, Curtin HD, editors. *Head & neck imaging*, vol. 2. 5th ed. St Louis: Mosby; 2011. p. 2287–383.
40. Kuriokose M. *Contemporary oral oncology*, vol. 1 and 2. Cham: Springer International Publishing; 2017.

Open Access This chapter is licensed under the terms of the Creative Commons Attribution 4.0 International License (<http://creativecommons.org/licenses/by/4.0/>), which permits use, sharing, adaptation, distribution and reproduction in any medium or format, as long as you give appropriate credit to the original author(s) and the source, provide a link to the Creative Commons license and indicate if changes were made.

The images or other third party material in this chapter are included in the chapter's Creative Commons license, unless indicated otherwise in a credit line to the material. If material is not included in the chapter's Creative Commons license and your intended use is not permitted by statutory regulation or exceeds the permitted use, you will need to obtain permission directly from the copyright holder.





Principles of Surgical Management of Oral Cancer

Sushma Mehta and Moni Abraham Kuriakose

82.1 Introduction

Management of oral cavity cancers in a curative intent setting mainly involves surgery. The other treatment modalities such as radiotherapy and chemotherapy are most commonly used as adjuvant treatment based on the histopathological features. However, it is to be noted that surgery alone is insufficient to treat oral cancer. Chemotherapy is either concurrent with radiotherapy or in very rare scenario used as induction therapy. The primary cancer treatment and risk factor reduction are of utmost importance to improve effectiveness of the primary treatment and to prevent development of second-primary cancers.

Ablative surgery has evolved over the years with the attempt to extirpate the tumor in its entirety with the understanding of the molecular tumor biology, pattern of tumor invasion of the tumors, as well as availability of better instrumentations.

With the advent of endoscopic assisted and robotic-assisted neck dissection, the branch of oral oncology has truly made progress, thus improving visualization and three-dimensional navigation; however it is still in its infancy and needs further research to understand the benefits over the conventional methods.

This chapter outlines details of ablative surgery and rationale for addressing neck (node positive/node negative) in patients with oral cavity cancers.

Electronic Supplementary Material The online version of this chapter (https://doi.org/10.1007/978-981-15-1346-6_82) contains supplementary material, which is available to authorized users.

S. Mehta
Mazumdar Shaw Cancer Center, Bengaluru, Karnataka, India

M. A. Kuriakose (✉)
Cochin Cancer Research Centre, Kochi, Kerala, India

82.2 Initial Evaluation and Staging

Initial evaluation as for any other medical condition includes history, a clinical examination and investigations to form a diagnosis. The other two important aspects influencing management of oral cavity cancer (mainly squamous cell carcinoma) are habit history and performance status. Table 82.1 describes the performance status scales.

Staging of the disease is particularly important as it helps the clinicians in better communication in a scientific forum and forming a treatment plan for a patient. Various phases in management of oral cancer include accurate diagnosis, appropriate treatment plan, and execution of the advised treatment with relevant reconstruction, rehabilitation, and surveillance. So, to help clinicians in decision-making, there are several guidelines that exist. As these guidelines have a more generalized approach, it is the clinician's knowledge

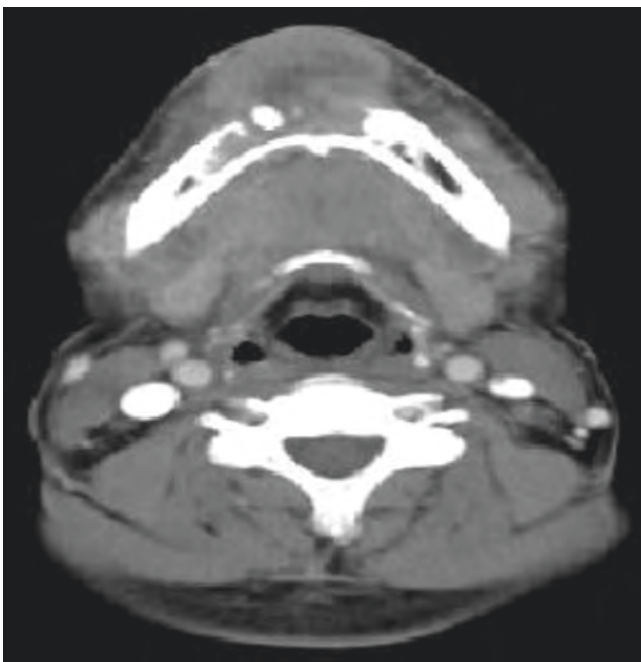
Table 82.1 Performance status scale: Zubrod scale and Karnofsky scale

Performance Status Scales [1]	
Zubrod scale	Karnofsky scale
“0” normal activity	“100” normal; no evidence of disease
	“90” able to perform normal activities with only minor symptoms.
“1” symptomatic and ambulatory cares for self	“80” normal activity with effort; some activities
	“70” able to care for self but unable to do normal activities
“2” ambulatory >50% of the time; occasional assistance	“60” requires occasional assistance; cares for most needs
“3” ambulatory ≤50% of the time; nursing care needed	“50” requires considerable assistance
	“40” disabled; requires special assistance
	“30” severely disabled
“4” bedridden	“20” very sick; requires active supportive treatment
	“10” moribund

and understanding and experience which will help in tailoring the treatment plan to each individual distinctly. This individualized approach cannot be implemented unless there are multidisciplinary tumor board meetings, which are crucial for clinicians practicing oncology and hence provides team-based practice keeping the patient in mind [2–4]. This is best done before initiating the treatment.

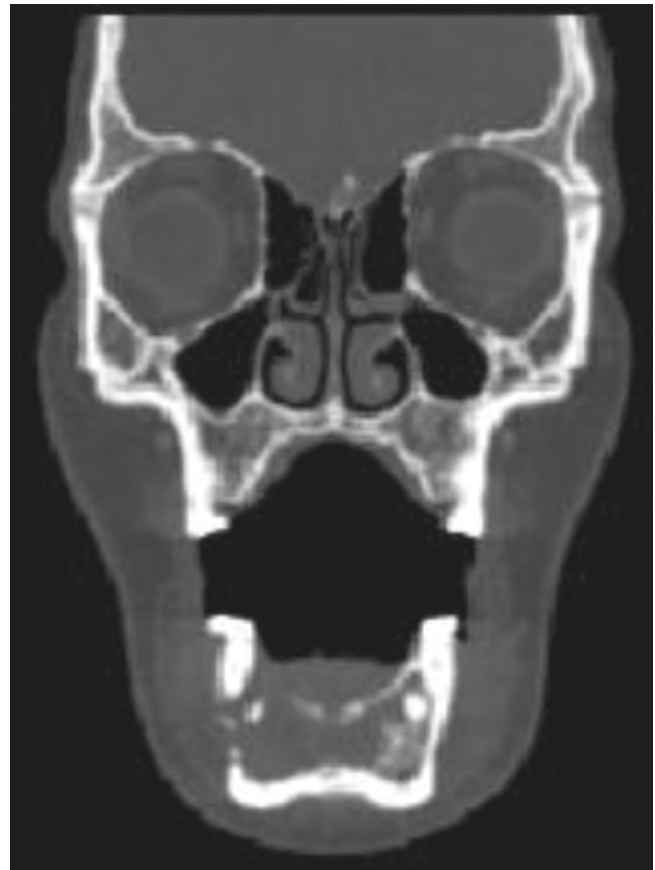To be able to know the extent of disease and decide the intent and modality of treatment, imaging plays a very important role. Precise imaging information is needed to determine the locoregional extent, erosion, and involvement of underlying bone and marrow space, lymph node involvement and to rule out distant metastasis—especially to the lungs. However the dilemma that most clinicians face is which is the imaging modality of choice for different clinical scenarios. In the following section, we attempt to provide indications of each imaging type available, which probably will help the clinicians in deciding what suits their needs.

Plain radiography is restricted to evaluation of pathological fractures or initial benign lesions. Contrast-enhanced computed tomography (CECT) is considered as the most popular, easily available, and cost-effective diagnostic imaging. It is the imaging modality of choice to know the presence of bone erosion and lymph node characteristic. Bony expansion is usually a feature of slow-growing/benign disease process; however destruction of bone and replacement by the tumor depicts the aggressiveness and hence is a feature of malignant process (Figs. 82.1, 82.2, 82.3 and 82.4).



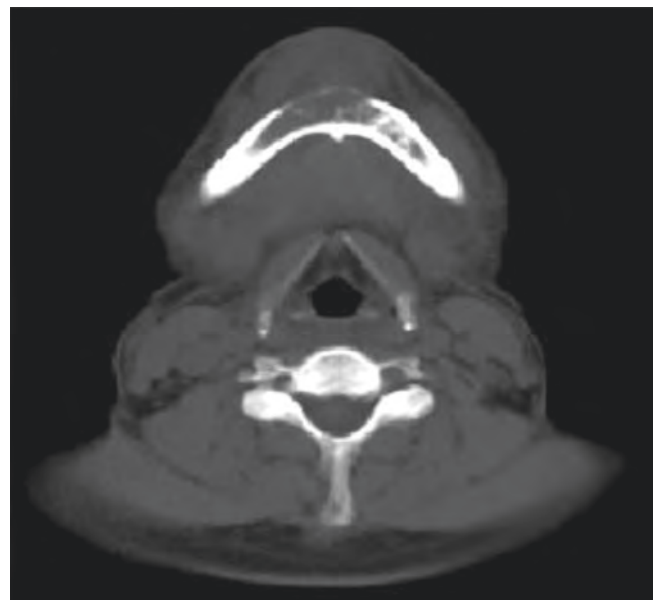
©Association of Oral and Maxillofacial Surgeons of India

Fig. 82.1 Axial section of contrast enhanced CECT showing an ill-defined heterogeneously enhancing mass lesion along the mandibular alveolus involving the central lateral incisors and canines with erosion of body of mandible



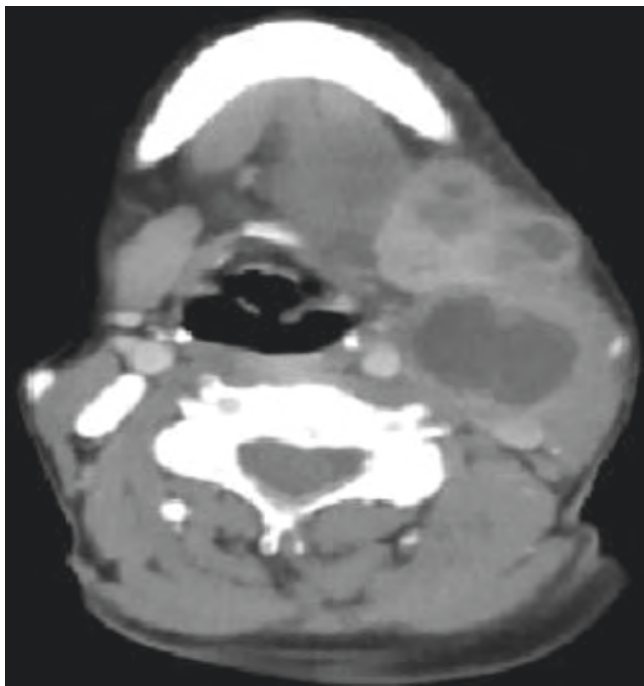
©Association of Oral and Maxillofacial Surgeons of India

Fig. 82.2 Sagittal section of the patient same as Fig. 82.1 to depict the extent of bony erosion and involvement providing a guide for the osteotomy



©Association of Oral and Maxillofacial Surgeons of India

Fig. 82.3 This is axial section in bony window for exact extent of bony erosion

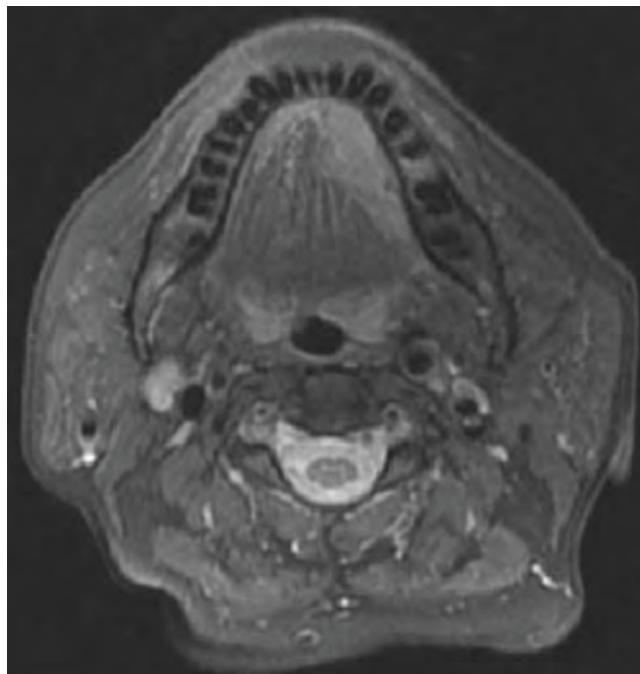


©Association of Oral and Maxillofacial Surgeons of India

Fig. 82.4 Axial section—contrast-enhanced computed tomography. A heterogeneously enhanced conglomerate of the lymph nodal mass at left level II with cystic areas highly suspicious of metastatic lymphadenopathy. The mass has partially compressed internal jugular vein and pushed it posterolaterally

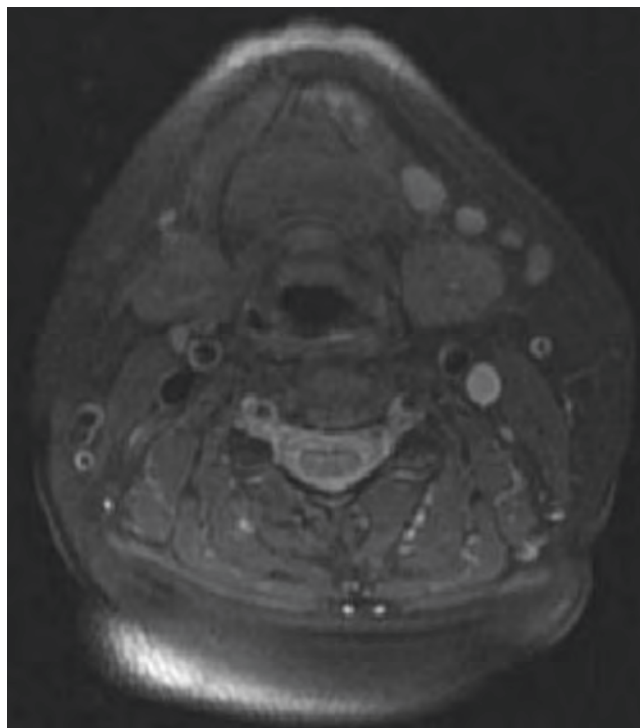
Magnetic resonance imaging (MRI) is usually indicated as an adjunct as it has better soft tissue delineation. It is also used for assessing dural invasion (linear or nodular), medullary bone involvement, and perineural invasion. Radiographic assessment of tumor extent is invaluable for treatment planning. In case of tongue cancers, MRI has gained popularity for assessment of tongue cancer especially as it is helpful in identifying tumor thickness, involvement of the contralateral side, and involvement of extrinsic muscles. With recent addition of depth of invasion in the AJCC classification for staging, MRI has proven its role. As for buccal mucosa tumors, assessment of masticatory muscles involvement is crucial because it has historically been considered unresectable. However, according to Liao, infra-notch lesions are still amenable for resection with favorable oncological outcome.

As oral cancers usually metastasize first to the lung, pre-operative chest imaging is a part of initial pre-operative work-up. This can be in the form of either plain film or 3D imaging such as computed tomography (CT). Fluorodeoxyglucose positron emission tomography (FDG-PET) scan has emerged as the imaging modality of choice in patient with recurrence and high clinical suspicion for distant metastasis (Figs. 82.5, 82.6, 82.7 and 82.8).



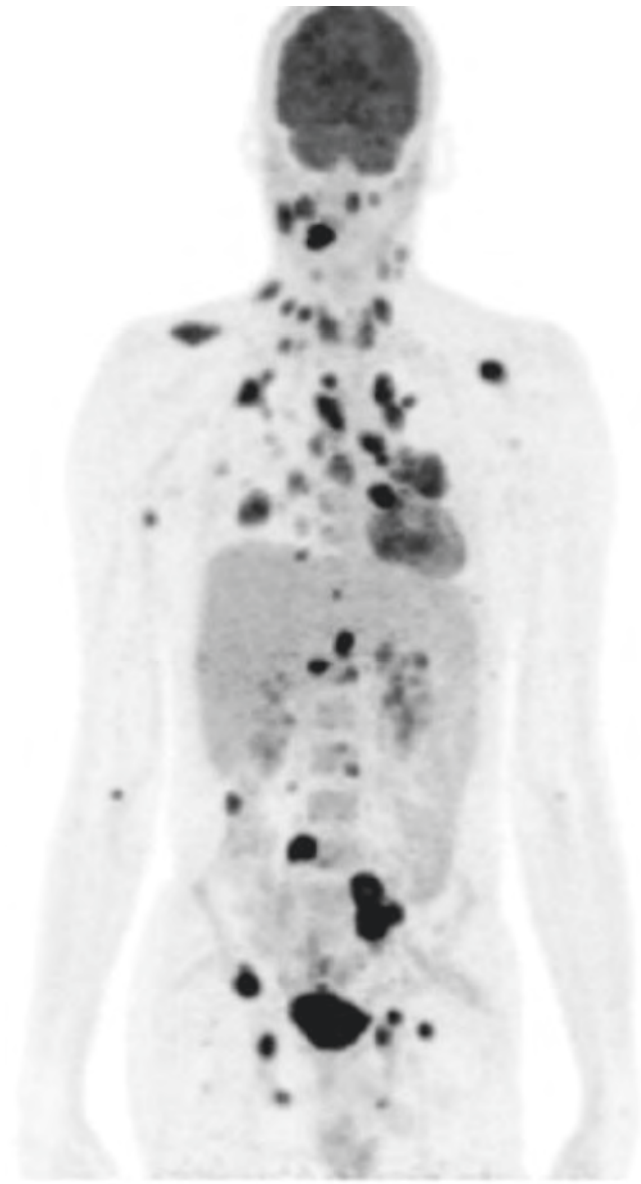
©Association of Oral and Maxillofacial Surgeons of India

Fig. 82.5 The contrast-enhanced T1-weighted MRI images depicting hyperintensity involving the left lateral tongue with extension till the midline and involving tip of the tongue



©Association of Oral and Maxillofacial Surgeons of India

Fig. 82.6 Axial section of an MRI (T2-weighted) showing multiple lymph node metastasis at level IB

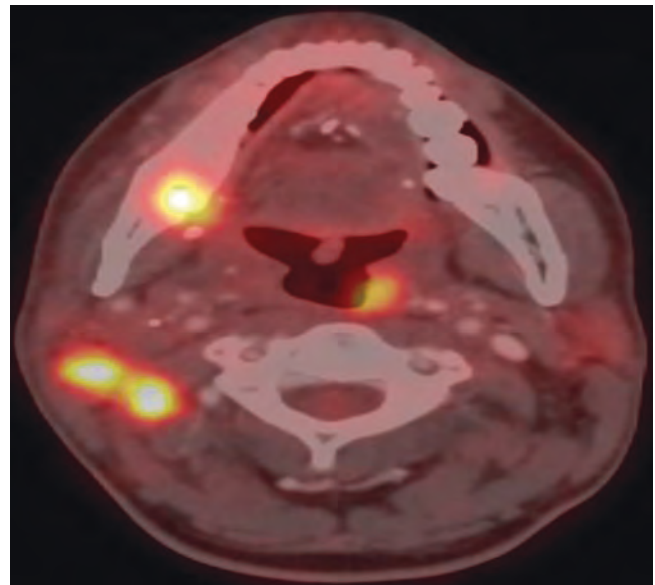


©Association of Oral and Maxillofacial Surgeons of India

Fig. 82.7 This is the whole body image of PET-CT scan depicting uptake in the multiple areas suggestive of metastatic disease

It is to be noted that any suspicious lesions in PET-CT scan needs to be corroborated with tissue diagnosis (direct or guided) as there are a subset of lesions with false-positive findings; however, PET-CT is considered to have the highest negative predictive value approaching 100%. Although as per the NCCN guidelines, PET-CT has to be advised for all stage III and IV disease, it is usually reserved for patients with recurrent or second primary disease in a resource-constrained setting [5, 6]. Tables 82.2 and 82.3 provide imaging considerations in oral cavity tumors.

Baseline follow-up imaging is usually done after 3 months, and CECT has established its role in ruling out recurrence/residual disease. To avoid misinterpretation, it is



©Association of Oral and Maxillofacial Surgeons of India

Fig. 82.8 FDG PET-CT images to show FDG avid lesion in the right lower alveolus and ipsilateral level II lymph nodes along with uptake in the right nasopharynx. All the lesion have a similar standard uptake value (SUV) of 15 corresponding to the metabolic activity

important that the concerned imaging radiologist is familiarized with postoperative sequelae of tissue changes or changes that occur following radiotherapy such as nonspecific tissue thickening, edema, or fibrosis and various bony and soft tissue reconstruction methods to facilitate interpretation.

Staging the disease is developed to provide ease of communication and helps in understanding the prognosis and planning the treatment. AJCC staging system has been followed for years and provides concise information on size characteristics and extent of primary tumor and involvement of lymph nodes. The recent eighth edition has features like tumor thickness, depth of invasion, and extranodal extension (clinical and pathological).

82.3 Category for Oral Cavity Cancer, Eighth Edition Staging Manual

Table 82.4 provides the categorization for oral cavity cancer [6].

82.4 Principles of Surgical Management

In majority of oral cavity squamous cell cancers, surgery has been the mainstay of treatment, and hence, the need to know intricate surgical aspects has to be emphasized. As there has been improved understanding of disease pattern, biologic behavior of the disease at the molecular level, and the poten-

Table 82.2 Imaging in oral cavity tumors

Radiological means	Indications	Advantages/Challenges
Computed tomography (CT)	Mainstay for imaging primary disease.	<ul style="list-style-type: none"> Bone details. Obscured to dental artifacts. Early perineural spread can be missed [7].
Magnetic resonance imaging (MRI)	<ul style="list-style-type: none"> Assessment of primarily oral tongue, floor of mouth, and hard palate lesions or bone marrow involvement along with assessment of nasopharyngeal, parotid, sinonasal tumors. Useful in providing information on encasement of carotid arteries. Promising results in early detection of perineural extension and detection of dural involvement or intracranial extension. 	<ul style="list-style-type: none"> Better contrast resolution. Superior detection of tumor spread into bone marrow. Swallowing artifacts [8].
Ultrasonography (USG)	<ul style="list-style-type: none"> To identify lymph node metastases. For assessment of tumor spread in tongue carcinoma, when MR imaging is contraindicated or unavailable [9]. 	
Positron emission tomography (PET)	<ul style="list-style-type: none"> Diagnosis of an unknown primary tumor, assessment of distant metastasis, response to therapy, surveillance/detection of recurrence. Limited role in neck node evaluation. 	<ul style="list-style-type: none"> Better localization of activity to normal vs abnormal structures, better identification of inflammatory lesions [5].

Table 82.3 Imaging considerations for various sites

Neck nodes	USG-guided FNAC—100% specificity [10, 11]
RMT	<ul style="list-style-type: none"> To look for bone erosion—Cortical bone or marrow involvement. To detect spread of lesion along pterygomandibular raphe.
Palate	<ul style="list-style-type: none"> To assess invasion of maxillary sinus, palatal bone, and nasal vault. Depth of invasion dictates extent of resection.
Infratemporal fossa	<ul style="list-style-type: none"> Pterygomandibular raphe provides pathway of spread of lesion into ITF. CT & MRI are useful.
Tongue	<ul style="list-style-type: none"> MRI is preferred; surrounding structure involvement will help in deciding the extent of resection [12, 13].
Bone invasion	<ul style="list-style-type: none"> MRI is superior for evaluating medullary space of mandible but inadequate for assessing cortical invasion.

Table 82.4 Category for oral cavity cancer, eighth edition staging manual [6]: Definition of primary tumor (T)

T category	T criteria
TX	Primary tumor cannot be assessed
Tis	Carcinoma in situ
T1	Tumor ≤2 cm with depth of invasion (DOI)* ≤ 5 mm
T2	Tumor ≤2 cm with DOI* > 5 mm Or tumor >2 cm and ≤ 4 cm with DOI* ≤ 10 mm
T3	Tumor >2 cm and ≤ 4 cm with DOI* > 10 mm Or tumor >4 cm with DOI* ≤ 10 mm
T4	Moderately advanced or very advanced local disease
T4a	Moderately advanced local disease Tumor >4 cm with DOI* > 10 mm Or tumor invades adjacent structures only (e.g., through cortical bone of the mandible or maxilla or involves the maxillary sinus or skin of the face) Note: Superficial erosion of bone/tooth socket (alone) by a gingival primary is not sufficient to classify a tumor as T4
T4b	Very advanced local disease Tumor invades masticator space, pterygoid plates, or skull base and/or encases the internal carotid artery

*DOI is depth of invasion and not tumor thickness

T suffix	Definition
(m)	Select if synchronous primary tumors are found in single organ

Definition of regional lymph node (N) clinical N (cN)

cN	Category cN criteria
NX	Regional lymph nodes cannot be assessed
N0	No regional lymph node metastasis
N1	Metastasis in a single ipsilateral lymph node, 3 cm or smaller in greatest dimension ENE(–)
N2	Metastasis in a single ipsilateral node larger than 3 cm but not larger than 6 cm in greatest dimension and ENE(–) Or metastases in multiple ipsilateral lymph nodes, none larger than 6 cm in greatest dimension and ENE(–) Or in bilateral or contralateral lymph nodes, none larger than 6 cm in greatest dimension, and ENE(–)
N2a	Metastasis in a single ipsilateral node larger than 3 cm but not larger than 6 cm in greatest dimension, and ENE(–)
N2b	Metastases in multiple ipsilateral nodes, none larger than 6 cm in greatest dimension, and ENE(–)
N2c	Metastases in bilateral or contralateral lymph nodes, none larger than 6 cm in greatest dimension, and ENE(–)
N3	Metastasis in a lymph node larger than 6 cm in greatest dimension and ENE(–); Or metastasis in any node(s) and clinically overt ENE(+)
N3a	Metastasis in a lymph node larger than 6 cm in greatest dimension and ENE(–)
N3b	Metastasis in any node(s) and clinically overt ENE(+)

Note: A designation of “U” or “L” may be used for any N category to indicate metastasis above the lower border of the cricoid (U) or below the lower border of the cricoid (L). Similarly, clinical and pathological ENE should be recorded as ENE(–) or ENE(+)

N suffix	Definition
(sn)	Select if regional lymph node metastasis identified by SLN biopsy only
(f)	Select if regional lymph node metastasis identified by FNA or core needle biopsy only
U	Metastasis above the lower border of the cricoid

(continued)

Table 82.4 (continued)

N suffix	Definition
L	Metastasis below the lower border of the cricoid
Pathological N (pN)	
pN category	pN criteria
NX	Regional lymph nodes cannot be assessed
N0	No regional lymph node metastasis
N1	Metastasis in a single ipsilateral lymph node, 3 cm or smaller in greatest dimension and ENE(–)
N2	Metastasis in a single ipsilateral lymph node, 3 cm or smaller in greatest dimension and ENE(+) Or larger than 3 cm but not larger than 6 cm in greatest dimension and ENE(–); Or metastases in multiple ipsilateral lymph nodes, none larger than 6 cm in greatest dimension and ENE(–) Or in bilateral or contralateral lymph node(s), none larger than 6 cm in greatest dimension, ENE(–)
N2a	Metastasis in single ipsilateral node 3 cm or smaller in greatest dimension and ENE(+) Or a single ipsilateral node larger than 3 cm but not larger than 6 cm in greatest dimension and ENE(–)
N2b	Metastases in multiple ipsilateral nodes, none larger than 6 cm in greatest dimension and ENE(–)
N2c	Metastases in bilateral or contralateral lymph node(s), none larger than 6 cm in greatest dimension and ENE(–)
N3	Metastasis in a lymph node larger than 6 cm in greatest dimension and ENE(–); Or metastasis in a single ipsilateral node larger than 3 cm in greatest dimension and ENE(+) Or multiple ipsilateral, contralateral, or bilateral nodes, any with ENE(+); Or a single contralateral node of any size and ENE(+)
N3a	Metastasis in a lymph node larger than 6 cm in greatest dimension and ENE(–)
N3b	Metastasis in a single ipsilateral node larger than 3 cm in greatest dimension and ENE(+) Or multiple ipsilateral, contralateral or bilateral nodes any with ENE(+); Or a single contralateral node of any size and ENE(+)
Note: A designation of “U” or “L” may be used for any N category to indicate metastasis above the lower border of the cricoid (U) or below the lower border of the cricoid (L). Similarly, clinical and pathological ENE should be recorded as ENE(–) or ENE(+)	
N suffix	Definition
(sn)	Select if regional lymph node metastasis identified by SLN biopsy only
(f)	Select if regional lymph node metastasis identified by FNA or core needle biopsy only
U	Metastasis above the lower border of the cricoid
L	Metastasis below the lower border of the cricoid
Definition of distant metastasis (M)	
M category	M criteria
cM0	No distant metastasis
cM1	Distant metastasis
pM1	Distant metastasis, microscopically confirmed

tial aggressive nature, the need has arisen for several technical modifications in this era. Hence as surgeons, we have to evolve and adapt to the required changes to improve outcomes of ablative surgery (oncological and functional) in patients with squamous cell carcinoma of oral cavity.

For early-stage oral cavity cancers, especially tongue, it has been proven that both surgery and radiotherapy/brachytherapy offer similar outcome (single modality). For advanced lesions with extensive disease, multimodality treatment is required; surgery being the primary modality and followed by adjuvant radiotherapy +/- chemotherapy (depending on the histopathological evaluation) has been the standard of care.

82.5 Treatment Decision Algorithm [14]

Critical decisions which have to be made are as follows:

1. Intent of treatment—curative vs. palliative treatment.
2. Primary modality—surgical vs. non-surgical treatment.
3. Need for addressing neck in clinically node-negative patients.
4. Type of neck dissection in patients with metastatic lymph nodes.
5. Need for adjuvant treatment.
6. Type of adjuvant treatment.
7. Best supportive care.

Decision 1 Primary intent of treatment: This is the first and most critical decision-making point. All patients other than those with technically unresectable tumors, distant metastasis, poor performance status, and major comorbidities precluding surgery must be considered for treatment with curative intent. However, it is to be noted that surgical excision with positive margins portends poor prognosis. Palliative care is usually when patient has distant metastasis and given only to relieve symptoms and control spread. This is in the form of chemotherapy, radiotherapy or metronomics.

Decision 2 Curative modality of treatment: The primary treatment for patients with oral cavity cancers is surgery. However, in selected scenarios, non-surgical treatment may be considered. This includes primary radiotherapy for tumors of the commissure of mouth and lip tumors where surgery can cause significant esthetic and functional disability. In addition, significant comorbidities that preclude long anes-

thesia may necessitate the need for primary radiotherapy or chemoradiotherapy. However primary chemoradiotherapy has very limited role in treatment of oral cancers.

Decision 3 Management of neck in N0 stage: Even with no radiographic evidence of significant suspicious lymph-nodes, rate of occult metastasis reaches up to as high as 30% [15]. Presence of lymph node metastasis and the number of lymph nodes involved have a direct relation with the prognosis of the disease; decreasing the overall survival rate by 50%. Moreover, a significant subset of metastatic nodes of less than 1 cm can have extranodal extension [16]. This further worsens the prognosis. There is now level I evidence from a randomized control trial, that addressing the neck surgically irrespective of the lymph node status improves overall survival to about 84% when compared to 69% in patients who were selected for wait-and-watch policy [17]. Therefore, almost all the patients with oral cavity cancer should undergo elective neck dissection. A subset analysis of the same study did not show benefit for primary tumors of depth less than 3 mm. This may be considered in selected patients with cancers of lower nodal metastatic prevalence such as lip and buccal mucosa.

Decision 4 Extent of neck dissection in N+ve oral squamous cell carcinoma: Conventional teaching is that any patients with N+ve neck should undergo modified radical neck dissection covering levels 1–5. This has been questioned by several observational studies. Large cohort of patients who have undergone radical neck dissection for N+ve disease has showed less than 3% incidence of level V nodes [17]. This also was observed only when there were pathologically positive level IV nodes [18]. There are reports of oncologic safety for clearing level I–III lymph nodes for alveolus and buccal mucosal cancers and to clear level IV in addition to levels I, II, and III lymph nodes in patients with oral tongue cancers as they bore high risk of skip metastasis [19]. It is to be noted that when a patient is found to have pathological nodal metastasis, in general, it is recommended for adjuvant radiation that covers all levels of the neck with additional boost in the levels which are positive for metastasis.

Decision 5 Indication for adjuvant radiotherapy: Any patients with more than one of the high risk features should be considered for adjuvant radiotherapy.

This includes (1) nodal metastasis without extracapsular extension, (2) perineural invasion, (3) lymphovascular invasion, (4) poor differentiation, (5) close margin (1–5 mm), and (6) depth of invasion over 1 cm.

But the absolute indication for radiotherapy is stage III and IV disease.

Decision 6 Indication for adjuvant chemoradiotherapy: Meta-analysis of two randomized trials has suggested that in patients with positive surgical margin (<1 mm) and neck nodes with extranodal extension would benefit from adjuvant chemoradiotherapy.

Decision 7 Best supportive care options: This is an important and critical decision. Once the decision for treatment with palliative intent is arrived at, the goal should be made clear with the treating team of doctors and the patient/patient attenders. Ambiguity at this stage may result in loss of trust between the treating team and the patient, causing delay in treatment and possible increase in morbidity. Although this decision is made in the multidisciplinary tumor board, it requires series of meetings with the family to convey the treatment goals. It is also essential to appreciate by treatment group that lack of active treatment does not mean stoppage of care, which needs to be provided by the same team till the end. The quality of death is equally important as quality of life.

The role of best supportive care is to palliate the symptoms the patients may have. In this situation, it is essential to balance the morbidity of treatment versus potential benefit the patient may receive. Often one may have ethical dilemma when faced with young patients with locoregionally advanced tumors. In this situation, temptation of surgery should be tempered. One should consider surgery as palliation to alleviate fungating ulcers or to close a cutaneous fistula. The goal of this surgery must be made very clear to the family. It is essential not to give false hope to the family, which will have deleterious consequence in the patient-physician relationship. In patients with good performance status, especially those who have not received previous radiotherapy, one may consider chemoradiotherapy with curative dose, with the goal to obtain durable palliation. In doubtful situations, induction chemotherapy followed by chemoradiotherapy could also be considered. Local radiation or re-radiation to a limited field may be considered for fungating ulcers. The dose, fractionation, and volume of radiation field need to be tailored for palliative purpose.

In patients with advanced metastatic disease, one needs to be very selective in recommending systemic therapy as the benefit is doubtful. Chemotherapy with targeted anti-EGFR treatment has shown improved survival up to 4 months, with significant morbidity associated with the regimen [20]. An alternate approach is chemotherapy at metronomic dosing regimen, especially the use of methotrexate and celecoxib [21]. Recent evidence of nivolumab, a checkpoint inhibitor, showing improved survival of about 3 months, and acceptable morbidity, is to be considered. However the cost of the treatment is a major deterrent for its wider application. Table 82.5 provides the indications for adjuvant RT and adjuvant CT + RT.

Table 82.5 Indications for adjuvant RT and adjuvant CT + RT

Indications for adjuvant RT		Indications for adjuvant CT + RT
Tumor factors	Nodal factors	
<ul style="list-style-type: none"> • Perineural invasion. • Lymphovascular invasion +pT3/T4 primary tumor. 	<ul style="list-style-type: none"> • Multiple positive nodes (without ECE). • Positive level IV/V nodes. 	<ul style="list-style-type: none"> • Extra-capsular nodal spread. • Positive margins.
<ul style="list-style-type: none"> • Bernier J et al. [22] 		

82.6 Indications for Adjuvant RT and Adjuvant CT + RT

After various comparative studies, it has been concluded that in adjuvant setting, postoperative IMRT has to be given at dose of 60 Gy in 30 fractions to surgical bed and first echelon nodal stations and the high-risk regions receive a total dose of 66 Gy. It has to be remembered that for salvage surgery cases, concept of re-irradiation should be explained to the patient. A minimum of 12-month duration gap is required prior to re-irradiation to allow for the spinal cord recovery.

In cases with postoperative histopathological features like extranodal extension or positive surgical margins, patients are treated with concurrent chemoradiation (usually 100 mg/m² of cisplatin for a maximum of 6 cycles in India). Indication of chemotherapy as described is usually in adjuvant setting in oral cavity cancers.

However role of chemotherapy as induction therapy is evolving. Chemotherapy usually exerts its cytotoxic effects systemically and hence associated with side effects. The major drawbacks of chemotherapeutic agents used commonly are the adverse toxicities and cellular resistance. In an induction setting, most commonly taxanes, platinum, and 5FU are used as 3 cycle regimen (also refer Chap. 84 of this book on Adjunctive therapy in Oral Cancer).

Tumors of oral cavity which are considered technically unresectable are as follows:

- Erosion of skull base, sphenoid bone, and widening of foramen ovale.
- Encasement of internal carotid artery, >270 degree.
- Involvement of mediastinal structures.
- Involvement of prevertebral fascia or cervical vertebrae.

These are considered unresectable not due to surgical technicality but because of the inability to get negative margins and to achieve R0 resection. However, with the superior skills such as endoscopic-assisted surgeries which are associated with less morbidity, and better adjuvant treatment including chemotherapy, an attempt has been made to con-

sider resection of tumors involving muscles of mastication and pterygoid plates especially with the anterior infratemporal fossa involved. Recent studies have shown that surgical resection of these tumors along with adjuvant treatment has shown survival benefit. Also studies from Tata Memorial Hospital, India have shown better outcome in patients who have undergone surgical resection following neoadjuvant chemotherapy.

82.7 Principles of Ablative Surgery

1. Adequate access to the tumor.
2. To achieve negative surgical margins.
3. Utilization of intraoperative frozen section for margin assessment.
4. Wide excision versus compartment resection.

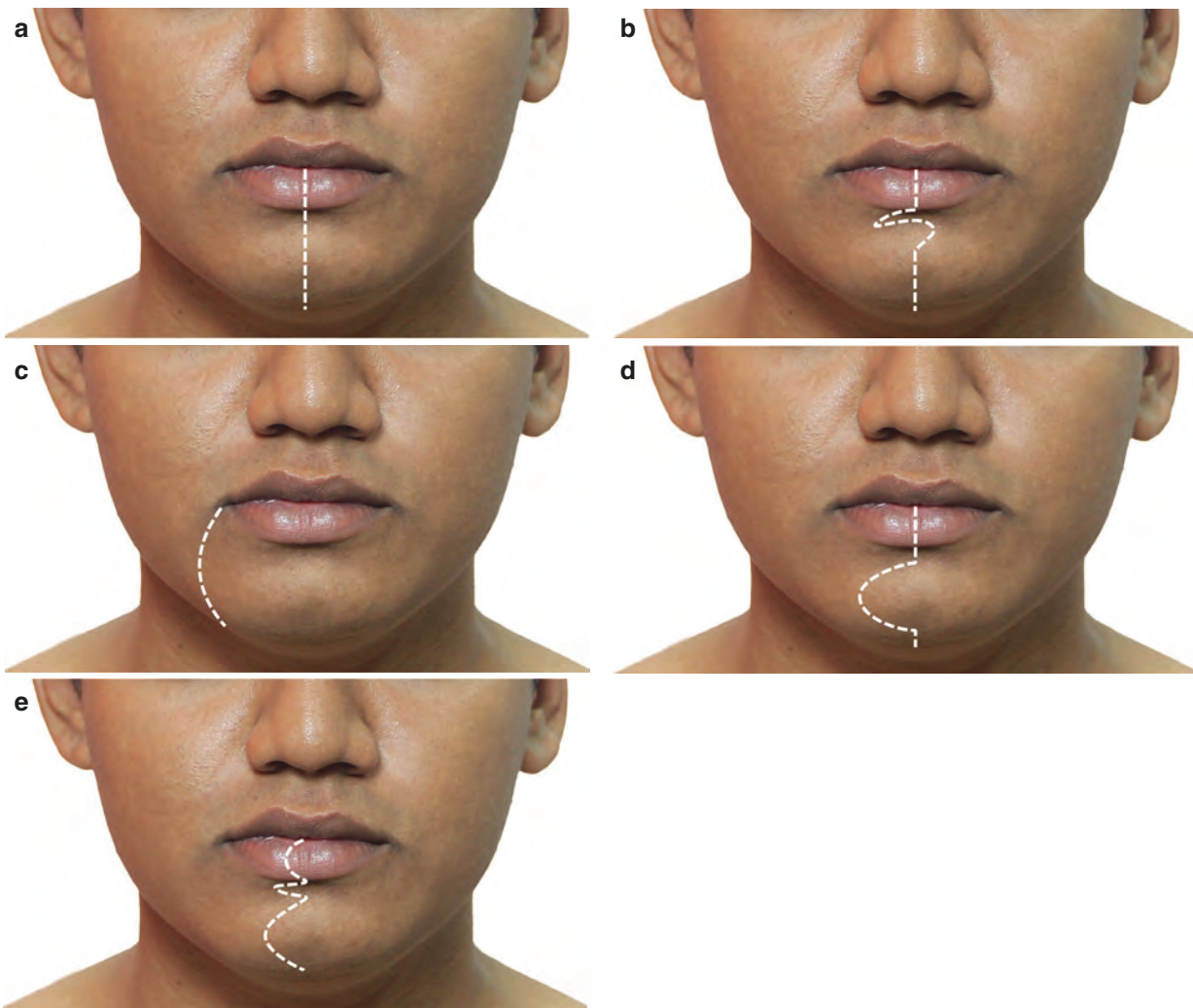
The surgical approaches for tumors of oral cavity depends primarily on the site of tumor (anterior versus posterior), its size, and its proximity to bone (maxilla or mandible). The various approaches frequently used for oral cavity cancers are shown in Figs. 82.9, 82.10, 82.11, 82.12, 82.13, and 82.14 (Also refer Chap. 85 of this book on Access Surgeries and Osteotomies of the Maxillofacial Region).

Types of mandibulotomy is shown in (Figs. 82.15, 82.16a, b) shows marginal mandibulectomy and segmental mandibulectomy.

82.8 Sub-Site-Wise Surgical Management

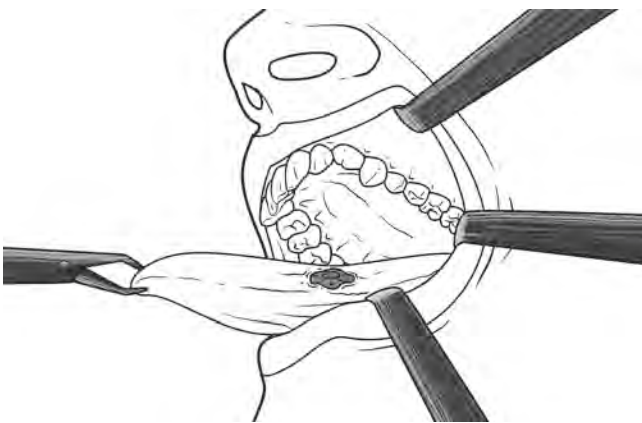
82.8.1 Tongue and Floor of Mouth

The tongue is a muscular organ which is composed of intrinsic and extrinsic muscles and divided anatomically into the oral tongue (falls in oral cavity cancers) and base of tongue (BOT, sub-site of oropharynx). The tongue is innervated by the hypoglossal nerve, and vascularity is by lingual artery (branch of external carotid artery). Pathway of tumor spread from the oral tongue can be into the floor of mouth, mandible, or/and base of tongue via local extension, the lingual septum being the barrier to tumor spread. For tumors abutting the mandible, marginal mandibulectomy is indicated for negative surgical margin encompassing the tumor and at the same time preserving the mandibular continuity. Segmental mandibulectomy is usually done when there is mandibular erosion or paramandibular spread. Anterior segmental mandibulectomy is more commonly indicated in floor of the mouth cancers.



©Association of Oral and Maxillofacial Surgeons of India

Fig. 82.9 Lip split incisions; (a) midline lip split (straight), (b) midline lip split with Z-plasty; (c) angle/commissure lip split; (d) straight midline with chin contour; (e) straight midline with chin contour and Z-plasty at vermilion and submental region



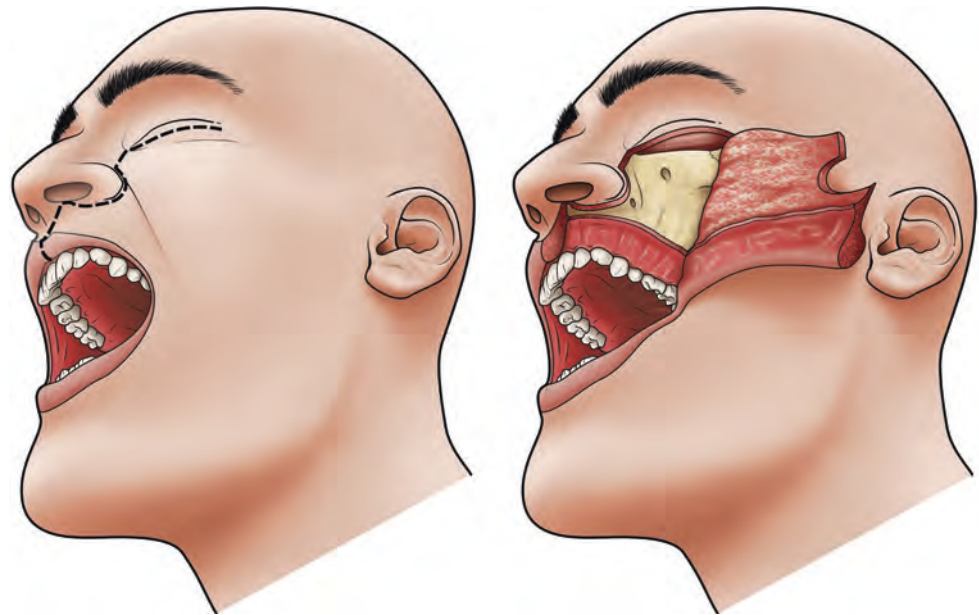
©Association of Oral and Maxillofacial Surgeons of India

Fig. 82.10 Pictorial representation of excision of lesionally per-orally. This is usually indicated for T1–2 lesion in patients with adequate mouth opening

Lingual artery is an end artery, and hence clinicians have to be careful in resections involving more than two-thirds of tongue mass as this may jeopardize the vascularity and utmost care to be taken to preserve the neurovascular bundle.

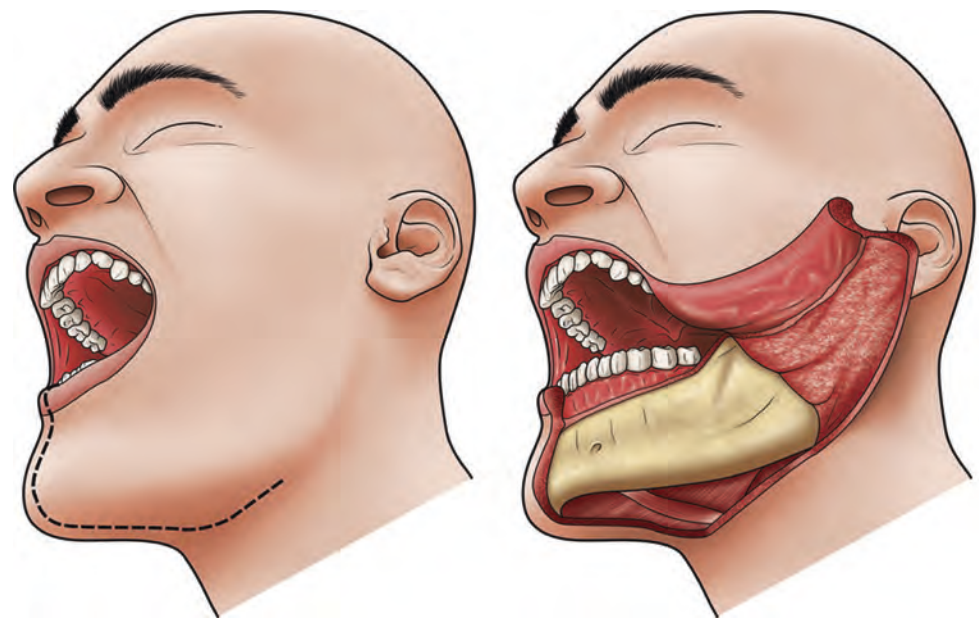
There is a recent concept of compartment resection in patients with infiltrative disease where the adjacent extrinsic musculature and neurovascular bundle is excised in continuity to ensure negative margins. This was proposed by Calabrese [23], and all cases underwent access mandibulotomy; hence it is not commonly followed. Tumors of floor of the mouth are usually infiltrative and lymph node metastasis is seen bilaterally. According to Byers, the rate of lymph node skip metastasis at level IV is observed in about 10–15% cases. According to the study by Kowalski [24], tumors of floor of the mouth, tongue cancers crossing the midline, and advanced stage of the disease have a propensity of developing contralateral lymph node metastasis.

Fig. 82.11 Weber-Ferguson incision for tumors of maxilla not amenable to per-oral excision and not requiring infratemporal fossa access. The upper cheek flap is raised as shown



©Association of Oral and Maxillofacial Surgeons of India

Fig. 82.12 A lower midline lip split incision continued and transverse neck skin crease incision followed by raising of a lower cheek flap. This gives the best access to infra-temporal fossa. The periosteum to be left on the mandible to preserve its periosteal blood supply. The mental neurovascular bundle has to be sacrificed

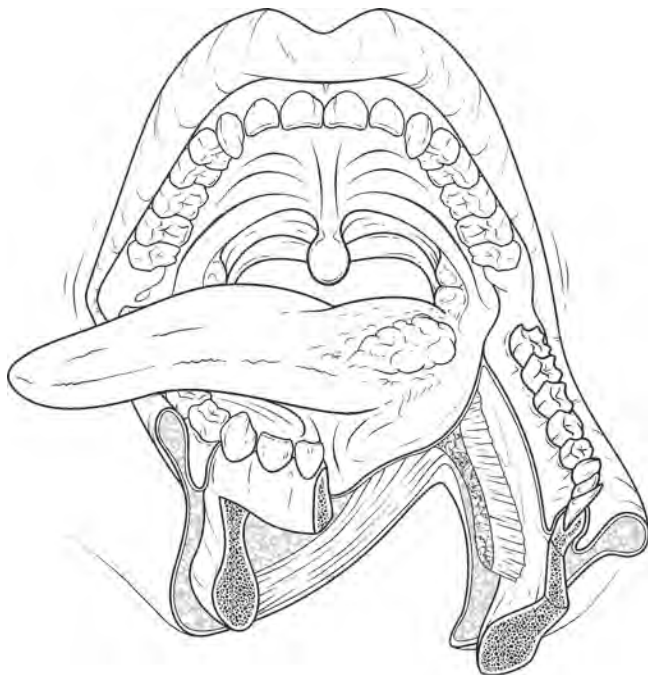

©Association of Oral and Maxillofacial Surgeons of India

82.8.1.1 Surgery

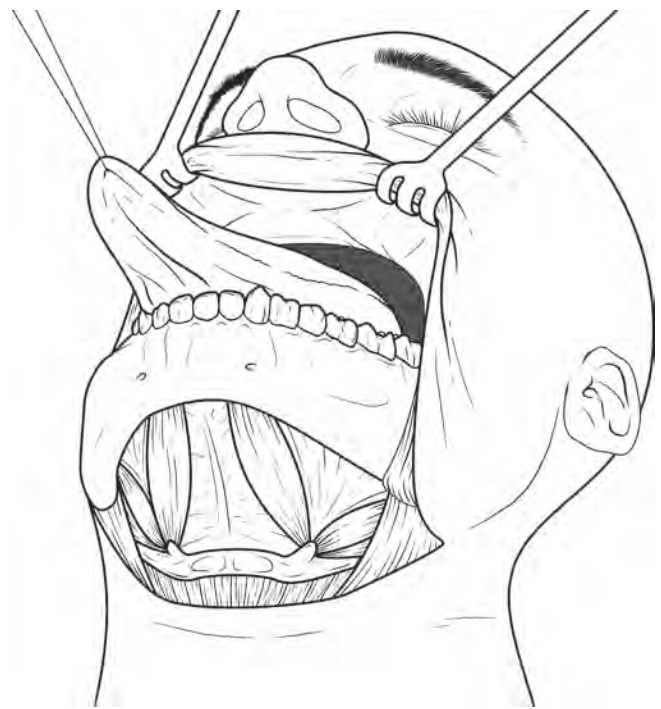
Wide local excision (WLE)/adequate glossectomy procedure with adequate surgical margins has been the procedure of choice for early tongue cancers, and this is amenable with per-oral approach. Before planning resection, thorough knowledge about the extent of lesion is important, and palpa-

tion of induration provides a guide for the same. Ideal margin for resection of tumour is all 1–1.5 cm all around. Usually it is the deep soft tissue margin which is prone for being close or positive, and this can be avoided by palpation method. In many institutions, it is a useful practice to ligate the lingual artery in the neck before performing WLE for



©Association of Oral and Maxillofacial Surgeons of India

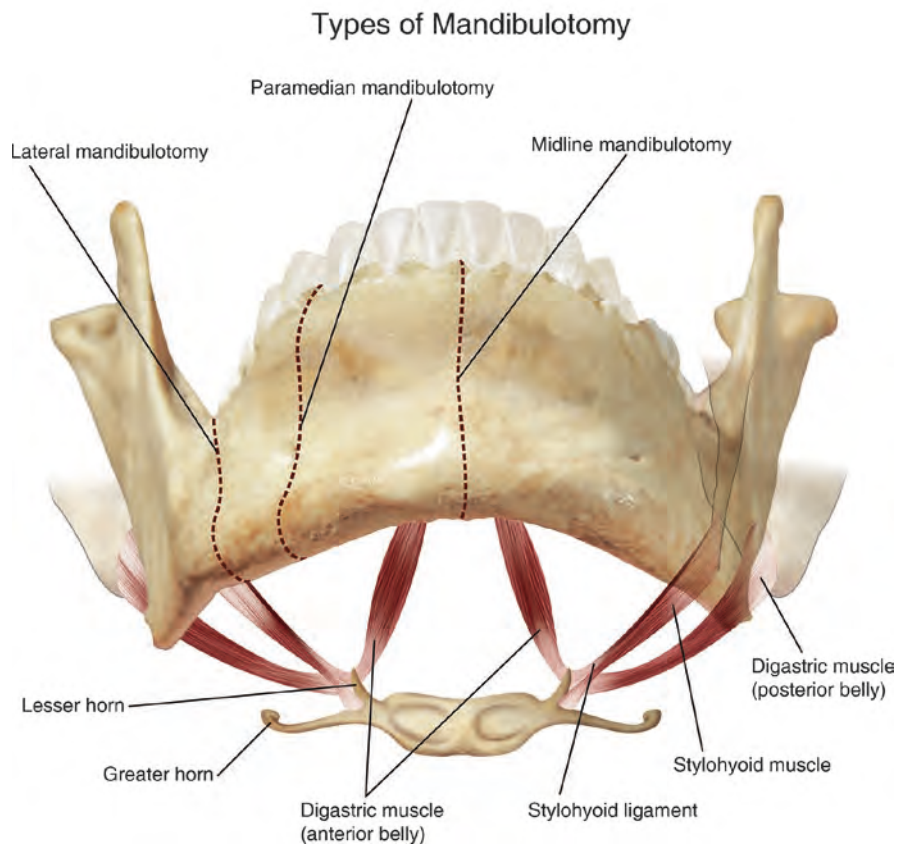
Fig. 82.13 This picture depicts access mandibulotomies for tumors situated in the posterior tongue. The other alternative is pull through approach



©Association of Oral and Maxillofacial Surgeons of India

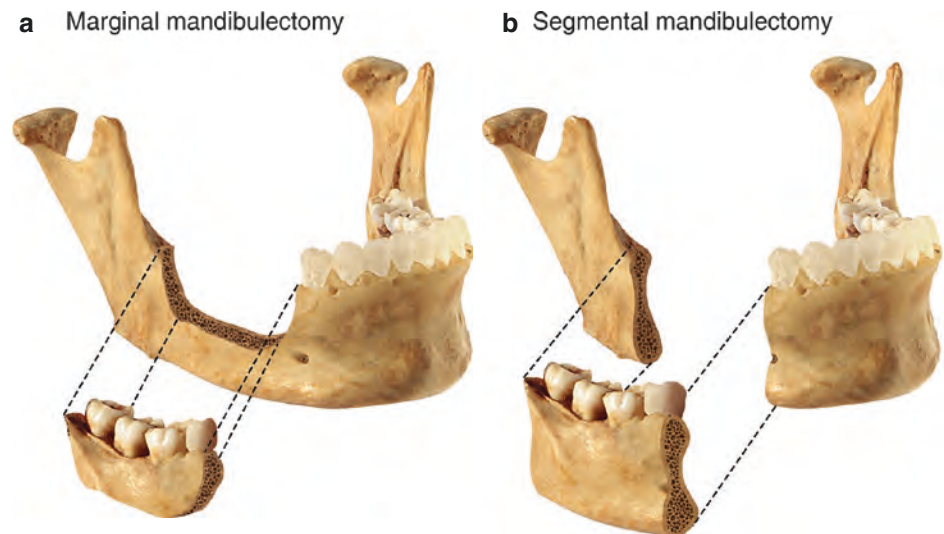
Fig. 82.14 Visor flap provides best access for total and subtotal glossectomy

Fig. 82.15 Depiction of various types of access mandibulotomies



©Association of Oral and Maxillofacial Surgeons of India

Fig. 82.16 Types of mandibulectomies (a) marginal and (b) segmental



©Association of Oral and Maxillofacial Surgeons of India

adequate bleeding control and clean surgical field. The resulting defects of adequate glossectomy for early lesions are usually closed primarily avoiding tethering of the tongue. Excisional biopsy for suspicious lesions is highly discouraged even if the lesion is about 1 cm.

Moderately advanced cancers of the tongue and floor of the mouth (T2–T3) warrant classical hemiglossectomy which sacrifices the tip jeopardizing the tongue mobility resulting in compromised speech and swallowing. Majority of these tumors are excised by combinations of per-oral and pull-through approaches, without the actual need for lip-split or access mandibulotomy. The pull through technique helps in avoiding positive posterior margins as the resection is done under direct vision. All these patients require reconstructive surgery (lining or bulk), along with long-term tracheostomy and feeding tube (ryles tube/PEG) dependence. Free-flap reconstructions have become inevitable following resection of tongue cancers. Locally advanced (T4a) cancers (tumor depth > 20 mm, restricted mobility and hypoglossal palsy) of tongue warrant total glossectomy or near-total glossectomy. Standard total glossectomy procedure involves complete removal of anatomical tongue from mandible to hyoid and from the tip of the tongue upto the vallecula.

The following is a brief outlay of surgical steps: anterior belly of digastric muscle is first divided through the cervical neck incision followed by intra-oral crevicular incision. Then the genioglossus, geniohyoid is divided from the genial tubercle and mylohyoid muscle from the mylohyoid line from the mandible. At the contralateral retromolar region come the division of buccopharyngeal fascia, styloglossus

muscle, and the palatoglossus muscle and incision at the vallecula. The same steps are repeated on the other side for total glossectomy. However in near-total/subtotal glossectomy, base of the tongue of uninvolved side is preserved. It is the extent of excision of the base of tongue which determines the postoperative swallowing function.

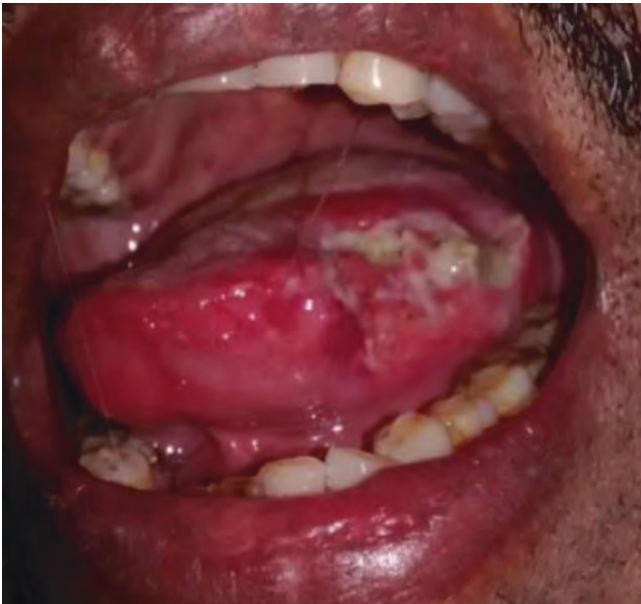Tongue and the FOM lesions involving or abutting mandible pose a unique challenge. Resecting the segment of mandible increases morbidity and reconstructive challenge by many times. In such situations an attempt should be made to preserve the mandible whenever possible.

Removal of the level V lymph node is reserved in situations when level IV or V is involved or in N3 nodal disease. According to Kowalski et al., the indications for addressing contralateral lymph nodes are lesions of the tongue crossing the midline, floor of the mouth tumors, and locally advanced T3 and T4 tumors [24].

Reconstruction of the tongue requires a soft tissue flap with large volume to provide the adequate bulk which in turn is believed to aid in swallowing. The drawback of a reconstructed tongue is the impaired mobility resulting in compromised speech. The most commonly used flap is radial forearm free flap and anterolateral thigh free flap. The other uncommon examples for free tissue transfer are lateral arm flap, gracilis flap, and local flap such as FAMM flap and submental flap.

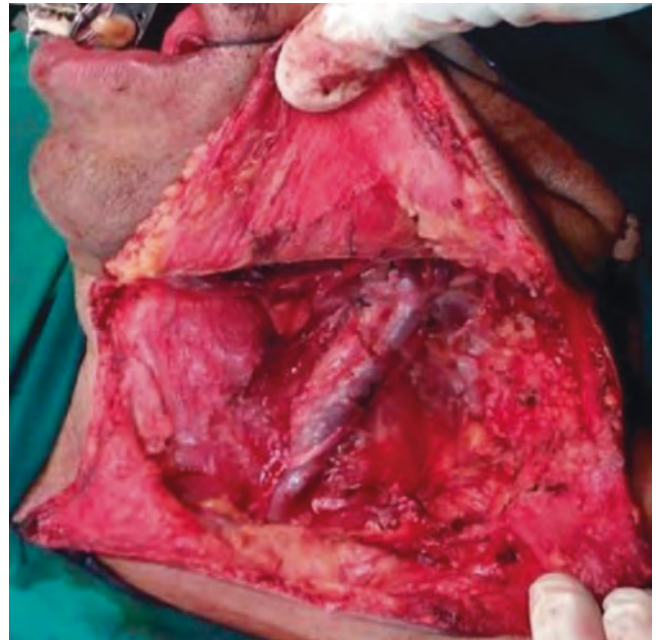
Reconstruction of tongue defect using radial forearm free flap (Figs. 82.17, 82.18, 82.19, 82.20 and 82.21).

Reconstruction of tongue defect with local flap: facial artery myomucosal flap (Figs. 82.22, 82.23, 82.24 and 82.25).



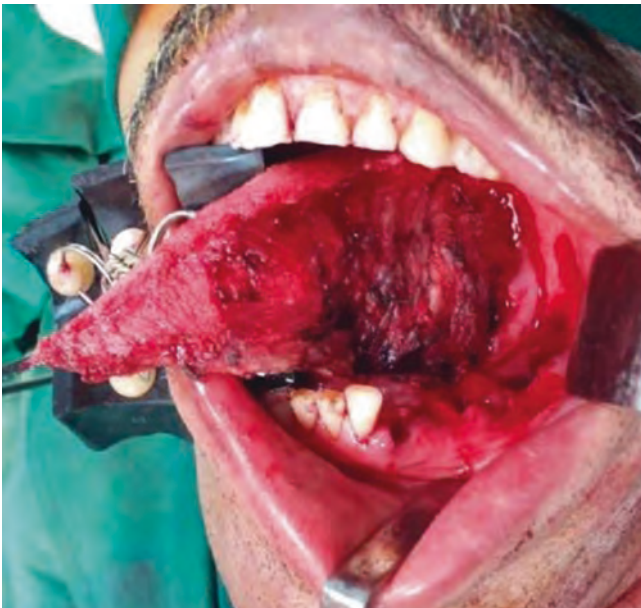©Association of Oral and Maxillofacial Surgeons of India

Fig. 82.17 Squamous cell carcinoma of left lateral border of the tongue with induration extending 1 cm short of midline not involving floor of mouth



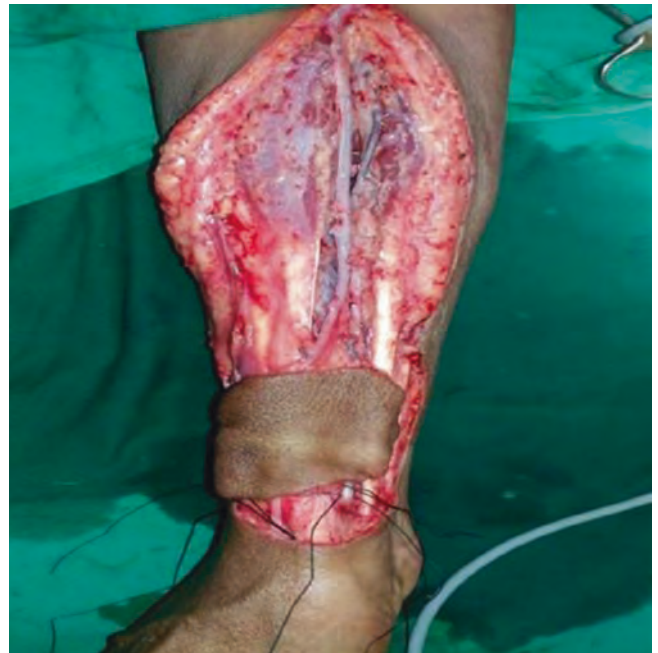©Association of Oral and Maxillofacial Surgeons of India

Fig. 82.19 Completed left modified radical neck dissection



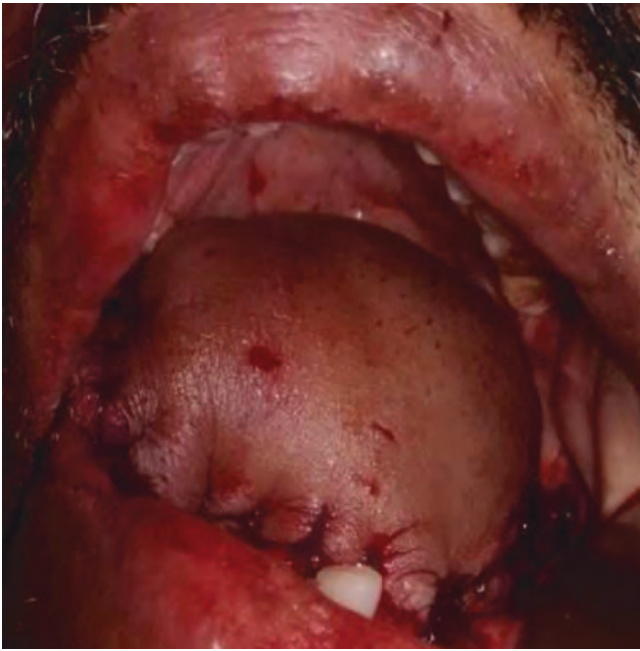©Association of Oral and Maxillofacial Surgeons of India

Fig. 82.18 Post-surgical defect following left hemiglossectomy and left marginal mandibulectomy



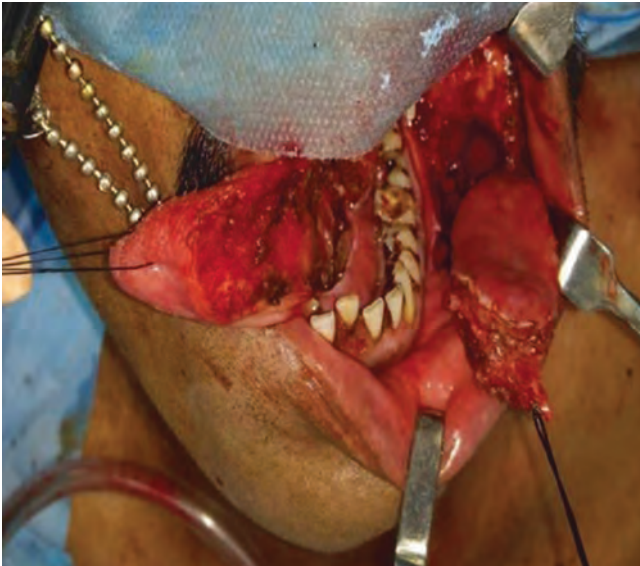
©Association of Oral and Maxillofacial Surgeons of India

Fig. 82.20 Left radial artery forearm free flap harvested for the defect



©Association of Oral and Maxillofacial Surgeons of India

Fig. 82.21 Radial forearm free flap inset into defect and anastomosed to left facial artery and tributary of left internal jugular vein



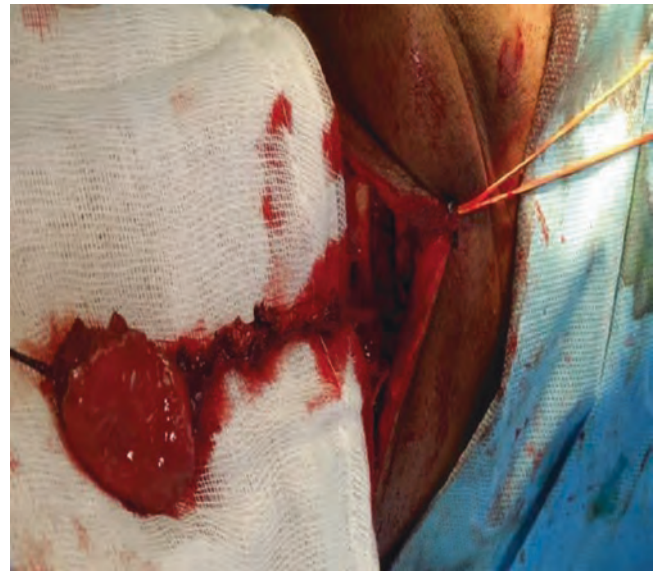©Association of Oral and Maxillofacial Surgeons of India

Fig. 82.22 Tongue defect following wide local excision of left lateral border tongue squamous cell carcinoma

82.8.2 Buccal Mucosa

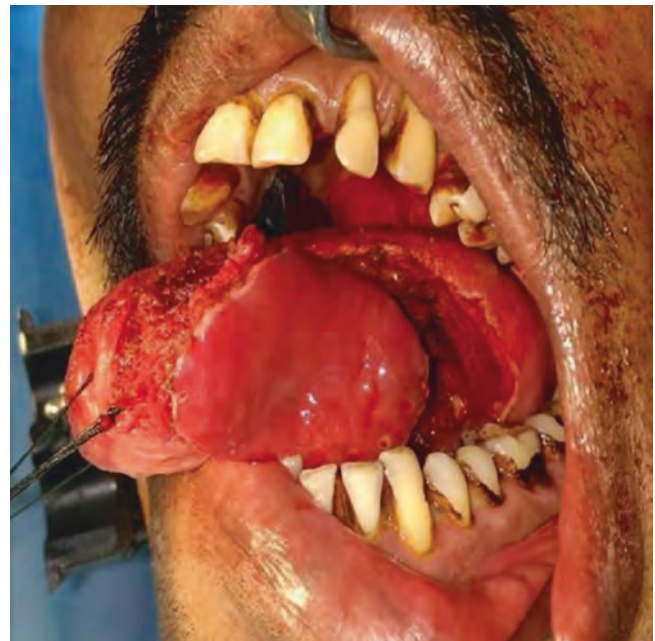82.8.2.1 T1/T2 Lesions

Surgical Steps: For Early Buccal Cancer Per-oral approach is adequate. It is important to ensure oncologic



©Association of Oral and Maxillofacial Surgeons of India

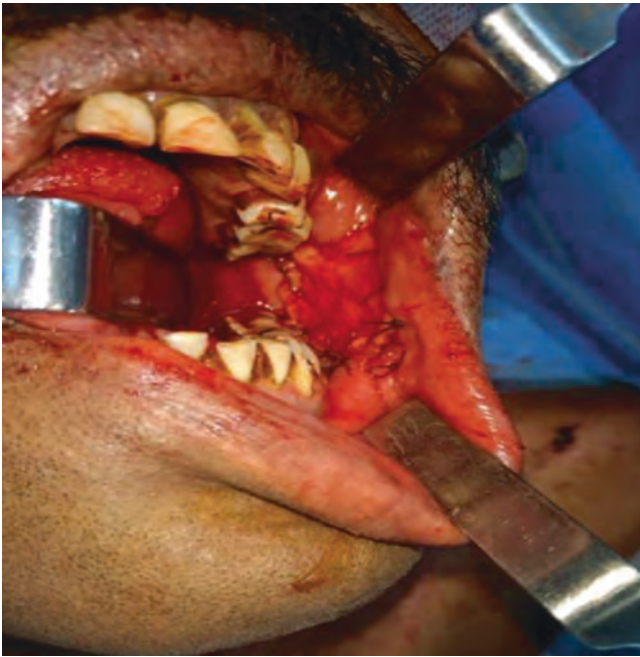Fig. 82.23 Harvesting of facial artery myomucosal flap (FAMM)



©Association of Oral and Maxillofacial Surgeons of India

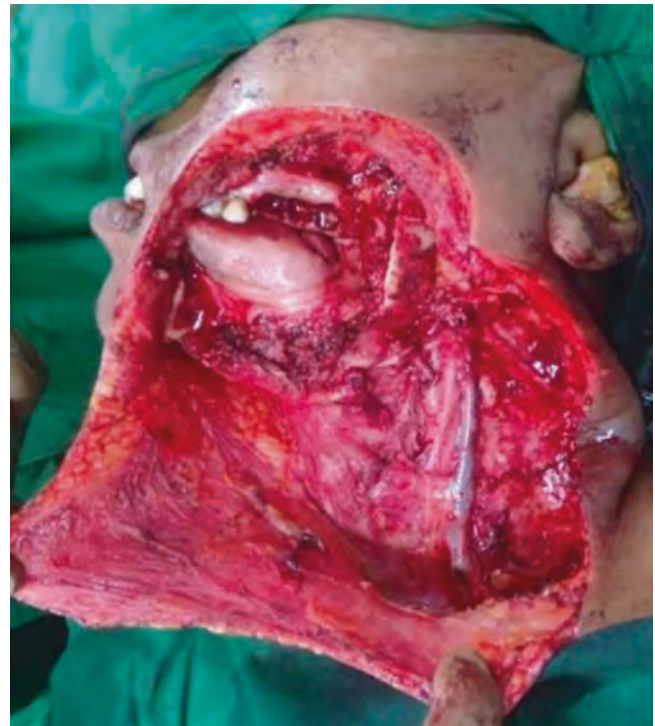Fig. 82.24 FAMM flap tunneled into the defect and reconstructed

completeness and appreciate depth. Inadvertent injury to the buccal branch of facial nerve and to the parotid duct should be avoided. Facial artery, facial vein, and parotid duct (if encountered or injured) should be ligated. Mucosal incision around the lesion, with adequate margin, taking the buccinator muscle in specimen forms the deep soft tissue margin. These defects can be reconstructed with split thickness skin grafts/buccal pad of fat/local flaps such as nasolabial flap.



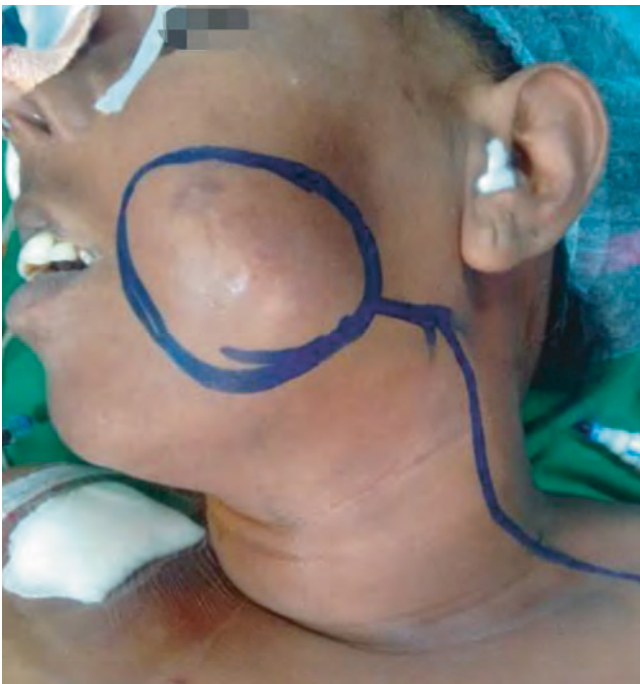©Association of Oral and Maxillofacial Surgeons of India

Fig. 82.25 Closure of the donor site



©Association of Oral and Maxillofacial Surgeons of India

Fig. 82.27 Defect following composite resection and modified radical neck dissection; this defect was reconstructed with anterolateral thigh free flap



©Association of Oral and Maxillofacial Surgeons of India

Fig. 82.26 Locally advanced T4a, left buccal mucosa lesion requiring composite resection with excision of the overlying involved skin

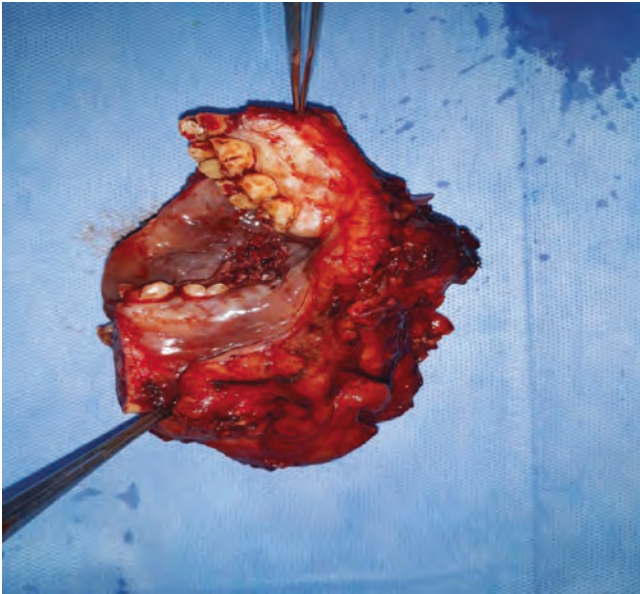
Advanced T3/T4 Lesions (Lesions with Skin Involvement/ Bone Involvement/Involvement of Muscles of Mastication) Pre-operative clinical examination revealing a subtle skin puckering and imaging studies shows stranding

of subcutaneous fat that is the early sign of skin involvement. If buccal space involvement is suspected, then buccal fat pad should be included in the specimen.

These advanced lesions require full-thickness cheek resection. The planning of incision may be a midline lip split or angle split, both of which will help in raising a lower cheek flap or when overlying skin is involved, an incision around the skin involved in continuity with the neck dissection incision. The muscle of mastication involvement warrants infra-temporal fossa clearance (Figs. 82.26, 82.27 and 82.28).

82.8.3 Gingivobuccal Sulcus

Gingivobuccal sulcus (GBS) tumors are tumors occurring in the upper or lower GBS, usually seen to abut the bone adjacent (Fig. 82.29). These occur almost exclusively in Southeast Asia due to high incidence of chewing tobacco use. Due to the high propensity for local invasion and close proximity of bone, skin, and masticator space, presentation is often advanced, and outcomes are poor. If there is superficial erosion of bone or if the lesion is abutting the mandible, then the resection should include marginal mandibulectomy. Superficial cortical erosion in alveolar tumors is not considered as T4 lesion, and marginal mandibulectomy may still suffice. Although MRI is consid-



©Association of Oral and Maxillofacial Surgeons of India

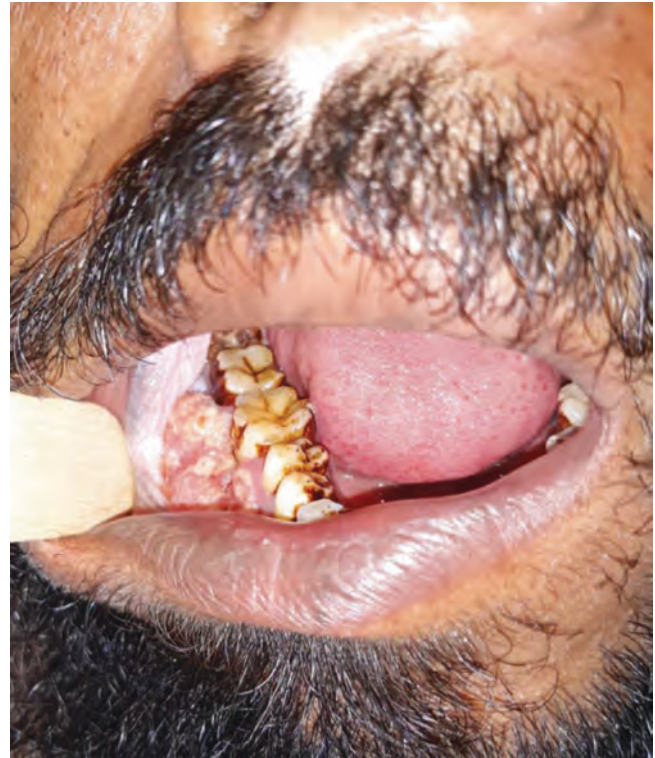Fig. 82.28 Excised specimen in toto (Same case shown in Figs. 82.26 and 82.27)

ered most sensitive imaging modality to determine extent of bony involvement, periosteal stripping is by far the best method to determine extent of bony erosion and helps in decision-making regarding extent of mandibulectomy. GBS tumors usually present at an advanced stage with gross mandibular erosion, paramandibular spread, or overlying skin involvement (skin involvement is never seen in the masseter region as it is a tumor barrier). These findings preclude the use of marginal mandibulectomy, and hence patients often require segmental mandibulectomy and bony reconstruction.

82.8.4 Retromolar Trigone Carcinoma

Retromolar trigone tumors are rare but more aggressive malignancies with poorer outcome. Higher incidence of local recurrence has been reported in squamous cell carcinoma of the retromolar trigone (RMT) and posterior GBS carcinomas. This is attributed to its higher propensity of infratemporal fossa (ITF) and pterygomandibular fissure involvement. Due to restricted mouth opening at the time of presentation, thorough clinical examination is hindered. For both oncologic and anatomic reasons, tumors with mandibular invasion are best managed surgically by segmental mandibulectomy including coronoid process of the mandible.

The reason to preserve condyle is as follows: (a) it may be used for secondary reconstruction, and (b) as the condyle lacks medullary bone, it does not act as a pathway of spread and hence can be oncologically safe to preserve it.



©Association of Oral and Maxillofacial Surgeons of India

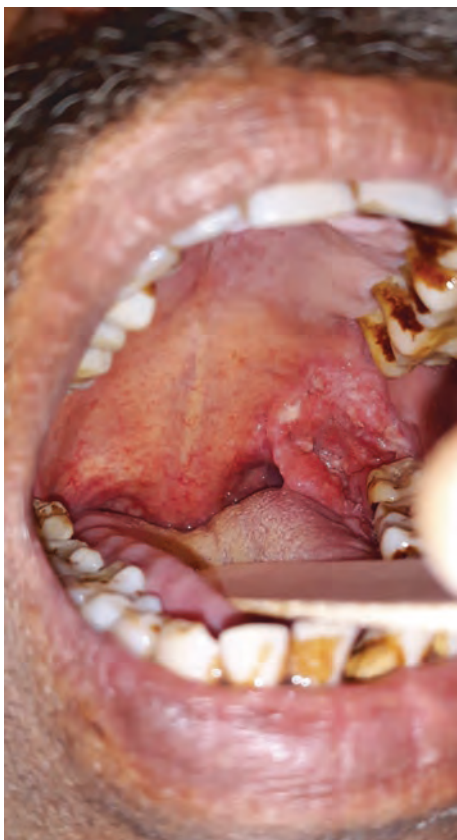Fig. 82.29 Classic example of a gingivo buccal tumor abutting the adjacent mandible

As a large proportion of the RMT tumors involve both the upper and lower jaw (Fig. 82.30), excision of ramus of mandible in the form of subsigmoid marginal mandibulectomy with at least an upper alveolectomy and ITF clearance (anterior ITF comprising masseter and medial pterygoid with or without pterygoid plates) is required. Selective neck dissection comprising of level I–V lymph nodes is usually performed electively for all stage cancers for purpose of staging.

82.8.5 Hard Palate

Tumors of the hard palate are less common when compared to tumors of the mandible, tongue, or buccal mucosa and are often of minor salivary gland etiology. Premaxilla provides support for the nose and midface; lesions involving anterior alveolus and hard palate will require bony reconstruction to prevent midface deformity. Lesions of the posterior alveolus and hard palate have a higher tendency to locally invade the orbital floor and skull base or through various neurovascular bundles (greater palatine foramen, sphenopalatine foramen, palatovaginal canal).

Lymph node involvement is very rare for salivary neoplasm of the palate, and neck dissection is reserved only for node-positive disease. However, maxillary alveolar carcinoma has a high propensity for occult lymph node metastasis



©Association of Oral and Maxillofacial Surgeons of India

Fig. 82.30 Left retromolar trigone squamous cell carcinoma extending to involve lingual surface of mandible, soft and hard palate ipsilaterally

(15–20%), and also in patients where neck is not addressed, they tend to present with nodal recurrences which are not salvageable in two-thirds of the cases; hence it is wise to consider elective neck dissection. The other point worthwhile and to be noted is that perifacial group of lymph nodes have to be cleared for effective disease control for the upper alveolus (Figs. 82.31, 82.32, 82.33 and 82.34).

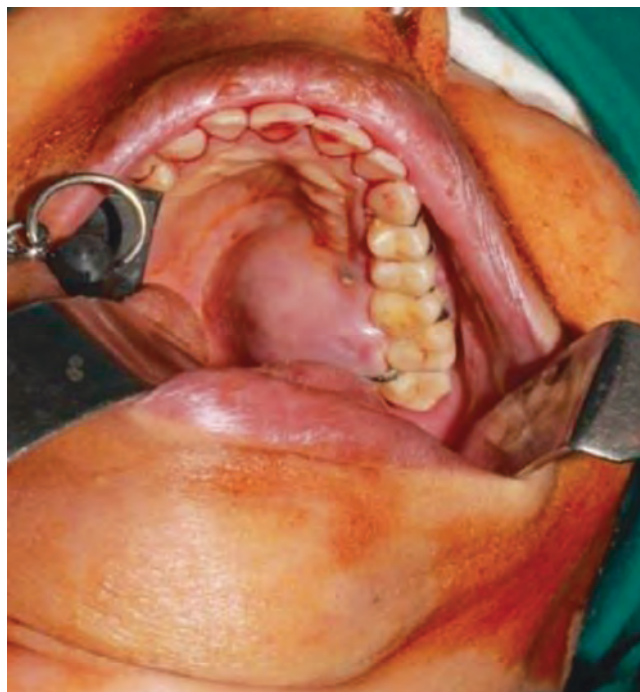82.8.5.1 Brown's Classification System for Maxillary Defects [25] (Fig. 82.35)

Vertical Component

- Class I, maxillectomy with no oroantral fistula.
- Class II, low maxillectomy.
- Class III, high maxillectomy.
- Class IV, radical maxillectomy.

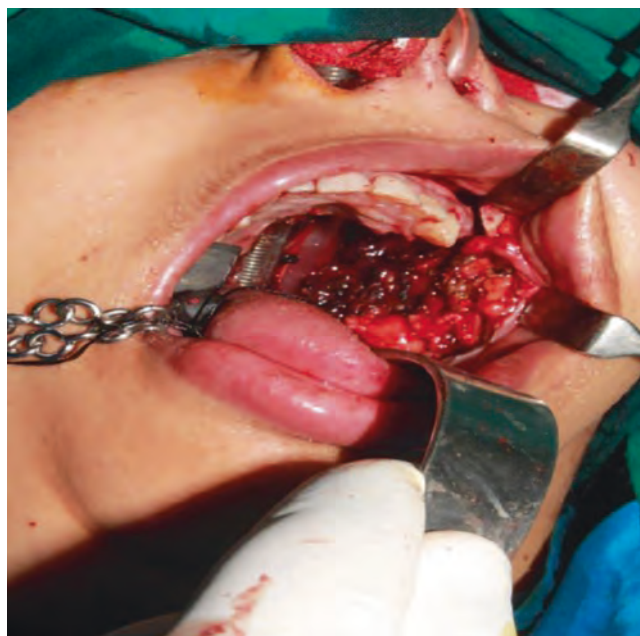Horizontal Component I, unilateral alveolar maxilla and resection of the hard palate;

(a) resection of less than or equal to half of the alveolar and hard palate, not involving the nasal septum or crossing the midline;



©Association of Oral and Maxillofacial Surgeons of India

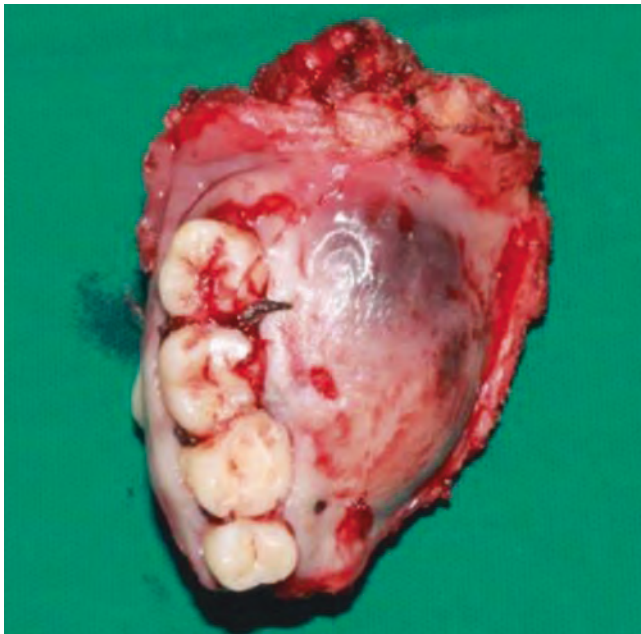
Fig. 82.31 Minor salivary gland tumour of the hard palate



©Association of Oral and Maxillofacial Surgeons of India

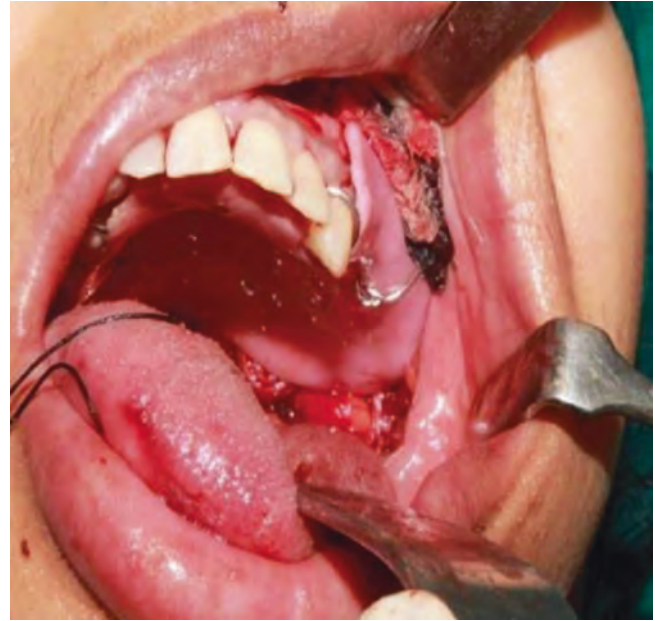Fig. 82.32 Defect following partial maxillectomy

(b) resection of the bilateral alveolar maxilla and hard palate, including a smaller resection that crosses the midline of the alveolar bone, including the nasal septum; and
(c) removal of the entire alveolar maxilla and hard palate.



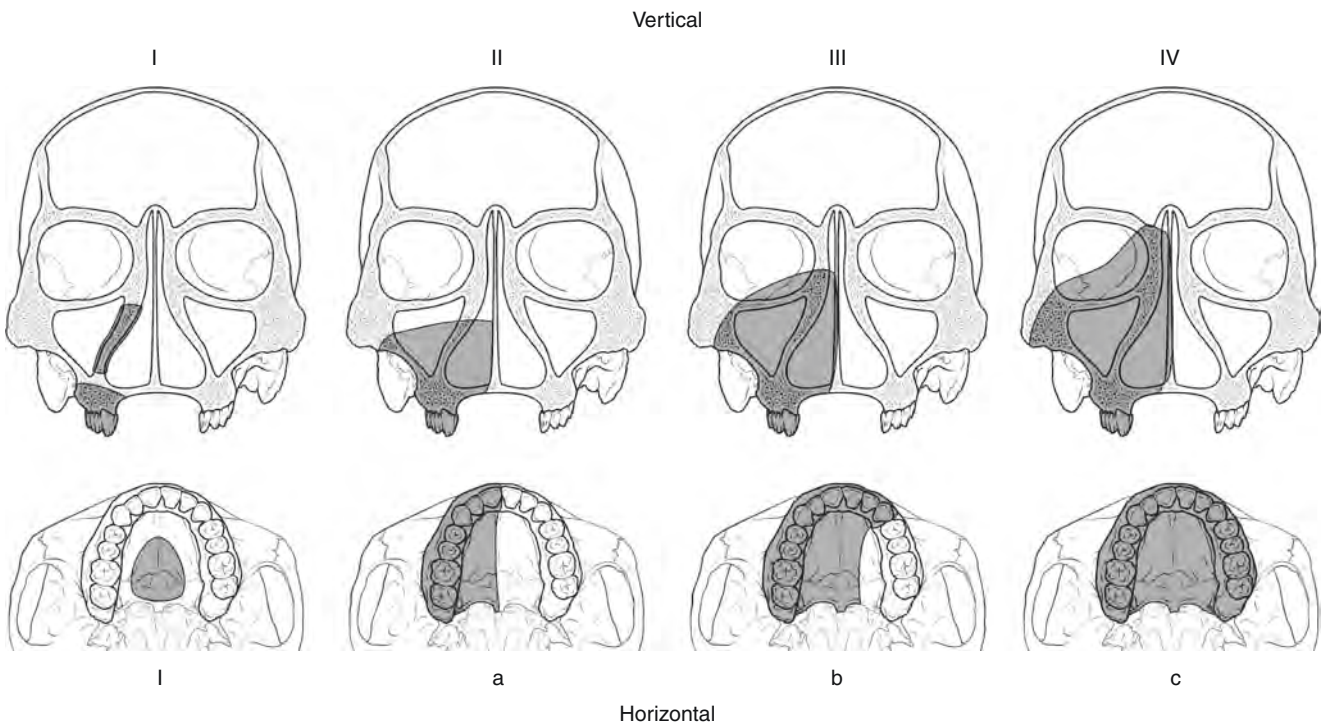
©Association of Oral and Maxillofacial Surgeons of India

Fig. 82.33 Specimen in toto



©Association of Oral and Maxillofacial Surgeons of India

Fig. 82.34 Defect reconstructed with conventional obturator placement



©Association of Oral and Maxillofacial Surgeons of India

Fig. 82.35 Brown's classification for maxillectomy defects

82.8.6 Lip Carcinoma

Squamous cell carcinoma of the lip is most frequently associated with sun exposure as the risk factor. Lower lip is more commonly involved than the upper lip. Submental and submandibular nodal basins are the primary echelon drainage path-

ways; regional nodal metastasis occurs in only 10% of patients. Full-thickness excision with up to 1 cm margin is necessary. Lesions that involve less than one-third of the lip are managed with simple wedge excision and primary closure and hence offer acceptable oncologic and reconstructive results. For lesions larger than one-third but less than two-thirds, Abbe-Estlander or

Table 82.6 Treatment modalities of use in oral cancer

T1/T2 N0	Radiotherapy/brachytherapy vs. surgery
T3/T4 N0/ N+	Surgery is mainstay of treatment followed by adjuvant therapy

Karapandzic flap can be utilized (refer Chap. 86 on Soft tissue reconstruction of the Maxillofacial Region). For defects more than two-thirds, free tissue transfer is preferred to achieve better cosmetic result and avoid microstomia and oral incompetence. To ensure oral competence, adjunctive procedures such as fascial sling, palmaris longus sling, or temporalis muscle sling can be used along with the adynamic soft tissue flap.

Table 82.6 describes the treatment modalities of use in oral cancer.

82.8.6.1 Management of the Neck in Oral Cavity

Introduction

Although skip metastasis can occur, lymph node metastasis usually follows a predictable fashion from the first echelon nodes to the second echelon nodes. Tumors of the oral cavity most commonly drain to levels I (submental and submandibular group) and level II (upper jugular group) in the neck. Level IA is between the two anterior belly of digastric muscle, and level IB is between anterior and posterior belly of digastric muscle on either side. The submental triangle drains the anterior portion of the oral cavity and hence can get involved in the tumors of the incisor region, the anterior floor of mouth, or anterior mandibular gingival/alveolar cancers. The level II nodes are found between the level of the hyoid bone inferiorly and anteriorly, the posterior belly of the digastric muscle superiorly, and the posterior border of the sternocleidomastoid muscle (SCM) posteriorly. In the jugular chain, the level III lymph node station is demarcated inferiorly by the omohyoid muscle as it crosses the internal jugular vein (IJV) and contains the mid-jugular lymph nodes particularly the prominent omohyoid node lying in close relationship to the muscle. Level IV (between the omohyoid muscle and the transverse cervical vessels, medially bound by the IJV) and V (between the posterior border of SCM and anterior border of trapezius muscle, further divided into levels A and B by the spinal accessory nerve) nodes are very rarely directly involved by early initial spread of oral SCC. In addition to these classical patterns of spread, buccal cancers may present with parotid nodes, and the posterior maxillary alveolus/hard palate may spread initially to retropharyngeal nodes. Tumors involving/crossing midline and tumors of the floor of the mouth generally require bilateral neck dissection.

82.9 Evaluation and Diagnosis

Evaluation of neck disease for the purpose of staging is best done by USG-guided FNAC, it being both highly sensitive and specific, simple, and cost-effective but observer depen-

dent. Although palpation is most commonly employed, it has a very low accuracy ranging between 50 and 65%. The limitations of palpation method are obese patients or patients with previously treated necks; examination is more difficult. Imaging with CT scan or MR has been said to improve accuracy for metastatic neck disease to approximately 90%. Chaukar et al. found contrast-enhanced CT to give better concordance with histology in the N0 neck than either US or PET/CT.

82.10 Management

Evolution of neck dissection [26, 27]:

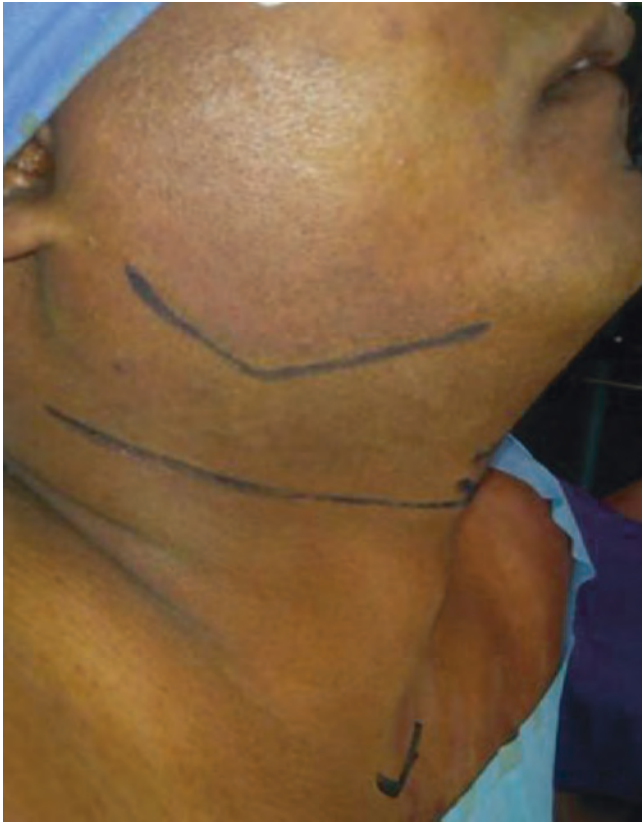- 1906—George Crile described the classic radical neck dissection (RND).
- 1933 and 1941—Blair and Martin popularized the RND.
- 1967—Bocca and Pignataro described the “functional neck dissection” (FND).
- 1975—Bocca established oncologic safety of the FND compared to the RND.

Technique:

- The incision is made through the skin and deepened to divide subcutaneous tissues. Thus exposing the platysma (Thin pink muscle layer) which is incised in a single stroke.
- This is followed by raising of the subplatysmal flaps with the superior limit being the lower border of the mandible; anteriorly it extends to the midline, posterior border of sternocleidomastoid (SCM) muscle posteriorly, and inferiorly till the clavicle [26].
- Neck dissection can be done either as an antero-posterior fashion or as a postero-anterior approach.
- Firstly the anterior belly of digastric muscle is identified, and mobilization of the fibrofatty tissue begins between the two anterior belly of digastric muscle and hyoid bone.
- In level IB dissection, marginal mandibular nerve is identified and preserved. The next step is to divide the fascia below the submandibular salivary gland, and the gland per se is retracted cephalad. This maneuver exposes the posterior belly of digastric muscle and helps in the identification of the facial artery. It is ligated close to the entry point at the posterior belly of digastric muscle and lower border of mandible. However full length of the facial artery may be preserved in case of full flap reconstruction [27, 28].
- The Sub mandibular gland (SMG), fibrofatty tissue, lymphatics and the prefacial LNs are mobilized off the mylohyoid and hence retracted it anteriorly.
- For the level II–IV lymph node dissection, the fascia over the SCM is raised till the posterior belly of digastric muscle superiorly. Level IIA dissection begins with identification of the Spinal accessory nerve (SAN) and Internal Jugular Vein (IJV) and removal of the LNs, lymphatics, and fibro-

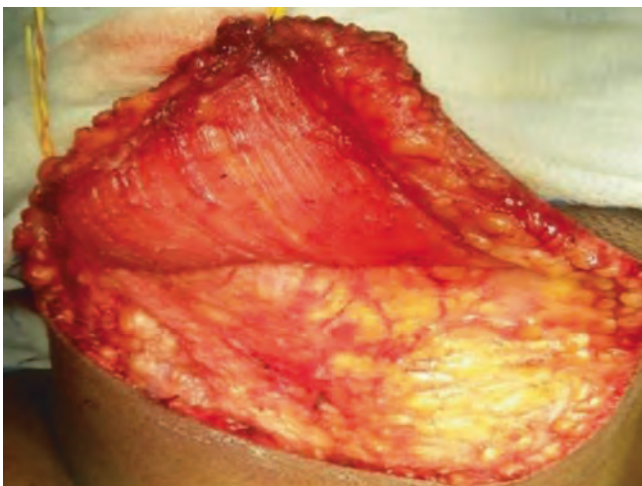
fatty tissue between these structures, the deep limit of dissection being the prepectoral fascia. At any given point on time tractional injury to the SAN has to be avoided.

- This is followed by release of the fascia and tissue along the posterior border of SCM till the clavicle inferiorly;



©Association of Oral and Maxillofacial Surgeons of India

Fig. 82.36 Incision marking for selective neck dissection



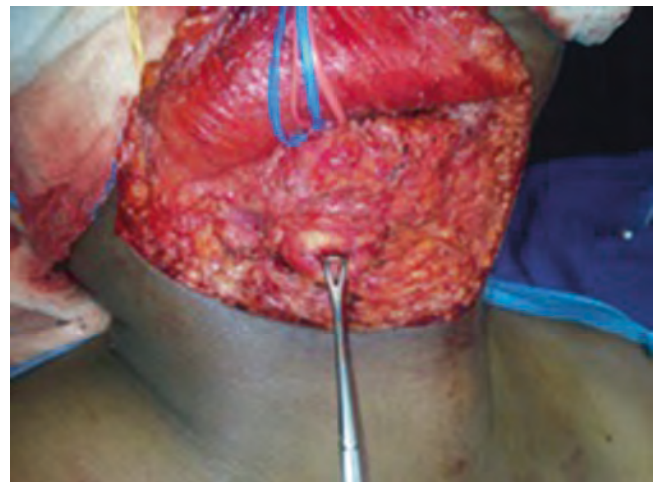
©Association of Oral and Maxillofacial Surgeons of India

Fig. 82.37 Raising of subplatysmal flap

mylohyoid muscle retracted inferiorly and lateral border of IJV identified. Care is taken to preserve deep cervical plexus. Now the level II–IV tissue is retracted anteriorly and peeled off the IJV and continued in the anterior triangle of the neck till the midline, preserved the superior thyroid vessels and tributary of IJV.

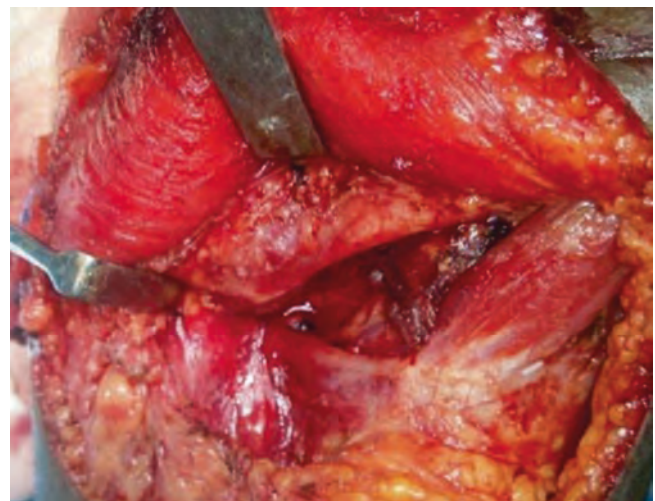
- Level IIB is dissected between the posterior belly of digastric and postero-superior to the SAN, posterior limit being SCM.

This completes the selective neck dissection (Figs. 82.36, 82.37, 82.38, 82.39, 82.40, 82.41, 82.42, 82.43, 82.44 and 82.45).



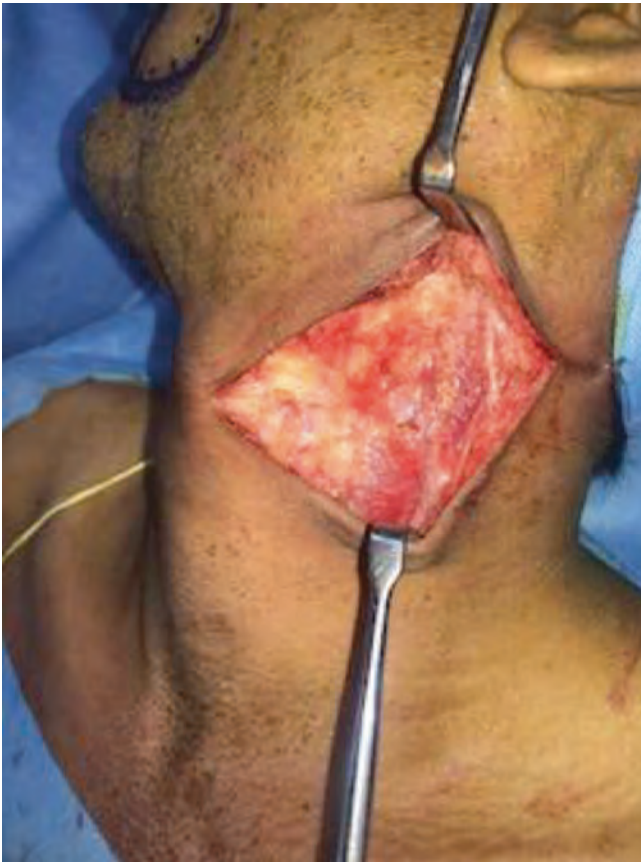©Association of Oral and Maxillofacial Surgeons of India

Fig. 82.38 Mobilization of submandibular salivary gland for level I dissection; also seen is isolation of facial vessels



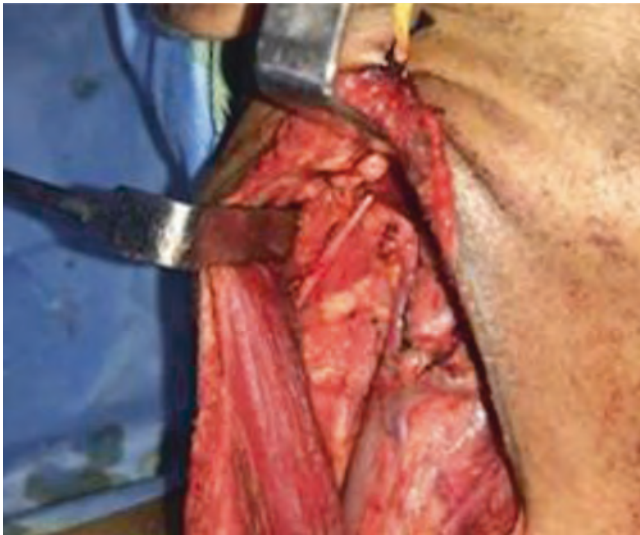©Association of Oral and Maxillofacial Surgeons of India

Fig. 82.39 Completed Level Ib dissection, boundaries well appreciated



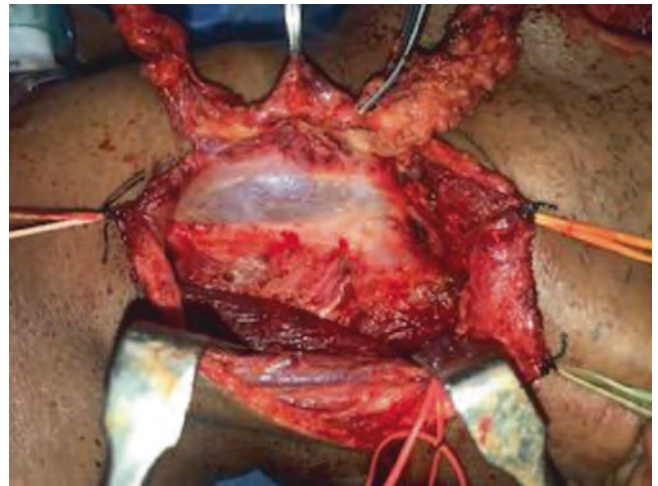
©Association of Oral and Maxillofacial Surgeons of India

Fig. 82.40 Exposed SCM, greater auricular nerve, and external jugular vein can be seen over the SCM



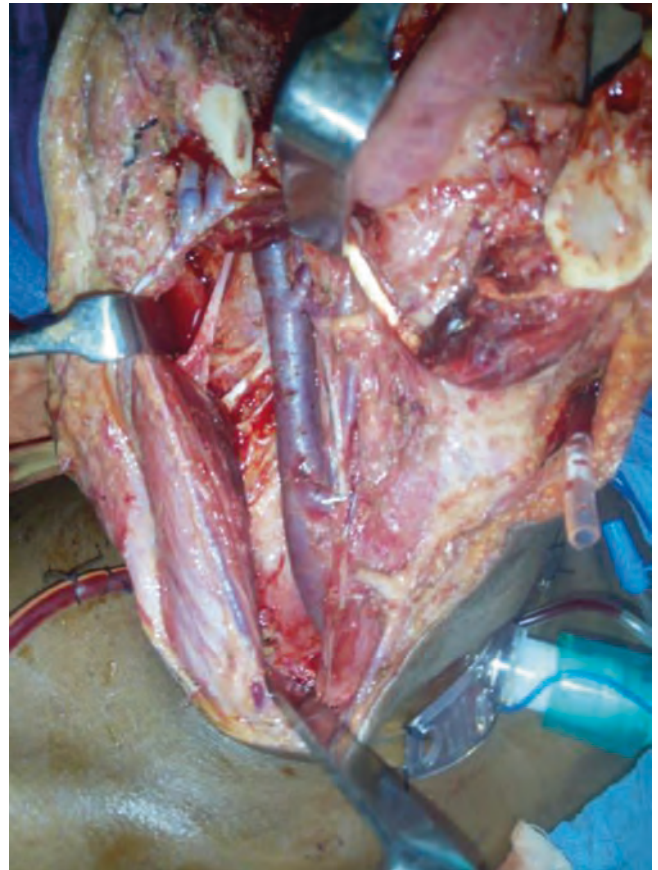
©Association of Oral and Maxillofacial Surgeons of India

Fig. 82.41 Spinal accessory nerve exposed in level II region



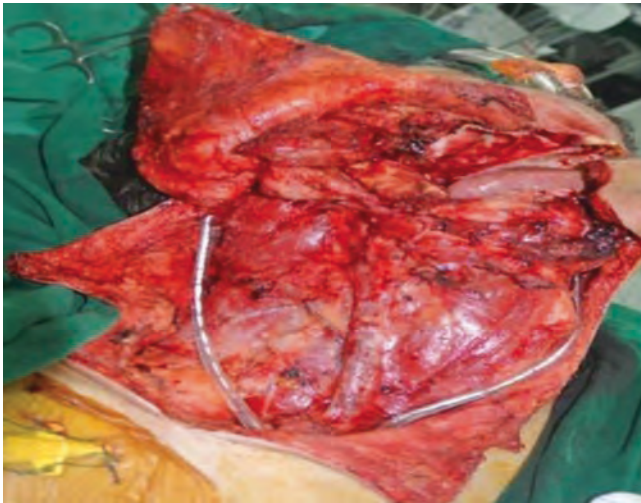©Association of Oral and Maxillofacial Surgeons of India

Fig. 82.42 Level II–IV Lymph node dissection mobilized over the IJV



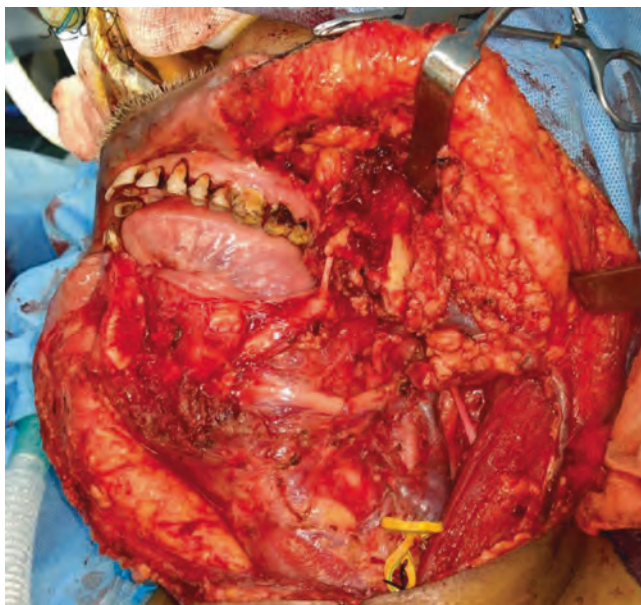©Association of Oral and Maxillofacial Surgeons of India

Fig. 82.43 Completed selective neck dissection (level I–IV) preserving sternocleidomastoid (SCM), spinal accessory nerve (SAN), internal jugular vein (IJV)



©Association of Oral and Maxillofacial Surgeons of India

Fig. 82.44 Intraoperative picture depicting right infraorbital maxillectomy, right hemimandibulectomy, modified radical neck dissection (level I–V) preserving only internal jugular vein with suction drains in situ



©Association of Oral and Maxillofacial Surgeons of India

Fig. 82.45 Composite resection with left hemimandibulectomy and selective neck dissection (Level I–IV) preserving the non-lymphatic structure

82.11 Complications of Neck Dissection

Table 82.7 provides a comprehensive view of the complications arising from neck dissection [29].

Disclosure Authors have no conflicts of interest to disclose.

Table 82.7 Complications of neck dissection [29]

Immediate complications and management	
Hemorrhage	Controlled by ligation or direct cauterization. If hematoma, “milking” the drains may result in evacuation. It is best to return the patient to the operating room and explore the wound if there is suspicion of active bleed and/or there is evidence of hypotension. Blood and blood products to be arranged for blood transfusions. Coagulation profile
Nerve injury	SAN in the level II may be injured either tractional or due to vascular compromise. Vagus, lingual, hypoglossal, and marginal mandibular branch of the facial nerves should be identified and preserved. All attempts should be made to preserve the greater auricular nerve too
Increased intra-cranial pressure	This usually occurs when the internal jugular vein is ligated. When one internal jugular vein is ligated, the pressure rises by three-fold and when both are ligated it increases by five-fold. This usually is temporary and will normalize in 24 h. If it persists, head end elevation, steroids, and mannitol can be used
Pneumothorax	Rare Any tears in the pleura should be identified and closed and their integrity tested
Intermediate complications and management	
Pulmonary	Basal atelectasis and bronchopneumonia may occur in patients who are smokers and have pre-existing chronic obstructive lung disease
Deep vein thrombosis	This is seen in patients in geriatric age group, prolonged duration of surgery, bedridden patients, and patients with previous history of deep vein thrombosis, pulmonary embolism, myocardial infarction and thrombophilia
Chylous fistula	Intra-operative identification can be aided by placing the patient in the Trendelenburg position or adopting a forced Valsalva maneuver. Postoperative leaks are usually identified when feeding is commenced. Multiple approaches to the treatment of an established leak have emerged including nutritional, surgical, and pharmacological therapy
Carotid blowout	Damage to the adventitial layer during surgery may be another contributory factor. If risk of exposure is anticipated, vessels should be covered, e.g., dermal graft, fascia lata or levator scapulae muscle flap. This is particularly important in the post-irradiation subject
Delayed complications and management	
Lymphedema	When both the internal jugular veins are ligated, lymphedema often follows owing to interruption of the lymphatic drainage channels. There are massages advocated as a temporary measure

References

- West H, Jin JO. Performance status in patients with Cancer. *JAMA Oncol.* 2015;1(7):998.
- Chen AM, Chen LM, Vaughan A. Tobacco smoking during radiation therapy for head-and-neck cancer is associated with unfavorable outcome. *Int J Radiat Oncol Biol Phys.* 2011;79:414–9.

3. Hoff CM, Grau C, Overgaard J. Effect of smoking on oxygen delivery and outcome in patients treated with radiotherapy for head and neck squamous cell carcinoma—a prospective study. *Radiother Oncol.* 2012;103:38–44.
4. Deleyiannis FW, Thomas DB, Vaughan TL, Davis S. Alcoholism: independent predictor of survival in patients with head and neck cancer. *J Natl Cancer Inst.* 1996;88:542–9.
5. National Comprehensive Cancer Network. Oral cavity cancer (version 2.2014). http://www.nccn.org/professionals/physician_gls/pdf/head-and-neck.pdf. Accessed 19 Dec 2014.
6. Edge SP, Byrd DR, Compton CC, et al., editors. *AJCC cancer staging manual*. 7th ed. New York: Springer; 2010.
7. Henrot P, Blum A, Toussaint B. Dynamic maneuvers in local staging of head and neck malignancies with current imaging techniques: principles and clinical applications. *Radiographics.* 2003;23:1201–13.
8. Pentenero M, Gandolfo S, Carrozzo M. Importance of tumor thickness and depth of invasion in nodal involvement and prognosis of oral squamous cell carcinoma: a review of the literature. *Head Neck.* 2005;27(12):1080–91.
9. Erkan M, Tolu I, Aslan T, Guney E. Ultrasonography in laryngeal cancers. *J Laryngol Otol.* 1993;17:293–7.
10. Curtin HD, Ishwaran H, Mancuso AA, Dalley RW, Caudry DJ, McNeil BJ. Comparison of CT and MR imaging in staging of neck metastases. *Radiology.* 1998;207:123–30.
11. Van den Brekel MW, Castelijns JA, Stel HV, Golding RP, Meyer CJ, Snow GB. Modern imaging techniques and ultrasound-guided aspiration cytology for the assessment of neck node metastases: a prospective comparative study. *Eur Arch Otorhinolaryngol.* 1993;250:11–7.
12. Okura M, Iida S, Aikawa T, Adachi T, Yoshimura N, Yamada T, et al. Tumor thickness and paralingual distance of coronal MR imaging predicts cervical node metastases in oral tongue carcinoma. *AJNR Am J Neuroradiol.* 2008;29:45–50.
13. Arya S, Chaukar D, Pai P. Imaging in oral cancers. *Indian J Radiol Imaging.* 2012;22:195–208.
14. Weiss MH, Harrison LB, Isaacs RS. Use of decision tree analysis in planning a management strategy for the stage N0 neck. *Arch Otolaryngol Head Neck Surg.* 1994;120(7):699–702.
15. Kuriakose MA. *Contemporary oral oncology*. Cham: Springer Nature; 2017.
16. Huang SH, Hwang D, Lockwood G, Goldstein DP, O'Sullivan B. Predictive value of tumor thickness for cervical lymph-node involvement in squamous cell carcinoma of the oral cavity: a meta-analysis of reported studies. *Cancer.* 2009;115(7):1489–97.
17. Shah JP. Patterns of cervical lymph node metastasis from squamous carcinomas of the upper aerodigestive tract. *Am J Surg.* 1990;160:405–9.
18. Pantvaidya GH, Pal P, Vaidya AD, Pai PS, D'Cruz AK. Prospective study of 583 neck dissections in oral cancers: implications for clinical practice. *Head Neck.* 2014;36(10):1503–7.
19. D'Cruz AK. Elective versus therapeutic neck dissection in node-negative oral cancer. *N Engl J Med.* 2015 Aug 6;373(6):521–9.
20. Mehanna H, Robinson M, Hartley A, Kong A, Foran B, Liew TF, et al. Radiotherapy plus cisplatin or cetuximab in low-risk human papillomavirus-positive oropharyngeal cancer (De-ESCALaTE HPV): an open-label randomised controlled phase 3 trial. *Lancet.* 2018;393:51–60.
21. Parikh PM, Hingmire SS, Deshmukh CD. Selected current data on metronomic therapy (and its promise) from India. *South Asian J Cancer.* 2016 Apr–Jun;5(2):37–47.
22. Bernier J, Cooper JS, Pajak TF, van Glabbeke M, Bourhis J, Forastiere A, et al. Defining risk levels in locally advanced head and neck cancers: a comparative analysis of concurrent postoperative radiation plus chemotherapy trials of the EORTC (#22931) and RTOG (# 9501). *Head Neck.* 2005 Oct;27(10):843–50. <https://doi.org/10.1002/hed.20279>.
23. Calabrese L. Compartmental surgery in tongue tumours: description of a new surgical technique. *Acta Otorhinolaryngol Ital.* 2009;29:259–64.
24. Kowalski LP, Bagietto R, Lara JR, Santos RL, Tagawa EK, Santos IR. Factors influencing contralateral lymph node metastasis from oral carcinoma. *Head Neck.* 1999;21:104–10.
25. Brown JS, Rogers SN, McNally DN, Boyle M. A modified classification for the maxillectomy defect. *Head Neck.* 2000;22(1):17–26. [https://doi.org/10.1002/\(sici\)1097-0347\(200001\)22:1<17::aid-hed4>3.0.co;2-2](https://doi.org/10.1002/(sici)1097-0347(200001)22:1<17::aid-hed4>3.0.co;2-2).
26. Robbins KT, Medina JE, Wolfe GT, Levine PA, Sessions RB, Pruet CW. Standardizing neck dissection terminology. Official report of the Academy's committee for head and neck surgery and oncology. *Arch Otolaryngol Head Neck Surg.* 1991;117:601–5.
27. Medina JE. A rational classification of neck dissections. *Otolaryngol Head Neck Surg.* 1989;100:169–76.
28. Spiro RH, Strong EW, Shah JP. Classification of neck dissection: variations on a new theme. *Am J Surg.* 1994;168:415–8.
29. Parnell FW. Complications of radical neck dissection. *Arch Otolaryngol.* 1968;88(2):180–3.

Open Access This chapter is licensed under the terms of the Creative Commons Attribution 4.0 International License (<http://creativecommons.org/licenses/by/4.0/>), which permits use, sharing, adaptation, distribution and reproduction in any medium or format, as long as you give appropriate credit to the original author(s) and the source, provide a link to the Creative Commons license and indicate if changes were made.

The images or other third party material in this chapter are included in the chapter's Creative Commons license, unless indicated otherwise in a credit line to the material. If material is not included in the chapter's Creative Commons license and your intended use is not permitted by statutory regulation or exceeds the permitted use, you will need to obtain permission directly from the copyright holder.



D'Souza Jacob and Boyapati Raghu

83.1 Introduction

Sarcomas are uncommon malignant tumours with incidence of less than 5% of all head and neck malignancies in adults [1, 2]. They are more common in children, accounting for 30% of head and neck sarcomas [2, 3]. They arise from either soft or hard tissue mesenchyme cells. There is a male predominance and presentation is usually in the third and fourth decade of life in 70% of cases [4, 5].

Metastasis at initial presentation is seen in only 10% of patients, usually from high-grade primary lesions [6–8]. Despite this, prognosis tends to be poor, partly due to the proximity of vital neurovascular structures leading to difficulty in obtaining adequate surgical clearance. Moreover, majority of the sarcomas are poorly differentiated, a poor prognostic marker [9].

Sarcomas tend not be related to the use of tobacco and alcohol. Predisposition to the development of sarcomas is seen in some conditions [4, 8, 10]. Notable examples include association of osteosarcoma in patients with Li-Fraumeni syndrome, angiosarcoma with chronic lymphoedema and Kaposi's sarcoma with HIV infection. Additionally, exposure to chemicals such as vinyl chloride is well-recognised risk factors [10].

83.2 Classification

Broadly speaking, sarcomas can be classified into two categories: soft tissue and hard tissue (bone and cartilage) sarcomas. This, however, is an oversimplification since precise classification is fraught with significant difficulties. For example, fibrosarcoma and malignant fibrous histiocytoma are soft tissue sarcomas that arise in hard tissues [11, 12]. In contrast, chondrosarcomas are classified as soft tissue

tumours. Additionally, some hard tissue tumours display extraosseous extension [1–3].

Ten or more main histological types and even more subtypes of sarcomas are described. Osteosarcoma, angiosarcoma and malignant fibrous histiocytoma make up the majority tumours in adults. In children, rhabdomyosarcoma is the most common sarcoma [1–3].

83.3 Staging

Soft and hard tissue sarcomas are staged using different systems (Tables 83.1 and 83.2). The American Joint Committee on Cancer (AJCC) and the International Union Against Cancer (UICC) staging systems are used in most centres [13]. Other systems may be used in selected cases such as the Memorial Sloan Kettering system [14].

83.4 Natural History and Prognostic Factors

Head and neck sarcomas tend to show poorer response to treatment compared to sarcomas affecting the trunk and extremities [5, 6]. This is despite the low rate of lymph node metastasis at presentation (less than 10% of cases) and the modern multimodality treatment with surgery, radiotherapy and chemotherapy [4, 5]. Local and regional nodal recurrence is common and is more likely to result in death than distant metastatic spread [5, 8, 10].

The reasons for treatment failure resulting in disease recurrence are multifactorial. Adequate surgical margins are hard to achieve given the complex anatomy of the maxillofacial and the skull base regions (Fig. 83.1). The morbidity of radical resections is unacceptable, both functional and aesthetic. This is especially true for primary tumour larger than 10 cm at presentation [8, 9, 11]. Resections aimed at minimising morbidity risk positive or involved surgical

D. S. Jacob (✉) · B. Raghu
Maxillofacial Unit, Royal Surrey County Hospital, Guilford, UK
e-mail: dsouzaj@icloud.com; raghusurgdent@doctors.org.uk

Table 83.1 TNM/UICC classification of soft tissue sarcomas

T classification	
Tx	Tumour cannot be assessed
T0	Tumour not evident
T1	Tumour size <5 cm
T2	Tumour size >5cm
N classification	
Nx	Regional lymph nodes cannot be assessed
N0	No regional lymph nodes evident
N1	Regional lymph node metastasis
M classification	
Mo	No distant metastasis
M1	Distant metastasis evident

Histological grading of soft tissue sarcomas

Gx: Grade cannot be assessed

G1: Well differentiated tumour

G2: Moderately differentiated tumour

G3: Poorly differentiated tumour

Staging:

Stage 1: Low grade tumour with no regional or distant lymph node metastasis.

Stage: 2 Intermediate, large or high grade, small tumour with no regional or distant metastasis

Stage 3: High grade, large tumour or any tumour with regional metastasis.

Stage 4: Distant Metastasis identified

Table 83.2 TNM/UICC staging of bone sarcomas

Stage	Grade	Metastasis
1	Low grade < 8 cm	Absent
1b	Low grade > 8 cm	Absent
2	High grade < 8 cm	Absent
2b	High grade > 8 cm	Absent
3	Any grade, any size	Skip metastasis
4	Any grade, any size	Distant metastasis

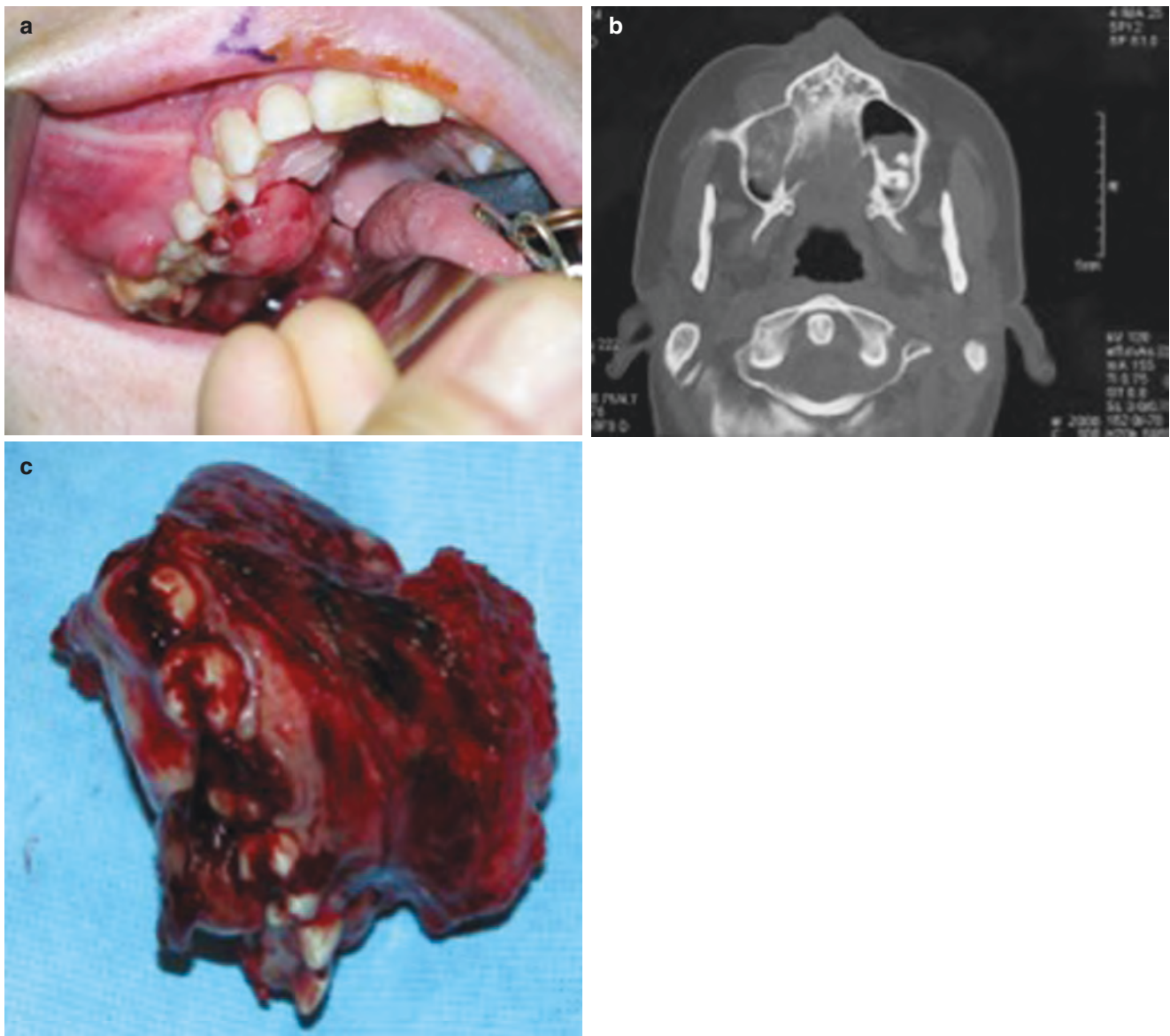
margins and are an independent predictor of treatment failure and hence survival [5, 7, 8]. The grade of tumour is another prognostic factor. For example, the 5-year survival rates for high-grade tumours such as malignant fibrous histiocytoma, osteosarcoma and angiosarcoma are in the range of 60%. This is in contrast with low-grade tumours such as chondrosarcoma or dermatofibrosarcoma protuberance which show survival approaching 100% at 5 years [8, 9, 15]. There is optimism, however, with modern combined treatment modalities, for example, patients with rhabdomyosarcomas are showing better survival outcomes. Finally, sarcomas arising in previously irradiated tissues have poor prognosis due to a multitude of factors: delayed diagnosis; high-grade, inadequate surgical margins; limited option of

adjuvant radiotherapy; and lack of proven chemotherapy regimens [10, 16, 17].

It is important to interpret the published treatment outcomes and survival rates with caution. Comparison between institutions is unreliable due to different study population, histological subtypes and follow-up regimens. Moreover, lack of standardisation in reporting leads to institutional bias of a selected treatment modality. Reported overall survival for bone sarcomas approach 80% at 2 years and 74% at 5 years [18, 19]. Radiation-induced sarcomas perhaps have the worse survival outcomes, as low as 25% at 5 years [19, 20].

83.5 Principles of Treatment

It is difficult to draw firm treatment guidelines for head and neck sarcomas because they are a rare group of heterogeneous tumours. The treatment philosophies vary between institutions due to multitude of factors as discussed previously in this chapter. Meta-analysis outcomes are therefore controversial and unreliable to draw firm conclusions. Furthermore, there are no randomised controlled trials [20, 21]. Despite this, there is consensus that early surgical resection with appropriately



©Association of Oral and Maxillofacial Surgeons of India

Fig. 83.1 (a, b, c) Osteosarcoma of the right posterior maxilla. Photograph showing osteosarcoma of the right maxilla. The extent of bone destruction from the tumour is seen in the scan. The resected specimen confirms the loss of the hemi-maxilla

timed adjuvant therapies can help improve outcomes. Needless to say, the role of multidisciplinary input/tumour board is vital.

Surgical resection of the tumour is the favoured primary treatment modality for patients with sarcomas of the hard tissues [22, 23]. Surgery is often preceded by chemotherapy on a neoadjuvant protocol [19, 22, 23]. The intention is to reduce tumour bulk and hence morbidity by minimising tissue loss. Elimination of micro-metastatic disease, mainly pulmonary deposits, is of added benefit. The role of adjuvant radiotherapy is limited to patients with positive surgical margins who often are not candidates for further resection [19, 24]. Further resections may not be feasible due to anatomical complexity or in those who have undergone complex recon-

struction. Note should be made of the evolving role of radiotherapy in Ewing's sarcoma.

The size of the tumour at presentation often restricts the use of surgery in patient presenting with soft tissue sarcoma. Adjuvant radiotherapy is an indication when the resection margins are positive; the tumours are of intermediate or high grade and in cases of recurrent disease [12, 16, 24, 25]. The feasibility of introducing neoadjuvant chemotherapy or pre-operative radiotherapy should be considered with diligence in patients with advanced disease at presentation with a view to reduce morbid resections [25, 26]. When surgery is not feasible, the role of palliative radiotherapy alone or in combination with chemotherapy should be considered.

83.6 Principles of Surgery

83.6.1 Hard Tissue Sarcomas

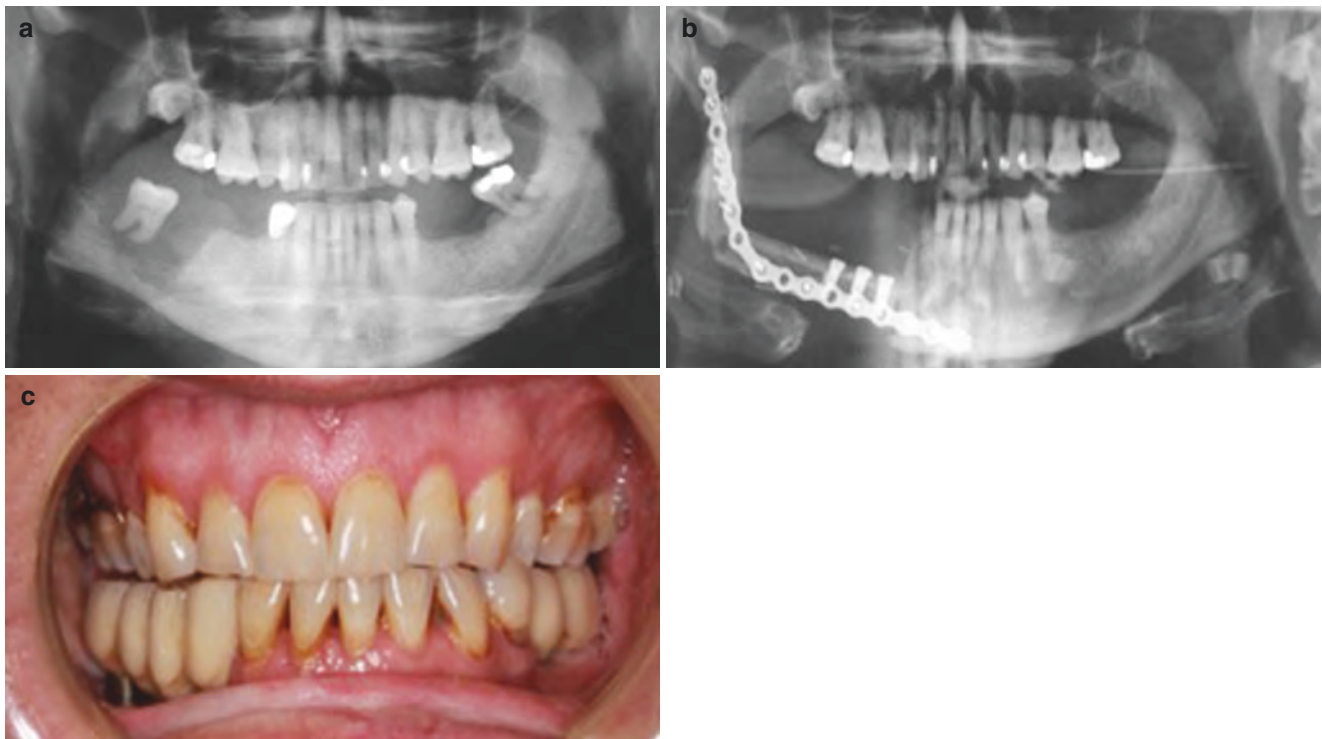
There is a consensus that achieving tumour-free zone of tissue at the resection margins maximises the chance of cure. However, what defines adequate margin remains debated. The current recommendation is resection of the tumour with a 2–3 cm macroscopic margin in patients who receive neoadjuvant chemotherapy aiming to sterilise the microscopic deposits around the main body of the tumour [24–28]. It is important to plan the resection on scans obtained prior to the neoadjuvant chemotherapy. This is because both the tumour-killing effect of the neoadjuvant chemotherapy and tissue shrinkage are unpredictable. Furthermore, one should aim for compartmental excision (Fig. 83.1) that allows for removal of all potentially involved structures beyond the radiographic margins such as intra-osseous extension of the tumour via marrow spaces [2, 19, 24]. Although this approach is radical, for instance, resection of the hemi-mandible to include disarticulation of the condyle in ramus tumours, the chance of surgical clearance can be maximised to 85% or greater [2].

83.6.2 Soft Tissue Sarcomas

Similar to hard tissue sarcomas, adequate surgical margins predict survival outcomes, both disease-free and overall survival. The recommendation is for 1–3 cm macroscopic margins [24, 29, 30]. Achieving this may be limited due to anatomical constraints and an infiltrative pattern of tumour spread that tends to characterise soft tissue sarcomas. One published series reported adequate surgical clearance in 85% of osteosarcomas vs. 64% soft tissue tumours [2]. The 2-year overall survival estimate for bone tumours (51 patients) was 91% vs. 67% for soft tissue tumours (50 patients) [2]. The 5-year overall survival estimates were 73 and 56%, respectively. These results were statistically significant. Other series with different patient cohort have reported 5-year overall survival rates of 74 vs. 57% for bone and soft tissue sarcomas, respectively [31, 32].

83.7 Clinical Assessment

Patients present with a wide range of signs and symptoms. These may range from indolent lumps to rapidly growing and locally destructive lesions (Figs. 83.1 and 83.2). Pain



©Association of Oral and Maxillofacial Surgeons of India

Fig. 83.2 (a, b, c) Osteosarcoma of the right posterior mandible. Plain radiograph showing tumour destruction of the right posterior mandible. A fibula free flap and dental implants are used for rehabilitation

is variable and there is a tendency for nocturnal bone pain [1, 4].

There may be a mass at the primary site, ulceration, sensory change affecting the skin or the mucosa, proptosis, epistaxis or nasal discharge, loosening of teeth and unexplained bleeding.

Involvement of the skull base by direct extension can lead to focal neurology. Metastatic lesions can present with a neck mass. Systemic symptoms tend to be non-specific such as malaise, loss of weight and appetite [8, 23].

83.8 Investigations

Magnetic resonance imaging (MRI) is usually the preferred investigation for primary lesions [30, 33]. They provide information regarding the nature of the primary tumour (solid, cystic, presence or absence of calcifications, internal vascularity, etc.). The relationship of the tumour to adjacent tissues can be accurately defined; this helps plan tumour resection [22, 34, 35]. Computer tomography (CT) scan of the facial bone may be used to complement the MRI scan, especially in patients requiring hard tissue resection and reconstruction (Figs. 83.1 and 83.2). The use of composite flaps with 3-D reconstruction with prefabricated plates is increasingly used in several centres [36, 37]. The use of dental implants has significantly improved outcomes following composite reconstructions (Fig. 83.2). CT scans of the thorax and upper abdomen complete the staging investigations. There is an evolving role for positron emission tomography (PET), both in the initial staging of the disease, the response to treatment and tumour surveillance [38, 39]. Blood tests include comprehensive baseline tests (full blood count, renal and bone profile) and serum alkaline phosphatase. Additional tests may be necessary, often dictated by individual patient profiles. Biopsy for tissue diagnosis must include an appropriate sample that in addition to routine staining provides tissue for immunocytochemistry [4, 12].

83.9 Osteosarcoma

Osteosarcomas are the commonest sarcomas of the bones in adults, representing 1% of all head and neck cancers. They do not show sex predilection. The peak incidence is between 20 and 30 years. However, tumours arising in area of Paget's disease of the bone are seen in older patient 60–70 years of age [25–27]. The mandible is the most frequently affected site, especially the angle/ramus region. In the maxilla, the tumour has a predilection to the alveolar ridge and sinus floor. Notable risk factors include chromosomal abnormalities (deletion of 13q14), germ line mutations (Li Fraumeni syndrome) and dysplasia of bone (Paget's disease and fibrous dysplasia) [25–28]. In some instances, these tumours arise in irradiated bone or de novo.

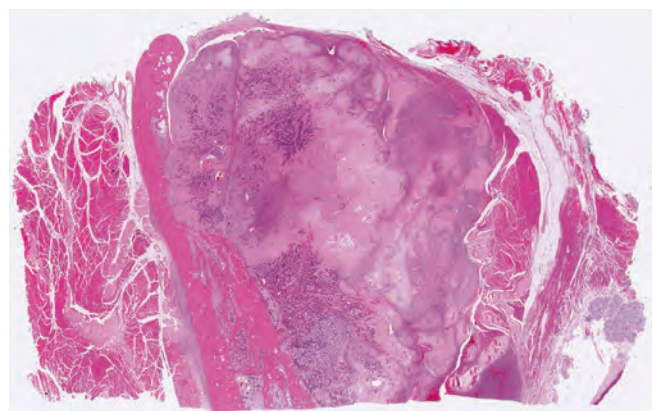
Patient may present with asymptomatic intra-oral mass, loose teeth and toothache.

Destructive lesions can cause soft tissue cheek swelling, sensory change, proptosis, nasal discharge or bleeding.

Three histological subtypes of osteosarcoma are recognised, namely, osteoblastic, chondroblastic and fibroblastic variants [31, 39].

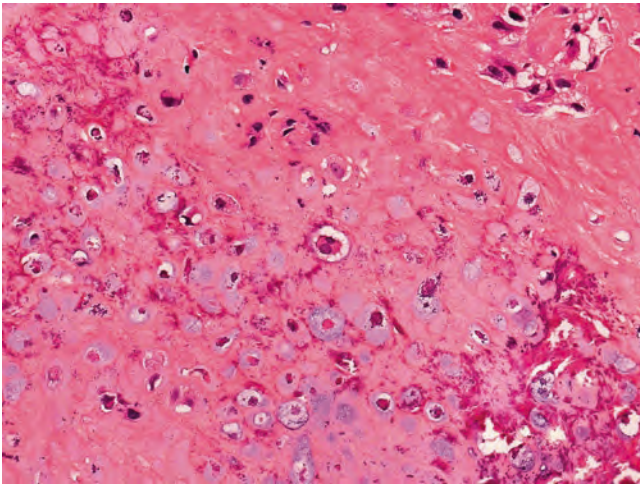
However, myxoid pattern is the norm (Fig. 83.3). The chondroblastic variant shows binucleated cell characteristic of the lesion (Fig. 83.4) The degree of differentiation classifies them as stage I (well-differentiated and low-grade) to stage IV (poorly differentiated and high-grade). Regional neck metastases at presentation are rare, seen in less than 10% of patients at presentation. Distant metastases are seen in up to 30% of patients at presentation, mostly pulmonary [23, 27, 31]. On rare occasions, patients may present with rapidly progressive, fatal multifocal disease. Imaging reveals local bone. The well-documented finding of subperiosteal bone formation (Codman triangle) is uncommonly seen in head and neck lesions.

Whilst surgery, radiotherapy and chemotherapy are offered as single or multimodality treatments, well-established treatment regimens are lacking in consensus. Various drug combinations have been tried and tested, leucovorin, Adriamycin, cisplatin, ifosfamide and cyclophosphamide, with unpredictable response. One study has shown 2- and 5-year overall survival rates of 100 and 67%, respectively, in those treated with neoadjuvant chemotherapy and surgery. This compares favourably with patient treated with surgery alone showing poorer 2- and 5-year overall survival rates of 66 and 41%, respectively [19, 23, 31]. The role of



©Association of Oral and Maxillofacial Surgeons of India

Fig. 83.3 Osteosarcoma-myxoid variant. H&E section of an axial slice through the masseter (far left), ramus of the mandible, tumour, medial pterygoid and palatal mucosa (far right bottom corner)



©Association of Oral and Maxillofacial Surgeons of India

Fig. 83.4 Osteosarcoma-chondroblastic variant. Photomicrograph showing binucleated cells, characteristic of the chondroblastic type

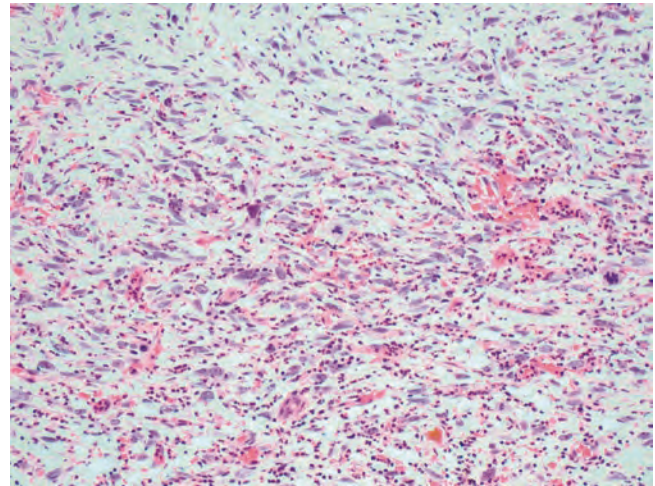
adjuvant radiotherapy is applicable in patients with inadequate or positive surgical margins; however, doses in excess of 60Gy are necessary given their radio-resistant behaviours [8, 16, 31].

In addition to high-grade disease and large tumours at presentation, some additional factors have prognostic significance. For example, the expression of the p-glycoprotein confers multidrug resistance negatively impacting on prognosis. Osteosarcomas arising in Paget's disease and elevated alkaline phosphate levels have poorer prognosis [9, 25, 27, 32].

83.10 Malignant Fibrous Histiocytoma

Malignant fibrous histiocytoma is the commonest soft tissue sarcoma affecting the trunks and extremities. However, it is rare in the head and neck region, with less than 3% occurring here. It shows a male predilection with a 2:1 ratio and mostly seen between 40 and 60 years of age. The commonest subsite is the sinonasal tract. There is a strong link to ionising radiation exposure [11].

Histology shows highly pleomorphic fibroblasts mixed with abnormal histiocytes in a storiform pattern with a background dense inflammation (Fig. 83.5). Phagocytised neutrophils with large nuclei/nucleoli are commonly seen. Necrosis is an uncommon feature, but bizarre giant cells or atypical mitotic figures can be seen on most occasions [30, 34, 40]. The commonest subtype is pleomorphic; less common are giant cell and myxoid types. Immune positivity is seen with α -1-antichymotrypsin, vimentin and Ki-67 [11].



©Association of Oral and Maxillofacial Surgeons of India

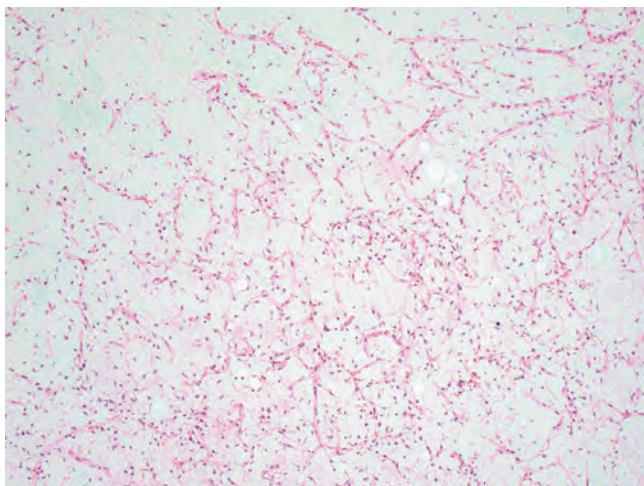
Fig. 83.5 Malignant fibrous histiocytoma. H&E section showing highly pleomorphic tumour cells with atypical mitotic figures amidst dense acute inflammation

Wide surgical resection is the primary treatment, with consideration given to adjuvant chemoradiotherapy [17, 23]. Whilst local recurrence is the norm, regional metastases to lymph nodes are rare. Positive margins predict for treatment failure locally and distant spread, usually to the lungs and liver [23, 33].

83.11 Liposarcoma

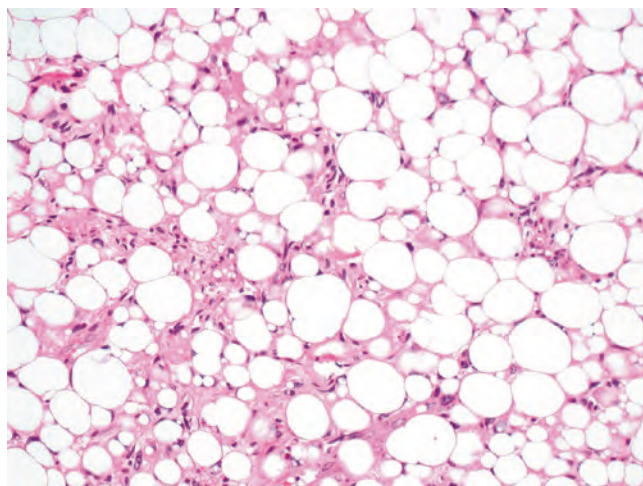
Although liposarcomas are second most common soft tissue tumours, less than 5% occur within the head and neck region. They show a slight male predominance, most commonly presenting between the ages of 30 and 60. Majority arise de novo rather than developing in a lipoma [24]. Patient may demonstrate risk factors such as repeated trauma, irradiation or genetic abnormality (NF-1 gene). The histological behaviour varies from high-grade (pleomorphic, round) to low-grade (myxoid) tumours. The myxoid variant shows lipoblasts arranged within a chicken-wire vascular network in a dense stroma (Fig. 83.6). The pleomorphic type shows significant numbers of highly atypical fat cells along with lipoblasts (Fig. 83.7). The epithelioid variant can be confused with carcinoma [40].

Whilst surgery remains the primary treatment modality, the role of adjuvant radiotherapy should be considered in patients with high-grade lesions and large tumours with positive resection margins. Published literature supports the use of adjuvant radiotherapy in reducing local recurrence from 60 to 40% [19, 20, 24].



©Association of Oral and Maxillofacial Surgeons of India

Fig. 83.6 Liposarcoma myxoid variant. H&E section showing myxoid tumour with lipoblasts arranged within a chicken-wire vascular network amidst dense myxoid stroma



©Association of Oral and Maxillofacial Surgeons of India

Fig. 83.7 Liposarcoma pleomorphic variant. H&E showing atypical adipocytes along with pleomorphic lipoblasts

83.12 Rhabdomyosarcoma

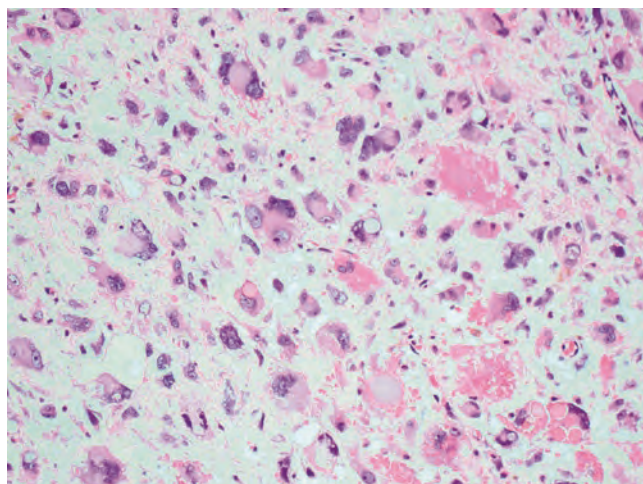
These are predominantly childhood tumours, usually affecting those below the age of 12 years [2, 4, 5]. They show slight male predilection. In contrast to adult sarcomas, up to half of all rhabdomyosarcomas occur in the head and neck sites. The favoured subsites are the orbits, the nasopharynx and the temporal bones [15].

Histologically, at least 70% of the tumours are of embryonal subtype; less commonly, the alveolar subtypes are seen (Fig. 83.8). Immune positivity to desmin, myoglobin and actin is well documented (Fig. 83.9). Cells show finely granular eosinophilic cytoplasm with cross striations with enlarged nucleus. More differentiated tumours may show elongated rhabdomyoblasts and occasional giant cells. Definitive diagnosis is based on myogenesis, multinucleated myoblasts, individual tumour cells with cross striations and dense eosinophilic cytoplasm [41].

Prognostic indicators include the location of the primary, age at presentation and metastatic disease. The survival rates have shown significant improvement: 71% in 2001 vs. 25% in the 1970s [15, 23, 31]. The orbital tumours show the best prognosis with 5-year survival rates exceeding 90% in children [15]. This contrasts with poor survival rates in adults at approximately 30%.

83.13 Chondrosarcoma

Chondrosarcomas are malignant tumours of the bone or cartilage, and 10% are located in the head and neck [2, 8]. The larynx is the most commonly involved subsite, closely fol-

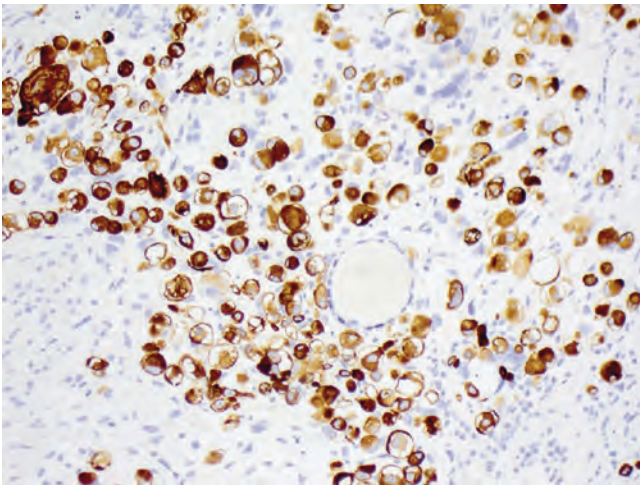


©Association of Oral and Maxillofacial Surgeons of India

Fig. 83.8 Rhabdomyosarcoma pleomorphic variant. H&E section showing high-grade sarcoma with pleomorphic rhabdomyoblasts

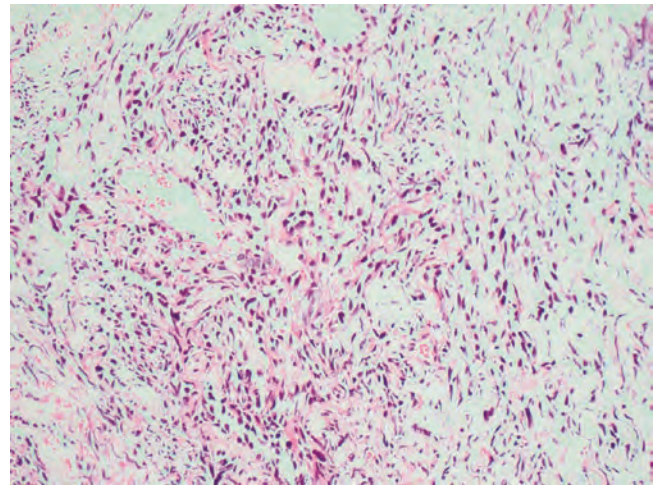
lowed by the maxilla and mandible. The peak incidence is 30–50 years. At least 80% arise de novo. Secondary tumours arise in abnormal bone in conditions such as Paget's disease and fibrous dysplasia [40]. Rarely, extrasosseous tumours are seen due to cartilaginous differentiation of primitive cells. Patient's symptoms depend on location and the extent of local tissue destruction. Despite slow initial progression, multiple metastases can develop rapidly [26]. Radiographic examination may show sunray speculation.

The degree of differentiation can range from well to poorly differentiated tumours. The common subtypes include myxoid and mesenchyme [26]. It is not uncommon for them



©Association of Oral and Maxillofacial Surgeons of India

Fig. 83.9 Rhabdomyosarcoma. Showing expression of desmin in rhabdomyoblasts



©Association of Oral and Maxillofacial Surgeons of India

Fig. 83.10 Angiosarcoma. H&E section showing pleomorphic tumour cell lining interconnecting atypical vascular channels

to show histological similarity to tumours such as chondroblastic osteosarcoma and malignant fibrous histiocytoma. Additionally, low-grade tumours may show benign histology such as chondromatosis or osteochondroma.

Surgery remains the primary treatment modality, possibly driven by the belief that these tumours are radio-resistant. Additionally, irradiating areas such as the skull base can be carried out with conventional external beam photon therapy particularly with new techniques like Intensity modulation radiation therapy (IMRT). The role of proton beam therapy delivering high-energy irradiation has shown local control rates of 85–100% at 5 years [42].

The site of the primary tumour has implications for prognosis; for example, laryngeal primaries do better compared to nasopharyngeal primaries. High-grade and dedifferentiation confers poor prognosis due to early local recurrence and distant metastases. The 5-year overall survival rates are less than 50% vs. 80% or greater for high- and low-grade tumours, respectively.

83.14 Angiosarcoma

These tumours arise from the endothelial cells lining the vascular or the lymphatic system. They are most common above the age of 62 years and show male predilection with a ratio of 2:1. They can arise in several different sites given the wide distribution of the endothelium. Some lesions are localised and nodular, whilst others are diffused. Regional metastases are less than 20% of patients at presentation. However, distant metastases may be present in up to 45% of patients at presentation, mostly involving the lungs and liver [6–8]. The tumours show immune positivity for CD31. Histological examination shows anastomosing and infiltrating channels

lined by multilayered endothelial cells with variable atypia (Fig. 83.10). Free-floating endothelial cells of ‘fish in the creek’ pattern with surrounding adnexae and dermal collagen can be a reliable feature [42].

Although surgery is the primary modality of treatment, diffuse lesions can make adequate surgical clearance a difficult task. The reported 5-year survival rates range from 12 to 40%. Predictors of poor survival include location of the primary tumour, size greater than 7 cm at presentation, high-grade and advancing age [1, 20, 23]. Local recurrence is seen in more than 50% of patients with inadequate or positive surgical margins, usually within 2 years. The role of adjuvant therapies is questionable in achieving adequate loco-regional control and improving survival.

83.15 Malignant Schwannoma

These are tumours arising in the nerve: peripheral or cranial. They usually affect the neck, followed by sinonasal areas. Involvement of the maxillofacial skeleton is rare. Although there is an association with von Recklinghausen’s disease or neurofibromatosis type 1, sporadic tumours are well recognised [43]. Surgery remains the primary treatment modality. Tracking of the tumour along the nerve sheath limits the resectability, hence the need of adjuvant therapies, be it radiotherapy or chemotherapy.

83.16 Fibrosarcoma

These tumours often present as an asymptomatic painless mass between 30 and 40 years of age. History is positive for previous radiation exposure in at least 10% of patients.

Histological similarities are seen with malignant fibrous histiocytoma [6, 7, 44]. Surgery remains the mainstay of treatment, with adjuvant radiotherapy aimed at those with inadequate surgical margin and lesions that are high-grade. The reported 5-year survival rates are 80% or greater [22, 23].

83.17 Kaposi's Sarcoma

Human herpes virus 8 is implicated in the aetiology of these tumours arising in patients with AIDS. It is worth noting that Kaposi's sarcomas represent up to 80% of oral cavity sarcomas and have poor prognosis [25, 45].

83.18 Synovial Sarcoma

Contrary to the name, synovial sarcomas arise from the pluripotent mesenchymal cells, not the synovial cells. They show a male predilection and a peak incidence between 20 and 40 years. The common head and neck subsites are the hypopharyngeal and retropharyngeal areas. It is worth noting that up to 50% of patients have pulmonary metastases at presentation [5, 7, 15].

All histological subtypes (monophasic, biphasic, poorly differentiated) are high-risk tumours. Up to 90% of patients have chromosomal translocation (tX: 18) [21]. Prognosis tends to be poor with less than 20% of patients with metastasis at presentation alive at 2 years. Increasing age, size greater than 5 cm and poor differentiation predict worst prognosis [18, 22].

83.19 Ewing Sarcoma

These tumours arise in primitive neuroectodermal cells and represent 5% of primary tumours. They are second most common malignant tumours of the bone in children. Subtypes include osseous and extraosseous. Metastases at presentation are seen in 20% of patients, mostly involving the lungs [46]. History may be positive of prior childhood malignancies treated with irradiation or chemotherapy. Most patients present with an enlarging mass that may be asymptomatic or painful. Destructive lesions due to osteolysis are evident on radiographs.

83.20 Conclusion

Sarcomas are aggressive tumours, fortunately rare in the head and neck regions except for rhabdomyosarcoma in children, which has shown good, improved outcomes with current treatment regimens. The primary treatment modality is

surgery, often preceded by neoadjuvant chemotherapy and followed by postoperative chemoradiotherapy. Large tumours with a risk of positive surgical margins and histologically high-grade tumours are adverse features. Age is an independent prognostic factor in children and adults with sarcomas arising in Paget's disease for bone.

Treatment regimens are often institution-dependent and biased. Given the lack of randomised controlled trials and difficulty in interpreting meta-analysis, close cooperation and data sharing between centres can go a long way in improving treatment outcomes for this diverse group of patients.

References

1. Kevin AP, Tristan G, Marilene BW. Head and neck sarcomas: analysis of the SEER database. *Otolaryngol Head Neck Surg*. 2014 Oct;151(4):627–33.
2. Vassiliou LV, Lalabekyan B, Jay A, Liew C, Whelan J, Newman L, et al. Head and neck sarcomas: A single institute series. *Oral Oncol*. 2017 Feb;65:16–22.
3. O'Neill JP, Bilsky MH, Kraus D. Head and neck sarcomas: epidemiology, pathology, and management. *Neurosurg Clin N Am*. 2013 Jan;24(1):67–78.
4. Meis-Kindblom JM, Kindblom LG. Angiosarcoma of soft tissue: a study of 80 cases. *Am J Surg Pathol*. 1998 Jun;22(6):683–97.
5. Kraus DH, Dubner S, Harrison LB, Strong EW, Hajdu SI, Kher U, et al. Prognostic factors for recurrence and survival in head and neck soft tissue sarcomas. *Cancer*. 1994;74:697–702.
6. Young RJ, Brown NJ, Reed MW, Hughes D, Woll PJ. Angiosarcoma. *Lancet Oncol*. 2010 Oct;11(10):983–91.
7. Sturgis EM, Potter BO. Sarcomas of the head and neck region. *Curr Opin Oncol*. 2003;15:239–52.
8. Tran LM, Mark R, Meier R, Calcaterra TC, Parker RG. Sarcomas of the head and neck. Prognostic factors and treatment strategies. *Cancer*. 1992 Jul 1;70(1):169–77.
9. Soliman H, Ferrari A, Thomas D. Sarcoma in the young adult population: an international view. *Semin Oncol*. 2009 Jun;36(3):227–36.
10. Huang NC, Wann SR, Chang HT, Lin SL, Wang JS, Guo HR. Arsenic, vinyl chloride, viral hepatitis, and hepatic angiosarcoma: a hospital-based study and review of literature in Taiwan. *BMC Gastroenterol*. 2011 Dec 26;11:142.
11. Enjoji M, Hashimoto H, Tsuneyoshi M, Iwasaki H. Malignant fibrous histiocytoma. A clinicopathologic study of 130 cases. *Acta Pathol Jpn*. 1980;30:727–41.
12. Beral V, Peterman TA, Berkelman RL, Jaffe HW. Kaposi's sarcoma among persons with AIDS: a sexually transmitted infection? *Lancet*. 1990;335:123–8.
13. Edge SB, Byrd DR. *AJCC cancer staging manual*. 7th ed. New York: Springer; 2010. p. 291–8.
14. Shuman AG, Brennan MF, Palmer FL, Kuk D, Moraco N, Singer S, et al. Soft tissue sarcoma of the head and neck: nomogram validation and analysis of staging systems. *J Surg Oncol*. 2015 May;111(6):690–5.
15. Meazza C, Ferrari A, Casanova M, Massimino M, Luksch R, Spreafico F, et al. Rhabdomyosarcoma of the head and neck region: experience at the paediatric unit of the Istituto Nazionale Tumori. *Milan J Otolaryngol*. 2006 Feb;35(1):53–9.
16. Parravicini C, Olsen SJ, Capra M, Poli F, Sirchia G, Gao SJ, et al. Risk of Kaposi's sarcoma-associated herpes virus transmission from donor allograft among Italian post transplants Kaposi's sarcoma patients. *Blood*. 1997 Oct 1;90(7):2826–9.

17. Patel SG, See AC, Williamson PA, Archer DJ, Evans PH. Radiation induced sarcoma of the head and neck. *Head Neck*. 1999 Jul;21(4):346–54.
18. Bentz BG, Singh B, Woodruff J, Shah PJ, Kraus D. Head and neck soft tissue sarcomas: a multivariate analysis of outcomes. *Ann Surg Oncol*. 2004 Jun;11(6):619–28.
19. Huber GF, Matthews TW, Dort JC. Soft tissue sarcomas of the head and neck: a retrospective analysis of the Alberta experience 1974 to 1999. *Laryngoscope*. 2006 May;116(5):780–5.
20. Jernstrom P. Synovial sarcoma of the pharynx; report of a case. *Am J Clin Pathol*. 1954 Aug;24(8):957–61.
21. Carrillo R, Rodriguez-Peralto JL, Batsakis JG. Synovial sarcomas of the head and neck. *Ann Otol Rhinol Laryngol*. 1992 Apr;101(4):367–70.
22. Wanebo HJ, Kness RJ, MacFarlane JK, Eilber FR, Byers RM, Elias EG, et al. Head and neck sarcoma: report of the head and neck sarcoma registry. Society of head and neck surgeons committee on research. *Head Neck*. 1992 Jan–Feb;14(1):1–7.
23. LeVay J, O'Sullivan B, Catton C, Bell R, Fornasier V, Cummings B, et al. Outcome and prognostic factors in soft tissue sarcoma in the adult. *Int J Radiat Oncol Biol Phys*. 1993 Dec 1;27(5):1091–9.
24. Fletcher CD. Distinctive soft tissue tumours of the head and neck. *Mod Pathol*. 2002 Mar;15(3):324–30.
25. Fernandes R, Nikitakis NG, Pazoki A, Ord RA. Osteogenic sarcoma of the jaw: a 10-year experience. *J Oral Maxillofac Surg*. 2007 Jul;65(7):1286–91.
26. Lee SY, Lim YC, Song MH, Seok JY, Lee WS, Choi EC. Chondrosarcoma of the head and neck. *Yonsei Med J*. 2005;46(2):228–32.
27. Krishnamurthy A, Palaniappan R. Osteosarcomas of the head and neck region: a case series with a review of literature. *J Maxillofac Oral Surg*. 2018 Mar;17(1):38–43.
28. Clair JM, Arshi A, Abemayor E, John MS. Synovial cell sarcoma of the head and neck: an analysis of 167 cases using the SEER database. *JAMA Otolaryngol Head Neck Surg*. 2016 Jun 1;142(6):576–83.
29. Gopalakrishnan V, Amini B, Wagner MJ, Nowell EN, Lazar AJ, Benjamin RS, et al. Synovial sarcoma of the head and neck: a single institution review. *Sarcoma*. 2017 Jun 5;2017:2016752.
30. Breakey RW, Crowley TP, Anderson IB, Milner RH, Ragbir M. The surgical management of head and neck sarcoma: the Newcastle experience. *J Plast Reconstr Aesthet Surg*. 2017 Jan;70(1):78–84.
31. Marina N, Gebhardt M, Teot L, Gorlick R. Biology and therapeutic advances for paediatric osteosarcoma. *Oncologist*. July 2004;9(4):422–41.
32. Abdelfatah E, Guzzetta AA, Nagarajan N, Wolfgang CL, Pawlik TM, Ahuja N, et al. Long-term outcomes in treatment of retroperitoneal sarcomas: a 15-year single-institution evaluation of prognostic features. *J Surg Oncol*. 2016 Jul;114(1):56–64.
33. Dangoor A, Seddon B, Gerrand C, Grimer R, Whelan J, Judson I. UK guidelines for the management of soft tissue sarcomas. *Clan Sarcoma Res*. 2016;6:20.
34. Gerrand C, Athanasou N, Brennan B, Grimer R, Judson I, Morland B, et al. British Sarcoma Group. UK guidelines for the management of bone sarcomas. *Clin Sarcoma Res*. 2016 May 4;6:7.
35. O'Sullivan B, Patel S, Sturgis E. AJCC cancer staging manual. In: Amin MB, Edge S, Greene F, Byrd DR, Brookland RK, Washington MK, editors. *AJCC cancer staging man*. 8th ed. New York: Springer; 2017. p. 1032.
36. Wu J, Wang C, Li M, Luo C, Liu X, Xie L, et al. 3D computed tomography angiography as a novel post-processing approach in diagnosis of paediatric malignant bone tumours. *J Xray Sci Technol*. 2018;26(1):147–54.
37. Ma L, Zhou Y, Zhu Y, Lin Z, Chen L, Mao C, et al. 3D-printed guiding templates for improved osteosarcoma resection. *Sci Rep*. 2016 Mar 21;6:23335.
38. Mücke T, Mitchell DA, Tannapfel A, Wolff KD, Loeffelbein DJ, Kanatas A. Effect of neoadjuvant treatment in the management of osteosarcomas of the head and neck. *J Cancer Res Clin Oncol*. 2014 Jan;140(1):127–31.
39. Liu CY, Yen CC, Chen WM, Chen TH, Chen PC, Yen CC, et al. Soft tissue sarcoma of extremities: the prognostic significance of adequate surgical margins in primary operation and reoperation after recurrence. *Ann Surg Oncol*. 2010;17:2102–11.
40. Fechner RE, Mills SE. *Atlas of tumour pathology*. Washington, DC: Armed Forces Institute of Pathology; 1993.
41. Tandon A, Sethi K, Singh AP. Oral rhabdomyosarcoma: a review. *J Clin Exp Dent*. 2012;4(5):e302–8.
42. Thariat J, Tessonier T, Bonvalot S, Lerouge D, Mammari H, Vogin G, et al. Proton therapy in soft tissue and bone sarcomas. *Bull Cancer*. 2018 Sep;105(9):830–8.
43. Sitenga JL, Aird GA, Nguyen A, Vaudreuil A, Huerter C. Clinical features and surgical treatment of schwannoma affecting the base of the tongue: a systematic review. *Int Arch Otorhinolaryngol*. 2017 Oct;21(4):408–13.
44. Wiener ES. Head and neck rhabdomyosarcoma. *Semin Pediatr Surg*. 1994 Aug;3(3):203–6.
45. Friedman-Kien AE, Laubenstein LJ, Rubinstein P, Buimovici-Klein E, Marmor M, Zolla-Pazner S, et al. Disseminated Kaposi's sarcoma in homosexual men. *Ann Intern Med*. 1982;96:693–700.
46. Kridis WB, Toumi N, Chaari H, Khanfir A, Ayadi K, Frikha M, et al. A review of Ewing sarcoma treatment: is it still a subject of debate? *Rev Recent Clin Trials*. 2017;12(1):19–23.

Open Access This chapter is licensed under the terms of the Creative Commons Attribution 4.0 International License (<http://creativecommons.org/licenses/by/4.0/>), which permits use, sharing, adaptation, distribution and reproduction in any medium or format, as long as you give appropriate credit to the original author(s) and the source, provide a link to the Creative Commons license and indicate if changes were made.

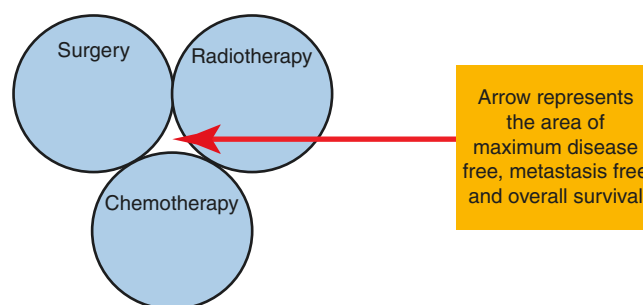
The images or other third party material in this chapter are included in the chapter's Creative Commons license, unless indicated otherwise in a credit line to the material. If material is not included in the chapter's Creative Commons license and your intended use is not permitted by statutory regulation or exceeds the permitted use, you will need to obtain permission directly from the copyright holder.



Amit Dhawan

84.1 Introduction

Oral cancer is the sixth most common cancer in the world, primarily caused by consuming tobacco and its products, alcoholism, nutritional deficiencies, poor oral hygiene, certain strains of human papillomavirus (HPV) and genetic predilection [1, 2]. Considering global incidence of oral cancer, more than 50% of overall head and neck cancer are occurring in Asian subcontinent with India having maximum numbers of these patients. According to some epidemiological studies in Asian Indian population, approximately 80,000 to 1,20,000 new patients of oral cancers are being diagnosed yearly, making oral cancer the third most common cancer in India after lung cancer [1]. Oral cavity cancers are primarily treated surgically owing to gross visual disease, easy accessibility, and less chance of obtaining the R1 resection (resection with positive margins). Retrospectively, all T1 and some of T2 lesions of oral cavity were treated with primary radiotherapy with curative intent, but the results were more promising with upfront surgery followed by some kind of adjuvant treatment depending upon the final histopathology report. Developing countries like India have nonstandardized oral cancer screening protocols due to which most of the oral cancer patients are missed at an early stage and are presented at an advanced stage (stage III–stage IV) with higher T stage (T3–T4) and dissemination of disease in the lymphatics of the neck which further reduces the prognosis for the survivability of the patients. There are other independent predictors on which prognosis of an oral cancer patient depends on like depth of invasion of tumor, involvement of lymph nodes in the neck (lymph node ratio), pattern of invasion of tumor, extranodal extension, and presence of positive margins after surgery. In the recent past, advanced-stage (stage III–stage IV) oral cancer was primarily managed by upfront ablative resection and neck dissection followed by postoperative



©Association of Oral and Maxillofacial Surgeons of India

Fig. 84.1 The three major treatment modalities available for the treatment of oral cancer

adjunctive radiotherapy depending upon the other predictors of prognosis. This dual modality approach of followed by radiotherapy has given promising results in advanced-stage cancers, but the overall survival benefit came out to be as low as 40% [2–5].

In 2004, two large-scale trials were conducted, Radiation Therapy Oncology Group (RTOG) 9501 in America and European organization for Research and Treatment of Cancer (EORTC) 22,931. The results of these trials had provided the new insights for the management of advanced head and neck squamous cell carcinoma. The evidence from these landmark trials confirms the use of chemotherapy to the adjuvant radiation regime in the treatment of advanced-stage squamous cell carcinoma patients [5, 6].

The addition of chemotherapy may result in better locoregional control, overall survival, and metastasis-free survival in these patients. The three major pillars of treatment for oral squamous cell carcinoma are surgery, radiotherapy, and chemotherapy. To get the maximum survival advantage from these treatment modalities, all the three treatment modalities have to be used as an adjunct to each other [2, 3] (Fig. 84.1).

A. Dhawan (✉)
Department of Oral and Maxillofacial Surgery, SGRD Dental
Institute, Amritsar, India

84.2 Basic Principles of Radiotherapy

When the radiation is used for the purpose of treatment, especially in the patients of oral cancer, it is referred to as radiation therapy or radiotherapy. Radiotherapy is frequently used in as an adjunctive therapy or adjuvant therapy, to improve both local-regional control and overall survival. Radiation therapy is thought to kill tumor cells via damage to their DNA. The amount of radiation is typically measured in the unit gray (Gy), which represents joules of energy per kilogram. The following gives the conversion between grays, radiation absorbed dose (rad), and centigrays: 1 Gy = 100 rad = 100 cGy [7, 8].

External beam radiotherapy refers to the treatment, when a targeted beam of energy in the form of radiation is directed from a machine placed outside the patient to an area to be irradiated located within the patient. However, a radioactive substance may be introduced directly within an existing tumor or tumor-bearing area which is referred to as brachytherapy. Arranging for a patient's radiation treatment involves a number of steps before treatment can commence, of which the first is a dental evaluation and appropriate dental care. After consultation, a patient is simulated, which usually involves obtaining a computed tomographic (CT) scan, while the patient is immobilized with a face mask. Afterward, the radiation oncologist outlines the disease on the scan (contouring). Then a medical physicist and dosimetrist devise a method to deliver the radiation safely to the patient while avoiding radiation to normal anatomical structures. At the time of treatment, the radiation therapists verify that the patient lines up appropriately before treatment can begin. Immobilization of the patient is carried out with a predesigned face mask made up of a thermoplastic material. It is to be noted that accurate positioning of the patient without movement and the ability to recreate the same position of the patient every time (up to 6 weeks) are important factors for overall effective radiation treatment of the patient [7–10].

84.2.1 Biology of Radiation Therapy

The current understanding of radiotherapy techniques makes use of radiobiological principles for better treatment planning and outcomes. These principles influence the response of both normal tissues and of tumor clonogens to ionizing radiation, and a basic understanding and application of these principles are vital to improve the narrow therapeutic ratio of tumor versus normal tissue damage.

The 5R' concept of radiobiology is as follows [9, 10]:

- *Reoxygenation*: This refers to the process by which surviving hypoxic tumor clonogens become reoxygenated after a period of radiotherapy.
- *Repair*: This refers to the process by which tumor clonogens damaged by radiation may restore cell integrity to its full potential.
- *Redistribution*: Distribution of tumor clonogens to a more even cell age distribution after selective cell killing in certain phases of the cell cycle.
- *Repopulation*: This refers to the process by which tumor clonogens can replenish number of cells following a period of radiation therapy.
- *Radiosensitivity*: This refers to a dosage of radiation required to make a defined level of cell inactivation after radiation exposure.

84.2.2 Primary Radiotherapy

This is also called as radical radiotherapy. The indications of primary radiotherapy only include early-stage oral cancers like carcinoma of lip, ventral surface of tongue, and floor of mouth. According to some reports, primary radiotherapy is indicated for treating T1 and T2 cancers with proliferative character. It is believed that the local control and overall survival of the patients are similar in these cases without upfront surgery with an added advantage of preservation of cosmetic, anatomic, and functional integrity of the head and neck region. The literature supports the use of postoperative radiotherapy instead of preoperative radiotherapy even for small-sized tumors as the locoregional recurrence is reported to be slightly more in primary radiotherapy group as compared to postoperative radiotherapy group, but the survival advantage is not statistically significant.

After radiation therapy, the preferred method for assessment of tumor response, in addition to clinical and endoscopic examination, is a posttreatment positron-emission tomographic (PET)/CT scan at 12 weeks. In most patients with a complete response to therapy and negative PET scan results, routine neck dissection is not recommended in the postoperative setting.

84.2.3 Indications of Adjuvant Radiotherapy

The treatment for the stage III and stage IV oral cancer is complex. According to current National Comprehensive Cancer

Network (NCCN) guidelines, single-modality treatment with either surgery or radiotherapy is recommended for approximately 30% to 40% of initial stage oral carcinoma patients (stage I and II). Both modalities of treatment have resulted in comparable survival benefit in these patients. On the other hand, combined modality treatment is generally recommended for the approximately 60% of patients with locally or regionally advanced disease at diagnosis. The treatment in these individuals depends on factors such as site of the disease, stage, pathological findings, and presence of adverse features in the resected specimen. Several studies have classified the oral cancer patients into low risk, medium risk, and high risk [2, 3].

Postsurgical adjuvant radiotherapy is indicated according to the presence of adverse features on final histopathology.

The adverse features refer to extranodal extension, lymphovascular invasion, and perineural invasion.

Patients who are classified as high or intermediate risk of relapse benefit the most from the addition of postoperative radiotherapy.

The indications of adjuvant radiotherapy after primary ablative surgery in oral cancer patients are as follows:

- Stage III and stage IV oral squamous cell carcinoma patients.
- Positive surgical margins: presence of invasive carcinoma at the border.
- Presence of extranodal extension.
- Involvement of more than two levels of lymph nodes (multiple nodal metastasis).
- Perineural invasion.

Often, radiation to the head and neck involves the selection of different doses depending on the amount of disease in

that area. Typically, gross disease receives a dose of 70 Gy. Areas at high risk of microscopic disease often receive a dose of between 60 and 66 Gy. Areas at low risk of microscopic disease typically receive a dose of 50–54 Gy. The areas designated at high risk and low risk will depend on the site of occurrence of disease, the stage, and presence of pathological adverse features. The most common fraction size is 2 Gy of radiation per day [10–13].

84.2.4 Effect of Radiation Treatment Delay

Postsurgical radiation delay has a profound effect on overall survival of patient. Tumati V et al. found an association between treatment delays and oncologic outcomes in patients treated with surgery followed by post-op radiotherapy in a total of 277 patients of oral and oropharyngeal carcinoma. On multivariate analysis it was observed that radiation treatment time had a significant impact on locoregional recurrence in these patients. The authors found out that delays in the postoperative radiation therapy >43 days were associated with statistically significant locoregional recurrences ($p = 0.02$) in patients with non-p16-positive cancers. Many investigators have studies in coherence with the above conclusions. An increase in distant metastasis appears to be the mechanism by which prolonged time to treatment initiation leads to worse overall survival [14].

84.3 Radiotherapy Techniques

Depending upon the indication and treatment plan, there are multiple techniques with which radiation therapy can be delivered to a patient undergoing treatment for oral cancer. The techniques of radiotherapy should deliver the calculated radiation dose to the patient as per treatment plan without much toxic effects to the normal tissues. Some of the radiation techniques are listed below (Table 84.1) [15–19].

Table 84.1 Radiation techniques

Radiotherapy technique	Indications	Advantages
Brachytherapy (a) Interstitial brachytherapy (b) Intraluminal brachytherapy	T1 and T2 tongue and floor of mouth cancers	Radiotherapy source placed directly into the tissues to be irradiated. Less chances of systemic toxicities and treatment interruption.
Conventional radiotherapy	For high-risk oral carcinoma patients	Well established with known pattern of response, local control, and toxicities
Intensity-modulated radiation therapy (IMRT)	Advanced approach to three-dimensional treatment planning and conformal approach. For dose calculated radiation delivery to target volume.	Allows for greater sparing of salivary glands, esophagus, optic nerve, spinal cord, and brain stem. Allows treatment to be delivered in single treatment phase. Offers the possibility of simultaneously delivering higher radiation to regions of gross disease and lower doses to areas of microscopic disease.
Image-guided radiation therapy (IGRT)	Advances in real-time imaging during radiotherapy	Targeted delivery of radiotherapy which spares the vital structures immediately adjacent to high-dose regions

84.3.1 Radiation Dosage and Fractionation Schedule

Radiotherapy schedule, conventionally, is followed for 5–7 days a week with defined breaks in the treatment for reoxygenation and repair of normal tissue cells of the body for target effectiveness of radiotherapy. According to the literature, the tumor cells repopulate in between the radiotherapy regime especially after fourth week, so unscheduled breaks between the course of radiotherapy are not recommended by the radiation oncologists. That's the reason different fractionation schedules have been advocated by the radiation oncologists for successful completion of the treatment without unnecessary treatment breaks which can have a negative impact on the final outcome of the patients [15–19].

- *Conventional fractionation:* Every week for 5 days Monday to Friday.
- *Hyperfractionation:* When more than one fraction of lower radiation dose is delivered to the patient in the same day, it is known as hyperfractionation. The advantage is the treatment can be completed in a shorter time than conventional fractionation, yet the same total dose is delivered with better disease control and without increase in the toxicity.
- *Accelerated hyperfractionation:* More than one fraction of radiotherapy is given everyday or radiotherapy is given more than 5 days per week, the disadvantage is the increase in the toxicity due to no treatment breaks.
- *Continuous hyperfractionated radiotherapy:* When the radiation fraction is delivered thrice daily for the whole week, it is known as continuous hyperfractionated radiotherapy. This uninterrupted radiotherapy regime finishes the total dosage of radiation in 12–14 days.

84.4 Complications of Radiotherapy

Though the dual-modality treatment (surgery and radiotherapy) has become a norm for the treatment of advanced-stage (stage III–stage IV) oral squamous cell carcinoma, there are some unavoidable toxic effects of radiation therapy which can affect the quality of life (QOL) of the patient. Radiotherapy has proved to be very effective in improving the locoregional control and overall survival of the patient, but there are short-term and long-term sequel of radiotherapy which sometimes limit the effectiveness of the therapy due to breaks in the treatment schedule. The intensity of the complications and toxic effects depends upon the dose of delivered radiation and the site exposed to the radiation therapy. Radiation techniques like intensity-modulated radiotherapy IMRT and image-guided radiotherapy IGRT are helpful in controlling the delivered dosage of radiation to the patient,

thereby decreasing the rate of complications and increasing the response of the patient toward the therapy.

Depending upon the response to radiation, the complications have been divided into acute toxic effects or short-term sequel and chronic toxic effects or long-term sequel.

IMRT requires that the radiation oncologist outline the tumor, the areas at risk for microscopic spreading, and the critical normal structures on every CT slice (contouring). Outlining the gross disease (gross tumor volume [GTV]) and areas at risk of microscopic spreading (clinical target volume [CTV]) requires a thorough understanding of the anatomy of the region and is significantly more labor-intensive than prior two-dimensional or conventional radiation therapy techniques.

84.5 Acute Toxic Effects

84.5.1 Xerostomia

Xerostomia is also referred to as dry mouth. It is one of the most common acute and chronic side effects of radiotherapy. Xerostomia starts from the first week of radiotherapy and is a more common complaint in the first 2 weeks in those patients in whom submandibular salivary glands have been removed as part of the neck dissection. As far as possible, contralateral submandibular salivary gland should be preserved in uninvolved neck when bilateral neck dissection has to be performed. With the traditional radiographic techniques, parotid gland was not spared which resulted in more profound effects of dry mouth leading to halitosis, stasis of thick saliva, dysphagia, and cervical caries. Stasis of thick saliva leads to dysphagia like symptoms and even aggravation of mucositis earlier in the course of therapy.

Intensity-modulated radiotherapy technique and image-guided radiotherapy have revolutionized the concept of delivery of radiotherapy, thereby minimizing the risks of development of unavoidable side effects like xerostomia leading to more acceptable quality of life. A randomized controlled trial by Nutting et al. confirmed the reduction in postradiation xerostomia significantly. They compared intensity-modulated radiotherapy without taking parotid gland in the radiation field and conventional radiation therapy for all patients. About 83% patients developed grade II or higher xerostomia with conventional radiotherapy as compared to 29% of patients who were adopted for parotid sparing intensity-modulated radiotherapy [19].

Many investigators have assessed the relationship of radiation dosage to parotid and submandibular gland and severity of xerostomia at weekly intervals. The inference from these studies point toward the damage to plasma membrane of secretory granules of glands. Another observation was that the flow of saliva from submandibular and parotid glands considerably decreases up to less than 20% of pretreatment

values by the end of the second week of radiation therapy. The recommendations are to use current radiotherapy techniques like intensity-modulated radiation therapy to spare the submandibular and parotid gland with lowest possible exposure. The treatment of xerostomia converges toward the usage of sialagogues, artificial saliva, and fluid therapy along with reassurance to the patient [20, 21].

84.5.2 Oral Mucositis

Oral mucositis due to radiotherapy and other systemic therapies in oral cancer treatment represents a major complication causing a wide spectrum of clinical signs and symptoms. Oral mucositis may hamper the quality of life, resulting from debilitating oral pain and bleeding from oral cavity, dysphagia, infections, and inability to chew food and may interfere with the ongoing radiation treatment, ultimately jeopardizing overall patient outcome. According to certain reports, third week of post-radiotherapy is the most crucial time when the mucositis begins to set in and the severity increases in the subsequent weeks. The severity and agony from mucositis is directly proportional to the total dosage of radiation delivered and the volume of irradiated tissue in a specified interval of time. Mild initial erythema to patchy mucositis (characterized by white patches of fibrinous exudate on an erythematous base) to confluent mucositis (where the exudative patches coalesce) are the presenting symptoms of progression of ongoing mucositis in the oral cavity. On the other hand, if there is an evidence of bleeding to touch from the oral ulcers, it is considered as severe to fulminant mucositis.

Confluent mucositis, common toxicity criteria (CTC) grade 3, is seen in 40–80% of patients receiving more than 60Gy (or equivalent), more frequently in those receiving concurrent chemotherapy or accelerated radiotherapy. The patients should be advised to keep good oral hygiene with 0.12% chlorhexidine gluconate along with sialagogues or artificial saliva which will have protective action for the underlying oral mucosa thus reducing the severity of symptoms and relieve the pain. A narcotic analgesic like tramadol is recommended for pain from mucositis. There are some reports which favor elemental zinc or zinc carnosine complex for relieving the symptoms of severe mucositis.

The role of nonalcohol-based mouthwash has been established by many authors for relieving the debilitating effects of mucositis. Topical steroids had been used in past for the treatment of mucositis in severe stages, but their use is constantly discouraged in the current settings. The radioprotectant drug amifostine has been investigated as a means of reducing the incidence of xerostomia and mucositis. The route of administration of amifostine is intravenous everyday prior to initiation of radiotherapy. Patient should be constantly monitored for hypotension and nausea postoperatively.

Moreover, WHO recommends the constant nutrition support to the patients undergoing radiotherapy which will have a positive effect on the recovery from acute mucositis. If oral route is jeopardized, the nasogastric feeding, PEG percutaneous endoscopic gastrostomy, and parenteral nutrition should be considered based on the severity of mucositis. Recovery of severe mucositis may not begin until 2–3 weeks after treatment completion then take up to 4–8 weeks to regain normal swallowing. The recovery is mostly complete; however, only <5% of patients may remain PEG dependent.

Other known acute toxic effects of radiotherapy are erythema of facial and skin of the neck, lethargy, loss of taste, and smell. Erythema of the skin takes about 7–10 days of complete remission after cessation of radiation therapy; however the skin remains photosensitive even after the completion of therapy [20–22].

84.6 Chronic Toxic Effects

There are multiple chronic toxic effects of radiotherapy enumerated in the literature by different authors and radiation oncologists (Table 84.2). It has been found out that the chronic effects of radiotherapy are more dependent on dosage than the acute effects of radiation.

84.6.1 Osteoradionecrosis of Maxilla and Mandible

Currently, one of the most serious long-term or chronic complications of radiotherapy to the head and neck region is osteoradionecrosis of the jaws. The associated morbidity of this complication and its subsequent treatment will include close observation and/or radical surgical resection followed by reconstruction with free fibula, deep circumflex iliac artery flap (DCIA), or a variety of pedicled and soft tissue free flaps depending upon the severity of necrosis and systemic condition of the patient.

The etiopathogenesis of osteoradionecrosis have been explained on the basis of current theory of Delanian and Lefaix [23]. It states that osteoradionecrosis of the jaws is a radiation-induced fibrosis with histopathological formation of phases which appear similar to those of chronic wounds. There is a histopathological picture of combination of dead or dying osteoblasts without replication of new osteoblasts and excessive proliferation of myofibroblasts. This condition is manifested as loss of trabeculae of existing bone and subsequent decrease in the quality and structure of underlying bone.

Among the risk factors for the development of osteoradionecrosis, total radiation dose delivered to the bone, in a specified period of time, remains the most important and crucial risk factor. The cumulative dose of radiation to the bone will

Table 84.2 Chronic effects of radiotherapy

Chronic toxicity	Risk factors	Prevention strategy
Osteoradionecrosis, mandible, maxilla	Primary bone surgery (marginal mandibulectomy), maxillary osteoradionecrosis is rare. Dentulous patients High radiation dose >65 Gy to the mandible. Traumatic extractions. Women > men. Conventional radiotherapy techniques. Age of the patient.	IMRT, IGRT, calculating the dose to be delivered to mandible. Proper dental consultation and rehabilitation before radiotherapy. Appropriate coverage of remaining bone with free vascularized soft tissue flaps
Trismus	Postoperative radiation to the masseter muscle and pterygoid muscles. Location of the tumor in the oral cavity. In case of maxillary tumors, reconstruction with temporalis flap pose greater risk of developing trismus after radiotherapy	Early institution of radiotherapy within 4–6 weeks of surgery Use of microvascular free flaps for reconstruction which provide extra soft and pliable tissue
Hypothyroidism	Irradiation of thyroid tissue at higher dose. Female patient	Dosage to the thyroid gland should be limited. Use of thyroid shield
Nerve injury (damage to spinal cord, optic nerve, vestibulocochlear nerve)	Radiation dosage >50–54 Gy pose more risk of development of nerve injuries	IMRT, IGRT, calculating the dose to be delivered
Radiation-induced cancers	Radiation-induced tumors are mostly sarcomatous and develop many years after institution of radiotherapy	Regular follow-up of the patient

produce an environment of hypo-cellularity and hypo-vascularity leading to the cause and effect relationship in the underlying bone. Maxillary bone is less susceptible to the development of necrosis than mandible as maxilla has a more porous structure of bone with more vascularity as compared to a single terminal inferior alveolar artery in mandible which undergoes fibrosis after high-dose radiation therapy. Moreover, muscles of facial expression and thick mucoperiosteum in maxilla prevent it from getting hypo-vascular in a shorter period of radiation therapy. Facial artery is notoriously unreliable to produce collateral blood supply to the mandible which is insufficient to prevent osteoradionecrosis. On the other hand, in case of post-neck dissection patients, the facial artery is most of the time ligated in the ipsilateral side during the clearance of level IB (submandibular) group of lymph nodes.

According to a comparative study conducted by Kuhnt et al. [22] on 776 patients with head and neck cancer who underwent intensity-modulated radiotherapy as radical radiotherapy for the treatment of head and neck cancer and as postoperative radiotherapy, the highest cumulative incidence of osteoradionecrosis was found to be 12.4%, and relative frequency was 6.6%. The interesting inference of this study is the actual risk for the development of osteoradionecrosis remains there for a lifetime of the patient and may increase by a factor of two in long-term survivors. There remains a highest risk for the development of osteoradionecrosis in patients who had undergone primary bone surgery during tumor resection (hazard ratio: 5.87 95% confidence interval) and in patients with tumor located in the oral cavity than other sub-sites in the head and neck region. This means the dental treatment including extractions and minor surgical

procedures should be performed well before in the patients advised for adjuvant radiotherapy in which mandibular resection (marginal mandibulectomy or segmental mandibulectomy) has been advised. Moreover, it is prudent to cover the marginal mandibulectomy defect with the free flap or a soft tissue pedicled flap to maintain vascularity so as to prevent postradiation chance of osteoradionecrosis.

Gender, dentition (dentulous vs edentulous), and concurrent chemotherapy have no significant clinically relevant influence on the development of osteoradionecrosis. Males are found to have three times more risk for the development of osteoradionecrosis than women. According to a study conducted by Gabriela et al., 25% of patients developed refractory osteoradionecrosis which required some kind of resection and subsequent reconstruction when the radiation dose delivered were more than 66Gy at a daily fraction exceeding up to 2.2Gy as compared to no evidence of osteoradionecrosis at or below 65 Gy of radiation dose [24]. On the other hand, as the daily dose of radiation decreases to 1.8 and 1.9 Gy, and a total dose of 69–75.6 Gy, the rate was 19.6%. Daily dose of radiation is thus considered to be a most significant factor in determining likelihood of developing osteoradionecrosis especially in cases of oral cancer. The close proximity of the cancer to the mandible (within 1 mm) receiving high dose of radiation remains the other risk factors for the development of osteoradionecrosis.

Prevention is better than the treatment of osteoradionecrosis. One study confirms the effectiveness of hyperbaric oxygen therapy in a very few number of patients. State-of-the-art radiotherapy techniques will limit the total absorbed dose to the mandible and potential sites in the oral cavity thus limiting the incidence of osteoradionecrosis [24, 25].

84.7 Principles of Chemotherapy

The oral cancer is considered as the sixth most common malignancy worldwide accounting up to 1,30,000 cases every year in a developing country like India. Due to poor screening facilities at primary examination level, lack of awareness among patients, and nonstandardization of public health sector, most of the cases are diagnosed when they have attained stage III and stage IV disease.

On the other hand, chemotherapy regimens for oral cancer treatment are evolving. There are multiple methods by which chemotherapy may be offered to the patients for the management of head and neck cancer to improve the overall outcomes in terms of survivability of patients.

Methods of providing chemotherapy for head and neck cancer patients are as follows:

- Single-modality treatment for palliation.
- As concomitant radiation therapy or concurrent chemoradiation (triple modality).
- As adjuvant therapy following surgical resection (dual modality).
- As definitive treatment for locoregionally advanced carcinoma primarily.
- As induction therapy or neoadjuvant therapy (NACT) before definitive treatment for prognostication of the primarily inoperable tumors.

Single-modality treatments usually have low efficacy in terms of locoregional recurrences. On the other hand, chemotherapy with or without radiotherapy poses the patient toward the risk of systemic toxicities and unwanted immunosuppression which may alter the overall result and outcomes of the patient undergoing cytotoxic therapy in any form [25–29].

84.7.1 Cytotoxic Chemotherapeutic Agents

While multiple cytotoxic drugs have been identified for the treatment of oral squamous cell carcinoma in addition to surgery and radiotherapy, some of the chemotherapy agents are listed below (Table 84.3).

84.7.2 Chemoradiation in Oral Cavity Cancers

Earlier it was thought that radiation therapy alone is effective for treating small T1 and T2 lesions of lower lip, floor of mouth, tongue, and palate within the oral cavity. After a decade, many centers adopted surgery alone for smaller lesions of oral cavity as primary treatment. Then a dual-modality approach (surgery followed by radiotherapy) was popularized for locally advanced carcinoma (stage III–stage IV AJCC eighth edition) of oral cavity. Hence, the dual-modality approach emerged as a conventional, widely accepted, and equally effective treatment option for the management of advanced (T3–T4) lesions. Conventionally, the combination of chemotherapy and radiotherapy, as primary treatment modality, had been reserved for those patients with unresectable disease or patients who refuse the surgical treatment.

It has been published by the RTOG trial reports that adjuvant radiotherapy improves the outcome of patients which received the surgical treatment for advanced-stage squamous cell carcinoma arising in the head and neck. At the same time, the disease-free survival and 5-year overall survival came out to be generally between 30 and 40% which is highly nonpromising. These trials also suggested that if the concurrent chemotherapy, using cytotoxic drugs, is added to the conventional postoperative radiotherapy regime, the effects of radiotherapy are intensified. This methodology of adjunctive treatment has significant amount of survival benefit than dual-modality treatment, and the chances of locore-

Table 84.3 Chemotherapy agents used in oral cancer

Chemotherapeutic drug	Mechanism of action	Toxicity and response
Platinum agents: Cisplatin, carboplatin, oxaliplatin	Inhibit DNA synthesis by forming intrastrand and interstrand cross-links between guanine-guanine pairs of DNA	Most active agent with response rates 20–50%. Dose range is 80–120 mg/m ² every 3–4 weeks. Renal toxicity, myelosuppression, neurological, and gastrointestinal toxicity (less with carboplatin)
Taxanes: Paclitaxel, docetaxel	Act by promoting the formation of tubulin dimers, stabilizing microtubules during cell division, and thereby leading to arrest of cells in G2/M phase of cell cycle	Particularly severe and life-threatening myelosuppression. Neutropenia, mucositis, and fluid retention Paclitaxel response up to 37% Docetaxel response 22–45%
5- fluorouracil: An antimetabolite	Depletion of nucleotides required for DNA synthesis and repair	Single-agent response is 15% Mucositis, diarrhea, myelosuppression
Methotrexate	Interferes with the use of folate used for DNA synthesis and repair inhibits dihydrofolate reductase (DHFR)	Most commonly used schedule is weekly intravenous bolus regime, using a dose of 40–60 mg/m ² . The objective response rate in this dose range is 10–30%
Cetuximab: a monoclonal antibody against human EGF receptor	It prevents binding of EGFR ligands, results in inhibition of function of the receptor	Significantly improved overall survival in head and neck squamous cell carcinoma patients Consistent severe acneiform skin rash

gional recurrences are likely to be less especially in high-risk patients postoperatively. In the last 10 years of research in the field of head and neck carcinoma treatment, the efficacy of triple-modality therapy has been justified in the literature for postoperative high-risk squamous cell carcinoma patients. Like RTOG a similar trial was conducted in Europe, the EORTC trial. This trial also reconfirmed the addition of adjuvant chemotherapy to the radiotherapy regime. The inference of this trial showed better rates of local control, disease-specific survival, and overall survival and significant decreased incidence of late toxic effects. Both these trials compared the addition of three planned cycles of concomitant cisplatin at 100 mg/m² every 3 weeks to radiotherapy (60–66 Gy, over 6–6.5 weeks, standard fractionation) with the same radiotherapy alone in patients with adverse feature of head and neck carcinoma. Therefore the concomitant therapy with cisplatin at 100 mg/m² every 3 weeks with adjuvant radiotherapy on day 1, day 22, and day 43 is the regimen of choice. The only limitations of these two trials were that these trials were not oral cancer specific. There are very few studies in the literature who have evaluated the concept of triple-modality therapy yet being site specific to oral cavity. Choi et al. retrospectively reviewed 861 patients with oral carcinoma treated in Korea from 1984 to 1996. Almost 63% of patients had stage III and stage IV cancer, and 36% had T3–T4 lesions. The authors concluded that triple-modality treatment (upfront surgery followed by postoperative chemoradiation) yielded a greater treatment response rate than dual-modality treatment [29]. On the other hand, Zhang et al. conducted a trial in oral cancer patients who received surgery followed by radiotherapy as a primary treatment modality. The trial found out that there is a 3.6 times more incidence to develop distant metastasis in surgery and radiation group as compared to surgery followed by chemoradiation group [3].

Box 84.1 Questions to be answered

Now the question arises.

1. Whether the addition of chemotherapy to the radiotherapy regime will improve the survival outcomes?
2. If the survival benefit is observed, does it have any effect on progression-free survival?
3. Is there any of incidence of chronic toxicities if the chemo radiation is used?
4. Does the technique of administering radiation have any profound effect in the outcome?
5. Whether the patients with adverse features (like: extranodal extension, lymphovascular invasion, and perineural spread) have improved outcomes with chemoradiation?

Explanation for Q1&2: Results of the recent study conducted by Stenson et al. revealed that patients who underwent chemoradiation as primary therapy for advanced-stage oral squamous cell carcinoma had a greater rate of metastasis-free and overall survival benefit with 66.9% disease-free or progression-free survival [30]. One of the recent single-institutional study conducted by Dhawan et al. on 128 patients of advanced-stage high-risk oral carcinoma shows an overall survival benefit of 10% in patients receiving chemoradiation as compared to patients receiving only radiation therapy after primary ablative surgery. This study was conducted in a subset of Asian Indian population to evaluate the benefits of multimodal therapy in the management of stage III/IV oral carcinoma [2]. Zhang et al. in their study showed a survival benefit of 11% in patients receiving chemoradiation as compared to radiation alone [3].

Explanation for Q-3: But the survival benefit doesn't come without a price to the patient. Along with improved survival comes the greater incidence of acute and chronic toxicities due to cytotoxic chemotherapeutic agents. The chances of recurrence always remain high even with the addition of chemotherapy due to the advanced stage and higher volume of the disease being treated. The recurrence potential of the lesion depends on the invasive pattern of tumor invasion at the first place and the presence of cancer stem cells in a given area. According to Pericot et al., high incidence of recurrence is associated with size of the primary tumor (T stage), and the difficulty in obtaining margins free of disease, after surgical resection. So obtaining a positive margin or a close margin (between 1 to less than 5 mm) after resection becomes an indication for administration of concurrent chemoradiation therapy. On the other hand, the development of myelosuppression, neutropenia, mucositis, and xerostomia is inevitable with triple-modality treatment [31].

Explanation for Q-4: The type of radiation (IMRT and routine radiotherapy) also affects the survival outcomes when used concurrently with chemotherapy as IMRT is more effective along with chemotherapy than with conventional radiotherapy.

Explanation for Q-5: Neck node involvement is also considered as an independent predictor of survival in oral cavity cancer. According to the literature, patients with nonpalpable disease in the neck or clinically N0 necks are having greater overall survival rate as compared to subsequent N stages. A recent study by Franceschi et al. found that among patients with involved neck nodes, survival rate was significantly lower when more than two levels of lymph nodes were involved, or when extranodal extension was observed. The adverse features which are found after final histopathological examination of primary as well as neck dissection specimen are currently addressed as extranodal extension, perineural invasion, and lymphovascular invasion. These

patients are particularly at higher risk of disease progression and have higher death rates [32]. According to Zhang et al. [3], patients with extranodal extension and perineural invasion had improved disease-specific and metastasis-free survival in the surgery followed by chemoradiation group ($p < 0.05$). In a retrospective study conducted in 2016, authors found out that overall survival was significantly influenced by the type of modality and regional spread of disease. Chemoradiation after primary ablative surgery group had improved overall, disease-specific, disease-free, and metastasis-free survival compared to surgery followed by radiotherapy group even in patients with extranodal extensions, perineural spread, and lymphovascular invasion.

According to RTOG and EORTC landmark trials, there are some absolute indications for postoperative chemoradiation. These studies provided the base for the risk-adapted strategies in postoperative adjuvant therapy and *established extranodal extension and positive surgical margin as the absolute indications for adding concomitant systemic chemotherapy to adjuvant radiation*. However, proper patient assessment preoperatively is mandatory keeping in view the systemic toxicity due to chemoradiation.

Absolute Indications of Adjuvant Chemotherapy in Oral Cavity Cancers

According to RTOG trial, the definition of high-risk patients is as follows:

- Presence of tumor at the surgical resection margins—positive surgical margin.
- Extranodal extension.
- Clinical or radiographic involvement of level IV and level V lymph nodes.
- Stage of pT3 or pT4 with any N except T3N0 of the larynx.
- N2–N3 neck.
- Perineural invasion.
- Vascular embolism.

84.7.3 Induction Chemotherapy Before Surgery

Since 1982, during the days of early clinical trials on chemotherapeutic agents and their clinical advantage in head and neck squamous cell carcinoma, induction chemotherapy was thought to have potential benefits for treating head and neck cancers. Unfortunately, the higher response rates of these chemotherapeutic results have failed to result in statistically significant survival benefit. Induction chemotherapy before surgery is generally instituted in primarily unresectable oral

cavity cancers at some centers. The efficacy of induction chemotherapy has yet to be proven in oral cancer treatment with regard to locoregional control and/or overall survival of these patients. The efficacy of induction chemotherapy to downstage oral cavity cancers was observed by a study conducted by Grau et al. in a prospective way with unresectable stage III–stage IV oral cavity cancers. They found out that disease-free survival at 5 years was 26% for patients undergoing resection and 22% for patients who received chemoradiation. Improved outcome is always at an expense of increased toxicity. There are other studies with comparable results which were carried out exclusively in oral cancer patients. Currently, induction chemotherapy cannot be recommended in resectable oral cancer patients for improvement in the survival [33].

84.7.4 Palliative Chemotherapy in Patients with Oral Cancer

Patients with recurrent and metastatic squamous cell carcinoma of head and neck are considered incurable with surgery or radiation. In these patients mainstay of treatment remains the systemic chemotherapy with cytotoxic chemotherapeutic drugs. Chemotherapeutic agents can be used either in combination regimen or as single agent in the management of metastatic oral cavity carcinomas. Radiation therapy with concurrent cetuximab, a monoclonal antibody to epidermal growth factor receptor (EGFR), has been shown to significantly improve overall survival rates compared with radiation therapy alone in the palliative setting. A direct randomized comparison of cetuximab versus platinum-based regimens is underway at many centers in the world. At present, platinum-based regimens (cisplatin, carboplatin) are preferred over other drugs, as long as patients can tolerate the regimen with acceptable complications [34–36].

84.8 Conclusions

Adjunctive therapies are included in the treatment regimen of oral squamous cell carcinoma to improve the disease-free, metastasis-free, and overall survival of the patients. Adjuvant radiotherapy is indicated in high-risk advanced-stage (stage III–stage IV) oral squamous cell carcinoma patients as dual modality. The complications and side effects of radiotherapy can be reduced by adopting advanced radiotherapy techniques like intensity-modulated radiotherapy, image-guided radiotherapy, and stereotactic radiotherapy. Concurrent chemoradiation therapy is adopted as primary treatment in patients with locally advanced oral cavity cancer whose disease is not amenable for surgical resection. Adjuvant chemo-

radiation is indicated in patients having postresection positive margins and with extranodal extensions or extracapsular invasion as a multimodality treatment. Consider cetuximab synchronously with radiotherapy in patients unsuitable for platinum-based chemoradiation.

References

1. Agarwal AK, Sethi A, Sareen D, Dhingra S. Oral and oropharyngeal squamous cell carcinoma in our population: the clinic-pathological and morphological description of 153 cases. *Int J Morphol*. 2011;29(3):686–93.
2. Dhawan A, Duggal P, Bhullar RS, Kaur T, Sandhu A, Kaur K. Efficacy of multimodal therapy in the survival outcomes of advanced-stage (stage III-stage IV) oral carcinoma patients: an institutional experience in Asian Indian population. *J Maxillofac Oral Surg*. 2018;17(1):89–94.
3. Zhang H, Dziegielewski PT, Biron VL, et al. Survival outcomes of patients with advanced oral cavity squamous cell carcinoma treated with multimodal therapy: a multi-institutional analysis. *J Otolaryngol Head Neck Surg*. 2013;42:30.
4. Cooper JS, Pajak TF, Forastiere A, et al. Precisely defining high-risk operable head and neck tumors based on RTOG #85–03 and #88–24: targets for postoperative radiochemotherapy? *Head Neck*. 1998;20:588–94.
5. Cooper JS, Pajak TF, Forastiere A, et al. Postoperative concurrent radiotherapy and chemotherapy for high risk squamous cell carcinoma of the head and neck. *N Engl J Med*. 2004;350:19.
6. Bernier J, Cooper JS, Pajak TF, et al. Defining risk levels in locally advanced head and neck cancers: a comparative analysis of concurrent postoperative radiation plus chemotherapy trials of the EORTC (#22931) and RTOG (#9501). *Head Neck*. 2005;27:843–50.
7. Liauw SL, Mancuso AA, Amdur RJ, Morris CG, Villaret DB, Werning JW, et al. Postradiotherapy neck dissection for lymph node-positive head and neck cancer: the use of computed tomography to manage the neck. *J Clin Oncol*. 2006;24(9):1421–7.
8. Fletcher GH. The role of irradiation in the management of squamous-cell carcinomas of the mouth and throat. *Head Neck Surg*. 1979;1:441–57.
9. Delclos L, Lindberg RD, Fletcher GH. Squamous cell carcinoma of the oral tongue and floor of mouth. Evaluation of interstitial radium therapy. *AJR Am J Roentgenol*. 1976;126:223–8.
10. NCCN Clinical Practice Guidelines in Oncology (NCCN Guidelines) Head and Neck Cancers. Version I. 2015. Available at: NCCN.org.
11. Chen PY, Chen HH, Hsiao JR, Yang MW, Hsueh WT, et al. Intensity-modulated radiotherapy improves outcomes in postoperative patients with squamous cell carcinoma of the oral cavity. *Oral Oncol*. 2012;48:747–52.
12. George JR, Yom SS, Wang SJ. Improved outcomes in adjuvant radiotherapy for oral cavity carcinoma at an academic center: a matched-pair analysis. *Laryngoscope*. 2014;124:1603–8.
13. Kreppel M, Eich HT, Bruggenolte C, Dreiseidler T, Rothamel D, et al. Preoperative vs. post-operative radiochemotherapy in patients with N2 squamous cell carcinoma of the oral cavity. *Oral Oncol*. 2012;48:1019–24.
14. Tumati V, Hoang L, Sumer BD, Truelson JM, Myers LL, Khan S, Hughes RS, Nedzi L, Sher DJ. Association between treatment delays and oncologic outcome in patients treated with surgery and radiotherapy for head and neck cancer. *Head Neck*. 2019 Feb;41(2):315–321.
15. Amit M, Yen TC, Liao CT, Chaturvedi P, Agarwal JP, et al. Improvement in survival of patients with oral cavity squamous cell carcinoma: an international collaborative study. *Cancer*. 2013;119:4242–8.
16. Hartley A, Cheah N. Postoperative radiotherapy in head and neck cancer. *Stell and Maran's textbook of head and neck surgery and oncology*, 5th edn, 2012.
17. Rowell N. Principles of radiotherapy. *Stell and Maran's textbook of head and neck surgery and oncology*, 5th edn, 2012.
18. Sher DJ, Thotakura V, Balboni TA, Norris CM Jr, Haddad RI, et al. Treatment of oral cavity squamous cell carcinoma with adjuvant or definitive intensity-modulated radiation therapy. *Int J Radiat Oncol Biol Phys*. 2011;81:e215–22.
19. Nutting CM, Morden JP, Harrington KJ, et al. Parotid-sparing intensity modulated versus conventional radiotherapy in head and neck cancer (PARSPORT): a phase 3 multi-centre randomised controlled trial. *Lancet Oncol*. 2011;12:127–36.
20. Overgaard J, Mohanti BK, Begum N, Ali R, Agarwal JP, et al. Five versus six fractions of radiotherapy per week for squamous-cell carcinoma of the head and neck (IAEA-ACC study): a randomised, multicentre trial. *Lancet Oncol*. 2010;11:553–60.
21. Beitler JJ, Zhang Q, Fu KK, Trotti A, Spencer SA, et al. Final results of local-regional control and late toxicity of RTOG 9003: a randomized trial of altered fractionation radiation for locally advanced head and neck cancer. *Int J Radiat Oncol Biol Phys*. 2014;89:13–20.
22. Kuhnt T, Stang A, Wienke A, Vordermark D, Schweyen R, Hey J. Potential risk factors for jaw osteoradionecrosis after radiotherapy for head and neck cancer. *Radiat Oncol*. 2016;11:101.
23. Delanian S, Lefaix JL. Current management for late normal tissue injury: radiation-induced fibrosis and necrosis. *Semin Radiat Oncol*. 2007 Apr;17(2):99–107.
24. Studer G, Bredell M, Studer S, et al. Risk profile for osteoradionecrosis of the mandible in IMRT era. *Strahlenther Onkol*. 2016;192:32.
25. Moon SH, Jung YS, Ryu JS, Choi SW, Park JY, et al. Outcomes of postoperative simultaneous modulated accelerated radiotherapy for head-and-neck squamous cell carcinoma. *Int J Radiat Oncol Biol Phys*. 2011;81:140–9.
26. Posner MR, Hershock DM, Blajman CR, Mickiewicz E, Winquist E, et al. Cisplatin and fluorouracil alone or with docetaxel in head and neck cancer. *N Engl J Med*. 2007;357:1705–15.
27. Bernier J, Domezge C, Ozsahin M, Matuszewska K, Lefebvre JL, et al. Postoperative irradiation with or without concomitant chemotherapy for locally advanced head and neck cancer. *N Engl J Med*. 2004;350:1945–1952.
28. Murthy V, Agarwal JP, Laskar SG, Gupta T, Budrukkar A, et al. Analysis of prognostic factors in 1180 patients with oral cavity primary cancer treated with definitive or adjuvant radio-therapy. *J Cancer Res Ther*. 2010;6:282–9.
29. Choi KK, Kim MJ, Yun PY, et al. Independent prognostic factors of 861 cases of oral squamous cell carcinoma in Korean adults. *Oral Oncol*. 2006;42:208–17.
30. Stenson KM, Kunnakkam R, Cohen EEW, et al. Chemoradiation for patients with advanced oral cavity cancer. *Laryngoscope*. 2010;120:93–9.
31. Pericot J, Escriba JM, Valdes A, et al. Survival evaluation of treatment modality in squamous cell carcinoma of the oral cavity and oropharynx. *J Cranio Maxillofac Surg*. 2000;28:49–55.
32. Franceschi D, Gupta R, Spiro RH, et al. Improved survival in the treatment of squamous carcinoma of the oral tongue. *Am J Surg*. 1993;166:360–5.

33. Grau JJ, Estapé J, Blanch JL, Vilalta A, Castro V, Biete A, Daniels M. Neoadjuvant or adjuvant chemotherapy in the multidisciplinary oral cancer stage III and stage IV. *Eur J Cancer B Oral Oncol.* 1996;32(4):238–41. issn: 0964–1955
34. Bachaud JM, Cohen-Jonathan E, Alzieu C, David JM, Serrano E, Daly-Schveitzer N. Combined postoperative radiotherapy and weekly cisplatin infusion for locally advanced head and neck carcinoma: nal report of a randomized trial. *Int J Radiat Oncol Biol Phys.* 1996;36(5):999–1004.
35. Bonner JA, Harari PM, Giralt J, Azarnia N, Shin DM, Cohen RB, et al. Radiotherapy plus cetuximab for squamous-cell carcinoma of the head and neck. *N Engl J Med.* 2006;354(6):567–78.
36. Denis F, Garaud P, Bardet E, Alfonsi M, Sire C, Germain T, et al. Final results of the 94–01 French head and neck oncology and radiotherapy group randomized trial comparing radiotherapy alone with concomitant radiochemotherapy in advanced-stage oropharynx carcinoma. *J Clin Oncol.* 2004;22:69–76.

Open Access This chapter is licensed under the terms of the Creative Commons Attribution 4.0 International License (<http://creativecommons.org/licenses/by/4.0/>), which permits use, sharing, adaptation, distribution and reproduction in any medium or format, as long as you give appropriate credit to the original author(s) and the source, provide a link to the Creative Commons license and indicate if changes were made.

The images or other third party material in this chapter are included in the chapter's Creative Commons license, unless indicated otherwise in a credit line to the material. If material is not included in the chapter's Creative Commons license and your intended use is not permitted by statutory regulation or exceeds the permitted use, you will need to obtain permission directly from the copyright holder.





Access Surgeries and Osteotomies for the Maxillofacial Region

85

Madan G. Ethunandan

85.1 Bicoronal Scalp Flap

The bicoronal flap was first described by Hartley and Kenyon [1] to access the cranium and popularised by Tessier [2] to provide additional access to the orbits and midface. Various modifications of the flap have been described and include a zigzag (stealth) incision [3], deeper plane of dissection in the temporal scalp region to avoid damage to the facial nerve [4, 5] and strategies to minimise alopecia [6].

The coronal flap provides access to the skull, anterior and middle cranial fossa, upper midface including the nasoethmoid region and orbits and temporal and infratemporal fossa.

The SCALP is an acronym consists of five layers: Skin, subCutaneous connective tissue, galea Aponeurotica, Loose areolar tissue and Pericranium. The first three layers are firmly attached to each other and are raised as a single layer, superficial to the loose areolar tissue (avascular plane of Merkel). The blood vessels and nerves run within the first three layers. The “perceived” complexity of the layers in the temporal region can be rationalised, if one was to consider the galea aponeurotica as a single layer which extends to the temporal region as the “temporoparietal fascia” (synonym—superficial temporal fascia/supra-zygomatic SMAS) and the pericranium extending as the “temporalis fascia” (synonym—deep temporal fascia) overlying the temporalis muscle. The deep temporal fascia divides about 2–3 cm superior to the zygomatic arch into a superficial and deep layers. The temporoparietal fascia, superficial layer of the deep temporal fascia and the periosteum of the zygomatic arch fuse together on the lateral aspect of the zygomatic arch and contain the frontal branch of the facial nerve. The superficial temporal fat pad is present between the superficial and deep layer of the deep temporal fascia, with the deep layer attached to the deep

aspect of the zygomatic arch. Dissection deep to the galea and the temporoparietal fascia affords a relatively bloodless plane and maintains and preserves the blood supply and avoids damage to the nerves, including the frontal branch of the facial nerve. This “safe” plane of dissection can be between the temporalis muscle and the “undivided” deep temporal fascia or (more inferiorly) between the superficial and deep layers of the “divided” deep temporal fascia (Fig. 85.1a).

The frontal branch of the facial nerve crosses the zygomatic arch at least 8 mm (range 8–32 mm) in front of the external auditory meatus, at least 1 cm anterior to the superior attachment of the helix to the scalp, and runs no further than 2 cm above the frontozygomatic suture (Fig. 85.1b).

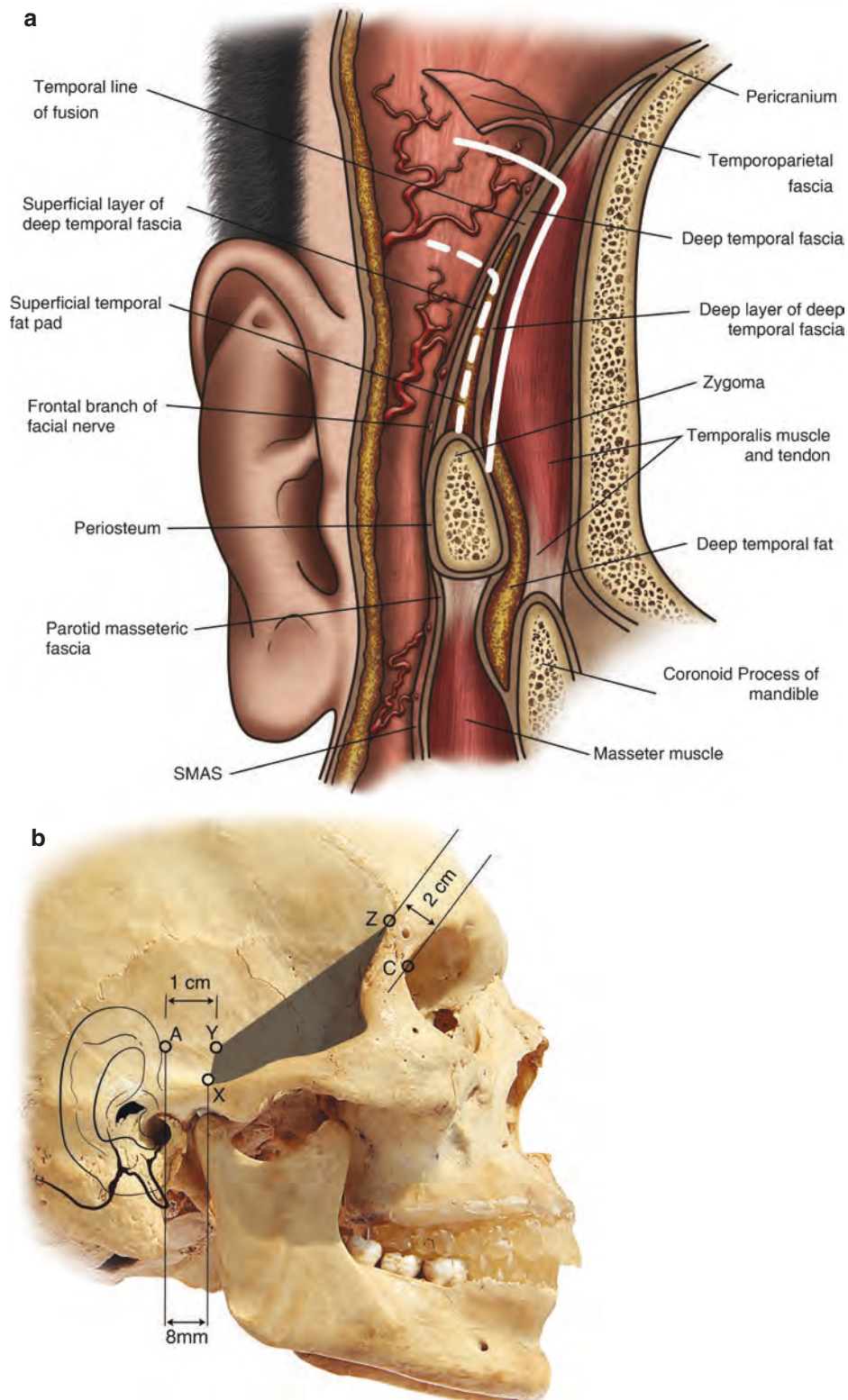
85.1.1 Procedure

The hair along the incision line can be parted or a small strip shaved. Local anaesthetic containing 1: 200,000 adrenaline is infiltrated above the galea for appropriate haemostasis (you know you are in the right plane if increased resistance is felt. If it is easy to inject, you are in the deeper loose areolar tissue plane). The incision is marked from the anterior attachment of the helix and carried over the vault to the opposite side, inside the hairline (Fig. 85.1c). It can stop at the midline, if only unilateral access is required. If repeated access is likely to be required to the cranial skeleton, it would be useful to incorporate a posteriorly directed “curve”, just above the helical attachment to the scalp, to try and avoid injury to the anterior branch of the superficial temporal artery and maintain additional vascularity to the flap. A “bevelled” incision can be made parallel to the hair follicles to minimise alopecia, and a “zigzag” can be incorporated to reduce parting of the hair along a straight incision line. When designing the flap in male patients, the likely influence of male pattern baldness should be taken into account.

The incision commences at the vertex between the superior temporal lines and is made with a blade through the

M. G. Ethunandan (✉)

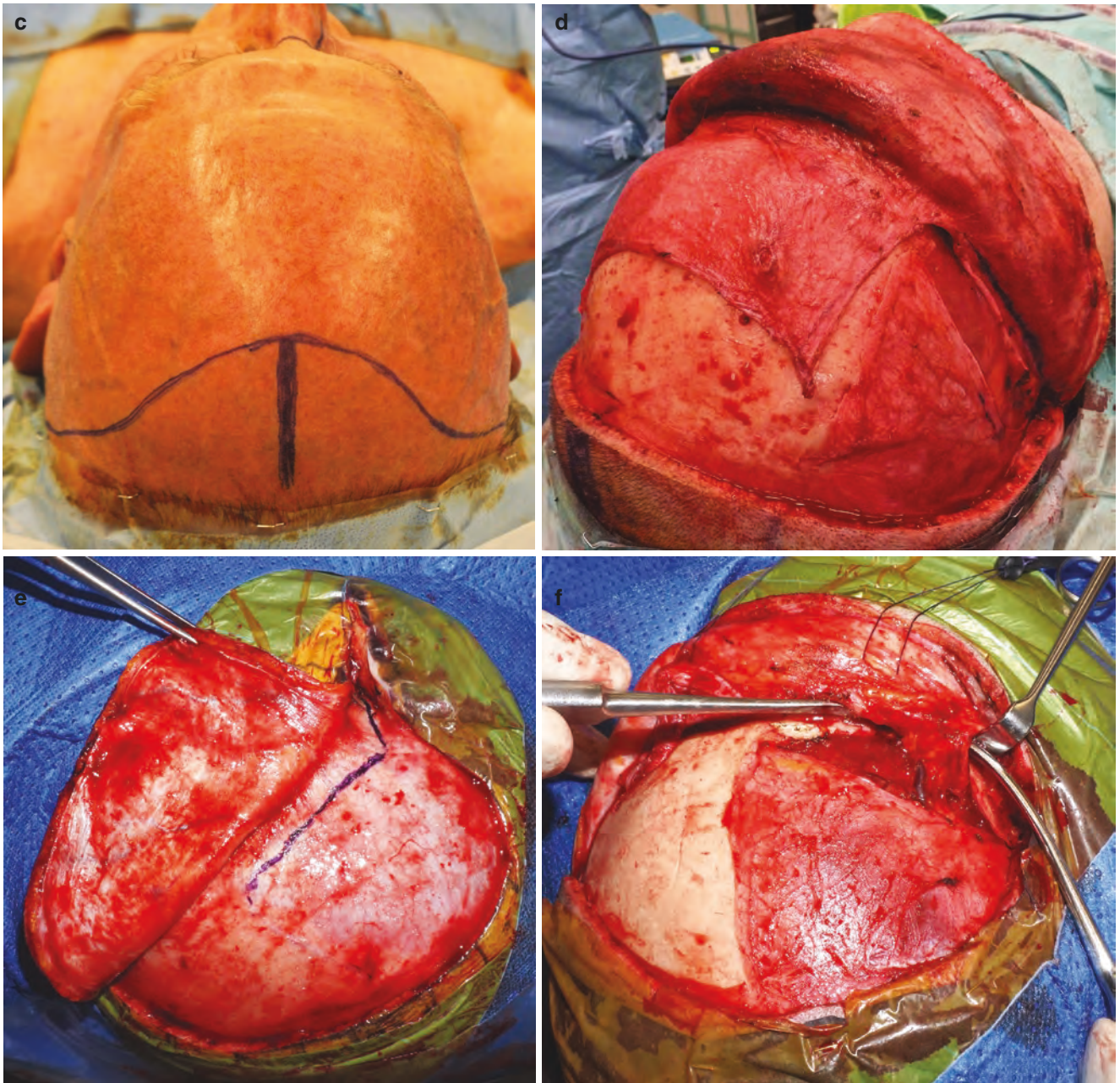
Consultant Oral and Maxillofacial/Skull Base Surgeon,
Honorary Senior Clinical Lecturer, Lead, Head and Neck Cancer,
University Hospital Southampton, Southampton, UK



©Association of Oral and Maxillofacial Surgeons of India

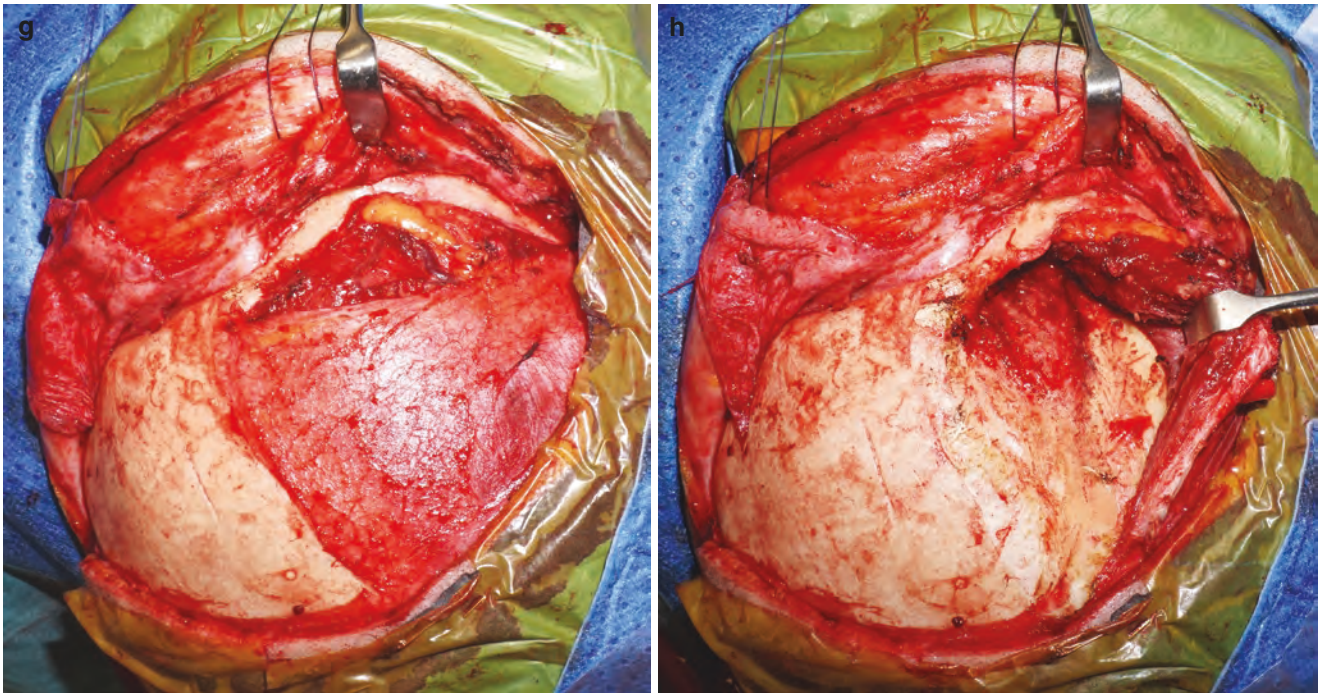
Fig. 85.1 Scalp flap. (a) Layers of the scalp in the temporal region. Dotted line—dissection between the superficial and deep layers of the (divided) deep temporal fascia. Solid line—dissection between the (undivided) deep temporal fascia and temporalis muscle. (b) Position of the frontal branch of the facial nerve. (c) Skin marking for a coronal flap. (d) Pericranial flap raised as an extension of the deep temporal

fascia incision (note same plane of dissection). (e) Incision marked on the undivided deep temporal fascia. (f) Periosteal tunnel created along the zygomatic arch, deep to the position of the frontal branch of the facial nerve. (g) Exposure of the lateral orbit and zygomatic arch. (h) Temporalis muscle retracted to expose the temporal fossa and lateral orbital wall



©Association of Oral and Maxillofacial Surgeons of India

Fig. 85.1 (continued)



©Association of Oral and Maxillofacial Surgeons of India

Fig. 85.1 (continued)

galea, up to the loose areolar tissue, and the superficial three layers are raised as a unit. Blunt scissors or a brain retractor can be used to undermine the incision line along this plane, down to the root of the helix, and with the brain retractor in situ, the incision is made down to it. This allows rapid elevation of the flap, without inadvertent damage to the underlying temporal fascia/temporalis muscle. Dissection is carried inferiorly in the subgaleal plane. The pericranium is incised approximately 3 cm above the superior orbital rim, and the dissection continued subperiosteally. Resistance can be encountered in the frontozygomatic and frontonasal suture region and around the supraorbital neurovascular bundles. If the supraorbital neurovascular bundle is present within a foramen, rather than a notch, the foramen can be opened with careful use of a fine osteotome (divergent cuts to minimise damage and ease of release).

A pericranial flap could be easily incorporated, by extending the pericranial incision superiorly to the required length, between the superior temporal lines, as an extension of the temporalis fascia incision (Fig. 85.1d). If a pericranial flap is to be utilised, the subgaleal dissection should stop 2 cm above the supraorbital rim, to maintain the vascularity of the pericranial flap.

Exposure of the nasal bones and frontal process of the maxilla can be facilitated by a vertical periosteal releasing incision in the midline. The medial canthal ligaments can be detached from the anterior lacrimal crest, which provides excellent exposure of the medial orbit up to the optic canal and the medial floor up to the infraorbital nerve.

The detached medial canthal tendon must be “tagged” through the periosteum with a unresorbable suture on a round-bodied needle, for subsequent reattachment to a microplate. Subperiosteal dissection medially is now possible as far as the floor of the orbit.

The skin incision is extended inferiorly in a naturally occurring skin crease, to just below the cartilaginous meatus, if exposure of the zygoma, lateral orbit or temporomandibular joint is considered. This could be modified to follow the free edge of the tragus, to make this section less conspicuous. The dissection is carried forward medially following the cartilaginous meatus. At the superior attachment of the helix, the temporalis fascia is incised –1 cm above the zygomatic arch, and angled forwards to join the supraorbital periosteal incision 3 cm above the supraorbital rim (Fig. 85.1e). The incision is extended vertically in along the temporal fascia to the root of the zygomatic arch, which can be felt on palpation above the cartilaginous meatus. A pocket is created at the root of the zygomatic arch, deep to the periosteum and the soft tissues tented with a periosteal elevator to expose the arch. The soft tissues superior to the arch, on the surface of the temporalis muscle, can be transected down to the periosteal elevator to expose the zygomatic arch, zygoma and lateral orbit, without damaging the frontal branch (Fig. 85.1f, g).

Retraction of the temporalis muscle posteriorly provides additional exposure to the temporal fossa and the superior boundary of the infratemporal fossa (Fig. 85.1h).

Closure of the galea and meticulous haemostasis is essential, and drains and/or head dressing can be additionally utilised to prevent haematomas.

85.1.2 Potential Complications and Solutions (Clinical Pearls)

Alopecia: Use a knife for skin incision, meticulous haemostasis with judicious use of bipolar diathermy and tension-free closure.

Frontal nerve damage: Appropriate plane of dissection, care during retraction and the use of diathermy in the temporal/preauricular region.

Supraorbital/supra-trochlear nerve damage: Care during dissection in the supraorbital rim region and judicious use of fine/sharp osteotomes when deroofting the supraorbital foramen.

Clinical Tips

- Inject vasoconstrictor above the galea, make the incision in segments with a blade and use bipolar diathermy to achieve meticulous haemostasis and reduce blood loss.
- Consider making the incision parallel to the hair follicles and use bipolar diathermy “judiciously” to minimise alopecia.
- Start the incision in between the superior temporal lines to “easily” identify the appropriate plane of dissection.
- Stay deep to the galea in the temporal region to avoid injury to the frontal branch of the facial nerve.
- An easier and safer plane of dissection would be between the temporalis muscle and the deep temporal fascia.
- Stop dissection in the subgaleal plane, 2 cm above the supraorbital rims, if a pericranial flap is planned, to preserve its vascularity.
- Place deep sutures along the galea for “tension-free” skin closure but away from the skin surface to minimise “stitch” abscesses.

Various modifications have been incorporated over the years, and the more commonly used ones include the midline lip incision being placed on the philtrum [9], lateral eyelid extension [10] and medial eyebrow extension [11]. The original lateral rhinotomy incision was described by Moure [12], and a modification of the nasal component to lie along the nasal subunits was described by Thankappan [13].

A modified Weber-Fergusson incision provides excellent access to the ipsilateral maxilla and, with appropriate extensions, provides additional exposure to the nasal cavity, orbit and ethmoid (Fig. 85.2a). The “nasal” part of the incision can be utilised for a lateral rhinotomy access.

A Le Fort I down-fracture osteotomy can also be utilised to access the nasal cavity, maxillary antrum, pterygopalatine fossa and clivus. However, with the widespread use of endonasal endoscopic techniques, its use has become limited. The technique is similar to that utilised in orthognathic surgery and is outlined in the orthognathic surgery chapter.

An intraoral vestibular incision can be joined with bilateral piriform fossa and intercartilaginous and septocolumellar transfixion incisions to “deglove” the upper lip, cheek and soft tissues of the nose to provide access to the maxilla and nasal cavity [14, 15].

A maxillary swing procedure can be utilised to access the posterior maxilla, pterygopalatine/infratemporal fossa and nasopharynx. However, with the widespread use of endoscopic techniques, its role has also become limited. Its principal use is in the management of recurrent nasopharyngeal tumours, which cannot be accessed endoscopically [16].

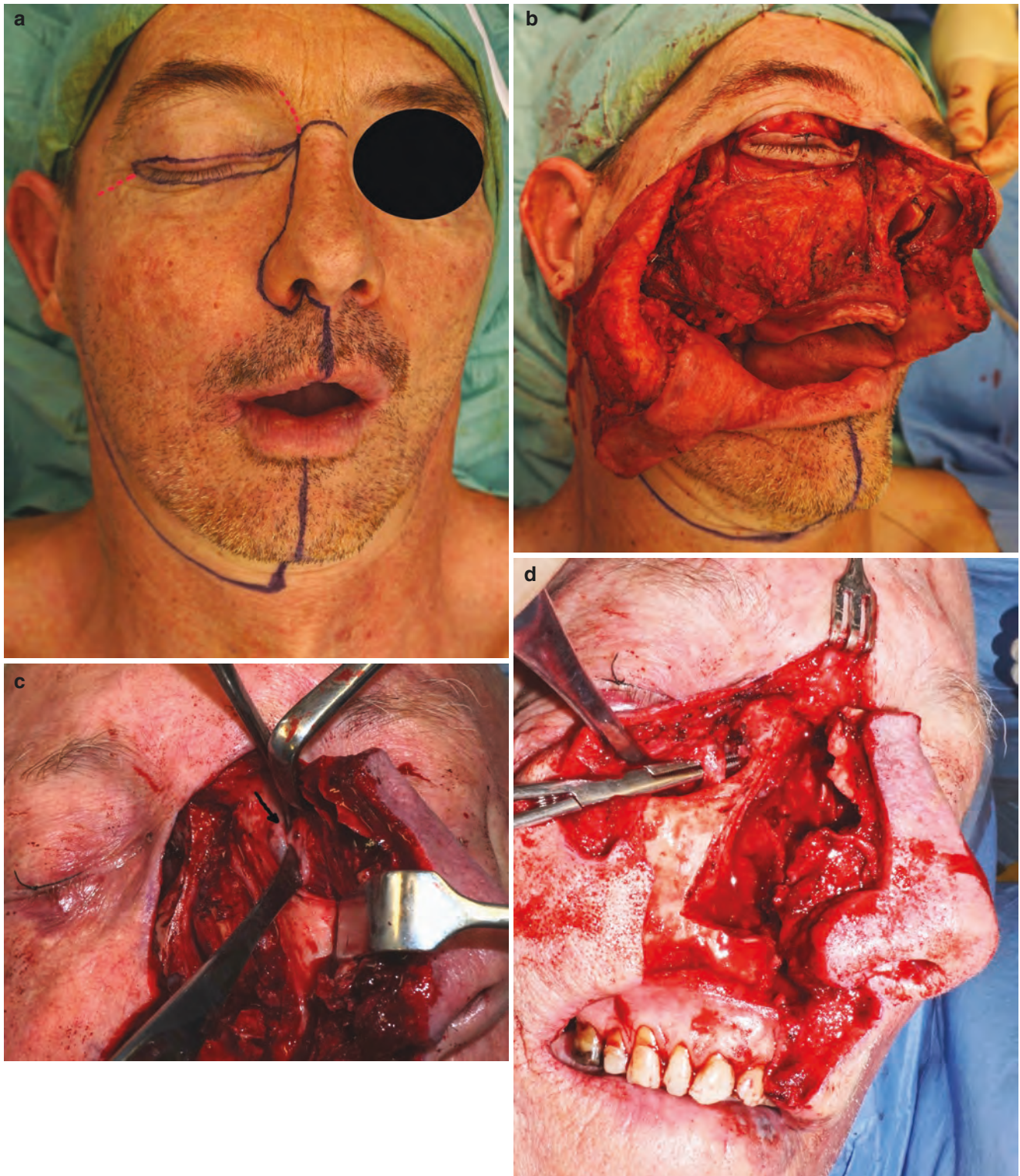
The modified Weber-Fergusson commences with an upper lip split incision that is made along the philtrum and extended along the alar margins. A “V” can be incorporated along the nasal floor to improve localisation of the flap during closure. The incision is carried along the alar margin and extended superiorly at the junction between the nasal side wall and dorsal nasal subunit (Fig. 85.2a).

The intraoral incisions are made along the gingival crevice or buccal vestibule and are principally determined by the location of the tumour. A “V” can be incorporated in the lip mucosa to facilitate accurate approximation during wound closure. The cheek flap is elevated to expose the maxilla (Fig. 85.2b). The plane of dissection is principally determined by the extension of the tumour. A “tonsil” swab can be placed in the nasal cavity and soft tissues along the piriform rim transected to gain access to the nasal cavity and avoid inadvertent damage to the nasal septum.

Lateral extensions can be incorporated, if additional access is required to the orbits and zygoma. This is made along the subciliary/mid tarsal skin crease and can be extended laterally along the crow’s feet skin crease (Fig. 85.2a). Care is taken to elevate the skin flap “superfi-

85.2 Midface Access

A modified Weber-Fergusson approach remains the most popular transfacial approach to the midface. This access was originally described well over 150 years ago by Weber [7] from Germany and Fergusson [8] from the United Kingdom.



©Association of Oral and Maxillofacial Surgeons of India

Fig. 85.2 Midface access, (a) Marking for a modified Weber-Fergusson incision respecting the nasal subunits. Lateral lower and upper eyelid extensions (for total maxillectomy with orbital exenteration) and medial glabella extension (for additional nasal access). Red

dotted lines with Lynch (superior) and crow's feet (lateral) extensions. (b) Exposure afforded by the incision. (c) Anterior ethmoid artery (arrow), exposed in the medial orbit along the frontoethmoid suture. (d) Lacrimal sac/nasolacrimal duct exposed in the lacrimal fossa

cial” to the orbicularis oculi muscle in the eyelid region to preserve function, and it is important to avoid “button holes” in the thin skin of the eyelids.

Superior extension (Lynch [11] modification) can be incorporated, if additional access is required to the medial orbit and ethmoids (Fig. 85.2a). The nasal sidewall incision is extended superiorly along the medial orbit at least, 5 mm medial to the medial canthus, up to the medial end of the eye brow/medial supraorbital rim. The incision deepened down to the bone and the frontal process of the maxilla, anterior lacrimal crest and frontonasal suture exposed. The medial canthal tendon is “formally” identified and detached. It is “tagged” with a 3.0 Prolene suture on a round body needle, for subsequent reattachment. The medial orbit can now be exposed with fine periosteal elevators. The frontoethmoidal suture (FES) in the medial orbit provides an excellent landmark for the position of the anterior and posterior ethmoid vessels and optic canal. These vessels are identified along the suture, skeletonised and ligated/diathermised (Fig. 85.2c). The optic canal lies posteriorly in superomedial orbit, in line with the suture. The number of ethmoidal vessels varies frequently [1–3] and the over-reliance of the distances between the vessels (24 mm, 12 mm, 6 mm) and the optic canal can be dangerous. The FES can often lie “above” the cribriform plate, and its relationship to the anterior cranial fossa should be “critically assessed” in the preoperative scans. Osteotomies are best placed below the FES, if “unintentional” intracranial extension is to be avoided.

The lacrimal sac is identified inferiorly in the lacrimal fossa and can be dissected free for retraction or transection (Fig. 85.2d).

A medial extension, along the glabella skin crease, can be incorporated if additional access is required to the nasal bones, roof of the nasal cavity, or if a “nasal” swing is considered (Fig. 85.2a).

The lower eyelid extension can be combined with a similar upper eyelid incision, if a lid-sparing orbital exenteration is planned (Fig. 85.2a).

85.2.1 Potential Complications and Solutions (Clinical Pearls)

Unnoticed scar: Use the modified Weber-Fergusson incision along the philtrum, nasal subunits with “v” in the nasal floor and lip mucosa—meticulous layered closure in layers and accurate alignment of the vermilion border.

Delayed bone healing (maxillary swing): Minimal soft tissue elevations along the osteotomy sites, pre-plating prior to completion of osteotomy, use fine saw blades and bur and copious irrigation.

Clinical Tips

- Inject vasoconstrictor, make the incision in segments and use diathermy to minimise blood loss.
- Extend the midline skin incision past the vermilion, prior to incorporating the mucosal “V” to facilitate accurate approximation of the vermilion.
- Tattoo or mark the vermilion, if you feel it would help in later approximation.
- Intraoral incisions and the plane of dissection are dictated by the location of the tumour.
- If a lower eyelid extension is planned, the plane of dissection is ideally above the orbicularis oculi muscle (if eye is preserved).
- Soft tissue “elevation” is kept to the minimum along the osteotomy sites, if a maxillary swing is planned.
- Formal identification and tagging of the medial canthus are necessary for later reattachment.
- Recognise the “orientation” value of the frontoethmoidal suture.
- Beware of using distances between the ethmoidal foramina and optic canal as the “sole” modality during deep dissection of the medial orbit.

85.3 Nasal Swing

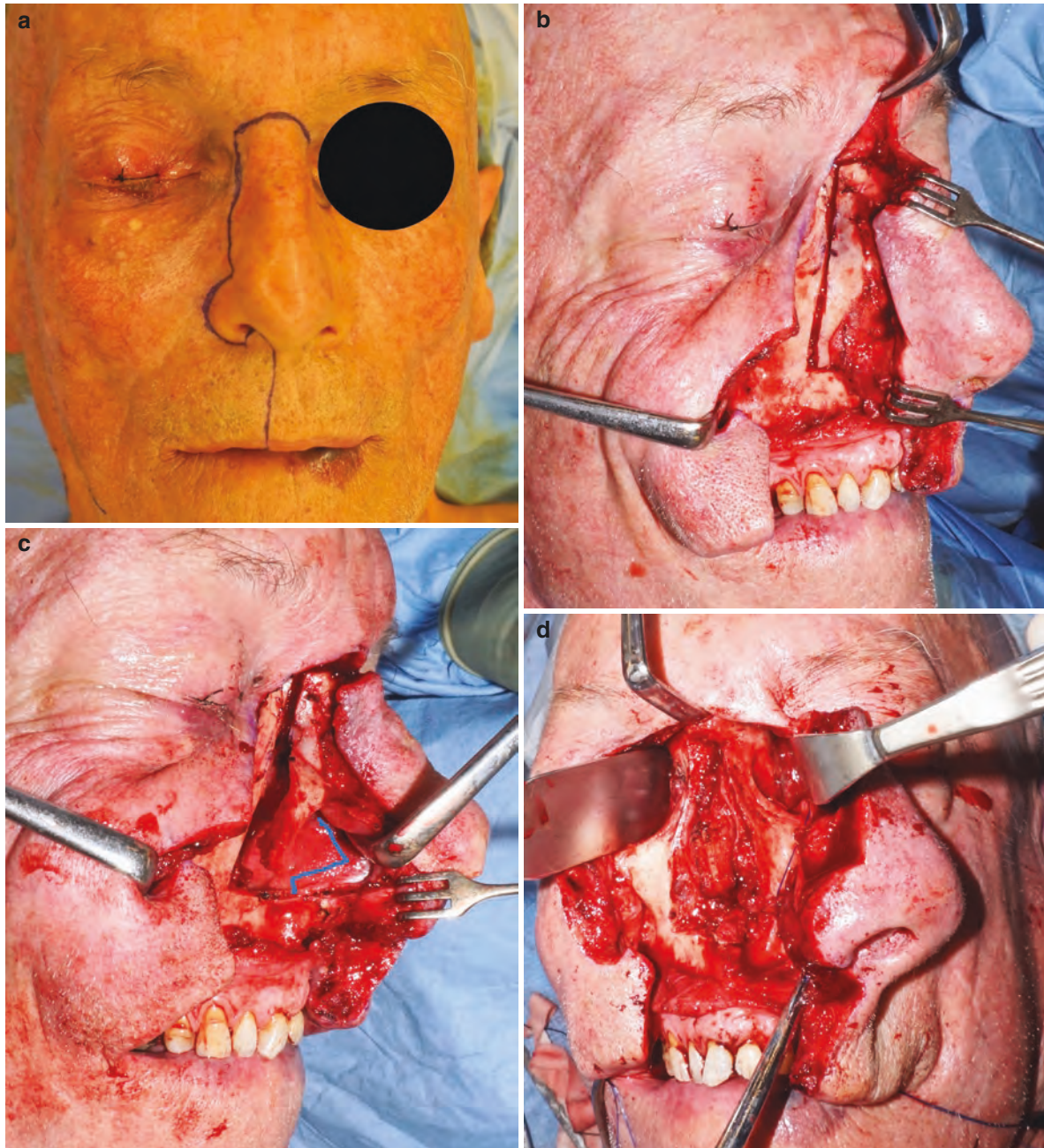
This provides access to the nasal cavity, ethmoids and nasal roof and can be considered for bilateral lesions, when the nasal skin/bones can be preserved. Currently, with the widespread use of endoscopic techniques, its role, as a “sole” access to these lesions, is restricted. It is often used for additional access, as part of a wider resection.

A modified Weber-Fergusson incision is made respecting the nasal subunits, and allowance is made for a transverse medial extension along the glabella skin crease (Fig. 85.3a). The soft tissues are retracted laterally and superiorly to obtain exposure of the nasal bones, frontal process of the maxilla and the piriform rims. The soft tissue overlying the nasal bone is left undisturbed. Exposure of the contralateral nasal bones is achieved by undermining in a subperiosteal plane. A fine bur/saw is used to make the bone cuts along the frontal process of the maxilla and across the nasal bones (Fig. 85.3b). The contralateral nasal osteotomy is carried out with fine osteotomes, if necessary, through separate stab incisions. The osteotomy sites are prelocalised with low-profile bone plates, removed and replaced during the procedure. The underlying nasal mucosa and soft tissue along the piriform rim are released with a diathermy. The soft tissue incisions and the bone cuts are stepped or staggered.

The nasal septum restricts complete lateral retraction. The septal cartilage is transected with a cutting diathermy—the damp tonsil swab in the other nostril can prevent accidental injury to the contralateral lateral nasal wall mucosa and the facial skin. The 1 cm strut of nasal septal cartilage is preserved along the dorsum and columella to prevent collapse (Fig. 85.3c). The nasal bones and the soft tissues can now be retracted to the opposite side (Fig. 85.3d).

A soft tissue only and soft and hard tissue nasal swing can be combined with a larger midface/craniofacial resection for pathologies involving adjacent structures. The nasal swing can be linked with a frontal craniotomy for resection of tumours that also involve the central compartment of the anterior cranial fossa (Fig. 85.3e, f).

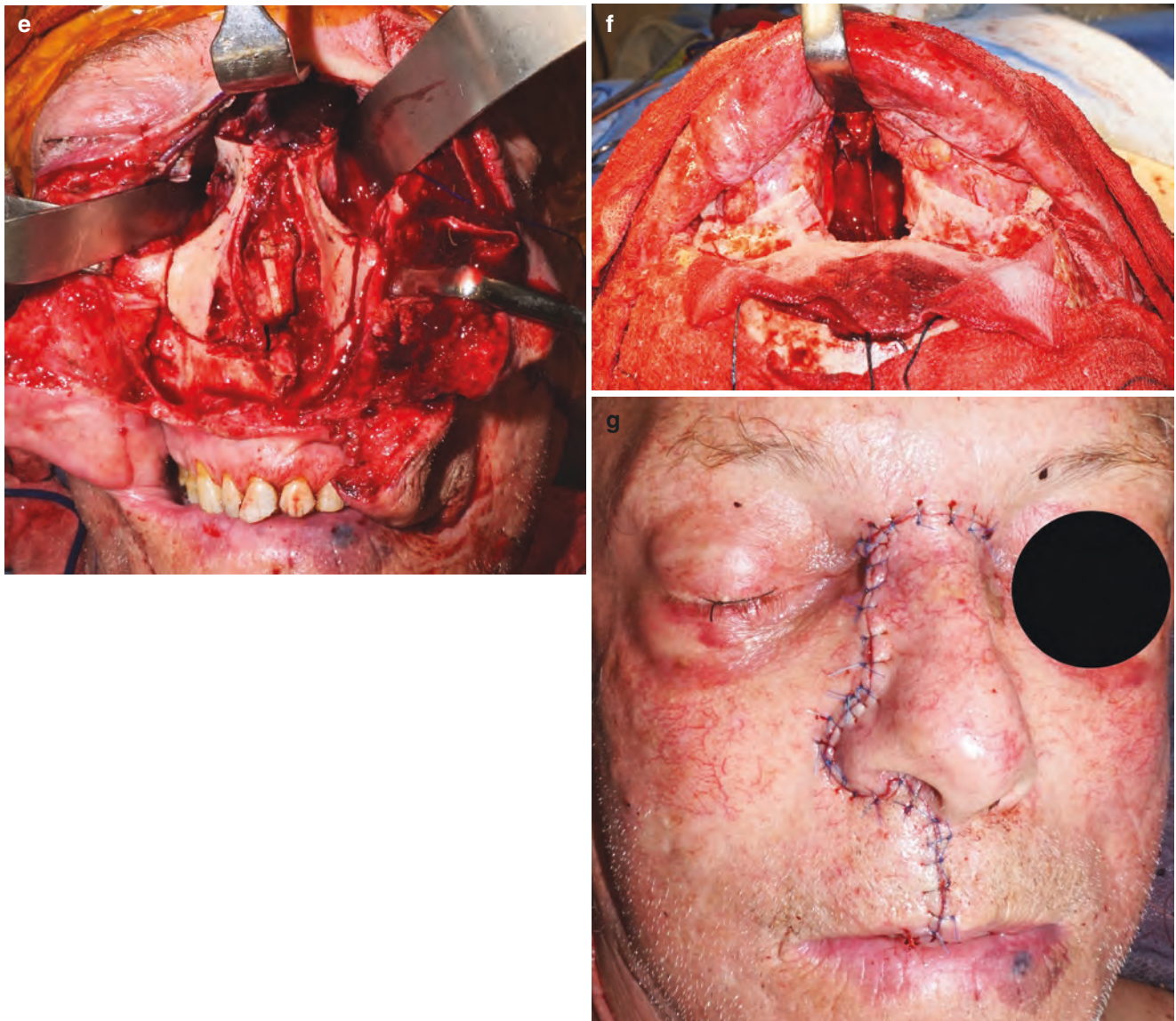
The plates are replaced, and the wound is closed in layers (Fig. 85.3g).



©Association of Oral and Maxillofacial Surgeons of India

Fig. 85.3 Nasal swing. (a) Skin marking, respecting the nasal sub units. (b) Bone cuts along the frontal process of the maxilla and nasal bones. (c) Marking for septal incision preserving dorsal and caudal strut. (d) Exposure of the nasal cavity following retraction of the nose.

(e) Bone cuts for “nasal/ethmoid clearance” as a part of a craniofacial resection. (f) Defect viewed from the cranial aspect following “nasal/ethmoid” clearance. (g) Wound closure following nasal swing



©Association of Oral and Maxillofacial Surgeons of India

Fig. 85.3 (continued)

85.3.1 Potential Complications and Solutions (Clinical Pearls)

Unsightly scar: Use the modified incision along the philtrum, nasal subunits with “v” in the nasal floor and lip mucosa. Carry out meticulous closure in layers and achieve accurate approximation of the vermilion border.

Delayed bone healing (nasal osteotomy): Minimal soft tissue elevations along the osteotomy sites, pre-plating prior to completion of osteotomy, use fine saw blades, burs and osteotomes and copious irrigation.

Nasal collapse: Attempt to preserve caudal/dorsal septal strut.

Clinical Tips

- The soft tissue dissection is kept to the minimum, overlying the nasal bones.
- The osteotomy is planned along the frontal process of the maxilla, which is mobilised along with the nasal bones.
- Create a contralateral subperiosteal pocket and use “stab” incisions and fine osteotomes to complete the osteotomy.
- Pre-plate the osteotomies prior to completion.
- Preserve at least a 1 cm caudal and dorsal strut of septum to prevent nasal collapse.

85.4 Per Oral Access

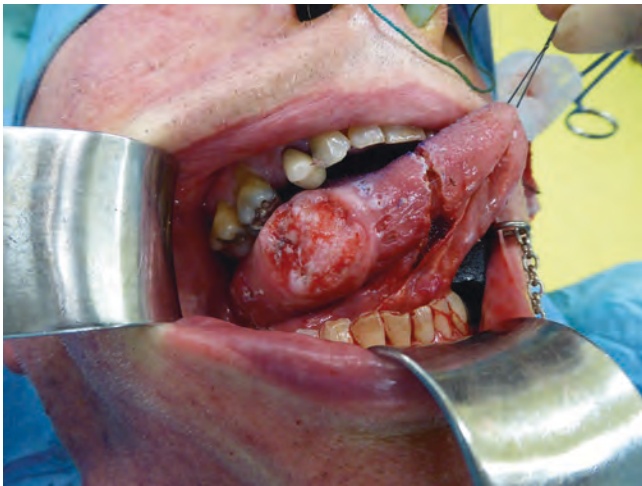A significant proportion of the oral lesions can be accessed and managed per orally. The use of a solely per oral access is dictated by the location and size of the lesion, the mouth opening and status of the dentition. An appropriately sized mouth prop/gag with cheek and tongue retractors and traction sutures can be utilised to provide the necessary access to safely carry out the procedure (Fig. 85.4).

Clinical Tips

- Utilise appropriate retraction to obtain the “best” access.
- “Orthodontic” cheek retractors can be very helpful for additional retraction and protecting the commissures.
- If teeth extractions are planned, these are best carried out prior to the resection to improve access.

85.5 Soft Tissue Lip Split

Lip split incisions to gain additional access to the oral cavity have been in practice for over 150 years. A midline chin incision was described by Roux [17] and subsequently popularised by Trotter [18] in the early 1900s. Further modifications by Macgregor [19] placed the chin component along the mentolabial fold, and Hayter [20] suggested incorporating a chevron in the vermillion and mentolabial area.



©Association of Oral and Maxillofacial Surgeons of India

Fig. 85.4 Per oral access. Per oral access for excision of a tongue lesion

Soft tissue only lip split can provide excellent access to the posterior buccal mucosa and mandible, for lesions that cannot be safely excised through a per oral or cervical approach. The principle disadvantage of this approach is the need for lip split scar and likely sacrifice the mental nerve; this must be weighed against improved access. The latter is not a consideration if the inferior alveolar nerve has to be sacrificed in the subsequent resection. A lip split through the commissure would have to be considered for tumours located close to the commissure to avoid devascularising the segment between the midline lip split and commissure. This would also be a consideration for composite resections involving the adjacent skin.

A full-thickness vertical incision is made through the lower lip in the midline and extended inferiorly along the midline of the chin/upper neck (Fig. 85.5a). It continues with an appropriately placed low-neck skin crease incision. A “V” can be incorporated in the mucosal aspect of the lower lip to facilitate accurate approximation. The cosmetic outcome with a midline chin incision is excellent and reduces the risk of numbness and ischemia of the ipsilateral chin, associated with a curvilinear incision along the mental fold.

The neck skin flap is raised in a plane deep to the platysma, up to the lower border of the mandible, taking care to avoid injury to the marginal mandibular branch of the facial nerve. The cheek flap is elevated by detaching the platysma from the lower border of the mandible in the subperiosteal plane. More posteriorly, the dissection can be continued superficial or deep to the masseter muscle (Fig. 85.5b).

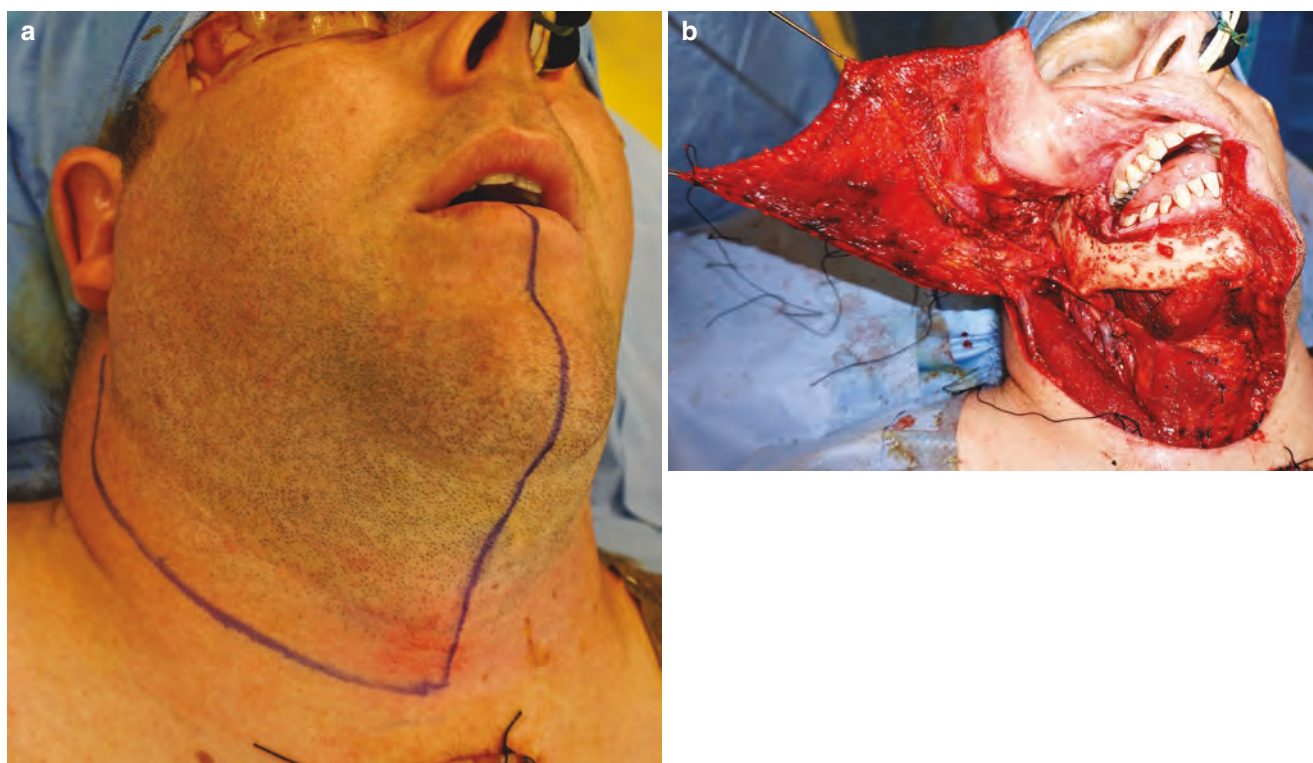
Intraoral soft tissue incisions are placed along the gingival crevice or the lower vestibule and are principally determined by the location of the tumour. The wound is meticulously closed in layers, taking care to accurately align the vermillion border.

85.5.1 Potential Complications and Solutions (Clinical Pearls)

Unightly scar: Accurate alignment of the vermillion border and meticulous layered closure.

Mental and marginal mandibular nerve damage: Appropriate plane of dissection and identification and protection of the nerves.

Lip necrosis: Avoid “additional” midline incision for tumours in the commissure region or composite buccal mucosa resections.



©Association of Oral and Maxillofacial Surgeons of India

Fig. 85.5 Soft tissue lip split. (a) Skin markings for a soft tissue lip split. (b) Exposure following flap elevation

Clinical Tips

- Dissection of the anterior mandible is in the subperiosteal plane to minimise injury to the facial and mental nerves.
- Identify the mental nerve and decide if it can be preserved, prior to sacrificing it.
- More posteriorly, the dissection can be superficial or deep to the masseter muscle. If superficial dissection is planned, care must be exercised to prevent injury to the facial nerve branches and parotid duct.
- Avoid midline lip split for tumours adjacent to the commissure and composite resections.

85.6 Visor Flap

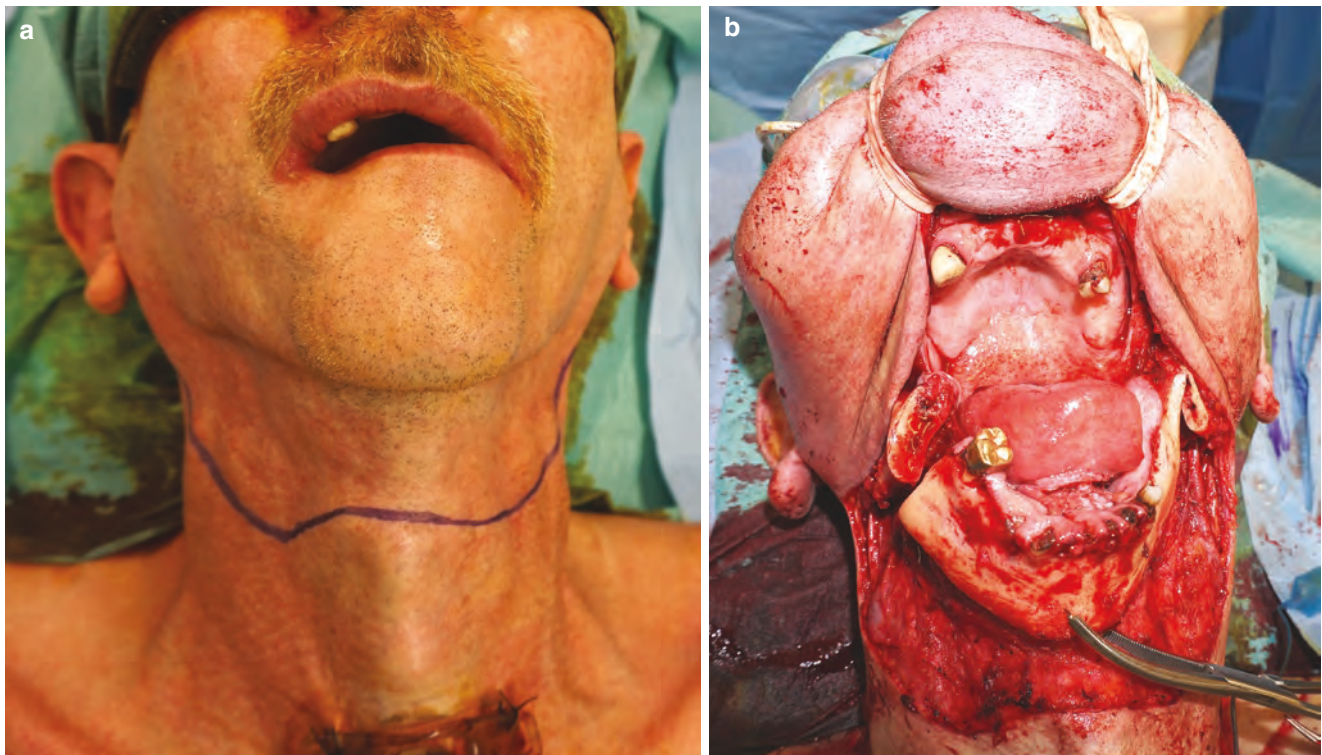
A visor flap can be utilised for lesions in the floor of mouth, tongue and mandible and can be combined with bilateral neck dissections. The incision is marked at an appropriate low-neck skin crease and extends from one mastoid tip process to the other (Fig. 85.6a). The skin flaps are raised in the sub-platysmal plane up to the lower border of the mandible, taking care to avoid injury to the marginal mandibular branch of the facial nerve. The periosteum is incised along the lower

border of the mandible and a mucoperiosteal flap elevated, taking care to identify the mental nerves. Intraoral mucosal incisions are determined by the location of the lesion, and the mental nerves might have to be sacrificed to obtain further access or adequate margins. The skin flaps are retracted cephalad with “penrose” rubber drains (Fig. 85.6b).

When used as a part of lingual release/pull-through procedure to access a floor of mouth/tongue lesion, the mental nerves and labial/buccal soft tissue can be left undisturbed [21, 22]. Resection of the lesions in the anterior floor of mouth along with the mandible results in detachment of the tongue to the mandible. It is essential that the geniohyoid and genioglossus muscles are reattached to the reconstructed mandible to prevent the tongue from falling back. The wound is closed in layers. An advantage of the visor incision is the avoidance of a lip split facial scar, which needs to be weighed against the risk of bilateral injury to the marginal mandibular branch of the facial and mental nerves.

85.6.1 Potential Complications and Solutions (Clinical Pearls)

Mental and marginal mandibular nerve damage: Appropriate plane of dissection and identification and protection of the nerves.



©Association of Oral and Maxillofacial Surgeons of India

Fig. 85.6 Visor flap. (a) Skin markings for a visor flap. (b) Exposure following flap retraction with “penrose” rubber drains

Clinical Tips

- Expose the mandible in the subperiosteal plane to identify the mental foramen and minimise damage to the facial nerve.
- The intraoral labial/buccal vestibular incision is determined by the location of the tumour and can be placed along the vestibule or crevicular margins.
- If the tongue and the hyoid apparatus is detached from the anterior mandible, the remnant genioglossus and geniohyoid should be “formally” suspended to the (reconstructed) mandible with non-resorbable sutures.

85.7 Transmandibular Approaches

85.7.1 Mandibular Swing

85.7.1.1 Lip Split Paramedian Mandibulotomy

Mandibulotomy to access oral cavity, oropharynx and skull base has been in use for over 150 years, since its initial description by Roux [17] and Trotter [18]. It was popularised by Spiro [23], who suggested a median mandibulotomy, and McGregor [19] described a paramedian location, anterior to the mental foramen. Though various sites and design of the osteotomy have been described, a straight line paramedian

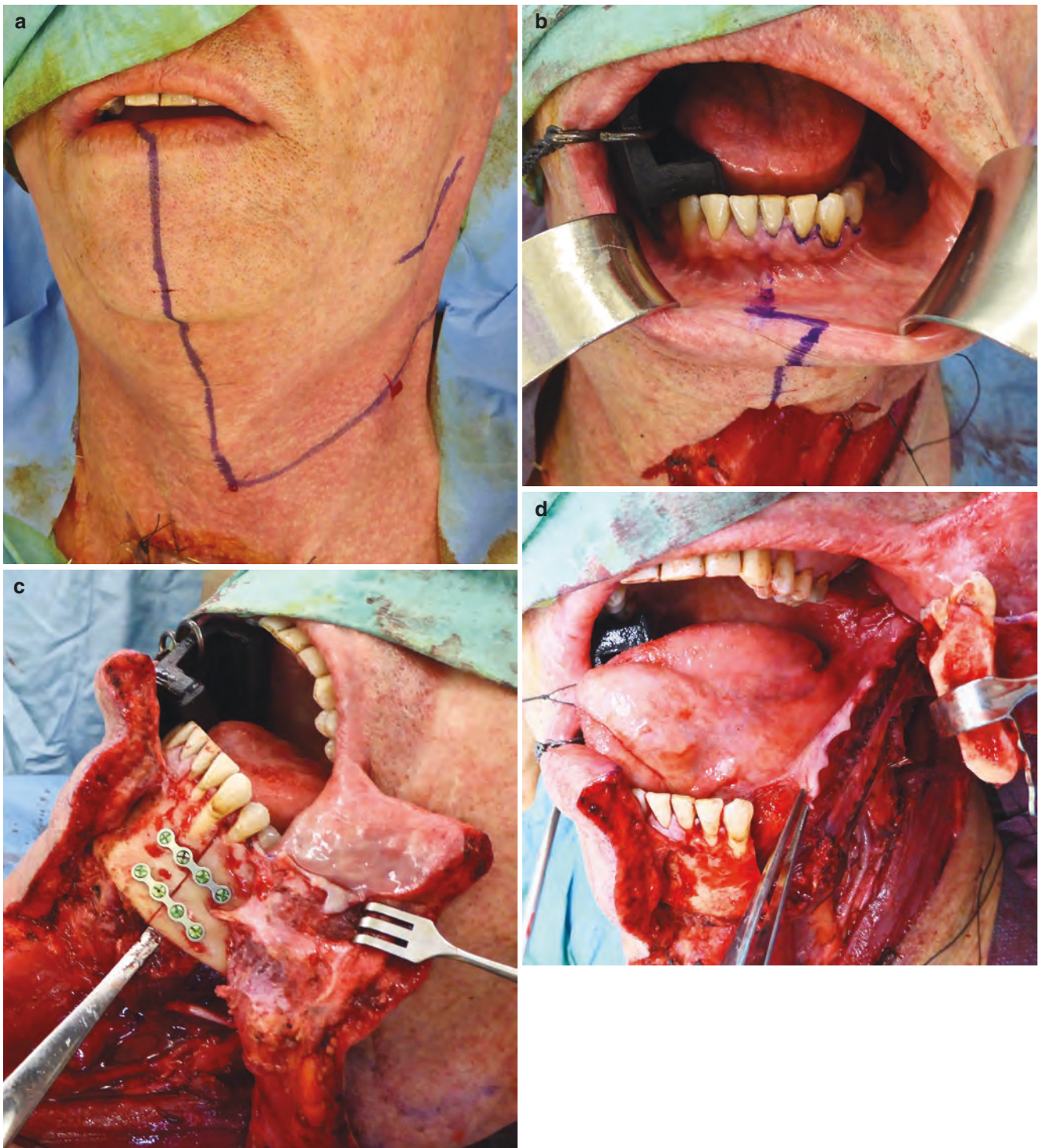
mandibulotomy is currently the most widely used option, as it preserves the attachment of the anterior belly of the digastric, geniohyoid and genioglossus muscles and mental nerve. The availability of rigid fixation and fine saws negate the need for step osteotomies and tooth extractions in most cases.

The lip split with a mandibulotomy provides excellent access to the mid and posterior third of the tongue, floor of the mouth, soft palate, tonsillar fossa, oropharynx/posterior pharyngeal wall and supraglottic larynx. It can be extended posteriorly to provide additional access to the infratemporal fossa and the parapharyngeal space with safe vascular control. It can be considered in three discrete stages; lower lip/chin division, paramedian mandibulotomy and soft tissue elevation on the lingual aspect of the mandible.

A vertical full-thickness incision is made through the midline of the lower lip and extended inferiorly across the midline of the chin/upper neck and continues with an appropriately placed low-neck skin crease incision (Fig. 85.7a). A “V” can be incorporated in the mucosal aspect of the lower lip to facilitate accurate approximation.

The cosmetic outcome with a midline chin incision is excellent and reduces the risk of numbness and ischemia of the ipsilateral chin, associated with a curvilinear incision along the mental fold.

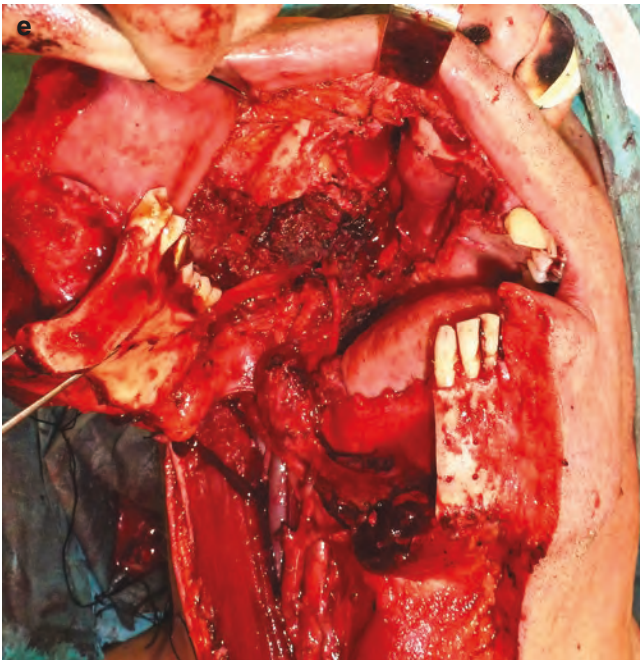
The neck skin flap is raised in a plane deep to the platysma, up to the lower border of the mandible, taking care to avoid injury to the marginal mandibular branch of the facial nerve. Intraorally, the incision through the labial mucosa and



©Association of Oral and Maxillofacial Surgeons of India

Fig. 85.7 Lip split paramedian mandibulotomy. (a) Skin marking for lip split mandibulotomy. (b) Mucosal marking for lip split mandibulotomy. (c) Lingual subperiosteal tunnel, bone cuts and pre-plating prior to completion of mandibulotomy. (d) Lingual crevicular incision and

mandible retracted laterally following release of mylohyoid muscle. (e) Additional exposure of the infratemporal fossa by tracing the inferior dental and lingual nerves. Defect following maxillectomy and infratemporal fossa clearance (different patients)



©Association of Oral and Maxillofacial Surgeons of India

Fig. 85.7 (continued)

attached gingiva is designed (stepped), so that it does not directly overlie the planned osteotomy (Fig. 85.7b). The elevation of the periosteum and mentalis muscle should be restricted to allow identification and protection of the mental nerve and placement of the plates.

A soft tissue pocket is created by elevating the lingual mucosa off the mandible adjacent to the osteotomy. A periosteal elevator is placed in the pocket, and an osteotomy is carried out between the lower lateral incisor/canine or canine/first premolar region (Fig. 85.7c). The mandible is osteotomised with a fine saw, taking care to avoid injury to the tooth roots. Occasionally a tooth would have to be removed to facilitate the osteotomy. The mandible is pre-plated prior to completion of the bone cuts, and these are removed and replaced during the procedure. The osteotomy cuts are in a straight line, as a stepped osteotomy neither aids fixation or bone union and can increase the risk of injury to the teeth apices and mental nerve.

Once the mandible is divided, it is gently retracted laterally, and an incision made along the lingual gingival crevice and the mucoperiosteum elevated off the lingual mandible (Fig. 85.7d). The mylohyoid muscle is detached along its attachment to the mylohyoid ridge. Further soft tissue dissection is dictated by the location of the tumour.

If additional access is required to the infratemporal fossa/parapharyngeal space, it will be necessary to detach the medial pterygoid muscle from the medial ramus of the mandible. In addition, the stylomandibular ligament (at the angle of the mandible) and the sphenomandibular ligament (at the lingula) have to be detached to obtain the best possible access (Fig. 85.7e). The inferior dental and lingual nerve

are identified early and protected and can be utilised as roadmaps to the foramen ovale and skull base. The maxillary artery can also be identified entering the infratemporal fossa, at the neck of the condyle by following the posterior border of the mandible. Early identification and ligation can help provide a relatively bloodless field for dissection of the infratemporal fossa.

The lingual gingival crevicular incision facilitates easy closure and avoids placement of the suture line at the depth (sump) of the wound. The mandible is held in occlusion, and the plates are replaced accurately to achieve the preorbital localisation. The wound is meticulously closed in layers.

85.7.2 Potential Complications and Solutions (Clinical Pearls)

Unightly scar: Accurate alignment of the vermilion and meticulous layered closure.

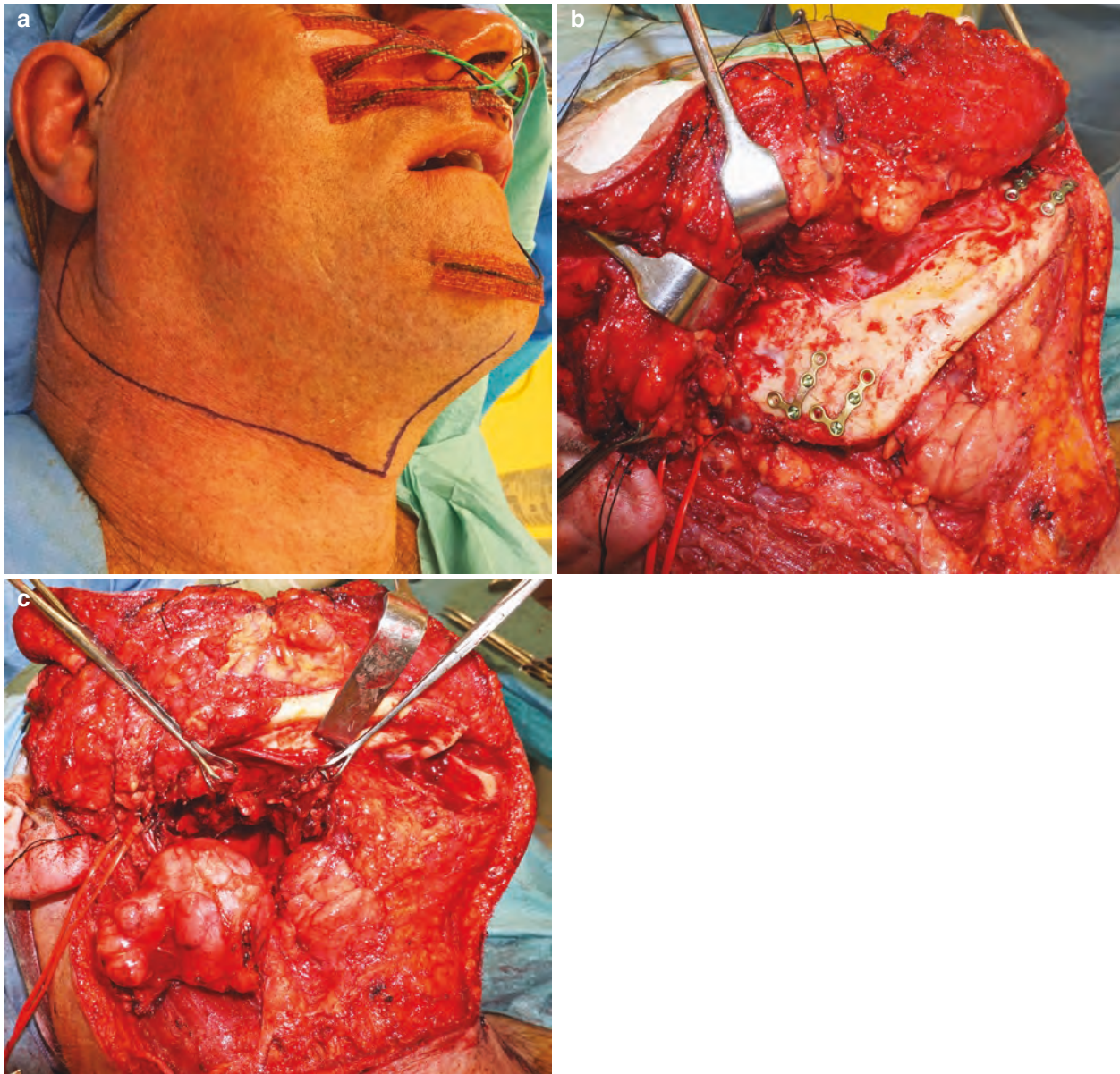
Mental and marginal mandibular nerve damage: Appropriate plane of dissection and identification and protection of the nerves.

Delayed bone healing: Minimal soft tissue elevations along the osteotomy sites, pre-plating prior to completion of osteotomy, use fine saw blades, burs, osteotomes and copious irrigation. Osteotomy ideally in the canine region.

Damage to adjacent teeth: Design osteotomy where space allows, use fine instruments and consider extraction.

Clinical Tips

- A straight osteotomy in the canine region is ideal and the site pre-plated prior to completion of the bone cuts.
- The soft tissue incision and bone osteotomies are stepped, so that they do not lie on the same plane.
- The lingual soft tissues are retracted following a lingual crevicular incision.
- The medial pterygoid muscle and stylomandibular and sphenomandibular ligaments have to be detached to obtain additional access to the infratemporal fossa.
- The lingual and inferior dental nerves provide excellent landmarks and can be utilised as roadmaps to the skull base and foramen ovale.
- The maxillary artery should be identified at the neck of the condyle, as it enters the infratemporal fossa and ligated early in the procedure to minimise blood loss and improve visibility during infratemporal fossa clearance.



©Association of Oral and Maxillofacial Surgeons of India

Fig. 85.8 Double mandibular osteotomy. (a) Skin markings for double mandibular osteotomy. (b) Bone cuts marked and mandible pre-plated. (c) Mandibular segment retracted laterally and superiorly to expose deep lobe parotid tumour

85.8 Double Mandibular Osteotomy

Mandibular osteotomies to access the parapharyngeal region can be broadly divided into those involving the oral cavity (lip split mandibulotomy) and those staying out with the oral cavity. Since it was initially popularised by Attia [24] to access parapharyngeal and pterygomaxillary region, several designs of osteotomies have been described, involving one, two and three osteotomies, variously placed in the paramedian and ramus/condylar region [25].

Double mandibular osteotomy provides excellent access to the infratemporal fossa, parapharyngeal space, deep lobe of the parotid and terminal extracranial internal carotid artery

adjacent to the skull base, when the oral cavity does not have to be entered.

A low-neck skin crease incision with submental extension is made (Fig. 85.8a), and the neck flap is raised in the subplatysmal plane up to the lower border of the mandible, preserving the marginal mandibular branch of the facial nerve. The lateral mandible is exposed in a subperiosteal plane and the mental nerve identified and protected anteriorly. The masseter muscle is detached from the lateral ramus of the mandible up to the sigmoid notch. The anterior bone cuts are fashioned anterior to the mental foramen, between the canine/lateral incisor or canine/first premolar teeth roots. The posterior bone cut is made from the sigmoid notch to the lower

border of the mandible, posterior to the lingula and inferior dental canal (similar to a vertical sub-sigmoid osteotomy). The mandible is pre-plated prior to completion of the bone cuts (Fig. 85.8b). The plates are removed and replaced during the procedure. Following completion of the osteotomy, the segment of the mandible containing the inferior dental nerve is retracted lateral and superiorly to provide wide access to the parapharyngeal and infra temporal areas (Fig. 85.8c).

Further soft tissue dissection is dictated by the necessity to access specific parts of the medial mandibular area.

The stylomandibular ligament can be detached from the posterior “condylar” segment to obtain further exposure of the stylomastoid area. The muscular and ligamentous attachments to the styloid process can be detached, and, if necessary, the styloid process is osteotomised to gain addition access to the “post-styloid” space, terminal extracranial internal carotid and the skull base close to the jugular foramen and lower cranial nerves.

This procedure avoids a lip split scar and helps preserve sensation to the lip while providing access to the more “difficult-to-reach” areas.

85.8.1 Potential Complications and Solutions (Clinical Pearls)

Mental and marginal mandibular nerve damage: Appropriate plane of dissection and identification and protection of the nerves. Osteotomies planned to avoid the course of the inferior dental nerve.

Delayed bone healing: Pre-plating prior to completion of osteotomy, use fine saw blades, burs, osteotomes and copious irrigation.

Damage to adjacent teeth: Design osteotomy where space allows, use fine instruments and consider extraction.

Clinical Tips

- This procedure is considered when intraoral access is “not” required.
- A lip split scar is avoided.
- The lateral mandible is exposed in the subperiosteal plane, and the mental and facial nerve branches are protected.
- The bone cuts are made anterior to the mental foramen and posterior to the mandibular foramen and inferior dental canal.
- The osteotomy site is pre-plated prior to completion of the bone cuts.
- Styloid process and its’ attachments can be detached to gain addition access to the post styloid and “stylomastoid” spaces.

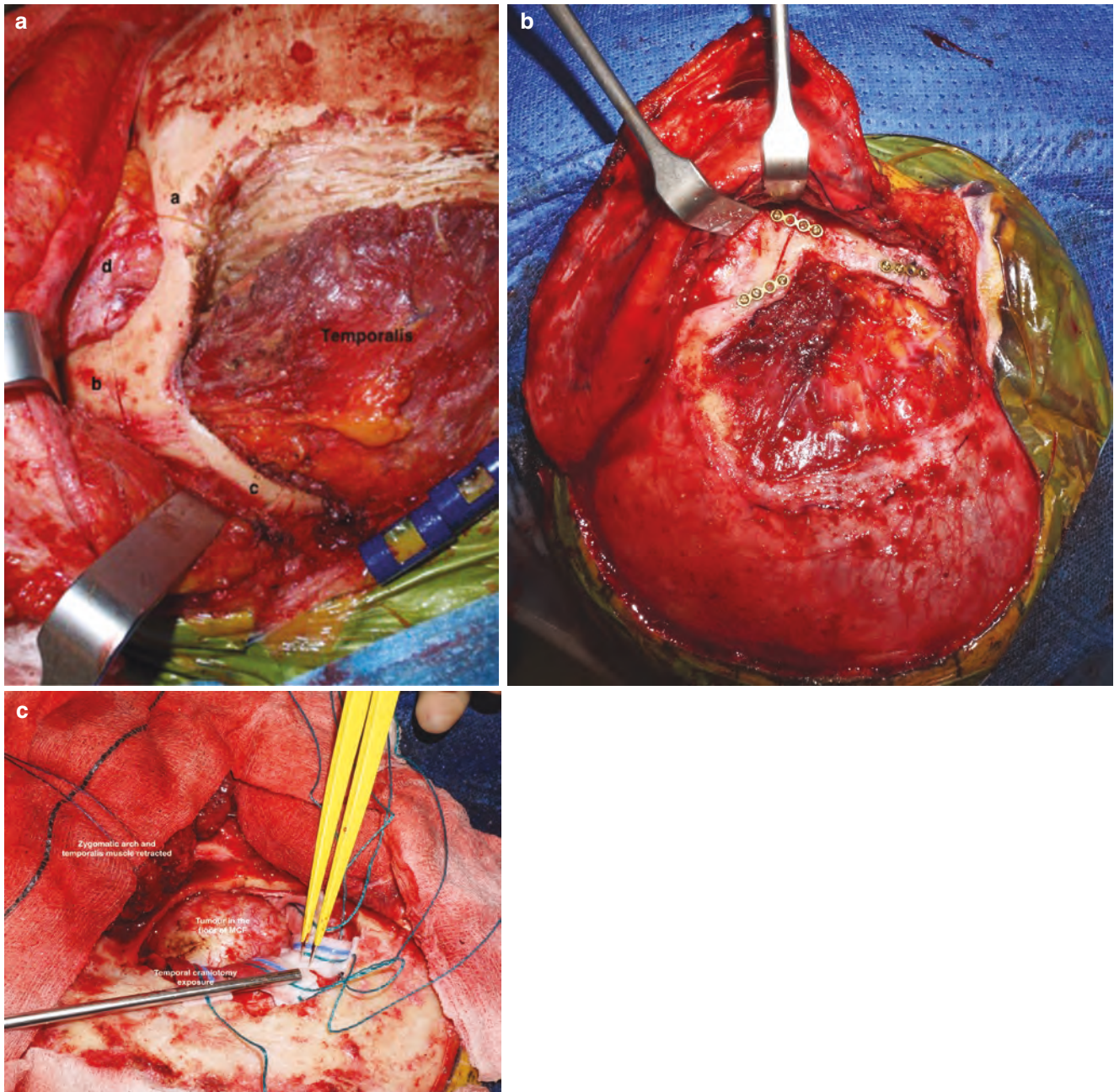
85.9 Zygomatic Osteotomy

Facial translocation techniques allow modular craniofacial disassembly of the facial skeleton to access “relatively” inaccessible regions of the skull base and nasopharynx. A variety of osteotomies have been described, but with the increased use of endoscopic approaches, the necessity for extensive procedures continues to diminish. Various modifications of zygomatic and orbital osteotomies in combination with craniotomies has been described since it was popularised by Lesoin [26], Hakuba [27] and Sindou [28] to access skull base lesions.

Zygomatic osteotomy, pedicled on the masseter muscle and its subsequent inferior displacement, provides simultaneous exposure of the temporal and infratemporal fossa and orbit. An additional frontotemporal craniotomy can link the middle and anterior cranial fossa and the middle cranial fossa with the infratemporal fossa. The extent of the “zygomatic” osteotomy and the direction of retraction of the temporalis is determined by the location of the pathology. For subcranial lesions, (temporal/infratemporal fossa/orbit), the temporalis is retracted superiorly following a coronoidectomy. For simultaneous exposure of the anterior/middle cranial fossa and temporal/infratemporal fossa/orbit, the temporalis is reflected inferiorly. The vascularity of the temporalis muscle can be at risk with both superior and inferior retraction.

The zygomatic body, arch and lateral and inferior orbital rims are exposed via a coronal flap (Fig. 85.1e, g). Meticulous subperiosteal orbital dissection is carried out to protect the orbital contents, which are retracted with thin malleable retractors. The temporalis is detached from the lateral orbit in the temporal fossa. The lateral end of the inferior orbital fissure is identified in the temporal fossa and orbit with a blunt hook. The bone cuts are made with a fine saw: superiorly at the frontozygomatic suture, infero-laterally from the lateral infraorbital rim through the body of the zygoma towards the inferior orbital fissure and posteriorly just anterior to the articular eminence. A sagittal bone cut is then made in the lateral orbital wall from the temporal fossa aspect, extending from the frontozygomatic suture osteotomy to the inferior orbital fissure (Fig. 85.9a). A more limited zygomatic arch osteotomy can be utilised, when orbital access is not required (Fig. 85.9b). The osteotomy is pre-plated, and plates are removed and replaced during the procedure (Fig. 85.9b). The cuts are completed, and the zygoma is mobilised and pedicled inferiorly on the masseter muscle.

Exposure to the infratemporal fossa is limited with a zygomatic osteotomy, which restricts its use to benign pathology, when utilised as a sole means of access. It can however be combined with frontotemporal craniotomy to widely access the anterior and middle cranial fossa, optic canal, superior orbital fissure and for combined middle cranial/infratemporal fossa resections (Figs. 85.1h and 85.9c).



©Association of Oral and Maxillofacial Surgeons of India

Fig. 85.9 Zygomatic osteotomy. (a) Bone cuts marked for a zygomatic osteotomy. (a) Osteotomy above frontozygomatic suture, (b) osteotomy across body of zygoma, (c) osteotomy across zygomatic arch and (d) orbital contents. (b) Bone cuts marked and pre-plated for zygomatic

arch osteotomy (extended to lateral orbital rim due to increased width of orbital rim). (c) Tumour exposed in the floor of the middle cranial fossa following temporal craniotomy and retraction of the zygomatic arch and temporalis

85.9.1 Potential Complications and Solutions (Clinical Pearls)

Delayed bone healing: Preserve masseter attachment, pre-plating prior to completion of osteotomy, use fine saw blades, burs, osteotomes and copious irrigation.

Damage to orbital contents: Meticulous intra-orbital subperiosteal dissection and haemostasis, fine malleable retractors for orbital retraction and bone cuts under “direct” vision.

Malposition of lateral canthus: Accurate bone reapproximation with pre-plating. Consider tagging lateral canthus prior to detachment and subsequent reattachment.

Clinical Tips

- The lateral limit of the inferior orbital fissure in the orbit and temporal fossa is an important landmark for orbital and zygomatic osteotomies. A “blunt hook” can help with its safe identification.
- The extent of the osteotomy is determined by the location of the lesion and the need to enter the orbit.
- The attachment of the masseter muscle to the osteotomised zygomatic complex should be preserved.
- The osteotomy along the zygomatic arch should be made anterior to the articular eminence, to avoid disturbing the temporomandibular joint.
- The osteotomy sites are pre-plated, prior to completion of the bone cuts.
- Trismus is often expected and can be minimised by jaw opening exercises.

85.10 Lateral and Superior Orbitotomies

Lateral orbitotomy was initially popularised by Kronlein [29] but with a reverse “C”-shaped incision overlying the temple. A variety of modifications, principally in the design of the skin incisions, have been described subsequently: lateral canthotomy [30, 31] “S”-shaped incision over the orbital rim, upper eyelid skin crease incision and coronal flap.

Superior/lateral orbitotomies, combined with frontal [32] and pterional [33] craniotomies have been extensively used since their original descriptions in the 1980s.

This approach is useful for lacrimal and lateral/superior/inferior extra and intraconal orbital lesions and provides additional access for “lookup” approaches to the anterior and middle cranial fossa and for reconstruction with a temporalis flap following orbital exenteration.

A coronal flap is raised, and the zygomatic complex is exposed as described above for the zygomatic osteotomy (Fig. 85.10a). For isolated lesions, a Stallard-Wright [31] “S”-shaped incision extending from the eyebrow, infero-laterally over the lateral orbital rim to the crow’s feet skin crease or an upper eyelid skin crease, can be utilised (Fig. 85.10b). The temporalis muscle is reflected posteriorly to expose the temporal aspect of the lateral orbit, and the orbital periosteum (periorbita) is elevated from lateral orbital wall (Fig. 85.10c). The lateral end of inferior orbital fissure is identified with a blunt hook, both within the orbit and the temporal fossa. Perforating blood vessels are identified and coagulated prior to division.

The orbital contents are protected with a malleable retractor, and the bone cuts are made with a thin saw. Superiorly, just above the frontozygomatic suture; inferiorly, inferior lateral orbital rim along the superior border of the zygomatic arch (the superior border of the zygomatic arch is at the same

level as the orbital floor) up to the lateral limit of inferior orbital fissure.

The posterior cut is made with a fine bur/piezo saw in the lateral orbital wall, joining the superior bone cut to the lateral limit of the inferior orbital fissure. This is more easily made from the temporal aspect. The bone cuts are pre-plated prior to removal of the osteotomised segment and plates replaced following completion of the procedure.

The lateral orbitotomy can be combined with a superior orbitotomy and is usually performed in conjunction with a frontotemporal craniotomy. The craniotomy is best performed initially, and the superior orbital wall is delineated from the cranial aspect. With malleable retractors in situ, the superior and lateral orbitotomy can be carried out under direct vision (Fig. 85.10d). This provides excellent exposure of the contents of the superior orbit, superior orbital fissure and optic nerve/canal (Fig. 85.10e). This can also be used for “lookup” approaches to the superior anterior and middle cranial fossa lesions. The bone flaps are replaced (Fig. 85.10f), and the wounds are closed in layers. The medial extent of the superior orbitotomy can be limited by the extent of the frontal sinus. The supraorbital neurovascular bundle will have to be protected/retracted.

85.10.1 Potential Complications and Solutions (Clinical Pearls)

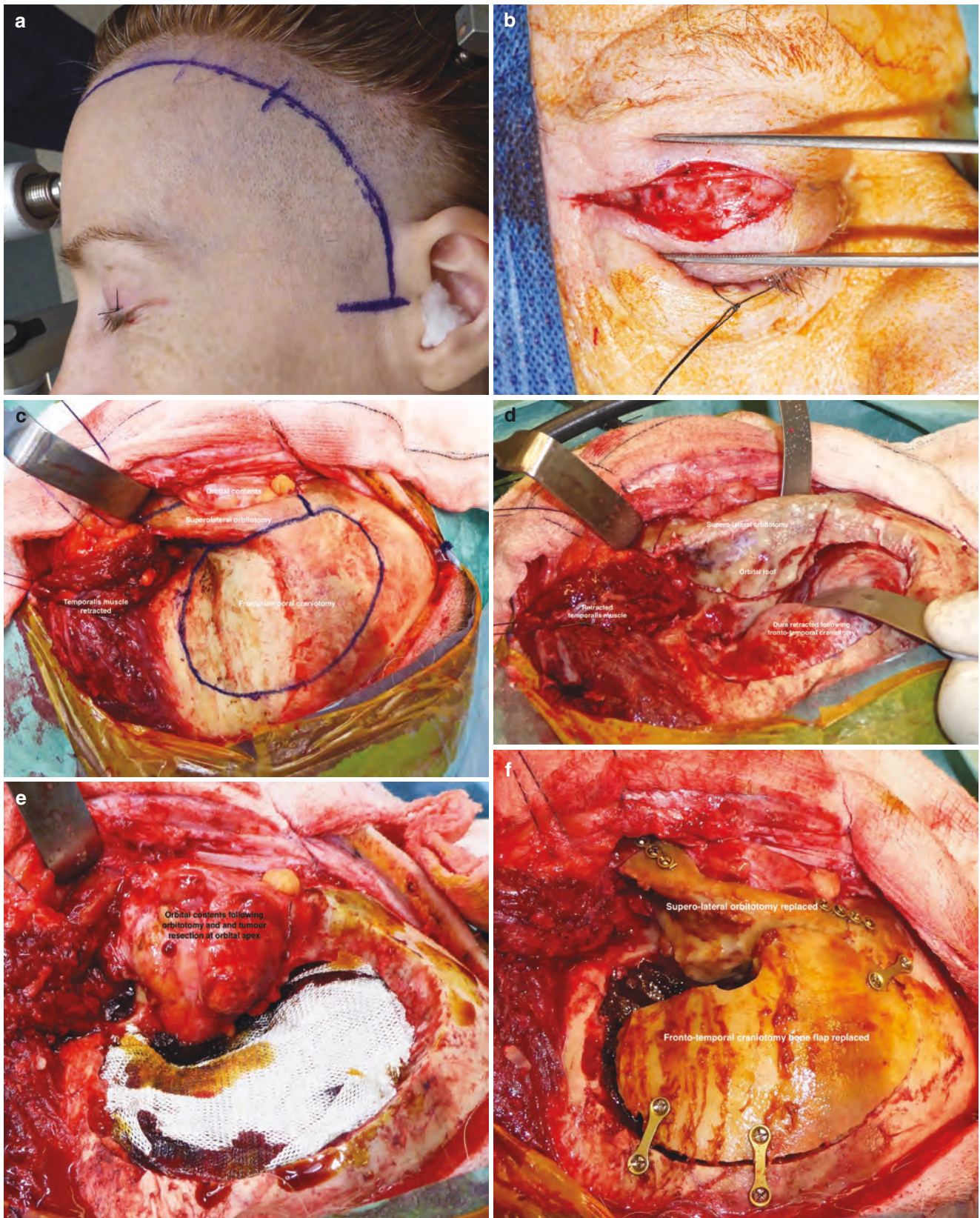
Delayed bone healing: Pre-plating prior to completion of osteotomy, use fine saw blades, burs, osteotomes and copious irrigation.

Damage to orbital contents: Meticulous intra-orbital subperiosteal dissection and haemostasis, fine malleable retractors for orbital retraction and bone cuts under “direct” vision.

Malposition of lateral canthus: Accurate bone reapproximation with pre-plating. Consider tagging lateral canthus prior to detachment and subsequent reattachment.

Clinical Tips

- The lateral limit of the inferior orbital fissure in the orbit and temporal fossa is an important landmark for orbital and zygomatic osteotomies. A “blunt hook” can help with its safe identification.
- The extent of the osteotomy is determined by the location of the lesion.
- The superior surface of the zygomatic arch is in line with the orbital floor and is a useful landmark for bone cuts in the lateral orbital rim.
- The osteotomy sites are pre-plated prior to completion of the bone cuts.



©Association of Oral and Maxillofacial Surgeons of India

Fig. 85.10 Lateral and superior orbitotomies. (a) Skin marking for a hemicoronal flap. (b) Upper eyelid skin crease incision for lateral orbitotomy. (c) Bone marking for superolateral orbitotomy and frontotemporal

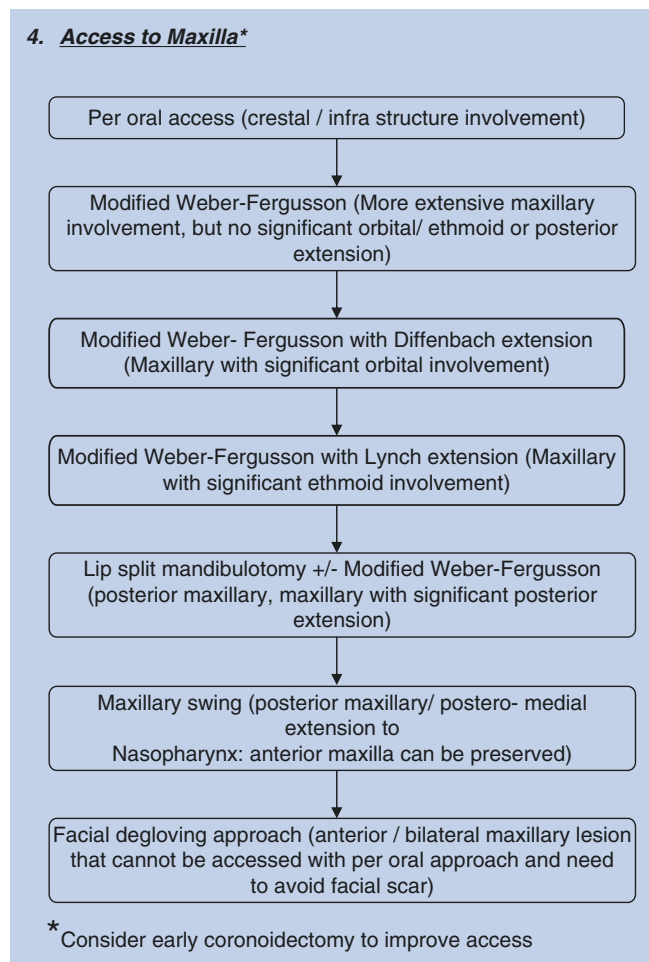
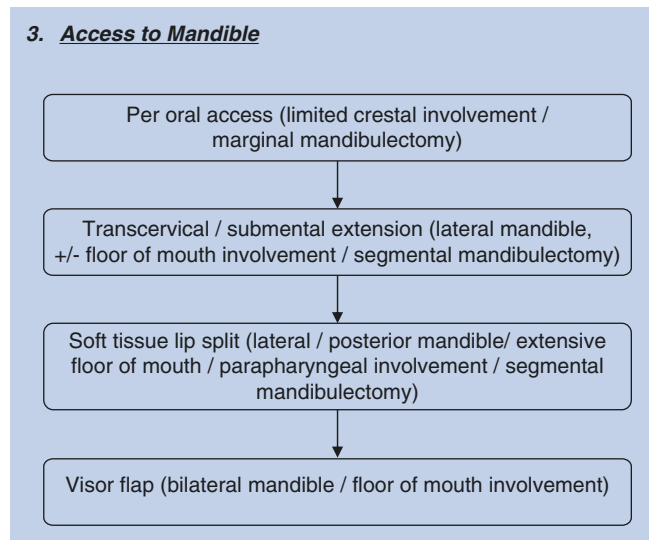
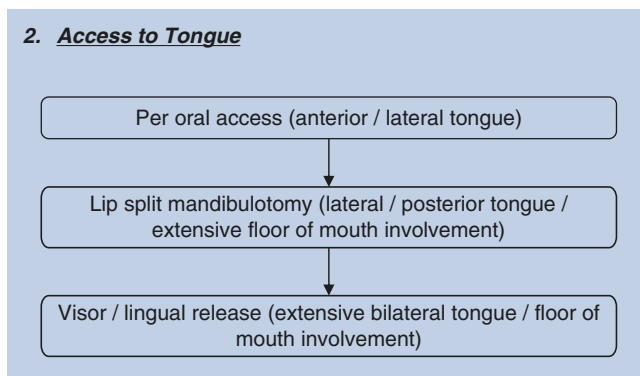
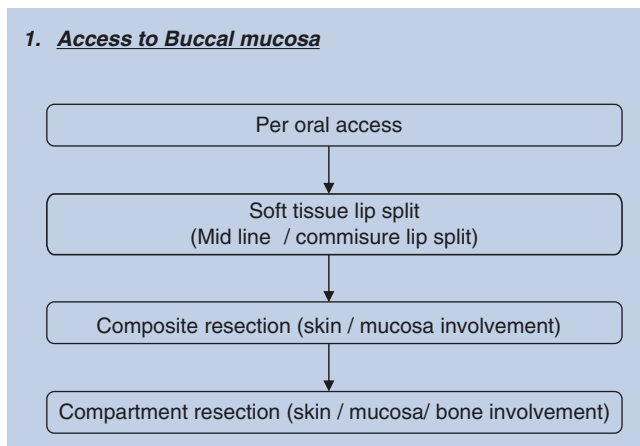
poral craniotomy. (d) Superolateral orbitotomy bone cuts following craniotomy. (e) Exposure of the orbital contents following orbitotomy. (f) Craniotomy and orbitotomy bone flaps replaced

85.11 Conclusion

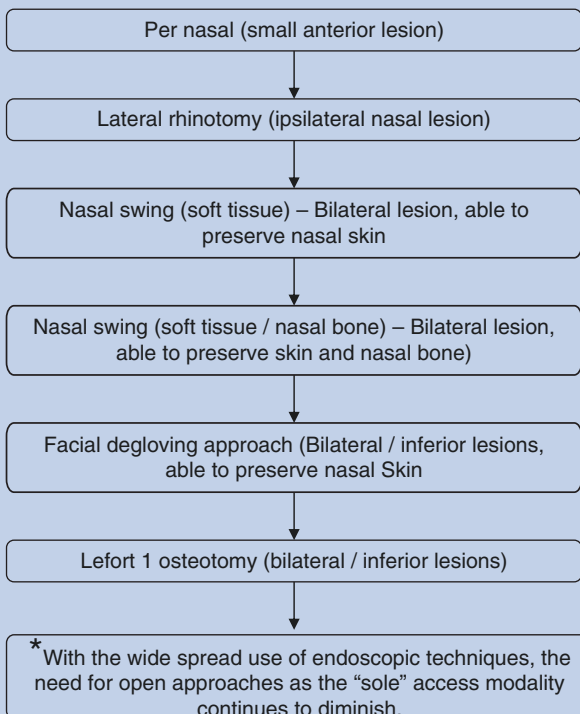
Multiple routes are available to the clinician to access the pathology in the craniomaxillofacial region. The technical aspects of the individual procedures are described in detail, along with the potential alternatives and a progressive algorithm. An understanding of the relevant anatomy, a critical analysis of the extent of the lesion, exposure required and potential reconstruction helps in determining the most appropriate choice of procedure. There is no substitute to working within well-functioning teams to obtain the relevant clinical experience.

85.12 Algorithms

The following algorithms provide a potential sequence that can be considered for progressive access for pathologies in the head and neck region. The algorithms “exclude” endoscopic approaches that can be used in isolation or in combination with open access for lesions especially in the nose, orbit, anterior skull base and retromaxilla.

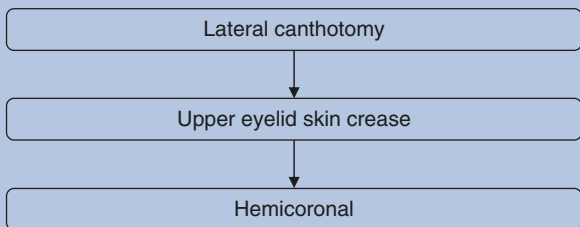


5. Access to Nasal cavity*



6. Access to Orbitotomies

(a) Lateral orbitotomy (lateral lesions / temporalis reconstruction)



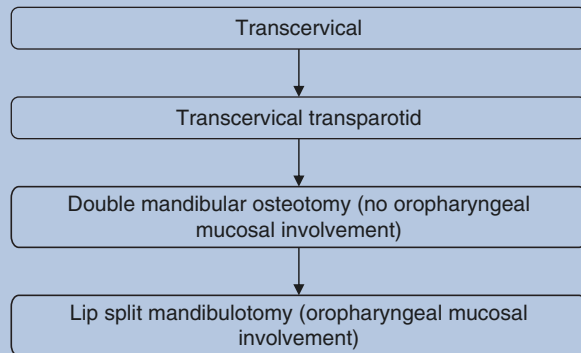
(b) Lateral / superior orbitotomy (supero-lateral lesions / combined cranio- orbital lesions)

Hemi coronal / Bicoronal flap with fronto-temporal craniotomy

(c) Inferior orbitotomy (inferior lesions)

Lower eyelid skin crease incision

7. Access to Parapharyngeal space (deep lobe parotid / post styloid compartment pathology)



Common access procedures to the various sites^a

Access	Procedure
Oral cavity	Per oral
	Soft tissue lip split
	Lip split with access mandibulotomy
	Visor flap
Maxilla	Per oral
	Modified Weber-Fergusson
	Modified Weber-Fergusson with Lynch and eyelid extensions
	Lip split mandibulotomy
	Facial degloving
	Combinations
Infratemporal fossa	Modified Weber-Fergusson with eyelid extension and early coronoidectomy (with maxillectomy)
	Lip split mandibulotomy
	Coronal flap with zygomatic osteotomy
	Maxillary swing
	Combinations
Nasal cavity	Per nasal
	Lateral rhinotomy
	Nasal swing
	Le fort 1 osteotomy
	Facial degloving
Pterygopalatine fossa/ nasopharynx	Maxillary swing
	Transpalatal approaches
	Le fort 1 down fracture ± midline split
Orbit	Various soft tissue incisions
	Lateral orbitotomy
	Superior orbitotomy
	Inferior orbitotomy
	Combinations

^aExcludes endoscopic approaches, which can be utilised alone or in combination with the open approaches

References

- Hartley F, Kenyon JH. Experiences in cerebral surgery. *Ann Surg.* 1907;45(4):481–530.
- Tessier P. The definitive plastic surgical treatment of the severe facial deformities of craniofacial dysostosis: Crouzon's and Apert's diseases. *Plast Reconstr Surg.* 1971;48(5):419–42.
- Munro IR, Fearon JA. The coronal flap revisited. *Plast Reconstr Surg.* 1994;93(1):185–7.
- Al-Kayat A, Bramley P. A modified pre-auricular approach to the temporomandibular joint and malar arch. *Br J Oral Surg.* 1979;17(2):91–103.
- Kleinberger AJ, Jumaily J, Spiegel JH. Safety of modified coronal approach with dissection deep to temporalis fascia for facial nerve preservation. *Otolaryngol Head Neck Surg.* 2015;152(4):655–60.
- Kadokia S, Badhey A, Ashai S, Lee TS, Ducic Y. Alopecia following bicoronal incisions. *JAMA Facial Plast Surg.* 2017;19(3):220–4.
- Weber O. Vorstellung einer kranken mit resection des unterkiefers verhandlungen des naturhist. Med Vereins z Heidelberg. 1845;4:80–2. (in German)
- Fergusson W. In operation of the upper jaw. A system of practical surgery. Edinburgh: John Churchill; 1842. p. 484.
- Altemir FH. Transfacial access to the retromaxillary area. *J Maxillofac Surg.* 1986;14(3):165–70.
- Dieffenbach JF. Die operative chirurgie. Leipzig: Brockhaus; 1845.
- Lynch RC. The technique of a radical frontal sinus operation which has given me the best results. *Laryngoscope.* 1921;31:1.
- Moure EJ. Traitement des tumeurs malignes primitives de l'ethmoïde. *Rev Laryngol Otol Rhinol (Bord).* 1902; 23401–412.
- Thankappan K, Sharan R, Iyer S, Kuriakose MA. Aesthetic and anatomic basis of modified lateral rhinotomy approach. *J Oral Maxillofac Surg.* 2009;67:231–4.
- Conley J, Price JC. Sublabial approach to the nasal cavity and nasopharyngeal cavities. *Am J Surg.* 1979;38:615–8.
- Maniglia AJ. Indications and techniques of midfacial degloving. *Arch Otolaryngol Head Neck Surg.* 1986;112(7):750–2.
- Wei WL, Lam KH, Sham JT. New approach to the nasopharynx: the maxillary swing approach. *Head Neck Surg.* 1991;12:200–7.
- Roux PJ, Butlin HT, Spencer GJ, editors. *Diseases of the tongue.* London: Cassell; 1900. p. 359.
- Trotter W. Operations for malignant diseases of the pharynx. *Br J Surgery.* 1929;16:485.
- McGregor IA, McDonald DG. Mandibular osteotomy in the surgical approach to the oral cavity. *Head Neck Surg.* 1983;5:457.
- Hayter JP, Vaughan ED, Brown JS. Aesthetic lip splits. *Br J Oral Maxillofac Surg.* 1996;34:432.
- Stanley RB. Mandibular lingual releasing approach to oral and oropharyngeal carcinomas. *Laryngoscope.* 1984;94:596–600.
- Stringer SP, Randall Jordan J, Mendenhall WM, et al. Mandibular lingual releasing approach. *Otolaryngol Head Neck Surg.* 1992;107:395–8.
- Spiro RH, Gerold FP, Strong EW. Mandibular swing approach for oral and oropharyngeal tumours. *Head Neck Surg.* 1981;3:371–8.
- Attia EL, Bentley KC, Head T, Mulder D. A new external approach to the pterygomaxillary fossa and parapharyngeal space. *Head Neck Surg.* 1984;6(4):884–91.
- Smith GI, Brennan PA, Webb AA, Ilankovan V. Vertical ramus osteotomy combined with a parasymphiseal mandibulotomy for improved access to the parapharyngeal space. *Head Neck.* 2003;25:1000–3.
- Lesoin F, Pellerian P, Villette L, Autricque A, Jomin M. Value of the mobilisation of the orbito-zygomatoco-malar flap. *Neurochirurgie.* 1986;32(1):90–3.
- Hakuba A, Liu S, Nishimura S. The orbitozygomatic infratemporal approach: a new surgical technique. *Surg Neurol.* 1986;26:271–6.
- Sindou M, Emery E, Acevedo G, Bem-David U. Respective indications for orbital rim, zygomatic arch and orbito-zygomatic osteotomies in the surgical approach to central skull base lesions. Critical, retrospective review in 146 cases. *Acta Neurochir (Wein).* 2001;143(10):967–75.
- Kronlein RU. Zur Pathologie und operativen behandlung der dermoidcysten der orbita. *Beitr Kilin Chir.* 1888;4:149.
- Berke RN. A modified Kronlein operation. *Arch Ophthalmol.* 1954;51:609.
- Stallard HB. A plea for lateral orbitotomy with certain modifications. *Brit J Ophthal.* 1960;44:718–23.
- Jane JA, Park TS, Poberskin LH, Winn HR, Butler AB. The supra-orbital approach: technical note. *Neurosurgery.* 1982;11(4):537–42.
- Al-Mefty O. Supra-orbital -pterional approach to skull base lesions. *Neurosurgery.* 1987;21:474–7.

Additional Readings

- Ethunandan M, Evans BT, Lang D. Access surgery. In: Langdon J, Patel M, Ord R, Brennan P, editors. *Operative oral & maxillofacial surgery.* 3rd ed. London: Hodder Arnold; 2017.
- Ethunandan M. Infra-temporal fossa and pterygopalatine fossa. In: Brenna PA, Standring S, Wiseman SM, editors. *Gray's surgical anatomy.* St. Louis, MO: Elsevier; 2019.
- Chatni SC, Sharan R, Patel D, Iyer S, Tiwari RM, Kuriakose MA. Transmandibular approach for excision of maxillary sinus tumors extending to the pterygopalatine and infratemporal fossa. *Oral Oncol.* 2009;45:720–6.
- Shahinian H, Dornier MD, Fisch U. Parapharyngeal space tumours: the infratemporal fossa approach. *Skull Base Surg.* 1995;5:73–81.
- Evans BT, Wiesenfeld D, Clauser L, Curioni C. Surgical approaches to the infratemporal fossa. In: Langdon J, BKB B, Moxham BJ, editors. *Surgical anatomy of the infratemporal fossa.* London: Martin Dunitz; 2003.

Lateral Rhinotomy

- Mertz JS, Pearson BW, Kern EB. Lateral rhinotomy. Indications, technique, and a review of 226 patients. *Arch Otolaryngol.* 1983;109(4):235–9.

Lip Split

- Rapidis AD, Valsamis S, Anterriotis DA, Skouteris CA. Functional and aesthetic results of various lip splitting incisions: a clinical analysis of 60 cases. *J Oral Maxillofac Surg.* 2001;59:1292–6.

Double Mandibular Osteotomies

- Kolokythas A, Eisle DW, El-Sayed I, Schmidt BL. Mandibular osteotomies for access to select parapharyngeal space neoplasms. *Head Neck.* 2009;31(1):102–10.
- Flood TR, Hislop WS. A modified surgical approach for parapharyngeal space tumours: use of the inverted "L" osteotomy. *Br J Oral Maxillofacial Surg.* 1991;29(2):82–6.
- Schlieve T, Carlson ER, Freeman M, Buckley R, Arnold J. The double mandibular osteotomy for vascular and tumour surgery of the parapharyngeal space. *J Oral Maxillofac Surg.* 2017;75:1046–61.

Open Access This chapter is licensed under the terms of the Creative Commons Attribution 4.0 International License (<http://creativecommons.org/licenses/by/4.0/>), which permits use, sharing, adaptation, distribution and reproduction in any medium or format, as long as you give appropriate credit to the original author(s) and the source, provide a link to the Creative Commons license and indicate if changes were made.

The images or other third party material in this chapter are included in the chapter's Creative Commons license, unless indicated otherwise in a credit line to the material. If material is not included in the chapter's Creative Commons license and your intended use is not permitted by statutory regulation or exceeds the permitted use, you will need to obtain permission directly from the copyright holder.



Part XXII

**Reconstructive Procedures of the Oral
and Maxillofacial Region**



Soft Tissue Reconstruction of the Maxillofacial Region

86

Benjamin Turner, John Collin, and Rui Fernandes

86.1 General Considerations

The general precept of reconstructive surgery is to assess what tissue and structures are missing and what is available to replace them, ensuring that where possible 'like should replace like'. Hard tissue defects are best restored with hard tissue and soft, soft tissue. Usually skin closest to the defect will give the best cosmetic match. Hard tissue reconstruction falls outwith the remit of this chapter, but where required it should be performed first to provide the foundation for successful soft tissue reconstruction. Next, muscle and fasciocutaneous tissue should be resuspended from the maxillofacial skeleton to restore muscle function and prevent ptosis of the soft tissues. The aerodigestive tract needs to be isolated from the cranial cavity, deep neck spaces and external skin to reduce the risk of spreading infection, fistula and sinus formation. Finally, the aphorism that form follows function is germane and careful reconstruction of normal anatomy will often meet the dual goals of cosmesis and restoration of function. Anatomical subunits should be respected, and generally if the defect is greater than 50% of a subunit, better results are obtained with removal and reconstruction of the entire subunit such that scars are camouflaged within their boundary lines (Table 86.1).

For any particular defect, the choice of reconstruction can range from simple to complex, along a continuum commonly described as the 'reconstructive ladder' (Table 86.2) [1]. The

Table 86.1 Key concepts of reconstructive surgery

Replace like with like
Hard tissue reconstruction first
Respect anatomical units/subunits
Local skin usually best cosmetic option
Consider options within reconstructive ladder/matrix

'reconstructive matrix' has also been described as a development of this linear concept to take into account technical requirements and potential risks to the patient on additional axes (Fig. 86.1) [2].

86.1.1 Healing by Secondary Intention

Where there has been soft tissue loss and/or the skin is not re-approximated, healing occurs via secondary intention with deposition of granulation tissue (Fig. 86.2). Typically this results in a broader area of scar tissue and is therefore inadvisable at most sites in the maxillofacial region. Superficial defects of concave subsites (e.g. medial canthus, conchal bowl) or mucosa are the exception and may be left to heal by secondary intention with good cosmetic results.

86.1.2 Primary Closure

Primary closure describes the apposition of skin edges to permit healing without granulation tissue formation and minimal scarring (Fig. 86.2). Ideally lines of primary closure should coincide with the boundaries of the anatomical subunits (Fig. 86.3), such that the scar is hidden in a natural skin crease or hairline or mimics the natural highlight of the white roll of the lip, for example. Similarly, for ablative procedures involving 50% or more of an anatomical subunit, it is preferred to remove the entire subunit for these reasons. Obviously reconstruction would then entail some kind of tissue transfer. A further consideration is orientation of closure

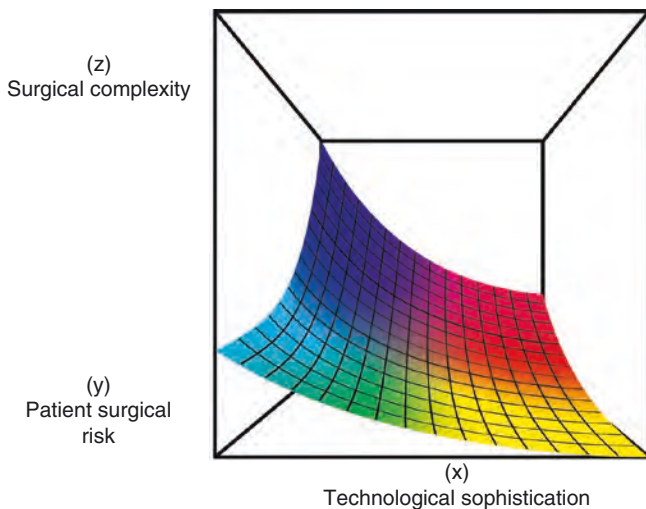
B. Turner · J. Collin
Head and Neck Oncologic and Microvascular Reconstructive Surgery, Fellowship, Jacksonville, Florida, USA
e-mail: Benjamin.Turner@jax.ufl.edu; John.Collin@jax.ufl.edu

R. Fernandes (✉)
Professor, Department of Oral and Maxillofacial Surgery,
University of Florida, Florida, USA

Division of Head and Neck Surgery, Jacksonville, Florida, USA
e-mail: Rui.Fernandes@jax.ufl.edu

Table 86.2 Reconstructive ladder

Transplantation			Biomaterials Decellularised material-Nerve/Bone/Cartilage Dermal matrices Synthetic materials-Hyaluronic acid/Silicone/PTFE Growth Factors
Flaps	Free	Distant	
	Pedicled	Regional	
	Local	Axial	
		Random Pattern	
Grafts	Full Thickness	+/- Tissue expansion	
	Split Thickness		
Primary closure		+/- plasties	
Secondary Intention		+/- negative pressure dressings	



©Association of Oral and Maxillofacial Surgeons of India

Fig. 86.1 The reconstructive matrix

with respect to the lines of relaxed skin tension that typically run perpendicular to underlying muscle fibres where possible. These two factors may dictate the decision to excise further tissue in a traumatic injury. The temptation to excise and close primarily out with these orientations should be avoided; however, as unless tissue is grossly contaminated or frankly necrotic, a straight surgical scar is usually more prominent than random pattern scars. The generous vascular supply of the face means that it is always best to err on the side of caution and perform minimal debridement such that a maximum of soft tissue is preserved.

Primary closure is appropriate for small defects that can be closed without significant tension or distortion of key areas such as the apertures of the mouth, nares and orbit. The latter is particularly sensitive to these effects and can result in ectropion and ocular sequelae if appropriate care is not taken. Techniques such as a creating a superior lateral canthal curve to the Mustarde flap, canthopexy and Frost sutures can be employed to reduce the risk of ectropion.

86.1.3 Grafts

The third rung of the reconstructive ladder is occupied by grafts, which may be further categorized as simple if composed of a single tissue type—commonly split or full-thickness skin but also mucosal grafts, or composite when containing more than one tissue type. Generally they are autografts, although xenografts and bioengineered material such as porcine collagen (Permacol), Polytetrafluoroethylene, fish skin and dermal matrix (e.g. Integra) have certain utility in maxillofacial reconstruction (Table 86.2).

86.1.4 Flaps

Flaps may be local, pedicled (regional or distant) or free. Local flaps transfer tissue to a defect by advancement and/or rotation and are typically supplied by a random vascular pattern. Axial flaps based on a named vessel can potentially pro-

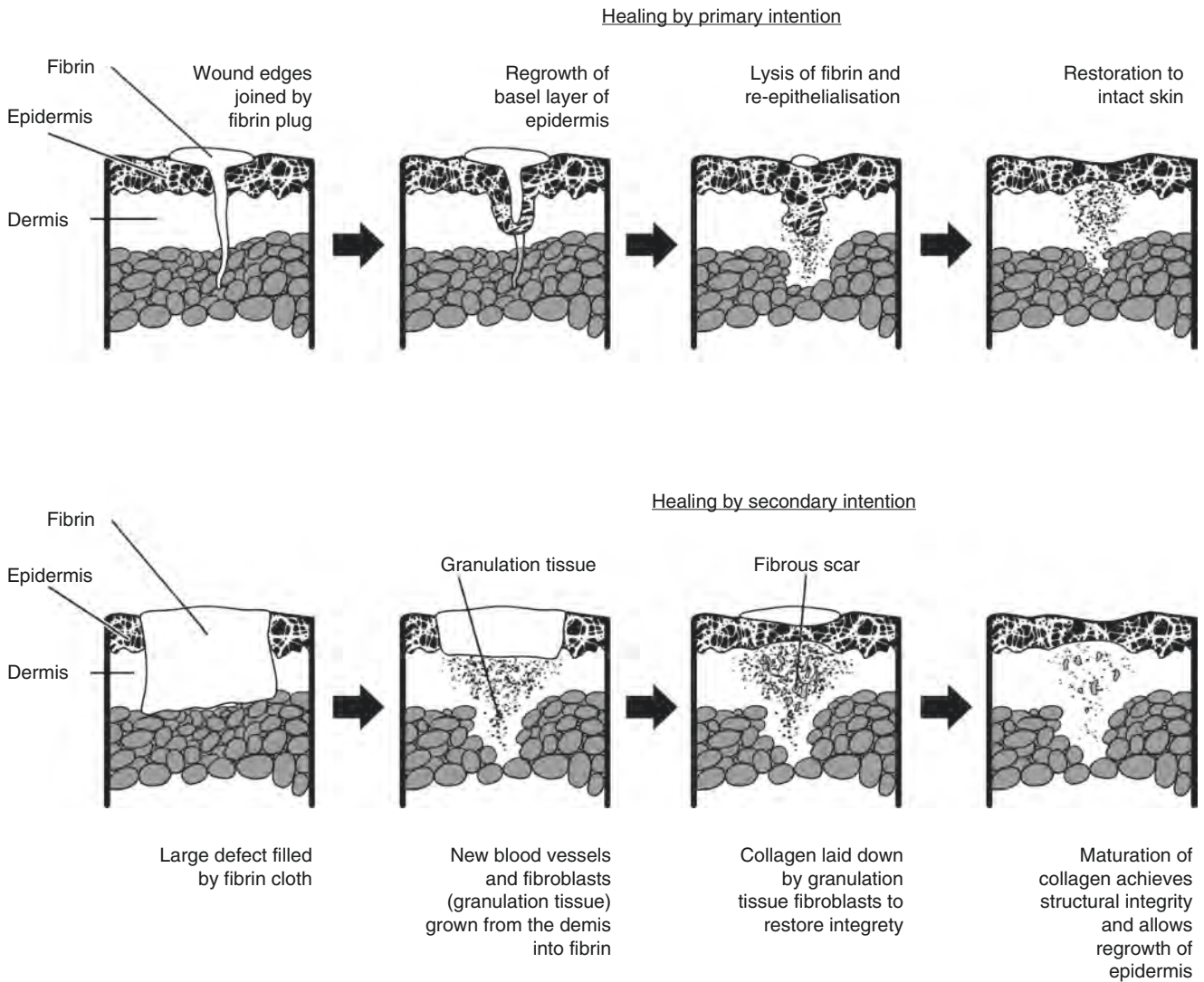


Fig. 86.2 Wound healing by primary and secondary intention

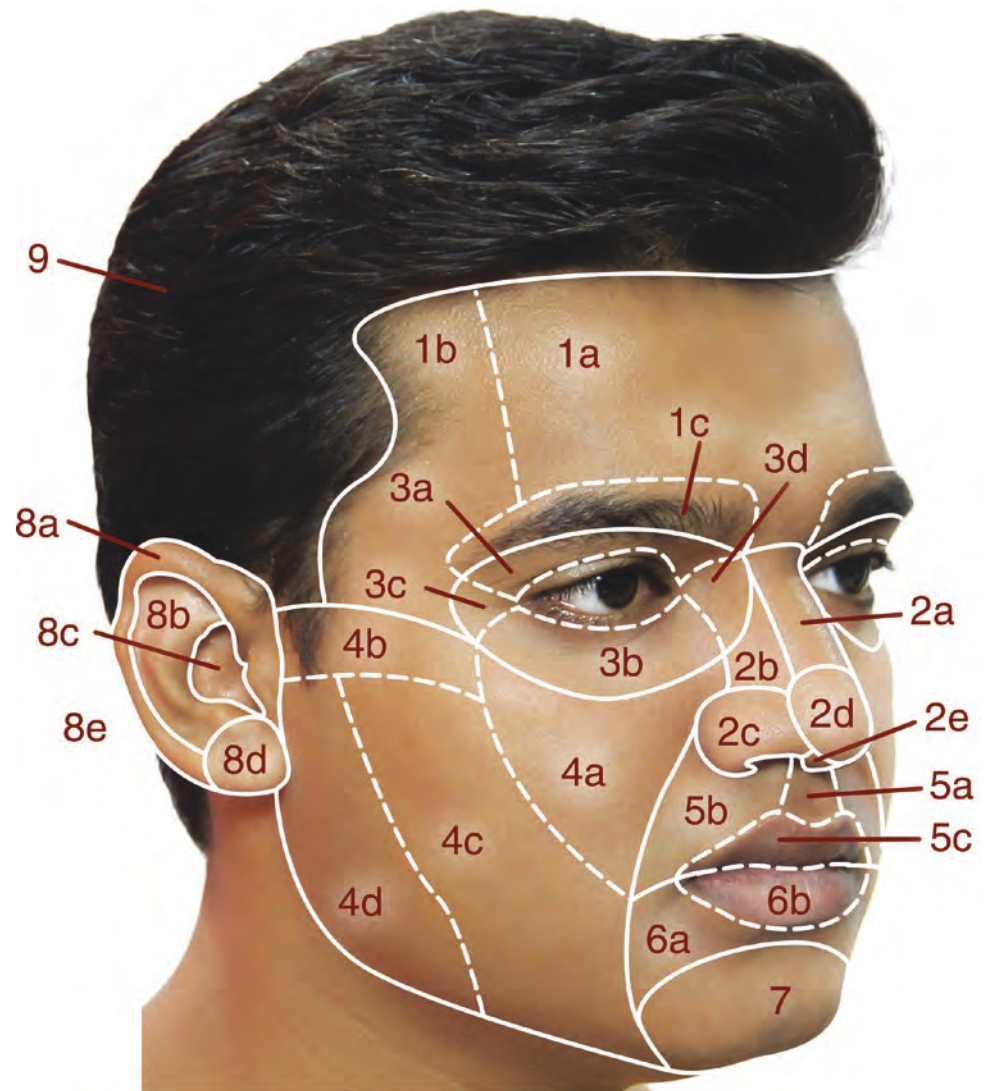
vide a flap of longer length to width ratio. Examples in the head and neck region include the paramedian forehead flap, nasolabial flap and facial artery myomucosal flap.

Regional pedicled flaps are able to provide a far greater area of soft tissue coverage than is possible with local flaps in the maxillofacial region, without requiring the facilities and expertise for microvascular reconstruction. They are generally less technique sensitive and susceptible to failure than microvascular free flaps; however, partial failure can still be problematic. For example, the pectoralis major myocutaneous flap has been reported to have a partial necrosis

rate of up to 29% [3, 4]. Furthermore, while pedicled flaps are versatile and can usually provide a good skin match, free tissue transfer can often be a better option.

Free flaps offer many reconstructive options and can provide good cosmetic and functional outcomes. They may be sub-classified according to the tissue they contain and whether the pedicle is a named vessel or from a perforator system. Free flaps are available to reconstruct practically any size of defect in the maxillofacial region. Freedom from a pedicle allows them to be placed in any location, native vessels permitting.

Fig. 86.3 Facial aesthetic units (Also refer Fig. 49.2)



Facial Cosmetic Units

1. Forehead:

- 1a. Central
- 1b. Lateral
- 1c. Brow

2. Nose:

- 2a. Dorsum
- 2b. Lateral wall
- 2c. Ala
- 2d. Tip
- 2e. Columella

3. Eyelid:

- 3a. Superior
- 3b. Inferior
- 3c. Lateral canthus
- 3d. Medial canthus

4. Cheek:

- 4a. Infraorbital
- 4b. Zygomatic

4. Cheek:

- 4a. Infraorbital
- 4b. Zygomatic
- 4c. Buccal
- 4d. Parotid-masseteric

5. Upper lip:

- 5a. Philtrum
- 5b. Lateral
- 5c. Vermilion

6. Lower lip:

- 6a. Central
- 6b. Vermilion

7. Chin

8. Ear:

- 8a. Helix
- 8b. Antihelix
- 8c. Concha
- 8d. Earlobe
- 8e. Retroauricular

9. Scalp

Disadvantages of flaps include:

- Their cost in resources and expertise.
- Increased operative time.
- Donor site morbidity.
- The risk of partial or complete failure.

86.1.5 Transplantation

Over recent years a number of partial and total facial transplants have been performed successfully. These cases are rare, requiring extremely careful selection and require a huge amount of resources. When indicated, however, this may be the only option to provide a cosmetic and to some extent functional outcome. Additional factors not associated with other reconstructive techniques, including donor selection, psychology, ethics and long-term immunosuppression require thorough consideration.

86.2 Reconstruction of the Oral Cavity

The functional roles of the oral cavity are among the most important in the body and are extremely sensitive to alteration resulting from even an apparently small defect. The coordinated action of structures within a relatively small anatomical region are critical for both nutrition (mastication and deglutition) and social interaction (speech and facial expression), two of the most vital activities that determine a patient's quality of life.

86.2.1 Reconstruction of the Lips

The aim of lip reconstruction should be to restore both function and aesthetics. Careful reconstitution of lip anatomy, such as the white roll, vermilion border and Cupid's bow, are required for a satisfactory cosmetic outcome. Continuity of the orbicularis oris muscle and adequate perioral sensation are needed to maintain lip competence. This is important during mastication and the oral stage of deglutition, particularly with fluids, and to prevent drooling in repose. The size of the reconstructed oral aperture will affect function too. All of these factors will contribute to the aesthetics of the lower third of the face.

The lips are unique in that they represent the transition from cutaneous tissue to keratinized dry and non-keratinized wet mucosa. As a result reconstruction of lip defects is best achieved by using remaining lip tissue when possible. This also often preserves contiguous, innervated orbicularis oris muscle and hence function as explained above.

Table 86.3 Time line of lip reconstruction techniques

Year	Author	Technique
1000 BC	Shushruta	First mention of lip repair
1597 AD	Tagliacozzi	Upper and lower lip repair using forearm flap
1768	Louie	Wedge excision described
1838	Sabattini	Full-thickness switch from lower to upper
1845	Dieffenbach	Cheek advancement for upper lip repair
1857	Von Bruns	Cheek advancement for lower lip repair
1872	Estlander	Upper to lower switch at commissure
1898	Abbe	Lip switch for bilateral cleft lip
1909	Lexer	Tongue flaps for lip repair
1954	Schuchardt	Sliding inferiorly based cheek flaps
1969	Bakamjian	Deltpectoral flap to lower lip defect
1974	Karapandzic	Advancement along nasolabial fold for lower lip defects

Therefore, local rotational, advancement and cross-lip flaps have become mainstays of reconstruction for larger deformities not amenable to direct or sliding lip closure (Table 86.3).

86.2.2 Reconstruction of the Vermillion

Deformity of the vermilion and the white roll of the lips is readily apparent to most observers; therefore careful reconstruction is vital for cosmesis. Small superficial defects that do not involve the underlying orbicularis muscle may be left to heal satisfactorily by secondary intention, although the process is slow (25 days on average) and can result in contracture [5, 6]. For these reasons, primary closure of a small vertically oriented fusiform excision is the preferred option, especially as often the defect will extend just beyond the vermilion, so control of the vermilion border re-approximation is required. Where redundant 'dog ear' mucosal tissue is likely to occur with primary closure of a mucosa only defect, a V-Y island of mucosa can be advanced from the labial mucosa or laterally from adjacent vermilion [7].

Large superficial defects of the upper or lower vermilion are best managed by resection of the entire vermilion subunit (lip shave) and advancement of a flap of labial mucosa. This provides a close cosmetic match, particularly in older patients. Sensation often returns with this approach; however, atrophy and contracture can be apparent particularly if the depth of the flap is not matched carefully to the depth of the defect. Alternatively, transfer of the vermilion of the opposing lip has been described, either as a single or bi-pedicle mucosal flap. Underlying muscle can be included as a myomucosal flap pedicled on the labial vessels [8]. These approaches require division and inset as a second procedure, arguably for minimal benefit compared with mucosal advancement from the labial mucosa. Reconstruction with tongue [9], buccal mucosal or myomucosal flaps can give

acceptable results. Finally, anal verge mucosa grafts to the lips has also been described [10].

86.2.3 Reconstruction of the Lower Lip

86.2.3.1 Defects Up to one Half of Lower Lip Width

Depending on the laxity of the lower lip, which is mainly related to the age of the patient, most defects of less than one third to half the width of the lower lip can be closed primarily with excellent cosmetic and functional outcomes. The defect is extended inferiorly along a 'v' or shield shape incision. The point of the 'v' can be curved laterally to follow the labiomental groove to camouflage the scar in wider defects. In even larger defects, this groove can be followed on one or both sides of the base of the resection to aid in tissue mobilization. Some surgeons utilize a 'w'-shaped incision at the base of the defect, but this may result in a less cosmetic scar. Defects that involve the commissure can be more challenging as blunting that results may require a further commissuroplasty procedure.

86.2.3.2 Defects Greater Than One Half Lower Lip Width

Lower lip defects of this proportion are unlikely to be able to be closed primarily without causing unacceptable microstomia.

Lip Switch Flaps

A reverse Abbe flap (see *upper lip reconstruction* below) can be used to reconstruct larger lower lip defects, whereby a segment of upper lip with the same vertical dimension, but around 50% of the width of the lower lip defect is pedicled

laterally on the labial artery. To prevent deformity of the upper lip, harvest should only be from lateral to the philtrum. In theory bilateral reverse Abbe flaps can be used, although the two pedicles that result make oral intake difficult until the flaps are inset.

Karapandzic Flap

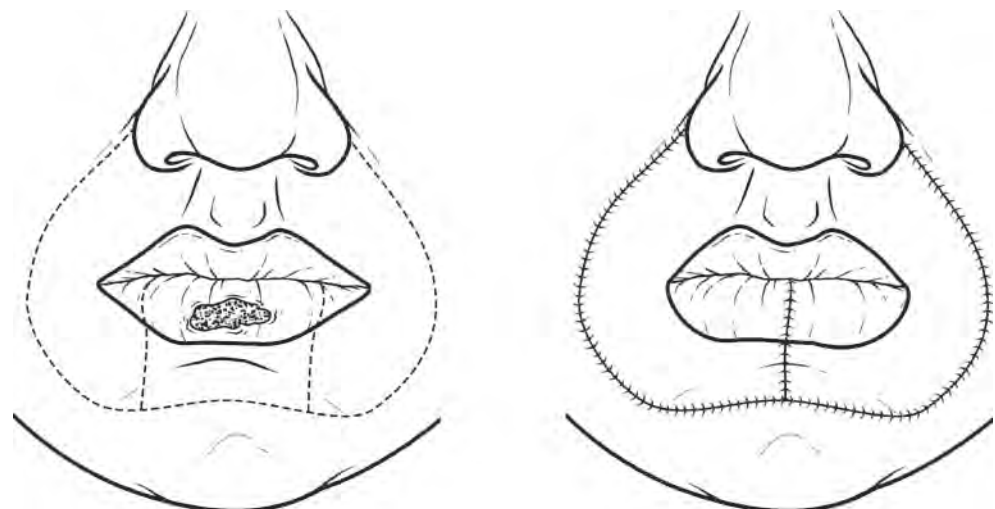
The Karapandzic flap allows reconstruction of lower lip defects up to 80% of the lower lip width [11], with good preservation of function and aesthetics (Fig. 86.4). Some degree of microstomia and blunting of the commissures is caused, however. Unilateral or bilateral transdermal curvilinear incisions that follow the nasolabial creases allow mobilization and re-approximation of the remaining lower lip [12]. The incision extends through dermis only, preserving the neurovascular supply to the remaining lower lip either side of the defect. This is the main advantage compared with the older advancement flaps such as the Gillie's fan flap (Fig. 86.5), which disrupt underlying neurovasculature due to full-thickness incisions.

86.2.3.3 Subtotal Defects

Cheek Advancement Flaps

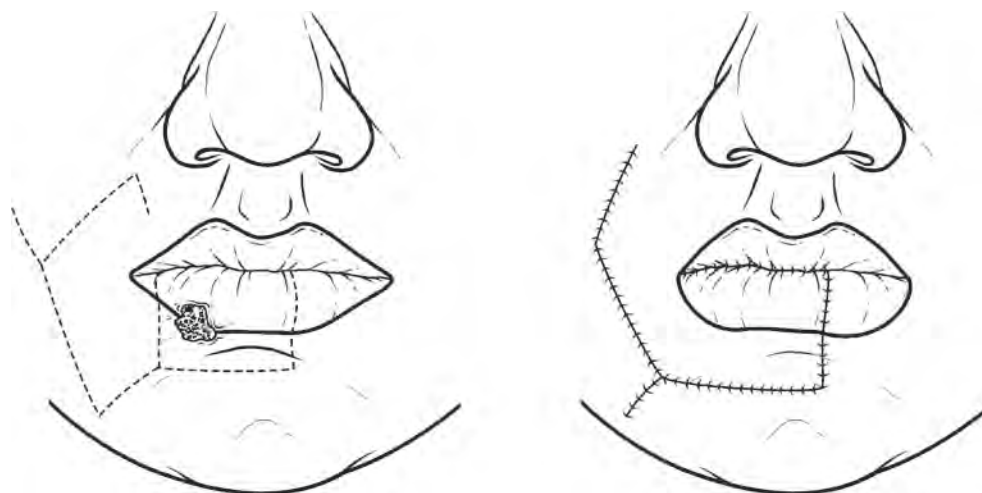
Bilateral horizontal cheek advancement flaps where described by Bernard (1852) and von Burow (1853) for reconstruction of large lip defects [13]. Tissue is advanced from the cheek by extending incisions laterally from the commissure and excising three triangles – two lateral Burow's triangles and one triangle around the defect of the lower lip itself. Webster refined this technique for reconstruction of lower lip defects using only partial-thickness incisions along the nasolabial and labiomental creases [14] (Figs. 86.6, 86.7 and 86.8). This concept was further refined

Fig. 86.4 Bilateral Karapandzic flaps for reconstruction of lower lip defect



Karapandzic flap

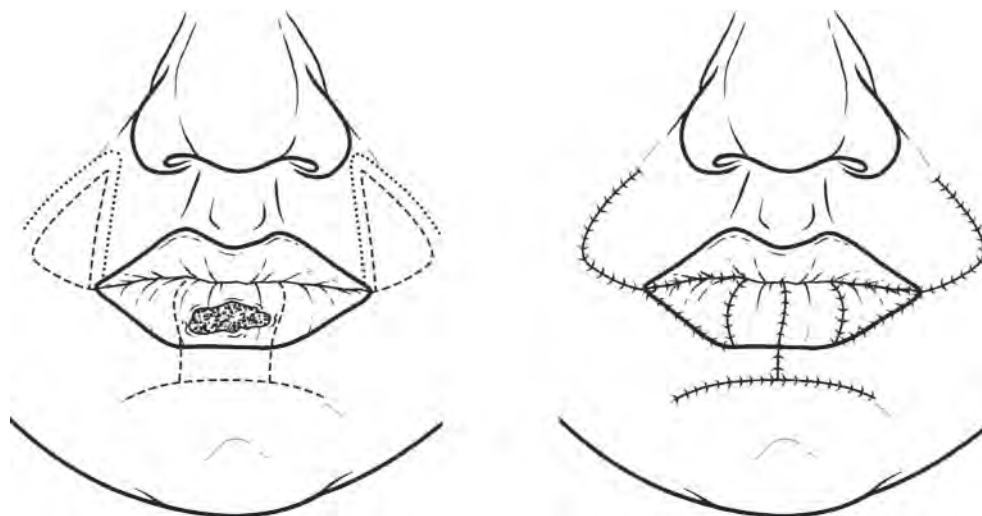
Fig. 86.5 Gillies fan flap for reconstruction of lower lip defects



Gillies fan flap

©Association of Oral and Maxillofacial Surgeons of India

Fig. 86.6 Webster modification of Bernard-von Burow flap for lower lip reconstruction



Bernard von burrow flap

©Association of Oral and Maxillofacial Surgeons of India

by Pirgousis and Fernandes for lower lip reconstruction [15] (Figs. 86.9 and 86.10).

Nasolabial Flaps

Fujimori described 'gate' flaps that are effectively nasolabial flaps, which can be combined with a lower labial mucosa advancement flap to reconstruct the entire lower lip [16]. A similar technique allows reconstruct of the upper lip [17] (Fig. 86.11).

86.2.3.4 Reconstruction of the Upper Lip

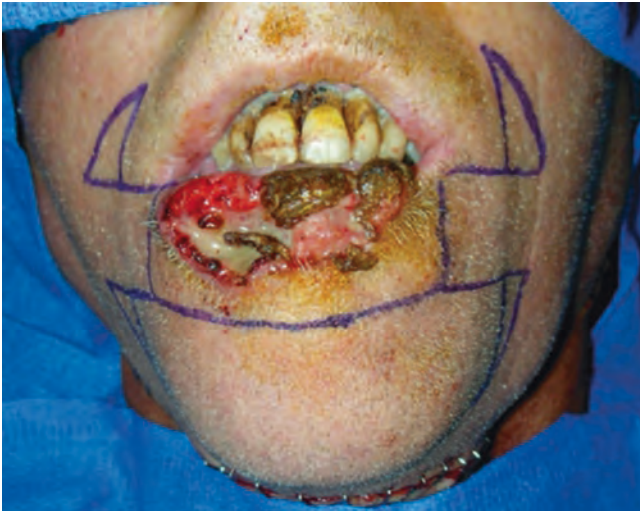Primary Closure

Defects of the upper lip are less amenable to primary closure than those of the lower lip. There is relatively less laxity, and asymmetry is more apparent because of deviation or distor-

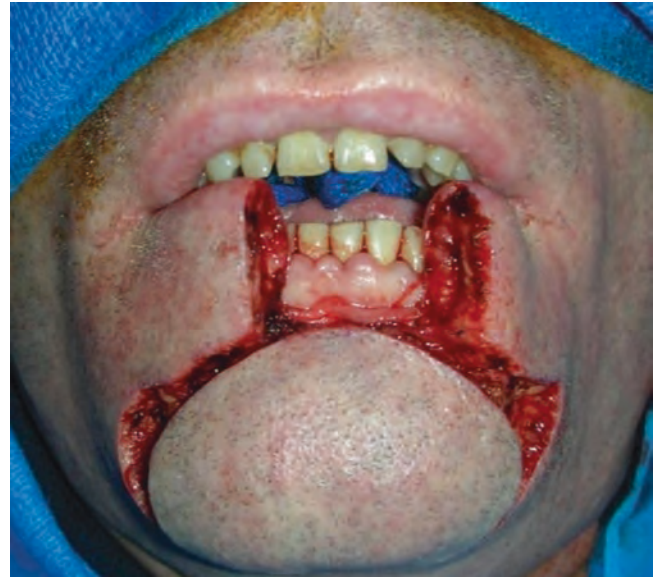tion of the philtrum and nasal base. Defects up to around one quarter to one third of upper lip width can still be re-approximated satisfactorily, particularly if laterally situated. The philtrum is less forgiving though and while defects up to around half the width can be closed primarily, there is a tendency for flattening and upwards retraction of the vermilion in this subsite.

Lip Switch Flaps

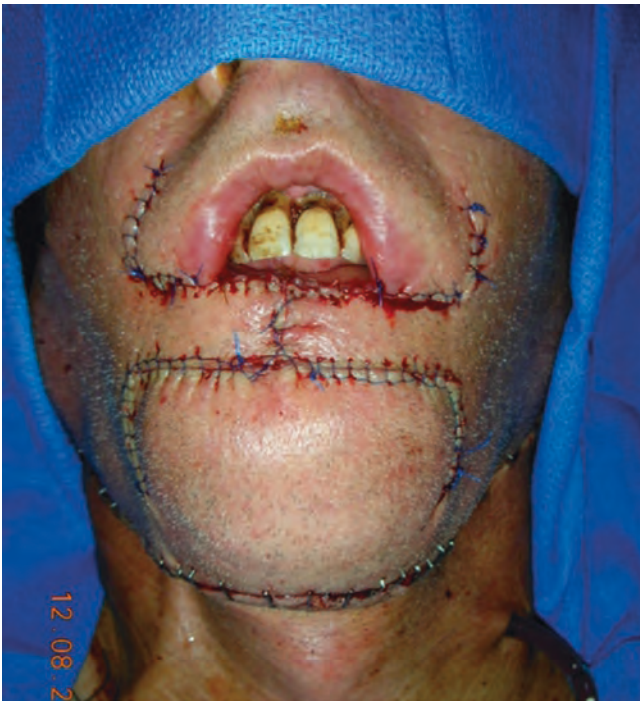The first report of a two-stage pedicled 'lip switch' flap was by Sabattini in 1838 [18]. The labial artery-based flap was popularized by Abbe in 1898, however, for use in cases of bilateral cleft lip [19]. The lower lip donor site is designed to be half the width of the upper lip defect (to equalized the horizontal discrepancy between upper and lower lips), equal to the height of the defect, and with a laterally based pedicle.



©Association of Oral and Maxillofacial Surgeons of India

Fig. 86.7 Webster-Bernard-Burrow flap markings prior to lower lip resection

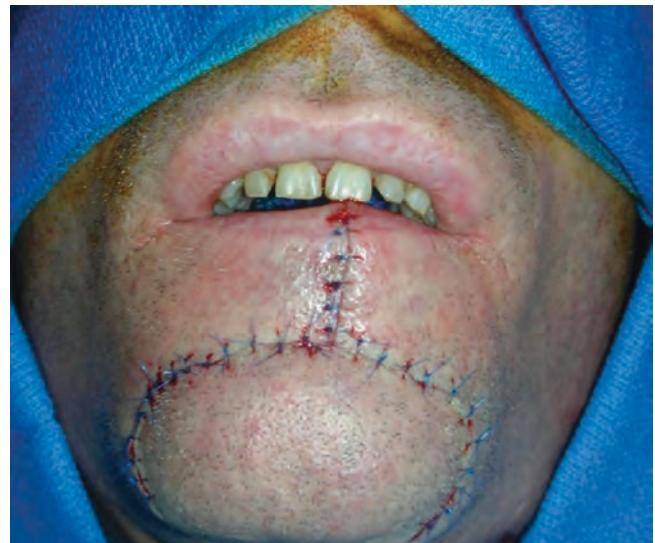©Association of Oral and Maxillofacial Surgeons of India

Fig. 86.9 Fernandes flap incisions following lower lip resection

©Association of Oral and Maxillofacial Surgeons of India

Fig. 86.8 Webster-Bernard-von Burow flap following closure

The central lower lip is the preferred donor site, as it is hair-bearing in males and leaves the least prominent scar. The white roll should be marked prior to incision and potential obscuration due to bleeding, oedema and pallor. The flap is raised including skin, muscle and mucosa but with preservation of the lateral vermillion incorporating the labial vessels. The flap is rotated and inset, taking care to re-approximate



©Association of Oral and Maxillofacial Surgeons of India

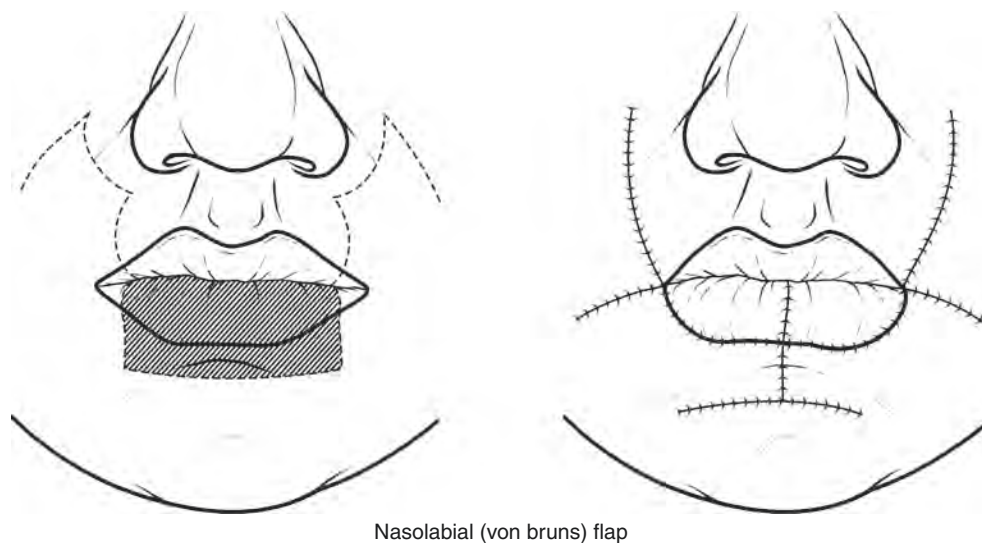
Fig. 86.10 Fernandes flap following closure

the orbicularis oris muscle and align the white roll (Fig. 86.12). After 2–3 weeks, the pedicle is divided and the flap inset. For defects of the commissure, Estlander described a similar flap where the commissure is the rotation point, and therefore no secondary inseting is required (Fig. 86.13).

Perialar Crescentic Advancement

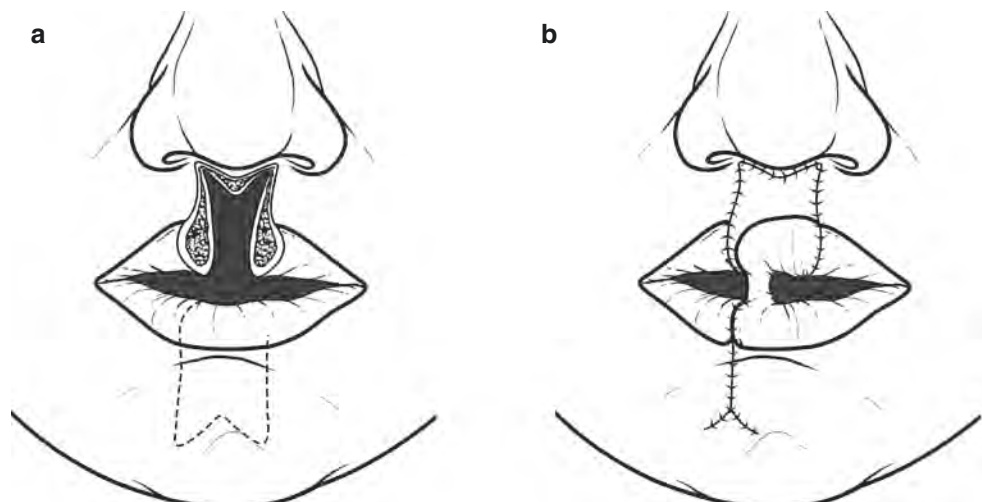
Initially described by Webster [20], a perialar incision can be made unilaterally or bilaterally to recruit lateral tissue for closure of upper lip defects (Figs. 86.14 and 86.15). This technique can also be combined with an Abbe flap to recon-

Fig. 86.11 Bilateral nasolabial flaps for lower lip reconstruction



©Association of Oral and Maxillofacial Surgeons of India

Fig. 86.12 Abbe flap for upper lip reconstruction. (a) Defect and flap markings. (b) Flap inset prior to division of pedicle



©Association of Oral and Maxillofacial Surgeons of India

struct the philtrum when defects involve the midline of the upper lip.

Reverse Karapandzic

Incisions following the melolabial groove upwards to join the superior margin of an upper lip defect can be used to advance lateral tissue in a similar fashion as the Karapandzic flap does for closure of lower lip defects.

86.2.3.5 Commissuroplasty

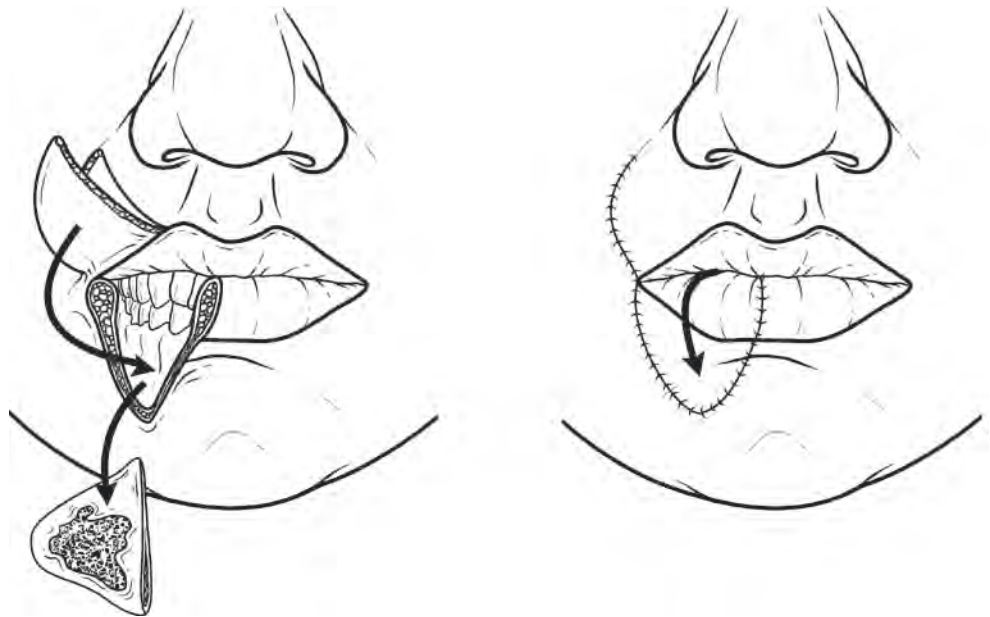
Most of the reconstructive techniques described above result in blunting and rounding of the oral aperture. The simplest way to correct this is to make a horizontal full-thickness incision through the blunted commissure, extending laterally to correspond with the position of the contralateral normal commissure. Epithelium superior and inferior to the incision

is excised and labial mucosa advanced from intraorally to recreate the vermilion (Fig. 86.16). An alternative method was described by Gillies and entails excision of a triangular segment of skin lateral to the rounded commissure, to a point comparable with the normal side. A vermilion flap from the opposite lip is then raised and rotated into this and a mucosal flap advanced to reconstruct the vermilion of the donor site (Fig. 86.17).

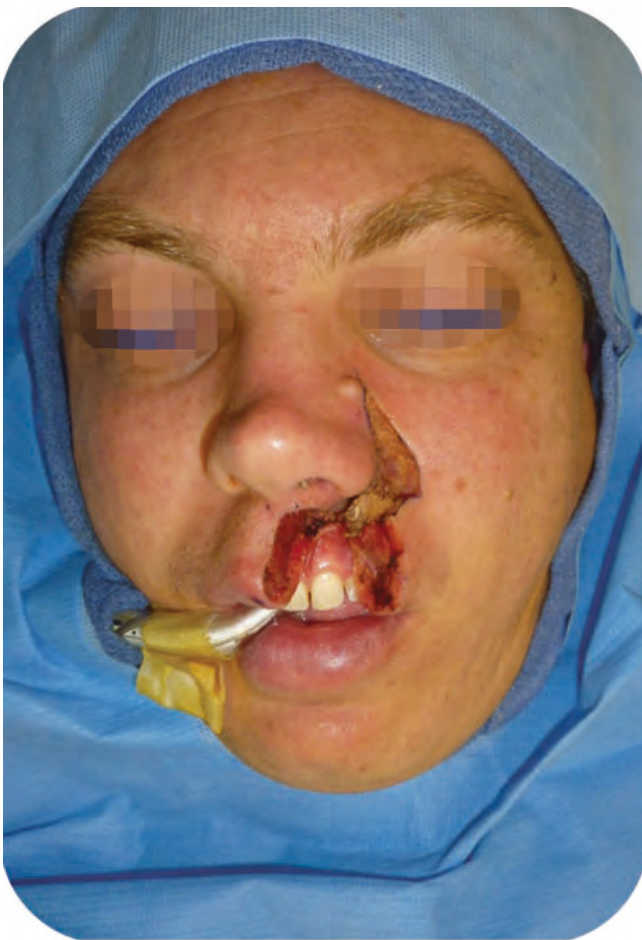86.2.3.6 Total Lip Defects

A combination of the techniques presented above can be employed to reconstruct total defects of one or other lip. Increasingly, free tissue transfer is used instead, however. The most commonly used flap for this purpose is the radial free flap (Figs. 86.18 and 86.19). This is mainly due to the thin, soft, pliable tissue offered and reliable, long pedicle.

Fig. 86.13 Estlander flap for reconstruction of defect involving commissure. A medially pedicled full-thickness flap half the width of the defect is raised from the upper lip and inset into the lower lip defect

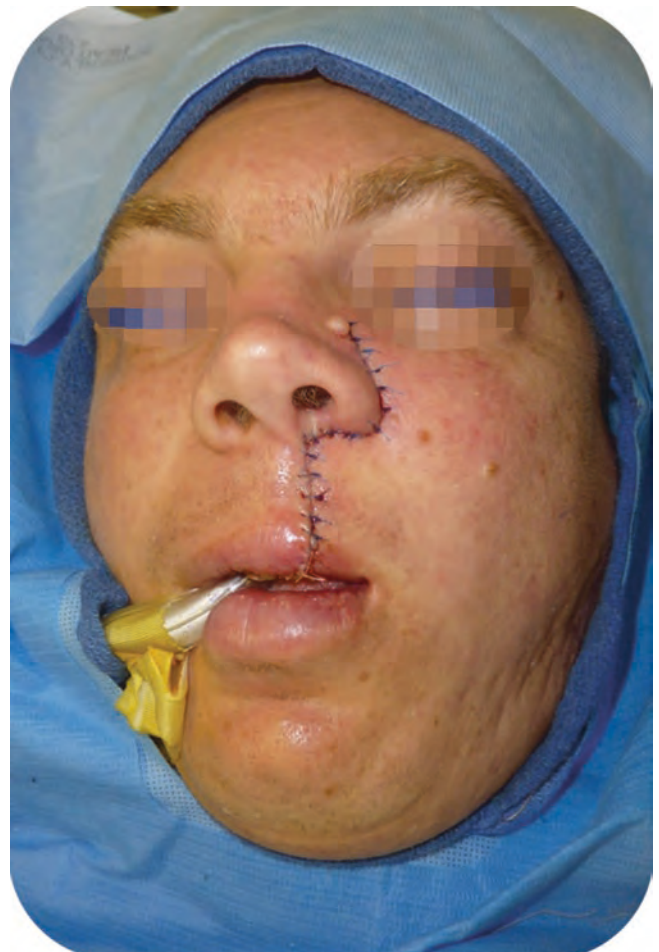

©Association of Oral and Maxillofacial Surgeons of India



©Association of Oral and Maxillofacial Surgeons of India

Fig. 86.14 Perialar crescentic flap to reconstruct upper lip defect



©Association of Oral and Maxillofacial Surgeons of India

Fig. 86.15 Perialar crescentic flap after closure

Fig. 86.16 (a–d) Commissuroplasty. A full thickness incision is made through the blunted commissure and an area de-epithelialised to mirror the normal side (dashed lines, **a**). This is then re-surfaced with mucosal flaps raised from intraorally (**b–d**)

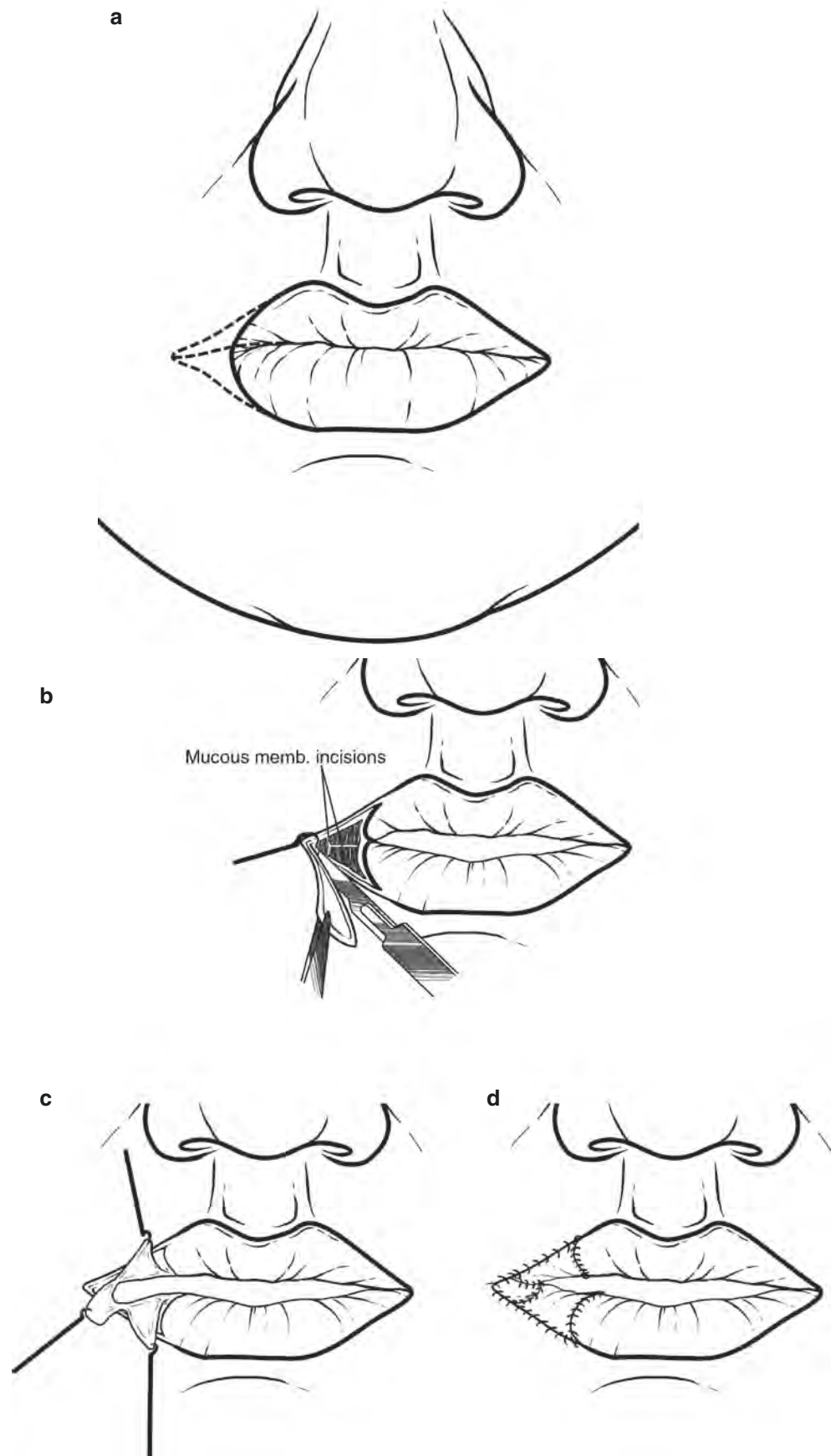
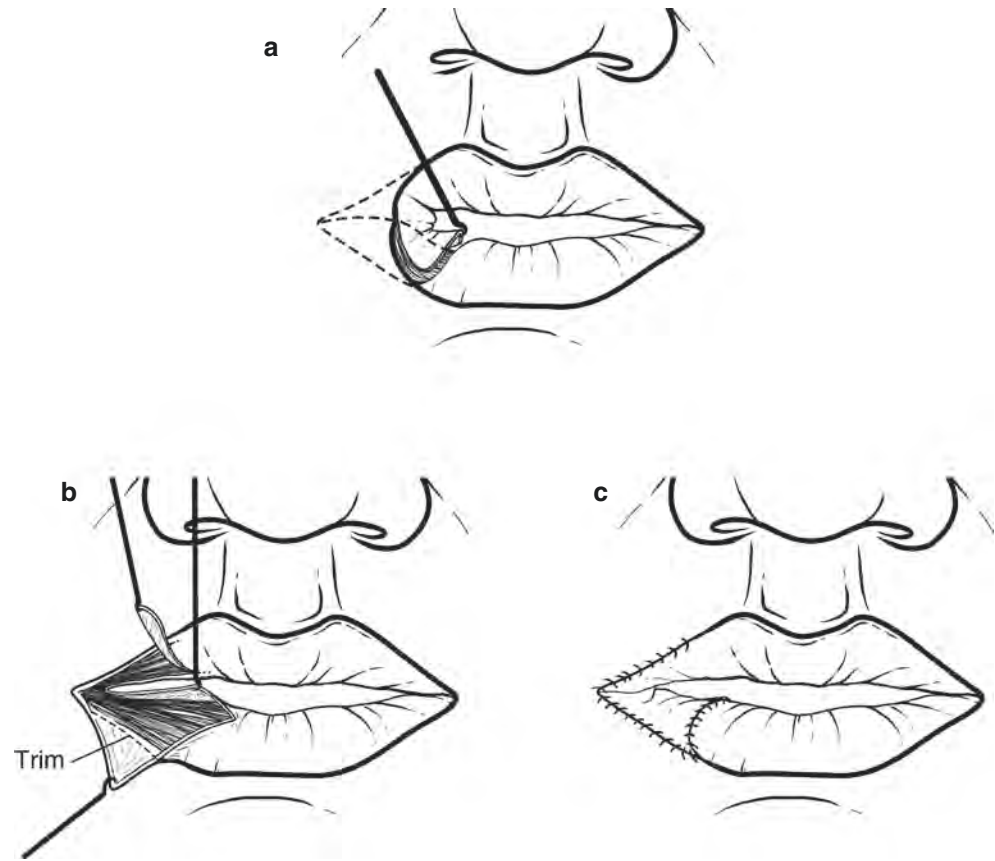


Fig. 86.17 (a–c) Gillies commissuroplasty. An area mirroring the normal commissure is de-epithelialised (dashed lines, **a**). Vermillion is raised from the lower lip and inset into the de-epithelialised upper lip (**a, b**). The lower vermilion is reconstructed with a mucosal flap raised from the labial mucosa (**b, c**)



©Association of Oral and Maxillofacial Surgeons of India

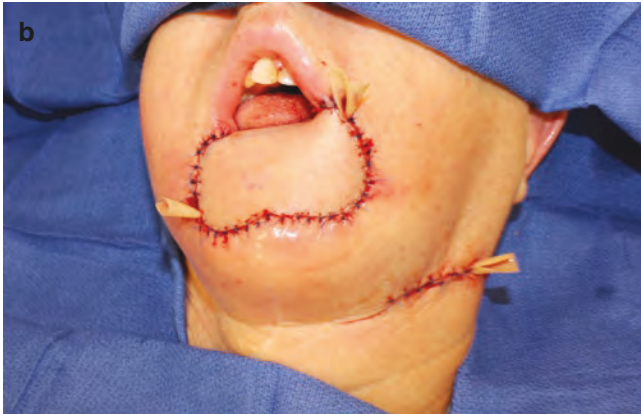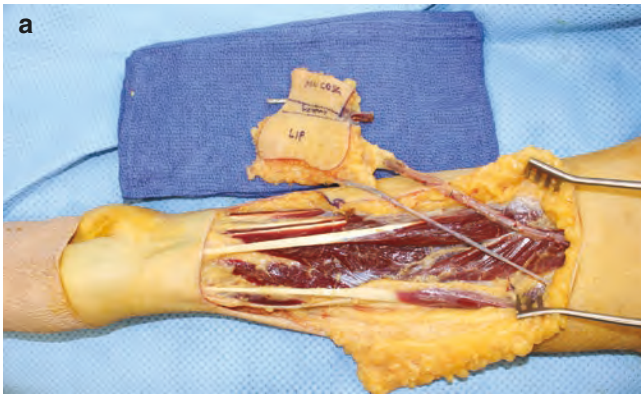
There is also the option to include palmaris longus tendon harvest [21]. This can be used as a sling between the commissures, or to the malar periosteum to improve lip form and oral competence. Alternatively, the flexor carpi radialis tendon or a nonvascularized fascia lata graft can be utilized for the same purpose. Coaptation of the lateral antebrachial cutaneous nerve to the mental nerve has been described to restore sensation to radial flap reconstruction of the lower lip [22]. Other free flaps that have been employed for total lip reconstruction include the gracilis for the lower lip [23–25] and temporal scalp for upper lip defects [26, 27].

86.3 Buccal Mucosa and Cheek

The main function of the cheek is to hold food between the occlusal surfaces of the teeth during mastication. Inadequate reconstruction can lead to excess tissue that interferes with mastication or insufficient tissue and scarring that results in trismus. Where possible the parotid duct should be repaired and/or re-sited in the buccal mucosa if involved in the defect or reconstruction to prevent obstructive parotitis. Small buccal mucosa defects can be closed primarily, but larger mucosal defects often benefit from reconstruction with a split-thickness skin graft or ipsilateral buccal fat pad [28]. As

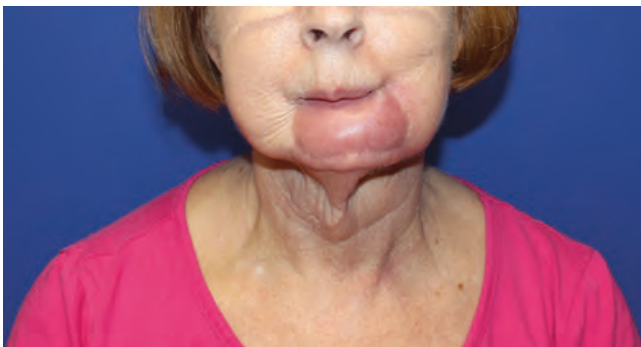size and depth of the defect increases, the use of regional flaps described in the part of this chapter that addresses floor of the mouth defects should also be considered. The radial forearm flap is the most commonly used flap for reconstruction of intraoral buccal defects due to its pliability and lack of bulk (Figs. 86.20 and 86.21). Thicker and more extensive defects may benefit from an anterolateral thigh flap, depending on the patient's body habitus. Full-thickness cheek defects often require reconstruction of both the intraoral and extraoral surfaces. A combination of techniques may be employed, for example, a regional or free flap for the skin and a split-thickness skin graft for mucosa, but often it is best to consider reconstructing with a folded or dual paddled flap. Both radial forearm [29] and anterolateral thigh [30] free flaps are well suited for bi-paddled designs. The first is more pliable and thinner; the second can be made larger and confers less donor site morbidity, as it can generally be closed primarily. The portion between the paddles is de-epithelialized where it will lie within the substance of the cheek. Alternatively, if the lip is involved in the defect, the intervening tissue can instead be used to reconstruct the lip. Obviously this will be a static repair and will therefore have an effect on oral competence.

Full-thickness cheek defects often involve the buccal or marginal mandibular branches of the facial nerve, with con-



©Association of Oral and Maxillofacial Surgeons of India

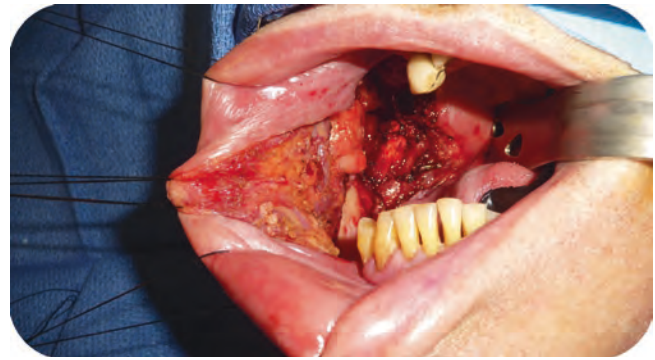Fig. 86.18 (a) Design of RFFF for lower lip reconstruction. (b) RFFF after inset to subtotal lower lip defect



©Association of Oral and Maxillofacial Surgeons of India

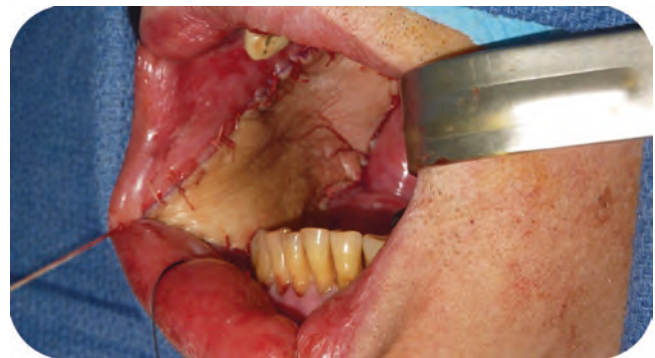Fig. 86.19 Late postoperative appearance of RFFF reconstruction of subtotal lower lip defect

sequent paralysis of the lower face. A detailed description of facial reanimation is outwith the scope of this chapter; however the methods can broadly be categorized as either static or dynamic. Static reanimation includes gold or platinum weights or springs to aid upper eyelid closure and resuspension of the oral commissure to deep temporal fascia with palmaris longus, fascia lata, acellular dermal matrix, PTFE or polypropylene [31]. Dynamic reanimation involves either



©Association of Oral and Maxillofacial Surgeons of India

Fig. 86.20 Buccal mucosa defect



©Association of Oral and Maxillofacial Surgeons of India

Fig. 86.21 RFFF inset to reconstruct buccal mucosa defect

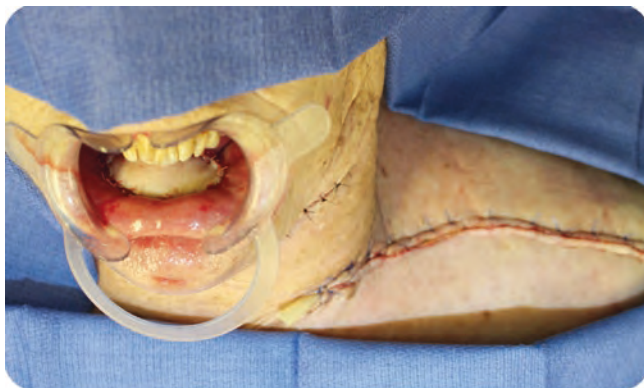the reinnervation, usually with nerve grafts or the interposition of innervated muscle, commonly temporalis transposition or a gracilis neuromuscular free flap [32].

86.4 Floor of Mouth

The floor of the mouth comprises the myomucosal diaphragm that extends from the ventral surface of the tongue, bounded anteriorly and laterally by the lingual aspect of the mandibular gingiva and posteriorly by the retromolar trigone. This inferior limit of the oral cavity provides a reservoir for food during mastication, while the muscles are also active during deglutition. The mylohyoid, geniohyoid and anterior digastric muscles raise the aerodigestive tract antero-superiorly during swallowing, anchoring the tongue and increasing the diameter of the fauces. At rest the same muscles, particularly genioglossus, prevent upper airway compromise by posterior displacement of the tongue: an important consideration when reconstructing this region. Finally, mobility of the tongue during speech, mastication and swallowing depends on adequate anterolateral separation from the mandible, and therefore reconstruction should

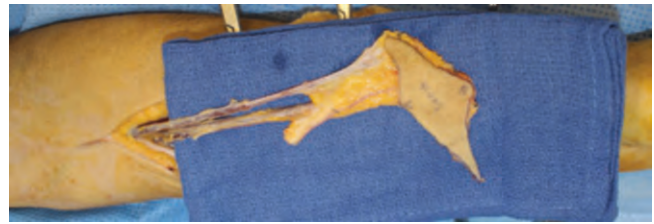
also aim to recreate the lingual sulcus and prevent ankyloglossia.

One commonly employed method to reconstruct floor of mouth defects is the submental artery island flap, first described by Martin et al. in 1993 [33]. It is easily raised with minimal donor site morbidity to provide a large and reliable paddle. The pedicle is up to 8 cm in length, and cutaneous dimensions up to 7 × 18 cm can be harvested, sufficient to reconstruct most pure floor of mouth defects. It confers less donor site morbidity than the main alternative of a radial forearm flap; often there is even a cosmetic improvement in the patient's soft tissue profile. The main concern with the use of this flap is in the oncological setting is due to potential compromise of nodal dissection in level I. In one small series, four of nine patients undergoing SIF suffered local or regional recurrence thought to be attributable to incomplete nodal harvest [34]. On the other hand, Howard et al. found that in 50 patients undergoing SIF, all with clinically negative level I nodes, none experienced recurrence attributable to the flap [35]. It is generally accepted that the flap is contraindicated in necks with clinically positive nodes, particularly in level I. A history of radiation is a relative contraindication, though good outcomes have been described despite this [36, 37]. Finally, since the submental vessels arise from the facial vessels, the flap cannot be performed in patients who have undergone a neck dissection with sacrifice of the facial vessels. In such patients or where tissue is required outside previous radiation fields, the infrahyoid island flap [38] is an alternative of similar size and character to the SIF. Supraclavicular island (Fig. 86.22) and pectoralis major flaps are also well-proven options that generally lie outside any previously operated or radiated field. They have broad pedicles, which unless skeletonized can introduce excess tissue into the defect or the tunnel from donor site. A radial forearm free flap may therefore be preferred, providing a thin, supple reconstruction with negligible pedicle bulk (Figs. 86.23 and 86.24).



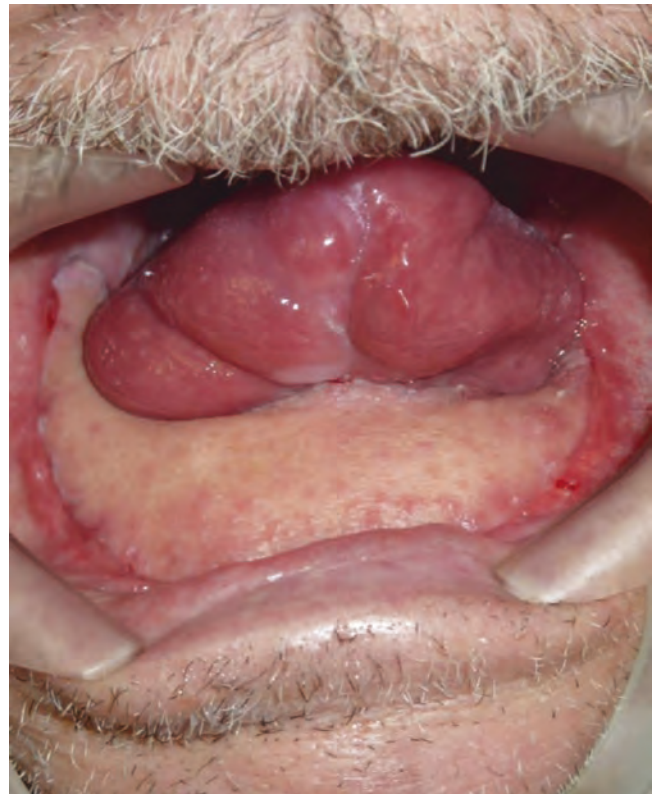©Association of Oral and Maxillofacial Surgeons of India

Fig. 86.22 SCIF inset to reconstruct floor of mouth defect



©Association of Oral and Maxillofacial Surgeons of India

Fig. 86.23 Design of RFFF for floor of mouth defect



©Association of Oral and Maxillofacial Surgeons of India

Fig. 86.24 RFFF reconstruction of floor of mouth defect demonstrating good tongue mobility

86.5 Tongue Reconstruction

Adequate tongue function requires interaction between sensory and motor components of both voluntary and involuntary nervous systems to achieve intelligible speech, mastication and swallowing. Therefore tongue defects have a significant effect on quality of life compared with other oropharyngeal structures, proportional to their volume. Tongue reconstruction that recreates the biomechanics of the healthy tongue leads to better function and even cortical adaptation to the neotongue [39]. In terms of speech, the ability for the anterior tongue to contact the palate is particularly important. Speech therapy following tongue reconstruction should

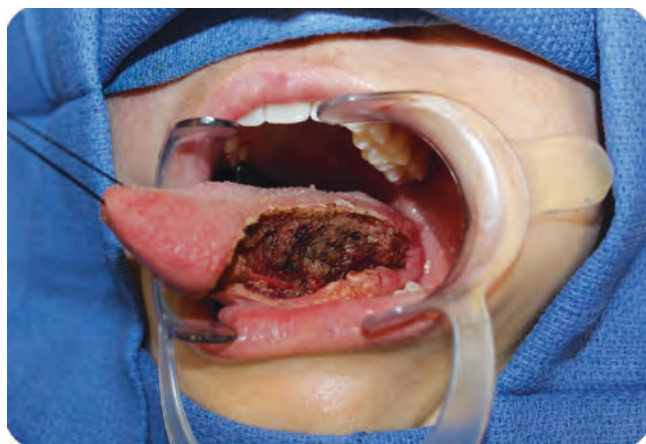be considered as it can improve proprioception of the reconstructed tongue and facilitate cortical plasticity.

86.5.1 Primary Closure

Small volume defects of the free oral tongue can often be closed primarily with satisfactory outcomes (Figs. 86.25 and 86.26). As the area of the defect increases, the option of healing by secondary intention should be considered as this can result in a more natural tongue morphology, while dehiscence is often the natural course for primary closure in any case.

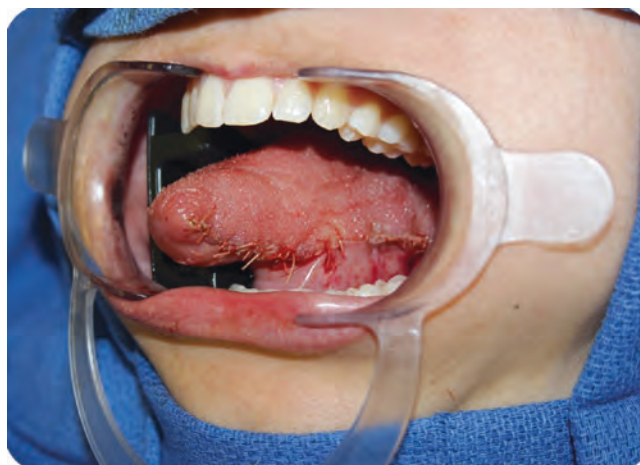86.5.2 Pedicled Flap Reconstruction

Tongue defects can be reconstructed with a variety of pedicled flaps, often utilized when free tissue transfer is precluded. Prior to development of free tissue transfer, the pectoralis major and deltopectoral flap were common options, with the facial artery myomucosal flap an alternative for smaller volume defects. There has been a renaissance in the use of other regional flaps over recent years, such as the submental (Figs. 86.27 and 86.28), supraclavicular, trapezius and infrahyoid island flaps.



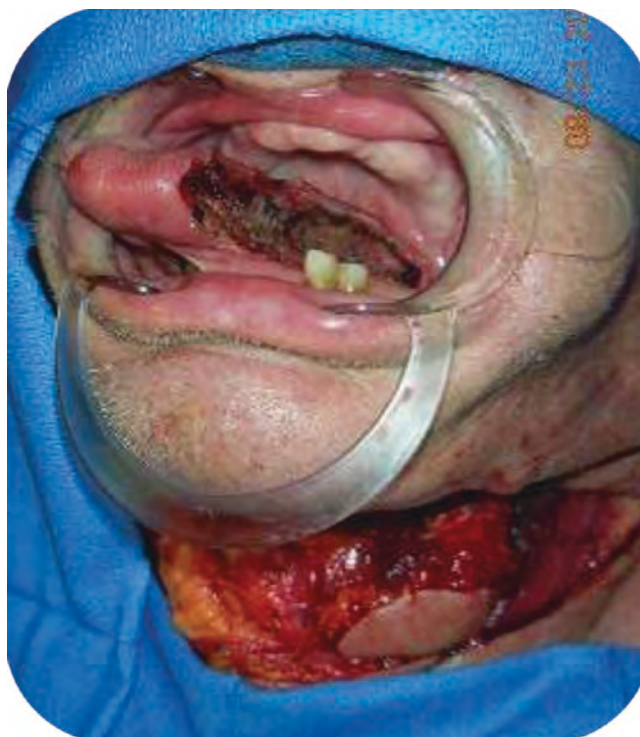©Association of Oral and Maxillofacial Surgeons of India

Fig. 86.25 Superficial defect of lateral tongue



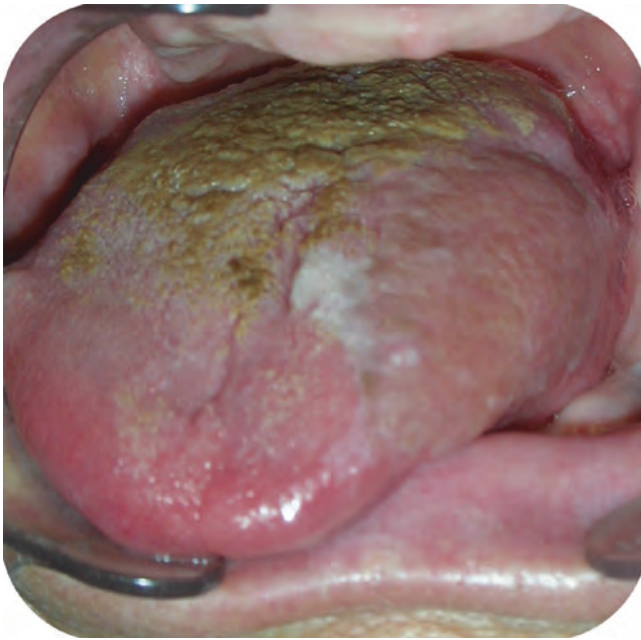©Association of Oral and Maxillofacial Surgeons of India

Fig. 86.26 Primary closure of lateral tongue defect



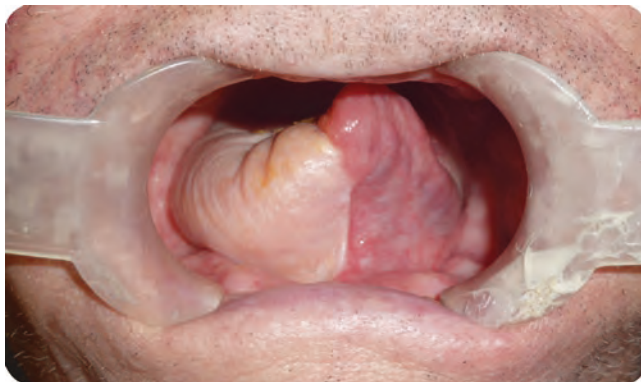©Association of Oral and Maxillofacial Surgeons of India

Fig. 86.27 Submental flap prior to reconstruction of lateral tongue defect



©Association of Oral and Maxillofacial Surgeons of India

Fig. 86.28 Late postoperative appearance of submental flap reconstruction of left lateral tongue



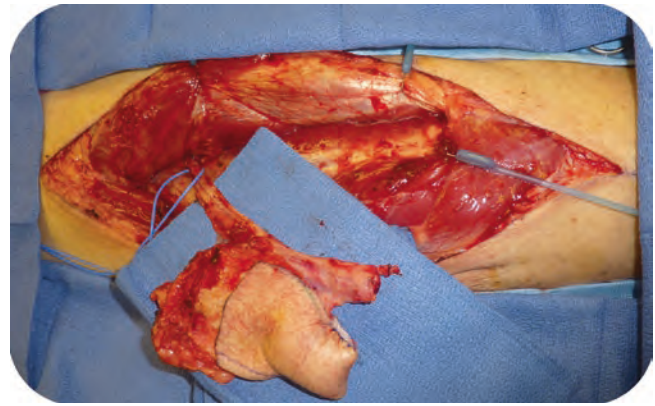
©Association of Oral and Maxillofacial Surgeons of India

Fig. 86.29 RFFF to reconstruct right hemiglossectomy

86.5.3 Free Flap Reconstruction

Tongue reconstruction with a microvascular free flap is usually recommended to restore form, resist contractures and tethering in defects greater than a quarter of the original tongue size [40]. The flap should be designed to recreate pre-morbid morphology in all three dimensions as far as possible.

The radial forearm free flap is the workhorse of tongue reconstruction for good reason (Fig. 86.29). It provides thin, pliable, soft tissue and large-calibre vessels of consistent



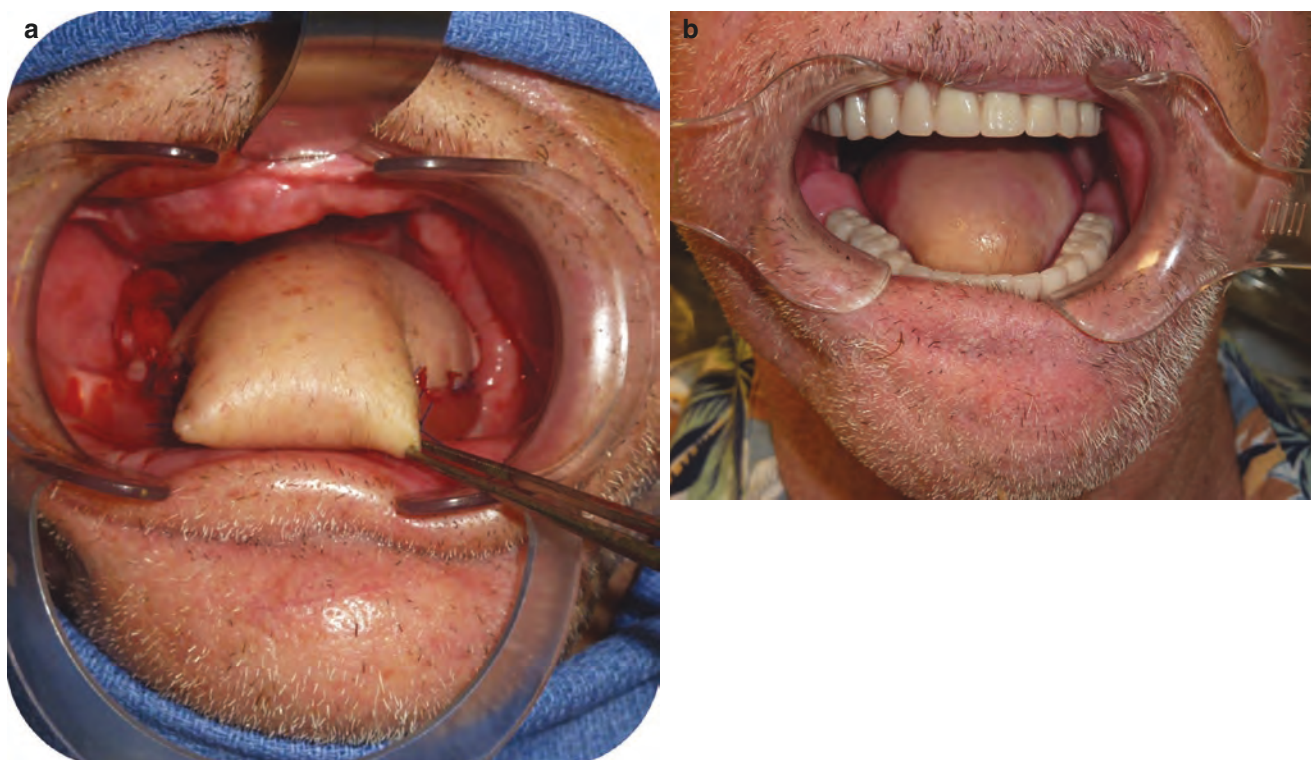©Association of Oral and Maxillofacial Surgeons of India

Fig. 86.30 Folded ALT flap for glossectomy reconstruction prior to pedicle division

anatomy and excellent length for microvascular anastomosis. Harvest can be simultaneous with resection and presents limited morbidity. The lateral antebrachial cutaneous nerve can be coapted to the lingual nerve to provide a sensate flap with some evidence of improved function and resistance to atrophy [41]. Defects greater than three quarters of the tongue may benefit from reconstruction with tissue of greater substance such as an anterolateral thigh (ALT) or rectus abdominis free flap. ALT harvest results in a more easily hidden scar and potential sensory loss is less troublesome. Total glossectomy reconstruction is particularly challenging. Recreation of three-dimensional morphology is critical, with emphasis on height and a tip protruberance, to facilitate speech and swallowing [42] (Figs. 86.30 and 86.31). A flap that is around one third greater than the defect is recommended to achieve this aim due to inevitable atrophy. Hyolaryngeal suspension should also be considered as an adjunct, to reduce the risk of persistent laryngeal aspiration [43].

86.6 Palatal Soft Tissue Defects

Simple mucosal defects overlying the hard palate can be left to close by secondary intention. Although the process is sometimes prolonged, pain and remucosalization can be aided by an acrylic cover plate retained by bone screws or dental cribs. Buccal mucosa with or without buccal fat pad can be advanced to repair palatal mucosa if the adjacent alveolus is edentulous. Palatal mucosal flaps, facial artery myomucosal flaps, temporalis or temporoparietal flaps and tongue flaps are alternatives. Functional reconstruction of the soft palate is difficult, but uvula, posterior pharyngeal wall or folded radial free flaps are options to consider.



©Association of Oral and Maxillofacial Surgeons of India

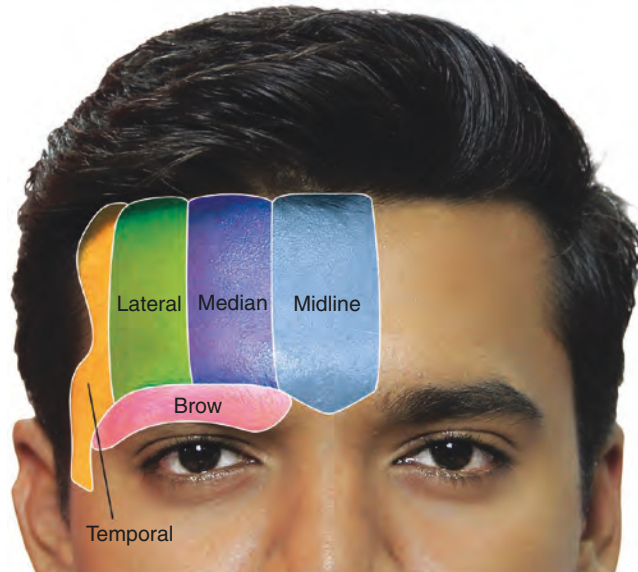
Fig. 86.31 (a) ALT flap inset for glossectomy reconstruction. (b) Late postoperative appearance

86.7 Facial Reconstruction

The aims of facial reconstruction differ from those of oral reconstruction. While the emphasis in the latter case is on function, without neglecting cosmesis, the priority here is reversed. Besides the disfigurement itself, patients will often suffer significant and irremediable social detriment due to inadequate facial reconstruction. Cosmetically acceptable results require a detailed understanding of facial anatomy. This is best considered in terms of the facial aesthetic units [44] (Fig. 86.3). This approach was first described by Gonzales-Ulloa [45–48], who demonstrated that scars can be hidden in the natural lines dividing units from one another. Menick later discussed the importance of human perception in reconstruction [49].

86.7.1 Forehead Reconstruction

The forehead comprises midline and paired median, lateral, temporal and brow subunits (Fig. 86.32). Small defects can be closed primarily parallel to horizontal RSTLs that run perpendicular to the underlying frontalis muscle fibres. The defect can be extended to an ellipse or with terminal



©Association of Oral and Maxillofacial Surgeons of India

Fig. 86.32 Aesthetic subunits of the forehead

M-plasties to achieve this. Midline defects may be closed vertically with acceptable results, particularly in the aged face. Undermining and careful closure of the galeal layer is important when closing larger defects primarily.

Split or full-thickness skin grafts can be used for large defects, although there will be a mismatch with the native skin particularly if split thickness. An alternative is tissue expansion either to provide full-thickness skin from a site such as the supraclavicular fossa or locally to provide tissue for a local flap.

Reconstruction of the forehead with local flaps usually has a better cosmetic outcome than skin grafts. Unilateral or bilateral horizontal 'H' advancement flaps work well, as does an 'A' to 'T' flap at the hairline. Finally, large forehead and scalp defects can be reconstructed with free tissue transfer. With this option, often the best cosmetic results are achieved with a radial flap or latissimus dorsi muscle flap combined with a skin graft.

86.7.2 Eyelid Reconstruction

The eyelids are of critical importance in protecting the globes and preventing loss of vision through exposure keratitis. The main goals of reconstruction are therefore to recreate a lid that lies passively against the globe without ectropion or entropion and permits full eye closure (Table 86.4). Both the upper and lower eyelids have a bilaminar structure, which has relevance to reconstructive options. The anterior lamella is composed of the thinnest skin in the body and underlying preseptal orbicularis oculi muscle. The posterior lamella is comprised of the tarsal plate and conjunctiva. The tarsal plates impart some rigidity to the eyelids and contain meibomian glands to produce the lipid component of tears. They are around 25 mm in width and 1 mm thick, with the upper plate 7–12 mm and the lower plate 3–4 mm in height. The upper tarsal plate is attached to the levator palpebrae superioris (oculomotor innervation) muscle via the levator aponeurosis and sympathetically innervated Muller's muscle. The lower plate is attached to orbital septum rather than an aponeurosis.

The orbicularis oculi muscle has three parts. The preseptal and pretarsal components are active in blinking, promoting lachrymal flow from gland to canaliculi and insert into the canthal tendons. The outermost orbital component is involved in voluntary eyelid closure and does not insert into the canthal tendons. There are two preaponeurotic fat pads present in the upper lid and three post septal fat pads in the lower lid (nasal, central and lateral). They are separated by fibrous septa, plus the inferior oblique muscle between nasal and central lower fat pads.

Table 86.4 Aims of eyelid reconstruction

Reconstruction of anterior and posterior lamellae
Adequate supple skin that permits normal eyelid movements
Avoidance of entropion or ectropion
Non-keratinized mucosa adjacent to globe
Degree of rigidity such that lid is applied to the globe in all areas

86.7.2.1 Healing by Secondary Intention

Small superficial defects limited to the anterior lamella may be left to heal by secondary intention particularly in the medial canthal region where the nasal bones resist scar contracture and therefore ectropion. This approach should generally be avoided in central or lateral lower eyelid defects due to the high risk of cicatricial ectropion.

86.7.2.2 Primary Closure and Grafts

Small defects not involving the ciliary margin can be closed parallel to relaxed skin tension lines if lagophthalmos does not result. For larger defects confined to the anterior lamella, full-thickness skin grafts from the opposing lid are ideal, providing a good match with minimal hair and resistance to the contraction associated with split-thickness grafts.

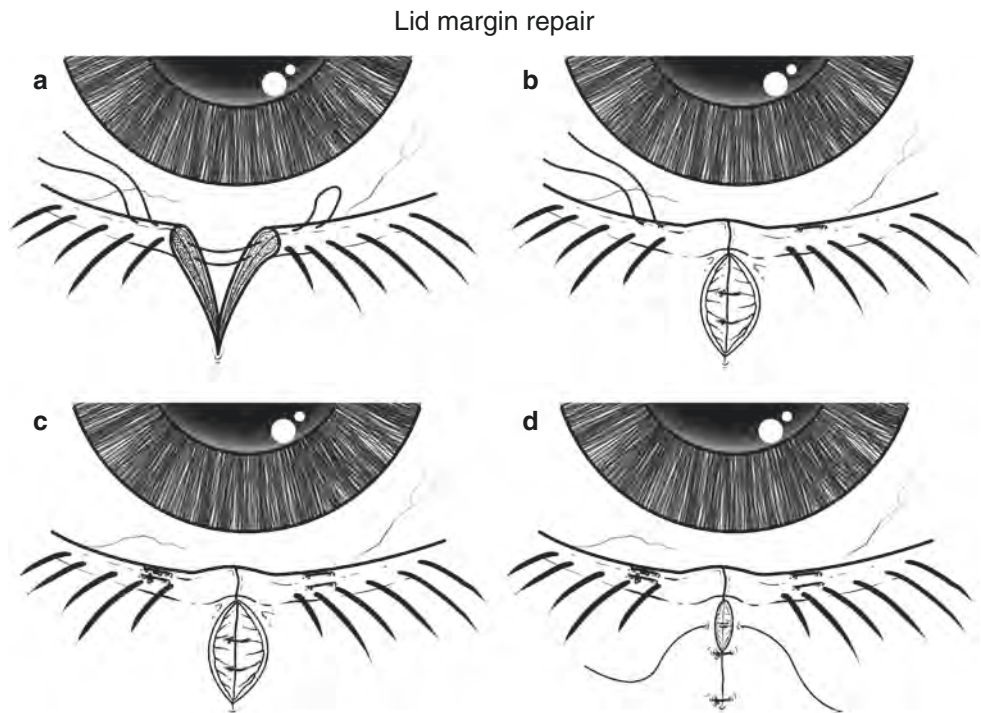
If the defect involves the ciliary margin, primary closure is possible up to one third of the lid width. Typically a 7/0 resorbable vertical mattress suture though meibomian gland orifices is used to align the ciliary margin, the tarsal plate is closed with 6/0 resorbable sutures and finally skin with 6/0 fast resorbing sutures (Fig. 86.33). Conversion to a pentagonal defect with squaring of the tarsal defect and a slight temporal slant to the anterior lamella portion can be helpful to prevent notching of the ciliary margin. A lateral canthotomy and superior or inferior cantholysis can help recruit lateral tissue. Care must be taken to appose both the tarsus and skin to avoid notching of the ciliary margin.

86.7.2.3 Local Flaps

Full-thickness defects up to 60% of the lower lid width can be repaired with a Tenzel flap [50] (Fig. 86.34), which rotates and advances tissue from the lateral canthus. Alternatively defects of this size can be repaired with a tarsoconjunctival graft and musculocutaneous advancement flap or a Hughes flap [51] (Fig. 86.35). The latter method is a two-stage procedure that involves a pedicled tarsoconjunctival flap from the upper lid covered with skin grafted from one of the upper lids. The pedicle is divided after 4–6 weeks. To prevent entropion of the upper lid, 3–4 mm of tarsus should be preserved. This method in reverse has also been described to repair defects of the upper eyelid [52]. A cervicofacial (Mustarde) flap can also be combined with a Hughes flap, free tarsoconjunctival or palatal mucosa or nasal septal graft to reconstruct lower lid defects.

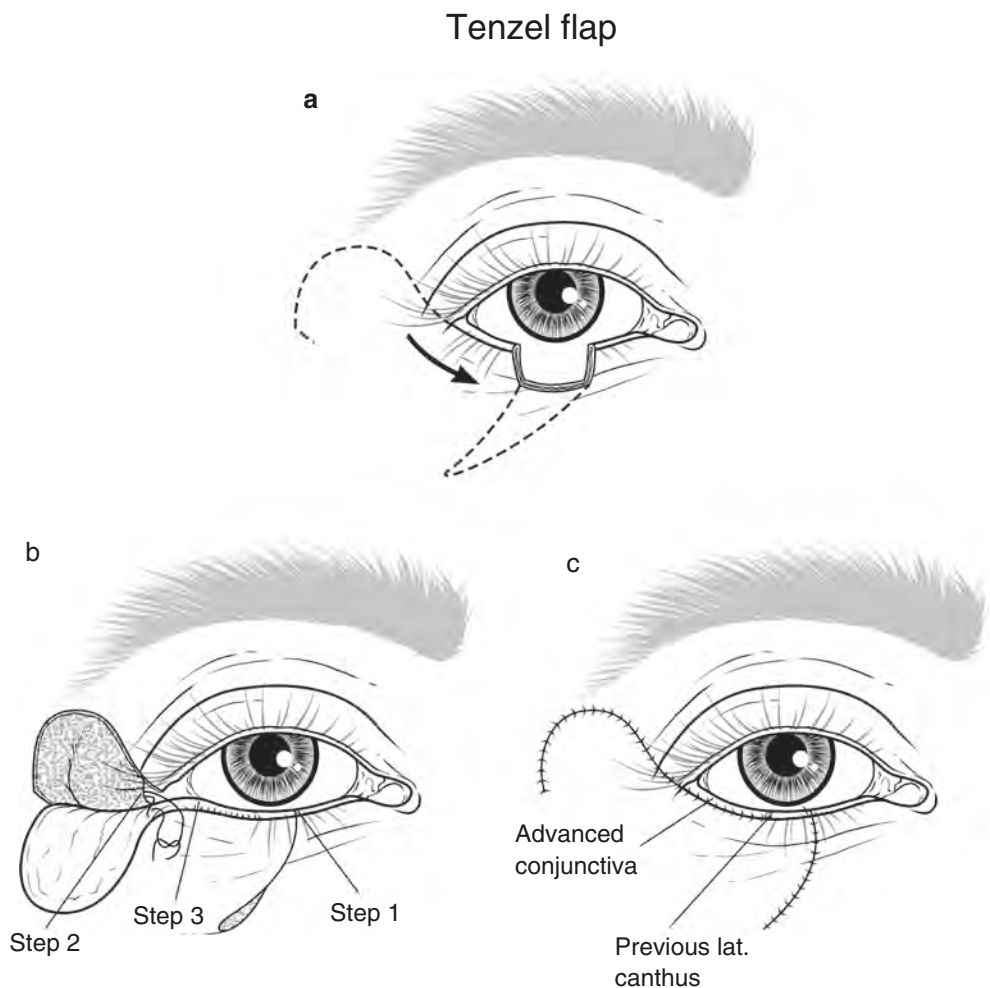
Defects one third to one half the upper lid width can be repaired with a reverse Tenzel flap or sliding tarsoconjunctival flap (Fig. 86.36) and skin graft. Larger defects can be repaired with a Cutler-Beard flap [53] that transfers an infratarsal full-thickness lower lid flap underneath a bridge of preserved lower ciliary margin (Fig. 86.37). The pedicle is divided after 6–8 weeks. Interposition of a cartilage or dermal matrix graft between the lamellae of the flap can improve the form of the reconstructed upper lid [54] (Table 86.5).

Fig. 86.33 (a–d) Primary closure for small defects involving the ciliary margin. A vertical mattress resorbable suture is placed through the meibian duct orifice region (a), to oppose the ciliary margin (b). The muscle (c) and skin (d) are then closed in layers



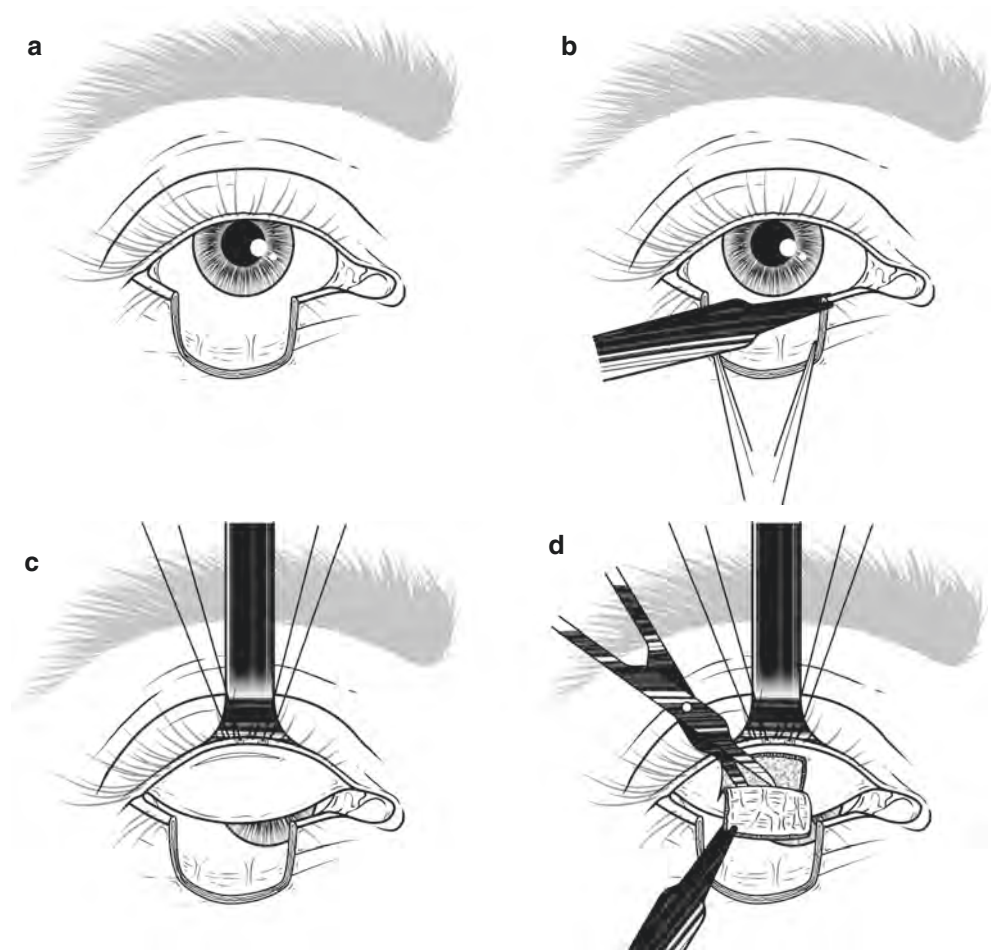
©Association of Oral and Maxillofacial Surgeons of India

Fig. 86.34 (a–c) Tenzel flap to advance lateral tissue into lower lid defect. A superiorly curved incision is extended laterally through the lateral canthus (a) to allow advancement of a partial thickness flap and remaining lateral lid to close a lower lid defect (b). Excess skin inferior to the defect is excised in the manner of a Burow’s triangle



©Association of Oral and Maxillofacial Surgeons of India

Fig. 86.35 (a–d) Hughes tarsoconjunctival flap from upper lid to reconstruct lower lid defect. A lower lid defect (a) is reconstructed with a superiorly based tarsoconjunctival flap raised from the deep aspect of the upper lid (b–d). The flap is covered with a skin graft from one of the upper lids and the pedicle divided after 4–6 weeks



©Association of Oral and Maxillofacial Surgeons of India

86.7.3 Ear Reconstruction (Also refer Chap. 35)

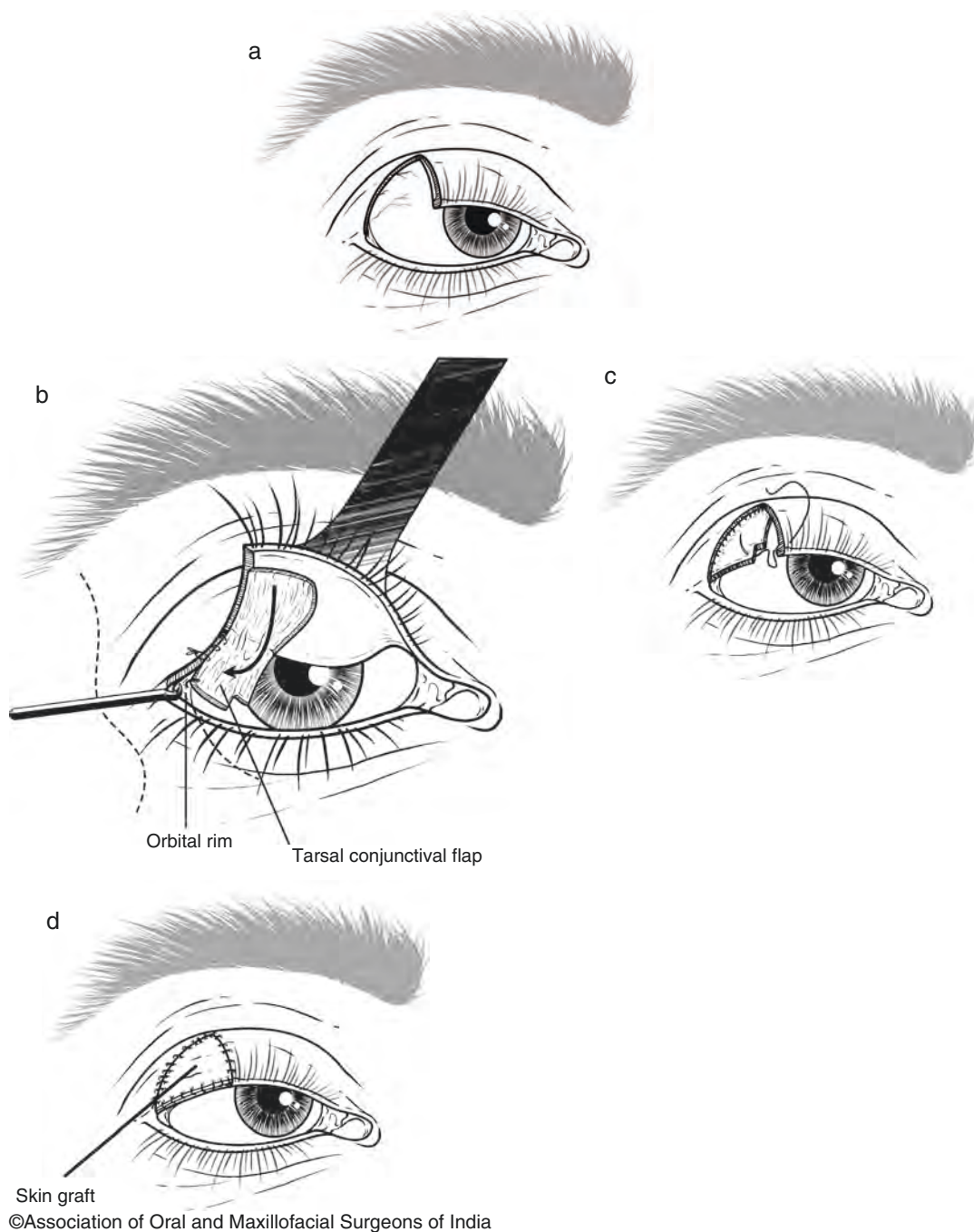
The external ear is a relatively isolated aesthetic unit with its own complex subunit anatomy (Fig. 86.38). Reconstruction requires attention to shape, angular orientation with respect to the adjacent skull, and symmetry with the contralateral ear [55]. Of these three points, the last is the most important. Finally, the reconstructed ear should serve as support for spectacles or hearing aids (Table 86.6).

The major constitutive subunits, working from peripheral to central, are the helix, scapha, antihelix and concha (subdivided into cyma and cavum). The tragus, antitragus and lobule are less critical to overall auricular aesthetics, as a defect involving these subunits has minimal effect on the shape of the remainder of the external ear.

Orientation with respect to the skull follows these general guidelines [55]:

1. Auricular height = distance between lateral orbital rim and root of helix at the level of the brow.
2. Approximately 15° deviation from the skull in the vertical axis.
3. Approximately 25–30° deviation from the skull in the horizontal axis.
4. Highest point of helix level with lateral brow.
5. Helical rim protrudes 1–2.5 cm from skull.

The following will concentrate on helical defects, since the helix is the most common site, and many lesions centred in other regions will extend to involve it as well [56]. The classical reconstructive ladder is somewhat modified for defects of the ear. For defects overlying intact perichondrium, a full-thickness skin graft is the optimal technique, rather than primary closure [55]. Alternative approaches must be used when perichondrium has been resected, as denuded cartilage will not support a skin graft. If the defect exposes cartilage in an area where it can be resected without altering the shape of the ear, it should be resected down to the opposing perichondrium, which should be covered with a skin graft [55]. The retroauricular skin is the best colour match, and the scar at the donor site is well hidden by the ear.



©Association of Oral and Maxillofacial Surgeons of India

Fig. 86.36 (a–d) Sliding tarsal conjunctival flap for upper lid defect repair. An upper lid defect (a) is repaired with a superiorly based tarsal conjunctival flap raised from the adjacent remaining lid (b). The flap is

transposed and inset into the defect (c), prior to coverage with a skin graft harvested from another eyelid (d)

Resection of shape-determining cartilage requires further subdivision. Small helical defects, ideally less than 1.5 cm, can be closed primarily [57]. Primary closure can be facilitated by the extension of the defect into a wedge excision.

For larger defects, the resulting distortion exaggerates the ear's lateral depth and makes it stand out too far from the skull. Defects between 1.5 and 2.5 cm, or roughly one third of the ear's height, can be closed by means of the helical advance-

ment flap first described by Antia and Buch [57–59] (Fig. 86.39). In this repair, the helical sulcus is incised superiorly and inferiorly through the cartilage, but sparing the posterior perichondrium and skin, which then serves as the vascular supply for the flap. A crescent of skin and cartilage can be resected from the scapha anterior to this incision, in order to decrease the size discrepancy between the helix and antihelix and thereby the degree of cupping in the final repair [57].

Fig. 86.37 (a-d) Cutler-Beard full-thickness lower lid flap to upper lid defect

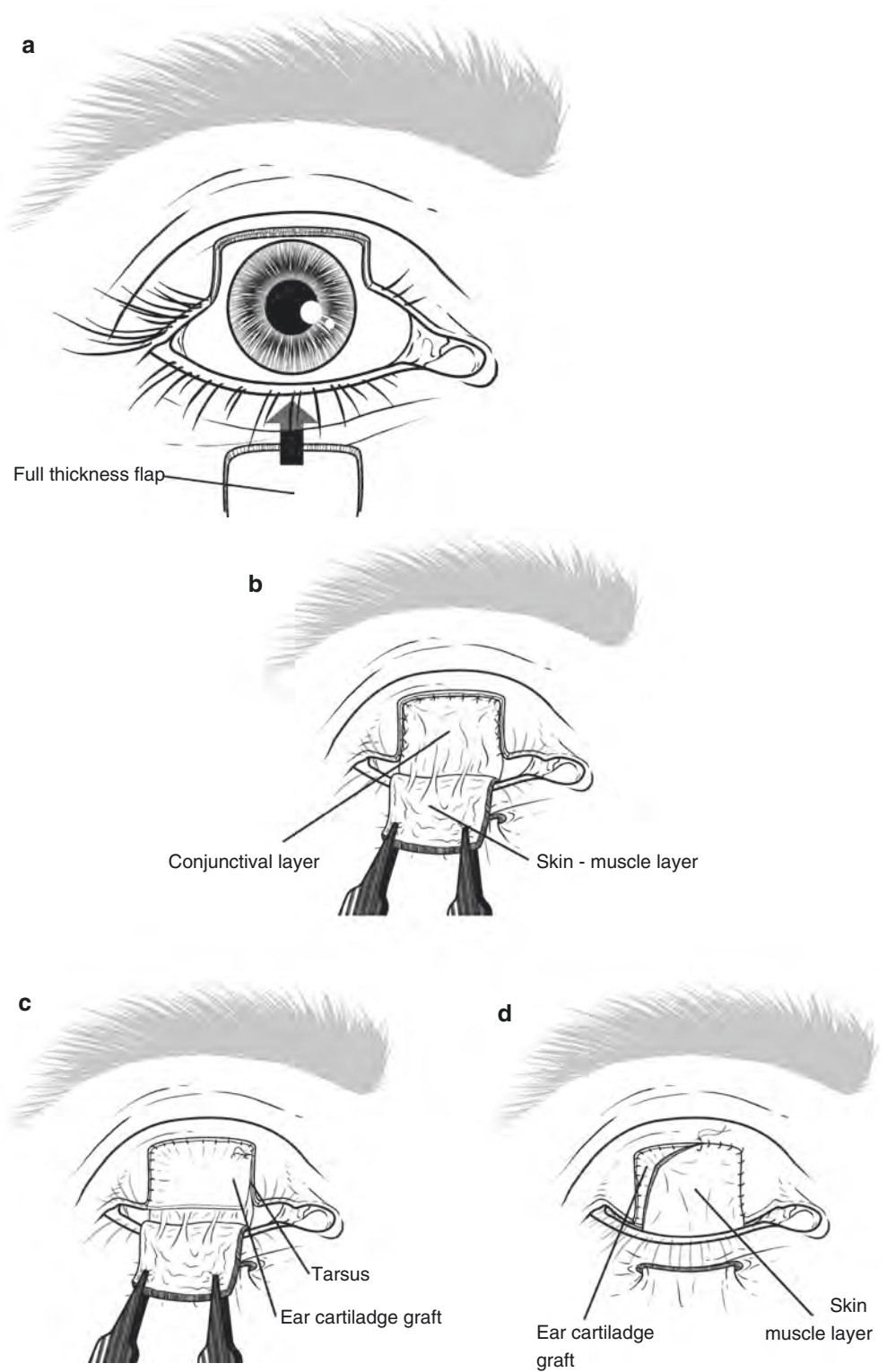
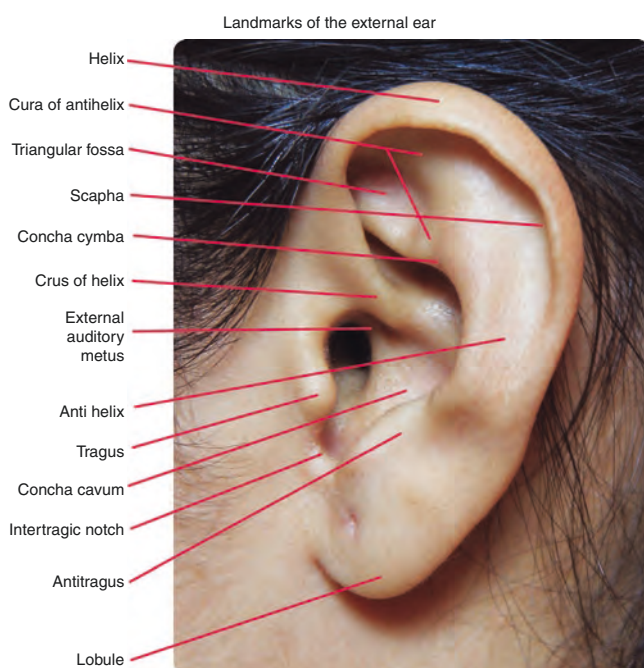


Table 86.5 Options for eyelid reconstruction

<i>Lower eyelid reconstruction</i>	
Direct closure (<30–45% defects)	
Lateral canthotomy and inferior cantholysis (gains 5 mm)	
Tenzel flap (<60% defects)	
Tarsconjunctival graft and musculocutaneous advancement	
Hughes flap	
Mustarde flap + graft for posterior lamella	
<i>Upper eyelid reconstruction</i>	
Direct closure	
Lateral canthotomy and superior cantholysis	
Sliding tarsconjunctival flap	
Cutler-Beard flap (60%–100% defects)	



©Association of Oral and Maxillofacial Surgeons of India

Fig. 86.38 Anatomy of the pinna**Table 86.6** Aims of ear reconstruction

Recreation of natural morphology	
Symmetry with contralateral ear	Height Projection Size
Support for spectacles/hearing aids	

Some authors suggest that the Antia-Buch approach is not appropriate for larger marginal defects, since it induces excessive microtia [55]. Others advocate a more aggressive Antia-Buch repair [57], arguing that the microtia will only be noticeable in those exceptional viewing situations when both ears are visible at once. Alternate strategies for a larger defect include adjacent tissue transfer such as a staged tubular pedicled graft [60] or retroauricular flap [61].

For near or complete loss of the external ear, the three options are:

1. No reconstruction.
2. Staged autogenous reconstruction.
3. Prosthetic reconstruction.

A patient wishing to avoid repeated surgery, or a poor surgical candidate, might be best served by the first option. Staged autogenous reconstruction was pioneered by Tanzer [62], who described a six-stage approach. This has since been simplified to a three or two-stage approach by the work of Brent [63] and then Nagata [64]. In summary, a cartilaginous framework is fashioned from costal cartilage, sutured to the remainder of the native ear and reposed beneath the skin as stage one. Stage two refashions the posterior aspect of the ear and establishes the correct angulation away from the skull. Exogenous cartilage substitutes can be used for this approach as well.

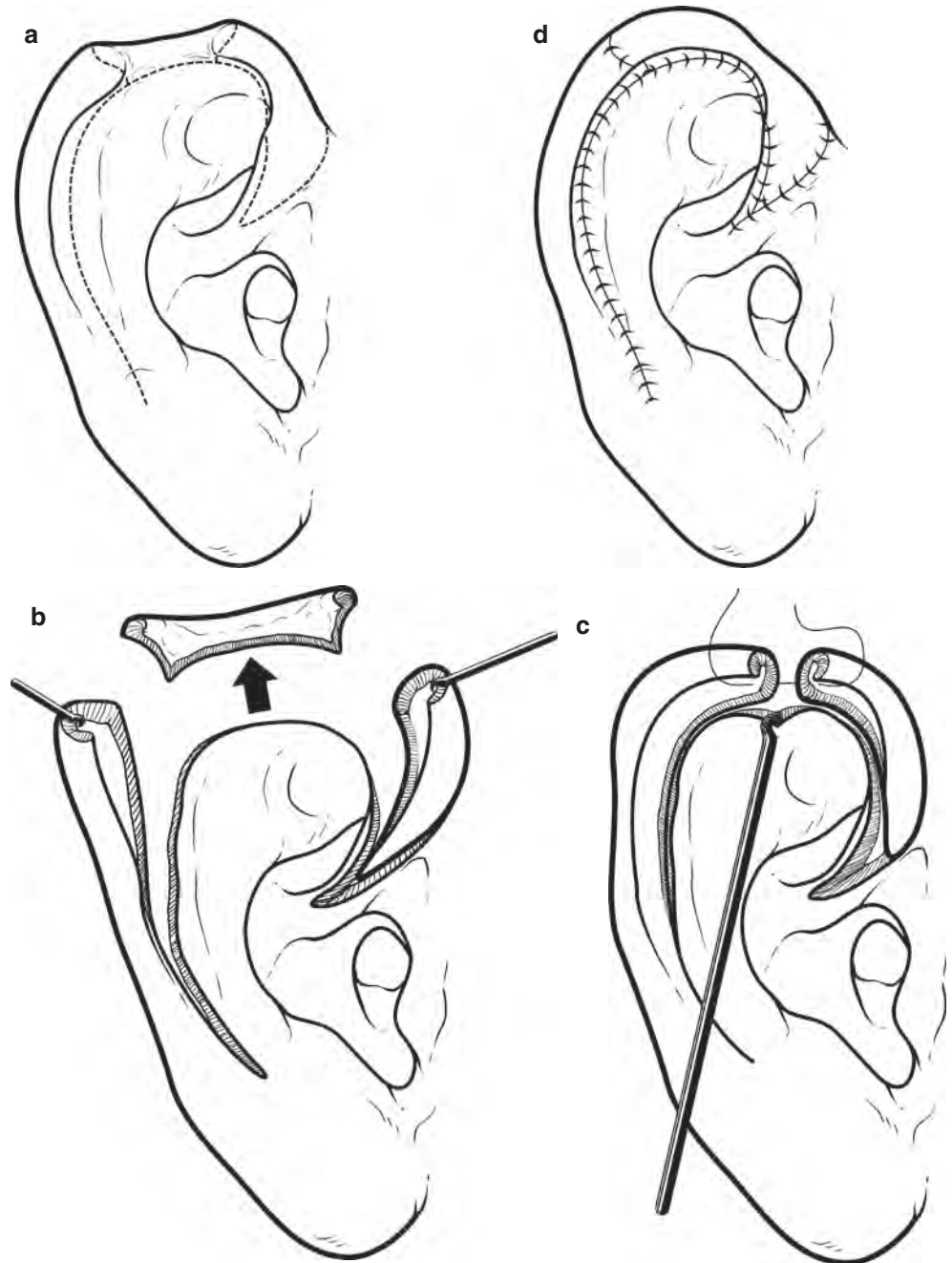
Finally, the entire external ear can be reconstructed with a prosthesis attached via adhesive or osseointegrated implants [65–67]. This solution is often best for patients in who the surrounding skin is compromised, for example by radiation or burns [55]. Typically implants require a minimum of 4 mm thickness of temporal bone and connect to the prosthesis via magnets.

86.7.4 Nasal Reconstruction

Nasal reconstruction must be considered with respect to aesthetic subunits (Fig. 86.40). The nine nasal subunits are the dorsum, lateral walls, tip, ala, soft triangles and columella. A detailed discussion of nasal aesthetics is beyond the scope of this text, but we will describe the approaches most pertinent to trauma and oncologic reconstruction. Only the smallest nasal defects can be closed primarily. However, the available regional flap options are versatile and highly cosmetically acceptable. Lateral defects can often be closed with a nasolabial flap, providing a good colour match and hiding the donor scar in the nasolabial fold [68]. Some blunting of the nasofacial angle can occur particularly if not resisted with deep sutures. Larger defects (>2 cm.) cannot be closed with the limited volume of tissue available, and the dorsum and tip are not accessible with this flap [69]. Other options are the bilobed rotation flap for sidewall defects or sliding Rintala flap for dorsal and tip defects.

Larger defects, and those centred near the midline, are generally best repaired with a paramedian forehead flap. This approach was first described by Sushruta in the sixth-century BC [70] and has undergone very little change since.

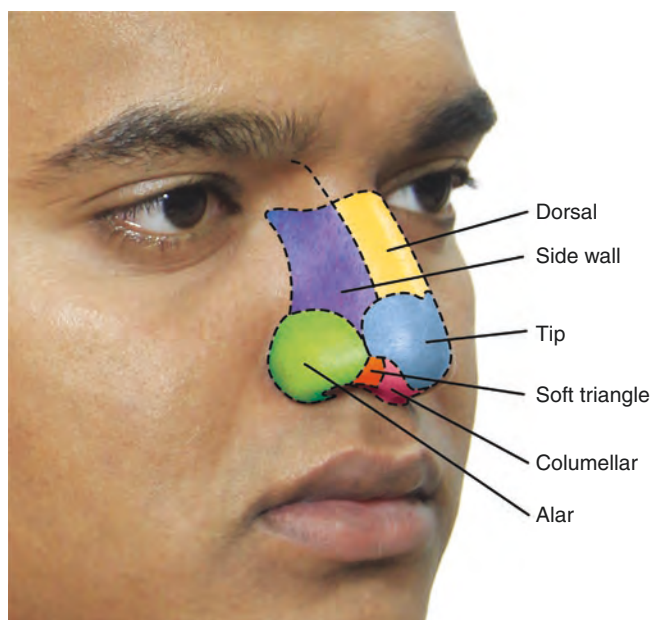
Fig. 86.39 (a–d) Antia-Buch helical rim advancement flap. A defect of the helix is repaired by advancement of adjacent helix. Full thickness incisions are made along the inside of the helix +/- a partial thickness incision anterior to the root of the helix (dotted lines). (a) A crescent or wedge of scaphal cartilage is excised (b) to reduce its circumference and permit approximation of the remaining helix (c). Finally, excess skin overlying the scaphal cartilage can be trimmed and the incisions closed (d)



©Association of Oral and Maxillofacial Surgeons of India

The flap provides skin of similar character and sufficient size to replace an entire nasal subunit and also a portion of nasal vestibule for alar defects, potentially improving aesthetic outcome [68, 69]. The first stage involves rotation of a paramedian skin paddle about a narrow pedicle based on the supratrochlear vessels. The flap is generally based on the contralateral vessels, as this produces less torsion of the vessels. The dissection is carried out in the subcutaneous plane at the distal aspect, to provide pliable skin for the repair, but transfers to the subgaleal and ultimately subperiosteal planes as it proceeds proximally towards the pedicle. The paddle is

sutured in place, with stents for the nares if necessary. The second stage is carried out approximately 3 weeks after the first, in order to provide for neovascularization. At this stage, the pedicle is divided and the superior edge of the flap inset. A third stage can be carried out to debulk the flap and is often required for ideal aesthetic outcome [69]. In patients with vascular disease, a greater proportion of the flap can be carried out in the subgaleal plane, and a debulking stage performed before division and inset, in order to decrease the chance of flap necrosis [70]. Reconstruction of alar nasal mucosa in full-thickness defects can be achieved with a



Subunits of contour

©Association of Oral and Maxillofacial Surgeons of India

Fig. 86.40 Aesthetic subunits of the nose

hinged nasal septum mucoperichondrial flap. Alar rim defects can also benefit from reconstruction with composite grafts harvested from the lobule or helical rim of the pinna.

Defects involving significant bony or cartilaginous destruction require repair with similar tissue. Small cartilaginous defects can be reconstructed with nasal septal cartilage [68], but only a limited volume can be harvested without impairing septal integrity and tip support. Grafts may also be taken from the ear or rib; the first confers less morbidity and has a favourable contour for alar reconstruction, while the second provides a larger volume of cartilage stock [55]. Many potential donor sites are available for bony defects, including calvarium, mandible, iliac crest and long bones (tibia or radius). The dorsal contour is the most important to reconstruct; this can be accomplished with an osseous strut graft [69].

In total or subtotal nasal defects, reconstruction of the internal and external soft tissue and hard tissue requires consideration. Most commonly a radial forearm free flap is employed and can be harvested with a portion of radial bone for use as a dorsal strut [71]. The best cosmetic outcome is generally achieved with this flap when combined with paramedian forehead flap to reconstruct the external skin. Finally, nasal prostheses require less surgery and can provide an excellent match in appearance to the pre-morbid nose. They can be retained with adhesive, spectacles or osseointegrated implants. Their chief disadvantage is cost, as they must be replaced every 1 to 2 years [68].

86.7.5 Reconstruction of the Extraoral Cheek

The greater laxity and simpler architecture of the skin of the cheek allows primary closure of most defects, usually by conversion to an ellipse. However, even moderate tension can result in a wide scar or distort adjacent aesthetic units, and ectropion of the lower eyelid is a particular concern here. If primary closure can be achieved to lie along the nasolabial or preauricular creases, this can give an excellent cosmetic outcome. For larger defects, these natural lines can be utilized with cervicofacial rotation flap reconstruction.

References

1. Ray E. Head and neck reconstructive surgery. In: Cancer treatment and research. New York, NY: Springer; 2018. p. 123–43.
2. Erba P, Ogawa R, Vyas R, Orgill DP. The reconstructive matrix: a new paradigm in reconstructive plastic surgery. *Plast Reconstr Surg*. 2010 Aug;126(2):492–8.
3. El-Marakby HH. The reliability of pectoralis major myocutaneous flap in head and neck reconstruction. *J Egypt Natl Canc Inst*. 2006 Mar;18(1):41–50.
4. Shah JP, Haribhakti V, Loree TR, Sutaria P. Complications of the pectoralis major myocutaneous flap in head and neck reconstruction. *Am J Surg*. 1990 Oct;160(4):352–5.
5. Zitelli JA. Wound healing by secondary intention. A cosmetic appraisal. *J Am Acad Dermatol*. 1983 Sep;9(3):407–15.
6. Leonard AL, Hanke CW. Second intention healing for intermediate and large postsurgical defects of the lip. *J Am Acad Dermatol*. 2007 Nov;57(5):832–5.
7. Jin X, Teng L, Zhang C, Xu J, Lu J, Zhang B, et al. Reconstruction of partial-thickness vermilion defects with a mucosal V–Y advancement flap based on the orbicularis oris muscle. *J Plast Reconstr Aesthetic Surg*. 2011 Apr;64(4):472–6.
8. Wagner DJD, Newman DMH. Bipedicled axial cross-lip flap for correction of major vermilion deficiency after cleft lip repair. Los Angeles, CA: Sage; 2017.
9. Ceran C, Demirseren ME, Sarici M, Durgun M, Tekin F. Tongue flap as a reconstructive option in intraoral defects. *J Craniofac Surg*. 2013 May;24(3):972–4.
10. Levi B, Ricci JA, Donelan MB. Vermilion reconstruction with anal verge transitional epithelium. *J Burn Care Res*. 2017 May 20;39(2):1.
11. Sood A, Paik A, Lee E. Lower lip reconstruction: karapandzic flap. *Eplasty*. 2013;13:ic17.
12. Karapandzic M. Reconstruction of lip defects by local arterial flaps. *Br J Plast Surg*. 1974 Jan;27(1):93–7.
13. Bernard C. Cancer de la levre inferieure opere par un procede nouveau. *Bull Mem Soc Chir Paris*. 1853;3:357–64.
14. Webster RC, Coffey RJ, Kelleher RE. Total and partial reconstruction of the lower lip with innervated muscle-bearing flaps. *Plast Reconstr Surg*. 1960 Apr;25(3):360–71.
15. Pirgousis P, Fernandes R. Reconstruction of subtotal defects of the lower lip: a review of current techniques and a proposed modification. *J Oral Maxillofac Surg*. 2011 Jan;69(1):295–9.
16. Fujimori R. Gate flap for the total reconstruction of the lower lip. *Br J Plast Surg*. 1980 Jul;33(3):340–5.
17. Aytakin A, Ay A, Aytakin O. Total upper lip reconstruction with bilateral Fujimori gate flaps. *Plast Reconstr Surg*. 2003 Feb;111(2):797–800.

18. Agostini T. The Sabattini-Abbé flap: a historical note. *Plast Reconstr Surg*. 2009 Feb;123(2):767.
19. Abbe R. A new plastic operation for the relief of deformity due to double harelip. *Plast Reconstr Surg*. 1968 Nov;42(5):481-3.
20. Webster JP. Crescentic peri-alar cheek excision for upper lip flap advancement with a short history of upper lip repair. *Plast Reconstr Surg*. 1955;16(6):434-64.
21. Fernandes R, Clemow J. Outcomes of total or near-total lip reconstruction with microvascular tissue transfer. *J Oral Maxillofac Surg*. 2012 Dec;70(12):2899-906.
22. Sakai S, Soeda S, Endo T, Ishii M, Uchiumi E. A compound radial artery forearm flap for the reconstruction of lip and chin defect. *Br J Plast Surg*. 1989;42(3):337-8.
23. Cordova A, D'Arpa S, Moschella F. Gracilis free muscle transfer for morpho-functional reconstruction of the lower lip. *Head Neck*. 2008 May;30(5):684-9.
24. Sacak B, Gurunluoglu R. The innervated gracilis muscle for micro-surgical functional lip reconstruction: review of the literature. *Ann Plast Surg*. 2015 Feb;74(2):204-9.
25. Gurunluoglu R, Glasgow M, Williams SA, Gurunluoglu A, Antrobus J, Eusterman V. Functional reconstruction of total lower lip defects using innervated gracilis flap in the setting of high-energy ballistic injury to the lower face: preliminary report. *J Plast Reconstr Aesthetic Surg*. Churchill Livingstone. 2012 Oct 1;65(10):1335-42.
26. Lyons GB, Milroy BC, Lendvay PG, Teston LM. Upper lip reconstruction: use of the free superficial temporal artery hair-bearing flap. *Br J Plast Surg*. 1989 May;42(3):333-6.
27. Chang K-P, Lai C-S, Tsai C-C, Lin T-M, Lin S-D. Total upper lip reconstruction with a free temporal scalp flap: long-term follow-up. *Head Neck*. 2003 Jul;25(7):602-5.
28. Dean A, Alamillos F, García-López A, Sánchez J, Peñalba M. The buccal fat pad flap in oral reconstruction. *Head Neck*. 2001 May;23(5):383-8.
29. Liu F, Wang L, Pang S, Kan Q. Reconstruction of full-thickness buccal defects with folded radial forearm flaps: a retrospective clinical study. *Medicine (Baltimore)*. 2017 Aug;96(32):e7344.
30. Liu Z-M, Wu D, Liu X-K, Liu W-W, Li H, Li Q, et al. Reconstruction of through-and-through cheek defects with folded free anterolateral thigh flaps. *J Oral Maxillofac Surg*. 2013 May;71(5):960-4.
31. Liu YM, Sherris DA. Static procedures for the management of the midface and lower face. *Facial Plast Surg*. 2008 May;24(2):211-5.
32. Coyle M, Godden A, Brennan PA, Cascarini L, Coombes D, Kerawala C, et al. Dynamic reanimation for facial palsy: an overview. *Br J Oral Maxillofac Surg*. 2013 Dec;51(8):679-83.
33. Martin D, Pascal JF, Baudet J, Mondie JM, Farhat JB, Athoum A, et al. The submental island flap: a new donor site. Anatomy and clinical applications as a free or pedicled flap. *Plast Reconstr Surg*. 1993 Oct;92(5):867-73.
34. Cariati P, Cabello Serrano A, Marin Fernandez AB, Perez de Perceval Tara M, Juliá MA, Ildefonso Martínez Lara M. Is submental flap safe for the oncological reconstruction of the oral cavity? *J Stomatol oral Maxillofac Surg*. 2018 Jun 27;119(4):284-7.
35. Howard BE, Nagel TH, Donald CB, Hinni ML, Hayden RE. Oncologic safety of the submental flap for reconstruction in oral cavity malignancies. *Otolaryngol Head Neck Surg*. 2014 Apr;150(4):558-62.
36. Wu Y, Tang P, Qi Y, Xu Z, He Y. Evaluation for submental island flap. *Zhonghua Kou Qiang Yi Xue Za Zhi*. 2002 Nov;37(6):418-20.
37. Taghinia AH, Movassaghi K, Wang AX, Pribaz JJ. Reconstruction of the upper aerodigestive tract with the submental artery flap. *Plast Reconstr Surg*. 2009 Feb;123(2):562-70.
38. Deganello A, Manciooco V, Dolivet G, Leemans CR, Spriano G. Infrahyoid fascio-myo-cutaneous flap as an alternative to free radial forearm flap in head and neck reconstruction. *Head Neck*. 2007 Mar;29(3):285-91.
39. Mosier K, Liu W-C, Behin B, Lee C, Baredes S. Cortical adaptation following partial Glossectomy with primary closure: implications for reconstruction of the Oral tongue. *Ann Otol Rhinol Laryngol*. 2005 Sep 28;114(9):681-7.
40. Brown L, Rieger JM, Harris J, Seikaly H. A longitudinal study of functional outcomes after surgical resection and microvascular reconstruction for Oral Cancer: tongue mobility and swallowing function. *J Oral Maxillofac Surg*. 2010 Nov;68(11):2690-700.
41. Biglioli F, Liviero F, Frigerio A, Rezzonico A, Brusati R. Function of the sensate free forearm flap after partial glossectomy. *J Cranio-Maxillofacial Surg*. 2006 Sep;34(6):332-9.
42. Kimata Y, Sakuraba M, Hishinuma S, Ebihara S, Hayashi R, Asakage T, et al. Analysis of the relations between the shape of the reconstructed tongue and postoperative functions after subtotal or total glossectomy. *Laryngoscope*. 2003;113(5):905-9.
43. Weber RS, Ohlms L, Bowman J, Jacob R, Goepfert H. Functional results after Total or near Total Glossectomy with laryngeal preservation. *Arch Otolaryngol Neck Surg*. 1991;117(5):512-5.
44. Fattahi TT. An overview of facial aesthetic units. *J Oral Maxillofac Surg*. 2003 Oct;61(10):1207-11.
45. González-Ulloa M. Restoration of the face covering by means of selected skin in regional aesthetic units. *Br J Plast Surg Elsevier*. 1956 Jan;9:212-21.
46. González-Ulloa M. Regional aesthetic units of the face. *Plast Reconstr Surg*. 1987 Mar;79(3):489-90.
47. Gonzalez-Ulloa M, Stevens E. Reconstruction of the nose and forehead by means of regional aesthetic units. *Br J Plast Surg*. 1961 Jan;13:305-9.
48. Gonzalez-Ulloa M, Castillo A, Stevens E, Alvarez Fuertes G, Leonelli F, Ubaldo F. Preliminary study of the total restoration of the facial skin. *Plast Reconstr Surg (1946)*. 1954 Mar;13(3):151-61.
49. Thompson S, Menick FJ. Aesthetic facial reconstruction: blending human perception and the facial subunit theory. *Plast Surg Nurs*. 1994;14(4):211-6. 224
50. Tenzel RR. Surgical techniques and problems in cosmetic blepharoplasty. *Trans Am Acad Ophthalmol Otolaryngol*. 1969;73(6):1154-61.
51. McClellan WT, Rawson AE, Wendell L. Hughes' life and contributions to plastic surgery. *Plast Reconstr Surg*. 2011 Dec;128(6):765e-72e.
52. Mauriello JA, Antonacci R. Single tarsoconjunctival flap (lower eyelid) for upper eyelid reconstruction, (reverse modified Hughes procedure). *Ophthalmic Surg*. 1994 Jun;25(6):374-8.
53. Cutler NL, Beard C. A method for partial and total upper lid reconstruction. *Am J Ophthalmol*. 1955 Jan;39(1):1-7.
54. Mandal SK, Fleming JC, Reddy SG, Fowler BT. Total upper eyelid reconstruction with modified cutler-beard procedure using autogenous auricular cartilage. *J Clin Diagn Res*. 2016 Aug;10(8):NC01-4.
55. Louis PJ, Aponte-Wesson RA, Fernandes RP, Clemow J. Autogenous and prosthetic reconstruction of the ear. *Oral Maxillofac Surg Clin North Am*. 2013 May;25(2):271-86.
56. Thomas SS, Matthews RN. Squamous cell carcinoma of the pinna: a 6-year study. *Br J Plast Surg*. 1994 Mar;47(2):81-5.
57. Tay S, Nikkhah D, Teo TC. The antia-buch flap revisited. *Clin Otolaryngol*. 2017 Aug;42(4):951-3.
58. Antia NH, Buch VI. Chondrocutaneous advancement flap for the marginal defect of the ear. *Plast Reconstr Surg*. 1967 May;39(5):472-7.
59. Kronic AL, Weitzul S, Taylor RS. Chondrocutaneous advancement flap for reconstruction of helical rim defects in dermatologic surgery. *Australas J Dermatol*. 2006 Nov;47(4):296-9.
60. Masud D, Tzafetta K. The "double headed slug flap": a simple technique to reconstruct large helical rim defects. *J Plast Reconstr Aesthet Surg*. 2012 Oct;65(10):1410-3.

61. Cordova A, Pirrello R, D'Arpa S, Moschella F. Superior pedicle Retroauricular Island flap for ear and temporal region reconstruction. *Ann Plast Surg.* 2008 Jun;60(6):652–7.
62. Tanzer RC. Total reconstruction of the auricle. The evolution of a plan of treatment. *Plast Reconstr Surg.* 1971 Jun;47(6):523–33.
63. Brent B. Ear reconstruction with an expansile framework of autogenous rib cartilage. *Plast Reconstr Surg.* 1974 Jun;53(6):619–28.
64. Nagata S. A new method of total reconstruction of the auricle for microtia. *Plast Reconstr Surg.* 1993 Aug;92(2):187–201.
65. Mevio E, Facca L, Mullace M, Sbrocca M, Gorini E, Artesi L, et al. Osseointegrated implants in patients with auricular defects: a case series study. *Acta Otorhinolaryngol Ital.* 2015 Jun;35(3):186–90.
66. Granström G, Bergström K, Tjellström A. The bone-anchored hearing aid and bone-anchored Epithesis for congenital ear malformations. *Otolaryngol Neck Surg.* 1993 Jul;109(1):46–53.
67. Gentile P, Bottini DJ, Colicchia GM, Trimarco A, Cervelli V. Burns: bone-anchored, extra-oral implantology. *J Burn Care Res.* 2008 Jul;29(4):627–31.
68. Fernandes JR, Pribaz JJ, Lim AA, Guo L. Nasal reconstruction. *Ann Plast Surg.* 2018 Dec;81(6S Suppl 1):S30–4.
69. Menick FJ. Nasal reconstruction. *Plast Reconstr Surg.* 2010 Apr;125(4):138e–50e.
70. Shokri T, Kadakia S, Saman M, Habal M, Kohlert S, Sokoya M, et al. The Paramedian forehead flap for nasal reconstruction. *J Craniofac Surg.* 2018 Dec;30(2):330–3.
71. Koshima I, Tsutsui T, Nanba Y, Takahashi Y, Akisada K. Free radial forearm osteocutaneous perforator flap for reconstruction of total nasal defects. *J Reconstr Microsurg* 2002 Oct;18(7):585–588. discussion 589–90.

Open Access This chapter is licensed under the terms of the Creative Commons Attribution 4.0 International License (<http://creativecommons.org/licenses/by/4.0/>), which permits use, sharing, adaptation, distribution and reproduction in any medium or format, as long as you give appropriate credit to the original author(s) and the source, provide a link to the Creative Commons license and indicate if changes were made.

The images or other third party material in this chapter are included in the chapter's Creative Commons license, unless indicated otherwise in a credit line to the material. If material is not included in the chapter's Creative Commons license and your intended use is not permitted by statutory regulation or exceeds the permitted use, you will need to obtain permission directly from the copyright holder.



Distraction Osteogenesis of the Maxillofacial Region

R. S. Neelakandan

87.1 Introduction

Reconstruction of the facial skeleton is a technique sensitive process for the reconstructive surgeon as the resulting outcome should improve the form and function of the patient. Distraction osteogenesis (DO) can be defined as the biologic process consisting of new bone formation between the bone segment surfaces that are gradually separated by incremental applied traction. It is a technique to which precludes donor site morbidity which is commonly performed to correct long bone deformities but gaining popularity in the maxillofacial reconstructive procedures in the recent times. The recent advancement of DO procedure is the transport distraction osteogenesis (TDO) which involves osteogenesis and histogenesis from the residual host tissues.

Following gradual movement of the transport segment, new bone regenerate formation occurs behind it filling the defect.

Ilizarov and his colleague's classified bone transport techniques as:

- Monofocal.
- Bifocal.
- Trifocal.

The bifocal and trifocal techniques play a major role in regenerating new bone across the continuity defects. TDO involves creating a new bone and soft tissue to cover the

Electronic Supplementary Material The online version of this chapter (https://doi.org/10.1007/978-981-15-1346-6_87) contains supplementary material, which is available to authorized users.

R. S. Neelakandan (✉)
Department of Oral and Maxillofacial Surgery, Meenakshi Ammal Dental College and Hospital, MAHER, Chennai, Tamil Nadu, India

defect by moving a segment of bone and new soft tissue formation behind it until the segment docks the receiving host bone. TDO can be achieved by movement of bone segments across the defect (Fig. 87.1a, b, and c).

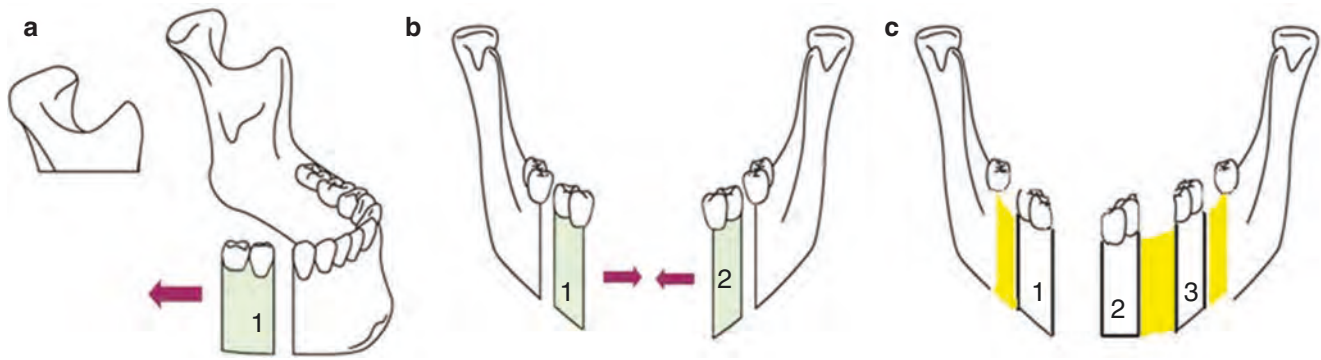
TDO is of three types:

- Bifocal.
- Trifocal.
- Quadrifocal.

Bifocal distraction is the incremental movement of one viable bone segment, trifocal distraction is the incremental movement of two viable bone segments and quadrifocal distraction is the incremental movement of three viable bone segments.

87.2 History of DO

Distraction osteogenesis (DO), a well-established technique used for several decades by orthopedic surgeons to repair long bone defects has over the past 15 years gained acceptance for correction of various craniofacial deformities. Bone distraction is not a new concept. Distraction was introduced first by Codvilla nearly a 100 years ago and was subsequently popularized during the 1940s by Ilizarov, who developed a single-stage procedure to lengthen long bones without the use of grafting material. The feasibility of applying Ilizarov's principles to different craniofacial deformities was not considered until several decades after his pioneering work in the peripheral skeleton. In the purest sense, the first reports of craniofacial DO were in the early 1960s, when rapid expansion of the palate was carried out in growing patients. This practice, however, involved distraction of a naturally occurring physis. Finally, in 1973, Snyder first described the Ilizarov technique to lengthen a surgical osteotomy of the



©Association of Oral and Maxillofacial Surgeons of India

Fig. 87.1 (a) Bifocal distraction, (b) Trifocal distraction, (c) Quadrifocal distraction

canine mandible. Interest in craniofacial distraction at first grew slowly, with sporadic experimental reports appearing over the ensuing two decades. However, in the early 1990s, experimental investigation intensified following reports from New York University on lengthening of dog mandibles and from Constantino and Friedman et al., who used DO to successfully close canine segmental lower jaw defects. Thereafter, several studies on various animal models demonstrated the application of osteodistraction at a number of different sites, including the mandible, midface, and cranial vault. It was Michieli and Miotti who first suggested the protocol for mandibular distraction in humans which included a latency period of 1 week after osteotomy followed by activation rate of 1 mm on alternate days and a minimum of 45 days consolidation period of every 15 mm distraction. In 1992, the first clinical results of craniofacial DO were reported by McCarthy et al. in a small series of patients with congenital mandible deformities. Since then, several larger series with longer follow-up periods have appeared. More recently, the technique has been successfully used for midfacial and upper craniofacial skeletal defects (Table 87.1) [1].

87.3 Biology of Transport Distraction

The adaptive function of bone to mechanical stimuli causing resorption of existing bone and formation of new bone is the continuous remodeling process of the bone tissue and was recognized as the Wolff's law. The principle behind DO is the application of defined mechanical strains to the reparative callus that is formed in the osteotomy gap. It is based on the law of tension stress by which states that gradual traction on living tissues creates stresses that can stimulate and maintain regeneration and active growth of these tissues.

Table 87.1 The history of DO is long and various researchers has contributed to its development, as summarized below

1728	Fauchard	Arch Expansion for accommodation of crowd teeth
1828	Wescott	Palatal arch expansion device
1893	Angel and Goddard	Modified Wescott's device
1905	Codivilla	Femur distraction
1927	Rosenthal	Intraoral tooth borne osteodistraction device for mandible
1937	Kazangian	Over the face appliance and distracted mandible using elastic traction
1948	Crawford	Demonstrated distraction force on a fracture callus
1959	Kole	Used traction to correct anterior open bite
Mid-twentieth century	Ilizarov	Long bone distraction
1973	Synder et al.	Distraction of membranous bone of facial skeleton
1976	Michieli and Miotti	Developed mandibular distraction. First suggested operative protocol for human mandibular distraction protocol
1989, 1992	McCarthy et al.	Used miniature orthopedic device for small bone lengthening. Reported first clinical case of mandibular DO in humans
1990	Constantino et al.	Reported the first bifocal distraction (TDO) of the mandible by using an external custom made distraction device
1997	Fedotov	Designed a semi-circular external distractor, very similar to the present day external distractors. Designed monofocal, bifocal, and trifocal distraction based on the size of the defect to be reconstructed
1987	Wolfson	Designed the first intra oral distractor—Considered as a landmark in TDO But was never used in patients

The sequence of DO is, osteotomy first, followed by latency period, which is the duration from bone division to the onset of traction. The third phase is the distraction phase which is the time when gradual traction is applied and distraction regenerate is formed, followed by the consolidation period which allows maturation and corticalization of the regenerate after traction forces are discontinued. The last

Sequence of DO

Osteotomy.
Latency period.
Distraction phase.
Consolidation period.
Remodeling phase.

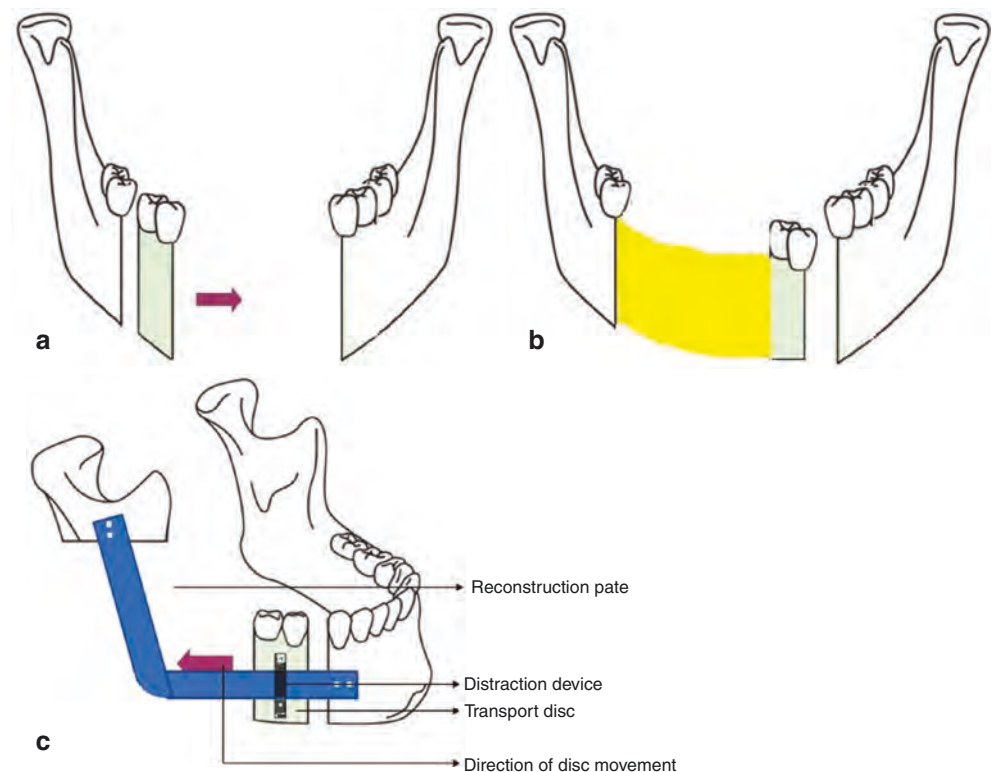
stage is the remodeling phase where there is completion of the regenerated bone remodeling [1] (Fig. 87.2a, b).

The entire healing process of TDO is similar to that of a fracture healing process. The osteotomy causes discontinuity of the skeletal segment which triggers an evolutionary pro-

cess of bone repair. It involves recruitment of osteoprogenitor cells, followed by cellular modulation or osteoinduction, and establishment of an environmental template or osteoconduction resulting in a reparative callus. The latency period is the period from bone division to the onset of traction. It represents the time allowed for reparative callus formation. On the fifth day after osteotomy, a mini-cellular network of growing capillary loops is formed in the medullary canal of both proximal and distal segments in the areas adjacent to the fracture line. This is a stage represented by soft callus where granulation tissue is converted to fibrous tissue by fibroblasts starting in the periphery.

During distraction phase traction force is applied to the bone segments and is slowly pulled apart, resulting in formation of new bony tissues which progressively increases the intersegmental gap. The cartilaginous callus is replaced by new bone formation due to various cellular activities, and this stage of hard callus remains for approximately 3–4 months. However, the normal fracture healing process is interrupted by the application of gradual traction to the soft callus. As distraction begins, the fibrous tissue of the soft callus becomes longitudinally oriented along the axis of distraction. In the second week of distraction, primary trabeculae

Fig. 87.2 (a, b) Traction force applied to the bone segments, slowly pulling them apart, resulting in formation of new bone. (c) Line diagram depicting process of TDO in a mandible requiring reconstruction for a segmental defect



©Association of Oral and Maxillofacial Surgeons of India

begin to form and the osteoid begins to mineralize. In TDO both membranous and endochondral processes play an important role in the process of new bone formation.

The consolidation period is defined as the time between cessation of traction forces to the removal of distraction device. It represents the time required for complete mineralization of the distraction regenerate. The remodeling period is the period from the application of full functional loading to the complete remodeling of the newly formed bone. The distraction regenerate is remodeled to mature bone during remodeling at a later stage.

87.4 Biology of Bone Transport

Biologically, bone transport techniques are based on two distinct processes, *distraction osteogenesis* and *transformational osteogenesis*. DO as previously described, is a biologic process of new bone formation between the surfaces of bone segments that are gradually separated by incremental traction. Transformational osteogenesis is a mechanically induced biologic process of pathologic bony tissue transformation into normal bone. Importantly, these two processes occur simultaneously during bifocal bone transport. Distraction osteogenesis occurs between the surfaces of the residual host bone segment and the trailing edge of the transport disc, while transformational osteogenesis occurs between the leading edge of the transport disc and the residual target bone segment (Figs. 87.3 and 87.4a, b).

In TDO the transport segments undergo stress due to compressive forces as well as distraction force. For instance, in bifocal transport, the leading edge realizes compression force, while the trailing edge realizes distraction force, and with trifocal transport, the leading edge of both segments realizes one common compressive force, and the trailing edge realizes two distraction forces one on either side.

87.5 Device Design

The concept of TDO has been increasingly applied to the craniofacial skeleton in the recent years. Initially used in experimental animal models, then gradually it gained popularity in the clinical setup. After encountering failures with avascularized and vascularized grafts in our patients with mandibular continuity defects, this modality of reconstruction was contemplated in our clinical practice. After treating 22 cases with earlier generation distraction devices, there were certain biological and mechanical problems resulting due to lack of vector control and inadequate tension stress effect. For these reasons various modifications were made in

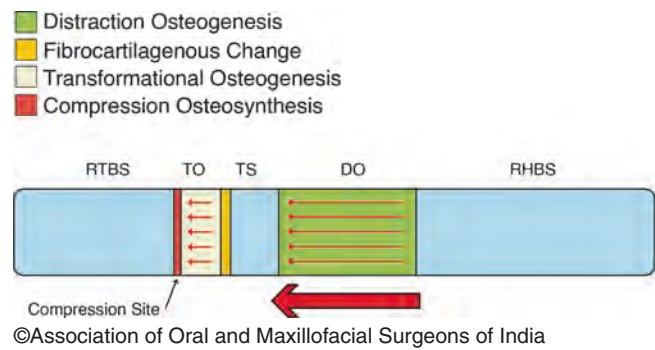


Fig. 87.3 Biology of bone transport. (DO distraction osteogenesis, RHBS residual host bone segment, TS transport segment (transport disc), RTBS residual target bone segment, TO transformational osteogenesis)

the initial design with an aim to improve the vector control and stability of the device.

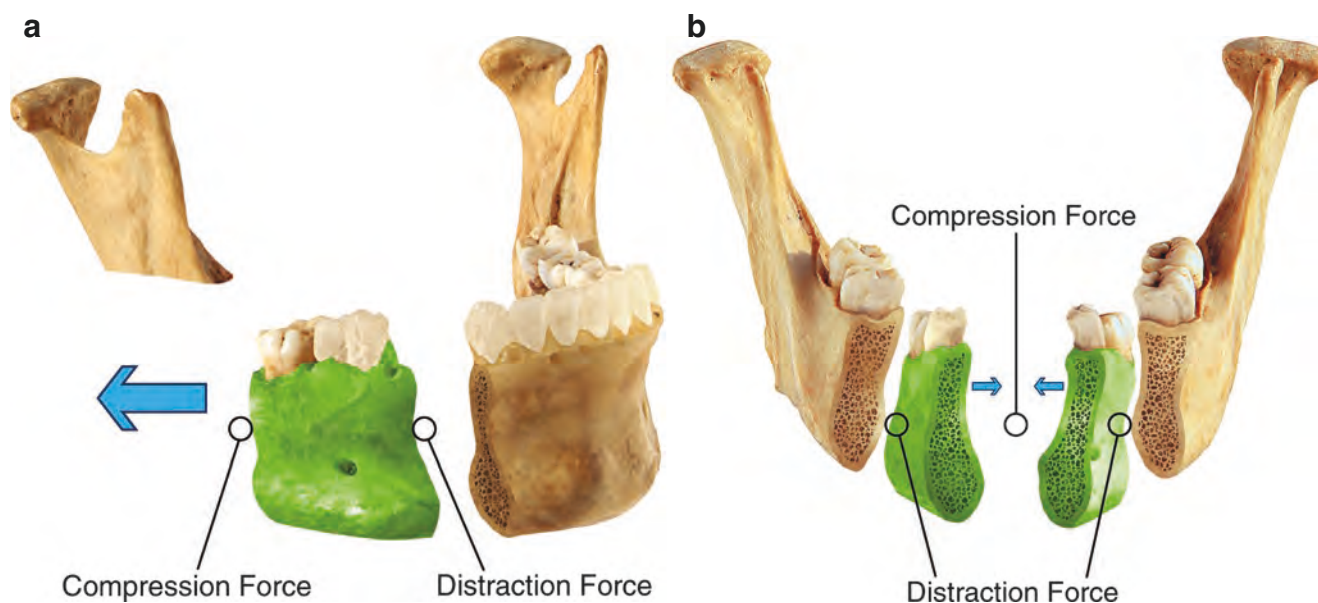
The transport distraction device may be divided into three components:

- The reconstruction plate for stability.
- The distractor component for mobilizing the transport segment on activation.
- The screws for anchorage.

A proper surgical plan and device design should be followed in each case to achieve the desired results. Few factors that are to be considered are the cross-sectional dimension of the transport disc and the length of the defect along with number of teeth in the disc which can be used for prosthetic rehabilitation as well as to monitor the movement of transport disc during the distraction. It is essential to decide if the condyle should be retained or disarticulated to incorporate the condylar component in the device. It is advisable to retain the condyle when possible so as to maintain the natural joint architecture (Table 87.2 and Figs. 87.5, 87.6, 87.7, 87.8, 87.9 and 87.10).

87.6 Biomechanical and Vector Consideration in Mandible and Selection of Device

The success of distraction osteogenesis is based on biological and biomechanical factors. The biological factors are the length and geometric shape of the defect (straight unilateral posterior/curved across midline), cross-sectional area, and



©Association of Oral and Maxillofacial Surgeons of India
Fig. 87.4 (a, b) Stress realized by transport segment in bifocal and trifocal distraction

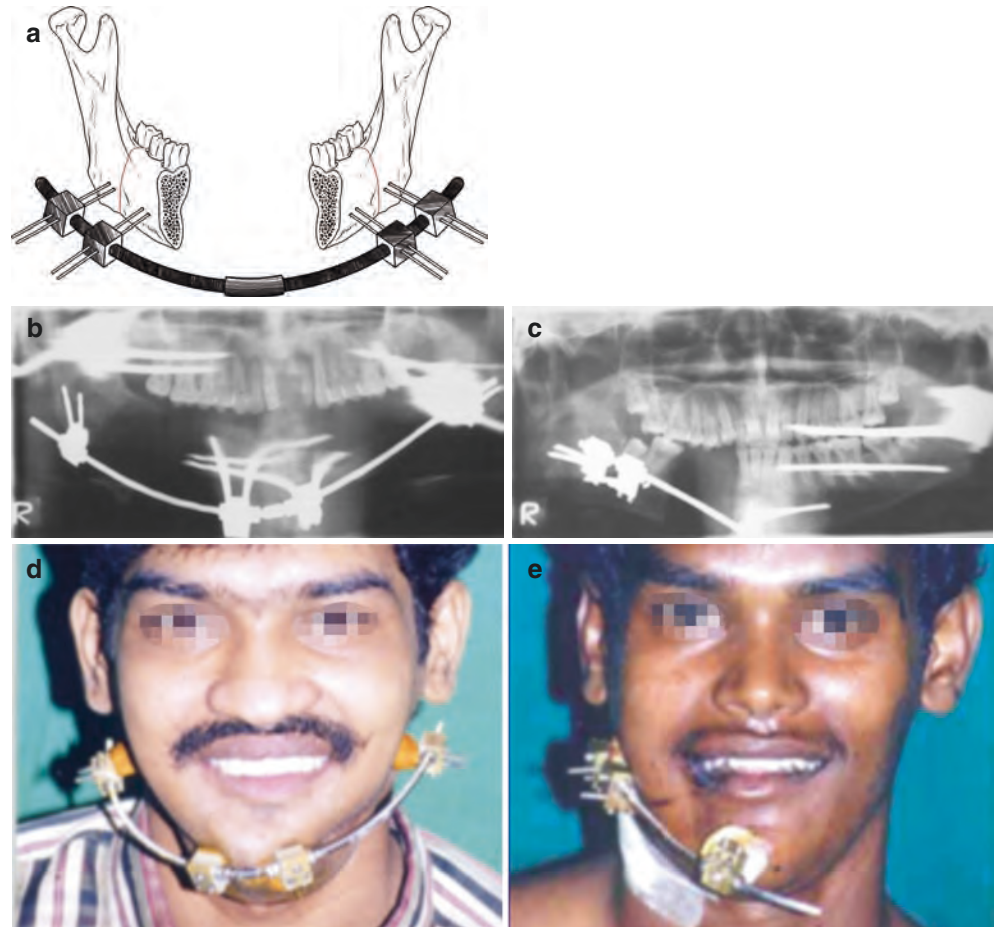
Table 87.2 Generations of transport distraction devices, its merits, and demerits

DO device	Design	Merits	Demerits
1st generation extraoral device (Fig. 87.5a, b, c, d, e)	A single guidance rod with a single anchorage fixator on either side of the cut ends of residual host bone without a reconstruction plate to stabilize the cut ends of the mandible		Unstable residual host bone with inadequate control of the transport segment producing sagittal deviations Pin tract scarring
2nd generation (Fig. 87.6a, b, c)	Reinforced with an additional guidance rod, and the device is anchored to the residual host bone of either side with double anchorage fixators The cut ends of the bone are stabilized with a reconstruction plate	Better control of the transport disc and improved anchorage Reduced incidence of sagittal deviation	
3rd generation cantilever distractor (Fig. 87.7a, b)	Used when there is no proximal bone available for fixing the anchorage fixator All the anchorage fixators are anchored to the available bone, proximal to the transport segment	Used when there is no proximal bone available	
4th generation internal distractor (Fig. 87.8a, b, c)	A straight device- and plate-guided internal distractor with 1 mm calibrated guidance rod with a transport device, attached directly to the reconstruction plate	Better vector control owing Better patient compliance No pin tract scar	Can be used only for straight regeneration
5th generation (Fig. 87.9a, b, c)	An arched device consisting of a reconstruction plate bent according to the contours of the defect and is tissue buried to which a 1 mm calibrated arched guidance rod is attached with a connecting vertical arm	Completely placed intraorally Can be used to regenerate bone across the midline for central defects	
6th generation push ball device (Fig. 87.10a, b)	Push ball device consists of a C-shaped cross-sectional hollow guidance rod with the transport device transfixed to the underlying transport segment that is moved through a series of metal balls within the guidance rod activated through a portal at the free end of the rod	It can be used for both straight and curved defect	Over-riding and clogging of the metal balls can happen

density of the transport disc and tension of the soft tissue envelope. The biomechanical factors are dependent on the length and geometric shape of the defect that dictates the selection of straight or curved device.

Every vector is a one-dimensional entity, whereas the desired movements are in most cases two- or three-dimensional. The base of the mandible is constituted by five linear vectors (Fig. 87.11). Two A-P linear vector running

Fig. 87.5 (a) first generation extraoral device. (b, c) Panoramic radiographs showing the placed first generation distractor device. (d, e) Clinical pictures with the first generation device



©Association of Oral and Maxillofacial Surgeons of India

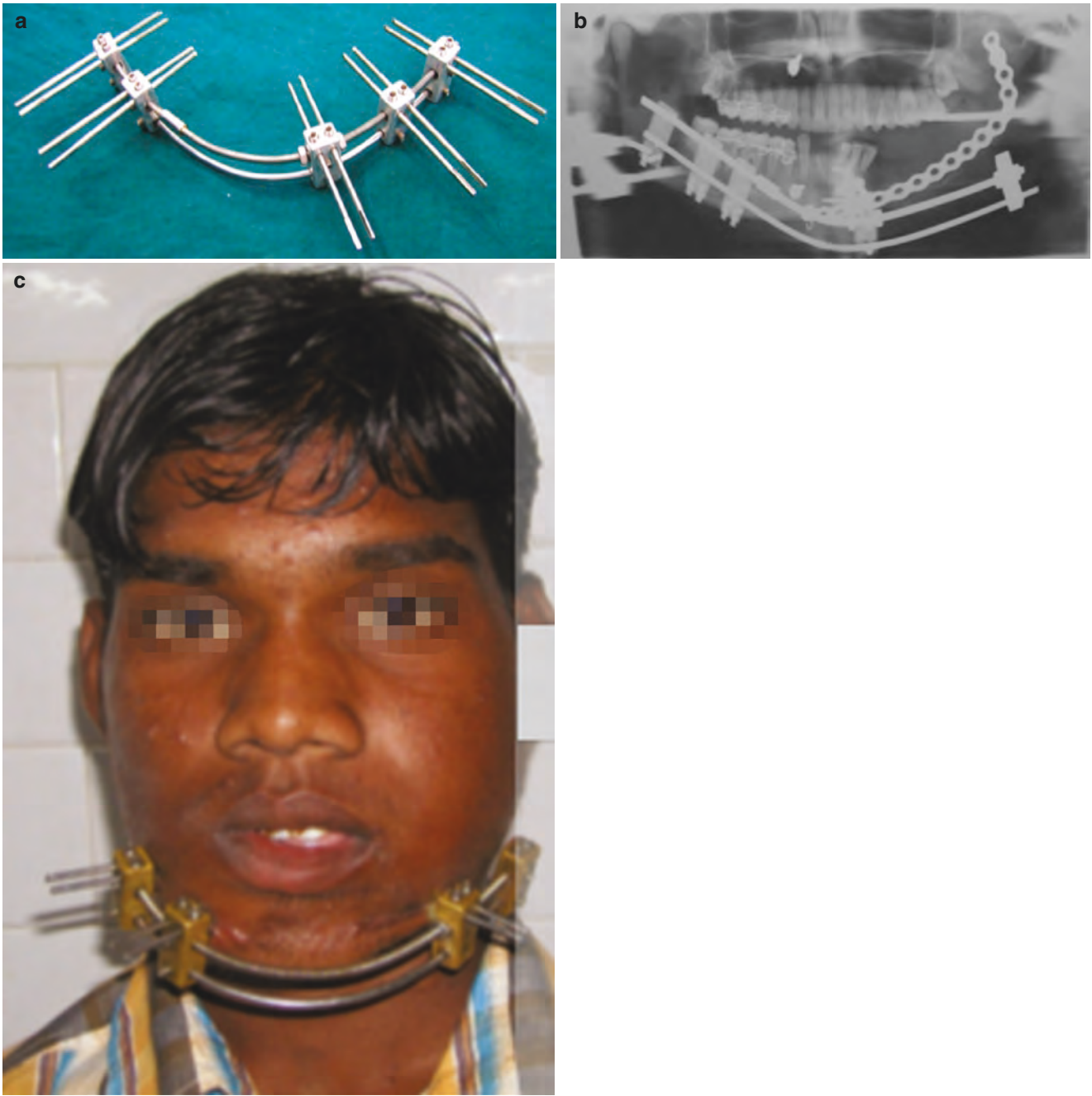parallel to the base of the mandible one on either side in the body region, two A-P linear vector running parallel to the base of the mandible in the parasymphysis region, and one horizontal linear vector running again parallel to the base of the mandible in the mid symphyseal region. If the defect is along a single vector, it is best reconstructed with straight regeneration, and if the defect is along more than single vector, it is best reconstructed with arched regeneration.

With the advent of various generations of devices for distraction osteogenesis, it is the author's contention that the straight tissue buried distraction device is preferred for unilateral defects, whereas, for bilateral defects crossing the midline, extraoral transcutaneous pin fixation device, either bifocal or trifocal is preferred, as it provides better vector control.

87.7 Classification of Mandibular Defects in TDO

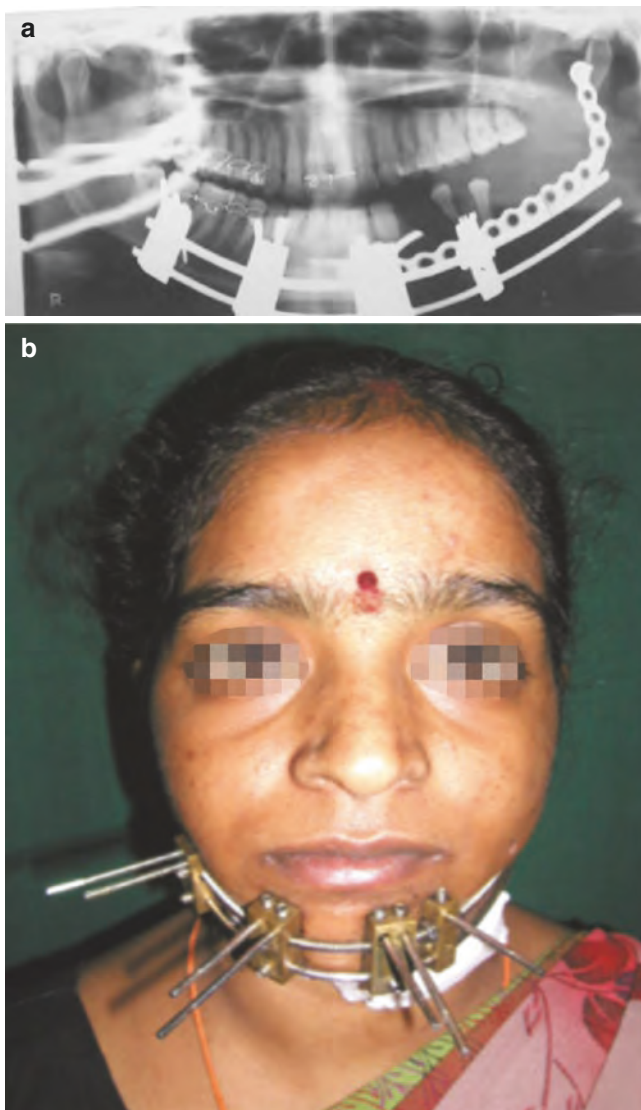
Mandibular defects for reconstruction purpose are classified as central and lateral defects. Central defects can be either symmetrical or asymmetrical, and lateral defects can be either straight, when the defect is posterior to the second premolar and arched when the defect is from anterior to second premolar (Fig. 87.12a, b).

For reconstruction of central defects, when there is a symmetrical central defect, arched regeneration could be contemplated trifocally with identical transport segment from either side and when there is an asymmetrical central defect arched regeneration could be contemplated quadrifocally with nonidentical transport segments (Fig. 87.13).



©Association of Oral and Maxillofacial Surgeons of India

Fig. 87.6 (a) second generation transport distraction device. (b) Panoramic radiograph showing placement of second generation device with a reconstruction plate. (c) Clinical picture showing second generation device



©Association of Oral and Maxillofacial Surgeons of India

Fig. 87.7 (a) Frontal profile view of patient with placement of third generation distractor device. (b) Panoramic radiograph showing the presence of third generation distractor device

When it comes to reconstruction of lateral defects, a single-vector defect posterior to the second premolar could be regenerated bifocally, and a two-vector defect anterior to canine could be regenerated either bifocally or trifocally depending upon the availability of horizontal ramus to create transport disc (Fig. 87.14a, b).

The choice of the transport distraction device is dependent upon the site of defect. For defects posterior to second premolar, a straight bar device with or without condylar prosthesis could be used and for defects anterior to first pre-

molar an arched bar device across the midline could be used. However, a curvilinear push ball device could be used for both the types of defects.

87.8 Indications of TDO

Transport regeneration is indicated when there is a continuity defect of mandible due to any cause. It is indicated not only as a primary modality of reconstruction following tumor ablative surgery or bone loss due to trauma but also as a secondary modality of reconstruction whenever there is failure with previous reconstruction. It can also be carried out on pediatric patients and even on irradiated patients.

However, it has a limitation when there are no horizontal rami available on either side to create transport segment. Even in such situation, bone grafting and subsequent transportation can be contemplated.

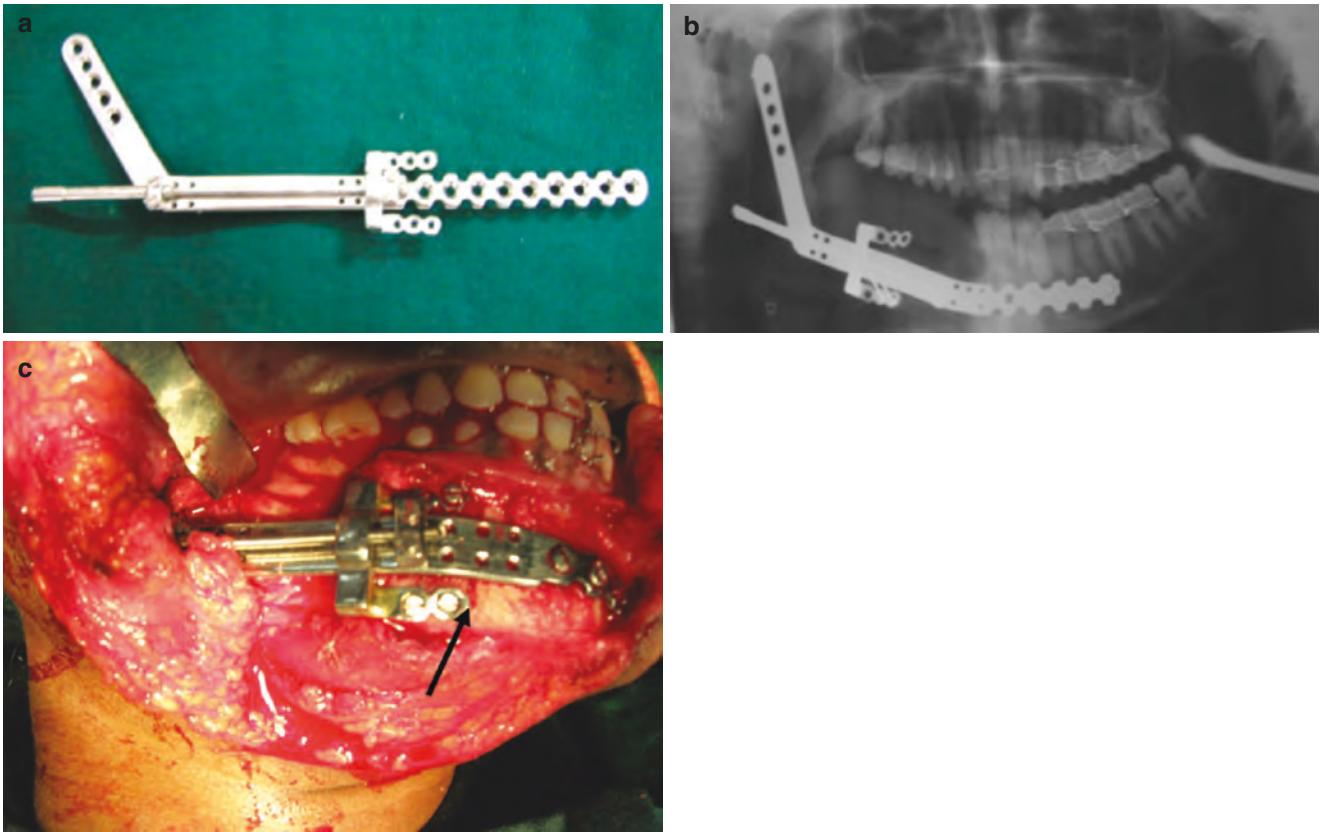
87.9 Presurgical Investigations

When it comes to investigations, panoramic radiograph and CT will help us to know the exact extension of the lesion and thereby to assume the type of defect we are dealing with. This helps in selection of device.

Stereolithographic 3D models help us in contouring the device exactly along the defect presurgically. This helps in minimizing the working time on the table (Fig. 87.15a, b, c, d).

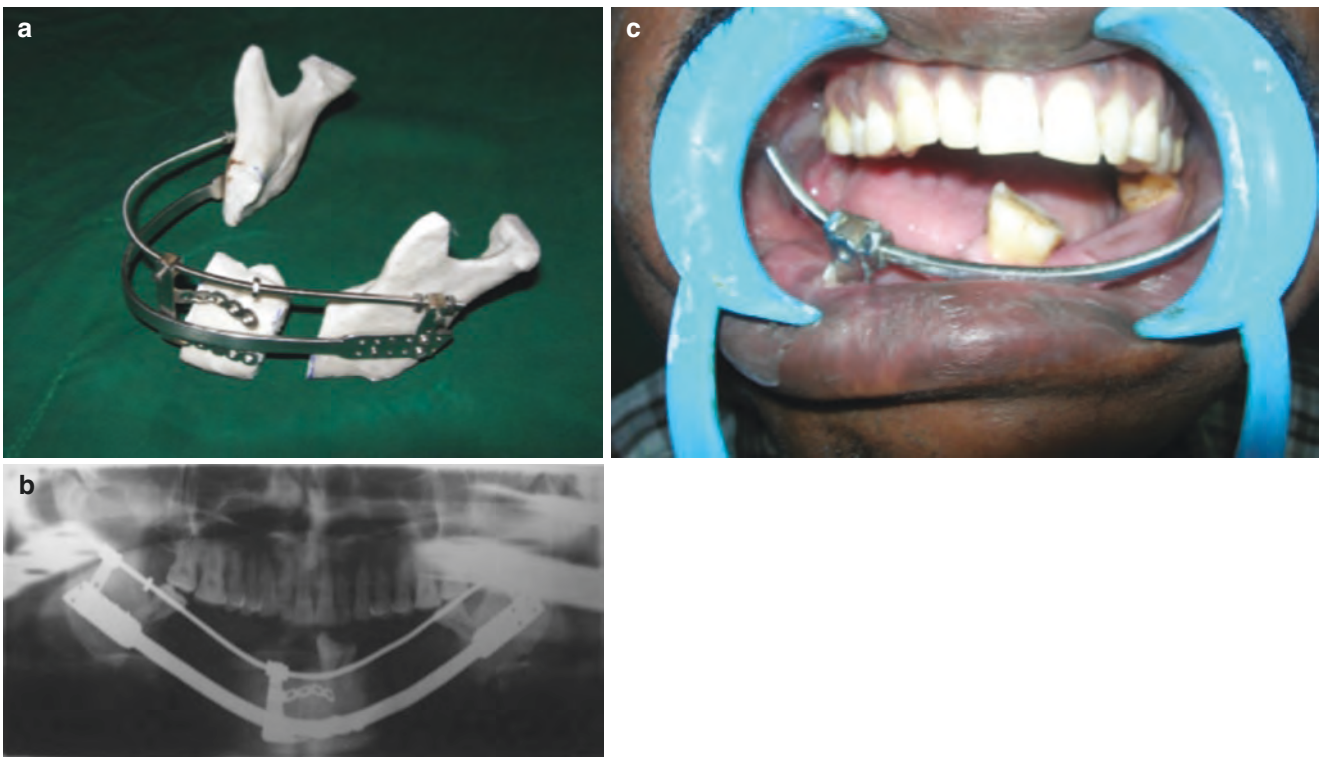
87.10 Surgical Procedure

Transport distraction involves creating a transport disc in the residual host bone stump, adjacent to a discontinuity defect or a resection site. The transport disc is then advanced 1.0 mm per day to span the discontinuity defect. As this transport disc advances toward the target host bone segment, callus forms at its trailing edge, which gradually matures and calcifies. Once the transport disc reaches the docking site, the segment is held in neutral fixation until a cortical outline is seen in the regenerate. At the time of distractor removal, a small bone graft may need to be positioned between the transport disc and the docking site because the transport disc becomes rounded and encased with a fibrocartilaginous cap on the advancing front. Osseous union between the disc and docking site necessitates removal of this intervening fibrocartilaginous cap.



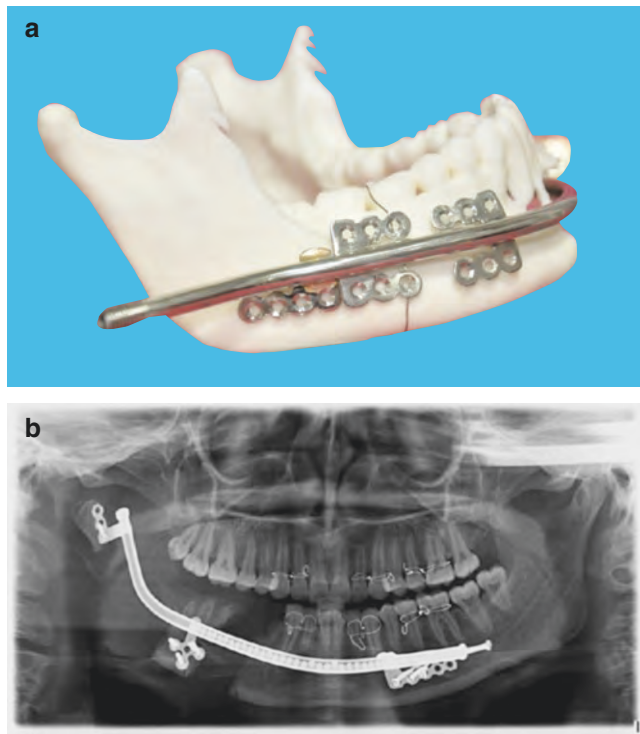
©Association of Oral and Maxillofacial Surgeons of India

Fig. 87.8 (a) fourth generation distractor device with an attached reconstruction plate. (b) Panoramic view showing presence of fourth generation device without a condylar component. (c) Placement of the device in the mandible after a lip split incision



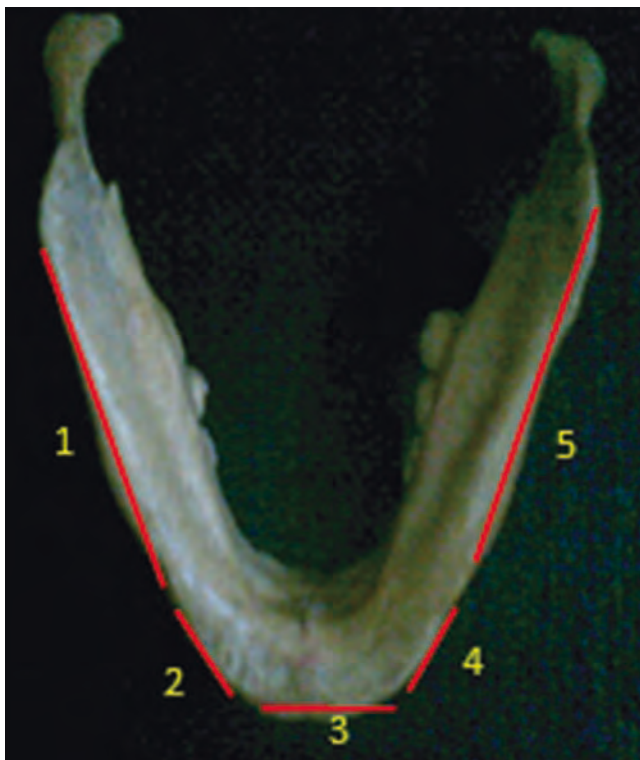
©Association of Oral and Maxillofacial Surgeons of India

Fig. 87.9 (a) fifth generation arc-shaped device, adapted on STL model. (b) Panoramic radiograph showing the placement of fifth generation device. (c) Clinical picture of fifth generation device



©Association of Oral and Maxillofacial Surgeons of India

Fig. 87.10 (a, b) Curvilinear ball device for straight and arched regeneration



©Association of Oral and Maxillofacial Surgeons of India

Fig. 87.11 Linear vectors in mandibular reconstruction

87.11 Biological Consideration While Designing Transport Disc

Periosteal preservation is the single most important biologic consideration while designing bone transport, for the transport segment solely depends on periosteal blood supply for its viability. Hence extreme care at every stage—right from making a small incision to minimal periosteal reflection to abundant irrigation and water tight mucosal closure over the transport segment—should be ensured.

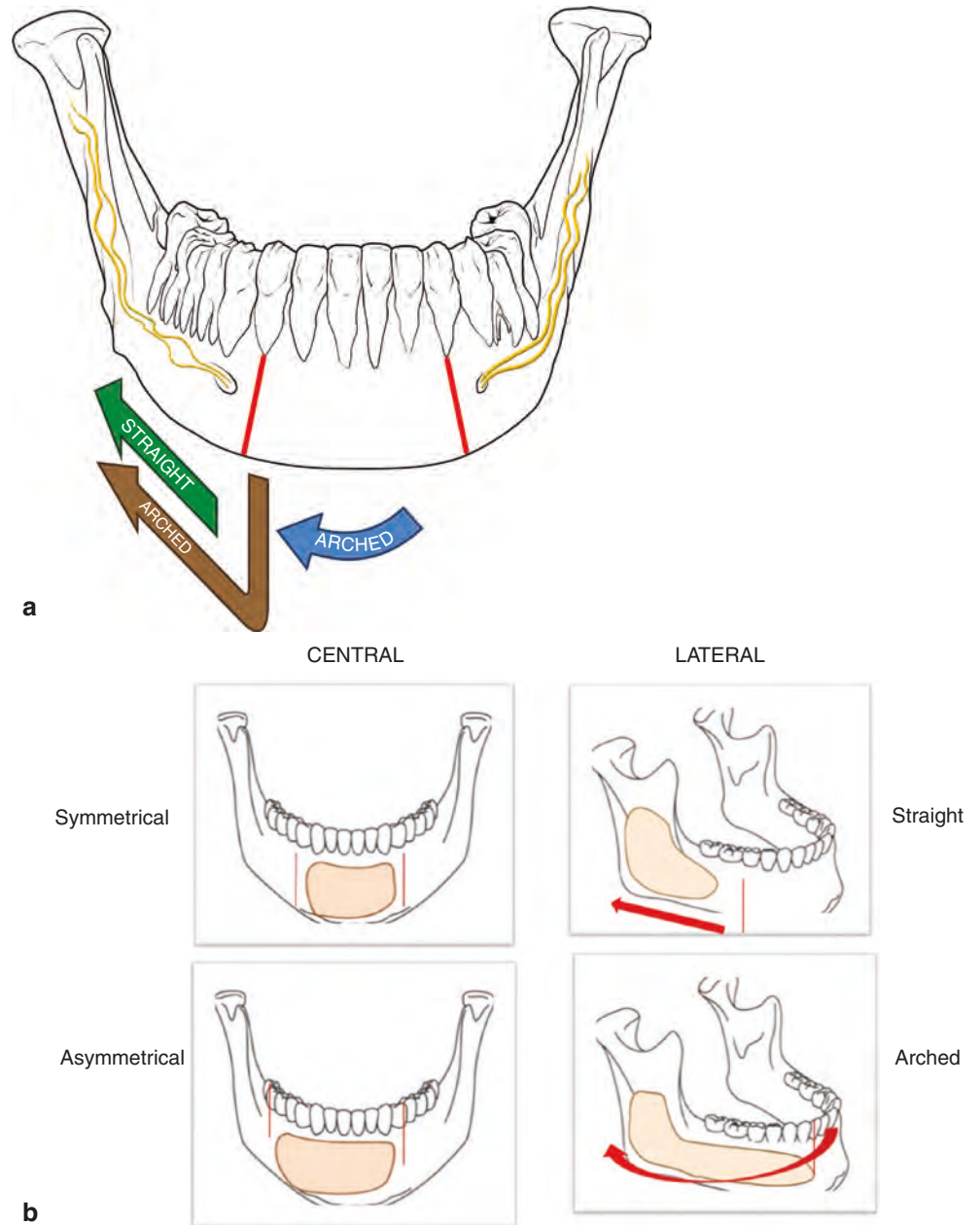
While designing the transport segment, parallelism of the cut edges of the residual host bone segment, transport segment, and target bone segment should be ensured to achieve even docking of the transport disc to the cut edges of residual target bone segment. This is carried out by taking the vertical osteotomy cut perpendicular to an imaginary baseline that runs between gonion and menton and parallel to maxillary occlusal plane (Fig. 87.16a–e) followed by implant rehabilitation (Figs. 87.17 and 87.18).

87.12 Vascular, Clinical, Radiological, and Histological Features of the Regenerated Bone

The process of TDO induces tensile stretching of the osteoblast-like cells that alters the local regulation of bone formation and increases the expression of the growth factors. This entire process is vascular-dependent and requires the maintenance of an adequate blood supply. DeCoster et al. in their animal experimental model on transport distraction osteogenesis used injection angiography to study the arterial response of the bone undergoing transport distraction. The angiographic techniques revealed that the transport segment had an intact arterial supply after the osteotomy cut was completed (adhering to surgical principles of TDO) and, also, after transport distraction was activated. They also showed an extensive increase in vessels in distracted limbs of the experimental animals with proximal stretching and distal kinking of the major artery in that limb. Such studies involving major facial vessels during TDO are awaited to be added to maxillofacial literature [2]. Formation of callus can be detected earliest with ultrasonography where it appears as a mixed to hyper echoic area depending upon the degree of maturation. The color Doppler study of the callus demonstrates the quantum of vascularity in the regenerate before maturation [1, 2] (Fig. 87.19).

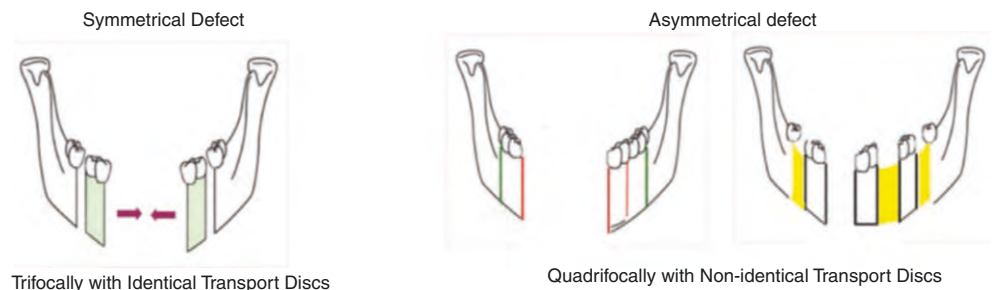
For radiological examination (Figs. 87.20 and 87.21) regular plain film radiographs remain the mainstay for screening the TDO during active distraction and consolidation period. Panoramic radiograph, submento-vertex view, lateral oblique mandibular projections, and posteroanterior and lateral skull views may all aid in planning and screening the

Fig. 87.12 (a) Defect posterior to second premolar, straight vector; defect anterior to second premolar, arched vector. (b) Classification of mandibular defects



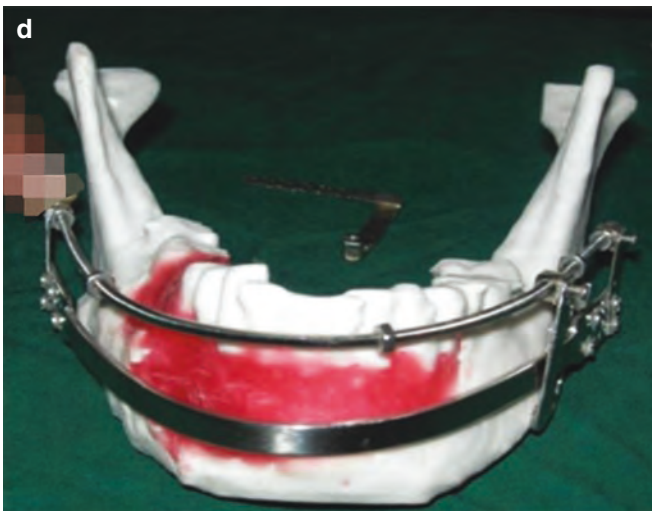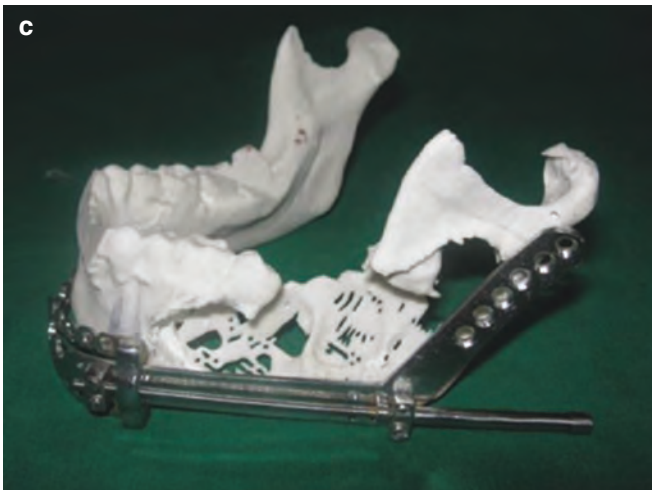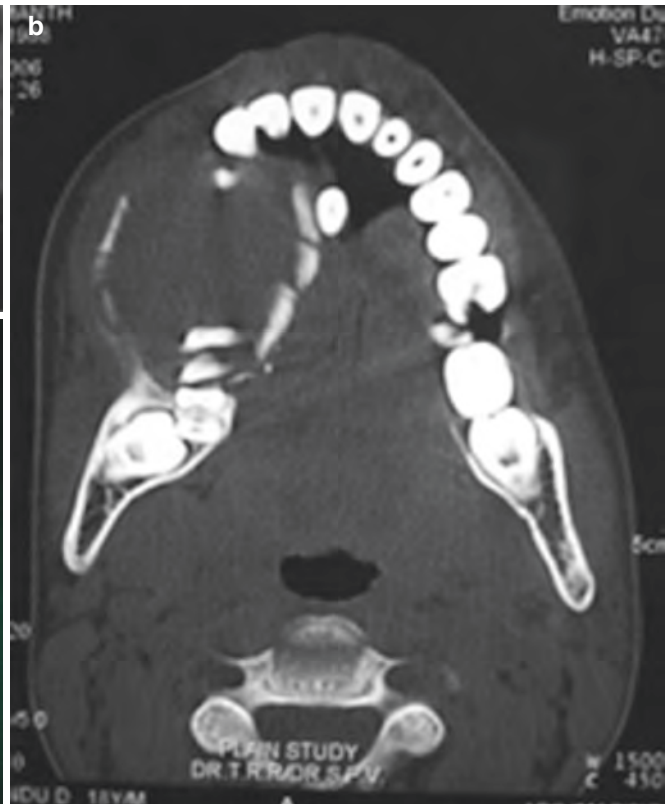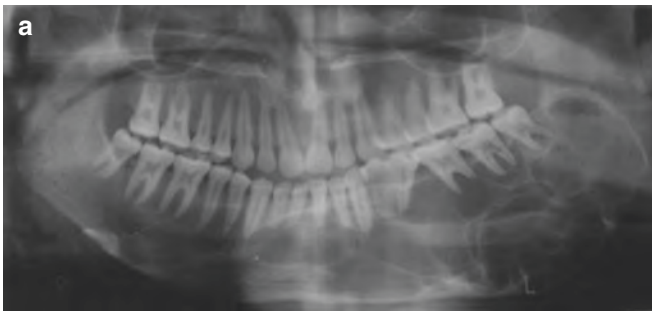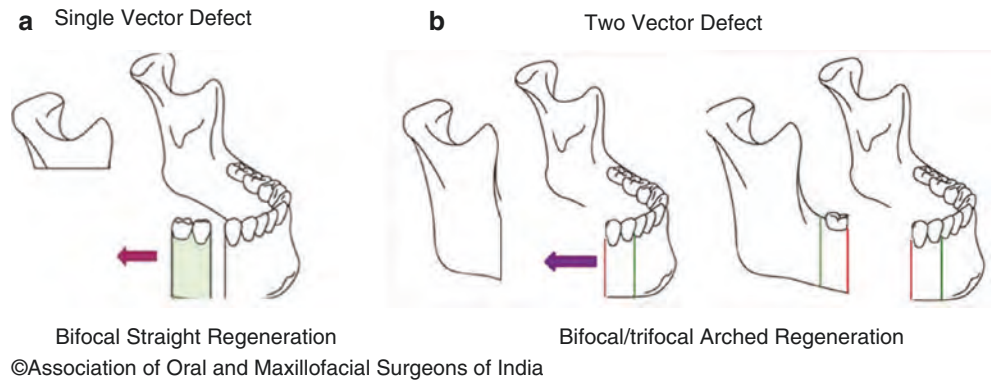
©Association of Oral and Maxillofacial Surgeons of India

Fig. 87.13 Reconstruction of central defects



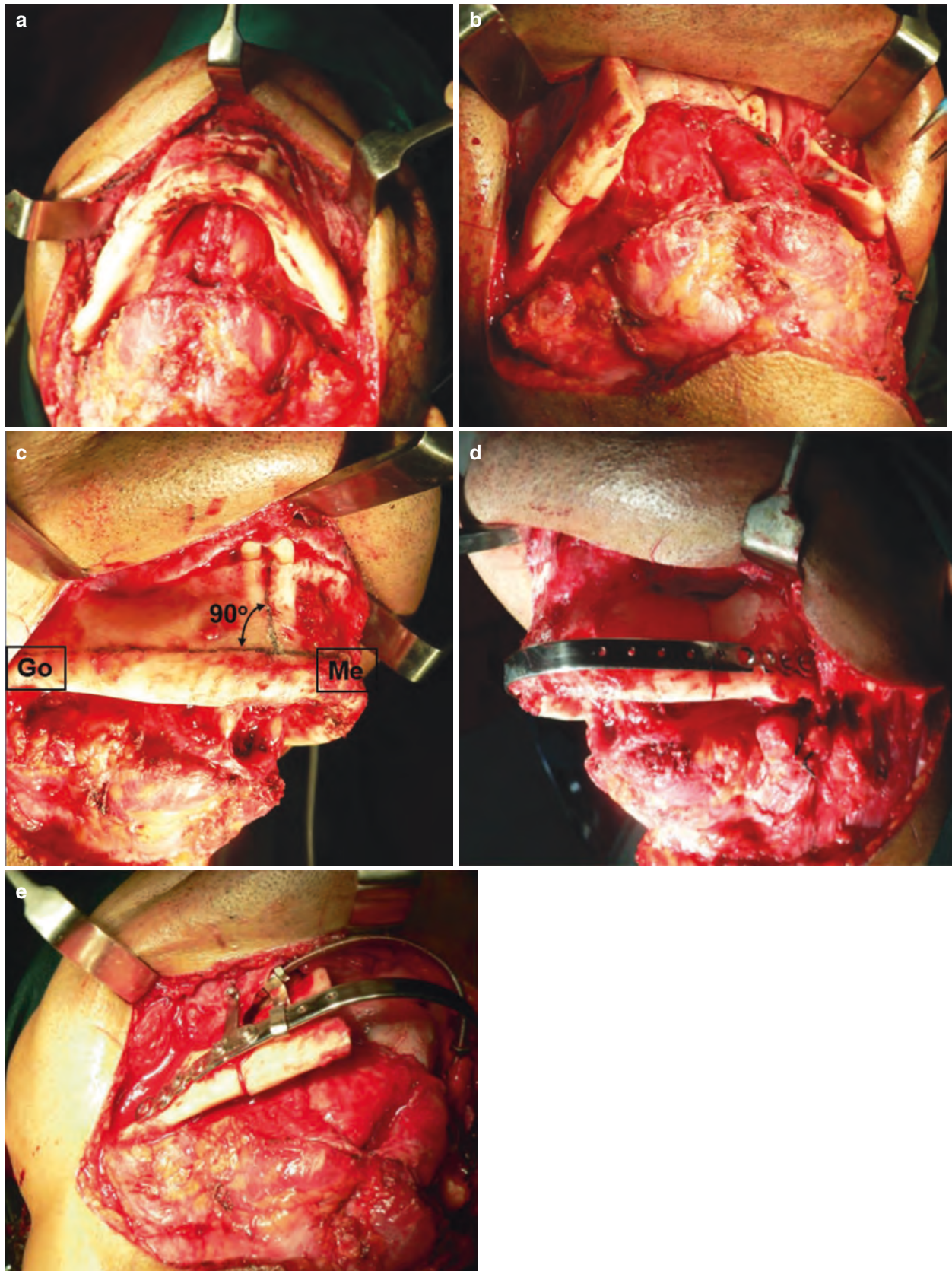
Trifocally with Identical Transport Discs
 Quadrifocally with Non-identical Transport Discs
 ©Association of Oral and Maxillofacial Surgeons of India

Fig. 87.14 (a, b) Reconstruction of lateral defects



©Association of Oral and Maxillofacial Surgeons of India

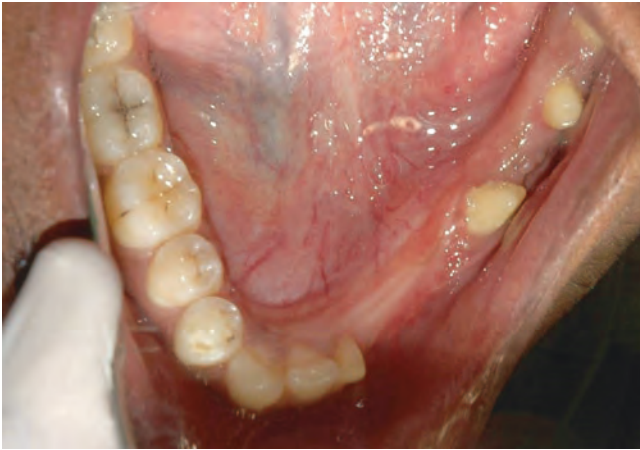Fig. 87.15 (a, b, c, d) Presurgical planning



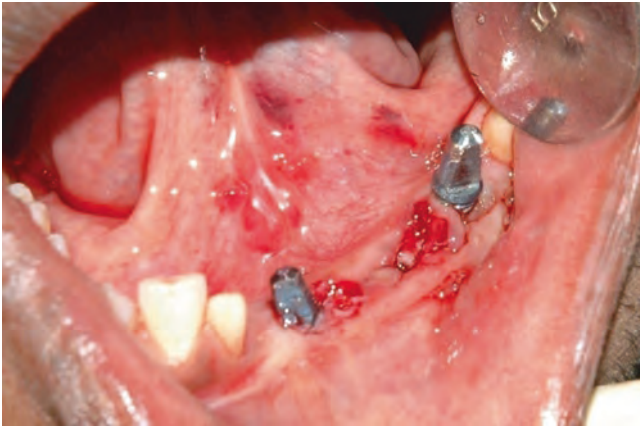©Association of Oral and Maxillofacial Surgeons of India

Fig. 87.16 (a) Incision extending bilaterally to expose the entire mandible inferiorly after layered dissection. (b) The lesion resected with clear margins of the preserved bone. The osteotomy should be kept par-

allel and free from the lesion. (c) Osteotomy cut perpendicular to an imaginary baseline that runs between Go and Me and parallel to maxillary occlusal plane. (d, e) Placement of fifth generation distractor



©Association of Oral and Maxillofacial Surgeons of India

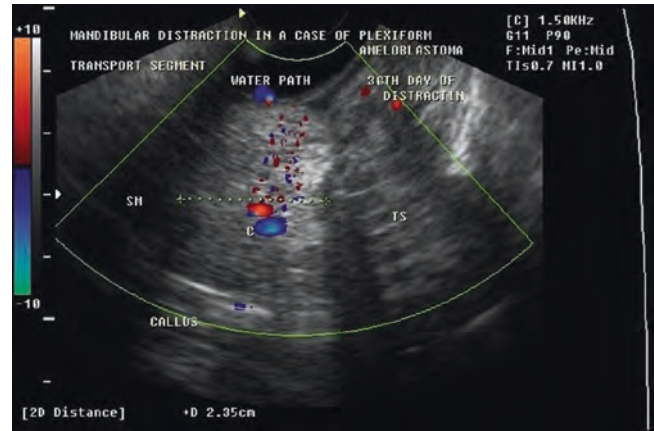
Fig. 87.17 Clinical appearance of regenerate of patient from Fig. 87.16

©Association of Oral and Maxillofacial Surgeons of India

Fig. 87.18 Implants placed on the regenerated bone after 1 year of the same patient from Fig. 87.16

TDO. These radiographs have their limitation of 2D view of the multivectorial 3D procedure.

Multi-slice-computed tomographic scans provide a better preview but have the limitation of excessive radiation exposure and scatter due to the distraction device when it is in situ. Elsalanty et al. have extensively experimented on cone-beam CT densitometry and three-dimensional histomorphometry in mandibular bone defects reconstructed with bone transport and found that the physical dimensions and architectural parameters of the new bone regenerated remain comparable to the contralateral normal bone in TDO [3]. In their study, the radiographic density comparison was done



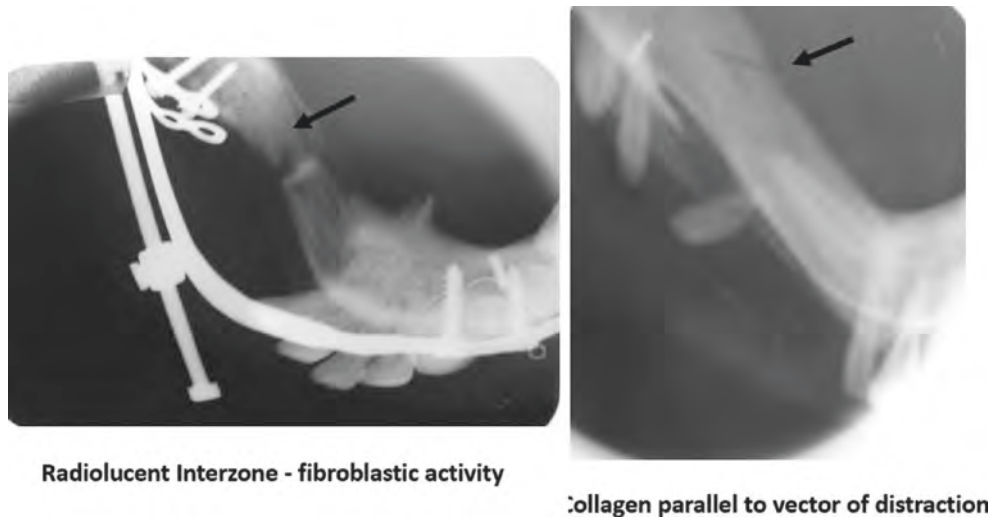
©Association of Oral and Maxillofacial Surgeons of India

Fig. 87.19 Ultrasound appearance of regenerate

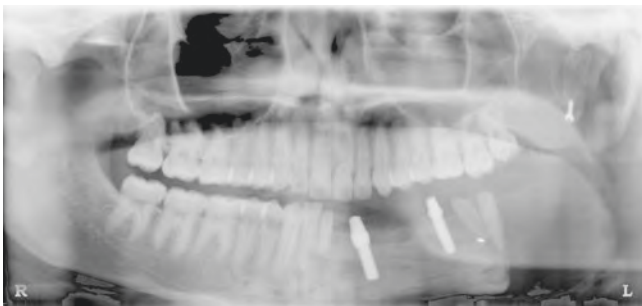
by studying the radiographic attenuation of the regenerate measuring in Hounsfield units (HU) and comparing it to the outer, inner, and inferior cortices of the bone on opposite side of the mandible (normal bone). Their results showed that the density of the distraction regenerate was comparable to the inner and outer cortices of the control bone, whereas the lower border of the control side of the mandible showed higher density than the regenerate at 1 month of consolidation. The Hounsfield unit value of the regenerate by TDO was toward the 2000 mark (2000 HU) after a month of consolidation. Microcomputed tomography-based three-dimensional histomorphometry used to assess percentage of bone volume, bone mineral density, degree of anisotropy, trabecular thickness, trabecular number, trabecular pattern factor, and trabecular separation showed no significant differences between the regenerate and the normal bone after a month of consolidation in all parameters except percent bone volume and the trabecular separation. Percentage bone volume is reported to be significantly less, while trabecular separation is significantly higher in the regenerate (Fig. 87.22a, b).

Garcia et al. studied the histology of the regenerate and docking site in bone transport in the tibial-diaphyseal defect of adult sheep model and concluded that there is a marked difference between the ossification of the docking site and of the regenerate. Intramembranous ossification plays a major role in the regenerate, with bone forming from the host bone segment to the target segment. The ossification of the docking site shows endochondral and intramembranous ossification simultaneously, but the intramembranous ossification is limited to rare and small foci [4].

Fig. 87.20 Radiological appearance of regenerate during active distraction



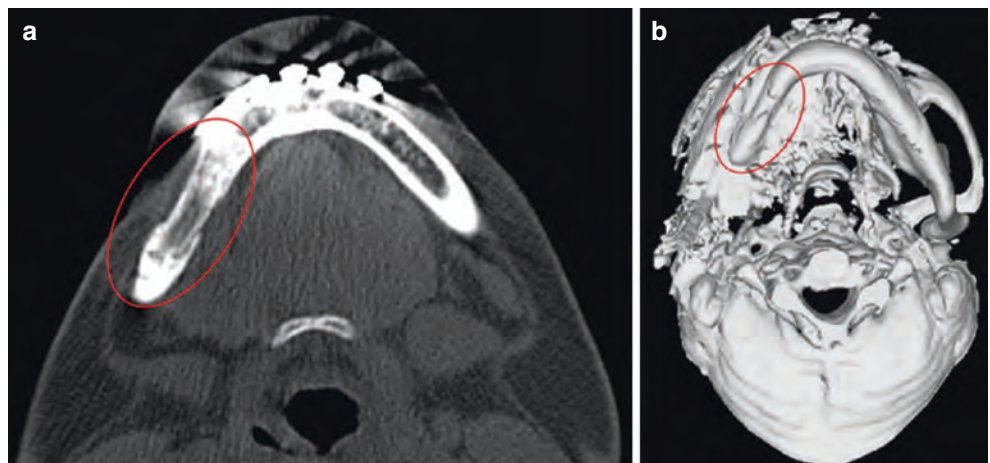
©Association of Oral and Maxillofacial Surgeons of India



©Association of Oral and Maxillofacial Surgeons of India

Fig. 87.21 Osseointegrated dental implants in the regenerated bone

Fig. 87.22 (a, b) CT appearance of regenerate



©Association of Oral and Maxillofacial Surgeons of India

Studies done on the architecture and microstructure of cortical bone regenerated with TDO, it has been found that at 12 weeks of consolidation, bone created during bone transport distraction osteogenesis was comparable to native bone in microstructure, architecture, and mechanical properties, and when appropriate time has lapsed, the properties of the regenerate bone were identical to the host bone.

Çakır-Özkan et al. in their study on immunohistochemical analysis of reconstructed sheep mandibles by transport distraction osteogenesis reported strong positive staining for BMP-2, -4, and TGF- β in the cells, and matrix components. These growth factors are believed to enhance the osteogenesis in TDO [5].

87.13 Transport Distraction Osteogenesis in Maxilla

Ever since the concept of transport distraction on long bone was initiated by Ilizarov and then after it was subsequently introduced on the facial skeleton by Constantino, Fodotov, Wolford, and many others, a lot of articles got published in the world literature affirming the possibility of regenerating quality bone for any length of mandibular defects [6]. It has even become a gold standard in comparison to other modalities of reconstruction. So, the question arises whether transport distraction has a role in maxillary reconstruction. [7, 8]

Cheung et al. were the first to publish their work on reconstruction of a maxillectomy defect using transport DO in animal experimental model [9]. Our contention is that when transport distraction has become an accepted norm in the reconstruction of mandibular continuity defects, maxilla with its multiple vascular perfusion, rich periosteal supply, and increased cancellous bone is

expected to biologically respond even better to the distraction force [10].

Here are a few cases showing our evolution in transport distraction osteogenesis for reconstruction of maxillary defects.

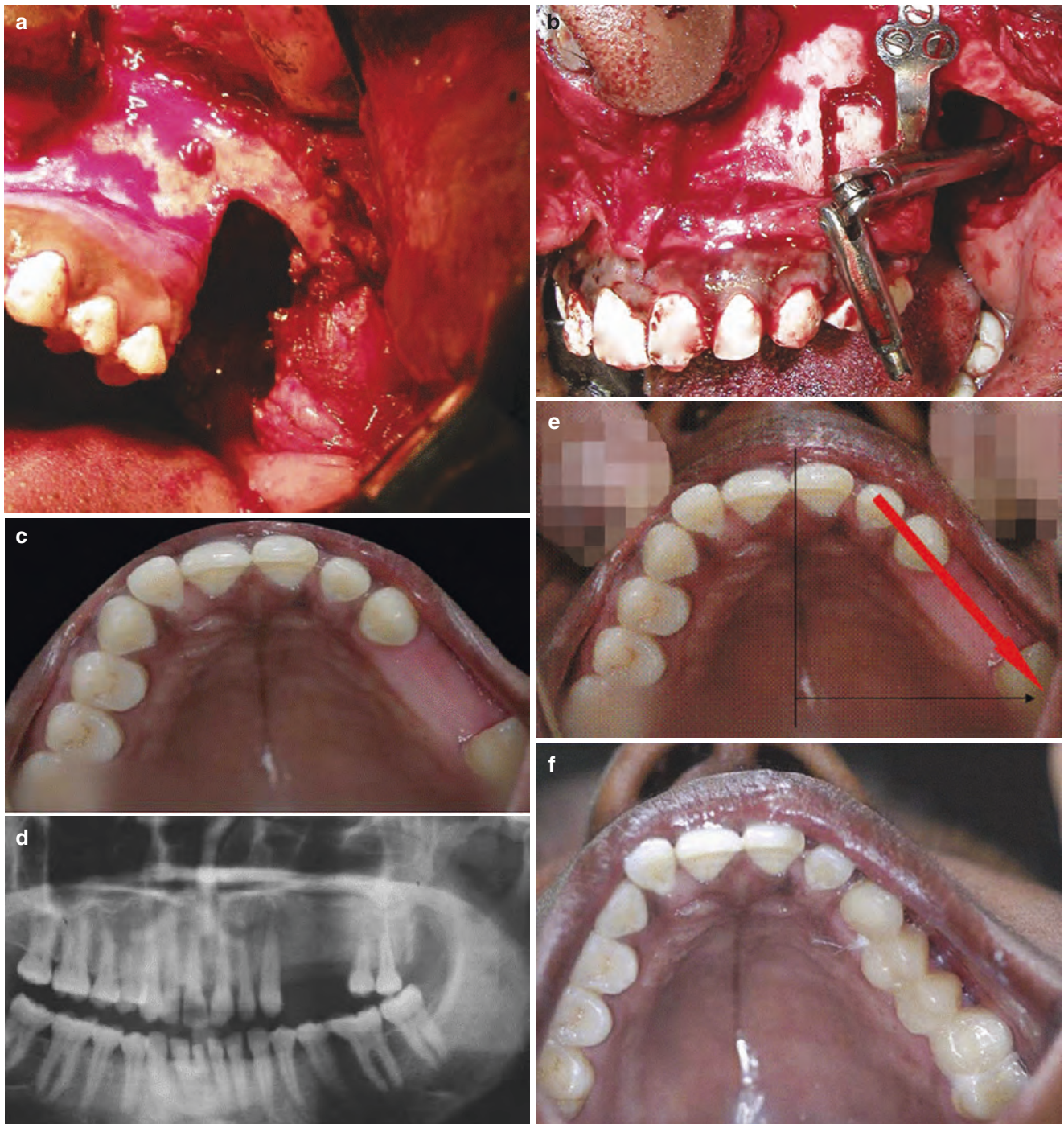
In our maiden clinical attempt at reconstructing a maxillary defect using TDO a straight distraction device was used. The limitation we had with straight bar device was that they were all buccally directed and not conforming to the posterior maxillary arch (Fig. 87.23a, b, c, d, e, f). Subsequently we have successfully employed bifocal transport distraction (Fig. 87.24a, b, c, d, e, f, g, h, i) and trifocal transport distraction (Fig. 87.25a, b, c, d, e, f, g, h) for reconstruction of maxillary defects. Maxillary TDO has also been successful to treat alveolar clefts of maxilla (Fig. 87.26a, b, c, d, e, f, g).

87.14 Advantages of TDO

Though bone transport may not be possible in all situations, when indicated, it has an edge over other modalities for it doesn't require any specialized hands or equipment, it doesn't prolong the duration of surgery and hence is cost-effective. Since no bone grafting is required, there is no donor site morbidity, and there is recreation of alveolar ridge with attached mucosa, buccal, and lingual sulci, all in near normal anatomy. TDO not only regenerates new bone but also every element of soft tissue around it as well. These are summarized in Table 87.2.

87.15 Complications of Bone Transport

The complications with bone transport in regenerating new bone formation can be discussed under biological and mechanical factors.



©Association of Oral and Maxillofacial Surgeons of India

Fig. 87.23 (a) Straight transport distraction device post-resection defect. (b) Transport disc with device. (c, d) Evidence of histogenesis and osteogenesis in the clinical picture and OPG respectively, after con-

solidation phase. (e) Buccal deviation of the regenerate. (f) Rehabilitation with FPD

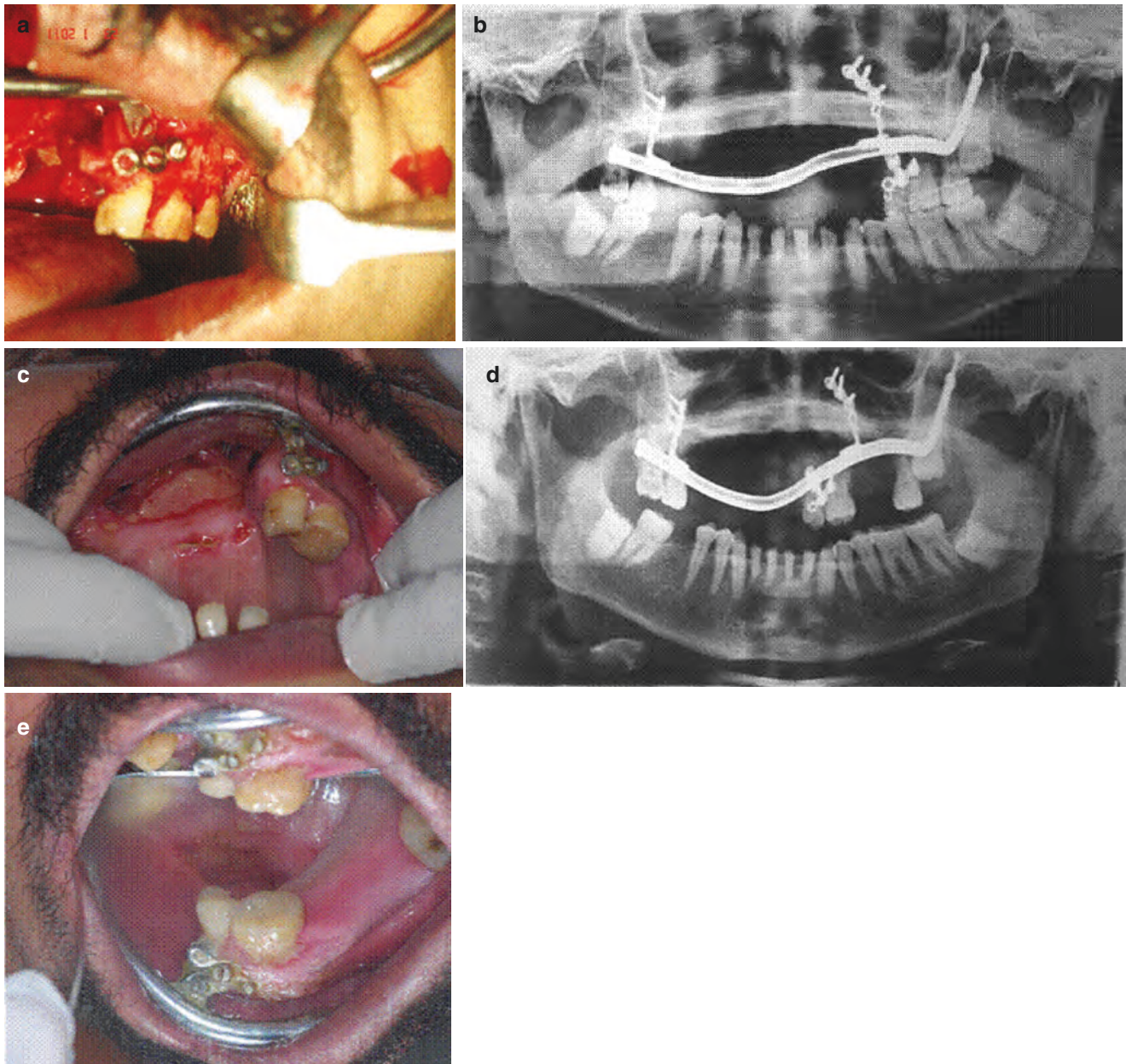
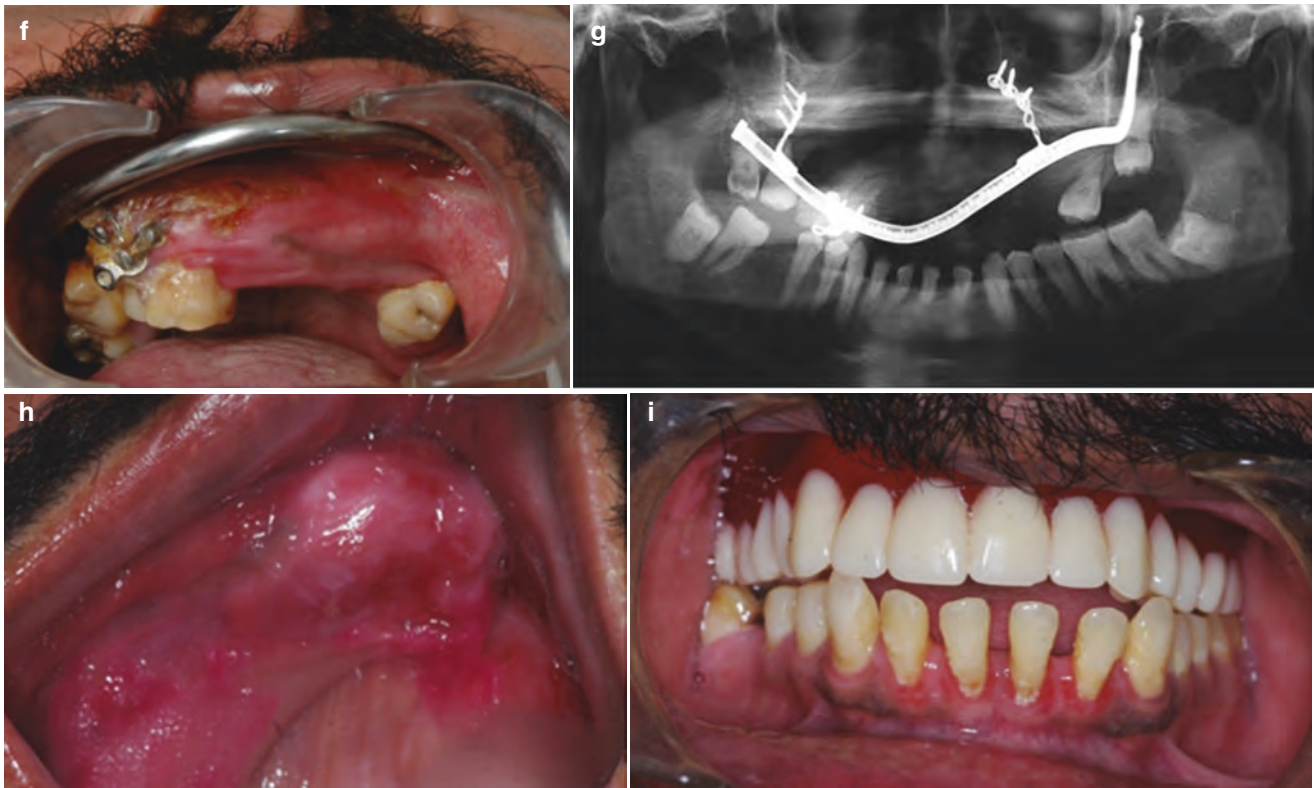


Fig. 87.24 (a) Arched bifocal regeneration with push ball device. (b) Bifocal push ball device in situ—latency period. (c, d) Transport distraction in progress on same side. (e) Transport distraction in progress across midline. (f, g) Transport disc on docking and consolidation. (h, i) Post-consolidation and rehabilitation with complete denture



©Association of Oral and Maxillofacial Surgeons of India

Fig. 87.24 (continued)

The biological factors are the ones which we have very little control over, whereas the mechanical factors of vector control and bodily movement of transport segment across the midline can be successfully carried out by modifying the device (Table 87.3) [11, 12].

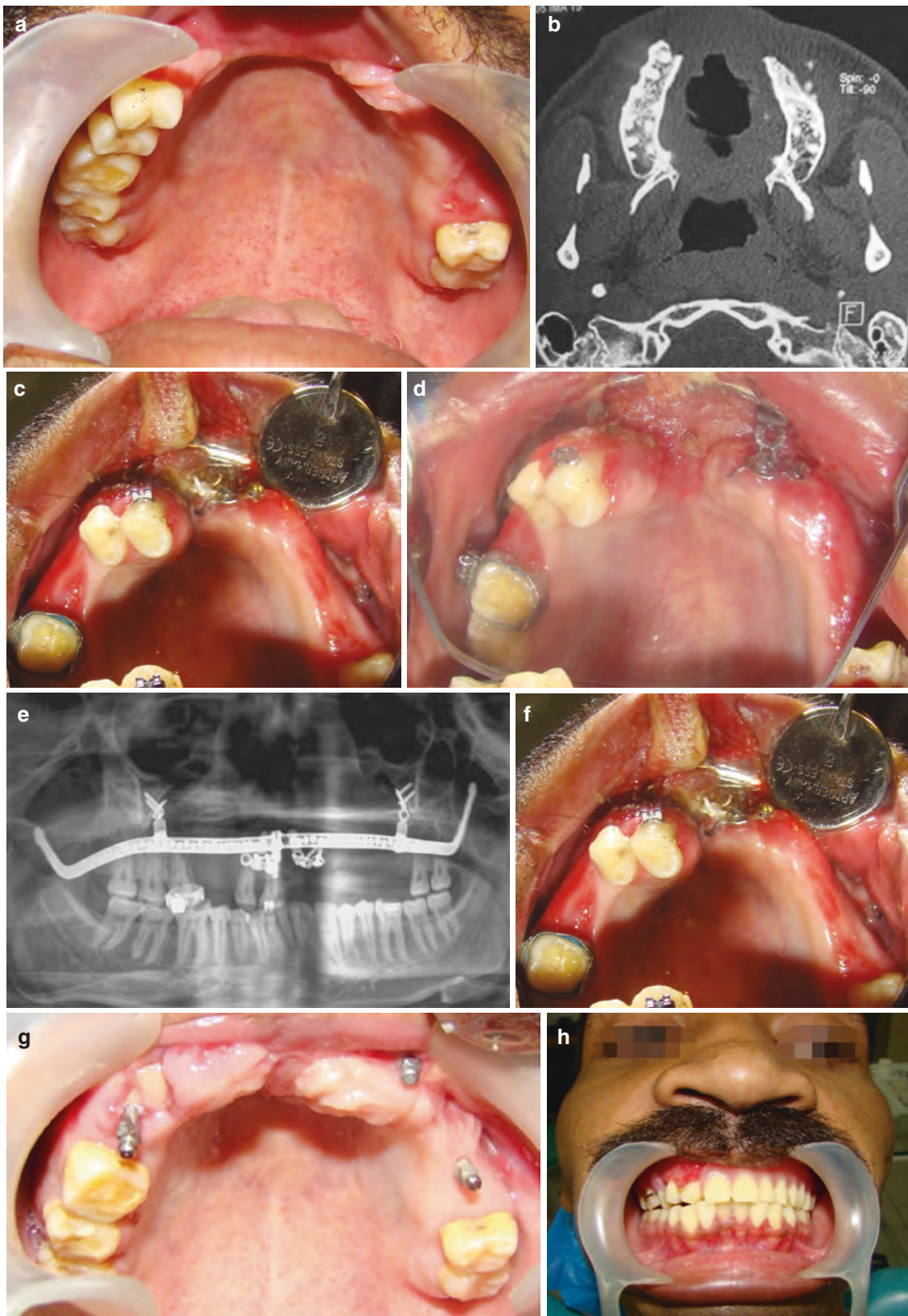
87.15.1 Hypertrophic Regenerate

This occurs when a single transport segment is designed to regenerate a lengthy defect, when the collagen fibers are overstretched with the central portion of the callus narrowing representing an hourglass appearance in

the radiograph (Fig. 87.27). This phenomenon can also occur when the cross-sectional thickness of the transport segment is not adequate to recreate good volume of bone.

87.15.2 Drifting of Teeth

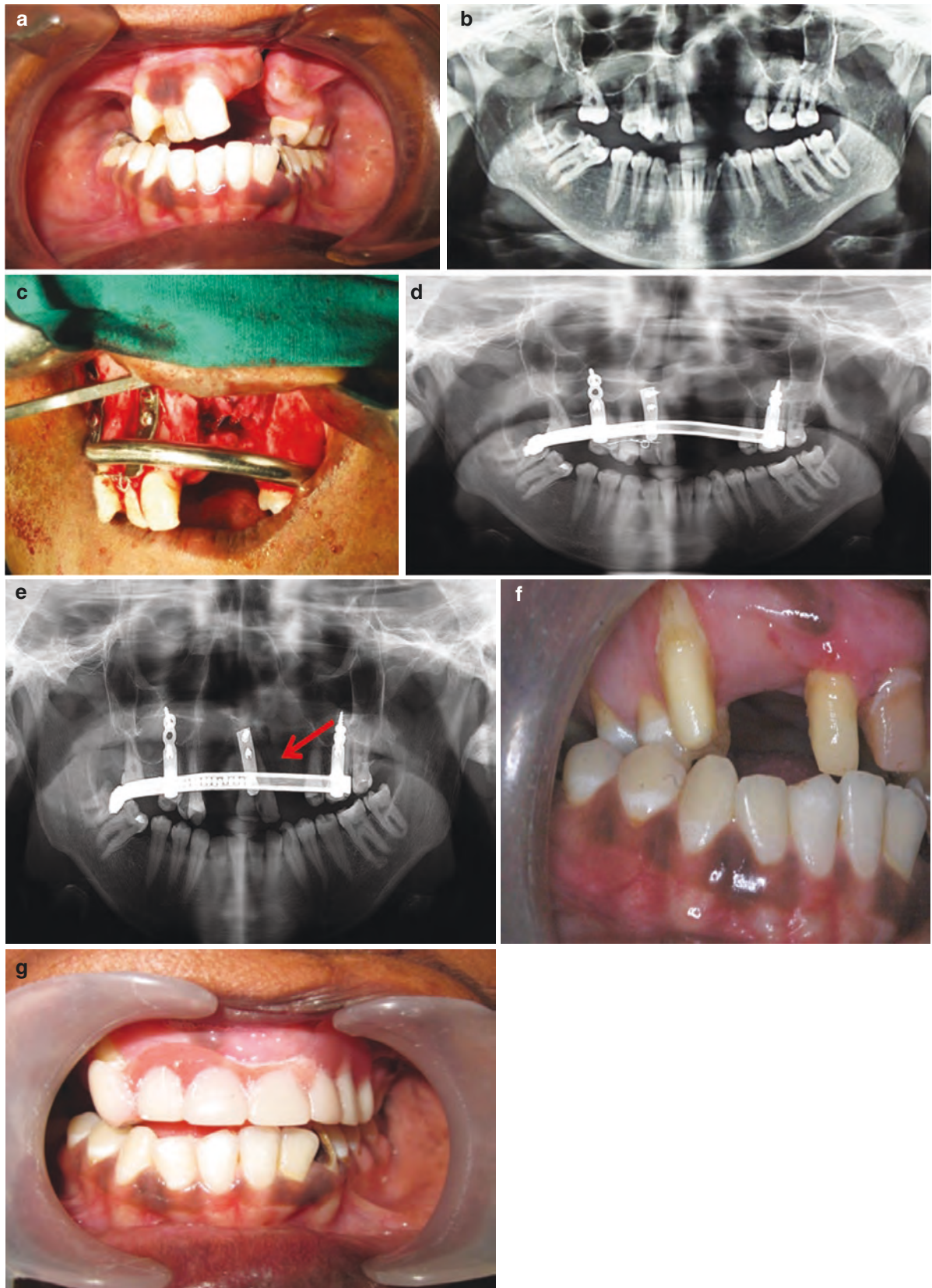
The teeth in the transport segment and RHBS tend to drift as distraction proceeds due to pull of transseptal fibers across the line of osteotomy. This problem could be overcome by applying a figure of eight wire to stabilize the teeth in each segment (Fig. 87.28a, b, c).



©Association of Oral and Maxillofacial Surgeons of India

Fig. 87.25 (a) A case of continuity defect across midline following gunshot injury in a soldier. (b) CT image of case in 25 a. (c, d) Trifocal distraction in progress. (e) OPG view showing the trifocal distraction in

progress. (f) Transport on docking and consolidation. (g, h) Dental rehabilitation using implants post-consolidation



©Association of Oral and Maxillofacial Surgeons of India

Fig. 87.26 (a, b) A case of maxillary cleft alveolus. (c, d) Latency period of 5 days. (e) Docking of the transport disk on eighth post-op day. (f, g) Post-consolidation phase rehabilitation

Table 87.3 Complications of TDO

Biological complications of TDO
<ul style="list-style-type: none"> • Hypotrophic regenerate. • Drifting of teeth. • Relapse. • Straight regeneration across midline.
Mechanical complications of TDO
<ul style="list-style-type: none"> • Misdirected vector. <ul style="list-style-type: none"> – Sagittal deviation. – Coronal deviation. • Midline consolidation.

87.15.3 Relapse

Relapse of the new bone regenerate can occur resulting in contracture of the regenerate that could be avoided either by using an acrylic space maintainer or by placing a fixed partial denture immediately after the intended length of bone regenerate is formed across abutment teeth on either segment. It is a wise practice to retain the teeth in the transport disc for this purpose.

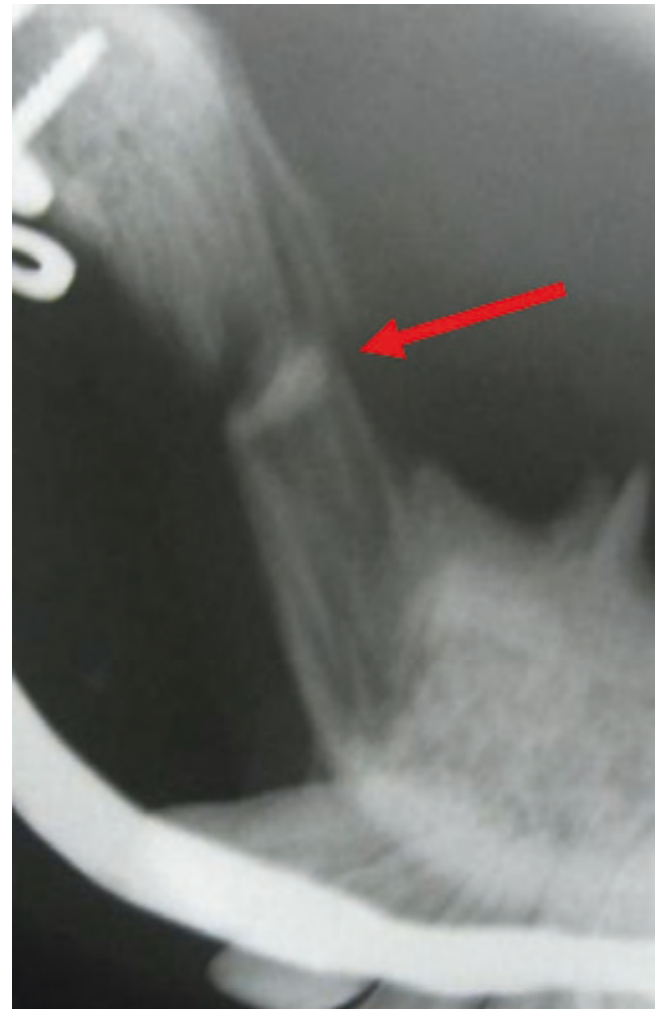87.15.4 Straight Regeneration

Straight regeneration occurs while transporting the disc across the midline because the collagen fibers does not follow arc architecture of the defect in the midline; instead they get stretched in a straight direction, similar to an elastic band (Fig. 87.29a, b).

Misdirected vector in sagittal and coronal plane can occur when the guidance rod is not kept parallel to the occlusal plane. When such misdirection takes place, it can be allowed to proceed in the same vector until the intended length of bone regenerate is achieved, which could be corrected by callus molding before consolidation of the regenerate. The callus is molded by the rate and rhythm of the distraction and plating is done to achieve stability of the device. IMF is done to keep the occlusion intact on the contralateral side (Fig. 87.30a, b, c, d, e, f).

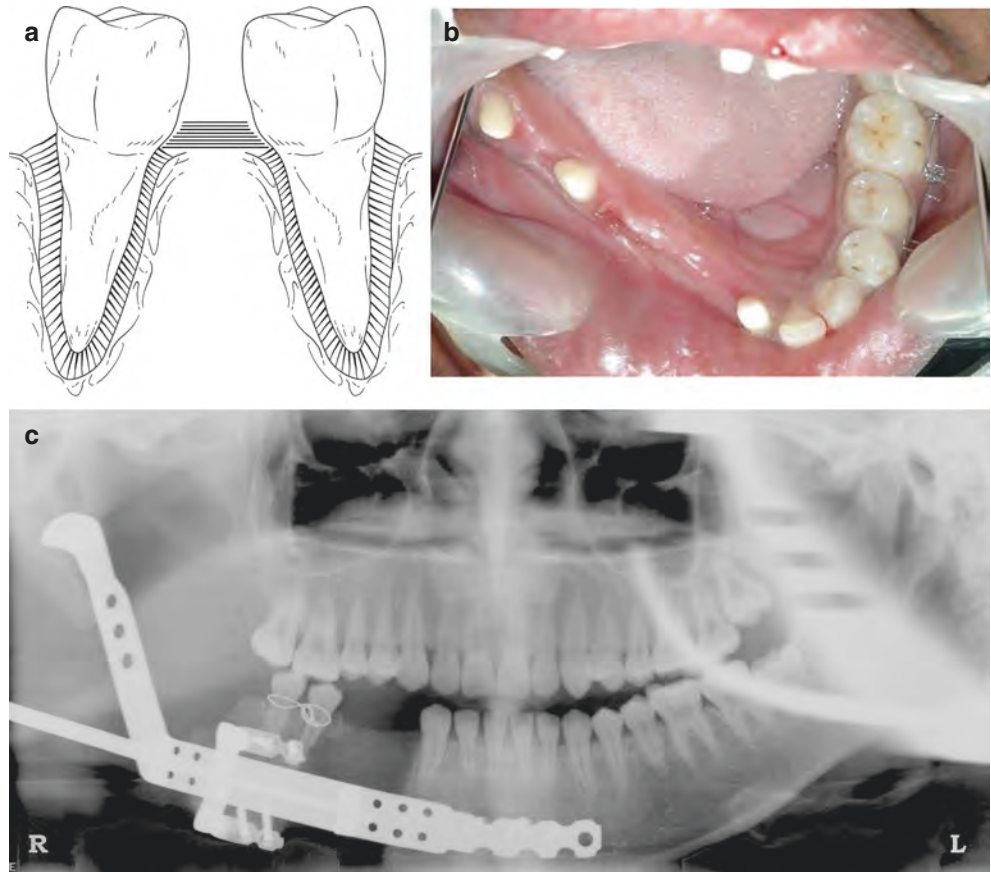
87.15.5 Midline Consolidation

The major limitation that we have with this modality of reconstruction is midline consolidation in both mandible and

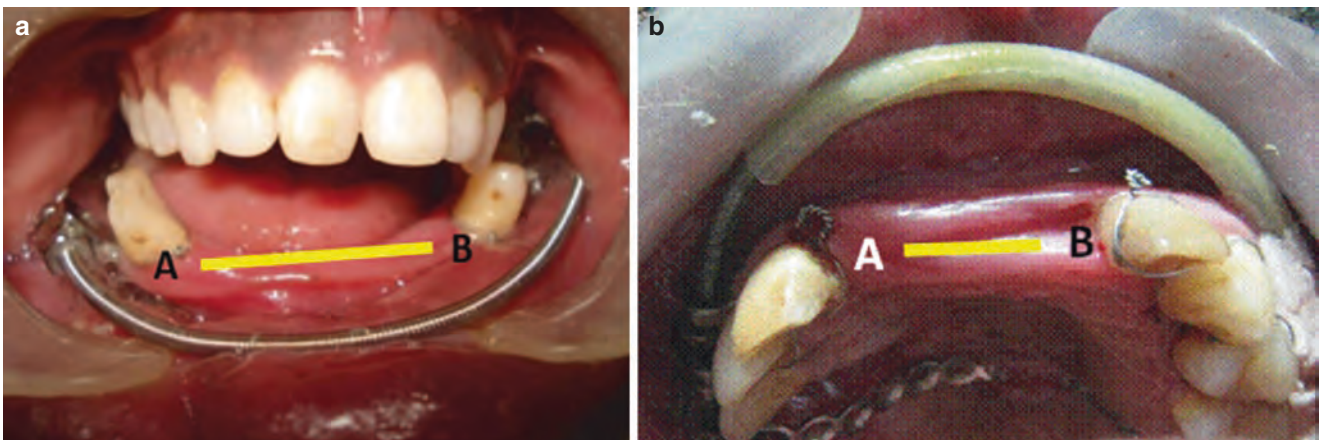
**Fig. 87.27** Hourglass deformity

maxilla with arched regeneration. The transport segment freezes by the time it reaches a point lateral to midline on the opposite side. The concept of midline consolidation is that as the distraction proceeds beyond canine across the midline, the buccal cortex of the transport segment expresses greater movement than the lingual cortex for the same degree of rotation, as with the long and short arm of a clock suggesting lingual cortical tipping movement less than the required 1 mm per day. This results in lingual consolidation. This can be overcome by further re-distracting the transport segment after performing a lingual cortical osteotomy alone (Fig. 87.31a, b, c, d, e).

Fig. 87.28 (a) Pull of the transseptal fibers. (b) Drifting of teeth. (c) Figure 8 wiring

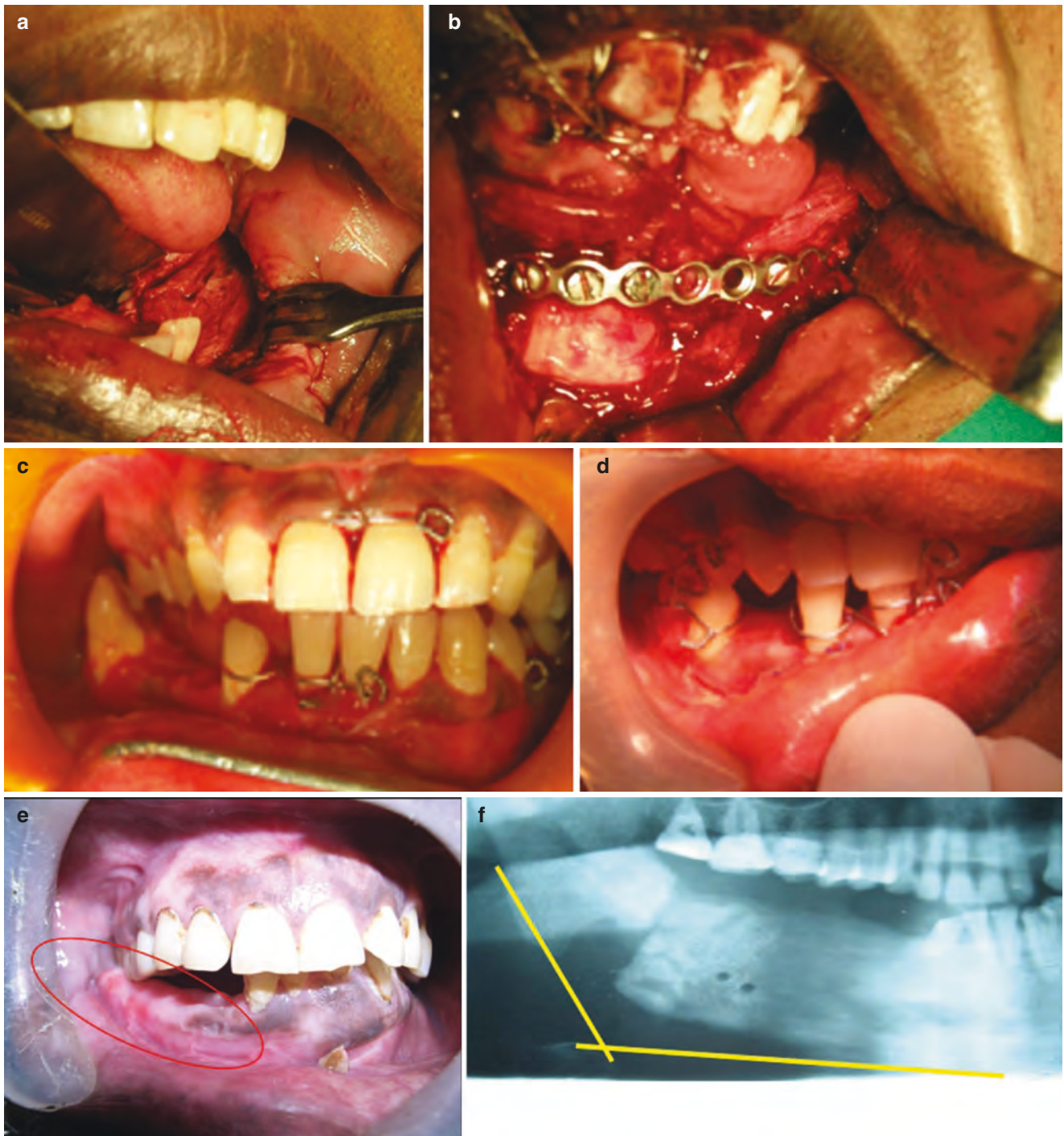


©Association of Oral and Maxillofacial Surgeons of India



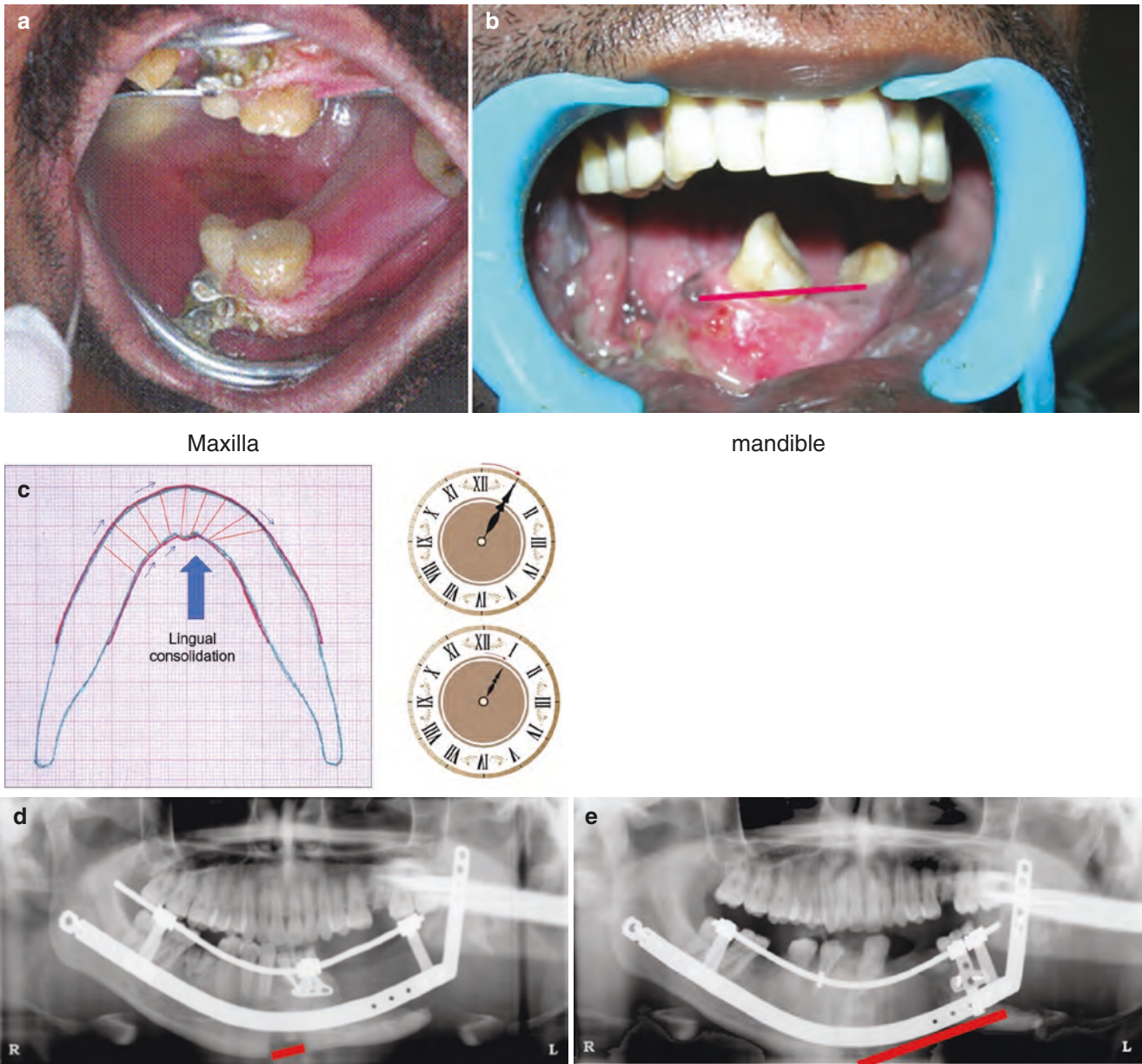
©Association of Oral and Maxillofacial Surgeons of India

Fig. 87.29 (a, b) Straight regeneration not conforming the arch form in mandible and maxilla



©Association of Oral and Maxillofacial Surgeons of India

Fig. 87.30 (a, b) Callous molding and plating done for lingual deviation. (c, d) Callous molding and IMF done for buccal deviation. (e, f) Coronal deviation



©Association of Oral and Maxillofacial Surgeons of India

Fig. 87.31 (a) Midline consolidation in maxilla (b) mandible. (c) Lingual consolidation as a result of lingual cortical tipping movement less than the required 1 mm per day (left) similar to the long and short hands of a clock. (d) Lingual consolidation (red line indicates the site

where callus will be formed after distraction). (e) Re-distraction after lingual cortical osteotomy (red line indicates the site where callus will be formed after distraction)

87.16 Role of Exogenous Growth Factors and Platelet-Rich Plasma (PRP) in TDO

Studies have highlighted that the transforming growth factor-beta, basic fibroblast growth factor, and insulin-like growth factor I are the chief upregulated factors during TDO. These factors are present in the bony matrix, in the cytoplasm of the cells, in osteoblasts, and in a few mesenchymal cells. Distraction at faster rate shows stronger presence of the growth factors but clinically a poor regenerate. An optimum distraction rate, presence of the growth factors, and strict adherence to the biomechanical principles of DO remains the key to successful clinical outcome. Currently, external administration of the exogenous growth factors remains controversial and is a subject of further research, with evidences both for and against it. It may be concluded that the optimum TGF-beta1 is present during the distraction phase in vivo and its exogenous administration may not be recommended based on the evidences from future research. Injection of platelet-rich plasma (PRP) is found to have more favorable clinical outcome to enhance bone healing during distraction osteogenesis. PRP releases platelet-derived growth factor and transforming factors (TGF-1 and TGF-2). Platelet-derived growth factors are the initial growth factors present in a wound and initiate connective tissue healing, bone regeneration, and repair. Platelet-derived growth factors are a cost-effective and safe alternative to enhance mineralization of the distraction chamber.

In our experience with bioregulators, limited to PRP, we have found that injecting PRP into the site of new bone regenerate chamber after achieving the desired length through TDO, we can reduce the time of consolidation phase by one-third compared to consolidation phase without PRP. PRP has proved to hasten the mineralization of the regenerate and we can achieve the quality of bone that is usually expected in 6 weeks without PRP in 2 weeks' time itself, thus reducing the duration of treatment [13].

87.17 Conclusion

As we understand, microvascular surgery is not restricted to a particular specialty and is a technique that can be mastered by any surgeons of any specialty. However, it requires a steep learning curve, whereas bone transport doesn't require any additional training or equipment. It involves only the routine plate bending and fixing. So, to conclude, distraction osteogenesis is a continually evolving field of research and study and an aesthetically and functionally acceptable option for managing extensive maxillo-mandibular defects and those

not amenable to conventional methods. It is akin to "old wine in new bottle" especially brewed to the taste of oral and maxillofacial surgeons, for it is the only contemporary modality of reconstruction that we maxillofacial surgeons can master ourselves and also one that we can call with pride as "our own (Refer Figs. 65.14, 65.15, and 65.17 for TMJ ankylosis cases where distraction osteogenesis has been used as a part of the overall treatment plan)."

Acknowledgments Figures 87.1 (a, b, c), 87.2 (a, b), 87.15c, 87.19, 87.22(a, b), 87.28 (a, b, c) are from Neelakandan RS, Bhargava D. Transport distraction osteogenesis for maxillo-mandibular reconstruction: current concepts and applications. *J Maxillofac Oral Surg.* 2012;11(3):291–299. Springer, <https://www.ncbi.nlm.nih.gov/pmc/articles/PMC3428445/>.

Figure 87.23 (a, b, c, f) from Neelakandan RS, Mathew PC. Intraoral maxillary transport distraction: a casereport. *J Oral Maxillofac Surg.* 2009 Aug; 67(8):1751–5. PubMed PMID: 19615594. <https://doi.org/10.1016/j.joms.2009.03.038>. License Number 4613700616915. License date Jun 21, 2019. Licensed Content Publisher Elsevier.

Figure 87.25 (a, c, e) from <https://www.ncbi.nlm.nih.gov/pmc/articles/PMC5328860/>, <https://doi.org/10.1007/s12663-015-0861-7>; Rajkumar K, Neelakandan RS, Devadoss P, Bandyopadhyay TK. Reconstruction of a Post Traumatic Anterior Maxillary Defect by Transport Distraction Osteogenesis. *J Maxillofac Oral Surg.* 2017 Mar;16(1):118–122. Springer.

Figure 87.31 (d, e) from S. Neelakandan, R & Bhargava, Darpan. (2011). Transport distraction along the mandibular midline. *International journal of stomatology and occlusion medicine.* 4. 123–126. <https://doi.org/10.1007/s12548-011-0018-3>. (open access).

References

1. Neelakandan RS, Bhargava D. Transport distraction osteogenesis for Maxillo-mandibular reconstruction: current concepts and applications. *J Maxillofac Oral Surg.* 2012;11(3):291–9.
2. DeCoster TA, Simpson AH, Wood M, Li G. Biologic model of bone transport distraction osteogenesis and vascular response. *J Orthop Res.* 1999;17(2):238–45.
3. Kontogiorgos E, Elsalanty ME, Zapata U, Zakhary I, Nagy WW, Dechow PC, Opperman LA. Three-dimensional evaluation of mandibular bone regenerated by bone transport distraction osteogenesis. *Calcif Tissue Int.* 2011 Jul;89(1):43–52.
4. Garcia FL, Picado CH, Garcia SB. Histology of the regenerate and docking site in bone transport. *Arch Orthop Trauma Surg.* 2009;129(4):549–58.
5. Çakır-Özkan N, Eyibilen A, Özkan F, Gülbahar MY, Kabak YB. Immunohistochemical analysis of reconstructed sheep mandibles: transport distraction osteogenesis versus autogenous bone grafting. *J Oral Maxillofac Surg.* 2011 Apr;69(4):1248–54.
6. Barber S, Carter L, Mannion C, Bates C. Distraction osteogenesis part 1: history and uses in the craniofacial region. *Orthod Update.* 2018;11(1):14.
7. Neelakandan RS, Mathew PC. Intraoral maxillary transport distraction: a case report. *J Oral Maxillofac Surg.* 2009;67(8):1751–5.
8. Rajkumar K, Neelakandan RS, Devadoss P, Bandyopadhyay TK. Reconstruction of a post traumatic anterior maxillary defect by transport distraction osteogenesis. *J Maxillofac Oral Surg.* 2017 Mar;16(1):118–22.

9. Cheung LK, Zhang Q, et al. Reconstruction of maxillectomy defect by transport distraction osteogenesis. *Int J Oral Maxillofac Surg.* 2003;32(2):515–20.
10. Neelakandan RS, Bhargava D. Transport distraction along the mandibular midline: conceptual analysis. *J Stomat Occ Med.* 2011;4:123–6.
11. Synder CC, Levine GA, Swanson HM, et al. Mandibular lengthening by gradual distraction: preliminary report. *Plast Reconstr Surg.* 1973;51:516.
12. Ruhaimi KA. Comparison of different distraction rates in mandible: an experimental investigation. *Int J Oral Maxillofac Surg.* 2001;30(1):216–20.
13. Chin M, Toth BA. Distraction osteogenesis in maxillofacial surgery using internal devices. Review of five cases. *J Oral Maxillofac Surg.* 1996;54:45–54.

Open Access This chapter is licensed under the terms of the Creative Commons Attribution 4.0 International License (<http://creativecommons.org/licenses/by/4.0/>), which permits use, sharing, adaptation, distribution and reproduction in any medium or format, as long as you give appropriate credit to the original author(s) and the source, provide a link to the Creative Commons license and indicate if changes were made.

The images or other third party material in this chapter are included in the chapter's Creative Commons license, unless indicated otherwise in a credit line to the material. If material is not included in the chapter's Creative Commons license and your intended use is not permitted by statutory regulation or exceeds the permitted use, you will need to obtain permission directly from the copyright holder.





Hard Tissue Reconstruction of the Maxillofacial Region

88

Srinivasa R. Chandra and Vijay Pillai

Abbreviations

ACS	acellular collagen sponge
BFGF	basic fibroblast growth factor
BMP	bone morphogenic protein
IGF-1,2	insulin-derived growth factor 1,2
PDGF	platelet derived growth factor
rh BMP-2	recombinant human bone morphogenic protein-2
TGF- β	transforming growth factor beta

88.1 Introduction

The maxillofacial skeleton can be visualised as a three-dimensional structure, and its integrity is essential for neurovisceral function like vision, airway conduction, nutritional luminal support, etc. The location and the size of the defect determine the hard tissue reconstruction and the donor site selection.

88.2 General Principles [1]

- The bone graft recipient site should have viable vascular and infection free environment.
- Adequate evaluation of the donor site morbidity has to be undertaken.

Electronic Supplementary Material The online version of this chapter (https://doi.org/10.1007/978-981-15-1346-6_88) contains supplementary material, which is available to authorized users.

S. R. Chandra (✉)
Department of Head and Neck Oncology and Reconstructive Microvascular and Oral and Maxillofacial Surgery, UNMC, Omaha, NE, USA

Nebraska Medicine Fred & Pamela Buffett Cancer Center, Omaha, NE, USA

V. Pillai
Department of Head and Neck Surgical Oncology, Mazumdar Shaw Cancer Center, Narayana Health, Bangalore, India

- Evaluation for vascular versus nonvascularized bone graft has to be done with adequate immobilization and if required vascular anastomosis.
- Comorbidities of the patient and surgical appropriateness have to be prioritized. Smoking, cicatrization, radiation, pain issues and functional status are considerations as well.

88.3 Principles of Reconstruction

- Age is a factor but not a contraindication for reconstruction.
- There is no 'ideal reconstruction' but there is 'optimal reconstruction'.
- Patient comorbidities and future adjuvant radiation should be strongly weighed.
- 'Like to like tissue' reconstruction especially hard tissue substitution is optimal.

88.4 Terminology

Autograft: Transplant between areas within the same individual.

Allograft: Transplant between individuals (same species).

Xenograft: Transplant between individuals of different species.

Isograft: Transplant between monozygotic twins.

Osteoconduction is the phenomenon of bone regeneration which needs a scaffold for ingrowth of capillaries, osteoprogenitor cells and perivascular tissue. The ingrowth of capillaries from the recipient bed causes differentiation of the osteoprogenitor cells and results in the formation of new bone. There are materials which promote osteoconduction as

grafts or scaffolds. These can be autologous or alloplastic, homologous, xenogeneic bone particles, bone glass and hydroxyapatite ceramic material.

Osteogenesis is the spontaneous growth of new bone. It can either be *spontaneous* from progenitor cells in the area of the bone defect, or it could be *transplanted* osteogenesis arising from grafted progenitor cells.

Osteoinduction is auto induction by differentiation of mesenchymal cells from the native bed into osteoblastic tissue. This requires inductive stimulation, either from the grafted bone material (there is natural bone morphogenetic protein release with the resumption by osteoclastic activity on the middle matrix) or by the addition of recombinant bone morphogenetic protein-2. This results in recruitment from the surrounding bed of mesenchymal cells, which then differentiate. This is mediated by graft-derived factors, viz. recombinant human bone morphogenetic protein-2 (rhBMP-2), in situ BMP, TGF- β , IGF-1 and IGF-2, BFGF, PDGF.

Clinical Pearls

Key concept in bone grafting which is a part of hard tissue reconstruction is the extent of ostial induction, ostial conduction and osteogenesis caused by the graft. The main tenet is that only autologous bone grafts can promote osteogenesis due to its volume of biocompetent viable cells. Allo- and xenografts do not have osteogenic potential.

88.5 Bone Grafts [2, 3]

88.5.1 Cortical vs Cancellous Grafts

Cancellous grafts revascularize more rapidly when compared to cortical grafts. For example, cranial bone revascularizes more rapidly than other cortical bone.

Mechanism of healing:

- Cancellous: Apposition and subsequent resorption.
 - Cancellous grafts repair more completely.
 - Cortical bone incompletely resorbed/remodelled
- Cortical: Resorption then apposition.
 - 50% reduction in strength at 6 weeks–6 months.

88.5.1.1 Considerations in Usage of rhBMP-2 [4]

In March 2007, the US Food and Drug Administration (FDA) approved the use of rhBMP-2 in maxillofacial surgical procedures for intraoral ridge augmentation.

Biologic concept—the mechanism is through osteoinduction by chemotactic osteoprogenitor cellular proliferation and differentiation causing osteoid maturation.

Technique—BMP is carried in the acellular collagen sponge (ACS) to the defect where the formed osteoid matures into an ossicle about 6 months after the cycle of resorption and remod-

elling. There are multiple case reports of allogenic freeze-dried, crushed cancellous bone with BMP and platelet-rich plasma used in large maxillofacial reconstructions. rhBMP-2 is a lyophilized powder mixed with prepackaged sterile water. Concentration of 1.5 mg/mL of rhBMP-2/ACS is advised. For molecular binding the mixture is kept soaked for 15 minutes. To prevent desiccation and protein loss, rhBMP/ACS mixture must be used within 2 hours. Informed consent, warning of swelling and tension-free closure are important considerations.

Indications: Approved by FDA—spinal fusions (2002), treating open tibial fractures (2004) and oral and maxillofacial sinus and ridge augmentations (2007).

Contraindications and precautions:

- Local health advisory or FDA issued black box warning.
- Pregnancy.
- History of malignancy.
- Active infection.
- Hypersensitivity to BMP or collagen matrix.
- Unknown evidence of safety in children and females of childbearing age.
- Proximity to airway due to severe oedema postoperatively.

88.5.2 Bone Graft Carriers and Fixation Techniques

- Mesh.
- Custom fabricated cribs, implants, plates, etc.
- Titanium plates and screws.
- Lag screws.
- Autologous or allogenic bone cribs (Fig. 88.1).

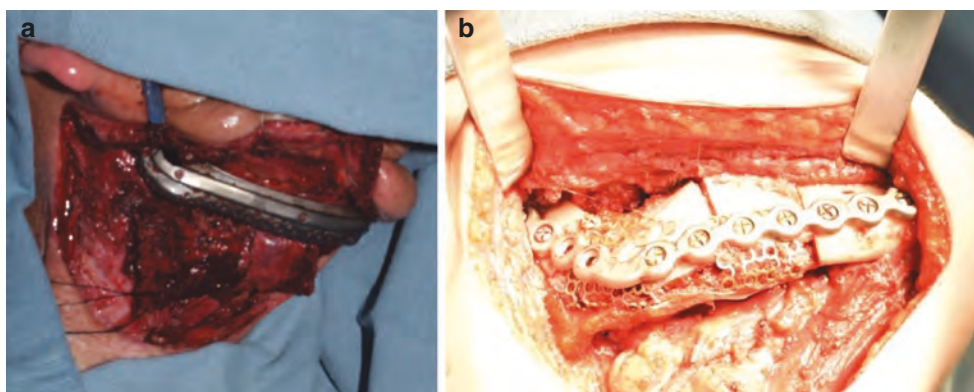
Autogenous Bone Donor Sources

The choice of donor site depends on:

- (a) Quantity.
- (b) Quality.
- (c) Anatomical contour (height, weight, volume).
- (d) Donor site morbidity.
- (e) Patient and anatomical access to harvest.
- (f) Type of carrier and fixation needed.
- (g) Surgical competence.

Common Locations of Autogenous Bone Donor Sites

- Iliac crest (anterior and posterior).
- Costochondral rib graft.
- Cranial bone.
- Tibia.
- Scapula.
- Maxilla.
- Mandible.



©Association of Oral and Maxillofacial Surgeons of India

Fig. 88.1 Bone graft carriers and fixation techniques(a–b) custom made implants compared to stock prosthesis. (a) Custom-built bone graft carrier and plate as patient specific implant—note that this can be planned for optimal areas of fixation (anchoring the crib to the plate, the

span and width of the screws, etc.). (b) The figure shows a reconstruction bar adapted with stock titanium mesh for carrying a non-vascularised iliac bone graft

88.5.3 Costochondral Graft

The costochondral rib graft came into vogue with the concept of transplanting a growth centre to the recipient site in reconstruction. This was initially used for temporomandibular joint arthroplasty and extended to the ramus condyle subunit, as it was a substitute for the growth centre at the condyle and was needed to maintain the growth potential of the joint.

88.5.3.1 Technique

A submammary incision is placed around the 5th–seventh rib, taking care not to extend beyond to avoid a flail segment. The incision is made in the mid-clavicular line, placed more medially if a costochondral graft is needed. It is deepened down to bone, and a circumferential subperiosteal dissection is done with a stripper. If the cartilage is harvested, a sleeve of periosteum is retained. Subperiosteal dissection is done avoiding pleural damage. Once the graft is removed, inspect the cavity with saline and check for any air leaks. A layered closure is performed with a drain.

88.5.3.2 Indications

Laryngotracheal reconstruction, nasal reconstruction, auricular reconstruction, facial augmentation in syndromic disorders.

Clinical Pearls

- Good cartilage yield.
- Superior strength.

Pitfalls

- Inferior pliability.
- High tendency for warpage.
- Subcostal scar, pneumothorax.

88.5.4 Autologous Rib Grafts

Rib grafts are a good source of corticocancellous membranous bone that can be used as onlay bone grafts for the craniofacial skeleton. Being soft and flexible, it is unable to withstand zones of high stress placement.

The harvest is similar to the costochondral graft; however, leaving the periosteum in situ would allow for regeneration of the rib but would reduce the take of the rib graft.

Pitfalls

- Subcostal scar.
- Pneumothorax.
- Atelectasis.
- Higher incidence of resorption if used as onlay grafts due to the higher cancellous component.

88.5.5 Iliac Crest

The ilium is a rich source for cortical, cancellous and a combination of corticocancellous bone grafts.

It is primarily utilized for arthrodesis, bony non-unions and alveolar clefts.

The anatomy of the ilium with the dense cortical bone permits grafts for high stress areas like the long bones and hands and also allows for rigid fixation. The outer table has numerous muscular attachments, thus is not preferred. The inner table is commonly harvested.

The iliac crest allows the harvest of large amounts of cancellous bone.

The cartilaginous apophysis in children must not be disturbed as it contributes to the normal growth and development.

88.5.5.1 Technique

The anterior approach is the most commonly utilized with the incision being placed after careful palpation to ensure the scar lies on the lateral aspect of the crest.

The incision is deepened through the skin, fascia, muscle and periosteum up to the bone. Ideally the inner or medial table is preferred for harvest as it does not cause disruption of the muscle attachments on the lateral side. The bone cuts should be placed preserving the crest so that it is hinged laterally and can be repositioned once the desired bone has been harvested. Maintaining the periosteal attachments of the crest would preserve its blood supply and further fixation would not be needed.

Good haemostasis, meticulous-layered closure with a drain in the subcutaneous tissue can help prevent a postoperative haematoma. It is also common practice to place an epidural catheter into the bed to permit infusion of a long acting local anaesthetic agent for the first 24 hours.

Most of the disadvantages of iliac bone harvest can be circumvented if the amount of bone graft needed is not too excessive by using the trephination technique.

Pitfalls

- Postoperative morbidity depending on the extent of bone harvested.
- Injury to the lateral femoral cutaneous nerve with prolonged post-surgical pain.
- Haematoma.
- Gait disturbances.

88.5.6 Tibia

88.5.6.1 Tibial Autogenous Cancellous Bone Harvest

This was first reported by Catone [5] in 1992 and is used in maxillofacial bone grafting techniques with a harvest volume of about 25–40 cc from a unilateral site. Harvest can be performed under local or general anaesthesia. The anatomical access to the tibial proximal head can be medial or lateral. Paediatric harvest has been reported, but the growth plate of the tibial plateau should be mature for adequate safety. The contraindications for tibial bone harvest cited are metal prostheses, athletes and history of knee trauma.

88.5.6.2 Technique

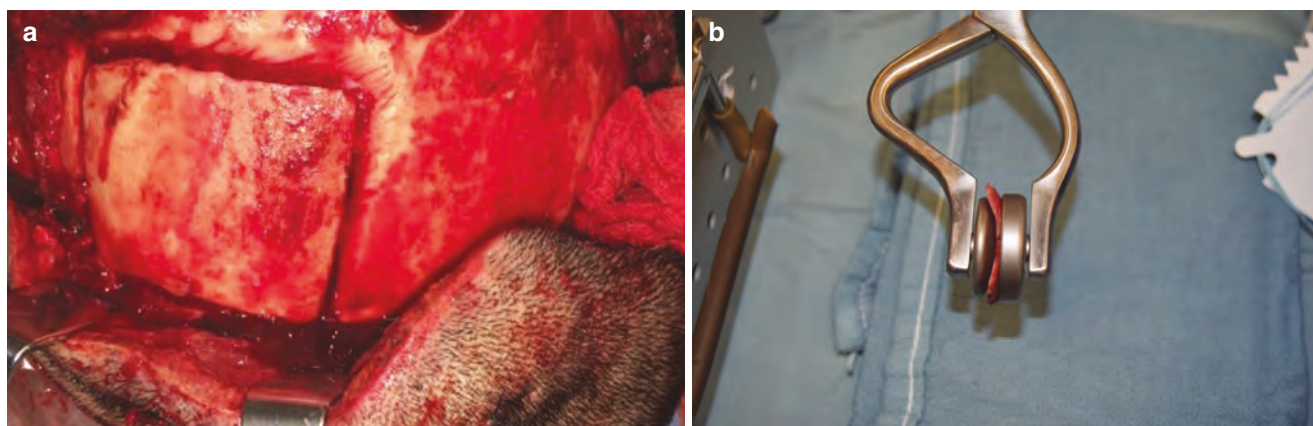
As mentioned the approach can be medial or lateral to the midline patellar tendon. In the lateral approach—Gerdy's

tubercle is the bony prominence which is palpated between the midline patellar tendon and the lateral proximal head of the fibula. This bony prominence has the attachment of the iliotibial fascial tract. In the medial approach, there is no significant bony prominence, and the only overlying structures to the tibial proximal head are just skin and subcutaneous tissue. Accordingly, an incision on either side goes through the skin and subcutaneous tissue and a self-retaining retractor can be used for retraction.

Once the tibial head is identified, using a narrow drill with a postage stamp technique, a window is created either supra or subperiosteally. This cortex can be left attached to the periosteum and repositioned at the end of the harvest if cortical bone is not needed. Cancellous bone can be curetted with adequate care not to perforate the superior tibial plateau entering the knee joint. Adequate haemostasis with local cauterly should be used to prevent any postoperative haematomas. Deep and superficial layer closures are performed. No immobilization is recommended, but active weight bearing is avoided for a couple of days. If there is any concern for superior tibial plateau perforation or knee joint violation, an orthopaedic review is mandated.

88.5.7 Cranial Bone [2]

It is well-known through craniofacial surgery that paediatric skull defects less than 1 cm with an intact pericranium can cause adequate bone healing with osseous regeneration. Calvarial bone grafts can be performed as mono- or bicortical harvest based on the surgeon's competence. Cortical bone shavings are commonly utilized. Just off the midline of the skull sagittal plane, parietal cortical calvarial bone is accessed through skin and the scalp layer incision. Adequate retraction is performed with a self-retaining retractor or assistance. The amount of bone needed is identified in the subperiosteal plane and marked with round bur of a narrow diameter. Adequate outer beveling is performed (as depicted in the figure) using a straight fissure bur for a flat osteotomy technique as parallel to the outer surface. Multiple fissuring osteotomies in a parallel fashion can be performed too. The intracortical medulla is carefully traversed through osteotomes and if any small dural perforations are made, they can be covered with artificial allografts or even haemostatic material. A neurosurgical review is needed in case of dural tear. Haemostasis with bone wax or electrocauterly and good pericranial adjacent tissue rotational coverage and closure of the scalp layers leads to reduced postoperative haematomas. The bone harvested can be contoured with a crimping forceps as shown in the figure (Fig. 88.2a and b).



©Association of Oral and Maxillofacial Surgeons of India

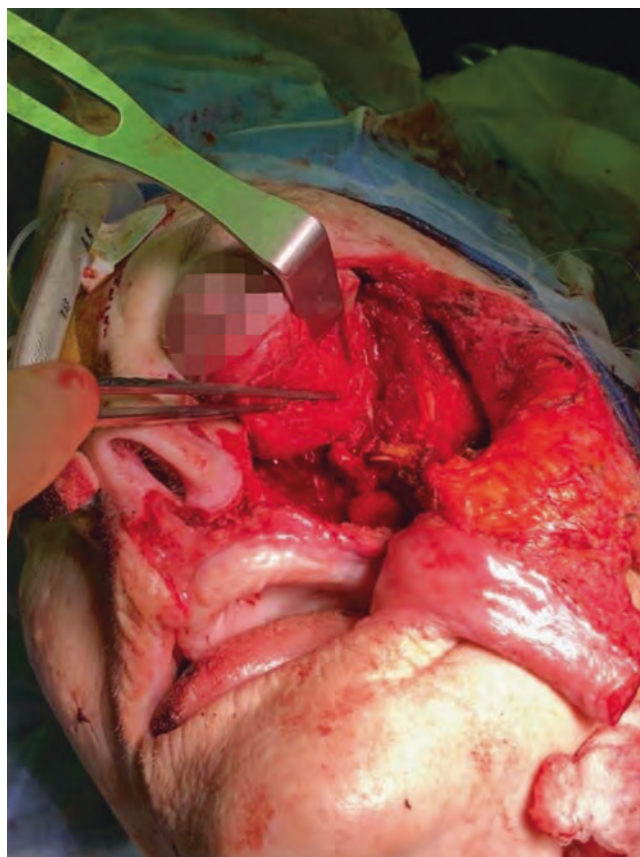
Fig. 88.2 (a) Cranial bone graft harvest with circumferential trough and beveling. It is ideal to harvest this in the parietal area. Narrow strips are ideal for harvest. (b) Cranial non vascular bone graft being contoured with pinch forceps

88.6 Microvascular Free Tissue Transfer

Most hard tissue grafting using this technique is a ‘composite’ bone and soft tissue transfer by arteriovenous anastomosis. This transferred bone is usually held in place by plates and/or screws. There is osteogenesis at the interface of the native and grafted bone interface. Current techniques of vascular free tissue using microvascular anastomosis along with minimal donor site morbidity have a success rate close to 98 percent. There is a potential for failure due to anastomotic complication. The vascularized free transferred tissue is resistant to infection and radiation to a degree of volume. There are concepts of creating a vascular envelope and subsequent allogenic or xenogeneic grafting for better osteoconduction by vascular ingrowth.

88.6.1 Osteocutaneous Radial Forearm Free Flap (OCRFFF)

The popular workhorse fasciocutaneous radial forearm free flap is very well-known for most reconstructive surgeons. Whereas an osteocutaneous variant of this flap is not the ‘go to’ flap in composite reconstructions. There is significant donor site morbidity with about 70% postharvest strength and an increased fracture risk of the distal radius. Distal radius can be reinforced with a prophylactic plate by internal fixation. Figure 88.3 shows osteocutaneous radial forearm free flap for maxillary reconstruction including the orbital rim. Figure 88.4a and b shows radial forearm flap for reconstruction of maxillary and mandibular defects.



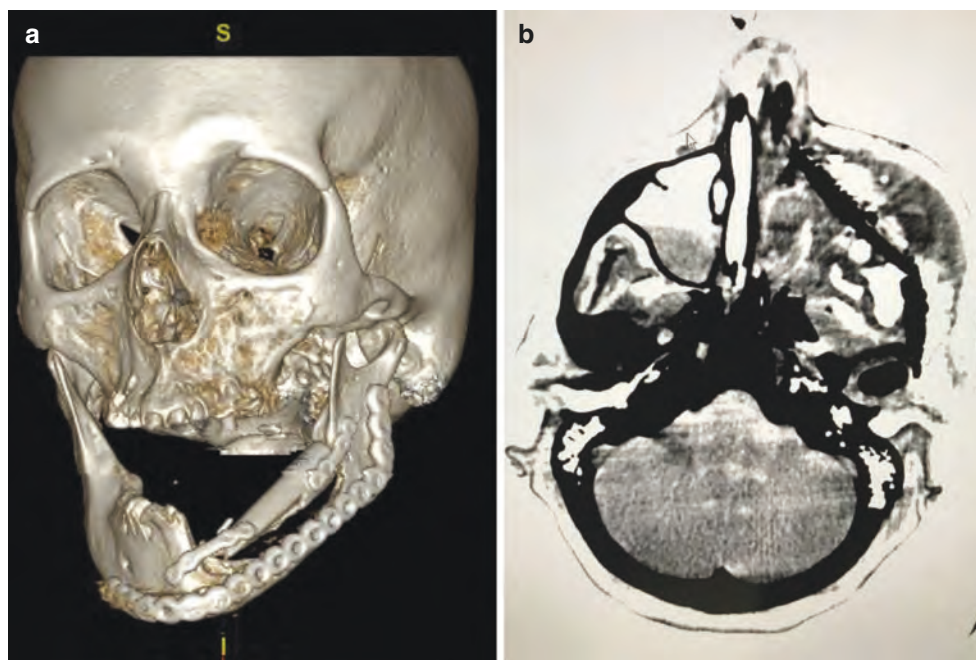
©Association of Oral and Maxillofacial Surgeons of India

Fig. 88.3 Osteocutaneous radial forearm free flap for maxillary reconstruction including the orbital rim

88.6.1.1 Indications

Periorbital, nasal and maxillary subunit reconstructions are the common indications for an osteocutaneous radial forearm free flap. It is a real alternative if other donor sites are not viable.

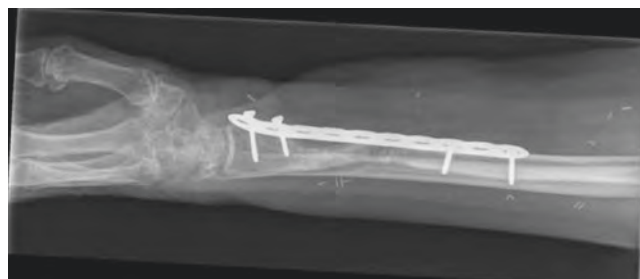Fig. 88.4 (a and b) Radial osteocutaneous flap as an alternative in mandible (a, 3D rendering) and (b) maxillary reconstruction (left maxilla CT)



©Association of Oral and Maxillofacial Surgeons of India

88.6.1.2 Technique

Surface markings of the soft tissue from the distal wrist skin crease as the horizontal line, the radial pedicle and the cephalic vein are outlined. The osseous part of the anterior lateral radius segment between the insertion of the pronator teres and the brachioradialis is harvested up to 10–13 cm in length and about 40 percent in circumference. The distal styloid aspect of the radius should have at least 2 cm to complete a bone plate fixation after the flap harvest. The fascial and muscular periosteal vascularity is retained in harvest. The flap can be raised from the radial or the ulnar side in a subfascial plane. The brachioradialis is retracted laterally protecting the superficial branch of the radial nerve. A sharp incision is made down to the periosteum preserving the attachment of the intermuscular septum. On the medial side, the flexor carpi radialis muscle is reached and retracted medially so the median nerve is protected. The muscle bellies of the pronator quadratus and the flexor pollicis longus are carefully dissected distal to proximal preserving enough muscular cuff to retain perforators to this segment perfusing from the radial artery in its lateral intermuscular septum. Once the radius periosteum is incised in length noting the curve of radius bone, multiple drill holes are used to outline the osteotomy. A boat-shaped harvest is completed of the cortex protecting the radial vasculature after distal ligation and the muscular perforators to the osseous part. The proximal harvest is completed of the pedicle similar to radial forearm harvest by radial artery and vena comitans ligation. A prebent compression plate is adapted and fixated using bicortical screws across the site of harvest (Fig. 88.5). Osteotomy can be performed of this



©Association of Oral and Maxillofacial Surgeons of India

Fig. 88.5 Post-radial osteocutaneous flap harvest with orthopaedic internal bicortical fixation of radius as prophylaxis for prevention of radial shaft fracture

donor segment with close attention for orbital rim reconstruction if needed.

88.6.2 Scapula Free Flap [6]

Theoretical conceptualization of the scapular flap was first described by Saijo in 1978 and popularized by Dos Santos [7] in 1979. This scapular system which got described includes a myriad of options based on the subscapular vessels. It can be used as two types of bony composite flaps with the utilization of angle of the scapula and the lateral border. The major branches of the subscapular system are the circumflex scapular artery and the thoracodorsal artery. Circumflex scapular artery and its associated vein with the lateral border of the scapula are the classical osseous flap. Scapular and parascapular flaps offer the most flexibility

with combinations of osseous, muscular, fasciocutaneous free tissue transfer based on the subscapular vascular system. Approximately 10–14 cm of the length with a thickness of 0.5–1.5 cm bone composing the lateral aspect of the scapula and or the angle of the scapula can be harvested.

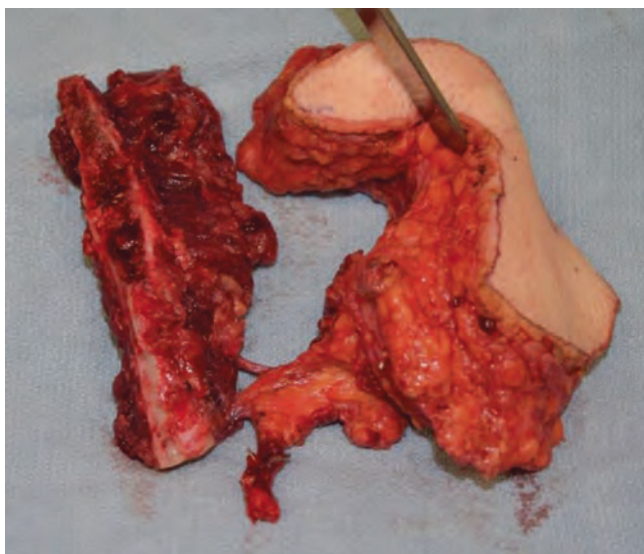
Figure 88.6 shows the advantage of this flap: independence of soft tissue pedicle in relation to the bone.

It can also be harvested using the angular artery, a branch of the thoracodorsal artery obtaining a longer vascular pedicle and teres major muscle along with the scapular tip. The medial border of the osseous scapular flap has been described; the flexibility of the overlying fasciocutaneous part is not very pliable. The medial border is comparatively narrow even in males for placement of osseointegrated implants.

Tips for donor site confirmation to the defect:

- Contralateral lateral border of scapula for mandibular reconstruction.
- Ipsilateral scapular tip for the palate and maxilla.
- The angle of the scapula can also be used for the mental prominence reconstruction.

Studies have shown good conformance between the scapular tip and the palate. The tip can be used horizontally for a palate and vertically for anterior maxillary reconstruction. There are reports of nonvascular scapular tip being used for orbital floor reconstructions.



©Association of Oral and Maxillofacial Surgeons of India

Fig. 88.6 The osteocutaneous scapular free flap. The great advantage of this flap is the independence of the soft tissue pedicle in relation to the bone

88.6.2.1 Indications

Composite and complex midfacial defects of the orbit, maxilla, skull base and mandible can be reconstructed using this chimeric flap.

88.6.2.2 Advantages

- Minimal donor site morbidity.
- Useful in elderly patients with peripheral vascular disease.

88.6.2.3 Disadvantages

- Concurrent flap harvest during ablation is not possible, as patient needs to be in the lateral decubitus or prone position.
- Inadequacy of the bone stock for osseointegrated implants.
- Variation in the anatomy with the circumflex scapular arising from the axillary artery.

88.6.2.4 Technique

Clear understanding of the scapular arteriovenous system and its branches composing the circumscapular, descending branch and parascapular vessel anatomy is essential.

The osseous branch of the circumflex scapular artery to the lateral border runs directly into it along with the vein. There is a gap between this and the cutaneous perforator which provides the flexibility of the skin paddle.

Patient can be positioned in a lateral decubitus or prone position for access between the axilla to the midline spine. The author's choice is use of a beanbag under the ipsilateral side and a protected axilla for the contralateral side. To increase the flexibility of the pedicle in relation to the lateral border of the scapula, a scapular or parascapular skin paddle can be based on the circumflex artery. The triangular space is made by the teres minor superiorly and teres major inferiorly, and the long head of the triceps laterally is identified using a Doppler 2 cm superior to the posterior axillary fold edge. The fasciocutaneous flap elevation is medial to lateral superior to the muscular fascia until the omotricipital triangle is reached. The circumflex vascular pedicle can be followed proximally to the subscapular and axillary arterial system with dissection between the teres minor and major muscles superiorly. The circumflex scapular artery is dissected in the lateral aspect of the scapular border with preservation of the muscular perforators to the bone by medial retraction of the teres minor and inferior retraction of the latissimus dorsi. An incision parallel to the lateral border of the scapula is made through the teres minor and infraspinatus muscle and periosteum. Protecting the vascular pedicle laterally on the glenohumeral joint superiorly osteotomy can be performed using a saw to the desired length with or without the angle of the scapula. Scapular angle can be harvested independently with identification of the angular perforators. Adequate care is taken to protect the underlying subscapu-

laris musculature. Teres major muscle is reattached with multiple drill holes to the new border of the lateral scapula donor site to prevent winging. Perioperative drain and post-operative immobilization of the arm after primary closure of the defect site are commonly utilized along with physiotherapy.

88.6.3 Fibula Free Flap [8, 9]

Taylor et al. first introduced the fibula flap in 1975 for extremity reconstruction but was reintroduced for mandible reconstruction by Hidalgo. Though designed as an osteocutaneous free flap, the initial reports of unreliability of the skin paddle did not find favour in its use as an osteocutaneous flap.

Clinical Pearls

- Ease of simultaneous two team harvest.
- Consistent anatomy.
- Reliable usable bone length of around 24 cms, with the capability of performing multiple osteotomies.
- Variable design as bone only, osteocutaneous or with cuff of flexor hallucis longus or soleus muscle and with accompanying fat and fascia.
- Adequate length of vascular pedicle and suitability of the peroneal vessels for anastomosis.
- Accepts dental implants and osseointegrates.
- Minimal donor site morbidity.

88.6.3.1 Anatomy

The fibula is a triangular bone in cross section, around 40 cm in length and 1.5–2.0 cms in diameter, articulates proximally with the tibia and distally with the tibia and talus and has dense cortical bone with a small amount of cancellous bone.

Blood supply: Dual endosteal and periosteal. The dominant endosteal nutrient pedicle enters posterior to the interosseous membrane at the junction of the upper and middle thirds of the fibula. It is the segmental periosteal blood supply arising from the peroneal artery that permits multiple osteotomies. Average pedicle length depending on the bone length harvested is from 5 to 10 cms with a diameter of 1.8–2.5 mm and venous drainage via paired venae comitantes.

Skin paddle: The skin territory for the flap harvest on the lateral aspect of the leg can be up to 25 cm in length and around 15 cms in width and is supplied by perforators from the peroneal system which can be either septocutaneous or musculocutaneous passing through the flexor hallucis longus and soleus. The number of perforators is around 4–8.

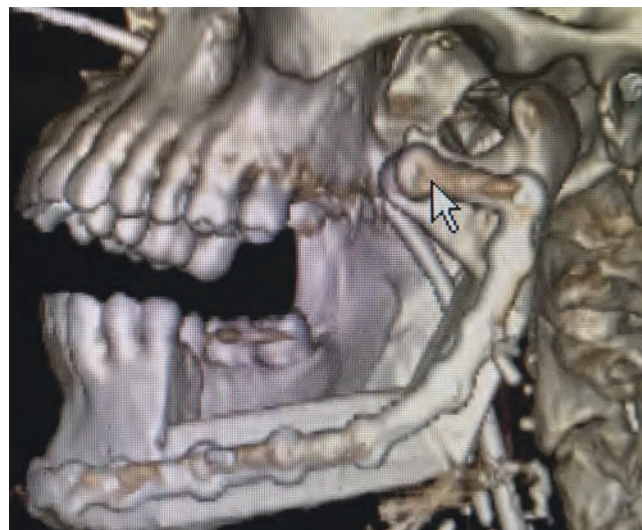88.6.3.2 Preoperative Assessment

- History of trauma or surgery to the lower limb, any peripheral vascular disease which might coexist.
- Examination of the circulation with the dorsalis pedis and posterior tibial pulse.
- *Imaging:* MR angiography, CT angiography to rule out peronea magna and also identify perforators. If angiographic studies are contraindicated, perform an arterial and venous duplex ultrasound demonstrating the flow pattern.

Figure 88.7 shows the fibula free flap reconstruction for the left mandible of the body, angle and ramus. Figure 88.8a–c shows the planning and execution for fibula free flap on a stereo lithographic model. The closing osteotomies are made with measurements using a ruler template; the smallest fibula segment is noted as marginally more than 2 centimetres. In Fig. 88.8b, one can see a sterile ruler held at the lateral fibula harvest with pedicle attached proximally and skin paddle. In Fig. 88.8c, the osteotomized fibula is immobilized to a reconstruction plate at the lower extremity donor site with the pedicle flowing intact.

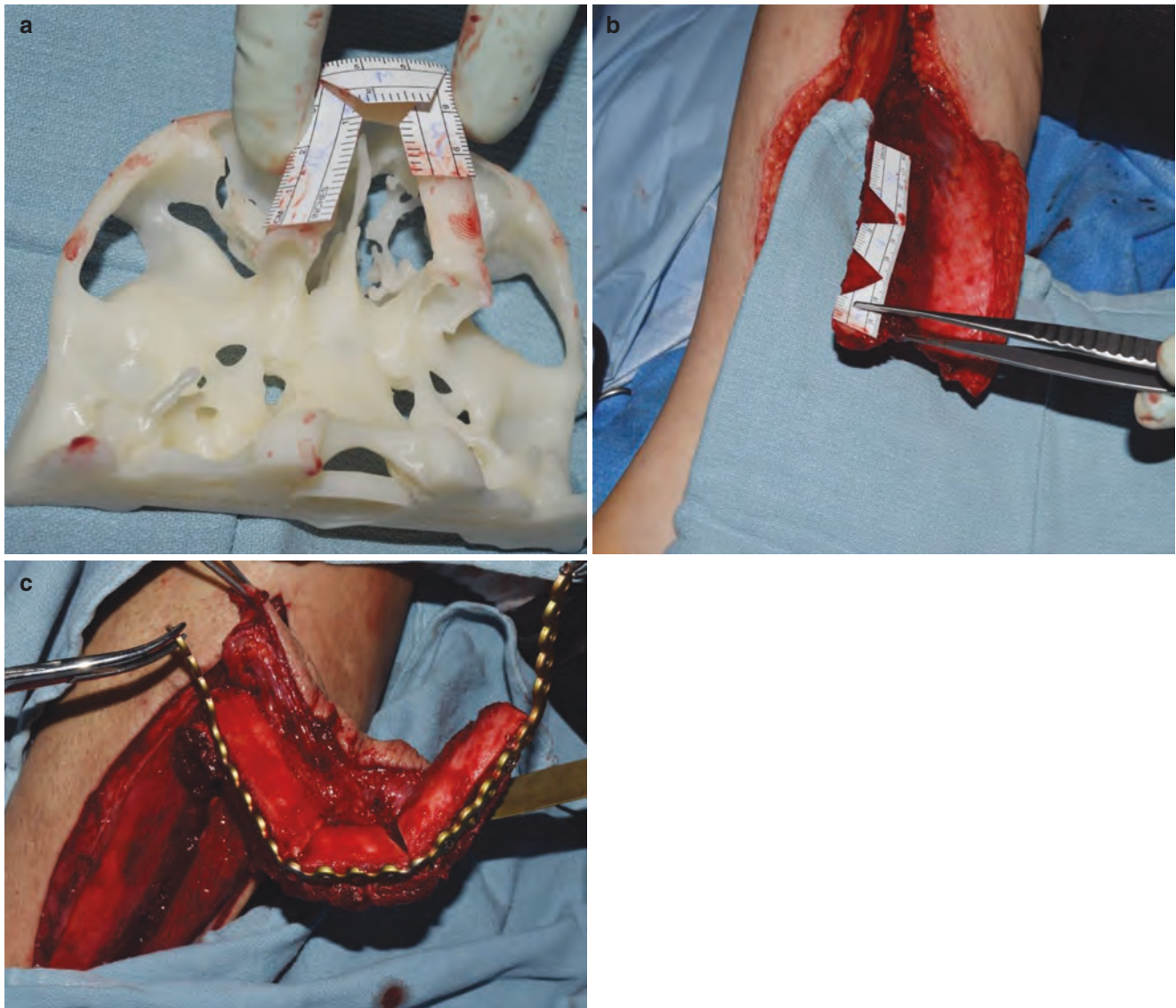88.6.3.3 Technique

Prepare the whole lower limb circumferentially from the calf downwards and the opposite limb for a skin graft. Perform the surface markings of the fibula, with the design of the skin paddle centred along the posterior border that corresponds to the intermuscular septum. Design the skin paddle after the perforators have been mapped out using a Doppler probe. Preserve at least 4–5 cm bone proximally and distally for the stability of the knee and ankle joint and to avoid injury to the



©Association of Oral and Maxillofacial Surgeons of India

Fig. 88.7 Fibula free flap reconstruction for the left mandible of the body, angle and ramus



©Association of Oral and Maxillofacial Surgeons of India

Fig. 88.8 Maxillary reconstruction planning for fibula osteotomies. (a) Planning for fibula free flap on a stereo lithographic model. The closing osteotomies are made with measurements using a ruler template; the smallest fibula segment is noted as marginally more than two centimetres. (b), the template being transferred to the fibula area for

planning the closing osteotomies. You see a sterile ruler held at the lateral fibula harvest with pedicle attached proximally and skin paddle; (c) The osteotomized fibula immobilized to a reconstruction plate at the lower extremity donor site with the pedicle flowing intact

superficial peroneal nerve. Carefully apply a tourniquet and exsanguinate the lower limb.

The incision begins anteriorly on the skin paddle deepened into the subfascial plane over the peroneus longus and brevis and dissected to identify suitable perforators. The incision is extended in a curvilinear manner proximally, and dissection in the lateral compartment is done keeping a cuff of peroneus muscle cobbledstoned on the bone.

The next step is the dissection in the anterior compartment of the extensor hallucis longus and extensor digitorum

longus up to the dense interosseous membrane which is incised. The anterior tibial vessels are seen anterolateral to the fibula and preserved.

Proximal and distal osteotomies are performed using a reciprocating saw, preserving the superficial peroneal nerve superiorly. Distally ligate the peroneal vessel once the bone is osteotomized.

The posterior compartment dissection is performed between the tibialis posterior and flexor hallucis longus which identify the peroneal vessels. Keep a cuff of flexor hallucis or soleus

muscle onto the graft depending on the soft tissue requirement and if the skin paddle is centred along the mid bone.

The posterior design of the skin paddle is made in a similar manner deep to the fascia over the soleus and lateral gastrocnemius preserving the saphenous vein and sural nerve.

Identify and preserve the posterior tibial vessels and tibial nerve 1–1.5 cm medial and parallel to the peroneal vessels.

Perforators to the soleus must be ligated, and additional length of the pedicle can be obtained by a subperiosteal dissection or ligation of the lateral posterior tibial vein.

Shaping of the fibula can be done on the benchside or while still connected with the circulation using either a pre-bent plate, cutting guides with virtual surgical planning. Closing wedge osteotomies are performed and fixation done.

Donor site closure should be meticulous with good haemostasis; suction drains closing the proximal and distal skin incisions and grafting the remaining donor site. Immobilization with a posterior splint with the ankle in 90 degrees flexion is recommended though not routinely practiced.

Postoperative physiotherapy for the lower limb can commence by the second day and with accompanying gradual weight bearing.

Pitfalls

- Vascular anomalies and variations can preclude the use.
- A double barrel segment might be needed due to inadequate bone height.
- The soft tissue component may be inadequate for extensive resections.

88.6.4 Deep Circumflex Iliac Artery-Based Composite Flap or Vascularized Iliac Crest Flap (DCIA)

Similar to the fibula the DCIA can be planned virtually. Opening osteotomies are performed instead of closing osteotomies in maxilla-mandibular reconstruction (Fig. 88.9a, b, c, d).

This flap can be harvested as an osseous or an osseocutaneous with the soft tissue component of the muscle and skin. This flap is based on the deep circumflex iliac artery and vein with the pedicle length as long as 8 cm with a diameter of the vessels between 1.5 and 3 mm. The iliac crest osteocutaneous free flap (ICFF) was described separately by Taylor [10] et al. and Sanders and Mayou in 1979 and popularized by Urken in 1989 for mandibular reconstruction and by Brown [11] in 1996 for maxillary reconstruction and use of internal oblique muscle [11]. The deep circumflex iliac artery and vein vessels arise from the external iliac vessels. The bone

quality and quantity are excellent for both the maxillary as well as mandibular reconstruction.

Maxilla and mandibular segments can be reconstructed using the iliac crest bone based on the deep circumflex branch of the external iliac artery. The authors prefer a harvest using the superior approach in reference to the spermatic cord or the round ligament. Donor site morbidity is not significant, and the patient can be supine allowing a two-team approach. Up to 14 cm of bicortical bone with internal oblique muscle can be harvested. The thickness can vary between 0.5 cm and 2.5 cm.

88.6.4.1 Indications and Contraindications

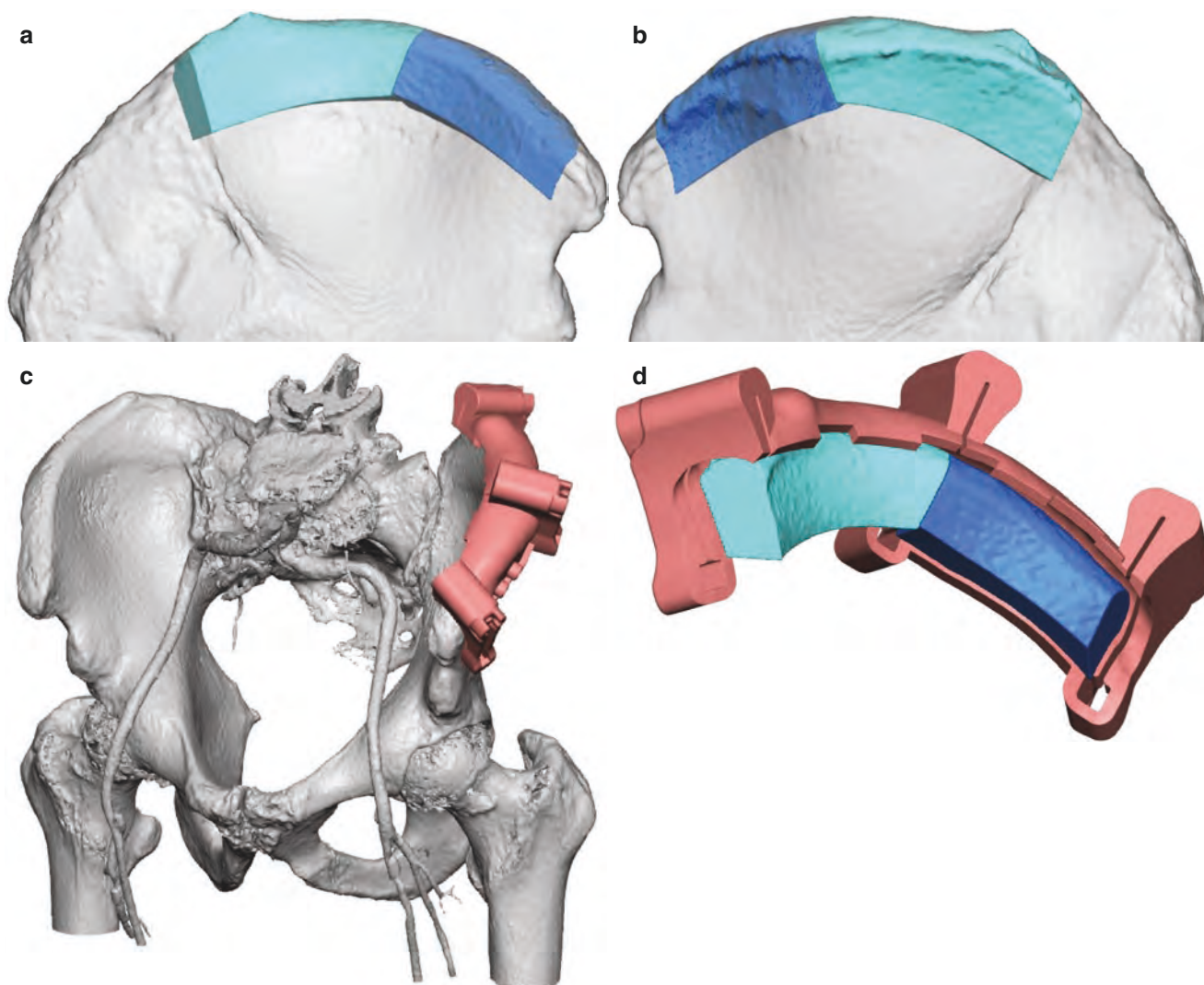
This composite flap offers optimal volume of bone for endosteal implants as well as segmental mandibular defects with need of reconstruction of the dentate contour. Maxillary palatal contour and the regional complex subunits after maxillectomy can be reconstructed. The relative contraindications for this harvest are inguinal hernia, obesity, hip prosthesis and polyparity in women.

88.6.4.2 Vascular Anatomy

Just above the inguinal ligament, the deep circumflex iliac artery (DCIA) branches off the posterolateral aspect of the external iliac artery. As it traverses laterally parallel to the inguinal ligament, the ascending branch takes off 1–2 cm medial to the anterior superior iliac spine. This is located between the internal oblique on the transversalis fascia with penetrating perforators. The DCIA has a diameter averaged at 2 mm and a pedicle length of 5–6 cm. Vena comitans accompanies the artery draining into the external iliac vein. The position of the DCIA is about 2 cm inferior to the surface of the iliac crest at the fusion of the transversalis fascia and iliacus muscle. The two variations reported are the ascending branch takeoff in medial relation to the anterior superior iliac spine (1–2 cm versus 2–4 cm) and multiple ascending branch perforators instead of a single identifiable ascending branch of the DCIA.

88.6.4.3 Technique

With the patient supine, a soft hip support is placed and the skin prepped from the midline pubis laterally to the midaxillary line, superiorly from the subcostal margin to the anterior thigh inferiorly with the greater trochanter included in the field. This includes the planned cutaneous paddle. The cutaneous perforators are concentrated 5 cm lateral to the anterior superior iliac spine and 4 cm superior to the iliac crest midpoint. Only internal oblique musculature for lining of the oral mucosal lining is included. Incision is made in a superomedial elliptical fashion through the Scarpa's and Camper's fascia up to the external oblique musculature. This is identified in its orientation from the lateral to medial direction, and as this is incised, the underlying 90 degree medial to lateral internal oblique muscle is identified. The external oblique musculature is included with the osteocutaneous



©Association of Oral and Maxillofacial Surgeons of India

Fig. 88.9 (a, b, c, d) Similar to fibula DCIA can be planned virtually. Opening osteotomies are performed instead of closing osteotomies in maxilla-mandibular reconstruction

flap. The external oblique incision extends from the lateral entirety of the whole length up to the border of the inguinal ligament. The superior part of the flap is retracted and the internal oblique muscle exposed, and the amount of this internal oblique muscle inclusion is identified for harvest superior to the iliac crest attachment. The internal oblique and transversalis fascia is dissected sharply from the superior lateral aspect to the inferior lateral direction with superior retraction and access. The ascending branch is visualized and dissection is directed to identify the DCIA itself. The ileacus muscle is visualized and preserved based on the pedicle position and harvesting about 2 cm of it. At least 4 cm of the internal oblique muscle is harvested lateral to medial towards the ilioinguinal ligament. The vein runs over the DCIA medially to the external iliac vein.

The bone harvest is performed after detaching the gluteus medius muscle from the outer aspect of the ilium. The medial

bone cut is made depending on the inclusion of the anterior crest of the ilium. The template as shown in the figure (anterior maxillary virtual finding figure) is used for making medial and lateral cuts using an oscillating saw. The medial side should be protected for pedicle integrity and peritoneum. If osteotomies are needed of the bony pedicle, they're performed with adequate care to gently greenstick the components.

The abdomen is closed in layers after adequate haemostasis of the donor osseous margins of the osteotomies. Multiple postage stamp holes are made in the bicortical iliac cortex and the residual muscular layers reattached with thicker non-resorbable sutures. And non-resorbable mesh can be used to reinforce the harvested internal oblique defect, and this can be sutured to the cortical holes as described above. The cutaneous closure is performed over suction drainage with multiple layer closure.

The quality and quantity of the bone of this flap are ideal for maxillofacial defect reconstruction. Maxillary reconstruction may need a rather lateralized bony segment harvest to gain adequate pedicle length for anastomosis into the neck. If the mandibular angle is to be reconstructed, the anterior iliac crest is included. An entire hemimandible can be reconstructed using the unilateral iliac crest.

88.6.5 Vascularized Rib Graft

There are other osteocutaneous flaps which are described like posterior costal osteocutaneous flap similar to the harvest of the costochondral part of the rib. These vascularized grafts can be from the right fifth rib in the ventral surface and up to the ninth rib in the dorsal surface. The intercostal vascular pedicle and subcutaneous venous pedicle or even the internal mammary perforators medially are used. The ribs can also be a part of the pectoralis major osteomyocutaneous flap, latissimus dorsi, serratus and trapezius muscular harvest with their pedicles. Of course the isolated rib graft with or without the costochondral graft has been the work horse for temporomandibular reconstruction for decades. The harvest has been documented well in surgical literature over the years.

88.6.5.1 Lateral Femoral Condyle Free Flap

The choice of this flap is for novelty in maxillofacial surgical needs. Femoral internal condyle with the descending genicular artery and vein as a pedicle can be harvested as free flap. The bony corticocancellous segment measuring up to $8 \times 1.5 \times 1.5$ cm can be harvested [12].

88.7 Conclusion

In conclusion the hard tissue regeneration and reconstruction have been a primary focus in clinical and research interests for all reconstructive maxillofacial surgeons. The techniques and molecular science have ongoing updates persistently for the optimal and ideal technique. The understanding of intercellular and molecular behaviour of regeneration and grafting procedure is sought by biomedical scientists by research. And with virtual surgery and planning with guided navigation, the future of hard tissue reconstruction is poised for technically predictable results.

Open Access This chapter is licensed under the terms of the Creative Commons Attribution 4.0 International License (<http://creativecommons.org/licenses/by/4.0/>), which permits use, sharing, adaptation, distribution and reproduction in any medium or format, as long as you give appropriate credit to the original author(s) and the source, provide a link to the Creative Commons license and indicate if changes were made.

The images or other third party material in this chapter are included in the chapter's Creative Commons license, unless indicated otherwise in a credit line to the material. If material is not included in the chapter's Creative Commons license and your intended use is not permitted by statutory regulation or exceeds the permitted use, you will need to obtain permission directly from the copyright holder.

References

1. Boyne PJ, Sands NR. Secondary bone grafting of residual alveolar and palatal clefts. *J Oral Surg.* 1972 Feb;30(2):87–92.
2. Marks R, Stevens M. Atlas of oral and extraoral bone harvesting. Hanover Park, IL: Quintessence; 2010.
3. Abubaker O, Oghalai M. Selected readings in oral and maxillofacial surgery. 2001 Dec; 9(6).
4. Melville JC, Shum JW, Chandra SR. Chapter 12: tissue engineering for transoral reconstruction of large mandibular continuity defects. In: Melville JC, Shum JW, Young S, Wong ME, editors. Regenerative strategies for maxillary and mandibular reconstruction: a practical guide. Cham: Springer; 2019. p. 143–54.
5. Catone G, Reimer B, Mcneir D, Ray R. Tibial autogenous cancellous bone as an alternative donor site in maxillofacial surgery: a preliminary report. *J Oral Maxillofac Surg.* 1992;50:1258–63.
6. Swartz WM, Banis JC, Newton ED, Ramasastry SS, Jones NF, Acland R. The osteocutaneous scapular flap for mandibular and maxillary reconstruction. *Plast Reconstr Surg.* 1986;77(4):530–45.
7. Dos Santos LF. Un novo retalho livre microcircucao. *Rev Bras Cit.* 1980;70:133.
8. Taylor GI, Miller GD, Ham FJ. The free vascularized bone graft. A clinical extension of microvascular techniques. *Plast Reconstr Surg.* 1975;55(5):533–44.
9. Hidalgo DA. Fibula free flap: a new method of mandible reconstruction. *Plast Reconstr Surg.* 1989;84(1):71–9.
10. Taylor GI, Townsend P, Corlett R. Superiority of the deep circumflex iliac vessels as the supply for free groin flaps. *Plast Reconstr Surg.* 1979;64(5):595–604.
11. Brown JS. Deep circumflex iliac artery free flap with internal oblique muscle as a new method of immediate reconstruction of maxillectomy defect. *Head Neck.* 1996;18(5):412–21.
12. Martin D, Bitonti-Grillo C, De Biscop J, Schott H, Mondie JM, Baudet J, Peri G. Mandibular reconstruction using a free vascularised osteocutaneous flap from the internal condyle of the femur British. *J Plast Surg.* 1991;44:397–402.

Suggested Reading List

1. Langdon JD. Operative Oral and Maxillofacial Surgery. second ed. London: Hodder Arnold; 2009.
2. Coleman III JJ. Plastic Surgery Indications, Operations and Outcomes. Volume Three Head and Neck Surgery. first ed. St Louis: Mosby; 2000.
3. Wolff KD. Raising of Microvascular Flaps. A Systematic Approach. second ed. Berlin: Springer; 2011.
4. Cheney ML. Facial Surgery Plastic and Reconstructive. second ed. FL: CRC Press Taylor & Francis Group; 2015.

