

We are IntechOpen, the world's leading publisher of Open Access books Built by scientists, for scientists

5,300

Open access books available

130,000

International authors and editors

155M

Downloads

Our authors are among the

154

Countries delivered to

TOP 1%

most cited scientists

12.2%

Contributors from top 500 universities



WEB OF SCIENCE™

Selection of our books indexed in the Book Citation Index
in Web of Science™ Core Collection (BKCI)

Interested in publishing with us?
Contact book.department@intechopen.com

Numbers displayed above are based on latest data collected.
For more information visit www.intechopen.com



Myasthenia Gravis: New Insights into the Effect of MuSK Antibodies and Acetylcholinesterase Inhibitors

Anna Rostedt Punga

*Uppsala University Hospital, Institute of Neuroscience,
Department of Clinical Neurophysiology
Sweden*

1. Introduction

Myasthenia Gravis (MG) is an autoimmune neuromuscular disorder in which autoantibodies are directed against muscle receptors. MG causes fluctuating muscle weakness, which often involves droopy eyelids, swallowing difficulties and generalized muscle fatigue in the neck and proximal muscles of the legs and arms. The prevalence of MG is two times higher in women than in men. Age is also a prevailing factor, affecting women whom are 20-30 years of age, whereas men are 60-80 years old (Osserman and Genkins 1971). The annual incidence of MG has been reported to be about 3-4 cases per million and the overall prevalence about 60 cases per million; however, higher rates have recently been suggested, indicating a potential prevalence as high as 20 per 100 000 persons. (Kalb, Matell et al. 2002; Phillips 2003). The most common form of MG is associated with antibodies against the nicotinic acetylcholine receptor (AChR), present in about 85% of patients with generalised MG (Vincent and Newsom Davis 1980). In 2001 antibodies against the muscle specific tyrosine kinase (MuSK) were identified in about 40-70% of patients without detectable AChR antibodies (Hoch, McConville et al. 2001). Furthermore, in approximately 5-10% of patients with the generalized disease no antibodies are present in the serum, but these cases all have the features of an autoimmune course. This chapter deals with the clinical phenotype, neurophysiology and consequences at the neuromuscular junction of the autoimmune attack associated with MG as well as treatment options. The focus will be on MuSK antibody seropositive (MuSK+) MG in human patients and the experimental murine model of MuSK+ MG.

2. Myasthenia gravis: Targets, consequences and treatment of the autoimmune attack

In 1960, the Scottish neurologist Simpson suggested that MG might be caused by an autoimmune mechanism based on the relatively high incidence of concomitant autoimmune diseases, e.g. rheumatoid arthritis and systemic lupus erythematosus, among the MG patients (Simpson 1960). Abnormalities of the thymus gland were discovered, as well as the presence of lymphorrhages in muscles, which further supported Simpson's hypothesis (Miller 1961). A

humoral factor was also implicated in the development of MG after it was found that approximately 20% of babies whose mothers had a diagnosis of MG developed transient neonatal MG (Strickroot 1942). Over the years, the targets of the autoimmune response, the mechanism at the neuromuscular junction (NMJ), clinical and neurophysiological features and treatment options have been outlined and improved.

2.1 Targets of the autoimmune attack

The MG autoimmune attack is directed against the receptors and proteins of the neuromuscular junction. Some patients have a thymoma which presents with antibodies against other proteins, seen in the case of thymic pathology. It is not yet clear what triggers the production of autoantibodies but MG is considered to be both a B- and T-cell mediated disorder. The autoimmune attack results in disruption of the postsynaptic endplate morphology and subsequently impaired neuromuscular transmission, which in turn causes the typical symptoms of fatigable skeletal muscle weakness.

2.1.1 Nicotinic acetylcholine receptors

About 80-85% of patients with generalized MG and 55% of patients with ocular MG have autoantibodies directed against the nicotinic AChR (AChR+) (Lindstrom, Seybold et al. 1976; Vincent and Newsom-Davis 1985). The AChR antibodies (Abs) are highly specific for MG and impair the function of the AChRs by three main mechanisms: (1) blocking of the acetylcholine (ACh) binding site (Lefvert, Cuenoud et al. 1981); (2) cross-linking of the AChRs that results in both a functional blockade and accelerated degradation of the AChRs (Drachman, Adams et al. 1981) and (3) complement activation that results in destruction of the postsynaptic muscle membrane (Engel, Lambert et al. 1977). The main immunogenic region (MIR), against which the majority of AChR-Abs in MG or experimental autoimmune MG (EAMG) are directed, is located at the extracellular end of $\alpha 1$ subunits. Pathologically significant autoantibodies must be directed at the extracellular surface of the AChR, where they can bind *in vivo* (Lindstrom, Luo et al. 2008). In MG and chronic EAMG in rats, autoantibodies bound to muscle AChRs target the postsynaptic membrane for complement-binding, which results in focal lysis and reduces the number of AChRs. This chain of events in turn disrupts the architecture of the postsynaptic membrane through an alteration of its normal position next to active zones of ACh release (Lindstrom 2000). The AChR-Abs are of IgG1 type and are typically measured using a standard radioimmunoassay in which the antigen consists of AChR from human muscle labelled with [125 I] α -bungarotoxin

2.1.2 Muscle specific tyrosine kinase (MuSK)

MuSK is essential in the early development of the NMJ, as well as in the maintenance of the organized structure of the postsynaptic apparatus through clustering of AChRs (Hopf and Hoch 1998; Liyanage, Hoch et al. 2002; Wang, Zhang et al. 2006) (Figure 1). It is further necessary for maintaining the organized structure and integrity of the neuromuscular synapse, as perturbations in MuSK protein expression cause a pronounced disassembly of the NMJ (Kong, Barzaghi et al. 2004; Hesser, Henschel et al. 2006). MuSK mutant mice do not experience successful synaptic differentiation and agrin mutant mice, have small AChR clusters which are scattered abnormally throughout the muscle (DeChiara, Bowen et al. 1996). Other players which are required for synaptogenesis include Dok-7, rapsyn and Lrp4. Dok-7 is a downstream adaptor protein to MuSK, and is important for maintaining the

structural integrity of the endplate (Okada, Inoue et al. 2006). Lrp4 was recently identified as the co-receptor for neural agrin and forms a complex which mediates MuSK activation upon agrin-binding (Kim, Stiegler et al. 2008; Zhang, Luo et al. 2008). Rapsyn is a membrane-associated cytoplasmic protein that is concentrated at the NMJ and crucial for the clustering of AChRs (Colledge and Froehner 1998).

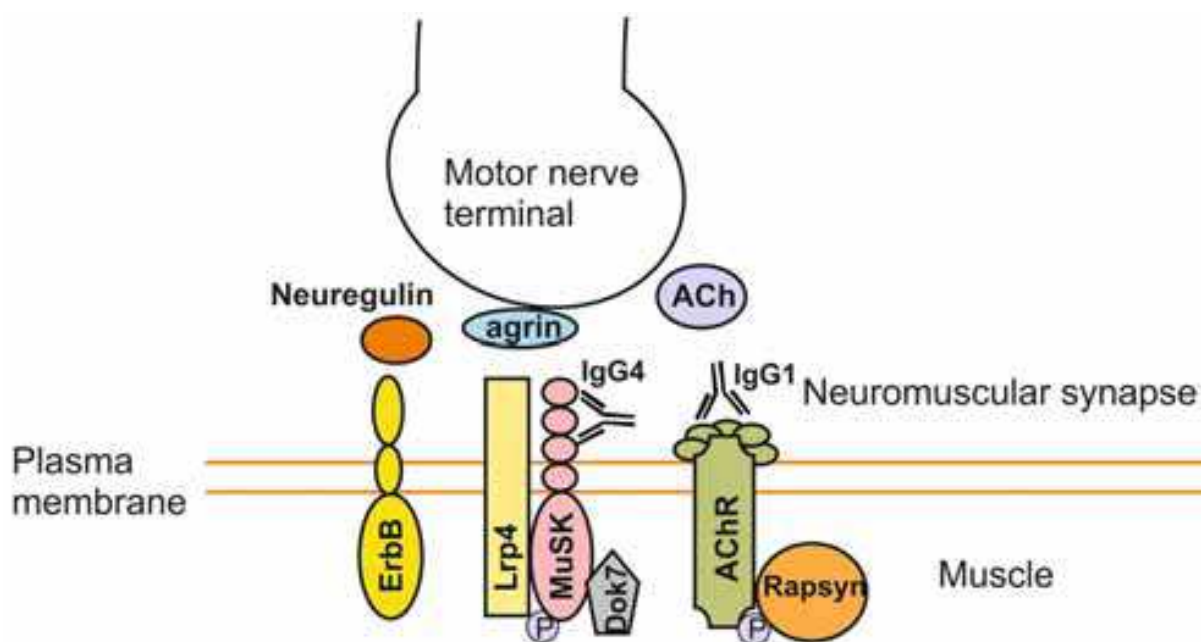


Fig. 1. Agrin-MuSK signalling at the neuromuscular synapse. Neural agrin is released from the motor nerve terminal and attaches to MuSK along with its co-receptor Lrp-4. This binding of agrin induces a cascade of phosphorylation on MuSK and then on other intracellular proteins, such as rapsyn, enabling the clustering of AChR. The autoantibodies in MuSK-antibody seropositive MG are mainly of IgG4-subtype and attach to the IgG-like domains in the extracellular domain of MuSK. The autoantibodies in AChR-antibody seropositive MG are of IgG1 subtype and bind to the main immunogenic region of the AChR, blocking the acetylcholine binding and activating complement pathways which destroy AChRs. Another important pathway at the synapse is ErbB with its neurotransmitter neuregulin.

In 2001, antibodies against the MuSK (MuSK-Ab) were identified and found to be present in about 40-70% of patients who are seronegative for AChR-Abs (Hoch, McConville et al. 2001; Bartocioni, Marino et al. 2003; Rostedt Punga, Ahlqvist et al. 2006). MuSK-Abs have also been identified in 14% of patients who have been characterized as having low titers of AChR-Abs; thus, MuSK-Abs are not entirely restricted to the AChR-Ab seronegative MG subgroup (Rostedt Punga, Ahlqvist et al. 2006). While MuSK-antibodies are predominantly of IgG4 subclass, up to 30% of the MuSK-antibodies belong to the IgG1 subclass (McConville, Farrugia et al. 2004). Despite the controversial pathogenicity of MuSK-Abs (Lindstrom 2004; Selcen, Fukuda et al. 2004), their role in disrupting the NMJ and development MG has been evidenced in animal studies with MuSK immunization (Shigemoto, Kubo et al. 2006) and passive transfer of sera from MuSK+ patients (Cole, Reddel et al. 2008). Patient-anti MuSK abs have been shown to inhibit neural agrin-mediated formation of AChR clusters in vitro (Hoch, McConville et al. 2001; Cole, Reddel et al. 2008).

2.1.3 Thymoma associated antibodies and rapsyn antibodies

MG patients with a tumour of the thymus, thymoma, may have antibodies not only directed to the AChR but also to other components of striated muscle. Two of these components strongly associated with a thymoma are the sarcomeric cytoskeletal protein titin and the calcium release channel of the sarcoplasmic reticulum, the ryanodine receptor (Aarli, Stefansson et al. 1990; Mygland, Tysnes et al. 1992). On the basis of their cross-striational pattern by immunofluorescent staining, they have been named antistriational antibodies.

A fifth antigen is the small postsynaptic AChR-associated protein rapsyn. Antibodies directed against rapsyn have been detected in about 15% of MG-patients, both in patients with and without AChR-Abs. Rapsyn is precisely colocalized with AChRs from the early stages of NMJ formation and similar to MuSK, rapsyn is necessary for the clustering of AChRs (Hall and Sanes 1993; Gautam, Noakes et al. 1995).

2.1.4 Seronegative myasthenia

A minority of MG patients is consistently negative for antibodies to the soluble native AChR or MuSK used in standard assays, and is often referred to as seronegative myasthenia gravis (SNMG). There could be antibodies to another neuromuscular junction protein, but given the clinical features which are very similar to AChR+ MG, it is likely that the failure of current assays to detect the antibodies due to a loss of antigenic determinants in the solubilized AChR used in the radioimmunoprecipitation assay, or because the AChR antibodies have only low affinity/avidity for the soluble AChR, is responsible. This was proven in 2008, when a cell-based assay showed that IgG from 66% of SNMG sera, binds to AChRs when they are clustered on the surface of a non-muscle cell line (HEK693 kidney cells) by co-transfecting with rapsyn (Leite, Jacob et al. 2008). This study also confirmed that these Abs are mainly complement activating IgG1, and some were able to induce complement deposition on the AChR clusters. SNMG patients typically behave as AChR+ MG with a similar clinical phenotype and improvement upon immunosuppressive treatment. Patients with symptoms of MG in whom no autoantibodies can be detected are called “seronegative” (AChR-). However, there are strong indicators that AChR- MG also has an autoimmune etiology. In fact a small proportion of AChR- patients were recently found to have autoantibodies to Lrp4, via an in-vitro luciferase-reporter immunoprecipitation method (Higuchi, Hamuro et al. 2011). These antibodies inhibit binding of Lrp4 to its ligand and predominantly belong to the immunoglobulin G1 (IgG1) subclass, a complement activator. Thus, in the future it is anticipated that antibodies in the sera from SNMG patients will be identified.

2.2 Clinical picture in different subsets of MG

The clinical hallmark of MG is painless, fatigable weakness, located primarily in the proximal muscle groups of the neck, face, shoulders, arms and legs. The muscle weakness may fluctuate daily, but typically worsens after physical activity and improves with rest. The course of MG is variable, although in most cases the disease is chronic and requires lifelong immunosuppressive medication. Long-lasting remissions are uncommon; however this has been reported in 10–20% of patients (Grob, Brunner et al. 2008). Many patients experience intermittent worsening of symptoms triggered by emotional stress, viral or bacterial infections, due to an upregulation of the immune system, and different medications, including certain antibiotics.

Weakness in the extraocular muscles results in ptosis and diplopia, whereas bulbar muscle weakness causes dysarthria, dysphagia and in worst cases also dyspnea necessitating respirator assistance (myasthenic crisis). Fatigue of the proximal leg and arm muscles causes difficulties in climbing stairs and holding the arms above the head. MG can be subdivided into an ocular and generalized form. In the ocular form, symptoms are restricted to the extraocular muscles resulting in ptosis and diplopia. Most patients, who generalize, i.e. develop symptoms of fatigue in muscles of proximal limbs, facial and bulbar muscles do so within 2 years. Studies have tried to identify factors to help predict prognosis but no such factors have been characterised, including neurophysiological examinations (Rostedt, Sanders et al. 2000). Patients with generalised MG can be divided into early-onset disease (onset <40 years of age) and late-onset disease. Female patients predominate the early-onset group, and often have AChR antibodies and an enlarged hyperplastic thymus gland. Patients with onset after the age of 40 years are more often male and usually have a normal appearance of the thymus. About 10–15% of patients with MG have a thymoma, a tumour of the thymus. MG associated with a thymoma, which is equally common in men and women, can occur at any age and the clinical presentation is often more severe with progressive generalized and oropharyngeal weakness (Evoli, Minisci et al. 2002)

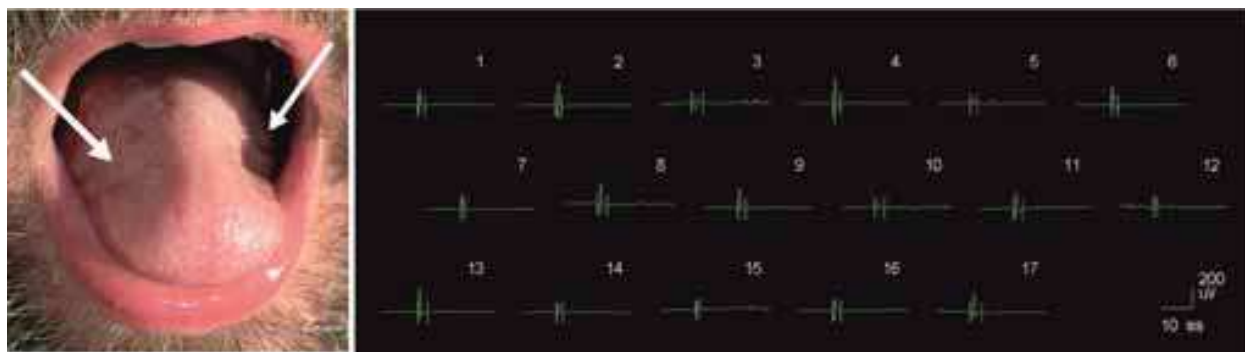


Fig. 2. Clinical and neurophysiological features which can be observed in MuSK+ MG. Left panel: A close-up of the tongue shows pronounced atrophy on the lateral sides of the glossus muscle. Right panel: EMG in these areas of the muscle revealed a myopathic picture.

MuSK+ patients usually differ from the AChR+ patients by having a very focal distribution of the muscle weakness, sometimes being limited to only the neck extensor muscles or to the bulbar muscles. A large Italian cohort of MuSK+ patients revealed a specific pattern of muscle weakness, with prevalent involvement of cranial and bulbar muscles and a high frequency of respiratory crises, and less severe and inconsistent involvement of limb muscles (Evoli, Tonali et al. 2003). This selective muscle weakness of faciobulbar and neck muscles is often very focal, with relative sparing of other muscles. Additionally, muscles which are usually not affected in AChR+ MG, including the paraspinal and esophageal muscles, may be involved (Sanders and Juel 2008). Contrary to conventional AChR+ MG patients, the majority of MuSK+ patients do not experience symptomatic relief from acetylcholine esterase inhibitors (AChEI) (Evoli, Tonali et al. 2003), but may respond with pronounced nicotinic adverse effects, such as muscle fasciculations and cramps (Punga, Flink et al. 2006). Pronounced muscle atrophy of facial muscles has also been described in MuSK+ patients and verified on MRI examinations of the temporalis, masseter and lingual muscles (Farrugia, Robson et al. 2006; Zouvelou, Rentzos et al. 2009). This facial muscle

weakness is often seen as a flattening of the forehead and in some patients atrophy of the tongue (Figure 2) is pronounced.

2.2.1 Neurophysiology in MG: disturbed neuromuscular transmission

Neurophysiological tests are essential in the diagnosis of MG. There are two different *in vivo* examinations to confirm disturbed neuromuscular transmission: (1) Repetitive nerve stimulation (RNS) and (2) Single-fiber EMG (SFEMG). At low frequency RNS (3 Hz) there is typically a progressive decline in the compound muscle action potential (CMAP) amplitude. This decrement is due to the “run down” of the amplitude of individual end plate potentials (EPP). In MG, a certain proportion of potentials are reduced to a subthreshold level and therefore insufficient to depolarize the muscle fiber. Since the CMAP constitutes the sum of activated muscle fibers, its amplitude is successively reduced with an increasing block of individual muscle fibers. If the amplitude drop, or decrement, exceeds a certain limit, e.g. 5%, the finding is considered significant. RNS is first performed at rest and then after 20 seconds of maximal voluntary muscle contraction, when an improvement of the decrement is typically seen, known as post-exercise facilitation. Additional tests after 1 and 3 minutes explore post-exercise exhaustion.

The amount of ACh released at the NMJ at different times varies minimally, resulting in comparable variations in the rise of EPP and the muscle fiber pair interpotential intervals. This variability is highly sensitive to neuromuscular transmission abnormalities and is increased in MG patients. SFEMG, which is the most sensitive test for MG, measures this variability and can be performed during voluntary muscle contraction or when the nerve is electrically stimulated (Stalberg, Ekstedt et al. 1974). SFEMG reveals deficits of neuromuscular transmission in 95%–99% of MG patients (Sanders 2002) and has proven to be a sensitive marker of early improvement in clinical trials in MG (Meriggioli and Rowin 2003). With an uptake area of about 300 μm the SFEMG electrode selectively records action potentials from a small number (usually 2 or 3) of muscle fibers innervated by a single motor unit and can detect subclinical defects in neuromuscular transmission. The variations in the difference in conduction times taken by impulses from the nerve branching point via the motor end plates along each muscle fiber to the recording site are called jitter. The jitter reflects the safety factor of neuromuscular transmission and in normal conditions the jitter is low. When jitter measurements are made in voluntarily activated muscle, activity from two muscle fibers innervated from the same axon is recorded and one action potential used as a time reference (Figure 3a). Increased jitter indicates a disturbed neuromuscular transmission (Figure 3b). Neuromuscular blockings occur if the jitter is high enough (usually more than 100 μsec), resulting from the failure of transmission of one of the potentials, when one of the muscle fibers fails to transmit an action potential because the EPP does not reach the necessary threshold (Figure 3c). Increased jitter is not pathognomonic for MG and can be seen in other conditions where there is denervation and reinnervation going on simultaneously, such as amyotrophic lateral sclerosis (ALS). Nevertheless, in combination with the clinical picture and immunological analysis of antibodies, the SFEMG is very sensitive for the MG diagnosis. Normal results on SFEMG in a clinically affected muscle basically rule out the diagnosis of MG. In most clinical neurophysiological laboratories, the arm muscle extensor digitorum communis (EDC) and either the facial muscles orbicularis oculi or frontalis are routinely examined.

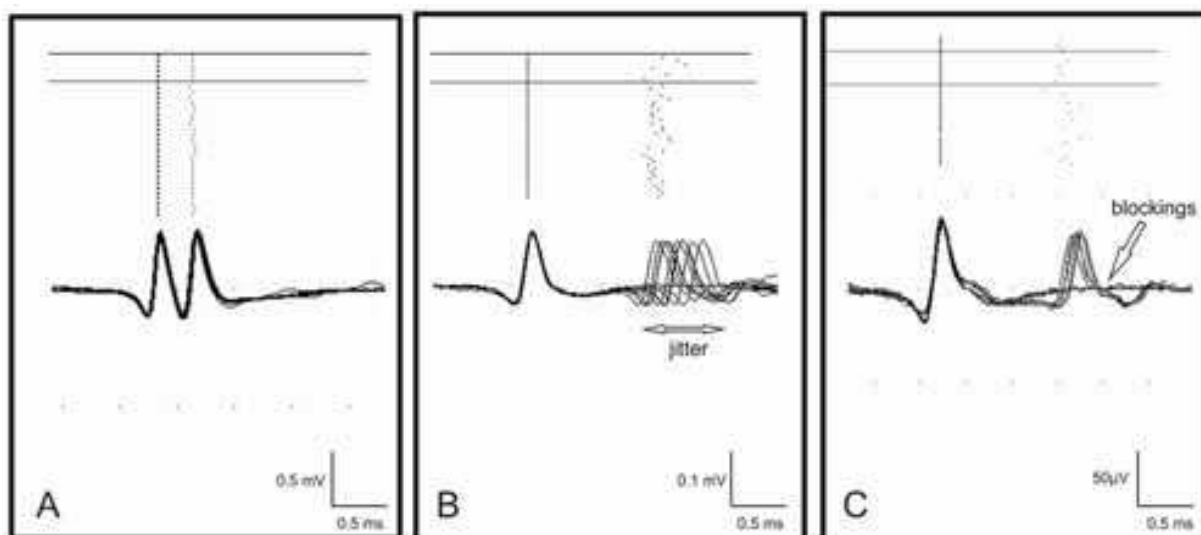


Fig. 3. Single-fiber EMG recording from the orbicularis oculi muscle (A) in a healthy control person and in a patient with MG (B and C). The vertical dotted lines represent the time line of a single muscle fiber and in each box, signals from two muscle fibers belonging to the same motor unit are displayed. A) Normal jitter, i.e. constant time variation in the variability of neuromuscular signaling to fiber 1 and 2. B) Increased jitter, and C) blockings.

2.2.2 Focal neurophysiology in MuSK+ MG

In patients with an extremely focal presentation of muscle fatigue and weakness, such as in MuSK+ MG, it may be necessary to specifically examine an involved muscle, such as the neck extensor muscles. Specific examination will help to prevent the oversight of selective defects of neuromuscular transmission (Sanders, El-Salem et al. 2003). In MuSK+ MG, SFEMG has been confirmed as the most sensitive examination in the neurophysiological diagnosis of MuSK+ MG, whereas repetitive nerve stimulation in limb muscles is only diagnostic in about 57% of cases (Evoli, Tonali et al. 2003). One of the standard limb muscles for SFEMG examinations, the EDC muscle, has been reported normal in many cases of MuSK+ MG, unlike AChR+ (Nemoto, Kuwabara et al. 2005; Stickler, Massey et al. 2005), which indicates differences in the distribution of abnormal neuromuscular transmission. In our experience, MuSK+ MG patients have comparable defects of neuromuscular transmission, on SFEMG; as AChR+ MG patients, when proximal muscles such as the deltoid or the orbicularis oculi muscles are examined (Rostedt Punga, Ahlqvist et al. 2006). One study has emphasized that the decrement in facial muscles, such as the orbicularis oculi muscle, is more often abnormal in the MuSK+ patients (Oh, Hatanaka et al. 2006), thus it is also important for RNS to be performed with recording from muscles in the facibulbar region.

Neurophysiological examinations are also important in MuSK+ MG to detect adverse effects from AChEIs. So-called extra discharges (EDs), which occur after the CMAP on motor nerve stimulation, are sometimes observed in MG patients who are receiving high doses of AChEIs and may signify impending cholinergic crisis (Punga and Stalberg 2009). EDs are more prominent in recordings from distal muscles, such as the abductor digiti minimi (ADM) in the hand (Punga, Sawada et al. 2008). In the same patient different

nerves/muscles display different grades of EDs. In some nerves, the discharges are clearly extra components, with increasing intervals from 4 to 12 ms (with a duration of at least 50 ms) and with an amplitude of approximately one third of the CMAP. In other nerves the EDs are seen as irregular discharges of low amplitude (<0.5 mV), with a duration up to 100 ms (Punga, Sawada et al. 2008). EDs may also occur directly after the neostigmine test in MuSK+ patients and then correlate with a worsening in muscle fatigue (Punga, Flink et al. 2006).

Examination using quantitative EMG (QEMG) is characterized by a myopathic pattern in approximately 70% of MuSK+ patients in neck extensor splenius capitis muscle and/or the deltoid muscle, which is considerably more than in the AChR+ group where it is found in approximately 23% of patients (Rostedt Punga, Ahlqvist et al. 2006). None of the above figures include patients treated with high doses of corticosteroids. An additional study using QEMG in MG revealed a myopathic pattern in the facial orbicularis oris muscle in 62% of MuSK+ patients and 50% of AChR+ patients; however, concomitant treatment with corticosteroids confounds pathophysiological conclusion (Farrugia, Kennett et al. 2007). Although denervation is not seen in AChR+ MG and also not in most MuSK+ patients, denervation activity in conjunction with a myopathic picture on QEMG has been observed in the tongue (glossus) muscle (Figure 2) (Punga, unpublished observations).

2.3 Treatment

Treatment of MG can be divided into two subclasses: immunosuppressive and symptomatic. Since MG is typically a chronic disorder, long-term immunosuppressive medications is often applied and include corticosteroids, corticosteroid sparing agents such as azathioprine and cyclosporine (which inhibit the T-cells) and antibody treatment with rituximab (which inhibits the B-cell response). Since autoimmune MG patients do not respond similarly to the same treatment, each regimen has to be tailored for each patient. For the acute treatment of exacerbations of weakness it may be necessary to employ plasmapheresis or intravenous immunoglobulins, which result in a prompt reduction of the autoimmune response. Patients with a thymoma or young patients usually undergo a thymectomy, removing the thymus which is hyperplastic, as in the majority of cases of AChR-antibodies. The most commonly used chronic symptomatic treatment consists of nonselective acetylcholinesterase inhibitors. These inhibitors render more acetylcholine available at the NMJ, thus temporarily decreasing fatigue. In general, patients with AChR-abs respond better to both immunosuppressive and symptomatic medication than MuSK+ patients.

2.3.1 Immunosuppressive treatment

2.3.1.1 Corticosteroids

Corticosteroids are generally considered to be an effective immunosuppressant for MG patients. Their therapeutic mechanism of action is through inhibition of transcription of inflammatory cytokines (interleukins, IL) and adhesion molecules, and a reduction in trafficking of inflammatory cells such as T-cells, thus reducing the inflammatory response. High doses may also induce apoptosis of inflammatory cells (Barnes 2001). Although widely accepted as an appropriate immunosuppressive therapy, the efficacy of glucocorticosteroid

treatment in MG has only been tested in a few randomized controlled studies (Howard, Duane et al. 1976; Lindberg, Andersen et al. 1998). Lindberg et al reported significant improvement in muscle function in the group of MG patients who received 2 g i v methylprednisolone on two consecutive days compared to the placebo group, duration of improvement ranged from 4 to 14 weeks. Intriguingly, no change in serum concentration of AChR abs was found after treatment in either of the two groups.

There is also a risk of worsening during the first days of initiation of the high doses, usually lasting less than one week. It appears that gradually increasing the steroid dose over one to two months may significantly reduce this risk. Pascuzzi et al reported improvement in as many as 95% of MG patients receiving long-term treatment with prednisone and remission (defined as no more than minimal eye closure weakness) in 28% of patients (Pascuzzi, Coslett et al. 1984). Additionally, corticosteroids appear to have direct effect on the neuromuscular junction, which may play a role for the early alterations and short-term fluctuations in myasthenic weakness seen in patients being treated with corticosteroids. In one study investigating the rat phrenic nerve-diaphragm, intracellular microelectrode recording of miniature end-plate potentials (MEPPs) was used to investigate the effect of prednisone on neuromuscular transmission. The results indicate that prednisone facilitates spontaneous release of acetylcholine (as manifested by a two- to three-fold increase in MEPP frequency) and decreases MEPP amplitude by about 50% (Wilson, Ward et al. 1974). The side effects, especially with long term treatment, are well known and include glucose intolerance, osteoporosis, weight gain, depression, mood swings, hypokalemia, septic ulcers, cushingoid features, myopathy and hypertension. Alternate day therapy is commonly applied in order to reduce side effects. It is also important to reduce the dose of corticosteroids slowly to a minimum that will maintain the remission or improvement in order to avoid worsening.

2.3.1.2 T-cell inhibiting medications

Azathioprine has been used extensively for treatment of MG patients and is considered important as a steroid-sparing agent. Its mechanism of action is to inhibit purine synthesis and hence cell proliferation (Elion 1972). The most rapidly dividing cells, including lymphocytes involved in the autoimmune response, are affected. Prolonged administration of azathioprine prevents the appearance of experimental autoimmune MG (EAMG), for at least four months, in rabbits immunized with AChR (Abramsky, Tarrab-Hazdai et al. 1976). Azathioprine has a delayed onset of effect, on average four to six months, and maximal benefit is reached after a period of approximately 14 months. However, 70-90% of patients have reported a decrease in their myasthenic weakness after some months (Lewis, Selwa et al. 1995). Adverse effects include anorexia, gastrointestinal upset, hepatotoxicity and bone marrow suppression, commonly involving a reduction in white blood cell count. Close monitoring of the blood cell counts, along with liver enzymes, is necessary since a few patients develop a flu-like idiosyncratic reaction which includes fever and malaise and/or a skin rash, requiring discontinuation. Long-term treatment is also associated with an increased risk of developing malignancies (Confavreux, Saddier et al. 1996). Azathioprine is considered important as a steroid-sparing agent in MG treatment, although most studies have described its usefulness in conjunction with corticosteroids. Azathioprine is administered orally with a preferred maintenance dose of 2 to 3 mg/kg per day. The initial dose is 50 mg/d and increases by 50 mg/d every week while monitoring for adverse effects.

Cyclosporine A is another steroid-sparing medication which acts through prohibition of the transcription of cytokine genes, including those of IL-2 and IL-4, in activated T cells (Kronke, Leonard et al. 1984). It is a highly specific inhibitor of T helper cell activation, and also acts to inhibit the phosphatase activity of calcineurin as well as the activation of c-Jun NH2-terminal kinase (JNK) in T lymphocytes and p38 signaling pathways triggered by antigen recognition (Matsuda, Moriguchi et al. 1998). Cyclosporine is widely used to prevent transplant rejection but is used in MG patients not responding to other immunosuppressants. In a therapeutic trial where cyclosporine was compared to placebo, patients in the cyclosporine group had improved strength and a reduction in AChR-Ab titer (Tindall, Phillips et al. 1993). Adverse effects include nephrotoxicity, hypertension and headache; hence, monitoring of blood urea nitrogen and creatinine is necessary. Most patients improve maximally after two to four months of therapy. The usual dose is 3 to 5 mg/kg per day, given orally at 12-hour intervals.

Mycophenolate mofetil (MyM) is the 2-morpholinoethyl ester of mycophenolic acid, which inhibits the proliferation of B and T lymphocytes through noncompetitive, reversible inhibition of inosine monophosphate dehydrogenase, a key enzyme in the *de novo* synthetic pathway of guanine nucleotides. Mycophenolic acid blocks inosine monophosphate dehydrogenase, an enzyme that is responsible for conversion of inosine monophosphate to guanosine monophosphate; hence, synthesis of adenosine is enhanced. This results in inhibition of purine synthesis selectively in lymphocytes, thereby inhibiting their proliferation (Allison, Kowalski et al. 1993). In a larger retrospective study, MyM was associated with clinical improvement in approximately 70% of patients after a period of approximately 11 weeks (Meriggioli, Ciafaloni et al. 2003). MyM is also well tolerated in most patients and only discontinued due to the adverse effects in a very small fraction of patients, the most common reason being gastrointestinal intolerance, such as diarrhea. The long-term safety of MyM is not known, but rates of malignancy do not appear to be higher in transplant recipients who receive MyM chronically (Haberal, Karakayali et al. 2002).

2.3.1.3 Other immunosuppressants

Cyclophosphamide is a nitrogen mustard with potent immunosuppressant effects and is used to treat MG patients who are resistant to other therapies. It affects the proliferation of B cells and thereby reduces antibody production (Fig 1). The use of cyclophosphamide in MG is limited, but undoubtedly beneficial in severe cases (Perez, Buot et al. 1981). The usual dose range from 1 to 3 mg/kg per day, orally. Nevertheless, adverse effects are prominent and include alopecia, hemorrhagic cystitis, leukopenia and nausea. Long-term treatment brings the risk of infertility and malignancy.

Etanercept, a soluble, recombinant human TNF-receptor that competitively blocks the action of TNF- α , has been shown to have steroid-sparing effects in studies on small patient groups. In 54% of patients, with low plasma IL-6 and IFN- γ levels, the clinical scores improved and patients with increased cytokine levels (IL-6, IFN- γ and TNF- α) had worse clinical outcomes (Tuzun, Meriggioli et al. 2005). TNF- α is involved in the generation of AChR-specific T and B cell responses during the development of EAMG and preclinical studies on AChR-immunized mice have shown that etanercept can suppress established EAMG without inducing significant immunosuppression (Christadoss and Goluszko 2002).

Rituximab (Mabtera®) Rituximab is a chimeric IgG1 κ monoclonal antibody that targets CD20, a transmembrane phosphoprotein on most B cells. Rituximab depletes B cells by binding to the CD20 molecule and initiating complement-dependent cytotoxicity or antibody-

dependent cell-mediated cytotoxicity (Monson, Cravens et al. 2005). Several case reports have demonstrated the effect of Rituximab in MuSK+ MG patients on the clinical course of bulbar and respiratory symptoms, thus making it an important alternative for the MuSK+ MG patients who are refractory to other immunosuppressive treatment (Hain, Jordan et al. 2006; Baek, Bashey et al. 2007).

2.3.1.4 Thymectomy

The reason for removing the thymus gland in MG patients has historically been due to the presence of hyperplastic germinal centers, mainly in AChR+ patients. Despite the absence of randomized, well-controlled studies, thymectomy in MG patients with and without thymoma is widely practised. Post-operative improvement can take months or years to appear, making it difficult to distinguish thymectomy effects from those of immunosuppressive drugs, which are often used concomitantly (Skeie, Apostolski et al. 2010). Thymectomy is usually performed using a transsternal approach, removing the entire thymus gland, usually in patients less than 60 years of age. In MG patients with a thymoma, the main aim of thymectomy is to preferentially treat the tumour. Once thymoma is diagnosed, thymectomy is indicated irrespective of the severity of MG. One study (Evoli, Tonali et al. 2003) could not prove any effect of thymectomy in 15 MuSK+ patients, whereas MuSK antibodies predicted a poor outcome of thymectomy in another study (Pompeo, Tacconi et al. 2009). Additionally, it has been reported that MuSK+ patients have normal histopathology of the thymus (Leite, Strobel et al. 2005). Thus, current evidence suggests that thymectomy should not be recommended in MuSK+ patients. However, early onset generalized MG without AChR and MuSK antibodies are recommended to have thymectomy in the same way as MG with AChR antibodies.

2.3.1.5 Plasmapheresis and immunoglobulins

Plasma exchange and intravenous immunoglobulin (IvIg) are used for short-term treatment of MG exacerbations and when it is desirable to achieve a rapid clinical response. Plasma exchange temporarily reduces the titer of circulating AChR- and MuSK-abs and usually produces immediate improvement (within days) in most MG patients (Newsom-Davis, Pinching et al. 1978). Circulating anti-AChR pathogenic factors can also be removed using immunoabsorption columns, some of which use immobilised AChR as an immunoabsorbent (Psaridi-Linardaki, Trakas et al. 2005). IvIg is widely used for patients with exacerbating MG. Support for its use comes from randomised controlled trials that show efficacy similar to plasma exchange (Gajdos, Chevret et al. 1997), equal efficacy of two doses (1 g/kg vs 2 g/kg) (Gajdos, Tranchant et al. 2005) and a recent double-blind, placebo controlled trial in patients with MG with worsening weakness (Zinman, Ng et al. 2007). The mechanisms by which intravenous immunoglobulins induce improvement are not clear, however studies in murine autoimmune models have implied that competition with autoantibodies and Fc-receptor binding are important factors in reducing the autoimmune response (Samuelsson, Towers et al. 2001).

2.3.2.1 Acetylcholinesterase inhibitors (AChEIs)

AChEIs interfere with the catalytic breakdown of the neurotransmitter ACh, rendering ACh available for a longer period of time at the NMJ and the nicotinic AChRs (nAChRs). The nonselective AChEIs affect both the nAChRs and the muscarinic receptors in exocrine glands. Common adverse effects include muscarinic symptoms, such as increased gut

motility, which may lead to stomach pain and diarrhea. Other muscarinic effects are increased gastric acid secretion, hyperhidrosis, increased sweating, salivation, and lacrimation. The presence of daily muscarinic adverse effects correlates with the baseline inhibition of AChE activity in the blood (Punga, Sawada et al. 2008). The most common form of nonselective AChEI is pyridostigmine bromide (PB Mestinon®), which is especially effective at the onset of MG. In some patients, typically those with purely ocular weakness, this treatment may be sufficient to manage the fatigue. Overdose of AChEIs can cause a cholinergic crisis, which is characterized by increasing muscle weakness, which results in dysphagia and respiratory insufficiency in severe cases. The distinction between a cholinergic and a myasthenic crisis, the latter being caused by myasthenic weakness, is important for the medical treatment of the patient. These two conditions have different clinical reactions related to the initial intake of the drug. During incipient overdose in cholinergic crisis, symptoms of weakness increase shortly after ingestion and wane before the next dose, a situation opposite to that seen in myasthenic crisis. This typical pattern may not always be easy to detect; therefore, other markers are useful. For example, the EDs observed on motor nerve stimulation are sometimes observed in MG patients who are receiving high doses of PB and may signify impending cholinergic crisis (Punga and Stalberg 2009).

Recent reports imply that patients with EDs are more prone to have daily nicotinic side effects, including muscle fasciculations and fatigue as a possible sign of overtreatment (Punga, Sawada et al. 2008). In this study, elderly MG patients were more prone to develop cholinergic side effects, as well as EDs. Additionally, MuSK+ MG patients often have a negative edrophonium test and are also reported to clinically benefit less from pyridostigmine bromide (Evoli, Bianchi et al. 2008). Instead, MuSK+ patients may worsen or develop pronounced nicotinic side effects including muscle cramps and fasciculations in response to PB treatment (Evoli, Tonali et al. 2003; Punga, Flink et al. 2006). Based on these observations of hypersensitivity to increased amounts of acetylcholine in MuSK+ patients, the general guidelines do not recommend AChEIs as a form of treatment in this group of patients (Skeie, Apostolski et al. 2010).

EN101 is a selective AChEI, an antisense oligodeoxynucleotide that acts at the mRNA level and selectively reduces the production of the enzymatic isoform of stress-related “read-through” (AChE-R) through destruction of AChE-R mRNA. This compound selectively lowers the levels of AChE-R in both blood and muscle, yet leaves the synaptic variant of AChE-S unaffected. EN101 treatment in rats with EAMG, in which daily oral or intravenous administration of EN101 reduced AChE in blood and muscle and improved survival, muscle strength and disease severity (Brenner, Hamra-Amitay et al. 2003). In this study, stabilization of the CMAP decrement on RNS and muscle strength over the entire course of treatment was also observed. Interestingly, a Phase 1b open-label trial with oral EN101 (Monarsen) was recently conducted in 16 MG patients who were receiving at least 180 mg of pyridostigmine bromide daily (Argov, McKee et al. 2007). This study reported an overall clinical improvement in approximately 47% of patients, as well as an improvement in the swallowing time component. Further, the effects of EN101 lasted for greater than 24 hours, indicating the possibility of a reduction in multiple dosing through the use of antisense therapy. Further studies are needed to conclude whether EN101 may also have immunomodulatory effects through an effect on the immune cholinergic system and thus mediation of neuroimmune interactions.

2.4 Establishment and phenotype of murine models of experimental autoimmune MG (EAMG)

Naturally occurring MG in animals is present in canine MG. This canine form of MG has a natural course of clinical and immunological remission in the majority of dogs, even without initiation of immunosuppressive treatment (Shelton and Lindstrom 2001). Therefore, the use of the canine MG in determining the effect of immunosuppressant medication is limited. EAMG can be induced in rabbits, rats and mice either by passive transfer of human antibodies/sera or by immunization of the antigen in adjuvant. In 1978 it was first shown that active immunization with AChR from *Torpedo* (ray fish) electric organ, in rabbits leads to flaccid paralysis and an MG-like disease. Since in rabbits the disease has an acute action and shortly leads to death, these animals are not routinely used for EAMG studies. Some studies have used guinea pigs and even primates, but the current most widely used model is EAMG induced in female young mice or rats. The disease in rats has a short acute phase and a chronic phase, which mimics the human disease, excluding the involvement of the thymus (Meinl, Klinkert et al. 1991). In the mice only a chronic phase is induced. EAMG is more difficult to induce in mice and usually requires multiple immunizations and only a fraction of the mice develop disease symptoms. However, the murine model has an advantage of a plethora of mouse-specific reagents and knock-out mouse strains, which enable analyses that cannot be performed in rats. One further advantage of using the mouse is that its immune system is well characterized and the availability of inbred and genetically modified strains permit genetic analysis.

2.4.1 AChR+ EAMG: Clinical phenotype

Immunization with purified denatured *Torpedo* AChR $\alpha 1$, $\beta 1$, γ , or δ subunits can cause EAMG, but it is inefficient compared to native AChR (Lindstrom, Einarson et al. 1978). Purified $\alpha 1$ -subunit is the most potent, as might be expected since its sequence is the most conserved. Also, there are two $\alpha 1$ in an AChR which permit cross-linking by antibodies, which may utilize renaturation to provoke antibodies to the main immunogenic region (MIR) (Lindstrom, Luo et al. 2008). It is of utmost importance to use a mouse strain which possesses IL-6, since mice deficient in IL-6 have been shown to be resistant to the development of EAMG upon immunization (Deng, Goluszko et al. 2002). In the acute phase of active EAMG or EAMG passively transmitted with serum, binding of AChR antibody and its complement target the postsynaptic membrane for attack by macrophages (Lindstrom 2000). Mice immunized with AChR in Complete Freund's Adjuvant (CFA) develop a flaccid paralysis (Figure 4a), a drooping of the head and tail and weakness primarily of the forelimbs, which may rapidly progress to respiratory failure (Berman and Patrick 1980). The myasthenic phenotype in the AChR+ EAMG mice has been reported to be restored in all cases to nearly normal after treatment with neostigmine intraperitoneally (Berman and Patrick 1980).

2.4.2 MuSK+ EAMG: Clinical phenotype

The antibodies in MuSK+ MG are directed against the extracellular domain of MuSK, which contains IgG-like domains. The first study which proved the pathogenic role of MuSK-antibodies in animals was done in 2006, when New Zealand White rabbits were repeatedly injected with 100-400 μ g of purified chimeric protein composed of the MuSK ectodomain

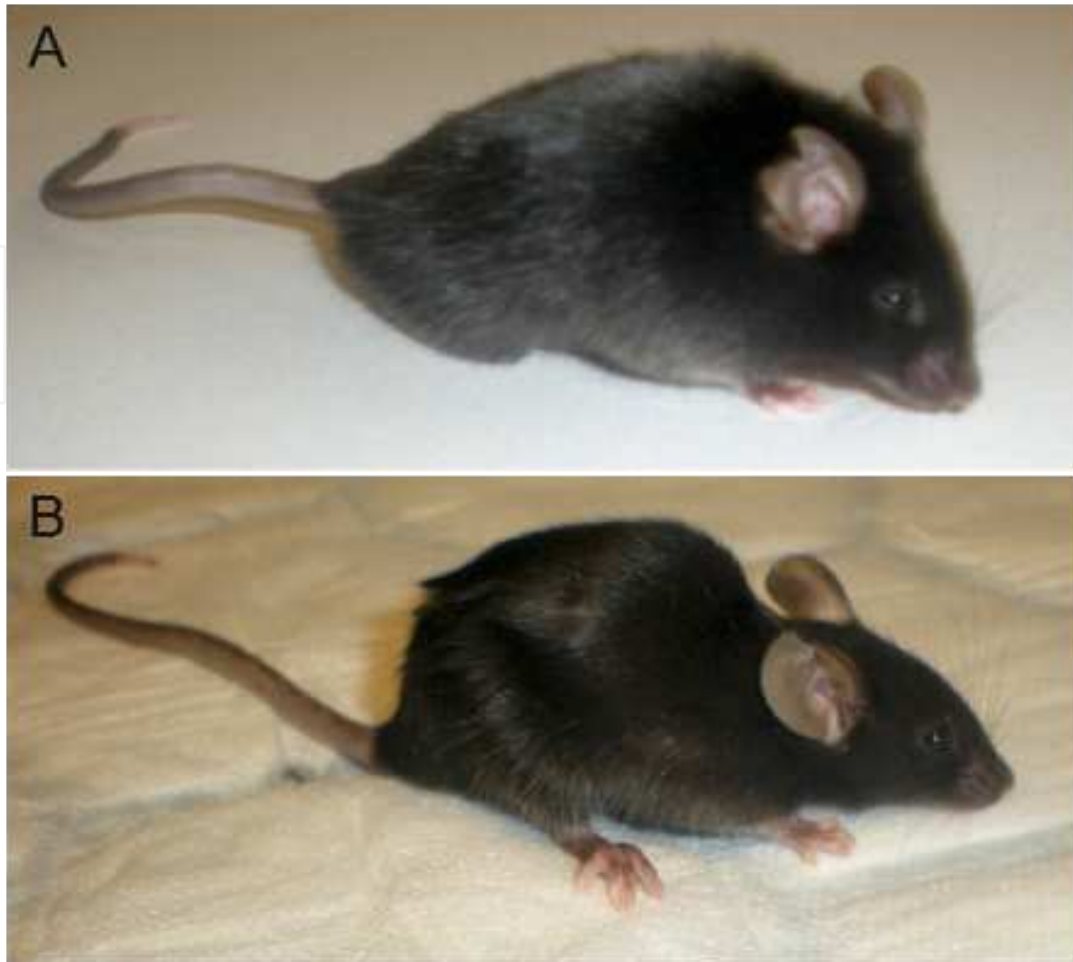


Fig. 4. A) One mouse with typical flaccid paralysis, especially of the limbs, after immunization with torpedo AChR. The clinical course in the AChR+ mice is progressive, however the response to intraperitoneal injection of neostigmine induces an improvement in clinical weakness. B) The phenotype of the mice immunized with rat MuSK shows a severe weakness of the neck extensor muscles, demonstrating a prominent cervical kyphosis and inability to raise the head. The mice are not as affected in the hind limbs as in the forelimbs and faciobulbar area, with difficulties ingesting food and water and subsequent significant weight loss. The MuSK+ mice do not show any clinical improvement from neostigmine injection, on the contrary muscle fasciculations and twitches are seen.

and the Fc region of human IgG1 (MuSK-Fc) (Shigemoto, Kubo et al. 2006). All of the 4 recipient rabbits manifested flaccid weakness after 3 or 4 repeated injections with MuSK-Fc. The actively induced murine model can be produced produced by injection of the extracellular domain of 10 μ g of recombinant rat MuSK (aa 21-491) (Jones, Moore et al. 1999) in a mix with CFA in emulsion (Jha, Xu et al. 2006). The prominent features of MuSK+ EAMG in mice resemble the human MuSK+MG phenotype with kyphosis, indicating weakness in the cervical extensor muscles and the thoracic paraspinal muscles (Figure 4b). Additionally, one prominent clinical feature of the MuSK+ mice is the weight loss, which is significant compared to the control mice (Punga, Lin et al, 2011). This finding further supports the involvement of faciobulbar weakness, preventing the MuSK+ EAMG mice to chew and swallow and therefore explaining the irreversible weight loss. Passively induced

MuSK+ EAMG has been accomplished by i.p. injections of plasma (Benveniste, Jacobson et al. 2005) or purified IgG from MuSK+ MG patients (Cole, Reddel et al. 2008) in C57BL6 mice. Cole et al also reported that mice injected with IgG from two of three anti-MuSK-positive patients lost weight, developed myasthenic muscle weakness and a prominent cervicothoracic hump, which may reflect cervical extensor weakness.

2.4.3 Morphological changes at the neuromuscular junction and muscle atrophy in EAMG

In experimental mice injected with anti-MuSK-positive patient IgG, postsynaptic AChR staining is reduced to as little as 22% of that seen in control mice in both the tibial and diaphragm muscles (Cole, Reddel et al. 2008). The mice which develop MuSK+ EAMG following this injection show reduced apposition of the nerve terminal and the postsynaptic AChR cluster. In later studies, mice injected with MuSK+ patient IgG have also been found to have reductions in postsynaptic MuSK staining and this loss preceded the impairment of postsynaptic AChRs (Cole, Ghazanfari et al. 2010). In this study, the residual level of MuSK correlated with the degree of impairment of postsynaptic AChR packing. The sera obtained from mice immunized with MuSK inhibit agrin-induced AChR aggregation in C2C12 myotubes (Jha, Xu et al. 2006). Further, disruption of neuromuscular junctions have been observed and it has been proposed that so called delayed synapsing muscles, including the diaphragm, tibialis posterior and sternomastoid are more severely affected than the so called fast-synapsing muscles (Xu, Jha et al. 2006).

In a recent study, morphological changes presynaptically and postsynaptically in whole mount preparations of muscle fibers from the bulbar sternomastoid and omohyoid muscles were examined in control mice and in mice immunized with MuSK (Punga, Lin et al, 2011). In the control mice, the postsynaptic clusters (labeled with α -bungarotoxin) were closely aligned with the presynaptic motor nerve terminal (Figure 5a). However, in the MuSK+ EAMG mice, a severe disruption of the NMJ morphology was observed, especially prominent in the facial and neck muscles (Punga, Lin et al, 2011). The AChR clusters were fragmented and dispersed along the muscle fiber (Figure 5b). Except for disruption of the postsynaptic area with less clustering of AChRs, the nerve terminal area was found to be smaller than in the control mice (Figure 5b), suggesting a secondary presynaptic effect of reduced MuSK signalling. When comparing the morphology of the NMJs in the bulbar omohyoid muscle, the AChR clusters were arranged in the junctional folds in the control mice (Figure 6a). In parallel rounds of mice immunized with MuSK or AChR confocal images revealed that the AChR clusters were severely fragmented in the MuSK+ mice (Figure 6b), whereas in the AChR+ EAMG mice a similar fragmentation of the AChRs was not observed, although the AChR clusters and the folding of the NMJs were simplified (Figure 6c).

Benveniste et al found increased protein levels of the muscle RING-finger protein 1 (MuRF-1), a marker for skeletal muscle atrophy, in the masseter muscle, but not in the gastrocnemius muscle, of mice injected with plasma from MuSK+ MG patients (Benveniste, Jacobson et al. 2005). Increased mRNA levels of MuRF-1 and atrogen-1 have also been found in the masseter of MuSK+ EAMG mice, but not in the limb muscles, further in support of a atrophy process localized to the facial muscles (Punga, Lin et al, 2011; Punga, unpublished data). There is a difference in the reaction to disturbed or exaggerated agrin-MuSK signalling in different skeletal muscles in the sense that muscles with high MuSK levels have

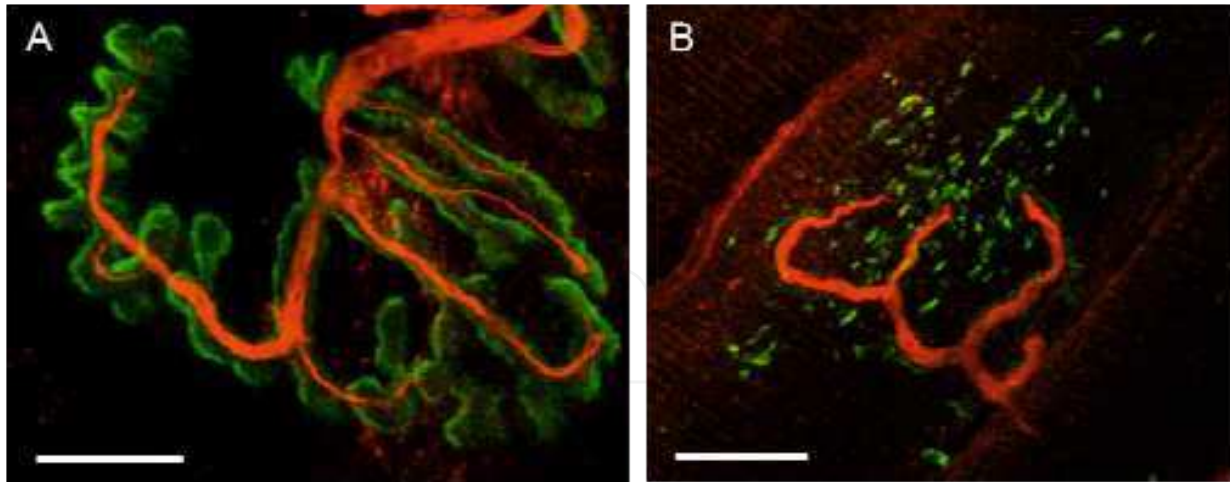


Fig. 5. The effect of MuSK-antibodies at the neuromuscular junction (NMJ) in mice immunized with MuSK. Confocal microscopy images with 100x magnification of immunostained whole mount muscle fibers from the sternomastoid muscle. A) A normal NMJ, where α -bungarotoxin labels the AChR clusters (green) and antibodies against synaptophysin and neurofilament labels the nerve terminal (red). Note the close alignment between the motor nerve terminal and clustered postsynaptic AChRs. B) In MuSK+ MG, the presynaptic nerve terminal area is significantly smaller and the AChR clusters are fragmented and scattered along the muscle fiber. Scale bar is 10 μ m.

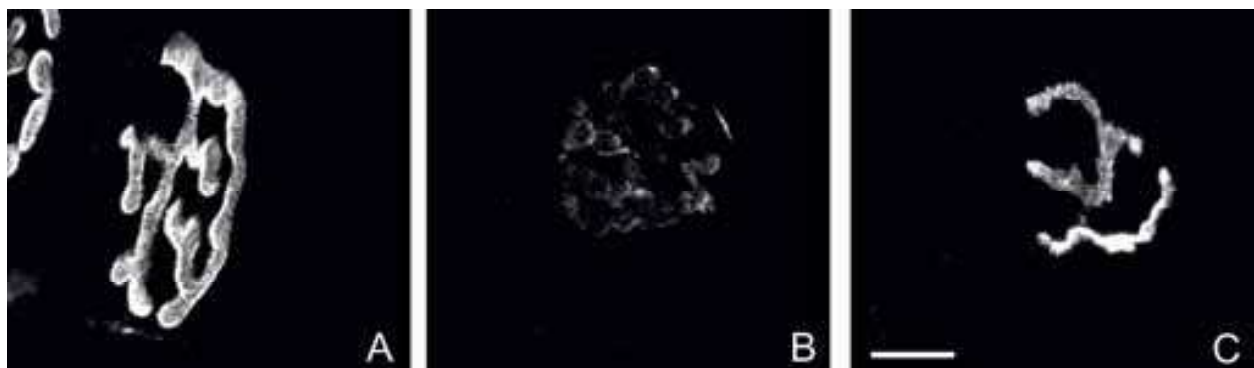

Fig. 6. Immunolabeling of whole mount muscle fibers from the omohyoid muscle, where postsynaptic acetylcholine receptors (AChRs) are labelled with α -bungarotoxin (white). In the control mice (A) a normal pattern with postsynaptic AChR clusters are seen in the junctional folds, adjacent to the motor nerve. In MuSK+ EAMG mice (B), the AChRs are very faint, with a subsequent reduction in postsynaptic AChR cluster area. In AChR+ EAMG mice (C), the staining intensity of the α -bungarotoxin was less reduced than in the MuSK+ EAMG mice, however there is a disruption in AChR cluster morphology with simplification of the postsynaptic morphology and less folding. Scale bar is 10 μ m.

an increased plasticity (Punga, Maj et al, 2011). In the contrary, low muscle-intrinsic MuSK levels render some muscles, such as the masseter, more vulnerable to the postsynaptic perturbation of MuSK antibodies with subsequent denervation and atrophy (Punga, Lin et al, 2011). This is hypothesized to play a role for the muscle selectivity also in MuSK+ MG and EAMG.

2.4.4 Cholinergic hyperactivity after AChEIs in EAMG

Evaluation of the response to AChEIs is usually performed by i.p. injection of a mix of neostigmine bromide (0.0375 mg/kg) and atropine sulfate (0.015 mg/kg) in mice with EAMG grade 2 and 3 (Berman and Patrick 1980).

In 3 MuSK+ EAMG mice, the opposite response to the common restoration of weakness in AChR+ EAMG was seen with more pronounced weakness which manifested itself as chin down even more along with nicotinic side effects including muscle fasciculations in the back- and limb muscles and abnormal twitches of the tail (Punga et al, unpublished observations). The observed fragmentation and dispersion of AChR clusters could explain why MuSK+ MG patients do not respond beneficially to AChEIs, since an increased acetylcholine level would not be able to induce a synchronous endplate potential due to the temporal dispersion of AChRs. Additionally, the reason for the cholinergic hyperactivity in MuSK+ MG, here also displayed in the MuSK+ EAMG mice, may be explained by the loss of MuSK at the NMJ, which in turn also diminishes the binding between MuSK-ColQ and AChE. This means that in the MuSK+ EAMG mice where MuSK antibodies disrupt the NMJ and reduce the amount of MuSK, the AChE is also down-regulated (Punga, Lin et al, 2011). Then, when exogenous AChEI is administered, a further blocking of AChE is taking place and consequently this mimics an overdose of AChEIs which causes the nicotinic side effects and in worst cases also cholinergic crisis.

3. Conclusion

In summary, studies in the recent years of the murine EAMG model provide further insights regarding the action of MuSK antibodies at the NMJ and give evidence for their pathogenetic role, especially in facial and bulbar muscles. The results of the MuSK antibody attack is fragmentation and dispersion of nicotinic AChRs, postsynaptic perturbation and a subsequent impaired neuromuscular transmission. Since MuSK+ MG is very focal in its clinical manifestations it is very important to examine the clinically weak muscles also neurophysiologically to confirm the diagnosis, and for morphological purpose when examining the NMJ pathophysiology. The findings of dispersion of AChRs may also indicate irreparable changes at the NMJ, explaining muscle atrophies in these patients. It is therefore of importance to identify MG patients as early as possible, and especially MuSK+ MG, since delayed treatment may result in muscle atrophies and even functional denervation due to long time of blocked neuromuscular transmission. Immunosuppressive treatment should always be the main medication in MG and AChEIs is not recommended as symptomatic treatment in MuSK+ patients due to the cholinergic hypersensitivity and unbeneficial effects.

4. Acknowledgment

I thank the group of Professor Markus A Rüegg in the department of Neurobiology/Pharmacology in Basel, Switzerland, for collaboration on the AChR+ and MuSK+ EAMG mouse model, especially professor Rüegg for the scientific discussions, Dr Shuo Lin for the work on the muscle morphology and Filippo Oliveri for production of recombinant rat MuSK. Professor emeritus Erik V Stålberg is acknowledged for guiding and supporting the initial MG studies, for teaching me SFEMG, for the scientific discussions and for the great friendship. I genuinely thank my family for their never-ending love and support.

Financial support was given by a postdoctoral fellowship from the Swedish Association for Medical Research (SSMF), Lars Hiertas memorial foundation and from European Union FP7 project number 242210 "FIGHT-MG".

5. References

- Aarli, J. A., K. Stefansson, et al. (1990). "Patients with myasthenia gravis and thymoma have in their sera IgG autoantibodies against titin." *Clin Exp Immunol* 82(2): 284-8.
- Abramsky, O., R. Tarrab-Hazdai, et al. (1976). "Immunosuppression of experimental autoimmune myasthenia gravis by hydrocortisone and azathioprine." *J Immunol* 117(1): 225-8.
- Allison, A. C., W. J. Kowalski, et al. (1993). "Mechanisms of action of mycophenolic acid." *Ann N Y Acad Sci* 696: 63-87.
- Argov, Z., D. McKee, et al. (2007). "Treatment of human myasthenia gravis with oral antisense suppression of acetylcholinesterase." *Neurology* 69(7): 699-700.
- Baek, W. S., A. Bashey, et al. (2007). "Complete remission induced by rituximab in refractory, seronegative, muscle-specific, kinase-positive myasthenia gravis." *J Neurol Neurosurg Psychiatry* 78(7): 771.
- Barnes, P. J. (2001). "Molecular mechanisms of corticosteroids in allergic diseases." *Allergy* 56(10): 928-36.
- Bartoccioni, E., M. Marino, et al. (2003). "Identification of disease-specific autoantibodies in seronegative myasthenia gravis." *Ann N Y Acad Sci* 998: 356-8.
- Benveniste, O., L. Jacobson, et al. (2005). "MuSK antibody positive myasthenia gravis plasma modifies MURF-1 expression in C2C12 cultures and mouse muscle in vivo." *J Neuroimmunol* 170(1-2): 41-8.
- Berman, P. W. and J. Patrick (1980). "Experimental myasthenia gravis. A murine system." *J Exp Med* 151(1): 204-23.
- Brenner, T., Y. Hamra-Amitay, et al. (2003). "The role of readthrough acetylcholinesterase in the pathophysiology of myasthenia gravis." *Faseb J* 17(2): 214-22.
- Christadoss, P. and E. Goluszko (2002). "Treatment of experimental autoimmune myasthenia gravis with recombinant human tumor necrosis factor receptor Fc protein." *J Neuroimmunol* 122(1-2): 186-90.
- Cole, R. N., N. Ghazanfari, et al. (2010). "Patient autoantibodies deplete postsynaptic muscle-specific kinase leading to disassembly of the ACh receptor scaffold and myasthenia gravis in mice." *J Physiol* 588(Pt 17): 3217-29.
- Cole, R. N., S. W. Reddel, et al. (2008). "Anti-MuSK patient antibodies disrupt the mouse neuromuscular junction." *Ann Neurol* 63(6): 782-9.
- Colledge, M. and S. C. Froehner (1998). "Signals mediating ion channel clustering at the neuromuscular junction." *Curr Opin Neurobiol* 8(3): 357-63.
- Confavreux, C., P. Saddinger, et al. (1996). "Risk of cancer from azathioprine therapy in multiple sclerosis: a case-control study." *Neurology* 46(6): 1607-12.
- DeChiara, T. M., D. C. Bowen, et al. (1996). "The receptor tyrosine kinase MuSK is required for neuromuscular junction formation in vivo." *Cell* 85(4): 501-12.
- Deng, C., E. Goluszko, et al. (2002). "Resistance to experimental autoimmune myasthenia gravis in IL-6-deficient mice is associated with reduced germinal center formation and C3 production." *J Immunol* 169(2): 1077-83.
- Drachman, D. B., R. N. Adams, et al. (1981). "Antibody-mediated mechanisms of ACh receptor loss in myasthenia gravis: clinical relevance." *Ann N Y Acad Sci* 377: 175-88.

- Elion, G. B. (1972). "Significance of azathioprine metabolites." *Proc R Soc Med* 65(3): 257-60.
- Engel, A. G., E. H. Lambert, et al. (1977). "Immune complexes (IgG and C3) at the motor end-plate in myasthenia gravis: ultrastructural and light microscopic localization and electrophysiologic correlations." *Mayo Clin Proc* 52(5): 267-80.
- Evoli, A., M. R. Bianchi, et al. (2008). "Response to therapy in myasthenia gravis with anti-MuSK antibodies." *Ann N Y Acad Sci* 1132: 76-83.
- Evoli, A., C. Minisci, et al. (2002). "Thymoma in patients with MG: characteristics and long-term outcome." *Neurology* 59(12): 1844-50.
- Evoli, A., P. A. Tonali, et al. (2003). "Clinical correlates with anti-MuSK antibodies in generalized seronegative myasthenia gravis." *Brain* 126(Pt 10): 2304-11.
- Farrugia, M. E., R. P. Kennett, et al. (2007). "Quantitative EMG of facial muscles in myasthenia patients with MuSK antibodies." *Clin Neurophysiol* 118(2): 269-77.
- Farrugia, M. E., M. D. Robson, et al. (2006). "MRI and clinical studies of facial and bulbar muscle involvement in MuSK antibody-associated myasthenia gravis." *Brain* 129(Pt 6): 1481-92.
- Gajdos, P., S. Chevret, et al. (1997). "Clinical trial of plasma exchange and high-dose intravenous immunoglobulin in myasthenia gravis. Myasthenia Gravis Clinical Study Group." *Ann Neurol* 41(6): 789-96.
- Gajdos, P., C. Tranchant, et al. (2005). "Treatment of myasthenia gravis exacerbation with intravenous immunoglobulin: a randomized double-blind clinical trial." *Arch Neurol* 62(11): 1689-93.
- Gautam, M., P. G. Noakes, et al. (1995). "Failure of postsynaptic specialization to develop at neuromuscular junctions of rapsyn-deficient mice." *Nature* 377(6546): 232-6.
- Grob, D., N. Brunner, et al. (2008). "Lifetime course of myasthenia gravis." *Muscle Nerve* 37(2): 141-9.
- Haberal, M., H. Karakayali, et al. (2002). "Malignant tumors after renal transplantation." *Artif Organs* 26(9): 778-81.
- Hain, B., K. Jordan, et al. (2006). "Successful treatment of MuSK antibody-positive myasthenia gravis with rituximab." *Muscle Nerve* 33(4): 575-80.
- Hall, Z. W. and J. R. Sanes (1993). "Synaptic structure and development: the neuromuscular junction." *Cell* 72 Suppl: 99-121.
- Hesser, B. A., O. Henschel, et al. (2006). "Synapse disassembly and formation of new synapses in postnatal muscle upon conditional inactivation of MuSK." *Mol Cell Neurosci* 31(3): 470-80.
- Higuchi, O., J. Hamuro, et al. (2011). "Autoantibodies to low-density lipoprotein receptor-related protein 4 in myasthenia gravis." *Ann Neurol* 69(2): 418-22.
- Hoch, W., J. McConville, et al. (2001). "Auto-antibodies to the receptor tyrosine kinase MuSK in patients with myasthenia gravis without acetylcholine receptor antibodies." *Nat Med* 7(3): 365-8.
- Hopf, C. and W. Hoch (1998). "Tyrosine phosphorylation of the muscle-specific kinase is exclusively induced by acetylcholine receptor-aggregating agrin fragments." *Eur J Biochem* 253(2): 382-9.
- Howard, F. M., Jr., D. D. Duane, et al. (1976). "Alternate-day prednisone: preliminary report of a double-blind controlled study." *Ann N Y Acad Sci* 274: 596-607.
- Jha, S., K. Xu, et al. (2006). "Myasthenia gravis induced in mice by immunization with the recombinant extracellular domain of rat muscle-specific kinase (MuSK)." *J Neuroimmunol* 175(1-2): 107-17.

- Jones, G., C. Moore, et al. (1999). "Constitutively active MuSK is clustered in the absence of agrin and induces ectopic postsynaptic-like membranes in skeletal muscle fibers." *J Neurosci* 19(9): 3376-83.
- Kalb, B., G. Matell, et al. (2002). "Epidemiology of myasthenia gravis: a population-based study in Stockholm, Sweden." *Neuroepidemiology* 21(5): 221-5.
- Kim, N., A. L. Stiegler, et al. (2008). "Lrp4 is a receptor for Agrin and forms a complex with MuSK." *Cell* 135(2): 334-42.
- Kong, X. C., P. Barzaghi, et al. (2004). "Inhibition of synapse assembly in mammalian muscle in vivo by RNA interference." *EMBO Rep* 5(2): 183-8.
- Kronke, M., W. J. Leonard, et al. (1984). "Cyclosporin A inhibits T-cell growth factor gene expression at the level of mRNA transcription." *Proc Natl Acad Sci U S A* 81(16): 5214-8.
- Lefvert, A. K., S. Cuenoud, et al. (1981). "Binding properties and subclass distribution of anti-acetylcholine receptor antibodies in myasthenia gravis." *J Neuroimmunol* 1(1): 125-35.
- Leite, M. I., S. Jacob, et al. (2008). "IgG1 antibodies to acetylcholine receptors in 'seronegative' myasthenia gravis." *Brain* 131(Pt 7): 1940-52.
- Leite, M. I., P. Strobel, et al. (2005). "Fewer thymic changes in MuSK antibody-positive than in MuSK antibody-negative MG." *Ann Neurol* 57(3): 444-8.
- Lewis, R. A., J. F. Selwa, et al. (1995). "Myasthenia gravis: immunological mechanisms and immunotherapy." *Ann Neurol* 37 Suppl 1: S51-62.
- Lindberg, C., O. Andersen, et al. (1998). "Treatment of myasthenia gravis with methylprednisolone pulse: a double blind study." *Acta Neurol Scand* 97(6): 370-3.
- Lindstrom, J. (2004). "Is 'seronegative' MG explained by autoantibodies to MuSK?" *Neurology* 62(11): 1920-1.
- Lindstrom, J., B. Einarson, et al. (1978). "Immunization of rats with polypeptide chains from torpedo acetylcholine receptor causes an autoimmune response to receptors in rat muscle." *Proc Natl Acad Sci U S A* 75(2): 769-73.
- Lindstrom, J., J. Luo, et al. (2008). "Myasthenia gravis and the tops and bottoms of AChRs: antigenic structure of the MIR and specific immunosuppression of EAMG using AChR cytoplasmic domains." *Ann N Y Acad Sci* 1132: 29-41.
- Lindstrom, J. M. (2000). "Acetylcholine receptors and myasthenia." *Muscle Nerve* 23(4): 453-77.
- Lindstrom, J. M., M. E. Seybold, et al. (1976). "Antibody to acetylcholine receptor in myasthenia gravis. Prevalence, clinical correlates, and diagnostic value." *Neurology* 26(11): 1054-9.
- Liyanage, Y., W. Hoch, et al. (2002). "The agrin/muscle-specific kinase pathway: new targets for autoimmune and genetic disorders at the neuromuscular junction." *Muscle Nerve* 25(1): 4-16.
- Matsuda, S., T. Moriguchi, et al. (1998). "T lymphocyte activation signals for interleukin-2 production involve activation of MKK6-p38 and MKK7-SAPK/JNK signaling pathways sensitive to cyclosporin A." *J Biol Chem* 273(20): 12378-82.
- McConville, J., M. E. Farrugia, et al. (2004). "Detection and characterization of MuSK antibodies in seronegative myasthenia gravis." *Ann Neurol* 55(4): 580-4.
- Meinl, E., W. E. Klinkert, et al. (1991). "The thymus in myasthenia gravis. Changes typical for the human disease are absent in experimental autoimmune myasthenia gravis of the Lewis rat." *Am J Pathol* 139(5): 995-1008.
- Meriggioli, M. N., E. Ciafaloni, et al. (2003). "Mycophenolate mofetil for myasthenia gravis: an analysis of efficacy, safety, and tolerability." *Neurology* 61(10): 1438-40.

- Meriggioli, M. N. and J. Rowin (2003). "Single fiber EMG as an outcome measure in myasthenia gravis: results from a double-blind, placebo-controlled trial." *J Clin Neurophysiol* 20(5): 382-5.
- Miller, J. F. (1961). "Immunological function of the thymus." *Lancet* 2(7205): 748-9.
- Monson, N. L., P. D. Cravens, et al. (2005). "Effect of rituximab on the peripheral blood and cerebrospinal fluid B cells in patients with primary progressive multiple sclerosis." *Arch Neurol* 62(2): 258-64.
- Mygland, A., O. B. Tysnes, et al. (1992). "Ryanodine receptor autoantibodies in myasthenia gravis patients with a thymoma." *Ann Neurol* 32(4): 589-91.
- Nemoto, Y., S. Kuwabara, et al. (2005). "Patterns and severity of neuromuscular transmission failure in seronegative myasthenia gravis." *J Neurol Neurosurg Psychiatry* 76(5): 714-8.
- Newsom-Davis, J., A. J. Pinching, et al. (1978). "Function of circulating antibody to acetylcholine receptor in myasthenia gravis: investigation by plasma exchange." *Neurology* 28(3): 266-72.
- Oh, S. J., Y. Hatanaka, et al. (2006). "Repetitive nerve stimulation of facial muscles in MuSK antibody-positive myasthenia gravis." *Muscle Nerve* 33(4): 500-4.
- Okada, K., A. Inoue, et al. (2006). "The muscle protein Dok-7 is essential for neuromuscular synaptogenesis." *Science* 312(5781): 1802-5.
- Osserman, K. E. and G. Genkins (1971). "Studies in myasthenia gravis: review of a twenty-year experience in over 1200 patients." *Mt Sinai J Med* 38(6): 497-537.
- Pascuzzi, R. M., H. B. Coslett, et al. (1984). "Long-term corticosteroid treatment of myasthenia gravis: report of 116 patients." *Ann Neurol* 15(3): 291-8.
- Perez, M. C., W. L. Buot, et al. (1981). "Stable remissions in myasthenia gravis." *Neurology* 31(1): 32-7.
- Phillips, L. H., 2nd (2003). "The epidemiology of myasthenia gravis." *Ann N Y Acad Sci* 998: 407-12.
- Pompeo, E., F. Tacconi, et al. (2009). "Long-term outcome of thoracoscopic extended thymectomy for nonthymomatous myasthenia gravis." *Eur J Cardiothorac Surg* 36(1): 164-9.
- Psaridi-Linardaki, L., N. Trakas, et al. (2005). "Specific immunoadsorption of the autoantibodies from myasthenic patients using the extracellular domain of the human muscle acetylcholine receptor alpha-subunit. Development of an antigen-specific therapeutic strategy." *J Neuroimmunol* 159(1-2): 183-91.
- Punga, A. R., R. Flink, et al. (2006). "Cholinergic neuromuscular hyperactivity in patients with myasthenia gravis seropositive for MuSK antibody." *Muscle Nerve* 34(1): 111-5.
- Punga A.R., M. Maj, et al. (2011). "MuSK levels differ between adult skeletal muscles and influence postsynaptic plasticity." *Eur J Neurosci* 33(5):890-8.
- Punga A.R., S. Lin, et al (2011). "Muscle-selective synaptic disassembly and reorganization in MuSK antibody positive MG mice." *Exp Neurol*, in press.
- Punga, A. R., M. Sawada, et al. (2008). "Electrophysiological signs and the prevalence of adverse effects of acetylcholinesterase inhibitors in patients with myasthenia gravis." *Muscle Nerve* 37(3): 300-7.
- Punga, A. R. and E. Stalberg (2009). "Acetylcholinesterase inhibitors in MG: to be or not to be?" *Muscle Nerve* 39(6): 724-8.
- Rostedt, A., L. L. Sanders, et al. (2000). "Predictive value of single-fiber electromyography in the extensor digitorum communis muscle of patients with ocular myasthenia gravis: a retrospective study." *J Clin Neuromuscul Dis* 2(1): 6-9.

- Rostedt Punga, A., K. Ahlqvist, et al. (2006). "Neurophysiological and mitochondrial abnormalities in MuSK antibody seropositive myasthenia gravis compared to other immunological subtypes." *Clin Neurophysiol* 117(7): 1434-43.
- Samuelsson, A., T. L. Towers, et al. (2001). "Anti-inflammatory activity of IVIG mediated through the inhibitory Fc receptor." *Science* 291(5503): 484-6.
- Sanders, D. B. (2002). "Clinical impact of single-fiber electromyography." *Muscle Nerve Suppl* 11: S15-20.
- Sanders, D. B., K. El-Salem, et al. (2003). "Clinical aspects of MuSK antibody positive seronegative MG." *Neurology* 60(12): 1978-80.
- Sanders, D. B. and V. C. Juel (2008). "MuSK-antibody positive myasthenia gravis: questions from the clinic." *J Neuroimmunol* 201-202: 85-9.
- Selcen, D., T. Fukuda, et al. (2004). "Are MuSK antibodies the primary cause of myasthenic symptoms?" *Neurology* 62(11): 1945-50.
- Shelton, G. D. and J. M. Lindstrom (2001). "Spontaneous remission in canine myasthenia gravis: implications for assessing human MG therapies." *Neurology* 57(11): 2139-41.
- Shigemoto, K., S. Kubo, et al. (2006). "Induction of myasthenia by immunization against muscle-specific kinase." *J Clin Invest* 116(4): 1016-24.
- Simpson, J. A. (1960). "Myasthenia Gravis, a new hypothesis. ." *Scottish Medical Journal*: 419-436.
- Skeie, G. O., S. Apostolski, et al. (2010). "Guidelines for treatment of autoimmune neuromuscular transmission disorders." *Eur J Neurol* 17(7): 893-902.
- Stalberg, E., J. Ekstedt, et al. (1974). "Neuromuscular transmission in myasthenia gravis studied with single fibre electromyography." *J Neurol Neurosurg Psychiatry* 37(5): 540-7.
- Stickler, D. E., J. M. Massey, et al. (2005). "MuSK-antibody positive myasthenia gravis: clinical and electrodiagnostic patterns." *Clin Neurophysiol* 116(9): 2065-8.
- Strickroot, F., Schaeffer, RL and Bergo, HE., (1942). "Myasthenia gravis occurring in an infant born of a myasthenic mother." *JAMA*(120): 1207-1209.
- Tindall, R. S., J. T. Phillips, et al. (1993). "A clinical therapeutic trial of cyclosporine in myasthenia gravis." *Ann N Y Acad Sci* 681: 539-51.
- Tuzun, E., M. N. Meriggioli, et al. (2005). "Myasthenia gravis patients with low plasma IL-6 and IFN-gamma benefit from etanercept treatment." *J Autoimmun* 24(3): 261-8.
- Wang, Q., B. Zhang, et al. (2006). "MuSK signaling at the neuromuscular junction." *J Mol Neurosci* 30(1-2): 223-6.
- Wilson, R. W., M. D. Ward, et al. (1974). "Corticosteroids: a direct effect at the neuromuscular junction." *Neurology* 24(11): 1091-5.
- Vincent, A. and J. Newsom-Davis (1985). "Acetylcholine receptor antibody as a diagnostic test for myasthenia gravis: results in 153 validated cases and 2967 diagnostic assays." *J Neurol Neurosurg Psychiatry* 48(12): 1246-52.
- Vincent, A. and J. Newsom Davis (1980). "Anti-acetylcholine receptor antibodies." *J Neurol Neurosurg Psychiatry* 43(7): 590-600.
- Xu, K., S. Jha, et al. (2006). "Delayed synapsing muscles are more severely affected in an experimental model of MuSK-induced myasthenia gravis." *Neuroscience* 143(3): 655-9.
- Zhang, B., S. Luo, et al. (2008). "LRP4 serves as a coreceptor of agrin." *Neuron* 60(2): 285-97.
- Zinman, L., E. Ng, et al. (2007). "IV immunoglobulin in patients with myasthenia gravis: a randomized controlled trial." *Neurology* 68(11): 837-41.
- Zouvelou, V., M. Rentzos, et al. (2009). "MRI Evidence of Early Muscle Atrophy in MuSK Positive Myasthenia Gravis." *J Neuroimaging* XX, 1-4.



**Autoimmune Disorders - Current Concepts and Advances from
Bedside to Mechanistic Insights**

Edited by Dr. Fang-Ping Huang

ISBN 978-953-307-653-9

Hard cover, 614 pages

Publisher InTech

Published online 14, November, 2011

Published in print edition November, 2011

Autoimmune disorders are caused due to break down of the immune system, which consequently fails in its ability to differentiate "self" from "non-self" in the context of immunology. The diseases are intriguing, both clinically and immunologically, for their diversified clinical phenotypes and complex underlying immunological mechanisms. This book offers cutting-edge information on some of the specific autoimmune disease phenotypes, respective diagnostic and prognostic measures, classical and new therapeutic options currently available, pathogenesis and underlying mechanisms potentially involved, and beyond. In the form of Open Access, such information is made freely available to clinicians, basic scientists and many others who will be interested regarding current advances in the areas. Its potential readers will find many of the chapters containing in-depth analysis, interesting discussions and various thought-provoking novel ideas.

How to reference

In order to correctly reference this scholarly work, feel free to copy and paste the following:

Anna Rostedt Punga (2011). Myasthenia Gravis: New Insights into the Effect of MuSK Antibodies and Acetylcholinesterase Inhibitors, Autoimmune Disorders - Current Concepts and Advances from Bedside to Mechanistic Insights, Dr. Fang-Ping Huang (Ed.), ISBN: 978-953-307-653-9, InTech, Available from: <http://www.intechopen.com/books/autoimmune-disorders-current-concepts-and-advances-from-bedside-to-mechanistic-insights/myasthenia-gravis-new-insights-into-the-effect-of-musk-antibodies-and-acetylcholinesterase-inhibitor>

INTECH
open science | open minds

InTech Europe

University Campus STeP Ri
Slavka Krautzeka 83/A
51000 Rijeka, Croatia
Phone: +385 (51) 770 447
Fax: +385 (51) 686 166
www.intechopen.com

InTech China

Unit 405, Office Block, Hotel Equatorial Shanghai
No.65, Yan An Road (West), Shanghai, 200040, China
中国上海市延安西路65号上海国际贵都大饭店办公楼405单元
Phone: +86-21-62489820
Fax: +86-21-62489821

© 2011 The Author(s). Licensee IntechOpen. This is an open access article distributed under the terms of the [Creative Commons Attribution 3.0 License](#), which permits unrestricted use, distribution, and reproduction in any medium, provided the original work is properly cited.

IntechOpen

IntechOpen