

Updates in Surgery

Ludovico Docimo
Luigi Brusciano *Editors*

Anal Incontinence

Clinical Management and
Surgical Techniques



OPEN ACCESS

 Springer

Updates in Surgery



The aim of this series is to provide informative updates on hot topics in the areas of breast, endocrine, and abdominal surgery, surgical oncology, and coloproctology, and on new surgical techniques such as robotic surgery, laparoscopy, and minimally invasive surgery. Readers will find detailed guidance on patient selection, performance of surgical procedures, and avoidance of complications. In addition, a range of other important aspects are covered, from the role of new imaging tools to the use of combined treatments and postoperative care.

The topics addressed by volumes in the series Updates in Surgery have been selected for their broad significance in collaboration with the Italian Society of Surgery. Each volume will assist surgical residents and fellows and practicing surgeons in reaching appropriate treatment decisions and achieving optimal outcomes. The series will also be highly relevant for surgical researchers.

More information about this series at <https://link.springer.com/bookseries/8147>

Ludovico Docimo • Luigi Brusciano
Editors

Anal Incontinence

Clinical Management and
Surgical Techniques

 Springer

Editors

Ludovico Docimo
Division of General, Mini-invasive
Oncological, and Bariatric Surgery
University of Campania Luigi Vanvitelli
Naples, Italy

Luigi Brusciano
Division of General, Mini-invasive
Oncological, and Bariatric Surgery
University of Campania Luigi Vanvitelli
Naples, Italy



This book is an open access publication.

The publication and the distribution of this volume have been supported by the Italian Society of Surgery.

ISSN 2280-9848

ISSN 2281-0854 (electronic)

Updates in Surgery

ISBN 978-3-031-08391-4

ISBN 978-3-031-08392-1 (eBook)

<https://doi.org/10.1007/978-3-031-08392-1>

© The Editor(s) (if applicable) and The Author(s) 2023

Open Access This book is licensed under the terms of the Creative Commons Attribution-NonCommercial-NoDerivatives 4.0 International License (<http://creativecommons.org/licenses/by-nc-nd/4.0/>), which permits any noncommercial use, sharing, distribution and reproduction in any medium or format, as long as you give appropriate credit to the original author(s) and the source, provide a link to the Creative Commons license and indicate if you modified the licensed material. You do not have permission under this license to share adapted material derived from this book or parts of it.

The images or other third party material in this book are included in the book's Creative Commons license, unless indicated otherwise in a credit line to the material. If material is not included in the book's Creative Commons license and your intended use is not permitted by statutory regulation or exceeds the permitted use, you will need to obtain permission directly from the copyright holder.

This work is subject to copyright. All commercial rights are reserved by the author(s), whether the whole or part of the material is concerned, specifically the rights of translation, reprinting, reuse of illustrations, recitation, broadcasting, reproduction on microfilms or in any other physical way, and transmission or information storage and retrieval, electronic adaptation, computer software, or by similar or dissimilar methodology now known or hereafter developed. Regarding these commercial rights a non-exclusive license has been granted to the publisher.

The use of general descriptive names, registered names, trademarks, service marks, etc. in this publication does not imply, even in the absence of a specific statement, that such names are exempt from the relevant protective laws and regulations and therefore free for general use.

The publisher, the authors, and the editors are safe to assume that the advice and information in this book are believed to be true and accurate at the date of publication. Neither the publisher nor the authors or the editors give a warranty, expressed or implied, with respect to the material contained herein or for any errors or omissions that may have been made. The publisher remains neutral with regard to jurisdictional claims in published maps and institutional affiliations.

Revision and editing: R. M. Martorelli, Scienzaperta (Novate Milanese, Italy)

This Springer imprint is published by the registered company Springer Nature Switzerland AG
The registered company address is: Gewerbestrasse 11, 6330 Cham, Switzerland

Foreword

Fecal incontinence is still today an important and underestimated disability that affects a portion of the general population and is caused by many different conditions, including also iatrogenic conditions. The topic is of major interest for surgeons and many different medical specialists because this disease requires a multidisciplinary approach and an integration of competences.

This volume examines in depth all the pathophysiological aspects of fecal incontinence and the role of surgeons in preventing and treating this complex disease. The authors are very accurate in clarifying to the reader some nebulous aspects of fecal incontinence, leaving open, at the same time, some still important questions. All the recent advancements in the diagnostic flowchart, fine differential etiopathogenetic diagnosis, and tailored choice of therapeutic strategies are, in the present book, well presented with remarkable illustrations.

All aspects such as treatments, rehabilitation, dietary regimen, social costs, and even DRG-related issues are very clearly and cleverly addressed, giving this book the value of an exhaustive guide and very up-to-date reference. For all the above-mentioned reasons, I'd like to express my gratitude to Professors Ludovico Docimo and Luigi Brusciano and to all the authors involved in this work for having successfully completed such a marvelous scientific endeavor, upholding, once again, the great tradition of Italian Society of Surgery.

Catania, Italy
September 2022

Francesco Basile
Italian Society of Surgery

Preface

Although benign, anal incontinence is a highly invalidating condition causing an important impairment to the patients' quality of life. Its related social stigma concurs in the underestimation of its prevalence. Nowadays, a high number of patients still tend to avoid seeking medical care or even talking about the condition, which is why it is reasonably thought to be more common than known.

Stool consistency, the efficiency of the rectum as a reservoir, the sphincter structures, and the innervation of the anatomic area of the perineum are all involved in the continence process. This book describes the multiple aspects of continence ranging from anatomical details to recent pathophysiological findings and nutritional profiles. A spotlight has been turned on the innovative and technologic diagnostic tools such as the 3D reconstruction of the whole sphincteric complex using endoanal ultrasound or the detailed evaluation of sphincter tone utilizing high-resolution manometry. Also addressed are the surgical procedures, from the most common ones performed in every operating room to the more complex approaches reserved for highly specialized centers and not neglecting the latest surgical options, such as sphincteroplasty by crossing puborectalis flaps.

The several nutritional and rehabilitation profiles are also discussed in detail. The complex interplay of the perineum itself with the diaphragm, the vertebral column, and the abdominal wall leads to a delicate equilibrium of what has been configured as the "imaginary cuboid", whose functional integrity is of utmost importance in the continence process. This partially explains why assessment of the integrity of the sphincter structures is not in itself enough to guarantee an appropriate diagnostic approach to anal incontinence.

A number of physicians with different expertise and specialties have given their contribution to the topic, providing a comprehensive expert discussion of anal incontinence that spans from its pathophysiology to the most innovative views on the diagnostic approach, including the need to analyze psychiatric parameters as an estimate of the wellness of the "imaginary cuboid". The older and more traditional treatments are here tightly interwoven with the most recent therapeutic approaches,

with attention also being paid to the functional treatment of pelvic floor rehabilitation. Objective data supporting the outcomes are also presented so the reader is provided with a clear and concise review of the literature on the subject.

Naples, Italy
Naples, Italy
September 2022

Ludovico Docimo
Luigi Brusciano

Contents

Part I Overview

- 1 History of Anal Incontinence and its Treatments.** 3
Corrado Rispoli and Gennaro Rispoli
- 2 Epidemiology, Anorectal Anatomy, Physiology and Pathophysiology of Continence** 9
Gaetano Gallo, Alberto Realis Luc, and Mario Trompetto

Part II Diagnosis

- 3 Clinical Evaluation, Etiology, and Classification of Anal Incontinence** 21
Mario Pescatori
- 4 Neurofunctional Diagnosis and Anorectal Manometry.** 29
Filippo Pucciani
- 5 Role of Ultrasonography for Anal Incontinence** 37
Giulio A. Santoro, Patrizia Pelizzo, Ugo Grossi, Rita Cian, Giacomo Zanus, and Luigi Brusciano
- 6 Cross-Sectional Imaging in Fecal Incontinence** 49
Alfonso Reginelli, Mariateresa Del Canto, Valentina Caliendo, Silvia Iovine, Ferdinando Schettino, Fabrizio Urraro, Salvatore Cappabianca, and Roberto Grassi

Part III Treatment

- 7 Medical Management and Supportive/Hygienic Measures** 63
Roberto Dino Villani and Daniela Di Nicola
- 8 Diet in Fecal Incontinence** 69
Marcellino Monda

9	Role of Pelvic Floor Rehabilitation: Patient Selection and Treatment	77
	Ludovico Docimo, Giorgia Gualtieri, Claudio Gambardella, and Luigi Brusciano	
10	Sacral and Percutaneous Tibial Nerve Stimulation, Stem Cell Therapy, and Transanal Irrigation Device	85
	Gabriele Naldini, Alessandro Sturiale, Claudia Menconi, Bernardina Fabiani, Rebecca Aglietti, Lisa Fralleone, Alfredo Annicchiarico, and Jacopo Martellucci	
11	Sphincter Reconstruction: Dynamic Myoplasty, Artificial Bowel Sphincter, Antegrade Colonic Enemas and Colostomy	93
	Francesco Selvaggi, Giacomo Fuschillo, Lucio Selvaggi, Vinicio Mosca, and Guido Sciaudone	
12	Surgical Reconstruction of Traumatic Perineal and Sphincter Muscle Defects	103
	Bruno Roche and Frédéric Ris	
13	Injectable Bulking Agents and SECCA Radiofrequency Treatment	115
	Carlo Ratto	
14	Implantation of Self-Expandable Solid Prostheses for Anal Incontinence	123
	Ludovico Docimo, Giorgia Gualtieri, Claudio Gambardella, and Luigi Brusciano	
15	When Everything Fails: Prevention and Therapy of Treatment Failures	131
	Donato F. Altomare, Arcangelo Picciariello, Michele De Fazio, and Marcella Rinaldi	
Part IV Special Considerations and Multidisciplinary Perspectives		
16	Cesarean Section Delivery to Prevent Anal Incontinence	141
	Marco Torella, Marika Pennacchio, and Nicola Colacurci	
17	Interrelatedness of Urological Conditions and Anal Incontinence	147
	Ferdinando Fusco, Marco De Sio, Davide Arcaniolo, Celeste Manfredi, Luigi Napolitano, Simone Morra, and Massimiliano Creta	
18	Coexistence of Fecal Incontinence and Constipation	155
	Francesco Saverio Mari, Edoardo Maria Muttillio, and Antonio Brescia	

19	Gut Microbiota Characterization in Fecal Incontinence and Irritable Bowel Syndrome	163
	Giovanni Marasco, Vincenzo Stanghellini, Giovanni Barbara, and Cesare Cremon	
20	Low Anterior Resection Syndrome	171
	Mario Morino and Antonella Nicotera	
21	Incontinence-Associated Dermatitis: An Insidious and Painful Condition	179
	Graziella Babino and Giuseppe Argenziano	
22	Perineal Descent and Incontinence	189
	Adolfo Renzi and Antonio Brilliantino	
23	Reconstruction of Wide Anal Sphincter Defects by Crossing Flaps of Puborectalis Muscle	197
	Antonio Longo	
24	Treatment Cost Reimbursement in Italy	205
	Vincenzo Landolfi and Adriana Maria Landolfi	

Part I

Overview



History of Anal Incontinence and its Treatments

1

Corrado Rispoli and Gennaro Rispoli

1.1 History of Anal Incontinence

All animals with a digestive system and an anus are generally provided with a sphincter system (a circular muscular structure) that creates rhythmicity in the expulsion of feces. Both humans and higher animals regulate defecation with a continence mechanism. The peristalsis that moves the feces down to the rectum is not controlled by will but by the vegetative nervous system, and therefore the only way in which animals regulate the elimination of feces is by retaining them with the mechanism of continence. In animals, continence is relevant for social interactions: with the deposition of excrement in specific places, some animals mark their territory or demonstrate their fertility. For that purpose many animals use their legs and tails to scatter droppings at a distance and thus cover wider areas.

In humans, continence is naturally acquired after some time (usually 3–4 years) but becomes important with the beginning of social life; it is necessary to separate this act from other people, not out of modesty (which will appear only centuries later), but for the management of excrement.

As evidenced by many archaeological findings, the Romans had collective latrines where they used to have discussions while defecating (Fig. 1.1).

Whereas the first description of urine incontinence dates back to 1500 B.C. (*Ebers Papyrus*), no data are available regarding the first description of fecal incontinence in ancient times [1]. Its first description was as a symptom of rectal prolapse.

Andreas Vesalius performed dissections on cadavers and described the colon, rectum and anus in meticulous detail, as illustrated in his *De Humani Corporis*

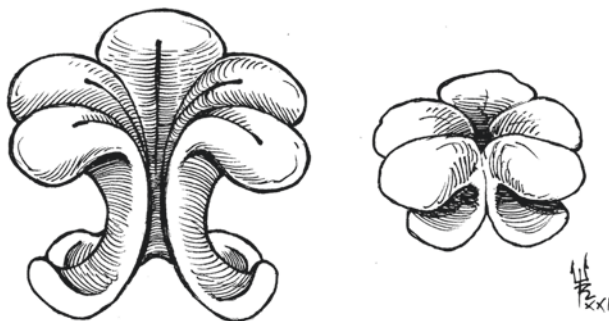
C. Rispoli (✉)
General Surgery Unit, Monaldi Hospital, Naples, Italy
e-mail: dott.rispoli@gmail.com

G. Rispoli
Museo delle Arti Sanitarie, Naples, Italy
e-mail: info@ilfarodippocrate.it



Fig. 1.1 The communal Roman latrine at Ostia, Italy (Photo by Carole Raddato, reproduced under CC-BY-SA license from <https://www.flickr.com/photos/carolemage/6681231029/in/photostream/>)

Fig. 1.2 Leonardo da Vinci's representation of the anal sphincter in relaxed (*left*) and contracted (*right*) position (details redrawn from Leonardo's original drawing, by courtesy of Roberto Toderico)



Fabrica, published in 1543. The anal sphincters as well as the levator ani muscle were clearly described by the author. However, the first illustration of the anal sphincter can be found in Leonardo da Vinci's anatomical drawing of the rectum from the fifteenth century. This drawing depicts the anal sphincter as a flower with five different petal-shaped muscular structures and is accompanied by a theory on its functioning (Fig. 1.2). The five-petal structure may derive from the hemorrhoids: three major and two minor.

No detailed information on physiology was known at that time. Nevertheless, the risks and consequences of vaginal delivery on fecal incontinence were already known in Rome in the second century A.D. but repair of the injured anal canal was not described by the Romans [2].

Until the eighteenth century, the theory that explained continence was entirely based on the muscular layer of the rectum which pushed the feces outside the anus (Jean Astruc).

In 1835, Daniel Oliver wrote his *First Lines of Physiology* in which he stated that “the concurrence of the voluntary muscles with the action of the intestine itself, is indispensable to overcome the contraction of the sphincter of the rectum”, designing the first scientific theory [3]. The theory of a rectal “reservoir” and a muscular sphincter complex was then refined and improved in the twentieth century by two great scientists of the colon and rectum: Alan Park and Ahmed Shafik [4, 5]. Their vision of the anatomy and physiology of the rectum and anus are still a key element of today’s theories.

1.2 History of Treatments for Anal Incontinence

1.2.1 Colonic Irrigation and Colostomy

Colonic irrigation was the first treatment described for anal incontinence although this was not its proper and exclusive indication; already in the fifth century B.C. the Egyptians “cleansed” themselves on three consecutive days every month, by using enemas to purify their body, as reported by Herodotus. This technique was also recorded in the Babylonian and Assyrian tables and in Hindu medicine. Though widely used through the centuries, no data were reported on the outcomes of colonic irrigation until the modern era.

The first surgical treatment for anal incontinence was stoma creation (first performed in 1776 by Pillore [6]); as in the case of colonic irrigation, this technique was mainly adopted for conditions other than incontinence.

1.2.2 Anal Sphincter Repair

The first description of a successful sphincter repair dates back to 1882; Warren performed a vaginal mucosal flap to protect the repair of the lacerated rectum and anus [7]. This technique was also reported by other authors in case series showing good results in the short-term follow-up [8].

Many techniques for the correction of incontinence caused by sphincter damage were subsequently developed by different surgical teams [9], but all of them were based mainly on end-to-end sphincter repair, which often had high failure rates [10, 11]. The first modern technique, overlapping sphincteroplasty, was developed in 1973 as an improvement of end-to-end repair. This technique is still performed with excellent results [12] and is also reported in the guidelines as a standard surgical treatment [13].

As regards “idiopathic” incontinence, however, it was not until 1975 that the first surgical technique was reported. That year, Sir Alan Parks described the so-called “postanal repair”, a technique aiming to increase the length of the anal canal, restore the anorectal angle, and create a flap valve mechanism. The promising short-term results of this technique were less favorable in the long-term follow-up, mainly because of misdetection of subclinical anterior sphincter defect after delivery [14].

In 1991, the introduction of endoanal ultrasound led to a dramatic change of view regarding the etiology of anal incontinence [15], and many cases of idiopathic incontinence could now be labelled as delivery sphincter damage and properly repaired with overlapping sphincteroplasty [16]. Postanal repair is now confined to a small minority of patients with anal incontinence and most of the international guidelines do not recommend it.

1.2.3 Muscle Transposition and Artificial Sphincter

Muscle transposition techniques mainly derived from the first experience with muscle fiber transposition for ocular palsy (1908, Hummelsheim) [17]. In the first half of the twentieth century, the idea of transposing muscle fibers or fascia to reinforce a weakened or damaged sphincter was developed. The first techniques based on anal encirclement by fascia date back to Harvey Stone in 1932 [18, 19] and were later modified in 1941 [20]; the results were promising, with a reported success rate of 70%. Other authors chose to suture together muscle fibers from both gluteal muscles anterior to the rectum, thus suspending it in a kind of muscular “hammock” [21, 22]. Merging these approaches, in 1952 Pickrell codified his “gracilis muscle transplant” that was later to take his name [23]. This technique is now performed with an implantable electrical pulse generator (stimulated muscle transposition) and will be discussed later in this book.

The first artificial sphincter for human use was developed for the treatment of urinary incontinence in 1973 by American Medical Systems (AMS, Minnetonka, MN, USA) and was later applied to anal incontinence by Christiansen and Lorentzen in 1987 [24]. New specific devices have been developed since then but, considering their recent introduction, they will be thoroughly discussed in another chapter of this book.

1.2.4 Bulking Agents

Like all innovators, Ahmed Shafik not only developed a theory of the mechanism of anal continence but also proposed a new kind of treatment option: the use of bulking agents. In 1993 he published a case series on polytetrafluoroethylene injection for the treatment of partial fecal incontinence [25], with no complications reported and with promising results (improvement or cure in all cases). This technique was then reproduced with the aid of endoanal ultrasound to improve proper positioning of the agent, and now all bulking agents require ultrasound-guided positioning.

New technologies and new materials developed during the last twenty years have expanded this field of incontinence treatment with continuous news from scientific research. On the other hand, this fragmentation of materials and techniques has made it difficult to compare the results achieved with bulking agents and therefore the evidence to support their use has remained scarce.

1.2.5 Other Treatments and Techniques

Many other invasive and noninvasive treatments are now available for anal incontinence (sacral nerve stimulation, biofeedback, etc.) but, because their development is recent, they will be discussed in a separate chapter.

References

1. Ebbell B. *The Papyrus Ebers: the greatest Egyptian medical document*. Copenhagen: Ejnar Munksgaard; 1937.
2. Briel JW. *Treatment of fecal incontinence*. Ridderkerk: Ridderprint BV; 2000. p. 11.
3. Oliver D. *First lines of physiology*. Boston: Marsh. James Munroe: Capen & Lyon; 1835.
4. Parks AG, Rob C, Smith R, Morgan CN. *Clinical Surgery: Abdomen and rectum and anus*. London: Butterworths; 1966.
5. Shafik A. A new concept of the anatomy of the anal sphincter mechanism and the physiology of defecation. The external anal sphincter: a triple-loop system. *Investig Urol*. 1975;12(5):412–9.
6. Hardy KJ. Surgical history. Evolution of the stoma. *Aust N Z J Surg*. 1989;59(1):71–7.
7. Warren JC. A new method of operation for the relief of rupture of the perineum through the sphincter and rectum. *Trans Am Gynecol Soc*. 1882;7:322–30.
8. Block IR, Rodriguez S, Olivares AL. The Warren operation for anal incontinence caused by disruption of the anterior segment of the anal sphincter, perineal body, and rectovaginal septum: report of five cases. *Dis Colon Rectum*. 1975;18(1):28–34.
9. Sistrunk WE. Contribution to plastic surgery: an open operation for extensive laceration of the anal sphincter. *Ann Surg*. 1927;85(2):185–93.
10. Lockhart-Mummery JP. *Diseases of the rectum & colon and their surgical treatment*. Toronto: Macmillan; 1923.
11. Blaisdell PC. Repair of the incontinent sphincter ani. *Am J Surg*. 1957;94(4):573–6.
12. Goetz LH, Lowry AC. Overlapping sphincteroplasty: is it the standard of care? *Clin Colon Rectal Surg*. 2005;18(1):22–31.
13. Paquette IM, Varma MG, Kaiser AM, et al. The American Society of Colon and Rectal Surgeons' clinical practice guideline for the treatment of fecal incontinence. *Dis Colon Rectum*. 2015;58:623–36.
14. Surgical management of faecal incontinence in: Madoff RD, Pemberton JH, Mimura T, Laurberg S, editors. *Faecal incontinence: the management of faecal incontinence in adults (NICE Clinical Guidelines, No 49)*. London: National Collaborating Centre for Acute Care; 2007. <https://www.nice.org.uk/guidance/cg49>. Accessed 28 Nov 2021.
15. Burnett SJD, Speakman CTM, Kamm MA, Bartram CI. Confirmation of endosonographic detection of external anal sphincter defects by simultaneous electromyographic mapping. *Br J Surg*. 1991;78(4):448–50.
16. Abrams P, Andersson KE, Birdir L, et al. *Fourth International Consultation on Incontinence Recommendations of the International Scientific Committee: Evaluation and treatment*

- of urinary incontinence, pelvic organ prolapse, and fecal incontinence. *Neurourol Urodyn.* 2010;29(1):213–40.
17. Baker DC, Conley J. Regional muscle transposition for rehabilitation of the paralyzed face. *Clin Plast Surg.* 1979;6(3):317–31.
 18. Stone HB. Plastic operation for anal incontinence. *Tr South Surg Assoc.* 1926;41:235–40.
 19. Stone HB. Plastic operation for anal incontinence. Further report. *Arch Surg.* 1932;24:120–5.
 20. Stone HB, McLanahan S. Results with the fascia plastic operation for anal incontinence. *Ann Surg.* 1941;114(1):73–7.
 21. Chittenden AS. Reconstruction of anal sphincter by muscle slips from the glutei. *Ann Surg.* 1930;92(1):152–4.
 22. Biström O. Plastischer Ersatz des M. Sphincter ani. *Acta Chir Scand.* 1944;90:431–48.
 23. Pickrell KL, Broadbent TR, Masters FW, Metzger JT. Construction of a rectal sphincter and restoration of anal continence by transplanting the gracilis muscle; a report of four cases in children. *An Surg.* 1952;135(6):853–62.
 24. Christiansen J, Lorentzen M. Implantation of artificial sphincter for anal incontinence. *Lancet.* 1987;330(8553):244–5.
 25. Shafik A. Polytetrafluoroethylene injection for the treatment of partial fecal incontinence. *Int Surg.* 1993;78(2):159–61.

Open Access This chapter is licensed under the terms of the Creative Commons Attribution-NonCommercial-NoDerivatives 4.0 International License (<http://creativecommons.org/licenses/by-nc-nd/4.0/>), which permits any noncommercial use, sharing, distribution and reproduction in any medium or format, as long as you give appropriate credit to the original author(s) and the source, provide a link to the Creative Commons license and indicate if you modified the licensed material. You do not have permission under this license to share adapted material derived from this chapter or parts of it.

The images or other third party material in this chapter are included in the chapter's Creative Commons license, unless indicated otherwise in a credit line to the material. If material is not included in the chapter's Creative Commons license and your intended use is not permitted by statutory regulation or exceeds the permitted use, you will need to obtain permission directly from the copyright holder.





Epidemiology, Anorectal Anatomy, Physiology and Pathophysiology of Continence

2

Gaetano Gallo, Alberto Realis Luc, and Mario Trompetto

2.1 Introduction and Epidemiology

Continence can be defined as the ability to retain flatus, liquid, or solid stools during normal daily life, including while physically exercising, coughing, sneezing, and changing position [1].

The anal canal is normally closed at rest and during sleep due to the steady activity of the internal anal sphincter (IAS) supported by the tonic activity of the external anal sphincter (EAS) and puborectalis.

The integrity of the continence and defecation mechanism is a multifactorial process that involves somatic and visceral functions and allows postponing defecation when necessary and avoiding the uncontrolled passage of feces or gas, causing patients to feel embarrassed with a negative impact on lifestyle, work, and interpersonal relationships [2].

Considering the heterogeneity of the problem, the incidence and prevalence of fecal incontinence (FI) are difficult to establish because they depend on the type and frequency of incontinence, age, and gender (Table 2.1) [3]. In fact, if the leading cause in women is post-obstetric injury, in men and the elderly, other factors such as anorectal surgery and diabetes mellitus must be considered [4, 5]. Moreover, the use of many terms to define FI has generated confusion and favored this trend.

Several authors have tried to quantify this phenomenon without achieving a definitive percentage [6–8]. According to Sharma et al. [6], the prevalence of FI ranges between 1.4% and 19.5%, whereas in the systematic review by Ng et al. [7] it has a median prevalence of 7.7%, without any difference between genders, but with a greater percentage in people older than 90 (15.9% vs. 5.7%) compared with people 15–34 years old.

G. Gallo (✉) · A. Realis Luc · M. Trompetto
Department of Colorectal Surgery, S. Rita Clinic, Vercelli, Italy
e-mail: dr.gaetanogallo@libero.it; alberto.realisluc@libero.it; trompetto.mario@libero.it

Table 2.1 Pathophysiological mechanisms leading to fecal incontinence

Structure		
Anal sphincter muscle	Obstetric injury Hemorrhoidectomy, anal dilatation, secondary to neuropathy	Sphincter weakness Loss of sampling reflex
Rectum	Inflammation, IBD, radiation, prolapse, aging, IBS	Sphincter weakness Loss of sampling reflex
Puborectalis muscle	Excessive perineal descent, aging, trauma	Obtuse anorectal angle Sphincter weakness
Pudendal nerve	Obstetrical/surgical injury Excessive straining/perineal descent	Sphincter weakness Sensory loss, impaired reflexes
CNS, spinal cord, ANS	Spinal cord injury, head injury, back surgery, multiple sclerosis, diabetes, stroke, avulsion injury	Loss of sensation, impaired reflexes, secondary myopathy, loss of accommodation
Function		
Anorectal sensation	Obstetrical, CNS, ANS injury	Loss of stool awareness Rectoanal agnosia
Fecal impaction	Dyssynergic defecation	Loss of stool awareness Rectoanal agnosia
Stool characteristics		
Volume and consistency	Infection, IBD, IBS, drugs, metabolic	Diarrhea and urgency Rapid stool transport Impaired accommodation
Irritants	Bile salt malabsorption, laxatives	Diarrhea
Hard stools/retention	Dyssynergia/drugs	Fecal retention with overflow
Miscellaneous		
Physical mobility/cognitive function	Aging, dementia, disability	Multifactorial changes
Psychosis	Willful soiling	Multifactorial changes
Drugs	Anticholinergics Laxatives Antidepressants Caffeine/muscle relaxants	Constipation Diarrhea Alter sensation/constipation Relaxes sphincter tone
Food intolerance	Lactose/fructose/sorbitol	Diarrhea/flatus Malabsorption

IBD, inflammatory bowel disease; *IBS*, irritable bowel syndrome; *CNS*, central nervous system; *ANS*, autonomic nervous system

Reproduced from [3] with permission from Elsevier

The higher prevalence among the elderly may be due to the physiological effects of aging on continence, such as impaired rectal sensation or dysfunction of both the IAS and EAS, which become thicker [9], as well as polypharmacy. In fact, the abuse of laxatives taken to avoid fecal impaction or constipation can exacerbate the condition. In this context, the highest prevalence currently recorded is among nursing home residents, where involvement reaches up to 50% [10].

The difficulty in establishing the extent of FI could be due to embarrassment in reporting the symptoms, as occurs with other proctological diseases [11]. Brown et al. [12], in an internet-based questionnaire study of 5817 women, showed that one-fifth of women over 45 in the USA suffer from at least one episode of FI per

year. A lack of knowledge and awareness of the problem as well as economic status represent further important barriers to patients' interaction with the health-care system.

2.2 Anatomy and Physiology of Continence

The continence process can be defined as a somatovisceral reflex and involves complex coordinated activity between several muscle groups – including the sphincter complex (Fig. 2.1) [3], ligaments and fascia of the pelvic floor—and rectal compliance, stool consistency and volume, and cognitive function. Thus, an abnormality in any of these factors may result in FI. In fact, up to 80% of patients with anal incontinence have more than one pathological abnormality in anorectal physiology.

The IAS (Fig. 2.2) [13] represents the continuation of the inner circular muscle layer of the rectum [14]. This smooth muscle under the control of the involuntary nervous system (sympathetic and parasympathetic) contributes to 80% of the resting anal pressure—normally 50–70 mmHg—and is the main barrier to the involuntary passage of gas and feces. The remaining 15–20% of resting anal pressure is regulated by the EAS, puborectalis, and hemorrhoids. All three contribute to the high-pressure zone, which is appreciated along the entire length of the anal canal and has 30% higher than found in the rectum. Interestingly, according to Penninckx et al. [15], the resting anal pressure is generated by the myogenic tone of the IAS (10%), by nerve-induced activity (45%), by the EAS (35%), and by the hemorrhoids (15%).

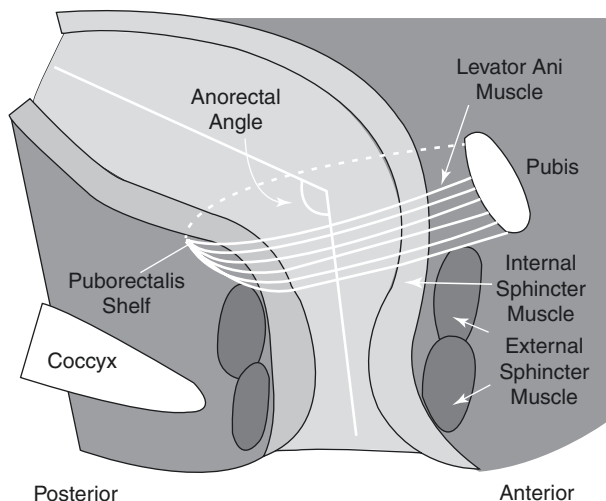


Fig. 2.1 Structure of the anorectum. The internal anal sphincter muscle provides between 70% and 85% of resting sphincter pressure. The anorectal angle, approximately 90 degrees at rest, becomes more obtuse during defecation. (Reproduced from [3] with permission from Elsevier)

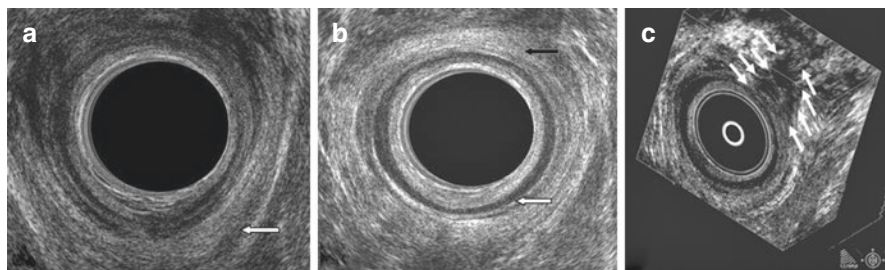


Fig. 2.2 (a) Endoanal scan demonstrating the U-shaped puborectalis muscle, which attaches to the pubic rami anteriorly. (b) Endoanal scan demonstrating the internal anal sphincter (*white arrow*) and the external anal sphincter (*black arrow*). (c) Three-dimensional endoanal ultrasound demonstrating the circumference/width as well as length of the anal sphincter defect. (Reproduced from [13] with permission from British Institute of Radiology)

The length of the IAS differs between genders and is smaller in women (2.0–3.0 cm vs. 2.5–3.5 cm), while its thickness varies between 2 and 4 mm. The IAS has a resting tone with cyclic variations, or rather short and ultrashort waves (1.5–3 cycles per minute). These waves are extremely important for reflex sampling. In fact, an intermittent relaxation of the IAS, lasting about 10–20 s, occurs approximately seven times per hour [16, 17] and allows rectal contents to come into contact with the sensitive mucosa of the anal canal.

The EAS (Fig. 2.2) [13] is a striated muscle that receives innervation from the pudendal nerve (S2, S3, S4), and its inhibition allows defecation [18]. It has a thickness of 4 mm and length of about 2.7 cm, although it is shorter anteriorly in women (1.5 cm), and it has three components: the subcutaneous, superficial, and deep anorectal elements. The EAS is responsible for the guarding reflex, a low spinal reflex, which contracts for 20–30 s after fecal contents arrive in the rectal ampulla.

The levator ani (Fig. 2.2) [13] has a pelvic floor support function and consists of three bundles: the pubococcygeus anteriorly, the iliococcygeus posteriorly, and the puborectalis inferiorly. The most important component for continence is the puborectalis muscle (PRM), which is a U-shaped loop muscle that forms a sling around the rectum, with an anorectal angle of approximately 90° that is at the basis of the flap-valve theory proposed by Parks [19], to which the three portions of the EAS also contribute. During normal defecation, relaxation of the PRM causes the anorectal angle to become more obtuse and widen ($>130^\circ$), facilitating the passage of the rectal content.

Recently, Broens et al. [20] introduced the concept of the “puborectalis continence reflex”, demonstrating that the PRM has also an involuntary contraction that is significantly stronger than the voluntary one with an equally increased pressure zone. This could confirm the role of the PRM in supporting dysfunctions of the other sphincter muscles in patients with impaired continence but who have not developed FI.

The conjoined longitudinal muscle, interposed between the IAS and EAS, consists of smooth muscle together with striated fibers from the levator ani, and its role

is controversial. It has a thickness of about 2.5 mm and seems involved in the shortening and widening of the anal canal. Shafik originally defined it as an “evertor ani muscle” [21] for its apparent action of eversion of the anal orifice. In addition, some studies have recently suggested its role in supporting continence after lateral internal sphincterotomy [22].

In addition to the muscular component, several other factors contribute to anal continence. The recto-anal inhibitory reflex (RAIR), also known as relaxation of the IAS, is certainly one of the best-established mechanisms linked to defecation and among the first to be activated.

It is regulated by the enteric nervous system, which is why it is absent in Hirschsprung’s disease, but it is still present after rectum or anus denervation or recovers with time [23].

The distension of the rectal wall caused by the arrival of the intestinal contents, made possible by the action of another important functional apparatus—the “recto-sigmoid sphincter” [24, 25]—thanks to colonic high-amplitude-propagated contractions, stimulates the multiple pressure receptors, allowing contact with the sensitive area of the anal canal. In this area, the stool contents are in contact with specialized sensory organs such as the Krause end-bulbs, Golgi-Mazzoni’s bodies and genital corpuscles, the sparse Meissner’s corpuscles, and Pacinian corpuscles [26, 27].

At this point, continence is maintained by the EAS (rectoanal excitatory reflex [RAER]) that may avoid anal leakage, and, to occur, intra-abdominal pressure should increase, with consequent relaxation of the PRM, widening of the anorectal angle, and rectification of the rectum. The reflex contraction of the EAS with the concomitant contraction of the PRM to restore the anorectal angle ends the process. If defecation is deemed inappropriate, it can be deferred by the voluntary contraction of both EAS and PRM [28]. In particular, the PRM induces closure of the pelvic diaphragm by generating horizontal forces with a consequent decrease of the anorectal angle. Both RAIR and RAER make up the sampling reflex, which has the fundamental function of advancing a part of the rectal content in the upper anal canal without causing an episode of incontinence.

Under physiological conditions, the rectum can passively undergo dilation without pressure changes. At a volume of approximately 200 mL, a sensation of urgency is perceived, with a maximum tolerated volume ranging from 300 to 500 mL.

Pathological alterations of the rectum, such as inflammatory bowel disease, in which rectal compliance decreases, or Hirschsprung’s disease, in which compliance is increased, favor altered continence.

Hemorrhoids are vascular cushions contributing to almost 15% of the anal resting pressure, and their importance has been seen in transient or permanent soiling episodes that can occur after excisional hemorrhoidectomy [29].

The volume and consistency of feces are essential, especially in elderly patients or patients with an already impaired continence, such as after low anterior resection [5].

Lastly, it is not only the peripheral nervous system with the sympathetic (L1–L3) and parasympathetic (S2–S4) components that is involved, but several studies have highlighted the role of the central nervous system. In fact, the sensation of rectal

filling or urgency has been shown to be associated with areas such as the insula, thalamus, secondary somatosensory cortex, or anterior cingulate gyrus [30], whereas Brodmann area 4, the primary motor cortex, seems involved in anal and rectal responses [31].

Onuf's nucleus, positioned at the level of the ventral horn gray matter of S2–S4, is in communication with the upper motor neurons responsible for voluntary sphincter complex contraction, usually located in the parasagittal motor cortex [32].

2.3 Pathophysiology of Fecal Incontinence

Given the complexity of the continence mechanism, several target areas of injuries can lead to the development of FI. Moreover, it appears that more than 80% of patients with FI have more than one alteration of the continence mechanism [33].

Depending on the type of muscle injury, FI can have different manifestations. Urge incontinence, or the loss of stools despite a voluntary attempt to avoid it, is caused by a lesion of the EAS. When the IAS is involved, it is referred to as passive incontinence, with involuntary loss of liquid or stool without awareness. Both conditions are very common after obstetric trauma, which can also be caused by the EAS, IAS, and the pudendal nerve being stretched, compressed, or suffering an ischemic injury (Fig. 2.2) [13]. The pudendal nerve, certainly the most studied but not the only nerve involved in the continence mechanism, can be damaged during childbirth at the exit from Alcock's canal, where its course is predominantly fixed on the pelvic sidewall [34].

Episiotomy appears to be related to damage to the sphincter complex, even if some studies show conflicting opinions [35, 36]. In particular, midline posterior episiotomy has been correlated with a higher incidence of sphincter trauma [37].

According to Dudding et al. [38], episiotomy and instrumental delivery, fetal occipito-posterior presentation, a prolonged second stage of labor, and birth weight greater than 4 kg are risk factors for injury. Interestingly, most women develop FI after menopause, maybe due to the deterioration of anorectal function with aging or withdrawal of hormonal input. Consequently, sphincter damage represents the first step for developing FI with the overlap of other factors [39].

Urge incontinence can also be secondary to anorectal surgery (hemorrhoidectomy, sphincterotomy, surgery for fistulas), albeit more frequently in men, with the contemporary loss of the sampling reflex.

Another component of the sphincter complex that can be damaged is the PRM, often following an accidental trauma, perineal descent, or aging, with loss of functionality of the anorectal angle.

Often, FI and constipation may coexist, and in this case we define incontinence as fecal seepage or the involuntary post-defecation loss of stool [40]. Fecal seepage results from an impaired rectal sensation plus an inappropriate increase of anal sphincter pressure with the contraction of the EAS after excessive straining.

In men, the causes of FI are less defined. Radical prostatectomy with consequent radiotherapy can lead to sphincter fibrosis, myenteric plexus degeneration, and a

reduction of the functionality of the EAS, which becomes thicker with reduced rectal compliance, especially in the elderly. The same phenomenon occurs during radiotherapy for anal or rectal cancer.

When the reservoir function of the rectum is no longer optimal, increased intrarectal pressure can cause FI. This scenario can occur in patients with inflammatory bowel disease, radiation proctitis, hysterectomy, rectal cancer, or spinal cord injury.

Among the functional mechanisms, the loss of anorectal sensation is certainly the most frequent.

In fact, an impaired anorectal sensation, which often occurs in children and the elderly, can lead to fecal impaction and a consequent fecal overflow. Some of the most common causes are represented by neuropathies such as multiple sclerosis, diabetes mellitus, and spinal cord injury or by inadvertent injury during colorectal surgery. Central nervous system diseases, such as Parkinson's disease, can alter cognitive functions, leading to pathological toilet habits due to the inability to carry out daily activities.

Hellström et al. [41] highlighted the influence of dementia on anal continence in a random sample of 485 subjects selected from the 85-year-old inhabitants of Gothenburg, reporting its presence in 34.8% of demented subjects and 6.7% of non-demented subjects.

Furthermore, fecal impaction, common in patients with obstructed bowel syndrome or pelvic floor dyssynergy, can result in stool leaks that bypass the impaction owing to persistent relaxation of the IAS. Overflow incontinence can also be present in patients with congenital malformations [42].

Another very common condition is soiling, which often occurs after anorectal surgery or in patients with obstructed defecation. Up to 63% of patients with grade II–IV hemorrhoidal disease or rectal prolapse may have soiling [43].

Finally, the change in stool volume and consistency due to inflammatory bowel disease, drugs (such as laxatives in the elderly), food intolerance, or metabolic disorders can cause diarrhea and urgency, fecal impaction, and malabsorption. In the case of diarrhea, increased activity of high-amplitude-propagated contractions can cause overwhelm of the reservoir capacity of the rectum [44, 45]. These motor complexes, extremely represented at the level of the rectosigmoid, are significantly increased in patients with urge incontinence [46].

References

1. Saldana Ruiz N, Kaiser AM. Fecal incontinence – Challenges and solutions. *World J Gastroenterol.* 2017;23(1):11–24.
2. Wald A. Clinical practice. Fecal incontinence in adults. *N Engl J Med.* 2007;356(16):1648–55.
3. Rao SS. Pathophysiology of adult fecal incontinence. *Gastroenterology.* 2004;126(1 Suppl 1):S14–22.
4. Nelson RL. Epidemiology of fecal incontinence. *Gastroenterology.* 2004;126(1 Suppl 1):S3–7.
5. Pucciani F. Post-surgical fecal incontinence. *Updat Surg.* 2018;70(4):477–84.
6. Sharma A, Yuan L, Marshall RJ, et al. Systematic review of the prevalence of faecal incontinence. *Br J Surg.* 2016;103(12):1589–97.

7. Ng KS, Sivakumaran Y, Nassar N, Gladman MA. Fecal incontinence: community prevalence and associated factors – a systematic review. *Dis Colon Rectum*. 2015;58(12):1194–209.
8. Macmillan AK, Merrie AEH, Marshall RJ, Parry BR. The prevalence of fecal incontinence in community-dwelling adults: a systematic review of the literature. *Dis Colon Rectum*. 2004;47(8):1341–9.
9. Lewicky-Gaupp C, Hamilton Q, Ashton-Miller J, et al. Anal sphincter structure and function relationships in aging and fecal incontinence. *Am J Obstet Gynecol*. 2009;200(5):559.e1–5.
10. Gorina Y, Schappert S, Bercovitz A, et al. Prevalence of incontinence among older Americans. *Vital Health Stat 3*. 2014;36:1–33.
11. Gallo G, Sacco R, Sammarco G. Epidemiology of hemorrhoidal disease. In: Ratto C, Parello A, Litta F, editors. *Hemorrhoids coloproctology*. Cham: Springer; 2018. p. 3–7.
12. Brown HW, Rogers RG, Wise ME. Barriers to seeking care for accidental bowel leakage: a qualitative study. *Int Urogynecol J*. 2017;28(4):543–51.
13. Abdool Z, Sultan AH, Thakar R. Ultrasound imaging of the anal sphincter complex: a review. *Br J Radiol*. 2012;85(1015):865–75.
14. Golia Pernicka JS, Sheedy SP, Ernst RD, et al. MR staging of anal cancer: what the radiologist needs to know. *Abdom Radiol (NY)*. 2019;44(11):3726–39.
15. Penninckx F, Lestar B, Kerremans R. The internal anal sphincter: mechanisms of control and its role in maintaining anal continence. *Baillieres Clin Gastroenterol*. 1992;6(1):193–214.
16. Read NW, Haynes WG, Bartolo DC, et al. Use of anorectal manometry during rectal infusion of saline to investigate function in incontinent patients. *Gastroenterology*. 1983;85:105–13.
17. Miller R, Lewis GT, Bartolo DC, et al. Sensory discrimination and dynamic activity in the anorectum evidence of a new ambulatory technique. *Br J Surg*. 1988;75:1003–7.
18. Barleben A, Mills S. Anorectal anatomy and physiology. *Surg Clin North Am*. 2010;90(1):1–15.
19. Parks AG, Porter NH, Hardcastle J. The syndrome of the descending perineum. *Proc R Soc Med*. 1966;59:477–82.
20. Broens PMA, Jonker JE, Trzpis M. The puborectal continence reflex: a new regulatory mechanism controlling fecal continence. *Int J Colorectal Dis*. 2018;33(5):627–33.
21. Shafik A. A new concept of the anatomy of the anal sphincter mechanism and the physiology of defecation. III. The longitudinal anal muscle: anatomy and role in anal sphincter mechanism. *Investig Urol*. 1976;13:271–7.
22. Perry WB, Dykes SL, Buie WD, Rafferty JF. Standards Practice Task Force of the American Society of Colon and Rectal Surgeons. Practice parameters for the management of anal fissures (3rd revision). *Dis Colon Rectum*. 2010;53(8):1110–5.
23. Lubowski DZ, Nicholls RJ, Swash M, Jordan MJ. Neural control of internal anal sphincter function. *Br J Surg*. 1987;74(8):668–70.
24. Wadhwa RP, Mistry FP, Bhatia SJ, et al. Existence of a high pressure zone at the rectosigmoid junction in normal Indian men. *Dis Colon Rectum*. 1996;39:1122–5.
25. Ballantyne GH. Rectosigmoid sphincter of O’Beirne. *Dis Colon Rectum*. 1986;29:525–31.
26. Duthie HL, Gaims FW. Sensory nerve-endings and sensation in the anal region of man. *Br J Surg*. 1960;47:585–95.
27. Goligher JC, Hughes ESR. Sensibility of the rectum and colon. Its rôle in the mechanism of anal continence. *Lancet*. 1951;1(6654):543–7.
28. Pucciani F, Trafeli M. Sampling reflex: pathogenic role in functional defecation disorder. *Tech Coloproctol*. 2021;25(5):521–30.
29. Gallo G, Martellucci J, Sturiale A, et al. Consensus statement of the Italian Society of Colorectal Surgery (SICCR): management and treatment of hemorrhoidal disease. *Tech Coloproctol*. 2020;24(2):145–64.
30. Bittorf B, Ringler R, Forster C, et al. Cerebral representation of the anorectum using functional magnetic resonance imaging. *Br J Surg*. 2006;93(10):1251–7.
31. Turnbull GK, Hamdy S, Aziz Q, et al. The cortical topography of human anorectal musculature. *Gastroenterology*. 1999;117(1):32–9.
32. Sultan AH, Nugent K. Pathophysiology and nonsurgical treatment of anal incontinence. *BJOG*. 2004;111(Suppl 1):84–90.

33. Rao SSC, Patel RS. How useful are manometric tests of anorectal function in the management of defecation disorders? *Am J Gastroenterol.* 1997;92(3):469–75.
34. Madoff RD, Parker SC, Varma MG, et al. Faecal incontinence in adults. *Lancet.* 2004;364(9434):621–32.
35. Green JR, Soohoo SL. Factors associated with rectal injury in spontaneous deliveries. *Obstet Gynecol.* 1989;73(5 Pt 1):732–8.
36. Nygaard IE, Rao SS, Dawson JD. Anal incontinence after anal sphincter disruption: a 30-year retrospective cohort study. *Obstet Gynecol.* 1997;89(6):896–901.
37. O’Herlihy C. Obstetric perineal injury: risk factors and strategies for prevention. *Semin Perinatol.* 2003;27(1):13–9.
38. Dudding TC, Vaizey CJ, Kamm MA. Obstetric anal sphincter injury: incidence, risk factors, and management. *Ann Surg.* 2008;247(2):224–37.
39. Oberwalder M, Dinnewitzer A, Baig MK, et al. The association between late-onset fecal incontinence and obstetric anal sphincter defects. *Arch Surg.* 2004;139:429–32.
40. Rao SS, Ozturk R, Stessman M. Investigation of the pathophysiology of fecal seepage. *Am J Gastroenterol.* 2004;99(11):2204–9.
41. Hellström L, Ekelund P, Milsom I, Skoog I. The influence of dementia on the prevalence of urinary and faecal incontinence in 85-year-old men and women. *Arch Gerontol Geriatr.* 1994;19(1):11–20.
42. Davies MC, Creighton SM, Wilcox DT. Long-term outcomes of anorectal malformations. *Pediatr Surg Int.* 2004;20(8):567–72.
43. Jóhannsson HO, Pählman L, Graf W. Randomized clinical trial of the effects on anal function of Milligan-Morgan versus Ferguson haemorrhoidectomy. *Br J Surg.* 2006;93(10):1208–14.
44. Bouchoucha M, Devroede G, Faye A, et al. Importance of colonic transit evaluation in the management of fecal incontinence. *Int J Colorectal Dis.* 2002;17(6):412–7; discussion 418–9
45. Chan CLH, Lunniss PJ, Wang D, et al. Rectal sensorimotor dysfunction in patients with urge fecal incontinence: evidence from prolonged manometric studies. *Gut.* 2005;54(9):1263–72.
46. Santoro GA, Eitan BZ, Pryde A, et al. Open study of low-dose amitriptyline in the treatment of patients with idiopathic fecal incontinence. *Dis Colon Rectum.* 2000;43(12):1676–81.

Open Access This chapter is licensed under the terms of the Creative Commons Attribution-NonCommercial-NoDerivatives 4.0 International License (<http://creativecommons.org/licenses/by-nc-nd/4.0/>), which permits any noncommercial use, sharing, distribution and reproduction in any medium or format, as long as you give appropriate credit to the original author(s) and the source, provide a link to the Creative Commons license and indicate if you modified the licensed material. You do not have permission under this license to share adapted material derived from this chapter or parts of it.

The images or other third party material in this chapter are included in the chapter’s Creative Commons license, unless indicated otherwise in a credit line to the material. If material is not included in the chapter’s Creative Commons license and your intended use is not permitted by statutory regulation or exceeds the permitted use, you will need to obtain permission directly from the copyright holder.



Part II

Diagnosis



Clinical Evaluation, Etiology, and Classification of Anal Incontinence

3

Mario Pescatori

3.1 Clinical Evaluation of Anal Incontinence

Anal continence is based on different factors: the integrity of anal sphincters, the integrity of the rectum, which behaves as a reservoir and has the “adaptation reflex”, and the consistency of the stool. Other factors involved in anal continence are as follows: the pudendal nerves, which are both sensorial and motor; the rectal valves or folds, which behave as barriers to the progression of the stool from the upper part to the lower part of the rectal reservoir; the rectosigmoid junction, which has a thicker smooth muscular tissue able to slow the transit of the stool; the integrity of the complex and rich innervation of the anal canal, responsible for the sampling reflex; the length of the anal canal, which is longer in males and shorter in females. Anal incontinence (AI) has to be evaluated with different approaches. First, the patient is assessed in the office and asked about their symptoms (clinical history). AI means that the patient loses flatus and/or stool without control. Patients affected by AI are more likely to be females or older males. Females’ anal sphincters are in fact weaker than males’ anal sphincters, because of vaginal deliveries. Older males can be affected by AI because of a weakening of their sphincter apparatus that occurs with age [1]. The patient suffering from AI has a worsened quality of life.

3.1.1 How to Examine the Patient

A holistic approach towards patients with AI is needed: the doctor has to evaluate both the body and mind of these patients, in order to thoroughly investigate the causes of AI. For this purpose, the coloproctology unit should have a psychologist. As for the clinical examination, patients have to be asked about possible local

M. Pescatori (✉)
Coloproctology Unit, Parioli Clinic, Rome, Italy
e-mail: ucpclub@virgilio.it

traumas or if they have frequent receptive anal intercourse, which are known to deteriorate the internal sphincter. When examining the patient, we might see a gaping anus, either spontaneously or after traction. Also, we have to investigate previous anorectal surgery. AI may develop after an internal sphincterotomy or even after a hemorrhoidectomy, especially in multiparous females, as nearly half of them have subclinical continence defects [2]. Once a detailed clinical history has been obtained, we may start to examine the patient, who will be placed in a left lateral Sims' position.

Firstly, we have to observe if the patient has a descended perineum, which refers to the perineum descending more than 2 cm on straining. We should also observe whether the anus is closed or gaping, and whether there is fecal material around it. The patient should then be asked to contract the anus, so we can see if there is a detectable contraction, and if it is strong or weak. The anal reflex is then assessed with pinprick stimulation of the anal region. If the patient does not even feel the light pinprick of the perianal skin, we should suspect a pudendal neuropathy, a frequent cause of AI.

Having completed the first part of the examination, we may gently insert our second finger into the patient's anus. The length of the anal canal can be measured as an important component of anal continence (4–5 cm). When our finger is inserted in the patient's anus, we first try to evaluate the tone of the internal sphincter; this is more precisely evaluated with anorectal manometry, but evaluation by an expert proctologist also has its importance [3]. At this point the patient should be asked to squeeze, so as to allow assessment not only of the strength but also of the duration of the contraction (normal duration is 30 s or more). Ask the patient to cough and, again, evaluate the contraction of the sphincters, both the external sphincter and the puborectalis.

Rectal sensation can then be evaluated by using different inflatable balloons inserted in the rectum. Sensation is usually reduced in patients with AI due to pudendal neuropathy. Ask the patient to tell you when she/he feels that you are inflating something in the rectum. The normal value of onset of feeling should be 20–30 mL of air, the normal value of call for stool is around 60 mL of air. Finally, keep inflating until the patient tells you that he/she feels the urge to rush to the toilet because of discomfort due to the balloon; this maximal urgency is normally around 120 mL of air.

Endoscopy does not play an important role in the diagnosis of AI, except in those clinical syndromes related to a form of "occult" incontinence due to "physiologically" hypotonic internal sphincter, where dynamic proctoscopy may be preferable.

The following diagnostic tests are available to the clinician:

- *Anorectal manometry* This minimally invasive examination allows recording of the resting tone in the anal canal, which ranges between 50 and 70 mmHg in a normal subject and may be lower in a patient with AI; squeeze pressure can also be recorded, which, if normal, ranges between 60 and more than 150 mmHg and is likely to be lower than 60 in patients with AI. Manometry is useful to evaluate a patient with anal fissure and plan an internal sphincterotomy that can be

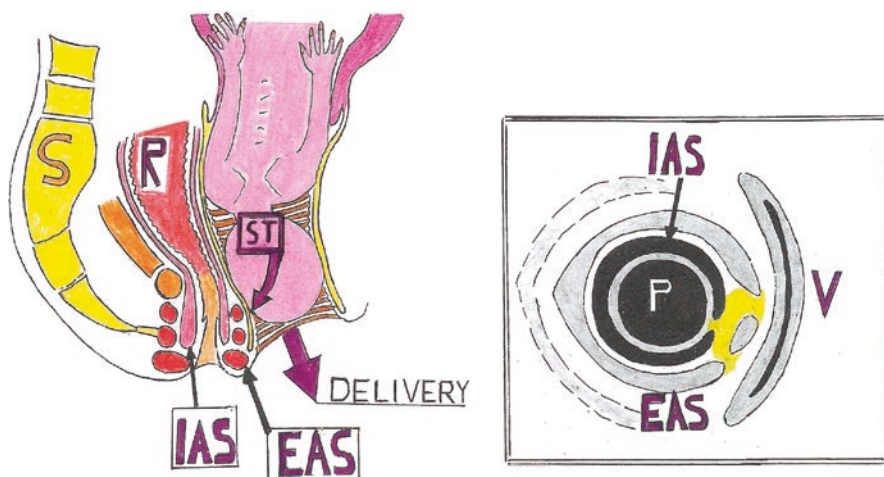


Fig. 3.1 Sagittal view of an obstetric trauma during delivery (*left*): S, sacrum; R, rectum; ST, sphincters' trauma; IAS, internal anal sphincter; dotted orange, vagina. Transanal ultrasound (*right*), patient in Sims' position: P, ultrasound probe; V, vagina; IAS: hypoechoic internal sphincter; EAS, superficial part of the external sphincter; yellow, muscles interrupted by the trauma. The patient with anal incontinence needs sphincter reconstruction

“tailored” to the degree of hypertone recorded at preoperative manometry, even if it is related to a number of recurrences compared to “standard” sphincterotomy. A parameter related to AI which may be evaluated by a manometry is the length of the anal canal.

- *Transanal and transvaginal ultrasound (US)* I personally carry out this examination in all patients suffering from AI (Fig. 3.1). 3D transanal US equipment may be better than a 2D device, mainly for the diagnosis of complex anal fistulae. The rotating probe has a reasonable diameter and does not hurt the patient, but injecting EMLA cream locally prior to the examination may protect from the vagal reflex. In our unit, the patient lies in a left lateral Sims' position, though many colleagues use the lithotomy position. The inventor, Dr. Bartram, suggests performing transanal US in the prone position in females, because he believes the anatomical structures are better detectable [4]. Sphincter lesions may be perfectly located and measured. A sphincter reconstruction will then be indicated in the case of large lesions, and neuromodulation (costly, but with an 80% success rate) if the disruption is minor. The puborectalis muscle, which appears as a hyperechogenic sling or boomerang at endoanal US, plays an important role in continence. This examination is also useful for detecting iatrogenic lesions, e.g., an unplanned division of either the smooth or striated sphincter, usually occurring during surgery for anal fistulae and abscesses, but sometimes even after an operation for anal fissure. Transanal and transvaginal US also allow detection of lesions of the sphincters and their position, or injury to the lower rectal muscle occurring after a procedure for prolapse and hemorrhoids (PPH); in this case, the

staples of a stapled transanal rectal resection (STARR) might even be seen attached to the puborectalis muscle [5].

- *Transperineal ultrasound* Based on a less expensive device, in expert hand this examination is also able to visualize both internal and external sphincter defects causing AI.
- *Defecography* This radiological test investigates anorectal morphology and function. It is carried out by introducing around 60 mL of barium into the rectum through the anus, with the patient sitting on a translucent chair. Several parameters, both anatomical and functional, may be investigated, such as the presence of incontinence, the anorectal angle at rest, and change of the anorectal angle on contraction. Subsequently, the radiologist asks the patient first to strain and then to evacuate, in order to exclude or confirm anismus, or non relaxation of the puborectalis on straining, as the anorectal angle should increase or widen on straining. If it does not, the patient has obstructed defecation.
- *Magnetic resonance imaging (MRI)* Endoanal MRI [6] has shown clear accuracy in the delineation of external sphincter defects suitable for surgical treatment and in the definition of internal anal sphincter damage potentially suitable for bioimplant deployment. As stated elsewhere [7], other examinations appear more useful than MRI for evaluating a patient with AI.

3.2 Etiology of Anal Incontinence

The potential causes of AI, as reported by the literature [7], are examined below.

3.2.1 Anal Incontinence after Operations for Anal Fissure

A correlation observed between internal sphincterotomy and AI [8] was the stimulus for treatment with “chemical” sphincterotomy, i.e., nitrates, botulin toxin etc. Indeed, postsphincterotomy AI is likely to be temporary. However, AI is more frequent when the surgeon carries out a posterior sphincterotomy, because of the weak (without muscles) area behind the divided internal sphincter. Therefore the correct procedure is a lateral internal sphincterotomy, where the surgical defect is “protected” by the adjacent external sphincter.

3.2.2 Anal Incontinence after Operations for Anal Fistula

When patients affected by anal fistula are afraid of being incontinent after the operation, ask them about bowel function and parity. In cases of diarrhea or vaginal multiparity, choose an operation which does not damage the sphincters, e.g., a fistulectomy and advanced rectal or cutaneous flap rather than fistulotomy; or alternatively, opt for an innovation, such as a fistula plug or Permacol, which leave the

sphincter intact (bearing in mind that the innovations like plugs or Permacol have a high rate of recurrence, up to 50%).

Reports show a low risk of AI in patients whose high fistulae were treated with a lay-open technique [9]. The simple lay-open procedure may have a success rate of 95% [10], but it is a fact that, in my experience at least, patients seem more concerned about losing their continence than having a fistula recurrence. That is why, in the past 20 years, the most frequently performed type of surgery for fistula changed from the lay-open to anal sphincter-preserving procedures.

3.2.3 Anal Incontinence after Operations for Hemorrhoids

AI may follow a hemorrhoidectomy performed in a patient who has already undergone a procedure for prolapse and hemorrhoids (PPH) [11].

3.2.4 Anal Incontinence after Operations for Anal Tumors

In local excision of an anal tumor, the surgeon has to excise tissues at a distance of 2 cm from the lower edge of the neoplasm in order to either avoid or minimize the risk of recurrence. Therefore some fibers of both the internal and the low external sphincter have to be removed. In this case, the surgeon may perform a sphincteroplasty at the end of the operation.

3.2.5 Anal Incontinence after Operations for Rectal Cancer

The risk of the so-called anterior resection syndrome is high (up to 90% in some series) [12] especially if the neoplasm is in the lower rectum. Oncologic radicality may impact on the structures involved in anal continence. The first structure to be impacted is the rectal reservoir, which has to be either totally or partially excised with the tumor. This, especially in cases of very low anterior resection of the rectum and coloanal anastomosis (with the suture just above the anus) or in cases of low intersphincteric resection, with the excision comprising the whole internal sphincter. The anterior resection syndrome also consists in anal pain or discomfort, diarrhea, lack of the “adaptation reflex” which is active if the rectum is present. Therefore, urgency and frequency may occur. Moreover, radiotherapy may worsen AI because the muscular tissue will become rigid, sclerotic, less elastic and will not function properly. In these cases, a Miles procedure and creating a colostomy may appear desirable. A sigmoidostomy evacuates formed stools and may be irrigated every other day, so that the patient might even avoid wearing the bag (except when going out) and wear just a smooth and flat cap to cover the stoma.

3.2.6 Anal Incontinence Following Operations for Slow-Transit Constipation

Colectomy and ileorectal anastomosis still have a place in the surgical management of slow transit constipation refractory to any conservative treatment (laxatives, enemas, etc.). According to some authors [13], it often worsens patients' quality of life. I have carried out around ten of these operations myself.

3.2.7 Anal Incontinence Following Operations for Anorectal Stricture

The most frequent cause of anorectal stricture is the Milligan-Morgan hemorrhoidectomy, when the surgeon does not leave enough mucocutaneous bridges after removing the piles. Sometimes an anoplasty operation is needed, but good results may be achieved just by periodical irrigation through the anorectum [14].

3.2.8 Anal Incontinence Following Surgery for Inflammatory Bowel Diseases

Proctocolectomy and ileoanal anastomosis with an ileal reservoir has become the operation of choice, i.e. the "gold standard" in cases of total ulcerative colitis and familial adenomatous polyposis. When the diseased rectum has to be excised, a reservoir function for anal continence may still be maintained by constructing an ileal reservoir just above the ileoanal anastomosis. Nevertheless either minor soiling or AI may occur in around 20% of these patients, especially at night, when the function of the anal sphincters is reduced. Biofeedback is the therapy of choice in these cases, or surgically constructing a four-loop or "W" large-capacity reservoir above the anal canal. Performing the ileoanal anastomosis above the anorectal ring by stapling, and thus leaving intact the tissues responsible for discriminating low intestine content, can be an option as well, but it may leave a site of disease persistence, become dysplasia or, worse, cancer.

3.3 Classification of Anal Incontinence

Detailed individual scoring systems have been proposed to classify the severity of AI, the most important of which are described below. The most commonly used are the Wexner or Cleveland Clinic score and the Vaizey or St. Mark's score. The patient's quality of life should also be evaluated. These AI scores do not generally incorporate psychometric evaluations and their interaction with other symptoms. More recently, attempts have been made to incorporate sexual dysfunction, urinary obstruction, fecal incontinence, obstructed defecation and urinary incontinence in a

dynamic map, where treatment affects map symmetry [15]. The Manchester Health Questionnaire consists of items a modified 5-point response scale including items in the eight domains of health-related quality of life (HRQoL), and incorporating a symptom severity scale [15]. The advantage of this classification is that it is simple and is the first that also takes into account quality of life. The St Mark's score [16] is often used, but less than Wexner's score.

The Pescatori scale, which was published before the abovementioned Wexner and Vaizey classifications, recalls the Dukes classification for colorectal cancer, as it uses A, B and C, plus 1, 2, 3. To obtain a final numerical score, as in the two preceding classifications, should you want to compare two or more groups of patients statistically, A counts as 1, B counts as 2 and C counts as 3. This classification, also defined PIS (Pescatori Incontinence Score) by Australian colorectal surgeons, was widely used before publication of the Cleveland Clinic score. The Rockwood Fecal Incontinence Quality of Life scale [17] is commonly used to estimate patients' quality of life. It consists of different scales, i.e., coping/behavior, depression/self perception, embarrassment, etc.

References

1. Nelson R, Norton N, Cautley E, Furner S. Community-based prevalence of anal incontinence. *JAMA*. 1995;274(7):559–61.
2. Sultan AH, Kamm MA, Hudson CN, et al. Anal-sphincter disruption during vaginal delivery. *N Engl J Med*. 1993;329(26):1905–11.
3. Coura MM, Silva SM, Almeida RM, et al. Is digital rectal exam reliable in grading anal sphincter defects? *Arq Gastroenterol*. 2016;53(4):240–5.
4. Williams AB, Bartram CI, Halligan S, et al. Anal sphincter damage after vaginal delivery using three-dimensional endosonography. *Obstet Gynecol*. 2001;97(5 Pt 1):770–5.
5. De Nardi P, Bottini C, Scucchi F, et al. Proctalgia in a patient with staples retained in the puborectalis muscle after STARR operation. *Tech Coloproctol*. 2007;11(4):353–6.
6. Pescatori M, Regadas FSP, Murad Regadas SM, Zbar P. *Imaging atlas of the pelvic floor and anorectal disease*. New York: Springer; 2008.
7. Jorge J, Wexner SD. Etiology and management of fecal incontinence. *Dis Colon Rectum*. 1993;36(1):77–97.
8. Khubchandani IT, Reed JF. Sequelae of internal sphincterotomy for chronic fissure-in-ano. *Br J Surg*. 1989;76(5):431–4.
9. Atkin GK, Martins J, Tozer P, et al. For many high anal fistulas, lay open is still a good option. *Tech Coloproctol*. 2011;15(2):143–50.
10. García-Aguilar J, Davey CS, Le CT, et al. Patient satisfaction after surgical treatment for fistula-in-ano. *Dis Colon Rectum*. 2000;43(9):1206–12.
11. Bruscianno L, Pescatori M, Ayabaca SM, et al. Reintervention after complicated or failed stapled hemorrhoidopexy. *Dis Colon Rectum*. 2004;47(11):1846–51.
12. Rizzo G, Pafundi DP, Sionne F, et al. Preoperative chemoradiotherapy affects postoperative outcomes and functional results in patients treated with transanal endoscopic microsurgery for rectal neoplasms. *Tech Coloproctol*. 2021;25(3):319–31.
13. Pfeifer J, Agachan F, Wexner SD. Surgery for constipation: a review. *Dis Colon Rectum*. 1996;39(4):444–60.
14. Crawshaw AP, Pigott L, Potter MA, Bartolo DC. A retrospective evaluation of rectal irrigation in the treatment of disorders of faecal continence. *Colorectal Dis*. 2004;6(3):185–90.

15. Altomare DF, Di Lena M, Giuratrabocchetta S, et al. The three-axial perineal evaluation (TAPE) score: a new scoring system for comprehensive evaluation of pelvic floor function. *Colorectal Dis.* 2014;16(6):459–68.
16. Vaizey CJ, Carapeti E, Cahill JA, Kamm MA. Prospective comparison of faecal incontinence grading systems. *Gut.* 1999;44(1):77–80.
17. Rockwood TH, Church JM, Fleshman JW, et al. Faecal Incontinence Quality of Life Scale: quality of life instrument for patients with fecal incontinence. *Dis Colon Rectum.* 2000;43(1):9–16; discussion 16–7

Open Access This chapter is licensed under the terms of the Creative Commons Attribution-NonCommercial-NoDerivatives 4.0 International License (<http://creativecommons.org/licenses/by-nc-nd/4.0/>), which permits any noncommercial use, sharing, distribution and reproduction in any medium or format, as long as you give appropriate credit to the original author(s) and the source, provide a link to the Creative Commons license and indicate if you modified the licensed material. You do not have permission under this license to share adapted material derived from this chapter or parts of it.

The images or other third party material in this chapter are included in the chapter's Creative Commons license, unless indicated otherwise in a credit line to the material. If material is not included in the chapter's Creative Commons license and your intended use is not permitted by statutory regulation or exceeds the permitted use, you will need to obtain permission directly from the copyright holder.





Neurofunctional Diagnosis and Anorectal Manometry

4

Filippo Pucciani

4.1 Introduction

Fecal incontinence (FI) is defined as the recurrent uncontrolled passage of fecal material for at least 3 months [1]. Anal incontinence is characterized by failure to control the elimination of stool and/or flatus [2]. The pathophysiology has a multifactorial etiology including anal sphincter lesions, rectal reservoir impairment, rectal sensation damage, loss of pelvic floor integrity, damage to the pelvic floor nerve supply, cortical awareness weakening, and stool volume and consistency. All these alterations combine variously with each other and provide different pathogenetic profiles of patients. The diagnostic work-up of FI is applied in any individual with a developmental age of at least 4 years [1] and it is based on imaging techniques, to study the morphological structure of the anal sphincters and pelvic floor, and on functional instrumental studies, to evaluate neuromuscular anorectum function. Among the latter, neurofunctional tests and anorectal manometry are the principal techniques used.

4.2 Neurofunctional Diagnosis

The pelvic floor muscles and the external anal sphincter (EAS) are innervated mainly by the pudendal nerve (S2–S4) branches: right and left inferior rectal nerves [3, 4]. The neurofunctional diagnosis, in patients affected by anal incontinence, uses tests that study these anatomic structures and may offer data that can be useful in identifying the pathophysiological profile of incontinence. A systematic literature review was recently published to provide clinicians with evidence-based recommendations on the use of neurophysiological tests in clinical practice [5]. It

F. Pucciani (✉)

Department of Experimental and Clinical Medicine, University of Florence, Florence, Italy
e-mail: filippo.pucciani@unifi.it

© The Author(s) 2023

L. Docimo, L. Bruscianno (eds.), *Anal Incontinence*, Updates in Surgery,
https://doi.org/10.1007/978-3-031-08392-1_4

concluded that the actual clinical usefulness of these tests has not yet been completely clarified and recommends pelvic floor neurophysiology studies when anal incontinence is present in patients affected by cauda equina and/or conus medullaris lesions, pudendal neuropathy, muscular diseases, spinal cord lesions and parkinsonisms [5].

Therefore, the neurophysiological evaluation of the pelvic floor should be reserved only for patients with a negative instrumental workup for anal incontinence and in whom there is a suspected neurological pathogenesis. The individual tests are described below.

4.2.1 Anal Electromyography

Electromyography (EMG) of the external anal sphincter and puborectalis muscle measures amplitude as well as duration of muscular action potentials during rest, voluntary anal contraction and attempted defecation [6]. EMG can be performed via three methods: using a needle electrode, a surface electrode on the perianal skin, or a cone-shaped plug in the anal canal. The needle electrode usually analyzes the anal area, which is subdivided into four quadrants, and may reveal, in incontinent patients, areas of sphincter damage that will display prolonged or absent action potentials. This method can also be helpful in mapping sphincter defects when there is dense scarring that can cause artefacts on endoanal ultrasound. Polyphasic potentials are an expression of reinnervation [7]. Needle electrode EMG use is limited by the anal pain induced during examination. The surface electrode and cone-shaped plug techniques can provide a global anal assessment rather than assessment of each EAS quadrant, but they are painless and more comfortable. They can be used for EMG biofeedback sessions.

4.2.2 Sacral Reflexes

Electrophysiological sacral reflexes are responses of the pelvic floor striated muscles to electric stimulation of the perineal skin, mucosa, or pelvic nerves [8]. These involve a spinal reflex arc. Sacral evoked potentials are responses recorded after pudendal nerve stimulation or stimulation of the urethral or anal skin. Stimulation of the dorsal nerves of the glans penis and clitoris, the mucosa of the rectum, bladder, and urethra, and the skin of the distal parts of the legs may give rise to an EAS response, and to a reflex response of the bulbocavernosus muscle. The first is named “pudendoanal reflex” with anal recording of the reflex, the second is the “bulbocavernosus reflex” recorded either with a concentric needle electrode or by placing two surface electrodes over the muscle site just below the scrotum. Both reflexes have an afferent limb and efferent fibers, with the sacral cord as reflection center. For this reason, the pudendal nerve terminal motor latency (PNTML)—induced by a fingertip electrode and with responses captured by another electrode at the base of the

finger—is considered only to be valid for the analysis of efferent pathways of the pudendal nerve and not for the evaluation of the entire spinal reflex arc. An abnormal prolonged PNTML can suggest a pudendal nerve lesion. This test is, however, considered to be operator-dependent because proper placement of the fingertip electrode over the pudendal nerve is critical.

In patients affected by anal incontinence, the latency of the pudendoanal reflex can be increased due to pudendal nerve damage causing slowed conduction; this reflex response is absent in conus medullaris and cauda equina lesions, but normal in spinal cord or brain injury [5].

4.2.3 Evoked Potentials

Evaluation of somatosensory evoked potentials (SSEP) provides information about the integrity of the somatosensory afferent pathways from the pudendal nerve to the parietal cortex. This test may provide a concrete demonstration of altered transmission of stool and gas perception to the cerebral cortex. Motor evoked potentials (MEP) are recorded after transcranial magnetic stimulation, and they may demonstrate the defective transmission of cortical signals to the pelvic floor muscles. SSEP and MEP can be useful in patients with spinal cord or cauda equina lesions and pelvic symptoms, but they are not routinely performed in anal incontinence.

4.3 Anorectal Manometry

Anorectal manometry (ARM) analyses fecal continence mechanisms and, when applied in anal incontinence patients, identifies anal sphincter weakness, anorectal reflex abnormalities, rectal sensation impairment, and poor rectal compliance.

Several systems and probes exist for performing ARM. The perfusion system, originally developed by Arndorfer et al. [9], employs catheters perfused with distilled water infused by a pneumohydraulic pump, to obtain a steady perfusion rate of 0.2–0.4 mL/min. Occlusion of the catheter channels increases intraluminal pressure and produces resistance to the flow of water. This resistance is measured by transducers, interpreted as compliance of the tissue and converted into pressure values shown on a trace. High sensitivity (92.2%) and good specificity (86.6%) are reached when ARM is applied in FI patients [10]. In 2007, high-resolution ARM (HRAM) was introduced into clinical practice [11], and a few years later high-definition 3D solid-state ARM (HDAM) was developed [12]. Currently, both these techniques employ multi-use solid-state catheters, and pressure values are expressed according to a color scale in ascending order from green, the lowest values, to purple, the maximum values. HADM, through dedicated software, displays 3D cylindrical topographical models of the anal canal which can be rotated and viewed from all sides; in this way focal sphincteric defects may be detected in anal incontinence [13].

Regardless of the manometric system adopted, the recording steps are identical.

Anal resting pressure (ARP) detects the basal tone of the anal canal: one study assigned approximately 55% of ARP to the internal anal sphincter (IAS), 15% to the vascular anal cushions and the remaining 30% to the EAS [14].

Maximal voluntary contraction (MVC) is the squeeze pressure obtained by asking the patient to contract the anus with maximal strength: it reflects the activity of the EAS and puborectalis muscle. ARP and MVC tend to be higher and the normal range of anal pressure is relatively wide when measured with HRAM.

Rectoanal inhibitory reflex (RAIR) is the reflex inhibition of IAS tone and is considered part of the sampling reflex. Transient relaxation of the IAS allows rectal content, with small fecal volumes or gas, to come into contact with sensory receptors placed in the upper anal mucosa. In this way, the rectal content may be cortically typified and the subject is alerted to discharge flatus or to defecate [15]. Detection of rectal sensation is obtained by inflating, with air, a balloon at the tip of the catheter. Increasing volumes are used until values are reached to identify the *conscious rectal sensitivity threshold* (CRST: the lowest volume for the first sensation), the *constant sensation* (CS: the volume with call to stool) and the *maximal tolerated volume* (MTV: the threshold volume for urgency to defecate and for pain). Finally, the monitoring of *rectal compliance* reflects the tonic adaptation of the rectal wall to increasing volumes, and is determined by the ratios $\Delta P/\Delta V$ measured at different volumes of inflated air.

According to the clinical guideline of the American College of Gastroenterology (ACG), ARM is worth implementing in patients affected by anal incontinence [16]. Recently, the International Anorectal Physiology Working Group (IAPWG) published standardized testing protocols for HRAM and the London Classification for disorders of anorectal function was developed [17]. In incontinent patients, HRAM provides data for identification/quantification of impaired anal sphincter function and abnormal rectal sensitivity (both hyper- and hyposensitivity types). ARM, as explained above, offers objective data on continence mechanisms and may suggest which mechanism may be malfunctioning in incontinent patients. However, the manometric findings must be complemented with data obtained using other diagnostic techniques assessing morphology (anoscopy, MRI, endoanal ultrasound) and function (anal neurophysiologic tests).

ARP may be lower in anal incontinence, and the related hypotonic anal canal is usually due to IAS impairment, especially if passive incontinence occurs [18]. Unfortunately, the discriminative power of ARP between continent and incontinent patients is low because of the wide range of normal pressures. HDAM could be useful in detecting structural anorectal abnormalities such as sphincter defects, descending perineum and rectoanal intussusception. Objective criteria for sphincter defects, moreover, might be useful to better select patients for endoanal ultrasound [13].

MVC is frequently impaired in patients affected by anal incontinence: the amplitude and duration of squeeze tone are lower than in healthy controls [19], or sometimes inappropriate relaxations may occur (Fig. 4.1). MVC impairment is related to EAS and puborectalis malfunctioning and is found in patients with urge incontinence who lose stools because of the failed suppression of defecation [18]. HADM

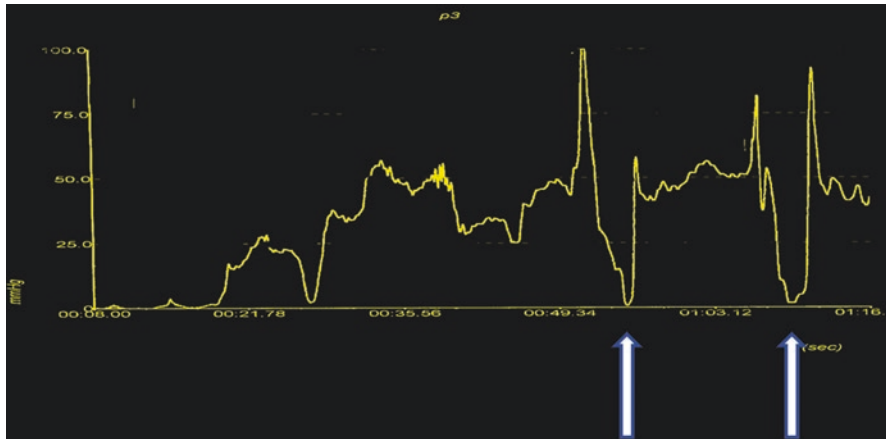


Fig. 4.1 Maximal voluntary contraction. Spontaneous inappropriate relaxations occur (white arrows) during anal contraction

may detect EAS defects, for example after obstetric injury or anal surgery. The absence of EAS defects could suggest pudendal neuropathy and the pudendoanal reflex should be used for diagnosing pudendal nerve injury.

Detection of RAIR is an important tool for evaluation of rectoanal coordination. This reflex often cannot be elicited when ARP is extremely low (<10 mmHg) and, therefore, in this condition it is not possible to judge if the reflex is present or absent, normal or impaired. However, there are some reports of RAIR impairment. A longer RAIR duration has been detected in patients with fecal soiling and pruritus ani [20]. The duration of RAIR is also longer in patients affected by idiopathic FI than in controls [21]: the reflex exhibits a prolonged contraction time with a slow return to basal prestimulation values. This prolonged inhibition impairs the continence mechanisms. Small amounts of feces reach the inhibited proximal anal canal but there is poor distal EAS recruitment: therefore, in the presence of a sensitivity threshold higher than the RAIR threshold, fecal passive incontinence may occur. The absence of RAIR is a manometric sign that is often detected in ultralow rectal anterior resection [22]. It is the consequence of the total excision of the rectum such as in ultralow anterior resection with coloanal anastomosis: the descending rectoanal pathway is easily interrupted. Thus, the RAIR may be abolished, and the coordinated sensory-motor integration of the rectum is distorted with a possible negative influence on fecal continence.

The last but not the least step of ARM is the detection of rectal sensation and rectal compliance. Significant alteration of rectal sensation (hyposensitivity with high volumes or hypersensitivity with low volumes, according to the London classification) may be detected in patients with diabetes mellitus [23] or multiple sclerosis [24]. Impaired recognition of impending defecation can lead to FI. Hyposensitivity means passive incontinence if the EAS reflex contraction is weakened in the presence of rectal content. Hypersensitivity is present in urge

incontinence when small volumes are involuntarily expelled because of impaired volumetric rectal capacity such as in patients with inflammatory disease (ulcerative colitis) or rectal fibrosis (actinic proctitis).

The compliance of the rectum expresses the elastic distensibility of the rectal wall while the MTV measures the volumetric capacity of the rectum. Both values are an expression of rectal containment capacity, the first adapting the wall tension to the contents without increasing endorectal pressure, the latter as the expression of the maximum filling volume. Impaired compliance, often combined with low MTV, is present after sphincter-saving surgery [22] and explains urge incontinence that is the main symptom of anterior resection syndrome.

In addition to its diagnostic aspects, ARM may assist in the selection of therapy for patients with anal incontinence. The selection of incontinent patients for overlapping sphincteroplasty may be appropriate when low ARP (<10 mmHg) and low MVC (<40 mmHg) are detected [25]. The same cutoff values identify rectal prolapse patients who are at high risk for FI after surgical repair and suggest adoption of sphincteric correction combined with the chosen surgical technique [26]. ARM can also play an important role in multimodal rehabilitation of FI patients [27]. The algorithm of this rehabilitation program is based on manometric data. Biofeedback and pelvic-perineal kinesiotherapy are suggested by low ARP or weak MVC. Volumetric rehabilitation (sensory retraining) is indicated for impaired rectal sensation and/or damaged compliance. Electrostimulation is only a preliminary step when patients need to better feel the anoperineal plane and increase their awareness. The usual sequence of techniques is: (1) volumetric rehabilitation; (2) electrostimulation; (3) pelvic-perineal kinesiotherapy; (4) biofeedback. The same protocol has been used in patients with FI after sphincter-saving surgery. Many patients showed improvement of the Wexner Incontinence Score (58%): impairment of both MTV and compliance was associated with bad postrehabilitation results [28].

In conclusion, ARM may be considered an important tool in the diagnostic work-up of anal incontinence. It also offers data for understanding the pathophysiology of incontinence and can help physicians to modify the therapeutic strategy appropriately.

References

1. Rao SSC, Bharucha AE, Chiarioni G, et al. Anorectal disorders. *Gastroenterology*. 2016;150(6):1430–42.e4.
2. Sultan AH, Nugent K. Pathophysiology and nonsurgical treatment of anal incontinence. *BJOG*. 2004;111(Suppl 1):84–90.
3. Grigorescu BA, Lazarou G, Olson TR, et al. Innervation of the levator ani muscles description of the nerve branches to the pubococcygeus, iliococcygeus, and puborectalis muscles. *Int Urogynecol J Pelvic Floor Dysfunct*. 2008;19(1):107–16.
4. Pucciani F. Anorectal functional anatomy. In: Bellini M, editor. *High resolution and high definition anorectal manometry*. New York: Springer; 2020. p. 1–10.
5. Bianchi F, Squintani GM, Osio M, et al. Neurophysiology of the pelvic floor in clinical practice: a systematic literature review. *Funct Neurol*. 2017;32(4):173–93.
6. Lei J, Nofi C, Rivadeneira DE. Introduction to methods of anorectal physiology evaluation. In: Oliveira LCC, editor. *Anorectal physiology*. New York: Springer; 2020. p. 65–86.

7. Podnar S, Zalewska E, Hausmanowa-Petrusewicz I. Evaluation of the complexity of motor unit potentials in anal sphincter electromyography. *Clin Neurophysiol.* 2005;116(4):948–56.
8. Uher EA, Swash M, Sacral reflexes. Physiology and clinical application. *Dis Colon Rectum.* 1998;41(9):1165–77.
9. Arndorfer RC, Stef JJ, Dodds WJ, et al. Improved infusion system for intraluminal esophageal manometry. *Gastroenterology.* 1977;73(1):23–7.
10. Sun WM, Donnelly TC, Read NW. Utility of a combined test of anorectal manometry, electromyography, and sensation in determining the mechanism of ‘idiopathic’ faecal incontinence. *Gut.* 1992;33(6):807–13.
11. Jones MP, Post J, Crowell MD. High-resolution manometry in the evaluation of anorectal disorders: a simultaneous comparison with a water-perfused manometry. *Am J Gastroenterol.* 2007;102(4):850–5.
12. Raizada V, Bhargava V, Karsten A, Mittal RK. Functional morphology of anal sphincter complex unveiled by high definition anal manometry and three dimensional ultrasound imaging. *Neurogastroenterol Motil.* 2011;23(11):1013–9.
13. Torresan F, Mandolesi D, Bonventre S, Usai-Satta P. Differences between conventional anorectal manometry and high resolution/high definition anorectal manometry. In: Bellini M, editor. *High resolution and high definition anorectal manometry.* New York: Springer; 2020. p. 49–68.
14. Lestar B, Penninckx F, Kerremans R. The composition of anal basal pressure. An in vivo and in vitro study in man. *Int J Colorectal Dis.* 1989;4(2):118–22.
15. Pucciani F, Trafeli M. Sampling reflex: pathogenic role in functional defecation disorders. *Tech Coloproctol.* 2021;25(5):521–30.
16. Wald A, Bharucha AE, Cosman BC, Whitehead WE. ACG clinical guideline: management of benign anorectal disorders. *Am J Gastroenterol.* 2014;109(8):1141–57.
17. Carrington EV, Heinrich H, Knowles CH, et al. The International Anorectal Physiology Working Group (IAPWG) recommendations: Standardized testing protocol and the London classification for disorders of anorectal function. *Neurogastroenterol Motil.* 2020;32(1):e13679. <https://doi.org/10.1111/nmo.13679>.
18. Engel AF, Kamm MA, Bartram CI, Nicholls RJ. Relationship of symptoms in fecal incontinence to specific sphincter abnormalities. *Int J Colorectal Dis.* 1995;10(3):152–5.
19. Chiarioni G, Scattolini G, Bonfante F, Vantini I. Liquid stool incontinence with severe urgency: anorectal function and effective biofeedback treatment. *Gut.* 1993;34(11):1576–80.
20. Evers AA, Thomson JP. Pruritus ani: is anal sphincter dysfunction important in aetiology? *BMJ.* 1979;2(6204):1549–51.
21. Pucciani F, Bologna A, Rottoli ML, et al. Idiopathic faecal incontinence and internal anal sphincter dysfunction: role of the rectoanal inhibitory reflex. *Tech Coloproctol.* 1997;1(5):14–8.
22. Pucciani F. A review on functional results of sphincter-saving surgery for rectal cancer: the anterior resection syndrome. *Updat Surg.* 2013;65(4):257–63.
23. Wald A, Tunuguntia AK. Anorectal sensorimotor dysfunction in fecal incontinence and diabetes mellitus. Modification with biofeedback therapy. *N Engl J Med.* 1984;310(20):1282–7.
24. Caruana BJ, Wald A, Hinds JP, Eidelman BH. Anorectal sensory and motor function in neurogenic fecal incontinence. Comparison between multiple sclerosis and diabetes mellitus. *Gastroenterology.* 1991;100(2):465–70.
25. Ternent CA, Shashidharan M, Blatchford GJ, et al. Transanal ultrasound and anorectal physiology findings affecting continence after sphincteroplasty. *Dis Colon Rectum.* 1997;40(4):462–7.
26. Yoshioka K, Hyland G, Keighley MR. Anorectal function after abdominal rectopexy: parameters of predictive value in identifying return of continence. *Br J Surg.* 1989;76(1):64–8.
27. Pucciani F, Iozzi L, Masi A, et al. Multimodal rehabilitation for faecal incontinence: experience of an Italian centre devoted to faecal disorder rehabilitation. *Tech Coloproctol.* 2003;7(3):139–47.
28. Pucciani F, Ringressi MN, Redditi S, et al. Rehabilitation of fecal incontinence after sphincter-saving surgery for rectal cancer: encouraging results. *Dis Colon Rectum.* 2008;51(10):1552–8.

Open Access This chapter is licensed under the terms of the Creative Commons Attribution-NonCommercial-NoDerivatives 4.0 International License (<http://creativecommons.org/licenses/by-nc-nd/4.0/>), which permits any noncommercial use, sharing, distribution and reproduction in any medium or format, as long as you give appropriate credit to the original author(s) and the source, provide a link to the Creative Commons license and indicate if you modified the licensed material. You do not have permission under this license to share adapted material derived from this chapter or parts of it.

The images or other third party material in this chapter are included in the chapter's Creative Commons license, unless indicated otherwise in a credit line to the material. If material is not included in the chapter's Creative Commons license and your intended use is not permitted by statutory regulation or exceeds the permitted use, you will need to obtain permission directly from the copyright holder.





Role of Ultrasonography for Anal Incontinence

5

Giulio A. Santoro, Patrizia Pelizzo, Ugo Grossi, Rita Cian, Giacomo Zanus, and Luigi Brusciano

5.1 Introduction

Continence depends on several anatomic and physiologic entities: integrity of the anal sphincters, pelvic floor function, rectal distensibility, anorectal sensation, anorectal reflexes, intact nervous system, mental functions, stool consistency and colonic transit. Deficiency of one or more of these factors can lead to anal incontinence (AI) [1]. AI is more frequent in women (females:males = 3:1) and it is estimated that about 40% of women over 70 years old are affected. Evaluation of the pelvic floor is generally clinical, but in the last two decades, the use of ultrasound has become a mainstream diagnostic tool in the investigation of female pelvic organ prolapse, urinary and fecal incontinence and other defecation disorders, providing an immediate objective confirmation of clinical examination findings [2]. Both AI and urinary incontinence are major health problems. They can be particularly embarrassing and affect 2–24% of community-dwelling adults, with 1–2% experiencing a significant impact on daily activities [3].

Tests to diagnose AI include anorectal manometry, electromyography, dynamic proctography, colon motility test, and endoanal ultrasonography (EAUS).

G. A. Santoro (✉) · P. Pelizzo · U. Grossi · R. Cian
Tertiary Referral Pelvic Floor and Incontinence Center, 2nd Surgery Unit,
Regional Hospital Ca' Foncello, Treviso, Italy
e-mail: giulioasantoro@yahoo.com; patrizia.pelizzo@aopd.veneto.it;
ugo.grossi@aulss2.veneto.it; rita.cian@aulss2.veneto.it

G. Zanus
Department of Surgery, Oncology and Gastroenterology, University of Padua, Padua, Italy
e-mail: giacomo.zanus@unipd.it

L. Brusciano
Division of General, Mini-invasive, Oncological, and Bariatric Surgery,
University of Campania Luigi Vanvitelli, Naples, Italy
e-mail: luigi.brusciano@unicampania.it

Different kinds of AI are diagnosed through different basic anorectal function tests: they help to discriminate between the bowel dysfunction related to spinal cord injuries and sphincter lesions [4]. Preoperative EAUS is a useful tool for the assessment of anal sphincter injury in patients with rectal prolapse [5]. Sphincter defects after delivery are classified according to the classification of obstetrical anal sphincter injuries (OASIS) [6], and EAUS was recommended by the sixth International Consultation on Incontinence (ICI, Tokyo 2017) [7] as the gold standard technique for assessment of anal sphincter integrity.

This chapter will focus on the ultrasound technique, normal ultrasound anatomy of the anal canal and the evaluation of anal sphincter injury.

5.2 Ultrasound Technique

Ultrasound is a useful and flexible modality in medical imaging, and often provides an additional or unique characterization of tissues, compared with other modalities such as conventional radiography or computed tomography. Ultrasound uses high-frequency sound waves. Sound is a mechanical form of energy generated by vibrations. While audible waves lie between 20 and 20,000 Hz, ultrasound uses greater frequencies, between 1 and 30 MHz. Increasing the frequency improves image resolution but decreases the penetration of waves through tissue. Sound waves do not exist in a vacuum, and their propagation in gases is poor because the molecules are widely separated [8]. The transducer creates the sound waves and receives those reflected by the tissues, which are displayed on an ultrasound screen as scale of grey values (B mode). Ultrasound is composed by five main components: the transducer crystal, the matching layers, damping material, the transducer case, and the electric cable. The images are displayed in a sector, vector, linear, or curved linear format.

EAUS is performed by a mechanical 360-degree rotating transducer with 9–16 MHz frequencies and high resolution. New probes allow for 3D automatic acquisition of the images. A 3D cube is formed by 300 transaxial 2D images over a distance of 60 mm with a distance of 0.2–0.3 mm between two adjacent images. Using 3D, the images can be visualized in the axial, coronal and sagittal planes and any other reconstructed oblique plane.

The patient may be placed in a dorsal lithotomy, prone or, more commonly, left lateral position. The anterior wall of the anal canal is at 12 o'clock and the posterior aspect is inferior at 6 o'clock. Laxative enemas may be sufficient for anorectal ultrasound. Endorectal ultrasound (ERUS) is performed by filling a balloon at the tip of the rigid probe to create an acoustic interface in direct contact between the rectum and the transducer. The transducer is inserted through a rectoscope to assess the entire length of the rectum up to 20 cm.

On the ultrasound screen the image is oriented with the anterior side at 12 o'clock, left lateral at 3 o'clock, posterior at 6 o'clock and right lateral at 9 o'clock position. The EAUS images are collected from the upper aspect of the puborectalis (PR) muscle to the anal margin. The probe is aligned with median raphe. EAUS may be also performed by linear electronic, high frequency transducer. This probe has

the advantage of allowing the assessment of vascularity by color doppler and elasticity of the tissue by elastography.

Elastography is a newer technique that exploits the fact that a pathological process alters the elastic properties of the involved tissue. Endoscopic ultrasound elastography enables highly accurate discrimination of colorectal adenocarcinomas from adenomas, while inflammatory bowel disease phenotypes can be distinguished based on strain ratio calculation [9]. Its role in AI is still under investigation.

5.3 Normal Ultrasound Anatomy

The anal canal is 2–4 cm in length. The inner circular fibers of the muscularis propria of the rectal wall become the internal anal sphincter (IAS) muscle within the anal canal. This is a smooth muscle and is visualized as a dark, hypoechoic ring. More externally, there is a hyperechoic layer that represents the longitudinal muscle (LM), in continuity with the longitudinal fibers of the muscularis propria of the rectal wall. The LM extends through the anal canal into the intersphincteric space and implants into the external anal sphincter (EAS) muscle. Deeper to that layer, the EAS is visualized as a mixed echogenic ring, larger but less distinct than the IAS [10].

EAUS can identify at least six layers in the middle third of anal canal: the inner layer is the hyperechoic interface with the plastic cap; the second layer is the hypoechoic mucosa; the third layer is the hyperechoic subepithelial tissue; the fourth layer is the hypoechoic IAS; the fifth is the hyperechoic LM, and the outer layer has mixed echogenicity [11].

In the upper third of the anal canal, the PR muscle is visualized which appears as a U-shaped hyperechoic structure. This muscle is part of the levator ani muscle (LA) and it is contiguous to the EAS.

In the lower third of the anal canal, the IAS is no longer visualized and only the subcutaneous part of the EAS can be seen (Fig. 5.1).

In the axial plane, normal measurements of the IAS range from 1.5 to 4 mm in thickness and those of the EAS range from 7.7 to 8.6 mm. In the coronal plane the anterior length of the EAS is between 12 and 15 mm in women and between 2 and 3 cm in men (Fig. 5.2).

5.4 Ultrasound in Anal Incontinence

In patients with AI, EAUS identifies if there is a combined lesion of the IAS and EAS, and of the PR, or if the lesion involves just one muscle. Number, circumferential (radial angle in degrees or in hours of the clock) and longitudinal (proximal, distal, or full length) extension of the defect, presence of scarring, differences in echogenicity and thickness of the sphincters, and other local alterations must be carefully assessed and always be described. However, finding a sphincter defect does not necessarily mean that it is the cause of AI. EAUS is able to detect

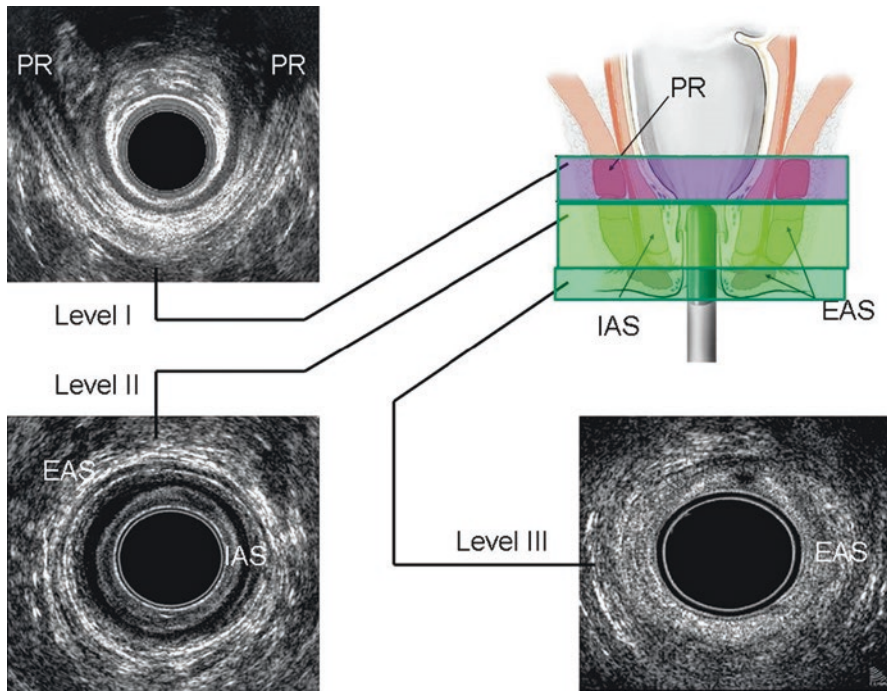


Fig. 5.1 Normal ultrasonographic anatomy of the anal canal. *EAS*, external anal sphincter; *IAS*, internal anal sphincter; *PR*, puborectalis muscle

sphincteric occult tears, which are reported in up 33% of primiparous females after vaginal deliveries [12].

There are different scores to classify the extent of sphincter damage by EAUS. Stark's score defines the severity of sphincter lesions with a range from 0 (no defect) to 16 (defect $\geq 180^\circ$ involving the whole length and depth of both sphincters) [13]. During the examination it is important to distinguish between natural gaps (hypochoic areas with smooth, regular edges, occurring in the upper part of the anal canal) and sphincter ruptures (mixed echogenicity due to scarring, with irregular edges and loss of symmetry) occurring at the upper anterior part of the anal canal [14].

5.5 Internal Anal Sphincter Lesions

IAS injuries can be caused by obstetric and iatrogenic (hemorrhoidectomy, mucoprolapsectomy, sphincterotomy) traumas, persistent manual dilatation [15] or fistulectomy.

Injuries of the IAS are displayed as hyperechoic breaks in the normally hypochoic ring. Incontinence related to a single IAS injury has a typical pattern of thickening of the remaining muscle due to retraction phenomenon ("halfmoon"

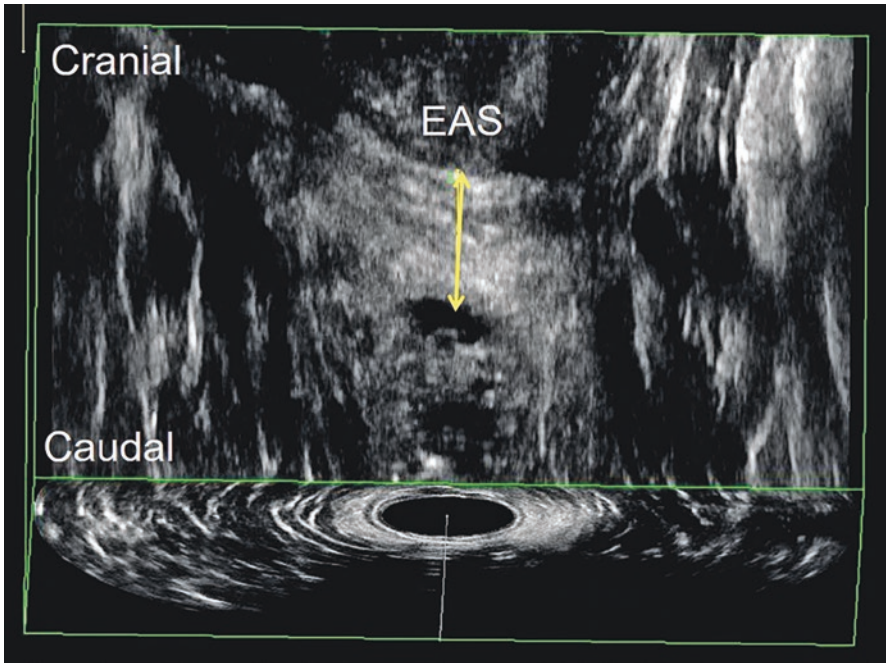
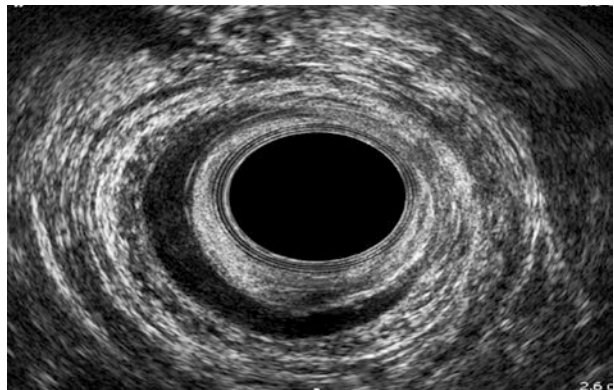


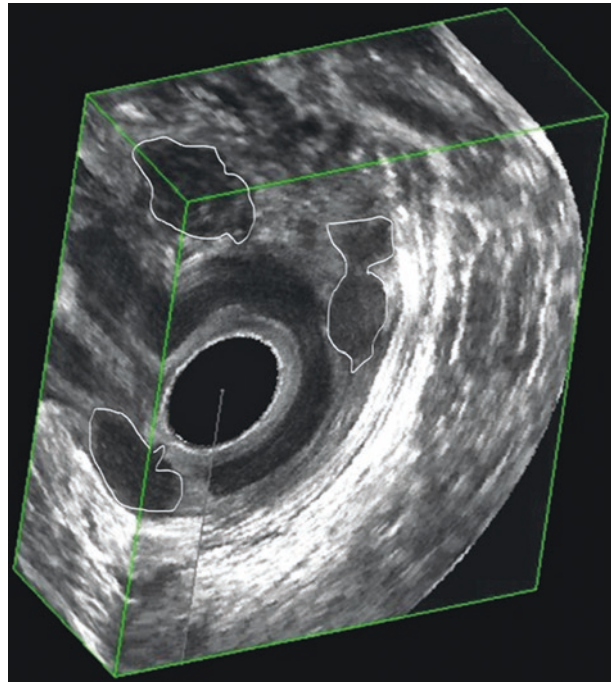
Fig. 5.2 Measurement of the external sphincter (EAS) by 3D endoanal ultrasound. This woman showed a normal thickness of 14 mm

Fig. 5.3 Lesion of the internal anal sphincter



sign) (Fig. 5.3). IAS lesions after hemorrhoidectomy appear as multiple defects in the positions of the hemorrhoidal plexus. AI related to OASIS is often associated with defects of both the EAS and IAS, rarely the IAS alone. Although IAS thickness increases with age, a thickness greater than 4 mm may be a sign of myopathy [16, 17].

Fig. 5.4 Placement of a prosthesis in the intersphincteric space in severe anal incontinence



EAUS is also used intraoperatively for the correct positioning of injectable substances or prostheses for the treatment of AI and to evaluate, postoperatively, their dislocation in patients with recurrence (Fig. 5.4). EAUS is also helpful to quantify how much IAS can be divided during fistulotomy for intersphincteric fistulas [18].

5.6 External Anal Sphincter Lesions

OASIS are due to pelvic traumas during delivery, and they increase the risk of developing AI either immediately following childbirth or later in life. Their prevalence is underestimated. EAUS performed 60 days after delivery is considered the gold standard modality for the diagnosis of OASIS. It is able to detect between 4% and 8.5% of sphincter defects in multiparous women and 27–35% of injuries in primiparous women [19].

OASIS can be classified into four grades of severity, and they always involve the sphincters anterior to a horizontal line through the mid canal. In most cases, there is a single break of the anterior part of the EAS (<50% of EAS thickness = OASIS 3a; or >50%/full thickness = OASIS 3b). A combined defect of the EAS and IAS is defined as OASIS 3c. In grade 4 OASIS, the anal mucosa is also disrupted (Fig. 5.5). Ultrasonographically, a lesion of the transverse perineal muscles appears as an

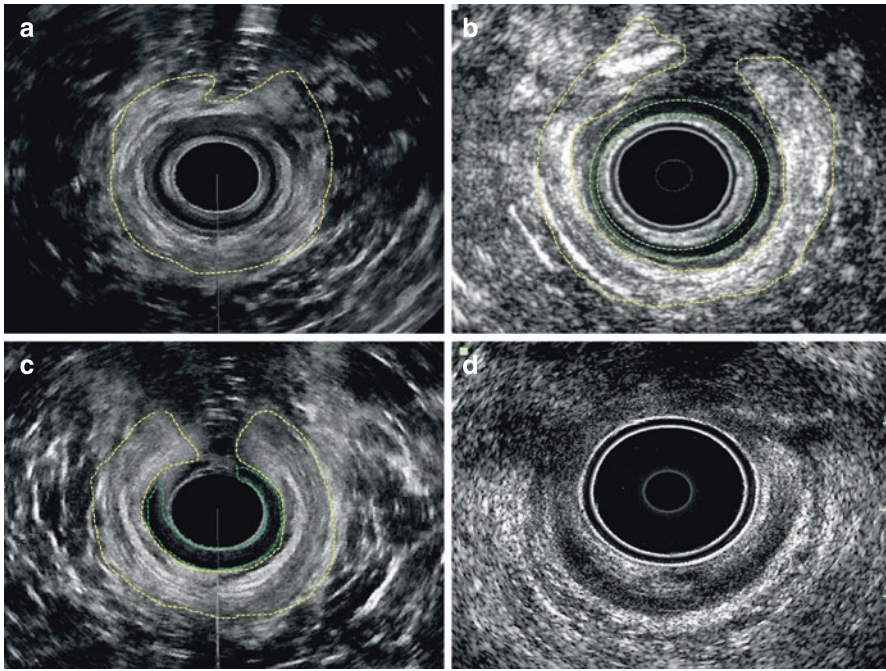


Fig. 5.5 Different grades of obstetric anal sphincter injuries (OASIS) on endoanal ultrasonography: (a) OASIS grade 3a; (b) OASIS grade 3b; (c) OASIS grade 3c; (d) OASIS grade 4

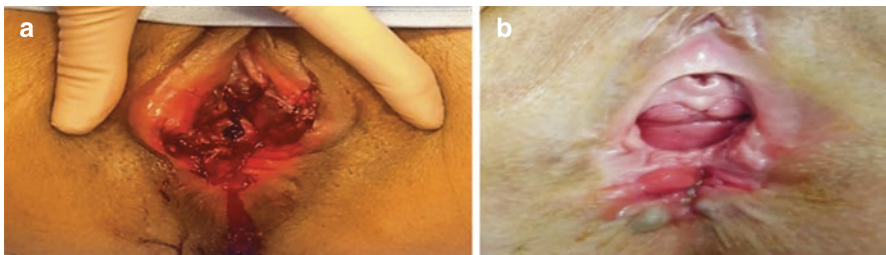
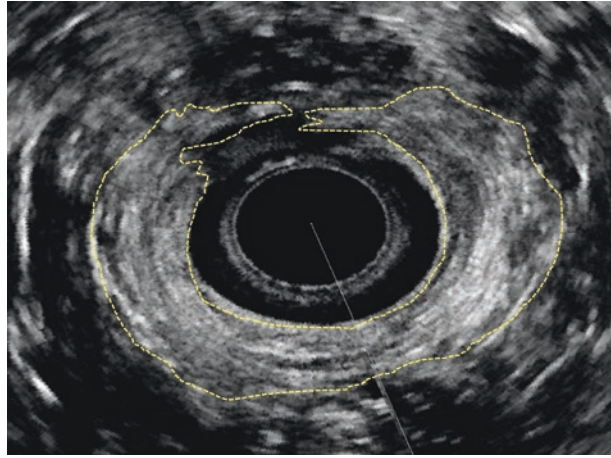


Fig. 5.6 Grade 4 obstetric anal sphincter injury: early lesion (a); scarring after 6 months (b)

asymmetrical area anterior to the EAS. A combined defect of the sphincter complex in the middle part of the anal canal is visualized as a disruption of regular continuity of both the EAS and IAS. Most injuries extend from 90° to 180° . Lesions of the IAS may show a “rubber band effect”, a classical sign of sphincter defect [20]. On ultrasound, EAS lesions appear as a low-intensity defect in the context of the brightest ring of the striated muscle. The poorly defined border of the EAS during tissue regeneration does not allow definition of the degree of atrophy of this muscle (Fig. 5.6). Fat replacement and loss of muscle fibers reduce the definition of the outer interface of the EAS [21]. However, by using volume render mode and

Fig. 5.7 Residual defect of the external anal sphincter and internal anal sphincter after repair of a grade 3c obstetric anal sphincter injury



3D-EAUS, it is possible to evaluate EAS atrophy by enhancing the intensity data of muscular fibers and fat tissue [22].

Many studies have reported good outcomes after immediate primary repair of OASIS, with improved quality of life in women and reduced AI symptoms [23]. Currently, there is no postpartum pathway to evaluate AI associated with obstetric sphincter injuries [24].

Sioutis et al. [24] reported that OASIS were clinically overestimated in 7% of women in whom 3D-EAUS did not demonstrate any damage. Late onset of AI in an elderly population can be related to undiagnosed previous anal sphincter defects after delivery [25].

3D-EAUS is useful to monitor the results after sphincteroplasty and to detect any residual injury, helping the management of subsequent pregnancies (Fig. 5.7). According to Fitzpatrick et al. [26], women experiencing AI after OASIS repair, must be referred for EAUS assessment.

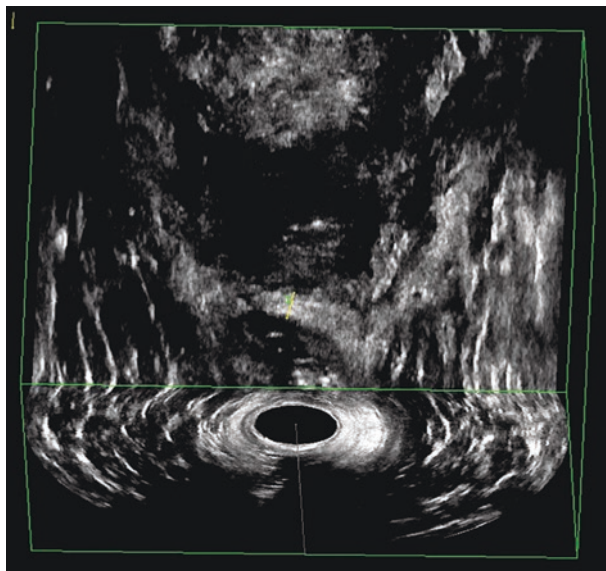
Moreover, EAS thickness was found by Soerensen et al. [27] to be related to recurrence of incontinence symptoms after OASIS repair (Fig. 5.8).

5.7 Puborectalis Muscle Lesions

LA and PR muscles are best investigated by endovaginal ultrasound (EVUS) and transperineal ultrasound (TPUS), because these modalities visualize the attachment of the muscles to the inferior pubic rami. EAUS, which remains the best technique for the assessment of the EAS and IAS, can only show the posterolateral aspect of the PR.

A stretch trauma of the LA is initially associated with hematoma and edema formation; later, the muscle fibers are replaced by scar tissue or fibrosis. By using TPUS, Van de Waarsenburg et al. demonstrated that hematoma appears as a hypo/

Fig. 5.8 Reduced thickness (4 mm) of the anterior external anal sphincter in a woman with recurring symptoms of anal incontinence after obstetric anal sphincter injury repair



anechoic area in the context of the LA, while scar tissue is visualized as an area of mixed/hyperechogenicity [28].

Lesions of the PR may be visualized by 3D-EAUS as reduced thickness or complete loss of one or both branches of the muscle.

In conclusion, 3D EAUS is the gold standard investigation to evaluate sphincter injuries related to AI [29]. However, it does not provide optimal information regarding EAS atrophy, which is best assessed by endoanal magnetic resonance imaging [30]. EVUS and TPUS provide additional information on pelvic floor muscle and levator hiatus damage [31].

References

1. Haylen BT, de Ridder D, Freeman RM, et al. An International Urogynecological Association (IUGA)/International Continence Society (ICS) joint report on the terminology for female pelvic floor dysfunction. *Int Urogynecology J.* 2010;21(1):5–26.
2. Vellucci F, Regini C, Barbanti C, Luisi S. Pelvic floor evaluation with transperineal ultrasound: a new approach. *Minerva Ginecol.* 2018;70(1):58–68.
3. Farage MA, Miller KW, Berardesca E, Maibach HI. Psychosocial and societal burden of incontinence in the aged population: a review. *Arch Gynecol Obstet.* 2008;277(4):285–90.
4. Santoro GA, Wieczorek AP, Sultan AH. Pelvic floor disorders. A multidisciplinary textbook. 2nd ed. New York: Springer; 2020.
5. Emile SH, Youssef M, Thabet W, et al. Role of endoanal ultrasonography in grading anal sphincter integrity in rectal prolapse and in predicting improvement in the continence state after surgical treatment. *Surg Laparosc Endosc Percutan Tech.* 2020;30(1):62–8.
6. Tejedor P, Plaza J, Bodega-Quiroga I, et al. The role of three-dimensional endoanal ultrasound on diagnosis and classification of sphincter defects after childbirth. *J Surg Res.* 2019;244:382–8.

7. Abrams P, Cardozo L, Wagg A, Wein A, editors. *Incontinence (Volume 1)*. 6th ed. Bristol, UK: International Continence Society; 2017.
8. Tole NM, Ostensen H, World Health Organization. *Diagnostic Imaging and Laboratory Technology Team. Basic physics of ultrasonic imaging*. Geneva: World Health Organization; 2005. <https://apps.who.int/iris/handle/10665/43179>. Accessed 24 Nov 2021
9. Cârțână ET, Gheonea DI, Săftoiu A. Advances in endoscopic ultrasound imaging of colorectal diseases. *World J Gastroenterol*. 2016;22(5):1756–66.
10. Bartram CI, Frudinger A. *Handbook of anal endosonography*. Petersfield: Wrightson Biomedical; 1997.
11. Bennett AE. Correlative anatomy of the anus and rectum. *Semin Ultrasound CT MR*. 2008;29(6):400–8.
12. Abramowitz L, Sobhani I, Ganansia R, et al. Are sphincter defects the cause of anal incontinence after vaginal delivery? Results of a prospective study. *Dis Colon Rectum*. 2000;43(5):590–6; discussion 596–598
13. Starck M, Bohe M, Valentin L. Results of endosonographic imaging of the anal sphincter 2–7 days after primary repair of third- or fourth-degree obstetric sphincter tears. *Ultrasound Obstet Gynecol*. 2003;22(6):609–15.
14. Sultan AH, Kamm MA, Hudson CN, et al. Anal-sphincter disruption during vaginal delivery. *N Engl J Med*. 1993;329(26):1905–11.
15. Speakman CT, Burnett SJ, Kamm MA, Bartram CI. Sphincter injury after anal dilatation demonstrated by anal endosonography. *Br J Surg*. 1991;78(12):1429–30.
16. Vaizey CJ, Kamm MA, Bartram CI. Primary degeneration of the internal anal sphincter as a cause of passive faecal incontinence. *Lancet*. 1997;349(9052):612–5.
17. Frudinger A, Halligan S, Bartram CI, et al. Female anal sphincter: age-related differences in asymptomatic volunteers with high-frequency endoanal US. *Radiology*. 2002;224(2):417–23.
18. Kołodziejczak M, Santoro GA, Obcowska A, et al. Three-dimensional endoanal ultrasound is accurate and reproducible in determining type and height of anal fistulas. *Colorectal Dis*. 2017;19(4):378–84.
19. Harvey MA, Pierce M, Alter JEW, et al. Obstetrical anal sphincter injuries (OASIS): prevention, recognition, and repair. *J Obstet Gynaecol Can*. 2015;37(12):1131–48.
20. Sakse A, Secher NJ, Ottesen M, Starck M. Defects on endoanal ultrasound and anal incontinence after primary repair of fourth-degree anal sphincter rupture: a study of the anal sphincter complex and puborectal muscle. *Ultrasound Obstet Gynecol*. 2009;34(6):693–8.
21. Cazemier M, Terra MP, Stoker J, et al. Atrophy and defects detection of the external anal sphincter: comparison between three-dimensional anal endosonography and endoanal magnetic resonance imaging. *Dis Colon Rectum*. 2006;49(1):20–7.
22. Stoker J, Rociu E, Zwamborn AW, et al. Endoluminal MR imaging of the rectum and anus: technique, applications, and pitfalls. *Radiographics*. 1999;19(2):383–98.
23. Walsh KA, Grivell RM. Use of endoanal ultrasound for reducing the risk of complications related to anal sphincter injury after vaginal birth. *Cochrane Database Syst Rev*. 2015;10:CD010826.
24. Sioutis D, Thakar R, Sultan AH. Overdiagnosis and rising rate of obstetric anal sphincter injuries (OASIS): time for reappraisal. *Ultrasound Obstet Gynecol*. 2017;50(5):642–7.
25. Sultan AH, Kamm MA, Talbot IC, et al. Anal endosonography for identifying external sphincter defects confirmed histologically. *Br J Surg*. 1994;81(3):463–5.
26. Fitzpatrick M, Cassidy M, Barassaud ML, et al. Does anal sphincter injury preclude subsequent vaginal delivery? *Eur J Obstet Gynecol Reprod Biol*. 2016;198:30–4.
27. Soerensen MM, Pedersen BG, Santoro GA, et al. Long-term function and morphology of the anal sphincters and the pelvic floor after primary repair of obstetric anal sphincter injury. *Colorectal Dis*. 2014;16(10):O347–55.
28. Van de Waarsenburg MK, van der Vaart CH, Withagen MIJ. Structural changes in puborectalis muscle after vaginal delivery. *Ultrasound Obstet Gynecol*. 2019;53(2):256–61.
29. Sentovich SM, Wong WD, Blatchford GJ. Accuracy and reliability of transanal ultrasound for anterior anal sphincter injury. *Dis Colon Rectum*. 1998;41(8):1000–4.

30. West RL, Dwarkasing S, Briel JW, et al. Can three-dimensional endoanal ultrasonography detect external anal sphincter atrophy? A comparison with endoanal magnetic resonance imaging. *Int J Colorectal Dis.* 2005;20(4):328–33.
31. Santoro GA, Wieczorek AP, Dietz HP, et al. State of the art: an integrated approach to pelvic floor ultrasonography. *Ultrasound Obstet Gynecol.* 2011;37(4):381–96.

Open Access This chapter is licensed under the terms of the Creative Commons Attribution-NonCommercial-NoDerivatives 4.0 International License (<http://creativecommons.org/licenses/by-nc-nd/4.0/>), which permits any noncommercial use, sharing, distribution and reproduction in any medium or format, as long as you give appropriate credit to the original author(s) and the source, provide a link to the Creative Commons license and indicate if you modified the licensed material. You do not have permission under this license to share adapted material derived from this chapter or parts of it.

The images or other third party material in this chapter are included in the chapter's Creative Commons license, unless indicated otherwise in a credit line to the material. If material is not included in the chapter's Creative Commons license and your intended use is not permitted by statutory regulation or exceeds the permitted use, you will need to obtain permission directly from the copyright holder.





Cross-Sectional Imaging in Fecal Incontinence

6

Alfonso Reginelli, Mariateresa Del Canto,
Valentina Caliendo, Silvia Iovine, Ferdinando Schettino,
Fabrizio Urraro, Salvatore Cappabianca, and Roberto Grassi

6.1 Introduction

A combination of several factors produces fecal continence. These factors include fecal composition, functional aspects, such as intestinal motility and filling awareness, and morphological aspects related to the anatomy of the rectum, anal canal, and sphincter apparatus [1]. Many causes can interfere with the balance between two or more of these factors, resulting in fecal incontinence. Therefore, each of these elements must be thoroughly evaluated to understand the genesis of fecal incontinence and choose the most appropriate treatment, whether medical, surgical, or a combination of these [2]. The most common causes include traumatic (obstetric, surgical) defects of the sphincter complex, pudendal nerve dysfunction, and rectal prolapse. In women, fecal incontinence is most frequently caused by childbirth, where the muscular sphincter fibers are commonly damaged [3]. Digital rectal examination is the first step in the clinical evaluation of patients with fecal incontinence, giving an initial qualitative assessment of the external sphincter tone at rest and during contraction. Functional competence of the sphincter apparatus can subsequently be tested by anorectal manometry, electromyography, and pudendal nerve terminal motor latency test [4]. Finally, diagnostic imaging is crucial for the morphological evaluation of the anatomical structures involved in fecal continence and for the assessment of functional abnormalities of the defecatory act. The role of endoanal ultrasound (EAUS) is consolidated in clinical practice as the surgeon usually performs it during the physical examination [5]. In addition, X-ray and

A. Reginelli (✉) · M. Del Canto · V. Caliendo · S. Iovine · F. Schettino · F. Urraro ·
S. Cappabianca · R. Grassi
Radiology Unit, Department of Precision Medicine,
University of Campania Luigi Vanvitelli, Naples, Italy
e-mail: alfonso.reginelli@unicampania.it; mariateresa.delcanto.9@gmail.com;
vale.caliendo@gmail.com; silviaiovine@hotmail.it; fer.schet@gmail.com;
fabriziourraro@libero.it; salvatore.cappabianca@unicampania.it;
roberto.grassi@unicampania.it

magnetic resonance defecography combine high spatial resolution, which allows detailed assessment of all structures involved in the genesis of incontinence, with functional assessment, to identify the most appropriate therapeutic approach [6].

6.2 Imaging Techniques

6.2.1 X-Ray Defecography

X-ray defecography is a cost-effective imaging technique for the evaluation of the defecatory act in the physiological sitting position [7].

6.2.1.1 Execution Protocol

The rectal ampulla is filled with a high-density barium sulfate paste, usually 150–200 mL. In some cases, this is followed by distension of the vaginal canal, using 45 mL of the same paste, and the bladder, through the injection of 400 cm³ of iodinated contrast medium. The intestinal loops can be identified by administering 200 mL of 60% barium sulphate orally, 1 h before the examination.

The examination is conducted with the patient sitting on an appropriate radiolucent support to evaluate the defecatory act in the physiological sitting position. First, anteroposterior and laterolateral scans are taken at rest, followed by the dynamic phases of the study, in particular contraction, straining, and evacuation, which are acquired in the laterolateral projection. Eventually, a final acquisition is made after evacuation.

6.2.1.2 Image Analysis

The analysis is focused on assessing the position of three specific landmarks (the anorectal junction, the posterior vaginal fornix, and the bladder base) from the reference line drawn between the two ischial tuberosities.

6.2.1.3 Imaging Findings

Due to poor spatial resolution, X-ray defecography fails to identify slight abnormalities of the anal canal and sphincter apparatus; thus, it may only show indirect signs of fecal incontinence. The most important findings are listed below [8]:

1. Barium leakage, due to the patient's inability to retain the contrast medium.
2. Distension of the anal canal by the barium paste: during the resting phase, the walls of the anal canal are not juxtaposed and have an average transverse diameter ≥ 10 mm.
3. Rectal hyperdistention, with a maximum transverse diameter >7.5 cm.
4. Ineffective squeezing due to an impaired anal sphincter contraction.
5. Anorectal angle $>116^\circ$ under resting conditions, implying puborectalis sling hypotonia.
6. Rectal prolapse, fall of the anorectal junction >4 cm below the bisischiatric line.

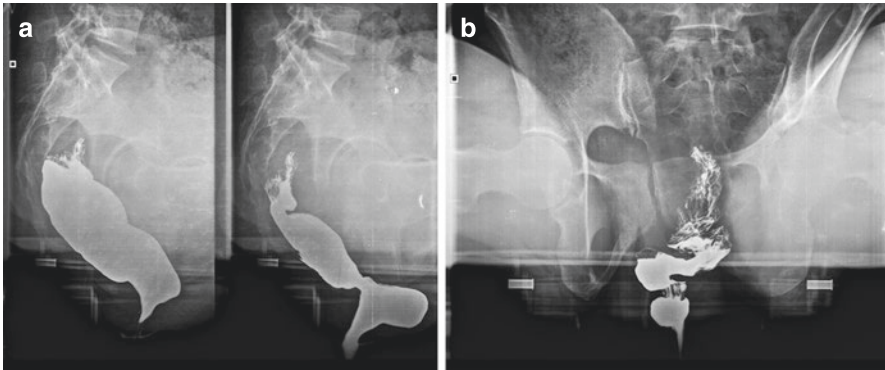


Fig. 6.1 X-ray defecography in the evacuation (a) and post-evacuation phase (b). Images show the presence of an anterior rectocele with incomplete expulsion of contrast medium

7. Rectoanal intussusception, manifesting as an annular filling defect extending into the anal canal.
8. Anterior rectocele, protrusion of the anterior wall of the rectum >3 cm beyond a reference line drawn upwards from the anterior margin of the anal canal (Fig. 6.1).

6.2.2 Magnetic Resonance Defecography

Due to its spatial resolution, magnetic resonance (MR) imaging provides a detailed anatomical representation of the anal canal, sphincter apparatus, and all muscles and ligaments involved in fecal continence, as well as a broad overview of the pelvic organs [8–10]. This imaging technique is also able to give crucial functional information through dynamic evaluation of the defecatory act [11, 12]. Using rapid sequences, MR defecography can assess the defecatory phases of rest, squeezing, straining and evacuation in a more accurate way than X-ray, to identify both anatomical and functional causes of fecal incontinence [13]. In addition to increased accuracy and reproducibility of measurements, MR defecography is also superior to the X-ray technique as it does not use ionizing radiation. Performance of the examination in the supine position is one disadvantage of this technique because the defecatory act is less physiological [14].

6.2.2.1 Acquisition Protocol

Patient compliance is crucial for a successful examination. The rectal ampulla should be distended with 150 mL of ultrasound gel administered via a syringe through the anus. An additional 30–50 mL of ultrasound gel should also be administered through the vaginal canal to properly visualize the posterior vaginal fornix, an essential landmark in the diagnosis of rectal prolapse [15].

The MR imaging protocol starts with a T1-weighted (T1W) localizer sequence with a wide field of view to identify the sagittal midline section, including the pubic symphysis, bladder neck, vagina, rectum, and coccyx. Subsequently, T2-weighted (T2W) turbo spin-echo sequences are acquired in the sagittal and axial planes.

By accurately depicting muscular structures and supporting ligaments, the T2W static sequences show muscular and fascial asymmetries, defects, pathological thickening or thinning, and irregularity of the contours, as well as the physiological thickness and integrity of the sphincter apparatus and the puborectalis sling [16].

The T2W static sequences are followed by T2W dynamic acquisitions (TRUE FISP, FIESTA, balanced FFE) in the midsagittal plane during rest, squeezing, straining and evacuation to define the position of the pelvic organs and detect perineal descent and pelvic prolapse.

6.2.3 Magnetic Resonance Anatomy of the Anal Canal

The anal canal is the terminal part of the large intestine located between the anal verge below and the rectum above. Its upper limit is the anorectal junction (ARJ), where the puborectalis muscle forms a U-shaped sling posteriorly [17]. On MR imaging, the mean length of the anal canal from the ARJ to the caudal tip of the subcutaneous external anal sphincter (EAS) is approximately 4.4 cm. The dentate (pectinate) line marks the transition between columnar epithelium (intestinal mucosa) and squamous epithelium, but it is not distinguishable at MR [16].

The anal canal shows a cylindrical morphology, with a three-layered wall of mucosa, submucosa, and muscle. The muscular layer is composed of an inner layer, the internal anal sphincter (IAS), and an outer layer, the external anal sphincter (EAS) [18]. On T2W images, the IAS appears as a moderately hyperintense circular smooth layer in the axial plane and as a longitudinal band in the coronal plane, with a mean thickness of 3.5 mm. Similarly, the EAS complex appears as a hypointense circular skeletal layer, with a mean thickness of 4 mm (Fig. 6.2) [18, 19].

The EAS complex is made up of three components (Fig. 6.3):

- a deep part surrounding the upper portion of the anal canal and merging with the puborectalis sling
- a superficial part surrounding the whole anal canal and continuing posteriorly with the anococcygeal ligament
- a subcutaneous portion, the outermost layer, surrounding the lower side of the IAS just beneath the perianal skin.

A T2W hyperintense intersphincteric space lies between the IAS and EAS. The best anatomical assessment of these counterparts is made on images taken in the midsection of the anal canal, where the two halves of the external sphincter join.

The midsagittal plane helps depict the supporting structures, particularly the anococcygeal ligament, posteriorly connecting the external sphincter to the coccygeal bone, and the puborectalis and bulbocavernosus muscles, both anterior, which support the EAS complex [20].

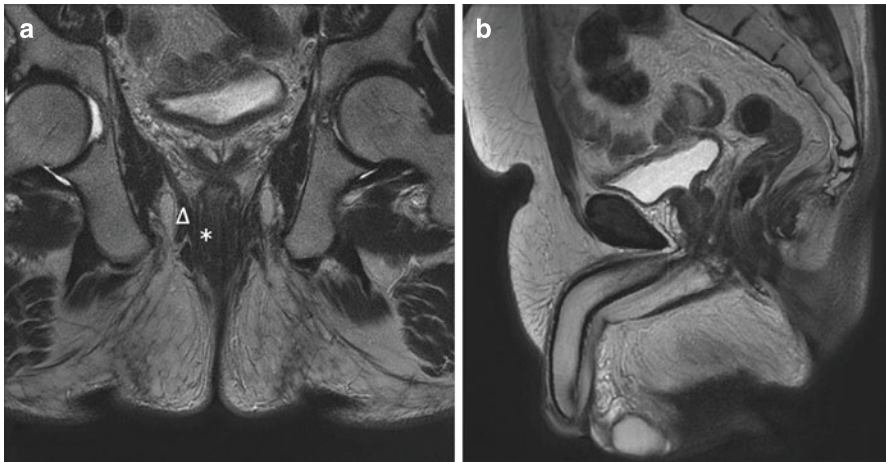


Fig. 6.2 Normal anatomy of the anal canal in the coronal (a) and sagittal (b) plane. The external layer corresponds to the external anal sphincter (*arrowhead*), the inner one corresponds to the internal anal sphincter (*asterisk*). The intersphincteric space is shown as a thin hyperintense line in the middle

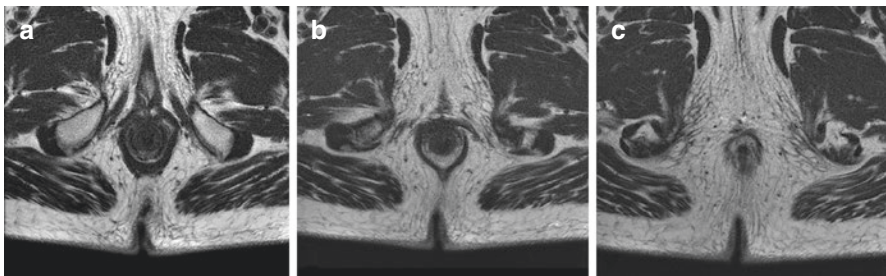


Fig. 6.3 Anal canal anatomy along its long axis, deep (a), superficial (b), and subcutaneous plane (c)

6.2.4 Morphologic Diagnostic Criteria

In MR imaging, the morphological findings of fecal incontinence concern primarily the sphincter complex, particularly the presence of defects or atrophy within the sphincteric ring, both internal and external.

A sphincteric defect is defined as a minimum of 30° discontinuity of the muscle ring (isolated or combined IAS and EAS; anatomical defect) (Fig. 6.4). At MR imaging, it appears as a low signal deformation of the muscle ring due to the replacement of muscular fibers by fibrous tissue [21] (Fig. 6.5).

Fecal incontinence may be caused by sphincter disruptions sustained during childbirth [22]. There is a correlation between anal sphincter atrophy, which might cause late-onset incontinence without evidence of any disorders within the

Fig. 6.4 Axial T2w fat saturation sequence shows a posterior lesion of the external anal sphincter (*asterisk*)

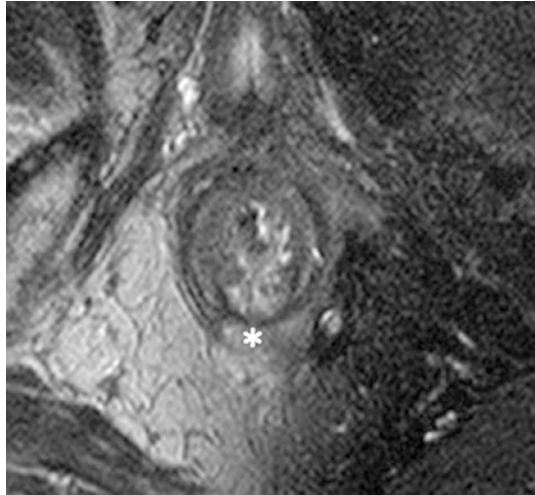
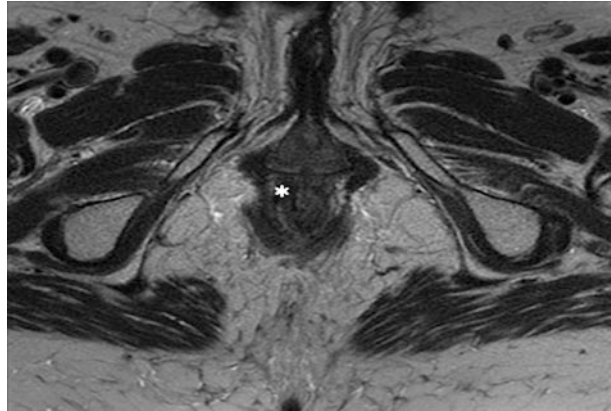


Fig. 6.5 Axial T2w sequence: a hypointense area, relating to fibrous scar tissue, may be appreciated in the context of the inner anal sphincter at 11 o'clock (*asterisk*)



sphincteric complex, and pudendal neuropathy, a condition favored by stretching during vaginal delivery [23] (Fig. 6.6). In particular, the pudendal nerve is the main nerve of the anorectal region, supplying both sensory and motor innervation [24].

Vaginal delivery, neurologic disorders, and diabetes may induce degeneration of the external anal sphincter with loss of muscle fibers and fatty infiltration and/or loss of anal sensation leading to fecal incontinence [25].

Anal sphincter atrophy is a condition sustained by a severe thinning of the sphincteric ring, responsible for passive fecal incontinence. When concerning the IAS, atrophy implies muscle degeneration characterized by a thickness <2 mm. EAS atrophy might indicate severe sphincter thinning or a regular consistency, with fatty replacement of skeletal muscle fibers.

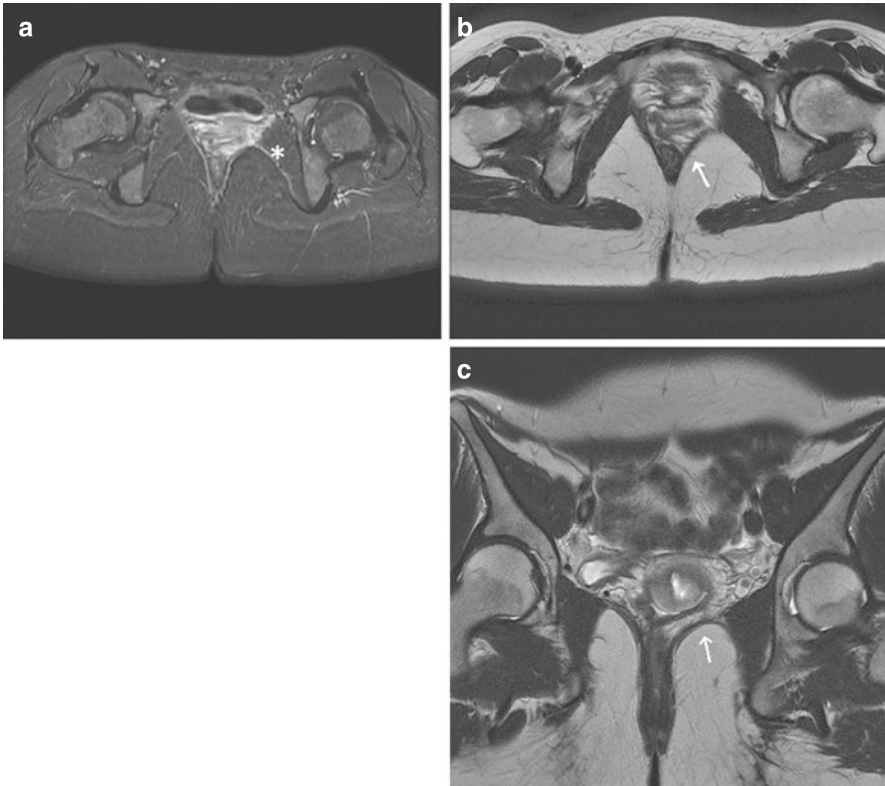


Fig. 6.6 Signal hyperintensity and increased thickness of the left pudendal nerve (**a**, *asterisk*), causing asymmetry of the puborectalis sling (**b** and **c**, *arrows*)

EAS atrophy can be stratified using a grading system proposed by Terra et al. [25]. This score considers the percentage of fat content of the EAS and measurements of the area of the remaining EAS:

- *no atrophy*: no thinning or replacement of the sphincter muscle by fat
- *mild atrophy*: <50% thinning or replacement of sphincter muscle by fat
- *severe atrophy*: $\geq 50\%$ thinning or replacement of sphincter muscle by fat

The clinical relevance of correctly diagnosing anal sphincter atrophy in the setting of fecal incontinence is high, as atrophy is a negative predictive factor for the outcome of secondary sphincter repair.

6.2.5 Functional Diagnostic Criteria

On dynamic MR acquisitions, the pelvic floor shows a physiological craniocaudal excursion of 2 cm. When assessing pelvic floor function on MR imaging, the most relevant anatomical landmark is the pubococcygeal line (PCL), drawn between the inferior margin of the pubic symphysis and the upper limit of the coccyx.

In patients without pelvic prolapse, during the straining and evacuation phases, the bladder base, the upper third of the vagina (posterior vaginal fornix), and the ARJ are located above the PCL [14].

During contraction, the pelvic organs show an upward displacement of 1–2 cm from the PCL. During straining and evacuation, they are displaced downwards within a range of 2–3 cm from the PCL, compared to the resting position [15].

The most frequent functional MR findings in fecal incontinence are described in the following sections.

6.2.5.1 Rectal Prolapse

According to the distance between the PCL and the lowest point of the prolapsed organ during evacuation, rectal prolapse is graded as:

- *mild*, if the distance is less than 3 cm (Baden-Walker grade 1–2),
- *moderate*, if the distance is between 3 and 6 cm (Baden-Walker grade 3)
- *severe*, if the distance is more than 6 cm (Baden-Walker grade 3–4).

6.2.5.2 Rectocele

Rectocele is an anatomical defect of the anorectal region manifesting as bulging of the anterior rectal wall within the posterior vaginal wall.

There are three different degrees of rectocele:

- *grade 1*: point of maximum convexity up to 2 cm from to the axis of the ARJ (non-pathological)
- *grade 2*: point of maximum convexity between 2 and 4 cm from to the axis of the ARJ
- *grade 3*: point of maximum convexity >4 cm from the axis of the ARJ.

6.2.5.3 Rectoanal Intussusception

Rectal intussusception is defined as the invagination of the rectal wall into the rectal lumen; at first, it may be only located on one side and is referred to as rectal wall inversion [26]. Rectoanal intussusception is classified as:

- *intra-rectal* when the invagination is confined to the rectum.
- *intra-anal* or *proctentia* if it extends into the anal canal.
- *extra-anal* when it extends beyond the anal sphincter.

6.3 Conclusions

MR defecography and 3D endoanal ultrasound (EAUS) are useful techniques for portraying morphologic changes in the anal sphincters that may result in fecal incontinence.

EAUS is usually the first imaging study to be performed, as it provides information about the morphology of a potentially damaged sphincter [27].

In selecting patients for sphincteroplasty, MR imaging is subsequently performed to detect areas of atrophy and fatty replacement of the anal sphincter complex that EAUS fails to identify [28]. MR defecography can also provide additional functional information and depict abnormalities associated with fecal incontinence, such as pelvic organ prolapse, rectoanal intussusception, rectocele, pelvic floor weakness, and pudendal nerve neuropathy [29]. Preoperative measurement of sphincteric thickness during both EAUS and MR imaging may represent a potential predictor of surgical outcome. EAUS can also depict any residual sphincter defect when performed in the postsurgical setting. In short, MR imaging qualifies as the recommended imaging technique in the preoperative evaluation, while EAUS is the preferred study in post-surgical evaluation.

Finally, although the role of X-ray defecography is limited nowadays, mostly because of radiation protection issues, the technique is still useful in selected cases, to depict fecal overflow incontinence and/or overactive, noncompliant rectal ampulla.

References

1. Rao SSC. Pathophysiology of Adult Fecal Incontinence. *Gastroenterology*. 2004;126(1):14–22.
2. Reginelli A, Mandato Y, Russo A, et al. Morphological rectal alterations following STARR performed for obstructed defecation syndrome. *BMC Geriatr*. 2011;11(Suppl 1):A51. <https://doi.org/10.1186/1471-2318-11-S1-A51>.
3. Sultan AH, Kamm MA, Bartram CI, Hudson CN. Anal sphincter trauma during instrumental delivery. *Int J Gynecol Obstet*. 1993;43(3):263–70.
4. Cho HM. Anorectal physiology: Test and clinical application. *J Korean Soc Coloproctol*. 2010;26(5):311–5.
5. Rociu E, Stoker J, Eijkemans MJC, et al. Fecal incontinence: Endoanal US versus endoanal MR imaging. *Radiology*. 1999;212(2):453–8.
6. Hetzer FH, Andreisek G, Tsagari C, et al. MR defecography in patients with fecal incontinence: Imaging findings and their effect on surgical management. *Radiology*. 2006;240(2):449–57.
7. Kelvin M, Maglinte DT, Hornback A, Benson JT. Pelvic prolapse: assessment with evacuation proctography (defecography). *Radiology*. 1992;184(2):547–51.
8. Piloni V, Ghiselli R. Practical imaging of faecal incontinence: the eyes of science. In: *Fecal incontinence – Causes, Management and Outcome*. London, UK: IntechOpen; 2014. <https://www.intechopen.com/chapters/46257>. Accessed 24 Nov 2021.
9. Reginelli A, Vacca G, Giovine S, et al. MRI of perianal fistulas in Crohn's disease. *Acta Biomed*. 2020;91(8-S):27–33.
10. Iacobellis F, Reginelli A, Berritto D, et al. Pelvic floor dysfunctions: how to image patients? *Jpn J Radiol*. 2020;38(1):47–63.

11. Reginelli A, Di Grezia G, Gatta G, et al. Role of conventional radiology and MRi defecography of pelvic floor hernias. *BMC Surg.* 2013;13(Suppl. 2):S53. <https://doi.org/10.1186/1471-2482-13-S2-S53>.
12. Balcı S, Onur MR, Karaosmanoğlu AD, et al. MRI evaluation of anal and perianal diseases. *Diagnostic Interv Radiol.* 2019;25(1):21–7.
13. Pescatori M, Regadas FSP, Regadas SMM, Zbar AP, editors. *Imaging atlas of the pelvic floor and anorectal diseases.* New York: Springer; 2008.
14. Melchior C, Bridoux V, Touchais O, et al. MRI defaecography in patients with faecal incontinence. *Colorectal Dis.* 2015;17(3):O62–9.
15. Colaiacomo MC, Masselli G, Poletini E, et al. Dynamic MR imaging of the pelvic floor: A pictorial review. *Radiographics.* 2009;29(3):e35. <https://doi.org/10.1148/rg.e35>.
16. DeSouza NM, Kmiot WA, Puni R, et al. High resolution magnetic resonance imaging of the anal sphincter using an internal coil. *Gut.* 1995;37(2):284–7.
17. Erden A. MRI of anal canal: normal anatomy, imaging protocol, and perianal fistulas: Part 1. *Abdom Radiol.* 2018;43(6):1334–52.
18. Hussain SM, Stoker J, Laméris JS. Anal sphincter complex: Endoanal MR imaging of normal anatomy. *Radiology.* 1995;197(3):671–7.
19. Briel JW, Stoker J, Rociu E, et al. External anal sphincter atrophy on endoanal magnetic resonance imaging adversely affects continence after sphincteroplasty. *Br J Surg.* 1999;86(10):1322–7.
20. Granata V, Fusco R, Reginelli A, et al. Radiological assessment of anal cancer: an overview and update. *Infect Agent Cancer.* 2016;11:52. <https://doi.org/10.1186/s13027-016-0100-y>.
21. Rociu E, Stoker J, Zwamborn AW, Laméris JS. Endoanal MR imaging of the anal sphincter in fecal incontinence. *Radiographics.* 1999;19(Suppl 1):171–7.
22. Chin K. Obstetrics and fecal incontinence. *Clin Colon Rectal Surg.* 2014;27(3):110–2.
23. Dobben AC, Terra MP, Slors JFM, et al. External anal sphincter defects in patients with fecal incontinence: comparison of endoanal MR imaging and endoanal US. *Radiology.* 2007;242(2):463–71.
24. Filler AG. Diagnosis and treatment of pudendal nerve entrapment syndrome subtypes: imaging, injections, and minimal access surgery. *Neurosurg Focus.* 2009;26(2):1–14.
25. Terra MP, Beets-Tan RGH, Van Der Hulst VPM, et al. MRI in evaluating atrophy of the external anal sphincter in patients with fecal incontinence. *Am J Roentgenol.* 2006;187(4):991–9.
26. Collinson R, Cunningham C, D’Costa H, Lindsey I. Rectal intussusception and unexplained faecal incontinence: Findings of a proctographic study. *Colorectal Dis.* 2009;11(1):77–83.
27. Reginelli A, Granata V, Fusco R, et al. Diagnostic performance of magnetic resonance imaging and 3D endoanal ultrasound in detection, staging and assessment post treatment, in anal cancer. *Oncotarget.* 2017;8(14):22980–90.
28. Dobben AC, Felt-Bersma RJF, Ten Kate FJW, Stoker J. Cross-sectional imaging of the anal sphincter in fecal incontinence. *Am J Roentgenol.* 2008;190(3):671–82.
29. Fuchsjaeger MH, Maier AG. Imaging fecal incontinence. *Eur J Radiol.* 2003;47(2):108–16.

Open Access This chapter is licensed under the terms of the Creative Commons Attribution-NonCommercial-NoDerivatives 4.0 International License (<http://creativecommons.org/licenses/by-nc-nd/4.0/>), which permits any noncommercial use, sharing, distribution and reproduction in any medium or format, as long as you give appropriate credit to the original author(s) and the source, provide a link to the Creative Commons license and indicate if you modified the licensed material. You do not have permission under this license to share adapted material derived from this chapter or parts of it.

The images or other third party material in this chapter are included in the chapter's Creative Commons license, unless indicated otherwise in a credit line to the material. If material is not included in the chapter's Creative Commons license and your intended use is not permitted by statutory regulation or exceeds the permitted use, you will need to obtain permission directly from the copyright holder.



Part III
Treatment



Medical Management and Supportive/ Hygienic Measures

7

Roberto Dino Villani and Daniela Di Nicola

7.1 Introduction

The causes of fecal incontinence are several and often due to a combination of different factors. This implies diversified therapeutic approaches, which depend on the causes. Medical treatment and especially hygienic support should be the first steps and should support the different surgical and rehabilitation treatments that will be applied later on.

Since fecal incontinence in adults can create a situation of discomfort that negatively affects quality of life and leads to embarrassment and social isolation, conservative treatment should be instituted as soon as the patient seeks medical attention.

Treatment should begin immediately by modifying the patient's lifestyle, reducing foods that trigger/aggravate the symptoms and using antidiarrheal/thickening agents. Treatment should also be tailored to the patient, considering the possibility to choose one or more strategies, according to the causes of incontinence, the patient's age and general health condition, and the impact of incontinence on quality of life. Unfortunately, the symptoms of anal incontinence are seldom reported spontaneously and/or openly by the patients, who often turn to us long after the onset of the problem or because of worsening of the condition.

Therefore, where possible, it is fundamental to identify the root cause as soon as possible and plan treatment accordingly.

A key determinant is the patient's recent and past medical history, such as previous surgery, ongoing drug therapies, possible intolerances, allergies, and comorbidities. Several medical history questionnaires may be found in the medical literature that can help classify the degree of incontinence and its impact on the patient's life [1].

R. D. Villani (✉) · D. Di Nicola

Proctology and Pelvic Floor Unit, Sassuolo Hospital, Sassuolo (Modena), Italy
e-mail: robertodino.villani@gmail.com; d.dinicola@ospedalesassuolo.it

Once a diagnosis has been formulated, then a therapeutic approach may start. This must include proper hygiene and dietary education, if necessary combined with drug therapy. Dietary recommendations are discussed in another chapter of this book, whereas the suggested drug therapy will be discussed below.

Pelvic floor rehabilitation techniques, patient education about the use of devices and the management of transanal irrigation will be considered at a later stage of the treatment, depending on the patient's response to this first approach. These methods may also be suggested in a nonsequential order, in relation to the current situation.

At the beginning, in order to put the person at ease and establish the patient care agreement, taking charge of the patient's care should include [1]:

- reception of the patient
- empathy
- relation with the patient.

7.2 Nursing Assessment

The initial nursing intervention should consist of an assessment of the patient's situation through a complete collection of all the patient data needed to devise the most appropriate treatment plan in collaboration with the multidisciplinary team.

Therefore, nurses should:

- collect a detailed patient history;
- collect the patient's defecation diary and educate the patient about the importance of establishing a routine to gradually achieve regular bowel movements;
- administer a test to evaluate the impact of incontinence on the patient's quality of life;
- evaluate the patient's ability to evacuate independently;
- assess fluid and fiber intake and inform both the patient and caregiver about the importance of regular hydration and diet for maintaining soft and bulky stool;
- evaluate the use of devices such as incontinence pads, sanitary napkins, incontinence briefs, stool collection systems;
- educate the patient about the use of containment devices, if necessary;
- verify perineal skin integrity and educate the patient about correct intimate hygiene and the use of zinc oxide and dimethicone moisture barriers, to prevent perianal and perineal complications;
- perform a manual check to evaluate possible fecal impaction;
- provide assistance to prepare the patient for the various tests.

At this stage, the nurse's role is to explain, educate, actively involve and interact with the person affected by fecal incontinence. This should result in the patient taking charge of his/her care and consequently an improvement in quality of life. It is also crucial that both the patient and health care provider use the same evaluation sheets in order to avoid ambiguous interpretations (e.g., Bristol Stool Chart) [1].

7.3 Hygiene and Dietary Guidelines

Already at the patient's first visit, the nurse can do the following to help alleviate the patient's complaint [1]:

- suggest stimulating daily bowel elimination after breakfast, possibly at the same time every day, as the gastrocolic reflex is triggered by food and drink intake;
- suggest insoluble fiber intake to obtain soft and bulky feces, especially in patients who have fragmented stool;
- promote the intake of natural stool-bulking agents such as rice, yogurt, and bananas, because of their absorption power;
- if possible, ensure a fluid intake of up to 3000 mL/day, or start fluid replacement therapy to compensate volume loss in the case of diarrhea;
- encourage the patient to do regular physical activity, when possible, in order to stimulate peristalsis;
- if necessary, suggest the use of a suppository, digital stimulation every 10–15 min, or direct stimulation of the rectal sphincter and lower colon to start peristalsis;
- suggest keeping assistive devices at hand to ensure immediate access to toileting facilities and avoid unpleasant “accidents”;
- promote a comfortable position for defecation (squatting position) as this will allow a more effective bowel evacuation.

7.4 Medical Treatment

The goals of medical therapy are to treat any disorders which may cause diarrhea or constipation and to:

- relieve annoying and embarrassing symptoms;
- restore bowel control;
- improve quality of life.

When the cause of defecation disorders is not easily identifiable or modifiable, medicines can only manage the symptoms. Pharmacological therapy is often combined with other therapeutic options and it is closely dependent on the root cause of incontinence symptoms [2].

The use of antidiarrheal drugs, such as loperamide or codeine phosphate in patients who tend to present liquid stool is extensively described. Loperamide presents minor systemic effects and is therefore generally prescribed at low dosages (2 to 4 mg/day); administration of loperamide should be optimized according to the clinical picture. Dosages may be increased in specific clinical settings, such as patients with ileoanal pouch. There does not seem to be any evidence regarding the use of such drugs in incontinent patients who have normal stool.

In the case of watery stool, thickening agents may be used in combination with loperamide. When incontinence is caused by fecal impaction, the use of laxatives in

combination with manual bowel disimpaction and/or evacuating enemas may help improve continence. Furthermore, some topical agents such as zinc-aluminum ointment, phenylephrine gel or sodium valproate may increase sphincter muscle tone. These products are not always readily available for this purpose and there is little evidence of their efficacy, although their use has been reported in the literature.

Transanal irrigation (TAI) is a good alternative or supplement to medical treatment and kits are commercially available (e.g., Peristeen). If well tolerated, the system offers unique advantages: it is simple to perform, reversible and minimally invasive and it may also be used with young children. It aims to clear the left colon and rectum, thanks to the introduction of a certain amount of water through a closed circuit by using an anal catheter equipped with a small retention balloon and connected to a water bag.

When performed regularly, TAI prevents stool leakage in between washouts. Therefore, it suggests a state of pseudo-continence and restores control over the time and place of evacuation. It is safe and effective, positively influencing the patient's quality of life, dignity, and independence [3]. It is suitable for patients with neurogenic bowel, multiple sclerosis and spinal cord injury, for patients with anterior rectal resection syndrome, and other forms of incontinence. The patient may perform the irrigation at home, if necessary with the help of a caregiver, after at least two treatments carried out under the supervision of a specialist [4].

A bedridden patient with fecal incontinence may develop other complications in addition to the sense of discomfort and hygienic problems related to incontinence. These patients may therefore benefit from a fecal diversion and collection system (e.g., Flexi-Seal FMS), which has the additional advantage of possibly reducing the nurses' workload as well as the duration of hospitalization and hospital costs [5].

7.5 Mechanical Treatments and Containment Devices

Available devices for the management of even the very first symptoms of fecal incontinence are external absorbent health aids, such as panty liners, absorbent stripes, absorbent briefs or panties and diapers up to more sophisticated items such as insert devices. The former cannot control incontinence or prevent odor problems or possible skin problems. The latter may be distinguished into anal and vaginal plugs, which are very simple devices designed to keep the anal canal closed while inserted. However, conformity and long-term benefits still need to be proven, given their side effects such as discomfort, displacement, and non-tolerability [6].

These devices apparently improve symptoms in over 70% of patients, but their efficacy has not been widely studied yet. Anal plugs may reduce incontinence episodes but are not well tolerated and this limits their use. A more recent device, the Renew anal insert, is a disposable, soft and flexible silicone anal insert. In an observational study on 91 patients who used the device for 1–12 weeks, over 75% showed at least 50% reduction in the frequency of fecal incontinence episodes [6].

An endovaginal device for fecal incontinence treatment is also available. Called the Eclipse system, it needs to be inserted by a qualified physician and it requires

continuous self-care to be used properly. The device is inserted into the vagina and is equipped with a small balloon that, once inflated, seals the anal canal. An observational study on 73 women who used the device for 12 months showed a high satisfaction rate: 79.6% of patients reported a significant improvement [7].

7.6 Mind and Incontinence

Psychological factors can originate from or cause incontinence and should be considered as part of the general management plan. Coexisting mental health conditions may influence successful treatment outcome and there is still very little evidence to support any treatment for over 3–6 months [8].

A person with pelvic floor and incontinence symptoms, who is well motivated and has good cognitive abilities and a non-seriously impaired psychological status, has a better chance of responding positively to the proposed therapies, especially if a good relationship has been established between the patient and his/her health care provider [9].

7.7 Conclusions

Hygiene and health measures, devices, bowel lavage and possible drug treatment should be considered the first-line treatment of fecal incontinence patients. Psychological support and a fruitful relationship between the physician, rehabilitation nurse, and patient may facilitate the pathway to rehabilitation or surgery, which may eventually become necessary.

The results that may be obtained—some of them decisive, others often only improving the patient's situation—require perseverance and regular follow-up, both of which are highly recommended.

References

1. Wayne G Bowel incontinence nursing care plan. Nurseslabs. <https://nurseslabs.com/bowel-incontinence>. Accessed 20 Jan 2022.
2. Carter D. Conservative treatment for anal incontinence. *Gastroenterol Rep (Oxf)*. 2014;2(2):85–91.
3. Christensen P, Krogh K. Trans-anal irrigation for disordered defecation: a systematic review. *Scand J Gastroenterol*. 2010;45(5):517–27.
4. Kelly MS. Malone antegrade continence enemas vs. cecostomy vs. trans-anal irrigation – What is new and how do we counsel our patients? *Curr Urol Rep*. 2019;20(8):41.
5. Yap WW, Massey J, Gatt M, et al. Re: Flexi-Seal continence device mimicking a pelvic collection. *Clin Radiol*. 2009;64(12):1244.
6. How P, Trivedi PM, Bearn PE, Thomas GP. Insert devices for faecal incontinence. *Tech Coloproctol*. 2021;25(3):255–65.
7. Richter HE, Matthews CA, Muir T, et al. A vaginal bowel-control system for the treatment of fecal incontinence. *Obstet Gynecol*. 2015;125(3):540–7.

8. Kuoch KL, Hebbard GS, O'Connell HE, et al. Urinary and faecal incontinence: psychological factors and management recommendations. *N Z Med J*. 2019;132(1503):25–33.
9. Bentsen D, Braun JW. Controlling fecal incontinence with sensory retraining managed by advanced practice nurses. *Clin Nurse Spec*. 1996;10(4):171–5.

Open Access This chapter is licensed under the terms of the Creative Commons Attribution-NonCommercial-NoDerivatives 4.0 International License (<http://creativecommons.org/licenses/by-nc-nd/4.0/>), which permits any noncommercial use, sharing, distribution and reproduction in any medium or format, as long as you give appropriate credit to the original author(s) and the source, provide a link to the Creative Commons license and indicate if you modified the licensed material. You do not have permission under this license to share adapted material derived from this chapter or parts of it.

The images or other third party material in this chapter are included in the chapter's Creative Commons license, unless indicated otherwise in a credit line to the material. If material is not included in the chapter's Creative Commons license and your intended use is not permitted by statutory regulation or exceeds the permitted use, you will need to obtain permission directly from the copyright holder.





Diet in Fecal Incontinence

8

Marcellino Monda

8.1 General Principles of Diet

A diet is correct and balanced when, on a daily basis, a series of suggestions and rules relating to the quantity, quality, and variety of foods eaten are followed [1]. The daily energy intake must be adequate for calorie consumption, and all the nutrients that allow you to derive health benefits must be present in a diet. There is no food that can be said to be truly complete (if we exclude breast milk for babies up to 8–12 months). The simplest and safest way to be able to assimilate, in the right quantities, all the nutrients necessary for the proper functioning of our body is to vary the foods eaten and combine them in the most appropriate way. The body contains almost all the nutritional elements that we find in food, the nutrients, that are divided into macronutrients (carbohydrates, lipids, and proteins) and micronutrients (vitamins and minerals). Macronutrients give energy, while micronutrients do not give energy, but they are necessary for biological functions [2, 3]. Alcohol is a particular macronutrient that gives energy, but it is not necessary for a healthy diet.

Water, despite being an indispensable element for many functions (and the composition itself!) of the human body, is not considered a nutrient.

To follow a balanced diet, it is advisable to take the correct quantities of macro- and micronutrients and that the daily calorie intake is divided into specific proportions. This means that 15% of the daily calories should come from protein, 25–30% from lipids, and 55–60% from carbohydrates.

M. Monda (✉)

Department of Experimental Medicine, Unit of Dietetics and Sports Medicine,
University of Campania Luigi Vanvitelli, Naples, Italy
e-mail: marcellino.monda@unicampania.it

© The Author(s) 2023

L. Docimo, L. Bruscianno (eds.), *Anal Incontinence*, Updates in Surgery,
https://doi.org/10.1007/978-3-031-08392-1_8

Table 8.1 Foods that should be avoided in fecal incontinence

<i>Foods with excess fructose</i>
peaches, persimmons, watermelon, pears, apricots, apples, mango, coconut, figs, blackberries, honey, corn syrup, glucose syrup, fruit concentrates, dried fruit
<i>Foods with lactose</i>
cow milk, sheep milk, goat milk, soft and fresh cheeses, ice cream, yogurt
<i>Foods with fructans and/or galactans</i>
asparagus, broccoli, artichoke, brussels sprout, cabbage, garlic, fennel, okra, leek, onion, shallot, chickpeas, beans, lentils, soy, peas
<i>Foods with polyols</i>
apples, apricots, avocado, cherries, longans, lychees, nashi pears, nectarines, peaches, pears, plum, prune, watermelon, cauliflower, mushroom, snow pea; sweeteners (isomalt, maltitol, mannitol, sorbitol, xylitol)

8.2 Dietary Therapeutic Strategies

The general principles of dietary strategies for the treatment of fecal incontinence [4] are the same as those for people without fecal incontinence. Some foods must be excluded from the diet of patients suffering from fecal incontinence (Table 8.1), but the proportion of macronutrients remains unchanged. A drastic reduction of many simple carbohydrates is an important strategy in dietary schemes to improve the symptoms of patients with fecal incontinence [5, 6].

8.2.1 Low FODMAP Diet

The carbohydrates that need to be drastically reduced are those known as FODMAPs, i.e., “fermentable oligosaccharides, disaccharides, monosaccharides, and polyols”. These are short-chain carbohydrates that are poorly absorbed by the small intestine and induce excessive fluid and gas accumulation, resulting in bloating, abdominal distention, and pain. FODMAPs are found in many foods, including those containing fructose, lactose, galacto-oligosaccharides, fructans, and polyols (such as mannitol, sorbitol, maltitol, and xylitol). The rapid fermentation of these carbohydrates causes important osmotic effects. FODMAPs are poorly absorbed for several reasons: (1) the absence of luminal enzymes capable of hydrolyzing the glycosidic bonds contained in carbohydrates, (2) low activity of brush border enzymes (e.g., lactase), or (3) the presence of low-capacity epithelial transporters, such as glucose transporter 5 and fructose (GLUT-5) and glucose transporter 2 (GLUT-2).

Fructose, which is an important FODMAP, is absorbed across villous epithelium through low-capacity, carrier-mediated diffusion involving GLUT-5. The absorption of free fructose is increased in the presence of glucose via GLUT-2. When fructose is present in excess of glucose, the fructose malabsorption is enhanced. Furthermore, several substances, such as polyols, are too large for simple diffusion. On the other hand, oligosaccharides are rapidly fermented, compared to polysaccharides. Fermentation produces hydrogen, carbon dioxide, and methane. Finally, osmotically active small molecules draw more water into the small intestine.

Thus, a diet low in FODMAPs is an important tool in the therapeutic strategy for fecal incontinence.

8.2.2 Percentage of Macronutrients

Meal composition influences the gastrocolic reflex. This is a physiological reflex that controls the motility of the lower gastrointestinal tract following a meal. The gastrocolic reflex is induced by the gastric stretch due to food ingestion and its activation results in the urge to defecate. Foods that stimulate this reflex too much should be drastically reduced in the diet of patients with fecal incontinence [7].

Carbohydrate meals induce a colonic motor response, but the effects are short lived when compared with fat meals. The prolonged, segmental, and retrograde phasic activity induced by a fat meal may delay colon transit. Thus, meal composition influences colonic motor response [8, 9].

It has been shown that meals containing fat delay gastric and small bowel transit. Experimental evidence showed that the infusion of fat into the duodenum induces a duodenal brake. These events are probably due to the stimulation of specialized mucosal cells (such as I cells of the duodenojejunum that secrete cholecystokinin) or due to the release of peptide YY, both of which can delay gastric emptying. In contrast, the shorter duration and more rapid onset of the colonic motor response after a carbohydrate meal may be due to the faster transit of this meal through the stomach and small bowel.

Considering that the recommended percentage of calories from carbohydrates ranges from 55% to 60%, the advisable percentage of energy from carbohydrates in patients with fecal incontinence should be closer to 55% than 60%; similarly, since the recommended percentage of calories from lipids ranges from 25% to 30%, the advisable percentage of energy from lipids should be closer to 30% than 25%.

8.2.3 Coffee

Although there is some experimental evidence showing that coffee stimulates the contraction of the gallbladder and the motor response of the colon, it is not conclusively proven that coffee induces a major increase in colonic motor activity [10]. Therefore, moderate coffee consumption should be allowed in patients with fecal incontinence, although the response should be monitored in a personalized manner.

8.2.4 Spices, Spicy and Smoked Foods

Spices, as well as spicy and smoked foods, should also be avoided or at least limited for their irritating action on the mucous membranes of the digestive system, as well as for their stimulating effect on secretions and motility.

8.2.5 Supplementation with Vitamins and Minerals

Micronutrient supplements should always be considered for patients with fecal incontinence. Vitamins and/or mineral salts should be used to supplement any deficiencies caused by dietary restrictions regarding the quality and quantity of food.

8.3 Importance of Healthy Foods

The importance of the preferential use of healthy foods should not be overlooked. In particular, the following foods should always be present: fruit and vegetables (obviously only those allowed in fecal incontinence), fish, and extra virgin olive oil (Table 8.2).

8.3.1 Fruit and Vegetables

Fruit and vegetables can be divided into five colors (the so-called colors of well-being):

- (a) Blue/Purple (e.g.: berries, eggplant, grape)
 Important substances: anthocyanin, carotenoids, vitamin C, potassium, and magnesium.

Table 8.2 Suggested diet tips for the patient with fecal incontinence^a

Breakfast
Aged cheese 60 g + Rice crackers 40 g
10 a.m.
Fruit 100 g
Lunch
(1) Cooked or raw vegetables (also pureed) 100 g
(2) Rice 110 g or potatoes 220 g
(3) Fish 200 g or meat 150 g
(4) Fruit 100 g
5 p.m.
Fruit 100 g
Dinner
(1) Cooked or raw vegetables (also pureed) 100 g
(2) Rice crackers 100 g
(3) Fat-free raw or fat-free cooked ham or bresaola 80 g or meat 150 g or fish 200 g
(4) Fruit 100 g
Foods
<i>Fish:</i> bluefish, cod, plaice, red snapper, sea bass, sea bream, sole, stockfish, swordfish, tuna
<i>Meat:</i> chicken (breast), lean beef, lean pork, rabbit, turkey (breast), tinned meat
<i>Fruit:</i> banana, berries, grapes, kiwi, mandarin, orange, pineapple, strawberries
<i>Vegetables:</i> cucumber, carrot, celery, clementine, eggplant, lettuce, peppers, pumpkin, tomatoes, zucchini
<i>Dressing:</i> extra virgin olive oil 40 g/day

^a The diet must always be tailored to the patient's needs

- (b) Green (e.g.: kiwi, lettuce, peppers, zucchini)
Important substances: chlorophyll, carotenoids, magnesium, vitamin C, folic acid and lutein
- (c) Red (e.g.: peppers, tomatoes, strawberries)
Important substances: lycopene, anthocyanins.
- (d) White (e.g.: celery, grape)
Important substances: polyphenols, flavonoids, potassium, vitamin C.
- (e) Yellow-Orange (e.g.: carrots, clementines, mandarins, oranges, peppers)
Important substances: flavonoids, carotenoids, vitamin C.

The phytochemicals contained in these foods have remarkable antitumoral and anti-aging effects.

8.3.2 Fish

Fish is a food with excellent nutritional properties and numerous beneficial effects for human health [11]. It contains a good amount of proteins, about 15–20% by weight, which are proteins with a high biological value and easily digestible (especially compared to meat proteins). Fish also contains omega-3 polyunsaturated fatty acids (PUFA), vitamins (especially vitamins D, B, and A), and mineral salts such as potassium, phosphorus, iodine, calcium, and iron [12].

Omega 3 PUFA contain two or more double bonds and are derived from the essential fatty acid alpha-linoleic acid. They are found in fish and fish oils and their health benefits are numerous as they serve various functions in our body. They are components of phospholipids in cell membranes, are involved in the metabolism of cholesterol, and are precursors of biologically active compounds such as prostaglandins, interleukins, and thromboxanes. All these functions indicate that they have pivotal roles in the immune response, blood clotting, and inflammation.

Thanks to these characteristics, fish is considered a “friend of health”. In particular, oily fish and fish with a high content of omega 3 PUFA, such as anchovies, sardines, mackerel, tuna, salmon, and cod, should be consumed more frequently. The consumption of fish is associated with numerous benefits that affect many aspects of health.

Specifically, evidence suggests that fish consumption is associated with a lower risk of cardiovascular disease, depression, and mortality. Furthermore, an inverse association exists between fish intake and risk of metabolic syndrome. Fish consumption is also associated with antiaging effects, cell protection, and improvement of cell functions and cognitive functions. Additionally, the anti-inflammatory properties of omega-3 PUFA may also have a beneficial effect on remission of aforementioned pathologies. Therefore, fish can be considered a healthy animal-based dietary source of protein.

8.3.3 Extra Virgin Olive Oil

Extra virgin olive oil (EVOO) is the product of the mechanical extraction process of olives deriving from *Olea europaea* L., commonly known as the olive tree. EVOO is a fundamental ingredient of the Mediterranean diet and is responsible for a great many health benefits associated with this diet [13]. The features of this food, which is also called “the golden food”, are in part due to the production process since it is obtained using exclusively mechanical procedures, and it has a free acidity that cannot be greater than 0.8%. Furthermore, to be defined as EVOO, it must not show sensory defects and it must have a fruity taste.

EVOO is characterized by a high concentration of bioactive components, such as phenolic compounds, but also vitamins A, D, and E, as well as β -carotene, and it exerts countless health benefits, mainly due to its antioxidant activity. It is also rich in oleic acid which possesses beneficial health effects [14]. Its antioxidant activity is linked to its ability to protect DNA, proteins, and lipids from damage caused by exposure to reactive oxygen species (ROS), which in turn are increased in patients with inflammation. Studies show a significant improvement in protein carbonylation, lipid peroxidation, and mental health status, and beneficial effects on several cardiovascular risk markers after a dietary intervention with EVOO. The biological activities related to the beneficial effects of consuming EVOO have been mainly attributed to the unsaturated fatty acid (UFA) composition and phytochemical compounds in these foods (polyphenols). Both UFA and polyphenols exert anti-inflammatory and antioxidant effects [15].

Furthermore, EVOO could improve health through positive effects on gut microbiota.

Therefore, evidence suggests that EVOO is a natural antioxidant that can be used in primary prevention and is recommended in preference to the use of antioxidant supplements.

References

1. Temple NJ, Guercio V, Tavani A. The Mediterranean diet and cardiovascular disease: gaps in the evidence and research challenges. *Cardiol Rev.* 2019;27(3):127–30.
2. Głąbska D, Guzek D, Groele B, Gutkowska K. Fruit and vegetable intake and mental health in adults: a systematic review. *Nutrients.* 2020;12(1):115. <https://doi.org/10.3390/nu12010115>.
3. Głąbska D, Guzek D, Groele B, Gutkowska K. Fruit and vegetables intake in adolescents and mental health: a systematic review. *Rocz Panstw Zakl Hig.* 2020;71(1):15–25.
4. Nakano K, Takahashi T, Tsunoda A, Shimizu Y. Effects of dietary guidance without dietary fiber supplements on the symptoms, quality of life, and dietary intake in patients with fecal incontinence. *J Anus Rectum Colon.* 2020;4(3):128–36.
5. Menees SB, Chandhrasekhar D, Liew EL, Chey WD. A low FODMAP diet may reduce symptoms in patients with fecal incontinence. *Clin Transl Gastroenterol.* 2019;10(7):e00060. <https://doi.org/10.14309/ctg.000000000000060>.
6. Zahedi MJ, Behrouz V, Azimi M. Low fermentable oligo-di-mono-saccharides and polyols diet versus general dietary advice in patients with diarrhea-predominant irritable bowel syndrome: a randomized controlled trial. *J Gastroenterol Hepatol.* 2018;33(6):1192–9.

7. Colavita K, Andy UU. Role of diet in fecal incontinence: a systematic review of the literature. *Int Urogynecol J*. 2016;27(5):1805–10.
8. Andy UU, Ejike N, Khanijow KD, et al. Diet modifications in older women with fecal incontinence: a qualitative study. *Pelvic Med Reconstr Surg*. 2020;26(4):239–43.
9. Bliss DZ, Savik K, Jung HJ, et al. Dietary fiber supplementation for fecal incontinence: a randomized clinical trial. *Res Nurs Health*. 2014;37(5):367–78.
10. Iriondo-DeHond A, Uranga JA, del Castillo MD, Abalo R. Effects of coffee and its components on the gastrointestinal tract and the brain–gut axis. *Nutrients*. 2021;13(1):88. <https://doi.org/10.3390/nu13010088>.
11. Karimi G, Heidari Z, Firouzi S, Haghghatdoost F. A systematic review and meta-analysis of the association between fish consumption and risk of metabolic syndrome. *Nutr Metab Cardiovasc Dis*. 2020;30(5):717–29.
12. Jayedi A, Shab-Bidar S. Fish consumption and the risk of chronic disease: an umbrella review of meta-analyses of prospective cohort studies. *Adv Nutr*. 2020;11(5):1123–33.
13. Campos VP, Portal VL, Markoski MM, et al. Effects of a healthy diet enriched or not with pecan nuts or extra-virgin olive oil on the lipid profile of patients with stable coronary artery disease: a randomised clinical trial. *J Hum Nutr Diet*. 2020;33(3):439–50.
14. Jimenez-Lopez C, Carpena M, Lourenço-Lopes C, et al. Bioactive compounds and quality of extra virgin olive oil. *Foods*. 2020;9(8):1014. <https://doi.org/10.3390/foods9081014>.
15. Mazza E, Fava A, Ferro Y, et al. Effect of the replacement of dietary vegetable oils with a low dose of extravirgin olive oil in the Mediterranean diet on cognitive functions in the elderly. *J Transl Med*. 2018;16(1):10. <https://doi.org/10.1186/s12967-018-1386-x>.

Open Access This chapter is licensed under the terms of the Creative Commons Attribution-NonCommercial-NoDerivatives 4.0 International License (<http://creativecommons.org/licenses/by-nc-nd/4.0/>), which permits any noncommercial use, sharing, distribution and reproduction in any medium or format, as long as you give appropriate credit to the original author(s) and the source, provide a link to the Creative Commons license and indicate if you modified the licensed material. You do not have permission under this license to share adapted material derived from this chapter or parts of it.

The images or other third party material in this chapter are included in the chapter's Creative Commons license, unless indicated otherwise in a credit line to the material. If material is not included in the chapter's Creative Commons license and your intended use is not permitted by statutory regulation or exceeds the permitted use, you will need to obtain permission directly from the copyright holder.





Role of Pelvic Floor Rehabilitation: Patient Selection and Treatment

9

Ludovico Docimo, Giorgia Gualtieri, Claudio Gambardella,
and Luigi Brusciano

9.1 Introduction

Anal incontinence (AI) is the occurrence of an involuntary loss of gas or feces that strongly impairs patients' quality of life. It affects individuals of all ages, races and gender; its overall prevalence in adults ranges from 11% to 15% and increases with age [1]. However, its real prevalence is probably underestimated as patients tend to avoid seeking medical care due to considerable embarrassment and stigma [2]. The manifestations of AI differ according to the severity of the condition, leading to a variety of heterogeneous clinical presentations, from the unintentional elimination of flatus or slight soilage, to the complete and unnoticed loss of feces. The mechanisms responsible for physiologic continence involve a complex interplay between stool consistency, compliance of the rectal reservoir, pelvic floor muscle groups, and proper functioning of the anal sphincter complex. Alterations in any of these elements—from stool consistency to muscular proficiency—may impact continence to flatus, liquid and solid stool and give rise to symptoms related to AI. It is known that the ideal stool consistency ranges between type 3 and 4 of the Bristol Stool Scale [3]. A change in stool consistency to the liquid pattern may impair continence even in the absence of sphincter lesions. Conversely, the presence of sphincter lesions or pelvic floor motility disorders may imply AI symptoms regardless of stool consistency. Alterations of the nervous system directly impairing the sampling reflex may also contribute to the occurrence of AI [4, 5]. AI may be also caused by the often-neglected functional alterations correlated to a thoraco-abdomino-perineal dyssynergia. The physiologic defecatory act in fact not only involves synchronism between the rectum and anus, but also requires correct thoraco-abdomino-perineal

L. Docimo · G. Gualtieri · C. Gambardella · L. Brusciano (✉)
Division of General, Mini-invasive, Oncological, and Bariatric Surgery,
University of Campania Luigi Vanvitelli, Naples, Italy
e-mail: ludovico.docimo@unicampania.it; giorgiagualtieri207@gmail.com;
claudio.gambardella2@unicampania.it; luigi.brusciano@unicampania.it

dynamics and vertebral position. Indeed, chest, abdomen, vertebral column and perineum are to be considered different parts of the same complex, all actively playing their role in patients with defecation disorders. Pelvic floor contraction and relaxation for physiologic defecation and urination depends on the harmonic integration of what can be schematized as the four sides of an “imaginary cuboid”: the diaphragm, the abdominal wall, the spine and the pelvic floor itself (Figs. 9.1 and 9.2) [6, 7]. For example, the correct movement of the diaphragm has a decisive role in increasing intra-abdominal pressure, a well-known and studied pattern of physiologic defecation [8]. AI severity depends on the type and frequency of episodes and, of course, on the extent to which the episodes affect the patients’ quality of life.

9.2 Clinical Physiatric Evaluation

Routinely, the diagnostic algorithm for defecation disorders, such as AI, includes clinical tests (e.g., the Cleveland Clinic Incontinence Score), proctologic examination, radiologic imaging, instrumental tests (3D endorectal ultrasonography and high-resolution anorectal manometry), performed to assign patients an incontinence level [9–11]. Medical history should include previous anal surgery, hysterectomy, or previous vaginal deliveries; however, although these represent predictive factors of AI, they do not help to select patients amenable to pelvic floor rehabilitation nor do they provide any information predicting the effectiveness of the rehabilitative treatment. In this setting, it is important to extend the assessment of the proctological patient to include a clinical-physiatric evaluation [12] to be carried out alongside the clinical examinations and instrumental tests, consisting of:

- *Puborectalis contraction* This parameter is useful to detect a paradoxical muscle contraction and an absent or incomplete relaxation.
- *Pubococcygeal test* Phasic and tonic contraction can be evaluated by hooking a finger in the anal canal and asking the patient to contract the anus for the longest possible period of time [13, 14]. Incontinent patients show significantly worse pubococcygeal test than healthy controls.
- *Perineal defense reflex* This evaluates the pelvic floor and abdominal muscle action following an increase in intra-abdominal pressure. The patient is asked to cough, so that the physician can observe and rate perineal muscle contraction as either a physiologic rising or a pathologic descending which, if marked, might be associated with emission of urine and flatulence [15–17]. The perineal defense reflex is evaluated as an expression of a correct thoraco-abdomino-perineal dynamics [16–18].
- *Muscular synergy* The activity of both agonist (glutei and abductors) and antagonist (abdominals, diaphragm) muscles has to be evaluated with the patient in Sims’ position. The physician places a hand over the abdominal wall and observes the gluteal and abductor contraction as the patient is asked to contract the anus [15, 16]. In the case of a request for anal sphincter contraction, in fact, the recruitment of agonist muscles, such as the gluteus and abductor groups, can be caused

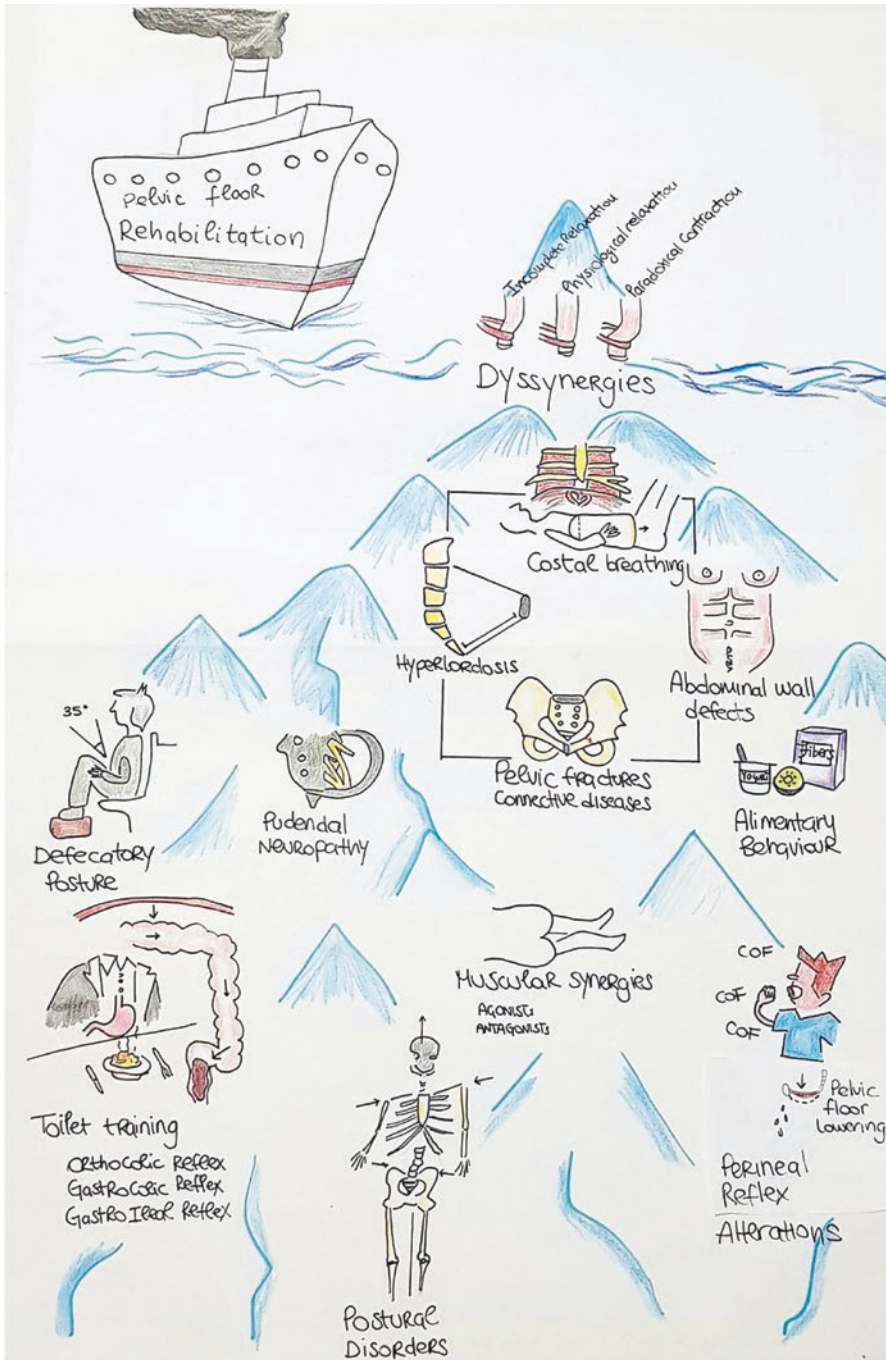


Fig. 9.1 Pelvic floor dyssnergies, defecatory posture, postural disorders, alimentary behavior, pudendal neuropathy, and the correct interaction and equilibrium among all the structures belonging to the “imaginary cuboid” are all parameters to be evaluated to indicate pelvic floor rehabilitation, which aims at the functional correction of any altered psychiatric parameters. (Reproduced from [6] with permission from Springer)

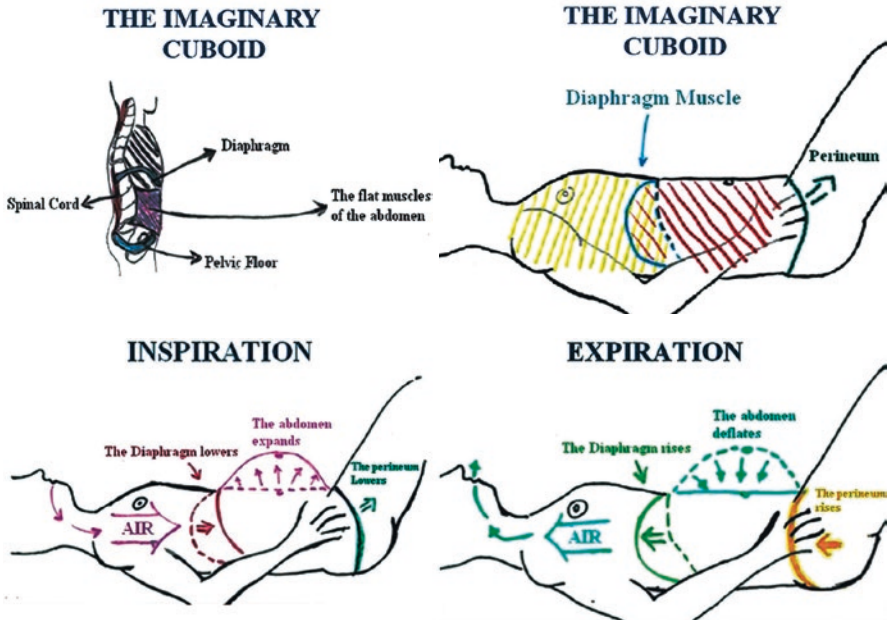


Fig. 9.2 A brief representation of the interaction of the different structures forming the “imaginary cuboid”, whose correct functional interplay is the goal of pelvic floor rehabilitation and the necessary basis for treating pelvic floor disorders. (Reproduced from [7] with permission from Springer)

by the patient’s incapacity to selectively recruit the correct muscles to comply with the request. Vice versa, the identification of antagonist muscles (abdominal muscles) during anal sphincter contraction also represents a conflict between the abdominal and perineal muscles [19]. A higher rate of agonist and antagonist muscle synergies has been noticed in incontinent patients.

- *Postural evaluation of lumbar lordosis* The distance between the plumb line and the spinous process of L3 is measured, considering a range between 25 and 40 mm as normal [20]. In patients with severe lumbar hyperlordosis, the sacrum is positioned almost horizontally while the pelvic promontory is displaced dorsally and the coccyx ventrally [21]. According to its severity, lumbar lordosis may alter the orientation of the sacral promontory, the anorectal angle, and the puborectalis tone and consequently affect defecation.
- *Breathing dynamics* During the first clinical examination it should be assessed whether or not the patient knows how to recruit the diaphragm and execute a correct breathing technique. In physiologic breathing, lowering of the diaphragm causes an increase in abdominal pressure, which is useful for the act of defecation. Regardless of the patient’s clinical presentation, the failure to recruit the diaphragm should be corrected through rehabilitation [22].

It is clear that a patient who might benefit from rehabilitation cannot be only clinically and instrumentally assessed: a psychiatric assessment appears necessary, to enable the identification and correction of the altered parameters that modify the harmony of the “imaginary cuboid”. A proper and complete evaluation of psychiatric parameters should therefore be included in every diagnostic protocol for incontinent patients [6, 7]. Only the finding of one or more altered psychiatric parameters can justify the indication for pelvic floor rehabilitation, which is otherwise inappropriately prescribed. Correction of the altered parameters aims at reconstructing the physiologic harmony of the pelvic floor and the other structures forming the “imaginary cuboid”; this harmony is a necessary, though not always sufficient, condition for achieving clinical resolution of the symptoms. Only after improvement of function can we assess whether there is also clinical benefit. An inappropriate indication to rehabilitation not only leads to unnecessary treatment, but also fails to benefit the patient, and is responsible for incorrectly associating pelviperineal rehabilitation to a poor outcome.

9.3 Pelvic Floor Rehabilitation Treatment

9.3.1 The Re-Education Phase

A conservative therapeutic approach such as pelviperineal rehabilitation could be the first-line option when incontinence is associated with proven functional alterations.

What constitutes an ideal and complete pelvic floor rehabilitation treatment is a holistic management of the patient affected by AI, starting with a phase of re-education. The re-education.

program should be based on four mandatory points [7]:

1. Knowledge of anatomic-physiologic notions of the pelvic floor and defecation.
2. Awareness of the role of correct breathing and defecatory posture.
3. The importance of perception of the gastrocolic and gastroileal reflexes after an abundant meal without procrastinating the defecatory stimulus.
4. The great importance of consuming, in the right quantity and quality, the constituent elements of the feces (water, fiber, lactic acid bacteria).

More precisely, the re-education phase starts with providing the patient with correct information about ideal stool consistency and the diet to be followed to achieve it, as well as teaching the patient about the pelvic floor as an anatomic entity and its physiologic function. The pelvic floor is pierced by organs belonging to the sexual, urinary and defecatory systems, and it is useful, as well as desirable, for patients to have knowledge of its functioning [7]. Patients’ awareness of the anatomy and physiology of the district actively helps them to be part of the rehabilitation treatment. The clinical-psychiatric approach and the re-educational phase aim to improve an altered bodily function; they are not merely cognitive steps, but they prepare the patient toward an active, rather than passive, role with deep participation during the healing process.

9.3.2 Pelvic Floor Rehabilitation “Tools”

Different pelvic floor rehabilitation techniques are used by the physician as different “tools”, depending on which physiatriac parameter is found altered. Electric stimulation, for example, is a useful rehabilitation treatment for inducing consciousness of the anal area, a feature that may be as useful as the stimulation itself [23, 24].

A rehabilitation treatment should be based on different techniques specifically tailored to correct each functional alteration, and not applied as a standard indiscriminating recipe. Pelvic floor rehabilitation should in fact not only be identified with biofeedback alone, but should employ all of the different rehabilitation techniques:

- External electrical stimulation helps patients to become aware of the perineal district [25] and to improve their muscular performance. An anal probe with a pulse generator is used to achieve adequate electrical stimulation, which has to be performed in cycles.
- Biofeedback [26, 27] is performed using an electromyographic biofeedback system. Visual feedback is provided by observing changes in pressure activity on a monitor. Patients are taught to mainly practice contraction and relaxation of the anal canal, while evaluating the activity of the abdominal or gluteal/abductor muscles by using surface electromyography.
- The principles of volumetric rehabilitation are based on the mechanical distension of the rectum [26, 27]. The aim of this technique is to restore impaired rectal sensation. The technique involves the twice daily administration of a tepid water enema. The goal of this rehabilitation technique is to help patients understand the three basic phases of the defecatory act (perception, retaining, passing), in order to become aware of the pelviperineal muscular activity.
- Augmented self-perception and muscle reinforcement can be achieved by extracorporeal magnetic stimulation as well as electrostimulation, but magnetic stimulation is noninvasive and not embarrassing as patients do not have to be undressed while undergoing rehabilitation and do not need insertion of an anal plug (as in electric stimulation). The stimulation is provided by an electromagnetic generator in the seat of a chair where patients sit during the whole treatment session. Different studies had already assessed the effectiveness of extracorporeal magnetic stimulation in urinary incontinence [28], and in our experience it proved to be an effective treatment for idiopathic fecal incontinence [29].
- Pelvic floor physical therapy, also referred to as pelvic floor muscle training, is a general term for the instruction of pelvic muscle strengthening, relaxation, and coordination exercises by a trained physical therapist [30] and comprises manipulations that have proven to be effective in reducing incontinence episodes, especially when associated with biofeedback [31].

9.3.3 Post-Rehabilitation Assessment

After the rehabilitation treatment, a follow-up clinical-physiatric evaluation should be carried out. The parameters found altered at the initial assessment and that supported the indication for pelvic floor rehabilitation should have been corrected by the treatment. This does not imply the clinical resolution of the symptoms but it represents the basis of a successful therapy, which will benefit from re-established harmony of the pelvic floor with the different sides of the “cuboid”.

References

1. Fattorini E, Brusa T, Gingert C, et al. Artificial muscle devices: innovations and prospects for fecal incontinence treatment. *Ann Biomed Eng.* 2016;44(5):1355–69.
2. Brown HW, Wexner SD, Segall MM, et al. Accidental bowel leakage in the mature women’s health study: prevalence and predictors. *Int J Clin Pract.* 2012;66(11):1101–8.
3. Chumpitazi BP, Self MM, Czyzewski DI, et al. Bristol Stool Form Scale reliability and agreement decreases when determining Rome III stool form designations. *Neurogastroenterol Motil.* 2016;28(3):443–8.
4. Jorge JM, Wexner SD. Etiology and management of fecal incontinence. *Dis Colon Rectum.* 1993;36(1):77–97.
5. Whitehead WE, Wald A, Norton NJ. Treatment options for faecal incontinence. *Dis Colon Rectum.* 2001;44(1):131–42.
6. Bruscianno L, Gualtieri G, Gambardella C, et al. Pelvic floor dyssynergia: the new iceberg syndrome. *Tech Coloproctol.* 2020;24(4):393–4.
7. Bruscianno L, Gambardella C, Tolone S, et al. An imaginary cuboid: chest, abdomen, vertebral column and perineum, different parts of the same whole in the harmonic functioning of the pelvic floor. *Tech Coloproctol.* 2019;23(6):603–5.
8. Hodges PW, Gandevia SC. Changes in intra-abdominal pressure during postural and respiratory activation of the human diaphragm. *J Appl Physiol* (1985). 2000;89(3):967–76.
9. Rentsch M, Paetzel C, Lenhart M, et al. Dynamic magnetic resonance imaging defecography: a diagnostic alternative in the assessment of pelvic floor disorders in proctology. *Dis Colon Rectum.* 2001;44(7):999–1007.
10. Beer-Gabel M, Teshler M, Schechtman E, Zbar AP. Dynamic transperineal ultrasound vs. defecography in patients with evacuatory difficulty: a pilot study. *Int J Colorectal Dis.* 2004;19(1):60–7.
11. Zbar AP, Beer-Gabel M. Manometric variables in rectocele patients with symptomatic constipation. *Tech Coloproctol.* 2003;7(1):65.
12. Bruscianno L, Limongelli P, del Genio G, et al. Clinical and instrumental parameters in patients with constipation and incontinence: their potential implications in the functional aspects of these disorders. *Int J Colorectal Dis.* 2009;24(8):961–7.
13. Artibani W, Benvenuti F, Di Benedetto P, et al. Staging of female urinary incontinence and pelvic floor disorders. Proposal of IPGH system. *Urodynamic.* 1996;6:1–5.
14. Blowman C, Pickles C, Emery S, et al. Prospective double blind controlled trial intensive physiotherapy with and without stimulation of the pelvic floor in treatment of genuine stress incontinence. *Physiotherapy.* 1991;77(10):661–4.
15. Laycock J. Clinical evaluation of the pelvic floor. In: Schussler B, Laycock J, Norton P, Stanton S, editors. *Pelvic floor re-education.* Springer; 1994. p. 42–8.
16. Di Benedetto P. La valutazione neuro-fisiatica perineale. In: Di Benedetto P, editor. *Riabilitazione uro-ginecologica.* Turin: Minerva Medica; 2004. p. 99–103.

17. Fabiani C, Lana LG, Mas N, et al. Pelvic floor muscles assessment in continent and incontinent women. *Urodynamic*. 1991;1:95–6.
18. Hay-Smith EJ, Dumoulin C. Pelvic floor muscle training versus no treatment, or inactive control treatments, for urinary incontinence in women. *Cochrane Database Syst Rev*. 2006;2006(1):CD005654. <https://doi.org/10.1002/14651858.cd005654>.
19. Bruscianno L, Limongelli P, del Genio G, et al. Short-term outcomes after rehabilitation treatment in patients selected by a novel rehabilitation score system (Bruscianno score) with or without previous stapled transanal rectal resection (STARR) for rectal outlet obstruction. *Int J Colorectal Dis*. 2003;28(6):783–9.
20. De Troyer A. Mechanical role of the abdominal muscles in relation to posture. *Respir Physiol*. 1983;53(3):341–53.
21. Kera T, Maruyama H. The effect of posture on respiratory activity of the abdominal muscles. *J Physiol Anthropol Appl Hum Sci*. 2005;24(4):259–65.
22. Bruscianno L, Limongelli P, del Genio G, et al. Useful parameters helping proctologists to identify patients with defaecatory disorders that may be treated with pelvic floor rehabilitation. *Tech Coloproctol*. 2007;11(1):45–50.
23. Pescatori M, Anastasio G, Bottini C, Mentasti A. New grading and scoring for anal incontinence. Evaluation of 335 patients. *Dis Colon Rectum*. 1992;35(5):482–7.
24. Agachan F, Chen T, Pfeifer J, et al. A constipation scoring system to simplify evaluation and management of constipated patients. *Dis Colon Rectum*. 1996;39(6):681–5.
25. Norton C, Gibbs A, Kamm MA. Randomized, controlled trial of anal electrical stimulation for fecal incontinence. *Dis Colon Rectum*. 2006;49(2):190–6.
26. Pucciani F, Iozzi L, Masi A, et al. Multimodal rehabilitation for faecal incontinence: experience of an Italian centre devoted to faecal disorder rehabilitation. *Tech Coloproctol*. 2003;7(3):139–47.
27. Pucciani F, Rottoli ML, Bologna A, et al. Pelvic floor dyssynergia and bimodal rehabilitation: results of combined pelviperineal kinesitherapy and biofeedback training. *Int J Colorect Dis*. 1998;13(3):124–30.
28. Galloway NTM, El-Galley RES, Sand PK, et al. Extracorporeal magnetic innervation therapy for stress urinary incontinence. *Urology*. 1999;53(6):1108–11.
29. Bruscianno L, Gambardella C, Gualtieri G, et al. Effects of Extracorporeal Magnetic Stimulation in Fecal Incontinence. *Open Med (Wars)*. 2020;15:57–64.
30. Herbert RD, Jamtvedt G, Mead J, et al. *Practical evidence-based physiotherapy*. 2nd ed. Oxford: Elsevier; 2011.
31. Ryn AK, Morren GL, Hallböök O, Sjödhahl R. Long-term results of electromyographic biofeedback training for fecal incontinence. *Dis Colon Rectum*. 2000;43(9):1262–6.

Open Access This chapter is licensed under the terms of the Creative Commons Attribution-NonCommercial-NoDerivatives 4.0 International License (<http://creativecommons.org/licenses/by-nc-nd/4.0/>), which permits any noncommercial use, sharing, distribution and reproduction in any medium or format, as long as you give appropriate credit to the original author(s) and the source, provide a link to the Creative Commons license and indicate if you modified the licensed material. You do not have permission under this license to share adapted material derived from this chapter or parts of it.

The images or other third party material in this chapter are included in the chapter's Creative Commons license, unless indicated otherwise in a credit line to the material. If material is not included in the chapter's Creative Commons license and your intended use is not permitted by statutory regulation or exceeds the permitted use, you will need to obtain permission directly from the copyright holder.





Sacral and Percutaneous Tibial Nerve Stimulation, Stem Cell Therapy, and Transanal Irrigation Device

10

Gabriele Naldini, Alessandro Sturiale, Claudia Menconi, Bernardina Fabiani, Rebecca Aglietti, Lisa Fralleone, Alfredo Annicchiarico, and Jacopo Martellucci

10.1 Sacral Nerve Stimulation

The early experiences with sacral nerve stimulation for refractory overactive bladder (OAB) [1] by urologists stimulated colorectal surgeons to use this procedure also for bowel dysfunctions, such as fecal incontinence (FI) [2] and chronic constipation (CC) [3, 4]. The first experience for FI was described by Matzel [2], and then the International Consultation on Incontinence in 2013 introduced sacral nerve stimulation (SNS) as a first-line treatment for FI in patients without or with minimal sphincter defect and as a second choice in those with moderate or large defects [5].

10.1.1 How It Works

The sacral nerves S2–S4 modulate pelvic sensitivity and the motility of the urologic and gastrointestinal functions of the pelvic floor. Electrical stimulation of the sacral roots creates a modulation of motor, sensory and autonomous nerve pathways in both the peripheral and central system, accounting for good outcomes in such different conditions as FI, CC, OAB, urinary incontinence, and low anterior resection syndrome (LARS) [6].

G. Naldini · A. Sturiale (✉) · C. Menconi · B. Fabiani · R. Aglietti · L. Fralleone
Proctology and Pelvic Floor Clinical Centre, Cisanello University Hospital, Pisa, Italy
e-mail: gabrielenaldini65@gmail.com; alexstur@yahoo.it; claudia.menconi14@gmail.com;
bernardina@hotmail.it; aglietti.rebe@gmail.com; lisa.fralleone@gmail.com

A. Annicchiarico · J. Martellucci
Emergency Surgery Unit, Careggi University Hospital, Florence, Italy
e-mail: alfredoannicchiarico90@gmail.com; jamjac64@hotmail.com

© The Author(s) 2023

L. Docimo, L. Bruscianno (eds.), *Anal Incontinence*, Updates in Surgery,
https://doi.org/10.1007/978-3-031-08392-1_10

10.1.2 Patient Selection

Patients with prevalent active fecal incontinence are the best candidates, even if they have a damaged sphincter [7]. A large group of patients may have associated symptoms such as urinary incontinence, chronic pelvic pain or CC, which may also improve with SNS. Patients are instructed to keep a bowel diary before and during the trial stimulation, which can last for 4–8 weeks. A $\geq 50\%$ improvement following the trial period is considered good, leading to the definitive implant. The contraindications for SNS are the need for magnetic resonance (MR) or therapeutic ultrasound, sacral skin sepsis, pregnancy or uncompliant patients. In 2020 MR-compatible devices, also with a rechargeable stimulator, were made available, which has extended the surgical indications.

10.1.3 Surgical Procedure

The procedure requires fluoroscopy. The patient lies in a prone position with the legs lower than the pelvis and a pillow under the lower abdomen to straighten the sacral curvature. The SNS trial may be performed using a temporary or a permanent electrode. In the first case, the temporary electrode remains connected to a stimulator for 14 days and is then removed; in the case of a permanent tined lead electrode, the definitive stimulator may be implanted 4–6 weeks after the trial stimulation. The procedure is generally performed under local anesthesia so as to allow testing of the sensory perception of flutter/vibration in the anovaginal/scrotal region or motor response.

The first step involves placing the needle in both S3 foramina, testing the response and choosing the better side. Then, the electrode is positioned with three poles placed further inside the medial sacral surface and connected through a subcutaneous tunnel with an external stimulator. In the case of failure, both the external stimulator and the electrode are removed, taking care to do this slowly and checking that the electrode is intact. In the case of a good response, instead, only the external connection is removed and the implantable stimulator is placed in the subcutaneous tissue, generally on the contralateral side to the electrode.

10.1.4 Complications

The most frequent complications are pain at the site of the implant, infection, and loss of efficacy occurring early (within 1 year) or after 2 years or more requiring surgical revision in 33% [8]. The pain at the site of the implant is managed by changing the site or the depth of stimulator placement. Local infection requires removal of all devices and planning a second implant after wound healing (at least 6 months). Sometimes the tined lead records high impedance during the follow-up and may be a cause of failure. In this case, simultaneous explantation and repositioning of a new electrode may solve the problem.

10.2 Percutaneous Tibial Nerve Stimulation

The first uses of tibial nerve stimulation (TNS) methods were reported in 1983 [9] through adhesive electrodes and then in 1999 [10] through needle electrodes in posterior tibial nerve stimulation (PTNS) to treat urinary dysfunctions such as lower urinary tract symptoms or OAB.

10.2.1 Procedure

The original technique consists of placing a 34-gauge needle in the lower leg, 3–4 cm above the medial malleolus and a grounding pad on the ipsilateral calcaneus. The patient lies supine with the knees adducted and flexed (frog position). Generally, the current levels have a range of 0.5–0.9 mA at 10–20 Hz and a pulse width of 200 μ s and the intensity of the current is adjusted to the patient's motor response often visible from the flexion of the big toe or extension of the entire foot or on the sensory response in the ankle area or on the sole of the foot.

Although some studies have shown the efficacy of TNS for both urinary and bowel dysfunctions, PTNS has been hypothesized to be more effective as the proximity of the needle to the tibial nerve attenuates the effect of skin impedance, and lower current intensities are sufficient to have a sensory and motor stimulation [11]. The duration of the treatment is about 20–30 min while the frequency of the treatments can be variable [12]. Some authors have already hypothesized that longer or more frequent treatments yield faster results [13].

10.2.2 Literature Results

Thomas et al. randomized 30 patients with fecal incontinence to receive treatment once a day or twice a week and demonstrated that patients in the daily group experienced a significant improvement in lifestyle and embarrassment on the Rockwood FI quality of life (QoL) assessment [14]. The actual benefits of PTNS on FI treatment are not yet reliably established. In 2015, Knowles et al. randomized 227 patients to receive PTNS or sham stimulation failing to demonstrate any effective benefit of PTNS to treat FI in adults [15]. The most recent results on PTNS use are more encouraging, as in most studies the manometric results intended as resting pressure and squeeze pressure and the Wexner score after treatment were improved [16, 17]. In a trial by Solon et al., 81 patients with FI performed PTNS with an 80% success rate. In these patients the rates of FI and defecatory urgency were significantly reduced in the first year and remained so until the end of the 2-year follow-up, also leading to an improvement in QoL [18].

10.3 Stem Cell Therapy

The current application of mesenchymal stem cells (MSCs) has its origin in the experiments of Caplan in 1991, who demonstrated that bone marrow (BM) transplantation into different sites induces a de novo ectopic bone and marrow [19].

BM, as well as adipose tissue (AT), dental pulp, and umbilical cord, is a source of MSCs/progenitor cells, but AT represents the ideal source due to the high concentration of regenerative cells, easy access and low risk associated with autologous therapies. Owing to these characteristics, new processing devices have now been developed and made available on the market to obtain ready-to-use, minimally manipulated autologous MSCs, such as Lipogems (Lipogems International S.p.A., Milan, Italy) [20].

In recent decades the use of human MSCs derived from AT has spread in different surgical fields [21], with a recent application to treat AI [22]. The whole surgical procedure including pre- and post-treatment 3D 360° transanal ultrasound has already been described [23].

However, autologous AT currently represents least common source of MSCs for AI treatment. In fact, in a recent review the most frequent sites were skeletal muscle and BM. In 44 studies, MSCs originated from muscle in 28 studies (17 skeletal and 11 smooth), from BM in 10, and from AT in 6. Eight studies used neural cells for bioengineered constructs and one publication used umbilical cord [24].

Hence, the overall preclinical and clinical results have demonstrated the safety of MSCs to treat AI. Although the preliminary results were highly promising, only three studies were controlled with placebo injection. Further studies are therefore needed to identify the source of MSCs guaranteeing the best outcome, considering the costs and the patient's involvement.

10.4 Transanal Irrigation

Transanal irrigation (TAI), also known as retrograde irrigation (RI), represents an alternative approach to the management of FI after the failure of conservative therapy or as additional treatment after surgical treatment. The use of this method goes back in time, and the control of continence with irrigation or enema was the first treatment described in history. In recent times, TAI was first used in 1987 in children with spina bifida suffering from FI. Subsequently, its use also spread for other disorders and in 1989 Iwama et al. used a conventional colostomy irrigation set through the anus in order to clean the last part of the colon in patients with defecatory urgency and impaired bowel control after low anterior resection [25]. The main goal of TAI is to restore a regular bowel routine and, for this reason, its field of application has expanded, with TAI being used for a series of intestinal dysfunctions ranging from incontinence, constipation, neurogenic diseases, up to LARS [26].

10.4.1 Procedure

The patient, sitting on the toilet, can autonomously introduce a short probe into the rectum through the anus. The probe is connected to a plastic bag that can be filled with lukewarm tap water. With a balloon catheter delivery system, once the catheter is inserted, the balloon is inflated inside the rectum, which allows continence to be maintained during administration of the enema. With a cone delivery system, the cone has to be held in place during instillation of the irrigation fluid and the patient needs a degree of flexibility. The water is instilled either by gravity or by means of a pump that the patient can activate or deactivate differently depending on the model. It is common to consider 400–500 cm³ of warm water to be an appropriate starting volume for irrigation in adults [27] but there is little evidence in the literature about optimal irrigation volumes. A randomized trial compared high- and low-volume irrigations in adult patients with CC [28] but the volume of water and the frequency of administrations can vary depending on the patient's requirements and bowel disorder.

10.4.2 How It Works

TAI does not appear to alter the function of the anorectal sphincter but rather it increases rectal tolerability and its distension. One study found that, in patients with FI treated with TAI, the resting and squeeze pressures were relatively lower in the follow-up. This finding, however, is to be attributed to the course of the disease rather than to TAI as the patients with CC treated with TAI did not show any alteration of sphincter function [29]. TAI is a type of treatment that requires the patients' commitment but has relatively rare side effects and can be stopped or resumed at any time. It is also relatively cheap and the training can be delivered entirely by the nursing staff without the aid of a doctor [30].

10.4.3 Literature Results

Most published studies analyze the efficacy of TAI simultaneously on FI and CC [31]. Alterations in lifestyle, coping, depression, social isolation and embarrassment are the fundamental elements lowering the QoL of patients suffering from FI [32]. Although most of the studies do not use validated questionnaires, the results tend to suggest an increase in the QoL of patients who perform TAI [30, 33]. In 2006, Christensen et al. found that TAI improved symptoms related to QoL in spinal cord-injured patients [34]; more recently, other studies have confirmed the marked improvement in QoL also in other categories of defecatory disorders [35, 36] and in patients with LARS [37]. Although it has generally been shown that TAI increases the QoL of patients with defecatory dysfunction, the drop-out rate with this therapy is still very high and, in some series, less than 50% of patients continued TAI [38]. The main reasons are dislike of the treatment, resolution of the symptoms, time

consumption, side effects, and practical problems such as fluid leakage or catheter expulsion [33, 39]. Recently, a retrospective series of 108 patients analyzed the predictors of compliance in the treatment of fecal disorders. In this study, patients with FI gave the best results and 54.5% remained compliant with TAI. In the analysis of predictive factors, training sessions were found to be the only factor that predicts patient compliance with TAI [38]. Patient education in TAI remains a key step in this treatment. Although the procedure is in most cases well tolerated and easy to perform, some cases of rectal and enterovaginal perforations have been described [36, 40]. A recent global audit that collected data from 2005 to 2013 has estimated a risk of perforation of less than 2 per million procedures [41]. Professional nurses experienced in the field of TAI have the task of carefully selecting motivated patients and instructing them by explaining the procedure and any relative and absolute contraindications.

References

1. Tanagho EA, Schmidt RA. Bladder pacemaker: scientific basis and clinical future. *Urology*. 1982;20(6):614–9.
2. Matzel KE, Stadelmaier U, Hohenfellner M, Gall FP. Electrical stimulation of sacral spinal nerves for treatment of faecal incontinence. *Lancet*. 1995;346(8983):1124–7.
3. Ganio E, Masin A, Ratto C, et al. Short-term sacral nerve stimulation for functional anorectal and urinary disturbances: results in 40 patients: evaluation of a new option for anorectal functional disorders. *Dis Colon Rectum*. 2001;44(9):1261–7.
4. Malouf AJ, Wiesel PH, Nicholls T, et al. Short-term effects of sacral nerve stimulation for idiopathic slow transit constipation. *World J Surg*. 2002;26(2):166–70.
5. Abrams P, Cardozo L, Wagg A, Wein A. *Incontinence (Volume 1)*. 6th ed. Bristol, UK: International Continence Society; 2017.
6. Huang Y, Koh CE. Sacral nerve stimulation for bowel dysfunction following low anterior resection: a systematic review and meta-analysis. *Colorectal Dis*. 2019;21(11):1240–8.
7. Ratto C, Litta F, Parello A, et al. Sacral nerve stimulation is a valid approach in fecal incontinence due to sphincter lesions when compared to sphincter repair. *Dis Colon Rectum*. 2010;53(3):264–72.
8. Hetzer FH, Bieler A, Hahnloser D, et al. Outcome and cost analysis of sacral nerve stimulation for faecal incontinence. *Br J Surg*. 2006;93(11):1411–7.
9. McGuire EJ, Zhang SC, Horwinski ER, Lytton B. Treatment of motor and sensory detrusor instability by electrical stimulation. *J Urol*. 1983;129(1):78–9.
10. Nuhuğlu B, Fidan V, Ayyıldız A, et al. Stoller afferent nerve stimulation in woman with therapy resistant over active bladder: a 1-year follow up. *Int Urogynecol J*. 2006;17(3):204–7.
11. van der Pal F, van Balken MR, Heesakkers JPFA, et al. Percutaneous tibial nerve stimulation in the treatment of refractory overactive bladder syndrome: is maintenance treatment necessary? *BJU Int*. 2006;97(3):547–50.
12. Sarveazad A, Babahajian A, Amini N, et al. Posterior tibial nerve stimulation in fecal incontinence: a systematic review and meta-analysis. *Basic Clin Neurosci*. 2019;10(5):419–31.
13. Yoong W, Ridout AE, Damodaram M, Dadswell R. Neuromodulative treatment with percutaneous tibial nerve stimulation for intractable detrusor instability: outcomes following a shortened 6-week protocol. *BJU Int*. 2010;106(11):1673–6.
14. Thomas GP, Dudding TC, Bradshaw E, et al. A pilot study to compare daily with twice weekly transcutaneous posterior tibial nerve stimulation for faecal incontinence. *Colorectal Dis*. 2013;15(12):1504–9.

15. Knowles CH, Horrocks E, Bremner SA, et al. Percutaneous tibial nerve stimulation versus sham electrical stimulation for the treatment of faecal incontinence in adults (CONFIDeNT): a double-blind, multicentre, pragmatic, parallel-group, randomised controlled trial. *Lancet*. 2015;386(10004):1640–8.
16. López-Delgado A, Arroyo A, Ruiz-Tovar J, et al. Effect on anal pressure of percutaneous posterior tibial nerve stimulation for faecal incontinence. *Colorectal Dis*. 2014;16(7):533–7.
17. Manso B, Alias D, Franco R, et al. Percutaneous electrical stimulation of the posterior tibial nerve for the treatment of fecal incontinence: manometric results after 6 months of treatment. *Int J Colorectal Dis*. 2020;35(11):2049–54.
18. Solon JP, Waudby P, O’Grady H. Percutaneous tibial nerve stimulation can improve symptoms and quality of life in selected patients with faecal incontinence – A single-centre 5-year clinical experience. *Surgeon*. 2020;18(3):154–8.
19. Caplan AI. Mesenchymal stem cells. *J Orthop Res*. 1991;9(5):641–50.
20. Bianchi F, Maioli M, Leonardi E, et al. A new nonenzymatic method and device to obtain a fat tissue derivative highly enriched in pericyte-like elements by mild mechanical forces from human lipoaspirates. *Cell Transplant*. 2013;22(11):2063–77.
21. Naldini G, Sturiale A, Fabiani B, et al. Micro-fragmented adipose tissue injection for the treatment of complex anal fistula: a pilot study accessing safety and feasibility. *Tech Coloproctol*. 2018;22(2):107–13.
22. Sarveazad A, Newstead GL, Mirzaei R, et al. A new method for treating fecal incontinence by implanting stem cells derived from human adipose tissue: preliminary findings of a randomized double-blind clinical trial. *Stem Cell Res Ther*. 2017;8(1):40. <https://doi.org/10.1186/s13287-017-0489-2>.
23. Sturiale A, Fabiani B, Celedon Porzio F, et al. Micro-fragmented autologous adipose tissue injection to treat anal incontinence – a video vignette. *Colorectal Dis*. 2020;22(11):1767–8.
24. Balaphas A, Meyer J, Meier RPH, et al. Cell therapy for anal sphincter incontinence: where do we stand? *Cell*. 2021;10(8):2086. <https://doi.org/10.3390/cells10082086>.
25. Iwama T, Imajo M, Yaegashi K, Mishima Y. Self washout method for defecational complaints following low anterior rectal resection. *Jpn J Surg*. 1989;19(2):251–3.
26. Annicchiarico A, Martellucci J, Solari S, et al. Low anterior resection syndrome: can it be prevented? *Int J Colorectal Dis*. 2021;36(12):2535–52.
27. Emmett C, Close H, Yiannakou Y, Mason J. Trans-anal irrigation therapy to treat adult chronic functional constipation: systematic review and meta-analysis. *BMC Gastroenterol*. 2015;15:139. <https://doi.org/10.1186/S12876-015-0354-7>.
28. Emmett C, Close H, Mason J, et al. Low-volume versus high-volume initiated trans-anal irrigation therapy in adults with chronic constipation: study protocol for a randomised controlled trial. *Trials*. 2017;18(1):151. <https://doi.org/10.1186/S13063-017-1882-Y>.
29. Faaborg PM, Christensen P, Buntzen S, et al. Anorectal function after long-term transanal colonic irrigation. *Colorectal Dis*. 2010;12(10 Online):e314–9.
30. Crawshaw AP, Pigott L, Potter MA, Bartolo DCC. A retrospective evaluation of rectal irrigation in the treatment of disorders of faecal continence. *Colorectal Dis*. 2004;6(3):185–90.
31. Mekhael M, Kristensen H, Larsen H, et al. Transanal irrigation for neurogenic bowel disease, low anterior resection syndrome, faecal incontinence and chronic constipation: a systematic review. *J Clin Med*. 2021;10(4):753. <https://doi.org/10.3390/jcm10040753>.
32. Bartlett L, Nowak M, Ho YH. Impact of fecal incontinence on quality of life. *World J Gastroenterol*. 2009;15(26):3276–82.
33. Juul T, Christensen P. Prospective evaluation of transanal irrigation for fecal incontinence and constipation. *Tech Coloproctol*. 2017;21(5):363–71.
34. Christensen P, Bazzocchi G, Coggrave M, et al. A randomized, controlled trial of trans-anal irrigation versus conservative bowel management in spinal cord-injured patients. *Gastroenterology*. 2006;131(3):738–47.
35. Koch S, Melenhorst J, van Gemert W, Baeten C. Prospective study of colonic irrigation for the treatment of defaecation disorders. *Br J Surg*. 2008;95(10):1273–9.

36. Emmanuel A, Kumar G, Christensen P, et al. Long-term cost-effectiveness of transanal irrigation in patients with neurogenic bowel dysfunction. *PLoS One*. 2016;11(8):e0159394. <https://doi.org/10.1371/journal.pone.0159394>.
37. Rosen H, Robert-Yap J, Tentschert G, et al. Transanal irrigation improves quality of life in patients with low anterior resection syndrome. *Colorectal Dis*. 2011;13(10):e335–8.
38. Bildstein C, Melchior C, Gourcerol G, et al. Predictive factors for compliance with transanal irrigation for the treatment of defecation disorders. *World J Gastroenterol*. 2017;23(11):2029–36.
39. Christensen P, Krogh K, Buntzen S, et al. Long-term outcome and safety of transanal irrigation for constipation and fecal incontinence. *Dis Colon Rectum*. 2009;52(2):286–92.
40. Gallo G, Graziani S, Realis Luc A, et al. Teaching transanal irrigation (TAI): why it is mandatory. *Tech Coloproctol*. 2018;22(3):239–41.
41. Christensen P, Krogh K, Perrouin-Verbe B, et al. Global audit on bowel perforations related to transanal irrigation. *Tech Coloproctol*. 2016;20(2):109–15.

Open Access This chapter is licensed under the terms of the Creative Commons Attribution-NonCommercial-NoDerivatives 4.0 International License (<http://creativecommons.org/licenses/by-nc-nd/4.0/>), which permits any noncommercial use, sharing, distribution and reproduction in any medium or format, as long as you give appropriate credit to the original author(s) and the source, provide a link to the Creative Commons license and indicate if you modified the licensed material. You do not have permission under this license to share adapted material derived from this chapter or parts of it.

The images or other third party material in this chapter are included in the chapter's Creative Commons license, unless indicated otherwise in a credit line to the material. If material is not included in the chapter's Creative Commons license and your intended use is not permitted by statutory regulation or exceeds the permitted use, you will need to obtain permission directly from the copyright holder.





Sphincter Reconstruction: Dynamic Myoplasty, Artificial Bowel Sphincter, Antegrade Colonic Enemas and Colostomy

11

Francesco Selvaggi, Giacomo Fuschillo, Lucio Selvaggi, Vinicio Mosca, and Guido Sciaudone

11.1 Introduction

Fecal incontinence (FI) is a debilitating condition that affects up to 18% of the general population and up to 55% of the elderly [1], and causes frequent hospitalization in nursing homes, worsening the quality of life (QoL) of those affected. Although treatment is difficult and the success rate is often not high, simply attempting to correct it can significantly improve the patients' QoL [2, 3]. The actual effectiveness of the surgical treatment of FI remains difficult to assess: most studies are retrospective and include only a limited number of patients, the data collection methods are not standardized, and no FI severity score has been universally accepted [4]. Several treatment options have been proposed over the last twenty years, but none of them can be considered the gold standard. The first step in a patient with FI is to rule out organic pathology (e.g., neoplasm); treatment involves the use of medications that reduce bowel motility, correction of the diet, and pelvic floor re-education. These three elements provide a solid basis for the initial treatment of FI, achieving some improvement in symptoms in almost half of the cases, without the need for further investigations or invasive procedures [5]. If medical nutritional therapy is insufficient to ensure improvement in the patient's QoL, surgical therapy must be considered. The patient being considered for surgical intervention must first be adequately examined by performing clinical-instrumental tests such as anorectal manometry, endoanal and pelviperineal ultrasound, dynamic defecography (or MRI defecography), and electrophysiological tests such as electromyography and pudendal nerve terminal motor latency [6].

F. Selvaggi (✉) · G. Fuschillo · L. Selvaggi · V. Mosca · G. Sciaudone
Department of Advanced Medical and Surgical Sciences,
University of Campania Luigi Vanvitelli, Naples, Italy
e-mail: francesco.selvaggi@unicampania.it; g.fuschillo92@libero.it;
lucio.selvaggi@unicampania.it; vinicio.mosca@gmail.com; guido.sciaudone@unicampania.it

This chapter presents the main surgical options that can be used in patients with FI.

11.2 Dynamic Myoplasty

Pickrell et al. [7] first described the use of transposition of the gracilis as a neosphincter in 1952. The first electrically stimulated graciloplasty was reported in 1968 [8], but the concept of converting fast fibers to slow fibers using an electrical stimulator was not proposed until 1991 by Baeten et al. [9] and Williams et al. [10]. Electrically stimulated graciloplasty (dynamic graciloplasty) was developed in an effort to improve the functional results of simple transposition of the gracilis. The major limitations of unstimulated graciloplasty included the inability of patients to contract the transposed muscle voluntarily and the physiological inability of the muscle to sustain a tonic contraction over a prolonged period of time.

11.2.1 Technique

The patient is positioned in the lithotomy position with the thighs flexed, to expose the perineal region; intraoperative curarization is not required. Surgery begins with incision and mobilization of the gracilis muscle. The surgeon makes an incision on the medial inner aspect of the thigh, a few centimeters below the origin of the thigh, up to 10 cm before the knee. Mobilization of the gracilis muscle must start from its central part to preserve the main neurovascular pedicle. The left index finger placed under the gracilis pulls the muscle out, allowing dissection of the nearby connective tissue and coagulation of additional secondary vascular pedicles. The middle finger of the surgeon's left hand penetrates the distal tendon to the pes anserinus (at the level of the internal tibial tuberosity), where a small incision is made. The distal gracilis tendon must be interrupted at this level. The muscle is then tipped over on the perineum, and it is important to avoid twisting or compressing its neurovascular pedicle. At this point, the perineorectal area must be prepared by making two lateral incisions of 4–5 cm each between the anal verge and ischium. To delineate the perineorectal area, a tunnel must be created between the origin of the thigh and the ipsilateral perineal incision. This tunnel must be large enough to allow the muscle to be laid without tension or obstruction, and special care must be taken to not twist the muscle. The gracilis muscle is rotated and passed through the perineorectal area to completely encircle the anal canal. It is important to avoid any contact between the muscle and the anal canal (because of the risk of ulceration) or excessive muscle tension (it must be possible to pass two fingers between the anal canal and the muscle). After checking for correct muscle tension, the distal tendon is fixed to the contralateral (gamma-shaped loop) or ipsilateral (alpha-shaped loop) ischium with an orthopedic tendon clamp. During fixation, the thigh must be positioned in full adduction to achieve adequate tightening and avoid secondary loosening. After hemostasis, the perineal incisions are closed without placing a drain. At this point,

two neurostimulation electrodes are positioned and inserted into the muscle, with the anode placed in the distal portion and the cathode in the proximal one. The electrodes are fixed with nonabsorbable 4/0 Prolene sutures. Positioning of the electrodes connected to the external stimulator allows determination of the stimulation threshold and the maximum stimulation value. Placement of the neuromuscular pacemaker requires an incision in the ipsilateral iliac fossa of the harvested muscle to provide subcutaneous access from the origin of the thigh to the anterior abdominal wall. Sheathed electrodes are then passed through this subcutaneous pathway to the rectus sheath and connected to the neuromuscular pacemaker. The pacemaker is placed in the subcutaneous space and secured to the fascia with a nonabsorbable suture. The procedure ends with closure of the thigh and cessation of electrical stimulation. A Redon suction drain is inserted into the thigh and drained through the tibial incision. After hemostasis, the subcutaneous tissue and muscular perimysium are approximated by a continuous suture layer of slowly absorbable material. The cutaneous plane is closed with a continuous non-absorbable suture. The stimulator is synchronized by telemetry with the stimulation parameters determined during electrode placement [11].

11.2.2 Results

Wexner et al. [12] reported the results of a multicenter study of 115 patients who underwent stimulated graciloplasty between 1993 and 1999. Overall success, defined as a 50% reduction in the frequency of incontinence episodes, was achieved at 1 year in 62% of patients, none of whom had a stoma at the time of graciloplasty. These results were confirmed at 18 and 24 months in 55% and 56% of patients, respectively; 15% of patients in this group reported complete continence; 42% had continence levels of 50% to 99%. The success rate for patients who had a stoma at the time of graciloplasty was 37.5% at 1 year. This result improved significantly to 62% at 18-month follow-up. Significant improvements were also noted in QoL. A systematic review of the literature on dynamic graciloplasty [13] showed that the procedure is associated with a non-negligible morbidity, on average 1.12 events per patient (range, 0.14 to 2.08). These data suggest that either all patients had at least one complication or that some patients experienced multiple complications such as infection (28% of the cases), stimulator or electrode malfunction (15%), and leg pain (13%). Other complications, with a frequency greater than 5%, were constipation or obstructed defecation, anal pain, rectal or gracilis injury, and pacemaker battery depletion. The efficacy of the procedure, as measured by the satisfaction rate with continence, ranged from 42% to 85%. Reasons for stimulator explantation, ranging from 0.14 to 1.07 per patient, included erosion of the anal canal by the gracilis muscle, rectal perforation from use of enemas, rejection of the electrodes or stimulator, constipation, migration of the electrodes, detachment of the gracilis tendon from the ischium, battery malfunction, perianal abscess, pain, fistula, or perineal hernia. Dynamic graciloplasty continues to be performed in Europe and Canada, but the hardware for the procedure is not yet approved in the United States.

Currently, its use is largely limited to a small number of centers where sufficient patient volume and surgical experience ensure low morbidity and satisfactory functional outcomes.

11.3 Artificial Bowel Sphincter

The first implantation of an artificial bowel sphincter (ABS) for FI was reported in 1987 [14]. Currently, there are two types of ABS: the one originally developed to replace the urinary sphincter but then used in patients with anal incontinence (Acticon neosphincter, American Medical Systems, Mn, USA) [15] and the newer magnetic anal sphincter (Fenix, Medical Thorax, Mn, USA) [16].

11.3.1 Acticon Neosphincter

The Acticon ABS is a fully implantable prosthesis made of a silicone elastomer. It consists of a perianal sphincter ring (cuff), a regulatory reservoir (balloon), and a control pump.

The ring is implanted in the upper anal canal. The three elements are connected by a kink-resistant tube. The pressure-regulating reservoir, which controls the pressure exerted on the anal canal by the closure ring, is implanted in the subperitoneal space of Retzius, lateral to the bladder. The control pump is implanted in the scrotum in males and in the labia majora in females and contains a resistor and a deactivation button in its upper part. The lower part of the pump consists of a piston that the patient squeezes to deliver the fluid inside the implant [15, 17]. The ABS works semiautomatically [15]. The sphincter muscle automatically provides constant anal closure at low pressure approaching physiological levels; the pressure is transmitted to the closure cuff by the pressure-regulating pump. Emptying is actively controlled by the patient: the anus is opened by transferring the fluid from the cuff to the pressure-regulating reservoir. Transfer is achieved by pressing the piston of the regulating pump five to ten times. Reclosure of the anus occurs automatically within minutes by gradually restoring the baseline pressure in the cuff.

11.3.1.1 Technique

The incision may be made perianally or laterally [17, 18], then a tunnel is created around the upper anal canal, about 5 cm deep, and dissected with the fingers. A long-curved forceps is then inserted along the dissection path around the anal canal to guide a tape (sizer) needed to determine the length of the occlusive cuff to be implanted.

The cuff is closed around the anal canal by passing the tubing through a slit at its end. Once the sphincter cuff is closed, a digital rectal examination can confirm the occlusive effect of the device.

A small suprapubic horizontal abdominal incision is made to create a space lateral to the bladder in the subperitoneal space of Retzius to accommodate the

pressure-regulating balloon. The sphincter cuff tube is passed subcutaneously from the perineal incision to the abdominal incision.

The sphincter cuff is then inflated, the empty pressure-regulating balloon is implanted at its subperitoneal site and pressurized with 40 mL of radiopaque isotonic fluid. A Hegar dilator is then used to create a subcutaneous tunnel from the abdominal incision to the scrotum or labia, into which the control pump is inserted.

11.3.1.2 Results

ABS has shown significant and consistent improvement in the continence of patients. However, in two recent prospective studies [19, 20] surgical revision was required in approximately 50% of patients and explantation of the device was required in 25–35%, but 85% of patients who had a properly functioning ABS were satisfied with the device and its operation [19]. Wong et al. [20] reported a six-year success rate of 67% with satisfactory functional outcomes and QoL. The experience of Darnis et al. [21] was instead less positive: at least one complication occurred in all included patients. Skin infection or ulceration was reported in 76% of patients, perineal pain in 29%, rectal voiding dysfunction in 38% and ABS explantation in 81%. Compared to sacral neurostimulation, Acticon ABS appears to offer better continence outcomes [22]. However, due to a higher incidence of terminal constipation after implantation and the greater invasiveness of the technique, it is suggested as a second-line procedure. It should be noted that the use of this device has recently been limited by the failure of health authorities to extend reimbursement for this device. Currently, the decision to implant an ABS requires prior case-by-case approval by health authorities, limiting the use of Acticon to a few specialized centers [6].

11.3.2 Fenix Neosphincter

The Fenix magnetic ABS is inspired by the Lynx anti-reflux device recently developed to treat gastroesophageal reflux. The device consists of a series of titanium beads with hermetically sealed neodymium-iron-boron (NdFeB) magnetic cores. The beads are connected by independent titanium threads to form a flexible ring that wraps around the external anal sphincter. The device is manufactured in different lengths depending on the number of beads (14 to 20) needed to accommodate variations in the circumference of the anal canal. A sizing device, very similar to the final device, is used to determine the appropriate configuration. The separation force required to open the adjacent beads is approximately equivalent to 100 g and was chosen based on animal studies and literature data on voiding forces in healthy individuals and individuals with defecation disorders [16, 23]. During defecation, the patient simply strains as in normal defecation. The force generated by the straining determines the number of beads required to facilitate the passage of stool through the device. The device was designed with an excessive diametric capacity and therefore does not restrict defecation or cause excessive strain [16].

11.3.2.1 Technique

The device is usually implanted under general anesthesia. A single incision is made at the perineal body, carefully cutting the anterior anorectal vaginal septum to a depth of approximately 3–5 cm proximal to the anal verge. A measuring instrument is then inserted to accurately measure the circumference of the anorectal junction. After correct sizing under fluoroscopic control, the measuring tool is removed and the device is selected and implanted according to the number of beads required to encircle the anal canal [16].

11.3.2.2 Results

The Fenix magnetic ABS shows promising early results. The passive reinforcement of the anal canal by the magnetic “cuff” accounts for the originality and simplicity of this technique. The patient does not have to do anything, other than reproduce the effort of straining to empty the rectum [23]. Lehur et al. [16] reported surgical site infections in 21.4% of cases, requiring device removal in 14.3%. After a median follow-up of six months, 21.4% of patients no longer had the magnetic sphincter in place. Compared with conventional ABS, the duration of surgery and hospital stay were significantly shorter with the magnetic ABS [24]. Short-term functional outcomes were similar for both sphincters in terms of revision and withdrawal rates. Although these results are encouraging, the use of the magnetic sphincter is currently limited to a few centers, where its efficacy is still under investigation [23].

11.4 Antegrade Colonic Enemas

The antegrade colonic enema (ACE) was first described by Malone et al. [25] in 1990 for the treatment of FI in children. It involves the creation of a continent stoma according to the Mitrofanoff principle [26]. The original procedure involved resection of the appendix and its cuff, while preserving the appendicular artery. A submucosal tunnel was then created, to which the distal end of the appendix was sutured. The appendix was then passed out of the right side of the lower abdominal wall as a stoma. Later, several modifications of this technique were described that used the terminal ileum [27], the cecum, the left colon, or the stomach [28]. In each case, a Foley catheter is placed in the stoma and left in place for 15 days until the antegrade enemas begin. This involves introducing water and/or enema solution antegrade into the colon and emptying the colon of stool, to relieve both constipation and incontinence [29].

11.4.1 Results

Very few studies have described the results. Chéreau et al. [29] analyzed 75 patients who underwent ACE and observed early complications in 5.3% and late complications (after 3 months) in 16% of patients. The early complications were iatrogenic perforation of the small bowel, ileus, and postoperative pelvic abscess. The main

late complication was stoma stenosis, with an incidence that varied from 8% to 50% [29, 30].

At a median follow-up of 48 months, treatment was considered successful in 86% of patients. Both the Wexner score for FI and the QoL score improved in all patients.

11.5 Colostomy

Colostomy may sometimes be considered as a first-line measure in FI, but traditionally it has been considered as a last therapeutic resort in patients in whom other treatments have failed [31]. Despite its curative potential, colostomy impacts on QoL, particularly because of altered body image and constant feeling of being sick [32]. However, in one study conducted on patients who underwent colostomy, acceptable social function was reported to be associated with higher QoL scores than patients with FI [33]. Norton et al. [34] reported that 84% of patients with a colostomy for FI would choose to have it again. The mortality rate after colostomy is approximately 2% [13], and complications mainly include bleeding and parastomal hernia [35]. Long-term complications include skin rashes, leaks, and edema, but these are mainly due to inadequate management of the ostomy pouching system [36]. In most cases, a sigmoid colostomy is performed, which has the advantage of being easy to perform. The stoma created with the sigmoid colon is indeed easier to manage with stoma devices due to the presence of formed stool. Nowadays, the recent improvements in stoma devices guarantee a better QoL and allow almost normal physical, social and sports activities [6]. As for the correct management of the rectosigmoid segment downstream from the stoma, this is still debated in the literature, with no clear opinions [31].

References

1. Landefeld C, Bowers B, Feld A, et al. National Institutes of Health state-of-the-science conference statement: prevention of fecal and urinary incontinence in adults. *Ann Intern Med.* 2008;148(6):449–58.
2. Bordeianou L, Rockwood T, Baxter N, et al. Does incontinence severity correlate with quality of life? Prospective analysis of 502 consecutive patients. *Colorectal Dis.* 2008;10(3):273–9.
3. Italian Society of Colorectal Surgery (SICCR), Pucciani F, Altomare DF, Dodi G, et al. Diagnosis and treatment of faecal incontinence: consensus statement of the Italian Society of Colorectal Surgery and the Italian Association of Hospital Gastroenterologists. *Dig Liver Dis.* 2015;47(8):628–45.
4. Madoff RD. Surgical treatment options for fecal incontinence. *Gastroenterology.* 2004;126(1 Suppl 1):S48–54.
5. Damon H, Vitton V, Soudan D. *Incontinence anale de l'adulte.* New York: Springer; 2013.
6. Meurette G, Duchalais E, Lehur PA. Surgical approaches to fecal incontinence in the adult. *J Visc Surg.* 2014;151(1):29–39.

7. Pickrell KL, Broadbent TR, Masters FW, Metzger JT. Construction of a rectal sphincter and restoration of anal continence by transplanting the gracilis muscle; a report of four cases in children. *Ann Surg.* 1952;135(6):853–62.
8. Dickson JAS, Nixon HH. Control by electronic stimulator of incontinence after operation for anorectal agenesis. *J Pediatr Surg.* 1968;3(6):696–701.
9. Baeten CG, Konsten J, Spaans F, et al. Dynamic graciloplasty for treatment of faecal incontinence. *Lancet.* 1991;338(8776):1163–5.
10. Williams NS, Patel J, George BD, et al. Development of an electrically stimulated neoanal sphincter. *Lancet.* 1991;338(8776):1166–9.
11. Sans A, Mege D, Sielezneck I. One-stage dynamic graciloplasty for anal incontinence. *J Visc Surg.* 2017;154(6):437–48.
12. Wexner SD, Baeten C, Bailey R, et al. Long-term efficacy of dynamic graciloplasty for fecal incontinence. *Dis Colon Rectum.* 2002;45(6):809–18.
13. Chapman AE, Geerdes B, Hewett P, et al. Systematic review of dynamic graciloplasty in the treatment of faecal incontinence. *Br J Surg.* 2002;89(2):138–53.
14. Christiansen J, Lorentzen M. Implantation of artificial sphincter for anal incontinence. *Lancet.* 1987;2(8553):244–5.
15. Lehur PA, Michot F, Glemain P, Mortreux JC. Le sphincter artificiel péri-anal AMS 800 dans le traitement de l'incontinence anale grave. Modalités de fonctionnement et technique d'implantation. *Lyon Chir.* 1996;92:251–5.
16. Lehur PA, McNevin S, Buntzen S, et al. Magnetic anal sphincter augmentation for the treatment of fecal incontinence: a preliminary report from a feasibility study. *Dis Colon Rectum.* 2010;53(12):1604–10.
17. O'Brien PE, Skinner S. Restoring control: the Acticon Neosphincter artificial bowel sphincter in the treatment of anal incontinence. *Dis Colon Rectum.* 2000;43(9):1213–6.
18. Christiansen J, Sparso B. Treatment of anal incontinence by an implantable prosthetic anal sphincter. *Ann Surg.* 1992;215(4):383–6.
19. Wong WD, Congliosi SM, Spencer MP, et al. The safety and efficacy of the artificial bowel sphincter for fecal incontinence: results from a multicenter cohort study. *Dis Colon Rectum.* 2002;45(9):1139–53.
20. Wong MTC, Meurette G, Wyart V, et al. The artificial bowel sphincter: a single institution experience over a decade. *Ann Surg.* 2011;254(6):951–6.
21. Darnis B, Faucheron JL, Damon H, Barth X. Technical and functional results of the artificial bowel sphincter for treatment of severe fecal incontinence: is there any benefit for the patient? *Dis Colon Rectum.* 2013;56(4):505–10.
22. Meurette G, La Torre M, Regenet N, et al. Value of sacral nerve stimulation in the treatment of severe fecal incontinence: a comparison to the artificial bowel sphincter. *Colorectal Dis.* 2009;11(6):631–5.
23. Bharucha AE, Croak AJ, Gebhart JB, et al. Comparison of rectoanal axial forces in health and functional defecatory disorders. *Am J Physiol Gastrointest Liver Physiol.* 2006;290(6):G1164–9.
24. Wong MTC, Meurette G, Stangherlin P, Lehur PA. The magnetic anal sphincter versus the artificial bowel sphincter: a comparison of 2 treatments for fecal incontinence. *Dis Colon Rectum.* 2011;54(7):773–9.
25. Malone PS, Ransley PG, Kiely EM. Preliminary report: the antegrade continence enema. *Lancet.* 1990;336(8725):1217–8.
26. Mitrofanoff P. Cystostomie continente trans-appendiculaire dans le traitement des vessies neurologiques. *Chir Pediatr.* 1980;21(4):297–305.
27. Christensen P, Kvitzau B, Krogh K, et al. Neurogenic colorectal dysfunction: use of new antegrade and retrograde colonic wash-out methods. *Spinal Cord.* 2000;38(4):255–61.
28. Kurzrock EA, Karpman E, Stone AR. Colonic tubes for the antegrade continence enema: comparison of surgical technique. *J Urol.* 2004;172(2):700–2.
29. Chéreau N, Lefèvre JH, Shields C, et al. Antegrade colonic enema for faecal incontinence in adults: long-term results of 75 patients. *Colorectal Dis.* 2011;13(8):e238–42.

30. Patel AS, Saratzis A, Arasaradnam R, Harmston C. Use of antegrade continence enema for the treatment of fecal incontinence and functional constipation in adults: a systematic review. *Dis Colon Rectum*. 2015;58(10):999–1013.
31. Bharucha AE, Rao SSC, Shin AS. Surgical interventions and the use of device-aided therapy for the treatment of fecal incontinence and defecatory disorders. *Clin Gastroenterol Hepatol*. 2017;15(12):1844–54.
32. Krouse RS, Grant M, Wendel CS, et al. A mixed-methods evaluation of health-related quality of life for male veterans with and without intestinal stomas. *Dis Colon Rectum*. 2007;50(12):2054–66.
33. Colquhoun P, Kaiser R Jr, Efron J, et al. Is the quality of life better in patients with colostomy than patients with fecal incontinence? *World J Surg*. 2006;30(10):1925–8.
34. Norton C, Burch J, Kamm MA. Patients' views of a colostomy for fecal incontinence. *Dis Colon Rectum*. 2005;48(5):1062–9.
35. Rao SSC. Current and emerging treatment options for fecal incontinence. *J Clin Gastroenterol*. 2014;48(9):752–64.
36. Nugent KP, Daniels P, Stewart B, et al. Quality of life in stoma patients. *Dis Colon Rectum*. 1999;42(12):1569–74.

Open Access This chapter is licensed under the terms of the Creative Commons Attribution-NonCommercial-NoDerivatives 4.0 International License (<http://creativecommons.org/licenses/by-nc-nd/4.0/>), which permits any noncommercial use, sharing, distribution and reproduction in any medium or format, as long as you give appropriate credit to the original author(s) and the source, provide a link to the Creative Commons license and indicate if you modified the licensed material. You do not have permission under this license to share adapted material derived from this chapter or parts of it.

The images or other third party material in this chapter are included in the chapter's Creative Commons license, unless indicated otherwise in a credit line to the material. If material is not included in the chapter's Creative Commons license and your intended use is not permitted by statutory regulation or exceeds the permitted use, you will need to obtain permission directly from the copyright holder.





Surgical Reconstruction of Traumatic Perineal and Sphincter Muscle Defects

12

Bruno Roche and Frédéric Ris

12.1 Introduction

Anal sphincter incontinence (ASI) results from a functional impairment of one or more of the anatomic components that allow normal continence: the internal anal sphincter (IAS), the external anal sphincter (EAS), the pelvic floor muscles, the anal cushions that ensure adequate rectal compliance, and the sensory-motor apparatus [1]. ASI is primarily managed conservatively but sphincter repair surgery is proposed for large defects of either the EAS, IAS, or both after conservative treatment failure [2, 3]. An underdiagnosed feature is levator ani (LA) avulsion, for which we recently proposed a surgical repair technique allowing restoration of LA and puborectalis anatomy [4].

12.2 Pathophysiology of Anal Sphincter Injuries

12.2.1 Mechanisms of Sphincter Injuries

In patients with ASI, there are at least two mechanisms leading to a modification in pelvic floor structure or function. First, the sphincters can be injured by perineal tearing, stretching and/or ischemia, most typically following an obstetrical trauma [5]. The episiotomy procedure is also often associated with anal incontinence [6]. The second mechanism involves the degeneration of the pelvic floor muscles, which appears with aging and particularly after the menopause as the pelvic floor structures are hormone-sensitive [5].

B. Roche (✉) · F. Ris
Proctology Unit, Service of Visceral Surgery, Department of Surgery,
University Hospitals of Geneva, Geneva, Switzerland
e-mail: bruno.roche@grangettes.ch; frederic.ris@hcuge.ch

12.2.2 Acute Anal Sphincter Injury and Healing

The classical clinical situation of acute anal sphincter and perineal injury is due to childbirth trauma, which still occurs in 10–35% of all vaginal deliveries and can extend to the IAS and sometimes even to the rectum [7].

Direct reconstruction of the muscle injury is the procedure of choice for traumatic tears and obstetrical laceration, as well as for iatrogenic sphincter section. We repair fresh lesions by end-to-end sphincter suture. For older defects, a secondary sphincter repair also gives good results as long as the LA muscle has a good function [8].

Assessment of perineal damage is clinical, and a reduction in anovulvar distance indicates anal sphincter damage. To be able to precisely describe the damage, define the sphincter involved (IAS, EAS, or both), and accurately evaluate the extent of the damage, we routinely use endoanal ultrasound. The most frequent symptom after sphincter injury is a degree of anal incontinence.

In the case of perineal asymmetry with anal deviation, LA avulsion has to be suspected. Ultrasound and magnetic resonance imaging are able to provide a precise assessment of the damage (Fig. 12.1). These lesions occur most of the time after

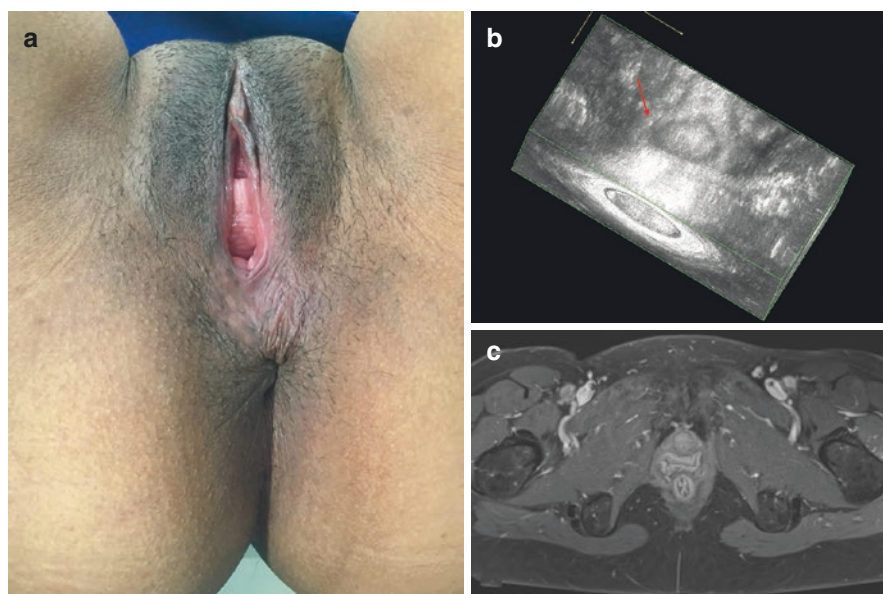


Fig. 12.1 Clinical examination and ultrasonographic assessment of a ruptured puborectalis muscle. (a) Absence of midline symmetry. In this patient, the anus is retracted and shifted to the left side, whereas the puborectalis muscle rupture is located on the right side. (b) 3D endoanal ultrasound image, with coronal antero-posterior (A-P) view of the same patient, demonstrating puborectalis muscle defect (*thin white arrow*) on the right and a normal puborectalis muscle on the left (*bold white arrow*). (c) MRI image of right levator ani and puborectalis disruption

Table 12.1 Reported symptoms after levator ani avulsion

Reported symptoms
Anal incontinence
– gas
– liquid stool
– hard stool
Urinary incontinence
Dyschezia
Digital maneuver
Vaginal gas (colpophony)
Dyspareunia
Loss of sensation during intercourse
Pain at the site of the levator ani tear

instrumental deliveries. The symptoms caused by these injuries are listed in Table 12.1 [4].

12.3 Anal Sphincter and Levator Ani Repair

12.3.1 General Considerations for Surgery

We position the patient in a lithotomy position. The patient receives a single shot of cephalosporin and metronidazole antibiotic prophylaxis. No bowel preparation is necessary, and no stoma is performed. To prevent postoperative pain, we routinely use a perineal bloc with a long-lasting anesthetic agent: typically, 20 mL of chirocaine 0.5% (AbbVie Inc., Lake Bluff, IL, USA) [9]. A Lone Star retractor (CooperSurgical Inc., Trumbull, CT, USA) is used. Infiltration of the surgical site is performed using lidocaine 1% solution with adrenalin (Sintetica SA Pharmaceuticals, Couvet, Switzerland).

In acute traumatic cases, when sphincter tears are associated with fracture of the pelvis and/or with laceration or perforation of the rectum, a protective colostomy is performed [10]. This is never the case for obstetrical damage.

12.3.2 Surgical Technique for Sphincter Repair

This procedure (Fig. 12.2) begins with a curvilinear incision parallel to the external sphincter in the anovolvar region, extending at least 180–200°. The sphincters are dissected with a wide margin. We do not separate the internal from the external sphincter. An accurate dissection of the muscle is done protecting innervation and vascularization at 3 and 9 o'clock. We tend not to use electrocoagulation; thanks to the ischemic surgical field, it is easy to differentiate the muscle from the different anatomical structures and not to create a false plane. We carry on with the dissection for the full length of the external sphincter up to the LA muscle. An overlapping

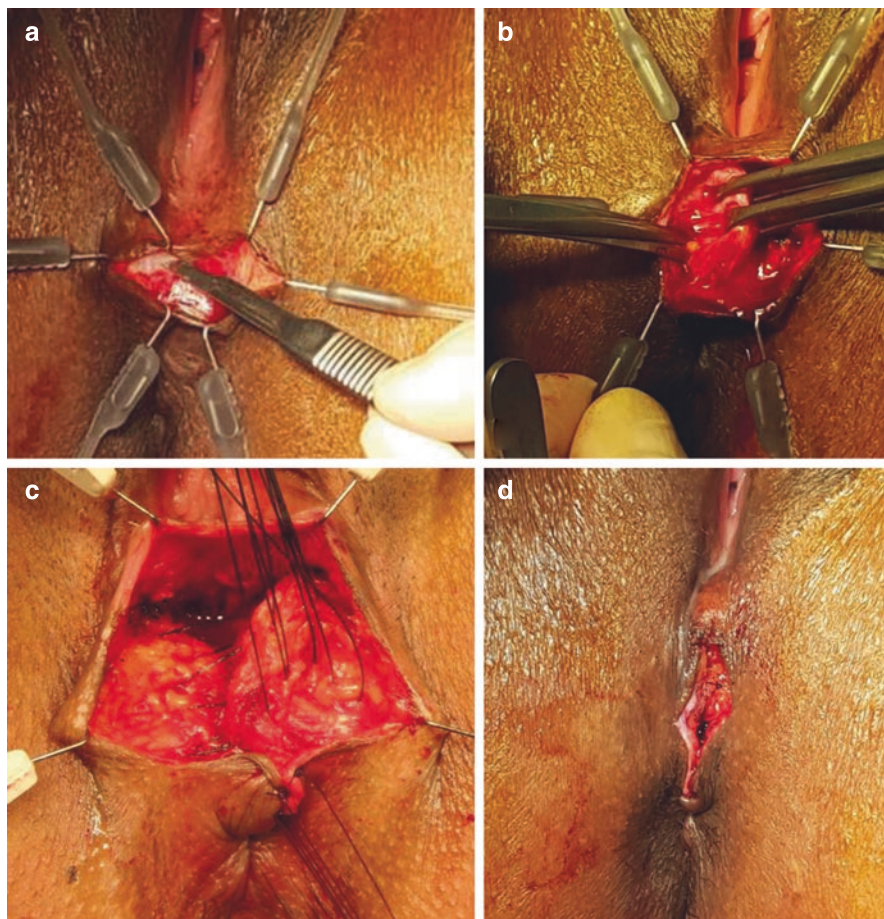


Fig. 12.2 Surgical technique for sphincter repair. (a) Curvilinear incision parallel to the external sphincter. (b) Dissection of the sphincters “en bloc” protecting innervation and vascularization at 3 and 9 o’clock. (c) Overlapping suture of the muscle with a 2/0 long-lasting resorbable suture. (d) Vertical closure of the perineal skin

suture of the muscle with a 2/0 long-lasting resorbable suture is then performed. The length of the anal canal is restored and the perineal skin can be closed vertically [11].

12.3.3 Surgical Technique for Levator Ani Repair

The procedure (Fig. 12.3) starts with a semi-circumferential incision on the posterior vaginal wall. We place the retractor and dissect the rectovaginal septum up to the top of the vaginal vault.

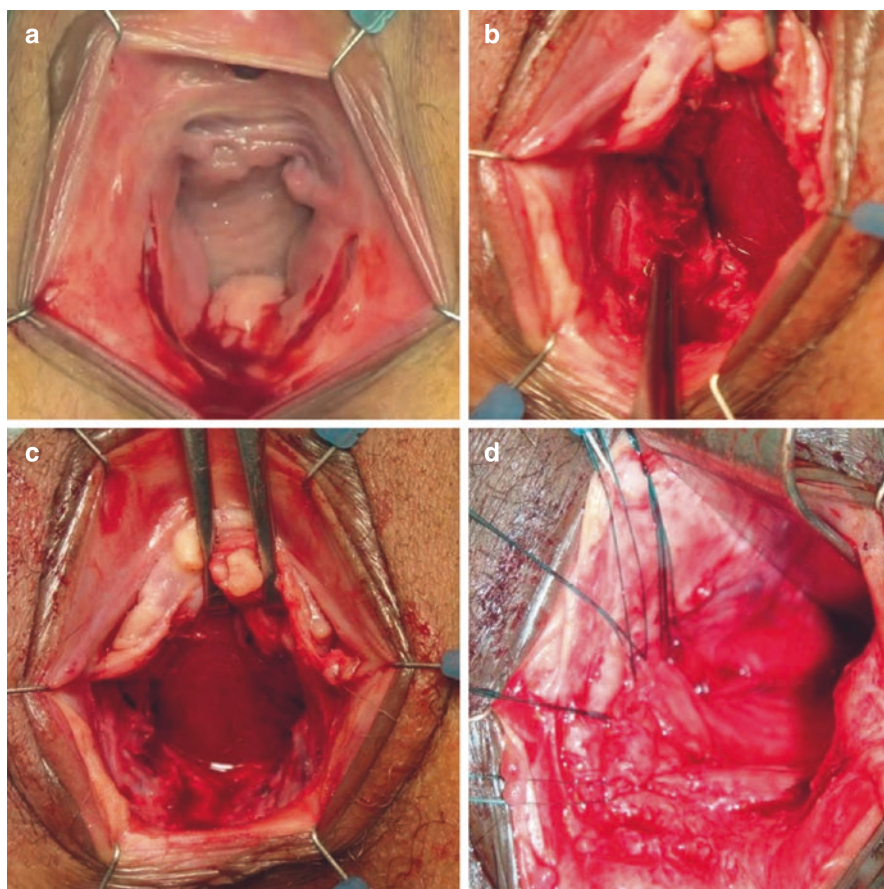


Fig. 12.3 Surgical technique for levator ani repair. (a) Semi-circumferential incision on the posterior vaginal wall. (b) Dissection of the rectovaginal septum up to the top of the vaginal vault. (c) Identification of the damaged levator ani on the right side. (d) Fixation of the muscle by U 2/0 monofilament resorbable sutures on the inferior part of the pubic bone

The damaged LA is identified by the presence of fat from the ischiorectal fossa replacing the muscle. The muscle can be partially or totally detached. When totally torn, the muscle is retracted under the rectum. A gentle liberation of the lateral part of the rectum is started from the ischiatic spine laterally to the upper part of the anal sphincter allowing visualization and freeing of the puborectal muscle. The muscle is then reinserted with two to five 2-0 Maxon GU46 U-sutures (Covidien, Dublin, Ireland). We fix the muscle on the inferior part of the pubic bone by palpation of the bone itself. Once the hemostasis is completed, we close the vaginal mucosa with a resorbable monofilament running suture. Finally, we insert a bladder catheter and a swab with estrogenic cream into the vagina for 24 h [12].

12.3.4 Postoperative Management

Patients receive a 125 mL enema on postoperative day 2. We add a myorelaxant (tizanidine 4 mg per day) for postoperative pain management and a nonsteroidal anti-inflammatory drug. Stool regulation is often prescribed after surgery. The patients clean the wound four to six times per day with only water (shower) [12].

12.3.5 Postoperative Complications

We use the Clavien-Dindo classification to define postoperative complications [13]. The postoperative complications are usually minor. In sphincter repair, the main complication is skin dehiscence, which occurs in 28.6% of the patients and requires close follow-up to prevent infection, but usually closes secondarily later on.

In LA repair, we found a 13.5% rate of complications:

- postoperative pain after 48 h (5.8%)
- hematoma with surgical drainage (1.9%)
- urinary retention (3.9%)
- perineal abscess (1.9%).

12.4 Functional Results of Sphincter and Levator Ani Repair

12.4.1 Early Postoperative Results of Sphincteroplasty

In most series, short-term outcomes with anterior sphincteroplasty of the EAS are excellent or good in terms of continence, with a 71% to 86% improvement [14–18]. The results after obstetrical injuries seem to be better than after traumatic (non-obstetrical injuries) or postsurgical lesions [10, 19]. This is probably due to the fact that the mechanism of the trauma leads to an interruption of the normal connections between the IAS and EAS, destroys part of the musculature, and induces nerve damage.

12.4.2 Prognostic Factors in Sphincter Repair Success

The predictors of the outcomes following anal sphincteroplasty are not well documented. Some studies have reported that age and innervation could have a negative impact on sphincter repair results.

12.4.2.1 Age

In contrast to some published studies, we did not observe any difference in the postoperative results between young and older patients (<62 and >62 years). Both groups showed the same improvement in their postoperative scores. The Cleveland

clinic group reported similar results when comparing patients under and over 60 years old in terms of:

- Fecal Incontinence Quality of Life Scale
- Fecal Incontinence Severity Index Score
- Cleveland Global Quality of Life Scale
- Patient satisfaction questionnaire.

They found comparable long-term Fecal Incontinence Severity Index Score and Fecal Incontinence Quality of Life Scale scores following overlapping sphincter repair. This suggests that age is not a predictor of outcome for overlapping sphincter repair, and that this procedure is feasible in young and older patients [20–22].

12.4.2.2 Pudendal Nerve Integrity

In a review study of 100 sphincteroplasties, Gilliland et al. [23] demonstrate that bilateral normal pudendal nerve terminal motor latencies are the only predictive factor of long-term success after overlapping sphincteroplasty.

The pudendal motor latency test has been abandoned. In a recent study, we were able to show that contraction of the puborectal sling measured preoperatively by ultrasound is a predictor of successful anal continence after sphincter repair [8].

This easy and noninvasive examination is a reliable preoperative prognostic test of the results of sphincter repair. Moreover, this ultrasonographic evaluation is accurate and reproducible [24].

12.4.3 Late Results of Sphincter Repair

Several authors have noticed a deterioration of the results with time. Data from St. Mark's hospital demonstrate that at 5 years only about 50% of the patients report sustained improvement [25].

Degradation of the results is due to the scar, to rupture of the reconstruction in some cases, to the denervation and devascularization linked to surgery, or to aging. Interestingly, it has been observed that the deterioration of functional clinical results over time does not impact on the patients' quality of life [26, 27].

12.4.4 What Is the Best Option for Failed Sphincter Repair?

In 2014, Hong et al. analyzed the best option to treat patients with a failed sphincteroplasty. They compared repeat sphincteroplasty (RS) with artificial bowel sphincter (ABS) and sacral nerve stimulation (SNS). They found that RS, ABS and SNS are associated with similar improvements in continence after failed sphincteroplasty. They concluded that due to increased complication and reoperation rates with ABS and SNS, RS may be the first step in managing these patients [28].

Table 12.2 Results of puborectalis repairs

Symptoms	Preoperative	Postoperative		
		Complete resolution	Partial improvement	No improvement
Dyschezia	53.9%	64.3%	35.7%	0
Colpophony	32.7%	47.1%	41.2%	11.7%
Dyspareunia	38.5%	45.0%	55.0%	0
Pain at tear site	46.2%	0	50.0%	50.0%

12.4.5 Results of Levator Ani Repair

In our study, we assessed bowel function preoperatively and at 6 months after surgery using the Wexner score. In terms of incontinence, the Wexner score decreased from 4.5 ± 6.78 before surgery to 0 ± 3.30 ($p < 0.0001$) after surgery.

At 6 months, we assessed the results on a visual analog scale. The results were classified into three categories: resolved, improved by 50%, unchanged. The results are reported in Table 12.2.

The majority of patients complaining of dyschezia, colpophony, or dyspareunia resolved or improved their symptoms after surgery. All patients with digital evacuation resolved this problem. Unfortunately, pain improved in only half of the patients. Interestingly, patients with urinary incontinence improved their condition after LA repair in 76% of cases. The remaining patients (24%) underwent surgical intervention (transobturator tape or tension-free vaginal tape) to restore their condition. Finally, only one patient reported persistence of urinary incontinence. We observed postoperative improvement of perineal symmetry in squeezing and resting positions in all cases. Finally, preoperatively, 65.4% of the patients reported complete absence of sexual activity due to embarrassment associated with the symptoms and, postoperatively, 91.18% reported resuming sexual intercourse after LA muscle repair [4].

12.5 Future in Sphincter and Perineum Repair

We have demonstrated that sphincter repair gives good results in the short term. Although we do not have data on LA repair, we expect the results to be similar.

The future lies probably in the use of cell therapy for anal sphincter repair. Preclinical and clinical studies have demonstrated the safety of multipotent cell use for ASI. Published controlled clinical studies with placebo injection have shown promising results [29–31]. These controlled studies had relatively short follow-up periods considering that ASI is a condition that evolves over a long time.

The ideal therapy for ASI should be cost-effective with a long-lasting effect. The routine use of cell therapy appears to be highly costly [32]. Trébol et al. estimated the maximal production costs in Spain to be 7400 USD for 40 million autologous fat-derived cells or 8500 € for 100 million allogeneic fat-derived cells [33]. In our hospital, the cost for a sphincteroplasty, with a typical length of stay of two days, is 5000 USD.

Recently, Gräs et al. proposed a cost-effective alternative to cell transplantation for anal sphincter regeneration. The authors discussed the possibility to inject fragmented muscle fibers, instead of expanded cells, into injured anal sphincters [34]. The exact underlying mechanism remains poorly understood, and research is still required to understand which factors and conditions lead to cell engraftment, differentiation and eventually tissue regeneration [35, 36]. A better understanding of the natural history of sphincter lesion/repair and sphincter healing is needed in order to select appropriate cell preparations and techniques.

Some groups reported a different approach, considering the use of cell therapy as an add-on to sphincter repair, either directly after injury to simulate a primary repair of an acute obstetrical tear or at a distance [37–44]. In the near future, we will have to determine the best use of stem cells and progenitor cells for ASI: as a substitute for surgery or as an adjunct to surgery.

12.6 Conclusions

Sphincteroplasty and LA repair are safe procedures to repair sphincter and perineal tears resulting from trauma, surgery or obstetrical damage. Success depends on precise preoperative evaluation and meticulous surgery.

Sphincteroplasty gives good results in continence for stool maintained for at least 3 years. There is no age limit for sphincter or perineal repair. The best prognostic factor for successful repair is a preserved puborectalis muscle contraction with an adequate translation. If we observe a clinical deterioration in anal continence in the long term, quality of life is not affected. Symptoms are corrected by surgery in two-thirds of patients with LA defects. Both procedures are well tolerated. As we do not use foreign material (synthetic meshes, for example), we minimize the risk of infection, erosion or other complications, and this reduces the overall cost of the surgery.

Stem cells and progenitor cells appear as a promising therapy in muscle defects. In the near future, we will have to determine the best use of stem cells and progenitor cells for ASI: as a substitute for surgery or as an adjunct to surgery.

In memory of our master and mentor Professor Marc Claude Marti 1941–2001.

References

1. Williams KS, Shalom DF, Winkler HA. Faecal incontinence: a narrative review of clinic-based management for the general gynaecologist. *J Obstet Gynaecol.* 2018;38(1):1–9.
2. Nandivada P, Nagle D. Surgical therapies for fecal incontinence. *Curr Opin Gastroenterol.* 2014;30(1):69–74.
3. Wexner SD, Bleier J. Current surgical strategies to treat fecal incontinence. *Expert Rev Gastroenterol Hepatol.* 2015;9(12):1577–89.
4. Alketbi MSG, Meyer J, Robert-Yap J, et al. Levator ani and puborectalis muscle rupture: diagnosis and repair for perineal instability. *Tech Coloproctol.* 2021;25(8):923–33.

5. Rao SSC. Pathophysiology of adult fecal incontinence. *Gastroenterology*. 2004;126(1 Suppl 1):S14–22.
6. LaCross A, Groff M, Smaldone A. Obstetric anal sphincter injury and anal incontinence following vaginal birth: a systematic review and meta-analysis. *J Midwifery Womens Health*. 2015;60(1):37–47.
7. Meister MR, Rosenbloom JI, Lowder JL, Cahill AG. Techniques for repair of obstetric anal sphincter injuries. *Obstet Gynecol Surv*. 2018;73(1):33–9.
8. Zufferey G, Perneger T, Robert-Yap J, et al. Measure of the voluntary contraction of the puborectal sling as a predictor of successful sphincter repair in the treatment of anal incontinence. *Dis Colon Rectum*. 2009;52(4):704–10.
9. Mölle B, Ommer A, Lange J, Girona J. *Chirurgische proktologie*. New York: Springer; 2018.
10. Roche B, Michel JW, Deleaval JP, et al. Lésions traumatiques de l'anorectum. *Swiss Surg*. 1998;4(5):249–52.
11. Markaryan DR, Tsarkov PV, Tulina IA, et al. Modern technique for sphincter repair after obstetric perineal trauma—a video vignette. *Colorectal Dis*. 2020;22(10):1456–7.
12. Ris F, Alketbi M, Scarpa CR, et al. Levator ani repair by transvaginal approach. *Tech Coloproctol*. 2019;23(2):167–9.
13. Clavien PA, Barkun J, de Oliveira ML, et al. The Clavien-Dindo classification of surgical complications: five-year experience. *Ann Surg*. 2009;250(2):187–96.
14. Engel AF, Kamm MA, Sultan AH, et al. Anterior anal sphincter repair in patients with obstetric trauma. *Br J Surg*. 1994;81(8):1231–4.
15. Young CJ, Mathur MN, Eyers AA, Solomon MJ. Successful overlapping anal sphincter repair: relationship to patient age, neuropathy, and colostomy formation. *Dis Colon Rectum*. 1998;41(3):344–9.
16. Zorcolo L, Covotta L, Bartolo DCC. Outcome of anterior sphincter repair for obstetric injury: comparison of early and late results. *Dis Colon Rectum*. 2005;48(3):524–31.
17. Barisic GI, Krivokapic ZV, Markovic VA, Popovic MA. Outcome of overlapping anal sphincter repair after 3 months and after a mean of 80 months. *Int J Colorectal Dis*. 2006;21(1):52–6.
18. Johnson E, Carlsen E, Steen TB, et al. Short- and long-term results of secondary anterior sphincteroplasty in 33 patients with obstetric injury. *Acta Obstet Gynecol Scand*. 2010;89(11):1466–72.
19. Sangalli MR, Marti MC. Results of sphincter repair in postobstetric fecal incontinence. *J Am Coll Surg*. 1994;179(5):583–6.
20. Zutshi M, Tracey TH, Bast J, et al. Ten-year outcome after anal sphincter repair for fecal incontinence. *Dis Colon Rectum*. 2009;52(6):1089–94.
21. El-Gazzaz G, Zutshi M, Hannaway C, Gurland B, Hull T. Overlapping sphincter repair: does age matter? *Dis Colon Rectum*. 2012;55(3):256–61.
22. Simmang C, Birnbaum EH, Kodner IJ, et al. Anal sphincter reconstruction in the elderly: does advancing age affect outcome? *Dis Colon Rectum*. 1994;37(11):1065–9.
23. Gilliland R, Altomare DF, Moreira H, et al. Pudendal neuropathy is predictive of failure following anterior overlapping sphincteroplasty. *Dis Colon Rectum*. 1998;41(12):1516–22.
24. Zufferey G, Perneger T, Robert-Yap J, et al. Accuracy of measurement of puborectal contraction by perineal ultrasound in patients with faecal incontinence. *Colorectal Dis*. 2011;13(8):e234–7.
25. Malouf AJ, Norton CS, Engel AF, et al. Long-term results of overlapping anterior anal-sphincter repair for obstetric trauma. *Lancet*. 2000;355(9200):260–5.
26. Glasgow SC, Lowry AC. Long-term outcomes of anal sphincter repair for fecal incontinence: a systematic review. *Dis Colon Rectum*. 2012;55(4):482–90.
27. Pla-Mart V, Martín-Arévalo J, Marti-Fernandez R, et al. Long-term evolution of continence and quality of life after sphincteroplasty for obstetric fecal incontinence. *Ann Coloproctol*. 2020;38(1):13–9.
28. Hong KD, da Silva G, Wexner SD. What is the best option for failed sphincter repair? *Colorectal Dis*. 2014;16(4):298–303.

29. Boyer O, Bridoux V, Giverne C, et al. Autologous myoblasts for the treatment of fecal incontinence: results of a phase 2 randomized placebo-controlled study (MIAS). *Ann Surg.* 2018;267(3):443–50.
30. Sarveazad A, Newstead GL, Mirzaei R, et al. A new method for treating fecal incontinence by implanting stem cells derived from human adipose tissue: preliminary findings of a randomized double-blind clinical trial. *Stem Cell Res Ther.* 2017;8(1):40. <https://doi.org/10.1186/s13287-017-0489-2>.
31. de la Portilla F, Guerrero JL, Maestre MV, et al. Treatment of fecal incontinence with autologous expanded mesenchymal stem cells: results of a pilot study. *Colorectal Dis.* 2021;23(3):698–709.
32. Lipsitz YY, Milligan WD, Fitzpatrick I, et al. A roadmap for cost-of-goods planning to guide economic production of cell therapy products. *Cytotherapy.* 2017;19(12):1383–91.
33. Trébol J, Carabias-Orgaz A, García-Arranz M, García-Olmo D. Stem cell therapy for faecal incontinence: current state and future perspectives. *World J Stem Cells.* 2018;10(7):82–105.
34. Gräs S, Tolstrup CK, Lose G. Regenerative medicine provides alternative strategies for the treatment of anal incontinence. *Int Urogynecol J.* 2017;28(3):341–50.
35. Balaphas A, Schiltz B, Liot E, et al. What is the role of stem cell therapy in the treatment of anal incontinence? *Colorectal Dis.* 2021;23(2):551–2.
36. de la Portilla F. Reply to Balaphas et al. *Colorectal Dis.* 2021;23(4):1002–3.
37. Lorenzi B, Pessina F, Lorenzoni P, et al. Treatment of experimental injury of anal sphincters with primary surgical repair and injection of bone marrow-derived mesenchymal stem cells. *Dis Colon Rectum.* 2008;51(4):411–20.
38. White AB, Keller PW, Acevedo JF, et al. Effect of myogenic stem cells on contractile properties of the repaired and unrepaired transected external anal sphincter in an animal model. *Obstet Gynecol.* 2010;115(4):815–23.
39. Pathi SD, Acevedo JF, Keller PW, et al. Recovery of the injured external anal sphincter after injection of local or intravenous mesenchymal stem cells. *Obstet Gynecol.* 2012;119(1):134–44.
40. Jacobs SA, Lane FL, Pham QA, et al. Safety assessment of myogenic stem cell transplantation and resulting tumor formation. *Female Pelvic Med Reconstr Surg.* 2013;19(6):362–8.
41. Lane FL, Jacobs SA, Craig JB, et al. In vivo recovery of the injured anal sphincter after repair and injection of myogenic stem cells: an experimental model. *Dis Colon Rectum.* 2013;56(11):1290–7.
42. Fitzwater JL, Grande KB, Sailors JL, et al. Effect of myogenic stem cells on the integrity and histomorphology of repaired transected external anal sphincter. *Int Urogynecol J.* 2015;26(2):251–6.
43. Mazzanti B, Lorenzi B, Borghini A, et al. Local injection of bone marrow progenitor cells for the treatment of anal sphincter injury: in-vitro expanded versus minimally-manipulated cells. *Stem Cell Res Ther.* 2016;7(1):85.
44. Kuismanen K, Juntunen M, Narra Girish N, et al. Functional outcome of human adipose stem cell injections in rat anal sphincter acute injury model. *Stem Cells Transl Med.* 2018;7(3):295–304.

Open Access This chapter is licensed under the terms of the Creative Commons Attribution-NonCommercial-NoDerivatives 4.0 International License (<http://creativecommons.org/licenses/by-nc-nd/4.0/>), which permits any noncommercial use, sharing, distribution and reproduction in any medium or format, as long as you give appropriate credit to the original author(s) and the source, provide a link to the Creative Commons license and indicate if you modified the licensed material. You do not have permission under this license to share adapted material derived from this chapter or parts of it.

The images or other third party material in this chapter are included in the chapter's Creative Commons license, unless indicated otherwise in a credit line to the material. If material is not included in the chapter's Creative Commons license and your intended use is not permitted by statutory regulation or exceeds the permitted use, you will need to obtain permission directly from the copyright holder.





Injectable Bulking Agents and SECCA Radiofrequency Treatment

13

Carlo Ratto

13.1 Injectable Bulking Agents

13.1.1 Background

Injectable bulking agents, already used with variable success rates for urinary incontinence (UI) in an outpatient setting without anesthesia and with minimal morbidity [1], have been adopted in the treatment of fecal incontinence (FI). Ideally, the injectable bulking agent should be biocompatible, non-allergenic, non-immunogenic, non-carcinogenic, easy to inject, and should not migrate within the tissues. Technically, the agents are diluted in a carrier: the particles of this solution should have a diameter of no more than 80 μm to avoid a difficult injection. However, agents with an excessively small dimension are at a higher risk for migration from the injection site. This less invasive approach seemed quite attractive, and a variety of agents have been proposed: however, the use of injectables has progressively reduced in popularity, mostly due to inconsistent results and loss of efficacy in the medium-long term.

13.1.2 Early Applications

The first use of injectable bulking agents was due to Shafik [2] who treated, in 1993, 11 patients with injections of polytetrafluoroethylene paste into the anal submucosa. He reported a complete cure in 64% and partial improvement in 36% of them at 18–24 months of follow-up. Thereafter, he injected autologous fat in 14 patients obtaining a 100% success rate at 2–3 months [3]. No complications were observed

C. Ratto (✉)

Proctology Unit, Fondazione Policlinico Universitario A. Gemelli,
Università Cattolica S. Cuore, Rome, Italy
e-mail: carloratto@tiscali.it

© The Author(s) 2023

L. Docimo, L. Bruscianno (eds.), *Anal Incontinence*, Updates in Surgery,
https://doi.org/10.1007/978-3-031-08392-1_13

115

using either agent. However, an analogous approach attempted to treat UI resulted in death from pulmonary fat embolism [4], and autologous fat is currently not used for FI.

Although used in the past, other injectables—including bovine dermal collagen, microballoons, and polyacrylamide hydrogel (Bulkamid)—have not achieved widespread use. Glutaraldehyde cross-linked synthetic bovine dermal collagen (Contigen) was first attempted in 17 patients with FI [5]; in 65% of them a significant improvement of FI was reported at 8-month follow-up. Later, in a larger series of 73 patients [6] receiving three collagen injections just proximally to the anal canal, an improvement was reported in 63% of cases and, in particular, in 49 patients with idiopathic incontinence. However, the allergenic potential and the risk of degradation over time were the major disadvantages of synthetic collagen. Cross-linked silicone microballoons were injected in six patients, obtaining a reduction of FI severity scores [7]. However, this material presented safety problems (sterilization) and was discontinued. A hydrogel of polyvinylpyrrolidone (Bioplastique) was used in pilot studies [8] on ten patients with passive FI: only two patients maintained the improvement at 6 months and, moreover, also anal pain and ulceration were recorded. Despite that, this product was renamed PTQ implant and used in Europe. In a large series of 82 patients with severe FI [9], patients were randomized to receive PTQ implants either with or without endoanal ultrasound (EAUS) guidance for injection. In general, the treatment produced a significant improvement in the patients' FI severity score and quality of life (QoL), significantly better when EAUS was used. Further series using PTQ [10–14] reported significant reduction of the FI severity scores.

The only report of long-term (5-year) results for injectable agents concerned the use of Bioplastique [15] but in only six patients: the median St. Mark's incontinence score remained unchanged. One patient had undergone a colostomy, four of the five remaining patients had subjective improvement of FI and better QoL scores.

Two bulking agents—cross-linked porcine dermal collagen (Permacol) and polyacrylamide hydrogel (Bulkamid)—were studied in a pilot study [16] including only ten patients with passive FI to liquid or solid stool, who were prospectively randomized to receive either of the two injectables. The St. Mark's severity score decreased at 6 months only in the Bulkamid group.

Internal anal sphincter injection of Permacol was used in a nonrandomized retrospective study including 110 patients, 100 of whom followed up for a minimum of 36 months [17]. The Wexner score improved from a median of 14 (range 5–14) to a median of 8 (range 5–14); however, this difference was not statistically significant. A subjective improvement was reported by 68% of patients at 3 years but with further deterioration with time; then, 38% of patients had a second injection and 15% a third one.

Variable results were observed after injection of several other agents. In a randomized controlled trial, 44 patients were treated with injections of polydimethylsiloxane elastomer silicone or saline into the intersphincteric space [18]. There was no difference in success rates, but more discomfort and more frequent adverse effects in the silicone injection group, which was then not recommended.

In one study, calcium hydroxylapatite ceramic microspheres (Coaptite) was injected in ten patients: the mean Fecal Incontinence Scoring System (FISS) score decreased from 85.6 to 28 at 12 months ($p = 0.008$) and three subscales of the Fecal Incontinence Quality of Life (FIQL) scale improved ($p < 0.05$); at anorectal manometry, a better resting pressure (40–47 mmHg, $p = 0.018$) was recorded. Although no complications were observed, a leakage of product from the injection site was reported, requiring another injection [19].

Ethylene vinyl alcohol was injected in 21 patients: at 12-month follow-up, the mean Fecal Incontinence Severity Index score decreased from 32.8 to 22 and the Wexner score from 11 to 6.9, and two subscales of the FIQL scale improved significantly. Some increase in anal canal length and resting pressures was recorded at anorectal manometry [20].

Pyrolytic carbon-coated zirconium oxide beads (Durasphere), a non-reactive and non-biodegradable bulking agent, have been injected in FI patients. Unfortunately, these beads need a large bore needle for injection and can migrate within the tissues. They were first used in 18 patients with an internal anal sphincter defect and injected in the submucosal plane at the site of the sphincter defect in one to four sites [21]. After 12 months, the Wexner score and patients' satisfaction score were both significantly improved; in 15 patients there was also an improvement in their incontinence episodes.

In a larger study [22], Durasphere injections were given to 33 patients with minor or intermediate severity FI, who were followed up for a mean period of 21 months. Both the Wexner and American Medical System scores significantly decreased but without relevant changes in the patients' QoL. An improvement of the Wexner score and coping and embarrassment subscales of the FIQL was observed in 11 patients at 6-month follow-up [23]. More recently, Durasphere was used in 23 FI patients, producing a decrease in the Wexner score and an increase in FIQL score, 12 months after injection [24].

Comparison in terms of safety and efficacy between PTQ and Durasphere was attempted in two trials [25, 26]. In the first study [25], 40 patients with FI were randomized: PTQ produced a greater reduction in the Wexner score up to 12 months, no complications, and significant improvements in FIQL and SF-12 scores. The second trial [26] was conducted in Australia in a total of 35 patients who were randomized; however, the trial was closed early due to the removal of PTQ from the Australian Pharmaceutical Benefits scheme. Both Wexner and SF-36 scores did not improve significantly at 12 months.

13.1.3 Recent Applications

More recently, the non-animal stabilized hyaluronic acid/dextranomer (NASHA/Dx) copolymers (Zuidex, Solesta) have been proposed. They consist of dextranomer microspheres suspended in non-animal stabilized hyaluronic acid. In a 2:1 randomized double-blind sham-controlled study including 206 patients, either NASHA Dx or placebo injection was used [27]. In the NASHA Dx group, a 50% or greater

reduction of FI episodes was observed in 52% of patients versus 31% of those randomized to the sham treatment ($p = 0.009$). However, the change in Wexner score due to the two treatments did not differ. Only the coping and behavior subscales of the FIQL were significantly improved in the NASHA Dx group compared to placebo. In both groups, the retreatment rate was high (82% vs. 87%, respectively, in the NASHA Dx patients and controls). Moreover, more adverse events were recorded in the NASHA Dx group.

In another study on 21 patients [28], NASHA Dx injections allowed a significant decrease in incontinence episodes in 56% and 61% of patients at 3 and 22 months of follow-up, respectively. Also the Wexner score decreased and the FIQL score improved but not significantly. In a study on 115 patients subjected to four NASHA Dx injections [29], 83 were followed up for 24 months: 62.7% of them had a significant reduction of FI episodes, a significant increase in the number of incontinence-free days, and a significant reduction in the Wexner and FIQL scores. In another trial [30], 34 patients had NASHA Dx injections; at 24-month follow-up, 26 patients reported a sustained improvement of FI, based on a reduction of the median number of incontinence episodes and Miller score. A significant improvement in QoL at 24 months was demonstrated only in patients with more than a 75% improvement in the number of incontinence episodes. In 2014 the NASHA Dx Study Group reported data from 136 patients at 3-year follow-up [31]. At least a 50% reduction in number of FI episodes was reported by 52% of patients at 6 months, 57% at 12 months, and 52% at 36 months. Also, significant decreases in the mean Wexner score and FIQL scores were recorded at 36-month follow-up.

Finally, the recent use of polyacrylate-polyalcohol [32] would need further confirmation: although injected in a non-consecutive series of 58 patients, only 34 and 22 patients were available at 6- and 36-month follow-up, respectively, and an improvement of at least 50% on the Wexner score was achieved in 60.4% of them.

13.1.4 Conclusions

Studies on injectable bulking agents seem unable to address minimal criteria of sufficient clinical efficacy. Moreover, most frequently they have been planned and carried out on very small patient series followed up for a short time; only very few randomized studies are available. Two systematic reviews [33, 34] and a Cochrane review [35] could not establish evidence to support the efficacy of any of these bulking agents.

Consequently, although the injection of bulking agents would appear very attractive for its methodological simplicity, different technical solutions are desirable in order to maintain a stable position of the agents at the injection site. This is especially important considering that the only mechanism of action (i.e., the bulking effect inside the anal canal) is dependent on the maintenance of the agents in place. It is also fundamental that no degradation should occur and that neither side effects nor severe complications should affect the patients.

13.2 SECCA Procedure

A temperature-controlled radiofrequency procedure (commercially known as SECCA) was first used to treat gastroesophageal reflux disease. Takahashi et al. [36] first used this approach in ten female FI patients observing a significant decrease in the Wexner score at 12-month follow-up. Later, this benefit was confirmed at 2-year follow-up [37], and then at 5-year follow-up in a larger group of 19 patients [38]. A larger multicenter study including 50 patients documented a less significant improvement on the Wexner score [39]. Quite controversial results have been reported in a few other studies with a very limited number of enrolled patients [40–42].

Much less promising were the results of Lam et al.'s study on 31 patients which showed only 6% of them maintaining a 50% reduction in Vaizey score at 3-year follow-up [43]. A very low long-term success rate (22%) of SECCA therapy was also observed by Abbas et al.; at 40-month follow-up, 52% of patients needed additional treatment of FI [44]. Finally, a review of all published studies included 220 patients [45]: the authors concluded that SECCA therapy is associated with moderate clinical benefit. The mechanism of action is thought to be related to scarring or fibrosis of the anal canal which progressively declines over time [46].

References

1. Kotb AF, Campeau L, Corcos J. Urethral bulking agents: techniques and outcomes. *Curr Urol Rep.* 2009;10(5):396–400.
2. Shafik A. Polytetrafluoroethylene injection for the treatment of partial fecal incontinence. *Int Surg.* 1993;78(2):159–61.
3. Shafik A. Perianal injection of autologous fat for treatment of sphincteric incontinence. *Dis Colon Rectum.* 1995;38(6):583–7.
4. Lee PE, Kung RC, Drutz HP. Periurethral autologous fat injection as treatment for female stress urinary incontinence: a randomized double-blind controlled trial. *J Urol.* 2001;165(1):153–8.
5. Kumar D, Benson MJ, Bland JE. Glutaraldehyde cross-linked collagen in the treatment of faecal incontinence. *Br J Surg.* 1998;85(7):978–9.
6. Stojkovic SG, Lim M, Burke D, et al. Intra-anal collagen injection for the treatment of faecal incontinence. *Br J Surg.* 2006;93(12):1514–8.
7. Feretis C, Benakis P, Dailianas A, et al. Implantation of microballoons in the management of fecal incontinence. *Dis Colon Rectum.* 2001;44(11):1605–9.
8. Malouf AJ, Vaizey CJ, Norton CS, Kamm MA. Internal anal sphincter augmentation for fecal incontinence using injectable silicone biomaterial. *Dis Colon Rectum.* 2001;44(4):595–600.
9. Tjandra JJ, Lim JF, Hiscock R, Rajendra P. Injectable silicone biomaterial for fecal incontinence caused by internal anal sphincter dysfunction is effective. *Dis Colon Rectum.* 2004;47(12):2138–46.
10. de la Portilla F, Fernández A, León E, et al. Evaluation of the use of PTQ implants for the treatment of incontinent patients due to internal anal sphincter dysfunction. *Colorectal Dis.* 2008;10(1):89–94.
11. Soerensen MM, Lundby L, Buntzen S, Laurberg S. Intersphincteric injected silicone biomaterial implants: a treatment for faecal incontinence. *Colorectal Dis.* 2009;11(1):73–6.
12. Bartlett L, Ho YH. PTQ anal implants for the treatment of faecal incontinence. *Br J Surg.* 2009;96(12):1468–75.

13. Oliveira LC, Jorge JMN, Yussuf S, et al. Anal incontinence improvement after silicone injection may be related to restoration of sphincter asymmetry. *Surg Innov.* 2009;16(2):155–61.
14. de la Portilla F, Vega J, Rada R, et al. Evaluation by three-dimensional anal endosonography of injectable silicone biomaterial (PTQ) implants to treat fecal incontinence: long-term localization and relation with the deterioration of the continence. *Tech Coloproctol.* 2009;13(3):195–9.
15. Maeda Y, Vaizey CJ, Kamm MA. Long-term results of perianal silicone injection for faecal incontinence. *Colorectal Dis.* 2007;9(4):357–61.
16. Maeda Y, Vaizey CJ, Kamm MA. Pilot study of two new injectable bulking agents for the treatment of faecal incontinence. *Colorectal Dis.* 2008;10(3):268–72.
17. Maslekar S, Smith K, Harji D, et al. Injectable collagen for the treatment of fecal incontinence: long-term results. *Dis Colon Rectum.* 2013;56(3):354–9.
18. Siproudhis L, Morcet J, Lainé F. Elastomer implants in faecal incontinence: a blind, randomized placebo-controlled study. *Aliment Pharmacol Ther.* 2007;25(9):1125–32.
19. Ganio E, Marino F, Giani I, et al. Injectable synthetic calcium hydroxylapatite ceramic microspheres (Coaptite) for passive fecal incontinence. *Tech Coloproctol.* 2008;12(2):99–102.
20. Stephens JH, Rieger NA, Farmer KC, et al. Implantation of ethylene vinyl alcohol copolymer for faecal incontinence management. *ANZ J Surg.* 2010;80(5):324–30.
21. Davis K, Kumar D, Poloniecki J. Preliminary evaluation of an injectable anal sphincter bulking agent (Durasphere) in the management of faecal incontinence. *Aliment Pharmacol Ther.* 2003;18(2):237–43.
22. Altomare DF, La Torre F, Rinaldi M, et al. Carbon-coated microbeads anal injection in outpatient treatment of minor fecal incontinence. *Dis Colon Rectum.* 2008;51(4):432–5.
23. Aigner F, Conrad F, Margreiter R, Oberwalder M, Coloproctology Working Group. Anal submucosal carbon bead injection for treatment of idiopathic fecal incontinence: a preliminary report. *Dis Colon Rectum.* 2009;52(2):293–8.
24. Beggs AD, Irukulla S, Sultan AH, et al. A pilot study of ultrasound guided Durasphere injection in the treatment of faecal incontinence. *Colorectal Dis.* 2010;12(9):935–40.
25. Tjandra JJ, Chan MKY, Yeh HCY. Injectable silicone biomaterial (PTQ) is more effective than carbon-coated beads (Durasphere) in treating passive faecal incontinence—a randomized trial. *Colorectal Dis.* 2009;11(4):382–9.
26. Morris OJ, Smith S, Draganic B. Comparison of bulking agents in the treatment of fecal incontinence: a prospective randomized clinical trial. *Tech Coloproctol.* 2013;17(5):517–23.
27. Graf W, Mellgren A, Matzel KE, et al. Efficacy of dextranomer in stabilised hyaluronic acid for treatment of faecal incontinence: a randomised, sham-controlled trial. *Lancet.* 2011;377(9770):997–1003.
28. Schwandner O, Brunner M, Dietl O. Quality of life and functional results of submucosal injection therapy using dextranomer hyaluronic acid for fecal incontinence. *Surg Innov.* 2011;18(2):130–5.
29. La Torre F, de la Portilla F. Long-term efficacy of dextranomer in stabilized hyaluronic acid (NASHA/Dx) for treatment of faecal incontinence. *Colorectal Dis.* 2013;15(5):569–74.
30. Danielson J, Karlbom U, Wester T, Graf W. Efficacy and quality of life 2 years after treatment for faecal incontinence with injectable bulking agents. *Tech Coloproctol.* 2013;17(4):389–95.
31. Mellgren A, Matzel KE, Pollack J, et al. Long-term efficacy of NASHA Dx injection therapy for treatment of fecal incontinence. *Neurogastroenterol Motil.* 2014;26(8):1087–94.
32. Rosato G, Piccinini P, Oliveira L, et al. Initial results of a new bulking agent for fecal incontinence: a multicenter study. *Dis Colon Rectum.* 2015;58(2):241–6.
33. Hussain ZI, Lim M, Stojkovic SG. Systematic review of perianal implants in the treatment of faecal incontinence. *Br J Surg.* 2011;98(11):1526–36.
34. Luo C, Samaranyake CB, Plank LD, Bissett IP. Systematic review on the efficacy and safety of injectable bulking agents for passive faecal incontinence. *Colorectal Dis.* 2010;12(4):296–303.
35. Maeda Y, Laurberg S, Norton C. Perianal injectable bulking agents as treatment for faecal incontinence in adults. *Cochrane Database Syst Rev.* 2013;(2):CD007959. <https://doi.org/10.1002/14651858.cd007959.pub3>.

36. Takahashi T, Garcia-Osogobio S, Valdovinos MA, et al. Radio-frequency energy delivery to the anal canal for the treatment of fecal incontinence. *Dis Colon Rectum*. 2002;45(7):915–22.
37. Takahashi T, Garcia-Osogobio S, Valdovinos MA, et al. Extended two-year results of radio-frequency energy delivery for the treatment of fecal incontinence (the Secca procedure). *Dis Colon Rectum*. 2003;46(6):711–5.
38. Takahashi-Monroy T, Morales M, Garcia-Osogobio S, et al. SECCA procedure for the treatment of fecal incontinence: results of five-year follow-up. *Dis Colon Rectum*. 2008;51(3):355–9.
39. Efron JE, Corman ML, Fleshman J, et al. Safety and effectiveness of temperature-controlled radio-frequency energy delivery to the anal canal (Secca procedure) for the treatment of fecal incontinence. *Dis Colon Rectum*. 2003;46(12):1606–16.
40. Felt-Bersma RJ, Szojda MM, Mulder CJ. Temperature-controlled radiofrequency energy (SECCA) to the anal canal for the treatment of faecal incontinence offers moderate improvement. *Eur J Gastroenterol Hepatol*. 2007;19(7):575–80.
41. Lefebvre B, Tuech JJ, Bridoux V, et al. Temperature-controlled radio frequency energy delivery (Secca procedure) for the treatment of fecal incontinence: results of a prospective study. *Int J Colorectal Dis*. 2008;23(10):993–7.
42. Kim DW, Yoon HM, Park JS, et al. Radiofrequency energy delivery to the anal canal: is it a promising new approach to the treatment of fecal incontinence? *Am J Surg*. 2009;197(1):14–8.
43. Lam TJ, Visscher AP, Meurs-Szojda MM, Felt-Bersma RJ. Clinical response and sustainability of treatment with temperature-controlled radiofrequency energy (Secca) in patients with faecal incontinence: 3 years follow-up. *Int J Colorectal Dis*. 2014;29(6):755–61.
44. Abbas MA, Tam MS, Chun LJ. Radiofrequency treatment for fecal incontinence: is it effective long-term? *Dis Colon Rectum*. 2012;55(5):605–10.
45. Frascio M, Mandolino F, Imperatore M, et al. The SECCA procedure for faecal incontinence: a review. *Colorectal Dis*. 2014;16(3):167–72.
46. Felt-Bersma RJF. Temperature-controlled radiofrequency energy in patients with anal incontinence: an interim analysis of worldwide data. *Gastroenterol Rep (Oxf)*. 2014;2(2):121–5.

Open Access This chapter is licensed under the terms of the Creative Commons Attribution-NonCommercial-NoDerivatives 4.0 International License (<http://creativecommons.org/licenses/by-nc-nd/4.0/>), which permits any noncommercial use, sharing, distribution and reproduction in any medium or format, as long as you give appropriate credit to the original author(s) and the source, provide a link to the Creative Commons license and indicate if you modified the licensed material. You do not have permission under this license to share adapted material derived from this chapter or parts of it.

The images or other third party material in this chapter are included in the chapter's Creative Commons license, unless indicated otherwise in a credit line to the material. If material is not included in the chapter's Creative Commons license and your intended use is not permitted by statutory regulation or exceeds the permitted use, you will need to obtain permission directly from the copyright holder.





Implantation of Self-Expandable Solid Prosthesis for Anal Incontinence

14

Ludovico Docimo, Giorgia Gualtieri, Claudio Gambardella, and Luigi Brusciano

14.1 Introduction

The physiological mechanisms behind normal anorectal function result from a perfect interaction among the anal sphincter complex, the rectal reservoir, and fecal consistency. Anal incontinence (AI) is defined as the involuntary passage of rectal contents (feces and/or gas) through the anal canal and the inability to defer evacuation to socially convenient times [1]. The main cause of AI is considered to be sphincter lesions, but frequently the dysfunction occurs also in subjects with intact sphincters. In some of those cases, neuropathy plays the major role by causing sensory-motor alterations [2, 3]. Symptom severity encompasses a wide clinical spectrum, from mild to severe, and can be specifically graded by several clinical scores commonly used to study patients [4, 5]. Soiling, seepage and incontinence to gas are commonly defined as “minor incontinence” whereas incontinence to liquid and solid stools is defined as “major incontinence”. Different classifications of AI divide its clinical presentation into two entities based on whether the patient is able to feel the defecation stimulus but is unable to hold it (urge incontinence) or not (passive incontinence). Although not as a rule, passive AI commonly results from internal anal sphincter (IAS) lesions [6], whereas a structurally compromised external anal sphincter (EAS) is typically associated with urge AI.

Pelvic floor rehabilitation is commonly advocated as the first-line therapy when the global clinical-physiatric evaluation of the patient indicates it [7]; if the clinical outcomes are not satisfactory, the use of intersphincteric injectable bulking agents has been suggested about two decades ago as a possible treatment option [8] providing a feasible and minimally invasive technique hopefully granting a higher clinical

L. Docimo · G. Gualtieri · C. Gambardella · L. Brusciano (✉)
Division of General, Mini-invasive, Oncological, and Bariatric Surgery,
University of Campania Luigi Vanvitelli, Naples, Italy
e-mail: ludovico.docimo@unicampania.it; giorgiagualtieri207@gmail.com;
claudio.gambardella2@unicampania.it; luigi.brusciano@unicampania.it

response than other more “aggressive” procedures. Among the different bulking agents, Gatekeeper (GK) self-expandable solid prostheses have shown promising short- and middle-term results [9, 10]. Previously, different types of bulking agent had been used [11–14], but only a short-term benefit from the injections was reported, regardless of the material used. The major problem with the previously used anal bulking agents was their reduced efficacy with time, probably due to a variable combination of degradation and/or diffusion through the tissue adjacent to the injection site or, sometimes, far from that site. The data presented by Ratto et al. in 2011 [8] suggested that the implantation of the GK device was able to overcome all of these potential problems.

14.2 Indications and Contraindications

The GK device currently used consists of a delivery instrument and solid prostheses ($n = 4$ in the first description, subsequently $n = 6$) made of inert hyexpan (polyacrylonitrile) that, once implanted, characteristically expands up to 700% of its former volume by slow water absorption within 48 h from implantation. The prostheses are compliant to external pressures without losing their original shape. For these reasons the implants are usually placed in the intersphincteric space, in the belief that this will achieve a more effective distribution of the bulking effect and minimize the potential risk of erosion, ulceration, fistulation of the anal canal and possible prosthesis displacement [8]. However, implantation methods, as well the volume and number of prostheses vary between studies [15]. Launched as the evolution of GK, Sphinkeeper (SK) features more and longer hyexpan prostheses [8, 9]. These are long enough (23 mm in final length) to reconstitute the normal anal canal length and wide enough (7 mm in final diameter) to ensure a significant filling ability, so SK allows treatment of more sizeable defects in the IAS or EAS.

Implantation of these devices is indicated in patients whose onset of AI is ≥ 6 months before the first visit and symptoms are refractory to all standard conservative measures (pharmacologic, behavioral, and pelvic floor rehabilitation). Before implantation, at baseline, patients are evaluated on the basis of a detailed medical history and physical examination; when indicated, a colonoscopy can be performed. Particular attention has to be paid to investigate previous surgery, trauma and/or local radiotherapy, congenital anorectal malformations, comorbidity, AI symptoms, characteristics and diary, ability to defer defecation, and need to wear pads and/or take constipating drugs. Health status and quality of life (QoL) are evaluated at baseline and then after implantation [16, 17]. Anorectal manometry and endoanal ultrasound (EAUS) should be performed to assess anorectal function and morphology and to identify and quantify any lesion of the anal sphincter complex, determine anal canal length and muscle tension as well as resting tone.

GK/SK are not indicated in the presence of: IAS lesion $>60^\circ$ and/or EAS lesion $>90^\circ$ identified on ultrasound; active perianal sepsis; severe anal scarring; bowel disease with anorectal involvement; active treatments for anal or rectal cancer. The presence of diabetes mellitus, pudendal neuropathy, and previous implantation of

sacral nerve stimulator do not represent contraindications for the GK procedure, although accurate preoperative evaluation of coexisting clinical conditions that may negatively impact outcomes is encouraged.

14.3 Surgical Technique

After spinal/local anesthesia [18], with the patient in the lithotomy position, small (2 mm) skin incisions are performed at 12, 3, 6, and 9 o'clock or at 1, 3, 5, 7, 9, and 11 o'clock in the intersphincteric groove to allow implantation of four or six prostheses by using a specifically designed delivery system, which is functionally similar whether GK or SK prostheses are being implanted; in the latter case, up to ten small skin incisions can be used. Under digital guidance, the introducer is inserted into the intersphincteric space through a short subcutaneous tunnel and pushed up to reach the upper part of the anal canal. The introducer is placed in the upper third of the anal canal, at the level of the puborectalis muscle. Once in place, the gun is fired resulting in retraction of the cannula and deployment of the prosthesis. When the proximal part of the prosthesis reaches the tip of the cannula, the whole cannula retracts completely inside the delivery system and the prosthesis is released in place in the desired position within the intersphincteric space. The delivery device is then withdrawn. The implants are distributed equally around the anal canal, as it is believed that the actual position does not influence the outcome, even in the presence of EAS or IAS tears. The prostheses are placed in the same position in all patients, irrespective of the location of possible EAS/IAS lesions. Beginning from the very first reports of GK implantation, the prostheses were placed at 3, 6, 9 and 12 o'clock positions for convenience but it is likely that, provided the implants are inserted correctly and distributed equally around the anal canal, the actual position does not influence the outcome. As for the number of prostheses implanted, it has been recently demonstrated that the greater the number of the prostheses, the better the clinical outcome [19]. Some authors [8] perform skin incisions about 2 cm away from the anal verge to minimize the risk of wound contamination during bowel movements. Nonlinear tunneling through the soft subcutaneous tissues to reach the intersphincteric plane from the skin incision is thought to avoid possible prosthesis extrusion along the track. In our procedure [18], all of the steps are verified by palpation and direct vision using the Eisenhammer anal speculum. However, prosthesis placement can also be performed under EAUS guidance to monitor the procedure step by step and ensure correct positioning of the prostheses, but this is not mandatory and simple digital palpations by an expert physician can be enough to guarantee proper positioning of the prostheses. When performed, EAUS is used to confirm the position of the prosthesis, which appears as a hyperechoic dot with a hypoechoic shadow behind it. Three-dimensional EAUS (3D-EAUS) was used by some groups and showed a continuous hyperechoic line after implantation [9]. Finally, the skin wounds are sutured with resorbable material. Patients are usually discharged on the same day and instructed to avoid any trauma or sexual practice during the first 48 h after implantation. Bed rest is usually recommended and aims at decreasing the risk

of early prosthesis dislocation. A 5-day course of antibiotics is also prescribed. Patients are assessed at follow-up and 3D-EAUS is performed to check the location of the prostheses.

14.4 Implantation Results

Implantation of GK/SK results in a significant improvement in episodes of major AI and on all the scores used to stratify AI severity preoperatively (Cleveland Clinic Fecal Incontinence Score [CCFIS], Vaizey score). The ability to postpone defecation for longer and postevacuation soiling are both significantly improved in the majority of patients undergoing GK/SK implantation. Of note is the improvement of QoL scores (FIQL, SF-36), suggesting regained health and comfort in patients treated with GK. The postimplantation anatomical changes in the sphincter complex—confirmed by ultrasound (Fig. 14.1)—are thought to play a major role in the functional improvements. Indeed, it has been fully demonstrated that increasing the *in vivo* length of the EAS complex increases its contraction [20, 21]; an overall increase in muscle tension of the anal sphincter complex has been observed and recently demonstrated after GK implantation. Such a positive change may be crucial in altering the pathophysiological mechanisms which are believed to be associated with the development of AI symptoms. Our results [18] show good initial improvements in CCFIS that were sustained up to 36 months after implantation. We also provided data regarding sphincter morphology and function by 3D-EAUS and high-resolution anal manometry (HRAM). Our rate of prosthesis displacement was lower (20%) and fully asymptomatic compared with another study (52%) [22]. Furthermore, in our experience, the GK procedure was not intraoperatively assisted by EAUS, confirming that prosthetic delivery into the intersphincteric space can be adequately accomplished after a short learning curve (minimum of five proctored cases). HRAM showed an overall increase in functional anal canal length, anal resting pressure, and maximum squeeze. Improvements in QoL following GK implantation have also been described elsewhere [10, 19].

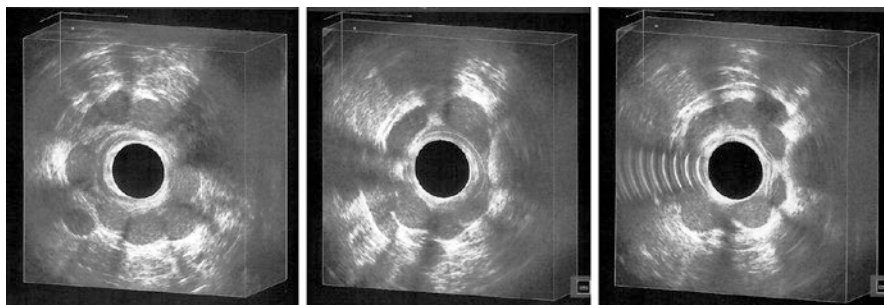


Fig. 14.1 Gatekeeper implantation in patients with anal incontinence: ultrasonographic evidence of prostheses located in the intersphincteric space, surrounding the anal canal

Few studies have compared GK and SK implantation results, and even fewer studies have investigated SK results beyond 1 year. Indeed, clinical improvements are observed at 1 year after implantation, regardless of the bulking agent system used. Apparently [19], SK confers the same benefits as GK in terms of morphofunctional remodeling of the sphincter complex and the increase in muscle tension is higher after implantation of a greater number of prostheses. The postimplantation increase in muscle tone (after controlling for baseline values) is significantly higher in patients undergoing SK than GK implantation, resulting in a better improvement in CCFIS at 12 months. In patients with loose, patulous, funnel-like or keyhole-shaped anal canal, SK could offer the opportunity to reconstitute the cylindrical shape of the anal canal, while in patients with sphincteric lesions it could reinforce the area of scarring and improve the contribution to continence of the remaining intact sphincters. Finally, SK could have a non-negligible role as adjunctive therapy in patients with incomplete resolution of symptoms after other procedures for AI. In conclusion, implantation of SK is as feasible as that of GK in patients with different types of AI, it does not give rise to major complications or dislodgement, and it enhances effectiveness due to the greater number and dimensions of the prostheses.

14.5 Adverse Effects: Displacement

Studies have been conducted searching for intra- and postoperative complications, in particular looking at clinical and/or EAUS evidence of bleeding at/from the sites of implantation, anorectal sepsis (anorectal abscess and/or fistula), signs of local and systemic inflammation, pain, duration of analgesic therapy and urinary retention [9]. Implantation is not followed by septic or adverse reactions, does not result in short-term dislodgement and is well tolerated. No acute sepsis at the site of implantation and around the prostheses was documented within a 90-day period. No long-lasting symptoms (including anorectal pain and discomfort) directly or indirectly related to the implanted prostheses have been recorded. This was confirmed in a large population that underwent GK implantation [9, 10] or in patients treated with SK implantation. Compared to other treatment options for fecal incontinence, in fact, these procedures boast a number of potential advantages including the minimally invasive approach (that may mitigate risk in frail patients) and repeatability (i.e., replacement after removal of protruding prosthesis).

GK/SK implantation is very safe. Acute sepsis at the site of implantation and around the prostheses is rarely recorded. The only adverse event of concern reported to date is prosthetic displacement. This was first described in a case report in 2014, in which EAUS demonstrated the migration of GK implants in a patient reporting no improvement in AI symptoms, as well as perianal pain and swelling [23]. This complication was then studied further and is now assessed with rates ranging between 6% and 49% [22].

References

1. Saldana Ruiz N, Kaiser AM. Fecal incontinence—challenges and solutions. *World J Gastroenterol.* 2017;23(1):11–24.
2. Hayden DM, Weiss EG. Fecal incontinence: etiology, evaluation, and treatment. *Clin Colon Rectal Surg.* 2011;24(1):64–70.
3. Nelson RL. Epidemiology of fecal incontinence. *Gastroenterology.* 2004;126(1 Suppl 1):S3–7.
4. Vaizey CJ, Carapeti E, Cahill JA, Kamm MA. Prospective comparison of faecal incontinence grading systems. *Gut.* 1999;44(1):77–80.
5. Thekkinkattil DK, Lim M, Stojkovic SG, et al. A classification system for faecal incontinence based on anorectal investigations. *Br J Surg.* 2008;95(2):222–8.
6. Rao SS. Pathophysiology of adult fecal incontinence. *Gastroenterology.* 2004;126(1 suppl 1):S14–22.
7. Bruscianno L, Limongelli P, del Genio G, et al. Useful parameters helping proctologists to identify patients with defaecatory disorders that may be treated with pelvic floor rehabilitation. *Tech Coloproctol.* 2007;11(1):45–50.
8. Ratto C, Parello A, Donisi L, et al. Novel bulking agent for faecal incontinence. *Br J Surg.* 2011;98(11):1644–52.
9. Ratto C, Donisi L, Litta F, et al. Implantation of Sphinkeeper: a new artificial anal sphincter. *Tech Coloproctol.* 2016;20(1):59–66.
10. Ratto C, Buntzen S, Aigner F, et al. Multicentre observational study of the gatekeeper for faecal incontinence. *Br J Surg.* 2016;103(3):290–9.
11. Maeda Y, Vaizey CJ, Kamm MA. Pilot study of two new injectable bulking agents for the treatment of faecal incontinence. *Colorectal Dis.* 2008;10(3):268–72.
12. Tjandra JJ, Lim JF, Hiscock R, Rajendra P. Injectable silicone biomaterial for fecal incontinence caused by internal anal sphincter dysfunction is effective. *Dis Colon Rectum.* 2004;47(12):2138–46.
13. Siproudhis L, Morcet J, Laine F. Elastomer implants in faecal incontinence: a blind, randomized placebo-controlled study. *Aliment Pharmacol Ther.* 2007;25(9):1125–32.
14. Tjandra JJ, Chan MKY, Yeh HCH. Injectable silicone biomaterial (PTQ) is more effective than carbon-coated beads (Durasphere) in treating passive faecal incontinence—a randomized trial. *Colorectal Dis.* 2009;11(4):382–9.
15. Luo C, Samaranyake CB, Plank LD, Bissett IP. Systematic review on the efficacy and safety of injectable bulking agents for passive faecal incontinence. *Colorectal Dis.* 2010;12(4):296–303.
16. Ware JE Jr, Sherbourne CD. The MOS 36-item short-form health survey (SF-36). I. Conceptual framework and item selection. *Med Care.* 1992;30(6):473–83.
17. Rockwood TH, Church JM, Fleshman JW, et al. Fecal incontinence quality of life scale: quality of life instrument for patients with fecal incontinence. *Dis Colon Rectum.* 2000;43(1):9–16; discussion 16–7.
18. Bruscianno L, Tolone S, Del Genio G, et al. Middle-term outcomes of gatekeeper implantation for fecal incontinence. *Dis Colon Rectum.* 2020;63(4):514–9.
19. Grossi U, De Simone V, Parello A, et al. Gatekeeper improves voluntary contractility in patients with fecal incontinence. *Surg Innov.* 2018;26(3):321–7.
20. Rajasekaran MR, Jiang Y, Bhargava V, et al. Novel applications of external anal sphincter muscle sarcomere length to enhance the anal canal function. *Neurogastroenterol Motil.* 2011;23(1):70–5, e7.
21. Mittal RK, Sheean G, Padda BS, et al. The external anal sphincter operates at short sarcomere length in humans. *Neurogastroenterol Motil.* 2011;23(7):643–e258. <https://doi.org/10.1111/j.1365-2982.2011.01700.x>.
22. Trenti L, Biondo S, Noguerales F, et al. Outcomes of gatekeeper prosthesis implantation for the treatment of fecal incontinence: a multicenter observational study. *Tech Coloproctol.* 2017;21(12):963–70.
23. Al-Ozaibi L, Kazim Y, Hazim W, et al. The gatekeeper for fecal incontinence: another trial and error. *Int J Surg Case Rep.* 2014;5(12):936–8.

Open Access This chapter is licensed under the terms of the Creative Commons Attribution-NonCommercial-NoDerivatives 4.0 International License (<http://creativecommons.org/licenses/by-nc-nd/4.0/>), which permits any noncommercial use, sharing, distribution and reproduction in any medium or format, as long as you give appropriate credit to the original author(s) and the source, provide a link to the Creative Commons license and indicate if you modified the licensed material. You do not have permission under this license to share adapted material derived from this chapter or parts of it.

The images or other third party material in this chapter are included in the chapter's Creative Commons license, unless indicated otherwise in a credit line to the material. If material is not included in the chapter's Creative Commons license and your intended use is not permitted by statutory regulation or exceeds the permitted use, you will need to obtain permission directly from the copyright holder.





When Everything Fails: Prevention and Therapy of Treatment Failures

15

Donato F. Altomare, Arcangelo Picciariello,
Michele De Fazio, and Marcella Rinaldi

15.1 Introduction

Surgery for fecal incontinence (FI) is very challenging and associated a high failure rate, particularly as far as the long-term success rate is concerned.

Traditionally, all the treatments proposed over the last 50 years, from the anal wire according to Thiersch to artificial anal sphincters, were aimed at repairing, reinforcing or replacing a damaged, functionally insufficient or even absent anal sphincter. However, in the last 25 years, the extension on the indication of sacral nerve modulation to FI, proposed by Klaus E. Matzel, has revolutionized the treatment algorithm for this common functional disturbance, making some of the traditional treatments obsolete [1].

The prevention and treatment of failures of the most frequent surgical approaches to FI are discussed in this chapter.

15.2 Sphincteroplasty with or Without Postanal Repair

Overlapping anal sphincteroplasty remains one of the milestones in the treatment of FI even if its indication is limited to cases with an overt lesion of the external anal sphincter, which represents a minority of the causes of FI in Italy. The success rate of this operation is reported to be around 50% in the long term [2], and several prognostic factors have been considered to prevent treatment failure, including the presence of pudendal neuropathy [3].

D. F. Altomare (✉) · A. Picciariello · M. De Fazio · M. Rinaldi
Department of Emergency and Organ Transplantation,
University Hospital Policlinic of Bari, Bari, Italy
e-mail: donatofrancesco.altomare@uniba.it; arcangelopicciariello@gmail.com;
michele.defazio@uniba.it; marcella.rinaldi@uniba.it

Nevertheless, the success rate of the operation cannot be easily predicted. An excessively large sphincter defect ($>90^\circ$) and the occurrence of postoperative wound infection can strongly influence the outcomes. The utility of a protective colostomy to prevent wound contamination has been investigated by several authors, but no consent has been reached [4]. On the other hand, morbidities related to stoma formation and closure discourage its use in routine clinical practice.

15.2.1 What to Do when Sphincteroplasty Fails?

One possible reason for unsuccessful sphincteroplasty may be an early or late disruption of the overlapping sutures on the muscle stumps. In these cases, a re-do sphincteroplasty has been demonstrated to be useful, with a success rate comparable with the first sphincteroplasty attempt [5].

Another possible option in the case of failure of the sphincteroplasty is to test sacral nerve stimulation (SNS), which has been shown to be successful even in selected cases of untreated sphincter lesions [6]. The unexpected result of SNS in these cases has been explained by considering the multiple and still unknown neurological effects of SNS on the mechanisms involved in the physiological control of continence.

15.3 Injectable Anal Bulking Agents

The proposal to treat minor or passive FI by creating a passive obstacle to the passage of feces through the injection of bulking agents into the submucosa or deeper into the anal canal has been an attractive mini-invasive surgical option in recent decades, and several materials have been experimented, including autologous fat, silicone, collagen, carbon-coated microbeads, polyacrylamide gel, and NASHA/Dx (dextranomer in non-animal stabilized hyaluronic acid) gel [7–17].

While the experience of the proponents of these techniques was successful in most of the cases, colorectal surgeons have lost interest in the injection of anal bulking agents despite the advantages of its minimal invasiveness and easy procedure because none of these treatments have stood the test of time or the comparison with other treatments, mainly SNS. In fact, the few studies addressing the middle/long-term outcome of these procedures failed to confirm the utility of these materials [18] and those comparing anal bulking agents against SNS show a clear advantage of SNS [9].

On the other hand, the procedure was not free of possible complications including anal abscesses or bleeding and, in rare cases, hemospermia (personal experience). Nowadays, injection of anal bulking agents is seldom performed in clinical practice.

Patients reporting unsatisfactory outcome are usually treated by biofeedback/physiotherapy or, in the case of more severe FI, by SNS.

15.4 Adynamic Anal Sphincter Reinforcement by Prosthetic Implants

Other surgical options to control the passive passage of feces involve the use of implantable adynamic prosthetic devices.

15.4.1 Gatekeeper and Sphinkeeper

The Gatekeeper and the newer Sphinkeeper involve the ultrasound-guided transanal implantation of 4–12 nonresorbable prostheses able to increase their volume by absorbing fluids from the interstitial spaces, thereby narrowing the anal canal and creating passive control to the loss of feces. This technique has been shown to be effective in about 50% of cases, even in the long-term follow-up [19–22].

Possible complications include anal abscess, migration of the prosthesis (possible in up to 50% of patients), mucosa ulceration and expulsion of the prosthesis. These complications could be prevented by careful monitoring of correct placement of the prostheses by transanal three-dimensional ultrasound guidance and wide spectrum antibiotic prophylaxis.

In cases of failure or distal migration, the procedure could be repeated if the distance between the prostheses allows for further transanal implants, or the patients could undergo SNS if the FI severity justifies that expensive procedure.

15.4.2 Fenix Device

Another surgical option involving adynamic prosthetic implants is the Fenix device. This magnetic sphincter augmentation (MSA) device consists of a flexible band of interlinked titanium beads with magnetic cores of variable length placed around the anal canal. The passive attraction of the magnetic beads keeps the anal canal narrow, but the voluntary passage of feces can open the anal canal allowing defecation [23].

Very few colorectal centers have experienced this device and therefore there is little information on its potential complications and true effectiveness. A randomized controlled trial versus SNS was stopped prematurely because of the very low success rate (about 10%) reported in both groups [24].

15.4.3 Silastic Band

The use of anal encirclement by a silastic band is actually an evolution of the Thiersch anal wire and was proposed by a German surgeon in 1991 [25] and recently reconsidered by Devesa et al. [26]. This simple, inexpensive surgical option could be considered in several patients after failure of more complex and expensive procedures including artificial bowel sphincter, SNS, sphincteroplasty and injectable

bulking agents. Careful preparation of the tunnel around the anal canal to host the elastic band is the only critical point of this operation because of the risk of rectal/vaginal perforation.

15.5 SECCA Radiofrequency Treatment

The SECCA procedure was designed to create deep thermal necrosis of segments of the internal anal sphincter by using a modified anoscope equipped with special needles to deliver radiofrequency energy, in order to produce anal scars able to narrow the anal canal thus preventing episodes of FI [27]. Despite some positive reports [28], this procedure has been abandoned owing to the great perplexity of most colorectal surgeons to further damage a weak anal sphincter [29]. A SNS test could be considered for patients not responding to this technique.

15.6 Dynamic Anal Neosphincters

15.6.1 Dynamic Graciloplasty

This fascinating and skill-demanding operation has been reserved for many years for the worst cases of FI or patients with anal malformation or after a perineal colostomy following a Miles operation for rectal cancer [30]. Nevertheless, the long-term success rate of this operation is unsatisfactory. One of the most recent reports on the long-term outcome of electro-stimulated graciloplasty concluded that “the individual patient can expect a 16% chance of normal fecal continence at 5 years with at least one surgical morbidity”, with 27% of them converted to an end colostomy [31]. As a consequence, this surgical option has been virtually abandoned, particularly after the company Medtronic decided to stop the production of the needle electrodes used to electro-stimulate the gracilis muscle. In fact, despite some recent reports on the use of adynamic graciloplasty [32], the unstimulated muscle becomes atrophic without electrostimulation, losing the ability to contract and therefore making the operation useless.

15.6.2 Artificial Bowel Sphincters

The great enthusiasm of about 20 years ago for the use of artificial sphincters, following the success of the urinary artificial sphincter, was replaced by a profound skepticism about its possible role in helping these patients when several papers addressing long-term effectiveness and outcomes became available in the literature [33, 34]. The excessive number of postoperative complications (mainly infections and skin/mucosal erosion), malfunction of the system components and the

long-term inefficacy of the device convinced the industry to stop its production worldwide, and all the other later attempts to produce artificial anal sphincters—such as the soft anal band, the prosthetic anal sphincter (PAS) [35], the German anal sphincter system (GASS) [36], the artificial anal sphincter system (AASS) [37]—remained in their early experimental phase.

Patients who have failed an operation with an artificial bowel sphincter or dynamic graciloplasty have very few chances to cure their incontinence. Nowadays, before considering an end colostomy or procedures for pseudocontinence, a last option could be a SNS test, although there is very little experience on this indication.

15.7 Sacral Nerve Stimulation

In the last 20 years, SNS has replaced most of the other surgical options to treat FI since the indication for this technique has greatly expanded, including incontinence due to sphincter lesions, incontinence after anterior resection of the rectum [38] and many other challenging conditions (but excluding patients with spinal lesions).

Few complications have been reported after SNS and most of them, like infection or malposition of the pacemaker, can be prevented by rigid observance of antisepsis and antibiotic prophylaxis and by correct positioning of the pulse generator in a subcutaneous pocket of the gluteal region. Correct positioning of the pacemaker is also necessary to prevent pain and skin erosion. Another rare but possible complication is liquor spillage during electrode positioning in patients with spina bifida (personal observation). In this case, prolonged compression and bed rest is sufficient to overcome the problem.

A major problem with SNS is the loss of efficacy in the long term. Several reports indicate that the long-term success rate is about 50% [39–41], making the management of the remaining patients very difficult because of the shortage of other surgical options.

15.8 Last Options for Patients Unsuccessfully Treated for Fecal Incontinence

The severe distress of untreatable fecal incontinence still needs to be managed to improve the quality of life of these patients. Some procedures such as the Peristeen enema or the Malone antegrade enema can help by maintaining the rectum empty and giving a pseudocontinence which can help to prevent episodes of incontinence [42, 43]. Finally, after full discussion and information with the patients, an end colostomy, could be considered the last option in selected cases of FI, since its management is easier than uncontrolled bowel movements and quality of life may be improved.

15.9 Conclusions

Critical revision of the outcomes of several surgical treatments have restricted our toolbox for treating patients with FI, relegating some of the traditional treatments to the annals of surgical history. Many surgical options such as artificial bowel systems, injectable bulking agents, the SECCA procedure, dynamic graciloplasty, adynamic artificial sphincters, initially presented with great enthusiasm and with very high success rates, did not stand the proof of time and repeatability of the initial experiences.

References

1. Matzel KE, Stadelmaier U, Hohenfellner M, Gall FP. Electrical stimulation of sacral spinal nerves for treatment of faecal incontinence. *Lancet*. 1995;346(8983):1124–7.
2. Altomare DF, De Fazio M, Giuliani RT, et al. Sphincteroplasty for fecal incontinence in the era of sacral nerve modulation. *World J Gastroenterol*. 2010;16(42):5267–71.
3. Gilliland R, Altomare DF, Moreira H Jr, et al. Pudendal neuropathy is predictive of failure following anterior overlapping sphincteroplasty. *Dis Colon Rectum*. 1998;41(12):1516–22.
4. Hasegawa H, Yoshioka K, Keighley MR. Randomized trial of fecal diversion for sphincter repair. *Dis Colon Rectum*. 2000;43(7):961–4; discussion 964–5.
5. Vaizey CJ, Norton C, Thornton MJ, et al. Long-term results of repeat anterior anal sphincter repair. *Dis Colon Rectum*. 2004;47(6):858–63.
6. Brouwer R, Duthie G. Sacral nerve neuromodulation is effective treatment for fecal incontinence in the presence of a sphincter defect, pudendal neuropathy, or previous sphincter repair. *Dis Colon Rectum*. 2010;53(3):273–8.
7. Jeong H, Hwang SH, Kim HR, et al. Effectiveness of autologous fat graft in treating fecal incontinence. *Ann Coloproctol*. 2019;35(3):144–51.
8. Hong KD, Kim JS, Ji WB, Um JW. Midterm outcomes of injectable bulking agents for fecal incontinence: a systematic review and meta-analysis. *Tech Coloproctol*. 2017;21(3):203–10.
9. Rydningen M, Dehli T, Wilsgaard T, et al. Sacral neuromodulation compared with injection of bulking agents for faecal incontinence following obstetric anal sphincter injury—a randomized controlled trial. *Colorectal Dis*. 2017;19(5):O134–44.
10. Altman D, Hjern F, Zetterstrom J. Transanal submucosal polyacrylamide gel injection treatment of anal incontinence: a randomized controlled trial. *Acta Obstet Gynecol Scand*. 2016;95(5):528–33.
11. Zutshi M, Ferreira P, Hull T, Gurland B, et al. Biological implants in sphincter augmentation offer a good short-term outcome after a sphincter repair. *Colorectal Dis*. 2012;14(7):866–71.
12. Altomare DF, La Torre F, Rinaldi M, et al. Carbon-coated microbeads anal injection in outpatient treatment of minor fecal incontinence. *Dis Colon Rectum*. 2008;51(4):432–5.
13. Graf W, Mellgren A, Matzel KE, et al. Efficacy of dextranomer in stabilised hyaluronic acid for treatment of faecal incontinence: a randomised, sham-controlled trial. *Lancet*. 2011;377(9770):997–1003.
14. Dodi G, Jongen J, de la Portilla F, et al. An open-label, noncomparative, multicenter study to evaluate efficacy and safety of NASHA/Dx gel as a bulking agent for the treatment of fecal incontinence. *Gastroenterol Res Pract*. 2010;2010:467136. <https://doi.org/10.1155/2010/467136>.
15. Bartlett L, Ho YH. PTQ anal implants for the treatment of faecal incontinence. *Br J Surg*. 2009;96(12):1468–75.
16. Ganio E, Marino F, Giani I, et al. Injectable synthetic calcium hydroxylapatite ceramic microspheres (Coaptite) for passive fecal incontinence. *Tech Coloproctol*. 2008;12(2):99–102.

17. Harran N, Herold J, Bentley A, Bebington BD. Efficacy of porcine dermal collagen (Permacol) injection for passive faecal incontinence in a dedicated colorectal unit at the Wits Donald Gordon medical Centre. *S Afr J Surg.* 2017;55(2):10–3.
18. Guerra F, La Torre M, Giuliani G, et al. Long-term evaluation of bulking agents for the treatment of fecal incontinence: clinical outcomes and ultrasound evidence. *Tech Coloproctol.* 2015;19(1):23–7.
19. Brusciano L, Tolone S, Del Genio G, et al. Middle-term outcomes of gatekeeper implantation for fecal incontinence. *Dis Colon Rectum.* 2020;63(4):514–9.
20. Trenti L, Biondo S, Nogueras F, et al. Outcomes of gatekeeper prosthesis implantation for the treatment of fecal incontinence: a multicenter observational study. *Tech Coloproctol.* 2017;21(12):963–70.
21. Ratto C, Donisi L, Litta F, et al. Implantation of SphinKeeper: a new artificial anal sphincter. *Tech Coloproctol.* 2016;20(1):59–66.
22. Ratto C, Buntzen S, Aigner F, et al. Multicentre observational study of the gatekeeper for faecal incontinence. *Br J Surg.* 2016;103(3):290–9.
23. Mantoo S, Meurette G, Podevin J, Lehur PA. The magnetic anal sphincter: a new device in the management of severe fecal incontinence. *Expert Rev Med Devices.* 2012;9(5):483–90.
24. Williams AE, Croft J, Napp V, et al. SaFaRI: sacral nerve stimulation versus the FENIX magnetic sphincter augmentation for adult faecal incontinence: a randomised investigation. *Int J Colorectal Dis.* 2016;31(2):465–72.
25. Stelzner F. Die anorektale Inkontinenz, Ursache und Behandlung. *Chirurg.* 1991;62(1):17–24.
26. Devesa JM, Hervás PL, Vicente R, et al. Anal encirclement with a simple prosthetic sling for faecal incontinence. *Tech Coloproctol.* 2011;15(1):17–22.
27. Frascio M, Mandolfino F, Imperatore M, et al. The SECCA procedure for faecal incontinence: a review. *Colorectal Dis.* 2014;16(3):167–72.
28. Efron JE, Corman ML, Fleshman J, et al. Safety and effectiveness of temperature-controlled radio-frequency energy delivery to the anal canal (Secca procedure) for the treatment of fecal incontinence. *Dis Colon Rectum.* 2003;46(12):1606–16; discussion 1616–8.
29. Vergara-Fernandez O, Arciniega-Hernandez JA, Trejo-Avila M. Long-term outcomes of radio-frequency treatment for fecal incontinence: are the results maintainable? *Int J Colorectal Dis.* 2020;35(1):173–6.
30. Altomare DF, et al. Electrostimulated gracilis neosphincter for faecal incontinence and in total anorectal reconstruction: still an experimental procedure? *Int J Colorectal Dis.* 1997;12(5):308–12.
31. Thornton MJ, et al. Long-term follow-up of dynamic graciloplasty for faecal incontinence. *Colorectal Dis.* 2004;6(6):470–6.
32. Knol ME, et al. Non-dynamic graciloplasty is an effective treatment for patients with passive fecal incontinence. *Tech Coloproctol.* 2021;25(7):849–55.
33. Altomare DF, Rinaldi M, Pannarale OC, Memeo V. Disappointing long-term results of the artificial anal sphincter for faecal incontinence. *Br J Surg.* 2004;91(10):1352–3.
34. Altomare DF, Dodi G, La Torre F, et al. Multicentre retrospective analysis of the outcome of artificial anal sphincter implantation for severe faecal incontinence. *Br J Surg.* 2001;88(11):1481–6.
35. Finlay IG, Richardson W, Hajivassiliou CA. Outcome after implantation of a novel prosthetic anal sphincter in humans. *Br J Surg.* 2004;91(11):1485–92.
36. Schrag HJ, Ruthmann O, Doll A, et al. German artificial sphincter system-GASS II: Erste in vivo evaluation eines neuen hochintegrativen Neosphinkters zur Therapie der hochgradigen Stuhlinkontinenz/short time in vivo evaluation of a novel and highly integrated sphincter prosthesis for therapy of major fecal incontinence. *Biomed Tech (Berl).* 2005;50(11):371–4.
37. Wang Y, Liu H, Xu Q, Yan G. Novel artificial anal sphincter system based on transcutaneous energy transmission system tested in vivo. *Int J Artif Organs.* 2013;36(12):900–6.
38. Eftaiha SM, Balachandran B, Marecik SJ, et al. Sacral nerve stimulation can be an effective treatment for low anterior resection syndrome. *Colorectal Dis.* 2017;19(10):927–33.

39. Altomare DF, Giuratrabocchetta S, Knowles CH, et al. Long-term outcomes of sacral nerve stimulation for faecal incontinence. *Br J Surg*. 2015;102(4):407–15.
40. Altomare DF, Ratto C, Ganio E, et al. Long-term outcome of sacral nerve stimulation for fecal incontinence. *Dis Colon Rectum*. 2009;52(1):11–7.
41. Hollingshead JR, Dudding TC, Vaizey CJ. Sacral nerve stimulation for faecal incontinence: results from a single centre over a 10-year period. *Colorectal Dis*. 2011;13(9):1030–4.
42. Altomare DF, Rinaldi M, Rubini D, et al. Long-term functional assessment of antegrade colonic enema for combined incontinence and constipation using a modified Marsh and Kiff technique. *Dis Colon Rectum*. 2007;50(7):1023–31.
43. Dale M, Morgan H, Carter K, et al. Peristeen transanal irrigation system to manage bowel dysfunction: a NICE medical technology guidance. *Appl Health Econ Health Policy*. 2019;17(1):25–34.

Open Access This chapter is licensed under the terms of the Creative Commons Attribution-NonCommercial-NoDerivatives 4.0 International License (<http://creativecommons.org/licenses/by-nc-nd/4.0/>), which permits any noncommercial use, sharing, distribution and reproduction in any medium or format, as long as you give appropriate credit to the original author(s) and the source, provide a link to the Creative Commons license and indicate if you modified the licensed material. You do not have permission under this license to share adapted material derived from this chapter or parts of it.

The images or other third party material in this chapter are included in the chapter's Creative Commons license, unless indicated otherwise in a credit line to the material. If material is not included in the chapter's Creative Commons license and your intended use is not permitted by statutory regulation or exceeds the permitted use, you will need to obtain permission directly from the copyright holder.



Part IV

Special Considerations and Multidisciplinary Perspectives



Cesarean Section Delivery to Prevent Anal Incontinence

16

Marco Torella, Marika Pennacchio, and Nicola Colacurci

16.1 Introduction

Spontaneous delivery is considered to be a risk factor for anorectal dysfunction, through pregnancy and injuries induced by labor and delivery to the pelvic floor muscles, the rectovaginal septum, the anal sphincter complex and the pudendal nerve. In the last few years, the demand for cesarean section has increased for several reasons, including the conviction that it can prevent the development of problems of the maternal pelvic floor. In this chapter we will analyze the impact of the mode of delivery on the perineal plane.

The anorectal canal is surrounded by a complex bundle of muscle fibers that make up the external and internal sphincters. The striated muscles of the external sphincter are subject to voluntary control and are responsible for the tone that keeps the rectal canal narrow. The smooth muscles of the internal sphincter, on the other hand, keep the tone at rest and are responsible for moment-to-moment fecal continence. The two muscle groups overlap at a distance of 2 cm and extend upward in the canal for 4 cm. The outer sphincter is inserted on the central perineal tendon and is surrounded by the puborectalis muscle.

Although both sphincters are important for maintaining continence, it has been shown that laceration of the external sphincter has greater impact on the anal sphincter.

The classification of lacerations validated by the Royal College of Obstetricians and Gynaecologists (RCOG) considers four degrees (Fig. 16.1) [1]. Third-degree lacerations include partial or complete laceration, with or without laceration of the internal sphincter, while fourth-degree lacerations include complete laceration of

M. Torella · M. Pennacchio · N. Colacurci (✉)
Department of Woman, Child, and General and Specialized Surgery,
University of Campania Luigi Vanvitelli, Naples, Italy
e-mail: marco.torella@unicampania.it; marikapennacchio@gmail.com;
nicola.colacurci@unicampania.it

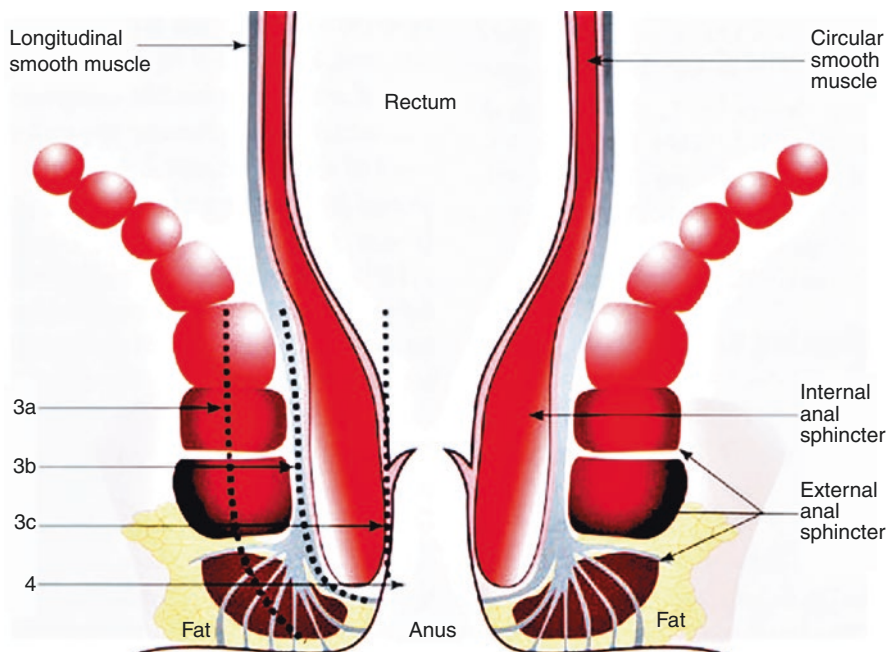


Fig. 16.1 Diagrammatic representation of the anal sphincters demonstrating the Sultan classification of major degrees of perineal tears (3a, 3b, 3c, and 4). Reproduced from [1] with permission from Springer

both sphincters, with extension to the rectal mucosa. Anal continence does not entirely depend on sphincter integrity, as neuromuscular function, the puborectalis muscle and the pudendal nerve also play a role.

Lacerations of the anal sphincter are classified further into “clinically recognizable” and “occult”. The former are identified and repaired at the time of delivery, while the latter, which are typically diagnosed by ultrasound, may occur below an intact perineum or in the presence of second- or first-degree lacerations [2].

16.2 Anal Incontinence and Mode of Delivery

Anal continence is a complex physiological mechanism that depends on factors such as intestinal disorders and habits, cortical awareness, integrity of the pelvic floor muscles and anal sphincter muscles in particular, as well as a number of psychological factors.

Anal incontinence is associated with advanced age, obesity, pregnancy, operative delivery, and obstetric lacerations of the anal sphincter. In addition to anal incontinence, laceration of the anal sphincter can also cause fecal urgency, perineal pain, and sexual dysfunction.

Anal incontinence, defined as “the involuntary loss of air or liquid and solid stools that constitutes a social and hygienic problem”, occurs in 15–59% of women with anal sphincter lacerations repaired at the time of delivery. Fecal urgency afflicts another 6–28% of women. Fecal incontinence, the loss of liquid or formed feces, is less frequent, occurring in 2–23% of cases. These symptoms may appear as a result of clinically recognizable or occult laceration [3].

No association between anal incontinence and delivery mode was shown by comparing women who had undergone cesarean sections and those who had a vaginal delivery [4]. However, when spontaneous childbirth is complicated by injuries to the anal sphincter, anal incontinence is tripled. In addition, both forceps and suction cups increase the risk of pelvic floor dysfunction. According to recent studies, women who had induction of labor with oxytocin, and in whom the neonatal head circumference is 34 cm or more, are significantly more at risk of developing anal incontinence and should be closely monitored after delivery.

Part of the complex physiological mechanism of continence may be compromised by injury to the muscles of the anal sphincter, and if one or more risk factors are needed during labor, their combination can potentially have a synergistic impact on the development of anal incontinence after childbirth and in the long term [5]. In addition, spontaneous delivery has been associated with an increase in the number of injuries to the levator ani muscle, increased mobility of the bladder neck and an enlargement of the genital hiatus, laying the foundations for the development of urinary incontinence and prolapse [6]. Maternal expulsive efforts during delivery and the force uterine contractions exert on the fetal head can induce stretching and compression of the pelvic floor nerves, which may lead to ischemia, neurapraxia or compromised nerve function. It is believed that nerve injury during delivery can result in muscle atrophy, hence altering pelvic floor function and morphology. The degree of muscular distension may lead to either a lesion or avulsion, which is associated with enlargement of the genital hiatus after delivery.

Factors not associated with delivery include advanced age, obesity, severity of disorders such as diarrhea and constipation, level of education and fecal urgency [7]. The effects of aging include reduced rectal compliance, reduced rectal sensitivity, perineal laxity, and delayed post-traumatic healing.

Among the factors associated with delivery, parity, operative delivery and macrosomia (birth weight of 4000 g of the first child) significantly increase the risk of anal sphincter injury and are more related to the development of long-term anal incontinence [8].

In severe lacerations, the five most important factors are: median episiotomy; use of forceps or obstetric cup; Asian ancestry; high weight at birth; first delivery.

Compared with vaginal delivery, cesarean delivery is associated with higher maternal and infant mortality, higher levels of complications in subsequent pregnancies, increased perinatal mortality, placenta previa or ectopic pregnancy, as well as higher health costs; hence, its recommendation, on the basis of its potential protective effect on the pelvic floor, is controversial and continues to arouse scientific debate [9].

There is conflicting evidence on the benefits of cesarean section in the prevention of postpartum anal incontinence [10]. Some studies suggest that the timing of a cesarean section, particularly when this is practiced in advanced labor, may have an impact on the mechanisms of continence.

Although cesarean section showed a protective effect on short-term anal incontinence, 6 months after delivery there is no longer a significant association between the mode of delivery and the development of anal incontinence. Nonetheless, it is essential to identify pregnant women with a higher risk of early anal incontinence after labor. In fact, although most cases of anal incontinence resolve within 6 months of delivery, even a short symptomatic period can negatively affect the quality of life of a young mother [11].

In conclusion, cesarean section does not appear to have a protective effect against the development of anal incontinence, in either the short or long term [12]. However, when vaginal delivery is operative or complicated by anal sphincter injury, the risk is significantly increased [13]. When anal incontinence occurs in old age and in obese woman it is more associated with factors independent of the mode of delivery [14]. Given that anal incontinence is still poorly reported due to social reasons, it is important to identify its risk factors, as early rehabilitation performed immediately after childbirth has been shown to reduce, and possibly prevent, anal incontinence later in life.

16.3 Conclusions

In conclusion, despite evidence of an increased risk of developing incontinence and pelvic organ prolapse following vaginal delivery, the recommendation of an elective cesarean section with the sole purpose of preserving the maternal pelvic floor should be taken with caution, as there is no direct evidence about the protective effect of elective cesarean section [15].

Although women with sphincter lacerations report more incontinence than those without lacerations, the symptoms increase in both groups with subsequent vaginal deliveries. The risk of sphincter lacerations during a second delivery increases by two to five times in women who had previous lacerations, compared to those with no history of clinically recognizable laceration [16]. Recurrence is greatest when the second delivery is vaginal or when episiotomy (especially median) is performed. A subsequent vaginal delivery also affects the severity of incontinence symptoms. However, because not all studies support the conclusion that subsequent deliveries contribute to anal incontinence, it is reasonable to ask whether the increases in anal incontinence are due to the large number of vaginal deliveries or to other influences such as age.

As regards occult lacerations, there may be an indication to perform ultrasound for the diagnosis and to proceed to immediate repair. Therefore, it is important to document the appearance of symptoms of transient or permanent anal incontinence after delivery. Ultrasound evaluation of the anal sphincters together with manometry can be indicated in all incontinent women.

During counseling, women should be informed of the increased risk of new lacerations in subsequent vaginal deliveries. Continent women are less likely to develop incontinence than those who previously had symptoms of transient or persistent anal incontinence. These outcomes are aggravated by episiotomy and operative delivery, which increase the risk of new lacerations and subsequent anal incontinence.

It is unclear whether the long-term symptoms after reiterated vaginal delivery in women with previous sphincter lacerations are different from those of women with no history of lacerations, and the issue should be investigated.

In summary, women with a history of anal sphincter lacerations during the first vaginal delivery are more likely to develop new lacerations and heightened incontinence symptoms with a subsequent one. Operative delivery and episiotomy (especially median) should be avoided because they aggravate the risk of further damage in all these women.

After a detailed discussion about the risks and benefits of attempting a new vaginal delivery, an election cesarean section may be considered in women with symptoms of anal incontinence [16].

References

1. Sultan AH, Thakar R. Posterior compartment trauma and management of acute obstetric anal sphincter injuries. In: Santoro GA, Wiczorek AP, Sultan AH, editors. *Pelvic floor disorders*. Milan: Springer; 2021.
2. Faltin DL, Boulvain M, Floris LA, Irion O. Diagnosis of anal sphincter tears to prevent fecal incontinence: a randomized controlled trial. *Obstet Gynecol*. 2005;106(1):6–13.
3. Pollack J, Nordenstam J, Brismar S, et al. Anal incontinence after vaginal delivery: a five-year prospective cohort study. *Obstet Gynecol*. 2004;104(6):1397–402.
4. Schei B, Johannessen HH, Rydning A, et al. Anal incontinence after vaginal delivery or cesarean section. *Acta Obstet Gynecol Scand*. 2019;98(1):51–60.
5. Nygaard IE, Rao SS, Dawson JD. Anal incontinence after anal sphincter disruption: a 30-year retrospective cohort study. *Obstet Gynecol*. 1997;89(6):896–901.
6. de Araujo CC, Coelho SA, Stahlschmidt P, Juliato CRT. Does vaginal delivery cause more damage to the pelvic floor than cesarean section as determined by 3D ultrasound evaluation? A systematic review. *Int Urogynecol J*. 2018;29(5):639–45.
7. Foulon A, Dupas JL, Sabbagh C, et al. Defining the most appropriate delivery mode in women with inflammatory bowel disease: a systematic review. *Inflamm Bowel Dis*. 2017;23(5):712–20.
8. Sultan AH, Kamm MA, Hudson CN, et al. Anal-sphincter disruption during vaginal delivery. *N Engl J Med*. 1993;329(26):1905–11.
9. Cattani L, Neefs L, Verbakel JY, et al. Obstetric risk factors for anorectal dysfunction after delivery: a systematic review and meta-analysis. *Int Urogynecol J*. 2021;32(9):2325–36.
10. Lal M, Mann CH, Callender R, Radley S. Does cesarean delivery prevent anal incontinence? *Obstet Gynecol*. 2003;101:305–12.
11. Drusany Starič K, Norčič G. Obstetric risk factors for early-onset anal incontinence. *Int J Colorectal Dis*. 2019;34(1):177–80.
12. Nelson RL, Furner SE, Westercamp M, Farquhar C. Cesarean delivery for the prevention of anal incontinence. *Cochrane Database Syst Rev*. 2010;2010(2):CD006756. <https://doi.org/10.1002/14651858.cd006756.pub2>.
13. Fynes M, Donnelly VS, O’Connell PR, O’Herlihy C. Cesarean delivery and anal sphincter injury. *Obstet Gynecol*. 1998;92(4 Pt 1):496–500.

14. Pretlove SJ, Radley S, Toozs-Hobson PM, et al. Prevalence of anal incontinence according to age and gender: a systematic review and meta-regression analysis. *Int Urogynecol J Pelvic Floor Dysfunct.* 2006;17(4):407–17.
15. López-López AI, Sanz-Valero J, Gómez-Pérez L, Pastor-Valero M. Pelvic floor: vaginal or caesarean delivery? A review of systematic reviews. *Int Urogynecol J.* 2021;32:1663–73.
16. Faltin DL, Sangalli MR, Roche B, et al. Does a second delivery increase the risk of anal incontinence? *BJOG.* 2001;108:684–8.

Open Access This chapter is licensed under the terms of the Creative Commons Attribution-NonCommercial-NoDerivatives 4.0 International License (<http://creativecommons.org/licenses/by-nc-nd/4.0/>), which permits any noncommercial use, sharing, distribution and reproduction in any medium or format, as long as you give appropriate credit to the original author(s) and the source, provide a link to the Creative Commons license and indicate if you modified the licensed material. You do not have permission under this license to share adapted material derived from this chapter or parts of it.

The images or other third party material in this chapter are included in the chapter's Creative Commons license, unless indicated otherwise in a credit line to the material. If material is not included in the chapter's Creative Commons license and your intended use is not permitted by statutory regulation or exceeds the permitted use, you will need to obtain permission directly from the copyright holder.





Interrelatedness of Urological Conditions and Anal Incontinence

17

Ferdinando Fusco, Marco De Sio, Davide Arcaniolo, Celeste Manfredi, Luigi Napolitano, Simone Morra, and Massimiliano Creta

17.1 Introduction

Anal incontinence (AI) has been reported to occur in patients with concomitant urological disease, as a result of the condition itself or its treatment. Surgical operations for prostate cancer and bladder cancer, as well as radiotherapy, can lead to loss of anal function. Moreover, AI has been associated with lower urinary symptoms (including urgency, frequency, and incontinence) and it is considered a risk factor for urinary tract infections.

17.2 Urological Diseases Associated with Anal Incontinence

17.2.1 Prostate Cancer

17.2.1.1 Anal Incontinence After Radical Prostatectomy

Radical prostatectomy (RP) has been related to a high incidence of anorectal complications [1, 2] including AI, and the incidence is significantly higher after radical perineal prostatectomy (RPP). Urologists first recognized alterations in anorectal functions after RP in 1998 through a study conducted by Bishoff et al. [2]. In their survey, the authors reported AI in 5% and 18% of patients undergoing radical

F. Fusco · M. De Sio · D. Arcaniolo · C. Manfredi (✉)
Urology Unit, Department of Woman, Child, and General and Specialized Surgery,
University of Campania Luigi Vanvitelli, Naples, Italy
e-mail: ferdinando-fusco@libero.it; marco.desio@unicampania.it;
davide.arcaniolo@unicampania.it; manfredi.celeste@gmail.com

L. Napolitano · S. Morra · M. Creta
Urology Unit, Department of Neurosciences, Reproductive Sciences,
and Odontostomatology, University of Naples Federico II, Naples, Italy
e-mail: luiginap89@gmail.com; simonemorra@outlook.com; massimiliano.creta@unina.it

retropubic prostatectomy (RRP) and RPP, respectively. Similarly, the frequency of AI (daily, weekly, monthly or less than monthly occurrences) was significantly higher after RPP (3%, 9%, 3% and 16%) compared to RRP (2%, 5%, 3%, and 8%). RPP patients were more likely to wear a pad for stool leakage, experienced more accidents, had larger amounts of stool leakage and had less formed stools compared to RRP patients. Unfortunately, AI following RP is often underreported. Bishoff et al. reported that less than 50% of patients with AI had told the physician. Moreover, only 14% of patients undergoing RPP and 7% of those undergoing RRP with AI had ever told a health care provider about it, even when the incontinence was severe [2].

Surgical injury to pelvic region muscles and the anal sphincter complex or potential neuropraxia of the related nerves during RP may result in loss of anal function. Aydemir et al. performed a prospective manometric study to evaluate anorectal functions after RP. Their study demonstrated that external anal sphincteric pressure and internal anal sphincteric pressure significantly decreased after RPP. Although external anal sphincteric pressure and internal anal sphincteric pressure were also decreased in RRP, the difference was statistically insignificant [1].

The Expanded Prostate Cancer Index Composite (EPIC) is a comprehensive instrument designed to evaluate patient function and bother after prostate cancer treatment. It consists of four domains: urinary, bowel, sexual and hormone functions [3]. In their study, Koike et al. recorded a significantly higher EPIC bowel function score at only the 3-month follow-up in patients who performed robot-assisted RP (RARP) vs. laparoscopic RP (LRP) (96.9 vs. 92.9, $p < 0.01$). The difference in bowel function disappeared at postoperative months 6 and 12 [4].

17.2.1.2 Anal Incontinence After Radiotherapy for Prostate Cancer

External beam radiotherapy is an established curative treatment for prostate cancer. It can be prescribed as curative therapy alone or in combination with radical prostatectomy with curative, adjuvant or salvage intent.

AI is a known sequela of radiotherapy for prostate cancer, although it has received little attention in comparison with other toxicities and complications [5].

The potential mechanisms of AI related to radiotherapy include the detrimental effects of radiation exposure on the structure of the sphincter complex, either the muscle itself or the myenteric plexus that innervates the sphincters [5]. Only few published studies have addressed the anorectal function of patients before and after radiotherapy for prostate cancer. Yeoh et al. first investigated the change of anorectal function and showed a statistically significant difference in both the anal sphincter resting and squeeze pressures (resting pressure 54 mmHg before vs. 49 mmHg after; squeeze pressure 111 mmHg before vs. 102 mmHg after) at 4–6 weeks after radiotherapy [6]. Yeoh et al. also demonstrated a reduced rectal volume at threshold sensation (36 mL at baseline vs. 22 mL at 1 year) 1 year after radiotherapy [7]. The same authors demonstrated a reduction of both sphincter resting and squeeze pressures and a decrease in rectal volume at threshold and urge sensation at 2 years after radiotherapy [8]. However, the precise mechanism is not known and the relationship

between dose-volume parameters and the severity of AI symptoms has not been fully established.

Overall, the incidence of soiling and AI after external beam radiotherapy has been reported to be 58% and 57% at 3 years, respectively, and 5% of patients have a moderate to severe complaint [5, 9].

Viani et al. reported that intensity-modulated radiotherapy (IMRT) reduced the delivery of significant radiation doses to the bladder and rectum using a similar target volume compared to three-dimensional conformal radiotherapy (3DCRT). This dosimetric advantage resulted in a lower rate of acute/late grade ≥ 2 gastrointestinal toxicity (such as AI) for IMRT compared with 3DCRT (7% vs. 24%, respectively) [10].

Commonly, AI presents during or shortly after radiotherapy. However, it may be persistent as a late radiation-related event and often does not resolve spontaneously. It has been reported that development of bowel symptoms during the acute phase of radiotherapy (up to 120 days post-treatment) is a predictor of the same problems in the medium to long term [9].

Studies show that it may still persist at 15 years after external beam radiotherapy in 20% of patients [11]. Some studies reported the new onset of AI at 2 years after radiotherapy while others reported an incidence gradually increasing throughout the follow-up period [12, 13].

Studies comparing the outcome and complications of RP alone, radiotherapy alone, or RP combined with radiotherapy for locally advanced prostate cancer, reported that the likelihood of RP patients developing bowel urgency was lower than those who had received radiotherapy alone [5].

It has been hypothesized that the radiation dose influences rectal damage and the severity of rectal toxicity. However, available studies evaluating the relationship of radiation dose and occurrence of AI have given contradictory conclusions.

Syndikus et al. found that the impairment of the subjective perception of sphincter control was higher in the group treated with dose-escalated conformal radiotherapy (74 Gy) compared to standard conformal radiotherapy (64 Gy), with a hazard ratio of 9.25 for incontinence [14].

In their large prospective study of conformal radiotherapy, Fellin et al. found only correlation between late rectal bleeding and dose-volume histogram parameters and failed to find a statistically significant relationship between the dose-volume histogram parameters and AI 3 years after the treatment [15].

The incidence of AI has been reported to be similar in patients treated with brachytherapy. A study on prostate cancer patients receiving high-dose brachytherapy showed 11–25% of patients reporting symptoms of AI that did not remit throughout the follow-up-period up to 88 months [16, 17].

Treatments for AI after radiotherapy include topical phenylephrine, an α_1 -adrenoceptor agonist that has been shown to increase internal anal sphincter pressures. Use of the phenylephrine gel was reported to improve incontinence scores in a small retrospective case series in which half of the patients had been treated for prostate cancer. However, the clinical significance of its efficacy is debatable as only half of the patients in the study felt the gel was of use [18].

17.2.2 Anal Incontinence Following Radical Cystectomy for Bladder Cancer

Radical cystectomy (RC) followed by a urinary diversion is the gold standard for localized muscle-invasive bladder cancer. During RC the entire bladder is removed, and it is recommended that this is combined with pelvic lymphadenectomy. Parts of the intestines may be used to create a urinary diversion.

Long-term bowel disorders after RC are an underestimated issue. Available data demonstrate that, overall, about 30% of the subjects undergoing RC report problems with the physiological emptying process of stool including bowel movement, awareness of need for defecation, motoric rectal and anal function, sensory rectal function, and straining ability [19]. Patients undergoing RC also complain of problems with sensing and controlling the rectum leading to a sense of decreased stool evacuation capacity, difficulties in the initiation of the emptying reflex and decreased straining capacity. Moreover, increased defecation frequency, urgency, leakage, soiling and flatulence also occur among these patients [19].

Nerve dysfunction due to direct surgical damage to nerves or altered metabolism (e.g., malabsorption of electrolytes and vitamins), as well as deficient physiological function of the pelvic floor muscles caused by direct injury to the muscles or nerves, may contribute to AI after RC [20].

Thulin et al. evaluated long-term defecation disturbances in patients who had undergone RC for bladder cancer [19]. Of all 452 patients with urinary diversion, 35 (8%) reported fecal leakage and 33 (7%) reported soiling at least every month. Moderate and much bother by the fecal leakage was reported by 31% (17 of 54) of those with noncontinent urostomy, 70% (19 of 27) of those with continent reservoir and 44% (25 of 57) of those with orthotopic neobladder. Bother due to soiling was correspondingly reported by 35% (16 of 46) of those with noncontinent urostomy, 70% (14 of 20) of those with continent reservoir and 51% (25 of 49) of those with orthotopic neobladder [19].

Henningsohn et al. compared patients with continent cutaneous reservoirs and noncontinent urostomies (conduits) with baseline data from a matched control group [20]. The incidence of fecal leakage was statistically significantly increased after RC compared to the control population with relative risks of 6.2 (95% CI 2.4–16.0) and 4.2 (95% CI 1.3–14.1) for fecal leakage in patients with noncontinent urostomy and continent reservoir, respectively [20].

Frees et al. evaluated stool habits in patients who underwent continent cutaneous diversion using the ileocecal segment (Mainz pouch I [MzPI]) with an intussuscepted ileal nipple as efferent segment with those receiving an ileal conduit (IC) after radical cystectomy [21]. An increased stool frequency was reported in 60% of patients with MzPI as compared to 38% with IC. Soft stool consistency was reported in 31% of patients with MzPI compared to 2% with IC. Moreover, Frees et al. reported higher rates of diarrhea in patients with MzPI vs. IC (62% vs. 20%) [21].

17.3 Coexistence of Anal Incontinence and Lower Urinary Tract Symptoms

Experimental human and animal data suggest that the bladder and distal colon interact under both normal and pathological conditions. Pathological alterations in one of these organs may induce the development of cross-organ sensitization in the pelvis and may be responsible for clinical comorbidity of genitourinary and gastrointestinal tract dysfunctions [22].

AI has been associated with lower urinary symptoms including urgency, frequency, and urge incontinence [22]. Data from large trials showed a parallelism between lower urinary tract symptoms and lower gastrointestinal symptoms. The EPILUTS study of 2160 individuals indicated that both men and women with overactive bladder were much more likely to have AI than patients without overactive bladder symptoms [23]. Logistic regression controlling for demographic factors and comorbid conditions confirmed that overactive bladder status was a very strong predictor of AI [23].

In a community-based study, the prevalence of combined anal and urinary incontinence was reported at 6–9% [24]. Furthermore, the age-adjusted relative odds ratio of AI among women with urinary incontinence was 1.8 [22]. In a group of patients with urinary incontinence, complaints of AI and constipation were found more often than in a control group [25]. Khullar et al. interviewed 465 women attending a urodynamic clinic and provided them with a detailed bowel questionnaire to investigate their urinary and bowel symptoms. The reported incidence of AI was 15.3% and 26% on direct questioning and on the postal questionnaire, respectively [26].

AI was more common in women with a urodynamic diagnosis of detrusor instability than among women diagnosed as having genuine stress incontinence (30% vs. 21%, respectively) [26]. Soligo et al. investigated the prevalence of AI in 504 women referred to an outpatient urogynecology clinic and evaluated the relationship between lower urinary tract dysfunction and AI. Overall, 0.2% of patients were anally incontinent. Women with double incontinence showed higher scores for urinary urgency, which reached the established level of significance only in the subgroup with urge AI. Interestingly, a higher prevalence of detrusor overactivity was observed in this group [27]. Manning et al. evaluated whether patients with lower urinary tract dysfunction have concomitant AI when compared with age- and gender-matched community controls and whether they have predisposing factors that have led to lower urinary tract symptoms and concomitant AI. Both frequent and occasional AI were significantly more prevalent among all cases than among community controls (5% vs. 0.72% and 24.6% vs. 8.4%, respectively). Although symptoms of fecal urgency and anal urge incontinence were significantly more prevalent among those with a urodynamic diagnosis of detrusor instability, AI was not significantly more prevalent among females with genuine stress incontinence (5.1%) when compared with females with detrusor instability (3.8%) or any other urodynamic diagnosis [28].

Although these findings suggest a shared pathophysiology for lower urinary tract and gastrointestinal tract dysfunction, further studies are needed to determine if successful treatment of one or more of these conditions is accompanied by commensurate improvements in symptoms referable to the other organ system [23].

17.4 Urinary Tract Infections in Patients with Anal Incontinence

AI is considered a risk factor for urinary tract infections. Patients with AI have been reported to develop urinary tract infections almost three times as frequently as their anal-continent counterparts. The majority of the isolates found in urine cultures of the sample population are normally present in the gastrointestinal tract [29].

References

1. Aydemir H, Albayrak S, Canguven O, et al. Anorectal functions after perineal and retropublic radical prostatectomy—a prospective clinical and anal manometric assessment. *Arch Med Sci.* 2011;7(1):138–42.
2. Bishoff JT, Motley G, Optenberg SA, et al. Incidence of fecal and urinary incontinence following radical perineal and retropublic prostatectomy in a national population. *J Urol.* 1998;160(2):454–8.
3. Crump RT, Peterson A, Charbonneau C, et al. Evaluating the measurement properties of the 26-item expanded prostate cancer index composite (EPIC-26) with a multicenter cohort. *Can Urol Assoc J.* 2019;14(4):111–7.
4. Koike H, Kohjimoto Y, Iba A, et al. Health-related quality of life after robot-assisted radical prostatectomy compared with laparoscopic radical prostatectomy. *J Robotic Surg.* 2017;11(3):325–31.
5. Maeda Y, Høyer M, Lundby L, Norton C. Faecal incontinence following radiotherapy for prostate cancer: a systematic review. *Radiother Oncol.* 2011;98(2):145–53.
6. Yeoh EK, Russo A, Botten R, et al. Acute effects of therapeutic irradiation for prostatic carcinoma on anorectal function. *Gut.* 1998;43(1):123–7.
7. Yeoh EK, Botten R, Russo A, et al. Chronic effects of therapeutic irradiation for localized prostatic carcinoma on anorectal function. *Int J Radiat Oncol Biol Phys.* 2000;47(4):915–24.
8. Yeoh EK, Holloway RH, Fraser RJ, et al. Anorectal dysfunction increases with time following radiation therapy for carcinoma of the prostate. *Am J Gastroenterol.* 2004;99(2):361–9.
9. Heemsbergen WD, Hoogeman MS, Hart GAM, et al. Gastrointestinal toxicity and its relation to dose distributions in the anorectal region of prostate cancer patients treated with radiotherapy. *Int J Radiat Oncol Biol Phys.* 2005;61(4):1011–8.
10. Viani GA, Viana BS, Martin JEC, et al. Intensity-modulated radiotherapy reduces toxicity with similar biochemical control compared with 3-dimensional conformal radiotherapy for prostate cancer. *Cancer.* 2016;122(13):2004–11.
11. Fransson P, Widmark A. 15-year prospective follow-up of patient-reported outcomes of late bowel toxicity after external beam radiotherapy for localized prostate cancer. A comparison with age-matched controls. *Acta Oncol.* 2007;46(4):517–24.

12. Crook J, Esche B, Futter N. Effect of pelvic radiotherapy for prostate cancer on bowel, bladder, and sexual function: the patient's perspective. *Urology*. 1996;47(3):387–94.
13. Odratzka K, Dolezel M, Vanasek J, et al. Time course of late rectal toxicity after radiation therapy for prostate cancer. *Prostate Cancer Prostatic Dis*. 2010;13(2):138–43.
14. Syndikus I, Morgan RC, Sydes MR, et al. Late gastrointestinal toxicity after dose-escalated conformal radiotherapy for early prostate cancer: results from the UK Medical Research Council RT01 trial (ISRCTN47772397). *Int J Radiat Oncol Biol Phys*. 2010;77(3):773–83.
15. Fellin G, Fiorino C, Rancati T, et al. Clinical and dosimetric predictors of late rectal toxicity after conformal radiation for localized prostate cancer: results of a large multicenter observational study. *Radiother Oncol*. 2009;93(2):197–202.
16. Borchers H, Kirschner-Hermanns R, Brehmer B, et al. Permanent 125I-seed brachytherapy or radical prostatectomy: a prospective comparison considering oncological and quality of life results. *BJU Int*. 2004;94(6):805–11.
17. Wahlgren T, Nilsson S, Lennernäs B, Brandberg Y. Promising long-term health-related quality of life after high-dose-rate brachytherapy boost for localized prostate cancer. *Int J Radiat Oncol Biol Phys*. 2007;69(3):662–70.
18. Badvie S, Andreyev HJN. Topical phenylephrine in the treatment of radiation-induced faecal incontinence. *Clin Oncol (R Coll Radiol)*. 2005;17(2):122–6.
19. Thulin H, Kreicbergs U, Onelöv E, et al. Defecation disturbances after cystectomy for urinary bladder cancer: defecation disturbances after cystectomy for urinary bladder cancer. *BJU Int*. 2011;108(2):196–203.
20. Henningsohn L, Wijkström H, Dickman PW, et al. Distressful symptoms after radical cystectomy with urinary diversion for urinary bladder cancer: a Swedish population-based study. *Eur Urol*. 2001;40(2):151–62.
21. Frees S, Schenk AC, Rubenwolf P, et al. Bowel function in patients with urinary diversion: a gender-matched comparison of continent urinary diversion with the ileocecal pouch and ileal conduit. *World J Urol*. 2017;35(6):913–9.
22. Malykhina AP, Wyndaele JJ, Andersson KE, et al. Do the urinary bladder and large bowel interact, in sickness or in health? ICI-RS 2011. *Neurourol Urodyn*. 2012;31(3):352–8.
23. Coyne KS, Cash B, Kopp Z, et al. The prevalence of chronic constipation and faecal incontinence among men and women with symptoms of overactive bladder. *BJU Int*. 2011;107(2):254–61.
24. Klingele CJ, Lightner DJ, Fletcher JG, et al. Dysfunctional urinary voiding in women with functional defecatory disorders. *Neurogastroenterol Motil*. 2010;22(10):1094–e284. <https://doi.org/10.1111/j.1365-2982.2010.01539.x>.
25. Wyndaele M, De Winter BY, Pelckmans P, Wyndaele JJ. Lower bowel function in urinary incontinent women, urinary continent women and in controls. *Neurourol Urodyn*. 2011;30(1):138–43.
26. Khullar V, Damiano R, Toozs-Hobson P, Cardozo L. Prevalence of faecal incontinence among women with urinary incontinence. *Br J Obstet Gynaecol*. 1998;105(11):1211–3.
27. Soligo M, Salvatore S, Milani R, et al. Double incontinence in urogynecologic practice: a new insight. *Am J Obstet Gynecol*. 2003;189(2):438–43.
28. Manning J, Eyers AA, Korda A, et al. Is there an association between fecal incontinence and lower urinary dysfunction? *Dis Colon Rectum*. 2001;44(6):790–8.
29. Lara LL, Troop PR, Beadleson-Baird M. The risk of urinary tract infection in bowel incontinent men. *J Gerontol Nurs*. 1990;16(5):24–6.

Open Access This chapter is licensed under the terms of the Creative Commons Attribution-NonCommercial-NoDerivatives 4.0 International License (<http://creativecommons.org/licenses/by-nc-nd/4.0/>), which permits any noncommercial use, sharing, distribution and reproduction in any medium or format, as long as you give appropriate credit to the original author(s) and the source, provide a link to the Creative Commons license and indicate if you modified the licensed material. You do not have permission under this license to share adapted material derived from this chapter or parts of it.

The images or other third party material in this chapter are included in the chapter's Creative Commons license, unless indicated otherwise in a credit line to the material. If material is not included in the chapter's Creative Commons license and your intended use is not permitted by statutory regulation or exceeds the permitted use, you will need to obtain permission directly from the copyright holder.





Coexistence of Fecal Incontinence and Constipation

18

Francesco Saverio Mari, Edoardo Maria Muttillo,
and Antonio Brescia

18.1 Introduction

Fecal incontinence (FI) is defined in the Rome IV criteria as the uncontrolled passage of solid or liquid stool with no distinction made based on presumed etiology [1]. This shows that there is now broad consensus on the multifactorial genesis of FI and that the primary distinction between functional and physical causes is no longer considered an effective guide to treatment. In fact, functional and physical factors are often simultaneously observed in incontinent patients and a careful assessment of associated factors is recommended before proposing a therapy.

FI and constipation (CS) are usually considered two distinct conditions, but in clinical practice they often overlap. Most published studies have focused on the evaluation of FI or CS alone, resulting in a lack of data on their coexistence. Even the latest update of the Rome diagnostic criteria (Rome IV) considers FI and CS to be distinct conditions without considering their possible combination as a nosologically entity [1, 2].

On the contrary, the coexistence of CS and FI is well known and studied in the pediatric population and in the elderly [1–3].

In adults, the theory that FI could result from ineffective rectal emptying is well known but often overlooked. Currently, there is a lack of epidemiological studies that assess in detail the coexistence of FI and CS in the adult population. Nevertheless, analysis of the data reported by some colorectal studies reveals the presence of many cases of patients with CS complaining of coexisting FI and vice versa.

F. S. Mari (✉)

Department of Surgery, S. Maria Goretti Hospital, Latina, Italy
e-mail: francescosaverio.mari@gmail.com

E. M. Muttillo · A. Brescia

Department of Medical and Surgical Sciences and Translational Medicine,
Sant' Andrea University Hospital, Rome, Italy
e-mail: edoardomaria.muttillo@uniroma1.it; antonio.brescia@uniroma1.it

© The Author(s) 2023

L. Docimo, L. Bruscianno (eds.), *Anal Incontinence*, Updates in Surgery,
https://doi.org/10.1007/978-3-031-08392-1_18

155

18.2 Evidence from Clinical Studies

In a 1996 study on FI, Agachan et al. reported the presence of CS symptoms in 16% of incontinent subjects, but they did not dwell on these data [4].

The strict correlation between CS and FI was also reported by Kalantar et al., who showed a statistically significant higher incidence of symptoms of obstructed defecation in patients with FI [5]. The close connection between FI and CS is also seen in studies focusing on pelvic floor disorders [6–9]. In the female population, naturally more exposed to the coexistence of these two conditions, it is evident that the single presence of birth injuries to the anal sphincter or pelvic floor is not sufficient to justify the incidence of FI.

In 2010, Burgell et al. conducted one of the first studies assessing the coexistence of CS and FI [10]. In a sample of 160 men, they reported anal sphincter injuries in only one-third of patients affected by FI while almost half of them complained of rectal evacuatory dysfunction, concluding that in most of the patients evaluated FI may represent a secondary phenomenon.

A recent cross-sectional study conducted by Vollebregt et al. on 4027 adults showed that in over 40% of patients with refractory FI and/or CS and meeting the Rome IV criteria the two conditions coexisted [11]. These patients mainly complained of gas incontinence, difficult discrimination between flatus and stool and rectal prolapse symptoms; the pathophysiological study, showed a higher incidence of sphincter dysfunctions compared to the group with CS alone and a greater presence of structural alterations on defecography compared to those with only FI. They also highlighted that the overlap of FI and CS symptoms had been missed by the referring physicians in over 80% of patients [11]. This was not attributable solely to the subjects' reluctance to talk about their embarrassing symptoms but was also likely due to doctors' unwillingness to investigate the two conditions in adults. In these cases, the lack of investigation by clinicians seems mainly related to a poor knowledge of their incidence in the adult population compared with children or the elderly rather than to the severity of the symptoms.

18.3 Patients' Quality of Life

The impact of FI and CS on normal daily activity is considerable and involves all aspects of quality of life (QoL). The coexistence of FI and CS has been shown to affect both the psychological and physical domains as well as normal social activity; sexual activity is also affected by the presence of FI and CS [12–14]. The need to organize one's daily activities based on effective intestinal emptying or the risk of FI episodes and the psychological impact of embarrassing symptoms have a significant impact on QoL. The simultaneous presence of FI and CS acts as a reinforcement, generating a double impairment of QoL [15]. There is also a close correlation between anxiety and FI or CS, with greater evidence of symptoms in subjects with coexistence of these two disorders [16].

In addition, Cauley et al. demonstrated that patients with coexisting FI and CS have different clinical and anorectal physiology test findings and worse overall QoL [13]. These patients have a different clinical presentation characterized mainly by difficult bowel emptying and milder symptoms of FI. In these cases, manometric studies show normal or increased sphincter tone while defecography often reveals intra-anal or recto-rectal intussusception and rectocele. Cauley et al. conclude by stating that the coexistence of FI and CS must be treated as a single nosological entity [13].

18.4 Pathophysiology

In adults, FI in association with CS is almost always a consequence of difficult hindgut emptying, in which the hyperaccumulation or stagnation of stools in the rectum leads to FI episodes. This theory is also supported by the fact that numerous manometric studies failed to show a higher incidence of sphincter muscle injury in patients with FI and CS compared to those with CS alone [11, 17, 18]. When FI and CS coexist, FI has multifactorial pathophysiology, and its onset can result from three main mechanisms: rectal overflow, incomplete rectal emptying, or pelvic floor weakness.

18.4.1 Rectal Overflow

In these forms, FI is related to overdistension of the rectum secondary to fecal impaction; the accumulation of a large amount of stool in the rectum distends the intestinal lumen and leads to relaxation of the internal anal sphincter, resulting in involuntary losses.

Rectal hyposensitivity appears to be the cause of fecal impaction in these patients. Impaired rectal sensitivity results in activation of the inhibitory rectal anal reflex, which in turn causes relaxation of the internal anal sphincter; failure to perceive stool in the rectum also compromises the possibility of a voluntary compensatory contraction of the external anal sphincter, with production of “passive” losses [19, 20]. Increased rectal compliance, as in rectal prolapse, rectocele, or megarectum, increases rectal fecal retention and represents an additional risk factor for FI [21]. Rectal stool retention also leads to fermentation of the bolus with filtration of liquid feces around the intrarectal solid bolus; moreover, the presence of a large mass of stool stimulates an overproduction of mucus, which worsens FI. Overflow incontinence can be made worse by using laxatives or constipating drugs [22].

18.4.2 Incomplete Rectal Emptying

The involuntary loss of small volumes of feces that usually occurs in the first hours after defecation is almost always related to insufficient rectal emptying. Some studies reported that the sense of incomplete evacuation is a significant risk factor for FI [5, 23].

These patients complain of small leaks which, however, are sufficient to soil the underwear and make intimate hygiene difficult; most often, they complain of discomfort or anal itching [24, 25]. A mechanical obstacle to rectal emptying, as in rectal prolapse, recto-rectal or recto-anal intussusception, anterior rectocele, or descending perineum, causes post-defecatory stagnation of a fair amount of stool. A failure to recognize these modest quantities, together with the presence of post-defecatory paradoxical contractions, appears to be at the basis of minor leaks [8, 26, 27]. Some authors report that in patients with coexisting FI and CS the symptoms of incontinence improve when rectal prolapse, intussusception and rectocele are surgically corrected [28–30]. On other hand, Rao et al. report incomplete rectal emptying secondary to dyssynergic defecation. In these patients, a lack of relaxation of the pelvic floor muscles during defecation results in incomplete rectal emptying [31]. In a population of women with FI, Stevenson et al. identified a high incidence of patients with dyssynergic defecation characterized by paradoxical contraction or inadequate sphincter relaxation [32].

In patients suffering from obstructed defecation, the dissipation of force vectors generated during evacuation can also cause excessive traction of the rectal tissues with consequent stretching of the nerve plexuses; this can induce changes in rectal sensitivity. In the presence of reduced sensitivity, the difficult recognition of small amounts of residual stool leads to small losses. On the contrary, some patients affected by obstructed defecation were reported to have increased rectal sensitivity [33, 34]. These patients usually complain of a sensation of urgency which does not allow them to retain stool.

18.4.3 Pelvic Floor Weakness

Childbirth sphincter injuries have long been recognized as the leading cause of FI in the female population. Recent endorectal manometric and ultrasound studies have shown a reduced incidence of sphincter muscle lesions in patients complaining of coexistent FI and CS; in these cases, pelvic floor weakness and denervation therefore appear to be stronger causes [8, 17, 18, 20].

Overloading and straining of the myofascial component of the pelvic floor during pregnancy and childbirth can lead to a traction-induced neuropathy resulting in lower pelvic floor and sphincteric muscle tone [8, 35, 36]. Some studies report that in the absence of muscle disruption, FI can be related to an impaired anal sphincter function due to the association between pelvic floor denervation and decreased anal sensation; these lead to a persistent inhibitory reflex to the internal anal sphincter and an inefficacious conscious contraction of the external anal sphincter [20, 22].

In addition to pregnancy and childbirth, aging and connective tissue disorders can also cause weakening of the muscle-tendon structures of the pelvic floor [37]. In these cases, chronic stresses as well as the misalignment of the muscular structures induced by the descending perineum lead to denervation of the pelvic floor and the formation of a more obtuse anorectal angle, resulting in FI episodes [8, 20, 35, 36].

18.5 Diagnosis and Therapy

In any adult patient presenting with either FI or CS it is important to investigate the possible coexistence of the two disorders. An accurate study of defecatory function should always be conducted before planning a treatment pathway. A thorough investigation of defecatory symptoms and their impact on QoL should precede clinical evaluation. The use of validated and widely used questionnaires is an efficacious tool for assessing symptoms [14, 38, 39].

In female patients it is also useful to use a score to assess the coexistence of pelvic organ prolapse; the Pelvic Organ Prolapse Inventory seems to be effective for evaluating symptoms related to bladder, vaginal or rectal prolapse and their emotional effects, such as frustration and embarrassment [40].

The instrumental evaluation of patients with coexistence of FI and CS must always include a functional evaluation of the anorectal complex. Anorectal manometry (better if at high resolution), the rectal sensory test, and the balloon expulsion test are the best-established investigations for objective assessment of anorectal muscular and sensorimotor functions [41].

In the presence of coexisting FI and CS, the functional evaluation should always involve a series of measurements that describe voluntary and involuntary control of the anal canal, voluntary and involuntary (reflex) rectoanal coordination, evacuatory function, and rectal sensation [17, 18]. The assessment of sphincter tone and contractility deficits, as well as alterations in rectal sensitivity or rectal emptying, is essential to guide treatment.

Morphological study by ultrasound or magnetic resonance (MR) imaging is essential to highlight the presence of muscle injuries, pelvic organ prolapse and/or obstructed defecation. MR defecography provides both structural and functional information for rectal voiding and prolapse; MR imaging could also reveal pelvic floor and sphincter weakness by abnormal descent at rest and anal leakage [42].

The treatment of CS is usually associated with improvement of the coexisting FI; it is therefore advisable to carefully assess and correct the underlying causes of the difficult hindgut emptying [28–30, 43]. By contrast, the treatment of FI does not appear to be effective in relieving CS symptoms and their impact on QoL [44].

Behavioral interventions as well as dietary modifications have not demonstrated certain improvements in patient with CS and FI [45]. Good results have, however, been reported for pelvic floor rehabilitation (especially biofeedback) in the presence of both muscle deficits and dyssynergic defecation [44, 46, 47].

In obstructed defecation syndrome, surgical correction of rectal prolapse, intussusception and rectocele are associated with a significant improvement of FI symptoms; treatment with ventral rectopexy is supported by more consistent data than transanal rectal resections [28–30, 43, 48–53]. Few data are reported on the efficacy, in terms of improving the symptoms of FI, of descending perineum correction with suspensive techniques [54, 55].

References

1. Rao SS, Bharucha AE, Chiarioni G, et al. Functional anorectal disorders. *Gastroenterology*. 2016;250(6):1430–42.e4.
2. Mearin F, Lacy BE, Chang L, et al. Bowel disorders. *Gastroenterology*. 2016;250(6):1393–1407.e5.
3. Gomez-Pinilla PJ, Gibbons SJ, Sarr MG, et al. Changes in interstitial cells of cajal with age in the human stomach and colon. *Neurogastroenterol Motil*. 2011;23(1):36–44.
4. Agachan F, Pfeifer J, Wexner SD. Defecography and proctography. Results of 744 patients. *Dis Colon Rectum*. 1996;39(8):899–905.
5. Kalantar JS, Howell S, Talley NJ. Prevalence of faecal incontinence and associated risk factors: an underdiagnosed problem in the Australian community? *Med J Aust*. 2002;176(2):54–7.
6. Boreham MK, Richter HE, Kenton KS, et al. Anal incontinence in women presenting for gynecologic care: prevalence, risk factors, and impact upon quality of life. *Am J Obstet Gynecol*. 2005;192(5):1637–42.
7. Amselem C, Puigdollers A, Azpiroz F, et al. Constipation: a potential cause of pelvic floor damage? *Neurogastroenterol Motil*. 2010;22(2):150–3, e48. <https://doi.org/10.1111/j.1365-2982.2009.01409.x>.
8. Carter D, Bardan E, Maradey-Romero C. Clinical and physiological risk factors for fecal incontinence in chronically constipated women. *Tech Coloproctol*. 2019;23(5):429–34.
9. Andy UU, Harvie HS, Pahwa AP, et al. The relationship between fecal incontinence, constipation and defecatory symptoms in women with pelvic floor disorders. *Neurourol Urodyn*. 2017;36(2):495–8.
10. Burgell RE, Bhan C, Lunniss PJ, Scott SM. Fecal incontinence in men: coexistent constipation and impact of rectal hyposensitivity. *Dis Colon Rectum*. 2012;55(1):18–25.
11. Vollebregt PF, Wiklendt L, Dinning PG, et al. Coexistent faecal incontinence and constipation: a cross-sectional study of 4027 adults undergoing specialist assessment. *EClinicalMedicine*. 2020;27:100572. <https://doi.org/10.1016/j.eclinm.2020.100572>.
12. Thomas GP, Maeda Y, Vaizey CJ. A review of the effect of faecal incontinence and constipation on sexual function. *Int J Colorectal Dis*. 2019;34(3):387–91.
13. Cauley CE, Savitt LR, Weinstein M, et al. A quality-of-life comparison of two fecal incontinence phenotypes: isolated fecal incontinence versus concurrent fecal incontinence with constipation. *Dis Colon Rectum*. 2019;62(1):63–70.
14. Brochard C, Chambaz M, Ropert A, et al. Quality of life in 1870 patients with constipation and/or fecal incontinence: constipation should not be underestimated. *Clin Res Hepatol Gastroenterol*. 2019;43(6):682–7.
15. Sailer M, Bussen D, Debus ES, et al. Quality of life in patients with benign anorectal disorders. *Br J Surg*. 1998;85(12):1716–9.
16. Singh P, Takazawa E, Rangan V, et al. Fecal urgency is common in constipated patients and is associated with anxiety. *Neurogastroenterol Motil*. 2019;31(4):e13545. <https://doi.org/10.1111/nmo.13545>.
17. Somers M, Peleman C, Van Malderen K, et al. Manometric and ultrasonographic characteristics of patients with coexisting fecal incontinence and constipation. *Acta Gastroenterol Belg*. 2017;80(4):463–9.
18. Mion F, Garros A, Brochard C, et al. 3D high-definition anorectal manometry: values obtained in asymptomatic volunteers, fecal incontinence and chronic constipation. Results of a prospective multicenter study (NOMAD). *Neurogastroenterol Motil*. 2017;29(8):e13049. <https://doi.org/10.1111/nmo.13049>.
19. Burgell RE, Scott SM. Rectal hyposensitivity. *J Neurogastroenterol Motil*. 2012;18(4):373–84.
20. Nurko S, Scott SM. Coexistence of constipation and incontinence in children and adults. *Best Pract Res Clin Gastroenterol*. 2011;25(1):29–41.
21. Gladman MA, Lunniss PJ, Scott SM, Swash M. Rectal hyposensitivity. *Am J Gastroenterol*. 2006;101(5):1140–51.

22. Read NW, Abouzekry L. Why do patients with faecal impaction have faecal incontinence. *Gut*. 1986;27(3):283–7.
23. Bharucha AE, Seide BM, Zinsmeister AR, Melton LJ 3rd. Relation of bowel habits to fecal incontinence in women. *Am J Gastroenterol*. 2008;103(6):1470–5.
24. Hoffmann BA, Timmcke AE, Gathright JB Jr, et al. Fecal seepage and soiling: a problem of rectal sensation. *Dis Colon Rectum*. 1995;38(7):746–8.
25. Sun WM, Read NW, Miner PB. Relation between rectal sensation and anal function in normal subjects and patients with faecal incontinence. *Gut*. 1990;31(9):1056–61.
26. Bharucha AE, Rao SS. An update on anorectal disorders for gastroenterologists. *Gastroenterology*. 2014;146(1):37–45.e2.
27. Bharucha AE, Zinsmeister AR, Schleck CD, Melton LJ 3rd. Bowel disturbances are the most important risk factors for late onset fecal incontinence: a population-based case-control study in women. *Gastroenterology*. 2010;139(5):1559–66.
28. Tsunoda A, Takahashi T, Kusanagi H. Transanal repair of rectocele: prospective assessment of functional outcome and quality of life. *Colorectal Dis*. 2020;22(2):178–86.
29. Lazorthes F, Gamagami R, Cabarrot P, Muhammad S. Is rectal intussusception a cause of idiopathic incontinence? *Dis Colon Rectum*. 1998;41(5):602–5.
30. Slawik S, Soulsby R, Carter H, et al. Laparoscopic ventral rectopexy, posterior colporrhaphy and vaginal sacrocolpopexy for the treatment of recto-genital prolapse and mechanical outlet obstruction. *Colorectal Dis*. 2008;10(2):138–43.
31. Rao SS, Tuteja AK, Vellema T, et al. Dyssynergic defecation: demographics, symptoms, stool patterns, and quality of life. *J Clin Gastroenterol*. 2004;38(8):680–5.
32. James-Stevenson T, Xu H, Heit M, Shin A. Age and dyssynergia subtypes associated with normal sphincter pressures in women with fecal incontinence. *Female Pelvic Med Reconstr Surg*. 2018;24(3):247–51.
33. Bharucha AE, Fletcher JG, Harper CM, et al. Relationship between symptoms and disordered continence mechanisms in women with idiopathic faecal incontinence. *Gut*. 2005;54(4):546–55.
34. Siproudhis L, El Abkari M, El Alaoui M, et al. Low rectal volumes in patients suffering from fecal incontinence: what does it mean? *Aliment Pharmacol Ther*. 2005;22(10):989–96.
35. Kiff ES, Barnes PR, Swash M. Evidence of pudendal neuropathy in patients with perineal descent and chronic straining at stool. *Gut*. 1984;25(11):1279–82.
36. Snooks SJ, Barnes PR, Swash M, Henry MM. Damage to the innervation of the pelvic floor musculature in chronic constipation. *Gastroenterology*. 1985;89(5):977–81.
37. Petros P, Swash M. The integral theory: a musculo-elastic theory of pelvic floor function and dysfunction. In: Santoro GA, Wiczorek AP, Bartram CI, editors. *Pelvic floor disorders*. Milan: Springer; 2010. p. 17–23.
38. Rockwood TH, Church JM, Fleshman JW, et al. Fecal incontinence quality of life scale: quality of life instrument for patients with fecal incontinence. *Dis Colon Rectum*. 2000;43(1):9–16; discussion 16–7.
39. Varma MG, Wang JY, Berian JR, et al. The constipation severity instrument: a validated measure. *Dis Colon Rectum*. 2008;51(2):162–72.
40. Barber MD, Kuchibhatla MN, Pieper CF, Bump RC. Psychometric evaluation of 2 comprehensive condition-specific quality of life instruments for women with pelvic floor disorders. *Am J Obstet Gynecol*. 2001;185(6):1388–95.
41. Carrington EV, Heinrich H, Knowles CH, et al. The international anorectal physiology working group (IAPWG) recommendations: standardized testing protocol and the London classification for disorders of anorectal function. *Neurogastroenterol Motil*. 2020;32(1):e13679. <https://doi.org/10.1111/nmo.13679>.
42. Bharucha AE. Outcome measures for fecal incontinence: anorectal structure and function. *Gastroenterology*. 2004;126(1 Suppl 1):S90–8.
43. Reichert M, Busse A, Hecker A, et al. Changes in dynamic pelvic floor magnet resonance imaging and patient satisfaction after resection rectopexy for obstructed defecation syndrome. *Rofo*. 2016;188(1):38–44.

44. Andy UU, Jelovsek JE, Carper B, et al. Impact of treatment for fecal incontinence on constipation symptoms. *Am J Obstet Gynecol.* 2020;222(6):590.e1–8.
45. Freeman KA, Riley A, Duke DC, Fu R. Systematic review and meta-analysis of behavioral interventions for fecal incontinence with constipation. *J Pediatr Psychol.* 2014;39(8):887–902.
46. Bruscianno L, Gambardella C, Del Genio G, et al. Outlet obstructed constipation and fecal incontinence: is rehabilitation treatment the way? Myth or reality. *Arq Gastroenterol.* 2020;5757(2):198–202.
47. Ko CY, Tong J, Lehman RE, et al. Biofeedback is effective therapy for fecal incontinence and constipation. *Arch Surg.* 1997;132(8):829–33; discussion 33–4.
48. Tsunoda A, Takahashi T, Hayashi K, et al. Laparoscopic ventral rectopexy in patients with fecal incontinence associated with rectoanal intussusception: prospective evaluation of clinical, physiological and morphological changes. *Tech Coloproctol.* 2018;22(6):425–31.
49. Gosselink MP, Adusumilli S, Gorissen KJ, et al. Laparoscopic ventral rectopexy for fecal incontinence associated with high-grade internal rectal prolapse. *Dis Colon Rectum.* 2013;56(12):1409–14.
50. Boenicke L, Kim M, Reibetanz J, et al. Stapled transanal rectal resection and sacral nerve stimulation—impact on faecal incontinence and quality of life. *Colorectal Dis.* 2012;14(4):480–9.
51. Boenicke L, Jayne DG, Kim M, et al. What happens in stapled transanal rectum resection? *Dis Colon Rectum.* 2011;54(5):593–600.
52. Mari FS, Pezzatini M, Gasparrini M, Antonio B. STARR with contour transtar for obstructed defecation syndrome: long-term results. *World J Surg.* 2017;41(11):2906–11.
53. Masoni L, Mari FS, Favi F, et al. Stapled transanal rectal resection with contour transtar for obstructed defecation syndrome: lessons learned after more than 3 years of single-center activity. *Dis Colon Rectum.* 2013;56(1):113–9.
54. Steele SR, Varma MG, Prichard D, et al. The evolution of evaluation and management of urinary or fecal incontinence and pelvic organ prolapse. *Curr Probl Surg.* 2015;52(3):92–136.
55. Mattsson NK, Karjalainen PK, Tolppanen AM, et al. Pelvic organ prolapse surgery and quality of life—a nationwide cohort study. *Am J Obstet Gynecol.* 2020;222(6):588.e1–10.

Open Access This chapter is licensed under the terms of the Creative Commons Attribution-NonCommercial-NoDerivatives 4.0 International License (<http://creativecommons.org/licenses/by-nc-nd/4.0/>), which permits any noncommercial use, sharing, distribution and reproduction in any medium or format, as long as you give appropriate credit to the original author(s) and the source, provide a link to the Creative Commons license and indicate if you modified the licensed material. You do not have permission under this license to share adapted material derived from this chapter or parts of it.

The images or other third party material in this chapter are included in the chapter's Creative Commons license, unless indicated otherwise in a credit line to the material. If material is not included in the chapter's Creative Commons license and your intended use is not permitted by statutory regulation or exceeds the permitted use, you will need to obtain permission directly from the copyright holder.





Gut Microbiota Characterization in Fecal Incontinence and Irritable Bowel Syndrome

19

Giovanni Marasco, Vincenzo Stanghellini,
Giovanni Barbara, and Cesare Cremon

19.1 Introduction

Anal incontinence (AI) is defined as the inability to delay evacuation until socially convenient (urge incontinence) or, more in general, as the involuntary passage of gut contents through the anus (passive incontinence or soiling/fecal seepage, the latter defining leakage of stool or mucus that occurs with normal continence and evacuation) [1]. Its prevalence is likely underestimated, due to embarrassment. Although it is known to increase with age, young individuals can also be affected, with no differences between males and females. Numerous idiopathic or secondary neuromuscular disorders of the pelvic floor and/or anal sphincter and/or rectum can be involved in causing its onset and are extensively described in this volume. Although diarrhea is more likely associated with incontinence, also severe constipation with fecal impaction and related pseudo-diarrhea can precipitate borderline anatomical and functional anorectal abnormalities.

The irritable bowel syndrome (IBS) is the most frequent clinical condition characterized by bowel abnormalities including diarrhea (IBS-D), constipation (IBS-C) and mixed bowel habits (IBS-M) [2]. AI has been reported to affect 15–20% of patients with IBS in a multicenter study [3]. Similarly, fecal incontinence occurring at least once per week was reported in 20% of IBS patients in a single-center study from the UK [4]. Compared with those who did not report AI, IBS patients affected by this severe complication had more frequently IBS-D, had undergone more gastroenterological consultations, and they were older, more frequently males, with higher body mass index and, not surprisingly, had more anxiety and depression [4].

G. Marasco · V. Stanghellini (✉) · G. Barbara · C. Cremon
Internal Medicine and Digestive Pathophysiology Unit,
IRCCS Azienda Ospedaliero-Universitaria di Bologna, Bologna, Italy
Department of Medical and Surgical Sciences, University of Bologna, Bologna, Italy
e-mail: giovanni.marasco4@unibo.it; v.stanghellini@unibo.it; giovanni.barbara@unibo.it;
cesare.cremon@aosp.bo.it

Still, these figures could be markedly underestimated, since a prevalence as high as 60% was reported in another study carried out at a secondary care level in the UK and one-fourth of included patients admitted never having disclosed their incontinence before [5]. Appropriate management of IBS is required to control incontinence in affected individuals. We will briefly summarize the current view on IBS with a specific focus on the role of changes and modulation of gut microbiota.

19.2 Clinical Features

IBS is a functional gastrointestinal disorder (FGID), now termed disorder of gut-brain interaction (DGBI) [6], characterized by symptoms including abdominal pain associated with a change in stool form or frequency [2]. IBS diagnosis is based on the patient's self-reported symptoms and no validated biomarkers for diagnosis are available.

IBS is defined by symptom-based diagnostic criteria known as the “Rome criteria”, which include recurrent abdominal pain, on average at least 1 day per week in the last 3 months, associated with 2 or more of the following: related to defecation, associated with a change in frequency of stool, associated with a change in form (appearance) of stool [2]. According to the Bristol Stool Form Scale, patients are categorized in IBS-D, IBS-C, and IBS-M [2].

Supportive symptoms include defecation straining, feeling of incomplete bowel movement, urgency, passing mucus, and bloating. IBS patients also often complain of mood problems, other gastrointestinal symptoms such as heartburn and extraintestinal symptoms such as fibromyalgia, headache, back pain, and genitourinary symptoms such as, in women, the so-called pelvic pain referred to as a bladder pain, worsening of symptoms during menstruation, dyspareunia or other gynecologic symptoms. AI is reported by up to 20% of IBS patients [3, 4]. These symptoms increase the severity of IBS and may be associated with psychological factors.

19.3 Epidemiology and Risk Factors

IBS prevalence is highly variable among different geographical regions with averages around 10% and it is higher in women than men and in subjects aged less than 50 years old [7]. The peak incidence of IBS was observed in the third and fourth decades of life [7], although in certain countries the condition is more prevalent in younger men aged 16–30 years. Even if it is not a life-threatening condition, IBS impacts significantly quality of life and places a considerable burden both on the individual sufferers and society as a whole. Due to the relevant reduction of quality of life, patients would sacrifice on average up to 15 years of their remaining life expectancy for an immediate cure. It has been estimated that the annual direct and indirect costs related to IBS are estimated to be up to €8 billion in Europe [8].

An ascertained risk factor for IBS is a previous enteric infection [9, 10], either bacterial, viral or protozoal, which is now termed postinfection IBS (PI-IBS) [11].

A recent meta-analysis [12] showed a fourfold risk increase in developing IBS in individuals exposed to an enteric infection, additionally reporting that female sex, severe infection course, antibiotic intake and previous psychological comorbidities were associated to the development of this condition. Interestingly, a long-term follow-up study over a 16-year period reported an IBS prevalence of 36.8% in a cohort with culture-proven *Salmonella enteritidis* infection [9].

19.4 Diagnosis

The most recent guidelines recommend a positive diagnosis of IBS simply using symptom-based diagnostic criteria included in the “Rome criteria”, in the absence of warning signs. In order to assess the presence of rectal disorders including both AI and outlet obstruction, clinicians should also ask about bladder and urinary symptoms and the need to strain or digitate the anal canal or vagina or support the perineum to facilitate the evacuation of stool [13].

In the presence of warning signs, a thorough evaluation is required that includes colonoscopy and other symptom-guided diagnostic tests [14]. A proctological examination should be performed to identify signs of pelvic floor and defecatory disorders, which should be further investigated by anorectal manometry, balloon expulsion test and defecography [14].

Among the laboratory tests suggested, a full blood count, C-reactive protein and serological screening for celiac disease should be performed. Differential diagnoses that should be considered include microscopic colitis, Crohn’s disease, bile acid diarrhea and small intestinal bacterial overgrowth for patients with IBS-D, and chronic constipation (without pain) for those with IBS-C.

19.5 Pathophysiology

In the past, IBS was considered to be the consequence of dysregulation of the brain-gut axis, associated with psychosocial factors, including stress, altered motility, and visceral hypersensitivity [6]. Current evidence views IBS as a disorder characterized by a complex interplay involving several peripheral and central factors, including: genetic predisposition, alterations in gastrointestinal sensory-motor function, intestinal dysbiosis, increased intestinal permeability, mucosal low-grade inflammation or immune activation, neuroendocrine abnormalities, food sensitivity/allergy and psychosocial factors [14, 15]. The main features of the current understanding of IBS pathophysiology are summarized in Fig. 19.1 [14, 15].

There are at least three clinical scenarios that link IBS with the gut microbiota, all characterized by disruption of the balance between the host and the intestinal microbial ecosystem: (1) more than 10% of patients with IBS develop their symptoms after infectious gastroenteritis (PI-IBS) [11, 15]; (2) disruption of gut microbiota with systemic antibiotics increases the risk of IBS; (3) treatments aimed at modifying gut microbiota composition can improve symptoms in IBS.

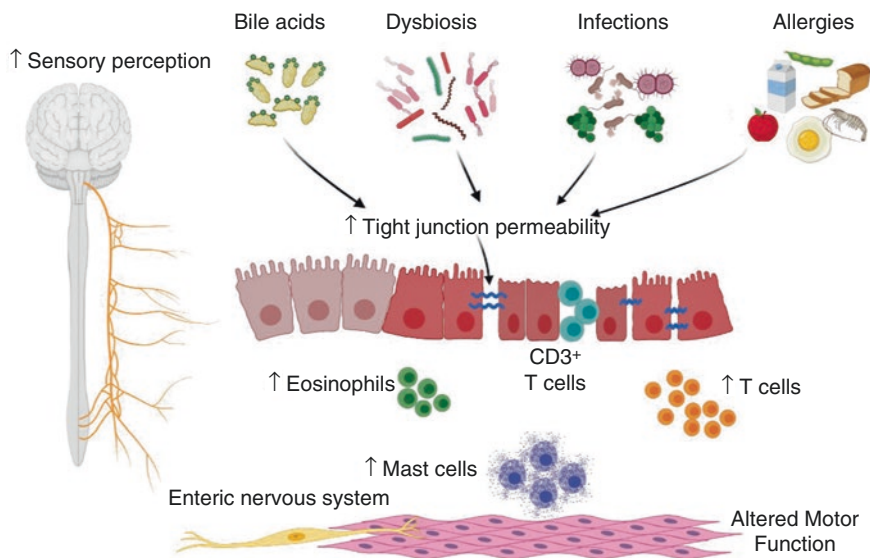


Fig. 19.1 Main pathophysiological mechanisms of intestinal dysfunction and symptom perception in patients with irritable bowel syndrome

Growing evidence indicates that dysbiosis, occurring when the diversity, composition, and/or functions of the intestinal microbial ecosystem are disrupted, could contribute to the alteration of the usual intestinal functions, with implications in the development, progression, and symptom flare-up of several diseases [15]. Among these, AI and IBS are both characterized by dysbiosis associated with impairment of the intestinal physiology [16].

19.6 Gut Microbiota Characterization

The human gut harbors a community of about 10^{14} microorganisms including bacteria, archaea, microeukaryotes (i.e., fungi and protists) and viruses, resulting in a mutually beneficial relationship with the host. The gut microbiota participates in digestive functions, shapes the host immune system, modulates host metabolisms, influences local and systemic processes (i.e., vitamin intake and nutrient metabolism), and protects against pathogens.

A reduced microbial diversity characterizes patients with IBS-D, suggesting that the microbial species involved in maintaining homeostasis may be missing [17]. An association between lower diversity and looser stool has been reported, suggesting a potential relevance in the pathophysiology of AI [18].

Most studies agree in showing increased *Firmicutes* and decreased *Bacteroidetes* in IBS. *Bacteroides* are increased in patients with IBS-D and associated with mucosal low-grade inflammation. Conversely, protective bacteria belong to *Clostridiales*, especially *Faecalibacterium prausnitzii*, an anaerobic butyrate-producing bacteria

which has already been extensively studied for its favorable role in controlling inflammation and maintaining gut-barrier homeostasis. Reduced diversity, reduced exhaled methane, relative reduction of *Methanobacteriales* and *Prevotella* enterotype and abundance of *Bacteroides* enterotype have been reported to be linked to symptom severity.

Recent advances in metabolomics and metagenomics analyses of microbiota have led to the idea that symptoms could be caused by modification of the function more than the structure of gut microbiota. A meta-analysis identified low levels of fecal propionate and butyrate in IBS-C and a higher proportion of butyrate in IBS-D, compared to controls [19]. Other studies suggested a role of SCFAs-producing bacteria such as *Ruminococcaceae*, unknown *Clostridiales* and *Erysipelotrichaceae* in dysbiosis of IBS-D patients. A decreased availability of butyrate represents a potential attractive therapeutic target in IBS, as suggested by a recent study showing that *Lactobacillus paracasei* CNCM I-1572 improves symptoms and modulates gut microbiota structure and function through increased levels of acetate and butyrate in patients with IBS [20]. A recent trial aimed at assessing stool metabolome and microbiome in female patients with AI and the potential implication of metabolites and microbial composition to predict response to therapy remains to be fully analyzed [21]. All together these data constitute the rationale for pharmacological and nonpharmacological treatments aimed at modulating the intestinal microbiota in patients with IBS and AI.

19.7 Gut Microbiota Modulation

Compelling evidence suggests a key therapeutic role of microbial modification, including diet, prebiotics, probiotics, poorly-absorbable antibiotics or fecal microbiota transplantation (FMT), in IBS.

The dietary approach represents an interesting first-line treatment opportunity for IBS with a potential impact on gut microbiome. A low fermentable oligo-, di-, and monosaccharide and polyol (FODMAP) diet reduces fermentation and improves global symptoms as well as abdominal pain in patients with IBS, particularly with IBS-D [22]. Notably, the low FODMAP diet has been reported to benefit both stool consistency and fecal incontinence in patients with AI associated with loose stool [23].

Increasing interest exists on the role of prebiotics, probiotics, and symbiotics in the management of IBS. Unfortunately, the clinical evidence of probiotic efficacy in disease states is still inconclusive. Although international guidelines suggest against the use of probiotics in IBS [24], recent well-performed trials using well-defined end-points show promising results [20]. Based on these data, the British Society of Gastroenterology (BSG) guidelines on the management of IBS suggest that probiotics, as a group, may be an effective treatment for global symptoms and abdominal pain in IBS [25]. Further studies are needed to clarify definitely the potential role of probiotics in the management of patients with IBS and AI.

Rifaximin, a poorly-absorbable nonsystemic antibiotic, was found to be more effective than placebo in reducing IBS global symptoms, bloating, abdominal pain and loose or watery stools of patients with IBS without constipation [25]. Furthermore, repeat treatment with rifaximin was found to be effective and safe, without developing bacterial resistance. The main international guidelines on IBS suggest the use of rifaximin to treat IBS-D [24].

Fecal microbiota transplantation (FMT)—the process of transferring intestinal microbiota from a healthy donor into the gastrointestinal tract of a patient with dysbiosis, which proved to be an effective treatment of recurrent *Clostridioides difficile* infection—has been evaluated in IBS with mixed results [26]. Recently, a large single-center trial including IBS of all subtypes showed that FMT (30 g and 60 g), acquired from a single superdonor in excellent health and delivered into the distal duodenum, was significantly more effective than placebo (autologous FMT) [27].

19.8 Conclusions

IBS is a frequent clinical condition characterized by pain and stool abnormalities. IBS-D represents the most frequent cause of chronic or recurrent diarrhea in industrialized countries, thus constituting a major threat for AI patients. IBS-D and AI also seem to share some common pathophysiological mechanisms. Treating AI without taking into consideration bowel functions as a whole would represent a major mistake. Thus, recognizing the treatable underlying causes of IBS is mandatory for a correct therapeutic management of these complex cases. Our understanding of IBS pathophysiology has enormously improved over the last two decades and several effective therapeutic approaches are available.

References

1. Rao SSC. Diagnosis and management of fecal incontinence. *Am J Gastroenterol*. 2004;99(8):1585–604.
2. Mearin F, Lacy BE, Chang L, et al. Bowel disorders. *Gastroenterology*. 2016;150(6):1393–407.e5.
3. Simrén M, Palsson OS, Heymen S, et al. Fecal incontinence in irritable bowel syndrome: prevalence and associated factors in Swedish and American patients. *Neurogastroenterol Motil*. 2017;29(2):e12919. <https://doi.org/10.1111/nmo.12919>.
4. Black CJ, Ford AC. Faecal incontinence is not rare in irritable bowel syndrome. *Frontline Gastroenterol*. 2020;11(6):494–6.
5. Atarodi S, Rafieian S, Whorwell PJ. Faecal incontinence—the hidden scourge of irritable bowel syndrome: a cross-sectional study. *BMJ Open Gastroenterol*. 2015;1(1):e000002. <https://doi.org/10.1136/bmjgast-2014-000002>.
6. Drossman DA. Functional gastrointestinal disorders: history, pathophysiology, clinical features, and Rome IV. *Gastroenterology*. 2016;150(6):1262–79.e2.
7. Lovell RM, Ford AC. Global prevalence of and risk factors for irritable bowel syndrome: a meta-analysis. *Clin Gastroenterol Hepatol*. 2012;10(7):712–21.e4.
8. Flacco ME, Manzoli L, De Giorgio R, et al. Costs of irritable bowel syndrome in European countries with universal healthcare coverage: a meta-analysis. *Eur Rev Med Pharmacol Sci*. 2019;23(7):2986–3000.

9. Cremon C, Stanghellini V, Pallotti F, et al. Salmonella gastroenteritis during childhood is a risk factor for irritable bowel syndrome in adulthood. *Gastroenterology*. 2014;147(1):69–77.
10. Card T, Enck P, Barbara G, et al. Post-infectious IBS: defining its clinical features and prognosis using an internet-based survey. *United European Gastroenterol J*. 2018;6(8):1245–53.
11. Barbara G, Grover M, Bercik P, et al. Rome Foundation working team report on post-infection irritable bowel syndrome. *Gastroenterology*. 2019;156(1):46–58.e7.
12. Donnachie E, Schneider A, Mehring M, Enck P. Incidence of irritable bowel syndrome and chronic fatigue following GI infection: a population-level study using routinely collected claims data. *Gut*. 2018;67(6):1078–86.
13. Camilleri M. Diagnosis and treatment of irritable bowel syndrome: a review. *JAMA*. 2021;325(9):865–77.
14. Ford AC, Sperber AD, Corsetti M, Camilleri M. Irritable bowel syndrome. *Lancet*. 2020;396(10263):1675–88.
15. Barbara G, Feinle-Bisset C, Ghoshal UC, et al. The intestinal microenvironment and functional gastrointestinal disorders. *Gastroenterology*. 2016;150(6):1305–18.e8.
16. Rao SSC, Bharucha AE, Chiarioni G, et al. Anorectal disorders. *Gastroenterology*. 2016;150(6):1430–42.e4.
17. Jeffery IB, Das A, O’Herlihy E, et al. Differences in fecal microbiomes and metabolomes of people with vs without irritable bowel syndrome and bile acid malabsorption. *Gastroenterology*. 2020;158(4):1016–28.e8.
18. Hollister EB, Cain KC, Shulman RJ, et al. Relationships of microbiome markers with extraintestinal, psychological distress and gastrointestinal symptoms, and quality of life in women with irritable bowel syndrome. *J Clin Gastroenterol*. 2020;54(2):175–83.
19. Sun Q, Jia Q, Song L, Duan L. Alterations in fecal short-chain fatty acids in patients with irritable bowel syndrome: a systematic review and meta-analysis. *Medicine (Baltimore)*. 2019;98(7):e14513. <https://doi.org/10.1097/md.00000000000014513>.
20. Cremon C, Guglielmetti S, Gargari G, et al. Effect of *Lactobacillus paracasei* CNCM I-1572 on symptoms, gut microbiota, short chain fatty acids, and immune activation in patients with irritable bowel syndrome: a pilot randomized clinical trial. *United Eur Gastroenterol J*. 2018;6(4):604–13.
21. Arya LA, Richter HE, Jelovsek E, et al. Metabolites and microbial composition of stool of women with fecal incontinence: study design and methods. *Neurourol Urodyn*. 2018;37(2):634–41.
22. van Lanen AS, de Bree A, Greyling A. Efficacy of a low-FODMAP diet in adult irritable bowel syndrome: a systematic review and meta-analysis. *Eur J Nutr*. 2021;60(6):3505–22.
23. Menees SB, Chandhrasekhar D, Liew EL, Chey WD. A low FODMAP diet may reduce symptoms in patients with fecal incontinence. *Clin Transl Gastroenterol*. 2019;10(7):e00060. <https://doi.org/10.14309/ctg.0000000000000060>.
24. Lacy BE, Pimentel M, Brenner DM, et al. ACG clinical guideline: management of irritable bowel syndrome. *Am J Gastroenterol*. 2021;116(1):17–44.
25. Vasant DH, Paine PA, Black CJ, et al. British Society of Gastroenterology guidelines on the management of irritable bowel syndrome. *Gut*. 2021;70(7):1214–40.
26. Ianiro G, Eusebi LH, Black CJ, et al. Systematic review with meta-analysis: efficacy of faecal microbiota transplantation for the treatment of irritable bowel syndrome. *Aliment Pharmacol Ther*. 2019;50(3):240–8.
27. El-Salhy M, Hatlebakk JG, Gilja OH, et al. Efficacy of faecal microbiota transplantation for patients with irritable bowel syndrome in a randomised, double-blind, placebo-controlled study. *Gut*. 2020;69(5):859–67.

Open Access This chapter is licensed under the terms of the Creative Commons Attribution-NonCommercial-NoDerivatives 4.0 International License (<http://creativecommons.org/licenses/by-nc-nd/4.0/>), which permits any noncommercial use, sharing, distribution and reproduction in any medium or format, as long as you give appropriate credit to the original author(s) and the source, provide a link to the Creative Commons license and indicate if you modified the licensed material. You do not have permission under this license to share adapted material derived from this chapter or parts of it.

The images or other third party material in this chapter are included in the chapter's Creative Commons license, unless indicated otherwise in a credit line to the material. If material is not included in the chapter's Creative Commons license and your intended use is not permitted by statutory regulation or exceeds the permitted use, you will need to obtain permission directly from the copyright holder.





Mario Morino and Antonella Nicotera

20.1 Definition and Risk Factors

Low anterior resection syndrome (LARS) represents a long-term complication of sphincter-saving rectal resection and includes a variety of symptoms of bowel dysfunction, such as urgency, gas and stool incontinence, stool fragmentation, and obstructed defecation. In 2012, Briant proposed a universally accepted definition of LARS: “disordered bowel function after rectal resection, leading to a detriment in quality of life” [1]. Restoration of intestinal function generally occurs within approximately 18 months after surgery, after which further improvement over time is unlikely. This means that a percentage of patients will have permanent changes in bowel function [2]. There are several risk factors for LARS, as the genesis is multifactorial. The main are listed below [3].

20.1.1 Anal Sphincter Injury

The anal sphincter consists of:

- a component of involuntary (visceral) smooth muscle, innervated by the parasympathetic system through the pelvic splanchnic plexus, or internal anal sphincter, responsible for contraction of the anus;
- a component of voluntary (somatic) striated muscle, innervated by the first branch of the pudendal nerve and the inferior rectal nerve, i.e., the external anal sphincter.

M. Morino · A. Nicotera (✉)

Department of Surgical Sciences, University of Turin, Turin, Italy

e-mail: mario.morino@unito.it; antonella.nicotera@gmail.com

A neurological and/or structural alteration of the internal sphincter causes passive incontinence of gas and stools, while alterations of the external sphincter cause defecatory urgency, or the inability to maintain a prolonged voluntary contraction of the anus, with consequent loss of gas and/or stool. One of the possible causes of internal sphincter dysfunction can be attributed to a reduction in mean anal pressure at rest after resection, which is not recovered over time [4], while alterations in the external sphincter cause a reduction in the tone of anal contraction.

20.1.2 Type of Anastomosis and Configuration of the Neorectum

The rectum represents a natural reservoir for stool; therefore this function is lost when it is removed. The rectal stump has a different capacity according to the residual rectum. The reduced capacity of the new reservoir associated with the end-to-end colorectal or end-to-end coloanal anastomosis is a risk factor for urgency and incontinence. For this reason, several alternative techniques for the configuration of a neorectum have been introduced, including the choice of latero-terminal anastomosis [5], a J-pouch anastomosis [6] or transverse colectomy [7]. In a Cochrane review published in 2005, Brown et al. showed that patients with colic J-pouch had a lower defecatory frequency compared with patients who had an end-to-end anastomosis performed up to 12 months after resection, although this difference tended to decrease after 18 months. The same result is obtained when the colic J-pouch is compared with the latero-terminal anastomosis [8]. Another important factor is the variation in the compliance of the neorectum after resection. Reduced compliance could be associated with defecatory urgency, fecal incontinence (FI) and increased defecatory frequency [9].

20.1.3 Motility of Neorectum

Peristaltic activity changes after resection of the rectum. Mochiki et al. in 2001 conducted a study on the motility of the colon proximal to the anastomosis induced by a standard meal, in patients undergoing rectal resection. They showed significantly increased colic activity after low anterior resection compared with healthy subjects [10]. Iizuka et al. in 2004 evaluated intestinal motility in 60 patients undergoing rectal resection, in 26 of whom they noted short and irregular peristaltic waves (so-called “spastic waves”) at the level of the neorectum; these patients reported soiling, defecatory urgency and multiple bowel movements [11]. The causes of these spastic waves are still unclear.

20.1.4 Neoadjuvant Radiotherapy/Radio-Chemotherapy

Adjuvant or neoadjuvant radiotherapy (nRT) is one of the main risk factors for LARS, as it is responsible for hyposensitivity to mechanical and thermal stimuli due

to reduced function of the afferent nervous plexus. In a study conducted by Hughes, the likelihood of developing major LARS was higher in patients who had previously undergone neoadjuvant radio-chemotherapy (nCRT) ($p < 0.001$) [12]. In Bondeven's study, nRT was found to be an independent risk factor for major LARS (OR: 3.5; 95% CI) even in the presence of a large residual rectal stump [13]. There are also several studies in the literature that focus on the specific type of nRT (short-course, long-course). Regarding hypofractionated nRT, Peeters and the Dutch group in 2005 demonstrated that patients undergoing short-course nRT followed by total mesorectal excision developed late side effects of intestinal dysfunction more frequently than patients not undergoing radiotherapy [14]. In 2019, Sun showed that patients undergoing long-course nRT had a more severe form of LARS and worse quality of life; in addition, multivariate analysis confirmed that nRT, diverting ileostomy and the height of the anastomosis represented independent risk factors for major LARS [15].

20.1.5 Total Mesorectal Excision and Height of Anastomosis

The height of the rectal neoplasia as well as the height of the colorectal anastomosis after resection associated with total mesorectal excision (TME) affects the functional outcome after resection. Localization in the lower/middle rectum, and consequently an anastomosis performed close to the anal margin, has been identified among the main risk factors for LARS. In a study by Battersby et al., localization of the tumor within 6 cm of the anal margin was a high-risk factor for major LARS, and the associated nRT increased the risk [16]. Similar results were obtained by Ekkarat with an anastomotic height less than 5 cm from the anal margin [17] and by Bregendahl, showing that TME, compared with partial mesorectal excision (PME), was an independent risk factor for the development of major LARS (OR adjusted for major LARS: 2.31; 95% CI 1.69–3.16) [18]. Using postoperative magnetic resonance imaging, Bondeven evaluated the correlation between the length of the rectal stump after resection and postoperative bowel function: the risk for major LARS was 46% in patients with less than 4 cm of residual rectal stump compared to 10% in patients over 4 cm ($p < 0.0001$) [13].

20.1.6 Diverting Stoma (Ileo-Colostomy)

Performing a diverting stoma (mainly ileostomy) seems to reduce the risk of anastomotic leak, although it compromises gas and stool continence, especially when stoma closure is delayed (>3–6 months) [19]. In this regard, Hughes highlighted a 3.7 times increased risk of developing LARS in patients with delayed stoma closure: with a median time to closure of 214 days (range 50–1194 days), multivariate analysis showed that stoma closure within 6 months was a protective factor (OR: 0.2; $p < 0.01$). Probably, inactivity of the pelvic floor and anal sphincter for a prolonged period with an ileostomy may explain this [12]. A systematic review and

meta-analysis on the impact of derivative ileostomy and timing of closure on bowel function in patients undergoing low anterior rectal resection has recently been published. The presence of a derivative ileostomy and its prolonged closing time seem to be associated with an increased rate of intestinal dysfunction. Etiopathogenesis is not univocal as the hypotheses are innumerable, from alteration of the bacterial flora to de-functionalization of the anal sphincter and pelvic floor muscles [20].

20.2 Prevalence

Epidemiological data relating to LARS are still very heterogeneous. Approximately more than 70% of patients undergoing colorectal surgery develop alterations in intestinal function, and some of them develop the actual syndrome. In 2018 Croese et al. published a meta-analysis focusing on the prevalence rate of LARS in 11 series with a median follow-up of 18 months or more. Over a wide range of prevalence rates from 17.8% to 56%, the estimated meta-analysis prevalence was 41% (95% CI 34–48) ($p < 0.001$) [3].

20.3 Diagnosis

Several tools are available for the classification of intestinal dysfunction and diagnosis of LARS. FI is generally measured through the Wexner Score, also known as the Cleveland Clinic Incontinence Score [21], the Rockwood Fecal Incontinence Severity Index and the St. Mark's Fecal Incontinence Grading Score [22]. Specific questionnaires for the diagnosis of LARS are the Memorial Sloan Kettering Cancer Center Bowel Function Instrument (MSKCC-BFI) [23] and the LARS score [24].

20.3.1 LARS Score

The LARS score was developed and published in 2012 by Emmertsen and Laurberg. Previous clinical studies used incontinence scores to assess intestinal function, but these did not consider other symptoms such as urgency, stool fragmentation and difficulty in bowel emptying. The authors' intent was to assess the impact of each symptom on quality of life (QoL): gas incontinence and urgency were the most disabling symptoms for patients. The study included all patients undergoing low anterior resection from 2001 to 2007 in Denmark, finally resulting in a sample of 961 patients. The questionnaire consists of five questions and the answers are associated with a score, whose sum constitutes the final score. The final score is interpreted as follows: from 0 to 20 absence of LARS, 21–29 minor LARS, 30–42 major LARS [24].

In 2018, Battersby et al. developed a mathematical model, called POLARS (Pre-Operative Low Anterior Resection Syndrome Score), in order to predict postoperative intestinal function, estimating the hypothetical corresponding LARS score. The

parameters are: age at surgery; gender; nRT, distance of the tumor from the anal margin; performance of TME or PME; diverting stoma. The online nomogram can be easily used in clinical practice and allows the patient to be fully informed on the postoperative course [25].

20.4 Treatment

To date, there is no specific treatment for LARS. Instead, management is empirical and symptom-based, using existing therapies for FI, fecal urgency, and rectal evacuation disorders, such as anti-diarrheal drugs, anal plugs, biofeedback therapy, pelvic floor rehabilitation, colon irrigation or minimally invasive procedures such as sacral nerve stimulation [26]. A sequential or combined approach is currently chosen, starting from less invasive therapy, up to a definitive stoma in the most refractory cases.

20.4.1 Medical Treatments

Dietary regimens, probiotics, bulking agents, antidiarrheal drugs, steroids have been used to treat the symptoms of LARS, as they increase the tone of the anal sphincter and improve fecal continence. Itagaki et al. demonstrated the efficacy of serotonin receptor antagonists (5-HT3), commonly applied in irritable bowel syndrome, on LARS patients [27]. However, medical therapy is used for the control of a single symptom, FI in most cases, the impact on patients' QoL is limited, and the literature is lacking [28].

20.4.2 Physiotherapy

Physiotherapy treatments include biofeedback, pelvic floor muscle rehabilitation (PFMT) and rectal balloon training (RBT) and aim to restore muscle tone, coordination and time of contractions. Biofeedback therapy (BFT) is the first-line treatment for patients with FI. BFT consists of electromyographic stimulation of the pelvic floor muscles and the transformation of muscle responses (contraction, relaxation) into visual or acoustic signals. Liang et al. showed that BFT for LARS patients after rectal cancer surgery significantly improves incontinence and bowel frequency, but equally satisfactory results have not been shown in relieving symptoms of urgency [29]. PFMT is a technique that aims to maximize the tone of the pelvic floor and anal sphincter muscles through selective voluntary contractions and relaxation. PFMT seems to improve some of the symptoms of LARS, such as FI and stool fragmentation [30]. Finally, RBT is a rectal sensitivity training system based on gradual variations in the distension of the balloon. Bols et al. evaluated the efficacy of RBT combined with PFMT, highlighting beneficial effects on the control of urgency and on the function of the external anal sphincter [31].

20.4.3 Transanal Irrigation

Transanal irrigation (TAI) is a simple and effective treatment for patients with defecatory changes. It is technically easy to learn and can be self-administered. Instillation of water through a rectal catheter, which is held in place by an inflated balloon, promotes emptying of the rectum. Rosen et al. evaluated the efficacy of TAI in patients with LARS in a prospective study, reporting significant improvements in terms of defecatory frequency and known FI scores [32].

20.4.4 Neuromodulation

The two main neuromodulation methods are sacral nerve stimulation (SNS) and percutaneous stimulation of the tibial nerve, and both improve FI in patients not responding to medical therapy.

SNS consists of two phases: an initial 3-week phase of percutaneous stimulation to evaluate the patient's response, and a second phase of definitive implantation of a pulse generator, which occurs only if a >50% reduction in FI episodes per week is achieved during the first phase [33]. It is still debated how SNS works. The initial hypothesis was a peripheral effect on the anal sphincters, increasing the pressure at rest and the pressure of contraction. Given the effects of this method also outside the anorectal complex, more recent studies argue instead that the SNS works on the pelvic or central afferent plexus [34].

Percutaneous tibial nerve stimulation modulates sacral nerve function with indirect, low-voltage stimulation of the tibial nerve at the ankle through a thin needle electrode connected to an external pulse generator. This procedure involves inserting a small electrode on the medial malleolus adjacent to the posterior tibial nerve. The adhesive surface electrode is placed under the arch of the foot. These two electrodes are connected to a neurostimulator which generates electricity. The effects of this technique are well defined with regard to urinary incontinence; however, they are less delineated for FI, for which only case series have been reported in the literature. As with SNS, percutaneous stimulation of the tibial nerve works through retrograde stimulation of the pelvic nerves, via the posterior tibial nerve.

20.4.5 Stoma

In the case of failure of all conservative therapies and refractory incontinence, a definitive stoma or, in highly selected cases, anal sphincteroplasty surgery should be considered.

References

1. Bryant CLC, Lunniss PJ, Knowles CH, et al. Anterior resection syndrome. *Lancet Oncol.* 2012;13(9):e403–8.
2. Ho Y. Techniques for restoring bowel continuity and function after rectal cancer surgery. *World J Gastroenterol.* 2006;12(39):6252–60.
3. Croese AD, Loniea JM, Trollope AF, et al. A meta-analysis of the prevalence of low anterior resection syndrome and systematic review of risk factors. *Int J Surg.* 2018;56:234–41.
4. Williamson ME, Lewis WG, Finan PJ, et al. Recovery of physiologic and clinical function after low anterior resection of the rectum for carcinoma: myth or reality? *Dis Colon Rectum.* 1995;38(4):411–8.
5. Machado M, Nygren J, Golman S, Ljungqvist O. Similar outcome after colonic pouch and side-to-end anastomosis in low anterior resection for rectal cancer: a prospective randomized trial. *Ann Surg.* 2003;238(2):214–20.
6. Parc R, Tiret E, Frileux P, et al. Resection and colo-anal anastomosis with colonic reservoir for rectal carcinoma. *Br J Surg.* 1986;73(2):139–41.
7. Z'graggen K, Maurer CA, Buchler MW. Transverse coloplasty pouch. A novel neorectal reservoir. *Dig Surg.* 1999;16(5):363–6.
8. Brown CJ, Fenech DS, McLeod RS. Reconstructive techniques after rectal resection for rectal cancer. *Cochrane Database Syst Rev.* 2008;2008(2):CD006040. <https://doi.org/10.1002/14651858.cd006040.pub2>.
9. Gosselink MP, Zimmerman DD, West RL, et al. The effect of neo-rectal wall properties on functional outcome after colonic J-pouch-anal anastomosis. *Int J Colorectal Dis.* 2007;22(11):1353–60.
10. Mochiki E, Nakabayashi T, Suzuki H, et al. Barostat examination of proximal site of the anastomosis in patients with rectal cancer after low anterior resection. *World J Surg.* 2001;25(11):1377–82.
11. Iizuka I, Koda K, Seike K, et al. Defecatory malfunction caused by motility disorder of the neorectum after anterior resection for rectal cancer. *Am J Surg.* 2004;188(2):176–80.
12. Hughes DL, Cornish J, Morris C. Functional outcome following rectal surgery—predisposing factors for low anterior resection syndrome. *Int J Colorectal Dis.* 2017;32(5):691–7.
13. Bondeven P, Emmertsen KJ, Laurberg S, Pedersen BG. Neoadjuvant therapy abolishes the functional benefits of a larger rectal remnant, as measured by magnetic resonance imaging after restorative rectal cancer surgery. *Eur J Surg Oncol.* 2015;41(11):1493–9.
14. Peeters KCMJ, van de Velde CJH, Leer JWH, et al. Late side effects of short-course pre-operative radiotherapy combined with total mesorectal excision for rectal cancer: increased bowel dysfunction in irradiated patients—a Dutch colorectal cancer group study. *J Clin Oncol.* 2005;23(25):6199–206.
15. Sun W, Dou R, Chen J, et al. Impact of long-course neoadjuvant radiation on postoperative low anterior resection syndrome and quality of life in rectal cancer: post hoc analysis of a randomized controlled trial. *Ann Surg Oncol.* 2019;26(3):746–55.
16. Battersby NJ, Juul T, Christensen P, et al. Predicting the risk of bowel-related quality-of-life impairment after restorative resection for rectal cancer: a multicenter cross-sectional study. *Dis Colon Rectum.* 2016;59(4):270–80.
17. Ekkarat P, Boonpipattanapong T, Tantiphlachiva K, Sangkhathat S. Factors determining low anterior resection syndrome after rectal cancer resection: a study in Thai patients. *Asian J Surg.* 2016;39(4):225–31.
18. Bregendahl S, Emmertsen KJ, Lous J, Laurberg S. Bowel dysfunction after low anterior resection with and without neoadjuvant therapy for rectal cancer: a population-based cross-sectional study. *Colorectal Dis.* 2013;15(9):1130–9.
19. Gadan S, Floodeen H, Lindgren R, Matthiessen P. Does a defunctioning stoma impair anorectal function after low anterior resection of the rectum for cancer? A 12-year follow-up of a randomized multicenter trial. *Dis Colon Rectum.* 2017;60(8):800–6.

20. Vogel I, Reeves N, Tanis PJ, et al. Impact of a defunctioning ileostomy and time to stoma closure on bowel function after low anterior resection for rectal cancer: a systematic review and meta-analysis. *Tech Coloproctol.* 2021;25(7):751–60.
21. Jorge JM, Wexner SD. Etiology and management of fecal incontinence. *Dis Colon Rectum.* 1993;36(1):77–97.
22. Vaizey CJ, Carapeti E, Cahill JA, et al. Prospective comparison of faecal incontinence grading systems. *Gut.* 1999;44(1):77–80.
23. Temple LK, Bacik J, Savatta SG, et al. The development of a validated instrument to evaluate bowel function after sphincter-preserving surgery for rectal cancer. *Dis Colon Rectum.* 2005;48(7):1353–65.
24. Emmertsen KJ, Laurberg S. Low anterior resection syndrome score: development and validation of a symptom-based scoring system for bowel dysfunction after low anterior resection for rectal cancer. *Ann Surg.* 2012;255(5):922–8.
25. Battersby NJ, Bouliotis G, Emmertsen KJ, et al. Development and external validation of a nomogram and online tool to predict bowel dysfunction following restorative rectal cancer resection: the POLARS score. *Gut.* 2018;67(4):688–96.
26. Dulskas A, Smolskas E, Kildusiene I, Samalavicius NE. Treatment possibilities for low anterior resection syndrome: a review of the literature. *Int J Colorectal Dis.* 2018;33(3):251–60.
27. Itagaki R, Koda K, Yamazaki M, et al. Serotonin (5-HT3) receptor antagonists for the reduction of symptoms of low anterior resection syndrome. *Clin Exp Gastroenterol.* 2014;7:47–52.
28. Martellucci J. Low anterior resection syndrome: a treatment algorithm. *Dis Colon Rectum.* 2016;59(1):79–82.
29. Liang Z, Ding W, Chen W, et al. Therapeutic evaluation of biofeedback therapy in the treatment of anterior resection syndrome after sphincter-saving surgery for rectal cancer. *Clin Colorectal Cancer.* 2016;15(3):e101–7.
30. Visser WS, Te Riele WW, Boerma D, et al. Pelvic floor rehabilitation to improve functional outcome after a low anterior resection: a systematic review. *Ann Coloproctol.* 2014;30(3):109–14.
31. Bols E, Berghmans B, de Bie R, et al. Rectal balloon training as add-on therapy to pelvic floor muscle training in adults with fecal incontinence: a randomized controlled trial. *Neurourol Urodyn.* 2012;31(1):132–8.
32. Rosen H, Robert-Yap J, Tentschert G, et al. Transanal irrigation improves quality of life in patients with low anterior resection syndrome. *Colorectal Dis.* 2011;13(10):e335–8.
33. Mege D, Meurette G, Vitton V, et al. Sacral nerve stimulation can alleviate symptoms of bowel dysfunction after colorectal resections. *Colorectal Dis.* 2017;19(8):756–63.
34. Carrington EV, Evers J, Grossi U, et al. A systematic review of sacral nerve stimulation mechanisms in the treatment of fecal incontinence and constipation. *Neurogastroenterol Motil.* 2014;26(9):1222–37.

Open Access This chapter is licensed under the terms of the Creative Commons Attribution-NonCommercial-NoDerivatives 4.0 International License (<http://creativecommons.org/licenses/by-nc-nd/4.0/>), which permits any noncommercial use, sharing, distribution and reproduction in any medium or format, as long as you give appropriate credit to the original author(s) and the source, provide a link to the Creative Commons license and indicate if you modified the licensed material. You do not have permission under this license to share adapted material derived from this chapter or parts of it.

The images or other third party material in this chapter are included in the chapter's Creative Commons license, unless indicated otherwise in a credit line to the material. If material is not included in the chapter's Creative Commons license and your intended use is not permitted by statutory regulation or exceeds the permitted use, you will need to obtain permission directly from the copyright holder.





Incontinence-Associated Dermatitis: An Insidious and Painful Condition

21

Graziella Babino and Giuseppe Argenziano

21.1 Introduction

Incontinence-associated dermatitis (IAD) is a common and under-recognized painful skin condition, caused by erosion of the skin from chronic exposure to urine, stool, or both, from incontinence [1]. Patients with IAD experience considerable discomfort, with pain, burning and itching in the affected areas (buttocks, perineum and gluteal clefts) [1–3]. IAD can result in loss of independence, depression, sleep disruption and worsening of urinary and fecal soiling [4–7]. It is considered to be one of the four clinical manifestations of moisture-associated skin damage (MASD). MASD is defined as “inflammation and erosion of the skin caused by prolonged exposure to various sources of moisture, including urine or stool, perspiration, wound exudate, mucus, or saliva” [2]. The other forms of MASD are intertriginous dermatitis, periwound moisture-associated dermatitis and peristomal moisture-associated dermatitis. Identifying the correct cause of and differentiating IAD from other skin conditions are imperative to guide prevention and treatment [1, 3, 7].

21.2 Prevalence

IAD is an under-reported health condition. Depending on the type of setting and population studied, prevalence ranges between 5.2% and 46%. Epidemiologic analysis of a multisite database revealed an overall IAD prevalence rate of 21.3%, and a rate of 45.7% among patients with incontinence [3].

In a study performed with 376 patients (average age of 62 years) from an Australian hospital, IAD was present in 10% of the elderly patients [8]. However, in a multicenter survey developed with 51,045 patients admitted to hospitals in the

G. Babino · G. Argenziano (✉)

Dermatology Unit, University of Campania Luigi Vanvitelli, Naples, Italy

e-mail: graziella.babino@hotmail.it; giuseppe.argenziano@unicampania.it

United States and Canada (average age was 65 years), the condition was detected in 4.1% of the elderly patients [9].

Patients in long-term care settings are at greater risk of IAD because they are older and are more likely to be incontinent [10, 11]. In a study of German long-term care facilities, 5.2% of the overall patient population was found to have IAD while prevalence among the incontinent sample was 21% [12]. In a study of long-term care facilities in the United States, the overall prevalence of IAD was 5.7%; prevalence among the incontinent population was not reported [11]. An interventional study conducted at a Belgian long-term care facility showed baseline IAD prevalence of 22.8% in the control group and 22.3% in the experimental group of chronically incontinent (urine, fecal, or dual) subjects [13].

In a recent retrospective analysis in multiple care settings in the US and Canada, IAD prevalence in the entire patient population was 4.3% while incontinence prevalence was 18%. Among incontinent patients, the prevalence of IAD ranged from 8.4% in long-term care facilities to 19% in acute care facilities. Facilities with higher rates of incontinence did not necessarily have a higher prevalence of IAD. IAD prevalence by incontinence type ranged from 12% for patients with urinary incontinence to 26% for patients with fecal management systems [9].

The prevalence of IAD (formerly known as “diaper dermatitis”) in infants is estimated to be 7–35%, with the peak occurring between 9 and 12 months [14]. In the acute care setting, Heimall et al. [15] reported a 24% prevalence, whereas Noonan et al. [16] reported a prevalence of 17%.

The variability in the prevalence of IAD can be attributed to the absence of an internationally approved method, as well as the difficulty in identifying it. The wide range of prevalence demonstrates this large variability can vary substantially depending on whether continent patients were included in the analysis, the types of incontinence included and the types of care setting studied, considering that most of the studies are developed in long-term care settings for the elderly.

21.3 Pathophysiology

IAD pathophysiology is related to both recurrent chemical and physical irritation of the skin barrier, triggering inflammation and subsequent skin damage. Repeated exposure to urine and/or feces can lead to changes in skin pH from the normal acidic pH of 4–6 to an alkaline pH (>7). Using alkaline soaps can also increase the skin’s pH. Once the skin pH is raised into the alkaline range, the skin lipids are altered, leaving the skin vulnerable to damage. This is because enzymes such as alkaline ceramidase have increased activity at alkaline pH levels [17, 18]. Higher activity of alkaline ceramidase has been found in older adult skin and may explain why older adult skin is more vulnerable to damage from incontinence [17–19]. Infant skin is not mature at birth, because the epidermal barrier is formed during the third trimester and increases during maturity. Hence, infants are at risk of increased transepidermal water loss, experience increased absorption of topical agents, and have increased susceptibility to chemical and mechanical injury [20, 21].

21.4 Risk Factors

Factors that predispose to IAD include immobility, obesity, illness, nutritional impairment, reduced cognitive status, immunosuppression, and any impairment that prevents adequate hygiene. Essentially, all patients with urinary and/or fecal incontinence are at risk of developing IAD [22]. Interestingly, although many of these risk factors are more common with aging, age itself does not appear to be an independent risk factor for the development of IAD. Some authors consider the age factor as important for the occurrence of this type of lesion, highlighting that the risk increases proportionally with age, as the increase in the year of life corresponds to a 3% increase in the risk of IAD. Indeed, the aging process favors the appearance of comorbidities and contributes to hospitalization, and factors such as diaper use, humidity, immobility and infectious agents, predispose to the development of skin lesions, such as IAD [23, 24].

21.5 Clinical Presentation

Typically, IAD presents as a form of irritant dermatitis with inflammation of the skin surface characterized by erythema and, in extreme cases, swelling and blister formation (Figs. 21.1 and 21.2) [4]. Erythema is caused by the dilatation of cutaneous blood vessels and is considered a key clinical sign of IAD [25]. The lesions mostly occur in areas of the skin exposed to urine or feces, generally affecting the labia in women and the scrotum in men, as well as the inner thighs and buttocks in both sexes [26]. IAD is often accompanied by discomfort, burning, tingling, itching and pain in the affected areas, due to the inflammatory nature of the condition and thus has a significant effect on overall quality of life [5].

Fig. 21.1 Incontinence-associated dermatitis: acute inflammatory phase associated with candidiasis, located on the perianal, gluteal, and sacral region

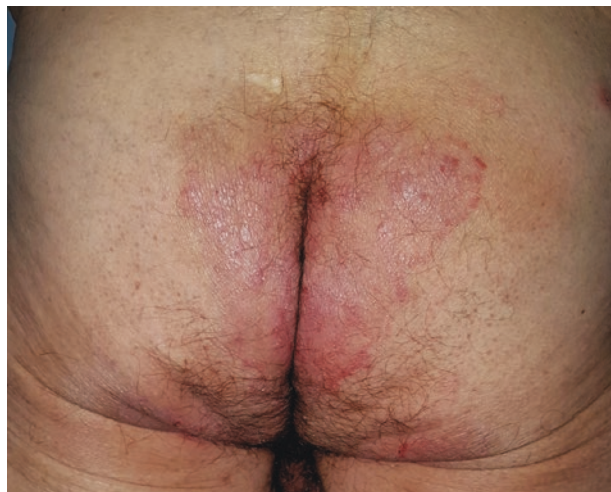
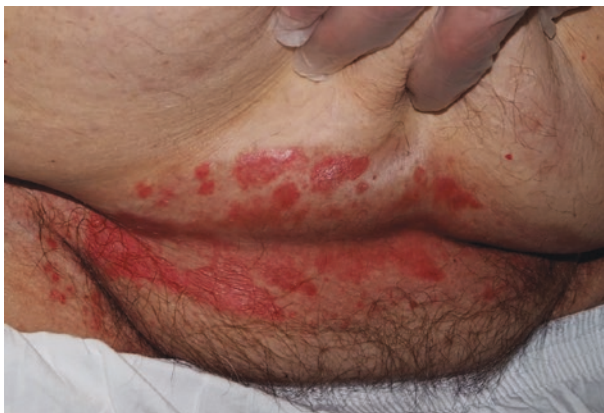
Fig. 21.2 Incontinence-associated dermatitis on the buttocks characterized by multiple erythematous macular lesions



If untreated, the lesions rapidly lead to excoriation and breakdown of the skin, which may subsequently become infected by the skin flora. Secondary infection by bacteria is suggested by the presence of purulent exudate and/or the green appearance in the wound bed, suggesting a *Pseudomonas aeruginosa* infection [27]. On the other hand, white pustules surrounding the open lesion (so-called “satellite lesions” or “islands in front of the coast”) indicate a possible contamination with yeast, suggesting a *Candida albicans* infection [28].

21.6 Differential Diagnosis

IAD can be difficult to diagnose and differentiate from other skin conditions and is often mistaken for a pressure ulcer [3, 4]. However, as patients with incontinence are often at increased risk of pressure ulcers, it can be difficult to distinguish between the two [29, 30]. Pressure ulcers are usually located over bony prominences, or where soft tissues experience pressure from a hard device such as a urinary catheter or a nasal cannula. In contrast, IAD is located in the anal cleft, perianal region and groin. IAD on the sacral region can be difficult to distinguish from superficial pressure ulcers. The shape of the majority of pressure ulcers is well delineated (round or oval) or, when caused by external devices, can be rectangular or linear. IAD lesions, on the other hand, are more diffuse and less delineated. A typical phenomenon in IAD is the symmetrical “kissing” which can be seen on both sides of the buttocks. Black necrosis may occur in pressure ulcers but is not seen in IAD. Yellow slough can be observed in both diagnoses. Pressure ulcers can be superficial to deep, whereas IAD remains superficial [31].

Moreover, the differential diagnosis includes a significant number of skin conditions. Psoriasis inversa and seborrheic dermatitis of the genital region resemble the clinical picture of IAD. In addition, when itching is a prominent symptom, it might be necessary to consider allergic contact dermatitis in the differential diagnosis. Acrodermatitis enteropathica and autoimmune bullous skin diseases such as bullous pemphigoid should be considered in IAD with vesicles and bullae or with skin loss.

21.7 Management: Prevention and Treatment

Prevention is the primary goal in the management of IAD and should consist of several evidence-based strategies aimed at maintaining skin integrity. Particularly, any patient with incontinence issues is at risk of developing IAD. Hence, appropriate selection of the type of containment device used, skin cleansing techniques, and the application of topical barrier products can help to avoid the development of IAD and to aid in healing [1, 32, 33].

21.7.1 Absorbent Devices: Diaper Selection

Expert opinion and research-based evidence support the use of diapers containing superabsorbent polymers for prevention and management of IAD [16, 34, 35]. Superabsorbent polymers aid in the rapid absorption and containment of fluids, thus reducing skin wetting and irritant skin contact. Furthermore, the breathable outer lining incorporated into some disposable diapers promotes vapor exchange, and dryness in the microenvironment between absorbent product and skin, thus minimizing overhydration of skin cells [34]. The use of diapers impregnated with a skin protectant was also found to reduce IAD severity, although the cost of these diapers may restrict their use [36].

21.7.2 Skin Cleansing Techniques

The use of disposable wipes for cleansing diapered skin is controversial. Preservatives in the wipes may cause skin irritation, but several manufacturers have attempted to minimize the type and number of preservative additives used [37]. In the infant population, disposable wipes are able to maintain skin integrity as well as water-moistened washcloths. The use of water-moistened washcloths or cotton products required more forceful scrubbing to remove contaminants, as water alone seems to be inadequate in the removal of fat-soluble waste products [38]. Conversely, most disposable wipes contain fat-soluble solvents that could aid in the removal of waste products [36]. A soft, nonwoven, nonfragrant, alcohol-free, pH-balanced wipe is preferred.

In adults, however, a no-rinse skin cleanser is highly recommended for use in lieu of soap and water or water alone [1]. No-rinse cleansers have the benefit of being quick drying, which prevents unnecessary friction during drying of skin, are usually pH-neutral, and are able to remove contaminants more effectively than water alone.

21.7.3 Skin Care Products

Topical or leave-on skin care products minimize skin contact with chemical irritants, urine, and fecal material or help maintain and restore the skin barrier [1, 25]. The majority of the authors assessed the efficacy of topical skin care products in the prevention and management of IAD, but no conclusions could be drawn to recommend the most effective product. Experts and guidelines recommend the application of skin protectants containing active ingredients such as zinc oxide, petrolatum, and dimethicone after the cleansing of the perineum to protect high-risk patients from IAD [15]. As the development of IAD is driven by an underlying inflammatory process, the use of products containing anti-inflammatory properties is also favored. Topical steroidal products such as hydrocortisone are frequently prescribed for its anti-inflammatory effects on various dermatoses such as IAD [39]. The application of a thick layer of skin protectants is consistently advocated in clinical guidelines, and care providers are cautioned against total removal of leave-on skin products at every diaper change.

21.7.4 Structured Skin Care Regimen

The benefits of a structured skin care regimen and the importance of caregivers' education in the prevention and management of IAD is also discussed. A structured skin care regimen comprising proper assessment, cleansing, and protection is recommended in multiple clinical guidelines [1, 7]. Because most IAD cases occur in the community, and more than half of them are managed without advice from a health care professional, providing IAD prevention and management education to caregivers will be beneficial in reducing the occurrence of IAD.

The acronym CPR (standing for cleanse, protect, restore) was developed by Beeckman et al. [1] to act as an aide memoire to support best practice in IAD prevention and management, reminding health professionals or caregivers to cleanse, protect and restore the skin. The main focus of IAD management is to remove the urine and/or feces from a patient's skin. Once that is done, the damage to the patient's skin needs to be repaired and then protected against any further exposure. This is achieved by implementing the following routine between each incontinence pad change, or after using the toilet [40].

21.8 Conclusion

IAD remains an important practice concern affecting as many as half of the patients with urinary or fecal incontinence. Information and guidelines about IAD exist in the literature, although adopting them in routine practice is still a challenge. Key factors in the successful prevention and management are careful patient assessment, good continence care, and clear evidence-based skincare protocols.

References

1. Beeckman D, Campbell J, Campbell K, et al. Incontinence-associated dermatitis: moving prevention forward. In: Proceedings from the global IAD expert panel. Wounds International, 2015. <https://www.woundsinternational.com/resources/details/incontinence-associated-dermatitis-moving-prevention-forward>. Accessed 30 Nov 2021.
2. Gray M, Black JM, Baharestani MM, et al. Moisture-associated skin damage: overview and pathophysiology. *J Wound Ostomy Cont Nurs*. 2011;38(3):233–41.
3. Gray M, Giuliano KK. Incontinence-associated dermatitis, characteristics and relationship to pressure injury: a multisite epidemiologic analysis. *J Wound Ostomy Cont Nurs*. 2018;45(1):63–7.
4. Beeckman D, Van Lancker A, Van Hecke A, Verhaeghe S. A systematic review and meta-analysis of incontinence-associated dermatitis, incontinence, and moisture as risk factors for pressure ulcer development. *Res Nurs Health*. 2014;37(3):204–18.
5. Minassian VA, Devore E, Hagan K, Grodstein F. Severity of urinary incontinence and effect on quality of life in women by incontinence type. *Obstet Gynecol*. 2013;121(5):1083–90.
6. Bartlett L, Nowak M, Ho YH. Impact of fecal incontinence on quality of life. *World J Gastroenterol*. 2009;15(26):3276–82.
7. Doughty D, Junkin J, Kurz P, et al. Incontinence-associated dermatitis: consensus statements, evidence-based guidelines for prevention and treatment, and current challenges. *J Wound Ostomy Cont Nurs*. 2012;39(3):303–17.
8. Campbell JL, Coyer FM, Osborne SR. Incontinence-associated dermatitis: a cross-sectional prevalence study in the Australian acute care hospital setting. *Int Wound J*. 2014;13(3):403–11.
9. Kayser SA, Phipps L, VanGilder CA, Lachenbruch C. Examining prevalence and risk factors of incontinence-associated dermatitis using the international pressure ulcer prevalence survey. *J Wound Ostomy Continence Nurs*. 2019;46(4):285–90.
10. Gray M. Optimal management of incontinence-associated dermatitis in the elderly. *Am J Clin Dermatol*. 2010;11(3):201–10.
11. Bliss DZ, Savik K, Harms S, et al. Prevalence and correlates of perineal dermatitis in nursing home residents. *Nurs Res*. 2006;55(4):243–51.
12. Boronat-Garrido X, Kottner J, Schmitz G, Lahmann N. Incontinence-associated dermatitis in nursing homes: prevalence, severity, and risk factors in residents with urinary and/or fecal incontinence. *J Wound Ostomy Continence Nurs*. 2016;43(6):630–5.
13. Beeckman D, Verhaeghe S, Defloor T, et al. A 3-in-1 perineal care washcloth impregnated with dimethicone 3% versus water and pH neutral soap to prevent and treat incontinence-associated dermatitis: a randomized, controlled clinical trial. *J Wound Ostomy Continence Nurs*. 2011;38(6):627–34.
14. Ward DB, Fleischer AB Jr, Feldman SR, Krowchuk DP. Characterization of diaper dermatitis in the United States. *Arch Pediatr Adolesc Med*. 2000;154(9):943–6.
15. Heimall LM, Storey B, Stellar JJ, Davis KF. Beginning at the bottom: evidence-based care of diaper dermatitis. *MCN Am J Matern Child Nurs*. 2012;37(1):10–6.
16. Noonan C, Quigley S, Curley MAQ. Skin integrity in hospitalized infants and children: a prevalence survey. *J Pediatr Nurs*. 2006;21(6):445–53.
17. Bender JK, Faergemann J, Sködl M. Skin health connected to the use of absorbent hygiene products: a review. *Dermatol Ther (Heidelb)*. 2017;7(3):319–30.
18. Matousek JL, Campbell KL. A comparative review of cutaneous pH. *Vet Dermatol*. 2002;13:292–300.
19. Rippeke FVS, Schwanitz HJ. The acidic milieu of the horny layer. New findings on the physiology of skin pH. *Am J Clin Dermatol*. 2002;3(4):261–72.
20. Oranges T, Dini V, Romanelli M. Skin physiology of the neonate and infant: clinical implications. *Adv Wound Care*. 2015;4(10):587–95.
21. Lund C. Medical adhesives in the NICU. *Newborn Infant Rev*. 2014;14(4):160–5.

22. Kottner J, Blume-Peytavi U, Lohrmann C, Halfens R. Associations between individual characteristics and incontinence-associated dermatitis: a secondary data analysis of a multi-centre prevalence study. *Int J Nurs Stud*. 2014;51(10):1373–80.
23. Gray M, Giuliano KK. Incontinence-associated dermatitis, characteristics and relationship to pressure injury: a multisite epidemiologic analysis. *J Wound Ostomy Continence Nurs*. 2018;45(1):63–7.
24. Chianca TCM, Goncales PC, Salgado PO, et al. Incontinence-associated dermatitis: a cohort study in critically ill patients. *Rev Gaucha Enferm*. 2016;37:1–8.
25. Gray M, Beeckman D, Bliss DZ, et al. Incontinence-associated dermatitis: a comprehensive review and update. *J Wound Ostomy Continence Nurs*. 2012;39(1):61–74.
26. Borchert K, Bliss DZ, Savik K, Radosevich DM. The incontinence-associated dermatitis and its severity instrument: development and validation. *J Wound Ostomy Continence Nurs*. 2010;37(5):527–35.
27. Park HS, Pham C, Paul E, et al. Early pathogenic colonisers of acute burn wounds: a retrospective review. *Burns*. 2017;43(8):1757–65.
28. Campbell JL, Coyer FM, Mudge AM, et al. *Candida albicans* colonization, continence status and incontinence-associated dermatitis in the acute care setting: a pilot study. *Int Wound J*. 2017;14(3):488–95.
29. Mahoney M, Rozenboom B, Doughty D. Challenges in classification of gluteal cleft and buttocks wounds: consensus session reports. *J Wound Ostomy Continence Nurs*. 2013;40(3):239–45.
30. Barakat-Johnson M, Barnett C, Lai M, et al. Incontinence, incontinence-associated dermatitis, and pressure injuries in a health district in Australia: a mixed-methods study. *J Wound Ostomy Cont Nurs*. 2018;45(4):349–55.
31. Defloor T, Schoonhoven L, Fletcher J, et al. Statement of the European pressure ulcer advisory panel—pressure ulcer classification: differentiation between pressure ulcers and moisture lesions. *J Wound Ostomy Cont Nurs*. 2005;32(5):302–6.
32. Blume-Peytavi U, Hauser M, Lünemann L, et al. Prevention of diaper dermatitis in infants: a literature review. *Pediatr Dermatol*. 2014;31(4):413–29.
33. Beeckman D, Schoonhoven L, Verhaeghe S, et al. Prevention and treatment of incontinence-associated dermatitis: literature review. *J Adv Nurs*. 2009;65(6):1141–54.
34. Odio M, Thaman L. Diapering, diaper technology, and diaper area skin health. *Pediatr Dermatol*. 2014;31(Suppl 1):9–14.
35. Clark-Greuel JN, Helmes CT, Lawrence A, et al. Setting the record straight on diaper rash and disposable diapers. *Clin Pediatr*. 2014;53(9 suppl):23S–6S.
36. Visscher MO. Recent advances in diaper dermatitis: etiology and treatment. *Pediatr Health*. 2009;3(1):81–98.
37. Atherton DJ. A review of the pathophysiology, prevention and treatment of irritant diaper dermatitis. *Curr Med Res Opin*. 2004;20(5):645–9.
38. Austin AP, Milligan MC, Pennington K, Tweito DH. A survey of factors associated with diaper dermatitis in thirty-six pediatric practices. *J Pediatr Health Care*. 1988;2(6):295–9.
39. Nnoruka EN, Daramola OOM, Ike SO. Misuse and abuse of topical steroids: implications. *Expert Rev Dermatol*. 2007;2(1):31–40.
40. Bardsley A. Prevention and management of incontinence-associated dermatitis. *Nurs Stand*. 2013;27(44):41–6.

Open Access This chapter is licensed under the terms of the Creative Commons Attribution-NonCommercial-NoDerivatives 4.0 International License (<http://creativecommons.org/licenses/by-nc-nd/4.0/>), which permits any noncommercial use, sharing, distribution and reproduction in any medium or format, as long as you give appropriate credit to the original author(s) and the source, provide a link to the Creative Commons license and indicate if you modified the licensed material. You do not have permission under this license to share adapted material derived from this chapter or parts of it.

The images or other third party material in this chapter are included in the chapter's Creative Commons license, unless indicated otherwise in a credit line to the material. If material is not included in the chapter's Creative Commons license and your intended use is not permitted by statutory regulation or exceeds the permitted use, you will need to obtain permission directly from the copyright holder.





Adolfo Renzi and Antonio Brillantino

22.1 Introduction

The descending perineum syndrome represents a complex clinical condition characterized by excessive pelvic floor relaxation occurring during straining or visible already at rest.

The recognition and definition of this syndrome is quite recent. A perineal bulging on straining was first illustrated by Porter in 1962 [1], whereas perineal descent was first included in the context of a distinct pathological entity by Parks in 1966 who used the definition “descending perineum syndrome” as a descriptive term, since perineal descent clearly represents both the main objective finding and the cause of the symptomatology [2, 3].

This syndrome may be associated with pelvic organ prolapse, rectal intussusception, perineal hernias, solitary rectal ulcer syndrome and pudendal neuropathy and is characterized by various signs and symptoms ranging from obstructed defecation to anal incontinence, according to the stage of the disorder. In particular, it is estimated that perineal descent may be recognizable in 75–84% of constipated patients and in at least 75% of incontinent patients, with an increasing prevalence in women and the elderly [4–7].

A. Renzi (✉)

Department of General Surgery, Buon Consiglio Fatebenefratelli Hospital, Naples, Italy
e-mail: adolfo.renzi@gmail.com

A. Brillantino

Department of General Surgery, Cardarelli Hospital, Naples, Italy
e-mail: antonio.brillantino@gmail.com

22.2 Definition and Diagnosis

Although perineal descent may be observed at physical examination in the Sims or lithotomy position and measured in the outpatients' clinic by the POP-Q system and the St. Mark's perineometer [8], a more accurate measurement—and consequently the most widely accepted definition of this condition—is based on the resting and straining phases of cinedefecography [5] (Fig. 22.1).

Radiologically, perineal descent is measured along a perpendicular line drawn from the pubococcygeal line (corresponding to levator plane) to the anorectal angle (Fig. 22.2). A >3 cm descent of the anorectal angle from the levator plane at rest and a >3 cm descent of the anorectal angle from the resting position during straining are generally considered pathological values and represent the most common definitions for “fixed” and “dynamic” perineal descent, respectively [9–13].

Alternatively, dynamic magnetic resonance imaging represents an excellent tool for detecting perineal descent and simultaneously depicting the complex anatomy of the pelvic floor, with accurate identification of the supportive elements, the prolapse and the functional abnormalities of pelvic organs. Moreover, compared with

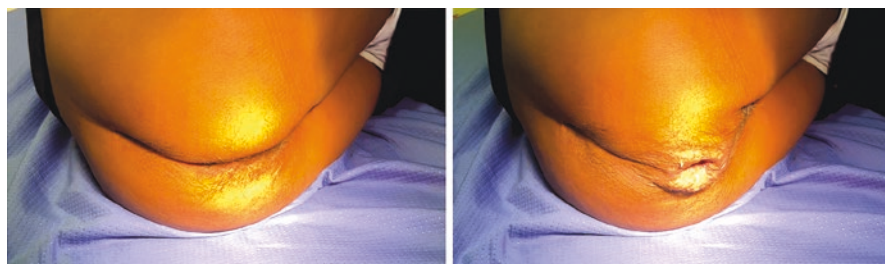


Fig. 22.1 Perineal descent observed at physical examination in the Sims position. At rest (left) and during bearing down (right)

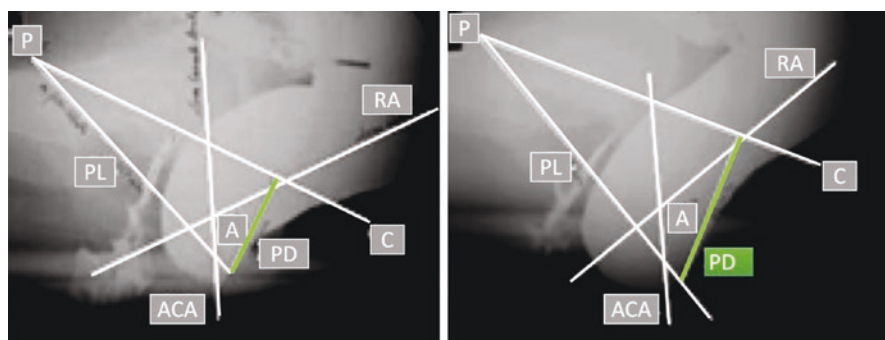


Fig. 22.2 Resting and straining phases observed at cinedefecography. *P* pubis, *C* tip of the coccyx, *PL* puborectal muscle line, *RA* rectal axis, *ACA* anal canal axis, *A* anorectal angle, *PD* perineal descent

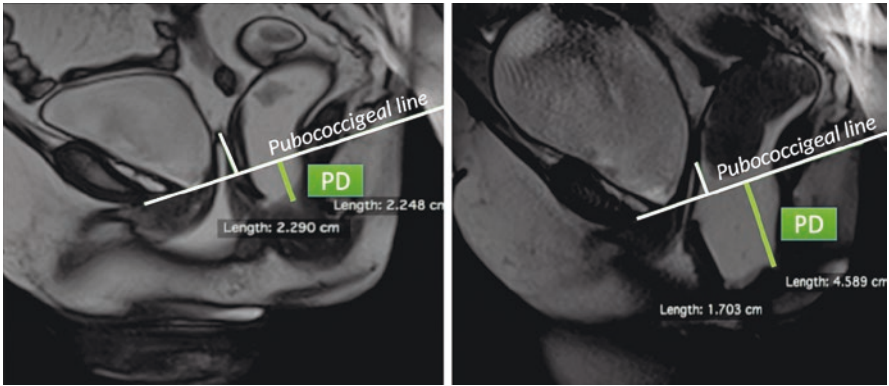


Fig. 22.3 Resting and straining phases observed with dynamic magnetic resonance imaging. *PD* perineal descent

cinedefecography, the theoretical disadvantage of the supine position does not seem to significantly affect identification of the dynamic descending perineum [12, 13] (Fig. 22.3).

22.3 Pathophysiology

As first described by Parks [1], the descending perineum is thought to be involved in a vicious cycle that, starting from excessive straining and passing through pelvic floor weakness, leads to exacerbation of rectal anatomical abnormalities, perineal ballooning and worsening of constipation. In particular, the event triggering the vicious cycle could be a primary difficult rectal emptying due to still not well-known causes and possibly related to dyssynergic defecation or anatomical rectal abnormalities (e.g., intussusception and/or rectocele) [14]. As a result of this impaired defecation, chronic, excessive and repetitive straining may occur, causing weakening of the pelvic floor musculature and sagging of the perineum over time [1].

Overall, the risk factors for increased perineal descent seem to be related to female gender, pregnancy, vaginal delivery, age, rectocele size, and rectal intussusception [4].

The weakened pelvic anatomical structures involved in perineal descent are several and include the levator ani muscles (that tend to stretch and weaken at the level of the urogenital hiatus and to assume a bowl-like configuration) [15], the complex network of pelvic organ ligaments (that tend to overstretch and weaken) [16] and the muscular fibers of the perineal membrane [17].

In particular, in normal subjects an important role in limiting excessive perineal descent would seem to be played by the functional activity of the superficial and deep transverse perineal muscles. As shown by electrophysiological studies, these muscles, differently from the levator ani, contract during defecation, supporting the

perineal floor and protecting the perineum against the high pressure produced by straining, which, if excessive and repetitive, may cause weakness, subluxation, and sagging of the perineal muscles, resulting in perineocele [18, 19]. Moreover, as demonstrated by anatomical studies [17], in the presence of an increased force directed caudally, these muscle fibers become tight and consequently resist further perineal displacement. In the same way, transection of these fibers in the cadaver leaves the rectum exposed and allows the distal rectum to prolapse downward.

In summary, in the presence of risk factors and, likely, congenital predisposition, a chronic and repetitive impaired defecation can cause excessive descent of the perineum. In an early stage, the perineum appears mobile (dynamic), when the normally positioned pelvic floor at rest descends >3 cm during straining and returns to normal position after evacuation. Subsequently, in a later stage, the perineum becomes fixed, when a descent >3 cm occurs already at rest.

The last step of the vicious cycle is represented by the worsening of obstructed defecation and of the initial rectal alteration induced by descending perineum. The interaction between constipation and perineal descent is probably sustained by abdominal straining during defecation. As is known, a satisfactory rectal emptying is finally obtained with simultaneous relaxation of the puborectalis/external sphincter muscles and an increase in intrabdominal pressure induced by abdominal straining. In particular, during this maneuver, flattening of the diaphragm downwards into the abdominal cavity and contraction of the abdominal muscles reduce, in patients without excessive perineal descent, the abdominal cavity volume; this, in consideration of Laplace's law, contributes to determine the increased abdominal pressure necessary for defecation. In patients with a pathological perineal descent, straining probably can induce a change in shape of the lower abdominal cavity without achieving a reduction of the abdominal volume. Thus, in this condition, the expected increase in intrabdominal and intrarectal pressure, cannot be obtained.

In the late stage of the disorder, mainly when a fixed descending perineum becomes evident due to advanced anatomical derangement of the pelvic floor, the perineal descent tends to be associated with anatomical and functional alterations predisposing to fecal incontinence, such as high-grade pelvic organ prolapse and specifically rectal prolapse, increased anorectal angle with decreased levator ani tone, decreased anal resting pressure and amplitude and duration of maximal voluntary contraction, and thinning of the external anal sphincter [20] (Fig. 22.4). The combination of these alterations, and their possible association with sphincter defects and advanced age may contribute to cause fecal incontinence in patients with a long history of impaired defecation and excessive perineal descent.

According to this multifactorial pathogenesis, the clinical forms of incontinence in this group of patients may be various and include urge incontinence in about 56% of patients, passive incontinence in about 20%, mixed incontinence in about 16% and post-defecatory incontinence in about 4% [20].

A theoretical sequela of perineal descent is pudendal neuropathy since chronic straining may be associated with nerve entrapment and/or stretching, resulting in up to 20% increase in nerve length, sufficient to cause neuropathy [4]. The pudendal nerve injury secondary to pelvic floor descent could lead to sphincter denervation

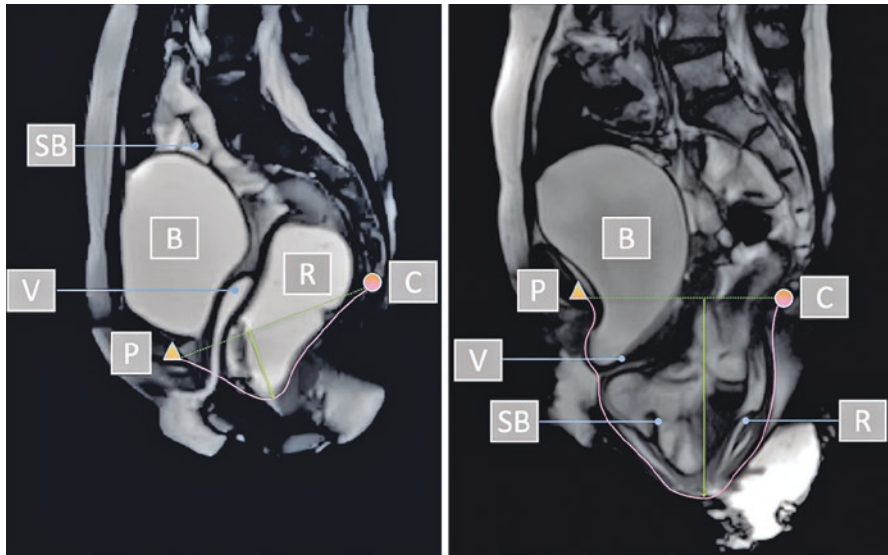


Fig. 22.4 Late stage of perineal descent syndrome with multiorgan and multilevel pelvic prolapse observed with dynamic magnetic resonance imaging, at rest (left) and during bearing down (right). *SB* small bowel, *B* bladder, *V* vagina, *R* rectum, *P* pubis, *C* coccyx

and contribute to the onset of anal incontinence [5]. However, despite these reasonable considerations, the theory of pudendal nerve strain leading to anal incontinence is strongly questioned by the conflicting results in the relationship between increased pudendal nerve motor latency values and increased perineal descent [21, 22].

22.4 Principles of Treatment

Therapy should be tailored on stage of the disorder, predominant symptoms, coexistence of pelvic organ prolapse and, in the latter case, on which pelvic support structures have primarily failed, according to DeLancey's levels [16, 17].

In the first stage of the syndrome, conservative measures (high fiber diet, laxatives, suppositories, enema) associated with biofeedback and kinesitherapy have been advocated. In patients nonresponsive to medical treatment, surgery could represent a further therapeutic option.

Surgical treatment should aim to correct the overall pelvic floor alterations, including both rectal and genital prolapse (associated with a deficit of support levels I and II) and perineal descent (associated with a deficit of support level III).

The surgical options for correction of pelvic organ prolapse can be distinguished into suspensive (e.g., pelvic organ prolapse suspension surgery, Dubuisson, ventral rectopexy, colposacropexy), resective (e.g., stapled transanal rectal resection, Delorme, Altemeier), or mixed.

The surgical techniques proposed to correct perineal descent are limited and are mainly represented by levatorplasty, levator plate myorrhaphy and transverse perineal support [23]. The last of these involves positioning of a mesh implant just above the perineum superficial fascia, sutured to the periosteum membrane of the two branches of the pubis, with the rationale of mimicking the role of superficial transverse perineal muscle and the aim of creating a support element for the pelvic floor. Concerning effectiveness, good preliminary short-term results were reported [23], even if other studies with larger sample size and longer follow-up are needed to confirm these data (Fig. 22.5).

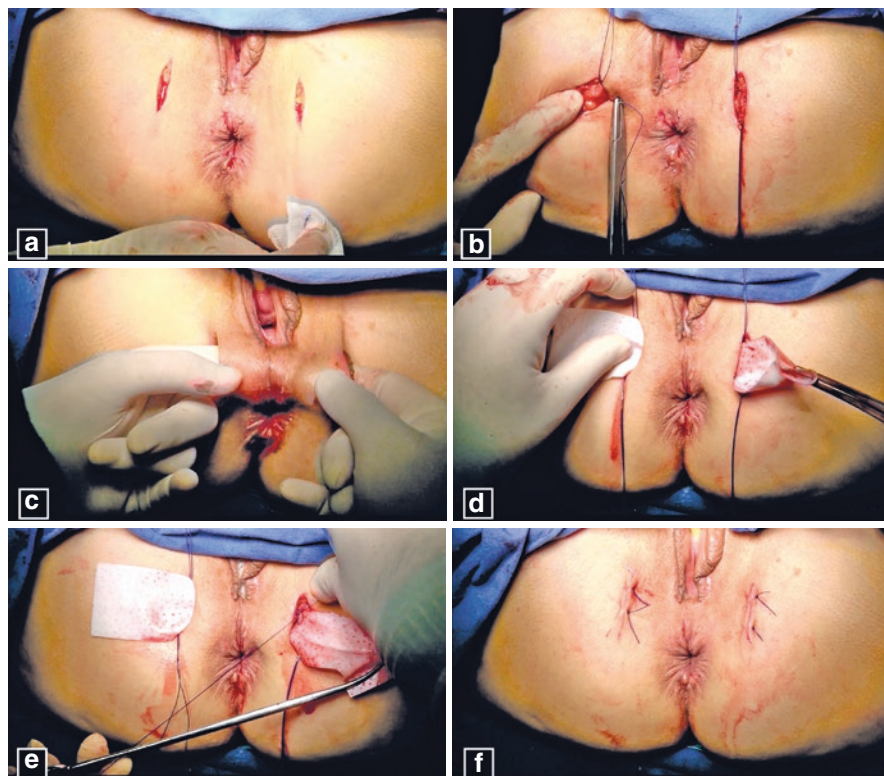


Fig. 22.5 Transverse perineal support procedure. (a) After the finger identification of the ischial tuberosities, the overlying skin is incised for 2 cm on each side. (b) Two stitches in nonabsorbable material and spaced 1 cm apart are affixed bilaterally to the periosteum membrane of the ascending branches of the pubis at the insertion of the superficial transverse perineal muscle. (c) A blunt dissection of the adipose tissue from the perineum superficial fascia, upward to create a tunnel between the two branches of the pubis, is carried out, and forceps are passed through the tunnel. (d) A porcine dermal implant (Permacol-Medtronic; size = 4 × 18 cm), tapered previously in the middle third, is positioned just above the perineum superficial fascia. (e) The implant is sutured to the periosteum membrane and the excess is trimmed away. (f) The skin incisions are eventually sutured

References

1. Porter NH. A physiological study of the pelvic floor in rectal prolapse. *Ann R Coll Surg Engl.* 1962;31(6):379–404.
2. Parks AG, Porter NH, Hardcastle J. The syndrome of the descending perineum. *Proc R Soc Med.* 1966;59(6):477–82.
3. Hardcastle JD. The descending perineum syndrome. *Practitioner.* 1969;203(217):612–9.
4. Chaudhry Z, Tarnay C. Descending perineum syndrome: a review of the presentation, diagnosis, and management. *Int Urogynecol J.* 2016;27(8):1149–56.
5. Timmke AE. Functional anorectal disorders. In: Beck DE, Wexner SD, editors. *Fundamentals of anorectal surgery.* London: WB Saunders; 1998. p. 90–8.
6. Read NW, Bannister JJ. Anorectal manometry: techniques in health and anorectal disease. In: Henry MM, Swash M, editors. *Coloproctology and pelvic floor.* London: Butterworth-Heinemann; 1985. p. 65–87.
7. Renzi A, Izzo D, Di Sarno G, et al. Cinedefecographic findings in patients with obstructed defecation syndrome. A study in 420 cases. *Minerva Chir.* 2006;61(6):493–9.
8. Henry MM, Parks AG, Swash M. The pelvic floor musculature in the descending perineum syndrome. *Br J Surg.* 1982;69(8):470–2.
9. Shorvon PJ, McHugh S, Diamant NE, et al. Defecography in normal volunteers: results and implications. *Gut.* 1989;30(12):1737–49.
10. Shorvon PJ, Stevenson GW. Defaecography: setting up a service. *Br J Hosp Med.* 1989;41(5):460–6.
11. Oettle GJ, Roe AM, Bartolo DC, Mortensen NJ. What is the best way of measuring perineal descent? A comparison of radiographic and clinical methods. *Br J Surg.* 1985;72(12):999–1001.
12. Iacobellis F, Reginelli A, Berritto D, et al. Pelvic floor dysfunctions: how to image patients? *Jpn J Radiol.* 2020;38(1):47–63.
13. Iacobellis F, Brillantino A, Renzi A, et al. MR imaging in diagnosis of pelvic floor descent: supine versus sitting position. *Gastroenterol Res Pract.* 2016;2016:6594152. <https://doi.org/10.1155/2016/6594152>.
14. Pucciani F. Descending perineum syndrome: new perspectives. *Tech Coloproctol.* 2015;19(8):443–8.
15. Singh K, Jakab M, Reid WM, et al. Three-dimensional magnetic resonance imaging assessment of levator ani morphologic features in different grades of prolapse. *Am J Obstet Gynecol.* 2003;188(4):910–5.
16. DeLancey JO. Anatomic aspects of vaginal eversion after hysterectomy. *Am J Obstet Gynecol.* 1992;166(6 Pt 1):1717–24; discussion 1724–8.
17. DeLancey JO. Structural anatomy of the posterior pelvic compartment as it relates to rectocele. *Am J Obstet Gynecol.* 1999;180(4):815–23.
18. Shafik A, Ahmed I, Shafik AA, et al. Surgical anatomy of the perineal muscles and their role in perineal disorders. *Anat Sci Int.* 2005;80(3):167–71.
19. Shafik A, Shafik AA, Shafik I, El-Sibai O. Study of the role of the transverse perineal muscles during rectal filling. *Int J Colorectal Dis.* 2006;21(7):698–704.
20. Pucciani F. Descending perineum syndrome: pathophysiology of fecal incontinence. *Pelvipерineology.* 2018;37:57–62.
21. Jones PN, Lubowski DZ, Swash M, Henry MM. Relation between perineal descent and pudendal nerve damage in idiopathic faecal incontinence. *Int J Colorectal Dis.* 1987;2(2):93–5.
22. Ho YH, Goh HS. The neurophysiological significance of perineal descent. *Int J Colorectal Dis.* 1995;10(2):107–11.
23. Renzi A, Brillantino A, Di Sarno G, et al. Transverse perineal support: a novel surgical treatment for perineal descent in patients with obstructed defecation syndrome. *Dis Colon Rectum.* 2016;59(6):557–64.

Open Access This chapter is licensed under the terms of the Creative Commons Attribution-NonCommercial-NoDerivatives 4.0 International License (<http://creativecommons.org/licenses/by-nc-nd/4.0/>), which permits any noncommercial use, sharing, distribution and reproduction in any medium or format, as long as you give appropriate credit to the original author(s) and the source, provide a link to the Creative Commons license and indicate if you modified the licensed material. You do not have permission under this license to share adapted material derived from this chapter or parts of it.

The images or other third party material in this chapter are included in the chapter's Creative Commons license, unless indicated otherwise in a credit line to the material. If material is not included in the chapter's Creative Commons license and your intended use is not permitted by statutory regulation or exceeds the permitted use, you will need to obtain permission directly from the copyright holder.





Reconstruction of Wide Anal Sphincter Defects by Crossing Flaps of Puborectalis Muscle

23

Antonio Longo

23.1 Introduction

The involuntary loss of air, mucus and feces has an important impact on quality of life. The incidence of fecal incontinence (FI) is overestimated because many authors include urgency, which is a condition characterized by different pathogenetic factors including inflammatory bowel disease, proctitis, rectal prolapse, colorectal resection, and pelvic dissynergy. This also accounts for the wide range of reported incidence rates for FI: from 1.4% to 19.5% of the population [1]. This chapter addresses FI due to wide defect of the anal sphincter. The causes, in order of incidence, are obstetric trauma, anorectal surgery, trauma (Table 23.1). Considering the high incidence of episiotomies and trauma due to childbirth, anterolateral sphincter defects are the most frequent, followed by unilateral and posterior defects. Patients with FI with a circumferential thinning of the anal sphincter, associated with excessive perineal descent, often have an obstructed defecation syndrome due to rectal prolapse and rectocele. Therefore, it is necessary to differentiate FI due to a sphincter defect from overflow incontinence. Anterior sphincter defects can be associated with a reduction in rectovaginal distance, rectovaginal fistula, and rectovaginal cloaca. Almost all the procedures proposed for anal sphincter insufficiency—including injectable bulking agents [2], SECCA procedure [3], sacral nerve stimulation [4], magnetic anal sphincter [5], and graciloplasty—achieve the result of compressing the anal canal and increasing its basal closing pressure, without variation at rest and at squeeze. The reported outcomes vary widely and in many cases the initial enthusiasm waned rapidly, with some techniques falling out of use, especially graciloplasty [6, 7] and the rarely practiced SECCA procedure.

A. Longo (✉)

Department of General Surgery, Madonna della Fiducia Clinic, Rome, Italy
e-mail: alongo@neomedia.it

© The Author(s) 2023

L. Docimo, L. Bruscianno (eds.), *Anal Incontinence*, Updates in Surgery,
https://doi.org/10.1007/978-3-031-08392-1_23

197

Table 23.1 Types and causes of anal sphincters and pelvic defects treated

Types of anal sphincter defect	No.	Causes	Sex	
			Females	Males
Anterolateral defect			51	1
• Only anal sphincters	23			
• Reduction of rectovaginal raphe	15	• Obstetric trauma		
• Rectovaginal cloaca	9	• Rectoanal fistula		
• Associated with rectovaginal fistula	5			
Unilateral wide defect	12	• Postfistulectomy • Anorectal surgery	7	5
Posterior wide defect	3	• Postfistulectomy • Anorectal surgery	1	2
Circumferential defect			10	5
• Circumferential thinning	15	• External rectal prolapse and/or pelvic organ prolapse • Traumatic • Anorectal surgery		
• Traumatic fragmentation				

23.2 Rational Bases for Crossing Flaps of Puborectalis Muscle

The innervation of the external anal sphincter and puborectalis muscle originates from S2 to S4. Both muscles are innervated by the same nerve branches. The external anal sphincter is anatomically and functionally connected to the puborectalis muscle [8]. The S2–S4 fibers follow a posteroanterior course. Therefore, dissection of a flap of puborectalis muscle from the pubis, leaving the posterior part intact, preserves the innervation of the flap and therefore its ability to contract and relax.

23.3 Exclusion Criteria

Preoperative investigations include rectal manometry, pudendal nerve terminal motor latency, three-dimensional endoanal ultrasound, pelvic magnetic resonance imaging, and X-ray cinedefecography.

Reconstruction by crossing flaps of puborectalis muscle (CFPRM) has no indications in patients with puborectalis muscle hypotrophy, denervation of the puborectalis muscle, neurological defects or dysmetabolic disorders. Patients with hyperdescended perineum always have an internal rectal prolapse with rectocele and sometimes an associated urogenital prolapse. In many of these patients, the FI is an overflow incontinence. In these cases, we first perform a stapled transanal rectal resection [9, 10] or a pelvic organ prolapse suspension [11, 12] as this lets us correct or improve the hyperdescended perineum in all cases and, in many, to improve the obstructed defecation syndrome and fecal continence. Only a few months later, these patients undergo CFPRM, if needed. We have previously demonstrated that descended perineum is a secondary alteration due to prolapse of one

or more of the pelvic organs; correction of the prolapse with adequate techniques will improve the descended perineum [9, 12], but in some cases the condition can persist because of the muscular and fascial dystrophy caused by prolonged downward stretching.

23.4 Surgical Technique

Reconstruction by CFPRM is obviously reserved for patients whose sphincter defect does not allow an end-to-end or overlap reconstruction.

The technique has some variants in relation to the location and extent of the anal sphincter defect [13] and whether this is associated with other perineal alterations. In cases of a unilateral wide defect, only one flap is prepared, whereas in cases of a bilateral, anterior, posterior or circumferential defect, two flaps are needed (Fig. 23.1). The thickness of the flaps, at their extremity, must be at least 1.5 cm and the length proportional to the width of the sphincter defect; therefore, the dissection begins at a variable distance from the pubis and extends up to the middle part of the anal canal. Dissecting the muscular fibers of the puborectalis muscle, the flap has a much wider base than the tip so blood supply and innervation are preserved.

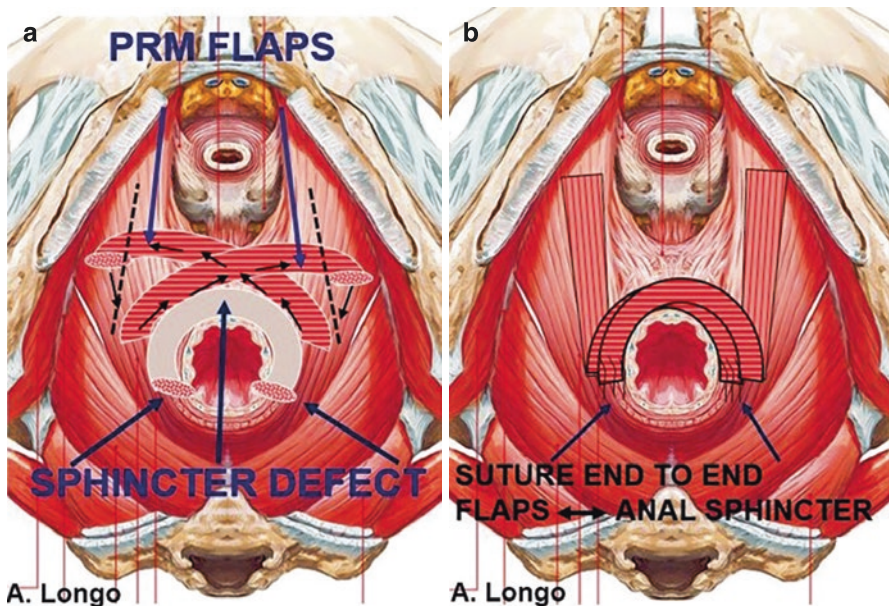


Fig. 23.1 (a) Wide anterolateral anal sphincter defect and resection line of the puborectalis muscle (PRM). (b) Crossing flaps of the puborectalis muscle and end-to-end suture with the tips of residual anal sphincters

23.4.1 Wide Defect of the Lateral Anal Sphincter

This defect is frequently a complication of fistulectomies. In these cases, an incision is made on the cutaneous margin of the anal canal, on the side of the sphincter defect. By dissecting the anal canal, the anterior and posterior tip of the residual anal sphincter are isolated. A second longitudinal incision, 4–5 cm in length, is made on the opposite side, just above the anal canal and 3 cm lateral to the perineal raphe. The superficial fascia is incised and, if possible, the transverse superficial muscles are preserved or reconstructed. The puborectalis muscle is medially isolated and a flap is dissected, calculating the right length, up to the middle part of the anal canal. Subsequently, a subcutaneous tunnel is made on the perineal medial skin bridge, and the flap is crossed on the opposite side. The end of the flap is sutured with Vycril 00 to the posterior tip of the residual anal sphincter. Accurate hemostasis is recommended before suturing the superficial perineal fascia and the skin.

23.4.2 Anterolateral or Circumferential Sphincter Defect

If the rectovaginal perineal skin is preserved, two semi-curved parallel incisions are made 2 cm laterally to the perineal raphe, extended from the skin below the vagina to the middle or posterior anal orifice, depending on the location of the sphincter defect (Fig. 23.2). By incising the superficial perineal fascia and the transverse superficial muscle, the anal canal is dissected and the tips of the residual sphincteric

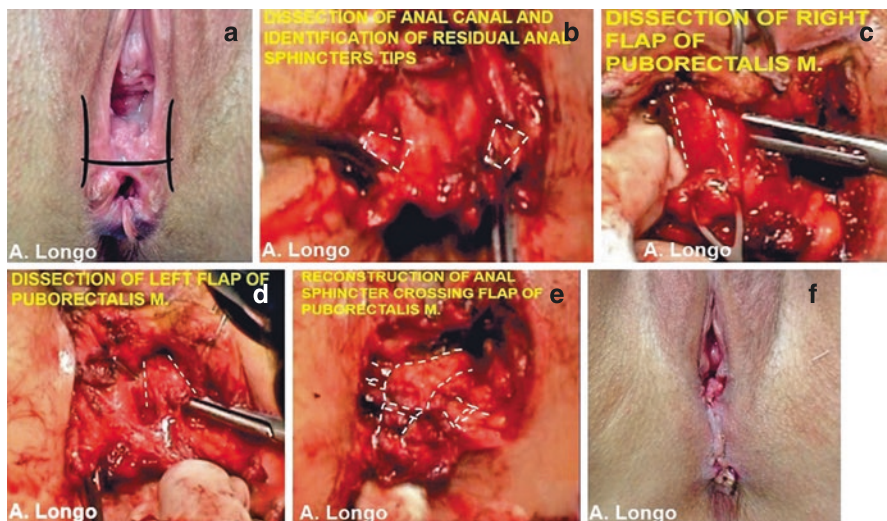


Fig. 23.2 Steps of reconstruction by crossing flaps of puborectalis muscle. (a) Incision in patient with reduction of rectovaginal raphe. (b) Dissection of anal canal and of residual anal sphincters tips. (c, d) Dissection of puborectalis flaps on both sides. (e) Crossing flaps of puborectalis muscle and end-to-end suture with sphincter tips. (f) Restoration of perineal raphe

stumps are isolated. The puborectalis flaps are bilaterally isolated and, after evaluation of the sufficient length to reach the tip of the contralateral anal sphincter, the two flaps are dissected. An anal dilator, 2 cm in diameter, is introduced into the anal canal. The flaps are crossed and sutured at the sphincter tip, as already described. Finally, a partial lower levatorplasty is performed to accentuate the anorectal angle. In the case of excessive reduction of the rectovaginal space, an H-shaped incision is performed and two lateral skin flaps are sutured medially to restore the correct rectovaginal distance (Fig. 23.2). In the case of circumferential defect, the two flaps are sutured to the anococcygeal ligament.

23.4.3 Anterolateral Sphincter Defect Associated with Rectovaginal Fistula

The first step is to circumferentially remove the fistula tract. An H-shaped perineal incision is then made. Once the rectum has been dissected from the vagina, both fistulous orifices are closed with a double introflexing suture with Vycril 00. The next step is dissection of the puborectalis muscle flaps and isolation of the residual anal sphincter tips. After crossing the flaps, sutures are made between the flaps and tips of residual sphincter. In these cases it is recommended to prepare thicker flaps to cover and separate the sutures on the fistula. We also perform a levatorplasty on the residual puborectalis muscle. We place a rectal probe for 4–5 days and the patient is kept on total parenteral nutrition. Preoperatively, we perform intestinal cleansing, but in wide rectovaginal fistulas it is better to make a colostomy.

23.4.4 Rectovaginal Cloaca

Rectovaginal cloaca is predominantly an obstetric complication: patients who underwent episiotomy extended to the anal sphincters and further laceration of the anal sphincters, anal canal, vaginal introitus and posterior vaginal wall. Rectovaginal cloaca [14] is the result of a suture limited to the mucosa and skin and postoperative dehiscence or full thickness laceration of the anterior pelvis. Additional causes include anterior anal fistulas and traumatic lacerations. Often this condition is associated with chronic perineal inflammation which is difficult to treat medically and which would compromise any surgical approach. For this reason, in some patients we initially perform a colostomy. This leads to resolution of the chronic inflammation and an anatomical improvement of the rectovaginal cloaca.

The steps of reconstruction by CFPRM in patients with rectovaginal cloaca are shown in Fig. 23.3. Two semicircular incisions are made on the skin close to the cloaca. The rectovaginal synechia is dissected and the rectal wall is reconstructed with continuous suture, trying to include also the muscular tunica. The puborectalis flaps are prepared and the residual anal sphincters tips are dissected. The flaps are crossed and sutured end-to-end with the tips of the residual anal sphincters. It is useful to perform a partial levatorplasty on the residual puborectalis muscle, just

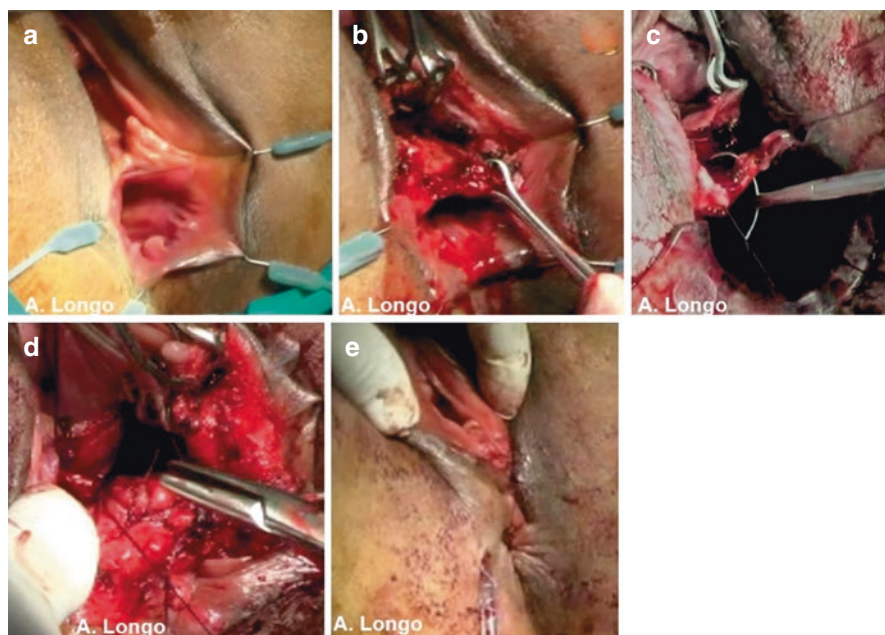


Fig. 23.3 (a) Rectovaginal cloaca. (b) Dissection of rectovaginal synechia. (c) Reconstruction of rectal wall and anal canal. (d) Crossing flap and partial levatorplasty. (e) Vagina wall and perineum reconstruction

above the crossed flaps. The vaginal wall is then reconstructed. If the ostium is too tight, two longitudinal incisions are made on the lateral vagina wall, and sutured transversally.

It is important to reconstruct the anterior perineal body by trying to plicate the superficial perineal fascia together with the superficial transverse muscle of the perineum. The two lateral cutaneous incisions are transversal U-shaped and sutured in order to restore the rectovaginal distance. The choice of a preoperative colostomy, when necessary, is determined by the severity and complexity of the case: in the most severe cases we perform colostomy. If the procedure fails, it becomes a permanent solution. After 1–2 months, in the absence of surgical complications, the patients undergo anorectal manometry and X-ray cinedefecography with fluid barium. If the patient shows sufficient continence, we restore the intestinal continuity.

23.5 Results

From March 2014 to March 2021 we treated 82 patients (69 women and 13 males) with CFPRM. The sphincter defects ranged from 80° to 360°. Follow-up ranged from 3 months to 3 years (average 14 months). The follow-up assessments carried out at 3 months, 1 year and 3 years included anorectal manometry and the Cleveland

Clinic Fecal Incontinence Score (CCFIS). The causes and types of sphincter injury and the associated pelvic injuries are reported in Table 23.1.

The preoperative manometry values ranged from 0 to 15 at rest (average 6 mmHg) and from 0 to 25 at squeeze (average 9 mmHg). At 3 months postoperatively, the range increased from 45 to 90 at rest (average 65 mmHg) and from 95 to 125 at squeeze (average 107 mmHg). No significant variations were detected at 1 year and 3 years. Preoperative CCFIS ranged from 14 to 20 (average 16.5). At 3 months postoperatively, it ranged from 0 to 2 (average 1.2). As with the manometric values, no significant variations in CCFIS were detected at 1 year and 3 years. Only five patients (6%) failed to experience any postoperative improvement of FI, four of them among the first 24 cases.

23.6 Conclusions

Before applying the technique to our patients, we tested the procedure on nine cadavers, seven women and two men. We started our experience with female patients presenting with a large anterolateral defect due to obstetric trauma. Subsequently, we enrolled other patients, including those with associated rectovaginal fistula and rectovaginal cloaca. The results progressively improved and we learned that it is important to achieve perfect hemostasis, because muscular dissections bleed easily and postoperative perineal hematomas are not easy to drain and can predispose to wound infection and dehiscence. Moreover, reconstruction of the perineal body and the superficial perineal fascia is very advantageous in terms of anatomical and physiological results. The preoperative diagnostic accuracy and exclusion criteria are fundamental. We recommend adequate training and gaining more experience with the simplest cases.

References

1. Sharma A, Yuan L, Marshall RJ, et al. Systematic review of the prevalence of faecal incontinence: prevalence of faecal incontinence. *Br J Surg.* 2016;103(12):1589–97.
2. Vaizey CJ, Kamm MA. Injectable bulking agents for treating faecal incontinence. *Br J Surg.* 2005;92(5):521–7.
3. Efron J. The SECCA procedure: a new therapy for treatment of fecal incontinence. *Surg Technol Int.* 2004;13:107–10.
4. Tjandra JJ, Chan MK, Yeh CH, et al. Sacral nerve stimulation is more effective than optimal medical therapy for severe fecal incontinence: a randomized, controlled study. *Dis Colon Rectum.* 2008;51(5):494–502.
5. Wong WD, Congliosi SM, Spencer MP, et al. The safety and efficacy of the artificial bowel sphincter for fecal incontinence: results from a multicenter cohort study. *Dis Colon Rectum.* 2002;45(9):1139–53.
6. Pickrell KL, Broadbent TR, Masters FW, et al. Construction of a rectal sphincter and restoration of anal continence by transplanting gracilis muscle: report of four cases in children. *Ann Surg.* 1952;135(6):853–62.

7. Chapman AE, Geerdes B, Hewett P, et al. Systematic review of dynamic graciloplasty in the treatment of faecal incontinence. *Br J Surg.* 2002;89(2):138–53.
8. Shafik A. A new concept of the anatomy of the anal sphincter mechanism and the physiology of defecation. The external anal sphincter: a triple-loop system. *Investig Urol.* 1975;12(5):412–9.
9. Longo A. Obstructed defecation because of rectal pathologies. Novel surgical treatment: stapled transanal rectal resection (STARR). Annual Cleveland clinic Florida colorectal disease symposium, 2004.
10. Corman ML, et al. Consensus conference on the stapled transanal rectal resection (STARR) for disordered defaecation. *Colorectal Dis.* 2006;8:98–101.
11. Longo A, Crafa F, Boller B, et al. Longo's original technique to correct multiorgan pelvic prolapses. Perspective trial. Preliminary results. In: Proceedings of the 23rd annual international colorectal diseases symposium. 14–22 February 2012, Fort Lauderdale, Florida.
12. Boccasanta P, Venturi M, Agradi S, et al. A minimally invasive technique for the 1-stage treatment of complex pelvic floor diseases: laparoscopic-pelvic organ prolapse suspension. *Female Pelvic Med Reconstr Surg.* 2021;27(1):28–33.
13. Norderval S, Delhi T, Vonen B. Three-dimensional endoanal ultrasonography: intraobserver and interobserver agreement using scoring systems for classification of anal sphincter defects. *Ultrasound Obstet Gynecol.* 2009;33(3):337–43.
14. Gehrich AP, McClellan E, Gillern S. Surgical repair of an obstetric cloaca with review of the literature. *BMJ Case Rep.* 2021;14(1):e234321. <https://doi.org/10.1136/bcr-2020-234321>.

Open Access This chapter is licensed under the terms of the Creative Commons Attribution-NonCommercial-NoDerivatives 4.0 International License (<http://creativecommons.org/licenses/by-nc-nd/4.0/>), which permits any noncommercial use, sharing, distribution and reproduction in any medium or format, as long as you give appropriate credit to the original author(s) and the source, provide a link to the Creative Commons license and indicate if you modified the licensed material. You do not have permission under this license to share adapted material derived from this chapter or parts of it.

The images or other third party material in this chapter are included in the chapter's Creative Commons license, unless indicated otherwise in a credit line to the material. If material is not included in the chapter's Creative Commons license and your intended use is not permitted by statutory regulation or exceeds the permitted use, you will need to obtain permission directly from the copyright holder.





Vincenzo Landolfi and Adriana Maria Landolfi

24.1 Introduction

The Italian National Health Service (NHS) is a system of facilities and services that aim to guarantee all citizens, under equal conditions, universal access to health care [1].

Reimbursements for acute day surgery and inpatient hospitalizations are established by the Diagnosis-Related Groups (DRG) system, whereby procedures are not reimbursed based on the total days of hospitalization, but on a “service-provision” basis, according to a predefined cost estimate [2]. The rate is an all-inclusive remuneration for the treatment profile on average associated with the corresponding hospitalization category. The DRG code is obtained by linking the ICD9-CM diagnosis code [3] with the procedure code. Furthermore, for the same DRG there are differences in the treatment cost reimbursement due to several factors:

- public or private nature of the facility;
- regional reimbursement rate;
- type of hospitalization (outpatient, day surgery, inpatient);
- days of hospitalization (increase over the threshold value).

The ICD9-CM code for fecal incontinence corresponds to 787.6.

Below we report the DRGs of surgical procedures for fecal incontinence, obtained by linking the main diagnosis code with the procedure codes.

V. Landolfi (✉)

Department of General Surgery, S. Giuseppe Moscati Hospital, Avellino, Italy
e-mail: vincenzo.landolfi@tiscali.it

A. M. Landolfi

Pelvic Floor Rehabilitation, Euromedica, Milan, Italy
e-mail: adriana.landolfi@hotmail.it

24.2 DRG Surgical Procedures for Fecal Incontinence

Anal Cerclage

- DRG 158
- *Diagnosis code*
 - 787.6 Fecal incontinence
- *Primary procedure code*
 - 49.72 Anal cerclage

Other Repair of Anal Sphincter

- DRG 158
- *Diagnosis code*
 - 787.6 Fecal incontinence
- *Primary procedure code*
 - 49.79 Other repair of anal sphincter (including anal sphincter tear complicating past delivery; excluding anal sphincter tear complicating recent delivery: code 75.62)

Implantation or Revision of Artificial Anal Sphincter

- DRG 147
- *Diagnosis code*
 - 787.6 Fecal incontinence
- *Primary procedure code*
 - 49.75 Implantation or revision of artificial anal sphincter/prosthesis

Removal of Artificial Anal Sphincter Without Replacement

- DRG 147
- *Diagnosis code*
 - 787.6 Fecal incontinence
- *Primary procedure code*
 - 49.76 Removal of artificial anal sphincter without replacement

Dynamic Graciloplasty

- DRG 171
- *Diagnosis code*
 - 787.6 Fecal incontinence
- *Primary procedure code*
 - 49.74 Gracilis muscle transplant for anal incontinence
- *Secondary procedure code*
 - 04.92 Implantation or replacement of peripheral neurostimulator electrode
- *Tertiary procedure code*
 - 86.94 Insertion or replacement of single-array neurostimulator pulse generator. Not specified as rechargeable
 - 86.95 Insertion or replacement of multiple-array neurostimulator pulse generator. Not specified as rechargeable

Electrode Review Without Replacement

- DRG 157
- *Diagnosis code*
 - 787.6 Fecal incontinence
- *Secondary diagnosis code*
 - 996.39 Other mechanical complication of device, implant and graft.
- *Primary procedure code*
 - 49.92 Insertion of subcutaneous electrical anal stimulator

Sacral Neuromodulation System Implantation: First Step (PNE Test)

- DRG 532
- *Primary diagnosis code*
 - 33.70 Idiopathic peripheral autonomic neuropathy
 - 33.79 Unspecified disorder of autonomic nervous system
 - 35.68 Other specified idiopathic peripheral neuropathy
- *Secondary diagnosis code*
 - 787.6 Fecal incontinence
- *Primary procedure code*
 - 03.93 Insertion/replacement of spinal neuromodulation

Sacral Neuromodulation System Implantation: Second Step

- DRG 8
- *Primary diagnosis code*
 - 33.70 Idiopathic peripheral autonomic neuropathy
 - 33.79 Unspecified disorder of autonomic nervous system
 - 35.68 Other specified idiopathic peripheral neuropathy
- *Secondary diagnosis code*
 - 787.6 Fecal incontinence
- *Primary procedure code*
 - 86.94 Insertion or replacement of single-array neurostimulator pulse generator, not specified as rechargeable
- *Secondary procedure code*
 - 86.95 Insertion or replacement of multiple-array neurostimulator pulse generator, not specified as rechargeable

Electrode Replacement

- DRG 532
- *Primary diagnosis code*
 - V53.02 Fitting and adjustment of neuropacemaker (brain, peripheral nerve, spinal cord)
- *Primary procedure code*
 - 03.93 Insertion/replacement of spinal neurostimulator

Generator Replacement

- DRG 8
- *Primary diagnosis code*
 - V53.02 Fitting and adjustment of neuropacemaker (brain, peripheral nerve, spinal cord)
- *Primary procedure code*
 - 86.94 Insertion or replacement of single-array neurostimulator pulse generator, not specified as rechargeable
- *Secondary procedure code*
 - 86.95 Insertion or replacement of multiple-array neurostimulator pulse generator, not specified as rechargeable

Electrode + Generator Replacement

- DRG 532
- *Primary diagnosis code*
 - V53.02 Fitting and adjustment of neuropacemaker (brain, peripheral nerve, spinal cord)
- *Primary procedure code*
 - 03.93 Insertion/replacement of spinal neurostimulator
- *Secondary procedure code*
 - 86.94 Insertion or replacement of single-array neurostimulator pulse generator, not specified as rechargeable
 - 86.95 Insertion or replacement of multiple-array neurostimulator pulse generator, not specified as rechargeable

Electrode Removal

- DRG 532
- *Primary diagnosis code*
 - *for ineffectiveness*
 - V53.02 Fitting and adjustment of neuropacemaker (brain, peripheral nerve, spinal cord)
 - *for infection*
 - 996.63 Infection and inflammatory reaction due to nervous system device, implant, and graft
 - *for mechanical complications*
 - 996.2 Mechanical complication of nervous system device, implant, and graft.
- *Primary procedure code*
 - 03.94 Removal of spinal neurostimulator

Generator Removal

- DRG 35
- *Primary diagnosis code*

- for ineffectiveness
 - V53.02 Fitting and adjustment of neuropacemaker (brain, peripheral nerve, spinal cord)
- for infection
 - 996.63 Infection and inflammatory reaction due to nervous system device, implant, and graft
- for mechanical complications
 - 996.2 Mechanical complication of nervous system device, implant, and graft.
- *Primary procedure code*
 - 86.05 Incision with removal of foreign body from skin and subcutaneous tissue

Electrode + Generator Removal

- DRG 532
- *Primary diagnosis code*
 - V53.02 Fitting and adjustment of neuropacemaker (brain, peripheral nerve, spinal cord)
- *Primary procedure code*
 - 03.94 Removal of spinal neurostimulator
- *Secondary procedure code*
 - 86.05 Incision with removal of foreign body from skin and subcutaneous tissue

Electrode/Generator Revision/Extension Without Replacement

- DRG 35
- *Primary diagnosis code*
 - V53.02 Fitting and adjustment of neuropacemaker (brain, peripheral nerve, spinal cord)
- *Primary procedure code*
 - 86.09 Other incision of skin and subcutaneous tissue

24.3 Reimbursement of DRGs

Annex 1 to the Decree of the Italian Ministry of Health of 18 October 2012 sets the rates for the remuneration of hospital care services for acute cases [2].

The national cost reimbursements for each DRG associated with fecal incontinence are presented in Table 24.1. These reimbursements were subsequently modified by the Italian Regions and the differences are very interesting. For example: the reimbursement for inpatient care hospitalization for DRG 8 ranges from a minimum of €1581 in the Campania Region to a maximum of €3684 in the Autonomous Province of Bolzano; for DRG 35 ranges from €1412 in Campania to €3735 in the Autonomous Province of Trento; for DRG 532 ranges from €5284 in Molise to €14,419 in Sicily.

Table 24.1 Italian national cost reimbursements for the DRGs of surgical procedures for fecal incontinence

DRG	Description	Inpatient hospitalization >1 day within the threshold value (€)	Short-stay inpatient hospitalization ≤1 day and day surgery hospitalization (€)	Days over threshold value (per day) (€)
8	Peripheral and cranial nerves and other nervous system procedures without CC	2326	2585	196
35	Other nervous system disorders without CC	2077	234	163
147	Rectal resection without CC	7475	2311	274
157	Anal and stomal procedures with CC	3808	1007	192
158	Anal and stomal procedures without CC	1202	1007	126
171	Other digestive system OR procedures without CC	4498	1578	193
468	Extensive OR procedure unrelated to principal diagnosis	10,158	3468	227
532	Spinal procedures without CC	8413	2782	330

DRG diagnosis-related groups, CC complications and/or comorbidities, OR operating room

Patient costs as well are reported differently in each European country and may include a varying number of cost categories because of specific national costing and reporting standards.

24.4 Reimbursement of Perineal Pelvis Rehabilitation

With regard to rehabilitation in fecal incontinence, we report below the codes for several treatments.

- Functional evaluation: 9301
- History and evaluation: 8903
- Manual evaluation of muscle function (PC test): 9304
- Exercises not elsewhere classified (awareness and relaxation) (postural): 9319
- Breathing exercises: 9318
- Active musculoskeletal exercises (Biofeedback): 9312
- Rehabilitation (pelviperineal): 9389
- Passive musculoskeletal exercises: 9317
- Assisted exercises (proprioceptive and awareness-raising): 9311

- Resistance exercises: 9313
- Manipulative treatment (osteopathy for general mobilization): 9361
- Stretching of the perineal muscles: 9327
- Band stretch: 9328
- Manual tractions: 9321
- Spinal mobilization: 9315

Linking these codes with the diagnosis code for fecal incontinence (787.6) we obtain DRG 183: “esophagitis, gastroenteritis and miscellaneous digestive disorders”. This DRG would be inappropriate as the rehabilitation is provided only in an outpatient setting and not on an inpatient basis.

The procedure code used for rehabilitation for fecal incontinence, urinary incontinence and both fecal and urinary incontinence is PR35B (cycle of 10 sessions). The medical prescription must specify code PR35B.001 for fecal incontinence, PR35B.002 for both fecal and urinary incontinence and PR35B.003 for urinary incontinence. The reimbursement will amount to €162.30.

References

1. Ministero della Salute. I principi del Servizio sanitario nazionale [Italian Ministry of Health. The principles of the National Health Service]. <https://www.salute.gov.it/portale/lea/dettaglioContenutiLea.jsp?lingua=italiano&id=5073&area=Lea&menu=vuoto>. Accessed 25 Oct 2021.
2. Ministero della Salute. Decreto del 18 ottobre 2012 (pubblicato nella Gazzetta Ufficiale, n. 23 del 28 gennaio 2013) [Italian Ministry of Health. Decree of 18 October 2012 (published in the Official Gazette no. 23 of 28 January 2013)]. <https://www.gazzettaufficiale.it/eli/id/2013/01/28/13A00528/sg>. Accessed 25 Oct 2021.
3. Ministero della Salute. Il manuale ICD9-CM [Italian Ministry of Health. ICD9-CM Manual]. https://www.salute.gov.it/portale/temi/p2_6.jsp?id=1278&area=ricoveriOspedalieri&menu=classificazione. Accessed 25 Oct 2021.

Open Access This chapter is licensed under the terms of the Creative Commons Attribution-NonCommercial-NoDerivatives 4.0 International License (<http://creativecommons.org/licenses/by-nc-nd/4.0/>), which permits any noncommercial use, sharing, distribution and reproduction in any medium or format, as long as you give appropriate credit to the original author(s) and the source, provide a link to the Creative Commons license and indicate if you modified the licensed material. You do not have permission under this license to share adapted material derived from this chapter or parts of it.

The images or other third party material in this chapter are included in the chapter's Creative Commons license, unless indicated otherwise in a credit line to the material. If material is not included in the chapter's Creative Commons license and your intended use is not permitted by statutory regulation or exceeds the permitted use, you will need to obtain permission directly from the copyright holder.

