

Updates in Surgery

Mario Testini  
Angela Gurrado *Editors*

# Thyroid Surgery



OPEN ACCESS

 Springer

---

# Updates in Surgery



The aim of this series is to provide informative updates on hot topics in the areas of breast, endocrine, and abdominal surgery, surgical oncology, and coloproctology, and on new surgical techniques such as robotic surgery, laparoscopy, and minimally invasive surgery. Readers will find detailed guidance on patient selection, performance of surgical procedures, and avoidance of complications. In addition, a range of other important aspects are covered, from the role of new imaging tools to the use of combined treatments and postoperative care.

The topics addressed by volumes in the series *Updates in Surgery* have been selected for their broad significance in collaboration with the Italian Society of Surgery. Each volume will assist surgical residents and fellows and practicing surgeons in reaching appropriate treatment decisions and achieving optimal outcomes. The series will also be highly relevant for surgical researchers.

---

Mario Testini • Angela Gurrado  
Editors

# Thyroid Surgery

 Springer

*Editors*

Mario Testini  
Department of Precision and Regenerative  
Medicine and Ionian Area  
University of Bari, Policlinic of Bari  
Bari, Italy

Angela Gurrado  
Department of Precision and Regenerative  
Medicine and Ionian Area  
University of Bari, Policlinic of Bari  
Bari, Italy



This is an Open access publication.

ISSN 2280-9848                      ISSN 2281-0854 (electronic)

Updates in Surgery

ISBN 978-3-031-31145-1                      ISBN 978-3-031-31146-8 (eBook)

<https://doi.org/10.1007/978-3-031-31146-8>

The publication and the distribution of this volume have been supported by the Italian Society of Surgery.

Società Italiana di Chirurgia

© The Editor(s) (if applicable) and The Author(s) 2024

**Open Access** This book is licensed under the terms of the Creative Commons Attribution-NonCommercial-NoDerivatives 4.0 International License (<http://creativecommons.org/licenses/by-nc-nd/4.0/>), which permits any noncommercial use, sharing, distribution and reproduction in any medium or format, as long as you give appropriate credit to the original author(s) and the source, provide a link to the Creative Commons license and indicate if you modified the licensed material. You do not have permission under this license to share adapted material derived from this book or parts of it.

The images or other third party material in this book are included in the book's Creative Commons license, unless indicated otherwise in a credit line to the material. If material is not included in the book's Creative Commons license and your intended use is not permitted by statutory regulation or exceeds the permitted use, you will need to obtain permission directly from the copyright holder.

This work is subject to copyright. All commercial rights are reserved by the author(s), whether the whole or part of the material is concerned, specifically the rights of translation, reprinting, reuse of illustrations, recitation, broadcasting, reproduction on microfilms or in any other physical way, and transmission or information storage and retrieval, electronic adaptation, computer software, or by similar or dissimilar methodology now known or hereafter developed. Regarding these commercial rights a non-exclusive license has been granted to the publisher.

The use of general descriptive names, registered names, trademarks, service marks, etc. in this publication does not imply, even in the absence of a specific statement, that such names are exempt from the relevant protective laws and regulations and therefore free for general use.

The publisher, the authors, and the editors are safe to assume that the advice and information in this book are believed to be true and accurate at the date of publication. Neither the publisher nor the authors or the editors give a warranty, expressed or implied, with respect to the material contained herein or for any errors or omissions that may have been made. The publisher remains neutral with regard to jurisdictional claims in published maps and institutional affiliations.

Revision and editing: R. M. Martorelli, Scienzaperta (Novate Milanese, Italy)

This Springer imprint is published by the registered company Springer Nature Switzerland AG  
The registered company address is: Gewerbestrasse 11, 6330 Cham, Switzerland

*To Concetta, Carlotta, and Alfio*

*To Gilberto and Edoardo*

---

## Foreword

The first Italian Society of Surgery's Biennial Report was released in 1994, almost 30 years ago. In this timeframe, in 60 monographs, highly relevant topics have been addressed by recognized expert Italian surgeons. Since 2007 the volumes have been published in the English language by Springer, as part of the series Updates in Surgery, and since last year the books have been made available in open access.

Thyroid surgery has never been addressed in English. The only two monographs on goiter and on thyroid cancer were written in Italian in 2001 and in 2006, respectively. Mario Testini and Angela Gurrado decided to publish this book for this reason, and I would like to express my heartfelt thanks to them for the excellent work they have done.

The topics addressed by the editors and authors in the 20 chapters of the volume range from a complete history of this surgery to the diagnosis and classification of thyroid surgical diseases, up to the description of open, minimally invasive, transoral and robotic surgical thyroidectomies. Particular attention is paid to the techniques of lymphadenectomy and nerve monitoring and to modern tools including energy devices, and optic and hemostatic systems. A thorough analysis of the most important complications of this surgery is also provided. Finally, an entire chapter is dedicated to training, teaching, and the learning curve in thyroid surgery.

I am sure this up-to-date and easy-to-read text will be a reference for young surgeons approaching this field of surgery and for experts wishing to delve into the topic.

Rome, Italy  
September 2023

Massimo Carlini  
President  
Italian Society of Surgery

---

## Foreword

The incidence of thyroid carcinoma has been increasing all over the world during the last 20 years. When considering that in several cases the only, or at least the main, available therapy is surgery, it is easy to understand how timely the present contribution comes to the attention of the surgical community. The authors are deeply knowledgeable in all thyroid procedures, from major and complex interventions to minimally invasive techniques. From the solid background of their outstanding experience, they explore the intriguing world of thyroid surgery as a whole: from the groundbreaking, most technologically demanding procedures to the consolidated but highly challenging extended oncological surgery.

Painstaking but very frank attention is also paid to the complications of this delicate but enthralling surgery.

In spite of the agile format of the volume, all the fields of the fascinating world of thyroidal interventions have been carefully explored with scientific rigor and thoughtful attitude. Readers will certainly understand that behind the authors' ability to manage the operative techniques in such an apparently easy manner lies the rock of robust knowledge of the relevant literature percolated through an extensive clinical experience.

Finally, we can easily assume that this book will represent not only a sound tool for all surgeons but also a source of inspiration for young residents who might be interested in neck surgery.

Pisa, Italy  
September 2023

Paolo Miccoli  
Emeritus Professor of Surgery  
University of Pisa



---

## Preface

Historically, following the first known reference to a successful treatment of goiter from Albucasis in 952 AD, for many centuries thyroidectomy recorded high mortality rates (up to 40%), and was even banned in 1850. At the beginning of the twentieth century, advancements in general anesthesia, antisepsis, surgical technique, and instrumentation contributed to a significant decrease in operative mortality, down to 0.18% recorded by Kocher in 1917. With the standardization of the technique of extracapsular dissection by William Thompson in 1973, the modern approach to thyroid surgery was born.

Nowadays, thyroidectomy is a safe procedure resulting from a sophisticated blend of thorough knowledge of surgical anatomy, adequate experience corroborated by continuous learning, competent application of technology, honed and standardized surgical technique. Early in his surgical experience in the late 1980s, at the beginning of his approach to thyroid surgery, the first editor of this book enthusiastically considered total thyroidectomy as the “perfect operation” for the gentleness of the surgical gestures, the anatomical knowledge involved, and the standardization of the surgical method.

Today, thyroid surgery is performed worldwide, for malignant and benign disease, by endocrine and general surgeons, surgical oncologists, and also otolaryngologists. In fact, in numerous university centers globally, there is discussion regarding who is qualified to perform thyroid surgery: in the USA, most departments of head and neck surgery have been performing thyroid surgery for many years. In contrast, thyroid surgery in many European countries is still dominated by general surgeons. Competence to perform thyroid surgery and hence qualification is not determined by the basic certification of surgical specialty, but it rather hinges on each surgeon’s skills and surgical experience; maintaining such expertise necessitates a sufficiently large volume of thyroid and neck surgeries after the training period. However, it still appears that the majority of thyroidectomies take place outside of large academic medical centers, with reports of more than 50% of thyroid surgery being performed by surgeons who operate less than five cases per year... As largely supported by the literature, we think that fragmentation of practice among several centers with small case volumes per year is, nowadays, counterproductive in

thyroid surgery, as in many modern specialties (HPB, upper GI, colorectal minimally invasive surgery, etc.) when aiming at optimal outcomes.

Bari, Italy  
September 2023

Mario Testini  
Angela Gurrado

---

# Contents

## Part I General Features and Indications for Surgery

- 1 History of Thyroid Surgery . . . . . 3**  
Guido Gasparri
- 2 General Preoperative Workup, Informed Consent, Antibiotic Prophylaxis, and Anesthesia in Thyroid Surgery . . . . . 11**  
Angela Gurrado, Lucia Iliaria Sgaramella, Elisabetta Poli, Walter Lavermicocca, Antonella Filoia, and Mario Testini
- 3 Non-Neoplastic and Indeterminate Thyroid Lesions . . . . . 21**  
Fabio Medas, Gian Luigi Canu, Federico Cappellacci, and Pietro Giorgio Calò
- 4 Suspected Malignancy and Malignant Thyroid Tumors . . . . . 27**  
Nunzia Cinzia Paladino, David Taïeb, and Frédéric Sebag
- 5 Retrosternal, Forgotten, and Recurrent Goiter . . . . . 39**  
Angela Gurrado, Francesco Paolo Prete, Giovanna Di Meo, Alessandro Pasculli, Elisabetta Poli, Lucia Iliaria Sgaramella, and Mario Testini

## Part II Surgery: Cervical and Remote Approaches

- 6 Conventional Open Thyroidectomy . . . . . 49**  
Mario Testini, Francesco Paolo Prete, Giovanna Di Meo, Alessandro Pasculli, Elisabetta Poli, Lucia Iliaria Sgaramella, and Angela Gurrado
- 7 Minimally Invasive Video-Assisted Thyroidectomy . . . . . 61**  
Marco Raffaelli, Carmela De Crea, Francesco Pennestrì, Pierpaolo Gallucci, Luca Revelli, Luca Sessa, Francesca Prioli, Celestino Pio Lombardi, and Rocco Bellantone
- 8 Cervical Lymphadenectomy in Papillary Thyroid Cancer . . . . . 71**  
Belinda W. Hii and Fausto F. Palazzo

<b>9</b>	<b>Robot-Assisted Transaxillary Thyroidectomy</b> .....	<b>83</b>
	Gabriele Materazzi and Leonardo Rossi	
<b>10</b>	<b>Robotic Bilateral Axillo-Breast Approach</b> .....	<b>93</b>
	Francesco Prete, Piercarmine Panzera, Giuseppe Massimiliano De Luca, Francesco Vittore, Carlotta Testini, Walter Lavermicocca, Angela Gurrado, and Mario Testini	
<b>11</b>	<b>Transoral Endoscopic Thyroidectomy Vestibular Approach: Lessons from a Five Years' Experience.</b> .....	<b>101</b>
	Daqi Zhang, Gianlorenzo Dionigi, Francesco Frattini, Andrea Cestari, Antonella Pino, Ozer Makay, Che-Wei Wu, Hoon Yub Kim, Andrea Casaril, and Hui Sun	
<b>Part III Prevention and Management of Perioperative Complications</b>		
<b>12</b>	<b>Laryngeal Nerves Monitoring in Thyroid Surgery</b> .....	<b>113</b>
	Marcin Barczyński	
<b>13</b>	<b>Autotransplantation of the Parathyroid Glands in Thyroidectomy: The Role of Autofluorescence and Indocyanine Green</b> .....	<b>123</b>
	Lodovico Rosato and Luca Panier Suffat	
<b>14</b>	<b>Energy Devices, Hemostatic Agents, and Optical Magnification in Thyroid Surgery</b> .....	<b>131</b>
	Roberto M. Romano, Marcello Filograna Pignatelli, Sonia Ferrandes, and Giovanni Docimo	
<b>15</b>	<b>Postoperative Hypoparathyroidism.</b> .....	<b>137</b>
	Maurizio Iacobone and Francesca Torresan	
<b>16</b>	<b>Laryngeal Nerve Palsy</b> .....	<b>145</b>
	Carmela De Crea, Giuseppe Marincola, Lucia D'Alatri, Francesco Pennestrì, Priscilla Francesca Procopio, Pierpaolo Gallucci, Luca Revelli, Rocco Bellantone, and Marco Raffaelli	
<b>17</b>	<b>Cervical Hematoma and Wound Complications</b> .....	<b>155</b>
	Paolo Carcoforo, Maria Grazia Sibilla, and Margherita Koleva Radica	
<b>18</b>	<b>Tracheal Injury</b> .....	<b>161</b>
	Andrea Polistena, Francesco Puma, Nicola Avenia, and Jacopo Vannucci	

**Part IV New Perspective Tools**

- 19 Training and Learning Curves in Thyroid Surgery. . . . . 171**  
Alessia Fassari, Marco Bononi, and Giuseppe Cavallaro
  
- 20 The Angiogenic Microenvironment of Thyroid Cancer:  
An Insight into the Research of New Prognostic Markers . . . . . 179**  
Alessandro Pasculli, Lucia Ilaria Sgaramella, Giovanna Di Meo,  
Francesco Paolo Prete, Angela Gurrado, Roberto Ria, Angelo Vacca,  
and Mario Testini

---

## Part I

# General Features and Indications for Surgery



# History of Thyroid Surgery

1

Guido Gasparri

## 1.1 Introduction

“The extirpation of the thyroid gland for goiter typifies, perhaps better than any operation, the supreme triumph of the surgeon’s art”. With this sentence William Halsted opened his magnificent monograph *The operative story of goitre* in 1920. It is certainly the best way to begin a chapter on the history of thyroid surgery to focus on the importance and difficulties of surgery in this field [1].

Considering both the thyroid and parathyroid, their histories offer interesting contrasts: in thyroid surgery, surgeons started to operate to relieve symptoms resulting from anatomic problems such as dislocation and compression of adjacent structures and then the physiologists were stimulated to seek laboratory answers to the complications of thyroid surgery and to study thyroid function. For the parathyroids, first physiologists studied the gland’s hormonal function and its interaction with kidney and bone and then the surgeons started to operate on patients to relieve symptoms.

For thousands of years, goiter was considered a familiar, fatal and inoperable disease. Patients suffered from suffocation, difficulty in swallowing, heart failure and distressing disfigurement.

Also, if the first mention of goiters in China dated as far back as 2700 BC, apparently the first successful excision of a goiter was carried out only around 1000 AD by Albucasis (Abū al-Qāsīm Khalaf al-Zahrāwī, 936–1013). Albucasis lived in Baghdad and undertook the operation with confidence following this experience: “A ‘homo ignarus’ had attempted a similar operation, and the patient having nearly bled to death from an injured artery. Albucasis knew very well how to control hemorrhage by ligature and the hot iron” [1].

---

G. Gasparri (✉)

Formerly at Department of Surgical Sciences, University of Turin, Turin, Italy

e-mail: [gasparri.guido@gmail.com](mailto:gasparri.guido@gmail.com)

© The Author(s) 2024

M. Testini, A. Gurrado (eds.), *Thyroid Surgery*, Updates in Surgery,  
[https://doi.org/10.1007/978-3-031-31146-8\\_1](https://doi.org/10.1007/978-3-031-31146-8_1)

3

---

## 1.2 Anatomical Recognition of the Thyroid Gland

It is interesting to see that the anatomy of a normal thyroid gland was not known until the Renaissance. Leonardo da Vinci (1452–1519) made the first description of the normal thyroid and, in doing so, recognized it as an anatomical organ and not simply as a pathological aberration as believed for centuries. He drew the thyroid as a globular, bilobate structure, which he regarded as two glands, filling up empty spaces in the neck that separated the trachea from the clavicle, but his drawings were unknown for three centuries. Others pondered the function of the thyroid (to lubricate the neck, make it more aesthetically pleasing or, considering the gland a blood buffer, to protect the brain from sudden increases in blood flow from the heart).

In 1543 the anatomist Andreas Vesalius (Andreas van Wesel, 1514–1564) gave the first anatomic description and illustration of the gland. Working during the same period as Vesalius, Bartholomæus Eustachius (Bartolomeo Eustachi, 1520–1674), who also discovered the adrenals, more accurately described the thyroid as a single “glandula thyroidea” with an isthmus connecting its lobes, but his work was not published until the beginning of the eighteenth century [2].

The term “glandula thyroidæa” was established in 1656 by the anatomist Thomas Wharton (1614–1673) in his work *Adenographia: sive glandularum totius corporis description* (Adenography, or description of the glands of the entire body), even though he still regarded the thyroid gland as consisting of two distinct glands. The name was attributed to the gland owing to its close contiguity to the thyroid cartilage, the name of which dates back to ancient Greek medical literature: in fact, Greek anatomists called this cartilage θυροειδής (thyreoides) because of its shape, which evoked that of a shield, in Greek θυρεός (thyreos).

---

## 1.3 First Attempts in Thyroid Surgery

Early developments in thyroid surgery came from the school of Salerno in the twelfth and thirteenth centuries using setons, hot irons and caustic powders, often with fatal results.

Guilielmus Fabricius Hildanus (Wilhelm Fabry, 1560–1634) reported that in 1596 “an empiric [i.e., a quack] attempted to remove a goitre in the case of a 10-year-old girl. She died under the operation, and the surgeon was imprisoned” [1].

In 1791 Pierre-Joseph Desault (1738–1795) successfully excised the greater part (so it is said in the text) of an enlarged thyroid gland. Another operation, which Desault performed on a woman, was described in the *Dictionnaire des Sciences Médicales*: “After beginning the operation the hemorrhage was so severe that he abandoned the attempt and contented himself with tying up the piece of gland which had been cut”. The patient died subsequently of convulsions [2].

Technical surgical improvement did not occur until the middle of the nineteenth century. By the 1850s, the mortality rate after thyroid surgery was approximately 40%. The French Academy of Medicine condemned any type of operation on the thyroid gland and Robert Liston (1794–1847), who had done five thyroid



operations, wrote in 1846 that it was "... a proceeding by no means to be thought of" [3]. In the same period, Samuel D. Gross (1805–1884), a prominent American surgeon wrote: "Can the thyroid gland, when in a state of enlargement, be removed with a reasonable hope of saving the patient? Experience emphatically answers NO. If a surgeon should be so foolhardy as to undertake it, every step of the way will be environed with difficulty, every stroke of his knife will be followed by a torrent of blood, and lucky will it be for him if his victim lives long enough to enable him to finish his horrid butchery. No honest and sensible surgeon would never engage in it" [2, 3].

In the 1850s a variety of incisions, longitudinal, oblique, and occasionally Y shaped were done: bleeding was generally inadequately controlled. Typically, wounds were left open and dead spaces were either packed or left to fill with blood.

---

## 1.4 Progress in Thyroid Surgery

Even with pronouncements against thyroid surgery, progress in surgery and medicine developed dramatically in the second half of the nineteenth century. The findings of Paul Sick (1836–1900), Jacques-Louis Reverdin (1849–1908), Theodor Billroth (1829–1894), Theodor Kocher (1841–1917), Victor Horsley (1857–1916), William Halsted (1852–1922), George Murray (1865–1939), and others reported that the behavior of patients after thyroidectomy changed significantly and the operation was becoming safer.

In the meantime, the importance of the function of the thyroid was being discovered. Paul Sick reported that an energetic and happy 10-year-old boy became "quiet and dull" following removal of his thyroid gland by another surgeon in Stuttgart (Germany). In 1882, Reverdin described several patients who became feeble and anemic 2–3 months after removal of the thyroid gland. Two of these patients developed edema of the hands and face and took on a cretinoid appearance [4].

Anesthesia, antisepsis, and surgical hemostatic instrumentation were among the major innovations that provided the basis for a new, safer surgical approach.

The era of modern surgical anesthesia began with William Morton (1819–1868): he demonstrated the efficacy of ether at Massachusetts General Hospital in Boston in 1846. In 1849, in St Petersburg, Russia, Nikolaj Ivanovič Pirogov (1810–1881) performed the first thyroidectomy under general anesthesia.

The introduction of antisepsis by Joseph Lister (1827–1912) in 1867 was the second step in the surgical revolution, followed by the concept of intraoperative asepsis introduced by Gustav Neuber (1850–1932). He brought cap and gown into the operating theater. In 1886 Ernst von Bergmann (1836–1907) in Berlin introduced steam sterilization of surgical instruments.

Hemostasis was achieved by Thomas Spencer Wells (1818–1897): he devised a simple, self-retaining arterial forceps to reduce operative bleeding and, ultimately, mortality.

From 1850 to 1875 mortality from thyroid surgery was reduced by half thanks to better control of the patient's pain and motion and improved hemostasis, so

surgeons had more time to attend to the underlying anatomy for a more successful thyroidectomy with a safe, nonseptic postoperative course.

In this period, another important factor was the presence of very skilled surgeons [5, 6].

---

## 1.5 Billroth and Kocher

Theodor Billroth was appointed chair of surgery at Zurich University at the age of 31: there, in a fine new university hospital located in one of the world's most highly endemic goiter regions, he initiated a cautious program of surgical attack on large suffocating goiters but, during his first 6 years, he performed 20 thyroidectomies with a mortality of 40%. Billroth considered the results disastrous and he virtually abandoned the procedure for a decade. He resumed thyroid surgery in 1877 after the advent of antisepsis, achieving a mortality rate of 8%. The Billroth procedure involved division of the sternocleidomastoid muscle, and hemostasis achieved with ligation.

In 1860 Billroth founded (with B. Langenbeck and G. Gurlt) the world's oldest medical journal of surgery *Archiv für klinische Chirurgie* (now *Langenbeck's Archives of Surgery*). In 1863 he published his textbook *Die Allgemeine Chirurgische Pathologie und Therapie* (General surgical pathology and therapy). In 1867 he accepted the chair at Vienna.

He was the most experienced surgeon in the world at that time and many important surgeons (such as von Mikulicz, von Eiselberg, Wolfler) studied under him. He also performed the first successful laryngectomy and the first esophagectomy.

It is, however, Theodor Kocher who has been universally and deservedly acclaimed as "the father of thyroid surgery", standing alone in the annals of thyroid surgery.

Kocher, the second of six children of an engineer father and a Pietist mother, was born in Bern, Switzerland. After graduation in 1865 from the University of Bern, he spent a year visiting and studying at foreign clinics. He visited Glasgow, where he witnessed Lister's revolutionary antisepsis work; London, where he observed Spencer Wells paving the way for surgery in the abdominal cavity, previously avoided for fear of lethal infection; Paris, where he met Pasteur and Verneuil; Zurich, where he met with Billroth.

After graduation he became assistant in the Surgical Clinic of Bern University. In that period, he was induced to open a private practice because a marriage to a wealthy young woman demanded that he earn something himself: so he studied hemostasis privately in animals. In 1872 he succeeded his former chief in Bern, Albert Lucke, as professor of surgery and, despite attempts to persuade him to move to Prague, Vienna and Berlin, he remained in Bern until his death.

At the time of Kocher's appointment to Bern, goiters were endemic in Switzerland. He noted that up to 90% of school children were afflicted with goiter. He quickly acquired extensive experience in thyroid surgery, performing more than 5000 thyroidectomies over the course of his career. He was a meticulous surgeon who paid

careful attention to hemostasis, and introduced ligation of the inferior thyroid arteries, which reduced the risk of hemorrhage. His advocacy of the use of antiseptics was manifest in his mortality rates. He reported a reduction in mortality from 12.6% in the 1870s to 0.2% in 1898. In this period Bern became the world capital of goiter surgery.

In 1867 Kocher noted that one of his early patients, a 10-year-old girl, had developed infantile hypothyroidism with cretinoid features after thyroidectomy. In 1883 he presented his historic paper to the fifth German Surgical Congress, in which he described the adverse effects of total thyroidectomy (*cachexia strumipriva*).

William Halsted, who attended the clinics of Kocher and Billroth during the 2 years he toured Europe as a postgraduate student to learn the techniques of the major surgeons, made an interesting comparative observation: “Most of Kocher’s thyroidectomy patients developed myxedema postoperatively, but rarely tetany. The reverse was true of Billroth’s patients. The origin of this phenomenon lay in Kocher’s and Billroth’s different surgical techniques. Whereas Kocher was known for his bloodless operative field, attention to detail, and removal of most of the thyroid while preserving surrounding structures, Billroth was known for a more rapid approach, resulting in parathyroid injury and larger retained segments of thyroid” [5].

Halsted brought Kocher’s surgical philosophy back to the United States where at that time little thyroid surgery was done. Halsted helped to found the Johns Hopkins Hospital, where he was appointed the first professor of surgery. There he introduced residency training and trained many surgeons (including Harvey, Cushing, Horace, Crile, Lahey).

Returning to Kocher, he was awarded the 1909 Nobel Prize in Medicine for his contributions to physiology, pathology and surgery of the thyroid, and thus for initiating endocrinology. Three years later he donated his Nobel Prize money to his University for a Research Institute in Biology. Although Kocher’s most significant contributions lay in the area of the thyroid, he was a surgeon of great versatility and breadth of interests. His operation for hernia, carcinoma of the rectum, his method of mobilizing the duodenum to expose retroperitoneal spaces and his maneuver for reducing dislocation of the shoulder are well known and still bear his name. Many professional honors were conferred upon him: President of the German Society of Surgeons, Honorary Fellow of the Royal College of Surgeons, Honorary member of the American Surgical Society. His *Chirurgische Operationslehre* (Textbook of operative surgery) reached six editions and was translated into six languages.

Talking about Kocher’s life we can cite a curious detail: in 1913 Kocher performed successful thyroidectomy on Nadežda Konstantinovna Krupskaja, a Russian revolutionary affected by Graves’ disease with goiter and exophthalmos, wife of Lenin, head of the Bolshevik Party [7].

In conclusion, Kocher’s new operative style, based on the precise identification of anatomical structures, permitted the radical surgical removal of all diseased tissue with minimal morbidity and mortality. We might justifiably say that, by 1920, the principles of safe and efficient thyroid surgery had been established.

By 1938 Frank Lahey (1880–1953) advocated wider exposure for visualization of the inferior laryngeal nerve during thyroidectomy. With this technique he reported a rate of injury of 0.3%. Despite many papers on avoidance of recurrent laryngeal nerve injury, little attention was paid to the surgical importance of the external branch of the superior laryngeal nerve until 1935 when a world-famous soprano, Amelita Galli-Curci, underwent goiter surgery with resultant loss of upper vocal registry. The comment was: “The surprising voice is gone forever. The sad specter of a ghost replaces the velvety softness” [2].

After the Second World War progress included ventilation and antithyroid drugs. Ultrasound has refined our skills in clinical examination and computerized tomography scanning has refined our view of large intrathoracic goiter. Fine needle aspiration cytology, described by Nils Söderström in 1952, has been generally available since the 1970s.

---

## 1.6 Recent Advances

A better surgical view, thanks to the magnification offered by new instruments has made the surgical procedure safe and the patient’s recovery easier. Conventional open surgery has been the standard surgical technique for almost a century. This initially involved a 10 cm transverse midline neck incision which, over the years, was greatly reduced to a standard 3–6 cm incision with the use of magnifying glasses to offer a better tridimensional view. Undoubtedly this surgery provides excellent exposure but the risk of scar hypertrophy and the search for better cosmetic results have led to the development of minimally invasive techniques such as video-assisted, endoscopic, and robotic surgery [8–10].

Minimally invasive video-assisted thyroidectomy (MIVAT) is the most widely accepted endoscopic technique and was developed by Miccoli in Pisa (2000) and then Bellantone in Rome. The desire to avoid neck scarring has resulted in the development of robotic thyroid surgery (robot-assisted transaxillary thyroidectomy, RATT). This procedure was initially described by Kang in 2009. In Italy, the two centers with the largest experience are in Pisa and Modena. Additionally, this procedure is associated with a significant learning curve, longer operative times, greater invasiveness due to the dissection needed to approach the neck from the axilla, and higher costs. The only technique that allows a scarless thyroidectomy is the transoral endoscopic thyroidectomy with vestibular approach (TOETVA) performed by Richmond in 2011. Some concerns about this approach persist, however, and regard oncologic completeness and technical feasibility.

In conclusion, the words of Giddings in the *Journal of the Royal Society of Medicine* in 1996 are still very apt as authoritative advice on the diagnosis and management of thyroid conditions [3]:

Every patient undergoing thyroidectomy should be confident that:

- The resection has been planned in the light of an accurate preoperative diagnosis
- The principles of complete lobectomy, including the isthmus and pyramidal lobe, will be observed

- The recurrent laryngeal nerve, the external branch of the superior laryngeal nerve and the cutaneous branches of the cervical plexus will be preserved
- The parathyroid glands will be protected.

These four principles are necessary components of good quality surgery and are essential if general standards are to rise to those of the best surgeons. In any case, whenever a nonconventional approach to the thyroid gland is planned it is highly recommended that these procedures be centralized to high-volume centers with skilled endocrine surgeons.

---

## References

1. Halsted WS. The operative story of goitre. *Johns Hopkins Hosp Rep.* 1920;19:71–257.
2. Slough CM, Rhian J, Randolph GW, et al. History of thyroid and parathyroid surgery. In: Randolph GW, editor. *Surgery of the thyroid and parathyroid glands.* Philadelphia: Saunders; 2003. p. 3–11.
3. Giddings AE. The history of thyroidectomy. *J R Soc Med.* 1998;91(Suppl 33):3–6.
4. Cady B. History of thyroid and parathyroid surgery. In: Cady B, Rossi RL, editors. *Surgery of the thyroid and parathyroid glands.* Philadelphia: Saunders; 1991. p. 1–4.
5. Rutkow IM. William Halsted and Theodor Kocher: “an exquisite friendship”. *Ann Surg.* 1978;188(5):630–7.
6. Becker WF. Pioneers in thyroid surgery. *Ann Surg.* 1977;185(5):493–504.
7. Russo M, Borzi G. The rebel thyroid of a revolutionary first lady. *J Endocrinol Investig.* 2020;43(3):395–6.
8. Rossi L, Materazzi G, Bakkar S, Miccoli P. Recent trends in surgical approach to thyroid cancer. *Front Endocrinol (Lausanne).* 2021;12:699805.
9. Tae K, Ji YB, Song CM, Ryu J. Robotic and endoscopic thyroid surgery: evolution and advances. *Clin Exp Otorhinolaryngol.* 2019;12(1):1–11.
10. Lombardi CP, Raffaelli M, De Crea C, et al. Video-assisted versus conventional total thyroidectomy and central compartment neck dissection for papillary thyroid carcinoma. *World J Surg.* 2012;36(6):1225–30.

**Open Access** This chapter is licensed under the terms of the Creative Commons Attribution-NonCommercial-NoDerivatives 4.0 International License (<http://creativecommons.org/licenses/by-nc-nd/4.0/>), which permits any noncommercial use, sharing, distribution and reproduction in any medium or format, as long as you give appropriate credit to the original author(s) and the source, provide a link to the Creative Commons license and indicate if you modified the licensed material. You do not have permission under this license to share adapted material derived from this chapter or parts of it.

The images or other third party material in this chapter are included in the chapter's Creative Commons license, unless indicated otherwise in a credit line to the material. If material is not included in the chapter's Creative Commons license and your intended use is not permitted by statutory regulation or exceeds the permitted use, you will need to obtain permission directly from the copyright holder.





# General Preoperative Workup, Informed Consent, Antibiotic Prophylaxis, and Anesthesia in Thyroid Surgery

## 2

Angela Gurrado, Lucia Ilaria Sgaramella, Elisabetta Poli, Walter Lavermicocca, Antonella Filoia, and Mario Testini

### 2.1 General Preoperative Workup

Patients with thyroid disease (TD) requiring surgery must be properly evaluated by obtaining their medical history; physical examination, laboratory testing, and imaging studies aim to define and confirm the diagnostic hypothesis and facilitate the choice of the most appropriate surgical approach and the extension of the surgical procedure [1].

#### 2.1.1 History and Clinical Characteristics

Medical history includes the search for exposure to previous neck or whole-body irradiation or ionizing radiation. The radiation-related risk factors are dose, age at exposure, latency period, female gender, and degree of iodine deficiency at exposure [2].

First-degree relatives suffering from syndromes that include thyroid cancer (TC) (Cowden syndrome, familial polyposis, Carney complex, MEN 2, Werner syndrome, etc.) must be identified. For instance, the presence of a familial RET mutation (MEN 2) may impact the extent of initial thyroid surgery (TS) or the decision to perform prophylactic TS [3].

The patient should be asked about how and when the condition was identified, and the rapidity of growth or change in thyroid nodules (TN); a history of autoimmune thyroiditis, hypothyroidism, or Grave's disease should also be obtained [3].

---

A. Gurrado (✉) · L. I. Sgaramella · E. Poli · W. Lavermicocca · A. Filoia · M. Testini  
Department of Precision and Regenerative Medicine and Ionian Area,  
University of Bari, Policlinic of Bari, Bari, Italy  
e-mail: [angela.gurrado@uniba.it](mailto:angela.gurrado@uniba.it); [ilaria.sgaram@gmail.com](mailto:ilaria.sgaram@gmail.com); [eli.poli81@gmail.com](mailto:eli.poli81@gmail.com);  
[wlavermicocca@tiscali.it](mailto:wlavermicocca@tiscali.it); [aeffe86@libero.it](mailto:aeffe86@libero.it); [mario.testini@uniba.it](mailto:mario.testini@uniba.it)

Non-thyroid malignancies must be investigated, as the gland could be the site of metachronous metastasis (renal cell, lung, colon, breast, melanoma, ovarian primaries) with a presentation similar to a primary TN [4].

The search for compressive symptoms includes solids dysphagia that suggests a mechanical obstruction [5]. Swallowing symptoms are reported by up to 50% of patients [3]. Dyspnea is frequent in goiter and should be differentiated from cardiac and pulmonary dysfunction while its rapid progression can be associated with an aggressive malignancy.

Symptoms related to TD may include fatigue, palpitations, anxiety, insomnia, weight fluctuations, and heat intolerance in the case of hyperthyroidism, whereas hypothyroidism may cause cold intolerance, constipation, dry skin, slowed thinking, and edema [3].

Comorbidities that increase operative risk are [3]:

- personal or family history of anesthetic complications (malignant hyperthermia, difficult intubation);
- prior neck surgery;
- possible or diagnosed bleeding or clotting disorder; use of antithrombotic or antiplatelet medications;
- celiac sprue, inflammatory bowel disease, Roux-en-Y gastric bypass, any condition of chronic diarrhea.

### 2.1.2 Physical Examination

Physical examination findings should suggest hyperthyroidism if elevated heart rate, hypertension, and exophthalmos are present; signs of hypothyroidism should be a slow heart rate and slowed Achilles heel reflex time.

Neck examination may identify palpable nodules (at least 1 cm in size); immobile nodules and lymphadenopathy are concerning for malignant disease. Goiter may be graded by World Health Organization criteria from Grade 0 (nonpalpable/nonvisible) to Grade 3 (visible at a distance) [6].

Substernal goiter (SG) is diagnosed when the full extent of an enlarged thyroid cannot be palpated with the patient's neck extended, even with deglutition or supine positioning. Obesity, a short thick neck, or kyphosis, need further imaging to fully appreciate a SG.

Voice assessment is part of the physical examination and voice abnormalities may change the indication or the extent of TS or delay the operation. Mirror examination and flexible laryngoscopy are the most commonly used methods and are routinely recommended [7].

### 2.1.3 Laboratory Tests

- Serum TSH level [1, 3].
- Calcitonin dosage to screen for medullary thyroid cancer is controversial in routine assessment. Current American guidelines do not recommend screening basal serum calcitonin levels in the evaluation of TN, but only targeted screenings in at-risk individuals [1, 3].
- Secondary level tests are: serum calcium to screen for primary hyperparathyroidism, followed by, serum phosphate and PTH assays if serum calcium is high; anti-TPO and anti-Tg if autoimmune disease is suspected; TSH-receptor antibody for diagnosis of Grave's disease.

### 2.1.4 Imaging Studies

Thyroid ultrasound (US) with color flow Doppler scanning is the crucial imaging study in all patients with a clinical suspicion of TN and nodular goiter (CT or MRI of the neck, thyroidal uptake on <sup>18</sup>FDG-PET scan, etc.). US allows an accurate anatomical evaluation of the thyroid and adjacent regional lymph nodes (LN), by giving relevant information on:

- location, size (possibly total gland volume);
- presence, number, size, and structure (solid, cystic, mixed) of the TN;
- vascular pattern of the TN on color Doppler;
- status of the contralateral lobe in the case of unilateral disease;
- nodular features indicative of malignancy (hypoechoogenicity, microcalcifications, absence of halo, irregular margins, chaotic intranodular vascularity, round shape);
- condition of the trachea (midline, displaced, compressed);
- status of regional LN (reactive or suspicious).

The 2020 guidelines of the American Association of Endocrine Surgeons summarized the US features predictive of TC, reconsidering the specificity of nodule hypoechoogenicity and focusing on microcalcification, irregular margins, and tall shape to guide the need for fine needle aspiration cytology (FNAC) for TN [3].

Several scoring systems have been proposed to establish the indication for FNAC and avoid unnecessary diagnostic TS [3, 8]. Among them is the Thyroid Imaging Reporting and Data System (TI-RADS), which uses US features to assign a predictive score from TR1 to TR5, related to the rate histological malignancy [9].

FNAC indications depend on the US features, but also the size of the TN is considered. Nodules <1 cm are usually not biopsied, because of the indolent behavior of TC of this size, unless they are suspicious for metastases or local invasion [10]. Other indications, regardless of nodule size, are the risk factors for malignancy identified during medical history or clinically suspicious findings (hoarseness, fixed nodule, laryngeal nerve dysfunction).



Cytology reports have been standardized using the Bethesda System for Reporting Thyroid Cytopathology, published in 2008 and updated in 2017, which provides six categories from I to VI, ranging from benign lesions to suspected malignancy or malignant lesions. In 2012 in Italy, a panel of experts introduced a subcategory of Tir 3 to reduce the number of nodules with intermediate cytology to be subjected to surgery (Tir 3a, low-risk indeterminate lesion; Tir 3b, high-risk indeterminate lesion). Washout fluid testing for thyroglobulin (TG) and calcitonin are not routinely performed; they may be useful to distinguish if the biopsied lesion is a LN or parathyroid and to identify metastatic node cancer in doubtful cases [1].

CT/MRI are needed only as second-level examinations for the assessment of large, rapidly growing lesions, or SG, or in the presence of invasive TC to define the involvement of extrathyroidal tissues.

Thyroid scintigraphy with radioactive iodine uptake test is not useful in euthyroid patients. Indications are limited to subclinical or overt hyperthyroidism, recurrent goiter, and suspicion of forgotten or ectopic goiter.

PET/CT ( $^{18}\text{F}$ FDG-PET) is not recommended for routine preoperative evaluation but may be worthwhile when aggressive histology is suggested as in poorly differentiated or anaplastic TC; 30–40% of accidentally discovered  $^{18}\text{F}$ FDG-PET-positive nodules may be malignant. Nonetheless, such nodules should be evaluated by US and FNAC at the same time. As regards the detection of cervical LN metastases, CT and MRI show higher sensitivity, while PET can identify inflammatory LNs [11].

Finally, the preadmission workup includes a complete preoperative assessment with blood chemistry, blood cell count and coagulation tests, electrocardiography and, depending on the patient's age and comorbidities, chest X-ray [1].

---

## 2.2 Informed Consent

The patient's right to informed consent is discussed in the European Chapter of Patients' Rights which establishes that each patient has the right to choose between various treatments based on appropriate information [12].

The patient should be informed about the results of the preoperative workup, the extent of TS, and the reasons for suggesting one procedure rather than others. A two-step surgery must be discussed in the case of a pre- or perioperative difficult diagnosis or higher risk of iatrogenic damage (TS, inflammation, previous irradiation of the neck, re-operation) [13].

The risks and benefits of the TS proposed should be analyzed. The information should be based on the literature data, the patient's situation, and the surgeon's experience, in particular distinguishing between the generic risks of TS and the specific risks related to the patient's characteristics. In detail, the patient should be informed about:

- postoperative hematoma and bleeding requiring re-intervention;
- unilateral or bilateral laryngeal palsy, temporary or definitive;

- transient and definitive hyperparathyroidism, increasing with central compartment LN resection, Graves-Basedow disease, needing temporary or permanent medication;
- rare complications such as surgical site infection, tracheal necrosis, minor swallowing disorders, pathological scar healing, as well as general nonspecific complications [3].

Patient information should include anesthesia and the possibility of extemporaneous anatomopathological examination.

Patients must be informed that the use of intraoperative neuromonitoring (IONM) does not completely avoid the risk of recurrent laryngeal nerve (RLN) dysfunction, especially in supposed difficult procedures. According to the International Neural Monitoring Study Group consensus statement of 2021, the patient should be told the purpose of IONM use (RLN identification, function prognostication, and intraoperative decision-making) [14].

Alternative treatment to TS and the consequences of refusing the proposed treatment should be discussed.

Hormone replacement therapy, with subsequent monitoring of thyroid function should be stressed [12].

Once correct verbal information has been provided in clear and simple terms to the patient himself and to a designated trusted person, a written document should be signed by the patient and the surgeon and attached to patient's chart [3].

---

## 2.3 Anesthesia in Thyroid Surgery

The real target for anesthesia in TS is to pay attention to the patient's various comorbidities, allowing for adequate monitoring while maintaining adequate anesthesia.

There are currently two types of anesthesia employed in clinical practice during TS: the most used are general anesthesia (GA) with tracheal intubation, and the cervical plexus nerve block.

TS under regional anesthesia is anecdotal, as reported in the literature, and remains limited in clinical practice especially to patients with underlying medical comorbidities that preclude GA [15]. By contrast, GA and tracheal intubation represent the methods of choice for TS. The complications generated by tracheal intubation and by TD with induction of anesthesia must be considered and avoided. Indeed, preoperative identification of TD and its implications is important for optimal patient management. The patient should be subjected to GA and TS in the case of a preoperative euthyroid state and only emergency procedures should be performed without euthyroidism. In the event of preoperative hypothyroidism, the clinician should pay attention to an increased tendency to depression of myocardial function, decreased spontaneous ventilation, abnormal baroreceptor function, reduced plasma volume, anemia, hypoglycemia, hyponatremia, and impaired hepatic drug metabolism. Conversely, in the event of a preoperative hyperthyroid state, thyroid crisis must be excluded. This could be triggered by surgery, trauma, or

infection and it must be managed with hydration, cooling, inotropes, steroids, beta-blockade, and antithyroid drugs as the first-line treatment.

In the literature, TS is also associated with difficult endotracheal intubation (DEI) because of the possibility of large goiter or TC infiltration, with a reported rate of 5.3–24.6% higher than the general population. An adequate airway assessment is therefore mandatory to detect and avoid potential difficult intubation [16]. Among factors linked to DEI, the presence of cancerous goiter causing tracheal infiltration and fibrosis which may reduce the mobility of laryngeal structure are considered major predictors of DEI. In these cases, with a higher risk of DEI and airway loss, if GA is induced, awake fiberoptic intubation could be indicated [17].

GA induces intubation through the injection of small doses of nondepolarizing muscle relaxants, including rocuronium bromide. IONM during TS and parathyroid surgery (PTS) has gained widespread acceptance as an adjunct to the gold standard of visual RLN identification but, at the same time, its routine application in surgical practice has modified the type of GA. The success of GA and airway control in TS is now related not only to correct tracheal intubation but also to correct positioning of the endotracheal electromyography tube necessary for precise IONM [18].

Starting from the evidence that quantitative neurophysiological evaluation of the RLN is based on the recording of evoked potential at the vocalis muscle, the unrestricted use of a neuromuscular blocking agent (NMBA) in GA for TS has been widely discussed. The neuromuscular blockade, indeed, may interfere with IONM of the RLN by reducing the signal to varying degrees, and generating confusion in the interpretation of IONM. To address this issue, some strategies have been proposed:

- *Tracheal intubation without muscle relaxant.* Although clinical experience and some studies have proposed tracheal intubation without muscle relaxant in the induction of GA, this requires deep anesthesia and is associated with a higher risk of airway injury, and is therefore now considered only if performed by experienced hands [19].
- *Succinylcholine.* Thanks to the rapid onset and short duration of muscular relaxation, succinylcholine was initially considered for TS with IONM. However, it is now avoided because of the association with a variety of adverse effects from minor to catastrophic, such as cardiac dysrhythmia, hyperkalemia, and malignant hyperthermia as a result of its membrane depolarizing effect and release of potassium [20].
- *Alternative nondepolarizing NMBA at different posology.* The current literature proposes an alternative of nondepolarizing NMBA with short onset and offset of neuromuscular block to replace succinylcholine for IONM. A single dose of rocuronium and atracurium at 0.5 mg/kg was considered adequate for tracheal intubation allowing for spontaneous gradual recovery of neuromuscular transmission and positive electromyography signals [21]. Moreover, a single reduced dose of rocuronium was proposed as a possible alternative [22].
- *Introduction of selective relaxant binding agents (SRBAs).* SRBAs have the potential to overcome the limitations of cholinesterase inhibitors, acting as a

selective relaxant binding agent for rapid neuromuscular blockade reversal. The first SRBA to be introduced is sugammadex with the function of rapidly restoring neuromuscular function suppressed by rocuronium [22].

The degree of neuromuscular blockade could be intraoperatively monitored by the train of four (TOF) count and ratio derived from the adductor pollicis muscle. Furthermore, anesthetic depth could be assessed by using the response entropy or bispectrality index [23].

---

## 2.4 Antibiotics in Thyroid Surgery

Postoperative infections in patients undergoing TS are uncommon. The absence of contact with the upper aerodigestive tract and the type of surgery, normally considered a clean procedure, justify the low rate of surgical site infection (SSI). Indeed, the incidence of SSI after TS and PTS ranges from 0.09% to 2.9% [24].

In the literature, a significant divergence appears to exist between guideline recommendations and clinical practice with regard to the use of antibiotic prophylaxis (AP). AP seems to be commonly used, often on an open basis, depending on the clinical practice and the behaviors of each center. In contrast, the international guidelines do not routinely recommend AP, since unnecessary courses are often associated with pathogen resistance and superinfection, potential toxicity, increased cost and hospital stay. The 2020 guidelines of the American Association of Endocrine Surgeons suggest avoiding AP in most cases of standard transcervical TS for the management of TD in adults because of the low risk of SSI, whereas no mention of AP is made in the guidelines of the American Thyroid Association [3, 14].

A recent metaanalysis of postoperative SSI analyzed the outcomes of nine studies (4 RCTs and 5 non-RCTs) showing that there are no significant differences between the SSI rate in patients undergoing TS and PTS with or without AP [25].

Nevertheless, a few studies report some risk factors for the development of SSI such as diabetes, cardiopulmonary comorbidity, ASA score and older age (above 65 or above 80 years), disease factors such as the presence of malignancy, and procedure-related factors such as prolonged operating time and lymphadenectomy [26, 27]. This evidence does not therefore justify the routine use of antibiotics in clean neck surgery but only a limited use if specific preconditions are present.

---

## References

1. Rosato L, De Crea C, Bellantone R, et al. Diagnostic, therapeutic, and health-care management protocol in thyroid surgery: a position statement of the Italian Association of Endocrine Surgery Units (U.E.C. CLUB). *J Endocrinol Investig.* 2016;39(8):939–53.
2. Iglesias ML, Schmidt A, Ghuzlan AA, et al. Radiation exposure and thyroid cancer: a review. *Arch Endocrinol Metab.* 2017;61(2):180–7.

3. Patel KN, Yip L, Lubitz CC, et al. The American Association of Endocrine Surgeons guidelines for the definitive surgical management of thyroid disease in adults. *Ann Surg.* 2020;271(3):e21–93.
4. Straccia P, Mosseri C, Brunelli C, et al. Diagnosis and treatment of metastases to the thyroid gland: a meta-analysis. *Endocr Pathol.* 2017;28(2):112–20.
5. Vansant MB, Kunduk M, McWhorter AJ. A review of postsurgical dysphagia in nonmalignant disease. *Curr Opin Otolaryngol Head Neck Surg.* 2016;24(6):477–82.
6. World Health Organization – Vitamin and mineral nutrition information system. Goitre as a determinant of the prevalence and severity of iodine deficiency disorders in populations (WHO/NMH/NHD/MNM/14.5). Geneva: World Health Organization; 2014. [https://apps.who.int/iris/bitstream/handle/10665/133706/WHO\\_NMH\\_NHD\\_EPG\\_14.5\\_eng.pdf](https://apps.who.int/iris/bitstream/handle/10665/133706/WHO_NMH_NHD_EPG_14.5_eng.pdf). Accessed 23 Sep 2022.
7. Maniakas A, Christopoulos A, Bissada E, et al. Perioperative practices in thyroid surgery: an international survey. *Head Neck.* 2017;39(7):1296–305.
8. Russ G, Bonnema SJ, Erdogan MF, et al. European thyroid association guidelines for ultrasound malignancy risk stratification of thyroid nodules in adults: the EU-TIRADS. *Eur Thyroid J.* 2017;6(5):225–37.
9. Tessler FN, Middleton WD, Grant EG, et al. ACR thyroid imaging, reporting and data system (TI-RADS): White paper of the ACR TI-RADS Committee. *J Am Coll Radiol.* 2017;14(5):587–95.
10. Cavallo A, Johnson DN, White MG, et al. Thyroid nodule size at ultrasound as a predictor of malignancy and final pathologic size. *Thyroid.* 2017;27(5):641–50.
11. Barrio M, Czernin J, Yeh MW, et al. The incidence of thyroid cancer in focal hypermetabolic thyroid lesions: an 18F-FDG PET/CT study in more than 6000 patients. *Nucl Med Commun.* 2016;37(12):1290–6.
12. SFORL Work Group; Santini J, Alfonsi JP, Bonichon F, et al. Patient information ahead of thyroid surgery. Guidelines of the French Society of Oto-Rhino-Laryngology and Head and neck surgery (SFORL). *Eur Ann Otorinolaryngol Head Neck Dis* 2013;130(6):363–368.
13. Demontis R, Pittau MR, Maturo A, et al. Medico legal aspects on neuromonitoring in thyroid surgery: informed consent on malpractice claims. *G Chir.* 2017;38(3):149–54.
14. Wu CW, Huang TY, Randolph GW, et al. Informed consent for intraoperative neural monitoring in thyroid and parathyroid surgery – consensus statement of the international neural monitoring study group. *Front Endocrinol (Lausanne).* 2021;12:795281.
15. Haugen TW, Andera LN, LaMadrid AB. Awake thyroidectomy. *Laryngoscope.* 2020;130(3):685–90.
16. Kalezić N, Milosavljević R, Paunović I, et al. The incidence of difficult intubation in 2000 patients undergoing thyroid surgery – a single center experience. *Vojnosanit Pregl.* 2009;66(5):377–82.
17. Bacuzzi A, Dionigi G, Del Bosco A, et al. Anaesthesia for thyroid surgery: perioperative management. *Int J Surg.* 2008;6(Suppl 1):S82–5.
18. Lu IC, Chu KS, Tsai CJ, et al. Optimal depth of NIM EMG endotracheal tube for intraoperative neuromonitoring of the recurrent laryngeal nerve during thyroidectomy. *World J Surg.* 2008;32(9):1935–9.
19. Hanci V, Erdoğan G, Okyay RD, et al. Effects of fentanyl-lidocaine-propofol and dexmedetomidine-lidocaine-propofol on tracheal intubation without use of muscle relaxants. *Kaohsiung J Med Sci.* 2010;26(5):244–50.
20. Miller R. Will succinylcholine ever disappear? *Anesth Analg.* 2004;98(6):1674–5.
21. Chu KS, Wu SH, Lu IC, et al. Feasibility of intraoperative neuromonitoring during thyroid surgery after administration of nondepolarizing neuromuscular blocking agents. *World J Surg.* 2009;33(7):1408–13.
22. Lu IC, Lin IH, Wu CW, et al. Preoperative, intraoperative and postoperative anesthetic prospective for thyroid surgery: what’s new. *Gland Surg.* 2017;6(5):469–75.

23. Donmez T, Erdem VM, Sunamak O, Ozcevik H. Thyroid surgery, IONM and sugammadex sodium relationships: benefits in sugammadex sodium use for IONM. *Acta Endocrinol (Buchar)*. 2019;15(4):454–9.
24. Qin Q, Li H, Wang LB, et al. Thyroid surgery without antibiotic prophylaxis: experiences with 1,030 patients from a teaching hospital in China. *World J Surg*. 2014;38(4):878–81.
25. Polistena A, Prete FP, Avenia S, et al. Effect of antibiotic prophylaxis on surgical site infection in thyroid and parathyroid surgery: a systematic review and meta-analysis. *Antibiotics (Basel)*. 2022;11(3):290.
26. Myssiorek D, Ahmed Y, Parsikia A, et al. Factors predictive of the development of surgical site infection in thyroidectomy – an analysis of NSQIP database. *Int J Surg*. 2018;60:273–8.
27. Caulley L, Johnson-Obaseki S, Luo L, Javidnia H. Risk factors for postoperative complications in total thyroidectomy: a retrospective, risk-adjusted analysis from the National Surgical Quality Improvement Program. *Medicine (Baltimore)*. 2017;96(5):e57521.

**Open Access** This chapter is licensed under the terms of the Creative Commons Attribution-NonCommercial-NoDerivatives 4.0 International License (<http://creativecommons.org/licenses/by-nc-nd/4.0/>), which permits any noncommercial use, sharing, distribution and reproduction in any medium or format, as long as you give appropriate credit to the original author(s) and the source, provide a link to the Creative Commons license and indicate if you modified the licensed material. You do not have permission under this license to share adapted material derived from this chapter or parts of it.

The images or other third party material in this chapter are included in the chapter's Creative Commons license, unless indicated otherwise in a credit line to the material. If material is not included in the chapter's Creative Commons license and your intended use is not permitted by statutory regulation or exceeds the permitted use, you will need to obtain permission directly from the copyright holder.





# Non-Neoplastic and Indeterminate Thyroid Lesions

# 3

Fabio Medas, Gian Luigi Canu, Federico Cappellacci, and Pietro Giorgio Calò

## 3.1 Non-Neoplastic Thyroid Lesions

### 3.1.1 Nondiagnostic Cytology

In approximately 15% of cases, fine-needle aspiration cytology (FNAC) results in a cytologically inadequate specimen. Nondiagnostic (or unsatisfactory) smears have an inadequate number of cells to allow a diagnosis, due to cystic fluid without cells, bloody smears or improper techniques in preparing slides. This category also includes thyroid cystic lesions, which are a frequent cause of inadequate results [1, 2].

The risk of malignancy for a nodule with nondiagnostic cytology is 1–4% [1].

In the case of an initial nondiagnostic cytology result, FNAC should be repeated with ultrasound (US) guidance and, if available, on-site cytologic evaluation. If the result is still nondiagnostic, close observation or diagnostic surgery may be considered [3].

Surgery is recommended if the nodule has clinical risk factors for malignancy, highly suspicious US features, growth >20% (in two dimensions, detected during US surveillance), or based on compressive symptoms and cosmetic concerns [3].

Percutaneous ethanol injection may be considered in cystic nodules with no suspicion of malignancy [3].

### 3.1.2 Benign Cytology

Benign diagnosis represents the most frequent result following FNAC, with a rate of 70%. The most common benign lesions are macrofollicular or adenomatoid/

---

F. Medas · G. L. Canu · F. Cappellacci · P. G. Calò (✉)

Department of Surgical Sciences, University of Cagliari, Policlinico Duilio Casula, Monserrato, Cagliari, Italy

e-mail: [fabio.medas@unica.it](mailto:fabio.medas@unica.it); [gianl.canu@unica.it](mailto:gianl.canu@unica.it); [fedcapp94@gmail.com](mailto:fedcapp94@gmail.com); [pgcalo@unica.it](mailto:pgcalo@unica.it)

hyperplastic nodules, colloid adenomas, nodular goiter, lymphocytic and granulomatous thyroiditis [1, 2]. The risk of malignancy in this category is 0–3% [1].

In nodules with benign cytology, further immediate diagnostic evaluations or treatment are not required. The follow-up of these lesions is mainly determined on the basis of the US features and secondarily according to the nodule growth [3]. In benign nodules with highly suspicious US characteristics, US and FNAC should be repeated within 12 months [3]. In lesions with low or intermediate suspicious US features, repeat US is recommended at 12–24 months. In the case of US evidence of new suspicious characteristics or growth (20% increase in at least two nodule dimensions with a minimal increase of 2 mm or more than a 50% change in volume), FNAC may be performed or follow-up may be continued with US, repeating FNAC only in the case of continued growth [3]. In nodules with very low suspicion US features, the utility of follow-up with US in order to assess the nodule growth, as an indicator for the repetition of FNAC, is limited. In these cases, if US is repeated, it should be performed at 24 months or more [3]. Follow-up is no longer indicated for a nodule undergoing repeat FNAC with a second benign cytology result [3].

Regarding therapy, routine TSH suppression treatment is not recommended. Surgery may be indicated for growing nodules that are benign after repeat FNAC if they are larger than 4 cm, in the case of structural or compressive symptoms or on the basis of clinical concern [3].

---

## 3.2 Indeterminate Thyroid Lesions

In approximately 20–25% of cases, FNAC leads to the diagnosis of indeterminate thyroid nodule. This result represents a clinical issue, since malignancy, although relatively low (up to 30%), cannot be ruled out with certainty. In this context, surgery, when indicated, has a diagnostic rather than therapeutic purpose, with almost 80% of surgical procedures being unnecessary [1–3].

The inability to assess any vascular or capsular invasion, which is the cornerstone of the diagnosis of differentiated thyroid carcinoma, is the main limitation of FNAC, which decreases its overall diagnostic accuracy [1, 2].

In order to solve the problem of unnecessary surgery without missing potentially malignant nodules, in the Bethesda System for Reporting Thyroid Cytology (BSRTC), proposed by the United States National Cancer Institute (NCI), indeterminate lesions were divided into category III or AUS/FLUS (atypia of undetermined significance or follicular lesion of undetermined significance) and category IV or FN/SFN (follicular neoplasms or suspicious for a follicular neoplasm), with different expected malignancy rates and therefore different management options [1].

The FLUS/AUS category is represented by lesions with focal architecture or nuclear atypia whose significance cannot be further determined and specimens that are limited due to poor fixation or obscuring blood [1]. The FN/SFN category includes cellular aspirates composed of follicular cells arranged in an altered architectural pattern characterized by cell crowding and/or microfollicle formation and



lacking nuclear features of papillary carcinoma or composed almost exclusively of oncocytic (Hürthle) cells [1].

The risk of malignancy is 5–15% for the AUS/FLUS category and 15–30% for the FN/ SFN category [1].

In the case of AUS/FLUS cytology, repeat FNA or molecular testing can be considered in order to integrate the malignancy risk evaluation. If either of them is not performed or inconclusive, on the basis of clinical risk factors, US features and patient preference, either surveillance or diagnostic surgery may be indicated [3].

Diagnostic surgery represents the long-established standard of care for nodules with FN/SFN cytology. However, after the consideration of clinical risk factors and US characteristics, molecular testing may be utilized to integrate the evaluation of malignancy risk [3].

The classification and malignancy rate of indeterminate nodules according to the BSRTC and the management recommended by the 2015 American Thyroid Association guidelines are summarized in Table 3.1.

As regards surgery, patients with thyroid nodular disease with indeterminate cytology may be subjected to total thyroidectomy or hemithyroidectomy. The choice between these two procedures depends on several factors: familial history of differentiated thyroid carcinoma, nodule size greater than 4 cm, highly suspicious US characteristics, previous radiation exposure and positivity for known molecular alterations specific for differentiated thyroid carcinoma. Furthermore, all these factors must be further associated with the possible coexistence of hyperthyroidism, the presence of bilateral nodules, the patient's medical comorbidities and the patient's preference [3].

If an intermediate or high-risk differentiated thyroid carcinoma is diagnosed after hemithyroidectomy, through final histopathological examination, it is recommended to perform a completion thyroidectomy, as hemithyroidectomy is considered oncologically inadequate in these cases [3].

It is important to emphasize that, even in the most experienced hands and in high-volume centers, thyroidectomy can lead to serious complications, including hypoparathyroidism, recurrent laryngeal nerve injury and postoperative cervical hematoma. These complications lead to a reduction in the quality of life of the patients and increased costs for healthcare systems [4]. For these reasons, there is an

**Table 3.1** Indeterminate thyroid lesions: classification<sup>a</sup>, malignancy rate<sup>a</sup>, and management<sup>b</sup>

Bethesda category	Diagnostic category	Malignancy rate	Management
III	Atypia of undetermined significance or follicular lesion of undetermined significance	5–15%	Repeat FNAC Molecular testing Surveillance/surgery
IV	Follicular neoplasms or suspicious for a follicular neoplasm	15–30%	Surgery (molecular testing)

FNAC fine-needle aspiration cytology

<sup>a</sup> According to the Bethesda System for Reporting Thyroid Cytopathology

<sup>b</sup> Recommended by the 2015 American Thyroid Association guidelines

increased emphasis on assessing the risk of malignancy of indeterminate nodules in order to minimize unnecessary surgical procedures.

As already mentioned, the application of molecular testing on cytological samples can provide a more precise assessment of the risk of malignancy in indeterminate nodules and a more accurate preoperative estimation of the aggressiveness of the neoplasm. Thus, these tests can help to avoid unnecessary surgery for benign nodules and distinguish more aggressive thyroid cancers that need to undergo total thyroidectomy rather than hemithyroidectomy. However, none of the available tests can decisively confirm the presence of malignancy, nor precisely establish its aggressiveness [5].

Recent progress in omics approaches (genomics, transcriptomics, proteomics and metabolomics) is improving the understanding of molecular alterations associated with thyroid cancer initiation and progression, allowing the detection of new biomarkers of malignancy that are useful for the management of indeterminate nodules [6–9]. In this context, a growing body of evidence is accumulating on the use of liquid biopsy for the diagnosis of thyroid carcinoma, as already occurs in many other tumor types (e.g., lung cancer). It represents a noninvasive approach that analyses biomarkers released by cancer cells (e.g., circulating free nucleic acids, proteins or metabolites) and detectable in body fluids (e.g., serum, saliva or urine) [9–13].

Finally, the development of modern techniques of artificial intelligence allows the elaboration of complex diagnostic algorithms to improve the accuracy of preoperative diagnosis. Also this approach, integrating clinical (e.g., age, sex and familial history), laboratory (e.g., serum thyroglobulin and thyroid autoantibodies), US, cytological and molecular features may help to differentiate between malignant and benign thyroid nodules in the case of indeterminate cytology [14, 15].

---

## References

1. Cibas ES, Ali SZ. The Bethesda system for reporting thyroid cytopathology. *Thyroid*. 2009;19(11):1159–65.
2. Tamhane S, Gharib H. Thyroid nodule update on diagnosis and management. *Clin Diabetes Endocrinol*. 2016;2:17.
3. Haugen BR, Alexander EK, Bible KC, et al. 2015 American Thyroid Association management guidelines for adult patients with thyroid nodules and differentiated thyroid cancer: the American Thyroid Association guidelines task force on thyroid nodules and differentiated thyroid cancer. *Thyroid*. 2016;26:1–133.
4. Lukinović J, Bilić M. Overview of thyroid surgery complications. *Acta Clin Croat*. 2020;59(Suppl 1):81–6.
5. Rossi ED, Larocca LM, Pantanowitz L. Ancillary molecular testing of indeterminate thyroid nodules. *Cancer Cytopathol*. 2018;126(Suppl 8):654–71.
6. Rao SN, Bernet V. Indeterminate thyroid nodules in the era of molecular genomics. *Mol Genet Genomic Med*. 2020;8(9):e1288.
7. Hosseinkhan N, Honardoost M, Blighe K, et al. Comprehensive transcriptomic analysis of papillary thyroid cancer: potential biomarkers associated with tumor progression. *J Endocrinol Invest*. 2020;43(7):911–23.
8. Ucal Y, Ozpinar A. Proteomics in thyroid cancer and other thyroid-related diseases: a review of the literature. *Biochim Biophys Acta Proteins Proteom*. 2020;1868(11):140510.

9. Coelho M, Raposo L, Goodfellow BJ, et al. The potential of metabolomics in the diagnosis of thyroid cancer. *Int J Mol Sci.* 2020;21(15):5272.
10. Romano C, Martorana F, Pennisi MS, et al. Opportunities and challenges of liquid biopsy in thyroid cancer. *Int J Mol Sci.* 2021;22(14):7707.
11. Fussey JM, Bryant JL, Batis N, et al. The clinical utility of cell-free DNA measurement in differentiated thyroid cancer: a systematic review. *Front Oncol.* 2018;8:132.
12. Salvianti F, Giuliani C, Petrone L, et al. Integrity and quantity of total cell-free DNA in the diagnosis of thyroid cancer: correlation with cytological classification. *Int J Mol Sci.* 2017;18(7):1350.
13. Zhang Y, Zhao W, Zhao Y, et al. Comparative glycoproteomic profiling of human body fluid between healthy controls and patients with papillary thyroid carcinoma. *J Proteome Res.* 2020;19(7):2539–52.
14. Cordes M, Götz TI, Lang EW, et al. Advanced thyroid carcinomas: neural network analysis of ultrasonographic characteristics. *Thyroid Res.* 2021;14(1):16.
15. Peng S, Liu Y, Lv W, et al. Deep learning-based artificial intelligence model to assist thyroid nodule diagnosis and management: a multicentre diagnostic study. *Lancet Digit Health.* 2021;3(4):e250–9.

**Open Access** This chapter is licensed under the terms of the Creative Commons Attribution-NonCommercial-NoDerivatives 4.0 International License (<http://creativecommons.org/licenses/by-nc-nd/4.0/>), which permits any noncommercial use, sharing, distribution and reproduction in any medium or format, as long as you give appropriate credit to the original author(s) and the source, provide a link to the Creative Commons license and indicate if you modified the licensed material. You do not have permission under this license to share adapted material derived from this chapter or parts of it.

The images or other third party material in this chapter are included in the chapter's Creative Commons license, unless indicated otherwise in a credit line to the material. If material is not included in the chapter's Creative Commons license and your intended use is not permitted by statutory regulation or exceeds the permitted use, you will need to obtain permission directly from the copyright holder.





# Suspected Malignancy and Malignant Thyroid Tumors

# 4

Nunzia Cinzia Paladino, David Taïeb, and Frédéric Sebag

## 4.1 Introduction

Thyroid cancer (TC) is the most common endocrine tumor, with an annual incidence of 3.4% of all cancers [1]. Recent years have seen an increase in the incidence of TC, which has been shown to be three times higher in women than in men, according to the 2012 European network of cancer registries. Data are variable from country to country with higher incidence rates in Lithuania (15.5 cases per 100,000 person-years), Italy (13.5) Croatia (11.4) and Luxembourg (11.1). However, mortality remains low: 0.7 and 0.5 cases per 100,000 person-years for women and men, respectively [2, 3]. The increase in incidence would appear to be related to improved diagnostic techniques in recent years that allow diagnosis of even small and sub-clinical cancers [2]. There was also found to be a smaller but consistent increase in thyroid cancers of larger size. Autopsy studies have demonstrated a high incidence of subclinical thyroid cancer, particularly small papillary thyroid cancers [4].

The challenge for physicians is to identify patients with advanced or high-risk disease and those with lower risk in such a way as to perform appropriate treatment for each case.

The surgical strategy must take into account that the clinical behavior of thyroid cancers varies from indolent tumors with low mortality to very aggressive malignancies [5].

---

N. C. Paladino (✉) · F. Sebag  
Department of General Endocrine and Metabolic Surgery,  
Conception University Hospital, Aix-Marseille University, Marseille, France  
e-mail: [nunzia.paladino@ap-hm.fr](mailto:nunzia.paladino@ap-hm.fr); [frederic.sebag@ap-hm.fr](mailto:frederic.sebag@ap-hm.fr)

D. Taïeb  
Department of Nuclear Medicine, La Timone University Hospital, Aix-Marseille University,  
Marseille, France  
e-mail: [david.taieb@ap-hm.fr](mailto:david.taieb@ap-hm.fr)

Differentiated thyroid cancer has a good prognosis and long-term survival [5]. However, follicular thyroid cancer, Hürthle cell thyroid cancer, and poorly differentiated thyroid cancers are high-risk with a tendency for hematogenous spread to distant sites, in particular to lung and bones [5].

The last decade has seen many advances in understanding the molecular basis of thyroid cancer [6].

Most thyroid cancers have mutations along the mitogen-activated protein kinase (MAPK) cellular signaling pathway that plays a central role in the regulation of cellular proliferation [5]. An accurate diagnostic strategy and referral to specialized centers are critical for the proper management of thyroid malignancies.

---

## 4.2 Suspected Malignancy

Thyroid nodules are common in clinical practice, so it is important to distinguish benign nodules from nodules suspicious for malignancy.

The first step is the clinical examination, which will distinguish a parenchymatous nodule from a firm one. If cancer is suspected, the patient must undergo a diagnostic-imaging workup.

The first-level imaging examination to be performed is ultrasonography. Ultrasonographic scoring systems are helpful in differentiating between benign and malignant thyroid nodules by offering a risk stratification model. Depending on the number of suspicious ultrasound features, a fine-needle biopsy is recommended [7, 8].

Over the years different classifications have been proposed.

Thyroid nodule risk stratification systems – called Thyroid Imaging Reporting and Data Systems (TIRADS), the first of which was proposed in 2009 by Horvath [9] – have been developed with the aim of:

- establishing a standard lexicon for nodule description and providing a standardized report;
- defining the suspicious characteristics;
- placing the nodule in a risk category;
- identifying nodules for which a fine-needle aspiration biopsy (FNAB) is indicated, also taking into account their size [10];
- helping define the surgical strategy.

In 2017 the executive committee of the European Thyroid Association set up a working group to create a standardized risk stratification system, called the EU-TIRADS score, now commonly used in expert centers. This system has five evaluation categories: from no thyroid nodules to benign, low risk, intermediate risk, and high risk. The nodule is thus assigned a number from 1 to 5 that reflects an increasing risk of malignancy [11].

In this context, EU-TIRADS 5 is considered a high-risk category with an incidence of malignancy of 26–87% [10, 11] and FNAB is indicated for nodules >10 mm in size. FNAB is also indicated in the presence of EU-TIRADS 5 nodules <10 mm but in progression, depending on risk context (case of irradiation, familiarity for cancer, or hypermetabolic nodule on PET scan), and in the search for a primary thyroid cancer.

With regard to risk classification in cytology, several classifications have been drafted to arrive at an evidence-based approach. The most widely used international classification is the Bethesda system that was originally developed in October 2007 in Bethesda, Maryland [12].

Knowledge of the Bethesda system is essential for clinical practice because cytology, besides giving a stratification of the risk of malignancy, defines the surgical indication and the extension of the surgery. The Bethesda system provides six different categories, with a precise definition of cytologic appearance and a malignancy risk range for each category.

Since its first publication in 2009, the Bethesda classification has been updated in 2010 and 2017. Major changes include the definition of NIFTP (noninvasive follicular thyroid neoplasm with papillary-like nuclear features) and recalculation of the expected risk of malignancy based on the exclusion of NIFTP from the diagnosis of malignancy, followed by the introduction of molecular biology as an aid to diagnosis and treatment decision [12].

According to the Bethesda system, Bethesda 6 is an at-risk category with a cancer incidence of 97–99%. This category includes all criteria for malignancy. The type of tumor should be mentioned: papillary, medullary, poorly differentiated, anaplastic, lymphoma, or metastasis.

Another category with suspected malignancy is Bethesda 5 with a cancer risk of 45–60% (after NIFTP).

It is important not to underestimate doubtful cytology, which includes Bethesda 3 and 4 categories.

Bethesda 4 designated as “follicular neoplasm and follicular oncocytic cell neoplasm” has a calculated risk of malignancy between 25% and 40% (10–40% post-NIFTP). In this category we can also find vesicular carcinoma (whose cytological diagnosis is impossible).

Finally, the Bethesda 3 category, known as “atypia of undetermined significance or follicular lesion of undetermined significance”, presents a cancer risk of 10–30% in the latest 2017 Bethesda classification (recalculated to 6–18% post-NIFTP). This is a controversial category because the cytologic abnormalities present cannot assure benignity but are insufficient to lead to surgical excision [13].

An ultrasound scan performed by an experienced radiologist, with nodule characterization according to the EU-TIRADS classification is essential to distinguish suspicious nodules to be referred for FNAB from benign nodules to be monitored.

Ultrasonography will also confirm the presence of suspected lymphadenopathy and the affected cervical compartments, thereby directing the surgical strategy.

### 4.3 Malignant Thyroid Tumors

Malignant tumors of the thyroid gland are divided into three main histological types (Table 4.1):

- differentiated thyroid cancer;
- undifferentiated: poorly differentiated and anaplastic thyroid cancer;
- medullary thyroid cancer.

Differentiated thyroid cancer is the most common cancer. It accounts for 90% of thyroid malignancies and includes:

- papillary thyroid cancer;
- follicular thyroid cancer;
- Hürthle cell thyroid cancer [1, 5].

Undifferentiated cancers are rare and include:

- poorly differentiated thyroid cancer (incidence of 5% median survival time of 5 years);
- anaplastic thyroid cancer (1% of incidence and survival of 6 months).

Medullary thyroid cancer accounts for 5% [1].

**Table 4.1** Classification of malignant thyroid tumors

Differentiated thyroid cancer	Papillary thyroid cancer	<ul style="list-style-type: none"> <li>• Classic</li> <li>• Follicular</li> <li>• Diffuse sclerosing</li> <li>• Tall cell</li> <li>• Columnar</li> <li>• Solid variant</li> <li>• Hobnail</li> </ul>	
	NIFTP <sup>a</sup>		
	Follicular thyroid cancer	<ul style="list-style-type: none"> <li>• Minimally invasive</li> <li>• Encapsulated angioinvasive</li> <li>• Widely invasive</li> </ul>	
	Hürthle cell thyroid cancer	<ul style="list-style-type: none"> <li>• Microfollicular</li> <li>• Solid</li> <li>• Trabecular</li> </ul>	<ul style="list-style-type: none"> <li>• Minimally invasive</li> <li>• Encapsulated angioinvasive</li> <li>• Widely invasive</li> </ul>
Undifferentiated thyroid cancer	Poorly differentiated thyroid cancer	<ul style="list-style-type: none"> <li>• Solid</li> <li>• Trabecular</li> <li>• Insular</li> </ul>	
	Anaplastic thyroid cancer		
Medullary thyroid cancer			

<sup>a</sup> *NIFTP* Noninvasive follicular thyroid neoplasm with papillary-like nuclear features [1]

The molecular pathogenesis of most TC involves dysregulation of MAPK and PI3K/AKT (phosphatidylinositol-3 kinase). MAPK activation is crucial for the onset of papillary thyroid cancer through point mutations of the *BRAF* and *RAS* genes. *TERT* promoter mutations have been described in all histological TC types with a significant prevalence in aggressive and undifferentiated cancers. *RET* mutations occur in most medullary thyroid cancers. *H-*, *K-*, and *N-RAS* mutations are responsible for a minority of sporadic medullary thyroid cancers [1].

The most frequent form of TC is papillary thyroid cancer.

---

## 4.4 Papillary Thyroid Cancer

Papillary thyroid cancer (PTC) is the most common and indolent TC with the best overall prognosis (90% of survival) in its classical and follicular variants [5, 14]. Metastases most commonly involve cervical lymph nodes and, less commonly, the lungs [5].

PTC has a relatively stable genome and that would explain the indolent trend of this cancer.

However, recurrent disease occurs in 25–35% of patients. In this rare case, the tumors are aggressive but nevertheless maintain some degree of functional differentiation (e.g., thyroglobulin production) [2]. Hence the importance of the early identification of patients in need of aggressive treatment [1].

The subtypes that occur as more aggressive variants include the following: diffuse sclerosing variant, tall cell variant, columnar cell variant, solid variant, and hobnail variant [2, 14, 15].

Several mutations have been associated with PTC malignancy. *RET* rearrangements or point mutations of *RAS* or *BRAF* proto-oncogenes have been described in 70% of patients. Based on a *BRAFV600E-RAS* gene expression score, PTC can be divided into *BRAFV600E*-like and *RAS*-like PTC [1]. A propensity for clinically aggressive PTC has been found in tumors bearing a *BRAF* mutation. However, despite about 50–70% of PTC having a *BRAF* mutation, most of these tumors remain indolent. This finding suggests that other events are involved in the development of more aggressive behavior. *TERT* mutation has been detected in more aggressive PTC [5].

Among the variants of PTC, NIFTP represents a novel entity with a genomic profile more similar to follicular thyroid cancer than PTC [1]. The estimated risk of recurrence of NIFTP is <1% [16].

According to a recent study by Brandler et al. [17], 67% of NIFTP had *RAS* mutations alone or in tandem with other mutations and *BRAF* mutation was not described; 22% of NIFTP had *PAX8/PPARG* and *THADA/IGF2BP3* gene fusion mutations. As a result, this overlap makes it difficult to identify NIFTP with FNAB.



---

## 4.5 Follicular Thyroid Cancer

In 2017, follicular thyroid cancer (FTC) was reclassified into the following subtypes:

- minimally invasive (miFTC)
- encapsulated angioinvasive (eaFTC)
- widely invasive (wiFTC).

The progression from miFTC to wiFTC is still not clear [1]. The most common mutation involves the *RAS* family genes and a recent study found no negative effect on prognosis [18]. The fusion gene *PAX8-PPAR $\gamma$*  was identified in 12–53% of cancers. *TERT* promoter mutations have been found in 15% of FTC. The presence of all mutations has a worse prognostic effect [1].

---

## 4.6 Hürthle Cell Thyroid Cancer

Hürthle-cell cancer (HCC) are noninvasive, encapsulated tumors composed of Hürthle cells with microfollicular or solid to trabecular architecture. HCC have overlapping but distinct clinical features from FTC [19, 20].

They are rare and demonstrate either capsular or vascular invasion. Prognosis is worse in patients with angioinvasion than in those with capsular invasion. According to the College of American Pathologists, HCC is divided into minimally invasive, encapsulated angioinvasive and widely invasive. Like FTC, HCC has high rates of distant metastasis due to its hematogenous spread. HCC exhibits *RAS* mutations in only 10–15% of cases and does not show *PAX8-PPAR $\gamma$*  rearrangements and *BRAFV600E* mutation [19].

---

## 4.7 Poorly Differentiated Thyroid Cancer

Poorly differentiated thyroid cancer (PDTC) is a more aggressive follicular-derived thyroid cancer than differentiated thyroid cancer [5]. Two main classifications of PDTC exist, depending on the histological features: the Turin criteria and the Memorial Sloan-Kettering Cancer Center (MSKCC) criteria.

The Turin criteria include a solid, trabecular or insular growth pattern in the absence of the conventional nuclear features of PTC and at least one of the following:

- convoluted nuclei;
- high mitotic rate;
- tumor necrosis.

The MSKCC criteria include a high mitotic rate and necrosis independently from the growth pattern.

*BRAF* mutations are described in 19–33% and *H*-, *K*-, and *N-RAS* mutations in 5–28% of PDTC.

*BRAF* and *RAS* are correlated with a different clinical behavior.

PDTC with *BRAF* mutation are associated with a higher rate of lymph node metastases compared with *RAS*-mutated PDTC, which have a higher rate of distant metastases. There is also a lowered expression of thyroid-specific genes related to radioiodine avidity in *BRAF*-mutated PDTC compared to *RAS*-mutated PDTC. These mutations can be associated with that of the *TERT* promoter that affects 33–40% of cases and is associated with a risk of distant metastasis and mortality. Another important difference with PTC is the chromosome number variation [21]. Identification of these mutations is decisive for choosing the type of treatment.

---

## 4.8 Anaplastic Thyroid Cancer

Anaplastic thyroid cancer (ATC) is a rare cancer with an incidence <1% that presents clinically as a rapidly evolving cervical mass [5]. In order to determine the therapeutic strategy, rapid patient care and biopsy of the neoplastic mass are indicated.

Distant metastases most commonly involve the lung followed by bones and brain. ATC originates from a differentiated tumor but can also occur *ex novo* [5]. The median survival is about 5 months and the 1-year overall survival is 20%; because of this, all patients with ATC are classified as stage IV according to the TNM system. Radiological tumor staging with computed tomography (CT) of the neck, chest, abdomen and pelvis, fluorodeoxyglucose positron emission tomography (FDG-PET)/CT, cerebral CT or magnetic resonance imaging (MRI) are necessary in order to establish patient care. It is important to assess the presence of vocal cord paralysis. Goals of care may be therapeutic and/or palliative depending on the stage and prognosis [22]. Each case should be analyzed and discussed in a specialized team.

In ATC the incidence of *BRAF* and *H*-, *K*- and *N-RAS* mutations is 19–45% and 9.5–27%, respectively. The two most frequent mutations are: *TERT* promoter mutation (43–73%) and *TP53* mutation (48–73%) [1, 21]. *PT53* is highly frequent and is considered pathognomonic for this aggressive cancer. *PTEN*, *PI3KCA* mutations and mutations in genes involved in cell-cycle regulation and in the chromatin remodeling complex were also found [21]. Identification of such mutations is critical for the development of chemotherapy treatment.

---

## 4.9 Medullary Thyroid Cancer

Medullary thyroid cancer (MTC) accounts for 1–2% of all thyroid cancers and it originates from parafollicular cells (C-cells) that produce calcitonin. Sometimes neck lymphadenopathy is the first manifestation and 70% of patients that present palpable MTC have cervical node metastases at surgery [5, 23].

The markers commonly used for the diagnosis are calcitonin and carcinoembryonic antigen that are also used for the follow-up. Before surgery it is essential to perform detailed neck ultrasound on lymph node stations, and genetic screening [5]. In the presence of very high markers (calcitonin >146 pmol/L) [5], a total body exploration with CT, MRI of the pelvis, spine, and liver and  $^{18}\text{F}$ -DOPA PET/CT is recommended [23, 24].

MTC can be sporadic (75–80%) and familial (20–25%) linked to a rearrangement *RET* mutation [23, 25]. However, the proto-oncogene *RET* has a crucial role in both cases. All familial cases have a germline *RET* mutation (>98%) [25]. *RET* mutations can occur sporadically as somatic events or as inherited germline events that exhibit autosomal dominant inheritance. Because 1–7% of patients with sporadic MTC had a *RET* germline mutation, genetic screening should be recommended to all patients with a diagnosis of MTC [5]. In sporadic MTC, *RET* mutation is the most common genetic variant and occurs in 44% of cases, followed by *RAS* mutations (13% of cases) [26]. Recent studies showed that patients with *RET* mutations have a lower survival than those with *RAS* mutations [1, 27].

Germline mutations in *RET* can predispose patients to the early development of MTC as in multiple endocrine neoplasia type 2A and 2B syndromes (MEN 2A and MEN2B). Prophylactic thyroidectomy is often indicated. In cases of MEN, associated endocrinopathies will need to be investigated [5].

Surgery is the only curative treatment in MTC and it should be complete since recurrence reflects the likely incompleteness of the initial surgery. The surgical strategy should always take into account that preoperative imaging often does not identify central compartment micrometastases [23].

According to a recent study [24], an important role in this context is played by  $^{18}\text{F}$ -DOPA PET/CT whose sensitivity in identifying locoregional and distant metastases was shown to be 75.6%; the authors emphasize that  $^{18}\text{F}$ -DOPA PET/CT is sensitive in the early diagnosis of a significant number of patients with distant metastases although its sensitivity in the detection of residual disease was limited.

Total thyroidectomy with central neck dissection is therefore recommended for patients with MTC, and incomplete interventions, such as removing only grossly involved nodes at initial surgery, should be avoided [5, 23]. Lymphadenectomy of the lateral compartments should be discussed depending on calcitonin rates and preoperative imaging from case to case.

Follow-up is lifelong and consists of surveillance of tumor markers and rapid identification of recurrences. Calcitonin and carcinoembryonic antigen doubling times are useful measures, as they are predictive of aggressive tumor behavior [5].

## 4.10 Treatment

Treatment decisions rely on a preoperative risk assessment that includes clinical, imaging and cytological data. The therapeutic choice depends on location and extension of the cancer. According to the American Thyroid Association 2015 guidelines, the therapeutic approach is more conservative than in the past.

Surgery is only curative treatment for resectable cancer and for MTC. After surgery, risk can be defined based on histological examination, and it can be determined whether to perform radioiodine ablation or TSH suppression, or both. This assessment is conventionally based on the TNM staging system which, however, was conceived to predict mortality and is less effective for estimating the probability of persistent or recurrent disease [5]. The need to estimate the risk of recurrence led to the introduction, in 2009, of a new system for risk stratification into high, intermediate and low [28].

The revised system of the American Thyroid Association 2015 guidelines provides more accurate information about the risk of recurrence [13].

Radioactive iodine treatment after total thyroidectomy is often performed with the aim of eliminating residual thyroid tissue and it can also be used in metastatic disease.

TSH-suppressive doses of thyroid hormone therapy are commonly used after surgery to reduce the risk of recurrence. Patients with differentiated thyroid cancer require follow-up including serum thyroglobulin assay. This follow-up is important since 77% of patients have a recurrence within 5 years after the first surgery.

Systemic treatment is reserved for cases of differentiated cancer with radioactive iodine-refractory disease. Metastasectomy can be taken into consideration for low-volume metastatic disease if it will delay or prevent morbidity.

Two kinase inhibitors have been approved for use in advanced-stage differentiated thyroid cancer: sorafenib and lenvatinib. These are multikinase inhibitors with antiangiogenic properties.

Treatment of anaplastic cancer should be prompt and provided by an experienced center.

The surgeon should determine whether the tumor is resectable. Biopsy is often indicated in order to define the histological profile of the tumor and to institute chemotherapy treatment.

External beam radiation is recommended soon after resection, preferably with radiosensitizing drugs. Palliative chemoradiation is reserved for patients with unresectable tumors [5, 13].

## References

1. Prete A, Borges de Souza P, Censi S, et al. Update on fundamental mechanisms of thyroid cancer. *Front Endocrinol (Lausanne)*. 2020;11:102.
2. Filetti S, Durante C, Hartl D, et al. Thyroid cancer: ESMO clinical practice guidelines for diagnosis, treatment and follow-up. *Ann Oncol*. 2019;30(12):1856–83.
3. Dal Maso L, Tavilla A, Pacini F, et al. Survival of 86,690 patients with thyroid cancer: a population-based study in 29 European countries from EUROCARE-5. *Eur J Cancer*. 2017;77:140–52.
4. Nabhan F, Dedhia PH, Ringel M. Thyroid cancer, recent advances in diagnosis and therapy. *Int J Cancer*. 2021;149(5):984–92.
5. Cabanillas ME, McFadden DG, Durante C. Thyroid cancer. *Lancet*. 2016;388(10061):2783–95.
6. Cancer Genome Atlas Research Network. Integrated genomic characterization of papillary thyroid carcinoma. *Cell*. 2014;159(3):676–90.
7. Schenke S, Seifert P, Zimny M, et al. Risk stratification of thyroid nodules using the thyroid imaging reporting and data system (TIRADS): the omission of thyroid scintigraphy increases the rate of falsely suspected lesions. *J Nucl Med*. 2019;60(3):342–7.
8. Scerrino G, Cocorullo G, Mazzola S, et al. Improving diagnostic performance for thyroid nodules classified as Bethesda category III or IV: how and by whom ultrasonography should be performed. *J Surg Res*. 2021;262:203–11.
9. Horvath E, Majlis S, Rossi R, et al. An ultrasonogram reporting system for thyroid nodules stratifying cancer risk for clinical management. *J Clin Endocrinol Metab*. 2009;94(5):1748–51.
10. Trimboli P, Castellana M, Piccardo A, et al. The ultrasound risk stratification systems for thyroid nodule have been evaluated against papillary carcinoma. A meta-analysis *Rev Endocr Metab Disord*. 2021;22(2):453–60.
11. Russ G, Bonnema SJ, Faik Erdogan M, et al. European thyroid association guidelines for ultrasound malignancy risk stratification of thyroid nodules in adults: the EU-TIRADS. *Eur Thyroid J*. 2017;6(5):225–37.
12. Cibas ES, Ali SZ, editors. *The Bethesda system for reporting thyroid cytopathology: definitions, criteria and explanatory notes*, vol. 19. Springer; 2009. p. 1159–65.
13. Haugen BR. 2015 American Thyroid Association management guidelines for adult patients with thyroid nodules and differentiated thyroid cancer: what is new and what has changed? *Cancer*. 2017;123(3):372–81.
14. Coca-Pelaz A, Shah JP, Hernandez-Prera JC, et al. Papillary thyroid cancer-aggressive variants and impact on management: a narrative review. *Adv Ther*. 2020;37(7):3112–28.
15. Asa SL. The current histologic classification of thyroid cancer. *Endocrinol Metab Clin N Am*. 2019;48(1):1–22.
16. Nikiforov YE, Seethala RR, Tallini G, et al. Nomenclature revision for encapsulated follicular variant of papillary thyroid carcinoma: a paradigm shift to reduce overtreatment of indolent tumors. *JAMA Oncol*. 2016;2(8):1023–9.
17. Brandler TC, Liu CZ, Cho M, et al. Does noninvasive follicular thyroid neoplasm with papillary-like nuclear features (NIFTP) have a unique molecular profile? *Am J Clin Pathol*. 2018;150(5):451–60.
18. Nicolson NG, Murtha TD, Dong W, et al. Comprehensive genetic analysis of follicular thyroid carcinoma predicts prognosis independent of histology. *J Clin Endocrinol Metab*. 2018;103(7):2640–50.
19. Wong KS, Angell TE, Barletta JA, Krane JF. Hürthle cell lesions of the thyroid: Progress made and challenges remaining. *Cancer Cytopathol*. 2021;129(5):347–62.
20. Ganly I, McFadden DG. Short review: genomic alterations in Hürthle cell carcinoma. *Thyroid*. 2019;29(4):471–9.
21. Landa I, Ibrahimipasic T, Boucai L, et al. Genomic and transcriptomic hallmarks of poorly differentiated and anaplastic thyroid cancers. *J Clin Invest*. 2016;126(3):1052–66.

22. Bible KC, Kebebew E, Brierley J, et al. 2021 American Thyroid Association guidelines for management of patients with anaplastic thyroid cancer. *Thyroid*. 2021;31(3):337–86.
23. Scerrino G, Cocorullo G, Orlando G, et al. Predictive factors for lymph node involvement in sporadic medullary thyroid microcarcinoma: a systematic review. *Eur Rev Med Pharmacol Sci*. 2022;26(3):1004–16.
24. Archier A, Heimburger C, Guerin C, et al. (18)F-DOPA PET/CT in the diagnosis and localization of persistent medullary thyroid carcinoma. *Eur J Nucl Med Mol Imaging*. 2016;43(6):1027–33.
25. Elisei R, Tacito A, Ramone T, et al. Twenty-five years experience on RET genetic screening on hereditary MTC: an update on the prevalence of germline RET mutations. *Genes (Basel)*. 2019;10(9):698.
26. Tate JG, Bamford S, Jubb HC, et al. COSMIC: the catalogue of somatic mutations in cancer. *Nucleic Acids Res*. 2019;47(D1):D941–7.
27. Ciampi R, Romei C, Ramone T, et al. Genetic landscape of somatic mutations in a large cohort of sporadic medullary thyroid carcinomas studied by next-generation targeted sequencing. *iScience*. 2019;20:324–36.
28. Cooper DS, Doherty GM, Haugen BR, et al. Revised American Thyroid Association management guidelines for patients with thyroid nodules and differentiated thyroid cancer. *Thyroid*. 2009;19(11):1167–214.

**Open Access** This chapter is licensed under the terms of the Creative Commons Attribution-NonCommercial-NoDerivatives 4.0 International License (<http://creativecommons.org/licenses/by-nc-nd/4.0/>), which permits any noncommercial use, sharing, distribution and reproduction in any medium or format, as long as you give appropriate credit to the original author(s) and the source, provide a link to the Creative Commons license and indicate if you modified the licensed material. You do not have permission under this license to share adapted material derived from this chapter or parts of it.

The images or other third party material in this chapter are included in the chapter's Creative Commons license, unless indicated otherwise in a credit line to the material. If material is not included in the chapter's Creative Commons license and your intended use is not permitted by statutory regulation or exceeds the permitted use, you will need to obtain permission directly from the copyright holder.





# Retrosternal, Forgotten, and Recurrent Goiter

# 5

Angela Gurrado, Francesco Paolo Prete, Giovanna Di Meo, Alessandro Pasculli, Elisabetta Poli, Lucia Ilaria Sgaramella, and Mario Testini

## 5.1 Retrosternal Goiter

Retrosternal goiter (RG) was first described by Haller [1]. The clinical significance of this condition increases progressively due to clinical features that include impingement on surrounding structures and onset of compressive symptoms. Goiter development is a multifactorial event, iodine deficiency being considered as one of the major environmental factors [2]. The diagnosis of RG is usually established in the fifth or sixth decade of life, with a female-to-male ratio of approximately 3–4:1 [2].

There is no standard definition for RGs [3]. Some authors have considered an RG as one that extends up to the fourth thoracic vertebra on chest x-ray, or reaches the aortic arch; others have defined a mediastinal thyroid as one in which most of the gland extends below the thoracic inlet with the patient in surgical position [3]. Terms such as retrosternal, substernal, and intrathoracic have been used to define an extension of >50% of the thyroid gland beyond the thoracic inlet [4]. The reported incidence of RG is highly variable, ranging from 1% to 45% of thyroidectomies in studies with different defining criteria [2, 3, 5].

The classification of RGs as primary or secondary is of surgical relevance because of differences in the blood supply. Primary RG is rare (1%), arising from ectopic thyroid tissue in the mediastinum, and is supplied by non-anatomic mediastinal vessels [2, 3, 5]. The majority of RGs are secondary, originating from

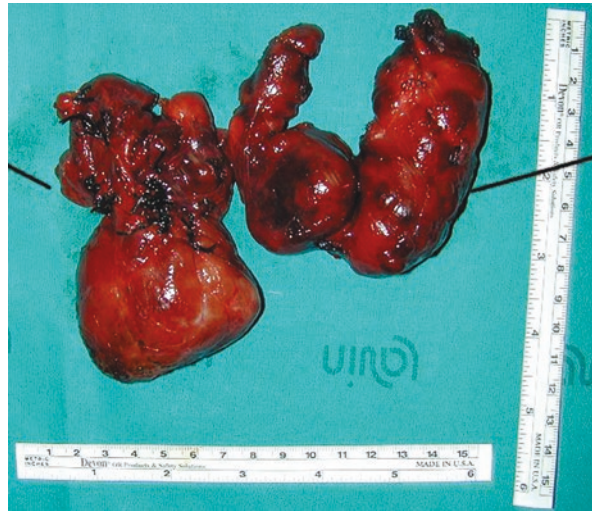
---

**Supplementary Information** The online version contains supplementary material available at [https://doi.org/10.1007/978-3-031-31146-8\\_5](https://doi.org/10.1007/978-3-031-31146-8_5).

---

A. Gurrado (✉) · F. P. Prete · G. Di Meo · A. Pasculli · E. Poli · L. I. Sgaramella · M. Testini  
Department of Precision and Regenerative Medicine and Ionian Area,  
University of Bari, Policlinic of Bari, Bari, Italy  
e-mail: [angela.gurrado@uniba.it](mailto:angela.gurrado@uniba.it); [francesco.prete@uniba.it](mailto:francesco.prete@uniba.it);  
[giovanna.dimeo@policlinico.ba.it](mailto:giovanna.dimeo@policlinico.ba.it); [pascullialessandro@gmail.com](mailto:pascullialessandro@gmail.com);  
[eli.poli81@gmail.com](mailto:eli.poli81@gmail.com); [ilaria.sgaram@gmail.com](mailto:ilaria.sgaram@gmail.com); [mario.testini@uniba.it](mailto:mario.testini@uniba.it)

**Fig. 5.1** Retrosternal goiter



extension of the cervical gland into the chest, with a blood supply arising from the cervical vessels (Fig. 5.1) [3].

RGs are located in the anterior mediastinum in 80–90% of cases and less frequently (10–15%) in the posterior compartment, posterior to the trachea or esophagus [2]. In the latter, the recurrent laryngeal nerve (RLN) may be severely anteriorly displaced, placing it at higher risk of accidental injury [6].

The Huins et al. [7] classification of RGs categorizes them as retroclavicular, upper border of the aortic arch or below the aortic arch. Goiters have also been classified according to their shape on coronal imaging with the Simo classification: “iceberg” or “conical”, “tubular” or “oval” [8].

Evaluation of a suspected RG involves full history taking and examinations, including fiberoptic nasendoscopy, baseline thyroid function tests, thyroid autoantibody screen, and neck ultrasound [3, 9]. Ultrasound-guided fine-needle aspiration cytology is not routinely applied in RGs [3, 10]. Therefore, computed tomography (CT) and/or magnetic resonance imaging (MRI) are essential in the surgical decision-making for RGs, since they provide a clear definition of the multidimensional size and morphology of the disease, defining the relevant and at-risk anatomical structures.

Most goiters grow very slowly over many decades. Therefore, most patients with RG are asymptomatic. If a cervical mass is palpated on physical examination but the examining physician is unable to palpate the most inferior portion of the mass at the thoracic inlet, the presence of an intrathoracic extension of the goiter should be strongly suspected. Airway compression is one of the most common findings in patients with RG. Other reported symptoms include exertional dyspnea, stridor or wheezing (when the luminal diameter is below 5 mm), unproductive cough, choking sensation due to dysphagia, hoarseness, vascular (e.g., superior vena cava syndrome) and neurologic symptoms (e.g., vocal cord paresis/paralysis, hoarseness, and Horner’s syndrome) [2, 11, 12].



Total thyroidectomy represents the treatment of choice for all RGs and is achieved through a cervical (CA) or extracervical approach (ECA). In most cases, thyroidectomy can be performed using a CA (up to 90%), but a manubriotomy, sternotomy, or thoracotomy is always necessary for primary RG, when the gland is predominantly intrathoracic or when preoperative assessment with CT scan suggests infiltration into surrounding structures [2–8, 10]. Therefore, RGs with giant intrathoracic extension, recurrence, or posterior extension to both trachea and esophagus, or between trachea and esophagus, and a diameter greater than the thoracic inlet diameter should be treated with an ECA [2–8, 10, 13]. Extension beyond the aortic arch and an “iceberg shape” are the strongest predictors of the need for sternotomy [2–8, 10].

RGs affecting both anterior and posterior mediastinum, moreover, ride over the brachiocephalic vascular bundle causing distortion of these vessels and possibly of the RLN [10]. Therefore, an anterior approach via midline sternotomy is preferred over a cranio-caudal one, as the former provides for a direct view (as shown in the Video 5.1).

The classic ECAs to an anterior mediastinal mass are median sternotomy, cervical mediastinoscopy and video-assisted thoracoscopic surgery [6], which is an excellent option for an ECA, with fewer side effects than median sternotomy.

Thyroid lobectomy can also be sufficient in selected high-risk patients, in whom a conservative strategy may resolve the symptoms, while reducing the risk of complications such as bilateral RLN paralysis, tracheostomy and permanent hyperparathyroidism [10].

Intraoperative nerve monitoring is a risk-reducing tool used to verify RLN integrity during thyroid surgery, and the literature supports its use in revision surgery, invasive malignancy, and large RGs [14].

The indications for surgery in symptomatic RGs take into account that radioiodine ablation implies a possible acute risk of radiation thyroiditis causing airway obstruction, that most RGs tend to grow, and that up to 25% of RGs harbor malignancy [2, 3].

A non-surgical approach, involving monitoring with serial CT scans, is preferred in older patients and poor surgical candidates, but also in asymptomatic patients with normal flow-volume loops [2].

Radioiodine, alone or following rhTSH stimulation to increase radioiodine efficacy, is a reasonable option for patients who cannot undergo surgery or refuse it.

Other minimally invasive local treatment modalities have been described, such as radiofrequency ablation and laser microfilament ablation, but these methods have yet to be validated in larger studies.

Literature data differ on the increased incidence of malignancy in cases of RG compared to cervical goiter; some authors reported a range from 10% to 35% [3, 8, 10], while others reported that malignancy is less common in RG than in cervical goiter [15].

In addition, the impossibility to perform fine-needle aspiration cytology in the presence of mediastinal disease, due to risks of bleeding or thoracic organ damage, limits the preoperative diagnosis of malignancy [16].

The literature shows an increased incidence of permanent hypoparathyroidism and definitive RLN palsy after total thyroidectomy for RG, rather than for cervical goiter [3, 5, 17–21].

The side effects of a CA include: transient (2–5.4%) or permanent (1–2%) unilateral RLN injury, transient (33.9%) or permanent (2.1%) hypocalcemia [2, 3, 19–21] and tracheomalacia (3%) [2].

A lesion that occupies space in the mediastinum has greater potential to distort the normal anatomy and, when coupled with an increase in gland size, involves a technically challenging procedure where the RLN may not be easily identifiable in its anatomic location. Bilateral RLN palsy is the main causative factor for tracheostomy in the RG patient, with tracheostomy rates of approximately 2–3% in this population [6].

Although the parathyroid glands can be identified and structurally preserved, an even more significant challenge arises in the RG patient in order to maintain an uninterrupted blood supply. Specifically in RG, while the inferior parathyroids are more likely to be displaced and have a truly intrathoracic location, the position of the superior ones is often unaffected [6].

Postoperative bleeding is rare but potentially fatal, occurring in 0.3–2% of cases [3]. Intraoperative bleeding complicates surgical dissection by staining and hiding important structures and causing indirect RLN- and parathyroid-related morbidity due to blind surgical maneuvers. Therefore, innovative devices such as the harmonic scalpel [22] and topical hemostatic agents [23] are commonly used.

Even considering the compressive pathological process of the RG, tracheomalacia is rarely described in the literature as a clinically significant concern. Significantly powered studies have shown little evidence, with rates reported as being <1.5% [6]. In patients with suspected tracheomalacia other causes of airway obstruction should immediately be ruled out. Generally, reintubation is uneventful even in confirmed tracheomalacia [6].

However, division of the sternum increases the morbidity of the treatment for benign disease. Complications of median sternotomy include deep space wound infections, dehiscence, arrhythmias, and sternal instability. Risks of cervical mediastinoscopy include severe bleeding due to the need for median sternotomy, RLN injury specifically on the patient's left and thoracic duct injury [6].

Mortality in RG surgical series ranges from 0% to 15.3% and is higher in patients who have malignant disease or when surgery becomes urgent due to severe worsening of respiratory symptoms [10]. The causes of death are related to severe postoperative complications such as sternotomy dehiscence and tracheobronchial fistula.

Therefore, strict preoperative diagnosis through proper imaging is important to avoid hazardous digital dissection and simultaneously improper sternal division. This can be explained by the fact that the sternal division provides the surgeon with control of all the structures of the neck and upper mediastinum. In contrast, during digital dissection of the mediastinal component, the removal of the intrathoracic part of the goiter through the CA forces the surgeon to perform blind maneuvers, placing the inferior parathyroids and the RLNs at risk of injury [3, 24].

When the upper mediastinum is occupied by a goiter, it could be considered a 'no man's land' [3]. Indeed, the endocrine surgeon is not usually familiar with the course of the RLNs and their anatomical variability in this district, and the cardiothoracic surgeon is not familiar with the endocrine-surgical challenges. Therefore, the ECA requires multidisciplinary collaboration.

---

## 5.2 Forgotten Goiter

Forgotten goiter (FG) was first described by Massard et al. in 1992 [25].

FG lacks any parenchymatous or vascular connection to the cervical thyroid and may represent remnants of an incompletely resected cervical goiter or perhaps the result of completely separate and autonomously functioning thyroid tissue that becomes hypertrophic following removal of the cervical gland [26]. Compensatory hypertrophy of residual thyroid tissue following partial thyroidectomy was first described by Wagner in 1884 and was confirmed in the succeeding decades by several authors [27]. Therefore, any thyroid tissue remaining after cervical thyroidectomy can grow or migrate inferiorly [28].

Furthermore, based on the embryology of the thyroid, although rarely, some anomalies may occur, and the gland can be located in the mediastinum, the so-called autonomous intrathoracic goiter (AIG) which must be distinguished from migratory goiters in partially resected glands after thyroidectomy. The gland arises from a saclike entodermal diverticulum, which appears in the midline of the ventral surface of the pharynx. This sac will form the parenchyma of the thyroid and is connected to the ventral floor of the pharynx via the thyroglossal duct. As the thyroglossal duct atrophies, the thyroid progressively relocates anterior to the trachea [29].

FG most likely represents a clinically silent goiter left behind at the time of original thyroidectomy, and the diagnosis is an incidental finding. Less commonly, patients may become symptomatic either from hormonally active thyroid tissue within the mediastinum or from mass effect causing tracheal compression and deviation.

In the literature there is no clear consensus as to the optimal approach for resection. The literature reaffirms that an FG, like the majority of RGs, can be safely and completely resected using a standard CA, after prompt diagnosis with MRI and, more recently, multidetector CT scan to provide better anatomical assessment [25–29]. The size, location, and benign characteristics remain the most relevant considerations in determining a cervical rather than a trans-sternal access, as in RG.

---

## 5.3 Recurrent Goiter

A recurrent goiter is the regrowth of thyroid tissues after thyroidectomy for benign disease or malignancy of the thyroid. In the literature, the recurrence rates after an incomplete thyroidectomy vary from 2% to 42%, and are mainly influenced by the definition of recurrence and the follow-up, with a peak of recurrence between 10

and 20 years after primary surgery [30]. On the other hand, in the case of total thyroidectomy, the recurrence rate is <1% [31].

While recurrence after surgery for benign disease should be preventable, recurrence after malignant disease depends on many factors. The causes of recurrence can be broadly attributed to inadequate surgery or postoperative levothyroxine therapy, missed embryological remnants, and recurrence of a thyroid cancer.

The three embryological remnants of thyroid at risk of regrowth are the pyramidal lobe, the tubercle of Zuckerkandl, and thyrothymic tissue; these may develop as isolated or combined recurrences [31, 32].

Reoperative thyroid surgery should be performed in case of symptomatic recurrent goiter, in case of suspected malignancy or in some cases of recurrent thyrotoxicosis [33].

In previous studies [34, 35], the rate of cancer incidence was reported to be higher in recurrent surgery even when the first surgery was performed for benign causes: Menegaux et al. [34] reported a cancer rate of 11.4% in recurrent surgery, while Levin et al. [35] found this rate to be 22%.

Surgery for recurrent goiter is associated with a higher complication rate because of scar tissue which makes it difficult to recognize and preserve neck structures such as the RLNs or the vascular pedicles of the parathyroid gland. A higher risk of complications is described when previous surgery has been performed on both sides and increases with the number of reoperations [33, 36]. In recurrent surgery, the rate of temporary and permanent RLN paralysis is 0–22% and 0–13%, respectively; the rate of transient and permanent hypoparathyroidism is 9–35% and 0–22%, respectively [31, 33, 37]. Thus, considering the increased risk of complications, the indication for recurrent surgery should be well identified.

In redo surgery, the lateral approach should be considered to avoid the infiltration by connective tissue of Kocher's approach and to identify the nerves in a previously undissected area [34]. The strap muscles are retracted medially followed by entry in a plane anterior to the sternocleidomastoid. The RLN should be always identified, usually in the lower neck, then followed along its cervical course. Intraoperative neuromonitoring is useful in redo surgery and may reduce the morbidity related to RLN injury, because it improves the detection of the nerve in the scar tissue [38, 39].

Little is known about the therapeutic outcome of <sup>131</sup>I therapy for recurrent goiters.

---

## References

1. Haller A. *Disputationes Anatomicae Selectae*. Gottingen: Vandenhoeck; 1749. p. 96.
2. Knobel M. An overview of retrosternal goiter. *J Endocrinol Investig*. 2021;44(4):679–91.
3. Testini M, Gurrado A, Avenia N, et al. Does mediastinal extension of the goiter increase morbidity of total thyroidectomy? A multicenter study of 19,662 patients. *Ann Surg Oncol*. 2011;18(8):2251–9.
4. Katic MR, Wang CA, Grillo HC. Substernal goiter. *Ann Thorac Surg*. 1985;39(4):391–9.
5. Testini M, Nacchiero M, Miniello S, et al. Management of retrosternal goiters: experience of a surgical unit. *Int Surg*. 2005;90(2):61–5.

6. Hanson MA, Shaha AR, Wu JX. Surgical approach to the substernal goiter. *Best Pract Res Clin Endocrinol Metab.* 2019;33(4):101312.
7. Huins CT, Georgalas C, Mehrzad H, Tolley NS. A new classification system for retrosternal goitre based on a systematic review of its complications and management. *Int J Surg.* 2008;6(1):71–6.
8. Tikka T, Nixon IJ, Harrison-Phipps K, Simo R. Predictors of the need for an extracervical approach to intrathoracic goitre. *BJS Open.* 2018;3(2):174–9.
9. Rosato L, De Crea C, Bellantone R, et al. Diagnostic, therapeutic and health-care management protocol in thyroid surgery: a position statement of the Italian Association of Endocrine Surgery Units (U.E.C. CLUB). *J Endocrinol Investig.* 2016;39(8):939–53.
10. Simó R, Nixon IJ, Vander Poorten V, et al. Surgical management of intrathoracic goitres. *Eur Arch Otorhinolaryngol.* 2019;276:305–14.
11. Testini M, Gurrado A, Lissidini G, et al. Emergency surgery for acute respiratory failure secondary to spontaneous thyroid hemorrhage. *Int Surg.* 2008;93(3):158–62.
12. Testini M, Logoluso F, Lissidini G, et al. Emergency total thyroidectomy due to non traumatic disease. Experience of a surgical unit and literature review. *World J Emerg Surg.* 2012;7:9.
13. Prete FP, Panzera PC, Di Meo G, et al. Risk factors for difficult thyroidectomy and postoperative morbidity do not match: retrospective study from an endocrine surgery academic referral Centre. *Updat Surg.* 2022;74(6):1943–51.
14. Prete FP, Sgaramella LI, Di Meo G, et al. Introducing routine intraoperative nerve monitoring in a high-volume endocrine surgery Centre: a health technology assessment. *Updat Surg.* 2021;73(6):2263–73.
15. White ML, Doherty GM, Gauger PG. Evidence-based surgical management of substernal goiter. *World J Surg.* 2008;32(7):1285–300.
16. Franco IF, Gurrado A, Lissidini G, et al. Floating left innominate vein neoplastic thrombus: a rare case of mediastinal extension of follicular thyroid carcinoma. *Phlebology.* 2015;30(2):140–4.
17. Chow TL, Chan TT, Suen DT, et al. Surgical management of substernal goitre: local experience. *Hong Kong Med J.* 2005;11(5):360–5.
18. Zambudio AR, Rodríguez J, Riquelme J, et al. Prospective study of postoperative complications after total thyroidectomy for multinodular goiters by surgeons with experience in endocrine surgery. *Ann Surg.* 2004;240(1):18–25.
19. Testini M, Gurrado A, Lissidini G, Nacchiero M. Hypoparathyroidism after total thyroidectomy. *Minerva Chir.* 2007;62(5):409–15.
20. Testini M, Gurrado A, Bellantone R, et al. Recurrent laryngeal nerve palsy and substernal goiter. An Italian multicenter study. *J Visc Surg.* 2014;151(3):183–9.
21. Gurrado A, Pasculli A, Pezzolla A, et al. A method to repair the recurrent laryngeal nerve during thyroidectomy. *Can J Surg.* 2018;61(4):278–82.
22. Testini M, Pasculli A, Di Meo G, et al. Advanced vessel sealing devices in total thyroidectomy for substernal goitre: a retrospective cohort study. *Int J Surg.* 2016;35:160–4.
23. Testini M, Marzaioli R, Lissidini G, et al. The effectiveness of FloSeal matrix hemostatic agent in thyroid surgery: a prospective, randomized, control study. *Langenbeck's Arch Surg.* 2009;394(5):837–42.
24. Testini M, Piccinni G, Lissidini G, Nacchiero M. The lifting of substernal goitres using a Fogarty catheter. *Ann R Coll Surg Engl.* 2005;87(1):63–4.
25. Massard G, Wihlm JM, Jeung MY, et al. Le goitre médiastinal oublié: sept observations [Forgotten mediastinal goiter: seven cases]. *Ann Chir.* 1992;46(8):770–3.
26. Sahbaz A, Aksakal N, Ozcinar B, et al. The “forgotten” goiter after total thyroidectomy. *Int J Surg Case Rep.* 2013;4(3):269–71.
27. Patel KM, Parsons CC. Forgotten goiter: diagnosis and management. A case report and literature review. *Int J Surg Case Rep.* 2016;27:192–4.
28. Calò PG, Tatti A, Medas F, et al. Forgotten goiter. Our experience and a review of the literature. *Ann Ital Chir.* 2012;83(6):487–90.
29. Netter FH, Forsham PH, editors. *The Ciba collection of medical illustrations, vol. 4. Section II.* West Caldwell, NJ: Ciba; 1974. p. 43–4.

30. Moalem J, Suh I, Duh QY. Treatment and prevention of recurrence of multinodular goiter: an evidence-based review of the literature. *World J Surg.* 2008;32(7):1301–12.
31. Snook KL, Stalberg PL, Sidhu SB, et al. Recurrence after total thyroidectomy for benign multinodular goiter. *World J Surg.* 2007;31(3):593–8. discussion 599–600
32. Cirocchi R, Trastulli S, Randolph J, et al. Total or near-total thyroidectomy versus subtotal thyroidectomy for multinodular non-toxic goitre in adults. *Cochrane Database Syst Rev.* 2015;2015(8):CD010370.
33. Medas F, Tuveri M, Canu GL, et al. Complications after reoperative thyroid surgery: retrospective evaluation of 152 consecutive cases. *Updat Surg.* 2019;71(4):705–10.
34. Menegaux F, Turpin G, Dahman M, et al. Secondary thyroidectomy in patients with prior thyroid surgery for benign disease: a study of 203 cases. *Surgery.* 1999;126(3):479–83.
35. Levin KE, Clark AH, Duh QY, et al. Reoperative thyroid surgery. *Surgery.* 1992;111(6):604–9.
36. Peix JL, Van Box SP, Olagne E, et al. Résultats des réinterventions pour goitres [Results of reoperations for goiter]. *Ann Chir.* 1997;51(3):217–21.
37. Lombardi CP, Raffaelli M, De Crea C, et al. Morbidity of central neck dissection: primary surgery vs reoperation. Results of a case-control study. *Langenbeck's Arch Surg.* 2014;399(6):747–53.
38. Wojtczak B, Barczyński M. Intermittent neural monitoring of the recurrent laryngeal nerve in surgery for recurrent goiter. *Gland Surg.* 2016;5(5):481–9.
39. Johnson S, Goldenberg D. Intraoperative monitoring of the recurrent laryngeal nerve during revision thyroid surgery. *Otolaryngol Clin N Am.* 2008;41(6):1147–51.

**Open Access** This chapter is licensed under the terms of the Creative Commons Attribution-NonCommercial-NoDerivatives 4.0 International License (<http://creativecommons.org/licenses/by-nc-nd/4.0/>), which permits any noncommercial use, sharing, distribution and reproduction in any medium or format, as long as you give appropriate credit to the original author(s) and the source, provide a link to the Creative Commons license and indicate if you modified the licensed material. You do not have permission under this license to share adapted material derived from this chapter or parts of it.

The images or other third party material in this chapter are included in the chapter's Creative Commons license, unless indicated otherwise in a credit line to the material. If material is not included in the chapter's Creative Commons license and your intended use is not permitted by statutory regulation or exceeds the permitted use, you will need to obtain permission directly from the copyright holder.



---

## **Part II**

# **Surgery: Cervical and Remote Approaches**



# Conventional Open Thyroidectomy

# 6

Mario Testini, Francesco Paolo Prete, Giovanna Di Meo, Alessandro Pasculli, Elisabetta Poli, Lucia Ilaria Sgaramella, and Angela Gurrado

## 6.1 Introduction

Thyroidectomy is one of the most commonly performed endocrine procedures, with over 90,000 cases performed each year in the United States, and approximately 40,000 each year in Italy [1, 2]. The proportion between thyroid diseases treated by conventional open thyroidectomy and by minimally invasive or remote access approaches varies significantly among the different centers, depending on indications, patient selection and surgical experience. In a large European series review, the frequency of minimally invasive procedures was less than 4% of all thyroidectomies [3], while in a South Korean report from a referral center the use of remote access thyroidectomy approached 20% [4].

Thyroidectomy is currently performed almost entirely as elective surgery and, in selected patients, it can be a one-day procedure [5]. Emergency thyroid surgery is exceptional [6–8].

## 6.2 Indications

Elective thyroidectomy represents the treatment of choice for: benign and malignant thyroid disease, fine-needle aspiration cytology that is either non-diagnostic, equivocal, indeterminate or unobtainable (e.g., in a retrosternal location), thyrotoxicosis, pressure symptoms such as breathing or swallowing difficulties, presence of an unsightly goiter, symptomatic retrosternal goiter, completion or prophylactic

---

M. Testini (✉) · F. P. Prete · G. Di Meo · A. Pasculli · E. Poli · L. I. Sgaramella · A. Gurrado  
Department of Precision and Regenerative Medicine and Ionian Area,  
University of Bari, Policlinic of Bari, Bari, Italy  
e-mail: [mario.testini@uniba.it](mailto:mario.testini@uniba.it); [francesco.prete@uniba.it](mailto:francesco.prete@uniba.it);  
[giovanna.dimeo@policlinico.ba.it](mailto:giovanna.dimeo@policlinico.ba.it); [pascullialessandro@gmail.com](mailto:pascullialessandro@gmail.com);  
[eli.poli81@gmail.com](mailto:eli.poli81@gmail.com); [ilaria.sgaram@gmail.com](mailto:ilaria.sgaram@gmail.com); [angela.gurrado@uniba.it](mailto:angela.gurrado@uniba.it)



thyroidectomy [9–12]. Conversely, emergency thyroidectomy is rare (<1% of all cases) and typically performed in patients with goiters presenting with acute airway obstruction due to intra-thyroid hemorrhage, tracheal compression, luminal invasion by the tumor or recurrent laryngeal nerve (RLN) infiltration [6, 13].

### 6.3 Technical Considerations

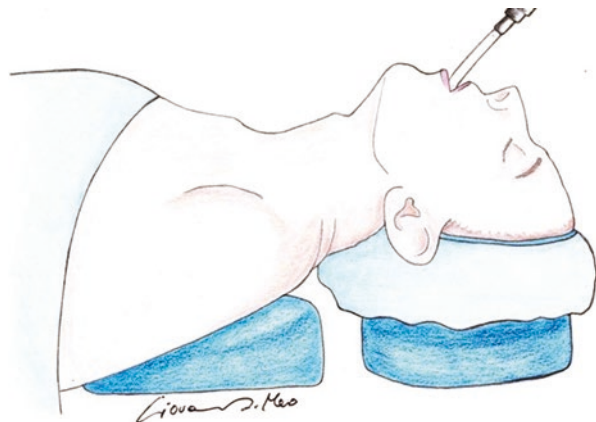
Whenever possible, the extent of thyroidectomy should always be discussed preoperatively with the patient, and can generally be classified as total or near-total thyroidectomy, or lobo-isthmectomy in accordance with current guidelines [9–12]. It is mandatory that the surgeons who perform thyroidectomy are familiar with the regional anatomy and its variations [14–17].

#### 6.3.1 Positioning

After induction of general anesthesia, the patient is placed supine with arms sideways and with their head stabilized; a support placed transversely underneath the shoulders helps extending the neck (Fig. 6.1). Local anesthesia with superficial cervical block has been utilized by some groups [18]. The operating table is tilted head up at 30° angle to the floor (reverse Trendelenburg). When a mini-invasive video-assisted thyroidectomy (MIVAT) is performed, this angle should be slightly less than 30° to facilitate camera assistance.

Obviously, exceptions to this setup may be needed for patients who have limitations to the range of motion of the cervical spine (as in cervical spondylosis), to avoid injuries. Attention is also paid to positioning the arms and protecting the elbows, so as to avoid neuropraxia of the brachial plexus from stretching of the ulnar nerve.

**Fig. 6.1** The patient is supine with shoulder support and with their neck extended. The operating table is tilted 30°, head up



The neck is prepped and draped; the operating field is squared off by positioning towels around the neck, including the chin, the trapezius muscles laterally and the upper chest caudally, about 5 cm below the clavicles.

When intraoperative nerve monitoring (IONM) is used, careful communication between surgeon and anesthesiologist should clarify which type of endotracheal tube is positioned and how to avoid long-lasting muscular blockade [19, 20].

### 6.3.2 Surgical Technique

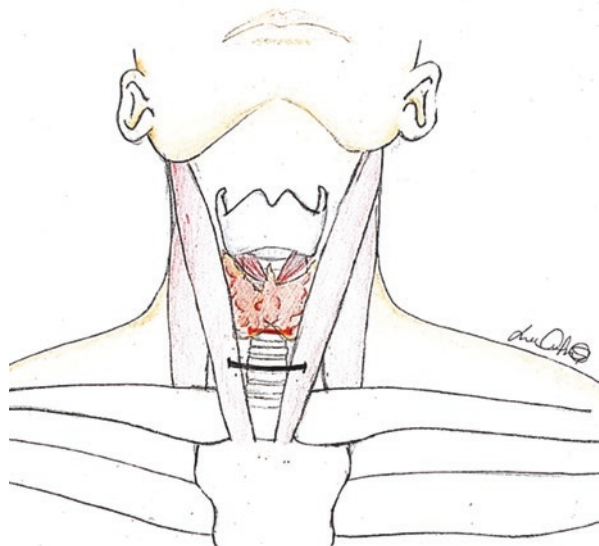
#### 6.3.2.1 Incision

The skin incision, called a Kocher incision in clinical practice is symmetrical, horizontal or slightly concave upwards, and variable in extent (on average 3–5 cm) depending on the surgeon's habit and the patient's features. It should lie in an arc above the clavicular heads and suprasternal notch, commonly two transverse fingers above the sternal notch (Fig. 6.2) and it typically runs in the direction of Langer's lines or in one of the skin creases of the neck, if visible.


In the MIVAT approach the skin incision, circa 2 cm long, is performed higher, about one transverse finger below the laryngeal prominence.

The edges of the skin incision may be extended laterally in the case of very large goiters or when a dissection of the lateral neck lymph nodes is required (Fig. 6.3). In this regard, an H-shaped incision, extending upwards and downwards the edges of the Kocher incision, is nowadays rarely used, as, intraoperative ultrasound (US) guidance during lymphadenectomy enables detection of nodes in remote positions without any need for an H incision [20].

**Fig. 6.2** Site of collar incision (Kocher incision), at the base of the neck, about two transverse fingers above the sternal notch. The incision is usually 3–5 cm long



**Fig. 6.3** A wider collar incision may be necessary when addressing large goiters or lateral node dissection



When a manubriotomy or sternotomy are necessary due to mediastinal or endo-thoracic extension of a goiter, a downward longitudinal extension of the incision, starting from the midline, is required (Fig. 6.4).

Then subplatysmal flaps are dissected to the laryngeal prominence superiorly and to the sternal notch inferiorly, respectively. In the early phase of thyroid surgery learning, attention must be paid to avoid perforation of the cutaneous flaps due to inadvertent use of the electrocautery, especially when the flaps are thin. The anterior jugular vein should also be kept lying in the anterior cervical fascia, to avoid wasting time controlling potential venous bleeding.

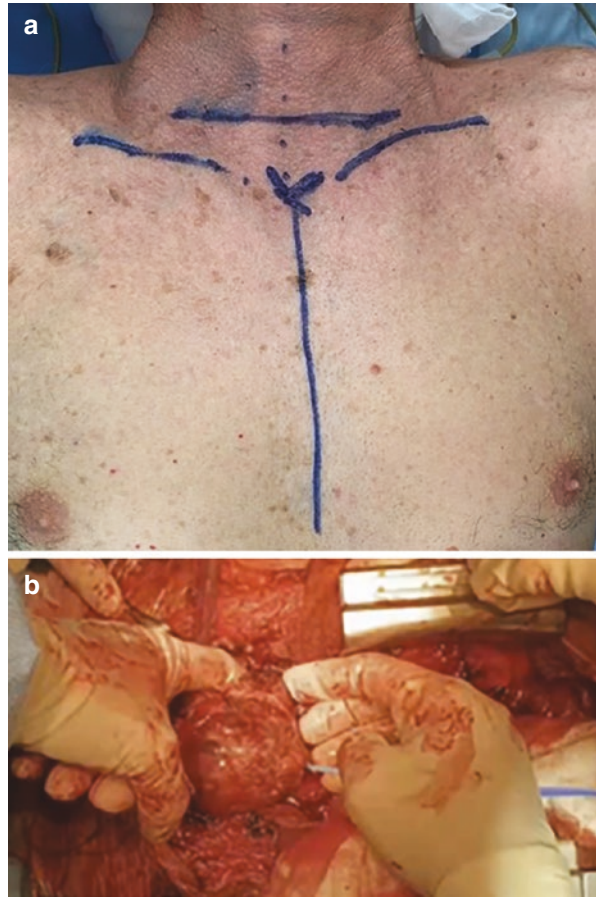
### 6.3.2.2 Exposure of the Thyroid Gland

The thyroid lodge is accessed by dividing the linea alba cervicalis between the infrahyoid strap muscles (sternohyoid, sternothyroid, and superior belly of the omohyoid), exposing the thyroid isthmus, cricoid cartilage, and the central compartment of the neck.

Adequate retraction of the sternohyoid muscle and of the deeper and slightly more lateral sternothyroid muscle is fundamental to comfortably approach and expose the vessels of the superior pole and the external branch of the superior laryngeal nerve (ebSLN) [19].

Routine division of the strap muscles is unnecessary in small glands, while it may facilitate thyroidectomy in large multinodular goiters and in obese patients, as it enhances exposure of the cricothyroid space with no significant impact on muscular function or cosmetic appearance; also, reconstructing the muscles at the end of thyroidectomy is simple [19, 21]. When dividing the strap muscles, preserving innervation via the ansa cervicalis at the lateral border of the sternothyroid muscle

**Fig. 6.4** Preoperative marking (a) of thoracic extension to the collar incision for sternotomy, to address a large cervico-mediastinal goiter (b)



is important. In the case of proven or suspected thyroid malignancy, resecting the muscle adherent to the gland en-bloc with the thyroid lobe is mandatory [19].

If IONM is used, the space between the thyroid and the carotid sheath is opened and the integrity of the vagus nerve loop is verified [22].

The main operating time during dissection and ligation of the superior pedicle is the preservation of the superior parathyroid glands (PGs) and ebSLN.

### 6.3.2.3 Superior Parathyroid Glands

The superior PGs derive from the fourth branchial pouch, have a short line of embryologic descent remaining close to the lateral lobe of the thyroid along the posterior surface, and are frequently symmetric [23]. In 80% of cases the superior PGs lie in the fat below the pretracheal fascia that is visible when the superior pole is dissected and rotated medially, within 1 cm cranial to the insertion of the articulation of the cricoid and thyroid cartilages, or 1 cm cranial to the intersection of the inferior thyroid artery (ITA) and RLN [23].

PGs are elliptical and flat, yellow-brown tending to salmon in color, and reveal soft firmness on palpation. The blood supply is mostly provided by terminal branches of the ITA, which exposes to the risk of devascularization during dissection; when this occurs, PG color shifts to marked brown, signaling the need for autotransplantation. The systematic use of magnification loupes (3x) during dissection enables faster identification of the PGs [24].

### **6.3.2.4 External Branch of the Superior Laryngeal Nerve**

The SLN originates from the vagus nerve. It divides at the level of the greater horn of the hyoid bone into an internal branch for the larynx mucosa and the ebSLN that supplies the cricothyroid muscle, which tenses the vocal cords increasing the pitch of the voice. Descending on the larynx beneath the sternothyroid muscle, the ebSLN crosses the avascular space below the tip of the superior thyroid pole and is at particularly high risk of injury during thyroidectomy because of its close but variable association with the superior thyroid artery (STA), as classified by Cernea et al.; in the presence of a low course (type 2b, 20%) of ebSLN, STA branches should be ligated in close proximity of the thyroid capsule [25].

In our experience, MIVAT or robot-assisted thyroidectomy (RAT) improves ebSLN visualization with camera assistance [26]. Nevertheless, in 20% of the cases the nerve is subfascial and cannot be visualized; in this case, IONM allows its identification in 100% of cases showing cricothyroid muscle twitching. By opening the avascular space between the thyroid gland and the cricothyroid muscle (cricothyroid space) and moving cephalad with dissection, the ebSLN may be seen, or avoided even if not directly viewed. Injury to ebSLN is less well described than damage to the RLN [27] and often underestimated: there is inability to reach high pitches, a loss of ability to project the voice, or easy vocal fatigue during prolonged speech [28]; often, association of voice changes with ebSLN injury can be demonstrated only on video-stroboscopic examination [29].

### **6.3.2.5 Superior Thyroid Artery**

The STA, the first branch of the external carotid artery, travels inferiorly and medially along the surface of the inferior constrictor of the pharynx muscle, accompanied by the ebSLN, and reaches the superior pole of the thyroid where it divides into posterior, lateral and anterior branches.

A superior parathyroid gland is identified in up to 2% of cases in this area [23].

The STA can be ligated close to the thyroid capsule of the superior pole to avoid inadvertent injury to the ebSLN, using ties or ultrasound scalpel, or radiofrequency/hybrid systems [30].

Once the superior vascular pedicle is detached, the gland is retracted medially by the assistant to prepare the approach to the inferior pedicle or to the middle vein, and RLN preparation and safeguard.

### **6.3.2.6 Middle Thyroid Vein, Isthmus Vessels**

A single vein, or sometimes a few venous branches, run from the gland to the internal jugular vein in front of the common carotid artery. Closure and section of the

middle vein allows mobilization and medial retraction of the lobe, exposing the area where the RLN lies before its entry in the larynx, that is below the ligament of Berry and the tubercle of Zuckerkandl (ZT), a thickening of the thyroid substance on the lateral border of each of the thyroid lobes. Identifying the anterior aspect of the trachea may help better localize this area and the tracheo-esophageal groove ahead of dissecting the RLN. The division of any centrally placed inferior thyroid veins defines the midline below the isthmus. Sometimes (<5% of patients) the thyroid ima artery (also called Neubauer artery) originating from the aortic arch or from the innominate artery may run as an odd and median vessel towards the isthmus, ventrally to the trachea. It may supply the inferior portion of the thyroid when proper inferior pole vessels are missing.

### **6.3.2.7 Inferior Thyroid Artery**

The ITA serves the lower pole and posterior surface of the two lobes. It originates from the thyrocervical trunk, climbs in the neck bilaterally behind the carotid artery fascia, and then curves medially to reach the inferior and posterior portion of the gland, giving off posterior, medial and inferior branches, respectively. The ITA sometimes divides proximally into several branches, and not infrequently the RLN runs through them. The ITA may be used as a landmark for RLN identification: modest traction on the trunk of the artery could be a useful artifice, facilitating exposure of the RLN and PGs. Almost always the ITA serves the PGs, so once the RLN has been preserved, its branches should be ligated individually on the capsule of the lobe after supplying the PGs.

### **6.3.2.8 Recurrent Laryngeal Nerve**

Preliminary identification of the nerve, and hence its preservation, is an undisputable phase of thyroidectomy. Use of the harmonic scalpel or electrothermal bipolar vessel sealing system must be careful throughout the procedure so as not to cause thermal damage [30].

The RLN (also called inferior laryngeal nerve) is the motor nerve to the intrinsic muscles of the larynx. The RLN innervates all the intrinsic muscles of the larynx except the cricothyroid, and the larynx mucosa below the vocal folds; its motor function is the abduction of the vocal cords from the midline. On the left hand side the RLN departs from the vagus nerve when it crosses the aortic arch and begins climbing upwards; the left RLN lies deeper than the right one, and before reaching the larynx it runs within the tracheo-esophageal groove, with which it has a closer (and more constant) relation than the right RLN, making its localization appear easier. The right RLN instead branches from the vagus at the level of the subclavian artery, runs posteriorly and obliquely upwards and is relatively more lateral within the tracheo-esophageal groove than the left nerve. Running deep and posterior to both thyroid lobes, the RLNs always remain outside the thyroid capsule and within the Berry ligament. High variability characterizes the relationship between the RLN and other anatomical structures of the anterior compartment of the neck, although in most cases it is consistently found within a few millimeters of the ITA and the ligament of Berry. Three are the most commonly described situations: RLN behind

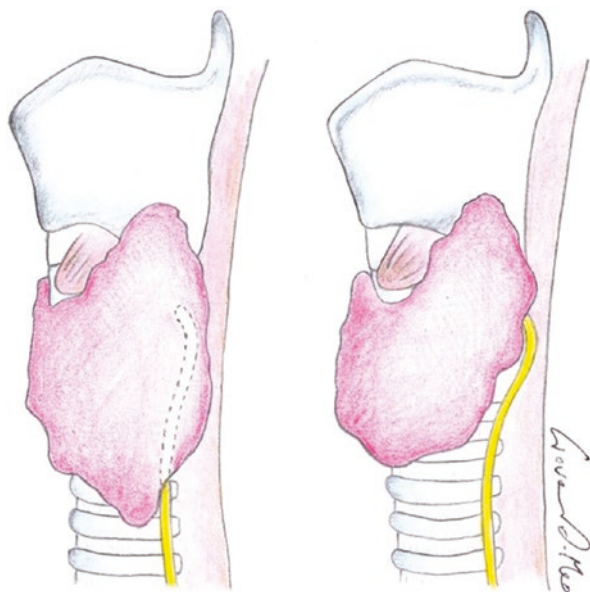
the ITA, anterior to the ITA, or running through its branches. On the left the RLN is more frequently posterior to the ITA, while on the right it is more frequently in between branches of the artery or in front of the artery. This is why selective and distal ligation of the tertiary branches of the ITA near the thyroid capsule is preferable, as a proximal ligature may risk damaging the nerve or its branches by entrapment: at variable distances from the larynx, even prior to encountering the thyroid itself, the nerve commonly divides into two branches supplying the abductor and adductor muscles of the larynx.

The ZT may be considered a clear clue of the presence of the RLN in its vicinity. More frequently, the nerve runs immediately behind the ZT; however, when enlarged, ZT may develop into a nodular process, with the RLN passing medial to it in a fissure. Prior to entering the larynx, the RLN travels just under, within, or even anterior to the Berry ligament, so careful mobilization is required, allowing the RLN to remain covered with a connective tissue sheath to minimize injury to its blood supply.

The nerve is best identified by the presence of the vasa nervorum on its surface; the use of loupe magnification is useful to show orientation and course of the vasa nervorum (regular course and parallel to the principal axis of the nerve) and vasa vasorum (mainly anarchic course) [24]. Indeed, sometimes the RLN mimics an artery, above all the inferior laryngeal artery that shows a similar course.

The nerve then continues superiorly and medially; it enters the larynx along the posterior aspect of the cricothyroid muscle, adjacent to the thyroid gland, where it is at its greatest danger. Moreover, the RLN could simulate entry into the thyroid and curve under the gland, especially in the presence of voluminous goiters (Fig. 6.5).

**Fig. 6.5** The course of the recurrent laryngeal nerve (RLN) may be obscured by a large goiter, especially in the proximity of its entry in the larynx. Sometimes the nerve may run within a fold of thyroid parenchyma, simulating entry in the gland. Mobilization of a large lobe should be cautious to prevent excessive traction on a RLN that has not yet been dissected free



A rare non-recurrent right laryngeal nerve (0.5–1% of cases) may originate directly from the cervical portion of the vagus, at the level of the thyroid or larynx, and enter the larynx without turning deeper down in the neck. Even more rarely there can be both a recurrent and a non-recurrent laryngeal nerve on the right side, joining below the inferior margin of the thyroid.

If one RLN is completely transected, inadvertently or deliberately for oncological reasons, the ipsilateral cord is adducted toward the midline in a paramedian position. However, if the ipsilateral eBSLN and RLN are damaged, the cord assumes an intermediate position [31]. If there is intraoperative evidence of iatrogenic transection or cancer invasion of the RLN, immediate microsurgical primary repair of the RLN can be performed [32]. Once the nerve is seen to be free of overlying thyroidal tissue, it is allowed to fall back away from the area of dissection into the tracheo-esophageal groove.

If IONM shows evidence of RLN damage (loss of signal) at the end of hemithyroidectomy, it is recommended to stop the procedure. For this reason, it is preferable to begin surgery on the side where disease is more evident.

### 6.3.2.9 Inferior Parathyroid Glands

The inferior PGs derive from the third branchial pouch and descend through a long line along with the thymus. Consequently, their position is much more variable than that of the superior PGs. Sometimes the inferior PGs are embedded in a small area of adipose tissue within the pretracheal fascia, in the posterior and inferior portion of the thyroid lobes, but they always sit in the vicinity of a terminal branch of the ITA. After identification, adequate blood supply is checked for each PG. Any PG that appears to be devascularized should be autotransplanted [33].

### 6.3.2.10 Procedure Completion

A pyramidal lobe, also called Lalouette pyramid, may be present in 15–80% of cases [34], variably extending cranially from the thyroid isthmus towards the hyoid bone.

When the thyroid is dissected off using energy devices incorrectly, the risk of thermal damage to the trachea is high; sometimes tracheal damage is evident only postoperatively when the scar falls, so great caution is mandatory when applying energy close to the trachea. The contralateral thyroid lobe is removed in a similar manner when total thyroidectomy is performed. In a near-total thyroidectomy a very small amount of thyroid tissue is left on the contralateral side to protect the PGs and above all the RLN.

After thyroidectomy, effective hemostasis is confirmed with a Valsalva maneuver. The strap muscles are approximated, leaving a window open inferiorly to prevent a potential hematoma in a closed deep space. When needed, a small suction drain is inserted and is generally removed within 24 hours. The platysma muscle (or, rather, the dermis) is approximated by interrupted 4–0 sutures, and the skin is approximated with a running subcuticular 4–0 or 5–0 absorbable suture. Usually, discharge occurs within 24–48 hours after an uncomplicated course. A circulating angiogenic cytokine profile can confirm adequate completion of total thyroidectomy in both benign and malignant diseases [35].



## References

1. Sun GH, DeMonner S, Davis MM. Epidemiological and economic trends in inpatient and out-patient thyroidectomy in the United States, 1996–2006. *Thyroid*. 2013;23(6):727–33.
2. Pierannunzio D, Fedeli U, Francisci S, et al. Thyroidectomies in Italy: a population-based national analysis from 2001 to 2018. *Thyroid*. 2022;32(3):263–72.
3. Barczyński M, Konturek A, Stopa M, et al. Minimally invasive video-assisted thyroidectomy: seven-year experience with 240 cases. *Wideochir Inne Tech Maloinwazyjne*. 2012;7(3):175–80.
4. Kim K, Kang SW, Kim JK, et al. Surgical outcomes of minimally invasive thyroidectomy in thyroid cancer: comparison with conventional open thyroidectomy. *Gland Surg*. 2020;9(5):1172–81.
5. Testini M, Nacchiero M, Miniello S, et al. One-day vs standard thyroidectomy. A perspective study of feasibility. *Minerva Endocrinol*. 2002;27(3):225–9.
6. Testini M, Logoluso F, Lissidini G, et al. Emergency total thyroidectomy due to non traumatic disease. Experience of a surgical unit and literature review. *World J Emerg Surg*. 2012;7:9.
7. Testini M, Gurrado A, Lissidini G, et al. Emergency surgery for acute respiratory failure secondary to spontaneous thyroid hemorrhage. *Int Surg*. 2008;93(3):158–62.
8. Testini M, Lissidini G, Gurrado A, et al. Acute airway failure secondary to thyroid metastasis from renal carcinoma. *World J Surg Oncol*. 2008;6:14.
9. Haugen BR, Alexander EK, Bible KC, et al. 2015 American Thyroid Association management guidelines for adult patients with thyroid nodules and differentiated thyroid cancer: the American Thyroid Association guidelines task force on thyroid nodules and differentiated thyroid cancer. *Thyroid*. 2016;26(1):1–133.
10. Smallridge RC, Ain KB, Asa SL, et al. American Thyroid Association guidelines for management of patients with anaplastic thyroid cancer. *Thyroid*. 2012;22(11):1104–39.
11. Wells SA Jr, Asa SL, Dralle H, et al. Revised American Thyroid Association guidelines for the management of medullary thyroid carcinoma: the American Thyroid Association guidelines task force on medullary thyroid carcinoma. *Thyroid*. 2015;25(6):567–610.
12. Prete F, Abdel-Aziz T, Morkane C, et al. Prophylactic thyroidectomy in children with multiple endocrine neoplasia type 2. *Br J Surg*. 2018;105(10):1319–27.
13. Abraham D, Singh N, Lang B, et al. Benign nodular goitre presenting as acute airway obstruction. *ANZ J Surg*. 2007;77(5):364–7.
14. Bliss RD, Gauger PG, Delbridge LW. Surgeon's approach to the thyroid gland: surgical anatomy and the importance of technique. *World J Surg*. 2000;24(8):891–7.
15. Chiang FY, Lu IC, Chen HC, et al. Anatomical variations of recurrent laryngeal nerve during thyroid surgery: how to identify and handle the variations with intraoperative neuromonitoring. *Kaohsiung J Med Sci*. 2010;26(11):575–83.
16. Ranade AV, Rai R, Pai MM, et al. Anatomical variations of the thyroid gland: possible surgical implications. *Singap Med J*. 2008;49(10):831–4.
17. Gurrado A, Bellantone R, Cavallaro G, et al. Can total thyroidectomy be safely performed by residents? A comparative retrospective multicenter study. *Medicine (Baltimore)*. 2016;95(14):e3241.
18. Wong P, Chieh Liew GH, Kothandan H. Anaesthesia for goitre surgery: a review. *Proc Singapore Healthc*. 2015;24(3):165–70.
19. Roman BR, Randolph GW, Kamani D. Conventional thyroidectomy in the treatment of primary thyroid cancer. *Endocrinol Metab Clin N Am*. 2019;48(1):125–41.
20. Prete FP, Sgaramella LI, Di Meo G, et al. Introducing routine intraoperative nerve monitoring in a high-volume endocrine surgery Centre: a health technology assessment. *Updat Surg*. 2021;73(6):2263–73.
21. Tinckler L. Strap muscles in thyroid surgery: to cut or not to cut? *Ann R Coll Surg Engl*. 1993;75(5):378–9.
22. Kim HY, Tufano RP, Chai YJ, et al. Intraoperative neural monitoring in thyroid surgery: role and responsibility of surgeon. *J Endocr Surg*. 2018;18(1):49–60.

23. Akerström G, Malmaeus J, Bergström R. Surgical anatomy of human parathyroid glands. *Surgery*. 1984;95(1):14–21.
24. Testini M, Nacchiero M, Piccinni G, et al. Total thyroidectomy is improved by loupe magnification. *Microsurgery*. 2004;24(1):39–42.
25. Cernea CR, Ferraz AR, Nishio S, et al. Surgical anatomy of the external branch of the superior laryngeal nerve. *Head Neck*. 1992;14(5):380–3.
26. Ambrosi A, Fersini A, Tartaglia N, et al. Tiroidectomia videoassistita con minicervicotomia Centrale. Esperienza iniziale in una divisione di endocrinochirurgia [video-assisted thyroidectomy with minimally invasive central cervicotomy: initial experience in an endocrine surgery division]. *Chir Ital*. 2006;58(5):549–56.
27. Droulias C, Tzinas S, Harlaftis N, et al. The superior laryngeal nerve: function and dysfunction. *Otolaryngol Clin North Am*. 1976;42(9):635–8.
28. Jansson S, Tisell LE, Hagne I, et al. Partial superior laryngeal nerve (SLN) lesions before and after thyroid surgery. *World J Surg*. 1988;12(4):522–7.
29. Teitelbaum BJ, Wenig BL. Superior laryngeal nerve injury from thyroid surgery. *Head Neck*. 1995;17(1):36–40.
30. Testini M, Pasculli A, Di Meo G, et al. Advanced vessel sealing devices in total thyroidectomy for substernal goitre: a retrospective cohort study. *Int J Surg*. 2016;35:160–4.
31. Testini M, Gurrado A, Bellantone R, et al. Recurrent laryngeal nerve palsy and substernal goiter. An Italian multicenter study. *J Visc Surg*. 2014;151(3):183–9.
32. Gurrado A, Pasculli A, Pezzolla A, et al. A method to repair the recurrent laryngeal nerve during thyroidectomy. *Can J Surg*. 2018;61(4):278–82.
33. Testini M, Gurrado A, Lissidini G, Nacchiero M. Hypoparathyroidism after total thyroidectomy. *Minerva Chir*. 2007;62(5):409–15.
34. Sadler GP, Clark OH, Van Heerden JA, et al. Thyroid and parathyroid. In: Schwartz SI, Shires GM, Spencer FC, et al., editors. *Principles of surgery*. 7th ed. New York: Mc Graw Hill; 1999.
35. Ria R, Prete F, Melaccio A, et al. Effect of thyroidectomy on circulating angiogenic cytokines in papillary thyroid carcinoma and benign goiter: potential for new biomarkers? *Surgery*. 2021;169(1):27–33.

**Open Access** This chapter is licensed under the terms of the Creative Commons Attribution-NonCommercial-NoDerivatives 4.0 International License (<http://creativecommons.org/licenses/by-nc-nd/4.0/>), which permits any noncommercial use, sharing, distribution and reproduction in any medium or format, as long as you give appropriate credit to the original author(s) and the source, provide a link to the Creative Commons license and indicate if you modified the licensed material. You do not have permission under this license to share adapted material derived from this chapter or parts of it.

The images or other third party material in this chapter are included in the chapter's Creative Commons license, unless indicated otherwise in a credit line to the material. If material is not included in the chapter's Creative Commons license and your intended use is not permitted by statutory regulation or exceeds the permitted use, you will need to obtain permission directly from the copyright holder.





# Minimally Invasive Video-Assisted Thyroidectomy

# 7

Marco Raffaelli, Carmela De Crea, Francesco Pennestrì,  
Pierpaolo Gallucci, Luca Revelli, Luca Sessa,  
Francesca Prioli, Celestino Pio Lombardi,  
and Rocco Bellantone

## 7.1 Introduction

Over the last few decades, different minimally invasive procedures have been proposed for the treatment of thyroid and parathyroid diseases with the primary aim of improving the cosmetic results [1]. Indeed, minimization or elimination of the cervical scar is particularly appealing to patients, particularly women, undergoing thyroid surgery.

In 1996, Gagner described the first endoscopic parathyroidectomy with a cervical access [2], later stating that “As for the other minimally invasive techniques, decreased pain and better cosmetic results may be the greatest expectations from this procedure due to the decreased size of skin incision” [3]. However, the concept of a minimally invasive approach should probably also imply the capability of an innovative technique to minimize the trauma of the surgical exposure, while providing equal operative mortality and morbidity to the traditional counterpart by means of proper application of technological developments and improvements [4]. Other approaches were soon developed, partly to avoid long insufflations in the neck and partly to find effective minimally invasive routes for thyroidectomy.

In 1997, Miccoli et al. described the first video-assisted procedure in the neck for a parathyroidectomy [5]. In 1999, we described the technique for minimally invasive, totally gasless video-assisted thyroid lobectomy [6]. Soon after, Miccoli et al. published their preliminary results with a minimally invasive approach to thyroidectomy [7].

M. Raffaelli · C. De Crea (✉) · F. Pennestrì · P. Gallucci · L. Revelli  
L. Sessa · F. Prioli · C. P. Lombardi · R. Bellantone

UOC Chirurgia Endocrina e Metabolica, Centro di ricerca in Chirurgia delle Ghiandole Endocrine e dell’Obesità, Fondazione Policlinico Universitario Agostino Gemelli IRCCS, Rome, Italy

e-mail: [marco.raffaelli@unicatt.it](mailto:marco.raffaelli@unicatt.it); [carmela.decrea@unicatt.it](mailto:carmela.decrea@unicatt.it);  
[francesco.pennestri@policlinicogemelli.it](mailto:francesco.pennestri@policlinicogemelli.it); [pierpaolo.gallucci@policlinicogemelli.it](mailto:pierpaolo.gallucci@policlinicogemelli.it);  
[luca.revelli@unicatt.it](mailto:luca.revelli@unicatt.it); [luca.sessa@policlinicogemelli.it](mailto:luca.sessa@policlinicogemelli.it);  
[francesca.prioli@guest.policlinicogemelli.it](mailto:francesca.prioli@guest.policlinicogemelli.it); [celestinopio.lombardi@unicamillus.org](mailto:celestinopio.lombardi@unicamillus.org);  
[rocco.bellantone@unicatt.it](mailto:rocco.bellantone@unicatt.it)

More than 20 years after its first description, minimally invasive video-assisted thyroidectomy (MIVAT) is one of the most widespread minimally invasive approaches to thyroidectomy [8–10]. Its peculiarity, and the reason for its success, resides in the advantages related to endoscopic magnification that allow the surgeon to perform the same steps as conventional thyroidectomy through a small single neck access [11–14]. Indeed, MIVAT is performed in part under endoscopic view and in part under direct vision. The endoscope magnification allows easier identification of structures located in the narrow space of the neck (inferior laryngeal nerve, external branch of the superior laryngeal nerve, parathyroid glands) that need to be preserved.

It has been demonstrated that MIVAT is a reproducible, safe, and effective technique that can yield the same results as conventional surgery, with advantages in terms of improved cosmetic outcome and reduced postoperative pain [15–19]. Multi-institutional series have further confirmed its efficacy and safety in different clinical settings [8]. MIVAT is comparable to conventional open thyroidectomy in terms of oncologic radicality, time, costs and complication rates [14, 17, 20–22].

In selected cases, MIVAT can be successfully accomplished under local anesthesia, to further minimize its invasiveness [23].

An accurate patient selection plays a key role in ensuring the success of MIVAT [24].

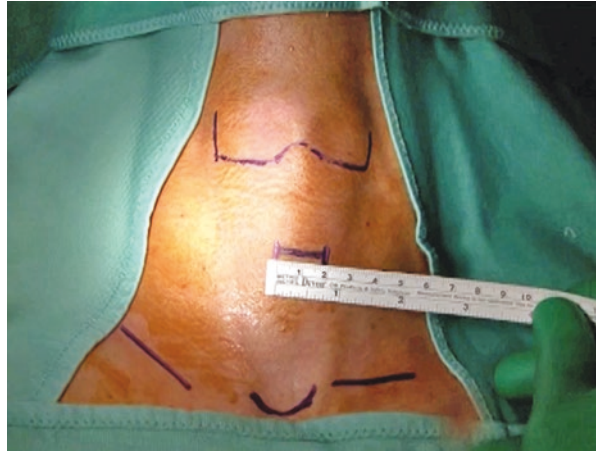
---

## 7.2 Surgical Technique

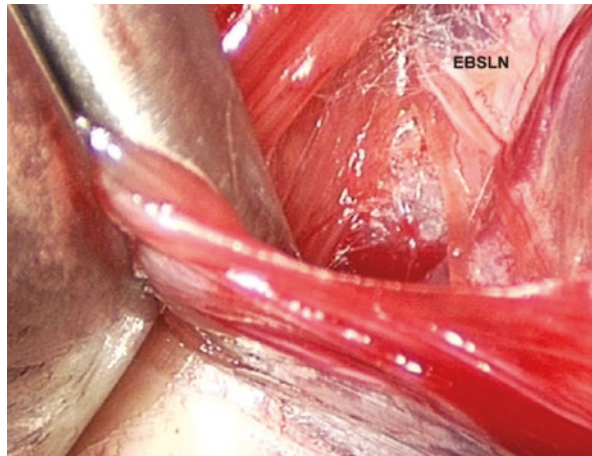
The operative technique has been previously described in detail [25, 26].

- *Patient and surgical team positions.* The patient is supine with the neck in slight extension. The surgical team is composed of the surgeon and two assistants, one of whom handles the endoscope. The absence of any external support allows the endoscope's position to be modulated and changed in relation to the different steps of the dissection.
- *Anesthesia.* MIVAT is usually performed under general anesthesia with endotracheal intubation. With increasing experience, MIVAT can be successfully performed under local anesthesia with superficial modified deep cervical block in selected patients [23].
- *Surgical equipment.* Most of the surgical equipment required for MIVAT is usually available in almost all operating rooms, and it is not a source of additional costs. The only dedicated instruments are small reusable dissection tools: ad hoc designed spatulas and spatula-shaped aspirator. Sealing systems are proven to be useful by allowing a decreased operative time [27].
- *Surgical procedure.* A small (1.5–2 cm) skin incision (Fig. 7.1) is performed between the cricoid cartilage and the sternal notch, in the midline. The cervical *linea alba* is opened as far as possible. The thyroid lobe is then separated from the strap muscles by means of Farabeuf retractors. The thyroid lobe is medially retracted while the strap muscles are laterally retracted. At this point, the

**Fig. 7.1** A small skin incision (1.5–2 cm) is performed between the cricoid cartilage and the sternal notch

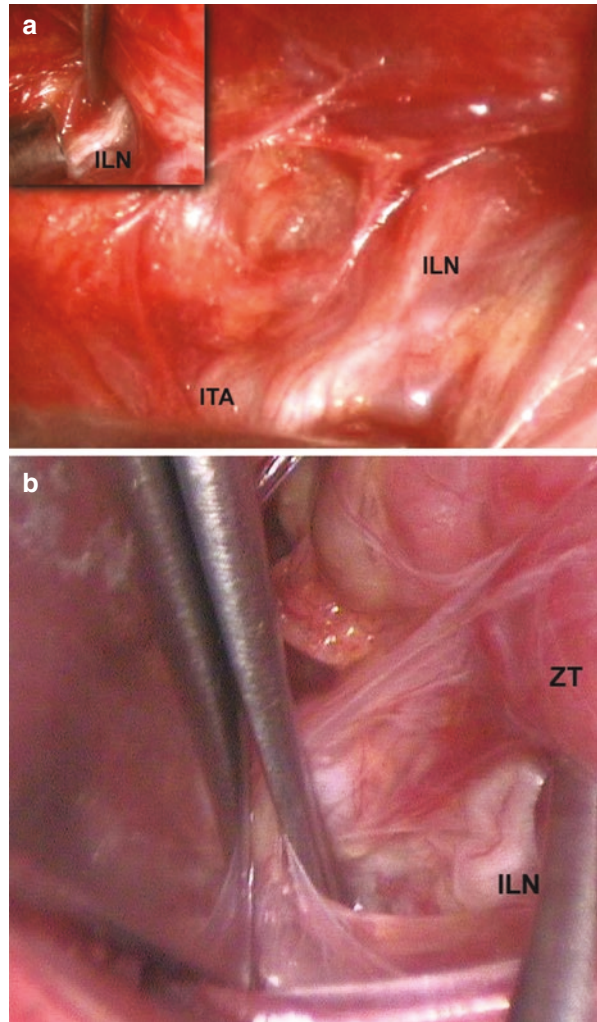


**Fig. 7.2** Identification of the external branch of the superior laryngeal nerve (EBSLN)

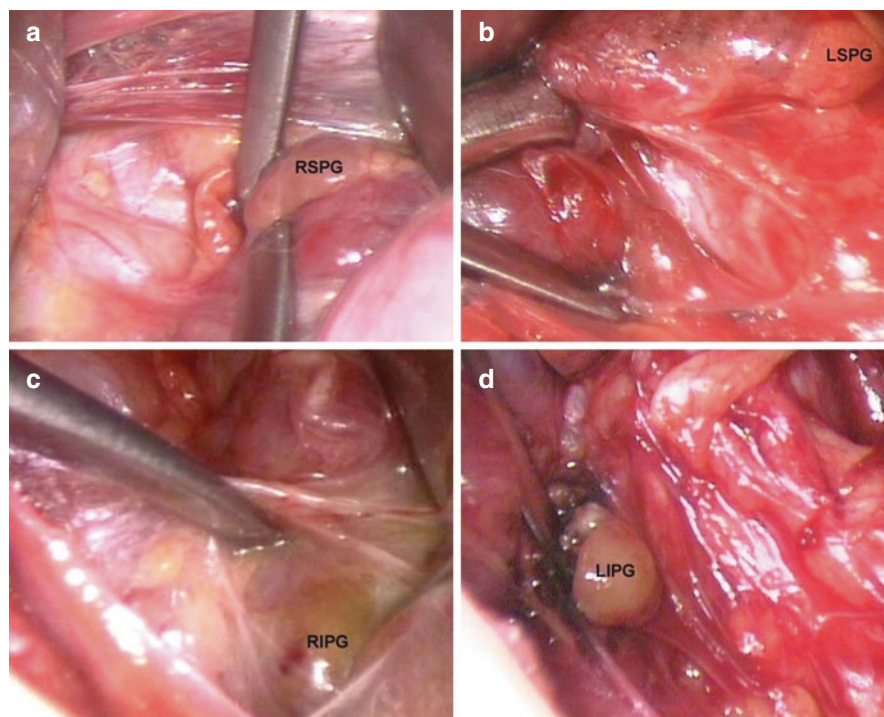


endoscope (5 mm, 30°) and instruments (2 mm in diameter) are introduced through the single skin incision. The first step of the procedure consists of completely freeing the thyroid gland from the strap muscles, down to the prevertebral fascia, which represents the posterior aspect of the dissection. The lateral edge of the dissection is represented by the medial aspect of the common carotid artery, and the medial edge is represented by the tracheoesophageal groove. The dissection is carried out by a blunt technique using two dedicated instruments (“spatulas”); one of the instruments is connected to an aspiration system. After its complete separation from the muscles, the thyroid lobe is retracted downwards, in order to expose the upper pole. During this step, it is usually possible to identify the external branch of the superior laryngeal nerve thanks to the magnification of the endoscope (Fig. 7.2). The thyroid lobe is then retracted medially and slightly upwards to identify the inferior laryngeal nerve (ILN) and the parathyroid glands. The ILN is identified where it crosses the inferior thyroid artery

**Fig. 7.3** (a) The inferior laryngeal nerve (*ILN*) is identified where it crosses the inferior thyroid artery (*ITA*). (b) The Zuckerkandl tubercle (*ZT*) can be another useful landmark to identify the *ILN*



(Fig. 7.3a). The Zuckerkandl tubercle can be another useful landmark to identify the *ILN* (Fig. 7.3b), as in the conventional procedure. The parathyroid glands are usually easily identified and preserved thanks to the assistance of endoscopic magnification (Fig. 7.4). At this point, the thyroid lobe is extracted and the procedure is completed under direct vision.



**Fig. 7.4** Identification of the parathyroid glands. (a) Right superior parathyroid gland (*RSPG*). (b) Left superior parathyroid gland (*LSPG*). (c) Right inferior parathyroid gland (*RIPG*). (d) Left inferior parathyroid gland (*LIPG*)

### 7.3 Indications

An accurate patient selection plays a key role in ensuring the success of MIVAT. In the early experience with MIVAT the indications were quite limited. Indeed, initial contraindications included thyroiditis and prior neck surgery. With increasing experience, the selection criteria for MIVAT have been widened. Patients with previous contralateral video-assisted neck surgery or thyroiditis can be selected for MIVAT. Similarly, other authors demonstrated that in selected patients with Graves' disease, MIVAT is feasible and safe [12, 28].

In our experience, MIVAT is indicated in the case of nodules  $\leq 35$  mm in the largest diameter and in patients with an estimated thyroid volume  $\leq 30$  mL [24].

Ideal candidates for MIVAT are patients with small nodules with indeterminate or suspicious cytology. In addition, small size hot nodules represent the best indication for this kind of surgery.

Selected patients with papillary thyroid carcinoma (PTC) could be eligible for MIVAT. Indeed, progressive extension of the indications for the video-assisted approach led to the use of MIVAT for the treatment of small PTC [29–32]. Findings

from previous small comparative studies have confirmed the hypothesis that MIVAT produces a complete operative resection comparable with that of conventional surgery [29, 30, 33] with no additional risk of seeding of cancer cells [17].

However, although we have successfully performed a large series of video-assisted lymph node dissections of the central node in PTC with unexpected intra-operative evidence of lymph node enlargement [20], preoperatively diagnosed lymph node involvement represents a contraindication for MIVAT [24].

*RET* mutation carriers in the absence of detectable nodules and basal/stimulated calcitonin in the normal range are excellent candidates for MIVAT [34].

We believe that an accurate preoperative ultrasound examination, even better if performed by the surgeon, plays a pivotal role in proper patient selection for MIVAT.

In our experience, the rate of patient selection for MIVAT according to the reported indications is about 30% [24]. Similarly, a rate of 30% has been reported in the United States [21, 35], whereas Miccoli et al. recently reported a rate of 20% [36].

---

## 7.4 Outcomes

### 7.4.1 Postoperative Outcome

In a review of our experience in a series of patients who underwent MIVAT over a 10-year period [37], we observed a conversion rate of 0.5% (7/1363), one definitive inferior laryngeal nerve palsy (2507 nerves at risk) and a rate of definitive hypoparathyroidism of 0.8% (10/1175 total thyroidectomies).

Indeed, the postoperative complication rate of MIVAT, similarly to other experiences [14, 36], is comparable to that of the conventional open procedure. In addition, compared with standard thyroidectomy MIVAT has no additional costs [38], and it improves postoperative pain, as demonstrated in a prospective randomized study [39].

The incidence and severity of early voice and swallowing post-thyroidectomy symptoms, in the absence of objective laryngeal nerve injury, are significantly reduced in patients who undergo MIVAT compared with conventional surgery (evidence level II B) [40].

### 7.4.2 Oncologic Outcome

The results of MIVAT in the case of small “low-risk” PTC are encouraging [31]. In addition, the minimally invasive approach allows adequate clearance of the central neck lymph nodes. Indeed, in a case-control study [41], we compared two groups of patients with PTC who underwent video-assisted or conventional central neck node dissection. The two groups had a similar mean operative time, complication rate, and number of removed and metastatic lymph nodes. Comparative analysis of the follow-up data showed no significant differences between the two groups in terms



of mean serum thyroglobulin levels off levothyroxine suppressive treatment and mean postoperative quantitative  $^{131}\text{I}$  neck uptake obtained prior to radioactive iodine therapy.

In order to evaluate the long-term oncologic outcome of PTC patients undergoing MIVAT, we considered all the patients with a minimum of 10 years follow-up [42]. We accurately focused our research on follow-up data including a series of 257 patients with an overall mean follow-up of  $144.2 \pm 37.3$  months (range 120–197). In this relatively long follow-up period, we observed no local recurrences and three lateral neck nodal recurrences 2, 3 and 11 years after the initial surgical treatment. It should be considered that the only recurrences we observed occurred in the lateral neck nodes and not on the thyroid bed. On this particular aspect, it should be stressed once more that the video-assisted approach with central access allows the surgeon to perform a formal central neck compartment dissection when needed, even though overt central neck involvement should be considered a contraindication for the video-assisted procedure.

The results of MIVAT for the treatment of selected PTC patients are encouraging, even in the long term. These results further confirm that MIVAT is a safe and effective option for selected patients with PTC, when strict selection criteria are followed.

---

## References

1. Dimitrios L. Minimally invasive thyroidectomy: a comprehensive appraisal of existing techniques. *Surgery*. 2011;150(1):17–24.
2. Gagner M. Endoscopic subtotal parathyroidectomy in patients with primary hyperparathyroidism. *Br J Surg*. 1996;83(6):875.
3. Naitoh T, Gagner M, Garcia-Ruiz A, Heniford BT. Endoscopic endocrine surgery in the neck. An initial report of endoscopic subtotal parathyroidectomy. *Surg Endosc*. 1998;12(3):202–5. discussion 206
4. Henry JF. Minimally invasive thyroid and parathyroid surgery is not a question of length of the incision. *Langenbeck's Arch Surg*. 2008;393(5):621–6.
5. Miccoli P, Pinchera A, Cecchini G, et al. Minimally invasive, video-assisted parathyroid surgery for primary hyperparathyroidism. *J Endocrinol Investig*. 1997;20(7):429–30.
6. Bellantone R, Lombardi CP, Raffaelli M, et al. Minimally invasive, totally gasless video-assisted thyroid lobectomy. *Am J Surg*. 1999;177(4):342–3.
7. Miccoli P, Berti P, Conte M, et al. Minimally invasive surgery for thyroid small nodules: preliminary report. *J Endocrinol Investig*. 1999;22(11):849–51.
8. Miccoli P, Bellantone R, Mourad M, et al. Minimally invasive video-assisted thyroidectomy: multiinstitutional experience. *World J Surg*. 2002;26(8):972–5.
9. Schabram J, Vorländer C, Wahl RA. Differentiated operative strategy in minimally invasive, video-assisted thyroid surgery. Results in 196 patients. *World J Surg*. 2004;28(12):1282–6.
10. Dionigi G, Dralle H, Materazzi G, et al. Happy 20th birthday to minimally invasive video-assisted thyroidectomy! *J Endocrinol Investig*. 2020;43(3):385–8.
11. Bellantone R, Lombardi CP, Raffaelli M, et al. Video-assisted thyroidectomy. *J Am Coll Surg*. 2002;194(5):610–4.
12. Lombardi CP, Raffaelli M, Princi P, et al. Video-assisted thyroidectomy: report on the experience of a single center in more than four hundred cases. *World J Surg*. 2006;30(5):794–800.

13. Kania R, Hammami H, V rillaud B, et al. Minimally invasive video-assisted thyroidectomy: tips and pearls for the surgical technique. *Ann Otol Rhinol Laryngol*. 2014;123(6):409–14.
14. Miccoli P, Biricotti M, Matteucci V, et al. Minimally invasive video-assisted thyroidectomy: reflections after more than 2400 cases performed. *Surg Endosc*. 2016;30(6):2489–95.
15. Miccoli P, Berti P, Raffaelli M, et al. Comparison between minimally invasive video-assisted thyroidectomy and conventional thyroidectomy: a prospective randomised study. *Surgery*. 2001;130(3):1039–43.
16. Bellantone R, Lombardi CP, Bossola M, et al. Video-assisted vs conventional thyroid lobectomy—a randomized trial. *Arch Surg*. 2002;137(3):301–4.
17. Lombardi CP, Raffaelli M, Princi P, et al. Safety of video-assisted thyroidectomy versus conventional surgery. *Head Neck*. 2005;27(1):58–64.
18. Pisanu A, Podda M, Reccia I, et al. Systematic review with meta-analysis of prospective randomized trials comparing minimally invasive video-assisted thyroidectomy (MIVAT) and conventional thyroidectomy (CT). *Langenbeck’s Arch Surg*. 2013;398(8):1057–68.
19. Zhang P, Zhang HW, Han XD, et al. Meta-analysis of comparison between minimally invasive video-assisted thyroidectomy and conventional thyroidectomy. *Eur Rev Med Pharmacol Sci*. 2015;19(8):1381–7.
20. Lombardi CP, Raffaelli M, De Crea C, et al. Report on 8 years of experience with video-assisted thyroidectomy for papillary thyroid carcinoma. *Surgery*. 2007;142(6):944–51.
21. Lai SY, Walvekar RR, Ferris RL. Minimally invasive video-assisted thyroidectomy: expanded indications and oncologic completeness. *Head Neck*. 2008;30(11):1403–7.
22. Scerrino G, Melfa G, Raspanti C, et al. Minimally invasive video-assisted thyroidectomy: analysis of complications from a systematic review. *Surg Innov*. 2019;26(3):381–7.
23. Lombardi CP, Raffaelli M, Modesti C, et al. Video-assisted thyroidectomy under local anesthesia. *Am J Surg*. 2004;187(4):515–8.
24. Sessa L, Lombardi CP, De Crea C, et al. Video-assisted endocrine neck surgery: state of the art. *Updat Surg*. 2017;69(2):199–204.
25. Bellantone R, Lombardi CP, Raffaelli M. Tiroidectomia video-assistita. In: *Trattato di tecniche chirurgiche, Chirurgia generale*. EMC, Elsevier Italia; 2004.
26. Raffaelli M, De Crea C, Pennestri F, et al. Video-assisted thyroidectomy. In: Shifrin A, editor. *Atlas of thyroid surgery*. Springer; 2022.
27. Miccoli P, Berti P, Raffaelli M, et al. Impact of harmonic scalpel on operative time during video-assisted thyroidectomy. *Surg Endosc*. 2002;16(4):663–6.
28. Berti P, Materazzi G, Galleri D, et al. Video-assisted thyroidectomy for graves’ disease: report of a preliminary experience. *Surg Endosc*. 2004;18(8):1208–10.
29. Bellantone R, Lombardi CP, Raffaelli M, et al. Video-assisted thyroidectomy for papillary thyroid carcinoma. *Surg Endosc*. 2003;17(10):1604–8.
30. Miccoli P, Pinchera A, Materazzi G, et al. Surgical treatment of low- and intermediate-risk papillary thyroid cancer with minimally invasive video-assisted thyroidectomy. *J Clin Endocrinol Metab*. 2009;94(5):1618–22.
31. Lombardi CP, Raffaelli M, De Crea C, et al. Video-assisted thyroidectomy for papillary thyroid carcinoma. *J Oncol*. 2010;2010:148542.
32. Wu CT, Yang LH, Kuo SJ. Comparison of video-assisted thyroidectomy and traditional thyroidectomy for the treatment of papillary thyroid carcinoma. *Surg Endosc*. 2010;24(7):1658–62.
33. Miccoli P, Elisei R, Materazzi G, et al. Minimally invasive video-assisted thyroidectomy for papillary carcinoma: a prospective study of its completeness. *Surgery*. 2002;132(6):1070–3. discussion 1073–4
34. Miccoli P, Elisei R, Berti P, et al. Video assisted prophylactic thyroidectomy and central compartment nodes clearance in two RET gene mutation adult carriers. *J Endocrinol Investig*. 2004;27(6):557–61.
35. Terris DJ, Angelos P, Steward DL, Simental AA. Minimally invasive video-assisted thyroidectomy: a multi-institutional north American experience. *Arch Otolaryngol Head Neck Surg*. 2008;134(1):81–4.

36. Miccoli P, Fregoli L, Rossi L, et al. Minimally invasive video-assisted thyroidectomy (MIVAT). *Gland Surg.* 2020;9(Suppl 1):S1–5.
37. Lombardi CP, Raffaelli M, De Crea C, et al. Video-assisted thyroidectomy: lessons learned after more than one decade. *Acta Otorhinolaryngol Ital.* 2009;29(6):317–20.
38. Byrd JK, Nguyen SA, Ketcham A, et al. Minimally invasive video-assisted thyroidectomy versus conventional thyroidectomy: a cost-effective analysis. *Otolaryngol Head Neck Surg.* 2010;143(6):789–94.
39. Miccoli P, Rago R, Massi M, et al. Standard versus video-assisted thyroidectomy: objective postoperative pain evaluation. *Surg Endosc.* 2010;24(10):2415–7.
40. Lombardi CP, Raffaelli M, D’Alatri L, et al. Video-assisted thyroidectomy significantly reduces the risk of early post-thyroidectomy voice and swallowing symptoms. *World J Surg.* 2008;32(5):693–700.
41. Bellantone R, Lombardi CP, Raffaelli M, et al. Central neck lymph node removal during minimally invasive video-assisted thyroidectomy for thyroid carcinoma: a feasible and safe procedure. *J Laparoendosc Adv Surg Tech A.* 2002;12(3):181–5.
42. Bellantone R, Raffaelli M, De Crea C, et al. Video-assisted thyroidectomy for papillary thyroid carcinoma: oncologic outcome in patients with follow-up  $\geq 10$  years. *World J Surg.* 2018;42(2):402–8.

**Open Access** This chapter is licensed under the terms of the Creative Commons Attribution-NonCommercial-NoDerivatives 4.0 International License (<http://creativecommons.org/licenses/by-nc-nd/4.0/>), which permits any noncommercial use, sharing, distribution and reproduction in any medium or format, as long as you give appropriate credit to the original author(s) and the source, provide a link to the Creative Commons license and indicate if you modified the licensed material. You do not have permission under this license to share adapted material derived from this chapter or parts of it.

The images or other third party material in this chapter are included in the chapter's Creative Commons license, unless indicated otherwise in a credit line to the material. If material is not included in the chapter's Creative Commons license and your intended use is not permitted by statutory regulation or exceeds the permitted use, you will need to obtain permission directly from the copyright holder.





# Cervical Lymphadenectomy in Papillary Thyroid Cancer

# 8

Belinda W. Hii and Fausto F. Palazzo

## 8.1 Introduction

Thyroid cancer is the commonest endocrine malignancy and is increasing in incidence mainly due to the increasing diagnosis of the most common histological subtype, papillary thyroid cancer (PTC). Papillary carcinoma represents up to 90% of all thyroid cancer diagnoses [1]. Its increasing incidence is largely due to the incidental ultrasonographic detection of microcarcinomas but also to a lesser extent to the diagnosis of larger locally advanced and metastatic thyroid cancers. However, the age-adjusted mortality from thyroid cancer remains the same or at most is marginally rising [2].

Lymph node metastases are common in PTC, in particular in the central neck compartment where 21–35% of patients may have a preoperative suggestion of nodal disease [3, 4]. This increases to as high as 85% when occult micrometastases found on histology are included in the calculation of node positivity [3–5]. There is a consensus view reflected in international guidelines (American Thyroid Association and National Comprehensive Cancer Network) that compartmental clearance of macroscopically involved central lymph nodes (cN1) reduces the risk of local disease recurrence and may, more controversially, impact on disease-free survival [6–8]. However, the clearance of nodal compartments, whether therapeutic or prophylactic, is associated with a higher risk of complications; with hypoparathyroidism and recurrent laryngeal nerve (RLN) injury being the principal hazards in central nodal clearance.

The prognosis for most PTC remains excellent, with overall 5-year survival of over 90% [3] but locoregional recurrence (LRR) can occur in up to 30% of patients [4]. The overall excellent prognosis and slow disease progression of PTC underlines the need for a careful assessment of the benefit of reduced LRR against the risk of

---

B. W. Hii (✉) · F. F. Palazzo

Department of Endocrine Surgery, Hammersmith Hospital, Imperial College, London, UK  
e-mail: [belinda.hii@gmail.com](mailto:belinda.hii@gmail.com); [f.palazzo@imperial.ac.uk](mailto:f.palazzo@imperial.ac.uk)

© The Author(s) 2024

M. Testini, A. Gurrado (eds.), *Thyroid Surgery*, Updates in Surgery,  
[https://doi.org/10.1007/978-3-031-31146-8\\_8](https://doi.org/10.1007/978-3-031-31146-8_8)

troublesome morbidity associated with a nodal dissection. This chapter will contextualize this debate by describing the indications for, and ongoing controversies regarding, cervical lymphadenectomy in PTC.

---

## 8.2 Definitions

There is varied anatomical and procedural terminology used in describing lymphadenectomy in PTC, particularly in relation to the central compartment. There are several iterations of thyroid cancer staging and the perceived clinical relevance of nodal metastases in PTC has evolved over the last few decades. This has been followed by changes in clinical management, which has created difficulties when comparing patient populations over time.

### 8.2.1 Anatomical Terminology

Robbins et al. first attempted to standardize the terminology used in the dissection of cervical lymph nodes in 1991 [9]. This classification was then adapted by the American Academy of Otolaryngology – Head and Neck Surgery. The purpose of the anatomical definitions was to standardize the description in the treatment of squamous cell carcinomas of the head and neck rather than thyroid cancer, which is associated with a different pattern of spread. There are at least four systems used for staging cervical nodal basins internationally [9–12].

The American Academy of Otolaryngology system divides the neck into six nodal compartments [9]. The central compartment is divided into levels Ia, Ib and VI, and the lateral into IIa, IIb, III, IV, Va, and Vb. The upper mediastinum is often referred to as level VII. This is relevant to thyroid cancer since level VI and VII are common sites for initial nodal spread in PTC. The margins of level VI are the hyoid bone cranially and the sternal notch caudally; the common carotid artery is the lateral limit and the trachea represents the midline. The prevertebral fascia marks the posterior limit of the central compartment. The prelaryngeal, pretracheal and paratracheal lymph nodes lie within the central compartment. The Delphian or precricoid node is contained within the prelaryngeal group. In thyroid cancer the described anatomical boundaries are not respected by PTC spread and are arguably mainly used for ease of communication and the identification of structures at risk during surgery [13].

The Japanese Society of Thyroid Surgery Classification [10] is similar to the American system in that the upper mediastinum is excluded. However, the central compartment is comprised of nodal groups I–IV (prelaryngeal, pretracheal, paratracheal and paraglandular groups, respectively) and lateral groups V–VII. The International Union Against Cancer (UICC) describes eight regions, with the central comprising groups 1, 2 and 8 and the lateral 3–7 [11]. Dralle et al. described the

Compartment Classification system for use in medullary thyroid cancer [12] but which can be adapted to PTC. They described four lymph node regions, and theirs is the only classification that includes the superior mediastinal compartment as part of its descriptive system (1a right central, 1b left central, 2 right lateral, 3 left lateral, 4a right upper mediastinum and 4b left upper mediastinum).

Each of these classification systems has its respective advantages and limitations and sadly they are largely reciprocally incompatible. Whilst not necessarily the best classification system specific for thyroid cancer, the American Academy of Otolaryngology system is the most prevalent in the English-speaking world and Europe. It is used in the American Thyroid Association (ATA), European Thyroid societies and the British Association of Endocrine and Thyroid Surgeons. It is also the system used in the authors' institution and will be referenced to in the rest of this chapter. In this classification system particular note should be made of levels VI and VII, which are the areas first involved by metastatic lymph nodes in PTC.

### 8.2.2 Operative Terminology

Cervical lymphadenectomy is the process of removal of the lymph nodes within a designated nodal compartment of the neck. In PTC, level I is almost never involved, so the neck dissection when indicated includes the central (level VI & VII) and lateral (levels II–V) compartments. Selective neck dissection – where lymph node compartments are removed and the key structures preserved if not involved – is the most common oncological strategy. This differs from head and neck malignancy where level I is included in the dissection. Radical neck dissection with additional sacrifice of the sternocleidomastoid and the accessory nerve are infrequently required in PTC but the sacrifice of the internal jugular vein and vagus nerve may occur especially when high volume level IV disease with extracapsular spread encases the carotid sheath [14].

If the patient is fit for surgery and lymph node metastases are detected either pre- or intraoperatively, a therapeutic lymphadenectomy is the uncontroversial recommendation. The surgical removal of macroscopic lymph node metastases is fundamental for PTC disease control and reduces local recurrence [15]. Equally uncontroversial is the abandonment of “berry picking”, where individual suspicious lymph nodes only are removed rather than a formal compartmental dissection. The berry picking approach is associated with a high local recurrence [14, 16] and the need for intervention in a re-operative field with higher associated operative risk [14].

A prophylactic (or “elective”) nodal dissection implies routine clearance of nodal tissue in a patient who has no clinical or radiological evidence of nodal involvement (cNO) [13]. This has been an area of controversy for several decades and the debate remains in part unresolved, although guidelines in the US and Europe have moved away from this except possibly in high-risk disease where it can be considered (Table 8.1) [6, 7, 17–19]. The technical principles of lymphadenectomy are beyond the scope of this chapter and are found in surgical technique textbooks.

**Table 8.1** International guidelines in regard to pCND

Guideline	Recommendation
American Thyroid Association 2015 [6]	Considered in cN0 PTC patients with T3/4 tumors, cN1b disease, or if the information will be used to plan further therapy
National Comprehensive Cancer Network 2022 [7]	Not recommended in cN0 patients with PTC
British Thyroid Association 2014 [17]	Not recommended in the absence of high-risk features. Bilateral pCND is recommended if high-risk features are present – Personalized decision-making recommended
European Thyroid Association 2019 [18]	For T3/4 tumors, pCND may improve regional control
Japanese Association of Endocrine Surgeons 2020 [19]	Routinely recommended in PTC

*pCND* prophylactic central node dissection, *PTC* papillary thyroid cancer

## 8.3 Controversies in the Management of Nodal Disease in Papillary Thyroid Cancer

### 8.3.1 Difficulties in Preoperative Diagnosis of Nodal Metastases in the Central Neck

Nodal clearance in PTC is performed with the aim of reducing LRR and disease-specific mortality. Staging of the lateral neck with high resolution ultrasound (US) or computed tomography (CT) is very effective at identifying nodal pathology and this can be biopsied for confirmation [15, 20]. There is no indication for prophylactic lateral nodal dissection; however, it may still be adopted in some countries [19] based on the unproven rationale that the non-use of radioiodine (RAI) mandates more aggressive surgery.

The preoperative staging of the central neck for nodal metastases is hindered by the presence of the thyroid and trachea that may obscure the view of level VI and the sternum and clavicles that obscure level VII. The sensitivity of US in identifying pathological lymph nodes in the central neck ranges from 23–55%, whereas the detection rate of US in the lateral neck is 94% [20, 21]. The sensitivity of CT in the central neck is 41–62% [20–22], but it has limited value in detecting small lymph node metastases and the use of iodine contrast may delay the use of RAI postoperatively. Normally the decision on therapeutic nodal clearance of the central compartment is made either if there is nodal disease on staging or intraoperatively, based on the presence of nodal pathology. Clinical features of metastatic lymph nodes include size >1 cm, dark discoloration and firmness on palpation. Intraoperative clinical judgement can be challenging and there is a notoriously low sensitivity and specificity (35.7% and 72.5%, respectively) and high rates of false positives and false negatives in the intraoperative diagnosis of central lymph node metastases [22].

The arrival of data suggesting that prophylactic central node dissection (pCND) can reduce the level of postoperative thyroglobulin [23–25] (a surrogate marker of disease burden), the need for RAI or the total RAI dosage as well as reducing the

rate of LRR started a move towards prophylactic level VI surgery at the beginning of the new millennium. Advocates of pCND promoted the view that prophylactic dissection should be performed on all PTC patients due to the high rates of occult lymph node metastases and their presumed consequence, namely the need for re-operation in the central neck.

### 8.3.2 Effect of pCND on Recurrence

Macrometastatic nodal disease in the central neck has been shown to represent an independent risk factor for recurrence [5, 26, 27] and reduced long-term survival [28–30]. Occult lymph node metastases are identified in up to 85% of patients after pCND [3]. The adoption of pCND in all PTC patients would theoretically ensure removal of all subclinical lymph node metastases in the central neck and offer better disease control. Barczyński et al. demonstrated a significant reduction in both LRR and disease specific survival after bilateral pCND in their study [8]. The 10-year LRR rate was 12.4% after total thyroidectomy alone and 5.5% after total thyroidectomy with pCND ( $p = 0.003$ ). The 10-year disease-specific survival rate was 98% after pCND, 5.5% higher than total thyroidectomy alone ( $p = 0.03$ ). Popadich et al. also found a reduction in central compartment recurrence after total thyroidectomy with pCND (4.6% less than total thyroidectomy alone,  $p = 0.004$ ) [25]. However, both of these were retrospective cohort studies with high rates of adjuvant RAI so the effect of pCND on outcome is difficult to measure with confidence. Two subsequent, large systematic reviews and meta-analyses also concluded that rates of central compartment recurrences were lower after pCND, but the reductions were of modest magnitude (1.76–2.3%) [31, 32].

The natural evolution of micrometastases is still not well understood and the data surrounding genuine clinical benefit is controversial [4, 15]. It is possible that the benefit of pCND will never be established because prospective studies are invariably underpowered. The ATA feasibility calculation for a randomized control trial of pCND in cN0 PTC estimated that 5840 patients would be needed for sufficient statistical power to detect differences in outcomes [33]. Despite this, five prospective randomized control trials have been identified [34–38] and none demonstrated a difference in recurrence with or without pCND after an average follow-up of 5 years. A systematic review and meta-analysis of these five studies yielded 763 patients [39] and no difference was found in structural or biochemical recurrence. The estimated number needed to treat per recurrence was 500. Nixon et al. performed a large retrospective analysis of 1798 cN0 patients who had total thyroidectomy without CND [40]. One-third ( $n = 539$ , 30%) had T3 or T4 tumors and 13.5% ( $n = 240$ ) had pN1a disease despite no formal level VI dissection being performed. Almost half (41.3%) of patients received RAI. The 5-year recurrence-free survival was 96.6%, and disease-specific mortality was 0. Only 12 patients had central neck recurrence (<1%) and all of these were salvaged successfully with re-operative surgery. This study had a relatively short median follow-up of 46 months but nevertheless suggests that prophylactic dissection offers limited benefit.



### 8.3.3 Effect of pCND on Staging and Radioiodine Use

Routine central nodal dissection on all PTC patients adds staging information over thyroidectomy alone. Patients who have intermediate risk tumors may have tailored RAI administration or more accurate dose calculations based on their nodal status after pCND [4]. However, upstaged patients, due to the presence of occult lymph nodes, may receive arguably unnecessary RAI as a result of this. This effect was demonstrated by both Bonnet et al. and Hughes et al., who found that performing pCND resulted in RAI being administered in 58% and 29% of patients, respectively, who otherwise would not have been given treatment [41, 42]. The argument that pCND in intermediate risk PTC patients allows the identification of pN0 patients – who can safely avoid RAI and possibly decrease the duration and intensity of surveillance [43] – is probably unjustified with current sensitive thyroglobulin assays.

The overtreatment with RAI due to the frequency of micrometastases in cN0 patients and the uncertain relationship between micrometastases and recurrence [15] is increasingly important as the value of RAI in lower risk disease appears to be highly questionable. The Hi-Lo trial was a randomized non-inferiority trial comparing low (1.1 GBq) vs high dose (3.5 GBq) as the initial dose of RAI in PTC [44]. They found that recurrence was not higher after low-dose RAI after a mean follow-up of 6.5 years; however, the study was not powered to assess long-term recurrence and there was a need for repeat RAI treatments in 10% of the low-dose group. Another randomized trial, the Iodine or Not (IoN) trial, aims to determine whether or not RAI is necessary for low-risk patients with differentiated thyroid cancer, but the results are not expected until 2031. It must also be noted that the importance of nodal disease in staging has been revisited and positive nodal status no longer upstages thyroid cancer in patients older than 55 years (AJCC Staging, 8th ed.) [45].

If pCND was without morbidity, it could be advocated even in the presence of a small benefit. However, any benefit of pCND has to be counterbalanced against the well-established morbidity of the procedure, in particular the hypoparathyroidism, which is much more common in patients that have a nodal dissection added to a total thyroidectomy.

### 8.3.4 Increased Rates of Operative Complications

Central node clearance requires more extensive dissection than thyroidectomy alone, particularly around the RLN and parathyroid glands. The higher rates of RLN palsy and postoperative hypoparathyroidism are thought to be due to more extensive manipulation and devascularization of these structures [4]. Considering that the benefit provided by performing pCND is contentious, it is vital to know whether performing pCND confers additional morbidity.

Volume-outcome is a robust tenant of endocrine surgery, with clear correlation between high surgeon volume and decreased morbidity [2]. A recent randomized control trial by Sippel et al. evaluated the complications after total thyroidectomy

alone and with pCND as the primary outcome [35]. They demonstrated that, in experienced hands, there was no difference between groups in regard to temporary or permanent hypoparathyroidism or vocal cord palsy. However, their rates of hypoparathyroidism and RLN injury were somewhat higher than those generally published by expert endocrine surgeons. This may be a result of a strict follow-up regimen and under-reporting in other series.

There is, nevertheless, a vast body of evidence suggesting an increased morbidity associated with total thyroidectomy and pCND (Table 8.2). This difference reaches statistical significance most commonly in transient hypoparathyroidism [8, 24, 32, 35, 46, 47], though many studies demonstrate that this difference persists in the long-term also [26, 32, 34, 46]. However, the data is again heterogenous as many studies did not differentiate between unilateral and bilateral pCND, and the practice of parathyroid reimplantation varies. Higher rates of hypoparathyroidism are seen more commonly after bilateral level VI dissection than in unilateral [48]. Some studies demonstrated significantly higher rates of temporary RLN palsy after pCND [25, 46, 47], but this is less common, particularly in high volume centers.

**Table 8.2** Complications after thyroidectomy with and without pCND

Complication		Thyroidectomy		P-value	Study	Design	Laterality of pCND
		alone (%)	+ pCND (%)				
Hypoparathyroidism	Temporary	16.3	32.2	<0.001	Kim [46]	RCS	NS
		17.5	28.7	<0.001	Zhao [32]	MA	Mixed
		4.1	9.7	0.026	Popadich [25]	RCS	Mixed
		8.7	18.3	0.017	Lang [24]	RCS	Unilateral
		14.8	25.8	<0.001	Chen [47]	MA	Mixed
		13.1	30.4	<0.001	Barczyński [8]	RCS	Bilateral
	Permanent	8.0	19.4	0.02	Viola [34]	RCT	Bilateral
		1.6	3.6	0.004	Kim	RCS	NS
		2.3	4.1	0.03	Zhao	MA	Mixed
		0.45	0.8	0.99	Popadich	RCS	Mixed
		1.0	2.4	1.0	Lang	RCS	Unilateral
		1.95	4.1	<0.001	Chen	MA	Mixed
		0.7	2.2	0.12	Barczyński	RCS	Bilateral
Recurrent laryngeal nerve injury	Temporary	2.6	5.9	0.04	Kim	RCS	NS
		2.3	0.4	0.05	Popadich	RCS	Mixed
		0	1.8	0.32	Lang	RCS	Unilateral
		1.99	3.5	0.006	Chen	MA	Mixed
		3.2	3.6	0.67	Barczyński	RCS	Bilateral
	Permanent	4.3	8.0	0.3	Viola	RCT	Bilateral
		0	0.2	1.0	Kim	RCS	NS
		1.8	0.4	0.12	Popadich	RCS	Mixed
		0.5	0.6	0.44	Lang	RCS	Unilateral
		0.75	0.9	0.34	Chen	MA	Mixed
		1.1	1.3	0.75	Barczyński	RCS	Bilateral

pCND prophylactic central node dissection, MA meta-analysis, NS not stated, RCS retrospective cohort study, RCT randomized control trial

---

## 8.4 Salvage Treatment for Central Node Recurrence

A key indication for pCND is the avoidance of reoperation in the central compartment, which is associated with greater morbidity than primary surgery [23]. However, there is increasing data to show that reoperation in the central neck is both effective and has comparable morbidity in expert hands [49, 50]. Ethanol and radio-frequency ablation of local recurrence are also emerging as non-operative treatments for nodal recurrence. While surgery remains the first-line treatment for recurrent PTC, these procedures can be performed under local anesthetic with minimal morbidity, particularly in patients with single detected lymph node metastases or who are not candidates for reoperation [51].

---

## 8.5 Conclusion

Nodal dissection of the lateral and central compartments in the presence of radiological or clinical metastases is universally accepted. The routine pCND in PTC remains controversial due to a debatable risk-benefit ratio. The largely favorable outcomes of most PTC render an adequately powered randomized controlled trial prohibitive in terms of resources and cost. The available evidence trends toward lower LRR in patients who have had total thyroidectomy in combination with pCND, although the risk of morbidity (particularly hypoparathyroidism) is significantly higher. Whether or not to perform CND rests on an individual patient risk-benefit assessment; however, based on the current literature, pCND in all patients cannot be recommended.

---

## References

1. Miranda-Filho A, Lortet-Tieulent J, Bray F, et al. Thyroid cancer incidence trends by histology in 25 countries: a population-based study. *Lancet Diabetes Endocrinol.* 2021;9(4):225–34.
2. Wang TS, Sosa JA. Thyroid surgery for differentiated thyroid cancer – recent advances and future directions. *Nat Rev Endocrinol.* 2018;14(11):670–83.
3. Hughes DT, Rosen JE, Evans DB, et al. Prophylactic central compartment neck dissection in papillary thyroid cancer and effect on locoregional recurrence. *Ann Surg Oncol.* 2018;25(9):2526–34.
4. Glover AR, Gundara JS, Norlen O, et al. The pros and cons of prophylactic central neck dissection in papillary thyroid carcinoma. *Gland Surg.* 2013;2(4):196–205.
5. Pereira JA, Jimeno J, Miquel J, et al. Nodal yield, morbidity, and recurrence after central neck dissection for papillary thyroid carcinoma. *Surgery.* 2005;138(6):1095–100.
6. Haugen BR, Alexander EK, Bible KC, et al. 2015 American Thyroid Association management guidelines for adult patients with thyroid nodules and differentiated thyroid cancer: the American Thyroid Association guidelines task force on thyroid nodules and differentiated thyroid cancer. *Thyroid.* 2016;26(1):1–133.
7. Haddad RI, Bischoff L, Ball D, et al. Thyroid carcinoma, version 2.2022, NCCN clinical practice guidelines in oncology. *J Natl Compr Cancer Netw.* 2022;20(8):925–51.
8. Barczyński M, Konturek A, Stopa M, Nowak W. Prophylactic central neck dissection for papillary thyroid cancer. *Br J Surg.* 2013;100(3):410–8.

9. Robbins KT, Medina JE, Wolfe GT, et al. Standardizing neck dissection terminology. Official report of the Academy's Committee for Head and Neck Surgery and oncology. *Arch Otolaryngol Head Neck Surg.* 1991;117(6):601–5.
10. The Japanese Society of Thyroid Surgery. General rules for the description of thyroid cancer. 5th ed. Tokyo: Kanehara; 1996.
11. Wittekind C, Greene FL, Henson DE, et al. *TNM Supplement.* 3rd ed. New York: Wiley-Liss; 2003. p. 25–30.
12. Dralle H, Becker S, Scheumann GFW. Präoperative Diagnostik, Indikation und Technik transsternaler Eingriffe bei benignen und malignen Struma. *Schilddrüse* 1989. 9. Konferenz u ber die menschliche Schilddrüse. Homburg/Saar. Borner W (Hrsg.) Walter de Gruyter Berlin. New York; 1991.
13. American Thyroid Association Surgery Working Group, American Association, of Endocrine Surgeons, American Academy of Otolaryngology-Head and Neck Surgery, et al. Consensus statement on the terminology and classification of central neck dissection for thyroid cancer. *Thyroid.* 2009;19(11):1153–8.
14. Uchino S, Noguchi S, Yamashita H, Watanabe S. Modified radical neck dissection for differentiated thyroid cancer: operative technique. *World J Surg.* 2004;28(12):1199–203.
15. Randolph GW, Duh QY, Heller KS, et al. The prognostic significance of nodal metastases from papillary thyroid carcinoma can be stratified based on the size and number of metastatic lymph nodes, as well as the presence of extranodal extension. *Thyroid.* 2012;22(11):1144–52.
16. Palazzo FF, Gosnell J, Savio R, et al. Lymphadenectomy for papillary thyroid cancer: changes in practice over four decades. *Eur J Surg Oncol.* 2006;32(3):340–4.
17. Perros P, Boelaert K, Colley S, et al. Guidelines for the management of thyroid cancer. *Clin Endocrinol.* 2014;81(Suppl 1):1–122.
18. Filetti S, Durante C, Hartl D, et al. Thyroid cancer: ESMO clinical practice guidelines for diagnosis, treatment and follow-up. *Ann Oncol.* 2019;30(12):1856–83.
19. Ito Y, Onoda N, Okamoto T. The revised clinical practice guidelines on the management of thyroid tumors by the Japan associations of endocrine surgeons: Core questions and recommendations for treatments of thyroid cancer. *Endocr J.* 2020;67(7):669–717.
20. Ahn JE, Lee JH, Yi JS, et al. Diagnostic accuracy of CT and ultrasonography for evaluating metastatic cervical lymph nodes in patients with thyroid cancer. *World J Surg.* 2008;32(7):1552–8.
21. Kim E, Park JS, Son KR, et al. Preoperative diagnosis of cervical metastatic lymph nodes in papillary thyroid carcinoma: comparison of ultrasound, computed tomography, and combined ultrasound with computed tomography. *Thyroid.* 2008;18:411–8.
22. Ji YB, Lee DW, Song CM, et al. Accuracy of intraoperative determination of central node metastasis by the surgeon in papillary thyroid carcinoma. *Otolaryngol Head Neck Surg.* 2014;150(4):542–7.
23. Sywak M, Cornford L, Roach P, et al. Routine ipsilateral level VI lymphadenectomy reduces postoperative thyroglobulin levels in papillary thyroid cancer. *Surgery.* 2006;140(6):1000–7.
24. Lang BH, Wong KP, Wan KY, Lo CY. Impact of routine unilateral central neck dissection on preablative and postablative stimulated thyroglobulin levels after total thyroidectomy in papillary thyroid carcinoma. *Ann Surg Oncol.* 2012;19(1):60–7.
25. Popadich A, Levin O, Lee JC, et al. A multicenter cohort study of total thyroidectomy and routine central lymph node dissection for cN0 papillary thyroid cancer. *Surgery.* 2011;150(6):1048–57.
26. Ito Y, Kudo T, Kobayashi K, et al. Prognostic factors for recurrence of papillary thyroid carcinoma in the lymph nodes, lung, and bone: analysis of 5,768 patients with average 10-year follow-up. *World J Surg.* 2012;36:1274–8.
27. White ML, Gauger PG, Doherty GM. Central lymph node dissection in differentiated thyroid cancer. *World J Surg.* 2007;31(5):895–904.
28. Podnos YD, Smith D, Wagman LD, Ellenhorn JD. The implication of lymph node metastasis on survival in patients with well-differentiated thyroid cancer. *Am Surg.* 2005;71(9):731–4.

29. Adam MA, Pura J, Goffredo P, et al. Presence and number of lymph node metastases are associated with compromised survival for patients younger than age 45 years with papillary thyroid cancer. *J Clin Oncol.* 2015;33(21):2370–5.
30. Tisell LE, Nilsson B, Mölne J, et al. Improved survival of patients with papillary thyroid cancer after surgical microdissection. *World J Surg.* 1996;20(7):854–9.
31. Liu H, Li Y, Mao Y. Local lymph node recurrence after central neck dissection in papillary thyroid cancers: a meta analysis. *Eur Ann Otorhinolaryngol Head Neck Dis.* 2019;136(6):481–7.
32. Zhao W, You L, Hou X, et al. The effect of prophylactic central neck dissection on locoregional recurrence in papillary thyroid cancer after total thyroidectomy: a systematic review and meta-analysis: pCND for the locoregional recurrence of papillary thyroid cancer. *Ann Surg Oncol.* 2017;24(8):2189–98.
33. Carling T, Carty SE, Ciarleglio MM, et al. American Thyroid Association design and feasibility of a prospective randomized controlled trial of prophylactic central lymph node dissection for papillary thyroid carcinoma. *Thyroid.* 2012;22(3):237–44.
34. Viola D, Materazzi G, Valerio L, et al. Prophylactic central compartment lymph node dissection in papillary thyroid carcinoma: clinical implications derived from the first prospective randomized controlled single institution study. *J Clin Endocrinol Metab.* 2015;100(4):1316–24.
35. Sippel RS, Robbins SE, Poehls JL, et al. A randomized controlled clinical trial: no clear benefit to prophylactic central neck dissection in patients with clinically node negative papillary thyroid cancer. *Ann Surg.* 2020;272(3):496–503.
36. Ahn JH, Kwak JH, Yoon SG, et al. A prospective randomized controlled trial to assess the efficacy and safety of prophylactic central compartment lymph node dissection in papillary thyroid carcinoma. *Surgery.* 2022;171(1):182–9.
37. Kim BY, Choi N, Kim SW, et al. Randomized trial of prophylactic ipsilateral central lymph node dissection in patients with clinically node negative papillary thyroid microcarcinoma. *Eur Arch Otorhinolaryngol.* 2020;277(2):569–76.
38. Lee DY, Oh KH, Cho JG, et al. The benefits and risks of prophylactic central neck dissection for papillary thyroid carcinoma: prospective cohort study. *Int J Endocrinol.* 2015;2015:571480.
39. Sanabria A, Betancourt-Agüero C, Sánchez-Delgado JG, García-Lozano C. Prophylactic central neck lymph node dissection in low-risk thyroid carcinoma patients does not decrease the incidence of locoregional recurrence: a meta-analysis of randomized trials. *Ann Surg.* 2022;276(1):66–73.
40. Nixon IJ, Wang LY, Ganly I, et al. Outcomes for patients with papillary thyroid cancer who do not undergo prophylactic central neck dissection. *Br J Surg.* 2016;103(3):218–25.
41. Bonnet S, Hartl D, Leboulleux S, et al. Prophylactic lymph node dissection for papillary thyroid cancer less 2 cm: implications for radioiodine treatment. *J Clin Endocrinol Metab.* 2009;94:1162–7.
42. Hughes DT, White ML, Miller BS, et al. Influence of prophylactic central lymph node dissection on postoperative thyroglobulin levels and radioiodine treatment in papillary thyroid cancer. *Surgery.* 2010;148(6):1100–7.
43. Mazzaferri EL, Doherty GM, Steward DL. The pros and cons of prophylactic central compartment lymph node dissection for papillary thyroid carcinoma. *Thyroid.* 2009;19(7):683–9.
44. Dehbi HM, Mallick U, Wadsley J, et al. Recurrence after low-dose radioiodine ablation and recombinant human thyroid-stimulating hormone for differentiated thyroid cancer (HiLo): long-term results of an open-label, non-inferiority randomised controlled trial. *Lancet Diabetes Endocrinol.* 2019;7(1):44–51.
45. Tuttle M, Morris LF, Haugen B, et al. Thyroid-differentiated and anaplastic carcinoma (Chapter 73). In: Amin MB, Edge SB, Greene F, et al., editors. *AJCC cancer staging manual.* 8th ed. New York City: Springer International Publishing; 2017.
46. Kim SK, Woo JW, Lee JH, et al. Prophylactic central neck dissection might not be necessary in papillary thyroid carcinoma: analysis of 11,569 cases from a single institution. *J Am Coll Surg.* 2016;222(5):853–64.

47. Chen L, Wu YH, Lee CH, et al. Prophylactic central neck dissection for papillary thyroid carcinoma with clinically uninvolved central neck lymph nodes: a systematic review and meta-analysis. *World J Surg.* 2018;42(9):2846–57.
48. Yan S, Yu J, Zhao W, et al. Prophylactic bilateral central neck dissection should be evaluated based on prospective randomized study of 581 PTC patients. *BMC Endocr Disord.* 2022;22(1):5.
49. Lang BH, Lee GC, Ng CP, et al. Evaluating the morbidity and efficacy of reoperative surgery in the central compartment for persistent/recurrent papillary thyroid carcinoma. *World J Surg.* 2013;37(12):2853–9.
50. Onuma AE, Beal EW, Nabhan F, et al. Long-term efficacy of lymph node reoperation for persistent papillary thyroid cancer: 13-year follow-up. *Ann Surg Oncol.* 2019;26(6):1737–43.
51. Suh CH, Baek JH, Choi YJ, Lee JH. Efficacy and safety of radiofrequency and ethanol ablation for treating locally recurrent thyroid cancer: a systematic review and meta-analysis. *Thyroid.* 2016;26(3):420–8.

**Open Access** This chapter is licensed under the terms of the Creative Commons Attribution-NonCommercial-NoDerivatives 4.0 International License (<http://creativecommons.org/licenses/by-nc-nd/4.0/>), which permits any noncommercial use, sharing, distribution and reproduction in any medium or format, as long as you give appropriate credit to the original author(s) and the source, provide a link to the Creative Commons license and indicate if you modified the licensed material. You do not have permission under this license to share adapted material derived from this chapter or parts of it.

The images or other third party material in this chapter are included in the chapter's Creative Commons license, unless indicated otherwise in a credit line to the material. If material is not included in the chapter's Creative Commons license and your intended use is not permitted by statutory regulation or exceeds the permitted use, you will need to obtain permission directly from the copyright holder.





# Robot-Assisted Transaxillary Thyroidectomy

9

Gabriele Materazzi and Leonardo Rossi

## 9.1 Introduction

Thyroid surgery is one of the most common surgical procedures performed worldwide, and its frequency is reported to be growing exponentially as a result of an increasing use of neck ultrasonography and fine-needle aspiration biopsy (FNAB) associated with other environmental factors.

The conventional open approach for thyroidectomy was initially proposed by Theodore Kocher in the late 1800s and it has essentially remained unchanged until now. Open thyroidectomy has been the standard approach for more than a century due to its excellent surgical efficacy and low morbidity and mortality. However, the anterior neck scar is undesirable, in particular for young women or patients with a history of keloid who are very sensitive to cosmesis [1].

This cosmetic issue led to the development in the last decade of a large number of different remote-access approaches for removing the thyroid gland. Several routes have been proposed over the years including infraclavicular, axillary, postauricular, and bilateral axilla-breast approaches.

These techniques were introduced to offer patients a better cosmetic option and often reflected the different habits and expectations of patients from different geographic regions and cultures. Although initially met with skepticism due to technical challenges, concerns about oncological safety and cost and the introduction of new complications, some remote-access techniques have become increasingly popular among the community of endocrine surgeons [1].

---

G. Materazzi (✉) · L. Rossi

Department of Endocrine Surgery, University Hospital of Pisa, Pisa, Italy

e-mail: [gmaterazzi@yahoo.com](mailto:gmaterazzi@yahoo.com); [rossi.leonardo.phd@gmail.com](mailto:rossi.leonardo.phd@gmail.com)

© The Author(s) 2024

M. Testini, A. Gurrado (eds.), *Thyroid Surgery*, Updates in Surgery, [https://doi.org/10.1007/978-3-031-31146-8\\_9](https://doi.org/10.1007/978-3-031-31146-8_9)

83

### 9.1.1 Background

Gasless transaxillary endoscopic thyroidectomy was first proposed in November 2001 in South Korea at the Yonsei University College of Medicine, Seoul, to satisfy the desire to avoid a neck scar [2]. However, endoscopic thyroidectomy showed several drawbacks, such as a two-dimensional view, difficulty in instrument handling, restricted vision, and fulcrum effect. The introduction of surgical robots was thought to overcome the limitations of endoscopic surgery and provide technical improvements: the magnified vision, the three-dimensional view, the tremor filtering system, and the endo-wrist technology along with the multi-articulations of the arms (7 degrees of freedom) allow a finer dissection and decrease interference between the robotic arms and the camera [3].

Robot-assisted transaxillary thyroidectomy (RATT), popularized by Chung et al. who published their experience with thousands of cases in 2018, became widely used in countries in the Far East, although its success in Europe and the United States came more slowly [4]. The negative connotation of a horizontal neck scar, which is thought to denote death in Asian culture, may have played a role in the rapid spread of this technique. Differences in body mass index (BMI), anthropometric characteristics, and greater size of goiters and cancers, combined with the elevated costs of the procedure and the need for training, have hindered the diffusion of this approach in the United States and Europe. To date, although RATT has shown promising results in feasibility, safety, and patient satisfaction, in the Western world it plays only a niche role in treating selected patients with appropriate pathology in high-volume centers [5].

### 9.1.2 Indications and Contraindications

The indications for RATT vary among the centers, but nowadays substantially both benign disease and well-differentiated low-risk thyroid carcinomas can be approached with this technique. Besides the characteristics of the thyroid, the patient's body habitus must also be assessed preoperatively as it can influence the decision to proceed with a robotic approach. Moreover, since proper positioning is an essential part of the procedure, certain conditions that may limit neck or arm mobility should also be considered preoperatively.

The guidelines recommended to restrict RATT to patients affected by well-circumscribed nodule <3 cm and with thyroid lobe <5–6 cm in the largest dimension [6]. Moreover, previous neck or breast surgery are usually considered contraindications, as are neck radiotherapy, pacemaker implant, shoulder arthrosis, previous shoulder surgery and substernal extension. Severe thyroiditis and Graves' disease may represent relative contraindications, especially at the beginning of the learning curve. With increasing experience, however, the indications have been progressively expanded and some institutions have performed RATT even in more advanced cases [4]. It is important to keep in mind that the best candidates for surgeons at the beginning of their robotic experience are young female patients with



small thyroid glands without thyroiditis, small body habitus (BMI <30), long neck, and scheduled for thyroid lobectomy.

### 9.1.3 Instruments

For the console time of the procedure, the da Vinci S, Si, or Xi system (Intuitive Surgical Inc., Sunnyvale, CA, USA) can be used along with a 30° endoscope, a 5-mm Maryland dissector (Intuitive Surgical Inc., Sunnyvale, CA, USA) and a 5-mm harmonic curved shear (Intuitive Surgical Inc., Sunnyvale, CA, USA). Three trocars can be inserted through the single axillary incision: two 5-mm trocars and one 12-mm trocar. During the procedure a 5-mm laparoscopic suction and irrigation device can be used by the first assistant to retract structures such as the sternocleidomastoid muscle (SCM) or the trachea [7]. Some institutions use an additional robotic arm with an 8-mm ProGrasp forceps (Intuitive Surgical Inc., Sunnyvale, CA, USA).

---

## 9.2 Surgical Procedure

### 9.2.1 Patient Position

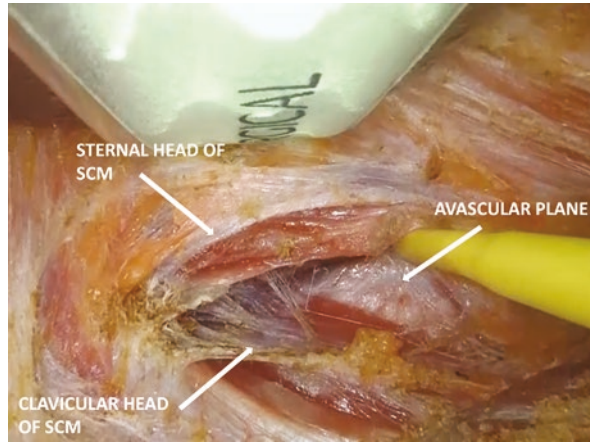
The axillary access is chosen according to the side of the thyroid lobe to be removed in the case of lobectomy, or to the side of the largest nodule in the case of a total thyroidectomy. The procedure is performed under general endotracheal anesthesia. The patient is placed supine with the neck slightly extended. The arm on the side of the access is extended cephalad and flexed at the elbow, and the wrist is positioned over the forehead, in the modified Ikeda arm position [8]. The arm is then padded and fixed to a frame. The position of the arm is checked before the incision in order to avoid any extreme position that may lead to a brachial plexus injury. The venous access is positioned in the contralateral arm, which is placed along the body.

### 9.2.2 The Remote Access: From the Axilla to the Thyroid

A 5–6 cm incision is performed along the posterior border of the anterior axillary pillar; it will remain completely hidden in the axillary fold. Mirroring Korean surgeons, at our institutions we create the working space under direct vision; however, other surgical teams do this by means of laparoscopic instruments under endoscopic vision with a 30° camera [9].

Dissection of the subcutaneous flap is performed by using a monopolar scalpel. The surgical space is maintained using a lighted retractor which elevates a subcutaneous flap above the pectoralis major muscle fascia, whose position is changed and adapted during the dissection. Subplatysmal dissection is performed after crossing the clavicle until the sternal and clavicular heads of the SCM are visualized. The

**Fig. 9.1** Opening the avascular plane between the two heads of the sternocleidomastoid muscle (SCM)



dissection proceeds through the avascular plane between the two SCM heads (Fig. 9.1). Care must be paid to avoid skin burns and injury to major vessels. The strap muscles are identified and gently dissected, and the thyroid lobe is exposed. If a total thyroidectomy has been scheduled, the dissection proceeds beyond the midline on the contralateral strap muscles. Once the access is completed, a specific self-retaining robotic-thyroidectomy retractor is placed in order to maintain the surgical space during the console time [7]. It is mounted at the contralateral side of the bed and placed below the sternal bound of the SCM and strap muscles, crossing the midline, in order to maintain the working space. This retractor is connected to a suction tube to aspirate the smoke from the sealing devices used during the console time [10].

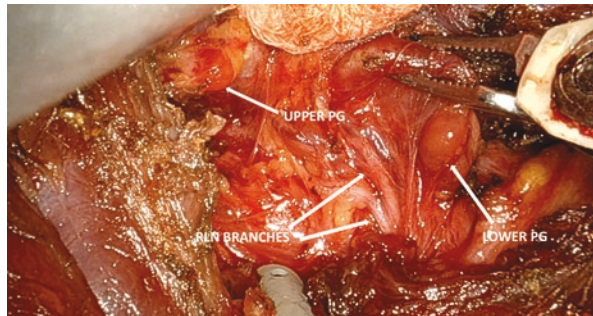
### 9.2.3 Docking Time

The robot is docked from the contralateral side of the table. We perform RATT by means of two instruments, the Maryland dissector and the harmonic shear, and a 30° robotic camera. We keep the fourth robotic arm folded, as this technique reduces the length of the incision and the encumbrance of the instruments; however, some institutions perform RATT by using an additional robotic arm with a ProGrasp forceps. The camera is inserted at the center of the incision in the upward direction. The Maryland dissector is placed at the caudal edge of the incision, and the harmonic shear at the cranial edge. The instruments should be as far apart as possible and inserted in the upward direction [10].

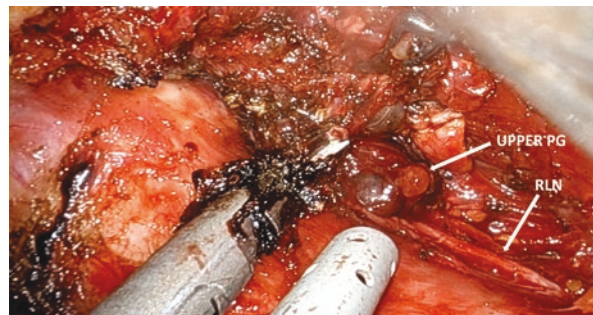### 9.2.4 Console Time: Thyroidectomy

Overall, RATT follows the same steps of open thyroidectomy. The upper pole of the thyroid is freed by pulling the lobe downward and medially with the Maryland dissector. The upper vessels are identified and dissected with the harmonic shear close to the thyroid lobe in order to avoid injury to the external branch of the superior laryngeal nerve. If the working space is narrow, the isthmus can be divided at this time. The recurrent laryngeal nerve (RLN) and the ipsilateral parathyroid glands are identified (Fig. 9.2). The inferior thyroid artery is divided with the harmonic shear (the first assistant may apply an endoscopic clip). The RLN is followed from bottom to top, up to its entrance in the larynx. The thyroid lobe is removed following the tracheal plane and extracted by means of an endobag to avoid potential seeding along the surgical track. When a total thyroidectomy is scheduled, the contralateral lobe is approached through the same surgical access. The lobe is freed from the strap muscles and the upper pedicle is dissected with the harmonic shear. Once the thyroid lobe has gained mobility, it is pulled upward with the Maryland dissector to visualize the noble structures. Identification of the contralateral RLN and parathyroid glands is more difficult than the ipsilateral side and requires experience. The first assistant uses a laparoscopic suction device to exert gentle traction on the trachea in order to expose the RLN, which is followed upward (Fig. 9.3). The lobe is removed and extracted by means of an endobag [7].

**Fig. 9.2** Identification of the ipsilateral recurrent laryngeal nerve (RLN) and parathyroid glands (PG)



**Fig. 9.3** Identification of the contralateral recurrent laryngeal nerve (RLN) and upper parathyroid gland (PG)



## 9.3 Controversies

### 9.3.1 Oncological Safety and Efficacy

When the selection criteria are accurately applied, RATT has proven safe for the treatment of differentiated thyroid carcinoma. Several systematic reviews and meta-analyses have reported comparable oncological efficacy between RATT and conventional thyroidectomy with virtually identical completeness and recurrence rate [11, 12].

Lee et al. assessed the safety of RATT in patients scheduled for total thyroidectomy with central neck dissection. The authors reported RATT as equivalent to the open approach in terms of number of retrieved lymph nodes, stimulated thyroglobulin levels acquired during whole-body scans and the ablation success rate. Moreover, the follow-up ultrasound examination documented no abnormal findings in either group [13]. The same group of authors evaluated the long-term follow-up of patients who underwent RATT: no statistically significant differences were documented compared to open thyroidectomy in terms of serum thyroglobulin and anti-thyroglobulin antibody levels, locoregional recurrence rate and disease-free survival [14].

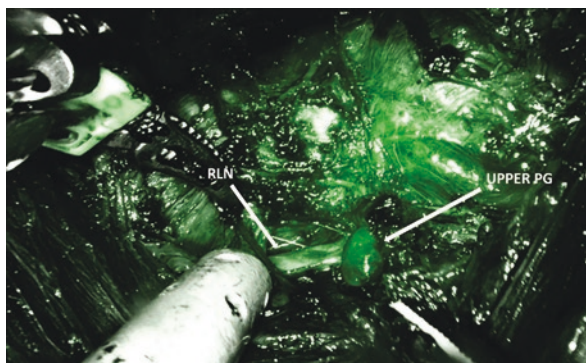
Lastly, with increasing experience, the indications gradually expanded. Recently, Kim et al. described their experience of RATT with lateral neck dissection in 500 patients [15]. They reported satisfactory results in both primary operation for thyroid cancer (476 patients) and lateral neck dissection for recurrence (24 patients). Clearly, lateral neck dissection must be performed in high-volume institutions with surgeons experienced in robotic and endocrine surgery.

### 9.3.2 Conventional and Unconventional Complications

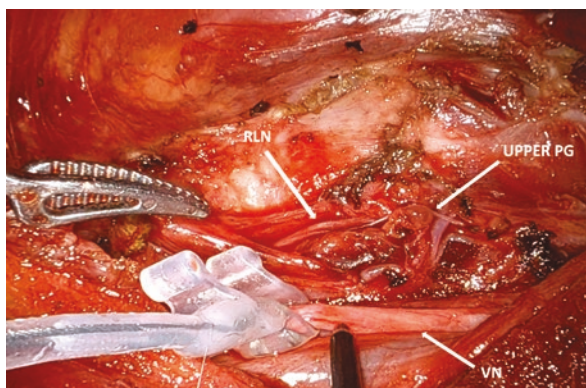
For the safe adoption of a novel technique, surgeons should ensure acceptable outcomes and minimize surgical complications. Several meta-analyses have reported a very similar rate of conventional complications (RLN palsy, postoperative hypocalcemia and bleeding) between robotic thyroidectomy and open thyroidectomy [12, 16]. The robotic platform provides optimal visualization of the RLN and parathyroid glands by means of a 3D magnified view and allows a gentle dissection thanks to the fine movements that potentially enable preservation of these noble structures.

Furthermore, the da Vinci robot system (Intuitive Surgical Inc., Sunnyvale, CA, USA) has recently been equipped with the Firefly system (Novadaq Technologies Inc., Mississauga, ON, CAN), which takes advantage of the indocyanine green (ICG) fluorescence of the parathyroid glands. This represents an emerging technique which helps surgeons to identify the parathyroid glands and to assess their blood supply at the end of the dissection (Fig. 9.4) [17]. Moreover, even during RATT it is possible to perform intraoperative nerve-monitoring, with both the intermittent or continuous setting, in order to evaluate RLN integrity (Fig. 9.5).

**Fig. 9.4** Identification of the upper parathyroid gland (*PG*) with indocyanine green fluorescence (*RLN*, recurrent laryngeal nerve)



**Fig. 9.5** Continuous intraoperative nerve monitoring during robot-assisted transaxillary thyroidectomy (*RLN* recurrent laryngeal nerve, *VN* vagus nerve, *PG* parathyroid gland)



Regarding hemostasis, the effectiveness of the harmonic shear helps in obtaining comparable results to open thyroidectomy. Moreover, the working space created during the access time allows the blood to drain into the vast subcutaneous pocket in the prepectoral region, reducing the risk of airway compression in the event of bleeding. Nonetheless, surgeons must pay attention to the active blade when using the ultrasonic shears because of the potential transfer of energy to the nearby *RLN*, parathyroid glands and trachea.

The introduction of unconventional complications, mainly related to the position of the patient on the operating bed and to the surgical access, initially hindered the spread of RATT in the Western world. These complications are mainly represented by brachial plexus palsy, surgical track seeding, seroma formation, great vessel injury and skin flap perforation. Brachial plexus injury is caused by extreme arm extension and usually occurs during the first 20 to 40 minutes of surgery [18]. To avoid this complication, caution has to be taken not to overextend the shoulder. Besides, nerve monitoring of the radial, median, and ulnar nerves using somatosensory evoked potential (Biotronic, Ann Arbor, MI) can be used to reduce the risk of stretching of any of these nerves [19]. Track seeding along the surgical access is another newly introduced complication, probably caused by cell exfoliation due to

the repeated trauma inflicted by the endoscopic instruments: the routine use of an endobag to retrieve resected specimens may reduce the incidence of this complication. Other access-related complications are skin flap perforation and seroma formation; some studies have also reported injury to the great vessels. However, these complications are very rare and may also occur during open thyroidectomy.

Overall, although RATT harbors the potential risk of new, technique-related complications, these are very rare and the approach can be considered safe in experienced hands. However, surgeons must keep in mind the possibility that these complications may indeed occur and know how to prevent them [18].

---

## 9.4 Conclusion

RATT is a feasible and safe approach in properly selected cases even when applied to Western world patients. It provides an excellent cosmetic result by avoiding a visible neck scar, and it is associated with reduced neck discomfort and higher ergonomics. The rate of conventional complications of RATT is comparable to that of the open approach, whereas procedure-related complications are very rare. RATT has been proven safe even for the treatment of thyroid cancer, with identical outcomes to open thyroidectomy. Moreover, some encouraging results of robotic lateral neck dissection are emerging. However, it is critical to stress that it is strongly recommended to perform this approach in high-volume institutions with surgeons experienced in robotic and endocrine surgery and to strictly adhere to the selection criteria.

---

## References

1. Rossi L, Materazzi G, Bakkar S, Miccoli P. Recent trends in surgical approach to thyroid cancer. *Front Endocrinol (Lausanne)*. 2021;12:699805.
2. Kang SW, Jeong JJ, Yun JS, et al. Gasless endoscopic thyroidectomy using trans-axillary approach; surgical outcome of 581 patients. *Endocr J*. 2009;56(3):361–9.
3. Moorthy K, Munz Y, Dosis A, et al. Dexterity enhancement with robotic surgery. *Surg Endosc*. 2004;18(5):790–5.
4. Kim MJ, Nam KH, Lee SG, et al. Yonsei experience of 5000 gasless transaxillary robotic thyroidectomies. *World J Surg*. 2018;42(2):393–401.
5. Aidan P, Arora A, Lorincz B, et al. Robotic thyroid surgery: current perspectives and future considerations. *ORL J Otorhinolaryngol Relat Spec*. 2018;80(3–4):186–94.
6. Berber E, Bernet V, Fahey TJ 3rd, et al. American Thyroid Association statement on remote-access thyroid surgery. *Thyroid*. 2016;26(3):331–7.
7. Fregoli L, Rossi L, Papini P, Materazzi G. Robotic transaxillary thyroidectomy: state of the art. *Gland Surg*. 2020;9(Suppl 1):S61–4.
8. Ikeda Y, Takami H, Niimi M, et al. Endoscopic thyroidectomy and parathyroidectomy by the axillary approach. A preliminary report. *Surg Endosc*. 2002;16(1):92–5.
9. Piccoli M, Mullineris B, Gozzo D, et al. Evolution strategies in transaxillary robotic thyroidectomy: considerations on the first 449 cases performed. *J Laparoendosc Adv Surg Tech A*. 2019;29(4):433–40.

10. Alzahrani HA, Mohsin K, Ali DB, et al. Gasless trans-axillary robotic thyroidectomy: the technique and evidence. *Gland Surg.* 2017;6(3):236–42.
11. Wang YC, Liu K, Xiong JJ, Zhu JQ. Robotic thyroidectomy versus conventional open thyroidectomy for differentiated thyroid cancer: meta-analysis. *J Laryngol Otol.* 2015;129(6):558–67.
12. Pan JH, Zhou H, Zhao XX, et al. Robotic thyroidectomy versus conventional open thyroidectomy for thyroid cancer: a systematic review and meta-analysis. *Surg Endosc.* 2017;31(10):3985–4001.
13. Lee S, Lee CR, Lee SC, et al. Surgical completeness of robotic thyroidectomy: a prospective comparison with conventional open thyroidectomy in papillary thyroid carcinoma patients. *Surg Endosc.* 2014;28(4):1068–75.
14. Lee SG, Lee J, Kim MJ, et al. Long-term oncologic outcome of robotic versus open total thyroidectomy in PTC: a case-matched retrospective study. *Surg Endosc.* 2016;30(8):3474–9.
15. Kim JK, Lee CR, Kang SW, et al. Robotic transaxillary lateral neck dissection for thyroid cancer: learning experience from 500 cases. *Surg Endosc.* 2022;36(4):2436–44.
16. Shen H, Shan C, Qiu M. Systematic review and meta-analysis of transaxillary robotic thyroidectomy versus open thyroidectomy. *Surg Laparosc Endosc Percutan Tech.* 2014;24(3):199–206.
17. Muraveika L, Kose E, Berber E. Near-infrared fluorescence in robotic thyroidectomy. *Gland Surg.* 2020;9(Suppl 2):S147–52.
18. Rossi L, Buoni V, Fregoli L, et al. Postsurgical complications after robot-assisted transaxillary thyroidectomy: critical analysis of a large cohort of European patients. *Updat Surg.* 2022;74(2):511–7.
19. Davis SF, Abdel Khalek M, Giles J, et al. Detection and prevention of impending brachial plexus injury secondary to arm positioning using ulnar nerve somatosensory evoked potentials during transaxillary approach for thyroid lobectomy. *Am J Electroneurodiagnostic Technol.* 2011;51(4):274–9.

**Open Access** This chapter is licensed under the terms of the Creative Commons Attribution-NonCommercial-NoDerivatives 4.0 International License (<http://creativecommons.org/licenses/by-nc-nd/4.0/>), which permits any noncommercial use, sharing, distribution and reproduction in any medium or format, as long as you give appropriate credit to the original author(s) and the source, provide a link to the Creative Commons license and indicate if you modified the licensed material. You do not have permission under this license to share adapted material derived from this chapter or parts of it.

The images or other third party material in this chapter are included in the chapter's Creative Commons license, unless indicated otherwise in a credit line to the material. If material is not included in the chapter's Creative Commons license and your intended use is not permitted by statutory regulation or exceeds the permitted use, you will need to obtain permission directly from the copyright holder.





# Robotic Bilateral Axillo-Breast Approach

# 10

Francesco Prete, Piercarmine Panzera,  
Giuseppe Massimiliano De Luca, Francesco Vittore,  
Carlotta Testini, Walter Lavermicocca, Angela Gurrado,  
and Mario Testini

## 10.1 Background

The bilateral axillo-breast approach (BABA) is currently one of the most popular endoscopic thyroidectomy techniques in the world [1]. Since the first endoscopic parathyroidectomy was reported in 1996 [2], the development of minimally invasive thyroidectomy has been fueled by the need to eliminate neck scars [3, 4]. Currently, there are two main models of endoscopic approach to thyroidectomy [2]. The first involves techniques that reduce the scar length, making it less obviously visible, and include the popular minimally invasive video-assisted thyroidectomy described by Miccoli, as well as approaches made through an endoscopic lateral incision, lateral mini-incision, or postauricular incision [2]. The second model is extracervical endoscopic thyroidectomy, developed for scarless neck surgery. This includes the transaxillary approach [5], the axillo-breast approach, the anterior chest/breast approach, the bilateral breast approach, and the transoral endoscopic approach. Conceived as a modification of the axillo-bilateral breast approach by Shimazu et al. [6], the BABA was developed in 2007 by Choe et al. [7]. The initial experiences with BABA endoscopic thyroidectomy (BABA-ET) recorded satisfactory cosmetic outcomes but were associated with many technical challenges and safety concerns: with the use of straight rigid instruments without articulations and a two-dimensional camera view within the limitations of a narrow working space, the operation proved

---

F. Prete (✉) · P. Panzera · G. M. De Luca · F. Vittore · W. Lavermicocca  
A. Gurrado · M. Testini  
Department of Precision and Regenerative Medicine and Ionian Area,  
University of Bari, Policlinic of Bari, Bari, Italy  
e-mail: [francesco.prete@uniba.it](mailto:francesco.prete@uniba.it); [piercarminepanzera@gmail.com](mailto:piercarminepanzera@gmail.com);  
[max-de-luca@libero.it](mailto:max-de-luca@libero.it); [f\\_vittore@yahoo.it](mailto:f_vittore@yahoo.it); [wlavermicocca@tiscali.it](mailto:wlavermicocca@tiscali.it);  
[angela.gurrado@uniba.it](mailto:angela.gurrado@uniba.it); [mario.testini@uniba.it](mailto:mario.testini@uniba.it)

C. Testini  
University of Florence School of Medicine, Florence, Italy  
e-mail: [carlotta.testini@stud.unifi.it](mailto:carlotta.testini@stud.unifi.it)



difficult to perform and the learning curve was longer than that of traditional surgical treatment [8]. Thus, BABA-ET could be applied to a small subset of patients only [3, 4]. With introduction of the da Vinci robotic system (Intuitive Surgical, Inc., Sunnyvale, CA, USA), hand tremor filtration, multi-articulated endo-wrist function, fine motion scaling, and three-dimensional magnification were used to overcome many technical disadvantages of BABA-ET, and the indications for BABA robotic thyroidectomy (BABA-RT) could be largely extended [9].

---

## 10.2 Indications and Patient Selection

A large body of evidence supports that BABA-RT can now be safely and effectively applied to the management of benign and malignant thyroid conditions [9–11].

BABA-RT currently has the following indications:

- low-risk differentiated thyroid carcinoma <4 cm in diameter
- minimal invasion of anterior thyroid capsule or strap muscle [11]
- benign thyroid nodule or follicular neoplasm <8 cm in diameter
- Graves' disease (recommended for <100 mL in volume),
- suspicious lateral neck metastasis limited to levels IIa, III, IV, and Vb (modified radical neck dissection can be safely accomplished by BABA-RT [11])

Absolute contraindications to BABA-RT include huge substernal goiter, thyroid malignancies that are likely to recur (e.g., medullary, undifferentiated, or poorly differentiated thyroid carcinoma), distant metastasis, extrathyroidal invasion to larynx, trachea, esophagus, or recurrent laryngeal nerve (RLN) and prior irradiation to the neck or breast.

Relative contraindications are:

- Large-sized thyroid nodules >8 cm in diameter
- Thyroid malignancy laid posteriorly around the ligament of Berry and the RLN (unpredictable risk of RLN involvement)
- Patient with breast malignancy

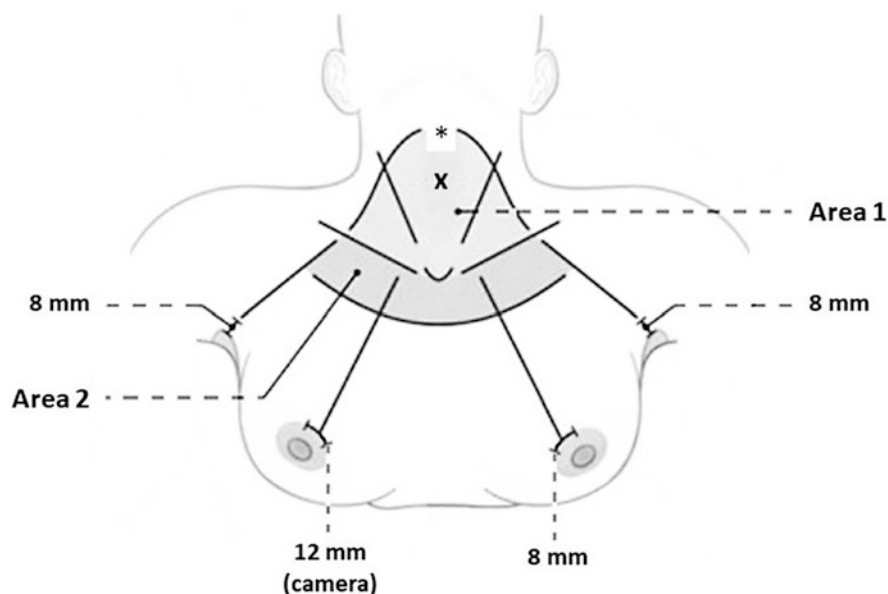
BABA does not involve the breast parenchyma in the subcutaneous dissection, so previous breast surgery (modified radical mastectomy, breast-conserving surgery or breast augmentation) is not contraindicated. Previous thyroid or parathyroid surgery or cervical spine surgery is not contraindicated.

Candidates for BABA-RT should be carefully selected on the basis of thyroid pathology and patient factors [1, 12]. Although there is no age limit for BABA-RT, most surgeons operate on patients <70 years of age [13]. BABA-RT can be safely conducted on both sexes, though male sex has been an independent factor predicting difficult surgery [14]. Obesity is generally considered a relative contraindication [15].

### 10.3 Procedure

BABA-RT uses a midline approach to the thyroid, which provides a 3D symmetrical view of both thyroid lobes with optimal visualization and dissection of vital structures, and enables large operative angles between the instruments that can prevent instrument crowding or fighting. The thyroid dissection method in BABA is similar to that of open thyroidectomy, so the operation process is familiar to surgeons. The learning curve of BABA-RT is about 40 cases [16].

The robotic platforms used are da Vinci S, Si or Xi (Intuitive, USA), with the following EndoWrist instruments: graspers (Maryland bipolar and ProGrasp forceps) and electrocautery hook. The patient is positioned supine on the operating table, with the armpits opened slightly to aid axillary incisions, and the neck extended by placing a pillow under the patient's shoulders. The operative field is prepped and draped as a large area including the neck and the patient's chest. The robot location is at the patient's shoulder for the da Vinci S, Si, while the da Vinci Xi system can be placed on either side. The ventilator is usually positioned at the patient's feet or right side of the patient. Guidelines are drawn with a marker along the landmarks of the anterior chest and the neck: midline, thyroid cartilage, cricoid cartilage, anterior border of the sternocleidomastoid muscle, the clavicles, suprasternal notch, four incisions, trajectory lines from the port site to the neck, and the working spaces (Fig. 10.1) [4].



**Fig. 10.1** Guidelines and port sites. Dissection should start in Area 2 and proceed to Area 1. Thyroid cartilage (\*), cricoid cartilage (x). Modified from Choi et al. [4] with permission of Springer Nature

Epinephrine-mixed saline solution (1:200,000) is injected in the working space under the platysma muscles in the neck and anterior chest, forming a saline pocket in the subplatysmal layer, which can reduce bleeding in the flap and make the dissection easier.

Two 8-mm incisions are made in both axillae and blunt dissection is performed to elevate the flap using straight mosquito hemostats and a vascular tunneler. The ports are then inserted through the incisions. Two ports should be inserted to meet in the middle. The working space is insufflated with CO<sub>2</sub> at 6 mmHg through the left axillary port. This pressure solved the earlier problems of hypercarbia, tachycardia, respiratory acidosis, subcutaneous emphysema, and air embolism with >10 mmHg of CO<sub>2</sub> [17].

Sharp dissection is started in Area 1 of the anterior chest with the harmonic shear and, once completed, two incisions are made at the superomedial margin of the areolae; the flap is now extended to Area 2, up to the cricoid cartilage (Fig. 10.1).

In the da Vinci S and Si systems, the robot column is aligned with the camera port of the right breast, while the da Vinci Xi system is placed in the middle. The robotic arms are docked to each 8-mm port and the camera is inserted through the 12-mm right breast port. A monopolar electrocautery or ultrasonic shear is inserted through the left breast port. Graspers are inserted through both axillary ports and further flap dissection is performed.

The midline between the strap muscles is divided from the suprasternal notch to the thyroid cartilage to expose the thyroid gland and the trachea. To help visualize the midline, the assistant may palpate the thyroid cartilage while inside it is marked with electrocautery. After dividing the midline, the isthmus is divided with the harmonic shear. Isthmectomy helps to retract the thyroid gland more easily.

The thyroid gland is retracted medially with ProGrasp forceps, and the right side of the strap muscles is retracted laterally using Maryland forceps. The strap muscles are thoroughly dissected off the thyroid capsule and lateral dissection is performed down to the common carotid artery. The thyroid lobe can be effectively retracted by manipulating the third and fourth robot arms, gradually pulling and switching their mutual positions.

While dissecting the lower pole, large vessels such as the inferior thyroid vein and the thyroid ima artery are ligated with bipolar electrocautery or ultrasonic shears, but only after the RLN has been identified. When lateral dissection is complete, the inferior thyroid artery and inferior parathyroid gland (PT) can be seen.

The RLN is found between the common carotid artery and trachea (tracheoesophageal groove). Once identified, the RLN can be confirmed using a nerve monitor. The inferior PT, which should be carefully preserved, sits around the lower pole of the gland, over the RLN.

Dissection is continued to the upper part near the point of RLN entry into the larynx under the cricopharyngeal muscle. The nerve may divide into a couple of branches along its course from the level of the inferior thyroid artery to the larynx. The ligament of Berry is the most frequent site of nerve injuries. A cotton ball is used to protect the nerve from thermal and mechanical damage.

Drawing the upper third of the strap muscles laterally with the Maryland forceps, the ultrasonic shears is used to dissect the vessels of the upper pole. Here, an antero-medial approach is recommended to avoid injury to the superior laryngeal nerve.

Care must be taken to preserve the superior PT, as it is usually located under the RLN.

After thyroid lobectomy is completed, the specimen wrapped in the endobag is pulled out through the left axillary port. If the left axillary incision is not wide enough to extract the specimen, it can be extended posteriorly along the axillary crease.

After meticulous hemostasis, the strap muscles are approximated with a continuous running suture. Optionally, a Jackson-Pratt drain can be placed into the operative fields through the right or left axillary incision.

The skin incisions are closed with a subcuticular absorbable suture and the incision is dressed. The anterior chest is compressed with a Robo-Bra to reduce emphysema, postoperative bleeding and pain.

---

## 10.4 Outcomes and Cost

The main purpose of robotic thyroidectomy is to achieve better patient satisfaction with cosmetic outcomes. BABA-RT consistently recorded better cosmetic satisfaction than open thyroidectomy (OT) [15, 17–19].

In the literature, the operating time of BABA-RT was 1.3–2.4 times longer than that of OT [16, 18, 20–22], which may increase medical expenses. In remote access robotic thyroidectomy flap dissection can be a time-limiting procedure. However, the time required for flap dissection and robot docking gradually decreases with the experience of the surgical team [16, 20].

Studies investigating postoperative pain suggest that BABA-RT caused similar or less pain to patients than OT [19, 21, 23]. Prospective observational studies reported that about 40% of patients experienced transient paresthesia of the anterior chest after BABA-RT, which normalized within 3 months [24].

Drain output [25, 26] and hospital stay (mean, 3 to 5 days) [11, 18, 20, 21, 23, 25, 27] were found to be similar between BABA-RT and OT.

No significant difference was observed between BABA-RT and OT in the rates of transient and permanent RLN injuries [11, 18–23, 25, 27, 28].

In most studies examining BABA-RT, hypoparathyroidism was defined by hypocalcemic symptoms and low parathyroid hormone level (<15 pg/dL), and it was permanent when symptoms continued for more than 6 months [19, 23, 29]. The rates of permanent hypoparathyroidism were comparable between BABA-RT and OT [11, 18, 19, 21–23, 25, 27–30].

The reported rates of postoperative bleeding and hematoma after BABA-RT was 0–0.9%, not significantly different from OT [11, 18–23, 25, 27, 29].

Current evidence supports that BABA-RT is comparable to OT in terms of completeness of surgical resection [28]. Central neck dissection can be performed down to the common carotid artery and distal innominate artery, although there are mixed results in the literature in terms of the lymph node yield of BABA-RT compared to OT [19]. No significant difference was observed in the absolute level of stimulated thyroglobulin between BABA-RT and OT [20, 22, 23, 25, 27–29]. No difference in the uptake on whole-body scan after radioactive iodine (RAI) therapy, number of RAI sessions, and the RAI dose between BABA-RT and OT [28].

The evidence on locoregional recurrence and disease-specific survival after BABA-RT is limited. In a study that compared BABA-RT and OT for 2–4 cm papillary thyroid carcinoma, no recurrence was observed in both groups in a median follow-up of 40.2 months [22].

BABA-RT is comparable to OT in terms of complications and is safe and feasible when performed by experienced surgeons and on carefully selected patients concerned about neck scarring.

Robotic surgery is more expensive than open or endoscopic surgery, with the cost of BABA-RT recorded at 2.5–6.2 times higher than OT [18, 23, 25]. With robotic systems and procedures evolving, it is likely that more cost-effective ways will be found to provide safe and complete surgery that offers improved quality of life.

---

## References

1. Berber E, Bernet V, Fahey TJ 3rd, et al. American Thyroid Association statement on remote-access thyroid surgery. *Thyroid*. 2016;26(3):331–7.
2. Wong KP, Lang BHH. Endoscopic thyroidectomy: a literature review and update. *Curr Surg Rep*. 2013;1(1):7–15.
3. Chung YS, Choe JH, Kang KH, et al. Endoscopic thyroidectomy for thyroid malignancies: comparison with conventional open thyroidectomy. *World J Surg*. 2007;31(12):2302–6.
4. Choi JY, Lee KE, Chung KW, et al. Endoscopic thyroidectomy via bilateral axillo-breast approach (BABA): review of 512 cases in a single institute. *Surg Endosc*. 2012;26(4):948–55.
5. Prete FP, Marzaioli R, Lattarulo S, et al. Transaxillary robotic-assisted thyroid surgery: technique and results of a preliminary experience on the Da Vinci xi platform. *BMC Surg*. 2019;18(Suppl 1):19.
6. Shimazu K, Shiba E, Tamaki Y, et al. Endoscopic thyroid surgery through the axillo-bilateral-breast approach. *Surg Laparosc Endosc Percutan Tech*. 2003;13(3):196–201.
7. Choe JH, Kim SW, Chung KW, et al. Endoscopic thyroidectomy using a new bilateral axillo-breast approach. *World J Surg*. 2007;31(3):601–6.
8. Liang TJ, Tsai CY, Liu SI, Chen IS. Multidimensional analyses of the learning curve of endoscopic thyroidectomy. *World J Surg*. 2021;45(5):1446–56.
9. Lee KE, do Koo H, Kim SJ, et al. Outcomes of 109 patients with papillary thyroid carcinoma who underwent robotic total thyroidectomy with central node dissection via the bilateral axillo-breast approach. *Surgery*. 2010;148(6):1207–13.
10. Lee HY, Yang IS, Hwang SB, et al. Robotic thyroid surgery for papillary thyroid carcinoma: lessons learned from 100 consecutive surgeries. *Surg Laparosc Endosc Percutan Tech*. 2015;25(1):27–32.
11. Kwon H, Yi JW, Song RY, et al. Comparison of bilateral axillo-breast approach robotic thyroidectomy with open thyroidectomy for graves' disease. *World J Surg*. 2016;40(3):498–504.
12. Liu SY, Ng EK. Robotic versus open thyroidectomy for differentiated thyroid cancer: an evidence-based review. *Int J Endocrinol*. 2016;2016:4309087.
13. Lee KE, Kim E, do Koo H, et al. Robotic thyroidectomy by bilateral axillo-breast approach: review of 1026 cases and surgical completeness. *Surg Endosc*. 2013;27(8):2955–62.
14. Kwak HY, Kim HY, Lee HY, et al. Predictive factors for difficult robotic thyroidectomy using the bilateral axillo-breast approach. *Head Neck*. 2016;38(Suppl 1):E954–60.
15. Lee HS, Chai YJ, Kim SJ, et al. Influence of body habitus on the surgical outcomes of bilateral axillo-breast approach robotic thyroidectomy in papillary thyroid carcinoma patients. *Ann Surg Treat Res*. 2016;91(1):1–7.
16. Kim WW, Jung JH, Park HY. The learning curve for robotic thyroidectomy using a bilateral axillo-breast approach from the 100 cases. *Surg Laparosc Endosc Percutan Tech*. 2015;25(5):412–6.

17. Yu HW, Yi JW, Seong CY, et al. Development of a surgical training model for bilateral axillo-breast approach robotic thyroidectomy. *Surg Endosc.* 2018;32(3):1360–7.
18. Kwak HY, Kim HY, Lee HY, et al. Robotic thyroidectomy using bilateral axillo-breast approach: comparison of surgical results with open conventional thyroidectomy. *J Surg Oncol.* 2015;111(2):141–5.
19. He Q, Zhu J, Fan Z, et al. Robotic thyroidectomy with central neck dissection using axillo-bilateral-breast approach: a comparison to open conventional approach. *Zhonghua Wai Ke Za Zhi.* 2016;54(1):51–5.
20. Kim WW, Jung JH, Park HY. A single surgeon's experience and surgical outcomes of 300 robotic thyroid surgeries using a bilateral axillo-breast approach. *J Surg Oncol.* 2015;111(2):135–40.
21. Chai YJ, Song J, Kang J, et al. A comparative study of postoperative pain for open thyroidectomy versus bilateral axillo-breast approach robotic thyroidectomy using a self-reporting application for iPad. *Ann Surg Treat Res.* 2016;90(5):239–45.
22. Chai YJ, Suh H, Woo JW, et al. Surgical safety and oncological completeness of robotic thyroidectomy for thyroid carcinoma larger than 2 cm. *Surg Endosc.* 2017;31(3):1235–40.
23. Cho JN, Park WS, Min SY, et al. Surgical outcomes of robotic thyroidectomy vs. conventional open thyroidectomy for papillary thyroid carcinoma. *World J Surg Oncol.* 2016;14(1):181.
24. Kim SJ, Lee KE, Myong JP, et al. Prospective study of sensation in anterior chest areas before and after a bilateral axillo-breast approach for endoscopic/robotic thyroid surgery. *World J Surg.* 2013;37(5):1147–53.
25. Seup Kim B, Kang KH, Park SJ. Robotic modified radical neck dissection by bilateral axillary breast approach for papillary thyroid carcinoma with lateral neck metastasis. *Head Neck.* 2015;37(1):37–45.
26. He QQ, Zhu J, Zhuang DY, et al. Comparative study between robotic total thyroidectomy with central lymph node dissection via bilateral axillo-breast approach and conventional open procedure for papillary thyroid microcarcinoma. *Chin Med J.* 2016;129(18):2160–6.
27. Kim WW, Kim JS, Hur SM, et al. Is robotic surgery superior to endoscopic and open surgeries in thyroid cancer? *World J Surg.* 2011;35(4):779–84.
28. Lee KE, do Koo H, Im HJ, et al. Surgical completeness of bilateral axillo-breast approach robotic thyroidectomy: comparison with conventional open thyroidectomy after propensity score matching. *Surgery.* 2011;150(6):1266–74.
29. Kim BS, Kang KH, Kang H, Park SJ. Central neck dissection using a bilateral axillo-breast approach for robotic thyroidectomy: comparison with conventional open procedure after propensity score matching. *Surg Laparosc Endosc Percutan Tech.* 2014;24(1):67–72.
30. Yu HW, Chai YJ, Kim SJ, et al. Robotic-assisted modified radical neck dissection using a bilateral axillo-breast approach (robotic BABA MRND) for papillary thyroid carcinoma with lateral lymph node metastasis. *Surg Endosc.* 2018;32(5):2322–7.

**Open Access** This chapter is licensed under the terms of the Creative Commons Attribution-NonCommercial-NoDerivatives 4.0 International License (<http://creativecommons.org/licenses/by-nc-nd/4.0/>), which permits any noncommercial use, sharing, distribution and reproduction in any medium or format, as long as you give appropriate credit to the original author(s) and the source, provide a link to the Creative Commons license and indicate if you modified the licensed material. You do not have permission under this license to share adapted material derived from this chapter or parts of it.

The images or other third party material in this chapter are included in the chapter's Creative Commons license, unless indicated otherwise in a credit line to the material. If material is not included in the chapter's Creative Commons license and your intended use is not permitted by statutory regulation or exceeds the permitted use, you will need to obtain permission directly from the copyright holder.





# Transoral Endoscopic Thyroidectomy Vestibular Approach: Lessons from a Five Years' Experience

# 11

Daqi Zhang, Gianlorenzo Dionigi, Francesco Frattini,  
Andrea Cestari, Antonella Pino, Ozer Makay, Che-Wei Wu,  
Hoon Yub Kim, Andrea Casaril, and Hui Sun

## 11.1 Introduction

Surgery on the thyroid gland is one of the most common procedures in head and neck surgery. Open thyroid surgery is considered safe, with a rate of 0.8–2.3% permanent recurrent nerve palsy, 9–10% permanent hypoparathyroidism, and < 1% mortality for benign nodular goiter [1]. The thyroid gland is traditionally accessed via the classic cross-section according to Theodor Kocher.

The neck is a highly visible part of the body and the desire for scarless thyroid surgery is increasing, especially among patients in Asian countries. Since the first clinical series on endoscopic parathyroid surgery published by Gagner in 1996 [2],

---

D. Zhang

Division of Thyroid Surgery, China-Japan Union Hospital of Jilin University,  
Changchun, Jilin, China  
e-mail: [daqizhang@yeah.net](mailto:daqizhang@yeah.net)

G. Dionigi

Division of General Surgery, IRCCS Istituto Auxologico Italiano, Milan, Italy  
Department of Pathophysiology and Transplantation, University of Milan, Milan, Italy  
e-mail: [gianlorenzo.dionigi@unimi.it](mailto:gianlorenzo.dionigi@unimi.it)

F. Frattini (✉) · A. Cestari · A. Pino

Division of General Surgery, IRCCS Istituto Auxologico Italiano, Milan, Italy  
e-mail: [f.frattini@auxologico.it](mailto:f.frattini@auxologico.it); [a.cestari@auxologico.it](mailto:a.cestari@auxologico.it); [pino.antonella@virgilio.it](mailto:pino.antonella@virgilio.it)

O. Makay

Department of General Surgery, Division of Endocrine Surgery, Ege University Hospital,  
Izmir, Turkey  
e-mail: [ozet.makay@ege.edu.tr](mailto:ozet.makay@ege.edu.tr)

C.-W. Wu

Department of Otolaryngology-Head and Neck Surgery, Kaohsiung Medical University  
Hospital, Kaohsiung, Taiwan  
e-mail: [cwwu@kmu.edu.tw](mailto:cwwu@kmu.edu.tw)

© The Author(s) 2024

M. Testini, A. Gurrado (eds.), *Thyroid Surgery*, Updates in Surgery,  
[https://doi.org/10.1007/978-3-031-31146-8\\_11](https://doi.org/10.1007/978-3-031-31146-8_11)

101

H. Y. Kim

Korea University College of Medicine Thyroid Center, Department of Surgery,  
Korea University Hospital, Seoul, South Korea  
e-mail: [hoonyubkim@korea.ac.kr](mailto:hoonyubkim@korea.ac.kr)

A. Casaril

Endocrine Surgery Unit, Pederzoli Hospital, Verona, Italy  
e-mail: [andrea.casaril@ospedalepederzoli.it](mailto:andrea.casaril@ospedalepederzoli.it)

H. Sun (✉)

Laboratory of Molecular Biology and Translational Medicine on Differentiated Thyroid  
Carcinoma, Changchun, Jilin, China  
e-mail: [s\\_h@jlu.edu.cn](mailto:s_h@jlu.edu.cn)

many different minimally invasive or endoscopic procedures of thyroid and parathyroid surgery have been described in the last twenty years. Minimally invasive surgery of the neck, which encompasses minimally invasive video-assisted thyroidectomy [3], bilateral axillary approach [4, 5] and other approaches [6], is not very popular due to its complexity and longer learning curve. Additionally, it often results in external scars.

With the goal of achieving a scar-free anterior neck and using direct transoral laparoscopy, Anuwong developed the transoral endoscopic thyroidectomy vestibular approach (TOETVA) and published the first large clinical series with 60 patients [7]. Due to its simplicity, his method is gaining acceptance in thyroid and parathyroid surgery [8–12].

In this chapter, we describe our clinical experience and discuss some technical issues regarding this new procedure.


---

## 11.2 Patients and Methods

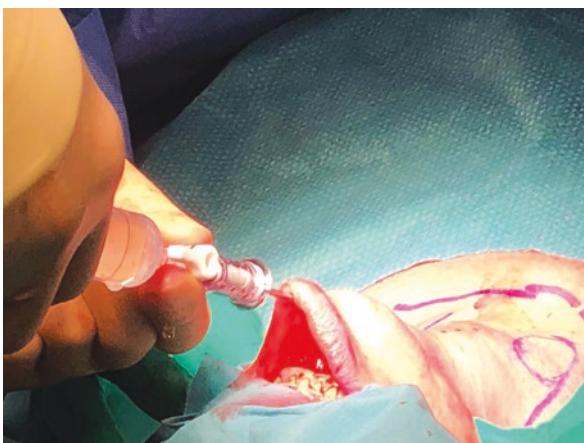
The series was conducted from 2017 to 2021. Prior approval was obtained from the local ethics committee. Of 210 eligible patients, 100 (47%) opted for endoscopic access. Surgery was performed under general anesthesia with orotracheal intubation. Patients were placed in the supine position with the head slightly tilted. The surgeon stood directly behind the patient's head, and the camera assistant was to the right of the surgeon. The laparoscopic tower was high-resolution and contributed to a magnified and optimized image. First, a 10-mm transverse incision was made in the middle of the oral vestibule, followed by injection of epinephrine and saline through a Veress cannula [1] with hydrodissection of the entire surgical field under the platysma muscle (Figs. 11.1, 11.2, and 11.3). Then, the blunt dissector rod was inserted and carefully moved in different directions and from left to right, manually sparing the external jugularis to create a space between the platysma, jugularis, and infrahyoid muscle. A 12-mm trocar could then be inserted, followed by a 30-degree telescope. The gas pressure was set at 6 mmHg. Two additional 5-mm trocars were introduced to the right and left of the middle trocar. The lateral trocars must be placed cranially and well lateral to the canines on the inside of the lower lip to avoid injury to the mental nerve. The working space was then prepared below the



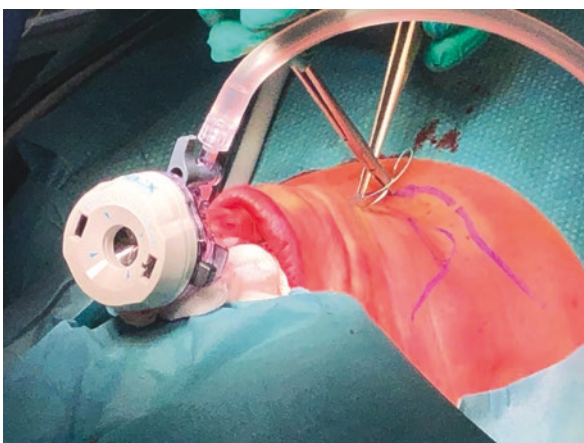
**Fig. 11.1** Vestibular incisions and trocar insertion



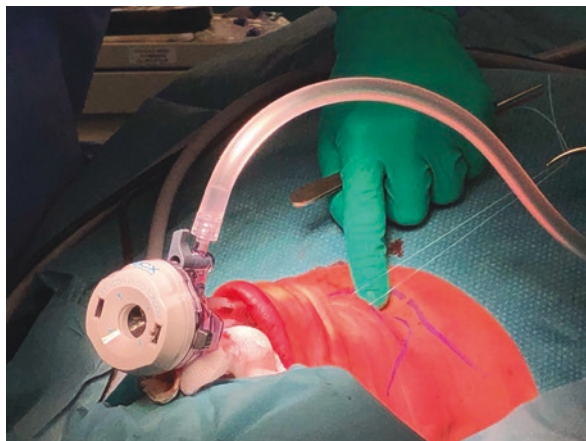
**Fig. 11.2** Veress needle insertion



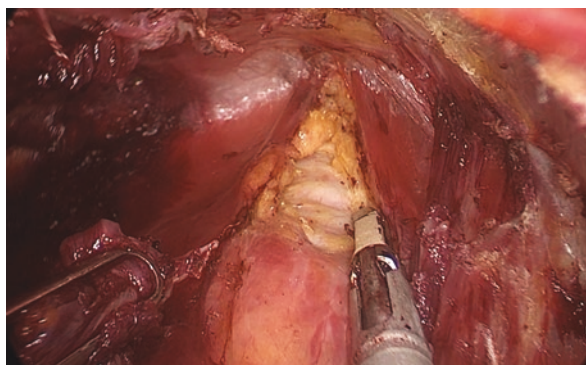
**Fig. 11.3** Trocar insertion



**Fig. 11.4** Outward retraction of cervical recti muscles

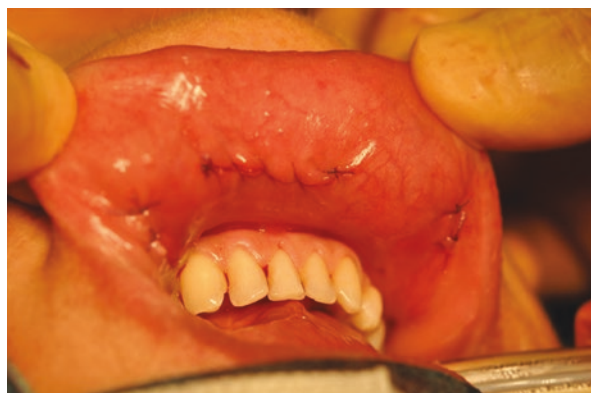

**Fig. 11.5** Intraoperative view



platysma. This was bounded cranially by the larynx, caudally by the jugulum, and laterally by the sternocleidomastoid muscles. Dissection of the thyroid gland began with dissection of the linea alba cervicalis. For better exposure, the cervical recti muscles were retracted laterally by the second assistant with a suture passed outward (Figs. 11.4 and 11.5). The isthmus of the thyroid gland was transected. Ultracision (Ethicon Endosurgery, Cincinnati, OH, USA) was used for dissection and closure of the vessels. Immediately after transection of the isthmus, the recurrent laryngeal nerve (RLN) was exposed. Dissection of the RLN was performed without electrocautery or ultrasonic scissors to avoid thermal damage. After transection of the superior polar vessels, dissection was performed from cranial to caudal, and the RLN could be visualized and followed retrogradely from its immersion in the larynx. Intraoperative neuromonitoring (IONM) was routinely performed with the C2 NerveMonitor (Inomed Medizintechnik GmbH, Emmendingen, Germany), either through a trocar or directly percutaneously through a 1-mm skin incision. In this way, the location and function of the RLN and superior laryngeal nerve could be verified. The specimen was retrieved through the midline 12-mm incision in a collection bag (Eco-Sac, Espiner medical, Measham, UK). The

**Fig. 11.6** Postoperative wound on the inside of the lower lip



infrahyoid musculature was adapted medially with VLOC 3–0 absorbable running suture (Covidien, Mainsfield, MA, USA). The oral incisions were closed with absorbable suture (Vicryl 5–0, Ethicon, Livingstone, UK). A pressure dressing was applied to compress the chin overnight. Perioperative antibiotic prophylaxis (sulbactam-ampicillin, UNACID) was administered i.v. 30 minutes before skin incision and then administered p.o. for a total of 5 days. In addition, patients performed a disinfecting mouth rinse after each meal for a total of 5 days (Fig. 11.6).

---

### 11.3 Results

One hundred patients underwent TOETVA, including 87 women and 13 men. The patients' neck morphology was not a criterion for selection or exclusion. Operative time was longer in patients with wide necks than in those with slender necks. Overweight or obesity was not a contraindication. Fifteen patients had a body mass index (BMI) between 25 and 30 kg/m<sup>2</sup> and five patients had a BMI >30 kg/m<sup>2</sup>. In this first case series, optimal access and visualization of the cervical anatomy was possible. All important anatomical structures (such as the parathyroid glands, the superior thyroid artery, the inferior thyroid artery, the RLN) could be imaged with excellent resolution and easily identified in overview. The parathyroid glands were identified and preserved. Nodule diameter measured on preoperative ultrasound ranged from 0.3 to 6.5 cm (mean 3.1 ± 1.8) with a mean volume ranging from 2.5 to 159 mm<sup>3</sup> (mean 24 ± 41.2 mm<sup>3</sup>). All patients had a nodule smaller than 7 cm. The procedures performed were 80 lobo-isthmectomies, and 20 total thyroidectomies. The average weight of surgical specimens was 21.9 ± 12.2 (10–110) g. The specimen was harvested through the 12-mm incision. Surgical times averaged 184 minutes. Five cases (5%) required conversion to an open cervical incision. Conversion was required due to hemorrhage.

No postoperative complications occurred, and the mean postoperative stay was 3 days. Transient leukocytosis was noted on postoperative day 1 and normalized by postoperative day 3. All patients resumed oral feeding in the evening of the

procedure. Cosmetic results were excellent, with no visible scars. During the first 3 postoperative days, the maximum pain intensity did not exceed 3 points on the visual analog pain scale in any case. Histologically, there were 15 papillary carcinomas (all were discovered at final pathology). All of these lesions were < 15 mm in size. There were 6 benign oncocytic nodules, 9 thyrotoxic nodules, and 70 benign nodules or goiters that were symptomatic. In six cases, a parathyroid gland was identified intraoperatively on the surgical specimen and systematically reimplanted into the sternocleidomastoid muscle. The pathologist found six parathyroid glands in the surgical specimens of six patients. There were no postoperative hematomas. However, ten patients (10%) experienced postoperative bruising or ecchymosis, which was transient and resolved within 10 days. Two patients developed a cervical seroma, which was treated with needle aspiration. There were no cases of surgical site infection. Five of 20 patients who underwent total thyroidectomy developed transient hypoparathyroidism (25%). No cases of permanent hypoparathyroidism. Six patients (6%) developed temporary paralysis of the RLN. Functional recovery was evidenced by normal vocal cord mobility seen by transnasal endoscopy between 1 and 4 months. There were no cases of permanent paralysis of the RLN. Sublabial and chin hypoesthesias or paresthesias were observed in the first 25 patients and lasted 3–12 weeks. Therefore, in subsequent patients, we preferred to avoid thermal coagulation and performed blunt dissection with Kelly forceps. Thereafter, we observed no further cases of postoperative dysesthesia lasting longer than 4 weeks. One patient had a cervical skin burn that occurred during creation of the workspace, which resolved with topical corticosteroids and showed a good cosmetic result after 2 months. One patient reported persistent sublabial paresthesias over an area of 1 cm<sup>2</sup> at the 3-month follow-up. Finally, on the first day after surgery one patient reported chest pain, after which a CT scan was performed revealing pneumomediastinum; this resolved spontaneously.

---

## 11.4 Discussion

Despite continuous progress for more than 20 years, the acceptance of the minimally invasive approach in thyroid surgery is still very low, partly due to the difficult learning curve of the proposed methods and possibly due to the remaining scars. The transoral approach has proven to be ideal because it leaves no cutaneous scars. It also provides anatomic and layered access to the surgical site on both sides of the trachea without muscle transection, thus minimizing surgical trauma. On the other hand, the transoral approach to the neck means that sterile surgery can lead to a potentially contaminated procedure with the disadvantage of deep wound infection.

Witzel et al. developed the concept of transoral thyroid surgery in studies of cadavers and animal models, initially using a sublingual approach [13]. Benhidjeb et al. and Wilhelm et al. described many potential problems with the peroral approach via the floor of the mouth [14, 15]. These include a higher conversion rate, postoperative swelling and dysphagia, which may affect patient safety.

Other investigators pursued the peroral approach. Nakajo et al. described their TOVANS (trans-oral video-assisted neck surgery) method as a gasless transoral endoscopic thyroidectomy with a single large incision as the premandibular approach and anterior neck skin lift [16]. They performed eight procedures. All patients had sensory disturbances of the chin that lasted more than 6 months after surgery. RLN palsy occurred in one patient, and no mental nerve palsy or infection was detected.

Yang et al. performed a study of 82 patients who underwent either endoscopic thyroidectomy via the oral vestibular approach (ETOVA) or endoscopic thyroidectomy via the areolar approach (ETAA) [8]. They showed no statistical differences in operative time, complications or patient satisfaction, but the transoral technique showed better cosmetic results.

Anuwong in Thailand refined the technique called TOETVA and reported excellent results in an initial study of 60 patients [7]. The results were as safe as conventional open thyroid surgery. In his last series of 425 cases, there were no cases of infection or permanent nerve palsy, 5.9% of patients had temporary vocal cord palsy, and 10.9% had temporary hypoparathyroidism [17]. In their landmark study in Europe, Dionigi et al. in Milan, Italy, reported their first experience with TOETVA performed in 15 cases, with a low complication rate [10]. As in our study and in contrast to Anuwong's series, the group used orotracheal rather than nasotracheal intubation, which simplified the intubation technique and IONM. The importance of IONM has been highlighted in many studies of open and minimally invasive thyroidectomy [18–24] and is recognized by our group. In our experience vagus nerve stimulation has been done in transoral endoscopic thyroidectomy as in the open procedure. The stimulation has been omitted in unilateral procedures only, but it must be performed in bilateral procedures [25, 26].

Our initial clinical experience showed longer operative times but with an excellent safety profile, with clear identification of critical anatomy and the use of IONM [27, 28]. The patients' postoperative pain scores were low and the cosmetic outcomes were excellent. Skin necrosis, major hematoma, sensory disturbances or end-oral damage did not occur in any of the patients in our case series. The technique could be performed with standard laparoscopic instruments, with minor modifications in initial dissection, insufflation, and team positioning. Although there is no reliable evidence for the use of perioperative antibiotics in transoral procedures [29], the authors still opted for perioperative antibiotic prophylaxis. This can certainly be significantly shortened or even omitted. The published series by Anuwong et al. did not show high infection rates [17]. The authors consider preoperative disinfecting mouth rinses to be as important as antibiotic prophylaxis, although the evidence is equally lacking. The following technical aspects have been identified:

- The team's position and technical advancement with the 4 K endoscopic tower is of great importance for better visualization of the anatomy [30–33].
- The lateral and far cranial positioning (approx. 1 cm caudal to the vermilion of the lips on the inside and opposite the canines) of the 5-mm trocars is intended to avoid damage to the mental nerve [34–37].
- The subplatysmal hydrodissection with adrenaline solution allows creation of a non-existent space [38–40].

- Use of the bougie rod/dilator through the 12-mm incision increases the surgical space in the anterior neck [41–43].
- Stubborn tissue bridges are resolved by monopolar or ultrasonic dissection. It is important to expose the subplatysmal area up to the jugular fossa [44].
- The infrahyoid muscles are temporarily retracted laterally using percutaneous sutures. Midline, support sutures are stitched subcutaneously to enlarge the surgical site by traction upwards [45].
- Routine IONM serves to assess the localization and function of the RLN. This can be done through the trocars or percutaneously through a 1-mm incision [46].
- The specimen is extracted in a recovery bag. In the case of large specimens, dissection of the thyroid within the pouch may be necessary, but this should be avoided at all costs in favor of histological evaluation [46].
- Drainage can usually be avoided [46].
- Perioperative and postoperative antibiotics and disinfecting mouth rinses are continued for 5 days postoperatively as infection prophylaxis [46].

**Funding** This work was supported by the Eurocrine Project (Auxologico IRCCS).

---

## References

1. Rayes N, Seehofer D, Neuhaus P. The surgical treatment of bilateral benign nodular goiter. Balancing invasiveness with complications. *Dtsch Arztebl Int.* 2014;111(10):171–8.
2. Gagner M. Endoscopic subtotal parathyroidectomy in patients with primary hyperparathyroidism. *Br J Surg.* 1996;83(6):875.
3. Miccoli P, Materazzi G. Minimally invasive, video-assisted thyroidectomy (MIVAT). *Surg Clin North Am.* 2004;84(3):735–41.
4. Shimazu K, Shiba E, Tamaki Y, et al. Endoscopic thyroid surgery through the axillo-bilateral-breast approach. *Surg Laparosc Endosc Percutan Tech.* 2003;13(3):196–201.
5. Strik MW, Anders S, Barth M, et al. Total-videoendoskopische Strumaresektion via “axillo-bilateral breast approach”. *Operative Technik und erste Ergebnisse [Total videoendoscopic thyroid resection by the axillo-bilateral breast approach. Operative method and first results]. Chirurg.* 2007;78(12):1139–44.
6. Phillips HN, Fiorelli RK, Queiroz MR, et al. Single-port unilateral transaxillary totally endoscopic thyroidectomy: a survival animal and cadaver feasibility study. *J Minim Access Surg.* 2016;12(1):63–7.
7. Anuwong A. Transoral endoscopic thyroidectomy vestibular approach: a series of the first 60 human cases. *World J Surg.* 2016;40(3):491–7.
8. Yang J, Wang C, Li J, et al. Complete endoscopic thyroidectomy via oral vestibular approach versus areola approach for treatment of thyroid diseases. *J Laparoendosc Adv Surg Tech A.* 2015;25(6):470–6.
9. Pai VM, Muthukumar P, Prathap A, et al. Transoral endoscopic thyroidectomy: a case report. *Int J Surg Case Rep.* 2015;12:99–101.
10. Dionigi G, Bacuzzi A, Lavazza M, et al. Transoral endoscopic thyroidectomy: preliminary experience in Italy. *Updat Surg.* 2017;69(2):225–34.
11. Wang C, Zhai H, Liu W, et al. Thyroidectomy: a novel endoscopic oral vestibular approach. *Surgery.* 2014;155(1):33–8.
12. Udelsman R, Anuwong A, Oprea AD, et al. Trans-oral vestibular endocrine surgery: a new technique in the United States. *Ann Surg.* 2016;264(6):e13–6.

13. Witzel K, von Rahden BH, Kaminski C, Stein HJ. Transoral access for endoscopic thyroid resection. *Surg Endosc.* 2008;22(8):1871–5.
14. Benhidjeb T, Wilhelm T, Harlaar J, et al. Natural orifice surgery on thyroid gland: totally transoral videoassisted thyroidectomy (TOVAT): report of first experimental results of a new surgical method. *Surg Endosc.* 2009;23(5):1119–20.
15. Wilhelm T, Metzigg A. Video. Endoscopic minimally invasive thyroidectomy: first clinical experience. *Surg Endosc.* 2010;24(7):1757–8.
16. Nakajo A, Arima H, Hirata M, et al. Trans-oral video-assisted neck surgery (TOVANS). A new transoral technique of endoscopic thyroidectomy with gasless premandible approach. *Surg Endosc.* 2013;27(4):1105–10.
17. Anuwong A, Ketwong K, Jitpratoom P, et al. Safety and outcomes of the transoral endoscopic thyroidectomy vestibular approach. *JAMA Surg.* 2018;153(1):21–7.
18. Dralle H, Sekulla C, Haerting J, et al. Risk factors of paralysis and functional outcome after recurrent laryngeal nerve monitoring in thyroid surgery. *Surgery.* 2004;136(6):1310–22.
19. Wang Y, Yu X, Wang P, et al. Implementation of intraoperative neuromonitoring for transoral endoscopic thyroid surgery: a preliminary report. *J Laparoendosc Adv Surg Tech A.* 2016;26(12):965–71.
20. Patel PN, Jayawardena ADL, Walden RL, et al. Evidence-based use of perioperative antibiotics in otolaryngology. *Otolaryngol Head Neck Surg.* 2018;158(5):783–800.
21. Oliva A, Grassi S, Zedda M, et al. Ethical and medico-legal issues of TOETVA procedure and simulation on cadavers: a scoping review. *Eur Rev Med Pharmacol Sci.* 2022;26(13):4550–6.
22. Celik S, Bilge O, Ozdemir M, et al. Modified Larssen solution (MLS)-fixed cadaver model for transoral endoscopic thyroidectomy vestibular approach (TOETVA) education: a feasibility study. *Surg Endosc.* 2022;36(7):5518–30.
23. Bertelli AAT, Lira RB, Gonçalves AJ, et al. Transoral endoscopic thyroidectomy vestibular approach (TOETVA): pioneers’s point of view. *Arch Endocrinol Metab.* 2021;65(6):858–9.
24. Zhang D, Wu CW, Wang T, et al. Drawbacks of neural monitoring troubleshooting algorithms in transoral endoscopic thyroidectomy. *Langenbeck's Arch Surg.* 2021;406(7):2433–40.
25. Cohen O, Tufano RP, Anuwong A, et al. Trans-oral endoscopic thyroidectomy vestibular approach (TOETVA) for the pediatric population: a multicenter, large case series. *Surg Endosc.* 2022;36(4):2507–13.
26. Zhang D, Fu Y, Zhou L, et al. Pictorial essay of vestibular incision outcomes from transoral endoscopic thyroidectomy. *Langenbeck's Arch Surg.* 2021;406(8):2869–77.
27. Zhang D, Sun H, Tufano R, et al. Recurrent laryngeal nerve management in transoral endoscopic thyroidectomy. *Oral Oncol.* 2020;108:104755.
28. Zhang D, Wang T, Kim HY, et al. Strategies for superior thyroid pole dissection in transoral thyroidectomy: a video operative guide. *Surg Endosc.* 2020;34(8):3711–21.
29. Erol V, Dionigi G, Barczyński M, et al. Intraoperative neuromonitoring of the RLNs during TOETVA procedures. *Gland Surg.* 2020;9(Suppl 2):S129–35.
30. Zhang D, Famá F, Caruso E, et al. How to avoid and manage mental nerve injury in transoral thyroidectomy. *Surg Technol Int.* 2019;35:101–6.
31. Zhang D, Fu Y, Dionigi G, et al. Human cadaveric model for studying the preservation of mental nerve during transoral endoscopic thyroidectomy. *Surg Radiol Anat.* 2020;42(1):55–62.
32. Zhang D, Li S, Dionigi G, et al. Animal study to evaluate the effect of carbon dioxide insufflation on recurrent laryngeal nerve function in transoral endoscopic thyroidectomy. *Sci Rep.* 2019;9(1):9365.
33. Zhang D, Li S, Dionigi G, et al. Stimulating and dissecting instrument for transoral endoscopic thyroidectomy: proof of concept investigation. *Surg Endosc.* 2020;34(2):996–1005.
34. Zhang D, Park D, Sun H, et al. Indications, benefits and risks of transoral thyroidectomy. *Best Pract Res Clin Endocrinol Metab.* 2019;33(4):101280.
35. Zhang D, Caruso E, Sun H, et al. Classifying pain in transoral endoscopic thyroidectomy. *J Endocrinol Investig.* 2019;42(11):1345–51.
36. Celik S, Makay O, Yoruk MD, et al. A surgical and anatomic-histological study on transoral endoscopic thyroidectomy vestibular approach (TOETVA). *Surg Endosc.* 2020;34(3):1088–102.

37. Zhang D, Wu CW, Inversini D, et al. Lessons learned from a faulty transoral endoscopic thyroidectomy vestibular approach. *Surg Laparosc Endosc Percutan Tech.* 2018;28(5):e94–9.
38. Russell JO, Anuwong A, Dionigi G, et al. Transoral thyroid and parathyroid surgery vestibular approach: a framework for assessment and safe exploration. *Thyroid.* 2018;28(7):825–9.
39. Zhang D, Li S, Dionigi G, et al. Feasibility of continuous intraoperative neural monitoring during transoral endoscopic thyroidectomy vestibular approach in a porcine model. *J Laparoendosc Adv Surg Tech A.* 2019;29(12):1592–7.
40. Dionigi G, Wu CW, Tufano RP, et al. Monitored transoral endoscopic thyroidectomy via long monopolar stimulation probe. *J Vis Surg.* 2018;4:24.
41. Dionigi G, Chai YJ, Tufano RP, et al. Transoral endoscopic thyroidectomy via a vestibular approach: why and how? *Endocrine.* 2018;59(2):275–9.
42. Anuwong A, Sasanakietkul T, Jitpratoom P, et al. Transoral endoscopic thyroidectomy vestibular approach (TOETVA): indications, techniques and results. *Surg Endosc.* 2018;32(1):456–65.
43. Anuwong A, Kim HY, Dionigi G. Transoral endoscopic thyroidectomy using vestibular approach: updates and evidences. *Gland Surg.* 2017;6(3):277–84.
44. Russell JO, Clark J, Noureldine SI, Anuwong A. Transoral thyroidectomy and parathyroidectomy – a north American series of robotic and endoscopic transoral approaches to the central neck. *Oral Oncol.* 2017;71:75–80.
45. Dionigi G, Lavazza M, Bacuzzi A, et al. Transoral endoscopic thyroidectomy vestibular approach (TOETVA): from a to Z. *Surg Technol Int.* 2017;30:103–12.
46. Dionigi G, Bacuzzi A, Lavazza M, et al. Transoral endoscopic thyroidectomy via vestibular approach: operative steps and video. *Gland Surg.* 2016;5(6):625–7.

**Open Access** This chapter is licensed under the terms of the Creative Commons Attribution-NonCommercial-NoDerivatives 4.0 International License (<http://creativecommons.org/licenses/by-nc-nd/4.0/>), which permits any noncommercial use, sharing, distribution and reproduction in any medium or format, as long as you give appropriate credit to the original author(s) and the source, provide a link to the Creative Commons license and indicate if you modified the licensed material. You do not have permission under this license to share adapted material derived from this chapter or parts of it.

The images or other third party material in this chapter are included in the chapter's Creative Commons license, unless indicated otherwise in a credit line to the material. If material is not included in the chapter's Creative Commons license and your intended use is not permitted by statutory regulation or exceeds the permitted use, you will need to obtain permission directly from the copyright holder.





---

## **Part III**

# **Prevention and Management of Perioperative Complications**



# Laryngeal Nerves Monitoring in Thyroid Surgery

# 12

Marcin Barczyński

## 12.1 Introduction

In recent years, intraoperative neuromonitoring (IONM) has been gaining more and more acceptance in thyroid and parathyroid surgery as a method complementing the standard of visual identification of the recurrent laryngeal nerve (RLN) and allowing for assessing preservation of its functional integrity during the procedure. The percentage of thyroid surgeries with neuromonitoring varies from country to country. The highest percentage of thyroid surgeries with neuromonitoring occurs in Germany, where over 95% of the nearly 80,000 thyroid surgeries performed annually are monitored in this way. In Europe, according to data from the EUROCRINE registry from 2022, approximately 84% of thyroid surgeries are monitored, of which 86% with intermittent neuromonitoring (i-IONM), and 14% with continuous neuromonitoring (c-IONM) ([www.eurocrine.eu](http://www.eurocrine.eu)). Barczyński et al. confirmed in a randomized trial involving 2000 nerves at risk of injury that the prevalence of early RLN injury (mainly transient) more often (about 5–7%) than permanent lesions (0.5–2%), it is significantly lower in the group of patients operated on with IONM compared to operations with visual visualization of the nerve, but without neuromonitoring (respectively: 3.8% vs. 1.9%,  $p = 0.011$ ) [1].

## 12.2 Standardization of Intraoperative Neuromonitoring

The International Neural Monitoring Study Group (INMSG) in Thyroid and Parathyroid Surgery published guidelines for recommended standards for the application of IONM of the RLN in 2011, and in 2013 also for neuromonitoring of the

---

M. Barczyński (✉)

Department of Endocrine Surgery, Third Chair of General Surgery, Jagiellonian University Medical College, University Hospital in Kraków, Kraków, Poland  
e-mail: [marbar@mp.pl](mailto:marbar@mp.pl)

© The Author(s) 2024

M. Testini, A. Gurrado (eds.), *Thyroid Surgery*, Updates in Surgery,  
[https://doi.org/10.1007/978-3-031-31146-8\\_12](https://doi.org/10.1007/978-3-031-31146-8_12)

113

external branch of the superior laryngeal nerve (EBSLN) [2, 3]. These recommendations were based on many years of multicenter experience of the research group members and focused on two essential aspects: standardization of equipment preparation for the procedure and assessment of the correct placement of surface electrodes on the endotracheal tube, as well as standardization of the procedure algorithm in cases of intraoperative signal loss, enabling precise differentiation of true loss of signal allowing prediction of RLN damage from the loss of a false signal resulting from various technical errors in the method application. In 2018, the INMSG published another two guidelines on staging bilateral thyroid surgery with monitoring loss of signal and on optimal RLN management for invasive thyroid cancer-incorporation of surgical, laryngeal, and neural electrophysiologic data [4, 5]. These guidelines are envisioned to assist the clinical decision-making process involved in RLN management during thyroid surgery by incorporating the important information domains of not only gross surgical findings but also intraoperative RLN functional status and preoperative laryngoscopy findings. The above-mentioned guideline statements are empowered by the most recently published recommendations on the desired informed consent for IONM in thyroid and parathyroid surgery and required format for the training courses in laryngeal nerve monitoring in thyroid and parathyroid surgery [6, 7].

Intraoperative laryngeal nerve monitoring currently comes in three formats:

1. intermittent neuromonitoring (i-IONM) of the RLN, including NerveTrend mode
2. continuous neuromonitoring (c-IONM) of the RLN
3. neuromonitoring of the external branch of the superior laryngeal nerve (EBSLN).

---

## 12.3 Intermittent Intraoperative Neuromonitoring

The i-IONM technique is useful in thyroid surgery in three main areas:

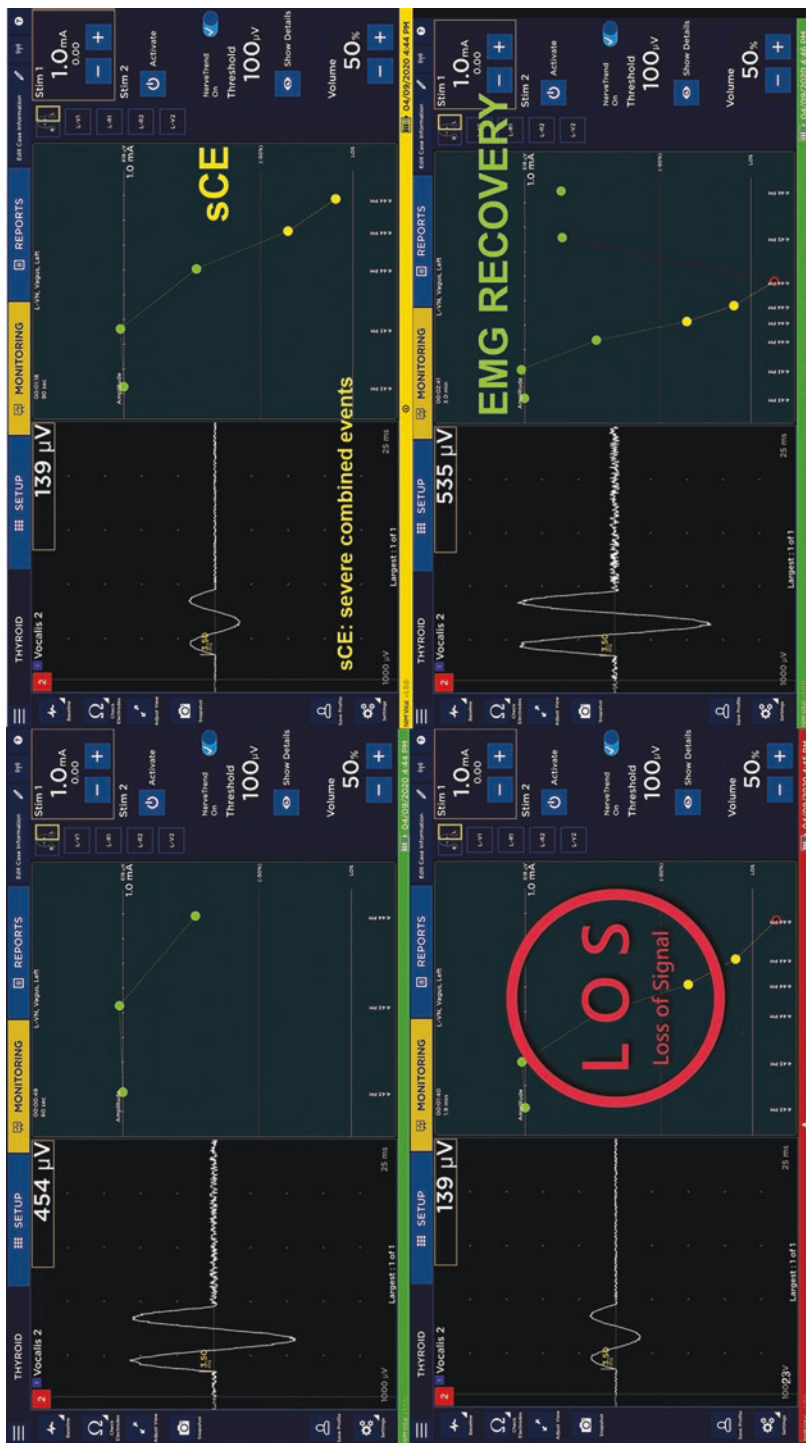
1. In aiding identification of the RLN (which includes both confirmation of the accuracy of the visual identification of RLN, as well as the use of the RLN neuromapping technique in the peritracheal area to identify the nerve before it is exposed in the operating field),
2. During tissue preparation, because after the identification of the RLN, repeated stimulation of the surrounding tissues and the nerve itself allows for the location of the further course of the nerve in the operating field, which is particularly important in cases of reoperation in a scarred operative field or operations in an altered field (e.g., advanced thyroid cancer),
3. In the intraoperative assessment of RLN activity and prognosis of postoperative nerve function and, in cases of loss of signal (LOS), also the identification of the nature of the damage (anatomical vs. functional while maintaining the anatomical integrity of the nerve), differentiating segmental (type I) from global (type II) lesions, and in cases of segmental (type I) lesions also locating the damage site and explaining the mechanism of RLN damage.

In practice, the very high negative predictive value of IONM method, exceeding 99.8%, allows for the safe continuation of the planned bilateral thyroidectomy if the correct neuromonitoring signal is maintained after the first lobe excision, practically eliminating the possibility of bilateral damage to the RLN. Hence, many authors believe that neuromonitoring is a tool that allows the risk of bilateral damage to the vocal folds to be reduced to zero, provided that the tactics of surgical treatment include the concept of staged thyroidectomy, in cases of neuromonitoring LOS on the first operated side.

---

## 12.4 NerveTrend Mode of Intermittent Intraoperative Neuromonitoring

The fourth generation of nerve integrity monitoring (NIM) systems introduced on the market in 2020 (NIM Vital) expanded the i-IONM format by adding a new NerveTrend mode in which electromyography (EMG) reporting – from vagus nerve (VN), RLN, or EBSLN – enables nerve condition tracking throughout a procedure, even when using intermittent nerve monitoring. After an initial probe stimulated EMG baseline trended readings at the same location on the nerve, NIM NerveTrend EMG reporting can enable comparisons of EMG amplitude and latency trends relative to the subsequent probe measurements manually captured throughout the case. A significant decrease in amplitude and/or increase in latency can signal degradation of the nerve condition. In addition, green, yellow and red color-coded EMG reporting and associated audible tones can help to understand when significant EMG changes occur and can help inform surgical strategy (Fig. 12.1). Potential benefits of NIM NerveTrend mode are: no additional cost over i-IONM, it is easy to use, it provides almost real-time feedback, it tracks functional status of the nerve, it is a step forward in prognostic calculation of the EMG tracings, its intuitive display is easy to follow even during challenging operations. Potential limitations of this mode are: it is an operator-dependent technique (manual trending); potential variability of stimulation site – VN vs. RLN – may occur; it may be more challenging to stimulate the VN in obese patients and in patients with a large thyroid volume; clinical evidence of its accuracy is in progress, as a randomized controlled trial (RCT) is ongoing (see details on: [www.clinicaltrials.gov](http://www.clinicaltrials.gov), NCT04794257). However, data recently presented by Barczyński et al. in Vienna during the International Association of Endocrine Surgeons (IAES) 2022 meeting which were based on the interim safety analysis of the ongoing RCT were favorable for the NerveTrend mode when compared to the i-IONM mode (personal communication; data not published). Of 132 nerves at risk in each group (NerveTrend vs. i-IONM), transient and permanent RLN injuries were found respectively in 1 (0.76%) vs. 7 (5.30%) nerves ( $p = 0.03$ ) and 0 (0%) vs. 2 (1.51%) nerves (non-significant difference). Severe combined events occurred in 12 (9.0%) nerves at risk operated on with NerveTrend but were reversible in 11 of 12 cases (91.66%). Hence, the system seems to alert the surgeon to the imminent nerve injury in time as the majority of intraoperative nerve events were reversible. This initial observation needs to be validated further in an ongoing RCT until a designated power of the study is reached.



**Fig. 12.1** NerveTrend mode allows for tracking the electromyographic (*EMG*) signals from the vocalis muscles and warns the surgeon on the impending nerve injury with severe combined events (*sCEs*) or loss of signal (*LOS*). *EMG* recovery allows for safe continuation of the surgical plan

## 12.5 Continuous Intraoperative Neuromonitoring

The c-IONM technique is based on the use of an electrode placed on the VN, through which the neuromonitor continuously and automatically checks the activity of the RLN by analyzing the EMG recordings from the vocal muscles, comparing the instantaneous parameters during the procedure with the initial baseline parameters at the beginning of the procedure.

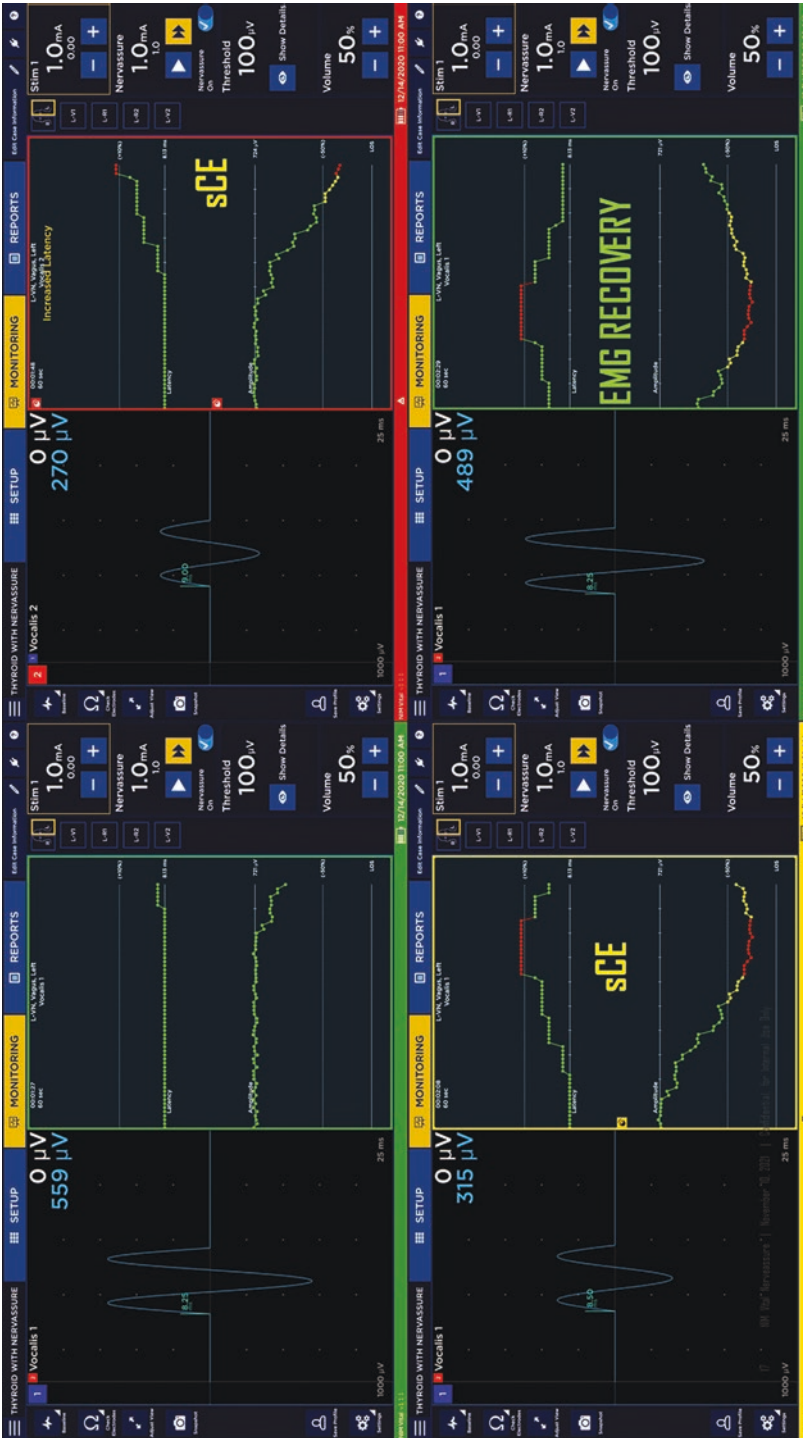
In the event of repeated EMG phenomena forecasting nerve damage (reduction of the signal amplitude by more than 50% and extension of the EMG signal latency by more than 10%), which are mostly reversible, the device warns the surgeon with an acoustic signal, allowing for corrective action to avoid complete LOS, which is synonymous with functional damage to the nerve (Fig. 12.2).

Taking into consideration that the majority of RLN injuries occur in a time-dissociated manner, as an accumulation of microinjuries to the nerve deriving from surgical manipulations (traction, pulling, pressure), a temporary cessation of tissue preparation until the EMG recording improves enables the occurrence of RLN damage to be prevented. Hence, c-IONM is a technology that allows the surgeon to: recognize impending RLN injury during thyroidectomy; correct surgical maneuvers so that RLN damage does not occur; and verify the return of RLN function after intraoperative EMG LOS.

Recently, it was shown in 788 patients (1314 nerves at risk) that immediate reaction by withdrawing nerve tension prevented progression to LOS in 80% (63/77 patients) of combined events [8]. More recently, a study of 455 continuously stimulated nerves at risk revealed that the immediate release of retraction successfully preserved the nerve function in all cases with impending injury [9].

As shown by an international multicenter study of 115 LOS cases at the end of surgery, 80% (92/115 patients) of LOS are caused by traction of the RLN [10]. It was established in an international multicenter study of 68 patients (68 nerves at risk) that amplitude recovery  $\geq 50\%$  relative to baseline reliably predicted normal early postoperative vocal cord function in all patients after transient segmental LOS or global LOS [11]. On receiver-operating characteristics analysis, relative and absolute amplitude recovery of 49% and 455  $\mu\text{V}$  (both  $p < 0.001$ ) after segmental LOS type 1 and 44% ( $p = 0.01$ ) or 253  $\mu\text{V}$  ( $p = 0.15$ ) after global LOS type 2 differentiated best between normal and impaired early postoperative vocal cord function. Practically then it may be justifiable to use one amplitude recovery threshold of  $\geq 50\%$  for both types of LOS. This single threshold accurately predicts normal early postoperative vocal cord function after segmental LOS, but may slightly underestimate normal early postoperative vocal cord function after global LOS (the less serious form of nerve injury).

Hence, the c-IONM technique has a potential of preventing unilateral RLN injury, which is not the case for the i-IONM technique. As shown by data published by Schneider et al. based on a total of 6029 patients, of whom 3139 underwent continuous and 2890 intermittent IONM (5208 vs. 5024 nerves at risk, respectively), c-IONM had a 1.7-fold lower early postoperative vocal cord palsy rate than i-IONM (1.5% vs. 2.5%). This translated into a 30-fold lower permanent vocal cord palsy



**Fig. 12.2** NerveAssure mode (c-IONM) allows for tracking the electromyographic (EMG) signals from the vocalis muscles and warns the surgeon on the impending nerve injury with severe combined events (sCEs), or loss of signal (LOS). EMG recovery allows for safe continuation of the surgical plan

rate (0.02% vs. 0.6%). In multivariable logistic regression analysis, c-IONM independently reduced early postoperative vocal cord palsy 1.8-fold (odds ratio [OR] 0.56) and permanent vocal cord palsy 29.4-fold (OR 0.034) compared with i-IONM. One permanent vocal cord palsy per 75.0 early vocal cord palsies was observed with c-IONM, compared with one per 4.2 after i-IONM. Early postoperative vocal cord palsies were 17.9-fold less likely to become permanent with c-IONM than with i-IONM [12]. These data have clearly demonstrated that c-IONM is superior to i-IONM in preventing vocal cord palsy. Similar conclusions were drawn based on the meta-analysis of recently published data in the field [13].

---

## 12.6 Monitoring of the External Branch of the Superior Laryngeal Nerve

When using the IONM method, one should not forget about the usefulness of this technique in identifying and maintaining EBSLN functional integrity.

The prevalence of EBSLN injury is underestimated and, according to many authors, reaches 20%. This injury causes paralysis of the cricothyroid muscle impairing the production of high tones, and altering the voice's fundamental frequency, which may be especially problematic for women and voice professionals. The EBSLN has a close anatomical relationship with the superior thyroid pedicle and is at risk of injury during dissection of these vessels in approximately one-third of patients.

In patients with a large goiter, a thyroid tumor localized within the upper thyroid pole or in patients with a short neck, the anatomical relationship between the nerve and the superior thyroid pole vessel can be much more intimate, making the EBSLN particularly prone to inadvertent injury. The most widely recognized surgical classification of the EBSLN was proposed in 1992 by Cernea et al.

The Cernea EBSLN classification scheme identifies three types of anatomical relationship:

- Type 1 nerve crosses the superior thyroid vessels more than 1 cm above the upper edge of the thyroid superior pole and occurs in 68% of patients with small goiter and in 23% of patients with large goiter.
- Type 2A nerve crosses the vessels less than 1 cm above the upper edge of the superior pole and occurs in 18% of patients with small goiter and 15% of patients with large goiter.
- Type 2B nerve crosses the superior thyroid pedicle below the upper border of the superior thyroid pole and occurs in 14% of patients with small goiters and 54% of patients with large goiters.

Types 2A and 2B are particularly prone to injury during dissection and ligation of the superior thyroid vessels due to their low-lying course.

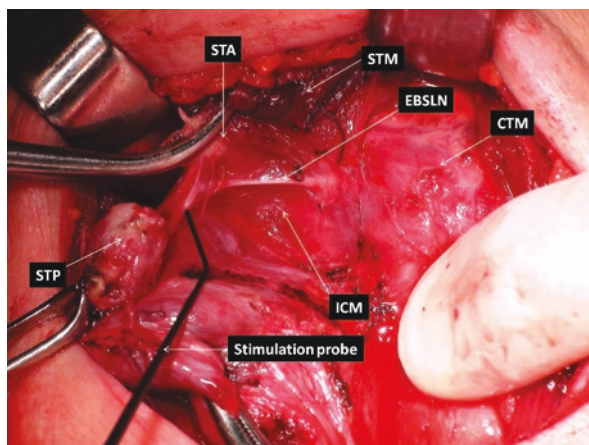
The use of tissue stimulation in the area of the upper pole of the thyroid gland before ligating these vessels allows for reliable identification of the EBSLN, as it



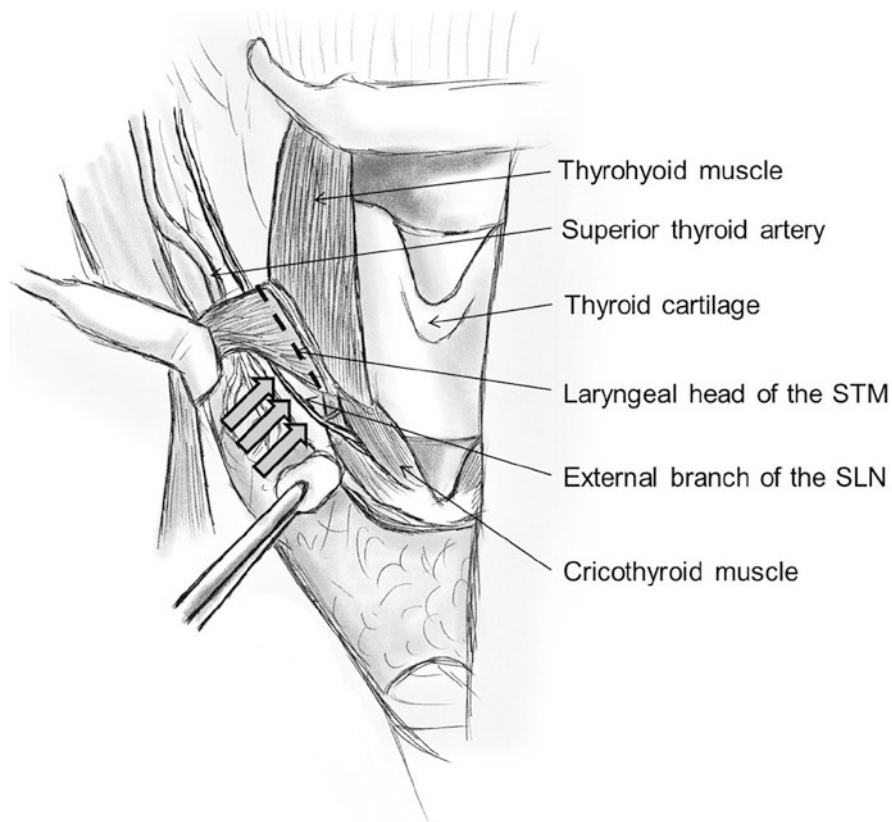
results in an easy to observe contraction of the cricothyroid muscle. Nevertheless, in contrast to RLN monitoring, EBSLN monitoring is based on two distinct outcome measures following the stimulation of the EBSLN: evaluation of cricothyroid twitch (present in all patients) and EMG glottis response of vocal cord depolarization identified on surface endotracheal tube electrode arrays in approximately 70–80% of patients when using standard EMG tubes. However, a novel EMG tube with additional and more proximally located anterior surface electrodes allowed for identification of EMG response after stimulation of the EBSLN in all (100%) patients.

Visual identification of the EBSLN can be confirmed by applying the stimulation probe directly to the nerve (if seen) above the entry point into the cricothyroid muscle (Fig. 12.3). To facilitate localization of the EBSLN it is recommended to stimulate tissues parallel and underneath the laryngeal head of the sternothyroid muscle which can be regarded as a highly reliable landmark for the identification of the EBSLN in its distal course before termination within the cricothyroid muscle (Fig. 12.4). A technique of toggling the stimulator probe between the tissue of the superior thyroid pole vessels (with negative stimulation) and the region of the laryngeal head of the sternothyroid muscle (with positive stimulation) is recommended to assure preservation of the EBSLN. The role of measuring the waveform amplitude in prognostication of EBSLN function is yet to be determined.

In conclusion, monitoring of the EBSLN is of enormous importance in improving the quality of life of patients undergoing surgery for various thyroid diseases, including thyroid cancer, as it increases the chances of preserving the timbre and voice register after surgery.



**Fig. 12.3** The right-sided intraoperative view: step by step ligation of individual branches of the superior thyroid artery can be undertaken under both visual control and stimulation of the external branch of the superior laryngeal nerve (*EBSLN*) to assure not only anatomical but also functional preservation of the nerve which can be documented as a positive cricothyroid twitch. *CTM* cricothyroid muscle, *ICM* inferior constrictor muscle, *STA* superior thyroid artery, *STM* sternothyroid muscle, *STP* superior thyroid pole



**Fig. 12.4** Stimulation of tissues parallel and underneath the laryngeal head of the sternothyroid muscle (marked with the dashed line) allows for the identification of the external branch of the superior laryngeal nerve in its distal course (*large arrows*) before entering the cricothyroid muscle. *STM* sternothyroid muscle, *SLN* superior laryngeal nerve

## References

1. Barczyński M, Konturek A, Cichoń S. Randomized clinical trial of visualization versus neuro-monitoring of recurrent laryngeal nerves during thyroidectomy. *Br J Surg.* 2009;96(3):240–6.
2. Randolph GW, Dralle H; International Nerve Monitoring Study Group, et al. Electrophysiologic recurrent laryngeal nerve monitoring during thyroid and parathyroid surgery: international standards guideline statement. *Laryngoscope* 2011;121(Suppl 1):S1–16.
3. Barczyński M, Randolph GW, Cernea CR, et al. External branch of the superior laryngeal nerve monitoring during thyroid and parathyroid surgery: international neural monitoring study group standards guideline statement. *Laryngoscope.* 2013;123(Suppl 4):S1–14.
4. Schneider R, Randolph GW, Dionigi G, et al. International neural monitoring study group guideline 2018 part I: staging bilateral thyroid surgery with monitoring loss of signal. *Laryngoscope.* 2018;128(Suppl 3):S1–17.
5. Wu CW, Dionigi G, Barczyński M, et al. International Neuromonitoring study group guidelines 2018: part II: optimal recurrent laryngeal nerve management for invasive thyroid

- cancer-incorporation of surgical, laryngeal, and neural electrophysiologic data. *Laryngoscope*. 2018;128(Suppl 3):S18–27.
6. Wu CW, Huang TY, Randolph GW, et al. Informed consent for intraoperative neural monitoring in thyroid and parathyroid surgery – consensus statement of the international neural monitoring study group. *Front Endocrinol (Lausanne)*. 2021;12:795281.
  7. Wu CW, Randolph GW, Barczyński M, et al. Training courses in laryngeal nerve monitoring in thyroid and parathyroid surgery – the INMSG consensus statement. *Front Endocrinol (Lausanne)*. 2021;12:705346.
  8. Schneider R, Sekulla C, Machens A, et al. Postoperative vocal fold palsy in patients undergoing thyroid surgery with continuous or intermittent nerve monitoring. *Br J Surg*. 2015;102(11):1380–7.
  9. Kandil E, Mohsin K, Murcy MA, Randolph GW. Continuous vagal monitoring value in prevention of vocal cord paralysis following thyroid surgery. *Laryngoscope*. 2018;128(10):2429–32.
  10. Schneider R, Randolph G, Dionigi G, et al. Prospective study of vocal fold function after loss of the neuromonitoring signal in thyroid surgery: the international neural monitoring study Group’s POLT study. *Laryngoscope*. 2016;126(5):1260–6.
  11. Phelan E, Schneider R, Lorenz K, et al. Continuous vagal IONM prevents recurrent laryngeal nerve paralysis by revealing initial EMG changes of impending neuropraxic injury: a prospective, multicenter study. *Laryngoscope*. 2014;124(6):1498–505.
  12. Schneider R, Machens A, Sekulla C, et al. Superiority of continuous over intermittent intraoperative nerve monitoring in preventing vocal cord palsy. *Br J Surg*. 2021;108(5):566–73.
  13. Ku D, Hui M, Cheung P, et al. Meta-analysis on continuous nerve monitoring in thyroidectomies. *Head Neck*. 2021;43(12):3966–78.

**Open Access** This chapter is licensed under the terms of the Creative Commons Attribution-NonCommercial-NoDerivatives 4.0 International License (<http://creativecommons.org/licenses/by-nc-nd/4.0/>), which permits any noncommercial use, sharing, distribution and reproduction in any medium or format, as long as you give appropriate credit to the original author(s) and the source, provide a link to the Creative Commons license and indicate if you modified the licensed material. You do not have permission under this license to share adapted material derived from this chapter or parts of it.

The images or other third party material in this chapter are included in the chapter’s Creative Commons license, unless indicated otherwise in a credit line to the material. If material is not included in the chapter’s Creative Commons license and your intended use is not permitted by statutory regulation or exceeds the permitted use, you will need to obtain permission directly from the copyright holder.





# Autotransplantation of the Parathyroid Glands in Thyroidectomy: The Role of Autofluorescence and Indocyanine Green

# 13

Lodovico Rosato and Luca Panier Suffat

## 13.1 Introduction

Recognition of the “glandulae parathyroideae” in humans has been defined as the last anatomical discovery. It dates back to 1877 and it is owed to Ivor Sandström, a medical student at the Uppsala Department of Anatomy [1].

In 1883, Emil Theodor Kocher observed, as suggested by Jacques-Louis Reverdin, that patients undergoing total thyroidectomy (TT) always presented myxedema and at times even tetany. On the contrary, those who underwent subtotal thyroidectomy, following Theodor Billroth’s preferred surgical technique, never manifested myxedema but often developed tetany. Therefore, Kocher empirically decided to adopt the following surgical strategy: only lobectomy in the first place, and subtotal resection of the contralateral lobe only in the case of relapse [2].

In 1891, Marcel Eugène Gley realized that post-thyroidectomy tetany in dogs was due to the concurrent removal of the parathyroid glands (PGs) [3]. However, even though this proved the causal link, it was not sufficient to explain the phenomenon. In 1908, William G. MacCallum and Carl Voegtlin discovered that the PGs regulate the blood level of calcium, and they started to treat post-thyroidectomy tetany by administering this electrolyte [4]. In 1923, Harald Salvesen demonstrated that post-surgical tetany was caused by the removal of the PGs. Since then, it was clear that, when performing TT, the PGs had to be identified and safeguarded so as to prevent parathyroprival tetany.

Thyroid surgery has been aptly termed surgery of the recurrent laryngeal nerves and PGs. In fact, these are the only anatomical structures that can suffer even significant damage after a TT. Hypocalcemia due to hypoparathyroidism is the most frequent complication. After TT, about 50% of patients have altered serum calcium

---

L. Rosato · L. Panier Suffat (✉)

Department of Oncology and Surgery, Unit of General Surgery, Ivrea Hospital, Ivrea, TO, Italy

e-mail: [lodovico.rosato@unito.it](mailto:lodovico.rosato@unito.it); [luca.panier@libero.it](mailto:luca.panier@libero.it)

© The Author(s) 2024

M. Testini, A. Gurrado (eds.), *Thyroid Surgery*, Updates in Surgery, [https://doi.org/10.1007/978-3-031-31146-8\\_13](https://doi.org/10.1007/978-3-031-31146-8_13)

123

values, which are associated with clinical signs of hypocalcemia in 14% of cases but which normalize in the vast majority of patients within a couple of weeks or within the first year after surgery at the latest [5]. In 2–3% of cases, hypocalcemia may persist throughout life, accompanied by very low or null values of parathyroid hormone (PTH) [6]. Multicenter studies have published much higher incidence rates of up to 16.7% which, if more uniform criteria to define hypocalcemia are applied, result in a 7.9% incidence of persistent hypoparathyroidism [7].

Even more evident is the incidence of forensic litigation for permanent hypocalcemia, which reaches 9% of all claims for post-thyroidectomy complications [8]. The epidemiological aspects and the repercussions, also in terms of the financial burden of chronic hypoparathyroidism on the expenditure of private individuals and national health services, remain to be assessed [9].

---

### 13.2 The Issue of Maintaining the Functionality of the Parathyroid Glands

How many PGs need to be preserved to maintain a normal serum calcium level? The PG is functionally unique, even though divided into four portions of about 30–40 mg each for a total of 120–160 mg. It follows that either the residual parathyroid tissue replaces the missing tissue to produce the necessary amount of PTH or parathyroid function will remain deficient. However, each individual parathyroid has its own calcium set point (which can be defined as the level of extracellular calcium that causes a 50% reduction of the maximum secretion of PTH) and can respond in a unique way to calcemic stimuli. Therefore, the number of PGs needed to ensure parathyroid function is not definable.

The arterial vascularization of the PGs is of the terminal type and any surgical maneuver that damages it will cause partial or total ischemia of the affected gland. The upper and lower PGs are supplied by the lower thyroid artery. In about 20% of cases, the upper PGs are supplied by the posterior branch of the superior thyroid artery [10], which should therefore not be tied and interrupted during thyroidectomy. The PGs must be carefully separated from the thyroid capsule and each small peripheral arterial branch will be interrupted distal to the PGs to preserve the blood supply.

Utmost care must be taken to safeguard PG vascularity. PGs, like all endocrine glands, do not have an excretory duct as hormone secretion occurs through the venous network. Therefore, ensuring integrity of the arterial supply, although necessary, is not sufficient to guarantee gland function, which requires as much care in safeguarding venous vascularity [11] as well. Preservation of the venous branches of the PGs that flow into the lower thyroid veins reduces the risk of postoperative hypocalcemia and allows for a faster recovery of normal calcium levels [12].

If the PGs are anatomically well protected within the parathyroid capsule, it will be easier for the surgeon to avoid damaging them. If, on the other hand, they adhere tenaciously to the thyroid capsule and take the venous vascularization largely or even exclusively, as occurs in 7–8% of cases, from the thyroid, they will have to be

carefully isolated, trying as much as possible to safeguard the residual venous vascularity [13]. In the case of venous congestion or glandular hemorrhagic infarction, an incision of the parathyroid capsule is needed for decompression purposes. Scrupulous surgical compliance with the anatomical and vascular integrity of the PGs during TT will not, however, always correspond to sufficient parathyroid function [11].

---

### 13.3 Requirements for Adequate Localization of the Parathyroid Glands

A surgeon experienced in thyroid and parathyroid surgery able to visually recognize the PGs is the first requirement. However, even experienced surgeons might not always be able to identify all the PGs during TT and they may be unable to identify any of them with certainty [14].

To this end, it is useful to repeatedly touch with the tip of a blunt instrument what is presumed to be parathyroid tissue since this, which is very similar in color to adipose tissue, will take on a characteristic chamois color within seconds, thus facilitating its identification. If the PGs do not manifest easily, one should not persist in the search owing to the risk of devascularizing them. It is important, however, to make sure that the glands are not attached to the removed thyroid capsule [15].

The combined use of magnification loupes (2.5× or 3.5×) with an ultrasound/radiofrequency device or bipolar forceps is recommended. Use of magnification loupes allows for a clearer and sharper view of the anatomy. The associated use of an appropriate device allows for more effective hemostasis, improving precision of the surgical gesture with a bloodless operating field and a significant reduction in operating times [16, 17].

To further minimize the risk of parathyroid lesions, it may be helpful to support naked eye recognition with near-infrared autofluorescence imaging (NIR-AF). As demonstrated by a pilot study published in 2011, the fluorescence intensity of PGs is consistently greater than that of the thyroid and all other neck tissues [18]. This allows recognition of the PGs, which display autofluorescence when imaged by the camera. At the end of the TT, after intravenous injection of indocyanine green (ICG), the good vascularity of the PGs can be verified by identifying their vessels. ICG is an inert, hydrosoluble organic dye containing 5% sodium iodine and which, when administered intravenously, binds to the plasma lipoproteins. It has a very short half-life ( $3.4 \pm 0.7$  minutes). Considering the presence of iodine, it must not be administered to those who are allergic to the substance.

NIR-AF imaging of the PGs during thyroidectomy can indeed help identify and preserve the PGs. This is particularly important if we consider that the incidence of involuntary removal of the PGs and the finding of parathyroid tissue on the pathology report is relatively frequent, being noted in almost 25% of cases [7, 19, 20].

However, NIR-AF does not significantly reduce the incidence of parathyroid hypocalcemia [21].

The combined use of NIR-AF to detect PGs and infusion of ICG after TT to verify preservation of PG vascularity is a promising technique. In fact, it appears to reduce the risk of transient postoperative hypocalcemia and it allows safer preservation of the PGs by evaluating their perfusion, thus avoiding unnecessary reimplantation [22].

However, recent studies show no significant difference in the number of auto-transplanted PGs, which is what we would expect [23, 24]. To date, in fact, conflicting opinions persist on a clear clinical benefit that might justify the routine use of this method [25, 26].

---

### 13.4 Reimplantation of Parathyroid Glands

A PG that accidentally remains devascularized should be reimplanted. Parathyroid autotransplantation during thyroidectomy was first described in 1926 by Frank H. Lahey [27]. Since then, many studies have shown that autotransplantation is an effective procedure in preserving against permanent [28, 29] and temporary [30] postoperative hypoparathyroidism.

The gland must first be fragmented into  $1 \times 2$ -mm segments to maximize its contact surface with the muscle pocket. One fragment is intended for extemporaneous histological examination to verify the diagnosis of parathyroid tissue. Hemostasis of the recipient pocket must be carefully managed to avoid the onset of hematomas that could compromise the engraftment. The muscle pocket is closed with a non-absorbable suture, on which a titanium clip can be affixed to allow recovery of the PG, should it be necessary in the future (hyperparathyroidism) [31].

The most commonly used sites for reimplantation are the brachioradial muscle of the non-dominant forearm or the subcutaneous tissue of the forearm [32], and the ipsilateral sternocleidomastoid muscle. However, the sternocleidomastoid is the preferred site both because it avoids further surgical access and because the risk of having to remove reimplanted parathyroid tissue that has become pathological is extremely low [31].

Already in 1975, Hickey and Wells demonstrated the effectiveness of the PTH production by the autotransplanted tissue [28, 33]. Therefore, any devascularized gland should be reimplanted as autotransplantation is an effective means of restoring parathyroid function and can prevent permanent hypoparathyroidism [29], with a graft survival rate of 93% [28]. It is clearly impossible to demonstrate with certainty the clinical efficacy of parathyroid autotransplantation after TT because the PGs are normally four, but they can also be three (3%) or five (13%) and it is uncommon for all of them to be removed or devascularized at the same time [10].

Reasonably, the greater the number of devascularized glands, the greater the patient's risk of having post-surgical hypocalcemia, even after reimplantation. In fact, the best guarantee for post-thyroidectomy normocalcemia is to preserve the anatomical and vascular integrity of all the PGs by means of an accurate and gentle surgical gesture.

Although not recently, some authors [34, 35] have recommended the routine prophylactic application of PG autotransplantation in all cases of TT, reporting 0% postoperative hypoparathyroidism, but a significantly higher rate of transient hypocalcemia. Nonetheless, this position does not seem to be embraceable, as the same result can be obtained if we undertake to respect the anatomical integrity and vascularity of the PGs.

---

## References

1. Sandström IV. On a new gland in man and several mammals – glandulae parathyroideae. *Upsala Läk Förenings Förh.* 1879-1880;15:441–71.
2. Hannan SA. The magnificent seven: a history of modern thyroid surgery. *Int J Surg.* 2006;4(3):187–91.
3. Gley ME. Sur les fonctions du corps thyroid. *C R Séances Soc Biol Fil.* 1891;43:841–3.
4. MacCallum WG, Voegtlin C. On the relation of tetany to the parathyroid glands and to calcium metabolism. *J Exp Med.* 1909;11(1):118–51.
5. Villarroya-Marquina I, Sancho J, Lorente-Poch L, et al. Time to parathyroid function recovery in patients with protracted hypoparathyroidism after total thyroidectomy. *Eur J Endocrinol.* 2018;178(1):103–11.
6. Rosato L, Avenia N, Bernante P, et al. Complications of thyroid surgery: analysis of a multicentric study on 14,934 patients operated on in Italy over 5 years. *World J Surg.* 2004;28(3):271–6.
7. Lončar I, van Kinschot CMJ, van Dijk SPJ, et al. Persistent post-thyroidectomy hypoparathyroidism: a multicenter retrospective cohort study. *Scand J Surg.* 2022;111(2):14574969221107282.
8. Padovano M, Scopetti M, Tomassi R, et al. Mapping complications in thyroid surgery: statistical data are useful for medico-legal management of a recurrent safety issue. *Updat Surg.* 2022;74(5):1725–32.
9. Bjornsdottir S, Ing S, Mitchell DM, et al. Epidemiology and financial burden of adult chronic hypoparathyroidism. *J Bone Miner Res.* 2022;37(12):2602–14.
10. Burger F, Fritsch H, Zwierzina M, et al. Postoperative hypoparathyroidism in thyroid surgery: anatomic-surgical mapping of the parathyroids and implications for thyroid surgery. *Sci Rep.* 2019;9(1):15700.
11. Rosato L, De Crea C, Bellantone R, et al. Diagnostic, therapeutic and health-care management protocol in thyroid surgery: a position statement of the Italian Association of Endocrine Surgery Units (U.E.C. CLUB). *J Endocrinol Investig.* 2016;39(8):939–53.
12. Lee DY, Cha W, Jeong WJ, et al. Preservation of the inferior thyroidal vein reduces post-thyroidectomy hypocalcemia. *Laryngoscope.* 2014;124(5):1272–7.
13. Cui Q, Li Z, Kong D, et al. A prospective cohort study of novel functional types of parathyroid glands in thyroidectomy: in situ preservation or auto-transplantation? *Medicine (Baltimore).* 2016;95(52):e5810.
14. Gschwandtner E, Seemann R, Bures C, et al. How many parathyroid glands can be identified during thyroidectomy?: evidence-based data for medical experts. *Eur Surg.* 2018;50(1):14–21.
15. Puzziello A, Rosato L, Innaro N, et al. Hypocalcemia following thyroid surgery: incidence and risk factors. A longitudinal multicenter study comprising 2,631 patients. *Endocrine.* 2014;47(2):537–42.
16. Sapalidis K, Papanastasiou A, Fyntanidou V, et al. Comparison between magnification techniques and direct vision in thyroid surgery: a systematic review and meta-analysis. *Medicina (Kaunas).* 2019;55(11):725.
17. Suffat LP, Lavorini E, Mondini G, et al. Does the combined use of magnification loupes and harmonic FOCUS improve the outcome of thyroid surgery? *World J Endoc Surg.* 2020;12(1):18–22.



18. Paras C, Keller M, White L, et al. Near-infrared autofluorescence for the detection of parathyroid glands. *J Biomed Opt.* 2011;16(6):067012.
19. Paek SH, Lee YM, Min SY, et al. Risk factors of hypoparathyroidism following total thyroidectomy for thyroid cancer. *World J Surg.* 2013;37(1):94–101.
20. Díez JJ, Anda E, Sastre J, et al. Prevalence and risk factors for hypoparathyroidism following total thyroidectomy in Spain: a multicentric and nation-wide retrospective analysis. *Endocrine.* 2019;66(2):405–15.
21. Wolf HW, Runkel N, Limberger K, et al. Near-infrared autofluorescence of the parathyroid glands during thyroidectomy for the prevention of hypoparathyroidism: a prospective randomized clinical trial. *Langenbeck's Arch Surg.* 2022;407(7):3031–8.
22. Iritani K, Teshima M, Shimoda H, et al. Intraoperative quantitative assessment of parathyroid blood flow during total thyroidectomy using indocyanine green fluorescence imaging – surgical strategies for preserving the function of parathyroid glands. *Laryngoscope Investig Otolaryngol.* 2022;7(4):1251–8.
23. Yin S, Pan B, Yang Z, et al. Combined use of autofluorescence and indocyanine green fluorescence imaging in the identification and evaluation of parathyroid glands during total thyroidectomy: a randomized controlled trial. *Front Endocrinol (Lausanne).* 2022;13:897797.
24. Barbieri D, Indelicato P, Vinciguerra A, et al. Autofluorescence and indocyanine green in thyroid surgery: a systematic review and meta-analysis. *Laryngoscope.* 2021;131(7):1683–92.
25. Di Marco A, Chotalia R, Bloxham R, et al. Does fluoroscopy prevent inadvertent parathyroidectomy in thyroid surgery? *Ann R Coll Surg Engl.* 2019;101(7):508–13.
26. Benmiloud F, Godiris-Petit G, Gras R, et al. Association of autofluorescence-based detection of the parathyroid glands during total thyroidectomy with postoperative hypocalcemia risk: results of the PARAFUO multicenter randomized clinical trial. *JAMA Surg.* 2020;155(2):106–12.
27. Lahey FH. The transplantation of parathyroids in partial thyroidectomy. *Surg Gynecol Obstet.* 1926;62:508–9.
28. Wells SA Jr, Gunnells JC, Shelburne JD, et al. Transplantation of the parathyroid glands in man: clinical indication and results. *Surgery.* 1975;78(1):34–44.
29. Hicks G, George R, Sywak M. Short and long-term impact of parathyroid autotransplantation on parathyroid function after total thyroidectomy. *Gland Surg.* 2017;6(Suppl 1):S75–85.
30. Testini M, Rosato L, Avenia N, et al. The impact of single parathyroid gland autotransplantation during thyroid surgery on postoperative hypoparathyroidism: a multicenter study. *Transplant Proc.* 2007;39(1):225–30.
31. D'Avanzo A, Parangi S, Morita E, et al. Hyperparathyroidism after thyroid surgery and autotransplantation of histologically normal parathyroid glands. *J Am Coll Surg.* 2000;190(5):546–52.
32. Cavallaro G, Iorio O, Centanni M, et al. Parathyroid reimplantation in forearm subcutaneous tissue during thyroidectomy: a simple and effective way to avoid hypoparathyroidism. *World J Surg.* 2015;39(8):1936–42.
33. Hickey RC, Samaan NA. Human parathyroid autotransplantation: proved function by radioimmunoassay of plasma parathyroid hormone. *Arch Surg.* 1975;110(8):892–5.
34. Zedenius J, Wadstrom C, Delbridge L. Routine autotransplantation of at least one parathyroid gland during total thyroidectomy may reduce permanent hypoparathyroidism to zero. *Aust N Z J Surg.* 1999;69(11):794–7.
35. Lo CY, Lam KY. Routine parathyroid autotransplantation during thyroidectomy. *Surgery.* 2001;129:318–23.

**Open Access** This chapter is licensed under the terms of the Creative Commons Attribution-NonCommercial-NoDerivatives 4.0 International License (<http://creativecommons.org/licenses/by-nc-nd/4.0/>), which permits any noncommercial use, sharing, distribution and reproduction in any medium or format, as long as you give appropriate credit to the original author(s) and the source, provide a link to the Creative Commons license and indicate if you modified the licensed material. You do not have permission under this license to share adapted material derived from this chapter or parts of it.

The images or other third party material in this chapter are included in the chapter's Creative Commons license, unless indicated otherwise in a credit line to the material. If material is not included in the chapter's Creative Commons license and your intended use is not permitted by statutory regulation or exceeds the permitted use, you will need to obtain permission directly from the copyright holder.





# Energy Devices, Hemostatic Agents, and Optical Magnification in Thyroid Surgery

# 14

Roberto M. Romano, Marcello Filograna Pignatelli,  
Sonia Ferrandes, and Giovanni Docimo

## 14.1 Energy Devices

Thyroid diseases are the most common endocrine disorders [1]. The thyroid is a richly vascularized organ and the achievement of hemostasis during surgery is an issue of great interest to the surgeon. Hemorrhage makes the surgical field dangerous, increasing the risk of damage to adjacent anatomical structures, such as the recurrent laryngeal nerve, the parathyroid glands and the esophagus [2]. Additionally, postoperative bleeding can cause hematoma or seroma, with upper airway obstruction and subsequent hypoxic brain damage. The techniques used for the management of hemostasis are many and include standard vessel ligation and section, monopolar or bipolar electrocautery and the use of monopolar, bipolar, ultrasound and mixed-energy devices. The temperatures generated during electrocautery are high (150–400 °C) and they are responsible for severe damage to adjacent tissues. Electrical and ultrasound energy are generally used in numerous surgical procedures, including thyroid surgery, and they have demonstrated their absolute safety and efficacy, as these devices stop working once the coagulum has already formed, limiting the possibility of overheating. Widely discussed in the literature is the issue of the temperature in the tissue, which decreases from the instrument tips to the periphery, and the damage due to the lateral spread of heat; safety margins are fixed between 3 and 5 mm from healthy tissue with a required cooling time of the tool [3–5]. In addition, various prospective randomized studies have shown how the use

---

R. M. Romano · M. Filograna Pignatelli · S. Ferrandes  
Thyroid Surgery Unit, University Hospital Luigi Vanvitelli, Naples, Italy  
e-mail: [robertomaria.romano@gmail.com](mailto:robertomaria.romano@gmail.com); [marcello991@hotmail.it](mailto:marcello991@hotmail.it);  
[soniaferrandes@tiscali.it](mailto:soniaferrandes@tiscali.it)

G. Docimo (✉)  
Department of Advanced Medical and Surgical Sciences, University of Campania Luigi  
Vanvitelli, Naples, Italy  
e-mail: [giovanni.docimo@unicampania.it](mailto:giovanni.docimo@unicampania.it)

of these devices can shorten operating times and reduce the incidence of postoperative complications [6]. Many devices have been proposed. One of them relies on an ultrasonic coagulating shear able to cut and coagulate by using temperatures that are lower than those delivered by conventional electrosurgical equipment, performing denaturation of proteins and subsequent coaptation, closing the vessel and avoiding bleeding. The design of this hand-operated shear device reproduces the familiar “Kelly clamp” shape, with very thin and delicate tips. The instrument allows the surgeon to easily dissect, as well as clean and cut vessels in tight spaces, lowering the rate of complications such as postoperative transient hypocalcemia, and decreasing operative time and the need for hemostatic agents and postoperative drainage [7]. Another such device consists of an energy generator and a manual tool produced in different shapes and sizes. This device simultaneously uses both the pressure exerted on the vessel by the tool jaws and bipolar electrical energy, which degrades the collagen and elastin making up the vessel wall, reaching temperatures above 42 °C. This system coagulates vessels up to 7 mm in diameter without causing the formation of an intravessel thrombus. It has been shown that the vessels, thus coagulated, resist higher than normal systolic pressures [8]. A newer device that integrates bipolar energy and ultrasound energy has recently been developed, which can seal and cut vessels up to 7 mm in diameter with little thermal diffusion. In previous studies, this device was shown to have a shorter coagulation and resection time than devices using monopolar or bipolar electrical current in a porcine model [9].

The complication rate of these energy devices is superimposable in terms of transient RLN palsy and transient hypocalcemia, as a result of the similar thermal injury caused to the neighboring tissues. Moreover, in the literature sutureless thyroidectomy is widely discussed as being safer and faster than typical surgery, allowing a shorter anesthesia with a low risk of postoperative complications [10].

---

## 14.2 Hemostatic Agents

Surgical treatment of thyroid gland diseases is associated with the possibility of severe postoperative complications. Bleeding after a thyroidectomy is a severe complication, and reoperation due to bleeding may entail further complications, including death [11]. The reported incidence of bleeding after thyroid surgery varies from 0% to 4.2% [12, 13]. In highly experienced departments the rate usually does not exceed 1% [14, 15]. Blood flow through the thyroid gland is high, as the gland has one of the highest blood flow rates in the human body. Hemorrhage in general surgery can be classified into three main categories: primary bleeding, which occurs within the intraoperative period and should be resolved during the operation; reactive bleeding, which may occur within 24 hours of operation and in most cases is caused by a ligature which slips off or by an unacknowledged vessel that starts to bleed once the blood pressure falls back into a normal range postoperatively [16]; secondary bleeding, which occurs 7–10 days postoperatively and is often due to erosion of a vessel from a spreading infection [17].

Standardization of the capsular dissection technique and precise ligation of the arterial supply by enabling meticulous dissection of the thyroid gland have decreased the morbidity and mortality associated with thyroid surgery to less than 1%. Nevertheless, postoperative hematoma remains an uncommon but potentially life-threatening complication of thyroid surgery. The conventional techniques for hemostasis are suture ligation, electrocautery, or surgical clips. Adjacent anatomical structures, such as the RLN and the parathyroid glands, could be inadvertently injured because of difficulties during bleeding control [18].

Over the last two decades, a number of adjuvant hemostatic agents have been developed for hemostasis in thyroid surgery [19]. Hemostatic agents can be divided according to the nature of the material (animal, human, plant and synthetic derivatives), the mechanism of action, and the class to which they belong. According to these criteria, some hemostatic agents belong to the class of drugs, while others were registered as medical devices. These agents have been broadly classified into three groups: topical hemostats, which cause blood to clot at a bleeding surface; sealants, which prevent leakage from tissues including vessels; and adhesives, which bond tissues [20]. Topical hemostats are the most used and typically consist of a mechanical face which promotes clot formation with either thrombin or fibrinogen, used separately or in combination. The most common hemostatic agent in thyroid surgery consists of soft, thin, pliable, flexible pads of collagen derived from bovine dermis, coated with pentaerythritol polyethylene glycol ether tetra-succinimide glutarate (NHS-PEG); it is a surgical sealant indicated for procedures in which control of bleeding or leakage of air or other body fluids is ineffective by conventional surgical techniques. Another very common device is a sterile, fibrous, resorbable hemostat made from pure natural cotton using controlled oxidation technology, which provides a fast and effective local hemostasis, usually within 2 minutes. Other studies support the use of a combination of bovine-derived gelatin matrix and human-derived thrombin as a first-line hemostatic agent in thyroidectomy [21]. It is indicated in surgical procedures as an adjunct to hemostasis, when control of bleeding by ligation or conventional procedures is ineffective. Moreover, some authors suggest that the increased cost of using this hemostatic agent is offset by the reduced operating times and shorter hospital stays [19]. A synthetic oxidized regenerated cellulose polymer has yielded better results in operating time and duration of drain use than a hemostatic agent composed of a layer of soft, lightweight oxidized regenerated cellulose [22].

A recent meta-analysis evaluated the safety of hemostatic agents in comparison to conventional techniques for hemostasis [18]. While hemostatic agents did not significantly decrease the incidence of complications such as hematomas, seromas, infection, RLN injury or hypoparathyroidism, there was a significant decrease in operative time, drain output and hospital stay through the use of hemostatic agents. Additionally, shorter drainage time may decrease the amount of postoperative discomfort. In conclusion, hemostatic agents appear to be useful tools for achieving hemostasis in thyroidectomies, and they have also been shown to decrease drain output and length of hospital stay following thyroidectomy.

### 14.3 Optical Magnification

The use of optical magnification has many potentialities in thyroid surgery. Binocular loupes, endoscopes, exoscopes and microscopes are used for magnification, allowing a detailed visualization of anatomy and tissues, getting also easier and more precise use of surgical instruments, achievement of hemostasis, and placement of sutures. Loupes reach a magnification of 2.5× to 5×, microscopes 6× to 40×, endoscopes and exoscopes 12× to 30×. Despite the many advantages, several surgeons do not yet use magnification because of the increased surgical time, the impractical use of some devices, lens clouding during surgery, and the limitation of the operating field [23].

Magnification can support traditional thyroid surgery in preventing the most common complications: injury to the RLN caused by traction, ligation, section, diathermy injury, clamping and ischemia; injury to the superior laryngeal nerve (SLN); injury to the parathyroid glands (PG); bleeding. Additionally, illumination of the operative field is increased by the led light worn by the operator. There are different routine uses of loupes in thyroid surgery and different authors have suggested using loupe magnification powers of 2.5×, 3×, 4.5×, or from 4× to 10× [24–27]. Use of the microscope is relatively quick to learn and has ergonomic benefits, as it reduces musculoskeletal risk and allows the operator to keep an upright posture during the surgery. The microscope also allows for video recording, which is very important for teaching and medico-legal purposes [26]. Loupe magnification significantly reduces temporary complications, such as hypocalcemia and dysphonia, by helping to identify the PGs and the RLN, without increasing the operating time [27].

A recent study shows that the combined use of loupes and harmonic scalpel led to an important reduction in operating time, by enabling the surgeon to operate in a bloodless field, with a consequent improvement of surgical outcomes [28]. Endoscopic magnification can be used as a routine dissection method to identify and preserve the external branch of the SLN (EBSLN), for preservation of voice quality in patients undergoing thyroid surgery: this “hybrid technique” involves only one additional step during traditional thyroid surgery, for identification of the EBSLN and its variants [29]. The Karl Storz 4 K 3D VITOM exoscope (Karl Storz SE & Co. KG, Germany) confers superior operative visualization in thyroid surgery: it consists of a 4 K endoscope and a 300 W xenon fiberoptic light source; the camera has 8–30× magnification allowing for a working distance of 20–50 mm; the operating team must wear 3D polarized glasses. The technology is similar to an endoscope, but it is external to the patient and offers ergonomic benefits and a similar visualization quality to that of robotic surgery without the loss of haptic feedback, as well as facilitating surgical training [24].

No doubt, mention should also be made of the minimally invasive techniques of thyroid surgery for their use of video magnification: minimally invasive video-assisted thyroidectomy (MIVAT), transoral endoscopic thyroidectomy (TOET), TOET with vestibular approach (TOETVA), and robot-assisted transaxillary thyroidectomy (RATT) [29].

Magnification offers many benefits, but it is important to remember that the surgeon's experience is fundamental in thyroid surgery, and similarly also the magnifications technique requires experience [30].

---

## References

1. Benvenega S, Elia G, Ragusa F, et al. Endocrine disruptors and thyroid autoimmunity. *Best Pract Res Clin Endocrinol Metab.* 2020;34(1):101377.
2. Docimo G, Ruggiero R, Casalino G, et al. Risk factors for postoperative hypocalcemia. *Updat Surg.* 2017;69(2):255–60.
3. Adamczewski Z, Król A, Kałużna-Markowska K, et al. Lateral spread of heat during thyroidectomy using different haemostatic devices. *Ann Agric Environ Med.* 2015;22(3):491–4.
4. Siu JM, McCarty JC, Gadkaree S, et al. Association of vessel-sealant devices vs conventional hemostasis with postoperative neck hematoma after thyroid operations. *JAMA Surg.* 2019;154(11):e193146.
5. Ruggiero R, Docimo L, Tolone S, et al. Effectiveness of an advanced hemostatic pad combined with harmonic scalpel in thyroid surgery. A prospective study *Int J Surg.* 2016;28(Suppl 1):S17–21.
6. Liu CH, Wang CC, Wu CW, et al. Comparison of surgical complications rates between LigaSure small jaw and clamp-and-tie hemostatic technique in 1,000 neuro-monitored thyroidectomies. *Front Endocrinol (Lausanne).* 2021;12:638608.
7. Canu GL, Medas F, Cappellacci F, et al. The use of harmonic Focus and Thunderbeat open fine jaw in thyroid surgery: experience of a high-volume center. *J Clin Med.* 2022;11(11):3062.
8. Yavuz N. Laparoscopic transperitoneal adrenalectomy using the LigaSure vessel sealing system. *J Laparoendosc Adv Surg Tech A.* 2005;15(6):591–5.
9. Patrone R, Gambardella C, Romano RM, et al. The impact of the ultrasonic, bipolar and integrated energy devices in the adrenal gland surgery: literature review and our experience. *BMC Surg.* 2019;18(Suppl 1):123.
10. Tolone S, Bondanese M, Ruggiero R, et al. Outcomes of sutureless total thyroidectomy in elderly. *Int J Surg.* 2016;33(Suppl 1):S16–9.
11. Wojtczak B, Aporowicz M, Kaliszewski K, Bolanowski M. Consequences of bleeding after thyroid surgery – analysis of 7805 operations performed in a single center. *Arch Med Sci.* 2018;14(2):329–35.
12. Tausanovic K, Zivaljevic V, Grujicic SS, et al. Case control study of risk factors for occurrence of postoperative hematoma after thyroid surgery: ten year analysis of 6938 operations in a tertiary center in Serbia. *World J Surg.* 2022;46(10):2416–22.
13. de Carvalho AY, Gomes CC, Chulam TC, et al. Risk factors and outcomes of postoperative neck hematomas: an analysis of 5,900 thyroidectomies performed at a cancer center. *Int Arch Otorhinolaryngol.* 2021;25(3):e421–7.
14. Reeve T, Thompson NW. Complications of thyroid surgery: how to avoid them, how to manage them, and observations on their possible effect on the whole patient. *World J Surg.* 2000;24(8):971–5.
15. Rosenbaum MA, Haridas M, McHenry CR. Life-threatening neck hematoma complicating thyroid and parathyroid surgery. *Am J Surg.* 2008;195(3):339–43.
16. Hiff HA, El-Boghdady K, Ahmad I, et al. Management of haematoma after thyroid surgery: systematic review and multidisciplinary consensus guidelines from the difficult airway society, the British Association of Endocrine and Thyroid Surgeons and the British Association of Otorhinolaryngology. *Head and Neck Surgery Anaesthesia.* 2022;77(1):82–95.
17. Pontin A, Pino EC, et al. Postoperative bleeding after thyroid surgery: care instructions. *Sisli Etfal Hastan Tip Bul.* 2019;53(4):329–36.

18. Khadra H, Bakeer M, Hauch A, et al. Hemostatic agent use in thyroid surgery: a meta-analysis. *Gland Surg.* 2018;7(Suppl 1):S34–41.
19. Testini M, Marzaioli R, Lissidini G, et al. The effectiveness of FloSeal matrix hemostatic agent in thyroid surgery: a prospective, randomized, control study. *Langenbeck's Arch Surg.* 2009;394(5):837–42.
20. Spotnitz WD, Burks S. Hemostats, sealants, and adhesives: components of the surgical toolbox. *Transfusion.* 2008;48(7):1502–16.
21. Docimo G, Tolone S, Conzo G, et al. A gelatin-thrombin matrix topical hemostatic agent (Floseal) in combination with harmonic scalpel is effective in patients undergoing total thyroidectomy: a prospective, multicenter, single-blind, randomized controlled trial. *Surg Innov.* 2016;23(1):23–9.
22. Amit M, Binenbaum Y, Cohen JT, Gil Z. Effectiveness of an oxidized cellulose patch hemostatic agent in thyroid surgery: a prospective, randomized, controlled study. *J Am Coll Surg.* 2013;217(2):221–5.
23. Kullar P, Tanna R, Ally M, et al. VITOM 4K 3D exoscope: a preliminary experience in thyroid surgery. *Cureus.* 2021;13(1):e12694.
24. D'Orazi V, Panunzi A, Di Lorenzo E, et al. Use of loupes magnification and microsurgical technique in thyroid surgery: ten years experience in a single center. *G Chir.* 2016;37(3):101–7.
25. Ravi KS, Naik KM, Swarna Priya M, Abhishek MP. Role of magnification and microscope in thyroid surgery safety and efficacy. *Int J Otorhinolaryngol. Head Neck Surg.* 2021;7(8):1259–62.
26. Omran HM, Elsayed OM, Hassan AA, Fadl EMA. Comparative study between using surgical loupe and direct vision to enhance preservation of parathyroid glands and minimize the risk of its injury during total thyroidectomy. *Ain-Shams J Surg.* 2022;15(1):9–16.
27. Suffat LP, Lavorini E, Mondini G, et al. Does the combined use of magnification loupes and harmonic FOCUS improve the outcome of thyroid surgery? *World J Endoc Surg.* 2020;12(1):18–22.
28. Kripamoy N, Sanchita K, Rohit T. The role of endoscope assisted intra-operative identification of external branch of superior laryngeal nerve in the outcome of voice following thyroid surgery. *IJRR.* 2017;4(6):14–9.
29. Rossi L, Materazzi G, Bakkar S, Miccoli P. Recent trends in surgical approach to thyroid cancer. *Front Endocrinol (Lausanne).* 2021;12:699805.
30. Sapalidis K, Papanastasiou A, Fyntanidou V, et al. Comparison between magnification techniques and direct vision in thyroid surgery: a systematic review and meta-analysis. *Medicina (Kaunas).* 2019;55(11):725.

**Open Access** This chapter is licensed under the terms of the Creative Commons Attribution-NonCommercial-NoDerivatives 4.0 International License (<http://creativecommons.org/licenses/by-nc-nd/4.0/>), which permits any noncommercial use, sharing, distribution and reproduction in any medium or format, as long as you give appropriate credit to the original author(s) and the source, provide a link to the Creative Commons license and indicate if you modified the licensed material. You do not have permission under this license to share adapted material derived from this chapter or parts of it.

The images or other third party material in this chapter are included in the chapter's Creative Commons license, unless indicated otherwise in a credit line to the material. If material is not included in the chapter's Creative Commons license and your intended use is not permitted by statutory regulation or exceeds the permitted use, you will need to obtain permission directly from the copyright holder.







Maurizio Iacobone and Francesca Torresan

## 15.1 Introduction

Hypoparathyroidism is a pathological clinical condition characterized by low serum calcium levels in the presence of absent or inappropriately low parathyroid hormone (PTH) levels. It is usually caused by reduced parathyroid gland (PG) function due to secondary (and often iatrogenic) causes (>75%); less frequently, it occurs as a primary disorder caused by intrinsic genetic defects (Di George syndrome) or an autoimmune disease [1].

The most common cause of secondary/acquired hypoparathyroidism is postoperative hypoparathyroidism (POH), caused by intraoperative injury to the PG through compromising the vascular supply, thermal injury or inadvertent excision [2]. The surgical procedures causing POH include thyroid, parathyroid, laryngeal, or other neck surgeries for both benign and malignant diseases. POH is the most frequent complication after thyroid surgery, and it is influenced by several operative factors, including the underlying thyroid disease and the extent of the surgical procedure; it occurs most often after a bilateral thyroid excisional procedure, followed by extensive bilateral parathyroid surgery (10–15%) [1, 3]. Iatrogenic hypoparathyroidism may be also caused by neck radiotherapy.

POH is usually defined as transient when lasting less than 6 months after surgery, or definitive if low calcemic and/or PTH levels and the need for calcium and/or vitamin D supplementation last more than 6 months from initial operation [4].

After total or completion thyroidectomy, various institutional and individual surgeon protocols have been developed to prevent POH or detect it at the earliest possible time point to be able to manage it promptly. However, as confirmed by a recent metaanalysis [5], the definition of POH is vastly heterogeneous in the literature, and the best approach for the early recognition of POH is not uniquely defined. The

---

M. Iacobone (✉) · F. Torresan  
Endocrine Surgery Unit, Department of Surgery, Oncology and Gastroenterology, Padua  
University Hospital, Padua, Italy  
e-mail: [maurizio.iacobone@unipd.it](mailto:maurizio.iacobone@unipd.it); [francesca.torresan@unipd.it](mailto:francesca.torresan@unipd.it)

© The Author(s) 2024

M. Testini, A. Gurrado (eds.), *Thyroid Surgery*, Updates in Surgery,  
[https://doi.org/10.1007/978-3-031-31146-8\\_15](https://doi.org/10.1007/978-3-031-31146-8_15)

137

most used definitions of POH are reduced PTH levels only, hypocalcemia only, reduced PTH or hypocalcemia, or a combination of both. Moreover, some studies included the presence or absence of symptoms to define the diagnosis of POH. Thus, considering the various definitions in the determination of postoperative recovery of PG function after thyroid surgery and the different biochemical assays used, also the incidence of POH varies widely in the surgical literature and even within the same center and in the same cohort of patients; it may range from 0% to 46% for transient POH and 0–15% for its definitive variant, depending on the definition used [6].

---

## 15.2 Etiology

The identification and preservation of the PG with their blood supply is the greatest technical issue during thyroid surgery. In fact, the main causes of transient and permanent POH are inadvertent resection or devascularization of PG.

In fact, PG identification and preservation during total thyroidectomy are critical to avoid POH and require, in addition to knowledge of their anatomical locations and vascular supply, an experienced surgeon. The PG are indeed difficult to distinguish from other cervical tissues because of their small size and similar color compared to the thyroid, fat, and lymph nodes. Therefore, an anticipatory visual approach using surgical landmarks by a skilled surgeon is crucial. Moreover, the anatomy of the PG is extremely variable and related to their embryologic development. While the area of distribution of the superior PG, which arise from the fourth branchial pouches, is fairly constant due to the short embryonic migration path, the normal distribution of the inferior PG, derived from the third branchial pouches, varies widely owing to the longer migration path [7]. The superior PG are found in over 80% of cases posterior to the thyroid lobe, above the intersection of the recurrent laryngeal nerve and the inferior thyroid artery; the inferior PG are located in half of the cases on the anterior surface of the inferior thyroid lobe, and in a quarter of cases along the thyrothymic ligament or in ectopic position. Moreover, more than four PG may be found in at least 10% of patients [8]. Hence, despite all efforts, inadvertent parathyroidectomy is reported in up to 20% of patients.

In addition to PG identification, the critical point is to preserve PG vitality by maintaining an adequate blood supply. In order to guarantee this, gentle handling of the PG and their vessels is required. The small vessels between the PG and the thyroid capsule should be preserved by careful dissection of the thyroid capsule from the perithyroid fatty tissues, without injuring or cauterizing the PG; if necessary, hemoclips or fine-tip bipolar forceps should be used to divide these vessels near the parathyroid gland.

Recently, near-infrared (NIR) autofluorescence of PG, a technique that uses the unique property of intrinsic autofluorescence of parathyroid tissue, has been proposed; this technique allows the surgeon to recognize and protect the PG since the spontaneous signal they emit is up to 11-times higher than surrounding tissues. Moreover, the intraoperative use of NIR combined with indocyanine green angiography to assess PG perfusion at the end of the operation seems to reliably predict PG

vascularization, potentially POH and the need for calcium-vitamin supplementation in patients with at least one well-perfused PG [9]. However, further studies are needed to obtain a standardized protocol and to replicate these results.

In cases of inadvertently removed or definitively devascularized PG, autotransplantation into a muscle pocket, where they will recover their vascular supply and secretory function, is usually suggested. In the past, systematic autotransplantation of at least one PG was proposed to decrease the risk of permanent POH [10]. However, it has been demonstrated that the autotransplantation of normal PG does not avoid permanent POH, while it increases the rate of transient POH; thus, autotransplantation is recommended only when the gland is completely devascularized or definitively removed, since PG function may be better preserved if the glands are left in situ rather than autotransplanted [11].

The preferred site for autotransplantation is the sternocleidomastoid muscle. Different techniques have been described, including the reimplantation of 10–20 small fragments of the gland, or the intramuscular injection of a suspension of parathyroid tissue in buffered saline [12].

---

### 15.3 Patient- and Disease-Related Risk Factors

Beside the surgery-related predictive factors of POH, several other individual and disease-related risk factors have been reported. As reported in some metanalysis [13], women and patients with Graves' disease had a significantly higher incidence of transient hypocalcemia. Other potential risk factors identified in multivariable analysis in individual studies included: heavier thyroid specimens [14] and longer duration of Graves' disease [15]. Permanent POH was found to be associated with more advanced stage of thyroid cancer [16].

---

## 15.4 Diagnosis

### 15.4.1 Clinical Presentation

The clinical manifestations of POH depend on the severity of hypocalcemia because low serum ionized calcium can alter neurological, cognitive, muscular, and cardiac function. The spectrum of symptoms can range from asymptomatic or mild disturbances to bronchospasm, laryngospasm, seizures, tetany, and cardiac rhythm disturbances [17].

Symptoms of neuromuscular irritability are the most common in the setting of acute hypocalcemia. They can range from numbness and tingling in the fingertips, toes and circumoral region in mild hypocalcemia, to paresthesias of the upper and lower extremities in moderate hypocalcemia and tetanic muscle cramps such as carpal spasms or diffuse tetany in the most severe forms. Rarely, bronchospasm and laryngospasm with acute respiratory failure may occur. Neurological symptoms,

including confusion, delirium, seizure, and cardiac abnormalities, such as prolonged QT interval on electrocardiogram and arrhythmias, can also occur [18].

The Chvostek and Trousseau signs are useful to detect a latent tetany. However, the Chvostek sign, consisting of a contraction of ipsilateral facial muscles after tapping the facial nerve, has low sensitivity and specificity; it has been reported to be present in up to 10–15% of normal individuals, while 29% of patients with biochemical confirmation of POH have a negative Chvostek sign. The Trousseau sign consists of a carpal spasm (extension of the wrist, extension of interphalangeal joints, adduction of the thumb) evoked by inflation of a sphygmomanometer above systolic blood pressure for a few minutes. Hyperventilation and the subsequent metabolic alkalosis, increasing the binding of calcium to albumin and decreasing the available ionized calcium, increases the sensitivity of this maneuver by worsening the symptoms.

### 15.4.2 Biochemical Testing

Several institutional and individual surgeon protocols have been reported for biochemical testing for POH, including calcium and PTH measurements.

Since low ionized calcium levels are the main factor responsible for symptoms, postoperative measurement of serum calcium levels alone has often been used to diagnose POH and prevent symptomatic hypocalcemia. Hypocalcemia is usually defined as calcium levels below the lower limit of normal for an institution's laboratory [4], usually 8 mg/dL. Some authors proposed to use the absolute value of serum calcium levels to define hypocalcemia, others preferred to use the decreasing trend or the rate of change of calcium measurements at different time points, as a predictive tool for POH [19]. However, because trending calcium often requires sampling over a 24-hour or even longer time period and because postoperative calcium levels may be confounded by prophylactic calcium and calcitriol administration or by low preoperative vitamin D levels, most authors have underlined the role of measuring PTH, which has the advantage of a short half-life (less than 5 minutes), at various time points in the early post-thyroidectomy period [20]. Despite the differences in study design, PTH assays used and timing of PTH sampling, all studies concluded that there is a strong correlation between postoperative PTH levels and hypocalcemia. Unfortunately, it is not possible to define an absolute PTH level or relative decline having 100% sensitivity and 100% specificity [21–24]. Thus, the earliest opportunity to predict POH reliably is through the measurement of serum PTH levels during the first 24 hours after thyroidectomy, which may allow the early detection and treatment of patients at risk of POH, and subsequently allow safe patient discharge. According to the American Thyroid Association [4], a PTH level < 15 pg/mL is usually predictive of impending hypocalcemia and requires a preemptive prescription of oral calcium and calcitriol and/or serial serum calcium measurements until calcium stability has been confirmed.

## 15.5 Postoperative Management of Postoperative Hypoparathyroidism

The objective of postoperative correction of POH is to avoid the symptoms and complications of hypocalcemia. Several protocols have been proposed to guide calcium and vitamin D supplementation after surgery.

The empirical prophylactic approach consists in the routine prescription of oral calcium with or without oral calcitriol, without testing PTH or calcium levels [25]. This prophylactic approach has the advantage of being fast and facilitating hospital discharge after thyroidectomy; however, it has a non-negligible risk of causing severe hypercalcemia and potential renal injury. Moreover, it requires biochemical monitoring for medication tapering in all discharged patients, which affects the cost-effectiveness of this strategy.

In the presence of early/mild hypocalcemia (calcemia below 8 mg/dL) and/or PTH < 15 ng/L, oral calcium supplementation (1–3 g of calcium carbonate daily) and calcitriol (typically 0.25–0.5 mcg twice daily) might be considered. If severe symptomatic hypocalcemia develops despite oral calcium and calcitriol therapy, intravenous calcium (1–2 g of calcium gluconate) is the most expeditious but also the least durable method for raising serum calcium rapidly.

The oral dose of calcium and calcitriol or other vitamin D metabolites should be individually tailored by checking serum calcium initially every week and then every 2–3 weeks or monthly. Once stable normocalcemia is achieved and serum phosphate normalizes, the doses can be gradually reduced or, if hypocalcemia develops while tapering down calcium-vitamin treatment, the previous effective dose should be restarted.

---

## 15.6 Long-Term Management and Complications of Postoperative Hypoparathyroidism

Long-standing POH may have a substantial impact on quality of life. The long-term consequences of POH are not negligible and include nephrolithiasis, nephrocalcinosis, basal ganglia calcification, ectopic soft tissue calcification, cataracts, and potential defects in bone metabolism [26].

Bone microarchitecture in hypoparathyroid patients is abnormal, with a low bone turnover; in fact, even if the mineral content and bone mass tend to be increased, there is also an augmented bone stiffness that may increase the risk of fractures. Hypercalcemia during treatment in the presence of hyperphosphatemia determines a high calcium phosphorus product that predisposes to the risk of calciphylaxis, with vascular calcification, basal ganglia calcification, and thrombosis. Moreover, the risk of ectopic mineralization in the kidney may accelerate the risk of renal failure [17].

The goals of long-term treatment of POH are to maintain serum calcium within the normal range with the minimal amount of calcium and vitamin D supplementation, in order to reduce the complications of treatment, such as hypercalcemia,

hypercalciuria, nephrolithiasis and nephrocalcinosis [4, 17]. Chronic treatment of POH requires oral calcium and vitamin D. Vitamin D in the active form of calcitriol is essential to increase calcium absorption and can be upwards titrated to reduce the amount of calcium supplementation. Some patients remain normocalcemic only by taking calcitriol. However, in some cases calcium homeostasis cannot be completely controlled by treatment with calcium and vitamin D metabolites. For this reason, alternative approaches have been studied, including the use of recombinant human PTH that was approved by the FDA in 2015. The randomized phase III REPLACE trial [27] demonstrated that the treatment with recombinant human PTH (1–84) reduces the need of calcium and vitamin D supplementation in half of the adult patients treated, improves quality of life, and achieves a significant benefit in bone metabolism. However, further studies with various PTH fragments and analogs are ongoing to confirm their use in clinical practice.

---

## 15.7 Conclusions

In conclusion, patients undergoing bilateral thyroid surgery are at risk for POH and should be routinely tested for serum calcium and intact PTH levels in the early 24-hour postoperative period.

A meticulous intraoperative handling of PG and careful preservation of the vascular supply could minimize the risks of POH, in particular of the long-term consequences of hypoparathyroidism and chronic treatment with calcium and calcitriol supplementation.

---

## References

1. Clarke BL, Brown EM, Collins MT, et al. Epidemiology and diagnosis of hypoparathyroidism. *J Clin Endocrinol Metab.* 2016;101(6):2284–99.
2. Sitges-Serra A. Etiology and diagnosis of permanent hypoparathyroidism after total thyroidectomy. *J Clin Med.* 2021;10(3):543.
3. Mihai R, Thakker RV. Postsurgical hypoparathyroidism: current treatments and future prospects for parathyroid allotransplantation. *Eur J Endocrinol.* 2021;184(5):R165–75.
4. Orloff LA, Wiseman SM, Bernet VJ, et al. American Thyroid Association statement on postoperative hypoparathyroidism: diagnosis, prevention, and management in adults. *Thyroid.* 2018;28(7):830–41.
5. Nagel K, Hendricks A, Lenschow C, et al. Definition and diagnosis of postsurgical hypoparathyroidism after thyroid surgery: meta-analysis. *BJS Open.* 2022;6(5):zrac102.
6. Mehanna HM, Jain A, Randeve H, et al. Postoperative hypocalcemia – the difference a definition makes. *Head Neck.* 2010;32(3):279–83.
7. Akerström G, Malmaeus J, Bergström R. Surgical anatomy of human parathyroid glands. *Surgery.* 1984;95(1):14–21.
8. Lappas D, Noutsios G, Anagnostis P, et al. Location, number and morphology of parathyroid glands: results from a large anatomical series. *Anat Sci Int.* 2012;87(3):160–4.
9. Vidal Fortuny J, Sadowski SM, Belfontali V, et al. Randomized clinical trial of intraoperative parathyroid gland angiography with indocyanine green fluorescence predicting parathyroid function after thyroid surgery. *Br J Surg.* 2018;105(4):350–7.

10. Wells SA Jr, Gunnells JC, Shelburne JD, et al. Transplantation of the parathyroid glands in man: clinical indications and results. *Surgery*. 1975;78(1):34–44.
11. Lorente-Poch L, Sancho JJ, Ruiz S, Sitges-Serra A. Importance of in situ preservation of parathyroid glands during total thyroidectomy. *Br J Surg*. 2015;102(4):359–67.
12. Hicks G, George R, Sywak M. Short and long-term impact of parathyroid autotransplantation on parathyroid function after total thyroidectomy. *Gland Surg*. 2017;6(Suppl 1):S75–85.
13. Edafe O, Antakia R, Laskar N, et al. Systematic review and meta-analysis of predictors of post-thyroidectomy hypocalcaemia. *Br J Surg*. 2014;101(4):307–20.
14. Hallgrímsson P, Nordenström E, Almquist M, Bergenfelz AO. Risk factors for medically treated hypocalcemia after surgery for graves' disease: a Swedish multicenter study of 1,157 patients. *World J Surg*. 2012;36(8):1933–42.
15. Erbil Y, Ozbey NC, Sari S, et al. Determinants of postoperative hypocalcemia in vitamin D-deficient graves' patients after total thyroidectomy. *Am J Surg*. 2011;201(5):685–91.
16. Burge MR, Zeise TM, Johnsen MW, et al. Risks of complication following thyroidectomy. *J Gen Intern Med*. 1998;13(1):24–31.
17. Shoback DM, Bilezikian JP, Costa AG, et al. Presentation of hypoparathyroidism: etiologies and clinical features. *J Clin Endocrinol Metab*. 2016;101(6):2300–12.
18. Cooper MS, Gittoes NJ. Diagnosis and management of hypocalcaemia. *BMJ*. 2008;336:1298–302.
19. Nahas ZS, Farrag TY, Lin FR, et al. A safe and cost-effective short hospital stay protocol to identify patients at low risk for the development of significant hypocalcemia after total thyroidectomy. *Laryngoscope*. 2006;116(6):906–10.
20. Grodski S, Serpell J. Evidence for the role of perioperative PTH measurement after total thyroidectomy as a predictor of hypocalcemia. *World J Surg*. 2008;32(7):1367–73.
21. Richards ML, Bingener-Casey J, Pierce D, et al. Intraoperative parathyroid hormone assay: an accurate predictor of symptomatic hypocalcemia following thyroidectomy. *Arch Surg*. 2003;138(6):632–6.
22. McLeod IK, Arciero C, Noordzij JP, et al. The use of rapid parathyroid hormone assay in predicting postoperative hypocalcemia after total or completion thyroidectomy. *Thyroid*. 2006;16(3):259–65.
23. Lombardi CP, Raffaelli M, Princi P, et al. Early prediction of postthyroidectomy hypocalcemia by one single iPTH measurement. *Surgery*. 2004;136(6):1236–41.
24. Lombardi CP, Raffaelli M, Princi P, et al. Parathyroid hormone levels 4 hours after surgery do not accurately predict post-thyroidectomy hypocalcemia. *Surgery*. 2006;140(6):1016–25.
25. Wang TS, Cheung K, Roman SA, Sosa JA. To supplement or not to supplement: a cost-utility analysis of calcium and vitamin D repletion in patients after thyroidectomy. *Ann Surg Oncol*. 2011;18(5):1293–9.
26. Bilezikian JP. Hypoparathyroidism. *J Clin Endocrinol Metab*. 2020;105(6):1722–36.
27. Mannstadt M, Clarke BL, Vokes T, et al. Efficacy and safety of recombinant human parathyroid hormone (1–84) in hypoparathyroidism (REPLACE): a double-blind, placebo-controlled, randomised, phase 3 study. *Lancet Diabetes Endocrinol*. 2013;1(4):275–83.

**Open Access** This chapter is licensed under the terms of the Creative Commons Attribution-NonCommercial-NoDerivatives 4.0 International License (<http://creativecommons.org/licenses/by-nc-nd/4.0/>), which permits any noncommercial use, sharing, distribution and reproduction in any medium or format, as long as you give appropriate credit to the original author(s) and the source, provide a link to the Creative Commons license and indicate if you modified the licensed material. You do not have permission under this license to share adapted material derived from this chapter or parts of it.

The images or other third party material in this chapter are included in the chapter's Creative Commons license, unless indicated otherwise in a credit line to the material. If material is not included in the chapter's Creative Commons license and your intended use is not permitted by statutory regulation or exceeds the permitted use, you will need to obtain permission directly from the copyright holder.







# Laryngeal Nerve Palsy

# 16

Carmela De Crea, Giuseppe Marincola, Lucia D'Alatri, Francesco Pennestrì, Priscilla Francesca Procopio, Pierpaolo Gallucci, Luca Revelli, Rocco Bellantone, and Marco Raffaelli

## 16.1 Applied Anatomy of the Laryngeal Nerves

The proper vagus nerve (VN) emerges from the cranial vault through the jugular foramen. It descends following the carotid axis, initially located medial to the internal jugular vein (IJV) and then in the posterior position between IJV and the internal carotid artery (ICA).

The cervical branches of the VN consist of the superior laryngeal nerve (SLN) and the inferior laryngeal nerve, also known as recurrent laryngeal nerve (RLN). The SLN arises from the center of the nodose ganglion, 3–4 cm below the jugular foramen. It descends medially to the ICA and, after 1.5–2 cm, to the external carotid artery. The SLN includes two branches: the internal branch, which supplies sensory fibers to the pharynx, and the external branch, which innervates the cricothyroid muscle [1]. The external branch is essential in the contraction of the true vocal fold, providing timbre to the voice. Moreover, it plays a role in the glottic closure reflex, which prevents aspiration during deglutition. The anatomy of the SNL is extremely variable. Cernea et al. [2] proposed a classification of the SNL anatomic variables: type 1 nerve, as the most common nerve variation, crossing the superior thyroid vessels >1 cm above the superior thyroid pole; types 2A and 2B, where the nerve crosses <1 cm above the superior pole or below its upper border, respectively.

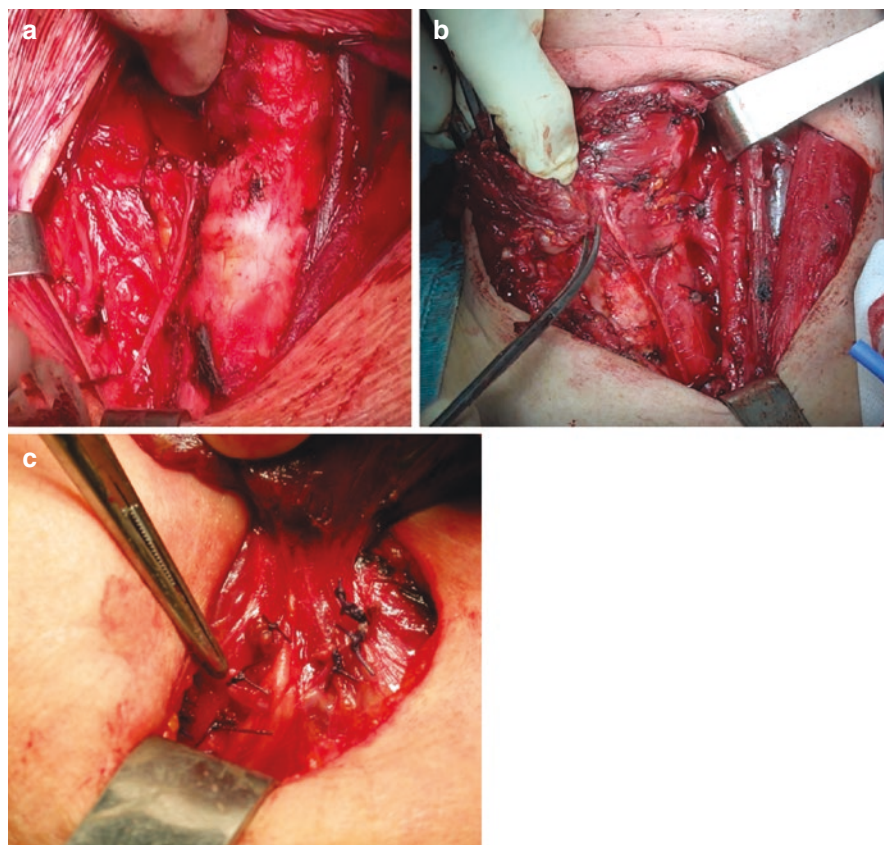
C. De Crea · G. Marincola · L. D'Alatri · F. Pennestrì · P. F. Procopio · P. Gallucci · L. Revelli  
R. Bellantone · M. Raffaelli (✉)

UOC Chirurgia Endocrina e Metabolica, Centro di ricerca in Chirurgia delle Ghiandole Endocrine e dell'Obesità, Fondazione Policlinico Universitario Agostino Gemelli IRCCS, Rome, Italy

e-mail: [carmela.decrea@unicatt.it](mailto:carmela.decrea@unicatt.it); [giuseppe.marincola@policlinicogemelli.it](mailto:giuseppe.marincola@policlinicogemelli.it);  
[lucia.dalatri@unicatt.it](mailto:lucia.dalatri@unicatt.it); [francesco.pennestri@policlinicogemelli.it](mailto:francesco.pennestri@policlinicogemelli.it);  
[priscilla.f.procopio@gmail.com](mailto:priscilla.f.procopio@gmail.com); [pierpaolo.gallucci@policlinicogemelli.it](mailto:pierpaolo.gallucci@policlinicogemelli.it);  
[luca.revelli@unicatt.it](mailto:luca.revelli@unicatt.it); [celestino.lombardi@unicamillus.org](mailto:celestino.lombardi@unicamillus.org);  
[rocco.bellantone@unicatt.it](mailto:rocco.bellantone@unicatt.it); [marco.raffaelli@unicatt.it](mailto:marco.raffaelli@unicatt.it)

The RLNs originate from the VN anterior to the aortic arches. Since the heart and great vessels migrate caudally and the neck elongates cranially during the embryological development, the RLNs are pulled down by the aortic arches. The right RLN loops around the subclavian artery and travels superiorly and medially toward the tracheal-esophageal groove. It runs for about 5–6 cm along the tracheal-esophageal groove with a more oblique angle on the sagittal plane compared to the left RLN [3]. Then, the nerve runs superiorly, it courses between the trachea and the thyroid gland before entering into the larynx. The left RLN passes anteriorly to the aortic arch before looping around the arch and traveling superiorly and medially toward the tracheal-esophageal groove.

The terminal part of the RLNs enters the larynx, underneath the thyroid gland, deep to the inferior border of the inferior pharyngeal constrictor muscle, posterior to the cricothyroid muscle (Fig. 16.1a,b). The nerve usually runs posterior to the middle thyroid vein and the cricothyroid joint. The relationships between the RLNs

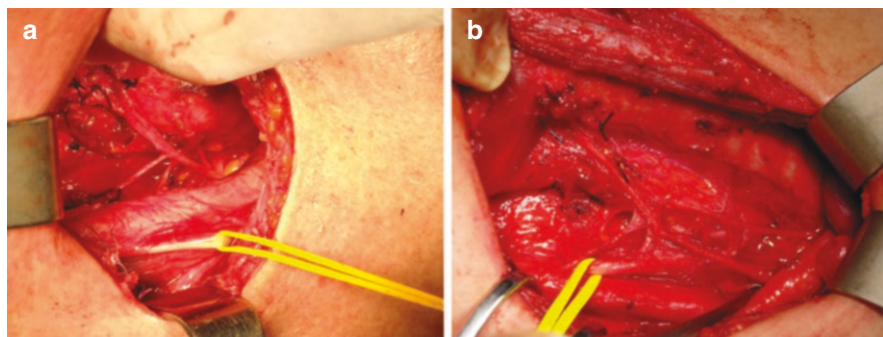


**Fig. 16.1** (a, b) Intraoperative view of recurrent laryngeal nerves (a right RLN, b left RLN) prepared along their entire cervical course, up to their entrance into the larynx. (c) Non-recurrent right inferior laryngeal nerve arising from the vagus nerve at cervical level

and the inferior thyroid artery (ITA), which represent one of the most important landmarks, is much more variable. On the left side, the nerve trunk lays posteriorly and anteriorly to the ITA in 52.1% and 13.7% of cases, respectively, while it may pass between the artery's branches in 25.4% of cases. On the right side, the nerve trunk lays posteriorly and anteriorly to the ITA in 23% and 25.5% of cases, and between its branches in 36.5% of cases [3]. The presence of an aberrant right subclavian artery, also known as *arteria lusoria*, originating from the aortic arch, is associated with the presence of a right non-recurrent inferior laryngeal nerve (NR-ILN) (Fig. 16.1c). The incidence of this rare anatomic variant is reported to be between 0.3% and 0.8% of cases. On the left side, the NR-ILN may exceptionally occur in 0.004% of cases and it is typically associated with a right aortic arch with *situs inversus*. The presence of a NR-ILN can be preoperatively anticipated by preoperative bedside ultrasound scan, indicating the presence of an aberrant right subclavian artery (*arteria lusoria*) [4].

Fibers that originate from the superior cervical sympathetic ganglion are connected with the RLN and develop the sympathetic-inferior laryngeal anastomotic branch (SILAB). They are usually thin, but sometimes have the same diameter as the RLN and are misinterpreted as a NR-ILN (Fig. 16.2a), which explains the reported coexistence of RLN and NR-ILN in the same patients [5]. A large SILAB, with the same diameter as the RLN, was found on the right side in 1.5% of right RLN in clinical studies and in 17% of cases in anatomical studies [6]. NR-ILNs may be connected with the sympathetic chain via large a SILAB mimicking a normal RLN (Fig. 16.2b).

Accurate knowledge of the aforementioned anatomical variants is crucial for the correct identification of structures during surgical dissection and the prevention of laryngeal nerve injury.



**Fig. 16.2** (a) A large sympathetic inferior laryngeal nerve anastomotic branch (SILAB) mimicking a non-recurrent inferior laryngeal nerve (NR-ILN). Following it along its entire course makes it possible to determine that it does not originate from the vagus nerve. (b) A large SILAB connecting a NR-ILN with the sympathetic chain (stellate ganglion) can be misinterpreted as a normally recurrent inferior laryngeal nerve if not followed up to its origin

## 16.2 Etiology, Prevalence and Risk Factors

Postoperative inferior laryngeal nerve injury can be transient or permanent, the latter defined by the lack of recovery of vocal cord function at 6–12 months after surgery. The prevalence of the post-thyroidectomy inferior laryngeal nerve injuries is widely variable, being influenced by the definition, based on routine or selective (in case of symptoms) laryngoscopic assessment, patient selection and surgical experience. The reported prevalence varies from 1.4% to 13.1% for transient palsy and from 0.4% to 3.5% for permanent lesions [7].

SLN damage may occur during the surgical dissection of the thyroid upper poles. To date, the incidence of lesions of the superior laryngeal branch is still unknown. Indeed, such surgical damage turns out to be extremely variable also based on the diagnostic techniques used to identify it. Whether laryngoscopy and phoniatric clinical evaluation are used, palsy rates range from 0% to 6%. When more accurate examinations, such as laryngeal electroneuromyography, are included in the analysis, higher rates are reported (up to 58% of cases) [8].

Disease- and patient-related factors (i.e., revisional surgery, large intrathoracic goiters, chronic thyroiditis or Grave's disease, malignancy with extrathyroidal extension and paratracheal lymph node dissection, old age, smoking habit, diabetes, small size RLN) and inadequate surgical experience represent risk factors for RLN injury.

The neural damage to the laryngeal nerves may differ, leading to different recovery times. The physical mechanisms that may lead to nerve damage are stretching, crushing, diathermal injury and transection. Neurapraxia is defined as a temporary block of nerve conduction, and it usually heals spontaneously and completely within a few weeks. Axonotmesis is a myelin sheath lesion, with macroscopically intact nerve. Since axonal regrowth is spontaneous, the resulting muscular contraction, as well as the voice, may be of poor quality. Neurotmesis is defined as an interruption of the endoneurial, perineurial and/or epineurial sheaths. In this case, the nerve regrowth has low quality and muscular contractions are poor or even absent. Despite the operative finding of a macroscopically intact nerve, axonal regrowth is a slow process and is considered definitive after a 12-month period. If the neural sheath is interrupted or the nerve is frankly divided, axonal regrowth is uncertain and often of poor quality. Of note, limited arytenoid movement and impaired vocal fold movement are reported in 11% of patients after arytenoid dislocation due to endotracheal intubation [9].

---

## 16.3 Clinical Manifestations and Diagnosis

The external branch of the SLN innervates the cricothyroid muscle, which contributes to lengthening of the vocal fold and (along with cricoarytenoid muscle) regulation of the vocal fundamental frequency; its injury is clinically mild and its identification is often difficult. The spoken voice tends to be only slightly affected, while the singing voice is more influenced. In particular, the voice is weak, breathy,

monotonous and characterized by inability to achieve high tones with weakness and increased effort to speak [10].

Clinical manifestations of a unilateral RLN nerve palsy are weak and breathy voice with a loss of vocal projection and phonation time, hoarseness, and dysphonia. Aspiration with dysphagia (in particular for liquids) may sometimes occur but is only rarely associated with aspiration pneumonia. The patient may also notice an inability to perform a Valsalva maneuver. Laryngospasm may occur because of a sudden, forceful, opposition of the glottic and supraglottic structures, and usually appears several weeks after surgery.

Bilateral RLN paralysis causes adduction of the vocal cords during inspiration, leading to obstruction of the airway with acute life-threatening dyspnea and aphonia and requiring emergent tracheotomy or re-intubation.

Laryngeal paralysis can also impair other functions that require tight glottal closure, such as coughing and stabilization of the thorax for heavy lifting. Symptoms frequently change over time because of the recovery of motion on the paralyzed side, the development of contralateral compensatory function or the shifting of vocal fold position toward the midline.

An essential component of the examination for dysphonia is inspection of the larynx via either flexible or rigid video laryngoscopy to assess the positioning and motility of the vocal cords. Laryngoscopy can detect a gradual shift of the paralyzed vocal fold toward median and paramedian position. In general, vocal symptoms are directly related to the distance of the paralyzed vocal fold from the midline. The voice is weak when the glottis cannot close completely during phonation, and it becomes breathy or aphonic when the glottic gap is large.

Laryngeal electromyography for the diagnosis and management of laryngeal paresis/paralysis is useful for differentiating neural disruption from structural immobility, evaluating the electrical activity of the muscles within the larynx and predicting which patients will not recover vocal fold motion after a nerve injury [11].

---

## 16.4 Prevention and Management

In cases of previous cervical surgery or clinical examination that suggests vocal abnormality, preoperative laryngeal examination is mandatory in order to detect pre-existing laryngeal dysfunction. In the other cases, preoperative laryngeal examination is recommended. About 20% of patients show vocal and swallowing impairments without evidence of RLN nerve injury and age > 50 years is reported as an independent risk factor [12].

Routine identification and dissection of the RLN course during thyroidectomy is the gold standard to prevent injury. A meticulous dissection technique, avoidance of excessive traction, a judicious choice of hemostatic techniques and correct nerve exposure maneuvers prove to be essential in order to preserve the nerve.

The use of intraoperative intermittent or continuous nerve monitoring (IONM) has been widely investigated to assess RLN functional integrity during surgery. However, it should not replace an appropriate and meticulous surgical technique

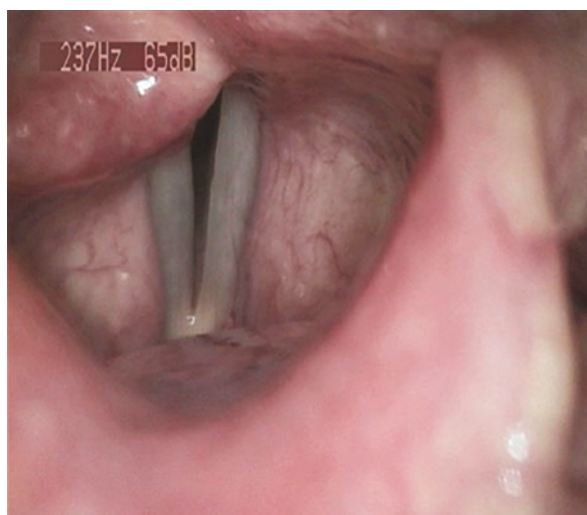and knowledge of RLN anatomy and its variations [13]. The use of IONM is recommended in thyroid cancer surgery, in patients with locally advanced disease and/or massive central neck nodal involvement, in reoperations and in the case of previous documented vocal cord paralysis. However, despite routine IONM use is not recommended by all the guidelines, it is a valuable adjunct in all thyroid surgeries, since complex anatomy and difficult dissection cannot be anticipated in all cases. IONM can confirm the visual identification of the RLN and provide guidance for the surgeon, particularly in difficult situations. It helps to identify anatomic variations of the nerve, and in particular to distinguish motor and sensory fibers in the case of extra laryngeal branches. IONM findings are accurate in predicting postoperative vocal cords motility. In a review by Schneider et al. [14] the negative predictive value of loss of neuromonitoring signal (LOS) and early vocal fold paralysis (VFP) for intermittent and continuous IONM ranged from 97.3–99.8% to 99.8–100%, respectively, while the positive predictive value from 37.8–80.5% to 47.6–88.2%, respectively. LOS is commonly subdivided into segmental LOS type I, with a clear point of injury, or global LOS type II, where the level of injury cannot be defined. Although IONM quite accurately predicts transient VFP in the first postoperative days, the transition to a permanent (6–12 months postoperatively) paralysis is not clear in the absence of intraoperative evidence of inadvertent or planned transection.

It has been recently demonstrated that type II LOS with preserved arytenoid motility on postoperative day 15, evaluated at fibro laryngoscopy, is associated with recovery of vocal cord motility [15].

Postoperative laryngoscopic examination should be performed in every patient who underwent thyroid surgery (Fig. 16.3).

Patients with VFP and dysphonia are best treated by a team effort between the otolaryngologist and a speech-language therapist. They can implement potentially useful compensatory strategies while identifying and eliminating behaviors that

**Fig. 16.3** Right vocal fold palsy in paramedian position

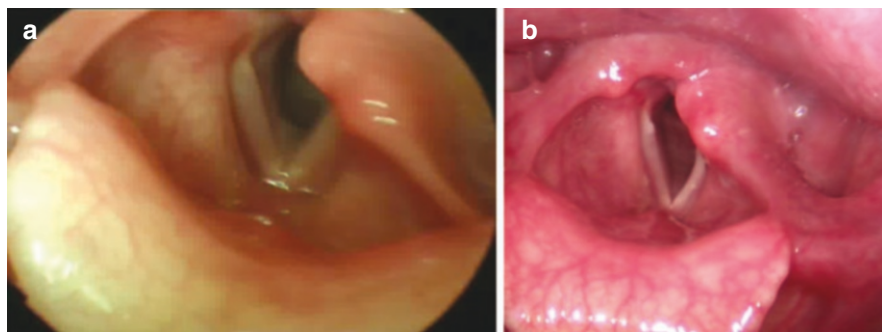


might be counterproductive. Early voice therapy may enable significant improvement in vocal function [16]. In addition, treatment with corticosteroid [17] and vitamin B complex may be useful in the early phases.

Although VFP is by definition a hypofunctional disorder, patients may exhibit a compensatory hyperfunctional behavior, such as muscle tension dysphonia [18]. VFP results in glottic insufficiency, reduced subglottic pressures and less airway protection during swallowing. This may determine aspiration, which can be identified by history or development of an aspiration pneumonia. Such a condition may be evaluated with a fiberoptic endoscopic examination of swallowing function or an upper gastrointestinal contrast study. Swallow therapy often includes the clinical observation of patients during meals and the teaching of techniques to obtain a safer swallow. Such techniques may include head inclination, chin tuck, effortful swallow and the supraglottic swallow technique.

When voice therapy does not provide a positive effect, in particular when the glottic gap is wide because the immobile vocal fold lies in abducted or intermediate position, injection laryngoplasty may be indicated. In this procedure, a bulking material is injected into the true vocal fold in an attempt to medialize the edge of the vocal fold. Some of the approved injection materials are hyaluronic acid, carboxymethylcellulose, and calcium hydroxyapatite. In addition, injection laryngoplasty can be performed using centrifuged autologous fat, which reduces the risk of allergic reactions and local granulomatosis possibly caused by synthetic materials [19] (Fig. 16.4).

Laryngeal reinnervation of a paralyzed vocal fold of a severed, avulsed or sacrificed RLN, with an intraoperative direct repair end-to-end anastomosis, does not restore normal motion but usually results in a vocal fold fixed in a favorable median or paramedian position. The reinnervated vocal folds are usually positioned toward the median position. This situation is better described as synkinesis, simultaneous contraction of adductors and abductors. In cases showing extreme misdirection in reinnervation, however, paradoxical motion of the vocal folds may occur. The most common indication for reinnervation is a unilateral neurogenic RLN injury with no



**Fig. 16.4** (a) Three-month laryngoscopy evaluation after autologous fat injection. (b) Six-month laryngoscopy evaluation after autologous fat injection

expectation for recovery. Reinnervation could thus be applied intraoperatively in cases where nerve sacrifice is expected or unavoidable [20].

Also, the ansa cervicalis-to-recurrent laryngeal nerve anastomosis is an established technique for the reconstruction of RLN involved in cancer or scar processes. The presence of a distal RLN stump and ansa cervicalis is necessary to proceed with this type of anastomosis. The nerve should be released to permit a tension-free anastomosis and the neuroorrhaphy has to be performed using 8–0 nylon sutures and placing two to four epineural sutures around the anastomosis. When this approach is chosen, a recovery time close to 6–12 months should be considered.

Bilateral vocal fold immobility (BVFI) is a different entity from unilateral dysfunction as it affects breathing more than voice. In cases of thyroidectomy, the underlying process will be neurogenic in the majority of cases, secondary to an injury to both RLNs. Bilateral RLN injury will result in flaccid paralysis of the bilateral vocal fold. In addition, a certain amount of laryngeal edema from the intubation and procedure is to be expected. This combination may create a restriction of airflow, especially if the vocal folds are fixed in a median or paramedian position. When BVFI occurs, especially if the vocal folds are in adducted position, the patient typically wakes up from surgery demonstrating acute, persistent and worsening inspiratory stridor, increased work of breathing and respiratory failure. These patients usually require urgent airway management, either intubation or surgical. After reintubation, treatment with high doses of corticosteroids for at least 24–48 hours may be useful with subsequent laryngoscopic reassessment [21].

In some cases, if presentation is mild, patients can be supported with positive pressure ventilation until they fully wake up and are able to better control their breathing. BVFI can be confirmed on-site using direct or indirect laryngoscopy. Other patients may be diagnosed later on as they present for routine postoperative follow-up or because they show signs of breathy dysphonia or dyspnea on exertion.

The treatment of BVFI is guided by the symptomatology of the patient and prognosis for recovery. Unless transected, the RLN holds potential for recovery over the next 6 to 12 months. Thus, in selected cases observation could be acceptable for patients with minimal symptoms. Tracheotomy can be an acceptable solution for patients with a permanent or transient palsy while waiting for nerve recovery. Vocal fold or arytenoid lateralization (or laterofixation) has also been described as a reversible approach to enlarge the airway in cases of temporary BVFI. More definitive surgical options include medial arytenoidectomy, described by Crumley [22], which attempts to improve airway size by creating a concavity along the glottic edge of the body of the arytenoid cartilage, leaving the vocal process and attachment of the vocal ligament intact. Transverse cordotomy, as described by Kashima [23], is performed by making a transverse cut through the vocal fold just anterior to the vocal process without exposing cartilage. Novel treatments exist, including adductor botulinum toxin injection, selective bilateral laryngeal reinnervation, and laryngeal pacing, but the evidence is still scarce, and the research is ongoing [24].



## 16.5 Conclusions

Laryngeal nerve palsy represents one of the most frequent complications of thyroid surgery. Thorough knowledge of anatomy, adequate surgical skills, meticulous dissection, possibly associated with IONM, are essential for its prevention. Nonetheless, if a laryngeal nerve palsy occurs proper patient information and adequate multidisciplinary management involving otolaryngologist and speech-language therapist are necessary.

## References

1. Droulias C, Tzinas S, Harlaftis N, et al. The superior laryngeal nerve. *Am Surg.* 1976;42(9):635–8.
2. Cernea CR, Ferraz AR, Nishio S, et al. Surgical anatomy of the external branch of the superior laryngeal nerve. *Head Neck.* 1992;14(5):380–3.
3. Haller JM, Iwanik M, Shen FH. Clinically relevant anatomy of recurrent laryngeal nerve. *Spine (Phila Pa 1976).* 2012;37(2):97–100.
4. Citton M, Viel G, Iacobone M. Neck ultrasonography for detection of non-recurrent laryngeal nerve. *Gland Surg.* 2016;5(6):583–90.
5. Raffaelli M, Iacobone M, Henry JF. The “false” nonrecurrent inferior laryngeal nerve. *Surgery.* 2000;128(6):1082–7.
6. Maranillo E, Vazquez T, Quer M, et al. Potential structures that could be confused with a nonrecurrent inferior laryngeal nerve: an anatomic study. *Laryngoscope.* 2008;118(1):56–60.
7. Jeannon JP, Orabi AA, Bruch GA, et al. Diagnosis of recurrent laryngeal nerve palsy after thyroidectomy: a systematic review. *Int J Clin Pract.* 2009;63(4):624–9.
8. Bellantone R, Boscherini M, Lombardi CP, et al. Is the identification of the external branch of the superior laryngeal nerve mandatory in thyroid operation? Results of a prospective randomized study. *Surgery.* 2001;130(6):1055–9.
9. Xu W, Han D, Hu R, et al. Characteristics of vocal fold immobility following endotracheal intubation. *Ann Otol Rhinol Laryngol.* 2012;121(10):689–94.
10. Potenza AS, Araujo Filho VJF, Cernea CR. Injury of the external branch of the superior laryngeal nerve in thyroid surgery. *Gland Surg.* 2017;6(5):552–62.
11. Meyer TK, Hillel AD. Is laryngeal electromyography useful in the diagnosis and management of vocal fold paresis/paralysis? *Laryngoscope.* 2011;121(2):234–5.
12. Sahli Z, Canner JK, Najjar O, et al. Association between age and patient-reported changes in voice and swallowing after thyroidectomy. *Laryngoscope.* 2019;129(2):519–24.
13. Lombardi CP, Carnassale G, Damiani G, et al. “The final countdown”: is intraoperative, intermittent neuromonitoring really useful in preventing permanent nerve palsy? Evidence from a meta-analysis *Surgery.* 2016;160(6):1693–706.
14. Schneider R, Machens A, Lorenz K, Dralle H. Intraoperative nerve monitoring in thyroid surgery – shifting current paradigms. *Gland Surg.* 2020;9(Suppl 2):S120–8.
15. Revelli L, Gallucci P, Marchese MR, et al. Is there any reliable predictor of functional recovery following post-thyroidectomy vocal fold paralysis? *World J Surg.* 2023;47(2):429–36.
16. D’Alatri L, Galla S, Rigante M, et al. Role of early voice therapy in patients affected by unilateral vocal fold paralysis. *J Laryngol Otol.* 2008;122(9):936–41.
17. Chandrasekhar SS, Randolph GW, Seidman MD, et al. Clinical practice guideline: improving voice outcomes after thyroid surgery. *Otolaryngol Head Neck Surg.* 2013;148(6 Suppl):S1–37.
18. Miller S. Voice therapy for vocal fold paralysis. *Otolaryngol Clin N Am.* 2004;37(1):105–19.
19. Ricci Maccarini A, Stacchini M, Mozzanica F, et al. Efficacy of trans-nasal fiberoptic injection laryngoplasty with centrifuged autologous fat in the treatment of glottic insufficiency due to unilateral vocal fold paralysis. *Acta Otorhinolaryngol Ital.* 2018;38(3):204–13.

20. Simó R, Nixon IJ, Rovira A, et al. Immediate intraoperative repair of the recurrent laryngeal nerve in thyroid surgery. *Laryngoscope*. 2021;131(6):1429–35.
21. Salik I, Winters R. Bilateral vocal cord paralysis. In: StatPearls. Treasure Island, FL: StatPearls Publishing; 2022. <https://www.ncbi.nlm.nih.gov/books/NBK560852>.
22. Crumley RL. Endoscopic laser medial arytenoidectomy for airway management in bilateral laryngeal paralysis. *Ann Otol Rhinol Laryngol*. 1993;102(2):81–4.
23. Kashima HK. Bilateral vocal fold motion impairment: pathophysiology and management by transverse cordotomy. *Ann Otol Rhinol Laryngol*. 1991;100(9 Pt 1):717–21.
24. Ekbohm DC, Garrett CG, Yung KC, et al. Botulinum toxin injections for new onset bilateral vocal fold motion impairment in adults. *Laryngoscope*. 2010;120(4):758–63.

**Open Access** This chapter is licensed under the terms of the Creative Commons Attribution-NonCommercial-NoDerivatives 4.0 International License (<http://creativecommons.org/licenses/by-nc-nd/4.0/>), which permits any noncommercial use, sharing, distribution and reproduction in any medium or format, as long as you give appropriate credit to the original author(s) and the source, provide a link to the Creative Commons license and indicate if you modified the licensed material. You do not have permission under this license to share adapted material derived from this chapter or parts of it.

The images or other third party material in this chapter are included in the chapter's Creative Commons license, unless indicated otherwise in a credit line to the material. If material is not included in the chapter's Creative Commons license and your intended use is not permitted by statutory regulation or exceeds the permitted use, you will need to obtain permission directly from the copyright holder.





# Cervical Hematoma and Wound Complications

# 17

Paolo Carcoforo, Maria Grazia Sibilla,  
and Margherita Koleva Radica

## 17.1 Introduction

Although thyroid surgery is a relatively safe procedure, it may be associated with some clinically concerning postoperative complications, including postoperative cervical hematoma, incision infection, hypocalcemia, and, in some cases, vocal cord paralysis. Postoperative hemorrhage is a well-recognized complication of thyroid surgery, with an incidence between 0.45% and 6.5% [1, 2]. While hemorrhage is the underlying mechanism, it is hematoma formation which usually requires immediate bedside intervention due to risks of airway obstruction, respiratory distress, or even death due to suffocation [3, 4]. In recent years, following the development of new instruments such as bipolar scalpels, ultrasonic shears, and energy platforms thyroid surgery has become more precise and is increasingly being performed on an outpatient basis as a result of short hospital stays and low costs [5]. However, postoperative cervical hematoma remains a potential life-threatening complication and is the main reason why patients are required to stay in the hospital overnight for monitoring after thyroid surgery.

## 17.2 Risk Factors

Bleeding complications are usually due to slippage of a ligature on one of the major arterial pedicles, to bleeding from the transected parenchymal surface or from traumatized muscles, or to a jugular vein injury. This usually occurs during retching, vomiting, bucking, Valsalva maneuver or increased blood pressure during recovery.

---

P. Carcoforo (✉) · M. G. Sibilla · M. Koleva Radica  
Department of Surgery, Unit of General Surgery, S. Anna University Hospital and University  
of Ferrara, Ferrara, Italy  
e-mail: [ccf@unife.it](mailto:ccf@unife.it); [mariagrazia.sibilla@unife.it](mailto:mariagrazia.sibilla@unife.it); [klvmgh@unife.it](mailto:klvmgh@unife.it)

Hematoma will not be seen beneath the skin if the strap muscles are tied without any gap which usually is not advocated. Sometimes, the clots may dissect below the strap muscles in the peritracheal area along the deep neck spaces. Total airway obstructions may progress very fast, in a tight compartment below the strap muscles leading to tracheal compression. Moreover, the impairment of venous and lymphatic drainage leads to laryngopharyngeal edema causing added laryngeal inlet obstruction.

Factors that may cause increased risk of hemorrhage include male sex, age, Graves' disease, hypertension, antithrombotic agent use, history of thyroid procedures in low-volume hospitals, previous thyroid surgery, bilateral thyroidectomy, and neck dissection [6, 7].

---

### 17.3 Recognition

Urgent recognition of the hematoma can avert major morbidity, so medical staff should be aware of the clinical features. Patients present with respiratory distress, pain or a pressure sensation in the neck or dysphagia. The signs include progressive neck swelling, suture line bleeding, dyspnea or stridor and a significant amount of drain losses. Minimum monitoring should include: wound inspection, early warning score (EWS: respiratory rate, heart rate, blood pressure, temperature, arterial oxygen saturations, Glasgow Coma Scale), and pain score, as well as awareness for more subtle signs (agitation, anxiety, difficulty in breathing; discomfort) [8]. To aid identification, the acronym DESATS has been created, which includes: difficulty swallowing/discomfort; increase in EWS or national EWS (NEWS); swelling; anxiety; tachypnea/difficulty breathing; stridor. This acronym has been developed as part of the recommended post-thyroid surgery regular review to act as a cognitive aid and support the early recognition of patients manifesting signs of potential postoperative hematoma [8]. Since hemorrhage superficial to the strap muscles never accompanied any deep hematoma, the discoloration of the laryngeal mucosa is a sign of hemorrhage deep to the strap muscles. Transient vocal cord paralysis is reported which disappears on hematoma evacuation [9]. Vocal cord movements should be checked after hematoma evacuation as re-ligation of the bleeders may damage the recurrent laryngeal nerve.

Hemorrhage and subsequent hematoma most frequently occur within the first 24 hours following thyroid surgery, with approximately half occurring within 6 hours [8]. Thus, routine patient observations should be carried out at least hourly for first 6 hours postoperatively. Following the initial 6-hour period, the frequency of observations may be tailored according to individual patient risk and local policies. Although several cases of hematoma following thyroid surgery have been reported after 24 hours, this is extremely rare. Patients are usually discharged one day following surgery [10].

## 17.4 Management

In the event of a suspected hematoma, management should start with concurrent oxygenation and clinical evaluation progressing to hematoma evacuation and tracheal intubation when indicated. The signs of airway compromise (arterial oxygen desaturation; difficulty breathing; stridor; tachypnea) or concern about deterioration due to rapidly expanding neck swelling indicate a need for immediate evacuation of the hematoma at the patient's bedside if necessary or in the operating theatre. Recent guidelines recommend using the SCOOP approach: skin exposure; cut sutures; open skin; open muscles; pack wound [11]. The urgent evacuation is followed by careful re-exploration of the operative site with copious lavage of blood clots to identify the source of bleeding, which is identified in only 73% of patients. Either passive or suction drains are placed depending on the circumstances. If a noncompressive hematoma is present, it can be decompressed by simple needle aspiration, but careful surveillance for recurrent collections is essential in all cases. Intravenous dexamethasone and tranexamic acid should be considered. Dexamethasone may improve upper airway obstruction and edema and tranexamic acid may reduce bleeding. Should hematoma evacuation fail to stabilize the patient, with no resolution of airway compromise and/or further patient deterioration, tracheal intubation is indicated. Intubation during re-exploration will be difficult because of considerable edema of the epiglottis, pharyngeal wall and vocal cords. Sometimes intubation will be successful after decompression of the hematoma. In "cannot intubate, cannot oxygenate" situations, scalpel cricothyroidotomy or emergency tracheostomy are used.

Post hematoma airway complications are common in older patients, large goiters having tracheal compression preoperatively.

Precautions to prevent post-thyroidectomy hemorrhage and hematoma should start preoperatively by control of hyperthyroidism and intraoperatively by rigorous and meticulous hemostasis and by performance of a Valsalva maneuver in coordination with the anesthesiologist after completion of the dissection to detect bleeding. Leaving a gap in the lower end while suturing the strap muscles in the midline allows the blood to come out of the relatively closed compartment into the subplatysmal space where it can be easily detected, and should be practiced. Dissection in the subplatysmal plane should be done meticulously as damage to the anterior jugular veins may cause bleeding later on. Drainage of the cervical space after thyroidectomy has been proven by a Cochrane Database meta-analysis to be of no utility [12]. Postoperatively, prompt resumption of antihypertensive medications is very important. Smooth extubation and avoiding coughing reduces the slippage of ligatures.

Surgical site infection (SSI) after thyroid surgery is uncommon and thyroidectomy is almost always classified as a clean case. In fact, the frequency of SSI after thyroid surgery has been estimated to be 0.3–2.9%, but the consequences can be costly and morbid for patients [13].

Clinical manifestations of SSI include wound cellulitis, treated with oral antibiotics, or infected seroma, which may require drainage and culture-directed treatment with intravenous antibiotics. The risk of developing an SSI increases in the case of prolonged operation time, use of drains, reoperation due to bleeding and concomitant lymph node dissection [14]. The use of preoperative antibiotic prophylaxis is generally not recommended due to the low incidence of SSI after thyroid surgery [15]. Whether or not there is a subgroup of patients at higher risk of SSI where prophylactic antibiotics could be considered is at present unclear. Patients who underwent lymph node dissection and were reoperated due to bleeding had increased risk of SSI [16]. Several studies have shown that the use of drains in thyroid surgery is associated with a high rate of SSI, prolonged hospital stay and a high pain score [17].

SSI after modified radical neck dissection due to cancer in the neck is a major complication estimated to occur in 13–20% of patients undergoing this procedure [18]. The reason for this is not clear, but could be due to prolonged operation time or the lymph node dissection *per se*. It might be considered that lymph node dissection may cause disruption to the immune system and reduce the local barrier for infection. The use of drains and concomitant lymph node dissection are associated independently with SSI in surgery for thyroid disease. Patients with these two risk factors constitute a subgroup in which prophylactic antibiotics might be considered [6].

In Italy, the rate of antibiotic prophylaxis use in thyroid surgery is 38.7% [19], whereas the figures on antibiotic prophylaxis in this surgery outside Italy are much lower. In a survey carried out in the United Kingdom, antibiotic prophylaxis was administered routinely in only 9% of patients, and in 16% of selected cases while 75% of patients did not receive the prophylaxis [20].

A recent review contributes to knowledge on the efficacy of antibiotic prophylaxis in thyroid and parathyroid surgery by examining the results of nine studies (4 RCTs and 5 nRCTs) that reported postoperative SSIs in patients who received antibiotic prophylaxis compared to those without. This is the largest meta-analysis on this topic to date, with 8170 participants included. The overall postoperative incidence of SSI in thyroid and parathyroid surgery was 1.5% (0.6% in the experimental group and 2.4% among controls). The meta-analysis showed no significant differences in the rate of postoperative SSIs between patients who received antibiotic prophylaxis and those who did not. These results do not support the routine use of antibiotic prophylaxis for thyroid surgery and are in line with recent SSI guidelines noting that the risk of SSI is not reduced by routine antibiotic prophylaxis in clean neck surgery [21].

The results of many studies shows that the rate of infections in thyroid surgery is 1% and that antibiotic prophylaxis was not efficient in reducing this rate. The concentration of several infections in one single center is of particular interest and potential concern [19].

Severe SSIs frequently are associated with Group A *Streptococcus* (GAS) because of the ability of these infections to evolve into necrotizing fasciitis. Few cases of post-thyroidectomy GAS SSI have been reported in the literature [22].

High fever and surgical site erythema in the early postoperative period after thyroid surgery can be signs of a GAS infection, which might lead to necrotizing, descending, life-threatening mediastinitis. GAS is isolated from 3% of postpartum infections and 1% of SSIs [23]. Early diagnosis with support of computed tomography scans, immediate therapy including wound opening, lavage, intravenous antibiotic treatment with penicillin and clindamycin are vital. If treatment resistance occurs, cervical negative pressure treatment should be considered [24]. Many of these cases were complicated by septic shock and death, underlining the importance of early identification and proper treatment of GAS SSI post-thyroidectomy. No description of the surgical approach to a necrotizing soft tissue infection after thyroid resection was identified in the current literature [25]. GAS frequently colonizes various sites in the body, including the skin, pharynx, vagina, and anus, asymptotically [26]. Rates of asymptomatic GAS colonization in adults range from 2% to 8%.

---

## References

1. Doran HE, Wiseman SM, Palazzo FF, et al. Post-thyroidectomy bleeding: analysis of risk factors from a national registry. *Br J Surg*. 2021;108(7):851–7.
2. Calò PG, Pisano G, Piga G, et al. Postoperative hematomas after thyroid surgery. Incidence and risks factors in our experience. *Ann Ital Chir*. 2010;81(5):343–7.
3. Farooq MS, Nouraei R, Kaddour H, Saharay M. Patterns, timing and consequences of post-thyroidectomy haemorrhage. *Ann R Coll Surg Engl*. 2017;99(1):60–2.
4. Edafe O, Cochrane E, Balasubramanian SP. Reoperation for bleeding after thyroid and parathyroid surgery: incidence, risk factors, prevention, and management. *World J Surg*. 2020;44(4):1156–62.
5. Sun GH, DeMonner S, Davis MM. Epidemiological and economic trends in inpatient and outpatient thyroidectomy in the United States, 1996–2006. *Thyroid*. 2013;23(6):727–33.
6. Fan C, Zhou X, Su G, et al. Risk factors for neck hematoma requiring surgical re intervention after thyroidectomy: a systematic review and meta-analysis. *BMC Surg*. 2019;19(1):98.
7. Promberger R, Ott J, Kober F, et al. Risk factors for postoperative bleeding after thyroid surgery. *Br J Surg*. 2012;99(3):373–9.
8. Iliff HA, El-Boghdadly K, Ahmad I, et al. Management of haematoma after thyroid surgery: systematic review and multidisciplinary consensus guidelines from the difficult airway society, the British Association of Endocrine and Thyroid Surgeons and the British Association of Otorhinolaryngology, Head and Neck Surgery. *Anaesthesia*. 2022;77(1):82–95.
9. Lee HS, Lee BJ, Kim SW, et al. Patterns of post-thyroidectomy hemorrhage. *Clin Exp Otorhinolaryngol*. 2009;2(2):72–7.
10. Leyre P, Desurmont T, Lacoste L, et al. Does the risk of compressive hematoma after thyroidectomy authorize 1-day surgery? *Langenbechcks Arch Surg*. 2008;393(5):733–7.
11. British Association of Endocrine and Thyroid Surgeons. Management of post-operative haemorrhage in thyroid and parathyroid surgery. <https://www.baets.org.uk/management-of-post-operative-haemorrhage-in-thyroid-and-parathyroid-surgery>. Accessed 23 Nov 2022.
12. Samraj K, Gurusamy KS. Wound drains following thyroid surgery. *Cochrane Database Syst Rev*. 2007;2007(4):CD006099
13. Salem FA, Almquist M, Nordenström E, et al. A nested case-control study on the risk of surgical site infection after thyroid surgery. *World J Surg*. 2018;42(8):2454–61.
14. Qin Q, Li H, Wang LB, et al. Thyroid surgery without antibiotic prophylaxis: experiences with 1030 patients from a teaching hospital in China. *World J Surg*. 2014;38(4):878–81.

15. Bergenfelz A, Jansson S, Kristoffersson A, et al. Complications to thyroid surgery: results as reported in a database from a multicenter audit comprising 3,660 patients. *Langenbeck's Arch Surg.* 2008;393(5):667–73.
16. Dionigi G, Rovera F, Boni L, et al. Surgical site infections after thyroidectomy. *Surg Infect.* 2006;7(Suppl. 2):S117–20.
17. Dionigi G, Rovera F, Boni L, Dionigi R. Surveillance of surgical site infections after thyroidectomy in a one-day surgery setting. *Int J Surg.* 2008;6(Suppl 1):S13–5.
18. Bratzler DW, Dellinger EP, Olsen KM, et al. Clinical practice guidelines for antimicrobial prophylaxis in surgery. *Surg Infect.* 2013;14(1):73–156.
19. Gentile I, Rosato L, Avenia N, et al. Do Italian surgeons use antibiotic prophylaxis in thyroid surgery? Results from a national study (UEC–Italian endocrine surgery units association). *Ann Ital Chir.* 2014;85(1):33–7.
20. Hardy RG, Forsythe JL. Uncovering a rare but critical complication following thyroid surgery: an audit across the UK and Ireland. *Thyroid.* 2007;17(1):63–5.
21. Polistena A, Prete FP, Avenia S, et al. Effect of antibiotic prophylaxis on surgical site infection in thyroid and parathyroid surgery: a systematic review and meta-analysis. *Antibiotics (Basel).* 2022;11(3):290.
22. Moalem J, Ruan DT, Farkas RL, et al. Patterns of antibiotic prophylaxis use for thyroidectomy and parathyroidectomy: results of an international survey of endocrine surgeons. *J Am Coll Surg.* 2010;210(6):949–56.
23. Urban JA. Cost analysis of surgical site infections. *Surg Infect.* 2006;7(Suppl 1):S19–22.
24. Buerba R, Roman SA, Sosa JA. Thyroidectomy and parathyroidectomy in patients with high body mass index are safe overall: analysis of 26,864 patients. *Surgery.* 2011;150(5):950–8.
25. Avenia N, Sanguinetti A, Cirocchi R, et al. Antibiotic prophylaxis in thyroid surgery: a preliminary multicentric Italian experience. *Ann Surg Innov Res.* 2009;3:10.
26. de Blacam C, Ogunleye AA, Momoh AO, et al. High body mass index and smoking predict morbidity in breast cancer surgery: a multivariate analysis of 26,988 patients from the national surgical quality improvement program database. *Ann Surg.* 2012;255(3):551–5.

**Open Access** This chapter is licensed under the terms of the Creative Commons Attribution-NonCommercial-NoDerivatives 4.0 International License (<http://creativecommons.org/licenses/by-nc-nd/4.0/>), which permits any noncommercial use, sharing, distribution and reproduction in any medium or format, as long as you give appropriate credit to the original author(s) and the source, provide a link to the Creative Commons license and indicate if you modified the licensed material. You do not have permission under this license to share adapted material derived from this chapter or parts of it.

The images or other third party material in this chapter are included in the chapter's Creative Commons license, unless indicated otherwise in a credit line to the material. If material is not included in the chapter's Creative Commons license and your intended use is not permitted by statutory regulation or exceeds the permitted use, you will need to obtain permission directly from the copyright holder.







Andrea Polistena, Francesco Puma, Nicola Avenia,  
and Jacopo Vannucci

Tracheal injury (TI) is a rare event with potentially life-threatening consequences mostly represented by mediastinitis and resultant sepsis. TI can be classified as traumatic from both blunt and penetrating injury or iatrogenic when it occurs during surgery, endotracheal intubation, or other operative endoscopic procedure approaching the airways [1–4].

## 18.1 Traumatic Tracheal Injury

The incidence of TI among patients after chest and neck injury can be estimated up to 2%, including those who die immediately after the trauma [5]. The rate of TI increases for neck penetrating injury (4.5%). Neck blunt trauma can be either followed by TI due to tracheal tears, fractures of the larynx and trachea, or even to

---

A. Polistena (✉)

Department of Surgery, Policlinico Umberto I University Hospital, Sapienza University of Rome, Rome, Italy

e-mail: [andrea.polistena@uniroma1.it](mailto:andrea.polistena@uniroma1.it)

F. Puma

Department of Surgical and Biomedical Sciences, S. Maria della Misericordia University Hospital, University of Perugia, Perugia, Italy

e-mail: [francesco.puma@unipg.it](mailto:francesco.puma@unipg.it)

N. Avenia

Department of Surgical and Biomedical Sciences, Santa Maria University Hospital of Terni, University of Perugia, Terni, Italy

e-mail: [nicola.avenia@unipg.it](mailto:nicola.avenia@unipg.it)

J. Vannucci

Department of General Surgery and Surgical Specialties, Policlinico Umberto I University Hospital, Sapienza University of Rome, Rome, Italy

e-mail: [jacopo.vannucci@uniroma1.it](mailto:jacopo.vannucci@uniroma1.it)

complete laryngo-tracheal separation following neck hyperextension from sudden deceleration [5]. A combination of both mechanisms is frequently observed when neck hyperextension during a vehicle accident is followed by direct collision of the neck with the steering wheel or the dashboard (“padded dashboard syndrome”) [5]. Another common mechanism of TI can be related to a sudden increase of intra-tracheal pressure against a closed glottis caused by the improper use of the seat belt in car accidents. In other events leading to a similar dynamic, chest compressive trauma may occur when there is a quick increase of the pressure in the airway while the glottis is reflexively closed [6, 7].

---

## 18.2 Iatrogenic Tracheal Injury

Iatrogenic TI can be the consequence of endotracheal intubation, an operative endoscopic procedure or it can also occur during esophageal or thyroid surgery. A specific condition of TI can be observed in the surgical treatment of locally advanced thyroid cancer invading the airways.

TIs occurring during tracheal intubation are rare considering the number of procedures performed for general anesthesia. The real occurrence of this complication might be underestimated considering that some short tears are probably misdiagnosed and undergo spontaneous healing [8].

In the last decade, the estimated incidence of iatrogenic TI following tracheal intubation ranges from 0.05% to 0.37% [9]. Double-lumen tube orotracheal intubation is potentially associated with a higher rate of TI due to a more complex procedure, but the frequency of this event remains low, being estimated under 1% [10]. The mechanisms of tracheobronchial rupture have been largely described. The main causes can be identified in overinflated cuff or excessive pushing of the tube. A direct tear caused by the tube itself remains rare. More often, TIs following intubation are located in the posterior aspect of the trachea in the membranous wall or at the junction between the membranous wall and the cartilage. A tear is more likely to occur after double-lumen intubation in consideration of the tube tips and irregular shape [9, 11]. Inadequate tube size is also considered a prominent cause of TI during the procedure, as reported in some case series and supported by the evidence that a higher rate of female patients with smaller body size compared to men present this rare complication [8]. Other risk factors for a TI are multiple vigorous attempts at intubation, intubation carried out in emergency settings, anesthesiologist’s lack of experience, inappropriate use of stylets, rapid inflation, rupture of the cuff, eccentric inflation of the tracheal cuff, malpositioning of the tube tip, tube repositioning without cuff deflation, repetitive coughing, abrupt head and neck movement, anatomic factors with weakness of the membranous trachea, malacia (mostly elderly women), congenital abnormalities, mediastinal compression with distortion of the trachea, inflammatory lesions of the tracheobronchial tree [11, 12].

TI can be also observed as a consequence of other operative procedures such as percutaneous tracheotomy, rigid bronchoscopy, tracheal or esophageal stent placement, endoscopic tracheal treatments (laser therapy, diathermy), and dilation of tracheal stenoses [2, 13].

Another important group of TI are related to direct tracheobronchial damage during open surgery (e.g., esophagectomy and thyroidectomy), when tumor invasion, compression or inflammatory adhesion affecting the airway are present [14].

---

## 18.3 Clinical Scenario

Undiagnosed patients with TI present subcutaneous emphysema in the postoperative course, which worsens after coughing and can be followed by mediastinal emphysema. Usually, pneumomediastinum is asymptomatic but it can generate complications such as compressive pneumothorax, and large pneumomediastinum can either be observed during mechanical ventilation or occur in the postoperative period or later [8].

### 18.3.1 Radiological Investigations

Primary radiological investigations include standard cervical and chest X-ray. Computed tomography (CT) can be used to better evaluate mediastinal emphysema in pneumothorax, mediastinal and neck effusions.

Fiberoptic bronchoscopy can be used to define the TI, by directly visualizing the lesion, possibly showing its exact location and extension (length and depth) and for operative purposes as well [14].

---

## 18.4 Special Clinical Conditions

The airway can be injured by either surgical manipulation or by tumor infiltration.

### 18.4.1 Tracheal Injury during Thyroid Surgery

Thyroid surgery is one of the most common procedures worldwide and it is considered a safe operation due to the standardization of surgical approaches, the improvement in operating skills, the application of new technologies, and the required training. Nevertheless, despite the improvements in technique and the fact that patients are increasingly centralized, thyroidectomy is not yet free from the risk of complications and death due to the complexity of the anatomy. In thyroid surgery, the overall incidence of complications is approximately 0–54.4% [15–17].

A review of more than 11,000 thyroid surgeries reported the incidence of TI to be 0.06% and the most common location of injury is the posterior lateral cartilage-membranous junction near the ligament of Berry. The injury is believed to be secondary to direct trauma resulting from the use of diathermy to dissect the thyroid off the trachea or to necrosis induced by thermal or ischemic compromise of the sub-mucosal plexus, usually with delayed presentation [18, 19].

TI is usually caused by endoscopic surgery or energy-delivering equipment and it might be difficult to detect during surgery, leading to severe

postoperative consequences [20]. Typically, TIs occurring during thyroidectomy are immediately recognized and repaired intraoperatively, with a good outcome and low morbidity. In other, less frequent, cases based on an ischemic lesion, TI occurs subacutely with delayed rupture secondary to tracheal necrosis, which can occur even 30–40 days after surgery [20]. The extent of surgery when performing hemithyroidectomy does not exclude the possibility of this occurrence [21].

When the tracheal laceration is detected, the choice of the best treatment depends on several factors, the most important being the lesion's longitudinal extent, position and size. Surgery is generally the best option for a definitive cure, but conservative treatment is suggested in small-size lesions or non-operable patients. The absolute contraindications to surgery for an acute iatrogenic trauma are very few. Endoscopy is mandatory and is the pivotal examination to diagnose and assess the lesion. If the lesion is small, the mucosa is healthy and surgery sounds like over-treatment, some authors suggest endoscopic treatment with glues and sealants, although the results are conflicting. This therapeutic option is debated when the tear is large and after initial failure. Surgery aims at restoring the airway wall and is usually performed with interrupted suture with absorbable stitches with or without a pedicle flap to help tissue healing. When the lesion is located in the upper airway, the best approach is cervicotomy, while for the lower trachea a right thoracotomy is best [22]. In selected cases a combined approach with the use of negative pressure wound therapy is an effective treatment option for massive pneumomediastinum and subcutaneous emphysema [23, 24].

#### **18.4.2 Thyroid Tumors Invading the Airways**

Complete invasion of the tracheal wall by a neoplasm accounts for a very limited number of cases but represents a particular condition. Intraluminal invasion from a thyroid tumor usually presents with hoarseness, hemoptysis and different grades of fatigue initially and dyspnea later on. In most cases, the airway invasion is misdiagnosed when a well-differentiated thyroid tumor is assessed. Since the symptoms are late and mild, patients are subjected to surgery and found to have compromised airway during neck exploration.

There is no chance to predict the tumor behavior considering that the biological basis of some differentiated tumors is really indolent, while others show a locally invasive attitude. Prevention of these phenomena is currently impossible, and the diagnosis should take this possible occurrence into account. Despite tracheal infiltration being a severe condition in the context of a thyroid tumor, it is mostly asymptomatic, making its misdiagnosis before thyroidectomy more than likely. When symptoms or neck ultrasound imaging are suggestive for tracheal invasion, bronchoscopy is mandatory. Tracheoscopy represents the gold standard and is very effective for achieving the diagnosis. Moreover, the endoscopic assessment of the airway allows for a fine evaluation of the length, grade, and level of the stenosis. In the case of possible surgery with radical intent, fiberoptic bronchoscopy is to be considered suboptimal whereas rigid bronchoscopy seems to be more appropriate,

as well as being useful for mechanical dilation when tumor invasion creates a consistent stenosis of the airway lumen.

Endoscopy is not the only required examination. A CT scan, magnetic resonance imaging and a barium swallow test are integrative and necessary for a definitive evaluation of the condition. CT imaging can identify the depth of invasion into the tracheal wall or lumen invasion along with airway surrounding tissues, tumor position, tumor size and anatomical relationships. When the tumors are bulky and the airway is highly compromised, the work-up must evaluate the esophagus as well. In the case of esophageal infiltration, the prognosis is worse and survival decreases [25].

When airway invasion occurs, the work-up is aimed at selecting the best treatment option. Treatment can have a curative intent or be primarily palliative. When the diagnosed tumor is an undifferentiated thyroid tumor, the treatment is usually palliative since the tumor is highly aggressive and mostly non-resectable at diagnosis while, in the case of well-differentiated thyroid tumors, the treatment is often with curative intent. The importance of a correct and margin-free resection is crucial. Several surgical techniques are reported: tracheal shaving, tracheal window and segmental resection and reconstruction. Shaving off the tumor from the external airway wall is reported in many series and has a strict limitation: it works only when the tumor is closely attached to a non-infiltrated trachea. Tracheal windows are performed with controversial results. When the infiltrated area of the trachea is a single and limited spot in the anterior trachea, the window is successful because the defect is efficiently repaired and covered by the surrounding tissues; however, it is likely to be restored with a permanent tracheal deformation when the window is wide and requires sectioning of more than three rings for more than 1/3 of the airway circumference. Even though some suggestions have been given regarding length, diameter and circumference thresholds for performing or abandoning the surgical technique, surgery must be tailored to each single case and planned with a tailoring approach. Segmental resection and end-to-end anastomosis is probably the best option. This operation can guarantee almost normal restoration of airway continuity, and it is the only possible option for wide and asymmetric infiltration with subglottic compromise. On the other hand, airway resection and reconstruction has more potential complications regarding voice, suture dehiscence and reflux/deglutition compared to tracheal shaving. When a curative intent is scheduled, the best surgical strategy is to perform thyroidectomy en-bloc with airway tract resection and lymph node removal. This happens relatively rarely considering the incidence of local recurrence after thyroidectomy with a necessary second operation to remove the compromised airway tract.

When a thyroid tumor invades the airway, the involved tract is usually from the larynx to the mid-trachea. Invasion of the lower trachea is anecdotal. Thus, the procedure to be performed varies largely according to the tumor characteristics. The surgery can be complex with anatomical adaptation of the airway stumps [26].

Considering the thyroid's position, the larynx, recurrent nerves, cricoid and the subglottic larynx can be involved by the disease. In this regard, a pure tracheal resection and reconstruction accounts for only a limited number of operations scheduled for this indication. Asymmetric reconstruction of the upper airway with partial or total cricoid or thyroid cartilage with or without sacrifice of a recurrent nerve is a common resection to be planned. These operations are possibly

technically demanding with specific expertise required. For this reason, patients with suspected thyroid tumor invading the airway should be referred to dedicated centers with specific experience with this tumor and surgery [27].

In the case of highly aggressive tumors or non-resectable disease, the only possible goal is to guarantee ventilation and avoid asphyxia. In this condition, endoscopic treatment can be suggested with airway lumen dilation with or without stenting. Tracheotomy is the very effective and final option [28].

---

## References

1. Prokakis C, Koletsis EN, Dedeilias P, et al. Airway trauma: a review on epidemiology, mechanisms of injury, diagnosis and treatment. *J Cardiothorac Surg.* 2014;9:117.
2. Schneider T, Storz K, Dienemann H, Hoffmann H. Management of iatrogenic tracheobronchial injuries: a retrospective analysis of 29 cases. *Ann Thorac Surg.* 2007;83(6):1960–4.
3. Koletsis E, Prokakis C, Baltayiannis N, et al. Surgical decision making in tracheobronchial injuries on the basis of clinical evidences and the injury's anatomical setting: a retrospective analysis. *Injury.* 2012;43(9):1437–41.
4. Grewal HS, Dangayach NS, Ahmad U, et al. Treatment of tracheobronchial injuries: a contemporary review. *Chest.* 2019;155(3):595–604.
5. Gómez-Caro A, Ausín P, Moradiellos FJ, et al. Role of conservative medical management of tracheobronchial injuries. *J Trauma* 2006;61(6):1426–34; discussion 1434–5.
6. Kiser AC, O'Brien SM, Dettlerbeck FC. Blunt tracheobronchial injuries: treatment and outcomes. *Ann Thorac Surg.* 2001;71(6):2059–65.
7. Rathlev NK, Medzon R, Bracken ME. Evaluation and management of neck trauma. *Emerg Med Clin North Am.* 2007;25(3):679–94. viii
8. Jougon J, Ballester M, Choukroun E, et al. Conservative treatment for postintubation tracheobronchial rupture. *Ann Thorac Surg.* 2000;69(1):216–20.
9. Miñambres E, Burón J, Ballesteros MA, et al. Tracheal rupture after endotracheal intubation: a literature systematic review. *Eur J Cardiothorac Surg.* 2009;35(6):1056–62.
10. Spaggiari L, Rusca M, Carbognani P, Solli P. Tracheobronchial laceration after double-lumen intubation for thoracic procedures. *Ann Thorac Surg.* 1998;65(6):1837–9.
11. Marty-Ané CH, Picard E, Jonquet O, Mary H. Membranous tracheal rupture after endotracheal intubation. *Ann Thorac Surg.* 1995;60(5):1367–71.
12. Oo S, Chia RHX, Li Y, et al. Bronchial rupture following endobronchial blocker placement: a case report of a rare, unfortunate complication. *BMC Anesthesiol.* 2021;21(1):208.
13. Aldemyati R, Paparoupa M, Kluge S, et al. Surgical correction of a percutaneous dilatational tracheostomy: a case report. *Int J Surg Case Rep.* 2022;95:107248.
14. Paraschiv M. Iatrogenic tracheobronchial rupture. *J Med Life.* 2014;7(3):343–8.
15. Jin S, Sugitani I. Narrative review of management of thyroid surgery complications. *Gland Surg.* 2021;10(3):1135–46.
16. Alqahtani SM, Almussallam B, Alatawi AS, et al. Post-thyroidectomy complications and risk factors in Tabuk, Saudi Arabia: a retrospective cohort study. *Cureus.* 2020;12(10):e10852.
17. Rossi L, Buoni V, Fregoli L, et al. Postsurgical complications after robot-assisted transaxillary thyroidectomy: critical analysis of a large cohort of European patients. *Updat Surg.* 2022;74(2):511–7.
18. Gosnell JE, Campbell P, Sidhu S, et al. Inadvertent tracheal perforation during thyroidectomy. *Br J Surg.* 2006;93(1):55–6.
19. Husain R, Alnasser A, Al Duhileb M, Madkhali T. First tracheal ring fracture in a complex thyroid surgery. *Int J Surg Case Rep.* 2020;66:309–12.

20. Shew M, Boyd C, Kraft S. Delayed multifocal tracheal injury following thyroidectomy: a case report and review of the literature. *Cureus*. 2020;12(5):e8164.
21. Windon MJ, Dhillon V, Tufano RP. Case report: presentation of delayed tracheal perforation after hemithyroidectomy. *AME Case Rep*. 2018;2:24.
22. Mathisen DJ. Main and lobar bronchoplasty. In: Grillo HC, editor. *Surgery of the trachea and bronchi*. Hamilton, Ontario: BC Decker Inc; 2004.
23. Kim YN, Chang YS, Cho KR, Kim BY. A case of massive subcutaneous emphysema and pneumomediastinum due to dehiscence of stoma after emergent tracheostomy. *Ear Nose Throat J*. 2023;102(5):307–11.
24. Janssen N, Laven IEWG, Daemen JHT, et al. Negative pressure wound therapy for massive subcutaneous emphysema: a systematic review and case series. *J Thorac Dis*. 2022;14(1):43–53.
25. Avenia N, Vannucci J, Monacelli M, et al. Thyroid cancer invading the airway: diagnosis and management. *Int J Surg*. 2016;28(Suppl 1):S75–8.
26. Grillo HC, Suen HC, Mathisen DJ, Wain JC. Resectional management of thyroid carcinoma invading the airway. *Ann Thorac Surg*. 1992;54(1):3–9. discussion 9–10
27. Gaissert HA, Honings J, Grillo HC, et al. Segmental laryngotracheal and tracheal resection for invasive thyroid carcinoma. *Ann Thorac Surg*. 2007;83(6):1952–9.
28. Puma F, Ceccarelli S, Potenza R, et al. Rescue tracheostomy for patients with unresectable large growing neck masses. *Ann Thorac Surg*. 2021;112(5):e383–6.

**Open Access** This chapter is licensed under the terms of the Creative Commons Attribution-NonCommercial-NoDerivatives 4.0 International License (<http://creativecommons.org/licenses/by-nc-nd/4.0/>), which permits any noncommercial use, sharing, distribution and reproduction in any medium or format, as long as you give appropriate credit to the original author(s) and the source, provide a link to the Creative Commons license and indicate if you modified the licensed material. You do not have permission under this license to share adapted material derived from this chapter or parts of it.

The images or other third party material in this chapter are included in the chapter's Creative Commons license, unless indicated otherwise in a credit line to the material. If material is not included in the chapter's Creative Commons license and your intended use is not permitted by statutory regulation or exceeds the permitted use, you will need to obtain permission directly from the copyright holder.



---

## Part IV

# New Perspective Tools





# Training and Learning Curves in Thyroid Surgery

# 19

Alessia Fassari, Marco Bononi, and Giuseppe Cavallaro

## 19.1 Introduction

In 1885 the German psychologist Herman Ebbinghaus first conceived the idea of measuring the improvement in a repeated task over time [1]. The learning curve (LC) concept was first introduced in 1936 by Theodore P. Wright, an aeronautical engineer measuring the effect of learning on production costs in the aircraft industry [2]. The measurement of skills and workforce is easy to define in the industrial world through the analysis of costs, production times and product quality. The common feeling is based on the assumption that if an operation is repeated it takes less time to perform. Since this concept was translated to the full spectrum of medical specialties and procedures, its definition has become more complex and controversial. Moreover, with the advent of minimally invasive techniques, the LC concept has become a fundamental “dogma”, with specific and potentially dramatic implications, particularly in all fields of surgery [3]. Over the years, with the ever-increasing demand for specific skills and excellent results, many studies have been performed on the learning process of individual surgical procedures, from the simplest to the most complex.

---

A. Fassari

General Surgery Unit, CHL-Luxembourg Hospital Center, Luxembourg, Luxembourg  
e-mail: [alessia.fassari@gmail.com](mailto:alessia.fassari@gmail.com)

M. Bononi

Department of Surgery, Sapienza University of Rome, General Surgery Unit, Policlinico Umberto I University Hospital, Rome, Italy  
e-mail: [marco.bononi@uniroma1.it](mailto:marco.bononi@uniroma1.it)

G. Cavallaro (✉)

Department of Medico-Surgical Sciences and Biotechnologies, Sapienza University of Rome, General and Laparoscopic Surgery Unit, ICOT Hospital, Latina, Italy  
e-mail: [giuseppe.cavallaro@uniroma1.it](mailto:giuseppe.cavallaro@uniroma1.it)

The surgical LC advances through four stages which include (1) the beginning of training, (2) a gradual escalation where the surgeon becomes progressively competent, (3) the stage of minimal improvement, and finally (4) a plateau where experience has minimal improvements. A decreasing curve follows due to advancing age or for the approach to increasingly difficult cases [4].

---

## 19.2 Assessment of Performance and Learning in Thyroid Surgery

Thyroidectomy is one of the most common surgical procedures carried out in general and endocrine surgery units worldwide. There have been several advances in thyroid surgery since the first successful procedure by Theodor Kocher in 1872. Minimally invasive thyroidectomy has been developed over the past 20 years in order to minimize surgical morbidity and neck scarring. The evolution of endoscopic surgery satisfies the esthetic demand, recovery, and limited trauma in nearly all surgical disciplines, including the treatment of differentiated thyroid cancer [5].

Robotic thyroidectomy has been introduced to overcome the limitations of endoscopic procedures by providing a three-dimensional 10–12-fold magnified view, allowing easier identification of the parathyroid glands and the recurrent laryngeal nerve (RLN) with a safer and more precise dissection. Unlike endoscopic thyroidectomy, the robotic approach provides fine motion scaling, hand-tremor filtering, innovative instrumentation with extended freedom of motion, as well as surgical education.

These new exciting technologies are complex and require experienced thyroid surgeons and surgical teams to ensure safe implementation. In this chapter we aim to investigate the learning process through the different surgical approaches to the thyroid gland, providing an overview of the parameters used in defining surgical proficiency.

The current literature shows how assessing a clinician's performance is challenging.

The traditional learning method for thyroid surgery involves a primary phase in which the young surgeon only plays an assistant role during the operation and, above all for minimally invasive techniques, he is obliged to follow training courses in order to learn how to use the dedicated instrumentation and to watch the videos of the various procedures. Only after passing this preliminary phase, the trainee surgeon should perform the surgery independently, under tutor supervision for the initial cases. A recently introduced method is parallel learning. Thyroidectomy like any surgical procedure consists of several steps, each of which must be meticulously mastered and repeated until the operator becomes proficient. The steps of the procedure can be approached sequentially according to the temporal order of the operation or even better by following an order of difficulty. When the trainee surgeon has gained experience in each single step, these can be reproduced all together, resulting in the reproduction of the entire procedure.

Measures of learning surgical technique fall into two categories: surgical process and patient outcome. A detailed knowledge of the operative technique and

anatomical details is required to achieve a low morbidity rate. A century ago, Kocher, the father of thyroid surgery, reported that, as his surgical experience increased from 100 to 5000 thyroidectomies, his patients' mortality rate decreased from 12.8% to 0.5% [6].

The relationship between surgeon experience and technical competence is controversial and a number of different methods for objective assessment of surgical skills have been developed [7, 8]. Furthermore, new techniques such as minimally invasive surgery require new skills with different LCs [9]. In this regard, it is important to highlight how the LC of conventional thyroidectomy is poorly investigated in the current literature. Based on our knowledge, only our previous study provides an initial estimate of the procedures necessary to complete the learning process in conventional thyroidectomy [10]. Conversely, the steps to achieve proficiency in endoscopic and robotic procedures, even if more recently introduced, are widely studied.

According to the most recent literature, the median number of operations required to achieve competence was established to be 37 procedures for a single surgeon for robotic thyroidectomy, 31 operations for minimally invasive video-assisted thyroidectomy (MIVAT), 30 procedures for endoscopic thyroidectomy through an extracervical approach, and 25–30 procedures for conventional thyroidectomy.

However, there are several confounding factors that can generate a bias in defining the learning process for thyroidectomy. These factors are essentially related to (1) the analysis criteria of the single studies, (2) the surgeon, (3) the procedure.

---

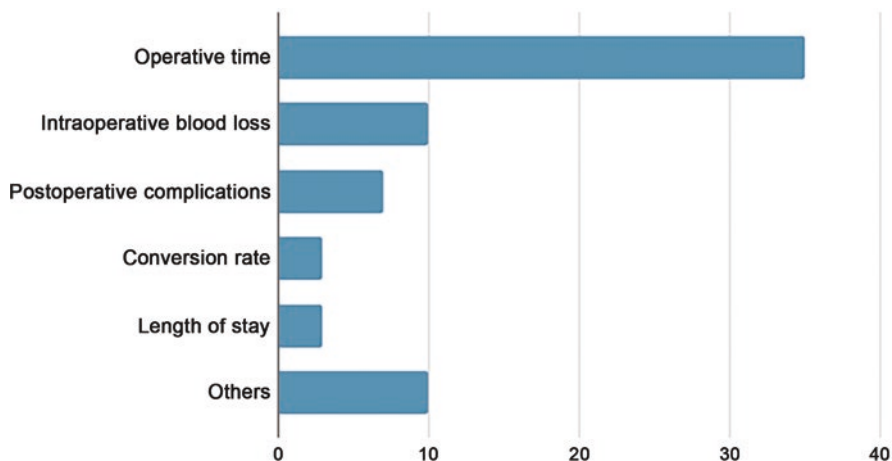
### 19.3 Analysis Criteria

What criterion is used to consider a surgeon more or less expert in a given procedure?

This concept has not been universally defined. Almost all studies use operative time to assess the LC. However, although operative time may be easily measured and compared, it is not necessarily the most appropriate marker of surgical proficiency [11]. Indeed, many studies considered other variables besides surgical time that seem to be equally or more important for patient care (Fig. 19.1): complication rate, blood loss, conversion rate, length of hospital stay, number of lymph nodes removed, tumor size, degree of complete resection, cosmetic results, intraoperative identification of the RLN and parathyroid glands, postoperative drainage volume, and postoperative pain. Only the study proposed by Ranvier et al. [12] used complication rate and severity without considering surgical time to determine the LC for transoral endoscopic thyroidectomy vestibular approach (TOETVA).

The concept of surgical time becomes even more ambiguous when applied to robotic surgery. In this field it may be subdivided into specific components such as initial robotic system setup, trocar insertion, docking, and console time, according to the steps of procedures [10, 12]. There is a lack of universal agreement on which operative time component is the most relevant for the learning process [13].

Another important variable is the size of the case series. Indeed, in the larger series the minimum number of cases to be performed for single surgeons is



**Fig. 19.1** Summary of the main evaluation items (definition and frequency) used in all studies that analyzed the learning curve for thyroid surgery

generally higher than in smaller series and above all it is possible to identify two peaks corresponding to an early and a late LC.

Finally, a large heterogeneity also derives from the statistical methodologies used in the various analyses. The cumulative sum (CUSUM) technique was adopted by the medical profession in the 1970s to analyze the LC for surgical procedures [14]. CUSUM is the running total of differences between the individual data points and the mean of all data points. It makes possible rapid and powerful assessments of changes in means, or in the slopes of trends, in data collected at regular intervals of time [14, 15]. Thus, CUSUM can be performed recursively and enables investigators to visualize the data for trends not discernable with other approaches [16].

## 19.4 Role of Surgeon's Experience

In many studies the LC for thyroidectomy is based on the experience of a single surgeon. Individual learning processes may differ from that of surgeons with different training backgrounds in other institutes. Other important variables that overlap with this are background and familiarity with a particular procedure and this is evident among minimally invasive techniques. Endoscopic/robotic thyroidectomy is usually approached when the surgeon has already gained anatomical and technical skills in other procedures. Conversely, open thyroidectomy represents the first step of surgical teaching and the learning process starts already during the training period involving several young trainees. Only in a few studies was the LC assessed for residents or surgeons who had just completed the training program. In most cases they were experienced surgeons. Endoscopic surgery requires the acquisition of new anatomical perspectives and hand-to-eye coordination and lacks both tactile feedback and 3D vision. The shift from an open to minimally invasive approach

represents a completely new experience for surgeons and this might take a longer LC for endoscopic thyroidectomy. A surgeon who begins robotic surgery generally has already passed all these steps and, moreover, draws many advantages from the robotic system, including the precision and accuracy of anatomical dissection with 3D vision, wristed instrumentation with seven degrees of freedom of motion, lack of tremor, and comfortable seated position.

---

## 19.5 Role of Procedures

The LC for minimally invasive thyroidectomy might differ depending on the approach. The alternative approaches to the thyroid gland can be divided into cervical minimally invasive, extracervical endoscopic (robot-assisted) and transoral operations (natural orifice transluminal endoscopic surgery, NOTES). Indeed, according to the use of carbon dioxide (CO<sub>2</sub>) gas insufflation and the site of incision, various remote-access thyroidectomy methods via axillary, breast, anterior chest, postauricular, and transoral routes have been developed to avoid neck scarring. MIVAT through a minimal-access cervical incision was first introduced by Miccoli et al. and is characterized by a single incision of 1.5–2 cm above the sternal notch [17, 18]. Transoral endoscopic thyroidectomy (TOET) is the only technique that enables thyroid surgery while completely avoiding a cutaneous incision, with better cosmetic results. The other techniques still need cutaneous incisions with substantial dissection through planes that are less familiar to the thyroid surgeon and require staged procedures or bilateral incisions to complete a total thyroidectomy [19]. Although various techniques for TOET are described, the most commonly used is the vestibular approach (TOETVA), first reported by Richmond and colleagues, due to its surgical outcomes and low complication rate [20, 21]. TOETVA and MIVAT allow for optimal bilateral visualization of anterior neck structures through familiar subplatysmal planes, and a two-sided procedure can be safely performed. The four common robotic approaches are the gasless transaxillary approach, the bilateral axillo-breast approach (BABA), the gasless postauricular facelift approach, and the transoral approach [22].

When we analyze the LC related to these procedures, we have to consider some technical aspects. First, the midline method is easier due to a similar operative view to conventional open thyroidectomy [23]. In contrast, the lateral approaches, such as transaxillary or retroauricular, might require additional time and more operations for the surgeon to familiarize with the anatomy and procedure, especially during contralateral side dissection in cases of total thyroidectomy [24]. For this reason, it would be appropriate to distinguish between hemi- and total thyroidectomies since there is a very different difficulty level between these procedures when minimally invasive techniques with lateral approach are performed. Moreover, endoscopic and robotic surgeries have a higher complication rate during the learning process [19] and above all they add unusual types of complications not seen with conventional thyroidectomy, such as lower lip hypoesthesia and weakness due to mental nerve injury and dissection of the chin area in the transoral approach, numbness of the

chest wall, CO<sub>2</sub> embolism, perforation of the neck, chyle leakage, Horner's syndrome, and burn and trauma of the skin flap. Esthetic results become a relatively new quality criterion, not evaluated in the conventional approach.

## 19.6 Conclusions

The current literature lacks an objective and universal definition of the LC concept considering both surgical process and patient care. The heterogeneity of the analysis methodologies and the quality criteria evaluated, the various surgical techniques and training background of the individual surgeons are all factors that make it impossible to draw univocal results. This is even more evident when applied to thyroid gland surgery, one of the most commonly performed procedures worldwide, which has evolved in recent years with alternative approaches responding to new needs, new quality standards, and new technologies. Indications and complexities change according to the technique adopted and consequently the proficiency level required is different. Future studies should consider confounding factors and establish parameters that should be consensually recognized in the assessment of surgical performance and skills.

## References

1. Ebbinghaus H. Über das Gedächtnis: Untersuchungen zur experimentellen Psychologie. Leipzig: Duncker & Humblot; 1885. [English translation: Memory: A contribution to experimental psychology. New York: Teachers College, Columbia University; 1913. Reprinted in: *Ann Neurosci*. 2013 Oct;20(4):155–6.]
2. Wright TP. Factors affecting the cost of airplanes. *J Aeronaut Sci*. 1936;3(2):122–8.
3. Sun HX, Gao HJ, Ying XY, et al. Robotic thyroidectomy via bilateral axillo-breast approach: experience and learning curve through initial 220 cases. *Asian J Surg*. 2020;43(3):482–7.
4. Yeolekar A, Qadri H. The learning curve in surgical practice and its applicability to rhinoplasty. *Indian J Otolaryngol Head Neck Surg*. 2018;70(1):38–42.
5. Lee J, Yun JH, Nam KH, et al. The learning curve for robotic thyroidectomy: a multicenter study. *Ann Surg Oncol*. 2011;18(1):226–32.
6. Becker WF. Pioneers in thyroid surgery. *Ann Surg*. 1977;185(5):493–504.
7. Brown C, Abdelrahman T, Patel N, et al. Operative learning curve trajectory in a cohort of surgical trainees. *Br J Surg*. 2017;104(10):1405–11.
8. Merola G, Cavallaro G, Iorio O, et al. Learning curve in open inguinal hernia repair: a quality improvement multicentre study about Lichtenstein technique. *Hernia*. 2020;24(3):651–9.
9. Bracale U, Merola G, Sciuto A, et al. Achieving the learning curve in laparoscopic inguinal hernia repair by Tapp: a quality improvement study. *J Investig Surg*. 2019;32:738–7.
10. Tarallo M, Crocetti D, Gurrado A, et al. Achieving the learning curve in total thyroidectomy: a prospective evaluation on resident's training by CUSUM and KPSS analysis. *Ann R Coll Surg Engl*. 2022;104(6):414–20.
11. Kassite I, Bejan-Angoulvant T, Lardy H, Binet A. A systematic review of the learning curve in robotic surgery: range and heterogeneity. *Surg Endosc*. 2019;33(2):353–65.
12. Fernandez-Ranvier G, Lieberman B, Guevara D, et al. Transoral endoscopic thyroidectomy vestibular approach (TOETVA) learning curve: a regression analysis of complication rates and severity. *Surg Endosc*. 2022;36(7):4839–44.

13. Kaul S, Shah NL, Menon M. Learning curve using robotic surgery. *Curr Urol Rep.* 2006;7(2):125–9.
14. Chaput de Saintonge DM, Vere DW. Why don't doctors use cusums? *Lancet.* 1974;1(7848):120–1.
15. Wohl H. The cusum plot: its utility in the analysis of clinical data. *N Engl J Med.* 1977;296(18):1044–5.
16. Liao HJ, Dong C, Kong FJ, et al. The CUSUM analysis of the learning curve for endoscopic thyroidectomy by the breast approach. *Surg Innov.* 2014;21(2):221–8.
17. Miccoli P, Berti P, Bendinelli C, et al. Minimally invasive video-assisted surgery of the thyroid: a preliminary report. *Langenbeck's Arch Surg.* 2000;385(4):261–4.
18. Miccoli P, Matteucci V. Video-assisted surgery for thyroid cancer patients. *Gland Surg.* 2015;4(5):365–7.
19. Duek I, Duek OS, Fliss DM. Minimally invasive approaches for thyroid surgery-pitfalls and promises. *Curr Oncol Rep.* 2020;22(8):77.
20. Anuwong A. Transoral endoscopic thyroidectomy vestibular approach: a series of the first 60 human cases. *World J Surg.* 2016;40(3):491–7.
21. Anuwong A, Sasanakietkul T, Jitpratoom P, et al. Transoral endoscopic thyroidectomy vestibular approach (TOETVA): indications, techniques and results. *Surg Endosc.* 2018;32(1):456–65.
22. Tae K. Robotic thyroid surgery. *Auris Nasus Larynx.* 2021;48(3):331–8.
23. Kim WW, Jung JH, Park HY. The learning curve for robotic thyroidectomy using a bilateral axillo-breast approach from the 100 cases. *Surg Laparosc Endosc Percutan Tech.* 2015;25(5):412–6.
24. Bae DS, do Koo H, Choi JY, et al. Current status of robotic thyroid surgery in South Korea: a web-based survey. *World J Surg.* 2014;38(10):2632–9.

**Open Access** This chapter is licensed under the terms of the Creative Commons Attribution-NonCommercial-NoDerivatives 4.0 International License (<http://creativecommons.org/licenses/by-nc-nd/4.0/>), which permits any noncommercial use, sharing, distribution and reproduction in any medium or format, as long as you give appropriate credit to the original author(s) and the source, provide a link to the Creative Commons license and indicate if you modified the licensed material. You do not have permission under this license to share adapted material derived from this chapter or parts of it.

The images or other third party material in this chapter are included in the chapter's Creative Commons license, unless indicated otherwise in a credit line to the material. If material is not included in the chapter's Creative Commons license and your intended use is not permitted by statutory regulation or exceeds the permitted use, you will need to obtain permission directly from the copyright holder.





# The Angiogenic Microenvironment of Thyroid Cancer: An Insight into the Research of New Prognostic Markers

# 20

Alessandro Pasculli, Lucia Ilaria Sgaramella, Giovanna Di Meo, Francesco Paolo Prete, Angela Gurrado, Roberto Ria, Angelo Vacca, and Mario Testini

## 20.1 Introduction

Thyroid cancer is the most common endocrine malignancy, and it has been characterized in recent decades by the fastest increase in incidence among all neoplasms [1, 2]. Among differentiated thyroid cancer (DTC), papillary thyroid cancer (PTC) is the most common and accounts for 90% of all histotypes. Usually, PTCs are slow-growing and indolent tumors associated with lymph node metastases in 30–90% of cases [3, 4].

The cornerstone of the PTC treatment is the surgical removal of the tumor with or without radioiodine therapy. Despite an overall good prognosis, a portion of cases progresses to aggressive and refractory disease, showing neck recurrence or distant metastases. The angiogenic switch is the critical process that leads a tumor to local invasion and distant metastases through the growth of new vessels [5]. A deep understanding of the molecular mechanisms that transform the thyroid cancer microenvironment into an angiogenic microenvironment is at the center of the research into new prognostic markers and therapeutic targets [6]. Examining these processes could improve many steps of thyroid cancer management: identifying cytologically indeterminate nodules needing surgical removal, thus reducing diagnostic thyroidectomies; differentiating aggressive cancers to modulate surgical removal extent and approach and the follow-up strategies; improving the targeted therapy of metastatic patients with refractory disease.

Therapeutic options for thyroid cancers, indeed, encompass the unilateral or total surgical removal of the thyroid, followed or not by thyroid hormone suppression

---

A. Pasculli (✉) · L. I. Sgaramella · G. Di Meo · F. P. Prete · A. Gurrado · R. Ria · A. Vacca · M. Testini

Department of Precision and Regenerative Medicine and Ionian Area, University of Bari, Policlinic of Bari, Bari, Italy

e-mail: [pascullialessandro@gmail.com](mailto:pascullialessandro@gmail.com); [ilaria.sgaram@gmail.com](mailto:ilaria.sgaram@gmail.com); [giovanna.dimeo@policlinico.ba.it](mailto:giovanna.dimeo@policlinico.ba.it); [francesco.prete@uniba.it](mailto:francesco.prete@uniba.it); [angela.gurrado@uniba.it](mailto:angela.gurrado@uniba.it); [roberto.ria@uniba.it](mailto:roberto.ria@uniba.it); [angelo.vacca@uniba.it](mailto:angelo.vacca@uniba.it); [mario.testini@uniba.it](mailto:mario.testini@uniba.it)



and ablative therapy with radioactive iodine (RAI) treatment. In addition, a lateral or central neck dissection is also performed in the case of intra- or preoperative evidence of lateral or central neck lymph node involvement. Distant metastatic patients need further therapies since their tumors are often refractory to T4-mediated thyroid-stimulating hormone (TSH) suppression and RAI therapy [7, 8]. Research in the field of new molecules for treating such patients is focused on the angiogenic processes.

The network of angiogenic cytokines and other mediators prompts the interaction between thyroid cancer cells, thyroid normal and stromal cells. Among these factors, there is evidence that genomic, transcriptomic and proteomic variables can be linked to prognosis and therapeutic purposes at different levels. Systems biology and multi-omic approaches are the new research strategies that trace the link between all these variables.

---

## 20.2 The Thyroid Cancer Microenvironment and Angiogenesis

The combination of stromal cells (SCs) and extracellular matrix (ECM) components is the core of the thyroid cancer microenvironment [9]. The interaction between SCs and ECM components gives support and nutrition to cancer cells through a series of mediators, such as growth factors and cytokines [10].

Cancer-associated fibroblasts (CAFs) produce mediators and drive inflammation, immune response, metabolism, and drug resistance [11]. Indeed, poor survival and lymphatic spread characterize a subtype of papillary thyroid cancer with peculiar CAF-related proteins associated with the mutation V600E of the *BRAF* gene (*BRAFV600E*) and the loss of *PTEN* [12–14].

Tumor-associated macrophages (TAMs) are another component of the thyroid cancer microenvironment that show high production of IL-10 and low production of IL-12 [15–17]. TAMs allow angiogenesis through the secretion of vascular endothelial growth factor (VEGF), platelet-derived growth factor (PDGF), and basic fibroblast growth factor (bFGF) and cause remodeling of the extracellular matrix through the synthesis of matrix metalloproteases (MMPs) [18, 19].

Tryptase-positive mast cells are another cellular marker of thyroid cancer invasiveness and extrathyroidal extension, showing a higher presence than adenoma [20]. Mast cells produce IL-6, TNF- $\alpha$ , CXCL8/IL-8, CCL25/TECK, CXCL10/IP-10, CXCL1/GRO- $\alpha$ , and VEGF, all involved in the transition from epithelium to mesenchyme, angiogenesis, and lymphangiogenesis [21].

Granulocyte colony-stimulating factor and CXCL8/IL-8, produced by thyroid cancer cells, recruit neutrophils that release oncostatin-M and VEGF-A, as well as granules containing elastase, promoting angiogenesis and cancer proliferation and invasiveness [22].

A differential gene expression characterizes the stroma of thyroid cancer compared to normal thyroid. Different genes, indeed, implied in the control of

apoptosis, metabolism, and cell response to hypoxia and proliferation, trigger these cellular and proteomic differences in the SCs and ECM components [23].

Neovascularization in the cancer microenvironment includes three different mechanisms [24]:

1. angiogenesis, the sprouting of new vessels from pre-existing ones;
2. vasculogenesis, the formation of new vessels starting from endothelial precursor cells (hemangioblasts);
3. vasculogenic mimicry, the ability of tumor cells or other non-endothelial cells to complete or form new vessels without vascular endothelial cells.

The first mechanism is the most important and accounts for the longitudinal splitting of existing vasculature into two functional vessels (intussusceptive angiogenesis) and the loop-shaped expansion of the vessel (looping angiogenesis) [25].

Multinodular goiter, Graves' disease, and cancer show increased vascularity. On the other hand, microvascular density (MVD) has been shown to correlate with disease-free survival in thyroid cancers, particularly in PTC and follicular thyroid carcinoma (FTC) [26]. The metastatic spread pattern differs among tumor types, probably because of the influence of proangiogenic and antiangiogenic factors on the phenotype, as well as the expression of receptors, extracellular matrix components and, finally the differential gene expression profile. Consequently, adenomas, microcarcinomas, PTCs, FTCs, undifferentiated, and medullary thyroid carcinomas show considerable differences in metastatic spread.

The following processes (and genes) are involved in the activity of the stromal cells surrounding thyroid cancer: cell survival (*RIPK5*), proliferation (*PTGS2*, *DUSP5*), apoptosis (*ZFP36L1*, *IER3*), metabolism (*SLCA2A3*), organization (*RAB7B*), response to hypoxia (*HIF1A*, *TUFT1*, *BHLHB2*), and protein degradation (*SKP1*, *KLK-4*) [23].

As already explained, a network of processes develops from these differentially expressed genes, allowing the components of stroma and matrix to communicate with cancer cells, inducing angiogenesis and aggressiveness. The release of exosomes by the thyroid cancer cells is another crucial moment of this communication [27].

From a transcriptomic point of view, dysregulation of miRNA influences the features of different types of thyroid cancers through the effects on proliferative signals, resistance to apoptosis, and epithelial-mesenchymal transition [28].

Thyroid hormones, T3 and T4, ligate their receptor site on the  $\alpha v \beta 3$  integrin and modulate, together with HIF-1 $\alpha$ , the activity of VEGF and bFGF on endothelial and other vascular cells [26]. TSH also shows a proangiogenic activity because it stimulates VEGF production through a protein C kinase pathway [24, 29].

In addition, thyroid microvascular activation depends on cAMP- and mTOR-mediated pathways, linked to the iodine deprivation and reactive oxygen species (ROS) production that causes VEGF release [30].

VEGF is not a single factor, but it encompasses a family of proteins, VEGF-A, -B, -C, -D, -E and PlGF, each with a receptor differentially expressed in various

cells [31]. Angiogenesis is mediated by VEGF-A, -E and VEGFR-2-neuropilin (NRP)-1, -2, while lymphangiogenesis by VEGF-C, -D and VEGFR-2, -3 [31]. Moreover, cells different from vascular ones, can undergo the influence of VEGF through autocrine and paracrine phenomena, including the following pathways: ROS production, lysophosphatidic acid signaling, c-Jun N-terminal kinase, NF- $\kappa$ B, PI3K/Akt signaling, AP-1 and SP-1 [32]. VEGF-C, angiopoietin-2, VEGFR-2 and -3 over-expression correlates with increased tumor size, aggressiveness and metastasis formation of thyroid cancer [33]. bFGF and FGFR, independently from VEGF, promote thyroid cancer angiogenesis [34].

MMPs, zinc-endopeptidases, contribute to angiogenesis because their degradation of ECM components stimulates the release of angiogenic factors stored with heparan sulphate [35]. MMP-9, in particular, is regulated by epidermal growth factor (EGF) through focal adhesion kinase (FAK) phosphorylation. The balance between MMPs and tissue inhibitors of metalloproteinases (TIMPs), produced by the tumor microenvironment, is at the basis of a switch towards an invasive phenotype, mainly due to increased MMP production [36].

---

### 20.3 Angiogenic Mediators and their Prognostic Value

The introduction of gene classifiers, primarily based on *BRAF* mutations, on the fine-needle aspiration specimen improved the selection of patients with cytologically indeterminate nodules affected by malignant disease [37]. However, even if every genomic variant of thyroid cancer were described, this information would not be fully useful in clinical practice: many mutations can even be found in normal cells, and many thyroid cancers do not show any mutation [38].

Aggressive DTC shows *BRAF* mutated, galectin-3, HBME-1, CK19 and estrogen receptor beta. In particular, *BRAFV600E* is typical of the tall cell variant of PTC, and the same is true for the following hub genes: *COL5A1*, *COL1A1*, *COL10A1*, *COL11A1*, *CCL20*, and *CXCL5* [39]. *BRAF* is also altered in the radioiodine refractory DTC and cases with central neck nodal metastases, mainly associated with miR-146b-3p, miR-146b-5p, and miR-222 [40]. Moreover, *BRAFV600E* identifies cases with a high risk of recurrence. In the case of anaplastic thyroid cancer, *BRAFV600E* reduces TSP-1 expression, inducing the stabilization of pericytes, which contributes to the secretion of VEGF, PDGF and other factors by vascular and stromal cells, with migration and invasion of neoplastic cells into the new vessels [41].

VEGF-A, -C, PDGF-BB and angiopoietin-2, although higher in patients with the neoplastic and benign disease compared with healthy patients, cannot identify aggressive disease, metastatic disease or large cancers [36]. Nevertheless, VEGF-C, angiopoietin-2, KDR, Flt-4, and TEK, are highly expressed during the angiogenic shift of thyroid cancer and correlate with tumor size, nodal and distant metastases. Both mechanisms, reduced TSP-1 expression induced by *BRAFV600E* and VEGF overexpression, are associated with an increased microvascular count [24].

Angiogenic stimulation accompanies cell cycle activation in thyroid cancer, which is proven by the association of VEGF with FAL1 and cyclin D1 [42]. However, a regulatory effect of VEGF production pertains to the effects of TSH, opening perspectives for therapies based on recombinant human TSH.

Among circulating markers, miRNAs play a predominant role: in addition to the already cited miR-146b-3p, miR-146b-5p, and miR-222, the exosomes containing miR-21-5p produced by thyroid cancer cells show a significant proangiogenic effect [27, 43].

Medullary thyroid carcinoma (MTC) with metastases is characterized by overexpression of VEGFR-2 and EGFR. Its adverse prognosis correlates with HIF-1 $\alpha$ , induced by hypoxia and other signals that coordinately induce VEGF expression [44].

Prostate-specific membrane antigen (PSMA) is a favorable prognostic marker of MTC when found in its neo-vessels, and it could be used as a target for radio-guided imaging and therapy [45]. Moreover, the MMP-2/TIMP-2 ratio is another prognostic factor for MTC [46].

*PTEN* loss and *BRAFV600E* seem to drive collagen deposition from an increased number of fibroblasts and its cross-linking, conferring an aggressive behavior to thyroid cancer [14, 47]. Meanwhile, the role of other factors, like macrophages and T lymphocytes, is still uncertain [9].

---

## References

1. Rahib L, Smith BD, Aizenberg R, et al. Projecting cancer incidence and deaths to 2030: the unexpected burden of thyroid, liver, and pancreas cancers in the United States. *Cancer Res.* 2014;74(11):2913–21.
2. Li M, Maso LD, Vaccarella S. Global trends in thyroid cancer incidence and the impact of overdiagnosis. *Lancet Diabetes Endocrinol.* 2020;8(6):468–70.
3. Kitahara CM, Sosa JA. The changing incidence of thyroid cancer. *Nat Rev Endocrinol.* 2016;12(11):646–53.
4. Jensen CB, Saucke MC, Francis DO, et al. From overdiagnosis to overtreatment of low-risk thyroid cancer: a thematic analysis of attitudes and beliefs of endocrinologists, surgeons, and patients. *Thyroid.* 2020;30(5):696–703.
5. Ribatti D, Nico B, Crivellato E, et al. The history of the angiogenic switch concept. *Leukemia.* 2007;21(1):44–52.
6. Melaccio A, Sgaramella LI, Pasculli A, et al. Prognostic and therapeutic role of angiogenic microenvironment in thyroid cancer. *Cancers (Basel).* 2021;13(11)
7. Cabanillas ME, Ryder M, Jimenez C. Targeted therapy for advanced thyroid cancer: kinase inhibitors and beyond. *Endoc Rev.* 2019;40(6):1573–604.
8. Lim SM, Chung WY, Nam KH, et al. An open label, multicenter, phase II study of dovitinib in advanced thyroid cancer. *Eur J Cancer.* 2015;51(12):1588–95.
9. MacDonald L, Jenkins J, Purvis G, et al. The thyroid tumor microenvironment: potential targets for therapeutic intervention and prognostication. *Horm Cancer.* 2020;11(5):205–17.
10. Turner HE, Harris AL, Melmed S, Wass JAH. Angiogenesis in endocrine tumors. *Endoc Rev.* 2003;24(5):600–32.
11. Östman A. Cancer-associated fibroblasts: recent developments and emerging challenges. *Semin Cancer Biol.* 2014;25:1–2.

12. Sun WY, Jung WH, Koo JS. Expression of cancer-associated fibroblast-related proteins in thyroid papillary carcinoma. *Tumor Biol.* 2016;37(6):8197–207.
13. Cho JG, Byeon HK, Oh KH, et al. Clinicopathological significance of cancer-associated fibroblasts in papillary thyroid carcinoma: a predictive marker of cervical lymph node metastasis. *Eur Arch Otorhinolaryngol.* 2018;275(9):2355–61.
14. Jolly LA, Novitskiy S, Owens P, et al. Fibroblast-mediated collagen remodeling within the tumor microenvironment facilitates progression of thyroid cancers driven by BrafV600E and Pten loss. *Cancer Res.* 2016;76(7):1804–13.
15. Crezee T, Rabold K, de Jong L, et al. Metabolic programming of tumor associated macrophages in the context of cancer treatment. *Ann Transl Med.* 2020;8(16):1028.
16. Zhang QW, Liu L, Gong CY, et al. Prognostic significance of tumor-associated macrophages in solid tumor: a meta-analysis of the literature. *PLoS One.* 2012;7(12):e50946.
17. Mantovani A, Marchesi F, Malesci A, et al. Tumour-associated macrophages as treatment targets in oncology. *Nat Rev Clin Oncol.* 2017;14(7):399–416.
18. Cheng N, Bai X, Shu Y, et al. Targeting tumor-associated macrophages as an antitumor strategy. *Biochem Pharmacol.* 2021;183:114354.
19. Ojalvo LS, Whittaker CA, Condeelis JS, Pollard JW. Gene expression analysis of macrophages that facilitate tumor invasion supports a role for Wnt-signaling in mediating their activity in primary mammary tumors. *J Immunol.* 2010;184(2):702–12.
20. Proietti A, Ugolini C, Melillo RM, et al. Higher intratumoral expression of CD1a, tryptase, and CD68 in a follicular variant of papillary thyroid carcinoma compared to adenomas: correlation with clinical and pathological parameters. *Thyroid.* 2011;21(11):1209–15.
21. Visciano C, Prevete N, Liotti F, Marone G. Tumor-associated mast cells in thyroid cancer. *Int J Endocrinol.* 2015;2015:705169.
22. Galdiero MR, Varricchi G, Loffredo S, et al. Potential involvement of neutrophils in human thyroid cancer. *PLoS One.* 2018;13(6):e0199740.
23. Ria R, Simeon V, Melaccio A, et al. Gene expression profiling of normal thyroid tissue from patients with thyroid carcinoma. *Oncotarget.* 2016;7(20):29677–88.
24. Rajabi S, Dehghan MH, Dastmalchi R, et al. The roles and role-players in thyroid cancer angiogenesis. *Endocr J.* 2019;66(4):277–93.
25. Bugyik E, Renyi-Vamos F, Szabo V, et al. Mechanisms of vascularization in murine models of primary and metastatic tumor growth. *Chin J Cancer.* 2016;35(1):19.
26. Mousa SA, Lin HY, Tang HY, et al. Modulation of angiogenesis by thyroid hormone and hormone analogues: implications for cancer management. *Angiogenesis.* 2014;17(3):463–9.
27. Feng K, Ma R, Zhang L, et al. The role of exosomes in thyroid cancer and their potential clinical application. *Front Oncol.* 2020;10:596132.
28. Santiago K, Chen Wongworawat Y, Khan S. Differential microRNA-signatures in thyroid cancer subtypes. *J Oncol.* 2020;2020:2052396–14.
29. Freudenthal B, Williams G. Thyroid stimulating hormone suppression in the long-term follow-up of differentiated thyroid cancer. *Clin Oncol.* 2017;29(5):325–8.
30. Craps J, Joris V, De Jongh B, et al. Involvement of mTOR and regulation by AMPK in early iodine deficiency-induced thyroid microvascular activation. *Endocrinology.* 2016;157(6):2545–59.
31. Ria R, Melaccio A, Racanelli V, Vacca A. Anti-VEGF drugs in the treatment of multiple myeloma patients. *J Clin Med.* 2020;9(6):1765.
32. Yoshinaga A, Kajihara N, Kukidome D, et al. Hypoglycemia induces mitochondrial reactive oxygen species production through increased fatty acid oxidation and promotes retinal vascular permeability in diabetic mice. *Antioxid Redox Signal.* 2021;34(16):1245–59.
33. Lewy-Trenda I, Wierzchniewska-Ławska A. Expression of vascular endothelial growth factor (VEGF) in human thyroid tumors. *Pol J Pathol.* 2002;53(3):129–32.
34. Ramsden J. Angiogenesis in the thyroid gland. *J Endocrinol.* 2000;166(3):475–80.
35. Quintero-Fabián S, Arreola R, Becerril-Villanueva E, et al. Role of matrix metalloproteinases in angiogenesis and cancer. *Front Oncol.* 2019;9:1370.

36. Ria R, Prete F, Melaccio A, et al. Effect of thyroidectomy on circulating angiogenic cytokines in papillary thyroid carcinoma and benign goiter: potential for new biomarkers? *Surgery*. 2021;169(1):27–33.
37. Patel KN, Angell TE, Babiarz J, et al. Performance of a genomic sequencing classifier for the preoperative diagnosis of cytologically indeterminate thyroid nodules. *JAMA Surg*. 2018;153(9):817–24.
38. Pagan M, Kloos RT, Lin CF, et al. The diagnostic application of RNA sequencing in patients with thyroid cancer: an analysis of 851 variants and 133 fusions in 524 genes. *BMC Bioinform*. 2016;17(Suppl 1):6.
39. Xia F, Jiang B, Chen Y, et al. Prediction of novel target genes and pathways involved in tall cell variant papillary thyroid carcinoma. *Medicine*. 2018;97(51):e13802.
40. Aragon Han P, Kim HS, Cho S, et al. Association of BRAFV600E mutation and microRNA expression with central lymph node metastases in papillary thyroid cancer: a prospective study from four endocrine surgery centers. *Thyroid*. 2016;26(4):532–42.
41. Huang Y, Qu S, Zhu G, et al. BRAF V600E mutation-assisted risk stratification of solitary intrathyroidal papillary thyroid cancer for precision treatment. *J Natl Cancer Inst*. 2018;110(4):362–70.
42. Jeong S, Lee J, Kim D, et al. Relationship of focally amplified long noncoding on chromosome 1 (FAL1) lncRNA with E2F transcription factors in thyroid cancer. *Medicine*. 2016;95(4):e2592.
43. Wu F, Li F, Lin X, et al. Exosomes increased angiogenesis in papillary thyroid cancer micro-environment. *Endocr Relat Cancer*. 2019;26(5):525–38.
44. Lodewijk L, van Diest P, van der Groep P, et al. Expression of HIF-1 $\alpha$  in medullary thyroid cancer identifies a subgroup with poor prognosis. *Oncotarget*. 2017;8(17):28650–9.
45. Lodewijk L, Willems SM, Dreijerink KM, et al. The theranostic target prostate-specific membrane antigen is expressed in medullary thyroid cancer. *Hum Pathol*. 2018;81:245–54.
46. Marečko I, Cvejić D, Tatić S, et al. Expression of matrix metalloproteinase-2 and its tissue inhibitor-2 in fetal and neoplastic thyroid tissue and their significance as diagnostic and prognostic markers in papillary carcinoma. *Cancer Biomark*. 2012;11(1):49–58.
47. Boufraqech M, Patel D, Nilubol N, et al. Lysyl oxidase is a key player in BRAF/MAPK pathway-driven thyroid cancer aggressiveness. *Thyroid*. 2019;29(1):79–92.

**Open Access** This chapter is licensed under the terms of the Creative Commons Attribution-NonCommercial-NoDerivatives 4.0 International License (<http://creativecommons.org/licenses/by-nc-nd/4.0/>), which permits any noncommercial use, sharing, distribution and reproduction in any medium or format, as long as you give appropriate credit to the original author(s) and the source, provide a link to the Creative Commons license and indicate if you modified the licensed material. You do not have permission under this license to share adapted material derived from this chapter or parts of it.

The images or other third party material in this chapter are included in the chapter's Creative Commons license, unless indicated otherwise in a credit line to the material. If material is not included in the chapter's Creative Commons license and your intended use is not permitted by statutory regulation or exceeds the permitted use, you will need to obtain permission directly from the copyright holder.

