



DEEPAK M. KALASKAR, PETER E. BUTLER & SHADI GHALI

---

# Textbook of Plastic & Reconstructive Surgery

**UCLPRESS**



# **Textbook of Plastic and Reconstructive Surgery**



# Textbook of Plastic and Reconstructive Surgery

---

Edited by

Deepak M. Kalaskar, Peter E. Butler, Shadi Ghali

 **UCL**PRESS

First published in 2016 by  
UCL Press  
University College London  
Gower Street  
London WC1E 6BT

Available to download free: [www.ucl.ac.uk/ucl-press](http://www.ucl.ac.uk/ucl-press)

Text © Contributors, 2016  
Images © Contributors and copyright holders named in the captions, 2016

A CIP catalogue record for this book is available from The British Library.

This book is published under a Creative Commons Attribution Non-commercial Non-derivative 4.0 International license (CC BY-NC-ND 4.0). This license allows you to share, copy, distribute and transmit the work for personal and non-commercial use providing author and publisher attribution is clearly stated. Further details about CC BY licenses are available at <http://creativecommons.org/licenses/by/4.0>

The publishers cannot guarantee the accuracy of any information about dosage and application contained in this book. The user is advised to always check the product information and clinical procedures with the most up-to-date published product information and the most recent codes of conduct and safety regulations. The authors and the publishers do not accept responsibility or legal liability for any errors in the text or misuse or misapplication of material in this work.

ISBN: 978-1-910634-37-0 (Hbk.)  
ISBN: 978-1-910634-38-7 (Pbk.)  
ISBN: 978-1-910634-39-4 (PDF)  
ISBN: 978-1-910634-40-0 (epub)  
ISBN: 978-1-910634-41-7 (mobi)  
DOI: 10.14324/111.978191063394

# Table of Contents

---

<i>List of Figures</i>	viii
<i>List of Tables</i>	xvi
<i>List of Abbreviations</i>	xxi
<i>List of Contributors</i>	xxvii

## SECTION 1: GENERAL

---

1	Principles of Plastic Surgery, Wound Healing, Skin Grafts and Flaps <i>George Adigbli, Feras Alshomer, Jekaterina Maksimcuka, Shadi Ghali</i>	3
2	Abdominal Wall Reconstruction <i>Ali Alhamdi, Shadi Ghali</i>	38

## SECTION 2: CANCER

---

3	Skin Cancer for the Plastic Surgeon <i>Sophia Opel, Shadi Ghali</i>	61
4	Oral and Oropharyngeal Cancer <i>Jatinder T. Virdee, Nicholas Kalavrezos</i>	77

## SECTION 3: BURNS AND TRAUMA

---

5	Burns <i>Sebastian Salinas, Salman Mofti, Naime Moimen</i>	103
---	---	-----

6	Burn Reconstructive Surgery <i>Barinder Takhar, Ahmad B. Al-Ali, Naime Moimen</i>	122
7	Soft Tissue Injuries of the Hand <i>Hiba Khan, Bran Sivakumar</i>	155
8	Lower Limb Trauma and Reconstruction <i>Rebecca Nicholas, Ayyaz Quddus, Jon Simmons</i>	193
9	Injuries of the Facial Skeleton <i>Tom W. Andrew, Nicholas Kalavrezos</i>	208

## SECTION 4: PAEDIATRIC PLASTIC SURGERY

---

10	Congenital Hand Abnormalities <i>Benjamin Way, Bran Sivakumar</i>	229
11	Ear Reconstruction <i>Aurora Almadori, Abdulaziz Khurshed, Ali Jafar, Ahmad B. Al-Ali, Peter E. Butler</i>	248
12	Craniofacial Surgery: Craniosynostosis Syndromes and Cleft Lip and Palate <i>Ahmed Al-Hadad, Shafiq Rahman</i>	263
13	Genital Reconstruction <i>Shomari Zack-Williams, Debbie Hunt, Asif Muneer, Sarah Creighton</i>	279
14	Vascular Anomalies <i>Wenceslao M. Calonge, Juan Carlos López-Gutiérrez, Neil Bulstrode</i>	313

## SECTION 5: AESTHETIC SURGERY

---

15	Liposuction <i>Nina Oliver, Omar Khan Pathan, Ash Mosahebi</i>	333
16	Facial Aesthetic Surgery <i>Muholan Kanapathy, Niall Kirkpatrick</i>	346
17	Blepharoplasty – Special Focus on Asian Blepharoplasty <i>Billy Ching Leung, Kimberley Lau, Hugo Henderson</i>	374
18	Aesthetic Breast Surgery <i>Log Murugesan, Julia Ruston, Patrick Mallucci</i>	387



19	Body Contouring <i>Zain Bukamal, Ash Mosahebi</i>	409
20	The Evolution of Hair Transplant Surgery <i>Farhana Akter, Greg Williams</i>	431
	<i>Index</i>	447

# List of Figures

---

## 1 PRINCIPLES OF PLASTIC SURGERY, WOUND HEALING, SKIN GRAFTS AND FLAPS

---

1.1.	The skin with its separate layers and appendages.	6
1.2.	The reconstructive ladder.	15
1.3.	Simple interrupted sutures.	17
1.4.	Simple continuous sutures.	17
1.5.	Mattress sutures: horizontal (left) and vertical (right).	18
1.6.	Subcuticular suture.	19
1.7.	The skin grafting process.	20
1.8.	Advancement flap.	26
1.9.	Rotation flap.	27
1.10.	Transposition flap.	27
1.11.	Limberg flap.	28
1.12.	Z-plasty.	28
1.13.	Interpolation (Littler's) flap.	29
1.14.	Cormack and Lamberty classification.	33
1.15.	Mathes and Nahai classification.	35

## 2 ABDOMINAL WALL RECONSTRUCTION

---

2.1.	Anterior abdominal wall layers.	39
2.2.	Blood supply to the anterior abdominal wall.	40
2.3.	Abdominal vascular zones.	41
2.4.	Component separation.	45
2.5.	Mesh positioning.	46

2.6.	Algorithmic approach for patients.	47
2.7.	Tensor fascia lata flap design.	50
2.8.	Rectus femoris anatomy and flap elevation.	51
2.9.	Anterolateral thigh flap: flap design.	52
2.10.	Groin flap design.	53
2.11.	Pedicled vastus lateralis with mesh reconstruction of abdominal wall defects after tumour excision.	54
2.12.	Latissimus dorsi anatomy and free flap design.	56

### 3 SKIN CANCER FOR THE PLASTIC SURGEON

---

3.1.	Elliptical excision with pre-defined excision margins.	64
3.2.	The 'ABCDE' rule.	68
3.3.	AJCC staging of malignant melanoma.	71

### 4 ORAL AND OROPHARYNGEAL CANCER

---

4.1.	Anatomy of the oral cavity.	78
4.2.	Age-standardised incidence (per 100,000) of men with oral cancer in 2012.	79
4.3.	Age-standardised incidence (per 100,000) of women with oral cancer in 2012.	79
4.4.	Age-standardised mortality (per 100,000) of men with oral cancer in 2012.	81
4.5.	Age-standardised mortality (per 100,000) of women with oral cancer in 2012.	81
4.6.	Variations in the clinical presentation of oral cancer.	86
4.7.	Variations in the visibility of oral lesions with different diagnostic tools.	88
4.8.	Variations in dysplasia in oropharyngeal squamous cell carcinoma.	90
4.9.	HPV-positive oropharyngeal cancer.	91
4.10.	Surgical approaches to oral cancer.	96

### 5 BURNS

---

5.1.	Depths of burn wounds.	117
5.2.	Jackson's areas of local response.	117
5.3.	'Head first, face down' sink immersion.	118
5.4.	Distribution of inflicted and unintentional burns on young children.	118
5.5.	Rule of nine.	119

## 6 BURN RECONSTRUCTIVE SURGERY

---

6.1.	Consultation and assessment flow diagram.	124
6.2.	Timing of surgery and procedures.	126
6.3.	The reconstructive ladder for post-burn reconstruction.	127
6.4.	Guidelines for the reconstructive process.	128
6.5.	The stages to graft healing 'take'.	130
6.6.	Factors affecting skin graft 'take'.	131
6.7.	Full-thickness skin graft.	132
6.8.	Advantages and disadvantages of tissue expansion.	138
6.9.	Guidelines for successful tissue expansion.	139
6.10.	Advancement flap.	147
6.11.	Z-plasty technique.	148

## 7 SOFT TISSUE INJURIES OF THE HAND

---

7.1.	Bones of the hand.	157
7.2.	Deep flexor compartment of the forearm.	158
7.3.	Extensor compartment of the forearm.	160
7.4.	Dorsal interossei.	161
7.5.	Palmar interossei.	162
7.6.	Arterial supply of hand.	163
7.7.	Diagram showing sensory innervation of the hand.	164
7.8.	Testing flexor digitorum profundus function.	167
7.9.	Testing flexor digitorum superficialis function.	167
7.10.	Testing extensor digitorum communis function.	167
7.11.	Structure of the tendon.	169
7.12.	Flexor pulley system.	170
7.13.	Flexor zones.	170
7.14.	Flexor tendon repair techniques.	171
7.15.	Diagrammatic representation of the extensor attachment in fingers.	173
7.16.	Extensor zones.	174
7.17.	Structure of the nerve.	176
7.18.	Diagrammatic representation of Seddon's classification of nerve injury.	177
7.19.	Diagrammatic representation of the cross-section of an artery.	180
7.20.	<b>A.</b> Diagrammatic representation of the nail. <b>B.</b> Cross-section of the fingertip.	182
7.21.	Allen's classification of finger-tip amputation.	184
7.22.	Incision and drainage of paronychia.	185

---

7.23.	Deep fascial spaces.	187
7.24.	Flexor sheaths of fingers and thumb.	188

## 8 LOWER LIMB TRAUMA AND RECONSTRUCTION

---

8.1.	The Gustilo & Anderson classification of open tibial fractures.	194
8.2.	The Mangled Extremity Severity Score (MESS).	195
8.3.	Cross-sectional anatomy of lower limb and approach to four-compartment fasciotomy in compartment syndrome.	199

## 9 INJURIES OF THE FACIAL SKELETON

---

9.1.	Illustration of frontal sinus anatomy.	214
9.2.	Illustration of naso-orbitoethmoid fracture classification.	216
9.3.	Illustration of Le Fort fractures.	217
9.4.	Illustration of facial buttresses.	220
9.5.	Illustration of mandibular fracture site frequency.	220
9.6.	Illustrations of ‘The Horizontal Rule of Fifths’ and ‘The Vertical Rule of Thirds’.	225

## 10 CONGENITAL HAND ABNORMALITIES

---

10.1.	Abbreviated Swanson’s classification of congenital hand abnormalities.	231
10.2.	Radial longitudinal deficiency with ulnar bowing and thumb hypoplasia.	233
10.3.	Soft tissue distractor for radial longitudinal deficiency. Marks indicate ulnocarpal alignment.	233
10.4.	Ulnar longitudinal deficiency.	234
10.5.	Type 2 cleft hand.	235
10.6.	Type 4 thumb hypoplasia.	236
10.7.	Simple, complete third web syndactyly with markings for interdigitating flaps.	238
10.8.	Interdigitating flaps in syndactyly release.	238
10.9.	Bilateral type 3 ulnar polydactyly.	240
10.10.	Wassel type 4 thumb duplication.	241
10.11.	Macroductyly of middle and ring digits.	243
10.12.	Symbrachydactyly managed by vascularised toe transfer.	244
10.13.	Constriction ring syndrome.	245

## 11 EAR RECONSTRUCTION

---

- |       |   |     |
|-------|---|-----|
| 11.1. | Lateral surface of the external ear.                      | 249 |
| 11.2. | The main components of an elastic cartilage.              | 250 |
| 11.3. | The therapeutic algorithm for partial ear reconstruction. | 255 |

## 12 CRANIOFACIAL SURGERY: CRANIOSYNOSTOSIS SYNDROMES AND CLEFT LIP AND PALATE

---

- |       |  |     |
|-------|--|-----|
| 12.1. | Lateral view of skull anatomy.   | 265 |
| 12.2. | Illustration of the main skull sutures (superior view).  | 265 |
| 12.3. | <b>A.</b> A unilateral left-sided CL/P deformity in a neonate. <b>B.</b> A bilateral CL/P defect present in a newborn. | 266 |
| 12.4. | Facial characteristics associated with Apert syndrome.   | 268 |
| 12.5. | <b>A.</b> Le Fort osteotomy I–III. <b>B.</b> Monobloc osteotomy with fronto-orbital advancement.                       | 271 |
| 12.6. | LAHSHAL classification.  | 273 |
| 12.7. | Summary of craniosynostosis syndromes and CL/P.  | 277 |

## 13 GENITAL RECONSTRUCTION

---

- |        |   |     |
|--------|---|-----|
| 13.1.  | Urogenital system at 6 weeks.   | 281 |
| 13.2.  | Androgen synthesis.   | 284 |
| 13.3.  | Foetal Leydig cell metabolism.  | 284 |
| 13.4.  | Neurovascular sparing clitoroplasty for clitoromegaly and corporal tissue excision. | 287 |
| 13.5.  | Vecchietti procedure.   | 288 |
| 13.6.  | Hypospadiac penis   | 290 |
| 13.7.  | Cryptorchidism testicular positions.  | 293 |
| 13.8.  | Appearance of bladder exstrophy.  | 295 |
| 13.9.  | Penile anatomy and layers.  | 299 |
| 13.10. | Singapore fasciocutaneous flaps.  | 305 |
| 13.11. | Gracilis myocutaneous flap boundaries.  | 305 |

## 14 VASCULAR ANOMALIES

---

- |       |  |     |
|-------|--|-----|
| 14.1. | <b>A.</b> and <b>B.</b> Ulcerated infantile haemangiomas on the upper lip ( <b>A.</b> ) and neck ( <b>B.</b> ).                        | 316 |
| 14.2. | <b>A.</b> , <b>B.</b> , <b>C.</b> and <b>D.</b> A case of infantile haemangioma after treatment by propranolol from 6–9 months of age. | 317 |

---

14.3.	Two cases of rapid involuting congenital haemangioma at different locations.	318
14.4.	Pyogenic granuloma of the left cheek.	319
14.5.	Three successive stages in the evolution of a kaposiform haemangioendothelioma treated by a combination of acetylsalicylate, vincristine and ticlopidine.	320
14.6.	A patient with Sturge–Weber syndrome.	323
14.7.	Venous malformation of the right arm.	324
14.8.	<b>A.</b> and <b>B.</b> Two cases of lymphatic malformations, respectively involving the neck and tongue.	325
14.9.	Arteriovenous malformation of the right buttock.	326

## 15 LIPOSUCTION

---

15.1.	Common areas of liposuction on the trunk.	335
15.2.	Common areas of liposuction on the upper and lower limbs.	335
15.3.	Water-assisted liposuction.	339
15.4.	Zones of adherence.	340
15.5.	Mercedes type cannula (three holes).	341

## 16 FACIAL AESTHETIC SURGERY

---

16.1.	Soft tissue layers of the face.	347
16.2.	Features of the ageing face.	351
16.3.	Surface anatomy of the eyelid.	358
16.4.	Cross-section of the upper eyelid.	358
16.5.	Blepharoplasty approaches on the lower eyelid.	361
16.6.	Alignment of the eyebrow.	362
16.7.	Topography and anatomy of the nose.	366

## 17 BLEPHAROPLASTY – SPECIAL FOCUS ON ASIAN BLEPHAROPLASTY

---

17.1.	Variations of Asian upper eyelids.	376
17.2.	The anatomical differences between Asian and Caucasian eyelids.	377
17.3.	Suture ligation technique.	379
17.4.	Surgical resection technique.	381
17.5.	<b>A.</b> and <b>B.</b> Sagittal view of the surgical resection technique.	381
17.6.	<b>A.</b> to <b>F.</b> Epicanthoplasty Z-plasty designs.	383

---

## 18 AESTHETIC BREAST SURGERY

---

18.1.	Mammary ridge (milk line) running from the anterior axillary line through the nipple to the pubic tubercle.	388
18.2.	Tanner stages of breast development.	388
18.3.	Surface anatomy of the female breast.	389
18.4.	Blood supply to the breast.	389
18.5.	Components of a breast implant.	390
18.6.	Shapes of breast implants.	391
18.7.	Dimensions of an implant.	391
18.8.	Profiles of breast implants.	392
18.9.	Pre-operative measures.	394
18.10.	Pinch test.	395
18.11.	Anterior pull skin stretch.	395
18.12.	Soft tissue pinch test at the inframammary fold.	395
18.13.	Lassus vertical scar mastopexy.	400
18.14.	Lejour vertical scar mastopexy.	401
18.15.	Hammond vertical scar mastopexy.	401
18.16.	Skin pattern for inverted-T mastopexy.	402

---

## 19 BODY CONTOURING

---

19.1.	Cannula 1, a standard single-slot cannula. Cannula 2, a two-slot cannula.	413
19.2.	The two subcutaneous adipose tissue layers: superficial and deep.	413
19.3.	Skin indentation as a result of liposuction overcorrection.	414
19.4.	Before and after image of mini abdominoplasty.	417
19.5.	Illustration of the mini abdominoplasty procedure once plication of the rectus muscle fascia is completed.	417
19.6.	Pre-operative marking for a full abdominoplasty.	419
19.7.	Full abdominoplasty: the technique.	420
19.8.	Circumferential body lift markings.	422
19.9.	Circumferential body lift markings in the posterior view, illustrating an estimation of the final scar's position above the gluteal crease.	423
19.10.	Massive weight loss patients usually present with excessive loose skin in the upper arm as well as other areas.	424
19.11.	Pre-operative upper arm skin markings.	425
19.12.	Thigh lift. Appearance of the medial thigh, <b>A.</b> before and <b>B.</b> after the procedure.	427



---

## 20 THE EVOLUTION OF HAIR TRANSPLANT SURGERY

---

20.1.	The human hair follicle: structure of the shaft.	432
20.2.	Embryology of hair.	433
20.3.	The human hair growth cycle.	434
20.4.	<b>A.</b> The Norwood–Hamilton classification of male pattern baldness. <b>B.</b> The Ludwig classification of female pattern baldness.	437
20.5.	<b>A.</b> Punch tool inserted. <b>B.</b> Hair removed with forceps. <b>C.</b> Hairs placed in Petri dishes and kept hydrated.	440
20.6.	Dissection of the donor strip.	441
20.7.	The trichophytic method of wound closure.	441
20.8.	Insertion of grafts with forceps.	443

# List of Tables

---

## 1 PRINCIPLES OF PLASTIC SURGERY, WOUND HEALING, SKIN GRAFTS AND FLAPS

---

1.1.	The process of wound healing.	7
1.2.	Factors affecting wound healing.	9
1.3.	Mathes and Nahai classification.	34

## 2 ABDOMINAL WALL RECONSTRUCTION

---

2.1.	Abdominal wall defect classification.	42
2.2.	Grading system for ventral hernia.	47
2.3.	Indications for planned hernia.	48
2.4.	Indication of free flaps in abdominal wall reconstruction.	55

## 3 SKIN CANCER FOR THE PLASTIC SURGEON

---

3.1.	Risk factors associated with BCC development.	62
3.2.	Assessing the patient in clinic.	63
3.3.	Prognostic factors for BCC.	63
3.4.	Indications for Mohs micrographic surgery.	65
3.5.	Risk factors associated with SCC development.	65
3.6.	Prognostic factors for SCC.	66
3.7.	Criteria for urgent referral to a local skin cancer multidisciplinary team.	69
3.8.	Minimum data set required in histopathological description for malignant melanoma.	70
3.9.	Follow-up for malignant melanoma.	72
3.10.	Quick reference of surgical excision margins.	73

## 4 ORAL AND OROPHARYNGEAL CANCER

---

4.1.	T staging for tumours of the lip, oral cavity and pharynx.	92
4.2.	N staging for oropharyngeal cancers.	93
4.3.	M staging for oropharyngeal cancers.	93
4.4.	Factors affecting treatment choice.	94
4.5.	Flaps used in oral reconstructive surgery.	96

## 5 BURNS

---

5.1.	Classification of burns by depth and surface area.	116
5.2.	Skin substitutes.	116

## 6 BURN RECONSTRUCTIVE SURGERY

---

6.1.	Specific challenges associated with burn reconstructive surgery.	123
6.2.	Donor sites, advantages and disadvantages of FTSG and STSG.	133
6.3.	The differences between skin grafts and flaps.	141
6.4.	Classification of muscle flaps: Mathes and Nahai.	143
6.5.	Indications for free flaps.	150
6.6.	Sources of donor sites for free flap transfers.	151

## 7 SOFT TISSUE INJURIES OF THE HAND

---

7.1.	Muscles of the flexor compartment of the forearm.	158
7.2.	Muscles of the lateral compartment of the forearm.	159
7.3.	Muscles of the extensor compartment of the forearm.	160
7.4.	Small muscles of the hand.	162
7.5.	Motor function of nerves to the hand.	164
7.6.	Motor and sensory tests specific to each nerve of the hand.	168

## 8 LOWER LIMB TRAUMA AND RECONSTRUCTION

---

8.1.	Local or distant flap recommendations based on zone of injury and type of soft tissue defect.	205
------	---	-----

## 11 EAR RECONSTRUCTION

---

- 11.1. Advantages and disadvantages of tissue-engineered constructs compared with the best-established surgical options for ear reconstruction. 259

## 12 CRANIOFACIAL SURGERY: CRANIOSYNOSTOSIS SYNDROMES AND CLEFT LIP AND PALATE

---

- 12.1. Developmental patterns of craniosynostosis. 267  
12.2. Relative incidence risk of CL/P deformities. 272  
12.3. Timing of primary surgery in CL/P defects. 274  
12.4. Summary of the common complications of CL/P and their respective management. 276

## 13 GENITAL RECONSTRUCTION

---

- 13.1. Summary of the main types of DSD and the genetic factors linked to congenital abnormalities. 282  
13.2. Various causative mutations responsible for masculinised females. 283  
13.3. Summary of 5 key enzymes, their function and presentation associated with congenital adrenal hyperplasia and Smith–Lemli–Opitz syndrome. 285  
13.4. Summary of surgical procedures for the management of distal hypospadias. 291  
13.5. Classification of palpable testicles. 292  
13.6. Classification of non-palpable testicles. 293  
13.7. The transition from paediatric to adult genital reconstruction. 298

## 14 VASCULAR ANOMALIES

---

- 14.1. Vascular anomalies. 313  
14.2. Vascular tumours. 314  
14.3. Vascular malformations. 314  
14.4. Rheological classification of vascular malformations. 322  
14.5. Schobinger’s staging of arteriovenous malformation. 326

---

## 15 LIPOSUCTION

---

- |       |   |     |
|-------|---|-----|
| 15.1. | List of patient parameters to note during a physical examination for liposuction. | 336 |
| 15.2. | Complications of liposuction.   | 342 |

---

## 16 FACIAL AESTHETIC SURGERY

---

- |       |   |     |
|-------|---|-----|
| 16.1. | Glogau classification of photoageing.             | 352 |
| 16.2. | Advantages and disadvantages of open rhinoplasty. | 366 |
| 16.3. | Types of chemical peel.                           | 368 |
| 16.4. | Fitzpatrick's sun-reactive skin types.            | 369 |
| 16.5. | Filler-related complications.                     | 370 |

---

## 17 BLEPHAROPLASTY – SPECIAL FOCUS ON ASIAN BLEPHAROPLASTY

---

- |       |   |     |
|-------|---|-----|
| 17.1. | Upper eyelid anatomical differences between Asians and Caucasians.  | 377 |
| 17.2. | Advantages and disadvantages of suture ligation and surgical resection techniques for Asian blepharoplasty. | 383 |

---

## 18 AESTHETIC BREAST SURGERY

---

- |       |  |     |
|-------|--|-----|
| 18.1. | Embryological development of the breast.     | 388 |
| 18.2. | Regnault classification of breast ptosis.    | 398 |
| 18.3. | Grolleau classification of tuberous breasts. | 403 |

---

## 19 BODY CONTOURING

---

- |       |   |     |
|-------|---|-----|
| 19.1. | Patient selection: descriptions of an ideal patient and a poor candidate for body contouring.             | 411 |
| 19.2. | Liposuction complications: local and systemic.  | 414 |
| 19.3. | A list of factors leading to abdominal wall laxity with consequent contour irregularities.                | 416 |
| 19.4. | Indications for a full abdominoplasty: general and specific.  | 418 |
| 19.5. | Comparison between the two categories of a circumferential lipectomy: belt lipectomy and lower body lift. | 421 |

19.6.	Structures coursing the medial aspect of the arm which are vulnerable to injury under the surgical field.	426
19.7.	Blood supply (skin overlying the rectus abdominis muscle)	430
19.8.	Body mass index.	430

## **20 THE EVOLUTION OF HAIR TRANSPLANT SURGERY**

---

20.1.	Classification of hair disorders.	435
-------	-----------------------------------	-----

## List of Abbreviations

---

ABC	airway, breathing, circulation
ADH	alcohol dehydrogenase
ADM	acellular dermal matrix
ADM	abductor digiti minimi
AER	apical ectodermal ridge
AJCC	American Joint Committee on Cancer
ALT	anterolateral thigh
AMH	anti-Müllerian hormone
AP	anteroposterior
AR	androgen receptor
ASA	American Association of Anesthesiologists
ASIS	anterior superior iliac spine
ASTRA	anterior sagittal transrectal approach
ATLS	Acute Trauma and Life Support
AVF	arteriovenous fistulas
AVM	arteriovenous malformation
BAD	British Association of Dermatology
BAPRAS	British Association of Plastic Reconstructive and Aesthetic Surgeons
BB	brush biopsy
BCC	basal cell carcinoma
BEEC	bladder exstrophy epispadia complex
BMI	body mass index
BMP	bone morphogenic proteins
BNR	bladder neck reconstruction
BOA	British Orthopaedic Association
CAH	congenital adrenal hyperplasia
CAIS	complete androgen insensitivity syndrome
CBE	classic bladder exstrophy

CEA	cultured epidermal autograft
CGRP	calcitonin gene-related peptide
CLOVES	congenital lipomatous overgrowth, vascular malformations, epidermal naevus, spinal/skeletal anomalies/scoliosis
CL/P	cleft lip and palate
CM	capillary malformations
CMCJ	carpometacarpal joint
CMJ	carpometacarpal joint
CRL	crown–rump length
CRP	C-reactive protein
CRS	constriction ring syndrome
CS	component separation
CSF	cerebrospinal fluid
CSL	cranial suspensory ligament
CST	component separation technique
CT	computed tomography
DCIA	descending circumflex iliac artery
DHT	dihydrotestosterone
DIEP	deep inferior epigastric perforator
DIME	debridement, infection/inflammation, moisture balance, edge of wound
DIPJ	distal interphalangeal joint
DP	deltpectoral
DSD	disorders of sexual development
DVT	deep vein thrombosis
ECM	extracellular matrix
EDC	extensor digitorum communis
EEC	ectrodactyly-ectodermal dysplasia clefting
EHE	epithelioid haemangioendothelioma
ENT	ear, nose and throat
EPL	extensor pollicis longus
ER	Estrogen receptor
EU	European Union
EXIT	<i>ex utero</i> intrapartum treatment
FB	Foreign body
FDA	US Food and Drug Administration
FDP	flexor digitorum profundus
FDS	flexor digitorum superficialis
FES	fat emboli syndrome
FGF	fibroblast growth factor



FGM	female genital mutilation
FPL	flexor pollicis longus
FRFF	free radial forearm flap
FtM	female to male
FTSG	full-thickness skin graft
FU	follicular unit
FUE	follicular unit extraction
FUT	follicular unit transplantation
GA	general anaesthesia
GCA	glycolic acid
GCS	Glasgow Coma Scale
GCT	gonadal cell tumour
GST	glutathione-S-transferase
GU	genitourinary
hCG	human chorionic gonadotropin
HNSCC	head and neck squamous cell carcinomas
HPV	human papillomavirus
IARC	International Agency for Research on Cancer
IC	intercostal
ICP	intracranial pressure
IGF-1	insulin-like growth factor 1
IM	intramedullary
IMF	inframammary fold
IP	interphalangeal
IPJ	interphalangeal joints
IPL	intense pulse light
IPV	interpersonal violence
ISH	in-situ hybridisation
ISSVA	International Society for the Study of Vascular Anomalies
KHE	kaposiform haemangioendothelioma
KS	Kaposi sarcoma
KSHV	Kaposi sarcoma herpes virus
KSP	Kasabach–Merritt phenomenon
LA	local anaesthesia
LAL	laser-assisted liposuction
LD	latissimus dorsi
LEAP	Lower Extremity Assessment Project
LHRH	luteinising hormone-releasing hormone
LM	lymphatic malformations
LSMDT	local skin cancer multidisciplinary team

MACS	minimal access cranial suspension
MAGPI	meatal advancement and glanuloplasty
MCP	metacarpophalangeal
MCPJ	metacarpophalangeal joint
MCT	medial canthal tendon
MDT	multidisciplinary team
MESS	Mangled Extremity Severity Score
MM	malignant melanoma
MMF	mandibular–maxillary fixation
MMS	Mohs Micrographic surgery
MRI	magnetic resonance imaging
MRKH	Mayer–Rokitansky–Kuster–Hauser
MSC	mesenchymal stem cells
MtF	male to female
NAT	<i>N</i> -acetyl transferases
NICH	non-involuting congenital haemangiomas
NOE	naso-orbitoethmoid
OC	oral cancer
OPC	oropharyngeal cancer
OPG	orthopantomogram
OPSCC	oropharyngeal squamous cell carcinomas
ORIF	open reduction and internal fixation
ORL	orbicularis retaining ligament
OSCC	oral squamous cell carcinoma
OT	optical tomography
PAH	polycyclic aromatic hydrocarbons
PAIS	partial androgen insensitivity syndrome
PAL	power-assisted liposuction
PCR	polymerase chain reaction
PDGF- $\beta$	platelet-derived growth factor beta
PE	pulmonary embolus
PGA	polyglycolic acid
PICH	partially involuting congenital haemangiomas
PIP	proximal interphalangeal
PIPJ	proximal interphalangeal joint
PMMF	pectoralis major myocutaneous flap
PT	prothrombin time
PTFE	polytetrafluoroethylene
PZ	progress zone
RAM	rectus abdominis myocutaneous

---

RAPD	relative afferent pupillary defect
RFAL	radiofrequency-assisted liposuction
RICH	rapid involuting congenital haemangiomas
RLD	radial longitudinal deficiency
RNA	ribonucleic acid
RSDL	reactive skin decontamination lotion
RSTL	relaxed skin tension lines
RTA	road traffic accident
SAL	suction-assisted liposuction
SC	subcostal
SCC	squamous cell carcinoma
SEF	spanning external fixation
SGAP	superior gluteal artery perforator
SIEF	simultaneous implant exchange with fat
SLNB	sentinel lymph node biopsy
SMAS	superficial musculoaponeurotic system
SOOF	sub-orbicularis oculi fat
SPM	second primary malignancy
SSG	split skin grafting
SSO	surgical site occurrence
ST	smokeless tobacco
StAR	steroidogenic acute regulatory protein
STSG	split-thickness skin graft
TAC	temporary abdominal closure
TAP	Thoracodorsal Artery Perforator (flap)
TAR	thrombocytopaenia absent radius
TB	toluidine blue
TBSA	total body surface area
TCA	trichloroacetic acid
TEARS	tears, ecchymosis, abrasions, redness and swelling
TGF- $\beta$	transforming growth factor beta
TH	thumb hypoplasia
TIP	tubularised incised plate
TMJ	temporomandibular joint
TNM	tumour–node–metastasis
TRAM	transverse rectus abdominis muscle musculocutaneous/myocutaneous
TSG	tumour-suppressor gene
TSNA	tobacco-specific nitrosamine
TUM	total urogenital mobilisation
UAL	ultrasound assisted liposuction

ULD	ulnar longitudinal deficiency
US	ultrasound
UV	ultraviolet
VAC	vacuum-assisted closure
VAH	ventral abdominal hernia
VAL	VASER-assisted liposuction
VEGF	vascular endothelial growth factor
VHWG	ventral hernia work group
VM	venous malformations
VRAM	vertical rectus abdominis myocutaneous
VY	V to Y advancement flap
WAL	water-assisted liposuction
WHO	World Health Organisation
XE	xenometabolising enzymes
YAG	yttrium aluminium garnet
ZMC	zygomaticomaxillary complex
ZPA	zone of polarising activity

## List of Contributors

---

**George Adigbli**

Transplantation Research Immunology Group,  
Nuffield Department of Surgical Sciences,  
University of Oxford

**Farhana Akter**

Department of Plastic and Reconstructive  
Surgery, Royal Free Hospital, London

**Ali Alhamdi**

Department of Plastic and Reconstructive  
Surgery, Royal Free Hospital, London

**Ahmad B. Al-Ali**

Department of Plastic and Reconstructive  
Surgery, Al-Babtain Center, Ibn sena  
Hospital, Kuwait

**Ahmed Al-Hadad**

Division of Surgery and Interventional Science,  
University College London

**Aurora Almadori**

Department of Plastic and Reconstructive  
Surgery, Royal Free Hospital, London

**Feras Alshomer**

Plastic and Reconstructive Surgery Resident,  
Saudi Training Program, King Khalid University  
Hospital, College of Medicine, Saudi Arabia

**Tom W. Andrew**

Division of Surgery and Interventional Science,  
University College London

**Peter E. Butler**

Consultant Plastic and Reconstructive Surgeon,  
Royal Free Hospital, London

**Zain Bukamal**

Department of Surgery, Arab Board Training  
Program, Salmaniya Medical Complex, Kingdom  
of Bahrain

**Neil Bulstrode**

Consultant Plastic Surgeon and the Lead  
Clinician for the Department of Plastic Surgery,  
Great Ormond Street Hospital, London

**Wenceslao M. Calonge**

Paediatric Surgeon, Établissements Hospitaliers  
du Nord Vaudois, Switzerland

**Sarah Creighton**

Consultant Gynaecologist, Department of  
Obstetrics & Gynaecology, University College  
London Hospital, London

**Shadi Ghali**

Consultant Plastic and Reconstructive Surgeon,  
Royal Free Hospital, London

**Hugo Henderson**

Consultant Ophthalmic and Oculoplastic Surgeon, Royal Free Hospital, London

**Debbie Hunt**

Specialty Registrar (ST3) Plastic Surgery, Royal Preston Hospital, Preston

**Ali Jafar**

UCL Division of Surgery and Interventional Science  
Royal Free Hospital Campus, UCL

**Deepak Kalaskar**

Deputy Director MSc Burns, Plastic and Reconstructive Surgery, Lecturer, Nanotechnology and Biomedical Engineering, Division of Surgery & Interventional Science, Royal Free Hospital Campus, University College London, London.

**Nicholas Kalavrezos**

Consultant Head & Neck Reconstructive and Maxillofacial Surgeon, University College London Hospital

**Muholan Kanapathy**

Division of Surgery and Interventional Science, University College London, London

**Hiba Khan**

Core Surgical Trainee, South London Hospitals, London

**Niall Kirkpatrick**

Consultant Craniofacial Plastic Surgeon, Chelsea & Westminster Hospital, London

**Abdulaziz Khurshed**

UCL Division of Surgery and Interventional Science  
Royal Free Hospital Campus, UCL

**Kimberley Lau**

Specialty Registrar (ST3) in ENT, Sheffield Teaching Hospital NHS Trust, Sheffield

**Billy Ching Leung**

Core Surgical Trainee, Department of Oral and Maxillofacial Surgery, Oxford University Hospital NHS Foundation Trust, Oxford

**Juan Carlos López-Gutiérrez**

Department of Paediatric Surgery, Hospital Universitario “La Paz”, Madrid, Spain

**Jekaterina Maksimcuka**

Department of Plastic and Reconstructive Surgery, Royal Free Hospital, London

**Patrick Mallucci**

Consultant Plastic and Cosmetic Surgery, Reconstructive Surgery, Weymouth Street Hospital, London

**Salman Mofti**

Department of Plastic and Reconstructive Surgery, Royal Free Hospital, London

**Naime Moimen**

Consultant Burns and Plastics Consultant, University Hospitals Birmingham NHS Foundation Trust, Birmingham

**Ash Mosahebi**

Consultant plastic surgeon and clinical lead, Royal Free Hospital, London

**Asif Muneer**

Consultant Urological Surgeon, Department of Urology, University College London Hospital, London

**Log Murugesan**

Specialist Registrar in Plastic Surgery, London Training Programme, London

**Rebecca Nicholas**

Specialist Registrar in Plastic Surgery, London  
Training Programme, London

**Nina Oliver**

Department of Plastic and Reconstructive  
Surgery, Oslo University Hospital

**Sophia Opel**

Specialist Registrar in Plastic and Reconstructive  
Surgery, London

**Omar Khan Pathan**

General Practice Trainee. Accident and Emergency,  
Eastbourne District General Hospital, East Sussex

**Ayyaz Quddus**

Foundation Trainee, North Central London  
Deanery, London

**Shafiq Rahman**

Foundation Trainee, Nottingham University  
Hospitals NHS Trust, Nottingham

**Julia Ruston**

Department of Plastic and Reconstructive  
Surgery, Royal Free Hospital, London

**Sebastian Salinas**

General Practitioner, Quito, Ecuador

**Jon Simmons**

Consultant Plastic Surgeon, Imperial College  
London NHS Trust, London

**Bran Sivakumar**

Consultant Plastic Surgeon, Department of  
Plastic Surgery, Great Ormond Street  
Hospital, London

**Barinder Takhar**

Division of Surgery and Interventional  
Science, University College London,  
London

**Jatinder T. Virdee**

Department of Plastic Surgery, The Royal  
London Hospital, London

**Benjamin Way**

Department of Plastic Surgery, Great Ormond  
Street Hospital, London

**Shomari Zack-Williams**

Specialty Registrar (ST3) Plastic  
Surgery, Countess of Chester Hospital,  
Chester

**Greg Williams**

Hair Transplant Surgeon, Farjo Hair Institute,  
Manchester





# **Section 1**

## **General**



# Principles of Plastic Surgery, Wound Healing, Skin Grafts and Flaps

---

George Adigbli, Feras Alshomer, Jekaterina Maksimcuka, Shadi Ghali

## 1. INTRODUCTION

---

Plastic and reconstructive surgery is a branch of surgery that specialises in restoring form and function to damaged or missing tissues and skin. The causes of such defects are usually related to surgery, injury, illness or congenital abnormality. This rapidly evolving specialty is based upon the exploitation of key principles of anatomy, physiology, pathology and surgery. Mastery of these principles as well as the acquisition of sound surgical technique enables plastic surgeons to constantly adapt to the wide variety of individual cases they face and provide functional and aesthetic solutions.

Comprehensively describing and explaining all of the principles of plastic and reconstructive surgery would require far more space and time than can be afforded in a single chapter. This chapter will therefore focus on key principles that will allow non-specialists to understand the fundamentals of this specialty. The first section concentrates on the basic sciences of skin anatomy and the pathology of wound healing relevant to plastic surgery. The second section will evaluate practical plastic surgery principles used every day in clinical and operative practice. Once completed, the reader should be well equipped to understand more sophisticated concepts conveyed in the literature.

## 2. THE SKIN

---

A detailed knowledge of the structure and function of the skin is essential in plastic and reconstructive surgery because every surgical procedure involves traversing the skin in some fashion.

### 2.1. Structure and function of the skin

---

The skin is the largest organ in the body. Some of the many functions carried out by this vast organ include (Richards, 2008):

- Physical protection
- Protection against ultraviolet light
- Protection against microbial invasion
- Prevention of fluid loss
- Regulation of body temperature
- Sensation
- Immunological surveillance
- Aesthetics and communication.

The skin is composed of three major tissue layers, the epidermis, dermis and hypodermis, and also of various structures known as appendages.

The epidermis is the outermost, protective layer of the skin. The thick dermis lies beneath this layer and contains most of the skin appendages. The hypodermis lies beneath the dermis and is predominantly composed of adipose tissue.

### 2.1.1. Epidermis

---

The superficial epidermis is composed of keratinised stratified squamous epithelium. The predominant cell type is the keratinocyte, which produces fibrous keratin to provide protective and waterproof functions to this layer. Three other cell types make up this layer:

- Melanocytes – produce melanin which dissipates ultraviolet radiation and aids the production of vitamin D from sunlight;
- Merkel cells – sensory cells associated with light touch discrimination; and
- Langerhans cells – immune surveillance dendritic cells (antigen-presenting cells).

Structurally, the epidermis is composed of five distinct layers, each of which has its own cellular make up and function. From deep to superficial they are:

- Stratum germinativum – the actively proliferating basal cell layer, containing melanocytes;
- Stratum spinosum – contains keratinocytes;
- Stratum granulosum – the site of protein synthesis – contains mature keratinocytes;
- Stratum lucidum – clear layer present only on the palms and feet; and
- Stratum corneum – contains thick, non-viable keratinised cells, which protect against trauma and sebaceous glands, which produce bactericidal sebum. This layer also insulates against fluid loss.

### 2.1.2. Dermis

---

The dermis is the middle layer of the skin. It is predominantly composed of connective tissue comprising collagen, elastin, ground substance and vascular plexus in a bundled and woven arrangement. Structurally it consists of two layers:

- The superficial papillary dermis, which consists of areolar (loose) connective tissue; and
- The deep reticular layer, which consists of dense irregular connective tissue.

The dermis confers elasticity and flexibility to the skin and at the same time helps it to resist distortion, wrinkling and sagging. It is also the part of the skin where blood vessels and nerves end. The dermis consists predominantly of fibroblasts, collagen and extracellular matrix.

### 2.1.3. Hypodermis

---

This is the deepest and thickest layer of the skin. It is often considered part of the dermis because it invaginates into it, by attachment via collagen and elastin. The hypodermis predominantly consists of adipocytes.

### 2.1.4. Skin appendages

---

Skin appendages are structures derived from the skin that serve particular functions. The appendages are:

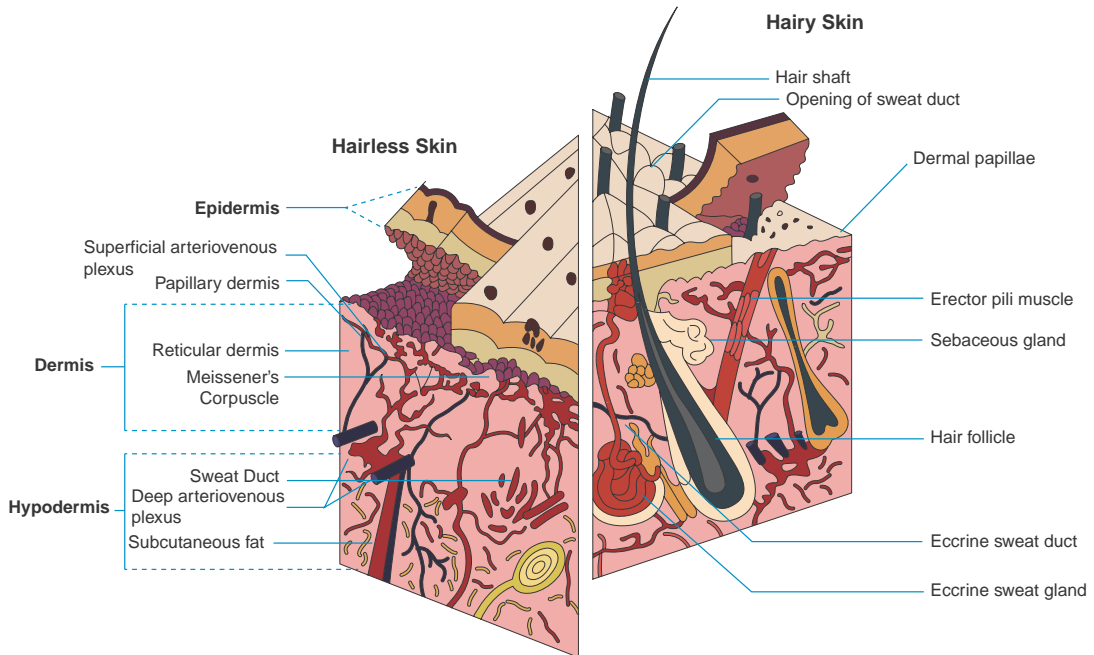
- Hair follicles
- Sweat glands
  - Eccrine glands
  - Apocrine glands
- Sebaceous glands.

Hair follicles are found in skin covering the entire surface of the body except for the palms, soles and glans penis. The face and scalp have the greatest densities of hair follicles. Each hair shaft is composed of a medulla, a cortex of keratinocytes and an outer cuticle. Each follicle consists of two root sheaths which surround the hair bulb. The inner root sheath is derived from the epidermis and the outer root sheath from the dermis. The follicles are lined by germinative cells and melanocytes, which produce keratin and pigment, respectively. Erector pili muscles are associated with each hair shaft. These muscles function to erect the hair follicles by contracting in the cold or during times of fear and emotion, leading to goose bumps. They also aid drainage of sebaceous glands into the hair follicles.

There are over 2.5 million sweat glands in the dermis over most of the body. Eccrine glands are found in the skin covering all body surfaces and secrete an odourless hypotonic fluid under sympathetic control. They are particularly abundant in the forehead, palms, soles and axillae.

Apocrine glands are larger than eccrine glands and emit thicker, odourless secretions, which are metabolised by skin bacteria to produce body odour. They are found in the axilla, the anogenital region and areolar tissue and emit secretions in response to heat, under sympathetic control.

Sebaceous glands are holocrine glands derived from the epidermis. They are closely associated with hair follicles and are therefore absent in hairless skin. In response to androgenic stimulation, sebaceous glands secrete cells which break down to release their lipid cytoplasm directly onto the skin (sebum). The functions of sebum include:



**Figure 1.1.** The skin with its separate layers and appendages.

- Antimicrobial action
- Provision of vitamin E to superficial skin layers
- Maintain integrity of skin barrier
- Thermoregulation.

### 3. WOUND HEALING

Wound healing is classically divided into four phases: haemostatic, inflammatory, proliferative and remodelling. It is worth noting, however, that some authors currently consider the haemostatic phase to be part of the inflammatory phase.

This simplified categorisation incorporates a wide array of immune cells, signalling pathways and chemical mediators, which contribute to the formation of a healed wound. When wounds penetrate the full thickness of the skin, they always produce a scar.

The haemostatic phase is typically an immediate and short-lived phase, lasting only from seconds to minutes. In response to injury, prostaglandins are released from endothelial cells and platelets, leading to vasoconstriction. Collagen exposed in the damaged vessel walls is adhered to by platelets, which then release chemoattractant substances that help to initiate the coagulation cascade. The result is formation of a fibrin–platelet matrix, which functions to control haemorrhage, concentrate growth factors at the site of damage and form the scaffold required for subsequent wound healing processes (Martin, 1997).

The inflammation phase typically lasts between 3 and 5 days. It is important for limiting wound contamination and induction of the proliferative phase of healing. Vasodilatation and increased capillary leakiness occur, promoting delivery of nutrients and immune cells to the site of injury and thus causing tissue oedema. The stimulus for this is provided by prostaglandins, kinins, histamine, serotonin and bacterial components. Inflammatory cytokines and other mediators (e.g. platelet-derived growth factor, tumour necrosis factor  $\alpha$ , interleukin-1) attract granulocytes to the site of injury soon after the injury has occurred. Neutrophils act by phagocytosing debris and microorganisms. These actions are facilitated by the release of proteases to break down damaged tissue and debris and the use of cellular reactive oxygen species to eliminate pathogens. Other immune cells involved in this phase are macrophages, which are terminally differentiated monocytes present in tissues. Monocytes migrate to the wound from local sites to become macrophages within 24–48 hours of injury. Macrophages participate in phagocytosis and are essential in the wound healing process via the release of growth factors. Regulation of the inflammatory phase is important because overstimulation or prolonged stimulation can damage local tissues and, in severe cases, can trigger the systemic inflammatory response syndrome. Conversely, insufficient inflammation and failure to induce proliferation can lead to development of a chronic wound.

The proliferative phase begins soon after an injury and lasts between 4 days and 2 weeks. Re-epithelialisation involves the migration of epithelial cells from the wound margins and other nearby skin appendages. The purpose of this process is to cover the wound and re-establish an intact epithelial barrier. Angiogenesis is stimulated by the low oxygen tension and high lactate levels typical of underperfused wound tissues. New vessels form under the influence of angiogenic growth factors and matrix metalloproteinases degrade the extracellular matrix to facilitate passage of these vessels. Once vascularisation is improved and the oxygen tension increases, the angiogenic stimulus is switched off and apoptosis occurs. Fibroblasts migrate into the wound to supplement the provisional wound matrix by the secretion of proteoglycans, glycosaminoglycans, collagen and other proteins. A number of fibroblasts

**Table 1.1.** The process of wound healing.

Phase	Cellular and biophysiological events
<b>Haemostasis</b>	Vasoconstriction Platelet aggregation, degranulation, fibrin thrombus formation
<b>Inflammation</b>	Neutrophil migration Monocyte migration and differentiation into macrophage Lymphocyte infiltration
<b>Proliferation</b>	Re-epithelialisation Angiogenesis Collagen synthesis Extracellular matrix formation
<b>Remodelling</b>	Collagen remodeling Vascular maturation and regression

Source: Guo and Dipietro, 2010.

will be stimulated to differentiate into myofibroblasts, thus causing wound contraction, an essential process that reduces the size of the wound.

The remodelling phase is the longest phase of wound healing, lasting up to a year after the injury. Collagen is synthesised for about 5 weeks, initially in a disorganised fashion, and predominantly consisting of type III collagen. Continued turnover produces stronger type I collagen, the fibrils of which are laid down in a more organised arrangement affording greater strength. At 1 week, the wound has 3% of normal breaking strength, at 3 weeks 30% and at approximately 3 months after injury, strength peaks at 70–80%.

## 4. WOUND MANAGEMENT

---

The fundamental principles of wound healing are essential in reconstructive surgery, regardless of the procedure being conducted. These principles are:

- Comprehensive debridement of the wound
- Diligent infection control
- Provision of an adequate blood supply.

From a clinical perspective, wounds can heal in three ways:

- Primary intention – skin edges are directly opposed and good healing occurs with minimal scar formation.
- Secondary intention – the wound is left open and closes naturally, usually via a combination of contraction and epithelialisation.
- Delayed primary intention – the wound is left open for some time and then closed if it is found to be clean. This is usually used when closing badly contaminated wounds to enable drainage of infected material.

Management of wounds involves at the first stage a comprehensive assessment of both the patient as a whole and the wound itself. Assessment of the patient should include a general health screen, focusing particularly on the conditions and factors known to affect wound healing (see [Table 1.2](#)). In plastic surgery, numerous wound assessment tools are used in different units. The DIME (Debridement, Infection/Inflammation, Moisture balance, Edge of wound) model is one such tool, and is very useful in assessing prognostic characteristics of wounds and assisting in the selection of suitable interventions such as dressings.

### 4.1. Debridement

---

This assesses the need to remove any unwanted material from the wound. Unwanted material may include necrotic or dead tissue, biofilms, senescent cells, foreign bodies or non-viable tissue (slough or



**Table 1.2.** Factors affecting wound healing.

Local factors	Systemic factors
<b>Infection</b>	Age and sex
<b>Foreign body</b>	Sex hormones
<b>Poor oxygenation</b>	Stress
<b>Venous insufficiency</b>	Ischaemia
	Diseases: diabetes, keloids, fibrosis, jaundice, uraemia, obesity
	Medications: steroids, NSAIDs, chemotherapy
	Alcohol and smoking
	Immunocompromise: cancer, radiotherapy, AIDS
	Malnutrition

eschar). Slough usually has the appearance of grey or yellow, soft or stringy material, whereas eschar is thick, leathery and either black or brown. Unwanted material within the wound is undesirable as it (1) impedes wound healing by harbouring infection; (2) prevents healing from progressing past the inflammatory phase; and (3) prevents wound contraction and re-epithelialisation.

There are five ways to debride wounds:

1. Autolytic
2. Mechanical
3. Enzymatic
4. Surgical/excisional
5. Biological/maggot.

Autolytic debridement occurs when macrophages and proteolytic enzymes cause separation and liquefaction of non-viable tissue. Autolytic debridement can occur naturally or be produced by dressings such as hydrogels, occlusive/semi-occlusive dressings (e.g. film/transparent dressings) or hydrocolloids.

Mechanical debridement uses physical force to remove necrotic tissue. Examples include hydrotherapy, wound-scrubbing and wet-to-dry dressings. Caution should be exercised with this technique because of the potential to debride healthy granulation tissue. Wet-to-dry dressings are moistened dressings, which are applied to the wound and attach to the wound tissues on drying. On removal of the dried gauze, the attached tissue (both necrotic and healthy) is debrided. As this method is non-selective and frequently causes pain, it is generally seen as an unfavourable method of debridement.

Enzymatic debridement involves application of synthetic enzymes (e.g. collagenase) to the wound bed to degrade bonds that link non-viable tissue to the wound (e.g. collagen).

Surgical/excisional debridement involves removal of non-viable tissue using scalpel, forceps, scissors or laser.

Biological/maggot therapy debridement involves the use of sterile larvae, which are applied to the wound. Secretions from these larvae selectively degrade necrotic tissue, reduce microorganism load and promote granulation. One shortcoming is that maggots cannot penetrate hard, dry eschar.

## 4.2. Infection and inflammation

---

The early stages of wound healing involve inflammation as a normal part of the process. This is characterised by heat, redness, swelling and pain. Inflammation can also be indicative of a bacterial burden anywhere along the spectrum of contamination > colonisation > critical colonisation > infection.

In *contaminated* wounds, low numbers of non-replicating bacteria are present. In *colonised* wounds, replicating bacteria are present without stimulating an inflammatory reaction. In *critically colonised* wounds, large numbers of bacteria cause delayed wound healing. *Infection* is caused by the invasion of wound tissue by an even greater number of bacteria, which subsequently stimulate an inflammatory reaction. The type and extent of infection is determined by the causative microorganism, its load and the host's ability to fight it. This information is commonly sought from wound cultures; however, the gold standard in microbial analysis is tissue biopsy.

Non-healing and chronic wounds require multiple modalities of treatment for successful healing. Within such wounds, physical barriers to healing are often found in the form of biofilms – variable collections of bacteria within an extracellular polymeric, glue-like substance – which protect bacteria and prevent their destruction by the immune system. In the management of such wounds, frequent debridement, topical antimicrobials, antiseptics and systemic antibiotics have proven beneficial.

Debridement is generally thought to be the most important treatment to reduce the bacterial burden because it removes dead tissue in which bacteria typically thrive and also assists in the removal of biofilms, thus exposing bacteria to the immune system and external treatments.

The use of topical antiseptics is controversial because of the need to weigh up the advantages of its use – wide spectrum of activity, general lack of bacterial resistance and low cost – against the main limitation – collateral cytotoxic damage to healthy cells. Antiseptics function on the wound surface and do not penetrate tissues; thus, current opinion is that they can be used for short periods of time in wounds with only little healthy tissue at the wound bed if the goal is to reduce the bacterial burden. They should not be used on clean wounds or to irrigate wounds. Commonly used topical antiseptics include povidone iodine (Betadine), chlorhexidine, hydrogen peroxide, alcohol, sodium hypochlorite (Dakin's solution) and acetic acid.

Topical antimicrobials are bacteriostatic and bacteriocidal against a number of microbes and are valuable because they do not harm healthy tissue. Examples include silver-containing products, cadexomer iodine, manuka honey, and methylene blue and crystal violet combination. Several antimicrobial dressings incorporate silver (e.g. sponges, foams, alginates and hydrofibres). Cadexomer iodine in dressings absorbs exudate and particulate matter from the granulating wound surface and releases iodine into the wound. For this reason, ointments, sheets or dressings containing cadexomer iodine are best suited for wounds that are relatively exudative.

Topical antibacterials have limited use in clinical practice – partially because of resistance and sensitisation reactions – and are generally used for only short periods of time (up to 2 weeks). Gram-positive infections are often treated with mupirocin and gentamicin. Neomycin is effective against Gram-positive and Gram-negative organisms but commonly causes sensitivity reactions. Metronidazole has antibacterial, antiprotozoal and amoebicidal activity and is very effective against anaerobic bacteria, which often

lead to offensive-smelling wounds. Further promise comes from the fact that its topical application is not known to cause antibiotic resistance.

### 4.3. Moisture balance

---

In the 1960s, evidence emerged demonstrating the advantages of moisture in accelerating the wound healing process. It is known that moist wounds demonstrate better granulation, tissue formation, angiogenesis and epithelialisation, as well as obtaining wound contraction at an earlier stage. When managing wounds clinically, it is important to remember that each is different and will have different requirements. Nonetheless, a useful model to guide general moisture management is based on the principle aims of promoting a moist environment for healing while managing the detrimental effects of excess exudate. Thus:

- If the wound is too dry, add moisture.
- If moisture is adequate, maintain it.
- If too wet, absorb moisture.

In this regard, most wound dressings are usefully categorised according to their effect on moisture. Hydrogels, hydrocolloids, film dressings and continuously saline moist gauze typically maintain or add moisture to wounds. Foams and alginates absorb moisture.

Whereas gauze is the most commonly used wound dressing, it requires significant management and is therefore labour- and resource-intensive. For example, saline moist gauze must not be allowed to dry if being used to donate moisture otherwise it will dry out the wound by osmosis. Thus, experts are advising a shift toward more advanced dressings.

### 4.4. Edge of wound

---

In a healing wound, a healthy edge promotes migration of epithelial cells to form a pearly white extension of tissue across the wound bed (epithelialisation). The success of this process correlates with the successful management of the previous three aspects of DIME. An unhealthy edge can occur when there is failure of migration or when tissue beneath the wound edge is destroyed – a process known as ‘undermining’. Failure of migration can be caused by inadequate debridement, failure of cessation of inflammation (consistently high protease levels degrade growth factors and extracellular matrix proteins vital for migration) or, in more chronic wounds, by fibroblasts and epithelial cells becoming senescent. Cells that remain at the edge and do not migrate can become hyperproliferative, leading to the appearance of a hypertrophic, rolled (epiboly), calloused ‘cliff-like’ edge. Problematic edges that impede the healing process may require surgical evaluation and debridement, skin grafting or the use of biological agents followed by diligent wound management.

As such a vast array of wound care products is available, clinicians must familiarise themselves with the functions and applicability of each. The selection of each type of product should be based on an assessment of the wound bed.

## 4.5. Complex wounds

---

Systemic disease and malnutrition often complicate the wound healing process; special attention should therefore be placed on correcting these problems (see [Table 1.2](#)). In malnourished patients (often identifiable by measuring albumin, prealbumin and electrolytes), providing nutrition and mineral supplementation enterally or parenterally improves healing. Patients with intercurrent illness (e.g. diabetes mellitus, liver or renal disease, malignancy, sepsis, immunosuppression) should be optimised as far as possible. Correcting these issues also improves the efficacy of adjunctive wound treatment for complex wounds.

## 4.6. Adjuncts to wound healing

---

### 4.6.1. Dressings

---

Dressings are important adjuncts to wound healing, providing a physical barrier to prevent entry of microorganisms and affording protection against disruption of the healing wound. When deciding on a suitable dressing for a specific wound, characteristics that need consideration include:

- Permeability to microorganisms
- Effect on wound bed moisture
- Haemostatic activity
- Adherence
- Absorption
- Antimicrobial activity
- Debriding activity
- Cost
- Labour intensity.

Most surgeons advise their patients to keep their wounds dry in the first instance; however, this is likely to be counterproductive because healing proceeds best in a moist environment (Janis, 2010).

### 4.6.2. Negative-pressure wound therapy

---

Negative-pressure wound therapy utilises a vacuum sponge dressing, which serves as an occlusive dressing, increases blood flow to the wound, reduces oedema, reduces bacterial contamination and

promotes contraction of the wound (Morykwas *et al.*, 2006; Argenta and Morykwas, 1997; Morykwas *et al.*, 1997; Argenta *et al.*, 2006). This technique is useful for large deep wounds with soft tissue at the base (e.g. chest, abdominal, fasciotomy and perineal wounds); however, it is contraindicated in wounds that contain freshly anastomosed blood vessels because it may cause disruption of the anastomoses (White *et al.*, 2005). Other structures such as intact blood vessels, tendons and bones are simply covered with non-adherent gauze or foam sponge beneath the standard polyurethane sponge to provide protection.

Although clinical uses of negative-pressure therapy vary, it is very much considered a tool for preparing wound beds and accelerating healing, rather than a reconstructive modality in its own right. Data suggest that wounds containing bone or poorly vascularised tissue which are treated with negative-pressure therapy are still at a higher risk of infection and osteomyelitis if they are not promptly covered (e.g. with grafts; Choudry *et al.*, 2008).

### 4.6.3. Growth factors

---

Growth factors have shown the potential to increase the speed of healing of several types of wounds including chronic wounds, diabetic foot wounds and pressure ulcers. Examples include platelet-derived growth factor, platelet gels, epidermal growth factor and macrophage colony-stimulating factor. Relatively few of these are frequently used at present but plenty of research is ongoing.

### 4.6.4. Hyperbaric oxygen

---

This treatment modality exposes patients to super-normal oxygen concentrations that cause vasoconstriction, increased arterial oxygen pressures, stimulation of angiogenesis, fibroblast proliferation and antibiotic synergy (Tibbles and Edelsberg, 1996). Hyperbaric oxygen is currently used in the treatment of osteoradionecrosis and carbon monoxide poisoning. Complications include barotrauma, seizures and worsening of congestive heart failure. Animal studies suggest a role in the treatment of chronic wounds and in improving graft and flap survival (Friedman *et al.*, 2006). However, a lack of human data, technical sophistication and the complication profile of hyperbaric oxygen therapy limit its clinical application.

## 5. HOW TO OBTAIN A FINE-LINE SCAR

---

A very common concern for patients undergoing surgical procedures is whether there will be a scar. It is important to inform patients that whenever an incision is made or the full thickness of the skin is injured, there will always be a scar. What is possible is to attempt to make the scar as inconspicuous as possible by obtaining a *fine-line scar*. This can be difficult to ensure for all patients, however, because several factors determine the final appearance of scars including the skin type and location on the body, the direction in which the wound runs, patient factors such as local and systemic disease, surgical technique, and the amount of tension placed on the closure. There are also unexplained differences between patients that sometimes make scarring different or problematic.

In general, pigmented and oily skin types tend to produce more conspicuous and unsightly scars compared with the thin, dry, less-pigmented skin seen in Anglo-Irish skin types.

Certain body areas also tend to produce less-sightly scars. Scars on the shoulder and sternum, for example, are frequently hypertrophic or wide compared with eyelid scars, which are commonly inconspicuous fine-line scars.

Loss of skin elasticity with ageing produces wrinkling, which makes scars less conspicuous and less prone to widening. In younger individuals, especially growing children, wounds heal faster but the quality of the scar is not as high as in the elderly. Scars frequently appear red and wide and are prone to changes in shape and size as the body grows. Scalp scars in small children therefore need consideration when making incisions or facing closure of a wound.

Wounds closed under tension generally lead to less aesthetically pleasing results. Elliptical excisional wounds also close with less pleasing results compared with simple incisional wounds because of the lack of normal tissue between the closed ends. In some areas of the body (e.g. extensor surfaces or over the heel), excisional wounds may require more tension than one would ideally apply to the closure, again contributing to a less aesthetically pleasing scar.

Skin tension lines are topological lines first recognised by Dupuytren in 1834 and further assessed by anatomist Karl Langer (Langer, 1861) after whom ‘Langer’s lines’ are known. They reflect the natural orientation of collagen fibres in the dermis and are otherwise known as relaxed skin tension lines. These are the same as wrinkle lines seen in older individuals and have a long axis perpendicular to the long axis of the underlying muscles. When making incisions, one should aim to place the final scars in parallel with the relaxed skin tension lines where possible in order to ‘hide’ the scar and obtain the most aesthetic result. When a scar crosses the relaxed skin tension lines at a right angle, contraction leads to puckering and a more conspicuous scar.

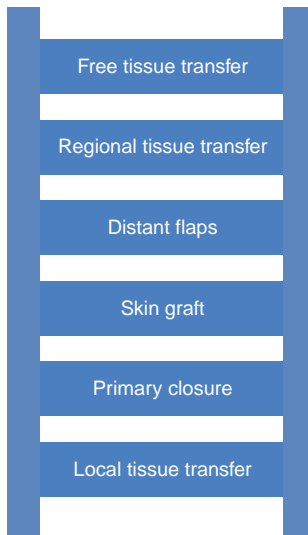
Other techniques employed to make scars less noticeable include hiding them at the junction of aesthetic units (e.g. at the junction of the lip and cheek, along the nasolabial fold). This is a perceptive change that takes advantage of the fact that the eye expects a change in contour at these junctions.

Good surgical technique with minimal trauma to skin edges, diligent debridement and ensuring no tension at closure are essential steps toward obtaining a fine-line scar. However, even with excellent technique, scar formation can be unpredictable. Additionally, one should avoid leaving ‘railroad tracks’ by placing sutures that will not leave permanent marks and by removing sutures at the earliest opportunity. The latter point is the more significant because even if heavy-gauge sutures are used, prompt removal can prevent unsightly scarring. Different units suggest different time frames for the removal of sutures; however, in general, facial sutures can be removed after 3–5 days, and after up to 7 days in other areas of the body. Sutures should remain in place for over a week only really for wounds over joints. In many wounds, subcutaneous closure with steri-strips is usually sufficient to prevent dehiscence.

## 6. RECONSTRUCTIVE LADDER

---

Options for closing cutaneous or complex wounds are evaluated by starting with the simplest methods and ascending the reconstructive ladder to more complex methods. A logical progression beginning with



**Figure 1.2.** The reconstructive ladder.

primary closure, before proceeding to skin grafts, local flaps, regional flaps and finally microvascular free flaps is adaptable for use in any reconstructive procedure. It is good practice to use the simplest option that meets the reconstructive requirement in the first instance because it leaves open the opportunity to try more involved treatments should this fail. There are, however, cases in which a specific technique higher up the ladder is more appropriate for a specific indication; under these circumstances, this can be employed directly. For example, local flaps for nasal defects may be preferable to grafts because of better aesthetic results.

## 7. WOUND CLOSURE

Wound closure is a fundamental skill in surgery and one in which plastic and reconstructive surgeons must possess expert proficiency. As mentioned above, the skin provides the aesthetic definition of the body and is also a major contributor to innate immunity, protecting our internal structures from environmental hazards. Maintaining the integrity of the skin is thus crucial for the preservation of health; lack of its maintenance invariably leads to significant morbidity and mortality through infection, heat loss, fluid imbalance and direct damage to internal structures.

The most common method of wound closure is suturing. This practice is believed to date back to ancient Egyptian times, when it was used to treat the living and also to prepare mummies for burial. Other wound closure techniques include staples, skin tape and tissue adhesives. The decision regarding which technique is used depends on the characteristics of the defect being closed and other circumstances that may affect closure of the wound or the health of the patient as a whole. For example, insertion of skin staples is faster than suturing and is associated with a lower risk of infection and tissue reaction. It is therefore often preferable when closing wounds to the trunk or lower limbs at the end of

a long operation. Whichever technique is used to close a specific wound, the accurate approximation of skin edges without tension leads to minimal scarring. Subdermal wounds are closed in layers with careful suturing to produce a strong and secure closure. The aims of such closure are to eliminate dead space and to provide enough strength to enable wound healing while preventing dehiscence. The strength of closure required varies depending on the function of the particular body area being closed. For example, as the scalp is not particularly mobile or regularly subjected to tension, it does not require as secure a closure as the lower limb. To achieve the additional strength in the latter situation, one might decide to close the individual layers separately, whereas this may not be necessary for closing other types of wounds.

## **7.1. Suturing techniques**

---

A key principle of suturing is ensuring the skin edges are everted. Everting the wound edges allows the dermal edges (which constitute 95% of the thickness of the skin) to come into contact and heal together. If the wound edges are not sufficiently everted, then the scar will widen and become depressed as the wound heals. Eversion may initially produce a slightly raised closure; however, as healing occurs and the wound spreads, the edge will flatten, leaving the best possible scar. The suturing technique used for individual wounds is important to achieve optimal healing. Different wound closure techniques are illustrated and described below.

### **7.1.1. Simple interrupted sutures**

---

This is the most commonly used suturing technique, named because each suture is individually placed and tied. The needle is first introduced into the skin at a 90° angle and then advanced through the dermis and out via the opposite dermal and epidermal layers using a rotational wrist movement. The angle of introduction causes the suture to be wider at its base in the dermal layer than at its entry and exit points in the epidermis. When seen in cross-section, this gives the suture a triangular appearance and leads to eversion of the skin edges. The sutures are usually placed 1–2 mm from the edge of the wound and approximately 5–7 mm from each other. Simple interrupted sutures are particularly useful if there is concern about the cleanliness of a wound. If any part of the wound looks suspicious for infection, the relevant sutures can be removed without disrupting the entire closure.

### **7.1.2. Simple continuous suture (over-and-over)**

---

This variation of the simple suture can be inserted rapidly. However, it lacks the precision of the simple interrupted suture. For a desirable result with this technique, the wound edges often need to be approximated to a degree before insertion. This suture is useful for closing scalp wounds.



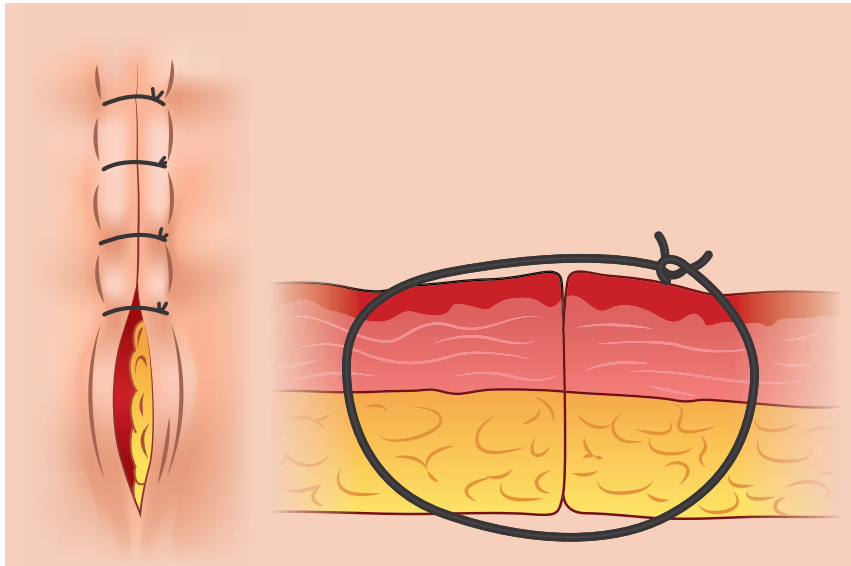


Figure 1.3. Simple interrupted sutures.

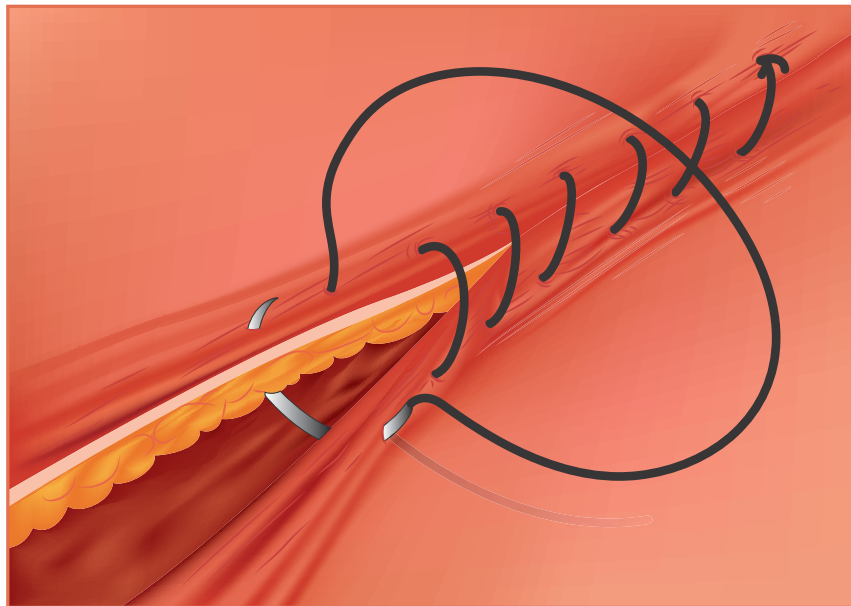
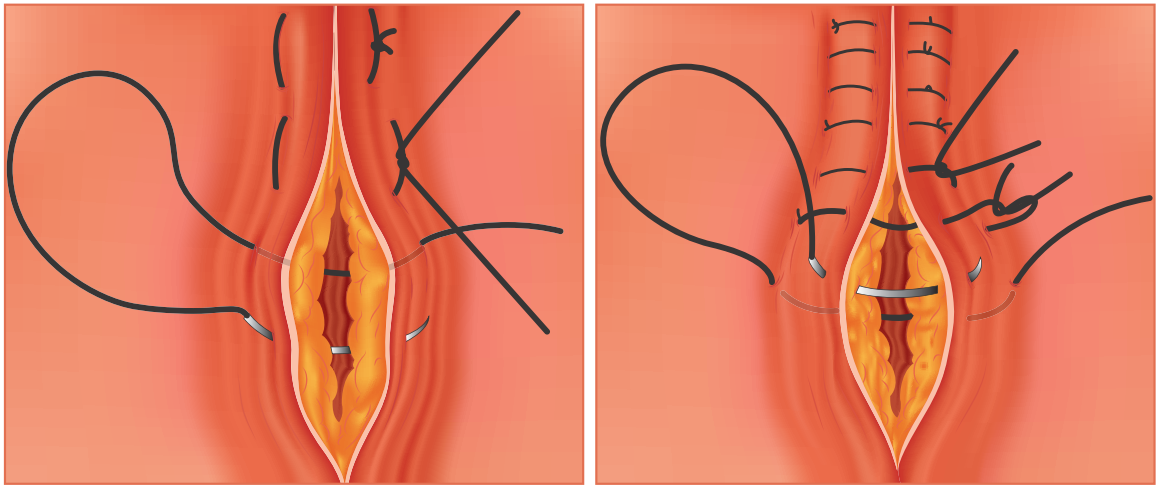


Figure 1.4. Simple continuous sutures.



**Figure 1.5.** Mattress sutures: horizontal (left) and vertical (right).

### 7.1.3. Mattress sutures

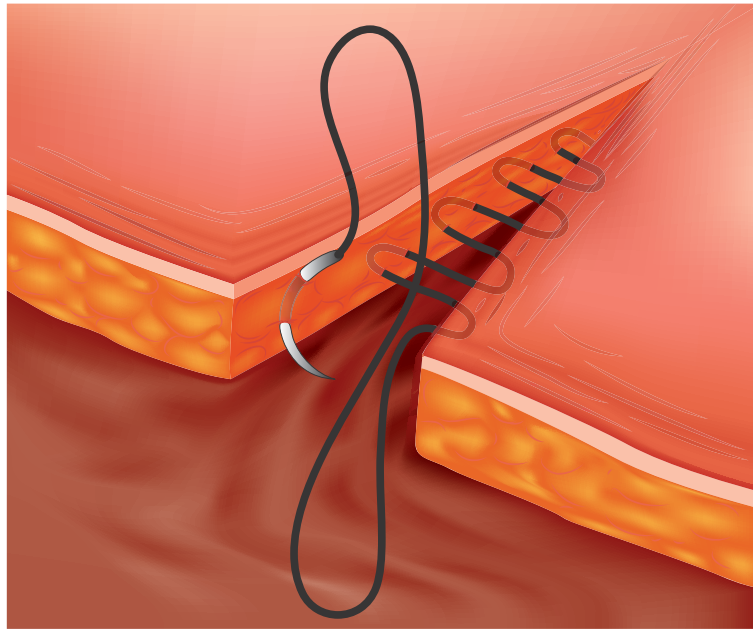
Mattress sutures are useful when eversion of the wound edges may be difficult. Horizontal mattress sutures are frequently used in areas with thick glabrous skin, such as the hands and feet. Vertical mattress sutures are often used where simple sutures are unlikely to successfully produce sufficient eversion of the skin edges. Mattress sutures can often lead to unsightly cross-hatching across the wound scar (railroad marks). However, early removal of the sutures can circumvent this.

### 7.1.4. Subcuticular (intra-dermal) sutures

This technique is useful for closing wide or gaping wounds and when there may be difficulty everting the skin edges. These buried sutures approximate the dermal layers, thus providing strength to the closure and enhancing healing. In this stitch, the knot is buried (i.e. does not emerge through the epidermis) to prevent it causing pain and irritation and affecting wound healing. This suture is placed using a cutting needle and absorbable suture material.

### 7.1.5. Half-buried horizontal mattress sutures (corner stitch)

This technique is commonly used to approximate angled skin flaps or corners without compromising the blood supply to the tissue tip. It also produces an aesthetically pleasing closure with all knots on one side of the suture line, leaving no suture marks on the opposite side. For this reason, it is often used when resetting the areola in breast reduction because it leaves all suture marks on the dark, texturised areola rather than on the skin of the breast.



**Figure 1.6.** Subcuticular suture.

## 7.2. Other closure techniques

### 7.2.1. Skin staples

The use of skin staples enables rapid closure of wounds. They are often used for long wounds or as a method of positioning a flap before suturing. The wound edges are everted using forceps. Staples are associated with prominent scars and so should be removed as soon as possible. They are often used on the scalp.

### 7.2.2. Skin tapes

Skin tapes are useful for approximating wound edges. However, they do not evert the skin edges and sometimes require buried sutures to align the dermal layers and produce eversion. They are commonly used in the hospital emergency department for closure of small, minor wounds and after removal of sutures to provide additional strength.

### 7.2.3. Skin adhesives

Skin adhesives bind the superficial skin layers. They are useful where there is no tension on the closure or where dermal sutures have been placed to reduce tension across the wound. They do not evert the skin edges and so rely on sutures to provide this.

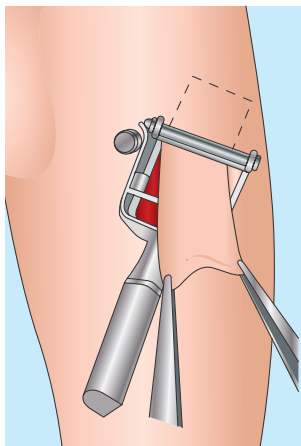
## 8. SKIN GRAFTING

A skin graft is a portion of epidermis along with some or all of the dermis which is used to close a defect not amenable to primary closure. Skin grafting is thus a means of reconstructing defects in the skin, regardless of the cause. As with all grafts, the tissue used has no vascular supply of its own and depends on obtaining vascularisation from the bed into which it is placed.

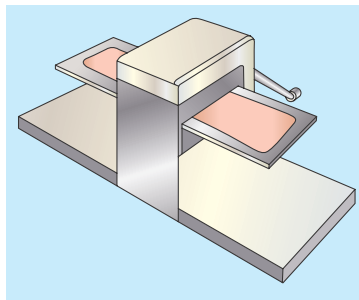
The principles of harvesting and transplanting skin date back up to 3000 years to the Hindu Tilemaker Caste. During this period, skin grafts were used to reconstruct the amputated noses of punished criminals. Today, its commonest use is for reconstruction after the surgical removal of skin cancers. Other uses include providing cover for chronic ulcers, replacing tissue lost in full-thickness burns and hair restoration in patients with alopecia.

Skin grafts are categorised according to the proportion of the dermis included: *split-thickness* skin grafts do not contain the whole dermis whereas *full-thickness* skin grafts do.

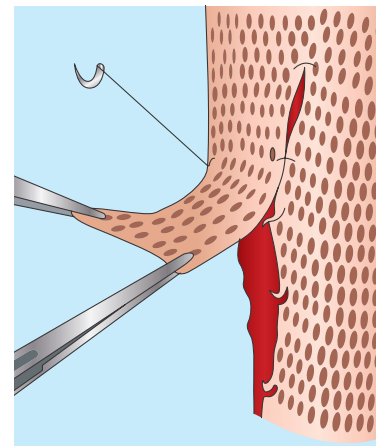
Transfer of skin appendages occurs with grafting; however, the degree of function of these appendages depends on the thickness of the graft used. Using sweat glands as an example, for grafted skin to maintain the ability to sweat a sufficient number of sweat glands need to be transferred, and these glands require sympathetic innervation. As sweat glands are of dermal origin, a graft containing a greater amount of dermal tissue is more likely to contain a significant number of sweat glands. In addition, as reinnervation of grafted tissue is reliant upon ingrowth of nerve fibres from wound margins and the graft bed and upon access of these fibres to neurilemmal sheaths, full-thickness grafts – which provide greater accessibility to these sheaths – lead to a greater extent of innervation.



Graft is taken from patient's healthy skin at the donor site



The graft can be meshed or fenestrated



Graft is stitched in place to cover the wound

**Figure 1.7.** The skin grafting process.

Full-thickness skin grafts also transport hair follicles and typically grow the hair of the donor site. In contrast, split-thickness skin grafts are typically hairless.

Some terminology relevant to the understanding of different graft types follows:

- *Autograft* – a graft taken from one part of an individual’s body that is transferred to a different part of the body of that same individual.
- *Isograft* – a graft from a donor that is genetically identical to the recipient (e.g. identical twins).
- *Allograft* – a graft taken from one individual that is transferred to another individual of the same species.
- *Xenograft* – a graft taken from one species that is transferred onto an individual of a different species.

## 8.1. Graft take

*Graft take* is the process by which skin grafts become incorporated into the host bed. The success of a graft is determined by how quickly and comprehensively the tissue can be perfused. Two qualities of a skin graft that determine its take are:

1. The blood supply of the skin from which the graft was harvested
2. How metabolically active the graft tissue is at the time of application.

A graft taken from well-vascularised donor sites typically take better than those taken from poorly vascularised areas.

As there is an inevitable period of ischaemia between graft harvest and take, the metabolic activity of the tissue determines how well it will tolerate this period. Those grafts that do not tolerate the ischaemic period well are less likely to survive.

Graft take occurs in three phases over approximately 6 days:

1. Plasmatic imbibition
2. Inosculatory phase
3. Capillary ingrowth.

### 8.1.1. Plasmatic imbibition

Although general consensus on the exact significance of plasmatic imbibition to graft take is yet to be reached, the general purpose of this phase is to bridge the period from ischaemia to the establishment of a vascular network capable of perfusing the graft. During this period, which lasts 24–48 hours, fluid migrates from the bed into the graft, adding up to 40% to its weight. This process is analogous to inflammatory oedema with increased ‘capillary leakiness’ and the accumulation of osmotically active metabolites.

The period of ischaemia varies between grafts but is essentially determined by the proliferative state of the wound bed at the time of graft application. Grafts used to cover fresh wounds are generally ischaemic for approximately 48 hours; however, grafts applied onto proliferative wound beds are ischaemic for only 24 hours. For the same reason, grafts applied to poorly vascularised beds are typically ischaemic for a greater duration than those applied to well-vascularised wound beds. Tolerance of the ischaemic period is influenced by the thickness of the graft, with thinner grafts demonstrating greater tolerance and take than thicker grafts.

### 8.1.2. Inosculation and capillary ingrowth

---

After approximately 48 hours, a vascular network is established in the fibrin layer between the graft and the recipient bed by contact between capillary buds in the bed and vessels within the graft. These 'kissing' vessels form patent channels enabling blood flow and thus perfusion of the skin graft. Various schools of thought exist regarding whether the final vascular network actually involves grafted vessels or whether in fact most functional vessels grow into the graft from the wound bed. Regardless of which theory is correct, proper blood flow to a graft usually takes between 4 and 7 days to establish and is clinically identified by pink colouration of the graft.

## 8.2. Graft healing

---

Immediately after harvesting, the skin graft is white and, as previously described, it gradually becomes pink over the days following its application to the recipient bed. Vascularisation can be clinically demonstrated by assessing the capillary refill time: this shows blanching upon pressure, with a prompt return of colour upon release. Another feature of grafted skin is its initial depression below the level of the surrounding skin. This resolves within 2–3 weeks.

## 8.3. Graft contraction

---

Skin grafts begin to contract and shrink immediately following harvest. Contraction is an inevitable consequence of skin grafting and typically occurs in two stages. Primary contraction occurs immediately after the graft has been removed from the donor site as a result of dermal elastin fibres. For this reason, full-thickness grafts show a greater degree of primary contraction compared with split-thickness grafts. Secondary contraction occurs when the graft has healed at the recipient site, presumably under the influence of myofibroblasts. Split-thickness skin grafts (especially thinner grafts) tend to undergo more secondary contraction compared with full-thickness grafts. It is possible to manipulate the degree of graft contraction to an extent by changing the thickness and amount of dermis contained within the graft. As the dermis inhibits contraction, the more of it is included, the less the graft will contract. Once wound contraction is complete, it is possible for full-thickness grafts to grow, whereas split-thickness grafts grow minimally, if at all. It is worth noting here that granulating wounds that heal by secondary

intention demonstrates the greatest degree of contraction and are more prone to hypertrophic scarring compared with either of the grafting techniques.

## 8.4. Graft reinnervation

---

Nerves grow into skin grafts from wound margins and the wound bed over varying time frames depending on the thickness of the graft and certain characteristics of the recipient site. Signs of sensory recovery are evident as early as 4–5 weeks after grafting, with complete sensation returning within 1–2 years. Infiltrating nerve fibres access neurilemmal sheaths on the graft tissue; the extent of these interactions determines the extent of reinnervation achieved. Full-thickness grafts provide greater access to neurilemmal sheaths compared with split-thickness grafts and therefore have better nervous reinnervation.

If healing is uneventful, two-point discrimination is relatively accurate. However, in many cases thermal and pain sensation are not regained to the same extent. This is likely to be caused by a lack of sensory corpuscle regeneration in grafted tissue.

## 8.5. Overgrafting

---

Dermal overgrafting is the application and ‘take’ of split- or full-thickness grafts on a bed of scar tissue or dermis after the epidermis has been removed (Trimble, 1983). Advantages of this technique include its simplicity, the preservation of subcutaneous tissues and the prospect of minimal tissue loss even if the graft fails (Rees and Casson, 1966). However, incomplete removal of the epidermis may leave remnants that can form cysts and granulomas. Overgrafting has been used effectively for the treatment of unstable, depressed, corrugated or hypertrophied scars; unstable or hyperpigmented skin grafts; large pigmented naevi (following excision of all pigment); and radiation skin damage and tattoos (Rees and Casson, 1966).

Several techniques are used. Rees and Casson described the principles in 1966:

1. Removal of surface epithelium (e.g. with electric dermatome)
2. Preparation of the dermal bed (e.g. dermabrasion with a rotating abrader)
3. Haemostasis (e.g. electrocautery or haemostatic agents)
4. Harvest of split-thickness skin graft – the overgraft (e.g. with a precision drum dermatome).

## 8.6. Graft failure

---

Good surgical technique is vital to improve the survival potential of skin grafts. Specific surgical factors requiring meticulous care include:

- Atraumatic handling of the graft
- Preparing a well-vascularised scar and debris-free recipient bed

- Ensuring good haemostasis and removing accumulated blood before dressing the wound
- Immobilising the recipient site post-operatively
- Tourniquet use when harvesting and transferring the graft
- Strict avoidance of constricting bandages proximal to the graft.

When preparing the recipient bed, one must ensure that it is clean, dead tissue is removed and an appropriate substrate is exposed (e.g. peritenon for tendon, periosteum for bone and endothelium for skin).

The most common cause of failure of skin grafts is haematoma. The haematoma effectively acts as a physical barrier to revascularisation by keeping the endothelial buds away from the graft undersurface (Flowers, 1970).

The second most common cause of graft failure is infection. It has been suggested that graft failure secondary to infection is caused by dissolution of fibrin by plasmin and proteolytic enzymes, which are abundant in bacteria-infected wounds. Fibrin is central to graft survival via an adherent action at the interface between the graft and the bed. One can avoid infection by ensuring the wound bed is clean and well prepared, by using quilting sutures, permitting egress of wound fluids by meshing or pie-crusting the graft surface, and by applying and frequently changing saline-soaked dressings (Flowers, 1970). Other proposed methods include administering low-dose erythromycin for 5 days post-graft, administering vitamin C and zinc for up to 10 days, and avoidance of alcohol (Thornton, 2004).

Another complication of subjacent fluid is graft necrosis. Excess fluid accumulation can be avoided by ensuring atraumatic tissue handling, cauterising lymphatics (which often cause seromas), minimising the use of diathermy in the graft bed and using light-pressure or vacuum-assisted closure dressings (Flowers, 1970).

Necrosis may also be caused by applying excessive pressure to a fresh graft. It has been suggested that 30 mmHg is the upper limit of pressure that may be applied. Tie-over dressings are useful in this regard because they do not exert excess pressure on wounds yet are able to immobilise the graft, reduce the dead space and prevent the formation of haematomas (Seymour and Giele, 2003). Other causes of graft failure include arterial insufficiency, gravitational dependency, venous congestion, movement of the area that creates shear forces, lymphatic stasis and surgical technique.

## 9. FLAPS

---

Flaps are units of tissue which maintain their own blood supply when transported from a donor to recipient site. They are different from grafts, which are transferred without a vascular source and are dependent on acquiring a blood supply from vessels at the recipient site. The spectrum of flaps ranges from simple advancement flaps containing skin and subcutaneous tissue to composites which can contain combinations of skin, fat, fascia, muscle and bone (Thornton, 2004). Flaps can be characterised by:

- Their component parts (e.g. cutaneous, musculocutaneous, osteocutaneous)
- Their relationship to the defect (e.g. local, regional, distant, free)



- The nature of blood supply (random or axial)
- The requirement of movement for the flap to fill the desired defect (e.g. advancement, pivot, transposition, interpolation).

The history of flap repair in plastic surgery dates back to 600 BC, with nasal reconstruction using cheek flaps documented by Sushruta Samita (Thornton, 2004). These were rotation flaps, which involve moving skin to an adjacent area by twisting or rotating a pedicle. Advancement flaps, which do not involve any torsion of the base, were first described by the French. Distant pedicled flaps, which involve movement of tissue to a remote site, were originally described in Italian Renaissance literature.

Flaps are usually required to cover poorly vascularised recipient beds and vital structures; for reconstructing the full thickness of cheeks, nose, ears, lips and eyelids; and for padding bony prominences (Thorne, 2007). They are also useful when a future operation through the wound may be required to repair underlying structures. Muscle flaps can provide motor function to a defect and can be used as a means of controlling infection in the recipient area, as demonstrated by reduced numbers of viable bacteria and increased oxygen tension beneath these flaps compared with random flaps (Gosain *et al.*, 1990). Flaps are also useful for their ability to confer more pleasing aesthetic results to certain defects. For example, defects left following excision of cutaneous or nasal cancers can be repaired with grafts; however, these leave more visible patches. Although more invasive, repairs using flaps are usually more pleasing in the long term.

Skin flaps comprise skin, subcutaneous tissue and their native blood vessels, which are transferred from one part of the body to another. Comprehensive planning of any flap is essential, with all possible sites and orientations requiring careful consideration.

Local skin flaps can be used to close defects or wounds adjacent to the donor site. Local flaps are subclassified according to the mechanism of movement into:

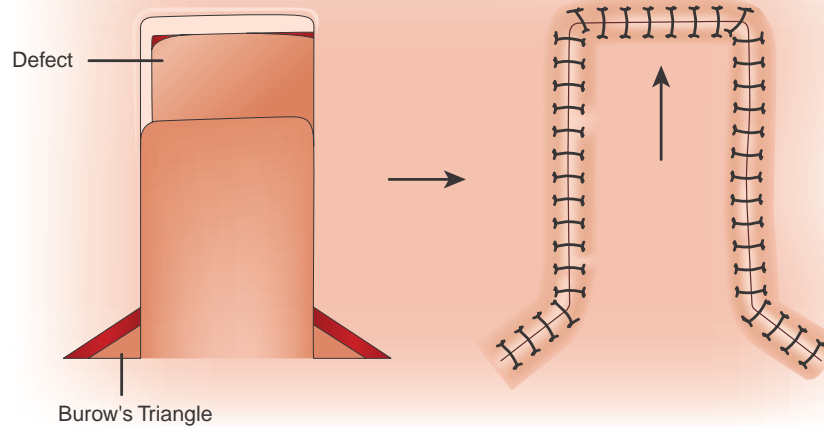
- Flaps that move in the direction of the long axis of the flap (V–Y, Y–V, single pedicle and bipedicle flaps).
- Flaps that pivot around a point (rotation, transposition and interpolation flaps).

Distant flaps use tissues from donor sites remote to the site of the defect. Distant flaps are subclassified into (Thorne, 2007):

- Direct flaps
- Tube flaps
- Free flaps.

## 9.1. Local flaps

*Advancement flaps* are formed by sliding donor skin longitudinally over defects. This can be achieved by simply stretching it along the long axis, with or without excising Burow's triangles laterally, which equalises the length of the flap and the adjacent wound edge (Suzuki *et al.*, 1996).



**Figure 1.8.** Advancement flap.

## 9.2. Flaps rotating about a pivot point

*Rotation flaps* are semicircular tissue flaps which are rotated about a pivot point into the defect to be closed. The donor site is subsequently closed by sutures or with a skin graft. Methods used to facilitate rotation along the arc of the flap include back-cutting at the pivot point along the base of the flap and excising a Burow's triangle at the external aspect of the pivot point. Back-cutting helps to release tension in flaps that are too tight along their radius; however, this should be done with caution because it reduces the blood supply to the flap.

*Transposition flaps* are square or rectangular pieces of skin and subcutaneous tissue which are rotated about a pivot point into an immediately adjacent defect. The donor site is closed by sutures, a skin graft or a secondary flap using the most lax skin at right angles to the primary flap (e.g. bilobed). As the effective length of the flap shortens with the degree of rotation, it is important to ensure that it is longer than the defect to be covered. The crucial measurement in this regard is the line of greatest tension, which is a line from the pivot point to the most distal part of the flap.

*Rhomboid (Limberg) flaps* are transposition flaps designed for parallelogram-shaped defects with sides of equal length and two angles of  $60^\circ$  and two of  $120^\circ$  (e.g. as created during excision of skin lesions). These angles, however, may be modified based on the shape of the defect or lesion to be filled. As many as four flaps can be raised from each rhomboid: the choice is made based on the location of the resultant scar, vascular supply to the flap and laxity of the skin (Chasmar, 2007). Limberg flaps are versatile flaps that are widely applicable for full-thickness defects anywhere on the body. They can be carried out safely with good cosmetic results because they fill defects with tissue of the same colour and thickness, with good vascular supply (Chasmar, 2007).

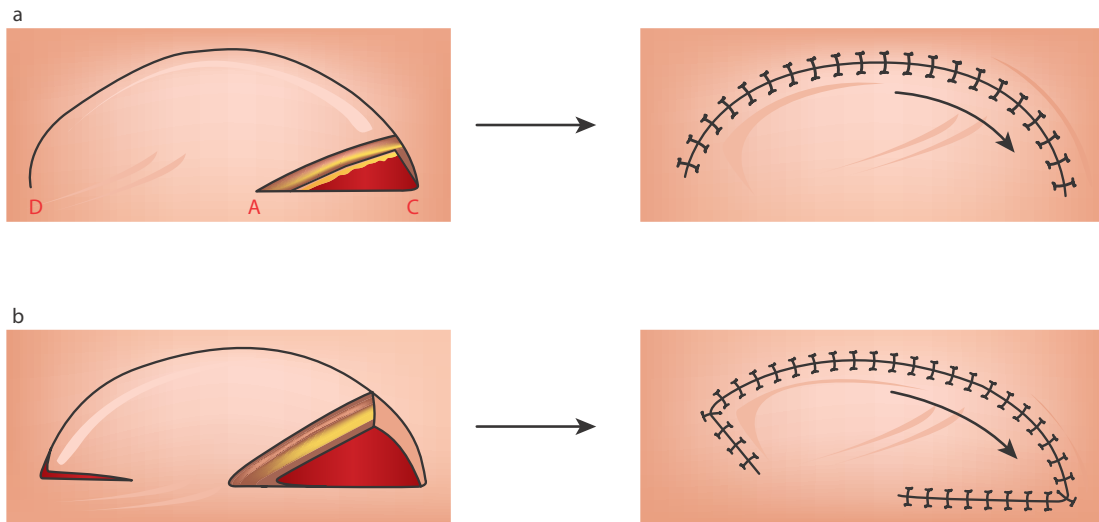


Figure 1.9. Rotation flap.

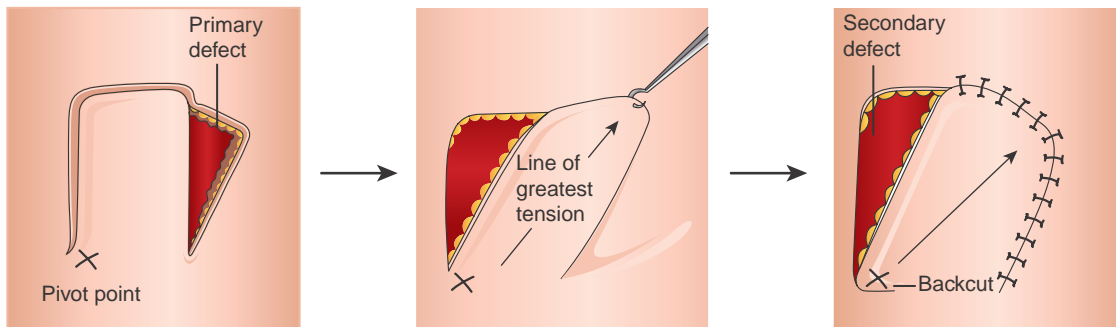
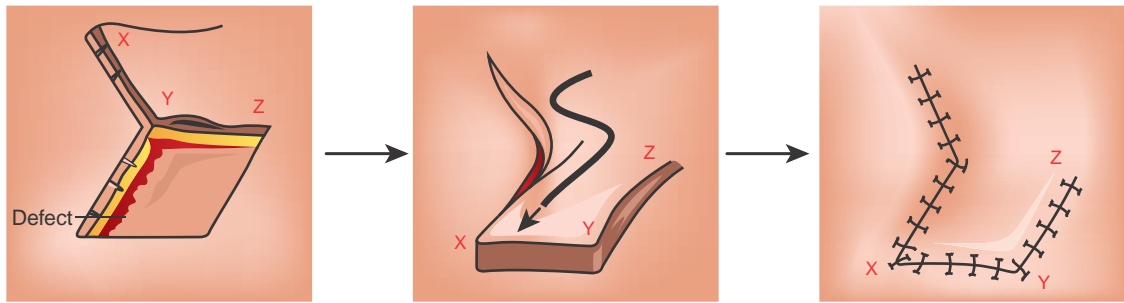
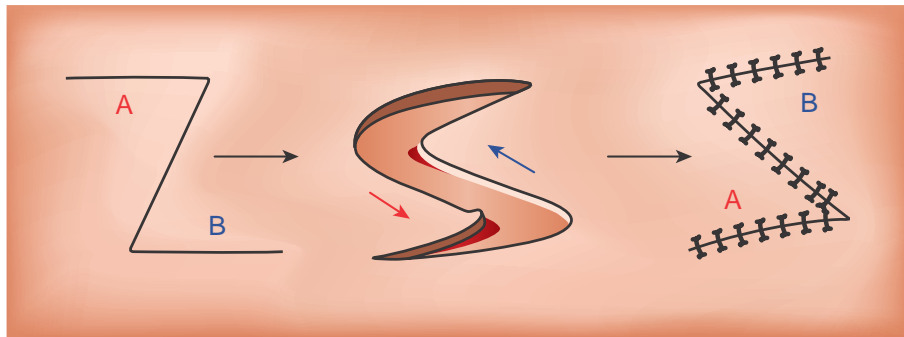


Figure 1.10. Transposition flap.

*Z-plasty* is a useful technique with many applications in plastic surgery such as revising and redirecting existing scars and lengthening scars in the setting of scar contracture by recruiting lateral tissue. The technique is a variation of the transposition flap in which two triangular flaps are reversed and rotated by 90°. The technique involves three limbs of equal length – two parallel lateral limbs, joined obliquely by a central limb – with equal angles between each of the lateral limbs and the central limb. These angles can vary from 30° to 90° depending on the increase in length required; however, 60° is the classic angle and provides a theoretical 75% increase in length in the direction of the central limb. Very acute angles increase the risk of tip of flap necrosis, whereas broader angles make for more difficult rotation. It is important to note that the theoretical gain in length does not account for mechanical properties of the skin and always overestimates the actual gain. The central limb that results from the flap transposition will be perpendicular to the original central limb. Therefore during planning (e.g. for scar revision) one



**Figure 1.11.** Limberg flap.

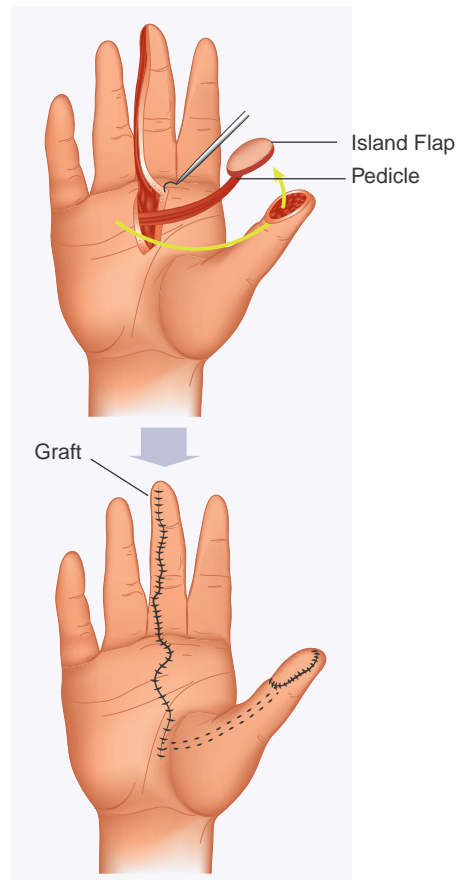


**Figure 1.12.** Z-plasty.

must design the flap with the resulting central limb lying in the direction of the skin lines. To ensure this, the central limb is selected first and then the Z-plasty is designed.

Lengthening of the skin in a desired direction (e.g. to release scar contractures) is commonly produced by Z-plasty. Multiple small Z-plasties can be designed in series to release a contracture or to break up the appearance of a straight line. This technique is especially useful in aesthetically important areas such as the face where large Z-plasties are not favourable. Other applications for Z-plasty include the correction of congenital skin webs, improvement of U-shaped ('trapdoor') scars and lengthening of circumferential scars, especially constricting scars.

*W-plasty* is a less common method of scar revision based on the principle of excising the scar in several small interdigitating triangles in order to change the direction of the linear scar. It is less commonly used than Z-plasty because it is less versatile and does not confer the same ability to position the resultant scar along skin tension lines. However, both types of flaps are able to increase the elasticity of a scar via producing an accordion-like arrangement. This can be important, for example, in restoring facial expressiveness. An important limitation to these techniques is that they often significantly increase the length of scars, which can worsen their appearance.



**Figure 1.13.** Interpolation (Littler's) flap.

*Interpolation flaps* rotate around a pivot point to fill a defect that is near to but not adjacent to the donor site. For this to occur, the flap pedicle needs to pass over or under the intervening tissue. This pedicle supports the flap in the recipient defect until inosculation and neovascularisation occur at the recipient site (Mellette and Ho, 2005). It is then released. Interpolation flaps are useful for reconstructing large or deep defects where adjacent local sites are unable to supply sufficient tissue for repair. The main disadvantage is that it is a two-stage process involving creation of the flap and then release of the pedicle.

### 9.3. Distant flaps

Distant flaps are made when donor and recipient sites are not close to each other. They are required when there is insufficient healthy soft tissue adjacent to an open wound to provide sufficient coverage. There are two types of distant flaps: *direct (attached)* and *free*.

Direct distant flaps are made by attaching tissue from the donor site to the open recipient wound, without first disconnecting it. For example, some open hand wounds require coverage and skin on the chest is often a suitable donor. Therefore, the hand is initially attached to the chest, with a flap of tissue from the chest wound providing coverage. The donor site is then covered by a skin graft.

Attached distant flaps initially derive their vascular supply from the pedicle while inosculation and neovascularisation from the recipient site occurs. Once this is complete, the pedicle is divided and the flap survives with its new vascular supply. Examples of direct flaps are the chest, thenar, cross-leg and groin flaps.

Free flaps are axial flaps (i.e. they receive blood supply from a recognised artery or group of arteries) which have their vascular pedicle detached from the donor site before being transferred to the recipient site and anastomosed microsurgically to vessels at that site. Direct flaps are less technically demanding for the clinician; however, they are more impractical, inconvenient and labour-intensive.

To anastomose the vessels when performing a free flap, one requires a microscope, tiny suture material (8-0, 9-0 nylon) and small, delicate instruments. Although they are long procedures, free flaps produce remarkable results, with over 90% success rates documented in most clinical series (Khoury, 1992). Indications include post-mastectomy breast reconstruction, tongue or jaw reconstruction after ablative oncologic surgery and coverage of open ankle fractures with loss of soft tissue.

An in-depth discussion about the array of free tissue transfer techniques at the disposal of the reconstructive surgeon is beyond the scope of this chapter. However, it is important to know the principles involved and to understand the influence of vascular supply in determining the options available.

### 9.3.1. Cutaneous flaps

---

Flaps were previously classified by McGregor and Morgan (Zoltie *et al.*, 1990) as random or axial. This classification is based on the arrangement of blood vessels supplying nutrition to the tissues. Random flaps are supplied by the subdermal plexus, which in turn is supplied by direct cutaneous (axial), musculocutaneous or fasciocutaneous vessels (Griffiths, 1996). Random flaps are traditionally subject to the 3:1 rule: for optimum circulation, the flap length should be no more than three times its width; and for large flaps, delay procedures (which are designed to enhance flap circulation, thus ensuring survival after advancement, transposition or transplantation) are required. This rule has since been challenged: the more recently proposed mechanism of survival is dependent on the means of vascularisation. Axial flaps contain a specific (named) direct artery or group of arteries within the longitudinal axis of the flap. Classification systems applicable to all cutaneous flaps have been created based on knowledge of fasciocutaneous perforator anatomy (Nakajima *et al.*, 1986; Daniel and Kerrigan, 1979).

Cormack and Lamberty (1984a,b) classified skin flaps as direct cutaneous, fasciocutaneous or musculocutaneous based on their vascular anatomy rather than their tissue components. Skin flaps are based on the fasciocutaneous plexus – a single vascular network present in subcutaneous tissue throughout the body (Nakajima *et al.*, 1986). This plexus includes component parts of the sub-, intra- and supra-fascial vascular plexuses, which supply the dermal, subdermal, superficial and deep adipofascial layers (Nakajima *et al.*, 1986; Thornton, 2004). The fasciocutaneous plexus receives its vascular supply from perforating vessels that either pierce the deep fascia directly or pierce muscles or intermuscular septa.

Perforators were defined by Hallock (2003) as any vessel that enters the suprafascial plane through a fenestration in the deep fascia, regardless of its origin. Flaps supplied by isolated perforator(s) are known as perforator flaps (Blondeel *et al.*, 2003a,b).

Nakajima *et al.* (1986) divided skin flaps into five groups, based on their pattern of vascularisation: cutaneous, fasciocutaneous, adipofascial, septocutaneous and musculocutaneous. All skin flaps receive their vascular supply from perforating vessels to the fasciocutaneous plexus. Fasciocutaneous flaps are subdivided into six groups based on the deep fascial perforator system.

### 9.3.2. Perforator flaps

*Perforator flaps* are typically composed of skin and subcutaneous tissue supplied by a deep fascial perforating vessel. Perforator flaps enable reconstruction with the tissue types that are most frequently missing: skin and subcutaneous fat. There are several potential perforator flap donor sites and flaps from these sites are often able to incorporate muscle, fat and bone. Perforators pass from their vessel of origin to the flap tissue either through or between deep tissues (predominantly muscle; Blondeel *et al.*, 2003a). Three different types of perforator vessels are recognised:

1. Indirect muscle perforators – give rise to musculocutaneous perforator flaps
2. Indirect septal perforators – give rise to septocutaneous perforator flaps
3. Direct cutaneous perforators.

Where one perforator supplies a perforator flap, the flap is named after the nutrient vessel, not the underlying muscle. In areas where multiple perforator flaps can be raised from a single vessel, each flap is named after its muscle or anatomic region (Blondeel *et al.*, 2003a). Examples include those flaps based on the lateral circumflex femoral vessels, e.g. anterolateral thigh flap and tensor fasciae latae perforator flap.

Advantages of perforator flaps include (Geddes *et al.*, 2003):

- Reduced donor site morbidity because neither a passive muscle carrier nor the underlying fascial plexus are necessary for flap survival.
- Muscle sparing, therefore the functional deficit is reduced.
- Ability to design flaps of varying sizes and thickness to improve the aesthetic result.
- Improved post-operative recovery.

Reduced donor site morbidity has been described in studies comparing the outcomes of deep inferior epigastric perforator (DIEP) flaps (muscle-sparing) and transverse rectus abdominis musculocutaneous ('TRAM') flaps (Blondeel *et al.*, 1997; Futter *et al.*, 2000; Kaplan and Allen, 2000; Kroll *et al.*, 2001a,b; Nahabedian *et al.*, 2002). The versatility of perforators is due to their large cutaneous territories, long pedicles which allow conventional and free transfer, the potential to be harvested as sensate or compound flaps and the ability to be thinned to the subdermal plexus (Kimura, 2002; Kimura and Satoh, 1996; Hyakusoku and Gao, 1994). These properties also make perforator flaps ideal for reconstructing soft tissues in areas where it should be thin and pliable, e.g. head and neck.

Disadvantages of perforator flaps include (Chen and Tang, 2003; Kimata *et al.*, 1998; Nahabedian *et al.*, 2002):

- Long duration and meticulous dissection of the pedicle.
- Variability of perforator location, size and anatomy.
- Greater risk of fat necrosis than with musculocutaneous flaps.

Taylor and Palmer identified 374 perforators with diameters greater than 0.5 mm, all of which supply cutaneous territories suitable as flaps (Taylor and Palmer, 1987, Taylor, 2003). The commonest perforator flaps in use are the DIEP, anterolateral thigh perforator, superior gluteal artery perforator and the thoracodorsal artery perforator. Essential characteristics of a potential perforator flap donor site include a reliable blood supply, one or more large perforators (>0.5 mm in diameter), pedicles of sufficient length for the anastomosis required (unless being used as a pedicled flap) and the ability to be closed primarily after harvest (preferably).

### 9.3.3. Fasciocutaneous flaps

---

Following characterisation of the vascular anatomy of muscle and the musculocutaneous system, vascular pedicles that emerged between muscles and entered the deep fascia were identified. This finding enabled the elevation of flaps of skin with their deep fascia.

Fasciocutaneous flaps (originally called axial flaps) include skin, subcutaneous tissue and the underlying fascia. Vessels supplying these flaps arise at the flap base from musculocutaneous perforators or from the branches of major arteries. Perforating vessels pass along fibrous septa between muscle bellies or compartments. They then spread out and form plexuses at the level of the deep fascia, and branches from this point supply the skin. Schafer (1975) identified three main vascular systems of the deep fascia:

1. Perforating arteries from underlying muscle that give off several radiating branches that perforate the fascia and then join the subdermal plexus.
2. Subcutaneous arteries within fat which anastomose with each other and with the superficial plexus of the deep fascia.
3. Subfascial arteries which arise from the intermuscular septa, run in the loose areolar tissue underneath the deep fascia and then join the deep and superficial plexuses.

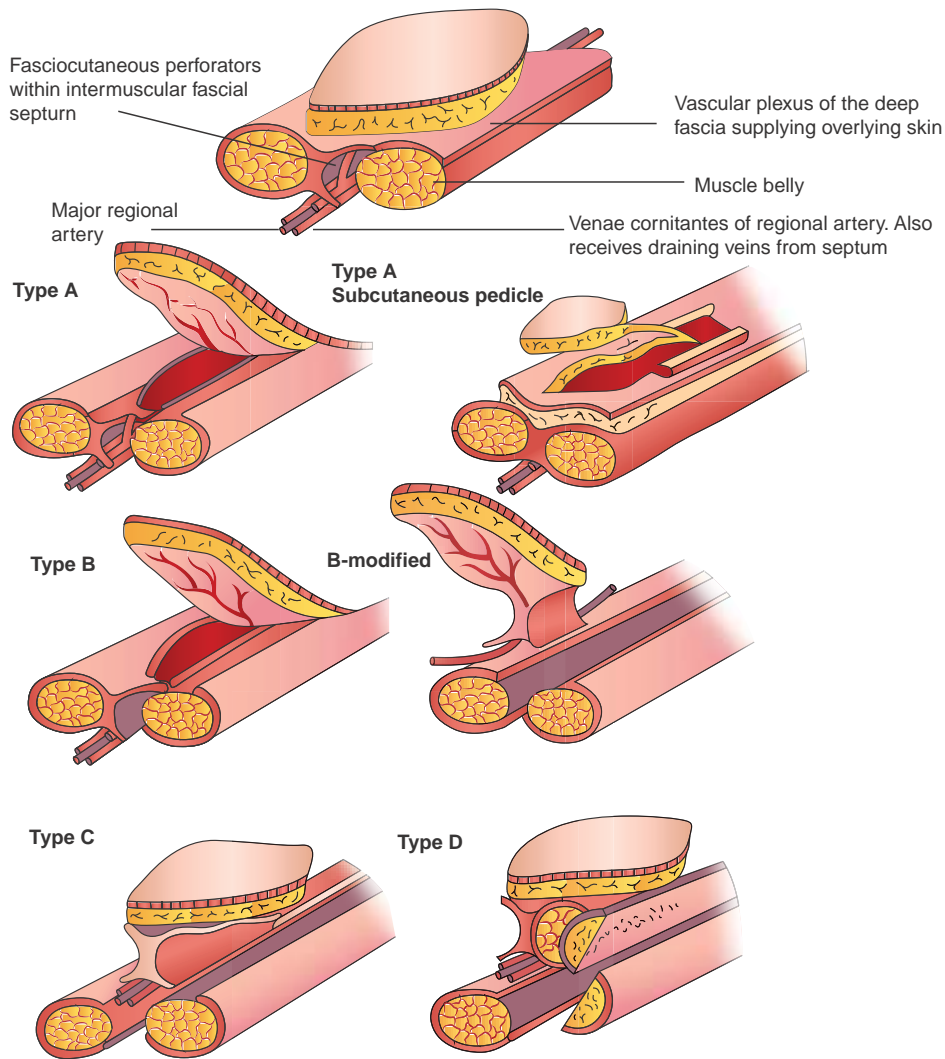
Fasciocutaneous flap pedicles consist of an artery and paired venae comitantes. Direct cutaneous and septocutaneous pedicles have less variability in location compared with musculocutaneous perforators.

Cormack and Lamberty (1984a,b) created a classification for fasciocutaneous flaps based on their vascular patterns:

*Type A* – Flaps supplied by multiple fasciocutaneous perforators, entering at the base of the flap and extending longitudinally throughout the length.

*Type B* – Flaps with a single fasciocutaneous perforator of moderate size which is consistently present in the same location.





**Figure 1.14.** Cormack and Lamberty classification.

*Type C* – Flaps based on multiple small perforators which run between muscles along a fascial septum.

The flap includes the supplying deep artery.

*Type D* – Osteomusculofasciocutaneous flap, which includes portions of adjacent muscle and bone.

### 9.3.4. Musculocutaneous flaps

Musculocutaneous flaps are composites of skin, subcutaneous tissue, and the underlying muscle and fascia supplied by a dominant vascular pedicle (Thornton, 2004). The first musculocutaneous flaps were

**Table 1.3.** Mathes and Nahai classification.

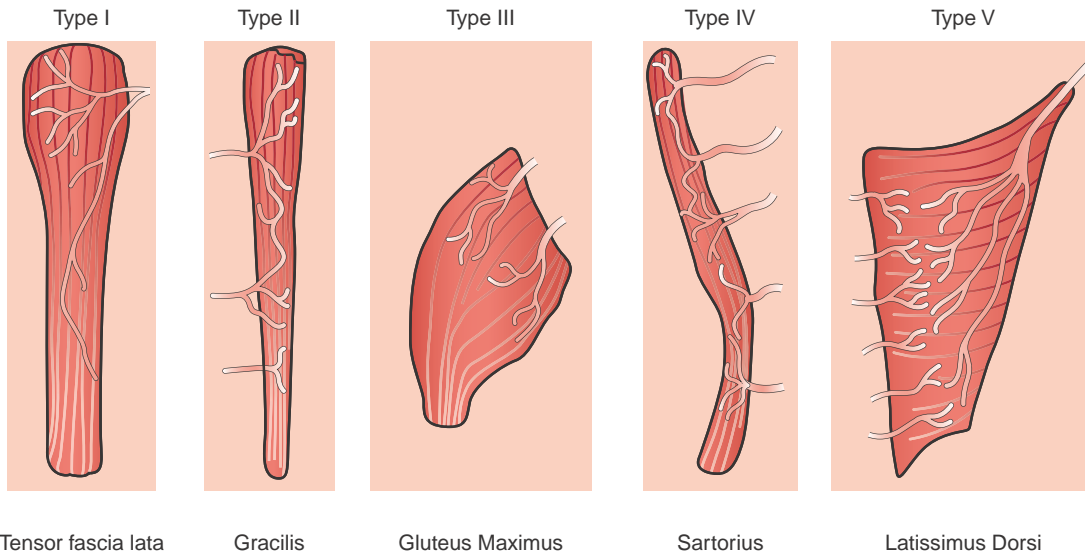
Type	Features	Example
<b>I</b>	Single vascular pedicle	Tensor fascia lata
<b>II</b>	Dominant pedicles and minor pedicles	Gracilis
<b>III</b>	Two dominant pedicles	Gluteus maximus
<b>IV</b>	Segmental vascular pedicles	Sartorius
<b>V</b>	Single dominant pedicle and secondary segmental pedicles	Latissimus dorsi

used in 1906 by Tansini in a breast reconstruction procedure using skin and latissimus dorsi raised as a single unit. Muscle flaps are advantageous because they fill the dead space with vascularised tissue, which increases resistance to infection (Chang and Mathes, 1982). Increased blood flow through musculocutaneous flaps and reduced bacterial concentration in the first 24 hours after flap elevation suggest greater resistance to infection and better ingrowth into inoculated tissue compared with fasciocutaneous flaps (Gosain *et al.*, 1990). Musculocutaneous flaps have been used successfully in the treatment of osteomyelitis (Ger, 1977; Stark, 1946), infected prosthetic grafts (Mixer *et al.*, 1989; Perler *et al.*, 1991), post-thoracotomy mediastinitis (Scully *et al.*, 1985) and chronic intrathoracic sepsis (Hammond *et al.*, 1993; Perkins *et al.*, 1995).

The disadvantages of muscle and musculocutaneous flaps are donor site morbidity, functional deficit and flap bulk. When designing these flaps, it is important to recognise the vascular architecture of the muscle and the distribution of the cutaneous perforators that supply the skin. Mathes and Nahai (1981) classified muscles as five types based on specific features of their vascular supply (Table 1.3 and Figure 1.15). The determinant features were:

- Regional source of the pedicle entering the muscle
- Number of pedicles and their sizes
- Location of the pedicle relative to the origin and insertion of the muscle
- Arrangement of the intramuscular vessels.

Type I muscles receive their vascular supply from a single pedicle. Type II muscles receive theirs from both a dominant and a minor vascular pedicle. This is the commonest vascular arrangement in human muscle. When flaps are elevated from type II muscles, the minor pedicles are divided and the larger dominant pedicle sustains flow to the flap. Type III muscles have two large pedicles from separate sources. The entire volume of the muscle can usually survive with only one of these pedicles, as occurs when one pedicle is divided during flap elevation. This vascular arrangement allows the muscle to be split; thus, part of the muscle can be used in a flap. Type IV muscles receive their vascular supply from segmental pedicles which enter along the course of the muscle belly. Each pedicle supplies a segment of the muscle. Division of three or more of these during flap elevation may result in distal necrosis. Type V muscles receive their supply from a single dominant pedicle near the muscle insertion and secondary segmental pedicles near the origin. Both of these pedicles are capable of independently sustaining circulation to the internal vasculature; therefore, flaps can be elevated on either.



**Figure 1.15.** Mathes and Nahai classification.

## 10. CONCLUSION

Knowledge and application of the fundamental principles of plastic surgery empowers the surgeon with a plethora of tools to aid the management of defects and the restoration of form and function. Through research and understanding of anatomical, physiological and surgical principles, ongoing development of treatment modalities will improve the spectrum of problems that can be overcome.

## REFERENCES

- Argenta, L. C. & Morykwas, M. J. 1997. Vacuum-assisted closure: A new method for wound control and treatment. Clinical experience. *Ann Plast Surg*, 38, 563–76.
- Argenta, L. C., Morykwas, M. J., Marks, M. W., DeFranzo, A. J., Molnar, J. A. & David L. R. 2006. Vacuum-assisted closure: State of clinic art. *Plast Reconstr Surg*, 117, 127S–42S.
- Blondeel, N., Vanderstraeten, G. G., Monstrey, S. J., Van Landuyt, K., Tonnard, P., Lysens, R., Boeckx, W. D. & Matton, G. 1997. The donor site morbidity of free DIEP flaps and free TRAM flaps for breast reconstruction. *Br J Plast Surg*, 50, 322–30.
- Blondeel, P. N., Van Landuyt, K., Hamdi, M. & Monstrey, S. J. 2003a. Perforator flap terminology: update 2002. *Clin Plast Surg*, 30, 343–6, v.
- Blondeel, P. N., Van Landuyt, K. H., Monstrey, S. J., Hamdi, M., Matton, G. E., Allen, R. J., Dupin, C., Feller, A. M., Koshima, I., Kostakoglu, N. & Wei, F. C. 2003b. The ‘Gent’ consensus on perforator flap terminology: Preliminary definitions. *Plast Reconstr Surg*, 112, 1378–83; quiz 1383, 1516; discussion 1384–7.
- Chang, N. & Mathes, S. J. 1982. Comparison of the effect of bacterial inoculation in musculocutaneous and random-pattern flaps. *Plast Reconstr Surg*, 70, 1–10.

- Chasmar, L. R. 2007. The versatile rhomboid (Limberg) flap. *Can J Plast Surg*, 15, 67–71.
- Chen, H. C. & Tang, Y. B. 2003. Anterolateral thigh flap: an ideal soft tissue flap. *Clin Plast Surg*, 30, 383–401.
- Choudry, U., Moran, S. & Karacor, Z. 2008. Soft-tissue coverage and outcome of Gustilo grade IIIB midshaft tibia fractures: A 15-year experience. *Plast Reconstr Surg*, 122, 479–85.
- Cormack, G. & Lamberty, B. 1984a. A classification of fascio-cutaneous flaps according to their patterns of vascularisation. *Br J Plast Surg*, 37, 80–7.
- Cormack, G. C. & Lamberty, B. G. 1984b. Fasciocutaneous vessels. Their distribution on the trunk and limbs, and their clinical application in tissue transfer. *Anat Clin*, 6, 121–31.
- Daniel, R. K. & Kerrigan, C. L. 1979. Skin flaps: An anatomical and hemodynamic approach. *Clin Plast Surg*, 6, 181–200.
- Dupuytren. 1834. Quoted by Cox, H.T. 1942. The cleavage lines of the skin. *Brit. J. Surg*, 29, 234.
- Flowers, R. S. 1970. Unexpected post-operative problems in skin grafting. *Surg Clin North Am*, 50, 439–56.
- Friedman, H. I., Fitzmaurice, M., Lefavre, J. F., Vecchiolla, T. & Clarke D. 2006. An evidence-based appraisal of the use of hyper-baric oxygen on flaps and grafts. *Plast Reconstr Surg*, 117, 175S–90S; discussion 191S–2S.
- Futter, C. M., Webster, M. H., Hagen, S. & Mitchell, S. L. 2000. A retrospective comparison of abdominal muscle strength following breast reconstruction with a free TRAM or DIEP flap. *Br J Plast Surg*, 53, 578–83.
- Geddes, C. R., Morris, S. F. & Neligan, P. C. 2003. Perforator flaps: Evolution, classification, and applications. *Ann Plast Surg*, 50, 90–9.
- Ger, R. 1977. Muscle transposition for treatment and prevention of chronic post-traumatic osteomyelitis of the tibia. *J Bone Joint Surg Am*, 59, 784–91.
- Gosain, A., Chang, N., Mathes, S., Hunt, T. K. & Vasconez, L. 1990. A study of the relationship between blood flow and bacterial inoculation in musculocutaneous and fasciocutaneous flaps. *Plast Reconstr Surg*, 86, 1152–62; discussion 1163.
- Griffiths, R. W. 1996. The arterial anatomy of skin flaps. *Ann R Coll Surg Engl*, 78, 75.
- Guo, S. & DiPietro, L. A. 2010. Factors Affecting Wound Healing. *J Dent Res*, 89(3), 219–29.
- Hallock, G. G. 2003. Direct and indirect perforator flaps: The history and the controversy. *Plast Reconstr Surg*, 111, 855–65; quiz 866.
- Hammond, D. C., Fisher, J. & Meland, N. B. 1993. Intrathoracic free flaps. *Plast Reconstr Surg*, 91, 1259–64.
- Hyakusoku, H. & Gao, J. H. 1994. The ‘super-thin’ flap. *Br J Plast Surg*, 47, 457–64.
- Janis, J. E., Kwon, R. K. & Lalonde, D.H. 2010. A practical guide to wound healing. *Plast Reconstr Surg*, 125(6), 230e–44e.
- Kaplan, J. L. & Allen, R. J. 2000. Cost-based comparison between perforator flaps and TRAM flaps for breast reconstruction. *Plast Reconstr Surg*, 105, 943–8.
- Khouri, R. K. 1992. Avoiding free flap failure. *Clin Plast Surg*, 19, 773–81.
- Kimata, Y., Uchiyama, K., Ebihara, S., Nakatsuka, T. & Harii, K. 1998. Anatomic variations and technical problems of the anterolateral thigh flap: A report of 74 cases. *Plast Reconstr Surg*, 102, 1517–23.
- Kimura, N. 2002. A microdissected thin tensor fasciae latae perforator flap. *Plast Reconstr Surg*, 109, 69–77; discussion 78–80.
- Kimura, N. & Satoh, K. 1996. Consideration of a thin flap as an entity and clinical applications of the thin anterolateral thigh flap. *Plast Reconstr Surg*, 97, 985–92.
- Koshima, I., Moriguchi, T., Fukuda, H., Yoshikawa, Y. & Soeda, S. 1991. Free, thinned, paraumbilical perforator-based flaps. *J Reconstr Microsurg*, 7, 313–6.
- Kroll, S. S., Reece, G. P., Miller, M. J., Robb, G. L., Langstein, H. N., Butler, C. E. & Chang, D. W. 2001a. Comparison of cost for DIEP and free TRAM flap breast reconstructions. *Plast Reconstr Surg*, 107, 1413–6; discussion 1417–8.
- Kroll, S. S., Sharma, S., Koutz, C., Langstein, H. N., Evans, G. R. D., Robb, G. L., Chang, D. W. & Reece, G. P. 2001b. Post-operative morphine requirements of free TRAM and DIEP flaps. *Plast Reconstr Surg*, 107, 338–41.
- Langer, K. 1861. Zur anatomic und Physiologie der haut, Sitzunbgsb. *D. K. Akad. D. Wissensch.*, 19, 179.

- Martin, P. 1997. Wound healing—Aiming for perfect skin regeneration. *Science*, 276, 75–81.
- Mathes, S. J. & Nahai, F. 1981. Classification of the vascular anatomy of muscles: experimental and clinical correlation. *Plast Reconstr Surg*, 67(2), 177–87.
- Mellette, J. R. & Ho, D. Q. 2005. Interpolation flaps. *Dermatol Clin*, 23, 87–112, vi.
- Mixter, R. C., Turnipseed, W. D., Smith, D. J., Jr., Acher, C. W., Rao, V. K. & Dibbell, D. G. 1989. Rotational muscle flaps: A new technique for covering infected vascular grafts. *J Vasc Surg*, 9, 472–8.
- Morykwas, M. J., Argenta, L. C., Shelton-Brown, E. I. & McGuirt, W. 1997. Vacuum-assisted closure: A new method for wound control and treatment. Animal studies and basic foundation. *Ann Plast Surg*, 38, 553–62.
- Morykwas, M. J., Simpson, J., Pungler, K., Argenta, A., Kremers, L. & Argenta, J. 2006. Vacuum-assisted closure: State of basic research and physiologic foundation. *Plast Reconstr Surg*, 117, 121S–6S.
- Nahabedian, M. Y., Momen, B., Galdino, G. & Manson, P. N. 2002. Breast reconstruction with the free TRAM or DIEP flap: patient selection, choice of flap, and outcome. *Plast Reconstr Surg*, 110, 466–75; discussion 476–7.
- Nakajima, H., Fujino, T. & Adachi, S. 1986. A new concept of vascular supply to the skin and classification of skin flaps according to their vascularization. *Ann Plast Surg*, 16, 1–19.
- Perkins, D. J., Lee, K. K., Pennington, D. G. & Stern, H. S. 1995. Free flaps in the management of intrathoracic sepsis. *Br J Plast Surg*, 48, 546–50.
- Perler, B. A., Vander Kolk, C. A., Dufresne, C. R. & Williams, G. M. 1991. Can infected prosthetic grafts be salvaged with rotational muscle flaps? *Surgery*, 110, 30–4.
- Rees, T. D. & Casson, P. R. 1966. The indications for cutaneous dermal overgrafting. *Plast Reconstr Surg*, 38, 522–8.
- Richards, A. 2008. *Key notes on plastic surgery*, Wiley.com.
- Schafer, K. 1975. [The subcutaneous vascular system (lower extremity): studies on micro-preparations]. *Gegenbaurs Morphol Jahrb*, 121, 492–514.
- Scully, H. E., Leclerc, Y., Martin, R. D., Tong, C. P., Goldman, B. S., Weisel, R. D., Mickleborough, L. L. & Baird, R. J. 1985. Comparison between antibiotic irrigation and mobilization of pectoral muscle flaps in treatment of deep sternal infections. *J Thorac Cardiovasc Surg*, 90, 523–31.
- Seymour, F. K. & Giele, H. P. 2003. Tie-overs under pressure. *Br J Plast Surg*, 56, 494–7.
- Stark, W. J. 1946. The use of pedicled muscle flaps in the surgical treatment of chronic osteomyelitis resulting from compound fractures. *J Bone Joint Surg Am*, 28, 343–50.
- Suzuki, S., Matsuda, K. & Nishimura, Y. 1996. Proposal for a new comprehensive classification of V-Y plasty and its analogues: the pros and cons of inverted versus ordinary Burow's triangle excision. *Plast Reconstr Surg*, 98, 1016–22.
- Taylor, G. I. 2003. The angiosomes of the body and their supply to perforator flaps. *Clin Plast Surg*, 30, 331–42, v.
- Taylor, G. I. & Palmer, J. H. 1987. The vascular territories (angiosomes) of the body: Experimental study and clinical applications. *Br J Plast Surg*, 40, 113–41.
- Thorne, C. 2007. *Grabb and Smith's plastic surgery*, Wolters Kluwer Health/Lippincott Williams & Wilkins.
- Thornton, J. F. 2004. Skin grafts and skin substitutes. *Selected Readings in Plastic Surgery*, 10, 1–23.
- Tibbles, P. M. & Edelsberg, J. S. 1996. Hyperbaric-oxygen therapy. *N Engl J Med*, 334, 1642–8.
- Trimble, J. R. 1983. Dermal overgrafting in dermatology. *J Dermatol Surg Oncol*, 9, 987–93.
- White, R. A., Miki, R. A., Kazmier, P. & Anglen, J. O. 2005. Vacuum-assisted closure complicated by erosion and hemorrhage of the anterior tibial artery. *J Orthop Trauma*, 19, 56–9.
- Zoltie, N., Chapman, P. & Joss, G. 1990. Tissue expansion: A unit review of non-scalp, non-breast expansion. *Br J Plast Surg*, 43, 325–7.

# Abdominal Wall Reconstruction

---

Ali Alhamdi, Shadi Ghali

## 1. INTRODUCTION

---

There are various types of abdominal wall defects, with various and sometimes overlapping management options. Interventions can vary from simple coverage and contouring to reconstruction with dynamic functional abdominal wall muscles (Garrido *et al.*, 2013) depending on factors relating to the defect, such as the type of tissue loss (skin, muscles or fascia), as well as factors relating to the size of the defect and degree of wound contamination. Other considerations including patient factors are also important, such as emergency versus elective presentation, patient co-morbidities and previous surgery. Furthermore, treatment of the abdominal defects is based on the following factors:

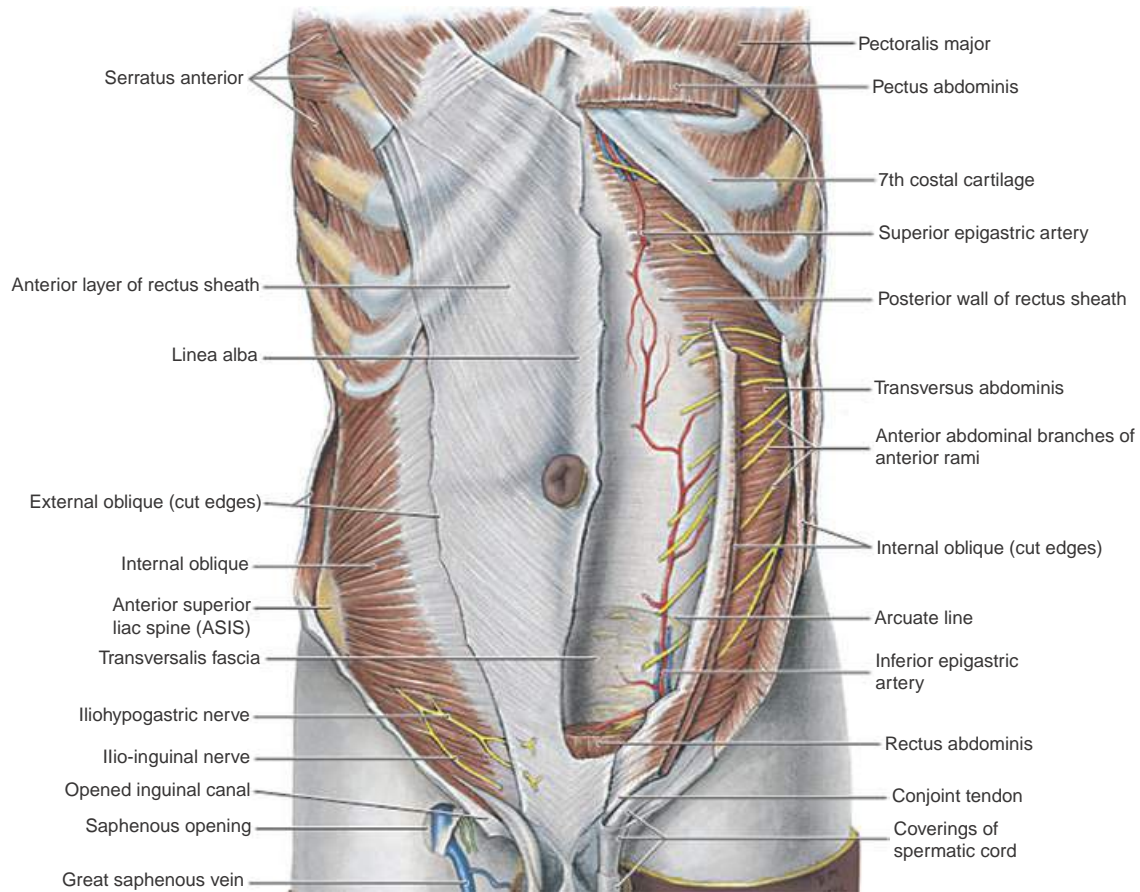
- Mechanical forces contributing to abdominal hernia.
- Open wound management with conversion of fistulae to ostomies.
- Consideration of the patient's general and nutritional status before definitive treatment of the abdominal defect.
- Crucially important is the maintenance of blood supply of the skin rather than wide undermining of the flap (Thorne *et al.*, 2007, 2014).
- Tension-free apposition of tissue edges in every stage of abdominal wall repair.

## 2. ANATOMY AND ZONES

---

The abdominal wall consists of five layers (Agur, 2013; Figure 2.1):

1. Skin
2. Superficial fascia (superficial fatty layer, Camper's fascia, Scarpa's fascia)
3. Muscles and their aponeuroses – external oblique, internal oblique, transversus abdominis, rectus abdominis and pyramidalis)

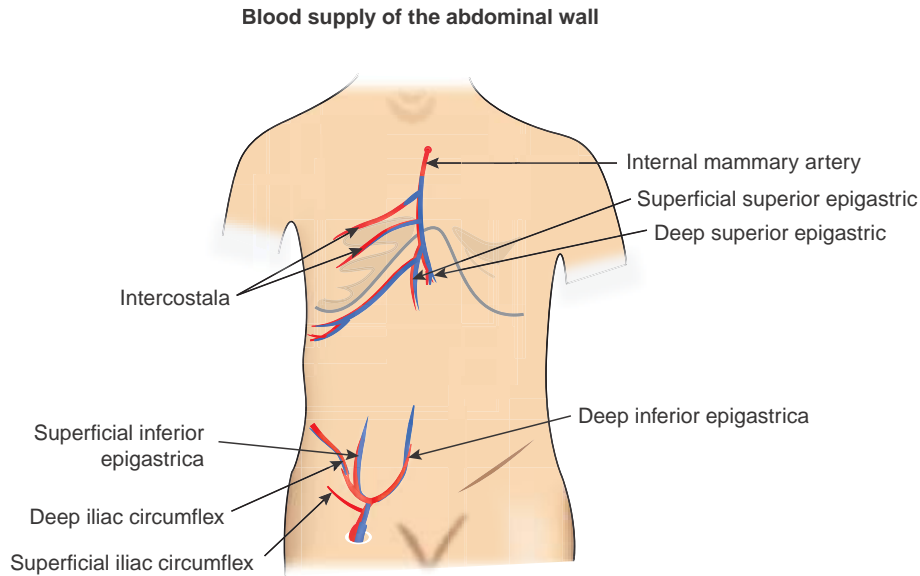


**Figure 2.1.** Anterior abdominal wall layers.

4. Properitoneal fat
5. Peritoneum.

The abdomen is made up of five paired muscles (Weinzweig, 2010):

1. *External oblique* – arises from the lower eight ribs and interdigitates with the serratus anterior and latissimus dorsi muscles. It inserts on the anterior half of the iliac crest.
2. *Internal oblique* – located deep to the external oblique and has fibres which course in an opposite direction to the external oblique. It originates from the lumbodorsal fascia, anterior two-thirds of the iliac crest and the lateral two-thirds of the inguinal ligament.
3. *Transversus abdominis* – this is the deepest and smallest of the muscles of the lateral abdominal wall. It originates from the lower six ribs, the lumbodorsal fascia, the anterior two-thirds of the iliac crest and the lateral third of the inguinal ligament.



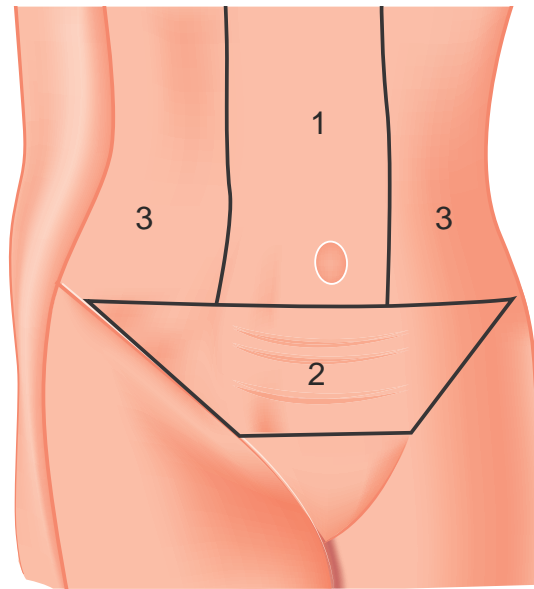
**Figure 2.2.** Blood supply to the anterior abdominal wall.

4. *Rectus abdominis* – this is a longitudinal muscle located in the medial aspect of the abdominal wall. It arises from the front of the symphysis and pubic crest and inserts on the xiphoid process and cartilage of the fifth to seventh ribs.
5. *Pyramidalis muscle* – this muscle is present in 80–90% of patients. It is a small triangular muscle that lies superficial to the rectus muscle.

The blood supply of the abdominal wall can be summarised as the follows (Figure 2.2):

1. *Thoracic and lumbar intercostal arteries* – these travel between the external oblique muscles anteriorly and the internal oblique muscles posteriorly, with direct lateral skin perforators.
2. *Superior epigastric artery* – the terminal branch of the internal mammary artery that supplies the upper central abdominal skin through the upper rectus muscle.
3. *Deep inferior epigastric artery* – the branch of the external iliac artery that enters the lower rectus muscle and supplies it and the accompanying vertical or transverse skin paddle.
4. *Deep circumflex iliac artery* – the branch of the external iliac artery that supplies the inner aspect of the ileum and the skin over the iliac crest.
5. *Superficial inferior epigastric artery* – the branch of the femoral artery that supplies the skin and subcutaneous tissue over the lower abdomen.
6. *Superficial circumflex iliac artery* – the branch of the femoral artery that supplies the skin and subcutaneous tissue over the anterosuperior iliac spine.





**Figure 2.3.** Abdominal vascular zones. *Source:* Huger *et al.* (1979).

7. *Superficial external pudendal artery* – the branch of the femoral artery that supplies the skin and subcutaneous tissue over the pubis.

Huger *et al.* described three vascular zones of the abdominal wall (Figure 2.3; Weinzweig, 2010):

*Zone I* (mid-abdomen) is supplied by the deep epigastric arcade

*Zone II* (lower abdomen) is supplied by the external iliac artery

*Zone III* (lateral abdomen) is supplied by the intercostal, subcostal and lumbar arteries.

## 2.1. Classification and aetiology

Abdominal wall defects can be classified as shown in Table 2.1:

- Simple versus complex
- Congenital versus acquired
- Emergency versus elective
- Clean versus infected
- Partial versus full thickness.

**Table 2.1.** Abdominal wall defect classification.

Type	Definitions/Examples
Simple	Simple ventral hernia with small defect less than 6 cm amenable to direct repair
Complex	Simple ventral hernia repair is not feasible because the defect is very large, there is a concomitant infection or failed previous repair attempt, or if there is not enough original skin to cover the repair (Leppäniemi and Tukiainen, 2013)
Congenital	Gastroschisis, omphalocele
Acquired	Infection, trauma, tumour resection, radiation wounds, postoperative defects
Emergency	Acute traumatic wounds from blast injuries, perforating wounds and burn
Elective	Incisional hernia, tumour resection
Clean	Surgical wound after tumor excision, hernia repairs
Infected	Necrotizing fasciitis, infected lapratomy wound, clostridial myonecrosis.
Partial thickness defect	Involves <b>one</b> or more of the abdominal layers but not <b>5</b> all of them
Full-thickness defect	Defect involves all the 5 abdominal layers

However, there is significant overlap between these classification types.

The most frequent causes of abdominal defect are:

- Post-operative incisional hernia
- Post-traumatic planned ventral hernia
- Blast injury
- Tumour resection
- Massive infection
- Radiation therapy
- Congenital defect.

## 2.2. Reconstructive options

These include:

- Direct repair
- STSG
- Vacuum-assisted closure (VAC) therapy
- Component separation technique (CST) and/or mesh (locoregional flap)
- Mesh without flap
- Flaps (local, regional, distant and free)
- Tissue expansion
- Abdominal transplant.

### 3. DEFECT APPROACH AND EVALUATION

There are numerous surgical options for individual cases, so each patient should be evaluated by taking a complete history and physical examination. This is imperative to establishing the potential risks and benefits of surgery for each individual patient.

Decisions regarding technique are based on an assessment of the overall clinical status of the patient, the location and size of the defect, and the depth of layers involved, as well as the aetiology (Garrido *et al.*, 2013). Examination should focus on the degree of rectus diastasis, the potential for mesh placement, the presence of active infection and the patient's functional and nutritional status. In addition to confirming the findings on physical examination, appropriate imaging studies will delineate the presence and location of hollow viscera, abdominal wall geometry, and the character, quality and exact location of the rectus abdominis musculature (Koltz *et al.*, 2013).

Investigations can be done for further assessment, including magnetic resonance imaging and computed tomography scanning for evaluating the extent of tumour invasion and the integrity of potential muscle or musculocutaneous flaps to be used in reconstruction. Colour flow duplex Doppler studies are also used for vascular evaluation.

Important considerations include (Weinzweig, 2010):

*Absolute versus relative loss of domain* – is there an absolute loss of abdominal wall tissue that may need to be replaced with local or distant flaps or is the defect relative in that the abdominal contents are swollen leading to a temporary inability to close the abdominal wall?

*Underlying disease process* – acute or chronic wound? Reconstruction can proceed either immediately, as in the case of tumour ablation or radiation, or in a staged/delayed fashion, as in the case of infection or trauma with contamination and/or visceral oedema.

*Wound stability* – ensuring that necrotic tissue has been adequately debrided.

*Gastrointestinal fistula.*

*Location of the defect.*

Reconstructive flap options by site can be summarised (Giele, 2008):

- Upper abdominal wall
  - Superiorly based rectus abdominis musculocutaneous flap
  - External oblique muscle and aponeurosis
  - Extended latissimus dorsi flap
- Lower abdominal wall
  - Tensor fascia lata flap
  - Rectus femoris flap – may include a fascial extension (the 'mutton chop' flap) to enable reach to the epigastrium
  - Inferiorly based rectus abdominis musculocutaneous flap
  - External oblique muscle and aponeurosis
  - Groin flap

- Options appraisal
  - Wound-specific – type of wound, presence of stoma or scars. These affect the vascularity and nerve supply to remaining muscles and skin/fat
  - Patient-specific – age, health and requirements of patient. Ability of patient to tolerate raised intra-abdominal pressure, and hence raised thoracic pressures once the abdomen is closed.

## 4. SURGICAL PROCEDURES

---

This section will summarise different surgical procedures according to the cause, from the more to the less common, with special emphasis on ventral abdominal wall hernia.

- Component separation (CS) ±mesh
- Mesh repair
- Endoscopic assisted CS
- Temporary abdominal closure (TAC)
- Flaps – pedicled, free and combined
- Tissue expansion
- Abdominal wall transplant.

### 4.1. Ventral abdominal wall hernia

---

The incidence of ventral hernias as a complication of abdominal operations is reported to be as high as 20% (Höer *et al.*, 2002).

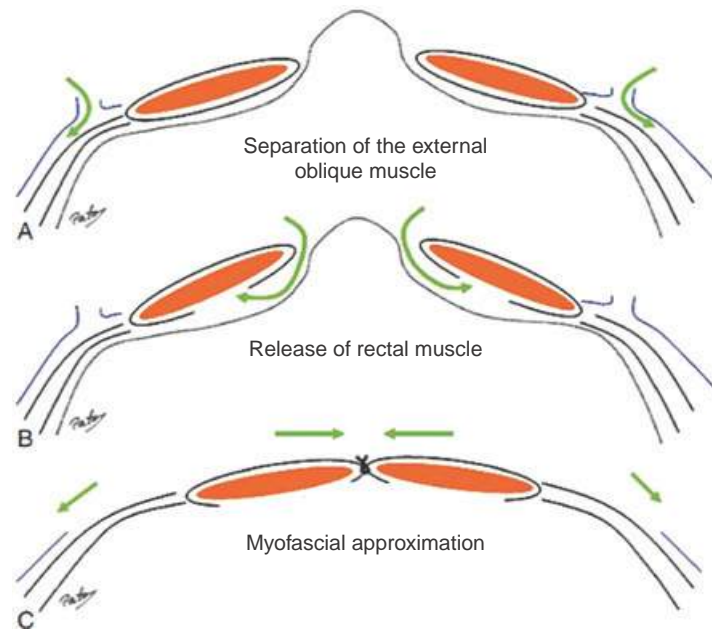
In spite of recent advances in ventral hernia repair, the recurrence rate is reported to be as high as 60% in the setting of primary repair alone (Gray *et al.*, 2008). The most common indications for repair of abdominal wall hernias are generalised pain (68.7%) and cosmesis (54.6%). Other indications include concern about the risk of incarceration or strangulation and a massive or enlarging hernia (Garrido *et al.*, 2013).

The introduction of CS as a new technique by Ramirez *et al.* (1990) and advances in the availability of biological mesh have both revolutionised the surgical management of ventral abdominal wall hernia.

### 4.2. Component separation

---

Ramirez *et al.* (1990) exemplified the separation of the overlapping anterior abdominal wall muscle for large midline abdominal hernias with preservation of their innervation and blood supply. More accurately, this can be described as elevation of the external oblique muscle in the vascular plane off the internal oblique anteriorly through incisions along the external oblique aponeurosis lateral to the linea



**Figure 2.4.** Component separation.

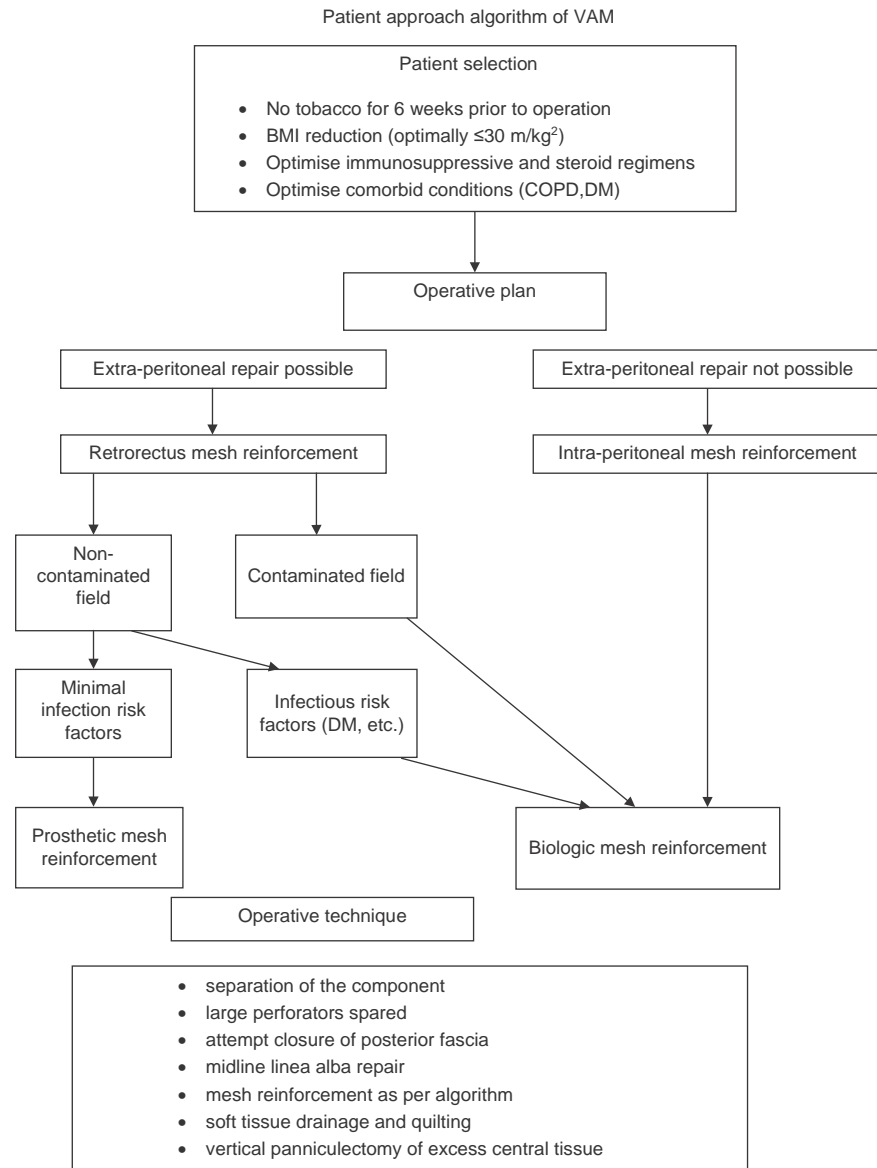
semilunaris, at the same time maintaining the neurovascular supply to the rectus, which travels in a segmental fashion between the internal oblique and transversus abdominis muscle. The rectus abdominis muscles can then be released from the posterior rectus sheath if further medialisation is required. The midline myofascial approximation of compound flaps composed of rectus abdominis with attached internal oblique/transversus abdominis is thus achieved (Weinzweig, 2010). A fascial defect up to 10 cm wide at the upper abdomen, 20 cm at the waist level and 6 cm at the suprapubic level can be closed using this method if the CS is performed bilaterally (Figure 2.4). It is important to emphasise that this technique is reserved for midline defects.

Wound complications with this technique are common because relatively large undermined skin flaps are produced. The most common complications are haematoma, seroma and infection (in up to 40% of patients; Bleichrodt *et al.*, 2004)

This technique will reduce the incidence of re-herniation in complex ventral hernia repair by two- to tenfold (Saulis and Dumanian, 2002).

#### 4.2.1. Patient selection and evaluation

Koltz *et al.* (2013) identified a unified algorithm with improved outcomes which includes bilateral CS, closure of the posterior fascia, preservation of the perforators, retrorectus mesh reinforcement or intra-peritoneal, closure of the linea alba and aggressive tissue drainage (Figure 2.5).



**Figure 2.5.** Mesh positioning.

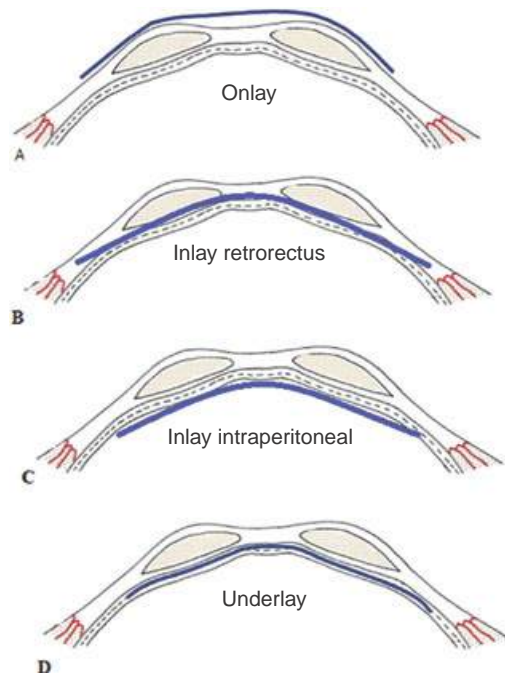
### 4.3. Mesh repair

Mesh reinforcement is a highly effective method used to decrease the recurrence rate of ventral hernia (Sailes *et al.*, 2010). There are two types of meshes: synthetic (e.g. Prolene, Marlex) and biological (e.g. Alloderm, Surgisis, Permacol, Strattice, Surgimed). Synthetic mesh is more durable than biological mesh, which is more resistant to infection and has a lower risk of tissue adhesion and enteric fistula.

**Table 2.2.** Grading system for ventral hernia.

Grade 1	Grade 2	Grade 3	Grade 4
<i>Low risk</i>	<i>Co-morbid</i>	<i>Potentially contaminated</i>	<i>Infected</i>
<ul style="list-style-type: none"> <li>• Low risk of complications</li> <li>• No history of wound infection</li> </ul>	<ul style="list-style-type: none"> <li>• Smoker</li> <li>• Obese</li> <li>• Diabetic</li> <li>• Immunosuppressed</li> <li>• COPD</li> </ul>	<ul style="list-style-type: none"> <li>• Previous wound infection</li> <li>• Stoma present</li> <li>• Violation of the gastrointestinal tract</li> </ul>	<ul style="list-style-type: none"> <li>• Infected mesh</li> <li>• Septic dehiscence</li> </ul>

COPD = chronic obstructive pulmonary disease.



**Figure 2.6.** Algorithmic approach for patients.

Decisions regarding synthetic versus biological meshes or open versus laparoscopic approaches are guided by a number of complex considerations. Recently, the Ventral Hernia Work Group described a novel grading system for ventral hernia by identifying the risk factors to developing surgical site occurrence with the objective of helping surgeons to select the most appropriate technique and mesh to optimise outcomes and minimise complications (Table 2.2; Breuing *et al.*, 2010).

Advances in mesh materials include the improvement of biomechanical properties, enhanced manufacturing and the creation of anti-adhesive lamination in synthetic meshes (Baumann and Butler, 2012).

A number of different locations for mesh placement have also been described, with some controversy about the ideal position. The different locations include mesh onlay or an inlay (retrorectus or intraperitoneal; [Figure 2.6](#)).

Each location has its preferable indications and every patient has to be approached individually because one size doesn't fit all and the location of the mesh has proved to have a bearing on the outcome of repair in terms of recurrence. The underlay or retrorectus mesh appears to be associated with a lower recurrence rate, while the highest surgical site infection rate is associated with the interposition type or 'bridged' repair ([Albino \*et al.\*, 2013](#)).

Recently, some surgeons have used fascia lata as a biological mesh and recommend its use to treat grade II, III and IV surgical site infection, where the prosthetic mesh is contraindicated ([Matros and Disa, 2013](#)).

#### 4.4. Endoscopically assisted component separation technique: minimally accessed surgery

This technique is performed by external oblique aponeurosis release with the aid of an endoscope and balloon dissector inserted through small separate incisions. It has been shown to decrease the overall wound complications by preserving the peri-umbilical rectus perforators and decreasing post-operative wound dehiscence ([Lowe \*et al.\*, 2000](#)).

#### 4.5. Staged abdominal reconstruction and planned hernia repair/ temporary abdominal closure

TAC is necessary in the presence of critical illness or intra-abdominal catastrophe or when it is not possible to safely close the fascial layer primarily, as may occur in the setting of abdominal compartment syndrome.

The indications for planned hernia repair are summarised in [Table 2.3](#) ([Leppäniemi and Tukiainen, 2013](#)).

**Table 2.3.** Indications for planned hernia.

Re-explorations are no longer needed (in the short term)
Inability to reapproximate the retracted abdominal wall edges
Sizeable tissue loss
Risk of tertiary Abdominal Compartment Syndrome if closure attempted
Anterior enteric fistula
Inadequate infection source control
Poor nutritional status



The aim of TAC is closure of the catabolic drain in the short term (Scott *et al.*, 2005) and prevention of enteric fistula and bowel adhesion.

The approaches and techniques for TAC have developed over time: first-generation closure involved the closure of skin by simple towel clips, ‘skin-only’ running sutures or, sometimes, plastic sheets. Second-generation closure used negative pressure with a vacuum dressing to take off excess fluid (vacuum pack dressing). Third-generation VAC developed later when negative-pressure therapy was applied. The fourth generation was reached when mechanical pressure traction and temporary mesh were combined with VAC therapy (Pettersson *et al.*, 2007; Acosta *et al.*, 2011).

#### 4.5.1. Enteric fistula

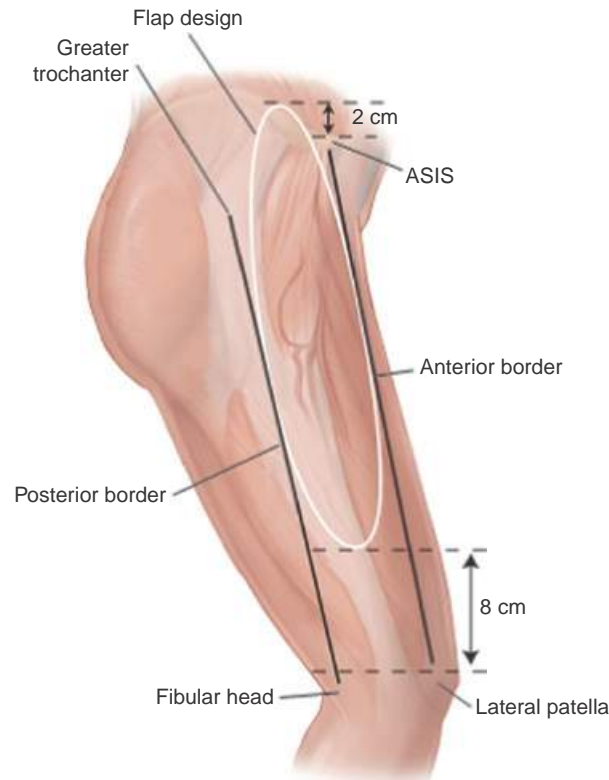
Enteric fistula is a major challenge in abdominal reconstruction. This needs a multidisciplinary specialist approach which is individualised to the patient (Leppäniemi, 2008). Management comprises three major steps (Leppäniemi and Tukiainen, 2013):

1. Control of infection and systemic sepsis – this may be achieved by the primary repair of intestinal defects or radiologically placed drains and/or colostomies/ileostomies. Once fistulae are controlled and granulation tissue has formed, skin grafts can be applied and allowed to mature for 6–12 months.
2. Nutritional support, preferably enteral, to provide a good healing environment.
3. Reconstruction, which may be achieved in a single stage involving both gastrointestinal and plastic surgeons, and carried out with or without CS and/or flap reconstruction depending on the defect.

### 4.6. Autologous flap for the abdominal wall: pedicled flaps

#### 4.6.1. Tensor fascia lata

Tensor fascia lata is the flap of choice for abdominal wall reconstruction. It is an ideal option because it is a dense, strong sheet of vascularised fascia and overlying skin (type I Mathes and Nahai musculocutaneous flap) supplied by the ascending branch of the lateral femoral circumflex artery that is transferred as a single unit in a single stage with minimal donor morbidity. It is well tolerated in irradiated and contaminated fields. Sensation is provided because the lateral femoral cutaneous nerve (T12) is included, and voluntary control is provided by the descending branch of the superior gluteal nerve. The donor site is usually closed primarily unless the defect is >8 cm wide. The skin paddle can be safely taken about 5–8 cm above the knee; the distal portion is essentially a random pattern flap. The dominant pedicle (i.e. the lateral femoral circumflex femoral vessels arising from the profunda femoris) pierces the medial aspect of the flap 8–10 cm below the anterosuperior iliac spine. The wide arc of rotation allows the tip of the flap to reach the ipsilateral lower chest wall and xiphoid, especially in a thin patient.



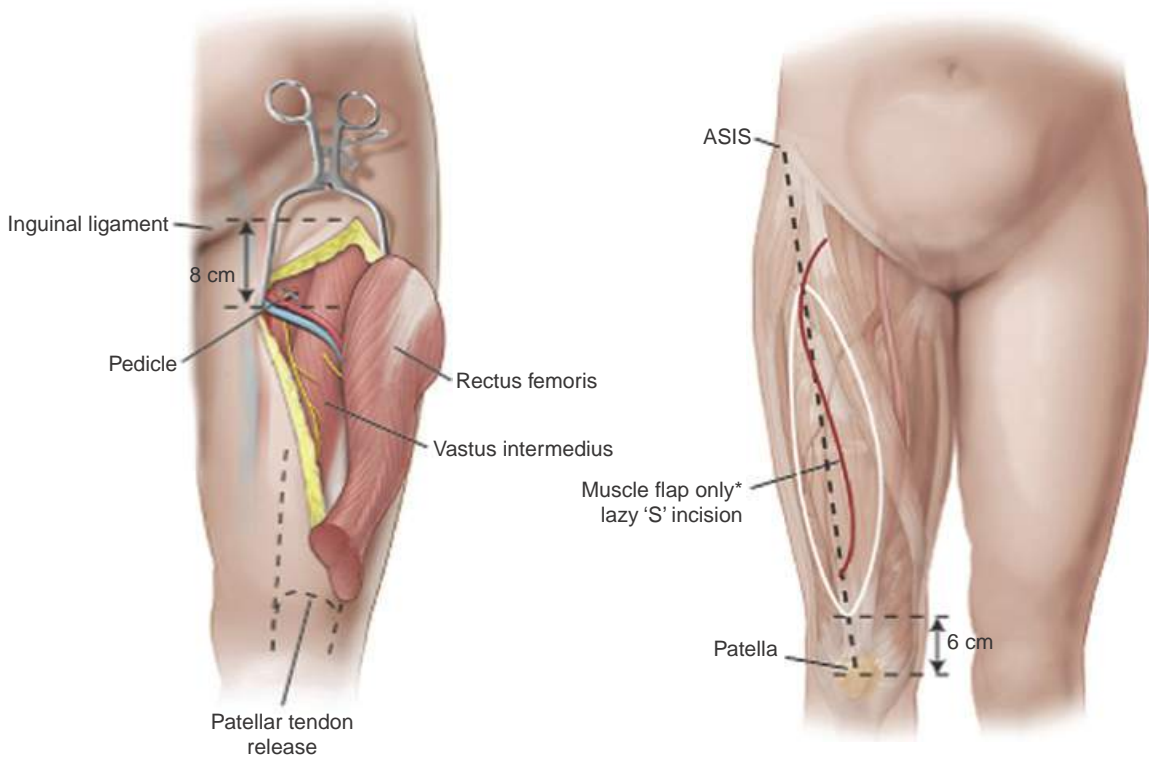
**Figure 2.7.** Tensor fascia lata flap design.

The flap can be used to resurface the entire suprapubic region, lower abdominal quadrants or ipsilateral abdomen (Figure 2.7).

#### 4.6.2. Rectus femoris

This is an excellent option for reconstruction of the lower abdomen. It is a type II Mathes and Nahai musculocutaneous flap with a dominant blood supply from the descending branch of the lateral circumflex artery and minor pedicles from musculocutaneous perforators located at the proximal portion of the muscle. It can be used for a defect around the suprapubic region and extending to the contralateral antero-superior iliac spine. Sensation can be maintained with the intermediate cutaneous nerve of the thigh.

It has been described as a functional flap with anastomosis to intercostal nerves for abdominal wall reconstruction. Native innervation can be maintained and the vascular pedicle transferred to recipient vessels closer to the abdominal wall defect (e.g. deep inferior epigastric vessels; Figure 2.8; Rosen, 2012).



**Figure 2.8.** Rectus femoris anatomy and flap elevation.

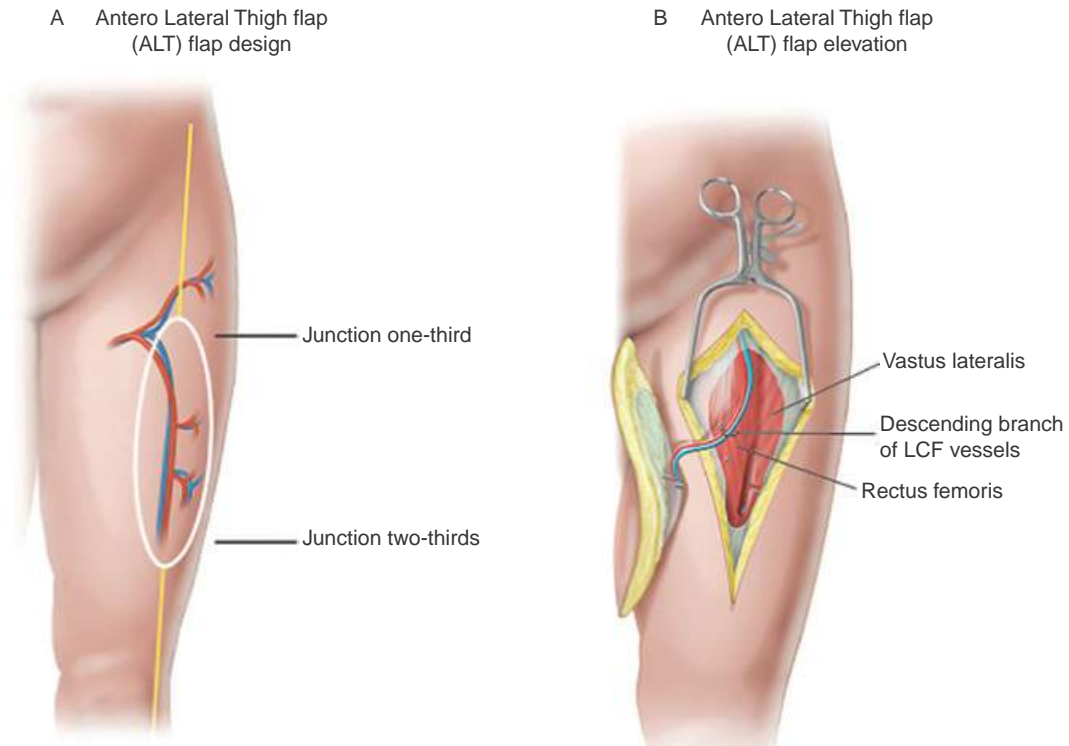
**4.6.2.1. Extended rectus femoris flap ('mutton chop' flap)**

This flap is used for the reconstruction of large full-thickness abdominal wall defects, including the epigastrium, without prosthetic material. However, its main drawback is the loss of the muscle strength of the thigh, resulting in a lack of full extension at the knee (Weinzweig, 2010).

**4.6.3. Anterolateral thigh flap**

This is a fasciocutaneous flap that includes the subcutaneous fat and fascia. It is a versatile flap that has recently become popular because of its ease of dissection, durability, variability in composition and volume (Ting *et al.*, 2010). The arterial supply is the descending branch of the lateral femoral circumflex (1–3 mm in diameter and 7–8 cm length), which emerges through the space between the rectus femoris muscle and the vastus lateralis muscle (Figure 2.9; Rosen, 2012).

The pedicled anterolateral thigh (ALT) flap is an ideal option for an extensive abdominal defect when recipient vessels (for free flaps) are damaged from a previous operation or when there is a significant potential for tumour recurrence (Joonchul Jang *et al.*, 2013).



**Figure 2.9.** Anterolateral thigh flap: flap design.

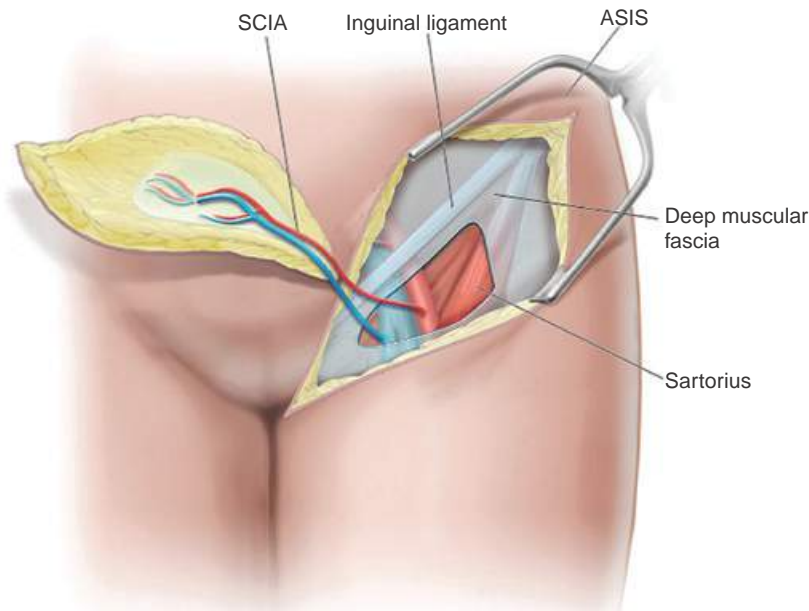
#### 4.6.4. Omental flap

The omentum, a double layer of fused peritoneum arising from the greater curvature of the stomach, is supplied by the right and left gastroepiploic arteries. An omental flap can cover the whole abdominal wall and perineum. It can be used with mesh and provides a good bed for a skin graft (Weinzweig, 2010). Full abdominal wall reconstruction can be uniquely achieved with a sandwiched omental flap, skin graft and prosthetic mesh (El-Muttardi *et al.*, 2005)

#### 4.6.5. Rectus abdominis muscle flaps

This flap has a type III Mathes and Nahai pattern blood supply with two dominant vessels (superior and inferior epigastric artery). It is widely used as a local or regional flap, a transverse rectus abdominis myocutaneous ('TRAM') flap or a vertical rectus abdominis myocutaneous ('VRAM') flap and can be either superiorly or inferiorly based for the superior half of zone I (superiorly based or advancement), the inferior half of zone I (inferiorly based or advancement), zone II (superiorly based) or zone III (inferiorly based) (Greer, 2004).

However, a high incidence of abdominal hernias (3.9% of 206 patients) following the use of a TRAM flap for breast reconstruction was reported (Rossetto *et al.*, 2010).



**Figure 2.10.** Groin flap design.

#### 4.6.5.1. Groin flap

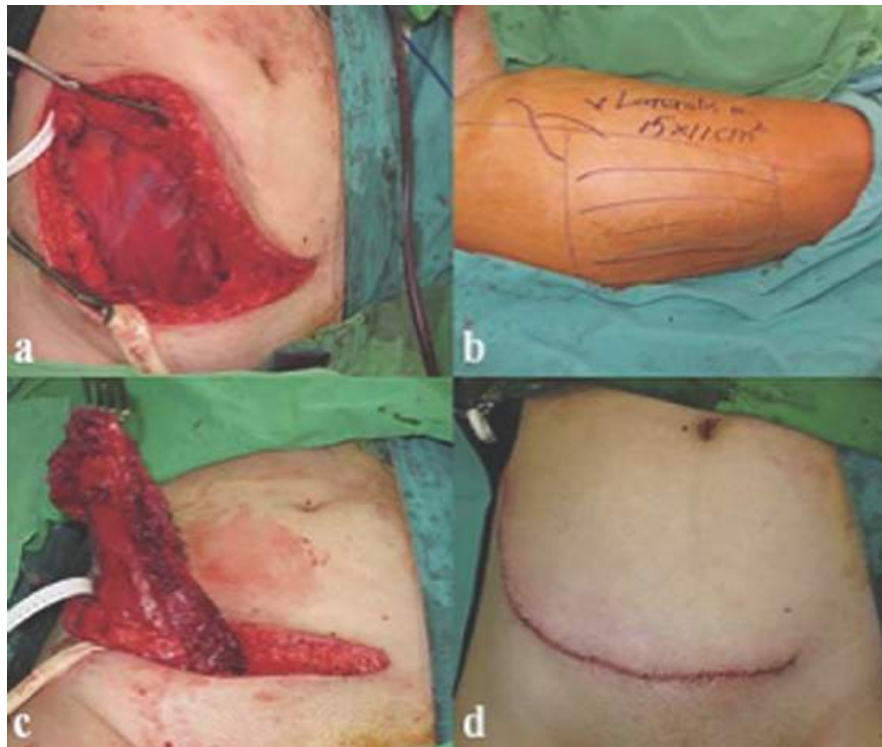This is a type A fasciocutaneous (Cormack and Lamberty pattern) flap with a direct blood supply from the superficial circumflex iliac artery at the level of inguinal ligament. The flap design is shown in [Figure 2.10](#). It is a good option for treating a lower abdominal defect with primary closure of the donor site ([Rosen, 2012](#)).

#### 4.6.6. Vastus lateralis

This flap has a type I Mathes and Nahai pattern of blood supply and can be used as a muscle and musculocutaneous flap (similar location to the ALT flap). The dominant pedicle is the descending branch of the lateral circumflex femoral artery and vein. The long pedicle and a wide arc of rotation means that, with the use of mesh, tension-free abdominal reconstruction and primary fascial closure can be achieved ([Figure 2.11](#); [Lin, 2011](#)).

#### 4.6.7. Gracilis flap

This is a type II Mathes and Nahai flap supplied by the ascending branch of the medial circumflex femoral artery (profunda femoris). Inferior pedicles are branches of the superficial femoral artery and vein. It can be used as muscle or myocutaneous flap for lower abdominal wall reconstruction and groin; it can



**Figure 2.11.** Pedicled vastus lateralis with mesh reconstruction of abdominal wall defects after tumour excision. A. Abnormal wall; B. Vastus lateralis flap design; C. Vastus lateralis flap elevation; D. Final closure.

be harvested vertically or horizontally (Greer, 2004). It has been used for treating a large defect after tumour extirpation (Staruch *et al.*, 2012).

#### 4.7. Tissue expansion in abdominal wall reconstruction

Tissue expansion is one of the available options for abdominal wall reconstruction commonly used for treating congenital defects. However, it can also be used to treat other conditions such as giant congenital naevi, tumours, burn scar contracture, post-traumatic defects, and loss of skin and the fascial domain following previous surgery or injury. Expansion can be applied to the skin. Regarding location, expanders can be inserted just below the skin and subcutaneous tissue resting on the underlying fascia to expand the skin layer alone. Other authors prefer to place the expander under the rectus muscle or between the external and internal oblique muscle, which allows expansion of the external oblique to provide a well-vascularised fasciocutaneous flap with wide range advancement (Rosen,

**Table 2.4.** Indication of free flaps in abdominal wall reconstruction.

1. Immunocompromised patients and patients with previous failed reconstruction with alloplastic materials resulting from infection or extrusion.
2. Contaminated or infected wounds in which the use of totally autologous tissue is preferred and the defects are more laterally located such that local flaps would be inadequate.
3. Patients with large midline defects precluding the use of component separation or in cases where the rectus abdominis and its fascia sheath are unavailable.

Source: Wong *et al.* (2009).

2012). In the case of congenital defects (e.g. omphaloceles), the expander can be inserted intraperitoneally (Adetayo *et al.*, 2012). Tissue expanders can also be used in staged abdominal wall reconstruction (Paletta *et al.*, 1999)

### 4.7.1. Free flaps

Free flap options have a distinct role in patients with huge defects. Closure of these defects is provided by a single-stage operation with difficult abdominal wounds when pedicled flaps are not appropriate (Table 2.4; Wong *et al.*, 2009).

#### 4.7.1.1. Tensor fascia lata

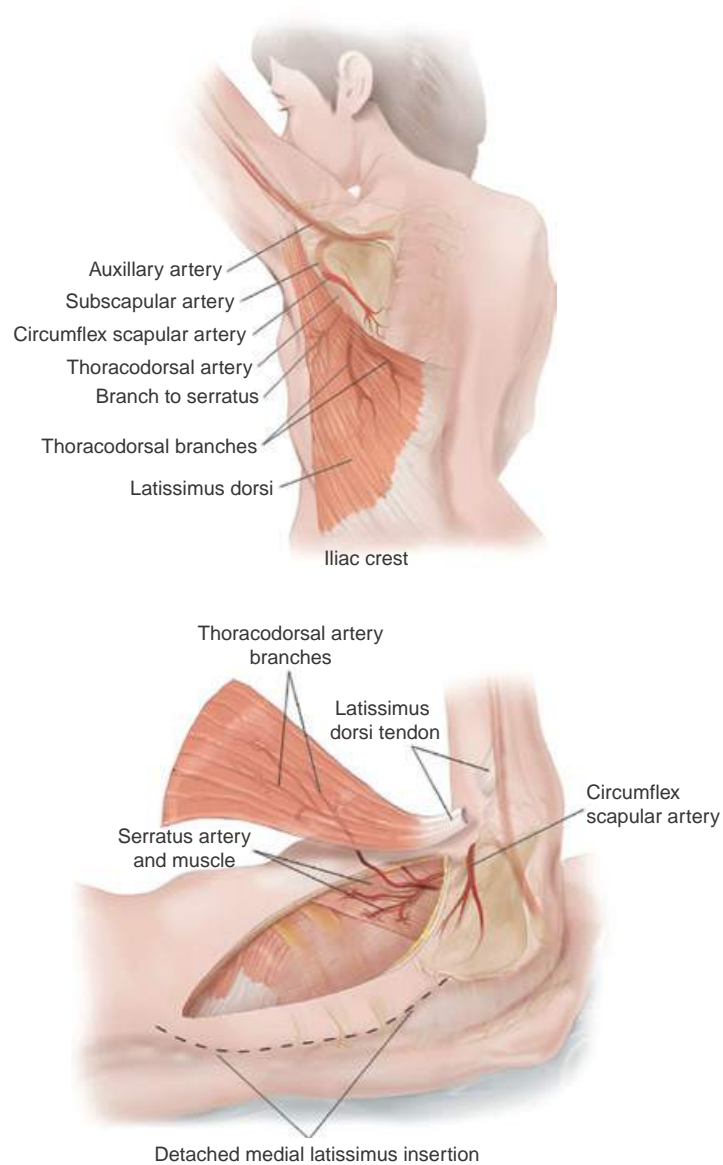
This flap type has already been described.

#### 4.7.1.2. Latissimus dorsi muscle or musculocutaneous flap

The latissimus dorsi muscle is the largest muscle in the body but it is quite thin (<1 cm thick). It is a type V Mathes and Nahai muscle with blood principally supplied by the thoracodorsal artery as the dominant pedicle and secondary segmental pedicles from the posterior intercostal and lumbar artery. It provides sufficient dynamic reconstruction of a full-thickness defect. The free latissimus dorsi offers a strong, contractile option after innervation and training of the transferred muscle (Perdikis *et al.*, 2011).

### 4.7.2. Combined free flap

A combination of more than one free flap can provide sufficient dynamic reconstruction of a full abdominal defect (e.g. vastus lateralis and ALT flap by co-optation of the vastus motor nerve to the intercostal nerve). This can also provide reconstruction of all components with a single flap and can decrease the post-operative risk of hernia by providing long-term abdominal wall stability (Iida *et al.*, 2013).



**Figure 2.12.** Latissimus dorsi anatomy and free flap design.

#### 4.8. Abdominal wall transplant

Abdominal wall transplant was introduced in the last decade for solid abdominal organ transplant patients, in whom abdominal closure is difficult. In terms of immune rejection, Quigley (2013) described a reliable model of full-thickness total abdominal transplant in rats. The patient must take immunosuppressive medication for their solid organ transplant; therefore, no additional medication is required



if an abdominal wall transplant is performed in conjunction with solid organ transplant (Giele and Vaidya, 2013).

## REFERENCES

- Acosta, S., Bjarnason, T., Petersson, U. Pålsson, B., Wanhainen, A., Svensson, M., Djavani, K. & Björck, M. 2011. Multicentre prospective study of fascial closure rate after open abdomen with vacuum and mesh-mediated fascial traction. *Br J Surg*, 98, 735–43.
- Adetayo, O. A., Aka, A. A. & Ray, A. O. 2012. The use of intra-abdominal tissue expansion for the management of giant omphaloceles: Review of literature and a case report. *Ann Plast Surg*, 69, 104–8.
- Agur, A. M. R. 2013. *Grant's Atlas of Anatomy*, Lippincott Williams & Wilkins.
- Albino, F. P., Patel, K. M., Nahabedian, M. Y., Sosin, M., Attinger, C. E. & Bhanot, P. 2013. Does mesh location matter in abdominal wall reconstruction? A systematic review of the literature and a summary of recommendations. *Plast Reconstr Surg*, 132, 1295–304.
- Baumann, D. P. & Butler, C. E. 2012. Bioprosthetic mesh in abdominal wall reconstruction. *Semin Plast Surg*, 26, 18–24.
- Bleichrodt, R. P., de Vries Reilingh, T.S., Malyar, A., *et al.* 2004. Component separation technique to repair large midline hernias. *Operative Techniques in General Surgery*, 6, 179–88.
- Breuing, K., Butler, C. E., Ferzoco, S., Franz, M., Hultman, C. S., Kilbridge, J. F., Rosen, M., Silverman, R. P. & Vargo, D. 2010. Incisional ventral hernias: Review of the literature and recommendations regarding the grading and technique of repair. *Surgery*, 148, 544–58.
- El-Muttardi, N., Lancaster, K., Ng, R. & Mercer, D. 2005. The sandwich omental flap for abdominal wall defect reconstruction. *Br J Plast Surg*, 58, 841–4.
- Garrido, D. E., Aponte, Y., Behnam, A.B., Keeshin, T., Sinha, V., Evans, K.K. & Salgado, C. J. 2013. Updates in abdominal wall reconstruction. *Anaplastology*, 2.
- Giele, H. 2008. *Plastic and Reconstructive Surgery*, Oxford University Press.
- Giele, H. & Vaidya, A. 2013. Oxford Transplant Centre carries out UK's first abdominal wall transplant. UK Oxford University Hospital, NHS foundation Trust. Available from: <http://www.ouh.nhs.uk/news/article.aspx?id=175>. [Accessed 21/12/2013.]
- Gray, S. H., Vick, C. C., Graham, L. A., Finan, K. R., Neumayer, L. A. & Hawn, M. T. 2008. Variation in mesh placement for ventral hernia repair: An opportunity for process improvement? *Am J Surg*, 196, 201–6.
- Greer, S. E. 2004. *Handbook of Plastic Surgery*, Marcel Dekker.
- Höer J., Lawong G., Klinge, U. & Schumpelick, V. 2002. Factors influencing the development of incisional hernia. *Chirurg*, 73, 474–80.
- Huger *et al.*, 1979. The anatomic rationale for abdominal lipectomy. *Am Surg*, 45, 612e7.
- Iida, T., Mihara, M., Narushima, M., Todokoro, T., Hara, H., Yoshimatu, H., Koshima, I. & Kadono, T. 2013. Dynamic reconstruction of full-thickness abdominal wall defects using free innervated vastus lateralis muscle flap combined with free anterolateral thigh flap. *Ann Plast Surg*, 70, 331–4.
- Joonchul Jang, M. D., Seong-Ho Jeong, Seung-Kyu Han & Woo-Kyung Kim. 2013. Reconstruction of extensive abdominal wall defect using an eccentric perforator-based pedicled anterolateral thigh flap. *Wiley Periodicals*, 33, 482–6.
- Koltz, P. F., Frey, J. D., Bell, D. E., Giroto, J. A., Christiano, J. G. & Langstein, H. N. 2013. Evolution of abdominal wall reconstruction: Development of a unified algorithm with improved outcomes. *Ann Plast Surg*, 71, 554–60.
- Leppäniemi A. 2008. The hostile abdomen – A systematic approach to a complex problem. *Scand J Surg*, 97, 218–9.
- Leppäniemi A. & Tukiainen E. 2013. Reconstruction of complex abdominal wall defects. *Scand J Surg*, 102, 14–9.

- Lin, C-T., Chen, S-G., Chen, T-M. & Fu, J-P. 2011. Reconstruction of a large abdominal wall defect by using a pedicled vastus lateralis muscle flap: A case report and literature review. *Journal of Medical Sciences*, 31, 279–82.
- Lowe, J. B., Garza, J. R., Bowman, J. L., Rohrich, R. J. & Strodel, W. E. 2000. Endoscopically assisted “components separation” for closure of abdominal wall defects. *Plast Reconstr Surg*, 105, 720–9; quiz 730.
- Matros, E. & Disa, J. J. 2013. Discussion: Fascia lata allografts as biological mesh in abdominal wall repair: preliminary outcomes from a retrospective case series. *Plast Reconstr Surg*, 132, 640e–1e.
- Paletta, C. E., Huang, D. B., Dehghan, K. & Kelly, C. 1999. The use of tissue expanders in staged abdominal wall reconstruction. *Annals of Plastic Surgery*, 42, 259–65.
- Perdikis, G., Koonce, S., Collis, G. & Eck, D. 2011. Latissimus dorsi myocutaneous flap for breast reconstruction: Bad rap or good flap? *Eplasty*, 11, e39.
- Petersson, U., Acosta, S. & Björck, M. 2007. Vacuum-assisted wound closure and mesh-mediated fascial traction – A novel technique for late closure of the open abdomen. *World J Surg*, 31, 2133–7.
- Quigley, M. A. 2013. Development of a reliable model of total abdominal wall transplantation. *Plastic and Reconstructive Surgery*, 132, 988.
- Ramirez, O. M., Ruas, E. & Dellon, A. L. 1990. ‘Components separation’ method for closure of abdominal-wall defects: An anatomic and clinical study. *Plast Reconstr Surg*, 86(3), 519–26.
- Rosen, M. J. 2012. *Atlas of Abdominal Wall Reconstruction*, Elsevier.
- Rossetto, L. A., Abla, L. E., Vidal, R., Garcia, E. B., Gonzalez, R. J., Gebrim, L. H., Neto, M. S. & Ferreira, L. M. 2010. Factors associated with hernia and bulge formation at the donor site of the pedicled TRAM flap. *Eur J Plast Surg*, 33, 203–8.
- Sailes, F. C., Walls, J., Guelig, D., Mirzabeigi, M., Long, W.D., Crawford, A., Moore, J.H. Jr., Copit, S.E., Tuma, G.A. & Fox, J. 2010. Synthetic and biological mesh incomponent separation: A 10-year single institution review. *Ann Plast Surg*, 64, 696–8.
- Saulis, A. S. & Dumanian, G. A. 2002. Periumbilical rectus abdominis perforator preservation significantly reduces superficial wound complications in ‘separation of parts’ hernia repairs. *Plast Reconstr Surg*, 109, 2275–80.
- Scott, B. G., Feanny, M. A. & Hirshberg, A. 2005. Early definitive closure of the open abdomen: A quiet revolution. *Scand J Surg*, 94, 9–14.
- Staruch, R., Haitham, K. & Karandikar, S. 2012. Pedicled vertical myocutaneous gracilis (VMG) flap for reconstruction of a large composite lower abdominal defect. *European Journal of Plastic Surgery*, 35, 633.
- Thorne, C., Chung, K. C., Gosain, A., Guntner, G. C. & Mehrara, B. J. 2014. *Grabb and Smith’s Plastic Surgery*, Wolters Kluwer/LippincottWilliams & Wilkins Health.
- Thorne, C., Grabb, W. C. & Smith, J. W. 2007. *Grabb and Smith’s Plastic Surgery*, Wolters Kluwer Health/Lippincott Williams & Wilkins.
- Ting, J., Trotter, D. & Grinsell, D. 2010. A pedicled anterolateral thigh (ALT) flap for reconstruction of the epigastrium. *J Plast Reconstr Aesthet Surg* 63, e65–7.
- Weinzeig, J. 2010. *Plastic Surgery Secrets Plus*, Mosby.
- Wong, C. H., Lin, C. H., Fu, B. & Fang, J. F. 2009. Reconstruction of complex abdominal wall defects with free flaps: Indications and clinical outcome. *Plastic and Reconstructive Surgery*, 124, 500–9.

## **Section 2**

### **Cancer**



## Skin Cancer for the Plastic Surgeon

---

Sophia Opel, Shadi Ghali

### 1. INTRODUCTION

---

Skin cancer is one of the most common types of cancer in the world and forms part of the daily experience of plastic surgeons. Therefore, it is imperative that clinicians are able to recognise clinical features suggestive of malignancy. Skin malignancies can be broadly grouped into non-melanocytic types of skin cancer (i.e. squamous cell carcinoma and basal cell carcinoma) and melanoma.

### 2. BASAL CELL CARCINOMA

---

Basal cell carcinoma (BCC) is the most frequently occurring form of all cancers in Europe, Australia and the USA, and its incidence is increasing (Harris *et al.*, 1990; Ko *et al.*, 1994). It is not uncommonly known as the ‘rodent ulcer’ and affects the basal cells of the skin, located in the deepest layer of the epidermis. It is a slow-growing malignancy that predominantly affects Caucasians and rarely metastasises (Lo *et al.*, 1991; Ting *et al.*, 2005), but has a high morbidity as a result of local invasion, often affecting the head and neck (Meads and Greenway, 2006).

The commonest cause of BCC is exposure to ultraviolet (UV) light from the sun or even from sunbeds, as well as genetic predisposition (Gailani *et al.*, 1996); the most commonly affected areas are sun-exposed sites (Roenigk *et al.*, 1986, Karagas *et al.*, 2002). Additionally, sun exposure at a young age seems to be a significant contributory factor (Corona *et al.*, 2001). Other factors that increase the risk of BCCs are increasing age, fair skin, blonde or red hair, previous BCC, immunosuppression, and a rare familial disease known as Gorlin syndrome (Gorlin, 2004). The risk factors are outlined in Table 3.1.

**Table 3.1.** Risk factors associated with BCC development.

---

Sun exposure (especially in childhood)
Age
Male sex
Fair skin types
Immunosuppression
Syndrome, e.g. Gorlin
Previous BCC

---

## 2.1. Diagnosis

---

A clinical diagnosis can be made by an experienced general practitioner, dermatologists or plastic surgeons. A summary of the history and examination factors to be taken into consideration are listed in [Table 3.2](#). Tissue sampling may be required prior to definitive management when a histological diagnosis would alter treatment or if the diagnosis is in doubt. Some patients may present with a scab that bleeds occasionally and does not heal, whereas others may present with a nodule with a pearly edge.

Investigations such as computed tomography or magnetic resonance imaging are indicated in cases in which deep structure involvement is suspected, such as the orbits (Leibovitch *et al.*, 2005b), nerves (Williams *et al.*, 2001), bone or parotid gland (Farley *et al.*, 2006).

## 2.2. Histology

---

Histological subtypes include nodular, superficial and pigmented forms, as well as morpoeic, micro-nodular, infiltrative and basosquamous. BCC cells have a high nucleus-to-cytoplasm ratio and therefore have a deep blue appearance on microscopy.

## 2.3. Management

---

Management guidelines have been published by both the British Association of Dermatology and the American Academy of Dermatology. Management, as for all cancers, should be guided by a multidisciplinary team and depends upon patient wishes, co-morbidities and prognostic factors. It is important that patients are treated as soon as possible. If left untreated, BCCs will continue to grow and can erode the skin, hence the term ‘rodent ulcer’. Treatment is generally curative but can be complicated by local invasion at the anatomical site, particularly if tumours have been neglected for a number of years.

Management can be broadly divided into non-surgical and surgical modalities. There are a number of prognostic factors that allow clinicians to broadly group patients into those at a ‘high’ or ‘low’ risk of recurrence; management depends upon which category the patient falls into, as well as patient factors ([Table 3.3](#)).

**Table 3.2.** Assessing the patient in clinic.

History
Age
Duration of lesion
Change in lesion/itching/bleeding
Risk factors including occupation, hobbies, sun exposure
Full past medical history
Drug history
Examination
Site
Change in size, shape, colour
Evidence of ulceration
Surrounding skin
Regional lymphadenopathy
Other suspicious lesions

**Table 3.3.** Prognostic factors for BCC.

Large tumour size
Tumour site (central face have higher risk of recurrence)
Poorly defined borders
Histology: subtype, perineural/perivascular invasion
Recurrence
Immunosuppression

Sources: Randle (1996) and Batra and Kelley (2002).

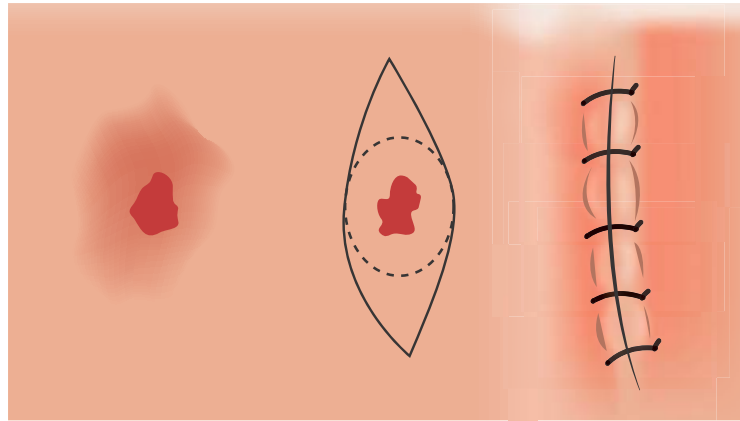### 2.3.1. Non-surgical management

Non-surgical management is often the mainstay of treatment employed by dermatologists for low-risk tumours, but is not appropriate for high-risk tumours. It is important to remember that some non-surgical options do not supply the tissue required for a histological diagnosis.

Curettage, cautery and liquid nitrogen cryotherapy can cure BCCs if experienced clinicians choose the appropriate lesion (i.e. low-risk, small, superficial BCCs; Spiller and Spiller, 1984; Barlow *et al.*, 2006).

Additionally, the use of the topical 5% Imiquimod cream, an immune-response modifier, has been demonstrated to histologically clear superficial BCCs 12 weeks after a 6-week treatment period (Geisse *et al.*, 2004). This treatment is not, however, without side effects such as erosion and ulceration.

Radiotherapy can also be used either as an adjuvant to surgery (for incompletely excised lesions) or in patients unwilling or unable to undergo surgery (Al-Othman *et al.*, 2001; Caccialanza *et al.*, 2001; Rio *et al.*, 2005).



**Figure 3.1.** Elliptical excision with pre-defined excision margins.

### 2.3.2. Surgical management

This involves excision of the lesion with predetermined margins (Telfer *et al.*, 2008). It is an effective treatment for BCC and has demonstrated a recurrence rate of <2% in 5 years in two clinical studies (Walker and Hill, 2006; Griffiths *et al.*, 2005). Additionally, the use of pre-operative curettage can improve the cure rate by accurately delineating the borders of the tumour (Johnson *et al.*, 1991). The accepted predetermined margins of 3 mm for a small (i.e. <2 cm) well-defined lesion will offer an 85% cure rate (Wolf and Zitelli, 1987; Kimyai-Asadi *et al.*, 2005). Morphoeic and larger BCCs require a greater excision margin; this is widely accepted as 5 mm.

## 2.4. Mohs micrographic surgery

Mohs micrographic surgery is a technique developed by Frederic Mohs in the 1940s and later refined (Mohs, 1976). It has been used by a number of dermatologists, ophthalmologists and plastic surgeons worldwide. It uses a technique that maximally preserves healthy, uninvolved tissue by combining surgical resection in a staged manner, with horizontal sections examined by the histopathologist until all traces of the tumour are excised. This procedure can be performed under local anaesthetic over a number of hours or days. Table 3.4 summarises the indications for Mohs micrographic surgery.

## 2.5. Follow-up

The ideal follow-up period for BCC is uncertain; however, it is clear that those who have had one recurrence are at high risk of another. In studies examining UK practice with regards to follow-up, a recurrence rate of less than 2% over 2 years was found. Additionally, new malignancies were detected in 6.3% of patients in the second year of follow-up (Motley *et al.*, 2003). Patients should therefore be seen for 3 years in order to detect recurrence or new lesions before being discharged with self-examination advice.



**Table 3.4.** Indications for Mohs micrographic surgery.

---

Tumour site: central face/eyes/nose/lips/ears
Large tumour
Histological subtype
Poor clinical definition of margins
Recurrent lesions
Perineural or perivascular involvement

---

Source: Telfer *et al.* (2008).

### 3. SQUAMOUS CELL CARCINOMA

---

Squamous cell carcinoma (SCC) is the second most common type of skin cancer in the UK, and its incidence is rising (Marks, 1996; Gray *et al.*, 1997). It is a cancer of the epithelial cells of the epidermis of the skin and is also linked to long-term UV light exposure (Karagas *et al.*, 1996, 2002) and (unlike BCCs) can develop in ‘normal’ skin or in skin previously damaged by burns (Chowdri and Darzi, 1996), ulcers (Baldursson *et al.*, 1995) or radiation exposure, and in pre-existing lesions such as Bowen’s disease and actinic keratoses (Hemminki and Dong, 2000). Immunosuppressed patients, such as those on long-term immunosuppressive medication after organ transplantation or those with lymphoma or leukaemia, are also at a greater risk of developing SCC (Lindelof *et al.*, 2006; Moloney *et al.*, 2006). The risk factors associated with the development of SCC are summarised in Table 3.5.

#### 3.1. Clinical presentation and diagnosis

---

SCC can develop in the skin or mucous membranes. They often look like scaly patches or open sores and can become crusted and bleed. The commonest sites are the scalp, ears, face, lower lip and dorsum of the hand. SCCs can develop from actinic keratoses (a premalignant condition), which can be indistinguishable clinically. Patients should be assessed for regional lymphadenopathy.

As for BCC, all patients suspected of having a diagnosis of SCC should be managed by a multidisciplinary team. Diagnosis is confirmed by tissue sampling and histological analyses including the subtype,

**Table 3.5.** Risk factors associated with SCC development.

---

Sun exposure
Age
Chronic wounds
Fair skin types
Immunosuppression
Bowen’s disease (SCC in situ)
Actinic keratoses
Previous BCC

---

border, grading, tumour depth (in mm), the level of dermal invasion and the presence or absence of perineural, vascular or lymphatic invasion (Motley *et al.*, 2003).

## 3.2. Management

SCC, similar to BCC, can be divided into high-risk and low-risk lesions (Table 3.6).

### 3.2.1. Surgical management

Most cutaneous SCCs should be managed and can be cured by surgical excision with predefined margins of normal skin around the tumour. If the SCC is well defined, <2 cm in diameter and low risk, it should be excised with a 4-mm margin: this will completely excise the tumour cells in 95% cases (Brodland and Zitelli, 1992). In cancers >2 cm in diameter that are high risk or extend into the subcutaneous tissue, a 6-mm margin should be taken to provide the same degree of confidence (Brodland and Zitelli, 1992).

### 3.2.2. Non-surgical management

Alternatives and adjuncts in the management of SCC include curettage, cryosurgery, radiotherapy and topical therapy.

Experienced clinicians using curettage are able to cure small, primary, well-differentiated tumours that are low-risk (Knox *et al.*, 1962, 1967; Tromovitch, 1965; Day and Rowe, 1993). However,

**Table 3.6.** Prognostic factors for SCC.

Prognostic factor	Description
Site (increasing metastatic potential) (Day and Rowe, 1993; Mohs and Snow, 1985)	<ul style="list-style-type: none"> <li>– Lip</li> <li>– Ear</li> <li>– Areas not exposed to sun</li> <li>– Areas of previous injury (e.g. burns, radiation, ulcers)</li> </ul>
Size	Tumours >2 cm are twice as likely to recur and three times as likely to metastasise (Day and Rowe, 1993; Clayman <i>et al.</i> , 2005)
Depth of invasion	Recurrence and metastatic potential are greater in tumours >4 mm in depth (Clayman <i>et al.</i> , 2005; Day and Rowe, 1993)
Histology	The less differentiated the tumour, the poorer prognosis they carry (Day and Rowe, 1993; Moore <i>et al.</i> , 2005)
Immunosuppressed patient	Perineural and perivascular invasion are poor prognostic factors (Moore <i>et al.</i> , 2005)
Previous SCC	Poorer prognosis as poor host response increases likelihood of recurrence and metastasis (Day and Rowe, 1993; Mohs and Snow, 1985; Mohs, 1980; Leibovitch <i>et al.</i> , 2005a)
	Locally recurrent disease is a risk factor for metastatic disease (Motley <i>et al.</i> , 2003)

curettage does not provide a definitive histological diagnosis according to the parameters mentioned above because the tissue is poorly oriented and the tumour is not excised completely. Cryotherapy is again effective in experienced hands, but only for the treatment of histologically proven SCC because this method provides no tissue for histological analysis (Kuflik and Gage, 1991; Day and Rowe, 1993; Kuflik, 2004).

Radiotherapy is effective in the treatment of SCC by experienced clinical radiation oncologists, who are able to provide a cure in over 90% of cases (Freeman *et al.*, 1964; Day and Rowe, 1993; Locke *et al.*, 2001; Tsao *et al.*, 2002). However, the tumour site and the patient should always be considered because, for example, tumour involving bone or cartilage may be better suited to surgical excision with radiotherapy and a tumour on the dorsum of the hand (where skin is thin and elastic) is more amenable to surgical excision.

### 3.3. Follow-up

---

Patients who are managed as early as possible do better. Therefore, once a cutaneous SCC has been managed it is imperative that a clinician monitors the patient for recurrence. Additionally, patients must be given prevention and self-examination advice (with written information leaflets provided as aide-memoires), as well as information about who seek advice from. As 75% of local and metastatic recurrence is detected within the first 2 years after management and 95% within 5 years, a reasonable time to follow-up the patient before discharge is 5 years (Day and Rowe, 1993; Motley *et al.*, 2003).

## 4. MALIGNANT MELANOMA

---

Malignant melanoma arises from the malignant conversion of melanocytes, the pigment-producing cells of the skin. The commonest site for melanoma to arise is the skin, and cutaneous melanoma is steadily increasing (Hussussian, 2007). According to the World Health Organisation (WHO), its incidence is increasing at a rate faster than that of any other cancer. Risk factors, as with BCC and SCC, are UV exposure and genetic predisposition; this is reflected in the variable worldwide incidence of malignant melanoma. For example, in Australia and New Zealand, incidence rates are far higher than in South-Central Asia (Ferlay *et al.*, 2010). Sun exposure that is intermittent and intense poses the highest risk of sun damage and should therefore be avoided, especially in those with characteristics that increase susceptibility such as fair skin, blue eyes, red or blonde hair, and freckling easily. The incidence of malignant melanoma is also related to age but, in contrast to non-melanocytic skin cancers, has an unusual pattern: between 2008 and 2010 in the UK, 27% of cases were diagnosed in those less than 50 years of age.

Some genetic mutations have been linked to malignant melanoma, some of which are being explored in clinical trials. These mutations affect p16, a tumor suppressor protein, that in humans plays an important role in cell cycle regulation by decelerating cells' progression from G1 phase to S phase, and

therefore acts as a tumour suppressor that is implicated in the prevention of cancers, notably melanoma. p16 is also an inhibitor of CDK4, a cyclin-dependent kinase which has also been targeted in clinical trials. In addition, *B-RAF*, a gene producing the B-Raf protein involved in sending signals inside cells, has also been targeted in clinical trials.

## 4.1. Diagnosis

Clinical suspicion should lead to a tissue diagnosis of malignant melanoma. Guidelines for the recognition of high-risk lesions are the following well-known ‘ABCDE’ criteria:

A – Asymmetry

B – Border (irregular)

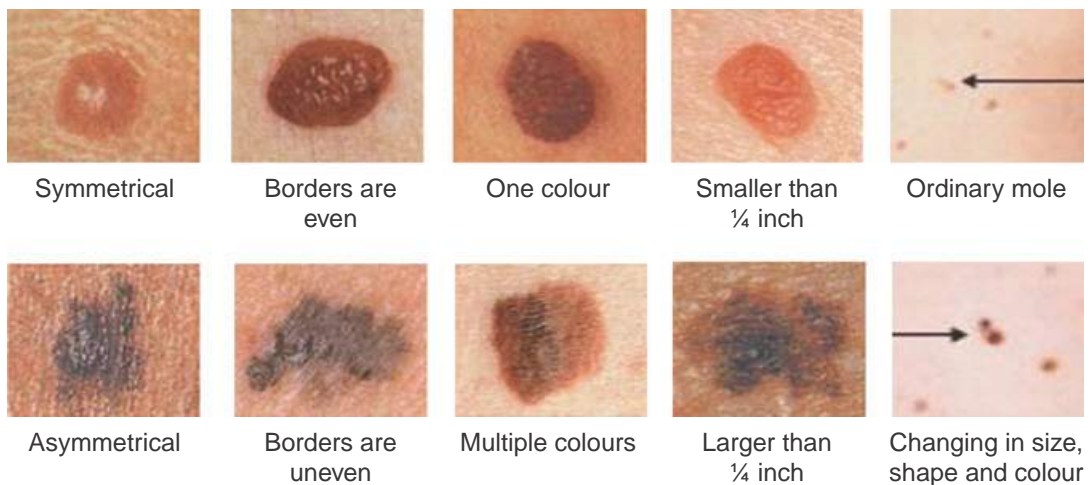
C – Colour variety (a number of different shades of brown or black, blue, etc.)

D – Diameter (>6 mm diameter)

E – Evolving (any change in size, shape, colour, elevation or any new symptom).

Although these criteria are useful, particularly for the public, it is worth remembering that in fact in the early stages malignant melanomas can be <6 mm in diameter and that approximately 5% of malignant melanomas are actually not pigmented.

Accurate diagnosis is dependent on tissue sampling, and an excisional biopsy is recommended after clinical photography. It is not recommended that this is done in primary care: instead, it should be performed by suitable members of the local skin cancer multidisciplinary team. It is appropriate that the lesion is excised in a manner that allows a further wide excision; excision should include the whole tumour with a 2-mm margin of normal skin and a cuff of fat in order to allow an accurate histological



**Figure 3.2.** The ‘ABCDE’ rule. *Source:* Skin Cancer Foundation (2013).

**Table 3.7.** Criteria for urgent referral to a local skin cancer multidisciplinary team.

---

A new mole in adulthood with changing shape, colour, size
Itching or bleeding
Any mole with asymmetry or three or more colours
Any new persistent skin lesion, especially if pigmented and the diagnosis is unclear
A new pigmented line in a nail
A lesion growing under a nail

---

Source: Marsden *et al.* (2010).

confirmation of diagnosis, Breslow thickness and Clark level (Lederman and Sober, 1985; Austin *et al.*, 1996). Incisional or punch biopsy is sometimes acceptable for specific situations such as facial lentigo maligna (melanoma *in situ*), but this decision should be made under the guidance of the local skin cancer multidisciplinary team.

The Royal College of Pathologists has produced guidelines for the dataset required in histopathological reports (Association of Directors of Anatomic and Surgical Pathology, 1998). These are summarised in Table 3.8.

The Breslow thickness describes how deeply the tumour cells have invaded and is measured using an ocular micrometer from the granular layer of the epidermis to the deepest dermal tumour cells (Breslow, 1970). It is not only an important prognostic factor but also guides clinicians as to the excision margins for wide excision and is one of the criteria used in predicting lymph node metastases.

It is different from Clark levels, which determine the level of anatomical invasion of the tumour cells. Clark levels have been superseded by Breslow thickness, except when the Breslow thickness is <1 mm, when they can offer prognostic value.

## 4.2. Staging

---

As already described, the most important factors in determining the stage of malignant melanoma is the Breslow thickness (except when <1 mm), along with the mitotic rate and presence of ulceration. The staging system used is the American Joint Committee on Cancer (AJCC) staging system (summarised in Figure 3.3; Balch *et al.*, 2009).

## 4.3. Investigations

---

Further investigations can be performed to determine disease progression. Patients with stages I, II and IIIA malignant melanoma do not require routine investigations. However, patients with stage IIIB or IIIC disease should undergo head, chest, abdominal and pelvic computed tomography. Those with stage IV disease require further investigation according to their clinical need.

**Table 3.8.** Minimum data set required in histopathological description for malignant melanoma.

Clinical information	Site	
	Procedure (excision, re-excision, punch biopsy)	
Macroscopic description	Contour	
	Colour	
	Size of tumour (mm)	
	Size of excised specimen (mm)	
Microscopic description	Ulceration	Presence or absence
	Thickness of the tumour	Measured from the granular layer of epidermis to the deepest dermal malignant cells to the nearest 0.1 mm
	Number of mitoses per mm <sup>2</sup>	In the area of greatest mitoses in the vertical growth phase
	Histological subtype	Superficial spreading, nodular, lentigo maligna, acral lentiginous melanoma
	Margins of excision	Indicates whether excision is complete at peripheral and deep margins
	Pathological staging	TNM staging should be used
	Growth phase	Invasive melanoma without a vertical growth phase is microinvasion
	Regression	
	Tumour-infiltrating lymphocytes	
	Lymphatic or vascular invasion	
	Perineural infiltration	Prognostic factor
	Microsatellites	Islands of tumour >0.05 mm in the tissue beneath the mass of melanoma, separated by 0.3 mm of normal collagen (Harrist <i>et al.</i> , 1984). This is predictive of lymph node metastases
	Precursor naevus	Presence should be recorded
Clark level	Less reliable than thickness	

Source: Marsden *et al.* (2010).

## 4.4. Management

The management of malignant melanoma is wide local excision with predefined margins as shown in Table 3.10. For malignant melanoma with a Breslow thickness of up to 1.0 mm, the recommended margins are based upon the WHO Melanoma Co-operative Group Trial 10 (Veronesi *et al.*, 1988; Veronesi and Cascinelli, 1991) comparing 1 cm and 3 cm margins, with similar overall survival rates. For malignant melanomas sized 1.01–2.0 mm, there have been four randomised trials: two comparing 1 cm and 3 cm margins (Veronesi *et al.*, 1988; Veronesi and Cascinelli, 1991), one comparing 2 cm and 4 cm margins (Balch *et al.*, 2001) and one comparing 2 cm and 5 cm margins (Khayat *et al.*, 2003). Unfortunately, none of these compare 1 cm and 2 cm margins directly; however, they suggest that 1 cm is the minimum margin required, while 2 cm margins are equally appropriate. Ultimately, discussion between the

Stage	Primary tumour (pT)	Lymph nodes (N)	Metastases (M)
IA	< 1 mm, no ulceration, mitoses < 1 mm <sup>-2</sup>		
IB	< 1 mm, with ulceration or mitoses ≥ 1 mm <sup>-2</sup> <sup>a</sup>		
IIA	1.01–2 mm, no ulceration		
IIB	1.01–2 mm, with ulceration		
IIC	2.01–4 mm, no ulceration		
IIIB	2.01–4 mm, with ulceration		
IIIC	> 4 mm, no ulceration		
IIIA	> 4 mm, with ulceration	Micrometastases 1–3 nodes	
IIIB	Any Breslow thickness, no ulceration	Micrometastases 1–3 nodes	
IIIB	Any Breslow thickness, with ulceration	1–3 palpable metastatic nodes	
IIIB	Any Breslow thickness, no ulceration	No nodes, but in-transit or satellite metastasis/es	
IIIC	Any Breslow thickness, with ulceration	Up to three palpable lymph nodes	
IIIC	Any Breslow thickness, with or without ulceration	Four or more nodes or matted nodes or in-transit disease + lymph nodes	
IIIC	Any Breslow thickness, with ulceration	No nodes, but in-transit or satellited metastasis/es	
IV, M1a			Skin, subcutaneous or distant nodal disease
IV, M1b			Lung metastases
IV, M1c			All other sites or any other sites of metastases with raised lactate dehydrogenase

<sup>a</sup>In the rare circumstances where mitotic count cannot be accurately determined, a Clark level of invasion of either IV or V can be used to define T1b melanoma. Every patient with melanoma should be accurately staged using the AJCC system; this may include performing a sentinel lymph node biopsy when this is recommended by the Specialist Skin Cancer Multidisciplinary Team. Staging should be updated following relapse.

**Figure 3.3.** AJCC staging of malignant melanoma.

Source: Marsden *et al.* (2010).

patient and the multidisciplinary team and consideration of the anatomical site will determine an excision margin of between 1 cm and 2 cm. Similarly, for patients with malignant melanoma with a Breslow thickness of 2.01–4.0 mm, trials have demonstrated no difference between 2 cm and 4 cm wide local excisions (Balch *et al.*, 2001); however, a trial comparing 1 cm and 3 cm margins demonstrated a benefit of wider excision (Thomas *et al.*, 2004). Thus, a 2 cm margin is the minimum in this cohort of patients, although patient wishes, anatomical site and multidisciplinary team advice should again be taken into consideration because a 3 cm margin is equally appropriate.

Patients with malignant melanomas with a Breslow thickness >4.01 mm are at a very high risk of recurrence and metastasis. One trial has compared 1 cm and 3 cm wide excisions and demonstrated a lower risk of recurrence with a 3 cm margin (Thomas *et al.*, 2004). There is no evidence to suggest that more than 3 cm should be excised.

## 4.5. Sentinel lymph node biopsy

Sentinel lymph node biopsy (SLNB) reliably diagnoses regional lymph node metastases before they are clinically evident and involves removing the first node that drains the melanoma site (Morton *et al.*, 1992). Although controversial, SLNB should be offered to all patients with stage IB to IIIC tumours and should not be offered to those with a Breslow thickness of >4 mm because these patients are likely to have metastases. There is no evidence to suggest any therapeutic benefit of biopsy, but it is an informative prognostic staging tool.

SLNB involves injecting the primary melanoma site with radioactive material (Technetium)<sup>99</sup> and methylene blue dye, which then travels to the sentinel lymph node. A pre-operative nuclear medicine scan and peri-operative use of a gamma probe, as well as the visually blue node, enables the surgeon to locate the sentinel lymph node. If positive, the patient should then be offered completion lymphadenectomy, having been made aware of this possibility prior to the SLNB. SLNB can be undertaken at the same time as wide local excision of the primary tumour.

## 4.6. Follow-up

Follow-up is an important part of the clinical care of patients with a diagnosis of malignant melanoma. Clinicians not only act as a source of support and reassurance but are also able to detect recurrence or further primary malignant melanoma. Table 3.9 shows the frequency and length of follow-up according to the AJCC stage.

**Table 3.9.** Follow-up for malignant melanoma.

Stage	Follow up
<i>In situ</i>	None required
IA	2–4 times for the first 12 months
IB–IIIA	3-monthly for 3 years 6-monthly to 5 years
IIIB, IIIC, resected IV	3-monthly for 3 years 6-monthly to 5 years 12-monthly to 10 years
Unresectable IV	As needed



**Table 3.10.** Quick reference of surgical excision margins.

Basal cell carcinoma	<2 cm; low risk	3 mm
	>2 cm; high risk	5 mm
Squamous cell carcinoma	<2 cm; low risk	4 mm
	>2 cm; high risk	6 mm
Malignant melanoma (Breslow thickness)	<i>In situ</i>	0.5 cm
	<1 mm	1 cm
	1.01–2 mm	1–2 cm
	2.1–4 mm	2–3 cm
	>4 mm	3 cm

## REFERENCES

- Al-Othman, M. O. F., Mendenhall, W. M. & Amdur, R. J. 2001. Radiotherapy alone for clinical T4 skin carcinoma of the head and neck with surgery reserved for salvage. *American Journal of Otolaryngology*, 22, 387–90.
- Association of Directors of Anatomic and Surgical Pathology. 1998. Recommendations for the reporting of tissues removed as part of the surgical treatment of cutaneous melanoma. *Pathology International*, 48, 168–70.
- Austin, J. R., Byers, R. M., Brown, W. D. & Wolf, P. 1996. Influence of biopsy on the prognosis of cutaneous melanoma of the head and neck. *Head and Neck—Journal for the Sciences and Specialties of the Head and Neck*, 18, 107–17.
- Balch, C. M., Soong, S., Smith, T., Ross, M. I., Urist, M. M., Karakousis, C. P., Temple, W. J., Mihm, M. C., Barnhill, R. L., Jewell, W. R., Wanebo, H. J., Desmond, R. & Investigators Intergroup, M. 2001. Long-term results of a prospective surgical trial comparing 2 cm vs. 4 cm excision margins for 740 patients with 1–4 mm melanomas. *Annals of Surgical Oncology*, 8, 101–8.
- Balch, C. M., Gershenwald, J. E., Soong, S.-J., Thompson, J. F., Atkins, M. B., Byrd, D. R., Buzaid, A. C., Cochran, A. J., Coit, D. G., Ding, S., Eggermont, A. M., Flaherty, K. T., Gimotty, P. A., Kirkwood, J. M., McMasters, K. M., Mihm, M. C., Jr., Morton, D. L., Ross, M. I., Sober, A. J. & Sondak, V. K. 2009. Final version of 2009 AJCC melanoma staging and classification. *Journal of Clinical Oncology*, 27, 6199–206.
- Baldursson, B., Sigurgeirsson, B. & Lindelof, B. 1995. Venous leg ulcers and squamous-cell carcinoma – A large-scale epidemiologic-study. *British Journal of Dermatology*, 133, 571–4.
- Barlow, J. O., Zalla, M. J., Kyle, A., Dicaudo, D. J., Lim, K. K. & Yiannias, J. A. 2006. Treatment of basal cell carcinoma with curettage alone. *Journal of the American Academy of Dermatology*, 54, 1039–45.
- Batra, R. S. & Kelley, L. C. 2002. A risk scale for predicting extensive subclinical spread of nonmelanoma skin cancer. *Dermatologic Surgery*, 28, 107–12.
- Breslow, A. 1970. Thickness, cross-sectional areas and depth of invasion in prognosis of cutaneous melanoma. *Annals of Surgery*, 172, 902–8.
- Brodland, D. G. & Zitelli, J. A. 1992. Surgical margins for excision of primary cutaneous squamous-cell carcinoma. *Journal of the American Academy of Dermatology*, 27, 241–8.
- Caccialanza, M., Piccinno, R. & Grammatica, A. 2001. Radiotherapy of recurrent basal and squamous cell skin carcinomas: A study of 249 re-treated carcinomas in 229 patients. *European Journal of Dermatology*, 11, 25–8.
- Chowdri, N. A. & Darzi, M. A. 1996. Postburn scar carcinomas in Kashmiris. *Burns*, 22, 477–82.
- Clayman, G. L., Lee, J. J., Holsinger, F. C., Zhou, X., Duvic, M., El-Naggar, A. K., Prieto, V. G., Altamirano, E., Tucker, S. L., Strom, S. S., Kripke, M. L. & Lippman, S. M. 2005. Mortality risk from squamous cell skin cancer. *Journal of Clinical Oncology*, 23, 759–65.

- Corona, R., Dogliotti, E., D'errico, M., Sera, F., Iavarone, I., Baliva, G., Chinni, L. M., Gobello, T., Mazzanti, C., Puddu, P. & Pasquini, P. 2001. Risk factors for basal cell carcinoma in a Mediterranean population – Role of recreational suit exposure early in life. *Archives of Dermatology*, 137, 1162–8.
- Day, C. L. & Rowe, D. E. 1993. Prognostic factors for local recurrence, metastases, and survival rates in squamous-cell carcinoma of the skin, ear, and lip – Reply. *Journal of the American Academy of Dermatology*, 28, 281–2.
- Farley, R. L., Manolidis, S. & Ratner, D. 2006. Aggressive basal cell carcinoma with invasion of the parotid gland, facial nerve, and temporal bone. *Dermatologic Surgery*, 32, 307–15.
- Ferlay, J., Shin, H.-R., Bray, F., Forman, D., Mathers, C. & Parkin, D. M. 2010. Estimates of worldwide burden of cancer in 2008: GLOBOCAN 2008. *International Journal of Cancer*, 127, 2893–917.
- Freeman, R. G., Heaton, C. L. & Knox, J. M. 1964. Treatment of skin cancer – Statistical study of 1341 skin tumors comparing results obtained with irradiation surgery and curettage followed by electrodesiccation. *Cancer*, 17, 535–8.
- Gailani, M. R., Leffell, D. J., Ziegler, A., Gross, E. G., Brash, D. E. & Bale, A. E. 1996. Relationship between sunlight exposure and a key genetic alteration in basal cell carcinoma. *Journal of the National Cancer Institute*, 88, 349–54.
- Geisse, J., Caro, I., Lindholm, J., Golitz, L., Stampone, P. & Owens, M. 2004. Imiquimod 5% cream for the treatment of superficial basal cell carcinoma: Results from two phase III, randomized, vehicle-controlled studies. *Journal of the American Academy of Dermatology*, 50, 722–33.
- Gorlin, R. J. 2004. Nevoid basal cell carcinoma (Gorlin) syndrome. *Genetics in Medicine*, 6, 530–9.
- Gray, D. T., Suman, V. J., Su, W. P. D., Clay, R. P., Harmsen, W. S. & Roenigk, R. K. 1997. Trends in the population-based incidence of squamous cell carcinoma of the skin first diagnosed between 1984 and 1992. *Archives of Dermatology*, 133, 735–40.
- Griffiths, R. W., Suvarna, S. K. & Stone, J. 2005. Do basal cell carcinomas recur after complete conventional surgical excision? *British Journal of Plastic Surgery*, 58, 795–805.
- Harris, D. W. S., Benton, E. C. & Hunter, J. A. A. 1990. The changing face of dermatology out-patient referrals in the south-east of Scotland. *British Journal of Dermatology*, 123, 745–50.
- Harrist, T. J., Rigel, D. S., Day, C. L., Sober, A. J., Lew, R. A., Rhodes, A. R., Harris, M. N., Kopf, A. W., Friedman, R. J., Golomb, F. M., Cosimi, A. B., Gorstein, F., Malt, R. A., Wood, W. C., Postel, A., Hennessey, P., Gumport, S. L., Roses, D. F., Mintzis, M. M., Raker, J. W., Fitzpatrick, T. B. & Mihm, M. C. 1984. Microscopic satellites are more highly associated with regional lymph-node metastases than is primary melanoma thickness. *Cancer*, 53, 2183–7.
- Hemminki, K. & Dong, C. H. 2000. Subsequent cancers after in situ and invasive squamous cell carcinoma of the skin. *Archives of Dermatology*, 136, 647–51.
- Hussussian, C. 2007. Malignant melanoma. In: Thorne, C. (ed.) *Grabb and Smith's Plastic Surgery*. Sixth ed.: Lippincott Williams & Wilkins.
- Johnson, T. M., Tromovitch, T. A. & Swanson, N. A. 1991. Combined curettage and excision – A treatment method for primary basal-cell carcinoma. *Journal of the American Academy of Dermatology*, 24, 613–17.
- Karagas, M. R., McDonald, J. A., Greenberg, E. R., Stukel, T. A., Weiss, J. E., Baron, J. A. & Stevens, M. 1996. Risk of basal cell and squamous cell skin cancers after ionizing radiation therapy. *Journal of the National Cancer Institute*, 88, 1848–53.
- Karagas, M. R., Stannard, V. A., Mott, L. A., Slattery, M. J., Spencer, S. K. & Weinstock, M. A. 2002. Use of tanning devices and risk of basal cell and squamous cell skin cancers. *Journal of the National Cancer Institute*, 94, 224–6.
- Khayat, D., Rixe, O., Martin, G., Soubrane, C., Banzet, M., Bazex, J. A., Lauret, P., Verola, O., Auclerc, R., Harper, P., Banzet, P. & French GRP Res Malignant, M. 2003. Surgical margins in cutaneous melanoma (2 cm versus 5 cm for lesions measuring less than 2.1-mm thick) – Long-term results of a large European multicentric phase III study. *Cancer*, 97, 1941–6.
- Kimyai-Asadi, A., Alam, M., Goldberg, L. F., Peterson, S. R., Silapunt, S. & Jih, M. H. 2005. Efficacy of narrow-margin excision of well-demarcated primary facial basal cell carcinomas. *Journal of the American Academy of Dermatology*, 53, 464–8.

- Knox, J. M., Freeman, R. G. & Heaton, C. L. 1962. Curettage and electrodesiccation in treatment of skin cancer. *Southern Medical Journal*, 55, 1212–5.
- Knox, J. M., Freeman, R. G., Duncan, W. C. & Heaton, C. L. 1967. Treatment of skin cancer. *Southern Medical Journal*, 60, 241–6.
- Ko, C. B., Walton, S., Keczkcs, K., Bury, H. P. R. & Nicholson, C. 1994. The emerging epidemic of skin-cancer. *British Journal of Dermatology*, 130, 269–72.
- Kuflik, E. G. 2004. Cryosurgery for skin cancer: 30-year experience and cure rates. *Dermatologic Surgery*, 30, 297–300.
- Kuflik, E. G. & Gage, A. A. 1991. The 5-year cure rate achieved by cryosurgery for skin-cancer. *Journal of the American Academy of Dermatology*, 24, 1002–4.
- Lederman, J. S. & Sober, A. J. 1985. Does biopsy type influence survival in clinical stage-I cutaneous melanoma. *Journal of the American Academy of Dermatology*, 13, 983–7.
- Leibovitch, I., Huilgol, S. C., Selva, D., Hill, D., Richards, S. & Paver, R. 2005a. Cutaneous squamous cell carcinoma treated with Mohs micrographic surgery in Australia II. Perineural invasion. *Journal of the American Academy of Dermatology*, 53, 261–6.
- Leibovitch, I., McNab, A., Sullivan, T., Davis, G. & Selva, D. 2005b. Orbital invasion by periocular basal cell carcinoma. *Ophthalmology*, 112, 717–23.
- Lindelof, B., Jarnvik, J., Ternesten-Bratel, A., Granath, F. & Hedblad, M. A. 2006. Mortality and clinicopathological features of cutaneous squamous cell carcinoma in organ transplant recipients: A study of the Swedish cohort. *Acta Dermato-Venereologica*, 86, 219–22.
- Lo, J. S., Snow, S. N., Reizner, G. T., Mohs, F. E., Larson, P. O. & Hruza, G. J. 1991. Metastatic basal-cell carcinoma – Report of 12 cases with a review of the literature. *Journal of the American Academy of Dermatology*, 24, 715–19.
- Locke, J., Karimpour, S., Young, G., Lockett, M. A. & Perez, C. A. 2001. Radiotherapy for epithelial skin cancer. *International Journal of Radiation Oncology Biology Physics*, 51, 748–55.
- Marks, R. 1996. Squamous cell carcinoma. *Lancet*, 347, 735–8.
- Marsden, J. R., Newton-Bishop, J. A., Burrows, L., Cook, M., Corrie, P. G., Cox, N. H., Gore, M. E., Lorigan, P., Mackie, R., Nathan, P., Peach, H., Powell, B. & Walker, C. 2010. Revised UK guidelines for the management of cutaneous melanoma 2010. *Journal of Plastic Reconstructive and Aesthetic Surgery*, 63, 1401–19.
- Meads, S. B. & Greenway, H. T. 2006. Basal cell carcinoma associated with orbital invasion: Clinical features and treatment options. *Dermatologic Surgery*, 32, 442–6.
- Mohs, F. E. 1976. Chemosurgery for skin cancer – Fixed tissue and fresh tissue techniques. *Archives of Dermatology*, 112, 211–15.
- Mohs, F. E. 1980. Chemosurgery. *Clinics in Plastic Surgery*, 7, 349–60.
- Mohs, F. E. & Snow, S. N. 1985. Microscopically controlled surgical-treatment for squamous-cell carcinoma of the lower lip. *Surgery Gynecology & Obstetrics*, 160, 37–41.
- Moloney, F. J., Comber, H., O’Lorcain, P., O’Kelly, P., Conlon, P. J. & Murphy, G. M. 2006. A population-based study of skin cancer incidence and prevalence in renal transplant recipients. *British Journal of Dermatology*, 154, 498–504.
- Moore, B. A., Weber, R. S., Prieto, V., El-Naggar, A., Holsinger, F. C., Zhou, X., Lee, J. J., Lippman, S. & Clayman, G. L. 2005. Lymph node metastases from cutaneous squamous cell carcinoma of the head and neck. *Laryngoscope*, 115, 1561–7.
- Morton, D. L., Wen, D. R., Wong, J. H., Economou, J. S., Cagle, L. A., Storm, F. K., Foshag, L. J. & Cochran, A. J. 1992. Technical details of intra-operative lymphatic mapping for early stage melanoma. *Archives of Surgery*, 127, 392–9.
- Motley, R., Kersey, P. & Lawrence, C. 2003. Multiprofessional guidelines for the management of the patient with primary cutaneous squamous cell carcinoma. *British Journal of Plastic Surgery*, 56, 85–91.
- NCI. 2012. *Types of Skin Cancer* [Online]. <http://visualsonline.cancer.gov>. [Accessed 1 January 2014.]
- Randle, H. W. 1996. Basal cell carcinoma – Identification and treatment of the high-risk patient. *Dermatologic Surgery*, 22, 255–61.

- Rio, E., Bardet, E., Ferron, C., Peuvrel, P., Supiot, S., Campion, L., De Montreuil, C. B., Mahe, M. A. & Dreno, B. 2005. Interstitial brachytherapy of periorificial skin carcinomas of the face: A retrospective study of 97 cases. *International Journal of Radiation Oncology Biology Physics*, 63, 753–7.
- Roenigk, R. K., Ratz, J. L., Bailin, P. L. & Wheeland, R. G. 1986. Trends in the presentation and treatment of basal-cell carcinomas. *Journal of Dermatologic Surgery and Oncology*, 12, 860–865.
- skcn.org. 2010. [www.skcn.org](http://www.skcn.org) [Online]. [Accessed 1 January 2014.]
- Skin Cancer Foundation. 2013. *Melanoma* [Online]. [www.skincancer.org](http://www.skincancer.org). [Accessed 1 January 2014.]
- Spiller, W. F. & Spiller, R. F. 1984. Treatment of basal-cell epithelioma by curettage and electrodesiccation. *Journal of the American Academy of Dermatology*, 11, 808–14.
- Telfer, N. R., Colver, G. B. & Morton, C. A. 2008. Guidelines for the management of basal cell carcinoma. *British Journal of Dermatology*, 159, 35–48.
- Thomas, J. M., Newton-Bishop, J., A'hern, R., Coombes, G., Timmons, M., Evans, J., Cook, M., Theaker, J., Fallowfield, M., O'Neill, T., Ruka, W., Bliss, J. M., United Kingdom Melanoma Study, G., British Assoc Plastic, S. & Scottish Canc Therapy, N. 2004. Excision margins in high-risk malignant melanoma. *New England Journal of Medicine*, 350, 757–66.
- Ting, P. T., Kasper, R. & Arlette, J. P. 2005. Metastatic basal cell carcinoma: Report of two cases and literature review. *Journal of Cutaneous Medicine and Surgery*, 9, 10–15.
- Tromovitch, T. A. 1965. Skin cancer; Treatment by curettage and desiccation. *California Medicine*, 103, 107–8.
- Tsao, M. N., Tsang, R. W., Liu, F. F., Panzarella, T. & Rotstein, L. 2002. Radiotherapy management for squamous cell carcinoma of the nasal skin: The Princess Margaret Hospital experience. *International Journal of Radiation Oncology Biology Physics*, 52, 973–9.
- Veronesi, U. & Cascinelli, N. 1991. Narrow excision (1-CM MARGIN) – A safe procedure for thin cutaneous melanoma. *Archives of Surgery*, 126, 438–41.
- Veronesi, U., Cascinelli, N., Adamus, J., Balch, C., Bandiera, D., Barchuk, A., Bufalino, R., Craig, P., Demarsillac, J., Durand, J. C., Vangeel, A. N., Holmstrom, H., Hunter, J. A., Jorgensen, O. G., Kiss, B., Kroon, B., Lacour, J., Lejeune, F., Mackie, R., Mechl, Z., Mitrov, G., Morabito, A., Nosek, H., Panizzon, R., Prade, M., Santi, P., Vanslooten, E., Tomin, R., Trapeznikov, N., Tsanov, T., Urist, M. & Wozniak, K. D. 1988. Thin stage-I primary cutaneous malignant-melanoma – Comparison of excision with margins of 1 or 3 cm. *New England Journal of Medicine*, 318, 1159–62.
- Walker, P. & Hill, D. 2006. Surgical treatment of basal cell carcinomas using standard post-operative histological assessment. *Australasian Journal of Dermatology*, 47, 1–12.
- Williams, L. S., Mancuso, A. A. & Mendenhall, W. M. 2001. Perineural spread of cutaneous squamous and basal cell carcinoma: CT and MR detection and its impact on patient management and prognosis. *International Journal of Radiation Oncology Biology Physics*, 49, 1061–9.
- Wolf, D. J. & Zitelli, J. A. 1987. Surgical margins for basal-cell carcinoma. *Archives of Dermatology*, 123, 340–4.

# Oral and Oropharyngeal Cancer

---

Jatinder T. Virdee, Nicholas Kalavrezos

## 1. INTRODUCTION

---

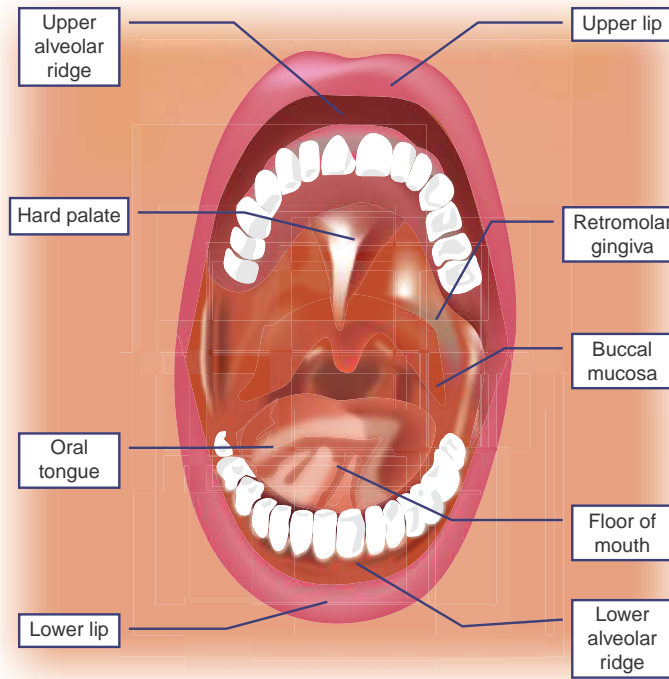
Oral cancer is the sixth most common cancer in the world, and is ranked as one of the top three cancers in areas of high incidence (Warnakulasuriya, 2010). It represents a significant component of the global cancer burden (Peterson, 2009) and is a major problem in regions in which tobacco chewing and smoking are common (Zini *et al.*, 2010). It is mostly preventable through lifestyle changes (Warnakulasuriya, 2010). In 2004, the International Head and Neck Cancer Epidemiology consortium was set up to obtain a better understanding of head and neck squamous cell carcinomas (HNSCCs) by studying large-scale pooled data (Conway *et al.*, 2009). However, despite the increased knowledge of the disease, many unanswered questions remain.

Historically, oral cancer was a self-induced disease of the ‘middle aged man who smokes and drinks excessively’; however, nowadays this pattern is changing, and younger people with a completely different set of risk factors are emerging as oral and oropharyngeal cancer sufferers. Over 90% of primary malignant neoplasms of the upper aerodigestive tract are squamous cell carcinomas (Warnakulasuriya, 2009), while tumours of the minor salivary glands are the second commonest and mucosal melanomas are extremely rare (Shah & Gil, 2009). This chapter will focus on oral and oropharyngeal squamous cell carcinomas (OPSCCs), concentrating on their risk factors, clinical presentation and treatment, with the intention of providing an overview to the topic and promoting an interest in further research.

## 2. ANATOMY

---

The oral cavity is bound anteriorly and laterally by the alveolar arches, and represents the first part of the mouth. Superiorly, it is roofed by the hard palate and inferiorly contains the floor of the mouth. Posteriorly it communicates with the oropharynx (see figure 4.1).



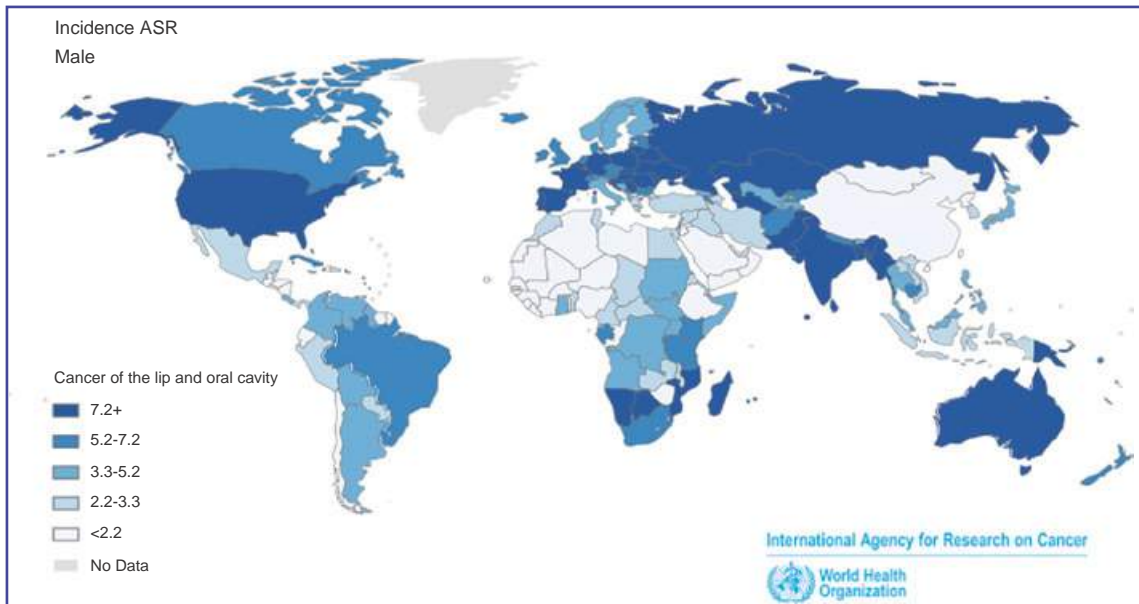
**Figure 4.1.** Anatomy of the oral cavity.

### 3. EPIDEMIOLOGY

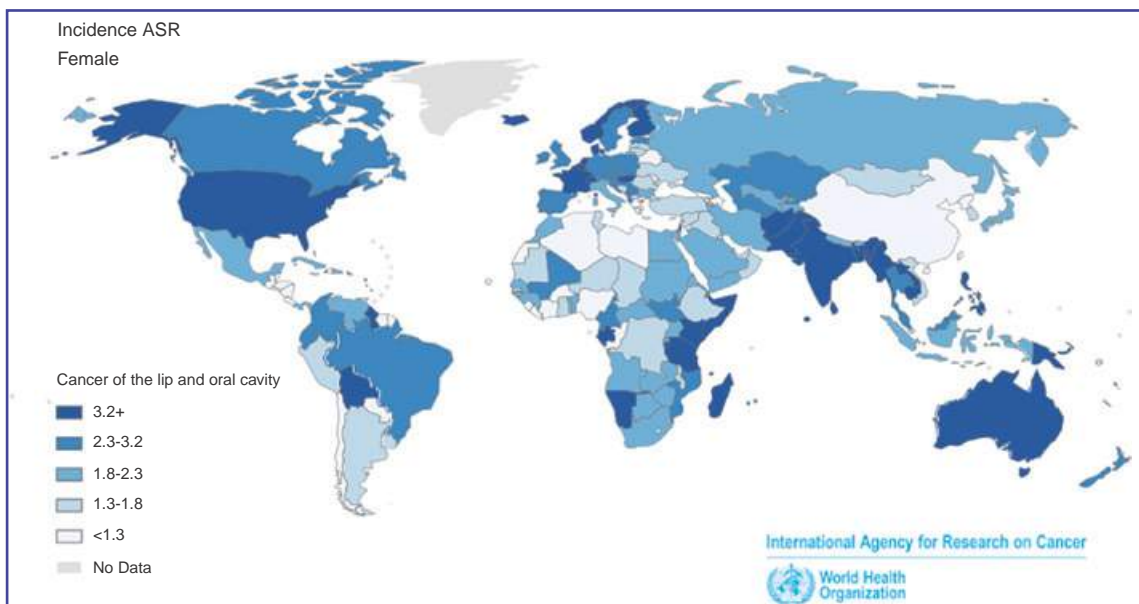
#### 3.1. Incidence

Oral and oropharyngeal cancer risk increases with age (Warnakulasuriya, 2010), with most cases occurring between the fifth and seventh decades of life, probably because of the length of exposure of the oral cavity to exogenous carcinogens (Johnson *et al.*, 2011). The annual estimated incidence of OPSCC (excluding those affecting the nasopharynx) is approximately 405,000 cases per year, with two-thirds of patients in developing countries (Warnakulasuriya, 2009). Geographical variation in the incidence of oropharyngeal cancer is vast, with the following areas showing a high incidence: South Asia (Sri Lanka, India, Pakistan, Taiwan); Hungary, Slovakia and Slovenia; Brazil, Uruguay, Puerto Rico and Cuba; and Melanesia (e.g. Papua New Guinea) (Peterson, 2010).

Geographical patterns of oral cancer clearly demonstrate differences in risk factors, with lip and oral cancer being highest in Melanesia, secondary to the popular chewing of areca nut and tobacco (Johnson *et al.*, 2011). Within the European Union, there were 67,000 new cases in 2004, with incidence highest in Western Europe, making OPSCC the seventh most common cancer (Warnakulasuriya, 2009). OPSCC are not common in the UK, with only 4660 cases diagnosed in 2003, accounting for 1.6% of all new cancers (Warnakulasuriya, 2009). Rates are typically higher in Scotland than in any other part of the UK for both men and women (Warnakulasuriya, 2009).



**Figure 4.2.** Age-standardised incidence (per 100,000) of men with oral cancer in 2012.  
 Source: Based on GLOBOCAN 2012 International Agency for Research on Cancer (<http://globocan.iarc.fr/Default.aspx>).



**Figure 4.3.** Age-standardised incidence (per 100,000) of women with oral cancer in 2012.  
 Source: Based on GLOBOCAN 2012 International Agency for Research on Cancer (<http://globocan.iarc.fr/Default.aspx>).

## 3.2. Mortality

---

Mortality rates are generally higher in men and lower in Westernised countries with good health provision (Peterson, 2009). Worldwide, almost three-quarters of a million people are alive 5 years after their OPSCC diagnosis, with survival rates exceeding 50% in countries with the best treatment centres (Johnson *et al.*, 2011). In the European Union, in contrast to the incidence pattern, mortality rates are highest in Eastern Europe (Warnakulasuriya, 2009).

## 4. AETIOLOGY

---

Cigarette smoking and alcohol excess represent the two major risk factors for oral cancer in the UK, with several key epidemiological studies worldwide confirming this association (Warnakulasuriya, 2009b). We will outline these major ‘traditional risk factors’, including what is known about their aetiopathogenesis. Emerging risk factors will be discussed and other controversial risks with poor clinical evidence will be examined.

### 4.1. Major risk factors

---

#### 4.1.1. Tobacco

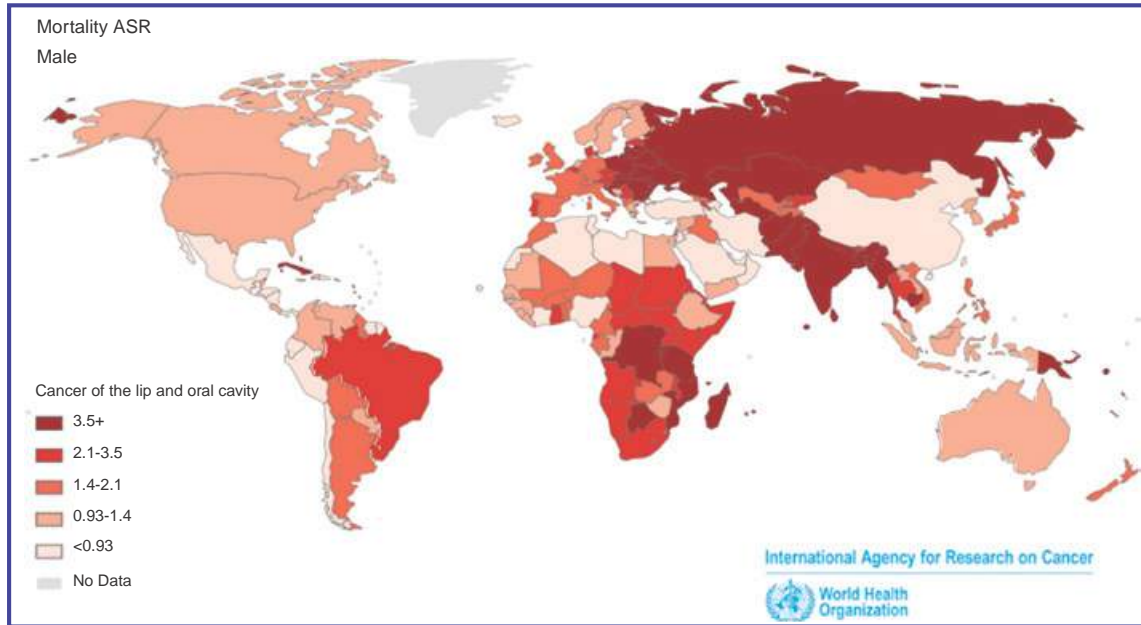
---

Approximately 1 billion men and 250 million women worldwide smoke tobacco, with an estimated 5.5 trillion cigarettes being produced every year (Petti, 2009). Worldwide studies report the OPSCC risk to be 3.43 times higher in smokers than in non-smokers (Gandini *et al.*, 2008). Therefore, OPSCC is one of the highest smoking-associated cancers, second only to lung cancer (Warnakulasuriya *et al.*, 2010). The OPSCC risk is linked to both the intensity and duration of smoking, being highest in patients with 20 smoking pack-years or more (Petti, 2009). Studies have highlighted the benefits of smoking cessation, with the risk falling from 3.43 to 1.40 in ex-smokers (Gandini *et al.*, 2008) and equalling that of ‘never smokers’ approximately 10 years after quitting (Warnakulasuriya *et al.*, 2010). Smokeless tobacco use also significantly increases the risk of OPSCC (Warnakulasuriya, 2009b). Smokeless tobacco usually comes in the form of snuff (finely ground or cut tobacco leaves) or chewing tobacco (loose leaf), and is currently banned from sale in the UK (Warnakulasuriya, 2009b). Smokeless tobacco consumption is more widespread in the USA, with an estimated 7% of high school students using smokeless tobacco (Gandini *et al.*, 2008).

OPSCC development (as for most cancers) is a multistage process in which DNA damage by exogenous carcinogens causes mutations, leading to the expression of oncogenes and the loss of tumour-suppressor genes (TSGs). There are over 60 known carcinogens in cigarette smoke and 16 in unburned tobacco; the two main ones are both linked to oral squamous cell carcinoma (Gandini *et al.*, 2008): tobacco-specific nitrosamines and polycyclic aromatic hydrocarbons. These carcinogens cause keratinocytes to undergo several genetic and epigenetic events until a malignant phenotype is acquired (i.e. cells become malignant) (Scully & Bagan, 2009).

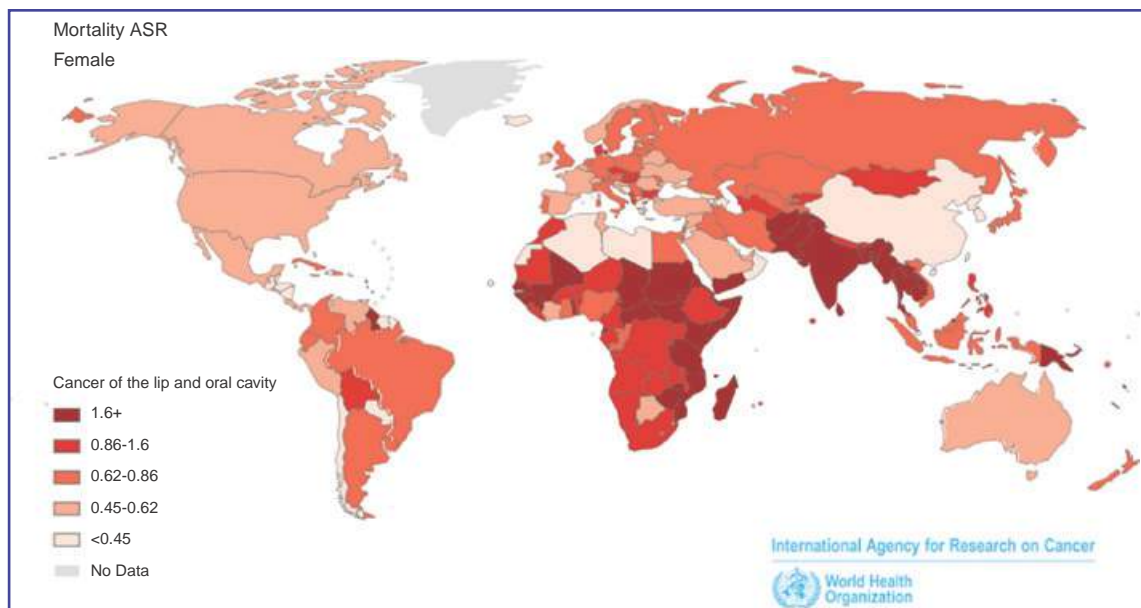
Normally, these carcinogens are metabolised by xenometabolising enzymes in the liver such as cytochrome P450 (CYP450). They can also be detoxified by antioxidant enzymes such as glutathione-S-transferase (GST) in the case of tobacco-specific nitrosamines (Warnakulasuriya *et al.*,





**Figure 4.4.** Age-standardised mortality (per 100,000) of men with oral cancer in 2012.

Source: Based on GLOBOCAN 2012 International Agency for Research on Cancer (<http://globocan.iarc.fr/Default.aspx>).



**Figure 4.5.** Age-standardised mortality (per 100,000) of women with oral cancer in 2012.

Source: Based on GLOBOCAN 2012 International Agency for Research on Cancer (<http://globocan.iarc.fr/Default.aspx>).

2010) or deactivated by *N*-acetyltransferases (NATs) for polycyclic aromatic hydrocarbons (Scully & Bagan, 2009) to non-toxic substances (Warnakulasuriya *et al.*, 2010). A failure in detoxification results in the formation of DNA adducts (Warnakulasuriya *et al.*, 2010), with the TSG *p53* commonly being mutated and loss of the chromosomal band 9p21–22 causing loss of the TSG *p16* (Hennessey, Westra & Califano, 2009). Normally *p16* blocks phosphorylation of the retinoblastoma protein (pRb), allowing it to control cell cycle regulation through association with the E2F transcription factor (Hennessey, Westra & Califano, 2009); therefore, loss of *p16* promotes cell cycle disruption and thus carcinogenesis.

#### 4.1.2. Alcohol

---

The World Health Organization estimates that almost 2 billion people worldwide consume alcohol, with almost 80 million of these having a diagnosable alcohol abuse disorder (Petti, 2009). In the UK, there is increasing evidence to suggest that the rise in OPSCC in the younger population is associated with an increased intake of alcohol (Warnakulasuriya, 2009b). Although this link has been established for some time, the mechanism of carcinogenesis has only recently been postulated.

Alcohol is oxidised to acetaldehyde by alcohol dehydrogenases in the oral epithelium and further degraded to acetate by aldehyde dehydrogenases (Scully & Bagan, 2009). Acetaldehyde is the molecule responsible for the oral carcinogenic effect of ethanol owing to its mutagenic effects on DNA (Petti, 2009). It causes DNA adducts, DNA cross-links, aneuploidy and chromosomal aberrations (Hooper, Wilson & Crean, 2009).

#### 4.1.3. Smoking and drinking

---

The synergistic effect between tobacco carcinogens and alcohol consumption in OPSCC is well documented (Warnakulasuriya, 2009b). Smokers exposed to ethanol demonstrated up to seven times higher concentrations of salivary acetaldehyde compared with non-smokers (Hooper, Wilson & Crean, 2009). Studies have also found a greater than multiplicative risk for oral cancer in people who are both alcohol drinkers and heavy tobacco smokers (Hashibe *et al.*, 2009). Proposed mechanisms are that smoking may increase the acetaldehyde burden and that alcohol enhances the activation of pro-carcinogens in tobacco (Seitz & Cho, 2009).

#### 4.1.4. Betel quid

---

Betel quid encompasses a variety of different ingredients. However, the most common are Betel (*Piper betle*) leaves, which are used to envelop the other ingredients, areca nut and alkaline agents (e.g. lime (calcium oxide), slaked lime (calcium hydroxide) or catechu extract) that are necessary for sublingual absorption, and various spices, flavourings and tobacco (Petti, 2009). Betel quid is popular in South and South-East Asia and in migrant communities in Western countries, with an estimated 10–20% of the world's population being consumers (Petti, 2009).

Betel quid is carcinogenic to humans (both with and without added tobacco) (Warnakulasuriya, 2009b) and was confirmed as a carcinogen by the International Agency for Research on Cancer (Scully & Bagan, 2009), although its mechanism of action is not fully understood. When chewed, it has been shown to produce carcinogenic nitrosamines and reactive oxygen species in the oral cavity (Petti, 2009).

Studies also show that arecoline (the main alkaloid in areca nut) can block the *p14* and *p15* TSGs, as well as *p16* and *p53* (Scully & Bagan, 2009). These effects may therefore trigger DNA damage and suppress its repair in the epithelial cells of users.

## 4.2. Emerging risk factors

### 4.2.1. Human papillomavirus

At the beginning of the 1980s, the incidence of OPSCC in Western countries had begun to decrease, a phenomenon linked to trends in smoking cessation (Westra, 2009). At the same time, human papillomavirus (HPV) prevalence began increasing in HNSCCs: the incidence of HPV-positive HNSCC had increased by 225% and the incidence of HPV-negative cancers had fallen by 50% by 2004 (Chaturvedi *et al.*, 2011). Current estimates suggest that 40–80% of HNSCC in the USA are caused by HPV, whereas in Europe the proportion varies from around 90% in Sweden to <20% in communities with the highest rates of tobacco use (Marur *et al.*, 2010). This increased incidence is occurring in white men aged 40–55 years with no history of tobacco or alcohol use (Marur *et al.*, 2010). The link between HPV and HNSCC is strongest for tonsillar cancer and OPSCC and weakest for oral cancer (Hennessey, Westra & Califano, 2009).

HPV is a 7.9 kb circular, non-enveloped, double-stranded DNA virus that infects squamous epithelial cells and HPV infection is manifested by skin warts, cervix lesions and anogenital cancers (Hennessey, Westra & Califano, 2009). Over 120 subtypes have been described, with further division made into high- and low-risk groups based on their ability to cause malignancy (Hennessey, Westra & Califano, 2009). Of the high-risk groups, up to 90% of HPV-associated HNSCCs are caused by HPV-16, the same subtype that causes anogenital cancers (Marur *et al.*, 2010). HPV-16 seropositivity is associated with an increased risk of developing HPV-positive oral squamous cell carcinoma (OSCC), regardless of a history of smoking or drinking (Hennessey, Westra & Califano, 2009).

Studies have shown that the prevalence of HPV-associated OPSCC is higher in men and in those infected with human immunodeficiency virus, and increases with the number of lifetime oral and vaginal sexual partners (Marur *et al.*, 2010). Additionally, a history of genital warts, a younger age at first intercourse (Hennessey, Westra & Califano, 2009) and a history of oral–anal sex are reported risk factors for HPV infection (Westra, 2009). The prevalence of HPV in cervical rather than penile tissue may increase the chances of HPV infection during oral sex, therefore explaining the higher rate of HPV-associated OSCC in men (Marur *et al.*, 2010).

High-risk HPVs target the reticulated epithelium of the tonsils, causing genomic instability by integration into the host DNA genome, leading to expression of the E6 and E7 viral oncoproteins (Marur *et al.*, 2010). E6 binding to p53 protein causes its degradation, thus diminishing its ability to induce programmed apoptosis (Marur *et al.*, 2010). In addition, E7 binds and degrades the pRb, resulting in the loss of cell cycle control (Hennessey, Westra & Califano, 2009). Therefore, unlike OPSCCs caused by traditional risk factors, HPV-positive OPSCCs show reduced expression of wild-type p53 with no depletion of p16 (Marur *et al.*, 2010).

### 4.2.2. Diet

---

The antioxidant properties of plant food components (e.g. vitamins A, C and E, flavonoids and folate) are well documented (Lucenteforte, 2009), as is their beneficial role in protecting against exogenous carcinogens (Scully & Bagan, 2009). Studies have shown a reduction in the risk of OPSCC of up to 50% in those who consume adequate amounts of fresh fruits and vegetables (Warnakulasuriya, 2009b); however, those who smoke and drink have been shown to consume low levels of these foods, suggesting the possibility of confounding (Petti, 2009). Smokers tend to consume fewer vegetables compared with non-smokers, and heavy alcohol drinkers also tend to limit their intake of essential nutrients (Lucenteforte, 2009).

### 4.2.3. Mate drinking

---

Mate (*Ilex paraguariensis*) is an infusion of leaves that is drunk through a hot metal straw in parts of South America. Several epidemiological studies conducted in the area, which were adjusted for other risk factors, estimated an increased risk of oral cancer of 2.11 times (Warnakulasuriya, 2009b). It is postulated that chronic irritation to oral mucosa caused by the hot temperature could explain its carcinogenic potential (Warnakulasuriya, 2009b).

## 4.3. Controversial factors: limited evidence

---

### 4.3.1. Ethnicity and race

---

OPSCC rates vary considerably among racial and ethnic groups through the world; however, this is most probably due to lifestyle differences as opposed to genetic factors.

### 4.3.2. Oral health and microorganisms

---

OPSCC is less likely to occur in those who receive regular dental care (Scully & Bagan, 2009). A modest association exists between periodontal disease (but not tooth loss) and OPSCC [21]; however, there is limited evidence to support this link. Instead, the effect of poor hygiene on OPSCC may be manifested through microbial interactions because dental plaque has been shown to have a mutagenic interaction with saliva, and both oral Streptococci and *Neisseria* spp. have been shown to synthesise acetaldehyde (Scully & Bagan, 2009).

The oral cavity contains over 750 distinct taxa of bacteria which reside in the normal individual without any pathological consequence. Cigarette smoking can cause the growth of selective tar-resistant *Staphylococcus aureus*, which has been implicated in oral carcinogenesis (Hooper, Wilson & Crean, 2009), and higher levels of *Candida albicans* (a species well known to cause premalignant lesions) have been found on OPSCC surfaces (Hooper, Wilson & Crean, 2009). OPSCC patients harbour more pathogenic bacteria (including *Clostridium*, *Haemophilus*, Enterobacteriaceae and *Streptococcus* spp.) on the biofilm surfaces of their tumours compared with controls (Hooper, Wilson & Crean, 2009).

### 4.3.3. Indoor air pollution

---

Some studies have demonstrated a link between OPSCC and daily exposure to fossil fuels from heating and cooking stoves (oil, coal or wood), thought to be perpetuated by volatile carcinogenic by-products (Warnakulasuriya, 2009b). However, there is little evidence for this, with no major epidemiological studies confirming a potential link.

## 4.4. Controversial factors: inconsistent evidence

---

There is no conclusive evidence that oral cancer has a hereditary basis or that it is associated with regular marijuana use (Warnakulasuriya, 2009b). In addition, the tenuous causality proposed between a low body mass index and OPSCC needs further clarification (Gaudet *et al.*, 2010). Khat (*Catha edulis*) chewing is often linked to OPSCC; however, despite causing oral leukoplakia in a few studies, no epidemiological studies have demonstrated such a link (Warnakulasuriya, 2009b). Nor is there a consistent link between nicotine replacement therapy (Warnakulasuriya, 2009b), human immunodeficiency virus infection (Warnakulasuriya, 2009b) or mouthwash use and OPSCC (La Vecchia, 2009).

## 5. DIAGNOSIS

---

### 5.1. Importance of early diagnosis

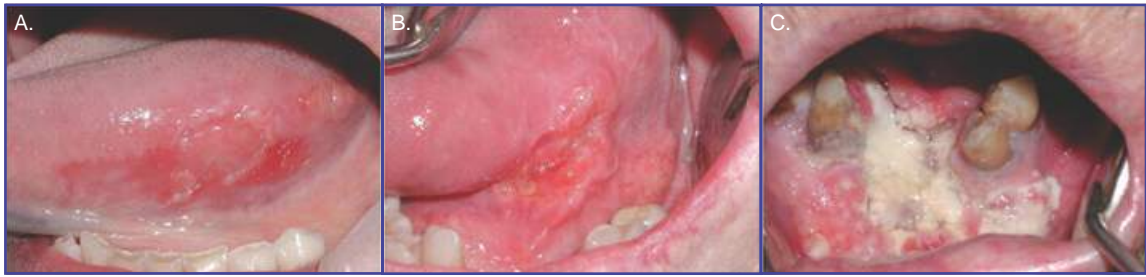---

Tumour staging at the time of OPSCC diagnosis is recognised to be an imperative prognostic marker for survival (Gomez *et al.*, 2009). Despite this, half of OPSCC diagnoses are made at stages III or IV, which have survival rates of 20–50% depending on the subsite (Gomez *et al.*, 2010; Gomez *et al.*, 2009). As well as improving survival rates (by up to 90% for early stage cancers) (Bagan, Sarrion & Jimenez, 2010), evidence suggests that an early diagnosis can also decrease the morbidity associated with treatment (Gomez *et al.*, 2010). *Diagnostic delay* is the number of days that elapsed from the patient noticing their first symptom or sign until a definitive diagnosis is reached (Gomez *et al.*, 2010), and reducing this delay is arguably pivotal in the battle against OPSCC.

### 5.2. Conventional oral examination

---

The preliminary part of OPSCC diagnosis involves a thorough visual examination of the oral cavity (especially the sides of the tongue and floor of mouth) by a trained clinician. OPSCC lesions vary in size, ranging from a few millimetres to several centimetres in advanced cases. The focus of a good examination includes the identification of abnormalities in any of the cervical lymph nodes. Incandescent white light is widely used to aid the visual examination of suspicious oral lesions; however, delineating boundaries using this method is not easy and choosing the correct biopsy site is thus greatly reliant on examiner experience (Roblyer *et al.*, 2009).



**Figures 4.6.** Variations in the clinical presentation of oral cancer. (A) An erythroplastic lesion on the tongue; (B) an ulcerated lesion of the tongue; (C) an advanced floor of mouth tumour.

Source: Bagan, Sarrion & Jimenez, 2010.

### 5.3. Clinical features

Most OPSCC lesions are preceded by white (leukoplakia) or red (erythroplakia) patches on the oral mucosa (Fedele, 2009), with a particular suspicion for single oral lesions lasting more than 3 weeks (Bagan, Sarrion & Jimenez, 2010).

#### 5.3.1. Symptoms

Early oral carcinomas are often asymptomatic. However, common symptoms are listed below.

- Early lesions are usually erythroleukoplakic
- Well-demarcated lesion
- Potentially 'indurated' lesion
- Pain (common symptom)
- Lesions involve the tongue or floor of mouth (Bagan, Sarrion & Jimenez, 2010), especially when the lesion is a significant size (Cuffari *et al.*, 2006).

Less common symptoms (Bagan, Sarrion & Jimenez, 2010):

- Ear pain
- Mobility of teeth
- Speech difficulties
- Dysphagia
- Trismus
- Paraesthesia
- Cervical lymphadenopathy (in the absence of other symptoms) ~5% of cases (Bagan, Sarrion & Jimenez, 2010).

Symptoms in the terminal stages (Bagan, Sarrion & Jimenez, 2010):

- Skin fistulas

- Bleeding
- Ulceration
- Fixation to underlying tissues
- Severe anaemia
- Cachexia may be present.

### 5.3.2. Location

---

OPSCC can appear in any location; however, it is commonly found on the tongue and the floor of the mouth (Hirata *et al.*, 1975; Mashberg *et al.*, 1989). The buccal mucosa, retromolar area, gingiva, soft palate and, less frequently, the back of the tongue and hard palate can also be involved (Hirata *et al.*, 1975; Mashberg *et al.*, 1989).

## 5.4. Tests to aid diagnosis

---

Ultimately, diagnostic confirmation of OPSCC requires an adequate tissue biopsy. A variety of diagnostic techniques currently exist to help identify malignant lesions that may otherwise be hidden from visual inspection with normal incandescent light (Fedele, 2009). These include:

- Toluidine blue (TB)
- Brush biopsy
- Chemiluminescence
- Autofluorescence
- Confocal endomicroscopy
- Optical tomography.

## 5.5. Toluidine blue staining

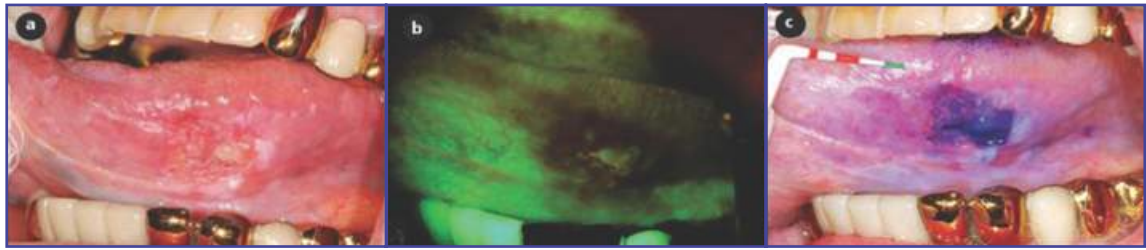
---

TB is a dye that stains nucleic acids and has therefore been used for years to identify suspicious mucosal lesions. Although studies show TB to be good at detecting carcinomas, it generates a high percentage of false positives. This puts its use in the primary care setting into question. Thus, it is best used by experienced clinicians (Fedele, 2009).

## 5.6. Brush biopsy

---

Brush biopsy (BB) is an intermediate diagnostic step that uses a specific brush to collect transepithelial cells from mucosal abnormalities. Any that test positive then undergo biopsy (Fedele, 2009). Although studies show BBs to be highly sensitive in high-risk populations, the rate of false positives increases in low-risk populations (Fedele, 2009).



**Figure 4.7.** Variations in the visibility of oral lesions with different diagnostic tools. (A) Appearance of an oral lesion under white light; (B) appearance of the same lesion under direct fluorescence visualisation; (C) the same lesion stained with toluidine blue dye.

Source: Poh *et al.*, 2008.

## 5.7. Chemiluminescence

This technique relies on the principle that normal oral mucosa appears blue and abnormal mucosa appears white when blue–white light of wavelength 490–510 nm is shone onto lesions (when pre-rinsed with 1% acetic acid) (Fedele, 2009). Although studies have advocated its use in differentiating normal tissue from carcinomas, there is less evidence that it can distinguish dysplasia from normal tissue (Fedele, 2009).

## 5.8. Autofluorescence

When stimulated with blue–violet light of wavelength 400–460 nm, redistribution of the fluorophores in oral tissue produces a light specific to that tissue that is known as autofluorescence (Fedele, 2009). The clinician can visualise the autofluorescence using certain filters: normal oral mucosa emits a pale green light and neoplastic lesions appear darker (Roblyer *et al.*, 2009). Autofluorescence has been shown to have sensitivities of 96–100% and a specificity of 91–96% when the images are compared with a histological analysis (Roblyer *et al.*, 2009), thus allowing the effective identification of lesions not otherwise visible to the naked eye (Fedele, 2009).

## 5.9. Confocal laser endomicroscopy

Using a laser scanner at the tip of a video endoscope, confocal laser endomicroscopy combines the power of a confocal microscope with the clinical benefits of an endoscope (Haxel *et al.*, 2010). This enables the clinician to examine the vascular, connective tissue and cellular components of the oral mucosa in ‘real time’, with studies showing it to be effective in examining the anterior parts of the oral cavity (Haxel *et al.*, 2010).



---

## 5.10. Optical tomography

---

Optical tomography is an imaging technique which uses the principles of ultrasound to examine subsurface reflections on tissue and produce a three-dimensional image to micrometre resolutions (Jerjes *et al.*, 2010). Compared with the histopathological analysis of oral lesions, studies found optical tomography to be good at identifying diseased areas; however, it is poor at providing an actual diagnosis or at differentiating between lesions (Jerjes *et al.*, 2010). Recent research found that delivery of gold nanoparticles to oral lesion sites enhanced *in vivo* optical tomography images of oral dysplasia; however, this was an animal study and further research in this field is therefore needed (Kim *et al.*, 2009).

---

## 5.11. Diagnosis from saliva

---

Measuring specific saliva molecules may represent an additional diagnostic branch in oral cancer diagnosis and prognosis (Nagler, 2009). Despite no validated markers being currently available, studies have shown alterations to many biomarkers in the saliva of oral cancer patients, including tumour necrosis factor alpha, some interleukins and cancer antigen 125 (Nagler, 2009; Pfaffe *et al.*, 2011). In addition, studies have shown that the microRNAs miR-125a and miR-200a are present in significantly lower levels in the saliva of OPSCC patients (Park *et al.*, 2009). Such salivary biomarkers could provide better diagnostic aids for oral cancer in the future.

---

## 5.12. Serum C-reactive protein

---

In a study to assess the predictive value of pre-operative C-reactive protein in oral cancer patients, raised values were shown to be associated with worse overall survival. In combination with tumour size and stage, they were able to give a better prediction of survival (Khandavilli *et al.*, 2009).

---

## 5.13. Human papillomavirus diagnosis

---

Currently, HPV can be detected using the polymerase chain reaction, *in situ* hybridisation and immunohistochemical methods to detect biomarkers such as p16 (Westra, 2009). Whereas studies have shown the polymerase chain reaction to be clinically limited, modifications to the *in situ* hybridisation process have made it very sensitive; when combined with its feasibility and cost-effectiveness, this makes it a popular tool in HPV diagnostics (Westra, 2009).

---

## 5.14. Screening

---

The World Health Organization and the International Agency for Research on Cancer advise that a significant number of preventable cancer cases can be reduced through effective screening, including

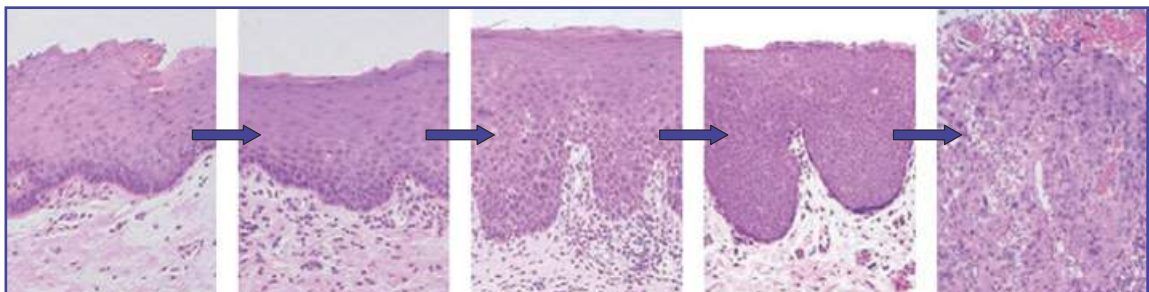
oral cancer (Fedele, 2009). Despite this, a lack of public awareness and poor detection by health-care providers means that oral cancer is still being diagnosed at advanced stages (Fedele, 2009). Randomised controlled trials in India have found that an active screening arm led to earlier detection (stages I or II) when compared with controls (Subramanian, 2009), with health professionals in the field concurring that screening can result in the detection of early oral cancers (Rethman *et al.*, 2010). Currently, there is no screening programme in the UK; thus, developing one may result in the reduction of morbidity and mortality in high-risk groups of individuals.

## 6. HISTOPATHOLOGY

Morphologically, HPV-negative OPSCCs differ from HPV-positive ones; therefore, their histology is described separately in this section.

### 6.1. HPV-negative OPSCC

HPV-negative cancers are usually moderately differentiated and keratinising and involve dysplastic changes to the epithelium of the oral mucosa (Marur *et al.*, 2010). Dysplasia is graded by the extent of involvement of the overall thickness of the epithelial layers, with mild dysplasia involving architectural changes confined to the lower third and severe dysplasia involving more than two-thirds of, but not the entire, thickness (Poh *et al.*, 2008). Carcinoma *in situ* occupies the entire epithelium thickness, whereas invasive squamous cell carcinoma invades the underlying connective tissue stroma through the basement membrane (Poh *et al.*, 2008).



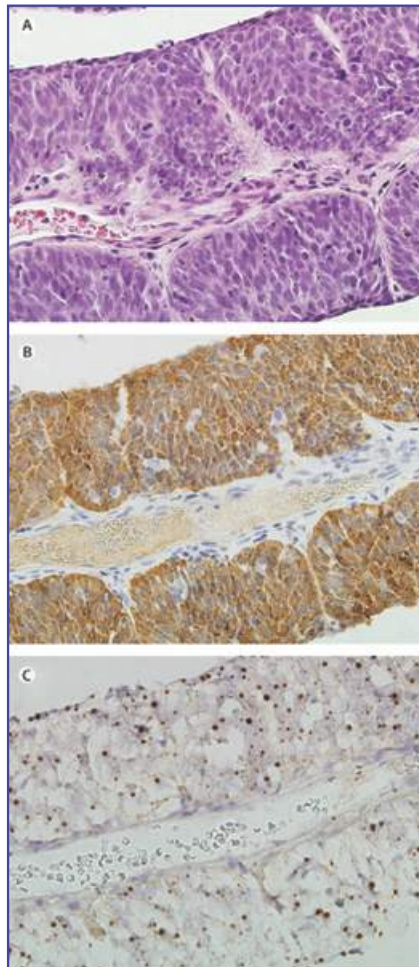
**Figure 4.8.** Variations in dysplasia in oropharyngeal squamous cell carcinoma. Slides demonstrating the histological progression from hyperplasia to mild dysplasia, moderate dysplasia and severe dysplasia. The final slide shows an invasive squamous cell carcinoma.

Source: Poh *et al.*, 2008.

## 6.2. HPV-positive OPSCC

Typically, HPV-positive OPSCC is not associated with dysplasia of the surface epithelium (Marur *et al.*, 2010). Instead, these cancers (Marur *et al.*, 2010):

- Show lobular growth
- Are permeated by infiltrating lymphocytes
- Undergo no significant keratinisation
- Have prominent basaloid morphology.



**Figure 4.9.** HPV-positive oropharyngeal cancer. Metastatic non-keratinised squamous cell carcinoma with (a) haematoxylin and eosin staining; (b) nuclear staining for p16 and (c) *in situ* hybridisation for HPV-16.

Source: Marur *et al.*, 2010.

## 7. STAGING

### 7.1. Pretreatment investigations

Not only is pretreatment staging imperative in OPSCC, but thorough documentation of tumour size and anatomical location (using photographs and diagrams) is also essential for the adequate management of affected patients. This can be achieved to some extent by a good physical examination and biopsy, but also relies heavily on radiological modalities to give accurate information about clinically hidden lesions. Most experts in the field agree that computed tomography imaging gives better overall information than magnetic resonance imaging regarding the cancer site and, especially, the extent of extracapsular nodal extension (Patel & Shah, 2005). An orthopantomogram is also a simple but useful radiological modality for assessing bone involvement.

### 7.2. TNM staging

The tumour–node–metastasis (TNM) system uses anatomical information to gauge the extent of tumour progression and local, regional or distant metastases. Currently, the TNM staging of HNSCC is in its 7th edition, with only minor modifications applied to the previously comprehensive 6th edition. However, despite advancements, this manual is still formulated to a great extent from clinical expertise and opinion, as a real absence of level I evidence in the field still exists (Patel & Shah, 2005). Interestingly, most HPV-associated tumours present at an early tumour stage but an advanced nodal stage, often with multilevel cystic nodal metastases (Marur *et al.*, 2010). Tables 4.1, 4.2 and 4.3 highlight the TNM staging guidelines for tumors attaching the lip, oral cavity and oropharynx outlined in the 6th edition.

**Table 4.1.** T staging for tumours of the lip, oral cavity and pharynx.

All	T <sub>x</sub>	Primary tumour cannot be assessed
	T <sub>0</sub>	No evidence of primary tumour
	T <sub>is</sub>	Carcinoma <i>in situ</i>
Lip and oral cavity	T <sub>1</sub>	Tumor 2 cm or less in greatest dimension
	T <sub>2</sub>	Tumor between 2 cm and 4 cm in the greatest dimension
	T <sub>3</sub>	Tumor >4 cm in greatest dimension
	T <sub>4a</sub>	Lip: tumour invades cortical bone, inferior alveolar nerve, floor of mouth or skin of face
		Oral cavity: tumor invades cortical bone, into deep (extrinsic) cavity muscle of tongue (genioglossus, hyoglossus, palatoglossus, and styloglossus), maxillary sinus or skin of the face
	T <sub>4b</sub>	Tumor involves masticator space, pterygoid plates or skull base and/or encases internal carotid artery

**Table 4.1.** (cont.)

Oropharynx	T <sub>1</sub>	Tumour 2 cm or less in greatest dimension
	T <sub>2</sub>	Tumour between 2 cm and 4 cm in greatest dimension
	T <sub>3</sub>	Tumour more than 4 cm in greatest dimension
	T <sub>4a</sub>	Tumour invades the larynx, deep/extrinsic muscle of tongue, medial pterygoid, hard palate, or mandible
	T <sub>4b</sub>	Tumour invades lateral pterygoid muscle, pterygoid plates, lateral nasopharynx, or skull base or encases carotid artery

Source: AJCC cancer staging Manual (2002). Chicago Springer, 17–80.

**Table 4.2.** N staging for oropharyngeal cancers.

N <sub>x</sub>	Regional lymph nodes cannot be assessed
N <sub>0</sub>	No regional lymph node metastasis
N <sub>1</sub>	Metastasis in a single ipsilateral lymph node, 3 cm or less in greatest dimension
N <sub>2a</sub>	Metastasis in a single ipsilateral lymph node between 3 cm and 6 cm in greatest dimension
N <sub>2b</sub>	Metastasis in multiple ipsilateral lymph nodes, none more than 6 cm in greatest dimension
N <sub>2c</sub>	Metastasis in bilateral or contralateral lymph nodes, none more than 6 cm in greatest dimension
N <sub>3</sub>	Metastasis in a lymph node more than 6 cm in greatest dimension

Source: AJCC cancer staging Manual (2002). Chicago Springer, 17–80.

**Table 4.3.** M staging for oropharyngeal cancers.

M <sub>x</sub>	Distant metastasis cannot be assessed
M <sub>0</sub>	No distant metastasis
M <sub>1</sub>	Distant metastasis

Source: AJCC cancer staging Manual (2002). Chicago Springer, 17–80.

## 8. MANAGEMENT

### 8.1. Rationale behind oral cancer treatment

Treatment of oral cancer can cause serious debilitation and disfigurement in patients, affecting their speech, swallowing, mastication and, most importantly, their ability to interact socially (Fedele, 2009). Therefore, those that provide the treatment should never lose sight of these issues. Surgery remains the mainstay of treatment for locally advanced oropharyngeal cancer (T<sub>3,4</sub> or N<sub>2,3</sub>), either with adjuvant radiotherapy or concurrent chemoradiation (Marur *et al.*, 2010). Regardless of treatment offered, the cancer should be eradicated and subsequent cancers prevented, while maintaining and restoring the

form and function where possible (Shah & Gil, 2009). Factors affecting the treatment of oral cancer are summarised in Table 4.4.

## 8.2. Surgical approaches to oral cancer

This section provides a brief overview on the surgical techniques used in the management of oral cancer, but does not give detailed descriptions of each approach. Regardless of the location of the tumour or the surgical approach chosen, an initial examination under anaesthesia can prove useful to accurately delineate the tumour boundaries. Following this, the main principles of surgical resection are (Kalavrezos & Bhandari, 2010):

- Adequate tumour exposure prior to removal
- The avoidance of unnecessary and conspicuous incisions
- Access for the reconstruction of any defects left.

The most commonly used approaches are (Shah & Gil, 2009):

- Intraoral
- Mandibulotomy
- Lower cheek flap approach
- Visor flap approach
- Upper cheek flap approach (Weber–Ferguson incision)

**Table 4.4.** Factors affecting treatment choice.

Tumour factors	Primary site	The biology of OSCC varies from site to site
	Size (T stage)	Larger tumours require more complex surgery
	Location	Anterior versus posterior – affects surgery and risk of dissemination
	Proximity to bone	Involvement of mandible or maxilla requires more complex surgery
	Cervical lymph node status	Affect overall outcome
	Previous treatment	Especially in same area – re-operating will be more difficult
Patient factors	Histology	Type, grade and depth of invasion: HPV can all affect prognosis and treatment success
	Age	Older patients tend not to do as well
	Co-morbidities	Increased post-operative complications
	Lifestyle factors	Refusing to stop smoking means cancers can come back
	Compliance	Poor compliance will affect patient outcome
Physician factors	Tolerance	Some patients less likely to tolerate aggressive therapies
	Expertise	Essential when dealing with complex cancers
	MDT	Need to provide support for the patient in a holistic manner, helping them deal with medical and non-medical problems they are likely to encounter
	Facilities	Specialist services may not be available in all areas

As tumours of the oral cavity spread through dental sockets and pores into the mandibular cancellous core, marginal mandibulectomy remains feasible where only limited invasion of the alveolar process has occurred (Shah & Gil, 2009). Caution must be taken in patients previously irradiated with radiotherapy because marginal mandibulectomy can cause pathological fractures (Shah & Gil, 2009). Segmental mandibulectomy can be used if extensive disease is present in the mandible, usually regardless of pathology (Shah & Gil, 2009).

### 8.3. Reconstructive surgery

The main goals of reconstructive surgery following any of the management options are (Kalavrezos & Bhandari, 2010):

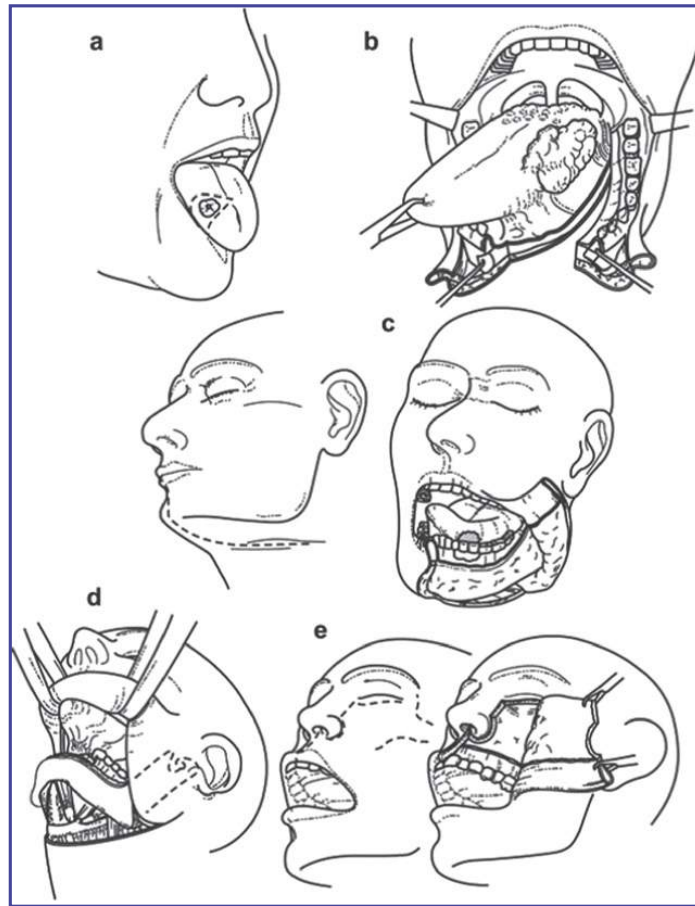
- External wound coverage
- Restoring bony stability
- Restoring dentition
- Restoring a stable oral cavity
- Allowing oral nutrition
- Minimising cosmetic defects.

Multiple flaps are used in oral reconstructive surgery, and deciding which one depends very much on the amount and types of tissue required to fill defects. Table 4.5 outlines the main flap types and their composition together with anatomical examples used.

## 9. PROGNOSIS

Despite surgical advancements for OPSCC, mortality rates remain largely unchanged (Marsh *et al.*, 2011). Other than actual tumour staging and treatment, co-morbidity burden, race and performance status are all factors which affect prognosis (Paleri *et al.*, 2010). Some studies suggest factors such as stromal involvement are the most accurate for predicting the outcome of OPSCC lesions (Marsh *et al.*, 2011), whereas others show that patterns of tumour invasion and differentiation, together with cervical node involvement, to be the most important (Rogers *et al.*, 2009). Indeed, lymph node density has consistently been shown to be a significant predictor of 5-year survival (Gil *et al.*, 2009), with nodal metastasis being significantly related to tumour grade, depth and invasion (Larsen *et al.*, 2009).

The co-morbidity burden is particularly important in OPSCC patients because almost 60% have concurrent illnesses at the time of diagnosis (Paleri *et al.*, 2010). Patients with numerous co-morbidities are more likely to have diagnostic delays and post-operative complications, and be limited in the aggressiveness of any treatment (Paleri *et al.*, 2010). Additionally, the interval from initial treatment to recurrence has been shown to affect prognosis, with those who demonstrate recurrence in less than 18 months more likely to die (Mücke *et al.*, 2009).



**Figure 4.10.** Surgical approaches to oral cancer: (a) preoral; (b) mandibulotomy; (c) lower cheek flap approach; (d) visor flap approach; (e) upper cheek flap approach.

*Source:* Shah and Gil, 2009.

**Table 4.5.** Flaps used in oral reconstructive surgery.

Fasciocutaneous	Skin, subcutaneous tissue and fascia	Radial forearm
Myocutaneous	Skin and muscle	Anterolateral thigh perforator flap
		Latissimus dorsi
		Rectus abdominis
		Pectoralis major flap
Composite	Bone and soft tissue	Fibula free flap
		Scapula free flap
		DCIA flap, either:
		– DCIA osseocutaneous perforator flaps; or
		– DCIA bone with internal oblique muscle flap

DCIA = descending circumflex iliac artery.

*Source:* Adapted from Kalavrezos & Bhandari, 2010.<sup>43</sup>



Studies have consistently shown that HPV-positive oropharyngeal cancer responds better to chemotherapy and radiation (Hennessey, Westra & Califano, 2009; Marur *et al.*, 2010), with overall survival at 2 years of 94% compared with 58% in HPV-negative cancers (Fakhry *et al.*, 2008). Additionally, HPV-positive cancers showed lower rates of locoregional failure to respond to treatment and of a second primary tumour. As this subset of patients is less likely to be exposed to the traditional lifestyle risk factors associated with oral cancer, they do not have the co-morbidity burdens associated with them, or the *field cancerisation* caused by them (Westra, 2009; Marur *et al.*, 2010), which explains why they may do better. As these patients also typically do not have a mutated *p53* gene, they possess a better apoptotic cellular response that helps to destroy any abnormal cells created by the treatment modalities (Hennessey, Westra & Califano, 2009).

## 9.1. Second primary malignancy

Second primary malignancies account for a third of deaths secondary to HNSCC (which is three times the amount caused by metastatic disease), thus making it the main long-term cause of mortality in HNSCC patients. They also illustrate the concept of field cancerisation, with their risk and distribution varying greatly by the subsite of the index cancer (Morris *et al.*, 2011).

## REFERENCES

- Bagan, J., Sarrion, G., Jimenez, Y. Oral cancer: clinical features. *Oral Oncol.* 2010;46(6):414–17.
- Chaturvedi, A. K., Engels, E. A., Pfeiffer, R. M., Hernandez, B. Y., Xiao, W., Kim, E., et al. Human papillomavirus and rising oropharyngeal cancer incidence in the United States. *J Clin Oncol.* 2011;29(32):4294–301.
- Conway, D. I., Hashibe, M., Boffetta, P., consortium, I., Wunsch-Filho, V., Muscat, J., et al. Enhancing epidemiologic research on head and neck cancer: INHANCE – The International Head and Neck Cancer Epidemiology Consortium. *Oral Oncol.* 2009;45(9):743–6.
- Cuffari, L., Tesseroli, de Siqueira, J. T., Nemr, K., Rapaport, A. Pain complaint as the first symptom of oral cancer: a descriptive study. *Oral Surg Oral Med Oral Pathol Oral Radiol Endod.* 2006;102(1):56–61.
- Divaris, K., Olshan, A.F., Smith, J., Bell, M.E., Weissler, M.C., Funkhouser, W.K., et al. Oral health and risk for head and neck squamous cell carcinoma: the Carolina Head and Neck Cancer Study. *Cancer Causes Control.* 2010;21(4):567–75.
- Fakhry, C., Westra, W. H., Li, S., Cmelak, A., Ridge, J. A., Pinto, H., et al. Improved survival of patients with human papillomavirus-positive head and neck squamous cell carcinoma in a prospective clinical trial. *J Natl Cancer Inst.* 2008;100(4):261–9.
- Fedele, S. Diagnostic aids in the screening of oral cancer. *Head Neck Oncol.* 2009;1:5.
- Gandini, S., Botteri, E., Iodice, S., Boniol, M., Lowenfels, A. B., Maisonneuve, P., et al. Tobacco smoking and cancer: a meta-analysis. *Int J Cancer.* 2008;122(1):155–64.
- Gaudet, M.M., Olshan, A.F., Chuang, S.C., Berthiller, J., Zhang, Z.F., Lissowska, J., et al. Body mass index and risk of head and neck cancer in a pooled analysis of case-control studies in the International Head and Neck Cancer Epidemiology (INHANCE) Consortium. *Int J Epidemiol.* 2010;39(4):1091–102.
- Gil, Z., Carlson, D. L., Boyle, J. O., Kraus, D. H., Shah, J. P., Shaha, A. R., Singh, B., Wong, R. J., Patel, S. G. Lymph node density is a significant predictor of outcome in patients with oral cancer. *Cancer.* 2009;5700–10.

- Gomez, I., Warnakulasuriya, S., Varela-Centelles, P.I., Lopez-Jornet, P., Suarez-Cunqueiro, M., Diz-Dios, P., et al. Is early diagnosis of oral cancer a feasible objective? Who is to blame for diagnostic delay? *Oral Dis.* 2010;16(4):333–42.
- Gomez, I., Seoane, J., Varela-Centelles, P., Diz, P., Takkouche, B. Is diagnostic delay related to advanced-stage oral cancer? A meta-analysis. *Eur J Oral Sci.* 2009;117:541–6.
- Hashibe, M., Brennan, P., Chuang, S. C., Boccia, S., Castellsague, X., Chen, C., et al. Interaction between tobacco and alcohol use and the risk of head and neck cancer: pooled analysis in the International Head and Neck Cancer Epidemiology Consortium. *Cancer Epidemiol Biomarkers Prev.* 2009;18(2):541–50.
- Haxel, B. R., Goetz, M., Kiesslich, R., Gosepath, J. Confocal endomicroscopy: a novel application for imaging of oral and oropharyngeal mucosa in human. *Eur Arch Otorhinolaryngol.* 2010;267(3):443–8.
- Hennessey, P. T., Westra, W. H., Califano, J. A. Human papillomavirus and head and neck squamous cell carcinoma: recent evidence and clinical implications. *J Dent Res.* 2009;88(4):300–6.
- Hirata, R. M., Jaques, D. A., Chambers, R., Tuttle, J. R., Mahoney, W. D. Carcinoma of the oral cavity. *Ann Surg.* 1975;182(2):98–103.
- Hooper, S. J., Wilson, M. J., Crean, S. J. Exploring the link between microorganisms and oral cancer: a systematic review of the literature. *Head Neck.* 2009;31(9):1228–39.
- Jerjes, W., Upile, T., Conn, B., Hamdoon, Z., Betz, C. S., McKenzie, G., et al. In vitro examination of suspicious oral lesions using optical coherence tomography. *Br J Oral Maxillofac Surg.* 2010;48(1):18–25.
- Johnson, N. W., Warnakulasuriya, S., Gupta, P. C., Dimba, E., Chindia, M., Otoh, E. C., et al. Global oral health inequalities in incidence and outcomes for oral cancer: causes and solutions. *Adv Dent Res.* 2011;23(2):237–46.
- Kalavrezos N, Bhandari R. Current trends and future perspectives in the surgical management of oral cancer. *Oral Oncol.* 2010;46(6):429–32.
- Khandavilli, S. D., Ceallaigh, P. O., Lloyd, C. J., Whitaker, R. Serum C-reactive protein as a prognostic indicator in patients with oral squamous cell carcinoma. *Oral Oncol.* 2009;45(10):912–4.
- Kim, C. S., Wilder-Smith P., Ahn, Y. C., Liaw, L. H., Chen, Z., Kwon, Y. J. Enhanced detection of early-stage oral cancer in vivo by optical coherence tomography using multimodal delivery of gold nanoparticles. *Journal of Biomedical Optics.* 2009;14(3):034008.
- Larsen, S. R., Johansen, J., Sorensen, J. A., Krogdahl, A. The prognostic significance of histological features in oral squamous cell carcinoma. *J Oral Pathol Med.* 2009;38(8):657–62.
- La Vecchia, C. Mouthwash and oral cancer risk: an update. *Oral Oncol.* 2009;45(3):198–200.
- Lucenteforte, E., Garavello, W., Bosetti, C., La Vecchia, C. Dietary factors and oral and pharyngeal cancer risk. *Oral Oncol.* 2009;45(6):461–7.
- Marsh, D., Suchak, K., Moutasim, K. A., Vallath, S., Hopper, C., Jerjes, W., Upile, T., Kalavrezos, N., Violette, S. M., Weinreb, P. H., Chester, K. A., Chana, J. S., Marshall, J. F., Hart, I. R., Hackshaw, A. K., Piper, K., Thomas, G. J. Stromal features are predictive of disease mortality in oral cancer patients. *J Pathol.* 2011;223:470–81.
- Marur, S., D'Souza, G., Westra, W. H., Foratiere, A. A. HPV-associated head and neck cancer: a virus related cancer epidemic. *Lancet Oncol.* 2010;11:781–89.
- Mashberg, A., Merletti, F., Boffeita, P., Gandolfo, M., Ozzello, F., Fracchia, F., Terracini, B. Appearance, site of occurrence, and physical and clinical characteristics of oral carcinoma in Torino, Italy. *Cancer.* 1989;2522–7.
- Morris, L. G. T., Sikora, A. G., Patel, S. G., Hayes, R. B., Ganly, I. Second primary cancers after an index head and neck cancer: subsite-specific trends in the era of human papillomavirus-associated oropharyngeal cancer. *J Clin Oncol.* 2011;29(6):739–46.
- Mücke, T., Wagenpfeil, S., Kesting, M. R., Hölzle, F., Wolff, K. Recurrence interval affects survival after local relapse of oral cancer. *Oral Oncol.* 2009;45:687–91.
- Nagler, R. M. Saliva as a tool for oral cancer diagnosis and prognosis. *Oral Oncol.* 2009;45(12):1006–10.

- Paleri, V., Wight, R. G., Silver, C. E., Haigentz, M., Takes, R. P., Bradley, P. J., Rinaldo, A., Sanabria, A., Bien, S., Ferlito, A. Comorbidity in head and neck cancer: a critical appraisal and recommendations. *Oral Oncol.* 2010;46:712–9.
- Park, N. J., Zhou, H., Elashoff, D., Henson, B. S., Kastratovic, D. A., Abemayor, E., et al. Salivary microRNA: discovery, characterization, and clinical utility for oral cancer detection. *Clin Cancer Res.* 2009;15(17):5473–7.
- Patel, S. G., Shah, J. P. TNM staging of cancers of the head and neck: striving for uniformity among diversity. *CA Cancer J Clin.* 2005;55:242–58.
- Petersen, P. E. Oral cancer prevention and control – the approach of the World Health Organization. *Oral Oncol.* 2009;45(4–5):454–60.
- Petti, S. Lifestyle risk factors for oral cancer. *Oral Oncol.* 2009;45(4–5):340–50.
- Pfaffe, T., Cooper-White, J., Beyerlein, P., Kostner, K., Punyadeera, C. Diagnostic potential of saliva: current state and future applications. *Clin Chem.* 2011;57(5):675–87.
- Poh, C. F., Ng, S., Berean, K. W., Williams, P. M., Rosin, M. P., Zhang, L. Biopsy and histopathologic diagnosis of oral premalignant and malignant lesions. *J Can Dent Assoc.* 2008;74(3):283–8.
- Rethman, M. P., Carpenter, W., Cohen, E. E. W., Epstein, J., Caswell, A. E., Flaitz, C. M., Graham, F. J., Hujoel, P. P., Kalmar, J. R., Koch, M. W., Lambert, P. M., Lingen, M. W., Oettmeier, B. W., Patton, L. L., Perkins, D., Reid, B. C., Sciubba, J. J., Tomar, S.L., Wyatt, A. D., Aravamudhan, K., Frantsve-Hawley, J., Cleveland, J. L., Meyer, D. M. Evidence-based clinical recommendations regarding screening for oral squamous cell carcinomas. *J Am Dent Assoc.* 2010;141(5):509–20.
- Roblyer, D., Kurachi, C., Stepanek, V., Williams, M. D., El-Naggar, A. K., Lee, J. J., et al. Objective detection and delineation of oral neoplasia using autofluorescence imaging. *Cancer Prev Res (Phila).* 2009;2(5):423–31.
- Rogers, S. N., Brown, J. S., Woolgar, J. A., Lowe, D., Magennis, P., Shaw, R. J., Sutton, D., Errington, D., Vaughan, D. Survival following primary surgery for oral cancer. *Oral Oncol.* 2009;45:201–11.
- Scully, C., Bagan, J. Oral squamous cell carcinoma: overview of current understanding of aetiopathogenesis and clinical implications. *Oral Dis.* 2009;15(6):388–99.
- Seitz, H. K., Cho C. H. Contribution of alcohol and tobacco use in gastrointestinal cancer development. *Methods Mol Biol.* 2009;472:217–41.
- Shah, J. P., Gil, Z. Current concepts in management of oral cancer – surgery. *Oral Oncol.* 2009;45(4–5):394–401.
- Subramanian, S. Cost-effectiveness of oral cancer screening: results from a cluster randomized controlled trial in India. *Bull WHO.* 2009;87(3):200–6.
- Warnakulasuriya, S. Causes of oral cancer – an appraisal of controversies. *Br Dent J.* 2009;207(10):471–5.
- Warnakulasuriya, S. Global epidemiology of oral and oropharyngeal cancer. *Oral Oncol.* 2009;45(4–5):309–16.
- Warnakulasuriya, S. Living with oral cancer: epidemiology with particular reference to prevalence and life-style changes that influence survival. *Oral Oncol.* 2010;46(6):407–10.
- Warnakulasuriya, S. D., Dietrich, T.; Bornstein, M.; Peidro, J.; Preshaw, P.; Walter, C.; Wennstrom, J., Bergstrom, J. Oral health risks of tobacco use and effects of cessation. *Int Dent J.* 2010;60:7–30.
- Westra, W. H. The changing face of head and neck cancer in the 21st century: the impact of HPV on the epidemiology and pathology of oral cancer. *Head Neck Pathol.* 2009;3(1):78–81.
- Zini, A., Czerninski, R., Sgan-Cohen, H. D. Oral cancer over four decades: epidemiology, trends, histology, and survival by anatomical sites. *J Oral Pathol Med.* 2010;39:299–305.



# **Section 3**

## **Burns and Trauma**



---

Sebastian Salinas, Salman Mofti, Naime Moimen

## 1. INTRODUCTION

---

The skin is the most extensive organ of the human body: it keeps it separate from the external environment, regulates its temperature and protects it from infection. However, this barrier can be destroyed in 1 second when burned.

Burns still constitute one of the main accidents in homes and industry, and are also linked to social and economic risk factors. A good education and awareness of this problem is the first pillar in decreasing the morbidity and mortality rates caused by burns. The second fundamental pillar is prompting assistance and adequate treatment to improve outcomes and avoid complications.

Despite the advances in tissue engineering and surgical techniques, burn wounds are a constant challenge for health-care professionals, from the emergency department doctor to the plastic surgeon.

## 2. EPIDEMIOLOGY

---

Burns are responsible for around 265,000 deaths every year worldwide and are an important cause of temporary and permanent disability in children. Approximately 11 million people worldwide required medical care for burns in 2004. According to recent data, the number of patients killed by exposure to smoke, fire and flames was 193 in 2012 in England and Wales.

Paediatric burn injuries usually occur at home while cooking. However, while most burns in women mostly occur at home, most burns in men occur outdoors and at work and most burns in the elderly occur in the bathroom (Radic *et al.*, 2002; WHO, 2008; CDC, 2008; Peck, 2011; Office of National Statistics, 2012).

### 3. TYPES OF BURNS

---

It is important to mention that different types of burns are classified according to the mechanism of injury; however, in general, burns are classified according to their depth and surface area (Table 5.1 and Figure 5.1). These are the most relevant types of burns (a complete description of cold-induced injuries is not included in this chapter).

#### 3.1. Thermal burns

---

##### 3.1.1. Flash and flame burns

---

Flame is the most common cause of burns in adults and elderly individuals are the main population affected by this type of burn in England and Wales. Flames produce deep burns especially if clothes have been on fire, and are usually associated with inhalational injury and trauma. On the other hand, flash burns produce injuries that differ depending on the type and amount of fuel that explodes (Hijar-Medina *et al.*, 1992; Forjuoh, 1998; Lentz, 2009; Sanford and Gamelli, 2014).

##### 3.1.2. Scalds

---

Scalds are the main cause of burns in children and frequently in elderly people. In Europe, 25% of patients hospitalised for thermal injuries are children aged 0–4 years; of these, 90% suffer from scalds and in 90%, the total body surface area (TBSA) affected was <20%. Scalds are usually caused by spilling hot water or by using too hot water for bathing. Toddlers that accidentally fall into a bath of hot water will struggle and move about, thus producing multiple splash burns and making the border of the injury ill-defined. This type of burn depends not only on the water temperature but also on the skin thickness and duration of exposure (Hijar-Medina *et al.*, 1992; Forjuoh, 1998; Lentz, 2009).

Scalds can also be caused by grease and hot oils, which produce deeper burns. Usually, patients who have grease burns on their lower extremities require surgery (Schubert *et al.*, 1990; Bill *et al.*, 1996; Klein *et al.*, 2005).

##### 3.1.3. Contact burns

---

Contact burns are common in industry; loss of consciousness (for different reasons) is the main cause. Hot metal, plastic, glass and coal are the main elements that produce this type of burn. Their severity hinges on the time of exposure (Steinstraesser and Al-Benna, 2013; Sanford and Gamelli, 2014).



---

### 3.1.4. Tar burns

---

Tar is a viscous, waxy substance derived from petroleum that has a high boiling point (140–232°C) and various industrial applications, such as surfacing roads and roofing (Stratta *et al.*, 1983; Steinstraesser and Al-Benna, 2013).

Tar is associated with deep burns for three reasons: (1) when splashed, it cools rapidly to between 93°C and 104°C in the air; (2) when it contacts the skin, it cools and solidifies; and (3) it adheres to the skin, producing a continuous injury (Demling *et al.*, 1980; Bose and Tredget, 1982; Stratta *et al.*, 1983).

If the tar is still hot when the patient arrives to the medical facility, it should be rapidly cooled with room temperature water to prevent deeper burns; however, removal is not essential despite allowing an early assessment of the injury. Mechanical or manual debridement is painful and will also remove viable underlying skin; therefore, the tar should only be removed by qualified personnel (Demling *et al.*, 1980; Bose and Tredget, 1982; Stratta *et al.*, 1983; Robinett *et al.*, 2010; Steinstraesser and Al-Benna, 2013).

---

## 3.2. Chemical burns

---

Different sorts of chemicals can affect not only the skin but also other organs. The most frequent substances that produce chemical burns are sodium hypochlorite, phenol, white phosphorous, sulphuric acid, mustards, arsenicals and halogenated oximes.

---

### 3.2.1. Sodium hypochlorite

---

Commonly known as household bleach, this is a strong alkaline solution that causes protein coagulation and, when ingested, oesophageal constriction and perforation of the stomach. This type of burn depends on the concentration of the solution rather than the duration of exposure. Therefore, skin should be washed thoroughly with a large volume of water (Racioppi *et al.*, 1994; Steinstraesser and Al-Benna, 2013).

---

### 3.2.2. Phenol (carbolic acid)

---

Carbolic acid or phenol is an aromatic hydrocarbon that was first used for its antiseptic properties by Joseph Lister in 1865 (Lister, 1867). It is also used in chemical face peels and as a topical anaesthetic for skin and mucous membranes. Superficial burns caused by phenol produce a light grey lesion and deep burns are black. This type of burn is usually painless or somewhat uncomfortable because it causes demyelination of nerves and the destruction of nerve endings. It is highly lipid-soluble and therefore easily absorbed through the skin causing, in the worst cases, death from dysrhythmias, haemolysis and cerebral oedema. Therefore, emergency treatment is cleaning the skin with a large volume of water and gently wiping away the chemical with a sponge soaked in undiluted polyethylene glycol (PEG 300 or

400). After that, the affected area should be washed with soap and water (Warner and Harper, 1985; Horch *et al.*, 1994; Newsom, 2003; Lin *et al.*, 2006).

### 3.2.3. White phosphorous

---

There are two form of phosphorous: red, which is insoluble, non-absorbable and non-toxic; and yellow, better known as white phosphorous, which has a scent like garlic and is highly toxic because of its high lipid solubility and easy penetration of the skin. White phosphorous is a yellowish, waxy, translucent solid element that melts at 44°C and spontaneously ignites at 34°C unless kept in oil. It is used in munitions, incendiary weapons, fireworks, insecticides and fertilisers. On the skin, white phosphorous causes both chemical and thermal injury. It oxidises adjacent tissue and generates heat to produce a painful thermal burn. The aim of treatment is to prevent further absorption and thus avoid systemic toxicity such as hypocalcaemia and acute central nervous system depression. Therefore, the skin should be cleaned with a large volume of water and removable pieces of phosphorous should be picked out. Non-removable pieces require excision in the operating theatre and should be kept wet to prevent spontaneous combustion (Eldad and Simon, 1991; Chou *et al.*, 2001).

### 3.2.4. Sulphuric acid

---

Sulphuric acid is a desiccant that has many industrial applications. It is used in lead–acid batteries, fertilisers, wastewater processing and chemical production. Its reaction with water is highly exothermic and it produces almost immediate coagulative necrosis of the skin and subcutaneous tissues. Deep dermal burns have a bronzed leathery appearance with deep ulceration underneath. The immediate treatment is to irrigate the skin with copious amounts of water and soap, and irrigation should continue until there is no pain or pH paper shows no acidic reaction. An experimental study showed that if sulphuric acid is left for more than a minute without treatment, then the burn will become full thickness, needing early excision and repair (Van, 1962; Husain *et al.*, 1989).

### 3.2.5. Sulphur mustard

---

Sulphur mustard is a transparent, amber-coloured, oily alkaline agent. It easily penetrates clothing and the skin, and inhalation causes necrosis of lung parenchyma. It binds to the DNA of skin cells, causing cell death and the formation of vesicles. Despite its well-known mechanism of action toward DNA, it is still not understood why the epidermis separates from the dermis to form vesicles. Immediate treatment is to remove contaminated clothing and perform skin decontamination with either a passive (Fuller's earth) or active substance (reactive skin decontamination lotion or Dutch powder). Superficial injuries will not require surgical intervention and will spontaneously resolve within a few days to a week; however, they are painful. A recent *in vivo* study showed that dermal application over the exposed area of a formulation composed of *N,N'*-dichloro-*bis*[2,4,6-trichlorophenyl]urea plus *Aloe vera* plus betaine (DRDE/WH-01) promotes re-epithelialisation, angiogenesis and fibroplasia and could be used as

decontaminant and wound healant for injuries caused by sulphur mustard (Mellor *et al.*, 1991; Wormser, 1991; Casillas *et al.*, 2000; Evison *et al.*, 2002; Lomash and Pant, 2014).

### 3.3. Electrical burns

---

Electrical burns are also caused by certain hazardous occupations (e.g. railway workers, electrical workers); therefore, a good diagnosis of the damage relies on a good medical history. Electrical burns are classified as high voltage ( $\geq 1000\text{V}$ ), low voltage ( $< 1000\text{V}$ ) and those caused by lightning (Mangelsdorff *et al.*, 2011; Sanford and Gamelli, 2014).

The degree of damage is usually more extensive than perceived on initial examination. Electricity generates heat while flowing through the body, thus affecting not only the skin but also all other tissues and organs it passes through on its way to the bone. Low-voltage burns cause a small partial-thickness injury in most cases. However, high-voltage injuries usually cause large skin lesions with necrosis at the contact point and even deeper, and thus a series of damage types from compartment syndrome to multiorgan injury need to be quickly identified so that the correct treatment can be started. These wounds are potentially life-threatening or disabling (Mangelsdorff *et al.*, 2011; Steintraesser and Al-Benna, 2013; Sanford and Gamelli, 2014).

### 3.4. Burns as a sign of abuse

---

Burns can be a sign of abuse: this is more common in the paediatric population but can also be seen in the elderly and people with disabilities. A thorough clinical and social history is especially important if there is a suspicion that burn wounds could be caused intentionally by another person. An inadequate social environment such as young parents, a dysfunctional family or a previous history of abuse should raise suspicion (O'Neill *et al.*, 1973; Hight *et al.*, 1979; Peck, 2012; Wibbenmeyer *et al.*, 2014).

Children aged less than 5 years are most commonly affected. Burns represent 44% of cases of abuse and scalds are the most common; most compromise  $< 5\%$  of TBSA (Figure 5.4; Hobbs, 1986; Wibbenmeyer *et al.*, 2014).

### 3.5. Recognise an accidental scalding

---

In the case of a true accidental burn, most adults are alarmed by the injuries produced and look for medical assistance. When taking the medical history of a burned patient, especially toddlers, the first thing to do (if possible) is to corroborate the history given by the care giver with the history given by the child, the social context and the appearance of the burn wounds. Accidental scalding burns tend to have an irregular shape and distribution, and children commonly suffer this type of burn because of their lack of stature. Hot liquid usually comes from above, giving a typical *cascade scald* involving the chin, neck, shoulder and chest regions (Daria *et al.*, 2004; Wibbenmeyer *et al.*, 2014).

### 3.6. Indicators for suspicion

---

Suspicion should be raised when there is a delay in seeking medical help, when burn injuries have clear edges, no splash marks and a limited anatomical distribution, and when an inconsistent history is provided by the carer, especially if the mode and time of injury given in the history do not correlate with the pattern and appearance of the wound. Suspicion should also be raised when the child does not seek the carer for comfort or when a toddler is quiet or unresponsive. There may also be other lesions that indicate physical abuse (Hobbs, 1986; Wibbenmeyer *et al.*, 2014)

### 3.7. Recognised patterns on injury

---

The same objects that cause accidental burns can also be used to cause intentional burns, but certain recognised patterns are useful for distinguishing these burn types. Usually accidental contact occurs for a short period of time and involves a small part of the hot object, leaving a burn area with unclear margins. However, premeditated burns are usually formed by a larger portion of the hot object, leaving a symmetrical deep injury with clear margins, sometimes affecting covered areas such as the buttocks and perineum (Daria *et al.*, 2004; Wibbenmeyer *et al.*, 2014).

#### 3.7.1. Cigarette burns

---

As a sign of abuse, cigarette injuries are usually multiple, are often found on the palms, soles and buttocks, and present as deep, circular burns approximately 1 cm in diameter. It is common to also find older scars on other parts of the body. In contrast, an accidental cigarette burn caused by the child brushing against a glowing cigarette tends to be oval or elongated in outline, superficial and single (O'Neill *et al.*, 1973; Hobbs, 1986).

#### 3.7.2. Electrical burns

---

Abusive electrical burns also tend to be multiple, affecting areas such as the face, trunk and upper limb and producing deep coagulative necrosing injuries. Accidental electrical burns in young children frequently occur at the corners of the mouth or on the hands (Hobbs, 1986).

#### 3.7.3. Scalds

---

Scalds are the most common type of abusive injury. Although it may be difficult to determine whether a scald is accidental (e.g. because the whole body may be affected), some small details should be considered.

If scalding happens in a sink or bath, the bottom of the vessel remains at a lower temperature than the water inside it; therefore, if a child is immersed in the water, the palms and soles will often not be

burned because they are in contact with the bottom of the bath. A similar pattern will appear in children who held their knees in a flexed position against their abdomen: the flexor areas of knees and the lower abdomen will not be affected, and nor will the anterior part of thighs. If the hands or feet were forcibly held in hot water, the typical scald pattern resembles a glove or stocking. In addition, in these cases the margins of the burn will be clear and it is rare to find splash marks.

Another scald burn pattern commonly called ‘head first, face down’ (Figure 5.3) occurs when the head (facing down) is immersed in a sink containing hot water. In this type of burn, the neck usually has little or no damage because it is compressed against the back wall of the sink; there may also be little damage around the eyes because the child has closed the eyes tightly (O’Neill *et al.*, 1973; Feldman *et al.*, 1978; Hight *et al.*, 1979; Hobbs, 1986; Stratman and Melski, 2002; Daria *et al.*, 2004; Wibbenmeyer *et al.*, 2014).

To summarise, some of the main aspects of burns as a sign of abuse are (see also Figure 5.4; Hobbs, 1986):

1. Repeated burns or burns occurring in a pattern of repeated injury
2. Injury incompatible with the history
3. Inappropriate parental response – delay seeking treatment, blaming the child or a sibling, denial that the lesion is a burn
4. Changes in the history; absence of eye-witness accounts
5. Site – hand, especially back and wrist, buttocks, and feet and legs
6. Type – contact burns in unusual sites showing clear outline of object or scalds with clear-cut edges or a glove and stocking distribution.

## 4. PATHOPHYSIOLOGY

---

Exposure of the skin to high temperatures results into two responses: local and systemic

### 4.1. Local response

---

In 1947, Jackson introduced the three areas of local response: zones of coagulation, stasis and hyperaemia. The zones are three-dimensional. Therefore, increased tissue loss will lead to both deepening and widening of the wound (Figure 5.2).

#### 4.1.1. Zone of coagulation

---

Cells in the immediate area of contact die and the surrounding tissue coagulates and denatures. There is no blood circulation in this area.

### 4.1.2. Zone of stasis

---

Blood perfusion is decreased but the tissue may be salvageable. Burn resuscitation is essential to prevent additional damage. Increased damage could occur because of prolonged hypoperfusion, oedema and infection.

### 4.1.3. Zone of hyperaemia

---

This is the outermost zone; perfusion is increased and tissue here will recover unless there is another insult such as sepsis or hypoperfusion (Hettiaratchy and Dziewulski, 2004; Evers *et al.*, 2010).

## 4.2. Systemic response

---

The whole body is affected by the release of cytokines and other inflammatory mediators from the wound site. However, when the TBSA exceeds 30%, a systemic effect becomes apparent. Systemic effects may be (Hettiaratchy and Dziewulski, 2004; Neligan *et al.*, 2013):

- *Cardiovascular* – decreased myocardial contractility, increased capillary permeability, and peripheral vasoconstriction, which may lead to systemic hypotension and end-organ hypoperfusion.
- *Respiratory* – bronchoconstriction caused by inflammatory mediators that, in severe cases, could result in adult respiratory distress syndrome.
- *Metabolic* – if the metabolic rate is increased to three times the original rate, early and aggressive enteral feeding may be needed to maintain gut integrity.
- *Immunological* – the immune response is downregulated, affecting both cell-mediated and humoral responses.

## 5. WOUND HEALING

---

Wound healing is a complex process requiring a number of biological and physiological phases to accomplish proper wound closure. These phases are haemostasis, inflammation, proliferation and remodelling.

### 5.1. Haemostasis

---

Loss of blood from damaged capillaries and vessels is halted by vasoconstriction and the formation of blood clots. Blood clots formed from fibrin and platelets act as a temporary matrix for the wound and prevent foreign body infiltration.

---

## 5.2. Inflammation

---

The degranulation of platelets and the release of different cytokines and growth factors act as a chemo-attractant for inflammatory cells, epithelial cells and inflammatory factors. For the wound to proceed to the next phase, it must be sterile. This usually occurs after 2–3 days for normal wounds.

## 5.3. Proliferation

---

Macrophages at the wound site release a number of growth factors that activate and attract endothelial cells, fibroblasts and keratinocytes. As granulation tissue forms, a microvascular network infiltrates the wound for perfusion. Together, the wound filling with granulation tissue and complete epithelialisation signal the end of the proliferative phase.

## 5.4. Remodelling

---

This phase lasts for 1–2 years and may take longer. It is characterised by increasing tension and strength of the tissue and by type 3 collagen being replaced by type 1. Normal dermis contains 80% type 1 collagen and 20% type 3; however, in injured wounds, the proportion of type 3 collagen may increase up to 40% (Velnar *et al.*, 2009; Zahedi *et al.*, 2010).

---

## 6. ACUTE MANAGEMENT AND ASSESSMENT

---

The first step in managing a burn victim is to remove them from the harmful environment. Burn patients are handled as critically ill patients by conducting an initial primary survey and then a detailed secondary survey. Initial assessment of the airway is crucial, accompanied by an assessment of breathing and circulation. Basically, ‘ABC’ (see [Section 6.1](#)) assessment is performed, followed by assessment of any coexisting injury that needs prompt attention. It is important to remember to remove any material that retains heat such as jewellery, clothing and watches. Oxygen should be delivered as soon as possible and an inhalation injury should always be suspected. Cooling of the wound with room temperature water to disperse heat from the wound can then be done, but cold water or ice water should not be used because they can cause hypothermia. Some burn injuries can be treated in primary care units but others need a specialised burn centre, including (Cancio, 2014):

- Those requiring burn shock resuscitation.
- Partial-thickness burns affecting >10% TBSA, especially in medically fragile patients.
- Burns involving the face, hands, feet, genitalia, perineum or major joints.
- Deep and full-thickness burns in any age of patient.

- Circumferential burns in any patient group.
- Special types of injuries – electrical, chemical and lightning.
- Where there is suspicion of an inhalation injury.
- A burn of any size accompanied by concomitant trauma or disease.

## 6.1. Primary survey

---

When arriving at the emergency department, the primary survey assesses ‘ABCDEF’:

A – Airway with cervical spine control

B – Breathing

C – Circulation

D – Neurological disability

E – Exposure

F – Fluid resuscitation.

A proper history is vital for appropriate treatment planning. Some key points in history taking are:

- The mechanism of the injury
  - The nature of the injury (scald, flame, flash, electrical, chemical)
  - Time of the injury
  - What the treatment was started
  - Any risk of associated injury (such as fall or explosion)
  - Loss of consciousness.
- Suspicion of inhalation injury
  - Whether it occurred in a closed or open area
  - How long the patient was exposed to smoke
  - When fluid resuscitation was started.
- Past medical history
  - Allergy
  - Medical illness
  - Asthma
  - Tetanus status.

Early intubation should be performed to secure the airway because smoke inhalation causes more than 50% of fire-related injuries. The airway can be examined by a laryngoscope and the bronchial tree by a bronchoscope. Patients who are breathing spontaneously and at risk of inhalation injury should be placed on high-flow humidified oxygen to reduce the risk of airway collapse. A chest X-ray should be done, although it lacks sensitivity for inhalation injuries. Carbon monoxide poisoning is a recognised complication of inhalation injury. Pulse oximetry does not accurately calculate carbon monoxide exposure, so other means such as arterial blood gas analysis and bronchoscopy should be performed. Patients



with carbon monoxide poisoning should be placed on 100% oxygen using a non-rebreather face mask (Neligan *et al.*, 2013; Cancio, 2014).

Signs of inhalation injury are:

- Flame burns
- Burns that occur in an enclosed space
- Full or deep-thickness burns to the face or neck
- Singed nasal hair and eyebrows
- Carbonaceous sputum
- Hoarseness, stridor or wheezing.

Indications for intubation are:

- Swelling of the oropharynx on direct visualisation
- Change in the voice, with hoarseness or a harsh cough
- Stridor, tachypnea or dyspnoea
- Carbonaceous particles on patient's face.

Fluid resuscitation should be initiated for adults with more than 20% of TBSA affected and for children with 10–15% of TBSA affected. The Parkland formula for burn resuscitation is the most used formula:  $4 \text{ ml} \times \text{kg} \times \text{TBSA}$ . This calculates the amount of fluid that should be given in 24 hours: half in the first 8 hours and the other half over the next 16 hours. If intravenous access cannot be established, an interosseous line should be placed through the tibia. Urine output should be measured by inserting a Foley catheter to assess the fluid balance. Urine output should be maintained at 0.5–1.0 ml/kg per hour and any signs of change in the urine should be noted. The pulse rate and blood pressure should be monitored closely. Non-invasive blood pressure measurements are sometimes unreliable because of interference by tissue oedema. A radial arterial line is the first choice, but if this is not possible then a femoral catheter could be established (Neligan *et al.*, 2013; Brown *et al.*, 2014).

## 6.2. Secondary survey

After completing the primary survey, a secondary survey should include an assessment of the depth and percentage TBSA of burn wounds. TBSA can be calculated in adults by the Wallace 'rule of nine'; for children, a unique calculation should be performed (see [Figure 5.5](#)). Depths of wounds are categorised into four parts (see [Figure 5.1](#); Vojvodic *et al.*, 2014):

- *Epidermal* – only the epidermis is involved and sensation is still intact, wound can be painful and should be allowed to heal by itself for about 7 days.
- *Superficial partial thickness* – epidermis and part of the papillary dermis is damaged, usually very painful. Blistering may occur and the wound blanches. These wounds should be left alone to heal for about 14 days.

- *Deep partial thickness* – the entire epidermis and the papillary dermis is destroyed with part of the reticular dermis. Sensation can be lost and large blisters may form. Proper care for this type of wound should be provided with surgery and dressing. These take about 14–21 days to heal.
- *Full thickness* – the entire thickness of the skin is lost, possibly with deeper tissue. There are no blisters or sensation. They don't heal spontaneously; a skin graft is needed if depth exceeds >1 cm.

## 7. WOUND MANAGEMENT

---

### 7.1. Topical ointments

---

Silver sulfadiazine is the most common ointment used. It has a half-life of 10 hours and a good antibacterial spectrum. It is important to consider that in some patients it causes temporary leucopaenia when used on large body areas; however, it does not increase the risk of infection (Caffee and Bingham, 1982; Choban and Marshall, 1987).

Mafenide is another ointment often used for full-thickness burns; it has a bacteriostatic action. It has two main side effects: it causes pain during initial applications; and when used for wide burns, it produces metabolic acidosis due to inhibition of carbonic anhydrase (Shuck and Moncrief, 1969; Liebman *et al.*, 1982; Lee *et al.*, 1988).

Silver nitrate is another compound used for burn wound healing. An alternative version of this compound (Acticoat) was developed using silver nanoparticles; however, studies have not proven its safety with regard to keratinocyte and fibroblast toxicity. Recently, a safer hydrogel was developed by modifying this compound using  $\gamma$ -irradiation. It has good antibacterial action against *Pseudomonas aeruginosa* and methicillin-resistant *Staphylococcus aureus*, but further research should be done to corroborate this effect (Fong and Wood, 2006; Boonkaew *et al.*, 2014).

### 7.2. Wound dressings

---

An ideal dressing should (Schiestl *et al.*, 2013):

- Provide maximal support for wound healing
- Provide maximal protection against infection
- Cause minimal pain during dressing changes without anaesthesia
- Have a minimal cost.

However, the ideal wound dressing does not exist and so research is continuing to find the best bio-material. The most basic and common wound burn dressing is gauze covered with soft paraffin, which

helps prevent adherence to the wound. A topical antiseptic can be applied and covered with gauze. However, this type of dressing is only useful for first- and second-degree burns (Schiestl *et al.*, 2013).

### 7.2.1. Biological wound dressings

---

The treatment of choice for excised burn wounds is an autograft but, in patients in whom a considerable surface area is affected, donor site may be very limited. Therefore, they need a temporary skin substitute that can be applied while donor sites re-epithelialise. For these patients, the main biological wound dressing is a skin allograft from a cadaver. If it is properly preserved, this skin is viable and revascularises in the patient wound bed. Patients with massive burns are immunocompromised, but will eventually start to develop an inflammatory infiltrate and this skin allograft will be rejected (Chan *et al.*, 2012; Steinstraesser and Al-Benna, 2013).

A good, cheaper alternative to this biological dressing is a cultured epidermal autograft made with cultured keratinocytes taken from neonatal foreskins obtained from circumcisions. However, they are only a temporary coverage because they are also rejected (Steinstraesser and Al-Benna, 2013).

Recent research focussing on the development of skin substitutes using stem cells obtained from debrided burn skin has shown promising results. The different layers of the skin can develop if they are added to an appropriate scaffold (Table 5.2; Chan *et al.*, 2012).

### 7.2.2. Physiological wound dressings

---

Synthetic dressings are an excellent alternative for covering burn wounds, especially for second-degree burns. Their function is to stimulate skin regeneration and act as a barrier to prevent infections. Therefore synthetic dressings do not work properly on full-thickness burn injuries because they do not adhere properly and become a risk factor for infections as they do not have antimicrobial properties. However, more complex synthetic dressings are not becoming widely available because of their cost (Singer and Dagum, 2008; Schiestl *et al.*, 2013; Steinstraesser and Al-Benna, 2013; Wasiak *et al.*, 2013).

## 8. CONCLUSION

---

Burn injuries are rarely conventional; most are associated with a number of insults. Each type of injury needs proper identification, assessment and management. The main goal in burn management is to deliver the necessary support for the cardiac, respiratory and renal systems and avoid end-organ damage. Secondary treatment includes the adequate debridement of dead tissue, repair of salvageable tissue with wound care and dressing changes, and skin grafting. Finally, the rehabilitation stage aims to return the patient to their pre-injured state. Proper judgement and actions contribute to decreased mortality and morbidity rates.

## 9. APPENDIX

**Table 5.1.** Classification of burns by depth and surface area.

Levels	Depth	Total body surface area	Appearance
First degree	Superficial	<10% in adults, <5% in children or elderly, <2% for full-thickness burn	Erythematous Painful
Second degree	Superficial partial thickness	10–20% in adults, 5–10% in children or elderly, 2–5% for full-thickness burn	Clear blisters Painful Sensitive Blanch to touch
	Deep partial thickness		Haemorrhagic blisters White or pale injured dermis Do not blanch to touch
Third degree	Full thickness	>20% in adults, >10% in children and elderly, >5% for full-thickness burn	Dark brown or tan Leathery texture Insensitive to touch

**Table 5.2.** Skin substitutes.

Product	Category	Wound uses	Method of use
Human allograft	Split thickness skin	Partial thickness	Temporary
Human amnion	Epidermis–dermis	Partial thickness	Temporary
Xenograft-pig skin	Dermis	Partial thickness	Temporary
Biobran®	Synthetic epidermis and dermis	Superficial partial thickness	Temporary
Oasis®	Bioactive dermal-like matrix	Superficial partial thickness	Temporary
Transcyte®	Bioactive dermal matrix	Superficial partial thickness	Temporary
Duoderm®	Synthetic epidermis and dermis	Superficial partial thickness	Temporary
Opsite®	Synthetic epidermis and dermis	Superficial partial thickness	Temporary
Suprathel®	Synthetic epidermis and dermis	Superficial partial thickness	Temporary
Tegaderm®	Synthetic epidermis and dermis	Superficial partial thickness	Temporary
Apligraf®	Composite of epidermis and dermis	Deep partial thickness	Permanent
OrCel®	Composite of epidermis and dermis	Deep partial thickness and donor site	Permanent
Epicel®	Epidermis	Deep partial and full thickness	Permanent
Aloderm®	Dermis	Deep partial and full thickness	Permanent
Integra®	Biosynthetic dermis	Full thickness	Permanent

Sources: Neligan *et al.* (2013), Snyder *et al.* (2012) and Shevchenko *et al.* (2010).

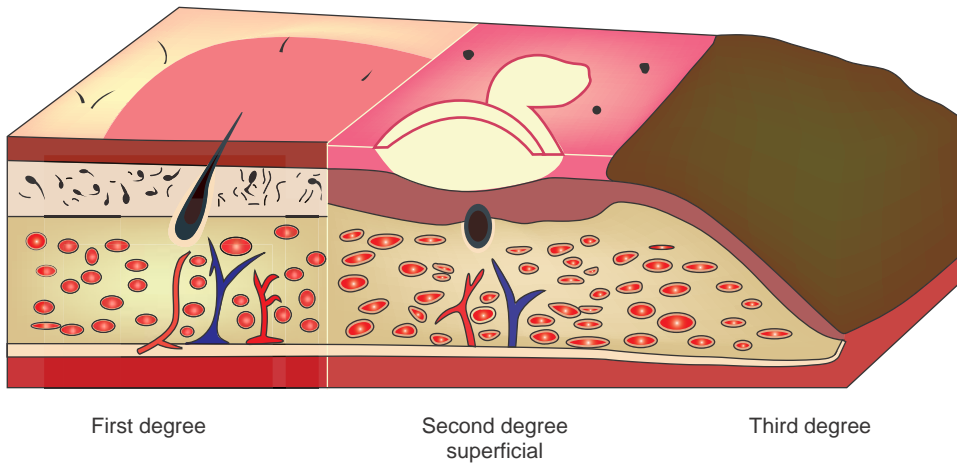


Figure 5.1. Depths of burn wounds.

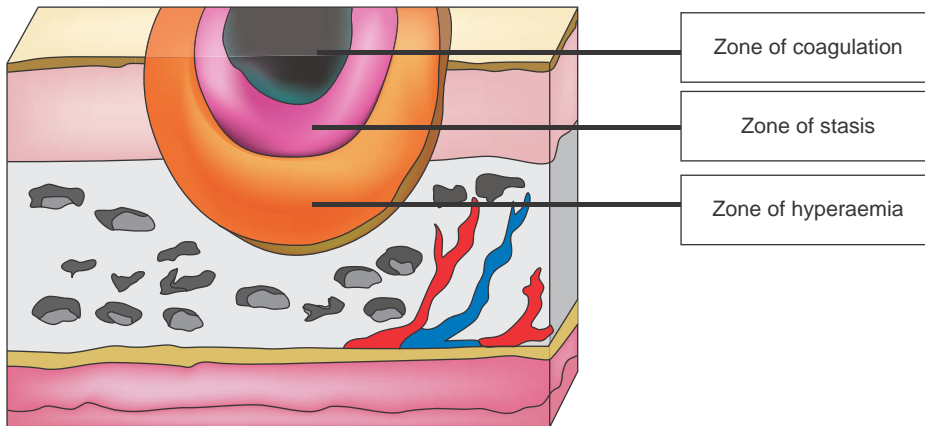
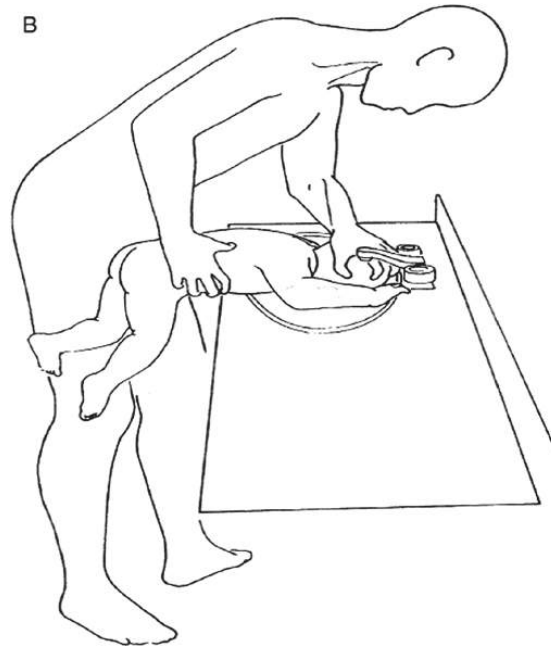
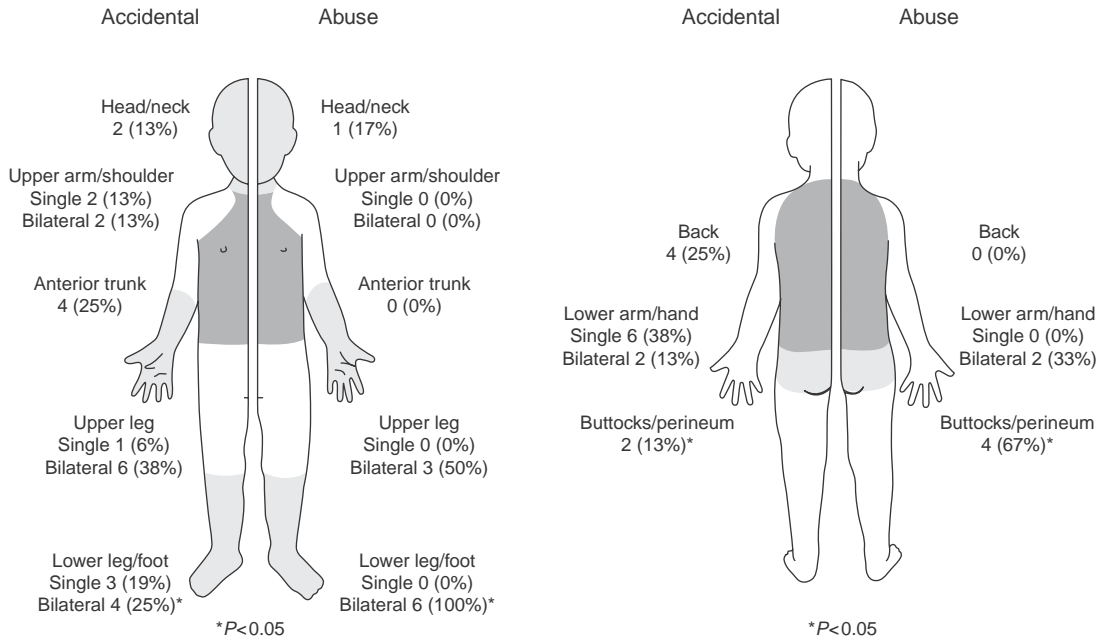


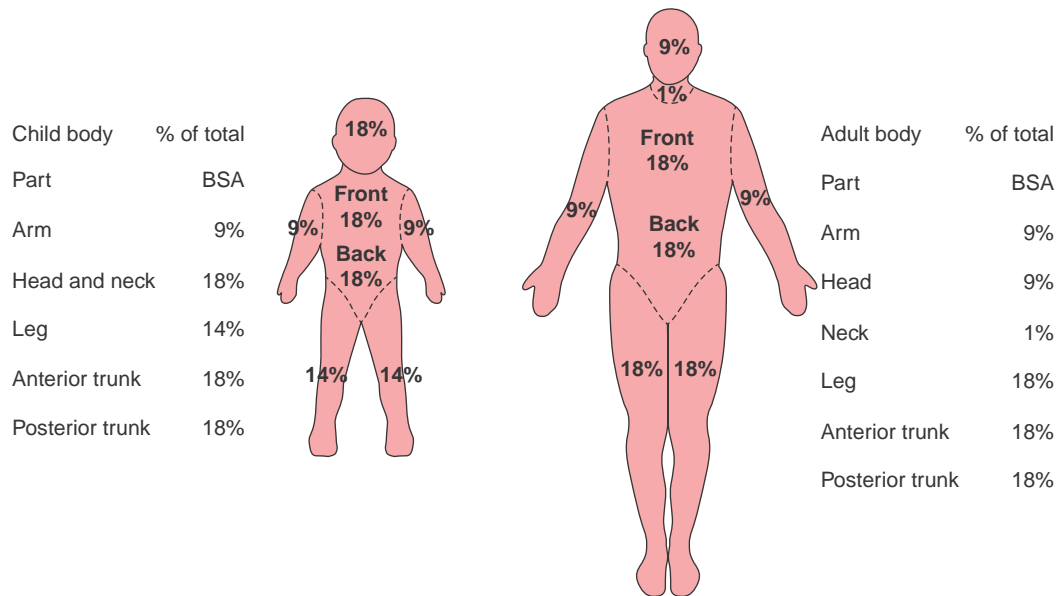
Figure 5.2. Jackson's areas of local response.



**Figure 5.3.** ‘Head first, face down’ sink immersion. *Source: Daria et al. (2004).*



**Figure 5.4.** Distribution of inflicted and unintentional burns on young children. *Source: Daria et al. (2004).*



**Figure 5.5.** Rule of nine. *Source:* <http://emedicine.medscape.com/article/934173-diagnosis>.

## REFERENCES

- Bill, T. J., Bentrem, D. J., Drake, D. B. & Edlich, R. F. 1996. Grease burns of the hand: Preventable injuries. *J Emerg Med*, 14, 351–5.
- Boonkaew, B., Barber, P. M., Rengpipat, S., Supaphol, P., Kempf, M., He, J., John, V. T. & Cuttle, L. 2014. Development and characterization of a novel, antimicrobial, sterile hydrogel dressing for burn wounds: Single-step production with gamma irradiation creates silver nanoparticles and radical polymerization. *J Pharm Sci*, 103, 3244–53.
- Bose, B. & Tredget, T. 1982. Treatment of hot tar burns. *Can Med Assoc J*, 127, 21–2.
- Brown, D. L., Borschel, G. H. & Levi, B. 2014. *Michigan Manual of Plastic Surgery*. Philadelphia, Lippincott Williams & Wilkins/Wolters Kluwer.
- Caffee, H. H. & Bingham, H. G. 1982. Leukopenia and silver sulfadiazine. *J Trauma*, 22, 586–7.
- Cancio, L. C. 2014. Initial assessment and fluid resuscitation of burn patients. *Surg Clin North Am*, 94, 741–54.
- Casillas, R. P., Kiser, R. C., Truxall, J. A., Singer, A. W., Shumaker, S. M., Niemuth, N. A., Ricketts, K. M., Mitcheltree, L. W., Castrejon, L. R. & Blank, J. A. 2000. Therapeutic approaches to dermatotoxicity by sulfur mustard. I. Modulation of sulfur mustard-induced cutaneous injury in the mouse ear vesicant model. *J Appl Toxicol*, 20 Suppl 1, S145–51.
- Center for Disease Control (CDC). 2008. *Fire deaths and injuries: Fact sheet overview* [Online]. Available: [www.cdc.gov/HomeandRecreationalSafety/Fire-Prevention/fires-factsheet.html](http://www.cdc.gov/HomeandRecreationalSafety/Fire-Prevention/fires-factsheet.html) [Accessed 9 December 2014].
- Chan, R. K., Zamora, D. O., Wrice, N. L., Baer, D. G., Renz, E. M., Christy, R. J. & Natesan, S. 2012. Development of a vascularized skin construct using adipose-derived stem cells from debrided burned skin. *Stem Cells Int*, 2012, 841203.
- Choban, P. S. & Marshall, W. J. 1987. Leukopenia secondary to silver sulfadiazine: Frequency, characteristics and clinical consequences. *Am Surg*, 53, 515–7.
- Chou, T.-D., Lee, T.-W., Chen, S.-L., Tung, Y.-M., Dai, N.-T., Chen, S.-G., Lee, C.-H., Chen, T.-M. & Wang, H.-J. 2001. The management of white phosphorus burns. *Burns*, 27, 492–7.

- Daria, S., Sugar, N. F., Feldman, K. W., Boos, S. C., Benton, S. A. & Ornstein, A. 2004. Into hot water head first: Distribution of intentional and unintentional immersion burns. *Pediatr Emerg Care*, 20, 302–10.
- Demling, R. H., Buerstatte, W. R. & Perea, A. 1980. Management of hot tar burns. *J Trauma*, 20, 242.
- Eldad, A. & Simon, G. A. 1991. The phosphorous burn – A preliminary comparative experimental study of various forms of treatment. *Burns*, 17, 198–200.
- Evers, L. H., Bhavsar, D. & Mailander, P. 2010. The biology of burn injury. *Exp Dermatol*, 19, 777–83.
- Evison, D., Hinsley, D. & Rice, P. 2002. Chemical weapons. *BMJ*, 324, 332–5.
- Feldman, K. W., Schaller, R. T., Feldman, J. A. & McMillon, M. 1978. Tap water scald burns in children. *Pediatrics*, 62, 1–7.
- Fong, J. & Wood, F. 2006. Nanocrystalline silver dressings in wound management: A review. *Int J Nanomedicine*, 1, 441–9.
- Forjuoh, S. N. 1998. The mechanisms, intensity of treatment, and outcomes of hospitalized burns: Issues for prevention. *J Burn Care Rehabil*, 19, 456–60.
- Hettiaratchy, S. & Dziewulski, P. 2004. ABC of burns: Pathophysiology and types of burns. *BMJ*, 328, 1427–9.
- Hight, D. W., Bakalar, H. R. & Lloyd, J. R. 1979. Inflicted burns in children. Recognition and treatment. *JAMA*, 242, 517–20.
- Hijar-Medina, M. C., Tapia-Yanez, J. R., Lozano-Ascencio, R. & Lopez-Lopez, M. V. 1992. [Home accidents in children less than 10 years of age: Causes and consequences.] *Salud Pública Mex*, 34, 615–25.
- Hobbs, C. J. 1986. When are burns not accidental? *Arch Dis Child*, 61, 357–61.
- Horch, R., Spilker, G. & Stark, G. B. 1994. Phenol burns and intoxications. *Burns*, 20, 45–50.
- Husain, M. T., Hasanain, J. & Kumar, P. 1989. Sulphuric acid burns: Report of a mass domestic accident. *Burns*, 15, 389–91.
- Klein, M. B., Gibran, N. S., Emerson, D., Sullivan, S. R., Honari, S., Engrav, L. H. & Heimbach, D. M. 2005. Patterns of grease burn injury: Development of a classification system. *Burns*, 31, 765–7.
- Lee, J. J., Marvin, J. A., Heimbach, D. M. & Grube, B. J. 1988. Use of 5% sulfamylon (mafenide) solution after excision and grafting of burns. *J Burn Care Rehabil*, 9, 602–5.
- Lentz, C. W. 2009. *National Burn Repository* [Online]. Chicago: American Burn Association. Available: [www.ameriburn.org/2009NBRAnnualReport.pdf](http://www.ameriburn.org/2009NBRAnnualReport.pdf) [Accessed 9 December 2014].
- Liebman, P. R., Kennelly, M. M. & Hirsch, E. F. 1982. Hypercarbia and acidosis associated with carbonic anhydrase inhibition: a hazard of topical mafenide acetate use in renal failure. *Burns Incl Therm Inj*, 8, 395–8.
- Lin, T.-M., Lee, S.-S., Lai, C.-S. & Lin, S.-D. 2006. Phenol burn. *Burns*, 32, 517–21.
- Lister, J. 1867. On the antiseptic principle in the practice of surgery. *BMJ*, 2, 246–8.
- Lomash, V. & Pant, S. C. 2014. A novel decontaminant and wound healant formulation of *N,N'*-dichloro-bis[2,4,6-trichlorophenyl]urea against sulfur mustard-induced skin injury. *Wound Rep Reg*, 22, 85–95.
- Mangelsdorff, G., Garcia-Huidobro, M. A., Nachari, I., Atenas, O., Whittle, S. & Villegas, J. 2011. High voltage electrical burns as a risk factor for mortality among burn patients. *Rev Méd Chile*, 139, 177–81.
- Mellor, S. G., Rice, P. & Cooper, G. J. 1991. Vesicant burns. *Br J Plast Surg*, 44, 434–7.
- Neligan, P., Warren, R. J., Van Beek, A. 2013. *Plastic Surgery*, London, New York: Elsevier Saunders.
- Newsom, S. W. B. 2003. Pioneers in infection control – Joseph Lister. *J Hosp Infect*, 55, 246–53.
- O'Neill, J. A., Jr., Meacham, W. F., Griffin, J. P. & Sawyers, J. L. 1973. Patterns of injury in the battered child syndrome. *J Trauma*, 13, 332–9.
- Office of National Statistics. 2012. *Mortality Statistics: Deaths Registered in 2012* [Online]. Available: <http://www.ons.gov.uk/ons/rel/vsob1/mortality-statistics--deaths-registered-in-england-and-wales--series-dr-/2012/dr-tables-2012.xls> [Accessed 11 December 2014].
- Peck, M. D. 2011. Epidemiology of burns throughout the world. Part I: Distribution and risk factors. *Burns*, 37, 1087–100.
- Peck, M. D. 2012. Epidemiology of burns throughout the World. Part II: Intentional burns in adults. *Burns*, 38, 630–7.



- Racioppi, F., Daskaleros, P. A., Besbelli, N., Borges, A., Deraemaeker, C., Magalini, S. I., Martinez Arrifta, R., Pulce, C., Ruggione, M. L. & Vlachos, P. 1994. Household bleaches based on sodium hypochlorite: Review of acute toxicology and poison control center experience. *Food Chem Toxicol*, 32, 845–61.
- Randic, L., Carley, S., Mackway-Jones, K. & Dunn, K. 2002. Planning for major burns incidents in the UK using an accelerated Delphi technique. *Burns*, 28, 405–12.
- Robinett, D. A., Shelton, B. & Dyer, K. S. 2010. Special considerations in hazardous materials burns. *J Emerg Med*, 39, 544–53.
- Sanford, A. & Gamelli, R. L. 2014. Lightning and thermal injuries. *Handb Clin Neurol*, 120, 981–6.
- Schiestl, C., Meuli, M., Trop, M. & Neuhaus, K. 2013. Management of burn wounds. *Eur J Pediatr Surg*, 23, 341–8.
- Schubert, W., Ahrenholz, D. H. & Solem, L. D. 1990. Burns from hot oil and grease: A public health hazard. *J Burn Care Rehabil*, 11, 558–62.
- Shevchenko, R. V., James, S. L. & James, S. E. 2010. A review of tissue-engineered skin bioconstructs available for skin reconstruction. *J R Soc Interface*, 7, 229–58.
- Shuck, J. M. & Moncrief, J. A. 1969. Safeguards in the use of topical mafenide (Sulfamylon) in burned patients. *Am J Surg*, 118, 864–70.
- Singer, A. J. & Dagum, A. B. 2008. Current management of acute cutaneous wounds. *N Engl J Med*, 359, 1037–46.
- Snyder, D. L., Sullivan, N. & Schoelles, K. M. 2012. AHRQ Technology Assessments. *Skin Substitutes for Treating Chronic Wounds*. Rockville (MD): Agency for Healthcare Research and Quality (US).
- Steintraesser, L. & Al-Benna, S. 2013. Acute management of burn/electrical injuries. In: Neligan, P. et al. (eds) *Plastic Surgery*. London: Elsevier.
- Stratman, E. & Melski, J. 2002. Scald abuse. *Arch Derm*, 138, 318–20.
- Stratta, R. J., Saffle, J. R., Kravitz, M. & Warden, G. D. 1983. Management of tar and asphalt injuries. *Am J Surg*, 146, 766–9.
- Van, R. L. 1962. An experimental study of chemical burns. *S Afr Med J*, 36, 754–9.
- Velnar, T., Bailey, T. & Smrkoli, V. 2009. The wound healing process: An overview of the cellular and molecular mechanisms. *J Int Med Res*, 37, 1528–42.
- Vojvodic, M., Young, A. & Medical Council of Canada. 2014. *The Toronto notes 2014: a comprehensive medical reference and review for the Medical Council of Canada Qualifying Exam, part 1 and the United States Medical Licensing Exam, step 2*, Toronto, Toronto Notes for Medical Students.
- Warner, M. A. & Harper, J. V. 1985. Cardiac dysrhythmias associated with chemical peeling with phenol. *Anesthesiology*, 62, 366–7.
- Wasiak, J., Cleland, H., Campbell, F. & Spinks, A. 2013. Dressings for superficial and partial thickness burns. *Cochrane Database Syst Rev*, 3, Cd002106.
- WHO (World Health Organization). 2008. *The Global Burden of Disease: 2004 Update* [Online]. Geneva: World Health Organization. Available: [www.who.int/healthinfo/global\\_burden\\_disease/GBD\\_report\\_2004update\\_full.pdf](http://www.who.int/healthinfo/global_burden_disease/GBD_report_2004update_full.pdf) [Accessed 9 December 2014].
- Wibbenmeyer, L., Liao, J., Heard, J., Kealey, L., Kealey, G. & Oral, R. 2014. Factors related to child maltreatment in children presenting with burn injuries. *J Burn Care Res*, 35, 374–81.
- Wormser, U. 1991. Toxicology of mustard gas. *Trends Pharmacol Sci*, 12, 164–7.
- Zahedi, P., Rezaeian, I., Ranaei-Siadat, S. O., Jafari, S. H. & Supaphol, P. 2010. A review on wound dressings with an emphasis on electrospun nanofibrous polymeric bandages. *Polym Adv Technol*, 21, 77–95.

## Burn Reconstructive Surgery

---

Barinder Takhar, Ahmad B. Al-Ali, Naime Moimen

### 1. INTRODUCTION

---

Burns can be horrific injuries and can vary greatly in severity, often resulting in significant physical and psychological impact on the patient's health and well-being. The resulting injuries can cause functional and aesthetic problems, as well as significant morbidity and mortality. This chapter describes the process of reconstructive surgery after burns, the reconstruction options available and the principles of reconstructive surgery including the reconstructive ladder.

Advances in reconstructive surgery due to new materials and techniques for the management of burns have benefited burn survivors via improving the physical appearance and function, thus improving their quality of life. However, a balance must be achieved for a realistic approach that harmonises the patient's expectations with the probable outcomes of reconstructive surgery (McGregor, 2001).

This chapter will discuss the reconstruction of burns following the initial stages of acute management, resuscitation and stabilisation. The options for reconstructive surgery will be discussed as well as the indications, advantages and disadvantages. Tips on surgical technique will be included about the timing of surgery and the essentials in management of these patients.

Any surgeon undertaking burn reconstruction must have a good understanding of wound healing and scar maturation to plan the time of reconstruction. The reconstructive surgeon must also have a sound knowledge of all surgical techniques and the aftercare required (usually in conjunction with a burn team).

### 2. AIMS AND CHALLENGES OF RECONSTRUCTIVE SURGERY

---

The aim of reconstructive surgery is primarily to restore function and then to restore aesthetics, thus improving the patient's quality of life. Burn patients will suffer late consequences as injuries due to burns can result in a variety of problems, such as scar contractures, resulting in limited movement, pain,

**Table 6.1.** Specific challenges associated with burn reconstructive surgery.

Extensive tissue loss	Limited tissue donor sites and available tissue
Scars, multiple burn sites	Need for multiple surgical procedures for reconstruction and skin coverage
Burns to sensitive areas (face, genitalia, hands, feet)	Post-operative pain
Impaired nutrition	Wounds, infections, burns
Lack of tissue pliability	Delayed wound healing in burns patients, hyper-metabolic response to burn injury

disfigurement, social embarrassment and isolation which can cause significant impact on a patient's quality of life.

The key to successful post-burn reconstruction is a well-planned and properly executed surgery combination with a well-defined and comprehensive post-operative physical therapy programme (Shelley *et al.*, 2006). The combination of surgery and early physical therapy requires a balance to be achieved between immobilisation of the patient to allow skin grafts and flaps to take and the healing and early mobilisation of affected areas to restore function and range of motion in affected scar formation and contractures. This aim of the multidisciplinary team is to help restore patients to society as active functional members (Shelley *et al.*, 2006).

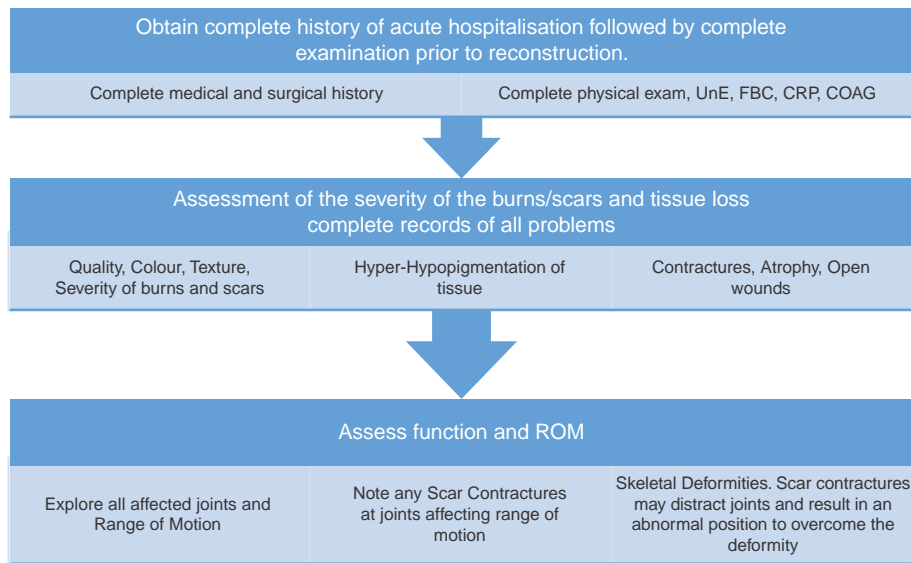
Table 6.1 lists some of the key factors that must be considered during the process of reconstructive surgery. The severity, extent and location of the burns as well as the availability of donor tissue and sites are key factors in reconstruction. A comprehensive examination of all areas of the patient, both damaged and undamaged, must be performed and then a plan for reconstructive surgery can be determined.

### 3. PATIENT–SURGEON RELATIONSHIP AND INITIAL CONSULTATION

The process of reconstructive surgery can be complex and involves multiple surgical procedures. The initial consultation with the surgeon is an important first step in the reconstructive process. At that time, a complete and accurate overview of the patient's problems is determined, possible solutions are considered and a relationship is initiated. The patient's motivation for surgery, expectations of the results of surgery and psychological status are determined.

All reconstructive possibilities are discussed with the patient, as well as the timing and order of procedures, so that the patient completely understands the process involved and the length of time required. The need for post-operative physiotherapy and rehabilitation are considered, and an inventory of all possible donor sites made (Shelley, 2006).

The initial consultation is a two-way process between the surgeon and patient. This is the initial stage of development of a relationship between both the patient and surgeon as they will both likely be present in each other's lives for several years due to the multiple surgical procedures, reviews and consultations that will take place. The patient will evaluate the surgeon's conduct, communication and knowledge and



**Figure 6.1.** Consultation and assessment flow diagram.

their own level of comfort. Patients require not only the surgeon's professional expertise but also time, realistic optimism and compassion.

The patients should also be reviewed by the burn therapy team at the initial consultation or at a separate consultation, depending on the patient's circumstances, so that they can fully understand all the factors including the surgeries, physiotherapy, rehabilitation, operative and post-operative complications involved as well as the commitment required. The use of complete pre-operative assessment and a photographic investigation is important to assist in the definitive pre-operative planning and post-operative care.

### 3.1. Initial physical assessment of a patient: A step-wise approach

A step-wise approach can be used at the initial assessment. [Figure 6.1](#) presents a methodological approach to the initial evaluation and assessment of patients so that a thorough understanding of the severity of the burn can be obtained.

## 4. BURN RECONSTRUCTION PROCEDURES AND TECHNIQUES

The process of reconstructive surgery for burns is complex, depends on many factors and requires planning. The location, severity and extent of burns will affect the reconstructive process and the timing and number of stages required for reconstruction and determine whether any urgent procedures are required (Barrett JP, 2004).

After the initial acute hospital management, the patient must then be completely assessed before leaving the hospital to determine the degree and severity of the burns, the occurrence of contractures of

scars and their effect on mobility, the range of motion of the joint, and whether any urgent procedures are required.

The timing of reconstructive surgery of burns is variable: some require immediate reconstruction to provide protection to vital organs or restore function, while definitive management is often usually delayed for up to 1 year and sometimes longer depending on scar maturation and the degree of reconstruction required.

## 5. TIMING OF SURGERY

---

The timing of surgery for the reconstruction of burns can be classified into three categories:

1. Urgent (immediate)
2. Essential (early)
3. Desirable (late).

### 5.1. Urgent (immediate) procedures

---

Urgent procedures must be performed immediately, i.e. before the patient leaves the hospital after the acute management of the burn. This category is restricted to procedures that are important for correction of a deformity or to provide coverage of exposed or severely damaged vital structures so as to preserve function in vital areas and prevent further impairment. Common examples are ectropion or neck contracture that compromises the airway.

### 5.2. Essential (early) procedures

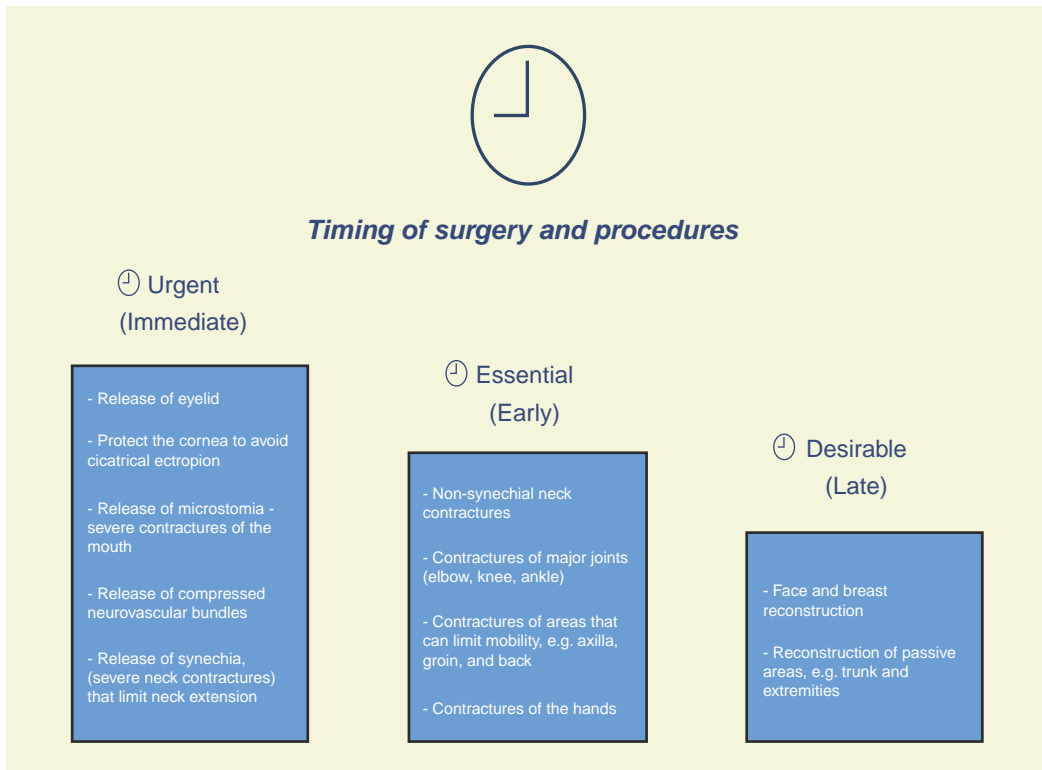
---

These procedures help with non-vital functions and rehabilitation. Some mature burn scar contractures are non-responsive to physical therapy and splinting, often as a result of hypertrophic scarring. This can prevent a patient from performing their everyday activities. Essential procedures may, if performed early, improve the patient's final appearance and rehabilitation. Examples of those requiring early surgical intervention are small or large joint contractures that fail to respond to the therapy regimen.

### 5.3. Desirable (late) procedures

---

These procedures are generally aesthetic in nature, often resulting from scar contractures, tightness, pain and discomfort. Late procedures are performed after burn scar maturation, often up to 1 year or longer after injury, and the aim is to address the aesthetic and functional aspects of the burn injury. Examples include face and breast reconstruction and reconstruction of passive areas of burns such as scar resurfacing (e.g. on the trunk and extremities).



**Figure 6.2.** Timing of surgery and procedures.

Figure 6.2 shows a list of morbidities that are associated with burns and the need for intervention in response to the injuries sustained. The timing or need for treatment is associated with certain pathologies and depends on the severity and location of the burn as well as the urgency for life-saving interventions. Patients suffering from burns can have life-threatening complications requiring immediate management and other procedures can be delayed as there is no immediate threat to life or resulting in long-term disability.

## 6. BURN RECONSTRUCTION PROCEDURES

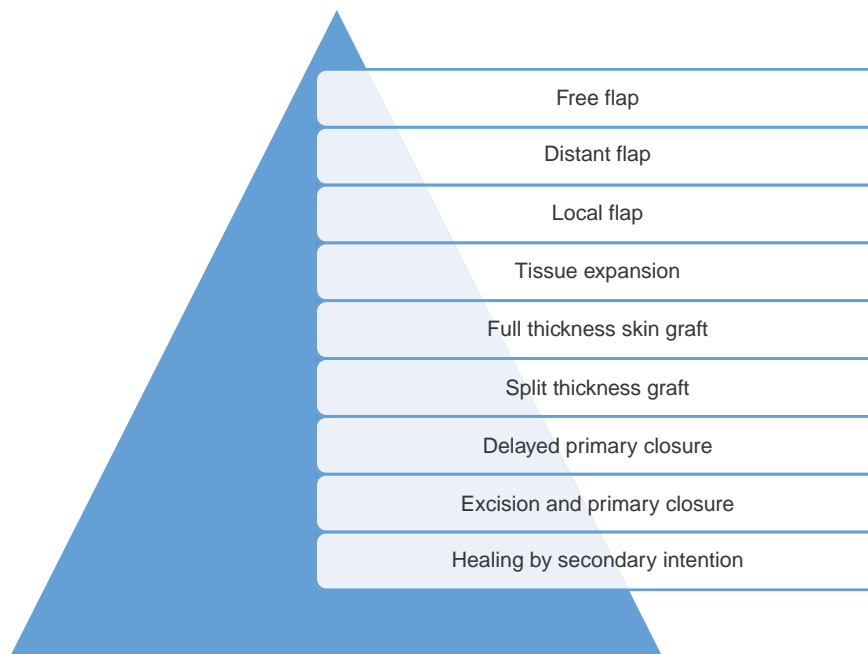
A variety of procedures and techniques developed over the years have been modified for the treatment of burns. This section aims to give an overview of the different recommended techniques and their indication, limitations, advantages and disadvantages. These methods are used in reconstruction to provide wound coverage and restore function and aesthetics. Often, the process of reconstruction will require a multidisciplinary team approach with multiple surgical procedures and phases in the management and rehabilitation of patients (Barrett JP, 2004).

## 6.1. Factors influencing the reconstruction process

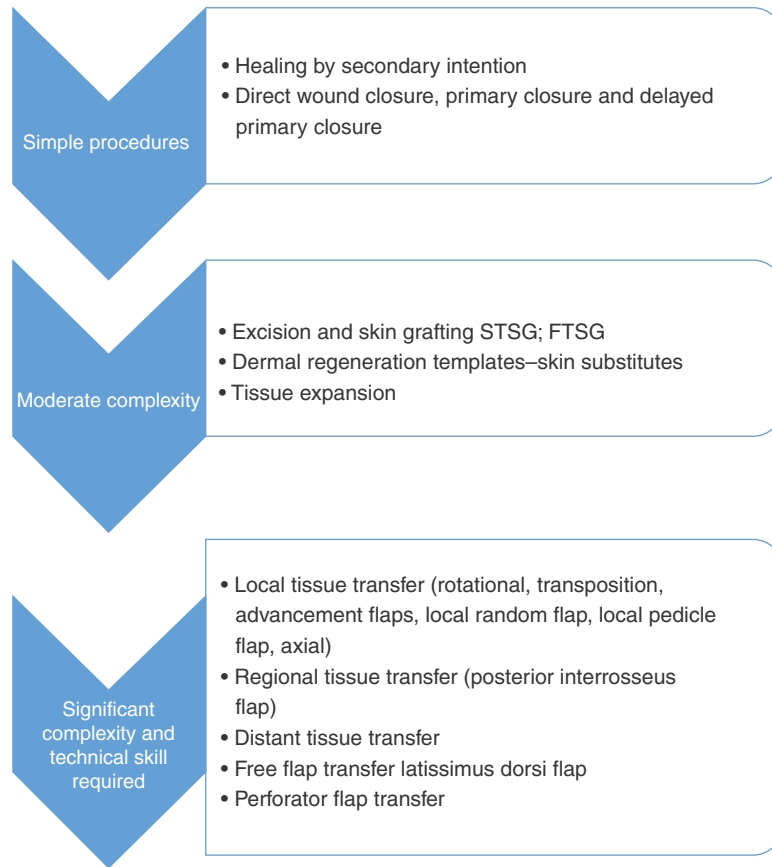
These include:

1. Patient's needs
2. Severity and extent of scarring
3. Stage of scar maturation
4. Disability
5. Patient's compliance
6. Available donor sites.

Patients will often require a combination of surgical procedures of varying degrees of complexity depending on the size and severity of the burns. Thus, a tailored approach to reconstruction is required. Surgeons should therefore be technically proficient in all aspects of reconstruction. The reconstructive ladder (see [Figure 6.3](#)) aims to provide a guidance pathway for the process of reconstruction in which the simplest means of reconstruction are first employed before proceeding to a more complex option. The reconstructive ladder is a guidance pathway that helps provide a step-by-step approach in reconstruction techniques, with the simplest techniques at the base of the pyramid and complexity and skill increasing at each level. Free flaps are at the peak of the pyramid as they are the most complex procedures requiring a high level of technical skill.



**Figure 6.3.** The reconstructive ladder for post-burn reconstruction.



**Figure 6.4.** Guidelines for the reconstructive process.

## 6.2. Guidelines for the reconstructive process

The process of reconstructive surgery for burns is a complex and often a long, protracted journey, involving several surgeries and long periods of rehabilitation. Often patients suffering from significant burns requiring surgery will require multiple procedures and often combinations of different techniques. [Figure 6.4](#) shows a table of procedures that can be employed in the management of burns. These all vary in terms of complexity and the skill and technical ability required of the surgeon to perform these techniques.

## 7. HEALING BY SECONDARY INTENTION AND PRIMARY CLOSURE

Healing via secondary intention refers to the natural healing of the body without any intervention, e.g. apposition of wound edges. The process of healing occurs via wound contraction and the formulation of granulation tissue followed by scarring (Barrett JP, 2004).



Excision and primary closure is a simple method for the management of small burns and burns scars. The scar is excised and closed by the immediate approximation of wound edges. The key principle is that no tension should be applied to the wound edges. This is useful in areas where elasticity allows for tension-free repair; it is only indicated for small, isolated, narrow scars.

Early primary wound closure is performed within 1–5 days, and delayed primary wound closure within 6–12 days has similar advantages in reducing risk of septicaemia, mortality, morbidity, hospital stay and the cost of treatment.

## 7.1. Advantages of primary closure

---

These include:

- Improved aesthetics
- Healing occurs more rapidly
- Simple, direct method that is not technically difficult.

## 7.2. Disadvantages of primary closure

---

These include:

- Only suitable for small, isolated scars
- Tension on the wound can result in wound dehiscence or delayed wound healing
- Distortion and unsightly scars
- Scar contracture painful scars.

## 8. EXCISION AND SKIN GRAFTING: FTSGS AND STSGS

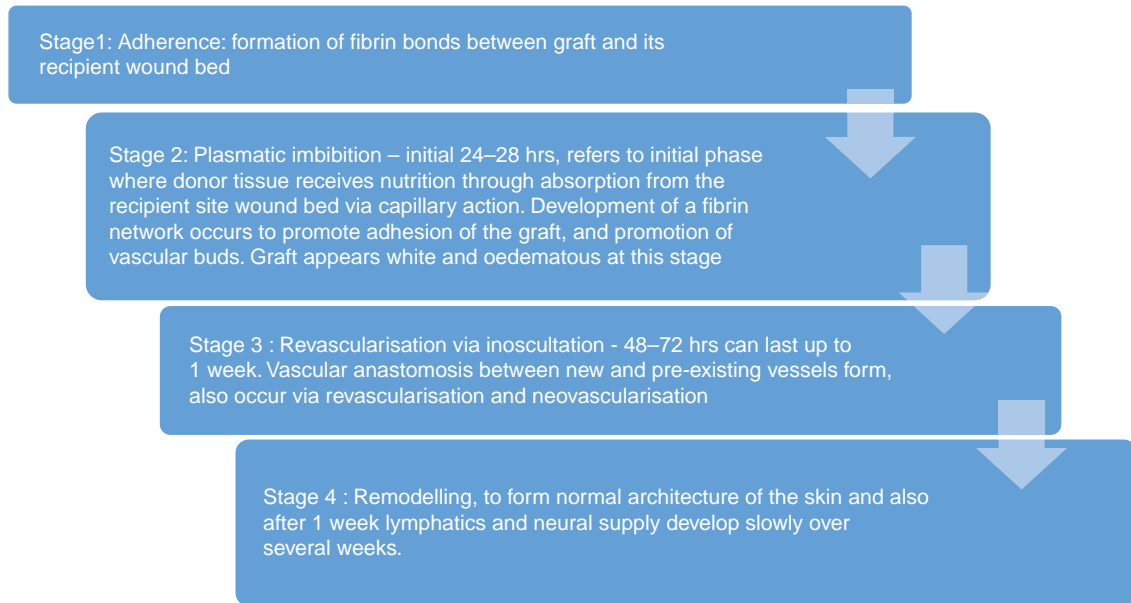
---

Skin grafting refers to the acute coverage of burns rather than to reconstruction. This technique is important because early excision and skin grafting reduces the presence of necrotic and infected tissue, thus helping to reduce morbidity and mortality. Studies have shown that early wound excision and closure (days 1–5) reduce the length of hospital stay and the costs of care. Early wound closure is associated with a reduced severity of hypertrophic scarring, joint contractures and stiffness, thus helping to promote faster rehabilitation (O'Brien, 2009).

### 8.1. Skin grafts

---

Skin grafts can be full thickness (i.e. full-thickness skin grafts [FTSGs]) or split thickness (i.e. split-thickness skin grafts [STSGs]). These are used as coverage for exposed tissues, tendons and bones, and consist of epidermis and variable amounts of dermis. Once transferred, the graft will establish a blood supply (Ong *et al.*, 2006).



**Figure 6.5.** The stages to graft healing 'take'.

The process by which a graft adheres to the recipient site is termed *take*. Graft take involves vascular ingrowth into the graft from the recipient bed and fibrous tissue fixation. Eventually, a lymphatic system and neural supply will develop, but this a very slow, gradual process; however, vascularisation is rapid.

The speed of vascularisation of the graft is dependent on the graft bed, the graft itself and the conditions under which the graft is applied. Limitations of skin grafting are based on the availability of unburned donor sites, the elasticity and pliability of the skin, and the vascular supply at the graft site.

The four stages of take are adherence, plasmatic imbibition, revascularisation and remodelling. [Figure 6.5](#) provides a summary of the four stages.

## 9. SPLIT-THICKNESS SKIN GRAFTS

A STSG is the most frequently used donor tissue type for skin coverage. It consists of the epidermis and varying amounts of dermis. The thickness can vary between 6/1000 and 12/1000 inch (0.196–0.294 mm) according to the reconstruction needs.

Grafts greater than 12/1000 inch are not usually harvested because vascular integration of the graft takes longer and there is an increased risk of delayed healing and the development of hypertrophic scarring at the donor site. STSGs of >12/1000 inch are in fact similar to FTSGs (Muller, 2000) and these grafts are taken with use of either hand-held (e.g. Watson's knife), electrical or air-powered dermatomes.

Repeat harvesting is possible for STSGs and expansion of the graft by the meshing method can be done to increase the area covered. Small incisions are made to perforate the STSG to facilitate the evacuation of blood exudate without compromising graft integrity. The combination of an STSG and dermal skin substitutes can help improve the quality, elasticity, pliability of reconstructed tissue and the aesthetic results (McCartan and Dinh, 2012; Wain *et al.*, 2012).

### 9.1. STSG survival

The survival or rate of take of an STSG is dependent on adequate vascularity, nutrition and the absence of infection (Muller, 2000).

STSG take is more reliable than FTSG take; therefore, an STSG can be applied to a potentially contaminated wound. A patient with burn wounds that has just healed and requires a release of neck contracture is an example of where an STSG is the ideal option, rather than an FTSG which requires a clean wound environment.

On the other hand, an STSG has the disadvantage of contracting to almost half its original dimensions. This has to be taken into consideration when planning surgery. In addition, hyperpigmentation in non-Caucasian patients can occur, and discoloration of the grafts in Caucasians can also occur; both are an unfavourable consequence of skin grafting. Choosing an anatomically similar site or the scalp as a donor site can help to produce better aesthetic results. There are multiple factors that contribute to skin graft ‘take’ – the process of graft adherence (see Figure 6.6). These factors are both local, for example, poor blood supply to grafted area and thus poor vascularisation so poor healing; or systemic, such as age and nutrition.

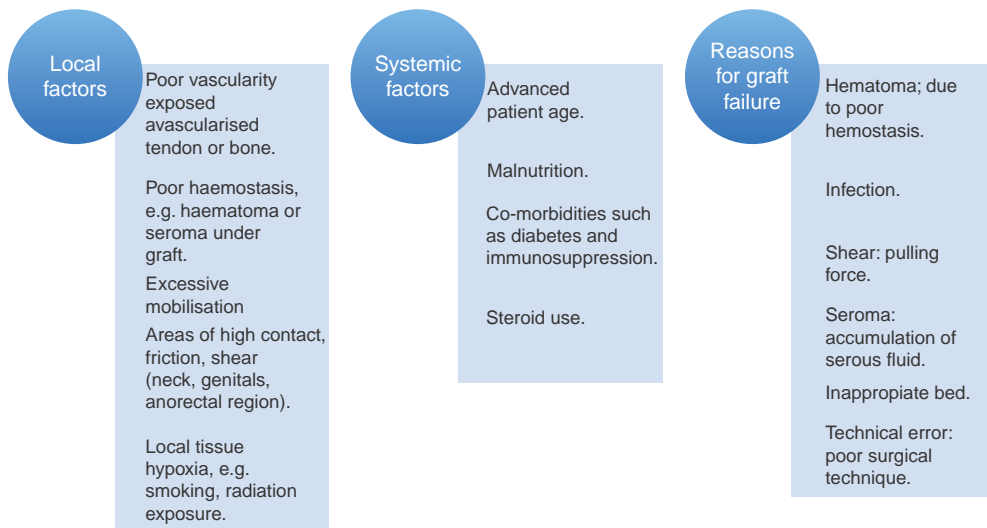


Figure 6.6. Factors affecting skin graft ‘take’.

## 10. FULL-THICKNESS SKIN GRAFTS

FTSGs are mainly used in areas of anatomical and functional importance, such as the face, head, eyelids, perioral areas and neck and functional areas such as the hands (Muller, 2000; Hales *et al.*, 2011).

FTSGs provide an aesthetic advantage over STSGs, but the colour, texture and thickness matches of FTSGs can vary depending on the location of the donor site; thus, attempts must be made to match these qualities.

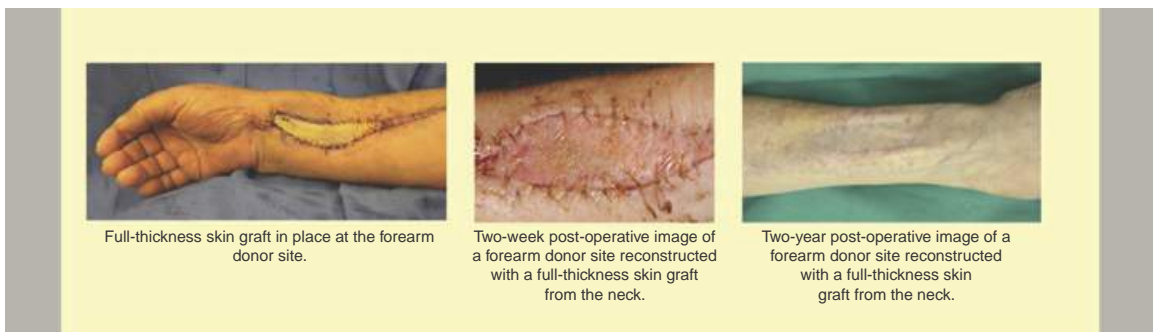An FTSG involves transfer of both the dermis and epidermis. Donor sites used for FTSGs are redundant pliable skin areas such as post-auricular sulcus, supraclavicular, groin, upper inner arm and lower abdominal or lateral thoracic skin (Field, 2010).

### 10.1. Tumescant infiltration

Tumescant infiltration is a procedure used to facilitate graft harvesting and reduce intra-operative blood loss and post-operative pain. Tumescant infiltration of the donor and burn sites with subdermal injections of diluted local anaesthetic (1% lidocaine plus 0.25% bupivacaine with or without 1:1000 adrenaline in 1 l normal saline can be used).

### 10.2. Application of FTSGs

An FTSG is harvested by hand without the use of a dermatome and haemostasis is achieved to prevent haematoma formation, exudate and infection. Tumescant infiltration at the donor and burn wound sites is done to reduce post-operative pain and bleeding (Taifour Suliman, 2009).



**Figure 6.7.** Full-thickness skin graft.

Source: Hanna *et al.* (2014).

**Table 6.2.** Donor sites, advantages and disadvantages of FTSG and STSG.

Donor sites for STSG	Advantages of STSG	Disadvantages of STSG
Thigh and upper arm Surface of torso Flexor aspect of forearm Lower leg	Ability to cover larger areas with less donor skin Donor sites can be re-harvested once healing complete. Usually within 10–15 days	Fragility of donor skin Abnormal pigmentation Lack of smooth texture, alopecia Contractures (due to lack of dermal elements, and thus limited pliability and elasticity more likely to form contractures) Pain at donor site
Donor sites for FTSG	Advantages of FTSG	Disadvantages of FTSG
Upper eyelid skin – for defects of other eye Post auricular skin – very good for face, good match, highly vascular Supraclavicular skin – useful for the face Upper arm skin, antecubital fossa, wrist crease, medial forearm useful flexion contractures at hand  Thigh and abdominal area use for palm and hands, not face (poor aesthetic match)	Improved texture, pliability, elasticity Better colour match  Increased resistance to secondary contractures	Limited availability of high-quality donor skin, Limits size of graft that can be taken  Limited ability to harvest at donor sites Limited vascularity at recipient sites will affect graft survival. FTSG have higher metabolic demands than STSG

FTSG = full-thickness skin graft; STSG = split-thickness skin graft.

All subcutaneous adipose tissue is removed from the dermis of an FTSG before grafting, and the donor site is managed with primary closure. The application of a bolster pressure dressing over the graft reduces the risk of complications and helps to improve graft take.

Figure 6.7 shows the sequence of events in the healing of a full-thickness graft, and the images show the stages immediately post graft to two years later. FTSG has the best composition of skin constituents and provides the best cosmetic and functional results.

Table 6.2 provides a summary of possible donor sites, advantages and disadvantages for both full-thickness skin grafts (FTSG) and split-thickness skin grafts (STSG).

### 10.3. Fixation of grafts

Several methods are used for the fixation of grafts: these include staples, sutures and glues. Glue fixation includes two types of materials:

1. Cyanoacrylates adhesive – used for graft fixation to recipient sites.
2. Fibrin-based glue preparations – have been shown to reduce haemorrhage, improve graft adhesion, possibly reduce bacterial wound infection and reduce the number of haematomas and seromas.

Fibrin glue is expensive; it is manufactured from pooled blood and should only be used under special circumstances such as bleeding tendency in a compromised patient.

### **Dermal regeneration templates: dermal skin substitutes**

---

The development of biosynthetic skin substitutes has allowed the development of further reconstructive options. They can be used alone to provide a temporary covering or in conjunction with an STSG to improve the outcome (Limova, 2010; Wain *et al.*, 2012).

The standard paradigm of using STSGs provides wound coverage that rarely restores pre-morbid function and aesthetics. There are two main challenges and significant clinical problems.

1. With extensive burns, exceeding 50–60% of total body surface area, there is donor site shortage for autologous skin transplantation; thus, an alternative source for covering is required.
2. Conventional techniques used for skin coverage are based on skin grafting with STSGs (the gold standard for defects). The STSG transfers all of the epidermis and part of the dermis; it often results in scarring and can result in hypertrophic and keloid scarring.

Dermal skin substitutes are a useful new tool for post-burn reconstruction. They allow the reconstructive surgeon to excise wide areas of scarring affected by the burn and cover the wound with a dermal template that forms a neodermis which provides a suitable bed for an STSG to be applied. This creates a skin cover that is of better quality than that obtained with an STSG alone, and with less post-operative contracture and recurrence of the deformity. However, this is still inferior to a full-thickness skin graft which is the gold standard in grafting as it provides the best cosmetic and functional results but is of limited availability (Moiemen *et al.*, 2011).

## **11. The ideal properties of skin substitutes**

---

Ideally skin substitutes should:

- Protect the wound from infection
- Protect the wound from fluid loss
- Provide a stable, biodegradable template for the synthesis of neodermal tissue
- Host or enable the influx of cells that will function as dermal cells
- Produce dermal tissue rather than scar tissue
- Allow ease of handling
- Resist tearing forces.

Over the last 30 years, significant advances have led to the development of several different types of skin substitutes to provide both permanent and temporary coverage. Skin substitutes are based primarily on acellular dermal matrices that allow neovascularisation and cellular infiltration from the wound bed.

This has enabled further reconstructive options to be available to patients, especially those with large surface areas affected and more severe burns.

## 11.1. Overview of currently available skin substitutes

---

During the last three decades, several dermal substitutes have been developed for both permanent use and temporary use prior to replacement with skin grafts or flaps. Skin substitutes can be of autologous, allogenic and xenogeneic sources. The most commonly used dermal substitute is an acellular dermal matrix, which is produced by decellularising allogenic or xenogeneic dermal tissue. In this process, the antigenic triggers of rejection are removed and a biodegradable scaffold for cell attachment is formed to facilitate handling, leaving behind a non-immunogenic framework for cellular integration and skin replacement. These dermal matrices aim to allow the ingrowth of fibroblasts, vascular tissues and cells to promote dermis regeneration and help provide a scaffold for tissue regeneration. They can be used in combination with STSGs.

## 11.2. Dermal skin substitutes

---

Dermal skin substitutes can be classified as:

1. Epidermal substitutes
2. Dermal substitutes
3. Dermo-epidermal substitutes.

### 11.2.1. Epidermal substitutes

---

Epidermal skin substitutes are composed of autologous keratinocytes grown in the presence of fibroblasts. They are known as cultured epidermal autografts, and examples of these products are Epidex<sup>®</sup>, Epicel<sup>®</sup> and Myskin<sup>®</sup>.

These are produced by taking a skin biopsy from the patient from which keratinocytes are grown into stratified cell sheets. It can take about 3–4 weeks until the final product is ready for use. This technique requires the use of a temporary wound covering while the epidermal sheet is produced. The main disadvantages are the slow preparation time, variable engraftment and take rates, difficult handling due to very thin fragile cellular layers, and the very high current production cost (Haberzeth *et al.*, 2010).

A second approach to epidermal cellular replacement is the use of cultured autologous keratinocytes in suspension (e.g. ReCell<sup>®</sup>). In this approach, the keratinocytes are sprayed directly onto the wound

bed after preparation. This method can lead to faster epithelisation and epidermal maturation but is not suitable for third-degree burns. Its clinical benefits are still being investigated (Wood, 2002).

Both of the above methods of cultured epidermal autografts, such as the production of a stratified keratinocyte cell sheet or the use of keratinocytes in suspension, have the disadvantage that they are missing the dermal component. The degree of epidermal attachment and the amount of scarring and contracture that occurs during healing and reconstruction are dependent on the quality and condition of the underlying wound bed. Thus, the dermal component of skin is important for manual stability and scarring, and the absence of a dermal component will affect the stability of the keratinocyte sheets and influence the degree of scar contracture that occurs.

### 11.2.2. Dermal substitutes

---

Dermal substitutes restore dermal tissue by promoting new tissue growth and optimising the healing environment. They need to be covered with an epidermal surface or substitute (such as an STSG or a skin substitute, e.g. acellular matrix: Alloderm<sup>®</sup>, Integra<sup>®</sup> or Matriderm<sup>®</sup>) to be incorporated into the wound bed. Thus, often a two-stage process is required in which the initial dermal layer is applied and, after a period of integration, a secondary covering (either an STSG or epidermal substitute) is applied (Haberzeth *et al.*, 2010).

After its application, the dermal substitute is colonised and vascularised by the underlying cells, resulting in the formation of an autologous neodermis. Vascularisation can take up to 3–4 weeks and then an STSG can be applied to the neodermis or epidermal substitute.

This two-stage process has been shown to improve scarring and the aesthetic outcome. Recent approaches that are being considered include the use of thinner dermal layers with the aim of transplanting both the dermal substitute and epidermal graft layers in a single stage, thus helping to reduce the duration of management.

### 11.2.3. Dermo-epidermal substitutes

---

These have been developed by combining human allogenic neonatal keratinocytes and fibroblasts within a scaffold. Substitutes such as Apligraf<sup>®</sup> and OrCel<sup>®</sup> can be used to provide a temporary covering to help with wound closure and protection (MacNeil, 2007). In burn patients, autologous cultured dermo-epidermal substitutes can be obtained from a biopsy taken from the burn patient. The biopsy is cultured using a collagen–glycosaminoglycan substrate to produce the keratinocytes and fibroblast substitute. It can take up to 4 weeks before the substrate can be transplanted. Only a few studies have been performed so far, but the results are promising, showing an improved scar appearance and improved outcome compared with conventional methods

The use of tissue-engineered skin substitutes has already had a significant impact both clinically and in the management of severe burns. They help by providing protection, improved management and improved survivability for these patients. Continuing advances in skin engineering have enormous potential for the future (Pham *et al.*, 2007).



### 11.2.4. Problems associated with dermal substitutes

These include:

- The attachment of a dermal substitute after transplantation promptly requires a well-prepared vascularised wound bed. This can be difficult to achieve for deep burns and chronic wounds.
- If a dermal substitute reaches a threshold thickness, then vascularisation can be too slow to assure adequate nutrition to the overlying epidermis, resulting in epidermal necrosis and graft loss. Therefore, dermal substitutes >1 mm thickness require a two-stage application (e.g. Integra<sup>®</sup>, Matriderm<sup>®</sup>), which can be a lengthy process. In contrast, dermal substitutes <1 mm thick can be placed in a single application.
- Transplanted skin substitutes can produce a varying quality of replacement tissue (e.g. different properties, lack of pigmentation) which may reduce the level of protection from ultraviolet radiation.

## 12. TISSUE EXPANSION

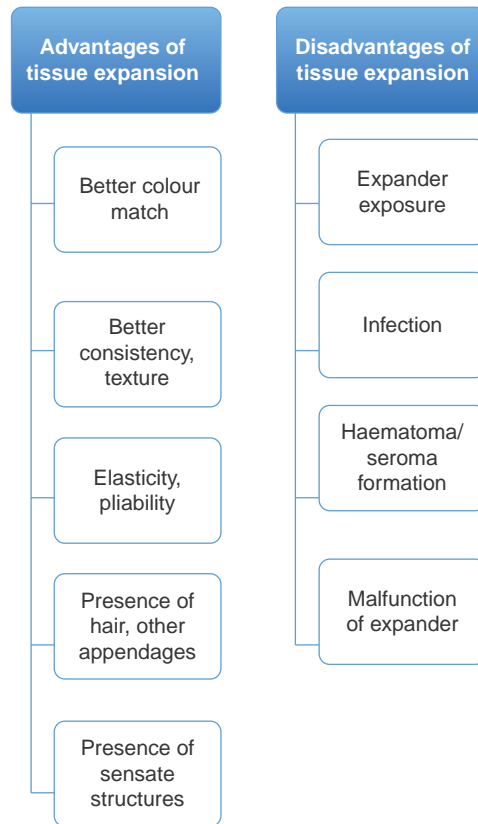
The definition of tissue expansion is an increase in the surface area of tissue due to the gradual forces of mechanical expansion (Motamed *et al.*, 2008). This method is used to gradually expand an area of pliable skin in preparation for its use as coverage for a burn defect or contracture. Stretching the skin using a prosthesis thus utilises the vascularity and elastic properties of the unburned skin and provides coverage by the process of advancement, rotation or transposition of the expanded tissue (Mangubat, 2013).

Tissue expansion is a two-stage process, creep substitution involving the constant mechanical force of expansion, and stress relaxation resulting in a gradual increase in size (Khansa *et al.*, 2014). The main advantage of tissue expansion is that it enables replacing 'like tissue with like'. Figure 6.8 gives a list of the main advantages and disadvantages associated with tissue expansion. An example is the expansion of the hair-bearing scalp to replace an area affected by alopecia. It is a prerequisite that the skin adjacent to the area to be resurfaced is unscarred and pliable to allow expansion without complications.

The technique of tissue expansion is very useful in providing expansion of areas of skin that can then be used in skin grafting, it is a very effective technique but is time-consuming, complex and can be technically difficult. Figure 6.9 gives a guide with useful tips in the pre-, intra- and post-operative phases in the process allowing for successful tissue expansion to be achieved.

## 13. FLAP RECONSTRUCTION OF BURNS

Flaps have been used throughout history in surgery. They have been used in the management of wounds for over 3000 years: they were first described in India 2500–1500 BC; Sushruta Samita described the forehead flap in 800 BC for nasal reconstruction; and modern plastics made significant advancements during the First and Second World Wars when flaps were reintroduced by Sir Harold Gillies.



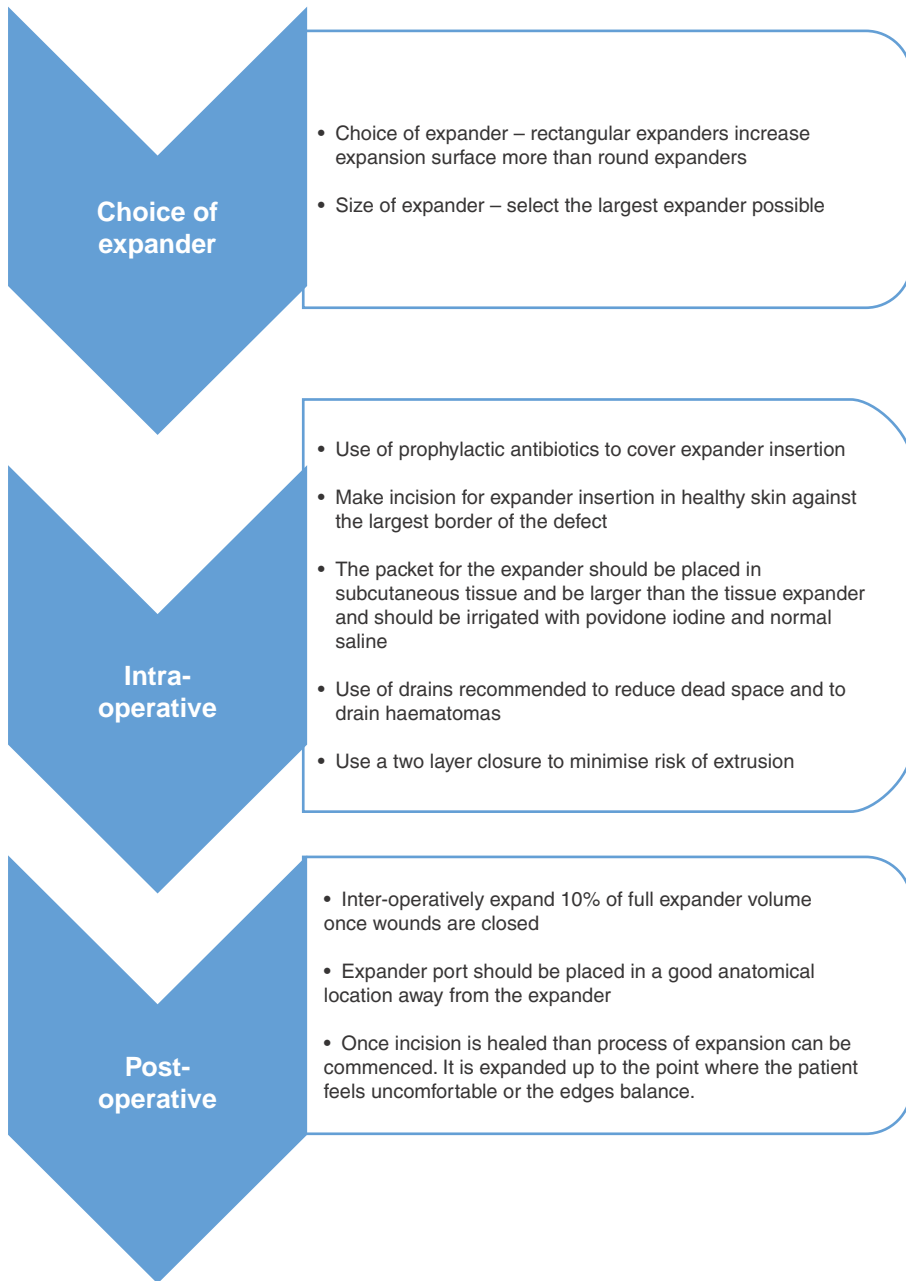
**Figure 6.8.** Advantages and disadvantages of tissue expansion.

The next period of advancement occurred during the 1950s, with the development of axial flaps which incorporate a named blood supply. In the 1970s, distinctions between random and axial flaps helped provide a greater understanding of composite flaps, leading to free tissue transfers in the 1980s. These advancements led to the introduction of perforator flaps in the 1990s.

Flap reconstruction allows the surgeon to reconstruct deeper defects than can be covered using skin grafts because they can be tailored to include the skin, subcutaneous fat, fascia and, in certain circumstances, muscle. In general, flap cover is used when bulk is needed. An assessment of the defect will determine the design of the flap.

Prior to determining the reconstructive options, a full assessment of the area to be reconstructed is required. This should include an assessment of the skin, subcutaneous tissue, fascia, muscle, blood vessels, nerves, cartilage and bone. Once a complete analysis of the injuries and defects has been made, along with the availability of donor tissue for reconstruction, the reconstructive options can be considered based on the relative importance of each area of the defect (Clark and Wang, 2001).

A flap can be considered a unit of issue that is transferred from a donor site to recipient site while maintaining the blood supply. Flaps can vary considerably, ranging from simple advancement of the skin



**Figure 6.9.** Guidelines for successful tissue expansion.

to composite flaps composed of different tissues. Flaps are segments of tissue that are partially or completely perfused with their own blood supply; and are vascularised blocks of tissue that are mobilised from the donor site and transferred to another location adjacent to or remote from region to be reconstructed.

The skin flap is the gold standard of reconstruction because the tissue matches the colour, texture and hair-bearing qualities of the burn site. Flaps are used to replace lost tissue; however, limitations of the use of skin flaps are mainly based on the availability of healthy, pliable, well-vascularised donor tissue.

### **13.1. Flaps anatomy and physiology**

---

Flaps are based on the body's anatomy, which therefore dictates where flaps can be taken from and the types of flaps that are possible. The skin is composed of a microcirculatory system and consists of a superficial, deep vascular plexus. The superficial plexus in the superficial dermal papillae in the papillary dermis supply the more metabolically active epidermis by means of diffusion. The deep vascular plexus lies at the junction of the subcutaneous fat and reticular dermis.

Physiological factors affecting flap survival are the blood supply to the flap through its base, the formation of new vascular channels between the flaps and wound recipient bed, and the perfusion pressure of the supplying blood vessels. Neovascularisation of the flap occurs within approximately 3–7 days via two processes, direct growth and inosculation, i.e. the anastomosis of surrounding recipient capillaries into pre-existing vessels in the flap.

Graft and flaps are both very useful techniques that can be applied in reconstructive surgery and provide very good results. [Table 6.3](#) shows the differences between grafts and flaps with regard to physiological factors and post-operative care.

### **13.2. Principles of flap surgery**

---

The formation of a flap, as for any form of surgery, has risks and benefits, and complications that cause significant problems can arise such as complete flap loss, which can be catastrophic. By using the following principles as guidelines, operative morbidity can be decreased and the optimum environment for successful reconstruction and flap survival can be improved (Chrysopoulo and de la Torre, 2013). Ralph Millard stated several principles for reconstructive surgery. He once said: 'when a part of a person is lost, it should be replaced in kind, bone for bone, muscle for muscle, hairless skin for hairless skin, an eye for an eye, a tooth for a tooth' (Chrysopoulo and de la Torre, 2013). Five principles were determined as guidelines for reconstruction.

1. Replace like with like – replace tissue with the same or similar tissue.
2. Think of reconstruction in terms of units – break down reconstruction into units.
3. Always have a pattern and a back-up plan – be prepared for all eventualities.
4. Steal from Peter to pay Paul – may need to take from region to repair another.
5. Never forget the donor site – always remember to take care of the donor site.

**Table 6.3.** The differences between skin grafts and flaps.

Grafts	Flaps
Limited to transplantation of skin	Can be composed of multiple tissues
Depends on recipient site for nutrition	Has own blood supply
Cosmetic – may discolour or contract	Better cosmetic result, colour match, less likely to contract
Less adaptable to weight-bearing	More adaptable to weight-bearing
Less able to survive on a bed with questionable nutrition	Can be used on a wound bed with questionable nutrition
Requires pressure dressing	Requires no pressure dressing
Cannot bridge defects	Can bridge a defect

### 13.2.1. Principle 1: replace like with like

This is particularly important because lost tissue should be replaced with tissue of the same type, e.g. muscle for muscle and skin replaced with skin of similar type. If this is not possible, then the next most similar tissue should be used. The aim is to minimise the impact of reconstruction and make the reconstructed tissue blend in as naturally as possible, e.g. if replacing skin, try to use skin of a similar colour match and consistency and with similar properties.

### 13.2.2. Principle 2: think of reconstruction in terms of units

The human body consists of seven main units (the head, neck, body, arms and legs), and each of these main parts can be further divided into smaller units; for example, the head is composed of the scalp, face, nose and ears. Thus, each unit has a unique feature or function, and these smaller functional units can be further subdivided into subunits such as sections of the ear or nose. This enables a breakdown of the constituent units of the defect. During the process of reconstruction, all units must be considered and reproduced if necessary.

The most important aspects of a regional unit are the borders of the unit: these are usually demarcated by creases, margins, angles and hair lines. Thus, the interaction and coming together of these units is important, and adherence to these natural borders should be maintained during reconstruction whenever possible.

### 13.2.3. Principle 3: always have a pattern and back-up plan

Plan the procedure and have a back-up plan. Compare all of the pros and cons of each surgical option. The reconstructive ladder is helpful for this because it is a mental exercise that helps the surgeon explore the available options, ranging from the simplest to the most complex. The aim is to restore the function and aesthetic form: that is the nature of plastic and reconstructive surgery.

Thus the approach should be to make a plan, rehearse the plan, make templates of the defects and compare the possible donor areas to determine the ease of harvesting, possible morbidity and closure. The required function and aesthetics both play a role in the choice of technique and surgical plan.

The surgeon should always have a secondary plan, in case of complications and problems, i.e. what will I do if I fail, the initial reconstruction fails or the primary surgical plan is not possible when unforeseen events occur in the operating theatre? What will be the secondary plan for surgery? Always keep an open mind and be ready to adapt and adjust the surgical plan as the situation within the operating room dictates.

#### **13.2.4. Principle 4: Millard talks of the Robin Hood principle**

---

The aim is to take from one area of the body to repair a deficit from another area, with minimal disturbance to the donor region. Using the body to reconstruct a deficit is essentially robbing the bank. The goal is to achieve the ultimate efficiency or, according to Millard, get something for almost nothing. Examples are the use of local flaps, e.g. interpolated flaps, rotation flaps and V–Y flaps. Try to minimise the impact of the reconstruction on the body and donor areas.

#### **13.2.5. Principle 5: always consider the donor region**

---

The final principle is to always remember to treat both the defect and donor region equally because both are very important in reducing morbidity and increasing success. In reality, there is always a price for something, nothing can be obtained for free and there is always a degree of consequence. Careful selection of the donor site is required, especially in consideration of closure of the donor site and the ease of healing at the site.

The aim is to provide coverage and repair the defect with minimal deformity and disability: that is the major principle of reconstructive surgery. Note that donor sites are not limitless; thus, careful planning and consideration are required prior to their selection. Overuse or carelessness can result in damage that is far greater than the original injury.

In conclusion, the aim of reconstruction is to consider all surgical options from the simplest to the most complex and to determine the technique that will have the best functional and aesthetic results. Knowledge of the anatomy, blood supply and quality of the tissue available is essential. Always be prepared for failure, have an alternative plan and be able to adapt accordingly if the first plan fails.

### **13.3. Classification of flaps**

---

There are many systems for the classification of flaps, but they can generally be simply classified into four categories (Kunert, 1995; Ciresi and Mathes, 1993; Hallock, 2004).

1. Circulation – the blood supply of the flap
2. Composition – type of tissue transferred
3. Contiguity – location of the donor site
4. Contour – method of flap transfer.

### 13.3.1. Circulation: blood supply of the flap

As with all tissue, flaps must receive adequate blood flow to survive. They can maintain their blood supply in two main ways. If the blood supply is not derived from a recognised artery but is derived from many little unnamed vessels, then the flap is referred to as a *random flap*. If the blood supply comes from a recognised artery or group of arteries, then it is referred to as an *axial flap*. Thus, classification of flaps is based on their blood supply.

### 13.3.2. Random flap

The blood supply is via small unnamed vessels, e.g. local cutaneous (skin) flaps.

### 13.3.3. Axial flap

The blood is supplied from a recognised vascular pedicle or group of pedicles; most muscle flaps have an axial blood supply. Blood supply can be direct or based on perforators.

Owing to the complexity of and variations in axial blood supply, a further subclassification of axial types I–V was made by Mathes and Nahai and this is shown in [Table 6.4](#). This classification method is commonly used to describe different types of muscle flaps.

Thus, circulation flaps are described as:

- Random flaps – local flaps, basic advancement, V–Y, bipedicle, single pedicle, rhomboid flaps, bilobed flaps.
- Axial flaps – pedicle flaps, free flaps, perforator flaps.

**Table 6.4.** Classification of muscle flaps: Mathes and Nahai.

Classification	Blood supply	Flap
I	One vascular pedicle	Tensor fascia lata
II	Dominant pedicle(s) and minor pedicle(s)	Gracilis
III	Two dominant pedicles	Gluteus maximus
IV	Segmental vascular pedicles	Sartorius
V	One dominant pedicle and secondary segmental pedicles	Latissimus dorsi

### 13.3.4. Flap tissue composition

---

Flaps may be composed of just one type of tissue or of several different types of tissue. A flap may thus comprise a single part of or composites of any component of the body as long as an adequate blood supply is present. Thus, the composition type of tissue that forms the flap can be used for classification.

### 13.3.5. Flaps composed of one type of tissue

---

- Cutaneous – skin
- Fascial – tensor fascia lata flap
- Muscular – muscle
- Osseous – bone
- Visceral – colon, small intestine, omentum.

### 13.3.6. Composite flaps: composed of two or more tissue types

---

- Fasciocutaneous – radial forearm flap
- Tendinocutaneous – dorsalis pedis flap
- Myocutaneous – transverse rectus abdominis muscle ('TRAM') flap
- Osseocutaneous – fibula flap
- Sensory or innervated flaps – dorsalis pedis flap with a deep peroneal nerve.

### 13.3.7. Contiguity: location of the donor site

---

In the formation of a flap, tissue is transferred from one area of the body to the area of the defect. Flaps can therefore be classified according to the location from which the flap is obtained. Thus, flaps can also be classified as local flaps, regional flaps, distant flaps and free flaps.

#### 13.3.7.1. Local flap

---

In a local flap, tissue is transferred from an area adjacent to the defect (Biswas *et al.*, 2014).

- Advancement flaps – single pedicle, bipedicle and V-Y.
- Pivotal (geometric) flaps – rotation, transposition and interpolation.

#### 13.3.7.2. Regional flap

---

Regional flaps are composed of tissue from the same anatomical region as the defect, for example the lower limb, trunk, or head and neck.



### 13.3.7.3. Distant flap

---

Distant flaps are transferred from a non-contiguous anatomical site, i.e. from a distant part of the body.

- Pedicle flaps are transferred while still attached to their original blood supply (Maciel-Miranda *et al.*, 2013).
- Free flaps are completely detached together with their blood supply from donor site and re-anastomosed to recipient vessels close to the defect via microsurgical techniques (De Lorenzi *et al.*, 2001).

### 13.3.8. Contour

---

*Contour* refers to the method used for flap transfer to the defect.

1. Advancement flap – the flap is advanced into defect.
2. Transposition flap – the flap is moved into the defect from adjacent tissue and the defect created is closed primarily.
3. Rotation flap – the flap rotated into the defect.
4. Interpolation flap – the flap is not directly adjacent to the defect. The pedicle of the flap passes over or under a skin bridge to the defect; once it has taken, the pedicle is released and the donor site closed.

## 13.4. Local flaps

---

These skin flaps are created using an FTSG with the intrinsic epidermal and dermal components intact, including the adjacent subcutaneous tissues (Clark and Wang, 2001).

### 13.4.1. Types of local flaps

---

1. Advancement flaps:
  - Single pedicle
  - Bipedicle
  - V–Y
  - Interdigitating Z-plasty principle
  - Alphanumeric (four-flap plasty, five-flap plasty)
  - Propeller flap
  - Bilobed flap.
2. Pivotal (geometric) flaps:
  - Rotation
  - Transposition
  - Interpolation.

#### 13.4.1.1. Advantages

---

- Best local cosmetic match
- Often simple procedure
- Can be done using local or general anaesthesia.

#### 13.4.1.2. Disadvantages

---

- Possible local tissue shortage
- Scarring may exacerbate the condition
- Poor surgical technique can compromise local resection.

### 13.4.2. Types of local flaps

---

#### 13.4.2.1. Advancement flaps

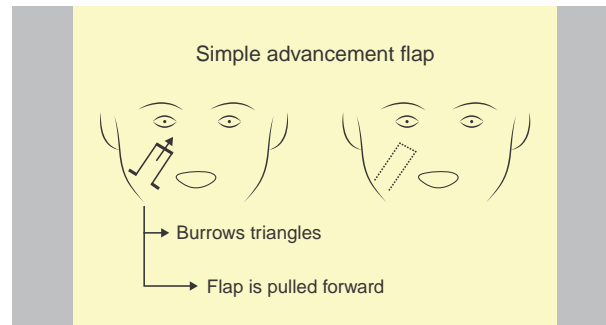
---

1. Advancement flap:
  - Simple flap in an area of skin laxity;
  - The flap is excised and pulled forward to cover the defect;
  - It is moved primarily in a straight line from the donor site;
  - No rotational or lateral movement is applied, e.g. rectangular advancement, V-Y advancement.
2. Modified advancement flap:
  - The base of the flap is modified by Z-plasty, burrows triangles or counter incisions, providing greater advancement and better aesthetic results.

#### 13.4.2.2. Pivotal (geometric flaps)

---

- *Rotation flap* – movement is in the direction of an arc around a fixed point and primarily in one plane; it is a semicircular flap.
- *Transposition flap* – this rectangular flap is rotated on a pivot; the more the flap is rotated, the shorter the flap length becomes. This type of flap is commonly used for head and neck defects.
  - *Rhomboid flap* – specially designed transposition flap for rhombic defects, i.e. the defect must have 60° and 120° angles.
  - *Bilobed flap* – another variation of the transposition flap, consists of two transposition flaps sharing a common pedicle. The first flap is used to reconstruct the defect and the second flap is used for the donor site defect.



**Figure 6.10.** Advancement flap.

- *Interpolation flap* – similar to the transposition flap. The difference is that the pedicle rests over or under the intervening tissue and is divided once the flap has taken and revascularisation has occurred at the site of the defect. The pedicle is then divided, e.g. median forehead flap and thenar flap.

#### 13.4.2.3. Simple advancement flap

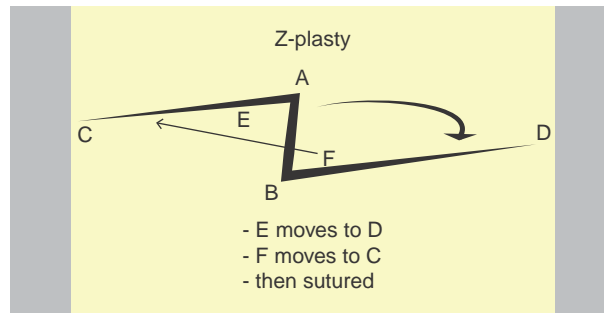
To perform a simple advancement flap, the laxity of skin in the area of defect is assessed. If sufficient, then the flap is excised and pulled to cover the defect. The incorporation of burrows triangles allows greater advancement of the flap and better aesthetic results.

#### 13.4.2.4. V–Y advancement flap

This requires the formation of a triangular flap with the base of the flap at the cut edge of the skin at the site of the defect; the flap should be as wide as the greatest width of the defect. The incision to make the triangle is made through the full-thickness of the skin and the flap is advanced over the defect and sutured in place at the superior edge of defect. Sutures placed at the corners prevent interference with the blood supply, converting the V shape to a Y shape.

## 13.5. Interdigitating flaps: Z-plasty principal

Z-plasty is a classical technique upon which almost all other plasty techniques are based. The term *plasty* refers to the repair or restoration of a body part or its function via surgical methods (Aasi, 2010). This technique of Z-plasty, shown in Figure 6.11, is very effective in the management of small burn contractures, and several variations of the Z-plasty technique exist, such as Y–V-plasty, V–M-plasty and the propeller flap.



**Figure 6.11.** Z-plasty technique.

Z-plasty involves the transposition of two interdigitating triangular flaps, derived from the shape of incision. Transposition of the flaps in Z-plasty has the following two effects:

1. Increase in the length of the area of contracture along the common scar line after release. This allows for lengthening of the scar.
2. Transposition of the flaps allows for a change in direction of the common line scar, which enables changing the direction of the scar to a more favourable line.
3. Interrupts scar linearity.

The Z-plasty technique is very useful in the management of certain defects. It has the following benefits when applied to certain wound defects.

1. Burn contracture – Z-plasty can increase the length of a scar via contracture release (Kobus and Flankowski, 1972).
2. Facial scars – a second effect of Z-plasty is that it can change the direction of the scar and can help break up a facial scar, thus improving the cosmetic result.
3. Prevention of scar contracture – Z-plasty can be useful in emergencies. For example, for burns to the hand, Z-plasty can increase the function and range of motion, helping to prevent contractures (Sari *et al.*, 2014).

When performing Z-plasty, the degree of elongation of the longitudinal axis that is achieved is directly proportional to the angle of its constituent flaps.

- 30° angle – 25% increase in length.
- 45° angle – 50% increase in length.
- 60° angle – 75% increase in length.
- Z-plasty is not possible beyond 60° because the ability to transpose flaps then becomes affected.

## 13.6. Regional and distant flaps

Regional and distant flaps can be composed of full-thickness skin, subcutaneous tissue, muscle and other tissues; they have a well-defined arterial supply.

- *Regional flaps* – pedicle flaps that derive their vascular supply from the region that is to be reconstructed. For example, a pedicle radial forearm flap with a pedicle in the radial artery can be used to cover a defect in the hand (Biswas *et al.*, 2014).
- *Distant flaps* – pedicle flaps that cover defects in a different anatomical region, e.g. pedicle transverse rectus abdominal flap, the pedicle is the superior epigastric artery and is used to cover breast defects.

As the distance of the transposition of the required flap increases from the defect, the presence of a well-defined blood supply becomes critical. Thus, these flaps are classified as axial flaps. However, most flaps have a random pattern at their distal ends and are often used to cover large defects that require bulk. Examples are the pectoralis major myocutaneous flap (PMMF), deltopectoral (DP) flap, trapezius flap and latissimus dorsi (LD) flap.

### 13.6.1. Pectoralis major myocutaneous flap

The PMMF is a very commonly used myocutaneous pedicle flap which is used in approximately 90% of head and neck reconstructions. The arterial blood supply is based upon the pectoral branch of the thoracoacromial artery off the second portion of the axillary artery. The advantages of this type of flap are that there is a very durable blood supply and the defect at the donor site can be closed primarily. The PMMF flap also provides a significant amount of tissue bulk to cover large defects.

### 13.6.2. Deltopectoral flap

The DP flap is a full-thickness fasciocutaneous flap which includes the fascia of the pectoral muscles. The DP flap is a medially based anterior chest wall flap with skin and fascia but, without the muscle, the blood supply is based on the 1st to 4th perforator branches of the internal mammary artery. It can be used for large surface covering.

### 13.6.3. Trapezius flap

The trapezius flap uses the trapezius muscle and the overlying soft tissue and skin. The blood supply is via the transverse cervical artery. Intra-operative repositioning of the patient is required during the process of harvesting the flap.

### 13.6.4. Latissimus dorsi flap

The LD flap is a very reliable and versatile type of flap. It can be transferred as a muscle flap or a myocutaneous flap, or even as a composite osteomyocutaneous flap when harvested with the underlying serratus muscle and rib. It can also be used as a free flap.

The LD muscle is supplied via two separate vascular systems. The primary system blood supply is via the thoracodorsal artery, which is the terminal branch of the subscapular artery. The secondary blood supply is via the segmental perforating branches from the intercostal and lumbar arteries.

### 13.6.5. Distant flaps: pedicle flaps

Distant flaps can be moved on long pedicles that contain the blood supply. The pedicle can be buried beneath the skin to create an island pedicle or left above the skin and formed into a tube. Distant flaps, as the name suggests, mean that this type of flap can be moved a long distance while still attached to the pedicles that contain a dominant blood supply, for example a myocutaneous flap (e.g. the latissimus dorsi flap for breast reconstruction), or the distant flap may be composed with a long fascial layer that contains a major septal blood supply, for example a fasciocutaneous flap. This means that these flaps can be larger in size as they are transferred still attached to a major vascular supply.

## 13.7. Free flaps: free microvascular tissue transfer

With modern advances in surgery, materials, instruments and microsurgery techniques, it is now possible to form free flaps in which the blood supply is disconnected from the donor site and then reconnected at the recipient site. Free tissue transfers now provide an excellent way of reconstructing major composite loss of tissue in the face, jaw, lower limb or breast. The free muscle transfer should be re-anastomosed within 1–2 hours in an efficient manner to minimise the time the flap is exposed to ischaemia.

A free flap may consist of skin, subcutaneous tissue, muscle and/or bone. It is detached from the donor site along with its accompanying vascular pedicle, which is anastomosed to recipient vascular pedicle. The formation of a free flap is complex and requires a significant level of training, planning and surgical expertise (Hallock, 2004).

Approximately 1% of surgically treated burns will require a free flap. It is suggested that these flaps should be performed within 5 days of the burn occurring or at the time of secondary reconstruction procedure after 6 weeks or more (De Lorenzi *et al.*, 2001).

**Table 6.5.** Indications for free flaps.

1	When less complex methods have failed, e.g. STSG, FTSG
2	When deep structures are exposed (frontal sinus, nasal pyramid, tibial crest, neurovascular structures, tendons)
3	When there is absolute need to combine reconstruction with cosmetic appearances, such as the facial structures or female breast
4	Unsalvageable deep burns
5	Resurfacing following release of scar contractures

FTSG = full-thickness skin graft; STSG = split-thickness skin graft.

### 13.7.1 Advantages of free flaps

- The most suitable tissue can be selected for transfer.
- Possible to take only the exact amount of tissue required, with no loss of excess tissue.
- These actions minimise donor site morbidity.

### 13.7.2. Disadvantages of free flaps

- A complex surgical technique that requires a high level of proficiency.
- Flap failure results in total loss of the transferred tissue.
- Duration of surgery can be very long, and a longer duration of general anaesthesia leads to increased risk.

There are many possible donor sites for free flaps, as shown in [Table 6.6](#). The possible donor sites are located throughout the body depending on the requirements of the graft site and the risk of morbidity at the donor site. Always remember to consider both the donor and recipient site in distant flaps to make sure that no additional problems are created at the donor site.

**Table 6.6.** Sources of donor sites for free flap transfers.

Type of flap	Source of flap
Muscle only	Latissimus dorsi Rectus abdominis Gracilis
Myocutaneous	Latissimus dorsi Transverse rectus abdominis
Fasciocutaneous	Radial forearm flap Scapular Lateral arm Groin
Osseous	Fibula Forearm Iliac crest
Fascial	Temporoparietal
Jejunum	Oesophageal reconstruction
Pectoralis minor	For facial reanimation
Omentum	Chest wall and limb defects

### 13.7.3. Monitoring flaps for success

---

This is done via examining the following characteristics:

- Colour of the flap tissue;
- Warmth and turgor of the region;
- Blanching – to determine circulation and presence of inflammation and necrosis; and
- Capillary refill time – to determine whether there is an adequate blood supply.

### 13.7.4. Possible complications associated with surgery

---

- Seroma formation
- Haematoma formation
- Superficial skin necrosis
- Wound separation and dehiscence with eventual partial and/or complete flap loss
- Fat necrosis
- Donor site infection.

### 13.7.5. Causes of flap failure

---

- Poor technique and anatomical knowledge when raising the flap can compromise the blood supply making it deficient from the beginning; thus, poor results when the flap does not take.
- Flap inset is attached with too much tension, which affects flap take and increases the risk of flap failure.
- Local sepsis or septicaemia in the patient.
- Dressing is applied too tightly around the pedicle, resulting in ischaemia.

## 13.8. Perforator flap concept

---

This flap consists of skin and subcutaneous tissue that is vascularised by a perforator artery. Its versatility has enabled the reconstruction of burns and scars at multiple anatomical sites (Geddes *et al.*, 2003).

The major advantage of perforator flaps is that a large cutaneous flap can be obtained from the same region from which a musculocutaneous flap is obtained without the need to include the muscle, which might not be expendable. Limitations to the use of perforator flaps are a traumatised subdermal plexus, an injured main perforator, a difficult dissection, obesity, bleeding and damage to the main pedicle (Maciel-Miranda *et al.*, 2013; Panse *et al.*, 2013).



Recommendations for reducing the incidence of complications in perforator flaps are:

- Pre-operative mapping and localisation of perforating arteries by hand-held Doppler
- Identification of the main perforator by making an exploratory incision
- Preservation of each perforator until a large one is encountered
- Selection of the best perforator
- Performing the easiest dissection
- Not discarding any perforators until completing the dissection.

## 14. FACIAL TRANSPLANTATION

The technique of facial transplantation is new and controversial, but it can offer patients with severe facial burns the possibility of reconstruction. However, the efficacy and value of this procedure has not yet been validated. There are many restrictions on performing this procedure, including the ethical quandary of facial transplantation as well as technical and psychological factors that must be considered.

The procedure is limited because of the poor availability of facial tissue allografts. It is also very complex, requiring a high level of skill and a multidisciplinary team approach as well as the need for lifelong immunosuppression. Thus, the technique is highly controversial and very limited in availability because of technical and ethical complications.

## 15. CONCLUSION

The aim of reconstructive surgery in burns patients is to restore function and cosmesis and to improve the patient's quality of life. This can be achieved by the reconstructive techniques described in this chapter. The use of grafts, tissue expansion, skin substitutes and flaps has greatly increased the reconstructive options available. Advancements in skin substitutes as well as facial transplantation are opening up new and innovative pathways in reconstructive surgery.

## REFERENCES

- Aasi, S. Z. 2010. Z-plasty made simple. *Dermatol Res Pract*, 2010, 982623.
- Barret, J. P. 2004. Burns reconstruction. *BMJ*, 329(7460), 274–6.
- Biswas, D., Wysocki, R. W., Fernandez, J. J. & Cohen, M. S. 2014. Local and regional flaps for hand coverage. *J Hand Surg Am*, 39, 992–1004.
- Chrysopoulos, M. T. & de la Torre, J. I. (eds). 2013. 'Tissue Flap Classification'. In: <http://emedicine.medscape.com/article/1284474-overview> [accessed 29 May 2013].
- Ciresi, K. F. & Mathes, S. J. 1993. The classification of flaps. *Orthop Clin North Am*, 24, 383–91.
- Clark, J. M. & Wang, T. D. 2001. Local flaps in scar revision. *Facial Plast Surg*, 17, 295–308.

- De Lorenzi, F., Van Der Hulst, R. & Boeckx, W. 2001. Free flaps in burn reconstruction. *Burns*, 27, 603–12.
- Field, L. M. 2010. Full-thickness graft donor sites: further options. *Dermatol Surg*, 36, 965–6.
- Geddes, C. R., Morris, S. F. & Neligan, P. C. 2003. Perforator flaps: Evolution, classification, and applications. *Ann Plast Surg*, 50, 90–9.
- Haberzeth S, Biedermann T, Reichman E. 2010. Tissue engineering of skin. *Burns*, 36, 450–60
- Hales, E., Simons, M., Laack, Z. & Kimble, R. 2011. A review of full-thickness and split-thickness graft outcomes in pediatric hand burns. *J Burn Care Res*, 32, e109.
- Hallock, G. G. 2004. The complete classification of flaps. *Microsurgery*, 24, 157–61.
- Hanna, T. C., McKenzie, W. S. & Holmes, J. D. 2014. Full-thickness skin graft from the neck for coverage of the radial forearm free flap donor site. *Journal of Oral and Maxillofacial Surgery*.
- Khansa, I., Hendrick, R. G., Jr., Shore, A., Meyerson, J., Yang, M. & Boehmler, J. H. T. 2014. Breast reconstruction with tissue expanders: Implementation of a standardized best-practices protocol to reduce infection rates. *Plast Reconstr Surg*, 134, 11–8.
- Kobus, K. & Flankowski, W. 1972. [Z-plasty in the treatment of contractures of the extremities following burns.] *Chir Narzadow Ruchu Ortop Pol*, 37, 529–34.
- Kunert, P. 1995. [A simple classification system for all skin flaps]. *Handchir Mikrochir Plast Chir*, 27, 124–31.
- Limova, M. 2010. Active wound coverings: Bioengineered skin and dermal substitutes. *Surg Clin North Am*, 90, 1237–55.
- Maciel-Miranda, A., Morris, S. F. & Hallock, G. G. 2013. Local flaps, including pedicled perforator flaps: Anatomy, technique, and applications. *Plast Reconstr Surg*, 131, 896e–911e.
- MacNeil S. Progress and opportunities for tissue engineered skin. *Nature* 2007;445:874–80
- Mangubat, E. A. 2013. Scalp repair using tissue expanders. *Facial Plast Surg Clin North Am*, 21, 487–96.
- McCartan, B. & Dinh, T. 2012. The use of split-thickness skin grafts on diabetic foot ulcerations: A literature review. *Plast Surg Int*, 2012, 715273.
- McGregor, A. D. 2001. *Fundamental Techniques of Plastic Surgery and Their Surgical Applications*. Edinburgh, Churchill Livingstone.
- Moiemen, N., Yarrow, J., Hodgson, E., Constantinides, J., Chipp, E., Oakley, H., Shale, E. & Freeth, M. 2011. Long-term clinical and histological analysis of Integra dermal regeneration template. *Plast Reconstr Surg*, 127, 1149–54.
- Motamed, S., Niazi, F., Atarian, S. & Motamed, A. 2008. Post-burn head and neck reconstruction using tissue expanders. *Burns*, 34, 878–84.
- Muller, W. 2000. [Split skin and full-thickness skin grafts]. *Mund Kiefer Gesichtschir*, 4 Suppl 1, S314–21.
- O'Brien, M. S. 2009. *Plastic and Hand Surgery in Clinical Practice*. London, Springer, 2009.
- Ong, Y. S., Samuel, M. & Song, C. 2006. Meta-analysis of early excision of burns. *Burns*, 32, 145–50.
- Panse, N., Sahasrabudhe, P. & Joshi, N. 2013. Perforator relocation in free style local perforator flaps. *World J Plast Surg*, 2, 47–49.
- Pham, C., Greenwood, J., Cleland, H., Woodruff, P. & Maddern, G. 2007. Bioengineered skin substitutes for the management of burns: A systematic review. *Burns*, 33, 946–57.
- Sari, E., Tellioglu, A. T., Altuntas, N., Seven, E. & Ozakpinar, H. R. 2014. Combination of rhomboid flap and double Z-plasty technique for reconstruction of palmar and dorsal web space burn contractures. *Burns*, 41(2), 408–12.
- Shelley, O. P., Van Nierkerk, W., Cuccia, G. & Watson, S. B. 2006. Dual benefit procedures: Combining aesthetic surgery with burn reconstruction. *Burns*, 32, 1022.
- Shelley, O. P. & Dziewulski, P. 2006. Late management of burns. *Surgery*, 24, 15–7.
- Taifour Suliman, M. 2009. A simple method to facilitate full-thickness skin graft harvest. *Burns*, 35, 87–8.
- Wain, R. A., Shah, S. H., Senarath-Yapa, K. & Laitung, J. K. 2012. Dermal substitutes do well on dura: Comparison of split skin grafting +/-artificial dermis for reconstruction of full-thickness calvarial defects. *Clin Plast Surg*, 39, 65–7.
- Wood, B. C. & Caputy, G. G. 2015. 'Skin Grafts'. In: <http://emedicine.medscape.com/article/1295109-overview> [accessed 17 January 2016].
- Wood, F. M. (2002) Clinical potential of cellular autologous epithelial suspension. *Wounds*, 15, 16–22.

## Soft Tissue Injuries of the Hand

---

Hiba Khan, Bran Sivakumar

### 1. INTRODUCTION

---

The human hand has evolved into one of the most complex structures in nature. This complexity affords the hand remarkable dexterity, fine motor control and tactile feedback. We are dependent on our hands for most activities of daily living: loss of hand function can have devastating consequences on quality of life, affecting a person's ability to work, communicate and live independently.

While the functional aspects of hand reconstruction remain the surgeon's main concern, it is important to appreciate the impact of the aesthetic result on a patient's quality of life. After the face, the hand is the most exposed body part and the one which is most often in the patient's own visual field (Coleman, 2002). As a result, deformities of the hand can have a significant psychological burden.

Early references to surgery of the hand go back as far as Hippocrates (460–377 BC), who described methods to reduce wrist fractures, and Heliodorus (AD 60–140), who described techniques for amputating digits with the use of skin flaps to cover exposed bone (Marble, 1966). The Second World War was the major driving force behind the development of modern hand surgery. In contrast to the trench warfare of the First World War, the Second World War involved open warfare with a greater use of explosives, leading to a larger number of upper limb and hand injuries. Regional hand referral centres were established in the USA to co-ordinate the growth in demand for hand surgery. In 1946, representatives from plastic surgery, orthopaedic surgery and general surgery combined to form the American Society for Surgery of the Hand (Chang, 2012).

The development of microsurgery during the 1960s and 1970s liberated the hand surgeon from the anatomical limitations of local tissue transfer and paved the way for many of the modern techniques used for hand reconstruction, including the use of free flaps (Chang, 2012). The first successful replantation of an amputated upper arm was carried out in 1962, and the first thumb replantation in 1968 (Chang, 2012).

The first successful hand transplant was carried out in Ecuador in 1964. Unfortunately, however, the hand had to be removed within 3 weeks because of immune rejection. More recently, research

and development into more effective immunosuppressant regimes, along with improvements in surgical technique, have allowed a number of successful hand transplantations to be carried out worldwide (Shores *et al.*, 2011).

Trauma is a major cause of hand dysfunction, with hand injuries making up the bulk of daily trauma lists in most plastic surgery units. Surgery is often only the first step in a long recovery process following injury, and care is co-ordinated through a multidisciplinary team comprised of surgeons, physiotherapists and occupational therapists. This chapter provides an overview of the anatomy of the hand followed by a description of soft injuries and their surgical management. Hand fractures and congenital hand defects are covered elsewhere.

## 2. ANATOMY

---

The hand is both a sensory and a mechanical tool. Its dexterity is dependent on co-ordinated movement between the small muscles of the hand and the larger muscles of the forearm. Many of the features of the upper limb are designed to allow positioning of the hand in space.

### 2.1. Bones

---

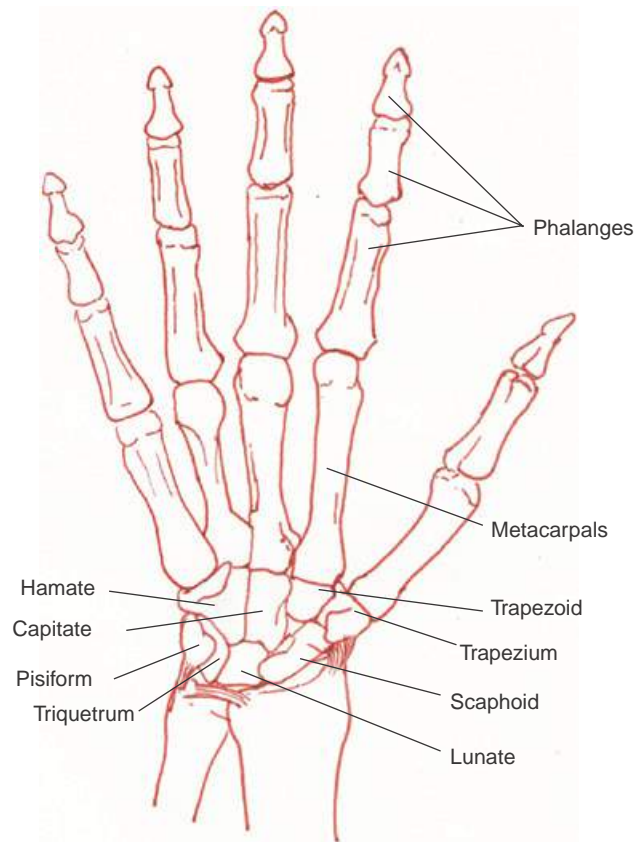
There are three groups of bones in the hand (Figure 7.1):

- Carpal bones (8) – scaphoid, lunate, triquetrum, pisiform, trapezium, trapezoid, capitate and hamate
- Metacarpal bones (5)
- Phalanges (14).

### 2.2. Joints

---

- *Wrist joint* – synovial joint between distal radius and ulna, and the scaphoid, lunate and triquetrum. It allows hand abduction, adduction, flexion and extension.
- *Carpal joints* – the synovial joints between carpal bones are relatively immobile and share a common articular cavity. They are reinforced by a number of ligaments.
- *Carpometacarpal joints* (CMJs) – five joints between the distal row of carpal bones and the five metacarpal bones. The first CMJ (I) is saddle-shaped and allows flexion, extension, abduction, adduction, rotation and circumduction of the thumb. The remaining four CMJs (II–V) are far less mobile, allowing limited gliding movements only.
- *Metacarpophalangeal joints* (MCPJ) – located between the distal heads of the metacarpal bones and the proximal phalanges. MCPJs allow flexion, extension, abduction, adduction, circumduction



**Figure 7.1.** Bones of the hand.

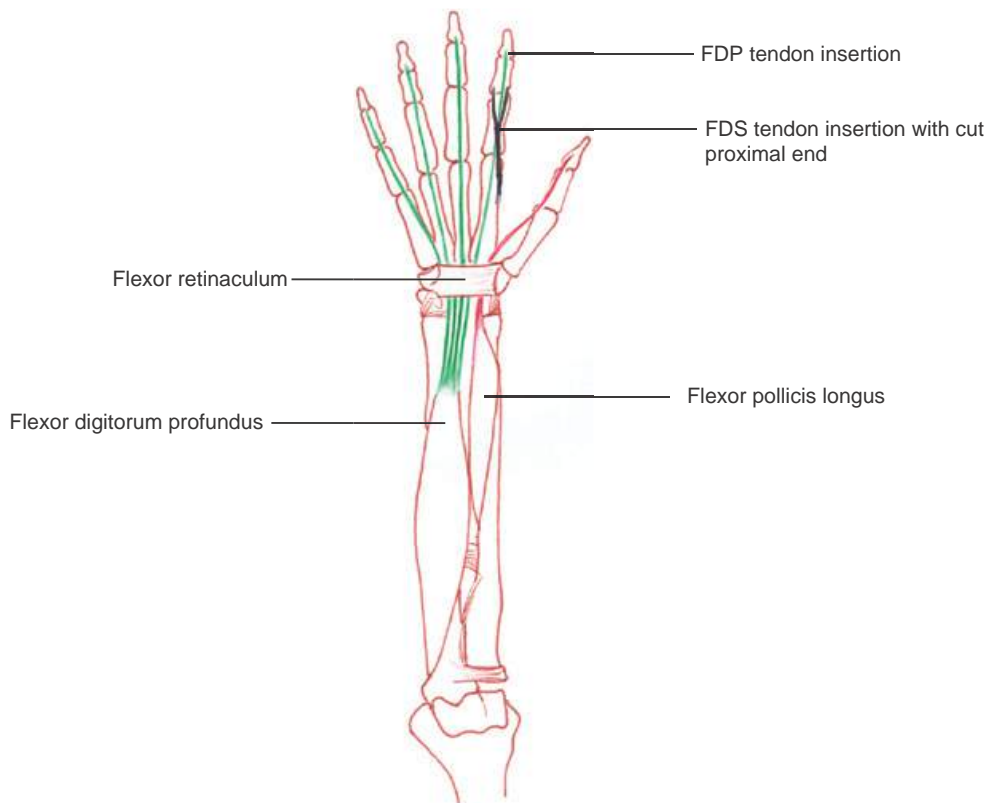
Source: Drake and Mitchell (2005).

and rotation. Each joint is reinforced by a volar plate and lateral and medial collateral ligaments. Three transverse metacarpal ligaments join the MCPJs of the finger together to provide a framework for the palm of the hand.

- *Interphalangeal joints (IPJs)* – hinge joints that allow flexion and extension. Reinforced by volar plates and lateral and medial collateral ligaments.

## 2.3. Muscles

Hand movements are controlled by long muscles from the forearm and intrinsic muscles of the hand. The muscles found in the forearm can be divided into the flexor compartment (Figure 7.2 and Table 7.1), the lateral compartment (Table 7.2) and the extensor compartment of the forearm (Figure 7.3).



**Figure 7.2.** Deep flexor compartment of the forearm.

Source: Drake and Mitchell (2005).

**Table 7.1.** Muscles of the flexor compartment of the forearm.

Compartment	Muscle	Origin	Insertion	Action
<b>Superficial</b>	Pronator teres	Medial epicondyle of humerus	Lateral mid-shaft radius	Pronation
	Flexor carpi radialis	Medial epicondyle of humerus	Base of metacarpal bones	Wrist flexion and abduction
	Palmaris longus	Medial epicondyle of humerus	Palmer aponeurosis	Wrist flexion
	Flexor carpi ulnaris	Olecranon process of ulna and medial epicondyle of humerus	Pisiform bone	Wrist flexion and adduction

**Table 7.1.** (cont.)

Compartment	Muscle	Origin	Insertion	Action
<b>Intermediate</b>	Flexor digitorum superficialis	Medial epicondyle of humerus, coronoid process of ulna and shaft of radius	Gives rise to four tendons that pass under the flexor retinaculum, each split in two and inserted into the sides of each middle phalynx	Proximal IPJ flexion
<b>Deep</b>	Flexor digitorum profundus	Anterior and medial surface of ulna and interosseous membrane	Distal phalynx of each finger	Distal IPJ flexion of fingers
	Flexor pollicis longus	Anterior surface of radius and interosseous membrane	Base of distal phalynx of thumb	IPJ flexion of thumb
	Pronator quadratus	Linear ridge of anterior ulna	Distal anterior radius	Pronation

IPJ = interphalangeal joint.

Sources: Drake and Mitchell (2005) and Nakhdjevani and Ahmadi (2007).

**Table 7.2.** Muscles of the lateral compartment of the forearm.

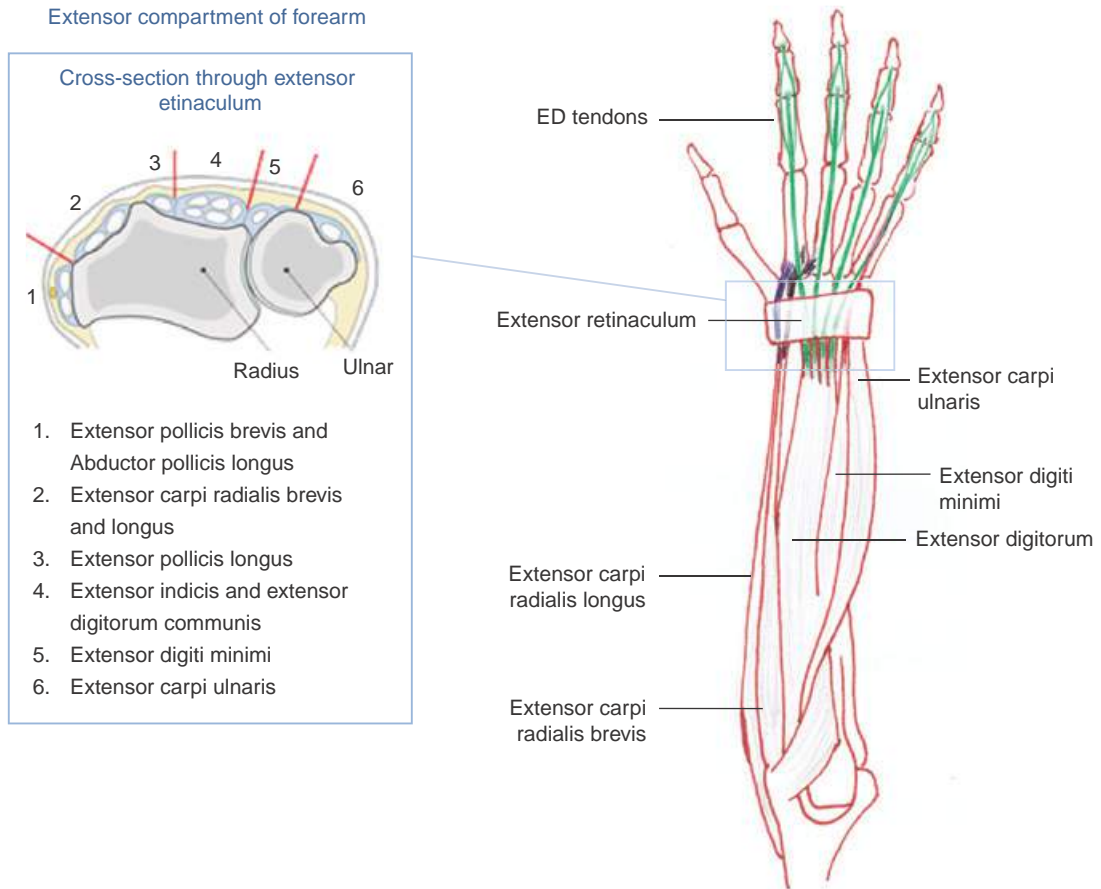
Compartment	Muscle	Origin	Insertion	Action
<b>Lateral</b>	Brachioradialis	Supracondylar ridge of humerus	Styloid process of radius	Elbow flexion, pronation
	Extensor carpi radialis longus	Supracondylar ridge of humerus	Second metacarpal base	Wrist extension and abduction

Sources: Drake and Mitchell (2005) and Nakhdjevani and Ahmadi (2007).

These muscles exert their effect their effect via a series of tendons that pass into the wrist. The smaller intrinsic muscles of the hand are important for fine motor control (Figures 7.5, 7.6 and Table 7.4).

## 2.4. Blood supply

The blood supply of the hand is derived from two major arteries, the radial and ulnar, which connect in the hand to form two arches, the superficial and deep palmar arches (Figure 7.7). The superficial palmar arch lies superficial to the long flexor tendons and deep to the palmar aponeurosis. The deep palmar arch passes between the metacarpal bones and the flexor tendons in the palm. Venous drainage is made up of superficial and deep veins. The deep veins follow a similar course to the arteries of the hand, draining into the cephalic and basilic veins.



**Figure 7.3.** Extensor compartment of the forearm.

Source: Drake and Mitchell (2005).

**Table 7.3.** Muscles of the extensor compartment of the forearm.

Compartment	Muscle	Origin	Insertion	Action
<b>Superficial</b>	Extensor digitorum	Lateral epicondyle of humerus	Divides into four tendons, that insert via 'extensor hoods' into dorsal base of middle and distal phalanges of fingers	Finger extension
	Extensor carpi radialis brevis	Lateral epicondyle of humerus	Third metacarpal base	Wrist extension and abduction
	Extensor digiti minimi	Lateral epicondyle of humerus	Dorsal hood little finger	Little finger MCPJ extension
	Extensor carpi ulnaris	Lateral epicondyle of humerus	Posterior base of fifth metacarpal	Wrist extension and adduction



Table 7.3. (Cont.)

Compartment	Muscle	Origin	Insertion	Action
Deep	Supinator	Lateral epicondyle of humerus	Neck and shaft of radius	Supination
	Abductor pollicis longus	Posterior surface of radius and ulna	Base of first metacarpal	Thumb abduction and extension
	Extensor pollicis brevis	Posterior surface of radius and ulna	Proximal phalanx of thumb base	MCPJ thumb extension
	Extensor pollicis longus	Posterior surface of radius and ulna	Distal phalanx of thumb base	IPJ thumb extension

IPJ = interphalangeal joint; MCPJ = metacarpophalangeal joint.

Sources: Drake and Mitchell (2005) and Nakhdejvani and Ahmadi (2007).

#### Small Muscles of the Hand

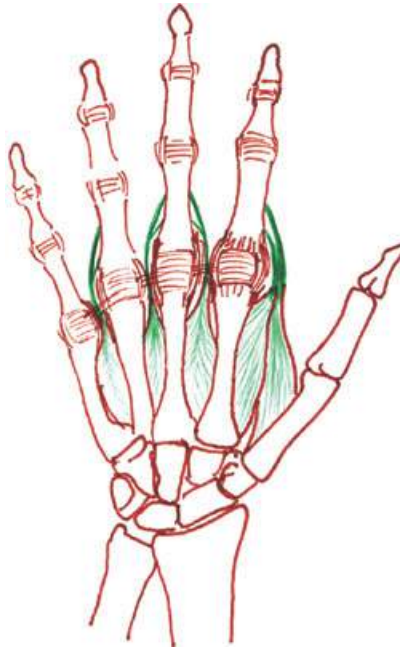
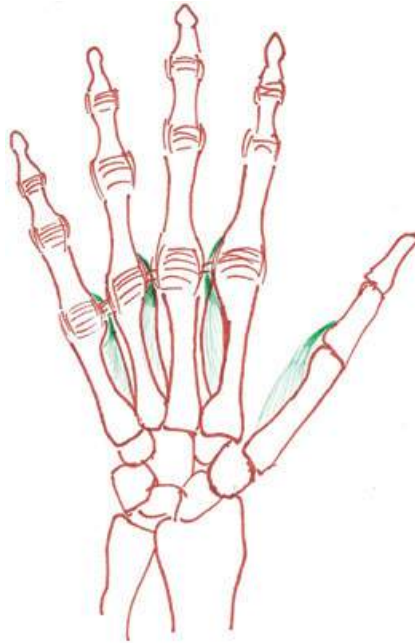


Figure 7.4. Dorsal interossei.

Source: Drake and Mitchell (2005).

Small Muscles of the Hand

**Figure 7.5.** Palmar interossei.

Source: Drake and Mitchell (2005).

**Table 7.4.** Small muscles of the hand.

Compartment	Muscle	Origin	Insertion	Action
<b>Hand</b>	Lumbricals	Tendons of FDP	Lateral side of extensor expansion	MCPJ flexion and IPJ extension
<b>Interossei</b>	Palmar interossei	Medial side of metacarpals	Extensor hoods of thumb, index ring and little fingers and proximal phalanx of thumb	Adduction of fingers
	Dorsal interossei	Sides of metacarpals	Extensor hoods and base of proximal phalanges of index, middle and ring	Abduction index, middle and ring fingers
<b>Thumb</b>	Abductor pollicis brevis	Scaphoid, trapezium and flexor retinaculum	Proximal phalanx and extensor hood of thumb	Thumb abduction
	Flexor pollicis brevis	Tubercle of trapezium	Proximal phalanx of thumb	MCPJ thumb flexion
	Opponens pollicis	Trapezium and flexor retinaculum	First metacarpal	Thumb medial rotation
	Adductor pollicis	Base of second and third metacarpals	Medial side or base of proximal phalanx of thumb	Thumb adduction

Table 7.4. (Cont.)

Compartment	Muscle	Origin	Insertion	Action
Little finger	Abductor digiti minimi	Pisiform	Proximal phalanx base of little finger	Little finger abduction
	Flexor digiti minimi	Flexor retinaculum	Proximal phalanx base of little finger	Little finger MCPJ flexion
	Opponens digiti minimi	Flexor retinaculum	Fifth metacarpal bone	Laterally rotates metacarpal 5

FDP = flexor digitorum profundus; IPJ = interphalangeal joint; MCPJ = metacarpophalangeal joint.

Sources: Drake and Mitchell (2005) and Nakhjjevani and Ahmadi (2007).

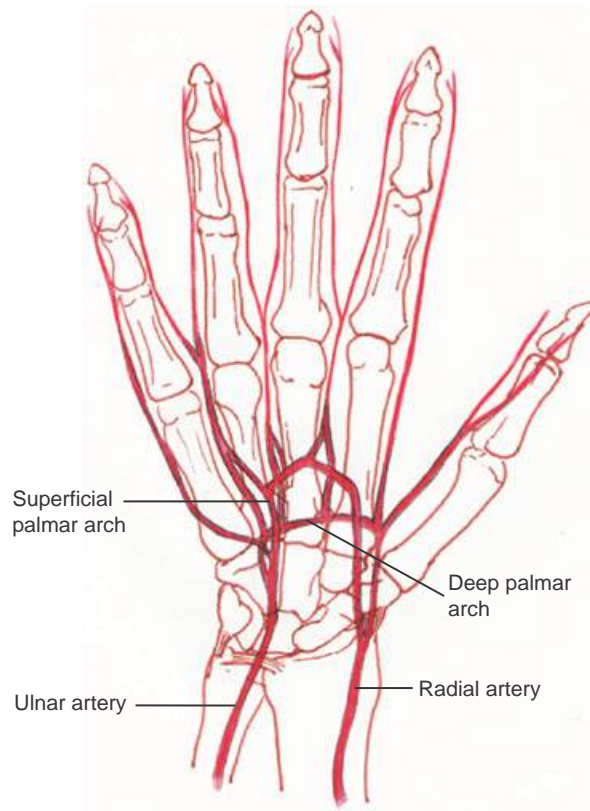


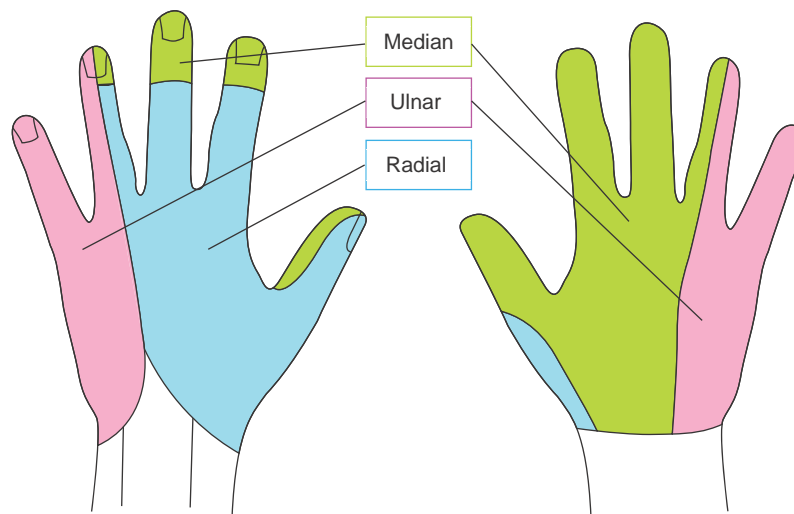
Figure 7.6. Arterial supply of hand.

Source: Drake and Mitchell (2005).

**Table 7.5.** Motor function of nerves to the hand.

Nerve	Muscles	Function
<b>Median</b>	FDS, FDP (to index and middle finger), FPL, palmaris longus, flexor carpi radialis, thenar muscles (abductor pollicis brevis and superficial head of flexor pollicis brevis), lumbricals (of index and middle fingers)	Fine precision and pinch function, grasp, thumb palmar abduction and opposition
<b>Ulnar</b>	FDP (to ring and little finger), flexor carpi ulnaris, hypothenar muscles (opponens digiti minimi, abductor digiti minimi, flexor digiti minimi and palmaris brevis), dorsal interossei	Grasp, co-ordination of digital flexion and extension, key pinch
<b>Radial</b>	Extensor digitorum, extensor pollicis brevis, extensor pollicis longus, abductor pollicis longus, extensor carpi radialis longus, extensor carpi radialis brevis, supinator, extensor carpi radialis brevis, extensor digiti minimi, extensor carpi ulnaris	Extension of wrist Extension of thumb Extension of MCPJ

FDP = flexor digitorum profundus; FDS = flexor digitorum superficialis; FPL = flexor pollicis longus;  
MCPJ = metacarpophalangeal joint.

**Figure 7.7.** Diagram showing sensory innervation of the hand.

## 2.5. Nerves

---

The hand is innervated by three nerves: median, ulnar and radial. Each nerve has a motor (Table 7.5) and sensory component (Figure 7.7).

## 3. PATHOPHYSIOLOGY

---

Blunt trauma, laceration, avulsion, ring avulsion and burns are all common causes of soft tissue damage to the hand. Injuries may affect the bone, ligaments, muscle, tendons, nerves, vasculature, superficial tissue and skin. While this chapter focuses on aspects of soft tissue reconstruction, it is important to assess and plan the reconstruction of all these structures concurrently when treating patients with hand trauma.

## 4. HISTORY

---

Following trauma, a detailed history of the mechanism of injury and an accurate account of the patient's previous medical and social history are required. The history should include the following:

- Age.
- Dominant hand.
- Mechanism of injury – crush (consider compartment syndrome), contamination and blood loss.
- Time of injury.
- Possibility of non-accidental injury or deliberate self-harm.
- Past medical history – diabetes, respiratory or cardiac problems.
- Drug history – including tetanus immunisation.
- Social history – smoking, alcohol, occupation.

## 5. EXAMINATION

---

As with all trauma situations, assessment of the patients begins with an ABC (i.e. airway, breathing, circulation) approach to identify and treat life- and limb-threatening injuries first. Once the patient is stable and concomitant serious injuries have been excluded, hand examination follows three steps: LOOK, FEEL and MOVE.

### 5.1. Inspection

---

Expose the entire limb and assess:

- The site of injury.
- The type of injury – laceration, crush, de-gloving, nail bed or amputation.

- Whether it's clean or contaminated – foreign bodies.
- Blood loss – signs of blood loss or active bleeding.
- Signs of infection – erythema.
- Other injuries which may have been missed.
- Finger positioning – may indicate tendon injury.

In addition:

- Always compare with other (undamaged) side.
- Look for obvious deformity – fractures, dislocations.

It is often useful to draw a diagram or take a photograph of the injury to keep as a record in the medical notes.

---

## 5.2. Palpation

---

This will determine:

- The temperature
- Capillary refill – to ensure adequate perfusion distal to injury
- Pulses – radial and ulnar
- The presence of oedema
- Surface irregularity
- Sensation.

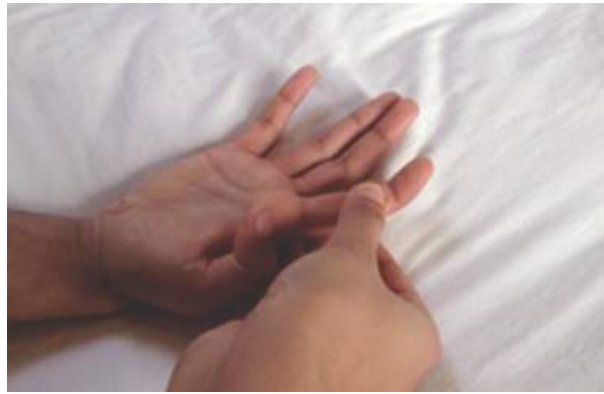---

## 5.3. Tendon examination

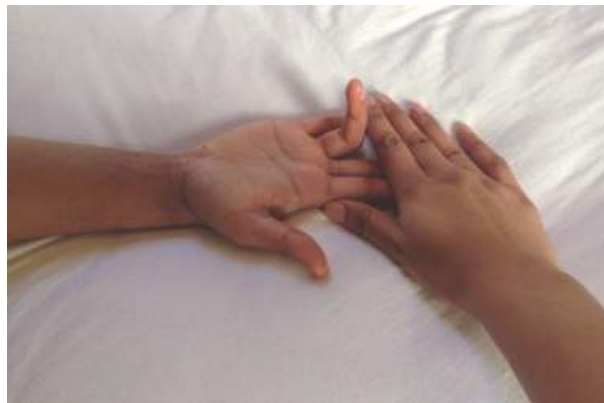---

This is done to compare the range of movement with that of the non-injured limb. For this, test each tendon systematically, first with passive movements and then against resistance (incomplete tendon rupture may still allow relatively normal movements).

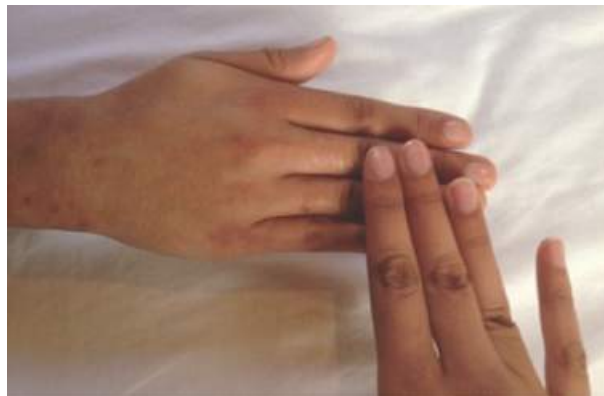- *Flexor digitorum profundus* (FDP) – hold the proximal interphalangeal joints (PIPJs) in extension and ask the patient to flex the distal interphalangeal joint (DIPJ), leaving the other digits free (Figure 7.8).
- *Flexor digitorum superficialis* (FDS) – hold all other fingers in full extension and ask the patient to bend at the PIPJ (Figure 7.9).
- *Extensor digitorum communis* – ask the patient to extend the fingers, both passively and against resistance (Figure 7.10).



**Figure 7.8.** Testing flexor digitorum profundus function.



**Figure 7.9.** Testing flexor digitorum superficialis function.



**Figure 7.10.** Testing extensor digitorum communis function.

**Table 7.6.** Motor and sensory tests specific to each nerve of the hand.

Nerve	Motor function	Sensation
Median	Thumb palmar abduction	Pulp of thumb and index finger
Ulnar	Little finger abduction	Pulp of little finger
Radial	Extension of MCPJ	Dorsal first web space

## 5.4. Neurological examination

When testing for neurology in the hand the motor and sensory components of the median, ulnar and radial nerve distributions should be examined (Table 7.6). In addition possible digital nerve injuries can be assessed by examining the sensation at the tip of each digit.

## 6. PRINCIPLES OF RECONSTRUCTION

The aim of surgery is to:

‘eliminate that which is superfluous, restore that which has been dislocated, separate that which has been united, join that which has been divided and repair the defects of nature’.

Ambroise Paré (sixteenth-century French surgeon)

The goal of trauma hand surgery is to salvage the extremities, restore and preserve function, optimise the aesthetic appearance and provide adequate analgesia. During hand trauma surgery, fractures and dislocations are dealt with first, followed by tendon injuries; neurovascular structures are repaired last because these are the most delicate.

## 7. TENDON INJURIES

### 7.1. Tendon structure

The function of the tendons is to allow the force generated by muscles to be transmitted to bones and enable joint movement. The extracellular matrix of tendons is mostly made up of collagen (mainly type 1) and elastin. Cells include tenocytes and tenoblasts (elongated fibrocytes and fibroblasts) (Kannus, 2000). The collagen is cross-linked to form insoluble microfibrils and fibrils, and fibrils in turn form fibres. The endotenon is a sheath of connective tissue that covers each collagen fibre and binds the fibres together. The whole tendon is surrounded by an outer epitenon sheath (Kannus, 2000) (Figure 7.11).

#### 7.1.1. After injury, healing occurs in three stages

1. *Inflammatory stage* (48–72 hours) – inflammatory cells move into the site of injury. They increase vascular permeability, initiate angiogenesis and stimulate proliferation of tenocytes.





**Figure 7.11.** Structure of the tendon.

2. *Proliferation stage* (5 days to 4 weeks) – fibroblastic and collagen-producing cells enter and proliferate.
3. *Remodelling stage* (6 weeks onwards) – tissue repair and fibrosis occur. Over time, the fibrous tissue is replaced by the scar-like tissue of the tendon.

The tendon is weakest between 5 and 10 days post-repair. This should be kept in mind when planning post-operative hand therapy and mobilisation (Griffin *et al.*, 2012).

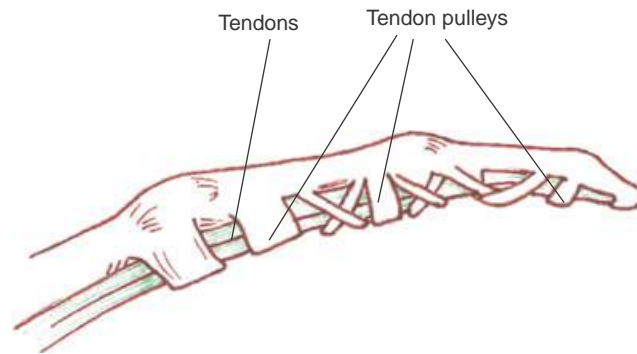
## 7.2. Flexor tendon

Each finger has two flexor tendons, the FDP and the FDS, the thumb has one (the FPL). As the tendons travel through the hand, they are surrounded by a synovial sheath. The flexor sheath consists of an inner synovial layer, which produces synovial fluid, and an outer fibrotic layer. Synovial fluid provides nutrition and lubrication for the tendons. The sheath thickens at certain points along its length to form a complex system of pulleys which act as fulcrums for the flexor tendons, thus allowing the joints of the fingers to flex without a bowstring effect to maximise grasp and power (Moutet, 2003) (Figure 7.12).

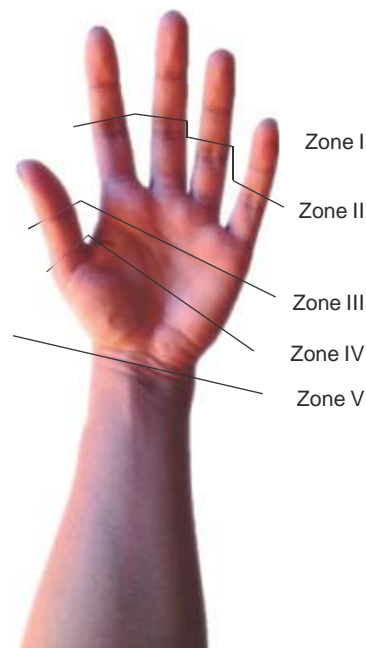### 7.2.1. Flexor zones

The anatomical location of flexor tendon injury can be described in terms of five zones (Figure 7.13) which help with planning management (Verdan, 1960):

- Zone I – distal to FDS insertion
- Zone II – between insertion of FDS and the edge of the flexor sheath in the palm
- Zone III – between the end of the flexor sheath and the carpal ligament
- Zone IV – within the carpal tunnel
- Zone V – in the forearm.



**Figure 7.12.** Flexor pulley system.



**Figure 7.13.** Flexor zones.

## 7.3. Treatment

### 7.3.1. Primary repair

Any laceration or wound over the palmar aspect of the hand and forearm should raise the suspicion of a flexor tendon injury. All suspected flexor tendon injuries require careful surgical exploration under general anaesthesia because the proximal cut end almost always retracts and is therefore difficult to locate (Nakhdehvari and Ahmadi, 2007). Surgical repair is required if 60% or more of the flexor tendon is cut

but, deceptively, a tendon may be 70–90% lacerated and still functional. Therefore, a high index of suspicion with a low threshold for surgical exploration is required to ensure these injuries are not missed.

Tendon repair is not an emergency; however, as time progresses the repair becomes more difficult as the cut ends retract, tissue becomes more oedematous and scarred, and the prognosis worsens. Therefore, repair should ideally be carried out within 7 days of injury. A delay of 10–14 days will require secondary repair owing to tendon swelling, tendon contraction and muscle fibrosis (Griffin *et al.*, 2012).

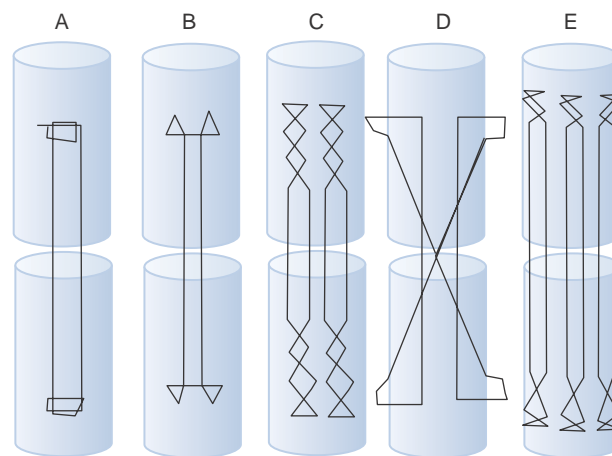
Tendons should be handled with care during surgery because excessive manipulation causes trauma and leads to scarring and adhesion formation. Proximal incisions in the flexor sheath are used to find retracted tendons; flexing the wrist and ‘milking’ the forearm can aid this process.

The first technique used for flexor tendon repair was described in 1917 (Kleinert *et al.*, 1995). Since then, several surgical approaches have been suggested; these implement contradictory ideas about optimal management. The strength of a tendon repair is affected by a number of factors, primarily (Griffin *et al.*, 2012):

1. The repair technique used.
2. The suture material used and knot security.

The simplest repair technique is a two-strand approach such as the Kessler technique (Figure 7.14) (Kessler, 1973). Increasing the number of sutures crossing the repair site has been shown to improve the strength of repair. However, a greater number of strands requires more handling of the tendon, increasing the risk of trauma and subsequent scarring. It is also technically more demanding and inappropriate placement of sutures can lead to a load imbalance on the tendon (Winters *et al.*, 1997).

The ideal suture material for flexor tendon should provide adequate tensile strength for long enough to allow the tendon to heal. It must also be easy to use and prevent gap formation. Non-absorbable synthetic sutures such as monofilament nylon, braided polyester and monofilament polypropylene have



**Figure 7.14.** Flexor tendon repair techniques. A. Tsuge, B. modified Kessler, C. augmented Becker, D. four-strand Savage and E. six-strand Savage.

been shown to provide these desired properties and are routinely used in flexor tendon repairs (Trail *et al.*, 1989).

A number of synthetic tendon devices have been invented with the aim of improving post-operative outcome. Mersilene mesh sleeves, Dacron splints and internal stainless steel anchors have been tried but all were found to be unsuitable for clinical use. To date, there is not enough supporting experimental evidence to warrant the use of any such devices, but research into this field continues (Griffin *et al.*, 2012).

### 7.3.2. Follow-up

---

In the immediate post-operative period, patients will be put into a resting splint (wrist flexed at 20°, the MCPJs flexed at 70° and the IPJs in extension) and referred to a hand therapy team. This resting position ensures that the collateral ligaments at the MCP and IP joints are splinted at their maximal length to prevent them tightening up and causing contractures. Rehabilitation after tendon repair is a balancing act between achieving functional movement and avoiding tendon rupture. It is best managed by a team of experienced physiotherapists. Early mobilisation of tendons has been shown to produce stronger repairs with fewer adhesions (Tang, 2007); however, this may lead to an increased risk of tendon rupture. Patients may not regain full use of their hand for up to 3 months and may have to be off work for this period (Nakhdjevani and Ahmadi, 2007).

### 7.3.3. Complications

---

Complications following flexor tendon repair can be divided into early and late:

- *Early complications* – infection, pain, tendon rupture, pulley rupture and poor tendon gliding.
- *Late complications* – adhesions, stiffness, scarring and complex regional pain syndrome.

Tendon rupture occurs in 3–9% of cases (Elliot *et al.*, 1994) and requires urgent secondary surgical intervention. Causes of rupture following surgery include tendon overload, oedema, misuse of the hand and early mobilisation (Griffin *et al.*, 2012).

Adhesions occur in approximately 20% of cases (Manske, 1988), causing stiffness and pain. They are treated with tenolysis, which can be performed 3–6 months after the initial tendon repair (Strickland, 1985).

Damage to the pulley system during surgery should be avoided. Loss of A2 and A4 pulleys following surgery can cause a bowstring effect across the IP and MCP joints, resulting in a weakened grasp and reduced function. The only treatment for bowstringing is surgical pulley reconstruction (Mehta and Phillips, 2005).

### 7.3.4. Tendon grafting

---

Secondary tendon repair consists of removing the diseased or non-functioning tendon and grafting the defect with an autograft or allograft. Traditional autologous grafts include the palmaris longus, extensor digitorum longus and plantaris tendons. Tendon grafting is performed as either a single or two-stage procedure.

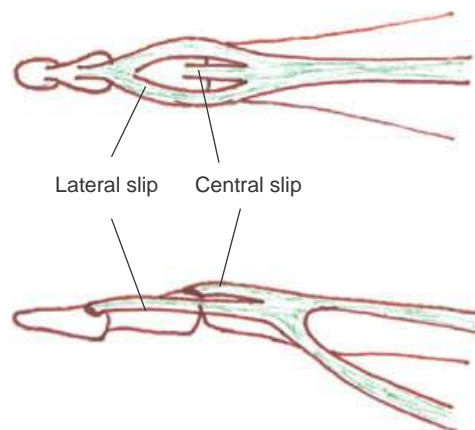
Single-stage grafting of the flexor tendon involves excision of the damaged tendon and its immediate replacement with the harvested tendon graft. However, this technique is usually not successful if the flexor sheath and pulley systems are disrupted. Mobilisation of the grafted tendon through a scarred sheath leads to trauma, the formation of adhesions and a poor functional outcome (Elliot, 2011). Therefore, this one-stage approach is rarely undertaken.

The alternative two-stage approach involves inserting a silicon rod as the first stage to form a pseudo-sheath and allow free tendon graft through the pseudo-sheath at the second stage. The advantage of two-stage grafting is that mobilisation of the tendon following the second stage is less traumatic because it is located in a smooth-walled pseudo-sheath; this leads to a less painful and more supple hand. This approach, despite its advantages, requires a great deal of patient co-operation and motivation; therefore, candidates should be carefully selected and given advice by hand therapists (Hunter *et al.*, 1988).

## 7.4. Extensor tendons

Extensor tendon injuries are not as well researched as flexor tendon injuries and are often treated with less respect. However, extensor tendon injuries and ruptures can be extremely debilitating and their potential to cause problems should not be underestimated.

The morphology of extensor tendons changes along their anatomical course: they are cylindrical in the forearm and wrist, become flat in the hand and fingers and expand into a wide fascia-like structure over the MCP and IP joints. The intrinsic muscles of the hand also exert their influence partly through the extensor apparatus. In the fingers, the extensor system has a complex arrangement, forming attachments to the bone via the central and lateral slips (Figure 7.15). The tendons are deep in the arm and wrist but become very superficial in the hand and fingers, making them highly vulnerable to injury. Extensor tendon repairs can usually be carried out under local anaesthetic because the tendons are superficial, tend to be quick to repair and don't retract as they are held in place by juncture tendineae (i.e. fibrous connections between individual extensor tendons).

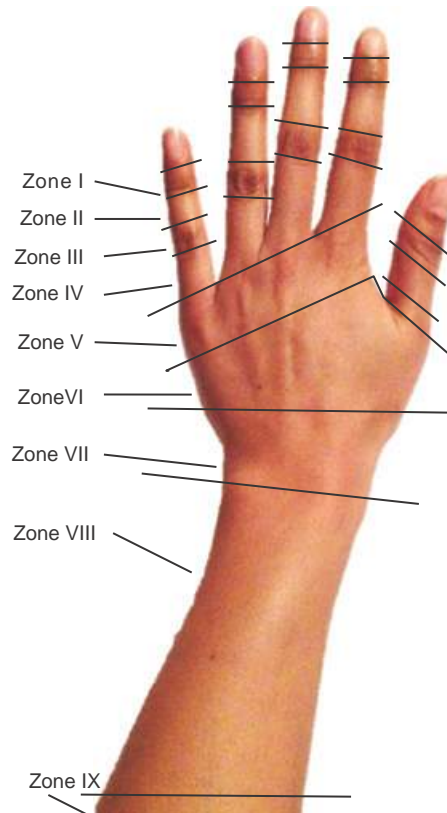


**Figure 7.15.** Diagrammatic representation of the extensor attachment in fingers.

### 7.4.1. Extensor zones

Extensor tendons are divided into nine anatomical zones (Figure 7.16):

- Zone 1 – DIP joint
- Zone 2 – middle phalanx
- Zone 3 – PIP joint
- Zone 4 – proximal phalanx
- Zone 5 – MCP joint
- Zone 6 – metacarpal
- Zone 7 – carpal and wrist joint
- Zone 8 – distal forearm
- Zone 9 – proximal forearm.



**Figure 7.16.** Extensor zones.

The anatomical zones in the thumb are:

- Zone T1 – IP joint
- Zone T2 – proximal phalanx
- Zone T3 – MCP joint
- Zone T4 – first metacarpal.

### 7.4.2. Treatment

Certain extensor injuries can be managed conservatively, while others need surgical intervention. Surgical intervention should be considered if:

- Tendon laceration is 50% or more.
- Tendon laceration is associated with a significant decrease in strength compared with the contralateral side.
- Tendon laceration is associated with joint space penetration, fracture, significant skin loss or a contaminated wound.
- Lacerations are proximal to zone VI.

Repair, as with flexor tendon injuries, is not an emergency but should be carried out within 7 days. If repair is to be delayed, the wound must be irrigated and the hand placed in a resting splint.

### 7.4.3. Mallet injuries (extensor zone I)

Mallet fingers commonly result from closed avulsion injuries. They are due to injury of the extensor tendon in zone I. This is caused by sudden forced flexion of the DIPJ, usually resulting from a sudden impact to the tip of an extended finger. Mallet injuries can be classified according to Doyle's classification system (Doyle, 1999):

- Type 1 – closed ± small avulsion fragment.
- Type 2 – open + tendon damage.
- Type 3 – open + loss of tendon substance.
- Type 4
  - Transepiphyseal plate fracture (children).
  - Fracture involving 20–50% of the articular surface (hyperflexion injury).
  - Fracture involving greater than 50% of the articular surface – volar subluxation (hyperextension injury).

Type 1 can be treated conservatively with a mallet splint for 6–8 weeks. It is important that the splint is worn continuously and the DIPJ kept in an extended position. Surgical fixation is indicated for all open injuries and after failed splinting (Cheung *et al.*, 2012). If zone I injuries are not treated correctly, they

can lead to a permanent *swan neck deformity* of the affected finger due to displacement of the extensor more proximally, focusing extensor forces over the PIP joint.

Injury can also be sustained in sharp laceration or crush injury. Lacerations involving less than 50% of the tendon are stable and do not require surgical repair. If the laceration is >50%, surgical repair is carried out under local anaesthesia. In this zone, it is extremely important to avoid shortening of the tendon because this can seriously impede flexion (Cheung *et al.*, 2012).

#### 7.4.4. Boutonniere deformity: zone 3

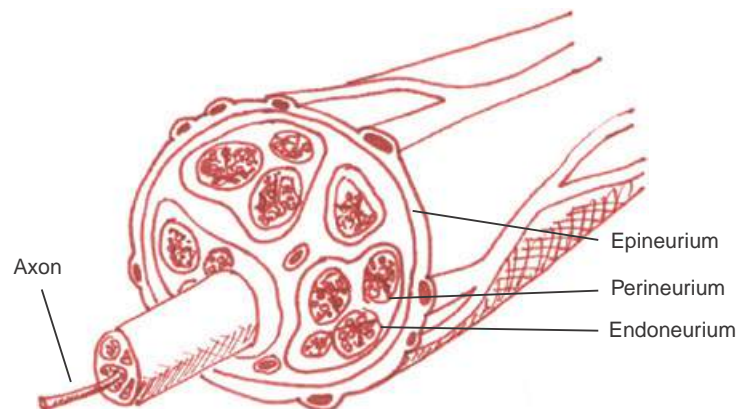
A Boutonniere deformity results from injury and disruption of the central slip at the PIP joint. These can usually be managed conservatively with a dorsal Boutonniere's splint. Operative management involves repair of the central slip.

#### 7.4.5. Extensor pollicis longus injuries

The intrinsic muscles of the thenar eminence insert onto the extensor mechanism and can weakly extend the IPJ. Therefore, injuries to the extensor pollicis longus (EPL) proximal to these insertions can easily be missed. It is therefore important to test the EPL by asking the patient to extend the thumb while keeping the palm flat on a table.

## 8. NERVE INJURIES

Nerves are commonly severed as a result of penetrating injuries but may also be damaged by blunt trauma and crush injuries.



**Figure 7.17.** Structure of the nerve.



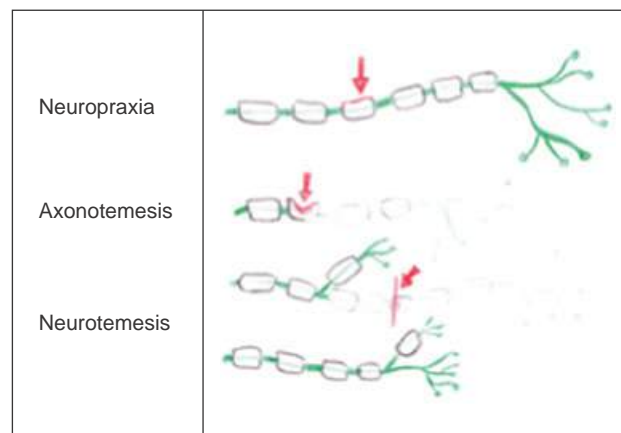
## 8.1. Structure

Axons are contained within protective connective tissues (epineurium, perineurium and endoneurium). The epineurium provides a supportive external barrier against outside stresses. The perineurium lies beneath the epineurium and is formed by a thin sheet of flat cells with tight junctions that regulate diffusion. The endoneurium is a loose collagen matrix that surrounds individual nerve fibres. One important aspect of nerve anatomy is that individual fasciculi do not run in a straight line, but instead form plexuses along a nerve fibre. An increased number of fascicles leads to an increased complexity of nerve repair.

## 8.2. Classification

The Seddon and Sunderland classification systems are used to describe nerve injury (Figure 7.18). Neurapraxia is usually caused by application of a blunt compressive force to a nerve and causes a temporary conduction block which will recover spontaneously. Axonotmesis describes axonal disruption with intact supportive tissue. The regeneration time is slower but can be estimated at a rate of 1 mm of regeneration per day (Isaacs, 2010). Higher-grade axonotmesis and neurotmesis (i.e. complete disruption of the nerve) do not allow spontaneous recovery because the axons cannot find their way to distal endoneurial tissue because of the distance or because passage is restricted by scar tissue. In these cases, surgical reconstruction offers the best chance of recovery. Failure to repair these injuries can lead to the formation of neuromas, comprised of disorganised axonal growth, which can be extremely painful.

Distal to the site of injury, Wallerian degeneration of the axons occurs within 24–48 hours. Especially with blunt trauma, the severity of damage is not always clear at initial presentation. Serial examinations can help to classify the injury. However, over time the denervated distal nerve tissue and muscle will lose their ability to support axonal regrowth; therefore, surgical reconstruction should be done as early as possible (Isaacs, 2010).



**Figure 7.18.** Diagrammatic representation of Seddon's classification of nerve injury.

## 8.3. Treatment

---

### 8.3.1. Direct end-to-end nerve repair

---

The aim of nerve repair is to provide a framework in which the axon can regenerate. Direct tensionless end-to-end epineural repair remains the first-line management and achieves the most predictable outcomes following a sharp nerve division with a minimal gap. The ideal setting for direct repair is an injury zone with a good blood supply and soft tissue coverage, and when repair is carried out in the first few days following injury. A gap of more than 2.5 cm at the site of injury will usually require nerve grafting (Isaacs, 2010). End-to-end repair should be carried out by suturing the epineurium together with fine non-absorbable sutures in a tension-free fashion.

Grouped fascicular repair has been suggested by some to have a prognostic benefit following nerve repair (Isaacs, 2010). This technique is similar to epineural repair but, in addition to epineurium alignment, the perineural sheaths of individual fascicles are repaired under microscope magnification. This approach attempts a more accurate approximation of regenerating axons, and is of benefit for larger proximal nerves with both motor and sensory function. The drawbacks are that this technique is time-consuming and requires more dissection and soft tissue disruption. In large mixed nerves, careful planning under microscopy is essential prior to repair; landmarks such as the vaso nervorum and the shape of fascicles are useful for ensuring that motor and sensory areas within the nerve are approximated correctly.

### 8.3.2. End-to-side repair

---

End-to-side repair may be favourable when the proximal aspect of the injured nerve is not salvageable. The distal portion of the injured nerve can be sutured to an adjacent nerve with subsequent collateral sprouting.

### 8.3.3. Fibrin glue

---

Fibrin glue has been suggested as an adjunct or alternative to epineurial suturing because it is quick and easy to use. Fibrin glue contains components of the clotting cascade and produces a gel-like clot that can be applied as adhesive glue around approximated nerve ends. This technique minimises trauma to the nerve ends and creates a barrier to invading scar tissue. The main disadvantage of fibrin glue is its inferior holding strength (Cruz *et al.*, 1986).

### 8.3.4. Nerve grafting

---

The current gold standard for bridging a nerve gap is autologous nerve grafting. This technique involves the dissection of both nerve stumps and then the grafts (for example, sural nerve grafts) are inserted

loosely with no tension to bridge the gaps between the nerves with end-to-end suturing. Dissection of the nerve stumps to isolate the major fasciculi individually can allow matched fasciculi grafting (Brown and Mackinnon, 2008). The disadvantages of nerve grafting are the limitation in available graft length and donor site morbidity.

### 8.3.5. Conduits

---

To bridge short gaps (<3 cm) where tensionless primary repair is not possible, conduits can be used. Autologous conduits consist of harvested vein and, occasionally, artery. These are sutured to the epineurium and provide a protective tube to aid axon regeneration. Synthetic alternatives avoid donor site problems and provide the additional benefit of being semi-rigid in nature, leading to less kinking and collapse (Rivlin *et al.*, 2010).

Current commercially available conduits are made from polyglycolic acid, collagen and polycaprolactone. The synthetic tubes provide a biodegradable protective tube with added growth factors between the nerve ends. They have varying degrees of permeability which aims to allow the diffusion of supportive nutrients while preventing the invasion of scar tissue. These conduits have shown promising results on small sensory nerves with short distances between the cut ends; however, their successful use for larger mixed nerves such as the ulnar or median nerves has not been reported (Isaacs, 2010).

### 8.3.6. Nerve transfers

---

Nerve transfer involves transection of a healthy nerve branch or the intraneural dissection of fascicles of a healthy nerve, which are then transferred locally to a more functionally important distal nerve stump. Motor function following an injury to a motor nerve is dependent on the number of motor axons which reach the motor end plate within a critical period of time. This is not easily achieved with nerve grafts; nerve transfer can provide a more reliable alternative (Isaacs, 2010).

## 9. VASCULAR INJURIES

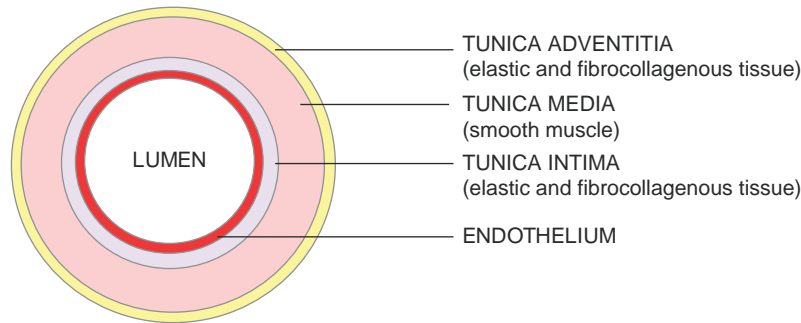
---

Vascular injuries to the hand can be caused by penetrating trauma, blunt trauma and iatrogenic injury.

### 9.1. Structure

---

Arteries have an outer fibrous layer, the tunica adventitia, which anchors them to the surrounding tissue; a middle layer of smooth muscle, known as the tunica media; and an inner layer, the tunica intima, which is divided into a connective tissue layer and the endothelium (Figure 7.19).



**Figure 7.19.** Diagrammatic representation of the cross-section of an artery.

## 9.2. Treatment

As already mentioned, it is important to identify these injuries at an early stage by performing a thorough examination of the affected limb, looking in particular for signs of active bleeding, haematoma formation, evidence of ischaemia, and weak or absent pulses. A history of pulsatile bleeding requires surgical exploration even if the bleeding has not persisted to the time of examination because there is a high risk of underlying arterial injury.

All arterial injuries resulting in distal ischaemia will require surgical repair. Venous injury in the upper limb rarely requires surgical repair because of the extensive network of collateral vessels. Ligation of an injured vein is usually well tolerated.

### 9.2.1. Radial or ulnar artery injury

Ligation of an isolated radial or ulnar artery is acceptable provided there is no evidence of distal ischaemia (Johnson *et al.*, 1993). If both the radial and ulnar arteries are damaged, at least one must be repaired. There is no evidence to suggest that repairing both arteries provides a better outcome than just repairing one (Ballard *et al.*, 1992).

### 9.2.2. Digital artery injury

Two small digital arteries supply blood to each finger (Figure 7.16). When one artery is damaged, with no signs of ischaemia in the affected digit, the injury can be managed conservatively. Bleeding from the affected artery may be controlled with local pressure or with a small suture to tie off the vessel. Caution must be taken not to damage the digital nerve. If both digital arteries are damaged, then surgical repair is required to restore circulation to the affected digit and prevent ischaemia of distal tissue.

### 9.3. Surgical repair

After adequate exposure has been achieved, the damaged vessel is dissected from surrounding tissue to allow tension-free anastomosis to be performed. Any tethering or side branches are cauterised. The operative field is irrigated with heparinised solution and vessels may be dilated with 1% lignocaine. Mechanical dilation may also be used; however, this has the added risk of damaging the vessel wall. The cut ends are examined under magnification and evaluated for evidence of vessel compromise such as damage to the endothelium, crush injury or thrombosis. The damaged tissue is cut back to normal vessel and the adventitial layer is stripped from the vessel wall. Approximator clamps are used to bring the cut ends together. Systemic anticoagulation is given prior to the vascular anastomosis.

The surgical technique used to treat vascular damage will depend on the extent of injury. Owing to the small size of these vessels, microsurgical techniques are often required:

- *End-to-end anastomosis* – If a tension-free anastomosis can be achieved, the vessel is repaired with a running or interrupted non-absorbable suture (7-0 to 8-0 for the radial and ulnar arteries and 8-0 to 10-0 for the palmar and digital arteries).
- *Vein grafting* – If the gap is too large to achieve a tension-free repair, autologous vein grafts can be used to bridge the gap. However, this technique has the added risks associated with the donor site.
- *Synthetic conduits* – Conduits such as polytetrafluoroethylene ('PTFE') grafts have been successfully used in trauma, but they increase infection risk and have an inferior patency rate, especially for small vessels (Feliciano *et al.*, 1985). Owing to such problems, these conduits are rarely used clinically.

All vascular repairs require adequate soft tissue cover. Post-operatively, external compression of the repair must be avoided and distal pulses should be monitored.

#### 9.3.1. Complications

- *Occlusion* of the anastomosis is a common early complication and requires re-opening for surgical exploration.
- *Nerve injury*.
- *Tissue death and necrosis* resulting from prolonged vascular compromise may require amputation of the necrotic tissue.
- *Infection* may require debridement and antibiotic treatment.
- *Arteriovenous fistulas and false aneurysms* are usually late complications and require surgical repair.

## 10. NAIL BED INJURIES

Trauma is a major cause of nail bed deformity. Injuries include subungual haematomas, lacerations, avulsion of the nail plate, amputation and paronychia tissue damage. Even without penetrating trauma, crush injuries can result in nail bed lacerations as the fragile nail bed tissue is squeezed between the hard nail plate and the bone of the distal phalanx.

### 10.1. Structure

*Perionychium* – The nail and surrounding structures (hyponychium, nail bed and nail fold).

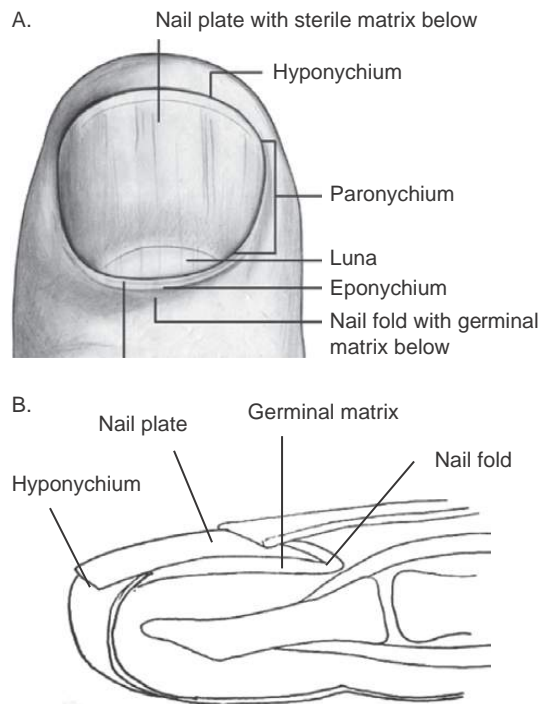
*Eponychium* – Soft tissue on the dorsal aspect of the nail which continues to the dorsal skin.

*Luna* – white arch visible on the nail distal to eponychium.

*Nail bed* – Lies underneath the nail plate. The nail bed proximal to the lunula is the *germinal matrix* and distal is the *sterile matrix*. Keratinous nail growth occurs mainly from the germinal matrix (Reardon *et al.*, 1999).

*Nail plate* – Keratinous nail. Its cells become anucleated and transparent, revealing the pink underlying nail bed.

*Nail fold* – Germinal matrix and eponychium. The fold is responsible for shaping the nail plate as it grows distally (Figure 7.20)



**Figure 7.20.** A. Diagrammatic representation of the nail. B. Cross-section of the fingertip.

## 10.2. Subungual haematoma

---

Subungual haematoma is usually caused by crush injuries, leading to the formation of a collection of blood between the nail bed and the nail plate. If the surface area of the haematoma is less than 25% of the nail surface and the patient is asymptomatic with no underlying fracture, the haematoma can be managed conservatively (Yeo *et al.*, 2010). If the affected surface area is 25–50% or if the patient is symptomatic, then the haematoma requires evacuation by trephination.

Haematomas covering greater than 50% of the nail or injuries with underlying distal phalynx fractures have traditionally been treated with surgical repair involving removal of the nail and suturing the underlying laceration (Gaston and Chadderdon, 2012). However, recent evidence suggests that, provided the nail plate still adheres to the bed and is not displaced from the nail fold, simple trephination has a similar prognosis to surgical repair (Roser and Gellman, 1999). Additionally, trephination causes less pain and a shorter stay in hospital.

*Trephination* is a technique that involves making a small hole in the nail plate over the site of the haematoma to allow the blood to escape. This can be done with an electric cautery device or with a heated paper clip or 18-gauge needle. Electrocautery is the safest option, with less risk of injuring the nail bed once the nail has been penetrated.

## 10.3. Nail bed lacerations

---

Lacerations of the nail bed require careful repair to prevent nail deformity. They can be performed under a digital nerve block. The nail is elevated using the blades of either fine or curved iris scissors or small elevator scissors. Lacerations are repaired using 6-0 or smaller absorbable sutures, with minimal debridement to preserve as much tissue as possible. All pieces of the damaged nail bed should be incorporated into the repair because isolated fragments can form painful nail horns or spicules.

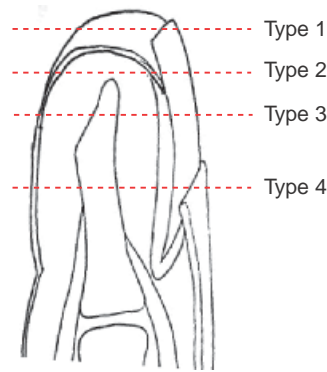
If the nail fold is involved, this must also be repaired and stented (Harrison and Hilliard, 1999). The stent can be in the form of the preserved nail plate which is re-inserted into the nail fold or, if the original nail is missing, an alternative splint can be used such as aluminium foil. This also provides a protective dressing for the repaired nail bed. A small hole is usually made in the nail plate to allow drainage of blood (Cohen *et al.*, 1990).

The nail bed is essential for nail growth; absence of a nail bed will result in deformity of the overlying nail. Partial nail bed loss can be replaced with a split-thickness nail bed graft from adjacent nail beds or from the big toe (Brown *et al.*, 1999, Hsieh *et al.*, 2004).

## 10.4. Fingertip amputations

---

Fingertip and pulp amputations are classified according to Allen's classification (Figure 7.21) (Allen, 1980):



**Figure 7.21.** Allen's classification of finger-tip amputation

- Type 1 – Pulp only.
- Type 2 – Pulp + nail bed.
- Type 3 – Distal phalynx fracture + pulp and nail loss.
- Type 4 – Distal phalynx fracture + pulp and nail loss involving the lunula.

### 10.4.1. Treatment

Fingertip amputations are treated according to the level of injury and the amount of viable tissue remaining. Options include conservative management (allowing healing by secondary intention), skin grafting, skin flaps, terminalisation and replantation of the amputated tip.

Allowing the injury to heal by secondary intention is preferred for type 1 amputations with superficial clean wounds that have no bone exposed (Yeo *et al.*, 2010). Healing can take several weeks and requires regular dressing changes and wound hygiene. Skin grafts may be used for deeper wounds with no exposed bone because healing times are generally shorter with a graft. However, there is the added risk of donor site problems and loss of sensation to the grafted section. Therefore, secondary intention healing is generally preferred for these injuries.

Exposed bone and extensive tissue loss require soft tissue coverage with local or free flaps. These include V–Y advancement flaps, cross finger flaps, neurovascular island flaps, reverse vascular island flaps and toe pulp transfers.

Traditionally, replantations of amputations distal to the DIPJ were considered to have a slow recovery time with poor functional results. However, recent literature reviews suggest that distal replants have a high success rate, especially with a clean-cut amputation rather than a crush injury (Sebastin and Chung, 2011). The results are especially promising in children; however, surgery is technically more demanding because of the size of the structures involved (Lim *et al.*, 2001). Distal replantation has the advantage of preserving the finger length and the nail for functional and aesthetic results (Goldner *et al.*, 1989). The disadvantage of distal replantation is that surgery is more complex, hospital stays are longer and



surgery has a higher cost and longer healing time. The healing time can be particularly important for adult patients who depend on the use of their hands for their livelihood. For example, farmers and manual workers may prefer the option of termination so they can return to work sooner.

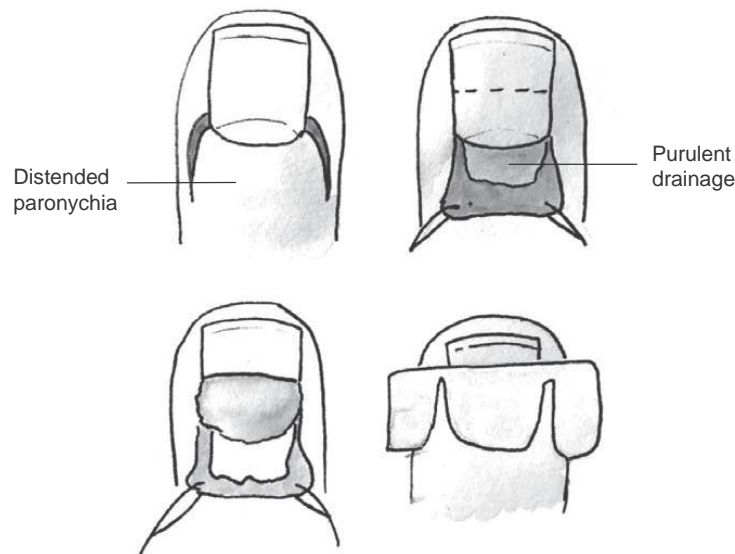
## 11. SOFT TISSUE INFECTIONS OF THE HAND

### 11.1. Paronychia

Paronychia is infection of the soft tissue adjacent to the fingernail. It is usually caused by a superficial trauma such as nail biting, manicure, hang-nails, and finger- or thumb-sucking (Franko and Abrams, 2013). The break in skin defences provides an entry point for bacteria which causes cellulitis of the area. This infection may progress to form a localised abscess or may even spread under the nail plate to form a subungual abscess (Canales *et al.*, 1989). Abscesses may spontaneously decompress but usually require drainage.

#### 11.1.1. Treatment

If there is no fluctuance, the infection can be treated with warm soaks alone (Rigopoulos *et al.*, 2008). However, if there is a history of diabetes or peripheral vascular disease or if the patient is immunocompromised, they should also be given a short course of antibiotics in accordance with local antimicrobial guidelines (Franko and Abrams, 2013).



**Figure 7.22.** Incision and drainage of paronychia.

In the presence of an abscess, the pus should be drained under a ring block. If the abscess is on one side, a scalpel held parallel angled away from the nail bed is used to elevate the lateral nail fold and allow the pus to drain. If the pus is under one corner of the nail root, the affected corner is cut. If the pus has already tracked to both sides of the nail root, then two incisions are made at the nail root, allowing the skin to be folded back and the proximal third of the nail to be excised (Figure 7.22) (Canale and Beaty, 2013). For a subungual abscess, trephination of the nail is performed to allow the pus to drain.

## 11.2. Felon

---

A felon is an infection of the pulp of the finger which forms a painful and extremely tender abscess. There is sometimes a history of superficial trauma to the finger, for example wooden splinters or small cuts. The causative organism in most cases is *Staphylococcus aureus* (Connolly *et al.*, 2000).

The infection can cause serious complications such as osteomyelitis of the distal phalanx and necrosis of soft tissue, and may spread to cause a flexor tenosynovitis.

### 11.2.1. Treatment

---

Felons are treated by incision and drainage. The digit is first anaesthetised with a ring block. A longitudinal incision is then made on the pad over the point of greatest fluctuance. The space is washed out thoroughly and packed with gauze. The gauze is removed after 24 hours and the wound washed in saline. If possible, the cavity is repacked and the dressing changed once or twice daily. If the cavity can no longer be packed, antibiotic ointment may be applied and the wound covered with a simple dressing.

## 11.3. Herpetic whitlow

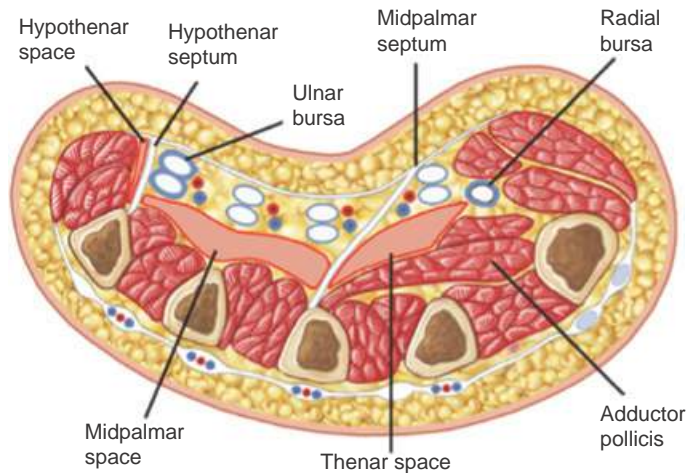
---

A herpetic whitlow is a herpetic infection. It is important to be aware of this viral infection as a differential diagnosis for paronychia and felon because the symptoms can be similar; however, the treatment is very different. The finger may be swollen but not very tender and small vesicles may form around the nail. Treatment does not involve incision and drainage because this carries a high risk of secondary bacterial infection. The infection will resolve spontaneously in 3–4 weeks and acyclovir may provide symptomatic relief (Rubright and Shafritz, 2011).

## 11.4. Deep space infection

---

There are three anatomical spaces within the hand: the thenar, midpalmar and hypotenar spaces (Figure 7.23). Deep fascial space infections involve one or more of these spaces, with infections of the thenar space being the most common. The infection is usually caused by penetrating trauma which introduces infection into the deep space or by infection spreading from a more superficial abscess or



**Figure 7.23.** Deep fascial spaces.

tenosynovitis. Symptoms include pain and oedema of the hand and occasionally a history of fever. Clinically, this condition is often difficult to distinguish from flexor tenosynovitis. There is, however, a relative lack of pain with passive movements of the fingers and less pain with direct palpation along the flexor sheath (Wiesel, 2012).

#### 11.4.1. Deep fascial spaces

- *The thenar space* – Bordered dorsally by the fascia of the adductor pollicis, volarly by the tendon sheath of the index finger, and radially by the insertion of the adductor pollicis tendon and fascia on the proximal phalanx of the thumb.
- *The midpalmar space* – Bordered dorsally by the fascia of the second and third palmar interosseous muscles, volarly by the flexor sheaths of the long, ring and small fingers and the palmar fascia, radially by the midpalmar septum and ulnarly by the hypothenar septum.
- *The hypothenar space* – Bordered dorsally by the periosteum of the fifth metacarpal, radially by the hypothenar septum and ulnarly by the fascia of the hypothenar muscles (Wiesel, 2012).

#### 11.4.2. Treatment

All deep space infections of the hand require surgical drainage under general anaesthesia. Pus should be sent for culture prior to administering intravenous antibiotics. Surgery involves thoroughly washing out the space with saline and debridement of non-viable tissue. Wounds can be closed loosely over an irrigation catheter. In severe infections or when there is doubt about the viability of tissue, the wound should be left open. Closure may be delayed or the wound may be allowed to heal by secondary intention. A second irrigation may be required at 48–72 hours in severe infections (Franko and Abrams, 2013).

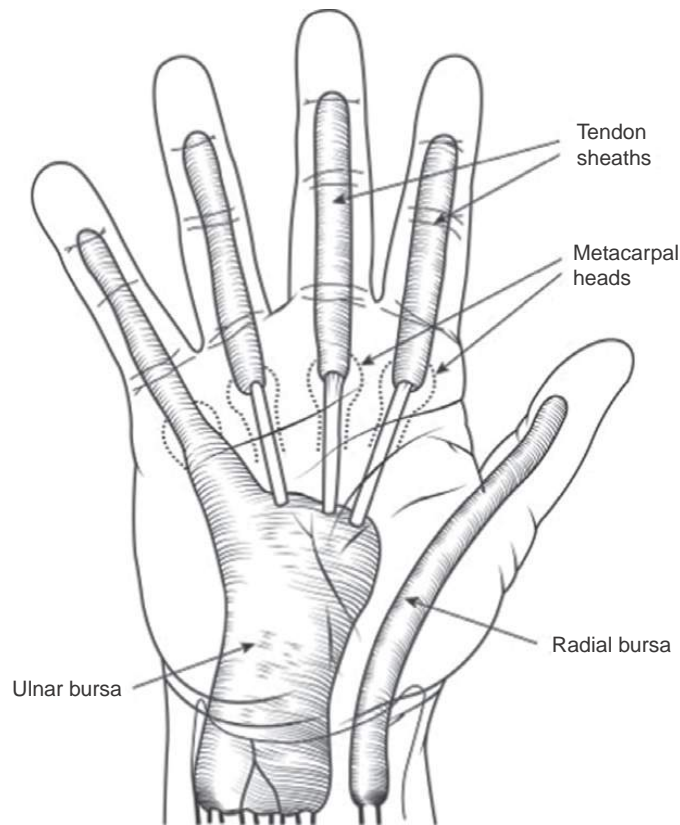
## 11.5. Flexor tenosynovitis

Infections of the flexor tendon sheath are usually caused by penetrating injuries (Siegel and Gelberman, 1988). They present with four cardinal signs (Franko and Abrams, 2013):

- Flexed posture of affected finger
- Diffuse swelling of the entire finger
- Tenderness along the flexor sheath
- Pain upon passive extension of the finger.

### 11.5.1. Flexor tendon sheath structure

The flexor sheath is a closed space that surrounds the flexor tendons along their course through the digits. The sheath is lined with mesothelium and extends from the A1 pulley to the distal interphalangeal joint. The flexor sheath of the thumb communicates with the radial bursa and the small finger sheath communicates with the ulnar bursa (Figure 7.24).



**Figure 7.24.** Flexor sheaths of fingers and thumb.

### 11.5.2. Treatment

Flexor sheath infections should be treated as emergencies because delay can result in vascular compromise to the tendon, leading to necrosis and adhesions. Infections which present within 24 hours of onset may be treated conservatively with close observation, elevation, a resting splint and intravenous antibiotics (Henry, 2011). However, if symptoms do not resolve within 24 hours, surgical intervention is required. All delayed presentations require surgical drainage.

Surgery is performed under general anaesthesia. Incisions are made at the proximal and distal ends of the flexor sheath and a catheter is inserted into one end for irrigation. After irrigation, the catheter may be left *in situ* for 48 hours to provide continuous irrigation. Wounds are left open and allowed to heal by secondary intention (Franko and Abrams, 2013).

## 12. EXTRAVASATION INJURIES

*Extravasation* is the leakage of fluid into surrounding tissue and usually occurs during intravenous drug administration. The resulting injury depends on the substance that extravasates, and can range from mild skin irritation to severe necrosis (Boyle and Engelking, 1995). Patients with small and fragile veins, such as the very young or very old, are at a greater risk of extravasation injuries (Brown *et al.*, 1979). Patients receiving chemotherapy are likely to develop more severe reactions due to the cytotoxic drugs involved (Langer, 2010).

Three main groups of chemicals can cause major tissue damage if they leak into soft tissue (Neligan and Song, 2012):

- *Osmotically active agents* – Disrupt cell transport mechanisms causing cell death. Can also cause precipitation of proteins, which damages cells (e.g. hypertonic potassium and calcium solutions, parenteral nutrition, and radiographic contrast solutions).
- *Vasoconstrictive agents* – Cause ischaemia and tissue necrosis (e.g. vasopressors, adrenaline, dopamine and dobutamine).
- *Cytotoxic agents* – Cause direct cell injury. Doxorubicin is the agent most commonly reported to cause tissue necrosis (Conde-Estevez *et al.*, 2010).

The symptoms and signs usually occur immediately and may include pain, swelling and erythema. If symptoms persistent for more than 24 hours, the injury is more likely to progress and develop ulceration (Heckler, 1989). Ulceration can occur up to 2 weeks after the injury and forms a dry, black eschar.

### 12.1. Treatment

Opinions are divided on the optimal management of extravasation. There is an argument for initial conservative observation because not all injuries will lead to ulceration (Larson, 1985). However, some

evidence suggests a benefit of early intervention to dilute or remove the causative agent using methods such as saline flush out or liposuction (Gault, 1993).

As soon as symptoms develop, the infusion should be stopped and the cannula removed from the affected vein. The hand should be elevated.

In saline flush out, the affected area is injected with hyaluronidase which breaks down connective tissue. Multiple stab wounds are made to allow exit of the solution prior to flushing the area with normal saline.

Blistering is treated as for a chemical burn. Small partial-thickness blisters will heal by wound contraction and re-epithelialisation. Larger blisters require excision and grafting. After debridement of necrotic tissue, exposed tendons may need coverage with dermal substitutes such as Integra® or with local rotational flaps.

## 13. SUMMARY

---

- Trauma is a major cause of hand dysfunction.
- Care is provided by a multidisciplinary team of surgeons, physiotherapists and occupational therapists.
- Following trauma, patients are managed by an ABC approach that deals with life- and limb-threatening injuries first.
- A detailed history including the mechanism of injury, previous medical history and social history is required, along with a thorough examination following three steps – LOOK, FEEL and MOVE.
- During surgery, fractures and dislocated joints are repaired first, followed by tendons and finally neurovascular structures, which are the most delicate.
- As medical science advances, the quality of hand reconstruction will improve. Hand transplantation and tissue-engineering approaches to hand surgery represent an exciting future for this field.

## REFERENCES

---

- Allen, M. J. 1980. Conservative management of finger tip injuries in adults. *The Hand*, 12, 257–65.
- Ballard, J. L., Bunt, T. J. & Malone, J. M. 1992. Management of small artery vascular trauma. *Am J Surg*, 164, 316–9.
- Boyle, D. M. & Engelking, C. 1995. Vesicant extravasation: Myths and realities. *Oncol Nurs Forum*, 22, 57–67.
- Brown, A. S., Hoelzer, D. J. & Piercy, S. A. 1979. Skin necrosis from extravasation of intravenous fluids in children. *Plast Reconstr Surg*, 64, 145–50.
- Brown, J. M. & Mackinnon, S. E. 2008. Nerve transfers in the forearm and hand. *Hand Clin*, 24, 319–40, v.
- Brown, R. E., Zook, E. G. & Russell, R. C. 1999. Fingertip reconstruction with flaps and nail bed grafts. *J Hand Surg Am*, 24, 345–51.
- Canale, S. T. and Beaty, J. H. 2013. *Campbell's Operative Orthopaedics*, Elsevier.

- Canales, F. L., Newmeyer, W. L., 3rd & Kilgore, E. S., Jr. 1989. The treatment of felons and paronychias. *Hand Clin*, 5, 515–23.
- Chang, J. 2012. Introduction: Plastic surgery contributions to hand surgery. In: Chang, J. (ed.) *Plastic Surgery, Volume 6: hand and upper limb*. 3rd edition, Elsevier.
- Cheung, J. P., Fung, B. & Ip, W. Y. 2012. Review on mallet finger treatment. *Hand Surg*, 17, 439–47.
- Cohen, M. S., Hennrikus, W. L. & Botte, M. J. 1990. A dressing for repair of acute nail bed injury. *Orthop Rev*, 19, 882–4.
- Coleman, S. R. 2002. Hand rejuvenation with structural fat grafting. *Plast Reconstr Surg*, 110, 1731–44; discussion 1745–7.
- Conde-Estevez, D., Saumell, S., Salar, A. & Mateu-De Antonio, J. 2010. Successful dexrazoxane treatment of a potentially severe extravasation of concentrated doxorubicin. *Anticancer Drugs*, 21, 790–4.
- Connolly, B., Johnstone, F., Gerlinger, T. & Puttler, E. 2000. Methicillin-resistant *Staphylococcus aureus* in a finger felon. *J Hand Surg Am*, 25, 173–5.
- Cruz, N. I., Debs, N. & Fiol, R. E. 1986. Evaluation of fibrin glue in rat sciatic nerve repairs. *Plast Reconstr Surg*, 78, 369–73.
- Doyle, J. 1999. *Green's Operative Hand Surgery: Extensor Tendons: Acute Injuries*, New York, Churchill Livingstone.
- Drake, R. L. V., W. Mitchell, A.W.M 2005. *Grey's Anatomy for Students*, Philadelphia, Elsevier.
- Elliot, D. 2011. Staged tendon grafts and soft tissue coverage. *Indian J Plast Surg*, 44, 327–36.
- Elliot, D., Moiemem, N. S., Flemming, A. F., Harris, S. B. & Foster, A. J. 1994. The rupture rate of acute flexor tendon repairs mobilized by the controlled active motion regimen. *J Hand Surg Br*, 19, 607–12.
- Feliciano, D. V., Mattox, K. L., Graham, J. M. & Bitondo, C. G. 1985. Five-year experience with PTFE grafts in vascular wounds. *J Trauma*, 25, 71–82.
- Franko, O. I. & Abrams, R. A. 2013. Hand infections. *Orthop Clin of North Am*, 44, 625–34.
- Gaston, R. G. & Chadderdon, C. 2012. Phalangeal fractures: Displaced/nondisplaced. *Hand Clin*, 28, 395–401, x.
- Gault, D. T. 1993. Extravasation injuries. *Br J Plast Surg*, 46, 91–6.
- Goldner, R. D., Stevanovic, M. V., Nunley, J. A. & Urbaniak, J. R. 1989. Digital replantation at the level of the distal interphalangeal joint and the distal phalanx. *J Hand Surg Am*, 14, 214–20.
- Griffin, M., Hindocha, S., Jordan, D., Saleh, M. & Khan, W. 2012. An overview of the management of flexor tendon injuries. *Open Orthop J*, 6, 28–35.
- Harrison, B. P. & Hilliard, M. W. 1999. Emergency department evaluation and treatment of hand injuries. *Emerg Med Clin North Am*, 17, 793–822, v.
- Heckler, F. R. 1989. Current thoughts on extravasation injuries. *Clin Plast Surg*, 16, 557–63.
- Henry, M. 2011. Septic flexor tenosynovitis. *J Hand Surg Am*, 36, 322–3.
- Hsieh, S. C., Chen, S. L., Chen, T. M., Cheng, T. Y. & Wang, H. J. 2004. Thin split-thickness toenail bed grafts for avulsed nail bed defects. *Ann Plast Surg*, 52, 375–9.
- Hunter, J. M., Singer, D. I., Jaeger, S. H. & Mackin, E. J. 1988. Active tendon implants in flexor tendon reconstruction. *J Hand Surg Am*, 13, 849–59.
- Isaacs, J. 2010. Treatment of acute peripheral nerve injuries: current concepts. *J Hand Surg Am*, 35, 491–7; quiz 498.
- Johnson, M., Ford, M. & Johansen, K. 1993. Radial or ulnar artery laceration. Repair or ligate? *Arch Surg*, 128, 971–4; discussion 974–5.
- Kannus, P. 2000. Structure of the tendon connective tissue. *Scand J Med Sci Sports*, 10, 312–20.
- Kessler, I. 1973. The “grasping” technique for tendon repair. *Hand*, 5, 253–5.
- Kleinert, H. E., Spokevicius, S. & Papas, N. H. 1995. History of flexor tendon repair. *J Hand Surg Am*, 20, S46–52.
- Langer, S. W. 2010. Extravasation of chemotherapy. *Curr Oncol Rep*, 12, 242–6.
- Larson, D. L. 1985. What is the appropriate management of tissue extravasation by antitumor agents? *Plast Reconstr Surg*, 75, 397–405.

- Lim, B. H., Tan, B. K. & Peng, Y. P. 2001. Digital replantations including fingertip and ring avulsion. *Hand Clin*, 17, 419–31, viii–ix.
- Manske, P. R. 1988. Flexor tendon healing. *J Hand Surg Br*, 13, 237–45.
- Marble, H. C. 1966. History of hand surgery. In: Je, F. (ed.) *Hand Surgery*, Baltimore, Williams & Wilkins.
- Mehta, V. & Phillips, C. S. 2005. Flexor tendon pulley reconstruction. *Hand Clin*, 21, 245–51.
- Moutet, F. 2003. [Flexor tendon pulley system: anatomy, pathology, treatment]. *Chir Main*, 22, 1–12.
- Nakhdjevani, A. B., B. Ahmadi, H. 2007. *Plastic Surgery Survival Guide*, London, Royal Society of Medicine Press.
- Neligan, P. C. and Song, D. H. 2012. *Plastic Surgery: Volume Four: Lower Extremity, Trunk and Burns*, Elsevier.
- Reardon, C. M., Mearthur, P. A., Survana, S. K. & Brotherston, T. M. 1999. The surface anatomy of the germinal matrix of the nail bed in the finger. *J Hand Surg Br*, 24, 531–3.
- Rigopoulos, D., Larios, G., Gregoriou, S. & Alevizos, A. 2008. Acute and chronic paronychia. *Am Fam Physician*, 77, 339–46.
- Rivlin, M., Sheikh, E., Isaac, R. & Beredjikian, P. K. 2010. The role of nerve allografts and conduits for nerve injuries. *Hand Clin*, 26, 435–46, viii.
- Roser, S. E. & Gellman, H. 1999. Comparison of nail bed repair versus nail trephination for subungual hematomas in children. *J Hand Surg Am*, 24, 1166–70.
- Rubright, J. H. & Shafritz, A. B. 2011. The herpetic whitlow. *Journal of Hand Surgery*, 36, 340–2.
- Sebastin, S. J. & Chung, K. C. 2011. A systematic review of the outcomes of replantation of distal digital amputation. *Plast Reconstr Surg*, 128, 723–37.
- Shores, J. T., Imbriglia, J. E. & Lee, W. P. 2011. The current state of hand transplantation. *J Hand Surg Am*, 36, 1862–7.
- Siegel, D. B. & Gelberman, R. H. 1988. Infections of the hand. *Orthop Clin North Am*, 19, 779–89.
- Strickland, J. W. 1985. Results of flexor tendon surgery in zone II. *Hand Clin*, 1, 167–79.
- Tang, J. B. 2007. Indications, methods, postoperative motion and outcome evaluation of primary flexor tendon repairs in Zone 2. *J Hand Surg Eur Vol*, 32, 118–29.
- Trail, I. A., Powell, E. S. & Noble, J. 1989. An evaluation of suture materials used in tendon surgery. *J Hand Surg Br*, 14, 422–7.
- Verdan, C. E. 1960. Primary repair of flexor tendons. *J Bone Joint Surg Am*, 42–a, 647–57.
- Wiesel, S. W. 2012. *Operative Techniques in Orthopaedic Surgery, Volume III*, Lippincott Williams & Wilkins.
- Winters, S. C., Seiler, J. G., 3rd, Woo, S. L. & Gelberman, R. H. 1997. Suture methods for flexor tendon repair. A biomechanical analysis during the first six weeks following repair. *Ann Chir Main Memb Super*, 16, 229–34.
- Yeo, C. J., Sebastin, S. J. & Chong, A. K. 2010. Fingertip injuries. *Singapore Med J*, 51, 78–86; quiz 87.



## Lower Limb Trauma and Reconstruction

---

Rebecca Nicholas, Ayyaz Quddus, Jon Simmons

### 1. INTRODUCTION

---

High-energy lower limb trauma can result in complex bone and soft tissue injury, with associated vascular and nerve damage. Advances since the mid-1990s in fracture fixation and soft tissue management, including microsurgical reconstruction, have altered the trend in favour of limb salvage as opposed to limb amputation (Ong & Levin, 2010). The joint British Association of Plastic Reconstructive and Aesthetic Surgeons (BAPRAS) and British Orthopaedic Association (BOA) Standards for the Management of Open Fractures of the Lower Limb, published in 2009, highlight the vital importance of a multidisciplinary approach between orthopaedic and plastic surgeons with appropriate clinical experience from the initial assessment in casualty to definitive surgery (BAPRAS, 2014). The primary goal of treatment is to preserve a limb that has greater functionality than that of an amputated limb. Where limb salvage is not possible, maximal functional length should be preserved (Georgiadis *et al.*, 1993). The BOA Standards for Trauma (BOAST 4), derived from the BAPRAS–BOA Standards for the Management of Open Fractures of the Lower Limb, highlight the importance of achieving the best outcomes by timely, specialist surgery rather than emergency surgery by less-experienced teams (BOA Standards for Trauma).

The annual incidence of open fractures of the long bones is reported to be 11.5 per 100,000 persons (Court-Brown *et al.*, 1998), of which approximately 40% occur in the lower limb, most commonly at the tibial diaphysis (Howard & Court-Brown, 1998). Complex lower limb injury is more common in men, in those aged 20–45 years and in people with a history of alcohol abuse (MacKenzie *et al.*, 2000).

### 2. CLASSIFICATION

---

Two of the classification systems in common use for lower limb trauma are the Gustilo–Anderson (Gustilo & Anderson, 1976; Gustilo *et al.*, 1984) and the Mangled Extremity Severity Score (MESS) classifications (Johansen *et al.*, 1990).

Gustilo and Anderson published their initial classification of open tibial injuries in 1976; it describes the escalating severity of open lower extremity wounds by grades I–III. The more severe injuries (grade III) were further subdivided into three groups in 1984, when Gustilo published a revised version of the classification system. The revised Gustilo classification system is widely cited in the literature; its utility has been confirmed by clinical studies and it remains the standard descriptive classification used by trauma and orthopaedic surgeons (Figure 8.1). Despite the widespread use of the Gustilo–Anderson classification, a significant limitation is its poor inter-observer reliability, shown by Brumback and Jones to be 60% (Brumback & Jones, 1994). It is important to be aware that surface injury does not always reflect the amount of deeper tissue damage and that the scoring system does not account for tissue viability and tissue necrosis, which tend to evolve with time. When used as part of the initial evaluation in the emergency department, it is easy to under-classify open fractures; a true classification of the wound can only be made in the operating theatre after completion of the surgical debridement of devitalised tissue (Kim & Leopold, 2012).

The MESS was designed to help a surgeon evaluate whether the limb is salvageable or not depending on four important parameters: the extent of skeletal and soft tissue injury, the degree of limb ischaemia, the presence of shock and the age of the patient. A total score of six or less favours the survival of the limb whereas a score of seven or above suggests that successful salvage of the limb is improbable (Figure 8.2).

The MESS was established by Johansen and colleagues in 1990 (Johansen *et al.*, 1990); however, since its inception, advances in reconstructive techniques combined with a multidisciplinary approach

### Gustilo & Anderson Classification

- Grade I:** A clean wound < 1cm in diameter with no crushing injury, minimal muscle contusion and a simple fracture
- Grade II:** A wound with a diameter of >1cm without extensive tissue disruption and a simple fracture without comminution
- Grade III:** High energy trauma with severe crushing component, extensive soft tissue disruption involving muscle and neurovasculature structures, comminuted and segmental fractures and traumatic amputation
  - IIla:** Grade III but with adequate soft tissue coverage
  - IIlb:** Tissue damage extending to the bone leading to periosteal stripping, bone exposure, bone loss or major wound contamination
  - IIlc:** Associated arterial injury requiring repair

**Figure 8.1.** The Gustilo & Anderson classification of open tibial injuries.

**MESS Score*****Skeletal and soft tissue injury***

- Low-energy injury (1)
- Medium-energy injury (open fractures) (2)
- High-energy injury (military gunshot wound) (3)
- Very high energy injury (major contamination) (4)

***Limb ischaemia\****

**\* the score in this parameter is doubled if limb ischaemia > 6 hours**

- Reduced or absent pulses but adequate perfusion (1)
- Pulseless, paraesthetic limb with decreased capillary refill time (2)
- Paralysed, cool insensate limb (3)

***Presence of shock***

- Systolic blood pressure consistently greater than 90mmHg (0)
- Transient hypotension (1)
- Persistently low systolic blood pressure of less than 90 (2)

***Age of the patient***

- Age less than 30 years (0)
- Age between 30-50 years (1)
- Age greater than 50 years (2)

**Figure 8.2.** The Mangled Extremity Severity Score (MESS).

involving orthopaedic, plastic and vascular surgeons have made a significant difference in limb salvage and secondary reconstruction (Fodor *et al.*, 2012). In addition, ongoing uncertainty for orthopaedic and plastic surgeons regarding the decision of whether to amputate or salvage the severely injured lower limb led to the development of the Lower Extremity Assessment Project (LEAP) study to answer this question. This study offered a wide variety of pre-injury, injury, treatment and outcome variables to examine lower extremity injuries. Although surgeons are now (as a result of the study) more capable of counselling their patients because of a better understanding of the prognostic variables, it is debatable whether they are better prepared to alter the outcome (Higgins *et al.*, 2010).

### 3. PRIMARY MANAGEMENT IN THE EMERGENCY DEPARTMENT

High-impact lower limb trauma is frequently associated with multisystem injuries ('polytrauma'). In such cases, the priority must always be life before limb. Initial evaluation and management should be conducted in accordance with the Advanced Trauma and Life Support (ATLS) guidelines (Bell *et al.*, 1999), with the aim of stabilising the patient systematically using the ABC (airway, breathing, circulation) approach. Cervical spine control should be maintained as part of the airway and breathing assessment, and haemorrhage control is integral to trauma circulation assessment. Haemorrhage control should be achieved promptly using direct pressure or with tourniquet assistance if direct pressure fails

(Bell *et al.*, 1999). A tourniquet should only ever be used as a temporary measure and all efforts should be made to prevent prolonged ischaemia of a limb. This will often necessitate emergency surgery.

Following a primary survey and life-saving measures, a brief medical history will identify potential risk factors that may have an impact upon subsequent surgical management (including anaesthetic risk) or lead to delayed healing. Screening should be done for factors including smoking, diabetes mellitus, peripheral vascular disease, malnutrition, osteoporosis, peripheral neuropathy and excessive alcohol intake. Such factors are associated with an increased risk of infection and fracture non-union and can ultimately affect surgical management (Richard *et al.*, 2014).

Following a primary survey and stabilisation of the patient, the viability of the limb should be assessed. The clinician should avoid handling the wound in the emergency department unless to remove large debris or reduce gross contamination (such as agricultural or marine waste). Photographs should be obtained prior to sealing the wound with saline-soaked gauze and a bio-occlusive dressing to protect it from further contamination. The limb should then be immobilised in a splint (BAPRAS, 2014).

Examination of the pulses, colour, temperature and turgor of the foot, in comparison to the non-injured contralateral limb, allows an evaluation of the vascular supply of the limb. Capillary refill time can be misleading in the distal limb and, if uncertainty persists, interpreting the waveform of pulse oximetry (Cook, 2001) and hand-held Doppler studies of the vessels can both be helpful. It is important to maintain a high index of suspicion for compartment syndrome and, if there is any doubt, to measure compartment pressures. A significant part of the neurological assessment of the limb involves evaluation of both motor and sensory components of the posterior tibial and peroneal nerves because complete disruption of these nerves can be a relative contraindication to limb salvage. However, the LEAP study found that absent plantar sensation at the time of presentation did not prove to be an indication for amputation, a predictor of functional outcome or even a predictor of eventual plantar sensation (Higgins *et al.*, 2010).

Fracture assessment is best evaluated by the orthopaedic surgeon using a combination of visual examination of the wound and interpretation of radiographic imaging of the tibia. This should include two orthogonal views including the knee and ankle joint and is mandatory in any suspected complex lower limb traumatic injury. The quality of the surrounding soft tissue (skin, subcutaneous tissue, muscle and periosteum) is difficult to assess in the emergency department and is best examined during primary debridement in the operating theatre by a plastic surgeon (BAPRAS, 2014).

Anti-tetanus prophylaxis and broad-spectrum antibiotics should be administered as soon as possible and categorically within 3 hours of the original injury. The first-line choice should be intravenous amoxicillin/clavulanic acid ('co-amoxiclav' 1.2 g, three times daily), clindamycin (600 mg, four times daily in those who have had previous penicillin anaphylaxis) or a cephalosporin such as cefuroxime (1.5 g, three times a day intravenously). Antibiotics should continue certainly until primary debridement and subsequently until definitive wound closure or for a maximum of 72 hours (whichever is earlier) (BAPRAS, 2014).

Serial examination of the neurovascular status of the injured limb is essential in order to recognise established or evolving limb-threatening compromise. The neurovascular status should be documented in the notes prior to handling or intervention.

---

## 4. TIMING OF SURGERY

---

The four major instances that warrant immediate surgical exploration are:

1. Presence of compartment syndrome.
2. Major contamination of the wound with agriculture, sewage or marine waste.
3. An arterial injury compromising the blood supply to the limb.
4. Multiply injured patients with another injury that warrants immediate surgery.

In the absence of these, debridement should be performed as a joint procedure by an experienced orthopaedic surgeon and an experienced plastic surgeon in the next available daytime trauma list within 24 hours (see below) (BAPRAS, 2014).

---

## 5. REFERRAL TO SPECIALIST CENTRES

---

Complex open lower limb fractures require a multidisciplinary approach involving plastic and orthopaedic surgeons with sufficient experience to manage such injuries. Usually, the initial assessment on the scene is carried out by the ambulance service and patients are appropriately triaged directly to a trauma centre that has the necessary expertise for the degree of injury. However, when patients present to a hospital in which such a team is unavailable, prompt referral and transfer to the nearest specialist centre is essential.

In addition, there are specific features of open tibial fractures that warrant referral to specialist centres and clinicians should be alert to these. These features are based on certain patterns of fractures and soft tissue injuries.

---

### 5.1. Fracture patterns

---

1. Transverse or oblique tibial fractures with fractures of the fibula at a similar level.
2. Segmental tibial fractures.
3. Fractures with bone loss either at the time of injury or following debridement.
4. Fractures of the tibia with comminution or butterfly fragments with concomitant fibular fracture at a similar level.

---

### 5.2. Soft tissue injury patterns

---

1. Degloving (avulsion type injury, where the skin and/or soft tissues are torn from their neighbouring tissues, culminating in disruption of blood supply to the affected tissues).
2. Loss of skin such that tension-free wound closure is not possible.

3. Injury to one or more of the major arteries of the lower limb.
4. Injury to the muscles that requires excision of devitalised muscle.

## 6. COMPARTMENT SYNDROME

---

The lower limb is divided into four discrete compartments by the investing deep fascia: the anterior, lateral, superficial and deep posterior compartments (Figure 8.3). An increase in pressure within these fixed osseofascial compartments can compromise tissue perfusion of the lower limb, resulting in myoneural necrosis and ultimately loss of limb function. Post-ischaemic reperfusion injury and direct crush injuries of the limb are frequently associated with an increase in intra-compartmental pressure. This is a surgical emergency which needs to be diagnosed and treated immediately.

Although compartment syndrome occurs more commonly after closed leg injuries, it can also occur following open tibial fractures (reported as 2–9%) (Park *et al.*, 2009). A high index of suspicion should be maintained for high-energy fractures and unconscious patients.

The principle signs of compartment syndrome include marked pain out of proportion to the injury, tenderness on palpation of the compartment, pain on passive movement of the muscles affected, paraesthesia and paralysis of the limb. Absent pulses are a late sign and are not specific to compartment syndrome. Therefore, their presence should not exclude a diagnosis of compartment syndrome. Pulses are characteristically lost in prolonged compartment syndrome where muscle necrosis has usually occurred, but should also alert the surgeon to the possibility of a vascular injury.

A definitive diagnosis of compartment syndrome can only be made upon measurement of compartment pressures. It is imperative that every effort is made to make an accurate diagnosis because inappropriate fasciotomies can be linked to significant morbidity.

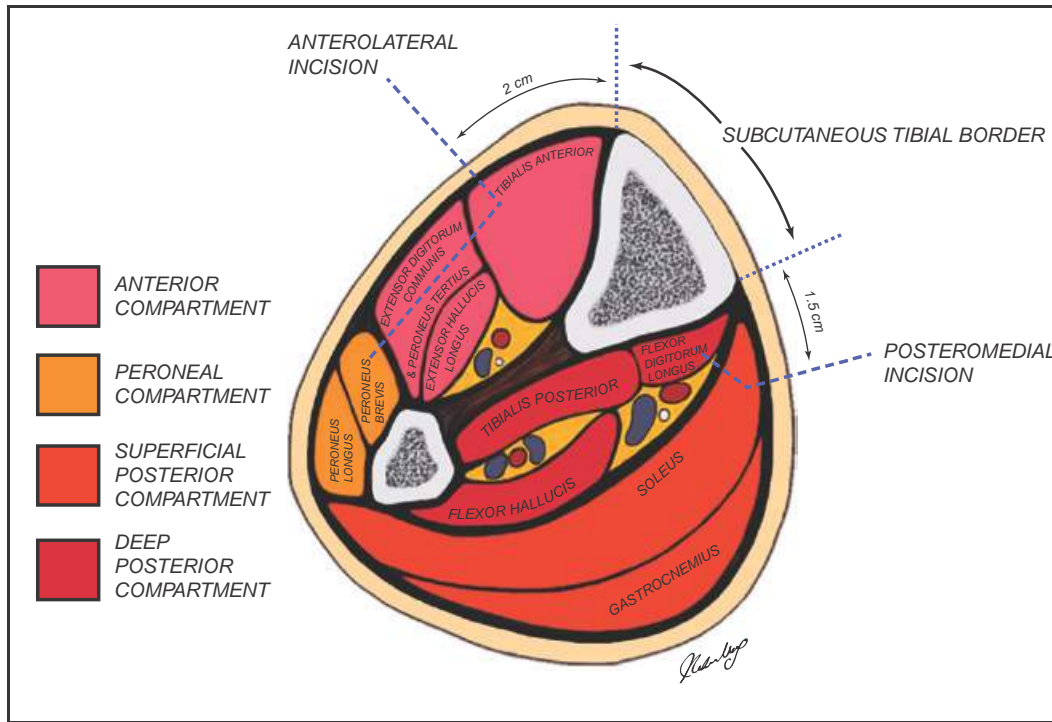
In any case of suspected compartment syndrome, compartment pressures should be estimated using a specific transducer such as the Stryker intra-compartmental pressure monitor, ideally from all four compartments. An increase from normal tissue pressure (2–7 mmHg) to 30 mmHg indicates a high likelihood of compartment syndrome, and pressures of 35–40 mmHg are an absolute indication for decompression. A more accurate measure of compartment pressure is the differential pressure (diastolic pressure minus compartment pressure). A differential pressure of <30 mmHg is an indication for fasciotomy or decompression (McQueen & Court-Brown, 1996).

### 6.1. Treatment of compartment syndrome

---

Diagnosis and early intervention are of the utmost importance in the management of compartment syndrome. Tissue injury becomes irreversible within a couple of hours, with resultant muscle and nerve loss. The definitive management in such a circumstance is four-compartment fasciotomy of the lower limb to decompress the compartments (Figure 8.3).

The subcutaneous borders of the tibia are identified and vertical skin incisions are placed at 15 mm from the medial border and 20 mm from the lateral border. The careful placement of these incisions is



**Figure 8.3.** Cross-sectional anatomy of lower limb and approach to four-compartment fasciotomy in compartment syndrome. *Source:* Rebecca Nicholas.

essential in order to preserve perforators which may be important for subsequent soft tissue reconstruction (see below). The superficial posterior compartment is decompressed through the medial incision. The fascia overlying the posterior tibial neurovascular bundle at the ankle is incised upward, detaching the soleus muscle from its origin from the tibia and subsequently decompressing the deep posterior compartment. The lateral incision decompresses the anterior compartment; from here, the lateral intramuscular septum is divided, releasing the peroneal compartment.

## 7. VASCULAR INJURIES

A devascularised limb is a surgical emergency and warrants immediate surgical exploration. The aim is to restore circulation within 3–4 hours, after which significant tissue ischaemia occurs. After 4 hours, irreversible myoneural necrosis starts to occur and further ischaemia leads into an unsalvageable limb. With a narrow window for muscle salvage, pre-operative angiography for a limb with suspected arterial injury is unlikely to confer a benefit and may delay definitive treatment. The likely site of vascular injury can be recognised from fracture configuration and any site of dislocation.

The degree of urgency of revascularisation of the lower limb is dependent upon which artery is injured. Disruption of the popliteal artery is seen in patients with posterior dislocations of the knee and

requires urgent revascularisation because the blood supply to the leg is dependent on the patency of this vessel. In cases of arterial injury distal to the trifurcation, where one vessel is patent, the decision to repair a second vessel is clinical because no studies have demonstrated differences in outcome in such situations (Thorne *et al.*, 2007).

Arterial shunting can restore circulation to the lower limb effectively and quickly, and markedly reduces the morbidity associated with ischaemia. Clinical assessment of the limb once circulation has been restored is important for determining the success of revascularisation and the salvage status of the limb. Skeletal stability should be achieved before definitive vascular repair because bone manipulation can disrupt the repair. Once definitive bony fixation has been achieved, temporary shunts can be replaced with reversed vein grafts. Four-compartment fasciotomies should be considered at the time of revascularisation surgery to prevent compartment syndrome.

## 8. PRIMARY DEBRIDEMENT

---

This should be performed on a scheduled daytime trauma list by experienced orthopaedic and plastic surgeons as a joint case within 24 hours of the injury.

The aim of debridement is to excise all non-viable tissue except for neurovascular bundles. Firstly, the limb is washed with soapy chlorhexidine solution and a tourniquet is placed on the thigh. Alcoholic chlorhexidine solution is used to prepare the skin. At the time of primary debridement, antibiotic prophylaxis in the form of Augmentin (co-amoxiclav; 1.2 g, intravenous) or a cephalosporin (cefuroxime; 1.5 g, intravenous) with gentamicin (5 mg/kg) should be administered; co-amoxiclav or cefuroxime should be continued until soft tissue closure or for a maximum of 3 days, whichever occurs first. The wound should be extended along fasciotomy incisions to enhance visualisation so that the extent of the soft tissue and bony injury can be assessed in detail. The skin excision should be extended until bleeding dermis is visualised.

The structures of the injured limb are evaluated in a systematic manner from the periphery of the wound to the centre, and from the most superficial layer of tissue to the deepest (skin, fat, muscle and bone). Colour, bleeding pattern and contractility are all good indicators of muscle viability. All devitalised and contaminated tissue should be removed. The bloodless field provided by the tourniquet enables excellent visualisation during soft tissue debridement; however, deflating the tourniquet is likely to enable a better assessment of viable bone because the ability of the end bone to bleed is a significant determinant. Loose fragments of bone which fail the 'tug test' are excised, as are fracture ends and any larger bone fragments which are non-viable. Once debridement is complete, the wound should be copiously irrigated with saline.

At this stage, the injury can be classified using the Gustilo–Anderson Classification. Depending on the state of the soft tissues and the pattern of bony injury, the joint orthopaedic and plastic surgical team can either perform definitive skeletal fixation at the time of primary debridement or make an alternative definitive reconstructive plan, ideally aiming for soft tissue closure within 72 hours of the original



injury. If soft tissue closure cannot be achieved during the initial procedure, a gentamicin bead pouch or, more commonly, a topical negative-pressure dressing should be applied. Negative-pressure dressings can promote wound contracture, promote granulation tissue formation, increase local microvascular blood flow, remove exudate and reduce peri-wound oedema (Herscovici *et al.*, 2003).

## 9. FRACTURE MANAGEMENT

Establishing skeletal stability is of the utmost importance in the management of a complex open tibial fracture. During primary assessment in the emergency department, it is recommended that a limb splint is used for immobilisation.

At the time of initial debridement, when definitive fracture treatment and wound coverage are not possible, spanning external fixation (SEF) is the method of choice in a severely damaged lower limb involving significant tissue loss owing to the wide zone of injury associated with Gustilo IIIb and IIIc fractures. This method of temporary fixation has a role in helping maintain limb length and provides increased pain relief (Egol *et al.*, 2005). SEF allows rigid fixation with minimal devascularisation and without causing further damage to the soft tissues of the lower limb. However, owing to its design, such fixation can potentially cause obstruction during microvascular free flap reconstruction. An awareness of this problem is important so that surgeons can plan the placement of pins and bars such that access to the posterior tibial artery is available and fracture stability is not compromised. Pin tract care should also be meticulous because it is a well-known source of infection. Prompt conversion from external fixation to internal fixation was previously advocated; however, today unilateral external fixators (such as a spatial frame) can be used as a primary and definitive treatment for tibial shaft fractures. They are associated with a low deep infection rate; re-operation or a change of the method of fixation should only be performed when there is a delay in callus formation (Beltsios *et al.*, 2009). Since the early 2000s, advances in the design of fixators and bone pins have provided an invaluable alternative for trauma surgeons.

If, at the time of primary debridement, there is adequate soft tissue coverage and minimal contamination, then internal fixation can be performed simultaneously. The most suitable type of permanent fixation is dependent on fracture patterns and degree of bone loss.

Intramedullary nails are a common method of definitive skeletal fixation. They can be used to achieve adequate bone alignment and fixation, are extremely stable and allow immediate weight-bearing in many cases. They are less suitable where there has been significant comminution or bone loss.

Internal fixation using plates and screws can provide rigid fixation and good quality bone alignment. However, it requires extensive periosteal/soft tissue stripping, which could further compromise tissue with poor vasculature. It also introduces considerable foreign material into the wound and is associated with an increased infective failure. Owing to these risks, internal fixation using plates and screws is now rare in the UK. In cases in which plating may previously have been advocated, the use of a spatial frame is now more common because it minimises these risks. If plating is still performed, then immediate soft tissue cover by either direct closure or soft tissue reconstruction is essential.

Where significant bone defects exist as a result of segmental loss, neither intramedullary nail fixation nor internal fixation with plate and screws alone will suffice. In such cases, a staged approach is often necessary. Initially, primary bone shortening (for segmental defects of <3–4 cm in length) or temporary bony spacer insertion (where shortening of >3–4 cm in length is likely to kink vessels, which may result in distal ischaemia) may be performed, with subsequent lengthening once soft tissue healing has been achieved. The three main methods of subsequent restoration of length are delayed cancellous bone grafting (ideal for bone gaps of 3 cm) and the use of a spatial frame distraction technique to either perform bone distraction at the site of the fracture or lengthen the bone at a site remote to the original fracture by performing osteotomy and bone transport. More recently, the Masquelet technique (the use of a temporary antibiotic cement spacer followed by staged bone grafting confirmed by an induced biomembrane) has also been shown to have a role in the management of osseous long bone defects (Wong *et al.*, 2014).

However, in practice, it is often the quality of the soft tissues and the extent of soft tissue injury, rather than the length of bone defect, which determines the choice of reconstruction (Lin *et al.*, 1999; Vasconez & Nicholls, 1991; Cierny *et al.*, 1992; Amr *et al.*, 2002).

## 10. DEFINITIVE SOFT TISSUE MANAGEMENT

---

The overall aim of soft tissue management is to provide stable wound coverage with an acceptable appearance and minimal donor site morbidity. Choice of the type of soft tissue coverage is dependent on the extent and location of the open tibial injury and patient factors such as age and co-morbidities. In circumstances such as type I, type II and even type IIIa open fractures, primary closure is often appropriate if the size of the wound and skin defect is localised (Kamath *et al.*, 2012). In type IIIb and IIIc fractures with large wounds with appreciable skin defects and exposed bone and tendon, more complex techniques are often necessary. These may include local or microvascular free flap reconstruction (Kamath *et al.*, 2012; Boyce & Shokrollahi, 2006).

However, the principles of soft tissue management remain the same: thorough wound debridement, control of wound infection by appropriate antibiotic treatment and coverage with healthy donor tissues harvested from outside the zone of injury. In high-energy tibial fractures, definitive soft tissue reconstruction should ideally be undertaken within 72 hours of the original injury and within a maximum of 7 days after the original injury to reduce the risk of osteomyelitis and fracture non-union (Ong & Levin, 2010).

### 10.1. Local flaps

---

A flap is a unit of tissue that can be transferred to cover a wound while maintaining its own vascular supply (Boyce & Shokrollahi, 2006). Flaps can be classified in several different ways. One way is to categorise them according to their circulation: they can be random pattern (no directional blood supply, common in the face) or axial, including fasciocutaneous and musculocutaneous flaps. The latter are particularly useful for covering defects in the proximal two-thirds of the lower limb.

## 10.2. Local muscle flaps

---

Muscle flaps can be classified according to their blood supply. Five different types were classified by Mathes and Nahai (Mathes & Nahai, 1981). Type I flaps are supplied by a single vascular pedicle such as the gastrocnemius. The soleus is classified as type II because it has one dominant pedicle and minor pedicles. Both these muscles are found in the superficial posterior compartment of the leg. The gastrocnemius, and less commonly the soleus, can be used for local flap reconstruction in complex open tibial fractures because of their good blood supply.

The gastrocnemius muscle has two heads (medial and lateral) arising from the medial femoral condyle and lateral femoral condyle, respectively. As the blood supply to this muscle is derived from the sural vessels above the knee, either head can theoretically be used to cover small defects of the knee and proximal tibia. In practice, the medial gastrocnemius muscle is most commonly used to cover defects in proximal third tibial fractures because it is larger and longer than the lateral head (Kamath *et al.*, 2012). The functional deficit on locomotion of losing one head of the gastrocnemius muscle is minimal.

The soleus muscle is located deep to the gastrocnemius muscle, and only half of the muscle (hemi-soleus) is usually harvested as a muscle flap in order to preserve muscle function (Hyodo *et al.*, 2004). It is easily and readily available and transposes well over large defects along the middle third of the tibia. Because of the arc of rotation, muscle flaps considerably larger than the defect are required in order to provide adequate coverage. Neither the gastrocnemius nor the soleus muscle flap is generally considered appropriate for the distal third of the leg.

A small defect over the middle tibia may rarely benefit from a turnover flap of the tibialis anterior muscle. Due to its segmental and less reliable blood supply (type IV), the tibialis anterior muscle should be split longitudinally, leaving an intact tendon. Furthermore, this muscle is extremely important in dorsiflexion of the foot and is thus less preferable to other local muscle flaps. The major problem with using local muscle flaps is that in extensive open wound injuries such as Gustilo IIIb and IIIc, the donor muscles are often severely injured and thus not available for transfer.

## 10.3. Fasciocutaneous flaps

---

Fasciocutaneous flaps are based on vessels running in close association with or within the fascia. They are commonly derived from the limbs and were categorised by Cormack and Lamberty into four types (A–D) according to the pattern of their blood supply (Cormack & Lamberty, 1984). Fasciocutaneous flap options in the lower limb include the saphenous flap and the medial or lateral distal fasciocutaneous flap. The most commonly used flap is a distal medial fasciocutaneous flap. This is most reliably based on the posterior tibial artery perforator arising approximately 10 cm above the medial malleolus, which is why the correct placement of fasciotomy incisions, when required, is paramount (see section 6). Saphenous flaps are useful for covering small defects around the proximal tibia in low-energy tibial fractures where the vasculature has not been compromised by the zone of injury or by degloving. The length of the flap can extend down the leg as far as the 15-cm perforator arising from the posterior tibial

artery. Fasciocutaneous flaps are insufficient to cover large defects requiring well-vascularised soft tissue coverage. In this case, the donor site will usually require a split-thickness skin graft.

## 10.4. Microvascular free flap reconstruction

---

A free flap is a unit of tissue harvested with its blood supply from a distant site in the body. It is completely detached from the source vessels and subsequently anastomosed to recipient vessels close to the defect using microsurgical techniques.

Microvascular free flap reconstruction has an important role in the management of high-energy lower limb trauma with associated bone, soft tissue and muscle loss as a result of its ability to provide versatile healthy tissue that can fill dead space and provide additional vascularity to the wound. Free flaps are particularly useful in the management of fractures involving the distal third of the tibia, ankle and foot, where local reconstructive options are limited.

In all cases, thorough debridement of contaminated or devascularised tissue from the site of injury is mandatory prior to free flap reconstruction. Investigations such as computed tomography angiography and plain angiography afford the analysis of distal arterial blood flow, thus allowing appropriate pre-operative planning. Microvascular free flap reconstruction should take place in a specialist centre on a scheduled daytime theatre list by plastic surgeons experienced in microsurgical techniques.

The most common free flaps selected for reconstruction of the lower limb include the anterolateral thigh flap, often used as a chimeric flap with the vastus lateralis muscle which provides a rich blood supply to the fracture site (see below); the free radial forearm flap; and the latissimus dorsi and gracilis muscle free flaps. The rectus abdominis free flap is now less frequently used for reconstruction of the lower limb. Recipient vessels must be carefully selected from outside the zone of injury to prevent post-operative thrombosis and end-to-side anastomosis should be performed where possible to preserve circulation to the distal limb.

Microvascular flap tissue transfer in the management of open tibial fractures was traditionally reserved for circumstances in which local or regional flap reconstruction was not feasible owing to the technically demanding nature of the surgery, longer operative time, greater medical complication rates, longer hospital stay and high incidence of flap loss (Kamath *et al.*, 2012). However, evidence now suggests that in experienced hands in specialised centres there are actually fewer complications with free flaps than with fasciocutaneous flaps and that patients previously thought to be inappropriate candidates for microvascular transfer, such as elderly patients and those with diabetes or peripheral vascular disease, are in fact most prone to complications following local flaps. No randomised clinical studies have compared the use of local fasciocutaneous flaps and free flaps. However, available experimental evidence from animal models favours muscle flap coverage for open tibial shaft fractures to promote more rapid bony healing when compared with fasciocutaneous flaps, which may be best reserved for coverage of metaphyseal fractures, particularly at the ankle. The division between local fasciocutaneous flap and free muscle transfer has become increasingly blurred with the growing use of the anterolateral thigh flap, which can be raised as a chimeric flap to include a portion of vastus lateralis muscle. This is a

**Table 8.1.** Local or distant flap recommendations based on zone of injury and type of soft tissue defect.

Zone of lower leg/tibial injury	Flap reconstruction	Alternative flap choice
Proximal third	Gastrocnemius + SSG	Saphenous artery based or microvascular free tissue transfer
Middle third	Soleus + SSG	Distally based fasciocutaneous flap or microvascular free tissue transfer
Distal third	Distally based medial fasciocutaneous flap	Distally based sural artery flap or microvascular free tissue transfer

SSG = split skin grafting.

particularly attractive option for the reconstruction of complex lower limb soft tissue defects because it not only provides well-vascularised healthy muscle from outside the zone of injury with a skin paddle, but has the added benefit of avoiding an unsightly skin grafted donor site that is typically associated with the local fasciocutaneous flap (Ong & Levin, 2010). Table 8.1 summarises some of the common options for soft tissue reconstruction by zone of tibial injury (proximal, middle and distal thirds of the lower limb) (Park *et al.*, 2009).

## 11. AMPUTATION

Unfortunately, in some cases it is clear that a limb is not salvageable and primary amputation is indicated. Perhaps the only absolute indication for primary amputation is a catastrophic injury with life-threatening haemorrhage. Relative indications include serious associated polytrauma, an unstable patient who is unlikely to survive a prolonged salvage procedure, severe ipsilateral foot injury, segmental tibial fractures or multiple zones of injury such as segmental muscle loss involving affecting two or more compartments.

Damage to the posterior tibial nerve and subsequent loss of plantar sensation is not an absolute indication for primary amputation but has to be taken into account along with all other factors when considering limb salvage. The overall aim of treatment of a lower limb injury is preservation of a limb that will be more functional than an amputation. However, where amputation is necessary, a key underlying principle is to provide a functional limb length. The levels of amputation can either be transtibial (i.e. below knee amputation), transfemoral (above knee amputation) and through knee amputation, depending on whether the knee is salvageable as a functional unit. Below knee amputations are preferable because patients have a much greater functional outcome and can participate in physical activities requiring a greater amount of energy than is possible for patients who have an above knee amputation. The daily distance travelled is also significantly higher in below knee amputee patients; this correlates with a much improved quality of life compared with patients undergoing transfemoral amputations.

The decision to amputate should be undertaken by two consultants and include discussion with the patient and, ideally, with family members wherever possible.

## 12. CONCLUSION

High-energy lower limb trauma can result in complex bone and soft tissue injury with associated vascular and nerve damage. It is mandatory that a multidisciplinary team approach involving the orthopaedic and plastic surgery teams is integrated with basic ATLS protocols for assessment in the emergency department. Broad-spectrum antibiotic prophylaxis and early surgical exploration combined with careful wound debridement, treatment of vascular injuries and subsequent definitive skeletal and soft tissue management form the mainstay of surgical management of complex open fractures.

The overall goal of treatment is always to restore form and function with pain-free bony union and a stable soft tissue envelope. To that end, limb salvage is aimed for wherever this would provide greater functionality compared with an amputated limb. Where the functionality of a reconstructed limb falls below that of a prosthesis, amputation with preservation of maximum functional limb length still has a valuable role in the management of these patients.

## REFERENCES

- Amr SM, El-Mofty AO, Amin SN. Anterior versus posterior approach in reconstruction of infected nonunion of the tibia using the vascularized fibular graft: potentialities and limitations. *Microsurgery*. 2002;22(3):91–107.
- BAPRAS. Open Fractures of the Lower Limb [Internet]. [2 December 2014]. Available from: <http://www.bapras.org.uk/professionals/clinical-guidance/open-fractures-of-the-lower-limb#ShortGuide>
- Bell RM, Krantz BE, Weigelt JA. ATLS: a foundation for trauma training. *Ann Emerg Med*. 1999;34(2):233–7.
- Beltsios M, Savvidou O, Kovanis J, Alexandropoulos P, Papagelopoulos P. External fixation as a primary and definitive treatment for tibial diaphyseal fractures. *Strategies Trauma Limb Reconstr*. 2009;4(2):81–7.
- BOA Standards for Trauma (BOASTs) – British Orthopaedic Association [Internet]. [cited Mar 21 2015]. Available from: <http://www.boa.ac.uk/publications/boa-standards-trauma-boasts/#toggle-id-4>
- Boyce DE, Shokrollahi K. Reconstructive surgery. *BMJ*. 2006;332(7543):710–2.
- Brumback RJ, Jones AL. Interobserver agreement in the classification of open fractures of the tibia. The results of a survey of two hundred and forty-five orthopaedic surgeons. *J Bone Joint Surg Am*. 1994;76(8):1162–6.
- Cierny G, Zorn KE, Nahai F. Bony reconstruction in the lower extremity. *Clin Plast Surg*. 1992;19(4):905–16.
- Cook LB. Extracting arterial flow waveforms from pulse oximeter waveforms. *Anaesthesia*. 2001;56(6):551–5.
- Cormack GC, Lamberty BG. A classification of fascio-cutaneous flaps according to their patterns of vascularisation. *Br J Plast Surg*. 1984;37(1):80–7.
- Court-Brown CM, Rimmer S, Prakash U, McQueen MM. The epidemiology of open long bone fractures. *Injury*. 1998;29(7):529–34.
- Egol KA, Tejwani NC, Capla EL, Wolinsky PL, Koval KJ. Staged management of high-energy proximal tibia fractures (OTA types 41): the results of a prospective, standardized protocol. *J Orthop Trauma*. 2005;19(7):448–55.
- Fodor L, Sobec R, Sita-Alb L, Fodor M, Ciuce C. Mangled lower extremity: can we trust the amputation scores? *Int J Burns Trauma*. 2012;2(1):51–8.
- Georgiadis GM, Behrens FF, Joyce MJ, Earle AS, Simmons AL. Open tibial fractures with severe soft-tissue loss. Limb salvage compared with below-the-knee amputation. *J Bone Joint Surg Am*. 1993;75(10):1431–41.
- Gustilo RB, Anderson JT. Prevention of infection in the treatment of one thousand and twenty-five open fractures of long bones: retrospective and prospective analyses. *J Bone Joint Surg Am*. 1976;58(4):453–8.

- Gustilo RB, Mendoza RM, Williams DN. Problems in the management of type III (severe) open fractures: a new classification of type III open fractures. *J Trauma*. 1984;24(8):742–6.
- Herscovici D, Sanders RW, Scaduto JM, Infante A, DiPasquale T. Vacuum-assisted wound closure (VAC therapy) for the management of patients with high-energy soft tissue injuries. *J Orthop Trauma*. 2003;17(10):683–8.
- Higgins TF, Klatt JB, Beals TC. Lower Extremity Assessment Project (LEAP) – the best available evidence on limb-threatening lower extremity trauma. *Orthop Clin North Am*. 2010;41(2):233–9.
- Howard M, Court-Brown CM. Epidemiology and management of open fractures of the lower limb. *Br J Hosp Med*. 1997;57(11):582–7.
- Hyodo I, Nakayama B, Takahashi M, Toriyama K, Kamei Y, Torii S. The gastrocnemius with soleus bi-muscle flap. *Br J Plast Surg*. 2004;57(1):77–82.
- Johansen K, Daines M, Howey T, Helfet D, Hansen ST. Objective criteria accurately predict amputation following lower extremity trauma. *J Trauma*. 1990;30(5):568–72.
- Kamath JB, Shetty MS, Joshua TV, Kumar A, Harshvardhan, Naik DM. Soft tissue coverage in open fractures of tibia. *Indian J Orthop*. 2012;46(4):462–9.
- Kim PH, Leopold SS. In brief: Gustilo-Anderson classification. [corrected]. *Clin Orthop Relat Res*. 2012;470(11):3270–4.
- Lin CH, Wei FC, Chen HC, Chuang DC. Outcome comparison in traumatic lower-extremity reconstruction by using various composite vascularized bone transplantation. *Plast Reconstr Surg*. 1999;104(4):984–92.
- MacKenzie EJ, Bosse MJ, Kellam JF, Burgess AR, Webb LX, Swiontkowski MF, et al. Characterization of patients with high-energy lower extremity trauma. *J Orthop Trauma*. 2000;14(7):455–66.
- Mathes SJ, Nahai F. Classification of the vascular anatomy of muscles: experimental and clinical correlation. *Plast Reconstr Surg*. 1981;67(2):177–87.
- McQueen MM, Court-Brown CM. Compartment monitoring in tibial fractures. The pressure threshold for decompression. *J Bone Joint Surg Br*. 1996;78(1):99–104.
- Ong YS, Levin LS. Lower limb salvage in trauma. *Plast Reconstr Surg*. 2010;125(2):582–8.
- Park S, Ahn J, Gee AO, Kuntz AF, Esterhai JL. Compartment syndrome in tibial fractures. *J Orthop Trauma*. 2009;23(7):514–8.
- Richard RD, Kubiak E, Horwitz DS. Techniques for the surgical treatment of distal tibia fractures. *Orthop Clin North Am*. 2014;45(3):295–312.
- Thorne CH, Beasley RW, Aston JS, et al. *Grabb and Smith's plastic surgery*. 6th edn. Philadelphia: Wolters Kluwer Health/Lippincott Williams & Wilkins; 2007.
- Vasconez HC, Nicholls PJ. Management of extremity injuries with external fixator or Ilizarov devices. Cooperative effort between orthopedic and plastic surgeons. *Clin Plast Surg*. 1991;18(3):505–13.
- Wong TM, Lau TW, Li X, Fang C, Yeung K, Leung F. Masquelet technique for treatment of posttraumatic bone defects. *ScientificWorldJournal*. 2014;2014:710302.

## Injuries of the Facial Skeleton

---

Tom W. Andrew, Nicholas Kalaverozos

### 1. INTRODUCTION

---

Facial trauma management is evolving, primarily owing to developments in imaging and bone fixation technology and the application of microsurgical techniques, including the recent potential for allograft reconstruction (Devauchelle *et al.*, 2006). An appreciation of the psychological complications of facial fractures, the shift toward early one-stage repair with immediate bone grafting and the use of cosmetic incisions highlights the change. Management is most effective within a multidisciplinary team; however, plastic surgeons are uniquely placed in this unit because they are trained to handle the full spectrum of pathology from urgent stabilisation to late surgical revision, without the discrimination of anatomical involvement. The plastic surgeon should be able to make an appropriate clinical assessment with imaging, construct a definitive operative plan with alternative strategies and, finally, be aware of their complications. This chapter will guide the reader through these methods according to anatomical fracture location.

A transformation in facial fracture has also occurred with regard to the mode of injury. An overall rise in craniomaxillofacial trauma is mostly attributable to a rise in interpersonal violence. There has been a prominent reduction in road traffic accident (RTA) facial trauma as a result of (Cox *et al.*, 2004):

- Legislation – 1966 Drink driving, 1983 Seat belt
- Car design – crumple zones, airbags and laminated windscreens.

The aetiology of such injuries is currently interpersonal violence, 36%; RTA, 32%; falls, 18%; sport, 11%; and occupational, 3% (Erdmann *et al.*, 2008). Despite the reduction in RTA incidence, injuries are often serious (43%) (Hutchison *et al.*, 1998). Alcohol increases the frequency and severity of facial injury, with 45% of facial fractures being related to its consumption (Hutchison *et al.*, 1998). The face is central to self-recognition and social interaction, respiration, nutritional intake, vision and communication. Facial injuries have high morbidity and mortality rates, reflecting the need for effective understanding and management.



---

## 2. EXAMINATION OF FACIAL INJURIES

---

### 2.1. Initial management

---

As with all traumatic injury, steps of the sequential Advanced Trauma Life Support ('ATLS') algorithm should be commenced. Isolated facial injuries are rarely life-threatening; however, in high-impact trauma, concomitant injuries are a concern, particularly for acute brain injury and visceral damage. Associated emergencies should be detected in the primary survey: this is primarily airway compromise. Airway compromise is the commonest cause of mortality, making its establishment and maintenance of the highest priority. Obstruction occurs by the tongue occluding the oropharynx (especially common in bilateral mandibular fractures because of central displacement), from foreign bodies such as teeth or from excessive upper airway haemorrhage, particularly in those with an altered Glasgow Coma Scale. The first-line treatment for securing an airway after the appropriate use of suction, forceps and tongue placement is tracheal intubation. This is often very difficult in laryngeal injury owing to haematoma; when oral attempts of intubation fail, the next approach is the fastest surgical one, cricothyroidotomy. If there is hoarseness, a palpable fracture and subcutaneous emphysema, the suggestion for a laryngeal fracture would promote the use of a tracheotomy avoiding the zone of injury. Although haemorrhage may cause airway concerns unless there is involvement of major vessels, severe consequences such as hypovolaemic shock are rare and will otherwise be detected in the secondary survey and treated urgently. Bleeding should be controlled by direct pressure. Bleeding of the maxillary artery territory is usually controlled by nasal balloons in the post-nasal space; these should be used with caution because of the risk of intracranial damage as a consequence of a co-existing cribriform plate fracture. To encourage haemostasis, several techniques may be applied: postural assistance, A–P packing, vasoconstrictors, controlling blood pressure, cauterisation and embolisation.

Cervical spine injuries in the context of facial fractures are challenging to quantify objectively; they are reported to be 0–8% (Elahi *et al.*, 2008). Despite being elusive, they are unanimously accepted as serious complications and require urgent management. Neurological injury is a common consequence of facial trauma: in one case series, 79.4% of facial fractures were reported to have a degree of traumatic brain injury (Martin *et al.*, 2002). Most patients with facial trauma will undergo head computed tomography (CT) as part of the complete trauma evaluation. If an acute brain injury is present, surgical repair of the facial fracture is postponed until it is stabilised because a deteriorating Glasgow Coma Scale (GCS) cannot be assessed under general anaesthetic and the fluid overload effects of surgery can worsen a neurological deficit.

### 2.2. Facial trauma evaluation

---

When assessing region-specific anatomy, the patient's medical history should be considered, along with pre-morbid occlusion and any facial deformities or ophthalmological pathologies. This is often more difficult because of the status of the patient; for example, those with midface fractures are often unconscious or intubated (Cornelius *et al.*, 2013).

### 2.3. Scalp

---

The scalp should be inspected for lacerations by carefully parting the hair. The skull vault should be palpated, feeling for crepitus or haematoma. Any suspected fracture of the skull requires the opinion of the neurosurgical team.

### 2.4. Eye examination

---

In any patient presenting with facial trauma involving the orbit, a thorough examination of the globe and associated structures is mandatory because 90% of patients with facial fractures sustained ocular injuries of various severities (Al-Qurainy *et al.*, 1991). Externally, the globes and periorbital region should be assessed for Raccoon's sign, suggestive of an anterior cranial fossa fracture, hyposphymia, crepitus and displacement. A visual examination is performed for every patient, often combined with a visual fields exam and colour desaturation, which will reflect any optic nerve damage. In retrobulbar haemorrhage, an accumulation of intraorbital pressure may cause the compression of neurovascular structures, leading to severe pain and a tense proptotic globe. Medical management consists of oxygen, mannitol, acetazolamide and intravenous steroid administration. The patient's visual impairment requires urgent decompression; there is a time frame of 1 hour before the onset of permanent blindness, of which colour vision is the most sensitive early indicator. Surgical decompression should come in the form of a lateral cantholysis, following which exploration with the evacuation of the haemorrhage must occur in the operating theatre.

Concerning signs include pulsating exophthalmos, which is typically a carotid-cavernous-sinus fistula and requires radiological examination pre-operatively. Emphysema is another orbital emergency which can significantly raise the intraorbital pressure and may also require release (i.e. valving). Entrapment of the extraocular muscle is more common in children (who can suffer greenstick fracture) and is detected by a forced duction test. Entrapment requires immediate release because of the dangers of necrosis and permanent strabismus. Direct and consensual pupillary responses are elicited to determine the function of the second and third cranial nerves. Anisocoria may be an indication of second or third nerve damage or of direct trauma to the iris. A relative afferent pupillary defect is indicative of optic nerve injury and can be elicited by a swinging flashlight test. Range of motion testing of each eye will determine the function of the third, fourth and sixth cranial nerves. Although these tests are helpful in the emergency department, ophthalmologic consultation should be considered in every case of orbital trauma and assessed under dilation.

### 2.5. Ear examination

---

Hearing should be assessed in both ears. Inspection for haematoma may require a bolster dressing to prevent the formation of a cauliflower ear through cartilage resorption or a reactive chondrogenesis.

Examination for laceration or collapse of the external canal should be performed, as should examination of the mastoid process for Battle's sign and of the tympanic membrane for rupture or a haemotympanum. Blood or cerebrospinal fluid (CSF) in the ear canal may indicate skull base fractures or external auditory canal lesions resulting from a condylar fracture owing to the location of glenoid fossa.

## **2.6. Nasal examination**

---

Examination of the nose starts with an inspection for swelling or asymmetry, followed by palpation and an assessment of nasal airway compromise.

Nasal inspection using a speculum enables examination of the nasal cavity. It is very important to rule out a septal haematoma because this has to be drained to avoid infection, which can result in septal perforation. Haematoma can also pull the periosteum from the nasal bone, causing mucosal necrosis and a saddle-nose deformity. Nasal packing or splints should be inserted to prevent the recurrence of haematoma.

## **2.7. Oral and throat examination**

---

Inspection should include the assessment of haematomas, lacerations, foreign body or malocclusion. Palpation should be commenced to feel for any fracture mobility and steps at the zygomaticomaxillary buttress. An anterior open bite deformity is commonly associated with Le Fort fractures.

## **2.8. Soft tissue injuries**

---

The sensitivity of head and neck examination may be significantly affected by facial swelling. Lacerations are a particular challenge to the aesthetic outcome over areas such as the eyelids, nasal alae and vermilion border. Pre-existing facial lacerations can be used and extended along relaxed lines of skin tension to assess fractures; this is not contraindicated by bacterial contamination. Lacerations and abrasions contaminated by dirt and small foreign particle should be scrubbed within 24 hours to avoid traumatic tattooing. Wounds should be monitored for infection and sutures removed at the appropriate healing phase. The patient should avoid sun exposure and be reminded that scars may take months to years to fully mature.

## **2.9. Peripheral nerve and parotid duct injuries**

---

There is a close anatomical relationship between the buccal branch of the facial nerve and the parotid duct. The functional importance of facial and trigeminal nerves are respected in primary repair

or tagged for secondary repair; the most important branches of these nerves supply eyelid closure. Parotid duct laceration may lead to a salivary fistula or sialocele. To close, a stent is placed through the intraoral orifice at the third molar through Stenson's duct and sutured using microsurgical techniques.

### **3. RADIOLOGICAL FINDINGS**

---

The availability of CT imaging has enabled the surgeon to better define fractures as well as the degree of fracture displacement and the need for reduction.

#### **3.1. Computed tomography**

---

By obtaining CT axial fine slices, the surgeon can obtain excellent reformatted coronal, oblique and parasagittal views. The surgeon can also obtain three-dimensional views.

#### **3.2. Cone beam technology**

---

Cone beam technology allows an adequate determination of hard tissue problems but is not equivalent to CT technology in terms of soft tissue assessment. Further limitations of cone beam technology result from a more limited scanning region. Because there is less exposure to radiation, cone beam scanning may be more suitable for follow-up.

#### **3.3. Plain X-rays**

---

Most centres with CT facilities seldom use two-dimensional imaging. Some centres find a post-operative anteroposterior and lateral view useful to document plate and screw placement. Two-dimensional imaging lacks precision particularly for the sagittal extent of the injury.

For dental and jaw trauma, standard orthopantomography is helpful. If there is uncertainty of the foreign body location, further X-rays are necessary and endoscopic measures may be appropriate for retrieval.

#### **3.4. Magnetic resonance imaging**

---

Magnetic resonance imaging might be indicated to better detect soft tissue problems such as ocular pathologies. Rarely, ultrasound may be indicated to detect intraocular or intraorbital disorders, e.g. haematoma.

---

## 4. FRONTAL SINUS

---

Patients with frontal sinus fractures may present with a laceration of the forehead. Any haematoma or ecchymosis over the glabellar region, as well as bony contours or crepitus locally, should raise the suspicion of sinus injury. Pneumatisation of the frontal sinus is not complete until late adolescence, making fractures rare before this stage (Yavuzer *et al.*, 2005). The frontal bone is the strongest bone of the craniofacial skeleton and requires between 360 and 1000 kg to fracture; however, this is easily achieved in an RTA (Nahum, 1975).

As illustrated in [Figure 9.1](#), concomitant injuries are common: 75% of fractures have regional pathology and 20% are associated with a CSF leak (Yavuzer *et al.*, 2005). If CSF leakage is suspected, the following diagnostic procedures may be performed:

- Checking for a positive halo sign
- CT scanning of the cribriform plate
- Comparing the concentration of glucose between fluid and the patient's serum
- Laboratory analysis for beta-transferrin
- Direct visualisation via transnasal endoscopy.

---

### 4.1. Decision

---

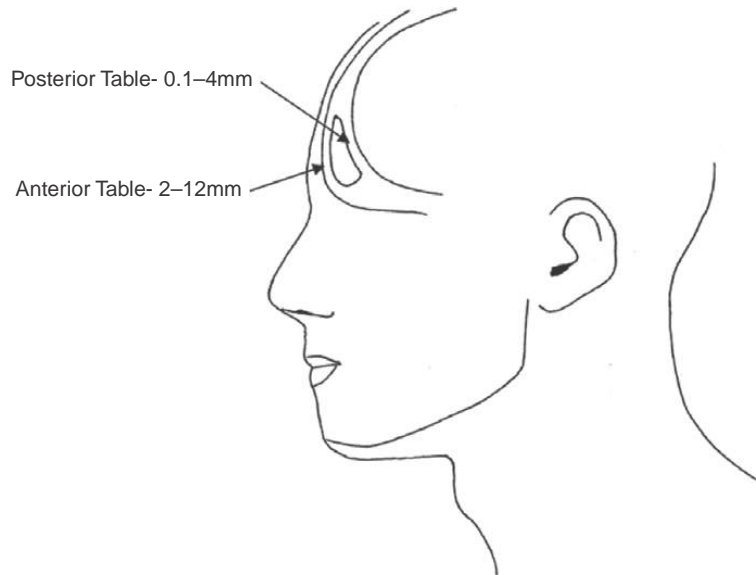
Patients with frontal sinus fractures may present with obvious contour deformities of the forehead, but the swelling associated with the injury often blunts the degree of deformity. Injury to the frontal sinus is commonly associated with injury to the central nervous system, and early evaluation should focus on this possibility. Axial cuts of the CT scan are useful for determining the degree of injury and involvement of the anterior table, posterior table and nasofrontal duct. These three structures are used in the classification of frontal sinus fractures, as well as their subsequent treatment.

---

### 4.2. Surgical approach

---

The objective of treatment is to create a safe sinus and restore aesthetic unity. The procedure begins with a bicoronal incision or incision through existing cuts in the forehead. The borders of the sinus are marked and an osteotome is used for trephination of the frontal sinus. All bony fragments should be collected and orientated on the table to help fixation and for replacement at the end of the operation. Any drainage compromise requires frontal sinus obliteration. Mucosa should be fastidiously removed, including from the vascular crypts of Breschet. Nasal communication should be eliminated and the sinus filled with graft tissue (Metzinger and Metzinger, 2009). This approach has been challenged based on the current understanding of osteoneogenesis. It is suggested that filling the sinus with non-vascularised material such as fat has no advantage over not filling it at all (Rohrich and Mickel, 1995). Any posterior



**Figure 9.1.** Illustration of frontal sinus anatomy. Local anatomy as depicted in this illustration justifies the frequency of serious concomitant injuries associated with frontal sinus fractures. These include ophthalmological, intracranial and skull base complications.

displacement of posterior table fractures requires cranialisation, in which the posterior table is removed and the brain is allowed to expand into the site previously occupied by the sinus.

The use of an endoscopic approach has not been discussed in detail here because it still has a minimal role in the management of frontal sinus fractures in most trauma centres; however, scarring and swelling may be reduced via an endoscopic brow lift, allowing a faster recovery (Simmons and Manson, 2009).

### 4.3. Aftercare

All patients should receive prophylactic antibiotics. Close attention is essential for the late sequelae of head injury, infectious complications and sinus clearance. A CT should be done if the patient complains of abnormal nasal drainage or frontal headaches, or if symptom-free at 6 months post-operatively to confirm their non-pathological state. Patients with sinus fractures in the periorbital region should not blow their nose in order to avoid additional emphysema due to acute pressure rise. Should sneezing occur, maintaining an open mouth posture minimises the increase in intranasal and intrasinus pressure.

Fractures of the posterior table place patients at a risk of acute meningitis, and the entrance of mucosa trapped within the cranial cavity creates the risk of mucocoele formation. Patients should be educated about the symptoms of sinusitis, mucocoele formation and intracranial infections. Late complications, although uncommon, are insidious and indicate serious pathology.

In the UK and USA, it is common to leave plating systems *in situ*. Cold intolerance is uncommon and its pathophysiology is not fully understood. Screws and plates, however, should be removed from a healed fracture site in children to allow growth.

## 5. ORBITAL FRACTURE

---

A full ophthalmological examination is essential, particularly for visual impairment and globe position, the accuracy of which is likely to be limited by prominent swelling of the eyelids. Important clinical signs include circumorbital ecchymoses and subconjunctival haemorrhage. After palpating around the orbital aperture, a CT scan should be done. This has superseded plain X-ray because it can display the site of fracture and its displacement, which are crucial for surgical planning. On radiological imaging, herniation of orbital contents into the maxillary antrum produces a teardrop sign, indicating an orbital floor blowout fracture.

### 5.1. Decision

---

Observation or surgical intervention is based on clinical and radiological findings. There are two well-documented scenarios in which an orbital fracture repair is performed: extraocular muscle entrapment and enophthalmos. The posteromedial aspect of the orbit is convex and inferior displacement will significantly increase intraorbital volume, leading to enophthalmos. This should be overcorrected to adjust for subacute swelling. Pure orbital fractures are blow-out fractures, requiring an oblique parasagittal view, and roof fractures should be assessed for CSF leakage owing to regional anatomy.

### 5.2. Surgical approach

---

Methods to protect the cornea during eyelid incisions vary according to the surgeon's personal preference, but most patients will require temporary tarsorrhaphy or a corneal shield. The most common complication from incisions used to access the orbital floor is lower eyelid retraction. This may result in ectropion or entropion. The surgeon should be cautious of the infraorbital nerve. Approaches include:

- The subciliary approach, often used for blepharoplasty and has the highest risk of associated retraction.
- The transconjunctival approach, which has consequently gained popularity because of the superior cosmetic result and may be extended by lateral canthotomy.
- A subtarsal incision can also be employed, especially in older patients, to conceal the incision with prominent lower lid rhytides. Scarring of the eyelid is usually inconspicuous with time because of the thinness of the skin at this site.

### 5.3. Orbital fracture reconstruction

To identify portions of the orbital wall that are intact and contiguous with the orbital apex, dissection is necessary. A periosteal elevator is used to dissect posteriorly, avoiding the infraorbital nerve within the orbital floor. There is more controversy regarding the appropriate material used for fracture repair than for anywhere else in the human body (Avashia *et al.*, 2012). Materials should be flexible to allow moulding and be radiopaque and relatively bioinert. A resorbable implant may be favoured in children to allow growth. After fitting, forced duction should be performed to ensure free movement of extraocular muscles.

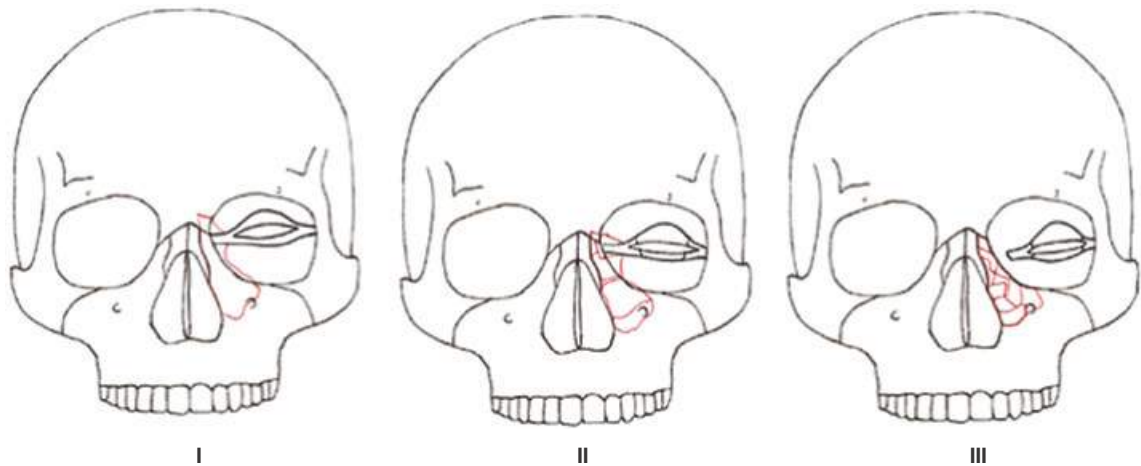
### 5.4. Aftercare

A full ophthalmological examination is necessary. Eye movement exercises are considered beneficial.

Often, there is an element of both enophthalmos and hypoglobus in malreduced orbital fractures. The most common presentation of these deformities is diplopia, which is corrected by restoring the orbital volume. If this occurs secondary to malunion, then reconstruction is challenging, requiring osteotomy of the entire zygomatic complex.

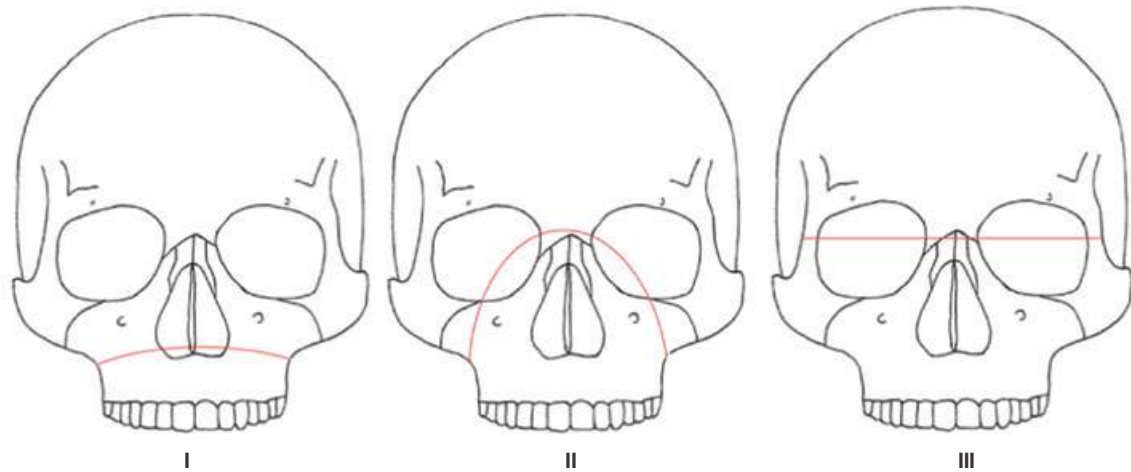
## 6. NASO-ORBITOETHMOID

The naso-orbitoethmoid (NOE) region is formed from several structures of the upper facial skeleton: the nose, orbit and ethmoid. Fractures of this region can be classified as shown in [Figure 9.2.1](#)



**Figure 9.2.** Illustration of naso-orbitoethmoid fracture classification. I. The medial canthal tendon (MCT) is attached to a relatively large central bone fragment. II. The MCT is attached to a comminuted bone fragment. III. Avulsion of the MCT from a bony insertion.





**Figure 9.3.** Illustration of Le Fort fractures. The force required for each Le Fort fracture increases from I to II; the pattern demanding the most force is III.

(Markowitz *et al.*, 1991). Although these go some way to describing the involvement of pertinent anatomy of the midface, another key structure that is intimately associated to the NOE region is the lacrimal system, which may cause epiphora and dacryocystitis.

## 6.1. Decision

Patients commonly present with pain and facial swelling. In addition to the standard protocol for ophthalmological examination, the canthal distance and bowstring test must be performed. The intercanthal distance was first defined by Waardenburg as 32–33 mm and >35 mm in Caucasian women and men is considered abnormal. A positive bowstring test, which provides no resistance, detects fracture segment movement (Waardenburg, 1951). Patients may complain of anosmia, and inspection of the nose may show it to be retruded due to lack of support. These patients should have an assessment of their nasal airway status.

Insertion of the two limbs of the medial canthal tendon into the frontal maxilla process forms the central components of the NOE region and surrounds the lacrimal fossa. A CT should visualise all relevant anatomy but will focus on this in particular.

## 6.2. Surgical approach

For NOE fractures, it is technically challenging to restore the normal appearance and contours of the nose and eyes, which is the general goal of surgery. Type 1 fractures are treated by the fixation of the bone fragment to the adjacent surrounding bone. Type 2 fractures can be fixed or wired if the fragment

is too small, potentially requiring bone grafting. Type 3 fractures also need reduction and bone grafting and will certainly need transnasal fixation of the medial canthal tendon. To avoid telecanthus, it is essential that after transnasal medial canthoplasty the tendon pulls in a posterior and superior direction, as opposed to anteriorly.

Damage to the nasolacrimal system should be treated surgically at the time of the primary surgery and managed with stenting or dacryocystorhinostomy.

After bony reduction, there may be a lack of definition at the epicanthal fold; many surgeons advocate the use of an external nasal splint. This is useful for ensuring that the overlying soft tissue adheres to the bone by compressing it and by preventing haematoma formation, but the surgeon should be cautious of potential skin necrosis.

### **6.3. Aftercare**

---

The patient is given topical ocular antibiotics and eyes are closed for 24 hours.

## **7. NASAL**

---

Nasal fractures are the most common facial fracture and, although more commonly isolated, it is important to consider other fractures because they are associated with maxillary, NOE and frontal sinus fractures (Rhee *et al.*, 2004). Isolated injuries are diagnosed clinically, which is best done on days 5–7 after allowing oedema to pass.

### **7.1. Surgical approach**

---

Management is based upon the appearance and function of the nose. To assess this fully, epistaxis should be controlled and the site cleaned. If there is no airway obstruction and non-displacement, observational management is best. Closed reduction of the fracture is ideally done immediately or during days 10–14 and done with the assistance of local anaesthesia. Open reduction is performed if the fracture is open or for a failed closed approach or complex fracture. Septorhinoplasty is performed according to the patient's or surgeon's preference or if presentation is too late for reduction and the fracture has healed inappropriately.

## **8. ZYGOMATICOMAXILLARY COMPLEX FRACTURES**

---

Zygomaticomaxillary fractures are some of the most common fractures treated by the plastic surgeon. As a result of the aetiology (most often interpersonal violence), left-sided fractures are much more common than right-sided and, as with most craniofacial fractures, they are more common in young men. Unfortunately, they are often treated incorrectly, resulting in post-operative complications or

unfavourable outcomes, such as enophthalmos, due to malposition of the fracture segment. Inspection should be from above and behind the head to show displacement and rotation of the zygoma. Swelling from the injury frequently conceals the malar recession and any evidence of enophthalmos.

## 8.1. Decision: zygomatic arch fractures

---

Pure arch fracture is suspected in a patient with pain, swelling and a palpable step-off without any findings of the zygomaticofrontal area or inferior orbital rim. A common sign is trismus. There may be an inability to move the mandible across as a result of coronoid impingement.

## 8.2. Decision: complex

---

This is a fracture involving the zygoma and surrounding bones. There are many classification systems, which clinically are not particularly helpful. The weakest bone of the zygomaticomaxillary complex (ZMC) is the orbital floor and, as a result, fractures of the internal orbit almost always occur; it is therefore especially important to make sure that the patient's visual acuity has not been compromised (Ellis and Reddy, 2004). A fracture of the ZMC may commonly cause numbness of the infraorbital nerve distribution. Axial and coronal CT are standard.

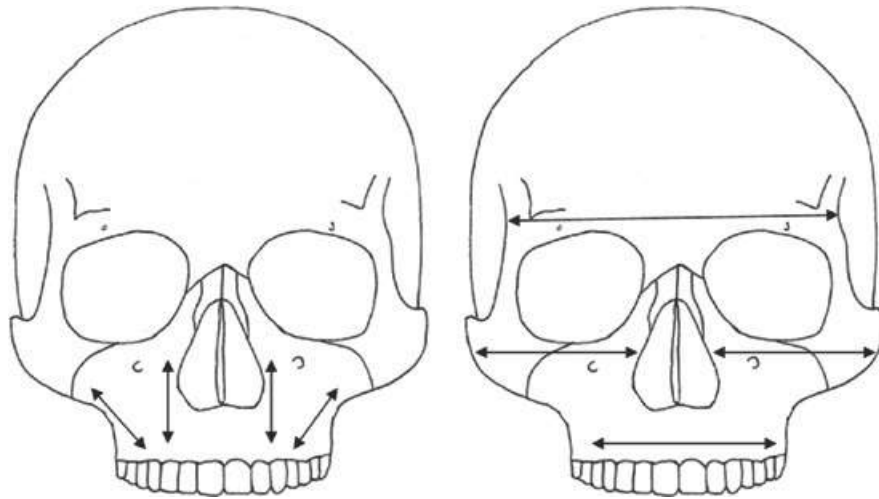
The lateral orbital wall is the site of articulation between the greater wing of the sphenoid and the zygoma; this site must be involved in a true ZMC fracture, thus determining the need for operative intervention. This site is palpated along with the maxilla and various sutures: the zygomaticofrontal, frontonasal and frontomaxillary. Intuitively, because of the anatomy, an ophthalmological examination and intraoral palpation of bony deformities are performed.

## 8.3. Surgical approach

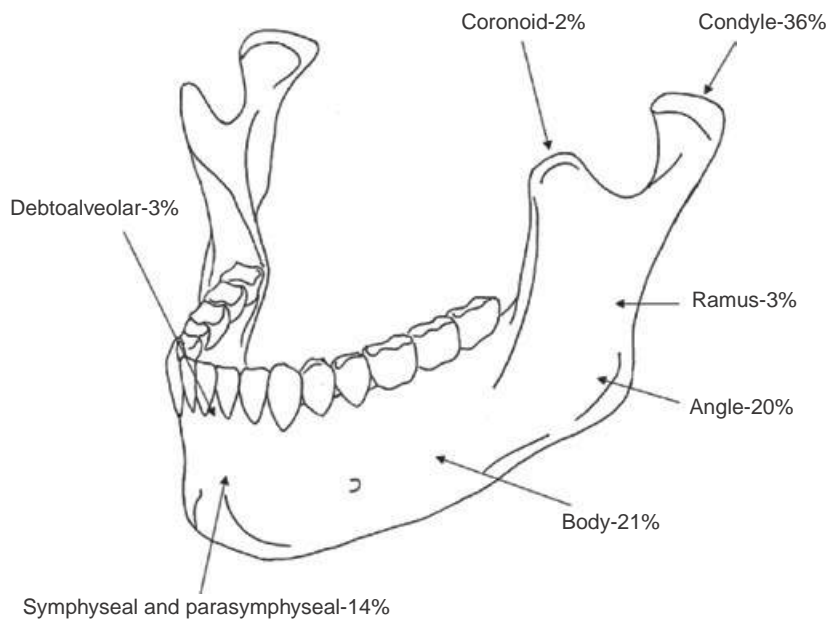
---

Historically, zygomaticomaxillary fractures were treated with a closed reduction approach via the Gillies lift. This is still appropriate in isolated arch fractures, but for a true ZMC fracture an open approach with precise internal fixation is necessary. Important landmarks of ZMC reconstruction, and for all midface fractures, are the buttresses, which are vital supporting structures (illustrated in [Figure 9.3.1](#)). Operative treatment of arch fractures is indicated for severe depression of the arch causing either a cosmetically significant contour depression or impingement on the coronoid process and trismus.

One goal of treatment is to restore orbital volume, orbital width, anteroposterior projection and height of the midface (Kelley *et al.*, 2007). The operative decision is largely dependent on CT imaging because swelling often precludes an accurate determination of the degree of deformity. Non-displaced fractures are safely managed by avoiding contraction of the masseter muscle, potentially destabilising the fracture, through a non-chewing diet. Closed techniques have the potential to become more appropriate as intra-operative CT is introduced into more operating theatres; however, surgeons may currently doubt perfectly stable reduction (Rabie *et al.*, 2011). Orbital reconstruction is indicated in most cases.



**Figure 9.4.** Illustration of facial buttresses. The midface is more resistant to vertical forces than horizontal ones. The four vertical buttresses are nasomaxillary (medial), zygomaticomaxillary (lateral), pterygomaxillary (posterior) and ethmoid–vomerial/septal (midline). The horizontal buttresses include superior orbital rims (superior), inferior orbital rims/zygomatic arch (central) and maxillary alveolus (inferior).



**Figure 9.5.** Illustration of mandibular fracture site frequency.

Incisions are made in the gingivobuccal sulcus and lower eyelid. The bone is then reduced and internally fixed, starting with the zygomaticofrontal suture that sets the vertical height or zygomaticomaxillary to re-establish the width and project. When so much comminution causes distortion of the anatomical landmarks, a coronal incision may be necessary to expose and align the zygoma.

An important secondary deformity resulting from the surgical approach is temporal hollowing. To avoid the temporal branch of the facial nerve, some surgeons recommend dissecting deep to the deep temporal fascia when approaching the zygomatic arch, which subsequently damages the temporal fat pad, causing a loss of volume (Stuzin *et al.*, 1989). To correct the defect, a synthetic implant or fat graft may be utilised; superficial dissection avoids fat devascularisation and preserves nerves by avoiding excessive traction.

## 9. LE FORT FRACTURES

---

The Le Fort classification is a historical classification that is still widely used to classify midfacial fractures. The Le Fort classification (René Le Fort, 1869–1951 (France)) is based on experiments in which 35 cadavers were exposed to frontal impacts. All had detached maxilla from the skull base involving the pterygoid plates.

As depicted in [Figure 9.2.2](#), Le Fort fractures pass through the pterygoid plate. Pure Le Fort fractures are rare: they commonly occur with multiple midface fractures. If the fracture is unilateral, it can be described as hemi-Le Fort. Type I is a horizontal maxillary fracture: its course goes from the piriform aperture through the maxilla and nasal walls. Posteriorly, it often includes a segment of the pterygoid plates. Type II is a pyramidal maxillary fracture: the fracture line starts under the zygomaticomaxillary buttress and travels toward the medial portion of the infraorbital rim behind the lacrimal bone up to the dorsum of the nose. These patients often present unconscious; therefore, particular attention should be paid to foreign bodies obstructing the airways. Type III is also known as craniofacial dysjunction when the entire mass of facial bones has separated from the cranial base. It begins at the frontozygomatic suture and passes along the lateral aspect of the internal orbit and along the sphenozygomatic suture line to the inferior orbital fissure toward the dorsum of the nose.

### 9.1. Decision

---

Pre-operative evaluation should be focused on the occlusal relationship, which may exist with or without the lengthening of the midface, causing gagging and an anterior open bite.

### 9.2. Surgical approach

---

Surgical access varies between Le Fort classification: I, through upper gingivobuccal sulcus incision and maxillary degloving; II, through lower lid excision; and III, through a combination of buccal sulcus and

lower lid incision. More severe injuries may require a bicoronal incision exposing more of the relevant anatomy. The aim of midface reconstruction is to re-establish the midfacial vertical buttresses. The role of the buttress is even more important for partial or complete edentulous patients. Those who receive open reduction and internal fixation will also receive mandibulomaxillary fixation to ensure appropriate occlusion – thus highlighting the reason for adopting nasotracheal intubation. A principle in all Le Fort fractures is to re-establish the premorbid dental occlusion. A bone graft may be utilised to fill defects to support facial soft tissues, restore the bony buttress and sustain facial height.

## 10. MANDIBLE

---

Mandibular fractures are the most common of the craniofacial skeleton. The proportion of mandibular, zygoma and maxillary fractures is 6:2:1 (Ceallaigh *et al.*, 2006). They have become much more prevalent in the spectrum of facial fracture; for a plastic surgeon, it is imperative to have a solid foundation in managing mandibular injuries. Multiple fracture sites of the mandible are common; therefore, when a mandibular fracture is identified the surgeon must always suspect another, particularly affecting the condylar region as it is the weakest (highlighted in [Figure 9.3.2](#)) (Stacey *et al.*, 2006). On examination, most patients will have a degree of malocclusion and disturbance of mental nerve distribution and of the teeth, which may affect management options. Bony anatomy should be palpated for steps, crepitus and pain; this is specifically tested at the temporomandibular joint by placing the index fingers within the external auditory meatus while the mouth is opened and closed.

### 10.1. Decision

---

The biomechanics of the mandible is a complex topic. Forces applied to the mandible by numerous muscles including the pterygo-masseteric sling, causing varying zones of tension and compression depending on where the bite force is located. The superior portion of the mandible is designated the *tension zone* and the inferior portion is designated the *compression zone*. These should be carefully managed with tension bands at the superior border and compression plates inferiorly. CT is by far the most sensitive imaging modality for mandibular pathology, but gives little information on dentition. Therefore, orthopantomography (Panorex) is useful with supplemented posteroanterior X-ray because of distortion anteriorly.

### 10.2. Surgical approach

---

Prior to beginning an operative procedure, occlusion and examination of the mandible should be performed under general anaesthesia. It is essential that the correct occlusion is restored when treating a fracture of the mandible. Failure to do so will result in temporomandibular joint and dentition morbidity.

Maxillary–mandibular fixation (MMF) is often used intra-operatively to achieve this and can be used as the primary intervention in the closed reduction of a simple fracture. Condylar fractures should be opened and close anatomically when MMF is contraindicated, when appropriate occlusion cannot be achieved or in bilateral fractures (Zide and Kent, 1983). When dissecting anteriorly, the mental nerves along with omohyoid and digastric insertion should be clearly identified. Anteriorly, two plates are required because of rotational forces; however, one plate is usually sufficient for fractures posterior to the mental foramen. Osteosynthesis should neutralise distraction and torsion during physiological stress and should therefore be fixed according to Champy's ideal lines.

An intraoral approach is recommended and is not contraindicated by oral contamination; however, a transfacial approach may provide better access in those suffering a complex fracture, i.e. a comminuted, edentulous or avulsive fracture. Alternative approaches include approaching through the existing laceration, a submandibular or submental approach, and an endoscopic approach. A transparotid approach is recommended for a condylar fracture. In an effort to avoid damage to the facial nerve (despite low incidence), endoscopic instrumentation has been developed to fix these fractures largely through an intraoral incision with small trochar sites externally (Martin and Lee, 2002).

For some mandibular fractures, especially condylar fractures, muscle relaxation is crucial to assist reduction manoeuvres. Malocclusion should be evaluated regularly throughout surgery and on completion. Any discrepancy seen in intercuspation and the alignment of wear facets must be corrected. When assessing occlusion, it is important that only gentle pressure is applied because relative mobility of the mandible will result in an absence of malocclusion if excessive force is applied.

### 10.3. Aftercare

When not necessary for fixation, MMF can usually be removed at the conclusion of fixation. An X-ray should be taken post-operatively and again at 4–6 weeks. If malocclusion is detected on X-ray, the aetiology must be determined. Soft tissue causes may be managed by banding in some cases; however, skeletal causes will require surgical revision.

Post-operatively, patients will have to adopt three basic instructions:

1. Diet – may be restricted depending on the stability of the fixation.
2. Oral hygiene – teeth and arch bars should be cleaned with a soft toothbrush and oral chlorhexidine rinse should be used three times a day.
3. Physiotherapy.

### 10.4. Complications

The mandible is the only facial bone that is movable; therefore, treatment is easily measurable but complications are relatively common. Teeth in the line of fracture with periodontal ligament involvement, excluding those unerupted, should be considered as open (contaminated) fracture and required systemic.

Non-union occurs when the mandible does not heal in an appropriate time frame, resulting in mobility of the fracture segment. This may occur from fixation failure and is treated by controlling any infection and surgical reconstruction. In periods of extended immobilisation (such as MMF), ankylosis of the temporomandibular joint may occur. Condylar head injuries are intra-articular and, for the most part, are not amenable to internal fixation techniques. They have a very high risk of ankylosis. Children are even more susceptible, and are therefore limited to just 2 weeks of MMF. Malunion and malocclusion occur for at least one of several reasons:

- Inadequate occlusal reduction during surgery
- Inadequate osseous reduction during surgery
- No osseous reduction (e.g. condyle fractures)
- Imprecise application of internal fixation devices
- Inadequate stability (lack of rigidity).

The treatment of a malunion must involve either orthodontics or osteotomies. The incidence of many complications are reduced by using a locking plate and screw system, which does not need precise plate adaptation to the underlying bone, thus avoiding malocclusion, disrupting cortical bone perfusion, loosening hardware and providing an unstable fixation.

## 11. PANFACIAL FRACTURE

---

Determination of the ideal sequencing of treatment for a complex panfacial trauma can be the greatest challenge to a maxillofacial surgeon. The goal is to restore the anatomy in all three dimensions, including plating the maxillofacial buttresses wherever necessary. When reconstructing the face it is important to respect the 'rule of fifths'. This divides the face into five transverse measurements equal to the width of the eye; it acts as a guideline for all facial reconstruction but is particularly valuable for panfacial fracture surgery (Figure 9.4).

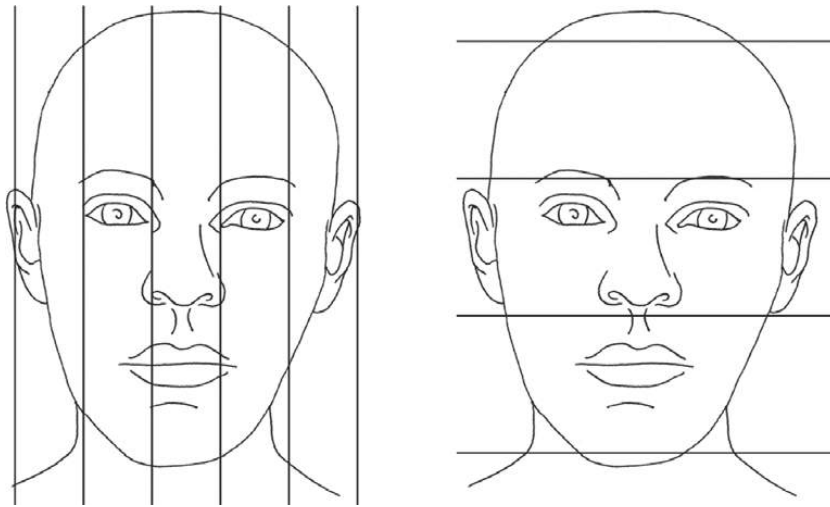
### 11.1. Two options for sequencing

---

There are two options for sequencing:

1. Bottom-up approach – re-establish the maxillomandibular unit as the first major step of the sequencing. Once the maxillomandibular unit is established, most surgeons start from the calvarium and proceed in a caudal direction with reduction and fixation.
2. Top-down approach – starting with the reduction and fixation at the level of the calvarium and working in a caudal direction.





**Figure 9.6.** Illustrations of ‘The Horizontal Rule of Fifths’ and ‘The Vertical Rule of Thirds’.

## REFERENCES

- Al-Qurainy, I. A., Stassen, L. F., Dutton, G. N., Moos, K. F. & El-Attar, A. 1991. The characteristics of midfacial fractures and the association with ocular injury: A prospective study. *Br J Oral Maxillofac Surg*, 29, 291–301.
- Avashia, Y. J., Sastry, A., Fan, K. L., Mir, H. S. & Thaller, S. R. 2012. Materials used for reconstruction after orbital floor fracture. *J Craniofac Surg*, 23, 1991–7.
- Ceallaigh, P. O., Ekanaykace, K., Beirne, C. J. & Patton, D. W. 2006. Diagnosis and management of common maxillofacial injuries in the emergency department. Part 1: Advanced trauma life support. *Emerg Med J*, 23, 796–7.
- Cornelius C, P., Gellrich N., Hillerup, S., Kusumoto K., Schubert W. 2013. *Examination of patients with midfacial injuries* [Online]. Available: [https://www2.aofoundation.org/wps/portal!/ut/p/c0/04\\_SB8K8xLLM9MSSzPy8xBz9CP0°s3hng7BARydDRwN39yBTAYMvLwOLUA93I4MQE\\_2CbEdFAF3RnT4!/?contentUrl=%2Fsrq%2Fpopup%2Fadditi%2F92%2FX70-examination.jsp&popupStyle=diagnosis&soloState=true&bone=CMF&segment=Midface&BackMode=true](https://www2.aofoundation.org/wps/portal!/ut/p/c0/04_SB8K8xLLM9MSSzPy8xBz9CP0°s3hng7BARydDRwN39yBTAYMvLwOLUA93I4MQE_2CbEdFAF3RnT4!/?contentUrl=%2Fsrq%2Fpopup%2Fadditi%2F92%2FX70-examination.jsp&popupStyle=diagnosis&soloState=true&bone=CMF&segment=Midface&BackMode=true).
- Cox, D., Vincent, D. G., McGwin, G., Maclennan, P. A., Holmes, J. D. & Rue, L. W., 3rd 2004. Effect of restraint systems on maxillofacial injury in frontal motor vehicle collisions. *J Oral Maxillofac Surg*, 62, 571–5.
- Devauchelle, B., Badet, L., Lengele, B., Morelon, E., Testelin, S., Michallet, M., D’Hauthuille, C. & Dubernard, J. M. 2006. First human face allograft: Early report. *Lancet*, 368, 203–9.
- Elahi, M. M., Brar, M. S., Ahmed, N., Howley, D. B., Nishtar, S. & Mahoney, J. L. 2008. Cervical spine injury in association with craniomaxillofacial fractures. *Plast Reconstr Surg*, 121, 201–8.
- Ellis, E., 3rd, Reddy, L. 2004. Status of the internal orbit after reduction of zygomaticomaxillary complex fractures. *J Oral Maxillofac Surg*, 62, 275–83.

- Erdmann, D., Follmar, K. E., Debruijn, M., Bruno, A. D., Jung, S. H., Edelman, D., Mukundan, S. & Marcus, J. R. 2008. A retrospective analysis of facial fracture etiologies. *Ann Plast Surg*, 60, 398–403.
- Hutchison, I. L., Magennis, P., Shepherd, J. P. & Brown, A. E. 1998. The BAOMS United Kingdom Survey of Facial Injuries Part 1: Aetiology and the association with alcohol consumption. *Br J Oral Maxillofac Surg*, 36, 3–13.
- Kelley, P., Hopper, R. & Gruss, J. 2007. Evaluation and treatment of zygomatic fractures. *Plast Reconstr Surg*, 120, 5S–15S.
- Markowitz, B. L., Manson, P. N., Sargent, L., Vander Kolk, C. A., Yaremchuk, M., Glassman, D. & Crawley, W. A. 1991. Management of the medial canthal tendon in nasoethmoid orbital fractures: The importance of the central fragment in classification and treatment. *Plast Reconstr Surg*, 87, 843–53.
- Martin, M. & Lee, C. 2002. Operative controversies: Thoughts on an intraoral endoscopic assisted method of condylar fracture repair. *Semin Plast Surg*, 16, 251–60.
- Martin, R. C., 2nd, Spain, D. A. & Richardson, J. D. 2002. Do facial fractures protect the brain or are they a marker for severe head injury? *Am Surg*, 68, 477–81.
- Metzinger, S. E. & Metzinger, R. C. 2009. Complications of frontal sinus fractures. *Craniomaxillofac Trauma Reconstr*, 2, 27–34.
- Nahum, A. M. 1975. The biomechanics of maxillofacial trauma. *Clin Plast Surg*, 2, 59–64.
- Rabie, A., Ibrahim, A. M., Lee, B. T. & Lin, S. J. 2011. Use of intraoperative computed tomography in complex facial fracture reduction and fixation. *J Craniofac Surg*, 22, 1466–7.
- Rhee, S. C., Kim, Y. K., Cha, J. H., Kang, S. R. & Park, H. S. 2004. Septal fracture in simple nasal bone fracture. *Plast Reconstr Surg*, 113, 45–52.
- Rohrich, R. J. & Mickel, T. J. 1995. Frontal-sinus obliteration – in search of the ideal autogenous material. *Plast Reconstr Surg*, 95, 580–5.
- Simmons, O. & Manson, P. N. 2009. Endoscopic management of orbital and frontal sinus fractures. *Craniomaxillofac Trauma Reconstr*, 2, 177–84.
- Stacey, D. H., Doyle, J. F., Mount, D. L., Snyder, M. C. & Gutowski, K. A. 2006. Management of mandible fractures. *Plast Reconstr Surg*, 117, 48e–60e.
- Stuzin, J. M., Wagstrom, L., Kawamoto, H. K. & Wolfe, S. A. 1989. Anatomy of the frontal branch of the facial nerve: The significance of the temporal fat pad. *Plast Reconstr Surg*, 83, 265–71.
- Waardenburg, P. J. 1951. A new syndrome combining developmental anomalies of the eyelids, eyebrows and nose root with pigmentary defects of the iris and head hair and with congenital deafness. *Am J Hum Genet*, 3, 195–253.
- Yavuzer, R., Sari, A., Kelly, C. P., Tuncer, S., Latifoglu, O., Celebi, M. C. & Jackson, I. T. 2005. Management of frontal sinus fractures. *Plast Reconstr Surg*, 115, 79e–93e.
- Zide, M. F. & Kent, J. N. 1983. Indications for open reduction of mandibular condyle fractures. *J Oral Maxillofac Surg*, 41, 89–98.

## **Section 4**

# **Paediatric Plastic Surgery**



## Congenital Hand Abnormalities

---

Benjamin Way, Bran Sivakumar

### 1. EMBRYOLOGY

---

Development of the upper limb begins at around day 24 of gestation, when arm buds of the somatopleuric lateral plate mesoderm, capped by their overlying ectoderm, begin proliferating bilaterally in the lower cervical regions. Over the following 4 weeks, these buds enlarge and differentiate, and with the added migration of other cell types into the buds from deeper embryonic structures, form all the tissues of the limb.

As the limb bud elongates, it must differentiate in three axes to provide the complex structures of the limb: proximodistal, craniocaudal and dorsoventral. The first manifestation of this patterning is the appearance of the apical ectodermal ridge (AER), a thickening of specialised ectoderm that runs craniocaudally along the rim of the limb bud tip. The AER maintains limb bud growth and influences the differentiation of the proliferating mesoderm, being laid down beneath it in a region called the progress zone (PZ) (Fernandez-Teran and Ros, 2008).

#### 1.1. Proximodistal

---

Factors secreted from the AER influence gene expression in the PZ mesoderm, most importantly the genes encoding fibroblast growth factors (FGFs). As the limb bud grows, it 'lays down' mesoderm and variations in PZ gene expression during this process result in the generation of different skeletal elements in each upper limb region. Central to this are the Hox genes in the PZ mesoderm, which undergo a transcription cascade with *HOXD9* and *HOXD10* expressed in the arm segment, *HOXD11* the forearm, and *HOXD12* and *HOXD13* in the carpus, metacarpals and phalanges. The principal signalling factors from the AER for this include FGF4 and FGF2.

## 1.2. Craniocaudal

---

The mesoderm deep to the caudal edge of the AER is called the zone of polarising activity (ZPA) and is stimulated (again, primarily by AER FGFs) to create a polarising signal gradient of the morphogen protein sonic hedgehog (Shh). At the caudal edge of the limb bud, the Shh concentration is highest, which creates the structures of the ulnar side of the hand; progressively more radial structures are formed as the gradient decreases cranially (Tickle, 2006). Shh acts via a variety of signalling pathways that include bone morphogenic proteins (BMPs) and it also stimulates sequential Hox gene activation.

## 1.3. Dorsoventral

---

Patterning to create the dorsal and palmar (volar) structures of the hand appears to be governed by expression of Wnt-7a, which is restricted to the dorsal ectoderm of the limb bud. Wnt-7a activity stimulates expression of the Lmx-1 transcription factor, while a different transcription factor, En-1, expressed in the ventral ectoderm, inhibits Wnt-7a expression. Again, this activity is probably linked to Shh secretion and sequential Hox gene expression (Al-Qattan, 2011).

## 1.4. Tissue types

---

These signalling mechanisms direct the lateral plate mesoderm of the limb bud to generate the bones, ligaments, tendons and vasculature of the limb. However, the musculature and nerves are derived from cells migrating into the bud as it forms. Somatic mesoderm migrates into the limb bud as separate dorsal and ventral condensations, giving rise to the extensor and flexor muscle groups, and with them the dorsal and ventral primary rami of spinal nerves C5–T1. The Schwann cells of these nerves and melanocytes in the limb are derived from neural crest cells which migrate in to the bud in a similar way.

## 1.5. Timetable of upper limb development

---

- Day 24 – limb bud growth initiated.
- Day 33 – arm, forearm and hand plate can be distinguished. Blood circulation has begun.
- Day 38 – hand has developed a carpal region and digital plate.
- Day 44 – digital rays are visible as the intervening digital plate mesenchyme undergoes apoptosis.
- Day 47 – the limb has rotated medially to lie in a parasagittal (rather than coronal) plane, bringing the hand medially and the elbow dorsally. The cutaneous innervation patterns to the limb, i.e. its dermatomes, spiral as a consequence.
- Day 56 – all regions are well defined. Fingers have visible tactile pads (pulp) and overlap in the midline.

## 2. CLASSIFICATION OF CONGENITAL HAND ABNORMALITIES

Although many classification systems of congenital upper limb abnormalities have been proposed, the International Federation of Societies for Surgery of the Hand has for a long time adopted is to use the system proposed by Swanson in 1976. This classifies seven groups on the basis of abnormal embryogenesis (Figure 10.1). However, given the enormous spectrum of congenital upper limb abnormalities, no system is comprehensive and around 10% do not fit neatly into Swanson’s classification (Ogino *et al.*, 1986). More recently Oberg, Manske and Tonkin (OMT) have put forward a classification system using dysmorphological terminology, placing conditions in one of three groups: Malformations, Deformations and Dysplasias. The predominant malformations group is then further subdivided according to whether the whole of the limb is affected or the hand plate alone, and whether the primary insult involves one of the three axes of limb development and patterning or is non-axial (Tonkin, 2015). The IFSSH has now adopted the OMT classification.

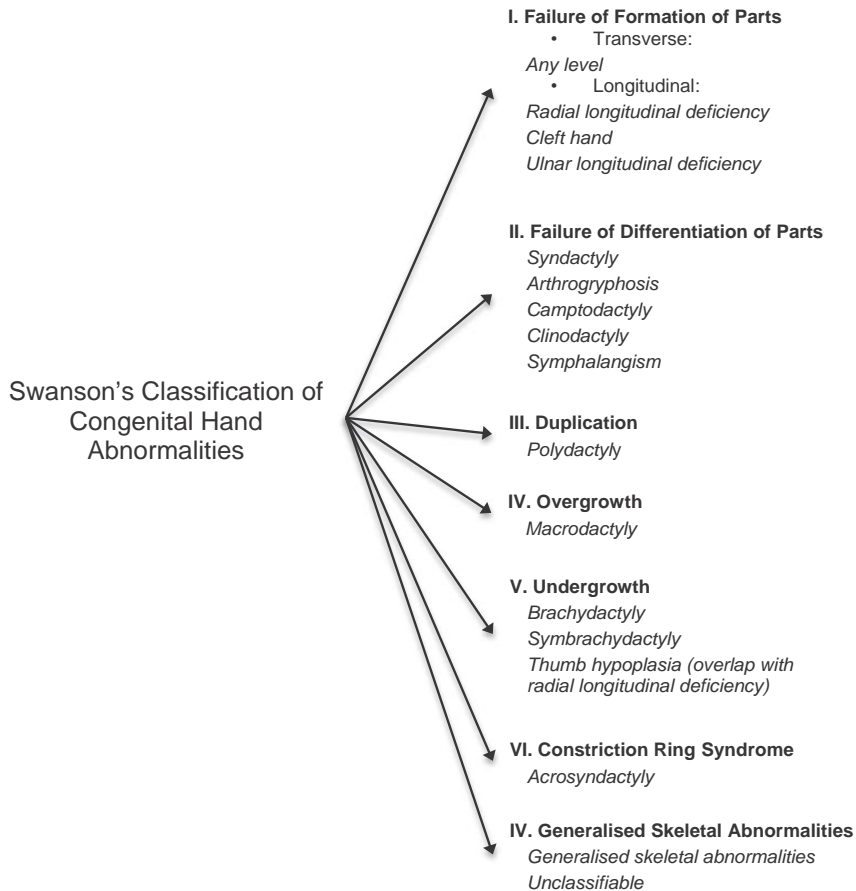


Figure 10.1. Abbreviated Swanson’s classification of congenital hand abnormalities.

### 3. FAILURE OF FORMATION OF PARTS: LONGITUDINAL

#### 3.1. Radial longitudinal deficiency

Previously termed radial club hand, radial longitudinal deficiency (RLD) is a variable failure of formation of the longitudinal radial (pre-axial) structures, primarily the radius itself. It occurs in 1:30,000–1:100,000 live births, is more common in males than in females and most prevalent among Caucasian populations.

RLD is associated with environmental and genetic factors, occurs in isolation or as part of a recognised syndrome, and is thought to be caused by a deficiency in ZPA morphogenic signalling. Associated environmental agents include thalidomide, phenobarbital and ethanol. The largest syndromic group is VACTERL (with a minimum of three out of the following: vertebral, anorectal, cardiac, tracheo-oesophageal, renal and limb abnormalities). However, Holt–Oram syndrome, Fanconi’s anaemia and thrombocytopenia-absent radius (‘TAR’) syndrome are also frequently associated.

Although the whole limb may be involved, the most significant deficiencies are always at the hand and wrist. The right side is affected twice as often as the left, but the condition is bilateral in up to 50% of cases. The forearm is short with an absent or distally deficient radius, causing the (usually) short, curved ulna to bend the forearm radially. The scaphoid and trapezium are affected or absent, and variable thumb hypoplasia is frequently seen. Metacarpophalangeal joints (MCPJ) are typically stiff, while proximal interphalangeal joints (PIPJ) exhibit flexion deformities, with the severity reducing from the radial to ulnar digits. The radial artery and superficial radial nerve are often absent, with an abnormal median nerve compensating for this. The condition is classified into four groups (Bayne and Klug, 1987):

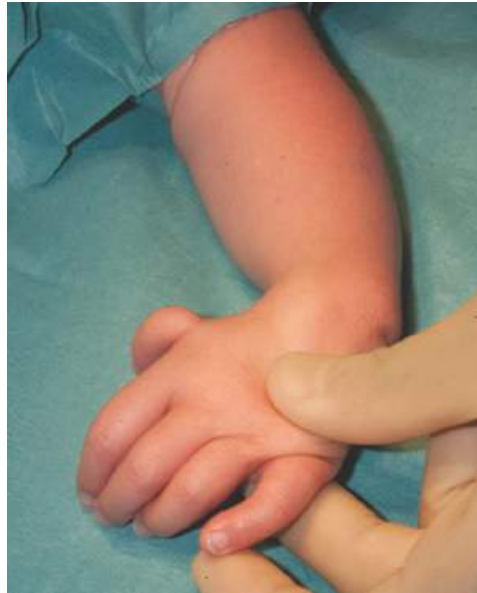- Type 1 – short distal radius (second commonest)
- Type 2 – hypoplastic radius (least common)
- Type 3 – partial radial aplasia
- Type 4 – complete radial aplasia (commonest)

Management commences in the neonatal period, the intention being to achieve a neutral wrist position that can later be stabilised surgically. In milder cases, this may be achieved by simple passive stretching and splinting, sometimes augmented with a simple tendon transfer from the dorsoradial muscle mass to the extensor carpi ulnaris, pulling the wrist ulnarly. However, in types 3 and 4, stretching and splinting alone will not be sufficient to overcome the tension caused by the radial soft tissue deficit. Consequently, soft tissue distraction is carried out using an external uniplanar or multiplanar distractor to align the carpus onto the end of the ulna, after which surgery to the wrist is undertaken to maintain this position. This is achieved either with radialisation, in which the carpus is placed in an overcorrected position in line with the second metacarpal (Buck-Gramcko, 1985) and stabilised using a tendon transfer, or via centralisation, in which a carpal notch is created to receive the ulna in line with the third metacarpal

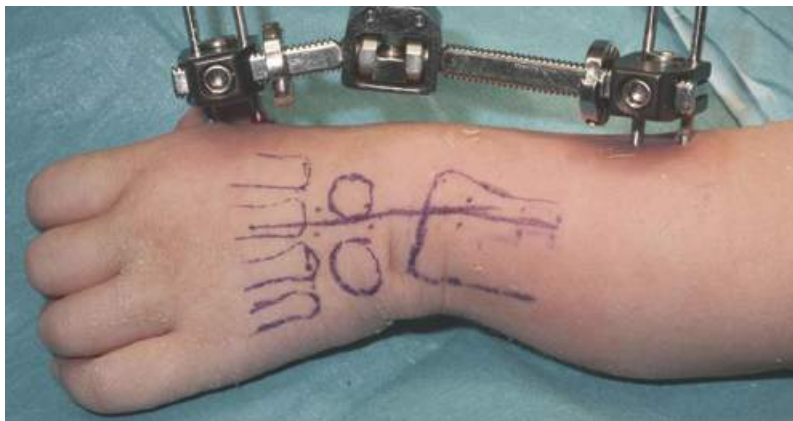


(Tonkin and Nanchahal, 1995). Again, a tendon transfer is carried out when possible to prevent recurrence and to rebalance the wrist as required. Surgery commences at around age 9 months and can be followed by the correction of thumb hypoplasia (pollicisation or reconstruction). Occasionally, an ulnar osteotomy may be required to correct bowing.

Forearm lengthening can be carried out during the teenage years to further improve cosmesis. Long-term follow-up is essential in all cases.



**Figure 10.2.** Radial longitudinal deficiency with ulnar bowing and thumb hypoplasia.



**Figure 10.3.** Soft tissue distractor for radial longitudinal deficiency. Marks indicate ulnocarpal alignment.

### 3.2. Ulnar longitudinal deficiency

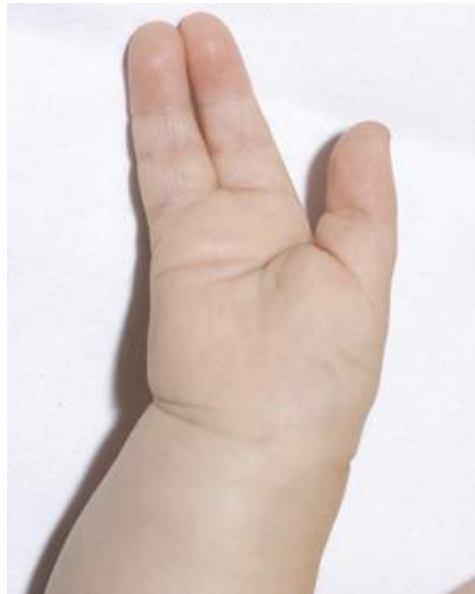Ulnar longitudinal deficiency (ULD) is a variable failure of formation of the longitudinal post-axial structures, primarily the ulna. It has an incidence of 1:100,000 live births and equal sex preponderance.

ULD is typically sporadic and is not associated with any syndrome, although 50% of cases are associated with other musculoskeletal abnormalities (e.g. fibular hemimelia). Its aetiology is linked to ZPA injury preventing adequate signalling to develop the ulnar structures.

There is a clinical spectrum of ulnar hypoplasia and, in contrast to RLD, the wrist is stable while the elbow is deficient, in the most severe cases with flexion contracture and pterygium. Ulnar sided digits are usually absent, but all digits may be affected and thumb hypoplasia may also be present. Syndactylies are also common: both simple and complex. The left side is more often affected than the right and the ratio of unilateral to bilateral is 4:1. Ulnar deficiency can be classified into four groups (Bayne, 1982):

- Type 1 – hypoplastic ulnar
- Type 2 – partial ulnar aplasia (proximal third present)
- Type 3 – complete ulnar aplasia
- Type 4 – humeroradial synostosis

Treatment initially consists of splinting but surgery may be required to correct radial bowing. Excision of the fibrous anlage present in place of the ulna in severe cases is advocated by some to improve wrist position. In type 4 humeroradial synostosis cases, a humeral derotational osteotomy may be required to place the limb and hand into a more functional position in front of the body.



**Figure 10.4.** Ulnar longitudinal deficiency.

### 3.3. Cleft hand (ectrodactyly)

Cleft hand is a variable failure of formation of the central ray, producing a characteristic cleft hand. It has an incidence of 1:30,000–1:100,000 live births.

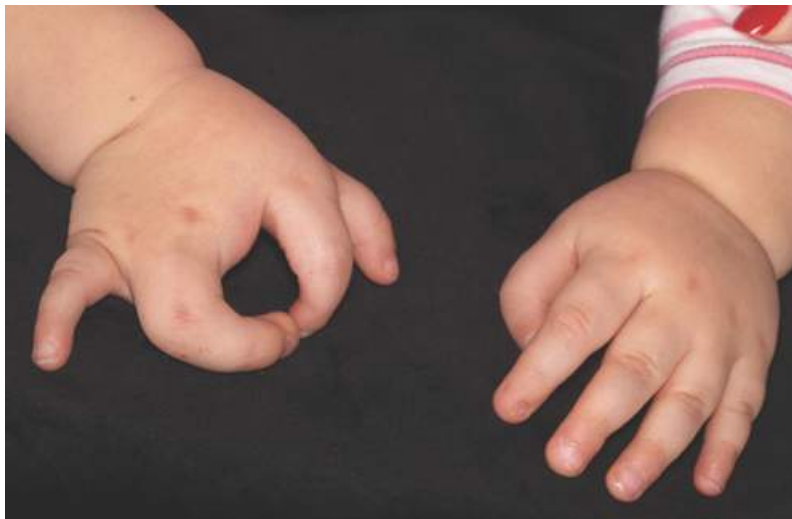
Unilateral clefting is usually sporadic, but the classical bilateral condition is autosomal dominant, affecting both hands and feet. It is associated with cleft lip and palate, syndactyly, polydactyly, ventricular septal defects, and ectrodactyly–ectodermal dysplasia clefting syndrome.

The cleft is caused by complete or partial absence of one or more of the central rays (phalanges and metacarpals), with frequent syndactyly of the thumb–index finger and the ring–little fingers. Abnormal phalanges may lie transversely in the cleft web, causing it to widen as they grow. With increasing severity, the radial structures of the hand become absent.

Children with cleft hand often have good function but suffer significant social stigma. Their main functional issues relate to the state of their first web space. The index finger often sits in a non-functional position too close to the thumb and is by-passed as a result. Hence, the classification system relates to the quality of the first web rather than to the cleft itself (Manske and Halikis, 1995).

- Type 1 – normal first web.
- Type 2 – narrowed first web.
- Type 3 – syndactylised first web.
- Type 4 – merged first web. Index digit is suppressed and the first web is merged with the cleft.
- Type 5 – absent first web. Thumb absent and only the ulnar rays remain.

The main aim of surgery is to transpose the index into a more useful position and widen the first web. This can be achieved in a number of ways including the Snow–Littler procedure, which involves the use of a long (usually volar-based) flap transposed from the cleft into the first web space (Snow and Littler, 1967).



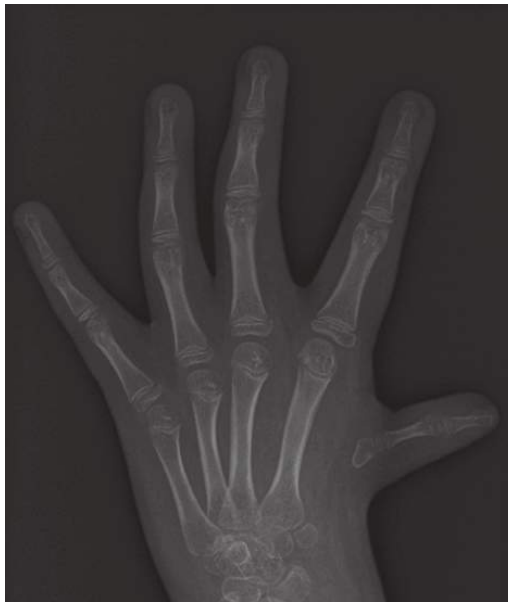**Figure 10.5.** Type 2 cleft hand.

### 3.4. Thumb hypoplasia

Although sometimes classified as undergrowth, congenital thumb hypoplasia is closely related to RLD. Blauth's classification is the most widely recognised (Blauth, 1967), but has been recently modified by Manske *et al.* (1995) (subdivision of type 3 thumbs) and Smith (2002) (subdivision of type 2 thumbs).

- Type I – small thumb, all structures present
- Type 2 – thenar hypoplasia, first web adduction contracture. MCPJ ligamentous laxity
  - Type 2a – uniplanar laxity, particularly that of the ulnar collateral ligament
  - Type 2b – global joint laxity
- Type 3 – variable thenar, metacarpal and thumb extrinsic muscle hypoplasia and MCPJ laxity
  - Type 3a – stable carpometacarpal joint (CMCJ)
  - Type 3b – unstable CMCJ
- Type 4 – metacarpal aplasia (pouce flottant)
- Type 5 – complete thumb aplasia

Although thumb hypoplasia is normally detected at birth, type 1 thumbs may have only subtle abnormalities that go unnoticed owing to their complete function. Type 2 thumbs first require a web space release and then a form of MCPJ stabilisation and augmentation of opposition using either Huber or flexor digitorum superficialis (FDS) ring opponensplasty. Type 3a thumbs are considered reconstructible by the same techniques. Type 3b (where the CMCJ is unstable) and onwards are best ablated and replaced with pollicisation of the index finger.



**Figure 10.6.** Type 4 thumb hypoplasia.

Pollicisation involves rotation and recessing of the index finger, which the child is already starting to use as a thumb, into a more functional position to facilitate opposition with the ulnar digits. Amputation of a thumb in favour of a pollicisation may be difficult for some parents to accept, despite the severity of the hypoplasia. However, pollicisation has been consistently shown to be the more functional option in such cases (Manske, 2010).

As part of pollicisation, the index finger is mobilised on its neurovascular pedicles and tendons, and the metacarpal shaft excised to the level of the distal epiphysis and then K-wired in pronation and abduction to the remaining metacarpal base. Thus, the index finger MCPJ becomes the new thumb CMCJ (Littler, 1953).

## 4. FAILURE OF DIFFERENTIATION OF PARTS

### 4.1. Syndactyly

Congenital syndactyly is a failure of digital separation during development. It is one of the commonest congenital hand abnormalities, and has an incidence of 1:650–1:2000 live births. Males are twice as likely to be affected as females.

The condition may be sporadic, inherited (20% of cases are autosomal dominant) or associated with various syndromes including Apert's, Poland, Aarskog's and many others. Acrosyndactyly, in which there are distal digital fusions and proximal fenestrations, is seen as part of constriction ring syndrome.

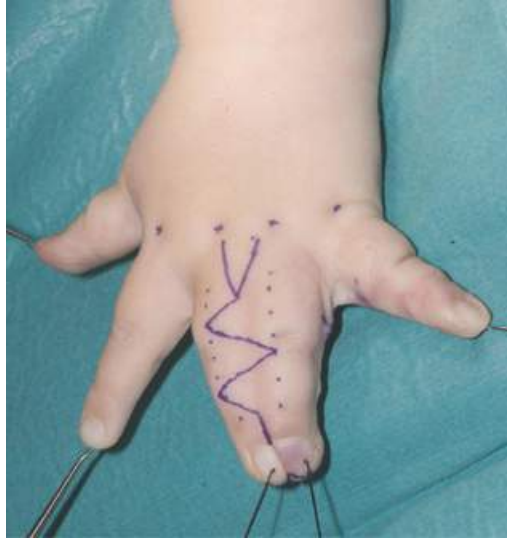
Syndactylies are classified as:

- Incomplete or complete (extending to digital tip)
- Simple (soft tissue only) or complex (bony synostosis)
- Single or multiple
- Unilateral or bilateral
- Hand, foot or both.

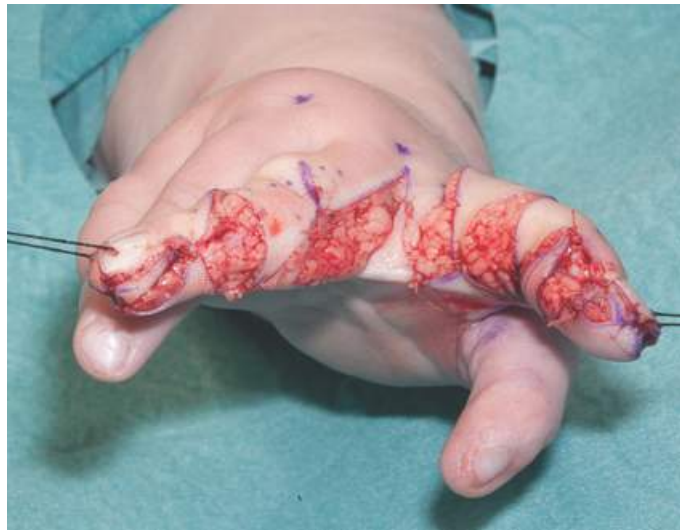The third web space is the most commonly affected in the hand and the second in the feet. In the hand, the first web is least commonly affected, but must be prioritised for release if present to ensure thumb function is optimised; hence, this should be carried out before 18 months of age. Where there is a length discrepancy between digits, the syndactyly should be released early to avoid tethering with growth and resultant deviation. With increasing skeletal abnormality, there is a parallel increasing chance of neurovascular anomalies in the web, which can increase the complexity of surgery. The release of less severe syndactylies can be delayed to reduce the likelihood of revision surgery with growth and to reduce the risk of anaesthetic complications.

Many techniques have been described for web reconstruction in syndactyly release. One of the commonest is the use of interdigitating triangular skin flaps from the dorsal and volar digital surfaces (Bauer *et al.*, 1956; Cronin, 1956). Straight scars along the web base must be avoided to prevent web

creep, where scar tissue grows to recreate the syndactyly. There is always insufficient skin to fully reconstruct the interdigital surfaces and full-thickness skin grafts are usually required. Graftless techniques have been described but most authors advocate the use of full-thickness skin grafts for optimal results.



**Figure 10.7.** Simple, complete third web syndactyly with markings for interdigitating flaps.



**Figure 10.8.** Interdigitating flaps in syndactyly release.

## 4.2. Arthrogryposis

---

Arthrogryposis describes a collection of non-progressive joint contractures affecting at least two areas that are present at birth. It affects 1:3000 live births and is usually sporadic. The principal aetiology is thought to be viral infection of the spinal cord anterior horn cells.

The upper limb has few skin creases because of the joint contractures and tight muscles, and assumes a characteristic posture of internal shoulder rotation, elbow extension, forearm pronation, wrist flexion and digital ulnar deviation with the thumb clasped in the palm. The lower limb shows hip and knee dislocation, talipes equinovarus and club foot.

Management commences with stretching and splinting, and surgery should aim to increase the passive range of motion, maintain bimanual function and position the hands in front of the body at desktop level. The greatest improvement in function can be achieved by elbow joint release to 90° of passive flexion; this is sometimes augmented with muscle transfers to gain active flexion. The upper limb can be re-positioned in front of the body with a humeral derotational osteotomy. At the wrist, a carpal wedge resection allows correction of the flexion deformity. When lower limb impairment necessitates a wheelchair, upper limb function must be maintained to allow independence.

## 4.3. Camptodactyly

---

Camptodactyly is defined as a congenital flexion deformity of the PIPJ. It affects 1% of the population and often goes unreported. It tends to present either in infancy, when the sex distribution is equal, or at the start of adolescence, when females tend to be more affected than males. Familial cases are inherited in an autosomal dominant fashion. Camptodactyly is also associated with a number of syndromes, but the underlying aetiology remains unclear.

The little finger is most commonly affected, but the condition may affect multiple digits. Bilateral presentation is more common than unilateral. X-ray findings in severe cases include joint space narrowing and flattening of the proximal phalanx head and middle phalanx base.

The principal treatment is stretching and splinting; surgery should be reserved for contractions of >60° where conservative therapy has failed, and in progressive cases. All structures that pass volar to the joint can be affected, but the primary anomalies are of the lumbrical and FDS. Secondary anomalies include those affecting the skin, retinaculum cutis, collateral ligaments, volar plate and joint capsule (Smith and Grobelaar, 1998). Tendon transfers of the lumbrical or one of the FDS slips can be used to augment PIPJ extension. Correction of the bony abnormality is not advised because of the increased risk of long-term stiffness and a poorer outcome.

## 4.4. Clinodactyly

---

Clinodactyly is a congenital inclination of a digit in the radioulnar (craniocaudal) axis, usually at the level of the middle phalanx. It is common and often familial (with autosomal dominant inheritance).

The little finger is most frequently affected (bent toward the ring finger), and most cases are bilateral. The cause is often an abnormal bracketed epiphysis which leads to the formation of a deviating delta or trapezoidal phalanx. The aetiology remains unclear.

Surgery should only be undertaken in severe cases of 50–70° angulation, where function is affected. In the early stages, the use of fat graft interposition into the bracketed epiphysis can initiate some corrective growth (Vickers, 1987). This procedure is best not repeated to avoid premature growth plate arrest. In established cases, the use of dome or wedge osteotomies allows more definitive correction but re-deviation can occur with growth.

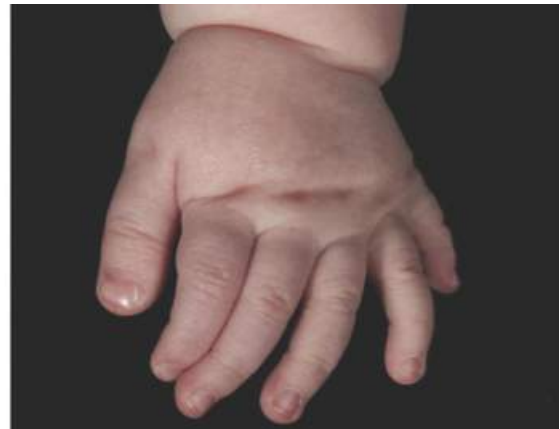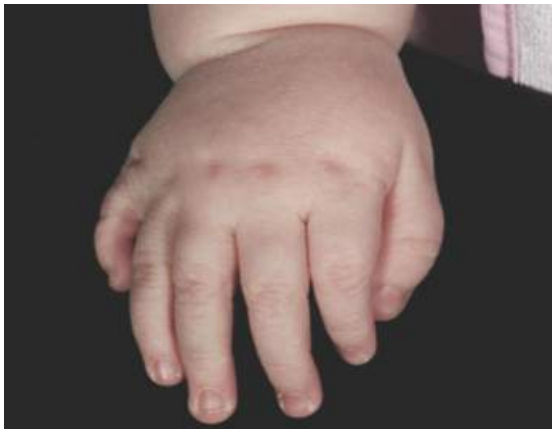## 5. DUPLICATION

### 5.1. Polydactyly

Polydactyly is the congenital formation of an extra digit (whole or part). Alongside syndactyly, it is the commonest congenital hand abnormality.

The duplication may be pre-axial (radial), i.e. thumb duplication, central (affecting index, middle or ring fingers) or post-axial (ulnar). The little finger is most commonly affected (ulnar polydactyly; inheritance is autosomal dominant) and most prevalent among Afro-Caribbean populations. Ulnar polydactyly is classified into three groups (Stelling, 1963):

- Type 1 – soft tissue mass without bone and often a small pedicle
- Type 2 – complete digit with all tissues
- Type 3 – complete ray including metacarpal.



**Figure 10.9.** Bilateral type 3 ulnar polydactyly.



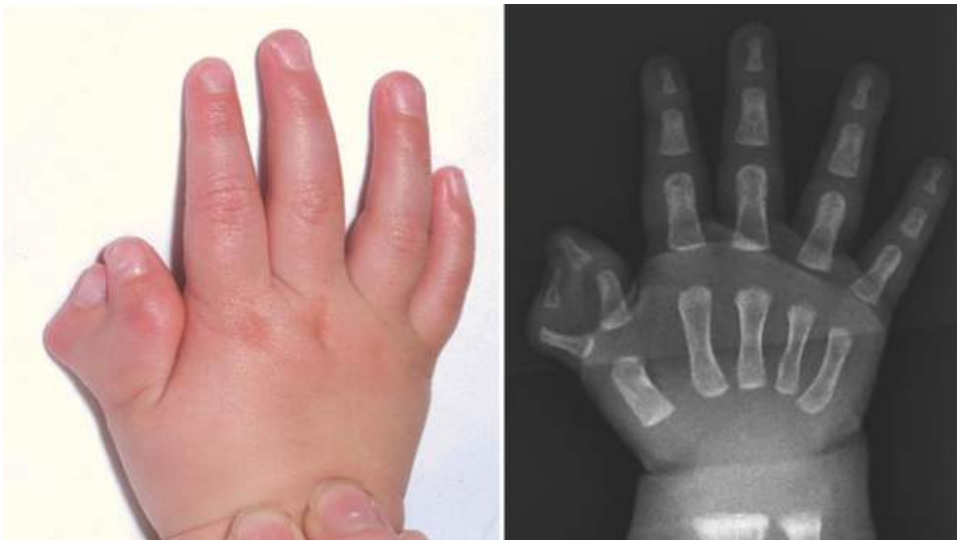Type 1 is very common, usually at the level of the proximal phalanx, and is easily excised under local anaesthesia in the first few weeks of life. Type 2 requires formal resection under general anaesthesia, with partial excision and reconstruction of the MCPJ, metacarpal or little finger phalanx (depending on the articulation of the extra digit). Type 3 is managed with ray amputation and reinsertion of the abductor digiti minimi tendon into the little finger.

Central polydactyly is often accompanied by a range of syndactylies. Such polysyndactylies are frequently seen with *HOXD19* mutations and syndromes such as trisomy 13 and Biemond's. Their anatomy is highly variable and any surgery to excise the central ray must include meticulous dissection of the neurovasculature.

## 5.2. Thumb duplication

Pre-axial (thumb) polydactyly occurs in 8:100,000 live births. It is usually unilateral and sporadic (with the exception of the triphalangeal thumb). It is described by the Wassel (1969) classification according to the level of duplication:

- Type 1 – bifid distal phalanx
- Type 2 – duplicated distal phalanx (second commonest)
- Type 3 – bifid proximal phalanx
- Type 4 – duplicated proximal phalanx (most common)
- Type 5 – bifid metacarpal
- Type 6 – duplicated metacarpal (third commonest)
- Type 7 – triphalangeal thumb.



**Figure 10.10.** Wassel type 4 thumb duplication.

Both parts of the duplicated thumb are usually hypoplastic, but the radial duplicate tends to be most affected. With unbalanced duplications, it is easier to decide which partner to retain. The more hypoplastic duplicate is excised but elements are salvaged for reconstruction of the retained thumb, such as the MCPJ radial collateral ligament in type IV cases. Realignment of the flexor and extensor tendons is also important, as is bony correction if required. In more distal balanced duplications, the modified Bilhaut–Cloquet procedure allows the reconstruction of a single larger thumb through combining the inner half of each thumb duplicate. However, this is often complicated by a split nail and limited interphalangeal joint (IPJ) motion and growth. Asymmetrical modifications of this procedure have been described using the entire nail from one duplicate to minimise some cosmetic issues.

In type 7 triphalangeal thumb, an on-top-plasty may be needed to transfer the distal segment of one thumb onto the base of the other with the better MCPJ. Failing that, formal pollicisation may be required.

## 6. OVERGROWTH

---

### 6.1. Macrodactyly

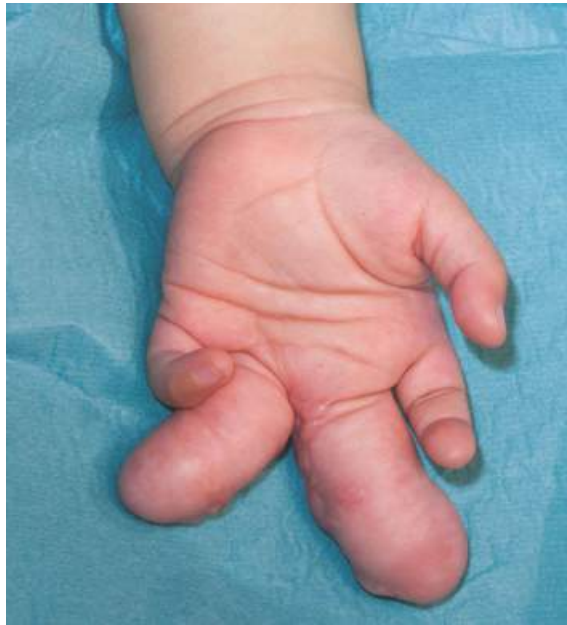---

Macrodactyly (digital gigantism) describes the congenital overgrowth of any digit. It is rare (2:100,000 live births), representing only 1% of all congenital hand abnormalities.

Primary and secondary causes are seen aetiologically. Primary cases are usually sporadic, and thought to be due to abnormal innervation resulting in generalised enlargement of the digital lipofibromatous tissue. This follows a varying distribution around the digital or median nerves, which also enlarge. Secondary cases are associated with syndromes or other conditions, and result in overgrowth of other tissue types, e.g. vascular malformations in Klippel–Trenaunay syndrome, congenital lymphoedema, bone overgrowth in acromegaly, neurofibromatosis and multitissue hyperplasia in Proteus syndrome.

Most presentations are unilateral and 70% involve more than one digit (index and middle, most commonly). The distal part of the digit is usually the worst affected. The enlargement may interfere with function, may be aesthetically debilitating and, in some cases, nerve compression can result, necessitating release. Two groups can be identified clinically: static and progressive. In the less common static type, the enlarged digit is noted at birth and continues to grow commensurately with the child. More commonly, the disease is progressive and the affected digits continue to grow out of proportion with the growth of the child (Barsky, 1967).

Management is extremely challenging and surgical debulking frequently needs revision because of continued growth. Excision of the affected tissues, preferably via a mid-axial incision along the convex side of the digit, can be supported with epiphysiodesis to halt further bony growth. Given these poor outcomes, amputation should be considered, particularly when only one or two digits are involved and other surgical management has failed.



**Figure 10.11.** Macrodactyly of middle and ring digits.

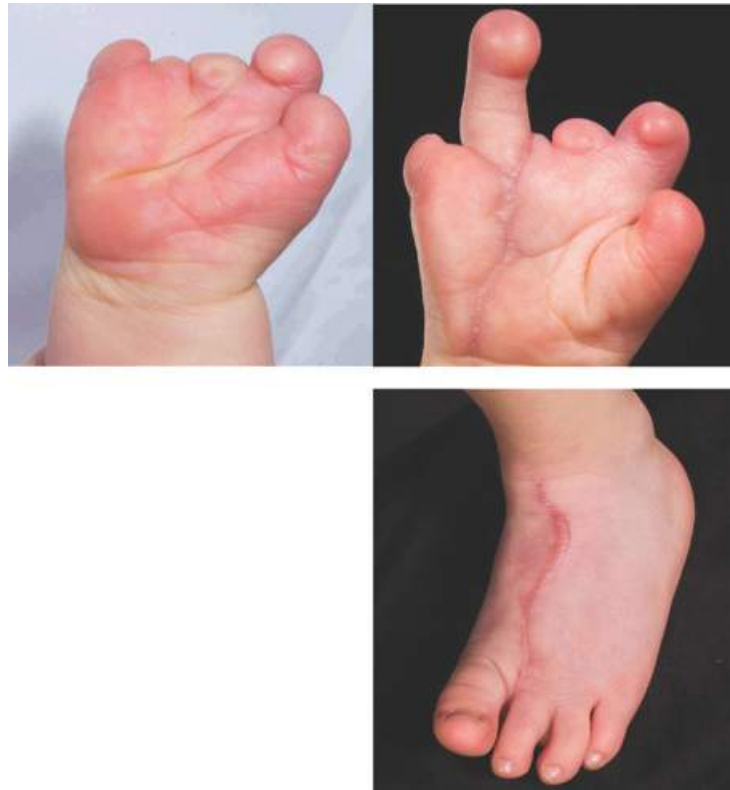## 7. UNDERGROWTH

### 7.1. Symbrachydactyly

This is a variable failure of formation of the digits, with a tendency to preserve the thumb. It has an incidence of 1:10,000–1:30,000 live births and, although usually sporadic, may be associated with Poland syndrome. It is thought to be due to a mesenchymal defect that leaves ectodermal remnants as skin and nail nubbins.

There is a broad spectrum of presentation, from mild cases with all digits present (but short and stiff) to peromelia and complete loss of the hand when the condition crosses over into a transverse failure of formation. There are four broad subtypes: short finger type; oligodactylous type, where the middle digits are short or absent, preserving the thumb and little fingers (previously considered as an atypical cleft hand); monodactylous type; and peromelic type (Blauth and Gekeler, 1971; Ogino *et al.*, 1989). The condition is nearly always unilateral.

In the short finger type, function is usually good and no surgery is required. Other types have functional and aesthetic impairments. In the oligodactylous type, the thumb and little finger lie in the same plane and must be adequately released to allow opposition and pinch. In the monodactylous type, the thumb has no digit to oppose, but this may be provided by means of free phalangeal transfers (if the patient has empty digital sacs) or vascularised toe transfers. Free microvascular toe-to-hand transfer



**Figure 10.12.** Symbrachydactyly managed by vascularised toe transfer.

was first carried out for a congenital hand abnormality in 1978 by O'Brien *et al.* (1978) and is now well established as the gold standard treatment for cases of digital insufficiency. The transferred toe has been shown to retain excellent growth potential (Chang and Jones, 2002) and avoids the donor site issues related to free phalangeal transfers.

## 8. CONSTRICTION RING SYNDROME

Also called amniotic band syndrome, constriction ring syndrome occurs when tight bands encircle the foetus *in utero*, impairing vascular and lymphatic function to create characteristic deformities distal to the ring. This occurs in 1:15,000 live births.

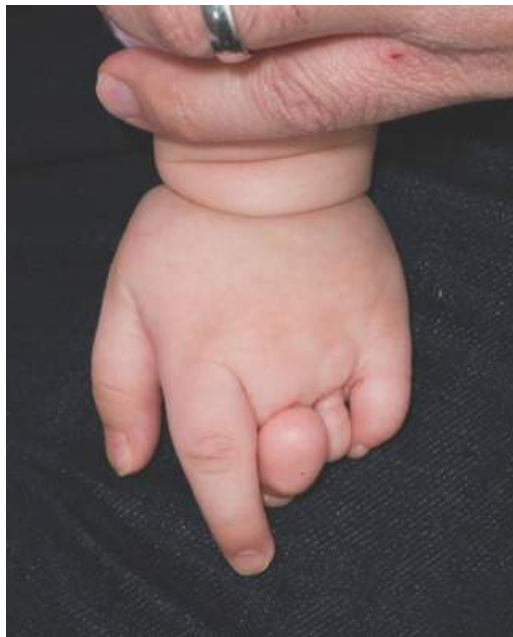The cause is still poorly understood and two aetiologies have been proposed: the intrinsic model suggests a germ cell layer defect that creates vascular disruption to the embryo, while the extrinsic model suggests that disruption to the amnion releases bands of this tissue which encircle and strangulate the growing foetus. It is associated with oligohydramnios in the mother, and affected children can also

suffer cleft lip and palate, talipes equinovarus and other congenital defects. No hereditary basis has been identified.

The constrictions can affect any part of the body, but are commonest in the limbs and may be complete or incomplete. Distal limb parts are worst affected, and defects are usually multiple on more than one limb. Four subtypes have been described (Patterson, 1961):

- Type 1 – simple circular groove with normal distal structures
- Type 2 – deeper groove with distal deformity  $\pm$  lymphoedema
- Type 3 – rings and associated distal acrosyndactyly
  - Type 3a – digits fused at tips
  - Type 3b – tips fused, and associated with web creep
  - Type 3c – complete syndactyly
- Type 4 – intra-uterine amputation.

Surgical management depends on severity. In rare severe cases where there is distal oedema and congestion, early decompression in the neonatal period is advised; however, more commonly, aesthetic correction of the constriction rings can be delayed. Traditionally, bands were released in two stages with multiple tension-relieving Z-plasties; however, many authors now advocate circumferential excision (Upton and Tan, 1991), except when the band is 1 cm or less from the digital tip. Bands often extend to the deep fascia and, if underlying tendons have been transected, then these will need reconstruction (by tendon graft or transfer).



**Figure 10.13.** Constriction ring syndrome.

In severe cases where patients have lost multiple digits or a thumb, vascularised toe transfer provides optimal reconstruction. Constriction ring cases are ideally suited to this form of reconstruction because all structures proximal to the ring tend to be relatively unaffected.

## REFERENCES

- Al-Qattan, M.M. 2011. WNT pathways and upper limb anomalies. *The Journal of Hand Surgery [European Volume]*. 36(1), 9–22.
- Barsky, A.J. 1967. Macrodactyly. *The Journal of Bone and Joint Surgery [American Volume]*. 49(7), 1255–66.
- Bauer, T.B., Tondra, J.M. and Trusler, H.M. 1956. Technical modification in repair of syndactylism. *Plastic and Reconstructive Surgery*. 17(5), 385–92.
- Bayne, L.G. 1982. Ulnar club hand (ulnar deficiencies). In: Green, D.P. (ed.) *Operative Hand Surgery*. New York: Churchill Livingstone, pp. 245–57.
- Bayne, L.G. and Klug, M.S. 1987. Long-term review of the surgical treatment of radial deficiencies. *The Journal of Hand Surgery [American Volume]*. 12(2), 169–79.
- Blauth, W. 1967. The hypoplastic thumb. *Archiv für Orthopädische und Unfall-Chirurgie*. 62(3), 225–46.
- Blauth, W. and Gekeler, J. 1971. Morphology and classification of symbrachydactylia. *Handchirurgie* 3(4), 123–8.
- Buck-Gramcko, D. 1985. Radialization as a new treatment for radial club hand. *The Journal of Hand Surgery [American Volume]*. 10(6 Pt 2), 964–8.
- Chang, J. and Jones, N.F. 2002. Radiographic analysis of growth in pediatric microsurgical toe-to-hand transfers. *Plastic and Reconstructive Surgery*. 109(2), 576–82.
- Cronin, T.D. 1956. Syndactylism: Results of zig-zag incision to prevent postoperative contracture. *Plastic and Reconstructive Surgery*. 18(6), 460–8.
- Fernandez-Teran, M. and Ros, M.A. 2008. The Apical Ectodermal Ridge: Morphological aspects and signaling pathways. *The International Journal of Developmental Biology*. 52(7), 857–71.
- Littler, J.W. 1953. The neurovascular pedicle method of digital transposition for reconstruction of the thumb. *Plastic and Reconstructive Surgery*. 12(5), 303–19.
- Manske, P.R. 2010. Index pollicization for thumb deficiency. *Techniques in Hand and Upper Extremity Surgery*. 14(1), 22–32.
- Manske, P.R. and Halikis, M.N. 1995. Surgical classification of central deficiency according to the thumb web. *The Journal of Hand Surgery [American Volume]*. 20(4), 687–97.
- Manske, P.R., McCarroll, H.R. and James, M. 1995. Type III-A hypoplastic thumb. *The Journal of Hand Surgery [American Volume]*. 20(2), 246–53.
- O'Brien, B.M., et al. 1978. Microvascular great toe transfer for congenital absence of the thumb. *The Hand*. 10(2), 113–24.
- Ogino, T., et al. 1986. Congenital anomalies of the upper limb among the Japanese in Sapporo. *The Journal of Hand Surgery [European Volume]*. 11(3), 364–71.
- Ogino, T., Minami, A. and Kato, H. 1989. Clinical features and roentgenograms of symbrachydactyly. *The Journal of Hand Surgery [European Volume]*. 14(3), 303–6.
- Patterson, T.J. 1961. Congenital ring-constrictions. *British Journal of Plastic Surgery*. 14, 1–31.
- Smith, P.J. 2002. *Lister's The Hand, Diagnosis and Indications, 4th edn*. London: Churchill Livingstone.
- Smith, P.J. and Grobbelaar, A.O. 1998. Camptodactyly: A unifying theory and approach to surgical treatment. *The Journal of Hand Surgery [American Volume]*. 23(1), 14–9.

- Snow, J.W. and Littler, J.W. 1967. Surgical treatment of cleft hand. In: *Transactions of the International Society of Plastic Reconstructive Surgery, 4th Congress in Rome*. Amsterdam: Excerpta Medica Foundation, pp. 888–93.
- Stelling, F. 1963. The upper extremity. In: Ferguson, A.B. (ed.) *Orthopedic Surgery in Infancy and Childhood*. Baltimore: Williams and Wilkins, pp. 282–402.
- Swanson, A.B. 1976. A classification for congenital limb malformations. *The Journal of Hand Surgery [American Volume]*. 1(1), 8–22.
- Tickle, C. 2006. Making digit patterns in the vertebrate limb. *Nature Reviews, Molecular Cell Biology*. 7(1), 45–53.
- Tonkin, M.A. and Nanchahal, J. 1995. An approach to the management of radial longitudinal deficiency. *Annals of the Academy of Medicine, Singapore*. 24(4 Suppl), 101–7.
- Tonkin, M.A. and Oberg, K. C. 2015. The OMT classification of congenital anomalies of the hand and upper limb. *Hand Surgery*. 20(3), 336–42.
- Upton, J. and Tan, C. 1991. Correction of constriction rings. *The Journal of Hand Surgery [American Volume]*. 16(5), 947–53.
- Vickers, D. 1987. Clinodactyly of the little finger: A simple operative technique for reversal of the growth abnormality. *The Journal of Hand Surgery [European Volume]*. 12(3), 335–42.
- Wassel, H.D. 1969. The results of surgery for polydactyly of the thumb. A review. *Clinical Orthopaedics and Related Research*. 64, 175–93.

## Ear Reconstruction

---

Aurora Almadori, Abdulaziz Khurshed, Ali Jafar,  
Ahmad B. Al-Ali, Peter E. Butler

### 1. INTRODUCTION

---

The external ear is composed of the auricle and the external acoustic meatus. It has a functional and aesthetic role: it participates in the transmission of the sound waves and represents a unique element of personality and aesthetic harmony owing to its peculiar symmetrical and specular shape and position on the head.

Several conditions can affect the auricle leading to a total or partial defect, which can be extremely disabling for the patient who may complain of diminished self-confidence, emotional distress and difficulties in social interaction (Ballantyne, 1976; Horlock *et al.*, 2005). The aim of reconstruction is to restore the normal appearance, position and symmetry with respect to the contralateral ear. However, reconstruction can be challenging for even the most experienced surgeons because of its complex three-dimensional architecture with subtle topographic details and delicate convolutions.

This chapter will focus on total and partial ear reconstruction, highlighting the conditions leading to total auricle lack or partial defects, the therapeutic options currently available, and future perspectives.

### 2. ANATOMY OF THE EXTERNAL EAR

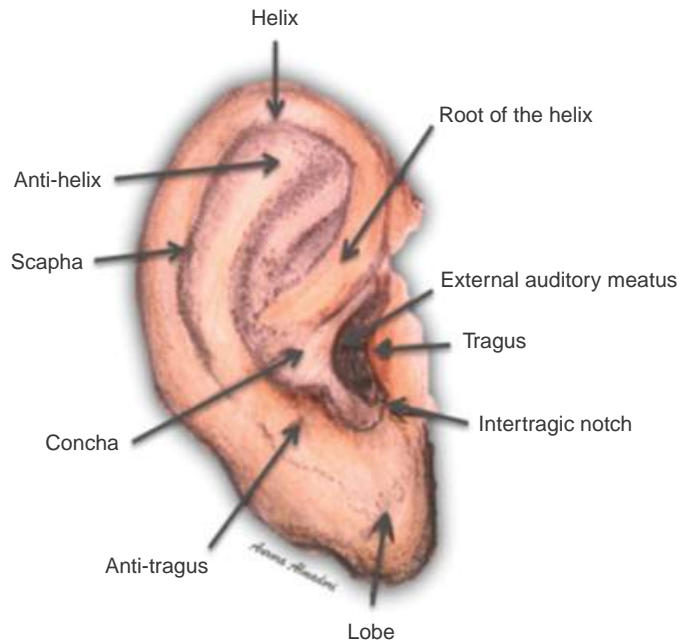
---

#### 2.1. Topographic anatomy

---

The external ear is positioned on the lateral sides of the head, below the temporal region, posteriorly to the temporomandibular joint and anteriorly to the mastoid region. It presents two faces: the lateral and posterior surfaces. The lateral surface is irregularly concave and presents many eminences and depressions. It can be divided into different subunits, as illustrated in [Figure 11.1](#). The posterior surface





**Figure 11.1.** Lateral surface of the external ear.

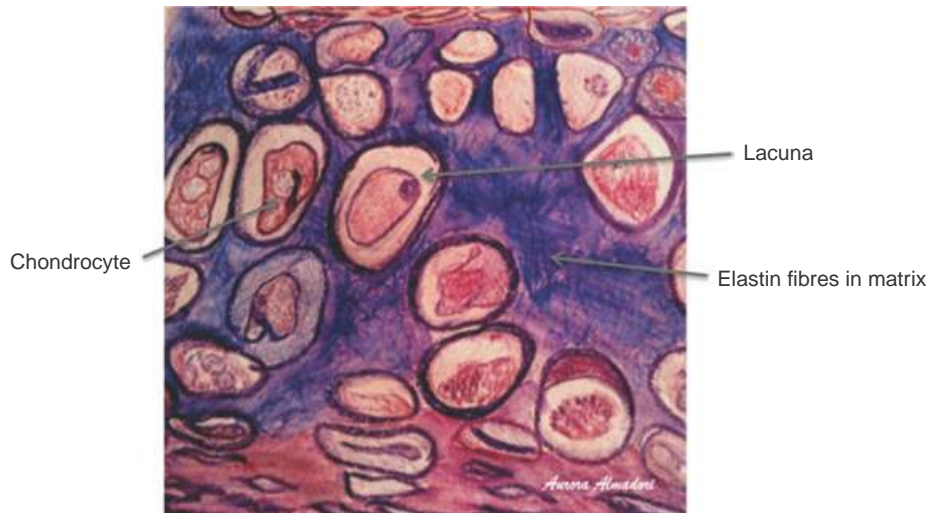
presents elevations that correspond to the depressions of the lateral surface: these are called the eminence of the concha and the triangular eminence.

## 2.2. Descriptive anatomy

The external ear is composed of cartilage and soft tissues including muscles, ligaments, subcutaneous adipose tissue, skin, nerves and vessels.

The skeletal structure is composed of a thin layer of fibrocartilage, which is present on the posterior and lateral surfaces and absent in the lobe and between the tragus and the helix; these spaces are composed of dense fibrous tissue. Ear cartilage is composed mainly of elastic fibres, which are responsible for mechanical support, shape retention and tissue elasticity. Chondrocytes and chondroblasts represent only a limited percentage of cartilage volume (Songu *et al.*, 2014). They are suspended in the extracellular matrix, which is composed of collagen fibres and ground substance rich in proteoglycans and elastin (Figure 11.2).

The cutaneous coverage of the anterior surface of the ear adheres tightly the underlying tissues and differs from the posterior surface, which is loosely adherent. Furthermore, the lateral surface of the auricle lacks subcutaneous tissue, which is well represented on the posterior surface. This allows the skin to slide on the underlying subcutaneous adipose tissue (Musumeci, 2013).



**Figure 11.2.** The main components of an elastic cartilage.

Cutaneous innervation to the skin of the auricle comes from the greater auricular nerve, the lesser occipital nerve and branches of the facial and vagus nerves (Brodland *et al.*, 2005).

The vasculature is composed of two main networks, originating from the superficial temporal artery and the posterior auricular artery (Ballantyne, 1976).

### 3. AETIOLOGY OF TOTAL AND PARTIAL EAR DEFECTS

#### 3.1. Congenital

Microtia ranges in severity: some patients express only mild structural defects, while others suffer from complete absence of the pinna. No gene defect has been associated with unilateral cases of microtia; however, several genetic mutations have been identified in disease patterns (Mastroiacovo *et al.*, 1995).

The condition is more common in men and more commonly affects the right ear (Brodland *et al.*, 2005). The mother's age at conception and education level, and multiparous mothers of Hispanic origin are more likely to bear a child with microtia. Fortunately, Ma and colleagues believe that supplementing mothers' diet with folic acid before conception reduces the likelihood of this developing (Mastroiacovo *et al.*, 1995).

Many studies have investigated possible links with microtia including defects in signalling pathways, human genetic mutations, disorders of the neural crest cells and vascular disruption. Unfortunately, further understanding of normal ear development is required to appreciate how microtia develops. However, microtia is known to occur in different syndromes with single gene mutations.

---

## 3.2. Trauma

---

The auricle has a high potential for trauma because of its exposed and unprotected position over the head. The principal traumatic injuries to the external auricle are avulsion or amputations followed by bites, chemical or thermal burns, and damage from extreme cold (i.e. frostbite) (Luquetti *et al.*, 2012).

### 3.2.1. Avulsion or amputations

---

The main cause of ear avulsion is car or motor accidents, followed by workplace and sport accidents (Bhandari *et al.*, 1998). The most frequent traumatic injuries are incomplete amputation of the ear, usually involving the helical rim. However, total ear loss is not rare and frequently occurs in association with major systemic or head and neck trauma.

### 3.2.2. Burns

---

The external ear, being situated prominently on the side of the face, is particularly vulnerable to thermal or chemical injury, including those caused by alkali or acid. It is estimated that 90% of facial burns involve the external ear (Anniko *et al.*, 2010). Deformity of the ear subsequent to a burn injury can range from minor scarring to complete loss of the pinna (Ihrai *et al.*, 2009). Total ear reconstruction following burns is extremely challenging and the outcome depends on the quality and quantity of the skin available around the auricular region (Ibrahim *et al.*, 2008).

### 3.2.3. Frostbite

---

Exposure of the ears to extreme outer temperatures may produce different degrees of thermal injury (Bhandari *et al.*, 1998). Temperatures of  $-23^{\circ}\text{F}$  or lower usually cause injury. Frostbite can be superficial, similar to a burn, resulting in erythema and oedema of the skin without (first degree) or with (second degree) bullae. Deep wounds associated with third- and fourth-degree frostbite cause irreversible damage to the underlying cartilage, leading to necrosis of the skin and severe cartilage deformity (Bhandari *et al.*, 1998).

## 3.3. Cancers

---

Squamous cell carcinoma, malignant melanoma and, occasionally, advanced basal cell carcinoma are the most frequent conditions leading to total excision of the auricle (Ballantyne, 1976). Most skin lesions of the external ear are squamous cell carcinomas; 30–40% are basal cell carcinomas and only 2–6% are melanomas. The helix is involved in 45–55% of these lesions. Approximately a third of cutaneous carcinomas of the ear extend directly into the underlying cartilage and require radical excision (Ballantyne, 1976).

## 4. TOTAL EAR RECONSTRUCTION

---

### 4.1. Microsurgical replantation

---

Advances in microsurgical techniques and the availability of surgeons trained in these techniques make replantation a first-line option in the treatment of most major amputation injuries (Kisilevsky *et al.*, 2003). Microsurgical replantation is technically challenging, but provides a single procedure option for auricular reconstruction. A more natural appearing pinna usually results with this technique than with others. Important prerequisites for successful replantation include short ischaemic intervals, appropriately preserved amputated parts and compliant patients. The best results can be achieved with anastomosis of both the artery and vein. However, identification of a suitable vein and venous anastomosis is particularly difficult (Lin *et al.*, 2010).

### 4.2. Cartilage rib graft

---

Autologous bone and cartilage grafts remain the gold standard treatments for major ear defects (Ibrahim *et al.*, 2008).

The decision about when to surgically intervene is complex. Many factors are taken into consideration, including the severity, size and position of the deformity and the quality of the microtic elements (Zim, 2003).

Most children first take notice of their ear deformity between the ages of 3 and 4 years and are teased by their peers when they start school, most commonly at around 10 years of age. Most surgeons choose to operate when the child presents a minimum chest circumference of 60 cm, which is not normally attained before the age of 8 years. This also allows the costal cartilage to be of an acceptable size for surgery to take place; as this is a preschool age in many countries, teasing at school may be prevented (Vannatta *et al.*, 2009). Operating on children prior to the preschool period is crucial because the psychosocial impact of this deformity will affect their development. Furthermore, the use of hearing aids has proven to aid learning during the child's development.

#### 4.2.1. Tanzer's technique

---

Pre-operatively, Tanzer recommends that two traced outlines should be made from a plaster model of the normal ear: the first is an outline of the whole ear and the second is the shape to be used on the rib cartilage to form the framework.

During the first stage of this procedure, any functional auricular tissue is repositioned in the most aesthetic manner. The lobular network is then rotated to the horizontal position, with closure of the vertical defect.

Next, Tanzer recommends that this stage should be performed as soon as the induration has softened. This involves formation of the cartilaginous framework and its insertion into the skin bed.

The traced outline is used to form the anti-helix from the 6th and 7th costal cartilages together as a unit. The floating cartilage of the 8th rib is used to form the helix of the ear. This process involves the use of surgical instruments to carve and construct the desired appearance of the ear. These are then stitched together to form the contour of the ear, which is next positioned into the skin. There are two methods of closure, depending on the availability of skin coverage. The first method involves the use of through-and-through silk sutures over gauze to collect the skin around the helix and anti-helix. The second requires the use of a full-thickness skin graft to close the defect.

Stage three takes place at 4 months, which allows the construct to strengthen. At this stage, the superior, posterior and inferior aspects of the ear are created by separating the cartilage framework from the head. Three stages are required to complete this process while maintaining a good blood supply for the ear. Overall, 6 months is needed to attain a successful result.

Six weeks following the latter procedure, formation of the tragus and the conchal floor can be started. This involves manipulation of skin, using free grafts to create the illusion of a canal orifice (Tanzer, 1959).

#### 4.2.2. Brent's technique

This technique is carried out in four stages. To begin, the surgeon has to construct the desired framework using autologous rib cartilage, which is subsequently implanted into the subcutaneous pocket. Measurements made on X-ray films enable anatomical landmarks to be drawn using the normal ear in unilateral cases or the parent's ear in bilateral cases.

The 6th, 7th and 8th contralateral ribs are used to create the base of the framework, and the helix uses the floating cartilage of the 8th rib. At this stage, the vestigial native cartilage is removed, a skin pocket is created and the framework is sutured using 4-0 nylon. A silicon suction drain is placed for 2–3 days. Brent recommends allowing 3 months before proceeding to the next stage to allow wound healing to take place (Li *et al.*, 2010).

The second stage involves creating an ear lobe. It is possible to perform this stage concurrently with stage one; however, it is safer and more accurate to wait until the healing process has taken place (Osorno, 2007).

The third stage involves lifting the assembled cartilaginous framework and covering it with a split-thickness graft. During this stage, Brent used a technique to camouflage the graft with the patient's natural hairline. This allowed it to be hidden from the lateral view (Chin *et al.*, 2009).

The final stage of this procedure is creation of the tragus.

#### 4.2.3. Nagata's technique

The Nagata technique is based on a modified version of Tanzer's method. The fabricated framework can be achieved in two stages. The first stage resembles the first three stages of Brent's method. However,

this technique uses the sixth, seventh, eighth and ninth costal cartilage of the ipsilateral side. The construct is built and configured using wire sutures. To reduce the chance of chest wall deformity, the posterior pericardium should be left intact. Rearrangement of the lobule is performed next by making a small W-shaped incision posteriorly and dividing it into an anterior tragus flap and a posteroanterior lobular skin flap (Nagata, 1995). To ensure a good blood supply, the posterior flap is not raised. A subcutaneous pocket is made and the framework is inserted within it. The flaps are sutured together via a Z-plasty technique, allowing the relocation of the lobule (Zim, 2003).

The second stage of this procedure takes place 6 months later. The surgeon returns to the chest and harvests cartilage from the 5th rib, which is used to elevate the fabricated framework through a posterior incision. A temporoparietal flap is used to cover the cartilage, and an occipital split-thickness skin graft is used to cover the construct (Brent, 1974).

Finally, the remainder of the microtic ear is removed 6 months after completion of stage two.

### **4.3. Porous polyethylene implant (Medpor®)**

---

The use of porous polyethylene implants in auricular reconstruction has gained much attention; they are known as Medpor®, which was introduced by Reinisch in 1991. The surgical technique involves placement of the implant under a temporoparietal flap in a one-stage procedure. Owing to its interconnecting framework, the Medpor® can be easily shaped while still exhibiting a high Young's module, thus making it an excellent alternative to the autologous surgical route; the latter is associated with donor site morbidity and important features of biocompatibility such as surface topography, good porosity and bioinertness. However, criticisms of the use of Medpor® relate to the high rates of extrusion.

### **4.4. External prosthesis**

---

Another option for aesthetic rehabilitation is prosthesis placement. This is particularly effective in older patients after a large tumour resection, in the cases of failed autogenous reconstruction and in the patients presenting with poor skin condition resulting from burns. An alloplastic ear is made from silicone and can be shaped to resemble the contralateral ear. Silicone colour matching is based on patient's skin tone; however, with sun exposure, the prosthesis may become more evident because of changes in the colour of surrounding skin. Several ways of attaching the prosthesis are available: it can be attached using an adhesive, hooked into a body edge or attached to a surgically implanted and osseointegrated titanium screw (Walton & Beahm, 2002). The latter is the most effective in ensuring higher retention of the prosthesis to the head; nevertheless, there are a few disadvantages, including the possibility of infection and inflammation around the screw.

## 5. PARTIAL EAR RECONSTRUCTION

Cancer and trauma are the main causes of a partial defect of the external ear. According to the affected area they are classified as marginal defects, non-marginal defects and conchal defects. Different surgical techniques for partial ear reconstruction are available, and the choice of the therapeutic option should be directed by the anatomical unit affected and the defect size (Figure 11.3).

### 5.1. Marginal defects

The marginal area of the external ear includes two different subunits: the helix and the lobe.

#### 5.1.1. Helix

The helix is a delicate chondrocutaneous structure. Deformities of different sizes and severities can affect the helix, ranging from a few millimetres to several centimetres, and the surgical technique for reconstruction depends on the size of the defect.

##### 5.1.1.1. Direct closure

Direct closure is indicated to repair a deficit of <1 cm. When the defect is bigger, direct suture of margins should be avoided because it can lead to margin distortion from excessive tension.

##### 5.1.1.2. Advancement flap

This flap is indicated to repair deficits <1 cm when direct closure is not possible. It is a cutaneous advancement flap involving the advancement of skin from the posterior surface of the auricle to the area to be repaired.

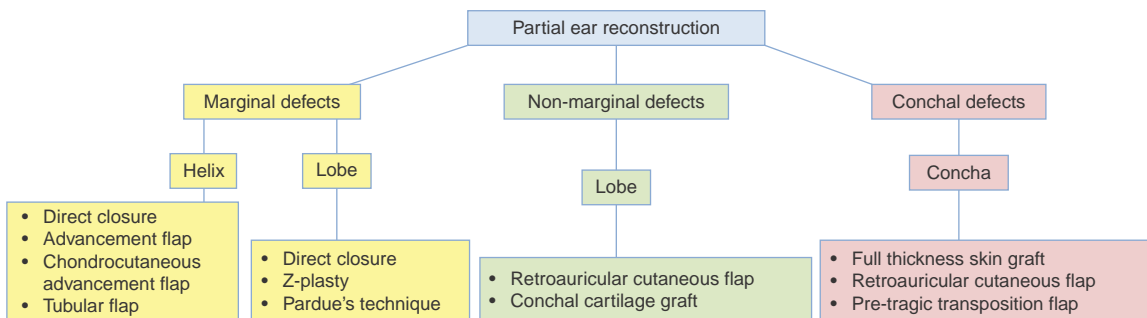


Figure 11.3. The therapeutic algorithm for partial ear reconstruction.

#### 5.1.1.3. Chondrocutaneous advancement flap

---

When a defect in the marginal area is wider than 1 cm, this type of flap has the advantage of being a one-stage procedure that uses intrinsic ear tissue. This technique is very useful to repair a defect located in the upper third of the helix; however, it has also been used in the middle and inferior third. Chondrocutaneous flaps are performed by advancing a caudal flap through mobilisation of the helix and the descending lobe. The incision can be extended to the lobe to distribute the tension from the edge of the helix to the lobe.

#### 5.1.1.4. Tubular flap

---

A tubular flap is indicated to reconstruct marginal defects larger than 2.5 cm without cartilage involvement or with minimal cartilage damage. Nowadays, this technique is rarely used because it presents disadvantages such as the need for multiple procedures and a high risk of flap vascular impairment. The surgical technique consists of three stages. In the first stage, the flap is designed on the skin using two parallel lines, and is prepared as a bipedicle. Next, the two margins are approximated to form a tubule, and the donor area is closed with direct suture. After about 3 weeks, one edge of the tubule is cut and transposed to the margin of the helix. After 3 more weeks, it is possible to detach the other edge of the flap, allowing the tubule to be transposed to cover the marginal defect.

### 5.1.2. Lobe

---

Deformity of the lobe may vary from a simple cleft to partial or total lobe loss. Different surgical techniques are available to repair or reconstruct the ear lobe.

#### 5.1.2.1. Direct closure

---

This is the simplest technique for lobe repair after a traumatic cleft injury, and consists of approximation of the margins by direct suture.

#### 5.1.2.2. Z-plasty

---

This technique is indicated in cases with a large lobe or an incomplete cleft and is useful to reduce and avoid scar retraction.

#### 5.1.2.3. Pardue's technique

---

This technique allows lobule reconstruction through the preparation and transposition of part of the cleft tissue. After incision of the internal and external cleft margins, the flap can be rotated and sutured with the lobe to form a new hole.



---

## 5.2. Non-marginal defects

---

Non-marginal areas of the ear include the scaphoid fossa, the triangular fossa and the antitragus. Non-marginal deformities can vary from a few millimetres to several centimetres, and can be repaired with different surgical techniques.

### 5.2.1. Retroauricular cutaneous flap

---

This flap involves two stages. In the first operation, the flap is marked and prepared from the retroauricular mastoid region. The flap is then transposed and sutured onto the lateral surface of the ear through an incision made on the skin and medial perichondrium. In the second stage, after about 3 weeks, the pedicle can be resected and sutured.

### 5.2.2. Conchal cartilage graft

---

This is indicated in cases in which there is loss of both soft and hard tissues, generally after trauma or tumour resection, and a need to graft cartilage from other areas. The most frequent site donor cartilage is the ipsilateral or contralateral concha and the rib. In the first stage, the graft cartilage is grafted and placed into the area of the defect and covered with a retroauricular flap. In the second stage, after 21 days, it is possible to resect the pedicle that has separated from the donor site and adapted to the defect.

---

## 5.3. Conchal defects

---

The entity of conchal defects can vary from a few millimetres to the entire subunit, and can be either partial thickness (involving only the skin) or total thickness (involving the underlying structures, i.e. cartilage and perichondrium). The most common cause is cutaneous tumours. Defects of a few millimetres can be left to heal by secondary intention, while larger defects require the addition of new tissue to be repaired.

### 5.3.1. Full-thickness skin graft

---

A full-thickness skin graft can be harvested from the retroauricular sulcus to avoid visible scarring at the donor site. This simple technique presents several advantages, including a good skin colour match.

### 5.3.2. Retroauricular cutaneous flap

---

In the first operation, the flap is marked and prepared from the retroauricular mastoid region. The flap is then transposed through an incision made in the conchal skin. In the second stage, after about 3 weeks, the pedicle can be resected and sutured.

### 5.3.3. Pre-tragic transposition flap

---

This flap is prepared from the pre-auricular area, anteriorly to the tragus, with an inferior pedicle. The donor site is closed to direct the approximation of margins. The flap is transposed into the conchal gap, passing over the intertragic notch.

## 6. TISSUE ENGINEERING

---

Tissue engineering is an interdisciplinary field that applies the principles of both engineering and the life sciences toward the development of biological substitutes that restore, maintain or improve tissue function. Tissue engineering has several advantages, including reduced infections, increased functionality, and better adaptability and longevity.

In the few last decades, many efforts have been made in the field of tissue engineering and regenerative surgery to repair and replace the external ear. One of the main challenges in tissue engineering for auricular reconstruction is the design of three-dimensional scaffolds on which cells, either chondrocytes or stem cells, can grow and regenerate.

### 6.1. Cell sources: chondrocytes or stem cells?

---

The main reason that the cell source is a challenging feature of tissue engineering is the limited availability of chondrocytes. The cartilage of the ear is of the elastic type and few sources are available in humans: it is mainly present in the ears, epiglottis and eustachian tube. Autologous chondrocytes are mainly isolated from auricular cartilage, costal cartilage, nasoseptal cartilage and articular cartilage. Depending on which type of cartilage is used for cell harvest, the resultant neocartilage will differ in its biomechanical and biochemical properties.

Stem cells are another valid source of cells. They can be easily harvested from the same patient, with limited donor site morbidity and no immunological reaction. The most used adult stem cell population is mesenchymal stem cells, which are usually harvested from bone marrow (bone marrow stem cells) or adipose tissue (adipose-derived stem cells). Stem cell differentiation can be regulated toward a chondrocyte phenotype with the use of growth factors.

### 6.2. Growth factors

---

One of the biggest challenges in tissue engineering of the ear is obtaining cells and biological growth factors suitable to maintain the phenotypic features and functions of the tissue. Several studies have investigated which growth factors are needed for neocartilage induction in auricular tissue engineering with stem cells. The main growth factors that were investigated were transforming growth factor beta

**Table 11.1.** Advantages and disadvantages of tissue-engineered constructs compared with the best-established surgical options for ear reconstruction.

Technique	Description	Advantages	Disadvantages
Cartilage graft	Surgical reconstruction: Nagata's technique; Brent's technique; Tanzer technique	Autologous: no immunogenicity; well-established technique; no need for laboratory facilities	Donor site morbidity Long operative time Multistage procedure Surgical expertise
Biomaterial implants	Replacement with Medpor® or others like HA and silicon	Limited costs No donor site morbidity Fewer stages Off the shelf	High extrusion rate High infection rate Mechanical shear
Cells and scaffold	Regeneration using principles of tissue-engineering triad combining cell, growth factors, and scaffolds	No immunogenicity, good biocompatibility, no donor site morbidity, one-stage procedure, lower extrusion rate	Limited source of chondrocytes Control of resorption/regeneration rate High costs

(TGF- $\beta$ ), platelet-derived growth factor beta (PDGF- $\beta$ ) and fibroblast growth factor 2 (FGF-2). TGF- $\beta$  promoted improved cell differentiation and matrix formation of auricular chondrocytes in a synergistic action with insulin-like growth factor 1 (IGF-1) both *in vitro* and *in vivo* (Li *et al.*, 2005; Wang *et al.*, 2005). PDGF- $\beta$  has promoted an enhanced differentiation capacity in auricular and nasal chondrocytes, but not costal chondrocytes (Tay *et al.*, 2004).

### 6.3. Scaffolds

Identifying a suitable scaffold is an important step in tissue engineering. The appropriate properties need to be selected to match the regenerative capacity of cartilage implanted *in vivo*. An optimal tissue-engineered scaffold should have a three-dimensional structure to maintain the cellular phenotype. Its surface chemistry and topography are important to promote cellular attachment, proliferation, differentiation and extracellular matrix production. Another important property is biocompatibility, which allows adequate adherence and integration into the surrounding native tissue. Biodegradable scaffolds are favoured because of their controllable rate of degradation to parallel the rate of native tissue regeneration in replacing the tissue defect.

Several scaffold designs have been used, involving both natural and synthetic types. The most widely used synthetic scaffolds are polylactic-glycolic acid and polyacrylonitrile-polyvinyl chloride, while the most common natural scaffolds are collagen and alginate. To date, there is a considerable lack of evidence regarding which types of scaffolds are the best for chondrogenesis.

## 6.4. Future perspectives

---

Although progress has been made in *in vitro* tissue production, the application of tissue engineering also involves critical aspects. The choice of cells used for tissue reconstruction is one such aspect because both chondrocytes and stem cells have their drawbacks. The current direction is to favour as much as possible chondrogenesis from stem cells in order to have a more widely available source compared with chondrocytes and to decrease the possibility of patient injury during harvesting. Moreover, the production of scaffolds with a specific architecture is often a very slow and expensive process and often does not use standardised techniques. These aspects should not be underestimated in the clinical setting.

Future research should focus on the mechanical properties of the scaffold in order to create a material which can integrate with skin better than those currently in use: in fact, the high percentage of implant failure (with Medpor<sup>®</sup>) is due to modular mismatch which causes inflammation, encapsulation and implant extrusion.

Although they have shown very positive effects, many experiments in this field were performed on animals, mainly nude mice. Therefore, there is too little evidence to say whether tissue-engineered constructs can be safe and effective in humans. Despite these limitations, tissue engineering is very promising for the future and is of interest to both scientists and clinicians; however, clinical trials are required to prove its safety and efficacy.

## 7. CONCLUSION

---

Auricular reconstruction is a challenging reconstructive entity complicated by the high ratio of skin coverage to cartilage, and a complex three-dimensional structure with subtle topographic details. The range of possibilities includes local flaps, skin grafts, costal cartilage grafts, alloplastic materials such as Medpor<sup>®</sup>, microsurgical replantation after traumatic amputation and external prosthesis. Nevertheless, those options have some limitations and it is not always possible to guarantee patients a satisfactory aesthetic outcome.

Currently, autologous auricular reconstruction is the preferred technique, particularly in young patients with a congenital malformation. This technique is reliable with a good outcome. The most common complications with cartilage graft include poor cosmetic result, scarring, haematoma and infection.

Microsurgical replantation is technically challenging, but allows a single procedure option for auricular reconstruction. A more natural appearing pinna usually results with this technique than with others; however, the outcome depends on the microsurgical expertise of the physician (Ibrahim *et al.*, 2008).

Alloplastic materials such as Medpor<sup>®</sup> can be useful for auricle reconstruction in adults. The advantages of alloplastic implants include their widespread availability, limited costs, consistent predetermined shape and short operating time. Furthermore, it can be easily shaped, sterilised and implanted with appropriate soft tissue coverage. Additional advantages include minimal donor site morbidity, the precise creation of a complex structure, donor site tissues being identical to recipient tissue and the

potential for implant growth. Disadvantages are the increased risk of infection, high extrusion rate and uncertain long-term durability.

To counteract some of these disadvantages, tissue engineering and regenerative surgery are being investigated using biodegradable polymers, growth factors and stem cells. In the last few decades, several scaffolds have been proposed and tissue-engineered constructs hold promise for future outcomes; however, more *in vitro* and *in vivo* studies are required before they can be implanted into humans.

## REFERENCES

- Anniko, M., et al. 'Otorhinolaryngology, Head and Neck Surgery', Springer 2010.
- Ballantyne, J. 'Ear', in *Operative Surgery*, 3rd Edition, *Butterworths*, London, 1976.
- Bhandari, P. S., et al. Total ear reconstruction in post burn deformity, *Burns*, 1998, Nov;24(7):661–70.
- Brent, B. Total auricular construction with sculpted costal cartilage, in Brent, B. (ed.): 'The Artistry of Reconstructive Surgery'. St Louis, MO, Mosby, 1974, pp. 113–27.
- Brodland, D. G., et al. Auricular reconstruction, *Dermatologic Clinics* 2005, 23(1):23–41.
- Chin, W. S., et al. Modifications of three-dimensional costal cartilage framework grafting in auricular reconstruction for microtia. *Plastic and Reconstructive Surgery*, 2009, 124(6):1940–6.
- Horlock, N., et al. Psychosocial outcome of patients after ear reconstruction: A retrospective study of 62 patients, *Annals of Plastic Surgery*, 2005, 54 (5).
- Ibrahim, S. M., et al. Burned ear: The use of a staged Nagata technique for ear reconstruction, *Journal of Plastic, Reconstructive & Aesthetic Surgery*, 2008, 61 Suppl 1:S52–8.
- Ibrahim, S. M., et al. Totally avulsed ear: New technique of immediate ear reconstruction, *Journal of Plastic, Reconstructive & Aesthetic Surgery*, 2008.
- Ihrai, T., et al. Surgical management of traumatic ear amputations: Literature review, *Annales de Chirurgie Plastique Esthétique*, 2009, 54 (2).
- Kisilevsky, E. V., et al. What to do about Ear Trauma: Investigating the Common Concerns, *The Canadian Journal of Diagnosis* 2003.
- Li, D., et al. Psychosocial outcomes among microtia patients of different ages and genders before ear reconstruction. *Aesthetic Plastic Surgery*, 2010.
- Li, W. J., et al. Multilineage differentiation of human mesenchymal stem cells in three-dimensional nanofibrous scaffold. *Biomaterials* 2005, Sep;26(25):5158–66.
- Lin, P.Y., Chiang, Y. C., Hsieh, C. H., & Jeng, S. F. Microsurgical replantation and salvage procedures in traumatic ear amputation. *J of Trauma and Acute Care Surgery*. Oct 2010, 69(4):E15–9.
- Luquetti, D. V., Heike, C. L., Hing, A. V., Cunningham, M. L. & Cox, T. C. Microtia: Epidemiology and genetics, *American Journal of Medical Genetics Part A*, 2012, 158a, 124–39.
- Mastroiacovo, P., et al. Epidemiology and genetics of microtia – anotia: A registry based study on over one million births, *Epidemiology* 1995, 32(6):453–7.
- Musumeci, G. New perspectives in the treatment of cartilage damage. Poly(ethylene glycol) diacrylate (PEGDA) scaffold, *Italian Journal of Anatomy and Embryology*, 2013, 118, 204–10.
- Nagata, S. Total auricular reconstruction with a three-dimensional costal cartilage framework. *Annales de Chirurgie Plastique Esthétique*, 1995 Aug;40(4):371–99.
- Osorno, G. A 20-year experience with the Brent technique of auricular reconstruction: Pearls and pitfalls. *Plastic and Reconstructive Surgery*, 2007.

- Songu, M., et al. A. Long-term psychosocial impact of otoplasty performed on children with prominent ears, *Journal of Laryngology and Otology*, 2014, 128(9).
- Tanzer, R. C. Total reconstruction of the external ear. *Plastic and Reconstructive Surgery and the Transplantation Bulletin*, 1959, Jan;23(1):1–15.
- Tay, A. G., et al. Cell yield proliferation, and postexpansion differentiation capacity of human ear, nasal and rib chondrocytes. *Tissue Engineering*. 2004 May–Jun;10(5–6):762–70.
- Vannatta, K., et al. Peer acceptance and social behaviour during childhood and adolescence: How important are appearance, athleticism, and academic competence? *International Journal of Behavioral Development*, 2009, 16.
- Walton, R. L. & Beahm, E. K. Auricular reconstruction for microtia: Part II. Surgical techniques. *Plastic Reconstructive Surgery*, 2002, Jul;110(1):234–49.
- Wang, Y., et al. *In vitro* cartilage tissue engineering with 3D porous aqueous-derived silk scaffolds and mesenchymal stem cells. *Biomaterials* 2005, Dec;26(34):7082–94.
- Zim, S. A. Microtia reconstruction: An update. *Curr Opin Otolaryngol Head Neck Surg*, 2003, 69(4):E15–9.

# Craniofacial Surgery: Craniosynostosis Syndromes and Cleft Lip and Palate

---

Ahmed Al-Hadad, Shafiq Rahman

## 1. INTRODUCTION

---

### 1.1. Introduction to craniofacial surgery

---

Craniofacial surgery is a growing subspecialty that seeks to manage congenital and acquired malformations of the face, skull and jaw. Craniofacial surgeons deal with a vast range of conditions including craniosynostosis and craniofacial clefts, as well as various miscellaneous congenital malformations. This chapter aims to cover the basic anatomy and embryology of the skull and palate, and then focuses on the common craniosynostosis syndromes, cleft lip and palate (CL/P).

Craniosynostosis dates back to 100 BC, when it was initially described by Hippocrates. It is defined as the premature fusion of one or more cranial sutures either during development *in utero* or soon after birth. More boys are affected than girls, with the sagittal suture being involved most often. It can be classified into syndromic and non-syndromic, with the former being less common (15–40%) despite over 100 reported syndromes (Cohen, 2000).

CL/P is one of the most common congenital craniofacial deformities encountered in newborns, affecting 1 in 600 live births. The defect develops from abnormalities in the growth of the foetal facial skeleton leaving an opening – a cleft. The most common forms that occur involve both the lip and palate (45%), the palate (40%) or the lip (15%) alone and are either unilateral or bilateral. Infants born with these conditions may also have other associated abnormalities, for example as part of Pierre Robin syndrome (Bailey *et al.*, 2013).

## 1.2. Embryological development

---

### 1.2.1. Skull embryology

---

The skull develops from the mesenchyme and is comprised of the (1) *neurocranium*, which envelops the brain; and (2) *viscerocranium*, which constitutes the facial skeleton.

The chondrocranium, which is the initial cartilaginous form of the neurocranium, undergoes endochondral ossification to form the bones of the base of the skull. This is followed by intramembranous ossification, forming the cranial vault (calvaria). The skull bones are separated by connective tissue, which constitutes the fibrous joints of the suture planes. The skull undergoes moulding during foetal life owing to its soft and malleable nature.

The cartilaginous viscerocranium is derived from the first two pairs of pharyngeal arches. The first arch cartilage is responsible for formation of the malleus and incus. The second arch cartilage results in the production of the stapes and styloid process. Following ossification, the membranous viscerocranium forms, resulting in formation of the squamous, temporal, zygomatic and maxillary bones (Moore *et al.*, 2013; Sadler and Langman, 2009).

### 1.2.2. Embryology of the palate

---

Palatogenesis stems from two embryological structures. The *primary palate* arises as the median palatine process during the 6th week of gestation after fusion of the median nasal processes. This contributes to the formation of the pre-maxillary part of the maxilla, which lies anterior to the incisive foramen. The *secondary palate* contributes to the formation of the hard and soft palate located posterior to the incisive foramen. It develops from the lateral palatine processes at the 6th week of gestation. These processes subsequently fuse within the median plane as well as with the posterior portion of the primary palate and the nasal septum (Moore *et al.*, 2013; Sadler and Langman 2009).

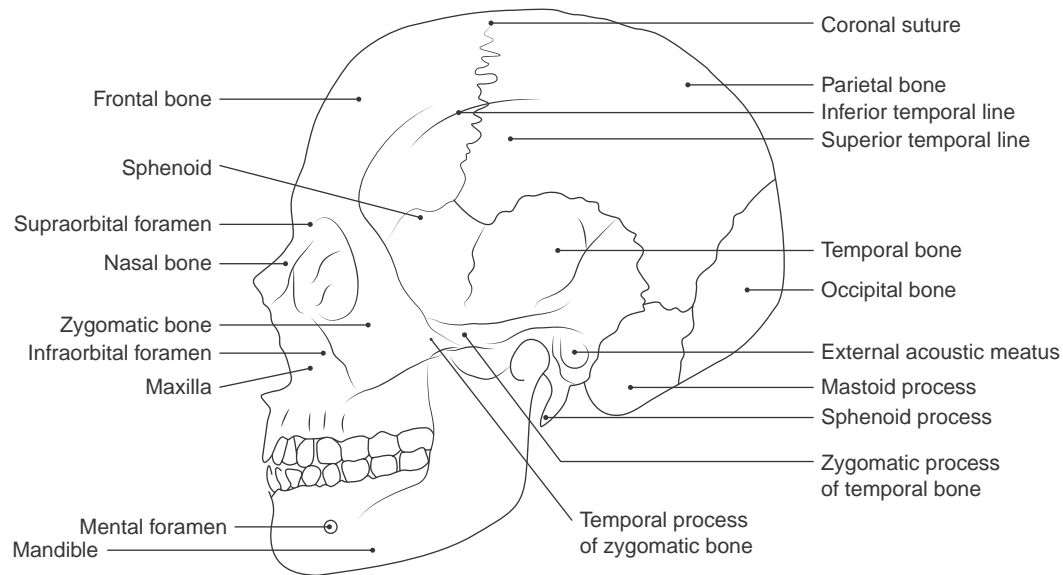
## 1.3. Functional anatomy

---

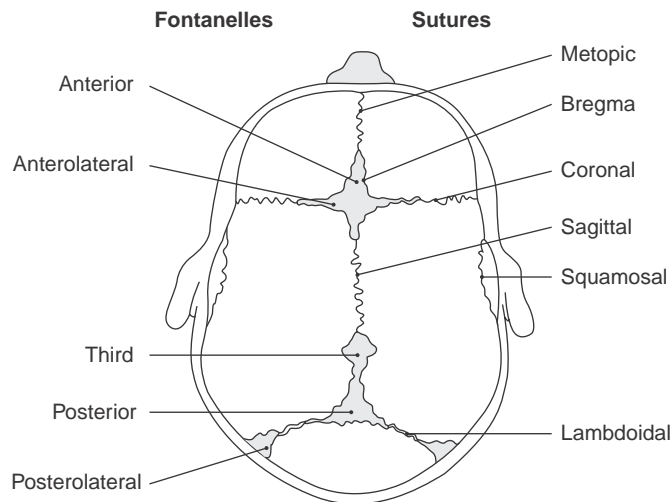
The cranium encloses the brain, the meninges and the remainder of the intracranial contents. The neurocranium is made up of eight bones and consists of a cap, the calvaria and a base (Figure 12.1). The cranial base is comprised mainly of the sphenoidal and temporal bones. The calvarium is formed by the frontal, occipital and parietal bones. The viscerocranium represents the facial skeleton and made up of three single bones and six paired bones (Sinnatamby and Last, 2011).

Sutures are immovable fibrous joints that unite the calvaria. In neonates, the fontanelles represent the normal, incomplete suture fusion points that facilitate expansion of the neurocranium during the early growth of the brain. The two major ones are the anterior (or frontal) and posterior (or occipital) fontanelles (Figure 12.2). The timed fusion of the fibrous sutures of a newborn is well co-ordinated with brain growth, enabling it to expand to its optimum size before fusing (Moore *et al.*, 2013).





**Figure 12.1.** Lateral view of skull anatomy. Bones of the neurocranium include the frontal, ethmoidal, sphenoidal, occipital and two sets of bones on either side of the skull: the temporal and parietal. The viscerocranium is made up of the following bones: mandible, vomer, ethmoid (three single bones), maxillae, inferior nasal conchae, zygomatic, palatine, nasal and lacrimal bones (six paired bones).



**Figure 12.2.** Illustration of the main skull sutures (superior view). The coronal suture lies between the frontal and parietal bones; the metopic suture lies between the frontal bone; the lambdoidal suture connects the parietal bones to the occipital bone; the sagittal suture lies between the parietal bones; and the squamosal suture connects the parietal and temporal bones. The posterior fontanelles commonly close at 1–2 months of age, whereas the anterior fontanelles shut at 9–18 months.

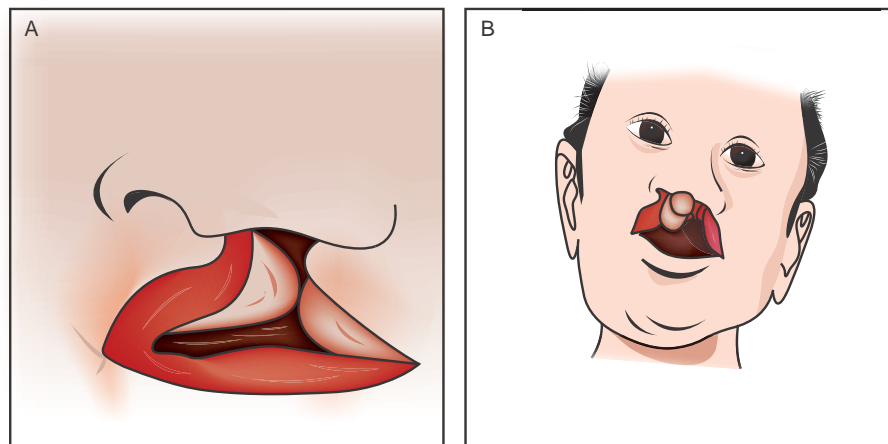
The *hard palate* is a bony structure which constitutes the roof of the mouth and is comprised of the palatine processes of the maxilla, as well as the horizontal plate of the palatine bone. It primarily functions in speech production and feeding. The *soft palate* is an aponeurotic extension commencing at the posterior aspect of the hard palate. It is an associated mobile flap which aids the functions of the hard palate. It is made up of a series of muscles which include tensor veli palatini, levator veli palatini, palatoglossus and palatopharyngeus (Drake *et al.*, 2010).

## 1.4. Developmental abnormalities

### 1.4.1. Cleft abnormalities

In *complete* cleft palate, an opening is evident between the two palatal processes throughout its complete length so that the nose and mouth are in communication. In *incomplete cleft palate*, the two halves of the palate unite from front to backwards; thus, the anterior part is normal. The last parts to fuse are the two halves of the uvula resulting in (1) a bifid uvula; (2) a bifid soft palate along its course; or (3) a bifid soft palate with involvement of the posterior part of the hard palate. Velopharyngeal inadequacy is observed in a *submucous cleft palate*: rather than forming a transverse sling across the posterior soft palate, the levator veli palatini muscles insert abnormally onto the posterior aspect of hard palate (Bailey *et al.*, 2013; Cuschieri *et al.*, 2003).

A failure of the maxillary prominence (on the affected side) to join with the merged medial nasal prominences results in a *unilateral* cleft lip (Figure 12.3A). A *bilateral* cleft lip, however, develops from the failure of mesenchymal masses of the maxillary prominences to meet and merge with the merged



**Figure 12.3.** A. A unilateral left-sided CL/P deformity in a neonate, showing the abnormal communication. B. A bilateral CL/P defect present in a newborn.

medial nasal prominences (Figure 12.3B). In addition, mesodermal deficiencies result in a *median* cleft lip by partial or complete failure of the medial nasal prominences to merge and form the intermaxillary segment (Moore *et al.*, 2013).

## 1.4.2. Craniosynostosis abnormalities

The sutures involved and deformities observed in craniosynostosis are described in Table 12.1 (Alden *et al.*, 1999).

**Table 12.1.** Developmental patterns of craniosynostosis.

Suture	Cranial deformity	Description	Incidence	Radiology
Sagittal	Scaphocephaly	Tall, narrow skull	1/5,000	Long narrow skull Small anterior fontanelle Absence of mid-line sagittal suture
Bilateral coronal	Brachycephaly	Short anteroposterior dimension and bitemporal widening	1/150,000	Absence or sclerosis of sutures Bilateral <i>harlequin eye</i> sign
Bilateral coronal (untreated)	Turricephaly	Tower skull with increased height of the cranium		Upward and outward peaking of orbital contour
Unilateral coronal	Plagiocephaly	Ipsilateral frontal flattening; contralateral frontal bossing	1/17,000	
Metopic	Trigonocephaly	Keel-shaped anterior skull with pointy forehead	1/25,000	Oval orbits Hypertelorism Small frontal bone with hyperostosis
Multiple	Turricephaly	Pointed head with a posteriorly tilted head		
	Kleeblattschädel	Trilobed 'cloverleaf' cranium		

Virchow postulated in 1851 that the cranial deformities observed were caused by the premature fusion of skull sutures.

Virchow's law states that brain growth is restricted along a plane perpendicular to the fused suture with compensatory overgrowth occurring at the non-fused suture sites resulting in the cranial deformities described. The commonest synostosed suture in craniosynostosis is the sagittal suture (40–55%), followed by the coronal (20–25%), metopic (5–15%) and lamboid (<5%) sutures.

*Source:* Adapted from Marks and Marks (1997).

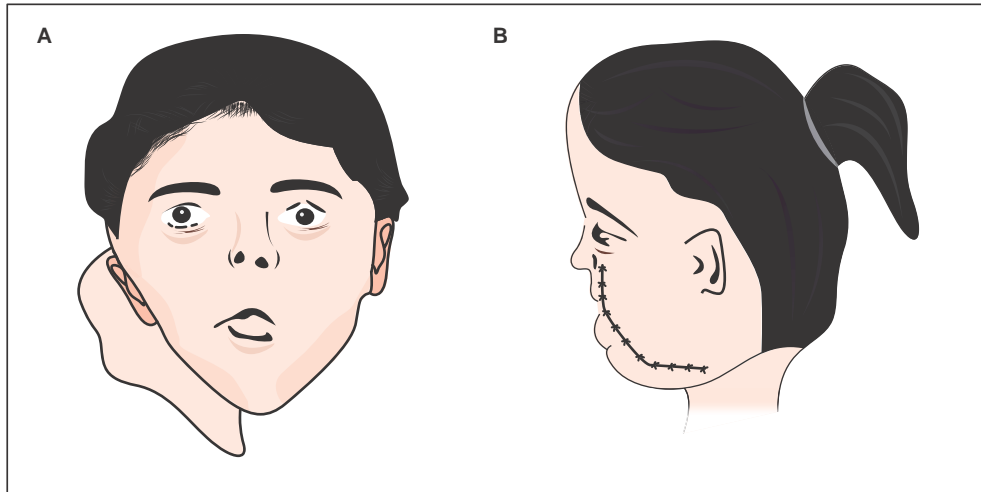
## 2. CRANIOSYNOSTOSIS SYNDROMES

### 2.1. Crouzon syndrome

Affecting 1 in 25,000 births, this syndrome may be inherited and is manifested in a similar manner to Apert syndrome with comparable skull and ocular characteristics but more prominent midface hypoplasia. Mandibular prognathism with lower jaw retrusion, a high palate or cleft palate may also be present. A distinguishing noticeable feature is the presence of normal hands. Raised intracranial pressure (ICP) may result in irreversible loss of vision due to atrophy of the optic disc and must be reversed immediately (Padmanabhan *et al.*, 2011).

### 2.2. Apert syndrome

Apert syndrome manifests with bicoronal synostosis that largely develops sporadically; however, some are inherited in an autosomal dominant pattern through mutation of the *FGFR2* gene. Craniofacial abnormalities are characterised by a turribrachycephaly, low-set ears and a small beaked nose (Figure 12.4). Typically, the midface is hypoplastic and pseudoprogathism is observed, in which class III malocclusion protrudes the mandible forward, causing an anterior open bite. Ocular features include hypertelorism and protruded eyeballs due to shallow orbits and exotropia. Obstructive sleep apnoea develops from reduced opening of the nasal choanae (Kabbani and Raghuvver, 2004).



**Figure 12.4.** Facial characteristics associated with Apert syndrome. A. Frontal view B. Profile view. Note the flat, elongated head with bitemporal widening and occipital flattening. The midface is hypoplastic with a small, beaked nose and low-set ears. Pseudoprogathism is also observed in this syndrome.

Other characteristic signs include congenital hand deformities. Syndactyly (fusion of the upper and lower limb digits) is observed commonly in the 2nd, 3rd and 4th digits. Mental retardation due to raised ICP or hydrocephalus may ensue if treatment is delayed.

### 2.3. Pfeiffer syndrome

---

As described by Pfeiffer in 1964, mutation of the *FGFR2* gene is apparent. The syndrome is inherited in an autosomal dominant manner. Broad thumbs and a widened big toe classically characterise this syndrome; however, these can be difficult to detect. Occasionally, syndactyly involving 2nd and 3rd digits is apparent. The craniofacial anomalies are similar to those of Apert and Crouzon syndromes, with midface hypoplasia, proptosis and hypertelorism. In addition, the nose is downturned and the nasal bridge is flat. Mental retardation, although uncommon, may also be observed (Thorne *et al.*, 2014).

### 2.4. Muenke syndrome

---

Caused by a *GFGR3* gene mutation, this syndrome has features overlapping with those of other GFGR-related craniosynostosis. More distinctive characteristics are unilateral or bilateral coronal synostosis, hypoplastic midface, broad toes and brachydactyly. Asymmetry of the face is also noticed. Ipsilaterally, the superior orbital rim and eyebrows are raised, the forehead is flattened and ears are displaced anteriorly. Contralaterally, there is prominent frontal bossing with eyebrow depression. Hearing loss is a common feature; thus, hearing assessment at a young age is vital to prevent learning difficulties (Agochukwu *et al.*, 1993).

### 2.5. Saethre–Chotzen syndrome

---

This syndrome is caused by mutation of the *TWIST1* gene. It is commonly characterised by brachycephaly, a low anterior hairline, bilateral ptosis and facial asymmetry. Irregularity of the face is commonly accompanied by nasal septum deviation and maxillary hypoplasia. The intelligence and midface is unaffected in this autosomal dominant disorder.

## 2.6. Management of craniosynostosis syndromes

---

### 2.6.1. Key to early intervention

---

Rapid correction of craniofacial dysmorphism is essential to take advantage of the fast-growing brain within the first 12 months of age. Management of raised ICP prevents disabling complications such as

blindness and mental retardation. Linear craniectomy and fragmentation of the vault may provide early temporary protection of the brain until definitive craniofacial procedures are undertaken. Tarsorrhaphy may be considered to protect the cornea of the eye. Early intervention may also be of psychosocial benefit for the child if the disfigurement is corrected at a young age.

## 2.6.2. Definitive craniofacial surgery

---

### 2.6.2.1. Fronto-orbital advancement

---

A coronal incision is made with the aim of releasing the synostosed suture to decompress the cranial vault. A frontal craniotomy is carried out to reshape the vault and elevate the frontal bone. The supra-orbital bar is also advanced providing protection to the eyeball and improving cosmesis.

### 2.6.2.2. Le Fort osteotomy

---

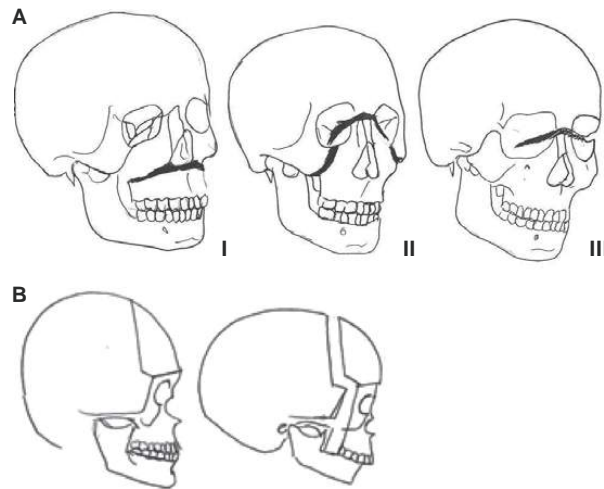
When the facial skeletal growth is complete, facial re-contouring can be offered for cosmetic and functional purposes (Figure 12.5A). (1) *Le Fort I osteotomy* is indicated for class III malocclusion following complete maturation of the maxilla and mandible. Either the mandible is protruding or the maxilla is retruded; thus, the nose, malar and upper maxilla bones are shifted forward. (2) *Le Fort II osteotomy* is indicated when the nasomaxillary area is retruded. (3) *Le Fort III osteotomy* involves the simultaneous movement of the lower orbit, maxilla and zygoma as a single unit. The bones are merged together and fixated at the nasolacrimal junction, lateral orbital wall and pterygomaxillary fissure. This procedure is usually performed between the ages of 7 and 9 years. At this age, orbital growth is near completion and can thus withstand fixation with screws. This, however, may need to be performed at a younger age if upper airway obstruction or ocular complications ensue. This technique may be combined with facial bipartition to correct hypertelorism, downslanting palpebral fissures and midface concavity (Thorne *et al.*, 2014).

### 2.6.2.3. Monobloc osteotomy

---

This procedure advances the fronto-orbital and Le Fort III segments simultaneously in one fragment to correct midface retrusion (Figure 12.5B). The age at which this is performed is debated among surgeons regarding whether it should be carried out early or left until complete skeletal development at puberty. Upper airway obstruction or severe exorbitism, however, may command early intervention.

The monobloc procedure alone remains controversial because of high infection rates. Contamination of the dead space created between the frontal lobe and bone develops from direct communication between the anterior cranial fossa and the paranasal sinus and nasopharynx. A staged procedure involving fronto-orbital advancement followed by Le Fort III or the use of monobloc distraction has thus become the more favourable technique for syndromic craniosynostosis. Distraction permits growth of the soft tissue envelope with monobloc advancement retaining the barrier between the nasal cavity and



**Figure 12.5.** A. Le Fort osteotomy I–III. B. Monobloc osteotomy with fronto-orbital advancement.

anterior fossa. Other advantages include a reduction in both surgery time and relapse rates. However, patients require further surgery to remove embedded devices following distraction surgery and must wear a halo frame around their head for several months (Bradley *et al.*, 2006).

## 2.7. Detecting sinister signs

Raised ICP can be detected clinically by examining for papilloedema and optic disc atrophy on funduscopy. At later stages, plain skull radiography may show a ‘thumb printing’ or ‘beaten copper’ appearance and towering of the head (i.e. turricephaly) may develop (Staatz *et al.*, 2007). Intraparenchymal monitoring using pressure-sensitive filaments remains the gold standard for measuring ICP.

Orbital signs must be recognised and managed appropriately. Exorbitism results in exposure of the cornea and subsequently keratitis, corneal ulcerations and possibly loss of vision. A thorough examination involving the assessment of visual acuity and slit lamp biomicroscopy is essential.

Hydrocephalus, although rare, can develop in syndromic craniosynostosis (commonly Apert syndrome). It may present with signs of raised ICP, which may be difficult to distinguish from these syndromes. Pre-operative computed tomography or ultrasound scanning detects those at a high risk, who are than best managed with a ventriculoperitoneal shunt (Marks and Marks, 1997).

## 3. CLEFT LIP AND PALATE

CL/P deformities in neonates are evident at birth and are recognised by the presence of clefts affecting the lip and/or palate with potential nasal extension. However, this may not be visible in the case of

**Table 12.2.** Relative incidence risk of CL/P deformities.

Genetic risk predisposition of cleft lip and palate	Risk (%)
One affected sibling	4
Two affected siblings	9
Either parent affected	4–6
Both parents affected	33–50
One sibling and one parent affected	17

submucous clefts. The aetiology is believed to be a combination of environmental and genetic influences. Environmental factors include drug exposure during pregnancy (steroids, diazepam, phenytoin). A positive family history predisposes toward an increased incidence of the anomaly (Table 12.2). Although the occurrence of CL/P in an isolated form is the usual mode of presentation, it can also be associated with a syndrome, of which Pierre Robin syndrome is the commonest (Bailey *et al.*, 2013).

One of the most common classification systems employed for CL/P is the LAHSHAL method (Figure 12.6). This system incorporates several features of the pathology, defining whether the CL/P lesion is present in combination or isolation, is unilateral or bilateral, and complete or incomplete (Thorne *et al.*, 2014).

Submucosal cleft is a variant cleft palate deformity that often goes undiagnosed in neonates because the deformity lies underneath the covering of the mucosa. Both the hard and soft palate can be affected and it has an incidence of 1:1250–1:6000. It is often characterised by a triad of signs: (1) a bifid uvula; (2) a translucent zone in the soft palate; and (3) the presence of a bony notch in the posterior edge of the hard palate. However, it is often detected incidentally after investigating for nasal speech. Complications include velopharyngeal insufficiency, otitis media and speech difficulties (Neligan *et al.*, 2013).

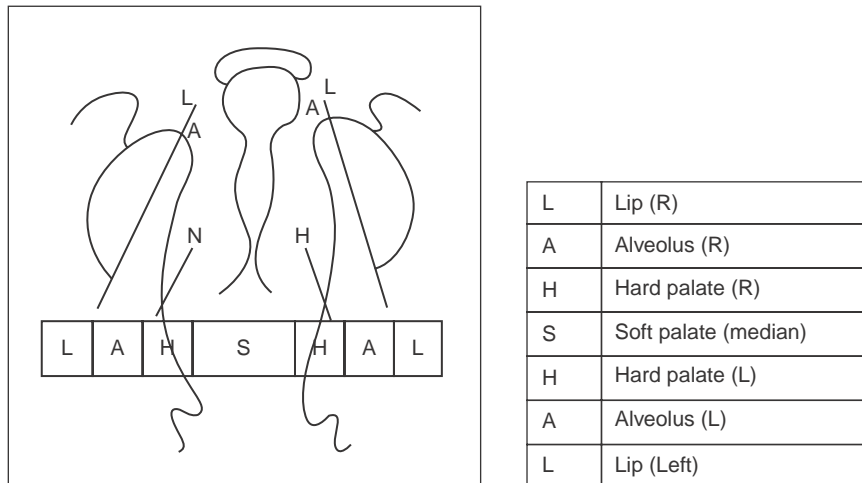
### 3.1. Management of cleft lip and palate

A multidisciplinary approach is key to the management of cleft deformities. The team of specialists should include plastic and maxillofacial surgeons, orthodontists, speech therapists, psychologists and dieticians. All forms of CL/P defects, with the exception of isolated cleft palate, can be detected during intra-uterine life by ultrasound. This may be ordered after 18 weeks of gestation have elapsed. The antenatal diagnosis is important because it allows clinicians to counsel parents in advance and plan the appropriate treatment protocols (Bailey *et al.*, 2013; Cuschieri *et al.*, 2003).

#### 3.1.1. Neonatal care

Initial neonatal care should centre on airway protection with the aid of nasopharyngeal tubes as required. Nursing in the prone position and labioglossopexy (tongue–lip adhesion) in more serious cases can be employed to prevent obstruction by the tongue. Moreover, the inability of newborn babies with CL/P





**Figure 12.6.** LAHSHAL classification. Capital letter = complete cleft; lower case letter = incomplete cleft. Example LAa: complete right cleft lip and alveolus with incomplete left cleft alveolus.

to produce a significant negative intraoral pressure impedes their suckling ability and thus nutritional status. This can be overcome with a special feeding teat (Bailey *et al.*, 2013).

### 3.1.2. Pre-surgical work up

Good planning prior to the procedure is vital to provide a good prognosis and involves different methods to objectively delineate the abnormality. It can also include moulding techniques, which attempt to reduce the magnitude of the deformity. The child must be in good health prior to the procedure and should not have any respiratory infections. Prior to surgical intervention, detailed anthropometric measurements are made of the CL/P deformity to accurately guide the reconstruction.

### 3.1.3. Photography

This is important for assessing cosmetic improvements after surgery. It enables pre- and post-operative comparisons to evaluate the success of the procedure. Serial photographs can help track facial development as the child gets older.

### 3.1.4. Moulding

This intervention aids surgical revision and is based on the malleable nature of tissues at an early age. Its implementation improves the surgical prognosis because some anatomical continuity is restored prior to surgery. Common techniques used to mould the tissues include lip taping, alveolar moulding and nasoalveolar moulding, as well as usage of the Latham device.

*Lip taping* provides mechanical pressure on the tissues to help mould them into shape and reduce the need for early orthodontia. *Alveolar moulding* involves the application of a plate that helps to adjust palatal growth. When an additional nasal stent is employed, the process can be modified to *nasoalveolar moulding*. However, this technique can lead to ulceration and mega nostril. The *Latham device* offers a mode of active moulding; however, it hasn't gained wide acceptance because it is carried out under general anaesthesia and can cause growth disturbances (Bailey *et al.*, 2013).

### 3.1.5. Primary surgery

The principles of surgery aim to restore the anatomical continuity of the defects so as to improve functional ability, improve the aesthetic outlook and encourage normal facial development. The time at which surgical intervention is recommended varies according to the type of CL/P present (Table 12.3). The 'rule of 10' can also aid in determining when to operate. This entails haemoglobin in excess of 10 g/dl, an age of 10 weeks and a weight of 10 lbs for cleft lip. In a cleft palate case, typically a 10-month-old infant weighing more than 10 kg with a total leukocyte count of less than 10,000/ $\mu$ l are operated on.

The basic principle of repair involves surgical incisions directed toward restoring the displaced tissues to their normal positions. It involves the use of local flaps to reconstruct the defects, as well as repositioning and suturing the displaced muscle fibres. *Millard's rotational advancement flap* is the most common approach employed in the case of unilateral cleft lip. It involves advancement of a mucocutaneous flap from the lateral portion of the lip into the cleft within the superior portion of the lip. It can also be used in a one- or two-stage form for bilateral cleft lip. A *triangular flap technique* (Tennison–Randall method) can be used to repair cleft lip but is reserved for more severe cases. The length of the medial lip can be extended by the application of a triangular flap from the lower part of the lateral lip. A drawback of this technique is that the scar may not be as cosmetically acceptable.

**Table 12.3.** Timing of primary surgery in CL/P defects.

---

Cleft lip alone
Unilateral: single operation at 5–6 months
Bilateral: single operation at 4–5 months
Cleft palate alone
Soft palate only: one operation at 6 months
Soft and hard palate: two operations with soft palate at 6 months and hard palate at 15–18 months
Cleft lip and palate
Unilateral: two operations with cleft lip and soft palate at 5–6 months. Hard palate with lip revision at 15–18 months
Bilateral: two operations
Cleft lip and soft palate at 4–5 months. Hard palate with lip revision at 15–18 months

---

*Source:* Adapted from Bailey *et al.* (2013).

The *Von Langenbeck procedure* is the oldest cleft palate operation and is still being used today. It involves the production of bipediced mucoperiosteal flaps from the edge of the cleft which are then advanced medially. By maintaining the anterior attachment of the flap with the alveolar margin, it enables the flap to be bipediced. Newer techniques such as V–Y retroposition of the palate can also be performed and are typically conducted at 12–18 months of age.

Asymptomatic submucosal cleft palates are managed conservatively; however, in the presence of speech defects and velopharyngeal incompetence, surgical correction is an accepted treatment modality. Surgery focuses on palatal repair and may be associated with pharyngoplasty. *Furlow palatoplasty* is one of the surgical techniques used and is effective when there is a small velopharyngeal gap (Thorne *et al.*, 2014; Zenn *et al.*, 2012; Marks and Marks, 1997).

### 3.1.6. Secondary surgery

Surgical revision should not be conducted until 2 years after the primary procedure. It aims to correct residual defects that have persisted or disproportional development of the face that may require augmentation. Common procedures include rhinoplasty, veloplasty, alveolar bone grafting, orthognathic surgery and pharyngoplasty.

#### 3.1.6.1. Alveolar bone grafting

This revisional procedure is conducted to correct residual alveolar clefts with the aim of promoting normal dental development and reducing the incidence of oronasal fistulas. Pre-surgical orthodontic treatment is often beneficial for improving the post-operative outcome. Alveolar bone grafting is best conducted between the ages of 8 and 11 years and employs cancellous bone from the iliac crest or tibia plateau. It has borne very good results until now and is thus a popular procedure.

#### 3.1.6.2. Orthognathic surgery

This is typically performed to correct poor maxillary growth but is delayed until facial growth has reached completion at 16–19 years of age. Poor maxillary growth can contribute to pseudoprognathism and may not be amenable to orthodontic device therapy alone.

#### 3.1.6.3. Septorhinoplasty

Open septorhinoplasty is effective for correcting persistent nasal cartilaginous deformities, usually on the side of the cleft deformity. The two most common deformities revised are a collapsed lateral nasal cartilage on the side of the cleft and dislocation of nasal septum into the non-cleft nostril.

**Table 12.4.** Summary of the common complications of CL/P and their management.

Complications	Presentation	Management
<b>Speech difficulties</b>	Hypernasality, articulation difficulty	Speech therapy and surgical correction
<b>Dental anomalies</b>	Hypodontia, hyperdontia, delayed development and eruption	Orthognathic surgery, regular dental surveillance, revisional surgery, dietary modification
<b>Airway compromise</b>	Respiratory difficulty, proportionally larger tongue	Nursing in prone position, nasopharyngeal airway, labioglossopexy
<b>Nutritional deficiency</b>	Inability of oral intake due to suckling difficulty	Feeding teat and plate
<b>Hearing difficulties</b>	Sensorineural and conductive hearing loss, otitis media	Audiological assessment, hearing aids, myringotomy
<b>Psychological and social stress for family</b>	Anxiety over prognosis and family planning	Genetic counselling, before and after pictures of previous cases to offer hope
<b>Facial disfigurement and abnormal anatomical development</b>	Disproportionate facial structures, visible clefts of lip and or alveolar margin unilateral or bilateral	Primary and secondary surgical intervention

#### 3.1.6.4. Pharyngoplasty

Pharyngoplasty or the pharyngeal flap procedure is effective in correcting velopharyngeal insufficiency and aids in improving soft palate function. The procedure usually involves the anterior transposition of posterior pharyngeal wall tissue to reduce the velopharyngeal gap by suturing two palatopharyngeal muscles in the middle. There are three types of pharyngoplasty in practice: (1) a single flap from the posterior pharyngeal wall united to the posterior section of the soft palate; (2) bilateral mucomuscular flaps transposed from the lateral pharyngeal walls to obtain a horizontal position on the posterior pharyngeal wall; and (3) an implant used behind the mucosa of the posterior pharyngeal wall (Thorne *et al.*, 2014; Zenn *et al.*, 2012; Marks and Marks, 1997).

#### 3.1.7. Post-operative care

Complications may ensue immediately after surgery, including wound dehiscence and infection. Late complications are more common and have been summarised in Table 12.4. In the post-operative period, good oral hygiene is essential and patients are started prophylactically on broad-spectrum antibiotics. Dehiscence secondary to infection should not be re-sutured until the lip has become soft. It is also recommended to commence a liquid diet within a few hours of surgery. Elbow restraints can be helpful in attempting to prevent the child from physically tampering with the repaired facial structures. To conclude, both CL/P and craniosyntosis syndromes have a strong genetic heritage and their respective management are closely tailored to each individual patient (summarised in Figure 12.7).

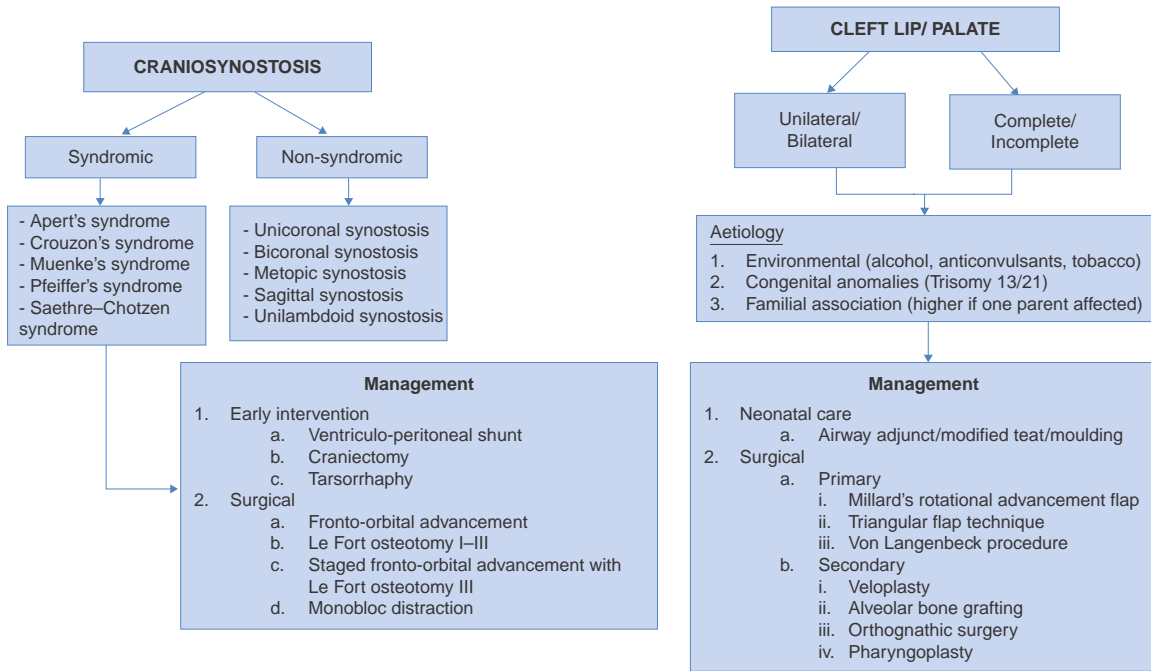


Figure 12.7. Summary of craniosynostosis syndromes and CL/P.

## REFERENCES

- Agochukwu, N. B., Doherty, E. S. & Muenke, M. 1993. Muenke Syndrome. In: Pagon, R. A., Adam, M. P., Ardinger, H. H., Bird, T. D., Dolan, C. R., Fong, C. T., Smith, R. J. H. & Stephens, K. (eds.) *GeneReviews(R)*. Seattle (WA): University of Washington, Seattle.
- Alden, T. D., Lin, K. Y. & Jane, J. A. 1999. Mechanisms of premature closure of cranial sutures. *Childs Nerv Syst*, 15, 670-5.
- Bailey, H., Love, R. J. M., Rains, A. J. H. & Capper, W. M. 2013. *Bailey & Love's Short Practice of Surgery*, London, Hodder Arnold.
- Bradley, J. P., Gabbay, J. S., Taub, P. J., Heller, J. B., O'Hara, C. M., Benhaim, P. & Kawamoto, H. K., Jr. 2006. Monobloc advancement by distraction osteogenesis decreases morbidity and relapse. *Plast Reconstr Surg*, 118, 1585-97.
- Cohen, M. M. J. 2000. Epidemiology of craniosynostosis. *Craniosynostosis*, 2nd Ed. New York: Oxford University Press.
- Cuschieri, A. 2003. *Clinical Surgery*, Oxford; Cambridge, MA, Blackwell Science.
- Drake, R. L., Vogl, W., Mitchell, A. W. M., Gray, H. & Gray, H. 2010. *Gray's Anatomy for Students*, Philadelphia, PA, Churchill Livingstone/Elsevier.
- Kabbani, H. & Raghuvver, T. S. 2004. Craniosynostosis. *Am Fam Physician*, 69, 2863-70.
- Marks, M. W. & Marks, C. 1997. *Fundamentals of Plastic Surgery*, Philadelphia, W.B. Saunders.
- Moore, K. L., Persaud, T. V. N. & Torchia, M. G. 2013. *The Developing Human: Clinically Oriented Embryology*, Philadelphia, PA, Saunders/Elsevier.
- Neligan, P., Warren, R. J. & Van Beek, A. 2013. *Plastic Surgery*, London; New York, Elsevier Saunders.

- Padmanabhan, V., Hegde, A. M. & Rai, K. 2011. Crouzon's syndrome: A review of literature and case report. *Contemp Clin Dent*, 2, 211–14.
- Pfeiffer, R. A. 1964. Dominant Hereditary Acrocephalosyndactylia. *Z Kinderheilkd*, 90, 301–20.
- Sadler, T. W. & Langman, J. 2009. *Langman's Medical Embryology*, Baltimore, MD, Lippincott William & Wilkins.
- Sinnatamby, C. S. & Last, R. J. 2011. *Last's Anatomy: Regional and Applied*, Edinburgh; New York, Churchill Livingstone/ Elsevier.
- Staatz, G, Honnef, D., Piroth, W., Radkow, T. 2007. *Direct Diagnosis in Radiology Pediatric Imaging*, New York, Thieme Medical Publishers; Stuttgart: Georg Thieme Verlag.
- Thorne, C., Chung, K. C., Gosain, A., Guntner, G. C. & Mehrara, B. J. 2014. *Grabb and Smith's Plastic Surgery* / editor-in-chief, Charles H. Thorne; editors, Kevin C. Chung, Arun Gosain, Geoffrey C. Gurtner, Babak Joseph Mehrara, J. Peter Rubin, Scott L. Spear, Philadelphia, Wolters Kluwer/Lippincott Williams & Wilkins Health.
- Zenn, M. R. & Jones, G. E. 2012. *Reconstructive Surgery: Anatomy, Technique, and Clinical Applications*, St. Louis, MO, Quality Medical Pub.

## Genital Reconstruction

---

Shomari Zack-Williams, Debbie Hunt, Asif Muneer, Sarah Creighton

### 1. PAEDIATRIC GENITAL RECONSTRUCTION

---

- Disorders of sexual development (DSDs) are the most common reasons for genital reconstruction in children
- A discussion of the genetics, molecular pathways and surgical management of DSDs is provided
- Disorders related to DSDs, e.g. cryptorchidism and hypospadias, are discussed

#### 1.1. Introduction

---

The art and practice of genital reconstruction is an area of much complexity and a challenge to the reconstructive surgeon. Successful genitourinary (GU) reconstruction involves the collaboration of medical, surgical and allied health professional teams working in a multidisciplinary setting to ensure that the best treatments are performed on these patients. The field of GU reconstruction ranges from congenital disorders of sexual development (DSD) all the way to gender reassignment. Every case should be uniquely managed, with a strong focus upon the physical, emotional and psychological effects of the life-changing surgery. Significant advances in the reconstruction of genitalia over the last 30 years have largely reflected improvements in microvascular skills. This chapter covers the embryology of GU disorders, as well as the progression from adolescent to adult conditions.

#### 1.2. Embryology of the genitourinary tract

---

##### 1.2.1. Internal genitalia

---

The internal and external genitalia arise in close conjunction with the urinary system. In the early phase of embryological development, the male and female GU tracts follow identical paths.

The gonadal tissues begin their development in the 5th week, when the embryo has a 5–7 mm crown–rump length (Acien, 1992). They develop from primordial germ cells which migrate from the embryonic yolk sac to populate the body wall posteriorly (Larsen, 2001). Gonads start to appear in the genital or gonadal ridges which are formed via the proliferation and a condensation of the underlying mesenchymal tissue (Sadler, 2012). The genital ridges contain cortical and medullary sections; both of these areas develop in the normal embryo. The gonadal tissues at this stage of development are known as indifferent gonads until the 6th week when they start to differentiate.

In the 6th week, both male and female embryos have two duct systems: the mesonephric and paramesonephric. The mesonephric (or Wolffian) duct extends from the mesonephros all the way to the cloaca and cloacal membrane. The paramesonephric (or Müllerian) duct forms lateral to the Wolffian system as an extension of the coelomic evaginations (Cohen *et al.*, 2004). Cranially, the paramesonephric duct opens into the abdomen caudally: it runs medial to the mesonephric duct to grow caudomedially (Sadler, 2012). The ducts eventually fuse in the lower midline to enter the sinusal or urogenital tubercle (Figure 13.1).

By default (i.e. without the stress of hormones), the embryo develops with female characteristics. Paramesonephric system development continues, with the Wolffian system only remaining in small remnants such as the epoophoron or paraoophoron in the ovaries (Larsen, 2001). As the urogenital tubercle fuses with the paramesonephric system, the primordial structure fuses along the caudal paramesonephric ducts fuse into a single tube known as the uterovaginal canal. The superior aspect of this structure becomes the upper vagina and uterus (Larsen, 2001). By 11 weeks, the uterovaginal primordium has formed, with the unfused sections developing into two fallopian tubes and their associated infundibula (Cohen *et al.*, 2004).

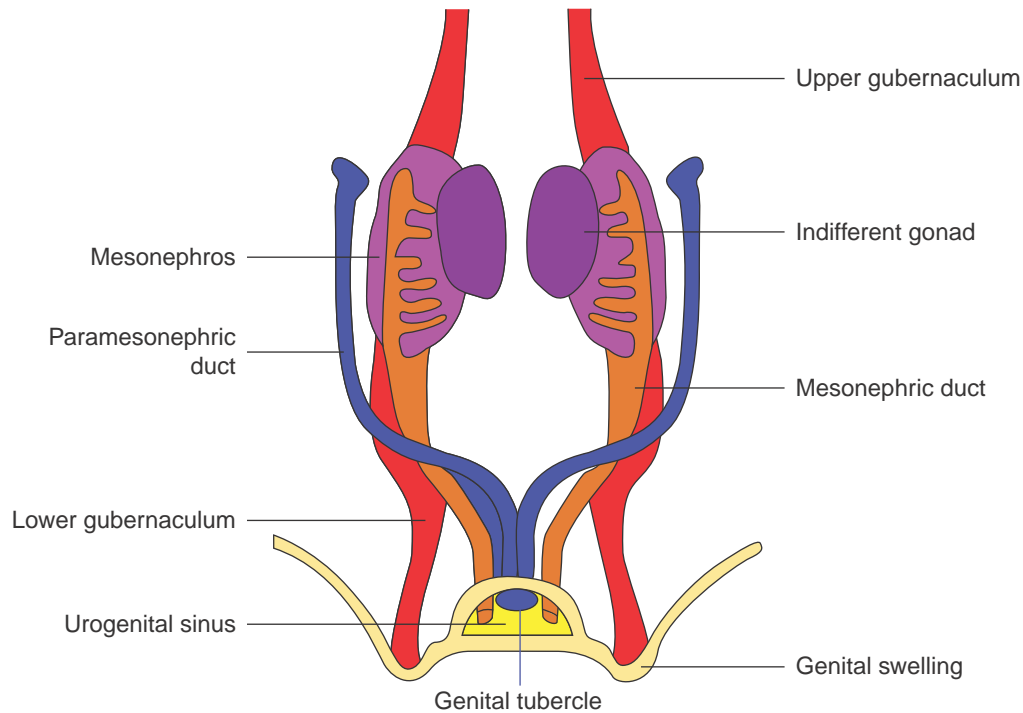
The Wolffian tubules continue to develop in the embryo, with male characteristics depending on two hormone-producing cell types. The primordial germ cells have receptors for human chorionic gonadotropin (hCG) and testosterone is released early in the Leydig cells (Acien, 1992). This stimulates the production of the ductuli efferentes, epididymis, ductus deferens and seminal vesicles. Sertoli cells secrete anti-Müllerian hormone (AMH) to induce regression of the Müllerian tubules and acts via phosphorylation of the AMH receptor (Josso and di Clemente, 2004).

### 1.2.2. External genitalia

---

The external genitalia develop from the same primordial tissue in embryos with male or female characteristics (Larsen, 2001). The genital tubercle, cloacal fold and membrane are the main external genital structures seen at this non-differentiated stage (around 5 weeks of development). Gradual fusion of the urorectal septum with the cloacal membrane forms the perineum (Larsen, 2001) that separates an anterior urogenital membrane and a posterior anal membrane. The urogenital membrane eventually breaks down, leaving the urethral plate underneath. Dihydrotestosterone (DHT) enables the phallus to lengthen and begin to form the penis (Acien, 1992). The urethral folds form the scrotal sacs as well as the spongy bodies of the penis. Urethral folds eventually fuse from the proximal aspect of the penis to the distal glans end. The urethra is thought to be ultimately formed by a number of lateral mesodermal proliferations meeting and midline





**Figure 13.1.** Urogenital system at 6 weeks.

fusion to enclose the now internalised endodermic urethral cells (Hynes and Fraher, 2004). The testes descend from their ventral medial position on the posterior abdominal wall in two phases (intra-abdominal and inguinoscrotal) to eventually end up within the scrotum (Hutson *et al.*, 2013).

Development of the female external genital system is simpler, characterised by the non-fusion of many of the structures which contributed to male external genitalia development. The phallus becomes the neoclitoris, the urethral folds become the labia minora and the labioscrotal tissue, which forms the labia majora (Larsen, 2001).

### 1.3. Congenital abnormalities

Congenital abnormalities of the GU system are uncommon, but the most common and relevant disorders will be mentioned in this text.

In 2005, a consensus statement led to a change in the nomenclature of congenital GU disorders (Hughes *et al.*, 2006). Traditionally used pejorative terms such as ‘hermaphrodite’ or ‘intersex’ were replaced by ‘disorder of sexual development’ (DSD). The incidence of DSD is between 1:10,000 and 2:10,000 and may be associated with defects of other organ systems (Woodward and Patwardhan, 2010).

These disorders may present at birth or within the adolescent period. Infants with this disorder have their individual cases discussed at a multidisciplinary team (MDT) meeting before a prompt decision regarding future gender is made after discussion with the parents.

Table 13.1 summarises the main types of DSD and the genetic factors linked to these disorders; this will be referenced later in the text.

### 1.3.1. 46, XX DSDs: genetically female but high virility

Patients with this genetic make-up are described as *masculinised females*. These patients tend to have an excess of DHT at the critical stage of sexual organ development (Auchus and Chang, 2010). There are several causative mutations, which are summarised in Table 13.2.

### 1.3.2. 46, XY DSD: genetically male but low virility

These patients are phenotypically male and have three underlying pathophysiological processes:

1. Disorders of androgen production
2. Disorders of testicular development
3. Other causes.

As shown in Figure 13.2, the production of androgens is a complex process involving multiple enzymes and there are many points at which abnormalities can occur. This figure is relevant to androgen production in overvirilised women and undervirilised men.

Disorders of androgen production may be caused by foetal disorders associated with deficiency of steroid production prior to or within the gonads/adrenals. These disorders are usually linked to deficiencies in the enzymes involved in the complex synthesis of androgens and their derivatives from cholesterol. The foetal Leydig cell shown in Figure 13.3 demonstrates the number of points at which androgen production may be affected.

**Table 13.1.** Summary of the main types of DSD and the genetic factors linked to congenital abnormalities.

46, XX DSD	46, XY DSD	Sex chromosome DSD
Disorders of ovarian development	Disorders of testicular development	47, XXY Klinefelter's syndrome
Androgen excess	Disorders in androgen synthesis	45, XO Turner syndrome
Other (cloacalexotrophy and MURCS)	Other (severe hypospadias, cloacalexotrophy)	45, X /46, XY (mixed gonadal dysgenesis) 46, XX / 46, XY (chimeric ovotesticular DSD)

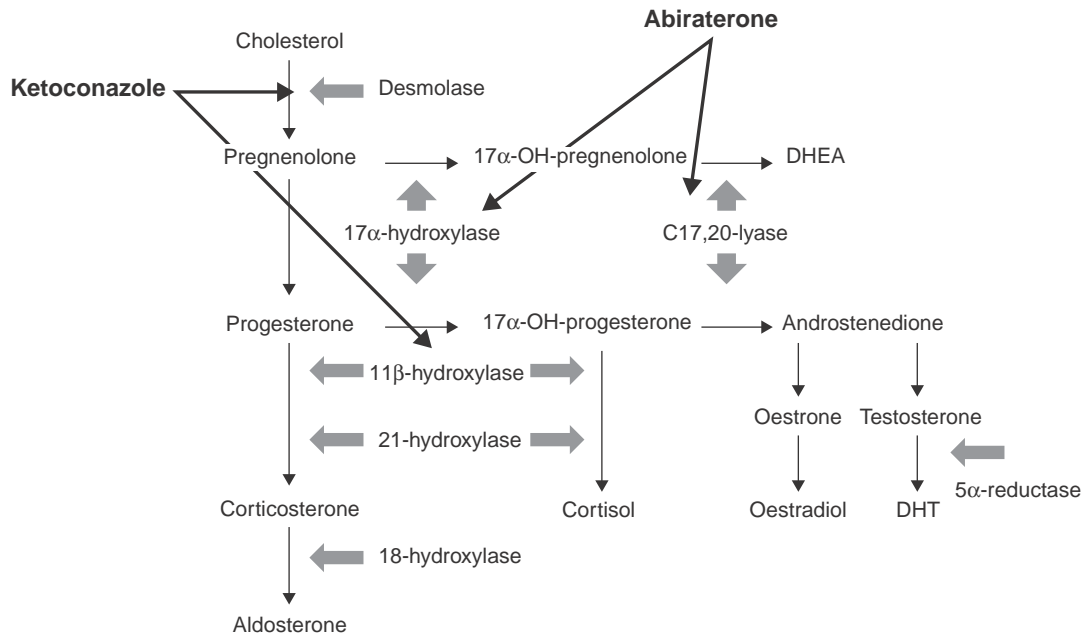
**Table 13.2.** Various causative mutations responsible for masculinised females.

Disease	Function	Presentation
<b>21-Hydroxylase deficiency (CYP21A2)*</b>	Involved in production of cortisol and aldosterone; closely linked also with CYP11B2 which further develops this pathway	Classic form: congenital salt wasting, mineralocorticoid and glucocorticoid failure and severe virilisation
<b>11-Hydroxylase deficiency (CYP11B1)*</b>	Involved in terminal production of cortisol from derivative along with CYP21A2	Patients present with salt/water retention at birth as well as virilisation similar to that seen in CYP21A2
<b>3 <math>\beta</math> HSD deficiency*</b>	Converts progesterones in cortisol and aldosterone	Congenital salt wasting state with ambiguous genitalia with less virilisation than CYP21A2
<b>Aromatase deficiency<sup>†</sup></b>	Involved in cytochrome function of multiple enzymes involved in steroidogenesis Converts maternal androgens into oestrogens <i>in utero</i>	Complete absence is incompatible with life; difficult to diagnose children present with virilisation Presents with maternal virilisation (autosomal recessive form) with severe foetal virilisation
<b>Luteoma of pregnancy<sup>†</sup></b>	Benign hyperplastic over growth of ovarian tissue	Variable virilisation in infants; causes maternal virilisation in minority of cases

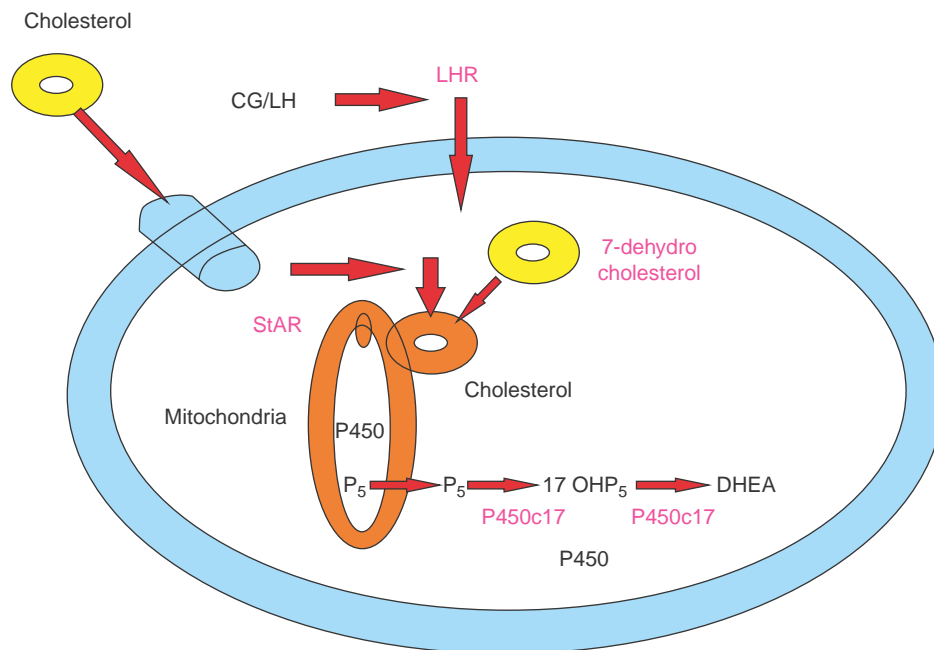
\* Associated with CAH. † Maternal-derived androgens.

The first step is governed by 7-dehydrocholesterol reductase, which produces cholesterol as the first step in the long process. Absence of this enzyme may lead to significant congenital malformations and is known as Smith–Lemli–Opitz syndrome (Tint *et al.*, 1994). In all, five enzyme deficiencies have been found to be causative of the syndrome. Three out of five of these disorders are congenital adrenal disorders and are thus associated with congenital adrenal hyperplasia (CAH) (Mendonca *et al.*, 2009). These enzymes are summarised in Table 13.3, and their function and the consequences of their deficiency is explained.

Defects in the androgen receptor (AR) also account for some of the androgenic insensitivities found in this group of patients (Werner *et al.*, 2010). The gene encoding AR was discovered many years ago (Brinkmann *et al.*, 1989), and different mutations of this gene are partly responsible for the severity of androgen insensitivity. Patients with complete androgen insensitivity syndrome classically present at birth, with female-appearing external genitalia and testicles which have not descended (Werner *et al.*, 2010). In contrast, infants with partial androgen insensitivity syndrome present with a greater range of phenotypes (Holterhus *et al.*, 2000).



**Figure 13.2.** Androgen synthesis.



**Figure 13.3.** Foetal Leydig cell metabolism.

**Table 13.3.** Summary of 5 key enzymes , their function and presentation associated with congenital adrenal hyperplasia and Smith–Lemli–Opitz syndrome.

Enzymatic deficiency	Function	Presentation
P450 scc*	Specific cytochrome complex involved in the cleavage of cholesterol side chains along with StAR	Severity of congenital abnormalities governed by whether associated with StAR loss. With StAR loss: severe early adrenal insufficiency or with StAR sparing later onset adrenal disorder and mild masculinisation
StAR *	Steroidogenesis regulatory protein essential in the production of pregnenolone	Congenital deficiencies of mineralocorticoid, glucocorticoid, sex steroid and gonadal damage (lipid infiltration)
3 $\beta$ -HSDII	3-Beta-hydroxysteroid dehydrogenase type II converts dehydroepiandrosterone to androstenedione	Presents with ambiguous external genitalia characterised by micropenis, perineal hypospadias and possible blind vaginal pouch
P450 c17 *	Complex interaction involved in the formation of testosterone from pregnenolone and progesterone	Presents with ambiguous genitalia, micropenis, perineal hypospadias and cryptorchidism
17 $\beta$ -HSD III	17 hydroxysteroid dehydrogenase type 3 involved in the conversion of androstenedione to testosterone (terminal step)	Patients present with female or ambiguous genitalia as well as blind vaginal pouch, intra-abdominal or inguinal testes

\* Associated with congenital adrenal hyperplasia. StAR = steroidogenic acute regulatory protein.

### 1.3.3. Sex chromosome DSD

In phenotypically female patients, this may present as Turner syndrome with a genotype of 45, XO. Typical features of these patients include a short webbed neck and presenting with primary amenorrhoea as adolescents.

In the phenotypically male patients, sex chromosome DSDs present as Klinefelter syndrome (47, XXY). Klinefelter syndrome occurs in around 1:660 newborn boys and is characterised by progressive testicular failure, causing small firm testes which are azoospermic (Akslaede and Juul, 2013).

The other patients who fit within this group include those suffering from mixed gonadal dysgenesis (45, XO/46, XY) or those who are chimeric (46, XX/XY). These two groups of patients are born with ovotesticular DSD and usually have ambiguous genitalia at the time of birth (Barbaro *et al.*, 2011). If these patients have undescended gonads, they are at high risk of malignancy.

## 1.4. Surgical management of DSD: childhood

The surgical management is largely dependent upon the individual patient and the associated genomic abnormalities. These patients are best treated in a multidisciplinary environment. There are no clear

worldwide clinical guidelines on the timing of surgery for DSDs (Creighton *et al.*, 2012). Often, children with associated CAH need to be reviewed by other specialists, such as the paediatric endocrinology team, for life-saving treatment before their surgical treatment can take place (Vidal *et al.*, 2010). Studies have also shown a relatively high proportion of visceral organ abnormalities associated with DSDs.

Clinicians who prefer early reconstructive surgery often feel it is anatomically easier to perform with a better aesthetic result, as well as less stigmatisation of the ambiguous genitalia (Creighton *et al.*, 2012). There is a strong counterargument from clinicians who believe the decision should ultimately rest with the patient and that any decision about assignment can be easily reversed if no surgery is initially performed (D'Alberton, 2010).

### 1.4.1. 46, XX DSD: surgical management

---

Around 90% of patients with the 46, XX DSD are eventually raised as girls (Dessens *et al.*, 2005). The surgical options are related to the anatomy associated with the disorder. These patients may have a urethra which is connected to the vagina, an enlarged genital tubercle and part fusion of the labioscrotal folds with empty gonad pouches (Vidal *et al.*, 2010).

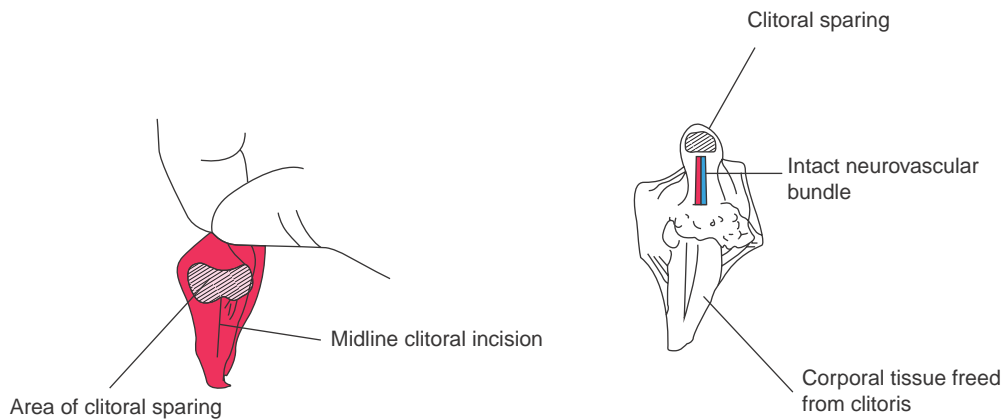
There are three stages to the feminisation reconstruction of these patients:

1. Clitoroplasty
2. Vaginoplasty
3. Perineoplasty.

#### 1.4.1.1. Clitoroplasty

---

Initial management of the masculinised clitoris originally involved clitorectomy (Gross *et al.*, 1966). This was a radical technique where the object was to remove as much clitoral tissue as possible. The benefits stated with this technique included a reduction in the incidence of recurrent cystitis caused by vaginal obstruction and urinary reflux. These patients were typically operated on during the first year of life. The first modification of this technique involved a ventral longitudinal incision which mobilised all the way from its attachments to the pubic arch (Spence and Allen, 1970). This was followed by surgical suturing of the glans of the clitoris to the pubic symphysis. This was one of the first procedures which documented the preservation of clitoral tissue and could be described as a dorsal reduction. The first technique which specifically aimed to preserve the neurovascular function of the clitoris was performed by Rajfer *et al.* in 1982: via ventrolateral skin incisions, the central aspect of the corpora cavernosa is excised in full. Kogan *et al.* (1983) described a subtunical approach with the removal of hypertrophied cavernous tissue of the clitoris. The subtunical approach maintains the blood supply to the glans. Sagehashi (1993) concentrated on removing the corporal tissue via a ventral approach (Figure 13.4) while removing some of the prepuce skin dorsally. He was able to maintain the neurovascular supply of this construct during the surgical procedure.



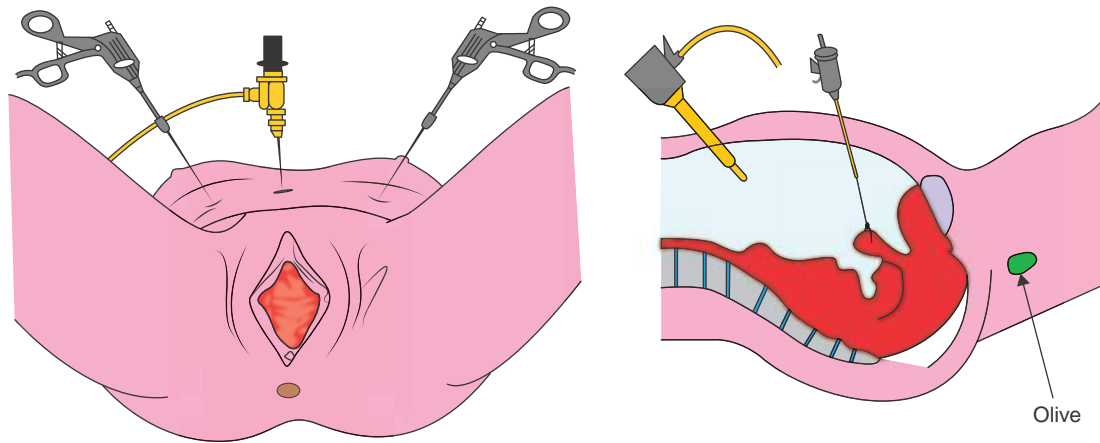
**Figure 13.4.** Neurovascular sparing clitoroplasty for clitoromegaly and corporal tissue excision.

#### 1.4.1.2. Vaginoplasty

Mayer–Rokitansky–Kuster–Hauser syndrome (also known as Müllerian agenesis) is characterised by primary amenorrhoea, infertility, and congenital aplasia of the uterus and upper vagina (Pizzo *et al.*, 2013). These patients also have a 46, XX genotype associated with an absent uterus and normal ovaries in most cases (Laterza *et al.*, 2011). These patients may present in the neonatal period with an absence of Müllerian-derived structures or present in puberty with primary amenorrhoea. The differential diagnosis for this condition includes an imperforate hymen and a low transverse vaginal septum.

The vagina essentially has no function in early childhood; therefore, vaginoplasty can be delayed until after puberty (Creighton *et al.*, 2012). Frank (1938) described a non-invasive method involving serial dilatation which was appropriate in certain types of patients with vaginal stumps at the appropriate age (usually adolescents). For this, patients of the appropriate age are required to place dilators for around 30 minutes per day. Another non-surgical method included patients sitting on a mobile bike seat stool while using Lucite dilators (Williams *et al.*, 1985). An alternative to these non-surgical procedures includes the Abbe–McIndoe procedure. This technique involves harvesting a split-thickness skin graft and stitching it to the inside of the vagina along with a mould (McIndoe and Banister, 1938). Post-operative dilatation continues to prevent a skin graft-related contracture. The Vecchietti procedure (Figure 13.5) involves the attachment of an ‘olive’ to the vaginal area, with threads of cord travelling from here to the navel along the abdominal wall (Davies and Creighton, 2007). A traction device is used externally to slowly lengthen the vagina.

Disorders of the urogenital sinus involve more complex procedures than those previously described in this section. Due to inadequate fusion of the urinary and genital systems, there is a permanent connection between the two. These disorders may be classified along a spectrum of high to low risk (Rink *et al.*, 2006). Current surgical techniques include total urogenital mobilisation (TUM) and anterior sagittal transrectal approach (ASTRA).



**Figure 13.5.** Vecchietti procedure.

Rink *et al.* (2006) described their method of performing TUM. The patient initially undergoes cystoscopy, followed by insertion of a Fogarty catheter into the vagina and a Foley catheter into the urethra. An omega-shaped perineal flap is raised and the urogenital system is separated from the rectum. The sinus is separated from the phallus and dissection continues to the pubic level. The urogenital sinus is identified while the surgeon carefully defines the planes of dissection. The final fixation of the neovagina can be obtained in a number of ways. Firstly, it may be sewn directly to the perineum if there is sufficient laxity within the tissues. Alternatively, with ventral dissection a posterior wall is produced by mobilisation of the sinus tissue, thus using a Fortunoff flap. An alternative to this technique involves mobilisation of the sinus tissue from its lateral borders to form a posterior flap. The vagina may then be pulled through to correct any mismatch between its walls and the perineum.

Dòmini *et al.* (1997) modified this procedure from previous work by Peña and colleagues (1992), who performed the original transrectal surgery. The ASTRA technique described by Pippi Salle *et al.* (2012) involves further modifications and has been shown to provide excellent exposure for severe urogenital abnormalities. This new technique is thought to be associated with fewer traumas to the vital musculature, which maintains continence integrity of the rectum and anus. Similar to the TUM approach, they describe how their patients undergo cystoscopy. The patient is placed prone and the surgical approach is made by a midline perineal incision. The posterior vaginal wall is dissected away from the urethra with the aid of adrenaline solution. Once this is complete, the openings of urethra and rectum are closed and the musculature of the rectum is reconstructed appropriately. The neovaginal tissue is attached to the perineum via direct closure or flaps from the perineum (Pippi Salle *et al.*, 2012).

#### 1.4.1.3. Perineoplasty

The literature indicates that this procedure is mainly performed alongside procedures described above on the clitoris and vaginoplasty. They may be performed as one-stage procedures which have



been shown to be safe in a number of studies (Farkas *et al.*, 2001; Roll *et al.*, 2006). Miranda *et al.* (2004) described a novel, successful way of rebuilding the perineum and vaginal introitus using bilateral modified island flaps based on the perineal and superficial branches of the internal pudendal arteries.

### 1.4.2. 46, XY DSD: genetically male but low virility

The management of these patients is more heterogeneous than that of the previously discussed DSDs. Traditionally, decisions were made at birth based on the phenotypes of these individuals (Massanyi *et al.*, 2012). A thorough understanding of the many variables associated with these cases must be considered before a decision is made. Hrabovszky *et al.* (2002) believe from animal models that androgenic imprinting occurs between 1 and 6 months. The implications of this are that patients may still have strong masculine behaviour ('tomboys') despite their assignment to a female phenotype. Newer multidisciplinary approaches incorporate this new fundamental understanding as well as the legal rights of the child and parents in any assignment surgery.

The spectrum of phenotypic appearances in this patient group poses a major challenge to the reconstructive genital surgeon. The disorder presents with a range internal and external features:

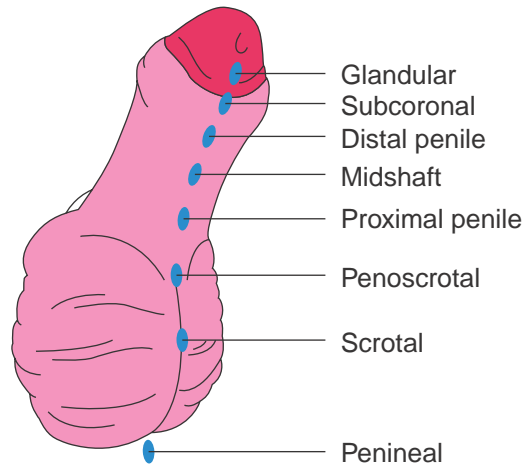
1. Hypospadias
2. Cryptorchidism
3. Gonadal dysgenesis
4. Persistent Müllerian structures.

The feminising procedures were described in detail in [Section 1.4.1](#). Masculinising or other types of surgery for 46, XY DSD individuals will be discussed in the following section.

#### 1.4.2.1. Hypospadias

Hypospadias result from maldevelopment of the ventral aspect of the penis, affecting around 1:200–1:300 boys (Baskin *et al.*, 2001). The severest forms of hypospadias have the strongest association with DSDs (around 30% in total). Hypospadias can occur in multiple regions of the penis, as shown in [Figure 13.6](#). A combination of genetic and environmental factors is believed to be responsible for most hypospadias (Kalfa *et al.*, 2011). At between 6 and 18 months of age, children pass through a psychological window; it was initially felt that operating beyond this period may lead to psychological disturbances (Schultz *et al.*, 1983). However, a more recent study has shown no difference in psychological adjustment of patients who underwent surgery at <18 or >18 months of age (Weber *et al.*, 2009). Hypospadias classically present with the following triad (Mouriquand *et al.*, 1995):

1. Ventral deviation of penis (also known as chordee)
2. A dorsal hood associated with a ventral prepuce defect
3. Ventral opening of the urethra.



**Figure 13.6.** Hypospadiac penis

Surgical management of hypospadias is very complicated, with over 400 techniques described in the literature (Stein, 2012). The choice of surgical procedure depends on all of the features of hypospadias; however, the anatomical position has the greatest influence on the choice of surgery. Surgery is performed under general anaesthesia, with caudal blocks for proximal hypospadias and dorsal blocks for the more distal lesion. A selection of the most commonly performed procedures for anatomical positions will be discussed in the following section.

A recent worldwide survey of plastic surgeons, paediatric urologists and surgeons has confirmed that the tubularised incised plate (TIP) procedure is used in around 71% of cases of distal hypospadias (Springer *et al.*, 2011). The TIP procedure was originally described by Snodgrass in 1994. It may be used in boys and involve full circumcision or foreskin-preserving surgery (Snodgrass, 2005). For distal hypospadias, the procedure begins with 5-0 suturing of a polypropylene stitch to the glans. Longitudinal incisions are then made along the glans to expose the urethral plate. The plate is incised to the corpora cavernosa and tubularisation of the urethra begins in a two-layered fashion using 7-0 polyglactin repair in a two-layered closure. In boys not undergoing foreskin reconstruction, a vascularised dartos flap is raised over the repair site for extra protection. The technique described in this section may also be used for hypospadias of the glans penis or proximal penis.

Springer *et al.* (2011) also reported the international preference for meatal advancement and glanuloplasty ('MAGPI'). This procedure may be used in anterior hypospadias with no associated chordee on erection testing (Duckett, 2002). It starts by a longitudinal incision from the dorsal edge of the meatus to the distal glans groove. Further dissection is carried out between the Bucks fascia and subcutaneous tissue all the way to the penoscrotal junction. The meatal tissues are brought into position using fine forceps and the procedure is completed using fine forceps and vertical mattress suture closure. Other surgical procedures for the management of this distal hypospadias are summarised in Table 13.4.

**Table 13.4.** Summary of surgical procedures for the management of distal hypospadias.

Name of procedure	Description
Mathieu procedure (Mathieu, 1932)	Popular in France using glans-based skin flaps
Mustarde flap (Mustarde, 1965)	V flap and tunnelling to deliver the neourethra into position
Devine-Horton flap (Devine-Horton, 1961)	Used in post-corrected chordee penises with distal hypospadias
Van Der Muelen (Van Der Muelen, 1971)	Spiralled dorsal foreskin to cover gland and obey the Denis-Browne principle

Springer *et al.* (2011) also reported that two-stage repair is generally preferred in the reconstruction of proximal hypospadias. The type of two-stage repair is dependent upon the severity of the hypospadias, the urethral plate quality and the presence or absence of chordee. Two-stage procedures are thought to provide superior cosmetic and functional outcomes in the long term (Shukla *et al.*, 2004).

The following discussion of two-stage techniques was adapted from Haxhirexha *et al.* (2008). In primary hypospadias surgery, the first stage involves removal of the ventral fibrous tissue which may be responsible for the chordee. Similar to the TIP procedure, the glans wings are developed and dissected off the corpora cavernosa. An artificial erection test is performed; if this is not satisfactory, a number of other methods of reconstruction may be performed. The defect created by fibrous tissue excision must be filled using a free graft. Free grafts have been shown to have an excellent take on the penis and scrotum (Gundeti *et al.*, 2005; Massanyi and McMahon, 2011). An alternative is the Byars flap which may be used to reconstruct the dissected ventral area on the volar aspect of the penis (Arshad, 2005).

The secondary stage of reconstruction is normally planned to take place around 6 months after the first. In an uncomplicated case, the graft is progressively tubularised. A glansplasty is performed, allowing the new urethra to be buried deep underneath multiple tissue layers for waterproofing. As a final step, urinary diversionary tools are used to redirect the urine away from the neourethra using either suprapubic or transurethral catheters.

#### 1.4.2.2. Cryptorchidism

The precise mechanism of cryptorchidism is not fully known. Many studies are based on rodent models, and testicular development occurs in two phases (Hutson *et al.*, 2013).

##### 1.4.2.2.1. Abdominal phase

This phase occurs while the testes are suspended from the ventral medial anterior abdominal wall. The testes are suspended by the cranial suspensory ligament or gubernaculum. Testis development at this stage is under the action of hormones including insulin-like hormone 3 (INSL3) and Mullerian Inhibiting Hormone (MIH). INSL3 synthesis is largely dependent on Leydig cell development; it is the most dominant

hormone in controlling the development of the gubernaculum. Under the influence of hormones, cells of the cranial suspensory ligament undergo hyperplasia and secrete extracellular matrix.

#### 1.4.2.2. Inguinoscrotal phase

From week 25, testicular development continues until the testicle descends into the scrotum along with the processus vaginalis. The processus vaginalis divides the gubernaculum into three sections: the outer rim, containing cremaster muscle; a central cord attached to the epididymis; and a distal mesenchymal tip known as the bulb (Hutson *et al.*, 2010). The mechanisms controlling further descent of the testes have not been fully investigated; however, interaction with the genitofemoral nerve and calcitonin gene-related peptide (CGRP) signalling are thought to be important for the chemotaxis of cells and structures (Hrabovszky *et al.*, 2001).

Around 3–4% of full-term boys are born with cryptorchidism (Saenger and Reiter, 1992). It is thought that around 30% of preterm infants may have this condition; 70% of cases are accounted for by preterm babies (Comploj and Pycha, 2012). The most commonly used classification system for cryptorchidism is that of Kaplan (1993). Patients may be classified as those with palpable vs. non-palpable testicles; this is shown in Tables 1.5 and 1.6. Figure 13.7 shows the different positions of cryptorchidism testicles.

Similar to those mentioned earlier, babies with cryptorchidism must be treated in a multidisciplinary fashion. The condition can sometimes be associated with the other congenital abnormalities shown below:

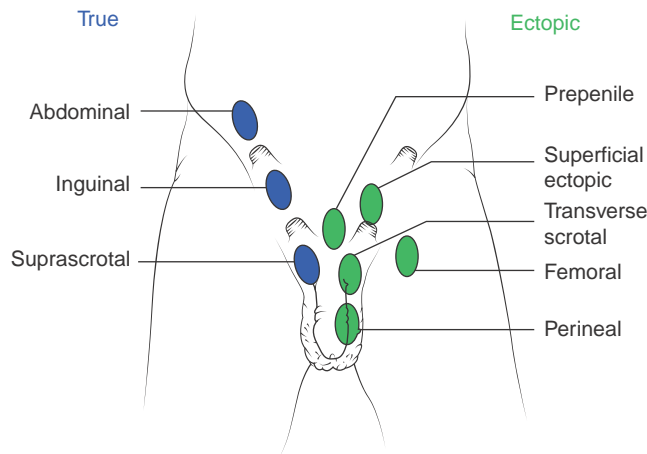
- Prader–Willi syndrome
- Kallmann syndrome
- Laurence–Moon–Biedl syndrome
- Intersexuality/CAH

**Table 13.5.** Classification of palpable testicles.

Normal	Retractile	Ectopic	Undescended (endocrine)	Undescended (non-endocrine)
Testes should be palpable within the scrotum while the patient is supine	Testes are located in the inguinal area when supine, but may be moved into the scrotum	Testes follow an aberrant path to descent; may be in the superficial inguinal area, perineum, femoral canal or penopubic area	Typically bilateral cryptorchidism with under virilisation accounted for by gonadotrophin deficiency	<i>True undescended</i> may occur when a hydrocele was originally mistaken for a testicle <i>Iatrogenic</i> may occur from tethering which may retract a previous descended testicle

**Table 13.6.** Classification of non-palpable testicles.

Canalicular	Intra-abdominal	Absent
This is known as the gliding testes and may occur in children in whom an excess amount of soft tissue exists within the inguinal canal. The testes naturally glide between the tissue planes	<i>Closed ring variant</i> occurs due to lack of development of the internal inguinal ring, processus vaginalis and gubernaculum; the testes remain within the pelvis  <i>Open ring variant</i> allows the testes to glide into the inguinal canal along with the gubernaculum	<i>Agenesis</i> testes never develop, thus Müllerian structures naturally develop  <i>Atrophic testes</i> characterised by blind ending vas deferens and vessels uni or bilaterally



**Figure 13.7.** Cryptorchidism testicular positions.

- Prune belly syndrome
- Neural tube defects
- Trisomy 21.

Some of these conditions, such as CAH, may be life-threatening; therefore, a high index of suspicion is required to prevent harm to a newborn presenting with cryptorchidism.

Treatment of a child with cryptorchidism largely depends on the age of the child at presentation. Over the last few decades, there has been a general trend to treat these patients at younger ages.

Hormonal therapy may be used in the treatment of patients with cryptorchidism. This is often used as adjuvant therapy in the form of synthetic hCG or luteinising hormone-releasing hormone (LHRH). Hormone therapy may be started at around 6 months of age (Schwentner *et al.*, 2005). This treatment is thought to optimise the potential fertility of the child undergoing treatment.

Surgical therapy is thought to be successful in 90% of general cryptorchidism cases and around 95% of cases in which the testicles are palpable (Saenger and Reiter, 1992). Several surgical approaches exist, including traditional inguinal orchidopexy or a high inguinal incision (Jones incision). Orchidopexy may be performed in one or two stages depending on the mobility of the individual's gonadal tissues. Fowler *et al.* (1959) initially described a one-stage process for orchidopexy. This was adapted to a two-stage process, in which initial fixation of the testes in a temporary location such as the pubic symphysis was done. The vasculature was ligated high on the testes to promote the formation of collaterals, allowing a more robust testicle for the second stage of the procedure. Some months later, a secondary procedure was carried out to mobilise the testes into intrascrotal positions. Elder (1992) modified Fowler's earlier procedures to involve a laparoscopic approach and found success in performing the two-stage procedure in 12 patients. Although Elder's procedures were performed on unilateral cases, the technique has been successfully adapted in cases of bilateral cryptorchidism (Kaye and Palmer, 2008). Complications of orchidopexy are:

- Testicular atrophy
- Haematoma
- Laparoscopic surgery risks
- Ilioinguinal nerve injury
- Post-operative torsion.

Testicular atrophy is a major complication which may occur following orchidopexy. Its incidence is thought to be around 11.3% in unilateral cases and 3.2% in bilateral cases of intra-abdominal testes (Alagaratnam *et al.*, 2010). Testicular orchidectomy may be required if the testes are severely damaged secondary to torsion or iatrogenic damage from surgical procedures. In this case, a prosthesis must be tailor-fitted to the patient undergoing this surgery.

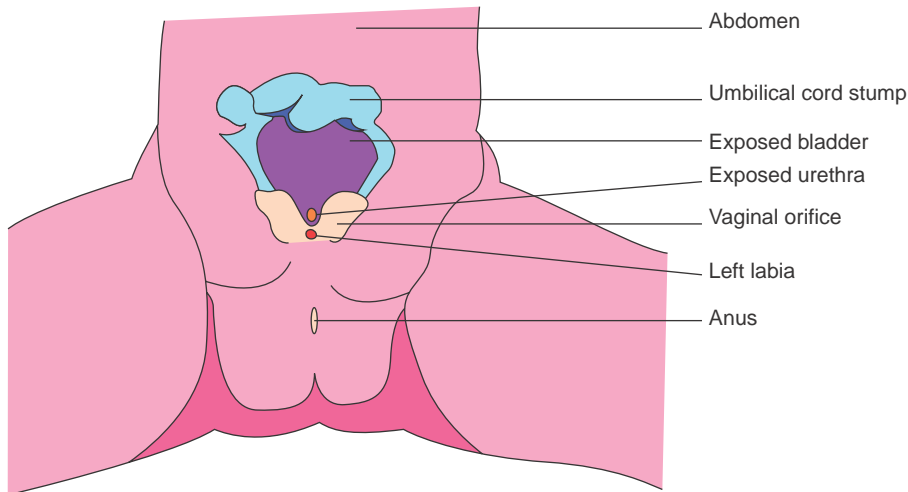
---

### 1.4.3. Other congenital disorders

#### 1.4.3.1. Bladder exstrophy

---

Bladder exstrophy is a congenital defect of the bladder, penis, abdominal wall and underlying bony pelvis. It is thought to occur in about 1:30,000–1:40,000 live births. Bladder exstrophy exists on a spectrum known as bladder exstrophy epispadia complex (Mahfuz *et al.*, 2013). It is multisystemic and may be associated with neurological, gastrointestinal, musculoskeletal and pelvic floor abnormalities. It may be diagnosed on an ultrasound at 15–32 weeks' gestation (Inouye *et al.*, 2013). The key principles of surgical correction include early abdominal wall closure, maintenance of continence and renal function, and stabilisation of any associated pelvic abnormalities. The basic perinatal appearance of bladder exstrophy is shown in [Figure 13.8](#). Surgical preferences and outcomes have changed dramatically since the mid-1980s. Surgical rates of success in case series in top centres are now around 95% (Mushtaq *et al.*, 2013). Success is generally determined by the prevention of wound dehiscence, prevention of hernia or



**Figure 13.8.** Appearance of bladder exstrophy.

recurrence of the exstrophy. The choice of surgery depends largely on the anatomy of the patient who is presented to the clinician. Surgery for boys and girls is slightly different secondary to the anatomical differences. The optimum timing for surgery in bladder exstrophy is yet to be determined; thus, there is variability among centres with regards to the timing of surgery. Surgery is often staged, with closure of the exstrophy a priority, followed by treatment of other associated GU abnormalities.

Surgery within the first 72 hours takes advantage of the maternal hormone relaxin, which allows manipulation and suturing of the pubic diastases without a requirement for external fixation and the associated complications. Suitable patients in this group fit into the classic bladder exstrophy group. The procedure involves dissection of the bladder plate from the rectus sheath. The bladder wall and the rectus sheath are then closed with absorbable sutures.

Exstrophy surgery beyond the first 72 hours of life generally requires orthopaedic specialist pelvic stabilisation (Inouye *et al.*, 2013). Accurate anatomical positions of the pelvis may be obtained by lower dose transverse slices on computed tomography imaging. Orthopaedic pelvic anatomical abnormalities are complex, and include hip and pelvic abnormalities. The aim of surgery is to relieve the pressure on the anterior abdominal wall caused by an externally rotated pelvic skeleton. Patients are placed in hip spicas with Bryant or Buck traction depending on the surgery which has been performed. In cases of failed primary closure, a combination of external fixation and 6–8 weeks of Buck traction with osteotomy enabled closure to persist in 96% of these patients (Meldrum *et al.*, 2003). In the same study, one patient suffered a pressure sore secondary to the insertion of a spica cast. However, in their review, Shnorhavorian *et al.* (2010) showed that the use of Bryant traction instead of spica led to no difference in the rate of urinary incontinence and was associated with twice the length of hospital stay (14.6 vs. 6.9 days).

Around 6–12 months after abdominal wall closure, the patient will undergo repair of the epispadias. The Canwell–Ransley procedure is most commonly performed, over three stages:

1. Corporal rotation
2. Urethral mobilisation
3. Improved glanuloplasty and dorsal skin coverage.

At around 4–8 years of age, the patient will undergo bladder neck reconstruction (BNR). The purpose of BNR is correction of the cystourethral reflux which may occur in these patients with the associated incontinence. The most of commonly performed BNR is that of Young–Dees–Leadbetter. The description of this technique is taken from Jones *et al.* (1993). A transverse incision is first made around the anterior segment of the distal urethra. The internal structure of the bladder is exposed with continuation of the incision in a posterior cephalad direction. The ureters may be reimplanted according to Politano–Leadbetter, Lich–Greogoir or Cohen methods (Steffens *et al.*, 2006). Politano–Leadbetter repair is thought to be a more reliable method of reimplanting the ureters because it can be performed bilaterally without significantly affecting overall bladder function (Steffens *et al.*, 2006). The ureter is tubularised in two layers, including suturing of the muscularis layer as well as the urethral mucosa. The bladder is closed and a sling is planned to be attached to the urethra. Post-operatively, a urethral catheter and cystostomy are positioned; the timing of their removal is at the surgeon's discretion.

#### 1.4.3.2. Micropenis

---

Micropenis is normally classified as a stretched penis length of less than two standard deviations below the mean for the chronological age (Tsang, 2010). It has a rare incidence at around 1–2 per 10,000 of the infant population. Normal penile development occurs as discussed earlier in the GU embryology section. Postnatally, there is a surge of testosterone within the first 3 months which accounts for much of the growth during this period. Over a period of 3–4 months following the initial rise, there is gradual senescence which lasts until the child reaches puberty. The causes of micropenis may include any of the three components of the hypothalamic–pituitary–gonadal axis. These are, broadly speaking, known as hypogonadotrophic (pituitary or hypothalamic failure) or hypergonadotrophic hypogonadism or may be idiopathic (Kayes *et al.*, 2012). Some patients such as those with hypogonadism secondary to pituitary failure may benefit from short courses of testosterone when treated in infancy and childhood, with increasing doses upon reaching pubertal age and adulthood (Bin-Abbas *et al.*, 1999). In patients who have failed endocrine therapy or who have female characteristics, gender reassignment may be reconsidered (as mentioned in previous sections). Any other surgical procedures are usually left until the child becomes an adult; these will be discussed later in this chapter.

#### 1.4.4. Sex chromosome DSD

---

As mentioned in an earlier section, children in this group may present with a spectrum of phenotypic features as a result of their genetic make-up. These patients have complete or partial gonadal dysgenesis, in which there is variation in the congenital loss of germ cells from the developing gonads. In the case of partial gonadal dysgenesis, there is a partial loss of cells which may be uni- or bilateral. In the case of



complete gonadal dysgenesis, there is complete loss of cells in a gonad leaving a ‘streak’ gonad. Capito *et al.* (2011) have suggested pathways of investigations depending on the clinical presentation of these patients. They may present with primary or secondary amenorrhoea, as well as precocious puberty, which are suggestive of a sex chromosome problem. The genetic variability results in a range of phenotypes which may be ambiguous or appear as male- or female-dominant (Donahoe *et al.*, 1979). In complete gonadal dysgenesis, there is a proposed 30% risk of developing a malignancy (Uehara *et al.*, 2002).

The most common malignancies in these patients are gonadoblastomas and dysgerminomas (Doherty and Rackow, 2011). Gonadoblastomas have a strong association with the presence of the Y chromosome in an affected individual. They are type II gonadal cell tumours, which are considered an *in situ* malignancy when the tumour is composed entirely of a gonadoblastoma (Talerman and Roth, 2007). However, they have malignant potential when they contain other tumours such as germinomas, embryonal carcinomas and choriocarcinomas. The other strong markers of malignant potential to form type II gonadal cell tumours include intra-abdominal gonadal tissues associated with hypovirilisation (Looijenga *et al.*, 2007). On routine histological and immunohistochemical studies, the seminomas and dysgerminomas have been found to have very similar genetic and staining characteristics (Looijenga *et al.*, 2007). The surgical management of gonadal dysgenesis depends on chromosome formation in the patient as well as the macroscopic appearance. ‘Streak’ or vanished gonads were previously thought to be safe to leave *in situ*; however, recent studies have demonstrated a potential for dysgerminoma to form in these lesions (Looijenga *et al.*, 2007).

#### 1.4.5. Summary of paediatric genital reconstruction

1. The GU system has a complex system of development.
2. DSDs are a common cause of congenital defects.
3. A multidisciplinary approach is best achieved to determine the best treatment for each child.
4. To carry out genital reconstruction, the surgeon must be aware of other strongly associated life-threatening associations.


## 2. ADULT GENITAL RECONSTRUCTION

The transition from paediatric to adult genital reconstruction, as for many conditions, is a continuum incorporating many disorders (see Table 13.7). Many conditions such as DSDs which were seen in the paediatric section still remain an issue in younger and older adult populations. This section will cover conditions which commonly require genital reconstruction within the adult population.

- Male and female genital trauma is covered, including female genital mutilation and penetrative vs. non-penetrative forms
- Reconstruction of male and female genital cancers
- Female-to-male and male-to-female gender reassignment is covered

**Table 13.7.** The transition from paediatric to adult genital reconstruction.

Paediatric		Adults	
Childhood	Adolescence	Young adults	Adults
DSD surgery	DSD	Trauma	Gender reassignment
Bladder exstrophy	Micropenis		Cancer
Cryptorchidism			
Hypospadias/epispadias			
Micropenis			



## 2.1. Male genital reconstruction

### 2.1.1. Trauma

Significant trauma to the external genitalia is rarely life-threatening, but their external position relative to the rest of the body means that they are vulnerable to trauma (Bartkiw *et al.*, 1995). Trauma in this specialised area may be categorised into blunt vs. penetrating trauma. Management follows the principles taught on the Advanced Trauma Life Support ('ATLS') course. The degree of injury to the external genitalia is strongly correlated with the specific injury mechanism. Trauma to individual components of the external genitalia will be considered in this section.

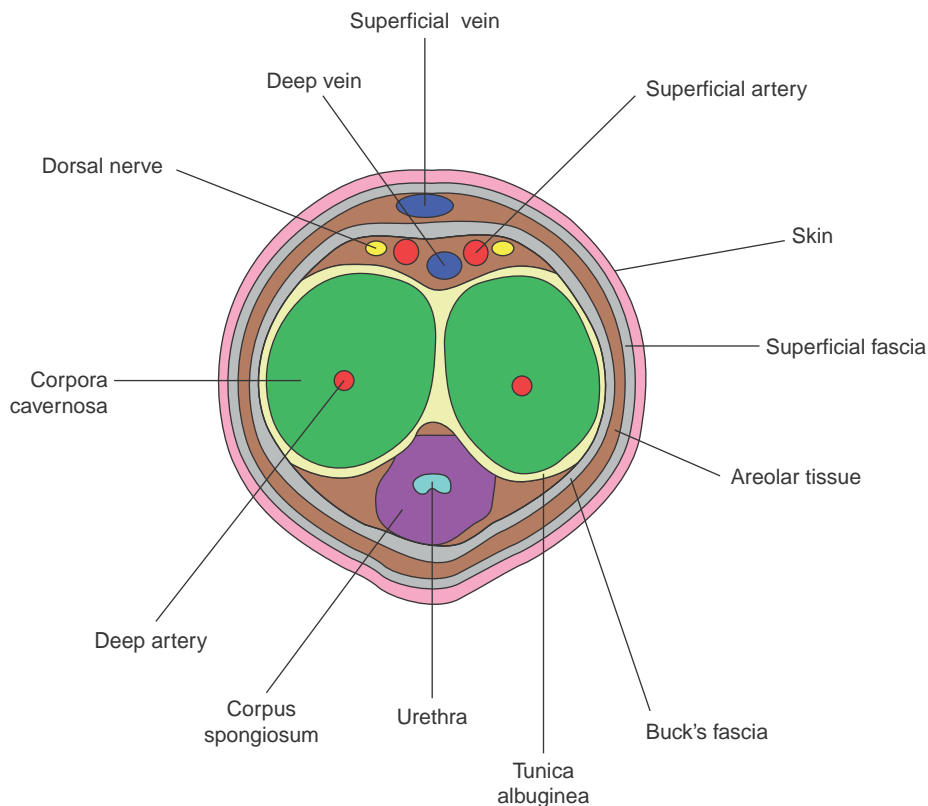
#### 2.1.1.1. Penis

Direct blunt trauma to the distal aspect of an erect penis may lead to penile fracture. A penile fracture occurs when there is direct injury to the corpus cavernosum, usually during sexual intercourse. Patients classically present having heard a snapping sound followed by pain and gross swelling, and immediate detumescence. However, there is variable presentation and many patients may damage surrounding penile tissue without specifically damaging the corpus cavernosum. The layers of the penis are shown in [Figure 2.1](#). Surgical exploration is warranted in all cases of presumed or a high risk of penis fracture. There is reported to be a 10–20% risk of having an associated urethral injury (Lynch *et al.*, 2005). Surgical repair is via a subcoronal or penoscrotal incision, evacuation of haematoma and debridement of tunica albuginea in relation to the corpus cavernosum. Repair of the corpus cavernosum is performed using 2-0 polydioxanone sutures and associated urethral trauma is repaired with 5-0 polyglactin sutures.

In the semi-erect or flaccid penis, direct injuries to the vasculature may be caused by blunt trauma. Priapism occurs when there is a persistent painful erection without sexual desire. Priapism may be categorised into ischaemic vs. non-ischaemic depending on the flow into the corpus cavernosum

(Stein and Martin, 1974). In non-ischaemic priapism, perineal trauma causes a fistula between the cavernosal artery and the lacunae. In this case, venous drainage is maintained, which prevents ischaemia of the underlying tissues. Ischaemic priapism is associated with stagnant blood within the corpus cavernosum which becomes progressively more ischaemic. Although most cases are idiopathic, common causes are haematological disorders such as sickle cell disease and leukaemia.

Traumatic penile amputations are rare occurrences in which the penis is severely traumatised, with division of the structures shown in Figure 2.1. Trauma may be caused by self-mutilation in an acutely unwell psychiatric patient or as a result of a physical assault. The first successful attempt to replant traumatically amputated penises was reported by Tamai *et al.* (1977). According to Ching *et al.* (2010), 'Microsurgical replantation is the standard method to treat penile amputation'. The penis is repaired in layers, starting with the urethral mucosa and corpus spongiosum which may be repaired with 5-0 Vicryl stitches (Chou *et al.*, 2008). The corpora cavernosa and tunica albuginea are repaired in a similar fashion. Repair of the dorsal veins and arteries follows; 10-0 nylon sutures can be used (Chou *et al.*, 2008).



**Figure 13.9.** Penile anatomy and layers.

### 2.1.1.2. Scrotum

---

Scrotal trauma is relatively rare and, similar to the penis, may present with a plethora of clinical syndromes. These range from a simple contusion to a testicular rupture depending on the traumatic load applied to the scrotal tissue. Rupture is classified as the complete loss of tunica albuginea coverage of a testicle. Studies have shown the rupture rate to be as high as 46% in cases of acute scrotal trauma (Buckley and McAninch, 2006). Ultrasound is a useful investigation that can form part of an algorithm to determine whether these patients require surgery. In the case of testicular rupture, if surgery is performed in the first 72 hours the testicular salvage rate may be 92% (Buckley and McAninch, 2006). The aim of surgery is to prevent the combined risks of secondary infection and atrophy within the injured testicle.

### 2.1.1.3. Penetrating trauma

---

The most common causes of penetrating genital trauma in the civilian population are gunshot and stab wounds. Penetrating injuries are associated with higher visceral injuries compared with blunt trauma injuries. The testicular salvage rate is reported to be 30–50%, which is much lower than for blunt injuries (Phonsombat *et al.*, 2008). Because of the nature of penetrating injuries, there may be a higher chance of damage to surrounding viscera. Associated life-threatening injuries are prioritised prior to genital organ salvage. Operatively, conservative debridement of devitalised tissues is performed, along with repair of deep fascial structures when possible. More simple lacerations of the scrotum can usually be closed directly secondary to the elasticity of the scrotal skin.

## 2.1.2. Malignancy

---

### 2.1.2.1. Penile cancer

---

Penile cancer is a rare malignancy with a considerably higher incidence in developing than developed countries. A large proportion of cancers are squamous cell in origin and they most commonly occur on the distal aspect of the penis. Surgical options are directly related to the extent of malignancy, both clinically and on radiological examination. For less-invasive lesions, surgical options include wide local excision, circumcision and penile-preserving surgery such as glans resurfacing. For more invasive lesions, glansectomy or partial penectomy may be performed. The lymph node status is assessed and dissection is carried out if there is evidence of lymph node disease. According to Monstrey *et al.* (2013), ‘In patients requiring total penectomy, observation for 1 year confirms adequate tumour margins without recurrence.’ Reconstruction in this case often requires microvascular expertise and the use of a free flap to reconstruct the penis. Options for this include the radial forearm and anterolateral thigh free flaps, as mentioned in the gender reassignment section.

### 2.1.2.2. Infection

---

Fournier gangrene is an uncommon ‘synergistic polymicrobial necrotising fasciitis of the perineum, scrotum, and penis which is characterised by obliterative endarteritis of the subcutaneous arteries, resulting in gangrene of the subcutaneous tissue and the overlying skin’ (Shyam and Rapsang, 2013). It has a high mortality rate ranging up to 67%. Mortality is strongly linked to factors such as the length of stay in hospital, source and type of organisms causing disease, heart and renal failure, as well as coagulopathy (Sorensen *et al.*, 2009). It often presents with non-specific symptoms and there may be a delay in presentation to hospital. Early aggressive surgical debridement, fluid therapy, appropriate antibiotic therapies and intensive care nursing are essential for managing this condition. Surgical debridement at the earliest opportunity is associated with decreased mortality (Fu *et al.*, 2010). Debridement begins from the site of the initial insult until healthy tissue or tissue of unknown viability is reached. On average, Fournier gangrene patients may undergo up to an average of 3.5 debridements before definitive reconstruction is achieved (Chawla *et al.*, 2003). Vacuum-assisted closure is used prior to definitive reconstruction to aid debridement and provide a suitable bed for skin grafts to adhere to. The choice of reconstructive procedure is dependent on the size, location and severity of defects and the volume of surrounding soft tissue available (Fu *et al.*, 2010). As mentioned in a previous section, the scrotal skin is elastic; therefore, partial defects to the scrotum may be closed directly. Scrotal advancement flaps can be used in small to medium-sized defects, providing aesthetically matched surrounding skin, but are limited in size by the blood supply (Fu *et al.*, 2010). Skin grafts, in contrast, can cover large defects and are technically easily performed but less aesthetically pleasing because of the associated secondary contraction and scarring. Fasciocutaneous flaps provide better cosmetic and functional outcomes compared with skin grafts alone. Fasciocutaneous flap types used in this area include the anterolateral thigh (ALT) and pudendal flaps. Myocutaneous flaps in the form of gracilis or ALT flaps can be used to eliminate dead space while providing more resistance to bacterial inocula in contaminated wounds (Fu *et al.*, 2010).

## 2.2. Female genital reconstruction

---

### 2.2.1. Trauma

---

The general management of female trauma patients follows the same principles mentioned [Section 2.1](#). However, the mechanisms of genital injuries differ between the sexes. The treatment of female genital trauma will be discussed with an emphasis on the anatomical differences compared with men.

#### 2.2.1.1. Female genital mutilation

---

Female genital mutilation (FGM), also known as ‘female circumcision’, involves all procedures causing partial or total removal of the external female genitalia for cultural or non-therapeutic reasons (Iavazzo *et al.*, 2013). The practice occurs most commonly in countries of eastern sub-Saharan Africa such as

Djibouti, Somalia and Eritrea. The practice also occurs in other parts of Africa, the Middle East and further afield in some ethnic groups in the Far East. Globally, around 130 million women have had FGM, with a further 2–3 million/year at risk of having the procedure. There are four classifications of FGM (Utz-Billing and Kentenich, 2008):

Type I (sunna) – removal of the clitoral foreskin;

Type II – removal of the clitoris with partial or total excision of the labia minora;

Type III – ‘infibulation’, in which there are features of type II and sewing up of the vaginal orifice; and

Type IV – includes a range of interventions including: piercing, clitoral stretching and scraping of the vagina.

The procedure is commonly carried out by individuals with no medical training under non-aseptic techniques and using equipment which has been used on other patients with insufficient sterilisation. Therefore women have significant complications after these operations. Recognised post-operative complications of these patients are:

- Immediate/early – damage to surrounding anatomical structures, lower urinary tract infection, pain, exposure to a wide range of pathogens.
- Intermediate – chronic urinary retention, dyspareunia, scarring, repeated human immunodeficiency virus (HIV) exposure, chronic inflammation of pelvic organs, infertility.
- Late – HIV/acquired immunodeficiency syndrome and other blood-borne viruses.

Although the practice of FGM is outlawed in the UK and Western Europe, many patients present to the reconstructive surgeon seeking treatment. A large proportion of reconstruction for these women has been performed by Foldès *et al.* in France. The most common reasons given by women requesting reconstructive surgery were the restoration of personal identity (99%) followed by improvement in sex life (81%) (Foldès *et al.*, 2012). The same restorative procedure was performed in each patient, with an emphasis on ‘restoring the clitoral anatomy’. For this, incisions are made around the clitoris to return it to a normal anatomical position. Sutures are used to secure the base of the clitoris to the vestibule. Most of the patients seen at follow-up had either an improvement or no change in symptoms from their pre-operative status.

#### 2.2.1.2. Physical assault

Physical non-FGM injuries to the external genitalia may occur during sexual intercourse. Prospective studies in gynaecological trauma services (excluding obstetric injuries) have shown coital injuries to represent 32.7% of genital injuries (Jana *et al.*, 2008). Legally, these injuries are classified according to whether intercourse was consensual (i.e. consent given) or non-consensual (i.e. no consent given). Consensual and non-consensual sexual relations show differences in the patterns of associated injuries. Non-consensual intercourse may be more violent and against a person’s will; therefore, there is more potential for damaging the genital structures. Prospective trials have shown the overall incidence of injury to be higher in cases of non-consensual intercourse (Lincoln *et al.*, 2013). Higher incidences of

injuries to the posterior fourchette of the vagina are reported following non-consensual sexual intercourse (Hilden *et al.*, 2005). The tears, ecchymosis, abrasions, redness and swelling ('TEARS') classification is one of the most common methods of examining genital injuries (Slaughter and Brown, 1992). Patients have a thorough gynaecological examination, usually within 48 hours of injury. Procedures include colposcopy, vaginal examination, toluidine blue staining and taking swabs for forensic evidence, as well as documenting any associated genital infections.

## 2.2.2. Malignancy

### 2.2.2.1. Vulval malignancy

According to Fowler (2009), 'The need for reconstruction after primary surgery for invasive vulvar neoplasia is less common as it has a lower frequency than other malignancies in the anatomical area.' Vulval defects are managed depending on the size of the defect that remains following the primary surgical excision. Smaller defects can be closed primarily. Larger vulval defects can be closed with split-thickness or full-thickness skin grafts. As mentioned previously, split-thickness skin grafts undergo secondary contracture and are therefore less aesthetically pleasing compared to full-thickness versions. There is abundant full-thickness skin available for harvest in the region of the groin. When full-thickness skin grafts take, they are more aesthetically pleasing; however, they require a well-vascularised bed to aid the take process. Larger vulval defects often require the use of local or regional flaps, especially when the disease or excision plane involves vaginal tissue.

### 2.2.2.2. Vagina

Vaginal defects may result from the resection of primary vaginal tumours or from invading tumours from surrounding structures such as the bladder, rectum or cervix. Major tumour excision or exenteration can result in large pelvic defects which require extensive reconstruction using some of the flaps discussed in previous sections. Vaginal defects can be divided into the following groups (Cordeiro *et al.*, 2001):

- Type IA – Anterior and lateral vaginal walls
- Type IB – Posterior wall
- Type IIA – Circumferential upper two-thirds of the vagina
- Type IIB – Circumferential vaginectomies.

#### 2.2.2.2.1. Type IA

Singapore flaps (also known as pudendal fasciocutaneous flaps) are the most useful flaps for defects of the anterior or lateral vaginal walls. The steps used in Singapore flaps are shown in Figure 13.10. Wee and Joseph (1989) were the first surgeons to describe its usage in pelvic reconstruction. The dissection is carried out lateral to the labia majora bilaterally, including the deep fascia and epimysium of

the adductor muscles; the flap is then undermined and mobilised subcutaneously (Woods *et al.*, 1992). The two flaps are sutured together in the midline placed to create a neovagina covering the previously exposed anterior and lateral walls. The skin surface becomes the inside of the neovagina and the vascularity and adipose tissue beds into the exenterated area.

#### 2.2.2.2.2. *Type IB*

The rectus abdominis myocutaneous (RAM) flap is used most commonly in patients with posterior exenteration defects of the vagina. These defects are usually secondary to rectal cancers and may extend as far as the coccyx (Cordeiro *et al.*, 2002). The RAM flap is robust, providing a reliable skin island associated with minimal early morbidity. The RAM can be raised vertically (VRAM) or transversely (TRAM) with dimensions of up to 10×20 cm in size (Soper *et al.*, 2007). The rectus muscle is dissected from the anterior and posterior rectus sheath and rotated medially into the pelvis, preserving the deep inferior epigastric vessels. The flap is placed into the bed of the excised vaginal wall and must reduce the dead space as well as vascularise the devitalised tissue removed during the pelvic exenteration.

#### 2.2.2.2.3. *Type IIA*

The defect involved here involves the circumferential upper two-thirds of the vagina. The chosen flap must be able to provide sufficient skin to cover the circumferential defect at the cranial end of the vagina. In an intact pelvic floor, the RAM is best for reconstruction because it doesn't compromise any of the muscles of this region. Use of the sigmoid colon is an alternative when trying to close the defect.

#### 2.2.2.2.4. *Type IIB*

Type IIB defects involve the whole vaginal circumference and the introitus. They often occur as a consequence of aggressive pelvic exenteration surgery. Bilateral gracilis flaps are often used with excellent outcomes in reconstruction of these defects. The technique for gracilis flap harvesting is taken from McGraw *et al.* (1976). The patient is placed in adjustable obstetric stirrups. The anterior borders of the flap extend proximally to the adductor longus tendon (pubic tubercle) and distally to the semitendinosus tendon (Figure 13.11). The cutaneous portion is centred directly over the adductor musculature to involve the greatest number of perforators (Cordeiro *et al.*, 2002). The initial dissection begins posteriorly where the gracilis is identified, dissected clear of the surrounding adductor musculature and raised along with the semimembranosus fascia. Anteriorly, the posterior border of the sartorius is identified while preserving the saphenous neurovascular bundle. A subcutaneous tunnel is formed to extend from the gracilis harvest site into the reconstructed pelvis. The gracilis myocutaneous flap is finally calculated and then placed within the exenterated vagina pelvic wall.



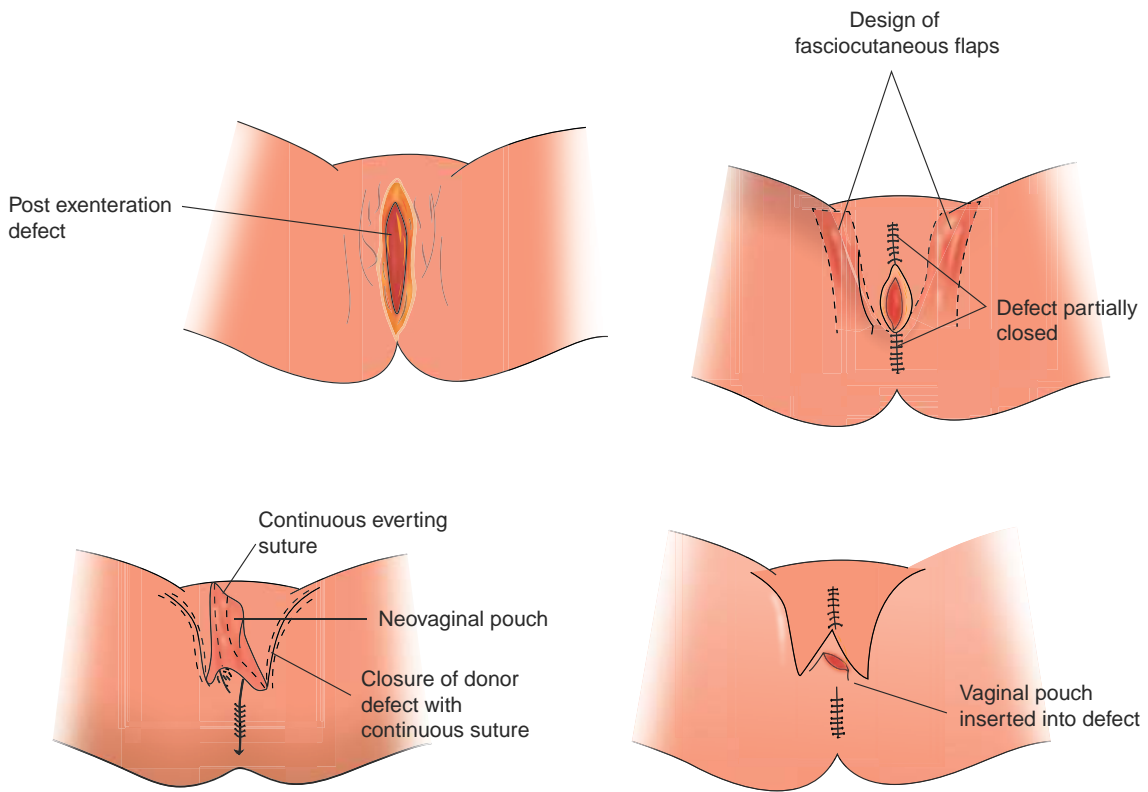


Figure 13.10. Singapore fasciocutaneous flaps.

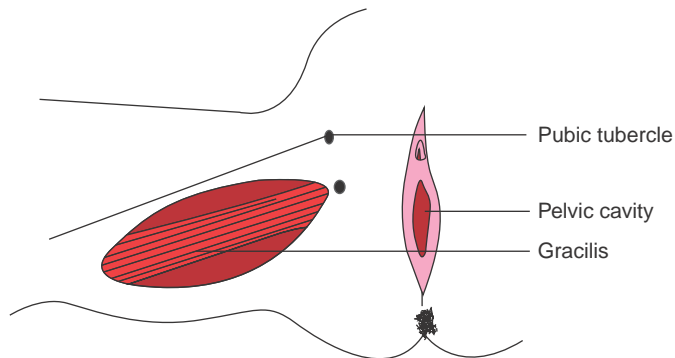


Figure 13.11. Gracilis myocutaneous flap boundaries.

## 2.3. Gender reassignment

---

According to Selvaggi and Bellringer (2011), ‘Gender reassignment surgery is indicated for the treatment of gender dysphoria.’ Gender dysphoria has an incidence of between 1:12,000 (men) and 1:100,000 (women) (Selvaggi *et al.*, 2005). Much of the early work demonstrating the benefits of gender reassignment was performed by Dr Harry Benjamin. Gender reassignment can be performed in a male-to-female (MtF) or female-to-male (FtM) direction. MtF is around four times more common than FtM (Selvaggi and Bellringer, 2011), although the reason for this is not entirely clear. All patients prior to consideration of surgery must have been assessed by two independent gender psychiatrists.

### 2.3.1. Male-to-female reassignment

---

Patients undergoing this process will undergo feminisation of many genital structures. The degree of feminisation is dependent on the patient’s anatomy as well as their own expectations and desires. The four core components of reconstruction for patients undergoing this form of genital reconstruction are described.

#### 2.3.1.1. Demasculinisation: orchidectomy and penile disassembly

---

Following correct positioning and preparation of the patient, orchidectomy may be performed via a midline incision (Amend *et al.*, 2013). The penis is gradually degloved, followed by dorsal dissection of the erectile tissue from the neurovascular structures. The urethra is freed from the glans penis. The individual components of the disassembled penis are placed inside the scrotum ready for the next stage of the reconstruction.

#### 2.3.1.2. Feminisation: neoclitoris, vaginoplasty and meatus construction

---

The previous scrotal incision is extended toward the perineum in a cephalad direction. The paired corpora cavernosa are then totally removed after identification of their individual blood supplies. The next stage is creation of the neovagina, which occurs by methods modified from those described in the DSD section. The fully grown male anatomy requires blunt dissection of the retroprostatic fascia as described by Selvaggi and Bellringer (2011) and Amend *et al.* (2013). The cavity created between the rectum and prostate may be lined by excessive penile skin (uncircumcised), skin grafts or bowel segments to form the epithelial lining of the neovagina. The neovagina is sutured into the surrounding ligamentous structures to aid stability and maintain its structure. The remains of the disassembled glans are used to form the neoclitoris, as described by Rubin *et al.* (1993). This technique has the advantage of providing a well-sensitised structure to aid sexual function. The urethra is shortened, spatulated and stitched onto the remaining penile fascia. The urethra is then fixed into its final anatomical position.

### 2.3.2. Female-to-male reassignment

---

The first step in the FtM genital reassignment involves the removal of excessive subcutaneous breast tissue and conversion to a more male-appearing breast. This procedure may be combined with hysterectomy

and oophorectomy prior to formal reconstruction of the genitals (Monstrey *et al.*, 2013). The combined procedures of phalloplasty are ideally performed in a single stage to reconstruct an aesthetically pleasing phallus with tactile sensation which enables the patient to void while standing and to have sexual intercourse like a natural man (Gilbert *et al.*, 1987).

### 2.3.2.1. Phalloplasty and scrotoplasty

The radial forearm free flap is the most commonly used method for phallic reconstruction because it is a reliable technique that provides the ability to void while standing and the ability to have sexual satisfaction (Monstrey *et al.*, 2009). Radial forearm free flap elevation is often performed by the plastic surgeon while the urologist performs vaginectomy, preparation of the urethra for tubularisation into the neophallus and scrotoplasty (Monstrey *et al.*, 2004). The recipient vessels of the groin (inferior epigastric artery and long saphenous vein) are anastomosed with the radial artery and cephalic veins, respectively. Two forearm cutaneous nerves are included; these are anastomosed to the ilioinguinal and dorsal clitoral nerves, respectively (Monstrey *et al.*, 2009). Patients are fitted with urinary diversion post-operatively (usually in the form of a suprapubic catheter). The technique for scrotoplasty is adopted from Selvaggi *et al.* (2009). The neoscrotum is designed using full-thickness skin flaps that include skin, subcutaneous fat, areolar tissue, and nerves and vessels from the labia majora. Testicular prostheses are inserted into the flaps labia and then exchanged for inflatable penile prosthesis, at which point the pump is exchanged for a single prosthesis. Both flaps are rotated medially while the skin of the clitoris is gradually lowered into the neophallic area. Excess amounts of scrotal skin are removed prior to the two flaps being sutured together. The donor perineum sites are closed directly using absorbable sutures. Scrotal and phallic erection implants are inserted as secondary and tertiary surgery at around 6 and 12 months respectively.

### 2.3.3. Summary of adult genital reconstruction

1. Genital reconstruction in adults can follow similar principles to those of children.
2. One of the main aims of genital reconstruction in adults is to maintain enjoyable sexual activity.
3. Genital trauma is a sensitive issue which must be dealt with sensitively in a multidisciplinary team environment.

## REFERENCES

- Acién, P. 1992. Embryological observations on the female genital tract. *Human Reproduction*, 7, 437–45.
- Aksghlaede, L., Juul, A. 2013. Testicular function and fertility in men with Klinefelter syndrome: A review. *European Journal of Endocrinology*, 168, R67–R76.
- Alagaratnam, S., Nathaniel, C., Cuckow, P., Mushtaq, I., Desai, D., Cherian, A., Drake, D., Kiely, E., Pierro, A., De Coppi, P. 2010. Testicular outcomes following laparoscopic second stage Fowler-Stephens orchidopexy. *Journal of Pediatric Urology*, 6, S71.

- Amend, B., Seibold, J., Toomey, P., Stenzl, A., Sievert, K.-D. 2003. Surgical reconstruction for male-to-female sex reassignment. *European Urology*, 64(1), 141–9.
- Arshad, A. R. 2005. Hypospadias repair: Byar's two stage operation revisited. *British Journal of Plastic Surgery*, 58, 481–6.
- Auchus, R., Chang, A. 2010. 46, XX DSD: the masculinised female. *Best Practice & Research Clinical Endocrinology & Metabolism*, 24, 219–42.
- Barbaro, M., Wedell, A., Nordenström, A. 2011. Disorders of sex development. *Seminars in Fetal and Neonatal Medicine*, Elsevier, 119–27.
- Bartkiw, T. P., Goldfarb, B., Trachtenberg, J. 1995. Male genital trauma: Diagnosis and management. *International Journal of Trauma Nursing*, 1, 99–107.
- Baskin, L. S., Himes, K., Colborn, T. 2001. Hypospadias and endocrine disruption: Is there a connection? *Environmental Health Perspectives*, 109, 1175.
- Bin-Abbas, B., Conte, F. A., Grumbach, M. M., Kaplan, S. L. 1999. Congenital hypogonadotropic hypogonadism and micropenis: Effect of testosterone treatment on adult penile size – Why sex reversal is not indicated. *The Journal of Pediatrics*, 134, 579–83.
- Brinkmann, A. O., Faber, P. W., Van Rooij, H. C., Kuiper, G. G., Ris, C., Klaassen, P., Van Der Korput, J. A., Voorhorst, M. M., Van Laar, J. H., Mulder, E. 1989. The human androgen receptor: Domain structure, genomic organization and regulation of expression. *The Journal of Steroid Biochemistry*, 34, 307–10.
- Buckley, J. C., McAninch, J. W. 2006. Use of ultrasonography for the diagnosis of testicular injuries in blunt scrotal trauma. *The Journal of Urology*, 175, 175–8.
- Capito, C., Leclair, M.-D., Arnaud, A., David, A., Baron, S., Corradini, N., Hérouy, Y. 2011. 46, XY pure gonadal dysgenesis: clinical presentations and management of the tumor risk. *Journal of Pediatric Urology*, 7, 72–5.
- Chawla, S., Gallop, C., Mydlo, J. 2003. Fournier's gangrene: An analysis of repeated surgical debridement. *European Urology*, 43, 572–5.
- Ching, W.-C., Liao, H.-T., Ulusal, B., Chen, C.-T., Lin, C.-H. 2010. Salvage of a complicated penis replantation using bipedicle scrotal flap following a prolonged ischaemia time. *Journal of Plastic, Reconstructive & Aesthetic Surgery*, 63, e639–43.
- Chou, E. K., Tai, Y. T., Wu, C. I., Lin, M. S., Chen, H. H., Chang, S. C. N. 2008. Penile replantation, complication management, and technique refinement. *Microsurgery*, 28, 153–6.
- Cohen, H., Kravets, F., Zucconi, W., Ratani, R., Shah, S., Dougherty, D. 2004. Congenital abnormalities of the genitourinary system. *Seminars in Roentgenology*, 39, 282–303.
- Comploj, E., Pycha, A. 2012. Diagnosis and management of cryptorchidism. *European Urology Supplements*, 11, 2–9.
- Cordeiro, P., Pusic, A., Disa, J. 2002. A classification system and reconstructive algorithm for acquired vaginal defects. *Plastic and Reconstructive Surgery*, 110, 1058–65.
- Creighton, S., Chernašek, S., Romao, R., Ransley, P., Salle, J. 2012. Timing and nature of reconstructive surgery for disorders of sex development – Introduction. *Journal of Pediatric Urology*, 8, 602–10.
- D'Alborton, F. 2010. Disclosing disorders of sex development and opening the doors. *Sexual Development*, 4, 304–9.
- Davies, M., Creighton, S. 2007. Vaginoplasty. *Current Opinion in Urology*, 17, 415–18.
- Dessens, A., Slijper, F. M. E., Drop, S. L. S. 2005. Gender dysphoria and gender change in chromosomal females with congenital adrenal hyperplasia. *Archives of Sexual Behavior*, 34, 389–97.
- Devine Jr, C. 1961. A one stage hypospadias repair. *The Journal of Urology*, 85, 166–72.
- Doherty, L. F., Rackow, B. W. 2011. Abnormal streak gonads in 46, XY complete gonadal dysgenesis. *Fertility and Sterility*, 96, 1415–16.
- Dòmini, R., Rossi, F., Ceccarelli, P. L., Castro, R. D. 1997. Anterior sagittal transanorectal approach to the urogenital sinus in adrenogenital syndrome: Preliminary report. *Journal of Pediatric Surgery*, 32, 714–16.
- Donahoe, P. K., Crawford, J. D., Hendren, W. H. 1979. Mixed gonadal dysgenesis, pathogenesis, and management. *Journal of Pediatric Surgery*, 14, 287–300.

- Duckett, J. W. 2002. MAGPI (meatoplasty and glanuloplasty) a procedure for subcoronal hypospadias. *The Journal of Urology*, 167, 2153–6.
- Elder, J. S. 1992. Two-stage Fowler-Stephens orchiopexy in the management of intra-abdominal testes. *The Journal of Urology*, 148, 1239–41.
- Farkas, A., Chertin, B., Hadas-Halpren, I. 2001. 1-Stage feminizing genitoplasty: 8 years of experience with 49 cases. *The Journal of Urology*, 165, 2341–6.
- Farrugia, M., Sebire, N., Achermann, J., Eisawi, A., Duffy, P., Mushtaq, I. 2013. Clinical and gonadal features and early surgical management of 45, X/46, XY and 45, X/47, XYY chromosomal mosaicism presenting with genital anomalies. *Journal of Pediatric Urology*, 9, 139–44.
- Foldès, P., Cuzin, B., Andro, A. 2012. Reconstructive surgery after female genital mutilation: A prospective cohort study. *The Lancet*, 380, 134–41.
- Fowler, J. 2009. Incorporating pelvic/vaginal reconstruction into radical pelvic surgery. *Gynecologic Oncology*, 115, 154–63.
- Fowler, R., Stephens, F. D. 1959. The role of testicular vascular anatomy in the salvage of high undescended testes. *Australian and New Zealand Journal of Surgery*, 29, 92–106.
- Frank, R. T. 1938. The formation of an artificial vagina without operation. *American Journal of Obstetrics and Gynecology*, 35, 20A.
- Fu, J.-P., Chen, T.-M., Chen, S.-G. 2011. Reconstruction of scrotal and perineal defects in Fournier's gangrene. *Journal of Plastic, Reconstructive & Aesthetic Surgery*, 64, 528–34.
- Fu, J.-P., Wang, C.-H., Lee, T.-P., Chen, S.-G. 2010. Fournier gangrene: A review of 41 patients and strategies for reconstruction. *Annals of Plastic Surgery*, 64, 765–9.
- Gilbert, D. A., Horton, C. E., Terzis, J. K., Devine, C. J., Winslow, B. H., Devine, P. C. 1987. New concepts in phallic reconstruction. *Annals of Plastic Surgery*, 18, 128–36.
- Gross, R. E., Randolph, J., Crigler, J. F. 1966. Clitorectomy for sexual abnormalities: Indications and technique. *Surgery*, 59, 300–8.
- Gundeti, M., Queteishat, A., Desai, D., Cuckow, P. 2005. Use of an inner preputial free graft to extend the indications of Snodgrass hypospadias repair (Snodgraft). *Journal of Pediatric Urology*, 1, 395–6.
- Haxhiresha, K., Castagnetti, M., Rigamonti, W., Manzoni, G. 2008. Two-stage repair in hypospadias. *Indian Journal of Urology*, 24, 226.
- Held-Warmkessel, J. 2012. Penile cancer. *Seminars in oncology nursing*, Elsevier, 190–201.
- Hilden, M., Schei, B., Sidenius, K. 2005. Genitoanal injury in adult female victims of sexual assault. *Forensic Science International*, 154, 200–5.
- Holterhus, P. M., Sinnecker, G. H., Hiort, O. 2000. Phenotypic diversity and testosterone-induced normalization of mutant L712F androgen receptor function in a kindred with androgen insensitivity. *The Journal of Clinical Endocrinology and Metabolism*, 85, 3245–50.
- Hrabovszky, Z., Hutson, J. M. 2002. Androgen imprinting of the brain in animal models and humans with intersex disorders: Review and recommendations. *The Journal of Urology*, 168, 2142–8.
- Hrabovszky, Z., Farmer, P. J., Hutson, J. M. 2001. Undescended testis is accompanied by calcitonin gene related peptide accumulation within the sensory nucleus of the genitofemoral nerve in trans-scrotal rats. *The Journal of Urology*, 165, 1015–8.
- Hughes, I. A., Houk, C., Ahmed, S. F., Lee, P. A. 2006. Consensus statement on management of intersex disorders. *Journal of Pediatric Urology*, 2, 148–62.
- Hutson, J., Southwell, B., Li, R., Lie, G., Ismail, K., Harisis, G., Chen, N. 2013. The regulation of testicular descent and the effects of cryptorchidism. *Endocrine Reviews*, 34, 725–52.
- Hutson, J. M., Balic, A., Nation, T., Southwell, B. 2010. Cryptorchidism. *Seminars in pediatric surgery*, Elsevier, 215–24.
- Hynes, P., Fraher, J. 2004. The development of the male genitourinary system. I. The origin of the urorectal septum and the formation of the perineum. *British Journal of Plastic Surgery*, 57, 27–36.

- Iavazzo, C., Sardi, T. A., Gkegkes, I. D. 2013. Female genital mutilation and infections: A systematic review of the clinical evidence. *Archives of Gynecology and Obstetrics*, 1–13.
- Inouye, B. M., Massanyi, E. Z., Di Carlo, H., Shah, B. B., Gearhart, J. P. 2013. Modern management of bladder exstrophy repair. *Current Urology Reports*, 1–7.
- Jana, N., Santra, D., Das, D., Das, A. K., Dasgupta, S. 2008. Nonobstetric lower genital tract injuries in rural India. *International Journal of Gynecology & Obstetrics*, 103, 26–9.
- Jones, J., Mitchell, M., Rink, R. 1993. Improved results using a modification of the Young–Dees–Leadbetter bladder neck repair. *British Journal of Urology*, 71, 555–61.
- Josso, N., di Clemente, N. 2004. *Anti-Mullerian Hormone*, France, Elsevier
- Kalfa, N., Philibert, P., Baskin, L., Sultan, C. 2011. Hypospadias: Interactions between environment and genetics. *Molecular and Cellular Endocrinology*, 335, 89–95.
- Kaplan, G. 1993. Nomenclature of cryptorchidism. *European Journal of Paediatrics*, 152, S17–9.
- Kaye, J., Palmer, L. 2008. Single setting bilateral laparoscopic orchiopexy for bilateral intra-abdominal testicles. *The Journal of Urology*, 180, 1795–9.
- Kayes, O., Shabbir, M., Ralph, D., Minhas, S. 2012. Therapeutic strategies for patients with micropenis or penile dysmorphic disorder. *Nature Reviews Urology*, 9(9), 449–507.
- Kogan, S. J., Smey, P., Levitt, S. B. 1983. Subtunicular total reduction clitoroplasty: A safe modification of existing techniques. *The Journal of Urology*, 130, 746–8.
- Korkut, M., İçöz, G., Dayanaç, M., Akgün, E., Yeniay, L., Erdoğan, O., Cal, C. 2003. Outcome analysis in patients with Fournier’s gangrene: Report of 45 cases. *Diseases of the Colon & Rectum*, 46, 649–652.
- Larsen, W. 2001. *Human Embryology*, USA, Churchill Livingstone.
- Laterza, R., De Gennaro, M., Tubaro, A., Koelbl, H. 2011. Female pelvic congenital malformations. Part I: Embryology, anatomy and surgical treatment. *European Journal of Obstetrics & Gynecology and Reproductive Biology*, 159, 26–34.
- Looijenga, L. H., Hersmus, R., Oosterhuis, J. W., Cools, M., Drop, S. L., Wolffenbuttel, K. P. 2007. Tumor risk in disorders of sex development (DSD). *Best Practice & Research Clinical Endocrinology & Metabolism*, 21, 480–95.
- Lynch, T. H., Martínez-Piñeiro, L., Plas, E., Serafetinides, E., Türkeri, L., Santucci, R. A., Hohenfellner, M. 2005. EAU guidelines on urological trauma. *European Urology*, 47, 1–15.
- Lincow, C., Perera, R., Jacobs, I., Ward, A. 2013. Macroscopically detected female genital injury after consensual and non-consensual vaginal penetration: A prospective comparison study. *Journal of Forensic and Legal Medicine*, 20(7), 884–901.
- Mahfuz, I., Darling, T., Wilkins, S., White, S., Cheng, W. 2013. New insights into the pathogenesis of bladder exstrophy–epispadias complex. *Journal of Pediatric Urology*, 9(6), 996–1005.
- Massanyi, E., McMahon, D. 2011. Technique for preservation of penile skin in genital reconstruction: Free graft to the scrotum. *Urology*, 78, 659–61.
- Massanyi, E. Z., Dicarlo, H. N., Migeon, C. J., Gearhart, J. P. 2012. Review and management of 46, XY Disorders of Sex Development. *Journal of Pediatric Urology*, 9(3), 368–79.
- Mathieu, P. 1932. Traitement en un temps de l’hypospadias balanique et juxtabalanique. *Journal de Chirurgie*, 481.
- McCraw, J. B., Massey, F. M., Shanklin, K. D., Horton, C. E. 1976. Vaginal reconstruction with gracilis myocutaneous flaps. *Plastic and Reconstructive Surgery*, 58, 176–83.
- McIndoe, A., Banister, J. B. 1938. An operation for the cure of congenital absence of the vagina. *British Journal of Obstetrics and Gynaecology*, 45, 490–4.
- Meldrum, K. K., Baird, A. D., Gearhart, J. P. 2003. Pelvic and extremity immobilization after bladder exstrophy closure: Complications and impact on success. *Urology*, 62, 1109–13.
- Mendonca, B. B., Domenice, S., Arnhold, I. J., Costa, E. M. 2009. 46, XY disorders of sex development (DSD). *Clinical Endocrinology*, 70(2), 173–87.
- Miranda, M. L., De Oliveira-Filho, A. G., Lemos-Marini, S. H. V., Guerra Jr, G., Murray Bustorff-Silva, J. 2004. Labioscrotal island flap in feminizing genitoplasty. *Journal of Pediatric Surgery*, 39, 1030–3.
- Monstrey, S. J., Ceulemans, P., Hoebeke, P. (eds.). 2011. Sex reassignment surgery in the female-to-male transsexual. *Seminars in Plastic Surgery*, Thieme Medical Publishers

- Monstrey, S., Ceulemans, P., Roche, N., Houtmeyers, P., Lumen, N., Hoebeke, P. 2013. Reconstruction of male genital defects. In: Neligan, P. (ed.) *Plastic Surgery: Lower Extremity, Trunk and Burns*, Third ed. London: Elsevier Saunders.
- Monstrey, S., Hoebeke, P., Dhont, M., Hamdi, M., Van Landuyt, K., Blondeel, P. 2004. Radial forearm phalloplasty: A review of 91 cases: ANIR ANHP, 6(4), 193–9.
- Monstrey, S., Hoebeke, P., Selvaggi, G., Ceulemans, P., Van Landuyt, K., Blondeel, P., Hamdi, M., Roche, N., Weyers, S., DeCuyper, G. 2009. Penile reconstruction: is the radial forearm flap really the standard technique? *Plastic and Reconstructive Surgery*, 124, 510–8.
- Mouriquand, P., Persad, R., Sharma 1995. Hypospadias repair: Current principles and practice. *British Journal of Urology*, 76, 9–22.
- Mushtaq, I., Garriboli, M., Smeulders, N., Cherian, A., Desai, D., Eaton, S., Duffy, P., Cuckow, P. 2013. Primary bladder exstrophy closure in neonates: challenging the traditions. *The Journal of Urology*, 191(1), 193–8.
- Mustarde, J. 1965. One stage correction of distal hypospadias and other people's fistulae. *British Journal of Plastic Surgery*, 18, 413.
- Peña, A., Filmer, B., Bonilla, E., Mendez, M., Stolar, C. 1992. Transanorectal approach for the treatment of urogenital sinus: Preliminary report. *Journal of Pediatric Surgery*, 27, 681–5.
- Phonsombat, S., Master, V. A., McAninch, J. W. 2008. Penetrating external genital trauma: A 30-year single institution experience. *The Journal of Urology*, 180, 192–6.
- Pippi Salle, J. L., Lorenzo, A. J., Jesus, L. E., Leslie, B., Alsaïd, A., Macedo, F. N., Jayanthi, V. R., De Castro, R. 2012. Surgical treatment of high urogenital sinuses using the anterior sagittal transrectal approach: A useful strategy to optimize exposure and outcomes. *The Journal of Urology*, 187, 1024–31.
- Rajfer, J., Ehrlich, R. M., Goodwin, W. E. 1982. Reduction clitoroplasty via ventral approach. *The Journal of Urology*, 128, 341–3.
- Rink, R., Metcalfe, P., Cain, M., Meldrum, K., Kaefer, M., Casale, A. 2006. Use of the mobilized sinus with total urogenital mobilization. *The Journal of Urology*, 176, 2205–11.
- Roll, M., Kneppo, C., Roth, H., Bettendorf, M., Waag, K.-L., Holland-Cunz, S. 2006. Feminising genitoplasty: One-stage genital reconstruction in congenital adrenal hyperplasia: 30 years' experience. *European Journal of Pediatric Surgery*, 16, 329–33.
- Rubin, S. 1993. Sex reassignment surgery male to female. *Scandinavian Journal of Urology and Nephrology*, 154, 1–28.
- Sadler, T. 2012. *Medical Embryology*, USA, Lippincott Williams & Wilkins.
- Saenger, P., Reiter, E. O. 1992. Management of cryptorchidism. *Trends in Endocrinology & Metabolism*, 3, 249–53.
- Sagehashi, N. 1993. Clitoroplasty for clitoromegaly due to adrenogenital syndrome without loss of sensitivity. *Plastic and Reconstructive Surgery*, 91, 950–5.
- Schultz, J. R., Klykylo, W. M., Wacksman, J. 1983. Timing of elective hypospadias repair in children. *Pediatrics*, 71, 342–51.
- Schwentner, C., Oswald, J., Kreczy, A., Lunacek, A., Bartsch, G., Deibl, M., Radmayr, C. 2005. Neoadjuvant gonadotropin-releasing hormone therapy before surgery may improve the fertility index in undescended testes: A prospective randomized trial. *The Journal of Urology*, 173, 974–7.
- Selvaggi, G., Bellringer, J. 2011. Gender reassignment surgery: An overview. *Nature Reviews. Urology*, 8, 274–82.
- Selvaggi, G., Ceulemans, P., DeCuyper, G., Vanlanduyt, K., Blondeel, P., Hamdi, M., Bowman, C., Monstrey, S. 2005. Gender identity disorder: General overview and surgical treatment for vaginoplasty in male-to-female transsexuals. *Plastic and Reconstructive Surgery*, 116, 135e–145e.
- Selvaggi, G., Hoebeke, P., Ceulemans, P., Hamdi, M., Van Landuyt, K., Blondeel, P., DeCuyper, G., Monstrey, S. 2009. Scrotal reconstruction in female-to-male transsexuals: A novel scrotoplasty. *Plastic and Reconstructive Surgery*, 123, 1710–18.
- Shnorhavorian, M., Song, K., Zamilpa, I., Wiater, B., Mitchell, M. M., Grady, R. W. 2010. Spica casting compared to Bryant's traction after complete primary repair of exstrophy: Safe and effective in a longitudinal cohort study. *The Journal of Urology*, 184, 669–74.

- Shukla, A. R., Patel, R. P., Canning, D. A. 2004. The 2-stage hypospadias repair. Is it a misnomer? *The Journal of Urology*, 172, 1714–16.
- Shyam, D. C., Rapsang, A. G. 2013. Fournier's gangrene. *The Surgeon*.
- Slaughter, L., Brown, C. R. 1992. Colposcopy to establish physical findings in rape victims. *American Journal of Obstetrics and Gynecology*, 166, 83–6.
- Snodgrass, W. T. 2005. Snodgrass technique for hypospadias repair. *BJU International*, 95, 683–93.
- Song, D. 2013. *Plastic Surgery Lower Extremity, Trunk and Burns*, London, Elsevier.
- Soper, J. T., Secord, A. A., Havrilesky, L. J., Berchuck, A., Clarke Pearson, D. L. 2007. Comparison of gracilis and rectus abdominis myocutaneous flap neovaginal reconstruction performed during radical pelvic surgery: Flap-specific morbidity. *International Journal of Gynecological Cancer*, 17, 298–303.
- Sorensen, M. D., Krieger, J. N., Rivara, F. P., Klein, M. B., Wessells, H. 2009. Fournier's gangrene: management and mortality predictors in a population based study. *The Journal of Urology*, 182, 2742–7.
- Spence, H. M., Allen, T. D. 1973. Genital reconstruction in the female with the adrenogenital syndrome. *British Journal of Urology*, 45, 126–30.
- Springer, A., Krois, W., Horcher, E. 2011. Trends in hypospadias surgery: Results of a worldwide survey. *European Urology*, 60, 1184–9.
- Steffens, J., Stark, E., Haben, B., Treiyer, A. 2006. Surgical Atlas Politano–Leadbetter ureteric reimplantation. *BJU International*, 98, 695–712.
- Stein, J. J., Martin, D. C. 1974. Priapism. *Urology*, 3, 8–14.
- Stein, R. 2012. Hypospadias. *European Urology Supplements*, 11, 33–45.
- Talerman, A., Roth, L. M. 2007. Recent advances in the pathology and classification of gonadal neoplasms composed of germ cells and sex cord derivatives. *International Journal of Gynecologic Pathology*, 26, 313–21.
- Tamai, S., Nakamura, Y., Motomiya, Y. 1977. Microsurgical replantation of a completely amputated penis and scrotum: Case report. *Plastic and Reconstructive Surgery*, 60, 287–91.
- Tint, G. S., Irons, M., Elias, E. R., Batta, A. K., Frieden, R., Chen, T. S., Salen, G. 1994. Defective cholesterol biosynthesis associated with the Smith–Lemli–Opitz syndrome. *New England Journal of Medicine*, 330, 107–13.
- Tsang, S. 2010. When size matters: A clinical review of pathological micropenis. *Journal of Pediatric Health Care*, 24, 231–40.
- Uehara, S., Hashiyada, M., Sato, K., Nata, M., Funato, T., Okamura, K. 2002. Complete XY gonadal dysgenesis and aspects of the Sry genotype and gonadal tumor formation. *Journal of Human Genetics*, 47, 279–84.
- Utz-Billing, I., Kentenich, H. 2008. Female genital mutilation: An injury, physical and mental harm. *Journal of Psychosomatic Obstetrics & Gynecology*, 29, 225–9.
- Van-Der-Muelen, J. 1971. Hypospadias and cryptospadias. *British Journal of Plastic Surgery*, 24, 101.
- Vidal, I., Gorduza, D., Haraux, E., Gay, C.-L., Chatelain, P., Nicolino, M., Mure, P.-Y., Mouriquand, P. 2010. Surgical options in disorders of sex development (DSD) with ambiguous genitalia. *Best Practice & Research Clinical Endocrinology & Metabolism*, 24, 311–24.
- Weber, D., Schonbucher, V., Gobet, R., Gerber, A., Landolt, M. 2009. Is there an ideal age for hypospadias repair? A pilot study. *Journal of Pediatric Urology*, 5, 345–50.
- Wee, J. T., Joseph, V. T. 1989. A new technique of vaginal reconstruction using neurovascular pudendal-thigh flaps: A preliminary report. *Plastic and Reconstructive Surgery*, 83, 701–9.
- Werner, R., Grötsch, H., Hiort, O. 2010. 46, XY disorders of sex development – The undermasculinised male with disorders of androgen action. *Best Practice & Research Clinical Endocrinology & Metabolism*, 24, 263–77.
- Williams, J., Lake, M., Ingram, J. M. 1985. The bicycle seat stool in the treatment of vaginal agenesis and stenosis. *Journal of Obstetric, Gynecologic, & Neonatal Nursing*, 14, 147–50.
- Woods, J. E., Alter, G., Meland, B., Podratz, K. 1992. Experience with vaginal reconstruction utilizing the modified Singapore flap. *Plastic and Reconstructive Surgery*, 90, 270–4.
- Woodward, M., Patwardhan, N. 2010. Disorders of sex development. *Paediatric Surgery II*, 28, 396–401.



Wenceslao M. Calonge, Juan Carlos López-Gutiérrez, Neil Bulstrode

## 1. INTRODUCTION AND CLASSIFICATION

Vascular anomalies (tumours and malformations) are the commonest congenital anomalies in humans. They constitute a broad spectrum of conditions ranging from lesions that resolve leaving no clinical signs to life-threatening lesions.

Their classification and nomenclature have now been unified. Historically, a plethora of histopathological terms and culinary comparisons in all hues of red has been used. In spite of continual efforts, many recent textbooks in paediatrics, surgery, dermatology and radiology persist in using this ancient terminology. In what remains the most cited article in the history of plastic surgery (Mulliken and Glowacki, 1982), Mulliken and Glowacki in 1982 proposed a comprehensive classification based on biological characteristics. This was adapted by the International Society for the Study of Vascular Anomalies (ISSVA) in 1986 and revised and expanded in 2014 during a workshop in Melbourne. The complete classification may be found on the ISSVA website <http://www.issva.org/>

The objective of this classification was to reduce the number of inadequately treated, misdiagnosed anomalies. However, for general practitioners and paediatricians, the most useful classification system only contemplates ‘haemangiomas and everything else’. Some infantile tumours and vascular malformations may be mistaken for common haemangiomas. Moreover, some haemangiomas may result in

**Table 14.1.** Vascular anomalies.

Vascular tumours	Vascular malformations
Benign	Simple
Locally aggressive or borderline	Combined
Malignant	Of major named vessels
	Associated with other anomalies

**Table 14.2.** Vascular tumours.

Benign vascular tumours	Locally aggressive tumours	Malignant tumours
Infantile haemangioma	Kaposiform haemangioendothelioma	Angiosarcoma
Congenital haemangioma	Retiform	Epithelioid
– Rapid involuting congenital haemangioma	haemangioendothelioma	haemangioendothelioma
– Non-involuting congenital haemangioma		
– Partially involuting		
Tufted angioma (angioblastoma of Nakagawa)	Papillary intralymphatic angioendothelioma	Others
Spindle cell haemangioma	Composite haemangioendothelioma	
Epithelioid haemangioma	Kaposi sarcoma	
Pyogenic granuloma (acquired)	Others	
Others		

**Table 14.3.** Vascular malformations.

Simple vascular malformations	Combined vascular malformations	Malformations of major vessels	Associated with other anomalies
Capillary	Capillary–venous		Klippel–Trenaunay syndrome
Lymphatic	Capillary–lymphatic		Parkes Weber syndrome
Venous	Capillary–arteriovenous		Servelle–Martorell syndrome
Arteriovenous	Lymphatic–venous		Sturge–Weber syndrome
Arteriovenous fistula	Capillary–lymphatic–venous		Limb CM + congenital non-progressive limb hypertrophy
	Capillary–lymphatic–arteriovenous		Maffucci syndrome
	Capillary–venous–arteriovenous		Macrocephaly without CM
	Capillary–lymphatic–venous–arteriovenous		Microcephaly without CM
			CLOVES syndrome
			Proteus syndrome
			Bannayan–Riley–Ruvalcaba syndrome

CLOVES = congenital lipomatous overgrowth, vascular malformations, epidermal naevus, spinal/skeletal anomalies/scoliosis; CM = capillary malformation

significant deformity, and many organs other than the skin may harbour haemangiomas. Management of these anomalies should involve a multidisciplinary team comprised of dermatology, interventional radiology, histopathology and plastic surgery specialists. Vascular anomaly teams in major paediatric centres are becoming a precious source of expertise and accurate treatment.

---

## 2. VASCULAR TUMOURS

---

### 2.1. Infantile haemangiomas

---

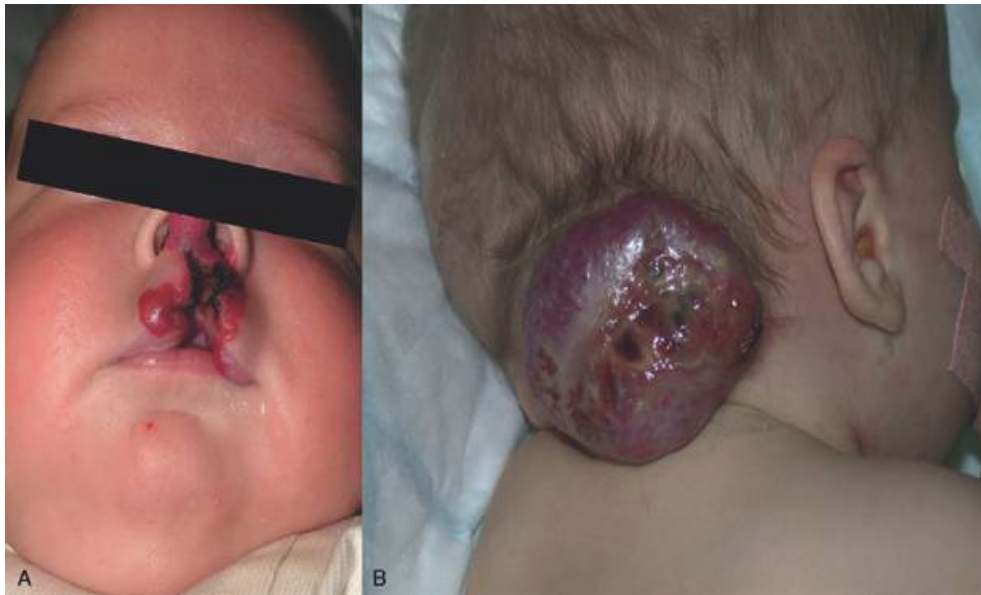Common infantile haemangiomas occur in as many as 4% of children (Kanada *et al.*, 2012); there is a sex ratio of three girls to one boy. These tumours consist of a packed nest of dividing endothelial cells that can release vascular endothelial growth factor (VEGF). They show immunopositive staining to solute carrier family 2, facilitated glucose transporter member 1 (also known as glucose transporter type 1 [GLUT-1]) (North *et al.*, 2000), type 3 iodothyronine deiodinase (also known as thyroxine 5-deiodinase), Fc-gamma receptor II (also known as low affinity immunoglobulin gamma Fc region receptor II [FcγRII]), merosin and Lewis Y antigen (Huang *et al.*, 2000). Some authors speculate that these features may indicate a common precursor with placental tissue (North *et al.*, 2001). Although there is a clear prevalence of solitary lesions in the head or neck, tumours may appear multifocal in several other locations. The liver is the most frequent site for extracutaneous haemangiomas; the presence of four or more cutaneous haemangiomas is a predictor of hepatic haemangiomas (Korii *et al.*, 2011).

Typical infantile haemangiomas appear in the first few weeks of life, grow during infancy and involute in early childhood (Chang *et al.*, 2008). They pass through a *proliferative phase* during the first year of life. Angiogenic factors such as VEGF and fibroblast growth factor (FGF) seem very active in this phase, without adequate counterbalancing of antiangiogenic factors. High levels of type IV collagenase, an enzyme that prepares the extracellular matrix to admit new vessels, are also observed. The *involuting phase* usually begins before 1 year of age. During this phase, the tumour will become less and less tumescent, while its colour will evolve from purple to grey. Tissue inhibitor of metalloproteinase 1 (also known as metalloproteinase inhibitor 1 [TIMP-1]) acts to suppress the formation of new vessels. The remaining skin in the *involved phase* may appear redundant; sometimes, only partial involution occurs.

Although most haemangiomas are clinically diagnosed, deep presentations and extracutaneous lesions may require imaging techniques. Doppler ultrasonography will show characteristic high flow in a focal mass. Ultrasound (US) is a non-invasive technique that does not require anaesthesia, but it may sometimes be difficult to distinguish between a haemangioma and arteriovenous malformation. Magnetic resonance imaging (MRI) would show a well-delineated tumour with flow voids during the proliferative phase. In the involuting phase, more lobular contours and adipose tissue may be observed (Calvio-Garcia *et al.*, 2015; Griauzde and Srinivasan, 2015). MRI is the technique of choice in the areas when US is inconclusive, as in extensive haemangiomas invading the periorbital tissue or airway. More sophisticated approaches may include the combined use of MRI and anti-GLUT-1 antibody-coupled nanoparticles in the near future (Sohn *et al.*, 2014).

Histopathological analysis may be indicated in some cases. Cutaneous hemangiomas typically show increased endothelial cellular turnover, mastocytes and thick basement membrane, as well as GLUT-1 positivity.

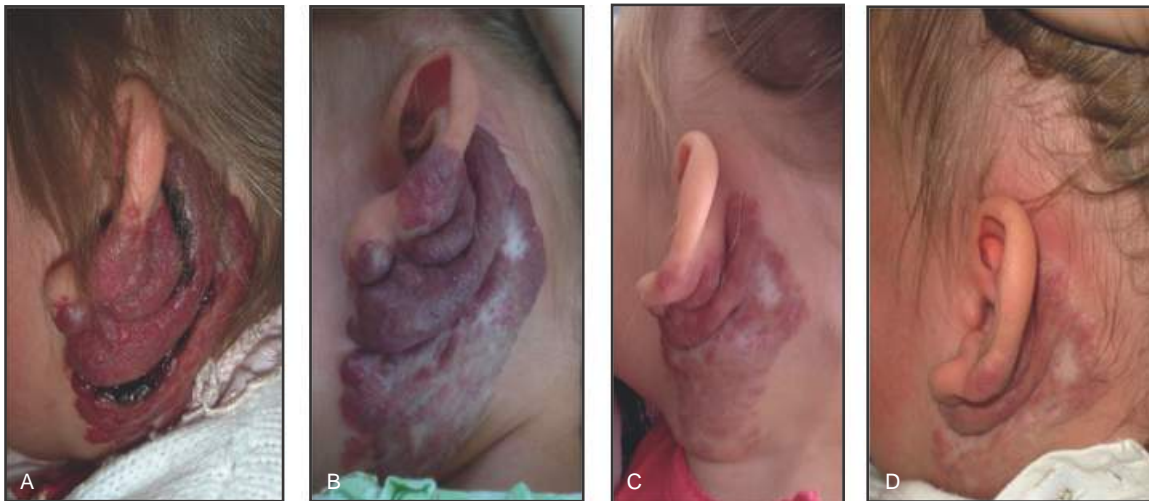
Most haemangiomas undergo spontaneous involution, but anxious parents must be counselled with care. Ulcerated and bleeding lesions may cause considerable stress because they can be very painful and bleed. Ulceration and bleeding are frightening, and must be carefully treated with appropriate dressings,



**Figure 14.1.** Ulcerated infantile haemangiomas on the upper lip [A] and neck [B].

as well as topical antibiotics and anaesthesia, (Mulliken, 2007) and often merit early surgical management. Classically, surgical excision has been reserved for lesions that cause functional emergencies such as airway obstruction, interference with vision (sometimes resulting in amblyopia) or recurrent erosion when located near the oral cavity or the anal sphincter (Low, 2011; Morelli *et al.*, 1991).

However, pharmacological treatment has become the first-line option for these benign vascular tumours. Although more than 20 agents have been used to treat haemangiomas and other vascular anomalies, rigorous studies are still scarce. Corticosteroids, interferon, vincristine, cyclophosphamide and bleomycin have been used for all kinds of vascular tumours (mostly haemangiomas and haemangi endotheliomas) (Blatt *et al.*, 2013). The important serendipitous discovery that propranolol, a common beta-blocker drug, acts as an inhibitor of the growth of haemangiomas has definitely changed the available therapeutic options. In 2008, Léauté-Labrèze *et al.* presented a case series including 11 patients. The first patient had received propranolol for obstructive hypertrophic cardiomyopathy, which resulted in a sudden improvement in her concomitant facial haemangioma. This observation was replicated in the following 10 patients in the series (Léauté-Labrèze *et al.*, 2008). The adverse effects of propranolol may include bradycardia, hypotension, bronchospasm, peripheral vasoconstriction, weakness and fatigue, sleep disturbance and hypoglycaemia (Graaf *et al.*, 2011). Great caution and close monitoring have been the rule before acceptance of the drug, and there is still some controversy about the need for hospitalisation in the first days of therapy. There is no official consensus about guidelines, but most vascular teams recommend an initial dose of 1 mg/kg per day, with a gradual increase to 2 mg/kg per day over several months (Sánchez-Carpintero *et al.*, 2011).



**Figure 14.2.** A., B., C. and D. A case of infantile haemangioma after treatment by propranolol from 6–9 months of age. Observation was made every month after 6 months, when treatment commenced.

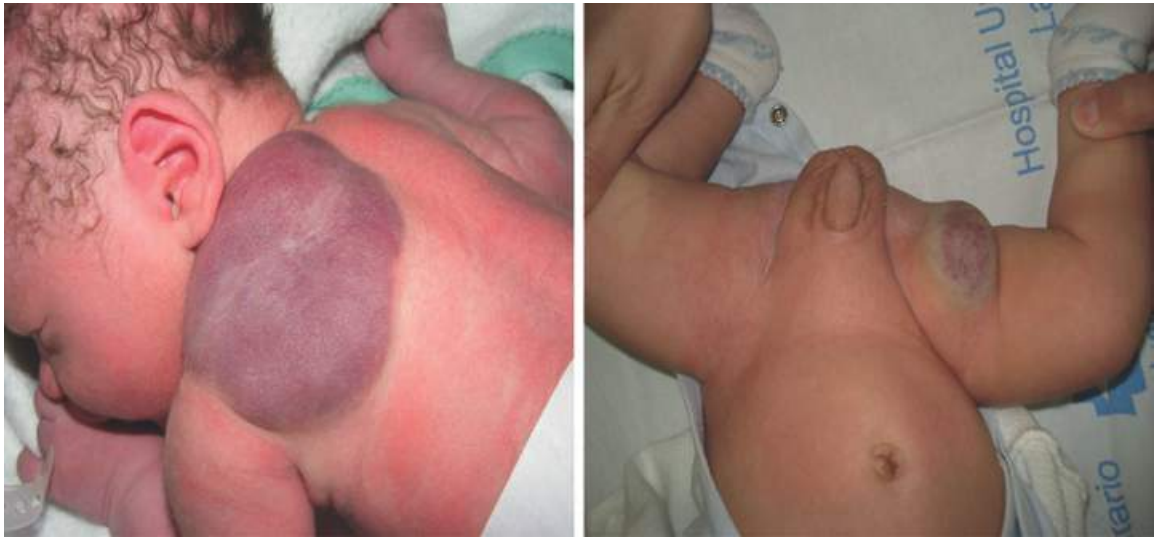### 3. CONGENITAL HAEMANGIOMAS: RICH, NICH AND PICH

These tumours are present at birth and may even be detected on prenatal ultrasonography. The tumours are fully grown at birth but their growth rate does not exceed that of the surrounding tissues (Berenguer *et al.*, 2003). Macroscopically, they appear as thick, exophytic masses. They consist of a fibrous stroma, dysplastic vessels and capillary proliferations. They sometimes include calcifications and thrombotic areas (Krol & MacArthur, 2005). They yield negative results in GLUT-1 immunohistochemical analysis.

According to their evolution, they have been divided in three subtypes: rapid involuting congenital haemangiomas (RICHs), non-involuting congenital haemangiomas (NICHs) and partially involuting congenital haemangiomas (PICHs).

Most RICHs will regress around the first year of life. They may result in areas of alopecia, hypopigmentation and atrophy. There occasionally persists some extent of telangiectasia or atrophy. Although several kinds of RICHs have been identified, there is no consensus on the new subclassification. NICHs do not disappear and may require some kind of intervention; in contrast, PICHs will not involute completely, remaining as a flat plaque (Nasseri *et al.*, 2014).

Most cases are diagnosed on the basis of clinical features, but US and MRI may be useful in selected patients. US shows a heterogeneous structure, frequent calcification and scattered vessels. MRI shows less-defined borders compared with infantile haemangiomas (Gorincour *et al.*, 2005).



**Figure 14.3.** Two cases of rapid involuting congenital haemangioma at different locations.

## 4. OTHER BENIGN TUMOURS

### 4.1. Tufted angioma: with or without Kasabach–Merritt phenomenon

The rare tufted angioma (formerly known as angioblastoma of Nakagawa) is characterised by lobules of pericyte-rich capillaries that produce ‘cannon-ball’ thickenings in the middle and lower third of the dermis (Munn *et al.*, 1994; Igarashi *et al.*, 2000). Tufted angioma (and the locally aggressive kaposiform haemangioendothelioma) may be accompanied by a Kasabach–Merritt phenomenon (KSP). Thrombocytopenia, a hallmark of KSP, results from platelet consumption and may cause secondary hypofibrinogenaemia and fibrinolysis with a normal prothrombin time and an activated partial thromboplastin time. Haemorrhage in intracranial, pleural and abdominal compartments may appear as a consequence of thrombocytopenia (el-Dessouky *et al.*, 1988; Kelly, 2010).

### 4.2. Spindle cell haemangioma

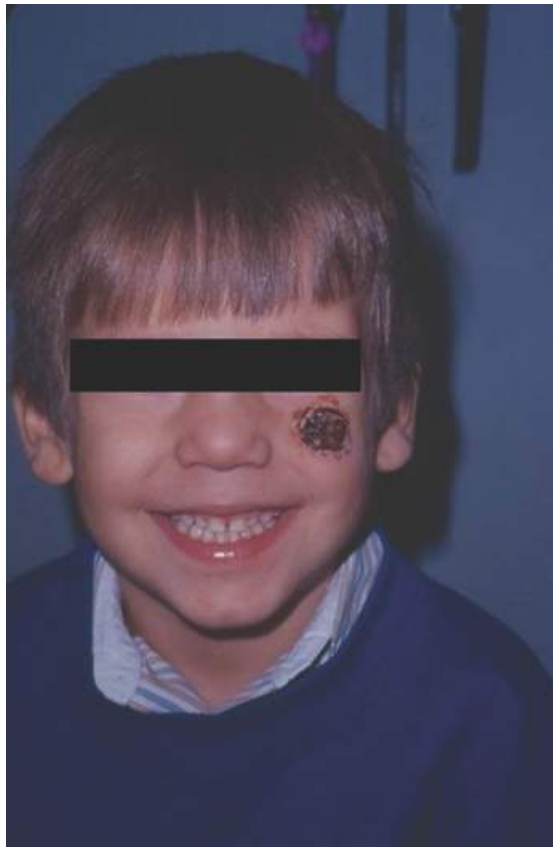These tumours may appear in children and adults as superficial, painful lesions. They grow slowly from a single nodule and spread to form multifocal, well-circumscribed nests of spindle cell proliferation surrounded by dilated blood vessels that include phleboliths. Surgical excision is the treatment of choice (Perkins & Weiss, 1996; Hoeger & Colmenero, 2014).

### 4.3. Epithelioid haemangioma

These rare tumours affect the skin and bone and may be associated with traumatic injuries. They produce pain and swelling. In a small proportion of cases, they generate lytic lesions in the long bones. Histopathological analysis shows narrow capillaries with large endothelial cells. These cells are characterised by a plump, vacuolated cytoplasm and a large, oval nucleus. The usual treatment involves intralesional curettage, excision or radiotherapy (Errani *et al.*, 2012).

### 4.4. Pyogenic granuloma

Pyogenic granulomas are acquired, reactive lesions within sites of trauma. They usually present as small, lobulated groups of venules and capillaries in children and young adults. They may bleed after minor injuries and, in some cases, may spontaneously regress. Surgical treatment can be achieved by laser, curettage or excision (Giblin *et al.*, 2007; Lin & Janniger, 2004).

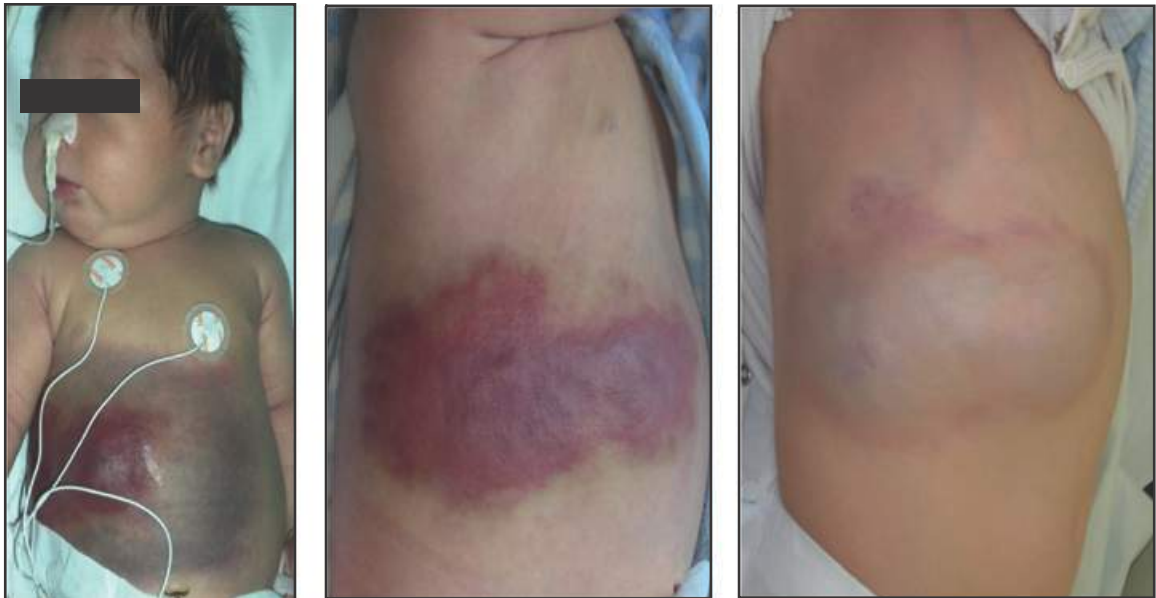


**Figure 14.4.** Pyogenic granuloma of the left cheek.

## 5. LOCALLY AGGRESSIVE TUMOURS

### 5.1. Kaposiform haemangioendothelioma

Kaposiform haemangioendothelioma is considered by many authors to be an exacerbated presentation of tufted angioma with an increased ability to cause KSP (Croteau *et al.*, 2013). It has been proposed that both descend from stem cells that can develop along both blood vessel endothelial and lymphatic lineages. They express endothelial markers such as cluster of differentiation 31 (CD31) and CD34 and lymphatic markers D2-40 and Prospero homeobox protein 1 (PROX1) (Arai *et al.*, 2006). Hence, they display aggregates of epithelioid cells surrounded by malformed lymphatic vessels. In spite of the name, no links to Kaposi sarcoma (KS) or Kaposi's sarcoma-associated herpesvirus (also known as human herpesvirus 8 [HHV8]) infection have been discovered. They mostly appear during the neonatal period or early childhood, but some cases have been described in adults. Their progression is slow, but there is a considerable danger of developing KSP and lethal disseminated intravascular coagulation. Many therapeutic agents have been proposed (steroids, methotrexate, vincristine, cyclophosphamide, rapamycin, propranolol), but results are not yet uniform (Zukerberg *et al.*, 1993). Surgical excision can be the treatment of choice to reverse the coagulopathy.



**Figure 14.5.** Three successive stages in the evolution of a kaposiform haemangioendothelioma treated by a combination of acetylsalicylate, vincristine and ticlopidine.



---

## 5.2. Retiform haemangioendothelioma

---

These flat, slow-growing tumours consist of long vessels arranged in a grid pattern lined by cuboidal endothelial cells and have been compared to *rete testis*. They express endothelial markers (CD31, CD34) and rarely metastasise. The usual treatment is excision with wide margins to prevent recurrence (Stojsic *et al.*, 2014).

---

## 5.3. Papillary intralymphatic angioendothelioma

---

Also known as Dabska tumour, this can appear at any age of life in any skin location as a purple nodule. It presents as a peculiar intravascular growth of differentiated endothelial cells in a columnar configuration with a high concentration of collagen type IV in the extracellular matrix. It shows positive staining for VEGF receptor 3 (VEGFR3), a lymphatic marker. Surgical excision is still the most common therapeutic option (Fanburg-Smith *et al.*, 1999).

---

## 5.4. Composite haemangioendothelioma

---

This is an extremely rare tumour, with <40 cases described to date. It possesses elements of other tumours such as epithelioid, retiform and spindle cell. Its malignant potential is variable to the point that some authors consider it to be a low-grade angiosarcoma (McNab *et al.*, 2013).

---

## 5.5. Kaposi sarcoma

---

KS may arise in skin and internal organs; it emerges after infection with HHV8. Although KS was first described as a disease of old people without apparent immunosuppression, most cases worldwide occur in patients who are immunosuppressed as a result of organ transplantation or human immunodeficiency virus infection. The four variants of KS correspond to four epidemiological groups:

1. Older men of Mediterranean and Jewish lineage (classic KS)
2. Patients from central Africa (endemic KS)
3. Iatrogenically immunosuppressed patients (or transplantation-associated KS)
4. Acquired immunodeficiency syndrome patients (epidemic KS).

All of these variants show similar histological findings (Stiller *et al.*, 2014). KS is a multifocal tumour with a preference for mucocutaneous tissues, but can affect the visceral organs (respiratory and gastrointestinal tract) and lymph nodes (Restrepo & Ocazonez, 2011; Radu & Pantanowitz, 2013). The most conspicuous mucocutaneous localisations are nodular or lobulated purple masses in the palate or gum (Wu *et al.*, 2014). Several chemotherapy options have been proposed, and surgery only plays a secondary role in treatment.

## 6. MALIGNANT TUMOURS

### 6.1. Angiosarcoma

Angiosarcomas are very rare tumours with an extremely poor prognosis (Ferrari *et al.*, 2002). Although they have been reported to occur at any age (even in neonates), they typically affect elderly people. Skin and soft tissues are their main locations, but they may occur in the lung, spleen and liver. Some isolated cases seem to have arisen from common haemangiomas, but the initial diagnosis is doubtful (Jeng *et al.*, 2014). Radiation, chronic lymphedema and exposure to vinyl chloride are known risk factors (Flucke *et al.*, 2013; Elliott & Kleinschmidt, 1997). Surgical excision may be indicated in a minority of localised lesions. Extended or metastatic disease may call for multimodal treatments (chemotherapy, radiotherapy and surgery). The 5-year overall survival rate is lesser than 35%.

### 6.2. Epithelioid haemangioendothelioma

Epithelioid haemangioendothelioma (EHE) may occur at any age and is associated with medium and large vessels in any area of the body. Characteristic skin lesions consist of a brownish plaque (Ravi & Patel, 2013). Histological features seem to be related to epithelioid lineages. More than 30% of EHEs have some degree of metastasis and multimodal treatments are mandatory. The mortality rate ranges from 13% in EHEs of soft tissues to 31% in EHEs of bone and 43% in EHEs of the liver (Mentzel *et al.*, 1997). Liver transplantation may be indicated for massive EHEs restricted to the liver.

## 7. VASCULAR MALFORMATIONS

The ISSVA classification divides vascular malformations according to the predominant type of affected vessels, but another accepted classification is based on their flow pattern (the rheologic classification; see Table 14.4). These malformations are due to errors in vascular embryogenesis. They are present at

**Table 14.4.** Rheologic classification of vascular malformations.

Slow-flow vascular malformations	Fast-flow vascular malformations	Combined
Capillary malformation	Arterial malformation	CVM, CLM, CAVM, LVM
Venous malformation	Arteriovenous fistula	CLVM, CLAVM, CVAM
Lymphatic malformation	Arteriovenous malformation	CLVAVM

CAVM = capillary–arteriovenous malformation; CLAVM = capillary–lymphatic–arteriovenous malformation; CLM = capillary–lymphatic malformation; CLVM = capillary–lymphatic–venous malformation; CLVAVM = capillary–lymphatic–venous–arteriovenous malformation; CVAM = capillary–arteriovenous malformation; CVM = capillary–venous malformation; LVM = lymphatic–venous malformation

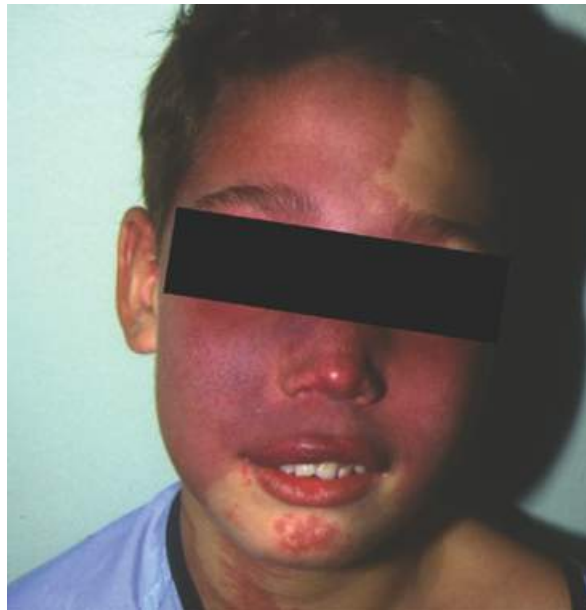the moment of birth and usually grow slightly faster than the other tissues of the patient. They may flare as a result of trauma or hormonal changes.

Some familial mutations in the *RASA1* gene are associated with hereditary capillary malformations (CMs), arteriovenous malformations (AVMs) or arteriovenous fistulas. Familial mutations in the *VEGFR3* gene may be associated with lymphatic malformations (LMs). Finally, mutations in the *TIE2* (also known as *TEK*) gene may result in inherited forms of venous malformation (VM) (Frigerio *et al.*, 2012).

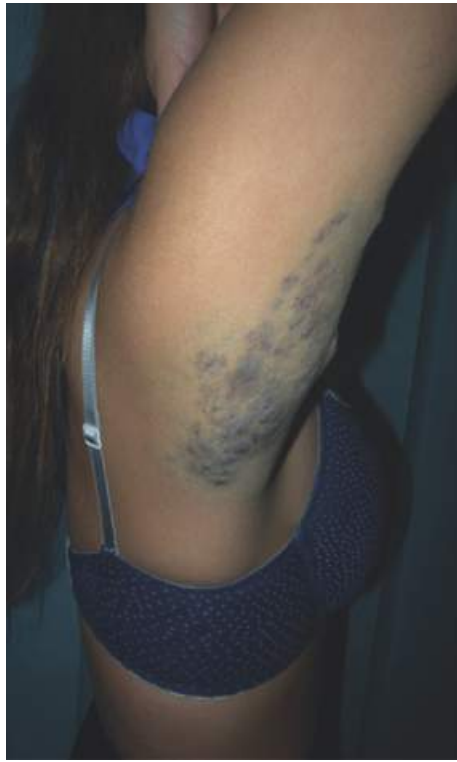## 7.1. Capillary malformations

CMs are usually purple or pink patches that follow a skin dermatome. They appear on the face, trunk or limbs and persist for the entire lifetime. After several years of development, facial CMs become associated with hypertrophic changes of the underlying soft tissues and bone. However, CMs affecting the limbs may involve a degree of hypertrophy from the moment of birth. As many complex syndromes (Sturge–Weber, Parkes–Weber and Klippel–Trenaunay) include a CM, clinical examination and investigations should check for neurological and ophthalmic anomalies (Nabbout & Juhász, 2013).

Although many authors advocate pulsed-dye laser as the main treatment for CMs, there is no current consensus. Users of lasers believe that the younger the child commences treatment, the better the final results; however, anaesthesia considerations must prevail for infants and toddlers (Azizkhan, 2003; Brauer & Geronemus, 2013). Hypertrophic soft tissues or bones may demand arduous surgical procedures. Selected cases may require excision and skin grafting.



**Figure 14.6.** A patient with Sturge–Weber syndrome.



**Figure 14.7.** Venous malformation of the right arm.

## 7.2. Venous malformations

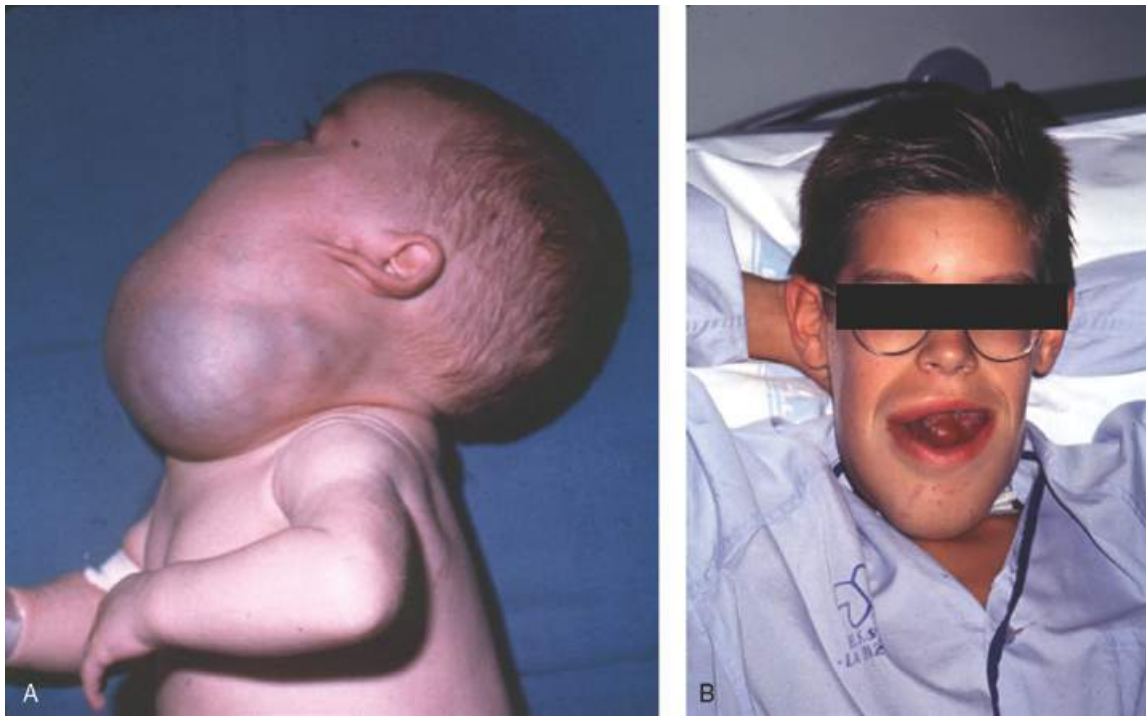---

VMs are usually blue, compressible and swollen depending on their position of the affected body part. Subtypes of VM include sporadic venous malformation, glomuvenous malformation and blue rubber bleb naevus syndrome (Bean syndrome) (Agnese *et al.*, 2010; Solovan *et al.*, 2012). Their vessels do not possess valves and their smooth muscle is scarce. Occasional phleboliths, small rounded calcification in a vein, and local thrombosis can be detected by US imaging. Increased D-dimer levels, decreased fibrinogen levels and a normal platelet count are found during episodes of intravascular coagulopathy (Mazoyer *et al.*, 2008). Intra-articular haemorrhage is seen with minor trauma. Common treatment options include compression garments, aspirin or prophylactic heparin. The lesion itself is treated by local sclerotherapy agents (ethanol, bleomycin, ethanolamine, sodium dodecyl sulfate, polidocanol). Surgical excision, radiofrequency or laser ablation are less usual options.

## 7.3. Lymphatic malformations

---

LMs grow in proportion with the patient and do not involute. They may appear in any anatomical area, but predominate in the head and neck. They are classified as macrocystic, microcystic and combined



**Figure 14.8.** A. and B. Two cases of lymphatic malformations, respectively involving the neck and tongue.

types (Eivazi & Werner, 2014). Macrocystic LMs predominate in the neck and can infiltrate the pleural space. Microcystic LMs may involve the tongue, salivary glands and oral cavity and can infiltrate the muscle and soft tissues. Osteolytic involvement is possible for all the three types of LMs (Lopez-Gutierrez *et al.*, 2012). LMs typically consist of cystic spaces filled with protein-rich contents and lined by a single layer of flattened endothelial cells. The smooth muscle has an abnormal, disorganised pattern.

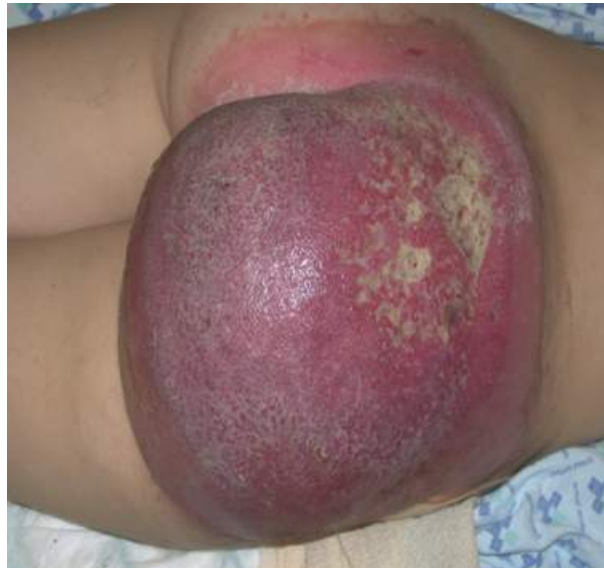Large LMs may compromise the upper airway during delivery. Prenatal diagnosis may prompt caesarean section and intrapartum orotracheal intubation before the umbilical cord is cut (i.e. the *ex utero* intrapartum treatment ['EXIT'] procedure) (Howell *et al.*, 2002). Although a small number of LMs resolve by themselves, sclerotherapy, embolisation, or laser or surgical excision is performed in most cases. Proposed sclerosants are bleomycin, ethanol, doxycycline, rapamycin and OK-432 (a streptococcal suspension) (Ogita *et al.*, 1991; Kim, 2014).

## 7.4. Arteriovenous malformations

AVMs are fast-flow malformations that may be exacerbated by trauma or hormonal changes at puberty and can be mistaken for infantile haemangiomas or CMs. They may appear in any organ and constitute a major challenge in neurosurgical practice. When they involve the skin, they present as warm, purple patches with variable degrees of pain and overgrowth of the affected body region. Clinical staging

**Table 14.5.** Schobinger's staging of arteriovenous malformation.

Stage	Description
Stage I	Cutaneous blush/warmth (quiescent patch of blue skin)
Stage II	Expanding lesion with audible pulsations (bruit)
Stage III	Mass with bleeding, ulceration, pain, infection
Stage IV	Decompensation (as for III with heart failure)

**Figure 14.9.** Arteriovenous malformation of the right buttock.

according to Schobinger's classification orientates the management (Table 14.5). Ultrasonography and MRI allow characterisation of AVMs. Therapeutic options include embolisation surgery or a combination of both, but an ultimate cure seems difficult to achieve. Early recurrence is common (Rangel-Castilla *et al.*, 2014; Potts *et al.*, 2014).

## 7.5. Conclusion

The treatment of vascular anomalies is a complex process that should be performed by an experienced multidisciplinary team. Agreement on the nomenclature and classification has been a key step in improving the management of these challenging patients. We hope that this brief overview will help to direct your further reading on the subject.

## REFERENCES

- Agnese M, Cipolletta L, Bianco MA, Quitadamo P, Miele E, Staiano A. Blue rubber bleb nevus syndrome. *Acta Paediatr.* 2010 Apr;99(4):632–5.
- Arai E, Kuramochi A, Tsuchida T, Tsuneyoshi M, Kage M, Fukunaga M, Ito T, Tada T, Izumi M, Shimizu K, Hirose T, Shimizu M. Usefulness of D2–40 immunohistochemistry for differentiation between kaposiform hemangioendothelioma and tufted angioma. *J Cutan Pathol.* 2006 Jul;33(7):492–7.
- Azizkhan RG. Laser surgery: New applications for pediatric skin and airway lesions. *Curr Opin Pediatr.* 2003 Jun;15(3):243–7.
- Berenguer B, Mulliken JB, Enjolras O, Boon LM, Wassef M, Josset P, Burrows PE, Perez-Atayde AR, Kozakewich HP. Rapidly involuting congenital hemangioma: Clinical and histopathologic features. *Pediatr Dev Pathol.* 2003;6(6):495–510.
- Blatt J, McLean TW, Castellino SM, Burkhart CN. A review of contemporary options for medical management of hemangiomas, other vascular tumors, and vascular malformations. *Pharmacol Ther.* 2013;139(3):327–33.
- Brauer JA, Geronemus RG. Laser treatment in the management of infantile hemangiomas and capillary vascular malformations. *Tech Vasc Interv Radiol.* 2013;16(1):51–4.
- Calvo-Garcia MA, Kline-Fath BM, Adams DM, Gupta A, Koch BL, Lim FY, Laor T. Imaging evaluation of fetal vascular anomalies. *Pediatr Radiol* 2015 Jul;45(8):1218-29.
- Chang LC, Haggstrom AN, Drolet BA, Baselga E, Chamlin SL, Garzon MC, Horii KA, Lucky AW, Mancini AJ, Metry DW, Nopper AJ, Frieden IJ; Hemangioma Investigator Group. Growth characteristics of infantile hemangiomas: Implications for management. *Pediatrics.* 2008;122(2):360–7.
- Croteau SE, Liang MG, Kozakewich HP, Alomari AI, Fishman SJ, Mulliken JB, Trenor CC 3rd. Kaposiform hemangioendothelioma: Atypical features and risks of Kasabach–Merritt phenomenon in 107 referrals. *J Pediatr.* 2013 Jan;162(1):142–7.
- el-Dessouky M, Azmy AF, Raine PA, Young DG. Kasabach–Merritt syndrome. *J Pediatr Surg.* 1988;23(2):109–11.
- Eivazi B, Werner JA. [Lymphatic malformations in the head and neck region. Clinical aspects and therapeutic options. *HNO.* 2014;62(1):6–11.
- Elliott P, Kleinschmidt I. Angiosarcoma of the liver in Great Britain in proximity to vinyl chloride sites. *Occup Environ Med.* 1997;54(1):14–8.
- Errani C, Zhang L, Panicek DM, Healey JH, Antonescu CR. Epithelioid hemangioma of bone and soft tissue: A reappraisal of a controversial entity. *Clin Orthop Relat Res.* 2012;470(5):1498–506.
- Fanburg-Smith JC, Michal M, Partanen TA, Alitalo K, Miettinen M. Papillary intralymphatic angioendothelioma (PILA): A report of twelve cases of a distinctive vascular tumor with phenotypic features of lymphatic vessels. *Am J Surg Pathol.* 1999 Sep;23(9):1004–10.
- Ferrari A, Casanova M, Bisogno G, Cecchetto G, Meazza C, Gandola L, Garaventa A, Mattke A, Treuner J, Carli M. Malignant vascular tumors in children and adolescents: A report from the Italian and German Soft Tissue Sarcoma Cooperative Group. *Med Pediatr Oncol.* 2002 Aug;39(2):109–14.
- Flucke U, Requena L, Mentzel T. Radiation-induced vascular lesions of the skin: An overview. *Adv Anat Pathol.* 2013 Nov;20(6):407–15.
- Frigerio A, Stevenson DA, Grimmer JF. The genetics of vascular anomalies. *Curr Opin Otolaryngol Head Neck Surg.* 2012;20(6):527–32.
- Giblin AV, Clover AJ, Athanassopoulos A, Budny PG. Pyogenic granuloma – The quest for optimum treatment: Audit of treatment of 408 cases. *J Plast Reconstr Aesthet Surg.* 2007;60(9):1030–5.
- Gorincour G, Kokta V, Rypens F, Garel L, Powell J, Dubois J. Imaging characteristics of two subtypes of congenital hemangiomas: Rapidly involuting congenital hemangiomas and non-involuting congenital hemangiomas. *Pediatr Radiol.* 2005;35(12):1178–85.

- Graaf M, Breur MJ, Raphae MF, *et al.* Adverse effects of propranolol when used in the treatment of haemangioma: A case series of 28 infants. *J Am Acad Dermatol.* 2011;65:320–7.
- Griauzde J, Srinivasan A. Imaging of vascular lesions of the head and neck. *Radiol Clin North Am.* 2015 Jan;53(1):197–213.
- Hoeger PH, Colmenero I. Vascular tumours in infants. Part I: Benign vascular tumours other than infantile haemangioma. *Br J Dermatol.* 2014;171(3):466–73.
- Horii KA, Drolet BA, Frieden IJ, Baselga E, Chamlin SL, Haggstrom AN, Holland KE, Mancini AJ, McCuaig CC, Metry DW, Morel KD, Newell BD, Nopper AJ, Powell J, Garzon MC; Hemangioma Investigator Group. Prospective study of the frequency of hepatic hemangiomas in infants with multiple cutaneous infantile hemangiomas. *Pediatr Dermatol.* 2011;28(3):245–53.
- Howell LJ, Burns KM, Lenghetti E, Kerr JC, Harkins LS. Management of fetal airway obstruction: An innovative strategy. *MCN Am J Matern Child Nurs.* 2002 Jul–Aug;27(4):238–43.
- Huang S, Tu HM, Harney JW, Venihaki M, Butte AJ, Kozakewich HPW, Fishman SJ, Larsen PR. Severe hypothyroidism caused by type 3 iodothyronine deiodinase in infantile hemangiomas. *N Engl J Med* 2000;343:185–9.
- Igarashi M, Oh-i T, Koga M. The relationship between angioblastoma (Nakagawa) and tufted angioma: Report of four cases with angioblastoma and a literature-based comparison of the two conditions. *J Dermatol.* 2000;27(8):537–42.
- Jeng MR, Fuh B, Blatt J, Gupta A, Merrow AC, Hammill A, Adams D. Malignant transformation of infantile hemangioma to angiosarcoma: Response to chemotherapy with bevacizumab. *Pediatr Blood Cancer.* 2014;61(11):2115–7.
- Kanada KN, Merin MR, Munden A, Friedlander SF. A prospective study of cutaneous findings in newborns in the United States: Correlation with race, ethnicity and gestational status using updated classification and nomenclature. *J Pediatr* 2012;161:240–5.
- Kelly M. Kasabach–Merritt phenomenon. *Pediatr Clin North Am.* 2010;57(5):1085–9.
- Kim DW. OK-432 sclerotherapy of lymphatic malformation in the head and neck: factors related to outcome. *Pediatr Radiol.* 2014;44(7):857–62.
- Krol A, MacArthur CJ. Congenital hemangiomas: Rapidly involuting and noninvoluting congenital hemangiomas. *Arch Facial Plast Surg.* 2005;7(5):307–11.
- Léauté-Labrèze C, Dumas de la Roque E, Hubiche T, Boralevi F, Thambo JB, Taïeb A. Propranolol for severe hemangiomas of infancy. *N Engl J Med* 2008;358:2649–51.
- Lin RL, Janniger CK. Pyogenic granuloma. *Cutis.* 2004;74(4):229–33.
- Lopez-Gutierrez JC, Miguel M, Diaz M, Ros Z, Tovar JA. Osteolysis and lymphatic anomalies: A review of 54 consecutive cases. *Lymphat Res Biol.* 2012;10(4):164–72.
- Low DW. Hemangiomas and vascular malformations in Mattei P (ed.) *Fundamentals of Pediatric Surgery*, 2011, pp. 819–28.
- Mazoyer E, Enjolras O, Bisdorff A, Perdu J, Wassef M, Drouet L. Coagulation disorders in patients with venous malformation of the limbs and trunk: A case series of 118 patients. *Arch Dermatol.* 2008 Jul;144(7):861–7.
- McNab PM, Quigley BC, Glass LF, Jukic DM. Composite hemangioendothelioma and its classification as a low-grade malignancy. *Am J Dermatopathol.* 2013;35(4):517–22.
- Mentzel T, Beham A, Calonje E, Katenkamp D, Fletcher CD. Epithelioid hemangioendothelioma of skin and soft tissues: Clinicopathologic and immunohistochemical study of 30 cases. *Am J Surg Pathol.* 1997;21:363–74.
- Morelli JG, Tan OT, Weston WI. Treatment of ulcerated hemangiomas with the pulsed tunable dye laser. *Am J Dis Child* 1991;145:1062.
- Mulliken JB. Vascular anomalies in Thorne CH (ed.) *Grabb and Smith’s Plastic Surgery*, 6th edn, 2007, pp. 191–200.
- Mulliken JB, Glowacki J. Hemangiomas and vascular malformations in infants and children: A classification based on endothelial characteristics. *Plast Reconstr Surg* 1982;69:412–22.
- Munn SE, Jackson JE, Jones RR. Tufted haemangioma responding to high-dose systemic steroids: A case report and review of the literature. *Clin Exp Dermatol.* 1994;19(6):511–14.
- Nabbout R, Juhász C. Sturge–Weber syndrome. *Handb Clin Neurol* 2013;111:315–21.



- Nasseri E, Piram M, McCuaig CC, Kokta V, Dubois J, Powell J. Partially involuting congenital hemangiomas: A report of 8 cases and review of the literature. *J Am Acad Dermatol*. 2014 Jan;70(1):75–9.
- North PE, Warner M, Mizeracki A, Mihm MC Jr. GLUT1: A newly discovered immunohistochemical marker for juvenile hemangiomas. *Human Pathology* 2000;31(1):11–22.
- North PE, Waner N, Mizeracki, Mrak RE, Nicholas R, Kincannon J, Suen JY, Mihm MC Jr. A unique microvascular phenotype shared by juvenile hemangiomas and human placenta. *Arch Dermatol* 2001;137:559.
- Ogita S, Tsuto T, Deguchi E, Tokiwa K, Nagashima M, Iwai N. OK-432 therapy for unresectable lymphangiomas in children. *J Pediatr Surg*. 1991 Mar;26(3):263–8.
- Perkins P, Weiss SW. Spindle cell hemangioendothelioma. An analysis of 78 cases with reassessment of its pathogenesis and biologic behavior. *Am J Surg Pathol*. 1996 Oct;20(10):1196–204.
- Potts MB, Zumofen DW, Raz E, Nelson PK, Riina HA. Curing arteriovenous malformations using embolization. *Neurosurg Focus*. 2014 Sep;37(3):E19.
- Radu O, Pantanowitz L. Kaposi sarcoma. *Arch Pathol Lab Med*. 2013;137(2):289–94.
- Rangel-Castilla L, Russin JJ, Martinez-Del-Campo E, Soriano-Baron H, Spetzler RF, Nakaji P. Molecular and cellular biology of cerebral arteriovenous malformations: A review of current concepts and future trends in treatment. *Neurosurg Focus*. 2014;37(3):E1.
- Ravi V, Patel S. Vascular sarcomas. *Curr Oncol Rep*. 2013 Aug;15(4):347–55.
- Restrepo CS, Ocazonez D. Kaposi's sarcoma: Imaging overview. *Semin Ultrasound CT MR*. 2011;32(5):456–69.
- Sánchez-Carpintero I, Ruiz-Rodríguez R, López-Gutiérrez JC. Propranolol in the treatment of infantile haemangioma: clinical effectiveness, risks, and recommendations. *Actas Dermosifiliogr*. 2011;102:766–79.
- Sohn CH, Park SP, Choi SH, Park SH, Kim S, Xu L, Kim SH, Hur JA, Choi J, Choi TH. MRI molecular imaging using GLUT1 antibody-Fe(3)O(4) nanoparticles in the hemangioma animal model for differentiating infantile hemangioma from vascular malformation. *Nanomedicine*. 2014 Aug 25. pii: S1549–9634(14)00426–2.
- Solovan C, Chiticariu E, Beinsan D, Zurac S, Baderca F. Multiple disseminated glomuvenous malformations: Do we know enough? *Rom J Morphol Embryol*. 2012;53(4):1077–80.
- Stojic Z, Brasanac D, Stojanovic M, Boricic M. Cutaneous composite hemangioendothelioma: Case report and review of published reports. *Ann Saudi Med*.2014;34(2):182–8.
- Stiller CA, Trama A, Brewster DH, Verne J, Bouchardy C, Navarro C, Chirlaque MD, Marcos-Gragera R, Visser O, Serraino D, Weiderpass E, Dei Tos AP, Ascoli V; RARECARE Working Group. Descriptive epidemiology of Kaposi sarcoma in Europe. Report from the RARECARE project. *Cancer Epidemiol*. 2014;38(6):670–8.
- Wu XJ, Pu XM, Kang XJ, Halifu Y, An CX, Zhang DZ, Yakeya B, Mijit J. One hundred and five Kaposi sarcoma patients: A clinical study in Xinjiang, Northwest of China. *J Eur Acad Dermatol Venereol*. 2014;28(11):1545–52.
- Zukerberg LR, Nickoloff BJ, Weiss SW. Kaposiform hemangioendothelioma of infancy and childhood. An aggressive neoplasm associated with Kasabach–Merritt syndrome and lymphangiomatosis. *Am J Surg Pathol*. 1993;17(4):321–8.



## **Section 5**

# **Aesthetic Surgery**



---

Nina Oliver, Omar Khan Pathan, Ash Mosahebi

## 1. INTRODUCTION

---

Liposuction is also known as lipectomy, lipoaspiration, liposculpture and lipoplasty. In Britain, there was a 41% increase in liposuction cases in 2013 (The British Association of Aesthetic Plastic Surgeons, 2014). In 2013, the American Association of Aesthetic Plastic Surgery reported liposuction as the most popular surgical procedure, with an increase of 16% from the previous year. Initially, liposuction was most popular in women, but over the years liposuction has become increasingly popular in the male population and now tops the list of aesthetic surgical procedures for both sexes (ASAPS, 2014).

Liposuction is a surgical procedure that involves the use of specialised cannulas to infiltrate and suction subcutaneous fat for the purpose of aesthetic body contouring and/or lipid transfer. Liposuction has evolved over the years to provide an adjunct to several other areas of reconstruction, including the breast, the head and neck area, and the upper and lower limbs.

## 2. BACKGROUND

---

### 2.1. History

---

In 1926, a French surgeon called Charles Dujarier agreed to operate on a young female model to sculpture the lateral aspect of her calves. He used a sharp uterine curette. Unfortunately, this procedure ended up damaging the patient's femoral artery, resulting in gangrene and subsequent amputation (Flynn and Coleman, 2000). Dujareir was sued for 200,000 Francs and died in the following months. The negative impact on the patient resulted in any form of body sculpture being boycotted in plastic surgery circles for decades (Glicenstein, 1989).

Most of the literature attributes the innovation of liposuction to Dr Yves-Gerard Illouz, a French surgeon, in the early 1980s. It was, however, first invented by Fischer, an Italian gynaecologist in the late 1970s (Flynn and Coleman, 2000). Illouz modified Fischer's technique by infiltrating a small volume of saline solution into the subcutaneous fat prior to suction. This technique was coined the 'wet technique'; Illouz was credited with the procedure, achieving global fame (Flynn and Coleman, 2000).

Later that decade, an American dermatologist, Jeffery Klein, introduced the 'tumescence technique' which involved infiltration of larger volumes of local anaesthesia and adrenaline before aspiration. This reduced intra-operative blood loss and post-operative haematomas. A vast array of tools and techniques such as power-assisted liposuction (PAL) and ultrasound-assisted liposuction (UAL) soon followed (Iverson and Pao, 2008).

## 2.2. Patient selection

---

Liposuction is an elective procedure in patients who are generally healthy. Careful patient selection is of utmost importance to achieve a satisfactory outcome. Other key factors include lifestyle changes (smoking, alcohol, recreation drugs), regular exercise and a well-balanced diet (Rohrich *et al.*, 2004).

Patients must be counselled so that they commit to these lifestyle changes, in addition to evaluating and discussing any concerns. Those who adhere to these lifestyle changes have shown significant improvements in their self-esteem and productivity (Stephan and Kenkel, 2010). Pregnancy, psychiatric history or body dysmorphic disorder, morbid obesity, unattainable expectations, co-morbidities, bleeding disorders and impaired wound healing should be addressed before the procedure is performed (Kenkel and Stephan, 2013).

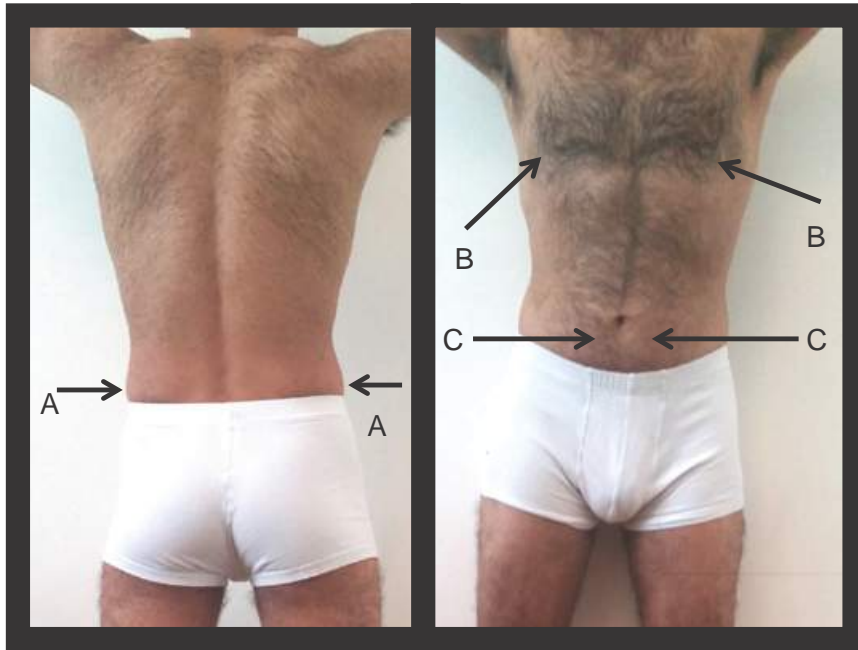
## 3. ANATOMY AND AREAS OF CONSIDERATION

---

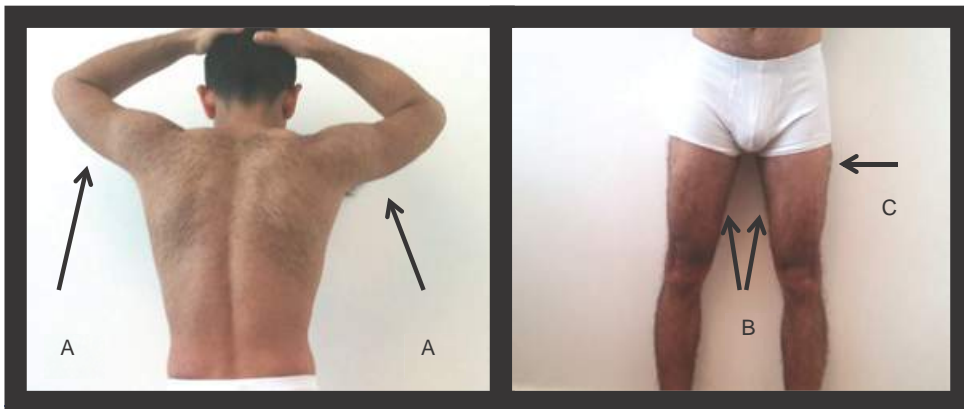Body contouring with liposuction requires a basic anatomical knowledge of subcutaneous fat and its relation to the underlying fascia to provide optimal results. Subcutaneous fat is variable in density, thickness and adherence throughout the body. It can be divided into three layers: the superficial, intermediate and deep layers (Kenkel and Stephan, 2013). As a rule, the superficial layer is avoided because of the higher risk of ecchymosis, bleeding, cutaneous trauma and body contour irregularities. Subcutaneous fat is connected to its underlying tissue through fibrous attachments within the layers that are continuous with the fascia inferiorly. Areas that have relatively thicker and denser attachments are responsible for the natural shape and contours of the patient, and are termed the *zones of adherence*. These zones may be traversed, but should not be directly suctioned.

Head and neck liposuction has gained in popularity in the past decade owing to the development of appropriate techniques and safer equipment. Jowl and submental liposuction are the most popular in this region, and have high overall satisfaction rates (Doerr, 2007). The trunk is by far the most popular area for liposuction in men and women. [Figure 15.1](#) shows the hypogastrium, flanks and lateral aspects of the chest, which are common areas of liposuction in the trunk. Limb contouring is an important aesthetic

procedure in massive weight loss patients (Bruschi *et al.*, 2009). Fat accumulates in the inferior aspect of the proximal upper limb, often referred to as ‘bingo wings’. The medial and lateral aspects of the upper thigh are frequently considered for liposuction. The surgeon should assess and advise the patient on the suitability of the requested area for liposuction, with regards to safety and the aesthetic outcome. Patients must be warned that formal surgical excision of the excess skin may be required after successful liposuction. Figure 15.2 shows common areas for liposuction in the upper and lower limbs.



**Figure 15.1.** Common areas of liposuction on the trunk. A. Flank, B. chest and C. hypogastrium.



**Figure 15.2.** Common areas of liposuction on the upper and lower limbs. A. Proximal upper limb, B. medial thigh and C. lateral thigh.

**Table 15.1.** List of patient parameters to note during a physical examination for liposuction.

Body	Treatment area
BMI	Scars
Skin laxity and tone	Striae
Obvious musculoskeletal deformities	Wrinkles
Cellulite	Skin thickness
Fat distribution (local or diffuse)	Estimate volume of aspirate
Hernias	Dimples
Body curvature	
Posture	
Asymmetry	

## 4. PRE-OPERATIVE ASSESSMENT

The pre-operative phase provides an opportunity to enhance rapport with the patient while obtaining a thorough history and examination. The surgeon should document the patient's medical history, current medications, allergies, smoking, alcohol consumption, expectations and anaesthesia preferences. Establishing realistic aims and committing to lifestyle changes is essential for long-term success. Patients who present with symptoms of body dysmorphic disorder must be further evaluated. Success rates in these patients are low and psychological support is advised (Glaser and Kaminer, 2005). Co-morbidities, both past and present, should be thoroughly investigated because some conditions increase the chance of deep vein thrombosis and can lead to suboptimal outcomes (Iverson and Pao, 2008). An American Association of Anaesthesiologists (ASA) classification should be noted and, if necessary, followed by an anaesthetic review.

Examination of the patient needs to be systematic and comprehensive (see Table 1.1). It is advisable to have a member of the nursing team present during the examination to offer additional support to the patient. Assessment of the aspirate estimation, skin laxity and fat deposition pattern is essential because these factors determine the success of aesthetic surgical changes. The patient is asked to relax all muscles for examination in a standing position, preferably in front of a mirror. This allows visualisation of the shape of the patient's body in its natural state and helps in examining muscular integrity. Any signs of cellulite, asymmetry, scarring and dimples must be brought to the patient's attention so as they are not attributed to the procedure post-operatively. Hernias must be thoroughly looked for and addressed if necessary. It is crucial to obtain formal medical photographs of the patient for record-keeping and future reference.

## 5. ANAESTHESIA OPTIONS

Anaesthesia options vary in each case and are critical in the pre-operative discussion and assessment of the patient. Factors that influence the choice of anaesthesia include the patient's general health (ASA



classification), the surgeon's/physician's preference, the patient's preference, the estimated volume of aspiration, the optimal patient position, the length of operating time, intra-operative progress and the available facilities. The three forms of anaesthesia used are local anaesthesia, intravenous sedation and general anaesthesia. Lidocaine is usually the local anaesthetic of choice. It is preferable to bupivacaine because of its safer profile and faster reversibility. The normal recommended dose of lidocaine is 7 mg/kg but, owing to vasoconstriction and the aspirate containing lidocaine, up to 35 mg/kg is accepted (Iverson and Pao, 2008). Lidocaine toxicity associated deaths are rare, but it is vital for the responsible physician to identify lidocaine toxicity peri- and post-operatively.

Smaller volumes of aspirate are usually treated under local anaesthesia, intravenous sedation or a combination of both. Intravenous sedation is used to provide patients a degree of comfort peri-operatively and, for the physician, a conscious patient who is responsive to verbal and tactile stimuli.

Patients who plan to have multiple areas treated or have severe co-morbidities, other surgical procedures planned, lengthy operations and estimated large aspirate volumes are more likely to receive general anaesthesia. Procedures using general anaesthesia are more costly, require trained personnel and warrant specific post-operative precautions.

Administering anaesthesia requires good comprehension of the changes in physiology that occur during liposuction. An understanding of intra-operative fluid loss, its replacement, intra-operative physiological monitoring and post-operative pain needs is vital prior to induction (Sood *et al.*, 2011).

## 6. INVASIVE LIPOSUCTION TECHNIQUES

---

Various techniques are currently available for performing liposuction. Before choosing the appropriate technique, several factors should be considered. These include the body areas involved, amount of lipoaspirate, fibrous areas, possibility of revision liposuction and skin redundancy. The most commonly used options include suction-assisted liposuction (SAL), PAL, UAL, VASER liposuction, water-assisted liposuction (WAL) and laser-assisted liposuction (LAL) (Kenkel and Stephan, 2013). A new technique called power WAL has also gained in popularity.

### 6.1. Suction-assisted liposuction

---

SAL was the first method described for liposuction and remains the one most commonly used (Ahmad *et al.*, 2011). It mechanically removes adipocytes along with other tissue. After the desired site is injected with a wetting solution, a period of time is allowed for the infiltrate to take effect.

At markings made pre-operatively on the body, small incisions (3–4 mm) are made with a sharp scalpel. The adipose tissue is then removed under negative pressure by a hollow cannula with a blunt tip. It is recommended to start with a larger cannula in a deeper plane and then use a smaller diameter cannula more superficially (Tabbal *et al.*, 2013). The SAL technique is easy to use and a broad variety of cannulas are available. One disadvantage is that it can be considerably laborious, particularly in fibrous areas.

## 6.2. Power-assisted liposuction

---

PAL uses an external power source as opposed to the surgeon. The cannula moves back and forth in small oscillating motions. The small rapid vibrations break up the adiposites so they can be suctioned out of the body. The power settings can be altered to control the rate. PAL is useful for large volumes, fibrous areas and in revision liposuction.

## 6.3. Ultrasound-assisted liposuction

---

UAL delivers fat-liquefying ultrasonic energy which breaks down the adipose tissue. The emulsified fat is then removed through a cannula. This is always a three-stage procedure because infiltration must be used. The ultrasonic energy is dispersed from the superficial to the deep layers, and there must be continuous movement to prevent thermal injury. The advantages of this technique are improved contouring and its suitability for revision and for fibrous areas. On the negative side, the equipment is more expensive, the operating time is longer and the risk of thermal injury is present if not used correctly. A newer type of UAL called VASER liposuction uses less energy because of more efficient probes.

## 6.4. Laser-assisted liposuction

---

LAL is designed to achieve adipocyte removal and skin tightening from the thermal effect of the laser on the dermis (Matarasso and Levine, 2013). A small laser fibre is inserted through an incision in the skin. The four-stage procedure consists of infiltration, application of energy to the subcutaneous tissues, evacuation and, finally, subdermal skin tightening.

## 6.5. Water-assisted liposuction

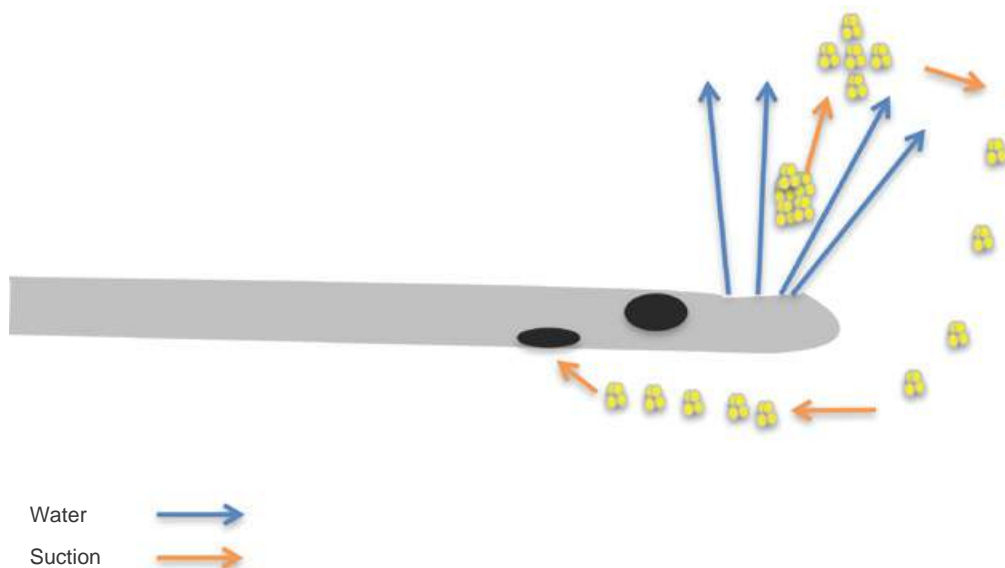
---

WAL is a technique in which instead of being destroyed, the adipocytes loosen, which facilitates a gentler removal. The process comprises a single step, with simultaneous injection and removal. It is considered to be gentle with less ecchymosis and a shorter recovery time due to less tissue trauma (see Figure 15.3).

## 7. APPLICATION OF WETTING SOLUTIONS

---

Liposuction was initially performed without any wetting solution, resulting in high rates of blood loss. With the introduction of infiltrates, the operation is now performed with markedly less complications



**Figure 15.3.** Water-assisted liposuction.

and with the removal of larger volumes. They may also provide some peri-operative analgesia. Wetting solutions are traditionally divided into four categories: dry, wet, superwet and tumescent (Sasaki, 2011).

The most commonly used wetting solutions combine a crystalloid with lidocaine, adrenaline and, not infrequently, sodium bicarbonate. A common example is Klein's formula, comprising 1000 ml normal saline, 50 ml 1% lidocaine, 1 ml 1:1000 adrenaline and 12.5 ml 8.4% sodium bicarbonate. In a recent study, Hatef *et al.* (2009) showed that varying doses of lidocaine did not affect intra- or post-operative analgesia requirements.

It is generally recommended not to use marcaine because of its possible cardiotoxicity, although Failey *et al.* (2009) demonstrated no significant difference in the incidence of complications or length of hospital stay when comparing bupivacaine and lidocaine.

Addition of adrenaline to the wetting solution adds a vasoconstrictive element which decreases blood loss. The addition of adrenaline to lidocaine results in less systemic absorption of lidocaine. The American Society of Plastic Surgeons has recommended that the total dose of adrenaline used in local anaesthesia should not exceed 0.07 mg/kg to limit the systemic effects (Iverson *et al.*, 2004).

Supplementing the wetting solution with sodium bicarbonate is known to decrease the painful sensation that lidocaine can produce. This occurs through reducing the acidity of lidocaine, thus making the pH more physiological.

As previously mentioned, wetting solutions reduce the amount of blood loss during liposuction. For a dry technique, blood loss can typically be up to 50% of the final aspirate, whereas blood loss for the wet, superwet and tumescent techniques is reported to be 10–30%, 1–4% and <1%, respectively (Iverson *et al.*, 2004).

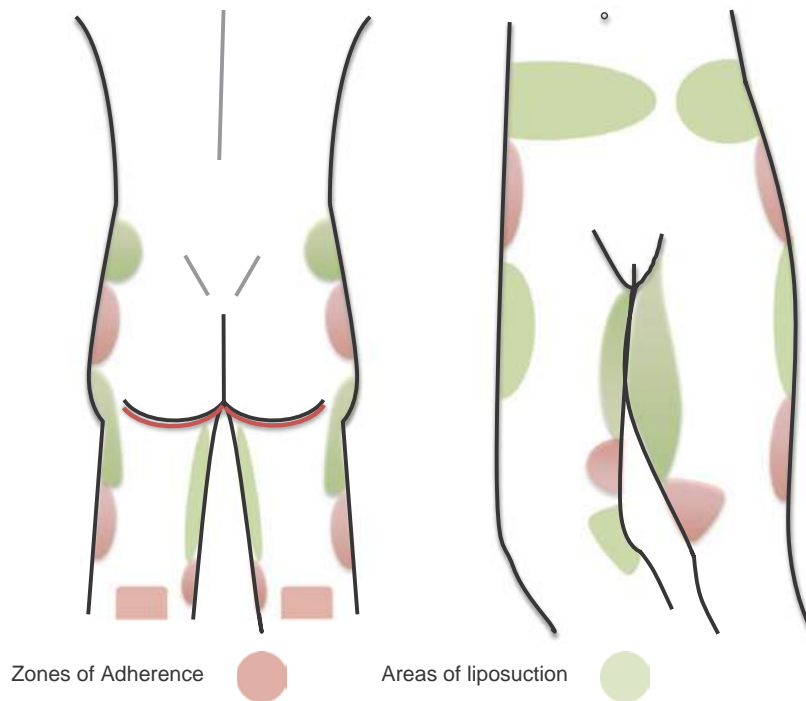
## 8. TECHNIQUES OF INFILTRATION

The dry technique uses no infiltrate and is now very uncommon. The wet method uses 200–300 ml/area and the volume aspirated is to the desired effect. The superwet technique applies 1 ml infiltrate to 1 ml aspirate. The tumescent method involves infiltrating to skin turgor and aspirating 2–3 ml aspirate/ml infiltrate.

## 9. SURGICAL PLANNING

### 9.1. Pre-operative marking

Prior to surgery, the patient's body is marked by the surgeon, ideally when the patient is in an upright position in front of a mirror and with the patient's involvement. The chosen areas for liposuction are marked with circles. The known areas of adherence should be delineated. These are the zones in which the more superficial structures adhere to the deeper structures ([Figure 15.4](#)).



**Figure 15.4.** Zones of adherence.

Pre-operative data sheets may be used to document the areas of contouring. Skin tone, asymmetry, cellulite and striae can also be included.

## 10. PATIENT POSITIONING

Most liposuction can be done with the patient in the prone position, and it is important to use adequate padding for all pressure points pre-operatively. Repositioning to the supine position and re-preparation should be performed with multiple staff to minimise the time taken. The upper chest, face, iliac crest, bony prominences of the extremities and genitalia should be supported. Prevention of hypothermia is important, as is the use of lower leg compression devices in the prevention of deep vein thrombosis. The lateral decubitus position is not frequently used because it does not allow symmetrical comparison.


## 11. SURGICAL INSTRUMENTS

Liposuction is achieved with cannulas through small access incisions. The three important features for determining the efficiency of a cannula are its tip, configuration and dimensions (diameter and length) (Mathes and Hentz, 2006). The tip of the cannula influences the speed and the efficacy of liposuction; most tips are blunt and have multiple openings. There are many different types of cannulas, which vary in both length and diameter. Cannula sizes are available from 1.8 mm to 1 cm in size, and the most common diameter is 2–5 mm (Kenkel and Stephan, 2013).

The length of the cannula varies from around 10 cm to 30 cm. Longer cannulas provide further access but shorter cannulas enable more accurate control.

Cannulas used for SAL and PAL have multiple openings set back from the tip. One of the most commonly used is the three-hole Mercedes-type cannula (see [Figure 15.5](#)). Cannulas used for PAL are similar to those used for SAL. As described earlier, they oscillate in a plane parallel to the long axis of the cannula. Power is provided by an electrical unit or a pneumatic hose (Mathes and Hentz, 2006).

UAL uses a hollow cannula or a solid probe. The VASER probes are solid with rings around them. The tip of the ultrasonic apparatus oscillates 10 times faster than that used for PAL. These probes can be solid or hollow. The hollow probe allows some fat to be extracted, although the openings are rather small; therefore, further evacuation of the liquefied fat is needed.



**Figure 15.5.** Mercedes type cannula (three holes).

## 12. COMPRESSION GARMENTS

Most patients should be able to go home within 24–48 hours, depending on the extent of the areas involved and their general fitness. Large volume liposuction patients should stay in hospital overnight. Compression stockings should be worn on the legs while in hospital to reduce the risk of thromboembolic events. Wearing compression garments is standard post-liposuction. Compressive bandages are often used in the first week if a customised garment is not available. Compression assists in contouring and decreases bruising and oedema. The recommended length of time for garment use varies among surgeons, but is usually a minimum of 6 weeks.

## 13. COMPLICATIONS

Possible complications from liposuction vary from minor to major, life-threatening events. They may be divided into peri-operative (0–48 hours), early (1–7 days) and late (1 week to 3 months), as shown in [Table 1.2](#).

### 13.1. Peri-operative complications

In the peri-operative period, there may be complications related to the general anaesthesia, such as cardiac events. It is therefore strongly recommended that patients are classified as ASA 1–2 and, if there is any pre-existing cardiopulmonary disease, a medical review is warranted. Other anaesthesia complications may include local effects of the tumescent infiltrate such as lidocaine toxicity or direct cardiac effects of adrenaline.

Organ or intestinal perforation is rare but well documented in the literature. The abdomen, thorax and retroperitoneum are all potentially affected areas, with perforations more commonly occurring through previous scars or hernias (Haeck *et al.*, 2009). The surgeon must always be aware of the location of the tip of the cannula.

**Table 15.2.** Complications of liposuction.

Peri-operative	Early	Late
Anaesthetic complications	Venous thromboembolism	Late seroma
Perforation of organs	Infection	Oedema and ecchymosis
Volume shift	Skin necrosis	Paraesthesia
Bleeding	Necrotising fasciitis	Hyperpigmentation
Hypothermia	Seroma	Contour irregularities
Fat emboli syndrome		

Fluid shifts can occur intra-operatively, especially during large volume liposuction. This may lead to hypovolaemia or potentially pulmonary oedema. It is therefore important for both the anaesthetist and the surgeon to document fluid input and output.

Bleeding during liposuction has become very rare after the introduction of wetting solutions.

The risk of hypothermia is higher in patients having multiple areas treated. It is associated with an increased risk of bleeding, cardiac events and sepsis.

Fat embolism syndrome (FES) is a rare complication of liposuction, in which fat becomes lodged in the small vessels of the lungs. The diagnostic criteria are at least two of the following: respiratory distress, cerebral involvement and petechial rash within 48 hours of the procedure. Hypoxia is often the first sign; others include fever, tachypnoea and bilateral X-ray changes. Treatment is mainly supportive. It is important to differentiate between a pulmonary embolism and FES.

## 13.2. Early complications

The incidence of venous thromboembolism in liposuction is thought to be relatively low, with a risk of <1%. It is important to review all pre-operative risk factors. The use of elastic compression stockings, intermittent pneumatic devices and low molecular weight heparin is recommended when necessary. Signs include lower extremity swelling, Homan's sign, tachypnoea and/or chest pain. Prompt treatment with anticoagulation for deep vein thrombosis and possible thrombectomy or thrombolysis for pulmonary embolism is indicated.

Small infections may occur within haematomas. Systemic infection is thought to be more likely in smokers, diabetics and immunocompromised patients. Local infection and fulminant necrotising fasciitis are well documented in liposuction. It is common practice to give one dose of antibiotic pre-operatively and to closely monitor and treat any post-operative fever and cellulitis. A large study of major and lethal complications of liposuction by Lehnhardt *et al.* (2008) showed that the most frequent complications were bacterial infection such as necrotising fasciitis, gas gangrene and other forms of sepsis.

Skin necrosis appears to be more common in smokers and in patients who undergo superficial liposuction.

## 13.3. Late complications

Seromas appear to be more frequent in the lower abdominal area and usually become more noticeable at around 1 week post-operatively. They are thought to be more likely if adequate pressure garments have not been used and in patients with a high body mass index. Some studies have suggested there is a higher risk of seromas with UAL. They appear to be more common in overtreated areas.

Oedema and ecchymosis are reduced with the use of compression garments for 4–6 weeks. There may be more swelling after UAL, and ecchymosis tends to be more frequently present in smokers or in patients on anticoagulants.

Post-operative aesthesia or dysaesthesia usually regresses within 10 weeks, but may infrequently last up to a year. Occasionally neurological pain may be associated with neuroma formation or damage to underlying fascia or muscle.

Contour irregularities are the most common late complication. Surgical treatment consists of corrective liposuction or lipofilling.

## 14. NON-INVASIVE LIPOSUCTION

---

The technologies used for non-invasive liposuction include ultrasound, laser, cryotherapy and injection mesotherapy. Mesotherapy involves a series of injections containing multiple ingredients which act in two ways: lipolytic agents stimulate lipolysis and ablative chemicals destroy adipocytes. This process is thought to increase blood and lymphatic flow in the mesoderm. The cells shrink, dissolve and are extracted (Rohrich, 2005).

## 15. CONCLUSION

---

Maintenance of a healthy diet and exercise in conjunction with liposuction can enable patients to achieve their desired body shape and contour. To achieve a satisfactory outcome, it is paramount that patients adhere to the recommended diet and level of physical activity. Liposuction is under continuous development with regards to technology and instrumentation. It is deemed safe and effective but, as with all invasive surgery, is not without side effects. Diligent patient selection and realistic expectations will give the most rewarding results.

## REFERENCES

---

- American Society for Aesthetic Plastic Surgery (ASAPS). 2014. Cosmetic Surgery National Data Bank: Statistics 2013. *Aesthet Surg J*, 34, 1–20.
- Ahmad, J., Eaves, F. F., 3rd, Rohrich, R. J. & Kenkel, J. M. 2011. The American Society for Aesthetic Plastic Surgery (ASAPS) survey: Current trends in liposuction. *Aesthet Surg J*, 31, 214–24.
- Bruschi, S., Datta, G., Bocchiotti, M. A., Boriani, F., Obbialero, F. D. & Fracalvieri, M. 2009. Limb contouring after massive weight loss: Functional rather than aesthetic improvement. *Obes Surg*, 19, 407–11.
- Doerr, T. D. 2007. Lipoplasty of the face and neck. *Curr Opin Otolaryngol Head Neck Surg*, 15, 228–32.
- Failley, C. L., Vemula, R., Borah, G. L. & Hsia, H. C. Intraoperative use of bupivacaine for tumescent liposuction: The Robert Wood Johnson experience. *Plast Reconstr Surg*, 124(4), 1304–11.
- Flynn, T. C., Coleman, W. P., 2nd, Field, L. M., Klein, J. A. & Hanke, C. W. 2000. History of liposuction. *Dermatol Surg*, 26, 515–20.
- Glaser, D. A. & Kaminer, M. S. 2005. Body dysmorphic disorder and the liposuction patient. *Dermatol Surg*, 31, 559–60; discussion 561.



- Glicenstein, J. 1989. Dujarier's case [in French]. *Ann Chir Plast Esthet*, 34, 290–2.
- Haeck, P. C., Swanson, J. A., Iverson, R. E., Schechter, L. S., Singer, R., Basu, C. B., Damitz, L. A., Glasberg, S. B., Glassman, L. S., McGuire, M. F. & Committee, A. P. S. 2009. Evidence-based patient safety advisory: Patient selection and procedures in ambulatory surgery. *Plast Reconstr Surg*, 124, 6S–27S.
- Hatef, D. A., Brown, S. A., Lipschitz, A. H. & Kenkel, J. M. 2009. Efficacy of lidocaine for pain control in subcutaneous infiltration during liposuction. *Aesthet Surg J*, 29, 122–8.
- Iverson, R. E., Lynch, D. J. & American Society of Plastic Surgeons Committee On Patient Safety. 2004. Practice advisory on liposuction. *Plast Reconstr Surg*, 113, 1478–90; discussion 1491–5.
- Iverson, R. E. & Pao, V. S. 2008. MOC-PS(SM) CME article: Liposuction. *Plast Reconstr Surg*, 121, 1–11.
- Kenkel J. M., Stephan P. J. 2013. Liposuction: A comprehensive review of techniques and safety. In: Warren, R. J. (ed.) *Plastic Surgery*. China: Elsevier.
- Lehnhardt, M., Homann, H. H., Daigeler, A., Hauser, J., Palka, P. & Steinau, H. U. 2008. Major and lethal complications of liposuction: A review of 72 cases in Germany between 1998 and 2002. *Plast Reconstr Surg*, 121, 396e–403e.
- Matarasso, A. & Levine, S. M. 2013. Evidence-based medicine: Liposuction. *Plast Reconstr Surg*, 132, 1697–705.
- Mathes S. J., Hentz V. R. 2006. *Plastic Surgery*, Michigan, Saunders Elsevier.
- Rohrich, R. J. 2005. Mesotherapy: What is it? Does it work? *Plast Reconstr Surg*, 115, 1425.
- Rohrich, R. J., Broughton, G., 2nd, Horton, B., Lipschitz, A., Kenkel, J. M. & Brown, S. A. 2004. The key to long-term success in liposuction: A guide for plastic surgeons and patients. *Plast Reconstr Surg*, 114, 1945–52; discussion 1953.
- Sasaki, G. H. 2011. Water-assisted liposuction for body contouring and lipoharvesting: Safety and efficacy in 41 consecutive patients. *Aesthet Surg J*, 31, 76–88.
- Sood, J., Jayaraman, L. & Sethi, N. 2011. Liposuction: Anaesthesia challenges. *Indian J Anaesth*, 55, 220–7.
- Stephan, P. J. & Kenkel, J. M. 2010. Updates and advances in liposuction. *Aesthet Surg J*, 30, 83–97.
- Tabbal, G. N., Ahmad, J., Lista, F. & Rohrich, R. J. 2013. Advances in liposuction: Five key principles with emphasis on patient safety and outcomes. *Plast Reconstr Surg Glob Open*, 1, e75.
- The British Association of Aesthetic Plastic Surgeons. 2014. *Britain Sucks* [Online]. BAAPS. Available: <http://baaps.org.uk/about-us/press-releases/1833-britain-sucks> [Accessed 31 October 2014].

## Facial Aesthetic Surgery

---

Muholan Kanapathy, Niall Kirkpatrick

### 1. PATIENT SELECTION

---

Facial aesthetic procedures have been rapidly growing in number across the globe over the past few decades. Globalisation and social media have played a major role in encouraging patients to undergo these procedures (The American Society for Aesthetic Plastic Surgery, 2010). Surgeons therefore have a greater responsibility to appropriately educate patients and use careful patient selection criteria to choose the appropriate candidates for the treatment.

Considerations regarding patient selection and pre-operative counselling for aesthetic surgery include a clear understanding of the patient's perception of their problem and their expectations of surgery as well as knowledge of a wide range of surgical techniques and their risks.

While most patients have clearly identifiable concerns and appropriate expectations, care should be taken with patients that are overly expectant and demanding, those requesting multiple interventions (i.e. 'the surgiholic' patients), those with marital breakdown or job loss, those pushed into surgery by others, those with body dysmorphic disorder, and those with whom the surgeon feels incompatible (Gorney, 2010). Careful patient selection will avoid disappointment for those who may not have understood the procedure or have underestimated the limitations of surgery.

### 2. SURGICAL ANATOMY OF THE FACE

---

A comprehensive description of facial anatomy is beyond the scope of this text. However, key anatomical points relating to facial aesthetic procedures will be emphasised.

## 2.1. Soft tissue layer

The soft tissue of the face consists of five basic layers which are arranged concentrically (Figure 16.1). Specific age-related changes occur in each facial layer; procedures to reposition tissues form the basis of facial rejuvenation surgery.

In the skin, flattening of the dermoepidermal layer coupled with a reduction in the levels of collagens III, IV and VII, chondroitin sulphate, elastin, oxytalan fibres, melanocytes and Langerhans cells determine susceptibility to age-related changes (Gilchrest, 1989; Contet-Audonneau *et al.*, 1999).

Subcutaneous tissue consists of two important components: the subcutaneous fat and retinacular cutis. The retinacular cutis is part of the retaining ligaments that pass through the subcutaneous tissue to provide support. In areas with a thick subcutaneous layer, the retinacular cutis fibres are susceptible to weakening and distension with age.

The superficial musculoaponeurotic system (SMAS) layer contains the mimetic muscles that are involved in facial expression. The SMAS is continuous with the platysma, temporoparietal fascia, frontalis and galea aponeurotica. Manipulation of the SMAS, as described by Mitz and Peyronie in 1976, has become a popular means of rejuvenating the face, with many later variations described (Mitz and Peyronie, 1976). In facelift procedures, greater tension can be applied to the SMAS than to the skin, and the SMAS may act as a carrier for other tissues such as muscle and fat pads. In addition, it forms a key landmark in facial nerve anatomy: below the zygomatic arch, all branches of the facial nerve are deep

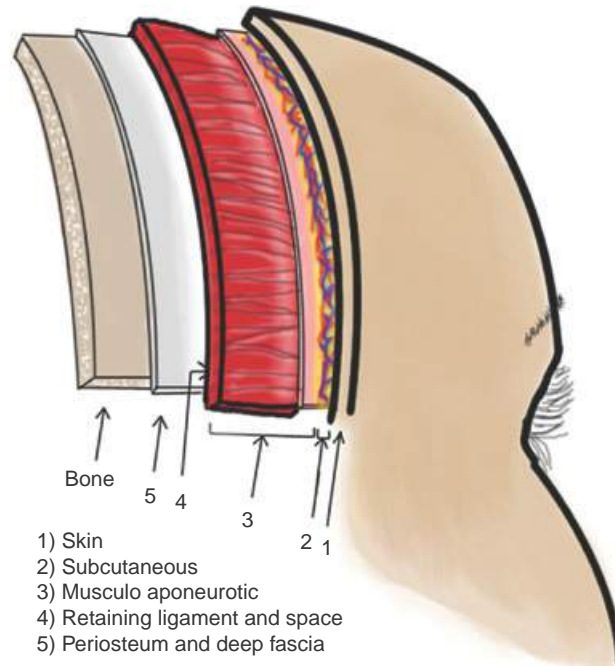


Figure 16.1. Soft tissue layers of the face.

to the SMAS (Mendelson and Wong, 2013). Only the mentalis, levator anguli oris and buccinator muscles are innervated on their superficial surface. All other muscles are innervated on their deep surface. Therefore, dissection in the plane superficial to these muscles is considered relatively safe.

The face also has a fibrous support system of retaining ligaments that prevents repositioning and fixation of facial soft tissues if not released. The retaining ligaments and soft tissue spaces make up the loose areolar tissue. This is an avascular potential space that allows the superficial layers to glide, enabling facial expression. This layer is safe for dissection because no structures cross within it. The retaining ligaments comprise both osteocutaneous ligaments and musculocutaneous ligaments. The osteocutaneous ligaments include the zygomatic ligament, which extends from the zygomatic arch and body (McGregor's patch) through the malar fat pad to the dermis, and the mandibular ligament, which extends from the parasymphyseal region to the dermis. The parotid and masseteric cutaneous ligaments, formed by union of the superficial and deep facial fascia, attach these structures to the overlying dermis.

## 2.2. Nerve anatomy

---

### 2.2.1. Sensory

---

The greater auricular nerve, a branch of the cervical plexus, is the symptomatic nerve most commonly injured during facelift surgery. The superior course of the greater auricular nerve falls within a 30° angle constructed using the vertical limb perpendicular to the Frankfurt horizontal and a second limb drawn posteriorly from the midlobule (Ozturk *et al.*, 2014). Division of this nerve leads to numbness of the earlobe and lateral pinna and also a potential for problematic neuroma if not repaired.

The midface receives sensory innervation from the zygomaticofacial, infraorbital and posterior maxillary nerves and motor innervation from the facial nerve. These nerves are at risk of injury during surgery.

### 2.2.2. Motor

---

The facial nerve emerges from the stylomastoid foramen and passes through the parotid gland, dividing into five main branches which provide motor innervations to mimetic muscles. The temporal branch courses superficially after crossing the zygomatic arch, in the plane deep to the temporoparietal fascia. It travels along a trajectory known as the Pitanguy line from the tragus to a point approximately 1.5 cm superior to the lateral brow (Pitanguy and Ramos, 1966). The buccal and zygomatic branches form multiple interconnections which may conceal injury to the buccal branch, the branch most commonly injured during facelift surgery. The marginal mandibular branch courses approximately 1–2 cm below the border of the mandible before crossing the facial vessels, in the plane deep to platysma.

The marginal mandibular and temporal branches are the most vulnerable to long-term dysfunction if injured.

### 3. AGEING FACE

---

Facial ageing is a dynamic, complex and multidimensional process whereby a complex interplay of several factors contributes to changes in each anatomical layer. The ageing process may vary dramatically between individuals and is thus influenced by genetic factors. When assessing the ageing face, it is important to consider the skeletal architecture, the soft tissue layers including anterior fat pads, the retaining ligament anchors and, finally, the overlying skin.

#### 3.1. Assessment of facial ageing

---

Surgical correction of facial ageing attempts to reverse gravitational changes to soft tissues and restore volume loss.

In the context of the surgical management of facial ageing, the face can be usefully separated into three anatomical areas:

1. The upper face, including the forehead, upper eyelids and eyebrows.
2. The midface, including the anterior cheek and lower eyelids.
3. The lower and lateral face, neck and perioral regions.

The upper face extends from the hairline down to the upper eyelids. Surgical procedures targeting the upper face include forehead and brow lifts, temporal lift, upper blepharoplasty and fat grafting to the brow.

The midface is a triangular area below the eyelid bounded medially by the nasofacial angle, inferiorly by the nasolabial fold and corner of the mouth, and superiorly by the lower eyelid and tear trough and the lateral canthus at the superolateral aspect (Mendelson and Wong, 2012). Key elements of midfacial ageing are gradual ptosis of the cheek skin below the infraorbital rim, creating infraorbital hollowness, descent of the malar fat pad with loss of malar prominence, deepening of the tear trough and associated exaggeration of the nasolabial fold (Owsley, 1993; Stuzin *et al.*, 1995; Hester, 2001; Paul *et al.*, 2006; Saltz and Ohana, 2012).

Surgical procedures directed at the midface may be approached via the temporal region or lower eyelid. It is important to emphasise that these procedures are complicated and involve dissection of the face at deep levels close to neurovascular structures (Hachach-Haram and Kirkpatrick, 2013). They may involve long downtimes and prolonged swelling for patients. Given the significant complication profile, these procedures should only be attempted by surgeons with a clear understanding of and thorough training in this area.

Most commonly, facial rejuvenation is directed at the lateral cheek and lower third of the face and encompasses many modern facelift techniques and neck procedures. To achieve harmony in facial rejuvenation surgery, procedures to correct ageing within different zones may be performed simultaneously or in a staged fashion.

### 3.1.1. Soft tissue changes in ageing face

---

Ageing of the soft tissues of the midface is multifactorial and attributed to a combination of increased laxity of the orbicularis oculi muscle and orbital septum, horizontal laxity of the tarsal plate component of the lower lid, laxity of the zygomaticus muscles and elevators of the upper lip with subsequent deepening of the nasolabial fold, and fat atrophy. Most significantly, attenuation of the osseocutaneous ligaments, including the orbitomalar and orbicularis-retaining ligament, with descent and inferior migration of the soft tissues, including the malar and other fat pads, into the anterior maxillary hollow inferomedially, results in an apparent volume loss in the anterior cheek with visible lengthening of the lower eyelids, giving the face a more squared, vertical appearance (Owsley, 1993; Krastinova-Lolov, 1989; Nahai, 2005; Mendelson and Wong, 2012).

In youth, the upper anterior cheek skin is firmly supported by the orbitomalar septum that allows little or no downward migration (Mendelson *et al.*, 2007). Facial septa extending from the SMAS through the malar fat pad to the overlying dermis further support the malar fat pad (Owsley, 1993). The repeated movements of animation, as well as repeated zygomaticus and levator muscle contraction and shortening, result in pressure within the overlying cheek and prominence of the nasolabial fold (Owsley, 1993).

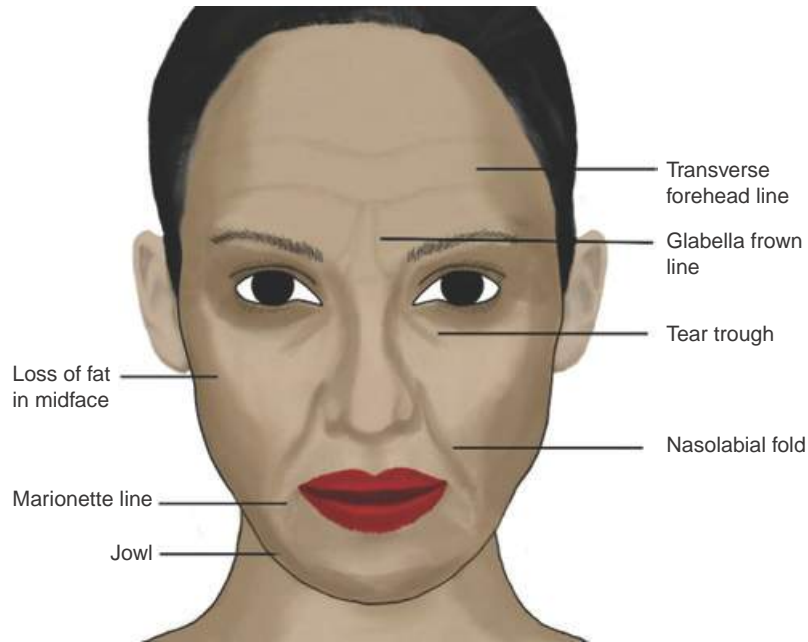
Over time, the supporting fat pad facial septa stretch and weaken, resulting in downward migration of the malar fat pad and the appearance of infraorbital flattening or hollowing, and permanent prominence of the nasolabial fold (Figure 16.2). The fat pads, which include suborbicularis oculi fat (SOOF), temporal fat, malar fat pad and the buccal fat pad, form an important part of the facial architecture. They are partitioned into discrete compartments. Variance in ageing suggests that ageing of these fat pads is not entirely confluent but is instead characterised by how these compartments independently change with age (Krastinova-Lolov, 1989; Owsley, 1993; Rohrich and Pessa, 2007; McCollough *et al.*, 2009). Disruption of the lower eyelid–cheek complex due to inferior migration of the malar fat pad and the SOOF results in a ‘double-contour’ deformity of the midface (Rohrich and Pessa, 2007; Ransom *et al.*, 2012).

The midface receives sensory innervation from the zygomaticofacial, infraorbital and posterior maxillary nerves and motor innervation from the facial nerve. These nerves are at risk of injury during midfacial dissection. Finally, skin changes and collagen degradation add to the ageing process by affecting the facial surface and skin thinning.

### 3.1.2. Skeletal architecture in the ageing face

---

The inferior orbital rim is composed of the zygoma, the lacrimal bone and the anterior maxilla; projection of these structures determines the vector of the midface and the skeletal support available for the soft tissues of the midface. It is important to recognise that the anterior maxilla is significantly concave. Skeletal resorption, at both the periorbital level and maxillary level, has been attributed to the decreased



**Figure 16.2.** Features of the ageing face.

malar projection and increased orbital aperture seen in ageing. This can have significant consequences on the projection and prominence of the maxilla and on the location of facial ligament attachments (Nahai, 2005; Mendelson *et al.*, 2007). The maxilla may undergo significant skeletal resorption, with up to a 10° loss in the maxillary angle contributing to the typical ageing cheek stigmata associated with loss of maxillary projection and resulting in the development of a lid–cheek continuum deformity and a prominent nasolabial fold (Mendelson and Wong, 2012).

### 3.2. Photoaging

Several factors accelerate the ageing process in the skin. Cumulative exposure to ultraviolet irradiation is an important factor that influences skin ageing. Clinical signs of photoaging include freckles, rhytides, telangiectasia, loss of elasticity and a sallow colour.

The Glogau classification of photoaging is most commonly used to describe skin changes due to photodamage and aging (Table 16.1) (Nguyen *et al.*, 2012). The Glogau scale is useful for estimating the overall amount of facial ageing and assists discussion of the potential outcome of cosmetic procedures.

**Table 16.1.** Glogau classification of photoageing.

Group	Age (years)	Findings
1	20–30	No wrinkles Change in homogeneity of colour
2	30–40	Wrinkles on animation as expression lines Early keratosis
2	50–60	Wrinkles at rest Actinic keratosis Make-up provides homogeneity of colour but accentuates the wrinkles
4	60 or older	Severe wrinkling Actinic keratosis and skin cancers Make-up creates ‘cracked mud’ appearance

## 4. SURGICAL AESTHETIC TREATMENT

### 4.1. Facelift

The youthful face is often defined by malar and lateral cheek fullness with associated submalar concavity, giving a smooth contour coupled with an aesthetically pleasing convex lower eyelid–cheek continuum (Hachach-Haram and Kirkpatrick, 2013). The lower mandibular jawline is even and smoothly defined, and the eyebrow convex and situated on or above the supraorbital margin, with the eyelid having a well-defined crease.

Facelift surgery started as early as 1901, and has evolved significantly since then (Warren, 2013). Since the mid-1990s, there has been increasing interest in the midface lift as a sophisticated component of facial rejuvenation, with the development of techniques other than the traditional pre- and post-auricular approaches (Berkowitz *et al.*, 2005). Newer approaches are based on the principle of lifting in a more vertical or superolateral vector (Berkowitz *et al.*, 2005).

#### 4.1.1. Operative techniques of facelift

##### 4.1.1.1. Subcutaneous facelift

The subcutaneous facelift evolved from the first facelift involving a simple skin incision at the temporal hairline and pre-auricular region to a more extensive subcutaneous dissection with skin repositioned in a superolateral vector (Warren, 2013). The skin flap is created by dissecting in the plane immediately superficial to the SMAS, thus preserving the subdermal plexus for vascular supply (Hoefflin, 1998). Despite being a relatively safe procedure, the subcutaneous facelift is rarely performed today because it relies on skin tension to produce the desired lift; this often leads to widened scars and early recurrence



and an unnatural ‘pulled’ appearance. However, this technique may be useful in selected patients such as those with pseudoxanthoma elasticum or with multiple previous facelifts.

#### 4.1.1.2. Subcutaneous facelift with SMAS manipulation

Upon raising a subcutaneous skin flap, several different techniques can be used to manipulate the SMAS to restore volume to the malar region, thus creating a more youthful appearance. Plication uses sutures to fold the SMAS and reposition fat from the lower face. SMAS imbrication requires incision and overlapping of the SMAS with suture fixation. The SMAS is advanced in a different vector from the skin, thereby avoiding the use of skin tension alone. However, recurrence of facial ptosis may occur if sutures pull through the skin.

The minimal access cranial suspension (MACS) lift, popularised by Tonnard and Verpaele (2007), uses permanent purse string sutures anchored to the deep temporal fascia to achieve superolateral suspension of the SMAS–platysma layer. Multiple small bites are taken during suture placement to create micro-imbrications of fat and SMAS. In the simple MACS lift, two purse string sutures are used to address the neck and lower third of the face. An additional third suture is included in the extended MACS lift to suspend the malar fat pad. The main disadvantage of the MACS lift is its reduced longevity of effect. MACS is most effective in younger patients who require minimal skin redraping.

#### 4.1.1.3. Subcutaneous facelift with a separate SMAS flap (plus variations)

Elevating separate skin and SMAS flaps provides greater flexibility in the direction and tension applied to each flap. The SMAS flap is usually advanced in a more vertical direction with firm suture fixation to immobile tissues, while the skin flap is redraped under minimal tension in a superolateral vector. This is crucial to avoid the ‘lateral sweep’ effect.

#### 4.1.1.4. Skoog facelift

In 1974, Skoog described raising the skin, subcutaneous fat and SMAS as a single unit (Skoog, 1974). Modifications of the technique have evolved to overcome tethering of the SMAS attachment to the lip elevators and thus improve the nasolabial fold (Barton and Hunt, 2003).

#### 4.1.1.5. Lateral SMASectomy

The lateral SMASectomy, as described by Baker, excises a strip of SMAS (obliquely from the angle of mandible to the lateral malar eminence) along with the overlying fat (Baker, 1997). The width of SMAS resection depends on the extent of laxity. The vector of elevation (perpendicular to the nasolabial fold) is not ideal and can produce an unnatural or ‘pulled’ appearance, otherwise known as ‘lateral sweep’ or ‘Nike swoosh’. Flattening, with loss of volume in the lateral cheek element, may also occur.

SMAS procedures can rejuvenate the middle third of the face by elevating tissues over the malar eminence with slight effacement of the nasolabial fold. The points of fixation for the most vertically elevated SMAS flap lie lateral to the orbit along the line of the zygoma and zygomatic arch. These techniques can address the jowls and produce an excellent jawline, as well as correcting laxity in the neck and the lateral cheek. However, these procedures do not address well the volume changes below the eyes and the problem of malar and anterior fat repositioning in its entirety. Consequently, they do not rejuvenate the true midface and their results on the midface are unpredictable. Enhancement of malar volume may therefore be achieved without adequately restoring the lower lid–cheek continuum. SMAS procedures may well produce acceptable results with a high satisfaction rate in younger patients, but in the older patient or those with more complex problems, SMAS procedures alone will generally fall short of ideal. Moreover, SMAS lifts can exacerbate the problem of the concavity and hollow appearance of the lower lid, giving a typical ‘lateral sweep facelift’ appearance. In contrast, re-elevating the midface using the orbicularis oculi flap as the primary vehicle, with or without subperiosteal dissection and re-suspension, can restore a more youthful convexity to the lower lid–cheek continuum; this is usually best seen in photographic three-quarter views.

The recent development of volume-enhancing minimally invasive techniques such as autologous fat transfer has led some surgeons to opt for simpler techniques with minimal post-operative oedema. Filling midface contour defects enables a quick return to normal life. However, the fundamental problem of midface descent is not addressed and may even be made worse by further weighting of the tissues. Irregularity of the tissues may also become apparent once post-surgical oedema resolves; often, these results are not forgiving. These patients may subsequently benefit from corrective midface surgery.

Although midface lifting techniques are more complex to perform and require careful patient assessment and choice of procedure, they can address ageing of the anterior cheek better than conventional facelift techniques. When performed either in isolation or in conjunction with other facelift or periorbital procedures, they produce harmonious and natural rejuvenation for patients. Furthermore, they can be used as powerful reconstructive tools for patients with soft tissue midface deficiencies.

#### 4.1.1.6. Subperiosteal facelift

---

Tessier advanced the subperiosteal approach for middle third facial rejuvenation and also highlighted the use of the coronal approach to achieve adequate lifting of the temporal and lateral canthal areas (Tessier, 1979). In the 1980s, Santana described the importance of subperiosteal dissection to allow traction of the deeper structures to improve the nasolabial fold and recommended resection of Bichat’s fat pad (buccal fat) to produce a more prominent malar appearance (Barton, 2002).

Mendelson described the use of extended SMAS dissection and periosteal fixation that refined the process of elevating the ptotic malar fat pad, resulting in effacement of the nasolabial fold (Stuzin *et al.*, 1995; Barton and Hunt, 2003).

Ramirez *et al.*, Ortiz-Monasterio, and Tapia *et al.*, were concerned with the risk of neurapraxia; they independently demonstrated that careful subperiosteal dissection using multiple subperiosteal

pockets minimises these risks (Barton, 2002). Furthermore, by dissecting beneath both layers of the temporal fascia, midface rejuvenation was achievable (Guerrerosantos, 1983; Feldman, 1990; Jones and Grover, 2004).

Subperiosteal dissection can be performed via lower eyelid incisions, limited temporal incisions (often in combination with intraoral sulcus incisions) and the coronal ‘mask lift’ approach. The decision regarding which approach to use largely depends on the need to control the lateral canthus and brow complex. Some patients will also require release of the parotid–masseteric ligaments because these can restrict midfacial elevation. Subperiosteal dissection along the zygomatic arch with inferior dissection on the superior surface of the masseter muscle allows the release of these ligaments.

Both subciliary and transconjunctival lower eyelid incisions can be used to elevate the midface in the subperiosteal plane alone. The subciliary approach is required to elevate the midface in the submuscular plane, allowing fashioning of the orbicularis flap as described by Hamra. This approach also allows separate subperiosteal dissection and elevation in a biplanar technique.

The temporal approach utilises a short incision and careful dissection deep to the frontal branch of the facial nerve to avoid injury. Temporal suprapariosteal dissection using an endoscopic method has also been described (Byrd and Andochick, 1996).

Berkowitz *et al.* described the use of the Endotine device (Coapt Systems, Palo Alto, CA, USA) for midface lifting (Berkowitz *et al.*, 2005). Endotine devices are biodegradable polylactide polymer devices that provide simultaneous elevation and fixation of tissue (Barton and Hunt, 2003). They are an excellent method of fixation for subperiosteal dissection because they provide a wide platform for purchase of these tissues, thus providing controlled and reliable fixation. These devices can be anchored either to the deep temporal fascia superiorly with sutures or with screw fixation to the inferolateral orbital rim and can be augmented with suture fixation to the inferior orbital rim where indicated.

Among the advantages of subperiosteal face lift are en bloc mobilisation of soft tissue, which provides better exposure and better visibility, a low risk of facial nerve injury, and exposure of the bony skeleton, allowing skeletal contouring such as insertion of facial implants and synchronous lifting of the midface and brow (Warren, 2013). Its disadvantages include the requirement for additional equipment, a longer post-operative recovery period and minimal effects on facial skin.

## 4.1.2. Complications of facelift procedures

### 4.1.2.1. Haematoma

Haematoma is the most common post-operative facelift complication, with an incidence of 3–4% in women, increasing to 8% in men. Development of haematoma is most likely to occur in the first 24 hours after surgery and requires urgent surgical evacuation. Prevention of haematoma may be facilitated by strict monitoring of blood pressure during the peri-operative period, with smooth awakening from anaesthesia avoiding valsalva manoeuvre.

#### 4.1.2.2. Nerve injury

---

##### 4.1.2.2.1. Motor nerves

Damage to the facial nerve is one of the most feared complications of facelift surgery. In the first few hours post-operatively, paralysis may be due to the effects of local anaesthesia. Subsequently, nerve injury may be related to cautery, traction, suture injury or division.

##### 4.1.2.2.2. Sensory nerves

The great auricular nerve is the one most commonly injured. Interruption of smaller, cutaneous sensory nerves may lead to self-limiting alterations in sensory innervation.

#### 4.1.2.3. Skin necrosis

---

Skin necrosis may occur in the central cheek or at the posterior edge of the skin flap. A watershed area is described in the central cheek between the zones supplied by the facial and superficial temporal arteries and may contribute to skin necrosis in this area. Other risk factors include haematoma, infection, thin skin flaps, excessive tension and smoking. Conservative management of skin loss is usually adopted.

#### 4.1.2.4. Facelift stigmata

---

Complications include distortion of the tragus and lobule, displacement of the hairline and bearded skin in men, the 'lateral sweep' effect and contour irregularities (as discussed previously). There are risks of asymmetry and lower eyelid inferior malposition.

#### 4.1.2.5. Other complications

---

Less common complications include infection (1%), hypertrophic scars, numbness, pigmentary changes, alopecia (up to 8.4%), parotid fistulae, and prolonged oedema or facial pain (Baker *et al.*, 1977; LeRoy *et al.*, 1994).

## 4.2. Upper third rejuvenation

---

Age-related changes in the upper third of the face can falsely project an appearance of tiredness, sadness, anger or lack of interest (O'Doherty and Joshi, 2013). Evaluation of the upper eyelid must include the eyebrow, and it is important to tailor upper eyelid blepharoplasty and brow rejuvenation to the individual.

### 4.2.1. Blepharoplasty

The eye is perhaps the most important aesthetic unit of the face because it plays a major role in determining youthfulness.

Blepharoplasty refers to excision of excess eyelid skin and muscles with or without the excision and manipulation of orbital fat for functional or aesthetic purpose (Biesman and Iwamoto, 2002).

#### 4.2.1.1. Upper blepharoplasty

---

##### 4.2.1.1.1. *Relevant surgical anatomy for upper blepharoplasty*

The two main goals for upper lid blepharoplasty include restoration of a naturally sharp and crisp tarsal fold and a pretarsal show (O'Doherty and Joshi, 2013).

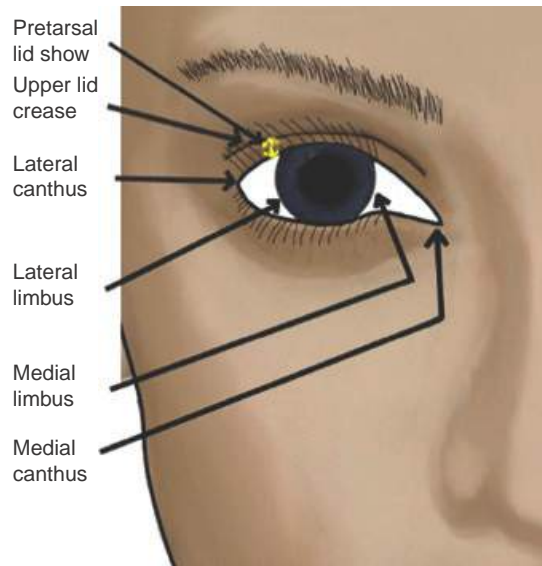
In aesthetically attractive eyes, the pretarsal eyelid show is often only 2–3 mm (Figure 16.3) (O'Doherty and Joshi, 2013). The upper eyelid can be divided into tarsal and orbital portions at the level of the supratarsal fold. In Caucasians, this skin crease is located about 7–10 mm from the palpebral margin, which results from fusion of the levator aponeurosis, orbital septum and fascia of the orbicularis oculi into the dermis (Figure 16.4).

In the ageing eyelid, orbicularis muscle becomes hypotonic and descends, accentuating the palpebro-malar crease. Ageing leads to a higher fold, with or without upper lid ptosis and/or skin laxity of the lid (O'Doherty and Joshi, 2013). Loss of crease attachments may cause the skin to rest toward or beyond the upper eyelid–eyelash margin, which may cause interference with upper outer visual fields. This is accompanied by elongation of the lower eyelid and descent of the lateral canthus. Orbital septum laxity causes the fat to herniate anteriorly, leading to formation of prominent eye bags.

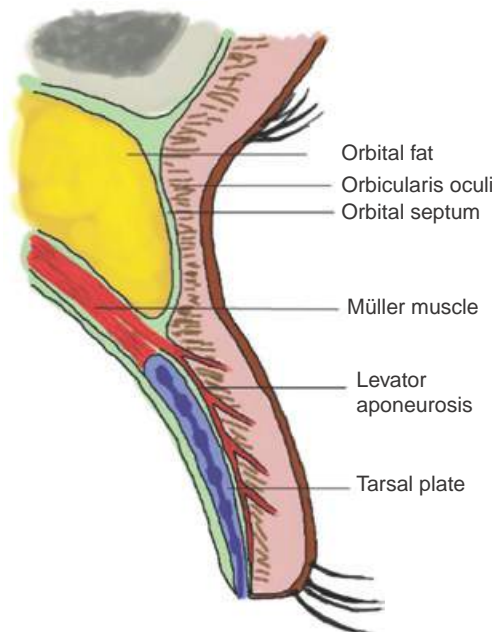
##### 4.2.1.1.2. *Clinical evaluation*

Prior to carrying out any procedure, the surgeon should obtain a good history from the patient. Medical conditions such as hypothyroidism and bleeding disorders need to be excluded. The upper eyelid margin usually rests 2 mm below the superior corneal limbus. Ptosis is the condition in which the upper eyelid drops further down. Ptosis can have a myogenic (affecting the levator or Müller muscle), neurogenic (myasthenia gravis), or mechanical or traumatic cause. The lower eyelid margin usually rests about 1 mm above the inferior corneal limbus. Visibility of white sclera below the inferior limbus is known as inferior scleral show. This inferior scleral show is normal in some populations.

Evaluation of the upper eyelid must include evaluation of the eyebrow. Brow ptosis, which may be compensated by frontalis contraction, should be corrected to achieve repositioning of heavy eyebrow skin. Ageing also causes the eyebrow fat to descend over the upper lid, giving it a full appearance. Eyelid skin resection may cause worsening of the brow ptosis because elevation by frontalis muscle is no longer needed for the visual field. This results in a more aged appearance (Flowers *et al.*, 1993). Brows will be discussed further Section 4.2.2.



**Figure 16.3.** Surface anatomy of the eyelid.



**Figure 16.4.** Cross-section of the upper eyelid.

#### 4.2.1.1.3. Pre-operative markings

Pre-operative marking is a crucial step in assessment of the patient and is best done with the patient in neutral gaze and sitting upright (O'Doherty and Joshi, 2013). Prior to marking, the brow should be elevated to the proper position. The supratarsal fold is usually located about 8–10 mm above the ciliary margin in women and about 7–8 mm in men. A mark is made on this fold and an upper mark must be made at least 10 mm from the lower edge of the brow. Excess skin is defined by pinching with forceps at multiple sites across the eyelid. More skin can be removed laterally and the index of safety becomes more critical as the incision proceeds medially (O'Doherty and Joshi, 2013). Lateral marking should not extend lateral to the orbital rim to prevent prominent scarring. Similarly, the medial markings should not be extended medial to the medial canthus because extensions onto nasal side wall result in webbing (O'Doherty and Joshi, 2013). If excessive skin is present medially, an additional medial triangle of skin maybe resected from the upper eyelid. The pre-operative markings should not be visible when the eyes are open in primary position to avoid unsightly scars.

#### 4.2.1.1.4. Operative procedure

Upper blepharoplasty is performed with the patient in a supine position and the head elevated. The skin, without muscle, is dissected off the underlying tissue while ensuring meticulous haemostasis to avoid haematoma (O'Doherty and Joshi, 2013). Upon removal of the skin, a strip of orbicularis muscle may be removed comprising the upper one-third to upper one-half of the muscle. If lateral brow elevation is required, more orbicularis muscle is removed at the lateral corner. In younger patients, the orbicularis muscle is not removed (O'Doherty and Joshi, 2013). If fat removal is deemed necessary, a small incision is made through the septum into the medial compartment of the eyelid. The fat is teased out and resected using a clamp, cautery and curved scissors (O'Doherty and Joshi, 2013).

### 4.2.1.2. Lower blepharoplasty

#### 4.2.1.2.1. Relevant surgical anatomy for lower blepharoplasty

The skin of the lower eyelid is the thinnest of the body and overlies scant subcutaneous fat (Collar *et al.*, 2013). The orbicularis oculi muscle is deep to the skin and originates from the medial palpebral ligament, frontal process of the maxilla and inferomedial orbital rim. It is attached to the periosteum of the maxilla by a ligamentous attachment, the orbital retaining ligament (ORL) in the deep lateral plane (Mendelson *et al.*, 2002). A youthful lower lid has a short vertical height because the orbicularis complex has a good tone without laxity or redundancy (Collar *et al.*, 2013). Posterior to orbicularis oculi is the orbital septum which maintains orbital fat within the orbit. Fat is subdivided into medial, central and lateral compartments by the inferior oblique muscle and condensation of the Lockwood ligaments (Yousif *et al.*, 1995).

Inferiorly, the malar fat pad of the cheek is in the subcutaneous compartment which extends over the orbital rim, providing a youthful smoothly contoured transition from eyelid to cheek.

With ageing, increased laxity of the orbital septum and weakening of the Lockwood suspensory ligament leads to pseudoherniation of orbital fat anteriorly (Collar *et al.*, 2013). Inferior displacement of the malar fat pad from the infraorbital rim creates inferior convexity as a second convexity inferior to the pseudoherniation of fat.

Lower lid blepharoplasty is often considered midface rejuvenation, and the best approach for lower blepharoplasty has been long debated (Collar *et al.*, 2013). Popularised in the 1970s by Rees after innovation by McIndoe, the skin–muscle flap was a workhorse into the 1990s because it was easily performed, broadly applicable and effectual (Rees and Dupuis, 1969). However, complications such as hollowing of the orbit, denervation atrophy of the orbicularis oculi, lower lid malposition and ectropion are not uncommon (McCord and Ellis, 1993). This led to the introduction of a transconjunctival approach by Bourgeut which gained popularity in the 1990s via Resnik (Zarem and Resnick, 1991), often employing fat resection combined with CO<sub>2</sub> laser resurfacing. This approach led to unique problems, including the inability to redrape skin and muscle and laser-derived hypopigmentation (Roberts, 1998). The debate surrounding transconjunctival vs transcutaneous approaches continues; the next sections (4.2.1.2.2 and 4.2.1.2.3) present a balanced view of both approaches.

#### 4.2.1.2.2. *Transconjunctival approach*

The widely accepted indication for transconjunctival blepharoplasty is the treatment of mild to moderate pseudoherniation of fat in young patients with minimal excess skin (Collar *et al.*, 2013). An incision is made with electrocautery between the tarsal plate and the first vascular arcade, stopping lateral to the medial punctum. Lower lid retractors are divided and the flap is elevated deep to the orbicularis oculi and superficial to the orbital septum (Figure 16.5). From this exposure, the surgeon may perform fat transposition, or release the ORL and malar–orbicularis attachment.

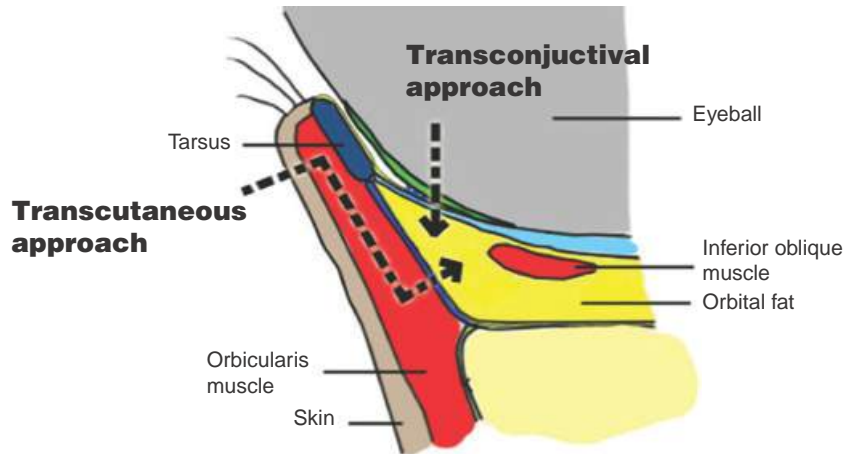
In patients with a palpebromalar sulcus and deep tear trough deformity, the ORL and medial orbicularis oculi attachments may be released (Stutman and Codner, 2012). Via such release, fat transposition may be employed via the transconjunctival approach to specifically recontour the tear trough and lid–cheek junction (Baker, 1999). This method highlights the modern principle of fat preservation whereby the orbital septum is transgressed and preseptal fat released. Pre-periosteal or post-periosteal pockets are created overlying the malar bone with blunt dissection. Using temporary transcutaneous mattress sutures, the fat is delivered and secured into a position over the orbital rim to smooth the orbitomalar sulcus.

In patients with moderate skin excess, a transconjunctival approach plus an adjunctive skin excision (skin pinch) can be performed (Kim and Bucky, 2008). This has the advantage of not undermining the skin, thus causing less contraction and lid malposition.

#### 4.2.1.2.3. *Transcutaneous approach*

The main advantage of this approach is that it provides the capacity to treat excess skin and muscle that require redraping for adequate lid recontouring (Collar *et al.*, 2013). Moreover, it provides broad





**Figure 16.5.** Blepharoplasty approaches on the lower eyelid.

exposure for wide release of the ORL, fat transposition and a myriad of mid-facelift procedures (Patipa, 2004). Notable disadvantages include a propensity for lower lid malposition, orbicularis denervation atrophy and ectropion (Baylis *et al.*, 1989, McCord and Ellis, 1993).

In this approach, an incision is made 2 mm below the lash line into the lateral crow’s feet, followed by subcutaneous dissection along the length of the lid (Collar *et al.*, 2013). The skin is transected sharply 2 mm below the lash line to the level of the medial punctum. Suborbicularis dissection ensues a few millimetres inferior to the skin incision and superficial to the orbital septum to the level of the orbital rim. If fat excision is indicated, the septum may be transgressed. Upon removal of fat, the skin and muscle are redraped and conservative skin excision is performed.

A SOOF lift may be performed via this open skin–muscle flap approach (Freeman, 2000). The SOOF is easily elevated and secured to the orbital rim to add volume overlying the rim for smoothing the lid–cheek junction and tear trough deformity (Freeman, 2000).

Contraindications for eyelid surgery include patients with psychological issues, dry eyes and uncontrolled inflammatory skin conditions such as eczema and psoriasis (O’Doherty and Joshi, 2013).

#### 4.2.1.2.4. Complications

Complications related to blepharoplasty include injury to the internal oblique muscle, leading to diplopia. Retrobulbar haematoma is a surgical emergency leading to ischaemic insults to the optic nerve, retina and central artery; it can lead to blindness and requires urgent decompression by releasing sutures especially over lateral canthus or lateral canthotomy. Mannitol and acetazolamide may be given to assist decompression. Scleral show due to overcorrection can lead to exposure keratopathy with dry eyes. Infection, chemosis, ectropion and asymmetry are also potential complications.

## 4.2.2. Brow lift

Brow lift is an integral part of upper facial rejuvenation. Age-related changes to the brow can be classified into two main types (O'Doherty and Joshi, 2013):

1. Deflationary – characterised by volume loss.
2. Positional – either higher or lower, depending on the level of overaction of the frontalis muscle.

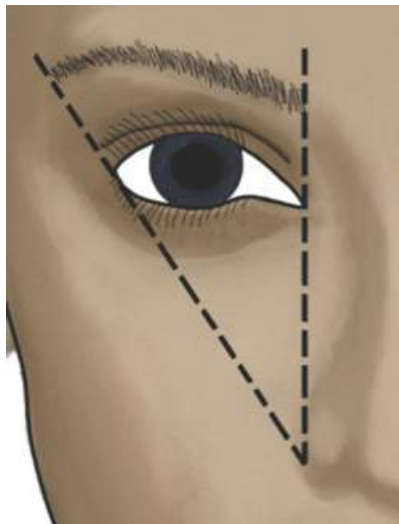
The brow is aesthetically positioned differently in men and women: in women, the lateral part of the eyebrow lies just above the supraorbital rim; in men, the eyebrow lies along the supraorbital rim (Miller *et al.*, 1996). The medial end of the eyebrow is aligned with the medial canthus. The lateral end of brow lies at an oblique line drawn through the lateral canthus and alar base (Figure 16.6). The brow curves upward to its apex at about two-thirds of its length. A more medially placed apex gives a sad expression. With ageing, the lateral part of the eyebrow sags, resulting in a more medial apex.

### 4.2.2.1. Techniques

Since the mid-1990s, brow lifting has taken an evolutionary course from the original coronal procedure to the newly endoscopic approach (Shiffman, 2013). The three most common brow lifting techniques practised are the endoscopic, direct and trichophytic approaches.

### 4.2.2.2. Endoscopic brow lift

The goal of endoscopic brow surgery is to elevate the eyebrow, decrease forehead rhytids, decrease vertical glabellar rhytids, improve lateral canthal hooding and decrease the infra-brow skin (Shiffman,



**Figure 16.6.** Alignment of the eyebrow.

2013). Two useful pre-operative quantitative measurements are the glide test and the frame height. The glide test measures brow excursion in the medial, central and lateral portions of the eyebrow. The frame height measures the distance from mid-pupil to the top of the brow. The best results of an endoscopic brow lift typically occur with frame heights of 1.5–2.0 cm and a glide test result of 2.0–3.0 cm (Shiffman, 2013). There are two planes of dissection: subperiosteal and subgaleal. The subperiosteal approach results in less blood loss, does not displace the hair line caudally and is the preferred choice of most surgeons (Shiffman, 2013).

The major landmarks for this procedure include the sentinel (zygomaticotemporal) vein and the temporal crest (Nahai, 2005). The sentinel vein denotes the danger zone for the frontal branch of the facial nerve because the nerve passes 1 cm above the level of the vein (Nahai, 2005). The temporal crest can be palpated along the lateral portion of the superior orbital rim, which is more pronounced when the patient clenches the teeth (Shiffman, 2013).

Two paracentral, two lateral and two temporal incisions can be made for an easy approach; however, the number and location of incisions might vary according to surgeon’s level of expertise (Shiffman, 2013). The central and paramedian incisions are made down to the periosteum while the temporal incisions are made down to the deep temporal fascia to avoid damage to the temporal branch of facial nerve.

After endoscopic dissection and elevation, fixation can be performed with external screws, outer cortical bone tunnels, LacroSorb screws or Endotine devices (Shiffman, 2013). Endotine provides a consistent and predictable result, and dissolves in approximately 6–8 months.

#### 4.2.2.3. Crenated direct brow lift technique

In older patients, a direct brow lift is favoured (O’Doherty and Joshi, 2013). The technique can be modified with a ‘crenated’ incision to help disguise the scar. Pre-operative marking is done along the full length of the superior border of the brow adjacent to the uppermost brow hairs. The brow is pulled up to its intended post-operative height and a marker is held at this point. The brow is then allowed to drop back to its ptotic position and the forehead skin is marked at the level of the pen. This manoeuvre is repeated at several points along the brow and the line is joined to form a zigzag pattern, dipping just into the brow hairs to form a crenated effect. The wound is closed in two layers (O’Doherty and Joshi, 2013).

#### 4.2.2.4. Pretrichial brow lift

A pretrichial brow lift involves making an incision into the front of the hairline and may be offered to younger patients with a lateral brow ptosis. It is effective especially in those with a low hairline laterally (O’Doherty and Joshi, 2013). The skin and subdermal tissue are incised and resected. Superficial subdermal plane dissection is carried downward with care because the facial nerve lies at a slightly deeper plane. A deep 4-0 Prolene® suture is used to elevate the undermined forehead section to the superior deep temporalis fascia. This technique elevates and reorients the ptotic lateral brow.

#### 4.2.2.5. Complications

---

Complications of brow lift include nerve injury (supraorbital, supra-trochlear, facial nerve), asymmetry, alopecia, scarring and recurrence of ptosis.

### 4.3. Skeletal augmentation

---

The facial skeleton is the essential determinant of facial appearance. Changing the skeletal morphology by augmentation can be done to enhance facial proportions and reconstruct defects. Facial skeletal augmentation is commonly done via autologous tissue or an allogenic or alloplastic implant.

#### 4.3.1. Implant

---

Implants are made of biocompatible materials and have predictable effect on host tissue. The use of implants has advantages over the use of autogenous bone or cartilage which is susceptible to remodeling, causing change in shape and volume. The main types of implants used are silicone and porous polyethylene implants (Yaremchuk, 2013). Silicone implants have the disadvantage of causing resorption of the underlying bone and a visible fibrous capsule if placed superficially under the soft tissue envelope. Polyethylene implants that lead to fewer complications are favoured by most surgeons. Implant augmentation can be used as an alternative or adjunct to orthognathic surgery.

#### 4.3.2. Genioplasty

---

A prominent jaw line is regarded to be aesthetically desirable, especially in men.

Genioplasty is mostly done to improve the mandibular profile; it can be used to shorten or lengthen the lower third of the face. Augmentation is done by advancement osteotomy or with an implant. Reduction is achieved by reduction osteotomy.

Cephalometric analysis is vital to ensure that skeletal and occlusal disparities are identified. The relationship between the dentition and the chin point needs to be understood. Importance should be placed on the position of maxilla. If the maxilla is appropriately positioned in the sagittal plane and only mild retrognathia (<3 mm), or if retrogenia is present, then genioplasty is appropriate (Hammoudeh, 2007). However, if maxillary developmental dysplasia is noted, a formal orthognathic investigation is necessary.

Implants can be strategically placed to increase a particular projection. For example, to increase anteroposterior projection the implant is placed in between the mental foramina, while to increase posterior jaw contour implants can be inserted on the posterolateral part of the mandible.

Chin implants can be inserted via a submental or intraoral approach. Placement of a chin implant depends on the distance between the lip and chin. The implant is placed lower if the distance is short and higher if the distance is large.

### 4.3.3. Midface skeletal augmentation

Aesthetic augmentation is most commonly performed for the middle and lower third of the face. Implants are mostly designed to augment the infraorbital rim, the malar and the pyriform aperture (Yaremchuk, 2013).

The malar prominence is formed by the maxilla and zygoma. Malar fullness provides a youthful appearance. Besides restoring malar fullness, malar implants can also obliterate lower eyelid wrinkles and secondary eye bags. Insertion of implants into the paranasal (pyriform) area can augment projection of the nasal base and lessen the depth of the nasolabial fold. Malar implants can be inserted via both intraoral or subciliary approach.

Common complications associated with midface skeletal augmentation are:

- Nerve injury
- Ectropion
- Extrusion of implant
- Over- or undercorrection
- Infection
- Malposition of implant.

## 4.4. Rhinoplasty

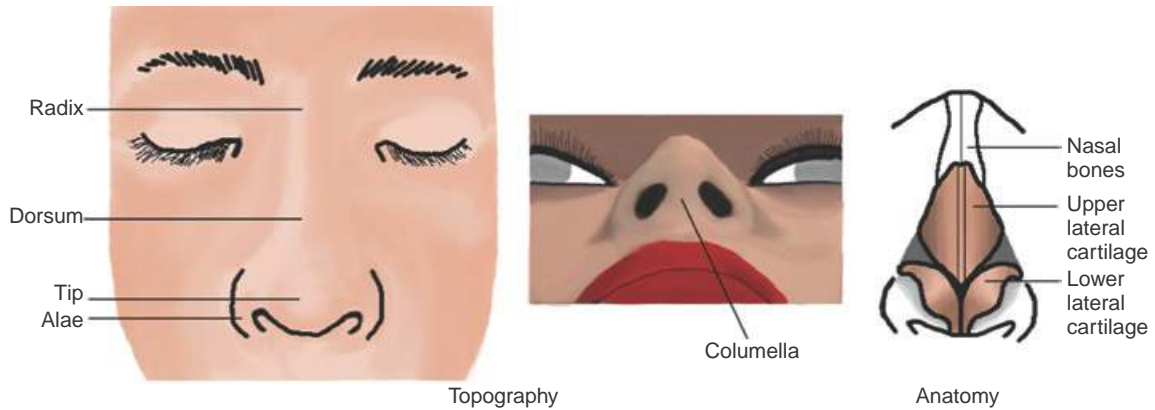
Rhinoplasty is one of the most commonly performed aesthetic procedures. The nose is made of a framework, support, external cover and internal lining. The framework consists of bone and cartilage. Support is established by connective tissue and ligaments that hold the framework together, while the external covering is composed of skin and soft tissue. There is an internal lining of skin and mucosa. The skin characteristics influence the outcome and recovery following rhinoplasty. Thicker skin is more prone to oedema and scarring after rhinoplasty and has a longer recovery duration (Rohrich and Ahmad, 2012).

The bony framework of nose can be divided into thirds (Figure 16.7):

1. Upper third – consists of paired nasal bones.
2. Middle third – consists of upper lateral cartilages attached caudally to nasal bones.
3. Lower third – consists of paired alar. These structures curve and meet at the apex, forming the tip of the nose.

The nasal septum divides the nose into equal halves. It consists of a quadrangular cartilage, perpendicular plate and vomer. The cartilaginous septum is connected to the medial crus of the alar cartilages by a membranous septum.

Prior to performing rhinoplasty, evaluation of the nasal airway is crucial. The key structures affecting nasal airflow are the inferior turbinates, external and internal nasal valves, and the nasal septum (Howard and Rohrich, 2002).



**Figure 16.7.** Topography and anatomy of the nose.

**Table 16.2.** Advantages and disadvantages of open rhinoplasty.

Advantages	Disadvantages
Binocular vision	External nasal incision (transcolumellar scar)
Better handling with both hands	Longer operative time
Direct control of haemostasis	Delayed wound healing with nasal tip oedema
More options with original tissue and cartilage graft	Often requires suture stabilisation of graft

#### 4.4.1. Approach to rhinoplasty

Rhinoplasty surgery can be performed via two separate approaches: closed (internal) and open (external). [Table 16.2](#) compares the advantages and disadvantages of the open and closed approaches (Gunter and Rohrich, 1987). Open rhinoplasty is done via a transcolumellar step incision or a V-incision at the narrowest part of the columella. This technique provides excellent exposure of the nasal framework, which is useful for treating a traumatic or congenital deformity. It is performed when significant nasal tip adjustment is necessary. Closed rhinoplasty is a good option for minimal tip adjustment.

#### 4.4.2. Options for incision

These include:

1. Intercartilaginous (done between upper lateral and alar cartilages).
2. Transcartilaginous (through the lower lateral cartilages) – gives access to the dorsum of the nose.
3. Infracartilaginous (inferior to lower lateral cartilage).
4. Rim incision – can be combined with transcolumellar incision to expose internal structures during open rhinoplasty.

5. Transfixion incision (through membranous septum).
6. Alar base excision – for a reduction in nasal width.

#### 4.4.3. Modifying nasal dorsum

---

A prominent nasal dorsal hump is a frequent complaint among patients; it can be reduced as a composite or via component reduction (Rohrich and Ahmad, 2011). Component reduction provides greater control and precision. It is performed via five essential steps (Rohrich and Ahmad, 2012):

1. Release of the upper lateral cartilage from the septum
2. Incremental septum reduction
3. Incremental reduction of bony dorsum
4. Verification by palpation
5. Final modifications.

A flat nasal dorsum following reduction can be corrected by performing osteotomies on the lateral aspects of the nasal bones or with the use of a dorsal onlay graft.

#### 4.4.4. Nasal tip

---

Nasal tip correction can be performed via cartilage graft or suture technique. Three types of grafts commonly used for tip correction are

1. Tip grafts (shield-like onlay graft)
2. Spreader grafts (used to widen middle third)
3. Autospreader grafts.

Suture techniques, on the other hand, modify the shape of the alar cartilages at the nasal tip. Autologous grafts are preferred for their biocompatibility and low extrusion and infection risks. They can be obtained from ear, septal and costal cartilage. Disadvantages include graft resorption, donor-site morbidity and limited resources.

## 5. NON-SURGICAL AESTHETIC TREATMENT

---

### 5.1. Chemical peels

---

Chemical peels cause controlled destruction to particular layers of the skin, which is followed by regeneration and remodelling. This results in improved texture of the skin without permanent scarring. Peeling agents act by a metabolic, caustic or toxic action. Chemical peels are classified into four groups by their depth of action, which determines their clinical application (Table 16.3) (Herbig *et al.*, 2009). The use

**Table 16.3.** Types of chemical peel.

Type of peel	Depth of action	Agents	Indication
<b>Very superficial</b>	Exfoliation of the stratum corneum	<ul style="list-style-type: none"> <li>– Alpha-hydroxy acid (30–50% GCA)</li> <li>– Beta-hydroxy acid (salicylic acid)</li> <li>– 10% TCA</li> <li>– Jessner’s solution, 1–3 coats</li> <li>– Resorcinol 20–30%</li> </ul>	Active acne, skin brightening/lightening
<b>Superficial</b>	Epidermal peel, not below basal layer	<ul style="list-style-type: none"> <li>– 50–70% GCA</li> <li>– 10–30% TCA</li> <li>– Jessner’s solution, 4–10 coats</li> <li>– 40–50% Resorcinol</li> </ul>	Epidermal melasma
<b>Medium</b>	Down to papillary dermis peel	<ul style="list-style-type: none"> <li>– 70% GCA</li> <li>– 35–50% TCA</li> <li>– 70% GCA plus 35% TCA</li> <li>– Jessner’s solution plus 35% TCA</li> </ul>	Lentigines, dermal melisma, superficial acne scar
<b>Deep</b>	Down to reticular dermis peel	<ul style="list-style-type: none"> <li>– 88% phenol</li> <li>– 45–50% TCA</li> </ul>	Superficial wrinkles

GCA = glycolic acid; TCA = trichloroacetic acid.

of chemical peels requires a good understanding of their properties, application methods, duration and possible side effects.

## 5.2. Dermabrasion

Dermabrasion involves skin resurfacing via sanding with a rotating abrasive tool that removes the epidermis and superficial dermis. It can be used to address hyperpigmentation, superficial rhytides, scar revision, acne scarring and enlarged pores. While chemical peels and laser resurfacing are often used over all of the face, dermabrasion is frequently used to treat specific areas of scar or wrinkles.

## 5.3. Laser resurfacing

Several different types of laser are used for skin resurfacing in the clinical setting. Laser light is absorbed and converted into thermal energy, which creates a desirable clinical effect (McClellan and Seckel, 2010). Laser used for skin resurfacing can be divided into two types: ablative and non-ablative.

Ablative laser causes epidermal evaporation and penetrates to the level of the dermis. Subsequent collagen remodelling within the dermis results in smoother and firmer skin. It is useful to treat fine



**Table 16.4.** Fitzpatrick’s sun-reactive skin types.

Skin type	Skin colour	Tanning response
<b>Type 1</b>	White	Always burns, never tans
<b>Type 2</b>	White	Usually burns, tans with difficulty
<b>Type 3</b>	White	Sometimes mild burns, tans average
<b>Type 4</b>	Brown	Rarely burns, tans with ease
<b>Type 5</b>	Dark brown	Very rarely burns, tans very easily
<b>Type 6</b>	Black	No burn, tans very easily

and deep rhytides, uncontrollable acne and acne scars, telangiectasias, and actinic keratosis, and for hair removal. Carbon dioxide and erbium:yttrium–aluminium–garnet (YAG) are two types of ablative laser. Non-ablative lasers selectively injure the dermis but preserve the epidermis, causing a better side-effect profile. Non-ablative lasers are useful for the treatment of mild to severe rhytides. Examples of non-ablative laser technologies are pulse dye laser and erbium laser.

Intense pulse light (IPL) differs from laser light in that it consists of polychromatic, non-coherent light covering a broad range of spectrum (McClellan and Seckel, 2010). IPL can be used to treat sun damage, telangiectasias and rosacea and for hair reduction. A common side effect related to IPL is redness which lasts for up to 4 days.

The most common complication of laser resurfacing is pigmentary changes, especially in skin types of Fitzpatrick class 4–6. The Fitzpatrick sun-reactive skin type denotes patients’ reactions to ultraviolet radiation and the existing degree of pigmentation (Table 16.4). It indicates the potential for dyschromia and the likelihood of post-inflammatory hyperpigmentation in the short term post-operatively and the potential for permanent hypopigmentation from the destruction of melanocytes. Fitzpatrick type 1–3 skin tolerates resurfacing without a significant risk of colour change. Fitzpatrick type 4–6 skin has a higher risk of pigmentary changes; patients with this skin type should be warned of the possibility of colour change post-treatment.

Active herpes infection is an absolute contraindication to prevent dissemination. Pre-operative anti-viral treatment is essential for patients with a history of oral herpes infection to prevent reactivation (Alster and Nanni, 1999).

## 5.4. Neuromodulators

Botulinum neuromodulators are a product of several strains of *Clostridium botulinum*. They bind to presynaptic autonomic nerve terminal receptors to inhibit the release of acetylcholine. The action is temporary and safe with the proper administration technique.

Botulinum toxin may spread or become diffuse after injection: ‘spread’ is influenced by the needle size, volume of injection and technique of injection, while ‘diffusion’ takes place as the toxin travels passively from the injection site after several days.

**Table 16.5.** Filler-related complications.

Immediate (0–2 days post-procedure)	Early (3–14 days post-procedure)	Late (>14 days post-procedure)
<ul style="list-style-type: none"> <li>– Under-/overcorrection</li> <li>– Vascular injury</li> <li>– Implant viability due to superficial injection</li> </ul>	<ul style="list-style-type: none"> <li>– Nodularity</li> <li>– Angioedema</li> <li>– Infection</li> <li>– Injection site discolouration</li> </ul>	<ul style="list-style-type: none"> <li>– Persistent erythema and telangiectasia</li> <li>– Filler migration</li> <li>– Granuloma formation</li> </ul>

Common adverse events experienced by patients are pain, infection, inflammation and local weakness that can be overcome with proper injection technique. Extra care needs to be taken during lower facial injections because of the adverse event of oral incompetence.

## 5.5. Fillers

There are various types of facial filler available for clinical application; their use for soft tissue augmentation has been extensive since the mid-2000s. Ideally, fillers should be non-toxic, biocompatible, reversible and available off the shelf, and lead to minimal downtime with a predictable action. Fillers can be classified into autologous, biological and synthetic types (Born *et al.*, 2013).

Autologous fillers have minimal issues with regards to toxicity, allergenicity and immunogenicity. The most commonly used autologous filler is fat grafting. Other autologous fillers include fascial grafts, e.g. fascia lata, lipodermal grafts, dermal grafts, cultured fibroblasts and platelet-rich fibrin matrix. However, issues such as infection, migration, inflammatory reaction and loss of persistence exist.

Biological fillers can be obtained off the shelf and are easy to use. The three major types are hyaluronic products, acellular soft tissue matrix and collagen. Hyaluronic acid fillers are the most widely used because of their good safety profile, 3–9-month duration of effect and lower potential for hypersensitivity reactions (0.6–0.8%) (Rohrich *et al.*, 2011; Born *et al.*, 2013)

Other synthetic fillers may offer permanence; however, they are often related to complications such as granuloma, infection and migration, as well as deformities from complications or removal of the material.

Filler-related complications can be classified based on the time of onset into immediate, early and late (Table 16.5) (Hachach-Haram *et al.*, 2013).

## REFERENCES

- Alster, T. S. & Nanni, C. A. 1999. Famciclovir prophylaxis of herpes simplex virus reactivation after laser skin resurfacing. *Dermatol Surg*, 25, 242–6.
- Baker, D. C. 1997. Lateral SMASectomy. *Plast Reconstr Surg*, 100, 509–13.

- Baker, S. R. 1999. Orbital fat preservation in lower-lid blepharoplasty. *Arch Facial Plast Surg*, 1, 33–7.
- Baker, T. J., Gordon, H. L. & Mosienko, P. 1977. Rhytidectomy: A statistical analysis. *Plast Reconstr Surg*, 59, 24–30.
- Barton, F. E., Jr. 2002. The ‘high SMAS’ face lift technique. *Aesthet Surg J*, 22, 481–6.
- Barton, F. E., Jr. & Hunt, J. 2003. The high-superficial musculoaponeurotic system technique in facial rejuvenation: An update. *Plast Reconstr Surg*, 112, 1910–7.
- Baylis, H. I., Long, J. A. & Groth, M. J. 1989. Transconjunctival lower eyelid blepharoplasty. Technique and complications. *Ophthalmology*, 96, 1027–32.
- Berkowitz, R. L., Jacobs, D. I. & Gorman, P. J. 2005. Brow fixation with the Endotine Forehead device in endoscopic brow lift. *Plast Reconstr Surg*, 116, 1761–7; discussion 1768–70.
- Biesman, B. S. & Iwamoto, M. A. 2002. Blepharoplasty. In: Kaminer, M. S., Dover, J. S. & Arndt, K. A. (eds.). *Atlas of cosmetic surgery*. Philadelphia. W. P Saunders.
- Born, T. M., Airan, L. E. & Motakis, D. 2013. Soft-tissue fillers. In: Nelligan, P. C. (ed.) *Plastic Surgery Third Edition*. London. Elsevier.
- Byrd, H. S. & Andochick, S. E. 1996. The deep temporal lift: A multiplanar, lateral brow, temporal, and upper face lift. *Plast Reconstr Surg*, 97, 928–37.
- Collar, R. M., Lyford-Pike, S. & Byrne, P. 2013. Algorithmic approach to lower lid blepharoplasty. *Facial Plast Surg*, 29, 32–9.
- Contet-Audonneau, J. L., Jeanmaire, C. & Pauly, G. 1999. A histological study of human wrinkle structures: Comparison between sun-exposed areas of the face, with or without wrinkles, and sun-protected areas. *Br J Dermatol*, 140, 1038–47.
- Feldman, J. J. 1990. Corset platysmaplasty. *Plast Reconstr Surg*, 85, 333–43.
- Flowers, R. S., Caputy, G. G. & Flowers, S. S. 1993. The biomechanics of brow and frontalis function and its effect on blepharoplasty. *Clin Plast Surg*, 20, 255–68.
- Freeman, M. S. 2000. Transconjunctival sub-orbicularis oculi fat (SOOF) pad lift blepharoplasty: A new technique for the effacement of nasojugal deformity. *Arch Facial Plast Surg*, 2, 16–21.
- Gilchrest, B. 1989. Skin aging and photoaging: An overview. *J Am Acad Dermatol*, 21(3 Pt 2), 610–13.
- Gorney, M. 2010. Recognition and management of the patient unsuitable for aesthetic surgery. *Plast Reconstr Surg*, 126, 2268–71.
- Guerrerosantos, J. 1983. Neck lift. Simplified surgical technique, refinements, and clinical classification. *Clin Plast Surg*, 10, 379–404.
- Gunter, J. P. & Rohrich, R. J. 1987. External approach for secondary rhinoplasty. *Plast Reconstr Surg*, 80, 161–74.
- Hachach-Haram, N., Gregori, M., Kirkpatrick, N., Young, R. & Collier, J. 2013. Complications of facial fillers: Resource implications for NHS hospitals. *BMJ Case Rep*, 2013, bcr-2012.
- Hachach-Haram, N. & Kirkpatrick, W. N. 2013. Midface-lifting: Evolution, indications, and technique. *Facial Plast Surg*, 29, 289–94.
- Hammoudeh, J., Low, A. C. & Baumann, A. 2007. Genioplasty, chin and malar augmentation. In: Kryger, Z. B. & Sisco, M. (eds.) *Practical Plastic Surgery*. Texas. Landes Bioscience.
- Herbig, K., Trussler, A. P., Khosla, R. K. & Rohrich, R. J. 2009. Combination Jessner’s solution and trichloroacetic acid chemical peel: Technique and outcomes. *Plast Reconstr Surg*, 124, 955–64.
- Hester, T. R., Jr. 2001. Evolution of lower lid support following lower lid/midface rejuvenation: The pretarsal orbicularis lateral canthopexy. *Clin Plast Surg*, 28, 639–52.
- Hoefflin, S. M. 1998. The extended supraplatysmal plane (ESP) face lift. *Plast Reconstr Surg*, 101, 494–503.
- Howard, B. K. & Rohrich, R. J. 2002. Understanding the nasal airway: Principles and practice. *Plast Reconstr Surg*, 109, 1128–46; quiz 1145–6.
- Jones, B. M. & Grover, R. 2004. Avoiding hematoma in cervicofacial rhytidectomy: A personal 8-year quest. Reviewing 910 patients. *Plast Reconstr Surg*, 113, 381–7; discussion 388–90.

- Kim, E. M. & Bucky, L. P. 2008. Power of the pinch: Pinch lower lid blepharoplasty. *Ann Plast Surg*, 60, 532–7.
- Krastinova-Lolov, D. 1989. [Subperiosteal face-lift]. *Ann Chir Plast Esthet*, 34, 199–211.
- LeRoy, J. L., Jr., Rees, T. D. & Nolan, W. B., 3rd 1994. Infections requiring hospital readmission following face lift surgery: Incidence, treatment, and sequelae. *Plast Reconstr Surg*, 93, 533–6.
- McClellan, W. T. & Seckel, B. R. 2010. Aesthetic laser surgery. In: Weinzwieg, J. (ed.) *Plastic Surgery Secret Plus*. Elsevier Health Sciences, 2010.
- McCullough, E. G., Scurry, W. C., Jr. & Shirazi, M. A. 2009. The ‘midface-lift’ as a misnomer for correctly identifying procedures designed to lift and rejuvenate the cheeks and malar regions of the face. *Arch Facial Plast Surg*, 11, 257–62.
- McCord, C. D., Jr. & Ellis, D. S. 1993. The correction of lower lid malposition following lower lid blepharoplasty. *Plast Reconstr Surg*, 92, 1068–72.
- Mendelson, B. & Wong, C.H. 2013. Anatomy of the aging face. *Plastic Surgery*, 3rd ed. Philadelphia. Elsevier Saunders, 78–92.
- Mendelson, B. & Wong, C. H. 2012. Changes in the facial skeleton with aging: Implications and clinical applications in facial rejuvenation. *Aesthetic Plast Surg*, 36, 753–60.
- Mendelson, B. C., Hartley, W., Scott, M., McNab, A. & Granzow, J. W. 2007. Age-related changes of the orbit and mid-cheek and the implications for facial rejuvenation. *Aesthetic Plast Surg*, 31, 419–23.
- Mendelson, B. C., Muzaffar, A. R. & Adams, W. P., Jr. 2002. Surgical anatomy of the midcheek and malar mounds. *Plast Reconstr Surg*, 110, 885–96; discussion 897–911.
- Miller, P. J., Wang, T. D. & Cook, T. A. 1996. Rejuvenation of the aging forehead and brow. *Facial Plast Surg*, 12, 147–55.
- Mitz, V. & Peyronie, M. 1976. The superficial musculo-aponeurotic system (SMAS) in the parotid and cheek area. *Plast Reconstr Surg*, 58, 80–8.
- Nahai, F. 2005. *The Art of Aesthetic Surgery: Principles and Techniques*. Missouri, Quality Medical Publishing.
- Nguyen, A. T., Ahmad, J., Fagien, S. & Rohrich, R. J. 2012. Cosmetic medicine: Facial resurfacing and injectables. *Plast Reconstr Surg*, 129, 142e–153e.
- O’Doherty, M. & Joshi, N. 2013. The ‘bespoke’ upper eyelid blepharoplasty and brow rejuvenation. *Facial Plast Surg*, 29, 264–72.
- Owsley, J. Q. 1993. Lifting the malar fat pad for correction of prominent nasolabial folds. *Plast Reconstr Surg*, 91, 463–74; discussion 475–6.
- Ozturk, C. N., Ozturk, C., Huettner, F., Drake, R. L. & Zins, J. E. 2014. A failsafe method to avoid injury to the great auricular nerve. *Aesthet Surg J*, 34, 16–21.
- Patipa, M. 2004. Transblepharoplasty lower eyelid and midface rejuvenation: Part II. Functional applications of midface elevation. *Plast Reconstr Surg*, 113, 1469–74, discussion 1475–7.
- Paul, M. D., Calvert, J. W. & Evans, G. R. 2006. The evolution of the midface lift in aesthetic plastic surgery. *Plast Reconstr Surg*, 117, 1809–27.
- Pitanguy, I. & Ramos, A. S. 1966. The frontal branch of the facial nerve: The importance of its variations in face lifting. *Plast Reconstr Surg*, 38, 352–6.
- Ransom, E. R., Stong, B. C. & Jacono, A. A. 2012. Persistent improvement in lower eyelid-cheek contour after a transtemporal midface lift. *Aesthetic Plast Surg*, 36, 1277–82.
- Rees, T. D. & Dupuis, C. C. 1969. Baggy eyelids in young adults. *Plast Reconstr Surg*, 43, 381–7.
- Roberts, T. L., 3rd 1998. Laser blepharoplasty and laser resurfacing of the periorbital area. *Clin Plast Surg*, 25, 95–108.
- Rohrich, R. & Ahmad, J. 2012. Open technique rhinoplasty. In: Nelligan, P. C. (ed.) *Plastic Surgery Aesthetic*. London, Elsevier.
- Rohrich, R. J. & Ahmad, J. 2011. Rhinoplasty. *Plast Reconstr Surg*, 128, 49e–73e.
- Rohrich, R. J., Hanke, C. W., Busso, M., Carruthers, A., Carruthers, J., Fagien, S., Fitzgerald, R., Glogau, R., Greenberger, P. E., Lorenc, Z. P., Marmur, E. S., Monheit, G. D., Pusic, A., Rubin, M. G., Rzany, B., Sclafani, A., Taylor, S., Weinkle, S., Mcguire, M. F., Pariser, D. M., Casas, L. A., Collishaw, K. J., Dailey, R. A., Duffy, S. C., Edgar, E. J., Greenan,

- B. L., Haenlein, K., Henrichs, R. A., Hume, K. M., Lum, F., Nielsen, D. R., Poulsen, L., Shoaf, L., Seward, W., Begolka, W. S., Stanton, R. G., Svedman, K. J., Thomas, J. R., Sykes, J. M., Wargo, C. & Weiss, R. A. 2011. Facial soft-tissue fillers conference: Assessing the state of the science. *Plast Reconstr Surg*, 127, 22S–S.
- Rohrich, R. J. & Pessa, J. E. 2007. The fat compartments of the face: Anatomy and clinical implications for cosmetic surgery. *Plast Reconstr Surg*, 119, 2219–27; discussion 2228–31.
- Saltz, R. & Ohana, B. 2012. Thirteen years of experience with the endoscopic midface lift. *Aesthet Surg J*, 32, 927–36.
- Shiffman, M. A. 2013. *Cosmetic Surgery Art and Techniques*. Berlin. Springer.
- Skoog, T. 1974. *Plastic Surgery: New Methods and Refinements*. Philadelphia, PA: WA Saunders.
- Stutman, R. L. & Codner, M. A. 2012. Tear trough deformity: Review of anatomy and treatment options. *Aesthet Surg J*, 32, 426–40.
- Stuzin, J. M., Baker, T. J., Gordon, H. L. & Baker, T. M. 1995. Extended SMAS dissection as an approach to midface rejuvenation. *Clin Plast Surg*, 22, 295–311.
- Tessier, P. 1979. Facial lifting and frontal rhytidectomy In: Fonseca J., ed. *Transactions of the VII International Congress of Plastic and Reconstructive Surgery*. Rio de Janeiro, Brazil.
- The American Society for Aesthetic Plastic Surgery, 2010. *Cosmetic surgery national data bank statistics* [Online]. Available: [www.surgery.org/sites/default/files/ASAPS-2011-Stats.pdf](http://www.surgery.org/sites/default/files/ASAPS-2011-Stats.pdf) [Accessed 2 December 2013].
- Tonnard, P. & Verpaele, A. 2007. The MACS-lift short scar rhytidectomy. *Aesthet Surg J*, 27, 188–98.
- Trussler, A. P. & Rohrich, R. J. 2008. MOC-PSSM CME article: Blepharoplasty. *Plast Reconstr Surg*, 121, 1–10.
- Warren, R. J. 2013. Facelift: Principles. In: Nelligan, P. C. (ed.) *Plastic Surgery Aesthetic*. London. Elsevier.
- Yaremchuk, M. J. 2013. Skeletal augmentation. In: Nelligan, P. C. (ed.) *Plastic Surgery Aesthetic*. London. Elsevier.
- Yousif, N. J., Sonderman, P., Dzwierzynski, W. W. & Larson, D. L. 1995. Anatomic considerations in transconjunctival blepharoplasty. *Plast Reconstr Surg*, 96, 1271–6; discussion 1277–8.
- Zarem, H. A. & Resnick, J. I. 1991. Expanded applications for transconjunctival lower lid blepharoplasty. *Plast Reconstr Surg*, 88, 215–20; discussion 221.

## Blepharoplasty – Special Focus on Asian Blepharoplasty

---

Billy Ching Leung, Kimberley Lau, Hugo Henderson

### INTRODUCTION

---

Asian blepharoplasty, i.e. the surgical creation of an upper eyelid crease, is one of the most popular types of aesthetic surgery performed on those of Asian descent (Chinese, Japanese, Korean); it was first described by Mikamo in 1896. A prominent upper lid crease is deemed by some to be more 'attractive' in Asian culture because it gives a more 'wide eyed' and expressive appearance. This chapter aims to summarise, and highlight through illustrations, the essential anatomy and surgical techniques of Asian blepharoplasty to enhance the understanding of the procedure of medical students and junior trainees. *Anatomy:* The lack, or absence, of a prominent upper lid crease is observed in 50% of Asians and is non-existent in Caucasians; it presents with fullness and a nasally tapered upper eyelid. Anatomically, there is abundant eyelid subcutaneous and preaponeurotic fat, low-lying perforating levator aponeurotic fibres, a short superior tarsal height, and a thick medial canthus. There are two techniques: the non-incisional technique (suture ligation) involves a through-and-through upper lid suture that creates the desired crease by compressing lid tissues. It is less challenging and yields a quick recovery, but may fail over time. The incisional technique involves upper lid tissue removal and suturing of lid skin onto the upper tarsal plate or levator aponeurosis. It is more complex and may yield more complications, but produces more permanent results. Epicanthoplasty can be performed in conjunction for selected patients. An understanding of the Asian upper lid anatomy is essential; via clear illustrations, trainees can gain an appreciation of the surgical techniques used for Asian blepharoplasty. The goal is not to create a 'Caucasian' eyelid, but to create a natural-looking Asian upper lid crease.

## 1. INTRODUCTION

Asian blepharoplasty, also known as the ‘double eyelid surgery’, describes the surgical creation of an upper eyelid crease (pretarsal or supratarsal crease). Approximately 50% of the Asian population or those of Han origin (Chinese, Japanese, Korean) do not possess a prominent upper lid crease, which is considered a marker of beauty because it gives a more ‘wide eyed’ and expressive appearance (Cho and Glavas, 2009; Nguyen *et al.*, 2009). The procedure is one of the most popular types of aesthetic surgery carried out on this population. The term ‘Asian blepharoplasty’ was first used in 1987 to differentiate its surgical approaches from the type of upper blepharoplasty traditionally done in Western populations (Chen, 1987).

The first double eyelid surgery was described and performed in Japan by Mikamo, a physician, in 1896 (Mikamo, 1896). At that time, after more than 250 years of national isolation during the Tokyogawa Period between 1603 and 1853, the country was undergoing major social transitions with the introduction of Western influences. Japanese women began to challenge society’s traditional attitude that women should be obedient and submissive. This gain in confidence altered the perception of beauty and attractiveness for Japanese women (Sergile and Obata, 1997).

Mikamo was alert to this transition and adopted approaches of Western aesthetic plastic surgery with the objective not of creating a Westernised lid appearance, but instead to replicate the natural-looking upper lid crease observed in some Asians (Mikamo, 1896). He reported that the absence of an upper lid crease (single lid) was due to minor defects within the muscle fibres that anchor the superficial dermis. A single lid was perceived as monotonous and expressionless, and not a marker of beauty, and suggested narrow vision (Mikamo, 1896). Mikamo’s inspiration was Dr Komomto, an ophthalmologist who corrected an entropion (inverted eyelid), which resulted in a more visible ‘attractive’ double eyelid appearance (Sergile and Obata, 1997).

Mikamo applied three through-and-through silk sutures positioned 6–8 mm above the upper lid margin to create an indentation in the upper lid skin, and thus the appearance of a prominent lid crease (Mikamo, 1896). He reported three cases, all with satisfying results. This was a milestone in modern Asian blepharoplasty, and his principles are still used to the current day (Chee and Choo, 2011). In 1929, Mauro pioneered another technique which involved making an incision over the superficial upper lid skin to allow suturing of the created skin edge onto the deep tarsal plate, resulting in a palpebral sulcus (Mauro, 1929). In contrast, in 1933, Hata extended Mikamo’s non-incisional technique by increasing the upper lid crease height to 10 mm, a margin observed in Caucasians but not Japanese, suggesting a growing acceptance of Western influence (Hata, 1933). At the time of the US occupation of Japan in World War II, several reported cases of lid surgery had involved the excision of eyelid tissue to structurally deepen the lid. Other pioneers were Hayaski (1939) and Sayoc (1954), who excised small shreds of orbicularis to further deepen the sulcus. In the 1950s to 1960s, Fernandez (1960) and Uchida (1962) popularised a technique that is still used to this day: an upper lid incision together with selective supraorbital fat removal, followed by the suturing of inferior free lid skin onto levator aponeurosis at the superior margin of the superior tarsus.


Despite abundant literature, the concept of this procedure is not commonly well understood by medical students and junior doctors. We aim to summarise and highlight through illustrations the essential anatomy and surgical techniques of Asian blepharoplasty.

## 2. ANATOMY

The Asian upper eyelid differs in its anatomy to those in Caucasians; these differences underpin the surgical approaches to Asian blepharoplasty. Approximately 50% of Asians do not have a prominent upper lid crease, and the upper lid tends to be thicker with excessive pretarsal and supratarsal fat, and potential hypertrophied orbicularis oculi (Figure 17.1) (Chen, 2006; Nguyen *et al.*, 2009; Lee *et al.*, 2013). In those that do possess a prominent upper lid crease, the crease is often closer to the lid margin with a variable amount of overlying preseptal skin, resulting in a more hooded appearance compared with the more prominent and high-set lid crease observed in Caucasians (Figure 17.1) (Chen, 2006; Cho and Glavas, 2009). There are two variants of Asian lid creases: nasally tapered or parallel-lying. It is important to consider the different natural variants because the goal in Asian blepharoplasty is to recreate a natural-looking Asian lid crease, and not a Westernised eyelid (Figure 17.1) (Chen and Park, 2013; Lee *et al.*, 2013). An absent lid crease is not a feature of Caucasian eyelids (Chen and Park, 2013; Nguyen *et al.*, 2009).

Overall, an Asian eyelid has several distinctive anatomical features that differ from those of a Caucasian eyelid: typically, upper lid fullness and an absent or low-set medially tapered lid crease. Anatomically, these are attributed to a combination of abundant subcutaneous and pre-aponeurotic fat, a low-set septal-aponeurotic attachment, low or absent perforating levator aponeurotic fibres, short superior tarsal height and a thick medial canthus (Table 17.1 and Figure 17.2) (Flowers, 2002; Nguyen *et al.*, 2009; Chen and Park, 2013; Lee *et al.*, 2013).

Firstly, the Asian orbital septum extends more inferiorly before attaching onto the levator aponeurosis (septal-aponeurotic attachment), which results in more orbital septal overhanging and pre-aponeurotic fat pad formation, thus contributing to the appearance of fullness in the Asian upper lid (Figure 17.2) (Goldberg *et al.*, 1992; Hwang *et al.*, 1998; Jeong *et al.*, 1999; Yuzuriha *et al.*, 2000; Cheng and Xu, 2001; Persichetti *et al.*, 2004; Kakizaki *et al.*, 2009). The precise septal-aponeurotic attachment position is still under debate, varying from 2 mm inferior or just superior to the upper margin of the superior

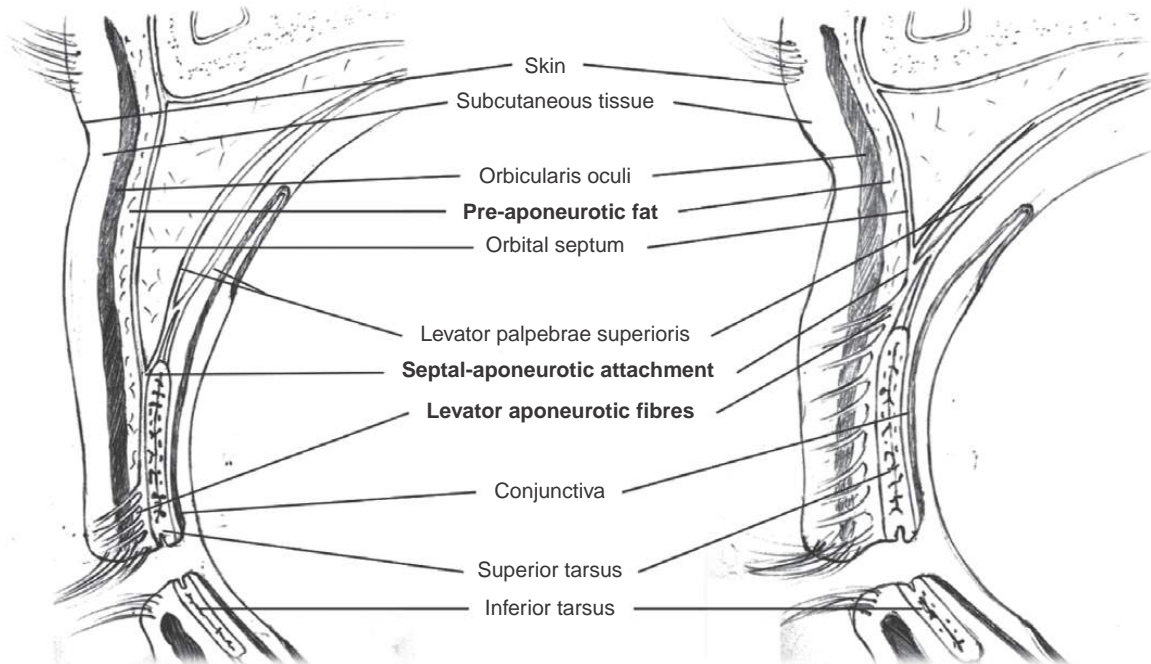


**Figure 17.1.** Variations of Asian upper eyelids. Left, absence of a lid crease; centre, nasally tapered low-lying crease with a prominent medial epicanthic fold; right, parallel-lying lid crease (similar to Caucasian upper eyelid).



**Table 17.1.** Upper eyelid anatomical differences between Asians and Caucasians.

	Asian eyelid	Caucasian eyelid
<b>Subcutaneous fat</b>	Abundant (hooded appearance)	Minimal
<b>Pre-aponeurotic fat</b>	Abundant and extends inferiorly	Minimal
<b>Septal-aponeurotic attachment</b>	Low	High
<b>Levator aponeurotic fibres</b>	Absence/low (low/absence lid crease)	High (high lid crease)
<b>Superior tarsal height</b>	6–8 mm	8–10 mm
<b>Medial canthus</b>	Thick (nasally tapered lid crease)	Thin

**Figure 17.2.** The anatomical differences between Asian (left) and Caucasian (right) eyelids. Asian eyelids contain more subcutaneous and pre-aponeurotic fat, a lower septal-aponeurotic attachment, lower or absent perforating levator aponeurotic fibres and short superior tarsus compared with Caucasian eyelids.

tarsus (Doxanas and Anderson, 1984; Jeong *et al.*, 1999; Kakizaki *et al.*, 2009). Regardless, the attachment position in Asian eyelids is comparatively lower than in Caucasian eyelids, where it is reported to be 5–10 mm above the upper margin of the superior tarsus (Jeong *et al.*, 1999).

Secondly, the formation of an upper lid crease is the result of levator aponeurotic fibres penetrating through the orbicularis oculi that anchors and pulls onto the overlying lid dermis (Figure 17.2) (Uchida, 1926). It is speculated that the extended pre-aponeurotic fat pad in Asian upper lids prevents this penetration, resulting in an absent or less-distinct lid crease (Figure 17.2) (Goldberg *et al.*, 1992;

Jeong *et al.*, 1999). Conversely, this fat pad is minimal in Caucasian eyelids, which maximises the amount of penetrative fibres to create a prominent lid crease (Flowers, 2002; Nguyen *et al.*, 2009; Chen and Park, 2013; Lee *et al.*, 2013).

Thirdly, the superior tarsal plate in Asian eyelids is shortened, averaging 6.5–8 mm compared with an average of 8–10 mm in Caucasian eyelids (Chen, 2006). Fourthly, the subcutaneous fat that overlies the upper lid is more abundant in Asians than in Caucasians; this further contributes to the full appearance of the Asian eyelid (Nguyen *et al.*, 2009; Chen and Park, 2013). The fat distribution of the Caucasian eyelid is predominately limited to the eyebrow region (Chen and Park, 2013). Furthermore, there is a variable amount of preseptal skin in Asian lids which can often overlie an actual crease line (Chen, 2007). Finally, the medial epicanthic fold in Asian eyelids is more prominent; this is an important feature of an Asian-looking eyelid (Figure 17.1) (Chee and Choo, 2011; Lee *et al.*, 2013).

### 3. SURGICAL TECHNIQUES

---

#### 3.1. Pre-operative considerations

---

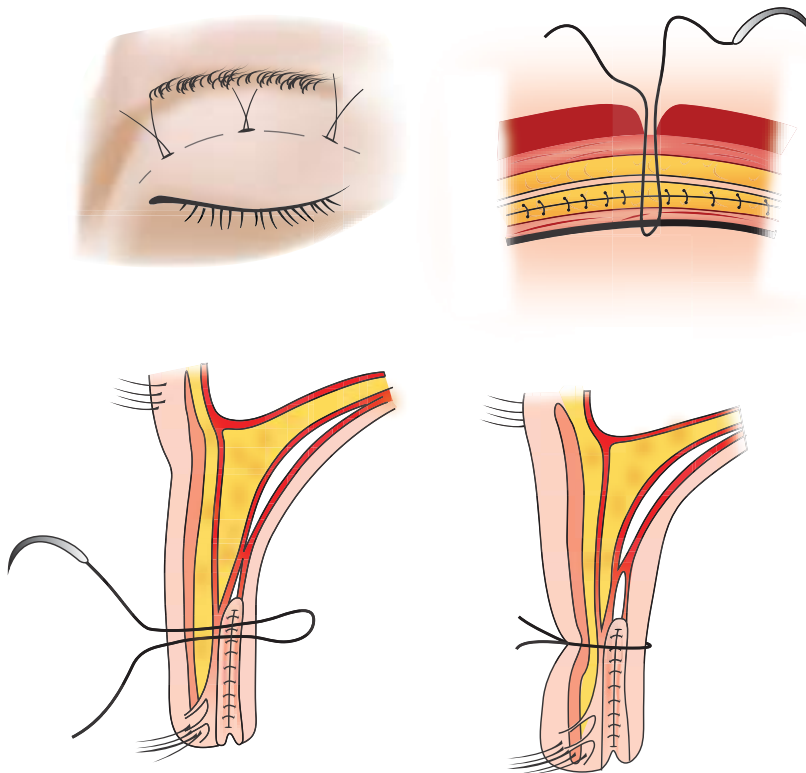
Most patients desire a natural-looking Asian upper eyelid crease, as opposed to those observed in Caucasians, which are often prominent and high-set (Figure 17.1) (Nguyen *et al.*, 2009; Chen and Park, 2013). Their specific expectations and goals must be elicited, and surgeons must determine whether the patient's expectations are attainable, realistic and based on positive motives (Flowers, 2002). Negative signs include disproportionate concerns regarding their appearance and a lack of understanding of the procedure, including complications and the type of post-operative care needed (Flowers, 2002). Patients must be informed that a definitive outcome is not completely predictable and that some asymmetry and irregularities may occur, requiring further surgery (Lam, 2007; Chen and Park, 2013). Patients undergoing a second blepharoplasty must be made aware of the added risk of scarring, malposition of the eyelid and lagophthalmos (inability to close the eyelid) (Chee and Choo, 2011; Chen and Park, 2013).

A detailed examination of the upper eyelid with thorough documentation, photographs and anatomical measurements is essential for the appropriate selection of surgical technique, post-operative comparison and potential medicolegal issues (Flowers, 2002; Chen and Park, 2013). These include eyelid position and contour, pretarsal fullness, eyelash orientation and any ptosis, asymmetry or irregularities of the eyelid. A prominent medial epicanthic fold is common and can give an impression of a short palpebral fissure medially, smaller eyes and pseudoesotropia, in which concomitant epicanthoplasty can be considered (Flowers, 2002; Chen and Park, 2013). However, it is often avoided because of the risk of hypertrophic scarring; this is common in Asian patients, especially those with thicker dermis (Flowers, 2002; Chee and Choo, 2011).

The surgical approach must be explained again clearly to the patient on the day of operation. There are numerous approaches and new advances in Asian blepharoplasty, including two core principal techniques: non-incisional (suture ligation) and incisional (surgical resection) (Flowers, 2002; Nguyen *et al.*, 2009; Chee and Choo, 2011; Chen and Park, 2013).

### 3.1.1. Non-incisional technique: suture ligation

Suture ligation Asian blepharoplasty was initially described by Mikamo in 1896, and was modified by surgeons in the 1950s; however, the basic principles remain the same (Uchida, 1926; Khoo, 1963; Mutou, 1972; Weng, 2009). It involves the placement of sutures through all the layers of upper eyelid at the level of the upper superior tarsal margin, resulting in adhesion between the subdermal tissues and underlying levator aponeurosis to create the lid crease (Figure 17.3) (Mikamo, 1896; Chee and Choo, 2011). Three suture marking is commonly made 6–8 mm above the lid margin at the medial third, midpoint and lateral third to form a three-dotted curved margin where the crease will be formed (Figure 17.3) (Nguyen *et al.*, 2009). The lateral marking is usually 1–1.5 mm higher than the central marking, while the medial marking is placed at the level of the central marking (Nguyen *et al.*, 2009; Chee and Choo, 2011). This technique generates a gently medially tapered natural-looking crease. A small 1–2-mm cut is made at the marking site under local anaesthesia, followed by the passage of, commonly, a 6-0 Prolene® monofilament non-absorbable suture through the tissue layers of the upper lid (Figure 17.3)



**Figure 17.3.** Suture ligation technique. Three stitches are made over the new crease line (top left); horizontal plane showing suture transecting through all layers (top right); sagittal plane showing suture transecting at the level of the septal-aponeurotic attachment and superior tarsal plate (bottom left); and creation of the supratarsal crease by knotting the suture.

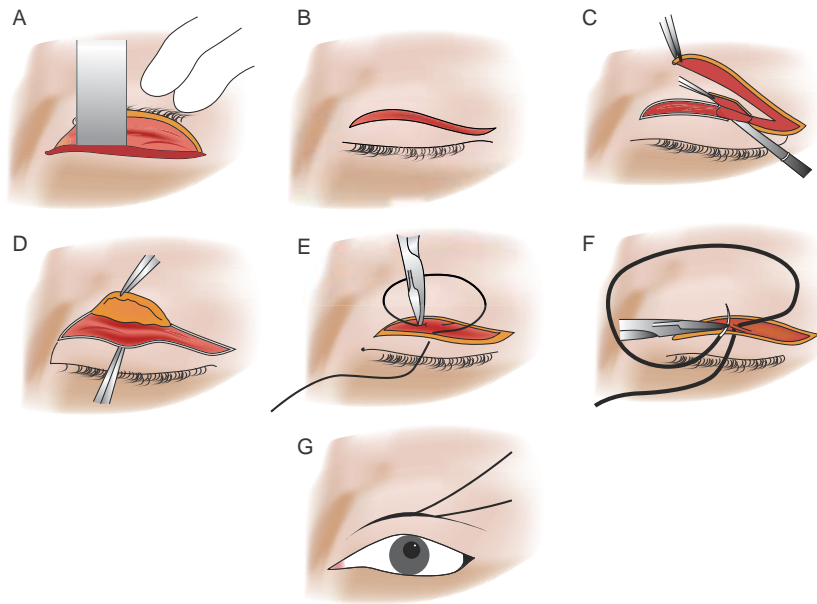
(Nguyen *et al.*, 2009; Chee and Choo, 2011; Flowers, 2002). The suture is anchored subcutaneously to form the lid crease, and the superficial puncture wound remains open for spontaneous closure (Figure 17.3) (Weng, 2009). There are numerous variations of suture ligation, including the use of two stitches with wider bites; a recent modification describes the use of continuous buried stitches between the eyelid skin and the anterior portion of the tarsal plate to form a wave-like intratarsal–interdermal fixation. The six-point fixation produces a lower risk of dehiscence and may produce less asymmetry (Wong, 2007; Weng, 2009). However, the authors do not believe that the modifications improved operative outcome compared with traditional techniques (Weng, 2009).

The benefit of suture ligation is that it is technically less challenging, with a short operative time, fast recovery, easy reversibility and minimal post-operative oedema (Table 17.2) (Nguyen *et al.*, 2009). However, the created lid crease is often static and fails to soften upon downward gaze; this normally occurs from levator relaxation (Nguyen *et al.*, 2009; Chee and Choo, 2011; Chen and Park, 2013). It is also less predictable, and asymmetry is more common than in the incisional technique (Chee and Choo, 2011). One major disadvantage is the failure to retain the crease line over time; this issue commonly affects patients with excessive subcutaneous and preseptal fat, which place the sutures under tremendous tension, leading to their eventual loosening (Table 17.2) (Nguyen *et al.*, 2009; Chen and Park, 2013). Therefore, this technique is most suitable for patients with thinner skin and less underlying eyelid fat (Nguyen *et al.*, 2009; Chee and Choo, 2011).

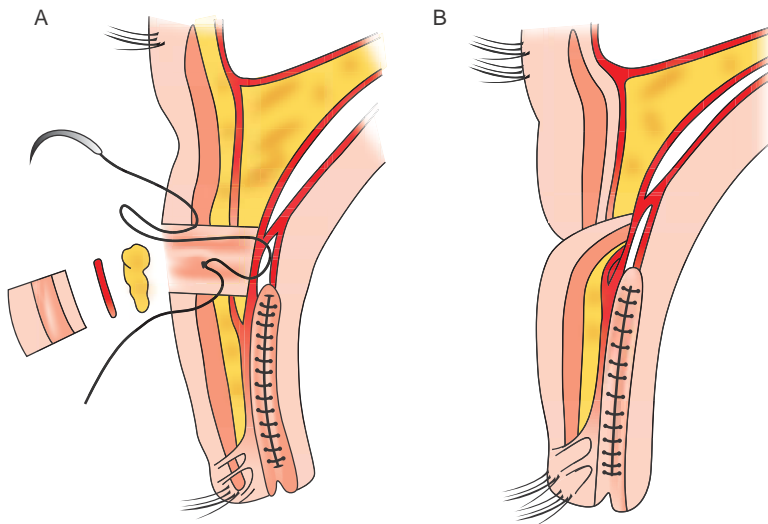
### 3.1.2. Incisional technique: surgical resection

Incisional or surgical resection Asian blepharoplasty involves making an incision across the upper eyelid down to levator aponeurotic fibres and removing excessive lid tissue, such as skin, subcutaneous fat, orbicularis oculi, orbital septum and preaponeurotic fat, followed by suturing the inferior portion of upper eyelid skin down onto the levator aponeurotic fibres (Figures 1.4 and 1.5) (Flowers, 2002; Kakizaki *et al.*, 2009; Nguyen *et al.*, 2009; Chee and Choo, 2011). This method mimics the normal supratarsal lid crease anatomy, thus creating a dynamic crease that is more permanent with a more precise position (Flowers, 2002; Nguyen *et al.*, 2009; Chee and Choo, 2011). Mauro first introduced this technique in 1929; since then, various full-length incisions to microincisions have been used depending on the surgeon's preference and experience, but the general principles have remained the same (Figures 1.4 and 1.5) (Mauro, 1929; Flowers, 2002; Chee and Choo, 2011).

The position of the incision must be carefully planned and marked, requiring a good understanding of the patient's desired outcome (Figure 17.4A). In general, a central marking is made 6–8 mm above the lid margin to demarcate the height of the desired lid crease, but can be 3–10 mm; a central marking of <6 mm is reserved for patients with a smaller palpebral fissure, while markings >8 mm are rare (Figure 17.4B) (Flowers, 2002; Nguyen *et al.*, 2009; Chen and Park, 2013). The medial marking is tapered nasally; it is made while tenting the upper lid skin with a gentle lift on the brow without everting the eyelashes. The medial marker tip should be placed beneath the epicanthal fold and should not extend beyond the medial canthus (Figure 17.4B) (Chen and Park, 2013). In patients who lack an epicanthal fold, a more superiorly placed marker can be made (Nguyen *et al.*, 2009). The lateral marking is made parallel to upper lid margin from the central marking and, in some cases,



**Figure 17.4.** Surgical resection technique. A. Tarsal plate measurement. B. Marking of the incision line. C. Excision of the skin with muscle, followed by separation of the orbital septum. D. Debulking of pre-aponeurotic fat. E. Inferior skin suture through orbicularis muscle and then horizontally across the levator aponeurosis. F. Superior skin suture. G. The first suture is tied down with the patient opening the eyes to check the lash position, followed by anchoring the medial and lateral suture.



**Figure 17.5.** Sagittal view of the surgical resection technique. A. Excision of the skin and muscle, orbital septum and pre-aponeurotic fat, with the suture passing inferiorly through the skin and orbicularis muscle onto the levator aponeurosis and then superiorly out through the skin. B. Anchoring of the lower skin edge onto the levator aponeurosis and superior margin of the tarsal plate to create the upper lid crease.

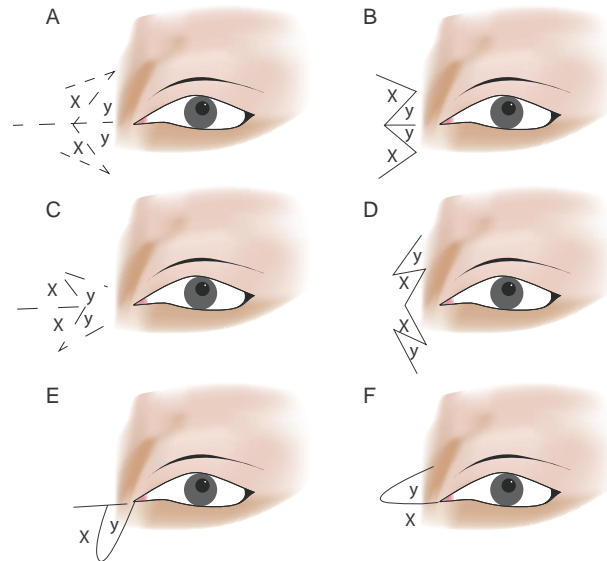
tapered down most laterally, and ends at the lateral orbital rim (Figure 17.4B) (Flowers, 2002; Chen *et al.*, 2013). In patients with dermatochalasis (excessive lid skin), the lateral margin can be extended (Flowers, 2002; Nguyen *et al.*, 2009). Another marking is made superiorly above the first marking to denote the area of skin to be resected; this will vary dependent on the amount of skin and subcutaneous fat present (Figure 17.4B) (Nguyen *et al.*, 2009). After the administration of local anaesthesia, the demarcated skin and a strip of orbicularis muscle 2–3 mm in height are excised (Figure 17.4C) (Nguyen *et al.*, 2009). The exposed septum is then injected with local anaesthetic, which balloons up the septal space, to reduce the risk of cutting the underlying levator aponeurosis. The orbital septum should be opened in a lateral to medial direction to allow clear visualisation, and thus protection, of the distal attachment of levator to the tarsal plate. Once the septum is opened, the pre-aponeurotic fat will be exposed to allow a certain degree of debulking to be carried out, depending on amount eyelid fullness (Figure 17.4D). The final stage of this operation is supratarsal fixation, in which the inferior exposed skin, fat, muscle and septal edge are attached to the levator aponeurosis and to some degree to the superior margin of the tarsal plate. This is commonly done using three 6-0 Prolene® sutures (Chee and Choo, 2011). There are variations in the direction of suture insertion: some authors pass the first bite into the levator and then into the inferior edge of the orbicularis muscle, while others pass the suture through the inferior skin and muscle and then transect the levator horizontally, allowing the lashes to evert perpendicular to the eye opening, and then penetrate superiorly across the opened skin edge above (Nguyen *et al.*, 2009; Chen and Park, 2013). Whichever technique is used, the principle is the same (Figure 17.4E, F). After tying the initial suture at mid-pupil, patients are asked to open their eyes with a forward gaze. The suture can now be adjusted to create the desired lash eversion and crease line. At this point, the crease will be higher than the definitive outcome secondary to oedema (Figure 17.4G). Once the surgeon is satisfied with the suture tension, the remaining two stitches are placed medially and laterally halfway between midpoint and medial and lateral limbus, respectively (Lam, 2007; Weng, 2009).

A full-length incision allows debulking of the orbicularis muscle, which reduces the hooded lid appearance. However, in patients with less excess eyelid skin, fat or muscle, a microincision can be used, which facilitates a faster recovery and less post-operative swelling (Chee and Choo, 2011). Some degree of pre-aponeurotic fat removal can be achieved with microincision (Kruavit, 2009; Chee and Choo, 2011).

The inherent advantage of the surgical resection technique is that it produces a more permanent and dynamic lid crease; however, it is more technically challenging, with longer recovery time and potential complications such as lagophthalmos caused by excessive removal of lid tissue (Table 17.2). Overall, the choice of technique is governed by the patient's specific anatomical characteristics and their choice and expectations, as well as the surgeon's preference and experience. The range of surgical variations is determined by whether the procedure is incisional or non-incisional, the incision length, the degree of debulking, the number of sutures used, whether it uses a beaded or non-beaded suture, the lid crease height, and whether it's performed with or without epicanthoplasty. All variations have their own advantages and disadvantages (Table 17.2)

**Table 17.2.** Advantages and disadvantages of suture ligation and surgical resection techniques for Asian blepharoplasty.

Non-incisional technique (suture ligation)	Incisional technique (surgical resection)
<p><b>Advantages</b></p> <ul style="list-style-type: none"> <li>Less complex and shorter operation</li> <li>Non-invasive</li> <li>Quicker recovery</li> <li>Less complications</li> </ul> <p><b>Disadvantages</b></p> <ul style="list-style-type: none"> <li>Static lid crease</li> <li>Fades in time (not permanent)</li> <li>Corneal irritation from underlying suture</li> </ul>	<p><b>Advantages</b></p> <ul style="list-style-type: none"> <li>Mimics normal anatomy</li> <li>Removal of excess skin, fat, muscle</li> <li>Dynamic and permanent lid crease</li> <li>In conjunction with epicanthoplasty</li> </ul> <p><b>Disadvantages</b></p> <ul style="list-style-type: none"> <li>More complex and longer operation</li> <li>Longer recovery</li> <li>Lagophthalmos (inability to close eyelid) from excessive debulking</li> </ul>



**Figure 17.6.** Epicanthoplasty Z-plasty designs. **A to D**, Mustarde’s jump-man and John’s double Z-plasty. **E and F**, Bottom row, Del Campo’s Z-plasty.

### 3.1.3. Epicanthoplasty

Reconstruction or trimming of the medial canthus can be performed concomitantly with Asian blepharoplasty. The procedure is suitable for patients with excessive medial epicanthic fold fullness or those who desire a more prominent medial lid crease. Patients must be aware of potential hypertrophic scarring over the medial canthal region, which is commonly observed in Asians (Chen and

Park, 2013). Several designs for this procedure include X- or Y-plasties, and Z-plasties (Mustarde's 'jumping man' flap, John's double Z-plasty and Del Campo's Z-plasty) (Del Campo, 1984; Park, 1996; Weng, 2009).

## 3.2. Post-operative considerations

---

The post-operative management may vary depending on the type of operation carried out, the surgeon's choice and the available resources, but the principles should remain the same. Ice compression over the eyes is warranted immediately after operation and continued for 1 day to reduce operative oedema, thus enhancing healing; the head should be held elevated using pillows (Flowers, 2002; Nguyen *et al.*, 2009). During the first week, some surgeons may advise the use of topical gentamicin–steroid ointment over the incision; patients are allowed to bathe but should avoid physical activities that may risk impact or contact with the eyes (Chen and Park, 2013). Sutures are removed 7 days after the operation.

## 3.3. Complications

---

Post-operative haemorrhage can occur within 48 hours of surgery and can result from the opening of sealed blood vessel stumps by coughing, sneezing or exertion. If bleeding occurs, the vessel must be cauterised and any clots must be removed because retrobulbar haemorrhage can result in blindness if left untreated (Weng, 2009). Excessive debulking can also cause serious complications, such as lagophthalmos, multiple creases and superior sulcus hollowing (Kruavit, 2009; Nguyen *et al.*, 2009). A high-anchored crease formed when the levator aponeurosis is attached too superiorly may also result in lagophthalmos or secondary ptosis (Flowers, 2002). These complications are more common in surgical resection Asian blepharoplasty, with around 5–10% requiring minor revision operations (Chen and Park, 2013). Although suture ligation has a lower risk of post-operative complications, the created crease line is often static on downward gaze and fails over time; some patients also complain of a foreign body sensation from the underlying suture touching the cornea (Nguyen *et al.*, 2009; Chen and Park, 2013). Suboptimal outcomes such as a mismatch with the patient's desired crease depth or position and asymmetry between the two created lid creases can occur in both techniques.

## 4. CONCLUSION

---

Asian blepharoplasty, i.e. the surgical creation of an upper eyelid crease, remains one of the most popular types of aesthetic surgery performed in the Asian population. The appearance of a lid crease is considered a mark of beauty in Asian culture, and is deemed more expressive and 'wide eyed'. A lid crease is absent in 50% of the Asian population.

An understanding of the anatomical difference between Asian and Caucasian upper eyelids has guided the optimisation of Asian blepharoplasty. A key factor contributing to the absence of a prominent upper



lid crease is abundant pre-aponeurotic fat extending over the superior tarsus that hinders interdigitation of the levator aponeurosis onto the superficial dermis to create dimpling of the upper eyelid.

Continuing technical advancements are optimising the outcomes of this procedure; selection of the technique is governed by the surgeon's preference and the patient's anatomy. Meticulous pre-operative planning is essential in order to select the best surgical approach to provide the required outcome, including making detailed measurements, documenting eye anatomy and function, eliciting the patients' expectations and desires, and providing a clear explanation of the possible complications.

The traditional suture non-incisional method enables a quicker recovery with minimal complications; however, it produces a static crease line with an increased likelihood of fading over time. The incisional technique allows debulking of preseptal tissue and mimics the normal crease anatomy, thus producing a more permanent lid crease. However, this technique is associated with more complications such as lagophthalmos and superior sulcus hollowing. The use of medial epicanthoplasty with blepharoplasty benefits some patients, but the high risk of scarring in the Asian population should be considered.

The main purpose of Asian blepharoplasty is not to create a 'Westernised' eyelid, but to create a natural-looking Asian upper lid crease; thus, surgeons must be aware of the natural variations in the Asian upper lid crease. With the growing acceptance of aesthetic surgery worldwide and the growing influence of celebrity culture, the demand for Asian blepharoplasty will inevitably increase.

This chapter summarises the current principles of Asian blepharoplasty that are often not well understood in the Western world. Illustrations are included to demonstrate the key concepts of the anatomy and surgical techniques to facilitate better understanding of this operation by medical students and junior doctors.

## REFERENCES

- Chee, E. & Choo, C. T. 2011. Asian blepharoplasty – An overview. *Orbit*, 30, 58–61.
- Chen, L., Zhou, Y., Zeng, J., Yang, P., Guo, Y. & Liu, T. 2013. Rejuvenation surgery through blepharoplasty incision for mild to moderate upper eyelid sagging in older Asian patients. *J Craniofac Surg*, 24, 1731–3.
- Chen, W. 1987. Asian blepharoplasty. Update on anatomy and techniques. *Ophthal Plast Reconstruc Surg*, 3, 135–140.
- Chen, W. P. 2006. *Asian Blepharoplasty and The Eyelid Crease*. 2nd Edition. Philadelphia: Butterworth Heinemann/Elsevier, 2006.
- Chen, W. P. & Park, J. D. 2013. Asian upper lid blepharoplasty: an update on indications and technique. *Facial Plast Surg*, 29, 26–31.
- Chen, W. P. D. 2007. The concept of a glide zone as it relates to upper lid crease, lid fold, and application in upper blepharoplasty. *Plast Reconstr Surg*, 119, 379–86.
- Cheng, J. & Xu, F. Z. 2001. Anatomic microstructure of the upper eyelid in the Oriental double eyelid. *Plast Reconstr Surg*, 107, 1665–8.
- Cho, M. & Glavas, I. P. 2009. Anatomic properties of the upper eyelid in Asian Americans. *Dermatol Surg*, 35, 1736–40.
- DelCampo, A. 1984. Strategies for a successful corrective Asian blepharoplasty after previously failed revisions. *Plast Reconstruct Surg*, 114, 1270–7.
- Doxanas, M. T. & Anderson, R. L. 1984. Oriental eyelids – An anatomic study. *Arch Ophthalmol*, 102, 1232–5.
- Fernandez, L. 1960. Double eyelid operation in the Oriental of Hawaii. *Plast Reconstr Surg*, 25, 257.

- Flowers, R. S. 2002. Asian blepharoplasty. *Aesthet Surg J*, 22, 558–68.
- Goldberg, R. A., Wu, J. C., Jesmanowicz, A. & Hyde, J. S. 1992. Eyelid anatomy revisited – Dynamic high-resolution magnetic-resonance images of Whitnall ligament and upper eyelid structures with the use of a surface coil. *Arch Ophthalmol*, 110, 1598–600.
- Hata, B. 1933. The bead method in the double eyelid operation. *Jpn Rev Clin Ophthalmol*, 28, 491.
- Hayashi, K. 1939. The modification of the Hotz method for plastic constructive of a double eyelid. *Jpn Rev Clin Ophthalmol*, 34, 369.
- Hwang, K., Kim, D. J., Chung, R. S., Lee, S. I. & Hiraga, Y. 1998. An anatomical study of the junction of the orbital septum and the levator aponeurosis in Orientals. *Br J Plast Surg*, 51, 594–8.
- Jeong, S., Lemke, B. N., Dortzbach, R. K., Park, Y. G. & Kang, H. K. 1999. The Asian upper eyelid: An anatomical study with comparison to the Caucasian eyelid. *Arch Ophthalmol*, 117, 907–12.
- Kakizaki, H., Leibovitch, I., Selva, D., Asamoto, K. & Nakano, T. 2009. Orbital septum attachment on the levator aponeurosis in Asians: In vivo and cadaver study. *Ophthalmology*, 116, 2031–5.
- Khoo, B. 1963. Plastic construction of the superior palpebral fold. *Plast Reconstruct Surg*, 31, 74–8.
- Kruavit, A. 2009. Asian blepharoplasty: An 18-year experience in 6215 patients. *Aesthet Surg J*, 29, 272–83.
- Lam, S. 2007. Asian blepharoplasty. *Operative Techniques in Otolaryngology–Head & Neck Surgery*, 18, 267–72.
- Lee, C. K., Ahn, S. T. & Kim, N. 2013. Asian upper lid blepharoplasty surgery. *Clin Plast Surg*, 40, 167–78.
- Mauro, M. 1929. Plastic reconstruction of a “double eyelid”. *Jpn J Clin Ophthalmol*, 24, 393.
- Mikamo, M. 1896. Plastic operation of the eyelid. *J Chugai Jishimpo*, 17, 1197.
- Mutou, Y. M., H 1972. Intradermal double eyelid operation and its follow-up results. *Br J Plast Surg*, 25, 285–91.
- Nguyen, M. Q., Hsu, P. W. & Dinh, T. A. 2009. Asian blepharoplasty. *Semin Plast Surg*, 23, 185–97.
- Park, J. I. 1996. Z-epicanthoplasty in Asian eyelids. *Plast Reconstr Surg*, 98, 602–9.
- Persichetti, P., DiLella, F., Delfino, S. & Scuderi, N. 2004. Adipose compartments of the upper eyelid: Anatomy applied to blepharoplasty. *Plast Reconstr Surg*, 113, 373–8; discussion 379–80.
- Sayoc, B. T. 1954. Plastic construction of the superior palpebral fold. *Am J Ophthalmol*, 38, 556–9.
- Sergile, S. L. & Obata, K. 1997. Mikamo’s double-eyelid operation: The advent of Japanese aesthetic surgery. *Plast Reconstr Surgery*, 99, 662–7.
- Uchida, J. 1962. A surgical procedure for blepharoptosis vera and for pseudo-blepharoptosis orientals. *Br J Plast Surg*, 15, 271.
- Uchida, K. 1926. The Uchida method for the double eyelid operation in 1523 cases. *Jpn J Ophthalmol*, 30, 593–6.
- Weng, C. 2009. Oriental Upper Blepharoplasty. *Semin Plast Surg*, 23 (1), 5–15.
- Wong, J. 2007. A method in creation of the superior palpebral fold in Asians using a continuous buried tarsal stitch. *Facial Plast Surg Clin N Am*, 337–341.
- Yuzuriha, S., Matsuo, K. & Kushima, H. 2000. An anatomical structure which results in puffiness of the upper eyelid and a narrow palpebral fissure in the Mongoloid eye. *Br J Plast Surg*, 53, 466–72.

## Aesthetic Breast Surgery

---

Log Murugesan, Julia Ruston, Patrick Mallucci

### INTRODUCTION

---

This chapter on aesthetic breast surgery provides key facts that are useful as a quick reference. To facilitate this, information is presented in bullet point format, but it should by no means be considered exhaustive. The reference section and the appendix should guide the reader to more in-depth information and are highly recommended. Important developmental and anatomical facts are introduced first, followed by information that provides a foundation to the constantly evolving fields of breast augmentation, mastopexy and breast reduction.

### 1. BASICS

---

#### 1.1. Breast embryology, development and anatomy

---

An understanding of the basic embryological, development and anatomical concepts will give the reader a better understanding of the key surgical concepts in aesthetic breast surgery.

##### 1.1.1. Embryology and development

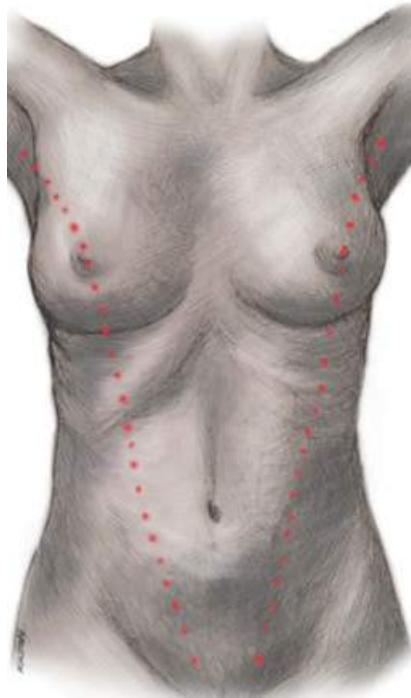
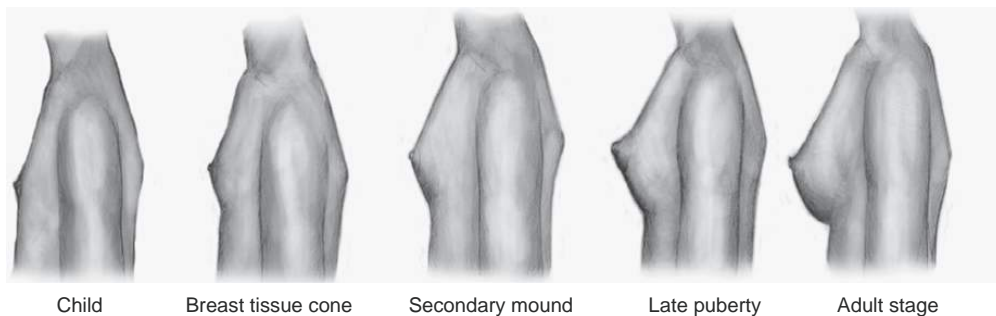
---

**Table 18.1** summarises the timeline of the embryonic developmental of the breast (Crosby, 2007; Schoenwolf *et al.*, 2008).

From birth to adolescence, development of the breast is quiescent. At puberty, multiple hormonal influences initiate breast development and maturation continues until maximal height is achieved (Azurin *et al.*, 2010). **Figure 18.2** shows the Tanner stages of breast development, which illustrate this

**Table 18.1.** Embryological development of the breast.

Week	Embryonic development
4	Mammary ridges develop from areas of future axillae and groins (Figure 18.1)
5	Primary bud formation; mammary ridges disappear except at breast sites
10	Branching of primary bud
12	Formation of several secondary buds which lengthen and branch
Birth	Opening of lactiferous ducts (15–20) into mammary pit (small superficial depression)

**Figure 18.1.** Mammary ridge (milk line) running from the anterior axillary line through the nipple to the pubic tubercle. (© J. Ruston.)

Child

Breast tissue cone

Secondary mound

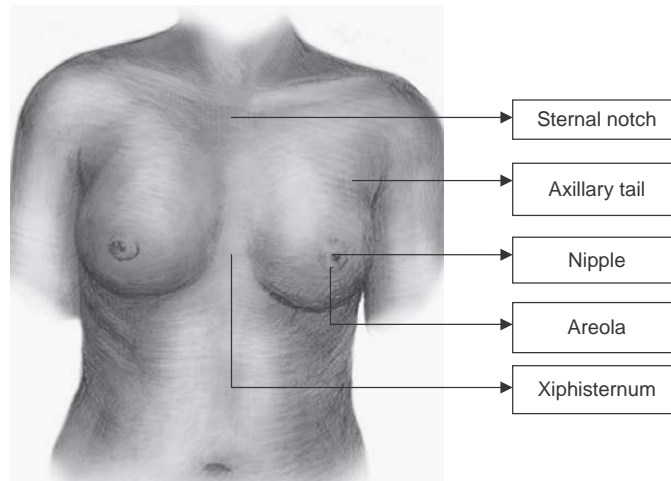
Late puberty

Adult stage

**Figure 18.2.** Tanner stages of breast development. (© J. Ruston.)

process (Herman-Giddens and Bourdony, 1995). Involution of the breast starts at menopause (Azurin *et al.*, 2010).

## 1.2. Anatomy

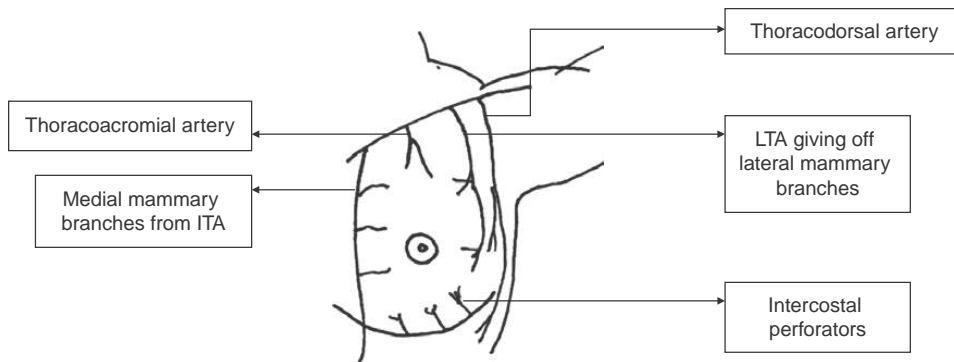


**Figure 18.3.** Surface anatomy of the female breast. (© J. Ruston.)

*Position of the breast* – overlies the second to sixth ribs. The nipple overlies the fourth intercostal space (Tunstall and Shah, 2012).

*Arterial supply* (Crosby, 2007; Netter, 2011):

- Medial mammary branches from the internal thoracic artery
- Lateral mammary branches from the lateral thoracic artery
- Lateral mammary branches from the lateral cutaneous branches of the posterior intercostals arteries.



**Figure 18.4.** Blood supply to the breast.

*Venous drainage* (Crosby, 2007; Netter, 2011):

- Superficial system (transverse and longitudinal vessels located subcutaneously)
- Deep drainage system (located in chest wall).

*Lymphatic drainage* (Crosby, 2007; Netter, 2011):

- Cutaneous
- Internal thoracic
- Posterior intercostals
- Axillary.

*Innervation* (Sarhadi *et al.*, 1996):

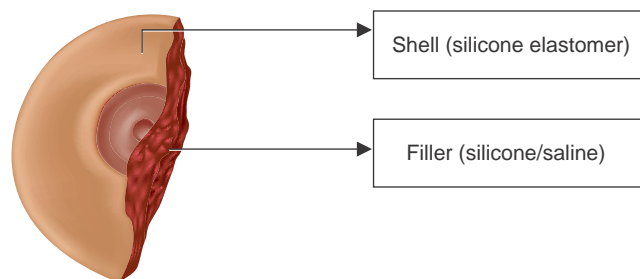
- Lateral and anterior cutaneous branches of the second to sixth intercostal nerves
- Supraclavicular nerves
- T2 and T6 innervate the breast skin only
- T4 is the main supply to the nipple–areolar complex.

## 1.3. Breast implants

### 1.3.1. History of implants in a nutshell

- The first silicone prosthesis was developed in 1961 by Cronin and Gerow.
- Currently, the fifth-generation silicone gel-filled breast implant is in use.
- The first saline-based implant was used in France in 1965.
- A silicone gel implant moratorium was announced in the USA in 1992.
- Silicone implants were removed from use from 1992 to 2006 they were considered a risk for systemic autoimmune diseases; however, no scientific link has been demonstrated (Adams and Mallucci, 2012).

### 1.3.2. Components of a breast implant



**Figure 18.5.** Components of a breast implant.

### 1.3.3. Characteristics of breast implants

The characteristics are (Mentor, 2010; Natrelle, 2012; Maxwell and Gabriel, 2013):

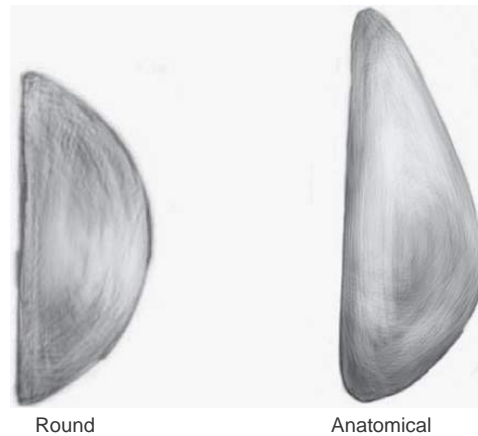
- Shell – smooth or textured.
- Shape – round or anatomical.

All anatomical implants are textured and round implants can either be smooth or textured.


### 1.3.4. Indications for shape of implants

The indications are shown below (Adams and Mallucci, 2012):

- Round – fuller appearance, good quality soft tissues, secondary surgery to avoid rotation.
- Anatomical – natural appearance, poor soft tissue quality, complex asymmetry, chest wall anatomy, constricted lower pole breast, breast reconstruction.

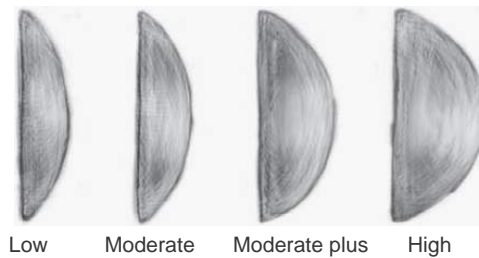


**Figure 18.6.** Shapes of breast implants. (© J. Ruston.)



**Figure 18.7.** Dimensions of an implant. (© J. Ruston.)

### 1.3.5. Profiles of breast implants



**Figure 18.8.** Profiles of breast implants. (© J. Ruston.)

Figure 18.8 shows a wide range of implant profiles, ranging from low to high (Mentor, 2010; Natrelle, 2012). The profile affects how far the implant will protrude from the chest wall.

## 2. AESTHETIC BREAST SURGERY

### 2.1. Breast augmentation

This section provides the reader with the essential basic steps to consider when offering this procedure to the patient.

#### 2.1.1. Background

Background information is shown below (Steinbrech and Lerman, 2009; Adams and Mallucci, 2012).

- Breast augmentation is the most common cosmetic procedure worldwide.
- Czerny was the first to attempt augmentation in the nineteenth century by transferring a lipoma to the breast.
- The use of injectable substances such as paraffin and liquid silicone in the first half of the twentieth century had disastrous consequences.
- Silicone prostheses are now more commonly used because of their superior feel and durability.

#### 2.1.2. Key components of the process of breast augmentation

The key components are (Adams and Mallucci, 2012):

- Patient education
- Pre-operative evaluation



- Tissue-based planning and implant selection
- Pre-operative marking
- Incisions
- Pocket plane
- Post-operative management
- Complications.

### 2.1.3. Patient education

---

It is imperative that patients are given full insight into the process of breast augmentation (Adams and Mallucci, 2012). During the initial consultation, the following should be addressed:

- The patient's aims and expectations
- The principles behind implant selection
- The surgical technique
- Complications related to the procedure
- Post-operative management
- The possibility of future surgery.

Prior to embarking upon surgery, the patient should be able to give their informed consent. Ideally, this should be done at the second consult. Clinical photography is also important for documentation.

### 2.1.4. Pre-operative assessment

---

Pre-operative assessment should include the patient's (Adams and Mallucci, 2012):

- Age
- Medical history
- Medication
- Allergies
- Smoking history
- Profession
- Previous surgery
- Family planning
- Breast feeding
- Cancer history
- History of weight loss/weight gain
- Reasons for surgery
- Aims.

Examination should include:

- Height
- Weight

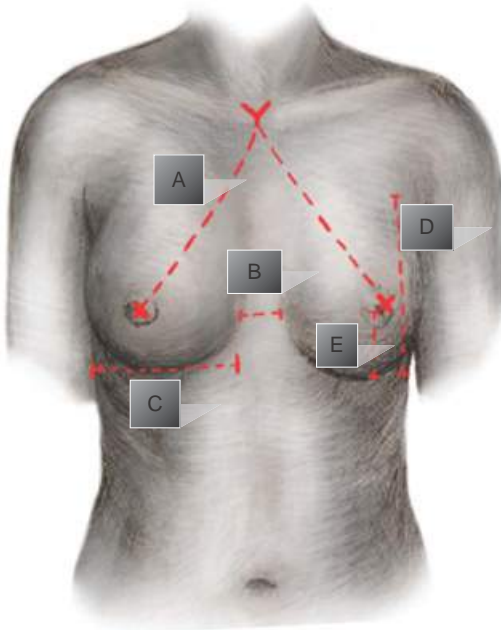
- Stature
- Skin quality
- Lie of the breast on the chest wall
- Intermammary distance
- Presence of structural deformity such as scoliosis
- Breast lump examination
- Soft tissue pinch test
- Ptosis.

For measurements, see [Figure 18.9](#).

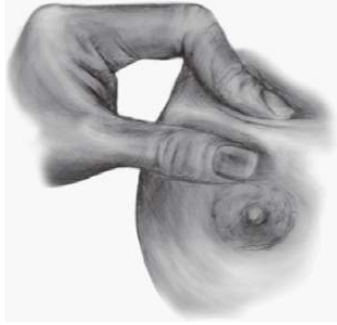When making pre-operative measurements, the pinch test is done by holding the superior pole of the breast between the thumb and the index finger. If there is <2 cm of tissue, placement of the implant should be submuscular (Tebbetts, 2002).

### 2.1.5. Tissue-based planning for implant selection

Through a series of five measurements proposed by Tebbetts (2002) and Adams (2005), the breast tissue can be evaluated and the best implant selected for the patient.



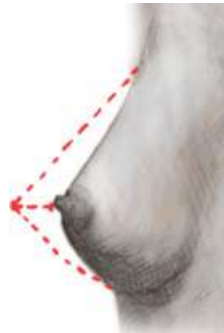**Figure 18.9.** Pre-operative measures. A. sternal notch to nipple distance (SN). B. Intermammary distance (IM). C. Breast width. D. Breast height. E. Nipple to inframammary fold distance (NIF). (© J. Ruston.)



**Figure 18.10.** Pinch test. (© J. Ruston.)

These measurements are:

1. Breast width
2. Anterior pull skin stretch

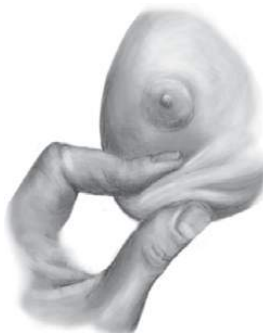

**Figure 18.11.** Anterior pull skin stretch. (© J. Ruston.)

With the anterior pull skin stretch, the amount of parenchyma that fills the stretched envelope can be evaluated.

3. Upper pole soft tissue pinch thickness
4. Soft tissue pinch thickness at inframammary fold (IMF)
5. Nipple to IMF under maximal stretch.

A



**Figure 18.12.** Soft tissue pinch test at the inframammary fold. (© J. Ruston.)

### 2.1.6. Pre-operative marking

---

The following must be marked (Adams and Mallucci, 2012):

- Midline
- Existing IMF
- Orientation at nipple
- Incision (1 cm medial to areolar and extending 4–4.5 cm along the marked IMF)
- Guide for pocket dissection (width and height).

### 2.1.7. Incisions

---

The incisions can be (Adams and Mallucci, 2012):

- Inframammary – more control, possibility of dual planes, less susceptible to contracture and infection.
- Periareolar – better scar.
- Transaxillary – hidden scar.
- Transumbilical – saline-filled prostheses.

### 2.1.8. Planes of dissection

---

In general, the subglandular option is chosen when the pinch test is >2 cm (Adams and Mallucci, 2012). Otherwise, the subpectoral approach is preferred. Benefits include better implant coverage, lower capsular contracture rates and good mammographic visibility of the breast. Tebbetts' (2001) dual plane techniques (I–III) involve varying degrees of subglandular dissection, followed by rotation of pectoralis major along the sternum medially. The main origins of the muscle are not divided. The total submuscular plane has also been described. This involves elevation of serratus fascia, which is continuous with the subpectoral plane; however, this is considered to be an unnatural plane.

### 2.1.9. Key steps in implant insertion

---

The key steps are (Adams and Mallucci, 2012):

- Adequate incision size to minimise trauma to the shell.
- Haemostasis.
- Pocket irrigation with an antimicrobial solution.

### 2.1.10. Post-operative management

---

Post-operative management should include (Adams and Mallucci, 2012):

- Early mobilisation
- Wearing a supportive non-wired soft sports bra for 6 weeks.

### 2.1.11. Complications of breast augmentation

---

Complications include (Adams and Mallucci, 2012):

- Infection
- Bleeding/haematoma
- Nipple/breast sensory changes
- Scarring
- Asymmetry
- Implant visibility, palpability, rippling, rotation or rupture
- Capsular contracture
- Future re-operations
- Symmastia.

### 2.1.12. Autologous fat transfer

---

This technique has been used together with breast implants (composite breast augmentation) in patients who do not have sufficient soft tissue to cover their implants (Auclair *et al.*, 2013). It has also been used for augmentation following a period of pre-tissue expansion using a vacuum-based external soft tissue expander (Brava, Miami, FL, USA) (Khouri *et al.*, 2012). In cases in which patients want their implants removed, lipofilling has been used both pre- and post-removal of prosthesis to restore volume (the simultaneous implant exchange with fat [‘SIEF’] technique) (Del Vecchio, 2012). Another application has been in covering the superior pole of the breast implant after subfascial transaxillary implant insertion (Auclair, 2009).

## 2.2. Mastopexy

---

### 2.2.1. Background

---

Mastopexy is surgery to ‘lift’ the ‘falling’ (ptotic) breast (Lemmon and Rios, 2007; Higdon and Grotting, 2013).

- It involves skin resection (lax and in excess) and re-draping of the parenchyma (lacking).
- Causes of ptosis – age, weight changes, pregnancy and developmental abnormalities.
- It may be combined with implant insertion or fat grafting (augmentation mastopexy).
- It may require a small parenchymal excision for reshaping.

### 2.2.2. Pre-operative assessment

Pre-operative assessment should include (Lemmon and Rios, 2007; Higdon and Grotting, 2013):

- Age and medical history, including conditions that may affect wound healing (e.g. diabetes).
- Family history (cancer) and family planning.
- Smoking.
- Physical examination (masses, symmetry, body mass index, degree of ptosis, tuberous deformity).

### 2.2.3. Evaluation of ptosis

In the Regnault classification, the degree of the ptotic breast is based upon nipple position in relation to the IMF (shown in Table 18.2) (Higdon and Grotting, 2013; Hidalgo and Spector, 2013).

### 2.2.4. Consent

Patients should be informed about the following risks prior to having the procedure (Higdon and Grotting, 2013; Hidalgo and Spector, 2013):

- Bleeding/haematoma.
- Infection.
- Wound breakdown/delayed healing.
- Scarring.
- Asymmetry.
- Loss of sensation.

**Table 18.2.** Regnault classification of breast ptosis.

Degree/severity of breast ptosis	Description
Grade I: mild	Nipple within 1 cm of IMF and above lower pole of breast
Grade II: moderate	Nipple is 1–3 cm below IMF but still above lower pole of breast
Grade III: severe	Nipple >3 cm below IMF. Nipple is lowest point on the breast
Grade IV: glandular/pseudoptosis	Nipple above IMF but majority of breast tissue rests below

IMF = inframammary fold

- Loss of nipple.
- Implant-related risks (as described in Section 2.1 on breast augmentation).

### 2.2.5. Pre-operative marking

---

Pre-operative marking should indicate (Higdon and Grotting, 2013):

- Sternal notch to nipple distance
- Nipple to IMF distance
- Breast base diameter (helps in implant selection).

### 2.2.6. Surgical techniques

---

Surgical techniques are based on the scarring pattern resulting from the skin excised. Four basic patterns are described in this section.

#### 2.2.6.1. Periareolar technique

---

Aspects of the periareolar technique are shown below (Benelli, 1990; Lemmon and Rios, 2007; Higdon and Grotting, 2013).

- It is useful in patients with mild to moderate ptosis and adequate parenchymal volume.
- The scar is hidden at the areola–skin junction.
- It can, however, result in a widened scar (as a result of excess tension on closure, skin quality and age) and depressed mammary projection.

In order to minimise complications, the following rules were proposed by Spear *et al.* (1990):

- The amount of non-pigmented skin excised should be less than the amount of pigmented skin excised.
- The design of the outside diameters should not be greater than twice that of the inside diameter.
- The final diameter is equal to half the sum of the inside and outside diameters.

Three possible methods are:

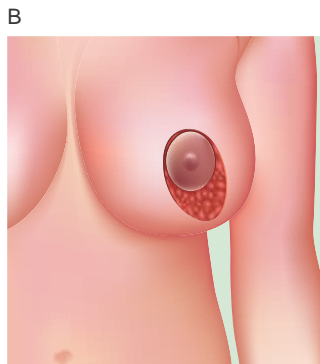
- Simple or concentric periareolar de-epithelialisation without parenchymal reshaping and closure (only for mild ptosis) (Lemmon and Rios, 2007; Higdon and Grotting, 2013). ‘Only the nipple–areola complex is moved and the amount of skin excised depends on its new location. The freed dermis can be tacked to a small amount of gland which can be freed from the skin around the de-epithelialised area superiorly. This will provide additional support to the breast. Closure is with a purse string suture’.

- Benelli mastopexy (larger breasts) (Benelli, 1990; Lemmon and Rios, 2007; Higdon and Grotting, 2013). ‘Glandular reshaping is achievable via a periareolar incision. Periareolar de-epithelialisation of the required size is done and dermoglandular flaps are created medially, laterally and superiorly. Intervening tissues are resected and the flaps are sutured over one another. The areola is fixed to the superior border of the ellipse and the breast is then redraped with the surrounding skin with a round block suture’.
- Góes technique with mesh support (correction of ptosis or slight reduction of hypertrophy with or without ptosis; reductions less than 500 g; contraindicated in obesity) (Góes, 2003; Higdon and Grotting, 2013). ‘An incision is made in the outer ellipse once the area between the skin and the nipple has been de-epithelialised after marking. Dissection is continued superiorly with increased fat thickness until the pectoral fascia is reached and this is continued 5 cm superiorly along the fascia and inferiorly, only until the fascia is reached. The base of the gland is undisturbed. Wedges of glandular tissues can be excised both superiorly and inferiorly. The remaining gland is then re-assembled and sutured to the chest wall. After the dermal flap has been attached to the fascia inferiorly and to the connective tissues superiorly, it is covered with either a synthetic or biological mesh which is itself secured to the pectoral fascia. The breast is then redraped with the surrounding skin.’

#### 2.2.6.2. Vertical scar technique

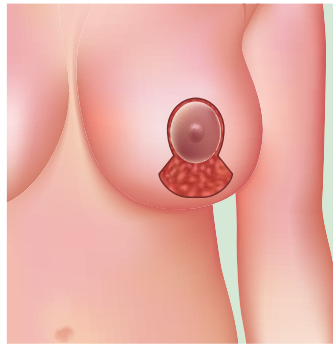
This technique can be applied to treat all degrees of ptosis; many variations of this technique have been described.

- *Lassus vertical scar technique* (Lassus, 1996; Lemmon and Rios, 2007; Higdon and Grotting, 2013). ‘Inferior en bloc wedge resection of skin, fat, gland and excess skin is carried out. No skin is undermined and the nipple is transposed superiorly. Lateral and medial breast blocs are then joined to eventually give a linear vertical scar’.
- Best candidate – young patient with elastic skin and a glandular breast.
- Contraindication – large ptotic breasts.

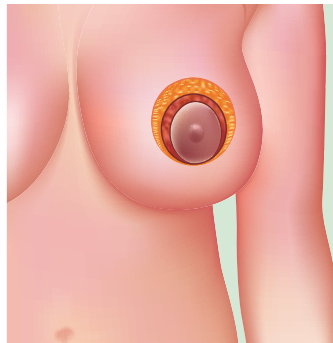


**Figure 18.13.** Lassus vertical scar mastopexy.



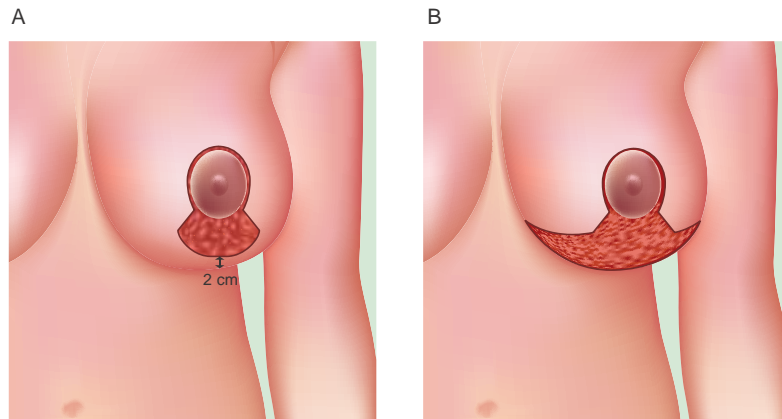


**Figure 18.14.** Lejour vertical scar mastopexy.



**Figure 18.15.** Hammond vertical scar mastopexy.

- *Lejour vertical scar technique* (Lejour 1994; Lemmon and Rios, 2007; Higdon and Grotting, 2013). ‘Breast liposuction is performed to reduce volume, make the breast softer and more pliable and easy to shape. Inferior skin, fat and gland are resected. Lower pole skin is undermined. The breast pillars are re-assembled and skin closed as redundant skin is gathered as fine wrinkles’.
- Drawback – time for skin to retract and wrinkles to eventually flatten.
- *Hammond (SPAIR) technique* (Hammond, 1999; Lemmon and Rios, 2007; Higdon and Grotting, 2013). Based on an inferior pedicle. A wedge of tissue is excised from lateral to superior to medial around the inferior pedicle; the nipple is transposed superiorly and skin closed. A vertical segment is de-epithelialised inferiorly for skin closure, leaving a vertical scar.
- *Hall-Findlay technique* (modified vertical reduction – medial pedicle) (Hall-Findlay, 1999; Lemmon and Rios, 2007; Higdon and Grotting, 2013). Lateral and inferior tissues are excised, leaving a medial pedicle which can be rotated superiorly. Medial and lateral breast pillars are then brought together and the skin approximated, leaving a vertical scar.
- *Inverted T-scar technique* (Wise pattern) (Wise *et al.*, 1963). Patient selection criteria for this procedure are moderate to severe ptosis, poor skin quality and a moderate amount of glandular tissue. In a Wise pattern skin excision, wider skin resection is possible. Only the skin envelope provides support to the breast’s shape upon closure and ptosis can subsequently recur.



**Figure 18.16.** Skin pattern for inverted-T mastopexy.

### 2.2.7. Post-operative care

Placement of drains is done at the discretion of the plastic surgeon. Drains should be removed once output is less than 30 ml. Patients should wear a supportive bra for 6 weeks.

### 2.2.8. Tuberos breast deformity

The breast is underdeveloped in both the horizontal and vertical dimensions (Karp, 2009). Patients present with the following (Lemmon and Rios, 2007; Karp, 2009):

- Narrow breast base
- High IMF
- Breast parenchymal herniation through the areola
- Constricting band around the breast
- Lower pole skin deficiency
- Asymmetry
- Lateralisation on the chest wall.

The breast parenchyma is thought to be covered by a superficial fascial layer which does not expand as the breast grows. Consequently, the parenchyma pushes through the areola, where no underlying fascia exists (Karp, 2009).

Grolleau *et al.* (1999) described three classes of tuberous breasts (shown in Table 18.3).

Treatment options for tuberous breasts include periareolar mastopexy, manipulation of breast parenchyma and lower pole skin flap, and the use of implants or expanders (Karp, 2009).

Ribeiro *et al.* (1998) described a one-stage technique using a periareolar approach. The breast is divided into an upper portion containing the areola and a lower portion containing an inferior pedicle. The incision is made down to the muscular level. Lateral and medial prolongations are resected and the

**Table 18.3.** Grolleau classification of tuberous breasts.

Type	Description
I	Lower medial quadrant deficiency
II	Entire lower pole deficiency causing the areola to point downward
III	Deficiency in all breast quadrants

inferior pedicle is bent over itself to enhance projection of the breast. The upper part of the breast is allowed to droop onto the pedicle and a round block suture technique is used for closure. The use of a prosthesis is not described in the original technique, but implants can be inserted using the same incision if required.

## 2.3. Breast reduction

### 2.3.1. Background

- Breast reduction is used as a treatment for mammary hypertrophy or macromastia (Fisher and Higdon, 2013).
- It has the highest satisfaction rates among all plastic surgery procedures (Davis *et al.*, 1995).

### 2.3.2. Clinical presentation

Clinical presentation includes (Nahai and Nahai, 2008):

- Neck, shoulder and back pain
- Intertrigo/rash
- Heaviness/indentation of skin by the bra straps (shoulder notching)
- Embarrassment
- Difficulty finding clothes that fit correctly
- Difficulty exercising.

### 2.3.3. Pre-operative assessment

Pre-operative assessment should include the following (Nahai and Nahai, 2008).

- Medical history, including conditions that may affect wound healing (diabetes).
- Smoking.

- Family history (e.g. of cancer) and family planning.
- Physical examination – masses, symmetry, ptosis, evidence of intertrigo, skin indentation, body mass index.

Patient should have a mammogram within 1 year prior to breast reduction.

#### 2.3.4. Consent

---

Patients should be well-informed regarding the possibility of (Nahai and Nahai, 2008):

- Bleeding/haematoma.
- Nipple loss (partial or total).
- Nipple sensory loss.
- Scarring – location, length, depressed, widened, hypopigmented, hypertrophy or keloid.
- Infection.
- Seroma.
- Delayed wound healing or wound breakdown.
- Asymmetry.
- Problems with breast feeding – may be difficult, reduced, impossible in free nipple grafting.

A patient will have more realistic expectations of surgery after these possibilities are discussed (Nahai and Nahai, 2008).

#### 2.3.5. Pre-operative marking

---

Pre-operative marking of the following should be done with the patient standing with their head up (Nahai and Nahai, 2008; Gabka and Bohmert, 2009):

- Midline and IMF
- Sternal notch to nipple distance (19–23 cm)
- Nipple to IMF distance (7–8 cm)
- Nipple to midline (9–11 cm).

The diameter of the nipple–areola complex should be around 38–45 mm in diameter. It is better if the new location is lower than initially planned rather than higher because this is more amenable to correction at a second stage (Rios and Potter, 2007; Nahai and Nahai, 2008).

#### 2.3.6. Surgery

---

Both breast parenchyma and skin are excised while maintaining the nipple's blood supply.

### 2.3.6.1. Pedicle designs

The remaining tissue bearing the nipple after the excision of excess parenchyma should have a reliable vascular supply and should easily be mobilised/rotated so that the nipple can sit in its new position without compromising its blood supply.

The pedicle can have one vascular base (monopedicle), which can be superior, inferior, lateral or medial, or two vascular bases (bipedicle) which can be horizontal, vertical or combined. The former is achieved by near total circumferential glandular excision, while the latter is achieved by wedge or base excision (Andrades and Prado, 2008).

Superior pedicles have limited arcs of rotation, while central or inferior pedicles have a higher chance of bottoming out as a result of gravity (Andrades and Prado, 2008).

### 2.3.6.2. Skin patterns

Excess longitudinal skin is removed with a horizontal excision, while excess horizontal skin is removed via a vertical excision. A combination of these two excisions will result in a T-shaped skin excision (Andrades and Prado, 2008). Other skin patterns are periareolar, dome shape, circumvertical and bipolar (Andrades and Prado, 2008).

Combinations of skin and pedicle patterns for breast reduction have been described by many surgeons. Some common techniques are:

- Superior–medial monopedicle and vertical scar (Hall-Findlay, 1999)
- Superior monopedicle with vertical scar (Lejour, 1994; Lassus, 1996)
- Superior monopedicle with periareolar scar (Benelli, 1990)
- Horizontal bipedicle with a T scar (Strombeck, 1964)
- Vertical bipedicle with a T scar (McKissock, 1976).

The technique used will usually depend on the patient's clinical presentation, the patient's wishes with regards to the size and scar, and the surgeon's preference.

Inverted T-skin resection is usually preferred in patients with very large and ptotic breasts (Nahai and Nahai, 2008). The Wise pattern (Wise, 1956) breast reduction is an inferiorly based pedicle breast reduction. After locating the new nipple position, a medial and a lateral limb are drawn down for a distance of 7 cm, with an angle between them of no more than 90°. The ends are connected to the ends of the IMF. A 4.5-cm diameter ring is drawn around the nipple, the inferior pedicle is de-epithelialised and incisions are made along the pedicle margins. Medial, lateral and superior breast tissues are excised down to the fascia. Closure is then achieved by joining the lateral and medial limbs at the inframammary midpoint. The T-junction and vertical wounds are closed and, at the superior end of the vertical wound, a nipple ring is used to mark the area through which the nipple is delivered (Giele and Cassell, 2008).

If the nipple–areola complex cannot be preserved, then amputation with free nipple grafting should be carried out (Nahai and Nahai, 2008). Liposuction can be used to remove minimal tissue excess in older patients with good skin quality (Nahai and Nahai, 2008).

### 2.3.7. Post-operative care

Placement of drains is at the discretion of the surgeon; drains should be removed once the volume of output is less than 30 ml/24 hours. Patients are advised to wear a non-wired sports bra for support for 6 weeks, not to perform strenuous upper body exercises and not to smoke.

## REFERENCES

- Adams W.P., Mallucci P. Breast augmentation. *Plast. Reconstr. Surg.* 2012; 130: 597e–611e.
- Andrades P., Prado A. Understanding modern breast reduction techniques with a simplified approach. *J. Plastic Reconstr. Aesthetic Surg.* 2008; 61: 1284–93.
- Auclair E. Apport du lipomodelage extraglandulaire dans les implantations mammaires à visée esthétique. *Annales de chirurgie plastique esthétique* 2009; 54, 491–5.
- Auclair E, Blondeel P, Del Vecchio DA. Composite breast augmentation: Soft-tissue planning using implants and fat. *Plast. Reconstr. Surg.* 2013; 132: 558–68.
- Azurin D.J., Fisher J., Maxwell G.P. Mastopexy. In: Weinzweig J. 2nd ed. *Plastic Surgery Secrets Plus*. Mosby Elsevier; 2010. pp 453–7.
- Benelli L. A new periareolar mammoplasty: The ‘round block’ technique. *Aesthetic Plast. Surg.* 1990; 14: 93–100.
- Crosby M.A. Breast anatomy and embryology. In: Janis J.E. ed. *Essentials of Plastic Surgery*. Quality Medical Publishing; 2007. pp 365–70.
- Davis G.M., Ringler S.L., Short K., Sherrick D., Bengtson B.P. Reduction mammoplasty: Long-term efficacy, morbidity, and patient satisfaction. *Plast. Reconstr. Surg.* 1995; Oct 96(5): 1106–10.
- Del Vecchio DA. ‘SIEF’-Simultaneous Implant Exchange with Fat: A new option in revision breast implant surgery. *Plast. Reconstr. Surg.* 2012; 130: 1187–96.
- Fisher J., Higdon K.K. Reduction mammoplasty. In: Grotting J.C. ed, Neligan P.C. ed. *Plastic Surgery. Breast*. 3rd ed. Elsevier Saunders; 2013. pp 119–51.
- Gabka C.J., Bohmert H. Mastopexy and reduction mammoplasty. In: *Plastic and Reconstructive Surgery of the Breast*. 2nd ed. Thieme; 2009. pp 37–65.
- Giele H, Cassell O. *Aesthetic Plastic and Reconstructive Surgery*. Oxford Specialist Handbooks in Surgery. Oxford University Press 2008; pp 667–9.
- Góes J.C. Periareolar mastopexy: Double skin technique with mesh support. *Aesthet. Surg. J.* 2003; 23: 129–35.
- Grolleau J.L, Lanfrey E., Lavigne B. Breast base anomalies: Treatment strategy for tuberous breasts, minor deformities, and asymmetry. *Plast. Reconstr. Surg.* 1999; 104: 2040–8.
- Hall-Findlay E.J. A simplified vertical reduction mammoplasty: Shortening the learning curve. *Plast. Reconstr. Surg.* 1999; 104: 748–59.
- Hammond D.C. Short scar periareolar inferior pedicle reduction (SPAIR) mammoplasty. *Plast. Reconstr. Surg.* 1999; 103: 890–901.

- Herman-Giddens M.E., Bourdony C.J. *Assessment of sexual maturity stages in girls*. Elk Grove Village, IL, USA: Pediatric Research in Office Settings, American Academy of Paediatrics 1995.
- Hidalgo D.A., Spector J.A. Mastopexy. *Plast. Reconstr. Surg.* 2013; 132: 642e–656e.
- Higdon K.K., Grotting J.C. Mastopexy. In: Grotting J.C. ed, Neligan P.C. ed. *Plastic Surgery. Breast*. 3rd ed. Elsevier Saunders; 2013. pp. 119–51.
- Karp N. Difficult breast augmentations. In: Aston S.J. ed, Steinbrech D.S. ed, Walden J.L. ed. Elsevier Saunders; 2009. pp 697–702.
- Khoury R.K., Eisenmann-Klein M., Cardoso E., Cooley B.C., Kacher D., Gombos E., Baker T.J. Brava and autologous fat transfer is a safe and effective breast augmentation alternative: Results of a 6-year, 81-patient, prospective multicenter study. *Plast. Reconstr. Surg.* 2012; 129: 1173–87.
- Lassus C. A 30-year experience with vertical mammoplasty. *Plast. Reconstr. Surg.* 1996; 97: 373–80.
- Lejour M. Vertical mammoplasty and liposuction of the breast. *Plast. Reconstr. Surg.* 1994; 94: 100–14.
- Lemmon J.A., Rios J.L. Mastopexy. In: Janis J.E ed. *Essentials of Plastic Surgery*. Quality Medical Publishing; 2007. pp 387–96.
- Maxwell G.P., Gabriel A. Breast augmentation. In: Grotting J.C. ed, Neligan P.C. ed. *Plastic Surgery Breast*. 3rd Ed. Elsevier Saunders; 2013. pp 13–38.
- Mentor. Mentor Breast Products. January 2010. Available from: <http://www.mentorwllc.com/global-us/Breast.aspx> [Accessed 20 October 2013].
- McKissock P.K. Reduction mammoplasty by the vertical bi-pedicle flap technique. Rationale and results. *Clin. Plast. Surg.* 1976; 3: 309–20.
- Nahai F.R., Nahai F. Breast reduction. *Plast. Reconstr. Surg.* 2008; 121: 1–13.
- Natrelle. The Natrelle collection. April 2012. Available from: <http://www.natrelle.co.uk/pages/default.aspx> [Accessed 20 October 2013].
- Netter F.H. *Atlas of Human Anatomy*. 5th ed. Philadelphia, PA: Saunders; 2011. plates 167–9.
- Rios J.L., Potter J.K. Breast reduction. In: Janis J.E. ed. *Essentials of Plastic Surgery*. Quality Medical Publishing; 2007. pp 397–406.
- Ribeiro L., Waldecir C., Buss Jr A., Accorsi Jr A. Tuberos breast: A new approach. *Plast. Reconstr. Surg.* 1998; 101: 42–9.
- Sarhadi N.S., Shaw Dunn J., Lee F.D., Soutar D.S. An anatomical study of the nerve supply of the breast, including the nipple and areola. *Br. J. Plast. Surg.* Apr 1996; 49(3): 156–64.
- Schoenwolf G.C., Bleyl S.B., Brauer P.R., Francis-West P.H. Development of the skin and its derivatives. In: Larsen's *Human Embryology*. 4th ed. Churchill Livingstone, Philadelphia, 2008. Chapter 7.
- Spear S.L., Kassan M. Little J.W. Guidelines in concentric mastopexy. *Plast. Reconstr. Surg.* 1990; 85(6): 961–6.
- Steinbrech D.S., Lerman O.Z. Breast implants: Background, safety and general considerations. In: Aston S.J. ed, Steinbrech D.S. ed, Walden J.L. ed. *Aesthetic Plastic Surgery* Elsevier Saunders; 2009. pp 645–9.
- Strombeck J.O. Breast reconstruction. I. Reduction mammoplasty. *Mod. Trends Plast. Surg.* 1964; 16: 237–55.
- Tebbetts J.B. A system for breast implant selection based on patient tissue characteristics and implant-soft tissue dynamics. *Plast. Reconstr. Surg.* 2002; 109: 1396–409.
- Tebbetts J.B., Adams W.P. Five critical decisions in breast augmentation using five measurements in 5 minutes: The high five decision support process. *Plast. Reconstr. Surg.* 2005; 116: 2005–16.
- Tebbetts J.B. Dual plane breast augmentation: Optimizing implant-soft-tissue relationships in a wide range of breast types. *Plast. Reconstr. Surg.* 2001; 107: 1255–72.
- Tunstall R., Shah N. Thorax. In: *Surface Anatomy*. Pocket tutor. JP Medical Ltd; 2012. pp 25–52.
- Wise R.J. A preliminary report on a method of planning the mammoplasty. *Plast. Reconstr. Surg.* 1956; 17: 367–75.
- Wise R.J., Gannon J.P., Hill J.R. Further experience with reduction mammoplasty. *Plast. Reconstr. Surg.* 1963; 32:12–20.

## APPENDIX: USEFUL DOCUMENTS AND MEDIA

---

Listed are some sources which readers might find useful.

Safety of silicone gel-filled implants: <http://www.fda.gov/downloads/MedicalDevices/ProductsandMedicalProcedures/ImplantsandProsthetics/BreastImplants/UCM260090.pdf>

Independent Review Group on silicone gel breast implants: <http://www.mhra.gov.uk/Committees/Devices/IndependentReviewGroupsiliconegelbreastimplants/index.htm>

### Breast augmentation videos

---

Links available from: Adams Jr W.P., Mallucci P. Breast augmentation. *Plast. Reconstr. Surg.* 2012; 130: 597e–611e. Accessible through PRSJJournal.com and by Ovid users.



---

Zain Bukamal, Ash Mosahebi

## 1. INTRODUCTION

---

Today self-image is largely influenced by self-perception; a small waist diameter has become a matter of concern to both women and men such that many people with various concerns including aesthetic and functional bodily issues are increasingly seeking surgical intervention (Achauer *et al.*, 2000). As a consequence, new techniques have been implemented in the aesthetic field of plastic surgery and have increasingly improved the long-term post-operative results, providing greater patient satisfaction.

Body contouring is defined as a procedure(s) that involves the removal of excess subcutaneous fat and skin; it mainly consists of liposuction with or without an open surgical method to correct body deformities. In addition, filler injections, implants and autologous fat grafting (Appendix 1) into areas which require volume enhancement are evolving constituents of body contouring and have been carried out for the purpose of liposculpture.

The population of weight loss patients has risen as a result of current progress in bariatric surgery (Appendix 1) (Thorne, 2006). This has subsequently increased the number of people seeking aesthetic body contouring procedures following massive weight loss to reach their desired figure. This in itself has encouraged researchers to develop more advanced techniques to overcome many of the body dysmorphic complications faced by overweight patients after gastric banding and gastric by-pass operations.

## 2. HISTORY OF LIPOSCULPTURE

---

Liposculpture was originally introduced and successfully carried out at the onset of the twentieth century; however, a French surgeon, Dr Yves-Gerard Illouz, was the first to perform a safe, modern liposuction procedure (Sterodimas *et al.*, 2012) in 1982, alongside his fellow French surgeons Dr Pierre Fournier and Dr Francis Otteni (Thorne, 2006).

For the past century, abdominoplasty has been described by many surgeons, using various surgical techniques aimed to improve outcomes and lessen complication rates. Limited dermolipectomy (i.e. excision of excess adipose tissue and skin, mainly in the abdomen) was first reported in France by two French surgeons in 1890: Demars and Marx (Shiffman and Mirrafati, 2010). In 1899, a gynaecologist, Kelly, reported performing the same procedure in the USA for the first time in John Hopkins Hospital, Baltimore (Shiffman and Mirrafati, 2010).

### 3. PATIENT SELECTION

---

The appropriate selection of patients for liposuction and body contouring is a vital factor in achieving a favourable aesthetic outcome. The patient's target outcome of a desired procedure(s) should be assessed by the surgeon; thereupon, an explanation of which procedure is possible to carry out and which is not should be given to the patient (Thorne, 2006). After assessment, some patients will require liposuction alone while others may also require an open surgical intervention as a consequence of differing body fat proportions and differing amounts of excess subcutaneous tissue and residual skin.

When it comes to determining whether a patient is suitable for body contouring, particularly those who have experienced massive weight loss, it is crucial to assess the patient's past history. Major weight fluctuation in the period prior to body contouring is a risk factor for regaining weight following the procedure (Thorne, 2006). Smoking, too, is an important consideration in body contouring because of the resultant compromised blood supply at operative sites. Smoking patients are at an increased risk of tissue necrosis; they are therefore asked to abstain from smoking for at least 2 weeks pre-operatively and 2 weeks post-operatively in order to prevent vascular compromise.

Patients who are considered poor candidates for body contouring surgery (Table 19.1) include 'idealists' with undetectable body deformities, those with eating disorders who present with severe depression and, finally, those who are extremely overweight and have consistently failed to reduce their weight.

Ideal patients for a good aesthetic outcome (Table 19.1), on the other hand, are those who have maintained a stable weight for at least 6–12 months, those following an effective diet and exercise routine, and those within 20% of their ideal weight or above chart weight by up to 50 lb (22.7 kg) (Thorne, 2006). The patient's general health status should be considered an integral part of the overall pre-operative assessment to determine whether the patient is sufficiently fit for anaesthesia. Body contouring procedures, particularly for patients who have experienced massive weight loss, are usually performed under general anaesthesia when more than one body part is targeted. Therefore, the patient's co-morbidities are addressed and managed prior to surgery in order to avoid concurrent post-operative complications.

A stable pre-operative weight has, again, been shown to reduce the risk of complications after body contouring surgery compared with variable and unstable body weights (van der Beek *et al.*, 2011). This concept is more applicable to massive weight loss patients who have been previously overweight or obese; however, stable weight maintenance before body contouring is a key consideration for all patient groups in general.

**Table 19.1.** Patient selection: descriptions of an ideal patient and a poor candidate for body contouring.

Ideal candidate	Poor candidate
Stable weight for at least 6–12 months Following an effective diet and exercise routine Within 20% of his/her ideal weight Above chart weight by 50 lbs (22.7 kg)	‘Perfectionists’ with undetectable body deformities Eating disorder problems with severe depression Extremely overweight, unable to lose excess weight

## 4. PRE-OPERATIVE MARKING

Pre-operative measurement of excess skin in the area being prepared for surgery and incision markings on skin should be carefully undertaken prior to body contouring surgery to ensure a better surgical outcome. Measurement of the excess tissue is estimated by pinching, and later by marking, the lines to be used for resection to indicate where the lines can be re-connected after excision of the excess skin and tissue.

The use of a permanent marker pen by the surgeon to mark the operative areas is an integral part of almost every pre-operative anaesthesia plan. Anatomical landmarks are often used to plan the marking of incisions because they provide accurate measurements of the area to be excised and can also predict the width of the post-operative scar. The markings are usually done with the patient positioned standing with the aim of creating surgical scars at the lowest level possible so that they can eventually be hidden by underwear (in the cases of abdominoplasty and circumferential body lift) (Vico *et al.*, 2010a).

## 5. TUMESCENT ANAESTHESIA

Anaesthetic practice in plastic surgery has evolved over time since the introduction of the tumescent technique in 1987 (Dhami and Agarwal, 2006) to yield a number of intra- and post-operative advantages over traditional anaesthesia. Initially, it was indicated as a means of anaesthesia for liposuction procedures; however, its popularity has expanded into other surgical fields including breast, vascular, and ear, nose and throat surgery (Conroy and O’Rourke, 2013).

Tumescent anaesthesia, also known as the ‘wet technique’, describes the local infiltration of an extensive amount of solution containing a low concentration of local anaesthetic, adrenaline and sodium bicarbonate (Conroy and O’Rourke, 2013). Adrenaline provides the vasoconstriction required to reduce bleeding at the operative site, while sodium bicarbonate is added to neutralise the acidity of the local anaesthetic, mainly lidocaine, therefore reducing pain at the injection site. This type of local anaesthesia has the advantage of covering a large area of subcutaneous adipose tissue.

As previously stated, the tumescent technique has proven main advantages, including:

1. Considerable reduction in intra- and post-operative bleeding rates.
2. Easy tissue dissection (Davila and Garcia-Doval, 2012).

3. Avoidance of risks associated with general anaesthesia.
4. Decreased systemic uptake of the employed anaesthetic due to a higher local concentration at the operating site (Thorne, 2006).

Additionally, this technique has exhibited minor tissue oedema during the course of post-operative healing (Dhami and Agarwal, 2006).

## 6. LIPOSUCTION

---

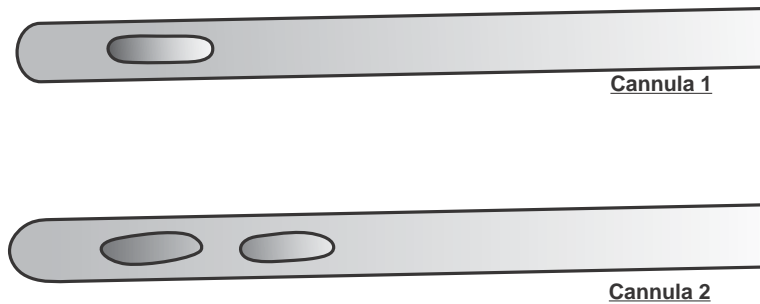
Liposuction is one of the major procedures involved in body contouring. The aspiration of excess body fat through cosmetic surgery been performed more routinely over the years, as more people have become concerned about their body image. Liposuction provides the body with a slim, weight loss appearance and a more defined figure by reducing excess subcutaneous fat proportions in areas throughout the body.

The leading, gold standard method of liposuction is suction-assisted liposuction (SAL), in which a cannula is used to tunnel through and break up subcutaneous fat after insertion through a minor skin incision. The cannula is connected to an aspirator which vibrates to assist the suction action. There are different cannula sizes with a variety of tip shapes containing differing numbers of holes (Figure 19.1) through which a wetting anaesthetic solution is infused and adipose tissue is aspirated from the body. Cannulas with different hole sizes are used for different purposes: a wide-holed cannula is used for speeding up the process of liposuction as well as increasing the amount of fat aspirated, whereas cannulas with smaller holes are used in areas that require less fat to be removed. In liposuction, the number of incisions made depends on the area to be liposculptured and the extent of contour deformity (Toledo, 1999).

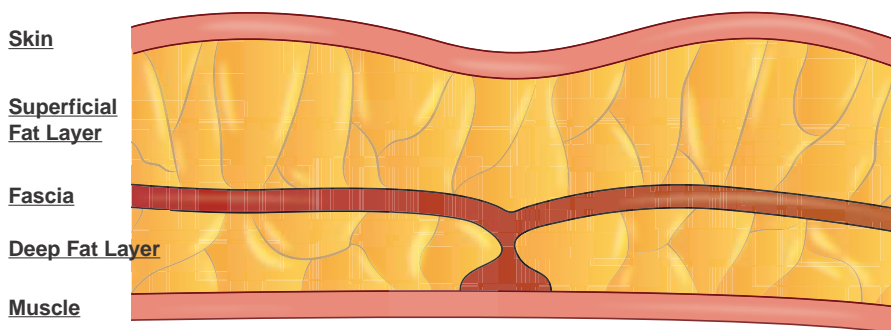
The subcutaneous fat is composed of two layers: a superficial fat layer and a deep fat layer (Figure 19.2). In liposuction, the latter is usually the first region targeted for suctioning, and requires the surgeon to make extensive in-and-out movements of the cannula. In contrast, superficial fat layer suctioning is performed last using smaller cannulas and with special attention paid to the amount of fat being removed because overcorrection of this region may lead to superficial contour deformities such as indentations and dimpling (Toledo, 1999).

Liposuction has been used in a wide range of areas of the body: the abdomen, flanks, back, thighs, buttocks, breasts, knees, arms, neck, face and lower eyelids. Most liposuction procedures are used for slimming and cosmetic purposes; however, it has also been used for functional reasons in morbid obesity cases. Patients who have been bed-ridden as a result of obesity require suctioning in areas such as the inner thighs and calves to allow at least partial mobilisation (Scharnagl *et al.*, 2013b).

Although SAL, also known as traditional liposuction, has been used most routinely, liposuction has advanced over the years to include other mechanisms which aim to provide for fewer complications and more effective outcomes (Roustaei *et al.*, 2009). Ultrasound-assisted liposuction was introduced in the mid-1990s. It induces thermal and micromechanical effects on subcutaneous fat by applying ultrasonic energy via an attached probe (Thorne, 2006).



**Figure 19.1.** Cannula 1, a standard single-slot cannula. Cannula 2, a two-slot cannula, very efficient for face and neck sculpting.



**Figure 19.2.** The two subcutaneous adipose tissue layers: superficial and deep.

Another technique is power-assisted liposuction, which was introduced in the late-1990s. It is very similar to SAL but uses a reciprocating cannula (Thorne, 2006), which makes surgery easier by requiring the surgeon to perform fewer manual movements. Radiofrequency-assisted liposuction (RFAL) is a recently developed technique which uses radiofrequency energy to destroy fat tissue and provide minimal skin tightening (Hurwitz and Smith, 2012). This method uses the Bodytite™ device, which has not yet been approved by the US Food and Drug Administration (Theodorou *et al.*, 2012). Moreover, clinical trials of RFAL have been carried out on patients with moderately loose skin and others who have experienced massive weight loss, yielding patient satisfaction rates of 85% and 82% with regard to body contouring and skin shrinkage, respectively (Theodorou *et al.*, 2012).

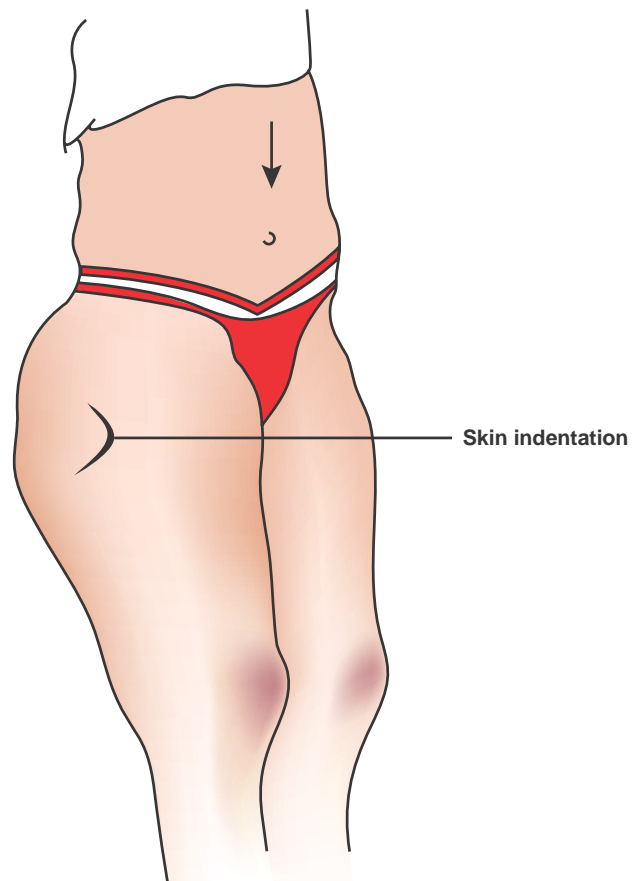
## 7. COMPLICATIONS OF LIPOSUCTION

Liposuction may be associated with local and/or systemic complications: the greater the amount of fat aspirated, the higher the risk of complications (Shiffman and Di Guiseppe, 2010).

**Table 19.2.** Liposuction complications: local and systemic.

Local	Systemic
Contour irregularity	Fat embolism/thromboembolism
Ecchymosis/skin discolouration/bruising	Fluid imbalance
Haematoma/seroma	Lidocaine toxicity
Infection	Perforation of visceral contents (rare)
Skin necrosis	Death (rare)
Dysaesthesia	

Source: Thorne (2006).

**Figure 19.3.** Skin indentation as a result of liposuction overcorrection.

Contour irregularity caused by undercorrection is adjusted by a revision liposuction procedure to remove the excess fat and smooth out the skin surface. On the other hand, overcorrection resulting in skin indentations (Figure 19.3) may be treated by liposuction of the surrounding area followed by injection of autologous fat into the depressions (Shiffman and Di Guisepe, 2010). Skin depression following liposuction is due to the aspiration of superficial fat that is very close to the skin surface.

The management of other complications will not be discussed in this chapter.

## 8. ABDOMINOPLASTY

### 8.1. Layers of the abdominal wall

The abdominal wall layers in the anterolateral aspect of the lower trunk are composed of (from outside to inside) the skin, superficial fascia, deep fascia, external oblique muscle, internal oblique muscle, transverse abdominis and its related aponeurosis, rectus abdominis muscle, pyramidalis muscle and transversalis fascia (Shiffman and Mirrafati, 2010).

Knowledge of the blood supply of the skin covering the rectus abdominis muscle is important when considering an abdominoplasty procedure. Knowledge of the anatomical position of blood vessels prevents their unintentional dissection during surgery and thus prevents post-operative skin necrosis (Appendix 2).

Abdominoplasty is a surgical procedure that involves excision of excess abdominal fat and skin (dermolipectomy) with or without plication of the rectus fascia in cases of rectus muscle diastasis. This procedure is performed in the lower truncal region, where body contouring procedures are usually extensive and lengthy; therefore, medical conditions which require stabilisation should be managed appropriately before surgery is planned. These include respiratory and cardiac conditions and diabetes (Thorne, 2006).

Similar to liposuction, motivation for abdominoplasty is not limited to aesthetic reasons. Functional indications are also present in a proportion of cases. Back pain, immobility, postural shifts and skin rashes under abdominal skin folds in the obese are considered functional concerns that may be alleviated by abdominoplasty (Shiffman and Di Guisepe, 2010).

Patients presenting for abdominoplasty have shared aesthetic needs: a flatter abdomen, tighter skin and an improved abdominal wall shape (Shiffman and Mirrafati, 2010). Abdominal wall contour irregularities have a number of causative factors (Table 19.3) which can develop in the body over time. These irregularities present as loose skin, excess adipose tissue and musculofascial laxity, i.e. rectus abdominis muscle and fascia widening. These deformities require surgical intervention when exercise and diet fail to correct the abdominal wall (Shiffman and Mirrafati, 2010).

In general, abdominoplasty can be generally classified as mini abdominoplasty, abdominoplasty and circumferential abdominoplasty. The type of surgery chosen depends on the extent of the abdominal wall irregularity and its relation to the umbilical region. Different indications apply to the three procedure types and each is carried out using a particular technique.

**Table 19.3.** A list of factors leading to abdominal wall laxity with consequent contour irregularities.

---

Causative factors
Ageing
Pregnancy
Weight changes
Gravity
Sequelae of previous surgical procedures involving the abdomen
Sedentary lifestyle
Medications/hormones

---

## 8.2. Mini abdominoplasty

---

Mini abdominoplasty is carried out on patients who present with infraumbilical abdominal wall laxity with minimal excess adiposities and loose skin in the same region. It is performed on patients who present with rectus abdominis diastasis which is restricted to the infraumbilical region or extends superiorly above the umbilicus by a maximum length of 1–2 cm. In areas where fat has accumulated without the presence of sagging skin, liposuction may be required during mini abdominoplasty (Shiffman and Mirrafati, 2010). Mini abdominoplasty provides outstanding correction of abdominal wall deformities confined to the lower abdomen (Figure 19.4), culminating in lower complication rates compared with full abdominoplasty. Additionally, the recovery time is shorter for mini abdominoplasty.

The ideal patient for a mini abdominoplasty is physically fit and not obese but is disturbed by the appearance of their lower abdominal bulge which is clearly evident from the lateral view. Upon consultation, the patient should be examined in the supine and sitting positions. The degree of rectus muscle diastasis is revealed by asking the patient to adopt a diving position, with the waist flexed and the arms extended in front (Shiffman and Mirrafati, 2010). In the sitting position, soft tissue excess and lower abdominal bulging are apparent.

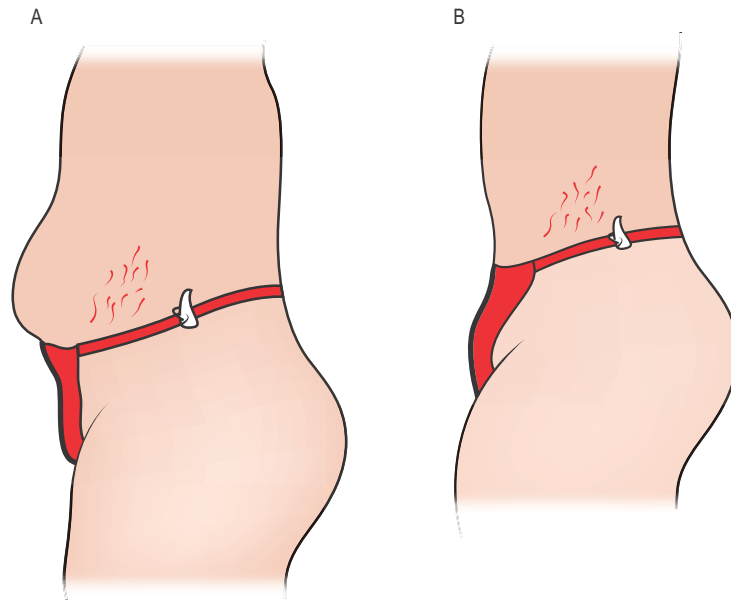
### 8.2.1. Mini abdominoplasty technique

---

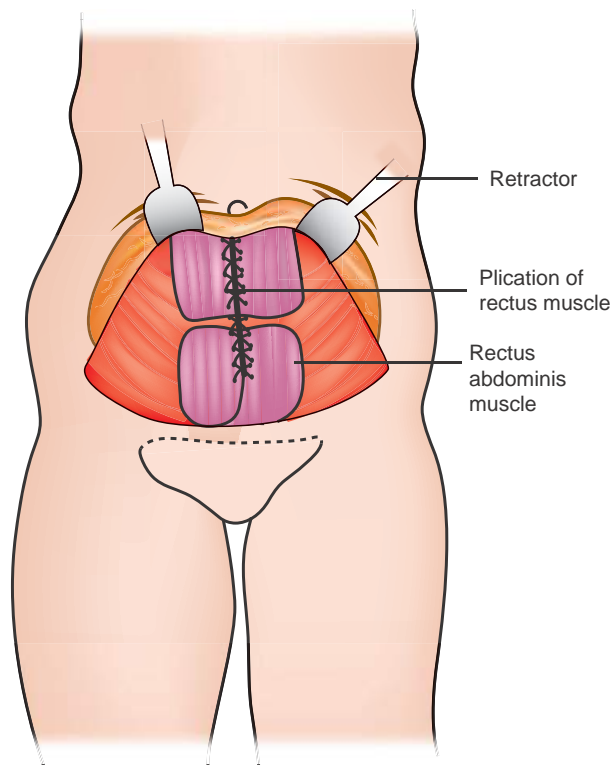
Mini abdominoplasty is initiated by marking the planned incision in the pubic area, which points to the actual incisional plane. A surgical incision is then made in the suprapubic crease and arched toward the anterior superior iliac spine (Thorne, 2006). It extends inward to reach the muscle fascia. An abdominal flap is then elevated, reaching up to the umbilical level. In the presence of a rectus muscle diastasis in the infraumbilical region, plication of the muscle fascia should be performed (Figure 19.5).

Contraindications to mini abdominoplasty include obesity, supraumbilical abdominal wall defects, generalised abdominal wall laxity with loose skin, the presence of incisional hernias in the supraumbilical region (Shiffman and Mirrafati, 2010), and a history of massive weight loss with excess skin above the umbilicus. For such patients, full abdominoplasty would be more suitable to yield the correct outcome.





**Figure 19.4.** Before and after image of mini abdominoplasty. A. Before mini abdominoplasty: infraumbilical abdominal wall laxity and bulging. B. After mini abdominoplasty: end-result after skin and subcutaneous tissue resection and rectus muscle plication.



**Figure 19.5.** Illustration of the mini abdominoplasty procedure once plication of the rectus muscle fascia is completed.

### 8.3. Full abdominoplasty

As mentioned in [Section 8.2](#), patients with deformities extending into the supraumbilical region are eligible to undergo full abdominoplasty. This procedure is performed in a more extensive manner than the mini abdominoplasty: there is infra- and supraumbilical abdominal wall laxity with excess adipose tissue and drooping skin that require excision. Rectus muscle diastasis, when present, extends far beyond the supraumbilical region, involving the whole vertical scope of the abdomen and necessitating rectus fascia plication. However, full abdominoplasty is performed on patients whose irregularities are limited to the anterior aspect of the abdomen.

In order to obtain optimal results from full abdominoplasty, intra-abdominal fat should be reduced to remove extra loose skin. Patients presenting with excess intra-abdominal fat that would restrict flattening of the abdomen are poor candidates for abdominoplasty because, in these cases, the outcome will be a convex-shaped abdominal contour, which is undesirable (Thorne, 2006). Therefore, a proper exercise and diet regime should be advised to patients presenting with excess intra-abdominal fat with the intention of weight, as well as subcutaneous fat, reduction prior to abdominoplasty.

Patients presenting with massive weight loss usually tend to have skin and subcutaneous tissue excess circumferentially, which requires circumferential excisions rather than standard abdominoplasty (Thorne, 2006). However, massive weight loss patients who manage to reach a close-to-normal body mass index (Appendix 2) frequently present with deformities limited to the anterior abdominal wall without involving circumferential areas, which makes them suitable for standard abdominoplasty.

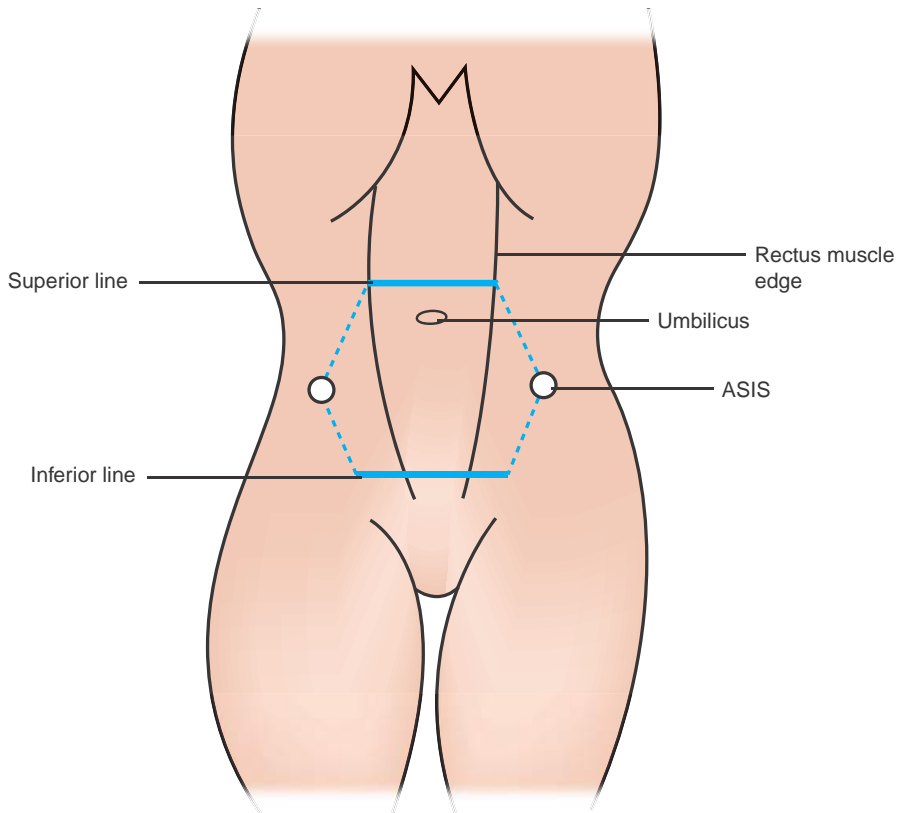
The pre-operative evaluation consists of a ‘pinch test’ (Shiffman and Mirrafati, 2010), which evaluates the amount of skin and subcutaneous tissue that requires excision. In addition, excess fat in the flank area can be observed in overweight patients who may require liposuction; however, at other times, the fat may necessitate lateral surgical removal. The examination should include assessing rectus muscle diastasis. Skin marking for incisions is performed as part of the pre-operative planning.

#### 8.3.1. Full abdominoplasty technique

Full, or standard, abdominoplasty consists of musculoaponeurotic tightening and dermolipectomy (Shiffman and Mirrafati, 2010). When in the supine position, the patient’s abdomen is draped from the mid-chest to the groin area. To mark the midline, a stitch is placed from the xiphoid process extending

**Table 19.4.** Indications for a full abdominoplasty: general and specific.

General	Specific
Excess adipose tissue removal	Loose skin that requires 6–8 cm of excision in the vertical plane
Redundant skin removal	Supra- and infraumbilical wall laxity and musculoaponeurotic defect
Body contour improvement	Noticeable epigastric fullness
Scar/striae removal	Ventral hernia associated with relaxation of the abdominal wall

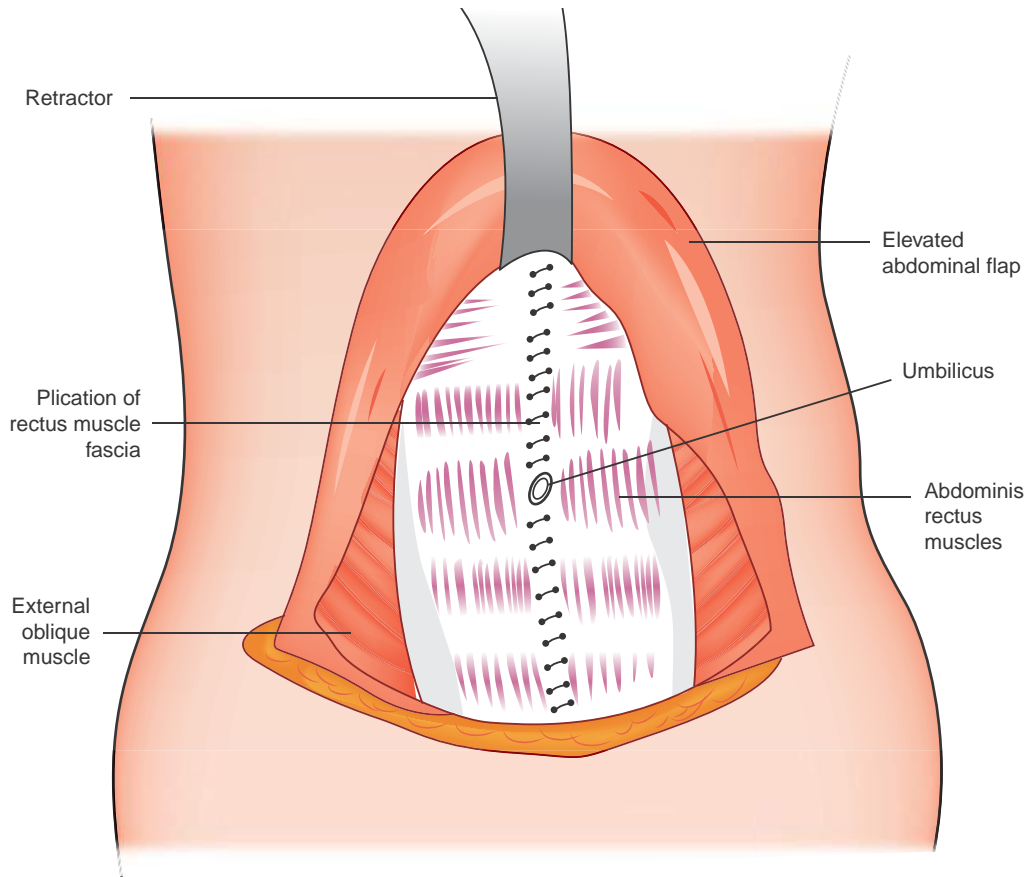


**Figure 19.6.** Pre-operative marking for a full abdominoplasty.

downward to the umbilicus and midpoint of the pubis. The vulvar commissure is a useful midpoint landmark in women.

Two lines, superior and inferior (in relation to the umbilicus), are marked by placing provisional sutures on the lateral margins of the recti muscles (Figure 19.6). The umbilicus is then excised down to the fascia level and retracted upward, with preservation of its stalk. A midline incision is made from the excised umbilical level down to the lower abdominal incision. This cut will divide the subcutaneous tissue into two hemi-flaps (Shiffman and Mirrafati, 2010), which are raised upward to the costal margins and xiphoid process level (Thorne, 2006).

The lower incision in an abdominoplasty is usually marked at the naturally occurring suprapubic crease, analogous to the mini abdominoplasty incision. The two hemi-flaps, consisting of skin and subcutaneous tissue, are excised with preservation of the lateral musculocutaneous perforators (Persichetti *et al.*, 2005). Salvage of the perforators will prevent vascular supply impairment and subsequent necrosis from taking place at the meeting point of the horizontal and vertical incisions, which lies in zone III (Appendix 1). This technique is called ‘anchor-line abdominoplasty’ and is most beneficial in patients with old scars (Persichetti *et al.*, 2005) where the blood supply has previously been severed.



**Figure 19.7.** Full abdominoplasty: the technique. Note that, compared with the incision level in [Figure 19.5](#), the superior line here extends above the umbilicus to target the supraumbilical subcutaneous tissue and loose skin.

Rectus muscle diastasis repair is achieved by plication of the muscle fascia and suturing of the fascia medially with double-stranded O-nylon (Shiffman and Mirrafati, 2010) to bring the muscles into closer contact with one another ([Figure 19.7](#)). Tightening of the abdominal wall is further carried out by bringing the external oblique aponeurosis medially and suturing the edges together to improve the abdominal wall shape.

The subcutaneous flaps are pulled inferiorly in order to assist in tailoring of the flap (excising the excess tissue). The customised flap is then approximated with the lower incision and a new umbilicus is shaped by being taken through the abdominal flap via a central incision. Lastly, the abdominal incision is closed in several layers; most importantly, the superficial fascia is closed with a permanent suture (Thorne, 2006). After closure of the final subcuticular layer, drains are placed bilaterally within the edges of the incisions.

## 9. CIRCUMFERENTIAL LIPECTOMY

Massive weight loss patients, particularly following bariatric surgery, make up the largest group of patients suitable for a circumferential lipectomy (Appendix 1), also called a ‘body lift’. The presence of generalised laxity and excess skin in areas surrounding the abdomen, thighs, back, buttocks and hips (Thorne, 2006) require excision via circumferential procedures. However, patients who are overweight or obese with no history of bariatric surgery but with some extent of laxity are also suitable candidates for circumferential excision (Vico *et al.*, 2010b).

Circumferential body contouring was performed on two groups of patients in one study, a bariatric surgery group and a non-bariatric surgery group, both presenting with varying degrees of weight loss and excess loose skin (Vico *et al.*, 2010b). It was reported that patients with no history of bariatric surgery had a higher degree of post-operative satisfaction with a better aesthetic outcome. The operative time for this group was shorter, there was less intra-operative blood loss and their weight loss prior to the procedure was lower.

Circumferential lipectomy can be classified into two categories: belt lipectomy and lower body lift (Thorne, 2006). The first category, belt lipectomy, corrects central deformities in the lower trunk; it mainly consists of standard abdominoplasty combined with a thigh and buttock lift, performed by a circumferential excisional procedure (Michaud *et al.*, 2007). The second category, lower body lift, adjusts deformities in the thighs and lower trunk via treating them as a single unit. Table 19.5 compares belt lipectomy and a lower body lift.

### 9.1. Circumferential lipectomy technique

The circumferential lipectomy procedure is complex and requires turning the patient into different positions intra-operatively: supine, lateral and prone. The order of position varies according to each

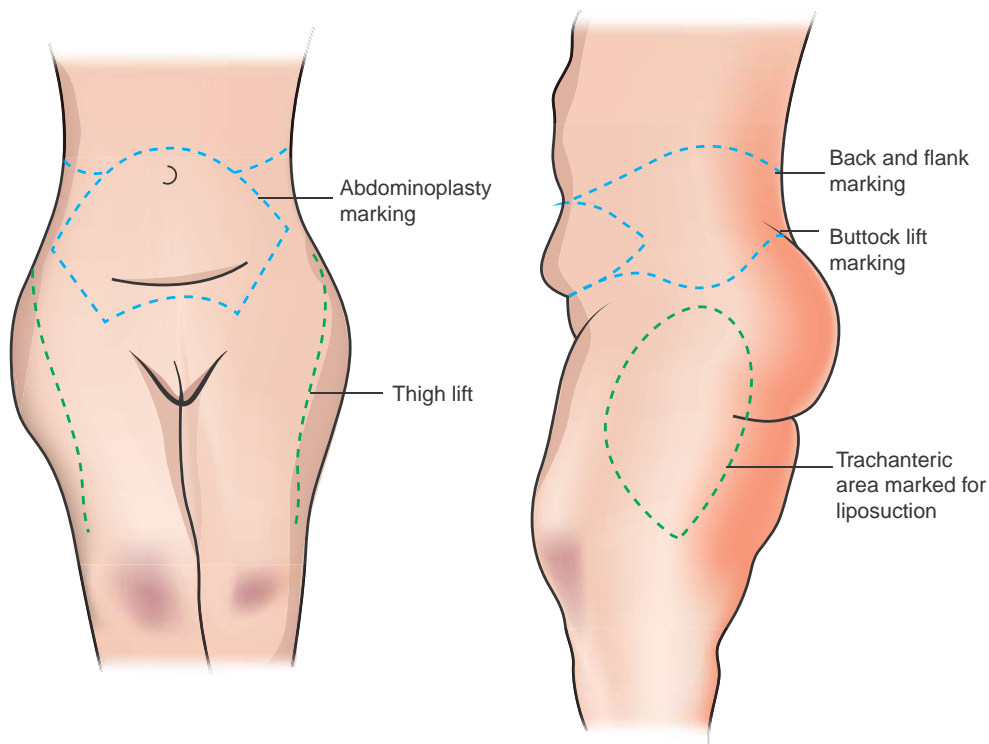
**Table 19.5.** Comparison between the two categories of a circumferential lipectomy: belt lipectomy and lower body lift.

Characteristic	Belt lipectomy	Lower body lift
Scar position	Intersection between lower back and buttocks	Buttocks proper
Waist definition	Enhances waist definition	Blunts waist definition
Preference	Women	Men
Drawbacks	<ul style="list-style-type: none"> <li>– Scar may be visible</li> <li>– Limited thigh lift distally</li> <li>– Post-operative pain</li> </ul>	<ul style="list-style-type: none"> <li>– Less effective in generating waist reduction</li> <li>– Less enhancement of buttocks shape due to scar position</li> <li>– Post-operative pain</li> </ul>

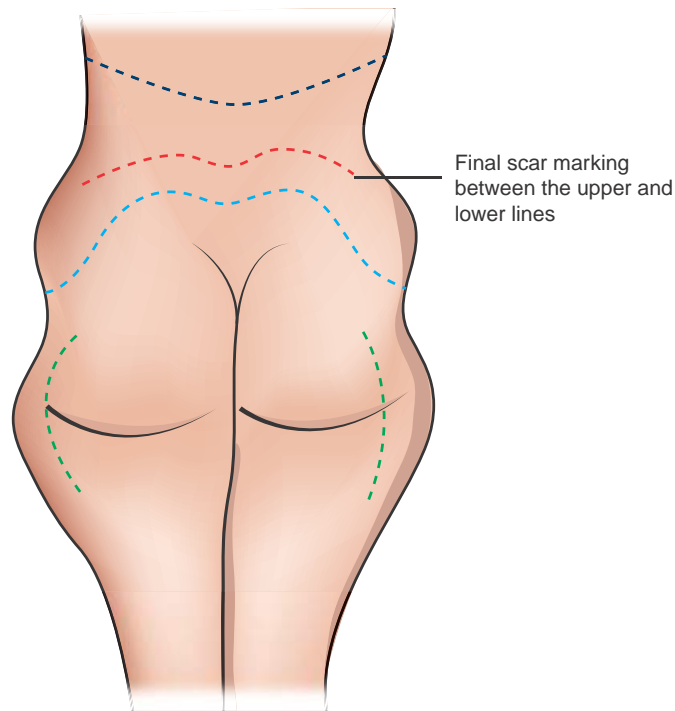
surgeon's preference. When abdominoplasty is commenced, the patient must adopt a supine position (Thorne, 2006). Pre-operative marking is performed with the patient standing upright.

Liposuction can be performed when needed before the circumferential excision is made. It decreases the amount of adipose tissue in areas planned for lipectomy, for example the lateral thigh region, abdomen or back. When no liposuction is required, the lateral thigh is the usual starting point; a cannula is used to undermine the trochanteric area and free the subcutaneous tissue for easier resection. With the patient in the prone position, the supragluteal tissue is resected and the flap is cut into two parts along the midline, which makes the area more accessible for resection. Later, the marked inferior and superior lines are incised, starting medially, and the subcutaneous tissue is resected. Finally, the gluteal flap is dragged upward over the underlying fascia (thoracolumbalis), muscle (external oblique) and aponeurosis (latissimus dorsi) in order to mark the suture plane, which reaches the lateral thigh (Figures 1.8 and 1.9) (Shiffman and Di Guiseppe, 2010).

Closure of the wound in the back starts in the midline, the middle part of the inferior flap and the aponeurosis of the fascia thoracolumbalis. Sutures are then placed on either sides of the midline, with less tension in these areas to promote formation of a good scar quality (Shiffman and Di Guiseppe, 2010). A tube is placed in the back for drainage purposes. Subcutaneous tissue is then closed, followed by subdermal layer closure.



**Figure 19.8.** Circumferential body lift markings.



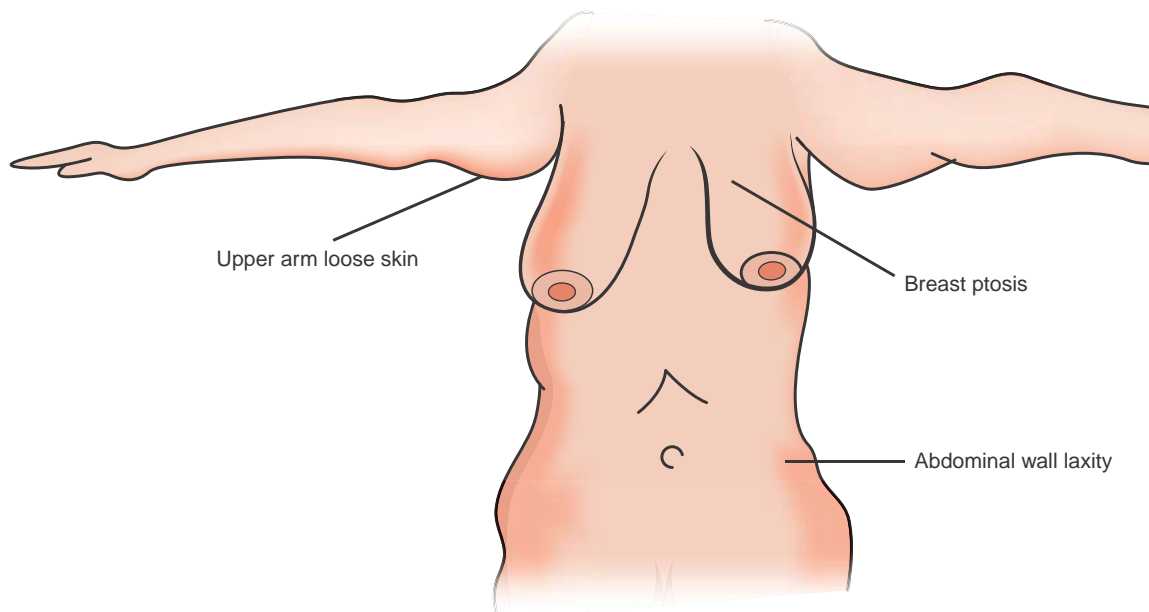
**Figure 19.9.** Circumferential body lift markings in the posterior view, illustrating an estimation of the final scar's position above the gluteal crease.

For abdominoplasty, the patient must be turned and placed into the supine position. The procedure is performed in a similar way to abdominoplasty (Section 8).

Complications associated with circumferential body contouring procedures include seroma, wound dehiscence (wound separation at the level of superficial fascia), infection, and scar widening and asymmetry (Shiffman and Di Guiseppe, 2010). Umbilical necrosis is also a potential complication that should be discussed with patients pre-operatively. Seroma formation can be prevented or reduced by placing drainage tubes in the back (Shiffman and Di Guiseppe, 2010). This is the most common cause of infection in patients undergoing lower truncal operations and presents in the form of cellulitis (uncommon), fever, fluid collection at operative sites and malaise (Thorne, 2006).

## 10. THE UPPER ARM

Aesthetic problems in the upper arm include loose-hanging skin, loss of arm definition and contour deformities. Post-bariatric surgery patients may seek upper arm plastic surgery to eradicate the lax skin resulting from excessive weight loss; they may also present with lower arm flaccid skin that requires



**Figure 19.10.** Massive weight loss patients usually present with excessive loose skin in the upper arm as well as other areas: the abdomen, thigh and back. Note the sagging breast appearance and asymmetry as a result of weight loss.

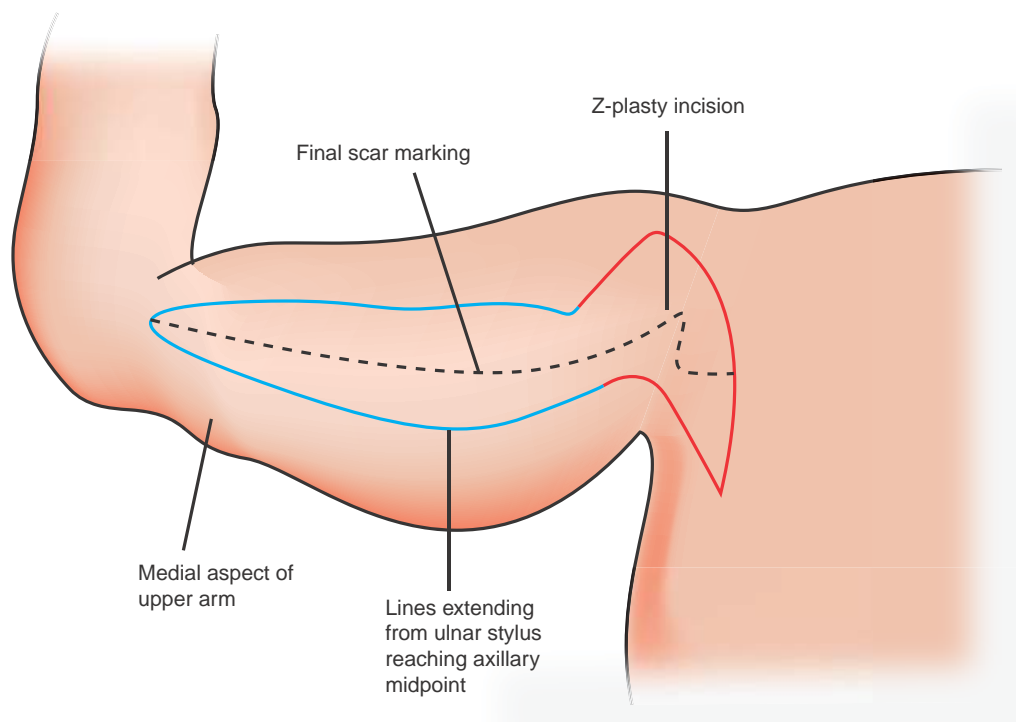
resection (Figure 19.10). Others desire an enhancement in the arm contour owing to changes in arm shape and definition resulting from weight fluctuations over time.

Brachioplasty, commonly known as an arm lift, is a procedure by which excess sagging skin is surgically resected from the arm. Liposuction can be performed to rid the arm of excess fat, leaving behind more loose skin for resection while preserving subcutaneous tissue, which accommodates nerves along with blood and lymphatic vessels that should not be disturbed (Scharnagl *et al.*, 2013a).

## 10.1. Arm lift technique

Brachioplasty is marked pre-operatively by two lines in the medial aspect with the arm stretched out, starting from the ulnar styloid and continuing on to the medial epicondyle to reach the axillary midpoint. Tissue between the two lines will be excised and the final scar can be marked between them. Liposuction may be performed to reduce the adipose tissue concentration, starting with the infusion of tumescent solution, followed by suction of excess adipose tissue. However, liposuction in the arm is challenging because irregularities in contour as well as asymmetry may result (Hoyos and Perez, 2012), necessitating proper planning and careful suction. The complication rate is also higher when liposuction is performed concomitantly with brachioplasty (Gusenoff *et al.*, 2008).





**Figure 19.11.** Pre-operative upper arm skin markings. The dotted line is an estimation of the location of the final scar.

The skin is finally excised and the wound is closed. Closure of the axillary incision is achieved via Z-plasty. The Z-plasty technique prevents retraction and consequent hypertrophy of the scar. Suction drainage is placed and remains for a period of one week (Shermak, 2010) or until the draining fluid reaches a level of 25–30 ml (Figure 19.11) (Shiffman and Di Guiseppe, 2010).

It is important to consider the amount of skin removed because over-resection of the skin may lead to wound tension and subsequent undesirable consequences. Paraesthesia, motor disturbances, swelling and lymphoedema may occur, in addition to a risk of compartment syndrome (Scharnagl *et al.*, 2013a). Disturbance to the deep subcutaneous fat layer during the procedure may cause injury to blood vessels, nerves or lymphatic vessels, possibly resulting in skin necrosis, loss of sensation or seroma formation, respectively. It is also important to identify and protect vital veins in the arm, i.e. the basilic and cephalic veins, to prevent post-operative oedema due to venous drainage obstruction (Table 19.6) (Shiffman and Di Guiseppe, 2010).

A new upper arm contouring technique for enhancement of limb definition using liposculpture and autologous fat grafting has been described (Hoyos and Perez, 2012). Liposuction is used to decrease the fat quantity in some areas in order to enhance the shape of the arm. However, patients with exaggerated skin laxity are not good candidates for this procedure. In men, arm contouring targets the removal of superficial and/or deep fat in specific muscle areas to bring out the desired shape: biceps, triceps and

**Table 19.6.** Structures coursing the medial aspect of the arm which are vulnerable to injury under the surgical field.

System	Structure
Nervous system (cutaneous)	<ul style="list-style-type: none"> <li>– Intercostobrachial</li> <li>– Medial antebrachial</li> <li>– Medial brachial</li> </ul>
Lymphatic system	<ul style="list-style-type: none"> <li>– Lymphatic vessels coursing with corresponding venous system</li> <li>– Axillary lymph nodes</li> </ul>
Venous system	<ul style="list-style-type: none"> <li>– Basilic vein</li> <li>– Cephalic vein</li> </ul>

deltoid. In women, on the other hand, the triceps muscle is not targeted for enhancement because women usually desire less volume in this area. Women desire a slimmer appearance in the upper arm, while men prefer a more muscular look. Therefore, some women will not require fat grafting and the procedure will be limited to liposuction alone.

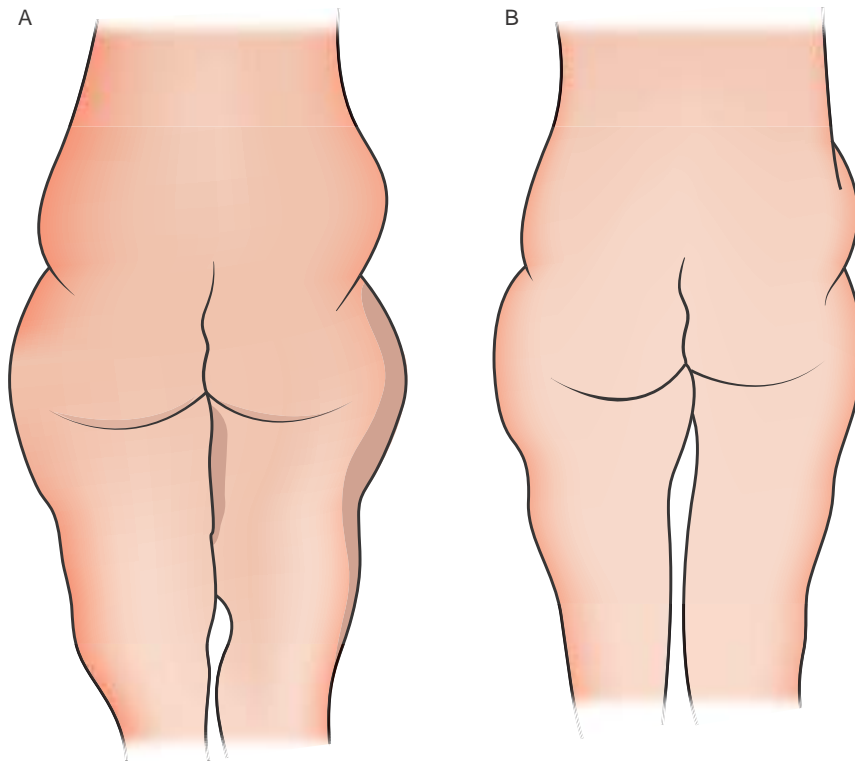
Fat grafting by a cannula is used to enhance the deltoid sulcus in both men and women after suctioning. Fat (50–100 ml) is injected intramuscularly through an incision in the posterior axillary fold (Hoyos and Perez, 2012), the same incision used for liposuction. The end result is improved muscular appearance and retracted skin without any skin excision.

## 11. THE THIGH

Medial or inner thigh ptosis can result from ageing or massive weight loss or may be hereditary. Its deformity represents a challenge to the plastic surgeon (Shiffman and Di Guiseppe, 2010) and absolute correction is difficult to achieve (Hurwitz *et al.*, 2004), especially in the post-bariatric population. Medial thigh laxity is corrected by a circumferential lipectomy procedure that also involves the lower trunk and back; it can alternatively be treated as a single unit via a thigh lift. Correcting thigh deformities includes both the medial and lateral aspects of the limb; however, medial thigh laxity is of more concern to patients.

### 11.1. Thigh lift technique

The choice of procedure depends on the patient's needs. Younger patients with better skin tone, for example, are suitable candidates for liposculpture alone (Toledo, 1999). This consists of liposuction of areas of excess adiposity and autologous fat injections into other sites to improve medial thigh definition. On the other hand, older patients as well as post-bariatric patients present with more flaccid skin, which requires dermolipectomy (Appendix 1).



**Figure 19.12.** Thigh lift. Appearance of the medial thigh, A. before and B. after the procedure.

Several thigh lift techniques can provide satisfying skin and subcutaneous tissue laxity correction. The DECLIVE thigh lift procedure was named by Italian surgeons: the Latin word means ‘a thing that moves downward’. It is a thigh lift that involves resection of a triangle from the perivulvar area to create a vertical scar and prevent its downward displacement (Spirito, 1998). Pre-operative marking in a thigh lift is done with the patient standing.

In the DECLIVE technique, the hips are flexed at 20–30° and the knees are placed a shoulder width apart (Shiffman and Di Guiseppe, 2010). The thighs are abducted for exposure according to the surgeon’s need throughout surgery. Liposuction of the medial thigh can be carried out prior to resection (Lockwood, 1988). The perivulvar triangle of skin is excised. An incision is made in the superior line anteriorly along the perineal crease, starting from the pubic tubercle and extending along the lateral edge of the pons pubis vertically (Shiffman and Di Guiseppe, 2010); it extends along the inner thigh with removal of excess skin and subcutaneous tissue (Figure 19.12) (Rieger *et al.*, 2013).

Colles fascia, i.e. the deep layer of the superficial perineal fascia, should be identified and attached to the thigh flap after completion of the resection. When pulled laterally, Colles fascia should not cause any vulvar alteration (Lockwood, 1988). The incision is closed and drain placement is not necessary. It is important to spare the soft tissue running between the femoral triangle and mons pubis to protect the external pudendal vessels and reduce the risk of lymphatic obstruction (Lockwood, 1988).

## 12. COMPLICATIONS

Early complications of thigh lifts include haematoma seroma, wound dehiscence, infection, pain and skin necrosis. Late complications are scar widening, recurrence of ptosis in the medial thigh, distortion in vulvar shape and unilateral residual adipose tissue (Lockwood, 1988).

## REFERENCES

- Achauer, B. M., Eriksson, E., Guyuron, B., Coleman III, J. J., Russell, R. C. & Vander Kolk, C. A. 2000. *Plastic Surgery Indication, Operations, and Outcomes*, St Louis: Mosby, 2631–71
- Conroy, P. H. & O'Rourke, J. 2013. Tumescence anaesthesia. *Surgeon*, 11, 210–21.
- Davila, P., Garcia-Doval, I. 2012. Tumescence anesthesia in dermatologic surgery. *Actas Dermo-Sifiliográficas (English Edition)*, Volume 104, 285–7.
- Dhami, L. D. & Agarwal, M. 2006. Safe total corporal contouring with large-volume liposuction for the obese patient. *Aesthetic Plastic Surgery*, 30, 574–88.
- Drake, R.L., Vogl, A.W., Mithchell, A.W.M. 2010. *Gray's anatomy for students*, Second Edition. Philadelphia: Churchill Livingstone. 30, 574–88.
- Finkelstein, E.A., et al. 2003. *National medical spending attributable to overweight and obesity: How much, and who's paying? Health affairs*. May 2003.
- Gusenoff, J. A., Coon, D. & Rubin, J. P. 2008. Brachioplasty and concomitant procedures after massive weight loss: A statistical analysis from a prospective registry. *Plastic and Reconstructive Surgery*, 122, 595–603.
- Hoyos, A. & Perez, M. 2012. Arm dynamic definition by liposculpture and fat grafting. *Aesthetic Surgery Journal*, 32, 974–87.
- Hurwitz, D. & Smith, D. 2012. Treatment of overweight patients by radiofrequency-assisted liposuction (RFAL) for aesthetic reshaping and skin tightening. *Aesthetic Plastic Surgery*, 36, 62–71.
- Hurwitz, D. J., Rubin, J. P., Risin, M., Sajjadian, A. & Sereika, S. 2004. Correcting the saddlebag deformity in the massive weight loss patient. *Plastic and Reconstructive Surgery*, 114, 1313–25.
- Lockwood, T. E. 1988. Fascial anchoring technique in medial thigh lifts. *Plastic and Reconstructive Surgery*, 82, 299–304.
- Michaud, A. P., Ronsenquist, R. W., Cram, A. E. & Aly, A. S. 2007. An evaluation of epidural analgesia following circumferential belt lipectomy. *Plastic and Reconstructive Surgery*, 120, 538–44.
- Persichetti, P., Simone, P. & Scuderi, N. 2005. Anchor-line abdominoplasty: A comprehensive approach to abdominal wall reconstruction and body contouring. *Plastic and Reconstructive Surgery*, 116, 289–94.
- Rieger, U. M., Djedovic, G., Bauer, T. & Pierer, G. 2013. Approach to the lower body after massive weight loss: The Innsbruck experience with abdomino-torso and thigh-contouring after massive weight loss. *European Surgery-Acta Chirurgica Austriaca*, 45, 66–74.
- Roustaei, N., Lari, S. J. M., Chalian, M., Chalian, H. & Bakhshandeh, H. 2009. Safety of ultrasound-assisted liposuction: A survey of 660 operations. *Aesthetic Plastic Surgery*, 33, 213–18.
- Scharnagl, E., Koch, H., Wiedner, M. & Spindel, S. 2013a. Approach to the upper body after massive weight loss. *European Surgery-Acta Chirurgica Austriaca*, 45, 57–65.

- Scharnagl, E., Wiedner, M. & Koch, H. 2013b. Examining and choosing patients for body contouring after massive weight loss. *European Surgery–Acta Chirurgica Austriaca*, 45, 50–6.
- Shermak, M.A. 2010. Brachioplasty following massive weight loss. *Bariatric Times*, 7(5), 16–18.
- Shiffman, M. A. & Di Guiseppe, A. 2010. *Body Contouring: Art, Science, and Clinical Practice*, Berlin: Springer.
- Shiffman, M. A. & Mirrafati, S. 2010. *Aesthetic Surgery of the Abdominal Wall*, Berlin: Springer.
- Spirito, D. 1998. Medial thigh lift and DE.C.L.I.V.E. *Aesthetic Plastic Surgery*, 22, 298–300.
- Sterodimas, A., Boriani, F., Magarakis, E., Nicaretta, B., Pereira, L. H. & Illouz, Y. G. 2012. Thirtyfour years of liposuction: Past, present and future. *European Review for Medical and Pharmacological Sciences*, 16, 393–406.
- Theodorou, S. J., Paresi, R. J. & Chia, C. T. 2012. Radiofrequency-assisted liposuction device for body contouring: 97 patients under local anesthesia. *Aesthetic Plastic Surgery*, 36, 767–79.
- Thorne, C. H. 2006. *Grabb and Smith's Plastic Surgery*, Philadelphia: Lippincott Williams & Wilkins.
- Toledo, L. S. 1999. *Refinements in Facial and Body Contouring*, Philadelphia: Lippincott Williams & Wilkins.
- Van Der Beek, E. S. J., Van Der Molen, A. M. & Van Ramshorst, B. 2011. Complications after body contouring surgery in post-bariatric patients: The importance of a stable weight close to normal. *Obesity Facts*, 4, 61–6.
- Vico, P. G., De Vooght, A. & Nokerman, B. 2010a. Circumferential body contouring in bariatric and non-bariatric patient. *Journal of Plastic, Reconstructive & Aesthetic Surgery*, 63, 814–19.
- Vico, P. G., De Vooght, A. & Nokerman, B. 2010b. Circumferential body contouring in bariatric and non-bariatric patient. *Journal of Plastic Reconstructive and Aesthetic Surgery*, 63, 814–19.

## APPENDIX 1 DEFINITIONS

*Autologous fat grafting*: the patient's own adipose tissue is aspirated from a body site where excess fat is not desired and subsequently injected into another area of the body or face.

*Bariatric surgery*: Also called 'weight loss surgery', comprises a number of surgical procedures that aid obese patients in losing weight. Examples of bariatric surgery are gastric by-pass surgery, gastric banding and sleeve gastrectomy.

*Sedentary lifestyle*: a way of living that involves very limited physical activity, in which calorie burning is reduced as a result of a low metabolic rate. A sedentary lifestyle has health consequences and contributes to obesity, particularly when calorie consumption is greater than calorie burning.

Zones of the abdominal wall in relation to blood supply: zone I, zone II and zone III.

*Lipectomy*: the surgical excision of adipose tissue.

*Dermolipectomy*: a combination of skin and subcutaneous tissue excision.

## APPENDIX 2

**Table 19.7.** Blood supply (skin overlying the rectus abdominis muscle).

Primary	Secondary
Arteries originating from:	Arteries derived from:
– Superior epigastric vessels	– IC* vessels
– Inferior epigastric vessels	– SC* vessels
	– Lumbar vessels

IC = intercostal; SC = subcostal.

**Table 19.8.** Body mass index.

BMI	Weight
< 18	Underweight
18–24.9	Normal weight
25–29.9	Overweight
≥ 30	Obese

BMI is calculated as body weight (kg) ÷ height (cm<sup>2</sup>). BMI = body mass index.

# The Evolution of Hair Transplant Surgery

---

Farhana Akter, Greg Williams

## 1. INTRODUCTION

---

Human hair performs a number of functions in the body including insulation, regulation of body temperature and protection from external factors. It also has an important aesthetic function; consequently, hair loss can cause immense psychological stress. Patients suffering from hair loss are more likely to suffer anxiety, social phobia and depression compared with the general population (Koo *et al.*, 1994), and the effect of unwanted hair loss is said to be comparable to bereavement (Egele and Tauschke, 1987). It is therefore understandable that hair restoration therapy is a major field in scientific research and aesthetic surgery.

In this chapter, we will discuss the biology of human hair and the surgical management of hair loss.

## 2. THE BIOLOGY OF HUMAN HAIR

---

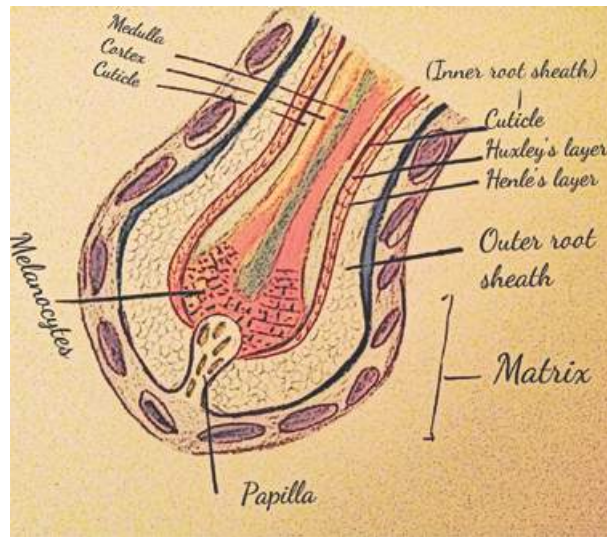
Hair is a biomaterial consisting of keratin. It is found abundantly over the biggest organ in the body, namely the skin. The hair transplant surgeon must know the anatomy of the hair follicle and understand the hair growth cycle to help plan and perform the procedure.

### 2.1. Anatomy of the hair follicle

---

Anatomically, hair is broadly divided into an upper, middle and lower segment. The upper segment contains the infundibulum and isthmus, the middle segment contains the bulge which stores stem cells and the inferior segment contains the bulb (Figure 20.1) (Schneider *et al.*, 2009).

The hair follicle is a part of the epidermis that extends down into the dermis. The hair follicular unit (FU) is the grouping of terminal hairs, which can be seen under a microscope and contains approximately one to four hairs (Bernstein *et al.*, 1998).



**Figure 20.1.** The human hair follicle: structure of the shaft.

The infundibulum is the superficial part of the follicle. The isthmus is the part between the sebaceous gland duct opening and the bulge. The bulb is the deepest portion of the follicle and houses the stem cells that form matrix cells. The matrix cells keratinise to form the hair cortex and divide to form the remaining hair layers (Kahle *et al.*, 1993). The bulb also surrounds the dermal papilla, a structure which is responsible for the embryonic generation of a hair follicle and, in the fully formed follicle, contains capillaries, nerves and melanocytes (Blume-Peytavi *et al.*, 2008).

The follicle is surrounded by many layers. From innermost to outermost are the layers of the hair shaft which can be seen above the skin: the medulla, cortex and outer cuticle. In the dermis, this is further enveloped by the inner root sheath, outer root sheath and connective tissue sheath (Figure 20.1).

### 2.1.1. Medulla

The medulla is in the centre of the shaft. It is sometimes absent in hair; when present (usually in coarse hair), it is often discontinuous along the length of hair (Krstic, 1991).

### 2.1.2. Cortex

The cortex represents 90% of the total weight of the shaft. It is made of spindle-shaped cortical cells filled with keratin. Young cortical cells contain melanin granules which determine the hair colour. These cells become elongated as they progress from the matrix. They are held within intercellular cement composed of keratin and lipids (Krstic, 1991; Kahle *et al.*, 1993).



### 2.1.3. Cuticle

The cuticle is the outermost layer of the shaft and is made of keratin. It protects the inside of the hair shaft from damage. The cells forming the cuticle are also held within intercellular cement which is rich in lipids. The cells overlap one another and are said to resemble the slates on a roof (Krstic, 1991).

### 2.1.4. Inner root sheath

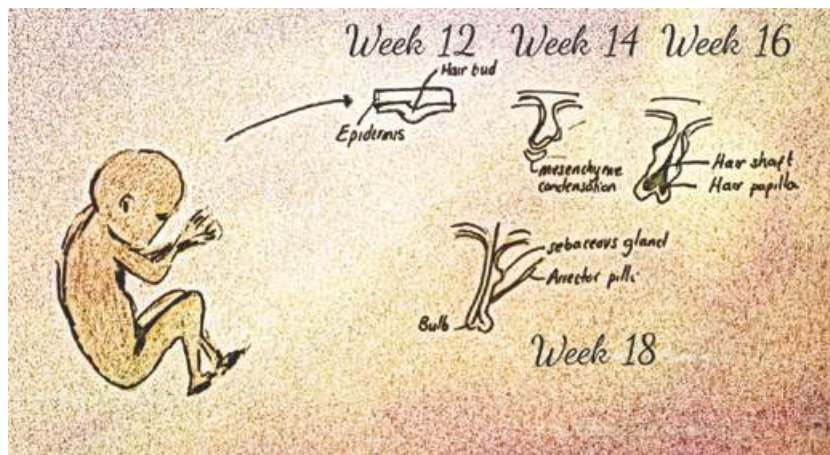
The inner root sheath extends from the isthmus to the base of the bulb. It consists of three layers: an inner cuticle, the Huxley layer and the outer Henle layer. The cells in these layers are identifiable by the presence of a structural protein called trichohyalin, which is a marker for hair follicular differentiation (Kahle *et al.*, 1993).

### 2.1.5. Outer root sheath

The outer root sheath is found at the periphery and continues within the epidermis. It contains Golgi complexes, mitochondria and glycogen. A ‘bulge’ can be seen on the outer sheath where the erector pili muscle inserts. This bulge sits below the sebaceous gland and causes the gland to secrete sebum when it contracts (Kahle *et al.*, 1993)

## 2.2. Embryology of the hair

Each hair on the body grows from a hair follicle. The induction and formation of an embryonic hair follicle is regulated by mesenchymal–epithelial interactions between dermal cells and epidermal stem cells. The primary hair germ begins as an epithelial bud. This bud projects down into the dermis to form the base of the follicle at week 12 (Figure 20.2). At week 14, the base of this follicle expands to form



**Figure 20.2.** Embryology of hair.

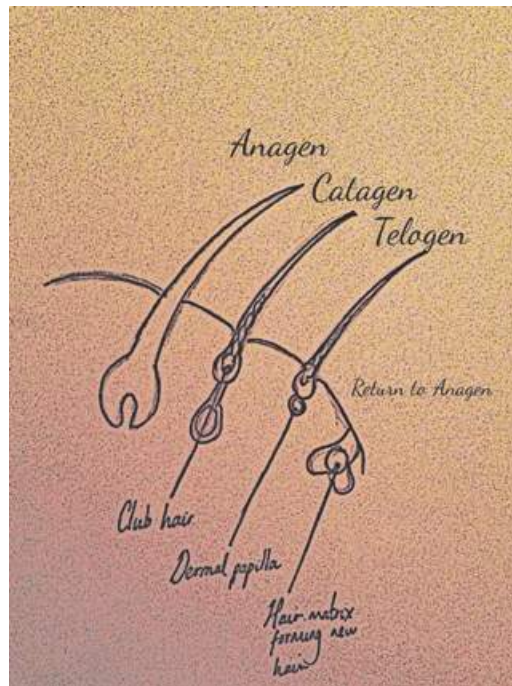
the hair bulb and is invaginated by mesoderm called the dermal papilla. By the 16th week of intrauterine life, the primary hair germ has grown deeper into the dermis and differentiates into many components of the primary hair follicle. By the 18th week of intrauterine life, the hair emerges through the skin surface and by week 22 all of the hair follicles are formed. At this stage of life, there are approximately 5 million hair follicles on the body and 100,000 on the head (Dudek, 2010).

## 2.3. Hair life cycle

The lower portions of the hair follicles are involved in a lifelong growth cycle; the isthmus and infundibulum, however, remain stable. The cycle is characterised by periods of growth (anagen), periods of transformation (catagen) and rest periods (telogen) (Figure 20.3). These three separate periods of hair growth are not synchronous and occur independently of one another, which is important to avoid periods of extreme hair growth or loss (Price, 1999).

### 2.3.1. Anagen

During the anagen phase, the matrix of the hair follicle undergoes increased mitotic activity. Most scalp hair follicles are in the anagen phase for 90% of the hair life cycle; this phase lasts for 2–7 years. The rate of scalp hair growth is approximately 0.3 mm per day (Price, 1999).



**Figure 20.3.** The human hair growth cycle.

### 2.3.2. Catagen

Approximately 1% of scalp hair is in this phase, which lasts for 2–3 weeks. The mitotic activity of the hair follicle decreases during this period and hair production diminishes. The deepest part of the hair follicle migrates up toward the isthmus (Price, 1999).

### 2.3.3. Telogen

Up to 10% of scalp follicles are in this phase, which lasts 2–3 months. It is characterised by the presence of club hair, i.e. fully keratinised hair that is ready for shedding from the hair follicle. Up to 100 telogen hairs are shed per day (Paus and Cotsarelis, 1999).

## 3. CLASSIFICATION OF HAIR LOSS DISORDERS

Hair loss disorders comprise a large group of conditions with different pathological findings and aetiologies. Hair loss can be classified into three broad groups: cicatricial (scarring) alopecia, non-scarring alopecia and structural hair disorders. Cicatricial alopecias cause irreversible cessation of the hair growth cycle, whereas non-scarring alopecia may be reversible. Well-known subtypes of the latter include alopecia areata, an autoimmune condition that results in focal hair loss and androgenetic alopecia, which results in patterned hair loss. Structural hair disorders can be congenital or acquired and usually affect the hair shaft, leading to shaft fragility (Price, 1999). A detailed discussion regarding the subtypes of hair loss disorders is beyond the scope of this chapter. A table of subtypes of the three broad types is presented in [Table 20.1](#).

**Table 20.1.** Classification of hair disorders.

Hair disorder	Subtypes	Examples
Cicatricial (scarring) alopecia	Lymphocytic primary cicatricial alopecias	Alopecia mucinosa Central centrifugal cicatricial alopecia Discoid lupus erythematosus Keratitis follicularis spinulosa decalvans Lichen planopilaris Pseudopelade of Brocq
	Neutrophilic primary cicatricial alopecias	Dissecting cellulitis of the scalp Folliculitis decalvans
	Mixed primary cicatricial alopecia	Acne keloidalis nuchae Acne necrotica Erosive pustular dermatosis of the scalp

Table 20.1. (cont.)

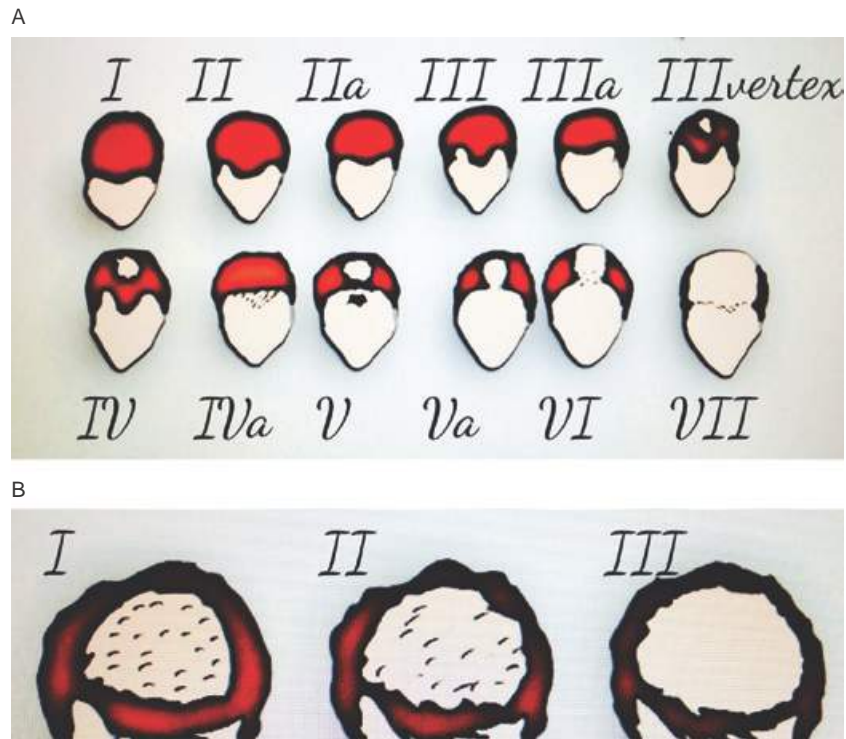
Hair disorder	Subtypes	Examples
Non-scarring alopecia	Focal hair loss	Alopecia areata Alopecia syphilitica Pressure-induced (post-operative) alopecia Temporal triangular alopecia Traction alopecia
	Patterned hair loss	Trichotillomania Androgenetic alopecia in men (male pattern hair loss) Female pattern hair loss
	Diffuse hair loss	Anagen effluvium Loose anagen syndrome Telogen effluvium
Structural	Inherited	Menkes disease, pili torti Monolithrex Trichothiodystrophy Trichorrhexis invaginata (bamboo hair)
	Acquired	Trichorrhexis nodosa Trichoptilosis Bubble hair

## 4. INDICATIONS FOR HAIR TRANSPLANTATION

### 4.1. Androgenetic alopecia

Androgenetic alopecia is the most common indication for hair transplantation. The condition involves thinning of the scalp hair and affects men and some women. The anagen phase of the hair cycle is shortened and there is an increased number of hairs in the telogen phase. It is thought to be triggered by both genetic and environmental factors. Hair follicles become smaller and depigmented and, at the cellular level, there is a reduction in the dermal papilla volume. This is thought to arise from the action of the dihydrotestosterone (DHT) hormone which is produced from testosterone by the enzyme 5 alpha-reductase. DHT has been shown to inhibit insulin-like growth factor 1 (IGF-1), which is involved in normal hair growth. The actions of IGF-1 are modulated by IGF-binding proteins produced in the dermal papillae (Demark-Wahnerfried *et al.*, 1997; Weger and Schlake, 2005).

Men usually present with hairline recession at the temples and balding at the vertex; women usually have thin hair diffusely over the midscalp and frontal areas. The Norwood–Hamilton and Ludwig classifications are used to classify the different phases in men and women, respectively (Figure 20.4). Hair transplantation for women has become increasingly popular. Common indications for women include



**Figure 20.4.** A. The Norwood–Hamilton classification of male pattern baldness. B. The Ludwig classification of female pattern baldness.

hair restoration for female pattern baldness and hairline lowering. A thorough assessment of both men and women must be made by primary care physicians and dermatologists to rule out medical conditions which predispose to hair loss.

## 4.2. Cicatricial alopecia

Cicatricial alopecia is another common indication for hair transplantation. It is classified into primary and secondary types. In the primary disease, there is destruction of the follicular epithelium, which can be seen in connective tissue diseases such as systemic lupus erythematosus. The cause of the destruction is unknown and patients suffering from hair loss only benefit from transplantation once their condition has been stable for a number of years. They should be informed that should their disease recur the transplanted hair will most likely be lost.

Secondary cicatricial alopecia is a disease in which there is indirect follicular destruction, e.g. from traumatic burns and surgery. These patients are good candidates for surgery (Pathomvanich and Imagawa, 2010).

## 5. HAIR TRANSPLANTATION

---

Modern hair transplantation in humans was first described in the Western medical literature by Norman Orentreich in 1959. He described a punch technique for obtaining hair grafts, with punch sizes of 4 mm containing 16–20 hairs each. These hairs were transplanted into various sites at least 1 mm apart. The end result of this technique, although successful in restoring hair growth, often left patients with large scars and ‘plugs’ of hair did not look natural (Orentreich, 1959). In the 1980s, a further breakthrough came with the advent of micrograft surgery. This technique involves extraction of thin strips of donor hair of size 1–2 mm containing 3–12 hairs, followed by further excision of one to four hair FUs. This technique for extracting hair donor strips became known as follicular unit transplantation (FUT). One of the major disadvantages of this technique, however, is the resultant linear donor scar left in patients. This problem has been more recently addressed with the use of trichophytic closures (Marzola, 2005). An alternative technique for obtaining donor hairs is the follicular unit extraction (FUE) method in which individual hair follicles are removed using a punch with a diameter as small as 0.6 mm (average 0.9–1 mm). This technique results in small round scars that allow patients to wear their hair short; however, there are several disadvantages, including a higher rate of transection to grafts, increased cost and longer duration of procedure.

A typical hair transplant session involves the insertion of 1500–2000 grafts and can last up to 7 hours (Dua and Dua, 2010). The procedure comprises numerous crucial stages, and it is useful to consider hair transplantation in three broad steps.

1. Pre-operative – patient assessment
2. Intra-operative
  - a. Anaesthesia
  - b. Harvesting donor FUs via strip excision or FUE
  - c. Creation of recipient incisions
  - d. Implantation of follicular grafts
3. Post-operative care and complications.

### 5.1. Pre-operative patient assessment

---

Both FUE and FUT have several indications and contraindications; thus, careful patient selection is vital.

It is important to check whether a patient is suitable for hair transplantation. FUE is certainly more useful in patients who have very short hair because the alternative procedure (using a donor strip) would lead to a prominent linear scar. For the same reason, patients who are more prone to developing hypertrophic scarring or keloid formation will also benefit from FUE. However, FUE is a long procedure and may require several sessions; therefore, FUE may also not be possible for very large areas.

An accurate assessment of donor density (i.e. the number of FU/mm<sup>2</sup>) is also important for planning. A donor density of at least 1 hair/mm<sup>2</sup> is required to ensure the donor area is adequately covered and will not appear too thin post procedure. This requirement is slightly less in patients with thicker, wavy hair (Bernstein *et al.*, 2004).

It is recommended that to increase the chance of a successful procedure the patient is evaluated correctly prior to the operation. A procedure called the FUE test or FOX test (FOLlicular case of eXtraction) can be carried out to check if a patient is suitable for direct follicular extraction and whether follicular extraction is likely to be successful. This involves the removal of approximately 100 grafts from the donor unit and evaluating the ratio of complete to incomplete FUs. The FOX test is used to grade the difficulty of FUE graft harvesting (Bernstein *et al.*, 2004).

---

## 5.2. Intra-operative techniques

---

### 5.2.1. Anaesthesia

Adequate anaesthesia is vital for hair transplantation, particularly as it can be a very lengthy procedure. The procedure can be performed under local anaesthesia with or without additional oral sedation. A typical regime may involve application of a combination of lignocaine and dilute adrenaline to the donor and recipient sites. This can be supplemented with additional anaesthesia prior to discharge from the operating theatre (Vogel *et al.*, 2013).

---

### 5.2.2. Harvesting of the donor site

Hair FUs can be obtained from the donor site using strip excision or FUE.

---

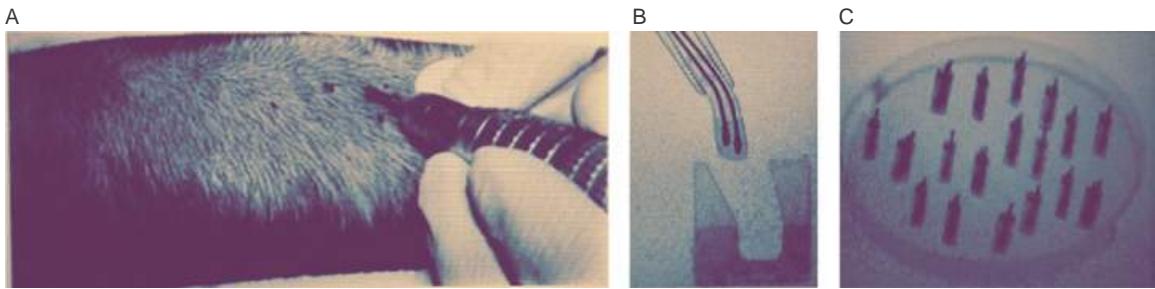
#### 5.2.2.1. Follicular unit extraction

---

FUE is a method of obtaining FUs for hair transplantation. The procedure begins with the use of small micro punches to extract the FU. Two different techniques can be used to extract the follicle (see below). The follicle is carefully removed with forceps and placed in a Petri dish (Figure 20.5).

Extraction may be done using two-step procedure (Dua and Dua, 2010):

- Step 1 – a sharp punch over the desired FU is followed by a rotational motion to penetrate the skin and isolate the FUs; and
- Step 2 – fine forceps are used to apply traction to the top of the FU and extract the FU from its deep dermal connections. A needle may need to be applied to help separate the FU.



**Figure 20.5.** A. Punch tool inserted. B. Hair removed with forceps. C. Hairs placed in Petri dishes and kept hydrated.

Extraction may also be performed using a three-step technique (Dua and Dua, 2010):

Step 1 – a sharp punch is applied to the desired FU involving the epidermis;

Step 2 – a dull punch applied via a twisting motion of the hand is then used to dissect the FU from the epidermis and dermis; and

Step 3 – the FU is removed from its remaining connections using fine forceps.

This technique is said to be superior to the two-step technique because the use of a dull punch reduces transection rates and allows easier extraction. Insertion of the blunt punch instrument into the dermis brings the follicles together upon opening the instrument. However, the additional step of inserting the blunt punch can bury grafts and thus reduce yield. Buried grafts can also lead to cyst formation, and a further incision may be needed to enlarge the opening and remove the graft. The third step of the procedure can lead to a problem called ‘capping’, in which the epidermis and dermis separate from other parts of the follicle during extraction of the FU. In this situation, the follicle remains behind; however, it is still capable of producing new hair (Ekrem *et al.*, 2009).

Following extraction, small puncture wounds will be left in the scalp. These will close by secondary intention.

#### 5.2.2.2. Strip procedure

Strip harvesting is a method of obtaining hair FUs for FUT in which a linear strip of hair is removed (Figure 20.6) from the patient’s donor site and subsequently dissected into FUs.

The donor hair site will be trimmed to a length of approximately 4–5 mm. This site is usually the posterior scalp in an area of good hair growth. The area to be excised can be marked with a pen and local anaesthesia is then applied. Incision is made with a scalpel blade parallel to the line of hair follicles at an angle and at a depth of approximately 5 mm to reach the deep subcutaneous tissue. The donor strip is dissected (Figure 20.6) and the wound is closed using monofilament sutures, absorbable sutures or staples. The wound can also be closed using the trichophytic closure, which leads to better cosmesis by enabling hair to grow through the scar (Figure 20.7) (Yamamoto, 2012). The individual FU grafts can



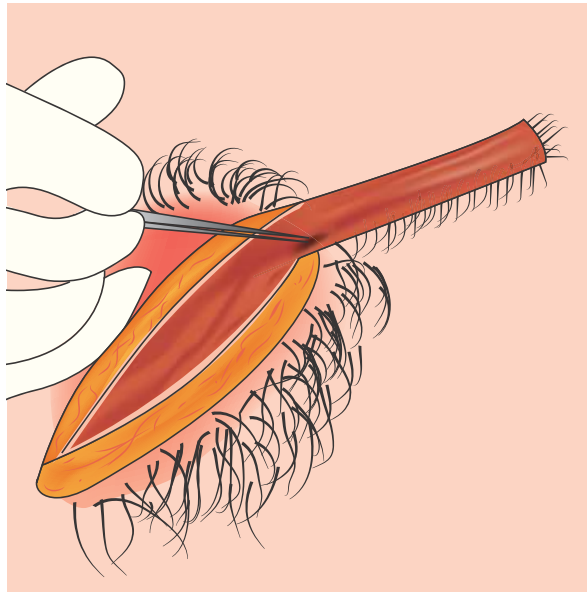


Figure 20.6. Dissection of the donor strip.

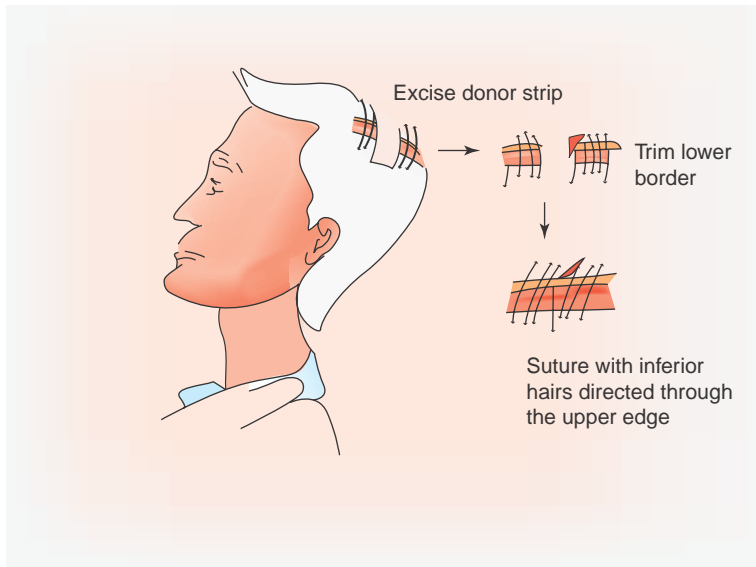


Figure 20.7. The trichophytic method of wound closure.

then be dissected. This process involves dividing the donor strip into slivers containing one or two rows of FUs, followed by further dissection to separate the FUs and remove excess fibrous and fatty tissue. Following strip excision, the donor tissue must be placed in a holding solution such as isotonic saline to stay moist and avoid desiccation before implantation (Jiménez-Acosta and Ponce, 2009).

### 5.2.3. Recipient site preparation

---

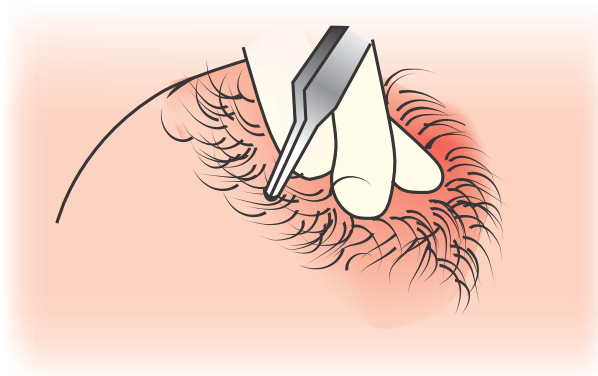
Once the donor site is adequately closed, the recipient site needs to be prepared. For a man with androgenetic alopecia, the frontal anterior hairline on the scalp is marked. This new hairline will be permanent so it is important to educate patients that the hairline may recede over time; therefore, patients who request a very low hairline may find this to look abnormal as they mature and continue to lose hair. The apex of the frontotemporal recession should have a gentle curve and should be convex in male patients (Vogel *et al.*, 2013).

The recipient area is anaesthetised using a local anaesthetic. Hypodermic needles or chisel-shaped scalpel blades can be used to incise the skin. The size of the incision is important because too large an incision will lead to the graft falling out and if too small the procedure will be more difficult. It is recommended that for 2–3 hair FUs, an incision size of approximately 1 mm diameter should be used. Incisions are made to a depth of 4–6 mm, closely following the direction of natural hair growth on the scalp. When creating the angle of the recipient site, the angles of non-transplanted existing hair growth can be used for guidance (Jiménez-Acosta and Ponce, 2009). The frontal incisions will accommodate smaller FUs, with the larger FUs placed behind these. This provides a gentle transition from the hairless skin of the forehead to the scalp and gives an appearance of more coverage. The aim should be to implant 20–40 FU/cm<sup>2</sup> of recipient area in order to achieve the right density of hair in the transplanted area (Jiménez-Acosta and Ponce, 2009), although higher densities may be achieved with single hair grafts at the hair line.

### 5.2.4 Graft implantation

---

Graft implantation can be a very laborious task and needs to be performed with considerable skill. The grafts must be grasped in a gentle manner with fine-tipped forceps (Figure 20.8) and positioned in such a way as to maintain the natural shape of the hair graft. If the grafts are not handled correctly, the follicular bulb can be damaged. The graft should also not remain too long outside the body before implantation. The non-survival rate of a graft outside the body can reduce from 9% after 2 hours to 54% after 48 hours; therefore, transplantation should be done within 6 hours (Limmer, 1996). The grafts can be placed individually at the same time as the recipient sites are created, which helps to improve the survival rate of grafts; alternatively, they can be positioned after all recipient sites have been created. In addition, grafts can also be inserted using implanters. When the graft is loaded, the implanter is inserted into the skin and the grafts inserted using a plunger prior to removal of the implanter from the skin.



**Figure 20.8.** Insertion of grafts with forceps.

### 5.3. Post-operative management and complications

Immediate post-operative management should include instructions such as elevating the head, applying ice to the recipient and donor sites, and analgesia. Patients can begin gentle hair washing with shampoo from day 1 or 2. The donor sutures or staples can be removed from day 10 onward. Patients should have been counselled pre-operatively about expected results; however, this should be reiterated and they should be reminded that full growth of the transplant may take up to 1 year following the procedure (Jiménez-Acosta and Ponce, 2009).

On the whole, hair transplantation is a safe procedure and serious clinical complications are not common. Post-operative complications include bleeding, infection of the wound and oedema in the forehead, which is temporary. Cysts may also develop but are easily treated with oral antibiotics and warm compresses (Vogel *et al.*, 2013). Pain around the donor site can be expected and some patients also experience headaches. Neurosensory changes such as hypoaesthesia are usually temporary (Jiménez-Acosta and Ponce, 2009). Aesthetic complaints post-operatively can include an unnatural appearance which can become worse as the hair recedes. Patients may also experience post-surgical effluvium, which is shedding of the non-transplanted hair. It is usually temporary, but its incidence can be reduced by minimising the number of recipient sites and using medical treatments such as minoxidil and finasteride during the post-operative period (Vogel *et al.*, 2013). Scarring is, of course, expected for the donor strip method, although the use of trichophytic closures has improved the appearance of the scars. Other rare complications include arteriovenous fistulas and frontal necrosis, which the patient should be informed of during the consent procedure (Jiménez-Acosta and Ponce, 2009).

## 6. ADVANCES IN HAIR RESTORATION SURGERY: WHERE ARE WE NOW?

---

### 6.1. Follicular unit extraction

---

This technique involves the use of a punch instrument to cut into the dermis just below the arrector pili muscle, followed by extraction of the graft. It requires a dermal depth analysis to judge the depth of the arrector pili muscle which varies among patients. The incision should be shallow enough to avoid transection of the hair follicles but deep enough so that the intact graft is extracted easily. The advantages of this technique include a low rate of follicle injury; however, it may take longer to perform (Dua and Dua, 2010).

### 6.2. Robotics in hair transplantation

---

The use of robotics to aid FUE hair transplantation was introduced in 2011 as a mean of reducing the length of the procedure. The current robot available in the market is the ARTAS® robot, which uses cameras to continuously scan video images of the donor area and collects information about the angle, density and orientation of the FU. Once this information is obtained, a robotic arm can deliver punches to perform FU dissection. One advantage is that the quality of the grafts is not confounded by fatigue of the physician: the graft implantation procedure remains the same throughout. The use of robots is more expensive than the traditional method and, as hair transplantation with other forms of FUE or strip surgery is already an expensive procedure, may not be as attractive to patients (Rose and Nusbaum, 2014).

### 6.3. Automated FUE hair transplantation

---

Automated machines are manually operated drills. They use sharp or dull punch dissection to assist with FUE transplantation and may give faster extraction rates (Dua and Dua, 2010). There are a number of devices available on the market, including some that utilise suction to simultaneously extract the grafts.

### 6.4. Stem cell therapy and cloning

---

Research around cloning hair follicles has largely been disappointing because the effective number of viable hairs following transplantation has been poor. However, one group recently reported a study with

data to support the idea that hair cloning may become possible. Dermal papillae from seven human donors were harvested and the cells were cloned in tissue culture. The cells were then transplanted into the layer between the dermis and epidermis of human skin and grafted onto seven mice. Five of these mice had new hair growth which lasted at least 6 weeks post-implantation and was shown to be human in origin via DNA analysis. However, some hairs grew with abnormalities such as an absence of pigmentation. Studies are, of course, ongoing and need to be continued for longer periods to ensure that reprogrammed cells continue to reproduce hair even after it naturally falls out (Higgins *et al.*, 2013).

## 7. CONCLUSION

Although there are many medical therapies for different forms of hair loss, the results are often temporary; for these patients, hair transplantation can offer significant relief. Hair transplant surgery has evolved into a highly skilled subspecialty of cosmetic surgery. It has the potential to transform the lives of people with hair loss, who can suffer immense psychological and social problems.

FUT is performed by excising a donor strip of hair followed by careful dissection of the FUs. This procedure, however, leaves patients with a linear scar which is not acceptable to those who wish to keep short hair. FUE involves the use of an instrument to ‘punch’ the desired area for removing FUs. This technique avoids a scar; however, it requires more precision and takes much longer. Advances in hair transplantation include the use of automated and robotic devices for FUE. The future of hair transplantation includes developing techniques for minimal access surgery, cell-based therapies and the possibility of hair cloning.

## REFERENCES

- Bernstein RM, Rassman WR, Seager D, Shapiro R. (1998). Standardizing the classification and description of follicular unit transplantation and mini-micrografting techniques. *Dermatologic Surgery*. 24. p. 957–63.
- Bernstein RM, Rassman WR, Anderson KW. (2004). Follicular unit extraction mega sessions: Evolution of a technique. *Hair Transplant Forum International*. 14. p. 97–9.
- Blume-Peytavi U, Whiting DA, Trueb RM. (2008). *Hair Growth and Disorders*. Berlin: Springer.
- Demark-Wahnefried W, Lesko SM, Conaway MR, Robertson CN, Clark RV, Lobaugh B, Mathias BJ, Strigo TS, Paulson DF. (1997). Serum androgens: Associations with prostate cancer risk and hair patterning. *Journal of Andrology*. 18 (5). p. 495–500.
- Dua A, Dua K. (2010). Follicular unit extraction hair transplant. *Journal of Cutaneous Aesthetic Surgery*. 3(2): 76–81.
- Dudek, RW. (2010). *Embryology*. 4th ed. Philadelphia: Lippincott Williams and Wilkins.
- Egele UT, Tauschke ED. (1987). Alopezie: ein psychosomatisches Krankheitsbild. *Psychosomatic Medical Psychotherapy*. 37. p. 315.
- Ekreem C, Aksoy M, Koc E, Aksoy B. (2009). Evaluation of three instruments used in FUE. *Hair Transplant Forum International*. 19. p. 14–5.
- Higgins CA, Chen JC, Cerise JE, Jahoda CAB, Christiano A. (2013). Microenvironmental reprogramming by three-dimensional culture enables dermal papilla cells to induce de novo human hair-follicle growth. *Proceedings of the National Academy Sciences*. 110 (49). p. 19679–88.

- Jiménez-Acosta F, Ponce I. (2009). Hair transplantation in triangular temporal alopecia. *Actas Dermosifiliogr.* 100. p. 913–15.
- Kahle W, Leonhardt H, Platzer W. (1993). *Colour atlas and textbook of human anatomy*. Stuttgart: Thieme.
- Koo JY, Shellow WV, Hallman CP, Edwards JE. (1994). Alopecia areata and increased prevalence of psychiatric disorders. *International Journal of Dermatology.* 33. p. 849–50.
- Krstic, R. (1991). *Human Microscopic Anatomy: An Atlas for Students of Medicine and Biology*. Berlin: Springer.
- Limmer BL. (1996). Micrografts survival. In: Stough DB, ed. *Hair Replacement: Surgical and Medical*. St. Louis: Mosby Press.
- Marzola M. (2005). Trichophytic closure of the donor area. *Hair Transplant Forum International.* 15 (4). p. 113–16.
- Orentreich N. (1959). Autografts in alopecia and other selected dermatological conditions. *Annals of New York Academic Sciences.* 83, p.463–79.
- Pathomvanich, D, Imagawa, I. (2010). *Hair Restoration Surgery in Asians*. New York: Springer.
- Paus R, Cotsarelis G. (1999). The biology of hair follicles. *New England Journal of Medicine*, 341(7). p. 491.
- Price VH. (1999). Treatment of hair loss. *New England Journal of Medicine*, 341(13). p. 964.
- Rose PT, Nusbaum B. (2014). Robotic hair restoration. *Dermatology Clinics.* 32(1). p. 97–107.
- Schneider MR, Schmidt-Ullrich R, Paus R. (2009). The hair follicle as a dynamic miniorgan. *Current Biology.* 19(3). p. R132–42.
- Vogel JE, Jimenez F, Cole J, Keene SA, Harris JA, Barrera A, Rose PT. (2013). Hair restoration surgery: the state of the art. *Aesthetic Surgery Journal.* 3(1), p. 128–51.
- Weger N, Schlake T. (2005). IGF-I Signalling Controls the Hair Growth Cycle and the Differentiation of Hair Shafts. *Journal of Investigative Dermatology.* 125 (5). p. 873–82.
- Yamamoto K. (2012). Double trichophytic closure with wavy two-layered closure for optimal hair transplantation scar. *Dermatologic Surgery.* 38. p. 664–9.

- Aarskog's syndrome, 237
- abdominal wall reconstruction
- abdominal wall transplant, 56–7
  - anatomy of the abdominal wall, 38–41
  - anterolateral thigh flap (ALT), 51
  - autologous pedicled flaps, 49–54
  - classification of defects, 41–2
  - component separation (CS) technique, 44–5
  - defect approach and evaluation, 43–4
  - endoscopically assisted CS technique, 48
  - enteric fistula, 49
  - etiologies of defects, 42
  - free flaps, 55
  - gracilis flap, 53–4
  - groin flap, 53
  - mesh repair, 46–8
  - minimally accessed surgery, 48
  - omental flap, 52
  - planned hernia repair, 48–9
  - reconstructive options, 42
  - rectus abdominus muscle flaps, 52–3
  - rectus femoris flap, 50–1
  - staged reconstruction, 48–9
  - surgical procedures, 44–57
  - temporary abdominal closure (TAC), 48–9
  - tensor fascia lata flap, 49–50
  - tissue expansion, 54–5
  - treatment considerations, 38
  - vascular zones, 41
  - vastus lateralis flap, 53
  - ventral abdominal wall hernia (VAH), 44
- abdominoplasty, 410, 415–20
- full abdominoplasty, 418–20
  - layers of the abdominal wall, 415
  - mini abdominoplasty, 416
- abuse
- burns as a sign of, 107–9
  - recognised patterns of intentional injury, 108–9
- acellular dermal matrix (ADM), 135
- acromegaly, 242
- acrosyndactyly, 237
- Acute Trauma Life Support (ATLS)
- course, 298
- adipose-derived stem cells (ASCs), 258
- adult genital reconstruction, 297
- female
    - female genital mutilation (FGM), 301–2
    - malignancy, 303–4
    - physical assault, 302–3
    - traumatic injuries, 301–3
    - vaginal malignancy, 303–4
    - vulval malignancy, 303
  - male
    - Fournier gangrene, 301
    - gunshot and stab wounds, 300
    - infection, 301
    - penetrating trauma, 300
    - penile cancer, 300
    - penile traumatic injuries, 298–9
    - scrotal blunt trauma, 300
    - scrotal penetrating trauma, 300
    - traumatic injuries, 298–300
- aesthetic breast surgery
- anatomy of the breast, 389–90
  - breast augmentation, 392–7
  - breast embryology and development, 387–9
  - breast implants, 390–2
  - breast reduction, 403–2
  - mastopexy, 397–403

- AIDS patients  
Kaposi sarcoma, 321
- alcohol  
risk factor for oropharyngeal squamous cell carcinoma, 82
- Alloderm®, 136
- allograft, 21
- amniotic band syndrome, 244–6
- androgen receptor (AR) gene defects, 283
- androgenetic alopecia, 436–7
- angioblastoma of Nakagawa, 318
- angiosarcoma, 322
- antimicrobials, 10–11
- antiseptics, 10
- Apert syndrome, 237, 268–9
- Apligraf®, 136
- apocrine glands, 5
- arteriovenous malformations (AVMs), 325–6
- arthrogryphosis, 239
- Asian blepharoplasty  
anatomy of Asian eyelids, 376–8  
complications, 384  
development of procedures, 375–6  
epicanthoplasty, 383–4  
goal of, 376  
incisional technique (surgical resection), 380–2  
non-incisional technique (suture ligation), 379–80  
patient information, 378  
popularity of the technique, 375  
postoperative considerations, 384  
preoperative considerations, 378  
surgical techniques, 378–84 *see also* blepharoplasty.
- autograft, 21
- basal cell carcinoma, 61–4  
diagnosis, 62  
follow up, 64  
histology, 62  
incidence, 61  
management, 62–4  
Mohs micrographic surgery (MMS), 64  
non-surgical management, 63  
risk factors, 61  
surgical management, 64
- Bean syndrome, 324
- Benjamin, Dr Harry, 306
- betel quid  
risk factor for oropharyngeal squamous cell carcinoma, 82–3
- Biemond's syndrome, 241
- biofilms, 10
- biological wound dressings for burns, 115
- bladder exstrophy, 294–6
- bladder exstrophy epispadia complex (BEEC), 294
- blepharoplasty, 357–61  
complications, 361  
contraindications, 361  
lower blepharoplasty, 359–61  
upper blepharoplasty, 357–9 *see also* Asian blepharoplasty.
- blue rubber bleb nevus syndrome, 324
- body contouring  
abdominoplasty, 415–20  
brachioplasty (arm lift), 423–5  
circumferential lipectomy, 421–3  
definition, 409  
fat grafting, 425–6  
following massive weight loss, 409  
history of liposculpture, 165  
importance of self-image, 409  
liposuction, 412–13  
liposuction complications, 413–15  
patient selection, 410  
preoperative marking, 411  
thigh, 426–8  
tumescent anesthesia, 411–12  
upper arm, 423–6
- body dysmorphic disorder, 336, 346
- bone marrow stem cells (BMSCs), 258
- botulinum neuromodulators  
facial aesthetic treatment, 369–70
- brachioplasty (arm lift), 423–5
- breast anatomy, 389–90
- breast augmentation, 392–7
- breast embryology and development, 387–9
- breast implants, 390–2
- breast reduction, 403–2
- brow lift, 362–4  
aesthetic positioning of the brow, 362  
ageing changes of the brow, 362  
brow position in men and women, 362  
complications, 364  
crenated direct browlift technique, 363  
endoscopic brow lift, 362–3  
pretrichial brow lift, 363  
techniques, 362–3
- bupivacaine, 337, 339
- burn pathophysiology, 109–10  
local response, 109–10  
systemic response, 110



- burn reconstruction techniques, 126
  - dermal regeneration templates (dermal skin substitutes), 134–7
  - excision and skin grafting, 129–34
  - facial transplantation, 153
  - factors influencing choice of techniques, 127
  - flap reconstruction, 137–53
  - guidelines for the reconstructive process, 128
  - healing by secondary intention, 128–9
  - primary closure, 128–9
  - tissue expansion, 137
- burn reconstructive surgery, 122
  - aim, 122–3
  - challenges, 122–3
  - initial consultation, 123–4
  - patient–surgeon relationship, 123–4
  - reconstructive process, 124–5
  - timing of surgery, 125
- burn types, 104–7
  - carbolic acid, 105–6
  - chemical burns, 105–7
  - cigarette burns, 108
  - contact burns, 104
  - electrical burns, 107, 108
  - flame burns, 104
  - flash burns, 104
  - household bleach, 105
  - phenol (carbolic acid), 105–6
  - scalds, 104, 107, 108–9
  - sodium hypochloride, 105
  - sulphur mustard, 106–7
  - sulphuric acid, 106
  - tar burns, 105
  - thermal burns, 104–5
  - white phosphorus, 106
- burns
  - abusive cigarette burns, 108
  - abusive electrical burns, 108
  - abusive scald patterns, 108–9
  - acute management and assessment, 111–14
  - as a sign of abuse, 107–9
  - challenges for healthcare professionals, 103
  - criteria for specialised burn unit treatment, 111–12
  - epidemiology, 103
  - external ear, 251
  - indicators for suspicion, 108
  - management goals, 115
  - recognise an accidental scalding, 107
  - recognised patterns of intentional injury, 108–9
  - topical ointments, 114
  - types of, 104–7
  - wound dressings, 114–15
  - wound healing stages, 110–11
  - wound management, 114–15
- cadexomer iodine, 10
- camptodactyly, 239
- capillary malformations, 323
- chemical peel, 367–8
- cicatricial alopecia, 437
- circumferential lipectomy, 421–3
- cleft hand (ectrodactyly), 235
- cleft lip and palate, 235, 245
  - aetiology, 271–2
  - antenatal diagnosis, 272
  - classification of features, 272
  - cleft abnormalities, 266–7
  - diagnosis, 272
  - forms of, 263
  - management, 272–6
  - moulding techniques, 273–4
  - multidisciplinary approach to management, 272
  - neonatal care, 272–3
  - photographic record of changes, 273
  - post-operative care, 276
  - pre-surgical work-up, 273
  - primary surgery, 274–5
  - recognition of the condition, 271–2
  - secondary surgery, 275–6
  - ultrasound antenatal detection, 272
- clinodactyly, 239–40
- clitoroplasty, 286
- Clostridium botulinum*, 369
- compartment syndrome, 198–9
- complete androgen insensitivity syndrome (CAIS), 283
- component separation (CS) technique, 44–5
- composite haemangioendothelioma, 321
- confocal endomicroscopy, 88
- congenital adrenal hyperplasia (CAH), 283, 293
- congenital ear defects, 250
- congenital haemangiomas, 317
- congenital hand abnormalities
  - amniotic band syndrome, 244–6
  - arthrogryphosis, 239
  - camptodactyly, 239
  - classification, 231–46
  - cleft hand (ectrodactyly), 235
  - clinodactyly, 239–40
  - constriction ring syndrome, 244–6
  - embryology of the upper limb, 229–30

- congenital hand abnormalities (*cont.*)  
  macroductyly, 242  
  polyductyly, 240–1  
  radial longitudinal deficiency, 232–3  
  sybrachyductyly, 243–4  
  syndactyly, 237–8  
  thumb duplication, 241–2  
  thumb hypoplasia, 236–7  
  ulnar longitudinal deficiency, 234
- congenital lymphodema, 242
- constriction ring syndrome, 244–6
- craniofacial surgery, 263  
  craniosynostosis syndromes, 270–1 *see also* cleft lip and palate.
- craniosynostosis  
  definition, 263
- craniosynostosis abnormalities, 267
- craniosynostosis syndromes, 268–9  
  Apert syndrome, 268–9  
  Crouzon syndrome, 268  
  definitive craniofacial surgery, 270–1  
  detecting sinister signs, 271  
  importance of early intervention, 269–70  
  management, 269–71  
  Muenkes syndrome, 269  
  Pfeiffer syndrome, 269  
  Saethre–Chotzen syndrome, 269
- cranium  
  cleft abnormalities, 266–7  
  craniosynostosis abnormalities, 267  
  embryological development, 264  
  fontanelles, 264  
  functional anatomy, 264–6  
  sutures, 264
- Crouzon syndrome, 268
- CRP (C-reactive protein) levels in serum, 89
- cryptorchidism, 291–4
- debridement of wounds, 8–9, 10
- dermabrasion, 368
- dermal regeneration templates (dermal skin substitutes), 134–7
- dermis, 4–5
- dermolipectomy, 410
- dihydrotestosterone (DHT), 280, 436
- DIME model for wound assessment, 8
- disorders of sexual development (DSD), 281–5  
  46, XX DSD, 282  
  46, XX DSD surgical management, 286–9  
  46, XY DSD, 282–3  
  46, XY DSD surgical management, 289–94
- clitoroplasty, 286
- cryptorchidism, 291–4
- dysgerminoma, 297
- gonadal dysgenesis, 296–7
- gonadoblastoma, 297
- hypospadias, 289–91
- malignancy in gonadal dysgenesis, 297
- orchidopexy, 294
- perineoplasty, 288–9
- sex chromosome DSD, 285
- sex chromosome DSD surgical management, 296–7
- surgical management, 285–94
- urogenital sinus disorders, 287–8
- vaginoplasty, 287–8
- disseminated intravascular coagulation, 320
- double eyelid surgery, *see* Asian blepharoplasty.
- dysgerminoma, 297
- ear  
  external ear descriptive anatomy, 249–50  
  external ear topographic anatomy, 248–9
- ear defects  
  avulsion or amputations, 251  
  burns, 251  
  caused by cancers, 251  
  congenital, 250  
  frostbite, 251  
  microtia, 250  
  traumatic causes, 251
- ear examination  
  facial trauma patient, 210–11
- ear reconstruction  
  advantages and limitations of various techniques, 260–1  
  aim of, 248  
  cartilage rib graft, 252–4  
  conchal defects, 257–8  
  external prosthesis, 254  
  helix, 255–6  
  lobe, 256  
  marginal defects, 255–6  
  microsurgical replantation, 252  
  non-marginal defects, 257  
  partial reconstruction, 255–8  
  porous polyethylene implants (Medpor®), 254  
  tissue engineering, 258–60  
  total ear reconstruction, 252–4
- eccrine glands, 5
- ectrodactyly (cleft hand), 235
- ectrodactyly-ectodermal dysplasia clefting syndrome (EEC), 235

- edge of wound healing, 11–12
- enteric fistula, 49
- epicanthoplasty, 383–4
- Epicel, 135
- epidermal growth factor, 13
- epidermis, 4
- Epidex, 135
- epithelioid haemangioendothelioma, 322
- epithelioid haemangioma, 319
- ethanol, 232
- eye examination  
     facial trauma patient, 210
- facelift, 352–6  
     complications, 355–6  
     lateral SMASectomy, 353  
     Skoog facelift, 353  
     SMAS procedures, 352–4  
     subcutaneous facelift, 352–3  
     subcutaneous facelift with separate  
         SMAS flap, 353  
     subcutaneous facelift with SMAS manipulation, 353  
     subperiosteal facelift, 354–5
- facial aesthetic surgery  
     assessing the ageing face, 349–51  
     blepharoplasty, 357–61  
     brow lift, 362–4  
     facelift, 352–6  
     nerves of the face, 348  
     patient selection, 346  
     photo-ageing of skin, 351  
     pre-operative counselling, 346  
     rhinoplasty, 365–7  
     skeletal architecture of the aging face, 350–1  
     skeletal augmentation, 364–5  
     soft tissue changes with ageing, 350  
     soft tissue layers of the face, 347–8  
     surgical anatomy of the face, 346–8  
     upper third rejuvenation, 356–64 *see also* Asian  
         blepharoplasty.
- facial aesthetic treatment (non-surgical), 367–70  
     botulinum neuromodulators, 369–70  
     chemical peel, 367–8  
     dermabrasion, 368  
     fillers, 370  
     laser resurfacing, 368–9  
     neuromodulators, 369–70
- facial injuries  
     aetiologies, 208  
     development of management approaches, 208  
     ear examination, 210–11  
     eye examination, 210  
     facial trauma evaluation, 209  
     frontal sinus fractures, 213–15  
     initial management, 209  
     Le Fort fractures, 221–2  
     mandibular fractures, 222–4  
     modes of injury, 208  
     nasal examination, 211  
     nasal fractures, 218  
     nasoorbitoethmoidal fractures, 216–18  
     oral/throat examination, 211  
     orbital fractures, 215–16  
     panfacial fracture surgery, 224  
     parotid duct injuries, 211–12  
     peripheral nerve injuries, 211–12  
     radiological findings, 212  
     scalp examination, 210  
     significance of facial injuries, 208  
     soft tissue injuries, 211  
     zygomaticomaxillary complex  
         fractures, 218–21
- facial skeletal augmentation, 364–5  
     genioplasty, 364  
     implants, 364  
     mid-face augmentation, 365
- facial transplantation, 153
- Fanconi's anaemia, 232
- fat emboli syndrome (FES), 343
- felon, 186
- female genital mutilation (FGM), 301–2
- fibroblast growth factor (FGF-2), 258–9
- fillers (facial), 370
- finger tip amputation, 183–5
- flap reconstruction of burns, 137–53  
     classification of flaps, 142–5  
     distant flaps, 148–50  
     flaps anatomy and physiology, 140  
     free flaps, 150–2  
     interdigitating flaps, 147–8  
     local flaps, 145–7  
     perforator flaps, 152–3  
     principles of flap surgery, 140–2  
     regional flaps, 148–50  
     Z-plasty technique, 147–8
- flaps  
     classification systems, 30–1  
     definition, 24–5  
     distant flaps, 25, 29–30  
     fasciocutaneous flaps, 32–3  
     flaps rotating about a pivot point, 26–9  
     history of flap repair, 25

- flaps (*cont.*)  
  local flaps, 25  
  musculocutaneous flaps, 33–4  
  perforator flaps, 31–2  
  uses for, 24–5 *see also* local flaps.
- Fournier, Dr Pierre, 409
- Fournier gangrene, 301
- frontal sinus fractures, 213–15
- frostbite  
  ear injury, 251
- gender reassignment, 296  
  demasculinisation, 306  
  female to male, 306–7  
  feminisation, 306  
  gender dysphoria, 306  
  male to female, 306  
  meatus construction, 306  
  neoclitoris, 306  
  phalloplasty, 306–7  
  scrotoplasty, 307  
  vaginoplasty, 306
- genioplasty, 364
- genital reconstruction  
  range of procedures, 279 *see also* adult genital reconstruction; gender reassignment; pediatric genital reconstruction.
- genitourinary tract embryology, 279–81
- gentamicin, 10
- Gillies, Sir Harold, 137
- glomovenous malformation, 324
- gonadal dysgenesis, 296–7  
  risk of malignancy, 297
- gonadoblastoma, 297
- growth factors, 258–9  
  use in wound healing, 13
- hair follicles, 5
- hair transplant surgery  
  anaesthesia, 439  
  androgenetic alopecia, 436–7  
  biology of the human hair, 431–3  
  cicatricial alopecia, 437  
  classification of hair loss disorders, 435  
  complications, 443  
  development of techniques, 438  
  donor density assessment, 439  
  embryology of hair, 433–4  
  follicular unit extraction (FUE) technique, 438  
  follicular unit transplantation (FUT) technique, 438  
  graft implantation, 442  
  hair follicle anatomy, 431–3  
  hair life cycle, 434–5  
  harvesting the donor site, 439–42  
  indications for, 436–7  
  postoperative management, 443  
  preoperative patient assessment, 438–9  
  recipient site preparation, 442  
  stages in the procedure, 438  
  stress caused by hair loss, 431
- hair transplantation advances  
  automated FUE transplantation, 444  
  cloning hair follicles, 444–5  
  follicular unit extraction, 444  
  robotics in hair transplantation, 444  
  stem cell therapy, 444–5
- hand anatomy, 156–65  
  blood supply, 159  
  bones, 156  
  joints, 156–7  
  muscles, 157–9  
  nerves, 165
- hand congenital abnormalities, *see* congenital hand abnormalities.
- hand infections, 185–9  
  deep space infections, 186–7  
  felon, 186  
  flexor tenosynovitis, 188–9  
  herpetic whitlow, 186  
  hypothenar space infection, 186–7  
  midpalmar space infection, 186–7  
  paronychia, 185–6  
  thenar space infection, 186–7
- hand surgery  
  functional and aesthetic considerations, 155  
  history of development, 155–6
- hand trauma, 156  
  approach to, 190  
  examination, 165–6  
  extravasation injuries, 189–90  
  finger tip amputation, 183–5  
  nail bed injuries, 183  
  nerve injuries, 176–9  
  pathophysiology of soft tissue injury, 165  
  patient history, 165  
  principles of reconstruction, 168  
  tendon injuries, 168–76  
  vascular injuries, 179–83
- hard palate, 266
- head and neck squamous cell carcinomas (HNSCC), 77
- herpetic whitlow, 186
- Hippocrates, 263

- Holt–Oram syndrome, 232  
*HOXD 19* gene mutations, 241  
 human papillomavirus (HPV)  
   diagnosis, 89  
   risk factor for oropharyngeal squamous cell carcinoma, 83  
 hyperbaric oxygen therapy, 13  
 hypergonatrophic hypogonadism, 296  
 hypodermis, 5  
 hypogonadotrophic hypogonadism, 296  
 hypospadias, 289–91  
 hypothalamic–pituitary–gonadal axis, 296
- Illouz, Dr Yves-Gerard, 334, 409  
 infantile haemangioma, 315–16  
 infection in wounds, 10–11  
 inflammation in wounds, 10–11  
 insulin-like growth factor-1 (IGF-1), 436  
 Integra®, 136, 137  
 International Head and Neck Cancer Epidemiology (INHANCE) consortium, 77  
 isograft, 21
- Kaposi sarcoma, 321  
 Kaposi sarcoma herpes virus (KSHV or HHV-8), 321  
 kaposiform haemangioendothelioma, 320  
 Kasabach–Merritt phenomenon, 318, 320  
 Klein, Jeffery, 334  
 Klinefelter syndrome, 285  
 Klippel–Trenaunay syndrome, 242, 323
- Langer’s lines, 14  
 laser resurfacing of skin, 368–9  
 Le Fort fractures, 221–2  
 lidocaine, 337, 339  
 liposculpture, *see* body contouring.  
 liposuction  
   anaesthetic options, 336–7  
   anatomy of subcutaneous fat, 334–5  
   and body dysmorphic disorder, 336  
   applications of wetting solutions, 338–9  
   areas of consideration, 334–5  
   complications, 342–4, 413–15  
   compression garments, 342  
   definition, 333  
   factors affecting patient satisfaction, 344  
   history of, 333–4  
   invasive liposuction techniques, 337–8  
   laser-assisted liposuction, 338  
   non-invasive liposuction, 344  
   patient positioning, 341  
   patient selection, 334  
   popularity of the procedure, 333  
   power-assisted liposuction (PAL), 338, 413  
   preoperative assessment, 336  
   preoperative marking, 340–1  
   radiofrequency-assisted liposuction (RFAL), 413  
   suction-assisted liposuction (SAL), 337, 412  
   surgical instruments, 341  
   surgical planning, 340–1  
   techniques of infiltration, 340  
   ultrasound-assisted liposuction (UAL), 338, 412  
   VASER-assisted liposuction, 338  
   water-assisted liposuction, 338 *see also* body contouring.  
 lower limb trauma  
   amputation, 205  
   classification systems, 193–5  
   compartment syndrome, 198–9  
   definitive soft tissue management, 202–5  
   fracture management, 201–2  
   goal of treatment, 193, 206  
   incidence, 193  
   multidisciplinary approach, 206  
   primary debridement, 200–1  
   primary management in the emergency department, 195–6  
   referral to specialist centres, 197–8  
   standards for management, 193  
   timing of surgery, 197  
   vascular injuries, 199–200  
 lymphatic malformations, 324–5
- macroductyly, 242  
 macrophage colony-stimulating factor, 13  
 malignant melanoma, 67–72  
   diagnosis, 68–9  
   follow up, 72  
   incidence, 67–8  
   investigations, 69  
   management, 70–1  
   risk factors, 67–8  
   sentinel lymph node biopsy (SLNB), 72  
   staging, 69  
 mandibular fractures, 222–4  
 marcaine, 339  
 Masquelet technique, 202  
 mastopexy, 397–403  
 mate drinking  
   risk of oropharyngeal squamous cell carcinomas, 84  
 Matriderm®, 136, 137

- Mayer–Rokitansky–Küster–Hauser (MRKH) syndrome, 287
- Medpor® (porous polyethylene implant), 254
- mesenchymal stem cells (MSCs), 258
- mesh repair
- abdominal wall, 46–8
- metronidazole, 10
- micropenis, 296
- microtia, 250
- Mohs micrographic surgery (MMS), 64
- moisture balance of wounds, 11
- Muenkes syndrome, 269
- Müllerian agenesis, 287
- mupirocin, 10
- Myskin, 135
- nail bed injuries, 183
- nasal examination
- facial trauma patient, 211
- nasal fractures, 218
- nasoorbitoethmoidal fractures, 216–18
- negative-pressure wound therapy, 12–13
- neomycin, 10
- neurofibromatosis, 242
- neuromodulators
- facial aesthetic treatment, 369–70
- optical tomography (OT), 89
- oral/throat examination
- facial trauma patient, 211
- orbital fractures, 215–16
- Orcel®, 136
- orchidopexy, 294
- oropharyngeal cancer
- epidemiology, 78
  - incidence, 77, 78
  - oral cavity anatomy, 77
  - risk factors, 77
- oropharyngeal squamous cell carcinomas
- aetiology, 80–5
  - alcohol risk factor, 82
  - autofluorescence, 88
  - betel quid risk factor, 82–3
  - biomarkers in saliva, 89
  - brush biopsy, 87
  - chemiluminescence, 88
  - clinical features, 86–7
  - confocal endomicroscopy, 88
  - conventional oral examination, 85
  - diagnosis, 85–90
  - diagnosis from saliva, 89
  - effects of diet on risk, 84
  - histopathology, 90–1
  - HPV diagnosis, 89
  - HPV risk factor, 83
  - importance of early diagnosis, 85
  - incidence, 77, 78
  - location, 87
  - management, 93–5
  - mortality, 80
  - optical tomography (OT), 89
  - pretreatment investigations, 92
  - prognosis, 95–7
  - rationale behind treatment, 93–4
  - reconstructive surgery, 95
  - risk factors, 77, 80–5
  - risk linked to mate drinking, 84
  - screening, 89–90
  - second primary malignancy, 97
  - serum C-reactive protein (CRP), 89
  - staging, 92
  - surgical approaches, 94–5
  - symptoms, 86–7
  - tests to aid diagnosis, 87–90
  - tobacco risk factor, 80–2
  - toluidine blue (TB) staining, 87
- Otteni, Dr Francis, 409
- palate embryology, 264
- panfacial fracture surgery, 224
- papillary intralymphatic angioendothelioma, 321
- Parkes–Weber syndrome, 323
- paronychia, 185–6
- partial androgen insensitivity syndrome (PAIS), 283
- pediatric genital reconstruction
- bladder exstrophy, 294–6
  - clitoroplasty, 286
  - congenital abnormalities, 281–5
  - cryptorchidism, 291–4
  - disorders of sexual development (DSD), 281–5
  - dysgerminoma, 297
  - embryology of the external genitalia, 280–1
  - embryology of the internal genitalia, 279–80
  - gonadal dysgenesis, 296–7
  - gonadoblastoma, 297
  - hypospadias, 289–91
  - malignancy in gonadal dysgenesis, 297
  - micropenis, 296
  - orchidopexy, 294
  - perineoplasty, 288–9
  - sex chromosome DSD, 285
  - sex chromosome DSD surgical management, 296–7

- surgical management of congenital disorders, 285–97
- urogenital sinus disorders, 287–8
- vaginoplasty, 287–8
- penile cancer, 300
- penis
  - traumatic injuries, 298–9
- perineoplasty, 288–9
- Pfeiffer syndrome, 269
- phalloplasty, 306–7
- phenobarbitol, 232
- physiological wound dressings for burns, 115
- Pierre Robin syndrome, 263
- plastic surgery
  - key principles, 3
- platelet gels, 13
- platelet-derived growth factor, 13
- platelet-derived growth factor- $\beta$  (PDGF-B), 258–9
- Poland syndrome, 237, 243
- polydactyly, 235, 240–1
- porous polyethylene implants (Medpor®), 254
- primary closure, 128–9
- primary intention wound healing, 8
- Proteus syndrome, 242
- pyogenic granuloma, 319
  
- RASA1* gene mutations, 323
- ReCell, 135
- reconstructive ladder for wound closure, 14–15
- reconstructive surgery
  - key principles, 3
- retiform haemangioendothelioma, 321
- rhinoplasty, 365–7
  - anatomy of the nose, 365
  - approaches to, 366
  - incision options, 366–7
  - modifying the nasal dorsum, 367
  - nasal tip, 367
  
- Saethre–Chotzen syndrome, 269
- scalp examination, 210
- scars
  - how to achieve a fine line scar, 13–14
- scrotoplasty, 307
- scrotum
  - blunt trauma injuries, 300
  - penetrating traumatic injuries, 300
- sebaceous glands, 5–6
- secondary intention wound healing, 8, 128–9
- sentinel lymph node biopsy (SLNB), 72
  
- sex chromosome disorders of sexual development (DSDs), 285
  - surgical management, 296–7
- skin
  - appendages, 5–6
  - dermis, 4–5
  - epidermis, 4
  - hypodermis, 5
  - structure and functions, 3–6
  - wound healing principles, 8
  - wound healing process, 6–8
- skin adhesives, 19
- skin cancer
  - basal cell carcinoma, 61–4
  - malignant melanoma, 67–72
  - squamous cell carcinoma, 65–7
  - types of, 61
- skin grafting
  - definition, 20
  - for burn reconstruction, 129–34
  - full-thickness grafts, 20–1
  - graft contraction, 22–3
  - graft failure, 23–4
  - graft healing, 22
  - graft reinnervation, 23
  - graft take, 21–2
  - overgrafting, 23
  - sources of grafts, 21
  - split-thickness grafts, 20–1
  - terminology of graft types, 21
  - uses for, 20
- skin staples, 19
- skin tapes, 19
- skull embryology, 264
- Smith–Lemli–Opitz syndrome, 283
- soft palate, 266
- spindle cell haemangioma, 318
- sporadic venous malformation, 324
- squamous cell carcinoma, 65–7
  - clinical presentation, 65–6
  - diagnosis, 65–6
  - follow up, 67
  - incidence, 65
  - management, 66–7
  - non-surgical management, 66–7
  - risk factors, 65
  - surgical management, 66
- stem cells, 258
- Sturge–Weber syndrome, 323
- suturing techniques, 16–18
  - corner stitch, 18

- suturing techniques (*cont.*)
  - half buried horizontal mattress sutures, 18
  - mattress sutures, 18
  - simple continuous suture, 16
  - simple interrupted suture, 16
  - subcuticular (intra dermal) sutures, 18
- sweat glands, 5
- symbachydactyly, 243–4
- syndactyly, 235, 237–8, 269
- synthetic wound dressings for burns, 115
- systemic lupus erythematosus, 437
  
- talipes equinovarus, 245
- temporary abdominal closure (TAC), 48–9
- tertiary intention wound healing, 8
- thalidomide, 232
- thigh
  - body contouring techniques, 426–8
- thrombocytopenia, 318
- thrombocytopenia absent radius (TAR)
  - syndrome, 232
- thumb duplication, 241–2
- thumb hypoplasia, 236–7
- TIE2/TEK* gene mutations, 323
- tissue engineering, 258–60
  - cell sources, 258
  - chondrocytes, 258
  - future perspectives, 260
  - growth factors, 258–9
  - scaffolds, 259
  - stem cells, 258
- tissue expansion
  - for abdominal wall reconstruction, 54–5
  - for burn reconstruction, 137
- tobacco
  - risk factor for oropharyngeal squamous cell carcinoma, 80–2
- toluidine blue (TB) staining, 87
- topical antibacterials, 10–11
- topical antimicrobials, 10–11
- topical antiseptics, 10
- transforming growth factor (TGF- $\beta$ ), 258–9
- trisomy 13 syndrome, 241
- tufted angioma, 318
- Turner syndrome, 285
  
- upper arm
  - body contouring, 423–6
  - brachioplasty (arm lift), 423–5
  - fat grafting, 425–6
  
- VACTERL, 232
- vaginal malignancy, 303–4
- vaginoplasty, 287–8, 306
- vascular anomalies
  - angiosarcoma, 322
  - arteriovenous malformations (AVMs), 325–6
  - capillary malformations, 323
  - classification, 313–14
  - composite haemangioendothelioma, 321
  - congenital haemangiomas, 317
  - epithelioid haemangioendothelioma, 322
  - epithelioid haemangioma, 319
  - infantile haemangioma, 315–16
  - Kaposi sarcoma, 321
  - kaposiform haemangioendothelioma, 320
  - locally aggressive tumours, 320–1
  - lymphatic malformations, 324–5
  - malignant tumours, 322
  - papillary intralymphatic angioendothelioma, 321
  - pyogenic granuloma, 319
  - retiform haemangioendothelioma, 321
  - spindle cell haemangioma, 318
  - tufted angioma, 318
  - tumours, 315–22
  - vascular malformations, 322–6
  - vascular tumours, 315–16
  - venous malformations, 324
- vascular malformations, 322–6
- VEGFR3* gene mutations, 323
- ventral abdominal wall hernia (VAH), 44
- ventricular septal defects, 235
- vulval malignancy, 303
  
- wound assessment tools, 8
- wound closure, 15–16
  - reconstructive ladder, 14–15
  - skin adhesives, 19
  - skin staples, 19
  - skin tapes, 19
  - suturing techniques, 16–18
- wound dressings, 12
- wound dressings for burns, 114–15
  - biological wound dressings, 115
  - physiological wound dressings, 115
  - synthetic wound dressings, 115
- wound healing
  - principles of, 8
  - process, 6–8
  - stages for burns, 110–11
  - types of, 8



## wound management

adjuncts to healing, 12–13

complex wounds, 12

debridement, 8–9, 10

dressings, 12

edge of wound healing, 11–12

effects of patient ill health, 12

growth factors, 13

how to achieve a fine line scar, 13–14

hyperbaric oxygen therapy, 13

infection, 10–11

inflammation, 10–11

moisture balance, 11

negative-pressure wound therapy, 12–13

xenograft, 21

zygomaticomaxillary complex fractures, 218–21



**W**ritten by experts from London's renowned Royal Free Hospital, *Textbook of Plastic and Reconstructive Surgery* offers a comprehensive overview of the vast topic of reconstructive plastic surgery and its various subspecialties for introductory plastic surgery and surgical science courses.

The book comprises five sections covering the fundamental principles of plastic surgery, cancer, burns and trauma, paediatric plastic surgery and aesthetic surgery, and covers the breadth of knowledge that students need to further their career in this exciting field. Additional coverage of areas in which reconstructive surgery techniques are called upon includes abdominal wall reconstruction, ear reconstruction and genital reconstruction. A section on aesthetic surgery includes facial aesthetic surgery and blepharoplasty, aesthetic breast surgery, body contouring and the evolution of hair transplantation.

The broad scope of this volume makes this a unique contribution to the field. Heavily illustrated throughout, *Textbook of Plastic and Reconstructive Surgery* is essential reading for anyone interested in furthering their knowledge of this exciting field.

---

**Deepak M. Kalaskar, B.Tech, PhD** is based at the renowned Royal Free hospital in London. He currently heads the MSc course in Burns, Plastic and Reconstructive Surgery at UCL.

**Peter E. Butler, MD, FRCSI, FRCS, FRCS** is Professor of Plastic and Reconstructive Surgery at UCL. He is consultant plastic surgeon and head of the face transplantation team at the Royal Free Hospital.

**Shadi Ghali, FRCS (Plast), MD, BSc** is a reconstructive surgeon at the Royal Free Hospital, with a special interest in complex microsurgical breast and lower limb reconstruction.

FRONT COVER IMAGE:  
Shutterstock  
COVER DESIGN:  
Rawshock design

£50.00



**UCLPRESS**  
www.ucl.ac.uk/ucl-press